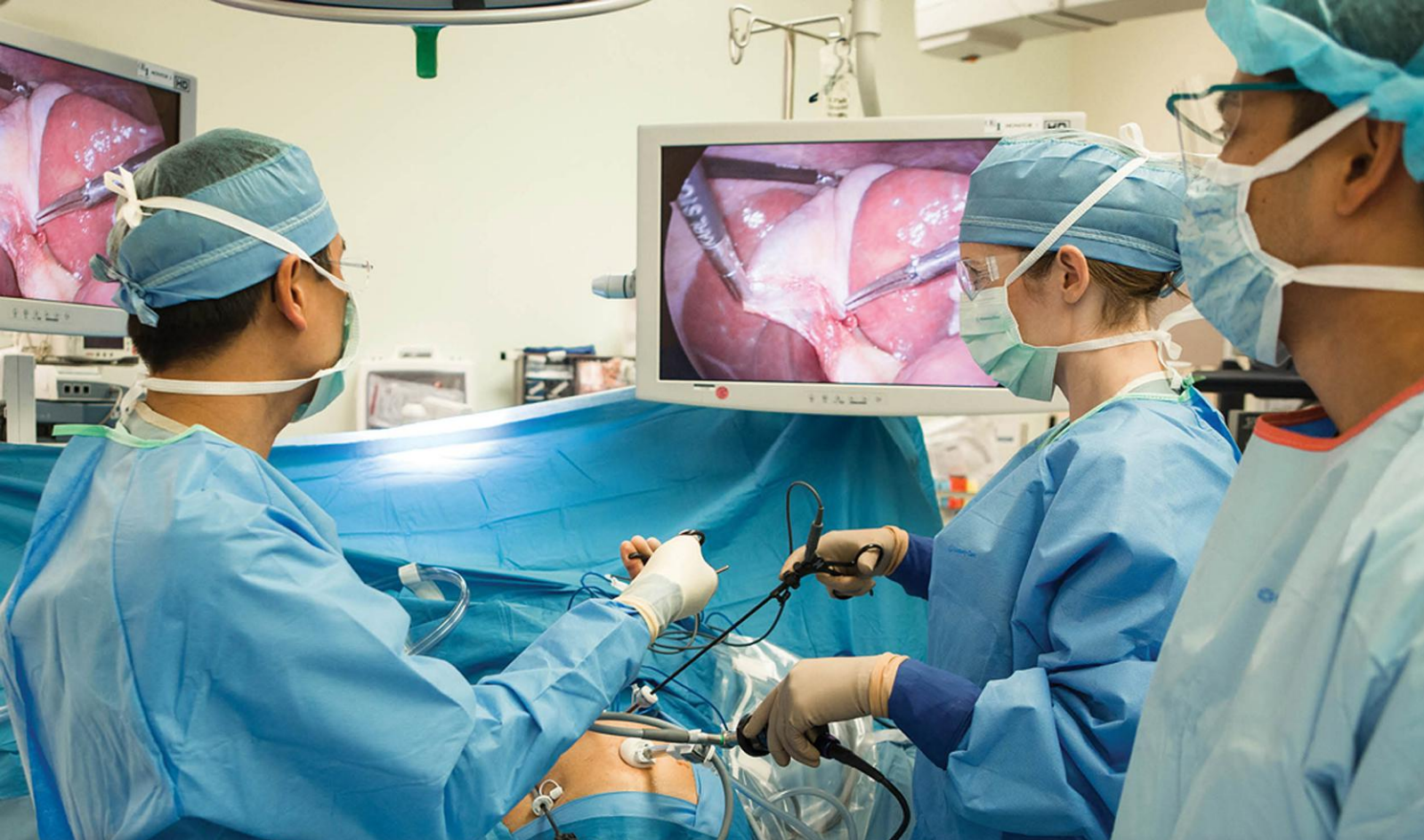



Mc
Graw
Hill
Education

Schwartz's

**PRINCIPLES OF
SURGERY**

TENTH EDITION

F. Charles Brunnicardi

Dana K. Andersen • Timothy R. Billiar

David L. Dunn • John G. Hunter

Jeffrey B. Matthews • Raphael E. Pollock

VRG Release: tahir99

Schwartz's Principles of Surgery

Tenth Edition

Notice

Medicine is an ever-changing science. As new research and clinical experience broaden our knowledge, changes in treatment and drug therapy are required. The authors and the publisher of this work have checked with sources believed to be reliable in their efforts to provide information that is complete and generally in accord with the standards accepted at the time of publication. However, in view of the possibility of human error or changes in medical sciences, neither the authors nor the publisher nor any other party who has been involved in the preparation or publication of this work warrants that the information contained herein is in every respect accurate or complete, and they disclaim all responsibility for any errors or omissions or for the results obtained from use of the information contained in this work. Readers are encouraged to confirm the information contained herein with other sources. For example and in particular, readers are advised to check the product information sheet included in the package of each drug they plan to administer to be certain that the information contained in this work is accurate and that changes have not been made in the recommended dose or in the contraindications for administration. This recommendation is of particular importance in connection with new or infrequently used drugs.

Schwartz's Principles of Surgery

Tenth Edition

Editor-in-Chief

F. Charles Brunicaudi, MD, FACS

Moss Foundation Chair in Gastrointestinal
and Personalized Surgery
Professor and Vice Chair Surgical Services
Chief of General Surgery, UCLA Santa Monica
Medical Center
Department of Surgery
David Geffen School of Medicine at UCLA
Los Angeles, California

Associate Editors

Dana K. Andersen, MD, FACS

Program Director
Division of Digestive Diseases and Nutrition
National Institute of Diabetes and Digestive
and Kidney Diseases
National Institutes of Health
Bethesda, Maryland

Timothy R. Billiar, MD, FACS

George Vance Foster Professor and Chairman
Department of Surgery
University of Pittsburgh School of Medicine
Pittsburgh, Pennsylvania

David L. Dunn, MD, PhD, FACS

Executive Vice President for Health Affairs
Professor of Surgery, Microbiology, and Immunology
University of Louisville
Louisville, Kentucky

John G. Hunter, MD, FACS

Mackenzie Professor and Chair
Department of Surgery
Oregon Health & Science University
Portland, Oregon

Jeffrey B. Matthews, MD, FACS

Surgeon-in-Chief and Chairman
Department of Surgery
Dallas B. Phemister Professor of Surgery
The University of Chicago
Chicago, Illinois

Raphael E. Pollock, MD, PhD, FACS

Professor and Director
Division of Surgical Oncology
Department of Surgery
Chief of Surgical Services, Ohio State University
Comprehensive Cancer Center, Arthur G. James
Cancer Hospital and Richard J. Solove
Research Institute
The Ohio State University Wexner Medical Center
Columbus, Ohio



New York Chicago San Francisco Athens London Madrid Mexico City Milan
New Delhi Singapore Sydney Toronto

Copyright © 2015 by McGraw-Hill Education. All rights reserved. Except as permitted under the United States Copyright Act of 1976, no part of this publication may be reproduced or distributed in any form or by any means, or stored in a database or retrieval system, without the prior written permission of the publisher, with the exception that the program listings may be entered, stored, and executed in a computer system, but they may not be reproduced for publication.

ISBN: 978-0-07-180092-1

MHID: 0-07-180092-1

The material in this eBook also appears in the print version of this title: ISBN: 978-0-07-179675-0,
MHID: 0-07-179675-4.

eBook conversion by codeMantra
Version 1.0

All trademarks are trademarks of their respective owners. Rather than put a trademark symbol after every occurrence of a trademarked name, we use names in an editorial fashion only, and to the benefit of the trademark owner, with no intention of infringement of the trademark. Where such designations appear in this book, they have been printed with initial caps.

McGraw-Hill Education eBooks are available at special quantity discounts to use as premiums and sales promotions or for use in corporate training programs. To contact a representative, please visit the Contact Us page at www.mhprofessional.com.

Previous editions © 2010, 2005, 1999, 1994, 1989, 1984, 1979, 1974, 1969 by The McGraw-Hill Companies, Inc.

TERMS OF USE

This is a copyrighted work and McGraw-Hill Education and its licensors reserve all rights in and to the work. Use of this work is subject to these terms. Except as permitted under the Copyright Act of 1976 and the right to store and retrieve one copy of the work, you may not decompile, disassemble, reverse engineer, reproduce, modify, create derivative works based upon, transmit, distribute, disseminate, sell, publish or sublicense the work or any part of it without McGraw-Hill Education's prior consent. You may use the work for your own noncommercial and personal use; any other use of the work is strictly prohibited. Your right to use the work may be terminated if you fail to comply with these terms.

THE WORK IS PROVIDED "AS IS." MCGRAW-HILL EDUCATION AND ITS LICENSORS MAKE NO GUARANTEES OR WARRANTIES AS TO THE ACCURACY, ADEQUACY OR COMPLETENESS OF OR RESULTS TO BE OBTAINED FROM USING THE WORK, INCLUDING ANY INFORMATION THAT CAN BE ACCESSED THROUGH THE WORK VIA HYPERLINK OR OTHERWISE, AND EXPRESSLY DISCLAIM ANY WARRANTY, EXPRESS OR IMPLIED, INCLUDING BUT NOT LIMITED TO IMPLIED WARRANTIES OF MERCHANTABILITY OR FITNESS FOR A PARTICULAR PURPOSE. McGraw-Hill Education and its licensors do not warrant or guarantee that the functions contained in the work will meet your requirements or that its operation will be uninterrupted or error free. Neither McGraw-Hill Education nor its licensors shall be liable to you or anyone else for any inaccuracy, error or omission, regardless of cause, in the work or for any damages resulting therefrom. McGraw-Hill Education has no responsibility for the content of any information accessed through the work. Under no circumstances shall McGraw-Hill Education and/or its licensors be liable for any indirect, incidental, special, punitive, consequential or similar damages that result from the use of or inability to use the work, even if any of them has been advised of the possibility of such damages. This limitation of liability shall apply to any claim or cause whatsoever whether such claim or cause arises in contract, tort or otherwise.

To obtain material from the disk that accompanies the printed version of this eBook, please [click here](#).



Stephen Lowry, MD, MBA (1947-2011)

Photograph used with permission johnemersonphotography.com

The tenth edition of *Schwartz's Principles of Surgery* is dedicated to the late Dr. Stephen Lowry, consummate surgeon-scientist, educator, colleague, mentor, and long-time contributor to *Schwartz's Principles of Surgery*. At the time of his death, Dr. Lowry served as Richard Harvey Professor and Chair of the Department of Surgery and Senior Associate Dean for Education at the Rutgers-Robert Wood Johnson Medical School (RWJMS) in New Brunswick, New Jersey. He was the inaugural holder of the Richard Harvey Professorship at RWJMS, which honors excellence in innovative teaching and exemplified his absolute dedication to medical education. Dr. Lowry's dedicated and distinguished surgical career produced valuable contributions to both scientific knowledge and patient care, including his seminal investigations utilizing the human endotoxemia model that defined important aspects of the host inflammatory response following injury. His investigations had been supported by continuous National Institute of Health (NIH) funding for more than 25 years and were recognized by the coveted Method to

Extend Research in Time (MERIT) award from the NIH. He authored more than 400 scientific publications and was the recipient of numerous honors that recognized his academic achievements. Although Dr. Lowry received many accolades and awards throughout his career, he was first and foremost an enthusiastic teacher and sincere supporter of people, their goals, and their lives. Dr. Lowry genuinely enjoyed listening, learning, and sharing his knowledge and did so with a depth of feeling that inspired and encouraged those around him. As his wife Susette wrote, "Steve knew he would be remembered for his professional accomplishments, but never imagined he would be honored and missed for his personality and style that set him apart from the rest. The world really was a better place with Steve in it!" The loss of his warmth, professionalism, intellect, and enthusiasm for medical education will be greatly missed.

**Siobhan Corbett, MD, and the editors of
Schwartz's Principles of Surgery, Tenth edition**



Robert S. Dorian, MD, MBA (1954-2014)

Photo provided by Saint Barnabas Medical Center. Used with permission.

The Editors of *Schwartz's Principles of Surgery* wish to dedicate this tenth edition to the memory of Dr. Robert S. Dorian, the sole author of the "Anesthesia" chapter in the last three editions. Dr. Dorian was born in Philadelphia and grew up in Livingston, New Jersey where his father was a prominent gynecologist. He received his undergraduate degree in Physics and Music from Tufts University in Boston while at the same time studying piano at the New England Conservatory of Music. Bob received his medical education at Rutgers Medical School in Piscataway, New Jersey. After completing an internship in surgery at Downstate Medical Center in Brooklyn, he trained in anesthesiology at Weill Cornell Medical College and New York Hospital in New York City. He completed a fellowship in pediatric anesthesiology at Boston Children's Hospital and Harvard Medical School. After his training, Bob established practice at the St. Barnabas Medical Center and rose to become the Chairman of the Department of Anesthesiology, a position he held for 14 years until his death. He was highly respected on both a national and international basis as an outstanding chairman.

Bob was a consummate anesthesiologist, educator, mentor, and wonderful friend. He was the greatest of clinical anesthesiologists and was dedicated to providing the highest level of care to his patients. He was an extraordinary teacher and as the Program Director of the St. Barnabas anesthesia residency program for ten years, he trained

scores of residents. His residents adored him because of the tremendous amount of attention he gave to each resident to assure they were highly trained in their craft and that they were placed in the top fellowships around the nation. Bob was also an incredibly gifted musician, scholar, and thinker. His intellect, humanity, and humor were inspiring to everyone who knew him. Bob was respected on an international basis for his humanitarian work with frequent medical missions to underserved populations around the world. In this endeavor, he was often accompanied by his wife, Linda, and their daughters, Rose and Zoe.

Dr. Dorian had a most special gift and that was to bring out the best in every person that he met and make them feel very special. He lit up every room and made each encounter an occasion to remember. Having a conversation with Bob was one of life's great pleasures. Colleagues, nurses, and patients would look forward to his arrival because he would make them laugh and brighten their day. He was loved by all and will be sorely missed. Bob's memory and legacy will live on in the thousands of patients that he cared for, in the academic programs that he fostered, in the generations of anesthesiologists that he trained, and in his remarkable family. His words and intellect will be preserved in this textbook of surgery.

**James R. Macho, MD, FACS, and the editors of
*Schwartz's Principles of Surgery, Tenth edition***

Contents

Contributors/ix

Acknowledgments/xix

Foreword/xxi

Preface/xxiii

Preface to the First Edition/xxv

Part I

Basic Considerations 1

1. **Fundamental Principles of Leadership Training in Surgery** 3
Amy L. Hill, James Wu, Mark D. Girgis, Danielle Hsu, Areti Tillou, James Macho, Vishad Nabili, and F. Charles Brunicaardi
2. **Systemic Response to Injury and Metabolic Support**13
Siobhan A. Corbett
3. **Fluid and Electrolyte Management of the Surgical Patient**.....65
G. Tom Shires III
4. **Hemostasis, Surgical Bleeding, and Transfusion**.....85
Bryan Cotton, John B. Holcomb, Matthew Pommerening, Kenneth Jastrow, and Rosemary A. Kozar
5. **Shock**109
Brian S. Zuckerbraun, Andrew B. Peitzman, and Timothy R. Billiar
6. **Surgical Infections**135
Greg J. Beilman and David L. Dunn
7. **Trauma**161
Clay Cothren Burlaw and Ernest E. Moore
8. **Burns**227
Jonathan Friedstat, Fred W. Endorf, and Nicole S. Gibran
9. **Wound Healing**.....241
Adrian Barbul, David T. Efron, and Sandra L. Kavalukas
10. **Oncology**273
Funda Meric-Bernstam and Raphael E. Pollock
11. **Transplantation**321
Angelika C. Gruessner, Tun Jie, Klearchos Papas, Marian Porubsky, Abbas Rana, M. Cristy Smith, Sarah E. Yost, David L. Dunn, and Rainer W.G. Gruessner
12. **Patient Safety**365
Catherine L. Chen, Michol A. Cooper, Mark L. Shapiro, Peter B. Angood, and Martin A. Makary
13. **Physiologic Monitoring of the Surgical Patient**.....399
Louis H. Alarcon and Mitchell P. Fink

14. **Minimally Invasive Surgery, Robotics, Natural Orifice Transluminal Endoscopic Surgery, and Single-Incision Laparoscopic Surgery**415
Donn H. Spight, John G. Hunter, and Blair A. Jobe
15. **Molecular and Genomic Surgery**443
Xin-Hua Feng, Xia Lin, Juehua Yu, John Nemunaitis, and F. Charles Brunicaardi

Part II

Specific Considerations 471

16. **The Skin and Subcutaneous Tissue**473
Sajid A. Khan, Jonathan Bank, David H. Song, and Eugene A. Choi
17. **The Breast**497
Kelly K. Hunt, John F.R. Robertson, and Kirby I. Bland
18. **Disorders of the Head and Neck**565
Richard O. Wein, Rakesh K. Chandra, C. René Leemans, and Randal S. Weber
19. **Chest Wall, Lung, Mediastinum, and Pleura**605
Katie S. Nason, Michael A. Maddaus, and James D. Luketich
20. **Congenital Heart Disease**695
Tara Karamlou, Yasuhiro Kotani, and Glen A. Van Arsdell
21. **Acquired Heart Disease**735
Shoichi Okada, Jason O. Robertson, Lindsey L. Saint, and Ralph J. Damiano, Jr.
22. **Thoracic Aneurysms and Aortic Dissection**785
Scott A. LeMaire, Raja R. Gopaldas, and Joseph S. Coselli
23. **Arterial Disease**827
Peter H. Lin, Mun Jye Poi, Jesus Matos, Panagiotis Kougiass, Carlos Bechara, and Changyi Chen
24. **Venous and Lymphatic Disease**915
Jason P. Jundt, Timothy K. Liem, and Gregory L. Moneta
25. **Esophagus and Diaphragmatic Hernia**941
Blair A. Jobe, John G. Hunter, and David I. Watson
26. **Stomach**1035
Yuko Kitagawa and Daniel T. Dempsey
27. **The Surgical Management of Obesity**1099
Philip R. Schauer and Bruce Schirmer
28. **Small Intestine**1137
Ali Tavakkoli, Stanley W. Ashley, and Michael J. Zinner
29. **Colon, Rectum, and Anus**1175
Kelli M. Bullard Dunn and David A. Rothenberger
30. **The Appendix**1241
Mike K. Liang, Roland E. Andersson, Bernard M. Jaffe, and David H. Berger

31. Liver	1263	41. Gynecology	1671
<i>Elaine Y. Cheng, Ali Zarrinpar, David A. Geller, John A. Goss, and Ronald W. Busuttill</i>		<i>Chad Hamilton, Michael Stany, W. Thomas Gregory, and Elise C. Kohn</i>	
32. Gallbladder and the Extrahepatic Biliary System	1309	42. Neurosurgery	1709
<i>Thai H. Pham and John G. Hunter</i>		<i>Casey H. Halpern and M. Sean Grady</i>	
33. Pancreas	1341	43. Orthopedic Surgery	1755
<i>William E. Fisher, Dana K. Andersen, John A. Windsor, Ashok K. Saluja, and F. Charles Brunnicardi</i>		<i>Bert J. Thomas, Freddie H. Fu, Bart Muller, Dharmesh Vyas, Matt Niesen, Jonathan Pribaz, and Klaus Draenert</i>	
34. Spleen	1423	44. Surgery of the Hand and Wrist	1787
<i>Adrian E. Park, Eduardo M. Targarona, and Igor Belyansky</i>		<i>Scott D. Lifchez and J. Alex Kelamis</i>	
35. Abdominal Wall, Omentum, Mesentery, and Retroperitoneum	1449	45. Plastic and Reconstructive Surgery	1829
<i>Neal E. Seymour and Robert L. Bell</i>		<i>Joseph E. Losee, Michael L. Gimbel, J. Peter Rubin, Christopher G. Wallace, and Fu-Chan Wei</i>	
36. Soft Tissue Sarcomas	1465	46. Anesthesia for the Surgical Patient	1895
<i>Janice N. Cormier, Alessandro Gronchi, and Raphael E. Pollock</i>		<i>Robert S. Dorian</i>	
37. Inguinal Hernias	1495	47. Surgical Considerations in the Elderly	1923
<i>Justin P. Wagner, F. Charles Brunnicardi, Parviz K. Amid, and David C. Chen</i>		<i>Rosemarie E. Hardin and Michael E. Zenilman</i>	
38. Thyroid, Parathyroid, and Adrenal	1521	48. Ethics, Palliative Care, and Care at the End of Life	1941
<i>Geeta Lal and Orlo H. Clark</i>		<i>Daniel E. Hall, Peter Angelos, Geoffrey P. Dunn, Daniel B. Hinshaw, and Timothy M. Pawlik</i>	
39. Pediatric Surgery	1597	49. Global Surgery	1955
<i>David J. Hackam, Tracy Grikscheit, Kasper Wang, Jeffrey S. Upperman, and Henri R. Ford</i>		<i>Raymond R. Price and Catherine R. deVries</i>	
40. Urology	1651	Index/1983	
<i>Karim Chamie, Jeffrey La Rochelle, Brian Shuch, and Arie S. Belldegrin</i>			

Contributors

Louis H. Alarcon, MD

Associate Professor of Surgery and Critical Care Medicine, Medical Director, Trauma Surgery, University of Pittsburgh School of Medicine, Pittsburgh, Pennsylvania

Chapter 13, Physiologic Monitoring of the Surgical Patient

Parviz K. Amid, MD, FACS, FRCS

Clinical Professor of Surgery, David Geffen School of Medicine at UCLA, Director Lichtenstein Amid Hernia Clinic at UCLA, Los Angeles, California

Chapter 37, Inguinal Hernias

Dana K. Andersen, MD, FACS

Program Director, Division of Digestive Diseases and Nutrition, National Institute of Diabetes and Digestive and Kidney Diseases, National Institutes of Health, Bethesda, Maryland

Chapter 33, Pancreas

Roland E. Andersson, MD, PhD

Associate Professor, Department of Surgery, County Hospital Ryhov, Jönköping, Department of Clinical and Experimental Medicine, Faculty of Health Sciences, Linköping University, Linköping, Sweden

Chapter 30, The Appendix

Peter Angelos, MD, PhD, FACS

Linda Kohler Anderson Professor of Surgery and Surgical Ethics, Chief, Endocrine Surgery, Associate Director, MacLean Center for Clinical Medical Ethics, The University of Chicago Medicine, Chicago, Illinois

Chapter 48, Ethics, Palliative Care, and Care at the End of Life

Peter B. Angood, MD, FRCS(C), FACS, MCCM

President and Chief Executive Officer, American College of Physician Executives, Tampa, Florida

Chapter 12, Patient Safety

Stanley W. Ashley, MD

Frank Sawyer Professor of Surgery, Department of Surgery, Brigham & Women's Hospital, Boston, Massachusetts

Chapter 28, Small Intestine

Jonathan Bank, MD

Department of Surgery, The University of Chicago Medicine & Biological Sciences, Chicago, Illinois

Chapter 16, The Skin and Subcutaneous Tissue

Adrian Barbul, MD, FACS

Vice-Chair, Department of Surgery, Surgical Director, Washington Hospital Center, Washington DC

Chapter 9, Wound Healing

Carlos Bechara, MD

Assistant Professor of Surgery, Division of Vascular Surgery & Endovascular Therapy, Michael E. DeBakey Department of Surgery, Baylor College of Medicine, Houston, Texas

Chapter 23, Arterial Disease

Greg J. Beilman, MD

Frank B. Cerra Professor of Critical Care Surgery, University of Minnesota, Minneapolis, Minnesota

Chapter 6, Surgical Infections

Robert L. Bell, MD, MA, FACS

Assistant Professor of Clinical Surgery, Columbia University College of Physicians and Surgeons, Summit Medical Group, Berkeley Heights, New Jersey

Chapter 35, Abdominal Wall, Omentum, Mesentery, and Retroperitoneum

Arie S. Belldegrün, MD, FACS

Director, Institute of Urologic Oncology, Professor & Chief of Urologic Oncology, Roy and Carol Doumani Chair in Urologic Oncology, David Geffen School of Medicine at UCLA, Los Angeles, California

Chapter 40, Urology

Igor Belyansky, MD

Director of Abdominal Wall Reconstruction Program, Department of General Surgery, Anne Arundel Medical Center, Annapolis, Maryland

Chapter 34, Spleen

David H. Berger, MD, FACS

Professor of Surgery, Vice President and Chief Medical Officer, Baylor College of Medicine, Houston, Texas

Chapter 30, The Appendix

x Timothy R. Billiar, MD, FACS
George Vance Foster Professor and Chairman,
Department of Surgery, University of Pittsburgh School
of Medicine, Pittsburgh, Pennsylvania
Chapter 5, Shock

Kirby I. Bland, MD
Professor and Chair, Department of Surgery, University
of Alabama at Birmingham, Birmingham, Alabama
Chapter 17, The Breast

F. Charles Brunicaardi, MD, FACS
Moss Foundation Chair in Gastrointestinal and
Personalized Surgery, Professor and Vice Chair, Surgical
Services, Chief of General Surgery, UCLA Santa
Monica Medical Center, Department of Surgery, David
Geffen School of Medicine at UCLA, Los Angeles,
California
*Chapter 1, Fundamental Principles of Leadership
Training in Surgery*
Chapter 15, Molecular and Genomic Surgery
Chapter 33, Pancreas
Chapter 37, Inguinal Hernias

Clay Cothren Burlew, MD, FACS
Director, Surgical Intensive Care Unit, Department
of Surgery, Denver Health Medical Center, Associate
Professor of Surgery, University of Colorado School of
Medicine, Denver, Colorado
Chapter 7, Trauma

Ronald W. Busuttill, MD, PhD
Professor and Executive Chairman, Department of
Surgery, University of California-Los Angeles, Los
Angeles, California
Chapter 31, Liver

Karim Chamie, MD, MSHS
Assistant Professor of Urology, Institute of Urologic
Oncology, Department of Urology, University of
California, Los Angeles, California
Chapter 40, Urology

Rakesh K. Chandra, MD
Associate Professor of Otolaryngology, Chief,
Rhinology & Skull Base Surgery, Department of
Otolaryngology-Head & Neck Surgery, Vanderbilt
University, Nashville, Tennessee
Chapter 18, Disorders of the Head and Neck

Catherine L. Chen, MD, MPH
Resident Physician, Department of Anesthesia
and Perioperative Care, University of California,
San Francisco, San Francisco, California
Chapter 12, Patient Safety

Changyi Chen, MD, PhD
Professor of Surgery, Division of Vascular Surgery
& Endovascular Therapy, Vice Chairman of Research,
Michael E. DeBakey Department of Surgery, Baylor
College of Medicine, Houston, Texas
Chapter 23, Arterial Disease

David C. Chen, MD
Clinical Director, Lichtenstein Amid Hernia Clinic at
UCLA, Physician, General Surgery, UCLA Center for
Esophageal Disorders, Los Angeles, California
Chapter 37, Inguinal Hernias

Elaine Y. Cheng, MD
Fellow in Abdominal Transplant Surgery, Division of
Liver and Pancreas Transplantation, Department of
Surgery, University of California-Los Angeles,
Los Angeles, California
Chapter 31, Liver

Eugene A. Choi, MD
Assistant Professor of Surgery, Department of Surgery,
The University of Chicago Medicine & Biological
Sciences, Chicago, Illinois
Chapter 16, The Skin and Subcutaneous Tissue

Orlo H. Clark, MD, FACS
Professor, Surgery, University of California, San
Francisco, California
Chapter 38, Thyroid, Parathyroid, and Adrenal

Michol A. Cooper, MD, PhD
General Surgery Resident, Department of Surgery, Johns
Hopkins Hospital, Baltimore, Maryland
Chapter 12, Patient Safety

Siobhan A. Corbett, MD
Associate Professor, Department of Surgery,
Rutgers-Robert Wood Johnson Medical School, Rutgers
Biomedical and Health Sciences, New Brunswick,
New Jersey
*Chapter 2, Systemic Response to Injury and Metabolic
Support*

Janice N. Cormier, MD, MPH
Professor, Departments of Surgical Oncology and
Biostatistics and Biomathematics, The University of
Texas MD Anderson Cancer Center, Houston, Texas
Chapter 36, Soft Tissue Sarcomas

Joseph S. Coselli, MD
Professor and Chief, Cullen Foundation Endowed Chair,
Division of Cardiothoracic Surgery, Michael E. DeBakey
Department of Surgery, Baylor College of Medicine,
Chief, Adult Cardiac Surgery, Texas Heart Institute,
Chief, Adult Cardiac Surgery Section and, Associate
Chief, Cardiovascular Service, Baylor St. Luke's
Medical Center, Houston, Texas
Chapter 22, Thoracic Aneurysms and Aortic Dissection

Bryan A. Cotton, MD, MPH
Associate Professor of Surgery, University of Texas
Health Science Center at Houston, Center for
Translational Injury Research, Houston, Texas
*Chapter 4, Hemostasis, Surgical Bleeding and
Transfusion*

Ralph J. Damiano, MD

John M. Schoenberg Professor of Surgery, Chief of Cardiac Surgery, Vice Chairman, Department of Surgery, Barnes-Jewish Hospital, Washington University School of Medicine, St Louis, Missouri
Chapter 21, Acquired Heart Disease

Daniel T. Dempsey, MD, FACS

Professor of Surgery, Perelman School of Medicine, University of Pennsylvania, Philadelphia, Pennsylvania
Chapter 26, Stomach

Catherine R. deVries, MD

Director, Center for Global Surgery, Professor, Department of Surgery, Associate Professor, Department of Family and Preventive Medicine, Division of Public Health, University of Utah, Salt Lake City, Utah
Chapter 49, Global Surgery

Robert S. Dorian, MD

Chairman, Department of Anesthesiology, Saint Barnabas Medical Center, Livingston, New Jersey
Chapter 46, Anesthesia for the Surgical Patient

Klaus Draenert, MD

Zentrum für Orthopädische, Wissenschaften, Gabriel-Max-Strasse 3, München, Germany
Chapter 43, Orthopaedic Surgery

David L. Dunn, MD, PhD, FACS

Executive Vice President for Health Affairs, Professor of Surgery, Microbiology and Immunology, University of Louisville, Louisville, Kentucky
Chapter 6, Surgical Infections
Chapter 11, Transplantation

Kelli M. Bullard Dunn, MD, FACS, FASCRS

Senior Associate Dean for Statewide Initiatives and Outreach, Associate Director for Clinical Programs, James Graham Brown Cancer Center, Professor of Surgery, University of Louisville, Louisville, Kentucky
Chapter 29, Colon, Rectum, and Anus

Geoffrey P. Dunn, MD

Medical Director, Department of Surgery, Hamot Medical Center, Erie, Pennsylvania
Chapter 48, Ethics, Palliative Care, and Care at the End of Life

David T. Efron, MD, FACS

Associate Professor of Surgery, Johns Hopkins Medical Institutions, Baltimore, Maryland
Chapter 9, Wound Healing

Fred W. Endorf, MD

Clinical Associate Professor, Department of Surgery, University of Minnesota, St. Paul, Minnesota
Chapter 8, Burns

Xin-Hua Feng, PhD

Professor of Molecular Cell Biology, Michael E. DeBakey Department of Surgery, and Department of Molecular & Cellular Biology Baylor College of Medicine, Houston, Texas
Chapter 15, Molecular and Genomic Surgery

Mitchell P. Fink, MD

Professor-in-Residence, Departments of Surgery and Anesthesiology, Vice Chair, Department of Surgery, David Geffen School of Medicine, UCLA, Los Angeles, California
Chapter 13, Physiologic Monitoring of the Surgical Patient

William E. Fisher, MD, FACS

Professor and Chief, Division of General Surgery, George L. Jordan, M.D. Chair of General Surgery, Director, Elkins Pancreas Center, Michael E. DeBakey Department of Surgery, Baylor College of Medicine, Houston, Texas
Chapter 33, Pancreas

Henri R. Ford, MD

Vice President and Chief of Surgery, Children's Hospital Los Angeles, Vice-Dean, Medical Education, Professor and Vice Chair for Clinical Affairs, Keck School of Medicine, University of Southern California, Los Angeles, California
Chapter 39, Pediatric Surgery

Jonathan Friedstat, MD

Clinical Instructor, Harborview Medical Center, Seattle, Washington
Chapter 8, Burns

Freddie H. Fu, MD, DSc (Hon), DPs (Hon)

Distinguished Service Professor, University of Pittsburgh, David Silver Professor and Chairman, Department of Orthopaedic Surgery, University of Pittsburgh School of Medicine, Head Team Physician, University of Pittsburgh Department of Athletics, Pittsburgh, Pennsylvania
Chapter 43, Orthopaedic Surgery

David A. Geller, MD

Richard L. Simmons Professor of Surgery, Co-Director, UPMC Liver Cancer Center, University of Pittsburgh, Pittsburgh, Pennsylvania
Chapter 31, Liver

Nicole S. Gibran, MD, FACS

Professor, Department of Surgery, Director, Medicine Regional Burn Center, Harborview Medical Center, Seattle, Washington
Chapter 8, Burns

Michael L. Gimbel, MD

Assistant Professor of Surgery, Department of Surgery, University of Pittsburgh, School of Medicine, Pittsburgh, Pennsylvania
Chapter 45, Plastic and Reconstructive Surgery

Mark D. Girgis, MD

Clinical Instructor, Department of Surgery, David Geffen School of Medicine at UCLA, Los Angeles, California
Chapter 1, Fundamental Principles of Leadership Training in Surgery

Raja R. Gopaldas, MD

Assistant Professor, Division of Cardiothoracic Surgery, Hugh E. Stephenson, Jr., MD, Department of Surgery, University of Missouri School of Medicine, Columbia, Missouri
Chapter 22, Thoracic Aneurysms and Aortic Dissection

John A. Goss, MD

Professor and Chief, Division of Abdominal Transplantation, Michael E. DeBakey Department of Surgery, Baylor College of Medicine, Houston, Texas
Chapter 31, Liver

M. Sean Grady, MD, FACS

Charles Harrison Frazier Professor, Chairman, Department of Neurosurgery, Perelman School of Medicine, University of Pennsylvania, Philadelphia, Pennsylvania
Chapter 42, Neurosurgery

W. Thomas Gregory, MD

Associate Professor, Division of Female Pelvic Medicine and Reconstructive Surgery, Department of Obstetrics and Gynecology, Oregon Health & Science University, Portland, Oregon
Chapter 41, Gynecology

Tracy Grikscheit, MD

Assistant Professor of Surgery, Department of Pediatric Surgery, Keck School of Medicine, University of Southern California, Los Angeles, California
Chapter 39, Pediatric Surgery

Alessandro Gronchi, MD

Department of Surgery - Sarcoma Service, Fondazione IRCCS Istituto Nazionale dei Tumori Via Venezian, Milan, Italy
Chapter 36, Soft Tissue Sarcomas

Angelika C. Gruessner, PhD

Professor of Public Health, University of Arizona, Tucson, Arizona
Chapter 11, Transplantation

Rainer W.G. Gruessner, MD, FACS

Professor of Surgery and Immunology, Chairman, Department of Surgery, University of Arizona, Tucson, Arizona
Chapter 11, Transplantation

David J. Hackam, MD, PhD

Roberta Simmons Associate Professor of Pediatric Surgery, University of Pittsburgh School of Medicine, Pittsburgh, Pennsylvania
Chapter 39, Pediatric Surgery

Daniel E. Hall, MD, MDiv, MHSc

Core Investigator, Center for Health Equity Research and Promotion, VA Pittsburgh Healthcare System, Pittsburgh, Pennsylvania and Associate Professor, Department of Surgery, University of Pittsburgh, Pittsburgh, Pennsylvania
Chapter 48, Ethics, Palliative Care, and Care at the End of Life

Casey H. Halpern, MD

Chief Resident, Department of Neurosurgery, University of Pennsylvania, Philadelphia, Pennsylvania
Chapter 42, Neurosurgery

Chad Hamilton, MD

Chief, Gynecologic Oncology Service, Department of Obstetrics and Gynecology, Walter Reed National Military Medical Center, Bethesda, Maryland
Chapter 41, Gynecology

Rosemarie E. Hardin, MD

Practice of Breast Oncology, Wheeling, West Virginia
Chapter 47, Surgical Considerations in the Elderly

Amy L. Hill, MD

Clinical Instructor, Department of Surgery, David Geffen School of Medicine at UCLA, Los Angeles, California
Chapter 1, Fundamental Principles of Leadership Training in Surgery

Daniel B. Hinshaw, MD

Professor, Department of Surgery, University of Michigan, Ann Arbor, Michigan
Chapter 48, Ethics, Palliative Care, and Care at the End of Life

John B. Holcomb, MD, FACS

Vice Chair and Professor of Surgery, Chief, Division of Acute Care Surgery, University of Texas Health Science Center at Houston, Center for Translational Injury Research, Houston, Texas
Chapter 4, Hemostasis, Surgical Bleeding and Transfusion

Danielle Hsu, MD

Clinical Instructor, Department of Surgery, David Geffen School of Medicine at UCLA, Los Angeles, California
Chapter 1, Fundamental Principles of Leadership Training in Surgery

Kelly K. Hunt, MD, FACS

Hamill Foundation Distinguished Professorship in Honor of Dr. Richard G. Martin, Sr., Chief, Surgical Breast Oncology, Department of Surgical Oncology, The University of Texas MD Anderson Cancer Center, Houston, Texas
Chapter 17, The Breast

John G. Hunter, MD, FACS

Professor and Chairman, Department of Surgery, Oregon Health & Science University, Portland, Oregon
Chapter 14, Minimally Invasive Surgery, Robotics, Natural Orifice Transluminal Endoscopic Surgery and Single Incision Laparoscopic Surgery
Chapter 25, Esophagus and Diaphragmatic Hernia
Chapter 32, Gallbladder and the Extrahepatic Biliary System

Bernard M. Jaffe, MD

Professor Emeritus, Department of Surgery, Tulane University School of Medicine, New Orleans, Louisiana
Chapter 30, The Appendix

Kenneth Jastrow, MD

Assistant Professor of Surgery, Department of Surgery, University of Texas Health Science Center at Houston, Houston, Texas
Chapter 4, Hemostasis, Surgical Bleeding and Transfusion

Tun Jie, MD, MS, FACS

Interim Chief, Division of Abdominal Transplant Surgery, Assistant Professor of Surgery, Department of Surgery, University of Arizona, Tucson, Arizona
Chapter 11, Transplantation

Blair A. Jobe, MD, FACS

Chair of Surgery, Western Pennsylvania Hospital, Director, Institute for the Treatment of Esophageal and Thoracic Disease, Allegheny Health Network, Pittsburgh, Pennsylvania
Chapter 14, Minimally Invasive Surgery, Robotics, Natural Orifice Transluminal Endoscopic Surgery and Single Incision Laparoscopic Surgery
Chapter 25, Esophagus and Diaphragmatic Hernia

Jason P. Jundt, MD

Vascular Resident, Division of Vascular Surgery, Department of Surgery and Knight Cardiovascular Institute, Oregon Health & Science University, Portland, Oregon
Chapter 24, Venous and Lymphatic Disease

Tara Karamlou, MD, MSc

Assistant Professor of Surgery, Division of Pediatric Cardiac Surgery, Benioff Children's Hospital University of California, San Francisco, California
Chapter 20, Congenital Heart Disease

Sandra L. Kavalukas, MS

Penn State College of Medicine, Hershey, Pennsylvania
Chapter 9, Wound Healing

J. Alex Kelamis, MD

Senior Resident, Department of Plastic and Reconstructive Surgery, Johns Hopkins University, University of Maryland Medical Center, Baltimore, Maryland
Chapter 44, Surgery of the Hand and Wrist

Sajid A. Khan, MD

Assistant Professor of Surgery, Department of Surgery, Section of Surgical Oncology, Yale University School of Medicine, New Haven, Connecticut
Chapter 16, The Skin and Subcutaneous Tissue

Yuko Kitagawa, MD, PhD, FACS

Professor and Chairman, Department of Surgery, Vice President, Keio University Hospital, Director of Keio Cancer Center, School of Medicine, Keio University, Tokyo, Japan
Chapter 26, Stomach

Elise C. Kohn, MD

Senior Investigator, Head, Molecular Signaling Section, Head, Medical Ovarian Cancer Clinic, Medical Oncology Branch, Center for Cancer Research National Cancer Institute, Bethesda, Maryland
Chapter 41, Gynecology

Yasuhiro Kotani, MD, PhD

Clinical Fellow, Cardiovascular Surgery, The Hospital for Sick Children, University of Toronto, Toronto, Ontario
Chapter 20, Congenital Heart Disease

Panagiotis Kougiyas, MD

Assistant Professor of Surgery, Division of Vascular Surgery & Endovascular Therapy, Michael E. DeBakey Department of Surgery, Baylor College of Medicine, Houston, Texas
Chapter 23, Arterial Disease

Rosemary A. Kozar, MD, PhD

Vice Chair of Research and Academic Development, "Red" Duke Professor of Surgery, University of Texas Health Science Center at Houston, Houston, Texas
Chapter 4, Hemostasis, Surgical Bleeding and Transfusion

Jeffrey La Rochelle, MD

Department of Urology, Oregon Health and Science University, Portland, Oregon
Chapter 40, Urology

Geeta Lal, MD, MSc, FRCS(C), FACS

Associate Professor, Surgery, University of Iowa, Iowa City, Iowa
Chapter 38, Thyroid, Parathyroid, and Adrenal

C. René Leemans, MD, PhD

Professor and Chairman, Department of Otolaryngology-Head & Neck Surgery, VU University Medical Center, Amsterdam, Netherlands
Chapter 18, Disorders of the Head and Neck

Scott A. LeMaire, MD

Professor and Director of Research, Division of Cardiothoracic Surgery, Vice Chair for Research, Michael E. DeBakey Department of Surgery, Baylor College of Medicine, Texas Heart Institute, Professional Staff, Department of Cardiovascular Surgery, Baylor St. Luke's Medical Center, Houston, Texas
Chapter 22, Thoracic Aneurysms and Aortic Dissection

Mike K. Liang, MD

Assistant Professor, Michael E. DeBakey Department of Surgery, Baylor College of Medicine, Houston, Texas
Chapter 30, The Appendix

Timothy K. Liem, MD, FACS

Associate Professor of Surgery, Vice-Chair for Quality, Department of Surgery, Knight Cardiovascular Institute, Oregon Health & Science University, Portland, Oregon
Chapter 24, Venous and Lymphatic Disease

Scott D. Lifchez, MD, FACS

Assistant Professor, Department of Plastic and Reconstructive Surgery, Johns Hopkins University, Director of Hand Surgery, Johns Hopkins Bayview Medical Center, Baltimore, Maryland
Chapter 44, Surgery of the Hand and Wrist

Xia Lin, PhD

Associate Professor of Surgery, Michael E. DeBakey Department of Surgery, Baylor College of Medicine, Houston, Texas
Chapter 15, Molecular and Genomic Surgery

Peter H. Lin, MD

Professor of Surgery, Chief, Division of Vascular Surgery & Endovascular Therapy, Michael E. DeBakey Department of Surgery, Baylor College of Medicine, Houston, Texas
Chapter 23, Arterial Disease

Joseph E. Losee, MD

Ross H. Musgrave Professor of Pediatric Plastic Surgery, Executive Vice-Chair, Department of Plastic Surgery, University of Pittsburgh Medical Center, Pittsburgh, Pennsylvania
Chapter 45, Plastic and Reconstructive Surgery

James D. Luketich, MD

Henry T. Bahnson Professor of Cardiothoracic Surgery, Chief, The Heart, Lung, and Esophageal Surgery Institute, Department of Surgery, Division of Thoracic and Foregut Surgery, University of Pittsburgh, Pittsburgh, Pennsylvania
Chapter 19, Chest Wall, Lung, Mediastinum, and Pleura

James R. Macho, MD, FACS

Emeritus Professor of Surgery, UCSF School of Medicine, Director of Surgical Critical Care, Saint Francis Memorial Hospital, San Francisco, California
Chapter 1, Fundamental Principles of Leadership Training in Surgery

Michael A. Maddaus, MD

Professor of Surgery, Department of Surgery, Division of General Thoracic and Foregut Surgery, University of Minnesota, Minneapolis, Minnesota
Chapter 19, Chest Wall, Lung, Mediastinum, and Pleura

Martin A. Makary, MD, MPH

Associate Professor of Surgery, Johns Hopkins University School of Medicine, Associate Professor of Health Policy & Management, Johns Hopkins Bloomberg School of Public Health, Director, Surgical Quality & Safety, Johns Hopkins Hospital, Baltimore, Maryland
Chapter 12, Patient Safety

Jeffrey B. Matthews, MD, FACS

Surgeon-in-Chief and Chairman, Department of Surgery, Dallas B. Phemister Professor of Surgery, The University of Chicago, Chicago, Illinois

Jesus Matos, MD

Assistant Professor of Surgery, Division of Vascular Surgery & Endovascular Therapy, Michael E. DeBakey Department of Surgery, Baylor College of Medicine, Houston, Texas
Chapter 23, Arterial Disease

Funda Meric-Bernstam, MD

Professor, Dept. of Surgical Oncology, Medical Director, Institute of Personalized Cancer Therapy, University of Texas M.D. Anderson Cancer Center, Houston, Texas
Chapter 10, Oncology

Gregory L. Moneta, MD, FACS

Professor and Chief, Division of Vascular Surgery, Department of Surgery and Knight Cardiovascular Institute, Oregon Health & Science University, Portland, Oregon
Chapter 24, Venous and Lymphatic Disease

Ernest E. Moore, MD, FACS, MCCM

Professor and Vice Chairman of Research, Department of Surgery, University of Colorado Denver, Editor, Journal of Trauma and Acute Care Surgery, Denver, Colorado
Chapter 7, Trauma

Vishad Nabili, MD, FACS

Associate Professor and Residency Program Director, Department of Head and Neck Surgery, David Geffen School of Medicine at UCLA, Los Angeles, California
Chapter 1, Fundamental Principles of Leadership Training in Surgery

Katie S. Nason, MD, MPH

Assistant Professor, Division of Thoracic Surgery, Department of General Surgery, University of Pittsburgh Medical Center, Pittsburgh, Pennsylvania
Chapter 19, Chest Wall, Lung, Mediastinum, and Pleura

John Nemunaitis, MD

Director, Mary Crowley Cancer Research Center, Dallas, Texas

Chapter 15, Molecular and Genomic Surgery

Matt Niesen, MD

Resident in Orthopaedic Surgery, UCLA Department of Orthopaedic Surgery, Santa Monica, California

Chapter 43, Orthopaedic Surgery

Shoichi Okada, MD

Department of Surgery, Washington University School of Medicine, St. Louis, Missouri

Chapter 21, Acquired Heart Disease

Klearchos Papas, PhD

Professor of Surgery, Scientific Director of the Institute for Cellular Transplantation, University of Arizona, Tucson, Arizona

Chapter 11, Transplantation

Adrian E. Park, MD, FRCS, FACS, FCS(ECSA)

Chair, Department of Surgery, Anne Arundel Medical Center, Professor of Surgery, PAR, Johns Hopkins University, Annapolis, Maryland

Chapter 34, Spleen

Timothy M. Pawlik, MD, MPH, PhD, FACS

Professor of Surgery and Oncology, John L. Cameron M.D. Professor of Alimentary Tract Diseases, Chief, Division of Surgical Oncology, Johns Hopkins Hospital, Baltimore, Maryland

Chapter 48, Ethics, Palliative Care, and Care at the End of Life

Andrew B. Peitzman, MD

Mark M. Ravitch Professor and Vice Chairman, Department of Surgery, University of Pittsburgh School of Medicine, Pittsburgh, Pennsylvania

Chapter 5, Shock

Thai H. Pham, MD, FACS

Assistant Professor of Surgery, Surgical Services, North Texas Veterans Affairs Medical Center and University of Texas Southwestern School of Medicine, Dallas, Texas

Chapter 32, Gallbladder and the Extrahepatic Biliary System

Mun Jye Poi, MD

Assistant Professor of Surgery, Division of Vascular Surgery & Endovascular Therapy, Michael E. DeBakey Department of Surgery, Baylor College of Medicine, Houston, Texas

Chapter 23, Arterial Disease

Raphael E. Pollock, MD, PhD, FACS

Professor and Director, Division of Surgical Oncology, Department of Surgery, Chief of Surgical Services, Ohio State University Comprehensive Cancer Center, Arthur G. James Cancer Hospital and Richard J. Solove Research Institute, The Ohio State University Wexner Medical Center, College of Medicine, Columbus, Ohio

Chapter 10, Oncology

Chapter 36, Soft Tissue Sarcomas

Matthew Pommerening, MD

Resident, Department of Surgery, University of Texas Health Science Center at Houston, Houston, Texas

Chapter 4, Hemostasis, Surgical Bleeding and Transfusion

Marian Porubsky, MD

Assistant Professor, Department of Surgery, Division of Adominal Transplantation, University of Arizona, Tucson, Arizona

Chapter 11, Transplantation

Jonathan Pribaz, MD

Resident in Orthopaedic Surgery, UCLA Department of Orthopaedic Surgery, Santa Monica, California

Chapter 43, Orthopaedic Surgery

Raymond R. Price, MD

Director Graduate Surgical Education, Intermountain Healthcare, Associate Director Center for Global Surgery, Adjunct Associate Professor, Department of Surgery, Adjunct Associate Professor, Department of Family and Preventive Medicine, Division of Public Health, University of Utah, Salt Lake City, Utah

Chapter 49, Global Surgery

Abbas Rana, MD

Assistant Professor of Surgery, Department of Surgery, University of Arizona, Tucson, Arizona

Chapter 11, Transplantation

John F.R. Robertson, MD, ChB, BSc, FRCS(Glasg)

Professor of Surgery, School of Medicine, University of Nottingham, Royal Derby Hospital, Derby, UK

Chapter 17, The Breast

Jason O. Robertson, MD, MS

Department of Surgery, Washington University School of Medicine, St. Louis, Missouri

Chapter 21, Acquired Heart Disease

David A. Rothenberger, MD

Jay Phillips Professor and Chairman, Department of Surgery, University of Minnesota, Minneapolis, Minnesota

Chapter 29, Colon, Rectum, and Anus

J. Peter Rubin, MD

UPMC Endowed Professor and Chair, Department of Plastic Surgery, University of Pittsburgh School of Medicine, Pittsburgh, Pennsylvania
Chapter 45, Plastic and Reconstructive Surgery

Lindsey L. Saint, MD

Clinical Instructor, Department of Surgery, Washington University School of Medicine, St. Louis, Missouri
Chapter 21, Acquired Heart Disease

Ashok K. Saluja, PhD

Eugene C & Gail V Sit Chair in Pancreatic & Gastrointestinal Cancer Research, Professor & Vice Chair of Research, Department of Surgery, University of Minnesota, Minneapolis, Minnesota
Chapter 33, Pancreas

Philip R. Schauer, MD

Professor of Surgery, Lerner College of Medicine, Director, Bariatric and Metabolic Institute Cleveland Clinic, Cleveland, Ohio
Chapter 27, The Surgical Management of Obesity

Bruce D. Schirmer, MD, FACS

Stephen H. Watts Professor of Surgery, University of Virginia Health System, Charlottesville, Virginia
Chapter 27, The Surgical Management of Obesity

Neal E. Seymour, MD

Professor, Department of Surgery, Tufts University School of Medicine, Chief of General Surgery, Baystate Medical Center, Springfield, Massachusetts
Chapter 35, Abdominal Wall, Omentum, Mesentery, and Retroperitoneum

Mark L. Shapiro, MD, FACS

Chief, Acute Care Surgery, Associate Director, Trauma, Duke University Medical Center, Durham, North Carolina
Chapter 12, Patient Safety

G. Tom Shires III, MD, FACS

John P. Thompson Chair, Surgical Services, Texas Health Presbyterian Hospital Dallas, Dallas, Texas
Chapter 3, Fluid and Electrolyte Management of the Surgical Patient

Brian Shuch, MD

Assistant Professor, Department of Urology, Yale School of Medicine, New Haven, Connecticut
Chapter 40, Urology

M. Cristy Smith, MD

Associate Director of Mechanical Circulatory Support, Cardiothoracic Surgery, Peacehealth St. Joseph Medical Center, Bellingham, Washington
Chapter 11, Transplantation

David H. Song, MD

Cynthia Chow Professor of Surgery, Chief, Section of Plastic and Reconstructive Surgery, Vice Chairman, Department of Surgery, The University of Chicago Medicine & Biological Sciences, Chicago, Illinois
Chapter 16, The Skin and Subcutaneous Tissue

Donn H. Spight, MD, FACS

Assistant Professor of Surgery, Department of Surgery, Oregon Health & Science University, Portland, Oregon
Chapter 14, Minimally Invasive Surgery, Robotics, Natural Orifice Transluminal Endoscopic Surgery and Single Incision Laparoscopic Surgery

Michael Stany, MD

Gynecologic Oncologist, Walter Reed National Military Medical Center, Assistant Professor, Uniformed Services University of the Health Sciences, Bethesda, Maryland
Chapter 41, Gynecology

Eduardo M. Targarona, MD, PhD, FACS

Chief of the Unit of Gastrointestinal and Hematological Surgery, Hospital Sant Pau, Professor of Surgery, Autonomous University of Barcelona, Barcelona, Spain
Chapter 34, Spleen

Ali Tavakkoli, MD

Assistant Professor of Surgery, Department of Surgery, Brigham & Women's Hospital, Boston, Massachusetts
Chapter 28, Small Intestine

Bert J. Thomas, MD

Chief, Joint Replacement Service, Department of Orthopedic Surgery, David Geffen School of Medicine at UCLA, Los Angeles, California
Chapter 43, Orthopaedic Surgery

Areti Tillou, MD, FACS

Associate Professor and Vice Chair for Education, Department of Surgery, David Geffen School of Medicine at UCLA, Los Angeles, California
Chapter 1, Fundamental Principles of Leadership Training in Surgery

Jeffrey S. Upperman, MD

Associate Professor of Surgery, Director of Trauma, Pediatric Surgery, Childrens Hospital Los Angeles, Keck School of Medicine, University of Southern California, Los Angeles, California
Chapter 39, Pediatric Surgery

Glen A. Van Arsdell, MD

Head, Cardiovascular Surgery, The Hospital for Sick Children, Professor of Surgery, University of Toronto, Toronto, Ontario
Chapter 20, Congenital Heart Disease

Justin P. Wagner, MD

Clinical Instructor, Department of Surgery, David Geffen School of Medicine, University of California, Los Angeles, California
Chapter 37, Inguinal Hernias

Christopher G. Wallace, MD, MS, FRCS (Plast)

Microsurgical Fellow, Department of Plastic Surgery, Chang Gung Memorial Hospital, Taipei, Taiwan
Chapter 45, Plastic and Reconstructive Surgery

Kasper S. Wang, MD

Associate Professor of Surgery, Keck School of Medicine, University of Southern California, Los Angeles, California

Chapter 39, Pediatric Surgery

David I. Watson, MBBS, MD, FRACS

Professor & Head, Department of Surgery, Flinders University of South Australia, Adelaide, South Australia, Australia

Chapter 25, Esophagus and Diaphragmatic Hernia

Randal S. Weber, MD, FACS

Professor and Chairman, Director of Surgical Services, Department of Head and Neck Surgery, University of Texas MD Anderson Cancer Center, Houston, Texas

Chapter 18, Disorders of the Head and Neck

Fu-Chan Wei, MD, FACS

Professor, Department of Plastic Surgery, Chang Gung Memorial Hospital, Chang Gung University and Medical College, Taipei, Taiwan

Chapter 45, Plastic and Reconstructive Surgery

Richard O. Wein, MD, FACS

Associate Professor, Department of Otolaryngology-Head & Neck Surgery, Tufts Medical Center, Boston, Massachusetts

Chapter 18, Disorders of the Head and Neck

John A. Windsor, BSc MD, FRACS, FACS

Professor of Surgery, Department of Surgery, University of Auckland, Auckland, New Zealand

Chapter 33, Pancreas

James Wu, MD

Clinical Instructor, Department of Surgery, David Geffen School of Medicine at UCLA, Los Angeles, California

Chapter 1, Fundamental Principles of Leadership Training in Surgery

Sarah E. Yost, PharmD, BCPS

Clinical Pharmacist in Abdominal Transplant, Department of Pharmacy, The University of Arizona Medical Center, Tucson, Arizona

Chapter 11, Transplantation

Juehua Yu, PhD

Postdoctoral Fellow, Department of Surgery, University of California, Los Angeles, Los Angeles, California

Chapter 15, Molecular and Genomic Surgery

Ali Zarrinpar, MD, PhD

Assistant Professor of Surgery, Division of Liver and Pancreas Transplantation, Department of Surgery, University of California Los Angeles, Los Angeles, California

Chapter 31, Liver

Michael E. Zenilman, MD

Professor and Vice-Chair of Surgery, Johns Hopkins University School of Medicine, Baltimore, Maryland, Director, National Capital Region, Johns Hopkins Medicine, Visiting Professor, SUNY Downstate School of Public Health, Brooklyn, New York, Surgeon-in-Chief, Johns Hopkins Suburban Hospital, Bethesda, Maryland

Chapter 47, Surgical Considerations in the Elderly

Michael J. Zinner, MD

Moseley Professor and Chairman, Department of Surgery, Brigham & Women's Hospital, Boston, Massachusetts

Chapter 28, Small Intestine

Brian S. Zuckerbraun, MD, FACS

Associate Professor of Surgery, Henry T. Bahnson Professor of Surgery, University of Pittsburgh, Chief, Trauma and Acute Care Surgery, University of Pittsburgh Medical Center, Pittsburgh, Pennsylvania

Chapter 5, Shock

VIDEO CONTRIBUTORS**Yolanda T. Becker, MD, FACS**

Professor of Surgery, Director, Kidney and Pancreas Transplant Program, Surgical Director of Perioperative Services, University of Chicago Medical Center, Chicago, Illinois

Kidney Transplant

Janet M. Bellingham, MD

Assistant Professor, Department of Surgery, University of Wisconsin School of Medicine, Madison, Wisconsin

Kidney Transplant

F. Charles Brunicaudi, MD, FACS

Moss Foundation Chair in Gastrointestinal and Personalized Surgery, Professor and Vice Chair, Surgical Services, Chief of General Surgery, UCLA Santa Monica Medical Center, Department of Surgery, David Geffen School of Medicine at UCLA, Los Angeles, California

Laparoscopic Cholecystectomy, Laparoscopic Inguinal Hernia Repair

Sally E. Carty, MD

Division Chief, Endocrine Surgery, Professor, Department of Surgery, University of Pittsburgh, Pittsburgh, Pennsylvania

Thyroidectomy

Giselle G. Hamad, MD

Associate Professor of Surgery, University of Pittsburgh, Pittsburgh, Pennsylvania
Laparoscopic Incisional Hernia Repair

Michael J. Rosen, MD, FACS

Professor of Surgery, Case Western Reserve University, Director, Case Comprehensive Hernia Center, Cleveland, Ohio

Open Posterior Component Separation

Konstantin Umanskiy, MD, FACS

Assistant Professor of Surgery, The University of Chicago Medicine, Chicago, Illinois
Right Colectomy, Sigmoid Colectomy

INTERNATIONAL ADVISORY BOARD**Gaurav Agarwal, MS (Surgery), FACS**

Professor, Department of Endocrine and Breast Surgery, Sanjay Gandhi Postgraduate Institute of Medical Sciences, Lucknow, India

Claudio Bassi, MD, FRCS, FACS, FEBS

Professor of Surgery, Surgical and Oncological Department, University of Verona, Pancreas Institute, Verona, Italy

Mordechai Gutman, MD

Head, Department of Surgery, Sheba Medical Center, Tel-Hashomer, Israel

Serafin C. Hilvano, MD, FPCS, FACS, American Surgical Association(Hon.)

Professor Emeritus, Department of Surgery, College of Medicine, University of the Philippines Manila, Manila, Philippines

Jamal J. Hoballah, MD, MBA

Professor and Chairman, Department of Surgery, American University of Beirut Medical Center, Beirut, Lebanon

Seon-Hahn Kim, MD

Professor and Chairman, Department of Surgery, Korea University College of Medicine, Seoul, South Korea

Yuko Kitagawa, MD, PhD, FACS

Professor and Chairman, Department of Surgery, Vice President, Keio University Hospital, Director of Keio Cancer Center, School of Medicine, Keio University, Tokyo, Japan

Miguel Angel Mercado Diaz, MD

Professor and Chairman, Department of General Surgery, National Institute of Medical Science and Nutrition, Mexico DF, Mexico

Gerald C. O'Sullivan, MD, FRCSI, FACS (Hon)

Professor of Surgery, University College Cork, Mercy University Hospital, Cork, Ireland

John F. Thompson, MD

Melanoma Institute Australia, Royal Prince Alfred and Mater Hospitals, Sydney, Australia, Discipline of Surgery, The University of Sydney, Sydney, Australia

John A. Windsor, BSc MD, FRACS, FACS

Professor of Surgery, Department of Surgery, University of Auckland, Auckland, New Zealand

Liwei Zhu, MD

Department of Surgery, Tianjin Medical University Hospital, Tianjin, China

Acknowledgments

The Editors would like to thank the following authors of the previous edition (9th) for their contributions. Portions of their work may have been revised, reconfigured, and/or serve as a foundation for chapters in the tenth edition:

Badar V. Jan, Ernest A. Gonzalez, Walter L. Biffi, Abhinav Humar, Patrick Cole, Lior Heller, Jamal Bullocks, Lisa A. Newman, Edward M. Copeland III, Karl F. Welke, Ross M. Ungerleider, Charles F. Schwartz, Gregory A.

Crooke, Eugene A. Grossi, Aubrey C. Galloway, Kapil Sharma, Catherine Cagiannos, Tam T. Huynh, Jeffrey H. Peters, Allan Tsung, Richard H. Bell Jr., Carlos D. Godinez Jr., Vadim Sherman, Kurt D. Newman, Joanna M. Cain, Wafic ElMasri, Michael L. Smith, Joel A. Bauman, Michael H. Heggeness, Francis H. Gannon, Jacob Weinberg, Peleg Ben-Galim, Charles A. Reitman, and Subhro K. Sen.

This page intentionally left blank

Foreword

The adjective “tenth” connotes a milestone, and, in the case of a “tenth edition” of a textbook, it is evidence of readership acceptability. This continued reader response would evoke parental pride from those who generated the original publication more than 45 years ago. I can still vividly recall the meeting in New York City at which John DeCarville, an editor at McGraw-Hill, brought together David M. Hume, Richard C. Lillehei, G. Thomas Shires, Edward H. Storer, Frank C. Spencer, and me to create a new surgical textbook. The new surgical publication was to serve as a companion to Harrison’s recently introduced medical textbook. The favorable reception of the first edition was most encouraging. The consistency of style and the deliberate inclusion of 52 chapters to allow for review of one chapter a week throughout the year were particularly appealing. Subsequent to the initial publication and following the tragic and premature deaths of Dr. Lillehei, Dr. Hume, and Dr. Storer, Dr. Shires, Dr. Spencer, and I were privileged to shepherd six additional editions over the ensuing 35 years. Under the direction of Dr. F. Charles Brunicaudi and his associate editors, a new vitality was infused over the three most recent editions.

The ten editions, as they are considered in sequence, serve as a chronicle of the dramatic evolution that has occurred in surgery over the past half century. Those, who have been charged with providing current information to the readership, have had to filter and incorporate extraordinary and unanticipated scientific breakthroughs and technical innovations. At the time of the genesis of the first edition, success had not been achieved in cardiac, hepatic, or intestinal transplantation. Adjuvant therapy for a broad variety of malignancies was in its infancy. Minimally invasive surgery would not become a reality for two decades. On the other side of the spectrum, operative procedures that occupied the focus of symposia have slipped into obscurity. Vagotomy for peptic ulcer has become a rarity, as a consequence of an appreciation of

the role of *Helicobacter pylori* and the efficacy of proton pump inhibitors. Surgical procedures to decompress portal hypertension in the treatment of bleeding esophagogastric varices have essentially disappeared from the operating room schedule. They have been replaced by transjugular intrahepatic portosystemic shunt (TIPS) and the liberal application of hepatic transplantation.

As Bob Dylan pointed out, “The Times They Are A-changin.” And they most assuredly will continue to change, and at an unanticipated rate. The scientific basis for the practice of surgery is increasing at an ever accelerating pace, and the technologic improvements and breakthroughs are equally extraordinary. The dissemination of the expansion of knowledge has resulted in a shrinking of the globe, necessitating an extension or adaptation of the more modern approaches to underdeveloped nations and underprivileged populations. Global medicine has become a modern concern. The importance of internationalism is manifest in the clinical trials and data acquisition provided by our surgical colleagues on the other sides of the oceans that surround us. It is therefore appropriate that a more international flavor has been developed for *Principles of Surgery* related both to citations and contributors. A distinct consideration of global medicine and, also, the qualities of leadership in surgery that must be nurtured are evidence of the editorial credo of “maintaining modernization” and “anticipating the future.”

As the editors and contributors continue to provide the most up-to-date information with a clarity that facilitates learning, it is the hope that the seed, which was planted almost a half century ago, will continue to flourish and maintain the approval of its audience.

Seymour I. Schwartz, MD, FACS
Distinguished Alumni Professor of Surgery
University of Rochester School of Medicine and
Dentistry

This page intentionally left blank

Preface

Each new edition of this book is approached by the editorial team with a dual vision keeping a dedicated eye affixed to the foundations of surgery while bringing into sharper focus on new and emerging elements. We are entering into a spectacular era of surgery in which the highest quality of care is merging with minimally invasive surgery, robotic surgery, the use of supercomputers, and personalized genomic surgery, all designed to improve the outcomes and quality of life for our patients. With these advances in mind, several new chapters have been added and all previous chapters have been updated with an emphasis on evidence-based, state-of-the-art surgical care. While this tried-and-true method remains the basis for upholding and maintaining the superb efforts and achievements of Dr. Seymour Schwartz and previous co-editors and contributors, this edition expands its vision to see beyond the operating theater and takes a look at the making of a surgeon as a whole, with the addition of the chapter, Fundamental Principles of Leadership Training in Surgery. Surely excellence in craft must be mastered and equal importance must also be given to the nontechnical training of what it means to be a leader of a surgical team.

To this effort, the editors were keen to include as the first chapter in this edition a comprehensive review of leadership methods and ideologies as well as underscoring the importance of instituting a formal leadership-training program for residents that emphasizes mentoring. Our own paths as surgeons have been defined by the mentoring

relationship and we have undoubtedly benefitted greatly from the efforts of our mentors; we sincerely hope that those with whom we have entered into this time-honored tradition have reaped the benefit as well. Simply stated, leadership skills can and should be taught to surgical trainees and in doing so this will help them improve quality of care.

The editors are thankful that this text is a relied-on source for training and crafting surgeons on a global basis. This is due in large part to the extraordinary efforts of our contributors, the leaders in their fields, who not only do so to train up-and-coming surgeons, but to impart their knowledge and expertise to the benefit of patients worldwide. The recent inclusion of many international authors to the chapters within is ultimately a testament to mentorship, albeit on a broader scale, and we thank them all, both near and far.

To our fellow editorial board members who have tirelessly devoted their time and knowledge to the integrity and excellence of their craft and this textbook, we extend our gratitude and thanks. We are to thankful to Brian Belval, Christie Naglieri, and all at McGraw-Hill for the continued belief in and support of this textbook. We wish to thank Katie Elsbury for her dedication to the organization and editing of this textbook. Last, we would like to thank our families who are the most important contributors of all.

F. Charles Brunicardi, MD, FACS

This page intentionally left blank

Preface to the First Edition

The raison d'être for a new textbook in a discipline which has been served by standard works for many years was the Editorial Board's initial conviction that a distinct need for a modern approach in the dissemination of surgical knowledge existed. As incoming chapters were reviewed, both the need and satisfaction became increasingly apparent and, at the completion, we felt a sense of excitement at having the opportunity to contribute to the education of modern and future students concerned with the care of surgical patients.

The recent explosion of factual knowledge has emphasized the need for a presentation which would provide the student an opportunity to assimilate pertinent facts in a logical fashion. This would then permit correlation, synthesis of concepts, and eventual extrapolation to specific situations. The physiologic bases for diseases are therefore emphasized and the manifestations and diagnostic studies are considered as a reflection of pathophysiology. Therapy then becomes logical in this schema and the necessity to regurgitate facts is minimized. In appreciation of the impact which *Harrison's Principles of Internal Medicine* has had, the clinical manifestations of the disease processes are considered in detail for each area. Since the operative procedure represents the one element in the therapeutic armamentarium unique to the surgeon, the indications, important technical considerations, and complications receive appropriate emphasis. While we appreciate that a textbook cannot hope to incorporate an atlas of surgical

procedures, we have provided the student a single book which will satisfy the sequential demands in the care and considerations of surgical patients.

The ultimate goal of the Editorial Board has been to collate a book which is deserving of the adjective "modern." We have therefore selected as authors dynamic and active contributors to their particular fields. The *au courant* concept is hopefully apparent throughout the entire work and is exemplified by appropriate emphasis on diseases of modern surgical interest, such as trauma, transplantation, and the recently appreciated importance of rehabilitation. Cardiovascular surgery is presented in keeping with the exponential strides recently achieved.

There are two major subdivisions to the text. In the first twelve chapters, subjects that transcend several organ systems are presented. The second portion of the book represents a consideration of specific organ systems and surgical specialties.

Throughout the text, the authors have addressed themselves to a sophisticated audience, regarding the medical student as a graduate student, incorporating material generally sought after by the surgeon in training and presenting information appropriate for the continuing education of the practicing surgeon. The need for a text such as we have envisioned is great and the goal admittedly high. It is our hope that this effort fulfills the expressed demands.

Seymour I. Schwartz, MD, FACS

This page intentionally left blank

Part

Basic Considerations

This page intentionally left blank

1 chapter

Fundamental Principles of Leadership Training in Surgery

Amy L. Hill, James Wu, Mark D. Girgis, Danielle Hsu, Areti Tillou, James Macho, Vishad Nabili, and F. Charles Brunicardi

Introduction	3	Vision / 3	Formal Leadership Training Programs in Surgery	9
Definitions of Leadership	3	Willingness / 4	Mentoring / 10	
Fundamental Principles of Leadership	3	Time Management / 7	Conclusion	11
		Leadership Styles		

INTRODUCTION

The field of surgery has evolved greatly from its roots, and surgical practice now requires the mastery of modern leadership principles and skills as much as the acquisition of medical knowledge and surgical technique. Historically, surgeons took sole responsibility for their patients and directed proceedings in the operating room with absolute authority, using a command-and-control style of leadership. Modern surgical practice has now evolved from single provider-based care toward a team-based approach, which requires collaborative leadership skills. Surgical care benefits from the collaboration of surgeons, anesthesiologists, internists, radiologists, pathologists, radiation oncologists, nurses, pharmacists, social workers, therapists, hospital staff, and administrators. Occupying a central role on the healthcare team, surgeons¹ have the potential to improve patient outcomes, reduce medical errors, and improve patient satisfaction through their leadership of the multidisciplinary team.

1▶ Thus, in the landscape of modern healthcare systems, it is imperative that surgical training programs include formal instruction on leadership principles and skills to cultivate their trainees' leadership capabilities.

Many medical and surgical communities, including residency training programs, acknowledge the need for improved physician leadership.² Surgical trainees identify leadership skills as important, but report themselves as “not competent” or “minimally competent” in this regard.^{2,3} While a small number of surgical training programs have implemented formal curriculum focused on teaching leadership principles, it is now imperative that all surgical training programs teach these important skills to their trainees.^{4,5} Interviews of academic chairpersons identified several critical leadership success factors,⁶ including mastery of visioning, communication, change management, emotional intelligence, team building, business skills, personnel management, and systems thinking. These chairpersons stated that the ability of emotional intelligence was “fundamental to their success and its absence the cause of their failures,” regardless of medical knowledge.⁶ Thus, training programs need to include leadership training to prepare trainees for success in modern healthcare delivery.

In the United States, the Accreditation Council for Graduate Medical Education (ACGME) has established six

core competencies—patient care, medical knowledge, practice-based learning and improvement, interpersonal and communication skills, professionalism, and systems-based practice (Table 1-1)⁴—that each contain principles of leadership. The ACGME has mandated the teaching of these core competencies but has not established a formal guide on how to teach the leadership skills described within the core competencies. Therefore, this chapter offers a review of fundamental principles of leadership and an introduction of the concept of a leadership training program for surgical trainees.

DEFINITIONS OF LEADERSHIP

Many different definitions of leadership have been described. Former First Lady Rosalynn Carter once observed that, “A leader takes people where they want to go. A *great* leader takes people where they don't necessarily want to go, but where they ought to be.” Leadership does not always have to come from a position of authority. Former American president John Quincy Adams stated, “If your actions inspire others to dream more, learn more, do more, and become more, you are a leader.” Another definition is that leadership is the process of using social influence to enlist the aid and support of others in a common task.⁷

FUNDAMENTAL PRINCIPLES OF LEADERSHIP

Clearly, leadership is a complex concept. Surgeons should strive to adopt leadership qualities that provide the best outcomes for their patients, based on the following fundamental principles.

Vision

The first and most fundamental principle of leadership is to establish a vision that people can live up to, thus providing direction and purpose to the constituency. Creating a vision is a declaration

2▶ of the near future that inspires and conjures motivation.⁸ A classic example of a powerful vision that held effective impact is President Kennedy's declaration in 1961 that “. . . this nation should commit itself to achieving the goal, before this decade is out, of landing a man on the moon and returning him safely to the earth.” Following his declaration of this vision with a timeline to achieve it, the United States mounted a remarkable unified effort, and by the end of the decade, Neil Armstrong

Key Points

- 1▶ Effective surgical leadership improves patient care.
- 2▶ A fundamental principle of leadership is to provide a vision that people can live up to, thereby providing direction and purpose to the constituency.
- 3▶ Surgical leaders have the willingness to lead through an active and passionate commitment to the vision.
- 4▶ Surgical leaders have the willingness to commit to lifelong learning.
- 5▶ Surgical leaders have the willingness to communicate effectively and resolve conflict.
- 6▶ Surgical leaders must practice effective time management.
- 7▶ Different leadership styles are tools to use based on the team dynamic.
- 8▶ Surgical trainees can be taught leadership principles in formal leadership training programs to enhance their ability to lead.
- 9▶ Mentorship provides wisdom, guidance, and insight essential for the successful development of a surgical leader.

took his famous walk and the vision had been accomplished (Fig. 1-1).

On a daily basis, surgeons are driven by a powerful vision: the vision that our surgical care will improve patients' lives. The great surgical pioneers, such as Hunter, Lister (Fig. 1-2), Halsted, von Langenbeck, Billroth, Kocher (Fig. 1-3), Carrel, Gibbon, Blalock, Wangenstein, Moore, Rhoads, Huggins, Murray, Kountz, Longmire, Starzl, and DeBakey (Fig. 1-4), each possessed visions that revolutionized the field of surgery. In the nineteenth century, Joseph Lister changed the practice of surgery with his application of Pasteur's germ theory. He set a young boy's open compound leg fracture, a condition with a 90% mortality rate at that time, using carbolic acid dressings and aseptic surgical technique. The boy recovered, and Lister gathered nine more patients. His famous publication on the use of aseptic technique introduced the modern era of sterile technique. Emil Theodor Kocher was the first to master the thyroidectomy, thought to be an impossible operation at the time, and went on to perform thousands of thyroidectomies with a mortality of less than 1%. He was awarded the Nobel Prize in Physiology or Medicine in 1909 for describing the thyroid's physiologic role in metabolism. Michael E. DeBakey's powerful vision led to the development of numerous groundbreaking procedures that helped pioneer the field of cardiovascular surgery. For example, envisioning an artificial

artery for arterial bypass operations, Dr. DeBakey invented the Dacron graft, which has helped millions of patients suffering from vascular disease and enabled the development of endovascular surgery. Dr. Frederick Banting, the youngest recipient of the Nobel Prize in Physiology or Medicine, had a vision to discover the biochemical link between diabetes and glucose homeostasis. His vision and perseverance led to the discovery of insulin.⁹ In retrospect, the power and clarity of their visions were remarkable, and their willingness and dedication were inspiring. By studying their careers and accomplishments, surgical trainees can appreciate the potential impact of a well-developed vision.

Leaders must learn to develop visions to provide direction for their team. The vision can be as straightforward as providing quality of care or as lofty as defining a new field of surgery. One can start developing their vision by brainstorming the answers to two simple questions: "Which disease needs to be cured?" and "How can it be cured?"¹⁰ The answers represent a vision and should be recorded succinctly in a laboratory notebook or journal. Committing pen to paper enables the surgical trainee to define their vision in a manner that can be shared with others.

Willingness

The Willingness Principle represents the active commitment of the leader toward their vision. A surgical leader must be willing

Table 1-1

Accreditation Council for Graduate Medical Education core competencies

CORE COMPETENCY	DESCRIPTION
Patient care	To be able to provide compassionate and effective healthcare in the modern-day healthcare environment
Medical knowledge	To effectively apply current medical knowledge in patient care and to be able to use medical tools (i.e., PubMed) to stay current in medical education
Practice-based learning and improvement	To critically assimilate and evaluate information in a systematic manner to improve patient care practices
Interpersonal and communication skills	To demonstrate sufficient communication skills that allow for efficient information exchange in physician-patient interactions and as a member of a healthcare team
Professionalism	To demonstrate the principles of ethical behavior (i.e., informed consent, patient confidentiality) and integrity that promote the highest level of medical care
Systems-based practice	To acknowledge and understand that each individual practice is part of a larger healthcare delivery system and to be able to use the system to support patient care




Figure 1-1. Apollo 11 Lunar Module moon walk. Astronaut Edwin “Buzz” Aldrin walks by the footpad of the Apollo 11 Lunar Module, July 1969. (Reproduced with permission from AP Photo/NASA. © 2014 The Associated Press.)

to lead, commit to lifelong learning, communicate effectively, and resolve conflict.

To Lead. A key characteristic of all great leaders is the willingness to serve as the leader. Dr. Martin Luther King, Jr., who championed the civil rights movement with a powerful vision of equality for all based on a commitment to non-violent methods,¹¹ did so at a time when his vocalization of this vision ensured harassment, imprisonment, and threats of violence against himself, his colleagues, and his family and friends (Fig. 1-5). King, a young, highly educated pastor, had the security of employment and family, yet was willing to accept enormous responsibility and personal risk and did so in order to lead a nation toward his vision of civil rights, for which he was awarded the Nobel Peace Prize in 1964. Steve Jobs, co-founder of Apple Inc., chose to remain in his position as chief executive officer (CEO) to pursue his vision of perfecting the personal computer at great personal expense. He described this experience as “. . . rough, really rough, the worst time in my life. . . . I would go to work at 7 a.m. and I’d get back at 9 at night, and the kids would be in bed. And I couldn’t speak, I literally couldn’t, I was so exhausted. . . . It got close

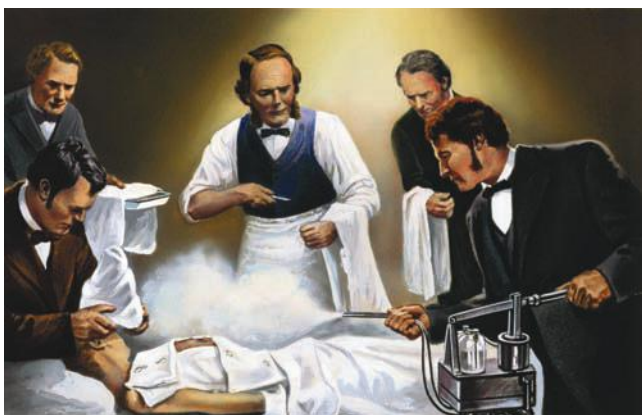



Figure 1-2. Joseph Lister directing use of carbolic acid spray in one of his earliest antiseptic surgical operations, circa 1865. (Copyright Bettmann/Corbis/AP Images.)



Emil Kocher

Figure 1-3. Emil Theodor Kocher. (Courtesy of the National Library of Medicine.)

to killing me.”¹² Both individuals demonstrated a remarkable tenacity and devotion to their vision.

Willingness to lead is a necessity in any individual who desires to become a surgeon. By entering into the surgical theater, a surgeon accepts the responsibility to care for and operate on patients despite the risks and burdens involved. They do so, believing fully in the improved quality of life that can be achieved. Surgeons must embrace the responsibility of leading surgical teams that care for their patients, as well as leading surgical trainees to become future surgeons. A tremendous sacrifice is required for the opportunity to learn patient care. Surgical trainees accept the hardships of residency with its

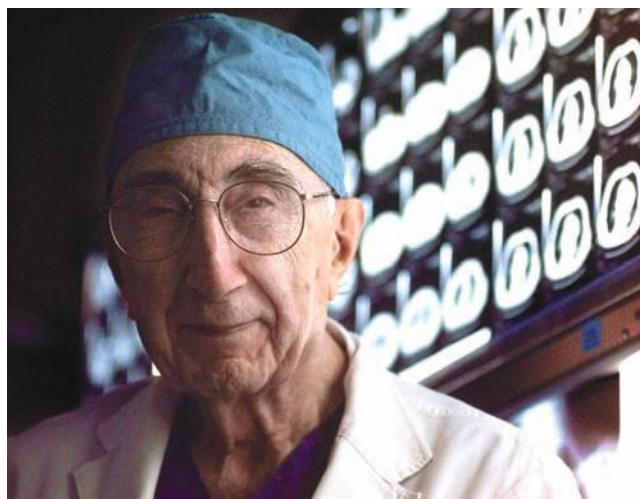

Figure 1-4. Michael E. DeBakey. (Reproduced with permission from AP Photo/David J. Phillip. © 2014 The Associated Press.)




Figure 1-5. Dr. Martin Luther King, Jr. acknowledges the crowd at the Lincoln Memorial for his “I Have a Dream” speech during the March on Washington, D.C., August 28, 1963. (Reproduced with permission from AP Photo. © 2014 The Associated Press.)

accompanying steep learning curve, anxiety, long work hours, and time spent away from family and friends. The active, passionate commitment to excellent patient care reflects a natural willingness to lead based on altruism and a sense of duty toward those receiving care. Thus, to ensure delivery of the utmost level of care, surgical trainees should commit to developing and refining leadership skills. These skills include a commitment to lifelong learning, effective communication, and conflict resolution.

3▶ To Learn. Surgeons and surgical trainees, as leaders, must possess willingness to commit to continuous learning. Modern surgery is an ever-changing field with dynamic and evolving healthcare systems and constant scientific discovery and innovation. Basic and translational science relating to surgical care is growing at an exponential rate. The sequencing of the human genome and the enormous advances in molecular biology and signaling pathways are leading to the transformation of personalized medicine and surgery in the twenty-first century (see Chap. 15).¹³ Performing prophylactic mastectomies with immediate reconstruction for *BRCA1* mutations and thyroidectomies with thyroid hormone replacement for *RET* proto-oncogene mutations are two of many examples of genomic information guiding surgical care. Technologic advances in minimally invasive surgery and robotic surgery as well as electronic records and other information technologies are revolutionizing the craft of surgery. The expansion of minimally invasive and endovascular surgery over the past three decades required surgeons to retrain

in new techniques using new skills and equipment. In this short time span, laparoscopy and endovascular operations are now recognized as the standard of care for many surgical diseases, resulting in shorter hospital stay, quicker recovery, and a kinder and gentler manner of practicing surgery. Remarkably, during the last century, the field of surgery has progressed at an exponential pace and will continue to do so with the advent of using genomic analyses to guide personalized surgery, which will transform the field of surgery this century. Therefore, surgical leadership training should emphasize and facilitate the continual pursuit of knowledge.

Fortunately, surgical organizations and societies provide surgeons and surgical trainees a means to acquire new knowledge on a continuous basis. There are numerous local, regional, national, and international meetings of surgical organizations that provide ongoing continuing medical education credits, also required for the renewal of most medical licenses. The American Board of Surgery requires all surgeons to complete meaningful continuing medical education to maintain certification.¹⁴ These societies and regulatory bodies enable surgeons and surgical trainees to commit to continual learning, and ensure their competence in a dynamic and rapidly growing field.

4▶ Surgeons and trainees now benefit from the rapid expansion of web-based education as well as mobile handheld technology. These are powerful tools to minimize nonproductive time in the hospital and make learning and reinforcement of medical knowledge accessible. Currently web-based resources provide quick access to a vast collection of surgical texts, literature, and surgical videos. Surgeons and trainees dedicated to continual learning should be well versed in the utilization of these information technologies to maximize their education. The next evolution of electronic surgical educational materials will likely include simulation training similar to laparoscopic and Da Vinci device training modules. The ACGME, acknowledging the importance of lifelong learning skills and modernization of information delivery and access methods, has included them as program requirements for residency accreditation.

To Communicate Effectively. The complexity of modern healthcare delivery systems requires a higher level and collaborative style of communication. Effective communication directly impacts patient care. In 2000, the U.S. Institute of Medicine published a work titled, *To Err Is Human: Building a Safer Health System*, which raised awareness concerning the magnitude of medical errors. This work showcased medical errors as the eighth leading cause of death in the United States with an estimated 100,000 deaths annually.¹⁵ Subsequent studies examining medical errors have identified communication errors as one of the most common causes of medical error.^{16,17} In fact, the Joint Commission identifies miscommunication as the leading cause of sentinel events. Information transfer and communication errors cause delays in patient care, waste surgeon and staff time, and cause serious adverse patient events.¹⁸ Effective communication between surgeons, nurses, ancillary staff, and patients is not only a crucial element to improved patient outcomes, but it also leads to less medical litigation.¹⁹⁻²¹

5▶ A strong correlation exists between communication and patient outcomes. Establishing a collaborative atmosphere is important since communication errors leading to medical mishaps are not simply failures to transmit information. Communication errors “are far more complex and relate to hierarchical differences, concerns

with upward influence, conflicting roles and role ambiguity, and interpersonal power and conflict.”^{17,22} Errors frequently originate from perceived limited channels of communication and hostile, critical environments. To overcome these barriers, surgeons and surgical trainees should learn to communicate in an open, universally understood manner and remain receptive to any team member’s concerns. A survey of physicians, nurses, and ancillary staff identified effective communication as a key element of a successful leader.²³ As leaders, surgeons and surgical trainees who facilitate an open, effective, collaborative style of communication reduce errors and enhance patient care. A prime example is that successful communication of daily goals of patient care from the team leader improves patient outcomes. In one recent study, the modest act of explicitly stating daily goals in a standardized fashion significantly reduced patient length of intensive care unit stay and increased resident and nurse understanding of goals of care.²⁴ Implementing standardized daily team briefings in the wards and preoperative units led to improvements in staff turnover rates, employee satisfaction, and prevention of wrong site surgery.²² In cardiac surgery, improving communication in the operating room and transition to the postanesthesia care unit was an area identified to decrease risk for adverse outcomes.²⁵ Behaviors associated with ineffective communication, including absence from the operating room when needed, playing loud music, making inappropriate comments, and talking to others in a raised voice or a condescending tone, were identified as patient hazards; conversely, behaviors associated with effective collaborative communication, such as time outs, repeat backs, callouts, and confirmations, resulted in improved patient outcomes.

One model to ensure open communication is through standardization of established protocols. A commonly accepted protocol is the “Time Out” that is now required in the modern operating room. During the Time Out protocol, all team members introduce themselves and state a body of critical information needed to safely complete the intended operation. This same standardization can be taught outside the operating room. Within the Kaiser system, certain phrases have been given a universal meaning: “I need you now” by members of the team is an understood level of urgency and generates a prompt physician response 100% of the time.²² As mentioned earlier, standardized forms can be useful tools in ensuring universally understood communication during sign-out. The beneficial effect of standardized communication further demonstrates how effective communication can improve patient care and is considered a vital leadership skill.

To Resolve Conflict. Great leaders are able to achieve their vision through their ability to resolve conflict. During the pursuit of any vision, numerous conflicts arise on a daily basis; numerous conflicts arise on a daily basis when surgeons and surgical trainees provide high-quality care. Therefore, the techniques for conflict resolution are essential for surgical leaders.

To properly use conflict resolution techniques, it is important for the surgeon and surgical trainee to always remain objective and seek personal flexibility and self-awareness. The gulf between self-perception and the perception of others can be profound; in a study of cooperation and collaboration among operating room staff, the quality of their own collaboration was rated at 80% by surgeons, yet was rated at only 48% by operating room nurses.²⁶ Systematic inclusion of modern conflict resolution methods that incorporate the views of all members of a multidisciplinary team help maintain objectivity. Reflection is

often overlooked in surgical residency training but is a critical component of learning conflict resolution skills. Introspection allows the surgeon to understand the impact of his or her actions and biases. Objectivity is the basis of effective conflict resolution, which can improve satisfaction among team members and help deliver optimal patient care.

Modern conflict resolution techniques are based on objectivity, willingness to listen, and pursuit of principle-based solutions.²⁷ For example, an effective style of conflict resolution is the utilization of the “abundance mentality” model, which attempts to achieve a solution that benefits all involved and is based on core values of the organization, as opposed to the utilization of the traditional fault-finding model, which identifies sides as right or wrong.²⁸ Application of the abundance mentality in surgery elevates the conflict above the affected parties and focuses on the higher unifying goal of improved patient care. Morbidity and mortality (M&M) conferences are managed in this style and have the purpose of practice improvement and improving overall quality of care within the system, as opposed to placing guilt or blame on the surgeon or surgical trainees for the complication being reviewed. The traditional style of command-and-control technique based on fear and intimidation is no longer welcome in any healthcare system and can lead to sanctions, lawsuits, and removal of hospital privileges or position of leadership.

Another intuitive method that can help surgical trainees learn to resolve conflict is the “history and physical” model of conflict resolution. This model is based on the seven steps of caring for a surgical patient that are well known to the surgical trainee.²⁹ (1) The “history” is the equivalent of gathering subjective information from involved parties with appropriate empathy and listening. (2) The “laboratory/studies” are the equivalent of collecting objective data to validate the subjective information. (3) A “differential diagnosis” is formed of possible root causes of the conflict. (4) The “assessment/plan” is developed in the best interest of all involved parties. The plan, including risks and benefits, is openly discussed in a compassionate style of communication. (5) “Preoperative preparation” includes the acquisition of appropriate consultations for clearances, consideration of equipment and supplies needed for implementation, and the “informed consent” from the involved parties. (6) The “operation” is the actual implementation of the agreed-upon plan, including a time-out. (7) “Postoperative care” involves communicating the operative outcome, regular postoperative follow-up, and the correction of any complications that arise. This seven-step method is an example of an objective, respectful method of conflict resolution. Practicing different styles of conflict resolution and effective communication in front of the entire group of surgical trainees attending the leadership training program is an effective means of teaching conflict resolution techniques.

Time Management

It is important for leaders to practice effective time management. Time is the most precious resource, as it cannot be bought, saved, or stored. Thus, management of time is essential for a productive and balanced life for those in the organization. The effective use of one’s time is best done through a formal time management program to improve one’s ability to lead by setting priorities and making choices to achieve goals. The efficient use of one’s time helps to improve both productivity and quality of life.

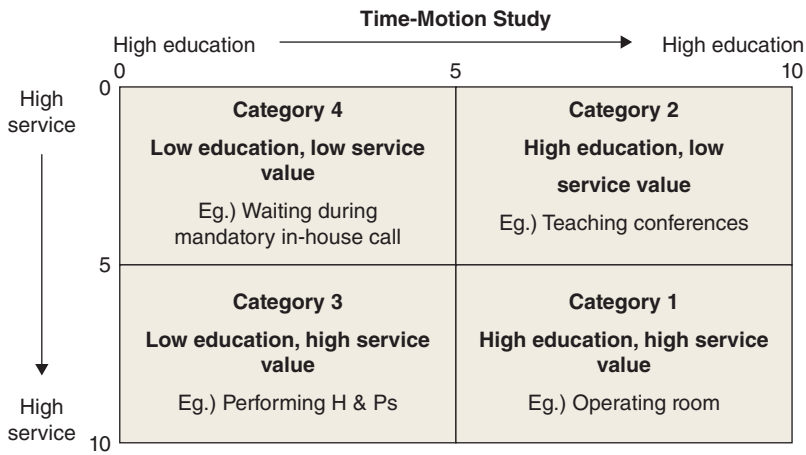


Figure 1-6. Surgery resident time-motion study. H & P = history and physical examination.

It is important for surgeons and surgical trainees to learn and use a formal time management program. There are ever-increasing demands placed on surgeons and surgical trainees to deliver the highest quality care in highly regulated environments. Furthermore, strict regulations on limitation of work hours demand surgical trainees learn patient care in a limited amount of time.³⁰ All told, these demands are enormously stressful and can lead to burnout, drug and alcohol abuse, and poor performance.³⁰ A time-motion study of general surgery trainees analyzed residents' self-reported time logs to determine resident time expenditure on educational/service-related activities (Fig. 1-6).³¹ Surprisingly, senior residents were noted to spend 13.5% of their time on low-service, low-educational value activities. This time, properly managed, could be used to either reduce work hours or improve educational efficiency in the context of new work hour restrictions. It is therefore critical that time be used wisely on effectively achieving one's goals.

Parkinson's law, proposed in 1955 by the U.K. political analyst and historian Cyril Northcote Parkinson, states that work expands to fill the time available for its completion, thus leading individuals to spend the majority of their time on insignificant tasks.³² Pareto's 80/20 principle states that 80% of goals are achieved by 20% of effort and that achieving the final 20% requires 80% of their effort. Therefore, proper planning of undertaking any goal needs to include an analysis of how much effort will be needed to complete the task.³² Formal time management programs help surgeons and surgical trainees better understand how their time is spent, enabling them to increase productivity and achieve a better balanced lifestyle.

Various time allocation techniques have been described.³² A frequently used basic technique is the "prioritized list," also known as the ABC technique. Individuals list and assign relative values to their tasks. The use of the lists and categories serves solely as a reminder, thus falling short of aiding the user in allocating time wisely. Another technique is the "time management matrix technique."²⁸ This technique plots activities on two axes: importance and urgency, yielding four quadrants (Fig. 1-7). Congruous with the Pareto's 80/20 principle and Parkinson's law, the time management matrix technique channels efforts into quadrant II (important but nonurgent) activities. The activities in this quadrant are high yield and include planning, creative activity, building relationships, and maintaining productivity. Too often, surgeons spend a majority of their time attending to

quadrant I (important and urgent) tasks. Quadrant I tasks include emergencies and unplanned or disorganized situations that require intensive and often inefficient effort. While most surgeons and surgical trainees have to deal with emergencies, they often develop the habit of inappropriately assigning activities into quadrant I; excess time spent on quadrant I tasks leads to stress or burnout for the surgeon and distracts from long-term goals. Efficient time management allows surgeons and surgical trainees to be proactive about shifting energy from quadrant I tasks to quadrant II, emphasizing preplanning and creativity over always attending to the most salient issue at hand, depending on the importance and not the urgency.

Finally, "the six areas of interest" is an alternative effective time management model that can help surgeons and surgical trainees achieve their goals, live a better balanced lifestyle, and improve the quality of their lives.³² The process begins by performing a time-motion study in which the activities of 6-hour increments of time over a routine week are chronicled. At the end of the week, the list of activities is analyzed to determine how the 168 hours in 1 week have been spent. The surgical trainee then selects six broad categories of areas of interest (i.e., family, clinical care, education, health, community service, hobbies, etc.), and sets a single activity goal in each category every day and monitors whether those goals are achieved. This technique is straightforward and improves one's quality of life by setting and achieving a balanced set of goals of personal interest, while eliminating time-wasting activities.

A formal time management program is essential for modern leadership. The practice and use of time management strategies can help surgeons and surgical trainees achieve and maintain their goals of excellent clinical care for their patients, while maintaining a more balanced lifestyle.

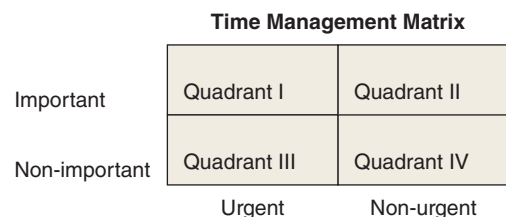


Figure 1-7. Time management. (From Covey S. *The Seven Habits of Highly Effective People*. New York: Simon & Schuster; 1989.)

LEADERSHIP STYLES

The principles of leadership can be practiced in a variety of styles. Just as there are many definitions of leadership, many classifications of styles exist as well. A landmark study by Daniel Goleman in *Harvard Business Review* identified six distinct leadership styles, based on different components of emotional intelligence.³³ Emotional intelligence is the ability to recognize, understand, and control the emotions in others and ourselves. By learning different styles, surgeons and trainees can recognize their own leadership style and the effect on the team dynamic. Furthermore, it teaches when the situation may demand change in style for the best outcome. The six leadership styles identified are *Coercive, Authoritative, Affiliative, Democratic, Pacesetter, and Coaching*.

The Coercive leader demands immediate compliance. This style reflects the command and control style that has historically dominated surgery. Excessive coercive leadership erodes team members' sense of responsibility, motivation, sense of participation in a shared vision, and ultimately, performance. However, it is effective in times of crisis to deliver clear, concise instruction. This style should be used sparingly and is best suited for emergencies.

The Authoritative leader embodies the phrase "Come with me," focusing on mobilizing the team toward a common, grand vision. This type of leader allows the team freedom to innovate, experiment, and devise its own means. Goleman's research indicates this style is often the most effective. These leaders display self-confidence, empathy, and proficiency in initiating new ideas and leading people in a new direction. This is best used when a shift in paradigm is needed.

The Affiliative leader creates harmony and builds emotional bonds. This requires employment of empathy, building relationships, and emphasis on communication. An affiliative leader frequently gives positive feedback. This style can allow poor performance to go uncorrected if too little constructive/critical advice is given. Affiliative leadership is most useful when motivating people during stressful circumstances or healing rifts in a team.

The Coaching style of leadership focuses on developing people for the future. Coaching is leadership through mentorship. The coach gives team members challenging tasks, counsels, encourages, and delegates. Unlike the affiliative leader who focuses on positive feedback, the coach helps people identify their weaknesses and improve their performance, and ties their work into their long-term career aspirations. This leadership style builds team capabilities by helping motivated learners improve. However, this style does not work well when team members are defiant and unwilling to change or learn, or if the leader lacks proficiency.

The Democratic leader forges consensus through participation. This leadership style listens to and values each member's input. It is not the best choice in an emergency situation, when time is limited, or when teammates cannot contribute informed guidance to the leader. It can also be exasperating if a clear vision does not arise from the collaborative process. This style is most appropriate when it is important to obtain team consensus, quell conflict, or create harmony.

The Pacesetter leader sets high standards for performance and exemplifies them. These leaders identify poor performers and demand more from them. However, unlike the coach, the pacesetter does not build the skills of those who are not keeping

up. Rather, a pacesetter will either take over the task himself or delegate the task to another team member. This leadership style works well when it is important to obtain high-quality results and there is a motivated, capable team. However, pacesetters can easily become micromanagers who have difficulty delegating tasks to team members, which leads to burn out on the part of the leader. Additionally, team members can feel overwhelmed and demoralized by the demands for excellence without an empathic counter balance.

Each of the above styles of leadership has strengths and weakness. Importantly, leaders who are the most successful do not rely only on one leadership style alone. They use several of them seamlessly depending on the situation and the team members at hand. Therefore, the more styles a leader has mastered, the better, with particular emphasis on the Authoritative, Affiliative, Democratic, and Coaching styles. Each leadership style is a tool that is ultimately employed to guide a team to realizing a vision or goal. Thus, leadership training programs should teach the proper use of all leadership styles while adhering to the principles of leadership.

FORMAL LEADERSHIP TRAINING PROGRAMS IN SURGERY

Since it has been shown that effective leadership can improve patient outcomes, leadership principles and skills should be taught to surgical trainees using formal leadership training programs. The importance of teaching leadership skills is reflected by the ACGME mandated core competencies (see Table 1-1). However, surgical trainees, most notably chief residents, find themselves in various leadership roles without ever having experienced formalized leadership training, which has been shown to result in a self-perceived lack of leadership ability.²³ When surveyed on 18 core leadership skills (Table 1-2), 92% of residents rated all 18 skills as important, but over half rated themselves as "minimally" or "not competent" in 10 out of 18 skills.² It has been documented that trainees are requesting leadership training and wish to close the gap between perceived need for training and the implementation of formal leadership training programs.³⁴⁻³⁷

A number of leadership workshops have been created. Extracurricular leadership programs have been designed mostly for physicians with an MBA or management background but have not been incorporated into the core residency training program.³⁸ Also, there are many institutions that have published experiences with leadership retreats or seminars for residents or young physicians.³⁹⁻⁴² The ACGME hosts multiple leadership skills workshops for chief residents, mostly targeted toward pediatricians, family practitioners, and psychiatrists.⁴³ Similarly, the American College of Surgeons leads an annual 3-day leadership conference focusing on leadership attributes, consensus development, team building, conflict resolution, and translation of leadership principles into clinical practice.⁴⁴ These programs were all received well by participants and represent a call for a formal leadership program for all surgical trainees.

An innovative leadership curriculum first implemented in 1999 taught general surgery trainees collaborative leadership skills, at a time when the traditional command-and-control leadership style predominated.⁴⁵ Surgical residents participated in 18-hour-long modules based on the leadership principles and skills listed in Table 1-2, taught by the surgical faculty.

Table 1-2

18 leadership training modules

SKILLS	IMPORTANCE MEAN SCORE	COMPETENCE MEAN SCORE
Academic program development	3.2	2.4*
Leadership training	3.8	2.3*
Leadership theory	3.2	2.1*
Effective communication	3.7	2.7*
Conflict resolution	3.8	3*
Management principles	3.7	2.7*
Negotiation	3.7	2.8*
Time management	4	2.8*
Private or academic practice, managed care	3.6	2*
Investment principles	3.5	2.2*
Ethics	3.6	3.2
Billing, coding, and compliance	3.5	1.7*
Program improvement	3	2*
Writing proposals	3.3	2.2*
Writing reports	3.4	2.4*
Public speaking	3.7	2.7*
Effective presentations	3.7	2.7*
Risk management	3.5	2.1*
Total	3.6	2.5*

Source: Reprinted with permission from Itani KMF, Liscum K, Brunicaudi FC. Physician leadership is a new mandate in surgical training. *Am J Surg.* 2004;187:328-331. © Copyright Elsevier.

* P<0.001 by Student t test between mean importance and mean competence scores.

A number of leadership techniques, including time management techniques and applied conflict resolution techniques described earlier, were designed and implemented as part of this leadership training program. Within 6 months of implementation, residents' self-perceived total commitment to the highest personal and professional standards, communication skills, visualization of clear missions of patient care, and leadership of others toward that mission increased significantly.⁴⁵ Remarkably, the positive impact of this leadership curriculum was significant when measured using tools, such as the Multifactor Leadership Questionnaire (MLQ), social skills inventory, personality inventory, and internal strength scorecard.^{2,37,45-47} The MLQ is a well-validated instrument that objectively quantifies leadership beliefs and self-perceived outcomes across medical and nonmedical disciplines. Based on the MLQ, surgical residents more often use a passive-avoidant style of leadership that emphasizes taking corrective action only after a problem is "significant and obvious."³⁷ This tool can also be used to track progress toward more effective, collaborative styles of leadership. These studies demonstrated the ability to measure leadership behavior of surgical trainees in a standardized, quantifiable format.^{2,37,45-47} Taken together, these studies support the concept that leadership skills can and should

be taught to surgical trainees, and there are many validated tools **8▶** to measure outcomes.

Mentoring

A formal leadership training program for surgical trainees should include mentoring. Mentoring is the active process by which an experienced, empathetic person guides another individual in the development and self-recognition of their own vision, learning, core competencies, and professional development. Halstead established the concept of a surgical mentor who directly provided the trainees with professional and technical guidance. Halstead's concept went beyond a simple preceptorship by emphasizing clinical decision making based on scientific evidence. His goal was to develop surgeons who would go on to become outstanding leaders and innovators in the field. Although surgery has changed dramatically since Halstead's era, mentorship remains crucial in surgical training. In addition to teaching technical skills, clinical judgment, and scientific inquiry, modern-day mentors must also model effective communication, empathy, humanism, and the prioritization of competing professional and personal activities.

The mentor must also be an experienced and trusted advisor committed to the success of the mentee. A greater level of trust and commitment distinguishes the mentor from the teacher. More than a teacher, a mentor is a coach. The goal of a teacher is to pass on a defined level of knowledge for each stage of a student's education. The underlying premise is a limited level of advancement for the student. The coach, on the other hand, has the sole purpose to make his or her student the best at their game with an unlimited level of advancement. Modern mentorship implies a partnership between the mentor and the mentee. Surgical residency program chairs and program directors must recruit and develop faculty "coaches" to mentor residents to optimize their potential. Emeritus Chair of University of California, Los Angeles Head and Neck Surgery, Dr. Paul Ward, said it best: "We strive to produce graduates of our residency program who are among those who change the way we think and practice . . ." Having more than 25 former residents become chairs of academic head and neck surgical programs, Dr. Ward embodied the role as a surgeon's coach. The responsibilities of an effective mentor are summarized by Baroness: "Mentoring, to be effective, requires of the mentor empathy, maturity, self-confidence, resourcefulness, and willingness to commit time and energy to another. The mentor must be able to offer guidance for a new and evolving professional life, to stimulate and challenge, to encourage self-realization, to foster growth, and to make more comprehensible the landscape in which the protégé stands."⁴⁸

One of the major goals of a mentor is to assess the aptitudes and abilities of the mentee with regard to the appropriateness of their vision for their surgical career. Proper selection of the appropriate mentor can bring to the mentee much needed wisdom, guidance, and resources and can expand the scope of their vision. In addition, the mentor can refine the leadership **9▶** skills taught to their mentees in formal training programs. Highly successful surgeons most often have had excellent surgical mentors. It is impressive to note that more than 50% of United States Nobel laureates have served under other Nobel laureates in the capacity of student, postdoctoral fellow, or junior collaborator.⁴⁹ In academic medicine, evidence-based studies have shown benefits to the mentees that include enhanced

research productivity, higher likelihood of obtaining research grants, and greater success in obtaining desired positions in practice or at academic institutions.⁵⁰ Mentoring provides benefits to the mentors themselves, including refinement of their own personal leadership skills and a strong sense of satisfaction and accomplishment.

Mentorship is essential to accomplish the successful development of surgical trainees and to help cultivate their vision. Therefore, formal leadership training programs that have a goal of training the future leaders in surgery should include mentoring.

CONCLUSION

Although there are several definitions of leadership and a variety of leadership styles, all end with the common goal of improving patient care in the modern era. All forms of leadership require a vision and willingness—the willingness to assume the responsibility to lead, continue learning, practice effective communication styles, and resolve conflict. Effective leadership can change surgical departments and improve patient care through innovation. A growing body of evidence suggests the mastery of leadership requires practice through intentional curriculum and reinforcement through mentorship.

Surgical leadership is bred through its training programs. Thus, innovation in surgical training programs is needed to enhance the development of leadership skills of surgical trainees, to prepare them for practice in modern healthcare systems, and to optimize patient care, as well as compliance with requirements set forth by regulatory institutions governing surgery and surgical education. A growing body of literature supports the value of effective leadership in improving patient care, productivity, and the work environment while it validates the ability to measure the impact of leadership training. Therefore, it is of paramount importance to teach modern leadership principles and skills to surgical trainees in order to create a new generation of surgeon leaders who will shape the modern era of surgery in the context of rapidly evolving science, technology, and systems of healthcare delivery.

REFERENCES

Entries highlighted in blue are key references.

1. Levinson W, Chaumeton N. Communication between surgeons and patients in routine office visits. *Surgery*. 1999;125:127-134.
2. **Itani KM, Liscum K, Brunicaardi FC. Physician leadership is a new mandate in surgical training. *Am J Surg*. 2004;187:328-331.**
3. Jensen AR, Wright A, Lance A, et al. The emotional intelligence of surgical residents: a descriptive study. *Am J Surg*. 2008;195:5-10.
4. Lee L, Brunicaardi FC, Scott BG, et al. Impact of a novel education curriculum on surgical training within an academic training program. *J Surg Res*. 2008;145:308-312.
5. Larkin AC, Cahan MA, Whalen G, et al. Human Emotion and Response in Surgery (HEARS): a simulation-based curriculum for communication skills, systems-based practice, and professionalism in surgical residency training. *J Am Coll Surg*. 2010;211:285-292.
6. Lobas JG. Leadership in academic medicine: capabilities and conditions for organizational success. *Am J Med*. 2006;119:617-621.
7. Chemers MM. *An Integrative Theory of Leadership*. Mahwah, NJ: Lawrence Erlbaum Associates; 1997:200.
8. Slap S. *Bury My Heart at Conference Room B: The Unbeatable Impact of Truly Committed Managers*. New York, NY: Portfolio Penguin; 2010:234.
9. NobelPrize.org. Frederick G. Banting: Biography. Available at: http://www.nobelprize.org/nobel_prizes/medicine/laureates/1923/banting-bio.html. Accessed June 23, 2013.
10. Brunicaardi FC. Presidential Address. Academic program development. *J Surg Res*. 1999;83(1):1-6.
11. **Brunicaardi FC, Cotton R, Cole G, et al. The leadership principles of Dr. Martin Luther King, Jr. and their relevance to surgery. *J Natl Med Assoc*. 2007;99:7-14.**
12. Isaacson W. *Steve Jobs*. New York, NY: Simon & Schuster; 2011.
13. Brunicaardi FC, Gibbs R, Wheeler D, et al. Overview of the development of personalized genomic medicine and surgery. *World J Surg*. 2011;35:1693-1699.
14. American Board of Surgery CME Requirements for Recertification. Available at: <http://www.absurgery.org/default.jsp?newscontinuingmedicaledrequirements>. Accessed October 2, 2013.
15. Kohn LT, Corrigan J, Donaldson MS. *To Err Is Human: Building a Safer Health System*. Washington, DC: National Academy Press; 2000.
16. Gawande AA, Zinner MJ, Studdert DM, et al. Analysis of errors reported by surgeons at three teaching hospitals. *Surgery*. 2003;133:614-621.
17. Sutcliffe KM, Lewton E, Rosenthal MM. Communication failures: an insidious contributor to medical mishaps. *Acad Med*. 2004;79:186-194.
18. Williams RG, Silverman R, Schwind C, et al. Surgeon information transfer and communication: factors affecting quality and efficiency of inpatient care. *Ann Surg*. 2007;245:159-169.
19. Ambady N, Laplante D, Nguyen T, et al. Surgeons' tone of voice: a clue to malpractice history. *Surgery*. 2002;132:5-9.
20. Nolin CE. Malpractice claims, patient communication, and critical paths: a lawyer's perspective. *Qual Manag Health Care*. 1995;3:65-70.
21. Stewart MA. Effective physician-patient communication and health outcomes: a review. *CMAJ*. 1995;152:1423-1433.
22. Leonard M. The human factor: the critical importance of effective teamwork and communication in providing safe care. *Qual Safe Health Care*. 2004;13(Suppl 1):i85-i90.
23. **Dine CJ, Kahn JM, Abella BS, et al. Key elements of clinical physician leadership at an academic medical center. *J Grad Med Educ*. 2011;3:31-36.**
24. Pronovost P, Berenholtz S, Dorman T, et al. Improving communication in the ICU using daily goals. *J Crit Care*. 2003;18:71-75.
25. Gurses AP, Kim G, Martinez E, et al. Identifying and categorising patient safety hazards in cardiovascular operating rooms using an interdisciplinary approach: a multisite study. *BMJ Qual Saf*. 2012;21:810-818.
26. Makary MA, Sexton JB, Freischlag JA, et al. Operating room teamwork among physicians and nurses: teamwork in the eye of the beholder. *J Am Coll Surg*. 2006;202:746-752.
27. Weeks D. *The Eight Essential Steps to Conflict Resolution: Preserving Relationships at Work, at Home, and in the Community*. New York, NY: J.P. Tarcher/Perigee; 1994:290.
28. Covey SR. *The Seven Habits of Highly Effective People: Restoring the Character Ethic*. New York, NY: Free Press; 2004.
29. **Lee L, Berger DH, Awad SS, et al. Conflict resolution: practical principles for surgeons. *World J Surg*. 2008;32:2331-2335.**
30. Antiel RM, Reed DA, Van Arendonk KJ, et al. Effects of duty hour restrictions on core competencies, education, quality of life, and burnout among general surgery interns. *JAMA Surg*. 2013;148:448-455.
31. Lyssa Ochoa M. Evaluation of resident training activities using a novel time-motion study prior to the implementation of the 80 hour work week. Chicago, IL: American College of Surgeons Annual Conference, 2006.

32. Brunnicardi FC, Hobson FL. Time management: a review for physicians. *J Natl Med Assoc.* 1996;88:581-587.
33. Goleman D. Leadership that gets results. *Harvard Business Review.* 2000;78:78-93.
34. Xirasagar S, Samuels ME, Stoskopf CH. Physician leadership styles and effectiveness: an empirical study. *Med Care Res Rev.* 2005;62:720-740.
35. Baird DS, Soldanska M, Anderson B, et al. Current leadership training in dermatology residency programs: a survey. *J Am Acad Dermatol.* 2012;66:622-625.
36. Kiesau CD, Heim KA, Parekh SG. Leadership and business education in orthopaedic residency training programs. *J Surg Orthop Adv.* 2011;20:117-121.
37. Horwitz IB, Horwitz S, Daram P, et al. Transformational, transactional, and passive-avoidant leadership characteristics of a surgical resident cohort: analysis using the multifactor leadership questionnaire and implications for improving surgical education curriculums. *J Surg Res.* 2008;148:49-59.
38. Ackerly DC, Sangvai DG, Udayakumar K, et al. Training the next generation of physician-executives: an innovative residency pathway in management and leadership. *Acad Med.* 2011;86:575-579.
39. Stoller JK, Rose M, Lee R, et al. Teambuilding and leadership training in an internal medicine residency training program. *J Gen Intern Med.* 2004;19:692-697.
40. Hanna WC, Mulder D, Fried G, et al. Training future surgeons for management roles: the resident-surgeon-manager conference. *Arch Surg.* 2012;147:940-944.
41. Boulanger B, Buencamino A, Dovichi S. Training young pediatricians as leaders. *Pediatrics.* 2005;116:518.
42. Leslie LK, Miotto MB, Liu GC, et al. Training young pediatricians as leaders for the 21st century. *Pediatrics.* 2005;115:765-773.
43. Accreditation Council for Graduate Medical Education. Leadership Skills for Chief Residents. Available at: <http://www.acgme.org/acgmeweb/>. Accessed January 1, 2014.
44. American College of Surgeons. Surgeons as leaders: from operating room to boardroom. Available at: <http://www.facs.org/education/surgeonsasleaders.html>. Accessed January 1, 2014.
45. Awad SS, Hayley B, Fagan SP, et al. The impact of a novel resident leadership training curriculum. *Am J Surg.* 2004;188:481-484.
46. Horwitz IB, Horwitz S, Brandt M, et al. Assessment of communication skills of surgical residents using the Social Skills Inventory. *Am J Surg.* 2007;194:401-405.
47. Horwitz IB, Horwitz S, Brunnicardi F, et al. Improving comprehensive surgical resident training through use of the NEO Five-Factor Personality Inventory: results from a cohort-based trial. *Am J Surg.* 2011;201:828-834.
48. Barondess JA. On mentoring. *J R Soc Med.* 1997;90:347-349.
49. Zuckerman H. *Scientific Elite: Nobel Laureates in the United States.* New York, NY: Free Press; 1977:335.
50. Sambunjak D, Straus SE, Marusic A. Mentoring in academic medicine: a systematic review. *JAMA.* 2006;296:1103-1115.

chapter 2

Systemic Response to Injury and Metabolic Support

Siobhan A. Corbett*

Overview: Injury-Associated Systemic Inflammatory Response	13		
The Detection of Cellular Injury	14		
The Detection of Injury is Mediated by Members of the Damage-Associated Molecular Pattern Family / 14			
DAMPs Are Ligands for Pattern Recognition Receptors / 16			
Pattern Recognition Receptor Signaling: Toll-Like Receptors and the Inflammasome / 18			
Central Nervous System Regulation of Inflammation in Response to Injury	18		
Neuroendocrine Response to Injury / 19			
The Cellular Stress Responses	23		
Reactive Oxygen Species and the Oxidative Stress Response / 23			
The Heat Shock Response / 23			
The Unfolded Protein Response / 23			
Autophagy / 24			
Apoptosis / 24			
Necroptosis / 25			
Mediators of Inflammation	26		
Cytokines / 26			
Eicosanoids / 31			
Plasma Contact System / 33			
Serotonin / 33			
Histamine / 34			
Cellular Response to Injury	34		
Cytokine Receptor Families and Their Signaling Pathways / 34			
JAK-STAT Signaling / 34			
Suppressors of Cytokine Signaling / 35			
Chemokine Receptors Are Members of the G-Protein-Coupled Receptor Family / 35			
Tumor Necrosis Factor Superfamily / 36			
Transforming Growth Factor- β Family of Receptors / 36			
Transcriptional and Translational Regulation of the Injury Response	36		
Transcriptional Events Following Blunt Trauma / 36			
Transcriptional Regulation of Gene Expression / 36			
Epigenetic Regulation of Transcription / 37			
Translation Regulation of Inflammatory Gene Expression / 38			
Cell-Mediated Inflammatory Response	38		
Platelets / 38			
Lymphocytes and T-Cell Immunity / 38			
Dendritic Cells / 39			
Eosinophils / 39			
Mast Cells / 39			
Monocyte/Macrophages / 39			
Neutrophils / 40			
Endothelium-Mediated Injury	40		
Vascular Endothelium / 40			
Neutrophil-Endothelium Interaction / 40			
Chemokines / 40			
Nitric Oxide / 41			
Prostacyclin / 42			
Endothelins / 42			
Platelet-Activating Factor / 43			
Natriuretic Peptides / 43			
Surgical Metabolism	43		
Metabolism during Fasting / 44			
Metabolism after Injury / 46			
Lipid Metabolism after Injury / 46			
Ketogenesis / 47			
Carbohydrate Metabolism / 48			
Protein and Amino Acid Metabolism / 50			
Nutrition in the Surgical Patient	50		
Estimation of Energy Requirements / 51			
Vitamins and Minerals / 51			
Overfeeding / 52			
Enteral Nutrition	52		
Rationale for Enteral Nutrition / 52			
Hypocaloric Enteral Nutrition / 53			
Enteral Formulas / 53			
Access for Enteral Nutritional Support / 55			
Parenteral Nutrition	56		
Rationale for Parenteral Nutrition / 56			
Total Parenteral Nutrition / 57			
Peripheral Parenteral Nutrition / 57			
Initiation of Parenteral Nutrition / 58			
Complications of Parenteral Nutrition / 58			

OVERVIEW: INJURY-ASSOCIATED SYSTEMIC INFLAMMATORY RESPONSE

The inflammatory response to injury or infection occurs as a consequence of the local or systemic release of “pathogen-associated” or “damage-associated” molecules, which use similar signaling pathways to mobilize the necessary resources required for the restoration of homeostasis. Minor host insults result in a localized inflammatory response that is transient and in most cases beneficial. Major host insults, however, may lead to amplified reactions, resulting in systemic inflammation, remote organ damage, and multiple organ failure in as many as 30% of those who are severely injured. Recent data support

this idea and suggest that severely injured patients who are destined to die from their injuries differ from survivors only in the degree and duration of their dysregulated acute inflammatory response.^{1,2}

This topic is highly relevant because systemic inflammation is a central feature³ of both sepsis and severe trauma. Understanding the complex pathways that regulate local and systemic inflammation is necessary to develop therapies to intervene during overwhelming sepsis or after severe injury. Sepsis, defined by a systemic inflammatory response to infection, is a disease process with an incidence of over 900,000 cases per year. Further, trauma is the leading cause of mortality and morbidity for individuals under age 45.

*This chapter is dedicated to its previous author, Dr. Stephen Lowry, my mentor and friend.

Key Points

- 1▶ Endogenous **damage-associated molecular patterns (DAMPs)** are produced following tissue and cellular injury. These molecules interact with immune and nonimmune cell receptors to initiate a “sterile” systemic inflammatory response following severe traumatic injury.
- 2▶ In many cases, DAMP molecules are sensed by **pattern recognition receptors (PRRs)**, which are the same receptors that cells use to sense invading pathogens. This explains, in part, the similar clinical picture of systemic inflammation observed in injured and/or septic patients.
- 3▶ The central nervous system receives information with regard to injury-induced inflammation via soluble mediators as well as **direct neural projections** that transmit information to regulatory areas in the brain. The resulting neuroendocrine reflex plays an important modulatory role in the immune response.
- 4▶ Inflammatory signals activate key **cellular stress responses** (the oxidative stress response, the heat shock protein response, the unfolded protein response, autophagy, and programmed cell death), which serve to mobilize cellular defenses and resources in an attempt to restore homeostasis.
- 5▶ The cells, mediators, signaling mechanisms, and pathways that compose and regulate the systemic inflammatory response are **closely networked** and **tightly regulated** by transcriptional events as well as by epigenetic mechanisms, posttranslational modification, and microRNA synthesis.
- 6▶ Nutritional assessments, whether clinical or laboratory guided, and intervention should be considered at an early juncture in all surgical and critically ill patients.
- 7▶ Management of critically ill and injured patients is optimized with the use of evidence-based and algorithm-driven therapy.

In this chapter, we will review what is known about the soluble and cellular effectors of the injury-induced inflammatory response; how the signals are sensed, transduced, and modulated; and how their dysregulation is associated with immune suppression. We will also discuss how these events are monitored and regulated by the central nervous system. Finally, we will review how injury reprograms cellular metabolism, in an attempt to mobilize energy and structural stores to meet the challenge of restoring homeostasis.

THE DETECTION OF CELLULAR INJURY

The Detection of Injury is Mediated by Members of the Damage-Associated Molecular Pattern Family

Traumatic injury activates the innate immune system to produce a systemic inflammatory response in an attempt to limit damage and to restore homeostasis. It includes two general responses: (a) an acute proinflammatory response resulting from innate immune system recognition of ligands, and (b) an anti-inflammatory response that may serve to modulate the proinflammatory phase and direct a return to homeostasis (Fig. 2-1). This is accompanied by a suppression of adaptive immunity.⁴ Rather than occurring sequentially, recent data indicate that all three responses are simultaneously and rapidly induced following severe traumatic injury.²

The degree of the systemic inflammatory response following trauma is proportional to injury severity and is an independent predictor of subsequent organ dysfunction and resultant mortality. Recent work has provided insight into the mechanisms by which immune activation in this setting is triggered. The clinical features of the injury-mediated systemic inflammatory response, characterized by increased body temperature, heart rate, respirations, and white blood cell count, are similar to those observed with infection (Table 2-1). While significant efforts have been devoted to establishing a microbial etiology for this response, it is now widely accepted that systemic inflammation following trauma is sterile. Although the mechanisms for the sterile response are

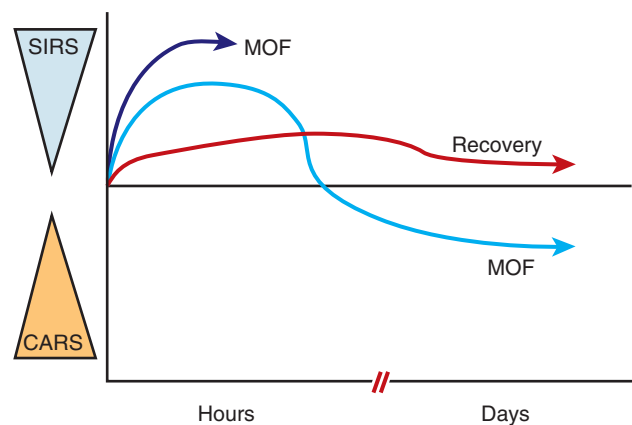


Figure 2-1. Schematic representation of the systemic inflammatory response syndrome (SIRS) after injury, followed by a period of convalescence mediated by the counterregulatory anti-inflammatory response syndrome (CARS). Severe inflammation may lead to acute multiple organ failure (MOF) and early death after injury (dark blue arrow). A lesser inflammatory response followed by excessive CARS may induce a prolonged immunosuppressed state that can also be deleterious to the host (light blue arrow). Normal recovery after injury requires a period of systemic inflammation followed by a return to homeostasis (red arrow). (Adapted with permission from Guirao X, Lowry SF. *Biologic control of injury and inflammation: Much more than too little or too late.* World J Surg. 1996;20:437. With kind permission from Springer Science + Business Media.)

less well understood, it is likely to result from endogenous molecules that are produced as a consequence of tissue damage or cellular stress, as may occur with hemorrhagic shock and resuscitation.⁵ Termed **alarmins or damage-associated molecular patterns (DAMPs)**, these effectors, along with the **pathogen-associated molecular patterns (PAMPs)**, interact with specific cell receptors that are located both on the cell surface and intracellularly.⁶ The best described of these receptors are members of the toll-like receptor family.

Table 2-1

Clinical spectrum of infection and systemic inflammatory response syndrome (SIRS)

TERM	DEFINITION
Infection	Identifiable source of microbial insult
SIRS	Two or more of following criteria are met: Temperature $\geq 38^{\circ}\text{C}$ (100.4°F) or $\leq 36^{\circ}\text{C}$ (96.8°F) Heart rate ≥ 90 beats per minute Respiratory rate ≥ 20 breaths per minute or $\text{Paco}_2 \leq 32$ mmHg or mechanical ventilation White blood cell count $\geq 12,000/\mu\text{L}$ or $\leq 4000/\mu\text{L}$ or $\geq 10\%$ band forms
Sepsis	Identifiable source of infection + SIRS
Severe sepsis	Sepsis + organ dysfunction
Septic shock	Sepsis + cardiovascular collapse (requiring vasopressor support)

Paco_2 = partial pressure of arterial carbon dioxide.

Trauma DAMPs are structurally diverse endogenous molecules that are immunologically active. Table 2-2 includes a partial list of DAMPs that are released either passively from necrotic/damaged cells or actively from physiologically “stressed” cells by upregulation or overexpression. Once they are outside the cell, DAMPs promote the activation of innate immune cells, as well as the recruitment and activation of antigen-presenting cells, which are engaged in host defense.⁷ The best-characterized DAMP with significant preclinical evidence for its release after trauma and with a direct link to the systemic inflammatory response is high-mobility group protein B1 (HMGB1). Additional evidence for the role of DAMP molecules in postinjury inflammation, including mitochondrial proteins and DNA, as well as extracellular matrix molecules, is also presented.

Table 2-2

Damage-associated molecular patterns (DAMPs) and their receptors

DAMP MOLECULE	PUTATIVE RECEPTOR(S)
HMGB1	TLRs (2,4,9), RAGE
Heat shock proteins	TLR2, TLR4, CD40, CD14
S100 protein	RAGE
Mitochondrial DNA	TLR9
Hyaluronan	TLR2, TLR4, CD44
Biglycan	TLR2 and TLR4
Formyl peptides (mitochondrial)	Formyl peptide receptor 1
IL-1 α	IL-1 receptor

HMGB1 = high-mobility group protein B1; IL = interleukin; RAGE = receptor for advanced glycosylation end products; TLK = toll-like receptor.

High-Mobility Group Protein B1. The best-characterized DAMP in the context of the injury-associated inflammatory response is HMGB1 protein, which is rapidly released into the circulation within 30 minutes following trauma. HMGB1 is highly evolutionarily conserved across species. It was first described as a constitutively expressed, nonhistone chromosomal protein that participated in a variety of nuclear events, including DNA repair and transcription. HMGB1 was also detected in the cytosol and extracellular fluids at low levels, although its function outside the cell was not clear. Subsequent studies have proven, however, that HMGB1 is actively secreted from immune-competent cells stimulated by PAMPs (e.g., endotoxin) or by inflammatory cytokines (e.g., tumor necrosis factor and interleukin-1). This process occurs outside the classic secretory pathway via a mechanism that is independent of endoplasmic reticulum and the Golgi complex. Moreover, recent data indicate that HMGB1 release can be regulated by the inflammasome.⁸ Stressed nonimmune cells such as endothelial cells and platelet also actively secrete HMGB1. Finally, passive release of HMGB1 can occur following cell death, whether it is programmed or uncontrolled (necrosis).

Once outside the cell, HMGB1 interacts with its putative receptors either alone or in concert with pathogenic molecules to activate the immune response, and in this way, functions as a proinflammatory cytokine. HMGB1 has been shown to signal via the toll-like receptors (TLR2, TLR4, TLR9), the receptor for advanced glycosylation end products (RAGE), CD24, and others. The activation of TLRs mainly occurs in myeloid cells, whereas RAGE is thought to be the receptor target in endothelial and somatic cells. The diverse proinflammatory biologic responses that result from HMGB1 signaling include: (a) the release of cytokines and chemokines from macrophages/monocytes and dendritic cells; (b) neutrophil activation and chemotaxis; (c) alterations in epithelial barrier function, including increased permeability; and (d) increased procoagulant activity on platelet surfaces, among others.⁹ In particular, HMGB1 binding to TLR4 triggers the proinflammatory cytokine release that mediates “sickness behavior.” This effect is dependent on the highly conserved domain structure of HMGB1 that can be recapitulated by a synthetic 20-amino acid peptide containing a critical cysteine residue at position 106.¹⁰

Recent data have explored the role of this cysteine residue, as well as two others that are highly conserved, in the biologic function of HMGB1. They demonstrate that the redox state of the three residues regulates the receptor binding ability of HMGB1 to influence its activity, including cytokine production. For example, a thiol at C106 is required for HMGB1 to promote macrophage tumor necrosis factor (TNF) release. In addition, a disulfide bond between C23 and C45 is also required for cytokine release because reduction of the disulfide linkage or further oxidation will reduce the ability of HMGB1 to function as a cytokine. Therefore, if all three cysteine residues are in reduced form, HMGB1 lacks the ability to bind and signal through TLR4, but gains the capacity to bind to CXCL12 to activate CXCR4 and serve as a chemotactic mediator. Importantly, shifts between the redox states have been demonstrated and indicate that redox state dynamics are important regulators of HMGB1.¹¹

Importantly, HMGB1 levels in human subjects following injury correlate with the Injury Severity Score, complement activation, and an increase in circulating inflammatory mediators such as TNF.¹² Unchecked, excessive HMGB1 has the capacity

to promote a self-injurious innate immune response. In fact, exogenous administration of HMGB1 to normal animals produces fever, weight loss, epithelial barrier dysfunction, and even death.

A Role for Mitochondrial DAMPs in the Injury-Mediated Inflammatory Response. Mitochondrial proteins and/or DNA can act as DAMPs by triggering an inflammatory response to necrosis and cellular stress. Specifically, the release of mitochondrial DNA (mtDNA) and formyl peptides from damaged or dysfunctional mitochondria has been implicated in activation of the macrophage **inflammasome**, a cytosolic signaling complex that responds to cellular stress. In support of this idea, plasma mtDNA has been shown to be thousands of times higher in both trauma patients and patients undergoing femoral fracture repair when compared to normal volunteers. Further, direct injection of mitochondria lysates in an animal model caused remote organ damage, including liver and lung inflammation.¹³ These data suggest that with stress or tissue injury, mtDNA and peptides are released from damaged mitochondria where they can contribute to a sterile inflammatory response. From an evolutionary perspective, given that eukaryotic mitochondria derive from bacterial origin, it would make sense that they retain bacterial features capable of eliciting a strong response that is typically associated with a pathogen trigger. For example, mtDNA is circular and contains hypomethylated CpG motifs that resemble bacterial CpG DNA. It is thus capable of producing formylated peptides, which potently induce an inflammatory phenotype in neutrophils, by increasing chemotaxis, oxidative burst, and cytokine secretion. In addition, the mitochondrial transcription factor A (TFAM), a highly abundant mitochondrial protein, is functionally and structurally homologous to HMGB1. It has also been shown to be released in high amounts from damaged cells where it acts in conjunction with mtDNA to activate TLR9 signaling.¹⁴

Extracellular Matrix Molecules Act as DAMPs. Recent work has explored the role of extracellular matrix (ECM) proteins in the TLR-mediated inflammatory response that follows tissue injury. These molecules, which are sequestered under normal conditions, can be released in a soluble form with proteolytic digestion of the ECM. Proteoglycans, glycosaminoglycans, and glycoproteins such as fibronectin have all been implicated as key players in the DAMP/TLR interaction. Proteoglycans, in particular, have also been shown to activate the intracellular inflammasomes that trigger sterile inflammation. These molecules, which consist of a protein core with one or more covalently attached glycosaminoglycan chains, can be membrane-bound, secreted, or proteolytically cleaved and shed from the cell surface.

Biglycan is one of the first proteoglycans to be described as a TLR ligand.¹⁵ It consists of a protein core containing leucine-rich repeat regions, with two glycosaminoglycan (GAG) side chains (chondroitin sulfate or dermatan sulfate). Although biglycan typically exists in a matrix-bound form, with tissue injury, it is released from the ECM in a soluble form where it interacts with TLR2 or TLR4 to generate an immediate inflammatory response.

Various proinflammatory cytokines and chemokines, including TNF- α and interleukin (IL)-1 β , are downstream effector molecules of biglycan/TLR2/4 signaling. Among these, the mechanism of biglycan-mediated autonomous

synthesis and secretion of mature IL-1 β is unique. Usually, release of mature IL-1 β from the cell requires two signals, one which is needed to initiate synthesis (TLR2/4-mediated) and the other to process pro-IL-1 β to its mature form (inflammasome-mediated). How is it possible for biglycan to provide both signals? Current evidence indicates that when soluble biglycan binds to the TLR, it simultaneously serves as a ligand for a purinergic receptor, which facilitates the inflammasome activation required for IL-1 β processing.¹⁶ These data support the idea that DAMP-mediated signals can initiate a robust inflammatory response.

DAMPs Are Ligands for Pattern Recognition Receptors

The inflammatory response that occurs following traumatic injury is similar to that observed with pathogen exposure.

▶ Not surprising, surface and cytoplasmic receptors that mediate the innate immune response to microbial infection have been implicated in the activation of sterile inflammation. In support of this idea, genes have been identified that are dysregulated acutely both in response to a microbial ligand administered to human volunteers and in response to traumatic injury in a large patient population.¹⁷ The classes of receptors that are important for sensing damaged cells and cell debris are part of the larger group of germline encoded **pattern recognition receptors** (PRRs). The best-described ligands for these receptors are microbial components, the PAMPs. The PRRs of the innate immune system fall into at least four distinct classes: TLRs, calcium-dependent (C-type) lectin receptors (CLRs), retinoic acid-inducible gene (RIG)-I-like receptors (RLRs), and the nucleotide-binding domain, leucine-rich repeat-containing (NBD-LRR) proteins (NLRs; also nucleotide-binding and oligomerization domain [NOD]-like receptors). Following receptor ligation, intracellular signaling modulates transcriptional and posttranslational events necessary for host defense by coordinating the synthesis and release of cytokines and chemokines to either initiate or suppress the inflammatory response. The best described of these, the TLRs, NLRs, and CLRs, are discussed in the following sections.

Toll-Like Receptors. The TLRs are evolutionarily conserved type I transmembrane proteins that are the best-characterized PRRs in mammalian cells. They were first identified in *Drosophila*, where a mutation in the *Toll* gene led to its identification as a key component in their immune defense against fungal infection. The first human TLR, TLR4, was identified shortly thereafter. Now, more than 10 human TLR family members have been identified, with distinct ligands that include lipid, carbohydrate, peptide, and nucleic acid components of various pathogens. TLRs are expressed on both immune and nonimmune cells. At first, the expression of TLR was thought to be isolated to professional antigen-presenting cells such as dendritic cells and macrophages. However, mRNA for TLR family members have been detected in most cells of myeloid lineage, as well as natural killer (NK) cells.¹⁸ In addition, activation of T cells increases their TLR expression and induces their survival and clonal expansion. Direct engagement of TLR in T-regulatory (Treg) cells promotes their expansion and reprograms them to differentiate into T helper cells, which in turn provides help to effector cells. In addition, B cells express a distinct subset of the TLR family that determines their ability to respond to DAMPs; however, the significance of restricted TLR expression in these cells is not yet clear.

All TLRs consist of an extracellular domain, characterized by multiple leucine-rich repeats (LRRs), and a carboxy-terminal, intracellular toll/IL-1 receptor (TIR) domain. The LRR domains recognize bacterial and viral PAMPs in the extracellular environment (TLR1, TLR2, TLR4, TLR5, TLR6, and TLR11) or in the endolysosomes (TLR3, TLR7, TLR8, TLR9, and TLR10). Although the role of TLRs in sepsis has been well described, more recent data indicate that a subset of the TLRs, TLR4 in particular, also recognizes DAMPs released from injured cells and tissues.¹⁹ Signal transduction occurs with receptor dimerization and recruitment of cytoplasmic adaptor proteins. These adaptor molecules initiate and amplify downstream signals, resulting in the activation of transcription. The transcription factors, which include nuclear factor- κ B (NF- κ B), activator protein (AP)-1, and interferon regulatory factor (IRF), bind to regulatory elements in promoters and/or enhancers of target genes leading to the upregulation of a large cohort of genes that include interferon (IFN)- α and IFN- β , nitric oxide synthase 2 (NOS2A), and TNF, which play critical roles in initiating innate immune responses to cellular injury and stress. Given the importance of TLR triggering of the innate immune response to immune homeostasis, it is no surprise that the process is tightly regulated. TLR expression is significantly increased following blunt traumatic injury. Further, TLR signaling is controlled at multiple levels, both posttranscriptionally via ubiquitination, phosphorylation, and microRNA actions that affect mRNA stability, as well as by the localization of the TLRs and their signaling complexes within the cell.

Nucleotide-Binding Oligomerization Domain-Like Receptor Family. The NLRs are a large family of proteins composed of intracellular PRRs that sense both endogenous (DAMPs) and exogenous (PAMPs) molecules to trigger innate immune activation. The best characterized of the NLRs is the NLR family pyrin domain-containing 3 (NLRP3), which is highly expressed in peripheral blood leukocytes. It forms the key “sensing” component of the larger, multiprotein **inflammasome** complex, which is composed of NLRP3; the adapter protein apoptosis-associated speck-like protein containing a CARD (ASC); and the effector protein, caspase 1.²⁰ In the cytoplasm, the receptor resides in an inactive form due to an internal interaction between two adjacent and highly conserved domains. In conjunction with a priming event, such as mitochondrial stress, phagocytosed DAMPs can be sensed by NLRP3, resulting in the removal of the self-repression. The protein can then oligomerize and recruit other complex members. The net result is the autoactivation of pro-caspase 1 to **caspase 1**. The NLRP3 inflammasome plays a central role in immune regulation by initiating the caspase 1-dependent processing and secretion of the proinflammatory cytokines IL-1 β and IL-18. In fact, NLRP3 is the key protein in the mechanism by which IL-1 β production is regulated in macrophages. NLRP3 inflammasome activity is tightly regulated by cell-cell interactions, cellular ion flux, and oxidative stress in order to maintain a balanced immune response to danger signals.

While the role of the NLRP3 inflammasome in the sterile inflammatory response following trauma has not been well described, recent evidence suggests that genetic variations in the *NLRP3* gene might affect the magnitude of immune inflammatory responses following trauma. Single nucleotide polymorphisms within the *NLRP3* gene were found to be associated with increased risk of sepsis and multiple organ dysfunction syndrome in patients with major trauma.²¹ In an animal model of burn injury, early

inflammasome activation has been detected in a variety of immune cells (NK cells, CD4/CD8 T cells, and B cells), as determined by the assessment of caspase 1 cleavage by flow cytometry.²² Further, inhibition of caspase 1 activity in vivo results in increased burn mortality, suggesting that inflammasome activation may play an unanticipated protective role in the host response to injury that may be linked to increased production of specific cytokines. In addition to the NLRP3 inflammasome, there are numerous other NLRP sensors that are capable of detecting a diverse range of molecular targets. Among them are those endogenous molecules that are released as a consequence of tissue injury and cellular stress (hypoxia/hypoperfusion).

C-Type Lectin Receptors. Macrophages and dendritic cells possess receptors that detect molecules released from damaged or dying cells in order to retrieve and process antigens from cell corpses for T-cell presentation. A key family of receptors that directs this process is the CLR family that includes the selectin and the mannose receptor families and that binds carbohydrates in a calcium-dependent fashion. Best described for their sensing of PAMPs, particularly fungal antigens, the CLRs can also act to promote the endocytosis and clearance of cell corpses. More recent work has demonstrated, however, that a subset of CLR receptors such as dendritic cell-NK lectin group receptor-1 (DNCR-1) and macrophage-inducible C-type lectin receptor (Mincle) recognize DAMPs of intracellular origin, such as F-actin and the ribonucleoprotein SAP-130.²³ Ligation and activation of Mincle promotes its interaction with an Fc γ receptor, which contains immunoreceptor tyrosine-based activation motifs. This leads to proinflammatory cytokine, chemokine, and nitric oxide production, in addition to neutrophil recruitment. In this way, Mincle may contribute to local inflammation at sites of tissue injury.

Soluble Pattern Recognition Molecules: The Pentraxins. Soluble pattern recognition molecules (PRMs) are a molecularly diverse group of molecules that share a conserved mode of action that is defined by complement activation, agglutination and neutralization, and opsonization. The best described of the PRMs are the **pentraxins**. PRMs can be synthesized at sites of injury and inflammation by macrophages and dendritic cells, while neutrophils can store PRMs and can release them rapidly following activation. In addition, epithelial tissues (the liver in particular) serve as a reservoir source for systemic mass release. The short pentraxin, **C-reactive protein (CRP)**, was the first PRM to be identified. Serum amyloid protein (SAP), which has 51% sequence similarity to human CRP, also contains the pentraxin molecular signature. CRP and SAP plasma levels are low (≤ 3 mg/L) under normal circumstances. However, CRP is synthesized by the liver in response to IL-6, increasing serum levels more than a 1000-fold. Thus, CRP is considered part of the **acute-phase protein response** in humans. For this reason, CRP has been studied as a marker of the proinflammatory response in many clinical settings, including appendicitis, vasculitis, and ulcerative colitis. CRP and SAP are ancient immune molecules that share many functional properties with antibodies: they bind bacterial polysaccharides, ECM components, apoptotic cells, and nuclear materials, as well as all three classes of Fc γ receptors (Fc γ R). Both molecules also participate in the activation and regulation of complement pathways. In this way, short pentraxins can link immune cells to the complement system.²⁴

Finally, significant data support a role for pentraxin 3 (PTX3), a long pentraxin family member, in the “sterile”

inflammatory response associated with cellular stress. While CRP is produced solely in the liver, PTX3 is produced by various cells in peripheral tissues, including immune cells. PTX3 plasma concentrations increase rapidly in various inflammatory conditions, including sepsis. Further, in a recent prospective study of polytraumatized patients, serum PTX3 concentrations were highly elevated, peaking at 24 hours. In addition, PTX3 concentrations at admission were associated with injury severity, whereas higher PTX3 serum concentrations 24 hours after admission correlated with lower probability for survival.²⁵

Pattern Recognition Receptor Signaling: Toll-Like Receptors and the Inflammasome

As noted earlier, members of the TLR family respond to endogenous molecules released from damaged or stressed cells. In animal models, activation of TLRs in the absence of bacterial pathogens correlates with the development of critical illness including “sterile inflammation.” What we know about TLR signaling events has largely been derived from the TLR-mediated response to bacterial pathogens. However, it is likely that the intracellular adaptors required for signal transmission by TLRs in response to exogenous ligands are conserved and used for “damage” sensing of endogenous (“self”) ligands as well. The intracellular domain structure of TLRs is highly conserved and is characterized by a cytoplasmic toll/IL-1R homology (TIR) domain. Binding of ligand to the receptor results in a receptor dimer, either a homodimer (e.g., TLR4/TLR4) or heterodimer (e.g., TLR2/TLR1), which recruits a number of adaptor proteins to the TIR domains, through TIR-TIR interaction.²⁶ With one exception (TLR3), the universal adaptor protein central to the TLR signaling complex is myeloid differentiation factor 88 (MyD88), a member of the IL-1 receptor subfamily. MyD88 works through the recruitment of a second TIR-containing adaptor, MyD88 adaptor-like protein (Mal), in the context of TLR4 and TLR2 signaling, which serves as a bridge between MyD88 and activated TLRs to initiate signal transduction. It is interesting that Mal’s adaptor function requires cleavage of the carboxy-terminal portion of the protein by **caspace 1**, a key effector of the inflammasome.²⁷ This finding suggests an important synergy between TLRs and NLRs that may potentiate TLR-mediated signaling. There are three other TIR domain-containing adaptor proteins that are also important to TLR-signaling events; these are TIR-domain-containing adapter-inducing INF- β (TRIF), TRIF-related adaptor molecule (TRAM), and sterile α - (SAM) and HEAT/armadillo (ARM) motif-containing protein (SARM). Two of these, TRIF and TRAM, are involved in the *MyD88-independent* signaling pathways, which are activated by TLR3 and TLR4.

Signaling through the MyD88-dependent pathway results in the activation of numerous cytoplasmic protein kinases including IL-1 receptor-associated kinases (IRAK-1 and IRAK-4), resulting in an interaction with TNF receptor-associated factor 6 (TRAF6). TRAF6, an E3 ubiquitin ligase, forms a complex with two other proteins, which together activate the complex that subsequently phosphorylates I κ B kinase (IKK)- β and the MAP kinases (MAPKs). Ultimately, the phosphorylation of I κ B by the IKK complex and NEMO (NF- κ B essential modulator) leads to its degradation, which frees NF- κ B and allows its translocation to the nucleus and the transcription of **NF- κ B target genes**. Simultaneously, MAPK activation is critical for activation of the activator protein-1 (AP-1) transcription factor, and thus production of **inflammatory cytokines**.

The MyD88-independent pathway acts through TRIF to activate NF- κ B, similar to the MyD88-dependent pathway. However, TRIF can also recruit other signaling molecules to phosphorylate interferon-regulatory factor 3 (IRF3), which induces expression of type I IFN genes.²⁶

Signaling from the Inflammasome. As discussed earlier, activation and assembly of the inflammasome in response to DAMP sensing result in the cleavage of pro-caspase 1 into two products. This event is pivotal to all known inflammasome signaling pathways. The caspase 1 products assemble to form the **IL-1 converting enzyme (ICE)**, which cleaves the IL-1 cytokines, IL-1 β , IL-18, and IL-33. This final step is required for activation and secretion of the cytokines from the cell.²⁰ IL-1 β and IL-18 are potent proinflammatory cytokines that promote key immune responses that are essential to host defense. Thus, the synthesis, processing, and secretion of these cytokines are tightly regulated, as successful cytokine release requires a two-step process. The first signal, which is typically TLR-mediated, initiates the synthesis and storage of the inactive cytokine precursors in the cytoplasm. The second signal, which is inflammasome-mediated, initiates proteolytic cleavage of the procytokine, which is a requirement for its activation and secretion from the cell. Of further interest, evidence has demonstrated that both IL-1 β and IL-18 lack a signal sequence, which is usually necessary for those proteins that are destined for cellular export. These signal peptides target proteins to the endoplasmic reticulum (ER) and to the Golgi complex, where they are packaged for secretion from the cell through the classical secretory pathway. More than 20 proteins in addition to IL-1 β and IL-18 undergo **unconventional protein secretion** independent of the ER and Golgi complex.²⁸ The list includes signaling molecules involved in inflammatory, cell survival, and repair responses, such as HMGB1, IL-1 α , galectins 1 and 3, and FGF2. Currently, the mechanisms responsible for unconventional protein secretion are not understood; however, the process is also evident in yeast under conditions of cellular stress. It makes evolutionary sense that a mechanism for rapid secretion of stored proteins essential to the stress response is highly conserved.

CENTRAL NERVOUS SYSTEM REGULATION OF INFLAMMATION IN RESPONSE TO INJURY

The central nervous system (CNS) communicates with the body through ordered systems of sensory and motor neurons, which receive and integrate information to generate a coordinated response. Rather than being an immune-privileged organ, recent work indicates that the CNS receives information with regard to injury-induced inflammation both via soluble mediators as well as direct neural projections that transmit information

3► to regulatory areas in the brain (Fig. 2-2). How does the CNS sense inflammation? DAMPs and inflammatory molecules convey stimulatory signals to the CNS via multiples routes. For example, soluble inflammatory signaling molecules from the periphery can reach neurons and glial cells directly through the fenestrated endothelium of the circumventricular organs (CVO) or via a leaky blood brain barrier in pathologic settings such as may occur following a traumatic brain injury.²⁹ In addition, inflammatory stimuli can interact with receptors located on the brain endothelial cells to generate a variety of proinflammatory mediators (cytokines, chemokines, adhesion molecules, proteins of the complement system, and immune receptors) that directly impact the brain parenchyma. Not surprising, this

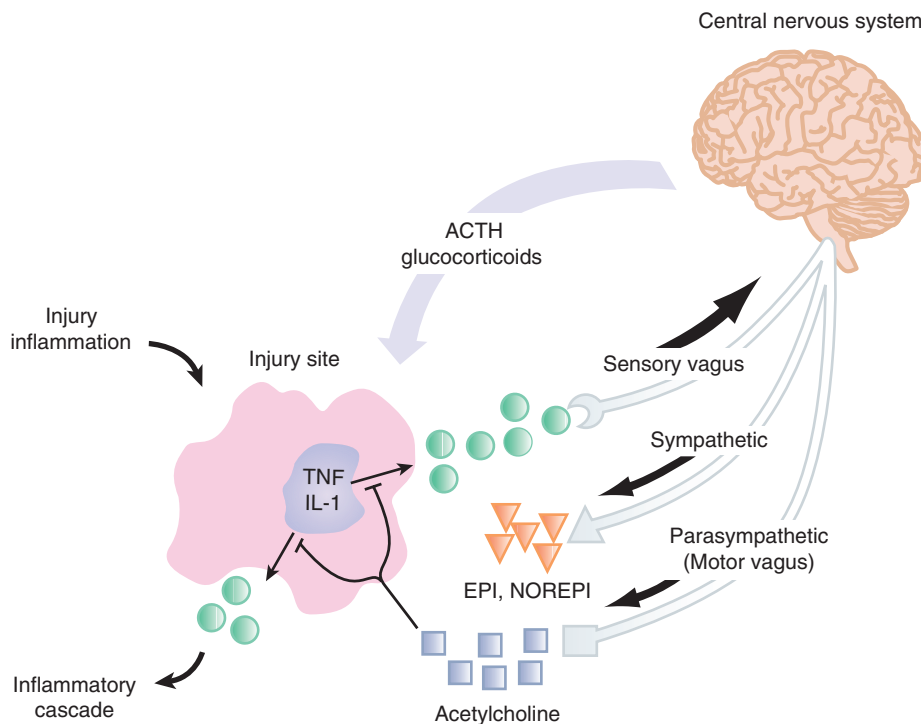


Figure 2-2. Neural circuit relaying messages of localized injury to the brain (nucleus tractus solitarius). The brain follows with a hormone release (adrenocorticotropic hormone [ACTH], glucocorticoids) into the systemic circulation and by sympathetic response. The vagal response rapidly induces acetylcholine release directed at the site of injury to curtail the inflammatory response elicited by the activated immunocytes. This vagal response occurs in real time and is site specific. EPI = epinephrine; IL-1 = interleukin-1; NOREPI = norepinephrine; TNF = tumor necrosis factor. (Adapted and re-created with permission from Macmillan Publishers Ltd. Tracey KJ. *The inflammatory reflex*. *Nature*. 2002;420:853. Copyright © 2002.)

response is countered by potent anti-inflammatory signaling, a portion of which is provided by the hypothalamic-pituitary-adrenal (HPA) axis and the release of systemic glucocorticoids. Inflammatory stimuli in the CNS result in behavioral changes, such as increased sleep, lethargy, reduced appetite, and the most common feature of infection, fever.

Information regarding peripheral inflammation and tissue damage can also be signaled to the brain via afferent neural fibers, particularly those of the vagus nerve.³⁰ These afferent fibers can interconnect with neurons that project to the hypothalamus to modulate the HPA axis. In addition, afferent vagal nerve impulses modulate cells in the brain stem, at the dorsal motor nucleus of the vagus, from which efferent preganglionic parasympathetic impulses originate. Axons from these cells, which comprise the visceromotor component of the vagus nerve, form an “inflammatory reflex” that feeds back to the periphery to regulate inflammatory signaling events.³¹ Although the mechanisms by which cholinergic signals from the CNS regulate immune cells in the periphery are incompletely understood, recent evidence has provided some mechanistic insight. The first line of evidence to support this idea is the observation that vagal stimulation reduces proinflammatory cytokine production from the spleen in several experimental models systems.³² This effect is dependent on both the vagal efferent signals and, in part, splenic catecholaminergic nerve fibers that originate in the celiac plexus and that terminate in a T-cell-rich area of the spleen. Interestingly, these signals propagated by adrenergic nerves result in measurable increases in acetylcholine (ACh) levels in the spleen. In addition, the resident immune cells in the spleen require the expression of cholinergic receptors,

specifically $\alpha 7$ nicotinic acetylcholine receptors ($\alpha 7nAChR$), for the suppression of cytokine synthesis.³³ How is this effect mediated? The apparent source of ACh is choline-acetyltransferase-expressing T cells, which compose 2% to 3% of CD4⁺ T cells in the spleen and are capable of ACh production. Data also indicate that the vagus nerve may regulate inflammation in tissues that it directly innervates.

Neuroendocrine Response to Injury

Traumatic injury results in complex neuroendocrine signaling from the brain that serves to enhance immune defense and rapidly mobilize substrates necessary to meet essential energy and structural needs. The two principle neuroendocrine pathways that orchestrate the host response are the **hypothalamic-pituitary-adrenal (HPA) axis**, which results in the release of glucocorticoid hormones, and the **sympathetic nervous system**, which results in release of the catecholamines, epinephrine, and norepinephrine. Virtually every hormone of the HPA axis influences the physiologic response to injury and stress (Table 2-3), but some with direct influence on the inflammatory response or immediate clinical impact are highlighted here, including growth hormone (GH), macrophage inhibitory factor (MIF), aldosterone, and insulin.

The Hypothalamic-Pituitary-Adrenal Axis. One of the main mechanisms by which the brain responds to injury-associated stress is through activation of the HPA axis. Following injury, corticotrophin-releasing hormone (CRH) is secreted from the paraventricular nucleus (PVN) of the hypothalamus. This action is mediated in part by circulating cytokines produced as

Table 2-3

Hormones regulated by the hypothalamus, pituitary, and autonomic system**Hypothalamic Regulation**

Corticotropin-releasing hormone
Thyrotropin-releasing hormone
Growth hormone–releasing hormone
Luteinizing hormone–releasing hormone

Anterior Pituitary Regulation

Adrenocorticotropic hormone
Cortisol
Thyroid-stimulating hormone
Thyroxine
Triiodothyronine
Growth hormone
Gonadotrophins
Sex hormones
Insulin-like growth factor
Somatostatin
Prolactin
Endorphins

Posterior Pituitary Regulation

Vasopressin
Oxytocin

Autonomic System

Norepinephrine
Epinephrine
Aldosterone

Renin-Angiotensin System

Insulin
Glucagon
Enkephalins

a result of the innate immune response to injury. These include TNF- α , IL-1 β , IL-6, and the type I IFNs (IFN- α/β). Cytokines that are produced as a result of the adaptive immune response (IL-2 and IFN- γ) are also capable of increasing cortisol release. Direct neural input via afferent vagal fibers that interconnect with neurons projecting to the hypothalamus can also trigger CRH release. CRH acts on the anterior pituitary to stimulate the secretion of adrenocorticotropic hormone (ACTH) into the systemic circulation. Interestingly, the cytokines that act on the hypothalamus are also capable of stimulating ACTH release from the anterior pituitary so that marked elevations in ACTH and in cortisol can occur that are proportional in magnitude to the injury severity. Additionally, pain, anxiety, vasopressin, angiotensin II, cholecystokinin, vasoactive intestinal peptide, and catecholamines all contribute to ACTH release in the injured patient.

ACTH acts on the zona fasciculata of the adrenal glands to synthesize and secrete glucocorticoids (Fig. 2-3). Cortisol is the major glucocorticoid in humans and is essential for survival during significant physiologic stress. The resulting increase in cortisol levels following trauma have several important anti-inflammatory actions.

Cortisol elicits its many actions through a cytosolic receptor, the glucocorticoid receptor (GR). Because it is lipid soluble, cortisol can diffuse through the plasma membrane to interact with its receptor, which is sequestered in the cytoplasm in a complex with heat shock proteins (Fig. 2-4). Upon ligand binding, the GR is activated and can employ a number of mechanisms to modulate proinflammatory gene transcription and signaling events, with a “net” anti-inflammatory effect.³⁴ For example, the activated GR complex can interact with transcription factors to sequester them in the cytoplasm, promote their degradation, or inhibit them through other mechanisms. Affected target genes include proinflammatory cytokines, growth factors, adhesion molecules, and nitric oxide. In addition, glucocorticoids can negatively affect the access of the transcription factor, NF- κ B,

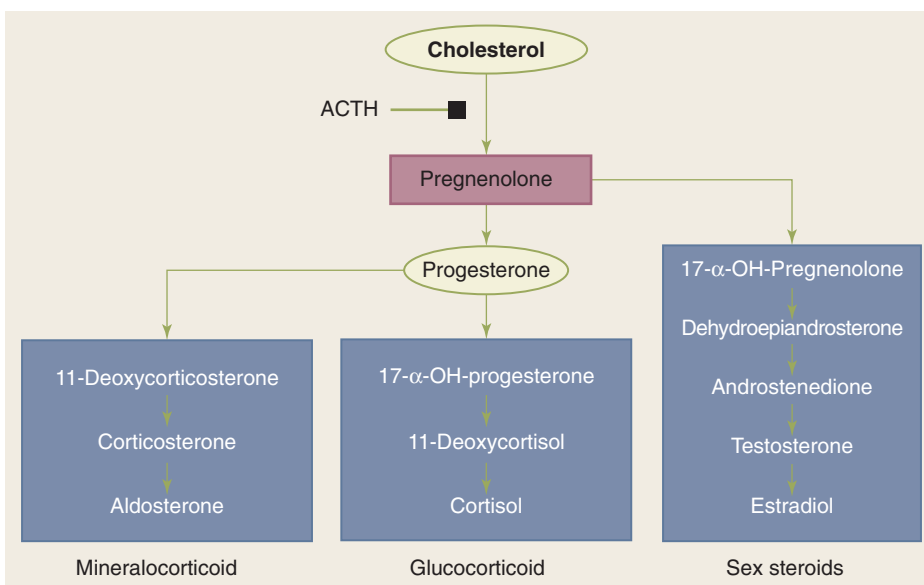


Figure 2-3. Steroid synthesis from cholesterol. Adrenocorticotropic hormone (ACTH) is a principal regulator of steroid synthesis. The end products are mineralocorticoids, glucocorticoids, and sex steroids.

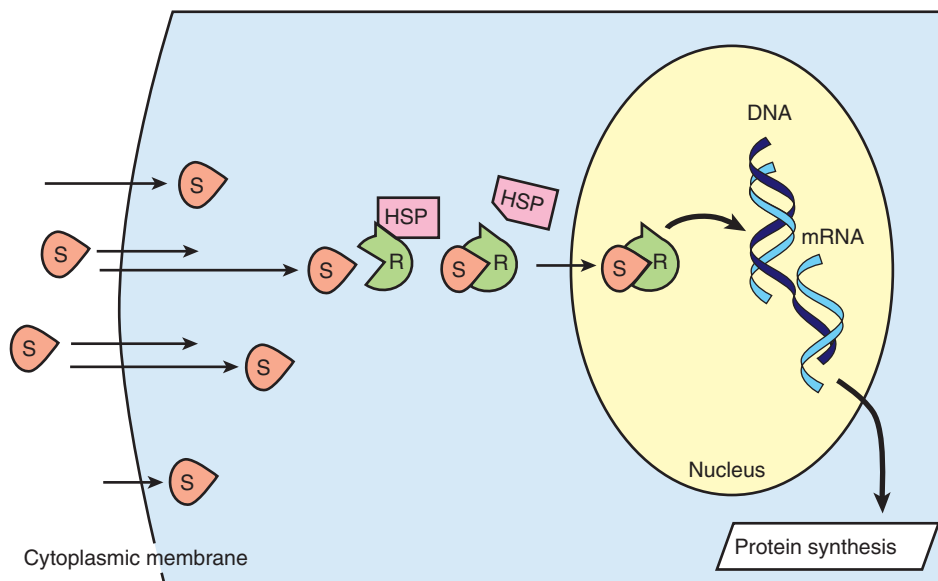


Figure 2-4. Simplified schematic of steroid transport into the nucleus. Steroid molecules (S) diffuse readily across cytoplasmic membranes. Intracellularly, the receptors (R) are rendered inactive by being coupled to heat shock protein (HSP). When S and R bind, HSP dissociates, and the S-R complex enters the nucleus, where the S-R complex induces DNA transcription, resulting in protein synthesis. mRNA = messenger RNA.

to the promoter regions of its target genes via a mechanism that involves histone deacetylase 2. In this way, glucocorticoids can inhibit a major mechanism by which TLR ligation induces proinflammatory gene expression.³⁵ The GR complex can also bind to specific nucleotide sequences (termed glucocorticoid response elements) to promote the transcription of genes that have anti-inflammatory functions. These include IL-10 and IL-1 receptor antagonist. Further, GR complex activation can indirectly influence TLR activity via an interaction with signaling pathways such as the mitogen-activated protein kinase and transforming growth factor-activated kinase-1 (TAK1) pathways. Finally, a recent report demonstrated that the GR complex can target both suppressor of cytokine signaling 1 (SOCS1) and type 1 IFNs to regulate TLR-induced STAT1 activation.³⁶

Adrenal insufficiency represents a clinical syndrome highlighted largely by inadequate amounts of circulating cortisol and aldosterone. Classically, adrenal insufficiency is described in patients with atrophic adrenal glands caused by exogenous steroid administration who undergo a stressor such as surgery. These patients subsequently manifest signs and symptoms such as tachycardia, hypotension, weakness, nausea, vomiting, and fever. Critical illness may be associated with a **relative adrenal insufficiency** such that the adrenal gland cannot mount an effective cortisol response to match the degree of injury. More recently, investigators have determined that critical illness-associated cortisol insufficiency in trauma patients occurs more frequently than previously thought.³⁷ It has a bimodal presentation in which the patient is at increased risk both early following the injury-associated inflammatory response and in a delayed fashion, with sepsis being the initiating event. Laboratory findings in adrenal insufficiency include hypoglycemia from decreased gluconeogenesis, hyponatremia from impaired renal tubular sodium resorption, and hyperkalemia from diminished kaliuresis. Rigorous testing to establish the diagnosis includes monitoring of basal and ACTH-stimulated cortisol levels, both of which are lower than normal during adrenal insufficiency. Treatment strategies remain controversial; however, they include low-dose steroid supplementation.³⁸

Macrophage Inhibitory Factor Modulates Cortisol Function. Macrophage inhibitory factor (MIF) is a proinflammatory

cytokine expressed by a variety of cells and tissues, including the anterior pituitary, macrophages, and T lymphocytes. Several important functions of MIF in innate and adaptive immune responses and in inflammation have been described, supporting the idea that MIF may function to counteract the anti-inflammatory activity of glucocorticoids.³⁹ For example, MIF has been reported to play a central role in the exacerbation of inflammation associated with acute lung injury, where it has been detected in the affected lungs and in alveolar macrophages. MIF has also been reported to upregulate the expression of TLR4 in macrophages.⁴⁰ Finally, an early increase in plasma MIF has been detected in severely injured patients and was found to correlate with NF- κ B translocation and respiratory burst in polymorphonuclear lymphocytes (PMNs) derived from severely injured patients. Further, nonsurvivors were shown to have higher serum MIF concentrations early after injury than survivors.⁴¹ These data suggest that targeting MIF after injury may be beneficial in preventing early PMN activation and subsequent organ failure in severely injured patients.

Growth Hormone, Insulin-Like Growth Factor, and Ghrelin.

Growth hormone (GH) is a neurohormone expressed primarily by the pituitary gland that has both metabolic and immunomodulatory effects. GH promotes protein synthesis and insulin resistance and enhances the mobilization of fat stores. GH secretion is upregulated by hypothalamic GH-releasing hormone and downregulated by somatostatin. GH primarily exerts its downstream effects through direct interaction with GH receptors and through the enhanced hepatic synthesis of insulin-like growth factor (IGF)-1, an anabolic growth factor that is known to improve the metabolic rate, gut mucosal function, and protein loss after traumatic injury. Less than 5% of IGF-1 circulates free in the plasma, with the remainder bound principally to one of six IGF-binding proteins (IGFBPs), the majority to IGFBP-3. In the liver, IGF stimulates protein synthesis and glycogenesis; in adipose tissue, it increases glucose uptake and lipid utilization; and in skeletal muscles, it mediates glucose uptake and protein synthesis. In addition to its effects on cellular metabolism, GH enhances phagocytic activity of immunocytes through increased lysosomal superoxide production. It also increases the

proliferation of T-cell populations.⁴² The catabolic state that follows severe injury has been linked to the suppression of the GH-IGF-IGFBP axis, as critical illness is associated with decreased circulating IGF levels. Not surprising, the administration of exogenous recombinant human GH (rhGH) has been studied in a prospective, randomized trial of critically ill patients where it was associated with increased mortality, prolonged ventilator dependence, and increased susceptibility to infection.⁴³ More recently, circulating GH levels were examined on admission in 103 consecutive critically ill adult patients. In this study, circulating GH levels were about seven-fold increased in the 24 nonsurvivors when compared with survivors, and GH level was an independent predictor of mortality, along with the APACHE II/SAPS II scores. In distinct contrast, the effect of rhGH administration in severely burned children, both acutely and following prolonged treatment, has been proven to be beneficial. Pediatric burn patients receiving rhGH demonstrated markedly improved growth and lean body mass, whereas hypermetabolism was significantly attenuated.⁴⁴ This finding was associated with significant increases in serum GH, IGF-1, and IGFBP-3.

Ghrelin, a natural ligand for the GH-secretagogue receptor 1a (GHS-R1a), is an appetite stimulant that is secreted by the stomach. GHS-R1a is expressed in a variety of tissues in different concentrations including the immune cells, B and T cells, and neutrophils. Ghrelin seems to play a role in promoting GH secretion and in glucose homeostasis, lipid metabolism, and immune function. In a rodent gut ischemia/reperfusion model, ghrelin administration inhibited proinflammatory cytokine release, reduced neutrophil infiltration, ameliorated intestinal barrier dysfunction, attenuated organ injury, and improved survival. It is interesting that this effect was dependent on an intact vagus nerve and that intracerebroventricular injection of ghrelin was also protective.⁴⁵ These data suggest that the effect of ghrelin is mediated via the CNS, most likely through the “cholinergic anti-inflammatory pathway.” More recently, high ghrelin levels were demonstrated in critically ill patients as compared to healthy controls, independent of the presence of inflammatory markers. Moreover, the high ghrelin levels were a positive predictor of intensive care unit survival in septic patients, matching previous results from animal models.

The Role of Catecholamines in Postinjury Inflammation. Injury-induced activation of the sympathetic nervous system results in secretion of ACh from the preganglionic sympathetic fibers innervating the adrenal medulla. The adrenal medulla is a special case of autonomic innervation and is considered a **modified postganglionic neuron**. Thus, ACh signaling to the resident chromaffin cells ensures that a surge of epinephrine (EPI) and norepinephrine (NE) release into the circulation takes place in a ratio that is tightly regulated by both central and peripheral mechanisms. Circulating levels of EPI and NE are three- to four-fold elevated, an effect that persists for an extended time. The release of EPI can be modulated by transcriptional regulation of phenylethanolamine *N*-methyltransferase (PNMT), which catalyzes the last step of the catecholamine biosynthesis pathway methylating NE to form EPI. PNMT transcription, a key step in the regulation of EPI production, is activated in response to stress and tissue hypoxia by hypoxia-inducible factor 1 α (HIF1A).

Catecholamine release almost immediately prepares the body for the “fight or flight” response with well-described effects on the cardiovascular and pulmonary systems and on metabolism. These include increased heart rate, myocardial contractility, conduction velocity, and blood pressure; the redirection

of blood flow to skeletal muscle; increased cellular metabolism throughout the body; and mobilization of glucose from the liver via glycogenolysis, gluconeogenesis, lipolysis, and ketogenesis. To compound the resulting hyperglycemia, insulin release is decreased mainly through the stimulation of α -adrenergic pancreatic receptors. Hyperglycemia, as will be discussed later, contributes to the proinflammatory response and to further mitochondrial dysfunction.

The goal of this well-orchestrated catecholamine response is to re-establish and maintain the systems’ homeostasis, including the innate immune system. Circulating catecholamines can directly influence inflammatory cytokine production.⁴⁶ Data indicate that basal EPI levels condition the activity and responsiveness of cytokine-secreting cells, which may explain large interindividual variability in innate cytokine profiles observed following injury. Epinephrine infusion at higher doses has been found to inhibit production of TNF- α *in vivo* and to enhance the production of the anti-inflammatory cytokine IL-10.⁴⁷ Additionally, *in vitro* studies indicate that stress levels of glucocorticoids and EPI, acting in concert, can inhibit production of IL-12, a potent stimulator of Th1 responses. Further, they have been shown *in vitro* to decrease Th1 cytokine production and increase Th2 cytokine production to a significantly greater degree compared to either adrenal hormone alone. Thus, catecholamines secreted from the adrenal gland, specifically EPI, play a role in both innate proinflammatory cytokine regulation and adaptive Th responses, and may act in concert with cortisol during the injury response to modulate cytokine activity.⁴⁸

How are these effects explained? It is well established that a variety of human immune cells (e.g., mononuclear cells, macrophages, granulocytes) express adrenergic receptors that are members of the family of G-protein-coupled receptors that act through the activation of intracellular second messengers such as cyclic adenosine monophosphate (cAMP) and calcium ion influx (discussed in more detail later). These second messengers can regulate a variety of immune cell functions, including the release of inflammatory cytokines and chemokines.

The sympathetic nervous system also has direct immunomodulatory properties via its innervation of lymphoid tissues that contain resting and activated immune cells. With stimulation of these postganglionic nerves, NE is released where it can interact with β_2 -adrenergic receptors expressed by CD4⁺ T and B lymphocytes, many of which also express α_2 -adrenergic receptors. Additionally, endogenous catecholamine expression has been detected in these cells, as has the machinery for catecholamine synthesis. For example, human peripheral blood mononuclear cells contain inducible mRNA for the catecholamine-generating enzymes, tyrosine-hydroxylase and dopamine- β -hydroxylase, and data suggest that cells can regulate their own catecholamine synthesis in response to extracellular cues. Exposure of peripheral blood mononuclear cells to NE triggers a distinct genetic profile that indicates a modulation of Th cell function. What the net effect of dopamine, NE, and EPI synthesis by circulating and resident immune cells may be relative to that secreted by the adrenal medulla is not clear and is an area that would certainly benefit from ongoing research efforts to identify novel therapeutic targets.

Aldosterone. Aldosterone is a mineralocorticoid released by the zona glomerulosa of the adrenal cortex. It binds to the mineralocorticoid receptor (MR) of principal cells in the collecting duct of the kidney where it can stimulate expression of genes involved in sodium reabsorption and potassium excretion

to regulate extracellular volume and blood pressure. MRs have also been shown to have effects on cell metabolism and immunity. For example, recent studies show aldosterone interferes with insulin signaling pathways and reduces expression of the insulin-sensitizing factors, adiponectin and peroxisome proliferator activated receptor- γ (PPAR- γ), which contribute to insulin resistance. In the immune system, mononuclear cells, such as monocytes and lymphocytes, have been shown to possess an MR that binds aldosterone with high specificity, regulating sodium and potassium flux, as well as plasminogen activator inhibitor-1 and p22 phox expression, in these cells.⁴⁹ Further, aldosterone inhibits cytokine-mediated NF- κ B activation in neutrophils, which also possess a functional MR.


Insulin. Hyperglycemia and insulin resistance are hallmarks of injury and critical illness due to the catabolic effects of circulating mediators, including catecholamines, cortisol, glucagon, and GH. The increase in these circulating proglycemic factors, particularly EPI, induces glycogenolysis, lipolysis, and increased lactate production independent of available oxygen in a process that is termed “aerobic glycolysis.” Although there is an increase in insulin production at the same time, severe stress is frequently associated with **insulin resistance**, leading to decreased glucose uptake in the liver and the periphery contributing to acute hyperglycemia. Insulin is a hormone secreted by the pancreas, which mediates an overall host anabolic state through hepatic glycogenesis and glycolysis, peripheral glucose uptake, lipogenesis, and protein synthesis.⁵⁰

The insulin receptor (IR) is widely expressed and consists of two isoforms, which can form homo- or heterodimers with insulin binding. Dimerization leads to receptor autophosphorylation and activation of intrinsic tyrosine kinase activity. Downstream signaling events are dependent on the recruitment of the adaptor proteins, insulin receptor substrate (IRS-1), and Shc to the IR. Systemic insulin resistance likely results from proinflammatory signals, which modulate the phosphorylation of IRS-1 to affect its function.

Hyperglycemia during critical illness is predictive of increased mortality in critically ill trauma patients.⁵¹ It can modulate the inflammatory response by altering leukocyte functions, and the resulting decreases in phagocytosis, chemotaxis, adhesion, and respiratory burst activities are associated with an increased risk for infection. In addition, glucose administration results in a rapid increase in NF- κ B activation and proinflammatory cytokine production. Insulin therapy to manage hyperglycemia has grown in favor and has been shown to be associated with both decreased mortality and a reduction in infectious complications in select patient populations. However, the trend toward tight glycemic control in the intensive care unit failed to show benefit when examined in several reviews.⁵² Thus, the ideal blood glucose range within which to maintain critically ill patients and to avoid hypoglycemia has yet to be determined.

THE CELLULAR STRESS RESPONSES

Reactive Oxygen Species and the Oxidative Stress Response

Reactive oxygen and nitrogen species (ROS and RNS, respectively) are small molecules that are highly reactive due to the presence of unpaired outer orbit electrons. They can cause cellular injury to both host cells and invading pathogens through  the oxidation of cell membrane substrates. Oxygen radicals

are produced as a by-product of oxygen metabolism in the mitochondria as well as by processes mediated by cyclooxygenases, NADPH oxidase (NOX), and xanthine oxidase. The main areas of ROS production include mitochondrial respiratory chain, peroxisomal fatty acid metabolism, cytochrome P450 reactions, and the respiratory burst of phagocytic cells. In addition, protein folding in the endoplasmic reticulum can also result in the formation of ROS.⁵³ Potent oxygen radicals include oxygen, superoxide, hydrogen peroxide, and hydroxyl radicals. RNS include NO and nitrite. The synthesis of ROS is regulated at several checkpoints and via several signaling mechanisms, including Ca²⁺ signaling, phosphorylation, and small G protein activation, which influence both the recruitment of the molecules required for NOX function and the synthesis of ROS in the mitochondria. NOX activation is triggered by a number of inflammatory mediators (e.g., TNF, chemokines, lysophospholipids, complement, and leukotrienes). Host cells are protected from the damaging effects of ROS through a number of mechanisms. The best described of these is via the upregulation and/or activation of endogenous antioxidant proteins. However, pyruvate kinase also provides negative feedback for ROS synthesis, as do molecules that react nonenzymatically with ROS. Under normal physiologic conditions, ROS production is balanced by these antioxidative strategies. In this context, ROS can act effectively as signaling molecules through their ability to modulate cysteine residues by oxidation and thus influence the functionality of target proteins.⁵⁴ This has recently been described as a mechanism in the regulation of phosphatases. ROS can also contribute to transcription activity both indirectly, through its effects on transcription factor lifespan, and directly, through the oxidation of DNA. An important role for ROS has been well described in phagocytes, which use these small molecules for pathogen killing. Recent data, however, indicate that ROS may mediate inflammasome activation by diverse agonists.⁵⁵ In addition, ROS appear to be involved in adaptive immunity. They have been described as a prime source of phosphatase activation in both B and T lymphocytes, which can regulate the function of key receptors and intracellular signaling molecules in these cells by affecting phosphorylation events.

The Heat Shock Response

Heat shock proteins (HSPs) are a group of intracellular proteins that are increasingly expressed during times of stress, such as burn injury, inflammation, oxidative stress, and infection. HSPs are expressed in the cytoplasm, nucleus, endoplasmic reticulum, and mitochondria, where they function as molecular chaperones that help monitor and maintain appropriate protein folding.⁵⁶ HSPs accomplish this task through the promotion of protein refolding, the targeting of misfolded proteins for degradation, and the assistance of partially folded proteins to appropriate membrane compartments. HSPs also bind foreign proteins and thereby function as intracellular chaperones for ligands such as bacterial DNA and endotoxin. HSPs are presumed to protect cells from the effects of traumatic stress and, when released by damaged cells, alert the immune system of the tissue damage. However, depending on their location and the type of immune cell in which they are expressed, HSPs may exert proinflammatory immune activating signals or anti-inflammatory immune dampening signals (Table 2-4).⁵⁷

The Unfolded Protein Response

Secreted, membrane-bound, and organelle-specific proteins fold in the lumen of the endoplasmic reticulum (ER) where they also

TABLE 2-4

The immunomodulatory functions of heat shock proteins (HSPs)

	CELL LOCATION	RECOGNIZED AS DAMP?	IMMUNOMODULATORY FUNCTION
HSP90	Cytoplasm, endoplasmic reticulum Can function both inside and outside the cell	May act as DAMP chaperone to activate innate immune response	Binds and optimizes RNA polymerase II action to regulate gene transcription Stabilizes glucocorticoid receptor in the cytoplasm Important for processing and membrane expression of TLR Chaperones include IKK Facilitates antigen presentation to dendritic cells
HSP70	Can function both inside and outside the cell Endoplasmic reticulum homolog is BiP	Exogenous HSP70 elicits cellular calcium flux, NF- κ B activation, cytokine production	Can have anti-inflammatory actions when expression is increased Inhibits TLR-mediated cytokine production via NF- κ B Reduces dendritic cell capacity for T-cell stimulation BiP sequesters proteins important to the unfolded protein response
HSP60	Mitochondria	Exogenous HSP60 inhibits NF- κ B activation	Plays a role in intracellular protein trafficking Modulates cytokine synthesis

BiP = binding immunoglobulin protein; DAMP = damage-associated molecular pattern; IKK = I κ B kinase; NF- κ B, nuclear factor- κ B; TLR = toll-like receptor

receive their posttranslational modifications. Millimolar calcium concentrations are required to maintain the normal cellular protein folding capacity. Cellular stress decreases calcium concentration in the ER, disrupting the machinery required for this process and leading to the accumulation of misfolded or unfolded proteins. These occurrences are sensed by a highly conserved array of signaling proteins in the ER, including inositol requiring enzyme 1 (IRE1), protein kinase RNA (PKR)-like ER kinase (PERK), and activating transcription factor 6 (ATF6). Together, this complex generates the **unfolded protein response (UPR)**, a mechanism by which ER distress signals are sent to the nucleus to modulate transcription in an attempt to restore homeostasis. Prolongation of the UPR, indicative of irreversible cellular damage, can result in cell death. Genes activated in the UPR result not only in the inhibition of translation, but also other potentially immunomodulatory events including induction of the acute-phase response, activation of NF- κ B, and the generation of antibody-producing B cells.⁵⁸

Burn injury leads to the marked reduction in ER calcium levels and activation of UPR sensing proteins. Moreover, recent data in a series of burn patients strongly link the UPR to insulin resistance and hyperglycemia in these patients.⁵⁹ Thus, a better understanding of the UPR, which is triggered by severe inflammation, may allow the identification of novel therapeutic targets for injury-associated insulin resistance.

Autophagy

Under normal circumstances, cells need to have a way of disposing of damaged organelles and debris aggregates that are too large to be managed by proteasomal degradation. In order to accomplish this housekeeping task, cells use a process referred to as “macroautophagy” (**autophagy**), which is thought to have originated as a stress response.⁶⁰ The steps of autophagy include the engulfment of cytoplasm/organelle by an “isolation membrane,” which is also called a phagophore. The edges of the phagophore then fuse to form the autophagosome, a double-membraned vesicle that sequesters the cytoplasmic material and that is a characteristic feature of autophagy. The autophagosome then fuses with a lysosome to form an autolysosome where the

contents, together with the inner membrane, are degraded. This process is controlled by numerous autophagy-specific genes and by the specific kinase, mammalian target of rapamycin (mTOR).

As noted earlier, autophagy is a normal cellular process that occurs in quiescent cells for cellular maintenance. However, under conditions of hypoxia and low cellular energy, autophagy is induced in an attempt to provide additional nutrients for energy production. The induction of autophagy promotes a shift from aerobic respiration to glycolysis and allows cellular components of the autophagosome to be hydrolyzed to energy substrates. Increased levels of autophagy are typical in activated immune cells and are a mechanism for the disposal of ROS and phagocytosed debris.

Recent data support the idea that autophagy may also play an important role in the immune response.⁶¹ Autophagy is stimulated by Th1 cytokines and with activation of TLR in macrophages, but is inhibited by Th2 cytokines. It is also recognized as an important regulator of cytokine secretion, particularly those cytokines of the IL-1 family that are dependent on inflammasome processing for activation. For example, autophagosomes can sequester and degrade pro-IL-1 β and inflammasome components. In animal models of sepsis, inhibition of autophagy results in increased proinflammatory cytokine levels that correlate with increased mortality.⁶² These data suggest that autophagy is a protective mechanism whereby the cell can regulate the levels of cytokine production.

Apoptosis

Apoptosis (regulated cell death) is an energy-dependent, organized mechanism for clearing senescent or dysfunctional cells, including macrophages, neutrophils, and lymphocytes, without promoting an inflammatory response. This contrasts with cellular necrosis that results in disorganized intracellular molecule release with subsequent immune activation and inflammatory response. Systemic inflammation modulates apoptotic signaling in active immunocytes, which subsequently influences the inflammatory response through the loss of effector cells.

Apoptosis proceeds primarily through two pathways: the extrinsic pathway and the intrinsic pathway. The extrinsic

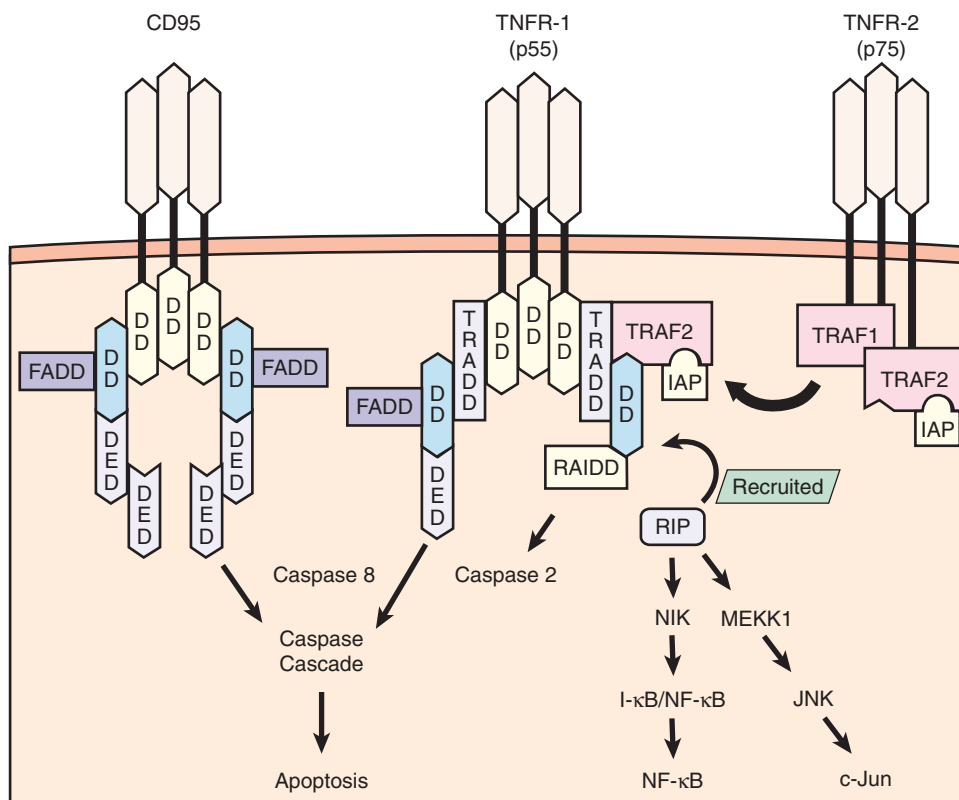


Figure 2-5. Signaling pathway for tumor necrosis factor receptor 1 (TNFR-1) (55 kDa) and TNFR-2 (75 kDa) occurs by the recruitment of several adapter proteins to the intracellular receptor complex. Optimal signaling activity requires receptor trimerization. TNFR-1 initially recruits TNFR-associated death domain (TRADD) and induces apoptosis through the actions of proteolytic enzymes known as *caspases*, a pathway shared by another receptor known as *CD95 (Fas)*. CD95 and TNFR-1 possess similar intracellular sequences known as *death domains (DDs)*, and both recruit the same adapter proteins known as *Fas-associated death domains (FADDs)* before activating caspase 8. TNFR-1 also induces apoptosis by activating caspase 2 through the recruitment of receptor-interacting protein (RIP). RIP also has a functional component that can initiate nuclear factor- κ B (NF- κ B) and c-Jun activation, both favoring cell survival and proinflammatory functions. TNFR-2 lacks a DD component but recruits adapter proteins known as TNFR-associated factors 1 and 2 (TRAF1, TRAF2) that interact with RIP to mediate NF- κ B and c-Jun activation. TRAF2 also recruits additional proteins that are antiapoptotic, known as inhibitor of apoptosis proteins (IAPs). DED = death effector domain; I- κ B = inhibitor of κ B; I- κ B/NF- κ B = inactive complex of NF- κ B that becomes activated when the I- κ B portion is cleaved; JNK = c-Jun N-terminal kinase; MEKK1 = mitogen-activated protein/extracellular regulatory protein kinase kinase kinase-1; NIK = NF- κ B-inducing kinase; RAIDD = RIP-associated interleukin-1 β -converting enzyme and ced-homologue-1-like protein with death domain, which activates proapoptotic caspases. (Adapted with permission from Lin E, Calvano SE, Lowry SF. Tumor necrosis factor receptors in systemic inflammation. In: Vincent J-L (series ed), Marshall JC, Cohen J, eds. Update in Intensive Care and Emergency Medicine: Vol. 31: Immune Response in Critical Illness. Berlin: Springer-Verlag; 2002:365. With kind permission from Springer Science + Business Media.)

pathway is activated through the binding of death receptors (e.g., Fas, TNFR), which leads to the recruitment of Fas-associated death domain protein and subsequent activation of caspase 3 (Fig. 2-5). On activation, caspases are the effectors of apoptotic signaling because they mediate the organized breakdown of nuclear DNA. The intrinsic pathway proceeds through protein mediators (e.g., Bcl-2, Bcl-2-associated death promoter, Bcl-2-associated X protein, Bim) that influence mitochondrial membrane permeability. Increased membrane permeability leads to the release of mitochondrial cytochrome C, which ultimately activates caspase 3 and thus induces apoptosis. These pathways do not function in a completely autonomous manner, because there is significant interaction and crosstalk between mediators of both extrinsic and intrinsic pathways. Apoptosis is modulated by several regulatory factors, including inhibitor of apoptosis proteins and regulatory caspases (e.g., caspases 1, 8, 10).

Apoptosis during sepsis may influence the ultimate competency of the acquired immune response. In a murine model of peritoneal sepsis, increased lymphocyte apoptosis was

associated with mortality, which may be due to a resultant decrease in IFN- γ release. In postmortem analysis of patients who expired from overwhelming sepsis, there was an increase in lymphocyte apoptosis, whereas macrophage apoptosis did not appear to be affected. Clinical trials have observed an association between the degree of lymphopenia and disease severity in sepsis. In addition, after the phagocytosis of apoptotic cells by macrophages, anti-inflammatory mediators such as IL-10 are released that may exacerbate immune suppression during sepsis. Neutrophil apoptosis is inhibited by inflammatory products, including TNF, IL-1, IL-3, IL-6, granulocyte-macrophage colony-stimulating factor (GM-CSF), and IFN- γ . This retardation in regulated cell death may prolong and exacerbate secondary injury through neutrophil free radical release as the clearance of senescent cells is delayed.⁶³

Necroptosis

Cellular necrosis refers to the premature uncontrolled death of cells in living tissue typically caused by accidental exposure

to external factors, such as ischemia, inflammation, or trauma, which result in extreme cellular stress. Necrosis is characterized by the loss of plasma membrane integrity and cellular collapse with extrusion of cytoplasmic contents, but the cell nuclei typically remain intact. Recent data have defined a process by which necrosis occurs through a series of well-described steps that are dependent on a signaling pathway that involves the receptor-interacting protein kinase (RIPK) complex. Termed “necroptosis,” it occurs in response to specific stimuli, such as TNF- and TLR-mediated signals.⁶⁴ For example, ligation of the TNF receptor 1 (TNFR1) under conditions in which caspase 8 is inactivated (e.g., by pharmacologic agents) results in the over-generation of ROS and a metabolic collapse. The net result is programmed necrosis (necroptosis). The effect of cell death by necroptosis on the immune response is not yet known. However, it is likely that the “DAMP” signature that occurs in response to necroptotic cell death is an important contributor to the systemic inflammatory response. Evidence to support this concept was provided by investigators who examined the role of necroptosis in murine models of sepsis. They demonstrated that *Ripk3*^{-/-} mice were capable of recovering body temperature better, exhibited lower circulating DAMP levels, and survived at higher rates than their wild-type littermates.⁶⁵ These data suggest that the cellular damage that occurs with programmed necrosis exacerbates the sepsis-associated systemic inflammatory response.

MEDIATORS OF INFLAMMATION

Cytokines

Cytokines are a class of protein signaling compounds that are essential for both innate and adaptive immune responses. Cytokines mediate a broad sequence of cellular responses, including cell migration, DNA replication, cell turnover, and immunocyte proliferation (Table 2-5). When functioning locally at the site of injury and infection, cytokines mediate the eradication of invading microorganisms and also promote wound healing. However, an exaggerated proinflammatory cytokine response to inflammatory stimuli may result in hemodynamic instability (i.e., septic shock) and metabolic derangements (i.e., muscle wasting). Anti-inflammatory cytokines also are released, at least in part, as an opposing influence to the proinflammatory cascade. These anti-inflammatory mediators may also result in immunocyte dysfunction and host immunosuppression. Cytokine signaling after an inflammatory stimulus can best be represented as a finely tuned balance of opposing influences and should not be oversimplified as a “black and white” proinflammatory/anti-inflammatory response. A brief discussion of the important cytokine molecules is included.

Tumor Necrosis Factor- α . TNF- α is a cytokine that is rapidly mobilized in response to stressors such as injury and infection and is a potent mediator of the subsequent inflammatory response. TNF is primarily synthesized by immune cells, such as macrophages, dendritic cells, and T lymphocytes, but nonimmune cells have also been reported to secrete low amounts of the cytokine.

TNF is generated in a precursor form called transmembrane TNF that is expressed as a trimer on the surface of activated cells. After being processed by the metalloproteinase TNF- α -converting enzyme (TACE; also known as ADAM-17), a smaller, soluble form of TNF is released, which mediates its biologic activities through type 1 and 2 TNF receptors

(TNFR1; TNFR2).⁶⁶ Transmembrane TNF- α also binds to TNFR1 and TNFR2, but its biologic activities are likely mediated through TNFR2. While the two receptors share homology in their ligand binding regions, there are distinct differences that regulate their biologic function. For example, TNFR1 is expressed by a wide variety of cells but is typically sequestered in the Golgi complex. Following appropriate cell signaling, TNFR1 is mobilized to the cell surface, where it sensitizes cells to TNF, or it can be cleaved from the surface in the form of a soluble receptor that can neutralize TNF.⁶⁷ In contrast, TNFR2 expression is confined principally to immune cells where it resides in the plasma membrane. Both TNF receptors are capable of binding intracellular adaptor proteins that lead to activation of complex signaling processes and mediate the effects of TNF.

Although the circulating half-life of soluble TNF is brief, it acts upon almost every differentiated cell type, eliciting a wide range of important cellular responses. In particular, TNF elicits many metabolic and immunomodulatory activities. It stimulates muscle breakdown and cachexia through increased catabolism, insulin resistance, and redistribution of amino acids to hepatic circulation as fuel substrates. TNF also mediates coagulation activation, cell migration, and macrophage phagocytosis, and enhances the expression of adhesion molecules, prostaglandin E₂, platelet-activating factor, glucocorticoids, and eicosanoids. Recent studies indicate that a significant early TNF response after trauma may be associated with improved survival in these patients.⁶⁸

Interleukin-1. IL-1 α and IL-1 β , which are encoded by two distinct IL-1 genes, were the first described members of the IL-1 cytokine family. Currently, the family has expanded to 11 members, with the three major forms being IL-1 α , IL-1 β , and IL-1 receptor antagonist (IL-1R α). IL-1 α and IL-1 β share similar biologic functions, but have limited sequence homology. They use the same cell surface receptor, termed IL-1 receptor type 1 (IL-1R1), which is present on nearly all cells. Although IL-1R α is synthesized and released in response to the same stimuli that lead to IL-1 production, it lacks the necessary domain to form a bioactive complex with the IL-1 receptor when bound. Thus, IL-1R α serves as a competitive antagonist for the receptor. IL-1R activation initiates signaling events, which result in the synthesis and release of a variety of inflammatory mediators.

The IL-1 α precursor is constitutively expressed and stored in a variety of healthy cells, including epithelium, endothelium, and platelets. Both the precursor and mature forms of IL-1 α are active. With appropriate signals, IL-1 α moves to the cell membrane where it can act on adjacent cells bearing the IL-1 receptor. It can also be released directly from injured cells. In this way, IL-1 α is believed to function as a DAMP, which promotes the synthesis of inflammatory mediators, such as chemokines and eicosanoids. These mediators attract neutrophils to the injured site, facilitate their exit from the vasculature, and promote their activation. Once they have reached their target, neutrophil lifespan is extended by the presence of IL-1 α .⁶⁹

IL-1 β , a multifunctional proinflammatory cytokine, is not detectable in healthy cells. Rather, its expression and synthesis occur in a more limited number of cells, such as monocytes, tissue macrophages, and dendritic cells, following their activation. IL-1 β expression is tightly regulated at multiple levels (e.g., transcription, translation, and secretion), although the rate-limiting step is its transcription. IL-1 β is synthesized and released in response to inflammatory stimuli, including cytokines

Table 2-5

Cytokines and their sources

CYTOKINE	SOURCE	COMMENT
TNF	<i>Macrophages/monocytes</i> Kupffer cells Neutrophils NK cells Astrocytes Endothelial cells T lymphocytes Adrenal cortical cells Adipocytes Keratinocytes Osteoblasts Mast cells Dendritic cells	Among earliest responders after injury; half-life <20 min; activates TNF receptors 1 and 2; induces significant shock and catabolism
IL-1	<i>Macrophages/monocytes</i> B and T lymphocytes NK cells Endothelial cells Epithelial cells Keratinocytes Fibroblasts Osteoblasts Dendritic cells Astrocytes Adrenal cortical cells Megakaryocytes Platelets Neutrophils Neuronal cells	Two forms (IL-1 α and IL-1 β); similar physiologic effects as TNF; induces fevers through prostaglandin activity in anterior hypothalamus; promotes β -endorphin release from pituitary; half-life <6 min
IL-2	<i>T lymphocytes</i>	Promotes lymphocyte proliferation, immunoglobulin production, gut barrier integrity; half-life <10 min; attenuated production after major blood loss leads to immunocompromise; regulates lymphocyte apoptosis
IL-3	<i>T lymphocytes</i> Macrophages Eosinophils Mast cells	
IL-4	<i>T lymphocytes</i> Mast cells Basophils Macrophages B lymphocytes Eosinophils Stromal cells	Induces B-lymphocyte production of IgG4 and IgE, mediators of allergic and anthelmintic response; downregulates TNF, IL-1, IL-6, IL-8
IL-5	<i>T lymphocytes</i> Eosinophils Mast cells Basophils	Promotes eosinophil proliferation and airway inflammation
IL-6	<i>Macrophages</i> B lymphocytes Neutrophils Basophils Mast cells Fibroblasts Endothelial cells Astrocytes	Elicited by virtually all immunogenic cells; long half-life; circulating levels proportional to injury severity; prolongs activated neutrophil survival

(Continued)

Table 2-5

Cytokines and their sources (continued)

CYTOKINE	SOURCE	COMMENT
	Synovial cells Adipocytes Osteoblasts Megakaryocytes Chromaffin cells Keratinocytes	
IL-8	<i>Macrophages/monocytes</i> T lymphocytes Basophils Mast cells Epithelial cells Platelets	Chemoattractant for neutrophils, basophils, eosinophils, lymphocytes
IL-10	<i>T lymphocytes</i> B lymphocytes Macrophages Basophils Mast cells Keratinocytes	Prominent anti-inflammatory cytokine; reduces mortality in animal sepsis and ARDS models
IL-12	<i>Macrophages/monocytes</i> Neutrophils Keratinocytes Dendritic cells B lymphocytes	Promotes Th1 differentiation; synergistic activity with IL-2
IL-13	<i>T lymphocytes</i>	Promotes B-lymphocyte function; structurally similar to IL-4; inhibits nitric oxide and endothelial activation
IL-15	<i>Macrophages/monocytes</i> Epithelial cells	Anti-inflammatory effect; promotes lymphocyte activation; promotes neutrophil phagocytosis in fungal infections
IL-18	<i>Macrophages</i> Kupffer cells Keratinocytes Adrenal cortical cells Osteoblasts	Similar to IL-12 in function; levels elevated in sepsis, particularly gram-positive infections; high levels found in cardiac deaths
IFN- γ	<i>T lymphocytes</i> NK cells Macrophages	Mediates IL-12 and IL-18 function; half-life of days; found in wounds 5–7 d after injury; promotes ARDS
GM-CSF	<i>T lymphocytes</i> Fibroblasts Endothelial cells Stromal cells	Promotes wound healing and inflammation through activation of leukocytes
IL-21	<i>T lymphocytes</i>	Preferentially secreted by Th2 cells; structurally similar to IL-2 and IL-15; activates NK cells, B and T lymphocytes; influences adaptive immunity
HMGB1	<i>Monocytes/lymphocytes</i>	High mobility group box chromosomal protein; DNA transcription factor; late (downstream) mediator of inflammation (ARDS, gut barrier disruption); induces “sickness behavior”

ARDS = acute respiratory distress syndrome; GM-CSF = granulocyte-macrophage colony-stimulating factor; IFN = interferon; Ig = immunoglobulin; IL = interleukin; NK = natural killer; Th1 = helper T cell subtype 1; Th2 = helper T cell subtype 2; TNF = tumor necrosis factor.

(TNF, IL-18) and foreign pathogens. IL-1 α or IL-1 β itself can also induce IL-1 β transcription. In contrast to IL-1 α , IL-1 β is synthesized as an inactive precursor molecule. The formation of mature IL-1 β requires the assembly of the inflammasome complex by the cell and the activation of caspase 1, which is required for the processing of stored pro-IL-1 β . Mature IL-1 β

is then released from the cell via an unconventional secretory pathway. IL-1 β has a spectrum of proinflammatory effects that are largely similar to those induced by TNF, and injection of IL-1 β alone is sufficient to induce inflammation. High doses of either IL-1 β or TNF are associated with profound hemodynamic compromise. Interestingly, low doses of both IL-1 β and TNF

combined elicit hemodynamic events similar to those elicited by high doses of either mediator, which suggests a synergistic effect.

There are two primary receptor types for IL-1: IL-1R1 and IL-1R2. IL-1R1 is widely expressed and mediates inflammatory signaling on ligand binding. IL-1R2 is proteolytically cleaved from the membrane surface to soluble form on activation and thus serves as another mechanism for competition and regulation of IL-1 activity. IL-1 α or IL-1 β binds first to IL-1R1. This is followed by recruitment of a transmembrane coreceptor, termed the IL-1R accessory protein (IL-1RAcP). A complex is formed of IL-1R1 plus IL-1 plus the coreceptor. The signal is initiated with recruitment of the adaptor protein MyD88 to the toll-IL-1 receptor (TIR) domains of the receptor complex and signal transduction then occurs via intermediates, which are homologous to the signal cascade initiated by TLRs. These events culminate in the activation of NF- κ B and its nuclear translocation.⁷⁰

Interleukin-2. IL-2 is a multifunctional cytokine produced primarily by CD4⁺ T cells after antigen activation, which plays a pivotal role in the immune response. Other cellular sources for IL-2 include CD8⁺ and NK T cells, mast cells, and activated dendritic cells. Discovered as a T-cell growth factor, IL-2 also promotes CD8⁺ T-cell and NK cell cytolytic activity and modulates T-cell differentiation programs in response to antigen. Thus, IL-2 promotes naïve CD4⁺ T-cell differentiation into T helper 1 (Th1) and T helper 2 (Th2) cells while inhibiting T helper 17 (Th17) and T follicular helper (Tfh) cell differentiation. Moreover, IL-2 is essential for the development and maintenance of T regulatory (Treg) cells and for activation-induced cell death, thereby mediating tolerance and limiting inappropriate immune reactions. The upregulation of IL-2 requires calcium as well as protein kinase C signaling, which leads to the activation of transcription factors such as nuclear factor of activated T cells (NFAT) and NF- κ B. MicroRNAs also play a role in the regulation of IL-2 expression.⁷¹

IL-2 binds to IL-2 receptors (IL-2R), which are expressed on leukocytes. IL-2Rs are formed from various combinations of three receptor subunits: IL-2R α , IL-2R β , and IL-2R γ ; these form low-, medium-, and high-affinity forms of the receptor depending on the subunit combination. IL-2R γ has been renamed the common cytokine receptor γ chain (γ_c), which is now known to be shared by IL-2, IL-4, IL-7, IL-9, IL-15, and IL-21. Constitutive IL-2 receptor expression is low and is inducible by T-cell receptor ligation and cytokine stimulation. Importantly, the transcription of each receptor subunit is individually regulated via a complex process to effect tight control of surface expression. Once the receptor is ligated, the major IL-2 signaling pathways that are engaged include Janus kinase (JAK) signal transducer and activator of transcription (STAT), Shc-Ras-MAPK, and phosphoinositol-3-kinase (PI3K)-AKT. Partly due to its short half-life of <10 minutes, IL-2 is not readily detectable after acute injury. IL-2 receptor blockade induces immunosuppressive effects and can be pharmacologically used for organ transplantation. Attenuated IL-2 expression observed during major injury or blood transfusion may contribute to the relatively immunosuppressed state of the surgical patient.⁷²

Interleukin-6. Following burn or traumatic injury, DAMPs from damaged or dying cells stimulate TLRs to produce IL-6, a pleiotropic cytokine that plays a central role in host defense. IL-6 levels in the circulation are detectable by 60 minutes, peak

between 4 and 6 hours, and can persist for as long as 10 days. Further, plasma levels of IL-6 are proportional to the degree of injury. In the liver, IL-6 strongly induces a broad spectrum of acute-phase proteins such as CRP and fibrinogen, among others, whereas it reduces expression of albumin, cytochrome P450, and transferrin. In lymphocytes, IL-6 induces B-cell maturation into immunoglobulin-producing cells and regulates Th17/Treg balance. IL-6 modulates T-cell behavior by inducing the development of Th17 cells and inhibiting Treg cell differentiation in conjunction with transforming growth factor- β . IL-6 also promotes angiogenesis and increased vascular permeability, which are associated with local inflammatory responses. To date, 10 IL-6 family cytokines have been identified, including IL-6, oncostatin M, neuropoietin, IL-11, IL-27, and IL-31, all of which use trans signaling.⁷³

The IL-6 receptor (IL-6R, gp80) is expressed on hepatocytes, monocytes, B cells, and neutrophils in humans. However, many other cells respond to IL-6 through a process known as trans signaling.⁷⁴ In this case, soluble IL-6Rs (sIL-6R) exist in the serum and bind to IL-6, forming an IL-6/sIL-6R complex. The soluble receptor is produced by proteolytic cleavage from the surface of neutrophils in a process that is stimulated by CRP, complement factors, and leukotrienes. The IL-6/sIL-6R complex can then bind to the gp130 receptor, which is expressed ubiquitously on cells. Upon IL-6 stimulation, gp130 transduces two major signaling pathways: the JAK-STAT3 pathway and the SHP2-Gab-Ras-Erk-MAPK pathway, which is regulated by cytoplasmic suppressor of cytokine signaling (SOCS3). These signaling events can lead to increased expression of adhesion molecules as well as proinflammatory chemokines and cytokines. High plasma IL-6 levels have been associated with mortality during intra-abdominal sepsis.⁷⁵

Interleukin-10. We have talked almost exclusively about the factors that initiate the inflammatory response following cellular stress or injury. The re-establishment of immune homeostasis following these events requires the resolution of inflammation and the initiation of tissue repair processes. IL-10 plays a central role in this anti-inflammatory response by regulating the duration and magnitude of inflammation in the host.

The IL-10 family currently has six members including IL-10, IL-19, IL-20, IL-22, IL-24, and IL-26. IL-10 is produced by a variety of immune cells of both myeloid and lymphoid origin. Its synthesis is upregulated during times of stress and systemic inflammation; however, each cell type that produces IL-10 does so in response to different stimuli, allowing for tight control of its expression. IL-10 exerts effects by binding to the IL-10 receptor (IL-10R), which is a tetramer formed from two distinct subunits, IL-10R1 and IL-10R2. Specifically, IL-10 binds first to the IL-10R1 subunit, which then recruits IL-10R2, allowing the receptor complex to form. Whereas IL-10R2 is widely expressed, IL-10R1 expression is confined to leukocytes so that this differential expression of the receptor confines the effects of IL-10 to the immune system. Once receptor ligation occurs, signaling proceeds by the activation of JAK1 and STAT3. In particular, STAT3 in conjunction with IL-10 is absolutely required for the transcription of genes responsible for the anti-inflammatory response. IL-10 inhibits the secretion of proinflammatory cytokines, including TNF and IL-1, partly through the downregulation of NF- κ B, and thereby functions as a negative feedback regulator of the inflammatory cascade.⁷⁶ In macrophages, IL-10 suppresses the transcription of 20% of all lipopolysaccharide (LPS)-induced genes. Further, experimental

models of inflammation have shown that neutralization of IL-10 increases TNF production and mortality, whereas restitution of circulating IL-10 reduces TNF levels and subsequent deleterious effects. Increased plasma levels of IL-10 also have been associated with mortality and disease severity after traumatic injury. IL-10 may significantly contribute to the underlying immunosuppressed state during sepsis through the inhibition and subsequent anergy of immunocytes. For example, IL-10 produced by Th2 cells directly suppresses Th1 cells and can feedback to suppress Th2 cell activity.⁷⁷

Interleukin-12. IL-12 is unique among the cytokines in being the only heterodimeric cytokine. This family, which includes IL-12, IL-23, IL-27, and IL-35, consists of an α -chain that is structurally similar to the IL-6 cytokine and a β -chain that is similar to the class I receptor for cytokines. The individual IL-12 family members are formed from various combinations of the α and β subunits. Despite the sharing of individual subunits and the similarities of their receptors, the IL-12 cytokines have different biologic functions. IL-12 and IL-23 are considered proinflammatory, stimulatory cytokines with key roles in the development of Th1 and Th17 subsets of helper T cells. In contrast, both IL-27 and IL-35 appear to have immunoregulatory functions that are associated with cytokine inhibition in specific Treg cell populations, particularly the Th17 cells.⁷⁸ The effects of these cytokines require specific receptor chains that are also shared among the cytokines. The complexity of signaling is evidenced by the fact that these receptor chains can function both as dimers and as monomers. Ligation of the IL-12 receptors initiates signaling events mediated by the JAK-STAT pathway. IL-12 synthesis and release are increased during endotoxemia and sepsis.⁷⁹ IL-12 stimulates lymphocytes to increase secretion of IFN- γ with the costimulus of IL-18 and also stimulates NK cell cytotoxicity and helper T-cell differentiation in this setting. IL-12 release is inhibited by IL-10. IL-12 deficiency inhibits phagocytosis in neutrophils. In experimental models of inflammatory stress, IL-12 neutralization conferred a mortality benefit in mice during endotoxemia. However, in a cecal ligation and puncture model of intraperitoneal sepsis, IL-12 blockade was associated with increased mortality. Furthermore, later studies of intraperitoneal sepsis observed no difference in mortality with IL-12 administration; however, IL-12 knockout mice exhibited increased bacterial counts and inflammatory cytokine release, which suggests that IL-12 may contribute to an antibacterial response. IL-12 administration in chimpanzees is capable of stimulating the release of proinflammatory mediators such as IFN- γ and also anti-inflammatory mediators, including IL-10, soluble TNFR, and IL-1 receptor antagonists. In addition, IL-12 enhances coagulation as well as fibrinolysis.

Interleukin-18. IL-18 is a member of the IL-1 superfamily of cytokines. First noted as an IFN- γ -inducing factor produced by LPS-stimulated macrophages, IL-18 expression is found both in immune cells and nonimmune cells at low to intermediate levels. However, activated macrophages and Kupffer cells produce large amounts of mature IL-18. Similar to IL-1 β , IL-18 is synthesized and stored as an inactive precursor form (pro-IL-18), and activation requires processing by caspase 1 in response to the appropriate signaling. It then exits the cell through a nontraditional secretory pathway. The IL-18 receptor (IL-18R) is composed of two subunits, IL-18R α and IL-18R β , and is a member of the IL-1R superfamily, which is structurally similar in its cytoplasmic domains to the TLR.

One unique biologic property of IL-18 is the potential, in conjunction with IL-12, to promote the Th1 response to bacterial infection. At the same time, exogenous IL-18 can also enhance the Th2 response and Ig-mediated humoral immunity, as well as augment neutrophil function. Recent studies suggest that IL-18 therapy may hold promise as effective therapy in promoting immune recovery after severe surgical stress.⁸⁰

Interferons. Interferons were first recognized as soluble mediators that inhibited viral replication through the activation of specific antiviral genes in infected cells. Interferons are categorized into three types based on receptor specificity and sequence homology. The two major types, type I and type II, are discussed here.

Type I interferons, of which there are 20, include IFN- α , IFN- β , and IFN- ω , which are structurally related and bind to a common receptor, IFN- α receptor. They are likely produced by most cell types and tissues in response to appropriate pathogens or DAMP signaling. Type I interferons are expressed in response to many stimuli, including viral antigens, double-stranded DNA, bacteria, tumor cells, and LPS. Type I interferons influence adaptive immune responses by inducing the maturation of dendritic cells and by stimulating class I major histocompatibility complex (MHC) expression. IFN- α and IFN- β also enhance immune responses by increasing the cytotoxicity of NK cells both in culture and in vivo. Further, they have been implicated in the enhancement of chemokine synthesis, particularly those that recruit myeloid cells and lymphoid cells. Thus, IFN/STAT signaling has important effects on the mobilization, tissue recruitment, and activation of immune cells that compose the inflammatory infiltrate. In contrast, IFN-I appears to inhibit inflammasome activity, possibly via IL-10.⁸¹

Many of the physiologic effects observed with increased levels of IL-12 and IL-18 are mediated through IFN- γ . IFN- γ is a type II interferon that is secreted by various T cells, NK cells, and antigen-presenting cells in response to bacterial antigens, IL-2, IL-12, and IL-18. IFN- γ stimulates the release of IL-12 and IL-18. Negative regulators of IFN- γ include IL-4, IL-10, and glucocorticoids. IFN- γ binding with a cognate receptor activates the JAK-STAT pathway, leading to subsequent induction of biologic responses. Macrophages stimulated by IFN- γ demonstrate enhanced phagocytosis and microbial killing and increased release of oxygen radicals, partly through an NADP-dependent phagocyte oxidase. IFN- γ mediates macrophage stimulation and thus may contribute to acute lung injury after major surgery or trauma. Diminished IFN- γ level, as seen in knockout mice, is associated with increased susceptibility to both viral and bacterial pathogens. In addition, IFN- γ promotes differentiation of T cells to the helper T-cell subtype 1 and also enhances B-cell isotype switching to immunoglobulin G.⁸²

Receptors of all IFN subtypes belong to the class II of cytokine receptors and use the JAK-STAT signaling pathway for nuclear signaling, although different STAT activation (e.g., STAT1 and STAT2) is favored by individual receptors.

Granulocyte-Macrophage Colony-Stimulating Factor/Interleukin-3/Interleukin-5. GM-CSF, IL-3, and IL-5 compose a small family of cytokines that regulate the growth and activation of immune cells. They are largely the products of activated T cells, which when released stimulate the behavior of myeloid cells by inducing cytokine expression and antigen presentation. In this way, GM-CSF, IL-3, and IL-5 are able to link the innate and acquired immune responses. With the exception

of eosinophils, GM-CSF, IL-3, and IL-5 are not essential for constitutive hematopoietic cell function. Rather, they play an important role when the host is stressed, by serving to increase the numbers of activated and sensitized cells required to bolster host defense.⁸³ Currently, GM-CSF is in clinical trials for administration to children with an Injury Severity Score >10 following blunt or penetrating trauma. The goal of the study is to provide evidence of the effectiveness of GM-CSF as an agent that can ameliorate posttraumatic immune suppression.

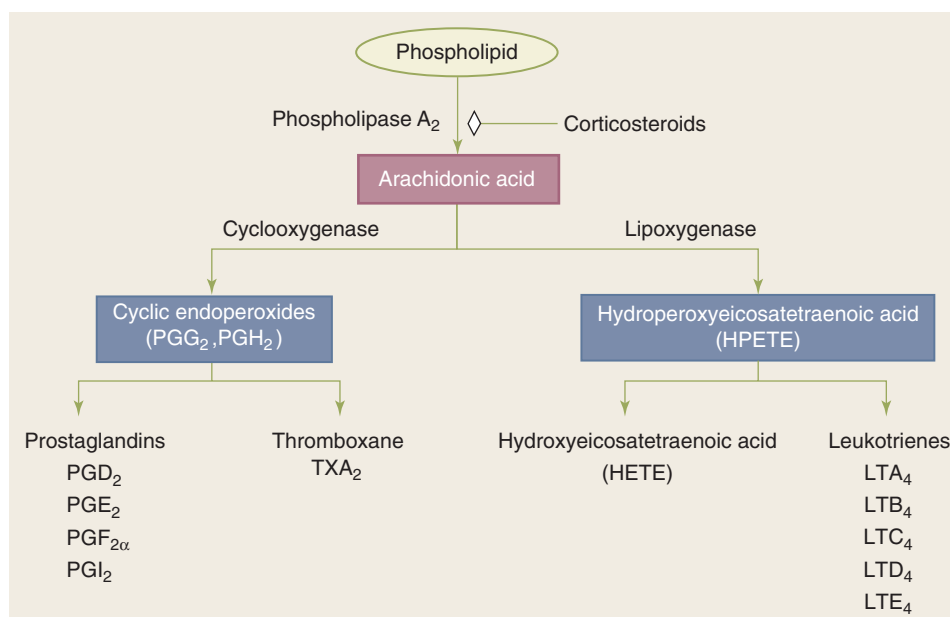
Receptors for the GM-CSF/IL-3/IL-5 family of cytokines are expressed at very low levels on hematopoietic cells. Similar to the other cytokine receptors discussed, they are heterodimers composed of a cytokine-specific α subunit and a common β subunit (β_c), which is shared by all three receptors and is required for high-affinity signal transduction. The binding of cytokine to its receptor activates JAK2-STAT-, MAPK-, and PI3K-mediated signaling events to regulate a variety of important cell behaviors including effector function in mature cells.

Eicosanoids

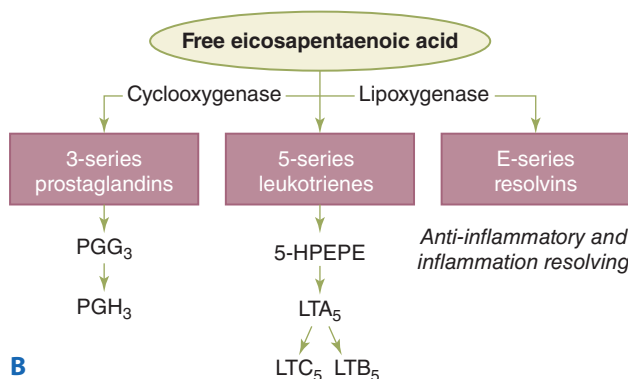
Omega-6 Polyunsaturated Fat Metabolites: Arachidonic Acid. Eicosanoids are derived primarily by oxidation of the membrane phospholipid, **arachidonic acid** [all-*cis*-5,8,11,14-eicosatetraenoic acid; 20:4(ω -6) eicosatetraenoic acid], which

is relatively abundant in the membrane lipids of inflammatory cells. They are composed of three families, which include prostaglandins, thromboxanes, and leukotrienes. Arachidonic acid is not stored free in the cell but in an esterified form in phospholipids and neutral lipids. When a cell senses the proper stimulus, arachidonic acid is released from phospholipids or diacylglycerols by the enzymatic activation of phospholipase A₂ (Fig. 2-6A). Prostanoids, which include all of the prostaglandins and the thromboxanes, result from the sequential action of the cyclooxygenase (COX) enzyme and terminal synthetases on arachidonic acid. In contrast, arachidonic acid may be oxidized along the lipoxygenase pathway via the central enzyme 5-lipoxygenase, to produce several classes of leukotrienes and lipoxins. In general, the effects of eicosanoids are mediated via specific receptors, which are members of a superfamily of G-protein-coupled receptors.

Eicosanoids are not stored within cells but are instead generated rapidly in response to many stimuli, including hypoxic injury, direct tissue injury, endotoxin (lipopolysaccharide), NE, vasopressin, angiotensin II, bradykinin, serotonin, ACh, cytokines, and histamine. Eicosanoid pathway activation also leads to the formation of the anti-inflammatory compound lipoxin, which inhibits chemotaxis and NF- κ B activation. Glucocorticoids, nonsteroidal anti-inflammatory drugs, and leukotriene



A



B

Figure 2-6. Schematic diagram of (A) arachidonic acid and (B) eicosapentaenoic acid metabolism. LT = leukotriene; PG = prostaglandin; TXA₂ = thromboxane A₂; HPEPE = hydroperoxyeicosapentaenoic acid.

inhibitors block the end products of eicosanoid pathways. Eicosanoids have a broad range of physiologic roles, including neurotransmission and vasomotor regulation. They are also involved in immune cell regulation (Table 2-6) by modulating the intensity and duration of inflammatory responses. The production of eicosanoids is cell- and stimulus-specific. Therefore, the signaling events that are initiated will depend on the concentrations and types of eicosanoids generated, as well as the unique complement of receptors expressed by their target cells. For example, prostaglandin E_2 (PGE_2) suppresses the effector function of macrophages (i.e., phagocytosis and intracellular pathogen killing) via a mechanism that is dependent on increased cAMP levels. PGE_2 also modulates chemokine

TABLE 2-6

Systemic stimulatory and inhibitory actions of eicosanoids

ORGAN/FUNCTION	STIMULATOR	INHIBITOR
<i>Pancreas</i>		
Glucose-stimulated insulin secretion	12-HPETE	PGE_2
Glucagon secretion	PGD_2 , PGE_2	
<i>Liver</i>		
Glucagon-stimulated glucose production		PGE_2
<i>Fat</i>		
Hormone-stimulated lipolysis		PGE_2
<i>Bone</i>		
Resorption	PGE_2 , PGE -m, 6-K- PGE_1 , $PGF_{1\alpha}$, PGI_2	
<i>Pituitary</i>		
Prolactin	PGE_1	
Luteinizing hormone	PGE_1 , PGE_2 , 5-HETE	
Thyroid-stimulating hormone	PGA_1 , PGB_1 , PGE_1 , PGE_1	
Growth hormone	PGE_1	
<i>Parathyroid</i>		
Parathyroid hormone	PGE_2	PGF_2
<i>Lung</i>		
Bronchoconstriction	$PGF_{2\alpha}$, TXA_2 , LTC_4 , LTD_4 , LTE_4	PGE_2
<i>Kidney</i>		
Stimulation of renin secretion	PGE_2 , PGI_2	
<i>Gastrointestinal system</i>		
Cytoprotective effect	PGE_2	
<i>Immune response</i>		
Suppression of lymphocyte activity	PGE_2	
<i>Hematologic system</i>		
Platelet aggregation	TXA_2	PGI_2

5-HETE = 5-hydroxyeicosatetraenoic acid; 12-HPETE = 12-hydroxyperoxyeicosatetraenoic acid; 6-K- PGE_1 = 6-keto-prostaglandin E_1 ; LT = leukotriene; PG = prostaglandin; PGE -m = 13,14-dihydro-15-keto- PGE_2 (major urine metabolite of PGE_2); TXA_2 = thromboxane A_2 .

production and enhances local accumulation of regulatory T cells and myeloid-derived suppressor cells. Prostacyclin (PGI_2) has an inhibitory effect on Th1- and Th2-mediated immune responses, while enhancing Th17 differentiation and cytokine production. Leukotrienes are potent mediators of capillary leakage as well as leukocyte adherence, neutrophil activation, bronchoconstriction, and vasoconstriction. Leukotriene B_4 is synthesized from arachidonic acid in response to acute Ca^{2+} signaling induced by inflammatory mediators.⁸⁴ High-affinity leukotriene receptors (BLT1) are expressed primarily in leukocytes, including granulocytes, eosinophils, macrophages, and differentiated T cells, whereas the low-affinity receptor is expressed in many cell types. Activation of BLT1 results in inhibition of adenylate cyclase and reduced production of cAMP. Not surprisingly, a role for leukotriene B_4 signaling in abrogating the effects of prostaglandins on macrophage effector function has recently been shown.⁸⁵

Recent evidence supports a role for **lipid droplets** (LDs) as an important intracellular source of arachidonic acid. LDs are neutral lipid storage organelles ubiquitous to eukaryotic cells that are a rich source of esterified arachidonic acid especially in leukocytes. Accumulation of LDs in response to TLR signaling has been reported with an associated increase in the generation of eicosanoid metabolites.⁸⁶

While experimental models of sepsis have shown a benefit to inhibiting eicosanoid production, human sepsis trials have failed to show a mortality benefit.⁸⁷ Eicosanoids also have several recognized metabolic effects. COX pathway products inhibit pancreatic β -cell release of insulin, whereas lipoxygenase pathway products stimulate β -cell activity. Prostaglandins such as PGE_2 can inhibit gluconeogenesis through the binding of hepatic receptors and also can inhibit hormone-stimulated lipolysis.⁸⁸

Omega-3 Polyunsaturated Fat Metabolites: All-*cis*-5,8,11,14,17-Eicosapentaenoic Acid [20:5(ω -3) Eicosapentaenoic Acid]. As noted earlier, polyunsaturated fatty acid (PUFA) metabolites of endogenous arachidonic acid function as inflammatory mediators and have significant roles in the inflammatory response. The major direct dietary source of arachidonic acid is from meat. However, a much larger quantity of ω -6 PUFAs is ingested as linoleic acid, which is found in many vegetable oils, including corn, sunflower, and soybean oils, and in products made from such oils, such as margarines. Linolenic acid is not synthesized in mammals; however, it can be converted to arachidonic acid through lengthening of the carbon chain and the addition of double bonds. The second major family of PUFAs is the ω -3 fatty acid. They can also be derived from shorter chain ω -3 fatty acids of plant origin such as α -linolenic acid, which can be converted after ingestion to eicosapentaenoic acid (EPA) and to docosahexaenoic acid (DHA). ω -3 fatty acids are found in cold water fish, especially tuna, salmon, mackerel, herring, and sardine, which can provide between 1.5 and 3.5 g of these long-chain ω -3 PUFAs per serving. EPA and DHA are also substrates for the COX and lipoxygenase (LOX) enzymes that produce eicosanoids, but the mediators produced have a different structure from the arachidonic acid-derived mediators, and this influences their potency (Fig. 2-6B). In addition, ω -3 fatty acids are reported to have specific anti-inflammatory effects, including inhibition of NF- κ B activity, TNF release from hepatic Kupffer cells, and leukocyte adhesion and migration. These are achieved via two purported mechanisms: (a) by decreasing the production of arachidonic

acid (ω -6)–derived proinflammatory mediators (by competition for the same enzymes) and (b) by generation of proresolving bioactive lipid mediators. In fact, key derivatives of ω -3 PUFAs, termed resolvins, have been identified and synthesized. Resolvins are now categorized as either E-series (from EPA) or D-series (from DHA). In a variety of model systems, resolvins have been shown to attenuate the inflammatory phenotypes of a number of immune cells.⁸⁹

The ratio of dietary ω -6 to ω -3 PUFAs is reflected in the membrane composition of various cells, including cells of the immune system, which has potential implications for the inflammatory response. For example, a diet that is rich in ω -6 PUFAs will result in cells whose membranes are “ ω -6 PUFA rich.” When ω -6 PUFAs are the main plasma membrane lipid available for phospholipase activity, more proinflammatory PUFAs (i.e., two-series prostaglandins) are generated. Many lipid preparations are soy-based and thus primarily composed of ω -6 fatty acids. These are thought to be “inflammation enhancing.” Nutritional supplementation with ω -3 fatty acid has the potential to dampen inflammation by shifting the cell membrane composition in favor of ω -3 PUFAs.

In experimental models of sepsis, ω -3 fatty acids inhibit inflammation, ameliorate weight loss, increase small-bowel perfusion, and may increase gut barrier protection. In human studies, ω -3 supplementation is associated with decreased production of TNF, IL-1 β , and IL-6 by endotoxin-stimulated monocytes. In a study of surgical patients, preoperative supplementation with ω -3 fatty acid was associated with reduced need for mechanical ventilation, decreased hospital length of stay, and decreased mortality with a good safety profile.⁹⁰

Plasma Contact System

Complement. Following traumatic injury, there is almost immediate activation of the complement system, which is a major effector mechanism of the innate immune system. The complement system was thought to act initially as the required “first line of defense” for the host against pathogens, by binding and clearing them from the circulation. Recent data indicate that complement also participates in the elimination of immune complexes as well as damaged and dead cells. In addition, complement is recognized as contributing to mobilization of hematopoietic stem/progenitor cells and lipid metabolism.⁹¹ Although complement activation is typically depicted as a linear process in which parallel pathways are activated, it actually functions more like a central node that is tightly networked with other systems. Then, depending on the activating signal, several initiation and regulatory events act in concert to heighten immune surveillance.

Complement activation proceeds via three different pathways. Initiation of these pathways occurs by the binding and activation of the recognition unit of each pathway to its designated ligand. The classical pathway, which is often referred to as “antibody dependent,” is initiated by direct binding of C1q to its common ligands, which include immunoglobulin (Ig) M/IgG aggregates. Alternately C1q can activate complement signaling by binding to soluble pattern recognition molecules such as pentraxins (e.g., CRP). In a series of subsequent activation and amplification steps, the pathway ultimately leads to the assembly of the C3 convertase, which cleaves C3 into C3a and C3b. As C3b then complexes with C3 convertase, the C5 convertase is activated, cleaving C5 into C5a and C5b. C3a and C5a are potent anaphylatoxins. C3b acts as an opsonin, whereas C5b initiates the formation of the membrane attack complex. When C5b

associates with C6 and C7, the complex becomes inserted into cell membrane and interacts with C8, inducing the binding of several units of C9 to form a lytic pore.

The lectin pathway of complement activation is initiated by mannose-binding lectins or ficolins, which act as the soluble PRM by binding specific carbohydrate structures that are often present on pathogens. The alternative pathway also includes a PRM-based initiation mechanism that resembles those found in the lectin pathway but involves properdin. The latter recognizes several PAMPs and DAMPs on foreign and apoptotic cells. Once bound, it initiates and propagates the complement response by attracting fluid-phase C3b to recognized surfaces and by stabilizing C3 convertase complexes. Despite its name, the alternative pathway may account for up to 80% to 90% of total complement activation.⁹²

The major source of the circulating complement components is the liver. Complement proteins can also be produced locally where they have been implicated in the regulation of adaptive immune processes. Complement protein synthesis has been demonstrated in immune cells, including T cells, which when surface bound, interact with C3 and C4 receptors. Also, complement synergistically enhances TLR-induced production of proinflammatory cytokines through convergence of their signaling pathways.

Kallikrein-Kinin System. The kallikrein-kinin system is a group of proteins that contribute to inflammation, blood pressure control, coagulation, and pain responses. Prekallikrein is synthesized in the liver and circulates in the plasma bound to high molecular weight kininogen (HK). A variety of stimuli lead to the binding of prekallikrein-HK complex to Hageman factor, (factor XII) followed by its activation, to produce the serine protease **kallikrein**, which plays a role in the coagulation cascade. HK, produced by the liver, is cleaved by kallikrein to form bradykinin (BK). The **kinins** (e.g., BK) mediate several physiologic processes, including vasodilation, increased capillary permeability, tissue edema, pain pathway activation, inhibition of gluconeogenesis, and increased bronchoconstriction. They also increase renal vasodilation and consequently reduce renal perfusion pressure. Kinin receptors are members of the rhodopsin family of G-protein–coupled receptors and are located on vascular endothelium and smooth muscle cells. Kinin receptors are rapidly upregulated following TLR4 signaling and in response to cytokines and appear to have important effects on both immune cell behavior and on immune mediators.⁹³ For example, B1 activation results in increased neutrophil chemotaxis, while increased B2 receptor expression causes activation of arachidonic-prostaglandin pathways. Bradykinin and kallikrein levels are increased during gram-negative bacteremia, hypotension, hemorrhage, endotoxemia, and tissue injury. The degree of elevation in the levels of these mediators has been associated with the magnitude of injury and mortality. Clinical trials using bradykinin antagonists have shown some benefit in patients with gram-negative sepsis.⁹⁴

Serotonin

Serotonin is a monoamine neurotransmitter (5-hydroxytryptamine [5-HT]) derived from tryptophan. Serotonin is synthesized by neurons in the CNS as well as by intestinal enterochromaffin cells, which are the major source of plasma 5-HT. Once in the plasma, 5-HT is taken up rapidly into platelets via the serotonin transporter (SERT) where it is either stored in the dense granules in millimolar concentrations or targeted for degradation. It is

interesting that the surface expression of SERT on platelets is sensitive to plasma 5-HT levels, which in turn modulates platelet 5-HT content. Receptors for serotonin are widely distributed in the periphery and are found in the gastrointestinal tract, cardiovascular system, and some immune cells.⁹⁵ Serotonin is a potent vasoconstrictor and also modulates cardiac inotropy and chronotropy through nonadrenergic cAMP pathways. Serotonin is released at sites of injury, primarily by platelets. Recent work has demonstrated an important role for platelet 5-HT in the local inflammatory response to injury. Using mice that lack the non-neuronal isoform of tryptophan hydroxylase (Tph1), the rate-limiting step for 5-HT synthesis in the periphery, investigators demonstrated fewer neutrophils rolling on mesenteric venules.⁹⁶ Tph1^{-/-} mice, in response to an inflammatory stimulus, also showed decreased neutrophil extravasation. Finally, survival of lipopolysaccharide-induced endotoxic shock was reduced in Tph1^{-/-} mice. Together, these data indicate an important role for nonneuronal 5-HT in neutrophil recruitment to sites inflammation and injury.

Histamine

Histamine is a short-acting endogenous amine that is widely distributed throughout the body. It is synthesized by histidine decarboxylase (HDC), which decarboxylates the amino acid histidine. Histamine is either rapidly released or stored in neurons, skin, gastric mucosa, mast cells, basophils, and platelets, and plasma levels are increased with hemorrhagic shock, trauma, thermal injury, and sepsis.⁹⁷ Not surprisingly, circulating cytokines can increase immune cell expression of HDC to further contribute to histamine synthesis. There are four histamine receptor (HR) subtypes with varying physiologic roles, but they are all members of the rhodopsin family of G-protein-coupled receptors. H1R binding mediates vasodilation, bronchoconstriction, intestinal motility, and myocardial contractility. H1R knockout mice demonstrate significant immunologic defects, including impaired B- and T-cell responses. H2R binding is best described for its stimulation of gastric parietal cell acid secretion. However, H2R can also modulate a range of immune system activities, such as mast cell degranulation, antibody synthesis, Th1 cytokine production, and T-cell proliferation. H3R was initially classified as a presynaptic autoreceptor in the peripheral nervous system and CNS. However, data using H3R knockout mice demonstrate that it also participates in inflammation in the CNS. H3R knockout mice display increased severity of neuroinflammatory diseases, which correlates with dysregulation of blood-brain barrier permeability and increased expression of macrophage inflammatory protein 2, IFN-inducible protein 10, and CXCR3 by peripheral T cells. H4R is expressed primarily in bone marrow but has also been detected in leukocytes, including neutrophils, eosinophils, mast cells, dendritic cells, T cells, and basophils. H4R is emerging as an important modulator of chemoattraction and cytokine production in these cells. Thus, it is clear that cells of both the innate and adaptive immune response can be regulated by histamine, which is upregulated following injury.⁹⁸

CELLULAR RESPONSE TO INJURY

Cytokine Receptor Families and Their Signaling Pathways

Cytokines act on their target cells by binding to specific membrane receptors. These receptor families have been organized

by structural motifs and include: type I cytokine receptors, type II cytokine receptors, chemokine receptors, TNF receptors (TNFRs), and transforming growth factor receptors (TGFs). In addition, there are cytokine receptors that belong to the immunoglobulin receptor superfamilies. Several of these receptors have characteristic signaling pathways that are associated with them. These will be reviewed in the following sections.

JAK-STAT Signaling

A major subgroup of cytokines, comprising roughly 60 factors, bind to receptors termed type I/II cytokine receptors. Cytokines that bind these receptors include type I IFNs, IFN- γ , many ILs (e.g., IL-6, IL-10, IL-12, and IL-13), and hematopoietic growth factors. These cytokines play essential roles in the initiation, maintenance, and modulation of innate and adaptive immunity for host defense. All type I/II cytokine receptors selectively associate with the Janus kinases (JAKs), which represent a family of tyrosine kinases that mediate the signal transduction for these receptors. JAKs are constitutively bound to the cytokine receptors, and on ligand binding and receptor dimerization, activated JAKs phosphorylate the receptor to recruit signal transducer and activator of transcription (STAT) molecules (Fig. 2-7). Activated STAT proteins further dimerize and translocate into

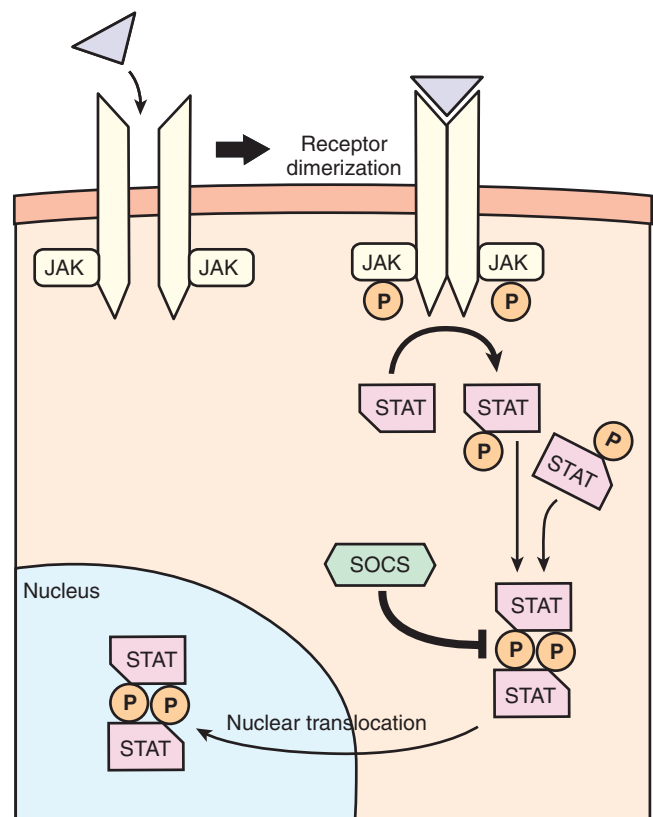


Figure 2-7. The Janus kinase/signal transducer and activator of transcription (JAK/STAT) signaling pathway also requires dimerization of monomeric units. STAT molecules possess “docking” sites that allow for STAT dimerization. The STAT complexes translocate into the nucleus and serve as gene transcription factors. JAK/STAT activation occurs in response to cytokines (e.g., interleukin-6) and cell stressors, and has been found to induce cell proliferation and inflammatory function. Intracellular molecules that inhibit STAT function, known as *suppressors of cytokine signaling* (SOCSs), have been identified. P = phosphate.

the nucleus where they modulate the transcription of target genes. Rather than being a strictly linear pathway, it is likely that individual cytokines activate more than one STAT. The molecular implications for this in terms of cytokine signaling are still being unraveled. Interestingly, STAT-DNA binding can be observed within minutes of cytokine binding. STATs have also been shown to modulate gene transcription via epigenetic mechanisms. Thus, JAKs and STATs are central players in the regulation of key immune cell function, by providing a signaling platform for proinflammatory cytokines (IL-6 via JAK1 and STAT3) and anti-inflammatory cytokines (IL-10 via STAT3) and integrating signals required for helper and regulatory T-cell development and differentiation. The JAK/STAT pathway is inhibited by the action of phosphatase, the export of STATs from the nucleus, and the interaction of antagonistic proteins.⁹⁹

Suppressors of Cytokine Signaling

Suppressor of cytokine signaling (SOCS) molecules are a family of proteins that function as a negative feedback loop for type I and II cytokine receptors by terminating JAK-STAT signaling. There are currently eight family members; SOCS1-3 are typically associated with cytokine receptor signaling, whereas SOCS4-8 are associated with growth factor receptor signaling. PRRs, including both TLR and C-type lectin receptors, have also been shown to activate SOCS. Interestingly, induction of SOCS proteins is also achieved through activators of JAK-STAT signaling, creating an inhibitory feedback loop through which cytokines can effectively self-regulate by extinguishing their own signal. SOCS molecules can positively and negatively influence the activation of macrophages and dendritic cells and are crucial for T-cell development and differentiation. All SOCS proteins are able to regulate receptor signaling through the recruitment of proteasomal degradation components to their target proteins,

whether the target is a specific receptor or an associated adaptor molecule. Once associated with the SOCS complex, target proteins are readily ubiquitinated and targeted to the proteasome for degradation. SOCS1 and SOCS3 can also exert an inhibitory effect on JAK-STAT signaling via their N-terminal kinase inhibitory region (KIR) domain, which acts as a pseudosubstrate for JAK. The KIR domain binds with high affinity to the JAK kinase domain to inhibit its activity. SOCS3 has been shown to be a positive regulator of TLR4 responses in macrophages via inhibition of IL-6 receptor-mediated STAT3 activation.¹⁰⁰ A deficiency of SOCS activity may render a cell hypersensitive to certain stimuli, such as inflammatory cytokines and GHs. Interestingly, in a murine model, SOCS knockout resulted in a lethal phenotype in part because of unregulated interferon signaling.

Chemokine Receptors Are Members of the G-Protein–Coupled Receptor Family

All chemokine receptors are members of the G-protein–coupled seven-transmembrane family of receptors (GPCR), which is one of the largest and most diverse of the membrane protein families. GPCRs function by detecting a wide spectrum of extracellular signals, including photons, ions, small organic molecules, and entire proteins. After ligand binding, GPCRs undergo conformational changes, causing the recruitment of heterotrimeric G proteins to the cytoplasmic surface (Fig. 2-8). Heterotrimeric G proteins are composed of three subunits, $G\alpha$, $G\beta$, and $G\gamma$, each of which has numerous members, adding to the complexity of the signaling. When signaling however, G proteins perform functionally as dimers because the signal is communicated either by the $G\alpha$ subunit or the $G\beta\gamma$ complex. The GPCR family includes the receptors for catecholamines, bradykinins, and leukotrienes, in addition to a variety of other ligands important to the inflammatory response.¹⁰¹ In general, GPCRs can

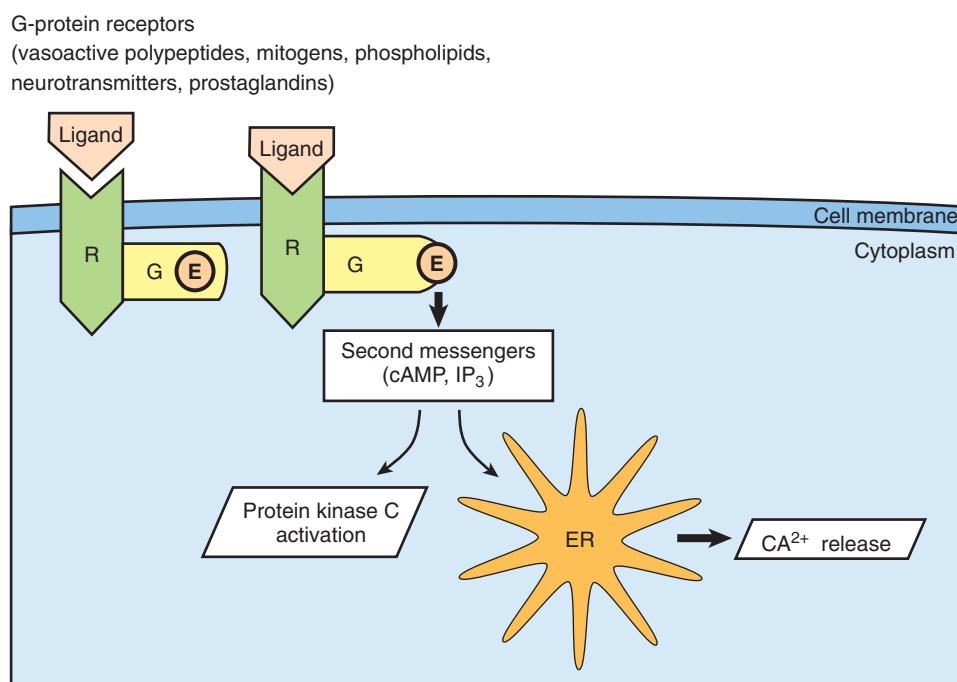


Figure 2-8. G-protein–coupled receptors are transmembrane proteins. The G-protein receptors respond to ligands such as adrenaline and serotonin. On ligand binding to the receptor (R), the G protein (G) undergoes a conformational change through guanosine triphosphate–guanosine diphosphate conversion and in turn activates the effector (E) component. The E component subsequently activates second messengers. The role of inositol triphosphate (IP₃) is to induce release of calcium from the endoplasmic reticulum (ER). cAMP = cyclic adenosine triphosphate.

be classified according to their pharmacologic properties into four main families: class A rhodopsin-like, class B secretin-like, class C metabotropic glutamate/pheromone, and class D frizzled receptors. As noted earlier, GPCR activation by ligand binding results in an extracellular domain shift, which is then transmitted to cytoplasmic portion of the receptor to facilitate coupling to its principle effector molecules, the heterotrimeric G proteins. Although there are more than 20 known $G\alpha$ subunits, they have been divided into four families based on sequence similarity, which has served to define both receptor and effector coupling. These include $G\alpha_s$ and $G\alpha_i$, which signal through the activation ($G\alpha_s$) or inhibition ($G\alpha_i$) of adenylate cyclase to increase or decrease cAMP levels, respectively. Increased intracellular cAMP can activate gene transcription through the activity of intracellular signal transducers such as protein kinase A. The $G\alpha$ subunits also include the Gq pathway, which stimulates phospholipase C- β to produce the intracellular messengers inositol triphosphate and diacylglycerol. Inositol triphosphate triggers the release of **calcium** from intracellular stores, whereas diacylglycerol recruits protein kinase C to the plasma membrane for activation. Finally, $G\alpha_{12/13}$ appears to act through Rho- and Ras-mediated signaling.

Tumor Necrosis Factor Superfamily

The signaling pathway for TNFR1 (55 kDa) and TNFR2 (75 kDa) occurs by the recruitment of several adapter proteins to the intracellular receptor complex. Optimal signaling activity requires receptor trimerization. TNFR1 initially recruits TNFR-associated death domain (TRADD) and induces apoptosis through the actions of proteolytic enzymes known as *caspases*, a pathway shared by another receptor known as *CD95 (Fas)*. CD95 and TNFR1 possess similar intracellular sequences known as *death domains (DDs)*, and both recruit the same adapter proteins known as *Fas-associated death domains (FADDs)* before activating caspase 8. TNFR1 also induces apoptosis by activating caspase 2 through the recruitment of receptor-interacting protein (RIP). RIP also has a functional component that can initiate NF- κ B and c-Jun activation, both favoring cell survival and proinflammatory functions. TNFR2 lacks a DD component but recruits adapter proteins known as TNFR-associated factors 1 and 2 (TRAF1, TRAF2) that interact with RIP to mediate NF- κ B and c-Jun activation. TRAF2 also recruits additional proteins that are antiapoptotic, known as inhibitor of apoptosis proteins (IAPs).

Transforming Growth Factor- β Family of Receptors

Transforming growth factor- β 1 (TGF- β 1) is a pleiotropic cytokine expressed by immune cells that has potent immunoregulatory activities. Specifically, recent data indicate that TGF- β is essential for T-cell homeostasis, as mice deficient in TGF- β 1 develop a multiorgan autoimmune inflammatory disease and die a few weeks after birth, an effect that is dependent on the presence of mature T cells. The receptors for TGF- β ligands are the TGF- β superfamily of receptors, which are type I transmembrane proteins that contain intrinsic serine/threonine kinase activity. These receptors comprise two subfamilies, the type I and the type II receptors, which are distinguished by the presence of a glycine/serine-rich membrane domain found in the type I receptors. Each TGF- β ligand binds a characteristic combination of type I and type II receptors, both of which are required for signaling. Whether the type I or the type II receptor

binds first is ligand-dependent, and the second type I or type II receptor is then recruited to form a heteromeric signaling complex. When TGF- β binds to the TGF- β receptor, heterodimerization activates the receptor, which then directly recruits and activates a receptor-associated Smad (Smad2 or Smad3) through phosphorylation. An additional “common” Smad is then recruited. The activated Smad complex translocates into the nucleus and, with other nuclear cofactors, regulates the transcription of target genes. TGF- β can also induce the rapid activation of the Ras-extracellular signal-regulated kinase (ERK) signaling pathway in addition to other MAPK pathways (JNK, p38MAPK). How does TGF- β inhibit immune responses? One of the most important effects is the suppression of IL-2 production by T cells. It also inhibits T-cell proliferation.¹⁰² More recently, it was noted that TGF- β can regulate the maturation of differentiated dendritic cells and dendritic cell-mediated T-cell responses. Importantly, TGF- β can induce “alternative activation” macrophages, designated M2 macrophages, which express a wide array of anti-inflammatory molecules, including IL-10 and arginase-1.

5 ▶ TRANSCRIPTIONAL AND TRANSLATIONAL REGULATION OF THE INJURY RESPONSE

Transcriptional Events Following Blunt Trauma

Recent data have examined the transcriptional response in circulating leukocytes in a large series of patients who suffered severe blunt trauma. This work identified an overwhelming shift in the leukocyte transcriptome, with more than 80% of the cellular functions and pathways demonstrating some alteration in gene expression. In particular, changes in gene expression for pathways involved in the systemic inflammatory, innate immune, compensatory anti-inflammatory, and adaptive immune responses were simultaneous and marked. Moreover, they occurred rapidly (within 4 to 12 hours) and were prolonged for days and weeks. When different injuries (i.e., blunt trauma, burn injury, human model of endotoxemia) were compared, the patterns of gene expression were surprisingly similar, suggesting that the stress response to both injury and inflammation is highly conserved and may follow a universal pathway that includes common denominators. Finally, delayed clinical recovery and organ injury were not associated with a distinct pattern of transcriptional response elements.² These data describe a new paradigm based on the observation of a rapid and coordinated transcriptional response to severe traumatic injury that involves both the innate and adaptive immune systems. Further, the data support the idea that individuals who are destined to die from their injuries are characterized primarily by the degree and duration of their dysregulated inflammatory response rather than a “unique signature” indicative of a “second hit.”

Transcriptional Regulation of Gene Expression

Many genes are regulated at the point of DNA transcription and thus influence whether messenger RNA (mRNA) and its subsequent product are expressed (Fig. 2-9). Gene expression relies on the coordinated action of transcription factors and coactivators (i.e., regulatory proteins), which are complexes that bind to highly specific DNA sequences upstream of the target gene known as the *promoter region*. Enhancer sequences of DNA mediate gene expression, whereas repressor sequences are non-coding regions that bind proteins to inhibit gene expression.

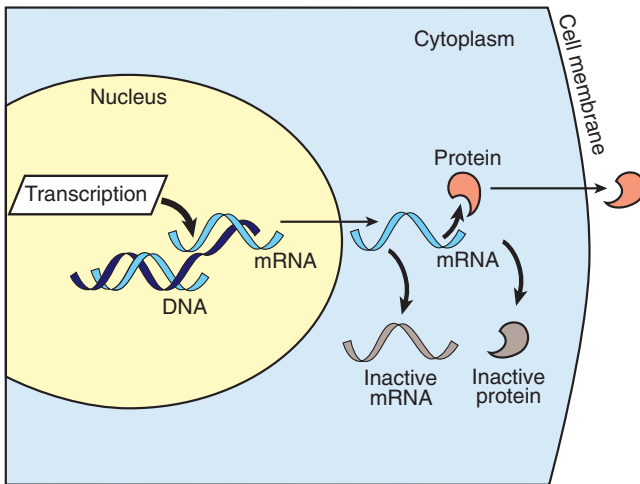


Figure 2-9. Gene expression and protein synthesis can occur within a 24-hour period. The process can be regulated at various stages: transcription, messenger RNA (mRNA) processing, or protein packaging. At each stage, it is possible to inactivate the mRNA or protein, rendering these molecules nonfunctional.

For example, NF- κ B is one of the best-described transcription factors, which has a central role in regulating the gene products expressed after inflammatory stimuli (Fig. 2-10). NF- κ B is composed of two smaller polypeptides, p50 and p65. NF- κ B resides in the cytosol in the resting state primarily through the inhibitory binding of inhibitor of κ B (I- κ B). In response to an inflammatory stimulus such as TNF, IL-1, or endotoxin, a sequence of intracellular mediator phosphorylation reactions leads to the degradation of I- κ B and subsequent release of NF- κ B. On release, NF- κ B travels to the nucleus and promotes gene expression. NF- κ B also stimulates the gene expression for I- κ B, which results in negative feedback regulation. In clinical

appendicitis, for example, increased NF- κ B activity was associated with initial disease severity, and levels returned to baseline within 18 hours after appendectomy in concert with resolution of the inflammatory response.³⁰

Epigenetic Regulation of Transcription

The DNA access of protein machineries involved in transcription processes is tightly regulated by **histones**, which are a family of basic proteins that associate with DNA in the nucleus. Histone proteins help to condense the DNA into tightly packed nucleosomes that limit transcription. Emerging evidence indicates that transcriptional activation of many proinflammatory genes requires nucleosome remodeling that is modulated by the post-translational modification of histone proteins through the recruitment of histone-modifying enzymes.¹⁰³ There are at least seven identified chromatin modifications including acetylation, methylation, phosphorylation, ubiquitinylation, sumoylation, ADP ribosylation, deimination, and proline isomerization. Recently, the development of chromatin immunoprecipitation (ChIP) coupled to massively parallel DNA sequencing technology (ChIP-Seq) has enabled the mapping of histone modifications in living cells in response to TLR signaling. In this way, it has allowed the identification of the large number of posttranslational histone modifications that are “written” and “erased” by histone-modifying enzymes. The role of histone modifications in the regulation of gene expression is referred to as “epigenetic” control.

Addition of an acetyl group to lysine residues on histones is an epigenetic mark associated with gene activation. These acetyl groups are reversibly maintained by **histone acetyltransferases (HATs)** and **histone deacetylases**. Ultimately, histone acetylation is monitored by bromodomain-containing proteins such as the bromodomain and extraterminal domain (BET) family of proteins, which can regulate a number of important epigenetically controlled processes.

Upon TLR4 activation, HATs are recruited to proinflammatory gene promoters where acetylation of specific histone

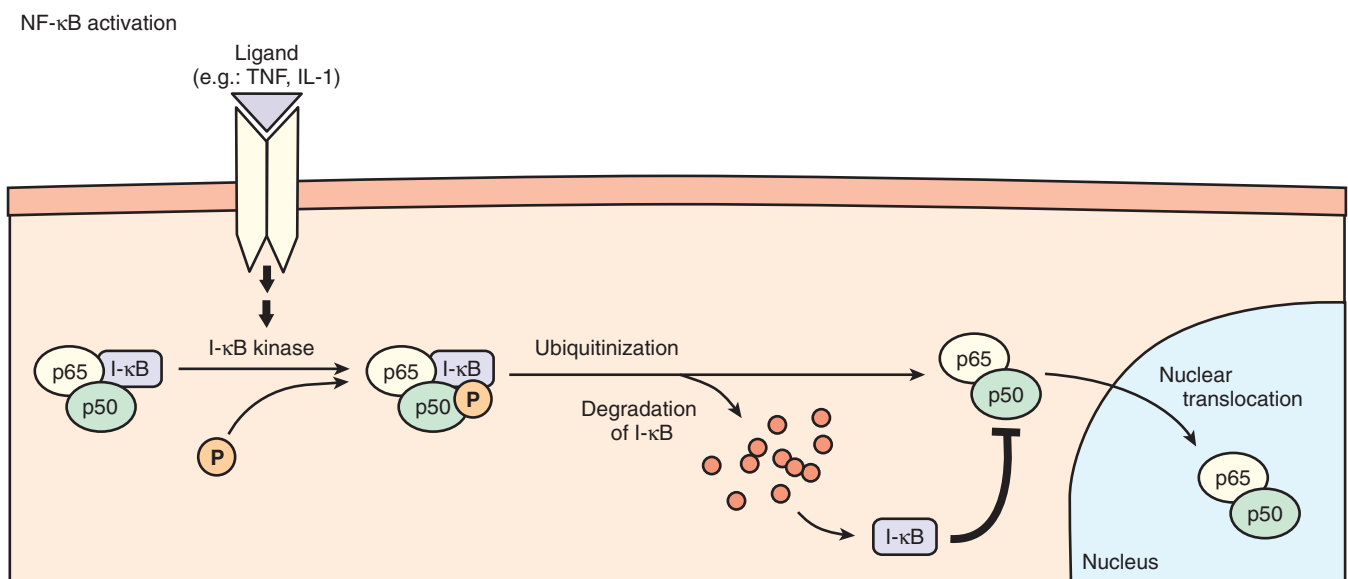


Figure 2-10. Inhibitor of κ B (I- κ B) binding to the p50-p65 subunits of nuclear factor κ B (NF- κ B) inactivates the molecule. Ligand binding to the receptor activates a series of downstream signaling molecules, of which I- κ B kinase is one. The phosphorylated NF- κ B complex further undergoes ubiquitination and proteasome degradation of I- κ B, activating NF- κ B, which translocates into the nucleus. Rapid resynthesis of I- κ B is one method of inactivating the p50-p65 complex. IL-1 = interleukin-1; P = phosphate; TNF = tumor necrosis factor.

residues serves as an organizing node for a complex of proteins that ultimately phosphorylate the large subunit of RNA polymerase II, promoting the elongation of inflammatory gene transcripts.¹⁰⁴ Recently, investigators used a novel pharmacologic approach that targeted inflammatory gene expression by interfering with the recognition of acetylated histones by BET proteins. A synthetic compound (I-BET) that “mimicked” acetylated histones functioned as a BET antagonist.¹⁰⁵ In this way, pretreatment decreased overall histone acetylation to reduce the expression of select inflammatory genes in LPS-activated macrophages. Additionally, I-BET conferred protection against bacteria-induced sepsis. Recent studies have also demonstrated a role for histone methyltransferases in proinflammatory gene programs.

Translation Regulation of Inflammatory Gene Expression

Once mRNA transcripts are generated, they can also be regulated by a variety of mechanisms, including (a) splicing, which can cleave mRNA and remove noncoding regions; (b) capping, which modifies the 5′ ends of the mRNA sequence to inhibit breakdown by exonucleases; and (c) the addition of a polyadenylated tail, which adds a noncoding sequence to the mRNA, to regulate the half-life of the transcript. Recent data have identified microRNAs (miRNAs) as important **translational regulators** of gene expression via their binding to partially complementary sequences in the 3′-untranslated region (3′-UTR) of target mRNA transcripts.¹⁰⁶ Binding of miRNA to the mRNA usually results in gene silencing. MicroRNAs are endogenous, single-stranded RNAs of approximately 22 nucleotides in length that are highly conserved in eukaryotes. miRNAs are encoded either singly or can be transcribed in “polycistronic” clusters and produced by an elaborate expression and processing mechanism. After a primary miRNA transcript is generated by RNA polymerase II or III, it is processed in the nucleus to produce a short hairpin precursor miRNA transcript. The precursor is then transported into the cytoplasm where the final mature miRNA is generated by a protein termed **Dicer**. The mature double-stranded miRNA is then incorporated into the RNA-induced silencing complex (**RISC**) in the cytoplasm. Once programmed with a small RNA, RISC can silence targeted genes by one of several distinct mechanisms, working at (a) the level of protein synthesis through translation inhibition, (b) the transcript level through mRNA degradation, or (c) the level of the genome itself through the formation of heterochromatin or by DNA elimination. Recent data indicate that miRNAs are involved in TLR signaling in the innate immune system by targeting multiple molecules in the TLR signaling pathways.¹⁰⁷ For example, evidence has shown that miR-146a can inhibit the expression of IRAK1 and TRAF6, impair NF- κ B activity, and suppress the expression of NF- κ B target genes such as IL-6, IL-8, IL-1 β , and TNF- α .

CELL-MEDIATED INFLAMMATORY RESPONSE

Platelets

Platelets are small (2 μ m), circulating fragments of a larger cell precursor, the megakaryocyte, that is located chiefly within the bone marrow. Although platelets lack a nucleus, they contain both mRNA and a large number of cytoplasmic and surface proteins that equip them for diverse functionality. While their role in hemostasis is well described, more recent work suggests that

platelets play a role in both local and systemic inflammatory responses, particularly following ischemia reperfusion. Platelets express functional scavenger and TLRs that are important detectors of both pathogens and “damage”-associated molecules.¹⁰⁸ At the site of tissue injury, complex interactions between platelets, endothelial cells, and circulating leukocytes facilitate cellular activation by the numerous local alarmins and immune mediators. For example, platelet-specific TLR4 activation can cause thrombocytes to bind to and activate neutrophils to extrude their DNA to form neutrophil extracellular traps (**NETs**), an action that facilitates the capacity of the innate immune system to trap bacteria, but also leads to local endothelial cell damage.¹⁰⁹

Once activated, platelets adopt an initial proinflammatory phenotype by expressing and releasing a variety of adhesion molecules, cytokines, and other immune modulators, including HMGB1, IL-1 β , and CD40 ligand (CD40L; CD154). However, activated platelets also express large amounts of the immunosuppressive factor TGF- β , which has been implicated in Treg cell homeostasis. Recently, in a large animal model of hemorrhage, TGF- β levels were shown to be significantly increased 2 hours after injury, suggesting a possible mechanism for injury-related immune dysfunction.¹¹⁰ And although soluble CD154 was not increased following hemorrhage and traumatic brain injury in that study, in a murine model of mesenteric ischemia-reperfusion injury platelet expression of CD40 and CD154 was linked to remote organ damage.

Lymphocytes and T-Cell Immunity

The expression of genes associated with the adaptive immune response is rapidly altered following severe blunt trauma.² In fact, significant injury is associated with adaptive immune suppression that is characterized by altered cell-mediated immunity, specifically the balance between the major populations of Th cells. In fact, Th lymphocytes are functionally divided into subsets, which principally include Th1 and Th2 cells, as well as Th17 and inducible Treg cells. Derived from precursor CD4⁺ Th cells, each of these groups produces specific effector cytokines that are under unique transcriptional control. CD4 T cells play central roles in the function of the immune system through their effects on B-cell antibody production and their enhancement of specific Treg cell functions and macrophage activation. The specific functions of these cells include the recognition and killing of intracellular pathogens (cellular immunity; Th1 cells), regulation of antibody production (humoral immunity; Th2 cells), and maintenance of mucosal immunity and barrier integrity (Th17 cells). These activities have been characterized as proinflammatory (Th1) and anti-inflammatory (Th2), respectively, as determined by their distinct cytokine signatures (Fig. 2-11). Activation of Th1 cytokine-producing cells following injury has been linked to signaling events triggered by endogenous ligands, often composed of intracellular proteins (e.g., mitochondrial and nuclear-binding proteins) or ECM fragments released with cellular damage. As discussed earlier, these DAMPs are recognized by members of the TLR superfamily, including TLR2, TLR4, and TLR9, and can activate innate immune pathways.

A healthy immune response depends on a balanced Th1/Th2 response. Following injury, however, there is a reduction in Th1 cell differentiation and cytokine production in favor of an increased population of Th2 lymphocytes and their signaling products. As a consequence, both macrophage activation and proinflammatory cytokine synthesis are inhibited. This imbalance,

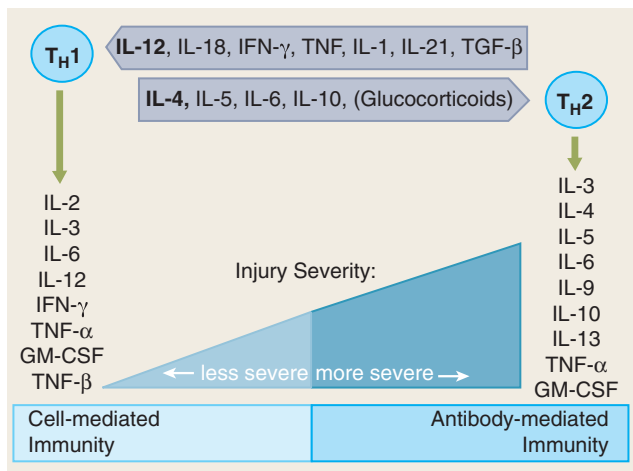


Figure 2-11. Specific immunity mediated by helper T lymphocytes subtype 1 (T_H1) and subtype 2 (T_H2) after injury. A T_H1 response is favored in lesser injuries, with intact cell-mediated and opsonizing antibody immunity against microbial infections. This cell-mediated immunity includes activation of monocytes, B lymphocytes, and cytotoxic T lymphocytes. A shift toward the T_H2 response from naïve helper T cells is associated with injuries of greater magnitude and is not as effective against microbial infections. A T_H2 response includes the activation of eosinophils, mast cells, and B-lymphocyte immunoglobulin 4 and immunoglobulin E production. (Primary stimulants and principal cytokine products of such responses are in **bold** characters.) Interleukin-4 (IL-4) and IL-10 are known inhibitors of the T_H1 response. Interferon- γ (IFN- γ) is a known inhibitor of the T_H2 response. Although not cytokines, glucocorticoids are potent stimulants of a T_H2 response, which may partly contribute to the immunosuppressive effects of cortisol. GM-CSF = granulocyte-macrophage colony-stimulating factor; IL = interleukin; TGF = transforming growth factor; TNF = tumor necrosis factor. (Adapted with permission from Lin E, Calvano SE, Lowry SF. *Inflammatory cytokines and cell response in surgery*. Surgery. 2000;127:117. Copyright Elsevier.)

which may be associated with decreased IL-12 production by activated monocytes/macrophages, has been associated with increased risk of infectious complications following surgery and trauma. What are the systemic mechanisms responsible for this shift? Several events have been implicated, including the direct effect of glucocorticoids on monocyte IL-12 production and T-cell IL-12 receptor expression. In addition, sympathoadrenal catecholamine production has also been demonstrated to reduce IL-12 production and proinflammatory cytokine synthesis.¹¹¹ Finally, more recent work has implicated circulating immature myeloid cells, termed **myeloid-derived suppressor cells**, that have immune suppressive activity particularly through their increased expression of arginase.¹¹² These cells have the potential to deplete the microenvironment of arginine, leading to further T-cell dysfunction.

Recent evidence suggests that Th17 cells and their effector cytokines, IL-17, IL-21, and IL-22, regulate mucosal immunity and barrier function. While their specific role in the inflammatory response following trauma is not well understood, both murine and human studies indicate that normal Th17 effector functions are disordered following burn injury, due to the inhibition of normal Th17 cell development by IL-10.¹¹³ These changes may contribute to remote organ damage and further susceptibility to infection in this setting.

Dendritic Cells

Recent studies have focused on the cellular components of the immune system in the context of polytrauma. While the activation of granulocytes and monocyte/macrophages following trauma has been well described, more recent work has also demonstrated that **dendritic cells (DCs)** are also activated in response to damage signals, to stimulate both the innate and the adaptive immune responses. For example, primary “danger signals” that are recognized and activated by DCs include debris from damaged or dying cells (e.g., HMGB1, nucleic acids including single nucleotides, and degradation products of the ECM). DCs are specialized antigen-presenting cells (APCs) that have three major functions. They are frequently referred to as “professional APCs” since their principal function is to capture, process, and present both endogenous and exogenous antigens, which, along with their costimulatory molecules, are capable of inducing a primary immune response in resting naïve T lymphocytes. In addition, they have the capacity to further regulate the immune response, both positively and negatively, through the upregulation and release of immunomodulatory molecules such as the chemokine CCL5 and the CXC chemokine CXCL5. Finally, they have been implicated both in the induction and maintenance of immune tolerance as well as in the acquisition of immune memory.¹¹⁴ There are distinct classes and subsets of DC, which are functionally heterogeneous. Further, subsets of DC at distinct locations have been shown to express different levels damage-sensing receptors (e.g., TLR) that dictate a preferential response to DAMP at that site. While relatively small in number relative to the total leukocyte population, the diverse distribution of DC in virtually all body tissues underlines their potential for a collaborative role in the initiation of the trauma-induced sterile systemic inflammatory response.

Eosinophils

Eosinophils are immunocytes whose primary functions are antihelminthic. Eosinophils are found mostly in tissues such as the lung and gastrointestinal tract, which may suggest a role in immune surveillance. Eosinophils can be activated by IL-3, IL-5, GM-CSF, chemoattractants, and platelet-activating factor. Eosinophil activation can lead to subsequent release of toxic mediators, including ROSs, histamine, and peroxidase.¹¹⁵

Mast Cells

Mast cells are important in the primary response to injury because they are located in tissues. TNF release from mast cells has been found to be crucial for neutrophil recruitment and pathogen clearance. Mast cells are also known to play an important role in the anaphylactic response to allergens. On activation from stimuli including allergen binding, infection, and trauma, mast cells produce histamine, cytokines, eicosanoids, proteases, and chemokines, which leads to vasodilatation, capillary leakage, and immunocyte recruitment. Mast cells are thought to be important cosignaling effector cells of the immune system via the release of IL-3, IL-4, IL-5, IL-6, IL-10, IL-13, and IL-14, as well as macrophage migration-inhibiting factor.¹¹⁶

Monocyte/Macrophages

Monocytes are mononuclear phagocytes that circulate in the bloodstream and can differentiate into macrophages, osteoclasts, and DCs on migrating into tissues. Macrophages are the main effector cells of the immune response to infection and

injury, primarily through mechanisms that include phagocytosis of microbial pathogens, release of inflammatory mediators, and clearance of apoptotic cells. Moreover, these cells fulfill homeostatic roles beyond host defense by performing important functions in the remodeling of tissues, both during development and in the adult animal.

In tissues, mononuclear phagocytes are quiescent. However, they respond to external cues (e.g., PAMPs, DAMPs, activated lymphocytes) by changing their phenotype. In response to various signals, macrophages may undergo classical M1 activation (stimulated by TLR ligands and IFN- γ) or alternative M2 activation (stimulated by type II cytokines IL-4/IL-13); these states mirror the Th1-Th2 polarization of T cells. The M1 phenotype is characterized by the expression of high levels of proinflammatory cytokines, like TNF- α , IL-1, and IL-6, in addition to the synthesis of ROS and RNS. M1 macrophages promote a strong Th1 response. In contrast, M2 macrophages are considered to be involved in the promotion of wound repair and the restoration of immune homeostasis through their expression of arginase-1 and IL-10, in addition to a variety of PRRs (e.g., scavenging molecules).¹¹⁷

In humans, downregulation of monocyte TNFR expression has been demonstrated experimentally and clinically during systemic inflammation. In clinical sepsis, nonsurviving patients with severe sepsis have an immediate reduction in monocyte surface TNFR expression with failure to recover, whereas surviving patients have normal or near-normal receptor levels from the onset of clinically defined sepsis. In patients with congestive heart failure, there is also a significant decrease in the amount of monocyte surface TNFR expression compared with control patients. In experimental models, endotoxin has been shown to differentially regulate over 1000 genes in murine macrophages with approximately 25% of these corresponding to cytokines and chemokines. During sepsis, macrophages undergo phenotypic reprogramming highlighted by decreased surface human leukocyte antigen DR (a critical receptor in antigen presentation), which also may contribute to host immunocompromise during sepsis.¹¹⁸

Neutrophils

Neutrophils are among the first responders to sites of infection and injury and, as such, are potent mediators of acute inflammation. Chemotactic mediators from a site of injury induce neutrophil adherence to the vascular endothelium and promote eventual cell migration into the injured tissue. Neutrophils are circulating immunocytes with short half-lives (4 to 10 hours). However, inflammatory signals may promote the longevity of neutrophils in target tissues, which can contribute to their potential detrimental effects and bystander injury. Once primed and activated by inflammatory stimuli, including TNF, IL-1, and microbial pathogens, neutrophils are able to enlist a variety of killing mechanisms to manage invading pathogens. Phagocytosed bacteria are killed using NADPH oxygenase-dependent generation of ROS or by releasing lytic enzymes and antibacterial proteins into the phagosome. Neutrophils can also dump their granule contents into the extracellular space, and many of these proteins also have important effects on the innate and adaptive immune responses. When highly activated, neutrophils can also extrude a meshwork of chromatin fibers, composed of DNA and histones that are decorated with granule contents. Termed neutrophil extracellular traps (NETs), this is an effective mechanism whereby neutrophils can immobilize bacteria to

facilitate their killing.¹¹⁹ NETs may also serve to prime T cells, making their threshold for activation lower.

Neutrophils do facilitate the recruitment of monocytes into inflamed tissues. These recruited cells are capable of phagocytosing apoptotic neutrophils to contribute to resolution of the inflammatory response.¹²⁰

ENDOTHELIUM-MEDIATED INJURY

Vascular Endothelium

Under physiologic conditions, vascular endothelium has overall anticoagulant properties mediated via the production and cell surface expression of heparin sulfate, dermatan sulfate, tissue factor pathway inhibitor, protein S, thrombomodulin, plasminogen, and tissue plasminogen activator. Endothelial cells also perform a critical function as barriers that regulate tissue migration of circulating cells. During sepsis, endothelial cells are differentially modulated, which results in an overall procoagulant shift via decreased production of anticoagulant factors, which may lead to microthrombosis and organ injury.

Neutrophil-Endothelium Interaction

The regulated inflammatory response to infection facilitates neutrophil and other immunocyte migration to compromised regions through the actions of increased vascular permeability, chemoattractants, and increased endothelial adhesion factors referred to as *selectins* that are elaborated on cell surfaces (Table 2-7). In response to inflammatory stimuli released from sentinel leukocytes in the tissues, including chemokines, thrombin, leukotrienes, histamine, and TNF, vascular endothelium are activated and their surface protein expression is altered. Within 10 to 20 minutes, prestored reservoirs of the adhesion molecule P-selectin are mobilized to the cell surface where it can mediate neutrophil recruitment (Fig. 2-12). After 2 hours, endothelial cell transcriptional processes provide additional surface expression of E-selectin. E-selectin and P-selectin bind P-selectin glycoprotein ligand-1 (PSGL-1) on the neutrophils to orchestrate the capture and rolling of these leukocytes and allow targeted immunocyte extravasation. Immobilized chemokines on the endothelial surface create a chemotactic gradient to further enhance immune cell recruitment.¹²¹ Also important are secondary leukocyte-leukocyte interactions in which PGSL-1 and L-selectin binding facilitates further leukocyte tethering. Although there are distinguishable properties among individual selectins in leukocyte rolling, effective rolling most likely involves a significant degree of functional overlap.¹²²

Chemokines

Chemokines are a family of small proteins (8 to 13 kDa) that were first identified through their chemotactic and activating effects on inflammatory cells. They are produced at high levels following nearly all forms of injury in all tissues, where they are key attractants for immune cell extravasation. There are more than 50 different chemokines and 20 chemokine receptors that have been identified. Chemokines are released from endothelial cells, mast cells, platelets, macrophages, and lymphocytes. They are soluble proteins, which when secreted, bind to glycosaminoglycans on the cell surface or in the ECM. In this way, the chemokines can form a fixed chemical gradient that promotes immune cell exit to target areas. Chemokines are distinguished (in general) from cytokines by virtue of their receptors, which are members of the G-protein-coupled receptor superfamily.

Table 2-7

Molecules that mediate leukocyte-endothelial adhesion, categorized by family

ADHESION MOLECULE	ACTION	ORIGIN	INDUCERS OF EXPRESSION	TARGET CELLS
<i>Selectins</i>				
L-selectin	Fast rolling	Leukocytes	Native	Endothelium, platelets, eosinophils
P-selectin	Slow rolling	Platelets and endothelium	Thrombin, histamine	Neutrophils, monocytes
E-selectin	Very slow rolling	Endothelium	Cytokines	Neutrophils, monocytes, lymphocytes
<i>Immunoglobulins</i>				
ICAM-1	Firm adhesion/transmigration	Endothelium, leukocytes, fibroblasts, epithelium	Cytokines	Leukocytes
ICAM-2	Firm adhesion	Endothelium, platelets	Native	Leukocytes
VCAM-1	Firm adhesion/transmigration	Endothelium	Cytokines	Monocytes, lymphocytes
PECAM-1	Adhesion/transmigration	Endothelium, platelets, leukocytes	Native	Endothelium, platelets, leukocytes
β_2 -(CD18) Integrins				
CD18/11a	Firm adhesion/transmigration	Leukocytes	Leukocyte activation	Endothelium
CD18/11b (Mac-1)	Firm adhesion/transmigration	Neutrophils, monocytes, natural killer cells	Leukocyte activation	Endothelium
CD18/11c	Adhesion	Neutrophils, monocytes, natural killer cells	Leukocyte activation	Endothelium
β_1 -(CD29) Integrins				
VLA-4	Firm adhesion/transmigration	Lymphocytes, monocytes	Leukocyte activation	Monocytes, endothelium, epithelium

ICAM-1 = intercellular adhesion molecule-1; ICAM-2 = intercellular adhesion molecule-2; Mac-1 = macrophage antigen 1; PECAM-1 = platelet-endothelial cell adhesion molecule-1; VCAM-1 = vascular cell adhesion molecule-1; VLA-4 = very late antigen-4.

Most chemokine receptors recognize more than one chemokine ligand, leading to redundancy in chemokine signaling.

The chemokines are subdivided into families based on their amino acid sequences at their N-terminus. For example, *CC chemokines* contain two N-terminus **cysteine** residues that are immediately adjacent (hence the “C-C” designation), whereas the N-terminal cysteines in *CXC chemokines* are separated by a single amino acid. The CXC chemokines are particularly important for neutrophil (PMN) proinflammatory function. Members of the CXC chemokine family, which include IL-8, induce neutrophil migration and secretion of cytotoxic granular contents and metabolites. Additional chemokine families include the C and CX3C chemokines.¹²¹

Nitric Oxide

Nitric oxide (NO) was initially known as *endothelium-derived relaxing factor* due to its effect on vascular smooth muscle. Normal vascular smooth muscle cell relaxation is maintained by a constant output of NO that is regulated in the endothelium by both flow- and receptor-mediated events. NO can also reduce microthrombosis by reducing platelet adhesion and aggregation (Fig. 2-13) and interfering with leukocyte adhesion to the endothelium. NO easily traverses cell membranes, has a short half-life of a few seconds, and is oxidized into nitrate and nitrite.

Endogenous NO formation is derived largely from the action of NO synthase (NOS), which is constitutively expressed in endothelial cells (NOS3). NOS generates NO by catalyzing the degradation of L-arginine to L-citrulline and NO, in the presence of oxygen and NADPH. There are two additional isoforms of NOS: neuronal NOS (NOS1) and inducible NOS (iNOS/NOS2). The vasodilatory effects of NO are mediated by **guanylyl cyclase**, an enzyme that is found in vascular smooth muscle cells and most other cells of the body. When NO is formed by endothelium, it rapidly diffuses into adjacent cells where it binds to and activates guanylyl cyclase. This enzyme catalyzes the dephosphorylation of guanosine triphosphate (GTP) to cyclic guanosine monophosphate (**cGMP**), which serves as a second messenger for many important cellular functions, particularly for signaling smooth muscle relaxation.

NO synthesis is increased in response to proinflammatory mediators such as TNF- α and IL-1 β , as well as microbial products, due to the upregulation of iNOS expression.¹²³ In fact, studies in both animal models and humans have shown that severe systemic injury and associated hemorrhage produce an early upregulation of iNOS in the liver, lung, spleen, and vascular system. In these circumstances, NO is reported to function as an immunoregulator, which is capable of modulating cytokine production and immune cell development. In particular, recent data support a role for iNOS in the regulation of T-cell

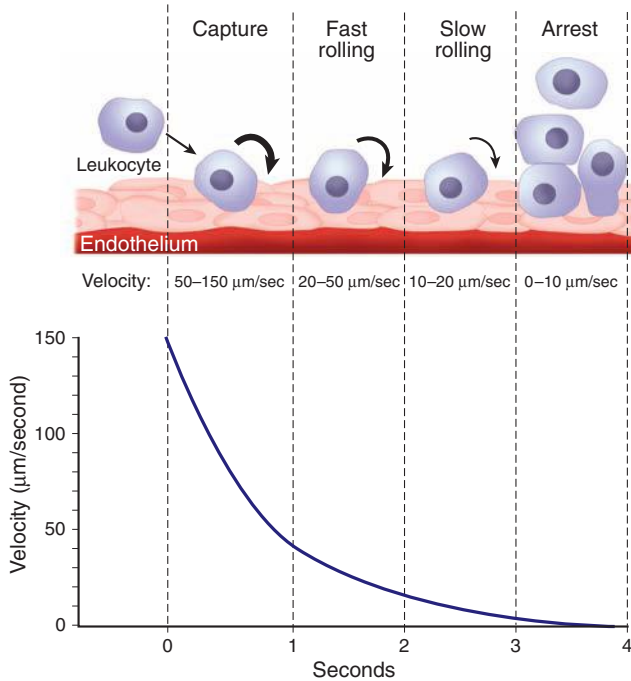


Figure 2-12. Simplified sequence of selectin-mediated neutrophil-endothelium interaction after an inflammatory stimulus. **CAPTURE** (tethering), predominantly mediated by cell L-selectin with contribution from endothelial P-selectin, describes the initial recognition between leukocyte and endothelium, in which circulating leukocytes marginate toward the endothelial surface. **FAST ROLLING** (20 to 50 $\mu\text{m/s}$) is a consequence of rapid L-selectin shedding from cell surfaces and formation of new downstream L-selectin to endothelium bonds, which occur in tandem. **SLOW ROLLING** (10 to 20 $\mu\text{m/s}$) is predominantly mediated by P-selectins. The slowest rolling (3 to 10 $\mu\text{m/s}$) before arrest is predominantly mediated by E-selectins, with contribution from P-selectins. **ARREST** (firm adhesion) leading to transmigration is mediated by β -integrins and the immunoglobulin family of adhesion molecules. In addition to interacting with the endothelium, activated leukocytes also recruit other leukocytes to the inflammatory site by direct interactions, which are mediated in part by selectins. (Adapted with permission from Lin E, Calvano SE, Lowry SF. *Selectin neutralization: does it make biological sense?* Crit Care Med. 1999;27:2050.)

dysfunction in the setting of trauma as evidenced by suppressed proliferative and Th1 cytokine release.¹²⁴

Increased NO is also detectable in septic shock, where it is associated with low peripheral vascular resistance and hypotension. Increased production of NO in this setting correlates with changes in vascular permeability and inhibition of noradrenergic nerve transmission. While the increased NO in sepsis is largely attributed to greater iNOS activity and expression, cytokines are reported to modulate NO release by increasing arginine availability through the expression of the cationic amino acid transporter (CAT) or by increasing tetrahydrobiopterin levels, a key cofactor in NO synthesis. Additional effects associated with excess NO include protein and membrane phospholipid alterations by nitrosylation and the inhibition of mitochondrial respiration. Inhibition of NO production seemed initially to be a promising strategy in patients with severe sepsis. However, a randomized clinical trial in patients with septic shock determined that treatment with a *nonselective* NOS inhibitor was

associated with an increase in mortality compared with placebo.¹²⁵ More recent data using an ovine model of peritonitis demonstrated that selective iNOS inhibition reduced pulmonary artery hypertension and gas exchange impairment and promoted higher visceral organ blood flow, coinciding with lower plasma cytokine concentrations.¹²⁶ These data suggest that specific targeting of iNOS in the setting of sepsis may remain a viable therapeutic option.

Prostacyclin

The immune effects of prostacyclin (PGI_2) were discussed earlier. The best described effects of PGI_2 are in the cardiovascular system, however, where it is produced by vascular endothelial cells. Prostacyclin is a potent vasodilator that also inhibits platelet aggregation. In the pulmonary system, PGI_2 reduces pulmonary blood pressure and bronchial hyperresponsiveness. In the kidneys, PGI_2 modulates renal blood flow and glomerular filtration rate. Prostacyclin acts through its receptor (a G-protein-coupled receptor of the rhodopsin family) to stimulate the enzyme adenylate cyclase, allowing the synthesis of cAMP from adenosine triphosphate (ATP). This leads to a cAMP-mediated decrease in intracellular calcium and subsequent smooth muscle relaxation.

During systemic inflammation, endothelial prostacyclin expression is impaired, and thus the endothelium favors a more procoagulant profile. Exogenous prostacyclin analogues, both intravenous and inhaled, have been used to improve oxygenation in patients with acute lung injury. Early clinical studies with prostacyclin have delivered some encouraging results, showing that infusion of prostacyclin improved cardiac index, splanchnic blood flow as measured by intestinal tonometry, and oxygen delivery in patients with sepsis. Importantly, there was no significant decrease in mean arterial pressure.¹²⁷

Endothelins

Endothelins (ETs) are potent mediators of vasoconstriction and are composed of three members: ET-1, ET-2, and ET-3. ETs are 21-amino-acid peptides derived from a 38-amino-acid precursor molecule. ET-1, synthesized primarily by endothelial cells, is the most potent endogenous vasoconstrictor and is estimated to be 10 times more potent than angiotensin II. ET release is upregulated in response to hypotension, LPS, injury, thrombin, TGF- β , IL-1, angiotensin II, vasopressin, catecholamines, and anoxia. ETs are primarily released to the abluminal side of endothelial cells, and very little is stored in cells; thus a plasma increase in ET is associated with a marked increase in production. The half-life of plasma ET is between 4 and 7 minutes, which suggests that ET release is primarily regulated at the transcriptional level. Three ET receptors, referred to as ET_A , ET_B , and ET_C , have been identified and function via the G-protein-coupled receptor mechanism. ET_B receptors are associated with increased NO and prostacyclin production, which may serve as a feedback mechanism. Atrial ET_A receptor activation has been associated with increased inotropy and chronotropy. ET-1 infusion is associated with increased pulmonary vascular resistance and pulmonary edema and may contribute to pulmonary abnormalities during sepsis. At low levels, in conjunction with NO, ETs regulate vascular tone. However, at increased concentrations, ETs can disrupt the normal blood flow and distribution and may compromise oxygen delivery to the tissue. Recent data link ET expression in pulmonary vasculature with persistent inflammation associated with the development of

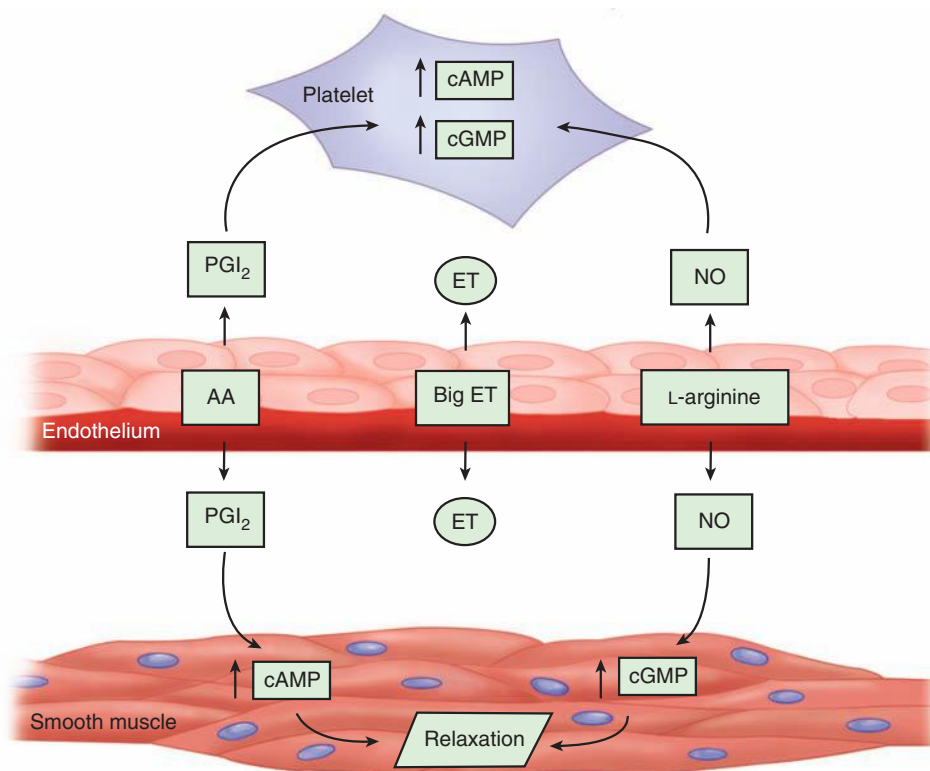


Figure 2-13. Endothelial interaction with smooth muscle cells and with intraluminal platelets. Prostacyclin (prostaglandin I₂, or PGI₂) is derived from arachidonic acid (AA), and nitric oxide (NO) is derived from L-arginine. The increase in cyclic adenosine monophosphate (cAMP) and cyclic guanosine monophosphate (cGMP) results in smooth muscle relaxation and inhibition of platelet thrombus formation. Endothelins (ETs) are derived from “big ET,” and they counter the effects of prostacyclin and NO.

pulmonary hypertension.¹²⁸ ET expression is linked to posttranslational and transcriptional initiation of the unfolded protein response in the affected cells, which results in the production of inflammatory cytokines. Finally, ET-1 levels correlate with levels of brain natriuretic peptide and CRP, as well as the Sequential Organ Failure Assessment score in septic patients.¹²⁹

Platelet-Activating Factor

Phosphatidylcholine is a major lipid constituent of the plasma membrane. Its enzymatic processing by cytosolic phospholipase A₂ (cPLA₂) or calcium-independent phospholipase A₂ (iPLA₂) generates powerful small lipid molecules, which function as intracellular second messengers. One of these is arachidonic acid, the precursor molecule for eicosanoids. Another is **platelet-activating factor** (PAF). During acute inflammation, PAF is released by immune cells following the activation of PLA₂. The receptor for PAF (PAFR), which is constitutively expressed by platelets, leukocytes, and endothelial cells, is a G-protein-coupled receptor of the rhodopsin family. Ligand binding to the PAFR promotes the activation and aggregation of platelets and leukocytes, leukocyte adherence, motility, chemotaxis, and invasion, as well as ROS generation.¹³⁰ Additionally, PAF activation of human PMNs induces extrusion of NETs, while platelet activation induces IL-1 via a novel posttranscriptional mechanism. Finally, PAFR ligation results not only in the upregulation of numerous proinflammatory genes including COX-2, iNOS, and IL-6, but also in the generation of lipid intermediates such as arachidonic acid and lysophospholipids through the activation of PLA₂. Antagonists to PAF receptors have been experimentally shown to mitigate the effects of ischemia and reperfusion injury. Of note, human sepsis is associated with a reduction in the levels of PAF-acetylhydrolase, which inactivates PAF by removing an acetyl group. Indeed,

PAF-acetylhydrolase administration in patients with severe sepsis has yielded some reduction in multiple organ dysfunction and mortality¹³¹; however, larger phase III clinical trials failed to show benefit.

Natriuretic Peptides

The natriuretic peptides, atrial natriuretic factor (ANF) and brain natriuretic peptide (BNP), are a family of peptides that are released primarily by atrial tissue but are also synthesized by the gut, kidney, brain, adrenal glands, and endothelium. The functionally active forms of the peptides are C-terminal fragments of a larger prohormone, and both N- and C-terminal fragments are detectable in the blood (referred to a N-terminal pro-BNP and pro-ANF, respectively). ANF and BNP share most biologic properties including diuretic, natriuretic, vasorelaxant, and cardiac remodeling properties that are effected by signaling through a common receptor: the guanylyl cyclase-A (GC-A) receptor. They are both increased in the setting of cardiac disorders; however, recent evidence indicates some distinctions in the setting of inflammation. For example, endotoxemia in healthy volunteers increased plasma N-terminal pro-BNP without changing heart rate and blood pressure. Also, elevated pro-BNP has been detected in septic patients in the absence of myocardial dysfunction and appears to have prognostic significance.¹³²

SURGICAL METABOLISM

The initial hours after surgical or traumatic injury are metabolically associated with a reduced total body energy expenditure and urinary nitrogen wasting. On adequate resuscitation and stabilization of the injured patient, a reprioritization of substrate use ensues to preserve vital organ function and to support repair of injured tissue. This phase of recovery also is characterized

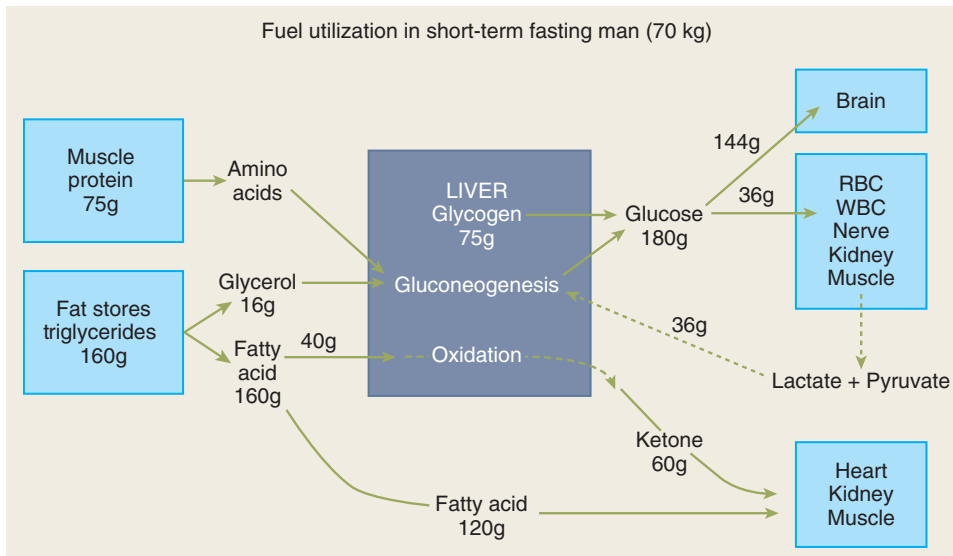


Figure 2-14. Fuel utilization in a 70-kg man during short-term fasting with an approximate basal energy expenditure of 1800 kcal. During starvation, muscle proteins and fat stores provide fuel for the host, with the latter being most abundant. RBC = red blood cell; WBC = white blood cell. (Adapted from Cahill GF: *Starvation in man*. N Engl J Med. 1970;282:668.)

by functions that participate in the restoration of homeostasis, such as augmented metabolic rates and oxygen consumption, enzymatic preference for readily oxidizable substrates such as glucose, and stimulation of the immune system. Understanding of the collective alterations in amino acid (protein), carbohydrate, and lipid metabolism characteristic of the surgical patient lays the foundation upon which metabolic and nutritional support can be implemented.

Metabolism during Fasting

Fuel metabolism during unstressed fasting states has historically served as the standard to which metabolic alterations after acute injury and critical illness are compared (Fig. 2-14). To maintain basal metabolic needs (i.e., at rest and fasting), a normal healthy adult requires approximately 22 to 25 kcal/kg per day drawn from carbohydrate, lipid, and protein sources. This requirement can be as high as 40 kcal/kg per day in severe stress states, such as those seen in patients with burn injuries.

In the healthy adult, principal sources of fuel during short-term fasting (<5 days) are derived from muscle protein and body fat, with fat being the most abundant source of energy (Table 2-8). The normal adult body contains 300 to 400 g of carbohydrates in the form of glycogen, of which 75 to 100 g are stored in the liver. Approximately 200 to 250 g of glycogen are stored within skeletal, cardiac, and smooth muscle cells. The greater glycogen stores within the muscle are not readily available for systemic use due to a deficiency in glucose-6-phosphatase but are available for the energy needs of muscle cells. Therefore, in the fasting state, hepatic glycogen stores are rapidly and preferentially depleted, which results in a fall of serum glucose concentration within hours (<16 hours).

During fasting, a healthy 70-kg adult will use 180 g of glucose per day to support the metabolism of obligate glycolytic cells such as neurons, leukocytes, erythrocytes, and the renal medullae. Other tissues that use glucose for fuel are skeletal muscle, intestinal mucosa, fetal tissues, and solid tumors.

Table 2-8

A. Body fuel reserves in a 70-kg man and B. Energy equivalent of substrate oxidation

A. COMPONENT			MASS (kg)	ENERGY (kcal)	DAYS AVAILABLE
Water and minerals			49	0	0
Protein			6.0	24,000	13.0
Glycogen			0.2	800	0.4
Fat			15.0	140,000	78.0
Total			70.2	164,800	91.4
B. SUBSTRATE	O ₂ CONSUMED (L/g)	CO ₂ PRODUCED (L/g)	RESPIRATORY QUOTIENT	kcal/g	RECOMMENDED DAILY REQUIREMENT
Glucose	0.75	0.75	1.0	4.0	7.2 g/kg per day
Dextrose	—	—	—	3.4	—
Lipid	2.0	1.4	0.7	9.0	1.0 g/kg per day
Protein	1.0	0.8	0.8	4.0	0.8 g/kg per day

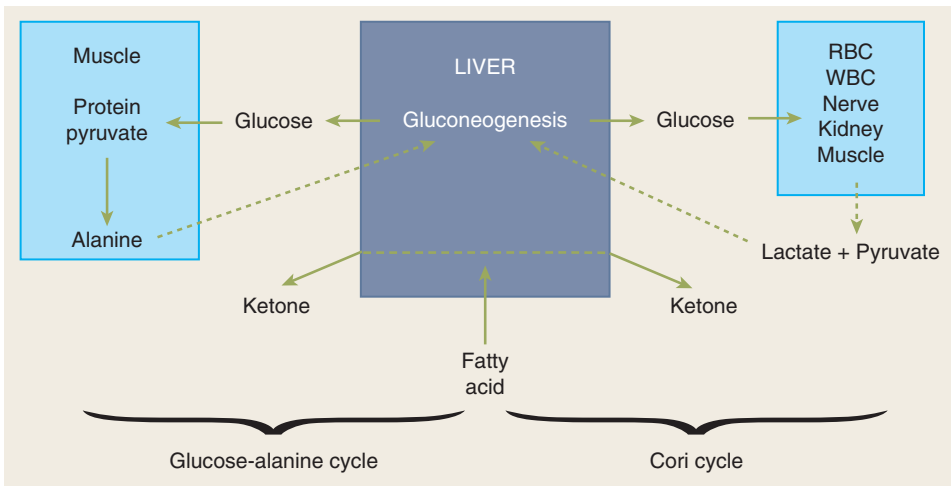


Figure 2-15. The recycling of peripheral lactate and pyruvate for hepatic gluconeogenesis is accomplished by the Cori cycle. Alanine within skeletal muscles can also be used as a precursor for hepatic gluconeogenesis. During starvation, such fatty acid provides fuel sources for basal hepatic enzymatic function. RBC = red blood cell; WBC = white blood cell.

Glucagon, NE, vasopressin, and angiotensin II can promote the utilization of glycogen stores (glycogenolysis) during fasting. Although glucagon, EPI, and cortisol directly promote gluconeogenesis, EPI and cortisol also promote pyruvate shuttling to the liver for gluconeogenesis. Precursors for hepatic gluconeogenesis include lactate, glycerol, and amino acids such as alanine and glutamine. Lactate is released by glycolysis within skeletal muscles, as well as by erythrocytes and leukocytes. The recycling of lactate and pyruvate for gluconeogenesis is commonly referred to as the *Cori cycle*, which can provide up to 40% of plasma glucose during starvation (Fig. 2-15).

Lactate production from skeletal muscle is insufficient to maintain systemic glucose needs during short-term fasting (simple starvation). Therefore, significant amounts of protein must be degraded daily (75 g/d for a 70-kg adult) to provide the amino acid substrate for hepatic gluconeogenesis. Proteolysis

during starvation, which results primarily from decreased insulin and increased cortisol release, is associated with elevated urinary nitrogen excretion from the normal 7 to 10 g per day up to 30 g or more per day.¹³³ Although proteolysis during starvation occurs mainly within skeletal muscles, protein degradation in solid organs also occurs.

In prolonged starvation, systemic proteolysis is reduced to approximately 20 g/d, and urinary nitrogen excretion stabilizes at 2 to 5 g/d (Fig. 2-16). This reduction in proteolysis reflects the adaptation by vital organs (e.g., myocardium, brain, renal cortex, and skeletal muscle) to using ketone bodies as their principal fuel source. In extended fasting, ketone bodies become an important fuel source for the brain after 2 days and gradually become the principal fuel source by 24 days.

Enhanced deamination of amino acids for gluconeogenesis during starvation consequently increases renal excretion of

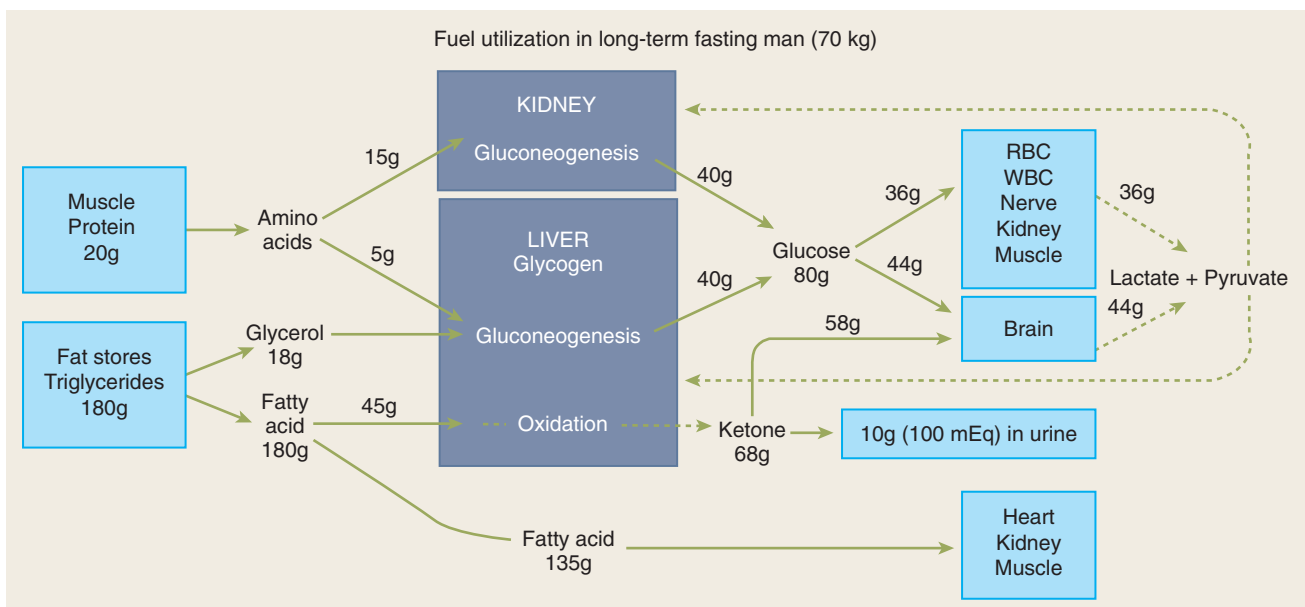


Figure 2-16. Fuel utilization in extended starvation. Liver glycogen stores are depleted, and there is adaptive reduction in proteolysis as a source of fuel. The brain uses ketones for fuel. The kidneys become important participants in gluconeogenesis. RBC = red blood cell; WBC = white blood cell. (Adapted from Cahill GF: *Starvation in man*. N Engl J Med. 1970;282:668.)

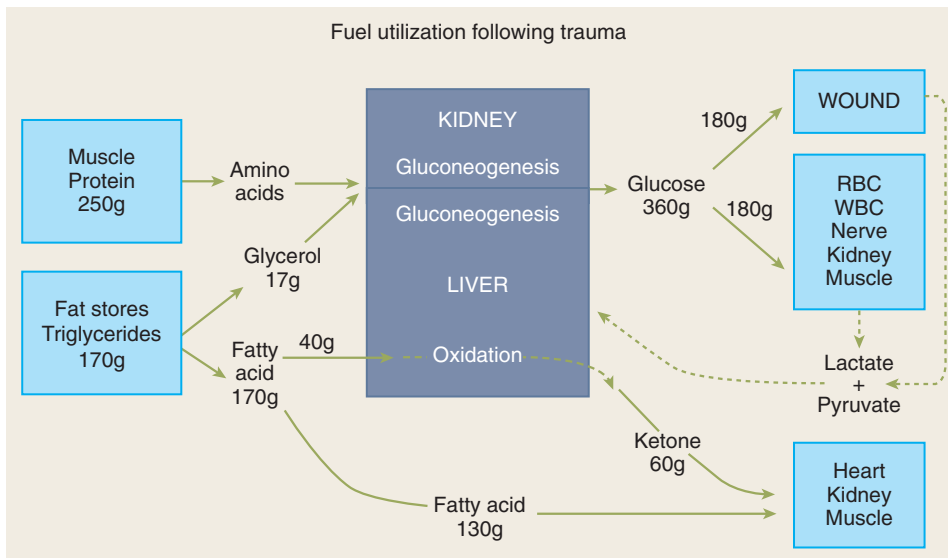


Figure 2-17. Acute injury is associated with significant alterations in substrate utilization. There is enhanced nitrogen loss, indicative of catabolism. Fat remains the primary fuel source under these circumstances. RBC = red blood cell; WBC = white blood cell.

ammonium ions. The kidneys also participate in gluconeogenesis by the use of glutamine and glutamate, and can become the primary source of gluconeogenesis during prolonged starvation, accounting for up to one half of systemic glucose production.

Lipid stores within adipose tissue provide 40% or more of caloric expenditure during starvation. Energy requirements for basal enzymatic and muscular functions (e.g., gluconeogenesis, neural transmission, and cardiac contraction) are met by the mobilization of triglycerides from adipose tissue. In a resting, fasting, 70-kg person, approximately 160 g of free fatty acids and glycerol can be mobilized from adipose tissue per day. Free fatty acid release is stimulated in part by a reduction in serum insulin levels and in part by the increase in circulating glucagon and catecholamine. Such free fatty acids, like ketone bodies, are used as fuel by tissues such as the heart, kidney (renal cortex), muscle, and liver. The mobilization of lipid stores for energy importantly decreases the rate of glycolysis, gluconeogenesis, and proteolysis, as well as the overall glucose requirement to sustain the host. Furthermore, ketone bodies spare glucose utilization by inhibiting the enzyme pyruvate dehydrogenase.

Metabolism after Injury

Injuries or infections induce unique neuroendocrine and immunologic responses that differentiate injury metabolism from that of unstressed fasting (Fig. 2-17). The magnitude of metabolic expenditure appears to be directly proportional to the severity of insult, with thermal injuries and severe infections having the highest energy demands (Fig. 2-18). The increase in energy expenditure is mediated in part by sympathetic activation and catecholamine release, which has been replicated by the administration of catecholamines to healthy human subjects. Lipid metabolism after injury is intentionally discussed first, because this macronutrient becomes the primary source of energy during stressed states.¹³⁴

Lipid Metabolism after Injury

Lipids are not merely nonprotein, noncarbohydrate fuel sources that minimize protein catabolism in the injured patient. Lipid metabolism potentially influences the structural integrity of cell membranes as well as the immune response during systemic inflammation. Adipose stores within the body (triglycerides) are

the predominant energy source (50% to 80%) during critical illness and after injury. Fat mobilization (lipolysis) occurs mainly in response to catecholamine stimulus of the hormone-sensitive triglyceride lipase. Other hormonal influences that potentiate lipolysis include adrenocorticotropic hormone (ACTH), catecholamines, thyroid hormone, cortisol, glucagon, GH release, and reduction in insulin levels.¹³⁵

Lipid Absorption. Although the process is poorly understood, adipose tissue provides fuel for the host in the form of free fatty acids and glycerol during critical illness and injury. Oxidation of 1 g of fat yields approximately 9 kcal of energy. Although the liver is capable of synthesizing triglycerides from carbohydrates and

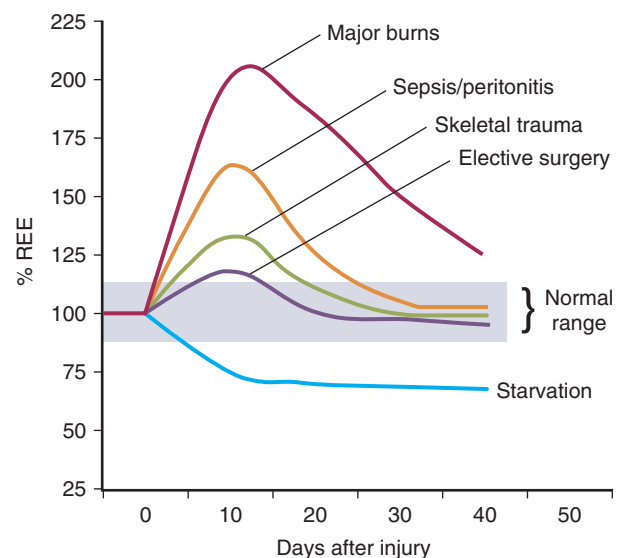


Figure 2-18. Influence of injury severity on resting metabolism (resting energy expenditure, or REE). The shaded area indicates normal REE. (From Long CL, Schaffel N, Geiger J, et al. *Metabolic response to injury and illness: estimation of energy and protein needs from indirect calorimetry and nitrogen balance*. JPEN J Parenter Enteral Nutr. 1979;3(6):452. Copyright © 1979 by A.S.P.E.N. Reprinted by permission of Sage Publications.)

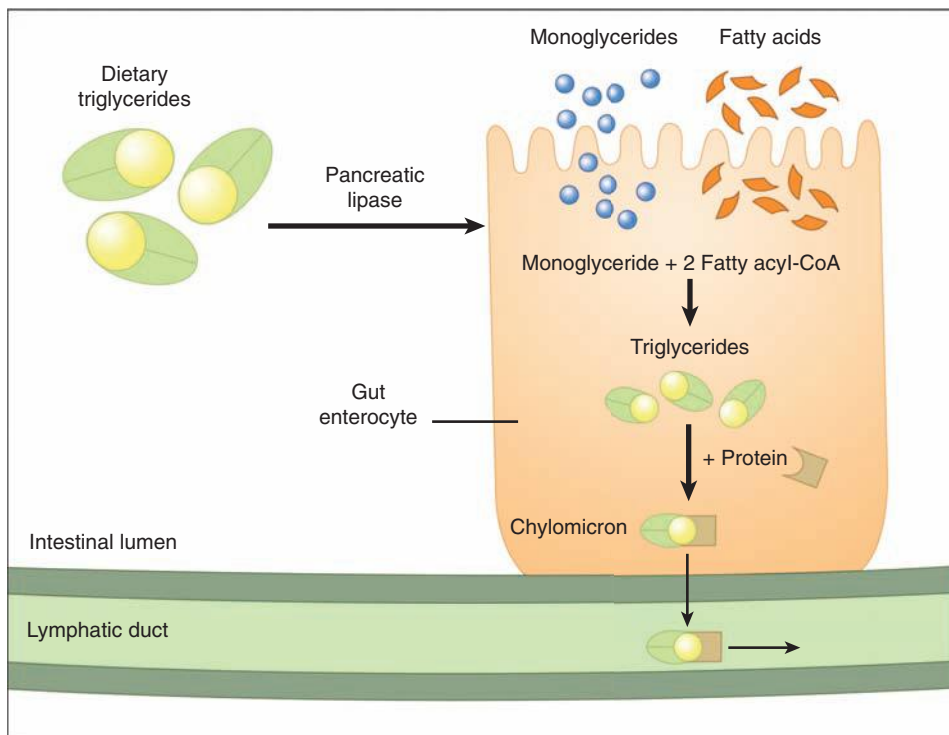


Figure 2-19. Pancreatic lipase within the small intestinal brush borders hydrolyzes triglycerides into monoglycerides and fatty acids. These components readily diffuse into the gut enterocytes, where they are re-esterified into triglycerides. The resynthesized triglycerides bind carrier proteins to form chylomicrons, which are transported by the lymphatic system. Shorter triglycerides (those with <10 carbon atoms) can bypass this process and directly enter the portal circulation for transport to the liver. CoA = coenzyme A.

amino acids, dietary and exogenous sources provide the major source of triglycerides. Dietary lipids are not readily absorbable in the gut but require pancreatic lipase and phospholipase within the duodenum to hydrolyze the triglycerides into free fatty acids and monoglycerides. The free fatty acids and monoglycerides are then readily absorbed by gut enterocytes, which resynthesize triglycerides by esterification of the monoglycerides with fatty acyl coenzyme A (acyl-CoA) (Fig. 2-19). Long-chain triglycerides (LCTs), defined as those with 12 carbons or more, generally undergo this process of esterification and enter the circulation through the lymphatic system as chylomicrons. Shorter fatty acid chains directly enter the portal circulation and are transported to the liver by albumin carriers. Hepatocytes use free fatty acids as a fuel source during stress states but also can synthesize phospholipids or triglycerides (i.e., very-low-density lipoproteins) during fed states. Systemic tissue (e.g., muscle and the heart) can use chylomicrons and triglycerides as fuel by hydrolysis with lipoprotein lipase at the luminal surface of capillary endothelium.¹³⁶ Trauma or sepsis suppresses lipoprotein lipase activity in both adipose tissue and muscle, presumably mediated by TNF.

Lipolysis and Fatty Acid Oxidation. Periods of energy demand are accompanied by free fatty acid mobilization from adipose stores. This is mediated by hormonal influences (e.g., catecholamines, ACTH, thyroid hormones, GH, and glucagon) on triglyceride lipase through a cAMP pathway (Fig. 2-20). In adipose tissues, triglyceride lipase hydrolyzes triglycerides into free fatty acids and glycerol. Free fatty acids enter the capillary circulation and are transported by albumin to tissues requiring this fuel source (e.g., heart and skeletal muscle). Insulin inhibits lipolysis and favors triglyceride synthesis by augmenting lipoprotein lipase activity as well as intracellular levels of glycerol-3-phosphate. The use of glycerol for fuel depends on the availability of tissue glycerokinase, which is abundant in the liver and kidneys.

Free fatty acids absorbed by cells conjugate with acyl-CoA within the cytoplasm. The transport of fatty acyl-CoA from the outer mitochondrial membrane across the inner mitochondrial membrane occurs via the carnitine shuttle (Fig. 2-21). Medium-chain triglycerides (MCTs), defined as those 6 to 12 carbons in length, bypass the carnitine shuttle and readily cross the mitochondrial membranes. This accounts in part for the fact that MCTs are more efficiently oxidized than LCTs. Ideally, the rapid oxidation of MCTs makes them less prone to fat deposition, particularly within immune cells and the reticuloendothelial system—a common finding with lipid infusion in parenteral nutrition.¹³⁷ However, exclusive use of MCTs as fuel in animal studies has been associated with higher metabolic demands and toxicity, as well as essential fatty acid deficiency.

Within the mitochondria, fatty acyl-CoA undergoes beta oxidation, which produces acetyl-CoA with each pass through the cycle. Each acetyl-CoA molecule subsequently enters the tricarboxylic acid (TCA) cycle for further oxidation to yield 12 ATP molecules, carbon dioxide, and water. Excess acetyl-CoA molecules serve as precursors for ketogenesis. Unlike glucose metabolism, oxidation of fatty acids requires proportionally less oxygen and produces less carbon dioxide. This is frequently quantified as the ratio of carbon dioxide produced to oxygen consumed for the reaction and is known as the *respiratory quotient (RQ)*. An RQ of 0.7 would imply greater fatty acid oxidation for fuel, whereas an RQ of 1 indicates greater carbohydrate oxidation (overfeeding). An RQ of 0.85 suggests the oxidation of equal amounts of fatty acids and glucose.

Ketogenesis

Carbohydrate depletion slows the entry of acetyl-CoA into the TCA cycle secondary to depleted TCA intermediates and enzyme activity. Increased lipolysis and reduced systemic carbohydrate availability during starvation diverts excess acetyl-CoA toward hepatic ketogenesis. A number of extrahepatic

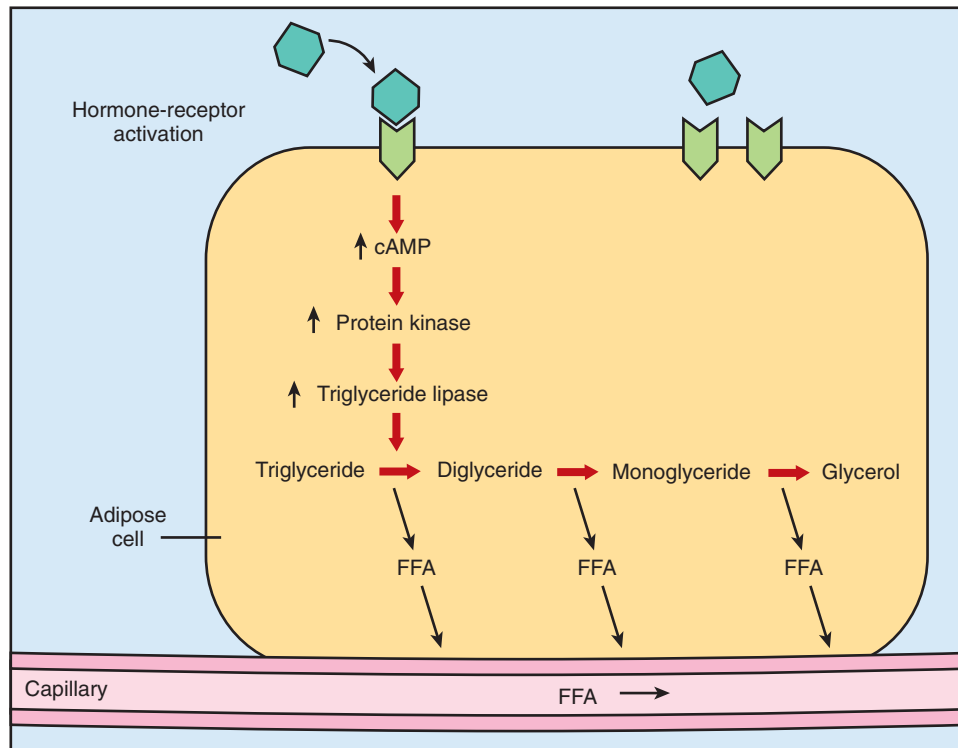


Figure 2-20. Fat mobilization in adipose tissue. Triglyceride lipase activation by hormonal stimulation of adipose cells occurs through the cyclic adenosine monophosphate (cAMP) pathway. Triglycerides are serially hydrolyzed with resultant free fatty acid (FFA) release at every step. The FFAs diffuse readily into the capillary bed for transport. Tissues with glycerokinase can use glycerol for fuel by forming glycerol-3-phosphate. Glycerol-3-phosphate can esterify with FFAs to form triglycerides or can be used as a precursor for renal and hepatic gluconeogenesis. Skeletal muscle and adipose cells have little glycerokinase and thus do not use glycerol for fuel.

tissues, but not the liver itself, are capable of using ketones for fuel. Ketosis represents a state in which hepatic ketone production exceeds extrahepatic ketone utilization.

The rate of ketogenesis appears to be inversely related to the severity of injury. Major trauma, severe shock, and sepsis attenuate ketogenesis by increasing insulin levels and by causing rapid tissue oxidation of free fatty acids. Minor injuries and infections are associated with modest elevations in plasma free fatty acid concentrations and ketogenesis. However, in minor stress states ketogenesis does not exceed that in nonstressed starvation.

Carbohydrate Metabolism

Ingested and enteral carbohydrates are primarily digested in the small intestine, where pancreatic and intestinal enzymes reduce the complex carbohydrates to dimeric units. Disaccharidases (e.g., sucrase, lactase, and maltase) within intestinal brush borders dismantle the complex carbohydrates into simple hexose units, which are transported into the intestinal mucosa. Glucose and galactose are primarily absorbed by energy-dependent active transport coupled to the sodium pump. Fructose absorption, however, occurs by concentration-dependent facilitated diffusion. Neither fructose or galactose within the circulation nor exogenous mannitol (for neurologic injury) evokes an insulin response. Intravenous administration of low-dose fructose in fasting humans has been associated with nitrogen conservation, but the clinical utility of fructose administration in human injury remains to be demonstrated.

Discussion of carbohydrate metabolism primarily refers to the utilization of glucose. The oxidation of 1 g of carbohydrate

yields 4 kcal, but sugar solutions such as those found in intravenous fluids or parenteral nutrition provide only 3.4 kcal/g of dextrose. In starvation, glucose production occurs at the expense of protein stores (i.e., skeletal muscle). Hence, the primary goal for maintenance glucose administration in surgical patients is to minimize muscle wasting. The exogenous administration of small amounts of glucose (approximately 50 g/d) facilitates fat entry into the TCA cycle and reduces ketosis. Unlike in starvation in healthy subjects, in septic and trauma patients, provision of exogenous glucose never has been shown to fully suppress amino acid degradation for gluconeogenesis. This suggests that during periods of stress, other hormonal and proinflammatory mediators have a profound influence on the rate of protein degradation and that some degree of muscle wasting is inevitable. The administration of insulin, however, has been shown to reverse protein catabolism during severe stress by stimulating protein synthesis in skeletal muscles and by inhibiting hepatocyte protein degradation. Insulin also stimulates the incorporation of elemental precursors into nucleic acids in association with RNA synthesis in muscle cells.

In cells, glucose is phosphorylated to form glucose-6-phosphate. Glucose-6-phosphate can be polymerized during glycogenesis or catabolized in glycogenolysis. Glucose catabolism occurs by cleavage to pyruvate or lactate (pyruvic acid pathway) or by decarboxylation to pentoses (pentose shunt) (Fig. 2-22).

Excess glucose from overfeeding, as reflected by RQs >1.0, can result in conditions such as glucosuria, thermogenesis, and conversion to fat (lipogenesis). Excessive glucose administration results in elevated carbon dioxide production, which may

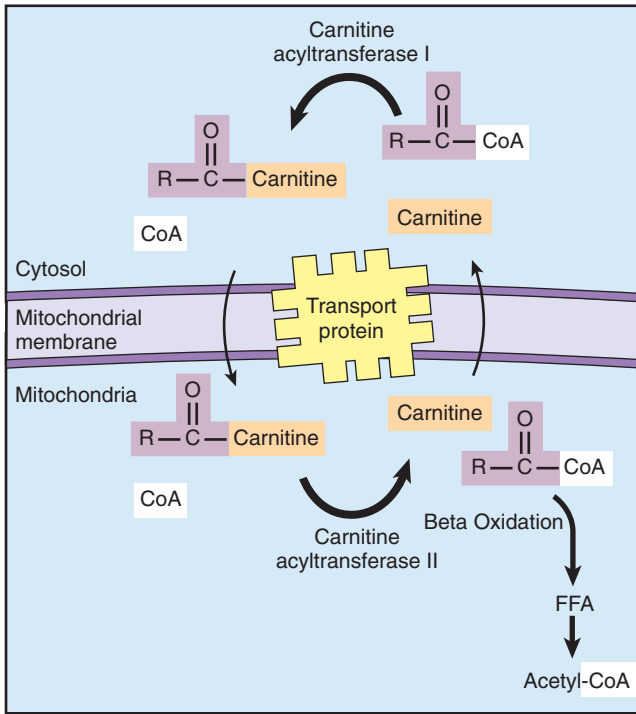


Figure 2-21. Free fatty acids (FFAs) in the cells form fatty acyl-coenzyme A (CoA) with CoA. Fatty acyl-CoA cannot enter the inner mitochondrial membrane and requires carnitine as a carrier protein (carnitine shuttle). Once inside the mitochondria, carnitine dissociates and fatty acyl-CoA is re-formed. The carnitine molecule is transported back into the cytosol for reuse. The fatty acyl-CoA undergoes beta oxidation to form acetyl-CoA for entry into the tricarboxylic acid cycle. “R” represents a part of the acyl group of acyl-CoA.

be deleterious in patients with suboptimal pulmonary function, as well as hyperglycemia, which may contribute to infectious risk and immune suppression.

Injury and severe infections acutely induce a state of peripheral glucose intolerance, despite ample insulin production at levels several fold above baseline. This may occur in part due to reduced skeletal muscle pyruvate dehydrogenase activity after injury, which diminishes the conversion of pyruvate to acetyl-CoA and subsequent entry into the TCA cycle. The three-carbon structures (e.g., pyruvate and lactate) that consequently accumulate are shunted to the liver as substrate for gluconeogenesis. Furthermore, regional tissue catheterization and isotope dilution studies have shown an increase in net splanchnic glucose production by 50% to 60% in septic patients and a 50% to 100% increase in burn patients.¹³⁷ The increase in plasma glucose levels is proportional to the severity of injury, and this net hepatic gluconeogenic response is believed to be under the influence of glucagon. Unlike in the nonstressed subject, in the hypermetabolic, critically ill patient, the hepatic gluconeogenic response to injury or sepsis cannot be suppressed by exogenous or excess glucose administration but rather persists. Hepatic gluconeogenesis, arising primarily from alanine and glutamine catabolism, provides a ready fuel source for tissues such as those of the nervous system, wounds, and erythrocytes, which do not require insulin for glucose transport. The elevated glucose concentrations also provide a necessary energy source for leukocytes in inflamed tissues and in sites of microbial invasions.

The shunting of glucose away from nonessential organs such as skeletal muscle and adipose tissues is mediated by catecholamines. Experiments with infusing catecholamines and glucagon in animals have demonstrated elevated plasma glucose levels as a result of increased hepatic gluconeogenesis and

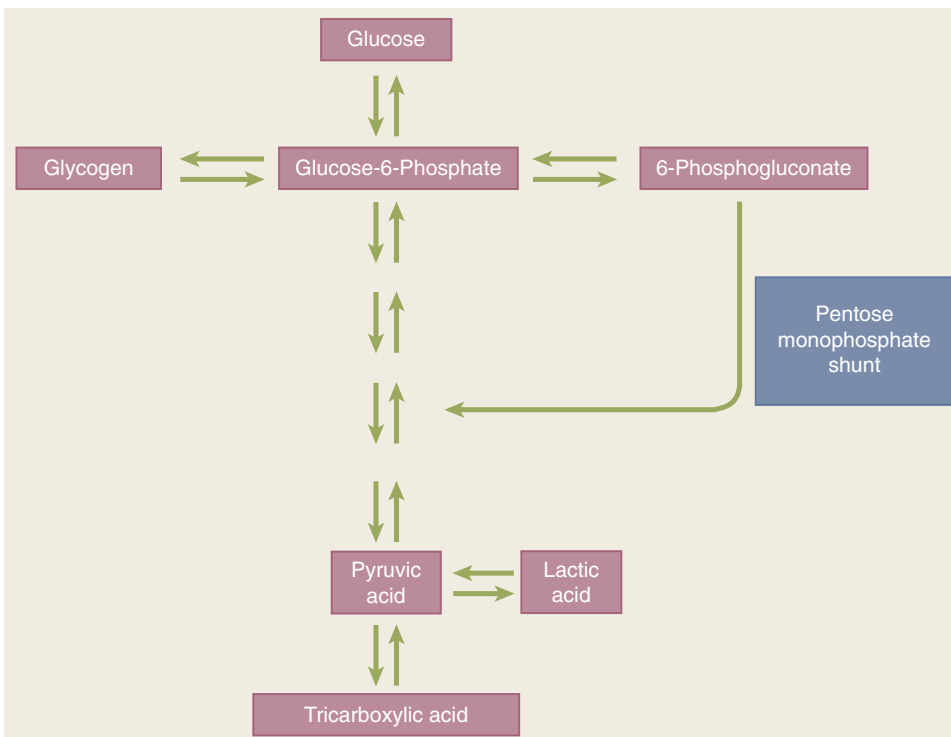


Figure 2-22. Simplified schema of glucose catabolism through the pentose monophosphate pathway or by breakdown into pyruvate. Glucose-6-phosphate becomes an important “crossroad” for glucose metabolism.

peripheral insulin resistance. Interestingly, although glucocorticoid infusion alone does not increase glucose levels, it does prolong and augment the hyperglycemic effects of catecholamines and glucagon when glucocorticoid is administered concurrently with the latter.

Glycogen stores within skeletal muscles can be mobilized by EPI activation of β -adrenergic receptors, GTP-binding proteins (G proteins), which subsequently activates the second messenger, cAMP. The cAMP activates phosphorylase kinase, which in turn leads to conversion of glycogen to glucose-1-phosphate. Phosphorylase kinase also can be activated by the second messenger, calcium, through the breakdown of phosphatidylinositol phosphate, which is the case in vasopressin-mediated hepatic glycogenolysis.¹³⁸

Glucose Transport and Signaling. Hydrophobic cell membranes are relatively impermeable to hydrophilic glucose molecules. There are two distinct classes of membrane glucose transporters in human systems. These are the facilitated diffusion glucose transporters (GLUTs) that permit the transport of glucose down a concentration gradient (Table 2-9) and the Na^+ /glucose secondary active transport system (SGLT), which transports glucose molecules against concentration gradients by active transport.

Numerous functional human GLUTs have been cloned since 1985. GLUT1 is expressed at its highest level in human erythrocytes, where it may function to increase the glucose carrying capacity of the blood. It is expressed on several other tissues, but little is found in the liver and skeletal muscle. GLUT1 plays a critical role in cerebral glucose uptake as the major GLUT isoform that is constitutively expressed by the endothelium in the blood-brain barrier. GLUT2 is the major glucose transporter of hepatocytes. It is also expressed by intestinal absorptive cells, pancreatic β -cells, renal tubule cells, and insulin-secreting β -cells of the pancreas. GLUT2 is important for glucose uptake and release in the fed and fasted states. GLUT3 is highly expressed in neuronal tissue of the brain and appears to be important to neuronal glucose uptake. GLUT4 is significant to human metabolism because it is the primary glucose transporter of insulin-sensitive tissues, adipose tissue, and skeletal and cardiac muscle. Under basal conditions, these transporters are usually packaged as intracellular vesicles, but when insulin levels rise, rapid translocation of these vesicles to the cell surface occurs, increasing glucose uptake and metabolism in these tissues and preventing chronic elevations in blood glucose levels.

Table 2-9

Human facilitated diffusion glucose transporter (GLUT) family

TYPE	AMINO ACIDS	MAJOR EXPRESSION SITES
GLUT1	492	Placenta, brain, kidney, colon
GLUT2	524	Liver, pancreatic β -cells, kidney, small intestine
GLUT3	496	Brain, testis
GLUT4	509	Skeletal muscle, heart muscle, brown and white fat
GLUT5	501	Small intestine, sperm

A defect in this insulin-mediated translocation of GLUT4 to the plasma membrane causes peripheral insulin resistance. GLUT4 therefore plays a critical role in the regulation of whole-body glucose homeostasis. GLUT5 has been identified in several tissues but is primarily expressed in the jejunum. Although it possesses some capacity for glucose transport, it is predominantly a fructose transporter.¹³⁹

SGLTs are distinct glucose transport systems found in the intestinal epithelium and in the proximal renal tubules. These systems transport both sodium and glucose intracellularly, and glucose affinity for this transporter increases when sodium ions are attached. SGLT1 is prevalent on brush borders of small intestine enterocytes and primarily mediates the active uptake of luminal glucose. In addition, SGLT1 within the intestinal lumen also enhances gut retention of water through osmotic absorption. SGLT1 and SGLT2 are both associated with glucose reabsorption at proximal renal tubules.

Protein and Amino Acid Metabolism

The average protein intake in healthy young adults ranges from 80 to 120 g/d, and every 6 g of protein yields approximately 1 g of nitrogen. The degradation of 1 g of protein yields approximately 4 kcal of energy, similar to the yield in carbohydrate metabolism.

After injury, the initial systemic proteolysis, mediated primarily by glucocorticoids, increases urinary nitrogen excretion to levels in excess of 30 g/d, which roughly corresponds to a loss in lean body mass of 1.5% per day. An injured individual who does not receive nutrition for 10 days can theoretically lose 15% lean body mass. Therefore, amino acids cannot be considered a long-term fuel reserve, and indeed excessive protein depletion (i.e., 25% to 30% of lean body weight) is not compatible with sustaining life.¹⁴⁰

Protein catabolism after injury provides substrates for gluconeogenesis and for the synthesis of acute-phase proteins. Radiolabeled amino acid incorporation studies and protein analyses confirm that skeletal muscles are preferentially depleted acutely after injury, whereas visceral tissues (e.g., the liver and kidney) remain relatively preserved. The accelerated urea excretion after injury also is associated with the excretion of intracellular elements such as sulfur, phosphorus, potassium, magnesium, and creatinine. Conversely, the rapid utilization of elements such as potassium and magnesium during recovery from major injury may indicate a period of tissue healing.

The net changes in protein catabolism and synthesis correspond to the severity and duration of injury (Fig. 2-23). Elective operations and minor injuries result in lower protein synthesis and moderate protein breakdown. Severe trauma, burns, and sepsis are associated with increased protein catabolism. The rise in urinary nitrogen and negative nitrogen balance can be detected early after injury and peak by 7 days. This state of protein catabolism may persist for as long as 3 to 7 weeks. The patient's prior physical status and age appear to influence the degree of proteolysis after injury or sepsis. Activation of the ubiquitin-proteasome system in muscle cells is one of the major pathways for protein degradation during acute injury. This response is accentuated by tissue hypoxia, acidosis, insulin resistance, and elevated glucocorticoid levels.

NUTRITION IN THE SURGICAL PATIENT

The goal of nutritional support in the surgical patient is to prevent or reverse the catabolic effects of disease or injury. Although several important biologic parameters have been used

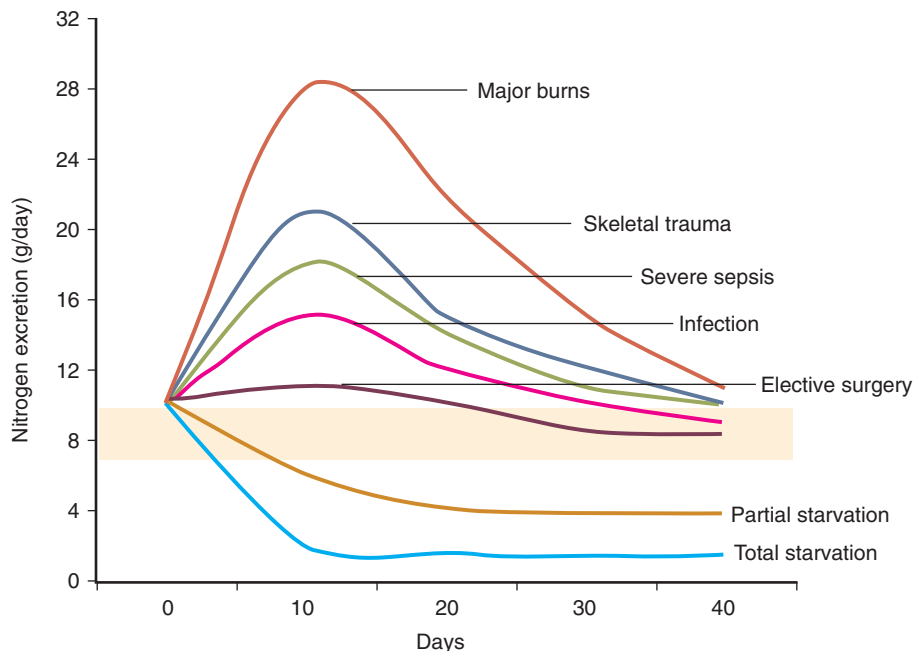


Figure 2-23. The effect of injury severity on nitrogen wasting. (From Long CL, Schaffel N, Geiger J, et al. *Metabolic response to injury and illness: estimation of energy and protein needs from indirect calorimetry and nitrogen balance*. JPEN J Parenter Enteral Nutr. 1979;3(6):452. Copyright © 1979 by A.S.P.E.N. Reprinted by permission of Sage Publications.)

to measure the efficacy of nutritional regimens, the ultimate validation for nutritional support in surgical patients should be improvement in clinical outcome and restoration of function.

Estimation of Energy Requirements

Overall nutritional assessment is undertaken to determine the severity of nutrient deficiencies or excess and to aid in predicting nutritional requirements. Pertinent information is obtained by determining the presence of weight loss, chronic illnesses, or dietary habits that influence the quantity and quality of food intake. Social habits predisposing to malnutrition and the use of medications that may influence food intake or urination should also be investigated. Physical examination seeks to assess loss of muscle and adipose tissues, organ dysfunction, and subtle changes in skin, hair, or neuromuscular function reflecting frank or impending nutritional deficiency. Anthropometric data (i.e., weight change, skinfold thickness, and arm circumference muscle area) and biochemical determinations (i.e., creatinine excretion, albumin level, prealbumin level, total lymphocyte count, and transferrin level) may be used to substantiate the patient's history and physical findings. However, it is imprecise to rely on any single or fixed combination of the findings to accurately assess nutritional status or morbidity. Appreciation for the stresses and natural history of the disease process, in combination with nutritional assessment, remains the basis for identifying patients in acute or anticipated need of nutritional support.

A fundamental goal of nutritional support is to meet the energy requirements for essential metabolic processes and tissue repair. Failure to provide adequate nonprotein energy sources will lead to consumption of lean tissue stores. The requirement for energy may be measured by indirect calorimetry and trends in serum markers (e.g., prealbumin level) and estimated from urinary nitrogen excretion, which is proportional to resting energy expenditure.¹³⁸ However, the use of indirect calorimetry, particularly in the critically ill patient, is labor intensive and often leads to overestimation of caloric requirements.

Basal energy expenditure (BEE) may also be estimated using the Harris-Benedict equations:

$$\begin{aligned} \text{BEE (men)} &= 66.47 + 13.75 (W) + 5.0 (H) - 6.76 (A) \text{ kcal/d} \\ \text{BEE (women)} &= 655.1 + 9.56 (W) + \\ &1.85 (H) - 4.68 (A) \text{ kcal/d} \end{aligned}$$

where W = weight in kilograms; H = height in centimeters; and A = age in years.

These equations, adjusted for the type of surgical stress, are suitable for estimating energy requirements in the majority of hospitalized patients. It has been demonstrated that the provision of 30 kcal/kg per day will adequately meet energy requirements in most postsurgical patients, with a low risk of overfeeding. After trauma or sepsis, energy substrate demands are increased, necessitating greater nonprotein calories beyond calculated energy expenditure (Table 2-10). These additional nonprotein calories provided after injury are usually 1.2 to 2.0 times greater than calculated resting energy expenditure, depending on the type of injury. It is seldom appropriate to exceed this level of nonprotein energy intake during the height of the catabolic phase.

The second objective of nutritional support is to meet the substrate requirements for protein synthesis. An appropriate nonprotein-calorie:nitrogen ratio of 150:1 (e.g., 1 g N = 6.25 g protein) should be maintained, which is the basal calorie requirement provided to limit the use of protein as an energy source. There is now greater evidence suggesting that increased protein intake and a lower calorie:nitrogen ratio of 80:1 to 100:1 may benefit healing in selected hypermetabolic or critically ill patients. In the absence of severe renal or hepatic dysfunction precluding the use of standard nutritional regimens, approximately 0.25 to 0.35 g of nitrogen per kilogram of body weight should be provided daily.¹⁴¹

Vitamins and Minerals

The requirements for vitamins and essential trace minerals usually can be met easily in the average patient with an

Table 2-10

Caloric adjustments above basal energy expenditure (BEE) in hypermetabolic conditions

CONDITION	kcal/kg PER DAY	ADJUSTMENT ABOVE BEE	GRAMS OF PROTEIN/ kg PER DAY	NONPROTEIN CALORIES: NITROGEN
Normal/moderate malnutrition	25–30	1.1	1.0	150:1
Mild stress	25–30	1.2	1.2	150:1
Moderate stress	30	1.4	1.5	120:1
Severe stress	30–35	1.6	2.0	90–120:1
Burns	35–40	2.0	2.5	90–100:1

uncomplicated postoperative course. Therefore, vitamins usually are not given in the absence of preoperative deficiencies. Patients maintained on elemental diets or parenteral hyperalimentation require complete vitamin and mineral supplementation. Commercial enteral diets contain varying amounts of essential minerals and vitamins. It is necessary to ensure that adequate replacement is available in the diet or by supplementation. Numerous commercial vitamin preparations are available for intravenous or intramuscular use, although most do not contain vitamin K and some do not contain vitamin B₁₂ or folic acid. Supplemental trace minerals may be given intravenously via commercial preparations. Essential fatty acid supplementation also may be necessary, especially in patients with depletion of adipose stores.

Overfeeding

Overfeeding usually results from overestimation of caloric needs, as occurs when actual body weight is used to calculate the BEE in patient populations such as the critically ill with significant fluid overload and the obese. Indirect calorimetry can be used to quantify energy requirements but frequently overestimates BEE by 10% to 15% in stressed patients, particularly if they are receiving ventilatory support. In these instances, estimated dry weight should be obtained from preinjury records or family members. Adjusted lean body weight also can be calculated. Overfeeding may contribute to clinical deterioration via increased oxygen consumption, increased carbon dioxide production and prolonged need for ventilatory support, fatty liver, suppression of leukocyte function, hyperglycemia, and increased risk of infection.

ENTERAL NUTRITION

Rationale for Enteral Nutrition

Enteral nutrition generally is preferred over parenteral nutrition based on the lower cost of enteral feeding and the associated risks of the intravenous route, including vascular access complications.¹⁴² Of further consideration are the consequences of gastrointestinal tract disuse, which include diminished secretory IgA production and cytokine production as well as bacterial overgrowth and altered mucosal defenses. For example, laboratory models have long demonstrated that luminal nutrient contact reduces intestinal mucosal atrophy compared with parenteral or no nutritional support.

The benefits of enteral feeding in patients undergoing elective surgery appear to be linked to their preoperative

nutritional status. Studies comparing postoperative enteral and parenteral nutrition in patients undergoing gastrointestinal surgery have demonstrated reduced infectious complications and acute-phase protein production in those fed by the enteral route. Yet prospectively randomized studies of patients with adequate nutritional status (albumin ≥ 4 g/dL) undergoing gastrointestinal surgery demonstrate no differences in outcome and complications between those administered enteral nutrition and those given maintenance intravenous fluids alone in the initial days after surgery.¹⁴³ Furthermore, intestinal permeability studies in well-nourished patients undergoing upper gastrointestinal cancer surgery demonstrated normalization of intestinal permeability and barrier function by the fifth postoperative day.¹⁴⁴ The data for critically ill or injured patients are more definitive as to the benefits of enteral nutrition. Meta-analysis of studies involving critically ill patients demonstrates a 44% reduction in infectious complications in those receiving enteral nutritional support compared with those receiving parenteral nutrition. Most prospectively randomized studies in patients with severe abdominal and thoracic trauma demonstrate significant reductions in infectious complications in patients given early enteral nutrition compared with those who were unfed or received parenteral nutrition. In critically ill patients, prospective studies have also demonstrated that early enteral nutrition is associated with better small-intestinal carbohydrate absorption, shorter duration of mechanical ventilation, and shorter time in the intensive care unit. The exception has been in studies of patients with closed-head injury, in whom no significant differences in outcome were demonstrated between early jejunal feeding and other nutritional support modalities. Moreover, early gastric feeding after closed-head injury was frequently associated with underfeeding and calorie deficiency due to the difficulties in overcoming gastroparesis and the high risk of aspiration. While current evidence remains inconclusive about the benefits of “early” (as defined by feeding in the first 24 hours) versus “late” (as defined by feeding >24 hours after burn) enteral nutrition in burn patients as to its impact on mortality rates, there is reason to believe that early enteral nutrition may positively modulate the initial hypermetabolic response and help to maintain mucosal immunity.

In summary, enteral nutrition is preferred for most critically ill patients—an evidence-based practice supported by clinical data involving a variety of critically ill patient populations, including those with trauma, burns, head injury, major surgery, and acute pancreatitis. For intensive care unit patients who are hemodynamically stable and have a

functioning gastrointestinal tract, early enteral feeding (within 24 to 48 hours of arrival in the intensive care unit) has become a recommended standard of care.¹⁴⁵ For patients undergoing elective surgery, healthy patients without malnutrition who are undergoing uncomplicated surgery can tolerate 10 days of partial starvation (i.e., maintenance intravenous fluids only) before any clinically significant protein catabolism occurs. Earlier intervention is likely indicated for patients in whom preoperative protein-calorie malnutrition has been identified. Other clinical scenarios for which the benefits of enteral nutritional support have been substantiated include permanent neurologic impairment, oropharyngeal dysfunction, short-bowel syndrome, and bone marrow transplantation.

Initiation of enteral nutrition should occur immediately after adequate resuscitation, most readily determined by adequate urine output. The presence of bowel sounds and the passage of flatus or stool are not absolute prerequisites for initiation of enteral nutrition, but in the setting of gastroparesis, feedings should be administered distal to the pylorus. Gastric residuals of 200 mL or more in a 4- to 6-hour period or abdominal distention requires cessation of feeding and adjustment of the infusion rate. Concomitant gastric decompression with distal small-bowel feedings may be appropriate in certain patients such as closed-head injury patients with gastroparesis. There is no evidence to support withholding enteric feedings for patients after bowel resection or for those with low-output enterocutaneous fistulas of <500 mL/d. In fact, a recent systematic review of studies of early enteral feeding (within 24 hours of gastrointestinal surgery) showed no effect on anastomotic leak and a reduction in mortality. Early enteral feeding is also associated with reduced incidence of fistula formation in patients with open abdomen. Enteral feeding should also be offered to patients with short-bowel syndrome or clinical malabsorption, but necessary calories, essential minerals, and vitamins should be supplemented using parenteral modalities.

Hypocaloric Enteral Nutrition

As noted earlier, critically ill and/or injured patients demonstrate increased resting energy expenditure associated with altered metabolism. While several methods exist to predict the energy requirement, the recommended caloric dose for critically ill patients varies, ranging from 25 to 30 kcal/kg. The perceived benefit of achieving the caloric target is to meet the patient's energy needs and to avoid the loss of lean body mass. However, recent evidence supports the idea of caloric restriction, attributing its benefits to improved cellular function in terms of effects on mitochondrial free radical generation, the plasma membrane redox system, and insulin sensitivity. Further support was offered by a single-center, randomized controlled trial that compared permissive underfeeding with target enteral feeding (caloric goal: 60% to 70% compared with 90% to 100% of calculated requirement) in critically ill medical and surgical patients.¹⁴⁶ This study demonstrated that permissive underfeeding was associated with lower mortality and morbidity than was target feeding. However, current guidelines do not recommend hypocaloric feeding without confirmation of these data from the multicenter trial that is currently ongoing. A recent study examined the use of trophic feedings in patients with acute lung injury. Trophic feedings refer to providing a minimal amount of enteral feedings, which are presumed to have beneficial effects despite not meeting daily caloric needs. When the trophic feeding group (enteral feeding at 10 mL/h) was compared with the

full-feeding group (25 mL/h) over the first 6 days of feeding, there was no improvement in ventilator-free days, 60-day mortality, or infectious complications.¹⁴⁷

Enteral Formulas

For most critically ill patients, the choice of enteral formula will be determined by a number of factors and will include a clinical judgment as to the "best fit" for the patients' needs. In general, feeding formulas to consider are gastrointestinal tolerance-promoting, anti-inflammatory, immune-modulating, organ supportive, and standard enteral nutrition. In addition, guidelines from professional nutrition societies identify certain populations of patients who can benefit from formulations with specific pharmacconutrients.¹⁴⁸ For many others, each physician must use his or her own clinical judgment about what formula will best meet the patient's needs.

The functional status of the gastrointestinal tract determines the type of enteral solutions to be used. Patients with an intact gastrointestinal tract will tolerate complex solutions, but patients who have not been fed via the gastrointestinal tract for prolonged periods are less likely to tolerate complex carbohydrates. In those patients who are having difficulty tolerating standard enteral formulas, peptide- and MCT-based formulas with prebiotics can lessen gastrointestinal tolerance problems. Additionally, in patients with demonstrated malabsorption issues, such as with inflammatory bowel diseases or short-bowel syndrome, current guidelines endorse the provision of hydrolyzed protein formulas to improve absorption. Guidelines have not yet been made with regard to the fiber content of enteral formulas. However, recent evidence indicates that supplementation of enteral formulas with soluble dietary fiber may be beneficial for improving stool consistency in patients suffering from diarrhea.

Factors that influence the choice of enteral formula also include the extent of organ dysfunction (e.g., renal, pulmonary, hepatic, or gastrointestinal), the nutrients needed to restore optimal function and healing, and the cost of specific products. There are still no conclusive data to recommend one category of product over another, and nutritional support committees typically develop the most cost-efficient enteral formula for the most commonly encountered disease categories within the institution.

As discussed extensively in the first sections of this chapter, surgery and trauma result in a significant "sterile" inflammatory response that impacts the innate and adaptive immune systems. The provision of immune-modulating nutrients, termed "immunonutrition," is one mechanism by which the immune response can be supported and an attempt made to lower infectious risk. At present, the best-studied immunonutrients are glutamine, arginine, and ω -3 PUFAs.

"Immunonutrients." Glutamine is the most abundant amino acid in the human body, comprising nearly two thirds of the free intracellular amino acid pool. Of this, 75% is found within the skeletal muscles. In healthy individuals, glutamine is considered a nonessential amino acid, because it is synthesized within the skeletal muscles and the lungs. Glutamine is a necessary substrate for nucleotide synthesis in most dividing cells and hence provides a major fuel source for enterocytes. It also serves as an important fuel source for immunocytes such as lymphocytes and macrophages and is a precursor for glutathione, a major intracellular antioxidant. During stress states such as sepsis, or in tumor-bearing hosts, peripheral glutamine stores are rapidly depleted, and the amino acid is preferentially shunted as a fuel

source toward the visceral organs and tumors, respectively.¹⁴⁹ These situations create, at least experimentally, a glutamine-depleted environment, with consequences including enterocyte and immunocyte starvation. Glutamine metabolism during stress in humans, however, may be more complex than is indicated in previously reported animal data. Although it is hypothesized that provision of glutamine may preserve immune cell and enterocyte function and enhance nitrogen balance during injury or sepsis, the clinical outcome is very strongly dependent on the patient population, as will be discussed later.

Arginine, also a nonessential amino acid in healthy subjects, first attracted attention for its immunoenhancing properties, wound-healing benefits, and association with improved survival in animal models of sepsis and injury.¹⁵⁰ As with glutamine, the benefits of experimental arginine supplementation during stress states are diverse. In clinical studies involving critically ill and injured patients and patients who have undergone surgery for certain malignancies, enteral administration of arginine has led to net nitrogen retention and protein synthesis, whereas isonitrogenous diets have not. Some of these studies also provide *in vitro* evidence of enhanced immunocyte function. The clinical utility of arginine supplementation in improving overall patient outcome remains an area of investigation.

As previously discussed, ω -3 PUFAs (canola oil or fish oil) displace ω -6 fatty acids in cell membranes, which theoretically reduces the proinflammatory response from prostaglandin production. Hence, there has been significant interest in reducing the ratio of ω -6 to ω -3 fatty acids.

Low-Residue Isotonic Formulas. Most low-residue isotonic formulas provide a caloric density of 1.0 kcal/mL, and approximately 1500 to 1800 mL are required to meet daily requirements. These low-osmolality compositions provide baseline carbohydrates, protein, electrolytes, water, fat, and fat-soluble vitamins (some do not have vitamin K) and typically have a nonprotein-calorie:nitrogen ratio of 150:1. These contain no fiber bulk and therefore leave minimum residue. These solutions usually are considered to be the standard or first-line formulas for stable patients with an intact gastrointestinal tract.

Isotonic Formulas with Fiber. Isotonic formulas with fiber contain soluble and insoluble fiber, which is most often soy based. Physiologically, fiber-based solutions delay intestinal transit time and may reduce the incidence of diarrhea compared with nonfiber solutions. Fiber stimulates pancreatic lipase activity and is degraded by gut bacteria into short-chain fatty acids (SCFAs), an important fuel for colonocytes. Recent data have also demonstrated the expression of SCFA receptors on leukocytes, suggesting that fiber fermentation by the colonic microbiome may indirectly regulate immune cell function. Future work in this area is likely to demonstrate important links between fiber type, microbiome composition, and immune health.

Immune-Enhancing Formulas. Immune-enhancing formulas are fortified with special nutrients that are purported to enhance various aspects of immune or solid organ function. Such additives include glutamine, arginine, ω -3 fatty acids, and nucleotides.¹⁵¹ Although several trials have proposed that one or more of these additives reduce surgical complications and improve outcome, these results have not been uniformly corroborated by other trials. The Canadian Clinical Practice Guidelines currently do not recommend the addition of arginine supplements for critically ill patients due to the potential for harm when used in septic patients.¹⁵² With regard to ω -3 PUFAs, results from

the EDEN-Omega study demonstrated that twice-daily enteral supplementation of ω -3 fatty acids, α -linolenic acid, and antioxidants did not improve the primary endpoint of ventilator-free days or other clinical outcomes in patients with acute lung injury and may be harmful.¹⁵³ Glutamine supplementation should be strictly guided by the individual patient condition. Enteral and parenteral supplementation with glutamine appears to have a harmful effect in critically ill patients with multiorgan failure as evidenced by significantly increased mortality (REDOXS study). However, for burn or trauma patients who are hemodynamically stable and without evidence of organ dysfunction, glutamine supplementation has been shown to be beneficial in terms of decreased LOS and infectious complications.

Calorie-Dense Formulas. The primary distinction of calorie-dense formulas is a greater caloric value for the same volume. Most commercial products of this variety provide 1.5 to 2 kcal/mL and therefore are suitable for patients requiring fluid restriction or those unable to tolerate large-volume infusions. As expected, these solutions have higher osmolality than standard formulas and are suitable for intragastric feedings.

High-Protein Formulas. High-protein formulas are available in isotonic and nonisotonic mixtures and are proposed for critically ill or trauma patients with high protein requirements. These formulas have nonprotein-calorie:nitrogen ratios between 80:1 and 120:1. While some observational studies show improved outcomes with higher protein intakes in critically ill patients, there are limited data from randomized trials, which prevents making strong conclusions about the dose of protein in critically ill patients.

Elemental Formulas. Elemental formulas contain predigested nutrients and provide proteins in the form of small peptides. Complex carbohydrates are limited, and fat content, in the form of MCTs and LCTs, is minimal. The primary advantage of such a formula is ease of absorption, but the inherent scarcity of fat, associated vitamins, and trace elements limits its long-term use as a primary source of nutrients. Due to its high osmolality, dilution or slow infusion rates usually are necessary, particularly in critically ill patients. These formulas have been used frequently in patients with malabsorption, gut impairment, and pancreatitis, but their cost is significantly higher than that of standard formulas. To date, there has been no evidence of their benefit in routine use.

Renal Failure Formulas. The primary benefits of renal formulas are the lower fluid volume and concentrations of potassium, phosphorus, and magnesium needed to meet daily calorie requirements. This type of formulation almost exclusively contains essential amino acids and has a high nonprotein-calorie:nitrogen ratio; however, it does not contain trace elements or vitamins.

Pulmonary Failure Formulas. In pulmonary failure formulas, fat content is usually increased to 50% of the total calories, with a corresponding reduction in carbohydrate content. The goal is to reduce carbon dioxide production and alleviate ventilation burden for failing lungs.

Hepatic Failure Formulas. Close to 50% of the proteins in hepatic failure formulas are branched-chain amino acids (e.g., leucine, isoleucine, and valine). The goal of such a formula is to reduce aromatic amino acid levels and increase the levels of branched-chain amino acids, which can potentially reverse encephalopathy in patients with hepatic failure.¹⁵⁴ The use of

these formulas is controversial, however, because no clear benefits have been proven by clinical trials. Protein restriction should be avoided in patients with end-stage liver disease, because such patients have significant protein-energy malnutrition that predisposes them to additional morbidity and mortality.¹⁵⁵

Access for Enteral Nutritional Support

The available techniques and repertoire for enteral access have provided multiple options for feeding the gut. Presently used methods and preferred indications are summarized in Table 2-11.¹⁵⁶

Nasoenteric Tubes. Nasogastric feeding should be reserved for those with intact mentation and protective laryngeal reflexes to minimize risks of aspiration. Even in intubated patients, nasogastric feedings often can be recovered from tracheal suction. Nasojejunal feedings are associated with fewer pulmonary complications including risk of pneumonia, but access past the pylorus requires greater effort to accomplish. Therefore, routine use of small-bowel feedings is preferred in units where small-bowel access is readily feasible. Where there may be difficulties obtaining access, small-bowel feedings may be considered a priority for those patients at high risk for intolerance to enteral nutrition (e.g., high gastric residuals).

Blind insertion of nasogastric feeding tubes is fraught with misplacement, and air instillation with auscultation is inaccurate for ascertaining proper positioning. Radiographic confirmation is usually required to verify the position of the nasogastric feeding tube.

Several methods have been recommended for the passage of nasoenteric feeding tubes into the small bowel, including use of prokinetic agents, right lateral decubitus positioning, gastric insufflation, tube angulation, and application of clockwise torque. However, the successful placement of feeding tubes by these methods is highly variable and operator dependent.

Furthermore, it is time consuming, and success rates for intubation past the duodenum into the jejunum by these methods are <20%. Fluoroscopy-guided intubation past the pylorus has a >90% success rate, and more than half of these intubations result in jejunal placement. Similarly, endoscopy-guided placement past the pylorus has high success rates, but attempts to advance the tube beyond the second portion of the duodenum using a standard gastroduodenoscope are unlikely to be successful.

Small-bowel feeding is more reliable for delivering nutrition than nasogastric feeding. Furthermore, the risks of aspiration pneumonia can be reduced by 25% with small-bowel feeding compared with nasogastric feeding. The disadvantages of the use of nasoenteric feeding tubes are clogging, kinking, and inadvertent displacement or removal of the tube and nasopharyngeal complications. If nasoenteric feeding will be required for longer than 30 days, access should be converted to a percutaneous one.¹⁵⁷

Percutaneous Endoscopic Gastrostomy. The most common indications for percutaneous endoscopic gastrostomy (PEG) include impaired swallowing mechanisms, oropharyngeal or esophageal obstruction, and major facial trauma. It is frequently used for debilitated patients requiring caloric supplementation, hydration, or frequent medication dosing. It is also appropriate for patients requiring passive gastric decompression. Relative contraindications for PEG placement include ascites, coagulopathy, gastric varices, gastric neoplasm, and lack of a suitable abdominal site. Most tubes are 18F to 28F in size and may be used for 12 to 24 months.

Identification of the PEG site requires endoscopic transillumination of the anterior stomach against the abdominal wall. A 14-gauge angiocatheter is passed through the abdominal wall into the fully insufflated stomach. A guidewire is threaded through the angiocatheter, grasped by snares or forceps, and

Table 2-11

Options for enteral feeding access

ACCESS OPTION	COMMENTS
Nasogastric tube	Short-term use only; aspiration risks; nasopharyngeal trauma; frequent dislodgment
Nasoduodenal/nasojejunal tube	Short-term use; lower aspiration risks in jejunum; placement challenges (radiographic assistance often necessary)
Percutaneous endoscopic gastrostomy (PEG)	Endoscopy skills required; may be used for gastric decompression or bolus feeds; aspiration risks; can last 12–24 mo; slightly higher complication rates with placement and site leaks
Surgical gastrostomy	Requires general anesthesia and small laparotomy; procedure may allow placement of extended duodenal/jejunal feeding ports; laparoscopic placement possible
Fluoroscopic gastrostomy	Blind placement using needle and T-prongs to anchor to stomach; can thread smaller catheter through gastrostomy into duodenum/jejunum under fluoroscopy
PEG-jejunal tube	Jejunal placement with regular endoscope is operator dependent; jejunal tube often dislodges retrograde; two-stage procedure with PEG placement, followed by fluoroscopic conversion with jejunal feeding tube through PEG
Direct percutaneous endoscopic jejunostomy (DPEJ)	Direct endoscopic tube placement with enteroscope; placement challenges; greater injury risks
Surgical jejunostomy	Commonly carried out during laparotomy; general anesthesia; laparoscopic placement usually requires assistant to thread catheter; laparoscopy offers direct visualization of catheter placement
Fluoroscopic jejunostomy	Difficult approach with injury risks; not commonly done

pulled out through the mouth. The tapered end of the PEG tube is secured to the guidewire and is pulled into position out of the abdominal wall. The PEG tube is secured without tension against the abdominal wall, and many have reported using the tube within hours of placement. It has been the practice of some to connect the PEG tube to a drainage bag for passive decompression for 24 hours before use, allowing more time for the stomach to seal against the peritoneum.

If endoscopy is not available or technical obstacles preclude PEG placement, the interventional radiologist can attempt the procedure percutaneously under fluoroscopic guidance by first insufflating the stomach against the abdominal wall with a nasogastric tube. If this also is unsuccessful, surgical gastrostomy tube placement can be considered, particularly with minimally invasive methods. When surgery is contemplated, it may be wise to consider directly accessing the small bowel for nutrition delivery.

Although PEG tubes enhance nutritional delivery, facilitate nursing care, and are superior to nasogastric tubes, serious complications occur in approximately 3% of patients. These complications include wound infection, necrotizing fasciitis, peritonitis, aspiration, leaks, dislodgment, bowel perforation, enteric fistulas, bleeding, and aspiration pneumonia.¹⁵⁸ For patients with significant gastroparesis or gastric outlet obstruction, feedings through PEG tubes are hazardous. In such cases, the PEG tube can be used for decompression and allow access for converting the PEG tube to a transpyloric feeding tube.

Percutaneous Endoscopic Gastrostomy-Jejunostomy and Direct Percutaneous Endoscopic Jejunostomy. Although gastric bolus feedings are more physiologic, patients who cannot tolerate gastric feedings or who have significant aspiration risks should be fed directly past the pylorus. In the percutaneous endoscopic gastrostomy-jejunostomy (PEG-J) method, a 9F to 12F tube is passed through an existing PEG tube, past the pylorus, and into the duodenum. This can be achieved by endoscopic or fluoroscopic guidance. With weighted catheter tips and guidewires, the tube can be further advanced past the ligament of Treitz. However, the incidence of long-term PEG-J tube malfunction has been reported to be >50% as a result of retrograde tube migration into the stomach, kinking, or clogging.

Direct percutaneous endoscopic jejunostomy (DPEJ) tube placement uses the same techniques as PEG tube placement but requires an enteroscope or colonoscope to reach the jejunum. DPEJ tube malfunctions are probably less frequent than PEG-J tube malfunctions, and kinking or clogging is usually averted by placement of larger-caliber catheters. The success rate of DPEJ tube placement is variable because of the complexity of endoscopic skills required to locate a suitable jejunal site. In such cases where endoscopic means are not feasible, surgical jejunostomy tube placement is more appropriate, especially when minimally invasive techniques are available.

Surgical Gastrostomy and Jejunostomy. For a patient undergoing complex abdominal or trauma surgery, thought should be given during surgery to the possible routes for subsequent nutritional support, because laparotomy affords direct access to the stomach or small bowel. The only absolute contraindication to feeding jejunostomy is distal intestinal obstruction. Relative contraindications include severe edema of the intestinal wall, radiation enteritis, inflammatory bowel disease, ascites, severe immunodeficiency, and bowel ischemia. Needle-catheter jejunostomies also can be done with a minimal learning curve.

The biggest drawback usually is possible clogging and knotting of the 6F catheter.¹⁵⁹

Abdominal distention and cramps are common adverse effects of early enteral nutrition. Some have also reported impaired respiratory mechanics as a result of intolerance to enteral feedings. These are mostly correctable by temporarily discontinuing feedings and resuming at a lower infusion rate.

Pneumatosis intestinalis and small-bowel necrosis are infrequent but significant problems in patients receiving jejunal tube feedings. Several contributing factors have been proposed, including the hyperosmolarity of enteral solutions, bacterial overgrowth, fermentation, and accumulation of metabolic breakdown products. The common pathophysiology is believed to be bowel distention and consequent reduction in bowel wall perfusion. Risk factors for these complications include cardiogenic and circulatory shock, vasopressor use, diabetes mellitus, and chronic obstructive pulmonary disease. Therefore, enteral feedings in the critically ill patient should be delayed until adequate resuscitation has been achieved. As alternatives, diluting standard enteral formula, delaying the progression to goal infusion rates, or using monomeric solutions with low osmolality requiring less digestion by the gastrointestinal tract all have been successfully used.

PARENTERAL NUTRITION

Parenteral nutrition is the continuous infusion of a hyperosmolar solution containing carbohydrates, proteins, fat, and other necessary nutrients through an indwelling catheter inserted into the superior vena cava. To obtain the maximum benefit, the calorie:protein ratio must be adequate (at least 100 to 150 kcal/g nitrogen), and both carbohydrates and proteins must be infused simultaneously. When the sources of calories and nitrogen are given at different times, there is a significant decrease in nitrogen utilization. These nutrients can be given in quantities considerably greater than the basic caloric and nitrogen requirements, and this method has proved to be highly successful in achieving growth and development, positive nitrogen balance, and weight gain in a variety of clinical situations. Clinical trials and meta-analysis of studies of parenteral feeding in the perioperative period have suggested that preoperative nutritional support may benefit some surgical patients, particularly those with extensive malnutrition. Short-term use of parenteral nutrition in critically ill patients (i.e., duration of <7 days) when enteral nutrition may have been instituted is associated with higher rates of infectious complications. After severe injury, parenteral nutrition is associated with higher rates of infectious risks than is enteral feeding (Table 2-12). Clinical studies have demonstrated that parenteral feeding with complete bowel rest results in augmented stress hormone and inflammatory mediator response to an antigenic challenge. However, parenteral feeding still is associated with fewer infectious complications than no feeding at all. In cancer patients, delivery of parenteral nutrition has not been shown to benefit clinical response, prolong survival, or ameliorate the toxic effects of chemotherapy, and infectious complications are increased.

Rationale for Parenteral Nutrition

The principal indications for parenteral nutrition are malnutrition, sepsis, or surgical or traumatic injury in seriously ill patients for whom use of the gastrointestinal tract for feedings is not possible. In some instances, intravenous nutrition may be used to supplement inadequate oral intake. The safe and

Table 2-12

Incidence of septic morbidity in parenterally and enterally fed trauma patients

COMPLICATION	BLUNT TRAUMA		PENETRATING TRAUMA		TOTAL	
	TEN N = 48	TPN N = 44	TEN N = 38	TPN N = 48	TEN N = 44	TPN N = 84
Abdominal abscess	2	1	2	6	4	7
Pneumonia	4	10	1	2	5	12
Wound infection	0	2	3	1	3	3
Bacteremia	1	4	0	1	1	5
Urinary tract	1	1	0	1	1	2
Other	5	4	1	1	6	5
Total complications	13	22	7	12	20	34
% Complications per patient group	27%	50%	18%	30%	23%	39%

Source: Reproduced with permission from Moore FA, Feliciano DV, Andrassy RJ et al. Early enteral feeding, compared with parenteral, reduces postoperative septic complications. *Ann Surg.* 1992;216(2):172-183.

successful use of parenteral nutrition requires proper selection of patients with specific nutritional needs, experience with the technique, and an awareness of the associated complications. In patients with significant malnutrition, parenteral nutrition can rapidly improve nitrogen balance, which may enhance immune function. Routine postoperative use of parenteral nutrition is not shown to have clinical benefit and may be associated with a significant increase in complication rate. As with enteral nutrition, the fundamental goals are to provide sufficient calories and nitrogen substrate to promote tissue repair and to maintain the integrity or growth of lean tissue mass. The following are patient groups for whom parenteral nutrition has been used in an effort to achieve these goals:

1. Newborn infants with catastrophic gastrointestinal anomalies, such as tracheoesophageal fistula, gastroschisis, omphalocele, or massive intestinal atresia
2. Infants who fail to thrive due to gastrointestinal insufficiency associated with short-bowel syndrome, malabsorption, enzyme deficiency, meconium ileus, or idiopathic diarrhea
3. Adult patients with short-bowel syndrome secondary to massive small-bowel resection (<100 cm without colon or ileocecal valve or <50 cm with intact ileocecal valve and colon)
4. Patients with enteroenteric, enterocolic, enterovesical, or high-output enterocutaneous fistulas (>500 mL/d)
5. Surgical patients with prolonged paralytic ileus after major operations (>7 to 10 days), multiple injuries, or blunt or open abdominal trauma, or patients with reflex ileus complicating various medical diseases
6. Patients with normal bowel length but with malabsorption secondary to sprue, hypoproteinemia, enzyme or pancreatic insufficiency, regional enteritis, or ulcerative colitis
7. Adult patients with functional gastrointestinal disorders such as esophageal dyskinesia after cerebrovascular accident, idiopathic diarrhea, psychogenic vomiting, or anorexia nervosa
8. Patients with granulomatous colitis, ulcerative colitis, or tuberculous enteritis in whom major portions of the absorptive mucosa are diseased
9. Patients with malignancy, with or without cachexia, in whom malnutrition might jeopardize successful use of a therapeutic option
10. Patients in whom attempts to provide adequate calories by enteral tube feedings or high residuals have failed
11. Critically ill patients who are hypermetabolic for >5 days or for whom enteral nutrition is not feasible

Patients in whom hyperalimentation is *contraindicated* include the following:

1. Patients for whom a specific goal for patient management is lacking or for whom, instead of extending a meaningful life, inevitable dying would be delayed
2. Patients experiencing hemodynamic instability or severe metabolic derangement (e.g., severe hyperglycemia, azotemia, encephalopathy, hyperosmolality, and fluid-electrolyte disturbances) requiring control or correction before hypertonic intravenous feeding is attempted
3. Patients for whom gastrointestinal tract feeding is feasible; in the vast majority of instances, this is the best route by which to provide nutrition
4. Patients with good nutritional status
5. Infants with <8 cm of small bowel, because virtually all have been unable to adapt sufficiently despite prolonged periods of parenteral nutrition
6. Patients who are irreversibly decerebrate or otherwise dehumanized

Total Parenteral Nutrition

Total parenteral nutrition (TPN), also referred to as *central parenteral nutrition*, requires access to a large-diameter vein to deliver the entire nutritional requirements of the individual. Dextrose content of the solution is high (15% to 25%), and all other macronutrients and micronutrients are deliverable by this route.

Peripheral Parenteral Nutrition

The lower osmolarity of the solution used for peripheral parenteral nutrition (PPN), secondary to reduced levels of dextrose (5% to 10%) and protein (3%), allows its administration

via peripheral veins. Some nutrients cannot be supplemented because they cannot be concentrated into small volumes. Therefore, PPN is not appropriate for repleting patients with severe malnutrition. It can be considered if central routes are not available or if supplemental nutritional support is required. Typically, PPN is used for short periods (<2 weeks). Beyond this time, TPN should be instituted.

Initiation of Parenteral Nutrition

The basic solution for parenteral nutrition contains a final concentration of 15% to 25% dextrose and 3% to 5% crystalline amino acids. The solutions usually are prepared in sterile conditions in the pharmacy from commercially available kits containing the component solutions and transfer apparatus. Preparation in the pharmacy under laminar flow hoods reduces the incidence of bacterial contamination of the solution. Proper preparation with suitable quality control is absolutely essential to avoid septic complications.

The proper provision of electrolytes and amino acids must take into account routes of fluid and electrolyte loss, renal function, metabolic rate, cardiac function, and the underlying disease state.

Intravenous vitamin preparations also should be added to parenteral formulas. Vitamin deficiencies are rare occurrences if such preparations are used. In addition, because vitamin K is not part of any commercially prepared vitamin solution, it should be supplemented on a weekly basis. During prolonged parenteral nutrition with fat-free solutions, essential fatty acid deficiency may become clinically apparent and manifests as dry, scaly dermatitis and loss of hair. The syndrome may be prevented by periodic infusion of a fat emulsion at a rate equivalent to 10% to 15% of total calories. Essential trace minerals may be required after prolonged TPN and may be supplied by direct addition of commercial preparations. The most frequent presentation of trace mineral deficiencies is the eczematoid rash developing both diffusely and at intertriginous areas in zinc-deficient patients. Other rare trace mineral deficiencies include a microcytic anemia associated with copper deficiency and glucose intolerance presumably related to chromium deficiency. The latter complications are seldom seen except in patients receiving parenteral nutrition for extended periods. The daily administration of commercially available trace mineral supplements will obviate most such problems.

Depending on fluid and nitrogen tolerance, parenteral nutrition solutions generally can be increased over 2 to 3 days to achieve the desired infusion rate. Insulin may be supplemented as necessary to ensure glucose tolerance. Administration of additional intravenous fluids and electrolytes may occasionally be necessary in patients with persistently high fluid losses. The patient should be carefully monitored for development of electrolyte, volume, acid-base, and septic complications. Vital signs and urinary output should be measured regularly, and the patient should be weighed regularly. Frequent adjustments of the volume and composition of the solutions are necessary during the course of therapy. Samples for measurement of electrolytes are drawn daily until levels are stable and every 2 or 3 days thereafter. Blood counts, blood urea nitrogen level, levels of liver function indicators, and phosphate and magnesium levels are determined at least weekly.

The urine or capillary blood glucose level is checked every 6 hours, and serum glucose concentration is checked at least once daily during the first few days of the infusion and at frequent

intervals thereafter. Relative glucose intolerance, which often manifests as glycosuria, may occur after initiation of parenteral nutrition. If blood glucose levels remain elevated or glycosuria persists, the dextrose concentration may be decreased, the infusion rate slowed, or regular insulin added to each bottle. The rise in blood glucose concentration observed after initiating parenteral nutrition may be temporary, as the normal pancreas increases its output of insulin in response to the continuous carbohydrate infusion. In patients with diabetes mellitus, additional insulin may be required.

Potassium is essential to achieve positive nitrogen balance and replace depleted intracellular stores. In addition, a significant shift of potassium ion from the extracellular to the intracellular space may take place because of the large glucose infusion, with resultant hypokalemia, metabolic alkalosis, and poor glucose utilization. In some cases as much as 240 mEq of potassium ion daily may be required. Hypokalemia may cause glycosuria, which would be treated with potassium, not insulin. Thus, before giving insulin, the serum potassium level must be checked to avoid exacerbating the hypokalemia.

Patients with insulin-dependent diabetes mellitus may exhibit wide fluctuations in blood glucose levels while receiving parenteral nutrition. This may require protocol-driven intravenous insulin therapy. In addition, partial replacement of dextrose calories with lipid emulsions may alleviate these problems in selected patients.

Lipid emulsions derived from soybean or safflower oils are widely used as an adjunctive nutrient to prevent the development of essential fatty acid deficiency, although recent data support reducing the overall ω -6 PUFA load in favor of ω -3 PUFAs or MCTs. There is no evidence of enhanced metabolic benefit when >10% to 15% of calories are provided as lipid emulsions. Although the administration of 500 mL of 20% fat emulsion one to three times a week is sufficient to prevent essential fatty acid deficiency, it is common to provide fat emulsions on a daily basis to provide additional calories. The triple mix of carbohydrate, fat, and amino acids is infused at a constant rate during a 24-hour period. The theoretical advantages of a constant fat infusion rate include increased efficiency of lipid utilization and reduction in the impairment of reticuloendothelial function normally identified with bolus lipid infusions. The addition of lipids to an infusion bag may alter the stability of some micro-nutrients in a dextrose–amino acid preparation.

The delivery of parenteral nutrition requires central intravenous access. Temporary or short-term access can be achieved with a 16-gauge percutaneous catheter inserted into a subclavian or internal jugular vein and threaded into the superior vena cava. More permanent access with the intention of providing long-term or home parenteral nutrition can be achieved by placement of a catheter with a subcutaneous port for access by tunneling a catheter with a substantial subcutaneous length or threading a long catheter through the basilic or cephalic vein into the superior vena cava.

Complications of Parenteral Nutrition

Technical Complications. One of the more common and serious complications associated with long-term parenteral feeding is sepsis secondary to contamination of the central venous catheter. Contamination of solutions should be also considered but is rare when proper pharmacy protocols have been followed. Central line–associated bloodstream infections (CLABSI) occur as a consequence of hematogenous seeding of the

catheter with bacteria. One of the earliest signs of systemic sepsis from CLA-BSI may be the sudden development of glucose intolerance (with or without temperature increase) in a patient who previously has been maintained on parenteral alimentation without difficulty. When this occurs, or if high fever ($>38.5^{\circ}\text{C}$ [101.3°F]) develops without obvious cause, a diligent search for a potential septic focus is indicated. Other causes of fever should also be investigated. If fever persists, the infusion catheter should be removed and submitted for culture. If the catheter is the cause of the fever, removal of the infectious source is usually followed by rapid defervescence. Some centers are now replacing catheters considered at low risk for infection over a guidewire. However, if blood cultures are positive and the catheter tip is also positive, then the catheter should be removed and placed in a new site. Should evidence of infection persist over 24 to 48 hours without a definable source, the catheter should be replaced into the opposite subclavian vein or into one of the internal jugular veins and the infusion restarted.¹⁶⁰

The use of multilumen catheters may be associated with a slightly increased risk of infection. This is most likely associated with greater catheter manipulation and intensive use. The rate of catheter infection is highest for those placed in the femoral vein, lower for those in the jugular vein, and lowest for those in the subclavian vein. When catheters are indwelling for <3 days, infection risks are negligible. If indwelling time is 3 to 7 days, the infection risk is 3% to 5%. Indwelling times of >7 days are associated with a catheter infection risk of 5% to 10%. Strict adherence to barrier precautions also reduces the rate of infection, as can the implementation of procedure checklists to ensure compliance with evidence-based guidelines shown to reduce infectious risk.¹⁶¹

Other complications related to catheter placement include the development of pneumothorax, hemothorax, hydrothorax, subclavian artery injury, thoracic duct injury, cardiac arrhythmia, air embolism, catheter embolism, and cardiac perforation with tamponade. All of these complications may be avoided by strict adherence to proper techniques. Further, the use of ultrasonographic guidance during central venous line placement has been demonstrated to significantly decrease the failure rate, complication rate, and number of attempts required for successful access.¹⁶²

Metabolic Complications. Hyperglycemia may develop with normal rates of infusion in patients with impaired glucose tolerance or in any patient if the hypertonic solutions are administered too rapidly. This is a particularly common complication in patients with latent diabetes and in patients subjected to severe surgical stress or trauma. Treatment of the condition consists of volume replacement with correction of electrolyte abnormalities and the administration of insulin. This complication can be avoided with careful attention to daily fluid balance and frequent monitoring of blood glucose levels and serum electrolytes.

Increasing experience has emphasized the importance of not overfeeding the parenterally nourished patient. This is particularly true for the depleted patient in whom excess calorie infusion may result in carbon dioxide retention and respiratory insufficiency. In addition, excess feeding also has been related to the development of hepatic steatosis or marked glycogen deposition in selected patients. Cholestasis and formation of gallstones are common in patients receiving long-term parenteral nutrition. Mild but transient abnormalities of serum transaminase, alkaline phosphatase, and bilirubin levels occur in many parenterally nourished patients. Failure of the liver

enzymes to plateau or return to normal over 7 to 14 days should suggest another etiology.

Intestinal Atrophy. Lack of intestinal stimulation is associated with intestinal mucosal atrophy, diminished villous height, bacterial overgrowth, reduced lymphoid tissue size, reduced IgA production, and impaired gut immunity. The full clinical implications of these changes are not well realized, although bacterial translocation has been demonstrated in animal models. The most efficacious method to prevent these changes is to provide at least some nutrients enterally. In patients requiring TPN, it may be feasible to infuse small amounts of feedings via the gastrointestinal tract.

REFERENCES

Entries highlighted in bright blue are key references.

1. Minei JP, Cuschieri J, Sperry J, et al. The changing pattern and implications of multiple organ failure after blunt injury with hemorrhagic shock. *Crit Care Med.* 2012;40(4):1129-1135.
2. Xiao W, Mindrinos MN, Seok J, et al. A genomic storm in critically injured humans. *J Exp Med.* 2011;208(13):2581-2590.
3. Bone RC. The pathogenesis of sepsis. *Ann Intern Med.* 1991;115(6):457-469.
4. Lowry SF. Human endotoxemia: a model for mechanistic insight and therapeutic targeting. *Shock.* 2005;24(Suppl 1):94-100.
5. Pugin J. How tissue injury alarms the immune system and causes a systemic inflammatory response syndrome. *Ann Intensive Care.* 2012;2(1):27.
6. Manson J, Thiernemann C, Brohi K. Trauma alarmins as activators of damage-induced inflammation. *Br J Surg.* 2012;99(Suppl 1):12-20.
7. Chan JK, Roth J, Oppenheim JJ, et al. Alarmins: awaiting a clinical response. *J Clin Invest.* 2012;122(8):2711-2719.
8. Lu B, Wang H, Andersson U, Tracey KJ. Regulation of HMGB1 release by inflammasomes. *Protein Cell.* 2013;4(3):163-167.
9. Andersson U, Tracey KJ. HMGB1 is a therapeutic target for sterile inflammation and infection. *Annu Rev Immunol.* 2011;29:139-162.
10. Yang H, Hreggvidsdottir HS, Palmblad K, et al. A critical cysteine is required for HMGB1 binding to Toll-like receptor 4 and activation of macrophage cytokine release. *Proc Natl Acad Sci USA.* 2010;107(26):11942-11947.
11. Yang H, Antoine DJ, Andersson U, Tracey KJ. The many faces of HMGB1: molecular structure-functional activity in inflammation, apoptosis, and chemotaxis. *J Leukoc Biol.* 2013;93(6):865-873.
12. Peltz ED, Moore EE, Eckels PC, et al. HMGB1 is markedly elevated within 6 hours of mechanical trauma in humans. *Shock.* 2009;32(1):17-22.
13. Zhang Q, Raoof M, Chen Y, et al. Circulating mitochondrial DAMPs cause inflammatory responses to injury. *Nature.* 2010;464(7285):104-107.
14. West AP, Shadel GS, Ghosh S. Mitochondria in innate immune responses. *Nat Rev Immunol.* 2011;11(6):389-402.
15. Moreth K, Iozzo RV, Schaefer L. Small leucine-rich proteoglycans orchestrate receptor crosstalk during inflammation. *Cell Cycle.* 2012;11(11):2084-2091.
16. Babelova A, Moreth K, Tsalastra-Greul W, et al. Biglycan, a danger signal that activates the NLRP3 inflammasome via toll-like and P2X receptors. *J Biol Chem.* 2009;284(36):24035-24048.
17. Haimovich B, Reddell MT, Calvano JE, et al. A novel model of common Toll-like receptor 4- and injury-induced

- transcriptional themes in human leukocytes. *Crit Care*. 2010;14(5):R177.
18. McGhan LJ, Jaroszewski DE. The role of toll-like receptor-4 in the development of multi-organ failure following traumatic haemorrhagic shock and resuscitation. *Injury*. 2012;43(2):129-136.
 19. Mollen KP, Levy RM, Prince JM, et al. Systemic inflammation and end organ damage following trauma involves functional TLR4 signaling in both bone marrow-derived cells and parenchymal cells. *J Leukoc Biol*. 2008;83(1):80-88.
 20. Latz E, Xiao TS, Stutz A. **Activation and regulation of the inflammasomes.** *Nat Rev Immunol*. 2013;13(6):397-411.
 21. Zhang AQ, Zeng L, Gu W, et al. Clinical relevance of single nucleotide polymorphisms within the entire NLRP3 gene in patients with major blunt trauma. *Crit Care*. 2011;15(6):R280.
 22. Osuka A, Hanschen M, Stoecklein V, Lederer JA. A protective role for inflammasome activation following injury. *Shock*. 2012;37(1):47-55.
 23. Sancho D, Reis e Sousa C. Sensing of cell death by myeloid C-type lectin receptors. *Curr Opin Immunol*. 2013;25(1):46-52.
 24. Kunes P, Holubcova Z, Kolackova M, Krejsek J. Pentraxin 3 (PTX 3): an endogenous modulator of the inflammatory response. *Mediators Inflamm*. 2012;2012:920517.
 25. Kleber C, Becker CA, Schmidt-Bleek K, Schaser KD, Haas NP. Are pentraxin 3 and transsignaling early markers for immunologic injury severity in polytrauma? A pilot study. *Clin Orthop Relat Res*. 2013;471(9):2822-2830.
 26. Qian C, Cao X. Regulation of Toll-like receptor signaling pathways in innate immune responses. *Ann N Y Acad Sci*. 2013;1283:67-74.
 27. Ulrichs P, Bovijn C, Lievens S, Beyaert R, Tavernier J, Peelman F. Caspase-1 targets the TLR adaptor Mal at a crucial TIR-domain interaction site. *J Cell Sci*. 2010;123(Pt 2):256-265.
 28. Stow JL, Murray RZ. Intracellular trafficking and secretion of inflammatory cytokines. *Cytokine Growth Factor Rev*. 2013;24(3):227-239.
 29. Fung A, Vizcaychipi M, Lloyd D, Wan Y, Ma D. Central nervous system inflammation in disease related conditions: mechanistic prospects. *Brain Res*. 2012;1446:144-155.
 30. Czura CJ, Tracey KJ. Autonomic neural regulation of immunity. *J Intern Med*. 2005;257(2):156-166.
 31. Olofsson PS, Rosas-Ballina M, Levine YA, Tracey KJ. **Rethinking inflammation: neural circuits in the regulation of immunity.** *Immunol Rev*. 2012;248(1):188-204.
 32. Borovikova LV, Ivanova S, Zhang M, et al. Vagus nerve stimulation attenuates the systemic inflammatory response to endotoxin. *Nature*. 2000;405(6785):458-462.
 33. Wang H, Yu M, Ochani M, et al. Nicotinic acetylcholine receptor alpha7 subunit is an essential regulator of inflammation. *Nature*. 2003;421(6921):384-388.
 34. Heitzer MD, Wolf IM, Sanchez ER, Witchel SF, DeFranco DB. Glucocorticoid receptor physiology. *Rev Endocr Metab Disord*. 2007;8(4):321-330.
 35. Silverman MN, Sternberg EM. Glucocorticoid regulation of inflammation and its functional correlates: from HPA axis to glucocorticoid receptor dysfunction. *Ann N Y Acad Sci*. 2012;1261:55-63.
 36. Hardy RS, Raza K, Cooper MS. Endogenous glucocorticoids in inflammation: contributions of systemic and local responses. *Swiss Med Wkly*. 2012;142:w13650.
 37. Walker ML. Critical illness related corticosteroid insufficiency in trauma: a review. *J Trauma Treat*. 2012;1(6):139-144.
 38. Dellinger RP, Levy MM, Carlet JM, et al. Surviving Sepsis Campaign: international guidelines for management of severe sepsis and septic shock: 2008. *Crit Care Med*. 2008;36(1):296-327.
 39. Flaster H, Bernhagen J, Calandra T, Bucala R. The macrophage migration inhibitory factor-glucocorticoid dyad: regulation of inflammation and immunity. *Mol Endocrinol*. 2007;21(6):1267-1280.
 40. Roger T, David J, Glauser MP, Calandra T. MIF regulates innate immune responses through modulation of Toll-like receptor 4. *Nature*. 2001;414(6866):920-924.
 41. Hayakawa M, Katabami K, Wada T, et al. Imbalance between macrophage migration inhibitory factor and cortisol induces multiple organ dysfunction in patients with blunt trauma. *Inflammation*. 2011;34(3):193-197.
 42. Agnese DM, Calvano JE, Hahm SJ, Calvano SE, Lowry SF. Insulin-like growth factor binding protein-3 is upregulated in LPS-treated THP-1 cells. *Surg Infect (Larchmt)*. 2002;3(2):119-125; discussion 25-26.
 43. Takala J, Ruokonen E, Webster NR, et al. Increased mortality associated with growth hormone treatment in critically ill adults. *N Engl J Med*. 1999;341(11):785-792.
 44. Jeschke MG, Finnerty CC, Kulp GA, Przkora R, Mlcak RP, Herndon DN. Combination of recombinant human growth hormone and propranolol decreases hypermetabolism and inflammation in severely burned children. *Pediatr Crit Care Med*. 2008;9(2):209-216.
 45. Cheyuo C, Jacob A, Wang P. Ghrelin-mediated sympathoinhibition and suppression of inflammation in sepsis. *Am J Physiol Endocrinol Metab*. 2012;302(3):E265-E272.
 46. Wong DL, Tai TC, Wong-Faull DC, et al. Epinephrine: a short- and long-term regulator of stress and development of illness: a potential new role for epinephrine in stress. *Cell Mol Neurobiol*. 2012;32(5):737-748.
 47. van der Poll T, Coyle SM, Barbosa K, Braxton CC, Lowry SF. Epinephrine inhibits tumor necrosis factor-alpha and potentiates interleukin 10 production during human endotoxemia. *J Clin Invest*. 1996;97(3):713-719.
 48. Flierl MA, Rittirsch D, Huber-Lang M, Sarma JV, Ward PA. Catecholamines-crafty weapons in the inflammatory arsenal of immune/inflammatory cells or opening pandora's box? *Mol Med*. 2008;14(3-4):195-204.
 49. Gilbert KC, Brown NJ. Aldosterone and inflammation. *Curr Opin Endocrinol Diabetes Obes*. 2010;17(3):199-204.
 50. Van den Berghe G. How does blood glucose control with insulin save lives in intensive care? *J Clin Invest*. 2004;114(9):1187-1195.
 51. Sung J, Bochicchio GV, Joshi M, Bochicchio K, Tracy K, Scalea TM. Admission hyperglycemia is predictive of outcome in critically ill trauma patients. *J Trauma*. 2005;59(1):80-83.
 52. Kansagara D, Fu R, Freeman M, Wolf F, Helfand M. Intensive insulin therapy in hospitalized patients: a systematic review. *Ann Intern Med*. 2011;154(4):268-282.
 53. Preiser JC. Oxidative stress. *JPEN J Parenter Enteral Nutr*. 2012;36(2):147-154.
 54. Nathan C, Cunninham-Bussell A. Beyond oxidative stress: an immunologist's guide to reactive oxygen species. *Nat Rev Immunol*. 2013;13:349-361.
 55. Tschopp J, Schroder K. NLRP3 inflammasome activation: the convergence of multiple signalling pathways on ROS production? *Nat Rev Immunol*. 2010;10(3):210-215.
 56. Quintana FJ, Cohen IR. Heat shock proteins as endogenous adjuvants in sterile and septic inflammation. *J Immunol*. 2005;175(5):2777-2782.
 57. Muralidharan S, Mandrekar P. Cellular stress response and innate immune signaling: integrating pathways in host defense and inflammation. *J Leukoc Biol*. 2013;Aug 29.
 58. Jeschke MG, Boehning D. Endoplasmic reticulum stress and insulin resistance post-trauma: similarities to type 2 diabetes. *J Cell Mol Med*. 2012;16(3):437-444.
 59. Jeschke MG, Finnerty CC, Herndon DN, et al. **Severe injury is associated with insulin resistance, endoplasmic**

- reticulum stress response, and unfolded protein response. *Ann Surg.* 2012;255(2):370-378.
60. Jones SA, Mills KH, Harris J. Autophagy and inflammatory diseases. *Immunol Cell Biol.* 2013;91(3):250-258.
 61. Levine B, Mizushima N, Virgin HW. Autophagy in immunity and inflammation. *Nature.* 2011;469(7330):323-335.
 62. Yen YT, Yang HR, Lo HC, et al. Enhancing autophagy with activated protein C and rapamycin protects against sepsis-induced acute lung injury. *Surgery.* 2013;153(5):689-698.
 63. Jean-Baptiste E. Cellular mechanisms in sepsis. *J Intensive Care Med.* 2007;22(2):63-72.
 64. Kaczmarek A, Vandenabeele P, Krysko DV. Necroptosis: the release of damage-associated molecular patterns and its physiological relevance. *Immunity.* 2013;38(2):209-223.
 65. Duprez L, Takahashi N, Van Hauwermeiren F, et al. RIP kinase-dependent necrosis drives lethal systemic inflammatory response syndrome. *Immunity.* 2011;35(6):908-918.
 66. Waters JP, Pober JS, Bradley JR. Tumour necrosis factor in infectious disease. *J Pathol.* 2013;230(2):132-147.
 67. Khalil AA, Hall JC, Aziz FA, Price P. Tumour necrosis factor: implications for surgical patients. *ANZ J Surg.* 2006;76(11):1010-1016.
 68. Namas R, Ghuma A, Torres A, et al. An adequately robust early TNF-alpha response is a hallmark of survival following trauma/hemorrhage. *PLoS One.* 2009;4(12):e8406.
 69. Dinarello CA. Interleukin-1 in the pathogenesis and treatment of inflammatory diseases. *Blood.* 2011;117(14):3720-3732.
 70. Stylianou E, Saklatvala J. Interleukin-1. *Int J Biochem Cell Biol.* 1998;30(10):1075-1079.
 71. Liao W, Lin JX, Leonard WJ. Interleukin-2 at the crossroads of effector responses, tolerance, and immunotherapy. *Immunity.* 2013;38(1):13-25.
 72. Bachmann MF, Oxenius A. Interleukin 2: from immunostimulation to immunoregulation and back again. *EMBO Rep.* 2007;8(12):1142-1148.
 73. Jawa RS, Anillo S, Huntoon K, Baumann H, Kulaylat M. Interleukin-6 in surgery, trauma, and critical care part II: clinical implications. *J Intensive Care Med.* 2011;26(2):73-87.
 74. Rose-John S. IL-6 trans-signaling via the soluble IL-6 receptor: importance for the pro-inflammatory activities of IL-6. *Int J Biol Sci.* 2012;8(9):1237-1247.
 75. Song M, Kellum JA. Interleukin-6. *Crit Care Med.* 2005;33(12 Suppl):S463-S465.
 76. Hutchins AP, Diez D, Miranda-Saavedra D. The IL-10/STAT3-mediated anti-inflammatory response: recent developments and future challenges. *Brief Funct Genomics.* 2013;Aug 12.
 77. Scumpia PO, Moldawer LL. Biology of interleukin-10 and its regulatory roles in sepsis syndromes. *Crit Care Med.* 2005;33(12 Suppl):S468-S471.
 78. Vignali DA, Kuchroo VK. IL-12 family cytokines: immunological playmakers. *Nat Immunol.* 2012;13(8):722-728.
 79. Weijer S, Florquin S, van der Poll T. Endogenous interleukin-12 improves the early antimicrobial host response to murine *Escherichia coli* peritonitis. *Shock.* 2005;23(1):54-58.
 80. Kinoshita M, Miyazaki H, Ono S, Seki S. Immunoenhancing therapy with interleukin-18 against bacterial infection in immunocompromised hosts after severe surgical stress. *J Leukoc Biol.* 2013;93(5):689-698.
 81. Kernbauer E, Maier V, Rauch I, Muller M, Decker T. Route of infection determines the impact of type I interferons on innate immunity to *Listeria monocytogenes*. *PLoS One.* 2013;8(6):e65007.
 82. Rauch I, Muller M, Decker T. The regulation of inflammation by interferons and their STATs. *JAKSTAT.* 2013;2(1):e23820-1-13.
 83. Kamp VM, Leentjens J, Pillay J, et al. Modulation of granulocyte kinetics by GM-CSF/IFN-gamma in a human LPS challenge model. *J Leukoc Biol.* 2013;94(3):513-520.
 84. Ott J, Hiesgen C, Mayer K. Lipids in critical care medicine. *Prostaglandins Leukot Essent Fatty Acids.* 2011;85(5):267-273.
 85. Soares EM, Mason KL, Rogers LM, Serezani CH, Faccioli LH, Aronoff DM. Leukotriene B4 enhances innate immune defense against the puerperal sepsis agent *Streptococcus pyogenes*. *J Immunol.* 2013;190(4):1614-1622.
 86. Dichlberger A, Kovanen PT, Schneider WJ. Mast cells: from lipid droplets to lipid mediators. *Clin Sci (Lond).* 2013;125(3):121-130.
 87. Bernard GR, Wheeler AP, Russell JA, et al. The effects of ibuprofen on the physiology and survival of patients with sepsis. The Ibuprofen in Sepsis Study Group. *N Engl J Med.* 1997;336(13):912-918.
 88. Cook JA. Eicosanoids. *Crit Care Med.* 2005;33(12 Suppl):S488-S491.
 89. Zhang MJ, Spite M. Resolvins: anti-inflammatory and pro-resolving mediators derived from omega-3 polyunsaturated fatty acids. *Annu Rev Nutr.* 2012;32:203-227.
 90. Calder PC. n-3 fatty acids, inflammation, and immunity: relevance to postsurgical and critically ill patients. *Lipids.* 2004;39(12):1147-1161.
 91. Ricklin D, Hajishengallis G, Yang K, Lambris JD. Complement: a key system for immune surveillance and homeostasis. *Nat Immunol.* 2010;11(9):785-797.
 92. Ricklin D, Lambris JD. Complement in immune and inflammatory disorders: pathophysiological mechanisms. *J Immunol.* 2013;190(8):3831-3838.
 93. Saxena P, Thompson P, d'Udekem Y, Konstantinov IE. Kallikrein-kinin system: a surgical perspective in post-aprotinin era. *J Surg Res.* 2011;167(1):70-77.
 94. Schmaier AH. The kallikrein-kinin and the renin-angiotensin systems have a multilayered interaction. *Am J Physiol Regul Integr Comp Physiol.* 2003;285(1):R1-13.
 95. Faerber L, Drechsler S, Ladenburger S, Gschaidmeier H, Fischer W. The neuronal 5-HT3 receptor network after 20 years of research: evolving concepts in management of pain and inflammation. *Eur J Pharmacol.* 2007;560(1):1-8.
 96. Duerschmied D, Suidan GL, Demers M, et al. Platelet serotonin promotes the recruitment of neutrophils to sites of acute inflammation in mice. *Blood.* 2013;121(6):1008-1015.
 97. de Esch IJ, Thurmond RL, Jongejan A, Leurs R. The histamine H4 receptor as a new therapeutic target for inflammation. *Trends Pharmacol Sci.* 2005;26(9):462-469.
 98. O'Mahony L, Akdis M, Akdis CA. Regulation of the immune response and inflammation by histamine and histamine receptors. *J Allergy Clin Immunol.* 2011;128(6):1153-1162.
 99. Leonard WJ, O'Shea JJ. Jaks and STATs: biological implications. *Annu Rev Immunol.* 1998;16:293-322.
 100. Trengove MC, Ward AC. SOCS proteins in development and disease. *Am J Clin Exp Immunol.* 2013;2(1):1-29.
 101. Sun L, Ye RD. Role of G protein-coupled receptors in inflammation. *Acta Pharmacol Sin.* 2012;33(3):342-350.
 102. Yoshimura A, Wakabayashi Y, Mori T. Cellular and molecular basis for the regulation of inflammation by TGF-beta. *J Biochem.* 2010;147(6):781-792.
 103. Licciardi PV, Karagiannis TC. Regulation of immune responses by histone deacetylase inhibitors. *ISRN Hematol.* 2012;2012:690901.
 104. Foster SL, Medzhitov R. Gene-specific control of the TLR-induced inflammatory response. *Clin Immunol.* 2009;130(1):7-15.
 105. Nicodeme E, Jeffrey KL, Schaefer U, et al. Suppression of inflammation by a synthetic histone mimic. *Nature.* 2010;468(7327):1119-1123.

106. Ameres SL, Zamore PD. Diversifying microRNA sequence and function. *Nat Rev Mol Cell Biol.* 2013;14(8):475-488.
107. O'Neill LA, Sheedy FJ, McCoy CE. MicroRNAs: the fine-tuners of Toll-like receptor signalling. *Nat Rev Immunol.* 2011;11(3):163-175.
108. Andonegui G, Kerfoot SM, McNagny K, Ebbert KV, Patel KD, Kubes P. Platelets express functional Toll-like receptor-4. *Blood.* 2005;106(7):2417-2423.
109. Clark SR, Ma AC, Tavener SA, et al. Platelet TLR4 activates neutrophil extracellular traps to ensnare bacteria in septic blood. *Nat Med.* 2007;13(4):463-469.
110. Sillesen M, Johansson PI, Rasmussen LS, et al. Platelet activation and dysfunction in a large-animal model of traumatic brain injury and hemorrhage. *J Trauma Acute Care Surg.* 2013;74(5):1252-1259.
111. Kimura F, Shimizu H, Yoshidome H, Ohtsuka M, Miyazaki M. Immunosuppression following surgical and traumatic injury. *Surg Today.* 2010;40(9):793-808.
112. Pillay J, Tak T, Kamp VM, Koenderman L. Immune suppression by neutrophils and granulocytic myeloid-derived suppressor cells: similarities and differences. *Cell Mol Life Sci.* 2013;Feb 20.
113. Rendon JL, Choudhry MA. Th17 cells: critical mediators of host responses to burn injury and sepsis. *J Leukoc Biol.* 2012;92(3):529-538.
114. Gallo PM, Gallucci S. The dendritic cell response to classic, emerging, and homeostatic danger signals. Implications for autoimmunity. *Front Immunol.* 2013;4:138.
115. Afshar K, Vucinic V, Sharma OP. Eosinophil cell: pray tell us what you do! *Curr Opin Pulm Med.* 2007;13(5):414-421.
116. Bachelet I, Levi-Schaffer F. Mast cells as effector cells: a stimulating question. *Trends Immunol.* 2007;28(8):360-365.
117. Wynn TA, Chawla A, Pollard JW. Macrophage biology in development, homeostasis, and disease. *Nature.* 2013;496(7446):445-455.
118. Cavaillon JM, Adib-Conquy M. Monocytes/macrophages and sepsis. *Crit Care Med.* 2005;33(12 Suppl):S506-S509.
119. Kaplan MJ, Radic M. Neutrophil extracellular traps: double-edged swords of innate immunity. *J Immunol.* 2012;189(6):2689-2695.
120. Alves-Filho JC, Tavares-Murta BM, Barja-Fidalgo C, et al. Neutrophil function in severe sepsis. *Endocr Metab Immune Disord Drug Targets.* 2006;6(2):151-158.
121. Kolaczowska E, Kubes P. Neutrophil recruitment and function in health and inflammation. *Nat Rev Immunol.* 2013;13(3):159-175.
122. Ley K, Laudanna C, Cybulsky MI, Nourshargh S. Getting to the site of inflammation: the leukocyte adhesion cascade updated. *Nat Rev Immunol.* 2007;7(9):678-689.
123. Fortin CF, McDonald PP, Fulop T, Lesur O. Sepsis, leukocytes, and nitric oxide (NO): an intricate affair. *Shock.* 2010;33(4):344-352.
124. Darwiche SS, Pfeifer R, Menzel C, et al. Inducible nitric oxide synthase contributes to immune dysfunction following trauma. *Shock.* 2012;38(5):499-507.
125. Cauwels A. Nitric oxide in shock. *Kidney Int.* 2007;72(5):557-565.
126. Su F, Huang H, Akieda K, et al. Effects of a selective iNOS inhibitor versus norepinephrine in the treatment of septic shock. *Shock.* 2010;34(3):243-249.
127. Zardi EM, Zardi DM, Dobrina A, Afeltra A. Prostacyclin in sepsis: a systematic review. *Prostaglandins Other Lipid Mediat.* 2007;83(1-2):1-24.
128. Yeager ME, Belchenko DD, Nguyen CM, Colvin KL, Ivy DD, Stenmark KR. Endothelin-1, the unfolded protein response, and persistent inflammation: role of pulmonary artery smooth muscle cells. *Am J Respir Cell Mol Biol.* 2012;46(1):14-22.
129. Piechota M, Banach M, Irzanski R, et al. Plasma endothelin-1 levels in septic patients. *J Intensive Care Med.* 2007;22(4):232-239.
130. Rondina MT, Weyrich AS, Zimmerman GA. Platelets as cellular effectors of inflammation in vascular diseases. *Circ Res.* 2013;112(11):1506-1519.
131. Zimmerman GA, McIntyre TM, Prescott SM, Stafforini DM. The platelet-activating factor signaling system and its regulators in syndromes of inflammation and thrombosis. *Crit Care Med.* 2002;30(5 Suppl):S294-S301.
132. Varpula M, Pulkki K, Karlsson S, Ruokonen E, Pettila V. Predictive value of N-terminal pro-brain natriuretic peptide in severe sepsis and septic shock. *Crit Care Med.* 2007;35(5):1277-1283.
133. Mitch WE, Price SR. Mechanisms activating proteolysis to cause muscle atrophy in catabolic conditions. *J Ren Nutr.* 2003;13(2):149-152.
134. Guirao X. Impact of the inflammatory reaction on intermediary metabolism and nutrition status. *Nutrition.* 2002;18(11-12):949-952.
135. Souba WW. Nutritional support. *N Engl J Med.* 1997;336(1):41-48.
136. Bistrian BR. Clinical aspects of essential fatty acid metabolism: Jonathan Rhoads Lecture. *JPEN J Parenter Enteral Nutr.* 2003;27(3):168-175.
137. Dahn MS, Mitchell RA, Lange MP, Smith S, Jacobs LA. Hepatic metabolic response to injury and sepsis. *Surgery.* 1995;117(5):520-530.
138. Vidal-Puig A, O'Rahilly S. Metabolism. Controlling the glucose factory. *Nature.* 2001;413(6852):125-126.
139. Mueckler M, Thorens B. The SLC2 (GLUT) family of membrane transporters. *Mol Aspects Med.* 2013;34(2-3):121-138.
140. Volpi E, Sheffield-Moore M, Rasmussen BB, Wolfe RR. Basal muscle amino acid kinetics and protein synthesis in healthy young and older men. *JAMA.* 2001;286(10):1206-1212.
141. Chernoff R. Normal aging, nutrition assessment, and clinical practice. *Nutr Clin Pract.* 2003;18(1):12-20.
142. Heslin MJ, Brennan MF. Advances in perioperative nutrition: cancer. *World J Surg.* 2000;24(12):1477-1485.
143. Heslin MJ, Latkany L, Leung D, et al. A prospective, randomized trial of early enteral feeding after resection of upper gastrointestinal malignancy. *Ann Surg.* 1997;226(4):567-577; discussion 77-80.
144. Brooks AD, Hochwald SN, Heslin MJ, Harrison LE, Burt M, Brennan MF. Intestinal permeability after early postoperative enteral nutrition in patients with upper gastrointestinal malignancy. *JPEN J Parenter Enteral Nutr.* 1999;23(2):75-79.
145. Abunnaja S, Cuvillo A, Sanchez JA. Enteral and parenteral nutrition in the perioperative period: state of the art. *Nutrients.* 2013;5(2):608-623.
146. Arabi YM, Tamim HM, Dhar GS, et al. Permissive underfeeding and intensive insulin therapy in critically ill patients: a randomized controlled trial. *Am J Clin Nutr.* 2011;93(3):569-577.
147. Rice TW, Wheeler AP, Thompson BT, et al. Initial trophic vs full enteral feeding in patients with acute lung injury: the EDEN randomized trial. *JAMA.* 2012;307(8):795-803.
148. Bankhead R, Boullata J, Brantley S, et al. Enteral nutrition practice recommendations. *JPEN J Parenter Enteral Nutr.* 2009;33(2):122-167.
149. Exner R, Tamandl D, Goetzinger P, et al. Perioperative GLY-GLN infusion diminishes the surgery-induced period of immunosuppression: accelerated restoration of the lipopolysaccharide-stimulated tumor necrosis factor-alpha response. *Ann Surg.* 2003;237(1):110-115.

150. Luiking YC, Ten Have GA, Wolfe RR, Deutz NE. Arginine de novo and nitric oxide production in disease states. *Am J Physiol Endocrinol Metab.* 2012;303(10):E1177-E1189.
151. Marik PE, Flemmer M. Immunonutrition in the surgical patient. *Minerva Anesthesiol.* 2012;78(3):336-342.
152. Canadian Clinical Practice Guidelines. Enteral Feeding Guidelines. 2013. Available at: http://www.criticalcarenutrition.com/docs/cpgs2012/Summary%20CPGs%202013%20vs%202009_24April2013.pdf.
153. Pontes-Arruda A, Martins LF, de Lima SM, et al. Enteral nutrition with eicosapentaenoic acid, gamma-linolenic acid and antioxidants in the early treatment of sepsis: results from a multicenter, prospective, randomized, double-blinded, controlled study: the INTERSEPT study. *Crit Care.* 2011;15(3):R144.
154. Btaiche IF. Branched-chain amino acids in patients with hepatic encephalopathy. 1982. *Nutr Clin Pract.* 2003;18(1):97-100.
155. Patton KM, Aranda-Michel J. Nutritional aspects in liver disease and liver transplantation. *Nutr Clin Pract.* 2002;17(6):332-340.
156. DiSario JA, Baskin WN, Brown RD, et al. Endoscopic approaches to enteral nutritional support. *Gastrointest Endosc.* 2002;55(7):901-908.
157. Heyland DK, Drover JW, Dhaliwal R, Greenwood J. Optimizing the benefits and minimizing the risks of enteral nutrition in the critically ill: role of small bowel feeding. *JPEN J Parenter Enteral Nutr.* 2002;26(6 Suppl):S51-S55; discussion S6-S7.
158. Scolapio JS. Methods for decreasing risk of aspiration pneumonia in critically ill patients. *JPEN J Parenter Enteral Nutr.* 2002;26(6 Suppl):S58-S61.
159. Vanek VW. Ins and outs of enteral access: part 2—long term access: esophagostomy and gastrostomy. *Nutr Clin Pract.* 2003;18(1):50-74.
160. Mermel LA, Allon M, Bouza E, et al. Clinical practice guidelines for the diagnosis and management of intravascular catheter-related infection: 2009 Update by the Infectious Diseases Society of America. *Clin Infect Dis.* 2009;49(1):1-45.
161. Agency for Healthcare Research and Quality. Tools for Reducing Central Line-Associated Blood Stream Infections. <http://www.ahrq.gov/legacy/qual/clabsitools/clabsitoolshtm-purpose>.
162. Maecken T, Grau T. Ultrasound imaging in vascular access. *Crit Care Med.* 2007;35(5 Suppl):S178-S185.

This page intentionally left blank

3 chapter

Fluid and Electrolyte Management of the Surgical Patient

G. Tom Shires III

Introduction	65	Volume Control / 68	Postoperative Fluid Therapy / 80
Body Fluids	65	Concentration Changes / 69	Special Considerations for the Postoperative Patient / 80
Total Body Water / 65		Composition Changes: Etiology and Diagnosis / 70	Electrolyte Abnormalities in Specific Surgical Patients 80
Fluid Compartments / 65		Acid-Base Balance / 73	Neurologic Patients / 80
Composition of Fluid Compartments / 65		Fluid and Electrolyte Therapy 76	Malnourished Patients: Refeeding Syndrome / 81
Osmotic Pressure / 66		Parenteral Solutions / 76	Acute Renal Failure Patients / 81
Body Fluid Changes	67	Alternative Resuscitative Fluids / 76	Cancer Patients / 81
Normal Exchange of Fluid and Electrolytes / 67		Correction of Life-Threatening Electrolyte Abnormalities / 77	
Classification of Body Fluid Changes / 67		Preoperative Fluid Therapy / 78	
Disturbances in Fluid Balance / 68		Intraoperative Fluid Therapy / 80	

INTRODUCTION

Fluid and electrolyte management is paramount to the care of the surgical patient. Changes in both fluid volume and electrolyte composition occur preoperatively, intraoperatively, and postoperatively, as well as in response to trauma and sepsis. The sections that follow review the normal anatomy of body fluids, electrolyte composition and concentration abnormalities and treatments, common metabolic derangements, and alternative resuscitative fluids. These concepts are then discussed in relationship to management of specific surgical patients and their commonly encountered fluid and electrolyte abnormalities.

BODY FLUIDS

Total Body Water

Water constitutes approximately 50% to 60% of total body weight. The relationship between total body weight and total body water (TBW) is relatively constant for an individual and is primarily a reflection of body fat. Lean tissues such as muscle and solid organs have higher water content than fat and bone. As a result, young, lean males have a higher proportion of body weight as water than elderly or obese individuals. Deuterium oxide and tritiated water have been used in clinical research to measure TBW by indicator dilution methods. In an average young adult male, TBW accounts for 60% of total body weight, whereas in an average young adult female, it is 50%.¹ The lower percentage of TBW in females correlates with a higher percentage of adipose tissue and lower percentage of muscle mass in most. Estimates of percentage of TBW should be adjusted downward approximately 10% to 20% for obese individuals and upward by 10% for malnourished individuals. The highest percentage of TBW is found in newborns, with approximately 80%

of their total body weight comprised of water. This decreases to approximately 65% by 1 year of age and thereafter remains fairly constant.

Fluid Compartments

TBW is divided into three functional fluid compartments: plasma, extravascular interstitial fluid, and intracellular fluid (Fig. 3-1). The extracellular fluids (ECF), plasma and interstitial fluid, together compose about one third of the TBW, and the intracellular compartment composes the remaining two thirds. The extracellular water composes 20% of the total body weight and is divided between plasma (5% of body weight) and interstitial fluid (15% of body weight). Intracellular water makes up approximately 40% of an individual's total body weight, with the largest proportion in the skeletal muscle mass. ECF is measured using indicator dilution methods. The distribution volumes of NaBr and radioactive sulfate have been used to measure ECF in clinical research. Measurement of the intracellular compartment is then determined indirectly by subtracting the measured ECF from the simultaneous TBW measurement.

Composition of Fluid Compartments

The normal chemical composition of the body fluid compartments is shown in Fig. 3-2. The ECF compartment is balanced between sodium, the principal cation, and chloride and bicarbonate, the principal anions. The intracellular fluid compartment is composed primarily of the cations potassium and magnesium, and the anions phosphate and sulfate, and proteins. The concentration gradient between compartments is maintained by adenosine triphosphate–driven sodium-potassium pumps located within the cell membranes. The composition of the plasma and interstitial fluid differs only slightly in ionic composition. The slightly higher protein content (organic anions)

Key Points

- 1▶ Proper management of fluid and electrolytes facilitates crucial homeostasis that allows cardiovascular perfusion, organ system function, and cellular mechanisms to respond to surgical illness.
- 2▶ Knowledge of the compartmentalization of body fluids forms the basis for understanding pathologic shifts in these fluid spaces in disease states. Although difficult to quantify, a deficiency in the functional extracellular fluid compartment often requires resuscitation with isotonic fluids in surgical and trauma patients.
- 3▶ Alterations in the concentration of serum sodium have profound effects on cellular function due to water shifts between the intracellular and extracellular spaces.
- 4▶ Different rates of compensation between respiratory and metabolic components of acid-base homeostasis require frequent laboratory reassessment during therapy.
- 5▶ Although active investigation continues, alternative resuscitation fluids have limited clinical utility, other than the correction of specific electrolyte abnormalities.
- 6▶ Most acute surgical illnesses are accompanied by some degree of volume loss or redistribution. Consequently, isotonic fluid administration is the most common initial intravenous fluid strategy, while attention is being given to alterations in concentration and composition.
- 7▶ Some surgical patients with neurologic illness, malnutrition, acute renal failure, or cancer require special attention to well-defined, disease-specific abnormalities in fluid and electrolyte status.

in plasma results in a higher plasma cation composition relative to the interstitial fluid, as explained by the Gibbs-Donnan equilibrium equation. Proteins add to the osmolality of the plasma and contribute to the balance of forces that determine fluid balance across the capillary endothelium. Although the movement of ions and proteins between the various fluid compartments is restricted, water is freely diffusible. Water is distributed evenly throughout all fluid compartments of the body so that a given volume of water increases the volume of any one compartment relatively little. Sodium, however, is confined to the ECF compartment, and because of its osmotic and electrical properties, it remains associated with water. Therefore, sodium-containing fluids are distributed throughout the ECF and add to the volume of both the intravascular and interstitial spaces. Although the administration of sodium-containing fluids expands the intravascular volume, it also expands the interstitial space by approximately three times as much as the plasma.

Osmotic Pressure

The physiologic activity of electrolytes in solution depends on the number of particles per unit volume (millimoles per liter, or mmol/L), the number of electric charges per unit volume

(milliequivalents per liter, or mEq/L), and the number of osmotically active ions per unit volume (milliosmoles per liter, or mOsm/L). The concentration of electrolytes usually is expressed in terms of the chemical combining activity, or equivalents. An equivalent of an ion is its atomic weight expressed in grams divided by the valence:

$$\text{Equivalent} = \text{atomic weight (g)/valence}$$

For univalent ions such as sodium, 1 mEq is the same as 1 mmol. For divalent ions such as magnesium, 1 mmol equals 2 mEq. The number of milliequivalents of cations must be balanced by the same number of milliequivalents of anions. However, the expression of molar equivalents alone does not allow a physiologic comparison of solutes in a solution.

The movement of water across a cell membrane depends primarily on osmosis. To achieve osmotic equilibrium, water moves across a semipermeable membrane to equalize the concentration on both sides. This movement is determined by the concentration of the solutes on each side of the membrane. Osmotic pressure is measured in units of osmoles (osm) or milliosmoles (mOsm) that refer to the actual number of osmotically

% of Total body weight	Volume of TBW	Male (70 kg)	Female (60 kg)
Plasma 5%	Extracellular volume	14,000 mL	10,000 mL
	Plasma	3500 mL	2500 mL
Interstitial fluid 15%	Interstitial	10,500 mL	7500 mL
	Intracellular volume	28,000 mL	20,000 mL
Intracellular volume 40%		42,000 mL	30,000 mL

Figure 3-1. Functional body fluid compartments. TBW = total body water.

Table 3-1

Water exchange (60- to 80-kg man)

ROUTES	AVERAGE DAILY VOLUME (mL)	MINIMAL (mL)	MAXIMAL (mL)
H₂O gain:			
Sensible:			
Oral fluids	800–1500	0	1500/h
Solid foods	500–700	0	1500
Insensible:			
Water of oxidation	250	125	800
Water of solution	0	0	500
H₂O loss:			
Sensible:			
Urine	800–1500	300	1400/h
Intestinal	0–250	0	2500/h
Sweat	0	0	4000/h
Insensible:			
Lungs and skin	600	600	1500

the compartments. Unlike with sodium, the concentration of most other ions in the ECF can be altered without significant change in the total number of osmotically active particles, producing only a compositional change. For instance, doubling the serum potassium concentration will profoundly alter myocardial function without significantly altering volume or concentration of the fluid spaces.

Disturbances in Fluid Balance

Extracellular volume deficit is the most common fluid disorder in surgical patients and can be either acute or chronic. Acute volume deficit is associated with cardiovascular and central nervous system signs, whereas chronic deficits display tissue signs, such as a decrease in skin turgor and sunken eyes, in addition to cardiovascular and central nervous system signs (Table 3-2). Laboratory examination may reveal an elevated blood urea nitrogen level if the deficit is severe enough to reduce glomerular filtration and hemoconcentration. Urine osmolality usually will be higher than serum osmolality, and urine sodium will be low, typically <20 mEq/L. Serum sodium concentration does not necessarily reflect volume status and therefore may be high, normal, or low when a volume deficit is present. The most common cause of volume deficit in surgical patients is a loss of GI fluids (Table 3-3) from nasogastric suction, vomiting, diarrhea, or enterocutaneous fistula. In addition, sequestration secondary to soft tissue injuries, burns, and intra-abdominal processes such as peritonitis, obstruction, or prolonged surgery can also lead to massive volume deficits.

Extracellular volume excess may be iatrogenic or secondary to renal dysfunction, congestive heart failure, or cirrhosis. Both plasma and interstitial volumes usually are increased. Symptoms are primarily pulmonary and cardiovascular (see Table 3-2). In fit patients, edema and hyperdynamic circulation are common and well tolerated. However, the elderly and patients with cardiac disease may quickly develop congestive

heart failure and pulmonary edema in response to only a moderate volume excess.

Volume Control

Volume changes are sensed by both osmoreceptors and baroreceptors. Osmoreceptors are specialized sensors that detect even small changes in fluid osmolality and drive changes in thirst and diuresis through the kidneys.² For example, when plasma osmolality is increased, thirst is stimulated and water consumption increases, although the exact cell mechanism is not known.³ Additionally, the hypothalamus is stimulated to secrete vasopressin, which increases water reabsorption in the kidneys.

Table 3-2

Signs and symptoms of volume disturbances

SYSTEM	VOLUME DEFICIT	VOLUME EXCESS
Generalized	Weight loss	Weight gain
	Decreased skin turgor	Peripheral edema
Cardiac	Tachycardia	Increased cardiac output
	Orthostasis/hypotension	Increased central venous pressure
	Collapsed neck veins	Distended neck veins
		Murmur
Renal	Oliguria	—
	Azotemia	
GI	Ileus	Bowel edema
Pulmonary	—	Pulmonary edema

Table 3-3

Composition of GI secretions

TYPE OF SECRETION	VOLUME (mL/24 h)	Na (mEq/L)	K (mEq/L)	Cl (mEq/L)	HCO ₃ ⁻ (mEq/L)
Stomach	1000–2000	60–90	10–30	100–130	0
Small intestine	2000–3000	120–140	5–10	90–120	30–40
Colon	—	60	30	40	0
Pancreas	600–800	135–145	5–10	70–90	95–115
Bile	300–800	135–145	5–10	90–110	30–40

Together, these two mechanisms return the plasma osmolality to normal. Baroreceptors also modulate volume in response to changes in pressure and circulating volume through specialized pressure sensors located in the aortic arch and carotid sinuses.⁴ Baroreceptor responses are both neural, through sympathetic and parasympathetic pathways, and hormonal, through substances including renin-angiotensin, aldosterone, atrial natriuretic peptide, and renal prostaglandins. The net result of alterations in renal sodium excretion and free water reabsorption is restoration of volume to the normal state.

Concentration Changes

Changes in serum sodium concentration are inversely proportional to TBW. Therefore, abnormalities in TBW are reflected by abnormalities in serum sodium levels.

3▶ Hyponatremia. A low serum sodium level occurs when there is an excess of extracellular water relative to sodium. Extracellular volume can be high, normal, or low (Fig. 3-3). In most cases of hyponatremia, sodium concentration is decreased as a consequence of either sodium depletion or dilution.⁵ Dilutional hyponatremia frequently results from excess extracellular water and therefore is associated with a high extracellular volume status. Excessive oral water intake or iatrogenic intravenous (IV) excess free water administration can cause hyponatremia. Post-operative patients are particularly prone to increased secretion of antidiuretic hormone (ADH), which increases reabsorption of free water from the kidneys with subsequent volume expansion and hyponatremia. This is usually self-limiting in that both hyponatremia and volume expansion decrease ADH secretion. Additionally, a number of drugs can cause water retention and subsequent hyponatremia, such as the antipsychotics and tricyclic antidepressants as well as angiotensin-converting enzyme inhibitors. The elderly are particularly susceptible to drug-induced hyponatremia. Physical signs of volume overload usually are absent, and laboratory evaluation reveals hemodilution. Depletional causes of hyponatremia are associated with either a decreased intake or increased loss of sodium-containing fluids. A concomitant ECF volume deficit is common. Causes include decreased sodium intake, such as consumption of a low-sodium diet or use of enteral feeds, which are typically low in sodium; GI losses from vomiting, prolonged nasogastric suctioning, or diarrhea; and renal losses due to diuretic use or primary renal disease.

Hyponatremia also can be seen with an excess of solute relative to free water, such as with untreated hyperglycemia or mannitol administration. Glucose exerts an osmotic force in the extracellular compartment, causing a shift of water from the

intracellular to the extracellular space. Hyponatremia therefore can be seen when the effective osmotic pressure of the extracellular compartment is normal or even high. When hyponatremia in the presence of hyperglycemia is being evaluated, the corrected sodium concentration should be calculated as follows:

For every 100-mg/dL increment in plasma glucose above normal, the plasma sodium should decrease by 1.6 mEq/L

Lastly, extreme elevations in plasma lipids and proteins can cause pseudohyponatremia, because there is no true decrease in extracellular sodium relative to water.

Signs and symptoms of hyponatremia (Table 3-4) are dependent on the degree of hyponatremia and the rapidity with which it occurred. Clinical manifestations primarily have a central nervous system origin and are related to cellular water intoxication and associated increases in intracranial pressure. Oliguric renal failure also can be a rapid complication in the setting of severe hyponatremia.

A systematic review of the etiology of hyponatremia should reveal its cause in a given instance. Hyperosmolar causes, including hyperglycemia or mannitol infusion and pseudohyponatremia, should be easily excluded. Next, depletional versus dilutional causes of hyponatremia are evaluated. In the absence of renal disease, depletion is associated with low urine sodium levels (<20 mEq/L), whereas renal sodium wasting shows high urine sodium levels (>20 mEq/L). Dilutional causes of hyponatremia usually are associated with hypervolemic circulation. A normal volume status in the setting of hyponatremia should prompt an evaluation for a syndrome of inappropriate secretion of ADH.

Hypernatremia. Hypernatremia results from either a loss of free water or a gain of sodium in excess of water. Like hyponatremia, it can be associated with an increased, normal, or decreased extracellular volume (see Fig. 3-3). Hypervolemic hypernatremia usually is caused either by iatrogenic administration of sodium-containing fluids, including sodium bicarbonate, or mineralocorticoid excess as seen in hyperaldosteronism, Cushing's syndrome, and congenital adrenal hyperplasia. Urine sodium concentration is typically >20 mEq/L, and urine osmolality is >300 mOsm/L. Normovolemic hypernatremia can result from renal causes, including diabetes insipidus, diuretic use, and renal disease, or from nonrenal water loss from the GI tract or skin, although the same conditions can result in hypovolemic hypernatremia. When hypovolemia is present, the urine sodium concentration is <20 mEq/L and urine osmolality

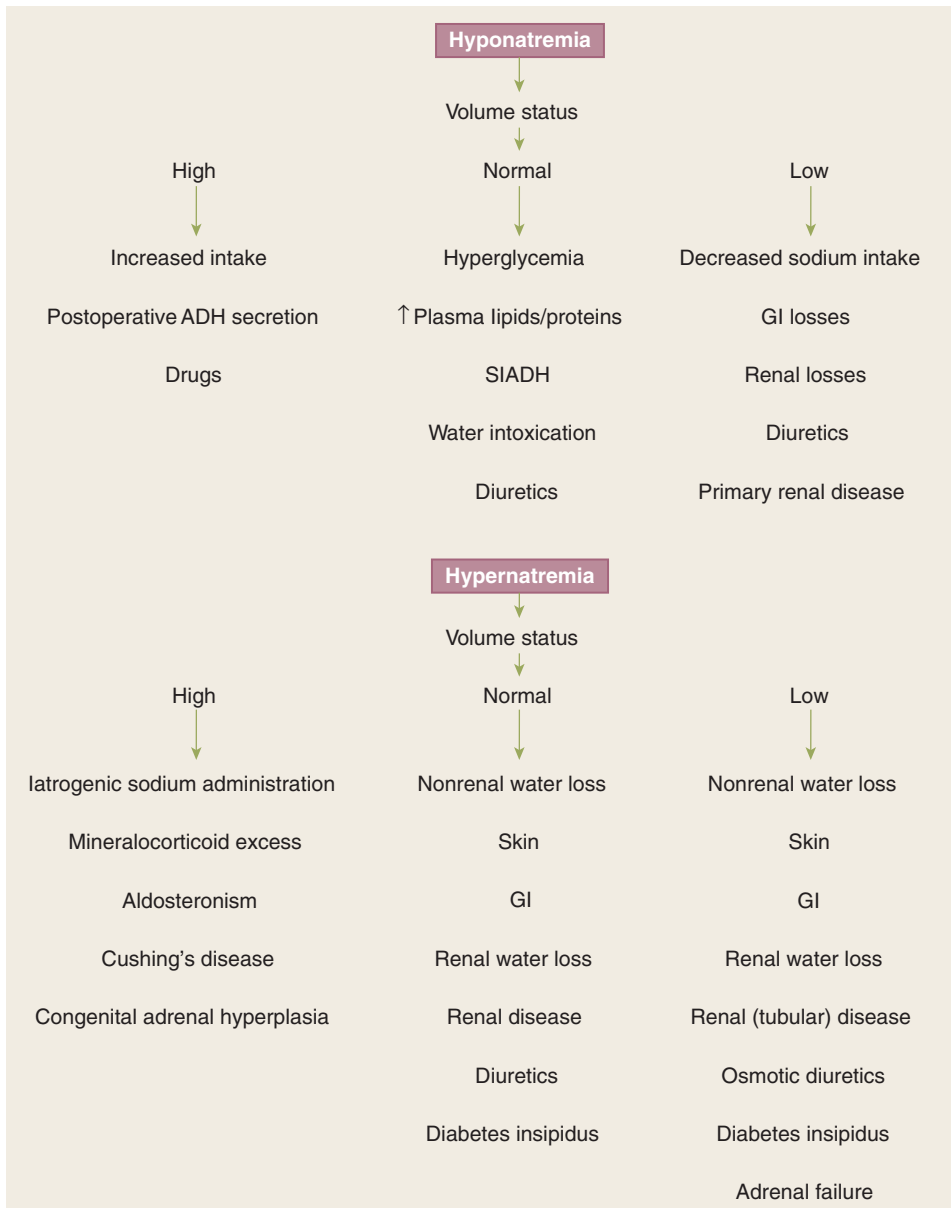


Figure 3-3. Evaluation of sodium abnormalities. ADH = antidiuretic hormone; SIADH = syndrome of inappropriate secretion of antidiuretic hormone.

is <300 to 400 mOsm/L. Nonrenal water loss can occur secondary to relatively isotonic GI fluid losses such as that caused by diarrhea, to hypotonic skin fluid losses such as loss due to fever, or to losses via tracheotomies during hyperventilation. Additionally, thyrotoxicosis can cause water loss, as can the use of hypertonic glucose solutions for peritoneal dialysis. With nonrenal water loss, the urine sodium concentration is <15 mEq/L and the urine osmolarity is >400 mOsm/L.

Symptomatic hypernatremia usually occurs only in patients with impaired thirst or restricted access to fluid, because thirst will result in increased water intake. Symptoms are rare until the serum sodium concentration exceeds 160 mEq/L but, once present, are associated with significant morbidity and mortality. Because symptoms are related to hyperosmolarity, central nervous system effects predominate (see Table 3-4). Water shifts from the intracellular to the extracellular space in response to a hyperosmolar extracellular space, which results in cellular dehydration. This can put traction on the cerebral vessels and lead to subarachnoid hemorrhage. Central nervous system symptoms

can range from restlessness and irritability to seizures, coma, and death. The classic signs of hypovolemic hypernatremia, (tachycardia, orthostasis, and hypotension) may be present, as well as the unique findings of dry, sticky mucous membranes.

Composition Changes: Etiology and Diagnosis

Potassium Abnormalities. The average dietary intake of potassium is approximately 50 to 100 mEq/d, which in the absence of hypokalemia is excreted primarily in the urine. Extracellular potassium is maintained within a narrow range, principally by renal excretion of potassium, which can range from 10 to 700 mEq/d. Although only 2% of the total body potassium ($4.5 \text{ mEq/L} \times 14 \text{ L} = 63 \text{ mEq}$) is located within the extracellular compartment, this small amount is critical to cardiac and neuromuscular function; thus, even minor changes can have major effects on cardiac activity. The intracellular and extracellular distribution of potassium is influenced by a number of factors, including surgical stress, injury, acidosis, and tissue catabolism.

Table 3-4

Clinical manifestations of abnormalities in serum sodium level

BODY SYSTEM	HYPONATREMIA
Central nervous system	Headache, confusion, hyperactive or hypoactive deep tendon reflexes, seizures, coma, increased intracranial pressure
Musculoskeletal	Weakness, fatigue, muscle cramps/twitching
GI	Anorexia, nausea, vomiting, watery diarrhea
Cardiovascular	Hypertension and bradycardia if intracranial pressure increases significantly
Tissue	Lacrimation, salivation
Renal	Oliguria
BODY SYSTEM	HYPERNATREMIA
Central nervous system	Restlessness, lethargy, ataxia, irritability, tonic spasms, delirium, seizures, coma
Musculoskeletal	Weakness
Cardiovascular	Tachycardia, hypotension, syncope
Tissue	Dry sticky mucous membranes, red swollen tongue, decreased saliva and tears
Renal	Oliguria
Metabolic	Fever

Hyperkalemia *Hyperkalemia* is defined as a serum potassium concentration above the normal range of 3.5 to 5.0 mEq/L. It is caused by excessive potassium intake, increased release of potassium from cells, or impaired potassium excretion by the kidneys (Table 3-5).⁶ Increased intake can be either from oral or IV supplementation, or from red cell lysis after transfusion. Hemolysis, rhabdomyolysis, and crush injuries can disrupt cell membranes and release intracellular potassium into the ECF. Acidosis and a rapid rise in extracellular osmolality from hyperglycemia or IV mannitol can raise serum potassium levels by causing a shift of potassium ions to the extracellular compartment.⁷ Because 98% of total body potassium is in the intracellular fluid compartment, even small shifts of intracellular potassium out of the intracellular fluid compartment can lead to a significant rise in extracellular potassium. A number of medications can contribute to hyperkalemia, particularly in the presence of renal insufficiency, including potassium-sparing diuretics, angiotensin-converting enzyme inhibitors, and non-steroidal anti-inflammatory drugs (NSAIDs). Spironolactone and angiotensin-converting enzyme inhibitors interfere with aldosterone activity, inhibiting the normal renal mechanism of potassium excretion. Acute and chronic renal insufficiency also impairs potassium excretion.

Symptoms of hyperkalemia are primarily GI, neuromuscular, and cardiovascular (Table 3-6). GI symptoms include nausea, vomiting, intestinal colic, and diarrhea. Neuromuscular symptoms range from weakness to ascending paralysis to respiratory failure. Early cardiovascular signs may be apparent from electrocardiogram (ECG) changes and eventually lead

Table 3-5

Etiology of potassium abnormalities

Hyperkalemia

Increased intake

- Potassium supplementation
- Blood transfusions
- Endogenous load/destruction: hemolysis, rhabdomyolysis, crush injury, gastrointestinal hemorrhage

Increased release

- Acidosis
- Rapid rise of extracellular osmolality (hyperglycemia or mannitol)

Impaired excretion

- Potassium-sparing diuretics
- Renal insufficiency/failure

Hypokalemia

Inadequate intake

- Dietary, potassium-free intravenous fluids, potassium-deficient TPN

Excessive potassium excretion

- Hyperaldosteronism
- Medications

GI losses

- Direct loss of potassium from GI fluid (diarrhea)
- Renal loss of potassium (to conserve sodium in response to gastric losses)

to hemodynamic symptoms of arrhythmia and cardiac arrest. ECG changes that may be seen with hyperkalemia include high peaked T waves (early), widened QRS complex, flattened P wave, prolonged PR interval (first-degree block), sine wave formation, and ventricular fibrillation.

Hypokalemia Hypokalemia is much more common than hyperkalemia in the surgical patient. It may be caused by inadequate potassium intake; excessive renal potassium excretion; potassium loss in pathologic GI secretions, such as with diarrhea, fistulas, vomiting, or high nasogastric output; or intracellular shifts from metabolic alkalosis or insulin therapy (see Table 3-5). The change in potassium associated with alkalosis can be calculated by the following formula:

Potassium decreases by 0.3 mEq/L for every 0.1 increase in pH above normal.

Additionally, drugs such as amphotericin, aminoglycosides, cisplatin, and ifosfamide that induce magnesium depletion cause renal potassium wastage.^{8,9} In cases in which potassium deficiency is due to magnesium depletion,¹⁰ potassium repletion is difficult unless hypomagnesemia is first corrected.

The symptoms of hypokalemia (see Table 3-6), like those of hyperkalemia, are primarily related to failure of normal contractility of GI smooth muscle, skeletal muscle, and cardiac muscle. Findings may include ileus, constipation, weakness, fatigue, diminished tendon reflexes, paralysis, and cardiac arrest. In the setting of ECF depletion, symptoms may be masked initially and then worsened by further dilution during volume repletion. ECG changes suggestive of hypokalemia include U waves, T-wave flattening, ST-segment changes, and arrhythmias (with digitalis therapy).

Table 3-6

Clinical manifestations of abnormalities in potassium, magnesium, and calcium levels

INCREASED SERUM LEVELS			
SYSTEM	POTASSIUM	MAGNESIUM	CALCIUM
GI	Nausea/vomiting, colic, diarrhea	Nausea/vomiting	Anorexia, nausea/vomiting, abdominal pain
Neuromuscular	Weakness, paralysis, respiratory failure	Weakness, lethargy, decreased reflexes	Weakness, confusion, coma, bone pain
Cardiovascular	Arrhythmia, arrest	Hypotension, arrest	Hypertension, arrhythmia, polyuria
Renal	—	—	Polydipsia
DECREASED SERUM LEVELS			
SYSTEM	POTASSIUM	MAGNESIUM	CALCIUM
GI	Ileus, constipation	—	—
Neuromuscular	Decreased reflexes, fatigue, weakness, paralysis	Hyperactive reflexes, muscle tremors, tetany, seizures	Hyperactive reflexes, paresthesias, carpopedal spasm, seizures
Cardiovascular	Arrest	Arrhythmia	Heart failure

Calcium Abnormalities. The vast majority of the body's calcium is contained within the bone matrix, with <1% found in the ECF. Serum calcium is distributed among three forms: protein bound (40%), complexed to phosphate and other anions (10%), and ionized (50%). It is the ionized fraction that is responsible for neuromuscular stability and can be measured directly. When total serum calcium levels are measured, the albumin concentration must be taken into consideration:

Adjust total serum calcium down by 0.8 mg/dL
for every 1 g/dL decrease in albumin.

Unlike changes in albumin, changes in pH will affect the ionized calcium concentration. Acidosis decreases protein binding, thereby increasing the ionized fraction of calcium.

Daily calcium intake is 1 to 3 g/d. Most of this is excreted via the bowel, with urinary excretion relatively low. Total body calcium balance is under complex hormonal control, but disturbances in metabolism are relatively long term and less important in the acute surgical setting. However, attention to the critical role of ionized calcium in neuromuscular function often is required.

Hypercalcemia *Hypercalcemia* is defined as a serum calcium level above the normal range of 8.5 to 10.5 mEq/L or an increase in the ionized calcium level above 4.2 to 4.8 mg/dL. Primary hyperparathyroidism in the outpatient setting and malignancy in hospitalized patients, from either bony metastasis or secretion of parathyroid hormone–related protein, account for most cases of symptomatic hypercalcemia.¹¹ Symptoms of hypercalcemia (see Table 3-6), which vary with the degree of severity, include neurologic impairment, musculoskeletal weakness and pain, renal dysfunction, and GI symptoms of nausea, vomiting, and abdominal pain. Cardiac symptoms can be manifest as hypertension, cardiac arrhythmias, and a worsening of digitalis toxicity. ECG changes in hypercalcemia include shortened QT interval, prolonged PR and QRS intervals, increased QRS voltage, T-wave flattening and widening, and atrioventricular block (which can progress to complete heart block and cardiac arrest).

Hypocalcemia *Hypocalcemia* is defined as a serum calcium level below 8.5 mEq/L or a decrease in the ionized calcium level below 4.2 mg/dL. The causes of hypocalcemia include pancreatitis, massive soft tissue infections such as necrotizing fasciitis, renal failure, pancreatic and small bowel fistulas, hypoparathyroidism, toxic shock syndrome, abnormalities in magnesium levels, and tumor lysis syndrome. In addition, transient hypocalcemia commonly occurs after removal of a parathyroid adenoma due to atrophy of the remaining glands and avid bone remineralization, and sometimes requires high-dose calcium supplementation.¹² Additionally, malignancies associated with increased osteoblastic activity, such as breast and prostate cancer, can lead to hypocalcemia from increased bone formation.¹³ Calcium precipitation with organic anions is also a cause of hypocalcemia and may occur during hyperphosphatemia from tumor lysis syndrome or rhabdomyolysis. Pancreatitis may sequester calcium via chelation with free fatty acids. Massive blood transfusion with citrate binding is another mechanism.^{14,15} Hypocalcemia rarely results solely from decreased intake, because bone reabsorption can maintain normal levels for prolonged periods.

Asymptomatic hypocalcemia may occur when hypoproteinemia results in a normal ionized calcium level. Conversely, symptoms can develop with a normal serum calcium level during alkalosis, which decreases ionized calcium. In general, neuromuscular and cardiac symptoms do not occur until the ionized fraction falls below 2.5 mg/dL (see Table 3-6). Clinical findings may include paresthesias of the face and extremities, muscle cramps, carpopedal spasm, stridor, tetany, and seizures. Patients will demonstrate hyperreflexia and may exhibit positive Chvostek's sign (spasm resulting from tapping over the facial nerve) and Trousseau's sign (spasm resulting from pressure applied to the nerves and vessels of the upper extremity with a blood pressure cuff). Hypocalcemia may lead to decreased cardiac contractility and heart failure. ECG changes of hypocalcemia include prolonged QT interval, T-wave inversion, heart block, and ventricular fibrillation.

Phosphorus Abnormalities. Phosphorus is the primary intracellular divalent anion and is abundant in metabolically active cells. Phosphorus is involved in energy production during glycolysis and is found in high-energy phosphate products such as adenosine triphosphate. Serum phosphate levels are tightly controlled by renal excretion.

Hyperphosphatemia Hyperphosphatemia can be due to decreased urinary excretion, increased intake, or endogenous mobilization of phosphorus. Most cases of hyperphosphatemia are seen in patients with impaired renal function. Hypoparathyroidism or hyperthyroidism also can decrease urinary excretion of phosphorus and thus lead to hyperphosphatemia. Increased release of endogenous phosphorus can be seen in association with any clinical condition that results in cell destruction, including rhabdomyolysis, tumor lysis syndrome, hemolysis, sepsis, severe hypothermia, and malignant hyperthermia. Excessive phosphate administration from IV hyperalimentation solutions or phosphorus-containing laxatives may also lead to elevated phosphate levels. Most cases of hyperphosphatemia are asymptomatic, but significant prolonged hyperphosphatemia can lead to metastatic deposition of soft tissue calcium-phosphorus complexes.

Hypophosphatemia Hypophosphatemia can be due to a decrease in phosphorus intake, an intracellular shift of phosphorus, or an increase in phosphorus excretion. Decreased GI uptake due to malabsorption or administration of phosphate binders and decreased dietary intake from malnutrition are causes of chronic hypophosphatemia. Most acute cases are due to an intracellular shift of phosphorus in association with respiratory alkalosis, insulin therapy, refeeding syndrome, and hungry bone syndrome. Clinical manifestations of hypophosphatemia usually are absent until levels fall significantly. In general, symptoms are related to adverse effects on the oxygen availability of tissue and to a decrease in high-energy phosphates, and can be manifested as cardiac dysfunction or muscle weakness.

Magnesium Abnormalities. Magnesium is the fourth most common mineral in the body and, like potassium, is found primarily in the intracellular compartments. Approximately one half of the total body content of 2000 mEq is incorporated in bone and is slowly exchangeable. Of the fraction found in the extracellular space, one third is bound to serum albumin. Therefore, the plasma level of magnesium may be a poor indicator of total body stores in the presence of hypoalbuminemia. Magnesium should be replaced until levels are in the upper limit of normal. The normal dietary intake is approximately 20 mEq/d and is excreted in both the feces and urine. The kidneys have a remarkable ability to conserve magnesium, with renal excretion <1 mEq/d during magnesium deficiency.

Hypermagnesemia Hypermagnesemia is rare but can be seen with severe renal insufficiency and parallel changes in potassium excretion. Magnesium-containing antacids and laxatives can produce toxic levels in patients with renal failure. Excess intake in conjunction with total parenteral nutrition (TPN), or rarely massive trauma, thermal injury, and severe acidosis, may be associated with symptomatic hypermagnesemia. Clinical examination (see Table 3-6) may find nausea and vomiting; neuromuscular dysfunction with weakness, lethargy, and hyporeflexia; and impaired cardiac conduction leading to hypotension and arrest. ECG changes are similar to those seen with hyperkalemia and include increased PR interval, widened QRS complex, and elevated T waves.

Hypomagnesemia Magnesium depletion is a common problem in hospitalized patients, particularly in the critically ill.¹⁶ The kidney is primarily responsible for magnesium homeostasis through regulation by calcium/magnesium receptors on the renal tubular cells that respond to serum magnesium concentrations.¹⁷ Hypomagnesemia may result from alterations of intake, renal excretion, and pathologic losses. Poor intake may occur in cases of starvation, alcoholism, prolonged IV fluid therapy, and TPN with inadequate supplementation of magnesium. Losses are seen in cases of increased renal excretion from alcohol abuse, diuretic use, administration of amphotericin B, and primary aldosteronism, as well as GI losses from diarrhea, malabsorption, and acute pancreatitis. The magnesium ion is essential for proper function of many enzyme systems. Depletion is characterized by neuromuscular and central nervous system hyperactivity. Symptoms are similar to those of calcium deficiency, including hyperactive reflexes, muscle tremors, tetany, and positive Chvostek's and Trousseau's signs (see Table 3-6). Severe deficiencies can lead to delirium and seizures. A number of ECG changes also can occur and include prolonged QT and PR intervals, ST-segment depression, flattening or inversion of P waves, torsades de pointes, and arrhythmias. Hypomagnesemia is important not only because of its direct effects on the nervous system but also because it can produce hypocalcemia and lead to persistent hypokalemia. When hypokalemia or hypocalcemia coexists with hypomagnesemia, magnesium should be aggressively replaced to assist in restoring potassium or calcium homeostasis.

Acid-Base Balance

Acid-Base Homeostasis. The pH of body fluids is maintained within a narrow range despite the ability of the kidneys to generate large amounts of HCO_3^- and the normal large acid load produced as a by-product of metabolism. This endogenous acid load is efficiently neutralized by buffer systems and ultimately excreted by the lungs and kidneys.

Important buffers include intracellular proteins and phosphates and the extracellular bicarbonate-carbonic acid system. Compensation for acid-base derangements can be by respiratory mechanisms (for metabolic derangements) or metabolic mechanisms (for respiratory derangements). Changes in ventilation in response to metabolic abnormalities are mediated by hydrogen-sensitive chemoreceptors found in the carotid body and brain stem. Acidosis stimulates the chemoreceptors to increase ventilation, whereas alkalosis decreases the activity of the chemoreceptors and thus decreases ventilation. The kidneys provide compensation for respiratory abnormalities by either increasing or decreasing bicarbonate reabsorption in response to respiratory acidosis or alkalosis, respectively. Unlike the prompt change in ventilation that occurs with metabolic abnormalities, the compensatory response in the kidneys to respiratory abnormalities is delayed. Significant compensation may not begin for 6 hours and then may continue for several days. Because of this delayed compensatory response, respiratory acid-base derangements before renal compensation are classified as acute, whereas those persisting after renal compensation are categorized as chronic.

4▶ The predicted compensatory changes in response to metabolic or respiratory derangements are listed in Table 3-7.¹⁸ If the predicted change in pH is exceeded, then a mixed acid-base abnormality may be present (Table 3-8).

Metabolic Derangements

Metabolic Acidosis Metabolic acidosis results from an increased intake of acids, an increased generation of acids, or an

Table 3-7

Predicted changes in acid-base disorders

DISORDER	PREDICTED CHANGE
Metabolic	
Metabolic acidosis	$P_{CO_2} = 1.5 \times HCO_3^- + 8$
Metabolic alkalosis	$P_{CO_2} = 0.7 \times HCO_3^- + 21$
Respiratory	
Acute respiratory acidosis	$\Delta pH = (P_{CO_2} - 40) \times 0.008$
Chronic respiratory acidosis	$\Delta pH = (P_{CO_2} - 40) \times 0.003$
Acute respiratory alkalosis	$\Delta pH = (40 - P_{CO_2}) \times 0.008$
Chronic respiratory alkalosis	$\Delta pH = (40 - P_{CO_2}) \times 0.017$

P_{CO_2} = partial pressure of carbon dioxide.

increased loss of bicarbonate (Table 3-9). The body responds by several mechanisms, including producing buffers (extracellular bicarbonate and intracellular buffers from bone and muscle), increasing ventilation (Kussmaul's respirations), and increasing renal reabsorption and generation of bicarbonate. The kidney also will increase secretion of hydrogen and thus increase urinary excretion of NH_4^+ ($H^+ + NH_3^+ = NH_4^+$). Evaluation of a patient with a low serum bicarbonate level and metabolic acidosis includes determination of the anion gap (AG), an index of unmeasured anions.

$$AG = (Na) - (Cl + HCO_3)$$

The normal AG is <12 mmol/L and is due primarily to the albumin effect, so that the estimated AG must be adjusted for albumin (hypoalbuminemia reduces the AG).¹⁹

$$\text{Corrected AG} = \text{actual AG} - [2.5(4.5 - \text{albumin})]$$

Metabolic acidosis with an increased AG occurs either from ingestion of exogenous acid such as from ethylene glycol, salicylates, or methanol, or from increased endogenous acid production of the following:

- β -Hydroxybutyrate and acetoacetate in ketoacidosis
- Lactate in lactic acidosis
- Organic acids in renal insufficiency

A common cause of severe metabolic acidosis in surgical patients is lactic acidosis. In circulatory shock, lactate is produced in the presence of hypoxia from inadequate tissue perfusion. The treatment is to restore perfusion with volume resuscitation rather than to attempt to correct the abnormality with exogenous bicarbonate. With adequate perfusion, the lactic acid is rapidly metabolized by the liver and the pH level returns to normal. In clinical studies of lactic acidosis and ketoacidosis, the administration of bicarbonate has not reduced morbidity or mortality or improved cellular function.²⁰ The overzealous administration of bicarbonate can lead to metabolic alkalosis, which shifts the oxyhemoglobin dissociation curve to the left; this interferes with oxygen unloading at the tissue level and can be associated with arrhythmias that are difficult to treat. An additional disadvantage is that sodium bicarbonate actually can exacerbate intracellular acidosis. Administered bicarbonate can combine with the excess hydrogen ions to form carbonic acid; this is then converted to CO_2 and water, which thus raises the partial pressure of CO_2 (P_{CO_2}). This hypercarbia could compound ventilation abnormalities in patients with underlying acute respiratory distress syndrome. This CO_2 can diffuse into cells, but bicarbonate remains extracellular, which thus worsens intracellular acidosis. Clinically, lactate levels may not be useful in directing resuscitation, although lactate levels may be higher in nonsurvivors of serious injury.²¹

Metabolic acidosis with a normal AG results from exogenous acid administration (HCl or NH_4^+), from loss of bicarbonate due to GI disorders such as diarrhea and fistulas or ureterosigmoidostomy, or from renal losses. In these settings, the bicarbonate loss is accompanied by a gain of chloride; thus, the AG remains unchanged. To determine whether the loss of bicarbonate has a renal cause, the urinary $[NH_4^+]$ can be measured. A low urinary $[NH_4^+]$ in the face of hyperchloremic acidosis would indicate that the kidney is the site of loss, and evaluation for renal tubular acidosis should be undertaken. Proximal renal tubular acidosis results from decreased tubular reabsorption of HCO_3^- , whereas distal renal tubular acidosis results from decreased acid excretion. The carbonic anhydrase

Table 3-8

Respiratory and metabolic components of acid-base disorders

		ACUTE UNCOMPENSATED		CHRONIC (PARTIALLY COMPENSATED)		
TYPE OF ACID-BASE DISORDER	pH	P_{CO_2} (RESPIRATORY COMPONENT)	PLASMA HCO_3^- ^a (METABOLIC COMPONENT)	pH	P_{CO_2} (RESPIRATORY COMPONENT)	PLASMA HCO_3^- ^a (METABOLIC COMPONENT)
Respiratory acidosis	↓↓	↑↑	N	↓	↑↑	↑
Respiratory alkalosis	↑↑	↓↓	N	↑	↓↓	↓
Metabolic acidosis	↓↓	N	↓↓	↓	↓	↓
Metabolic alkalosis	↑↑	N	↑↑	↑	↑?	↑

^aMeasured as standard bicarbonate, whole blood buffer base, CO_2 content, or CO_2 combining power. The base excess value is positive when the standard bicarbonate is above normal and negative when the standard bicarbonate is below normal.

N = normal; P_{CO_2} = partial pressure of carbon dioxide.

Table 3-9

Etiology of metabolic acidosis**Increased Anion Gap Metabolic Acidosis**

- Exogenous acid ingestion
 - Ethylene glycol
 - Salicylate
 - Methanol
- Endogenous acid production
 - Ketoacidosis
 - Lactic acidosis
 - Renal insufficiency

Normal Anion Gap

- Acid administration (HCl)
- Loss of bicarbonate
- GI losses (diarrhea, fistulas)
- Ureterosigmoidostomy
- Renal tubular acidosis
- Carbonic anhydrase inhibitor

inhibitor acetazolamide also causes bicarbonate loss from the kidneys.

Metabolic Alkalosis Normal acid-base homeostasis prevents metabolic alkalosis from developing unless both an increase in bicarbonate generation and impaired renal excretion of bicarbonate occur (Table 3-10). Metabolic alkalosis results from the loss of fixed acids or the gain of bicarbonate and is worsened by potassium depletion. The majority of patients also will have hypokalemia, because extracellular potassium ions exchange with intracellular hydrogen ions and allow the hydrogen ions to buffer excess HCO_3^- . Hypochloremic and hypokalemic metabolic alkalosis can occur from isolated loss of gastric contents in infants with pyloric stenosis or adults with duodenal ulcer disease. Unlike vomiting associated with an open pylorus,

Table 3-10

Etiology of metabolic alkalosis**Increased bicarbonate generation**

1. Chloride losing (urinary chloride >20 mEq/L)
 - Mineralocorticoid excess
 - Profound potassium depletion
2. Chloride sparing (urinary chloride <20 mEq/L)
 - Loss from gastric secretions (emesis or nasogastric suction)
 - Diuretics
3. Excess administration of alkali
 - Acetate in parenteral nutrition
 - Citrate in blood transfusions
 - Antacids
 - Bicarbonate
 - Milk-alkali syndrome

Impaired bicarbonate excretion

1. Decreased glomerular filtration
2. Increased bicarbonate reabsorption (hypercarbia or potassium depletion)

which involves a loss of gastric as well as pancreatic, biliary, and intestinal secretions, vomiting with an obstructed pylorus results only in the loss of gastric fluid, which is high in chloride and hydrogen, and therefore results in a hypochloremic alkalosis. Initially the urinary bicarbonate level is high in compensation for the alkalosis. Hydrogen ion reabsorption also ensues, with an accompanied potassium ion excretion. In response to the associated volume deficit, aldosterone-mediated sodium reabsorption increases potassium excretion. The resulting hypokalemia leads to the excretion of hydrogen ions in the face of alkalosis, a paradoxical aciduria. Treatment includes replacement of the volume deficit with isotonic saline and then potassium replacement once adequate urine output is achieved.

Respiratory Derangements. Under normal circumstances blood PCO_2 is tightly maintained by alveolar ventilation, controlled by the respiratory centers in the pons and medulla oblongata.

Respiratory Acidosis Respiratory acidosis is associated with the retention of CO_2 secondary to decreased alveolar ventilation. The principal causes are listed in Table 3-11. Because compensation is primarily a renal mechanism, it is a delayed response. Treatment of acute respiratory acidosis is directed at the underlying cause. Measures to ensure adequate ventilation are also initiated. This may entail patient-initiated volume expansion using noninvasive bilevel positive airway pressure or may require endotracheal intubation to increase minute ventilation. In the chronic form of respiratory acidosis, the partial pressure of arterial CO_2 remains elevated and the bicarbonate concentration rises slowly as renal compensation occurs.

Respiratory Alkalosis In the surgical patient, most cases of respiratory alkalosis are acute and secondary to alveolar hyperventilation. Causes include pain, anxiety, and neurologic disorders, including central nervous system injury and assisted ventilation. Drugs such as salicylates, fever, gram-negative bacteremia, thyrotoxicosis, and hypoxemia are other possibilities. Acute hypocapnia can cause an uptake of potassium and phosphate into cells and increased binding of calcium to albumin, leading to symptomatic hypokalemia, hypophosphatemia, and hypocalcemia with subsequent arrhythmias, paresthesias, muscle cramps, and seizures. Treatment should be directed at the underlying cause, but direct treatment of the hyperventilation using controlled ventilation may also be required.

Table 3-11

Etiology of respiratory acidosis: hypoventilation

- Narcotics
- Central nervous system injury
- Pulmonary: significant
 - Secretions
 - Atelectasis
 - Mucus plug
 - Pneumonia
 - Pleural effusion
- Pain from abdominal or thoracic injuries or incisions
- Limited diaphragmatic excursion from intra-abdominal pathology
 - Abdominal distention
 - Abdominal compartment syndrome
 - Ascites

Table 3-12

Electrolyte solutions for parenteral administration

SOLUTION	ELECTROLYTE COMPOSITION (mEq/L)						
	Na	Cl	K	HCO ₃ ⁻	Ca	Mg	mOsm
Extracellular fluid	142	103	4	27	5	3	280–310
Lactated Ringer's	130	109	4	28	3		273
0.9% Sodium chloride	154	154					308
D ₅ 0.45% Sodium chloride	77	77					407
D ₅ W							253
3% Sodium chloride	513	513					1026

D₅ = 5% dextrose; D₅W = 5% dextrose in water.

FLUID AND ELECTROLYTE THERAPY

Parenteral Solutions

A number of commercially available electrolyte solutions are available for parenteral administration. The most commonly used solutions are listed in Table 3-12. The type of fluid administered depends on the patient's volume status and the type of concentration or compositional abnormality present. Both lactated Ringer's solution and normal saline are considered isotonic and are useful in replacing GI losses and correcting extracellular volume deficits. Lactated Ringer's is slightly hypotonic in that it contains 130 mEq of lactate. Lactate is used rather than bicarbonate because it is more stable in IV fluids during storage. It is converted into bicarbonate by the liver after infusion, even in the face of hemorrhagic shock. Evidence has suggested that resuscitation using lactated Ringer's may be deleterious because it activates the inflammatory response and induces apoptosis. The component that has been implicated is the D isomer of lactate, which unlike the L isomer is not a normal intermediary in mammalian metabolism.²² However, subsequent *in vivo* studies showed significantly lower levels of apoptosis in lung and liver tissue after resuscitation with any of the various Ringer's formulations.²³

Sodium chloride is mildly hypertonic, containing 154 mEq of sodium that is balanced by 154 mEq of chloride. The high chloride concentration imposes a significant chloride load on the kidneys and may lead to a hyperchloremic metabolic acidosis. Sodium chloride is an ideal solution, however, for correcting volume deficits associated with hyponatremia, hypochloremia, and metabolic alkalosis.

The less concentrated sodium solutions, such as 0.45% sodium chloride, are useful for replacement of ongoing GI losses as well as for maintenance fluid therapy in the post-operative period. This solution provides sufficient free water for insensible losses and enough sodium to aid the kidneys in adjustment of serum sodium levels. The addition of 5% dextrose (50 g of dextrose per liter) supplies 200 kcal/L, and dextrose is always added to solutions containing <0.45% sodium chloride to maintain osmolality and thus prevent the lysis of red blood cells that may occur with rapid infusion of hypotonic fluids. The addition of potassium is useful once adequate renal function and urine output are established.

Alternative Resuscitative Fluids

A number of alternative solutions for volume expansion and resuscitation are available (Table 3-13).²⁴ Hypertonic saline 5► solutions (3.5% and 5%) are used for correction of severe sodium deficits and are discussed elsewhere in this chapter. Hypertonic saline (7.5%) has been used as a treatment modality in patients with closed head injuries. It has been shown to increase cerebral perfusion and decrease intracranial pressure, thus decreasing brain edema.²⁵ However, there have also been concerns about increased bleeding, because hypertonic saline is an arteriolar vasodilator. A trial of 853 patients receiving hypertonic saline versus hypertonic saline/dextran 70 vs. 0.9% saline as initial resuscitation in the field showed a higher 28-day mortality in both hypertonic saline groups compared to 0.9% saline.²⁶ Colloids also are used in surgical patients, and their effectiveness as volume expanders compared with isotonic crystalloids has long been debated. Due to their molecular weight, they are confined to the intravascular space, and their infusion results in more efficient transient plasma volume expansion. However, under conditions of

Table 3-13

Alternative resuscitative fluids

SOLUTION	MOLECULAR WEIGHT	OSMOLALITY (mOsm/L)	SODIUM (mEq/L)
Hypertonic saline (7.5%)	—	2565	1283
Albumin 5%	70,000	300	130–160
Albumin 25%	70,000	1500	130–160
Dextran 40	40,000	308	154
Dextran 70	70,000	308	154
Hetastarch	450,000	310	154
Hextend	670,000	307	143
Gelofusine	30,000	NA	154

NA = not available.

severe hemorrhagic shock, capillary membrane permeability increases; this permits colloids to enter the interstitial space, which can worsen edema and impair tissue oxygenation. The theory that these high molecular weight agents “plug” capillary leaks, which occur during neutrophil-mediated organ injury, has not been confirmed.^{27,28} Four major types of colloids are available—albumin, dextrans, hetastarch, and gelatins—that are described by their molecular weight and size in Table 3-13. Colloid solutions with smaller particles and lower molecular weights exert a greater oncotic effect but are retained within the circulation for a shorter period of time than larger and higher molecular weight colloids.

Albumin (molecular weight 70,000) is prepared from heat-sterilized pooled human plasma. It is typically available as either a 5% solution (osmolality of 300 mOsm/L) or 25% solution (osmolality of 1500 mOsm/L). Because it is a derivative of blood, it can be associated with allergic reactions. Albumin has been shown to induce renal failure and impair pulmonary function when used for resuscitation in hemorrhagic shock.²⁹

Dextrans are glucose polymers produced by bacteria grown on sucrose media and are available as either 40,000 or 70,000 molecular weight solutions. They lead to initial volume expansion due to their osmotic effect but are associated with alterations in blood viscosity. Thus dextrans are used primarily to lower blood viscosity rather than as volume expanders. Dextrans have been used, in association with hypertonic saline, to help maintain intravascular volume.

Hydroxyethyl starch solutions are another group of alternative plasma expanders and volume replacement solutions. Hetastarches are produced by the hydrolysis of insoluble amylopectin, followed by a varying number of substitutions of hydroxyl groups for carbon groups on the glucose molecules. The molecular weights can range from 1000 to 3,000,000. The high molecular weight hydroxyethyl starch hetastarch, which comes as a 6% solution, is the only hydroxyethyl starch approved for use in the United States. Administration of hetastarch can cause hemostatic derangements related to decreases in von Willebrand’s factor and factor VIII:C, and its use has been associated with postoperative bleeding in cardiac and neurosurgery patients.^{30,31} Hetastarch also can induce renal dysfunction in patients with septic shock and was associated with a significant increased risk of mortality and acute kidney injury in the critically ill.^{32,33} Currently, hetastarch has a limited role in massive resuscitation because of the associated coagulopathy and hyperchloremic acidosis (due to its high chloride content). Hextend is a modified, balanced, high molecular weight hydroxyethyl starch that is suspended in a lactate-buffered solution, rather than in saline. A phase III clinical study comparing Hextend to a similar 6% hydroxyethyl starch in patients undergoing major abdominal surgery demonstrated no adverse effects on coagulation with Hextend other than the known effects of hemodilution.³⁴ Hextend has not been tested for use in massive resuscitation, and not all clinical studies show consistent results.³⁵

Gelatins are the fourth group of colloids and are produced from bovine collagen. The two major types are urea-linked gelatin and succinylated gelatin (modified fluid gelatin, Gelifusine). Gelifusine has been used abroad with mixed results.³⁶ Like many other artificial plasma volume expanders, it has been shown to impair whole blood coagulation time in human volunteers.³⁷

Correction of Life-Threatening Electrolyte Abnormalities

Sodium

Hypertremia Treatment of hypertremia usually consists of treatment of the associated water deficit. In hypovolemic patients, volume should be restored with normal saline before the concentration abnormality is addressed. Once adequate volume has been achieved, the water deficit is replaced using a hypotonic fluid such as 5% dextrose, 5% dextrose in ¼ normal saline, or enterally administered water. The formula used to estimate the amount of water required to correct hypertremia is as follows:

$$\text{Water deficit (L)} = \frac{\text{serum sodium} - 140}{140} \times \text{TBW}$$

Estimate TBW as 50% of lean body mass in men and 40% in women

The rate of fluid administration should be titrated to achieve a decrease in serum sodium concentration of no more than 1 mEq/h and 12 mEq/d for the treatment of acute symptomatic hypertremia. Even slower correction should be undertaken for chronic hypertremia (0.7 mEq/h), because overly rapid correction can lead to cerebral edema and herniation. The type of fluid used depends on the severity and ease of correction. Oral or enteral replacement is acceptable in most cases, or IV replacement with half- or quarter-normal saline can be used. Caution also should be exercised when using 5% dextrose in water to avoid overly rapid correction. Frequent neurologic evaluation as well as frequent evaluation of serum sodium levels also should be performed. Hypertremia is less common than hyponatremia, but has a worse prognosis, and is an independent predictor of mortality in critical illness.³⁸

Hyponatremia Most cases of hyponatremia can be treated by free water restriction and, if severe, the administration of sodium. In patients with normal renal function, symptomatic hyponatremia usually does not occur until the serum sodium level is ≤ 120 mEq/L. If neurologic symptoms are present, 3% normal saline should be used to increase the sodium by no more than 1 mEq/L per hour until the serum sodium level reaches 130 mEq/L or neurologic symptoms are improved. Correction of asymptomatic hyponatremia should increase the sodium level by no more than 0.5 mEq/L per hour to a maximum increase of 12 mEq/L per day, and even more slowly in chronic hyponatremia. The rapid correction of hyponatremia can lead to pontine myelinolysis,³⁹ with seizures, weakness, paresis, akinetic movements, and unresponsiveness, and may result in permanent brain damage and death. Serial magnetic resonance imaging may be necessary to confirm the diagnosis.⁴⁰

Potassium

Hyperkalemia Treatment options for symptomatic hyperkalemia are listed in Table 3-14. The goals of therapy include reducing the total body potassium, shifting potassium from the extracellular to the intracellular space, and protecting the cells from the effects of increased potassium. For all patients, exogenous sources of potassium should be removed, including potassium supplementation in IV fluids and enteral and parenteral solutions. Potassium can be removed from the body using a cation-exchange resin such as Kayexalate that binds potassium in exchange for sodium. It can be administered either

Table 3-14

Treatment of symptomatic hyperkalemia**Potassium removal****Kayexalate**

Oral administration is 15–30 g in 50–100 mL of 20% sorbitol

Rectal administration is 50 g in 200 mL of 20% sorbitol

Dialysis**Shift potassium**

Glucose 1 ampule of D₅₀ and regular insulin 5–10 units IV

Bicarbonate 1 ampule IV

Counteract cardiac effects

Calcium gluconate 5–10 mL of 10% solution

D₅₀ = 50% dextrose.

orally, in alert patients, or rectally. Immediate measures also should include attempts to shift potassium intracellularly with glucose and bicarbonate infusion. Nebulized albuterol (10 to 20 mg) may also be used. Use of glucose alone will cause a rise in insulin secretion, but in the acutely ill, this response may be blunted, and therefore both glucose and insulin may be necessary. Circulatory overload and hypernatremia may result from the administration of Kayexalate and bicarbonate, so care should be exercised when administering these agents to patients with fragile cardiac function. When ECG changes are present, calcium chloride or calcium gluconate (5–10 mL of 10% solution) should be administered immediately to counteract the myocardial effects of hyperkalemia. Calcium infusion should be used cautiously in patients receiving digitalis, because digitalis toxicity may be precipitated. All of the aforementioned measures are temporary, lasting from 1 to approximately 4 hours. Dialysis should be considered in severe hyperkalemia when conservative measures fail.

Hypokalemia Treatment for hypokalemia consists of potassium repletion, the rate of which is determined by the symptoms (Table 3-15). Oral repletion is adequate for mild, asymptomatic hypokalemia. If IV repletion is required, usually no more than 10 mEq/h is advisable in an unmonitored setting. This amount can be increased to 40 mEq/h when accompanied by continuous ECG monitoring, and even more in the case of imminent cardiac arrest from a malignant arrhythmia-associated hypokalemia. Caution should be exercised when oliguria or impaired renal function is coexistent.

Calcium

Hypercalcemia Treatment is required when hypercalcemia is symptomatic, which usually occurs when the serum level exceeds 12 mg/dL. The critical level for serum calcium is 15 mg/dL, when symptoms noted earlier may rapidly progress to death. The initial treatment is aimed at repleting the associated volume deficit and then inducing a brisk diuresis with normal saline. Treatment of hypercalcemia associated with malignancies is discussed later in this chapter.

Hypocalcemia Asymptomatic hypocalcemia can be treated with oral or IV calcium (see Table 3-15). Acute symptomatic hypocalcemia should be treated with IV 10% calcium gluconate to achieve a serum concentration of 7 to 9 mg/dL. Associated deficits in magnesium, potassium, and pH must also be corrected.

Hypocalcemia will be refractory to treatment if coexisting hypomagnesemia is not corrected first. Routine calcium supplementation is no longer recommended in association with massive blood transfusions.⁴¹

Phosphorus

Hyperphosphatemia Phosphate binders such as sucralfate or aluminum-containing antacids can be used to lower serum phosphorus levels. Calcium acetate tablets also are useful when hypocalcemia is simultaneously present. Dialysis usually is reserved for patients with renal failure.

Hypophosphatemia Depending on the level of depletion and tolerance to oral supplementation, a number of enteral and parenteral repletion strategies are effective for the treatment of hypophosphatemia (see Table 3-15).

Magnesium

Hypermagnesemia Treatment for hypermagnesemia consists of measures to eliminate exogenous sources of magnesium, correct concurrent volume deficits, and correct acidosis if present. To manage acute symptoms, calcium chloride (5 to 10 mL) should be administered to immediately antagonize the cardiovascular effects. If elevated levels or symptoms persist, hemodialysis may be necessary.

Hypomagnesemia Correction of magnesium depletion can be oral if asymptomatic and mild. Otherwise, IV repletion is indicated and depends on severity (see Table 3-15) and clinical symptoms. For those with severe deficits (<1.0 mEq/L) or those who are symptomatic, 1 to 2 g of magnesium sulfate may be administered IV over 15 minutes. Under ECG monitoring, it may be given over 2 minutes if necessary to correct torsades de pointes (irregular ventricular rhythm). Caution should be taken when giving large amounts of magnesium, because magnesium toxicity may develop. The simultaneous administration of calcium gluconate will counteract the adverse side effects of a rapidly rising magnesium level and correct hypocalcemia, which is frequently associated with hypomagnesemia.

Preoperative Fluid Therapy

The administration of maintenance fluids should be all that is required in an otherwise healthy individual who may be under orders to receive nothing by mouth for some period before the time of surgery. This does not, however, include replenishment of a pre-existing deficit or ongoing fluid losses. The following is a frequently used formula for calculating the volume of maintenance fluids in the absence of pre-existing abnormalities:

For the first 0–10 kg	Give 100 mL/kg per day
For the next 10–20 kg	Give an additional 50 mL/kg per day
For weight >20 kg	Give an additional 20 mL/kg per day

For example, a 60-kg female would receive a total of 2300 mL of fluid daily: 1000 mL for the first 10 kg of body weight (10 kg × 100 mL/kg per day), 500 mL for the next 20 kg (10 kg × 50 mL/kg per day), and 800 mL for the last 40 kg (40 kg × 20 mL/kg per day).

An alternative approach is to replace the calculated daily water losses in urine, stool, and insensible loss with a hypotonic saline solution rather than water alone, which allows

Table 3-15

Electrolyte replacement therapy protocol

Potassium

Serum potassium level <4.0 mEq/L:

Asymptomatic, tolerating enteral nutrition: KCl 40 mEq per enteral access \times 1 dose

Asymptomatic, not tolerating enteral nutrition: KCl 20 mEq IV q2h \times 2 doses

Symptomatic: KCl 20 mEq IV q1h \times 4 doses

Recheck potassium level 2 h after end of infusion; if <3.5 mEq/L and asymptomatic, replace as per above protocol

Magnesium

Magnesium level 1.0–1.8 mEq/L:

Magnesium sulfate 0.5 mEq/kg in normal saline 250 mL infused IV over 24 h \times 3 d

Recheck magnesium level in 3 d

Magnesium level <1.0 mEq/L:

Magnesium sulfate 1 mEq/kg in normal saline 250 mL infused IV over 24 h \times 1 d, then 0.5 mEq/kg in normal saline 250 mL infused IV over 24 h \times 2 d

Recheck magnesium level in 3 d

If patient has gastric access and needs a bowel regimen:

Milk of magnesia 15 mL (approximately 49 mEq magnesium) q24h per gastric tube; hold for diarrhea

Calcium

Ionized calcium level <4.0 mg/dL:

With gastric access and tolerating enteral nutrition: Calcium carbonate suspension 1250 mg/5 mL q6h per gastric access; recheck ionized calcium level in 3 d

Without gastric access or not tolerating enteral nutrition: Calcium gluconate 2 g IV over 1 h \times 1 dose; recheck ionized calcium level in 3 d

Phosphate

Phosphate level 1.0–2.5 mg/dL:

Tolerating enteral nutrition: Neutra-Phos 2 packets q6h per gastric tube or feeding tube

No enteral nutrition: KPHO_4 or NaPO_4 0.15 mmol/kg IV over 6 h \times 1 dose

Recheck phosphate level in 3 d

Phosphate level <1.0 mg/dL:

Tolerating enteral nutrition: KPHO_4 or NaPO_4 0.25 mmol/kg over 6 h \times 1 dose

Recheck phosphate level 4 h after end of infusion; if <2.5 mg/dL, begin Neutra-Phos 2 packets q6h

Not tolerating enteral nutrition: KPHO_4 or NaPO_4 0.25 mmol/kg (LBW) over 6 h \times 1 dose; recheck phosphate level 4 h after end of infusion; if <2.5 mg/dL, then KPHO_4 or NaPO_4 0.15 mmol/kg (LBW) IV over 6 h \times 1 dose

3 mmol KPHO_4 = 3 mmol Phos and 4.4 mEq K^+ = 1 mL

3 mmol NaPO_4 = 3 mmol Phos and 4 mEq Na^+ = 1 mL

Neutra-Phos 1 packet = 8 mmol Phos, 7 mEq K^+ , 7 mEq Na^+

Use patient's lean body weight (LBW) in kilograms for all calculations.

Disregard protocol if patient has renal failure, is on dialysis, or has a creatinine clearance <30 mL/min.

the kidney some sodium excess to adjust for concentration. Although there should be no “routine” maintenance fluid orders, both of these methods would yield an appropriate choice of 5% dextrose in 0.45% sodium chloride at 100 mL/h as initial therapy, with potassium added for patients with normal renal function. However, many surgical patients have volume and/or electrolyte abnormalities associated with their surgical disease. Preoperative evaluation of a patient's volume status and pre-existing electrolyte abnormalities is an important part of overall preoperative assessment and care. Volume deficits should be considered in patients who have obvious GI losses, such as through emesis or diarrhea, as well as in patients with poor oral intake secondary to their disease. Less obvious are those fluid losses known as *third-space* or *nonfunctional* ECF losses that occur with GI obstruction, peritoneal or bowel inflammation, ascites, crush injuries, burns, and severe soft tissue infections such as necrotizing fasciitis. The diagnosis of an acute volume

deficit is primarily clinical (see Table 3-2), although the physical signs may vary with the duration of the deficit. Cardiovascular signs of tachycardia and orthostasis predominate with acute volume loss, usually accompanied by oliguria and hemoconcentration. Acute volume deficits should be corrected as much as possible before the time of operation.

Once a volume deficit is diagnosed, prompt fluid replacement should be instituted, usually with an isotonic crystalloid, depending on the measured serum electrolyte values. Patients with cardiovascular signs of volume deficit should receive a bolus of 1 to 2 L of isotonic fluid followed by a continuous infusion. Close monitoring during this period is imperative. Resuscitation should be guided by the reversal of the signs of volume deficit, such as restoration of acceptable values for vital signs, maintenance of adequate urine output ($\frac{1}{2}$ –1 mL/kg per hour in an adult), and correction of base deficit. Patients whose volume deficit is not corrected after this initial volume challenge and

those with impaired renal function and the elderly should be considered for more intensive monitoring in an intensive care unit setting. In these patients, early invasive monitoring of central venous pressure or cardiac output may be necessary.

If symptomatic electrolyte abnormalities accompany volume deficit, the abnormality should be corrected to the point that the acute symptom is relieved before surgical intervention. For correction of severe hyponatremia associated with a volume deficit, an unsafe rapid fall in extracellular osmolarity from 5% dextrose infusion is avoided by slowly correcting the hyponatremia with 0.45% saline or even lactated Ringer's solution rather than 5% dextrose alone. This will safely and slowly correct the hyponatremia while also correcting the associated volume deficit.

Intraoperative Fluid Therapy

With the induction of anesthesia, compensatory mechanisms are lost, and hypotension will develop if volume deficits are not appropriately corrected before the time of surgery. Hemodynamic instability during anesthesia is best avoided by correcting known fluid losses, replacing ongoing losses, and providing adequate maintenance fluid therapy preoperatively. In addition to measured blood loss, major open abdominal surgeries are associated with continued extracellular losses in the form of bowel wall edema, peritoneal fluid, and the wound edema during surgery. Large soft tissue wounds, complex fractures with associated soft tissue injury, and burns are all associated with additional third-space losses that must be considered in the operating room. These represent distributional shifts, in that the functional volume of ECF is reduced but fluid is not externally lost from the body. These functional losses have been referred to as *parasitic losses*, *sequestration*, or *third-space edema*, because the lost volume no longer participates in the normal functions of the ECF.

Until the 1960s saline solutions were withheld during surgery. Administered saline was retained and was felt to be an inappropriate challenge to a physiologic response of intraoperative salt intolerance. Basic and clinical research began to change this concept,^{42,43} eventually leading to the current concept that saline administration is necessary to restore the obligate ECF losses noted earlier. Although no accurate formula can predict intraoperative fluid needs, replacement of ECF during surgery often requires 500 to 1000 mL/h of a balanced salt solution to support homeostasis. The addition of albumin or other colloid-containing solutions to intraoperative fluid therapy is not necessary. Manipulation of colloid oncotic forces by albumin infusion during major vascular surgery showed no advantage in supporting cardiac function or avoiding the accumulation of extravascular lung water.⁴⁴

Postoperative Fluid Therapy

Postoperative fluid therapy should be based on the patient's current estimated volume status and projected ongoing fluid losses. Any deficits from either preoperative or intraoperative losses should be corrected, and ongoing requirements should be included along with maintenance fluids. Third-space losses, although difficult to measure, should be included in fluid replacement strategies. In the initial postoperative period, an isotonic solution should be administered. The adequacy of resuscitation should be guided by the restoration of acceptable values for vital signs and urine output and, in more complicated cases, by the correction of base deficit or lactate. If uncertainty

exists, particularly in patients with renal or cardiac dysfunction, a central venous catheter or Swan-Ganz catheter may be inserted to help guide fluid therapy. After the initial 24 to 48 hours, fluids can be changed to 5% dextrose in 0.45% saline in patients unable to tolerate enteral nutrition. If normal renal function and adequate urine output are present, potassium may be added to the IV fluids. Daily fluid orders should begin with assessment of the patient's volume status and assessment of electrolyte abnormalities. There is rarely a need to check electrolyte levels in the first few days of an uncomplicated postoperative course. However, postoperative diuresis may require attention to replacement of urinary potassium loss. All measured losses, including losses through vomiting, nasogastric suctioning, drains, and urine output, as well as insensible losses, are replaced with the appropriate parenteral solutions as previously reviewed.

Special Considerations for the Postoperative Patient

Volume excess is a common disorder in the postoperative period. The administration of isotonic fluids in excess of actual needs may result in excess volume expansion. This may be due to the overestimation of third-space losses or to ongoing GI losses that are difficult to measure accurately. The earliest sign of volume overload is weight gain. The average postoperative patient who is not receiving nutritional support should lose approximately 0.25 to 0.5 lb/d (0.11 to 0.23 kg/d) from catabolism. Additional signs of volume excess may also be present as listed in Table 3-2. Peripheral edema may not necessarily be associated with intravascular volume overload, because overexpansion of total ECF may exist in association with a deficit in the circulating plasma volume.

Volume deficits also can be encountered in surgical patients if preoperative losses were not completely corrected, intraoperative losses were underestimated, or postoperative losses were greater than appreciated. The clinical manifestations are described in Table 3-2 and include tachycardia, orthostasis, and oliguria. Hemoconcentration also may be present. Treatment will depend on the amount and composition of fluid lost. In most cases of volume depletion, replacement with an isotonic fluid will be sufficient while alterations in concentration and composition are being evaluated.

ELECTROLYTE ABNORMALITIES IN SPECIFIC SURGICAL PATIENTS

Neurologic Patients

Syndrome of Inappropriate Secretion of Antidiuretic Hormone. The syndrome of inappropriate secretion of antidiuretic hormone (SIADH) can occur after head injury or surgery to the central nervous system, but it also is seen in association with administration of drugs such as morphine, nonsteroidals, and oxytocin, and in a number of pulmonary and endocrine diseases, including hypothyroidism and glucocorticoid deficiency. Additionally, it can be seen in association with a number of malignancies, most often small cell cancer of the lung but also pancreatic carcinoma, thymoma, and Hodgkin's disease.⁴⁵ SIADH should be considered in patients who are euvolemic and hyponatremic with elevated urine sodium levels and urine osmolality. ADH secretion is considered inappropriate when it is not in response to osmotic or volume-related conditions. Correction of the underlying problem should be attempted

when possible. In most cases, restriction of free water will improve the hyponatremia. The goal is to achieve net water balance while avoiding volume depletion that may compromise renal function. Furosemide also can be used to induce free water loss. If hyponatremia persists after fluid restriction, the addition of isotonic or hypertonic fluids may be effective. The administration of isotonic saline may sometimes worsen the problem if the urinary sodium concentration is higher than the infused sodium concentration. The use of loop diuretics may be helpful in this situation by preventing further urine concentration. In chronic SIADH, when long-term fluid restriction is difficult to maintain or is ineffective, demeclocycline and lithium can be used to induce free water loss.

Diabetes Insipidus. Diabetes insipidus (DI) is a disorder of ADH stimulation and is manifested by dilute urine in the case of hypernatremia. Central DI results from a defect in ADH secretion, and nephrogenic DI results from a defect in end-organ responsiveness to ADH. Central DI is frequently seen in association with pituitary surgery, closed head injury, and anoxic encephalopathy.⁴⁶ Nephrogenic DI occurs in association with hypokalemia, administration of radiocontrast dye, and use of certain drugs such as aminoglycosides and amphotericin B. In patients tolerating oral intake, volume status usually is normal because thirst stimulates increased intake. However, volume depletion can occur rapidly in patients incapable of oral intake. The diagnosis can be confirmed by documenting a paradoxical increase in urine osmolality in response to a period of water deprivation. In mild cases, free water replacement may be adequate therapy. In more severe cases, vasopressin can be added. The usual dosage of vasopressin is 5 U subcutaneously every 6 to 8 hours. However, serum electrolytes and osmolality should be monitored to avoid excess vasopressin administration with resulting iatrogenic SIADH.

Cerebral Salt Wasting. Cerebral salt wasting is a diagnosis of exclusion that occurs in patients with a cerebral lesion and renal wasting of sodium and chloride with no other identifiable cause.⁴⁷ Natriuresis in a patient with a contracted extracellular volume should prompt the possible diagnosis of cerebral salt wasting. Hyponatremia is frequently observed but is nonspecific and occurs as a secondary event, which differentiates it from SIADH.

Malnourished Patients: Refeeding Syndrome

Refeeding syndrome is a potentially lethal condition that can occur with rapid and excessive feeding of patients with severe underlying malnutrition due to starvation, alcoholism, delayed nutritional support, anorexia nervosa, or massive weight loss in obese patients.⁴⁸ With refeeding, a shift in metabolism from fat to carbohydrate substrate stimulates insulin release, which results in the cellular uptake of electrolytes, particularly phosphate, magnesium, potassium, and calcium. However, severe hyperglycemia may result from blunted basal insulin secretion. The refeeding syndrome can be associated with enteral or parenteral refeeding, and symptoms from electrolyte abnormalities include cardiac arrhythmias, confusion, respiratory failure, and even death. To prevent the development of refeeding syndrome, underlying electrolyte and volume deficits should be corrected. Additionally, thiamine should be administered before the initiation of feeding. Caloric repletion should be instituted slowly and should gradually increase over the first week.⁴⁹ Vital signs, fluid balance, and electrolytes should be closely monitored and any deficits corrected as they evolve.

Acute Renal Failure Patients

A number of fluid and electrolyte abnormalities are specific to patients with acute renal failure. With the onset of renal failure, an accurate assessment of volume status must be made. If prerenal azotemia is present, prompt correction of the underlying volume deficit is mandatory. Once acute tubular necrosis is established, measures should be taken to restrict daily fluid intake to match urine output and insensible and GI losses. Oliguric renal failure requires close monitoring of serum potassium levels. Measures to correct hyperkalemia as reviewed in Table 3-14 should be instituted early, including consideration of early hemodialysis. Hyponatremia is common in established renal failure as a result of the breakdown of proteins, carbohydrates, and fats, as well the administration of free water. Dialysis may be required for severe hyponatremia. Hypocalcemia, hypermagnesemia, and hyperphosphatemia also are associated with acute renal failure. Hypocalcemia should be verified by measuring ionized calcium, because many patients also are hypoalbuminemic. Phosphate binders can be used to control hyperphosphatemia, but dialysis may be required in more severe cases. Metabolic acidosis is commonly seen with renal failure, as the kidneys lose their ability to clear acid by-products. Bicarbonate can be useful, but dialysis often is needed. Although dialysis may be either intermittent or continuous, renal recovery may be improved by continuous renal replacement.⁵⁰

Cancer Patients

Fluid and electrolyte abnormalities are common in patients with cancer. The causes may be common to all patient populations or may be specific to cancer patients and their treatment.⁵¹ Hyponatremia is frequently hypovolemic due to renal loss of sodium caused by diuretics or salt-wasting nephropathy as seen with some chemotherapeutic agents such as cisplatin. Cerebral salt wasting also can occur in patients with intracerebral lesions. Normovolemic hyponatremia may occur in association with SIADH from cervical cancer, lymphoma, and leukemia, or from certain chemotherapeutic agents. Hypernatremia in cancer patients most often is due to poor oral intake or GI volume losses, which are common side effects of chemotherapy. Central DI also can lead to hypernatremia in patients with central nervous system lesions.

Hypokalemia can develop from GI losses associated with diarrhea caused by radiation enteritis or chemotherapy, or from tumors such as villous adenomas of the colon. Tumor lysis syndrome can precipitate severe hyperkalemia from massive tumor cell destruction.

Hypocalcemia can be seen after removal of a thyroid or parathyroid tumor or after a central neck dissection, which can damage the parathyroid glands. Hungry bone syndrome produces acute and profound hypocalcemia after parathyroid surgery for secondary or tertiary hyperparathyroidism because calcium is rapidly taken up by bones. Prostate and breast cancer can result in increased osteoblastic activity, which decreases serum calcium by increasing bone formation. Acute hypocalcemia also can occur with hyperphosphatemia, because phosphorus complexes with calcium. Hypomagnesemia is a side effect of ifosfamide and cisplatin therapy. Hypophosphatemia can be seen in hyperparathyroidism, due to decreased phosphorus reabsorption, and in oncogenic osteomalacia, which increases the urinary excretion of phosphorus. Other causes of hypophosphatemia in cancer patients include renal tubular dysfunction from multiple myeloma, Bence Jones proteins, and certain chemotherapeutic agents.

Acute hypophosphatemia can occur as rapidly proliferating malignant cells take up phosphorus in acute leukemia. Tumor lysis syndrome or the use of bisphosphonates to treat hypercalcemia also can result in hyperphosphatemia.

Malignancy is the most common cause of hypercalcemia in hospitalized patients and is due to increased bone resorption or decreased renal excretion. Bone destruction occurs from bony metastasis as seen in breast or renal cell cancer but also can occur in multiple myeloma. With Hodgkin's and non-Hodgkin's lymphoma, hypercalcemia results from increased calcitriol formation, which increases both absorption of calcium from the GI tract and mobilization from bone. Humoral hypercalcemia of malignancy is a common cause of hypercalcemia in cancer patients. As in primary hyperparathyroidism, a parathyroid-related protein is secreted that binds to parathyroid receptors, stimulating calcium resorption from bone and decreasing renal excretion of calcium. The treatment of hypercalcemia of malignancy should begin with saline volume expansion, which will decrease renal reabsorption of calcium as the associated volume deficit is corrected. Once an adequate volume status has been achieved, a loop diuretic may be added. Unfortunately, these measures are only temporary, and additional treatment is often necessary. A variety of drugs are available with varying times of onset, durations of action, and side effects.⁵² The bisphosphonates etidronate and pamidronate inhibit bone resorption and osteoclastic activity. They have a slow onset of action, but effects can last for 2 weeks. Calcitonin also is effective, inhibiting bone resorption and increasing renal excretion of calcium. It acts quickly, within 2 to 4 hours, but its use is limited by the development of tachyphylaxis. Corticosteroids may decrease tachyphylaxis in response to calcitonin and can be used alone to treat hypercalcemia. Gallium nitrates are potent inhibitors of bone resorption. They display a long duration of action but can cause nephrotoxicity. Mithramycin is an antibiotic that blocks osteoclastic activity, but it can be associated with liver, renal, and hematologic abnormalities, which limits its use to the treatment of Paget's disease of bone. For patients with severe, refractory hypercalcemia who are unable to tolerate volume expansion due to pulmonary edema or congestive heart failure, dialysis is an option.

Tumor lysis syndrome results when the release of intracellular metabolites overwhelms the kidneys' excretory capacity. This rapid release of uric acid, potassium, and phosphorus can result in marked hyperuricemia, hyperkalemia, hyperphosphatemia, and hypocalcemia, and acute renal failure. It is typically seen with poorly differentiated lymphomas and leukemias but also can occur with a number of solid tumor malignancies. Tumor lysis syndrome most commonly develops during treatment with chemotherapy or radiotherapy. Once it develops, volume expansion should be undertaken and any associated electrolyte abnormalities corrected. In this setting, hypocalcemia should not be treated unless it is symptomatic to avoid metastatic calcifications. Dialysis may be required for management of impaired renal function or correction of electrolyte abnormalities.

REFERENCES

Entries highlighted in blue are key references.

1. Aloia JF, Vaswani A, Flaster E, et al. Relationship of body water compartment to age, race and fat-free mass. *J Lab Clin Med.* 1998;132:483.
2. Bourque CW, Oliet SHR. Osmoreceptors in the central nervous system. *Annu Rev Physiol.* 1997;59:601.
3. Verbalis JG. How does the brain sense osmolality? *J Am Soc Nephrol.* 2007;18(12):3056.
4. Stauss HM. Baroreceptor reflex function. *Am J Physiol Regul Integr Comp Physiol.* 2002;283:R284.
5. Miller M. Syndromes of excess antidiuretic hormone release. *Crit Care Clin.* 2001;17:11.
6. Kapoor M, Chan G. Fluid and electrolyte abnormalities. *Crit Care Clin.* 2001;17:571.
7. Adroge HJ, Lederer ED, Suki WN, et al. Determinants of plasma potassium in diabetic ketoacidosis. *Medicine.* 1986;65:163.
8. Zietse R, Zuotendijk R, Hoorn EJ. Fluid, electrolyte and acid-base disorders associated with antibiotic therapy. *Nat Rev Nephrol.* 2009;5(4):193.
9. Cobos E, Hall RR. Effects of chemotherapy on the kidney. *Semin Nephrol.* 1993;13:297.
10. Gennari FJ. Hypokalemia. *N Engl J Med.* 1998;339:451.
11. French S, Subauste J, Geraci S. Calcium abnormalities in hospitalized patients. *South Med J.* 2012;105(4):231.
12. Witteveen JE, van Theil S, Romijn JA. Therapy of endocrine disease: hungry bone syndrome. *Eur J Endocrinol.* 2013;168(3):R45.
13. Bushinsky DA, Monk RD. Calcium. *Lancet.* 1998;352:306.
14. Dunlay RW, Camp MA, Allon M, et al. Calcitriol in prolonged hypocalcemia due to tumor lysis syndrome. *Ann Intern Med.* 1989;110:162.
15. Reber PM, Heath H. Hypocalcemic emergencies. *Med Clin North Am.* 1995;19:93.
16. Tong GM, Rude RK. Magnesium deficiency in critical illness. *J Intensive Care Med.* 2005;20(1):3.
17. Quamme GA. Renal magnesium handling: new insights in understanding old problems. *Kidney Int.* 1997;52:1180.
18. Marino PL. Acid-base interpretations. In: Marino PL, ed. *The ICU Book.* 2nd ed. Baltimore: Williams & Wilkins; 1998:581.
19. Gluck SL. Acid-base. *Lancet.* 1998;352:474.
20. Kraut JA, Madias NE. Treatment of acute metabolic acidosis: a pathophysiologic approach. *Nat Rev Nephrol.* 2012;8(10):589.
21. Pal JD, Victorino GP, Twomey P, et al. Admission serum lactate levels do not predict mortality in the acutely injured patient. *J Trauma.* 2006;60:583.
22. Koustova E, Standon K, Gushchin V, et al. Effects of lactated Ringer's solution on human leukocytes. *J Trauma.* 2002;53:782.
23. Shires GT, Browder LK, Steljes TP, et al. The effect of shock resuscitation fluids on apoptosis. *Am J Surg.* 2005;189:85.
24. Roberts JS, Bratton SL. Colloid volume expanders: problems, pitfalls, and possibilities. *Drugs.* 1998;55:621.
25. Cottenceau V, Masson F, Mahamid E, et al. Comparison effects of equiosmolar doses of mannitol and hypertonic saline on cerebral blood flow and metabolism in traumatic brain injury. *J Neurotrauma.* 2011;28(10):2003.
26. Bulger EM, May S, Kerby JD, et al. Out-of-hospital hypertonic resuscitation after traumatic hypovolemic shock: a randomized, placebo-controlled trial. *Ann Surg.* 2011;253(3):431.
27. Ley K. Plugging the leaks. *Nat Med.* 2001;7:1105.
28. Conhaim RL, Watson KE, Potenza BM, et al. Pulmonary capillary sieving of hetastarch is not altered by LPS-induced sepsis. *J Trauma.* 1999;46:800.
29. Lucas CE. The water of life: a century of confusion. *J Am Coll Surg.* 2001;192:86.
30. de Jonge E, Levi M. Effects of different plasma substitutes on blood coagulation: a comparative review. *Crit Care Med.* 2001;29:1261.
31. Navickis RJ, Haynes GR, Wilkes MM. Effect of hydroxyethyl starch on bleeding after cardiopulmonary bypass: a meta-analysis of randomized trials. *J Thorac Cardiovasc Surg.* 2012;144(4):223.

32. Schortgen F, Lacherade JC, Bruneel F, et al. Effects of hydroxyethylstarch and gelatin on renal function in severe sepsis: a multicenter randomized study. *Lancet*. 2001;357:911.
33. Zarychanski R, Abou-Setta AM, Turgeon AF, et al. Association of hydroxyethyl starch administration with mortality and acute kidney injury in critically ill patients requiring volume resuscitation: a systematic review and meta-analysis. *JAMA*. 2013;309(7):678.
34. Gan TJ, Bennett-Guerrero E, Phillips-Bute B, et al. Hextend, a physiologically balanced plasma expander for large volume use in major surgery: a randomized phase III clinical trial. *Anesth Analg*. 1999;88:992.
35. Boldt J, Haisch G, Suttner S, et al. Effects of a new modified, balanced hydroxyethyl starch preparation (Hextend) on measures of coagulation. *Br J Anaesth*. 2002;89:772.
36. Rittoo D, Gosling P, Bonnici C, et al. Splanchnic oxygenation in patients undergoing abdominal aortic aneurysm repair and volume expansion with eloHAES. *Cardiovasc Surg*. 2002;10:128.
37. Coats TJ, Brazil E, Heron M, et al. Impairment of coagulation by commonly used resuscitation fluids in human volunteers. *Emerg Med J*. 2006;23:846.
38. Overgaard-Steensen C, Ring T. Clinical Review: Practical approach to hyponatremia and hypernatremia in critically ill patients. *Crit Care*. 2013;17(1):206.
39. Norenberg MD. Central pontine myelinolysis: historical and mechanistic considerations. *Metab Brain Dis*. 2010;25(1):97.
40. Graff-Radford J, Fugate JE, Kauffmann TJ. Clinical and radiologic correlations of central pontine myelinolysis syndrome. *Mayo Clin Proc*. 2011;86(11):1063.
41. American College of Surgeons. Shock. In: *American College of Surgeons Advanced Trauma Life Support Manual*. 9th ed. Chicago: American College of Surgeons; 2012.
42. Shires GT, Williams J, Brown F. Acute changes in extracellular fluids associated with major surgical procedures. *Ann Surg*. 1961;154:803.
43. Shires GT, Jackson DE. Postoperative salt tolerance. *Arch Surg*. 1962;84:703.
44. Shires GT III, Peitzman AB, Albert SA, et al. Response of extravascular lung water to intraoperative fluids. *Ann Surg*. 1983;197:515.
45. Ellison DH, Burl T. Clinical practice. The syndrome of inappropriate antidiuresis. *N Engl J Med*. 2007;356(20):2064.
46. Tisdall M, Crocker M, Watkiss J, et al. Disturbances of sodium in critically ill adult neurologic patients: a clinical review. *J Neurosurg Anesthesiol*. 2006;18(1):57.
47. Yee AH, Burns JD, Wijdicks EF. Cerebral salt wasting: pathophysiology, diagnosis, and treatment. *Neurosurg Clin N Am*. 2010;21(2):339.
48. Kozar RA, McQuiggan MM, Moore FA. Nutritional support in trauma patients. In: Shikora SA, Martindale RG, Schwaitzberg SD, eds. *Nutritional Considerations in the Intensive Care Unit*. 1st ed. Dubuque, IA: Kendall/Hunt Publishing; 2002:229.
49. Boateng AA, Sriram K, Mequid MM, et al. Refeeding syndrome: treatment considerations based on collective analysis of literature case reports. *Nutrition*. 2010;26(2):156.
50. Glassford NJ, Bellomo R. Acute kidney injury: how can we facilitate recovery? *Curr Opin Crit Care*. 2011;17(6):562.
51. Kapoor M, Chan GZ. Fluid and electrolyte abnormalities. *Crit Care Clin*. 2002;17:503.
52. Clines GA. Mechanisms and treatment of hypercalcemia of malignancy. *Curr Opin Endocrinol Diabetes Obes*. 2011;18(6):339.

This page intentionally left blank

chapter

Hemostasis, Surgical Bleeding, and Transfusion

Bryan Cotton, John B. Holcomb, Matthew Pommerening, Kenneth Jastrow, and Rosemary A. Kozar

Biology of Hemostasis	85	Acquired Hypofibrinogenemia / 92	Indications for Replacement of Blood and Its Elements / 97
Vascular Constriction / 85		Myeloproliferative Diseases / 92	Volume Replacement / 98
Platelet Function / 85		Coagulopathy of Liver Disease / 92	New Concepts in Resuscitation / 98
Coagulation / 86		Coagulopathy of Trauma / 93	Complications of Transfusion / 100
Fibrinolysis / 88		Acquired Coagulation Inhibitors / 93	Tests of Hemostasis and Blood Coagulation
Congenital Factor Deficiencies	88	Anticoagulation and Bleeding / 94	102
Coagulation Factor Deficiencies / 88		Transfusion	Evaluation of Excessive Intraoperative or Postoperative Bleeding
Platelet Functional Defects / 89		Background / 96	104
Acquired Hemostatic Defects	90	Replacement Therapy / 96	
Platelet Abnormalities / 90			

BIOLOGY OF HEMOSTASIS

Hemostasis is a complex process whose function is to limit blood loss from an injured vessel. Four major physiologic events participate in the hemostatic process: vascular constriction, platelet plug formation, fibrin formation, and fibrinolysis. Although each tends to be activated in order, the four processes are interrelated so that there is a continuum and multiple reinforcements. The process is shown schematically in Fig. 4-1.

Vascular Constriction

Vascular constriction is the initial response to vessel injury. It is more pronounced in vessels with medial smooth muscles and is dependent on local contraction of smooth muscle. Vasoconstriction is subsequently linked to platelet plug formation. Thromboxane A₂ (TXA₂) is produced locally at the site of injury via the release of arachidonic acid from platelet membranes and is a potent constrictor of smooth muscle. Similarly, endothelin synthesized by injured endothelium and serotonin (5-hydroxytryptamine [5-HT]) released during platelet aggregation are potent vasoconstrictors. Lastly, bradykinin and fibrinopeptides, which are involved in the coagulation schema, are also capable of contracting vascular smooth muscle.

The extent of vasoconstriction varies with the degree of vessel injury. A small artery with a lateral incision may remain open due to physical forces, whereas a similarly sized vessel that is completely transected may contract to the extent that bleeding ceases spontaneously.

Platelet Function

Platelets are anucleate fragments of megakaryocytes. The normal circulating number of platelets ranges between 150,000 and 400,000/ μ L. Up to 30% of circulating platelets may be sequestered in the spleen. If not consumed in a clotting reaction,

platelets are normally removed by the spleen and have an average life span of 7 to 10 days.

Platelets play an integral role in hemostasis by forming a hemostatic plug and by contributing to thrombin formation (Fig. 4-2). Platelets do not normally adhere to each other or to the vessel wall but can form a plug that aids in cessation of bleeding when vascular disruption occurs. Injury to the intimal layer in the vascular wall exposes subendothelial collagen to which platelets adhere. This process requires von Willebrand factor (vWF), a protein in the subendothelium that is lacking in patients with von Willebrand's disease. vWF binds to glycoprotein (GP) I/IX/V on the platelet membrane. Following adhesion, platelets initiate a release reaction that recruits other platelets from the circulating blood to seal the disrupted vessel. Up to this point, this process is known as primary hemostasis. Platelet aggregation is reversible and is not associated with secretion. Additionally, heparin does not interfere with this reaction, and thus, hemostasis can occur in the heparinized patient. Adenosine diphosphate (ADP) and serotonin are the principal mediators in platelet aggregation.

Arachidonic acid released from the platelet membranes is converted by cyclooxygenase to prostaglandin G₂ (PGG₂) and then to prostaglandin H₂ (PGH₂), which, in turn, is converted to TXA₂. TXA₂ has potent vasoconstriction and platelet aggregation effects. Arachidonic acid may also be shuttled to adjacent endothelial cells and converted to prostacyclin (PGI₂), which is a vasodilator and acts to inhibit platelet aggregation. Platelet cyclooxygenase is irreversibly inhibited by aspirin and reversibly blocked by nonsteroidal anti-inflammatory agents, but is not affected by cyclooxygenase-2 (COX-2) inhibitors.

In the second wave of platelet aggregation, a release reaction occurs in which several substances including ADP, Ca²⁺, serotonin, TXA₂, and α -granule proteins are discharged. Fibrinogen is a required cofactor for this process, acting as a bridge for

Key Points

- 1▶ The life span of platelets ranges from 7 to 10 days. Drugs that interfere with platelet function include aspirin, clopidogrel, prasugrel, dipyridamole, and the glycoprotein IIb/IIIa (GP IIb/IIIa) inhibitors. Approximately 5 to 7 days should pass from the time the drug is stopped until an elective procedure is performed.
- 2▶ The acute coagulopathy of trauma results from a combination of activation of protein C and hyperfibrinolysis. It is distinct from disseminated intravascular coagulation, is present on arrival to the emergency department, and is associated with an increase in mortality.
- 3▶ Newer anticoagulants like dabigatran and rivaroxaban have no readily available method of detection of the degree of anticoagulation and may not be readily reversible.
- 4▶ Therapeutic anticoagulation preoperatively and postoperatively is becoming increasingly more common. The patient's risk of intraoperative and postoperative bleeding should guide the need for reversal of anticoagulation therapy preoperatively and the timing of its reinstatement postoperatively.
- 5▶ Damage control resuscitation has three basic components: permissive hypotension, minimizing crystalloid-based resuscitation, and the administration of predefined blood products.
- 6▶ The need for massive transfusion should be anticipated, and guidelines should be in place to provide early and increased amounts of red blood cells, plasma, and platelets.

the GP IIb/IIIa receptor on the activated platelets. The release reaction results in compaction of the platelets into a plug, a process that is no longer reversible. Thrombospondin, another protein secreted by the α -granule, stabilizes fibrinogen binding to the activated platelet surface and strengthens the platelet-platelet interactions. Platelet factor 4 (PF4) and α -thromboglobulin are also secreted during the release reaction. PF4 is a potent heparin antagonist. The second wave of platelet aggregation is inhibited by aspirin and nonsteroidal anti-inflammatory drugs, by cyclic adenosine monophosphate (cAMP), and by nitric oxide. As a consequence of the release reaction, alterations occur in the phospholipids of the platelet membrane that allow calcium and clotting factors to bind to the platelet surface, forming enzymatically active complexes. The altered lipoprotein surface (sometimes referred to as platelet factor 3) catalyzes reactions that are involved in the conversion of prothrombin (factor II) to

thrombin (factor IIa) by activated factor X (Xa) in the presence of factor V and calcium, and it is involved in the reaction by which activated factor IX (IXa), factor VIII, and calcium activate factor X. Platelets may also play a role in the initial activation of factors XI and XII.

Coagulation

Hemostasis involves a complex interplay and combination of interactions between platelets, the endothelium, and multiple circulating or membrane-bound coagulation factors. While a bit simplistic and not reflective of the depth or complexity of these interactions, the coagulation cascade has traditionally been depicted as two possible pathways converging into a single common pathway (Fig. 4-3). While this pathway reflects the basic process and sequences that lead to the formation of a clot, the numerous feedback loops, endothelial interplay, and platelet

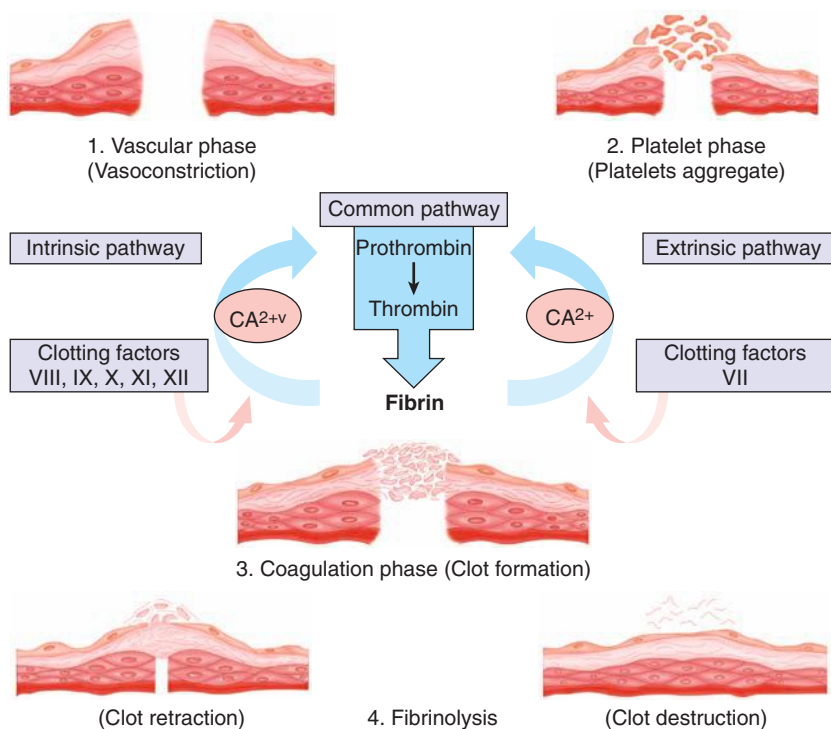


Figure 4-1. Biology of hemostasis. The four physiologic processes that interrelate to limit blood loss from an injured vessel are illustrated and include vascular constriction, platelet plug formation, fibrin clot formation, and fibrinolysis.

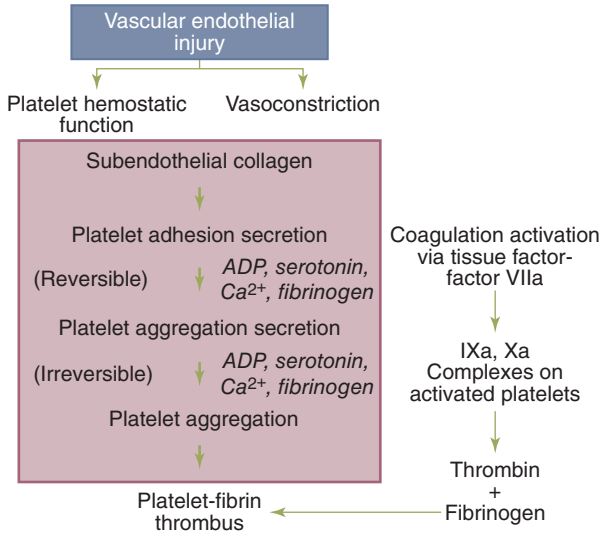


Figure 4-2. Schematic of platelet activation and thrombus function.

functions are not included. The intrinsic pathway begins with the activation of factor XII that subsequently activates factors XI, IX, and VIII. In this pathway, each of the primary factors is “intrinsic” to the circulating plasma, whereby no surface is required to initiate the process. In the extrinsic pathway, tissue factor (TF) is released or exposed on the surface of the endothelium, binding to circulating factor VII, facilitating its activation to VIIa. Each of these pathways continues on to a common sequence that begins with the activation of factor X to Xa (in the presence of VIIIa). Subsequently, Xa (with the help of factor Va) converts factor II (prothrombin) to thrombin and then factor I (fibrinogen) to fibrin. Clot formation occurs after fibrin monomers are cross-linked to polymers with the assistance of factor XIII.

One convenient feature of depicting the coagulation cascade with two merging arms is that commonly used laboratory

tests segregate abnormalities of clotting to one of the two arms. An elevated activated partial thromboplastin time (aPTT) is associated with abnormal function of the intrinsic arm of the cascade (II, IX, X, XI, XII), while the prothrombin time (PT) is associated with the extrinsic arm (II, VII, X). Vitamin K deficiency or warfarin use affects factors II, VII, IX, and X

Expanding from the basic concept of Fig. 4-3, the primary pathway for coagulation is initiated by TF exposure following subendothelial injury. Clot propagation ensues with what is a sequence of four similar enzymatic reactions, each involving a proteolytic enzyme generating the next enzyme by cleaving its proenzyme, a phospholipid surface (e.g., platelet membrane) in the presence of ionized calcium, and a helper protein. TF binds to VIIa, and this complex catalyzes the activation of factor X to Xa. This complex is four orders of magnitude more active at converting factor X than is factor VIIa alone and also activates factor IX to IXa. Factor Xa, together with Va, calcium, and phospholipid, composes the prothrombinase complex that converts prothrombin to thrombin. The prothrombinase complex is significantly more effective at catalyzing its substrate than is factor Xa alone. Thrombin is then involved with the conversion of fibrinogen to fibrin and activation of factors V, VII, VIII, XI, and XIII.

In building on the redundancy inherent in the coagulation system, factor VIIIa combines with IXa to form the intrinsic factor complex. Factor IXa is responsible for the bulk of the conversion of factor X to Xa. This complex (VIIIa-IXa) is 50 times more effective at catalyzing factor X activation than is the extrinsic (TF-VIIa) complex and five to six orders of magnitude more effective than factor IXa alone.

Once formed, thrombin leaves the membrane surface and converts fibrinogen by two cleavage steps into fibrin and two small peptides termed fibrinopeptides A and B. Removal of fibrinopeptide A permits end-to-end polymerization of the fibrin molecules, whereas cleavage of fibrinopeptide B allows side-to-side polymerization of the fibrin clot. This latter step is facilitated by thrombin-activatable fibrinolysis inhibitor (TAFI), which acts to stabilize the resultant clot.

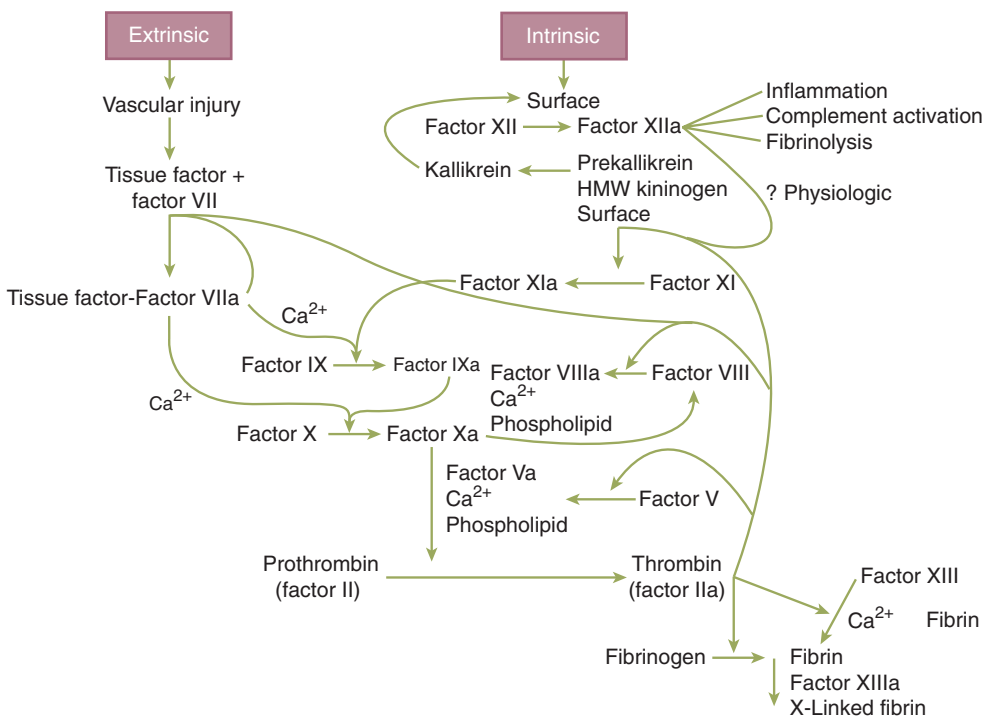


Figure 4-3. Schematic of the coagulation system. HMW = high molecular weight.

In seeking to balance profound bleeding with overwhelming clot burden, several related processes exist to prevent propagation of the clot beyond the site of injury.¹ First, feedback inhibition on the coagulation cascade deactivates the enzyme complexes leading to thrombin formation. Thrombomodulin (TM) presented by the endothelium serves as a “thrombin sink” by forming a complex with thrombin, rendering it no longer available to cleave fibrinogen. This then activates protein C (APC) and reduces further thrombin generation by inhibiting factors V and VIII. Second, tissue plasminogen activator (tPA) is released from the endothelium following injury, cleaving plasminogen to initiate fibrinolysis. APC then consumes plasminogen activator inhibitor-1 (PAI-1), leading to increased tPA activity and fibrinolysis. Building on the anticoagulant response to inhibit thrombin formation, tissue factor pathway inhibitor (TFPI) is released, blocking the TF-VIIa complex and reducing the production of factors Xa and IXa. Antithrombin III (AT-III) then neutralizes all of the procoagulant serine proteases and also inhibits the TF-VIIa complex. The most potent mechanism of thrombin inhibition involves the APC system. APC forms a complex with its cofactor, protein S, on a phospholipid surface. This complex then cleaves factors Va and VIIIa so they are no longer able to participate in the formation of TF-VIIa or prothrombinase complexes. This is of interest clinically in the form of a genetic mutation, called factor V Leiden. In this setting, factor V is resistant to cleavage by APC, thereby remaining active as a procoagulant. Patients with factor V Leiden are predisposed to venous thromboembolic events.

Degradation of fibrin clot is accomplished by plasmin, a serine protease derived from the proenzyme plasminogen. Plasmin formation occurs as a result of one of several plasminogen activators. tPA is made by the endothelium and other cells of the vascular wall and is the main circulating form of this family of enzymes. tPA is selective for fibrin-bound plasminogen so that endogenous fibrinolytic activity occurs predominately at the site of clot formation. The other major plasminogen activator, urokinase plasminogen activator (uPA), also produced by endothelial cells as well as by urothelium, is not selective for fibrin-bound plasminogen. Of note, the thrombin-TM complex activates TAFI, leading to a mixed effect on clot stability. In addition to inhibiting fibrinolysis directly, removal of the terminal lysine on the fibrin molecule by TAFI renders the clot more susceptible to lysis by plasmin.

Fibrinolysis

Fibrin clot breakdown (lysis) allows restoration of blood flow during the healing process following injury and begins at the same time clot formation is initiated. Fibrin polymers are degraded by plasmin, a serine protease derived from the proenzyme plasminogen. Plasminogen is converted to plasmin by one of several plasminogen activators, including tPA. Plasmin then degrades the fibrin mesh at various places, leading to the production of circulating fragments, termed fibrin degradation products (FDPs), cleared by other proteases or by the kidney and liver (Fig. 4-4). Fibrinolysis is directed by circulating kinases, tissue activators, and kallikrein present in vascular endothelium. tPA is synthesized by endothelial cells and released by the cells on thrombin stimulation. Bradykinin, a potent endothelial-dependent vasodilator, is cleaved from high molecular weight kininogen by kallikrein and enhances the release of tPA. Both tPA and plasminogen bind to fibrin as it forms, and this trimolecular complex cleaves fibrin very efficiently. After plasmin is generated, however, it cleaves fibrin somewhat less efficiently.

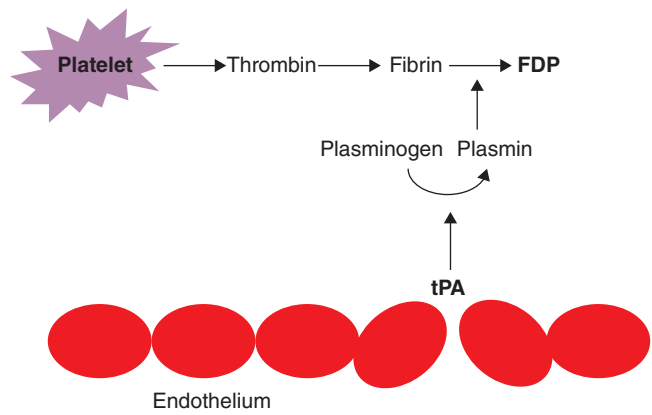


Figure 4-4. Formation of fibrin degradation products (FDPs). tPA = tissue plasminogen activator.

As with clot formation, fibrinolysis is also kept in check through several robust mechanisms. tPA activates plasminogen more efficiently when it is bound to fibrin, so that plasmin is formed selectively on the clot. Plasmin is inhibited by α_2 -antiplasmin, a protein that is cross-linked to fibrin by factor XIII, which helps to ensure that clot lysis does not occur too quickly. Any circulating plasmin is also inhibited by α_2 -antiplasmin and circulating tPA or urokinase. Clot lysis yields FDPs including E-nodes and D-dimers. These smaller fragments interfere with normal platelet aggregation, and the larger fragments may be incorporated into the clot in lieu of normal fibrin monomers. This may result in an unstable clot as seen in cases of severe coagulopathy such as hyperfibrinolysis associated with trauma-induced coagulopathy or disseminated intravascular coagulopathy. The presence of D-dimers in the circulation may serve as a marker of thrombosis or other conditions in which a significant activation of the fibrinolytic system is present. Another inhibitor of the fibrinolytic system is TAFI, which removes lysine residues from fibrin that are essential for binding plasminogen.

CONGENITAL FACTOR DEFICIENCIES

Coagulation Factor Deficiencies

Inherited deficiencies of all of the coagulation factors are seen. However, the three most frequent are factor VIII deficiency (hemophilia A and von Willebrand’s disease), factor IX deficiency (hemophilia B or Christmas disease), and factor XI deficiency. Hemophilia A and hemophilia B are inherited as sex-linked recessive disorders with males being affected almost exclusively. The clinical severity of hemophilia A and hemophilia B depends on the measurable level of factor VIII or factor IX in the patient’s plasma. Plasma factor levels less than 1% of normal are considered severe disease, factor levels between 1% and 5% moderately severe disease, and levels between 5% and 30% mild disease. Patients with severe hemophilia have spontaneous bleeds, frequently into joints, leading to crippling arthropathies. Intracranial bleeding, intramuscular hematomas, retroperitoneal hematomas, and gastrointestinal, genitourinary, and retropharyngeal bleeding are added clinical sequelae seen with severe disease. Patients with moderately severe hemophilia have less spontaneous bleeding but are likely to bleed severely after trauma or surgery. Mild hemophiliacs do not bleed spontaneously and have only minor bleeding after major trauma or surgery. Since platelet function is normal in hemophiliacs, patients may not bleed immediately after an injury or minor surgery as

they have a normal response with platelet activation and formation of a platelet plug. At times, the diagnosis of hemophilia is not made in these patients until after their first minor procedure (e.g., tooth extraction or tonsillectomy).

Patients with hemophilia A or B are treated with factor VIII or factor IX concentrate, respectively. Recombinant factor VIII is strongly recommended for patients not treated previously and is generally recommended for patients who are both human immunodeficiency virus (HIV) and hepatitis C virus (HCV) seronegative. For factor IX replacement, the preferred products are recombinant or high-purity factor IX. In general, activity levels should be restored to 30% to 40% for mild hemorrhage, 50% for severe bleeding, and 80% to 100% for life-threatening bleeding. Up to 20% of hemophiliacs with factor VIII deficiency develop inhibitors that can neutralize FVIII. For patients with low titers, inhibitors can be overcome with higher doses of factor VIII. For patients with high titer inhibitors, alternate treatments should be used and may include porcine factor VIII, prothrombin complex concentrates, activated prothrombin complex concentrates, or recombinant factor VIIa. For patients undergoing elective surgical procedures, a multidisciplinary approach with preoperative planning and replacement is recommended.²

von Willebrand's Disease. von Willebrand's disease (vWD), the most common congenital bleeding disorder, is characterized by a quantitative or qualitative defect in vWF, a large glycoprotein responsible for carrying factor VIII and platelet adhesion. The latter is important for normal platelet adhesion to exposed subendothelium and for aggregation under high shear conditions. Patients with vWD have bleeding that is characteristic of platelet disorders such as easy bruising and mucosal bleeding. Menorrhagia is common in women. vWD is classified into three types. Type I is a partial quantitative deficiency, type II is a qualitative defect, and type III is total deficiency. For bleeding, type I patients usually respond well to desmopressin (DDAVP). Type II patients may respond, depending on the particular defect. Type III patients are usually unresponsive. These patients may require vWF concentrates.³

Factor XI Deficiency. Factor XI deficiency, an autosomal recessive inherited condition sometimes referred to as hemophilia C, is more prevalent in the Ashkenazi Jewish population but found in all races. Spontaneous bleeding is rare, but bleeding may occur after surgery, trauma, or invasive procedures. Treatment of patients with factor XI deficiency who present with bleeding or in whom surgery is planned and who are known to have bled previously is with fresh frozen plasma (FFP). Each milliliter of plasma contains 1 unit of factor XI activity, so the volume needed depends on the patient's baseline level, the desired level, and the plasma volume. Antifibrinolytics may be useful in patients with menorrhagia. Factor VIIa is recommended for patients with anti-factor XI antibodies, although thrombosis has been reported.⁴ There has been renewed interest in factor XI inhibitors as antithrombotic agents, because patients with factor XI deficiency generally have only minimal bleeding risk unless a severe deficiency is present and seem to be protected from thrombosis.⁵

Deficiency of Factors II (Prothrombin), V, and X. Inherited deficiencies of factors II, V, and X are rare. These deficiencies are inherited as autosomal recessive. Significant bleeding in homozygotes with less than 1% of normal activity is encountered. Bleeding with any of these deficiencies is treated with FFP. Similar to factor XI, FFP contains one unit of activity

of each per milliliter. However, factor V activity is decreased because of its inherent instability. The half-life of prothrombin (factor II) is long (approximately 72 hours), and only about 25% of a normal level is needed for hemostasis. Prothrombin complex concentrates can be used to treat deficiencies of prothrombin or factor X. Daily infusions of FFP are used to treat bleeding in factor V deficiency, with a goal of 20% to 25% activity. Factor V deficiency may be coinherited with factor VIII deficiency. Treatment of bleeding in individuals with the combined deficiency requires factor VIII concentrate and FFP. Some patients with factor V deficiency are also lacking the factor V normally present in platelets and may need platelet transfusions as well as FFP.

Factor VII Deficiency. Inherited factor VII deficiency is a rare autosomal recessive disorder. Clinical bleeding can vary widely and does not always correlate with the level of FVII coagulant activity in plasma. Bleeding is uncommon unless the level is less than 3%. The most common bleeding manifestations involve easy bruising and mucosal bleeding, particularly epistaxis or oral mucosal bleeding. Postoperative bleeding is also common, reported in 30% of surgical procedures.⁶ Treatment is with FFP or recombinant factor VIIa. The half-life of recombinant factor VIIa is only approximately 2 hours, but excellent hemostasis can be achieved with frequent infusions. The half-life of factor VII in FFP is up to 4 hours.

Factor XIII Deficiency. Congenital factor XIII (FXIII) deficiency, originally recognized by Duckert in 1960, is a rare autosomal recessive disease usually associated with a severe bleeding diathesis.⁷ The male-to-female ratio is 1:1. Although acquired FXIII deficiency has been described in association with hepatic failure, inflammatory bowel disease, and myeloid leukemia, the only significant association with bleeding in children is the inherited deficiency.⁸ Bleeding is typically delayed because clots form normally but are susceptible to fibrinolysis. Umbilical stump bleeding is characteristic, and there is a high risk of intracranial bleeding. Spontaneous abortion is usual in women with factor XIII deficiency unless they receive replacement therapy. Replacement can be accomplished with FFP, cryoprecipitate, or a factor XIII concentrate. Levels of 1% to 2% are usually adequate for hemostasis.

Platelet Functional Defects

Inherited platelet functional defects include abnormalities of platelet surface proteins, abnormalities of platelet granules, and enzyme defects. The major surface protein abnormalities are thrombasthenia and Bernard-Soulier syndrome. Thrombasthenia, or Glanzmann thrombasthenia, is a rare genetic platelet disorder, inherited in an autosomal recessive pattern, in which the platelet glycoprotein IIb/IIIa (GP IIb/IIIa) complex is either lacking or present but dysfunctional. This defect leads to faulty platelet aggregation and subsequent bleeding. The disorder was first described by Dr. Eduard Glanzmann in 1918.⁹ Bleeding in thrombasthenic patients must be treated with platelet transfusions. The Bernard-Soulier syndrome is caused by a defect in the GP Ib/IX/V receptor for vWF, which is necessary for platelet adhesion to the subendothelium. Transfusion of normal platelets is required for bleeding in these patients.

The most common intrinsic platelet defect is storage pool disease. It involves loss of dense granules (storage sites for ADP, adenosine triphosphate [ATP], Ca²⁺, and inorganic phosphate) and α -granules. Dense granule deficiency is the most prevalent of these. It may be an isolated defect or occur with

partial albinism in the Hermansky-Pudlak syndrome. Bleeding is variable, depending on the severity of the granule defect. Bleeding is caused by the decreased release of ADP from these platelets. A few patients have been reported who have decreased numbers of both dense and α -granules. They have a more severe bleeding disorder. Patients with mild bleeding as a consequence of a form of storage pool disease can be treated with DDAVP. It is likely that the high levels of vWF in the plasma after DDAVP somehow compensate for the intrinsic platelet defect. With more severe bleeding, platelet transfusion is required.

ACQUIRED HEMOSTATIC DEFECTS

Platelet Abnormalities

Acquired abnormalities of platelets are much more common than acquired defects and may be quantitative or qualitative, although some patients have both types of defects. Quantitative defects may be a result of failure of production, shortened survival, or sequestration. Failure of production is generally a result of bone marrow disorders such as leukemia, myelodysplastic syndrome, severe vitamin B₁₂ or folate deficiency, chemotherapeutic drugs, radiation, acute ethanol intoxication, or viral infection. If a quantitative abnormality exists and treatment is indicated either due to symptoms or the need for an invasive procedure, platelet transfusion is utilized. The etiologies of both qualitative and quantitative defects are reviewed in Table 4-1.

Table 4-1

Etiology of platelet disorders

- A. Quantitative Disorders
 1. Failure of production: related to impairment in bone marrow function
 - a. Leukemia
 - b. Myeloproliferative disorders
 - c. B₁₂ or folate deficiencies
 - d. Chemotherapy or radiation therapy
 - e. Acute alcohol intoxication
 - f. Viral infections
 2. Decreased survival
 - a. Immune-mediated
 - 1) Idiopathic thrombocytopenia (ITP)
 - 2) Heparin-induced thrombocytopenia
 - 3) Autoimmune disorders or B-cell malignancies
 - 4) Secondary thrombocytopenia
 - b. Disseminated intravascular coagulation (DIC)
 - c. Related to platelet thrombi
 - 1) Thrombocytopenic purpura (TTP)
 - 2) Hemolytic uremic syndrome (HS)
 3. Sequestration
 - a. Portal hypertension
 - b. Sarcoid
 - c. Lymphoma
 - d. Gaucher's Disease
- B. Qualitative Disorders
 1. Massive transfusion
 2. Therapeutic platelet inhibitors
 3. Disease states
 - a. Myeloproliferative disorders
 - b. Monoclonal gammopathies
 - c. Liver disease

Quantitative Defects. Shortened platelet survival is seen in immune thrombocytopenia, disseminated intravascular coagulation, or disorders characterized by platelet thrombi such as thrombotic thrombocytopenic purpura and hemolytic uremic syndrome. Immune thrombocytopenia may be idiopathic or associated with other autoimmune disorders or low-grade B-cell malignancies, and it may also be secondary to viral infections (including HIV) or drugs. Secondary immune thrombocytopenia often presents with a very low platelet count, petechiae and purpura, and epistaxis. Large platelets are seen on peripheral smear. Initial treatment consists of corticosteroids, intravenous gamma globulin, or anti-D immunoglobulin in patients who are Rh positive. Both gamma globulin and anti-D immunoglobulin are rapid in onset. Platelet transfusions are not usually needed unless central nervous system bleeding or active bleeding from other sites occurs. Survival of the transfused platelets is usually short.

Primary immune thrombocytopenia is also known as idiopathic thrombocytopenic purpura (ITP). In children, it is usually acute in onset, short lived, and typically follows a viral illness. In contrast, ITP in adults is gradual in onset, chronic in nature, and has no identifiable cause. Because the circulating platelets in ITP are young and functional, bleeding is less for a given platelet count than when there is failure of platelet production. The pathophysiology of ITP is believed to involve both impaired platelet production and T cell-mediated platelet destruction.¹⁰ Management options are summarized in Table 4-2.¹¹ Treatment of drug-induced immune thrombocytopenia may simply entail withdrawal of the offending drug, but corticosteroids, gamma globulin, and anti-D immunoglobulin may hasten recovery of the count. Heparin-induced thrombocytopenia (HIT) is a form of drug-induced immune thrombocytopenia. It is an immunologic event during which antibodies against platelet factor 4 (PF4) formed during exposure to heparin affect platelet activation and endothelial function with resultant thrombocytopenia and intravascular thrombosis.¹² The platelet count typically begins to fall 5 to 7 days after

Table 4-2

Management of idiopathic thrombocytopenic purpura (ITP) in adults

First Line

- a. Corticosteroids: The majority of patients respond but only a few long term
- b. Intravenous immunoglobulin (IVIG) or anti-D immunoglobulin: indicated for clinical bleeding

Second Line. Required in most patients

- a. Splenectomy: open or laparoscopic. Criteria include severe thrombocytopenia, high risk of bleeding, and continued need for steroids. Failure may be due to retained accessory splenic tissue.
- b. Rituximab, an anti-CD 20 monoclonal antibody
- c. Thrombopoietin (TPO) receptor agonists such as romiplostim and eltrombopag

Third Line. To be used after failure of splenectomy and rituximab

- a. TPO receptor agonists
- b. Immunosuppressive agents. For failure of TPO receptor agonists

heparin has been started, but if it is a re-exposure, the decrease in count may occur within 1 to 2 days. HIT should be suspected if the platelet count falls to less than 100,000 or if it drops by 50% from baseline in a patient receiving heparin. While HIT is more common with full-dose unfractionated heparin (1%–3%), it can also occur with prophylactic doses or with low molecular weight heparins. Interestingly, approximately 17% of patients receiving unfractionated heparin and 8% receiving low molecular weight heparin develop antibodies against PF4, yet a much smaller percentage develop thrombocytopenia and even fewer develop clinical HIT.¹³ In addition to the mild to moderate thrombocytopenia, this disorder is characterized by a high incidence of thrombosis that may be arterial or venous. Importantly, the absence of thrombocytopenia in these patients does not preclude the diagnosis of HIT.

The diagnosis of HIT may be made by using either a serotonin release assay (SRA) or an enzyme-linked immunosorbent assay (ELISA). The SRA is highly specific but not sensitive, so a positive test supports the diagnosis but a negative test does not exclude HIT.¹² On the other hand, the ELISA has a low specificity, so although a positive ELISA confirms the presence of anti-heparin-PF4, it does not help in the diagnosis of clinical HIT. A negative ELISA, however, essentially rules out HIT.

The initial treatment of suspected HIT is to stop heparin and begin an alternative anticoagulant. Stopping heparin without addition of another anticoagulant is not adequate to prevent thrombosis in this setting. Alternative anticoagulants are primarily thrombin inhibitors. The most recent guideline by the American College of Chest Physicians recommends lepirudin, argatroban, or danaparoid for patients with normal renal function and argatroban for patients with renal insufficiency.¹⁴ Because of warfarin's early induction of a hypercoagulable state, warfarin should be instituted only once full anticoagulation with an alternative agent has been accomplished and the platelet count has begun to recover.

These are also disorders in which thrombocytopenia is a result of platelet activation and formation of platelet thrombi. In thrombotic thrombocytopenic purpura (TTP), large vWF molecules interact with platelets, leading to activation. These large molecules result from inhibition of a metalloproteinase enzyme, ADAMTS13, which cleaves the large vWF molecules.¹⁵ TTP is classically characterized by thrombocytopenia, microangiopathic hemolytic anemia, fever, and renal and neurologic signs or symptoms. The finding of schistocytes on a peripheral blood smear aids in the diagnosis. Plasma exchange with replacement of FFP is the treatment for acute TTP.¹⁶ Additionally, rituximab, a monoclonal antibody against the CD20 protein on B lymphocytes, has shown promise as an immunomodulatory therapy directed against patients with acquired TTP, of which the majority are autoimmune mediated.¹⁷

Hemolytic uremic syndrome (HUS) often occurs secondary to infection by *Escherichia coli* 0157:H7 or other Shiga toxin-producing bacteria. The metalloproteinase is normal in these cases. HUS is usually associated with some degree of renal failure, with many patients requiring renal replacement therapy. Neurologic symptoms are less frequent. A number of patients develop features of both TTP and HUS. This may occur with autoimmune diseases, especially systemic lupus erythematosus and HIV infection, or in association with certain drugs (such as ticlopidine, mitomycin C, gemcitabine) or immunosuppressive agents (such as cyclosporine and tacrolimus). Discontinuation of the involved drug is the mainstay of therapy. Plasmapheresis

is frequently used, but it is not clear what etiologic factor is being removed by the pheresis.

Sequestration is another important cause of thrombocytopenia and usually involves trapping of platelets in an enlarged spleen typically related to portal hypertension, sarcoid, lymphoma, or Gaucher's disease. The total body platelet mass is essentially normal in patients with hypersplenism, but a much larger fraction of the platelets are in the enlarged spleen. Platelet survival is mildly decreased. Bleeding is less than anticipated from the count because sequestered platelets can be mobilized to some extent and enter the circulation. Platelet transfusion does not increase the platelet count as much as it would in a normal person because the transfused platelets are similarly sequestered in the spleen. Splenectomy is not indicated to correct the thrombocytopenia of hypersplenism caused by portal hypertension.

Thrombocytopenia is the most common abnormality of hemostasis that results in bleeding in the surgical patient. The patient may have a reduced platelet count as a result of a variety of disease processes, as discussed earlier. In these circumstances, the marrow usually demonstrates a normal or increased number of megakaryocytes. By contrast, when thrombocytopenia occurs in patients with leukemia or uremia and in patients on cytotoxic therapy, there are generally a reduced number of megakaryocytes in the marrow. Thrombocytopenia also occurs in surgical patients as a result of massive blood loss with product replacement deficient in platelets. Thrombocytopenia may also be induced by heparin administration during cardiac and vascular cases, as in the case of HIT, or may be associated with thrombotic and hemorrhagic complications. When thrombocytopenia is present in a patient for whom an elective operation is being considered, management is contingent upon the extent and cause of platelet reduction. A count of greater than 50,000/ μ L generally requires no specific therapy.

Early platelet administration has now become part of massive transfusion protocols.^{18,19} Platelets are also administered preoperatively to rapidly increase the platelet count in surgical patients with underlying thrombocytopenia. One unit of platelet concentrate contains approximately 5.5×10^{10} platelets and would be expected to increase the circulating platelet count by about 10,000/ μ L in the average 70-kg person. Fever, infection, hepatosplenomegaly, and the presence of antiplatelet alloantibodies decrease the effectiveness of platelet transfusions. In patients refractory to standard platelet transfusion, the use of human leukocyte antigen (HLA)-compatible platelets coupled with special processors has proved effective.

Qualitative Platelet Defects. Impaired platelet function often accompanies thrombocytopenia but may also occur in the presence of a normal platelet count. The importance of this is obvious when one considers that 80% of overall strength is related to platelet function. The life span of platelets ranges from 7 to 10 days, placing them at increased risk for impairment by medical disorders and prescription and over-the-counter medications.

1▶ Impairment of ADP-stimulated aggregation occurs with massive transfusion of blood products. Uremia may be associated with increased bleeding time and impaired aggregation. Defective aggregation and platelet dysfunction are also seen in patients with thrombocythemia, polycythemia vera, and myelofibrosis.

Drugs that interfere with platelet function include aspirin, clopidogrel, prasugrel, dipyridamole, and GP IIb/IIIa inhibitors. Aspirin, clopidogrel, and prasugrel all irreversibly inhibit

platelet function. Clopidogrel and prasugrel do so through selective irreversible inhibition of ADP-induced platelet aggregation.²⁰ Aspirin works through irreversible acetylation of platelet prostaglandin synthase.

There are no prospective randomized trials in general surgical patients to guide the timing of surgery in patients on aspirin, clopidogrel, or prasugrel.²¹ The general recommendation is that approximately 5 to 7 days should pass from the time the drug is stopped until an elective procedure is performed.²² Timing of urgent and emergent surgeries is even more unclear. Preoperative platelet transfusions may be beneficial, but there are no good data to guide their administration. However, new functional tests are becoming available that may better demonstrate defects in platelet function and may serve to guide the timing of operation or when platelet transfusions might be indicated.

Other disorders associated with abnormal platelet function include uremia, myeloproliferative disorders, monoclonal gammopathies, and liver disease. In the surgical patient, platelet dysfunction of uremia can often be corrected by dialysis or the administration of DDAVP. Platelet transfusion may not be helpful if the patient is uremic when the platelets are given and only serve to increase antibodies. Platelet dysfunction in myeloproliferative disorders is intrinsic to the platelets and usually improves if the platelet count can be reduced to normal with chemotherapy. If possible, surgery should be delayed until the count has been decreased. These patients are at risk for both bleeding and thrombosis. Platelet dysfunction in patients with monoclonal gammopathies is a result of interaction of the monoclonal protein with platelets. Treatment with chemotherapy or, occasionally, plasmapheresis to lower the amount of monoclonal protein improves hemostasis.

Acquired Hypofibrinogenemia

Disseminated Intravascular Coagulation (DIC). DIC is an acquired syndrome characterized by systemic activation of coagulation pathways that result in excessive thrombin generation and the diffuse formation of microthrombi. This disturbance ultimately leads to consumption and depletion of platelets and coagulation factors with the resultant classic picture of diffuse bleeding. Fibrin thrombi developing in the microcirculation may cause microvascular ischemia and subsequent end-organ failure if severe. There are many different conditions that predispose a patient to DIC, and the presence of an underlying condition is required for the diagnosis. For example, injuries resulting in embolization of materials such as brain matter, bone marrow, or amniotic fluid can act as potent thromboplastins that activate the DIC cascade.²³ Additional etiologies include malignancy, organ injury (such as severe pancreatitis), liver failure, certain vascular abnormalities (such as large aneurysms), snake bites, illicit drugs, transfusion reactions, transplant rejection, and sepsis.²⁴ In fact, DIC frequently accompanies sepsis and may be associated with multiple organ failure. As of yet, scoring systems for organ failure do not routinely incorporate DIC. The important interplay between sepsis and coagulation abnormalities was demonstrated by Dhainaut et al who showed that activated protein C was effective in septic patients with DIC.²⁵ The diagnosis of DIC is made based on an inciting etiology with associated thrombocytopenia, prolongation of the prothrombin time, a low fibrinogen level, and elevated fibrin markers (FDPs, D-dimer, soluble fibrin monomers). A scoring system developed by the International Society for Thrombosis and Hemostasis has been shown to have high sensitivity and specificity for diagnosing DIC as well as a strong

correlation between an increasing DIC score and mortality, especially in patients with infections.²⁶

The most important facets of treatment are relieving the patient's causative primary medical or surgical problem and maintaining adequate perfusion. If there is active bleeding, hemostatic factors should be replaced with FFP, which is usually sufficient to correct the hypofibrinogenemia, although cryoprecipitate, fibrinogen concentrates, or platelet concentrates may also be needed. Given the formation of microthrombi in DIC, heparin therapy has also been proposed. Most studies, however, have shown that heparin is not helpful in acute forms of DIC, but may be indicated in cases where thrombosis predominates, such as arterial or venous thromboembolism and severe purpura fulminans.

Primary Fibrinolysis. An acquired hypofibrinogenemic state in the surgical patient can be a result of pathologic fibrinolysis. This may occur in patients following prostate resection when urokinase is released during surgical manipulation of the prostate or in patients undergoing extracorporeal bypass. The severity of fibrinolytic bleeding is dependent on the concentration of breakdown products in the circulation. Antifibrinolytic agents, such as ϵ -aminocaproic acid and tranexamic acid, interfere with fibrinolysis by inhibiting plasminogen activation.

Myeloproliferative Diseases

Polycythemia, or an excess of red blood cells, places surgical patients at risk. Spontaneous thrombosis is a complication of polycythemia vera, a myeloproliferative neoplasm, and can be explained in part by increased blood viscosity, increased platelet count, and an increased tendency toward stasis. Paradoxically, a significant tendency toward spontaneous hemorrhage also is noted in these patients. Thrombocytosis can be reduced by the administration of low-dose aspirin, phlebotomy, and hydroxyurea.²⁷

Coagulopathy of Liver Disease

The liver plays a key role in hemostasis because it is responsible for the synthesis of many of the coagulation factors (Table 4-3). Patients with liver disease, therefore, have decreased production of several key non-endothelial cell-derived coagulation factors as well as natural anticoagulant proteins, causing a disturbance in the balance between procoagulant and anticoagulant pathways. This disturbance in coagulation mechanisms causes a complex paradigm of both increased bleeding risk and increased thrombotic risk. The most common coagulation abnormalities

Table 4-3

Coagulation factors synthesized by the liver

Vitamin K–dependent factors: II (prothrombin factor), VII, IX, X
Fibrinogen
Factor V
Factor VIII
Factors XI, XII, XIII
Antithrombin III
Plasminogen
Protein C and protein S

associated with liver dysfunction are thrombocytopenia and impaired humoral coagulation function manifested as prolongation of the prothrombin time and international normalized ratio (INR). The etiology of thrombocytopenia in patients with liver disease is typically related to hypersplenism, reduced production of thrombopoietin, and immune-mediated destruction of platelets. The total body platelet mass is often normal in patients with hypersplenism, but a much larger fraction of the platelets is sequestered in the enlarged spleen. Bleeding may be less than anticipated because sequestered platelets can be mobilized to some extent and enter the circulation. Thrombopoietin, the primary stimulus for thrombopoiesis, may be responsible for some cases of thrombocytopenia in cirrhotic patients, although its role is not well delineated. Finally, immune-mediated thrombocytopenia may also occur in cirrhotics, especially those with hepatitis C and primary biliary cirrhosis.²⁸ In addition to thrombocytopenia, these patients also exhibit platelet dysfunction via defective interactions between platelets and the endothelium, and possibly due to uremia and changes in endothelial function in the setting of concomitant renal insufficiency. Hypocoagulopathy is further exacerbated with low platelet counts because platelets help facilitate thrombin generation by assembling coagulation factors on their surfaces. In conditions mimicking intravascular flow, low hematocrit and low platelet counts contributed to decreased adhesion of platelets to endothelial cells, although increased vWF, a common finding in cirrhotic patients, may offset this change in patients with cirrhosis.²⁹ Hypercoagulability of liver disease has recently gained increased attention, with more evidence demonstrating the increased incidence of thromboembolism despite thrombocytopenia and a hypocoagulable state on conventional blood tests.^{30,31} This is attributed to decreased production of liver-synthesized proteins C and S, antithrombin, and plasminogen levels, as well as elevated levels of endothelial-derived vWF and factor VIII, a potent driver of thrombin generation.^{32,33} Given the concomitant hypo- and hypercoagulable features seen in patients with liver disease, conventional coagulation tests may be difficult to interpret, and alternative tests such as thromboelastography (TEG) may be more informative of the functional status of clot formation and stability in cirrhotic patients. Several studies imply that TEG provides a better assessment of bleeding risk than standard tests of hemostasis in patients with liver disease; however, no studies have directly tested this, and future prospective trials are needed.³⁴

Before instituting any therapy to ameliorate thrombocytopenia, the actual need for correction should be strongly considered. In general, correction based solely on a low platelet count should be discouraged. Most often, treatment should be withheld for invasive procedures and surgery. Platelet transfusions are the mainstay of therapy; however, the effect typically lasts only several hours. Risks associated with transfusions in general and the development of antiplatelet antibodies in a patient population likely to need recurrent correction should be considered. A potential alternative strategy involves administration of interleukin-11 (IL-11), a cytokine that stimulates proliferation of hematopoietic stem cells and megakaryocyte progenitors.²⁶ Most studies using IL-11 have been in cancer patients, although some evidence exists that it may be beneficial in cirrhotics as well. Significant side effects limit its usefulness.³⁵ A less well-accepted option is splenectomy or splenic embolization to reduce hypersplenism. In addition to the risks associated with these techniques, reduced splenic blood flow can reduce portal vein flow with subsequent portal vein thrombosis. Results are

mixed following insertion of a transjugular intrahepatic portosystemic shunt (TIPS). Therefore, treatment of thrombocytopenia should not be the primary indication for a TIPS procedure.

Decreased production or increased destruction of coagulation factors as well as vitamin K deficiency can all contribute to a prolonged PT and INR in patients with liver disease. As liver dysfunction worsens, so does the liver's synthetic function, which results in decreased production of coagulation factors. Additionally, laboratory abnormalities may mimic those of DIC. Elevated D-dimers have been reported to increase the risk of variceal bleeding. The absorption of vitamin K is dependent on bile production. Therefore, liver patients with impaired bile production and cholestatic disease may be at risk for vitamin K deficiency.

Similar to thrombocytopenia, correction of coagulopathy should be reserved for treatment of active bleeding and prophylaxis for invasive procedures and surgery. Treatment of coagulopathy caused by liver disease is usually done with FFP, but because the coagulopathy is usually not a result of decreased levels of factor V, complete correction is not usually possible. If the fibrinogen is less than 200 mg/dL, administration of cryoprecipitate may be helpful. Cryoprecipitate is also a source of factor VIII for the rare patient with a low factor VIII level.

Coagulopathy of Trauma

Traditional teaching regarding trauma-related coagulopathy attributed its development to acidosis, hypothermia, and dilution of coagulation factors. Recent data, however, have shown that over one third of injured patients have evidence of coagulopathy at the time of admission.³⁶ More importantly, patients arriving with coagulopathy are at a significantly higher risk of mortality, especially in the first 24 hours after injury. In light of these findings, a dramatic increase in research focused on the optimal management of the acute coagulopathy of trauma (ACoT) has been observed over the past several years. ACoT is not a simple dilutional coagulopathy but a complex problem with multiple mechanisms.³⁷ Whereas multiple contributing factors exist, the key initiators to the process of ACoT are shock and tissue injury. ACoT is a separate and distinct process from DIC, with its own specific components of hemostatic failure. Brohi et al have demonstrated that only patients in shock arrive coagulopathic and that it is the shock that induces coagulopathy through systemic activation of anticoagulant and fibrinolytic pathways.³⁸ As shown in Fig. 4-5, hypoperfusion causes activation of TM on the surface of endothelial cells. Thrombin-TM complexes induce an anticoagulant state through activation of protein C and enhancement of fibrinolysis. This same complex also limits the availability of thrombin to cleave fibrinogen to fibrin, which may explain why injured patients rarely have low levels of fibrinogen.

Acquired Coagulation Inhibitors

Among the most common acquired coagulation inhibitors is the antiphospholipid syndrome (APLS), which includes the lupus anticoagulant and anticardiolipin antibodies. These antibodies may be associated with either venous or arterial thrombosis, or both. In fact, patients presenting with recurrent thrombosis should be evaluated for APLS. Antiphospholipid antibodies are very common in patients with systemic lupus but may also be seen in association with rheumatoid arthritis and Sjögren's syndrome. There are also individuals who will have no autoimmune disorders but develop transient antibodies in response to infections or those who develop drug-induced APLS. The hallmark of

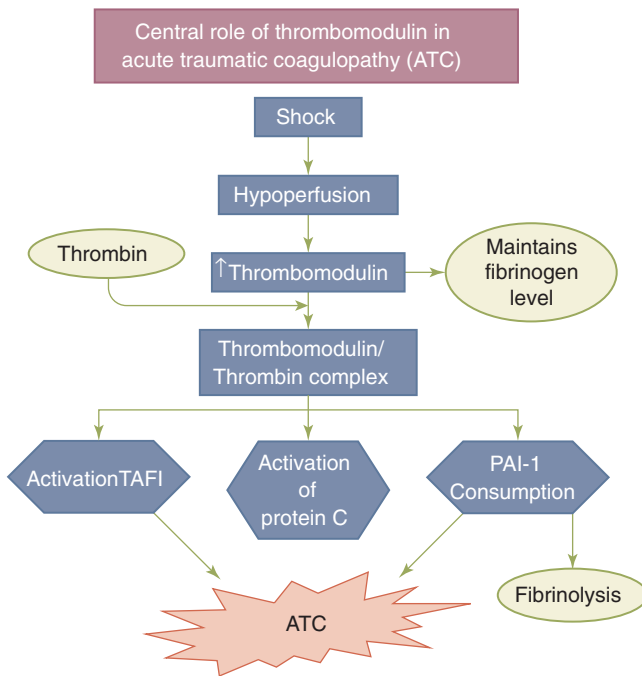


Figure 4-5. Illustration of the pathophysiologic mechanism responsible for the acute coagulopathy of trauma. PAI-1 = plasminogen activator inhibitor 1; TAFI = thrombin-activatable fibrinolysis inhibitor.

APLS is a prolonged aPTT in vitro but an increased risk of thrombosis in vivo.

Anticoagulation and Bleeding

Spontaneous bleeding can be a complication of any anticoagulant therapy whether it is heparin, low molecular weight heparins, warfarin, factor Xa inhibitors, or new direct thrombin inhibitors. The risk of spontaneous bleeding related to heparin is reduced with a continuous infusion technique. Therapeutic anticoagulation is more reliably achieved with a low molecular weight heparin. However, laboratory testing is more challenging with these medications, as they are not detected with conventional coagulation testing. However, their more reliable therapeutic levels (compared to heparin) make them an attractive option for outpatient anticoagulation and more cost-effective for the inpatient setting. If monitoring is required (e.g., in the presence of renal insufficiency or severe obesity), the drug effect should be determined with an assay for anti-Xa activity.

Warfarin is used for long-term anticoagulation in various clinical conditions including deep vein thrombosis, pulmonary embolism, valvular heart disease, atrial fibrillation, recurrent systemic emboli, recurrent myocardial infarction, prosthetic heart valves, and prosthetic implants. Due to the interaction of the P450 system, the anticoagulant effect of the warfarin is reduced (e.g., increases dose required) in patients receiving barbiturates as well as in patients with diets low in vitamin K. Increased warfarin requirements may also be needed in patients taking contraceptives or estrogen-containing compounds, corticosteroids, and adrenocorticotropic hormone (ACTH). Medications that can alter warfarin requirements are shown in Table 4-4.

Although warfarin use is often associated with a significant increase in morbidity and mortality in acutely injured and emergency surgery patients, with rapid reversal, these complications

Table 4-4

Medications that can alter warfarin dosing

↓ warfarin effect ↑ warfarin requirements	Barbiturates, oral contraceptives, estrogen-containing compounds, corticosteroids, adrenocorticotropic hormone
↑ warfarin effect ↓ warfarin requirements	Phenylbutazone, clofibrate, anabolic steroids, L-thyroxine, glucagons, amiodarone, quinidine, cephalosporins

can be dramatically reduced. There are several reversal options that include vitamin K administration, plasma, cryoprecipitate, recombinant factor VIIa, and factor concentrates. Urgent reversal for life-threatening bleeding should include vitamin K and a rapid reversal agent such as plasma or prothrombin complex concentrate. In the elderly or those with intracranial hemorrhage, concentrates are preferred, whereas in situations with hypovolemia from hemorrhage, plasma should be used.

Newer anticoagulants like dabigatran and rivaroxaban have no readily available method of detection of the degree of anticoagulation. More concerning is the absence of any available reversal agent. Unlike warfarin, the nonreversible coagulopathy associated with dabigatran and rivaroxaban is of great concern to those providing emergent care to these patients.³⁹

The only possible strategy to reverse the coagulopathy associated with dabigatran may be emergent dialysis. Unfortunately, the ability to rapidly dialyze the hemodynamically unstable bleeding patient or rapidly dialyze the anticoagulated patient with an intracranial bleed is challenging even at large medical centers. Recent data suggest that rivaroxaban, however, may be reversed with the use of prothrombin complex concentrates (four-factor concentrates only: II, VII, IX, and X).⁴⁰ In less urgent states, these drugs can be held for 36 to 48 hours prior to surgery without increased risk of bleeding in those with normal renal function. Alternatively, activated clotting time (stand alone or with rapid TEG) or ecarin clotting time can be obtained in those on dabigatran, and anti-factor Xa assays can be obtained in those taking rivaroxaban.

Bleeding complications in patients on anticoagulants include hematuria, soft tissue bleeding, intracerebral bleeding, skin necrosis, and abdominal bleeding. Bleeding secondary to anticoagulation therapy is also not an uncommon cause of a rectus sheath hematomas. In most of these cases, reversal of anticoagulation is the only treatment that is necessary. Lastly, it is important to remember that symptoms of an underlying tumor may first present with bleeding while on anticoagulation.

Surgical intervention may prove necessary in patients receiving anticoagulation therapy. Increasing experience suggests that surgical treatment can be undertaken without full reversal of the anticoagulant, depending on the procedure being performed.⁴¹ When the aPTT is less than 1.3 times control in a heparinized patient or when the INR is less than 1.5 in a patient on warfarin, reversal of anticoagulation therapy may not be necessary. However, meticulous surgical technique is mandatory, and the patient must be observed closely throughout the postoperative period.

Certain surgical procedures should not be performed in concert with anticoagulation. In particular, cases where even

minor bleeding can cause great morbidity, such as the central nervous system and the eye, surgery should be avoided. Emergency operations are occasionally necessary in patients who have been heparinized. The first step in these patients is to discontinue heparin. For more rapid reversal, protamine sulfate is effective. However, significant adverse reactions, especially in patients with severe fish allergies, may be encountered when administering protamine.⁴² Symptoms include hypotension, flushing, bradycardia, nausea, and vomiting. Prolongation of the aPTT after heparin neutralization with protamine may also be a result of the anticoagulant effect of protamine. In the elective surgical patient who is receiving coumarin-derivative therapy sufficient to effect anticoagulation, the drug can be discontinued several days before operation and the prothrombin concentration then checked (a level >50% is considered safe).⁴³ Rapid reversal of anticoagulation can be accomplished with plasma or prothrombin complex concentrates in the emergent situation. Parenteral administration of vitamin K also is indicated in elective surgical treatment of patients with biliary obstruction or malabsorption who may be vitamin K deficient. However, if low levels of factors II, VII, IX, and X (vitamin K–dependent factors) exist as a result of hepatocellular dysfunction, vitamin K administration is ineffective.

The perioperative management of patients receiving long-term oral anticoagulation therapy is an increasingly common problem. Definitive evidence-based guidelines regarding which patients require perioperative “bridging” anticoagulation and the most effective way to bridge are lacking. However, the American College of Chest Physicians Evidence-Based Clinical Practice Guidelines do serve as best practice for these situations.⁴⁴ A few clinical scenarios exist where the patient should be transitioned to intravenous heparin from oral anticoagulants. A heparin infusion should be held for 4 to 6 hours before the procedure and restarted within 12 to 24 hours of the end of its completion. The primary indication for this level of aggressiveness is patients with mechanical heart valves. Other indications include a recent (within 30 days) myocardial infarction, stroke, or pulmonary embolism. Situations such as thromboembolic events greater than 30 days prior, hypercoagulable history, and atrial fibrillation do not require such stringent restarting strategies.

Cardiopulmonary Bypass. Under normal conditions, homeostasis of the coagulation system is maintained by complex interactions between the endothelium, platelets, and coagulation factors. In patients undergoing cardiopulmonary bypass (CPB), contact with circuit tubing and membranes results in abnormal platelet and clotting factor activation, as well as activation of inflammatory cascades, that ultimately result in excessive fibrinolysis and a combination of both quantitative and qualitative platelet defects. Platelets undergo reversible alterations in morphology and their ability to aggregate, which causes sequestration in the filter, partially degranulated platelets, and platelet fragments. This multifactorial coagulopathy is compounded by the effects of shear stress in the system, induced hypothermia, hemodilution, and anticoagulation.⁴⁵

While on pump, activated clotting time measurements are obtained along with blood gas measurements; however, conventional coagulation assays and platelet counts are not normally performed until rewarming and after a standard dose of protamine has been given. TEG may give a better estimate of the extent of coagulopathy and may also be used to anticipate transfusion requirements if bleeding is present.⁴⁵

Empiric treatment with FFP and cryoprecipitate is often used for bleeding patients; however, there are no universally

accepted transfusion thresholds. Platelet concentrates are given for bleeding patients in the immediate postoperative period; however, studies have shown that indiscriminate platelet therapy conferred no therapeutic advantage.⁴⁶ It is in these patients where rapid coagulation testing is required to assist with directed transfusion therapy.⁴⁷ Many institutions now use antifibrinolytics, such as ϵ -aminocaproic acid and tranexamic acid, at the time of anesthesia induction after several studies have shown that such treatment reduced postoperative bleeding and reoperation. Aprotinin, a protease inhibitor that acts as an antifibrinolytic agent, has been shown to reduce transfusion requirements associated with cardiac surgery.⁴⁸ Desmopressin acetate stimulates release of factor VIII from endothelial cells and may also be effective in reducing blood loss during cardiac surgery. The use of recombinant factor VIIa has also been studied but with conflicting results between improved hemostasis and thrombotic events and mortality, and thus its use is often employed only as a measure of last resort.^{45,49}

Local Hemostasis. Significant surgical bleeding is usually caused by ineffective local hemostasis. The goal is therefore to prevent further blood loss from a disrupted vessel that has been incised or transected. Hemostasis may be accomplished by interrupting the flow of blood to the involved area or by direct closure of the blood vessel wall defect.

Mechanical Procedures. The oldest mechanical method of bleeding cessation is application of direct digital pressure, either at the site of bleeding or proximally to permit more definitive action. An extremity tourniquet that occludes a major vessel proximal to the bleeding site or the Pringle maneuver for liver bleeding are good examples. Direct digital pressure is very effective and has the advantage of being less traumatic than hemostatic or even “atraumatic” clamps.

When a small vessel is transected, a simple ligature is usually sufficient. However, for larger pulsating arteries, a transfixion suture to prevent slipping is indicated. All sutures represent foreign material, and selection should be based on their intrinsic characteristics and the state of the wound. Direct pressure applied by “packing” a wound with gauze or laparotomy pads affords the best method of controlling diffuse bleeding from large areas, such as in the trauma situation. Packing bone wax on the raw surface to effect pressure can control bleeding from cut bone.

Thermal Agents. Heat achieves hemostasis by denaturation of protein that results in coagulation of large areas of tissue. Electrocautery generates heat by induction from an alternating current source, which is then transmitted via conduction from the instrument directly to the tissue. The amplitude setting should be high enough to produce prompt coagulation, but not so high as to set up an arc between the tissue and the cautery tip. This avoids thermal injury outside of the operative field and also prevents exit of current through electrocardiographic leads, other monitoring devices, or permanent pacemakers or defibrillators. A negative grounding plate should be placed beneath the patient to avoid severe skin burns, and caution should be used with certain anesthetic agents (diethyl ether, divinyl ether, ethyl chloride, ethylene, and cyclopropane) because of the hazard of explosion.

A direct current also can result in hemostasis. Because the protein moieties and cellular elements of blood have a negative surface charge, they are attracted to a positive pole where a thrombus is formed. Direct currents in the 20- to 100-mA range have successfully controlled diffuse bleeding from raw surfaces, as has argon gas.

Topical Hemostatic Agents. Topical hemostatic agents can play an important role in helping to facilitate surgical hemostasis. These agents are classified based on their mechanism of action, and many act at specific stages in the coagulation cascade and take advantage of natural physiologic responses to bleeding.⁵⁰ The ideal topical hemostatic agent has significant hemostatic action, minimal tissue reactivity, nonantigenicity, in vivo biodegradability, ease of sterilization, low cost, and can be tailored to specific needs.⁵¹

In 2010, Achneck et al published a comprehensive overview of absorbable, biologic, and synthetic agents.⁵² Absorbable agents include gelatin foams (Gelfoam), oxidized cellulose (Surgicel), and microfibrillar collagens (Avitene). Both gelatin foam and oxidized cellulose provide a physical matrix for clotting initiation, while microfibrillar collagens facilitate platelet adherence and activation. Biologic agents include topical thrombin, fibrin sealants (FloSeal), and platelet sealants (Vitagel). Human or recombinant thrombin derivatives, which facilitate the formation of fibrin clots and subsequent activation of several clotting factors, take advantage of natural physiologic processes, thereby avoiding foreign body or inflammatory reactions.⁵¹ Caution must be taken in judging vessel caliber in the wound because thrombin entry into larger caliber vessels can result in systemic exposure to thrombin with a risk of disseminated intravascular clotting or death. They are particularly effective in controlling capillary bed bleeding when pressure or ligation is insufficient; however, the bovine derivatives should be used with caution due to the potential immunologic response and worsened coagulopathy. Fibrin sealants are prepared from cryoprecipitate (homologous or synthetic) and have the advantage of not promoting inflammation or tissue necrosis.⁵³ Platelet sealants are a mixture of collagen and thrombin combined with plasma-derived fibrinogen and platelets from the patient, which requires the additional need for centrifugation and processing.

Topical agents are not a substitute for meticulous surgical technique and only function as adjuncts to help facilitate surgical hemostasis. The advantages and disadvantages of each agent must be considered, and use should be limited to the minimum amount necessary to minimize toxicity, adverse reactions, interference with wound healing, and procedural costs.

TRANSFUSION

Background

Human blood replacement therapy was accepted in the late nineteenth century. This was followed by the introduction of blood grouping by Landsteiner who identified the major A, B, and O groups in 1900, resulting in widespread use of blood products in World War I. Levine and Stetson in 1939 followed with the concept of Rh grouping. These breakthroughs established the foundation from which the field of transfusion medicine has grown. Whole blood was considered the standard in transfusion until the late 1970s when component therapy began to take prominence. This change in practice was made possible by the development of improved collection strategies, infectious disease testing, and advances in preservative solutions and storage.

Replacement Therapy

Typing and Cross-Matching. Serologic compatibility for A, B, O, and Rh groups is established routinely. Cross-matching between the donors' red blood cells and the recipients' sera (the major cross-match) is performed. Rh-negative recipients should

be transfused only with Rh-negative blood. However, this group represents only 15% of the population. Therefore, the administration of Rh-positive blood is acceptable if Rh-negative blood is not available. However, Rh-positive blood should not be transfused to Rh-negative females who are of child-bearing age.

In emergency situations, type O-negative blood may be transfused to all recipients. O-negative and type-specific red blood cells are equally safe for emergency transfusion. Problems are associated with the administration of four or more units of O-negative blood because there is a significant increase in the risk of hemolysis. In patients with clinically significant cold agglutinins, blood should be administered through a blood warmer. If these antibodies are present in high titer, hypothermia is contraindicated.

In patients who have been multiply transfused and who have developed alloantibodies or who have autoimmune hemolytic anemia with pan-red blood cell antibodies, typing and cross-matching is often difficult, and sufficient time should be allotted preoperatively to accumulate blood that might be required during the operation. Cross-matching should always be performed before the administration of dextran because it interferes with the typing procedure.

The use of autologous transfusion is growing. Up to 5 units can be collected for subsequent use during elective procedures. Patients can donate and store their own blood if their hemoglobin concentration exceeds 11 g/dL or if the hematocrit is greater than 34%. The first procurement is performed 40 days before the planned operation, and the last one is performed 3 days before the operation. Donations can be scheduled at intervals of 3 to 4 days. Recombinant human erythropoietin (rHuEPO) accelerates generation of red blood cells and allows for more frequent harvesting of blood.

Banked Whole Blood. Once the gold standard, whole blood is rarely available in Western countries. With sequential changes in storage solutions, the shelf life of red blood cells is now 42 days. Recent evidence has demonstrated that the age of red cells may play a significant role in the inflammatory response and incidence of multiple organ failure.⁵⁴ The changes in the red blood cells that occur during storage include reduction of intracellular ADP and 2,3-diphosphoglycerate (2,3-DPG), which alters the oxygen dissociation curve of hemoglobin, resulting in a decrease in oxygen transport. Stored RBCs progressively becomes acidotic with elevated levels of lactate, potassium, and ammonia.

Red Blood Cells and Frozen Red Blood Cells. Red blood cells are the product of choice for most clinical situations requiring resuscitation. Concentrated suspensions of red blood cells can be prepared by removing most of the supernatant plasma after centrifugation. The preparation reduces but does not eliminate reactions caused by plasma components. Frozen red blood cells are not currently available for use in emergencies, as the thawing and preparation time is measured in hours. They are used for patients who are known to have been previously sensitized. The red blood cell viability is improved, and the ATP and 2,3-DPG concentrations are maintained.

Leukocyte-Reduced and Leukocyte-Reduced/Washed Red Blood Cells. These products are prepared by filtration that removes about 99.9% of the white blood cells and most of the platelets (leukocyte-reduced red blood cells) and, if necessary, by additional saline washing (leukocyte-reduced/washed red blood cells). Leukocyte reduction prevents almost all febrile,

nonhemolytic transfusion reactions (fever and/or rigors), alloimmunization to HLA class I antigens, and platelet transfusion refractoriness and cytomegalovirus transmission. In most Western nations, it is the standard red blood cell transfusion product. Supporters of universal leukocyte reduction argue that allogenic transfusion of white cells predisposes to postoperative bacterial infection and multiorgan failure. Reviews of randomized trials and meta-analyses have not provided convincing evidence either way,^{55,56} although a large Canadian retrospective study suggests a decrease in mortality and infections.⁵⁷

Platelet Concentrates. The indications for platelet transfusion include thrombocytopenia caused by massive blood loss and replacement with platelet-poor products, thrombocytopenia caused by inadequate production, and qualitative platelet disorders. The shelf life of platelets is 120 hours from time of donation. One unit of platelet concentrate has a volume of approximately 50 mL. Platelet preparations are capable of transmitting infectious diseases and can account for allergic reactions similar to those caused by red blood cell transfusion. A therapeutic level of platelets is in the range of 50,000 to 100,000/ μ L but is very dependent on the clinical situation. Recent evidence suggests that earlier use of platelets may improve outcomes in bleeding patients.⁵⁸

In rare cases, in patients who become alloimmunized through previous transfusion or patients who are refractory from sensitization through prior pregnancies, HLA-matched platelets can be used.

Fresh Frozen Plasma. Fresh frozen plasma (FFP) prepared from freshly donated blood is the usual source of the vitamin K-dependent factors and is the only source of factor V. FFP carries similar infectious risks as other component therapies. Use of plasma as a primary resuscitation modality in patients who are rapidly bleeding has received attention over the last few years, and ongoing studies are under way to evaluate this concept. FFP can be thawed and stored for up to 5 days, greatly increasing its immediate availability. In an effort to increase the shelf life and avoid the need for refrigeration, lyophilized plasma is being tested. Preliminary animal studies suggest that it preserves the beneficial effects of FFP.⁵⁹

Concentrates and Recombinant DNA Technology. Technologic advancements have made the majority of clotting factors and albumin readily available as concentrates. These products are readily available and carry none of the inherent infectious risks as other component therapies.

Tranexamic Acid. Tranexamic acid (TXA; trade name: Cyklokapron), an antifibrinolytic agent, has been used to decrease bleeding and the need for blood transfusions in coronary artery bypass grafting (CABG), orthotopic liver transplantation, hip and knee arthroplasty, and other surgical settings. The safety and efficacy of using TXA to treat trauma patients was recently evaluated in a large randomized, placebo-controlled clinical trial.⁶⁰ In this trial, 20,211 adult trauma patients in 274 hospitals in 40 countries with significant hemorrhage (heart rate >110 beats per minute and systolic blood pressure <90 mmHg or both) or judged to be at risk for significant hemorrhage were randomized to either TXA or placebo administered as a loading dose of 1 g over 10 minutes followed by an infusion of 1 g over 8 hours. It is important to understand that the responsible physician did not randomize patients with either a clear indication or a clear contraindication to TXA. The overall mortality rate in the cohort studied was 15.3%, of whom 35.3% died on the day of randomization. A total of 1063 patients died due to

hemorrhage, and the majority died on the day of randomization. The authors reported that TXA use resulted in a statistically significant reduction in the relative risk (RR) of all-cause mortality of 9% (14.5 vs. 16.0%, RR 0.91, confidence interval [CI] 0.85–0.97; $P = .0035$). A recent post hoc analysis of the CRASH-2 data showed that the greatest benefit of TXA administration occurred when patients received the medication soon after injury.⁶¹ In this analysis, TXA given between 1 and 3 hours after trauma reduced the risk of death due to bleeding by 21% (147/3037 [4.8%] vs. 184/2996 [6.1%], RR 0.79, CI 0.64–0.97; $P = .03$). Treatment given after 3 hours increased the risk of death due to bleeding (144/3272 [4.4%] vs. 103/3362 [3.1%], RR 1.44, CI 1.12–1.84; $P = .004$). Finally, a recent meta-analysis reported that TXA is effective for preventing blood loss in surgery and reducing transfusion and was not associated with increased vascular occlusive events.⁶²

Adverse events associated with TXA use have been reported. These include acute gastrointestinal disturbances (nausea, vomiting, and diarrhea, generally dose-related), visual disturbances (blurred vision and changes in color perception, especially with prolonged use), and occasional thromboembolic events (e.g., deep venous thrombosis and pulmonary embolism, generally observed in the setting of active intravascular clotting). Its use is thus contraindicated in the settings of acquired defective color vision and active intravascular clotting. TXA should be used with caution in the setting of urinary tract bleeding because ureteral obstruction due to clotting has been reported. TXA is contraindicated in patients with aneurysmal subarachnoid hemorrhage; however, there have been no reported complications associated with intra- or extracranial hemorrhage associated with trauma. TXA should not be given with activated prothrombin complex concentrate or factor IX complex concentrates because these may increase the risk of thrombosis.

TXA is an antifibrinolytic that inhibits both plasminogen activation and plasmin activity, thus preventing clot breakdown rather than promoting new clot formation. TXA is an inhibitor of plasminogen activation and an inhibitor of plasmin activity. It occupies the lysine binding sites on plasminogen, thus preventing its binding to lysine residues on fibrin. This reduces plasminogen activation to plasmin. Similarly, blockade of lysine-binding sites on circulating plasmin prevents binding to fibrin and thus prevents clot breakdown. TXA is 10 times more potent *in vitro* than aminocaproic acid. At therapeutically relevant concentrations, TXA does not affect platelet count or aggregation or coagulation parameters. It is excreted largely unchanged in urine and has a half-life of about 2 hours in circulation. While prolonged use requires that dosing be adjusted for renal impairment, use in the acute trauma situation does not appear to require adjustment. No adjustment is needed for hepatic impairment. Based on the CRASH-2 trial, TXA is becoming more widely used in the United States for patients with ongoing bleeding, especially those with documented evidence of fibrinolysis. Careful analysis of recently ongoing trials will further elucidate the safety profile of this powerful drug.⁶³

Indications for Replacement of Blood and Its Elements

Improvement in Oxygen-Carrying Capacity. Oxygen-carrying capacity is primarily a function of the red blood cells. Thus, transfusion of red blood cells should augment oxygen-carrying capacity. Additionally, hemoglobin is fundamental to

arterial oxygen content and thus oxygen delivery. Despite this obvious association, there is little evidence that actually supports the premise that transfusion of red blood cells equates with enhanced cellular delivery and utilization. The reasons for this apparent discrepancy are related to changes that occur with storage of blood. The decrease in 2,3-DPG and P50 impair oxygen offloading, and deformation of the red cells impairs microcirculatory perfusion.⁶⁴

Treatment of Anemia: Transfusion Triggers. A 1988 National Institutes of Health Consensus Report challenged the dictum that a hemoglobin value of less than 10 g/dL or a hematocrit level less than 30% indicates a need for preoperative red blood cell transfusion. This was verified in a prospective randomized controlled trial in critically ill patients that compared a restrictive transfusion threshold to a more liberal strategy and demonstrated that maintaining hemoglobin levels between 7 and 9 g/dL had no adverse effect on mortality. In fact, patients with APACHE II scores of ≤ 20 or patients age < 55 years actually had a lower mortality.⁶⁵

Despite these results, change in daily clinical practice has been slow. Critically ill patients still frequently receive transfusions, with the pretransfusion hemoglobin approaching 9 g/dL in a recent large observational study.⁶⁶ This outdated approach unnecessarily exposes patients to increased risk and little benefit.

One unresolved issue related to transfusion triggers is the safety of maintaining a hemoglobin of 7 g/dL in a patient with ischemic heart disease. Data on this subject are mixed, and many studies have significant design flaws, including their retrospective nature. However, the majority of the published data favors a restrictive transfusion trigger for patients with non-ST elevation acute coronary syndrome, with many reporting worse outcomes in those patients receiving transfusions.^{67,68}

Volume Replacement

The most common indication for blood transfusion in surgical patients is the replenishment of the blood volume; however, a deficit is difficult to evaluate. Measurements of hemoglobin or hematocrit levels are frequently used to assess blood loss. These measurements can be occasionally misleading in the face of acute loss. Both the amount and the rate of bleeding are factors in the development of signs and symptoms of blood loss.

Loss of blood in the operating room can be roughly evaluated by estimating the amount of blood in the wound and on the drapes, weighing the sponges, and quantifying blood suctioned from the operative field. In patients with normal preoperative values, blood loss up to 20% of total blood volume can be replaced with crystalloid or colloid solutions. Blood loss above this value may require the addition of a balanced resuscitation including red blood cells, FFP, and platelets (detailed later in this chapter) (Table 4-5).

New Concepts in Resuscitation

Traditional resuscitation algorithms are sequentially based on crystalloid followed by red blood cells and then plasma and platelet transfusions and have been in widespread use since the 1970s. No quality clinical data supported this concept. Recently the damage control resuscitation (DCR) strategy, aimed at halting and/or preventing rather than treating the lethal triad of coagulopathy, acidosis, and hypothermia, has challenged traditional thinking on early resuscitation strategies.⁶⁹

Rationale. In civilian trauma systems, nearly half of all deaths happen before a patient reaches the hospital, and many

are nonpreventable.⁷⁰ Patients who survive to an emergency center have a high incidence of truncal hemorrhage, and deaths in this group of patients may be potentially preventable. Truncal hemorrhage patients in shock often present with the early coagulopathy of trauma in the emergency department and are at significant risk of dying.⁷¹⁻⁷³

Many of these patients have suffered substantial bleeding and may receive a significant transfusion, generally defined as the administration of ≥ 4 to 6 units of red blood cells within 4 to 6 hours of admission. This definition is admittedly arbitrary. Although 25% of all trauma admissions receive a unit of blood early after admission, only a small percentage of patients receive a massive transfusion. In the military setting, the percentage of massive transfusion patients almost doubles.⁷⁴

Damage Control Resuscitation. Standard advanced trauma life support guidelines start resuscitation with crystalloid, followed by packed red blood cells.⁷⁵ Only after several liters of crystalloid have been transfused does transfusion of units of plasma or platelets begin. This conventional massive transfusion practice was based on a several small uncontrolled retrospective studies that used blood products containing increased amounts of plasma, which are no longer available.⁷⁶ Because of the known early coagulopathy of trauma, the current approach to managing the exsanguinating patient involves early implementation of damage control resuscitation **5►** (DCR). Although most of the attention to hemorrhagic shock resuscitation has centered on higher ratios of plasma and platelets, DCR is actually composed of three basic components: permissive hypotension, minimizing crystalloid-based resuscitation, and the immediate release and administration of predefined blood products (red blood cells, plasma, and platelets) in ratios similar to those of whole blood.

In Iraq and Afghanistan, DCR practices are demonstrating unprecedented success with improved overall survival.⁷⁷ Civilian data also suggest that a balanced resuscitation approach yields improved outcome in severely injured and bleeding trauma patients.⁶⁹ To verify military and single-institution civilian data on DCR, a multicenter retrospective study of modern transfusion practice at 17 leading civilian trauma centers was performed.⁷⁸ It was found that plasma:platelet:red blood cell ratios varied from 1:1:1 to 0.3:0.1:1, with corresponding survival rates ranging from 71% to 41%. A significant center effect was seen, documenting wide variation in both transfusion practice and outcomes between Level 1 trauma centers. This variation correlated with blood product ratios. Increased plasma- and platelet-to-RBC ratios significantly decreased truncal hemorrhagic death and 30-day mortality without a concomitant increase in multiple organ failure as a cause of death. A prospective observational study evaluating current transfusion practice at 10 Level 1 centers was recently published, again documenting the wide variability in practice and improved outcomes with earlier use of increased ratios of plasma and platelets.⁷⁹ Patients receiving ratios less than 1:2 were four times more likely to die than patients with ratios of 1:1 or higher.

Regardless of the optimal ratio, it is essential that the trauma center has an established mechanism to deliver these products quickly and in the correct amounts to these critically injured patients. In fact, several authors have shown that a well-developed massive transfusion protocol is associated with improved outcomes independent of the ratios chosen.⁸⁰ This aggressive delivery of predefined blood products should begin prior to any laboratory-defined anemia or coagulopathy.

Table 4-5

Replacement of clotting factors

FACTOR	NORMAL LEVEL	LIFE SPAN IN VIVO (HALF-LIFE)	FATE DURING COAGULATION	LEVEL REQUIRED FOR SAFE HEMOSTASIS	IDEAL AGENT ACD BANK BLOOD (4°C [39.2°F])	IDEAL AGENT FOR REPLACING DEFICIT
I (fibrinogen)	200–400 mg/100 mL	72 h	Consumed	60–100 mg/100 mL	Very stable	Bank blood; concentrated fibrinogen
II (prothrombin)	20 mg/100 mL (100% of normal level)	72 h	Consumed	15%–20%	Stable	Bank blood; concentrated preparation
V (proaccelerin, accelerator globulin, labile factor)	100% of normal level	36 h	Consumed	5%–20%	Labile (40% of normal level at 1 wk)	Fresh frozen plasma; blood under 7 d
VII (proconvertin, serum prothrombin conversion accelerator, stable factor)	100% of normal level	5 h	Survives	5%–30%	Stable	Bank blood; concentrated preparation
VIII (antihemophilic factor, antihemophilic globulin)	100% of normal level (50%–150% of normal level)	6–12 h	Consumed	30%	Labile (20%–40% of normal level at 1 wk)	Fresh frozen plasma; concentrated antihemophilic factor; cryoprecipitate
IX (Christmas factor, plasma thromboplastin component)	100% of normal level	24 h	Survives	20%–30%	Stable	Fresh-frozen plasma; bank blood; concentrated preparation
X (Stuart-Prower factor)	100% of normal level	40 h	Survives	15%–20%	Stable	Bank blood; concentrated preparation
XI (plasma thromboplastin antecedent)	100% of normal level	Probably 40–80 h	Survives	10%	Probably stable	Bank blood
XII (Hageman factor)	100% of normal level	Unknown	Survives	Deficit produces no bleeding tendency	Stable	Replacement not required
XIII (fibrinase, fibrin-stabilizing factor)	100% of normal level	4–7 d	Survives	Probably <1%	Stable	Bank blood
Platelets	150,000–400,000/μL	8–11 d	Consumed	60,000–100,000/μL	Very labile (40% of normal level at 20 h; 0 at 48 h)	Fresh blood or plasma; fresh platelet concentrate (not frozen plasma)

ACD = acid-citrate-dextrose.

Source: Reproduced with permission from Salzman EW: Hemorrhagic disorders. In: Kinney JM, Egdahl RH, Zuidema GD, eds. *Manual of Preoperative and Postoperative Care*. 2nd ed. Philadelphia: WB Saunders; 1971:157. Copyright Elsevier.

Table 4-6

Adult Transfusion Clinical Practice Guideline

A. Initial Transfusion of Red Blood Cells (RBCs):

1. Notify blood bank immediately of urgent need for RBCs.
O negative uncross-matched (available immediately).
As soon as possible, switch to O negative for females and O positive for males.
Type-specific uncross-matched (available in approximately 5–10 min).
Completely cross-matched (available in approximately 40 min).
2. A blood sample must be sent to blood bank for a type and cross.
3. The Emergency Release of Blood form must be completed. If the blood type is not known and blood is needed immediately, O-negative RBCs should be issued.
4. RBCs will be transfused in the standard fashion. All patients must be identified (name and number) prior to transfusion.
5. Patients who are unstable or receive 1–2 RBCs and do not rapidly respond should be considered candidates for the massive transfusion (MT) guideline.

B. Adult Massive Transfusion Guideline:

1. The Massive Transfusion Guideline (MTG) should be initiated as soon as it is anticipated that a patient will require massive transfusion (≥ 10 U RBCs in 24 h). The Blood Bank should strive to deliver plasma, platelets, and RBCs in a 1:1:1 ratio. To be effective and minimize further dilutional coagulopathy, the 1:1:1 ratio must be initiated early, ideally with the first 2 units of transfused RBCs. Crystalloid infusion should be minimized.
2. Once the MTG is activated, the Blood Bank will have 6 RBCs, 6 FFP, and a 6 pack of platelets packed in a cooler available for rapid transport. If 6 units of thawed FFP are not immediately available, the Blood Bank will issue units that are ready and notify appropriate personnel when the remainder is thawed. Every attempt should be made to obtain a 1:1:1 ratio of plasma:platelets:RBCs.
3. Once initiated, the MT will continue until stopped by the attending physician. MT should be terminated once the patient is no longer actively bleeding.
4. No blood components will be issued without a pickup slip with the recipient's medical record number and name.
5. Basic laboratory tests should be drawn immediately on ED arrival and optimally performed on point-of-care devices, facilitating timely delivery of relevant information to the attending clinicians. These tests should be repeated as clinically indicated (e.g., after each cooler of products has been transfused). Suggested laboratory values are:
 - CBC
 - INR, fibrinogen
 - pH and/or base deficit
 - TEG, where available

CBC = complete blood count; ED = emergency department; FFP = fresh frozen plasma; INR = international normalized ratio; TEG = thromboelastography.

An example of an adult massive transfusion clinical guideline specifying the early use of component therapy is shown in Table 4-6. Specific recommendations for the administration of component therapy during a massive transfusion are shown in Table 4-7. Because only a small percentage of trauma patients require a massive transfusion and because blood products in general are in short supply, the need for early prediction models has been studied and a comparison of results from both civilian and military studies is shown in Table 4-8.^{81–85} While compelling, none of these algorithms have been prospectively validated.

Complications of Transfusion (Table 4-9)

Transfusion-related complications are primarily related to blood-induced proinflammatory responses. Transfusion-related events are estimated to occur in approximately 10% of all transfusions, but less than 0.5% are serious in nature. Transfusion-related deaths, although rare, do occur and are related primarily to transfusion-related acute lung injury (TRALI) (16%–22%), ABO hemolytic transfusion reactions (12%–15%), and bacterial contamination of platelets (11%–18%).⁸⁶

Nonhemolytic Reactions. Febrile, nonhemolytic reactions are defined as an increase in temperature ($>1^{\circ}\text{C}$) associated with a transfusion and are fairly common (approximately 1% of all

transfusions). Preformed cytokines in donated blood and recipient antibodies reacting with donated antibodies are postulated etiologies. The incidence of febrile reactions can be greatly reduced by the use of leukocyte-reduced blood products. Pretreatment with acetaminophen reduces the severity of the reaction.

Bacterial contamination of infused blood is rare. Gram-negative organisms, which are capable of growth at 4°C , are the most common cause. Most cases, however, are associated with the administration of platelets that are stored at 20°C or, even more commonly, with apheresis platelets stored at room temperature. Cases from FFP thawed in contaminated water baths have also been reported.⁸⁷ Bacterial contamination can result in sepsis and death in up to 25% of patients.⁸⁸ Clinical manifestations include systemic signs such as fever and chills, tachycardia and hypotension, and gastrointestinal symptoms (abdominal cramps, vomiting, and diarrhea). If the diagnosis is suspected, the transfusion should be discontinued and the blood cultured. Emergency treatment includes oxygen, adrenergic blocking agents, and antibiotics.

Allergic Reactions. Allergic reactions are relatively frequent, occurring in about 1% of all transfusions. Reactions are usually mild and consist of rash, urticaria, and flushing. In rare instances, anaphylactic shock develops. Allergic reactions are

Table 4-7

Component therapy administration during massive transfusion

Fresh frozen plasma (FFP)	As soon as the need for massive transfusion is recognized. For every 6 red blood cells (RBCs), give 6 FFP (1:1 ratio).
Platelets	For every 6 RBCs and plasma, give one 6 pack of platelets. 6 random-donor platelet packs = 1 apheresis platelet unit. Platelets are in every cooler. Keep platelet counts >100,000.
Cryoprecipitate	After first 6 RBCs, check fibrinogen level. If ≤ 200 mg/dL, give 20 units cryoprecipitate (2 g fibrinogen). Repeat as needed, depending on fibrinogen level, and request appropriate amount of cryoprecipitate.

caused by the transfusion of antibodies from hypersensitive donors or the transfusion of antigens to which the recipient is hypersensitive. Allergic reactions can occur after the administration of any blood product but are commonly associated with FFP and platelets. Treatment and prophylaxis consist of the administration of antihistamines. In more serious cases, epinephrine or steroids may be indicated.

Respiratory Complications. Respiratory compromise may be associated with transfusion-associated circulatory overload (TACO), which is an avoidable complication. It can occur with rapid infusion of blood, plasma expanders, and crystalloids, particularly in older patients with underlying heart disease. Central venous pressure monitoring should be considered whenever large amounts of fluid are administered. Overload is manifest by a rise in venous pressure, dyspnea, and cough. Rales can generally be heard at the lung bases. Treatment consists of diuresis, slowing the rate of blood administration, and minimizing fluids while blood products are being transfused.

Table 4-8

Comparison of massive transfusion prediction studies

AUTHOR	VARIABLES	ROC AUC VALUE
McLaughlin et al ⁸¹	SBP, HR, pH, Hct	0.839
Yücel et al ⁸²	SBP, HR, BD, Hgb, Male, + FAST, long bone/pelvic fracture	0.892
Moore et al ⁸³	SBP, pH, ISS >25	0.804
Schreiber et al ⁸⁴	Hgb ≤ 11 , INR >1.5, penetrating injury	0.80
Cotton et al ⁸⁵	HR, SBP, FAST, penetrating injury	0.83-0.90

AUC = area under the curve; BD = base deficit; FAST = Focused assessment with sonography for trauma; Hct = hematocrit; Hgb = hemoglobin; HR = heart rate; INR = international normalized ratio; ISS = injury severity score; ROC = receiver operating characteristic; SBP = systolic blood pressure.

The syndrome of TRALI is defined as noncardiogenic pulmonary edema related to transfusion.⁸⁹ It can occur with the administration of any plasma-containing blood product. Symptoms are similar to circulatory overload with dyspnea and associated hypoxemia. However, TRALI is characterized as noncardiogenic and is often accompanied by fever, rigors, and bilateral pulmonary infiltrates on chest x-ray. It most commonly occurs within 1 to 2 hours after the onset of transfusion but virtually always before 6 hours. Toy et al recently reported a decrease in the incidence of TRALI with the reduction transfusion of plasma from female donors, due to a combination of reduced transfusion of strong cognate HLA class II antibodies and HNA antibodies in patients with risk factors for acute lung injury.⁹⁰ Treatment of TRALI entails discontinuation of any transfusion, notification of the transfusion service, and pulmonary support, which may vary from supplemental oxygen to mechanical ventilation.

Hemolytic Reactions. Hemolytic reactions can be classified as either acute or delayed. Acute hemolytic reactions occur with the administration of ABO-incompatible blood and can be fatal in up to 6% of cases. Contributing factors include errors in the laboratory of a technical or clerical nature or the administration of the wrong blood type. Immediate hemolytic reactions are characterized by intravascular destruction of red blood cells and consequent hemoglobinemia and hemoglobinuria. DIC can be initiated by antibody-antigen complexes activating factor XII and complement, leading to activation of the coagulation cascade. Finally, acute renal insufficiency results from the toxicity associated with free hemoglobin in the plasma, resulting in tubular necrosis and precipitation of hemoglobin within the tubules.

Delayed hemolytic transfusion reactions occur 2 to 10 days after transfusion and are characterized by extravascular hemolysis, mild anemia, and indirect (unconjugated) hyperbilirubinemia. They occur when an individual has a low antibody titer at the time of transfusion, but the titer increases after transfusion as a result of an anamnestic response. Reactions to non-ABO antigens involve immunoglobulin G-mediated clearance by the reticuloendothelial system.

If the patient is awake, the most common symptoms of acute transfusion reactions are pain at the site of transfusion, facial flushing, and back and chest pain. Associated symptoms include fever, respiratory distress, hypotension, and tachycardia. In anesthetized patients, diffuse bleeding and hypotension are the hallmarks. A high index of suspicion is needed to make the diagnosis. The laboratory criteria for a transfusion reaction are hemoglobinuria and serologic criteria that show incompatibility of the donor and recipient blood. A positive Coombs' test indicates transfused cells coated with patient antibody and is diagnostic. Delayed hemolytic transfusions may also be manifest by fever and recurrent anemia. Jaundice and decreased haptoglobin usually occur, and low-grade hemoglobinemia and hemoglobinuria may be seen. The Coombs' test is usually positive, and the blood bank must identify the antigen to prevent subsequent reactions.

If an immediate hemolytic transfusion reaction is suspected, the transfusion should be stopped immediately, and a sample of the recipient's blood drawn and sent along with the suspected unit to the blood bank for comparison with the pretransfusion samples. Urine output should be monitored and adequate hydration maintained to prevent precipitation of hemoglobin within the tubules. Delayed hemolytic transfusion reactions do not usually require specific intervention.

Table 4-9

Transfusion-related complications

ABBREVIATION	COMPLICATION	SIGNS AND SYMPTOMS	FREQUENCY	MECHANISM	PREVENTION
NHTR	Febrile, nonhemolytic transfusion reaction	Fever	0.5%–1.5% of transfusions	Preformed cytokines Host Ab to donor lymphocytes	Use leukocyte-reduced blood Store platelets <5 d
	Bacterial contamination	High fever, chills Hemodynamic changes DIC Emesis, diarrhea Hemoglobinuria	<<0.05% of blood 0.05% of platelets	Infusion of contaminated blood	
	Allergic reactions	Rash, hives Itching	0.1%–0.3% of units	Soluble transfusion constituents	Provide antihistamine prophylaxis
TACO	Transfusion-associated circulatory overload	Pulmonary edema	? 1:200–1:10,000 of transfused patients	Large volume of blood transfused into an older patient with CHF	Increase transfusion time Administer diuretics Minimize associated fluids
TRALI	Transfusion-related acute lung injury	Acute (<6 h) hypoxemia Bilateral infiltrates ± Tachycardia, hypotension		Anti-HLA or anti-HNA Ab in transfused blood attacks circulatory and pulmonary leukocytes	Limit female donors
	Hemolytic reaction, acute	Fever Hypotension DIC Hemoglobinuria Hemoglobinemia Renal insufficiency	1:33,000–1:1,500,000 units	Transfusion of ABO-incompatible blood Preformed IgM Ab to ABO Ag	Transfuse appropriately matched blood
	Hemolytic reaction, delayed (2–10 d)	Anemia Indirect hyperbilirubinemia Decreased haptoglobin level Positive result on direct Coombs' test		IgG mediated	Identify patient's Ag to prevent recurrence

Ab = antibody; Ag = antigen; CHF = congestive heart failure; DIC = disseminated intravascular coagulation; HLA = human leukocyte antigen; HNA = anti-human neutrophil antigen; IgG = immunoglobulin G; IgM = immunoglobulin M.

Transmission of Disease. Malaria, Chagas' disease, brucellosis, and, very rarely, syphilis are among the diseases that have been transmitted by transfusion. Malaria can be transmitted by all blood components. The species most commonly implicated is *Plasmodium malariae*. The incubation period ranges from 8 to 100 days; the initial manifestations are shaking chills and spiking fever. Cytomegalovirus (CMV) infection resembling infectious mononucleosis also has occurred.

Transmission of hepatitis C and HIV-1 has been dramatically minimized by the introduction of better antibody and nucleic acid screening for these pathogens. The residual risk among allogeneic donations is now estimated to be less than 1 per 1,000,000 donations. The residual risk of hepatitis B is approximately 1 per 300,000 donations.⁹¹ Hepatitis A is very rarely transmitted because there is no asymptomatic carrier state. Improved donor selection and testing are responsible for

the decreased rates of transmission. Recent concerns about the rare transmission of these and other pathogens, such as West Nile virus, are being addressed by current trials of "pathogen inactivation systems" that reduce infectious levels of all viruses and bacteria known to be transmittable by transfusion. Prion disorders (e.g., Creutzfeldt-Jakob disease) also are transmissible by transfusion, but there is currently no information on inactivation of prions in blood products for transfusion.

TESTS OF HEMOSTASIS AND BLOOD COAGULATION

The initial approach to assessing hemostatic function is a careful review of the patient's clinical history (including previous abnormal bleeding or bruising), drug use, and basic laboratory testing. Common screening laboratory testing includes platelet count, PT or INR, and aPTT. Platelet dysfunction can occur

at either extreme of platelet count. The normal platelet count ranges from 150,000 to 400,000/ μL . Whereas a platelet count greater than 1,000,000/ μL may be associated with bleeding or thrombotic complications, increased bleeding complications may be observed with major surgical procedures when the platelets are below 50,000/ μL and with minor surgical procedures when counts are below 30,000/ μL , and spontaneous hemorrhage can occur when the counts fall below 20,000/ μL . Despite a lack of evidence supporting their use, platelet transfusions are still recommended in ophthalmologic and neurosurgical procedures when the platelet count is less than 100,000/ μL .

The PT and aPTT are variations of plasma recalcification times initiated by the addition of a thromboplastic agent. The PT reagent contains thromboplastin and calcium that, when added to plasma, leads to the formation of a fibrin clot. The PT test measures the function of factors I, II, V, VII, and X. Factor VII is part of the extrinsic pathway, and the remaining factors are part of the common pathway. Factor VII has the shortest half-life of the coagulation factors, and its synthesis is vitamin K dependent. The PT test is best suited to detect abnormal coagulation caused by vitamin K deficiencies and warfarin therapy.

Due to variations in thromboplastin activity, it can be difficult to accurately assess the degree of anticoagulation on the basis of PT alone. To account for these variations, the INR is now the method of choice for reporting PT values. The International Sensitivity Index (ISI) is unique to each batch of thromboplastin and is furnished by the manufacturer to the hematology laboratory. Human brain thromboplastin has an ISI of 1, and the optimal reagent has an ISI between 1.3 and 1.5.

The INR is a calculated number derived from the following equation:

$$\text{INR} = (\text{measured PT}/\text{normal PT})^{\text{ISI}}$$

The aPTT reagent contains a phospholipid substitute, activator, and calcium, which in the presence of plasma leads to fibrin clot formation. The aPTT measures function of factors I, II, and V of the common pathway and factors VIII, IX, X, and XII of the intrinsic pathway. Heparin therapy is often monitored by following aPTT values with a therapeutic target range of 1.5 to 2.5 times the control value (approximately 50 to 80 seconds). Low molecular weight heparins are selective Xa inhibitors that may mildly elevate the aPTT, but therapeutic monitoring is not routinely recommended.

The bleeding time is used to evaluate platelet and vascular dysfunction, although not as frequently as in the past. Several standard methods have been described; however, the Ivy bleeding time is most commonly used. It is conducted by placing a sphygmomanometer on the upper arm and inflating it to 40 mmHg, and then a 5-mm stab incision is made on the flexor surface of the forearm. The time is measured to cessation of bleeding, and the upper limit or normal bleeding time with the Ivy test is 7 minutes. A template aids in administering a uniform test and adds to the reproducibility of the results. An abnormal bleeding time suggests platelet dysfunction (intrinsic or drug-induced), vWD, or certain vascular defects. Many laboratories are replacing the template bleeding time with an *in vitro* test in which blood is sucked through a capillary and the platelets adhere to the walls of the capillary and aggregate. The closure time in this system appears to be more reproducible than the bleeding time and also correlates with bleeding in vWD, primary platelet function disorders, and patients who are taking aspirin.

Additional medications may significantly impair hemostatic function, such as antiplatelet agents (clopidogrel and GP IIb/IIIa inhibitors), anticoagulant agents (hirudin, chondroitin sulfate, dermatan sulfate), and thrombolytic agents (streptokinase, tPA). If abnormalities in any of the coagulation studies cannot be explained by known medications, congenital abnormalities of coagulation or comorbid disease should be considered.

Unfortunately, while these conventional tests (PT, aPTT) capture the classic intrinsic and extrinsic coagulation cascade, they do not reflect the complexity of *in vivo* coagulation.⁹² Although they are useful to follow warfarin and heparin therapies, they poorly reflect the status of actively bleeding patients. This is not surprising given that these tests use only plasma and not whole blood to provide their assessment of the patient's clotting status. To better assess the complex and rapidly changing interactions of an actively bleeding patient, many centers have moved to whole blood-viscoelastic testing such as TEG or rotational thromboelastometry (ROTEM). In addition, some centers have demonstrated that the graphical display options allow for more rapid return of results and that these tests are actually less expensive than standard coagulation panels.

TEG was originally described by Hartert in 1948.⁹³ Continuous improvements in this technique have made this test a valuable tool for the medical personnel interested in coagulation. The TEG monitors hemostasis as a dynamic process rather than revealing information of isolated conventional coagulation screens.⁹⁴ The TEG measures the viscoelastic properties of blood as it is induced to clot under a low-shear environment (resembling sluggish venous flow). The patterns of change in shear-elasticity enable the determination of the kinetics of clot formation and growth as well as the strength and stability of the formed clot. The strength and stability provide information about the ability of the clot to perform the work of hemostasis, while the kinetics determines the adequacy of quantitative factors available for clot formation. A sample of celite-activated whole blood is placed into a prewarmed cuvette, and the clotting process is activated with kaolin with standard TEG and kaolin plus tissue factor with rapid TEG. A suspended piston is then lowered into the cuvette that moves in rotation of a 4.5-degree arc backward and forward. The normal clot goes through acceleration and strengthening phase. The fiber strands that interact with activated platelets attach to the surface of the cuvette and the suspended piston. The clot forming in the cuvette transmits its movement onto the suspended piston. A "weak" clot stretches and therefore delays the arc movement of the piston, which is graphically expressed as a narrow TEG. A strong clot, in contrast, will move the piston simultaneously and proportionally to the cuvette's movements, creating a thick TEG. The strength of a clot is graphically represented over time as a characteristic cigar-shape figure (Fig. 4-6).

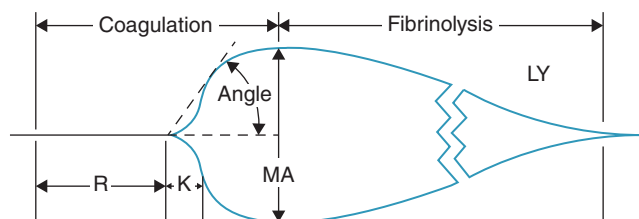


Figure 4-6. Illustration of a thromboelastogram (TEG) tracing. K = clot kinetics; LY = lysis; MA = maximal amplitude; R = reaction time.

Several parameters are generated from the TEG tracing. The r-value (reaction time) represents the time between the start of the assay and initial clot formation. This reflects clotting factor activity and initial fibrin formation and is increased with factor deficiency or severe hemodilution. The k-time (clot kinetics) is the time needed to reach specified clot strength and represents the interactions of clotting factors and platelets. As such, the k-time is prolonged with hypofibrinogenemia and significant factor deficiency. Prolonged r-value and k-time are commonly addressed with plasma transfusions. The alpha or angle (∞) is the slope of the tracing and reflects clot acceleration. The angle reflects the interactions of clotting factors and platelets. The slope is decreased with hypofibrinogenemia and platelet dysfunction. Decreased angles are treated with cryoprecipitate transfusion or fibrinogen administration. The maximal amplitude (mA) is the greatest height of the tracing and represents clot strength. Its height is reduced with dysfunction or deficiencies in platelets or fibrinogen. Decreased mA is addressed with platelet transfusion and, in cases where the angle is also decreased, with cryoprecipitate (or fibrinogen) as well. The G-value is a parametric measure derived from the mA value and reflects overall clot strength or firmness. An increased G-value is associated with hypercoagulability, whereas a decrease is seen with hypocoagulable states. Finally, the LY30 is the amount of lysis occurring in the clot, and the value is the percentage of amplitude reduction at 30 minutes after mA is achieved. The LY30 represents clot stability and when increased fibrinolysis is present.

TEG is the only test measuring all dynamic steps of clot formation until eventual clot lysis or retraction. TEG has also been shown to identify on admission those patients likely to develop thromboembolic complications after injury and postoperatively.⁹⁵⁻⁹⁷

Recent trauma data have shown TEG to be useful in predicting early transfusion of red blood cells, plasma, platelets, and cryoprecipitate.⁹⁸ TEG can also predict the need for life-saving interventions shortly after arrival and to predict 24-hour and 30-day mortality.⁹⁹ Lastly, TEG can be useful to guide administration of TXA to injured patients with hyperfibrinolysis.¹⁰⁰ Our center now uses TEG rather than PT and a PTT to evaluate injured patients in the emergency room.¹⁰¹

EVALUATION OF EXCESSIVE INTRAOPERATIVE OR POSTOPERATIVE BLEEDING

Excessive bleeding during or after a surgical procedure may be the result of ineffective hemostasis, blood transfusion, undetected hemostatic defect, consumptive coagulopathy, and/or fibrinolysis. Excessive bleeding from the operative field unassociated with bleeding from other sites usually suggests inadequate mechanical hemostasis.

Massive blood transfusion is a well-known cause of thrombocytopenia. Bleeding following massive transfusion can occur due to hypothermia, dilutional coagulopathy, platelet dysfunction, fibrinolysis, or hypofibrinogenemia. Another cause of hemostatic failure related to the administration of blood is a hemolytic transfusion reaction. The first sign of a transfusion reaction may be diffuse bleeding. The pathogenesis of this bleeding is thought to be related to the release of ADP from hemolyzed red blood cells, resulting in diffuse platelet aggregation, after which the platelet clumps are removed out of the circulation.

Transfusion purpura occurs when the donor platelets are of the uncommon PIA^1 group. This is an uncommon cause of thrombocytopenia and associated bleeding after transfusion.

The platelets sensitize the recipient, who makes antibody to the foreign platelet antigen. The foreign platelet antigen does not completely disappear from the recipient circulation but attaches to the recipient's own platelets. The antibody then destroys the recipient's own platelets. The resultant thrombocytopenia and bleeding may continue for several weeks. This uncommon cause of thrombocytopenia should be considered if bleeding follows transfusion by 5 or 6 days. Platelet transfusions are of little help in the management of this syndrome because the new donor platelets usually are subject to the binding of antigen and damage from the antibody. Corticosteroids may be of some help in reducing the bleeding tendency. Posttransfusion purpura is self-limited, and the passage of several weeks inevitably leads to subsidence of the problem.

DIC is characterized by systemic activation of the coagulation system, which results in the deposition of fibrin clots and microvascular ischemia and may contribute to the development of multiorgan failure. Consumption and subsequent exhaustion of coagulation proteins and platelets due to the ongoing activation of the coagulation system may induce severe bleeding complications.

Lastly, severe hemorrhagic disorders due to thrombocytopenia have occurred as a result of gram-negative sepsis. Defibrination and hemostatic failure also may occur with meningococemia, *Clostridium perfringens* sepsis, and staphylococcal sepsis. Hemolysis appears to be one mechanism in sepsis leading to defibrination.

REFERENCES

Entries highlighted in blue are key references.

1. Brohi K, Cohen MJ, Davenport RA. Acute coagulopathy of trauma: mechanism, identification and effect. *Curr Opin Crit Care*. 2007;13:680-685.
2. Kulkarani R. Comprehensive care of the patient with haemophilia and inhibitors undergoing surgery: practical aspects. *Hemophilia*. 2013;19(1):2-10.
3. Federicini AB, Mannucci PM. Management of inherited von Willebrand disease in 2007. *Ann Med*. 2007;39(5):346-358.
4. Girolami A, de Marinis GB, Bonamigo E, Lombardi AM. Recombinant FVIIa concentrate-associated thrombotic events in congenital bleeding disorders other than hemophilias. *Hematology*. 2012;17(6):346-349.
5. Peyvandi F, Bolton-Maggs PHB, Batorova A, De Moerloose P. Rare bleeding disorders. *Haemophilia*. 2012;18(Suppl 4):148-153.
6. Peyvandi F, Mannucci PM. Rare coagulation disorders. *Thromb Haemost*. 1999;82(4):1207-1214.
7. Anwar R, Miloszewski KJ. Factor XIII deficiency. *Br J Haematol*. 1999;107(3):468-484.
8. Anwar R, Minford A, Gallivan L, Trinh CH, Markham AF. Delayed umbilical bleeding—a presenting feature for factor XIII deficiency: clinical features, genetics, and management. *Pediatrics*. 2002;109(2):E32.
9. George JN, Caen JP, Nurden AT. Glanzmann's thrombasthenia: the spectrum of clinical disease. *Blood*. 1990;75(7):1383-1395.
10. Stasi R, Evangelista ML, Stipa E, et al. Idiopathic thrombocytopenic purpura: current concepts in pathophysiology and management. *Thromb Haemost*. 2008;99:4-13.
11. George JN. Sequence of treatments for adults with primary immune thrombocytopenia. *Am J Hematol*. 2012;87:S12-S15.
12. Baldwin ZK, Spitzer AL, Ng VL, Harkin AH. Contemporary standards for the diagnosis and treatment of heparin-induced thrombocytopenia (HIT). *Surgery*. 2008;143:305-312.

13. Amiral J, Peynaud-Debayle E, Wolf M, et al. Generation of antibodies to heparin-PF4 complexes without thrombocytopenia in patients treated with unfractionated or low-molecular weight heparin. *Am J Hematol*. 1996;52:90-95.
14. Linkins LA, Dans AL, Moores LK, Bona R, Davidson BL, Schulman S, Crowther M; American College of Chest Physicians. Treatment and prevention of heparin-induced thrombocytopenia: Antithrombotic Therapy and Prevention of Thrombosis, 9th ed: American College of Chest Physicians Evidence-Based Clinical Practice Guidelines. *Chest*. 2012;141(2 Suppl):e495S-530S.
15. Zimrin AB, Hess JR. Thrombocytopenic purpura: going against the evidence. *Crit Care Med*. 2006;34:2247-2248.
16. Kremer Hovinga JA, Meyer SC. Current management of thrombotic thrombocytopenic purpura. *Curr Opin Hematol*. 2008;15(5):445-450.
17. Fakhouri F, Vernant JP, Veyradier A, et al. Efficiency of curative and prophylactic treatment with rituximab in ADAMT13-deficient thrombotic thrombocytopenic purpura: a study of 11 cases. *Blood*. 2005;106:1932-1937.
18. Brown LM, Call MS, Knudson M, et al. A normal platelet count may not be enough: the impact of admission platelet count on mortality and transfusion in severely injured trauma patients. *J Trauma*. 2011;71(2 Suppl 3):S337-S342.
19. Holcomb JB, Zarzabal LA, Michalek JE, et al. Increased platelet: RBC ratios are associated with improved survival after massive transfusion. *J Trauma*. 2011;71(2 Suppl 3): S318-S328.
20. Eikelboom JW, Hirsh J, Spencer FA, Baglin TP, Weitz JI. Antiplatelet Drugs: Antithrombotic Therapy and Prevention of Thrombosis, 9th ed: American College of Chest Physicians Evidence-Based Clinical Practice Guidelines. *Chest* 2012;141(2 Suppl):e89S-e119S.
21. Sarode R. How do I transfuse platelets (PLTs) to reverse anti-PLT drug effect? *Transfusion*. 2012;52:695-701.
22. Lavelle WF, Lavell EA, Uhl R. Operative delay for orthopedic patients on clopidogrel (Plavix): a complete lack of consensus. *J Trauma*. 2008;64:996.
23. Hess JR, Lawson JH. The coagulopathy of trauma versus disseminated intravascular coagulation. *J Trauma*. 2006;60:S12-S19.
24. Taylor FB, Toh CH, Hoots WK, Wada H, Levi M. Towards definition, clinical and laboratory criteria, and a scoring system for disseminated intravascular coagulation. *Thromb Haemost*. 2001;86:1327-1330.
25. Dhainaut JF, Yan SB, Joyce DE, et al. Treatment effects of drotrecogin alfa (activated) in patients with or without overt disseminated intravascular coagulation. *J Thromb Haemost*. 2004;2:1924-1933.
26. Angstwurm MW, Dempfle CE, Spannagl M. New disseminated intravascular coagulation score: a useful tool to predict mortality in comparison with Acute Physiology and Chronic Health Evaluation II and Logistic Organ Dysfunction scores. *Crit Care Med*. 2006;34:314-320.
27. Tefferi A. Polycythemia vera and essential thrombocythemia: 2012 update on diagnosis, risk stratification, and management. *Am J Hematol*. 2012;87(3):285-293.
28. Feistauer SM, Penner E, Mayr WR, et al. Target platelet antigen of autoantibodies in patients with primary biliary cirrhosis. *Hepatology*. 1997;25:1343.
29. Lisman T, Bongers TN, Adelmeijer J, et al. Elevated levels of von Willebrand factor in cirrhosis support platelet adhesion despite reduced functional capacity. *Hepatology*. 2006;44:53-61.
30. Northup PG, McMahon MM, Ruhl AP, et al. Coagulopathy does not fully protect hospitalized cirrhosis patients from peripheral venous thromboembolism. *Am J Gastroenterol*. 2006;101:1524.
31. Gatt A, Riddell A, Calvaruso V, et al. Enhanced thrombin generation in patients with cirrhosis-induced coagulopathy. *J Thromb Haemost*. 2010;8:1994.
32. Tripodi A, Mannucci PM. The coagulopathy of chronic liver disease. *N Engl J Med*. 2011;365:147.
33. Tripodi A, Primignani M, Lemma L, et al. Detection of the imbalance of procoagulant versus anticoagulant factors in cirrhosis by a simple laboratory method. *Hepatology*. 2010;52:249-255.
34. Stavitz RT. Potential applications of thromboelastography in patients with acute and chronic liver disease. *Gastroenterol Hepatol*. 2012;8:513-520.
35. Ghalib R, Levine C, Hassan M, et al. Recombinant human interleukin-11 improves thrombocytopenia in patients with cirrhosis. *Hepatology*. 2003;37:1165-1171.
36. Nunez TC, Cotton BA. Transfusion therapy in hemorrhagic shock. *Curr Opin Crit Care*. 2009;15:536-541.
37. Hess JR, Brohi K, Dutton RP, et al. The coagulopathy of trauma: a review of mechanisms. *J Trauma*. 2008;65:748-754.
38. Brohi K, Cohen MJ, Ganter MT, et al. Acute coagulopathy of trauma: hypoperfusion induces systemic anticoagulation and hyperfibrinolysis. *J Trauma*. 2008;64:1211-1217.
39. Cotton BA, McCarthy J, Holcomb JB. The (irreversible) harm of dabigatran etexilate in acutely injured patients. *N Eng J Med*. 2011;365(21):2039-2040.
40. Eerenberg ES, Kamphuisen PW, Sijpkens MK, et al. Reversal of rivaroxaban and dabigatran by prothrombin complex concentrate. A randomized, placebo-controlled, crossover study in healthy subjects. *Circulation*. 2011;124:1573-1579.
41. Kearon C, Hirsh J. Management of anticoagulation before and after elective surgery. *N Engl J Med*. 1997;336:1506.
42. Lindblad B. Protamine sulfate: a review of its effects—hypersensitivity and toxicity. *Eur J Vasc Surg*. 1989;3:195.
43. Dentali F, Ageno W, Crowther M. Treatment of coumarin-associated coagulopathy: a systematic review and proposed treatment algorithms. *J Thromb Haemost*. 2006;4:1853.
44. Douketis JD, Spyropoulos AC, Spencer FA, et al. Perioperative Management of Antithrombotic Therapy Antithrombotic Therapy and Prevention of Thrombosis, 9th ed: American College of Chest Physicians Evidence-Based Clinical Practice Guidelines. *Chest*. 2012;141(2 Suppl):e326S-e350S.
45. Besser MW, Klein AA. The coagulopathy of cardiopulmonary bypass. *Crit Rev Clin Lab Sci*. 2011;47(5-6):197-212.
46. Simon TL, Akl BF, Murphy W. Controlled trial of routine administration of platelet concentrates in cardiopulmonary bypass surgery. *Ann Thorac Surg*. 1984;37:359-364.
47. Taneja R, Fernandes P, Marwaha G, Cheng D, Bainbridge D. Perioperative coagulation management and blood conservation in cardiac surgery: a Canadian survey. *J Cardiothorac Vasc Anesth*. 2008;22:662-669.
48. Murkin JM, Lux J, Shannon NA, et al: Aprotinin significantly decreases bleeding and transfusion requirements in patients receiving aspirin and undergoing cardiac operations. *J Thorac Cardiovasc Surg*. 1994;107:554.
49. Andersen ND, Syamal D, Williams JB, et al. Intraoperative use of low-dose recombinant activated Factor VII during thoracic aortic operations. *Ann Thoracic Surg*. 2012;93(6):1921-1929.
50. Palm M, Altman J. Topical hemostatic agents: a review. *Dermatol Surg*. 2008;34:431-445.
51. Larson PO. Topical hemostatic agents for dermatologic surgery. *J Dermatol Surg Oncol*. 1988;14:623-632.
52. Achneck HE, Sileshi B, Jamiolkowski, RM, et al. A Comprehensive review of topical hemostatic agents: Efficacy and recommendations for use. *Ann Surg* 2010; 25:217-228.
53. Martinowitz U, Schulman S. Fibrin sealant in surgery of patients with a hemorrhagic diathesis. *Thromb Haemost*. 1995;74:486-492.
54. Kiraly LN, Underwood S, Differding JA, Schreiber MA. Transfusion of aged packed red blood cells results in decreased tissue oxygenation in critically injured trauma patients. *J Trauma*. 2009;67(1):29-32.

55. McAlister FA, Clark HD, Wells PS, Laupacis A. Perioperative allogeneic blood transfusion does not cause adverse sequelae in patients with cancer: a meta-analysis of unconfounded studies. *Br J Surg*. 1998;85:171-178.
56. Vamvakas EC, Blajchman MA. Universal WBC reduction: the case for and against. *Transfusion*. 2001;41:691-712.
57. Hebert PC, Fergusson D, Blajchman MA, Leukoreduction Study Investigators. Clinical outcomes following institution of the Canadian universal leukoreduction program for red blood cell transfusions. *JAMA*. 2003;289(15):1941-1949.
58. Inaba K, Lustenberger T, Rhee P, et al. The impact of platelet transfusion in massively transfused trauma patients. *J Am Coll Surg*. 2010;211(5):573-579.
59. Sondeen JL, Prince MD, Medina L, et al. Comparison of lyophilized swine plasma to fresh frozen plasma plus two ratios of packed red blood cells in a cold, coagulopathic, poly trauma severe hemorrhage shock swine model. *Shock*. 2008;29(suppl 1):13-14.
60. CRASH-2 Collaborators, Shakur H, Roberts I, et al. Effects of tranexamic acid on death, vascular occlusive events, and blood transfusion in trauma patients with significant haemorrhage (CRASH-2): a randomised, placebo-controlled trial. *Lancet*. 2010 Jul 3;376(9734):23-32.
61. CRASH-2 Collaborators, Roberts I, Shakur H, Afolabi A, et al. The importance of early treatment with tranexamic acid in bleeding trauma patients: an exploratory analysis of the CRASH-2 randomized controlled trial. *Lancet*. 2011;377:1096.
62. Henry DA, Carless PA, Moxey AJ, et al. Antifibrinolytic use for minimizing perioperative allogeneic blood transfusion. *Cochrane Database Syst Rev*. 2011;(3):CD001886.
63. Kirkpatrick AW, Holcomb JB, Stephens MH, Gruen R; Members of the Evidence-Based Reviews in Surgery Group. Tranexamic acid effects in trauma patients with significant hemorrhage. *J Am Coll Surg*. 2012;215(3):438-440.
64. Gerber DR. Transfusion of packed red blood cells in patients with ischemic heart disease. *Crit Care Med*. 2008;36:1068-1074.
65. Herbert PC, Wells GW, Blajchman MA, et al. A multicenter, randomized, controlled clinical trial of transfusion requirement in critical care. *N Engl J Med*. 1999;340:409-417.
66. Corwin HL, Gettinger A, Pearl RG, et al. The CRIT Study: anemia and blood transfusion in the critically ill—current clinical practice in the United States. *Crit Care Med*. 2004;32:399-352.
67. Carson JL, Terrin ML, Noveck H, et al. Liberal or restrictive transfusion in high-risk patients after hip surgery. *N Engl J Med*. 2011;365(26):2453-2462.
68. Carson JL, Carless PA, Hebert PC. Transfusion thresholds and other strategies for guiding allogeneic red blood cell transfusion. *Cochrane Database Syst Rev*. 2012;4:CD002042.
69. Cotton BA, Reddy N, Hatch QM, et al. Damage control resuscitation is associated with a reduction in resuscitation volumes and improvement in survival in 390 damage control laparotomy patients. *Ann Surg*. 2011;254(4):598-605.
70. Kauvar DS, Lefering R, Wade CE. Impact of hemorrhage on trauma outcome: an overview of epidemiology, clinical presentations, and therapeutic considerations. *J Trauma*. 2006;60(6 Suppl):S3.
71. Niles SE, McLaughlin DF, Perkins J, et al. Increased mortality associated with early coagulopathy after trauma in combat casualties. *J Trauma*. 2008;64:1459-1463.
72. Macleod J, Lynn M, McKenney MG, Jeroukhimov I, Cohn SM. Predictors of mortality in trauma patients. *Am Surg*. 2004;70:805-810.
73. Brohi K, Singh J, Heron M, Coats T. Acute traumatic coagulopathy. *J Trauma*. 2003;54:1127-1130.
74. Cap AP, Spinella PC, Borgman MA, Blackbourne LH, Perkins JG. Timing and location of blood product transfusion and outcomes in massively transfused combat casualties. *J Trauma Acute Care Surg*. 2012;73(2 Suppl 1):S89-S94.
75. Carrico CJ, Canizaro PC, Shires GT. Fluid resuscitation following injury: rationale for the use of balanced salt solutions. *Crit Care Med*. 1976;4:46.
76. Harrigan C, Lucas CE, Ledgerwood AM, et al. Serial changes in primary hemostasis after massive transfusion. *Surgery*. 1985;98:836.
77. Borgman MA, Spinella PC, Perkins JG, et al. The ratio of blood products transfused affects mortality in patients receiving massive transfusions at a combat support hospital. *J Trauma*. 2007;63:805.
78. Holcomb JB, Wade CE, Michalek JE, et al. Increased plasma and platelet to red blood cell ratios improves outcome in 466 massively transfused civilian trauma patients. *Ann Surg*. 2008;248:447-458.
79. Holcomb JB, del Junco DJ, Fox EE, et al, for the PROM-MTT Study Group. The prospective, observational, multicenter, massive transfusion study, PROMMTT: comparative effectiveness of a time-varying treatment and competing risks. *Arch Surg*. 2012;15:1-10.
80. Cotton BA, Au BK, Nunez TC, et al. Predefined massive transfusion protocols are associated with a reduction in organ failure and postinjury complications. *J Trauma*. 2009;66:41-48; discussion 48-49.
81. McLaughlin DF, Niles SE, Salinas J, et al. A predictive model for massive transfusion in combat casualty patients. *J Trauma*. 2008;64(2 Suppl):S57.
82. Yücel N, Lefering R, Maegele M, et al. Trauma-Associated Severe Hemorrhage (TASH) score: probability of mass transfusion as surrogate for life threatening hemorrhage after multiple trauma. *J Trauma*. 2006;60:1228.
83. Moore FA, Nelson T, McKinley BA, et al. Massive transfusion in trauma patients: tissue hemoglobin oxygen saturation predicts poor outcome. *J Trauma*. 2008;64:1010.
84. Schreiber MA, Perkins J, Kiraly L, et al. Early predictors of massive transfusion in combat casualties. *J Am Coll Surg*. 2007;205:541.
85. Cotton BA, Dossett LA, Haut ER, et al. Multicenter validation of a simplified score to predict massive transfusion in trauma. *J Trauma*. 2010;69(Suppl 1):S33-S39.
86. Despotis GJ, Zhang L, Lublin DM. Transfusion risks and transfusion-related pro-inflammatory responses. *Hematol Oncol Clin N Am*. 2007;21:147.
87. Pandey S, Vyas GN. Adverse-effects of plasma transfusion. *Transfusion*. 2012;52:65S-79S.
88. Goodnough LT, Brecher ME, Kanter MH. Transfusion medicine: blood transfusion. *N Engl J Med*. 1999;340:438.
89. Looney MR, Gropper MA, Matthay MA. Transfusion-related acute lung injury. *Chest*. 2004;126:249.
90. Toy P, Gajic O, Bacchetti P, et al. Transfusion-related acute lung injury: incidence and risk factors. *Blood*. 2012;119(7):1757-1767.
91. Zou S, Stramer SL, Dodd RY. Donor testing and risk: current prevalence, incidence, and residual risk of transfusion-transmissible agents in US allogeneic donations. *Transfusion Med Rev*. 2012;26(2):119-128.
92. Hoffman M, Monroe DM. Coagulation 2006: a modern view of hemostasis. *Hematol Oncol Clin North Am*. 2007;21:1-11.
93. Hartert H. Blutgerinnungsstudien mit der thrombelastographie, einem neuen untersuchungsverfahren. *Klin Wochenschr*. 1948;26:577.
94. Mallet SV, Cox DJA. Thromboelastography: a review article. *Br J Anaesth*. 1992;69:307.
95. Cotton BA, Radwan ZA, Matijevic N, et al. Admission rapid thromboelastography (rTEG) predicts development of pulmonary embolism in trauma patients. *J Trauma*. 2012;72(6):1470-1477.

96. Caprini JA, Arcelus JI, Laubach M, et al. Postoperative hypercoagulability and deep-vein thrombosis after laparoscopic cholecystectomy. *Surg Endosc*. 1995;9:304-309.
97. Dai Y, Lee A, Critchley LA, et al. Does thromboelastography predict postoperative thromboembolic events? A systematic review of the literature. *Anesth Analg*. 2009;108:734-742.
98. Cotton BA, Faz G, Hatch Q, et al. Rapid thromboelastography (r-TEG) delivers real-time results that predict transfusion within one hour of admission. *J Trauma*. 2011;71(2):407-417.
99. Schöchl H, Cotton BA, Inaba K, et al. FIBTEM provides early prediction of massive transfusion in trauma. *Crit Care*. 2011;15:R265-R271.
100. Cotton BA, Harvin JA, Kostousouv V, et al. Hyperfibrinolysis on admission is an uncommon but highly lethal event associated with shock and pre-hospital fluid administration. *J Trauma*. 2012;72(2):365-370.
101. Holcomb JB, Minei KM, Scerbo ML, et al. Admission rapid thromboelastography (r-TEG) can replace conventional coagulation tests in the emergency department: experience with 1974 consecutive trauma patients. *Ann Surg*. 2012;256(3):476-486.

This page intentionally left blank

5 chapter

Shock

Brian S. Zuckerbraun, Andrew B. Peitzman, and
Timothy R. Billiar

Evolution in Understanding Shock / 109			
Overview / 109			
Historical Background / 109			
Current Definitions and Challenges / 110			
Pathophysiology of Shock / 111			
Neuroendocrine and Organ-Specific Responses to Hemorrhage / 112			
Afferent Signals / 112			
Efferent Signals / 113			
	Circulatory Homeostasis / 114		
	Metabolic Effects / 114		
	Cellular Hypoperfusion / 115		
	Immune and Inflammatory Responses / 115		
	Cytokines/Chemokines / 116		
	Complement / 118		
	Neutrophils / 118		
	Cell Signaling / 118		
		Forms of Shock / 119	
		Hypovolemic/Hemorrhagic / 119	
		Traumatic Shock / 123	
		Septic Shock (Vasodilatory Shock) / 124	
		Cardiogenic Shock / 126	
		Obstructive Shock / 128	
		Neurogenic Shock / 129	
		Endpoints in Resuscitation / 130	
		Assessment of Endpoints in Resuscitation / 130	

“Shock is the manifestation of the rude unhooking of the machinery of life.”¹

—Samuel V. Gross, 1872

EVOLUTION IN UNDERSTANDING SHOCK

Overview

Shock, at its most rudimentary definition and regardless of the etiology, is the failure to meet the metabolic needs of the cell and the consequences that ensue. The initial cellular injury that occurs is reversible; however, the injury will become irreversible if tissue perfusion is prolonged or severe enough such that, at the cellular level, compensation is no longer possible. Our evolution in the understanding of shock and the disease processes that result in shock made its most significant advances throughout the twentieth century as our appreciation for the physiology and pathophysiology of shock matured. Most notably, this includes the sympathetic and neuroendocrine stress responses on the cardiovascular system. The clinical manifestations of these physiologic responses are most often what lead practitioners to the diagnosis of shock as well as guide the management of patients in shock. However, hemodynamic parameters such as blood pressure and heart rate are relatively insensitive measures of shock, and additional considerations must be used to help aid in early diagnosis and treatment of patients in shock. The general approach to the management of patients in shock has been empiric: assuring a secure airway with adequate ventilation, control of hemorrhage in the bleeding patient, and restoration of vascular volume and tissue perfusion.

Historical Background

Integral to our understanding of shock is the appreciation that our bodies attempt to maintain a state of homeostasis. Claude Bernard suggested in the mid-nineteenth century that the

organism attempts to maintain constancy in the internal environment against external forces that attempt to disrupt the *milieu interieur*.² Walter B. Cannon carried Bernard’s observations further and introduced the term *homeostasis*, emphasizing that an organism’s ability to survive was related to maintenance of homeostasis.³ The failure of physiologic systems to buffer the organism against external forces results in organ and cellular dysfunction, what is clinically recognized as shock. He first described the “*fight or flight response*,” generated by elevated levels of catecholamines in the bloodstream. Cannon’s observations on the battlefields of World War I led him to propose that the initiation of shock was due to a disturbance of the nervous system that resulted in vasodilation and hypotension. He proposed that secondary shock, with its attendant capillary permeability leak, was caused by a “toxic factor” released from the tissues.

In a series of critical experiments, Alfred Blalock documented that the shock state in hemorrhage was associated with reduced cardiac output due to volume loss, not a “toxic factor.”⁴ In 1934, Blalock proposed four categories of shock: hypovolemic, vasogenic, cardiogenic, and neurogenic. *Hypovolemic shock*, the most common type, results from loss of circulating blood volume. This may result from loss of whole blood (hemorrhagic shock), plasma, interstitial fluid (bowel obstruction), or a combination. *Vasogenic shock* results from decreased resistance within capacitance vessels, usually seen in sepsis. *Neurogenic shock* is a form of vasogenic shock in which spinal cord injury or spinal anesthesia causes vasodilation due to acute loss of sympathetic vascular tone. *Cardiogenic shock* results from failure of the heart as a pump, as in arrhythmias or acute myocardial infarction (MI).

This categorization of shock based on etiology persists today (Table 5-1). In recent clinical practice, further classification has described six types of shock: hypovolemic, septic (vasodilatory), neurogenic, cardiogenic, obstructive, and traumatic shock.

Key Points

- 1▶ Shock is defined as a failure to meet the metabolic demands of cells and tissues and the consequences that ensue.
- 2▶ A central component of shock is decreased tissue perfusion. This may be a direct consequence of the etiology of shock, such as in hypovolemic/hemorrhagic, cardiogenic, or neurogenic etiologies, or may be secondary to elaborated or released molecules or cellular products that result in endothelial/cellular activation, such as in septic shock or traumatic shock.
- 3▶ Physiologic responses to shock are based on a series of afferent (sensing) signals and efferent responses that include neuroendocrine, metabolic, and immune/inflammatory signaling.
- 4▶ The mainstay of treatment of hemorrhagic/hypovolemic shock includes volume resuscitation with blood products. In the case of hemorrhagic shock, timely control of bleeding is essential and influences outcome.
- 5▶ Prevention of hypothermia, acidemia, and coagulopathy is essential in the management of patients in hemorrhagic shock.
- 6▶ The mainstay of treatment of septic shock is fluid resuscitation, initiation of appropriate antibiotic therapy, and control of the source of infection. This includes drainage of infected fluid collections, removal of infected foreign bodies, and débridement of devitalized tissues.
- 7▶ A combination of physiologic parameters and markers of organ perfusion/tissue oxygenation are used to determine if patients are in shock and to follow the efficacy of resuscitation.

Obstructive shock is a form of cardiogenic shock that results from mechanical impediment to circulation leading to depressed cardiac output rather than primary cardiac failure. This includes etiologies such as pulmonary embolism or tension pneumothorax. In *traumatic shock*, soft tissue and bony injury leads to the activation of inflammatory cells and the release of circulating factors, such as cytokines and intracellular molecules that modulate the immune response. Recent investigations have revealed that the inflammatory mediators released in response to tissue injury (damage-associated molecular patterns [DAMPs]) are recognized by many of the same cellular receptors (pattern recognition receptors [PRRs]) and activate similar signaling pathways as do bacterial products elaborated in sepsis (pathogen-associated molecular patterns), such as lipopolysaccharide.⁵ These effects of tissue injury are combined with the effects of hemorrhage, creating a more complex and amplified deviation from homeostasis.

In the mid to later twentieth century, the further development of experimental models contributed significantly to the understanding of the pathophysiology of shock. In 1947, Wiggers developed a sustainable, irreversible model of hemorrhagic shock based on uptake of shed blood into a reservoir to maintain a set level of hypotension.⁶ G. Tom Shires added further understanding of hemorrhagic shock with a series of clinical studies demonstrating that a large extracellular fluid deficit, greater than could be attributed to vascular refilling alone, occurred in severe hemorrhagic shock.^{7,8} The phenomenon of fluid redistribution after major trauma involving blood loss was termed *third spacing* and described the translocation of intravascular volume

into the peritoneum, bowel, burned tissues, or crush injury sites. These seminal studies form the scientific basis for the current treatment of hemorrhagic shock with red blood cells and lactated Ringer's solution or isotonic saline.

As resuscitation strategies evolved and patients survived the initial consequences of hemorrhage, new challenges of sustained shock became apparent. During the Vietnam War, aggressive fluid resuscitation with red blood cells and crystalloid solution or plasma resulted in survival of patients who previously would have succumbed to hemorrhagic shock. Renal failure became a less frequent clinical problem; however, a new disease process, acute fulminant pulmonary failure, appeared as an early cause of death after seemingly successful surgery to control hemorrhage. Initially called *DaNang lung* or *shock lung*, the clinical problem became recognized as acute respiratory distress syndrome (ARDS). This led to new methods of prolonged mechanical ventilation. Our current concept of ARDS is a component in the spectrum of multiple organ system failure.

Studies and clinical observations over the past two decades have extended the early observations of Canon, that "restoration of blood pressure prior to control of active bleeding may result in loss of blood that is sorely needed," and challenged the appropriate endpoints in resuscitation of uncontrolled hemorrhage.⁹ Core principles in the management of the critically ill or injured patient include: (a) definitive control of the airway must be secured, (b) control of active hemorrhage must occur promptly (delay in control of bleeding increases mortality, and recent battlefield data would suggest that in the young and otherwise healthy population commonly injured in combat, control of bleeding is the paramount priority), (c) volume resuscitation with blood products (red blood cells, plasma, and platelets) with limited volume of crystalloid must occur while operative control of bleeding is achieved, (d) unrecognized or inadequately corrected hypoperfusion increases morbidity and mortality (i.e., inadequate resuscitation results in avoidable early deaths from shock), and (e) excessive fluid resuscitation may exacerbate bleeding (i.e., uncontrolled resuscitation is harmful). Thus both inadequate and uncontrolled volume resuscitation is harmful.

Table 5-1

Classification of shock

Hypovolemic
Cardiogenic
Septic (vasogenic)
Neurogenic
Traumatic
Obstructive

Current Definitions and Challenges

A modern definition and approach to shock acknowledges that shock consists of inadequate tissue perfusion marked by

decreased delivery of required metabolic substrates and inadequate removal of cellular waste products. This involves failure of oxidative metabolism that can involve defects of oxygen (O_2) delivery, transport, and/or utilization. Current challenges include moving beyond fluid resuscitation based on endpoints of tissue oxygenation, and using therapeutic strategies at the cellular and molecular level. This approach will help to identify compensated patients or patients early in the course of their disease, initiate appropriate treatment, and allow for continued evaluation for the efficacy of resuscitation and adjuncts.

Current investigations focus on determining the cellular events that often occur in parallel to result in organ dysfunction, shock irreversibility, and death. This chapter will review our current understanding of the pathophysiology and cellular responses of shock states. Current and experimental diagnostic and therapeutic modalities for the different categories of shock are reviewed, with a focus on hemorrhagic/hypovolemic shock and septic shock.

PATHOPHYSIOLOGY OF SHOCK

Regardless of etiology, the initial physiologic responses in shock are driven by tissue hypoperfusion and the developing cellular energy deficit. This imbalance between cellular supply and demand leads to neuroendocrine and inflammatory responses, the magnitude of which is usually proportional to the degree and duration of shock. The specific responses will differ based on the etiology of shock, as certain physiologic responses may be limited by the inciting pathology. For example, the cardiovascular response driven by the sympathetic nervous system is markedly blunted in neurogenic or septic shock. Additionally, decreased perfusion may occur as a consequence of cellular activation and dysfunction, such as in septic shock and to a lesser extent traumatic shock (Fig. 5-1). Many of the organ-specific responses are aimed at maintaining

perfusion in the cerebral and coronary circulation. These are regulated at multiple levels including (a) stretch receptors and baroreceptors in the heart and vasculature (carotid sinus and aortic arch), (b) chemoreceptors, (c) cerebral ischemia responses, (d) release of endogenous vasoconstrictors, (e) shifting of fluid into the intravascular space, and (f) renal reabsorption and conservation of salt and water.

Furthermore, the pathophysiologic responses vary with time and in response to resuscitation. In hemorrhagic shock, the body can compensate for the initial loss of blood volume primarily through the neuroendocrine response to maintain hemodynamics. This represents the *compensated phase* of shock. With continued hypoperfusion, which may be unrecognized, cellular death and injury are ongoing and the *decompensation phase* of shock ensues. Microcirculatory dysfunction, parenchymal tissue damage, and inflammatory cell activation can perpetuate hypoperfusion. Ischemia/reperfusion injury will often exacerbate the initial insult. These effects at the cellular level, if untreated, will lead to compromise of function at the organ system level, thus leading to the “*vicious cycle*” of shock (Fig. 5-2). Persistent hypoperfusion results in further hemodynamic derangements and cardiovascular collapse. This has been termed the *irreversible phase* of shock and can develop quite insidiously and may only be obvious in retrospect. At this point, there has occurred extensive enough parenchymal and microvascular injury such that volume resuscitation fails to reverse the process, leading to death of the patient. In experimental animal models of hemorrhagic shock (modified Wiggers model), this is represented by the “*uptake phase*” or “*compensation endpoint*” when shed blood must be returned to the animal to sustain the hypotension at the set level to prevent further hypotension and death.¹⁰ If shed blood volume is slowly returned to maintain the set level of hypotension, eventually the injury progresses to irreversible shock, where further volume will not reverse the process and the animal dies (Fig. 5-3).

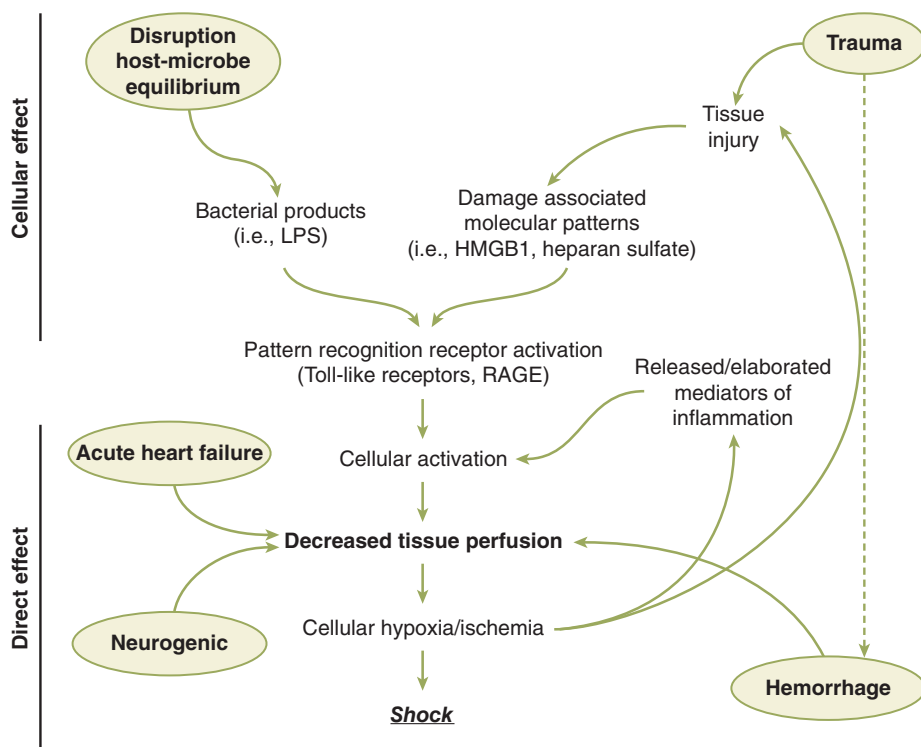


Figure 5-1. Pathways leading to decreased tissue perfusion and shock. Decreased tissue perfusion can result directly from hemorrhage/hypovolemia, cardiac failure, or neurologic injury. Decreased tissue perfusion and cellular injury can then result in immune and inflammatory responses. Alternatively, elaboration of microbial products during infection or release of endogenous cellular products from tissue injury can result in cellular activation to subsequently influence tissue perfusion and the development of shock. HMGB1 = high mobility group box 1; LPS = lipopolysaccharide; RAGE = receptor for advanced glycation end products.

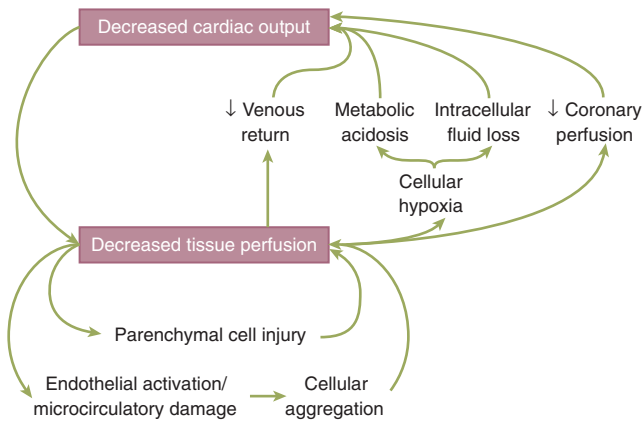


Figure 5-2. The “vicious cycle of shock.” Regardless of the etiology, decreased tissue perfusion and shock results in a feed-forward loop that can exacerbate cellular injury and tissue dysfunction.

Neuroendocrine and Organ-Specific Responses to Hemorrhage

The goal of the neuroendocrine response to hemorrhage is to maintain perfusion to the heart and the brain, even at the expense of other organ systems. Peripheral vasoconstriction occurs, and fluid excretion is inhibited. The mechanisms include autonomic control of peripheral vascular tone and cardiac contractility, hormonal response to stress and volume depletion, and local microcirculatory mechanisms that are organ specific and regulate regional blood flow. The initial stimulus is loss of circulating blood volume in hemorrhagic shock. The magnitude of the neuroendocrine response is based on both the volume of blood lost and the rate at which it is lost.

Afferent Signals

Afferent impulses transmitted from the periphery are processed within the central nervous system (CNS) and activate the reflexive effector responses or efferent impulses. These effector responses are designed to expand plasma volume, maintain

peripheral perfusion and tissue O_2 delivery, and restore homeostasis. The afferent impulses that initiate the body’s intrinsic adaptive responses and converge in the CNS originate from a variety of sources. The initial inciting event usually is loss of circulating blood volume. Other stimuli that can produce the neuroendocrine response include pain, hypoxemia, hypercarbia, acidosis, infection, change in temperature, emotional arousal, or hypoglycemia. The sensation of pain from injured tissue is transmitted via the spinothalamic tracts, resulting in activation of the hypothalamic-pituitary-adrenal axis, as well as activation of the autonomic nervous system (ANS) to induce direct sympathetic stimulation of the adrenal medulla to release catecholamines.

Baroreceptors also are an important afferent pathway in initiation of adaptive responses to shock. Volume receptors, sensitive to changes in both chamber pressure and wall stretch, are present within the atria of the heart. They become activated with low volume hemorrhage or mild reductions in right atrial pressure. Receptors in the aortic arch and carotid bodies respond to alterations in pressure or stretch of the arterial wall, responding to larger reductions in intravascular volume or pressure. These receptors normally inhibit induction of the ANS. When activated, these baroreceptors diminish their output, thus disinhibiting the effect of the ANS. The ANS then increases its output, principally via sympathetic activation at the vasomotor centers of the brain stem, producing centrally mediated constriction of peripheral vessels.

Chemoreceptors in the aorta and carotid bodies are sensitive to changes in O_2 tension, H^+ ion concentration, and carbon dioxide (CO_2) levels. Stimulation of the chemoreceptors results in vasodilation of the coronary arteries, slowing of the heart rate, and vasoconstriction of the splanchnic and skeletal circulation. In addition, a variety of protein and nonprotein mediators are produced at the site of injury as part of the inflammatory response, and they act as afferent impulses to induce a host response. These mediators include histamine, cytokines, eicosanoids, and endothelins, among others that are discussed in greater detail later in this chapter in the Immune and Inflammatory Responses section.

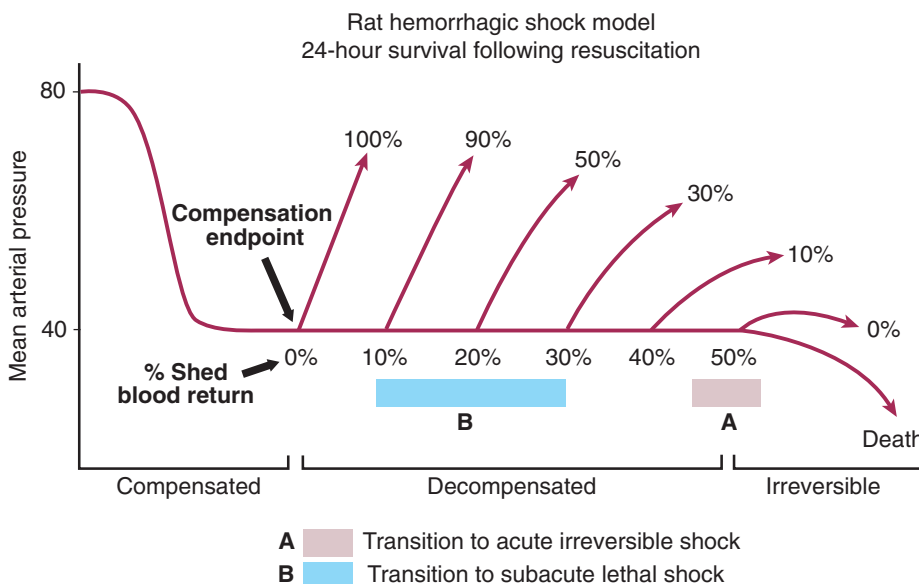


Figure 5-3. Rat model of hemorrhagic shock through the phases of compensation, decompensation, and irreversibility. The percentages shown above the curve represent survival rates. (Adapted with permission from Lippincott Williams & Wilkins/Wolters Kluwer Health: Shah NS, Kelly E, Billiar TR, et al. Utility of clinical parameters of tissue oxygenation in a quantitative model of irreversible hemorrhagic shock. *Shock*. 1998;10:343-346. Copyright © 1998.)

Efferent Signals

Cardiovascular Response. Changes in cardiovascular function are a result of the neuroendocrine response and ANS response to shock, and constitute a prominent feature of both the body's adaptive response mechanism and the clinical signs and symptoms of the patient in shock. Hemorrhage results in diminished venous return to the heart and decreased cardiac output. This is compensated by increased cardiac heart rate and contractility, as well as venous and arterial vasoconstriction. Stimulation of sympathetic fibers innervating the heart leads to activation of β_1 -adrenergic receptors that increase heart rate and contractility in this attempt to increase cardiac output. Increased myocardial O_2 consumption occurs as a result of the increased workload; thus, myocardial O_2 supply must be maintained or myocardial dysfunction will develop. The cardiovascular response in hemorrhage/hypovolemia differs from the responses elicited with the other etiologies of shock. These are compared in Table 5-2.

Direct sympathetic stimulation of the peripheral circulation via the activation of α_1 -adrenergic receptors on arterioles induces vasoconstriction and causes a compensatory increase in systemic vascular resistance and blood pressure. The arterial vasoconstriction is not uniform; marked redistribution of blood flow results. Selective perfusion to tissues occurs due to regional variations in arteriolar resistance, with blood shunted away from less essential organ beds such as the intestine, kidney, and skin. In contrast, the brain and heart have autoregulatory mechanisms that attempt to preserve their blood flow despite a global decrease in cardiac output. Direct sympathetic stimulation also induces constriction of venous vessels, decreasing the capacitance of the circulatory system and accelerating blood return to the central circulation.

Increased sympathetic output induces catecholamine release from the adrenal medulla. Catecholamine levels peak within 24 to 48 hours of injury and then return to baseline. Persistent elevation of catecholamine levels beyond this time suggests ongoing noxious afferent stimuli. The majority of the circulating epinephrine is produced by the adrenal medulla, while norepinephrine is derived from synapses of the sympathetic nervous system. Catecholamine effects on peripheral tissues include stimulation of hepatic glycogenolysis and gluconeogenesis to increase circulating glucose availability to peripheral tissues, an increase in skeletal muscle glycogenolysis, suppression of insulin release, and increased glucagon release.

Hormonal Response. The stress response includes activation of the ANS as discussed earlier in the Afferent Signals section, as well as activation of the hypothalamic-pituitary-adrenal axis. Shock stimulates the hypothalamus to release corticotropin-releasing hormone, which results in the release of adrenocorticotropic hormone (ACTH) by the pituitary. ACTH subsequently stimulates the adrenal cortex to release cortisol. Cortisol acts synergistically with epinephrine and glucagon to induce a catabolic state. Cortisol stimulates gluconeogenesis and insulin resistance, resulting in hyperglycemia as well as muscle cell protein breakdown and lipolysis to provide substrates for hepatic gluconeogenesis. Cortisol causes retention of sodium and water by the nephrons of the kidney. In the setting of severe hypovolemia, ACTH secretion occurs independently of cortisol negative feedback inhibition.

The renin-angiotensin system is activated in shock. Decreased renal artery perfusion, β -adrenergic stimulation, and increased renal tubular sodium concentration cause the release of renin from the juxtaglomerular cells. Renin catalyzes the conversion of angiotensinogen (produced by the liver) to angiotensin I, which is then converted to angiotensin II by angiotensin-converting enzyme (ACE) produced in the lung. While angiotensin I has no significant functional activity, angiotensin II is a potent vasoconstrictor of both splanchnic and peripheral vascular beds, and also stimulates the secretion of aldosterone, ACTH, and antidiuretic hormone (ADH). Aldosterone, a mineralocorticoid, acts on the nephron to promote reabsorption of sodium and, as a consequence, water. Potassium and hydrogen ions are lost in the urine in exchange for sodium.

The pituitary also releases vasopressin or ADH in response to hypovolemia, changes in circulating blood volume sensed by baroreceptors and left atrial stretch receptors, and increased plasma osmolality detected by hypothalamic osmoreceptors. Epinephrine, angiotensin II, pain, and hyperglycemia increase production of ADH. ADH levels remain elevated for about 1 week after the initial insult, depending on the severity and persistence of the hemodynamic abnormalities. ADH acts on the distal tubule and collecting duct of the nephron to increase water permeability, decrease water and sodium losses, and preserve intravascular volume. Also known as *arginine vasopressin*, ADH acts as a potent mesenteric vasoconstrictor, shunting circulating blood away from the splanchnic organs during hypovolemia.¹¹ This may contribute to intestinal ischemia and predispose to intestinal mucosal barrier dysfunction

Table 5-2

Hemodynamic responses to different types of shock

TYPE OF SHOCK	CARDIAC INDEX	SVR	VENOUS CAPACITANCE	CVP/PCWP	SVO ₂	CELLULAR/METABOLIC EFFECTS
Hypovolemic	↓	↑	↓	↓	↓	Effect
Septic	↑↑	↓	↑	↑↓	↑↓	Cause
Cardiogenic	↓↓	↑↑	→	↑	↓	Effect
Neurogenic	↑	↓	→	↓	↓	Effect

The hemodynamic responses are indicated by arrows to show an increase (↑), severe increase (↑↑), decrease (↓), severe decrease (↓↓), varied response (↑↓), or little effect (→). CVP = central venous pressure; PCWP = pulmonary capillary wedge pressure; Svo₂ = mixed venous oxygen saturation; SVR = systemic vascular resistance.

in shock states. Vasopressin also increases hepatic gluconeogenesis and increases hepatic glycolysis.

In septic states, endotoxin directly stimulates arginine vasopressin secretion independently of blood pressure, osmotic, or intravascular volume changes. Proinflammatory cytokines also contribute to arginine vasopressin release. Interestingly, patients on chronic therapy with ACE inhibitors are more at risk of developing hypotension and vasodilatory shock with open heart surgery. Low plasma levels of arginine vasopressin were confirmed in these patients.¹²

Circulatory Homeostasis

Preload. At rest, the majority of the blood volume is within the venous system. Venous return to the heart generates ventricular end-diastolic wall tension, a major determinant of cardiac output. Gravitational shifts in blood volume distribution are quickly corrected by alterations in venous capacity. With decreased arteriolar inflow, there is active contraction of the venous smooth muscle and passive elastic recoil in the thin-walled systemic veins. This increases venous return to the heart, thus maintaining ventricular filling.

Most alterations in cardiac output in the normal heart are related to changes in preload. Increases in sympathetic tone have a minor effect on skeletal muscle beds but produce a dramatic reduction in splanchnic blood volume, which normally holds 20% of the blood volume.

The normal circulating blood volume is maintained within narrow limits by the kidney's ability to manage salt and water balance with external losses via systemic and local hemodynamic changes and hormonal effects of renin, angiotensin, and ADH. These relatively slow responses maintain preload by altering circulating blood volume. Acute responses to intravascular volume include changes in venous tone, systemic vascular resistance, and intrathoracic pressure, with the slower hormonal changes less important in the early response to volume loss. Furthermore, the net effect of preload on cardiac output is influenced by cardiac determinants of ventricular function, which include coordinated atrial activity and tachycardia.

Ventricular Contraction. The Frank-Starling curve describes the force of ventricular contraction as a function of its preload. This relationship is based on force of contraction being determined by initial muscle length. Intrinsic cardiac disease will shift the Frank-Starling curve and alter mechanical performance of the heart. In addition, cardiac dysfunction has been demonstrated experimentally in burns and in hemorrhagic, traumatic, and septic shock.

Afterload. Afterload is the force that resists myocardial work during contraction. Arterial pressure is the major component of afterload influencing the ejection fraction. This vascular resistance is determined by precapillary smooth muscle sphincters. Blood viscosity also will increase vascular resistance. As afterload increases in the normal heart, stroke volume can be maintained by increases in preload. In shock, with decreased circulating volume and therefore diminished preload, this compensatory mechanism to sustain cardiac output is impeded. The stress response with acute release of catecholamines and sympathetic nerve activity in the heart increases contractility and heart rate.

Microcirculation. The microvascular circulation plays an integral role in regulating cellular perfusion and is significantly influenced in response to shock. The microvascular bed is

innervated by the sympathetic nervous system and has a profound effect on the larger arterioles. Following hemorrhage, larger arterioles vasoconstrict; however, in the setting of sepsis or neurogenic shock, these vessels vasodilate. Additionally, a host of other vasoactive proteins, including vasopressin, angiotensin II, and endothelin-1, also lead to vasoconstriction to limit organ perfusion to organs such as skin, skeletal muscle, kidneys, and the gastrointestinal (GI) tract to preserve perfusion of the myocardium and CNS.

Flow in the capillary bed is heterogeneous in shock states, which likely is secondary to multiple local mechanisms, including endothelial cell swelling, dysfunction, and activation marked by the recruitment of leukocytes and platelets.¹³ Together, these mechanisms lead to diminished capillary perfusion that may persist after resuscitation. In hemorrhagic shock, correction of hemodynamic parameters and restoration of O₂ delivery generally lead to restoration of tissue O₂ consumption and tissue O₂ levels. In contrast, regional tissue dysoxia often persists in sepsis, despite similar restoration of hemodynamics and O₂ delivery. Whether this defect in O₂ extraction in sepsis is the result of heterogeneous impairment of the microcirculation (intraparenchymal shunting) or impaired tissue parenchymal cell oxidative phosphorylation and O₂ consumption by the mitochondria is not resolved.¹⁴ Interesting data suggest that in sepsis the response to limit O₂ consumption by the tissue parenchymal cells is an adaptive response to the inflammatory signaling and decreased perfusion.¹⁵

An additional pathophysiologic response of the microcirculation to shock is failure of the integrity of the endothelium of the microcirculation and development of capillary leak, intracellular swelling, and the development of an extracellular fluid deficit. Seminal work by Shires helped to define this phenomenon.^{8,16} There is decreased capillary hydrostatic pressure secondary to changes in blood flow and increased cellular uptake of fluid. The result is a loss of extracellular fluid volume. The cause of intracellular swelling is multifactorial, but dysfunction of energy-dependent mechanisms, such as active transport by the sodium-potassium pump, contributes to loss of membrane integrity.

Capillary dysfunction also occurs secondary to activation of endothelial cells by circulating inflammatory mediators generated in septic or traumatic shock. This exacerbates endothelial cell swelling and capillary leak, as well as increases leukocyte adherence. This results in capillary occlusion, which may persist after resuscitation, and is termed *no-reflow*. Further ischemic injury ensues as well as release of inflammatory cytokines to compound tissue injury. Experimental models have shown that neutrophil depletion in animals subjected to hemorrhagic shock produces fewer capillaries with no-reflow and lower mortality.¹³

METABOLIC EFFECTS

Cellular metabolism is based primarily on the hydrolysis of adenosine triphosphate (ATP). The splitting of the phosphoanhydride bond of the terminal or γ -phosphate from ATP is the source of energy for most processes within the cell under normal conditions. The majority of ATP is generated in our bodies through aerobic metabolism in the process of oxidative phosphorylation in the mitochondria. This process is dependent on the availability of O₂ as a final electron acceptor in the electron transport chain. As O₂ tension within a cell decreases, there is a decrease in oxidative phosphorylation, and the generation

of ATP slows. When O_2 delivery is so severely impaired such that oxidative phosphorylation cannot be sustained, the state is termed *dysoxia*.¹⁷ When oxidative phosphorylation is insufficient, the cells shift to anaerobic metabolism and glycolysis to generate ATP. This occurs via the breakdown of cellular glycogen stores to pyruvate. Although glycolysis is a rapid process, it is not efficient, allowing for the production of only 2 mol of ATP from 1 mol of glucose. This is compared to complete oxidation of 1 mol of glucose that produces 38 mol of ATP. Additionally, under hypoxic conditions in anaerobic metabolism, pyruvate is converted into lactate, leading to an intracellular metabolic acidosis.

There are numerous consequences secondary to these metabolic changes. The depletion of ATP potentially influences all ATP-dependent cellular processes. This includes maintenance of cellular membrane potential, synthesis of enzymes and proteins, cell signaling, and DNA repair mechanisms. Decreased intracellular pH also influences vital cellular functions such as normal enzyme activity, cell membrane ion exchange, and cellular metabolic signaling.¹⁸ These changes also will lead to changes in gene expression within the cell. Furthermore, acidosis leads to changes in calcium metabolism and calcium signaling. Compounded, these changes may lead to irreversible cell injury and death.

Epinephrine and norepinephrine have a profound impact on cellular metabolism. Hepatic glycogenolysis, gluconeogenesis, ketogenesis, skeletal muscle protein breakdown, and adipose tissue lipolysis are increased by catecholamines. Cortisol, glucagon, and ADH also contribute to the catabolism during shock. Epinephrine induces further release of glucagon, while inhibiting the pancreatic β -cell release of insulin. The result is a catabolic state with glucose mobilization, hyperglycemia, protein breakdown, negative nitrogen balance, lipolysis, and insulin resistance during shock and injury. The relative underuse of glucose by peripheral tissues preserves it for the glucose-dependent organs such as the heart and brain.

Cellular Hypoperfusion

Hypoperfused cells and tissues experience what has been termed *oxygen debt*, a concept first proposed by Crowell in 1961.¹⁹ The O_2 debt is the deficit in tissue oxygenation over time that occurs during shock. When O_2 delivery is limited, O_2 consumption can be inadequate to match the metabolic needs of cellular respiration, creating a deficit in O_2 requirements at the cellular level. The measurement of O_2 deficit uses calculation of the difference between the estimated O_2 demand and the actual value obtained for O_2 consumption. Under normal circumstances, cells can “repay” the O_2 debt during reperfusion. The magnitude of the O_2 debt correlates with the severity and duration of hypoperfusion. Surrogate values for measuring O_2 debt include base deficit and lactate levels and are discussed later in the Hypovolemic/Hemorrhagic section.

In addition to induction of changes in cellular metabolic pathways, shock also induces changes in cellular gene expression. The DNA binding activity of a number of nuclear transcription factors is altered by hypoxia and the production of O_2 radicals or nitrogen radicals that are produced at the cellular level by shock. Expression of other gene products such as heat shock proteins, vascular endothelial growth factor, inducible nitric oxide synthase (iNOS), heme oxygenase-1, and cytokines also are clearly increased by shock.²⁰ Many of these shock-induced gene products, such as cytokines, have the ability to

subsequently alter gene expression in specific target cells and tissues. The involvement of multiple pathways emphasizes the complex, integrated, and overlapping nature of the response to shock.

IMMUNE AND INFLAMMATORY RESPONSES

The inflammatory and immune responses are a complex set of interactions between circulating soluble factors and cells that can arise in response to trauma, infection, ischemia, toxic, or autoimmune stimuli.²⁰ The processes are well regulated and can be conceptualized as an ongoing surveillance and response system that undergoes a coordinated escalation following injury to heal disrupted tissue or restore host-microbe equilibrium, as well as active suppression back to baseline levels. Failure to adequately control the activation, escalation, or suppression of the inflammatory response can lead to systemic inflammatory response syndrome and potentiate multiple organ failure.

Both the innate and adaptive branches of the immune system work in concert to rapidly respond in a specific and effective manner to challenges that threaten an organism’s well-being. Each arm of the immune system has its own set of functions, defined primarily by distinct classes of effector cells and their unique cell membrane receptor families. Alterations in the activity of the innate host immune system can be responsible for both the development of shock (i.e., septic shock following severe infection and traumatic shock following tissue injury with hemorrhage) and the pathophysiologic sequelae of shock such as the proinflammatory changes seen following hypoperfusion (see Fig. 5-1). When the predominantly paracrine mediators gain access to the systemic circulation, they can induce a variety of metabolic changes that are collectively referred to as the *host inflammatory response*. Understanding of the intricate, redundant, and interrelated pathways that comprise the inflammatory response to shock continues to expand. Despite limited understanding of how our current therapeutic interventions impact the host response to illness, inappropriate or excessive inflammation appears to be an essential event in the development of ARDS, multiple organ dysfunction syndrome (MODS), and posttraumatic immunosuppression that can prolong recovery.²¹

Following direct tissue injury or infection, there are several mechanisms that lead to the activation of the active inflammatory and immune responses. These include release of bioactive peptides by neurons in response to pain and the release of intracellular molecules by broken cells, such as heat shock proteins, mitochondrial products, heparan sulfate, high mobility group box 1, and RNA. Only recently has it been realized that the release of intracellular products from damaged and injured cells can have paracrine and endocrine-like effects on distant tissues to activate the inflammatory and immune responses.²² This hypothesis, which was first proposed by Matzinger, is known as *danger signaling*. Under this novel paradigm of immune function, endogenous molecules are capable of signaling the presence of danger to surrounding cells and tissues. These molecules that are released from cells are known as *damage-associated molecular patterns (DAMPs)* (Table 5-3). DAMPs are recognized by cell surface receptors to effect intracellular signaling that primes and amplifies the immune response. These receptors are known as *pattern recognition receptors (PRRs)* and include the Toll-like receptors (TLRs) and the receptor for advanced glycation end products.

Table 5-3

Endogenous damage-associated molecular pattern molecules

Mitochondrial DNA
Hyaluronan oligomers
Heparan sulfate
Extra domain A of fibronectin
Heat shock proteins 60, 70, Gp96
Surfactant Protein A
β -Defensin 2
Fibrinogen
Biglycan
High mobility group box 1
Uric acid
Interleukin-1 α
S-100s
Nucleolin

Interestingly, TLRs and PRRs were first recognized for their role in signaling as part of the immune response to the entry of microbes and their secreted products into a normally sterile environment. These bacterial products, including lipopolysaccharide, are known as *pathogen-associated molecular patterns*. The salutary consequences of PRR activation most likely relate to the initiation of the repair process and the mobilization of antimicrobial defenses at the site of tissue disruption. However, in the setting of excessive tissue damage, the inflammation itself may lead to further tissue damage, amplifying the response both at the local and systemic level.²⁰ PRR activation leads to intracellular signaling and release of cellular products including cytokines (Fig. 5-4).

Before the recruitment of leukocytes into sites of injury, tissue-based macrophages or mast cells act as sentinel responders, releasing histamines, eicosanoids, tryptases, and cytokines (Fig. 5-5). Together these signals amplify the immune response

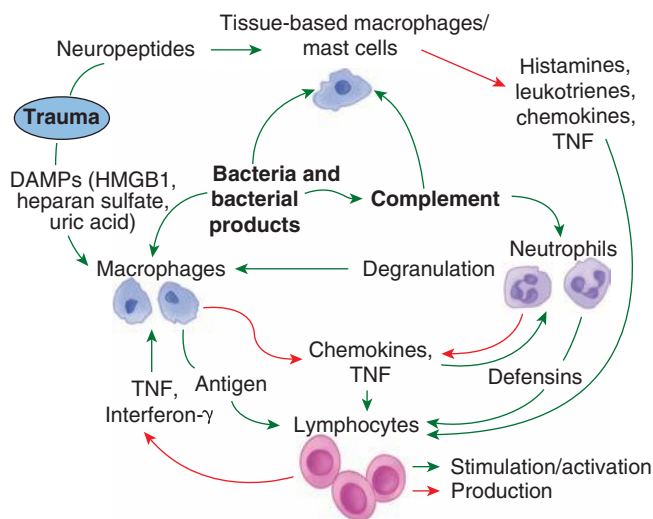


Figure 5-4. A schema of information flow between immune cells in early inflammation following tissue injury and infection. Cells require multiple inputs and stimuli before activation of a full response. DAMPs = damage-associated molecular patterns; HMGB1 = high mobility group box 1; TNF = tumor necrosis factor.

by further activation of neurons and mast cells, as well as increasing the expression of adhesion molecules on the endothelium. Furthermore, these mediators cause leukocytes to release platelet-activating factor, further increasing the stickiness of the endothelium. Additionally, the coagulation and kinin cascades impact the interaction of endothelium and leukocytes.

Cytokines/Chemokines

The immune response to shock encompasses the elaboration of mediators with both proinflammatory and anti-inflammatory properties (Table 5-4). Furthermore, new mediators, new relationships between mediators, and new functions of known mediators are continually being identified. As new pathways are uncovered, understanding of the immune response to injury and the potential for therapeutic intervention by manipulating the immune response following shock will expand. What seems clear at present, however, is that the innate immune response can help restore homeostasis, or if it is excessive, promote cellular and organ dysfunction.

Multiple mediators have been implicated in the host immune response to shock. It is likely that some of the most important mediators have yet to be discovered, and the roles of many known mediators have not been defined. A comprehensive description of all of the mediators and their complex interactions is beyond the scope of this chapter. For a general overview, a brief description of the more extensively studied mediators, and some of the known effects of these substances, see the discussion below. A more comprehensive review can be found in Chap. 2.

Tumor necrosis factor alpha (TNF- α) was one of the first cytokines to be described and is one of the earliest cytokines released in response to injurious stimuli. Monocytes, macrophages, and T cells release this potent proinflammatory cytokine. TNF- α levels peak within 90 minutes of stimulation and return frequently to baseline levels within 4 hours. Release of TNF- α may be induced by bacteria or endotoxin and leads to the development of shock and hypoperfusion, most commonly observed in septic shock. Production of TNF- α also may be induced following other insults, such as hemorrhage and ischemia. TNF- α levels correlate with mortality in animal models of hemorrhage.²³ In contrast, the increase in serum TNF- α levels reported in trauma patients is far less than that seen in septic patients.²⁴ Once released, TNF- α can produce peripheral vasodilation, activate the release of other cytokines, induce procoagulant activity, and stimulate a wide array of cellular metabolic changes. During the stress response, TNF- α contributes to the muscle protein breakdown and cachexia.

Interleukin-1 (IL-1) has actions similar to those of TNF- α . IL-1 has a very short half-life (6 min) and primarily acts in a paracrine fashion to modulate local cellular responses. Systemically, IL-1 produces a febrile response to injury by activating prostaglandins in the posterior hypothalamus, and causes anorexia by activating the satiety center. This cytokine also augments the secretion of ACTH, glucocorticoids, and β -endorphins. In conjunction with TNF- α , IL-1 can stimulate the release of other cytokines such as IL-2, IL-4, IL-6, IL-8, granulocyte-macrophage colony-stimulating factor, and interferon- γ .

IL-2 is produced by activated T cells in response to a variety of stimuli and activates other lymphocyte subpopulations and natural killer cells. The lack of clarity regarding the role of IL-2 in the response to shock is intimately associated

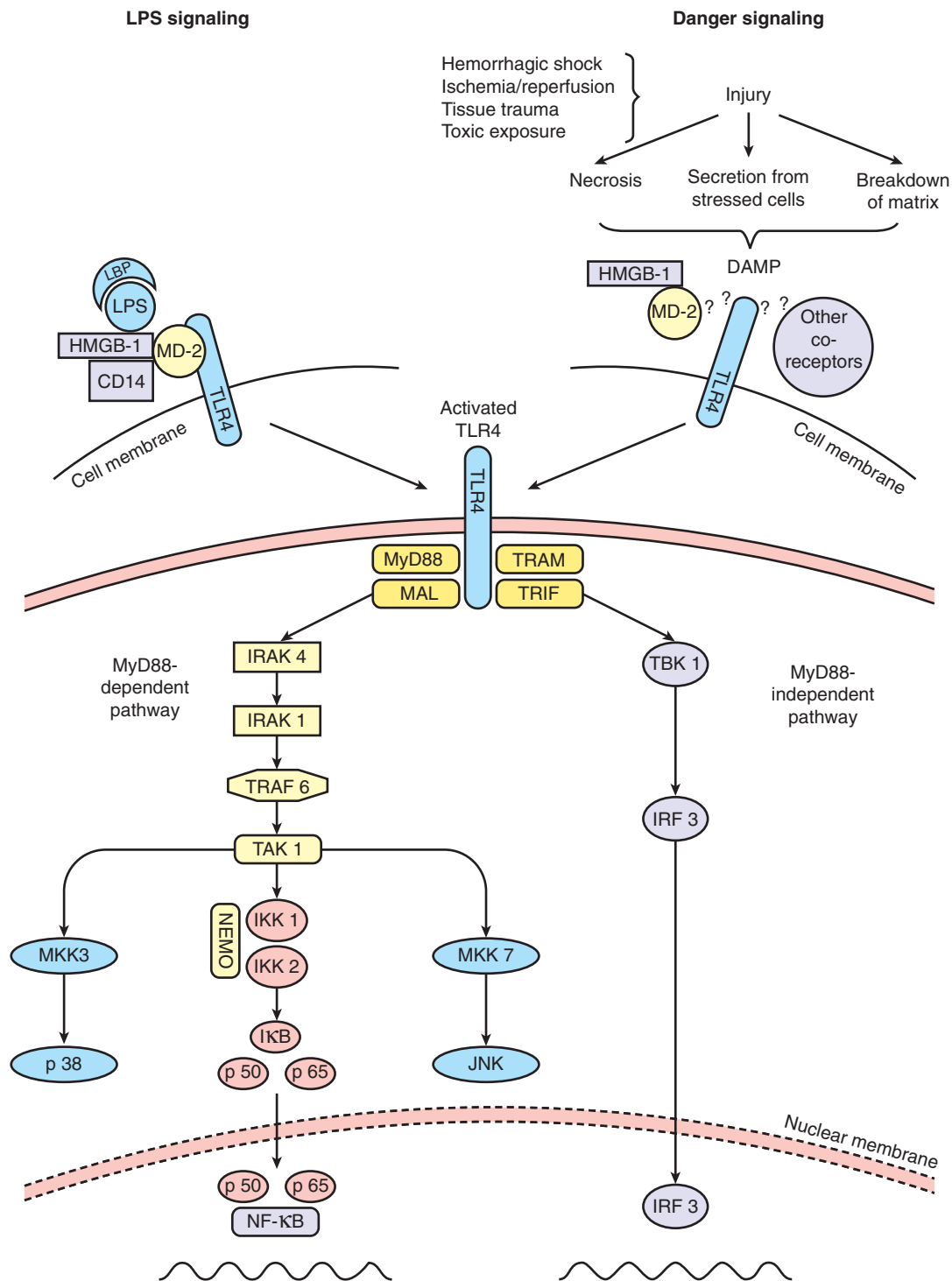


Figure 5-5. Signaling via the pattern recognition receptor TLR4. LPS signaling via TLR4 requires the cofactors LPS binding protein (LBP), MD-2, and CD14. Endogenous danger signals released from a variety of sources also signal in a TLR4-dependent fashion, although it is as yet unknown what cofactors may be required for this activity. Once TLR4 is activated, an intracellular signaling cascade is initiated that involves both a MyD88-dependent and independent pathway. DAMP = damage-associated molecular pattern; LPS = lipopolysaccharide; MD-2 = myeloid differentiation factor-2; MyD88 = myeloid differentiation primary response gene 88; NF-κB = nuclear factor-κB; TLR4 = Toll-like receptor-4. (Reproduced with permission from Mollen KP, Anand RJ, Tsung A, et al.⁸³ Emerging paradigm: toll-like receptor 4-sentinel for the detection of tissue damage. *Shock*. 2006;26:430–437.)

with that of understanding immune function after injury. Some investigators have postulated that increased IL-2 secretion promotes shock-induced tissue injury and the development of shock. Others have demonstrated that depressed IL-2 production is associated with, and perhaps contributes to, the depression in immune function after hemorrhage that may

increase the susceptibility of patients who develop shock to suffer infections.^{25,26} It has been postulated that overly exuberant proinflammatory activation promotes tissue injury, organ dysfunction, and the subsequent immune dysfunction/suppression that may be evident later.²¹ Emphasizing the importance of temporal changes in the production of mediators, both the

Table 5-4

Inflammatory mediators of shock

PROINFLAMMATORY	ANTI-INFLAMMATORY
Interleukin-1 α/β	Interleukin-4
Interleukin-2	Interleukin-10
Interleukin-6	Interleukin-13
Interleukin-8	Prostaglandin E ₂
Interferon	TGF β
TNF	
PAF	

PAF = platelet activating factor; TGF β = transforming growth factor beta; TNF = tumor necrosis factor.

initial excessive production of IL-2 and later depressed IL-2 production are probably important in the progression of shock.

IL-6 is elevated in response to hemorrhagic shock, major operative procedures, or trauma. Elevated IL-6 levels correlate with mortality in shock states. IL-6 contributes to lung, liver, and gut injury after hemorrhagic shock.²⁷ Thus, IL-6 may play a role in the development of diffuse alveolar damage and ARDS. IL-6 and IL-1 are mediators of the hepatic acute phase response to injury; enhance the expression and activity of complement, C-reactive protein, fibrinogen, haptoglobin, amyloid A, and α_1 -antitrypsin; and promote neutrophil activation.²⁸

IL-10 is considered an anti-inflammatory cytokine that may have immunosuppressive properties. Its production is increased after shock and trauma, and it has been associated with depressed immune function clinically, as well as an increased susceptibility to infection.²⁹ IL-10 is secreted by T cells, monocytes, and macrophages, and inhibits proinflammatory cytokine secretion, O₂ radical production by phagocytes, adhesion molecule expression, and lymphocyte activation.^{29,30} Administration of IL-10 depresses cytokine production and improves some aspects of immune function in experimental models of shock and sepsis.^{31,32}

Recent studies point to the importance of chemokines, a specific set of cytokines, that have the ability to induce chemotaxis of leukocytes. Chemokines bind to specific chemokine receptors and transduce chemotactic signals to leukocytes. The significance of this large family of chemoattractant cytokines in immunology is difficult to understate, as almost every facet of the immune system is influenced by chemokines, including immune system development, immune surveillance, immune priming, effector responses, and immune regulation.³³

Complement

The complement cascade can be activated by injury, shock, and severe infection, and contributes to host defense and proinflammatory activation. Significant complement consumption occurs after hemorrhagic shock.³⁴ In trauma patients, the degree of complement activation is proportional to the magnitude of injury and may serve as a marker for severity of injury. Patients in septic shock also demonstrate activation of the complement pathway, with elevations of the activated complement proteins C3a and C5a. Activation of the complement cascade can contribute to the development of organ dysfunction. Activated complement factors C3a, C4a, and

C5a are potent mediators of increased vascular permeability, smooth muscle cell contraction, histamine and arachidonic acid by-product release, and adherence of neutrophils to vascular endothelium. Activated complement acts synergistically with endotoxin to induce the release of TNF- α and IL-1. The development of ARDS and MODS in trauma patients correlates with the intensity of complement activation.³⁵ Complement and neutrophil activation may correlate with mortality in multiply injured patients.

Neutrophils

Neutrophil activation is an early event in the upregulation of the inflammatory response; neutrophils are the first cells to be recruited to the site of injury. Polymorphonuclear leukocytes (PMNs) remove infectious agents, foreign substances that have penetrated host barrier defenses, and nonviable tissue through phagocytosis. However, activated PMNs and their products may also produce cell injury and organ dysfunction. Activated PMNs generate and release a number of substances that may induce cell or tissue injury, such as reactive O₂ species, lipid-peroxidation products, proteolytic enzymes (elastase, cathepsin G), and vasoactive mediators (leukotrienes, eicosanoids, and platelet-activating factor). Oxygen free radicals, such as superoxide anion, hydrogen peroxide, and hydroxyl radical, are released and induce lipid peroxidation, inactivate enzymes, and consume antioxidants (such as glutathione and tocopherol). Ischemia-reperfusion activates PMNs and causes PMN-induced organ injury. In animal models of hemorrhagic shock, activation of PMNs correlates with irreversibility of shock and mortality, and neutrophil depletion prevents the pathophysiologic sequelae of hemorrhagic and septic shock. Human data corroborate the activation of neutrophils in trauma and shock and suggest a role in the development of MODS.³⁶ Plasma markers of PMN activation, such as elastase, correlate with severity of injury in humans.

Interactions between endothelial cells and leukocytes are important in the inflammatory process. The vascular endothelium contributes to regulation of blood flow, leukocyte adherence, and the coagulation cascade. Extracellular ligands such as intercellular adhesion molecules, vascular cell adhesion molecules, and the selectins (E-selectin, P-selectin) are expressed on the surface of endothelial cells and are responsible for leukocyte adhesion to the endothelium. This interaction allows activated neutrophils to migrate into the tissues to combat infection, but also can lead to PMN-mediated cytotoxicity and microvascular and tissue injury.

Cell Signaling

A host of cellular changes occur following shock. Although many of the intracellular and intercellular pathways that are important in shock are being elucidated, undoubtedly there are many more that have yet to be identified. Many of the mediators produced during shock interact with cell surface receptors on target cells to alter target cell metabolism. These signaling pathways may be altered by changes in cellular oxygenation, redox state, high-energy phosphate concentration, gene expression, or intracellular electrolyte concentration induced by shock. Cells communicate with their external environment through the use of cell surface membrane receptors, which, once bound by a ligand, transmit their information to the interior of the cell through a variety of signaling cascades. These signaling pathways may subsequently alter the activity of specific enzymes or the expression or breakdown of important proteins or affect

intracellular energy metabolism. Intracellular calcium (Ca^{2+}) homeostasis and regulation represent one such pathway. Intracellular Ca^{2+} concentrations regulate many aspects of cellular metabolism; many important enzyme systems require Ca^{2+} for full activity. Profound changes in intracellular Ca^{2+} levels and Ca^{2+} transport are seen in models of shock.³⁷ Alterations in Ca^{2+} regulation may lead to direct cell injury, changes in transcription factor activation, alterations in the expression of genes important in homeostasis, and the modulation of the activation of cells by other shock-induced hormones or mediators.^{38,39}

A proximal portion of the intracellular signaling cascade consists of a series of kinases that transmit and amplify the signal through the phosphorylation of target proteins. The O_2 radicals produced during shock and the intracellular redox state are known to influence the activity of components of this cascade, such as protein tyrosine kinases, mitogen activated kinases, and protein kinase C.⁴⁰⁻⁴² Either through changes in these signaling pathways, changes in the activation of enzyme systems through Ca^{2+} -mediated events, or direct conformational changes to oxygen-sensitive proteins, O_2 radicals also regulate the activity of a number of transcription factors that are important in gene expression, such as nuclear factor- κB , APETALA1, and hypoxia-inducible factor 1.^{43,44} It is therefore becoming increasingly clear that oxidant-mediated direct cell injury is merely one consequence of the production of O_2 radicals during shock.

The study of the effects of shock on the regulation of gene expression as an important biologic effect was stimulated by the work of Buchman and colleagues.⁴⁵ The effects of shock on the expression and regulation of numerous genes and gene products has been studied in both experimental animal models and human patients. These studies include investigations into single genes of interest as well as large-scale genomic and proteomic analysis.⁴⁶⁻⁴⁸ Changes in gene expression are critical for adaptive and survival cell signaling. Polymorphisms in gene promoters that lead to a differential level of expression of gene products are also likely to contribute significantly to varied responses to similar insults.^{49,50} In a recent study, the genetic responses to traumatic injury in humans or endotoxin delivery to healthy human volunteers demonstrated that severe stresses produce a global reprioritization affecting >80% of the cellular functions and pathways.⁵¹ The similarities in genomic responses between different injuries revealed a fundamental human response to stressors involving dysregulated immune responses (Fig. 5-6). Furthermore, in the traumatic injury patients, complications like nosocomial infections and organ failure were not associated with any genomic evidence of a second hit and differed only in the magnitude and duration of this genomic reprioritization.

FORMS OF SHOCK

Hypovolemic/Hemorrhagic

The most common cause of shock in the surgical or trauma patient is loss of circulating volume from hemorrhage. Acute blood loss results in reflexive decreased baroreceptor stimulation from stretch receptors in the large arteries, resulting in decreased inhibition of vasoconstrictor centers in the brain stem, increased chemoreceptor stimulation of vasomotor centers, and diminished output from atrial stretch receptors. These changes increase vasoconstriction and peripheral arterial resistance. Hypovolemia also induces sympathetic stimulation, leading to epinephrine and norepinephrine release, activation of the renin-angiotensin cascade, and increased vasopressin release. Peripheral vasoconstriction

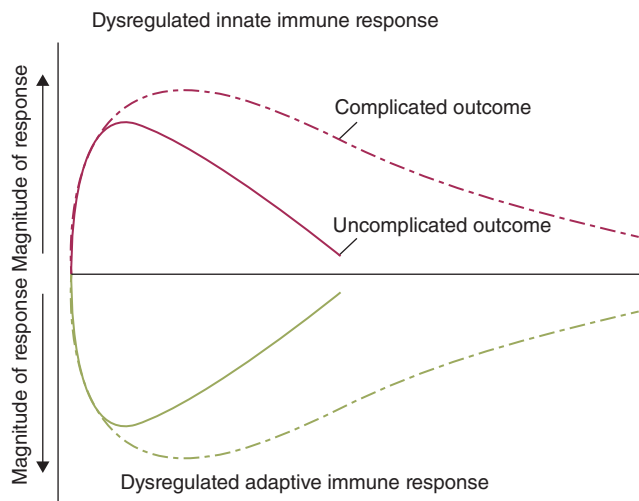


Figure 5-6. The concurrent dysregulated innate immune responses that promote inflammation and dysregulated adaptive immune responses that result in immunosuppression occur in patients following traumatic injury. However, these genetic responses can result in complicated outcomes in trauma patients if the magnitude or duration of these responses is pronounced. (Reproduced with permission from Xiao W, Mindrinos MN, Seok J, et al. A genomic storm in critically injured humans. *J Exp Med*. 2011;208:2581–2590. © 2011 Xiao et al. doi: 10.1084/jem.20111354.)

is prominent, while lack of sympathetic effects on cerebral and coronary vessels and local autoregulation promote maintenance of cardiac and CNS blood flow.

Diagnosis. Treatment of shock is initially empiric. A secure airway must be confirmed or established and volume infusion initiated while the search for the cause of the hypotension is pursued. Shock in a trauma patient or postoperative patient should be presumed to be due to hemorrhage until proven otherwise. The clinical signs of shock may be evidenced by agitation, cool clammy extremities, tachycardia, weak or absent peripheral pulses, and hypotension. Such apparent clinical shock results from at least 25% to 30% loss of the blood volume. However, substantial volumes of blood may be lost before the classic clinical manifestations of shock are evident. Thus, when a patient is significantly tachycardic or hypotensive, this represents both significant blood loss and physiologic decompensation. The clinical and physiologic response to hemorrhage has been classified according to the magnitude of volume loss. Loss of up to 15% of the circulating volume (700–750 mL for a 70-kg patient) may produce little in terms of obvious symptoms, while loss of up to 30% of the circulating volume (1.5 L) may result in mild tachycardia, tachypnea, and anxiety. Hypotension, marked tachycardia (i.e., pulse greater than 110–120 beats per minute [bpm]), and confusion may not be evident until more than 30% of the blood volume has been lost; loss of 40% of circulating volume (2 L) is immediately life threatening and generally requires operative control of bleeding (Table 5-5). Young healthy patients with vigorous compensatory mechanisms may tolerate larger volumes of blood loss while manifesting fewer clinical signs despite the presence of significant peripheral hypoperfusion. These patients may maintain a near-normal blood pressure until a precipitous cardiovascular collapse occurs. Elderly patients may be taking medications that either promote bleeding (e.g., warfarin or aspirin) or mask the compensatory responses

Table 5-5

Classification of hemorrhage

PARAMETER	CLASS			
	I	II	III	IV
Blood loss (mL)	<750	750–1500	1500–2000	>2000
Blood loss (%)	<15	15–30	30–40	>40
Heart rate (bpm)	<100	>100	>120	>140
Blood pressure	Normal	Orthostatic	Hypotension	Severe hypotension
CNS symptoms	Normal	Anxious	Confused	Obtunded

bpm = beats per minute; CNS = central nervous system.

to bleeding (e.g., β -blockers). In addition, atherosclerotic vascular disease, diminishing cardiac compliance with age, inability to elevate heart rate or cardiac contractility in response to hemorrhage, and overall decline in physiologic reserve decrease the elderly patient's ability to tolerate hemorrhage. Recent data in trauma patients suggest that a systolic blood pressure (SBP) of less than 110 mmHg is a clinically relevant definition of hypotension and hypoperfusion based on an increasing rate of mortality below this pressure (Fig. 5-7).⁵²

In addressing the sensitivity of vital signs and identifying major thoracoabdominal hemorrhage, a study retrospectively identified patients with injury to the trunk and an abbreviated injury score of 3 or greater who required immediate surgical intervention and transfusion of at least 5 units of blood within the first 24 hours. Ninety-five percent of patients had a heart rate greater than 80 bpm at some point during their postinjury course. However, only 59% of patients achieved a heart rate greater than 120 bpm. Ninety-nine percent of all patients had a recorded blood pressure of less than 120 mmHg at some point. Ninety-three percent of all patients had a recorded SBP of less than 100 mmHg.⁵³ A more recent study corroborated that tachycardia was not a reliable sign of hemorrhage following trauma and was present in only 65% of hypotensive patients.⁵⁴

Serum lactate and base deficit are measurements that are helpful to both estimate and monitor the extent of bleeding and shock. The amount of lactate that is produced by anaerobic respiration is an indirect marker of tissue hypoperfusion, cellular O₂ debt, and the severity of hemorrhagic shock. Several studies have demonstrated that the initial serum lactate and serial lactate levels are reliable predictors of morbidity and mortality

with hemorrhage following trauma (Fig. 5-8).⁵⁵ Similarly, base deficit values derived from arterial blood gas analysis provide clinicians with an indirect estimation of tissue acidosis from hypoperfusion. Davis and colleagues stratified the extent of base deficit into mild (–3 to –5 mmol/L), moderate (–6 to –9 mmol/L), and severe (less than –10 mmol/L), and from this established a correlation between base deficit upon admission and transfusion requirements, the development of multiple organ failure, and death (Fig. 5-9).⁵⁶ Both base deficit and lactate correlate with the extent of shock and patient outcome, but interestingly do not firmly correlate with each other.^{57–59} Evaluation of both values may be useful in trauma patients with hemorrhage.

Although hematocrit changes may not rapidly reflect the total volume of blood loss, admission hematocrit has been shown to be associated with 24-hour fluid and transfusion requirements and more strongly associated with packed red blood cell transfusion than tachycardia, hypotension, or acidosis.⁶⁰ It must be noted that lack of a depression in the initial hematocrit does not rule out substantial blood loss or ongoing bleeding.

In management of trauma patients, understanding the patterns of injury of the patient in shock will help direct the evaluation and management. Identifying the sources of blood loss in patients with penetrating wounds is relatively simple because potential bleeding sources will be located along the known or suspected path of the wounding object. Patients with penetrating injuries who are in shock usually require operative intervention. Patients who suffer multisystem injuries from blunt trauma have multiple sources of potential hemorrhage. Blood loss sufficient to cause shock is generally of a large volume, and there are a limited number of sites that can harbor sufficient extravascular

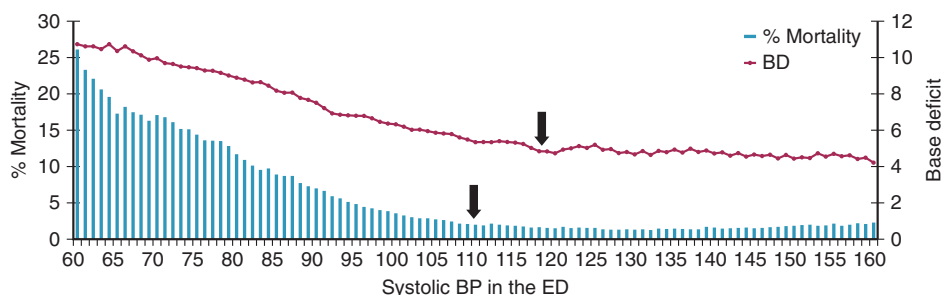


Figure 5-7. The relationship between systolic blood pressure and mortality in trauma patients with hemorrhage. These data suggest that a systolic blood pressure of less than 110 mmHg is a clinically relevant definition of hypotension and hypoperfusion based on an increasing rate of mortality below this pressure. Base deficit (BD) is also shown on this graph. ED = emergency department. (Reproduced with permission from Eastridge BJ, Salinas J, McManus JG, et al.⁵² Hypotension begins at 110 mmHg: redefining “hypotension” with data. *J Trauma*. 2007;63:291–297.)

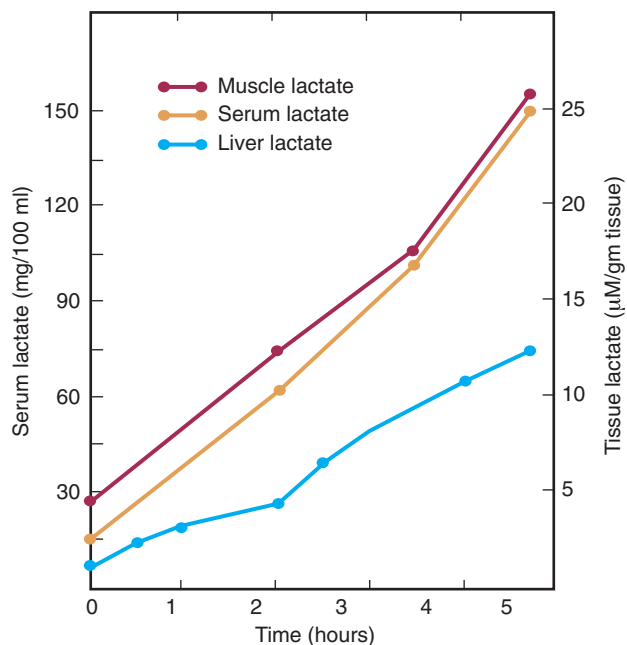


Figure 5-8. Progressive increases in serum lactate, muscle lactate, and liver lactate in a baboon model of hemorrhagic shock. (From Peitzman et al,⁷ with permission. Reprinted with permission from the Journal of the American College of Surgeons, formerly Surgery Gynecology & Obstetrics)

blood volume to induce hypotension (e.g., external, intrathoracic, intra-abdominal, retroperitoneal, and long bone fractures). In the nontrauma patient, the GI tract must always be considered as a site for blood loss. Substantial blood loss externally may be suspected from prehospital medical reports documenting a substantial blood loss at the scene of an accident, history of massive blood loss from wounds, visible brisk bleeding, or presence of a large hematoma adjacent to an open wound. Injuries to major arteries or veins with associated open wounds may cause massive blood loss rapidly. Direct pressure must be applied and

sustained to minimize ongoing blood loss. Persistent bleeding from uncontrolled smaller vessels can, over time, precipitate shock if inadequately treated.

When major blood loss is not immediately visible in the setting of trauma, internal (intracavitary) blood loss should be suspected. Each pleural cavity can hold 2 to 3 L of blood and can therefore be a site of significant blood loss. Diagnostic and therapeutic tube thoracostomy may be indicated in unstable patients based on clinical findings and clinical suspicion. In a more stable patient, a chest radiograph may be obtained to look for evidence of hemothorax. Major retroperitoneal hemorrhage typically occurs in association with pelvic fractures, which is confirmed by pelvic radiography in the resuscitation bay. Intraperitoneal hemorrhage is probably the most common source of blood loss inducing shock. The physical exam for detection of substantial blood loss or injury is insensitive and unreliable; large volumes of intraperitoneal blood may be present before physical examination findings are apparent. Findings with intra-abdominal hemorrhage include abdominal distension, abdominal tenderness, or visible abdominal wounds. Hemodynamic abnormalities generally stimulate a search for blood loss before the appearance of obvious abdominal findings. Adjunctive tests are essential in the diagnosis of intraperitoneal bleeding; intraperitoneal blood may be rapidly identified by diagnostic ultrasound or diagnostic peritoneal lavage. Furthermore, patients who have sustained high-energy blunt trauma who are hemodynamically stable or who have normalized their vital signs in response to initial volume resuscitation should undergo computed tomography scans to assess for head, chest, and/or abdominal bleeding.

Treatment. Control of ongoing hemorrhage is an essential component of the resuscitation of the patient in shock. As mentioned in the earlier Diagnosis section, treatment of hemorrhagic shock is instituted concurrently with diagnostic evaluation to identify a source. Patients who fail to respond to initial resuscitative efforts should be assumed to have ongoing active hemorrhage from large vessels and require prompt

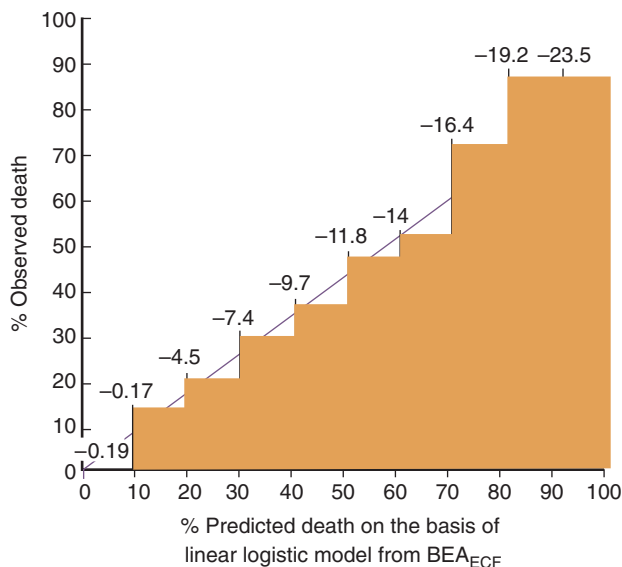
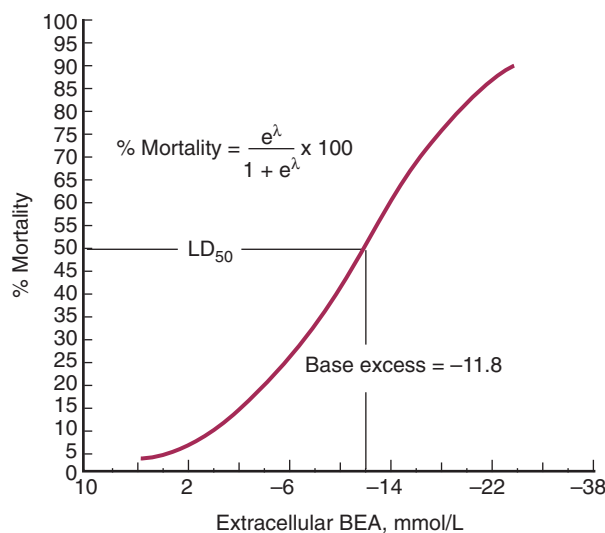


Figure 5-9. The relationship between base deficit (negative base excess) and mortality in trauma patients. BEA = base excess arterial; ECF = extracellular fluid. (Reproduced with permission from Siegel JH, Rivkind AI, Dalal S, et al. Early physiologic predictors of injury severity and death in blunt multiple trauma. Arch Surg. 1990;125:498. Copyright © 1990 American Medical Association. All rights reserved.)

operative intervention. Based on trauma literature, patients with ongoing hemorrhage demonstrate increased survival if the elapsed time between the injury and control of bleeding is decreased. Although there are no randomized controlled trials, retrospective studies provide compelling evidence in this regard. To this end, Clarke and colleagues⁶¹ demonstrated that trauma patients with major injuries isolated to the abdomen requiring emergency laparotomy had an increased probability of death with increasing length of time in the emergency department for patients who were in the emergency department for 90 minutes or less. This probability increased approximately 1% for each 3 minutes in the emergency department.

The appropriate priorities in these patients are (a) secure the airway, (b) control the source of blood loss, and (c) intravenous (IV) volume resuscitation. In trauma, identifying the body cavity harboring active hemorrhage will help focus operative efforts; however, because time is of the essence, rapid treatment is essential and diagnostic laparotomy or thoracotomy may be indicated. The actively bleeding patient cannot be resuscitated until control of ongoing hemorrhage is achieved. Our current understanding has led to the management strategy known as *damage control resuscitation*.⁶² This strategy begins in the emergency department and continues into the operating room and into the intensive care unit (ICU). Initial resuscitation is limited to keep SBP around 80 to 90 mmHg. This prevents renewed bleeding from recently clotted vessels. Resuscitation and intravascular volume resuscitation are accomplished with

4▶ blood products and limited crystalloids, which is addressed further later in this section. Too little volume allowing persistent severe hypotension and hypoperfusion is dangerous, yet too vigorous of a volume resuscitation may be just as deleterious. Control of hemorrhage is achieved in the operating room, and efforts to warm patients and to prevent coagulopathy using multiple blood products and pharmacologic agents are used in both the operating room and ICU.

Cannon and colleagues first made the observation that attempts to increase blood pressure in soldiers with uncontrolled sources of hemorrhage is counterproductive, with increased bleeding and higher mortality.³ This work was the foundation for the “hypotensive resuscitation” strategies. Several laboratory studies confirmed the observation that attempts to restore normal blood pressure with fluid infusion or vasopressors were rarely successful and resulted in more bleeding and higher mortality.⁶³ A prospective, randomized clinical study compared delayed fluid resuscitation (upon arrival in the operating room) with standard fluid resuscitation (with arrival by the paramedics) in hypotensive patients with penetrating torso injury.⁶⁴ The authors reported that delayed fluid resuscitation resulted in lower patient mortality. Further laboratory studies demonstrated that fluid restriction in the setting of profound hypotension resulted in early deaths from severe hypoperfusion. These studies also showed that aggressive crystalloid resuscitation attempting to normalize blood pressure resulted in marked hemodilution, with hematocrits of 5%.⁶³ Reasonable conclusions in the setting of uncontrolled hemorrhage include: Any delay in surgery for control of hemorrhage increases mortality; with uncontrolled hemorrhage attempting to achieve normal blood pressure may increase mortality, particularly with penetrating injuries and short transport times; a goal of SBP of 80 to 90 mmHg may be adequate in the patient with penetrating injury; and profound hemodilution should be avoided by early transfusion of red blood cells. For the patient with blunt injury, where the major

cause of death is a closed head injury, the increase in mortality with hypotension in the setting of brain injury must be avoided. In this setting, an SBP of 110 mmHg would seem to be more appropriate.

Patients who respond to initial resuscitative effort but then deteriorate hemodynamically frequently have injuries that require operative intervention. The magnitude and duration of their response will dictate whether diagnostic maneuvers can be performed to identify the site of bleeding. However, hemodynamic deterioration generally denotes ongoing bleeding for which some form of intervention (i.e., operation or interventional radiology) is required. Patients who have lost significant intravascular volume, but whose hemorrhage is controlled or has abated, often will respond to resuscitative efforts if the depth and duration of shock have been limited.

A subset of patients exists who fail to respond to resuscitative efforts despite adequate control of ongoing hemorrhage. These patients have ongoing fluid requirements despite adequate control of hemorrhage, have persistent hypotension despite restoration of intravascular volume necessitating vaso-
5▶ pressor support, and may exhibit a futile cycle of uncorrectable hypoperfusion, acidosis, and coagulopathy that cannot be interrupted despite maximum therapy. These patients have deteriorated to decompensated or irreversible shock with peripheral vasodilation and resistance to vasopressor infusion. Mortality is inevitable once the patient manifests shock in its terminal stages. Unfortunately, this is often diagnosed in retrospect.

Fluid resuscitation is a major adjunct to physically controlling hemorrhage in patients with shock. The ideal type of fluid to be used continues to be debated; however, crystalloids continue to be the mainstay of fluid choice. Several studies have demonstrated increased risk of death in bleeding trauma patients treated with colloid compared to patients treated with crystalloid.⁶⁵ In patients with severe hemorrhage, restoration of intravascular volume should be achieved with blood products.⁶⁶

Ongoing studies continue to evaluate the use of hypertonic saline as a resuscitative adjunct in bleeding patients.⁶⁷ The benefit of hypertonic saline solutions may be immunomodulatory. Specifically, these effects have been attributed to pharmacologic effects resulting in decreased reperfusion-mediated injury with decreased O₂ radical formation, less impairment of immune function compared to standard crystalloid solution, and less brain swelling in the multi-injured patient. The reduction of total volume used for resuscitation makes this approach appealing as a resuscitation agent for combat injuries and may contribute to a decrease in the incidence of ARDS and multiple organ failure.

Transfusion of packed red blood cells and other blood products is essential in the treatment of patients in hemorrhagic shock. Current recommendations in stable ICU patients aim for a target hemoglobin of 7 to 9 g/dL^{68,69}; however, no prospective randomized trials have compared restrictive and liberal transfusion regimens in trauma patients with hemorrhagic shock. The current standard in severely injured patients is termed damage control resuscitation and consists of transfusion with red blood cells, fresh frozen plasma (FFP), and platelet units given in equal number.⁷⁰ Civilian and military trauma data show that the development of coagulopathy of trauma is predictive of mortality.⁷¹ Data collected from a U.S. Army combat support hospital helped to propagate this practice, showing in patients who received massive transfusion of packed red blood cells (>10 units in 24 hours) that a high plasma-to-RBC ratio (1:1.4 units) was independently

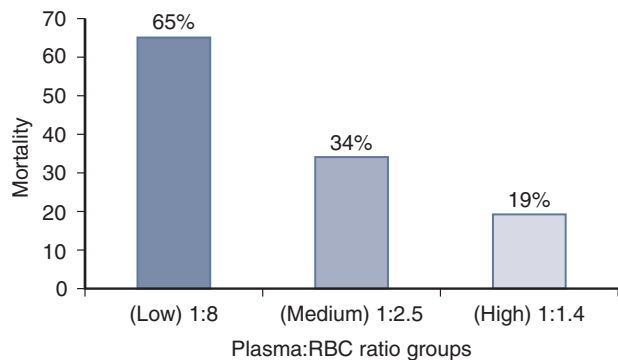


Figure 5-10. Increasing ratio of transfusion of fresh frozen plasma to red blood cells improves outcome of trauma patients receiving massive transfusions. RBC = red blood cell. (Reproduced with permission from Borgman MA, Spinella PC, Perkins JG, et al.⁷² *The ratio of blood products transfused affects mortality in patients receiving massive transfusions at a combat support hospital.* J Trauma. 2007;63:805-813.)

associated with improved survival (Fig. 5-10).⁷² A number of civilian studies have demonstrated similar results.⁷³ Similarly, platelet transfusion is important. Studies have demonstrated that low platelet counts in trauma patients were associated with increased mortality⁷⁴ and that increased platelet use appears to improve outcome.^{75,76} The benefit of platelet transfusion may be most pronounced in trauma patients with brain injury.⁷⁷ Platelets should be transfused in the bleeding patient to maintain counts above $50 \times 10^9/L$.

There is a potential role for other coagulation factor-based products, such as fibrinogen concentrates and prothrombin complex concentrates. Use of these agents may be guided by a drop in fibrinogen levels to less than 1 g/L or, less specifically, by thromboelastogram findings to suggest hyperfibrinolysis. Data also support the use of antifibrinolytic agents in bleeding trauma patients, specifically tranexamic acid (a synthetic lysine analogue that acts as a competitive inhibitor of plasmin and plasminogen). The multinational Clinical Randomization of an Antifibrinolytic in Significant Haemorrhage 2 (CRASH-2) trial suggested that early use of tranexamic acid limits rebleeding and reduces mortality⁷⁸ (Fig. 5-11). In the past, coagulopathy associated with the bleeding patient was presumed to be due solely to dilution and depletion of clotting factors and platelets. We now understand that an acute coagulopathy of trauma occurs as an immediate consequence of injury, with abnormal admission coagulation as a predictor of high mortality.⁷⁹ Traditional measurement of platelets, international normalized ratio, and partial thromboplastin time may not reflect the coagulopathy of trauma or response to therapy effectively. Recently, thromboelastography (TEG) has been used as a quicker, more comprehensive determination of coagulopathy and fibrinolysis in the injured patient. Holcomb and colleagues recently reported that TEG predicted patients with substantial bleeding and red cell transfusion better than conventional coagulopathy tests, need for platelet transfusion better than platelet count, and need for plasma transfusion better than fibrinogen levels.⁸⁰

Additional resuscitative adjuncts in patients with hemorrhagic shock include minimization of heat loss and maintaining normothermia. The development of hypothermia in the bleeding patient is associated with acidosis, hypotension, and coagulopathy.

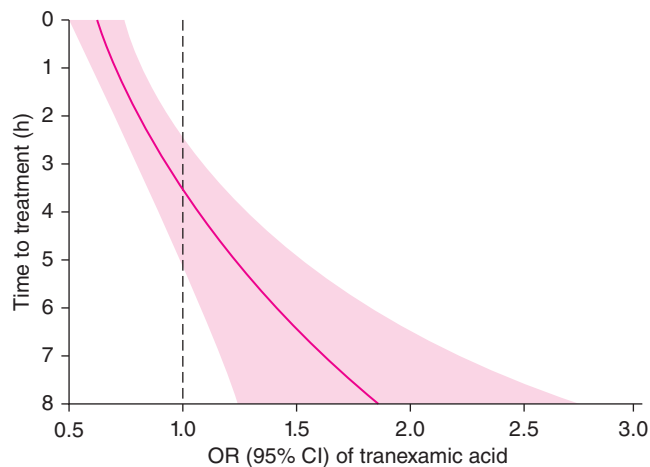


Figure 5-11. Early treatment (within 3 hours) of trauma patients with tranexamic acid reduces mortality. However, later treatment exacerbated outcome. OR = odds ratio. (Reprinted from Roberts I, Shakur H, Afolabi A, et al.⁷⁸ *The importance of early treatment with tranexamic acid in bleeding trauma patients: an exploratory analysis of the CRASH-2 randomised controlled trial.* The Lancet. 2011;377:1096-1101. Copyright ©2011 with permission from Elsevier.)

Hypothermia in bleeding trauma patients is an independent risk factor for bleeding and death. This likely is secondary to impaired platelet function and impairments in the coagulation cascade. Several studies have investigated the induction of controlled hypothermia in patients with severe shock based on the hypothesis of limiting metabolic activity and energy requirements, creating a state of “suspended animation.” These studies are promising and continue to be evaluated in large trials.

Traumatic Shock

The systemic response after trauma, combining the effects of soft tissue injury, long bone fractures, and blood loss, is clearly a different physiologic insult than simple hemorrhagic shock. Multiple organ failure, including ARDS, develops relatively often in the blunt trauma patient, but rarely after pure hemorrhagic shock (such as a GI bleed). The hypoperfusion deficit in traumatic shock is magnified by the proinflammatory activation that occurs following the induction of shock. In addition to ischemia or ischemia-reperfusion, accumulating evidence demonstrates that even simple hemorrhage induces proinflammatory activation that results in many of the cellular changes typically ascribed only to septic shock.^{81,82} At the cellular level, this may be attributable to the release of cellular products termed *damage-associated molecular patterns* (DAMPs; i.e., ribonucleic acid, uric acid, and high mobility group box 1) that activate the same set of cell surface receptors as bacterial products, initiating similar cell signaling.^{5,83} These receptors are termed *pattern recognition receptors* (PRRs) and include the TLR family of proteins. Examples of traumatic shock include small-volume hemorrhage accompanied by soft tissue injury (femur fracture, crush injury) or any combination of hypovolemic, neurogenic, cardiogenic, and obstructive shock that precipitates rapidly progressive proinflammatory activation. In laboratory models of traumatic shock, the addition of a soft tissue or long bone injury to hemorrhage produces lethality with significantly less blood loss when the animals are stressed by hemorrhage. Treatment of

traumatic shock is focused on correction of the individual elements to diminish the cascade of proinflammatory activation and includes prompt control of hemorrhage, adequate volume resuscitation to correct O₂ debt, débridement of nonviable tissue, stabilization of bony injuries, and appropriate treatment of soft tissue injuries.

6▶ Septic Shock (Vasodilatory Shock)

In the peripheral circulation, profound vasoconstriction is the typical physiologic response to the decreased arterial pressure and tissue perfusion with hemorrhage, hypovolemia, or acute heart failure. This is not the characteristic response in vasodilatory shock. Vasodilatory shock is the result of dysfunction of the endothelium and vasculature secondary to circulating inflammatory mediators and cells or as a response to prolonged and severe hypoperfusion. Thus, in vasodilatory shock, hypotension results from failure of the vascular smooth muscle to constrict appropriately. Vasodilatory shock is characterized by peripheral vasodilation with resultant hypotension and resistance to treatment with vasopressors. Despite the hypotension, plasma catecholamine levels are elevated, and the renin-angiotensin system is activated in vasodilatory shock. The most frequently encountered form of vasodilatory shock is septic shock. Other causes of vasodilatory shock include hypoxic lactic acidosis, carbon monoxide poisoning, decompensated and irreversible hemorrhagic shock, terminal cardiogenic shock, and postcardiotomy shock (Table 5-6). Thus, vasodilatory shock seems to represent the final common pathway for profound and prolonged shock of any etiology.⁸⁴

Despite advances in intensive care, the mortality rate for severe sepsis remains at 30% to 50%. In the United States, 750,000 cases of sepsis occur annually, one third of which are fatal.⁸⁵ Sepsis accounts for 9.3% of deaths in the United States, as many yearly as MI. Septic shock is a by-product of the body's response to disruption of the host-microbe equilibrium, resulting in invasive or severe localized infection.

In the attempt to eradicate the pathogens, the immune and other cell types (e.g., endothelial cells) elaborate soluble mediators that enhance macrophage and neutrophil killing effector mechanisms, increase procoagulant activity and fibroblast activity to localize the invaders, and increase microvascular blood flow to enhance delivery of killing forces to the area of invasion. When this response is overly exuberant or becomes systemic rather than localized, manifestations of sepsis may be evident.

Table 5-6

Causes of septic and vasodilatory shock

Systemic response to infection
Noninfectious systemic inflammation
Pancreatitis
Burns
Anaphylaxis
Acute adrenal insufficiency
Prolonged, severe hypotension
Hemorrhagic shock
Cardiogenic shock
Cardiopulmonary bypass
Metabolic
Hypoxic lactic acidosis
Carbon monoxide poisoning

These findings include enhanced cardiac output, peripheral vasodilation, fever, leukocytosis, hyperglycemia, and tachycardia. In septic shock, the vasodilatory effects are due, in part, to the upregulation of the inducible isoform of nitric oxide synthase (iNOS or NOS 2) in the vessel wall. iNOS produces large quantities of nitric oxide for sustained periods of time. This potent vasodilator suppresses vascular tone and renders the vasculature resistant to the effects of vasoconstricting agents.

Diagnosis. Attempts to standardize terminology have led to the establishment of criteria for the diagnosis of sepsis in the hospitalized adult. These criteria include manifestations of the host response to infection in addition to identification of an offending organism. The terms sepsis, severe sepsis, and septic shock are used to quantify the magnitude of the systemic inflammatory reaction. Patients with sepsis have evidence of an infection, as well as systemic signs of inflammation (e.g., fever, leukocytosis, and tachycardia). Hypoperfusion with signs of organ dysfunction is termed severe sepsis. Septic shock requires the presence of the above, associated with more significant evidence of tissue hypoperfusion and systemic hypotension. Beyond the hypotension, maldistribution of blood flow and shunting in the microcirculation further compromise delivery of nutrients to the tissue beds.^{86,87}

Recognizing septic shock begins with defining the patient at risk. The clinical manifestations of septic shock will usually become evident and prompt the initiation of treatment before bacteriologic confirmation of an organism or the source of an organism is identified. In addition to fever, tachycardia, and tachypnea, signs of hypoperfusion such as confusion, malaise, oliguria, or hypotension may be present. These should prompt an aggressive search for infection, including a thorough physical examination, inspection of all wounds, evaluation of intravascular catheters or other foreign bodies, obtaining appropriate cultures, and adjunctive imaging studies, as needed.

Treatment. Evaluation of the patient in septic shock begins with an assessment of the adequacy of their airway and ventilation. Severely obtunded patients and patients whose work of breathing is excessive require intubation and ventilation to prevent respiratory collapse. Because vasodilation and decrease in total peripheral resistance may produce hypotension, fluid resuscitation and restoration of circulatory volume with balanced salt solutions is essential. This resuscitation should be at least 30 mL/kg within the first 4 to 6 hours. Incremental fluid boluses should be continued based on the endpoint of resuscitation, including clearance of lactate. Starch-based colloid solutions should be avoided, as recent evidence suggests that these fluids may be deleterious in the setting of sepsis.^{86,88,89} Empiric antibiotics must be chosen carefully based on the most likely pathogens (gram-negative rods, gram-positive cocci, and anaerobes) because the portal of entry of the offending organism and its identity may not be evident until culture data return or imaging studies are completed. Knowledge of the bacteriologic profile of infections in an individual unit can be obtained from most hospital infection control departments and will suggest potential responsible organisms. Antibiotics should be tailored to cover the responsible organisms once culture data are available, and if appropriate, the spectrum of coverage narrowed. Long-term, empiric, broad-spectrum antibiotic use should be minimized to reduce the development of resistant organisms and to avoid the potential complications of fungal overgrowth and antibiotic-associated colitis from overgrowth of *Clostridium difficile*.

IV antibiotics will be insufficient to adequately treat the infectious episode in the settings of infected fluid collections, infected foreign bodies, and devitalized tissue. These situations require source control and involve percutaneous drainage and operative management to target a focus of infection. These situations may require multiple operations to ensure proper wound hygiene and healing.

After first-line therapy of the septic patient with antibiotics, IV fluids, and intubation if necessary, vasopressors may be necessary to treat patients with septic shock. Catecholamines are the vasopressors used most often, with norepinephrine being the first-line agent followed by epinephrine. Occasionally, patients with septic shock will develop arterial resistance to catecholamines. Arginine vasopressin, a potent vasoconstrictor, is often efficacious in this setting and is often added to norepinephrine.

The majority of septic patients have hyperdynamic physiology with supranormal cardiac output and low systemic vascular resistance. On occasion, septic patients may have low cardiac output despite volume resuscitation and even vasopressor support. Dobutamine therapy is recommended for patients with cardiac dysfunction as evidenced by high filling pressures and low cardiac output or clinical signs of hypoperfusion after achievement of restoration of blood pressure following fluid resuscitation. Mortality in this group is high. Despite the increasing incidence of septic shock over the past several decades, the overall mortality rates have changed little. Studies of interventions, including immunotherapy, resuscitation to pulmonary artery endpoints with hemodynamic optimization (cardiac output and O_2 delivery, even to supranormal values), and optimization of mixed venous O_2 measurements up to 72 hours after admission to the ICU, have not changed mortality.

Over the past decade, multiple advances have been made in the treatment of patients with sepsis and septic shock and collaborative groups such as the Surviving Sepsis Campaign continue to evaluate, modify, and put forth recommendations based on data (Fig. 5-12).⁸⁶ Negative results from previous studies have led to the suggestion that earlier interventions directed at improving global tissue oxygenation may be of benefit. To this end, Rivers and colleagues reported that goal-directed therapy of septic shock and severe sepsis initiated in the emergency department and continued for 6 hours significantly improved outcome.⁹⁰ This approach involved adjustment of cardiac preload, afterload, and contractility to balance O_2 delivery with O_2

demand. They found that goal-directed therapy during the first 6 hours of hospital stay (initiated in the emergency department) had significant effects, such as higher mean venous O_2 saturation, lower lactate levels, lower base deficit, higher pH, and decreased 28-day mortality (49.2% vs. 33.3%) compared to the standard therapy group. The frequency of sudden cardiovascular collapse was also significantly less in the group managed with goal-directed therapy (21.0% vs. 10.3%). Interestingly, the goal-directed therapy group received more IV fluids during the initial 6 hours, but the standard therapy group required more IV fluids by 72 hours. The authors emphasize that continued cellular and tissue decompensation is subclinical and often irreversible when obvious clinically. Goal-directed therapy allowed identification and treatment of these patients with insidious illness (global tissue hypoxia in the setting of normal vital signs).

Hyperglycemia and insulin resistance are typical in critically ill and septic patients, including patients without underlying diabetes mellitus. A recent study reported significant positive impact of tight glucose management on outcome in critically ill patients.⁹¹ The two treatment groups in this randomized, prospective study were assigned to receive intensive insulin therapy (maintenance of blood glucose between 80 and 110 mg/dL) or conventional treatment (infusion of insulin only if the blood glucose level exceeded 215 mg/dL, with a goal between 180 and 200 mg/dL). The mean morning glucose level was significantly higher in the conventional treatment as compared to the intensive insulin therapy group (153 vs. 103 mg/dL). Mortality in the intensive insulin treatment group (4.6%) was significantly lower than in the conventional treatment group (8.0%), representing a 42% reduction in mortality. This reduction in mortality was most notable in the patients requiring longer than 5 days in the ICU. Furthermore, intensive insulin therapy reduced episodes of septicemia by 46%, reduced duration of antibiotic therapy, and decreased the need for prolonged ventilatory support and renal replacement therapy.

Another treatment protocol that has been demonstrated to increase survival in patients with ARDS investigated the use of lower ventilatory tidal volumes compared to traditional tidal volumes.⁹² The majority of the patients enrolled in this multicenter, randomized trial developed ARDS secondary to pneumonia or sepsis. The trial compared traditional ventilation treatment, which involved an initial tidal volume of 12 mL/kg of predicted body weight, with ventilation with a lower tidal

Surviving Sepsis Campaign Bundles

To be Completed Within 3 Hours:

- 1) Measure lactate level
- 2) Obtain blood cultures prior to administration of antibiotics
- 3) Administer broad spectrum antibiotics
- 4) Administer 30 mL/kg crystalloid for hypotension or lactate \geq 4 mmol/L

To be Completed Within 6 Hours:

- 5) Apply vasopressors (for hypotension that does not respond to initial fluid resuscitation) to maintain a mean arterial pressure (MAP) \geq 65 mm Hg
- 6) In the event of persistent arterial hypotension despite volume resuscitation (septic shock) or initial lactate \geq 4 mmol/L (36 mg/dL):
 - Measure central venous pressure (CVP)*
 - Measure central venous oxygen saturation (Scvo₂)*
- 7) Remeasure lactate if initial lactate was elevated*

*Targets for quantitative resuscitation included in the guidelines are CVP of \geq 8 mm Hg, Scvo₂ of \geq 70%, and normalization of lactate.

Figure 5-12. Updated bundles of care from the Surviving Sepsis Campaign 2012. (From Dellinger RP, Levy MM, Rhodes A, et al. Surviving Sepsis Campaign: international guidelines for management of severe sepsis and septic shock, 2012. Intensive Care Med. 2013;39:165-228, Figure 1. With kind permission from Springer Science + Business Media.)

volume, which involved an initial tidal volume of 6 mL/kg of predicted body weight. The trial was stopped after the enrollment of 861 patients because mortality was lower in the group treated with lower tidal volumes than in the group treated with traditional tidal volumes (31.0% vs. 39.8%, $P = .007$), and the number of days without ventilator use during the first 28 days after randomization was greater in this group (mean \pm SD, 12 ± 11 vs. 10 ± 11 days; $P = .007$). The investigators concluded that in patients with acute lung injury and ARDS, mechanical ventilation with a lower tidal volume than is traditionally used results in decreased mortality and increases the number of days without ventilator use. Additional strategies in ARDS management include higher levels of positive end expiratory pressure (PEEP), alveolar recruitment maneuvers, and prone positioning.

The use of corticosteroids in the treatment of sepsis and septic shock has been controversial for decades. The observation that severe sepsis often is associated with adrenal insufficiency or glucocorticoid receptor resistance has generated renewed interest in therapy for septic shock with corticosteroids. A single IV dose of 50 mg of hydrocortisone improved mean arterial blood pressure response relationships to norepinephrine and phenylephrine in patients with septic shock and was most notable in patients with relative adrenal insufficiency. A more recent study evaluated therapy with hydrocortisone (50 mg IV every 6 hours) and fludrocortisone (50 μ g orally once daily) versus placebo for 1 week in patients with septic shock.⁹³ As in earlier studies, the authors performed corticotropin tests on these patients to document and stratify patients by relative adrenal insufficiency. In this study, 7-day treatment with low doses of hydrocortisone and fludrocortisone significantly and safely lowered the risk of death in patients with septic shock and relative adrenal insufficiency. In an international, multicenter, randomized trial of corticosteroids in sepsis (CORTICUS study; 499 analyzable patients), steroids showed no benefit in intent-to-treat mortality or shock reversal.⁹⁴ This study suggested that hydrocortisone therapy cannot be recommended as routine adjuvant therapy for septic shock. However, if SBP remains less than 90 mmHg despite appropriate fluid and vasopressor therapy, hydrocortisone at 200 mg/d for 7 days in four divided doses or by continuous infusion should be considered.

Additional adjunctive immune modulation strategies have been developed for the treatment of septic shock. These include the use of antiendotoxin antibodies, anticytokine antibodies, cytokine receptor antagonists, immune enhancers, a non-isoform-specific nitric oxide synthase inhibitor, and O₂ radical scavengers. These compounds are each designed to alter some aspect of the host immune response to shock that is hypothesized to play a key role in its pathophysiology. However, most of these strategies have failed to demonstrate efficacy in human patients despite utility in well-controlled animal experiments. It is unclear whether the failure of these compounds is due to poorly designed clinical trials, inadequate understanding of the interactions of the complex host immune response to injury and infection, or animal models of shock that poorly represent the human disease.

Cardiogenic Shock

Cardiogenic shock is defined clinically as circulatory pump failure leading to diminished forward flow and subsequent tissue hypoxia, in the setting of adequate intravascular volume. Hemodynamic criteria include sustained hypotension (i.e., SBP <90 mmHg for at least 30 minutes), reduced cardiac index

(<2.2 L/min per square meter), and elevated pulmonary artery wedge pressure (>15 mmHg).⁹⁵ Mortality rates for cardiogenic shock are 50% to 80%. Acute, extensive MI is the most common cause of cardiogenic shock; a smaller infarction in a patient with existing left ventricular dysfunction also may precipitate shock. Cardiogenic shock complicates 5% to 10% of acute MIs. Conversely, cardiogenic shock is the most common cause of death in patients hospitalized with acute MI. Although shock may develop early after MI, it typically is not found on admission. Seventy-five percent of patients who have cardiogenic shock complicating acute MIs develop signs of cardiogenic shock within 24 hours after onset of infarction (average 7 hours).

Recognition of the patient with occult hypoperfusion is critical to prevent progression to obvious cardiogenic shock with its high mortality rate; early initiation of therapy to maintain blood pressure and cardiac output is vital. Rapid assessment, adequate resuscitation, and reversal of the myocardial ischemia are essential in optimizing outcome in patients with acute MI. Prevention of infarct extension is a critical component. Large segments of nonfunctional but viable myocardium contribute to the development of cardiogenic shock after MI. In the setting of acute MI, expeditious restoration of cardiac output is mandatory to minimize mortality; the extent of myocardial salvage possible decreases exponentially with increased time to restoration of coronary blood flow. The degree of coronary flow after percutaneous transluminal coronary angioplasty correlates with in-hospital mortality (i.e., 33% mortality with complete reperfusion, 50% mortality with incomplete reperfusion, and 85% mortality with absent reperfusion).⁹⁶ Inadequate cardiac function can be a direct result of cardiac injury, including profound myocardial contusion, blunt cardiac valvular injury, or direct myocardial damage (Table 5-7).⁹⁵⁻⁹⁸ The pathophysiology of cardiogenic shock involves a vicious cycle of myocardial ischemia that causes myocardial dysfunction, which results in more myocardial ischemia. When sufficient mass of the left ventricular wall is necrotic or ischemic and fails to pump, the stroke

Table 5-7

Causes of cardiogenic shock

Acute myocardial infarction
Pump failure
Mechanical complications
Acute mitral regurgitation
Acute ventricular septal defect
Free wall rupture
Pericardial tamponade
Arrhythmia
End-stage cardiomyopathy
Myocarditis
Severe myocardial contusion
Left ventricular outflow obstruction
Aortic stenosis
Hypertrophic obstructive cardiomyopathy
Obstruction to left ventricular filling
Mitral stenosis
Left atrial myxoma
Acute mitral regurgitation
Acute aortic insufficiency
Metabolic
Drug reactions

volume decreases. An autopsy series of patients dying from cardiogenic shock has found damage to 40% of the left ventricle.⁹⁹ Ischemia distant from the infarct zone may contribute to the systolic dysfunction in patients with cardiogenic shock. The majority of these patients have multivessel disease, with limited vasodilator reserve and pressure-dependent coronary flow in multiple areas of the heart. Myocardial diastolic function is impaired in cardiogenic shock as well. Decreased compliance results from myocardial ischemia, and compensatory increases in left ventricular filling pressures progressively occur.

Diminished cardiac output or contractility in the face of adequate intravascular volume (preload) may lead to underperfused vascular beds and reflexive sympathetic discharge. Increased sympathetic stimulation of the heart, either through direct neural input or from circulating catecholamines, increases heart rate, myocardial contraction, and myocardial O₂ consumption, which may not be relieved by increases in coronary artery blood flow in patients with fixed stenoses of the coronary arteries. Diminished cardiac output may also decrease coronary artery blood flow, resulting in a scenario of increased myocardial O₂ demand at a time when myocardial O₂ supply may be limited. Acute heart failure may also result in fluid accumulation in the pulmonary microcirculatory bed, decreasing myocardial O₂ delivery even further.

Diagnosis. Rapid identification of the patient with pump failure and institution of corrective action are essential in preventing the ongoing spiral of decreased cardiac output from injury causing increased myocardial O₂ needs that cannot be met, leading to progressive and unremitting cardiac dysfunction. In evaluation of possible cardiogenic shock, other causes of hypotension must be excluded, including hemorrhage, sepsis, pulmonary embolism, and aortic dissection. Signs of circulatory shock include hypotension, cool and mottled skin, depressed mental status, tachycardia, and diminished pulses. Cardiac exam may include dysrhythmia, precordial heave, or distal heart tones. Confirmation of a cardiac source for the shock requires electrocardiogram and urgent echocardiography. Other useful diagnostic tests include chest radiograph, arterial blood gases, electrolytes, complete blood count, and cardiac enzymes. Invasive cardiac monitoring, which generally is not necessary, can be useful to exclude right ventricular infarction, hypovolemia, and possible mechanical complications.

Making the diagnosis of cardiogenic shock involves the identification of cardiac dysfunction or acute heart failure in a susceptible patient. In the setting of blunt traumatic injury, hemorrhagic shock from intra-abdominal bleeding, intrathoracic bleeding, and bleeding from fractures must be excluded, before implicating cardiogenic shock from blunt cardiac injury. Relatively few patients with blunt cardiac injury will develop cardiac pump dysfunction. Those who do generally exhibit cardiogenic shock early in their evaluation. Therefore, establishing the diagnosis of blunt cardiac injury is secondary to excluding other etiologies for shock and establishing that cardiac dysfunction is present. Invasive hemodynamic monitoring with a pulmonary artery catheter may uncover evidence of diminished cardiac output and elevated pulmonary artery pressure.

Treatment. After ensuring that an adequate airway is present and ventilation is sufficient, attention should be focused on support of the circulation. Intubation and mechanical ventilation often are required, if only to decrease work of breathing and facilitate sedation of the patient. Rapidly excluding hypovolemia

and establishing the presence of cardiac dysfunction are essential. Treatment of cardiac dysfunction includes maintenance of adequate oxygenation to ensure adequate myocardial O₂ delivery and judicious fluid administration to avoid fluid overload and development of cardiogenic pulmonary edema. Electrolyte abnormalities, commonly hypokalemia and hypomagnesemia, should be corrected. Pain is treated with IV morphine sulfate or fentanyl. Significant dysrhythmias and heart block must be treated with antiarrhythmic drugs, pacing, or cardioversion, if necessary. Early consultation with cardiology is essential in current management of cardiogenic shock, particularly in the setting of acute MI.⁹⁵

When profound cardiac dysfunction exists, inotropic support may be indicated to improve cardiac contractility and cardiac output. Dobutamine primarily stimulates cardiac β_1 receptors to increase cardiac output but may also vasodilate peripheral vascular beds, lower total peripheral resistance, and lower systemic blood pressure through effects on β_2 receptors. Ensuring adequate preload and intravascular volume is therefore essential prior to instituting therapy with dobutamine. Dopamine stimulates receptors (vasoconstriction), β_1 receptors (cardiac stimulation), and β_2 receptors (vasodilation), with its effects on β receptors predominating at lower doses. Dopamine may be preferable to dobutamine in treatment of cardiac dysfunction in hypotensive patients. Tachycardia and increased peripheral resistance from dopamine infusion may worsen myocardial ischemia. Titration of both dopamine and dobutamine infusions may be required in some patients.

Epinephrine stimulates α and β receptors and may increase cardiac contractility and heart rate; however, it also may have intense peripheral vasoconstrictor effects that impair further cardiac performance. Catecholamine infusions must be carefully controlled to maximize coronary perfusion, while minimizing myocardial O₂ demand. Balancing the beneficial effects of impaired cardiac performance with the potential side effects of excessive reflex tachycardia and peripheral vasoconstriction requires serial assessment of tissue perfusion using indices such as capillary refill, character of peripheral pulses, adequacy of urine output, or improvement in laboratory parameters of resuscitation such as pH, base deficit, and lactate. Invasive monitoring generally is necessary in these unstable patients. The phosphodiesterase inhibitors amrinone and milrinone may be required on occasion in patients with resistant cardiogenic shock. These agents have long half-lives and induce thrombocytopenia and hypotension, and use is reserved for patients unresponsive to other treatment.

Patients whose cardiac dysfunction is refractory to cardiotonics may require mechanical circulatory support with an intra-aortic balloon pump.¹⁰⁰ Intra-aortic balloon pumping increases cardiac output and improves coronary blood flow by reduction of systolic afterload and augmentation of diastolic perfusion pressure. Unlike vasopressor agents, these beneficial effects occur without an increase in myocardial O₂ demand. An intra-aortic balloon pump can be inserted at the bedside in the ICU via the femoral artery through either a cutdown or using the percutaneous approach. Aggressive circulatory support of patients with cardiac dysfunction from intrinsic cardiac disease has led to more widespread application of these devices and more familiarity with their operation by both physicians and critical care nurses.

Preservation of existing myocardium and preservation of cardiac function are priorities of therapy for patients who have suffered an acute MI. Ensuring adequate oxygenation and O₂

delivery, maintaining adequate preload with judicious volume restoration, minimizing sympathetic discharge through adequate relief of pain, and correcting electrolyte imbalances are all straightforward nonspecific maneuvers that may improve existing cardiac function or prevent future cardiac complications. Anticoagulation and aspirin are given for acute MI. Although thrombolytic therapy reduces mortality in patients with acute MI, its role in cardiogenic shock is less clear. Patients in cardiac failure from an acute MI may benefit from pharmacologic or mechanical circulatory support in a manner similar to that of patients with cardiac failure related to blunt cardiac injury. Additional pharmacologic tools may include the use of β -blockers to control heart rate and myocardial O_2 consumption, nitrates to promote coronary blood flow through vasodilation, and ACE inhibitors to reduce ACE-mediated vasoconstrictive effects that increase myocardial workload and myocardial O_2 consumption.

Current guidelines of the American Heart Association recommend percutaneous transluminal coronary angiography for patients with cardiogenic shock, ST elevation, left bundle-branch block, and age less than 75 years.^{101,102} Early definition of coronary anatomy and revascularization is the pivotal step in treatment of patients with cardiogenic shock from acute MI.¹⁰³ When feasible, percutaneous transluminal coronary angioplasty (generally with stent placement) is the treatment of choice. Coronary artery bypass grafting seems to be more appropriate for patients with multiple vessel disease or left main coronary artery disease.

Obstructive Shock

Although obstructive shock can be caused by a number of different etiologies that result in mechanical obstruction of venous return (Table 5-8), in trauma patients, this is most commonly due to the presence of tension pneumothorax. Cardiac tamponade occurs when sufficient fluid has accumulated in the pericardial sac to obstruct blood flow to the ventricles. The hemodynamic abnormalities in pericardial tamponade are due to elevation of intracardiac pressures with limitation of ventricular filling in diastole with resultant decrease in cardiac output. Acutely, the pericardium does not distend; thus small volumes of blood may produce cardiac tamponade. If the effusion accumulates slowly (e.g., in the setting of uremia, heart failure, or malignant effusion), the quantity of fluid producing cardiac tamponade may reach 2000 mL. The major determinant of the degree of hypotension is the pericardial pressure. With either cardiac tamponade or tension pneumothorax, reduced filling

of the right side of the heart from either increased intrapleural pressure secondary to air accumulation (tension pneumothorax) or increased intrapericardial pressure precluding atrial filling secondary to blood accumulation (cardiac tamponade) results in decreased cardiac output associated with increased central venous pressure.

Diagnosis and Treatment. The diagnosis of tension pneumothorax should be made on clinical examination. The classic findings include respiratory distress (in an awake patient), hypotension, diminished breath sounds over one hemithorax, hyperresonance to percussion, jugular venous distention, and shift of mediastinal structures to the unaffected side with tracheal deviation. In most instances, empiric treatment with pleural decompression is indicated rather than delaying to wait for radiographic confirmation. When a chest tube cannot be immediately inserted, such as in the prehospital setting, the pleural space can be decompressed with a large-caliber needle. Immediate return of air should be encountered with rapid resolution of hypotension. Unfortunately, not all of the clinical manifestations of tension pneumothorax may be evident on physical examination. Hyperresonance may be difficult to appreciate in a noisy resuscitation area. Jugular venous distention may be absent in a hypovolemic patient. Tracheal deviation is a late finding and often is not apparent on clinical examination. Practically, three findings are sufficient to make the diagnosis of tension pneumothorax: respiratory distress or hypotension, decreased lung sounds, and hypertympany to percussion. Chest x-ray findings that may be visualized include deviation of mediastinal structures, depression of the hemidiaphragm, and hypo-opacification with absent lung markings. As discussed earlier, definitive treatment of a tension pneumothorax is immediate tube thoracostomy. The chest tube should be inserted rapidly, but carefully, and should be large enough to evacuate any blood that may be present in the pleural space. Most recommend placement in the fourth intercostal space (nipple level) at the anterior axillary line.

Cardiac tamponade results from the accumulation of blood within the pericardial sac, usually from penetrating trauma or chronic medical conditions such as heart failure or uremia. Although precordial wounds are most likely to injure the heart and produce tamponade, any projectile or wounding agent that passes in proximity to the mediastinum can potentially produce tamponade. Blunt cardiac rupture, a rare event in trauma victims who survive long enough to reach the hospital, can produce refractory shock and tamponade in the multiply-injured patient. The manifestations of cardiac tamponade, such as total circulatory collapse and cardiac arrest, may be catastrophic, or they may be more subtle. A high index of suspicion is warranted to make a rapid diagnosis. Patients who present with circulatory arrest from cardiac tamponade require emergency pericardial decompression, usually through a left thoracotomy. The indications for this maneuver are discussed in Chap. 7. Cardiac tamponade also may be associated with dyspnea, orthopnea, cough, peripheral edema, chest pain, tachycardia, muffled heart tones, jugular venous distention, and elevated central venous pressure. Beck's triad consists of hypotension, muffled heart tones, and neck vein distention. Unfortunately, absence of these clinical findings may not be sufficient to exclude cardiac injury and cardiac tamponade. Muffled heart tones may be difficult to appreciate in a busy trauma center, and jugular venous distention and central venous pressure may be diminished by coexistent bleeding. Therefore, patients at risk for cardiac tamponade

Table 5-8

Causes of obstructive shock

Pericardial tamponade
Pulmonary embolus
Tension pneumothorax
IVC obstruction
Deep venous thrombosis
Gravid uterus on IVC
Neoplasm
Increased intrathoracic pressure
Excess positive end-expiratory pressure
Neoplasm

IVC = inferior vena cava.

whose hemodynamic status permits additional diagnostic tests frequently require additional diagnostic maneuvers to confirm cardiac injury or tamponade.

Invasive hemodynamic monitoring may support the diagnosis of cardiac tamponade if elevated central venous pressure, pulsus paradoxus (i.e., decreased systemic arterial pressure with inspiration), or elevated right atrial and right ventricular pressure by pulmonary artery catheter is present. These hemodynamic profiles suffer from lack of specificity, the duration of time required to obtain them in critically injured patients, and their inability to exclude cardiac injury in the absence of tamponade. Chest radiographs may provide information on the possible trajectory of a projectile, but rarely are diagnostic because the acutely filled pericardium distends poorly. Echocardiography has become the preferred test for the diagnosis of cardiac tamponade. Good results in detecting pericardial fluid have been reported, but the yield in detecting pericardial fluid depends on the skill and experience of the ultrasonographer, body habitus of the patient, and absence of wounds that preclude visualization of the pericardium. Standard two-dimensional and transesophageal echocardiography are sensitive techniques to evaluate the pericardium for fluid and are typically performed by examiners skilled at evaluating ventricular function, valvular abnormalities, and integrity of the proximal thoracic aorta. Unfortunately, these skilled examiners are rarely immediately available at all hours of the night, when many trauma patients present; therefore, waiting for this test may result in inordinate delays. In addition, although both ultrasound techniques may demonstrate the presence of fluid or characteristic findings of tamponade (large volume of fluid, right atrial collapse, poor distensibility of the right ventricle), they do not exclude cardiac injury *per se*. Pericardiocentesis to diagnose pericardial blood and potentially relieve tamponade may be used. Performing pericardiocentesis under ultrasound guidance has made the procedure safer and more reliable. An indwelling catheter may be placed for several days in patients with chronic pericardial effusions. Needle pericardiocentesis may not evacuate clotted blood and has the potential to produce cardiac injury, making it a poor alternative in busy trauma centers.

Diagnostic pericardial window represents the most direct method to determine the presence of blood within the pericardium. The procedure is best performed in the operating room under general anesthesia. It can be performed through either the subxiphoid or transdiaphragmatic approach. Adequate equipment and personnel to rapidly decompress the pericardium, explore the injury, and repair the heart should be present. Once the pericardium is opened and tamponade relieved, hemodynamics usually improve dramatically and formal pericardial exploration can ensue. Exposure of the heart can be achieved by extending the incision to a median sternotomy, performing a left anterior thoracotomy, or performing bilateral anterior thoracotomies (“clamshell”).

Neurogenic Shock

Neurogenic shock refers to diminished tissue perfusion as a result of loss of vasomotor tone to peripheral arterial beds. Loss of vasoconstrictor impulses results in increased vascular capacitance, decreased venous return, and decreased cardiac output. Neurogenic shock is usually secondary to spinal cord injuries from vertebral body fractures of the cervical or high thoracic region that disrupt sympathetic regulation of peripheral vascular tone (Table 5-9). Rarely, a spinal cord injury without

Table 5-9

Causes of neurogenic shock

Spinal cord trauma
Spinal cord neoplasm
Spinal/epidural anesthetic

bony fracture, such as an epidural hematoma impinging on the spinal cord, can produce neurogenic shock. Sympathetic input to the heart, which normally increases heart rate and cardiac contractility, and input to the adrenal medulla, which increases catecholamine release, may also be disrupted, preventing the typical reflex tachycardia that occurs with hypovolemia. Acute spinal cord injury results in activation of multiple secondary injury mechanisms: (a) vascular compromise to the spinal cord with loss of autoregulation, vasospasm, and thrombosis; (b) loss of cellular membrane integrity and impaired energy metabolism; and (c) neurotransmitter accumulation and release of free radicals. Importantly, hypotension contributes to the worsening of acute spinal cord injury as the result of further reduction in blood flow to the spinal cord. Management of acute spinal cord injury with attention to blood pressure control, oxygenation, and hemodynamics, essentially optimizing perfusion of an already ischemic spinal cord, seems to result in improved neurologic outcome. Patients with hypotension from spinal cord injury are best monitored in an ICU and carefully followed for evidence of cardiac or respiratory dysfunction.

Diagnosis. Acute spinal cord injury may result in bradycardia, hypotension, cardiac dysrhythmias, reduced cardiac output, and decreased peripheral vascular resistance. The severity of the spinal cord injury seems to correlate with the magnitude of cardiovascular dysfunction. Patients with complete motor injuries are over five times more likely to require vasopressors for neurogenic shock compared to those with incomplete lesions.¹⁰⁴ The classic description of neurogenic shock consists of decreased blood pressure associated with bradycardia (absence of reflexive tachycardia due to disrupted sympathetic discharge), warm extremities (loss of peripheral vasoconstriction), motor and sensory deficits indicative of a spinal cord injury, and radiographic evidence of a vertebral column fracture. Patients with multisystem trauma that includes spinal cord injuries often have head injuries that may make identification of motor and sensory deficits difficult in the initial evaluation. Furthermore, associated injuries may occur that result in hypovolemia, further complicating the clinical presentation. In a subset of patients with spinal cord injuries from penetrating wounds, most of the patients with hypotension had blood loss as the etiology (74%) rather than neurogenic causes, and few (7%) had the classic findings of neurogenic shock.¹⁰⁵ In the multiply injured patient, other causes of hypotension, including hemorrhage, tension pneumothorax, and cardiogenic shock, must be sought and excluded.

Treatment. After the airway is secured and ventilation is adequate, fluid resuscitation and restoration of intravascular volume often will improve perfusion in neurogenic shock. Most patients with neurogenic shock will respond to restoration of intravascular volume alone, with satisfactory improvement in perfusion and resolution of hypotension. Administration of vasoconstrictors will improve peripheral vascular tone, decrease vascular capacitance, and increase venous return, but should only be considered once hypovolemia is excluded as the cause of the

hypotension and the diagnosis of neurogenic shock established. If the patient's blood pressure has not responded to what is felt to be adequate volume resuscitation, dopamine may be used first. A pure α agonist, such as phenylephrine, may be used primarily or in patients unresponsive to dopamine. Specific treatment for the hypotension is often of brief duration, as the need to administer vasoconstrictors typically lasts 24 to 48 hours. On the other hand, life-threatening cardiac dysrhythmias and hypotension may occur up to 14 days after spinal cord injury.

The duration of the need for vasopressor support for neurogenic shock may correlate with the overall prognosis or chances of improvement in neurologic function. Appropriate rapid restoration of blood pressure and circulatory perfusion may improve perfusion to the spinal cord, prevent progressive spinal cord ischemia, and minimize secondary cord injury. Restoration of normal blood pressure and adequate tissue perfusion should precede any operative attempts to stabilize the vertebral fracture.

ENDPOINTS IN RESUSCITATION

Shock is defined as inadequate perfusion to maintain normal organ function. With prolonged anaerobic metabolism, tissue acidosis and O_2 debt accumulate. Thus, the goal in the treatment of shock is restoration of adequate organ perfusion and tissue oxygenation. Resuscitation is complete when O_2 debt is repaid, tissue acidosis is corrected, and aerobic metabolism is restored. Clinical confirmation of this endpoint remains a challenge.

Resuscitation of the patient in shock requires simultaneous evaluation and treatment; the etiology of the shock often is not initially apparent. Hemorrhagic shock, septic shock, and traumatic shock are the most common types of shock encountered on surgical services. To optimize outcome in bleeding patients, early control of the hemorrhage and adequate volume resuscitation, including both red blood cells and crystalloid solutions, are necessary. Expedient operative resuscitation is mandatory to limit the magnitude of activation of multiple mediator systems and to abort the microcirculatory changes, which may evolve insidiously into the cascade that ends in irreversible hemorrhagic shock. Attempts to stabilize an actively bleeding patient anywhere but in the operating room are inappropriate. Any intervention that delays the patient's arrival in the operating room for control of hemorrhage increases mortality, thus the important concept of *operating room resuscitation* of the critically injured patient.

Recognition by care providers of the patient who is in the compensated phase of shock is equally important, but more difficult based on clinical criteria. Compensated shock exists when inadequate tissue perfusion persists despite normalization of blood pressure and heart rate. Even with normalization of blood pressure, heart rate, and urine output, 80% to 85% of trauma patients have inadequate tissue perfusion, as evidenced by increased lactate or decreased mixed venous O_2 saturation.^{55,106} Persistent, occult hypoperfusion is frequent in the ICU, with a resultant significant increase in infection rate and mortality in major trauma patients. Patients failing to reverse their lactic acidosis within 12 hours of admission (acidosis that was persistent despite normal heart rate, blood pressure, and urine output) developed an infection three times as often as those who normalized their lactate levels within 12 hours of admission. In addition, mortality was fourfold higher in patients who developed infections. Both injury severity score and occult hypotension

Table 5-10

Endpoints in resuscitation

Systemic/global
Lactate
Base deficit
Cardiac output
Oxygen delivery and consumption
Tissue specific
Gastric tonometry
Tissue pH, oxygen, carbon dioxide levels
Near infrared spectroscopy
Cellular
Membrane potential
Adenosine triphosphate

(lactic acidosis) longer than 12 hours were independent predictors of infection.¹⁰⁷ Thus, recognition of subclinical hypoperfusion requires information beyond vital signs and urinary output.

Endpoints in resuscitation can be divided into *systemic* or *global parameters*, *tissue-specific parameters*, and *cellular parameters*. Global endpoints include vital signs, cardiac output, pulmonary artery wedge pressure, O_2 delivery and consumption, lactate, and base deficit (Table 5-10).

Assessment of Endpoints in Resuscitation

Inability to repay O_2 debt is a predictor of mortality and organ failure; the probability of death has been directly correlated to the calculated O_2 debt in hemorrhagic shock. Direct measurement of the O_2 debt in the resuscitation of patients is difficult. The easily obtainable parameters of arterial blood pressure, heart rate, urine output, central venous pressure, and pulmonary artery occlusion pressure are poor indicators of the adequacy of tissue perfusion. Therefore, surrogate parameters have been sought to estimate the O_2 debt; serum lactate and base deficit have been shown to correlate with O_2 debt.

Lactate. Lactate is generated by conversion of pyruvate to lactate by lactate dehydrogenase in the setting of insufficient O_2 . Lactate is released into the circulation and is predominantly taken up and metabolized by the liver and kidneys. The liver accounts for approximately 50% and the kidney for about 30% of whole body lactate uptake. Elevated serum lactate is an indirect measure of the O_2 debt, and therefore an approximation of the magnitude and duration of the severity of shock. The admission lactate level, highest lactate level, and time interval to normalize the serum lactate are important prognostic indicators for survival. For example, in a study of 76 consecutive patients, 100% survival was observed among the patients with normalization of lactate within 24 hours, 78% survival when lactate normalized between 24 and 48 hours, and only 14% survivorship if it took longer than 48 hours to normalize the serum lactate.⁵⁵ In contrast, individual variability of lactate may be too great to permit accurate prediction of outcome in any individual case. Base deficit and volume of blood transfusion required in the first 24 hours of resuscitation may be better predictors of mortality than the plasma lactate alone.

Base Deficit. Base deficit is the amount of base in millimoles that is required to titrate 1 L of whole blood to a pH of 7.40 with the sample fully saturated with O_2 at 37°C (98.6°F) and

a partial pressure of CO₂ of 40 mmHg. It usually is measured by arterial blood gas analysis in clinical practice as it is readily and quickly available. The mortality of trauma patients can be stratified according to the magnitude of base deficit measured in the first 24 hours after admission.⁶⁰ In a retrospective study of over 3000 trauma admissions, patients with a base deficit worse than 15 mmol/L had a mortality of 70%. Base deficit can be stratified into mild (3–5 mmol/L), moderate (6–14 mmol/L), and severe (15 mmol/L) categories, with a trend toward higher mortality with worsening base deficit in patients with trauma. Both the magnitude of the perfusion deficit as indicated by the base deficit and the time required to correct it are major factors determining outcome in shock.

Indeed, when elevated base deficit persists (or lactic acidosis) in the trauma patient, ongoing bleeding is often the etiology. Trauma patients admitted with a base deficit greater than 15 mmol/L required twice the volume of fluid infusion and six times more blood transfusion in the first 24 hours compared to patients with mild acidosis. Transfusion requirements increased as base deficit worsened, and ICU and hospital lengths of stay increased. Mortality increased as base deficit worsened; the frequency of organ failure increased with greater base deficit.⁵⁶ The probability of trauma patients developing ARDS has been reported to correlate with severity of admission base deficit and lowest base deficit within the first 24 hours postinjury.⁵⁸ Persistently high base deficit is associated with abnormal O₂ utilization and higher mortality. Monitoring base deficit in the resuscitation of trauma patients assists in assessment of O₂ transport and efficacy of resuscitation.⁵⁷

Factors that may compromise the utility of the base deficit in estimating O₂ debt are the administration of bicarbonate, hypothermia, hypocapnia (overventilation), heparin, ethanol, and ketoacidosis. However, the base deficit remains one of the most widely used estimates of O₂ debt for its clinical relevance, accuracy, and availability.

Gastric Tonometry. Lactate and base deficit indicate global tissue acidosis. Several authors have suggested that tissue-specific endpoints, rather than systemic endpoints, are more predictive of outcome and adequate resuscitation in trauma patients. With heterogeneity of blood flow, regional tissue beds may be hypoperfused. Gastric tonometry has been used to assess perfusion of the GI tract. The concentration of CO₂ accumulating in the gastric mucosa can be sampled with a specially designed nasogastric tube. With the assumption that gastric bicarbonate is equal to serum levels, gastric intramucosal pH (pHi) is calculated by applying the Henderson-Hasselbalch equation. pHi should be greater than 7.3; pHi will be lower in the setting of decreased O₂ delivery to the tissues. pHi is a good prognostic indicator; patients with normal pHi have better outcomes than those patients with pHi less than 7.3.^{108,109} Goal-directed human studies, with pHi as an endpoint in resuscitation, have shown normalization of pHi to correlate with improved outcome in several studies and with contradictory findings in other studies. Use of pHi as a singular endpoint in the resuscitation of critically ill patients remains controversial.¹¹⁰

Near Infrared Spectroscopy. Near infrared (NIR) spectroscopy can measure tissue oxygenation and redox state of cytochrome a,a₃ on a continuous, noninvasive basis. The NIR probe emits multiple wavelengths of light in the NIR spectrum (650 to 1100 nm). Photons are then either absorbed by the tissue or reflected back to the probe. Maximal exercise in laboratory studies

resulted in reduction of cytochrome a,a₃; this correlated with tissue lactate elevation. NIR spectroscopy can be used to compare tissue oxyhemoglobin levels (indicating tissue O₂ supply to cytochrome a,a₃ with mitochondrial O₂ consumption), thus demonstrating flow-independent mitochondrial oxidative dysfunction and the need for further resuscitation. Trauma patients with decoupled oxyhemoglobin and cytochrome a,a₃ have redox dysfunction and have been shown to have a higher incidence of organ failure (89% vs. 13%).^{111,112}

Tissue pH, Oxygen, and Carbon Dioxide Concentration. Tissue probes with optical sensors have been used to measure tissue pH and partial pressure of O₂ and CO₂ in subcutaneous sites, muscle, and the bladder. These probes may use transcutaneous methodology with Clark electrodes or direct percutaneous probes.^{113,114} The percutaneous probes can be inserted through an 18-gauge catheter and hold promise as continuous monitors of tissue perfusion.

Right Ventricular End-Diastolic Volume Index. Right ventricular end-diastolic volume index (RVEDVI) seems to more accurately predict preload for cardiac index than does pulmonary artery wedge pressure.¹¹⁵ Chang and colleagues reported that 50% of trauma patients had persistent splanchnic ischemia that was reversed by increasing RVEDVI. RVEDVI is a parameter that seems to correlate with preload-related increases in cardiac output. More recently, these authors have described left ventricular power output as an endpoint (LVP >320 mmHg·L/min per square meter), which is associated with improved clearance of base deficit and a lower rate of organ dysfunction following injury.¹¹⁶

REFERENCES

Entries highlighted in bright blue are key references.

1. Gross S. *A System of Surgery: Pathologic, Diagnostic, Therapeutic and Operative*. Philadelphia: Lea and Febiger; 1872.
2. Bernard C. *Lecons sur les Phenomenes de la Via Communs aux Animaux et aux Vegetaux*. Paris: JB Ballieve; 1879.
3. Cannon W. *Traumatic Shock*. New York: Appleton and Co.; 1923.
4. Blalock A. *Principles of Surgical Care, Shock and Other Problems*. St. Louis: CV Mosby; 1940.
5. Mollen KP, Levy RM, Prince JM, et al. Systemic inflammation and end organ damage following trauma involves functional TLR4 signaling in both bone marrow-derived cells and parenchymal cells. *J Leukoc Biol*. 2008;83(1):80-88.
6. Wiggers C. *Experimental Hemorrhagic Shock. Physiology of Shock*. New York: Commonwealth; 1950.
7. Peitzman AB, Corbett WA, Shires GT III, Illner H, Shires GT, Inamdar R. Cellular function in liver and muscle during hemorrhagic shock in primates. *Surg Gynecol Obstet*. 1985;161(5):419-424.
8. Carrico CJ, Canizaro PC, Shires GT. Fluid resuscitation following injury: rationale for the use of balanced salt solutions. *Crit Care Med*. 1976;4(2):46-54.
9. Shaftan GW, Chiu CJ, Dennis C, Harris B. Fundamentals of physiologic control of arterial hemorrhage. *Surgery*. 1965;58(5):851-856.
10. Shah NS, Kelly E, Billiar TR, et al. Utility of clinical parameters of tissue oxygenation in a quantitative model of irreversible hemorrhagic shock. *Shock*. 1998;10(5):343-346.
11. Dunser MW, Wenzel V, Mayr AJ, Hasibeder WR. Management of vasodilatory shock: defining the role of arginine vasopressin. *Drugs*. 2003;63(3):237-256.

12. Argenziano M, Chen JM, Choudhri AF, et al. Management of vasodilatory shock after cardiac surgery: identification of predisposing factors and use of a novel pressor agent. *J Thorac Cardiovasc Surg.* 1998;116(6):973-980.
13. Barroso-Aranda J, Schmid-Schonbein GW, Zweifach BW, Engler RL. Granulocytes and no-reflow phenomenon in irreversible hemorrhagic shock. *Circ Res.* 1988;63(2):437-447.
14. Ince C, Sinaasappel M. Microcirculatory oxygenation and shunting in sepsis and shock. *Crit Care Med.* 1999;27(7):1369-1377.
15. Singer M, De Santis V, Vitale D, Jeffcoate W. **Multior-gan failure is an adaptive, endocrine-mediated, metabolic response to overwhelming systemic inflammation.** *Lancet.* 2004;364(9433):545-548.
16. Shires T, Coln D, Carrico J, Lightfoot S. Fluid therapy in hemorrhagic shock. *Arch Surg.* 1964;88:688-693.
17. Robin ED. Of men and mitochondria: coping with hypoxic dysoxia. The 1980 J. Burns Amberson Lecture. *Am Rev Respir Dis.* 1980;122(4):517-531.
18. Stacpoule PW. Lactic acidosis and other mitochondrial disorders. *Metabolism.* 1997;46(3):306-321.
19. Crowell JW, Smith EE. Oxygen deficit and irreversible hemorrhagic shock. *Am J Physiol.* 1964;206:313-316.
20. Nathan C. Points of control in inflammation. *Nature.* 2002;420(6917):846-852.
21. Sauaia A, Moore FA, Moore EE, Haenel JB, Read RA, Lezotte DC. Early predictors of postinjury multiple organ failure. *Arch Surg.* 1994;129(1):39-45.
22. Matzinger P. The danger model: a renewed sense of self. *Science.* 2002;296(5566):301-305.
23. Jiang J, Bahrami S, Leichtfried G, Redl H, Ohlinger W, Schlag G. Kinetics of endotoxin and tumor necrosis factor appearance in portal and systemic circulation after hemorrhagic shock in rats. *Ann Surg.* 1995;221(1):100-106.
24. Endo S, Inada K, Yamada Y, et al. Plasma endotoxin and cytokine concentrations in patients with hemorrhagic shock. *Crit Care Med.* 1994;22(6):949-955.
25. Puyana JC, Pellegrini JD, De AK, Kodys K, Silva WE, Miller CL. Both T-helper-1- and T-helper-2-type lymphokines are depressed in posttrauma anergy. *J Trauma.* 1998;44(6):1037-1045; discussion 1045-1046.
26. Faist E, Schinkel C, Zimmer S, Kremer JP, Von Donners-marck GH, Schildberg FW. Inadequate interleukin-2 synthesis and interleukin-2 messenger expression following thermal and mechanical trauma in humans is caused by defective trans-membrane signalling. *J Trauma.* 1993;34(6):846-853; discus-sion 853-854.
27. Meng ZH, Dyer K, Billiar TR, Tweardy DJ. Essential role for IL-6 in postresuscitation inflammation in hemorrhagic shock. *Am J Physiol Cell Physiol.* 2001;280(2):C343-C351.
28. Meng ZH, Dyer K, Billiar TR, Tweardy DJ. Distinct effects of systemic infusion of G-CSF vs. IL-6 on lung and liver inflammation and injury in hemorrhagic shock. *Shock.* 2000;14(1):41-48.
29. Neidhardt R, Keel M, Steckholzer U, et al. Relationship of interleukin-10 plasma levels to severity of injury and clinical outcome in injured patients. *J Trauma.* 1997;42(5):863-870; discussion 870-871.
30. Kasai T, Inada K, Takakuwa T, et al. Anti-inflammatory cyto-kine levels in patients with septic shock. *Res Commun Mol Pathol Pharmacol.* 1997;98(1):34-42.
31. Kahlke V, Dohm C, Mees T, Brotzmann K, Schreiber S, Sch-roder J. Early interleukin-10 treatment improves survival and enhances immune function only in males after hemorrhage and subsequent sepsis. *Shock.* 2002;18(1):24-28.
32. Karakozis S, Hinds M, Cook JW, Kim D, Provido H, Kirkpat-rick JR. The effects of interleukin-10 in hemorrhagic shock. *J Surg Res.* 2000;90(2):109-112.
33. Comerford I, McColl SR. Mini-review series: focus on che-mokines. *Immunol Cell Biol.* 2011;89(2):183-184.
34. Younger JG, Sasaki N, Waite MD, et al. Detrimental effects of complement activation in hemorrhagic shock. *J Appl Physiol.* 2001;90(2):441-446.
35. Moore EE, Moore FA, Franciose RJ, Kim FJ, Biffl WL, Banerjee A. The postschismic gut serves as a priming bed for circulating neutrophils that provoke multiple organ failure. *J Trauma.* 1994;37(6):881-887.
36. Adams JM, Hauser CJ, Livingston DH, Lavery RF, Fekete Z, Deitch EA. Early trauma polymorphonuclear neutro-phil responses to chemokines are associated with develop-ment of sepsis, pneumonia, and organ failure. *J Trauma.* 2001;51(3):452-456; discussion 456-457.
37. Lau YT, Hwang TL, Chen MF, Liu MS. Calcium transport by rat liver plasma membranes during sepsis. *Circ Shock.* 1992;38(4):238-244.
38. Somogyi R, Zhao M, Stucki JW. Modulation of cytosolic-[Ca²⁺] oscillations in hepatocytes results from cross-talk among second messengers. The synergism between the alpha 1-adrenergic response, glucagon and cyclic AMP, and their antagonism by insulin and diacylglycerol manifest themselves in the control of the cytosolic-[Ca²⁺] oscillations. *Biochem J.* 1992;286(Pt 3):869-877.
39. Trump BF, Berezesky IK. Calcium-mediated cell injury and cell death. *FASEB J.* 1995;9(2):219-228.
40. Powers KA, Szasz K, Khadaroo RG, et al. Oxidative stress generated by hemorrhagic shock recruits Toll-like recep-tor 4 to the plasma membrane in macrophages. *J Exp Med.* 2006;203(8):1951-1961.
41. Suzuki YJ, Forman HJ, Sevanian A. Oxidants as stimulators of signal transduction. *Free Radic Biol Med.* 1997;22(1-2):269-285.
42. Mollen KP, McCloskey CA, Tanaka H, et al. Hypoxia activates c-Jun N-terminal kinase via Rac1-dependent reactive oxygen species production in hepatocytes. *Shock.* 2007;28(3):270-277.
43. Bertges DJ, Fink MP, Delude RL. Hypoxic signal transduction in critical illness. *Crit Care Med.* 2000;28(4 Suppl):N78-86.
44. Guillemin K, Krasnow MA. The hypoxic response: huffing and HIFing. *Cell.* 1997;89(1):9-12.
45. Buchman TG, Cabin DE, Vickers S, et al. Molecular biol-ogy of circulatory shock. Part II. Expression of four groups of hepatic genes is enhanced after resuscitation from cardiogenic shock. *Surgery.* 1990;108(3):559-566.
46. Cobb JP, O'Keefe GE. Injury research in the genomic era. *Lancet.* 2004;363(9426):2076-2083.
47. Cobb JP, Laramie JM, Stormo GD, et al. Sepsis gene expression profiling: murine splenic compared with hepatic responses determined by using complementary DNA microar-rays. *Crit Care Med.* 2002;30(12):2711-2721.
48. Wiegand G, Selleng K, Grundling M, Jack RS. Gene expres-sion pattern in human monocytes as a surrogate marker for systemic inflammatory response syndrome (SIRS). *Mol Med.* 1999;5(3):192-202.
49. Gray IC, Campbell DA, Spurr NK. Single nucleotide poly-morphisms as tools in human genetics. *Hum Mol Genet.* 2000;9(16):2403-2408.
50. Mira JP, Cariou A, Grall F, et al. Association of TNF2, a TNF-alpha promoter polymorphism, with septic shock susceptibility and mortality: a multicenter study. *JAMA.* 1999;282(6):561-568.
51. Xiao W, Mindrinos MN, Seok J, et al. **A genomic storm in critically injured humans.** *J Exp Med.* 2011;208(13):2581-2590.
52. **Eastridge BJ, Salinas J, McManus JG, et al. Hypotension begins at 110 mm Hg: redefining "hypotension" with data.** *J Trauma.* 2007;63(2):291-297; discussion 297-299.
53. Luna GK, Eddy AC, Copass M. The sensitivity of vital signs in identifying major thoracoabdominal hemorrhage. *Am J Surg.* 1989;157(5):512-515.

54. Victorino GP, Battistella FD, Wisner DH. Does tachycardia correlate with hypotension after trauma? *J Am Coll Surg.* 2003;196(5):679-684.
55. Abramson D, Scalea TM, Hitchcock R, Trooskin SZ, Henry SM, Greenspan J. Lactate clearance and survival following injury. *J Trauma.* 1993;35(4):584-588; discussion 588-589.
56. Davis JW, Parks SN, Kaups KL, Gladen HE, O'Donnell-Nicol S. Admission base deficit predicts transfusion requirements and risk of complications. *J Trauma.* 1996;41(5):769-774.
57. Kincaid EH, Miller PR, Meredith JW, Rahman N, Chang MC. Elevated arterial base deficit in trauma patients: a marker of impaired oxygen utilization. *J Am Coll Surg.* 1998;187(4):384-392.
58. Rixen D, Raum M, Bouillon B, Lefering R, Neugebauer E. Base deficit development and its prognostic significance in posttrauma critical illness: an analysis by the trauma registry of the Deutsche Gesellschaft für Unfallchirurgie. *Shock.* 2001;15(2):83-89.
59. Rutherford EJ, Morris JA Jr., Reed GW, Hall KS. Base deficit stratifies mortality and determines therapy. *J Trauma.* 1992;33(3):417-423.
60. Thorson CM, Van Haren RM, Ryan ML, et al. Admission hematocrit and transfusion requirements after trauma. *J Am Coll Surg.* 2013;216(1):65-73.
61. Clarke JR, Trooskin SZ, Doshi PJ, Greenwald L, Mode CJ. Time to laparotomy for intra-abdominal bleeding from trauma does affect survival for delays up to 90 minutes. *J Trauma.* 2002;52(3):420-425.
62. Holcomb JB, Jenkins D, Rhee P, et al. **Damage control resuscitation: directly addressing the early coagulopathy of trauma.** *J Trauma.* 2007;62(2):307-310.
63. Marshall HP Jr., Capone A, Courcoulas AP, et al. Effects of hemodilution on long-term survival in an uncontrolled hemorrhagic shock model in rats. *J Trauma.* Oct 1997;43(4):673-679.
64. Bickell WH, Wall MJ Jr., Pepe PE, et al. Immediate versus delayed fluid resuscitation for hypotensive patients with penetrating torso injuries. *N Engl J Med.* 1994;331(17):1105-1109.
65. Human albumin administration in critically ill patients: systematic review of randomised controlled trials. Cochrane Injuries Group Albumin Reviewers. *BMJ.* 1998;317(7153):235-240.
66. Mann DV, Robinson MK, Rounds JD, et al. Superiority of blood over saline resuscitation from hemorrhagic shock: a 31P magnetic resonance spectroscopy study. *Ann Surg.* 1997;226(5):653-661.
67. Vassar MJ, Fischer RP, O'Brien PE, et al. A multicenter trial for resuscitation of injured patients with 7.5% sodium chloride. The effect of added dextran 70. The Multicenter Group for the Study of Hypertonic Saline in Trauma Patients. *Arch Surg.* 1993;128(9):1003-1011; discussion 1011-1013.
68. Hebert PC, Yetisir E, Martin C, et al. Is a low transfusion threshold safe in critically ill patients with cardiovascular diseases? *Crit Care Med.* 2001;29(2):227-234.
69. Hebert PC, Wells G, Blajchman MA, et al. A multicenter, randomized, controlled clinical trial of transfusion requirements in critical care. Transfusion Requirements in Critical Care Investigators, Canadian Critical Care Trials Group. *N Engl J Med.* 1999;340(6):409-417.
70. Holcomb JB, Del Junco DJ, Fox EE, et al. The Prospective, Observational, Multicenter, Major Trauma Transfusion (PROMTTT) study: comparative effectiveness of a time-varying treatment with competing risks. *Arch Surg.* 2012;1-10.
71. Gonzalez EA, Moore FA, Holcomb JB, et al. Fresh frozen plasma should be given earlier to patients requiring massive transfusion. *J Trauma.* 2007;62(1):112-119.
72. Borgman MA, Spinella PC, Perkins JG, et al. **The ratio of blood products transfused affects mortality in patients receiving massive transfusions at a combat support hospital.** *J Trauma.* 2007;63(4):805-813.
73. Stansbury LG, Dutton RP, Stein DM, Bochicchio GV, Scalea TM, Hess JR. Controversy in trauma resuscitation: do ratios of plasma to red blood cells matter? *Transfus Med Rev.* 2009;23(4):255-265.
74. Hess JR, Lindell AL, Stansbury LG, Dutton RP, Scalea TM. The prevalence of abnormal results of conventional coagulation tests on admission to a trauma center. *Transfusion.* 2009;49(1):34-39.
75. Cosgriff N, Moore EE, Sauaia A, Kenny-Moynihan M, Burch JM, Galloway B. Predicting life-threatening coagulopathy in the massively transfused trauma patient: hypothermia and acidosis revisited. *J Trauma.* 1997;42(5):857-861; discussion 861-862.
76. Holcomb JB, Wade CE, Michalek JE, et al. Increased plasma and platelet to red blood cell ratios improves outcome in 466 massively transfused civilian trauma patients. *Ann Surg.* 2008;248(3):447-458.
77. Brasel KJ, Vercruyse G, Spinella PC, et al. The association of blood component use ratios with the survival of massively transfused trauma patients with and without severe brain injury. *J Trauma.* 2011;71(2 Suppl 3):S343-352.
78. **Roberts I, Shakur H, Afolabi A, et al. The importance of early treatment with tranexamic acid in bleeding trauma patients: an exploratory analysis of the CRASH-2 randomised controlled trial.** *Lancet.* 2011;377(9771):1096-1101, 1101 e1091-1092.
79. Niles SE, McLaughlin DF, Perkins JG, et al. Increased mortality associated with the early coagulopathy of trauma in combat casualties. *J Trauma.* 2008;64(6):1459-1463; discussion 1463-1465.
80. Holcomb JB, Minei KM, Scerbo ML, et al. Admission rapid thrombelastography can replace conventional coagulation tests in the emergency department: experience with 1974 consecutive trauma patients. *Ann Surg.* 2012;256(3):476-486.
81. Roumen RM, Redl H, Schlag G, et al. Inflammatory mediators in relation to the development of multiple organ failure in patients after severe blunt trauma. *Crit Care Med.* 1995;23(3):474-480.
82. Leone M, Boutiere B, Camoin-Jau L, et al. Systemic endothelial activation is greater in septic than in traumatic-hemorrhagic shock but does not correlate with endothelial activation in skin biopsies. *Crit Care Med.* 2002;30(4):808-814.
83. Mollen KP, Anand RJ, Tsung A, Prince JM, Levy RM, Billiar TR. Emerging paradigm: toll-like receptor 4-sentinel for the detection of tissue damage. *Shock.* 2006;26(5):430-437.
84. Landry DW, Oliver JA. The pathogenesis of vasodilatory shock. *N Engl J Med.* 2001;345(8):588-595.
85. Angus DC, Linde-Zwirble WT, Lidicker J, Clermont G, Carcillo J, Pinsky MR. Epidemiology of severe sepsis in the United States: analysis of incidence, outcome, and associated costs of care. *Crit Care Med.* 2001;29(7):1303-1310.
86. **Dellinger RP, Levy MM, Rhodes A, et al. Surviving Sepsis Campaign: international guidelines for management of severe sepsis and septic shock, 2012.** *Intensive Care Med.* 2013;39(2):165-228.
87. Dellinger RP, Levy MM, Carlet JM, et al. Surviving Sepsis Campaign: international guidelines for management of severe sepsis and septic shock: 2008. *Crit Care Med.* 2008;36(1):296-327.
88. Myburgh JA, Finfer S, Billot L. Hydroxyethyl starch or saline in intensive care. *N Engl J Med.* 2013;368(8):775.
89. Perner A, Haase N, Guttormsen AB, et al. Hydroxyethyl starch 130/0.42 versus Ringer's acetate in severe sepsis. *N Engl J Med.* 2012;367(2):124-134.
90. Rivers E, Nguyen B, Havstad S, et al. Early goal-directed therapy in the treatment of severe sepsis and septic shock. *N Engl J Med.* 2001;345(19):1368-1377.

91. van den Berghe G, Wouters P, Weekers F, et al. Intensive insulin therapy in critically ill patients. *N Engl J Med.* 2001;345(19):1359-1367.
92. Ventilation with lower tidal volumes as compared with traditional tidal volumes for acute lung injury and the acute respiratory distress syndrome. The Acute Respiratory Distress Syndrome Network. *N Engl J Med.* 2000;342(18):1301-1308.
93. Annane D, Sebille V, Charpentier C, et al. Effect of treatment with low doses of hydrocortisone and fludrocortisone on mortality in patients with septic shock. *JAMA.* 2002;288(7):862-871.
94. Sprung CL, Annane D, Keh D, et al. Hydrocortisone therapy for patients with septic shock. *N Engl J Med.* 2008;358(2):111-124.
95. Hollenberg SM, Kavinsky CJ, Parrillo JE. Cardiogenic shock. *Ann Intern Med.* 1999;131(1):47-59.
96. Webb JG, Lowe AM, Sanborn TA, et al. Percutaneous coronary intervention for cardiogenic shock in the SHOCK trial. *J Am Coll Cardiol.* 2003;42(8):1380-1386.
97. Edens JW, Chung KK, Pamplin JC, et al. Predictors of early acute lung injury at a combat support hospital: a prospective observational study. *J Trauma.* 2010;69(Suppl 1):S81-86.
98. Aji J, Hollenberg S. Cardiogenic shock: giving the heart a break. *Crit Care Med.* 2006;34(4):1248-1249.
99. Alonso DR, Scheidt S, Post M, Killip T. Pathophysiology of cardiogenic shock. Quantification of myocardial necrosis, clinical, pathologic, and electrocardiographic correlations. *Circulation.* 1973;48(3):588-596.
100. Goldstein DJ, Oz MC. Mechanical support for postcardiotomy cardiogenic shock. *Semin Thorac Cardiovasc Surg.* 2000;12(3):220-228.
101. Thygesen K, Alpert JS, Jaffe AS, et al. Third universal definition of myocardial infarction. *J Am Coll Cardiol.* 2012;60(16):1581-1598.
102. Gibbons RJ, Smith SC Jr., Antman E. American College of Cardiology/American Heart Association clinical practice guidelines: Part II: evolutionary changes in a continuous quality improvement project. *Circulation.* 2003;107(24):3101-3107.
103. Menon V, Hochman JS. Management of cardiogenic shock complicating acute myocardial infarction. *Heart.* 2002;88(5):531-537.
104. Levi L, Wolf A, Belzberg H. Hemodynamic parameters in patients with acute cervical cord trauma: description, intervention, and prediction of outcome. *Neurosurgery.* 1993;33(6):1007-1016; discussion 1016-1007.
105. Zipnick RI, Scalea TM, Trooskin SZ, et al. Hemodynamic responses to penetrating spinal cord injuries. *J Trauma.* 1993;35(4):578-582; discussion 582-583.
106. Abou-Khalil B, Scalea TM, Trooskin SZ, Henry SM, Hitchcock R. Hemodynamic responses to shock in young trauma patients: need for invasive monitoring. *Crit Care Med.* 1994;22(4):633-639.
107. Claridge JA, Crabtree TD, Pelletier SJ, Butler K, Sawyer RG, Young JS. Persistent occult hypoperfusion is associated with a significant increase in infection rate and mortality in major trauma patients. *J Trauma.* 2000;48(1):8-14; discussion 14-15.
108. Ivatury RR, Simon RJ, Havriliak D, Garcia C, Greenberg J, Stahl WM. Gastric mucosal pH and oxygen delivery and oxygen consumption indices in the assessment of adequacy of resuscitation after trauma: a prospective, randomized study. *J Trauma.* 1995;39(1):128-134; discussion 134-126.
109. Maynard N, Beale R, Smithies M, Bihari D. Gastric intramucosal pH in critically ill patients. *Lancet.* 1992;339(8792):550-551.
110. Gomersall CD, Joynt GM, Freebairn RC, Hung V, Buckley TA, Oh TE. Resuscitation of critically ill patients based on the results of gastric tonometry: a prospective, randomized, controlled trial. *Crit Care Med.* 2000;28(3):607-614.
111. Cairns CB, Moore FA, Haenel JB, et al. Evidence for early supply independent mitochondrial dysfunction in patients developing multiple organ failure after trauma. *J Trauma.* 1997;42(3):532-536.
112. Cohn SM, Crookes BA, Proctor KG. Near-infrared spectroscopy in resuscitation. *J Trauma.* 2003;54(5 Suppl):S199-202.
113. Knudson MM, Bermudez KM, Doyle CA, Mackersie RC, Hopf HW, Morabito D. Use of tissue oxygen tension measurements during resuscitation from hemorrhagic shock. *J Trauma.* 1997;42(4):608-614; discussion 614-606.
114. McKinley BA, Marvin RG, Cocanour CS, Moore FA. Tissue hemoglobin O₂ saturation during resuscitation of traumatic shock monitored using near infrared spectrometry. *J Trauma.* 2000;48(4):637-642.
115. Cheatham ML, Nelson LD, Chang MC, Safcsak K. Right ventricular end-diastolic volume index as a predictor of preload status in patients on positive end-expiratory pressure. *Crit Care Med.* 1998;26(11):1801-1806.
116. Chang MC, Meredith JW, Kincaid EH, Miller PR. Maintaining survivors' values of left ventricular power output during shock resuscitation: a prospective pilot study. *J Trauma.* 2000;49(1):26-33; discussion 34-37.

chapter 6

Surgical Infections

Greg J. Beilman and David L. Dunn

Historical Background	135	General Principles / 141	Postoperative Nosocomial Infections / 152
Pathogenesis of Infection	137	Source Control / 141	Sepsis / 154
Host Defenses / 137		Appropriate Use of Antimicrobial Agents / 142	Blood-Borne Pathogens / 156
Definitions / 138			
Microbiology of Infectious Agents	139	Infections of Significance in Surgical Patients	147
Bacteria / 139		Surgical Site Infections / 147	
Fungi / 140		Intra-Abdominal Infections / 149	
Viruses / 140		Organ-Specific Infections / 150	
		Infections of the Skin and Soft Tissue / 151	
Prevention and Treatment of Surgical Infections	141		Biologic Warfare Agents
			Bacillus anthracis (Anthrax) / 156
			Yersinia pestis (Plague) / 157
			Smallpox / 157
			Francisella tularensis (Tularemia) / 157

HISTORICAL BACKGROUND

Although treatment of infection has been an integral part of the surgeon's practice since the dawn of time, the body of knowledge that led to the present field of surgical infectious disease was derived from the evolution of germ theory and antiseptics. Application of the latter to clinical practice, concurrent with the development of anesthesia, was pivotal in allowing surgeons to expand their repertoire to encompass complex procedures that previously were associated with extremely high rates of morbidity and mortality due to postoperative infections. However, until recently the occurrence of infection related to the surgical wound was the rule rather than the exception. In fact, the development of modalities to effectively prevent and treat infection has occurred only within the last several decades.

A number of observations by nineteenth-century physicians and investigators were critical to our current understanding of the pathogenesis, prevention, and treatment of surgical infections. In 1846, Ignaz Semmelweis, a Magyar physician, took a post at the Allgemeines Krankenhaus in Vienna. He noticed that the mortality from puerperal ("childbed") fever was much higher in the teaching ward (1:11) than in the ward where patients were delivered by midwives (1:29). He also made the interesting observation that women who delivered prior to arrival on the teaching ward had a negligible mortality rate. The tragic death of a colleague due to overwhelming infection after a knife scratch received during an autopsy of a woman who had died of puerperal fever led Semmelweis to observe that pathologic changes in his friend were identical to those of women dying from this postpartum disease. He then hypothesized that puerperal fever was caused by putrid material transmitted from patients dying of this disease by carriage on the examining fingers of the medical students and physicians who frequently went from the autopsy room to the wards. The low mortality noted in the midwives' ward, Semmelweis realized, was

because midwives did not participate in autopsies. Fired with the zeal of his revelation, he posted a notice on the door to the ward requiring all caregivers to rinse their hands thoroughly in chlorine water prior to entering the area. This simple intervention reduced mortality from puerperal fever to 1.5%, surpassing the record of the midwives. In 1861, he published his classic work on childbed fever based on records from his practice. Unfortunately, Semmelweis' ideas were not well accepted by the authorities of the time.¹ Increasingly frustrated by the indifference of the medical profession, he began writing open letters to well-known obstetricians in Europe, and was committed to an asylum due to concerns that he was losing his mind. He died shortly thereafter. His achievements were only recognized after Pasteur's description of the germ theory of disease.

Louis Pasteur performed a body of work during the latter part of the nineteenth century that provided the underpinnings of modern microbiology, at the time known as "germ theory." His work in humans followed experiments identifying infectious agents in silkworms. He was able to elucidate the principle that contagious diseases are caused by specific microbes and that these microbes are foreign to the infected organism. Using this principle he developed techniques of sterilization critical to oenology, and identified several bacteria responsible for human illnesses, including *Staphylococcus* and *Streptococcus pneumoniae* (pneumococcus).

Joseph Lister, the son of a wine merchant, was appointed professor of surgery at the Glasgow Royal Infirmary in 1859. In his early practice, he noted that over 50% of his patients undergoing amputation died because of postoperative infection. After hearing of Pasteur's theory, Lister experimented with the use of a solution of carbolic acid, which he knew was being used to treat sewage. He first reported his findings to the British Medical Association in 1867 using dressings saturated with carbolic acid on 12 patients with compound fractures; 10 recovered

Key Points

- 1▶ Sepsis is both the presence of infection and the host response to infection (systemic inflammatory response syndrome, SIRS). Sepsis is a clinical spectrum, ranging from sepsis (SIRS plus infection) to severe sepsis (organ dysfunction), to septic shock (hypotension requiring vasopressors). Outcomes in patients with sepsis are improved with an organized approach to therapy that includes rapid resuscitation, antibiotics, and source control.
- 2▶ Source control is a key concept in the treatment of most surgically relevant infections. Infected or necrotic material must be drained or removed as part of the treatment plan in this setting. Delays in adequate source control are associated with worsened outcomes.
- 3▶ Principles relevant to appropriate antibiotic prophylaxis for surgery: (a) select an agent with activity against organisms commonly found at the site of surgery, (b) the initial dose of the antibiotic should be given within 30 minutes prior to the creation of the incision, (c) the antibiotic should be redosed during long operations based upon the half-life of the agent to ensure adequate tissue levels, and (d) the antibiotic regimen should not be continued for more than 24 hours after surgery for routine prophylaxis.
- 4▶ When using antimicrobial agents for therapy of serious infection, several principles should be followed: (a) identify likely sources of infection, (b) select an agent (or agents) that will have efficacy against likely organisms for these sources, (c) inadequate or delayed antibiotic therapy results in increased mortality, so it is important to begin therapy rapidly with broader coverage, (d) when possible, obtain cultures early and use results to refine therapy, (e) if no infection is identified after 3 days, strongly consider discontinuation of antibiotics, based upon the patient's clinical course, (f) discontinue antibiotics after an appropriate course of therapy.
- 5▶ The incidence of surgical site infections can be reduced by appropriate patient preparation, timely perioperative antibiotic administration, maintenance of perioperative normothermia and normoglycemia, and appropriate wound management.
- 6▶ The keys to good outcomes in patients with necrotizing soft tissue infection are early recognition and appropriate debridement of infected tissue with repeated debridement until no further signs of infection are present.
- 7▶ Transmission of HIV and other infections spread by blood and body fluid from patient to health care worker can be minimized by observation of universal precautions, which include routine use of barriers when anticipating contact with blood or body fluids, washing of hands and other skin surfaces immediately after contact with blood or body fluids, and careful handling and disposal of sharp instruments during and after use.

without amputation, one survived with amputation, and one died of causes unrelated to the wound. In spite of initial resistance, his methods were quickly adopted throughout Europe.

From 1878 until 1880, Robert Koch was the District Medical Officer for Wollstein, which was an area in which anthrax was endemic. Performing experiments in his home, without the benefit of scientific equipment and academic contact, Koch developed techniques for culture of *Bacillus anthracis* and proved the ability of this organism to cause anthrax in healthy animals. He developed the following four postulates to identify the association of organisms with specific diseases: (a) the suspected pathogenic organism should be present in all cases of the disease and absent from healthy animals, (b) the suspected pathogen should be isolated from a diseased host and grown in a pure culture in vitro, (c) cells from a pure culture of the suspected organism should cause disease in a healthy animal, and (d) the organism should be reisolated from the newly diseased animal and shown to be the same as the original. He used these same techniques to identify the organisms responsible for cholera and tuberculosis. During the next century, Koch's postulates, as they came to be called, became critical to our understanding of surgical infections and remain so today.²

The first intra-abdominal operation to treat infection via "source control" (i.e., surgical intervention to eliminate the source of infection) was appendectomy. This operation was pioneered by Charles McBurney at the New York College of Physicians and Surgeons, among others.³ McBurney's classic report on early operative intervention for appendicitis was presented before the New York Surgical Society in 1889. Appendectomy for the treatment of appendicitis, previously an often fatal disease, was popularized after the 1902 coronation of King

Edward VII of England was delayed due to his need for an appendectomy, which was performed by Sir Frederick Treves. The king desperately needed an appendectomy but strongly opposed going into the hospital, protesting, "I have a coronation on hand." However, Treves was adamant, stating, "It will be a funeral, if you don't have the operation." Treves carried the debate, and the king lived.

During the twentieth century the discovery of effective antimicrobials added another tool to the armamentarium of modern surgeons. Sir Alexander Fleming, after serving in the British Army Medical Corps during World War I, continued work on the natural antibacterial action of the blood and antiseptics. In 1928, while studying influenza virus, he noted a zone of inhibition around a mold colony (*Penicillium notatum*) that serendipitously grew on a plate of *Staphylococcus*, and he named the active substance penicillin. This first effective antibacterial agent subsequently led to the development of hundreds of potent antimicrobials, set the stage for their use as prophylaxis against postoperative infection, and became a critical component of the armamentarium to treat aggressive, lethal surgical infections.

Concurrent with the development of numerous antimicrobial agents were advances in the field of clinical microbiology. Many new microbes were identified, including numerous anaerobes; the autochthonous microflora of the skin, gastrointestinal tract, and other parts of the body that the surgeon encountered in the process of an operation were characterized in great detail. However, it remained unclear whether these organisms, anaerobes in particular, were commensals or pathogens. Subsequently, the initial clinical observations of surgeons such as Frank Meleney, William Altemeier, and others provided the key, when they observed that aerobes and anaerobes could

synergize to cause serious soft tissue and severe intra-abdominal infection.^{4,5} Thus, the concepts that resident microbes were nonpathogenic until they entered a sterile body cavity at the time of surgery, and that many, if not most, surgical infections were polymicrobial in nature, became critical ideas, and were promulgated by a number of clinician-scientists over the last several decades.^{6,7} These tenets became firmly established after microbiology laboratories demonstrated the invariable presence of aerobes and anaerobes in peritoneal cultures obtained at the time of surgery for intra-abdominal infection due to a perforated viscus or gangrenous appendicitis. Clinical trials provided ample evidence that optimal therapy for these infections required effective source control, plus the administration of antimicrobial agents directed against both types of pathogens.

William Osler, a prolific writer and one of the fathers of American medicine, made an observation in 1904 in his treatise *The Evolution of Modern Medicine* that was to have profound implications for the future of treatment of infection: “Except on few occasions, the patient appears to die from the body’s response to infection rather than from it.”⁸ The discovery of the first cytokines began to allow insight into the human organism’s response to infection, and led to an explosion in our understanding of the host inflammatory response. Expanding knowledge of the multiple pathways activated during the response to invasion by infectious organisms has permitted the design of new therapies targeted at modifying the inflammatory response to infection, which seems to cause much of the organ dysfunction and failure. Preventing and treating this process of multiple organ failure during infection is one of the major challenges of modern critical care and surgical infectious disease.

PATHOGENESIS OF INFECTION

Host Defenses

The mammalian host possesses several layers of endogenous defense mechanisms that serve to prevent microbial invasion, limit proliferation of microbes within the host, and contain or eradicate invading microbes. These defenses are integrated and redundant so that the various components function as a complex, highly regulated system that is extremely effective in coping with microbial invaders. They include site-specific defenses that function at the tissue level, as well as components that freely circulate throughout the body in both blood and lymph. Systemic host defenses invariably are recruited to a site of infection, a process that begins immediately upon introduction of microbes into a sterile area of the body. Perturbation of one or more components of these defenses (e.g., via immunosuppressants, foreign body, chronic illness, and burns) may have substantial negative impact on resistance to infection.

Entry of microbes into the mammalian host is precluded by the presence of a number of barriers that possess either an epithelial (integument) or mucosal (respiratory, gut, and urogenital) surface. Barrier function, however, is not solely limited to physical characteristics. Host barrier cells may secrete substances that limit microbial proliferation or prevent invasion. Also, resident or commensal microbes (endogenous or autochthonous host microflora) adherent to the physical surface and to each other may preclude invasion, particularly of virulent organisms (colonization resistance).⁹

The most extensive physical barrier is the integument or skin. In addition to the physical barrier posed by the epithelial

surface, the skin harbors its own resident microflora that may block the attachment and invasion of noncommensal microbes. Microbes are also held in check by chemicals that sebaceous glands secrete and by the constant shedding of epithelial cells. The endogenous microflora of the integument primarily comprises gram-positive aerobic microbes belonging to the genera *Staphylococcus* and *Streptococcus*, as well as *Corynebacterium* and *Propionibacterium* species. These organisms plus *Enterococcus faecalis* and *faecium*, *Escherichia coli* and other Enterobacteriaceae, and yeast such as *Candida albicans* can be isolated from the infraumbilical regions of the body. Diseases of the skin (e.g., eczema and dermatitis) are associated with overgrowth of skin commensal organisms, and barrier breaches invariably lead to the introduction of these microbes.

The respiratory tract possesses several host defense mechanisms that facilitate the maintenance of sterility in the distal bronchi and alveoli under normal circumstances. In the upper respiratory tract, respiratory mucus traps larger particles, including microbes. This mucus is then passed into the upper airways and oropharynx by ciliated epithelial cells, where the mucus is cleared via coughing. Smaller particles arriving in the lower respiratory tract are cleared via phagocytosis by pulmonary alveolar macrophages. Any process that diminishes these host defenses can lead to development of bronchitis or pneumonia.

The urogenital, biliary, pancreatic ductal, and distal respiratory tracts do not possess resident microflora in healthy individuals, although microbes may be present if these barriers are affected by disease (e.g., malignancy, inflammation, calculi, or foreign body), or if microorganisms are introduced from an external source (e.g., urinary catheter or pulmonary aspiration). In contrast, significant numbers of microbes are encountered in many portions of the gastrointestinal tract, with vast numbers being found within the oropharynx and distal colon or rectum, although the specific organisms differ.

One would suppose that the entire gastrointestinal tract would be populated via those microbes found in the oropharynx, but this is not the case.⁹ This is because after ingestion these organisms routinely are killed in the highly acidic, low-motility environment of the stomach during the initial phases of digestion. Thus, small numbers of microbes populate the gastric mucosa $\sim 10^2$ to 10^3 colony-forming units (CFU)/mL. This population expands in the presence of drugs or disease states that diminish gastric acidity. Microbes that are not destroyed within the stomach enter the small intestine, in which a certain amount of microbial proliferation takes place, such that approximately 10^5 to 10^8 CFU/mL are present in the terminal ileum.

The relatively low-oxygen, static environment of the colon is accompanied by the exponential growth of microbes that comprise the most extensive host endogenous microflora. Anaerobic microbes outnumber aerobic species approximately 100:1 in the distal colon, and approximately 10^{11} to 10^{12} CFU/g are present in feces. Large numbers of facultative and strict anaerobes (*Bacteroides fragilis*, *distasonis*, and *thetaiotaomicron*, *Bifidobacterium*, *Clostridium*, *Eubacterium*, *Fusobacterium*, *Lactobacillus*, and *Peptostreptococcus* species) as well as several orders of magnitude fewer aerobic microbes (*Escherichia coli* and other Enterobacteriaceae, *Enterococcus faecalis* and *faecium*, *Candida albicans* and other *Candida* spp.) are present. Intriguingly, although colonization resistance on the part of this extensive, well-characterized host microflora effectively prevents invasion of enteric pathogens such as *Salmonella*, *Shigella*, *Vibrio*, and other enteropathogenic bacterial species, these same organisms

provide the initial inoculum for infection should perforation of the gastrointestinal tract occur. It is of great interest that only some of these microbial species predominate in established intra-abdominal infections.

Once microbes enter a sterile body compartment (e.g., pleural or peritoneal cavity) or tissue, additional host defenses act to limit and/or eliminate these pathogens. Initially, several primitive and relatively nonspecific host defenses act to contain the nidus of infection, which may include microbes as well as debris, devitalized tissue, and foreign bodies, depending on the nature of the injury. These defenses include the physical barrier of the tissue itself, as well as the capacity of proteins, such as lactoferrin and transferrin to sequester the critical microbial growth factor iron, thereby limiting microbial growth. In addition, fibrinogen within the inflammatory fluid has the ability to trap large numbers of microbes during the process in which it polymerizes into fibrin. Within the peritoneal cavity, unique host defenses exist, including a diaphragmatic pumping mechanism whereby particles, including microbes within peritoneal fluid are expunged from the abdominal cavity via specialized structures (stomata) on the undersurface of the diaphragm that lead to thoracic lymphatic channels. Concurrently, containment by the omentum, the so-called “gatekeeper” of the abdomen and intestinal ileus, serves to wall off infections. However, the latter processes and fibrin trapping have a high likelihood of contributing to the formation of an intra-abdominal abscess.

Microbes also immediately encounter a series of host defense mechanisms that reside within the vast majority of tissues of the body. These include resident macrophages and low levels of complement (C) proteins and immunoglobulins (e.g., antibodies).¹⁰ The response in macrophages is initiated by genome-encoded pattern recognition receptors which respond to invading microbes. With exposure to a foreign organism, these receptors recognize microbial pathogen-associated molecular patterns (PAMPs) and endogenous danger-associated molecular patterns (DAMPs). Toll-like receptors (TLRs) are one well-defined example of a PAMP that plays an important role in pathogen signaling.¹¹ Resident macrophages secrete a wide array of substances in response to the above-mentioned processes, some of which appear to regulate the cellular components of the host defense response. This results in recruitment and proliferation of inflammatory cells. Macrophage cytokine synthesis is upregulated. Secretion of tumor necrosis factor- α (TNF- α), of interleukins (IL)-1 β , 6, and 8; and of gamma interferon (IFN- γ) occurs within the tissue milieu, and, depending on the magnitude of the host defense response, the systemic circulation.¹² Concurrently, a counterregulatory response is initiated consisting of binding protein (TNF-BP), cytokine receptor antagonists (e.g., IL-1ra), and anti-inflammatory cytokines (IL-4 and IL-10).

The interaction of microbes with these first-line host defenses leads to microbial opsonization (C1q, C3bi, and IgFc), phagocytosis, and both extracellular (C5b6-9 membrane attack complex) and intracellular microbial destruction (via cellular ingestion into phagocytic vacuoles). Concurrently, the classical and alternate complement pathways are activated both via direct contact with and via IgM>IgG binding to microbes, leading to the release of a number of different complement protein fragments (C3a, C4a, C5a) that are biologically active, acting to markedly enhance vascular permeability. Bacterial cell wall components and a variety of enzymes that are expelled from

leukocyte phagocytic vacuoles during microbial phagocytosis and killing act in this capacity as well.

Simultaneously, the release of substances to which polymorphonuclear leukocytes (PMNs) in the bloodstream are attracted takes place. These consist of C5a, microbial cell wall peptides containing *N*-formyl-methionine, and macrophage secretion of cytokines such as IL-8. This process of host defense recruitment leads to further influx of inflammatory fluid into the area of incipient infection, and is accompanied by diapedesis of large numbers of PMNs, a process that begins within several minutes and may peak within hours or days. The magnitude of the response and eventual outcome generally are related to several factors: (a) the initial number of microbes, (b) the rate of microbial proliferation in relation to containment and killing by host defenses, (c) microbial virulence, and (d) the potency of host defenses. In regard to the latter, drugs or disease states that diminish any or multiple components of host defenses are associated with higher rates and potentially more grave infections.

Definitions

Several possible outcomes can occur subsequent to microbial invasion and the interaction of microbes with resident and recruited host defenses: (a) eradication, (b) containment, often leading to the presence of purulence—the hallmark of chronic infections (e.g., a furuncle in the skin and soft tissue or abscess within the parenchyma of an organ or potential space), (c) locoregional infection (cellulitis, lymphangitis, and aggressive soft tissue infection) with or without distant spread of infection (metastatic abscess), or (d) systemic infection (bacteremia or fungemia). Obviously, the latter represents the failure of resident and recruited host defenses at the local level, and is associated with significant morbidity and mortality in the clinical setting. In addition, it is not uncommon that disease progression occurs such that serious locoregional infection is associated with concurrent systemic infection. A chronic abscess also may intermittently drain and/or be associated with bacteremia.

Infection is defined by the presence of microorganisms in host tissue or the bloodstream. At the site of infection the classic findings of rubor, calor, and dolor in areas such as the skin or subcutaneous tissue are common. Most infections in normal individuals with intact host defenses are associated with these local manifestations, plus systemic manifestations such as elevated temperature, elevated white blood cell (WBC) count, tachycardia, or tachypnea. The systemic manifestations noted previously comprise the *systemic inflammatory response syndrome* (SIRS). A documented or suspected infection with some of the findings of SIRS define *sepsis*.¹³

SIRS can be caused by a variety of disease processes, including pancreatitis, polytrauma, malignancy, transfusion reaction, as well as infection (Fig. 6-1). There are a variety of systemic manifestations of infection, with the classic factors of fever, tachycardia, and tachypnea, broadened to include a variety of other variables (Table 6-1).¹³ Sepsis (SIRS caused by infection) is mediated by the production of a cascade of pro-inflammatory mediators produced in response to exposure to microbial products. These products include lipopolysaccharide (endotoxin, LPS) derived from Gram-negative organisms; peptidoglycans and teichoic acids from gram-positive organisms; many different microbial cell wall components, such as mannan from yeast and fungi; and many others.

Severe sepsis is characterized as sepsis (defined previously) combined with the presence of new-onset organ failure.

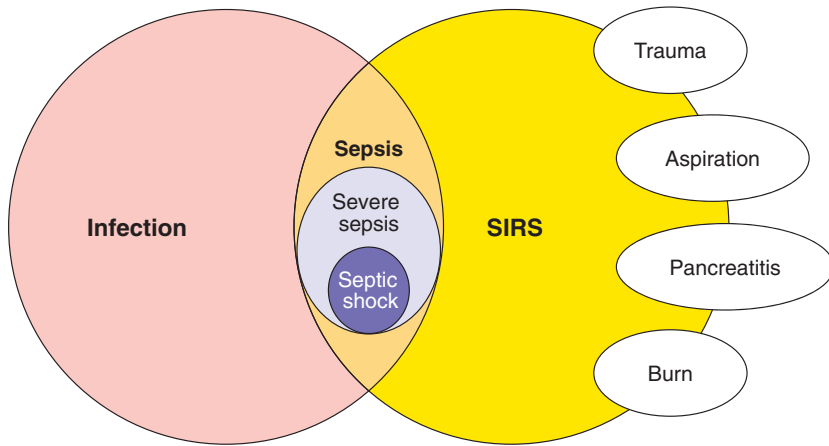


Figure 6-1. Relationship between infection and systemic inflammatory response syndrome (SIRS). Sepsis is the presence both of infection and the systemic inflammatory response, shown here as the intersection of these two areas. Other conditions may cause SIRS as well (trauma, aspiration, etc.). Severe sepsis (and septic shock) are both subsets of sepsis.

Severe sepsis is the most common cause of death in noncoronary critical care units and the 11th most common cause of death overall in the United States, with a mortality rate of 10.3 cases/100,000 population in 2010.¹⁴ A number of organ dysfunction scoring systems have been described.^{15,16,17} With

respect to clinical criteria, a patient with sepsis and the need for ventilatory support, with oliguria unresponsive to aggressive fluid resuscitation, or with hypotension requiring vasopressors should be considered to have developed severe sepsis. *Septic shock* is a state of acute circulatory failure identified by the presence of persistent arterial hypotension (systolic blood pressure <90 mm Hg) despite adequate fluid resuscitation, without other identifiable causes. Septic shock is the most severe manifestation of infection, occurring in approximately 40% of patients with severe sepsis; it has an attendant mortality rate of 30% to 66%.^{18,19}

While classification of severity of shock has been successful in driving efforts to improve patient outcomes, staging of sepsis by other patient characteristics remains in its infancy. The impetus for development of such a scheme is related to the heterogeneity of the patient population developing sepsis, an example of which would include two patients, both in the intensive care unit (ICU), who develop criteria consistent with septic shock. While both have infection and sepsis-associated hypotension, one might expect a different outcome in a young, healthy patient who develops urosepsis than in an elderly, immunosuppressed lung transplant recipient who develops invasive fungal infection. One schema for providing such a classification is the predisposition, infection, response and organ failure (PIRO) classification.²⁰ This scheme has borrowed from the tumor-node-metastasis staging scheme developed for oncology. The PIRO staging system stratifies patients based on their predisposing conditions (P), the nature and extent of the infection (I), the nature and magnitude of the host response (R), and the degree of concomitant organ dysfunction (O). Clinical trials using this classification system have confirmed the validity of this concept.^{21,22}

Table 6-1

Criteria for systemic inflammatory response syndrome (SIRS)

General variables

Fever (core temp >38.3°C)
Hypothermia (core temp <36°C)
Heart rate >90 bpm
Tachypnea

Altered mental status

Significant edema or positive fluid balance (>20 mL/kg over 24 h)
Hyperglycemia in the absence of diabetes

Inflammatory variables

Leukocytosis (WBC >12,000)
Leukopenia (WBC <4000)
Bandemia (>10% band forms)
Plasma C-reactive protein >2 s.d. above normal value
Plasma procalcitonin >2 s.d. above normal value

Hemodynamic variables

Arterial hypotension (SBP <90 mm Hg, MAP <70, or SBP decrease >40 mm Hg)

Organ dysfunction variables

Arterial hypoxemia
Acute oliguria
Creatinine increase
Coagulation abnormalities
Ileus
Thrombocytopenia
Hyperbilirubinemia

Tissue perfusion variables

Hyperlactatemia
Decreased capillary filling

bpm = beats per minute; MAP = mean arterial pressure; SBP = systolic blood pressure; s.d. = standard deviations; Svo₂ = venous oxygen saturation; WBC = white blood cell count.

MICROBIOLOGY OF INFECTIOUS AGENTS

A partial list of common pathogens that cause infections in surgical patients is provided in Table 6-2.

Bacteria

Bacteria are responsible for the majority of surgical infections. Specific species are identified using Gram's stain and growth characteristics on specific media. The Gram's stain is an important evaluation that allows rapid classification of bacteria by color. This color is related to the staining characteristics of the bacterial cell wall: gram-positive bacteria stain blue and Gram-negative bacteria stain red. Bacteria are classified based upon

Table 6-2

Common Pathogens in Surgical Patients

Gram-positive aerobic cocci

Staphylococcus aureus
Staphylococcus epidermidis
Streptococcus pyogenes
Streptococcus pneumoniae
Enterococcus faecium, *E. faecalis*

Gram-negative aerobic bacilli

Escherichia coli
Haemophilus influenzae
Klebsiella pneumoniae
Proteus mirabilis
Enterobacter cloacae, *E. aerogenes*
Serratia marcescens
Acinetobacter calcoaceticus
Citrobacter freundii
Pseudomonas aeruginosa
Xanthomonas maltophilia

Anaerobes

Gram-positive
Clostridium difficile
Clostridium perfringens, *C. tetani*, *C. septicum*
Peptostreptococcus spp.
 Gram-negative
Bacteroides fragilis
Fusobacterium spp.

Other bacteria

Mycobacterium avium-intracellulare
Mycobacterium tuberculosis
Nocardia asteroides
Legionella pneumophila
Listeria monocytogenes

Fungi

Aspergillus fumigatus, *A. niger*, *A. terreus*, *A. flavus*
Blastomyces dermatitidis
Candida albicans
Candida glabrata, *C. parapsilosis*, *C. krusei*
Coccidioides immitis
Cryptococcus neoformans
Histoplasma capsulatum
Mucor/Rhizopus

Viruses

Cytomegalovirus
 Epstein-Barr virus
 Hepatitis A, B, C viruses
 Herpes simplex virus
 Human immunodeficiency virus
 Varicella zoster virus

a number of additional characteristics, including morphology (cocci and bacilli), the pattern of division (e.g., single organisms, groups of organisms in pairs [diplococci], clusters [staphylococci], and chains [streptococci]), and the presence and location of spores.

Gram-positive bacteria that frequently cause infections in surgical patients include aerobic skin commensals (*Staphylococcus*

aureus and *epidermidis* and *Streptococcus pyogenes*) and enteric organisms such as *Enterococcus faecalis* and *faecium*. Aerobic skin commensals cause a large percentage of surgical site infections (SSIs), either alone or in conjunction with other pathogens; enterococci can cause nosocomial infections (urinary tract infections [UTIs] and bacteremia) in immunocompromised or chronically ill patients, but are of relatively low virulence in healthy individuals.

There are many pathogenic Gram-negative bacterial species that are capable of causing infection in surgical patients. Most Gram-negative organisms of interest to the surgeon are bacilli belonging to the family Enterobacteriaceae, including *Escherichia coli*, *Klebsiella pneumoniae*, *Serratia marcescens*, and *Enterobacter*, *Citrobacter*, and *Acinetobacter* spp. Other Gram-negative bacilli of note include *Pseudomonas* spp., including *Pseudomonas aeruginosa* and *fluorescens* and *Xanthomonas* spp.

Anaerobic organisms are unable to grow or divide poorly in air, as most do not possess the enzyme catalase, which allows for metabolism of reactive oxygen species. Anaerobes are the predominant indigenous flora in many areas of the human body, with the particular species being dependent on the site. For example, *Propionibacterium acnes* and other species are a major component of the skin microflora and cause the infectious manifestation of acne. As noted previously, large numbers of anaerobes contribute to the microflora of the oropharynx and colon.

Infection due to *Mycobacterium tuberculosis* was once one of the most common causes of death in Europe, causing one in four deaths in the seventeenth and eighteenth centuries. In the nineteenth and twentieth centuries, thoracic surgical intervention was often required for severe pulmonary disease, now an increasingly uncommon occurrence in developed countries. This organism and other related organisms (*M avium-intracellulare* and *M leprae*) are known as acid-fast bacilli. Other acid-fast bacilli include *Nocardia* spp. These organisms typically are slow-growing, sometimes necessitating observation in culture for weeks to months prior to final identification, although deoxyribonucleic acid (DNA)-based analysis is increasingly available to provide a means for preliminary, rapid detection.

Fungi

Fungi typically are identified by use of special stains (e.g., potassium hydroxide (KOH), India ink, methenamine silver, or Giemsa). Initial identification is assisted by observation of the form of branching and septation in stained specimens or in culture. Final identification is based on growth characteristics in special media, similar to bacteria, as well as on the capacity for growth at a different temperature (25°C vs. 37°C). Fungi of relevance to surgeons include those that cause nosocomial infections in surgical patients as part of polymicrobial infections or fungemia (e.g., *Candida albicans* and related species), rare causes of aggressive soft tissue infections (e.g., *Mucor*, *Rhizopus*, and *Absidia* spp.), and so-called opportunistic pathogens that cause infection in the immunocompromised host (e.g., *Aspergillus fumigatus*, *niger*, *terreus*, and other spp., *Blastomyces dermatitidis*, *Coccidioides immitis*, and *Cryptococcus neoformans*). Agents currently available for antifungal therapy are described in Table 6-3.

Viruses

Due to their small size and necessity for growth within cells, viruses are difficult to culture, requiring a longer time than is typically optimal for clinical decision making. Previously, viral

Table 6-3

Antifungal agents and their characteristics

ANTIFUNGAL	ADVANTAGES	DISADVANTAGES
Amphotericin B	Broad-spectrum, inexpensive	Renal toxicity, premeds, IV only
Liposomal Amphotericin B	Broad-spectrum	Expensive, IV only, renal toxicity
<i>Azoles</i>		
Fluconazole	IV and PO availability	Narrow-spectrum, drug interactions
Itraconazole	IV and PO availability	Narrow spectrum, no CSF penetration Drug interactions, decreased cardiac contractility
Posaconazole	Broad-spectrum, zygomycete activity	PO only
Voriconazole	IV and PO availability, broad-spectrum	IV diluent accumulates in renal failure (PO) Visual disturbances
<i>Echinocandins</i>		
Anidulafungin, caspofungin, micafungin	Broad-spectrum	IV only, poor CNS penetration

infection was identified by indirect means (i.e., the host antibody response). Recent advances in technology have allowed for the identification of the presence of viral DNA or ribonucleic acid (RNA) using methods such as polymerase chain reaction. Similarly to many fungal infections, most clinically relevant viral infections in surgical patients occur in the immunocompromised host, particularly those receiving immunosuppression to prevent rejection of a solid organ allograft. Relevant viruses include adenoviruses, cytomegalovirus, Epstein-Barr virus, herpes simplex virus, and varicella-zoster virus. Surgeons must be aware of the manifestations of hepatitis B and C virus, as well as human immunodeficiency virus infections, including their capacity to be transmitted to health care workers (see *General Principles* section). Prophylactic and therapeutic use of antiviral agents is discussed in Chap. 11.

PREVENTION AND TREATMENT OF SURGICAL INFECTIONS

General Principles

Maneuvers to diminish the presence of exogenous (surgeon and operating room environment) and endogenous (patient) microbes are termed *prophylaxis*, and consist of the use of mechanical, chemical, and antimicrobial modalities, or a combination of these methods.

As described previously, the host resident microflora of the skin (patient and surgeon) and other barrier surfaces represent a potential source of microbes that can invade the body during trauma, thermal injury, or elective or emergent surgical intervention. For this reason, operating room personnel are versed in mild mechanical exfoliation of the skin of the hands and forearms using antibacterial preparations, and the intraoperative aseptic technique is employed. Similarly, application of an antibacterial agent to the skin of the patient at the proposed operative site takes place prior to creating an incision. Also, if necessary, hair removal should take place using a clipper rather than a razor; the latter promotes overgrowth of skin microbes in small nicks and cuts. Dedicated use of these modalities clearly

has been shown to diminish the quantity of skin microflora, and although a direct correlation between praxis and reduced infection rates has not been demonstrated, comparison to infection rates prior to the use of antisepsis and sterile technique makes clear their utility and importance.

The aforementioned modalities are not capable of sterilizing the hands of the surgeon or the skin or epithelial surfaces of the patient, although the inoculum can be reduced considerably. Thus, entry through the skin, into the soft tissue, and into a body cavity or hollow viscus invariably is associated with the introduction of some degree of microbial contamination. For that reason, patients who undergo procedures that may be associated with the ingress of significant numbers of microbes (e.g., colonic resection) or in whom the consequences of any type of infection due to said process would be dire (e.g., prosthetic vascular graft infection) should receive an antimicrobial agent.

Source Control

The primary precept of surgical infectious disease therapy consists of drainage of all purulent material, débridement of all infected, devitalized tissue, and debris, and/or removal of foreign bodies at the site of infection, plus remediation of the underlying cause of infection.²³ A discrete, walled-off purulent fluid collection (i.e., an abscess) requires drainage via percutaneous drain insertion or an operative approach in which incision and drainage take place. An ongoing source of contamination (e.g., bowel perforation) or the presence of an aggressive, rapidly spreading infection (e.g., necrotizing soft tissue infection) invariably requires expedient, aggressive operative intervention, both to remove contaminated material and infected tissue (e.g., radical débridement or amputation) and to remove the initial cause of infection (e.g., bowel resection). Other treatment modalities such as antimicrobial agents, albeit critical, are of secondary importance to effective surgery with regard to treatment of surgical infections and overall outcome. Rarely, if ever, can an aggressive surgical infection be cured only by the administration of antibiotics, and never in the face of an ongoing source of contamination. Also, it has been repeatedly demonstrated that delay in operative intervention, whether due

to misdiagnosis or the need for additional diagnostic studies, is associated with increased morbidity and occasional mortality.²⁴

Appropriate Use of Antimicrobial Agents

A classification of antimicrobial agents, mechanisms of action, and spectrum of activity is shown in Table 6-4. *Prophylaxis* consists of the administration of an antimicrobial agent or agents prior to initiation of certain specific types of surgical procedures in order to reduce the number of microbes that enter the tissue or body cavity. Agents are selected according to their activity against microbes likely to be present at the surgical site, based on knowledge of host microflora. For example, patients undergoing elective colorectal surgery should receive antimicrobial prophylaxis directed against skin flora, gram negative aerobes, and anaerobic bacteria. There are a wide variety of agents that meet these criteria with recently published guidelines.²⁵

By definition, prophylaxis is limited to the time prior to and during the operative procedure; in the vast majority of cases only a single dose of antibiotic is required, and only for certain types of procedures (see Surgical Site Infections). However, patients who undergo complex, prolonged procedures in which the duration of the operation exceeds the serum drug half-life should receive an additional dose or doses of the antimicrobial agent.²⁵ There is no evidence that administration of postoperative doses of an antimicrobial agent provides additional benefit, and this practice should be discouraged, as it is costly and is associated with increased rates of microbial drug resistance. Guidelines for prophylaxis are provided in Table 6-5.

Empiric therapy comprises the use of an antimicrobial agent or agents when the risk of a surgical infection is high, based on the underlying disease process (e.g., ruptured appendicitis), or when significant contamination during surgery has occurred (e.g., inadequate bowel preparation or considerable spillage of colon contents). Obviously, prophylaxis merges into empirical therapy in situations in which the risk of infection increases markedly because of intraoperative findings. Empirical therapy also often is employed in critically ill patients in whom a potential site of infection has been identified and severe sepsis or septic shock occurs. Invariably, empirical therapy should be limited to a short course of drug (3 to 5 days), and should be curtailed as soon as possible based on microbiologic data (i.e., absence of positive cultures) coupled with improvements in the clinical course of the patient.

Similarly, empirical therapy merges into therapy of established infection in some patients as well. However, among surgical patients, the manner in which therapy is employed, particularly in relation to the use of microbiologic data (culture and antibiotic sensitivity patterns), differs depending on whether the infection is monomicrobial or polymicrobial. Monomicrobial infections frequently are nosocomial infections occurring in postoperative patients, such as UTIs, pneumonia, or bacteremia. Evidence of systemic inflammatory response syndrome (fever, tachycardia, tachypnea, or elevated leukocyte count) in such individuals, coupled with evidence of local infection (e.g., an infiltrate on chest roentgenogram plus a positive Gram's stain in bronchoalveolar lavage samples) should lead the surgeon to initiate empirical antibiotic therapy. An appropriate approach to antimicrobial treatment involves de-escalation therapy, where initial antimicrobial selection is broad, with a later narrowing of agents based on patient response and culture results. Initial drug selection must be based on initial evidence (Gram-positive vs.

Gram-negative microbes, yeast), coupled with institutional and unit-specific drug sensitivity patterns. It is important to ensure that antimicrobial coverage chosen is adequate, since delay in appropriate antibiotic treatment has been shown to be associated with significant increases in mortality. A critical component of this approach is appropriate collection of culture specimens to allow for thorough analysis, since within 48 to 72 hours, culture and sensitivity reports will allow refinement of the antibiotic regimen to select the most efficacious agent. The clinical course of the patient is monitored closely, and in some cases (e.g., UTI) follow-up studies (urine culture) should be obtained after completion of therapy.

Although the primary therapeutic modality to treat polymicrobial surgical infections is source control as delineated previously, antimicrobial agents play an important role as well. Culture results are of lesser importance in managing these types of infections, as it has been repeatedly demonstrated that only a limited cadre of microbes predominate in the established infection, selected from a large number present at the time of initial contamination. Invariably it is difficult to identify all microbes that comprise the initial polymicrobial inoculum. For this reason, the antibiotic regimen should not be modified solely on the basis of culture information, as it is less important than the clinical course of the patient. For example, patients who undergo appendectomy for gangrenous, perforated appendicitis, or bowel resection for intestinal perforation, should receive an antimicrobial agent or agents directed against aerobes and anaerobes for 3 to 5 days, occasionally longer. If the patient regains bowel function during this time, conversion from an intravenous to an oral regimen (e.g., ciprofloxacin plus metronidazole) can occur. This is safe, and may facilitate earlier discharge.

A survey of several decades of clinical trials examining the effect of antimicrobial agent selection on the treatment of intra-abdominal infection revealed striking similarities in outcome among regimens that possessed aerobic and anaerobic activity (~10% to 30% failure rates): most failures could not be attributed to antibiotic selection, but rather were due to the inability to achieve effective source control.²⁶

Duration of antibiotic administration should be decided at the time the drug regimen is prescribed. As mentioned previously, prophylaxis is limited to a single dose administered immediately prior to creating the incision. Empiric therapy should be limited to 3 to 5 days or less, and should be curtailed if the presence of a local site or systemic infection is not revealed.²⁷ In fact, prolonged use of empirical antibiotic therapy in culture-negative critically ill patients is associated with increased mortality, highlighting the need to discontinue therapy when there is no proven evidence of infection.²⁸

Therapy for monomicrobial infections follows standard guidelines: 3 to 5 days for UTIs, 7 to 10 days for pneumonia, and 7 to 14 days for bacteremia. Longer courses of therapy in this setting do not result in improved care and are associated with increased risk of superinfection by resistant organisms.^{29,30} There is some evidence that measuring and monitoring serum procalcitonin trends in the setting of infection allows earlier cessation of antibiotics without decrement in the rate of clinical cure.³¹ Antibiotic therapy for osteomyelitis, endocarditis, or prosthetic infections in which it is hazardous to remove the device consists of prolonged courses of an antibiotic or several agents in combination for 6 to 12 weeks. The specific agents are selected based on analysis of the degree to which the organism is killed *in vitro* using the minimum inhibitory concentration

Table 6-4

Antimicrobial agents

ANTIBIOTIC CLASS, GENERIC NAME	TRADE NAME	MECHANISM OF ACTION	ORGANISM									
			S. PYOGENES	MSSA	MRSA	S. EPIDERMIDIS	ENTEROCOCCUS	VRE	E. COLI	P. AERUGINOSA	ANAEROBES	
Penicillins		Cell wall synthesis inhibitors (bind penicillin-binding protein)										
Penicillin G			1	0	0	0	+/-	0	0	0		1
Nafcillin	Nallpen, Unipen		1	1	0	+/-	0	0	0	0		0
Piperacillin	Pipracil		1	0	0	0	+/-	0	1	1		+/-
Penicillin/beta lactamase inhibitor combinations		Cell wall synthesis inhibitors/beta lactamase inhibitors										
Ampicillin-sulbactam	Unasyn		1	1	0	+/-	1	+/-	1	0		1
Ticarcillin-clavulanate	Timentin		1	1	0	+/-	+/-	0	1	1		1
Piperacillin-tazobactam	Zosyn		1	1	0	1	+/-	0	1	1		1
First-generation cephalosporins		Cell wall synthesis inhibitors (bind penicillin-binding protein)										
Cefazolin, cephalexin	Ancef, Keflex		1	1	0	+/-	0	0	1	0		0
Second-generation cephalosporins		Cell wall synthesis inhibitors (bind penicillin-binding protein)										
Cefoxitin	Mefoxin		1	1	0	+/-	0	0	1	0		1
Cefotetan	Cefotan		1	1	0	+/-	0	0	1	0		1
Cefuroxime	Ceftin		1	1	0	+/-	0	0	1	0		0
Third- and fourth-generation cephalosporins		Cell wall synthesis inhibitors (bind penicillin-binding protein)										

(Continued)

Table 6-4

Antimicrobial agents (continued)

ANTIBIOTIC CLASS, GENERIC NAME	TRADE NAME	MECHANISM OF ACTION	ORGANISM								
			S. PYOGENES	MSSA	MRSA	S. EPIDERMIDIS	ENTEROCOCCUS	VRE	E. COLI	P. AERUGINOSA	ANAEROBES
Ceftriaxone	Rocephin		1	1	0	+/-	0	0	1	0	0
Ceftazidime	Fortaz		1	+/-	0	+/-	0	0	1	1	0
Cefepime	Maxipime		1	1	0	+/-	0	0	1	1	0
Cefotaxime	Cefotaxime		1	1	0	+/-	0	0	1	+/-	0
ceftaroline	Teflaro		1	1	1	1	0	0	1	0	0
Carbapenems		Cell wall synthesis inhibitors (bind penicillin-binding protein)									
Imipenem-cilastatin	Primaxin		1	1	0	1	+/-	0	1	1	1
Meropenem	Merrem		1	1	0	1	0	0	1	1	1
Ertapenem	Invanz		1	1	0	1	0	0	1	+/-	1
Aztreonam	Azactam		0	0	0	0	0	0	1	1	0
Aminoglycosides		Alteration of cell membrane, binding and inhibition of 30S ribosomal unit									
Gentamicin			0	1	0	+/-	1	0	1	1	0
Tobramycin, amikacin			0	1	0	+/-	0	0	1	1	0
Fluoroquinolones		Inhibit topoisomerase II and IV (DNA synthesis inhibition)									
Ciprofloxacin	Cipro		+/-	1	0	1	0	0	1	1	0
Levofloxacin	Levaquin		1	1	0	1	0	0	1	+/-	0
Glycopeptides		Cell wall synthesis inhibition (peptidoglycan synthesis inhibition)								0	0
Vancomycin	Vancocin		1	1	1	1	1	0	0	0	0

Quinupristin-Dalfopristin	Synercid	Inhibits 2 sites on 50S ribosome (protein synthesis inhibition)	1	1	1	1	1	1	0	0	+/-
Linezolid	Zyvox	Inhibits 50S ribosomal activity (protein synthesis inhibition)	1	1	1	1	1	1	0	0	+/-
Daptomycin	Cubicin	Binds bacterial membrane, results in depolarization, lysis	1	1	1	1	1	1	0	0	0
Rifampin		Inhibits DNA-dependent RNA polymerase	1	1	1	1	+/-	0	0	0	0
Clindamycin	Cleocin	Inhibits 50S ribosomal activity (protein synthesis inhibition)	1	1	0	0	0	0	0	0	1
Metronidazole	Flagyl	Production of toxic intermediates (free radical production)	0	0	0	0	0	0	0	0	1
Macrolides		Inhibit 50S ribosomal activity (protein synthesis inhibition)									
Erythromycin			1	+/-	0	+/-	0	0	0	0	0
Azithromycin	Zithromax		1	1	0	0	0	0	0	0	0
Clarithromycin	Biaxin		1	1	0	0	0	0	0	0	0
Trimethoprim-sulfamethoxazole	Bactrim, Septra	Inhibits sequential steps of folate metabolism	+/-	1	0	+/-	0	0	1	0	0
Tetracyclines		Bind 30S ribosomal unit (protein synthesis inhibition)									
Minocycline	Minocin		1	1	0	0	0	0	0	0	+/-
Doxycycline	Vibromycin		1	+/-	0	0	0	0	1	0	+/-
Tigacycline	Tygacil	1	1	1	1	1	1	1	1	0	1

E coli = *Escherichia coli*; MRSA = methicillin-resistant *Staphylococcus aureus*; MSSA = methicillin-sensitive *Staphylococcus aureus*; *P aeruginosa* = *Pseudomonas aeruginosa*; *S epidermidis* = *Staphylococcus epidermidis*; *S pyogenes* = *Streptococcus pyogenes*; VRE = vancomycin-resistant enterococcus.

1 = Reliable activity; +/- = variable activity; 0 = no activity.

The sensitivities presented are generalizations. The clinician should confirm sensitivity patterns at the locale where the patient is being treated since these patterns may vary widely depending on location.

Table 6-5

Prophylactic use of antibiotics (adapted from ref 25)

SITE	ANTIBIOTIC	ALTERNATIVE (E.G., PENICILLIN ALLERGIC)
Cardiovascular surgery	Cefazolin, cefuroxime	Vancomycin, clindamycin
Gastroduodenal area; small intestine, nonobstructed	Cefazolin	Clindamycin or vancomycin + aminoglycoside or aztreonam or fluoroquinolone
Biliary tract: open procedure, laparoscopic high risk	Cefazolin, cefoxitin, cefotetan, ceftriaxone, ampicillin-sulbactam,	Clindamycin or vancomycin + aminoglycoside or aztreonam or fluoroquinolone Metronidazole + aminoglycoside or fluoroquinolone
Biliary tract: laparoscopic low risk	None	none
Appendectomy, uncomplicated	Cefoxitin, cefotetan, cefazolin + metronidazole	Clindamycin + aminoglycoside or aztreonam or fluoroquinolone Metronidazole + aminoglycoside or fluoroquinolone
Colorectal surgery, obstructed small intestine	Cefazolin or ceftriaxone plus metronidazole, Ertapenem, cefoxitin, cefotetan, ampicillin-sulbactam	Clindamycin + aminoglycoside or aztreonam or fluoroquinolone, metronidazole + aminoglycoside or fluoroquinolone
Head and neck; clean contaminated	Cefazolin or cefuroxime + metronidazole, ampicillin-sulbactam	clindamycin
Neurosurgical procedures	Cefazolin	Clindamycin, Vancomycin
Orthopedic surgery	Cefazolin, ceftriaxone	Clindamycin, Vancomycin
Breast, hernia	Cefazolin	Clindamycin, Vancomycin

(MIC) of a standard pure inoculum of 10^5 CFU/mL of the organism isolated from the site of infection or bloodstream. Sensitivities are reported in relation to the achievable blood level of each antibiotic in a panel of agents. The least toxic, least expensive agent to which the organism is most sensitive should be selected, although the latter parameter is of paramount importance. Serious or recrudescence infection may require therapy with two or more agents, particularly if a multidrug-resistant pathogen is causative, limiting therapeutic options to drugs to which the organism is only moderately sensitive. Commonly an agent may be administered intravenously for 1 to 2 weeks, following which the treatment course is completed with an oral drug. However, this should only be undertaken in patients who demonstrate progressive clinical improvement, and the oral agent should be capable of achieving high serum levels as well (e.g., fluoroquinolones).

The majority of studies examining the optimal duration of antibiotic therapy for the treatment of polymicrobial infection have focused on patients who develop peritonitis. CoGeNT data exist to support the contention that satisfactory outcomes are achieved with 12 to 24 hours of therapy for penetrating gastrointestinal trauma in the absence of extensive contamination, 3 to 5 days of therapy for perforated or gangrenous appendicitis, 5 to 7 days of therapy for treatment of peritoneal soilage due to a perforated viscus with moderate degrees of contamination, and 7 to 14 days of therapy to adjunctively treat extensive peritoneal soilage (e.g., feculent peritonitis) or that occurring in the immunosuppressed host.³² It bears repeating that the eventual outcome is more closely linked to the ability of the surgeon to achieve effective source control than to the duration of antibiotic administration. One small randomized trial has reported

similar outcomes of 3 day vs. standard duration therapy in secondary microbial peritonitis.³³

In the later phases of postoperative antibiotic treatment of serious intra-abdominal infection, the absence of an elevated white blood cell (WBC) count, lack of band forms of PMNs on peripheral smear, and lack of fever ($<100.5^\circ\text{F}$) provide close to complete assurance that infection has been eradicated.³⁴ Under these circumstances, antibiotics can be discontinued with impunity. However, the presence of one or more of these indicators does not mandate continuing antibiotics or altering the antibiotic(s) administered. Rather, a search for an extra-abdominal source of infection or a residual or ongoing source of intra-abdominal infection (e.g., abscess or leaking anastomosis) should be sought, the latter mandating maneuvers to effect source control.

Allergy to antimicrobial agents must be considered prior to prescribing them. First, it is important to ascertain whether a patient has had any type of allergic reaction in association with administration of a particular antibiotic. However, one should take care to ensure that the purported reaction consists of true allergic symptoms and signs, such as urticaria, bronchospasm, or other similar manifestations, rather than indigestion or nausea. Penicillin allergy is quite common, the reported incidence ranging from 0.7% to 10%. Although avoiding the use of any beta-lactam drug is appropriate in patients who manifest significant allergic reactions to penicillins, the incidence of cross-reactivity appears low for all related agents, with 1% cross-reactivity for carbapenems,³⁵ 5% to 7% cross-reactivity for cephalosporins, and extremely small or nonexistent cross-reactivity for monobactams.

Severe allergic manifestations to a specific class of agents, such as anaphylaxis, generally preclude the use of any agents in

that class, except under circumstances in which use of a certain drug represents a lifesaving measure. In some centers, patients undergo intradermal testing using a dilute solution of a particular antibiotic to determine whether a severe allergic reaction would be elicited by parenteral administration. A pathway, including such intradermal testing, has been effective in reduction of vancomycin use to 16% in surgical patients with reported allergy to penicillin.³⁶ This type of testing is rarely employed because it is simpler to select an alternative class of agent. Should administration of a specific agent to which the patient is allergic become necessary, desensitization using progressively higher doses of antibiotic can be undertaken, providing the initial testing does not cause severe allergic manifestations.

Misuse of antimicrobial agents is rampant in both the inpatient and outpatient setting, and is associated with an enormous financial impact on health care costs, adverse reactions due to drug toxicity and allergy, the occurrence of new infections such as *Clostridium difficile* colitis, and the development of multiagent drug resistance among nosocomial pathogens. Each of these factors has been directly correlated with overall drug administration. It has been estimated that in the United States, in excess of \$20 billion is spent on antibiotics each year, and the appearance of so-called “super bugs”—microbes sensitive to few if any agents—has been sobering.³⁷ The responsible practitioner limits prophylaxis to the period during the operative procedure, does not convert prophylaxis into empirical therapy except under well-defined conditions, sets the duration of antibiotic therapy from the outset, curtails antibiotic administration when clinical and microbiologic evidence does not support the presence of an infection, and limits therapy to a short course in every possible instance. Prolonged treatment associated with drains and tubes has not been shown to be beneficial.

INFECTIONS OF SIGNIFICANCE IN SURGICAL PATIENTS

Surgical Site Infections

Surgical site infections (SSIs) are infections of the tissues, organs, or spaces exposed by surgeons during performance of an invasive procedure. SSIs are classified into incisional and organ/space infections, and the former are further subclassified into superficial (limited to skin and subcutaneous tissue) and deep incisional categories.^{38,39} The development of SSIs is related to three factors: (a) the degree of microbial contamination of the wound during surgery, (b) the duration of the procedure, and (c) host factors such as diabetes, malnutrition, obesity, immune suppression, and a number of other underlying disease states. Table 6-6 lists risk factors for development of SSIs. By definition, an incisional SSI has occurred if a surgical wound drains purulent material or if the surgeon judges it to be infected and opens it.

Surgical wounds are classified based on the presumed magnitude of the bacterial load at the time of surgery (Table 6-7).⁴⁰ *Clean wounds* (class I) include those in which no infection is present; only skin microflora potentially contaminate the wound, and no hollow viscus that contains microbes is entered. Class I D wounds are similar except that a prosthetic device (e.g., mesh or valve) is inserted. *Clean/contaminated wounds* (class II) include those in which a hollow viscus such as the respiratory, alimentary, or genitourinary tracts with indigenous

Table 6-6

Risk factors for development of surgical site infections

Patient factors	
	Older age
	Immunosuppression
	Obesity
	Diabetes mellitus
	Chronic inflammatory process
	Malnutrition
	Smoking
	Renal failure
	Peripheral vascular disease
	Anemia
	Radiation
	Chronic skin disease
	Carrier state (e.g., chronic <i>Staphylococcus</i> carriage)
	Recent operation
Local factors	
	Open compared to laparoscopic surgery
	Poor skin preparation
	Contamination of instruments
	Inadequate antibiotic prophylaxis
	Prolonged procedure
	Local tissue necrosis
	Blood transfusion
	Hypoxia, hypothermia
Microbial factors	
	Prolonged hospitalization (leading to nosocomial organisms)
	Toxin secretion
	Resistance to clearance (e.g., capsule formation)

bacterial flora is opened under controlled circumstances without significant spillage of contents.

While elective colorectal cases have classically been included as class II cases, a number of studies in the last decade have documented higher SSI rates (9% to 25%).⁴¹⁻⁴³ One study identified two-thirds of infections presenting after discharge from hospital, highlighting the need for careful follow-up of these patients.⁴¹ Infection is also more common in cases involving entry into the rectal space.⁴² In a recent single center quality improvement study using a multidisciplinary approach, one group of clinicians has demonstrated the ability to decrease SSI from 9.8% to 4.0%.⁴³

Contaminated wounds (class III) include open accidental wounds encountered early after injury, those with extensive introduction of bacteria into a normally sterile area of the body due to major breaks in sterile technique (e.g., open cardiac massage), gross spillage of viscus contents such as from the intestine, or incision through inflamed, albeit nonpurulent tissue. *Dirty wounds* (class IV) include traumatic wounds in which a significant delay in treatment has occurred and in which necrotic tissue is present, those created in the presence of overt infection as evidenced by the presence of purulent material, and those created to access a perforated viscus accompanied by a high degree of contamination. The microbiology of SSIs is reflective of the initial host microflora such that SSIs following creation of a class I wound are invariable, due solely to skin microbes found

Table 6-7

Wound class, representative procedures, and expected infection rates

WOUND CLASS	EXAMPLES OF CASES	EXPECTED INFECTION RATES
Clean (class I)	Hernia repair, breast biopsy specimen	1%–2%
Clean/contaminated (class II)	Cholecystectomy, elective GI surgery (not colon)	2.1%–9.5%
Clean/contaminated (class II)	Colorectal surgery	4%–14%
Contaminated (class III)	Penetrating abdominal trauma, large tissue injury, enterotomy during bowel obstruction	3.4%–13.2%
Dirty (class IV)	Perforated diverticulitis, necrotizing soft tissue infections	3.1%–12.8%

on that portion of the body, while SSIs subsequent to a class II wound created for the purpose of elective colon resection may be caused by either skin microbes or colonic microflora, or both.

In the United States, hospitals are required to conduct surveillance for the development of SSIs for a period of 30 days after the operative procedure.⁴⁴ Such surveillance has been associated with greater awareness and a reduction in SSI rates, probably in large part based upon the impact of observation and promotion of adherence to appropriate care standards. Beginning in 2012, all hospitals receiving reimbursement from the Center for Medicare and Medicaid Services are required to report SSIs.

A recent refinement of risk indexes has been implemented through the National Healthcare Safety Network, a secure, web-based system of surveillance utilized by the Centers for Disease Control and Prevention for surveillance of health care associated infections. This refinement utilized data reported from 847 hospitals in nearly one million patients over a two-year period to develop procedure-specific risk indices for SSIs.⁴⁵

SSIs are associated with considerable morbidity and occasional lethality, as well as substantial health care costs and patient inconvenience and dissatisfaction.⁴⁶ For that reason, surgeons strive to avoid SSIs by using the maneuvers described in the previous section. Also, the use of prophylactic antibiotics may serve to reduce the incidence of SSI rates during certain types of procedures. For example, it is well accepted that a single

dose of an antimicrobial agent should be administered immediately prior to commencing surgery for class I D, II, III, and IV types of wounds. It seems reasonable that this practice should be extended to patients in any category with high National Nosocomial Infection Surveillance (NNIS) scores, although this remains to be proven. Thus, the utility of prophylactic antibiotics in reducing the rate of wound infection subsequent to clean surgery remains controversial, and these agents should not be employed under routine circumstances (e.g., in healthy young patients). However, because of the potential dire consequences of a wound infection after clean surgery in which prosthetic material is implanted into tissue, patients who undergo such procedures should receive a single preoperative dose of an antibiotic.

A number of health care organizations within the United States have become interested in evaluating performance of hospitals and physicians with respect to implementing processes that support delivery of standard of care. One major process of interest is reduction in SSIs, since the morbidity (and subsequent cost) of this complication is high. Several of these organizations are noted in Table 6-8. Appropriate guidelines in this area incorporating the principles discussed previously have been developed and disseminated.⁴⁷ However, observers have noted that adherence to these guidelines has been poor.⁴⁸ Most experts believe that better adherence to evidence-based practice recommendations and implementing systems of care

Table 6-8

Quality improvement organizations in the United States of interest to surgeons

ABBREVIATION	ORGANIZATION	WEBSITE
SCIP	Surgical Care Improvement Project	www.premierinc.com/safety/topics/scip/
NSQIP	National Surgical Quality Improvement Program	www.acsnsqip.org
IHI	Institute for Healthcare Improvement	www.ihl.org
CMS	Center for Medicare and Medicaid Services	www.cms.gov
NCQA	National Committee for Quality Assurance	www.ncqa.org
SIS	Surgical Infection Society	www.sisna.org
CDC	Centers for Disease Control and Prevention	www.cdc.gov/HAI/ssi/ssi.html

with redundant safeguards will result in reduction of surgical complications and better patient outcomes. More important, the Center for Medicare and Medicaid Services, the largest third party insurance payer in the United States, has required reporting by hospitals of many processes related to reduction of surgical infections, including appropriate use of perioperative antibiotics. This information, which is currently reported publicly by hospitals, has led to significant improvement in reported rates of these process measures. However, the effect of this approach on the incidence of SSIs is not known at this time.

Surgical management of the wound also is a critical determinant of the propensity to develop a SSI. In healthy individuals, class I and II wounds may be closed primarily, while skin closure of class III and IV wounds is associated with high rates of incisional SSIs (~25% to 50%). The superficial aspects of these latter types of wounds should be packed open and allowed to heal by secondary intention, although selective use of delayed primary closure has been associated with a reduction in incisional SSI rates.⁴⁹ It remains to be determined whether NNIS-type stratification schemes can be employed prospectively in order to target specific subgroups of patients which will benefit from the use of prophylactic antibiotic and/or specific wound management techniques. One clear example based on CoGeNT data from clinical trials is that class III wounds in healthy patients undergoing appendectomy for perforated or gangrenous appendicitis can be primarily closed as long as antibiotic therapy directed against aerobes and anaerobes is administered. This practice leads to SSI rates of approximately 3% to 4%.⁵⁰

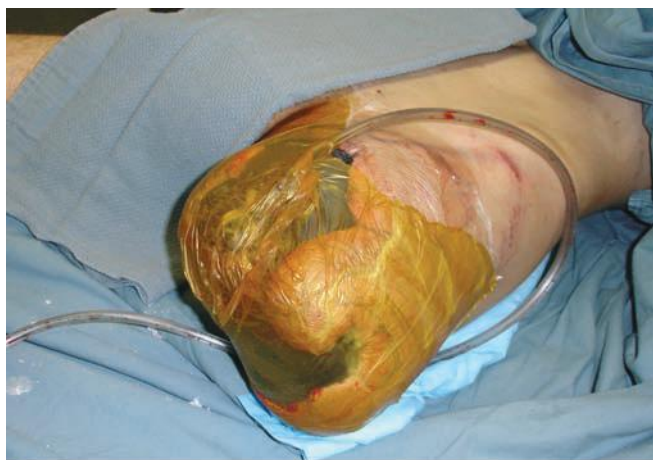Recent investigations have studied the effect of additional maneuvers in an attempt to further reduce the rate of SSIs. The adverse effects of hyperglycemia on WBC function have been well described.⁵¹ A number of recent studies in patients undergoing several different types of surgery describe increased risk of SSI in patients with hyperglycemia.^{52,53} Although randomized trials have not been performed, it is recommended that clinicians maintain appropriate blood sugar control in patients in the perioperative period to minimize the occurrence of SSI.

The respective effects of body temperature and the level of inhaled oxygen during surgery on SSI rates also have been studied, and both hypothermia and hypoxia during surgery are associated with a higher rate of SSIs. Although an initial study provided evidence that patients who received high levels of inhaled oxygen during colorectal surgery developed fewer SSIs,⁵⁴ a recent meta-analysis suggests that the overall benefit is small and may not warrant use.⁵⁵ Further evaluation via multicenter studies is needed prior to implementation of hyperoxia as standard therapy, but it is clear that intraoperative hypothermia and hypoxia should be prevented.

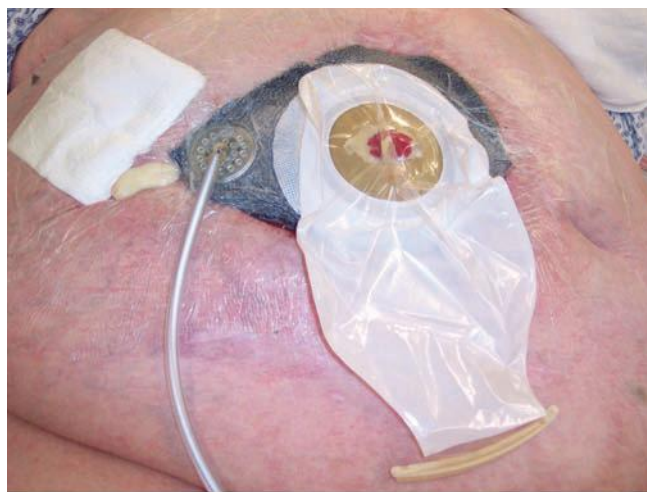Effective therapy for incisional SSIs consists solely of incision and drainage without the additional use of antibiotics. Antibiotic therapy is reserved for patients in whom evidence of significant cellulitis is present, or who concurrently manifest a systemic inflammatory response syndrome. The open wound often is allowed to heal by secondary intention, with dressings being changed twice a day. The use of topical antibiotics and antiseptics to further wound healing remains unproven, although anecdotal studies indicate their potential utility in complex wounds that do not heal with routine measures.⁵⁶ Despite a paucity of prospective studies,⁵⁷ vacuum-assisted closure is increasingly used in management of large, complex open wounds and can be applied to wounds in locations that are difficult to manage with dressings (Fig. 6-2). One also should consider obtaining wound cultures in patients who develop SSIs and whom have been hospitalized or reside in long-term care facilities due to the increasing incidence of infection caused by multidrug resistant organisms. The treatment of organ/space infections is discussed in the following section.

Intra-Abdominal Infections

Microbial contamination of the peritoneal cavity is termed *peritonitis* or *intra-abdominal infection*, and is classified according to etiology. *Primary microbial peritonitis* occurs when microbes invade the normally sterile confines of the peritoneal cavity via hematogenous dissemination from a distant source of infection or



A



B

Figure 6-2. Negative pressure wound therapy in a patient after amputation for wet gangrene (A), and in a patient with enterocutaneous fistula (B). It is possible to adapt these dressings to fit difficult anatomy and provide appropriate wound care while reducing frequency of dressing change. It is important to evaluate the wound under these dressings if patient demonstrates signs of sepsis with an unidentified source, since typical clues of wound sepsis such as odor and drainage are hidden by the suction apparatus.

direct inoculation. This process is more common among patients who retain large amounts of peritoneal fluid due to ascites, and among those individuals who are being treated for renal failure via peritoneal dialysis. These infections invariably are monomicrobial and rarely require surgical intervention. The diagnosis is established based on identification of risk factors as noted previously, physical examination that reveals diffuse tenderness and guarding without localized findings, absence of pneumoperitoneum on an imaging study, the presence of more than 100 WBCs/mL, and microbes with a single morphology on Gram's stain performed on fluid obtained via paracentesis. Subsequent cultures typically will demonstrate the presence of gram positive organisms in patients undergoing peritoneal dialysis. In patients without this risk factor organisms can include *E. coli*, *K. pneumoniae*, pneumococci, and others, although many different pathogens can be causative. Treatment consists of administration of an antibiotic to which the organism is sensitive; often 14 to 21 days of therapy are required. Removal of indwelling devices (e.g., a peritoneal dialysis catheter or a peritoneovenous shunt) may be required for effective therapy of recurrent infections.

Secondary microbial peritonitis occurs subsequent to contamination of the peritoneal cavity due to perforation or severe inflammation and infection of an intra-abdominal organ. Examples include appendicitis, perforation of any portion of the gastrointestinal tract, or diverticulitis. As noted previously, effective therapy requires source control to resect or repair the diseased organ; débridement of necrotic, infected tissue and debris; and administration of antimicrobial agents directed against aerobes and anaerobes.⁵⁸ This type of antibiotic regimen should be chosen because in most patients the precise diagnosis cannot be established until exploratory laparotomy is performed, and the most morbid form of this disease process is colonic perforation, due to the large number of microbes present. A combination of agents or single agents with a broad spectrum of activity can be used for this purpose; conversion of a parenteral to an oral regimen when the patient's ileus resolves provides results similar to those achieved with intravenous antibiotics. Effective source control and antibiotic therapy is associated with low failure rates and a mortality rate of approximately 5% to 6%; inability to control the source of infection is associated with mortality greater than 40%.⁵⁹

The response rate to effective source control and use of appropriate antibiotics has remained approximately 70% to 90% over the past several decades.⁶⁰ Patients in whom standard therapy fails typically develop one or more of the following: an intra-abdominal abscess, leakage from a gastrointestinal anastomosis leading to postoperative peritonitis, or *tertiary (persistent) peritonitis*. The latter is a poorly understood entity that is more common in immunosuppressed patients in whom peritoneal host defenses do not effectively clear or sequester the initial secondary microbial peritoneal infection. Microbes such as *Enterococcus faecalis* and *faecium*, *Staphylococcus epidermidis*, *Candida albicans*, and *Pseudomonas aeruginosa* commonly are identified, typically in combination, and their presence may be due to their lack of responsiveness to the initial antibiotic regimen, coupled with diminished activity of host defenses. Unfortunately, even with effective antimicrobial agent therapy, this disease process is associated with mortality rates in excess of 50%.⁶¹

Formerly, the presence of an intra-abdominal abscess mandated surgical reexploration and drainage. Today, the vast

majority of such abscesses can be effectively diagnosed via abdominal computed tomographic (CT) imaging techniques and drained percutaneously. Surgical intervention is reserved for those individuals who harbor multiple abscesses, those with abscesses in proximity to vital structures such that percutaneous drainage would be hazardous, and those in whom an ongoing source of contamination (e.g., enteric leak) is identified. The necessity of antimicrobial agent therapy and precise guidelines that dictate duration of catheter drainage have not been established. A short course (3 to 7 days) of antibiotics that possess aerobic and anaerobic activity seems reasonable, and most practitioners leave the drainage catheter *in situ* until it is clear that cavity collapse has occurred, output is less than 10 to 20 mL/d, no evidence of an ongoing source of contamination is present, and the patient's clinical condition has improved.

Organ-Specific Infections

Hepatic abscesses are rare, currently accounting for approximately 15 per 100,000 hospital admissions in the United States. Pyogenic abscesses account for approximately 80% of cases, the remaining 20% being equally divided among parasitic and fungal forms.⁶² Formerly, pyogenic liver abscesses mainly were caused by pyelephlebitis due to neglected appendicitis or diverticulitis. Today, manipulation of the biliary tract to treat a variety of diseases has become a more common cause, although in nearly 50% of patients no cause is identified. The most common aerobic bacteria identified in recent series include *E. coli*, *K pneumoniae*, and other enteric bacilli, enterococci, and *Pseudomonas* spp., while the most common anaerobic bacteria are *Bacteroides* spp., anaerobic streptococci, and *Fusobacterium* spp. *Candida albicans* and other related yeast cause the majority of fungal hepatic abscesses. Small (<1 cm), multiple abscesses should be sampled and treated with a 4 to 6 week course of antibiotics. Larger abscesses invariably are amenable to percutaneous drainage, with parameters for antibiotic therapy and drain removal similar to those mentioned previously. Splenic abscesses are extremely rare and are treated in a similar fashion. Recurrent hepatic or splenic abscesses may require operative intervention—unroofing and marsupialization or splenectomy, respectively.

Secondary pancreatic infections (e.g., infected pancreatic necrosis or pancreatic abscess) occur in approximately 10% to 15% of patients who develop severe pancreatitis with necrosis. The surgical treatment of this disorder was pioneered by Bradley and Allen, who noted significant improvements in outcome for patients undergoing repeated pancreatic débridement of infected pancreatic necrosis.⁶³ Current care of patients with severe acute pancreatitis includes staging with dynamic, contrast material-enhanced helical CT scan to evaluate the extent of pancreatitis (unless significant renal dysfunction exists in which case one should forego the use of contrast material) coupled with the use of one of several prognostic scoring systems. Patients who exhibit clinical signs of instability (e.g., oliguria, hypoxemia, large-volume fluid resuscitation) should be carefully monitored in the ICU and undergo follow-up contrast enhanced CT examination when renal function has stabilized to evaluate for development of local pancreatic complications (Fig. 6-3). A recent change in practice has been the elimination of the routine use of prophylactic antibiotics for prevention of infected pancreatic necrosis. Enteral feedings initiated early, using nasojejunal feeding tubes placed past the ligament of Treitz, have been associated with decreased development of infected pancreatic

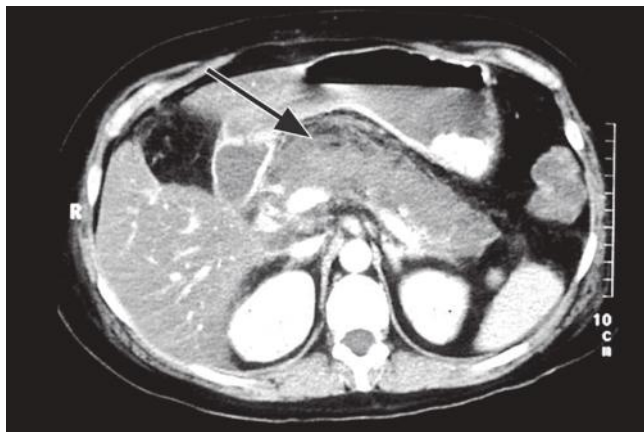

Figure 6-3. Contrast-enhanced CT scan of pancreas 1½ weeks after presentation showing large central peripancreatic fluid collection.

necrosis, possibly due to a decrease in gut translocation of bacteria. These topics have been recently reviewed.^{64,65}

The presence of secondary pancreatic infection should be suspected in patients whose systemic inflammatory response (fever, elevated WBC count, or organ dysfunction) fails to resolve, or in those individuals who initially recuperate, only to develop sepsis syndrome 2 to 3 weeks later. CT-guided aspiration of fluid from the pancreatic bed for performance of Gram's stain and culture analysis can be useful. A positive Gram's stain or culture from CT-guided aspiration, or identification of gas within the pancreas on CT scan, mandate surgical intervention.

The approach of open necrosectomy with repeated debridements, although life saving, is associated with significant morbidity and prolonged hospitalization. Efforts to reduce the amount of surgical injury, while still preserving the improved outcomes associated with debridement of the infected sequestrum have led to a variety of less invasive approaches.⁶⁶ These include endoscopic approaches, laparoscopic approaches and other minimally invasive approaches. There are a limited number of randomized trials reporting the use of these new techniques currently. An important concept common to all of these approaches, however, is the attempt to delay surgical intervention, since a number of trials have identified increased mortality when intervention occurs during the first two weeks of illness.

Data supporting the use of endoscopic approaches to this problem include nearly a dozen case series and a randomized trial.^{67,68} The reported mortality rate was 5%, with a 30% complication rate. Most authors noted the common requirement for multiple endoscopic debridements (similar to the open approach), with a median of 4 endoscopic sessions required. Fewer series report experience with the laparoscopic approach, either transgastric or transperitoneal, entering the necrosis through the transverse mesocolon or gastrocolic ligament. The laparoscopic technique is carefully described in a recent publication.⁶⁹ Laparoscopic intervention is limited by the difficulty in achieving multiple debridements and the technical expertise required to achieve an adequate debridement. Mortality in 65 patients in 9 case series reported was 6% overall.

Debridement of necrosis through a lumbar approach has been advocated by a number of authors. This approach, developed with experience in a large number of patients,⁷⁰ has been recently subjected to a single center randomized prospective

trial.⁷¹ This approach includes delay of intervention when possible until 4 weeks after the onset of disease. Patients receive transgastric or preferably retroperitoneal drainage of the sequestrum. If patients do not improve over 72 hours, they are treated with video-assisted retroperitoneal drainage (VARD), consisting of dilation of the retroperitoneal drain tract, placement of and irrigation, and debridement of the pancreatic bed (Fig. 6-4).

Repeat debridements are performed as clinically indicated, with most patients requiring multiple debridements. In the trial reported, patients randomized to VARD ($n=43$) compared to those randomized to the standard open necrosectomy ($n=45$) had a decreased incidence of the composite endpoint of complications and death (40% vs. 69%), with comparable mortality rate, hospital, and ICU lengths of stay. Patients randomized to VARD had fewer incisional hernias, new-onset diabetes, and need for pancreatic enzyme supplementation.

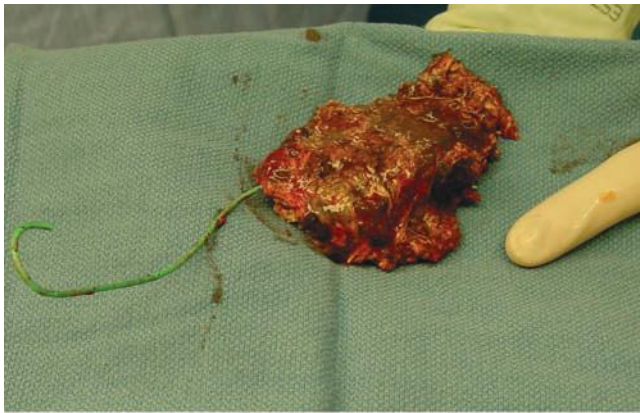
It is apparent that patients with infected pancreatic necrosis can safely undergo procedures that are more minimal than the gold-standard open necrosectomy with good outcomes. However, to obtain good outcomes these approaches require an experienced multidisciplinary team consisting of interventional radiologists, gastroenterologists, surgeons, and others. Important concepts for successful management include careful preoperative planning, delay (if possible) to allow maturation of the fluid collection, and the willingness to repeat procedures as necessary till the majority if not all nonviable tissue has been removed.

Infections of the Skin and Soft Tissue

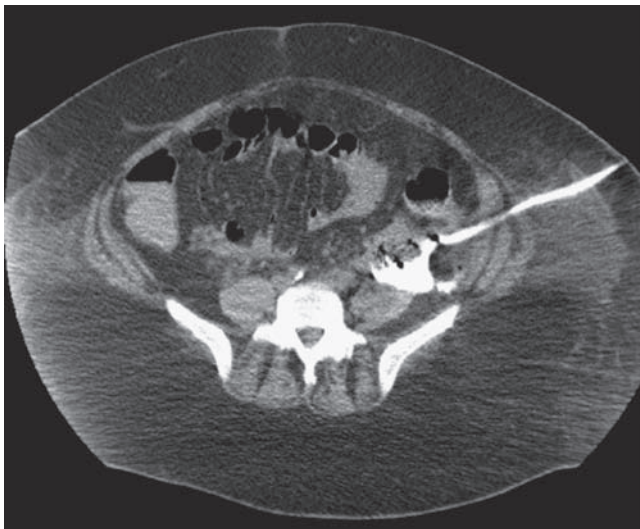
These infections can be classified according to whether or not surgical intervention is required. For example, superficial skin and skin structure infections such as cellulitis, erysipelas, and lymphangitis invariably are effectively treated with antibiotics alone, although a search for a local underlying source of infection should be undertaken. Generally, drugs that possess activity against the causative gram-positive skin microflora are selected. Furuncles or boils may drain spontaneously or require surgical incision and drainage. Antibiotics are prescribed if significant cellulitis is present or if cellulitis does not rapidly resolve after surgical drainage. Community-acquired methicillin resistant *Staphylococcus aureus* (MRSA) infection should be suspected if infection persists after treatment with adequate drainage and administration of first line antibiotics. These infections may require more aggressive drainage and altered antimicrobial therapy.⁷²

Aggressive soft tissue infections are rare, difficult to diagnose, and require immediate surgical intervention plus administration of antimicrobial agents. Failure to do so results in an extremely high mortality rate (~80%–100%), and even with rapid recognition and intervention, current mortality rates are high (16%–24%).⁷³ Eponyms and classification in the past have been a hodgepodge of terminology, such as Meleney's synergist gangrene, rapidly spreading cellulitis, gas gangrene, and necrotizing fasciitis, among others. Today it seems best to delineate these serious infections based on the soft tissue layer(s) of involvement (e.g., skin and superficial soft tissue, deep soft tissue, and muscle) and the pathogen(s) that cause them.

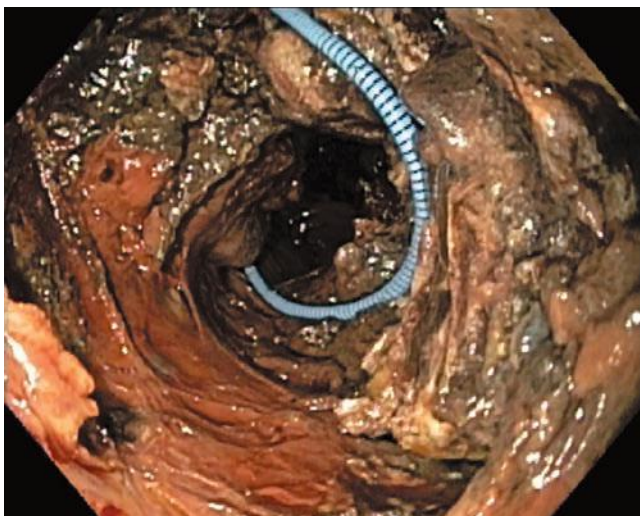
Patients at risk for these types of infections include those who are elderly, immunosuppressed, or diabetic; those who suffer from peripheral vascular disease; or those with a combination of these factors. The common thread among these host factors appears to be compromise of the fascial blood supply to some degree, and if this is coupled with the introduction of



A



B



C

Figure 6-4. Infected pancreatic necrosis. (A) Open necrosectomy specimen with pancreatic stent in situ. It is important to gently debride only necrotic pancreatic tissue, relying on repeated operation to ensure complete removal. (B) For video-assisted retroperitoneal debridement (VARD), retroperitoneal access is gained through radiologic placement of a drain, followed by dilation 2-3 days later. (C) Retroperitoneal cavity seen through endoscope during VARD.

exogenous microbes, the result can be devastating. However, it is of note that over the last decade, extremely aggressive necrotizing soft tissue infections among healthy individuals due to streptococci have been described as well.

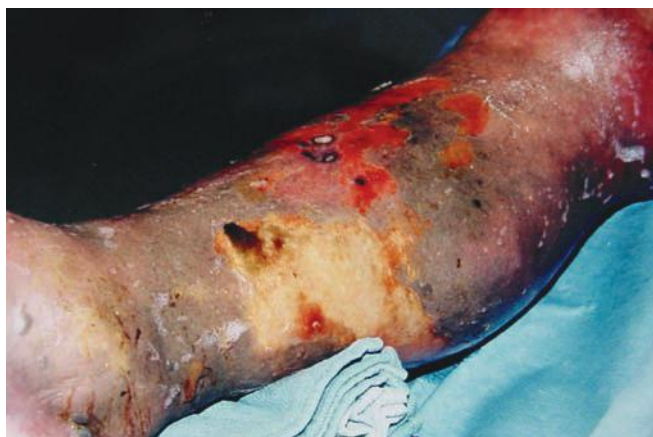Initially, the diagnosis is established solely upon a constellation of clinical findings, not all of which are present in every patient. Not surprisingly, patients often develop sepsis syndrome or septic shock without an obvious cause. The extremities, perineum, trunk, and torso are most commonly affected, in that order. Careful examination should be undertaken for an entry site such as a small break or sinus in the skin from which grayish, turbid semipurulent material (“dishwater pus”) can be expressed, as well as for the presence of skin changes (bronze hue or brawny induration), blebs, or crepitus. The patient often develops pain at the site of infection that appears to be out of proportion to any of the physical manifestations. Any of these findings mandates immediate surgical intervention, which should consist of exposure and direct visualization of potentially infected tissue (including deep soft tissue, fascia, and underlying muscle) and radical resection of affected areas. Radiologic studies should not be undertaken in patients in whom the diagnosis seriously is considered, as they delay surgical intervention and frequently provide confusing information. Unfortunately, surgical extirpation of infected tissue frequently entails amputation and/or disfiguring procedures; however, incomplete procedures are associated with higher rates of morbidity and mortality (Fig. 6-5).

During the procedure a Gram’s stain should be performed on tissue fluid. Antimicrobial agents directed against Gram-positive and Gram-negative aerobes and anaerobes (e.g., vancomycin plus a carbapenem), as well as high-dose aqueous penicillin G (16,000,000 to 20,000,000 U/d), the latter to treat clostridial pathogens, should be administered. Approximately 50% of such infections are polymicrobial, the remainder being caused by a single organism such as *Streptococcus pyogenes*, *Pseudomonas aeruginosa*, or *Clostridium perfringens*. The microbiology of these polymicrobial infections is similar to that of secondary microbial peritonitis, with the exception that Gram-positive cocci are more commonly encountered. Most patients should be returned to the operating room on a scheduled basis to determine if disease progression has occurred. If so, additional resection of infected tissue and debridement should take place. Antibiotic therapy can be refined based on culture and sensitivity results, particularly in the case of monomicrobial soft tissue infections. Hyperbaric oxygen therapy may be of use in patients with infection caused by gas-forming organisms (e.g., *Clostridium perfringens*), although the evidence to support efficacy is limited to underpowered studies and case reports. In the absence of such infection, hyperbaric oxygen therapy has not shown to be effective.⁷⁴

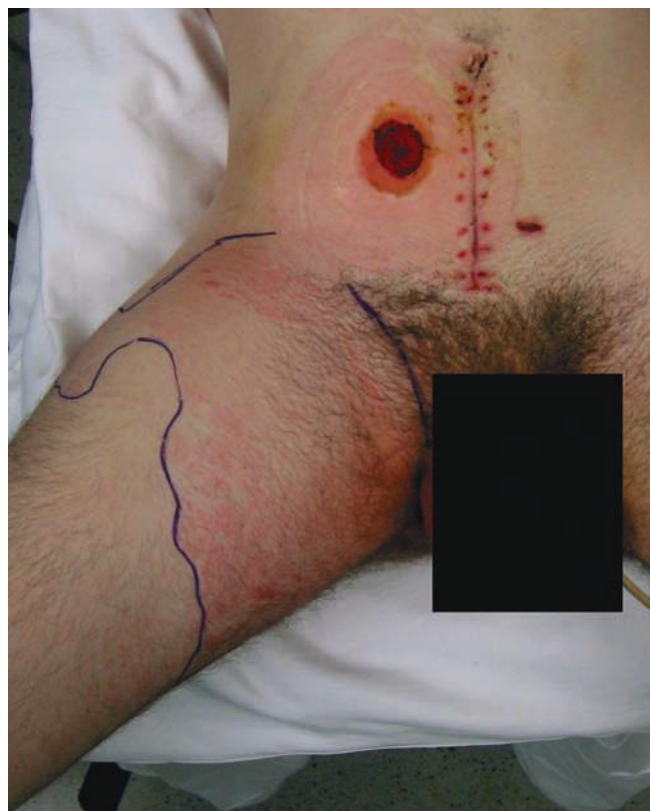Postoperative Nosocomial Infections

Surgical patients are prone to develop a wide variety of nosocomial infections during the postoperative period, which include SSIs, UTIs, pneumonia, and bacteremia. SSIs are discussed earlier, and the latter types of nosocomial infections are related to prolonged use of indwelling tubes and catheters for the purpose of urinary drainage, ventilation, and venous and arterial access, respectively.

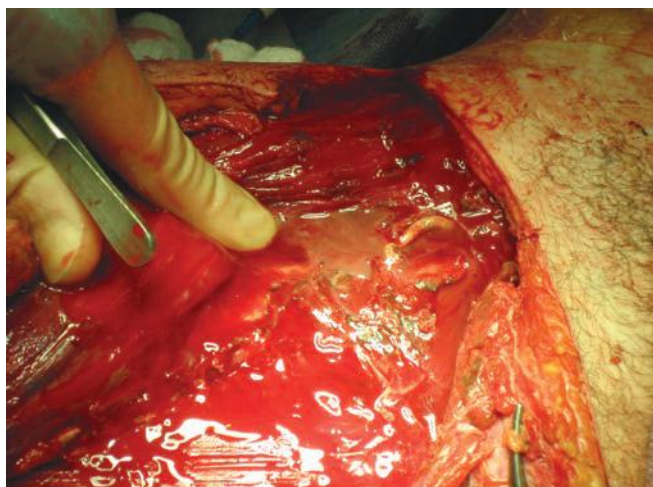
The presence of a postoperative UTI should be considered based on urinalysis demonstrating WBCs or bacteria, a positive test for leukocyte esterase, or a combination of these elements. The diagnosis is established after $>10^4$ CFU/mL of microbes are identified by culture techniques in symptomatic patients,



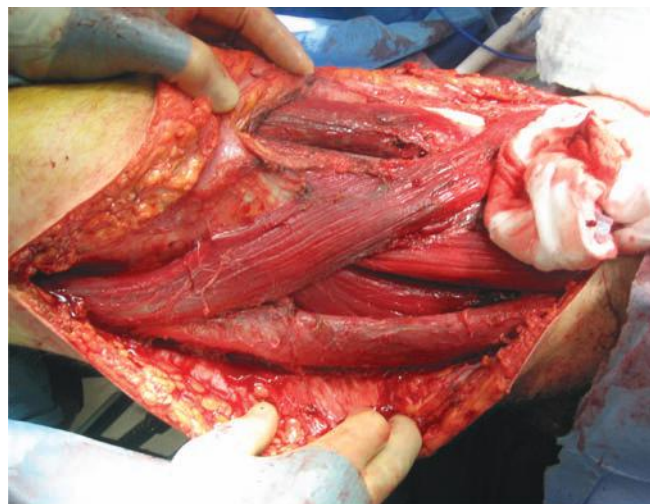
A



B



C



D

Figure 6-5 Necrotizing soft tissue infection. (A) This patient presented with hypotension due to severe late necrotizing fasciitis and myositis due to beta-hemolytic streptococcal infection. The patient succumbed to his disease after 16 hours despite aggressive debridement. (B) This patient presented with spreading cellulites and pain on motion of his right hip 2 weeks after total colectomy. Cellulitis on right anterior thigh is outlined. (C) Classic dishwater edema of tissues with necrotic fascia. (D) Right lower extremity after debridement of fascia to viable muscle.

or $>10^5$ CFU/mL in asymptomatic individuals. Treatment for 3 to 5 days with a single antibiotic directed against the most common organisms (e.g., *E. Coli*, *K. pneumonia*) that achieves high levels in the urine is appropriate. Initial therapy is directed by Gram's stain results and is refined as culture results become available. Postoperative surgical patients should have indwelling urinary catheters removed as quickly as possible, typically within 1 to 2 days, as long as they are mobile, to avoid the development of a UTI.

Prolonged mechanical ventilation is associated with nosocomial pneumonia. These patients present with more severe disease, are more likely to be infected with drug-resistant pathogens, and suffer increased mortality compared to patients who develop community-acquired pneumonia. The diagnosis of pneumonia is established by presence of a purulent sputum, elevated leukocyte count, fever, and new chest X-ray abnormalities, such as consolidation. The presence of two of the clinical findings, plus chest X-ray findings, significantly increases

the likelihood of pneumonia.⁷⁵ Consideration should be given to performing bronchoalveolar lavage to obtain samples for Gram's stain and culture. Some authors advocate quantitative cultures as a means to identify a threshold for diagnosis.⁷⁶ Surgical patients should be weaned from mechanical ventilation as soon as feasible, based on oxygenation and inspiratory effort, as prolonged mechanical ventilation increases the risk of nosocomial pneumonia.

Infection associated with indwelling intravascular catheters has become a common problem among hospitalized patients. Because of the complexity of many surgical procedures, these devices are increasingly used for physiologic monitoring, vascular access, drug delivery, and hyperalimentation. Among the several million catheters inserted each year in the United States, approximately 25% will become colonized, and approximately 5% will be associated with bacteremia. Duration of catheterization, insertion or manipulation under emergency or nonsterile conditions, use for hyperalimentation, and the use of multilumen catheters increase the risk of infection. Use of a central line insertion protocol that includes full barrier precautions and chlorhexidine skin prep has been shown to decrease the incidence of infection.⁷⁷ Although no randomized trials have been performed, peripherally inserted central venous catheters have a catheter-related infection rate similar to those inserted in the subclavian or jugular veins.⁷⁸

Many patients who develop intravascular catheter infections are asymptomatic, often exhibiting solely an elevation in the blood WBC count. Blood cultures obtained from a peripheral site and drawn through the catheter that reveal the presence of the same organism increase the index of suspicion for the presence of a catheter infection. Obvious purulence at the exit site of the skin tunnel, severe sepsis syndrome due to any type of organism when other potential causes have been excluded, or bacteremia due to Gram-negative aerobes or fungi should lead to catheter removal. Selected catheter infections due to low-virulence microbes such as *Staphylococcus epidermidis* can be effectively treated in approximately 50% to 60% of patients with a 14- to 21-day course of an antibiotic, which should be considered when no other vascular access site exists.⁷⁹ The use of antibiotic-bonded catheters and chlorhexidine sponges at the insertion site have been associated with lower rates of colonization.⁷⁷ Use of ethanol or antimicrobial catheter "locks" have shown promise in reducing incidence of infection in dialysis catheters.⁸⁰ The surgeon should carefully consider the need for any type of vascular access device, rigorously attend to their maintenance to prevent infection, and remove them as quickly as possible. Use of systemic antibacterial or antifungal agents to prevent catheter infection is of no utility and is contraindicated.

Sepsis

Severe sepsis is increasing in incidence, with over 1.1 million cases estimated per year in the United States with an annual cost of 24 billion dollars. This rate is expected to increase as the population of aged in the United States increases. One third of sepsis cases occur in surgical populations and sepsis is a major cause of morbidity and mortality.⁸¹ The treatment of sepsis has improved dramatically over the last decade, with mortality rates dropping to under 30%. Factors contributing to this improvement in mortality relate both to recent randomized prospective trials demonstrating improved outcomes with new therapies, and to improvements in the process of care delivery to the sepsis patient. The "Surviving Sepsis Campaign," a multidisciplinary

group that worked to develop treatment recommendations has published guidelines incorporating evidence-based treatment strategies most recently in 2013.¹³ These guidelines are summarized in Table 6-9.

Patients presenting with severe sepsis should receive resuscitation fluids to achieve a central venous pressure target of 8-12 mm Hg, with a goal of mean arterial pressure of ≥ 65 mmHg and urine output of ≥ 0.5 mL/kg/h. Delaying this resuscitative step for as little as 3 hours until arrival in the ICU has been shown to result in poor outcome.⁸² Typically this goal necessitates early placement of central venous catheter.

A number of studies have demonstrated the importance of early empirical antibiotic therapy in patients who develop sepsis or nosocomial infection. This therapy should be initiated as soon as possible with broad spectrum antibiotics directed against most likely organisms, since early appropriate antibiotic therapy has been associated with significant reductions in mortality, and delays in appropriate antibiotic administration are associated with increased mortality. Use of institutional and unit specific sensitivity patterns are critical in selecting an appropriate agent for patients with nosocomial infection. It is key, however, to obtain cultures of appropriate areas without delaying initiating antibiotics so that appropriate adjustment of antibiotic therapy can take place when culture results return.

Additionally, early identification and treatment of septic sources is key for improved outcomes in patients with sepsis. Although there are no randomized trials demonstrating this concept, repeated evidence in studies of patients who develop intraabdominal infection, necrotizing soft tissue infection, and other types of infections demonstrate increased mortality with delayed treatment. As discussed earlier, one exception is that of infected pancreatic necrosis.

Multiple recent trials have evaluated the use of vasopressors and inotropes for treatment of septic shock. The current first-line agent for treatment of hypotension is norepinephrine. It is important to titrate therapy based on other parameters such as mixed venous oxygen saturation and plasma lactate levels as well as mean arterial pressure to reduce the risk of vasopressor-induced perfusion deficits. Several recent randomized trials have failed to demonstrate benefit with use of pulmonary arterial catheterization, leading to a significant decrease in its use.

A number of other adjunctive therapies are useful in treatment of the patient with severe sepsis and septic shock. Low-dose corticosteroids (hydrocortisone at ≤ 300 mg/day) can be used in patients with septic shock who are not responsive to fluids and vasopressors. However, a recent randomized trial failed to show survival benefit. Patients with acute lung injury associated with sepsis should receive mechanical ventilation with tidal volumes of 6 mL/kg and pulmonary airway plateau pressures of ≤ 30 cm H₂O. Finally, red blood cell transfusion should be reserved for patients with hemoglobin of <7 grams/dL, with a more liberal transfusion strategy reserved for those patients with severe coronary artery disease, ongoing blood loss, or severe hypoxemia.

Resistant Organisms: In the 1940s, penicillin was first produced for widespread clinical use. Within a year of its introduction, the first resistant strains of *Staphylococcus aureus* were identified. There are two major components that are responsible for antibiotic resistance. First, there may be a genetic component innate to the organism that prevents an effect of a particular antibiotic. For instance, if an organism does not have a target receptor specific to the mechanism of action of a particular antibiotic,

Table 6-9

Summary of Surviving Sepsis Campaign guidelines**Initial Evaluation and Infection Issues**

Initial resuscitation: Begin resuscitation immediately in patients with hypotension or elevated serum lactate with resuscitation goal of central venous pressure (CVP) 8 to 12 mm Hg, mean arterial pressure of ≥ 65 mm Hg, urine output of ≥ 0.5 mL/kg/h, and mixed venous oxygen saturation of 65%.

Target resuscitation to normalize lactate in patients with elevated lactate levels.

Diagnosis: Obtain appropriate cultures prior to antibiotics but do not delay antibiotic therapy. Use rapid antigen assays in patients with suspected fungal infection. Imaging studies should be performed promptly to confirm a source of infection.

Antibiotic therapy: Begin IV antibiotic therapy as early as possible: should be within the first hour after recognition of severe sepsis/septic shock. Use broad spectrum antibiotic regimen with penetration into presumed source, reassess regimen daily with deescalation as appropriate. Discontinue antibiotics in 7–10 d for most infections, stop antibiotics for noninfectious issues.

Source control: Establish anatomic site of infection as rapidly as possible, implement source control measures immediately after initial resuscitation. Remove intravascular access devices if potentially infected.

Infection prevention: Selective oral and digestive tract decontamination.

Hemodynamic Support and Adjunctive Therapy

Fluid therapy: Fluid resuscitate using crystalloid, using fluid volumes of 1000 mL (crystalloid), target CVP of 8 to 12 mm Hg.

Vasopressors/Inotropic Therapy: Maintain MAP of ≥ 65 mm Hg, centrally-administered norepinephrine is first-line choice. Dopamine should not be used for “renal protection,” insert arterial catheters for patients requiring vasopressors. Phenylephrine is not recommended in treatment of septic shock. Dobutamine infusion can be used in setting of myocardial dysfunction. Do not use strategy of targeting supranormal cardiac index.

Steroids: Consider intravenous hydrocortisone (dose ≤ 300 mg/d) for adult septic shock when hypotension responds poorly to fluids and vasopressors.

Other Supportive Therapy

Blood product administration: Transfuse red blood cells when hemoglobin decreases to < 7.0 g/dL.

Mechanical ventilation: Target an initial tidal volume of 6 mL/kg body weight and plateau pressure of ≤ 30 cm H₂O in patients with acute lung injury. Use positive end-expiratory pressure to avoid lung collapse. Use a weaning protocol to evaluate the potential for discontinuing mechanical ventilation. Pulmonary artery catheter is not indicated for routine monitoring.

Sedation: Minimize sedation using specific titration endpoints.

Glucose control: Use protocolized approach to blood glucose management targeting upper blood glucose target of 180 mg/dL.

Prophylaxis: Use stress ulcer (proton pump inhibitor or H₂ blocker) and deep venous thrombosis (low-dose unfractionated or fractionated heparin) prophylaxis.

Limitation of support: Discuss advance care planning with patients and families and set realistic expectations.

Adapted from Dellinger et. al¹³

the antibiotic will not be effective against this organism. A good example is penicillin and Gram-negative organisms, as these microbes lack penicillin-binding proteins. The second component driving resistance is that related to antibiotic selection. Over generations of exposure to a particular antibiotic, selection pressure will drive proliferation of more organisms resistant to that antibiotic. It is this mechanism that leads to antibiotic resistance in the world today, given that there are millions of kilograms of antibiotics used annually in people, in agriculture, and for animal use. This has led to antibiotic resistance described in all classes of antibiotics in common use today. Antibiotic resistance comes at a high cost, with a significant increase in mortality associated with infection from resistant organisms, and an economic cost of billions of dollars per year.

Resistance mechanisms are varied, and include one of three routes. Resistance can be intrinsic to the organism (natural resistance), can be mutational and mediated by changes in the chromosomal makeup of the organism, and finally can be mediated by extrachromosomal transfer of genetic material via

transposons or plasmids. Resistance due to mutation includes mechanisms mediated by target site modification, reduced permeability/uptake, metabolic bypass, or derepression of multi-drug efflux systems. Genes transferred via plasmid or transposon include those that cause drug inactivation, increases in antibiotic efflux systems, target site modification, and metabolic bypass.

There are several drug resistant organisms of interest to the surgeon. MRSA occurs as a hospital-associated infection more common in chronically ill patients receiving multiple courses of antibiotics. However, recent strains of MRSA have emerged in the community among patients without preexisting risk factors for disease.⁷² These strains, which produce a toxin known as *Panton-Valentin leukocidin*, make up an increasingly high percentage of surgical site infections since they are resistant to commonly employed prophylactic antimicrobial agents.⁸³ Extended spectrum β -lactamase (ESBL)-producing strains of *Enterobacteraceae*, originally geographically localized and infrequent, have become much more widespread and common in the last decade.⁸⁴ These strains, typically *Klebsiella* or *E coli*

species, produce a plasmid-mediated inducible β -lactamase. Commonly encountered plasmids also confer resistance to many other antibiotic classes (multidrug resistance). A common laboratory finding with ESBL is sensitivity to first-, second-, or third- generation cephalosporins with resistance to others. Unfortunately, use of this seemingly active agent leads to rapid induction of resistance and failure of antibiotic therapy. The appropriate antibiotic choice in this setting is a carbapenem. While *Enterococcus* used to be considered a low virulence organism in the past, infections caused by *E. faecium* and *faecalis* have been found to be increasingly virulent, especially in the immunocompromised host. The last decade has seen increased isolation of a vancomycin-resistant strain of *Enterococcus*.⁸⁵ This resistance is transposon-mediated via the *vanA* gene and is typically seen in *E. faecium* strains. A real concern in this setting is transfer of genetic material to *S. aureus* in a host coinfecting with both organisms. This is thought to be the mechanism behind the half dozen recently described cases of vancomycin resistance in *S. aureus*.

Blood-Borne Pathogens

While alarming to contemplate, the risk of human immunodeficiency virus (HIV) transmission from patient to surgeon is low. As of May 2011, there had been six cases of surgeons with HIV seroconversion from a possible occupational exposure, with no new cases reported since 1999. Of the numbers of health care workers with likely occupationally acquired HIV infection ($n = 200$), surgeons were one of the lower risk groups (compared to nurses at 60 cases and nonsurgeon physicians at 19 cases).⁸⁶ The estimated risk of transmission from a needlestick from a source with HIV-infected blood is estimated at 0.3%. Transmission of HIV (and other infections spread by blood and body fluid) from patient to health care worker can be minimized by observation of universal precautions, which include the following: (a) routine use of barriers (such as gloves and/or goggles) when anticipating contact with blood or body fluids, (b) washing of hands and other skin surfaces immediately after contact with blood or body fluids, and (c) careful handling and disposal of sharp instruments during and after use.

7► Postexposure prophylaxis for HIV has significantly decreased the risk of seroconversion for health care workers with occupational exposure to HIV. Steps to initiate postexposure prophylaxis should be initiated within hours rather than days for the most effective preventive therapy. Postexposure prophylaxis with a two- or three-drug regimen should be initiated for health care workers with significant exposure to patients with an HIV-positive status. If a patient's HIV status is unknown, it may be advisable to begin postexposure prophylaxis while testing is carried out, particularly if the patient is at high risk for infection due to HIV (e.g., intravenous narcotic use). Generally, postexposure prophylaxis is not warranted for exposure to sources with unknown status, such as deceased persons or needles from a sharps container.

The risks for surgeons of acquiring HIV infection have recently been evaluated by Goldberg and coauthors.⁸⁷ They noted that the risks are related to the prevalence of HIV infection in the population being cared for, the probability of transmission from a percutaneous injury suffered while caring for an infected patient, the number of such injuries sustained, and the use of postexposure prophylaxis. Annual calculated risks in Glasgow, Scotland, ranged from one in 200,000 for general surgeons not utilizing postexposure prophylaxis to as low as

one in 10,000,000 with use of routine postexposure prophylaxis after significant exposures.

Hepatitis B virus (HBV) is a DNA virus that affects only humans. Primary infection with HBV generally is self-limited, but can cause fulminant hepatitis or progress to a chronic carrier state. Death from chronic liver disease or hepatocellular cancer occurs in roughly 30% of chronically infected persons. Surgeons and other health care workers are at high risk for this blood-borne infection and should receive the HBV vaccine; children are routinely vaccinated in the United States.⁸⁸ This vaccine has contributed to a significant decline in the number of new cases of HBV per year in the United States, from approximately 250,000 annually in the 1980s to 3,350 in 2010.^{89,90} This is truly one of the unsung victories in vaccination strategy in the last 20 years.

Hepatitis C virus (HCV), previously known as non-A, non-B hepatitis, is a RNA flavivirus first identified specifically in the late 1980s. This virus is confined to humans and chimpanzees. A chronic carrier state develops in 75% to 80% of patients with the infection, with chronic liver disease occurring in three-fourths of patients who develop chronic infection. The number of new infections per year has declined since the 1980s due to routine testing of blood donors for this virus. Fortunately, HCV is not transmitted efficiently through occupational exposures to blood, with the seroconversion rate after accidental needlestick approximately 1.8%.⁹¹ To date, a vaccine to prevent HCV infection has not been developed. Experimental studies in chimpanzees with HCV immunoglobulin using a model of needlestick injury have failed to demonstrate a protective effect, and no effective antiviral agents for postexposure prophylaxis are available. Treatment of patients who develop HCV infection includes ribavirin and pegylated gamma interferon.⁹²

BIOLOGIC WARFARE AGENTS

Several infectious organisms have been studied by the United States and the former Soviet Union and presumably other entities for potential use as biologic weapons. Programs involving biologic agents in the United States were halted by presidential decree in 1971. However, concern remains that these agents could be used by rogue states or terrorist organizations as weapons of mass destruction, as they are relatively inexpensive to make in terms of infrastructure development. A related issue is the recent controversy regarding publication of genetic sequences and synthesis of virulent viruses, such as the 1918 influenza strain, responsible for death of an estimated 3% of the world population. Given these concerns, physicians, including surgeons should familiarize themselves with the manifestations of infection due to these pathogens. The typical agent is selected for the ability to be spread via the inhalational route, as this is the most efficient mode of mass exposure. Several potential agents are discussed in the following sections.

Bacillus anthracis (Anthrax)

Anthrax is a zoonotic disease occurring in domesticated and wild herbivores. The first identification of inhalational anthrax as a disease occurred among woolsorters in England in the late 1800s. The largest recent epidemic of inhalational anthrax occurred in Sverdlovsk, Russia, in 1979 after accidental release of anthrax spores from a military facility. Inhalational anthrax develops after a 1- to 6-day incubation period, with

nonspecific symptoms, including malaise, myalgia, and fever. Over a short period of time, these symptoms worsen, with development of respiratory distress, chest pain, and diaphoresis. Characteristic chest roentgenographic findings include a widened mediastinum and pleural effusions. A key aspect in establishing the diagnosis is eliciting an exposure history. Rapid antigen tests are currently under development for identification of this gram-positive rod. Postexposure prophylaxis consists of administration of either ciprofloxacin or doxycycline.⁹³ If an isolate is demonstrated to be penicillin-sensitive, the patient should be switched to amoxicillin. Inhalational exposure followed by the development of symptoms is associated with a high mortality rate. Treatment options include combination therapy with ciprofloxacin, clindamycin, and rifampin; clindamycin added to block production of toxin, while rifampin penetrates into the central nervous system and intracellular locations.

***Yersinia pestis* (Plague)**

Plague is caused by the Gram-negative organism *Yersinia pestis*. The naturally occurring disease in humans is transmitted via flea bites from rodents. It was the first biologic warfare agent, and was used in the Crimean city of Caffa by the Tartar army, whose soldiers catapulted bodies of plague victims at the Genoese. When plague is used as a biologic warfare agent, clinical manifestations include epidemic pneumonia with blood-tinged sputum if aerosolized bacteria are used, or bubonic plague if fleas are used as carriers. Individuals who develop a painful enlarged lymph node lesion termed a “bubo” associated with fever, severe malaise, and exposure to fleas should be suspected to have plague. Diagnosis is confirmed via aspirate of the bubo and a direct antibody stain to detect plague bacillus. Typical morphology for this organism is that of a bipolar safety-pin-shaped Gram-negative organism. Postexposure prophylaxis for patients exposed to plague consists of doxycycline. Treatment of the pneumonic or bubonic/septicemic form includes administration of either streptomycin, an aminoglycoside, doxycycline, ciprofloxacin, levofloxacin, or chloramphenicol.⁹⁴

Smallpox

Variola, the causative agent of smallpox, was a major cause of infectious morbidity and mortality until its eradication in the late 1970s. During the European colonization of North America, British commanders may have used it against native inhabitants and the colonists by distribution of blankets from smallpox victims. Even in the absence of laboratory-preserved virus, the prolonged viability of variola virus has been demonstrated in scabs up to 13 years after collection; the potential for reverse genetic engineering using the known sequence of smallpox also makes it a potential biologic weapon. This has resulted in the United States undertaking a vaccination program for key health care workers.⁹⁵ Variola virus is highly infectious in the aerosolized form; after an incubation period of 10 to 12 days, clinical manifestations of malaise, fever, vomiting, and headache appear, followed by development of a characteristic centripetal rash (which is found to predominate on the face and extremities). The fatality rate may reach 30%. Postexposure prophylaxis with smallpox vaccine has been noted to be effective for up to 4 days postexposure. Cidofovir, an acyclic nucleoside phosphonate analogue, has demonstrated activity in animal models of poxvirus infections and may offer promise for the treatment of smallpox.⁹⁶

***Francisella tularensis* (Tularemia)**

The principal reservoir of this Gram-negative aerobic organism is the tick. After inoculation, this organism proliferates within macrophages. This organism has been considered a potential bioterrorist threat due to a very high infectivity rate after aerosolization. Patients with tularemia pneumonia develop a cough and demonstrate pneumonia on chest roentgenogram. Enlarged lymph nodes occur in approximately 85% of patients. The organism can be cultured from tissue samples, but this is difficult, and the diagnosis is based on acute-phase agglutination tests. Treatment of inhalational tularemia consists of administration of an aminoglycoside or second-line agents such as doxycycline and ciprofloxacin.

REFERENCES

Entries highlighted in bright blue are key references.

1. Nuland SB. *The Doctors' Plague: Germs, Childbed Fever, and the Strange Story of Ignaz Semmelweis*. New York: WW Norton & Co.: 2003:1.
2. Wangenstein OH, Wangenstein SD. Germ theory of infection and disease. In: Wangenstein OH, Wangenstein SD: *The Rise of Surgery: From Empiric Craft to Scientific Discipline*. Minneapolis: University of Minnesota Press: 1978:387.
3. Rutkow E. Appendicitis: The quintessential American surgical disease. *Arch Surg*. 1998; 133:1024.
4. Meleney F. Bacterial synergism in disease processes with confirmation of synergistic bacterial etiology of certain types of progressive gangrene of the abdominal wall. *Ann Surg*. 1931;94:961-981.
5. Altemeier WA. *Manual of Control of Infection in Surgical Patients*. Chicago: American College of Surgeons Press: 1976:1.
6. Bartlett JG. Intra-abdominal sepsis. *Med Clin North Am*. 1995;79:599-617.
7. Dunn DL, Simmons RL. The role of anaerobic bacteria in intra-abdominal infections. *Rev Infect Dis*. 1984;6:S139-S146.
8. Osler W. *The Evolution of Modern Medicine*. New Haven, CT: Yale University Press: 1913:1.
9. Dunn DL. Autochthonous microflora of the gastrointestinal tract. *Perspect Colon Rectal Surg*. 1990;2:105-119.
10. van Till JW, van Veen SQ, van Ruler O, et al. The innate immune response to secondary peritonitis. *Shock*. 2007 Nov; 28(5):504-517.
11. Zeytun A, Chaudhary A, Pardington P, et al. Induction of cytokines and chemokines by Toll-like receptor signaling: strategies for control of inflammation. *Crit Rev Immunol*. 2010;30(1): 53-67.
12. Aziz M, Jacob A, Yang WL, et al. Current trends in inflammatory and immunomodulatory mediators in sepsis. *J Leukoc Biol*. 2013;(3)320-342.
13. Dellinger RP, Levy MM, Rhodes A, et al. **Surviving sepsis campaign: international guidelines for management of severe sepsis and septic shock: 2012.** *Crit Care Med*. 2013; 41: 580-637.
14. Murphy SL, Xu Jiaquan, Kochanek KD. Deaths: preliminary data for 2010. *National Vital Statistics Reports*. 2012;60(4): 1-52.
15. Marshall JC, Cook DJ, Christou NV, et al. Multiple organ dysfunction score: a reliable descriptor of a complex clinical outcome. *Crit Care Med*. 1995;23:1638-1652.
16. Ferreira FL, Bota DP, Bross A, et al. Serial evaluation of the SOFA score to predict outcome in critically ill patients. *JAMA*. 2002;286:1754-1758.
17. Sauerblich A, Moore FA, Moore EE, Lezotte DC. Early risk factors for postinjury multiple organ failure. *World J Surg*. 1996;20:392-400.

18. Zahar JR, Timsit JF, Garrouste-Orgeas M, et al. Outcomes in severe sepsis and patients with septic shock: pathogen species and infection sites are not associated with mortality. *Crit Care Med.* 2011;39(8):1886-1895.
19. Dreiherr J, Almog Y, Sprung CL, et al. Temporal trends in patient characteristics and survival of intensive care admissions with sepsis: a multicenter analysis. *Crit Care Med.* 2012;40(3):855-860.
20. Levy MM, Fink MP, Marshall JC, et al. 2001 SCCM/ESICM/ACCP/ATS/SIS International Sepsis Definitions Conference. *Crit Care Med.* 2003 Apr;31(4):1250-1256.
21. Howell MD, Talmor D, Schuetz P, et al. Proof of principle: the predisposition, infection, response, organ failure sepsis staging system. *Crit Care Med.* 2011 Feb;39(2):322-327.
22. Nguyen HB, Van Ginkel C, Batech M, Banta J, Corbett SW. Comparison of predisposition, insult/infection, response, and organ dysfunction, Acute physiology and chronic health evaluation II, and mortality in emergency department sepsis in patients meeting criteria for early goal-directed therapy and the severe sepsis resuscitation bundle. *J Crit Care.* 2012 Aug;27(4):362-369.
23. Dunn DL. The biological rationale. In: Schein M, Marshall JC (eds): *Source Control: A Guide to the Management of Surgical Infections*. New York: Springer-Verlag; 2003:9.
24. Pieracci FM, Barie PS. Management of severe sepsis of abdominal origin. *Scand J Surg.* 2007;96(3):184-196.
25. Bratzler DW, Dellinger EP, Olson KM, et al. Clinical practice guidelines for antimicrobial prophylaxis in surgery. *Am J Health Syst Pharm.* 2013;70:195-283.
26. Solomkin JS, Meakins JL Jr., Allo MD, et al. Antibiotic trials in intra-abdominal infections: a critical evaluation of study design and outcome reporting. *Ann Surg.* 1984;200:29-39.
27. **Kumar A. Optimizing antimicrobial therapy in sepsis and septic shock. *Crit Care Clin.* 2009;25(4):733-751.**
28. Aarts MA, Brun-Buisson C, Cook DJ, et al. Antibiotic management of suspected nosocomial ICU-acquired infection: does prolonged empiric therapy improve outcome? *Intensive Care Med.* 2007;33(8):1369-1378.
29. Hillier S, Roberts Z, Dunstan F, et al. Prior antibiotics and risk of antibiotic-resistant community-acquired urinary tract infection: a case-control study. *J Antimicrob Chemother.* 2007;60:92-99.
30. Smith BP, Fox N, Fakhro A, et al. "SCIP" ping antibiotic prophylaxis guidelines in trauma: The consequences of noncompliance. *J Trauma Acute Care Surg.* 2012;73(2):452-456.
31. **Schuetz P, Müller B, Christ-Crain M, et al. Procalcitonin to initiate or discontinue antibiotics in acute respiratory tract infections. *Cochrane Database Syst Rev.* 2012; 9:CD007498.**
32. Mazuski JE, Sawyer RG, Nathans AB, et al. The Surgical Infection Society guidelines on antimicrobial therapy for intra-abdominal infections: an executive summary. *Surg Infect (Larchmt).* 2002;3(3):161-173.
33. Basoli A, Chirletti P, Cirino E, et al. A prospective, double-blind, multicenter, randomized trial comparing ertapenem 3 vs ≥ 5 days in community-acquired intraabdominal infection. *J Gastrointest Surg.* 2008;12(3):592-600.
34. **Stone HH, Bourneuf AA, Stinson LD. Reliability of criteria for predicting persistent or recurrent sepsis. *Arch Surg.* 1985;120:17-20.**
35. Romano A, Viola M, Guéant-Rodríguez RM, et al. Imipenem in patients with immediate hypersensitivity to penicillins. *N Engl J Med.* 2006;354(26):2835-2837.
36. Park M, Markus P, Matesic D, Li JT. Safety and effectiveness of a preoperative allergy clinic in decreasing vancomycin use in patients with a history of penicillin allergy. *Ann Allergy Asthma Immunol.* 2006;97:681-687.
37. Galán JC, González-Candelas F, Rolain JM, Cantón R. Antibiotics as selectors and accelerators of diversity in the mechanisms of resistance: from the resistome to genetic plasticity in the β -lactamases world. *Front Microbiol.* 2013;4:9.
38. Rosenberger LH, Politano AD, Sawyer RG. The surgical care improvement project and prevention of post-operative infection, including surgical site infection. *Surg Infect (Larchmt).* 2011;12(3):163-168. doi: 10.1089/sur.2010.083.
39. **Alexander JW, Solomkin JS, Edwards MJ. Updated recommendations for control of surgical site infections. *Ann Surg.* 2011;253(6):1082-1093.**
40. Martone WJ, Nichols RL. Recognition, prevention, surveillance, and management of surgical site infections: introduction to the problem and symposium overview. *Clin Infect Dis.* 2001;33:S67-S68.
41. Kobayashi M, Mohri Y, Inoue Y, Miki C, Kusunoki M. Continuous follow-up of surgical site infections for 30 days after colorectal surgery. *World J Surg.* 2008;32:1142-1146.
42. Konishi T, Watanabe T, Kishimoto J, Nagawa H. Elective colon and rectal surgery differ in risk factors for wound infection: results of prospective surveillance. *Ann Surg.* 2006;244:758-763.
43. **Cima R, Dankbar E, Lovely J, et al. Colorectal surgery surgical site infection reduction program: a national surgical quality improvement program-driven multidisciplinary single-institution experience. *J Am Coll Surg.* 2013;216(1):23-33.**
44. Weiss CAIII, Statz CL, Dahms RA, et al. Six years of surgical wound infection surveillance at a tertiary care center: review of the microbiologic and epidemiological aspects of 20,007 wounds. *Arch Surg.* 1999;134:1041-1048.
45. Mu Y, Edwards JR, Horan TC, et al. Improving risk-adjusted measures of surgical site infection for the national health-care safety network. *Infect Control Hosp Epidemiol.* 2011;32(10):970-986.
46. Scott RD II. The direct medical costs of healthcare-associated infections in U.S. hospitals and the benefits of prevention. 2009. Available at: http://www.cdc.gov/HAI/pdfs/hai/Scott_CostPaper.pdf, Accessed March 3, 2013.
47. Bratzler DW, Houck PM. Surgical Infection Prevention Guidelines Writers Workgroup, et al. Antimicrobial prophylaxis for surgery: an advisory statement from the National Surgical Infection Prevention Project. *Clin Infect Dis.* 2004;38:1706-1715.
48. Meeks DW, Lally KP, Carrick MM, et al. Compliance with guidelines to prevent surgical site infections: as simple as 1-2-3? *Am J Surg.* 2011;201(1):76-83.
49. Duttaroy DD, Jitendra J, Duttaroy B, et al. Management strategy for dirty abdominal incisions: primary or delayed primary closure? A randomized trial. *Surg Infect (Larchmt).* 2009;10(2):129-136.
50. Margenthaler JA, Longo WE, Virgo KS, et al. Risk factors for adverse outcomes after the surgical treatment of appendicitis in adults. *Ann Surg.* 2003;238:59-66.
51. McManus LM, Bloodworth RC, Prihoda TJ, et al. Agonist-dependent failure of neutrophil function in diabetes correlates with extent of hyperglycemia. *J Leukoc Biol.* 2001;70:395-404.
52. Richards JE, Kauffmann RM, Obremskey WT, May AK. Stress-induced hyperglycemia as a risk factor for surgical-site infection in nondiabetic orthopedic trauma patients admitted to the intensive care unit. *J Orthop Trauma.* 2013;27(1):16-21.
53. Ata A, Lee J, Bestle SL, et al. Postoperative hyperglycemia and surgical site infection in general surgery patients. *Arch Surg.* 2010;145(9):858-864.
54. Greif R, Akca O, Horn EP, et al. Supplemental perioperative oxygen to reduce the incidence of wound infection. *N Engl J Med.* 2000;342:161-167.
55. Kao LS, Millas SG, Pedroza C, et al. Should perioperative supplemental oxygen be routinely recommended for surgery patients? A Bayesian meta-analysis. *Ann Surg.* 2012;256(6):894-901.
56. Grubbs BC, Statz CL, Johnson EM, et al. Salvage therapy of open, infected surgical wounds: a retrospective review using Techni-Care. *Surg Infect.* 2000;1:109-114.

57. Roberts DJ, Zygun DA, Grendar J, et al. Negative-pressure wound therapy for critically ill adults with open abdominal wounds: a systematic review. *J Trauma Acute Care Surg.* 2012;73(3):629-639.
58. Solomkin JS, Mazuski JE, Baron EJ, et al. Infectious Diseases Society of America: Guidelines for the selection of anti-infective agents for complicated intra-abdominal infections. *Clin Infect Dis.* 2003;37:997-1005.
59. Solomkin JS, Dellinger EP, Christou NV, et al. Results of a multicenter trial comparing imipenem/cilastatin to tobramycin/clindamycin for intra-abdominal infections. *Ann Surg.* 1990;212:581-591.
60. Solomkin JS, Yellin AE, Rotstein OD, et al. Protocol 017 Study Group. Ertapenem versus piperacillin/tazobactam in the treatment of complicated intraabdominal infections: results of a double-blind, randomized comparative phase III trial. *Ann Surg.* 2003;237:235-245.
61. Chromik AM, Meiser A, Hölling J, et al. Identification of patients at risk for development of tertiary peritonitis on a surgical intensive care unit. *J Gastrointest Surg.* 2009;13(7):1358-1367.
62. Pang TC, Fung T, Samra J, et al. Pyogenic liver abscess: an audit of 10 years' experience. *World J Gastroenterol.* 2011;17(12):1622-1630.
63. Bradley EL III, Allen K. A prospective longitudinal study of observation versus surgical intervention in the management of necrotizing pancreatitis. *Am J Surg.* 1991;161:19.
64. Charbonney E, Nathens AB. Severe acute pancreatitis: a review. *Surg Infect (Larchmt).* 2008;9(6):573-578.
65. Freeman ML, Werner J, van Santvoort HC, et al. Interventions for necrotizing pancreatitis: summary of a multidisciplinary consensus conference. *Pancreas.* 2012;41(8):1176-1194.
66. Wysocki AP, McKay CJ, Carter CR. Infected pancreatic necrosis: minimizing the cut. *ANZ J Surg.* 2010;80(1-2):58-70.
67. Haghshenasaskashani A, Laurence JM, Kwan V, et al. Endoscopic necrosectomy of pancreatic necrosis: a systematic review. *Surg Endosc.* 2011;25(12):3724-3730.
68. Bakker OJ, van Santvoort HC, van Brunshot S, et al. Endoscopic transgastric vs surgical necrosectomy for infected necrotizing pancreatitis: a randomized trial. *JAMA.* 2012;307(10):1053-1061.
69. Fink D, Soares R, Matthews JB, Alverdy JC. History, goals, and technique of laparoscopic pancreatic necrosectomy. *J Gastrointest Surg.* 2011;15(7):1092-1097.
70. van Santvoort HC, Bakker OJ, Bollen TL, et al. A Conservative and Minimally Invasive Approach to Necrotizing Pancreatitis Improves Outcome. *Gastroenterology.* 2011;141(4):1254-1263.
71. van Santvoort HC, Besselink MG, Bakker OJ, et al. A step-up approach or open necrosectomy for necrotizing pancreatitis. *N Engl J Med.* 2010;362(16):1491-1502.
72. Beilman GJ, Sandifer G, Skarda D, et al. Emerging infections with community-associated methicillin-resistant *Staphylococcus aureus* in outpatients at an Army Community Hospital. *Surg Infect (Larchmt).* 2005;6(1):87-92.
73. Kao LS, Lew DF, Arab SN, et al. Local variations in the epidemiology, microbiology, and outcome of necrotizing soft-tissue infections: a multicenter study. *Am J Surg.* 2011;202(2):139-145.
74. George ME, Rueth NM, Skarda DE, et al. Hyperbaric oxygen does not improve outcome in patients with necrotizing soft tissue infection. *Surg Infect (Larchmt).* 2009;10(1):21-28.
75. Klompas M. Does this patient have ventilator-associated pneumonia? *JAMA.* 2007;297(14):1583-1593.
76. Riaz OJ, Malhotra AK, Aboutanos MB, et al. Bronchoalveolar lavage in the diagnosis of ventilator-associated pneumonia: to quantitate or not, that is the question. *Am Surg.* 2011;77(3):297-303.
77. O'Grady NP, Alexander M, Burns LA, et al. Guidelines for the prevention of intravascular catheter-related infections. *Clin Infect Dis.* 2011;52(9):e162-e193.
78. Safdar N, Maki DG. Risk of catheter-related bloodstream infection with peripherally inserted central venous catheters used in hospitalized patients. *Chest.* 2005;128(2):489-495.
79. Marr KA, Sexton DJ, Conlon PJ, et al. Catheter-related bacteremia and outcome of attempted catheter salvage in patients undergoing hemodialysis. *Ann Intern Med.* 1997;127:275.
80. Broom JK, Krishnasamy R, Hawley CM, et al. A randomised controlled trial of Heparin versus EthAnol Lock THERapY for the prevention of Catheter Associated infection in Haemodialysis patients – the HEALTHY-CATH trial. *BMC Nephrol.* 2012;13:146.
81. Moore LJ, Moore FA. Epidemiology of sepsis in surgical patients. *Surg Clin North Am.* 2012;92(6):1425-1443.
82. Otero RM, Nguyen HB, Huang DT, et al. Early goal-directed therapy in severe sepsis and septic shock revisited: Concepts, controversies, and contemporary findings. *Chest.* 2006;130(5):1579-1595.
83. Miller LG, McKinnell JA, Vollmer ME, Spellberg B. Impact of methicillin-resistant *Staphylococcus aureus* prevalence among *S aureus* isolates on surgical site infection risk after coronary artery bypass surgery. *Infect Control Hosp Epidemiol.* 2011;32(4):342-350.
84. Han JH, Nachamkin I, Zaoutis TE, et al. Risk factors for gastrointestinal tract colonization with extended-spectrum β -lactamase (ESBL)-producing *Escherichia coli* and *Klebsiella* species in hospitalized patients. *Infect Control Hosp Epidemiol.* 2012;33(12):1242-1245.
85. Calfee DP. Methicillin-resistant *Staphylococcus aureus* and vancomycin-resistant enterococci, and other Gram-positives in healthcare. *Curr Opin Infect Dis.* 2012;25(4):385-394.
86. Centers for Disease Control and Prevention. Surveillance of Occupationally Acquired HIV/AIDS in Healthcare Personnel, as of December 2010, <http://www.cdc.gov/HAI/organisms/hiv/Surveillance-Occupationally-Acquired-HIV-AIDS.html>. Accessed March 3, 2013.
87. Goldberg D, Johnston J, Cameron S, et al. Risk of HIV transmission from patients to surgeons in the era of post-exposure prophylaxis. *J Hosp Infect.* 2000;44:99-105.
88. Recommended Adult Immunization Schedule-United States. Available at: <http://www.cdc.gov/vaccines/schedules/hcp/adult.html> Accessed March 4, 2013.
89. Centers for Disease Control. Hepatitis B vaccination-United States, 1982-2002. *MMWR.* 2002;51:549.
90. Centers for Disease Control, Viral Hepatitis Statistics and Surveillance, <http://www.cdc.gov/hepatitis/Statistics/2010Surveillance/Table3.1.htm>. Accessed March 3, 2013.
91. MacCannell T, Laramie AK, Gomma A, Perz JF. Occupational exposure of health care personnel to hepatitis B and hepatitis C: prevention and surveillance strategies. *Clin Liver Dis.* 2010;14(1):23-36.
92. Katz LH, Goldvaser H, Gafer-Gvili A, Tur-Kaspa R. Extended peginterferon plus ribavirin treatment for 72 weeks versus standard peginterferon plus ribavirin treatment for 48 weeks in chronic hepatitis C genotype 1 infected slow-responder adult patients. *Cochrane Database Syst Rev.* 2012;9:CD008516.
93. Inglesby TV, O'Toole T, Henderson DA, et al. Anthrax as a biological weapon, 2002: updated recommendations for management. *JAMA.* 2002;287:2236-2252.
94. Inglesby TV, Dennis DT, Henderson DA, et al. Plague as a biological weapon; medical and public health management. Working group on civilian biodefense. *JAMA.* 2000;283:2281-2290.
95. Russell PK, Gronvall GK. U.S. medical countermeasure development since 2001: a long way yet to go. *Biosecur Bioterror.* 2012;10(1):66-76.
96. DeClercq E. Cidofovir in the treatment of poxvirus infections. *Antiviral Res.* 2002;55:1-13.

This page intentionally left blank

7 chapter

Trauma

Clay Cothren Burlew and Ernest E. Moore

Introduction	161	Transfusion Practices / 184	Extremity Vascular Injuries, Fractures, and Compartment Syndromes / 214	
Initial Evaluation and Resuscitation of the Injured Patient	161	Prophylactic Measures / 185	Surgical Intensive Care Management	215
Primary Survey / 161		Operative Approaches and Exposure / 187	Postinjury Resuscitation / 215	
Secondary Survey / 173		Damage Control Surgery / 192	Abdominal Compartment Syndrome / 217	
Mechanisms and Patterns of Injury / 173		Treatment of Specific Injuries	Special Populations	218
Regional Assessment and Special Diagnostic Tests / 174		Head Injuries / 195	Pregnant Patients / 218	
General Principles of Management	183	Cervical Injuries / 197	Geriatric Patients / 221	
		Chest Injuries / 200	Pediatric Patients / 222	
		Abdominal Injuries / 203		
		Pelvic Fracture Hemorrhage Control / 212		

INTRODUCTION

Trauma, or injury, is defined as cellular disruption caused by an exchange with environmental energy that is beyond the body's resilience which is compounded by cell death due to ischemia/reperfusion. Trauma remains the most common cause of death for all individuals between the ages of 1 and 44 years and is the third most common cause of death regardless of age.¹ It is also the leading cause of years of productive life lost. Unintentional injuries account for over 110,000 deaths per year, with motor vehicle collisions accounting for over 40%. Homicides, suicides, and other causes are responsible for another 50,000 deaths each year. However, death rate underestimates the magnitude of the societal toll. For example, in 2004 there were approximately 167,000 injury-related deaths, but 29.6 million injured patients treated in emergency departments (EDs). Injury-related medical expenditures are estimated to be \$117 billion each year in the United States.² The aggregate lifetime cost for all injured patients is estimated to be in excess of \$260 trillion. For these reasons, trauma must be considered a major public health issue. The American College of Surgeons Committee on Trauma addresses this issue by assisting in the development of trauma centers and systems. The organization of trauma systems has had a significant favorable impact on patient outcomes.³⁻⁵

INITIAL EVALUATION AND RESUSCITATION OF THE INJURED PATIENT

Primary Survey

The Advanced Trauma Life Support (ATLS) course of the American College of Surgeons Committee on Trauma was developed in the late 1970s, based on the premise that appropriate and timely care can significantly improve the outcome for the injured patient.⁶ ATLS provides a structured approach to

the trauma patient with standard algorithms of care; it emphasizes the “golden hour” concept that timely, prioritized interventions are necessary to prevent death and disability. The ATLS format and basic tenets are followed throughout this chapter, with some modifications. The initial management of seriously injured patients consists of phases that include the primary survey/concurrent resuscitation, the secondary survey/diagnostic evaluation, definitive care, and the tertiary survey. The first step in patient management is performing the primary survey, the goal of which is to identify and treat conditions that constitute an immediate threat to life. The ATLS course refers to the primary survey as assessment of the “ABCs” (Airway with cervical spine protection, Breathing, and Circulation). Although the concepts within the primary survey are presented in a sequential fashion, in reality they are pursued simultaneously in coordinated team resuscitation. Life-threatening injuries must be identified (Table 7-1) and treated before being distracted by the secondary survey.

Airway Management with Cervical Spine Protection Ensuring a patent airway is the first priority in the primary survey. This is essential, because efforts to restore cardiovascular integrity will be futile unless the oxygen content of the blood is adequate. Simultaneously, all patients with blunt trauma require cervical spine immobilization until injury is excluded. This is typically accomplished by applying a hard collar or placing sandbags on both sides of the head with the patient's forehead taped across the bags to the backboard. Soft collars do not effectively immobilize the cervical spine. For penetrating neck wounds, however, cervical collars are not believed useful because they provide no benefit, but may interfere with assessment and treatment.^{7,8}

In general, patients who are conscious, without tachypnea, and have a normal voice are unlikely to require early airway intervention. Exceptions are penetrating injuries to the neck with an expanding hematoma; evidence of chemical or thermal

Key Points

- 1▶ Trauma remains the most common cause of death for all individuals between the ages of 1 and 44 years and is the third most common cause of death regardless of age.
- 2▶ The initial management of seriously injured patients consists of performing the primary survey (the “ABCs”—Airway with cervical spine protection, Breathing, and Circulation); the goals of the primary survey are to identify and treat conditions that constitute an immediate threat to life.
- 3▶ All patients with blunt injury should be assumed to have unstable cervical spine injuries until proven otherwise; one must maintain cervical spine precautions and in-line stabilization.
- 4▶ Patients with ongoing hemodynamic instability, whether “nonresponders” or “transient responders,” require prompt intervention; one must consider the four categories of shock that may represent the underlying pathophysiology: hemorrhagic, cardiogenic, neurogenic, and septic.
- 5▶ Indications for immediate operative intervention for penetrating cervical injury include hemodynamic instability and significant external arterial hemorrhage; the management algorithm for hemodynamically stable patients is based on the presenting symptoms and anatomic location of injury, with the neck being divided into three distinct zones.
- 6▶ The gold standard for determining if there is a blunt descending torn aorta injury is CT scanning; indications are primarily based on injury mechanisms.
- 7▶ The abdomen is a diagnostic black box. However, physical examination and ultrasound can rapidly identify patients requiring emergent laparotomy. Computed tomographic (CT) scanning is the mainstay of evaluation in the remaining patients to more precisely identify the site and magnitude of injury.
- 8▶ Manifestation of the “bloody vicious cycle” (the lethal combination of coagulopathy, hypothermia, and metabolic acidosis) is the most common indication for damage control surgery. The primary objectives of damage control laparotomy are to control bleeding and limit GI spillage.
- 9▶ Blunt injuries to the carotid and vertebral arteries are usually managed with systemic antithrombotic therapy.
- 10▶ The abdominal compartment syndrome may be primary (i.e., due to the injury of abdominal organs, bleeding, and packing) or secondary (i.e., due to reperfusion visceral edema, retroperitoneal edema, and ascites).

injury to the mouth, nares, or hypopharynx; extensive subcutaneous air in the neck; complex maxillofacial trauma; or airway bleeding. Although these patients may initially have an adequate airway, it may become obstructed if soft tissue swelling, hematoma formation, or edema progresses. In these cases, pre-emptive intubation should be performed before airway access becomes challenging.

Table 7-1

Immediately life-threatening injuries to be identified during the primary survey

Airway
Airway obstruction
Airway injury
Breathing
Tension pneumothorax
Open pneumothorax
Massive air leak
Flail chest with underlying pulmonary contusion
Circulation
Hemorrhagic shock
Massive hemothorax
Massive hemoperitoneum
Mechanically unstable pelvis fracture with bleeding
Extremity blood loss
Cardiogenic shock
Cardiac tamponade
Neurogenic shock
Disability
Intracranial hemorrhage/mass lesion
Cervical spine injury

Patients who have an abnormal voice, abnormal breathing sounds, tachypnea, or altered mental status require further airway evaluation. Blood, vomit, the tongue, foreign objects, and soft tissue swelling can cause airway obstruction; suctioning affords immediate relief in many patients. In the comatose patient, the tongue may fall backward and obstruct the hypopharynx; this can be relieved by either a chin lift or jaw thrust. An oral airway or a nasal trumpet is also helpful in maintaining airway patency, although the former is not usually tolerated by an awake patient. Establishing a definitive airway (i.e., endotracheal intubation) is indicated in patients with apnea; inability to protect the airway due to altered mental status; impending airway compromise due to inhalation injury, hematoma, facial bleeding, soft tissue swelling, or aspiration; and inability to maintain oxygenation. Altered mental status is the most common indication for intubation. Agitation or obtundation, often attributed to intoxication or drug use, may actually be due to hypoxia.

Options for endotracheal intubation include nasotracheal, orotracheal, or operative routes. Nasotracheal intubation can be accomplished only in patients who are breathing spontaneously. Although nasotracheal intubation is frequently used by prehospital providers, the application for this technique in the ED is limited to those patients requiring emergent airway support in whom chemical paralysis cannot be used. Orotracheal intubation is the preferred technique used to establish a definitive airway. Because all patients are presumed to have cervical spine injuries, manual in-line cervical immobilization is essential.⁶ Correct endotracheal placement is verified with 3▶ direct laryngoscopy, capnography, audible bilateral breath sounds, and finally a chest film. The GlideScope®, a video laryngoscope that uses fiber optics to visualize the vocal cords, is being employed more frequently.⁹ Advantages of orotracheal intubation include the direct visualization of the vocal cords, ability to use larger-diameter endotracheal tubes, and applicability to apneic patients. The disadvantage of orotracheal

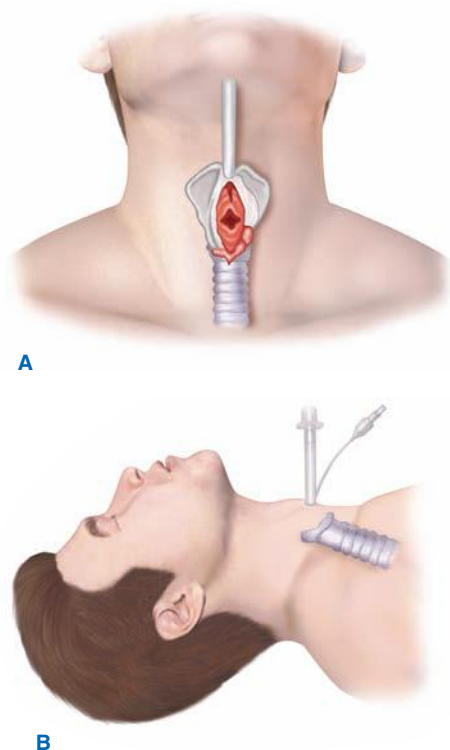


Figure 7-1. Cricothyroidotomy is recommended for emergent surgical establishment of a patent airway. A vertical skin incision avoids injury to the anterior jugular veins, which are located just lateral to the midline. Hemorrhage from these vessels obscures vision and prolongs the procedure. When a transverse incision is made in the cricothyroid membrane, the blade of the knife should be angled inferiorly to avoid injury to the vocal cords. **A.** Use of a tracheostomy hook stabilizes the thyroid cartilage and facilitates tube insertion. **B.** A 6.0 endotracheal tube is inserted after digital confirmation of airway access.

intubation is that conscious patients usually require neuromuscular blockade, which may result in inability to intubate, aspiration, or medication complications. Those who attempt rapid-sequence induction must be thoroughly familiar with the procedure (see Chap. 13).

Patients in whom attempts at intubation have failed or who are precluded from intubation due to extensive facial injuries require operative establishment of an airway. Cricothyroidotomy (Fig. 7-1) is performed through a generous vertical incision, with sharp division of the subcutaneous tissues. Visualization may be improved by having an assistant retract laterally on the neck incision using army-navy retractors. The cricothyroid membrane is verified by digital palpation and opened in a horizontal direction. The airway may be stabilized before incision of the membrane using a tracheostomy hook; the hook should be placed under the thyroid cartilage to elevate the airway. A 6.0 endotracheal tube (maximum diameter in adults) is then advanced through the cricothyroid opening and sutured into place. In patients under the age of 11, cricothyroidotomy is relatively contraindicated due to the risk of subglottic stenosis, and tracheostomy should be performed.

Emergent tracheostomy is indicated in patients with laryngotracheal separation or laryngeal fractures, in whom cricothyroidotomy may cause further damage or result in complete loss

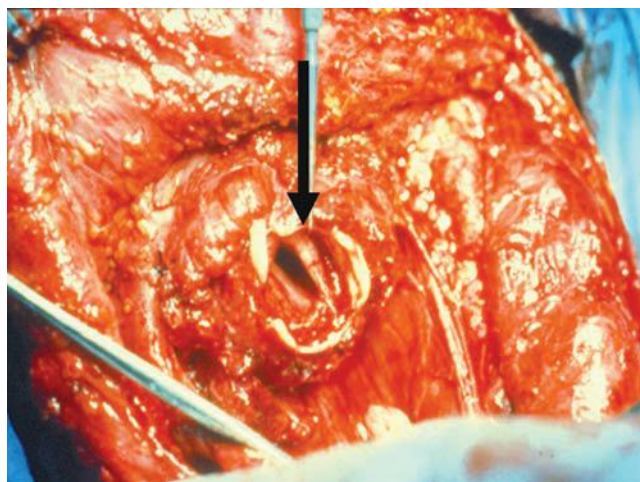


Figure 7-2. A “clothesline” injury can partially or completely transect the anterior neck structures, including the trachea. With complete tracheal transection, the endotracheal tube is placed directly into the distal aperture, with care taken not to push the trachea into the mediastinum.

of the airway. This procedure is best performed in the OR where there is optimal lighting and availability of more equipment (e.g., sternal saw). In these cases, often after a “clothesline” injury, direct visualization and instrumentation of the trachea usually is done through the traumatic anterior neck defect or after a generous collar skin incision (Fig. 7-2). If the trachea is completely transected, a nonpenetrating clamp should be placed on the distal aspect to prevent tracheal retraction into the mediastinum; this is particularly important before placement of the endotracheal tube.

Breathing and Ventilation Once a secure airway is obtained, adequate oxygenation and ventilation must be ensured. All injured patients should receive supplemental oxygen and be monitored by pulse oximetry. The following conditions constitute an immediate threat to life due to inadequate ventilation and should be recognized during the primary survey: tension pneumothorax, open pneumothorax, flail chest with underlying pulmonary contusion, and massive air leak. All of these diagnoses should be made during the initial physical examination.

The diagnosis of tension pneumothorax is presumed in any patient manifesting respiratory distress and hypotension in combination with any of the following physical signs: tracheal deviation away from the affected side, lack of or decreased breath sounds on the affected side, and subcutaneous emphysema on the affected side. Patients may have distended neck veins due to impedance of venous return, but the neck veins may be flat due to concurrent systemic hypovolemia. Tension pneumothorax and simple pneumothorax have similar signs, symptoms, and examination findings, but hypotension qualifies the pneumothorax as a tension pneumothorax. Although immediate needle thoracostomy decompression with a 14-gauge angiocatheter in the second intercostal space in the midclavicular line may be indicated in the field, tube thoracostomy should be performed immediately in the ED before a chest radiograph is obtained (Fig. 7-3). Recent studies suggest the preferred location for needle decompression may be the 5th intercostal space in the anterior axillary line due to body habitus.¹⁰ In cases of tension pneumothorax, the parenchymal tear in the lung acts as a one-way valve, with each inhalation allowing additional air to

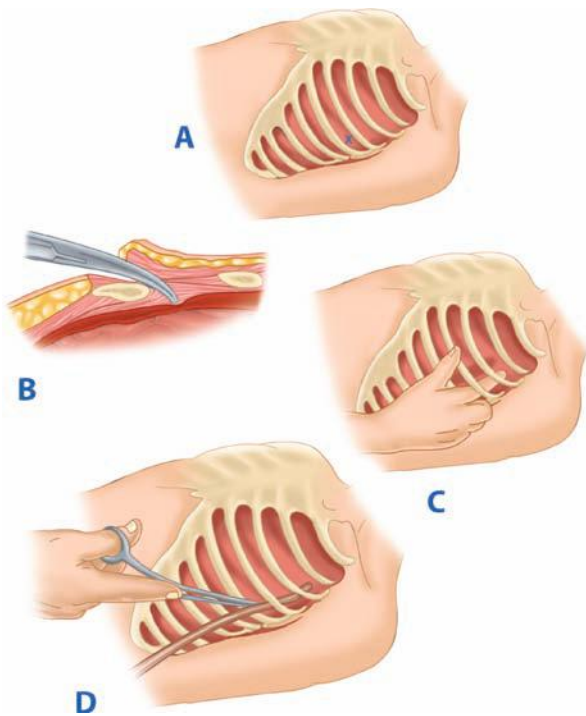
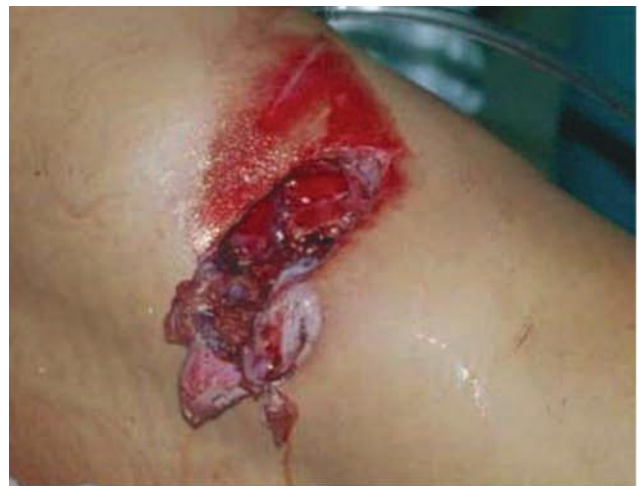

Figure 7-3. **A.** Tube thoracostomy is performed in the midaxillary line at the fourth or fifth intercostal space (inframammary crease) to avoid iatrogenic injury to the liver or spleen. **B.** Heavy scissors are used to cut through the intercostal muscle into the pleural space. This is done on top of the rib to avoid injury to the intercostal bundle located just beneath the rib. **C.** The incision is digitally explored to confirm intrathoracic location and identify pleural adhesions. **D.** A 28F chest tube is directed superiorly and posteriorly with the aid of a large clamp.

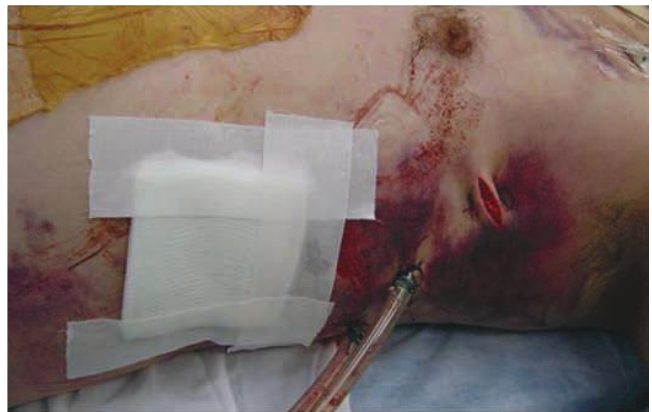accumulate in the pleural space. The normally negative intrapleural pressure becomes positive, which depresses the ipsilateral hemidiaphragm and shifts the mediastinal structures into the contralateral chest. Subsequently, the contralateral lung is compressed and the heart rotates about the superior and inferior vena cava; this decreases venous return and ultimately cardiac output, which culminates in cardiovascular collapse.

An open pneumothorax or “sucking chest wound” occurs with full-thickness loss of the chest wall, permitting free communication between the pleural space and the atmosphere (Fig. 7-4). This compromises ventilation due to equilibration of atmospheric and pleural pressures, which prevents lung inflation and alveolar ventilation, and results in hypoxia and hypercarbia. Complete occlusion of the chest wall defect without a tube thoracostomy may convert an open pneumothorax to a tension pneumothorax. Temporary management of this injury includes covering the wound with an occlusive dressing that is taped on three sides. This acts as a flutter valve, permitting effective ventilation on inspiration while allowing accumulated air to escape from the pleural space on the untaped side, so that a tension pneumothorax is prevented. Definitive treatment requires closure of the chest wall defect and tube thoracostomy remote from the wound.

Flail chest occurs when three or more contiguous ribs are fractured in at least two locations. Paradoxical movement of this free-floating segment of chest wall is usually evident in patients with spontaneous ventilation, due to the negative intrapleural pressure of inspiration. However, the additional work of breathing



A



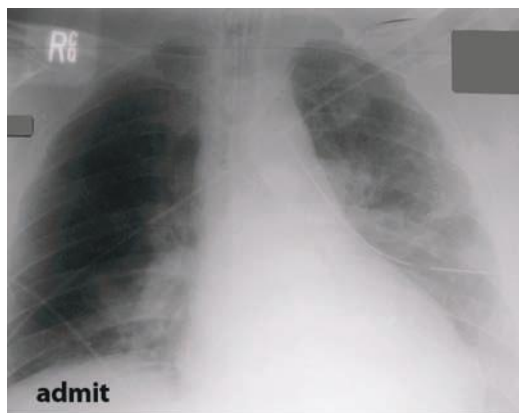
B

Figure 7-4. **A.** Full-thickness loss of the chest wall results in an open pneumothorax. **B.** The defect is temporarily managed with an occlusive dressing that is taped on three sides, which allows accumulated air to escape from the pleural space and thus prevents a tension pneumothorax. Repair of the chest wall defect and tube thoracostomy remote from the wound is definitive treatment.

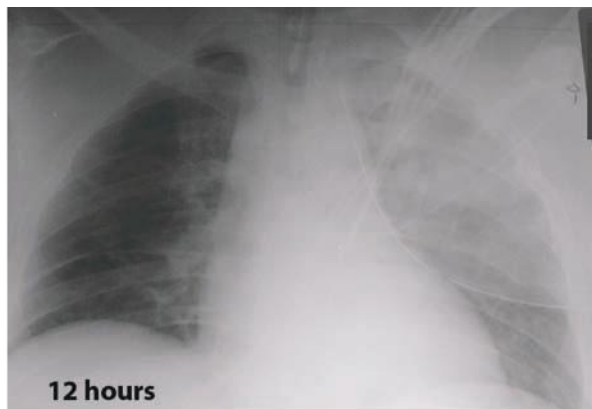
and chest wall pain caused by the flail segment is rarely sufficient to compromise ventilation. Instead, it is the decreased compliance and increased shunt fraction caused by the associated pulmonary contusion that is the source of acute respiratory failure. Pulmonary contusion often progresses during the first 12 hours. Resultant hypoventilation and hypoxemia may require intubation and mechanical ventilation. The patient’s initial chest radiograph often underestimates the extent of the pulmonary parenchymal damage (Fig. 7-5); close monitoring and frequent clinical re-evaluation are warranted.

Massive air leak occurs from major tracheobronchial injuries. Type I injuries are those occurring within 2 cm of the carina.^{11,12} These are often not associated with a pneumothorax due to the envelopment in the mediastinal pleura. Type II injuries are more distal injuries within the tracheobronchial tree and manifest with pneumothorax. Bronchoscopy confirms diagnosis and directs management.

Circulation with Hemorrhage Control With a secure airway and adequate ventilation established, circulatory status is the next priority. An initial approximation of the patient’s cardiovascular



A



B

Figure 7-5. A. Admission chest film may not show the full extent of the patient's pulmonary parenchymal injury. B. This patient's left pulmonary contusion blossomed 12 hours later, and its associated opacity is noted on repeat chest radiograph.

status can be obtained by palpating peripheral pulses. In general, systolic blood pressure (SBP) must be 60 mm Hg for the carotid pulse to be palpable, 70 mm Hg for the femoral pulse, and 80 mm Hg for the radial pulse. Any episode of hypotension (defined as a SBP <90 mm Hg) is assumed to be caused by hemorrhage until proven otherwise. Patients with acute massive blood loss may have paradoxical bradycardia.¹³ Blood pressure and pulse should be measured at least every 5 minutes in patients with significant blood loss until normal vital sign values are restored. High energy auto-pedestrian victims should have their pelvis wrapped with a sheet until radiography can be done.

IV access for fluid resuscitation is obtained with two peripheral catheters, 16-gauge or larger in adults. For patients in whom peripheral angiocatheter access is difficult, intraosseous (IO) needles can be rapidly placed in the proximal tibia of the lower extremity (Fig. 7-6).^{14,15} All medications administered IV may be administered in a similar dosage intraosseously. Although safe for emergent use, the needle should be removed once alternative access is established to prevent osteomyelitis. Blood should be drawn simultaneously for a bedside hemoglobin level and routine trauma laboratory tests. In the seriously injured patient arriving in shock, an arterial blood gas, cross-matching for possible red blood cell (RBC) transfusion, and a coagulation panel should be obtained. In these patients, secondary large bore cannulae should be obtained via the femoral or subclavian

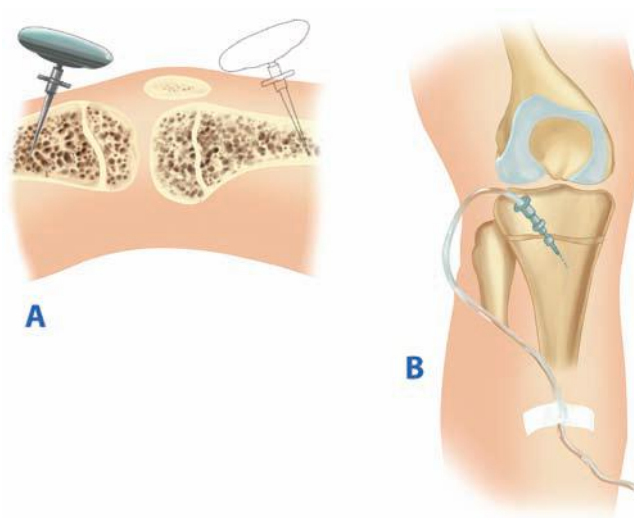


Figure 7-6. Intraosseous infusions are indicated for children <6 years of age in whom one or two attempts at IV access have failed. A. The proximal tibia is the preferred location. Alternatively, the distal femur can be used if the tibia is fractured. B. The needle should be directed away from the epiphyseal plate to avoid injury. The position is satisfactory if bone marrow can be aspirated and saline can be easily infused without evidence of extravasation.

veins, or saphenous vein cutdown; Cordis introducer catheters are preferred over triple-lumen catheters. In general, initial access in trauma patients is best secured in the groin or ankle, so that the catheter will not interfere with the performance of other diagnostic and therapeutic thoracic procedures. Saphenous vein cutdowns at the ankle provide excellent access (Fig. 7-7). The saphenous vein is reliably found 1 cm anterior and 1 cm superior to the medial malleolus. Standard 14-gauge catheters can be quickly placed, even in an exsanguinating patient with

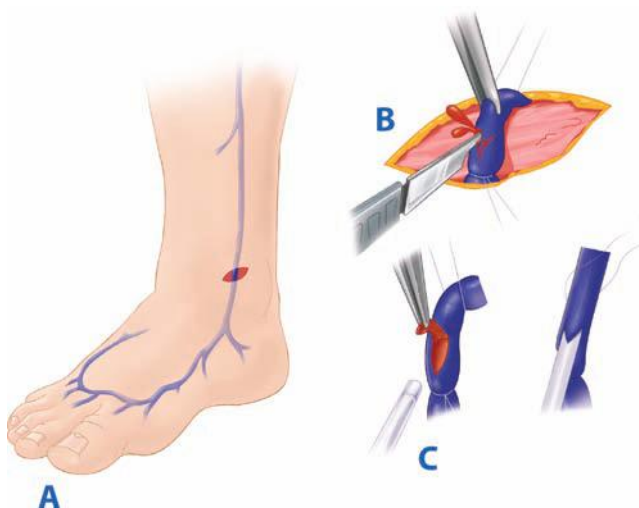


Figure 7-7. Saphenous vein cutdowns are excellent sites for fluid resuscitation access. A. The vein is consistently found 1 cm anterior and 1 cm superior to the medial malleolus. B. Proximal and distal traction sutures are placed with the distal suture ligated. C. A 14-gauge IV catheter is introduced and secured with sutures and tape to prevent dislodgment.

collapsed veins. If IV access cannot be achieved readily, the IO route is very useful, particularly for drug administration.^{14,15} Additional venous access often is obtained through the femoral or subclavian veins with Cordis introducer catheters. A rule of thumb to consider for secondary access is placement of femoral access for thoracic trauma and jugular or subclavian access for abdominal trauma. However, jugular or subclavian catheters provide a more reliable measurement of central venous pressure (CVP), which may be helpful in determining the volume status of the patient and in excluding cardiac tamponade. In severely injured children < 6 years of age, the preferred venous access is peripheral intravenous catheters followed by an IO needle. Central venous catheter placement or saphenous vein cutdown may be considered as the third choice of access based upon provider experience. Inadvertent femoral artery cannulation, however, may result in limb-threatening distal arterial spasm.

External control of any visible hemorrhage should be achieved promptly while circulating volume is restored. Manual compression of open wounds with ongoing bleeding should be done with a single 4 × 4 gauze and a gloved hand. Covering the wound with excessive dressings may permit ongoing unrecognized blood loss that is hidden underneath the dressing. Blind clamping of bleeding vessels should be avoided because of the risk to adjacent structures, including nerves. This is particularly true for penetrating injuries of the neck, thoracic outlet, and groin, where bleeding may be torrential and arising deep within the wound. In these situations, a gloved finger is placed through the wound directly onto the bleeding vessel and enough pressure is applied to control active bleeding. The surgeon performing this maneuver must then walk with the patient to the OR for definitive treatment. For bleeding of the extremities it is tempting to apply tourniquets for hemorrhage control, but digital occlusion will usually control the bleeding, and complete vascular occlusion risks permanent neuromuscular impairment. Patients in shock have a lower tolerance to warm ischemia, and an occluded extremity is prone to small vessel thrombosis.

For patients with open fractures, fracture reduction with stabilization via splints will limit bleeding both externally and into the subcutaneous tissues. Scalp lacerations through the galea aponeurotica tend to bleed profusely; these can be temporarily controlled with skin staples, Raney clips, or a large full-thickness continuous running nylon stitch.

During the circulation section of the primary survey, four life-threatening injuries must be identified promptly: (a) massive hemothorax, (b) cardiac tamponade, (c) massive hemoperitoneum, and (d) mechanically unstable pelvic fractures with bleeding. Massive hemoperitoneum and mechanically unstable pelvic fractures are discussed in “Emergent Abdominal Exploration” and “Pelvic Fractures and Emergent Hemorrhage Control,” respectively. Three critical tools used to differentiate these in the multisystem trauma patient are chest radiograph, pelvis radiograph, and focused abdominal sonography for trauma (FAST) (see “Regional Assessment and Special Diagnostic Tests”). A massive hemothorax (life-threatening injury number one) is defined as >1500 mL of blood or, in the pediatric population, >25% of the patient’s blood volume in the pleural space (Fig. 7-8). Although it may be estimated on chest radiograph, tube thoracostomy is the only reliable means to quantify the amount of hemothorax. After blunt trauma, a major hemothorax usually is due to multiple rib fractures with severed intercostal arteries, but occasionally bleeding is from lacerated lung parenchyma which is usually associated with an air leak. After penetrating trauma, a great vessel or pulmonary hilar vessel injury should be presumed. In either scenario, a massive hemothorax is an indication for operative intervention, but tube thoracostomy is critical to facilitate lung re-expansion, which may improve oxygenation and cardiac performance as well as tamponade venous bleeding.

Cardiac tamponade (life-threatening injury number two) occurs most commonly after penetrating thoracic wounds, although occasionally blunt rupture of the heart, particularly the atrial appendage, is seen. Acutely, <100 mL of pericardial

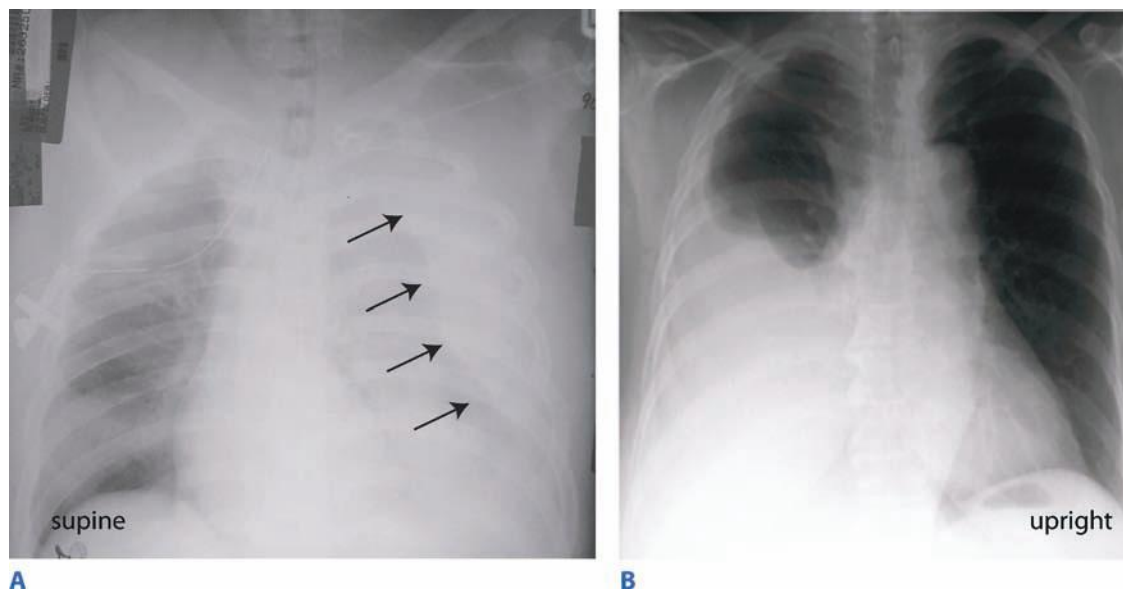


Figure 7-8. More than 1500 mL of blood in the pleural space is considered a massive hemothorax. Chest film findings reflect the positioning of the patient. **A.** In the supine position, blood tracks along the entire posterior section of the chest and is most notable pushing the lung away from the chest wall. **B.** In the upright position, blood is visible dependently in the right pleural space.

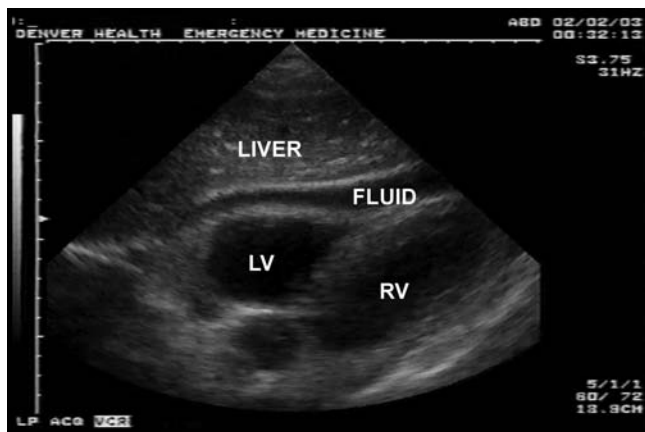


Figure 7-9. Subxiphoid pericardial ultrasound reveals a large pericardial fluid collection.

blood may cause pericardial tamponade.¹⁶ The classic Beck's triad—dilated neck veins, muffled heart tones, and a decline in arterial pressure—is usually not appreciated in the trauma bay because of the noisy environment and associated hypovolemia. Because the pericardium is not acutely distensible, the pressure in the pericardial sac will rise to match that of the injured chamber. When this pressure exceeds that of the right atrium, right atrial filling is impaired and right ventricular preload is reduced. This ultimately leads to decreased right ventricular output. Additionally, increased intrapericardial pressure impedes myocardial blood flow, which leads to subendocardial ischemia and a further reduction in cardiac output.

Diagnosis of hemopericardium is best achieved by bedside ultrasound of the pericardium (Fig. 7-9). Early in the course of tamponade, blood pressure and cardiac output will transiently improve with fluid administration due to increased central venous pressure. In patients with any hemodynamic disturbance, a pericardial drain is placed using ultrasound guidance (Fig. 7-10). Removing as little as 15 to 20 mL of blood will often temporarily stabilize the patient's hemodynamic status,

Table 7-2

Current indications and contraindications for emergency department thoracotomy

Indications

Salvageable postinjury cardiac arrest:

- Patients sustaining witnessed penetrating trauma to the torso with <15 min of prehospital CPR
- Patients sustaining witnessed blunt trauma with <10 min of prehospital CPR
- Patients sustaining witnessed penetrating trauma to the neck or extremities with <5 min of prehospital CPR

Persistent severe postinjury hypotension (SBP \leq 60 mm Hg) due to:

- Cardiac tamponade
- Hemorrhage—intrathoracic, intra-abdominal, extremity, cervical
- Air embolism

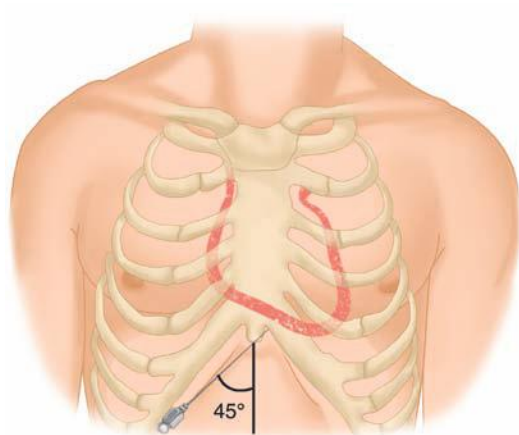
Contraindications

- Penetrating trauma: CPR >15 min and no signs of life (pupillary response, respiratory effort, motor activity)
- Blunt trauma: CPR >10 min and no signs of life or asystole without associated tamponade

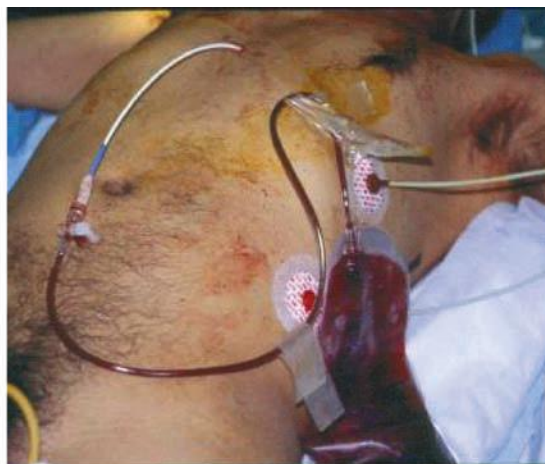CPR = cardiopulmonary resuscitation; SBP = systolic blood pressure.

and alleviate subendocardial ischemia with associated lethal arrhythmias, and allow safe transport to the OR for sternotomy. Pericardiocentesis is successful in decompressing tamponade in approximately 80% of cases; the majority of failures are due to the presence of clotted blood within the pericardium. Patients with a SBP <60 mm Hg warrant resuscitative thoracotomy (RT) with opening of the pericardium for rapid decompression and to address the injury.

The utility of RT has been debated for decades. Current indications are based on 30 years of prospective data, supported by a recent multicenter prospective study (Table 7-2).^{17,18} RT



A



B

Figure 7-10. Pericardiocentesis is indicated for patients with evidence of pericardial tamponade. **A.** Access to the pericardium is obtained through a subxiphoid approach, with the needle angled 45 degrees up from the chest wall and toward the left shoulder. **B.** Seldinger technique is used to place a pigtail catheter. Blood can be repeatedly aspirated with a syringe or the tubing may be attached to a gravity drain. Evacuation of unclotted pericardial blood prevents subendocardial ischemia and stabilizes the patient for transport to the operating room for sternotomy.

is associated with the highest survival rate after isolated cardiac injury; 35% of patients presenting in shock and 20% without vital signs (i.e., no pulse or obtainable blood pressure) are salvaged after isolated penetrating injury to the heart. For all penetrating wounds, survival rate is 15%. Conversely, patient outcome is poor when RT is done for blunt trauma, with 2% survival among patients in shock and <1% survival among those with no vital signs. Thus, patients undergoing cardiopulmonary resuscitation upon arrival to the ED should undergo RT selectively based on injury and transport time (Fig. 7-11). RT is best accomplished using a generous left anterolateral thoracotomy, with the skin incision started to the right of the sternum (Fig. 7-12). A longitudinal pericardiotomy anterior to the phrenic nerve is used to release cardiac tamponade and permits access to the heart for cardiac repair and open cardiac massage. Cross-clamping of the aorta improves central circulation, augments cerebral and coronary blood flow, and limits further abdominal blood loss (Fig. 7-13). The patient must sustain a SBP of 70 mm Hg after RT and associated interventions to be considered resuscitatable, and hence transported to the OR.^{17,18}

Disability and Exposure The Glasgow coma scale (GCS) score should be determined for all injured patients (Table 7-3). It is calculated by adding the scores of the best motor response, best verbal response, and the best eye response. Scores range from 3 (the lowest) to 15 (normal). Scores of 13 to 15 indicate mild head injury, 9 to 12 moderate injury, and ≤ 8 severe injury.

The GCS is a quantifiable determination of neurologic function that is useful for triage, treatment, and prognosis.

Neurologic evaluation is critical before administration of neuromuscular blockade for intubation. Subtle changes in mental status can be caused by hypoxia, hypercarbia, or hypovolemia, or may be an early sign of increasing intracranial pressure. An abnormal mental status should prompt an immediate re-evaluation of the ABCs and consideration of central nervous system injury. Deterioration in mental status may be subtle and may not progress in a predictable fashion. For example, previously calm, cooperative patients may become anxious and combative as they become hypoxic. However, a patient who is agitated and combative from drugs or alcohol may become somnolent if hypovolemic shock develops. Patients with neurogenic shock are typified by hypotension with relative bradycardia, and are often first recognized due to paralysis, decreased rectal tone or priapism. Patients with high spinal cord disruption are at greatest risk for neurogenic shock due to physiologic disruption of sympathetic fibers; treatment consists of volume loading and a dopamine infusion which is both inotropic and chronotropic. Seriously injured patients must have all of their clothing removed to avoid overlooking limb- or life-threatening injuries.

Shock Classification and Initial Fluid Resuscitation Classic signs and symptoms of shock are tachycardia, hypotension, tachypnea, altered mental status, diaphoresis, and pallor (Table 7-4). In general, the quantity of acute blood loss correlates

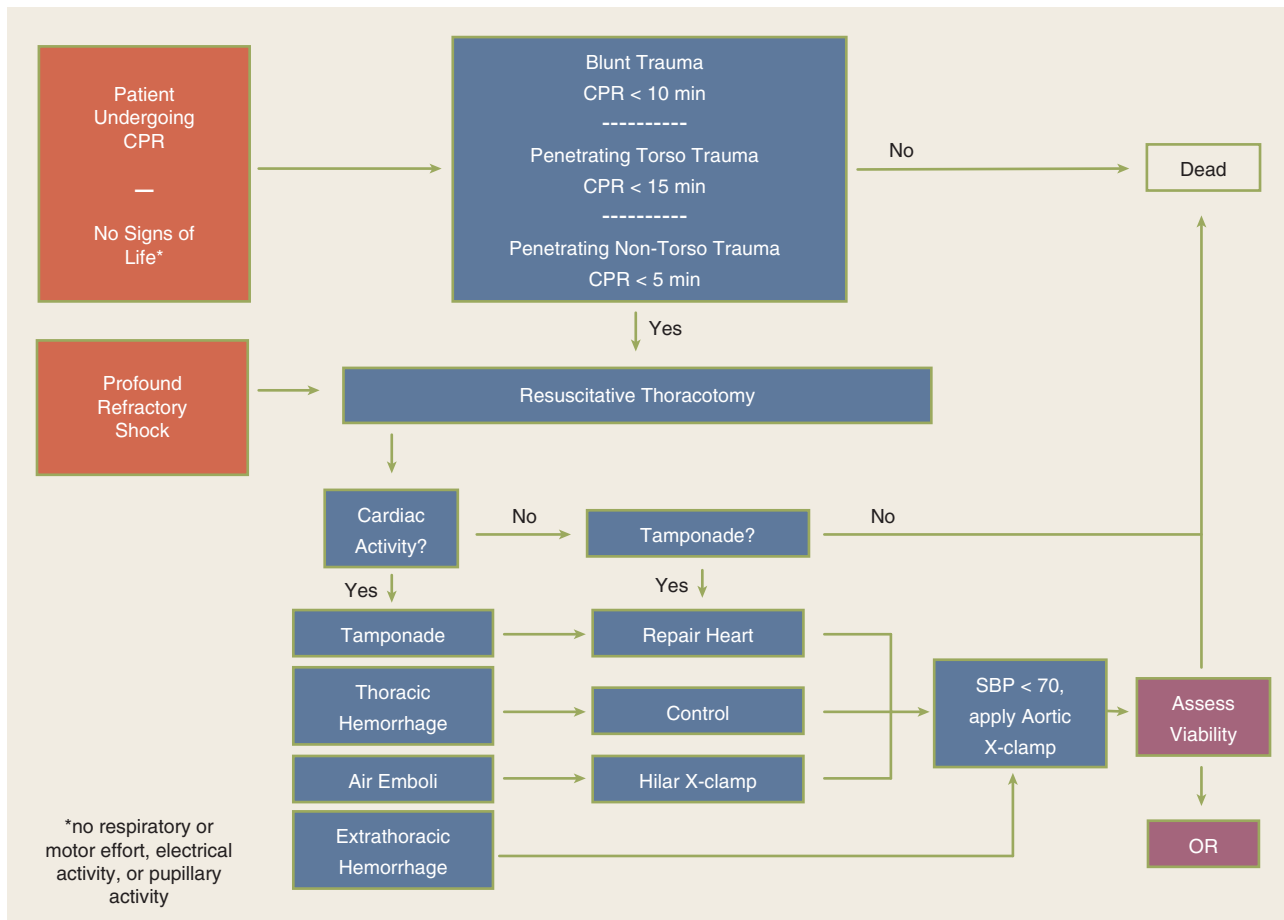


Figure 7-11. Algorithm directing the use of resuscitative thoracotomy (RT) in the injured patient undergoing cardiopulmonary resuscitation (CPR). ECG = electrocardiogram; OR = operating room; SBP = systolic blood pressure.

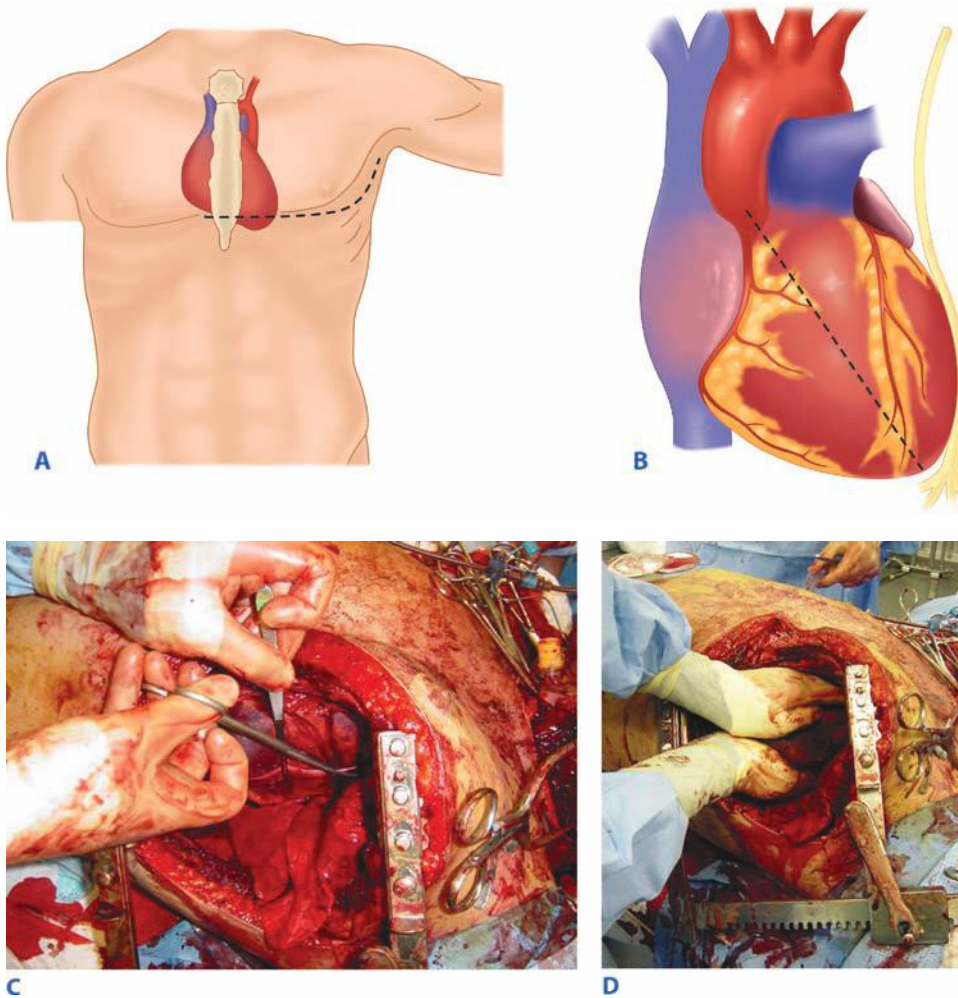


Figure 7-12. A. Resuscitative thoracotomy (RT) is performed through the fifth intercostal space using the anterolateral approach. B and C. The pericardium is opened anterior to the phrenic nerve, and the heart is rotated out for evaluation. D. Open cardiac massage should be performed with a hinged, clapping motion of the hands, with sequential closing from palms to fingers. The two-handed technique is strongly recommended because the one-handed massage technique poses the risk of myocardial perforation with the thumb.

with physiologic abnormalities. For example, patients in class II shock are tachycardic but they do not exhibit a reduction in blood pressure until over 1500 mL of blood loss, or class III shock. Physical findings should be used as an aid in the evaluation of the patient's response to treatment. The goal of fluid resuscitation is to re-establish tissue perfusion. Fluid resuscitation begins with a 2 L (adult) or 20 mL/kg (child) IV bolus

of isotonic crystalloid, typically Ringer's lactate. For persistent hypotension (SBP <90 mm Hg in an adult), the current trend is to activate a massive transfusion protocol (MTP) in which red blood cells (RBC) and fresh-frozen plasma (FFP) are administered early. The details of a MTP are discussed later. Patients who have a good response to fluid infusion (i.e., normalization of vital signs, clearing of the sensorium) and evidence of good

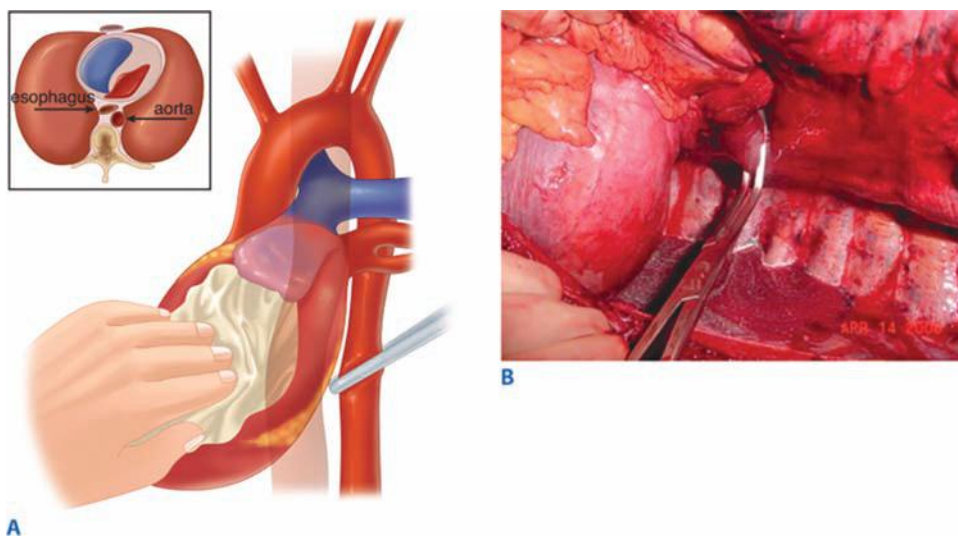


Figure 7-13. Aortic cross-clamp is applied with the left lung retracted superiorly, below the inferior pulmonary ligament, just above the diaphragm. The flaccid aorta is identified as the first structure encountered on top of the spine when approached from the left chest.

Table 7-3

Glasgow coma scale^a

		ADULTS	INFANTS/CHILDREN
Eye opening	4	Spontaneous	Spontaneous
	3	To voice	To voice
	2	To pain	To pain
	1	None	None
Verbal	5	Oriented	Alert, normal vocalization
	4	Confused	Cries, but consolable
	3	Inappropriate words	Persistently irritable
	2	Incomprehensible words	Restless, agitated, moaning
	1	None	None
Motor response	6	Obeys commands	Spontaneous, purposeful
	5	Localizes pain	Localizes pain
	4	Withdraws	Withdraws
	3	Abnormal flexion	Abnormal flexion
	2	Abnormal extension	Abnormal extension
	1	None	None

^aScore is calculated by adding the scores of the best motor response, best verbal response, and eye opening. Scores range from 3 (the lowest) to 15 (normal).

peripheral perfusion (warm fingers and toes with normal capillary refill) are presumed to have adequate overall perfusion. Urine output is a quantitative, reliable indicator of organ perfusion. Adequate urine output is 0.5 mL/kg per hour in an adult, 1 mL/kg per hour in a child, and 2 mL/kg per hour in an infant <1 year of age. Because measurement of this resuscitation-related variable is time dependent, it is generally more useful in the OR and intensive care unit (ICU) setting, than in initial evaluation in the trauma bay.

There are several caveats to be considered when evaluating the injured patient for shock. Tachycardia is often the earliest sign of ongoing blood loss, but the critical issue is change over time. Furthermore, individuals in good physical condition with a resting pulse rate in the fifties may manifest a relative tachycardia in the nineties; although clinically significant, this does

not meet the standard definition of tachycardia. Conversely, patients receiving cardiac medications such as beta blockers may not be capable of increasing their heart rate to compensate for hypovolemia. Bradycardia can occur with rapid severe blood loss¹³; this is an ominous sign, often heralding impending cardiovascular collapse. Other physiologic stresses, aside from hypovolemia, may produce tachycardia, such as hypoxia, pain, anxiety, and stimulant drugs (cocaine, amphetamines). As noted previously, decreased SBP is not a reliable early sign of hypovolemia, because blood loss must exceed 30% before hypotension occurs. Additionally, younger patients may maintain their SBP due to sympathetic tone despite severe intravascular deficits until they are on the verge of cardiac arrest. Pregnant patients have a progressive increase in circulating blood volume over gestation; therefore, they must lose a relatively larger volume of

Table 7-4

Signs and symptoms of advancing stages of hemorrhagic shock

	CLASS I	CLASS II	CLASS III	CLASS IV
Blood loss (mL)	Up to 750	750–1500	1500–2000	>2000
Blood loss (%BV)	Up to 15%	15%–30%	30%–40%	>40%
Pulse rate	<100	>100	>120	>140
Blood pressure	Normal	Normal	Decreased	Decreased
Pulse pressure (mm Hg)	Normal or increased	Decreased	Decreased	Decreased
Respiratory rate	14–20	>20–30	30–40	>35
Urine output (mL/h)	>30	>20–30	5–15	Negligible
CNS/mental status	Slightly anxious	Mildly anxious	Anxious and confused	Confused and lethargic

BV = blood volume; CNS = central nervous system.

blood before manifesting signs and symptoms of hypovolemia (see *Special Trauma Populations*).

Based on the initial response to fluid resuscitation, hypovolemic injured patients can be separated into three broad categories: responders, transient responders, and nonresponders. Individuals who are stable or have a good response to the initial fluid therapy as evidenced by normalization of vital signs, mental status, and urine output are unlikely to have significant ongoing hemorrhage, and further diagnostic evaluation for occult injuries can proceed in an orderly fashion (see “Secondary Survey”). At the other end of the spectrum are patients classified as “nonresponders” who have persistent hypotension despite aggressive resuscitation. These patients mandate immediate identification of the source of hypotension with appropriate intervention to prevent a fatal outcome. Transient responders are those who respond initially to volume loading with improvement in vital signs, but then deteriorate hemodynamically again. This group of patients can be challenging to triage for definitive management.

Persistent Hypotension Patients with ongoing hemodynamic instability, whether “nonresponders” or “transient responders,”

4▶ require systematic evaluation and prompt intervention. The spectrum of disease in patients with persistent hypotension ranges from overwhelming multisystem injury to easily reversible problems such as a tension pneumothorax. One must first consider the four categories of shock that may be the underlying cause: hemorrhagic, cardiogenic, neurogenic, and septic. In patients with persistent hypotension and tachycardia, cardiogenic or hemorrhagic shock are the likely causes. Ultrasound evaluation of the pericardium, pleural cavities, and abdomen in combination with plain radiographs of the chest and pelvis will usually identify the source of hemorrhagic and/or cardiogenic shock. Evaluation of the CVP may further assist in distinguishing between these two categories. A patient with distended neck veins and a CVP of >15 cm H_2O is likely to be in cardiogenic shock. The CVP may be falsely elevated, however, if the patient is agitated and straining, or fluid administration is overzealous; isolated readings must be interpreted with caution. A patient with flat neck veins and a CVP of <5 cm H_2O is likely hypovolemic due to ongoing hemorrhage. Serial base deficit measurements are helpful; a persistent base arterial deficit of >8 mmol/L implies ongoing cellular shock.^{19,20} Serum lactate is also used to monitor the patient’s physiologic response to resuscitation.²¹ Evolving technology, such as near infrared spectroscopy, may provide noninvasive monitoring of oxygen delivery to tissue.²² Except for patients transferred from outside facilities >12 hours after injury, few patients present in septic shock in the trauma bay. Patients with neurogenic shock as a component of hemodynamic instability often are recognized during the disability section of the primary survey to have paralysis, but those patients chemically paralyzed before physical examination may be misdiagnosed.

The differential diagnosis of cardiogenic shock in trauma patients is: (a) tension pneumothorax, (b) pericardial tamponade, (c) blunt cardiac injury, (d) myocardial infarction, and (e) bronchovenous air embolism. Tension pneumothorax, the most frequent cause of cardiac failure, and pericardial tamponade have been discussed earlier. Although as many as one-third of patients sustaining significant blunt chest trauma experience some degree of blunt cardiac injury, few such injuries result in hemodynamic embarrassment. Patients with electrocardiographic

(ECG) abnormalities or dysrhythmias require continuous ECG monitoring and antidysrhythmic treatment as needed. Unless myocardial infarction is suspected, there is no role for routine serial measurement of cardiac enzyme levels—they lack specificity and do not predict significant dysrhythmias.²³ In patients who have no identified injuries who are being considered for discharge from the ED, the combination of a normal EKG and troponin level at admission and 8 hours later, rules out significant blunt cardiac injury.²⁴ The patient with hemodynamic instability requires appropriate resuscitation and may benefit from hemodynamic monitoring to optimize preload and guide inotropic support. Echocardiography (ECHO) is performed to exclude valvular or septal injuries, and the most common finding is right ventricular dyskinesia due to the anterior orientation of the right versus left ventricle. Transthoracic and transesophageal ECHO are now becoming routine in many surgical intensive care units (SICUs).^{25,26} Patients with refractory cardiogenic shock may occasionally require placement of an intra-aortic balloon pump to decrease myocardial work and enhance coronary perfusion. Acute myocardial infarction may be the cause of a motor vehicle collision or other trauma in older patients. Although optimal initial management includes treatment for the evolving infarction, such as lytic therapy and emergent angioplasty, these decisions must be individualized in accordance with the patient’s other injuries.

Air embolism is a frequently overlooked lethal complication of pulmonary injury. Air emboli can occur after blunt or penetrating trauma, where air from an injured bronchus enters an adjacent injured pulmonary vein (bronchovenous fistula) and returns air to the left heart. Air accumulation in the left ventricle impedes diastolic filling, and during systole air is pumped into the coronary arteries, disrupting coronary perfusion. The typical case is a patient with a penetrating thoracic injury who is hemodynamically stable but experiences cardiac arrest after being intubated and placed on positive pressure ventilation. The patient should immediately be placed in Trendelenburg’s position to trap the air in the apex of the left ventricle. Emergency thoracotomy is followed by cross-clamping of the pulmonary hilum on the side of the injury to prevent further introduction of air (Fig. 7-14). Air is aspirated from the apex of the left ventricle and then the aortic root with an 18-gauge needle and 50-mL syringe. Vigorous massage is used to force the air bubbles through the coronary arteries; if this is unsuccessful, a tuberculin syringe is used to aspirate air bubbles from the right coronary artery. Once circulation is restored, the patient should be kept in Trendelenburg’s position with the pulmonary hilum clamped until the pulmonary venous injury is controlled operatively.

Persistent hypotension due to uncontrolled hemorrhage is associated with high mortality. A rapid search for the source or sources of hemorrhage includes visual inspection with knowledge of the injury mechanism, FAST, and chest and pelvic radiographs. During diagnostic evaluation, type O RBCs (O-negative for women of childbearing age) and thawed AB plasma should be administered at a ratio of 2:1. Type-specific RBCs should be administered as soon as available. The acute coagulopathy of trauma is now well recognized, and underscores the importance of pre-emptive blood component administration. The resurgent interest in viscoelastic hemostatic assays (thrombelastography [TEG] and thrombelastometry [ROTEM]) has facilitated the appropriate and timely use of clotting adjuncts, including the prompt recognition of fibrinolysis. In patients with clear indications for operation, essential films should be taken and the

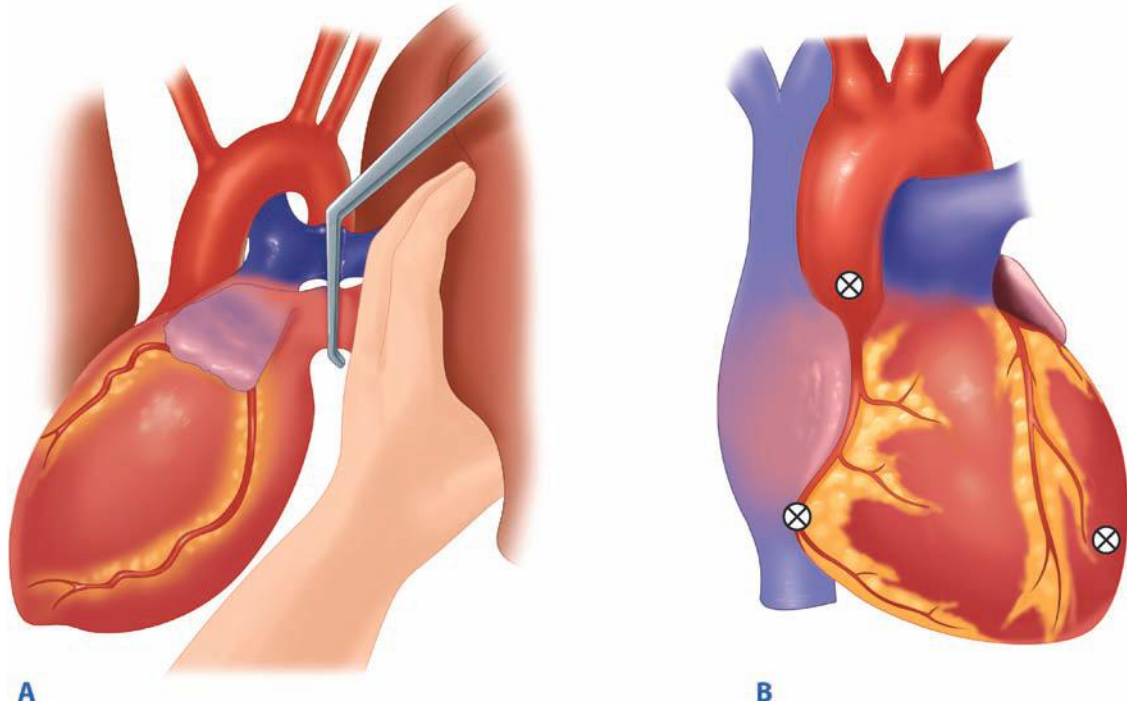


Figure 7-14. **A.** A Satinsky clamp is used to clamp the pulmonary hilum to prevent further bronchovenous air embolism. **B.** Sequential sites of aspiration include the left ventricle, the aortic root, and the right coronary artery.

patient transported to the OR immediately. Such patients include those with blunt trauma and massive hemothorax, those with penetrating trauma and an initial chest tube output of >1 L, and those with abdominal trauma and ultrasound evidence of extensive hemoperitoneum. In patients with gunshot wounds to the chest or abdomen, a chest and abdominal film, with radiopaque markers at the wound sites, should be obtained to determine the trajectory of the bullet or location of a retained fragment. For example, a patient with a gunshot wound to the upper abdomen should have a chest radiograph to ensure that the bullet did not traverse the diaphragm causing intrathoracic injury. Similarly, a chest radiograph is important in a patient with a gunshot wound to the right chest to evaluate the left hemithorax. If a patient arrives with a penetrating weapon remaining in place, the weapon should *not* be removed in the ED, because it could be tamponading a lacerated blood vessel (Fig. 7-15). The surgeon should extract the offending instrument in the controlled

environment of the OR, ideally once an incision has been made with adequate exposure. In situations where knives are embedded in the head or neck, preoperative imaging may be useful to anticipate arterial injuries.

In patients without clear operative indications and persistent hypotension, one should systematically evaluate the five potential sources of blood loss: scalp, chest, abdomen, pelvis, and extremities. Significant bleeding at the scene may be noted by paramedics, but its quantification is unreliable. Examination should seek active bleeding from a scalp laceration that may be readily controlled with clips or staples. Thoracoabdominal trauma should be evaluated with a combination of chest radiograph, FAST, and pelvic radiograph. If the FAST results are negative and no other source of hypotension is obvious, diagnostic peritoneal aspiration should be entertained.²⁷ Extremity examination and radiographs should be used to search for associated fractures. Fracture-related blood loss, when additive, may

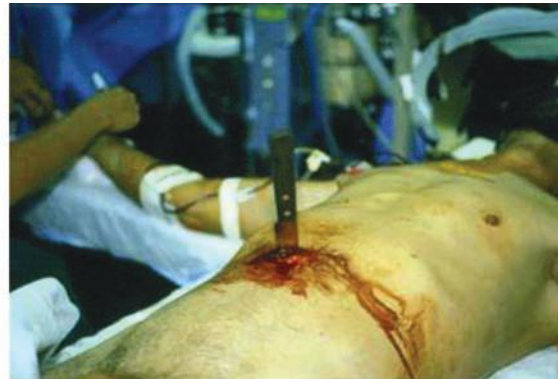
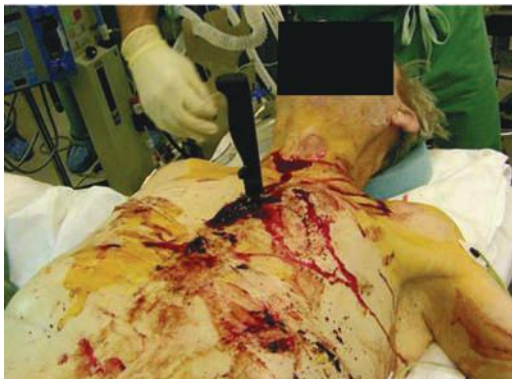
Figure 7-15. If a weapon is still in place, it should be removed in the operating room, because it could be tamponading a lacerated blood vessel.

be a potential source of the patient's hemodynamic instability. Each rib fracture can produce 100 to 200 mL of blood loss; for tibial fractures, 300 to 500 mL; for femur fractures, 800 to 1000 mL; and for pelvic fractures >2000 mL. Although no single injury can account for the patient's hemodynamic instability, the sum of the injuries may result in life-threatening blood loss. The diagnostic measures advocated earlier are those that can be easily performed in the trauma bay. Transport of a hypotensive patient out of the ED for computed tomographic (CT) scanning is hazardous; monitoring is compromised, and the environment is suboptimal for dealing with acute problems. The surgeon must accompany the patient and be prepared to abort the CT scan with diversion to the OR. This dilemma is becoming less common in many trauma centers where CT scanning is done in the ED.

The concept of hypotensive resuscitation in the ED remains controversial, and it is primarily relevant for patients with penetrating vascular injuries. Experimental work suggests that an endogenous sealing clot of an injured artery may be disrupted at an SBP of >90 mm Hg²⁸; thus, many believe that this should be the preoperative blood pressure target for patients with potential torso arterial injuries. On the other hand, optimal management of traumatic brain injury (TBI) includes maintaining the SBP >100 mm Hg,²⁹ and thus, hypotensive resuscitation is not appropriate for most blunt trauma patients.

Secondary Survey

Once the immediate threats to life have been addressed, a thorough history is obtained and the patient is examined in a systematic fashion. The patient and surrogates should be queried to obtain an AMPLE history (Allergies, Medications, Past illnesses or Pregnancy, Last meal, and Events related to the injury). The physical examination should be literally head to toe, with special attention to the patient's back, axillae, and perineum, because injuries here are easily overlooked. All potentially seriously injured patients should undergo digital rectal examination to evaluate for sphincter tone, presence of blood, rectal perforation, or a high-riding prostate; this is particularly critical in patients with suspected spinal cord injury, pelvic fracture, or transpelvic gunshot wounds. Vaginal examination with a speculum should be performed in women with pelvic fractures to exclude an open fracture. Specific injuries, their associated signs and symptoms, diagnostic options, and treatments are discussed in detail later in this chapter.

Adjuncts to the physical examination include vital sign and CVP monitoring, ECG monitoring, nasogastric tube placement, Foley catheter placement, radiographs, hemoglobin, urinalysis, and base deficit measurements, and repeat FAST exam. A nasogastric tube should be inserted in all intubated patients to decrease the risk of gastric aspiration but may not be necessary in the awake patient. Nasogastric tube placement in patients with complex mid-facial fractures is contraindicated; rather, a tube should be placed orally if required. Nasogastric tube evaluation of stomach contents for blood may suggest occult gastroduodenal injury or the errant path of the nasogastric tube on a chest film may indicate a left diaphragm injury. A Foley catheter should be inserted in patients unable to void to decompress the bladder, obtain a urine specimen, and monitor urine output. Gross hematuria demands evaluation of the genitourinary system for injury. Foley catheter placement should be deferred until urologic evaluation in patients with signs of urethral injury: blood at the meatus, perineal or scrotal hematomas, or a high-riding prostate. Although policies vary at individual institutions,

most agree patients in extremis with need for Foley catheter placement should undergo one attempt at catheterization; if the catheter does not pass easily, a percutaneous suprapubic cystostomy should be considered.

Selective radiography and laboratory tests are done early in the evaluation after the primary survey. For patients with severe blunt trauma, chest and pelvic radiographs should be obtained. Historically, a lateral cervical spine radiograph was also obtained, hence the reference to *the big three* films, but currently patients preferentially undergo CT scanning of the spine rather than plain film radiography. For patients with truncal gunshot wounds, anteroposterior and at times lateral radiographs of the chest and abdomen are warranted. It is important to mark the entrance and exit sites of penetrating wounds with ECG pads, metallic clips, or staples so that the trajectory of the missile can be estimated. Limited one-shot extremity radiographs also may be taken. In critically injured patients, blood samples for a routine trauma panel (type and cross-match, complete blood count, blood chemistries, coagulation studies, and arterial blood gas analysis) should be sent to the laboratory. For less severely injured patients only a complete blood count and urinalysis may be required. Because older patients may present in subclinical shock, even with minor injuries, routine analysis of an arterial blood gas in patients over the age of 55 should be considered. Repeat FAST is performed if there are any signs of abdominal injury or unexplained blood loss.

Many trauma patients cannot provide specific information about the mechanism of their injury. Emergency medical service personnel and police are trained to evaluate an injury scene and should be questioned while they are present in the ED. For automobile collisions, the speed of the vehicles involved, angle of impact, use of restraints, airbag deployment, condition of the steering wheel and windshield, amount of intrusion, ejection of the patient from the vehicle, and fate of other passengers should be ascertained. For other injury mechanisms, critical information includes such things as height of a fall, surface impact, helmet use, and weight of an object by which the patient was crushed. In patients sustaining gunshot wounds, velocity, caliber, distance, and presumed path of the bullet are important, if known. For patients with stab wounds, the length and type of object is helpful. Finally, some patients experience a combination of blunt and penetrating trauma. Do not assume that someone who was stabbed was not also assaulted; the patient may have a multitude of injuries and cannot be presumed to have only injuries associated with the more obvious penetrating mechanism. In short, these details of information are critical to the clinician to determine overall mechanism of injury and anticipate its associated injury patterns.

Mechanisms and Patterns of Injury

In general, more energy is transferred over a wider area during blunt trauma than from a penetrating wound. As a result, blunt trauma is associated with multiple widely distributed injuries, whereas in penetrating wounds the damage is localized to the path of the bullet or knife. In blunt trauma, organs that cannot yield to impact by elastic deformation are most likely to be injured, namely, the solid organs (liver, spleen, and kidneys). For penetrating trauma, organs with the largest surface area when viewed from the front are most prone to injury (small bowel, liver, and colon). Additionally, because bullets and knives usually follow straight lines, adjacent structures are commonly injured (e.g., the pancreas and duodenum).

Trauma surgeons often separate patients who have sustained blunt trauma into categories according to their risk for multiple injuries: those sustaining high energy transfer injuries and those sustaining low energy transfer injuries. Injuries involving high energy transfer include auto-pedestrian accidents, motor vehicle collisions in which the car's change of velocity (ΔV) exceeds 20 mph or in which the patient has been ejected, motorcycle collisions, and falls from heights >20 ft.³⁰ In fact, for motor vehicle accidents the variables strongly associated with life-threatening injuries, and hence reflective of the magnitude of the mechanism, are death of another occupant in the vehicle, extrication time of >20 minutes, $\Delta V >20$ mph, lack of restraint use, and lateral impact.³⁰ Low-energy trauma, such as being struck with a club or falling from a bicycle, usually does not result in widely distributed injuries. However, potentially lethal lacerations of internal organs can occur, because the net energy transfer to any given location may be substantial.

In blunt trauma, particular constellations of injury or injury patterns are associated with specific injury mechanisms. For example, when an unrestrained driver sustains a frontal impact, the head strikes the windshield, the chest and upper abdomen hit the steering column, and the legs or knees contact the dashboard. The resultant injuries can include facial fractures, cervical spine fractures, laceration of the thoracic aorta, myocardial contusion, injury to the spleen and liver, and fractures of the pelvis and lower extremities. When such patients are evaluated, the discovery of one of these injuries should prompt a search for the others. Collisions with side impact also carry the risk of cervical spine and thoracic trauma, diaphragm rupture, and crush injuries of the pelvic ring, but solid organ injury usually is limited to either the liver or spleen based on the direction of impact. Not surprisingly, any time a patient is ejected from the vehicle or thrown a significant distance from a motorcycle, the risk of any injury exists.

Penetrating injuries are classified according to the wounding agent (i.e., stab wound, gunshot wound, or shotgun wound). Gunshot wounds are subdivided further into high- and low-velocity injuries, because the speed of the bullet is much more important than its weight in determining kinetic energy. High-velocity gunshot wounds (bullet speed >2000 ft/s) are infrequent in the civilian setting. Shotgun injuries are divided into close-range (<20 feet) and long-range wounds. Close-range shotgun wounds are tantamount to high-velocity wounds because the entire energy of the load is delivered to a small area, often with devastating results. In contrast, long-range shotgun blasts result in a diffuse pellet pattern in which many pellets miss the victim, and those that do strike are dispersed and of comparatively low energy.

Regional Assessment and Special Diagnostic Tests

Based on mechanism, location of injuries identified on physical examination, screening radiographs, and the patient's overall condition, additional diagnostic studies often are indicated. However, the seriously injured patient is in constant jeopardy when undergoing special diagnostic testing; therefore, the surgeon must be in attendance and must be prepared to alter plans as circumstances demand. Hemodynamic, respiratory, and mental status will determine the most appropriate course of action. With these issues in mind, additional diagnostic tests are discussed on an anatomic basis.

Head Evaluation of the head includes examination for injuries to the scalp, eyes, ears, nose, mouth, facial bones, and intracranial

structures. Palpation of the head will identify scalp lacerations, which should be evaluated for depth, and depressed or open skull fractures. The eye examination includes not only pupillary size and reactivity, but also examination for visual acuity and for hemorrhage within the globe. Ocular entrapment, caused by orbital fractures with impingement on the ocular muscles, is evident when the patient cannot move his or her eyes through the entire range of motion. It is important to perform the eye examination early, because significant orbital swelling may prevent later evaluation. A lateral canthotomy may be needed to relieve periorbital pressure. The tympanic membrane is examined to identify hemotympanum, otorrhea, or rupture, which may signal an underlying head injury. Otorrhea, rhinorrhea, raccoon eyes, and Battle's sign (ecchymosis behind the ear) suggest a basilar skull fracture. Although such fractures may not require treatment, there is an association with blunt cerebrovascular injuries, cranial nerve injuries, and risk of meningitis.

Anterior facial structures should be examined to rule out fractures. This entails palpating for bony step-off of the facial bones and instability of the midface (by grasping the upper palate and seeing if this moves separately from the patient's head). A good question to ask awake patients is whether their bite feels normal to them; abnormal dental closure suggests malalignment of facial bones and a possibility for a mandible or maxillary fracture. Nasal fractures, which may be evident on direct inspection or palpation, typically bleed vigorously. This may result in the patient's having airway compromise due to blood running down the posterior pharynx, or there may be vomiting provoked by swallowed blood. Nasal packing or balloon tamponade may be necessary to control bleeding. Examination of the oral cavity includes inspection for open fractures, loose or fractured teeth, and sublingual hematomas.

All patients with a significant closed head injury (GCS score <14) should undergo CT scanning of the head. Additionally, elderly patients or those patients on antiplatelet agents or anticoagulation should be imaged despite a GCS of 15.^{31,32} For penetrating injuries, plain skull films may be helpful in the trauma bay to determine the trajectory of injury in hemodynamically unstable patients who cannot be transported for CT scan. The presence of lateralizing findings (e.g., a unilateral dilated pupil unreactive to light, asymmetric movement of the extremities either spontaneously or in response to noxious stimuli, or unilateral Babinski's reflex) suggests an intracranial mass lesion or major structural damage.

Such lesions include hematomas, contusions, hemorrhage into ventricular and subarachnoid spaces, and diffuse axonal injury (DAI). Epidural hematomas occur when blood accumulates between the skull and dura, and are caused by disruption of the middle meningeal artery or other small arteries in that potential space, typically after a skull fracture (Fig. 7-16). Subdural hematomas occur between the dura and cortex and are caused by venous disruption or laceration of the parenchyma of the brain. Due to associated parenchymal injury, subdural hematomas have a much worse prognosis than epidural collections. Hemorrhage into the subarachnoid space may cause vasospasm and further reduce cerebral blood flow. Intraparenchymal hematomas and contusions can occur anywhere within the brain. DAI results from high-speed deceleration injury and represents direct axonal damage from shear effects. CT scan may demonstrate blurring of the gray and white matter interface and multiple small punctate hemorrhages, but magnetic resonance imaging is a more accurate test. Although prognosis for these injuries

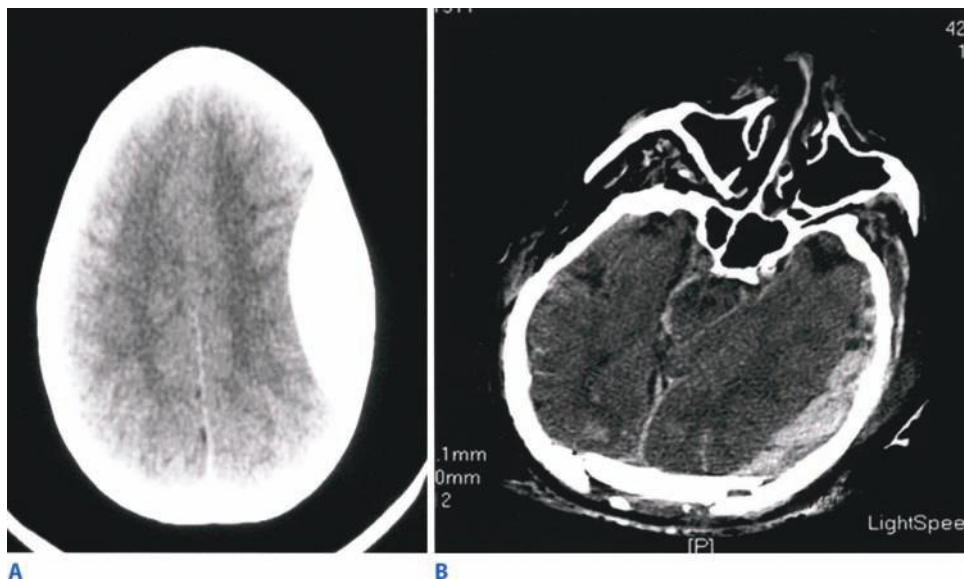


Figure 7-16. Epidural hematomas (A) have a distinctive convex shape on computed tomographic scan, whereas subdural hematomas (B) are concave along the surface of the brain.

is extremely variable, early evidence of DAI is associated with a poor outcome. Stroke syndromes should prompt a search for carotid or vertebral artery injury using multislice CT angiography (CTA) (Fig. 7-17).

Significant intracranial penetrating injuries usually are produced by bullets from handguns, but an array of other weapons or instruments can injure the cerebrum via the orbit or through the thinner temporal region of the skull. Although the diagnosis usually is obvious, in some instances wounds in the auditory canal, mouth, and nose can be elusive. Prognosis is variable, but virtually all supratentorial wounds that injure both hemispheres are fatal.

Neck All blunt trauma patients should be assumed to have cervical spine injuries until proven otherwise. During cervical examination one must maintain cervical spine precautions

and in-line stabilization. Due to the devastating consequences of quadriplegia, a diligent evaluation for occult cervical spine injuries is mandatory. In the awake patient, the presence of posterior midline pain or tenderness should provoke a thorough radiologic evaluation. Additionally, intubated patients, patients with distracting injuries, or another identified spine fracture should undergo CT imaging. A ligamentous injury may not be visible with standard imaging techniques.³³ Flexion and extension views or MRI are obtained to further evaluate patients at risk or those with persistent symptoms, but generally are not done in the acute setting.

Spinal cord injuries can vary in severity. Complete injuries cause either quadriplegia or paraplegia, depending on the level of injury. These patients have a complete loss of motor function and sensation two or more levels below the bony injury.

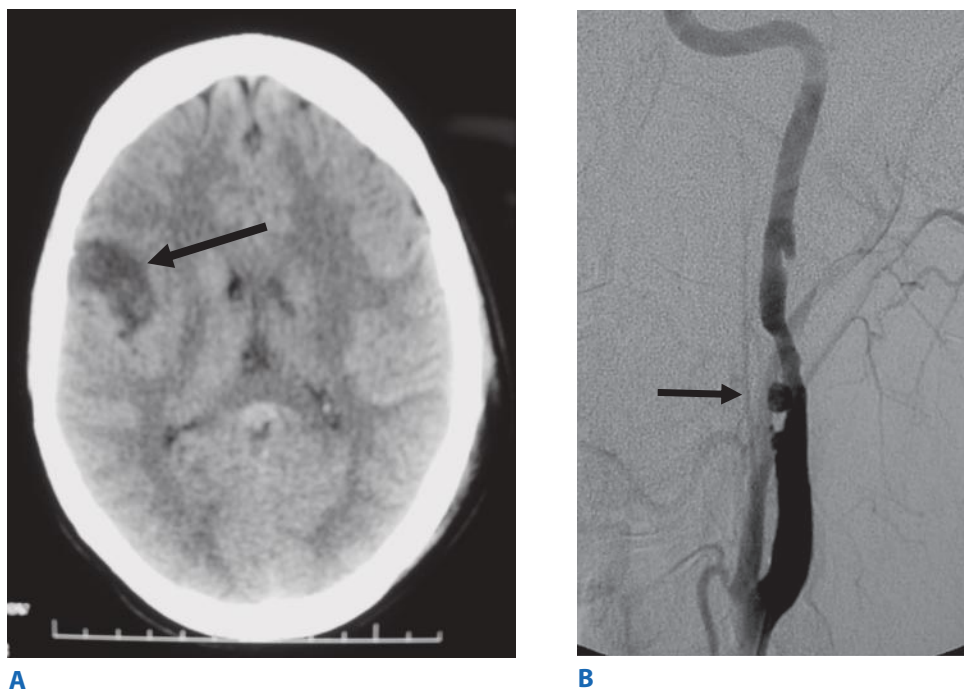


Figure 7-17. A. A right middle cerebral infarct noted on a computed tomographic scan of the head. Such a finding should prompt imaging to rule out an associated extracranial cerebrovascular injury. B. An internal carotid artery pseudoaneurysm documented by angiography.

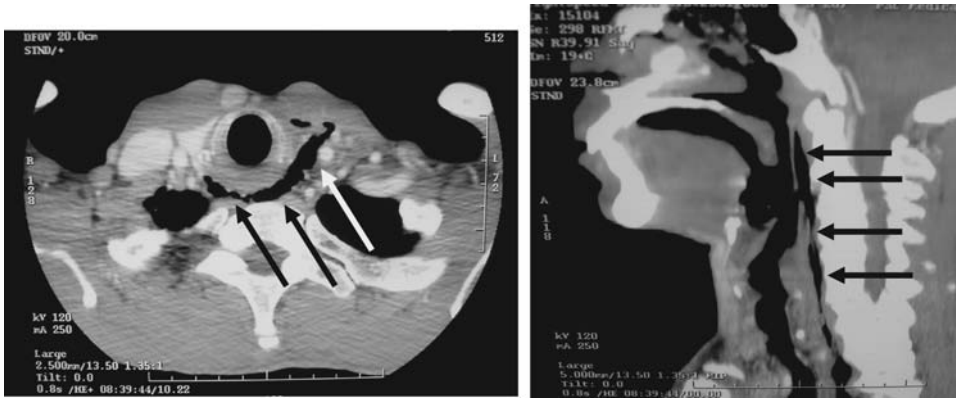


Figure 7-18. A laryngeal fracture results in air tracking around the trachea along the prevertebral space (arrows).

Patients with high spinal cord disruption are at risk for shock due to physiologic disruption of sympathetic fibers. Significant neurologic recovery is rare. However, there are several partial or incomplete spinal cord injury syndromes where the prognosis is better. Central cord syndrome typically occurs in older persons who experience hyperextension injuries. Motor function, pain, and temperature sensation are preserved in the lower extremities but diminished in the upper extremities. Some functional recovery usually occurs, but is often not a return to normal. Anterior cord syndrome is characterized by diminished motor function, pain, and temperature sensation below the level of the injury, but position sensing, vibratory sensation, and crude touch are maintained. Prognosis for recovery is poor. Brown-Séquard syndrome is usually the result of a penetrating injury in which one-half of the spinal cord is transected. This lesion is characterized by the ipsilateral loss of motor function, proprioception,

and vibratory sensation, whereas pain and temperature sensation are lost on the contralateral side.

During the primary survey, identification of injuries to the neck with exsanguination, expanding hematomas, airway obstruction, or aerodigestive injuries is a priority. A more subtle injury that may not be identified is a fracture of the larynx due to blunt trauma. Signs and symptoms include hoarseness, subcutaneous emphysema (Fig. 7-18), and a palpable fracture. Penetrating injuries of the anterior neck that violate the platysma are potentially life-threatening because of the density of critical structures in this region. Although operative exploration is appropriate in some circumstances, selective nonoperative management has been proven safe (Fig. 7-19).³⁴ Indications for immediate operative intervention for penetrating cervical injury include hemodynamic instability, significant external hemorrhage, or evidence of aerodigestive injury. The management

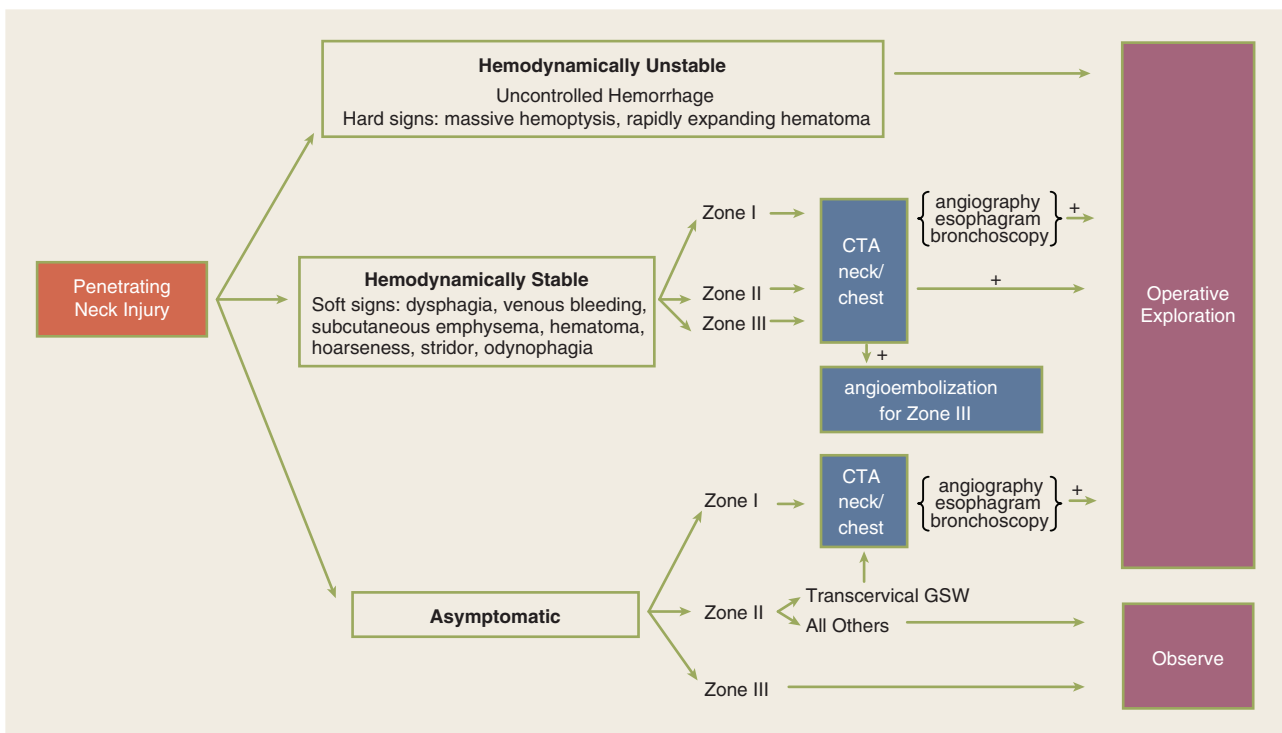


Figure 7-19. Algorithm for the management of penetrating neck injuries. CT = computed tomography; CTA = computed tomographic angiography; GSW = gunshot wound.

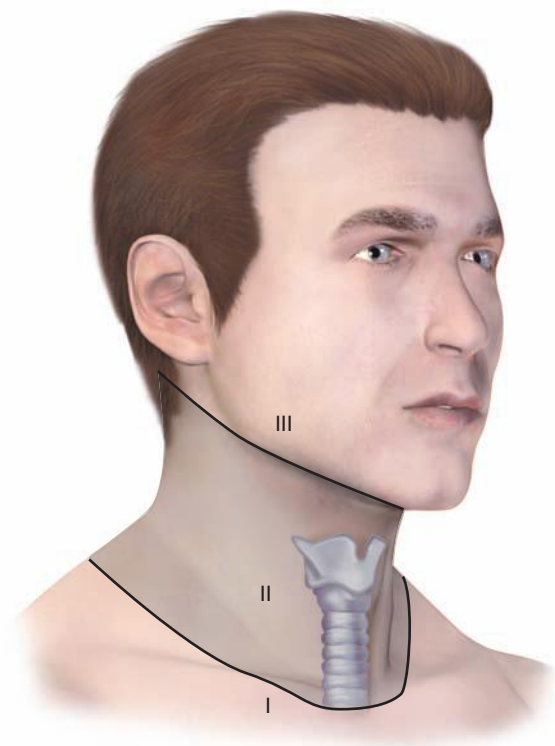


Figure 7-20. For the purpose of evaluating penetrating injuries, the neck is divided into three zones. Zone I is to the level of the clavicular heads and is also known as the *thoracic outlet*. Zone II is located between the clavicles and the angle of the mandible. Zone III is above the angle of the mandible.

algorithm for hemodynamically stable patients is based on the presenting symptoms and anatomic location of injury, with the neck being divided into three distinct zones (Fig. 7-20).

5▶ Zone I is inferior to the clavicles encompassing the thoracic outlet structures, zone II is between the thoracic outlet and the angle of the mandible, and zone III is above the angle of the mandible. Due to technical difficulties of injury exposure and varying operative approaches, a precise preoperative diagnosis is desirable for symptomatic zone I and III injuries. Therefore, these patients should ideally undergo diagnostic imaging before operation if they remain hemodynamically stable. Management of patients is further divided into those who are symptomatic and those who are not (Fig. 7-19). Specific symptoms or signs that should be identified include dysphagia, hoarseness, hematoma, venous bleeding, minor hemoptysis, and subcutaneous emphysema. Symptomatic patients should undergo CTA with further evaluation or operation based upon the imaging findings; less than 15% of penetrating cervical trauma requires neck exploration.³⁵ Asymptomatic patients are typically observed for 6 to 12 hours. The one caveat is asymptomatic patients with a transcervical gunshot wound; these patients should undergo CTA to determine the track of the bullet. CTA of the neck and chest determines trajectory of the injury tract; further studies are performed based on proximity to major structures.³⁵ Such additional imaging includes angiography, soluble contrast esophagram followed by barium esophagram, esophagoscopy, or bronchoscopy. Angiographic diagnosis, particularly of zone III injuries, can then be managed by selective angioembolization.

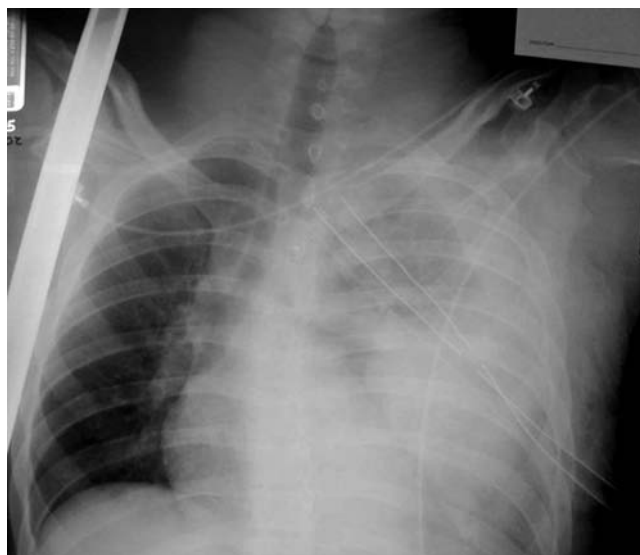


Figure 7-21. Persistence of a hemothorax despite two tube thoracostomies is termed a *caked hemothorax* and is an indication for prompt thoracotomy.

Chest Blunt trauma to the chest may involve the chest wall, thoracic spine, heart, lungs, thoracic aorta and great vessels, and rarely the esophagus. Most of these injuries can be evaluated by physical examination and chest radiography, with supplemental CT scanning based on initial findings. Any patient who undergoes an intervention in the ED—endotracheal intubation, central line placement, tube thoracostomy—needs a repeat chest radiograph to document the adequacy of the procedure. This is particularly true in patients undergoing tube thoracostomy for a pneumothorax or hemothorax. Patients with persistent pneumothorax, large air leaks after tube thoracostomy, or difficulty ventilating should undergo fiber-optic bronchoscopy to exclude a tracheobronchial injury or presence of a foreign body. Patients with hemothorax must have a chest radiograph documenting complete evacuation of the chest; a persistent hemothorax that is not drained by two chest tubes is termed a *caked hemothorax* and mandates immediate thoracotomy (Fig. 7-21).

Occult thoracic vascular injury must be diligently sought due to the high mortality of a missed lesion. Widening of the mediastinum on initial anteroposterior chest radiograph, caused by a hematoma around an injured vessel that is contained by the mediastinal pleura, suggests an injury of the great vessels. The mediastinal abnormality may suggest the location of the arterial injury (i.e., left-sided hematomas are associated with descending torn aortas, whereas right-sided hematomas are commonly seen with innominate injuries) (Fig. 7-22). Posterior rib fractures, sternal fractures with laceration of small vessels, and mediastinal venous bleeding also can produce similar hematomas. Other chest radiographic findings suggestive of an aortic tear are summarized in Table 7-5 (Fig. 7-23). However, at least 7% of patients with a descending torn aorta have a normal chest radiograph.³⁶ Therefore, screening spiral CT

6▶ scanning is performed based on the mechanism of injury: high-energy deceleration motor vehicle collision with frontal or lateral impact (> 30 mph frontal impact and >23 mph lateral impact), motor vehicle collision with ejection, falls of >25 ft, or direct impact (horse kick to chest, snowmobile or ski collision

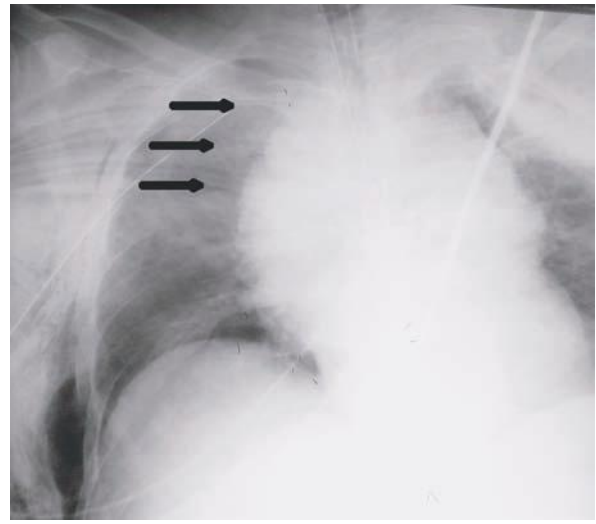
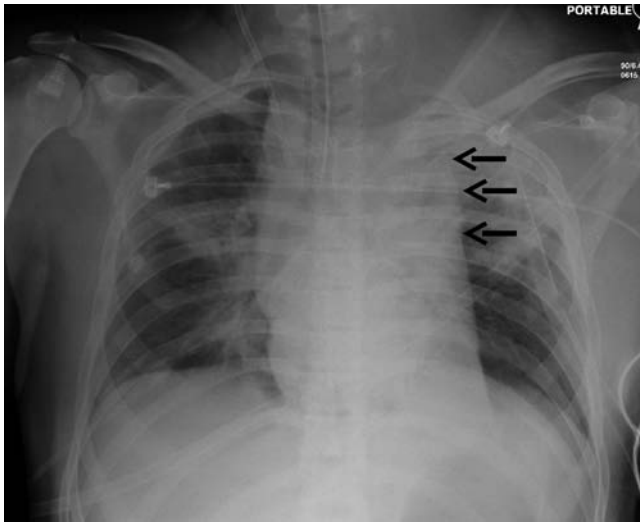
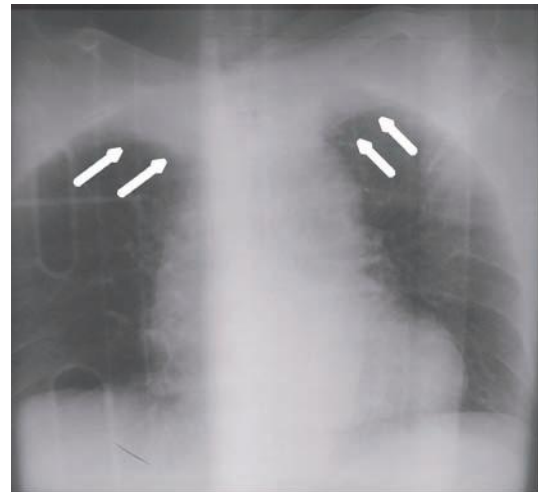


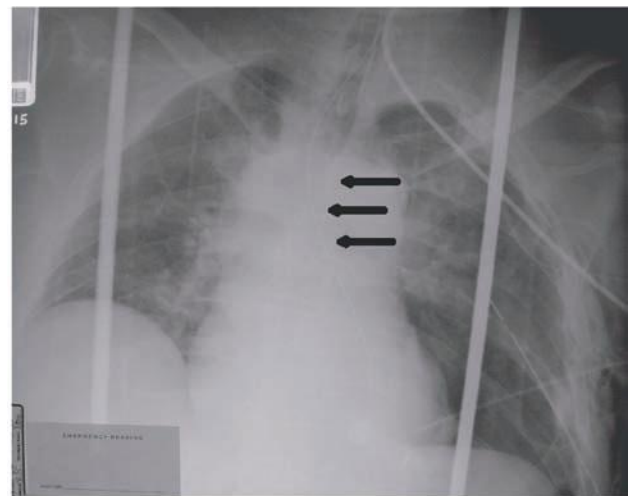
Figure 7-22. Location of the hematoma within the mediastinal silhouette suggests the type of great vessel injury. A predominant hematoma on the left suggests the far more common descending torn aorta (**A**; arrows), whereas a hematoma on the right indicates a relatively unusual but life-threatening innominate artery injury (**B**; arrows).

with tree).^{37,38} In >95% of patients who survive to reach the ED, the aortic injury occurs just distal to the left subclavian artery, where it is tethered by the ligamentum arteriosum (Fig. 7-24). In 2% to 5% of patients the injury occurs in the ascending aorta, in the transverse arch, or at the diaphragm. Reconstructions with multislice CTA obviate the need for invasive arteriography.³⁷

For penetrating thoracic trauma, physical examination, plain posteroanterior and lateral chest radiographs with metallic markings of wounds, pericardial ultrasound, and CVP measurement will identify the majority of injuries. Injuries of the esophagus and trachea are exceptions. Bronchoscopy should be performed to evaluate the trachea in patients with a persistent air leak from the chest tube or mediastinal air. Because esophagoscopy can miss injuries following an apparent normal endoscopy, patients at risk should undergo soluble contrast esophagography followed by barium examination to look for extravasation of contrast to identify an injury.³⁹ As with neck injuries, hemodynamically stable patients with transmediastinal gunshot wounds should undergo CT scanning to determine the path of the bullet; this identifies the vascular or visceral structures at risk for injury



A



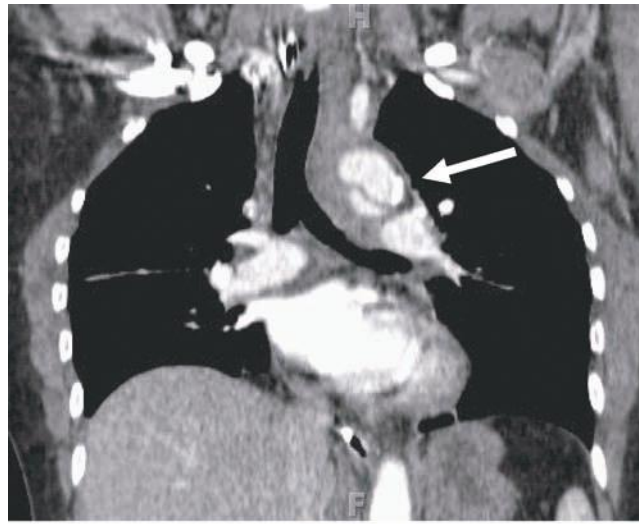B

Figure 7-23. Chest film findings associated with descending torn aorta include apical capping (**A**; arrows) and tracheal shift (**B**; arrows).

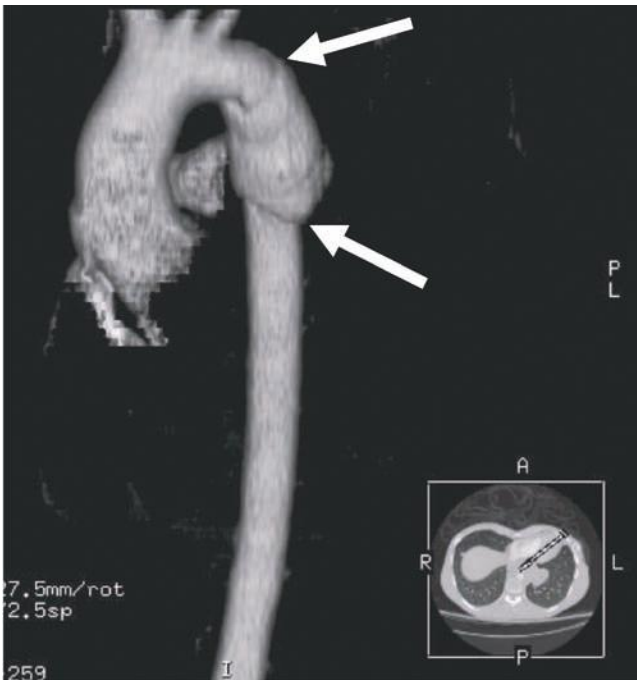Table 7-5

Findings on chest radiograph suggestive of a descending thoracic aortic tear

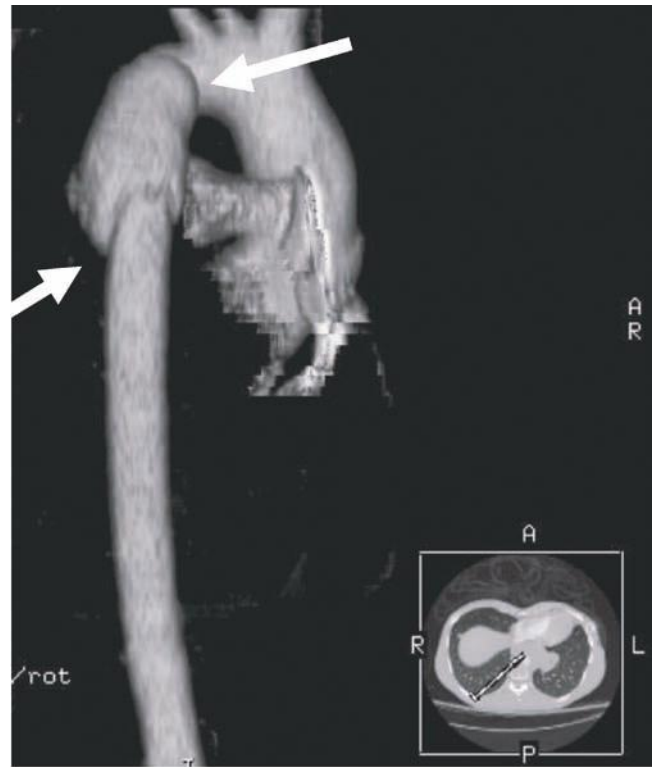1. Widened mediastinum
2. Abnormal aortic contour
3. Tracheal shift
4. Nasogastric tube shift
5. Left apical cap
6. Left or right paraspinal stripe thickening
7. Depression of the left main bronchus
8. Obliteration of the aorticopulmonary window
9. Left pulmonary hilar hematoma



A



B



C

Figure 7-24. Imaging to diagnose descending torn aorta includes computed tomographic angiography (A), with three-dimensional reconstructions (B, anterior; C, posterior) demonstrating the proximal and distal extent of the injury (arrows).

and directs angiography or endoscopy as appropriate. If there is a suspicion of a subclavian artery injury, brachial-brachial indices should be measured, but >60% of patients with an injury may not have a pulse deficit.⁴⁰ Therefore, CTA should be performed based on injury proximity to intrathoracic vasculature. Finally, with wounds identified on the chest, penetrating trauma should not be presumed to be isolated to the thorax. Injury to contiguous body cavities (i.e., the abdomen and neck) must be excluded; plain radiographs are a rapid, effective screening modality.

Abdomen The abdomen is a diagnostic black box. Fortunately, with few exceptions, it is not necessary to determine in the

7▶ emergency department which intra-abdominal organs are injured, only whether an exploratory laparotomy is necessary. However, physical examination of the abdomen can be unreliable in making this determination, and drugs, alcohol, and head and spinal cord injuries complicate clinical evaluation. The presence of abdominal rigidity and hemodynamic compromise is an undisputed indication for prompt surgical exploration. For the remainder of patients, a variety of diagnostic adjuncts are used to identify abdominal injury.

The diagnostic approach differs for penetrating trauma and blunt abdominal trauma. As a rule, minimal evaluation is

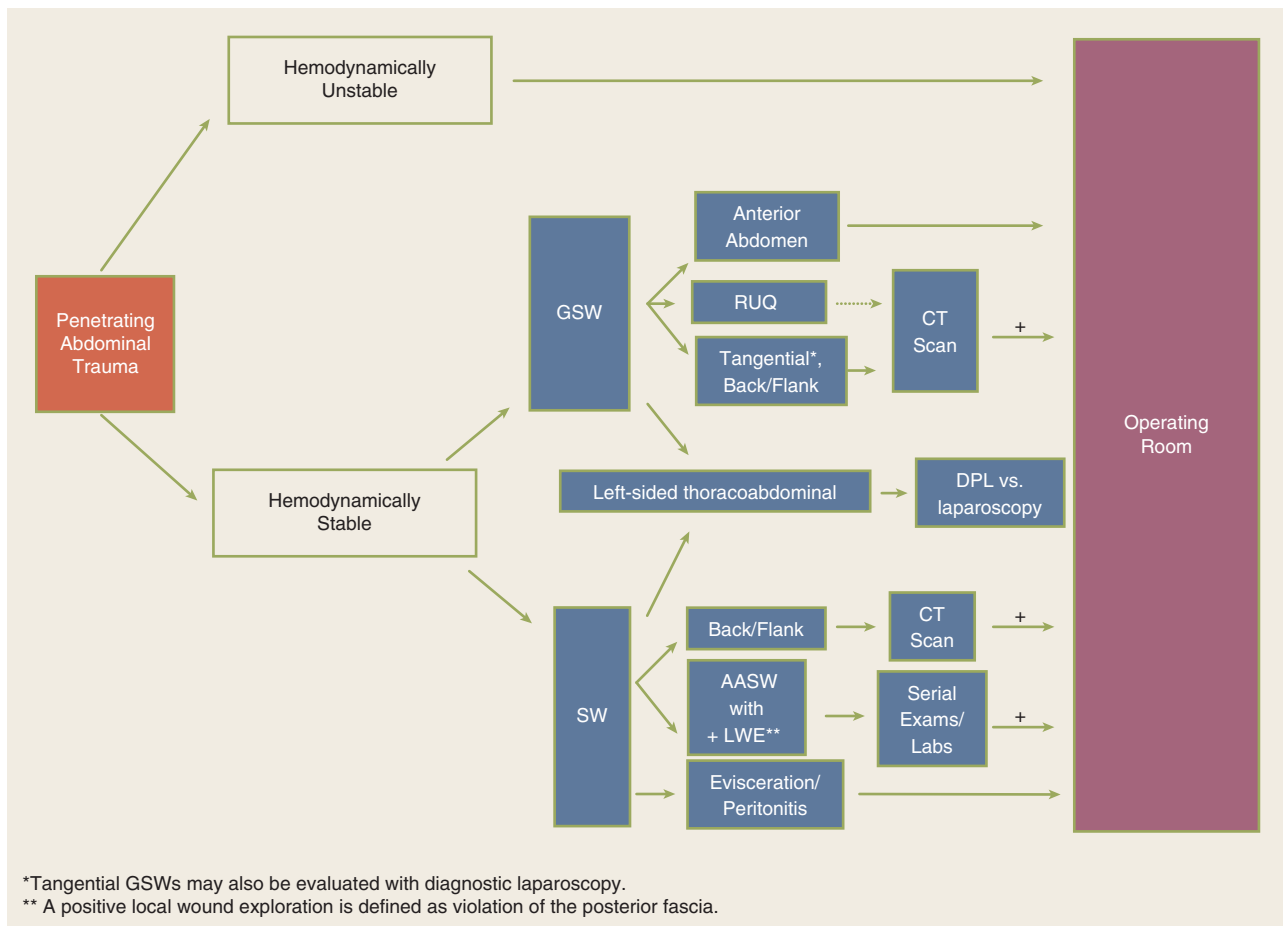


Figure 7-25. Algorithm for the evaluation of penetrating abdominal injuries. AASW = anterior abdominal stab wound; CT = computed tomography; DPL = diagnostic peritoneal lavage; GSW = gunshot wound; LWE = local wound exploration; RUQ = right upper quadrant; SW = stab wound.

required before laparotomy for gunshot or shotgun wounds that penetrate the peritoneal cavity, because over 90% of patients have significant internal injuries. Anterior truncal gunshot wounds between the fourth intercostal space and the pubic symphysis whose trajectory as determined by radiograph or wound location indicates peritoneal penetration should undergo laparotomy (Fig. 7-25). The exception is penetrating trauma isolated to the right upper quadrant; in hemodynamically stable patients with trajectory confined to the liver by CT scan, nonoperative observation may be reasonable.⁴¹ In obese patients, if the gunshot wound is thought to be tangential through the subcutaneous tissues, CT scan can delineate the track and exclude peritoneal violation. Laparoscopy is another option to assess peritoneal penetration for tangential wounds. If there is doubt, however, it is always safer to explore the abdomen. In the scenario of tangential high energy GSWs, however, it is possible to sustain a transmitted intraperitoneal hollow visceral injury due to a blast insult. Gunshot wounds to the back or flank are more difficult to evaluate because of the retroperitoneal location of the injured abdominal organs. Triple-contrast CT scan can delineate the trajectory of the bullet and identify peritoneal violation or retroperitoneal entry, but may not identify the specific injuries. In contrast to gunshot wounds, stab wounds that penetrate the peritoneal cavity are less likely to injure intra-abdominal organs. Anterior abdominal stab wounds (from costal margin to inguinal

ligament and bilateral midaxillary lines) should be explored under local anesthesia in the ED to determine if the fascia has been violated. Injuries that do not penetrate the peritoneal cavity do not require further evaluation, and the patient may be discharged from the ED. Patients with fascial penetration must be further evaluated for intra-abdominal injury, because there is up to a 50% chance of requiring laparotomy. Debate remains over whether the optimal diagnostic approach is serial examination, diagnostic peritoneal lavage (DPL), or CT scanning; the most recent evidence supports serial examination and laboratory evaluation.^{42,43} Patients with stab wounds to the right upper quadrant can undergo CT scanning to determine trajectory and confinement to the liver for potential nonoperative care.⁴¹ Those with stab wounds to the flank and back should undergo triple-contrast CT to assess for the potential risk of retroperitoneal injuries of the colon, duodenum, and urinary tract.

Penetrating thoracoabdominal wounds may cause occult injury to the diaphragm. Patients with gunshot or stab wounds to the left lower chest should be evaluated with diagnostic laparoscopy or DPL to exclude diaphragmatic injury. For patients undergoing DPL evaluation, laboratory value cutoffs to rule out diaphragm injury are different from traditional values formerly used for abdominal stab wounds (see Table 7-6). An RBC count of $>10,000/\mu\text{L}$ is considered a positive finding and an indication for abdominal evaluation; patients with a DPL RBC count

Table 7-6

Criteria for “positive” finding on diagnostic peritoneal lavage

	ABDOMINAL TRAUMA	THORACOABDOMINAL STAB WOUNDS
Red blood cell count	>100,000/mL	>10,000/mL
White blood cell count	>500/mL	>500/mL
Amylase level	>19 IU/L	>19 IU/L
Alkaline phosphatase level	>2 IU/L	>2 IU/L
Bilirubin level	>0.01 mg/dL	>0.01 mg/dL

between 1000/ μ L and 10,000/ μ L should undergo laparoscopy or thoracoscopy. Diagnostic laparoscopy may be preferred in patients with a positive chest radiograph (hemothorax or pneumothorax) or in those who would not tolerate a DPL.

Blunt abdominal trauma is evaluated initially by FAST examination in most major trauma centers, and this has largely supplanted DPL (Fig. 7-26). FAST is not 100% sensitive, however, so diagnostic peritoneal aspiration is warranted in hemodynamically unstable patients without a defined source of blood loss to rule out abdominal hemorrhage.²⁷ FAST is used to identify free intraperitoneal fluid (Fig. 7-27) in Morrison’s pouch, the left upper quadrant, and the pelvis. Although this method is exquisitely sensitive for detecting intraperitoneal fluid of >250 mL, it does not reliably determine the source of hemorrhage nor grade solid organ injuries.⁴⁴ Patients with fluid on FAST examination, considered a “positive FAST,” who do not have immediate indications for laparotomy and are hemodynamically stable undergo CT scanning to quantify their injuries. Injury grading using the American Association for the Surgery of Trauma grading scale (Table 7-7) is an important component of nonoperative management of solid organ injuries. Additional findings that should be noted on CT scan in patients with solid organ injury include contrast extravasation (i.e., a “blush”), the amount of intra-abdominal hemorrhage, and presence of pseudoaneurysms (Fig. 7-28). CT also is indicated for hemodynamically

stable patients for whom the physical examination is unreliable. Despite the increasing diagnostic accuracy of multidetector CT scanners, identification of intestinal injuries remains a limitation. Bowel injury is suggested by findings of thickened bowel wall, “streaking” in the mesentery, free fluid without associated solid organ injury, or free intraperitoneal air.^{45,46} Patients with free intra-abdominal fluid without solid organ injury are closely monitored for evolving signs of peritonitis; if patients have a significant closed head injury or cannot be serially examined, DPL should be performed to exclude bowel injury. If DPL is pursued, an infraumbilical approach is used (Fig. 7-29). After placement of the catheter, a 10-mL syringe is connected and the abdominal contents aspirated (termed a *diagnostic peritoneal aspiration*). The aspirate is considered to show positive findings if >10 mL of blood is aspirated. If <10 mL is withdrawn, a liter of normal saline is instilled. The effluent is withdrawn via siphoning and sent to the laboratory for RBC count, white blood cell (WBC) count, and determination of amylase, bilirubin, and alkaline phosphatase levels. Values representing positive findings are summarized in Table 7-6.

Pelvis Blunt injury to the pelvis may produce complex fractures with major hemorrhage (Fig. 7-30). Plain radiographs will reveal gross abnormalities, but CT scanning is necessary to determine the precise geometry. Sharp spicules of bone can lacerate the bladder, rectum, or vagina. Alternatively, bladder rupture may result from a direct blow to the torso if the bladder is full. CT cystography is performed if the urinalysis findings are positive for RBCs. Urethral injuries are suspected if examination reveals blood at the meatus, scrotal or perineal hematomas, or a high-riding prostate on rectal examination. Urethrograms should be obtained for stable patients before placing a Foley catheter to avoid false passage and subsequent stricture. Major vascular injuries causing exsanguination are uncommon in blunt pelvic trauma; however, thrombosis of either the arteries or veins in the iliofemoral system may occur, and CT angiography should be performed for evaluation. Life-threatening hemorrhage can be associated with pelvic fractures and may initially preclude definitive imaging. Treatment algorithms for patients with complex pelvic fractures and hemodynamic instability are presented later in the chapter.

Extremities Physical examination often identifies arterial injuries, and findings are classified as either hard signs or soft signs of vascular injury (Table 7-8). In general, hard signs constitute

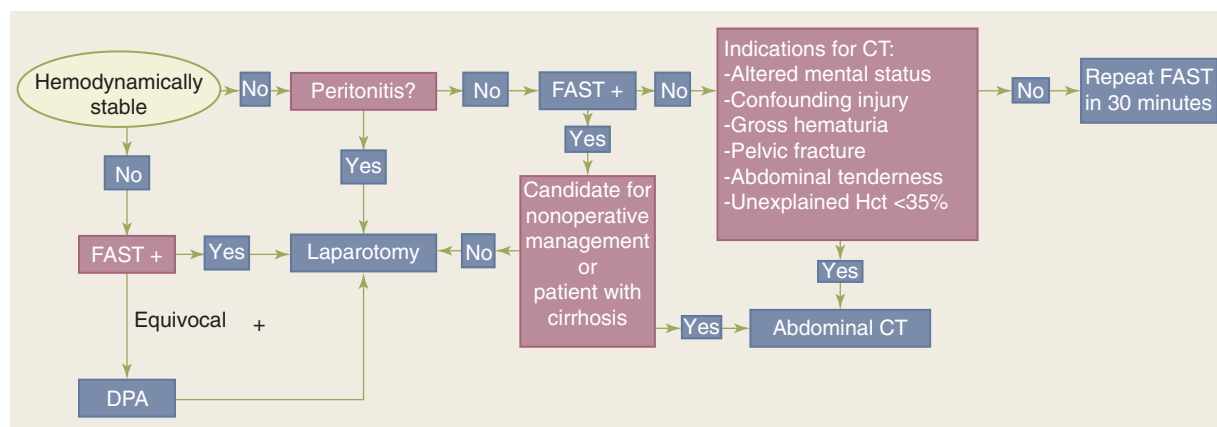


Figure 7-26. Algorithm for the initial evaluation of a patient with suspected blunt abdominal trauma. CT = computed tomography; DPA = diagnostic peritoneal aspiration; FAST = focused abdominal sonography for trauma; Hct = hematocrit.

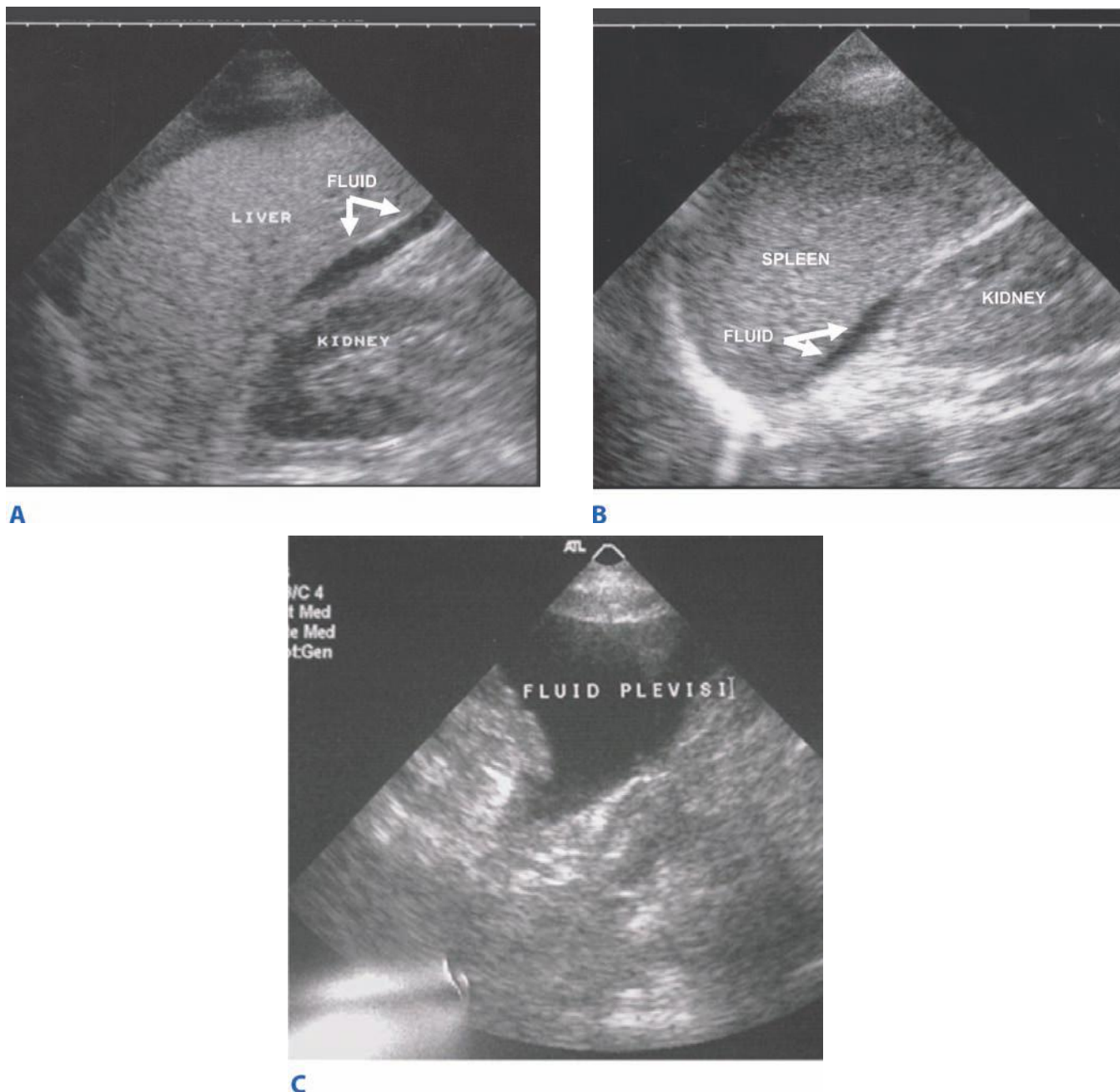


Figure 7-27. Focused abdominal sonography for trauma imaging detects intra-abdominal hemorrhage. Hemorrhage is presumed when a fluid stripe is visible between the right kidney and liver (**A**), between the left kidney and spleen (**B**), or in the pelvis (**C**).

indications for operative exploration, whereas soft signs are indications for further testing or observation. Bony fractures or knee dislocations should be realigned before definitive vascular examination. On-table angiography may be useful to localize the arterial injury and thus, limit tissue dissection in patients with hard signs of vascular injury. For example, a patient with an absent popliteal pulse and femoral shaft fracture due to a bullet that entered the lateral hip and exited below the medial knee could have injured either the femoral or popliteal artery anywhere along its course (Fig. 7-31). In management of vascular trauma, controversy exists regarding the treatment of patients with soft signs of injury, particularly those with injuries in proximity to major vessels. It is known that some of these patients will have arterial injuries that require repair. The most common

approach has been to measure SBP using Doppler ultrasonography and compare the value for the injured side with that for the uninjured side, termed the *A-A index*.⁴⁷ If the pressures are within 10% of each other, a significant injury is unlikely and no further evaluation is performed. If the difference is >10%, CT angiography or arteriography is indicated. Others argue that there are occult injuries, such as pseudoaneurysms or injuries of the profunda femoris or peroneal arteries, which may not be detected with this technique. If hemorrhage occurs from these injuries, compartment syndrome and limb loss may occur. Although busy trauma centers continue to debate this issue, the surgeon who is obliged to treat the occasional injured patient may be better served by performing CT angiography in selected patients with soft signs. Blunt or penetrating trauma to the

Table 7-7

American Association for the Surgery of Trauma grading scales for solid organ injuries

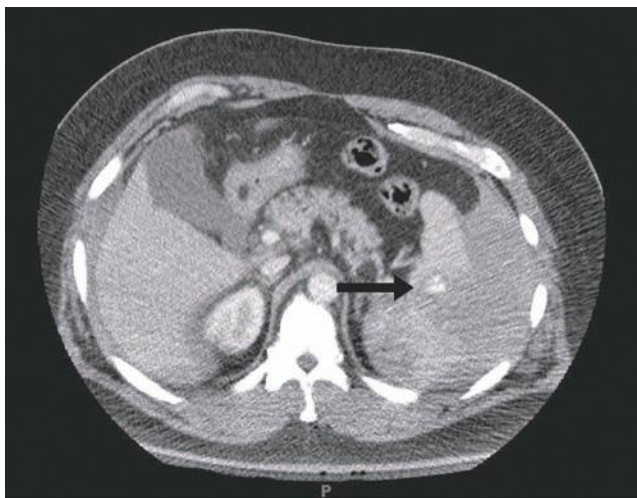
	SUBCAPSULAR HEMATOMA	LACERATION
Liver Injury Grade		
Grade I	<10% of surface area	<1 cm in depth
Grade II	10%–50% of surface area	1–3 cm
Grade III	>50% of surface area or >10 cm in depth	>3 cm
Grade IV	25%–75% of a hepatic lobe	
Grade V	>75% of a hepatic lobe	
Grade VI	Hepatic avulsion	
Splenic Injury Grade		
Grade I	<10% of surface area	<1 cm in depth
Grade II	10%–50% of surface area	1–3 cm
Grade III	>50% of surface area or >10 cm in depth	>3 cm
Grade IV	>25% devascularization	Hilum
Grade V	Shattered spleen Complete devascularization	

extremities requires an evaluation for fractures, ligamentous injury, and neurovascular injury. Plain radiographs are used to evaluate fractures, whereas ligamentous injuries, particularly those of the knee and shoulder, can be imaged with magnetic resonance imaging.

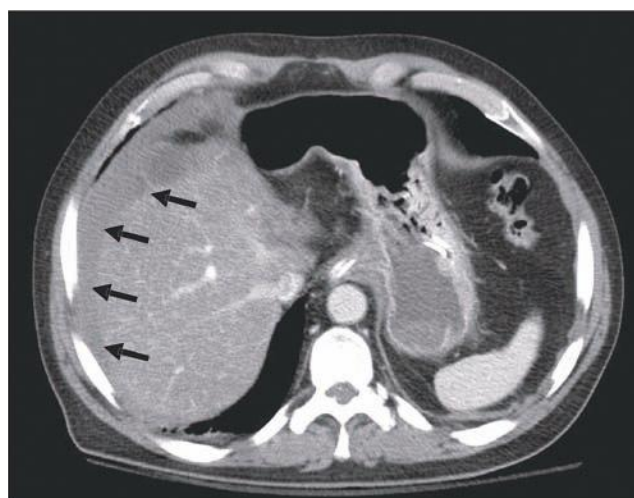GENERAL PRINCIPLES OF MANAGEMENT

Over the past 25 years there has been a remarkable change in management practices and operative approach for the injured patient. With the advent of CT scanning, nonoperative management of solid organ injuries has replaced routine operative exploration. Those patients who do require operation may be treated with less radical resection techniques, such as splenorrhaphy or

partial nephrectomy. Colonic injuries, previously mandating colostomy, are now repaired primarily in virtually all cases. Additionally, the type of anastomosis has shifted from a double-layer closure to a continuous running single-layer closure; this method is technically equivalent to and faster than the interrupted multilayer techniques.⁴⁸ Adoption of damage control surgical techniques in physiologically deranged patients has resulted in limited initial operative time, with definitive injury repair delayed until after resuscitation in the surgical intensive care unit (SICU) with physiologic restoration.⁴⁹ Abdominal drains, once considered mandatory for parenchymal injuries and some anastomoses, have disappeared; fluid collections are managed by percutaneous techniques. Newer endovascular techniques such as stenting of arterial injuries and angioembolization are routine



A



B

Figure 7-28. Computed tomographic images reveal critical information about solid organ injuries, such as associated contrast extravasation from a grade IV laceration of the spleen (**A**; arrows) and the amount of subcapsular hematoma in a grade III liver laceration (**B**; arrows).

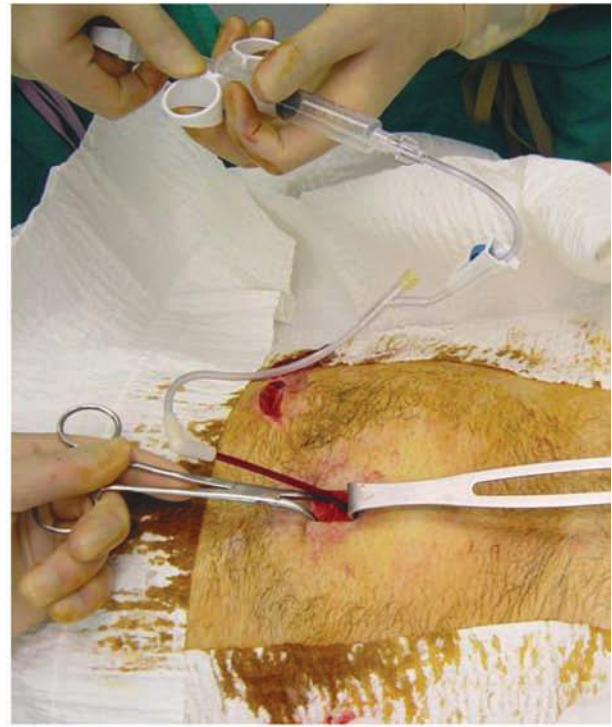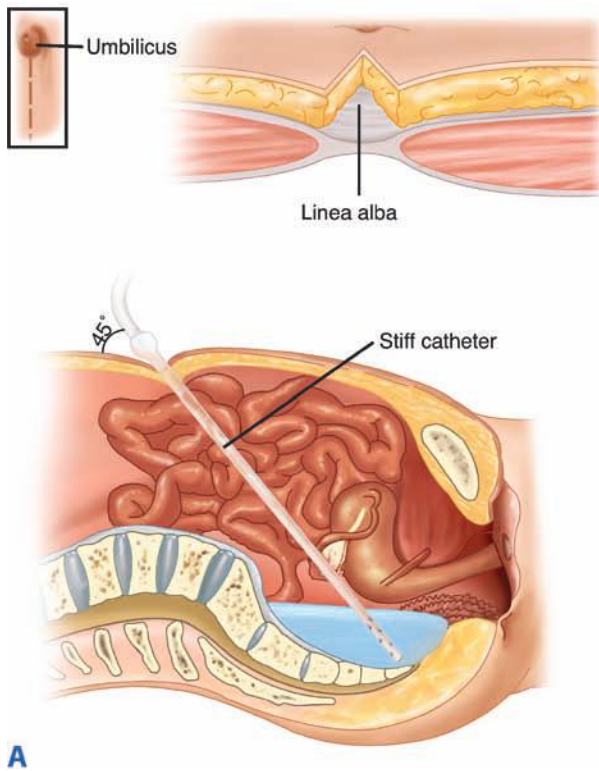


Figure 7-29. Diagnostic peritoneal lavage is performed through an infraumbilical incision unless the patient has a pelvic fracture or is pregnant. **A.** The linea alba is sharply incised, and the catheter is directed into the pelvis. **B.** The abdominal contents should initially be aspirated using a 10-mL syringe.

adjuncts. Blunt cerebrovascular injuries have been recognized as a significant, preventable source of neurologic morbidity and mortality. The use of preperitoneal pelvic packing for unstable pelvic fractures as well as early fracture immobilization with external fixators are paradigm shifts in management. Finally, the institution of massive transfusion protocols balances the benefit of blood component therapy against immunologic risk. Viscoelastic hemostatic assays (TEG and ROTEM) have been shown to be superior to traditional laboratory tests, and have been central to the evolving concept of goal-directed hemostasis.⁵⁰ These conceptual changes have significantly improved survival of critically injured patients; they have been promoted and critically reviewed by academic trauma centers via forums such as the American College of Surgeons Committee on Trauma, the American Association for the Surgery of Trauma, the International Association of Trauma Surgery and Intensive Care, the Pan-American Trauma Congress, and other surgical organizations.

Transfusion Practices

Injured patients with life-threatening hemorrhage develop an acute coagulopathy of trauma (ACOT). Cohen et al⁵¹ have shown convincingly that activated protein C is a key element, although the complete mechanism remains to be elucidated. Fibrinolysis is another important component of the ACOT; present in only 5% of injured patients requiring hospitalization, but 20% in those requiring massive transfusion.⁵² Fresh whole blood, arguably the optimal replacement, is not available in the United States. Rather, its component parts, packed red blood cells (PRBCs), fresh-frozen plasma, platelets, and cryoprecipitate, are administered. Specific transfusion triggers

for individual blood components exist. Although current critical care guidelines indicate that PRBC transfusion should occur once the patient's hemoglobin level is <7 g/dL,⁵³ in the acute phase of resuscitation a hemoglobin of 10 g/dL is suggested to facilitate hemostasis.⁵⁴ The traditional thresholds for blood component replacement in the patient manifesting a coagulopathy have been INR >1.5 , PTT >1.5 normal, platelet count $>50,000/\mu\text{L}$, and fibrinogen >100 mg/dl. However, these guidelines have been replaced by TEG and ROTEM criteria in many trauma centers. Such guidelines are designed to limit the transfusion of immunologically active blood components and decrease the risk of transfusion-associated lung injury and secondary multiple organ failure.^{55,56}

In the critically injured patient requiring large amounts of blood component therapy, a massive transfusion protocol should be followed (Fig. 7-32). This approach calls for administration of various components in a specific ratio during transfusion to achieve restoration of blood volume and correction of coagulopathy. Although the optimal ratio is yet to be determined, current scientific evidence indicates a presumptive 1:2 red cell:plasma ratio in patients at risk for massive transfusion (10 units of PRBCs in 6 hours).⁵⁷⁻⁶⁰ Because complete typing and cross-matching takes up to 45 minutes, patients requiring emergent transfusions are given type O, type-specific, or biologically compatible RBCs. Blood typing, and to a lesser extent cross-matching, is essential to avoid life-threatening intravascular hemolytic transfusion reactions. Trauma centers and their associated blood banks must have the capability of transfusing tremendous quantities of blood components, because it is not unusual to have 100 component units transfused during one procedure and have the patient survive. Massive transfusion

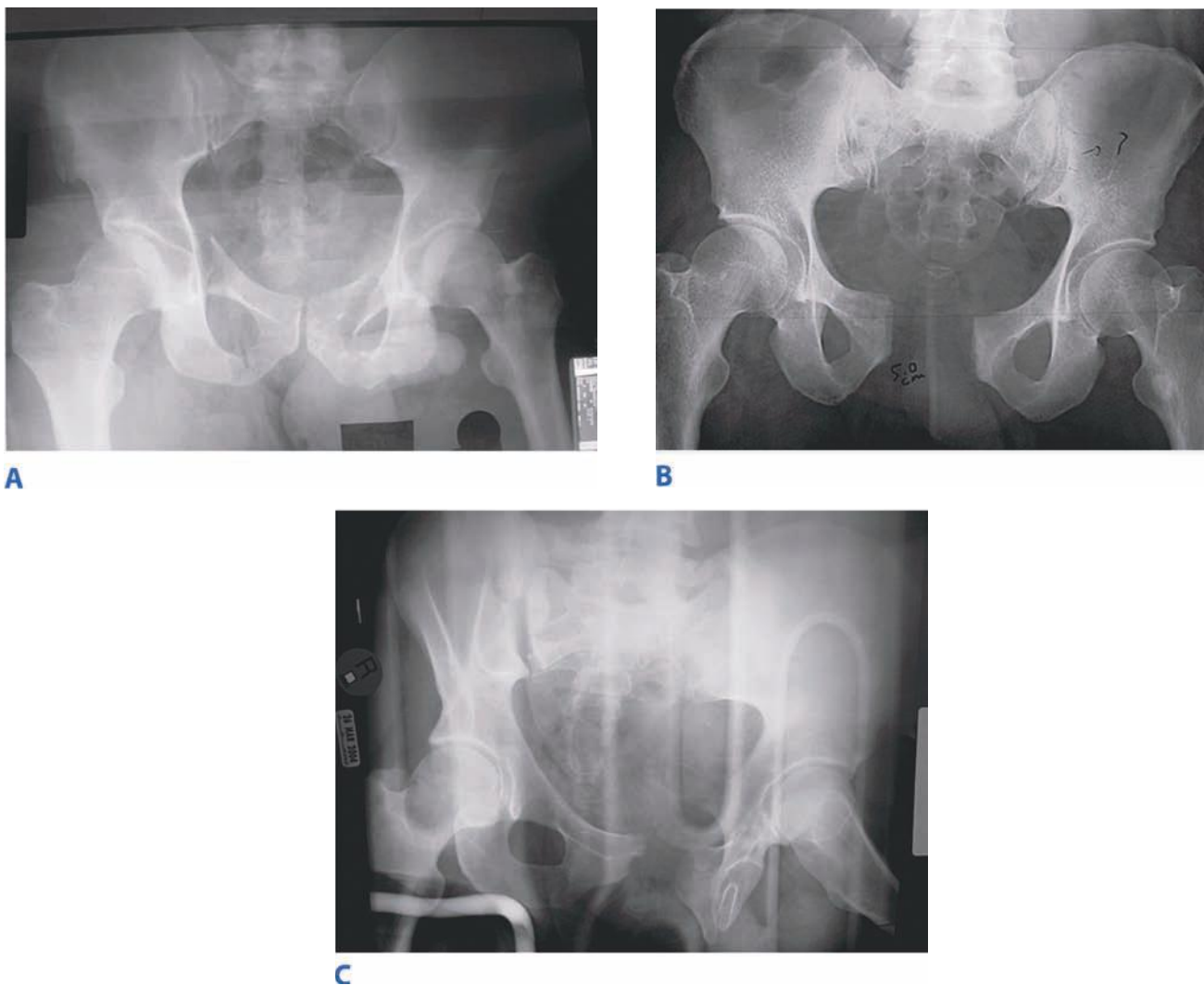


Figure 7-30. The three types of mechanically unstable pelvis fractures are lateral compression (A), anteroposterior compression (B), and vertical shear (C).

protocols, established preemptively, permit coordination of the activities of surgeons, anesthesiologists, and blood bank directors to facilitate transfusion at these rates should a crisis occur.

Postinjury coagulopathy is associated with core hypothermia and metabolic acidosis, termed the *bloody vicious cycle*.⁴⁹

8► The pathophysiology is multifactorial and includes

inhibition of temperature-dependent enzyme-activated coagulation cascades, platelet dysfunction, endothelial abnormalities, and fibrinolytic activity. Such coagulopathy may be insidious, so the surgeon must be cognizant of subtle signs such as excessive bleeding from the cut edges of skin. Although the coagulopathic “ooze” may seem minimal compared with the torrential hemorrhage from a hole in the aorta, blood loss from the entire area of dissection can lead to exsanguination. Point-of-care TEG results, which provide a comprehensive assessment of clot capacity and fibrinolysis, can be available within 10 minutes. This concept has been termed . In contrast, traditional laboratory tests of coagulation capability (i.e., INR, PTT, fibrinogen levels, and platelet count) requires at least 30 minutes. Such a delay is particularly troublesome for patients who have lost two blood volumes while waiting for the test results to return. Using damage control techniques to limit operative time and provide physiologic restoration in the SICU can be lifesaving (see section *Damage Control Surgery*).

Prophylactic Measures

All injured patients undergoing an operation should receive preoperative antibiotics. The type of antibiotic is determined

Table 7-8

Signs and symptoms of peripheral arterial injury

HARD SIGNS (OPERATION MANDATORY)	SOFT SIGNS (FURTHER EVALUATION INDICATED)
Pulsatile hemorrhage	Proximity to vasculature
Absent pulses	Significant hematoma
Acute ischemia	Associated nerve injury
	A-A index of <0.9
	Thrill or bruit

A-A index = systolic blood pressure on the injured side compared with that on the uninjured side.

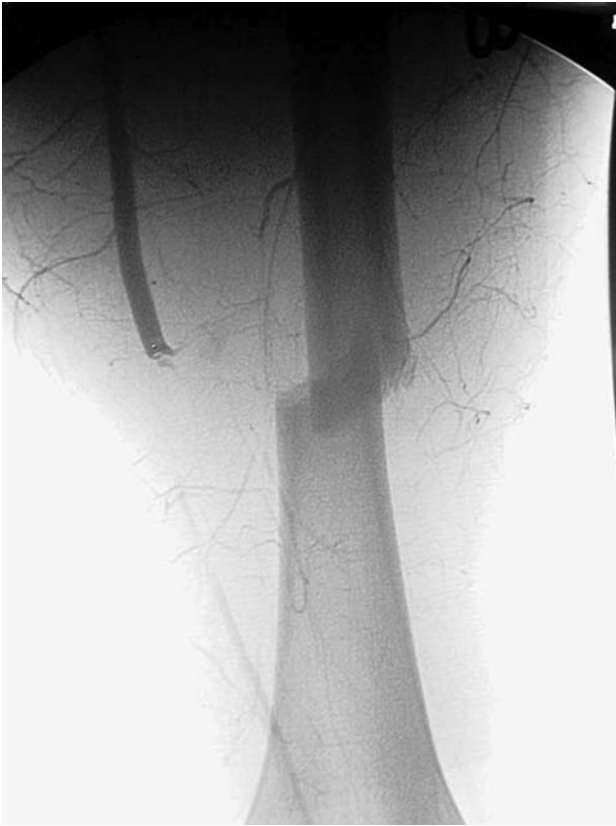

Figure 7-31. On-table angiography in the operating room isolates the area of vascular injury to the superficial femoral artery in a patient with a femoral fracture after a gunshot wound to the lower extremity.

by the anticipated source of contamination in the abdomen or other operative region; additional doses should be administered during the procedure based on blood loss and the half-life of the antibiotic. Extended postoperative antibiotic therapy is administered only for contaminated open fractures. Tetanus prophylaxis is administered to all patients according to published guidelines.

Trauma patients are at risk for venous thromboembolism and its associated morbidity and mortality. In fact, pulmonary embolus can occur much earlier in the patient's hospital course than previously believed.⁶¹ Patients at higher risk for venous thromboembolism are those with multiple fractures of the pelvis and lower extremities, coma or spinal cord injury, and requiring ligation of large veins in the abdomen and lower extremities. Morbidly obese patients and those over 55 years of age are at additional risk. Administration of low molecular weight heparin (LMWH) is initiated as soon as bleeding has been controlled and there is stable intracranial pathology. Higher doses of LMWH are required in injured patients to attain adequate anti-Xa levels, and antiplatelet therapy should probably be added. In high-risk patients, removable inferior vena caval filters should be considered if there are prolonged contraindications to administration of LMWH. Additionally, pulsatile compression stockings (also termed *sequential compression devices*) are used routinely unless there is a fracture.

A final prophylactic measure that is usually not considered is thermal protection. Hemorrhagic shock impairs perfusion and metabolic activity throughout the body, with resultant decrease in heat production and body temperature. Removing the patient's clothes causes a second thermal insult, and infusion of cold PRBCs or room temperature crystalloid exacerbates the

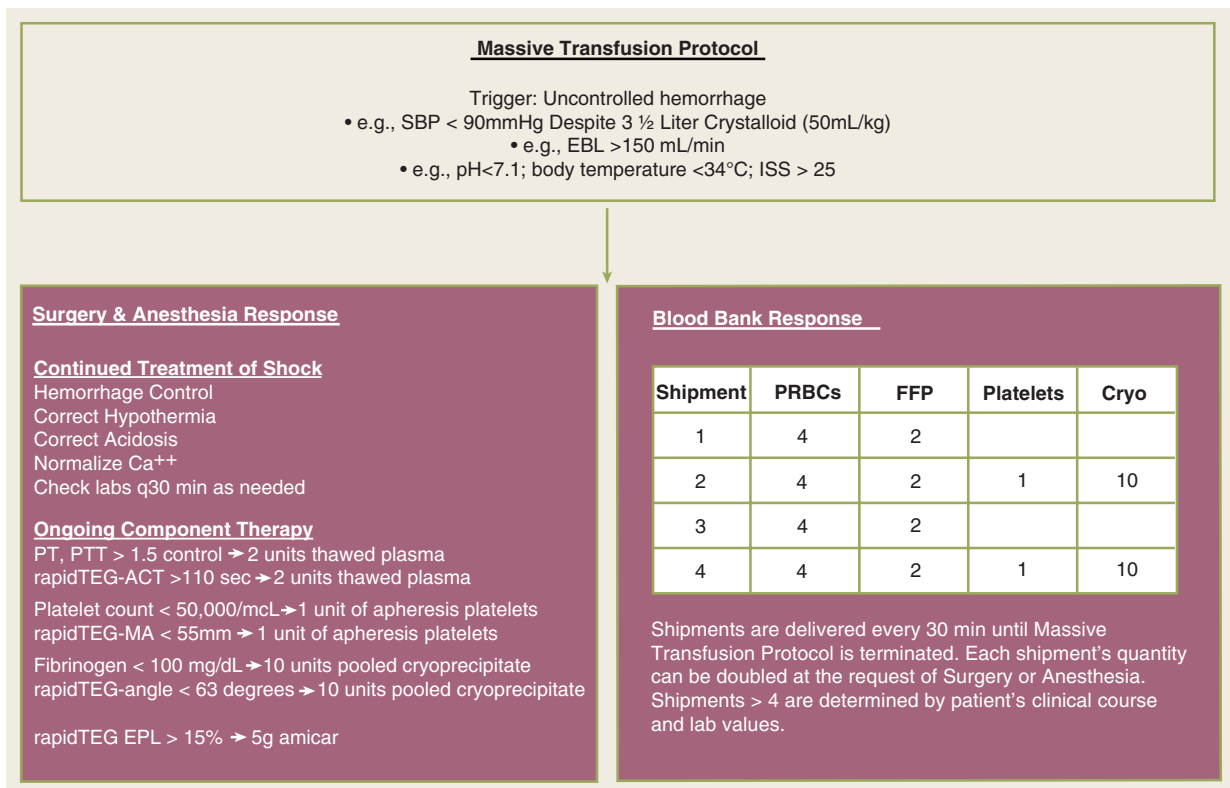


Figure 7-32. Denver Health Medical Center's Massive Transfusion Protocol. ACT = activated clotting time; Cryo = cryoprecipitate; FFP = fresh-frozen plasma; INR = International Normalized Ratio; MA = maximum amplitude; PRBCs = packed red blood cells; PTT = partial thromboplastin time; SBP = systolic blood pressure; TEG = thromboelastography; EPL = estimated percent lysis.

problem. As a result, injured patients can become hypothermic, with temperatures below 34°C (93.2°F) upon arrival in the OR. Hypothermia aggravates coagulopathy and provokes myocardial irritability. Therefore, prevention must begin in the ED by maintaining a comfortable ambient temperature, covering patients with warm blankets, and administering warmed IV fluids and blood products. Additionally, in the OR a Bair Hugger® warmer (the upper body or lower body blanket) and heated inhalation via the ventilatory circuit is instituted. For cases of severe hypothermia (temperature <30°C [86°F]), arteriovenous rewarming should be considered.

Operative Approaches and Exposure

Cervical Exposure Operative exposure for midline structures of the neck (e.g., trachea, thyroid, bilateral carotid sheaths) is

obtained through a collar incision; this is typically performed two finger breadths above the sternal notch, but can be varied based on the level of anticipated injury. After subplatysmal flap elevation, the strap muscles are divided in the midline to gain access to the central neck compartment. More superior and lateral structures are accessed by extending the collar incision upward along the sternocleidomastoid muscle; this may be done bilaterally if necessary. Unilateral neck exploration is done through an incision extending from the mastoid down to the clavicle, along the anterior border of the sternocleidomastoid muscle (Fig. 7-33). The carotid sheath, containing the carotid artery, jugular vein, and vagus nerve, is opened widely to examine these structures. The facial vein, which marks the carotid bifurcation, is usually ligated for exposure of the internal carotid artery.

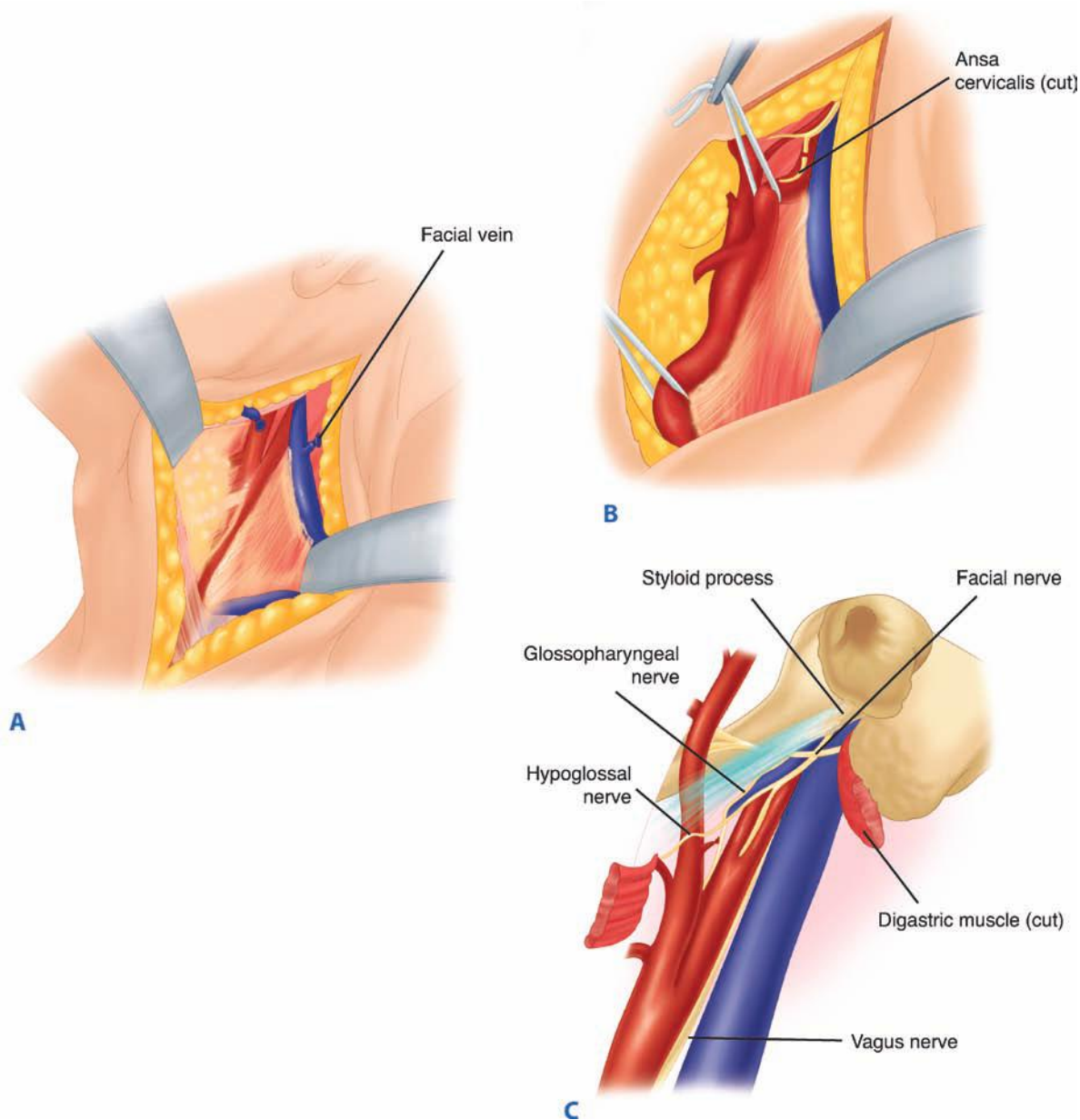


Figure 7-33. **A.** Unilateral neck exploration is performed through an incision along the anterior border of the sternocleidomastoid muscle; exposure of the carotid artery requires early division of the facial vein. **B.** The distal internal carotid artery is exposed by dividing the ansa cervicalis, which permits mobilization of the hypoglossal nerve. **C.** Further exposure is facilitated by resection of the posterior belly of the digastric muscle.

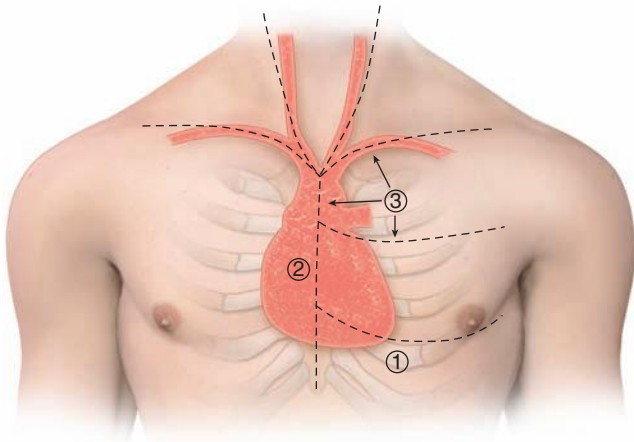
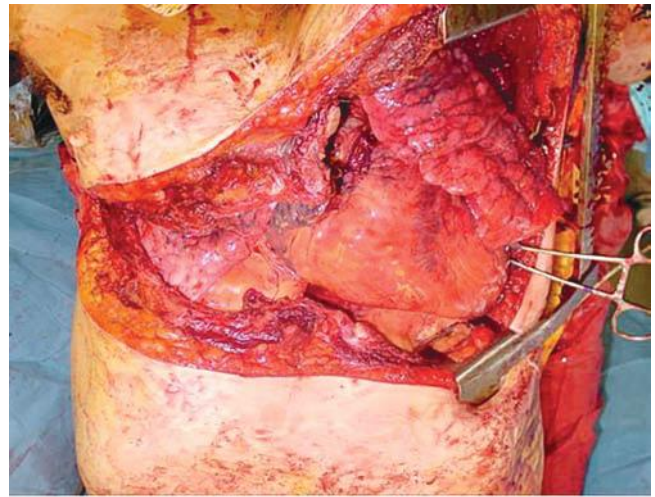


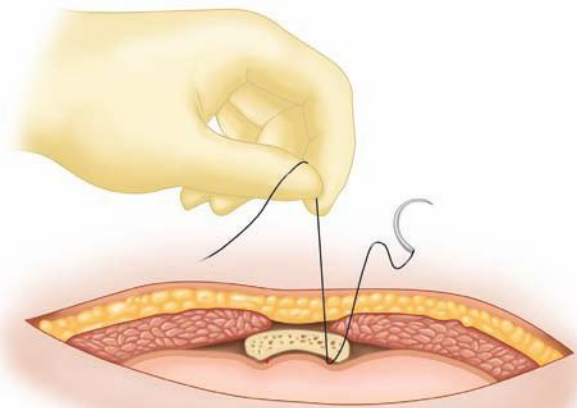
Figure 7-34. Options for thoracic exposure include the most versatile incision, the anterolateral thoracotomy (1), as well as a median sternotomy (2) and a “trap door” thoracotomy (3). Any thoracic incision may be extended into a supraclavicular or anterior neck incision for wider exposure.

Exposure of the distal carotid artery in zone III is difficult (see Fig. 7-33). The first step is division of the ansa cervicalis to facilitate mobilization of the hypoglossal nerve. Next, the posterior portion of the digastric muscle, which overlies the internal carotid, is transected. The glossopharyngeal and vagus nerves are also mobilized and retracted as necessary. If accessible, the styloid process and attached muscles are removed. At this point anterior displacement of the mandible (subluxation) may be helpful. In desperate situations, the vertical ramus of the mandible may be divided. However, this maneuver often entails resection of the parotid gland and the facial nerve is at risk for exposure of the distal internal carotid.

Thoracic Incisions An anterolateral thoracotomy, with the patient placed supine, is the most versatile incision for emergent thoracic exploration. The location of the incision is in the fifth interspace, in the inframammary line (Fig. 7-34). If access is needed to both pleural cavities, the original incision can be extended across the sternum with a Lebsche knife, into a “clamshell” thoracotomy (Fig. 7-35). If the sternum is divided, the internal mammary arteries should be ligated to prevent blood loss. The heart, lungs, descending aorta, pulmonary hilum, and esophagus are accessible with this approach. For control of the great vessels, the superior portion of the sternum may be divided with extension of the incision into the neck considered. A method advocated for access to the proximal left subclavian artery is through a fourth interspace anterolateral thoracotomy, superior sternal extension, and left supraclavicular incision (“trap door” thoracotomy). Although the trap door procedure is appropriate after resuscitative thoracotomy, the proximal left subclavian artery can be accessed more easily via a sternotomy with a supraclavicular extension. If the left subclavian artery is injured outside the thoracic outlet, vascular control can be obtained via the sternotomy and definitive repair done through the supraclavicular incision. Emergent median sternotomy is limited to anterior stab wounds to the heart. Typically, these patients have pericardial tamponade and undergo placement of a pericardial drain before a semiurgent median sternotomy is performed. Patients in extremis, however, should undergo anterolateral thoracotomy.



A



B

Figure 7-35. A. A “clamshell” thoracotomy provides exposure to bilateral thoracic cavities. B. Sternal transection requires individual ligation of both the proximal and distal internal mammary arteries on the undersurface of the sternum.

Median sternotomy with cervical extension is used for rapid exposure in patients with presumed proximal subclavian, innominate, or proximal carotid artery injuries. Care must be taken to avoid injury to the phrenic and vagus nerves that pass over the subclavian artery and to the recurrent laryngeal nerve passing posteriorly. Posterolateral thoracotomies are used for exposure of injuries to the trachea or main stem bronchi near the carina (right posterolateral thoracotomy), tears of the descending thoracic aorta (left posterolateral thoracotomy with left heart bypass), and intrathoracic esophageal injuries.

Emergent Abdominal Exploration Abdominal exploration in adults is performed using a generous midline incision because of its versatility. For children under the age of 6, a transverse incision may be advantageous. Making the incision is faster with a scalpel than with an electrocautery unit; incisional abdominal wall bleeding should be ignored until intra-abdominal sources of hemorrhage are controlled. Liquid and clotted blood are evacuated with multiple laparotomy pads to identify the major source(s) of active bleeding. After blunt trauma the spleen and liver should be palpated first and packed if fractured, and

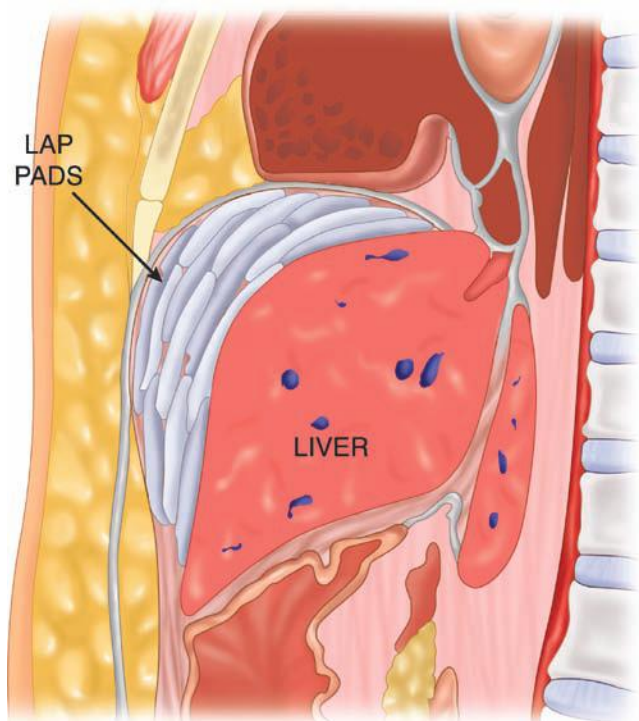


Figure 7-36. A sagittal view of packs placed to control hepatic hemorrhage. Lap = laparotomy.

the infracolic mesentery inspected to exclude a zone I vascular injury. In contrast, after a penetrating wound the search for bleeding should pursue the trajectory of the penetrating device. If the patient has an SBP of <70 mmHg when the abdomen is opened, digital pressure or a clamp should be placed on the aorta at the diaphragmatic hiatus. After the source of hemorrhage is localized, direct digital occlusion (vascular injury) or laparotomy pad packing (solid organ injury) is used to control bleeding (Fig. 7-36). If the liver is the source in a hemodynamically unstable patient, additional control of bleeding is obtained by clamping the hepatic pedicle with a vascular clamp or Rummel tourniquet (Pringle maneuver) (Fig. 7-37). Similarly, clamping the splenic hilum may more effectively control bleeding than packing alone. When the spleen is mobilized, it should be gently rotated medially to expose the lateral peritoneum; this peritoneum and endoabdominal fascia are incised, which allows blunt

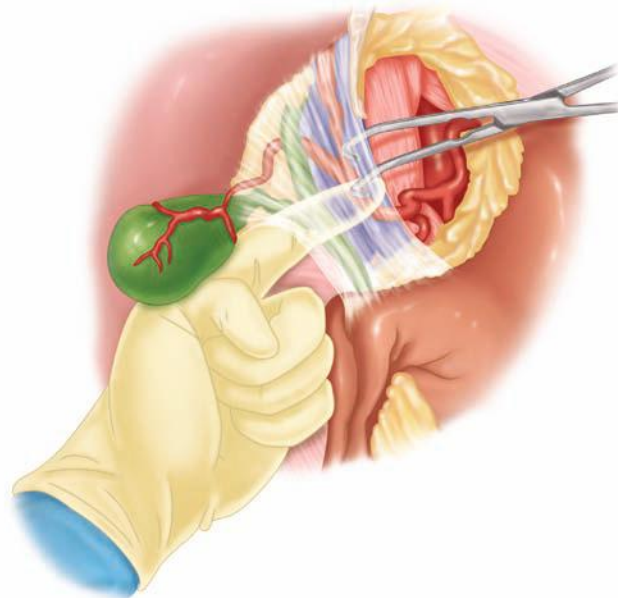


Figure 7-37. The Pringle maneuver, performed with a vascular clamp, occludes the hepatic pedicle containing the portal vein, hepatic artery, and common bile duct.

dissection of the spleen and pancreas as a composite from the retroperitoneum anterior to Gerota's fascia (Fig. 7-38).

Rapid exposure of the intra-abdominal vasculature can prove challenging in the face of exsanguinating hemorrhage. Proximal control of the aorta is obtained at the diaphragmatic hiatus; if an aortic injury is supraceliac, transecting the left crus of diaphragm or extending the laparotomy via a left thoracotomy may be necessary. The first decision is whether the patient has a supracolic or an infracolic vascular injury. Supracolic injuries (aorta, celiac axis, proximal superior mesenteric artery [SMA], and left renal arteries) are best approached a left medial visceral rotation (Fig. 7-39). This is done by incising the lateral peritoneal reflection (white line of Toldt) beginning at the distal descending colon and extending the incision along the colonic splenic flexure, around the posterior aspect of the spleen, and behind the gastric fundus, ending at the esophagus. The left

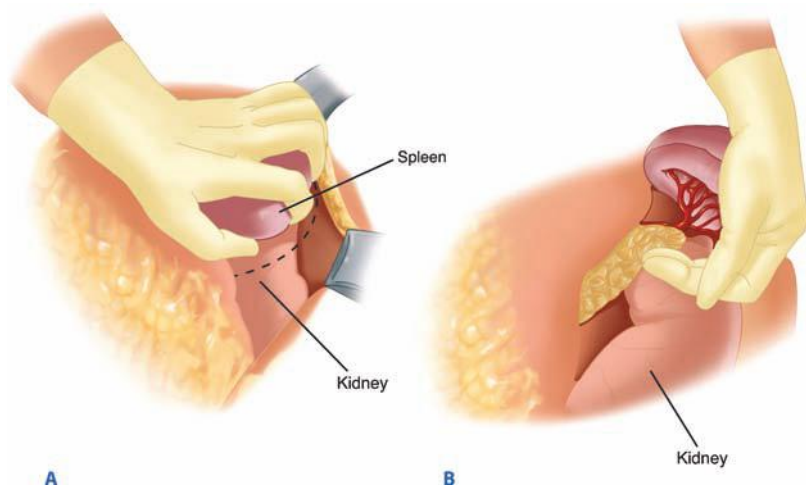


Figure 7-38. To mobilize the spleen, an incision is made into the endoabdominal fascia 1 cm lateral to the reflection of the peritoneum onto the spleen (A). While the spleen is gently rotated medially, a plane is developed between the pancreas and left kidney (B). With complete mobilization, the spleen can reach the level of the abdominal incision.

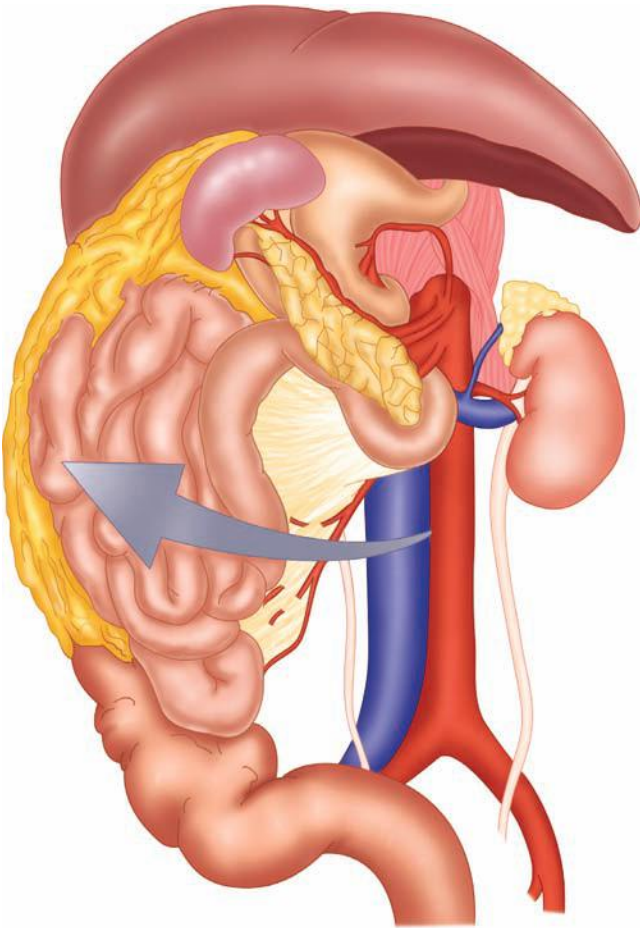


Figure 7-39. A left medial visceral rotation is used to expose the abdominal aorta.

colon, spleen, pancreas, and stomach are then rotated toward the midline. The authors prefer to leave the kidney in situ when mobilizing the viscera because this exaggerates the separation of the renal vessels from the SMA. The operative approach for SMA injuries is based on the level of injury. Fullen zone I SMA injuries, located posterior to the pancreas, are best exposed by a left medial visceral rotation. Fullen zone II SMA injuries, extending from the pancreatic edge to the middle colic branch, on the other hand, are approached via the lesser sac along the inferior edge of the pancreas at the base of the transverse mesocolon; the pancreatic body may be divided to gain proximal vascular access. More distal SMA injuries, Fullen zones III and IV, are approached directly within the mesentery. A venous injury behind the pancreas, from the junction of the superior mesenteric, splenic, and portal veins, is accessed by dividing the neck of the pancreas. Inferior vena cava injuries are approached by a right medial visceral rotation (Fig. 7-40). Proximal control is obtained just above the iliac bifurcation with direct pressure via a sponge stick; the injury is identified by cephalad dissection along the anterior surface of the inferior vena cava. A Satinsky clamp can be used to control anterior caval wounds.

Injuries of the iliac vessels pose a unique problem for emergent vascular control due to the number of vessels, their close proximity, and cross circulation. Proximal control at the infra-renal aorta arrests the arterial bleeding and avoids splanchnic and renal ischemia; however, venous injuries are not controlled with aortic clamping. Tamponade with a folded laparotomy pad

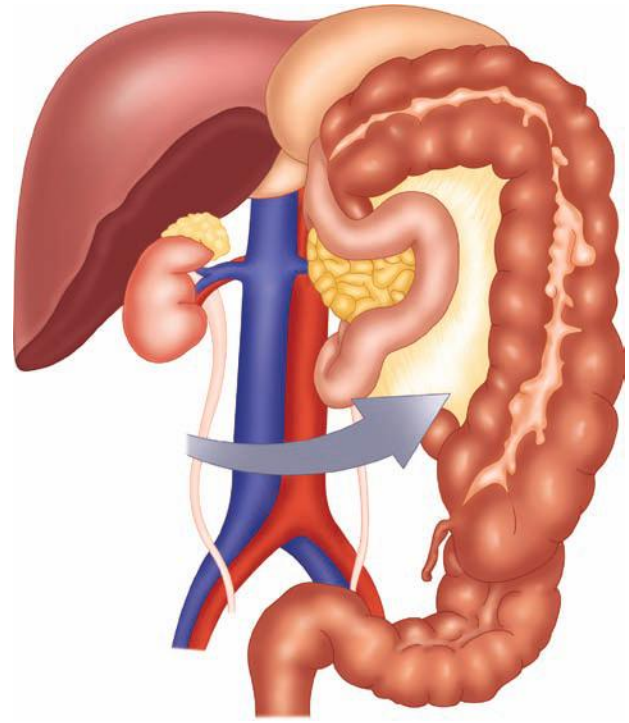


Figure 7-40. A right medial visceral rotation is used to expose the infrahepatic vena cava.

held directly over the bleeding site usually will establish hemostasis sufficient to prevent exsanguination. If hemostasis is not adequate to expose the vessel proximal and distal to the injury, sponge sticks can be strategically placed on either side of the injury and carefully adjusted to improve hemostasis. Alternatively, complete pelvic vascular isolation (Fig. 7-41) may be required to control hemorrhage for adequate visualization of the

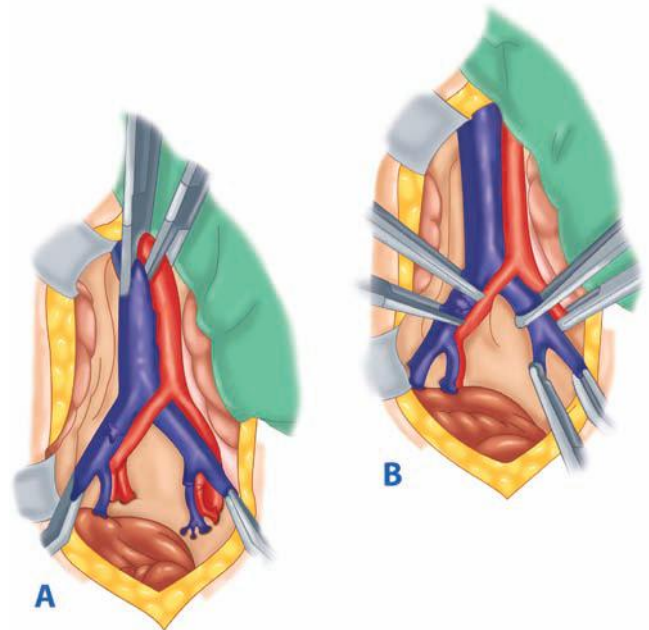


Figure 7-41. Pelvic vascular isolation. **A.** Initially, clamps are placed on the aorta, inferior vena cava, and bilateral external iliac vessels. **B.** With continued dissection, the clamps can be moved progressively closer to the vascular injury to limit unwarranted ischemia.

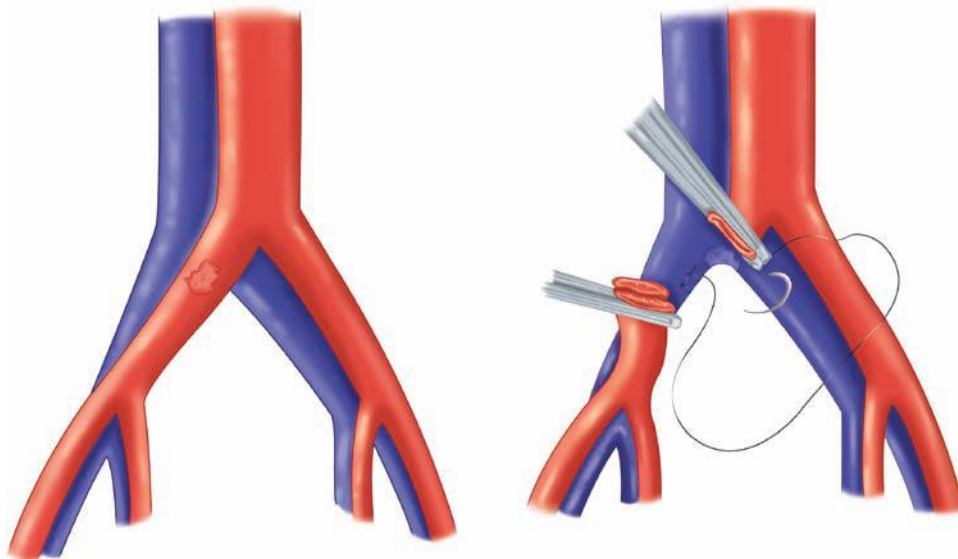


Figure 7-42. The right common iliac artery can be divided to expose the bifurcation of the inferior vena cava and the right common iliac vein.

injuries. The right common iliac artery obscures the bifurcation of the vena cava and the right iliac vein; the iliac artery may require division to expose venous injuries in this area (Fig. 7-42). The artery must be repaired after the venous injury is treated, however, because of limb-threatening ischemia.

Once overt hemorrhage is controlled, sources of enteric contamination are identified by serially running along the small and large bowel, looking at all surfaces. Associated hematomas should be unroofed to rule out adjacent bowel injury. The anterior and posterior aspects of the stomach should be inspected, which requires opening the lesser sac for complete visualization. Duodenal injuries should be evaluated with a wide Kocher maneuver. During exploration of the lesser sac, visualization and palpation of the pancreas is done to exclude injury. Palpating the anterior surface is not sufficient, because the investing fascia may mask a pancreatic injury; mobilization, including evaluation of the posterior aspect, is critical. After injuries are identified, whether to use damage control techniques or perform primary repair of injuries is based on the patient's intraoperative physiologic status (see sections, *Damage Control Surgery* and *Treatment of Specific Injuries*). In a patient with multisystem trauma, enteral access via gastrostomy tube or needle-catheter jejunostomy should be considered. If abdominal closure is indicated after the patient's injuries are addressed, the abdomen is irrigated with warm saline and the midline fascia is closed with a running heavy suture. The skin is closed selectively based on the amount of intra-abdominal contamination.

Vascular Repair Techniques Initial control of vascular injuries is accomplished digitally by applying enough direct pressure to stop the hemorrhage. Sharp dissection with fine scissors is used to define the injury and mobilize sufficient length for proximal and distal control. Fogarty thromboembolectomy should be done proximally and distally to optimize collateral blood flow. Heparinized saline (50 units/mL) is then injected into the proximal and distal ends of the injured vessel to prevent small clot formation on the exposed intima and media. Ragged edges of the injury site should be débrided using sharp dissection. Intravascular shunts are used when there are multiple life-threatening injuries or the arterial injury is anticipated to require saphenous vein interposition reconstruction.

Options for the treatment of vascular injuries are listed in Table 7-9. Arterial repair should always be done for the aorta, carotid, innominate, brachial, superior mesenteric, proper hepatic, renal, iliac, femoral, and popliteal arteries. Named arteries that usually tolerate ligation include the right or left hepatic artery and the celiac artery. In the lower extremities, at least one artery with distal runoff should be salvaged. Arterial injuries that may be treated nonoperatively include small pseudoaneurysms, intimal dissections, small intimal flaps, and small arteriovenous fistulas in the extremities. Follow-up imaging is performed 1 to 2 weeks after injury to confirm healing. Venous repair should be performed for injuries of the superior vena cava, the inferior vena cava proximal to the renal veins, and the portal vein, although the portal vein may be ligated in extreme cases. The SMV should be repaired optimally, but >80% of patients will survive following ligation. Similarly the left renal vein can usually be ligated adjacent to the IVC due to collateral decompression.

The type of operative repair for a vascular injury is based on the extent and location of injury. Lateral suture repair is preferred for arterial injuries with minimal loss of tissue. End-to-end

Table 7-9

Options for the treatment of vascular injuries

Observation
Ligation
Lateral suture repair
End-to-end primary anastomosis
Interposition grafts
Autogenous vein
Polytetrafluoroethylene graft
Dacron graft
Transpositions
Extra-anatomic bypass
Interventional radiology
Stents
Embolization

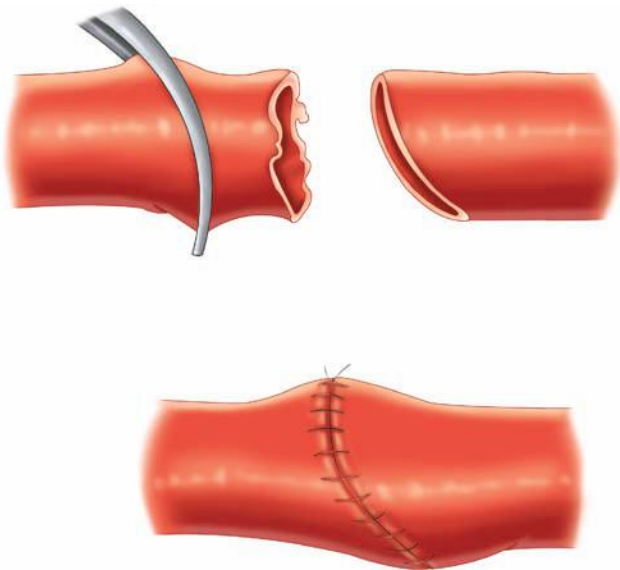


Figure 7-43. Small arteries repaired with an end-to-end anastomosis are prone to stricture. Enlarging the anastomosis by beveling the cut ends of the injured vessel can minimize this problem. A curved hemostat is a useful adjunct to create the curve.

primary anastomosis is performed if the vessel can be repaired without tension. Arterial defects of 1 to 2 cm often can be bridged by mobilizing the severed ends of the vessel after ligating small branches. The surgeon should not be reluctant to divide small branches to obtain additional length, because most injured patients have normal vasculature, and the preservation of potential collateral flow is not as important as in revascularization for atherosclerosis. The aorta, subclavian artery, and brachial artery, however, are difficult to mobilize for additional length. To avoid postoperative stenosis, particularly in smaller arteries, beveling or spatulation should be used so that the completed anastomosis is slightly larger in diameter than the native artery (Fig. 7-43). The authors emphasize the parachute technique to ensure precision placement of the posterior suture line (Fig. 7-44). If this technique is used, traction must be maintained on both ends of the suture, or leakage from the posterior aspect of the suture line may occur. A single temporary suture 180 degrees from the posterior row may be used to maintain alignment for challenging anastomoses.

Interposition grafts are used when end-to-end anastomosis cannot be accomplished without tension despite mobilization. For vessels <6 mm in diameter (e.g., internal carotid, brachial, superficial femoral, and popliteal arteries), autogenous saphenous vein from the contralateral groin should be used, because polytetrafluoroethylene (PTFE) grafts of <6 mm have a prohibitive rate of thrombosis. Larger arteries (e.g., subclavian, innominate, aorta, common iliac) are bridged by PTFE grafts. PTFE is preferred over Dacron because of the reported decreased risk of infection.⁶² Aortic or iliac arterial injuries may be complicated by enteric contamination from colon or small bowel injuries. There is a natural reluctance to place artificial grafts in such circumstances, but graft infections are rare and the time required to perform an axillofemoral bypass is excessive.⁶³ Therefore, after the control of hemorrhage, bowel contamination is contained and the abdomen irrigated before placing PTFE grafts.⁶⁴ After placement of the graft, it is covered with peritoneum or omentum before definitive treatment of the enteric injuries.

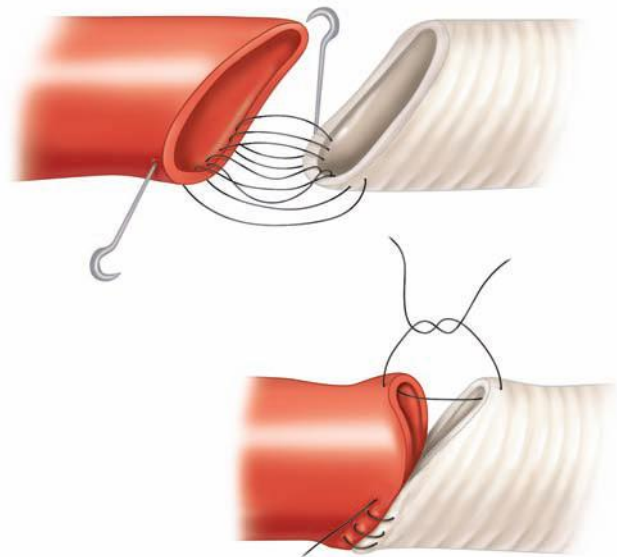


Figure 7-44. The parachute technique is helpful for accurate placement of the posterior sutures of an anastomosis when the arterial end is fixed and an interposition graft is necessary. Traction must be maintained on both ends of the suture to prevent loosening and leakage of blood. Six stitches should be placed before the graft is pulled down to the artery.

Transposition procedures can be used when an artery has a bifurcation and one vessel can be ligated safely. Injuries of the proximal internal carotid can be treated by mobilizing the adjacent external carotid, dividing it distal to the internal injury, and performing an end-to-end anastomosis between it and the distal internal carotid (Fig. 7-45). The proximal stump of the internal carotid is oversewn, with care taken to avoid a blind pocket where a clot may form. Injuries of the common and external iliac arteries can be handled in a similar fashion (Fig. 7-46), while maintaining flow in at least one internal iliac artery.

Venous injuries are inherently more difficult to reconstruct due to their propensity to thrombose. Small injuries without loss of tissue can be treated with lateral suture repair. More complex repairs with interposition grafts may thrombose but this typically occurs gradually over 1 to 2 weeks. During this time adequate collateral circulation develops, which is sufficient to avoid acute venous hypertension. Therefore, it is reasonable to use ringed PTFE for venous interposition grafting and accept a gradual, but eventual, thrombosis while allowing time for collateral circulation to develop. Such an approach is reasonable for venous injuries of the superior vena cava, suprarenal vena cava, SMV, and popliteal vein because ligation of these is associated with significant morbidity. In the remainder of venous injuries the vein may be ligated. In such patients, chronic venous hypertensive complications in the lower extremities often can be avoided by (a) temporary use of elastic bandages (Ace wraps) applied from the toes to the hips at the end of the procedure, and (b) temporary continuous elevation of the lower extremities to 30 to 45 degrees. These measures should be maintained for 1 week; if the patient has no peripheral edema with ambulation, these maneuvers are no longer required.

Damage Control Surgery

The recognition of the bloody vicious cycle and the introduction of damage control surgery (DCS) have improved the

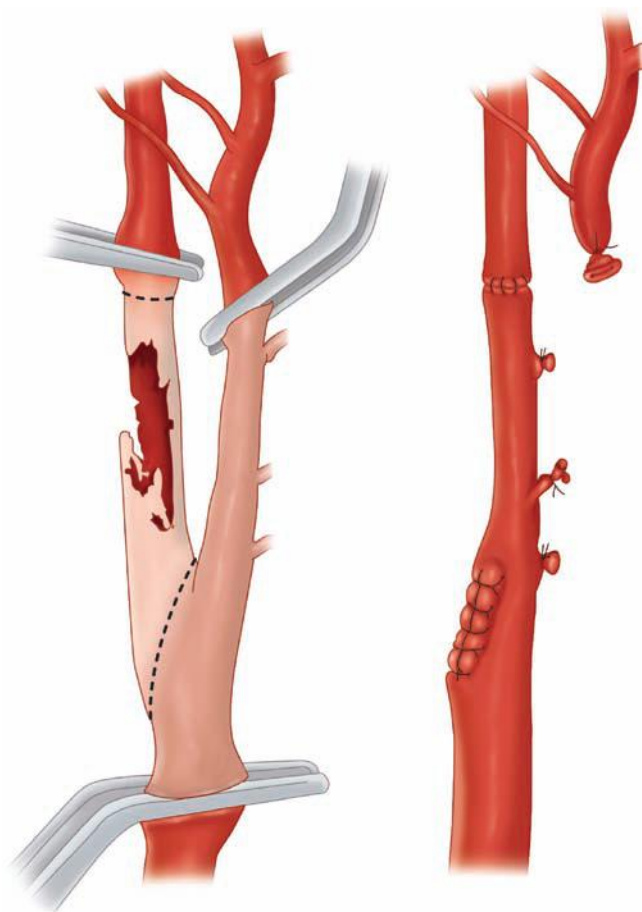


Figure 7-45. Carotid transposition is an effective approach for treating injuries of the proximal internal carotid artery.

survival of critically injured patients. Conceptually, the bloody vicious cycle, first described in 1981, is the lethal combination of coagulopathy, hypothermia, and metabolic acidosis (Fig. 7-47).⁴⁹ Hypothermia from evaporative and conductive heat loss and diminished heat production occurs despite the use of warming blankets and blood warmers. The metabolic acidosis of shock is exacerbated by aortic clamping, administration of vasopressors, massive RBC transfusions, and impaired myocardial performance. The acute coagulopathy of trauma, described previously, is compounded by hemodilution, hypothermia, and acidosis. Once the cycle starts, each component magnifies the other, which leads to a downward spiral and ultimately a fatal arrhythmia. The purpose of DCS is to limit operative time so that the patient can be returned to the SICU for physiologic restoration and the cycle thereby broken. Indications to limit the initial operation and institute DCS techniques include a combination of refractory hypothermia (temperature $<35^{\circ}\text{C}$), profound acidosis, (arterial pH <7.2 , base deficit <15 mmol/L), and refractory coagulopathy.^{49,65} The decision to abbreviate a trauma laparotomy is made intraoperatively as the patient's clinical course becomes clearer and laboratory values become available.⁶⁶

The goal of DCS is to control surgical bleeding and limit GI spillage. The operative techniques used are temporary measures, with definitive repair of injuries delayed until the patient is physiologically replete. Controlling surgical bleeding while preventing ischemia is of utmost importance during DCS. Aortic injuries must be repaired using an interposition PTFE graft. Although celiac artery injuries may be ligated, the SMA must maintain flow, and the early insertion of an intravascular shunt is advocated. Similarly, perfusion of the iliac system and infrainguinal vessels can be restored with a vascular shunt, with interposition graft placement delayed until hours later. Venous injuries are

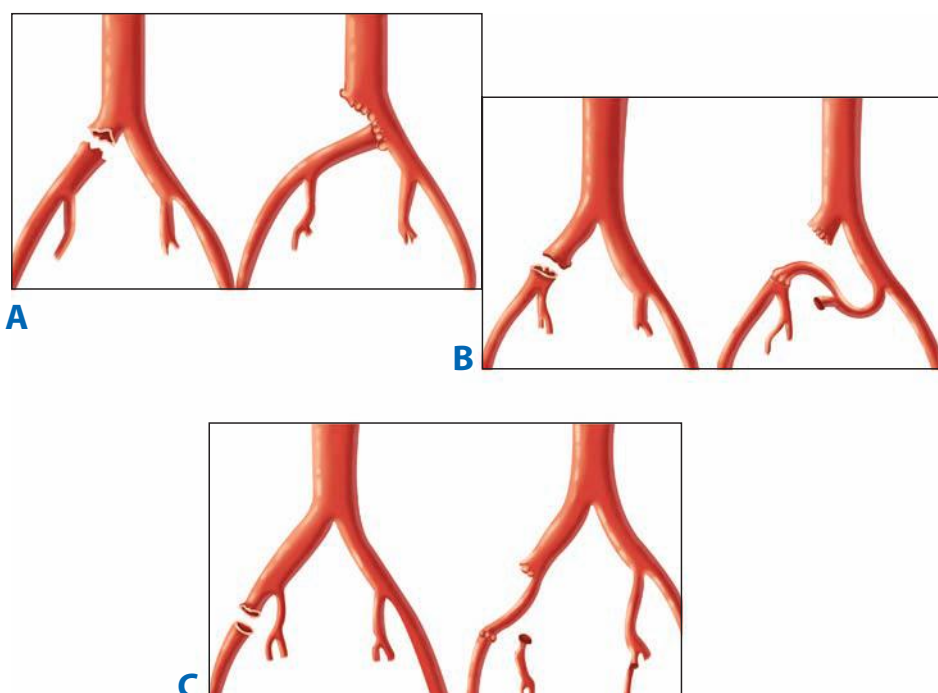


Figure 7-46. Transposition procedures can be used for iliac artery injuries to eliminate the dilemma of placing an interposition polytetrafluoroethylene graft in the presence of enteric contamination. **A.** Right common iliac artery transposed to left common iliac artery. **B.** Left internal iliac artery transposed to the distal right common iliac artery. **C.** Right internal iliac artery transposed to the right external iliac artery.

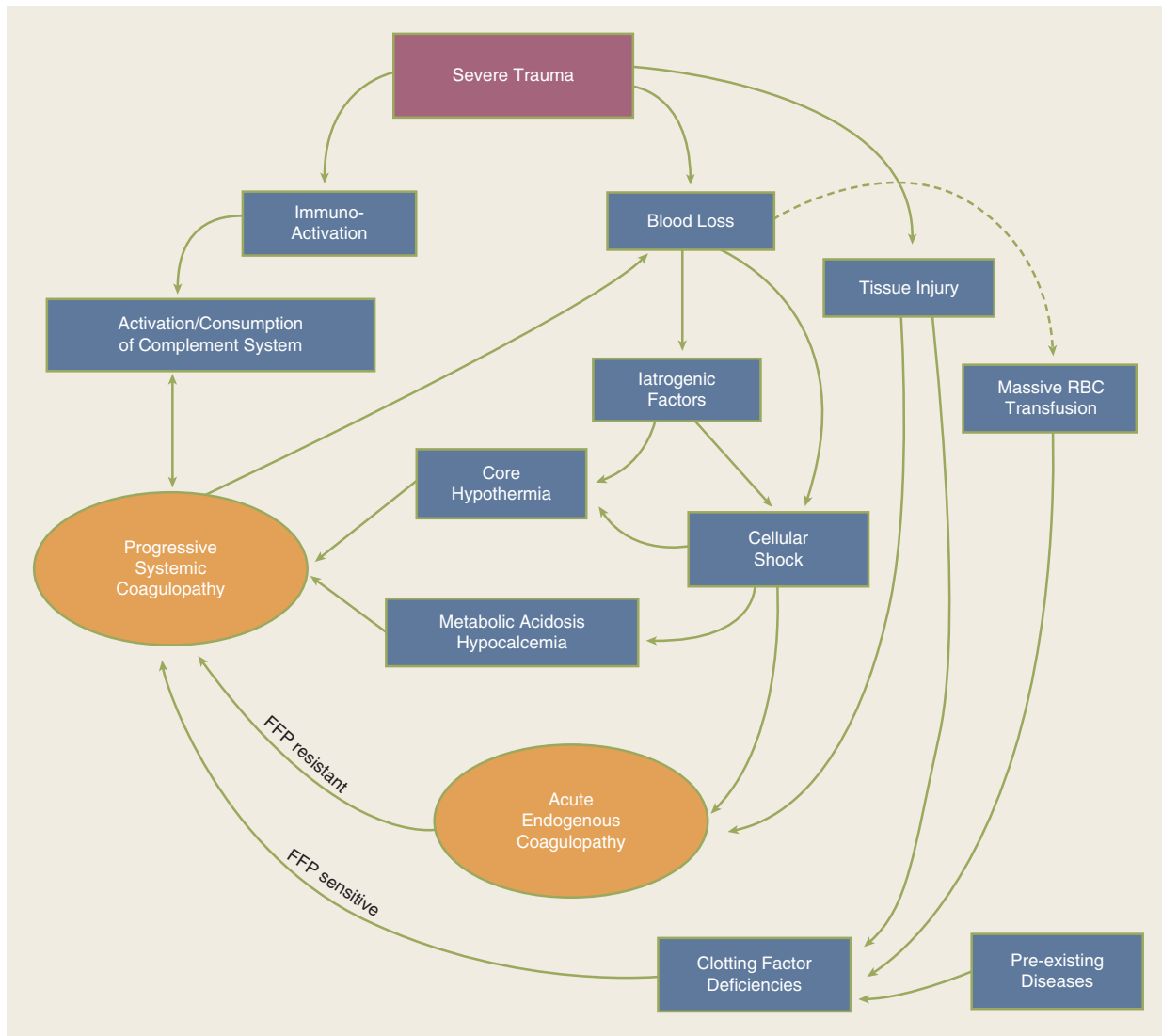


Figure 7-47. The bloody vicious cycle. FFP = fresh-frozen plasma; RBC = red blood cell.

preferentially treated with ligation in damage control situations, except for the suprarenal inferior vena cava and popliteal vein. For extensive solid organ injuries to the spleen or one kidney, excision is indicated rather than an attempt at operative repair. For hepatic injuries, perihepatic packing of the liver will usually

tamponade bleeding (see Fig. 7-36). Translobar gunshot wounds of the liver are best controlled with balloon catheter tamponade, whereas deep lacerations can be controlled with Foley catheter inflation deep within the injury track (Fig. 7-48). For thoracic injuries requiring DCS several options exist. For

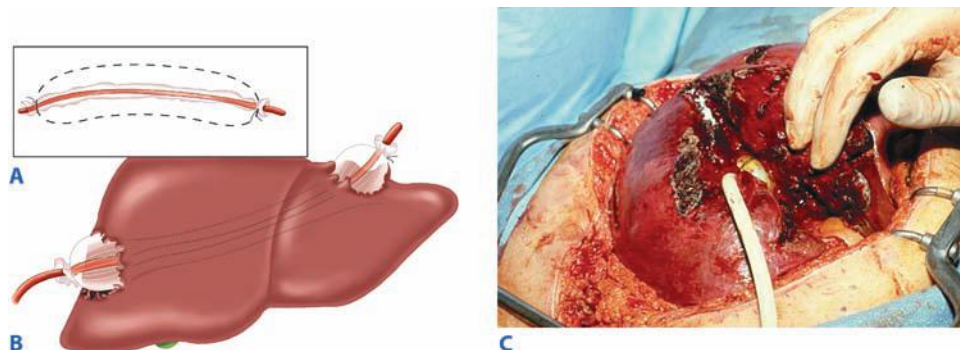


Figure 7-48. **A.** An intrahepatic balloon used to tamponade hemorrhage from transhepatic penetrating injuries is made by placing a red rubber catheter inside a 1-inch Penrose drain, with both ends of the Penrose drain ligated. **B.** Once placed inside the injury tract, the balloon is inflated with saline until hemorrhage stops. **C.** A Foley catheter with a 30-mL balloon can be used to halt hemorrhage from deep lacerations to the liver.

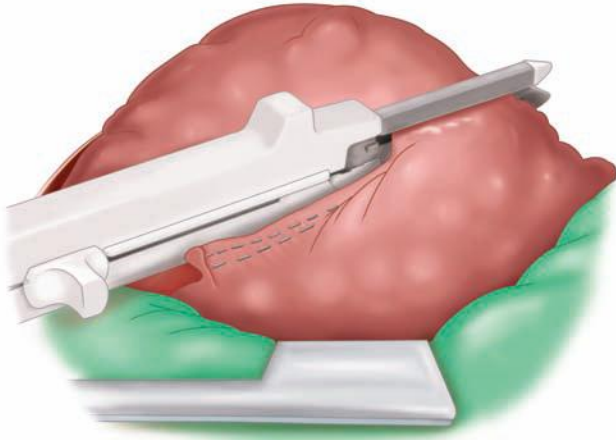


Figure 7-49. Pulmonary tractotomy divides the pulmonary parenchyma using either a transection/anastomosis (TA) or gastrointestinal anastomosis (GIA) stapler. The opened track permits direct access to injured vessels or bronchi for individual ligation.

bleeding peripheral pulmonary injuries, wedge resection using a stapler is performed. In penetrating injuries, pulmonary tractotomy is used to divide the parenchyma (Fig. 7-49); individual vessels and bronchi are then ligated using a 3-0 polydioxanone suture (PDS) and the track left open. Patients who sustain more proximal injuries may require formal pulmonary resection but pneumonectomy is poorly tolerated. Cardiac injuries may be temporarily controlled using a running 3-0 nonabsorbable polypropylene suture or skin staples. Pledged repair should be performed for the relatively thin right ventricle.

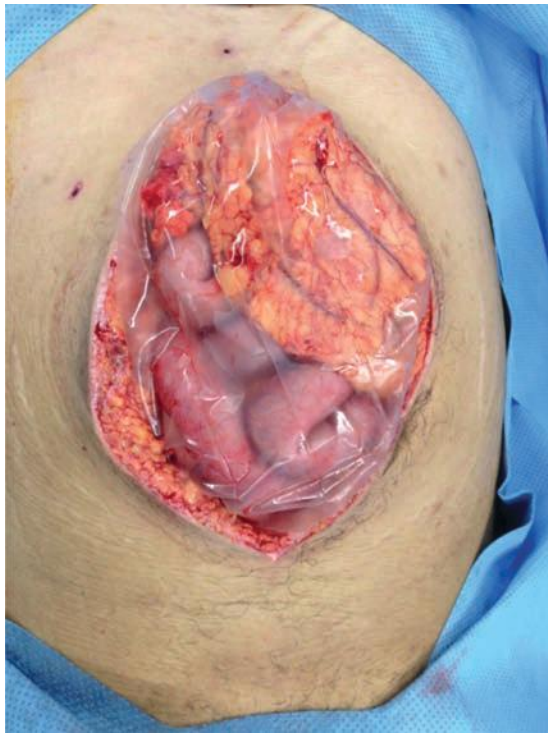The second key component of DCS is limiting enteric content spillage. Small GI injuries (stomach, duodenum, small intestine, and colon) may be controlled using a rapid whipstitch of 2-0 polypropylene. Complete transection of the bowel or segmental damage is controlled using a GIA stapler, often with resection of the injured segment. Alternatively, open ends of the bowel may be ligated using umbilical tapes to limit spillage. Pancreatic injuries, regardless of location, are packed and the evaluation of ductal integrity postponed. Urologic injuries may require catheter diversion. Before the patient is returned to the SICU, the abdomen must be temporarily closed. Originally, penetrating towel clips were used to approximate the skin; however, the ensuing bowel edema often produces a delayed abdominal compartment syndrome. Currently, temporary closure of the abdomen is accomplished using an antimicrobial surgical incise drape (Ioban, 3M Health Care, St Paul, MN) (Fig. 7-50). In this technique, the bowel is covered with a fenestrated subfascial sterile drape (45 × 60 cm Steri-Drape 3M Health Care), and two Jackson-Pratt drains are placed along the fascial edges; this is then covered using an Ioban drape, which allows closed suction to control reperfusion-related ascitic fluid egress while providing adequate space for bowel expansion to prevent abdominal compartment syndrome. During the initial DCS stage, the subfascial sterile drape is not covered by a blue towel so that the status of the bowel and hemorrhage control can be assessed. Return to the OR within 24 hours is planned once the patient clinically improves, as evidenced by normothermia, normalization of coagulation test results, and correction of acidosis.

Head Injuries

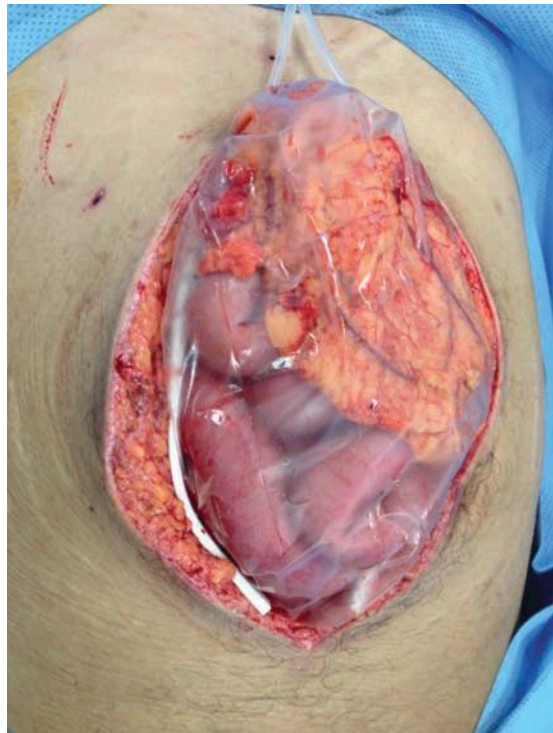Intracranial Injuries CT scanning, performed on all patients with a significant closed head injury (GCS score <14), identifies and quantitates intracranial lesions. Patients with intracranial hemorrhage, including epidural hematoma, subdural hematoma, subarachnoid hemorrhage, intracerebral hematoma or contusion, and diffuse axonal injury, are admitted to the SICU. In patients with abnormal findings on CT scans and GCS scores of ≤8, intracranial pressure (ICP) should be monitored using fiberoptic intraparenchymal devices or intraventricular catheters.²⁹ Although an ICP of 10 mm Hg is believed to be the upper limit of normal, therapy generally is not initiated until ICP is >20 mm Hg.²⁹ Indications for operative intervention to remove space-occupying hematomas are based on the clot volume, amount of midline shift, location of the clot, GCS score, and ICP.²⁹ A shift of >5 mm typically is considered an indication for evacuation, but this is not an absolute rule. Smaller hematomas that are in treacherous locations, such as the posterior fossa, may require drainage due to brain stem compression or impending herniation. Removal of small hematomas may also improve ICP and cerebral perfusion in patients with elevated ICP that is refractory to medical therapy. Patients with diffuse cerebral edema resulting in excessive ICP may require a decompressive craniectomy, although a recent AAST multicenter trial questions the benefits.^{67,68} Patients with open or depressed skull fractures, with or without sinus involvement, may require operative intervention for hemorrhage control, evacuation of blood, skull fracture fixation, or débridement.

General surgeons in communities without emergency neurosurgical coverage should have a working knowledge of burr hole placement in the event that emergent evacuation is required for a life-threatening epidural hematoma (Fig. 7-51).⁶⁹ The typical clinical course of an epidural hematoma is an initial loss of consciousness, a lucid interval, and recurrent loss of consciousness with an ipsilateral fixed and dilated pupil. While decompression of subdural hematomas may be delayed, epidural hematomas require evacuation within 70 minutes.⁶⁸ The final stages of this sequence are caused by blood accumulation that forces the temporal lobe medially, with resultant compression of the third cranial nerve and eventually the brain stem. The burr hole is made on the side of the dilated pupil to decompress the intracranial space. After stabilization, the patient is transferred to a facility with neurosurgical capability for formal craniotomy.

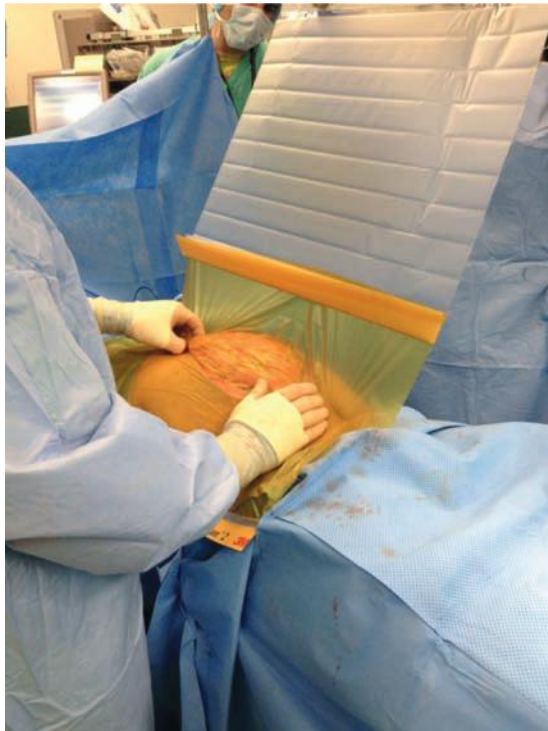
In addition to operative intervention, postinjury care directed at limiting secondary injury to the brain is critical. The goal of resuscitation and management in patients with head injuries is to avoid hypotension (SBP of <100 mm Hg) and hypoxia (partial pressure of arterial oxygen of <60 or arterial oxygen saturation of <90).²⁹ Attention, therefore, is focused on maintaining cerebral perfusion rather than merely lowering ICP. Resuscitation efforts aim for a euolemic state and an SBP of >100 mm Hg. Cerebral perfusion pressure (CPP) is equal to the mean arterial pressure minus the ICP, with a target range of >50 mm Hg.²⁹ CPP can be increased by either lowering ICP or raising mean arterial pressure. Sedation, osmotic diuresis, paralysis, ventricular drainage, and barbiturate coma are used in sequence, with coma induction being the last resort. The partial pressure of carbon dioxide (Pco₂) should be maintained in a normal range (35–40 mm Hg), but for temporary management of acute



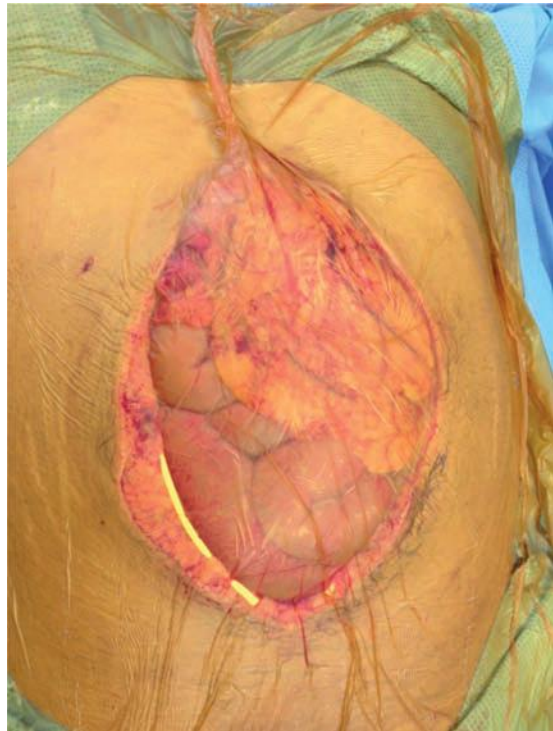
A



B



C



D

Figure 7-50. Temporary closure of the abdomen entails covering the bowel with a fenestrated subfascial 45×60 cm sterile drape (A), placing Jackson-Pratt drains along the fascial edge (B), and then occluding with an Ioban drape (C, D).

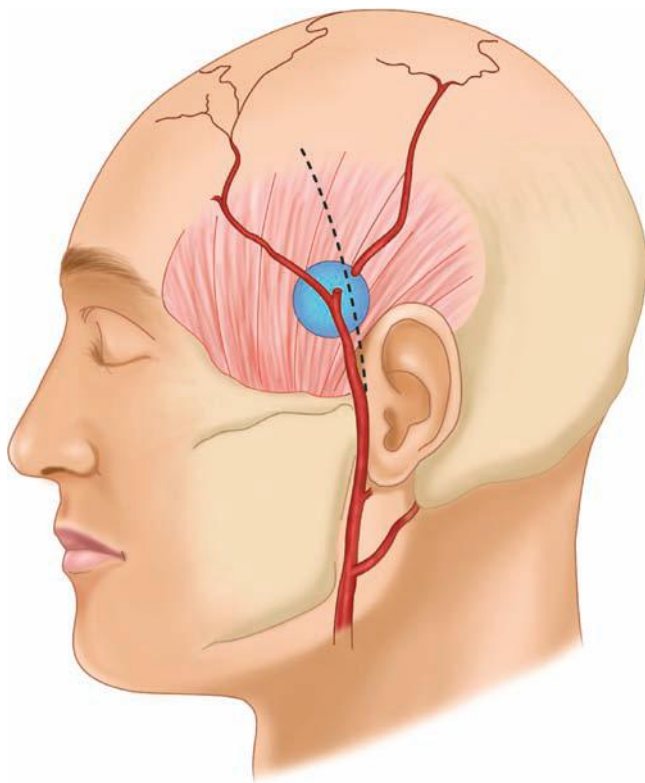


Figure 7-51. A burr hole is made for decompression of an epidural hematoma as a life-saving maneuver. One or more branches of the external carotid artery usually must be ligated to gain access to the skull. No attempt should be made to control intracranial hemorrhage through the burr hole. Rather, the patient's head should be wrapped with a bulky absorbent dressing and the patient transferred to a neurosurgeon for definitive care.

intracranial hypertension, inducing cerebral vasoconstriction by hyperventilation to a P_{CO_2} of <30 mm Hg is occasionally warranted. Moderate hypothermia (32° – 33° C [89.6° – 91.4° F]) has been proposed to improve neurologic outcomes when maintained for at least 48 hours, but studies to date have not validated this concept.^{29,70,71} Patients with intracranial hemorrhage should be monitored for postinjury seizures, and prophylactic anticonvulsant therapy (e.g., phenytoin [dilantin]) is indicated for 7 days after injury.^{29,72}

Maxillofacial Injuries Maxillofacial injuries are common with multisystem trauma and require coordinated management by the trauma surgeon and the specialists in otolaryngology, plastic surgery, ophthalmology, and oral and maxillofacial surgery. Delay in addressing these systems that control vision, hearing, smelling, breathing, eating, and phonation may produce dysfunction and disfigurement with serious psychological impact. The maxillofacial complex is divided into three regions; the *upper face* containing the frontal sinus and brain, the *mid-face* containing the orbits, nose, and zygomaticomaxillary complex, and the *lower face* containing the mandible. High-impact kinetic energy is required to fracture the frontal sinus, orbital rims, and mandible, whereas low-impact forces will injure the nasal bones and zygoma.

The most common scenario, which at times may be life-threatening, is bleeding from facial fractures.⁷³ Temporizing measures include nasal packing, Foley catheter tamponade of

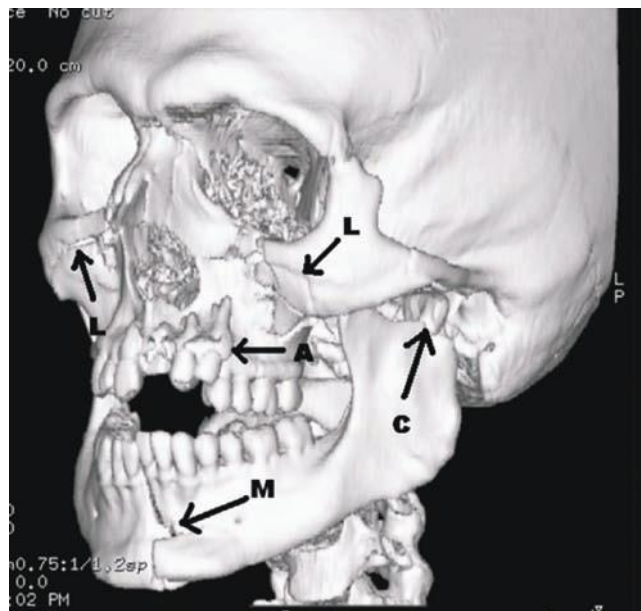


Figure 7-52. Three-dimensional computed tomographic scan illustrating Le Fort II maxillary (L) and alveolar (A) fractures, and fracture of the mandible (M) at the midline and at the weaker condyle (C). (Image used with permission from Vincent D. Eusterman, MD, DDS.)

posterior nasal bleeding, and oropharyngeal packing. Prompt angioembolization will halt exsanguinating hemorrhage. Fractures of tooth-bearing bone are considered open fractures and require antibiotic therapy and semiurgent repair to preserve the airway as well as the functional integrity of the occlusion (bite) and the aesthetics of the face. Orbital fractures may compromise vision, produce muscle injury causing diplopia, or change orbital volume to produce a sunken appearance to the orbit. Nose and nasoethmoidal fractures should be assessed carefully to identify damage to the lacrimal drainage system or to the cribriform plate producing cerebrospinal fluid rhinorrhea. After initial stabilization, a systematic physical examination of the head and neck should be performed that also includes cranial nerve examination and three-dimensional CT scanning of the maxillofacial complex (Fig. 7-52).

Cervical Injuries

Spine Treatment of injuries to the cervical spine is based on the level of injury, the stability of the spine, the presence of subluxation, the extent of angulation, the level of neurologic deficit, and the overall condition of the patient. In general, physician-supervised axial traction, via cervical tongs or the more commonly used halo vest, is used to reduce subluxations and stabilize the injury. Immobilization of injuries also is achieved with spinal orthoses (braces), particularly in those with associated thoracolumbar injuries. Surgical fusion typically is performed in patients with neurologic deficit, those with angulation of >11 degrees or translation of >3.5 mm, and those who remain unstable after halo placement. Indications for immediate operative intervention are deterioration in neurologic function and fractures or dislocations with incomplete deficit. Historically, methylprednisolone was administered to patients with acute spinal cord injury after blunt injury, with clinical data suggesting

a small benefit to initiating a 24-hour infusion if started within 3 hours and a 48-hour infusion if started 3 to 8 hours.⁷⁴ Current guidelines, however, no longer recommend steroids for acute injuries.⁷⁵ The role and timing of operative surgical decompression after acute spinal cord injury is debated. However, evidence supports urgent decompression of bilateral locked facets in patients with incomplete tetraplegia or with neurologic deterioration. Urgent decompression in acute cervical spinal cord injury is safe. Performing surgery within 24 hours may decrease length of stay and complications.⁷⁶ Complete injuries of the spinal cord remain essentially untreatable. Yet, approximately 3% of patients who present with flaccid quadriplegia have concussive injuries, and these patients represent the very few who seem to have miraculous recoveries.

Vascular Cervical vascular injuries due to either blunt or penetrating trauma can result in devastating neurologic sequelae or exsanguination. Penetrating injuries to the carotid artery and internal jugular vein usually are obvious on operative neck exploration. The principles of vascular repair techniques (discussed previously) apply to carotid injuries, and options for repair include end-to-end primary repair (often possible with mobilization of the common carotid), graft interposition, and transposition procedures. All carotid injuries should be repaired except in patients who present in coma with a delay in transport. Prompt revascularization of the internal carotid artery, using a

temporary Pruitt-Inahara shunt, should be considered in patients arriving in profound shock. Otherwise, carotid shunting should be done selectively as in elective carotid endarterectomy but the patient should be systemically anticoagulated. Currently, we administer heparin with an ACT target of 250 sec. Tangential wounds of the internal jugular vein should be repaired by lateral venorrhaphy, but extensive wounds are efficiently addressed by ligation. However, it is not advisable to ligate both jugular veins due to potential intracranial hypertension. Vertebral artery injuries due to penetrating trauma are difficult to control operatively because of the artery's protected location within the foramen transversarium. Although exposure from an anterior approach can be accomplished by removing the anterior elements of the bony canal and the tough fascia covering the artery between the elements, typically the most efficacious control of such injuries is angioembolization. Fogarty catheter balloon occlusion, however, is useful for controlling acute bleeding if encountered during neck exploration.

Blunt injury to the carotid or vertebral arteries may cause dissection, thrombosis, or pseudoaneurysm, typically in the surgically inaccessible distal internal carotid (Fig. 7-53).⁷⁷ Early recognition and management of these injuries is paramount, because patients treated with antithrombotics have a stroke rate of <1% compared with stroke rates of 20% in untreated patients. Because treatment must be instituted during the latent period

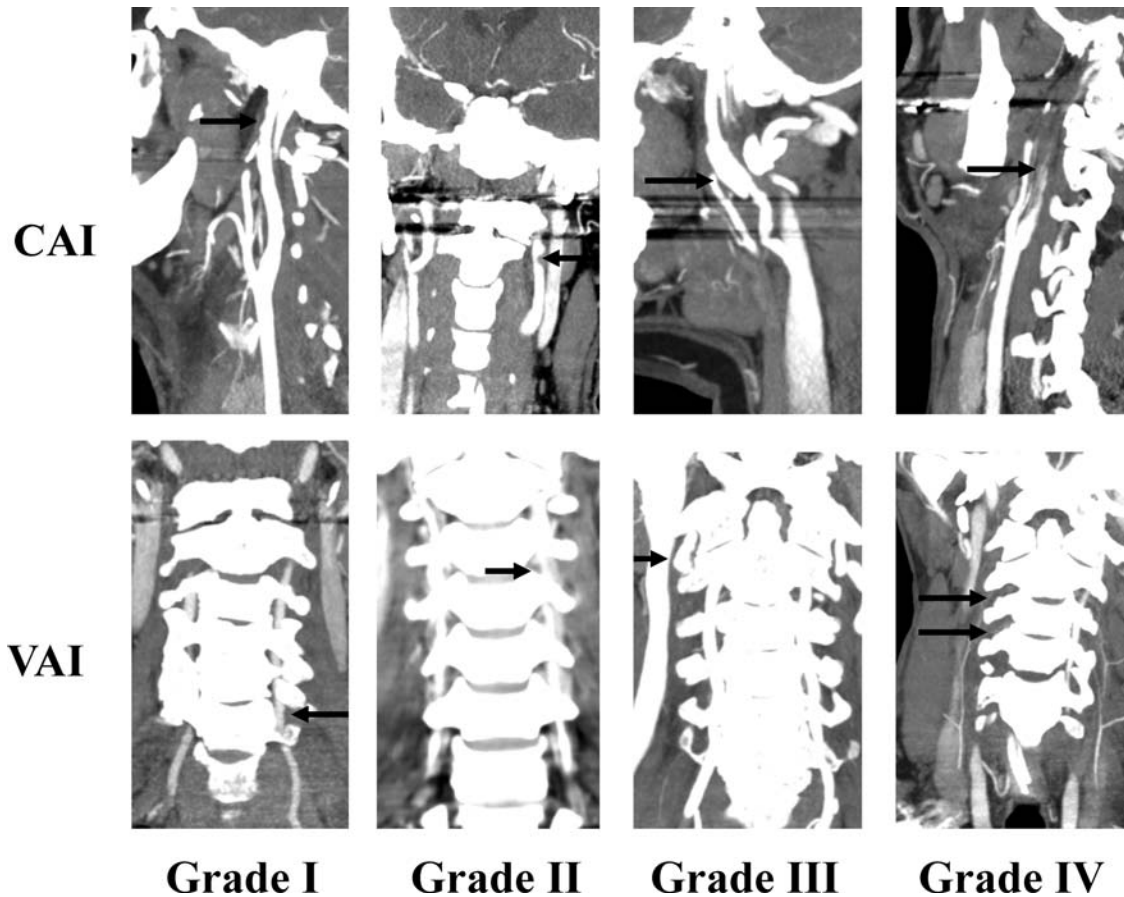


Figure 7-53. The Denver grading scale for blunt cerebrovascular injuries. Grade I: irregularity of the vessel wall, dissection/intramural hematoma with <25% luminal stenosis. Grade II: visualized intraluminal thrombus or raised intimal flap, or dissection/intramural hematoma with 25% or more luminal narrowing. Grade III: pseudoaneurysm. Grade IV: vessel occlusion. Grade V: vessel transection. CAI = carotid artery injury; VAI = vertebral artery injury.

9► between injury and onset of neurologic sequelae, diagnostic imaging is performed based on identified risk factors (Fig. 7-54).⁷⁸ After identification of an injury, antithrombotics are administered if the patient does not have contraindications (intracranial hemorrhage, falling hemoglobin level with solid organ injury or pelvic fracture). Heparin, started without a loading dose at 15 units/kg per hour, is titrated to achieve a PTT between 40 and 50 seconds or antiplatelet agents are initiated

(aspirin 325 mg/d or clopidogrel 75 mg/d). The types of anti-thrombotic treatment appear equivalent in published studies to date, and the duration of treatment is empirically recommended to be 6 months.^{79,80} The role of carotid stenting for grade III internal carotid artery injuries remain controversial. Thrombosis of the internal jugular veins caused by blunt trauma can occur unilaterally or bilaterally and is often discovered incidentally, because most patients are asymptomatic. Bilateral thrombosis

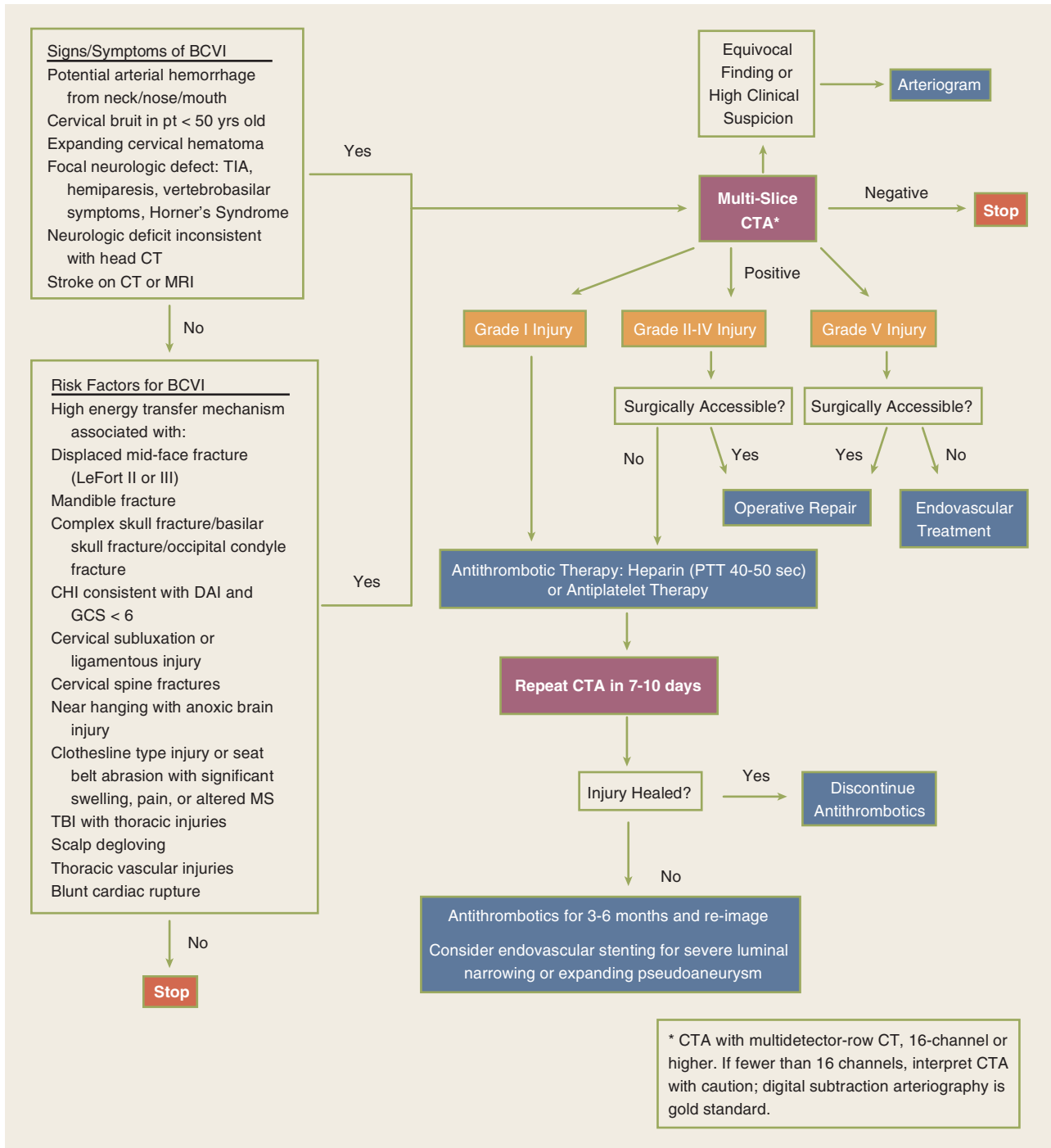


Figure 7-54. Screening and treatment algorithm for blunt cerebrovascular injuries (BCVIs). Angio = angiography; ASA = acetylsalicylic acid; BRB = bright red blood; CHI = closed head injury; C-spine = cervical spine; CT = computed tomography; DAI = diffuse axonal injury; GCS = Glasgow Coma Scale score; MRI = magnetic resonance imaging; MS = mental status; Neg = negative; pt = patient; PTT = partial thromboplastin time; TIA = transient ischemic attack.

can aggravate cerebral edema in patients with serious head injuries; stent placement should be considered in such patients if ICP remains elevated.

Aerodigestive Subclinical fractures of the larynx and trachea may manifest as cervical emphysema. Fractures documented by CT scan are usually repaired. Common injuries include thyroid cartilage fractures, rupture of the thyroepiglottic ligament, disruption of the arytenoids or vocal cord tears, and cricoid fractures. After débridement of devitalized tissue, tracheal injuries are repaired end-to-end using a single layer of interrupted absorbable sutures. Associated injuries of the esophagus are common in penetrating injuries due to its close proximity. After débridement and repair, vascularized tissue is interposed between the repaired esophagus and trachea, and a closed suction drain is placed. The sternocleidomastoid muscle or strap muscles are useful for interposition and help prevent postoperative fistulas.

Chest Injuries

The most common injuries from both blunt and penetrating thoracic trauma are hemothorax and pneumothorax. More than 85% of patients can be definitively treated with a chest tube. The indications for thoracotomy include significant initial or ongoing hemorrhage from the tube thoracostomy and specific imaging-identified diagnoses (Table 7-10). One caveat concerns the patient who presents after a delay. Even when the initial chest tube output is 1.5 L, if the output ceases and the lung is re-expanded, the patient may be managed nonoperatively if hemodynamically stable.

Great Vessels Over 90% of thoracic great vessel injuries are due to penetrating trauma, although blunt injury to the innominate, subclavian, or descending aorta may cause a pseudoaneurysm or frank rupture.^{40,81,82} Simple lacerations of the ascending or transverse aortic arch can be repaired with lateral aortorrhaphy. Repair of posterior injuries, or those requiring interposition grafting of the arch, require full cardiopulmonary bypass, and repair of complex injuries may require circulatory arrest. Innominate artery injuries are repaired using the bypass exclusion technique,⁸² which avoids the need for cardiopulmonary

Table 7-10

Indications for operative treatment of thoracic injuries

- Initial tube thoracostomy drainage of >1000 mL (penetrating injury) or >1500 mL (blunt injury)
- Ongoing tube thoracostomy drainage of >200 mL/h for 3 consecutive hours in noncoagulopathic patients
- Caked hemothorax despite placement of two chest tubes
- Selected descending torn aortas
- Great vessel injury (endovascular techniques may be used in selected patients)
- Pericardial tamponade
- Cardiac herniation
- Massive air leak from the chest tube with inadequate ventilation
- Tracheal or main stem bronchial injury diagnosed by endoscopy or imaging
- Open pneumothorax
- Esophageal perforation
- Air embolism

bypass. Bypass grafting from the proximal aorta to the distal innominate with a prosthetic tube graft is performed before the postinjury hematoma is entered. The PTFE graft is anastomosed end to side from the proximal undamaged aorta and anastomosed end-to-end to the innominate artery (Fig. 7-55). The origin of the innominate is then oversewn at its base to exclude the pseudoaneurysm or other injury. Subclavian artery injuries can be repaired using lateral arteriorrhaphy or PTFE graft interposition; due to its multiple branches and tethering of the artery, end-to-end anastomosis is not advocated if there is a significant segmental loss.

Descending thoracic aortic injuries may require urgent if not emergent intervention. However, operative intervention for intracranial or intra-abdominal hemorrhage or unstable pelvic fractures takes precedence. To prevent aortic rupture,

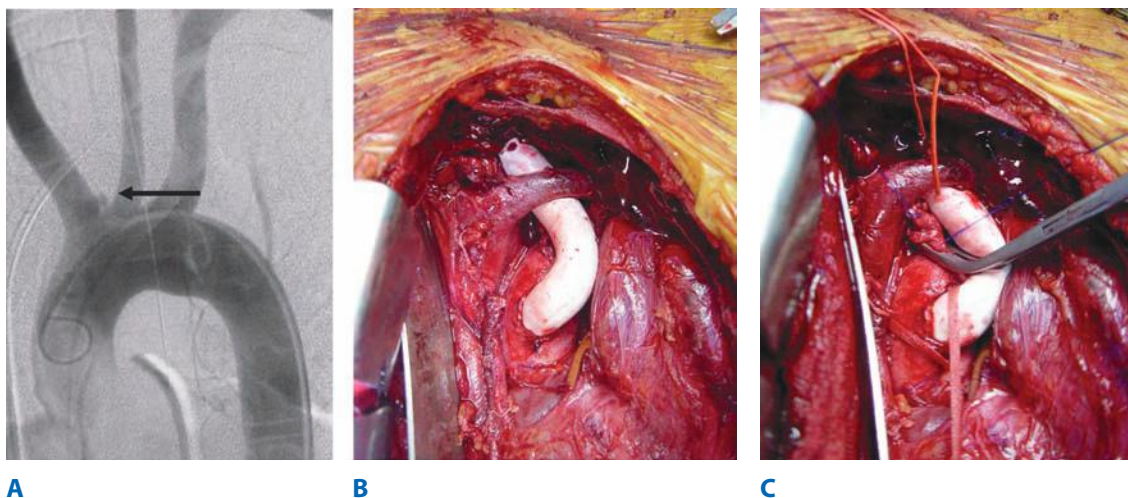


Figure 7-55. **A.** Angiography reveals a 1-cm pseudoaneurysm of the innominate artery origin. **B.** In the first stage of the bypass exclusion technique, a 12-mm polytetrafluoroethylene graft is anastomosed end to side from the proximal undamaged aorta, tunneled under the vein, and anastomosed end to end to the innominate artery. **C.** The origin of the innominate is then oversewn at its base to exclude the pseudoaneurysm.

pharmacologic therapy with a selective β_1 antagonist, esmolol, should be instituted in the trauma bay, with a target SBP of <100 mm Hg and heart rate of <100 /min.^{36,83} Endovascular stenting is now the mainstay of treatment, but open operative reconstruction is warranted, or necessary, in select patients.^{84,85} Endovascular techniques are particularly appropriate in patients who cannot tolerate single lung ventilation, patients >60 - years-old who are at risk for cardiac decompensation with aortic clamping, or patients with uncontrolled intracranial hypertension. While endograft sizing has improved, the major question is long-term outcome in younger patients. Open repair of the descending aorta is accomplished using partial left heart bypass.⁸⁶ With the patient in a right lateral decubitus position, the patient's hips and legs are rotated 45 degrees toward the supine position to gain access to the left groin for common femoral artery cannulation. Using a left posterolateral thoracotomy, the fourth rib is transected to expose the aortic arch and left pulmonary hilum. Partial left heart bypass is performed by cannulating the superior pulmonary vein with return through the left common femoral artery (Fig. 7-56). A centrifugal pump is used to provide flow rates of 2.5 to 4 L/min to maintain a distal perfusion pressure of >65 mm Hg. This prevents ischemic injury of the spinal cord as well as the splanchnic bed, and reduces left ventricular afterload.³⁶ Heparinization is not required, a significant benefit in patients with multiple injuries, particularly in those with intracranial hemorrhage. Unless contraindicated, however, low-dose heparin (100 units/kg) typically is administered to a target ACT of 250 sec to prevent thromboembolic events. Once bypass is initiated, vascular clamps are applied on the aorta between the left common carotid and left subclavian arteries, on the left subclavian, and on the aorta distal to the injury. In most patients a short PTFE graft (usually 18 mm in diameter) is placed using a running 3-0 polypropylene suture. However, primary arterial repair should be done when possible. Air and thrombus are flushed from the aortic graft before the final suture is tied, and the occluding vascular clamps are removed. The patient is then weaned from the centrifugal pump, the cannulas are removed, and primary repair of the cannulated vessels is performed. Removal of air or potential clot in the pulmonary vein is important during decannulation to avoid left heart emboli to the systemic circulation.

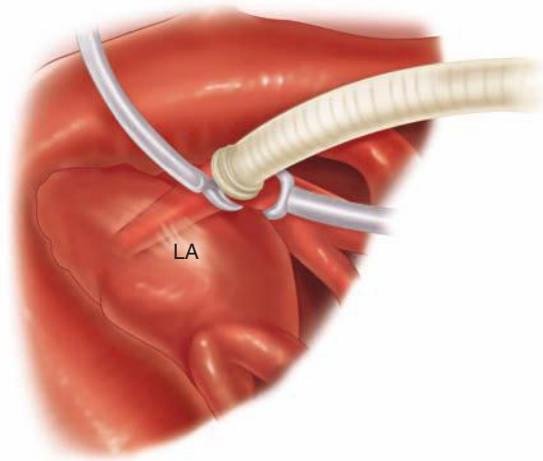


Figure 7-56. When repairing a tear of the descending thoracic aorta, perfusion of the spinal cord while the aorta is clamped is achieved by using partial left heart bypass. The venous cannula is inserted into the left superior pulmonary vein because it is less prone to tearing than the left atrium (LA).

Heart Blunt and penetrating cardiac injuries have widely differing presentations and therefore disparate treatments. Survivable penetrating cardiac injuries consist of wounds that can be repaired operatively; most are stab wounds. Before repair of the injury is attempted, hemorrhage should be controlled; injuries to the atria can be clamped with a Satinsky vascular clamp, whereas digital pressure is used to occlude the majority of ventricular wounds. Foley catheter occlusion of larger stellate lesions may be effective, but even minimal traction may enlarge the original injury. Temporary control of hemorrhage, and at times definitive repair, may be accomplished with skin staples for left ventricular lacerations; the myocardial edges of the laceration must coapt in diastole for stapling to be technically feasible. Definitive repair of cardiac injuries is performed with either running 3-0 polypropylene suture or interrupted, pledgeted 2-0 polypropylene suture (Fig. 7-57).⁸⁷ Use of

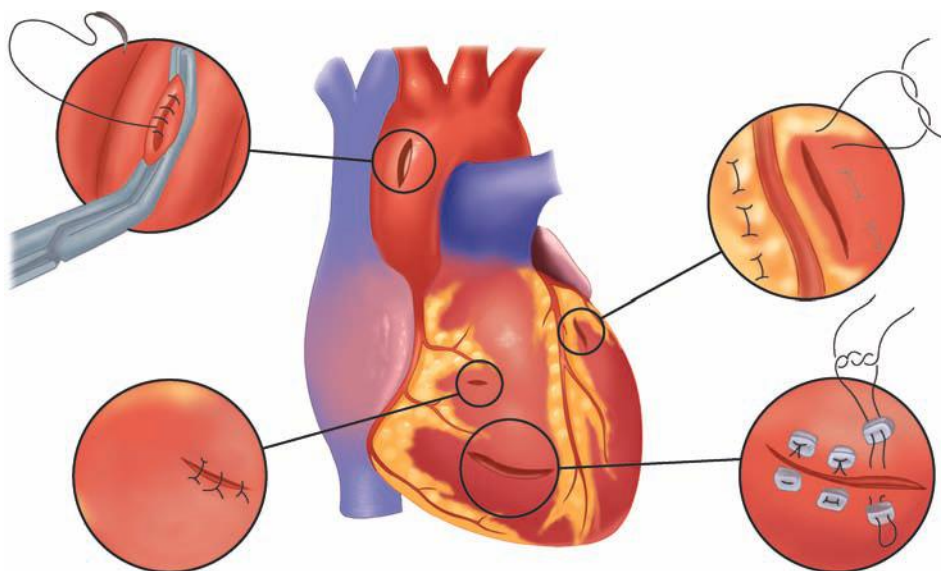


Figure 7-57. A variety of techniques may be necessary to repair cardiac wounds. Generally, pledget support is used for the relatively thin-walled right ventricle.

pledgets may be particularly important in the right ventricle to prevent sutures from pulling through the thinner myocardium. Injuries adjacent to coronary arteries should be repaired using horizontal mattress sutures, because use of running sutures results in coronary occlusion and distal infarction. Gunshot wounds may result in stellate lesions or contused, extremely friable myocardium adjacent to the wound. When the edges of such complex wounds cannot be fully approximated and hence the repair is not hemostatic, the authors have used surgical adhesive (BioGlue) to achieve hemostasis.⁸⁸ Occasionally, interior structures of the heart may be damaged. Intraoperative auscultation or postoperative hemodynamic assessment usually identifies such injuries.⁸⁹ Echocardiography (ECHO) can diagnose the injury and quantitate its effect on cardiac output. Immediate repair of valvular damage or septal defects rarely is necessary and would require cardiopulmonary bypass, but structural intracardiac lesions may progress and, thus, patients must have a follow-up ECHO.

Patients with blunt cardiac injury typically present with persistent tachycardia or conduction disturbances, but occasionally present with tamponade due to atrial or right ventricular rupture. There are no pathognomonic ECG findings, and cardiac enzyme levels do not correlate with the risk of cardiac complications.²³ Therefore, patients for whom there is high clinical suspicion of cardiac contusion and who are hemodynamically stable should be monitored for dysrhythmias for 24 hours by telemetry. Patients with hemodynamic instability should undergo ECHO to evaluate for wall motion abnormalities, pericardial fluid, valvular dysfunction, chordae rupture, or diminished ejection fraction. If such findings are noted or if vasoactive agents are required, cardiac function can be continuously monitored using a pulmonary artery catheter and serial SICU transthoracic or transesophageal ECHO.

Trachea, Bronchi, and Lung Parenchyma Less than 1% of all injured patients sustain intrathoracic tracheobronchial injuries, and only a small number require operative intervention. Although penetrating injuries may occur throughout the tracheobronchial system, blunt injuries most commonly occur within 2.5 cm of the carina. For patients with a massive air leak requiring emergent exploration, initial control of the injury to provide effective ventilation is obtained by passing an endotracheal tube either beyond the injury or into the contralateral mainstem bronchus. Principles of repair are similar to those for repair of cervical tracheal injuries. Devitalized tissue is débrided, and primary end-to-end anastomosis with 3-0 PDS suture is performed. Dissection should be limited to the area of injury to prevent disruption of surrounding bronchial vasculature and ensuing ischemia and stricture. Suture lines should be encircled with vascularized tissue, either pericardium, intercostal muscle, or pleura. Expectant management is employed for bronchial injuries that are less than one-third the circumference of the airway and have no evidence of a persistent major air leak.^{11,12} In patients with peripheral bronchial injuries, indicated by persistent air leaks from the chest tube and documented by endoscopy, bronchoscopically directed fibrin glue sealing may be useful.

The majority of pulmonary parenchymal injuries are suspected based upon identification of a pneumothorax; the vast majority is managed by tube thoracostomy. Identified parenchymal injuries encountered during thoracic exploration for a massive hemothorax are managed without resection as much

as possible. Peripheral lacerations with persistent bleeding can be managed with stapled wedge resection using a stapler. For central injuries, the current treatment is pulmonary tractotomy, which permits selective ligation of individual bronchioles and bleeders, prevents the development of an intraparenchymal hematoma or air embolism, and reduces the need for formal lobar resection (see Fig. 7-49).^{90,91} A stapling device, preferably the longest stapler available, is inserted directly into the injury track and positioned along the thinnest section of overlying parenchyma. The injury track is thus filleted open, which allows direct access to the bleeding vessels and leaking bronchi. The majority of injuries are definitively managed with selective ligation, and the defect is left open. Occasionally, tractotomy reveals a more proximal vascular injury that must be treated with formal lobectomy. Injuries severe enough to mandate pneumonectomy usually are fatal because of right heart decompensation.⁹²

One parenchymal injury that may be discovered during thoracic imaging is a posttraumatic pulmonary pseudocyst, colloquially termed a *pneumatocele*.⁹³ Traumatic pneumatoceles typically follow a benign clinical course and are treated with aggressive pain management, pulmonary toilet, and serial chest radiography to monitor for resolution of the lesion. If the patient has persistent fever or leukocytosis, however, chest CT is done to evaluate for an evolving abscess, because pneumatoceles may become infected. CT-guided catheter drainage may be required in such cases, because 25% of patients do not respond to antibiotic therapy alone. Surgery, ranging from partial resection to anatomic lobectomy, is indicated for unresolving complex pneumatoceles or infected lesions refractory to antibiotic therapy and drainage.

The most common complication after thoracic injury is development of an empyema. Management is based on CT diagnostic criteria.⁹⁴ Percutaneous drainage is indicated for a single loculation without appreciable rind. While fibrinolytics are often used for empyema there is a paucity of data to support their use. Early decortication via video-assisted thoracic surgery should be done promptly in patients with multiple loculations or a pleural rind of >1 cm.⁹⁵ Antibiotic treatment is based on definitive culture results, but presumptive antibiotics should cover MRSA in the SICU.

Esophagus Due to the proximity of the structures, esophageal injuries often occur with tracheobronchial injuries, particularly in cases of penetrating trauma. Operative options are based on the extent and location of esophageal injury. With sufficient mobilization, a primary single-layer end-to-end anastomosis may be performed after appropriate débridement. As with cervical repairs, if there are two suture lines in close approximation (trachea or bronchi and esophagus) interposition of a vascularized pedicle is warranted to prevent fistula formation. Perforations at the gastroesophageal junction may be treated with repair and Nissan fundoplication or, for destructive injuries, segmental resection and gastric pull-up. With large destructive injuries or delayed presentation of injuries, esophageal exclusion with wide drainage, diverting loop esophagostomy, and placement of a gastrostomy tube should be considered.

Chest Wall and Diaphragm Virtually all chest wall injuries, consisting of rib fractures and laceration of intercostal vessels, are treated nonoperatively with pain control, pulmonary toilet or ventilatory management, and drainage of the pleural

space as indicated. Early institution of effective pain control is essential. The authors advocate pre-emptive rib blocks with 0.25% bupivacaine hydrochloride (Marcaine) in the trauma bay, followed by thoracic wall pain catheters.⁹⁶ Epidural anesthesia is reserved for multiple segmental fractures. Persistent hemorrhage from a chest tube after blunt trauma most often is due to injured intercostal arteries; for unusual persistent bleeding (see Table 7-10), thoracotomy with direct ligation or angioembolization may be required to arrest hemorrhage. In cases of extensive flail chest segments or markedly displaced rib fractures, open reduction and internal fixation of the fracture with plates may be warranted. The current role of operative rib fixation remains controversial. Chest wall defects, particularly those seen with open pneumothorax, are repaired using local approximation of tissues or tissue transfer for coverage. Scapular and sternal fractures rarely require operative intervention but are markers for significant thoracoabdominal force during injury; significant displacement may benefit from sternal plating (Fig. 7-58). Careful examination and imaging should exclude associated injuries, including blunt cardiac injury and descending aortic tears. On the other hand, clavicle fractures often are isolated injuries and should be managed with pain control and immobilization. The exception is posterior dislocation of the clavicular head, which may injure the subclavian vessels.

Blunt diaphragmatic injuries usually result in a linear tear, and most injuries are large, whereas penetrating injuries are variable in size and location depending on the agent of injury.

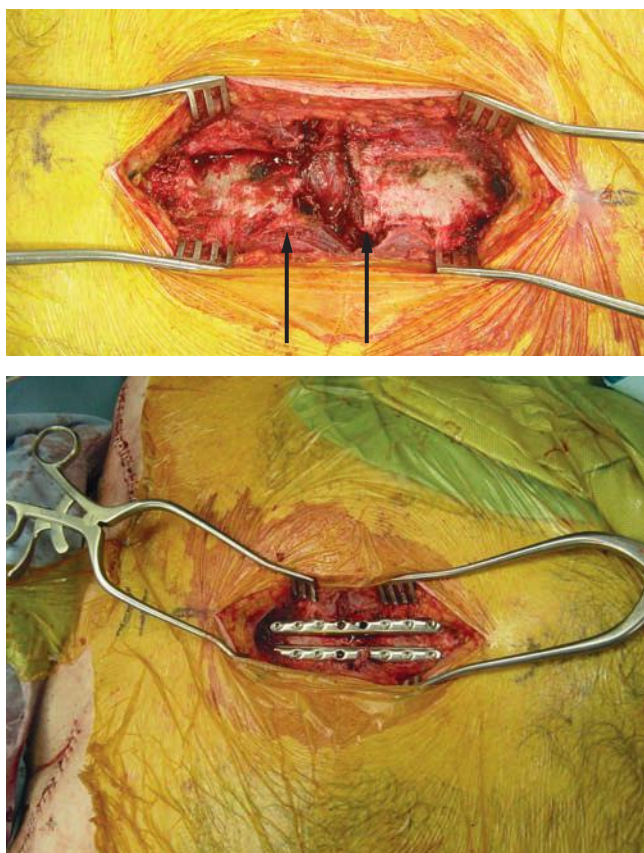


Figure 7-58. Significant sternal displacement (**A**; arrows) can be reduced and stabilized with sternal plating (**B**).

Regardless of the etiology, acute injuries are usually repaired through an abdominal approach to manage potential associated intraperitoneal visceral injury. After delineation of the injury, the chest should be evacuated of all blood and particulate matter, and thoracostomy tube placed if not previously done. Allis clamps are used to approximate the diaphragmatic edges, and the defect is closed with a running No. 1 polypropylene suture. Occasionally, large avulsions or shotgun wounds with extensive tissue loss will require polypropylene or biologic mesh to bridge the defect. Alternatively, transposition of the diaphragm cephalad one to two intercostal spaces may allow repair without undue tension.⁶¹

Abdominal Injuries

Liver and Extrahepatic Biliary Tract The liver's large size makes it the organ most susceptible to blunt trauma, and it is frequently involved in upper torso penetrating wounds. Nonoperative management of solid organ injuries is pursued in hemodynamically stable patients who do not have overt peritonitis or other indications for laparotomy. Patients with > grade II injuries should be admitted to the SICU with frequent hemodynamic monitoring, determination of hemoglobin, and abdominal examination. The only absolute contraindication to nonoperative management is hemodynamic instability. Factors such as high injury grade, large hemoperitoneum, contrast extravasation, or pseudoaneurysms may predict complications or failure of nonoperative management. Angioembolization and endoscopic retrograde cholangiopancreatography (ERCP) are useful adjuncts that can improve the success rate of nonoperative management.^{97,98} The indication for angiography to control hepatic hemorrhage is transfusion of 4 units of RBCs in 6 hours or 6 units of RBCs in 24 hours without hemodynamic instability.

In the 15% of patients for whom emergent laparotomy is mandated, the primary goal is to arrest hemorrhage. Initial control of hemorrhage is best accomplished using perihepatic packing and manual compression. With extensive injuries and major hemorrhage a Pringle maneuver should be done immediately. Intermittent release of the Pringle is helpful to attenuate hepatic cellular loss. In either case, the edges of the liver laceration should be opposed for local pressure control of bleeding. Hemorrhage from most major hepatic injuries can be controlled with effective perihepatic packing. The right costal margin is elevated, and the pads are strategically placed over and around the bleeding site (see Fig. 7-36). Additional pads should be placed between the liver, diaphragm, and anterior chest wall until the bleeding has been controlled. Sometimes 10 to 15 pads may be required to control the hemorrhage from an extensive right lobar injury. Packing of injuries of the left lobe is not as effective, because there is insufficient abdominal and thoracic wall anterior to the left lobe to provide adequate compression with the abdomen open. Fortunately, hemorrhage from the left lobe usually can be controlled by mobilizing the lobe and compressing it between the surgeon's hands. If the patient has persistent bleeding despite packing, injuries to the hepatic artery, portal vein, and retrohepatic vasculature should be considered. A Pringle maneuver can help delineate the source of hemorrhage. In fact, hemorrhage from hepatic artery and portal vein injuries will halt with the application of a vascular clamp across the portal triad; whereas, bleeding from the hepatic veins and retrohepatic vena cava will continue.

Injuries of the portal triad vasculature should be addressed immediately. In general, ligation from the celiac axis to the

level of the common hepatic artery at the gastroduodenal arterial branch is tolerated due to the extensive collaterals, but the proper hepatic artery should be repaired. The right or left hepatic artery, or in urgent situations the portal vein, may be selectively ligated; occasionally, lobar necrosis will necessitate delayed anatomic resection. If the right hepatic artery is ligated, cholecystectomy also should be performed. If the vascular injury is a stab wound with clean transection of the vessels, primary end-to-end repair is done. If the injury is destructive, temporary shunting should be performed followed by interposition reversed saphenous vein graft (RSVG). Blunt avulsions of the portal structures are particularly problematic if located at the hepatic plate, flush with the liver; hemorrhage control at the liver can be attempted with directed packing or Fogarty catheters. If the avulsion is more proximal, at the superior border of the pancreatic body or even retropancreatic, the pancreas must be transected to gain access for hemorrhage control and repair.

If massive venous hemorrhage is seen from behind the liver despite use of the Pringle maneuver, the patient likely has a hepatic vein or retrohepatic vena cava injury. If bleeding can be controlled with perihepatic packing, the packing should be left undisturbed and the patient observed in the SICU. Placement of a hepatic vein stent by interventional radiology may be considered. If bleeding continues despite repeated attempts at packing, then direct repair, with or without hepatic vascular isolation, should be attempted. Three techniques have been used to accomplish hepatic vascular isolation: (a) direct repair with suprahepatic and infrahepatic clamping of the vena cava and stapled assisted parenchymal resection;⁹⁹ (b) temporary shunting of the retrohepatic vena cava; and (c) venovenous bypass (Fig. 7-59).¹⁰⁰

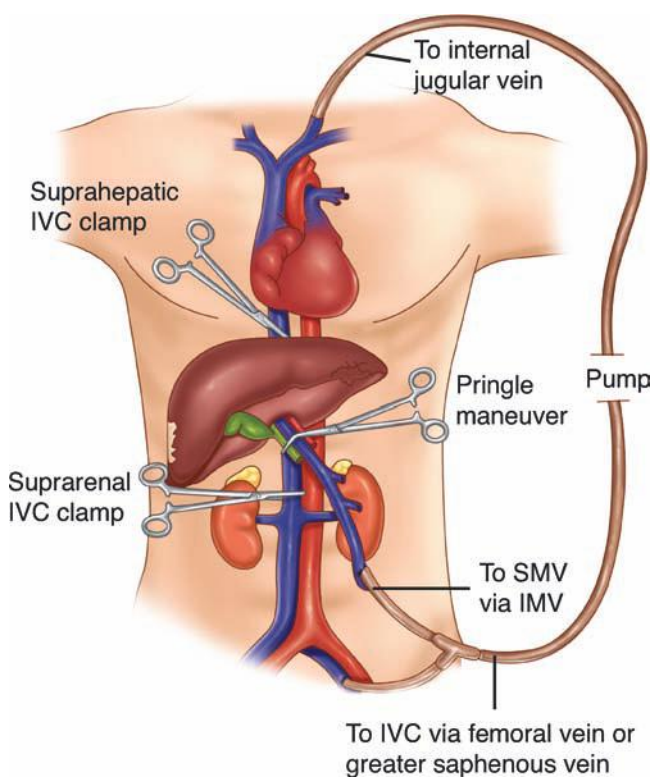


Figure 7-59. Venovenous bypass permits hepatic vascular isolation with continued venous return to the heart. IMV = inferior mesenteric vein; IVC = inferior vena cava; SMV = superior mesenteric vein.

Numerous methods for the definitive control of hepatic parenchymal hemorrhage have been developed. Minor lacerations may be controlled with manual compression applied directly to the injury site. Topical hemostatic techniques include the use of an electrocautery (with the device set at 100 watts), argon beam coagulator, microcrystalline collagen, thrombin-soaked gelatin foam sponge, fibrin glue, and BioGlue. Suturing of the hepatic parenchyma with a blunt tipped 0 chromic suture (e.g., a “liver suture”) can be an effective hemostatic technique. A running suture is used to approximate the edges of shallow lacerations, whereas deeper lacerations are approximated using interrupted horizontal mattress sutures placed parallel to the edge of the laceration. When the suture is tied, tension is adequate when visible hemorrhage ceases or the liver blanches around the suture. Caution must be used to prevent hepatic necrosis. This technique of placing large liver sutures controls bleeding through reapproximation of the liver laceration rather than direct ligation of bleeding vessels. Aggressive finger fracture to identify bleeding vessels followed by individual clip or suture ligation was advocated previously but currently has a limited role in hemostasis. Hepatic lobar arterial ligation may be appropriate for patients with recalcitrant arterial hemorrhage from deep within the liver and is a reasonable alternative to a deep hepatotomy, particularly in unstable patients. Omentum can be used to fill large defects in the liver. The tongue of omentum not only obliterates potential dead space with viable tissue but also provides an excellent source of macrophages. Additionally, the omentum can provide buttressing support for parenchymal sutures.

Translumbar penetrating injuries are particularly challenging, because the extent of the injury cannot be fully visualized. As discussed later in “Damage Control Surgery,” options include intraparenchymal tamponade with a Foley catheter or balloon occlusion (see Fig. 7-48).¹⁰¹ If tamponade is successful with either modality, the balloon is left inflated for 24 to 48 hours followed by sequential deflation and removal at a second laparotomy. Hepatotomy with ligation of individual bleeders occasionally may be required; however, division of the overlying viable hepatic tissue may cause considerable blood loss in the coagulopathic patient. Finally, angioembolization is an effective adjunct in any of these scenarios and should be considered early in the course of treatment.

Several centers have reported patients with devastating hepatic injuries or necrosis of the entire liver who have undergone successful hepatic transplantation.¹⁰² Clearly this is dramatic therapy, and the patient must have all other injuries delineated, particularly those of the central nervous system, and have an excellent chance of survival excluding the hepatic injury. Because donor availability will limit such procedures, hepatic transplantation for trauma will continue to be performed only in extraordinary circumstances.

Cholecystectomy is performed for injuries of the gallbladder and after operative ligation of the right hepatic artery. Injuries of the extrahepatic bile ducts are a challenge due to their small size and thin walls. Because of the proximity of other portal structures and the vena cava, associated vascular injuries are common. These factors may preclude primary repair. Small lacerations with no accompanying loss or devitalization of adjacent tissue can be treated by the insertion of a T tube through the wound or by lateral suturing using 6-0 monofilament absorbable suture. Virtually all transections and any injury associated with significant tissue loss will require a Roux-en-Y choledochojejunostomy.¹⁰³

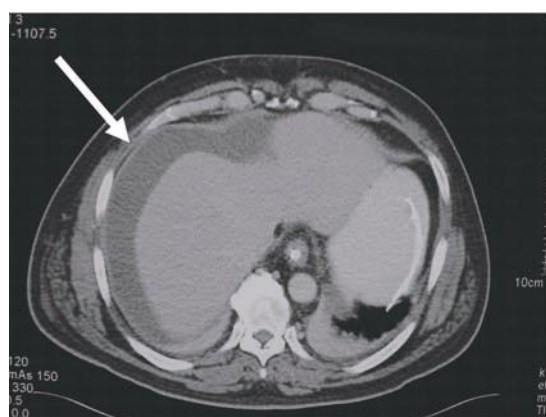The anastomosis is performed using a single-layer interrupted technique with 5-0 monofilament absorbable suture. To reduce anastomotic tension, the jejunum should be sutured to the areolar tissue of the hepatic pedicle or porta hepatis. Injuries of the hepatic ducts are almost impossible to satisfactorily repair under emergent circumstances. One approach is to intubate the duct for external drainage and attempt a repair when the patient recovers or attempt stenting via ERC. Alternatively, the duct can be ligated if the opposite lobe is normal and uninjured.

Patients undergoing perihepatic packing for extensive liver injuries typically are returned to the OR for pack removal 24 hours after initial injury. Earlier exploration may be indicated in patients with evidence of ongoing hemorrhage. Signs of rebleeding are usually conspicuous, and include a falling hemoglobin, accumulation of blood clots under the temporary abdominal closure device, and bloody output from drains; the magnitude of hemorrhage is reflected in ongoing hemodynamic instability and metabolic monitoring. Postoperative hemorrhage should be re-evaluated in the OR once the patient's coagulopathy is corrected. Alternatively, angioembolization is appropriate for complex injuries. Patients with hepatic ischemia due to prolonged intraoperative use of the Pringle maneuver have an expected elevation but subsequent resolution of transaminase levels, whereas patients requiring hepatic artery ligation may have frank hepatic necrosis. Although febrile patients should be

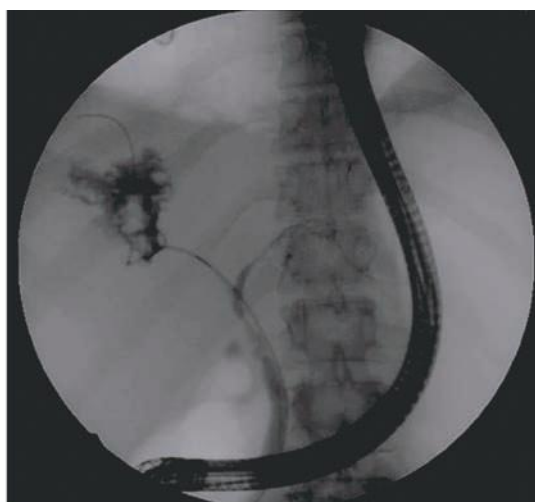
evaluated for infectious complications, patients with complex hepatic injuries typically have intermittent "liver fever" for the first 5 days after injury.

Aside from hemorrhage and hepatic necrosis, additional complications after significant hepatic trauma include bilomas, arterial pseudoaneurysms, and biliary fistulas (Fig. 7-60). Bilomas are loculated collections of bile, which may or may not be infected. If infected, they should be treated like an abscess via percutaneous drainage. Although small, sterile bilomas eventually will be reabsorbed, larger fluid collections should be drained. Biliary ascites, due to the disruption of a major bile duct, often requires reoperation and wide drainage. Primary repair of the injured intrahepatic duct is unlikely to be successful. Resectional débridement is indicated for the removal of peripheral portions of nonviable hepatic parenchyma.

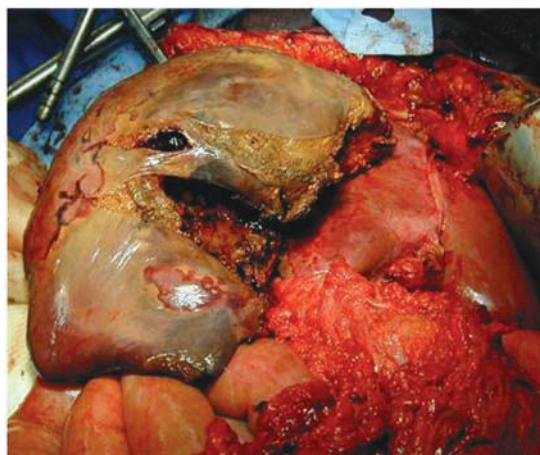
Pseudoaneurysms and biliary fistulas are rare complications in patients with hepatic injuries. Because hemorrhage from hepatic injuries often is treated without isolating individual bleeding vessels, arterial pseudoaneurysms may develop, with the potential for rupture. Rupture into a bile duct results in hemobilia, which is characterized by intermittent episodes of right upper quadrant pain, upper GI hemorrhage, and jaundice. If the aneurysm ruptures into a portal vein, portal venous hypertension with bleeding esophageal varices may occur. Either scenario is best managed with hepatic arteriography and



A



B



C

Figure 7-60. Complications after hepatic trauma include bilomas (A; arrow), hepatic duct injuries (B), and hepatic necrosis after hepatic artery ligation or embolization (C).

embolization. Biliovenous fistulas, causing jaundice due to rapid increases in serum bilirubin levels, should be treated with ERCP and sphincterotomy. Rarely, a biliary fistulous communication will form with intrathoracic structures in patients with associated diaphragm injuries, resulting in a bronchobiliary or pleurobiliary fistula. Due to the pressure differential between the biliary tract (positive) and the pleural cavity (negative), the majority require operative closure. Occasionally, endoscopic sphincterotomy with stent placement will be required to address the pressure differential, and the pleurobiliary fistula will close spontaneously.

Spleen Until the 1970s, splenectomy was considered mandatory for all splenic injuries. Recognition of the immune function of the spleen refocused efforts on operative splenic salvage in the 1980s.^{104,105} After demonstrated success in pediatric patients, however, nonoperative management has become the preferred means of splenic salvage. The identification of contrast extravasation as a risk factor for failure of nonoperative management led to liberal use of angioembolization. The role of selective angioembolization (SAE) in splenic salvage remains controversial with some groups advocating pre-emptive SAE.¹⁰⁶ It is clear, however, that up to 20% of patients with splenic trauma warrant early splenectomy and that failure of nonoperative management often represents inappropriate patient selection.^{107,108} Unlike hepatic injuries, which usually rebleed within 48 hours, delayed hemorrhage or rupture of the spleen can occur up to weeks after injury. Indications for early intervention include initiation of blood transfusion within the first 12 hours and hemodynamic instability.

Splenic injuries are managed operatively by splenectomy, partial splenectomy, or splenic repair (splenorrhaphy), based on the extent of the injury and the physiologic condition of the patient. Splenectomy is indicated for hilar injuries, pulverized splenic parenchyma, or any >grade II injury in a patient with coagulopathy or multiple injuries. The authors use autotransplantation of splenic implants (Fig. 7-61) to achieve partial immunocompetence in younger patients who do not have an associated enteric injury. Drains are not used. Partial splenectomy can be employed in patients in whom only the superior or inferior pole has been injured. Hemorrhage from the raw splenic

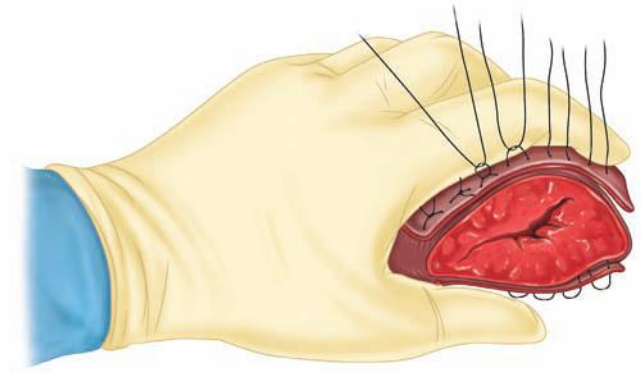


Figure 7-62. Interrupted pledgeted sutures may effectively control hemorrhage from the cut edge of the spleen.

edge is controlled with horizontal mattress sutures, with gentle compression of the parenchyma (Fig. 7-62). As with hepatic injuries, splenorrhaphy hemostasis is achieved by topical methods (electrocautery; argon beam coagulation; application of thrombin-soaked gelatin foam sponges, fibrin glue, or BioGlue), envelopment of the injured spleen in absorbable mesh, and pledgeted suture repair.

After splenectomy or splenorrhaphy, postoperative hemorrhage may be due to loosening of a tie around the splenic vessels, an improperly ligated or unrecognized short gastric artery, or recurrent bleeding from the spleen if splenic repair was used. An immediate postsplenectomy increase in platelets and WBCs is normal; however, beyond postoperative day 5, a WBC count above 15,000/mm³ and a platelet/WBC ratio of <20 are strongly associated with sepsis and should prompt a thorough search for underlying infection.¹⁰⁹ A common infectious complication after splenectomy is a subphrenic abscess, which should be managed with percutaneous drainage. Additional sources of morbidity include a concurrent but unrecognized iatrogenic injury to the pancreatic tail during rapid splenectomy resulting in pancreatic ascites or fistula, and a gastric perforation during short gastric ligation. Enthusiasm for splenic salvage was driven by the rare, but often fatal, complication of overwhelming postsplenectomy

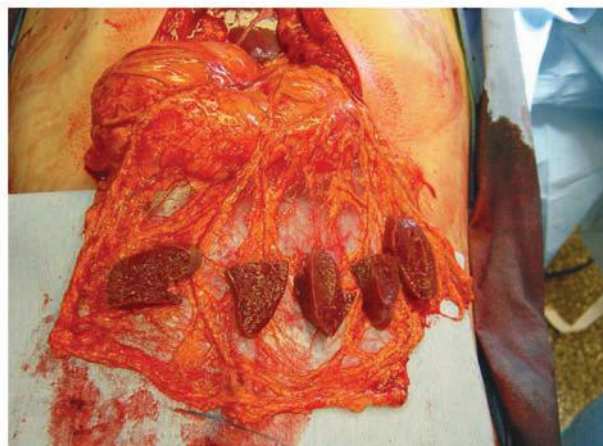
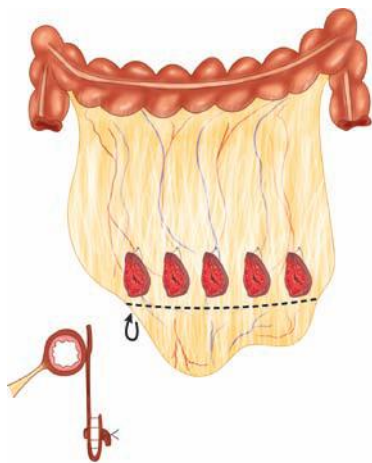


Figure 7-61. Autologous splenic transplantation is performed by placing sections of splenic parenchyma, 40 × 40 × 3 mm in size, into pouches in the greater omentum.

sepsis. Overwhelming postsplenectomy sepsis is caused by encapsulated bacteria, *Streptococcus pneumoniae*, *Haemophilus influenzae*, and *Neisseria meningitidis*, which are resistant to antimicrobial treatment. In patients undergoing splenectomy, prophylaxis against these bacteria is provided via vaccines administered optimally at 14 days.¹¹⁰

Stomach and Small Intestine Little controversy exists regarding the repair of injuries to the stomach or small bowel because of a rich blood supply. Gastric wounds can be oversewn with a running single-layer suture line or closed with a stapler. If a single-layer closure is chosen, full-thickness bites should be taken to ensure hemostasis from the well-vascularized gastric wall. The most commonly missed gastric injury is the posterior wound of a totally penetrating injury. Injuries also can be overlooked if the wound is located within the mesentery of the lesser curvature or high in the posterior fundus. To delineate a questionable injury, the stomach can be digitally occluded at the pylorus while methylene blue-colored saline is instilled via a nasogastric tube. Alternatively, air can be introduced via the NG tube with the abdomen filled with saline. Partial gastrectomy may be required for destructive injuries, with resections of the distal antrum or pylorus reconstructed using a Billroth procedure. Patients with injuries that damage both Latarjet nerves or vagi should undergo a drainage procedure (see Chap. 26). Small intestine injuries can be repaired using a transverse running 3-0 PDS suture if the injury is less than one-third the circumference of the bowel. Destructive injuries or multiple penetrating injuries occurring close together are treated with segmental resection followed by end-to-end anastomosis using a continuous, single-layer 3-0 polypropylene suture.¹¹¹ Mesenteric injuries may result in an ischemic segment of intestine, which mandates resection.

Following repair of GI tract injuries, there is an obligatory postoperative ileus. Return of bowel function is indicated by a decrease in gastrostomy or nasogastric tube output. The topic of nutrition is well covered in other chapters, but a few issues warrant mention. Multiple studies have confirmed the importance of early total enteral nutrition (TEN) in the trauma population, particularly its impact in reducing septic complications.¹¹² The route of enteral feedings (stomach vs. small bowel) tends to be less important, because gut tolerance appears equivalent unless there is upper GI tract pathology. Although early enteral nutrition is the goal, evidence of bowel function should be apparent before advancing to goal tube feedings. Overzealous jejunal feeding can lead to small bowel necrosis in the patient recovering from profound shock. Patients undergoing monitoring for nonoperative management of grade II or higher solid organ injuries should receive nothing by mouth for at least 48 hours in case they require an operation. Although there is general reluctance to initiate TEN in patients with an open abdomen, a recent multicenter trial demonstrates TEN in the postinjury open abdomen is feasible.¹¹³ For those patients without a bowel injury, TEN was associated with higher fascial closure rates, decreased complications, and decreased mortality. TEN in patients with bowel injuries does not appear to alter fascial closure rates, complications, or mortality; hence EN appears to be neither advantageous nor detrimental in these patients. Prospective randomized controlled trials are warranted to further clarify the role of EN in this subgroup. Once resuscitation is complete, initiation of TEN, even at trophic levels (20 mL/h), should be considered in all injured patients with an open abdomen.

Duodenum and Pancreas The spectrum of injuries to the duodenum includes hematomas, perforation (blunt blow-outs, lacerations from stab wounds, or blast injury from gunshot wounds), and combined pancreaticoduodenal injuries. The majority of duodenal hematomas are managed nonoperatively with nasogastric suction and parenteral nutrition. Patients with suspected associated perforation, suggested by clinical deterioration or imaging with retroperitoneal free air or contrast extravasation, should undergo operative exploration. A marked drop in nasogastric tube output heralds resolution of the hematoma, which typically occurs within 2 weeks; repeat imaging to confirm these clinical findings is optional. If the patient shows no clinical or radiographic improvement within 3 weeks, operative evaluation is warranted.

Small duodenal perforations or lacerations should be treated by primary repair using a running single-layer suture of 3-0 monofilament. The wound should be closed in a direction that results in the largest residual lumen. Challenges arise when there is a substantial loss of duodenal tissue. Extensive injuries of the first portion of the duodenum (proximal to the duct of Santorini) can be repaired by débridement and end-to-end anastomosis because of the mobility and rich blood supply of the distal gastric atrium and pylorus. In contrast, the second portion is tethered to the head of the pancreas by its blood supply and the ducts of Wirsung and Santorini; therefore, no more than 1 cm of duodenum can be mobilized away from the pancreas, and this does not effectively alleviate tension on the suture line. Moreover, suture repair using an end-to-end anastomosis in the second portion often results in an unacceptably narrow lumen. Therefore, defects in the second portion of the duodenum should be patched with a vascularized jejunal graft. Duodenal injuries with tissue loss distal to the papilla of Vater and proximal to the superior mesenteric vessels are best treated by Roux-en-Y duodenojejunostomy with the distal portion of the duodenum oversewn (Fig. 7-63). In particular, injuries in the distal third and fourth portions of the duodenum (behind the mesenteric vessels) should be resected, and a duodenojejunostomy performed on the left side of the superior mesenteric vessels.

Optimal management of pancreatic trauma is determined by where the parenchymal damage is located and whether the intrapancreatic common bile duct and main pancreatic duct remain intact. Patients with pancreatic contusions (defined as injuries that leave the ductal system intact) can be treated nonoperatively or with closed suction drainage if undergoing laparotomy for other indications. Patients with proximal pancreatic injuries, defined as those that lie to the right of the superior mesenteric vessels, are also managed with closed suction drainage.¹¹⁴ In contrast, distal pancreatic injuries are managed based upon ductal integrity. Pancreatic duct disruption can be identified through direct exploration of the parenchymal laceration, operative pancreatography, ERCP, or magnetic resonance cholangiopancreatography. Patients with distal ductal disruption undergo distal pancreatectomy, preferably with splenic preservation.

Injuries to the pancreatic head add an additional element of complexity because the intrapancreatic portion of the common bile duct traverses this area and often converges with the pancreatic duct. In contrast to diagnosis of pancreatic duct injuries, identification of intrapancreatic common bile duct disruption is relatively simple. The first method is to squeeze the gallbladder and look for bile leaking from the pancreatic wound. Otherwise,

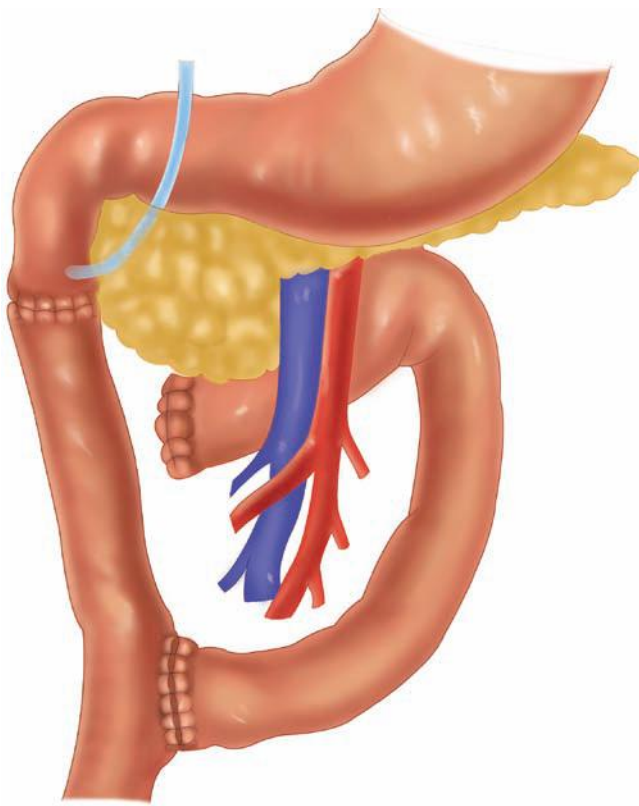


Figure 7-63. Roux-en-Y duodenojejunostomy is used to treat duodenal injuries between the papilla of Vater and superior mesenteric vessels when tissue loss precludes primary repair.

cholangiography, optimally via the cystic duct, is diagnostic. Definitive treatment of this injury entails division of the common bile duct superior to the first portion of the duodenum, with ligation of the distal duct and reconstruction with a Roux-en-Y choledochojejunostomy. For injuries to the head of the pancreas that involve the main pancreatic duct but not the intrapancreatic bile duct, there are few options. Distal pancreatectomy alone is rarely indicated due to the extended resection of normal gland and the resultant risk of pancreatic insufficiency. Central pancreatectomy preserves the common bile duct, and mobilization of the pancreatic body permits drainage into a Roux-en-Y pancreaticojejunostomy (Fig. 7-64). Although this approach avoids a pancreaticoduodenectomy (Whipple procedure), the complexity may make the pancreaticoduodenectomy more appropriate in patients with multiple injuries. Some injuries of the pancreatic head do not involve either the pancreatic or common bile duct; if no clear ductal injury is present, drains are placed. Rarely, patients sustain destructive injuries to the head of the pancreas or combined pancreaticoduodenal injuries that require pancreaticoduodenectomy. Examples of such injuries include transection of both the intrapancreatic bile duct and the main pancreatic duct in the head of the pancreas, avulsion of the papilla of Vater from the duodenum, and destruction of the entire second portion of the duodenum. In these cases of extensive injuries, damage control principles are often employed.

In contrast to proximal injuries, pancreatic resection continues to be advocated for major ductal disruption in the more distal pancreas. Several options exist for treating injuries of the pancreatic body and tail. In stable patients, spleen-preserving distal pancreatectomy should be performed. An alternative,

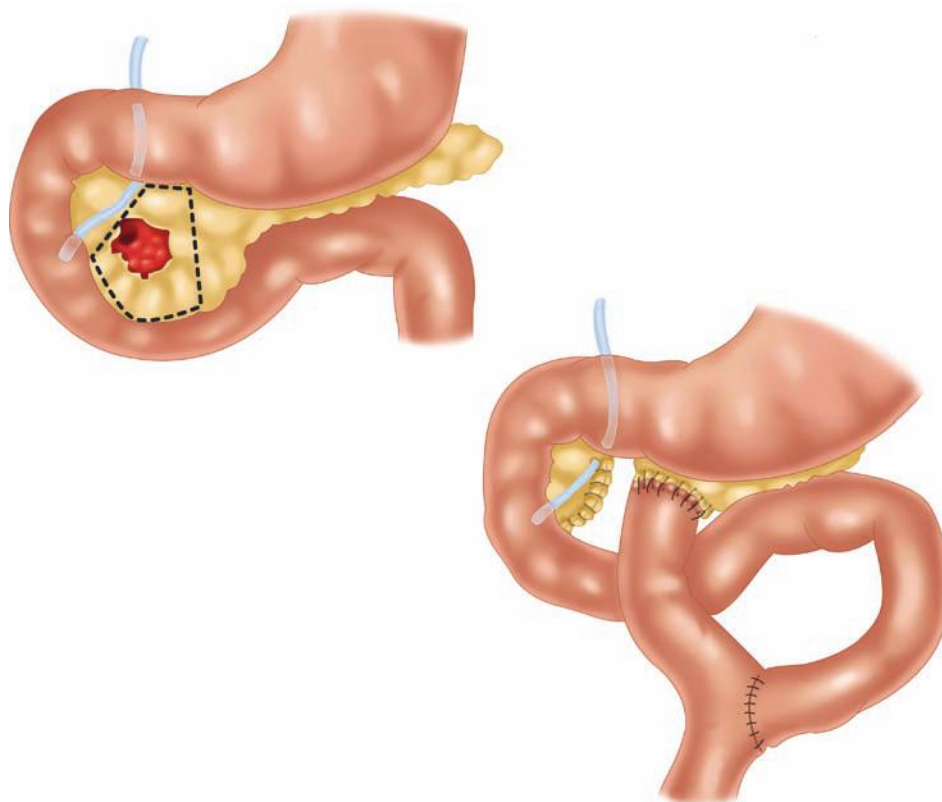


Figure 7-64. For injuries of the pancreatic head that involve the pancreatic duct but spare the common bile duct, central pancreatic resection with Roux-en-Y pancreaticojejunostomy prevents pancreatic insufficiency.

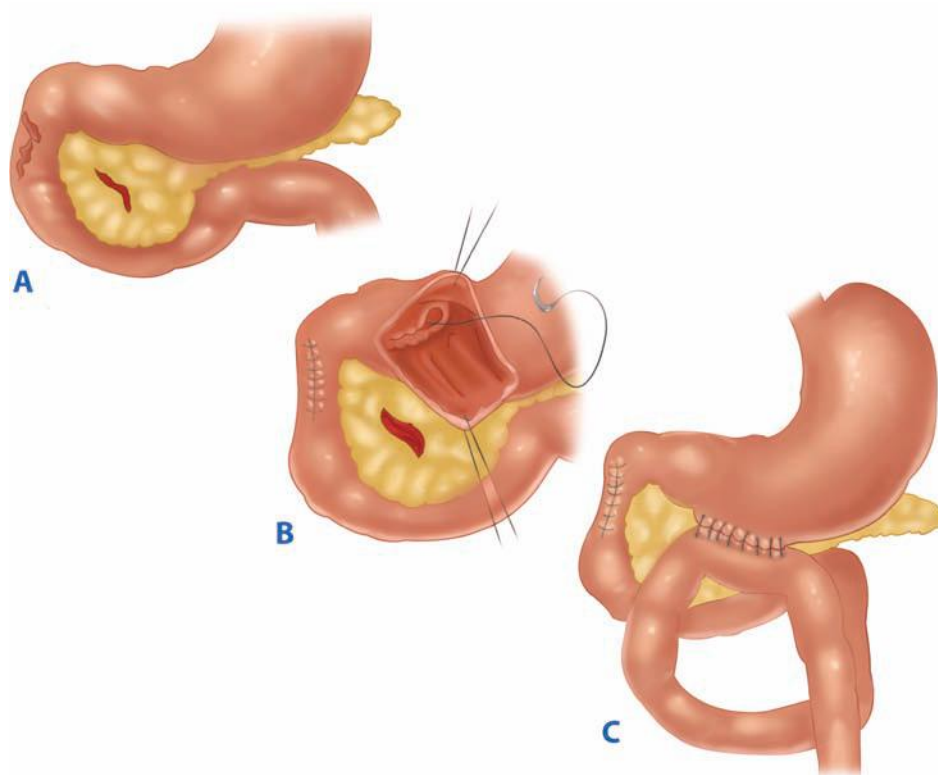


Figure 7-65. A. Pyloric exclusion is used to treat combined injuries of the duodenum and the head of the pancreas as well as isolated duodenal injuries when the duodenal repair is less than optimal. B and C. The pylorus is oversewn through a gastrotomy, which is subsequently used to create a gastrojejunostomy. The authors frequently use needle-catheter jejunostomy tube feedings for these patients.

which preserves both the spleen and distal transected end of the pancreas, is either a Roux-en-Y pancreaticojejunostomy or pancreaticogastrostomy. If the patient is physiologically compromised, distal pancreatectomy with splenectomy is the preferred approach. Regardless of the choice of definitive procedure, the pancreatic duct in the proximal edge of transected pancreas should be individually ligated or occluded with a TA stapler. Application of fibrin glue over the stump may be advantageous.

Pyloric exclusion often is used to divert the GI stream after high-risk, complex duodenal repairs (Fig. 7-65).¹¹⁵ If the duodenal repair breaks down, the resultant fistula is an end fistula, which is easier to manage and more likely to close than a lateral fistula. To perform a pyloric exclusion, first a gastrotomy is made on the greater curvature near the pylorus. The pylorus is then grasped with a Babcock clamp, via the gastrotomy, and oversewn with an O polypropylene suture. A gastrojejunostomy restores GI tract continuity. Vagotomy is not necessary because a risk of marginal ulceration has not been documented. Perhaps surprisingly, the sutures maintain diversion for only 3 to 4 weeks. Alternatively, the most durable pyloric closure is a double external staple line across the pylorus using a TA stapler.

Complications should be expected after major pancreaticoduodenal injuries. Delayed hemorrhage is rare but may occur with pancreatic necrosis or abdominal infection; this usually can be managed by angioembolization. If closed suction drains have been inserted for major pancreatic trauma, these should remain in place until the patient is tolerating an oral diet or enteral nutrition. Pancreatic fistula is diagnosed after postoperative day 5 in patients with drain output of >30 mL/d and a drain amylase

level three times the serum value. Pancreatic fistula develops in over 20% of patients with combined injuries and should be managed similar to fistulas after elective surgery (see Chap. 33). Similarly, a duodenal fistula, presumptively an end fistula if a pyloric exclusion has been done, will typically heal in 6 to 8 weeks with adequate drainage and control of intra-abdominal sepsis. Pancreatic pseudocysts in patients managed nonoperatively suggest a missed injury, and ERCP should be done to evaluate the integrity of the pancreatic duct. Late pseudocysts may be a complication of operative management and are treated much like those in patients with pancreatitis (see Chap. 33). Intra-abdominal abscesses are common and routinely managed with percutaneous drainage.

Colon and Rectum Currently, three methods for treating colonic injuries are used: primary repair, end colostomy, and primary repair with diverting ileostomy. Primary repairs include lateral suture repair or resection of the damaged segment with reconstruction by ileocolostomy or colocolostomy. All suturing and anastomoses are performed using a running single-layer technique (Fig. 7-66).¹¹¹ The advantage of definitive treatment must be balanced against the possibility of anastomotic leakage if suture lines are created under suboptimal conditions. Alternatively, although use of an end colostomy requires a second operation, an unprotected suture line with the potential for breakdown is avoided. Numerous large retrospective and several prospective studies have now clearly demonstrated that primary repair is safe and effective in virtually all patients with penetrating wounds.¹¹⁶ Colostomy is still appropriate in a

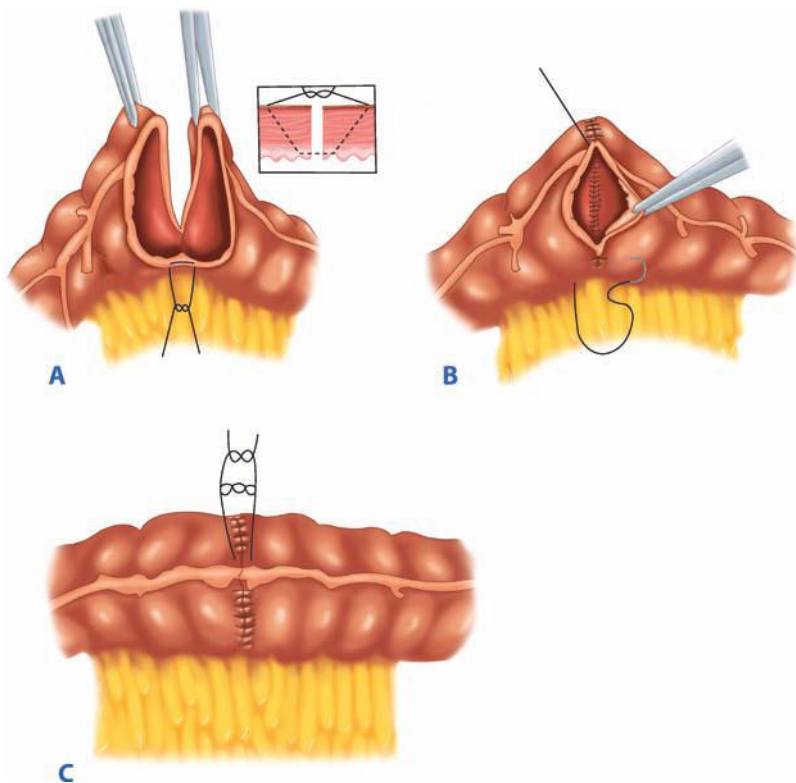


Figure 7-66. Technique for bowel repair and anastomosis. **A.** The running, single-layer suture is started at the mesenteric border. **B.** Stitches are spaced 3 to 4 mm from the edge of the bowel and advanced 3 to 4 mm, including all layers except the mucosa. **C.** The continuous suture is tied near the antimesenteric border.

few patients, but the current dilemma is how to select which patients should undergo the procedure. Currently, the overall physiologic status of the patient, rather than local factors, directs decision making. Patients with devastating left colon injuries requiring damage control are clearly candidates for temporary colostomy. Diverting ileostomy with colocolostomy, however, is used for most other high-risk patients.

Rectal injuries are similar to colonic injuries with respect to the ecology of the luminal contents, overall structure, and blood supply of the wall, but access to extraperitoneal injuries is limited due to the surrounding bony pelvis. Therefore, indirect treatment with intestinal diversion usually is required. The current options are loop ileostomy and sigmoid loop colostomy. These are preferred because they are quick and easy to perform, and provide essentially total fecal diversion. For sigmoid colostomy, technical elements include: (a) adequate mobilization of the sigmoid colon so that the loop will rest on the abdominal wall without tension, (b) maintenance of the spur of the colostomy (the common wall of the proximal and distal limbs after maturation) above the level of the skin with a one-half-inch nylon rod or similar device, (c) longitudinal incision in the tenia coli, and (d) immediate maturation in the OR (Fig. 7-67). If the injury is accessible (e.g., in the posterior intraperitoneal portion of the rectum), repair of the injury should also be attempted. However, it is not necessary to explore the extraperitoneal rectum to repair a distal perforation. If the rectal injury is extensive, another option is to divide the rectum at the level of the injury, oversew or staple the distal rectal pouch if possible, and create an end colostomy (Hartmann's procedure). Extensive injuries may warrant presacral drainage with Penrose drains placed along Waldeyer's fascia via a perianal incision (see Fig. 7-67). In rare instances in which destructive injuries are present, an abdominoperineal resection may be necessary to avert lethal pelvic sepsis.

Complications related to colorectal injuries include intra-abdominal abscess, fecal fistula, wound infection, and stomal complications. Intra-abdominal abscesses occur in approximately 10% of patients, and most are managed with percutaneous drainage. Fistulas occur in 1% to 3% of patients and usually present as an abscess or wound infection with subsequent continuous drainage of fecal output; the majority will heal spontaneously with routine care (see Chap. 29). Stomal complications (necrosis, stenosis, obstruction, and prolapse) occur in 5% of patients and may require either immediate or delayed reoperation. Stomal necrosis should be carefully monitored, because spread beyond the mucosa may result in septic complications, including necrotizing fasciitis of the abdominal wall. Penetrating injuries that involve both the rectum and adjacent bony structures are prone to development of osteomyelitis. Bone biopsy is performed for diagnosis and bacteriologic analysis, and treatment entails long-term IV antibiotic therapy and occasionally débridement.

Abdominal and Pelvic Vasculature Injury to the major arteries and veins in the abdomen can be a technical challenge.¹¹⁷⁻¹²¹ Although penetrating trauma indiscriminately affects all blood vessels, blunt trauma most commonly involves renal vasculature and occasionally the abdominal aorta. Patients with a penetrating aortic wound who survive to reach the OR frequently have a contained hematoma within the retroperitoneum. Due to lack of mobility of the abdominal aorta, few injuries are amenable to primary repair. Small lateral perforations may be controlled with 4-0 polypropylene suture or a PTFE patch, but end-to-end interposition grafting with a PTFE tube graft is the most common repair. Blunt injuries are typically extensive intimal tears of the infrarenal aorta and are exposed via a direct approach; most require an interposition graft. To avoid future vascular-enteric fistulas, the vascular suture lines should be covered with omentum.

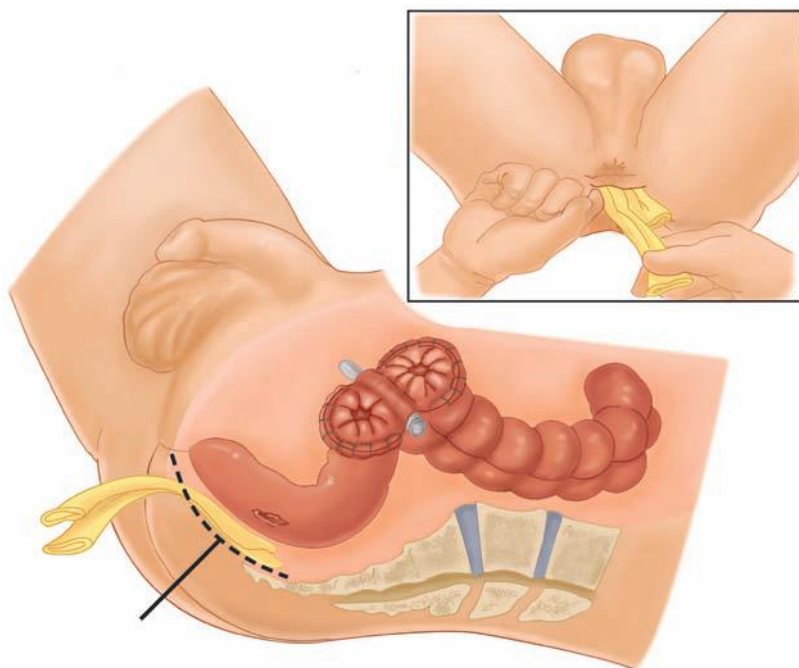


Figure 7-67. Loop colostomy will completely divert the fecal flow, allowing the low rectal injury to heal. For extensive wounds, presacral drains are inserted through a perianal incision (*box*) and advanced along Waldeyer's fascia (*dashed line*).

Penetrating wounds to the superior mesenteric artery (SMA) are typically encountered upon exploration for a gunshot wound, with “black bowel” and associated supramesocolic hematoma being pathognomonic. Blunt avulsions of the SMA are rare but should be considered in patients with a seat belt sign who have midepigastria pain or tenderness and associated hypotension. For injuries of the SMA, temporary damage control with a Pruitt-Inahara shunt can prevent extensive bowel necrosis; additionally, temporary shunting allows control of visceral contamination before placement of a PTFE graft. For definitive repair, end-to-end interposition RSVG from the proximal SMA to the SMA past the point of injury can be performed if there is no associated pancreatic injury. Alternatively, if the patient has an associated pancreatic injury, the graft should be tunneled from the distal aorta beneath the duodenum to the distal SMA. For proximal SMV injuries, digital compression for hemorrhage control is followed by attempted venorrhaphy; ligation is an option in a life-threatening situation, but the resultant bowel edema requires aggressive fluid resuscitation. Temporary abdominal closure and a second-look operation to evaluate bowel viability should be done.

Transpelvic gunshot wounds or blunt injuries with associated pelvic fractures are the most common scenarios in patients with iliac artery injuries. As with abdominal vascular injuries, a Pruitt-Inahara shunt can be used for temporary shunting of the vessel for damage control. Definitive interposition grafting with excision of the injured segment is appropriate (see “Vascular Repair Techniques”). Careful monitoring for distal embolic events and reperfusion injury necessitating fasciotomy is imperative.

In general, outcome after pelvic vascular injuries is related to (a) the technical success of the vascular reconstruction and (b) associated soft tissue and nerve injuries. Vascular repairs rarely fail after the first 12 hours, whereas, soft tissue infection is a limb threat for several weeks. Following aortic interposition grafting, the patient's SBP should not exceed 120 mm Hg for at least the first 72 hours postoperatively. Patients requiring

ligation of an inferior vena cava injury often develop marked bilateral lower extremity edema. To limit the associated morbidity the patient's legs should be wrapped with elastic bandages from the toes to the hips and elevated at a 45- to 60-degree angle. For superior mesenteric vein injuries, either ligation or thrombosis after venorrhaphy results in marked bowel edema; fluid resuscitation should be aggressive and abdominal pressure monitoring routine in these patients. Prosthetic graft infections are rare complications, but prevention of bacteremia is imperative⁶⁷; administration of antibiotics perioperatively and treatment of secondary infections is indicated. Long-term arterial graft complications such as stenosis or pseudoaneurysms are uncommon, and routine graft surveillance rarely is performed. Consequently, long-term administration of antiplatelet agents or antithrombotics is not routine.

Genitourinary Tract When undergoing laparotomy for trauma, the best policy is to explore all penetrating wounds to the kidneys.¹²² Parenchymal renal injuries are treated with hemostatic and reconstructive techniques similar to those used for injuries of the liver and spleen: topical methods (electrocautery; argon beam coagulation; application of thrombin-soaked gelatin foam sponge, fibrin glue, or BioGlue) and pledgeted suture repair. Two caveats are recognized, however: The collecting system should be closed separately, and the renal capsule should be preserved to close over the repair of the collecting system (Fig. 7-68). Renal vascular injuries are common after penetrating trauma and may be deceptively tamponaded, which results in delayed hemorrhage. Arterial reconstruction using graft interposition should be attempted for renal preservation. For destructive parenchymal or irreparable renovascular injuries, nephrectomy may be the only option; a normal contralateral kidney must be palpated, because unilateral renal agenesis occurs in 0.1% of patients.

Over 90% of blunt renal injuries are treated nonoperatively. Hematuria typically resolves within a few days with bed rest, although rarely bleeding is so persistent that bladder

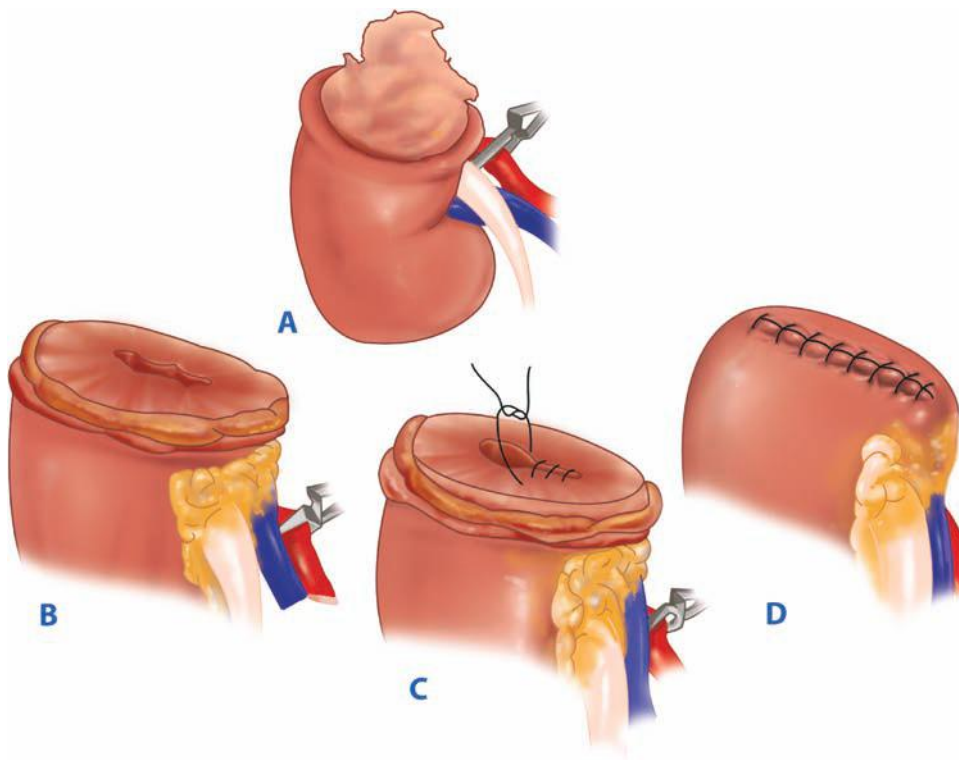


Figure 7-68. When renorrhaphy is undertaken, effective repair is assisted by attention to several key points: **A.** Vascular occlusion controls bleeding and permits adequate visualization. **B.** The renal capsule is carefully preserved. **C.** The collecting system is closed separately with absorbable suture. **D.** The preserved capsule is closed over the collecting system repair.

irrigation to dispel blood clots is warranted. Persistent gross hematuria may require embolization, whereas urinomas can be drained percutaneously. Operative intervention after blunt trauma is limited to renovascular injuries and destructive parenchymal injuries that result in hypotension. The renal arteries and veins are uniquely susceptible to traction injury caused by blunt trauma. As the artery is stretched, the inelastic intima and media may rupture, which causes thrombus formation and resultant stenosis or occlusion. The success rate for renal artery repair approaches 0%, but an attempt is reasonable if the injury is <5 hours old or if the patient has a solitary kidney or bilateral injuries.¹²³ Image-guided endostent placement is now employed for many of these injuries recognized by CT scanning. Reconstruction after blunt renal injuries may be difficult, however, because the injury is typically at the level of the aorta. If repair is not possible within this time frame, leaving the kidney in situ does not necessarily lead to hypertension or abscess formation. The renal vein may be torn or completely avulsed from the vena cava due to blunt trauma. Typically, the large hematoma causes hypotension, which leads to operative intervention. During laparotomy for blunt trauma, expanding or pulsatile perinephric hematomas should be explored. If necessary, emergent vascular control can be obtained by placing a curved vascular clamp across the hilum from an inferior approach. Techniques of repair and hemostasis are similar to those described earlier.

Injuries to the ureters are uncommon but may occur in patients with pelvic fractures and penetrating trauma. An injury may not be identified until a complication (i.e., a urinoma) becomes apparent. If an injury is suspected during operative exploration but is not clearly identified, methylene blue or indigo carmine is administered IV with observation for extravasation. Injuries are repaired using 5-0 absorbable monofilament, and mobilization of the kidney may reduce

tension on the anastomosis. Distal ureteral injuries can be treated by reimplantation facilitated with a psoas hitch and/or Boari flap. In damage control circumstances, the ureter can be ligated on both sides of the injury and a nephrostomy tube placed.

Bladder injuries are subdivided into those with intraperitoneal extravasation and those with extraperitoneal extravasation. Ruptures or lacerations of the intraperitoneal bladder are operatively closed with a running, single-layer, 3-0 absorbable monofilament suture. Laparoscopic repair is becoming common in patients not requiring laparotomy for other injuries. Extraperitoneal ruptures are treated nonoperatively with bladder decompression for 2 weeks. Urethral injuries are managed by bridging the defect with a Foley catheter, with or without direct suture repair. Strictures are not uncommon but can be managed electively.

Female Reproductive Tract Gynecologic injuries are rare. Occasionally the vaginal wall will be lacerated by a bone fragment from a pelvic fracture. Although repair is not mandated, it should be performed if physiologically feasible. More important, however, is recognition of the open fracture, need for possible drainage, and potential for pelvic sepsis. Penetrating injuries to the vagina, uterus, fallopian tubes, and ovaries are also uncommon, and routine hemostatic techniques are used. Repair of a transected fallopian tube can be attempted but probably is unjustified, because a suboptimal repair will increase the risk of tubal pregnancy. Transection at the injury site with proximal ligation and distal salpingectomy is a more prudent approach.

Pelvic Fracture Hemorrhage Control

Patients with pelvic fractures who are hemodynamically unstable are a diagnostic and therapeutic challenge for the trauma team. These injuries often occur in conjunction with other life-threatening injuries, and there is no universal agreement

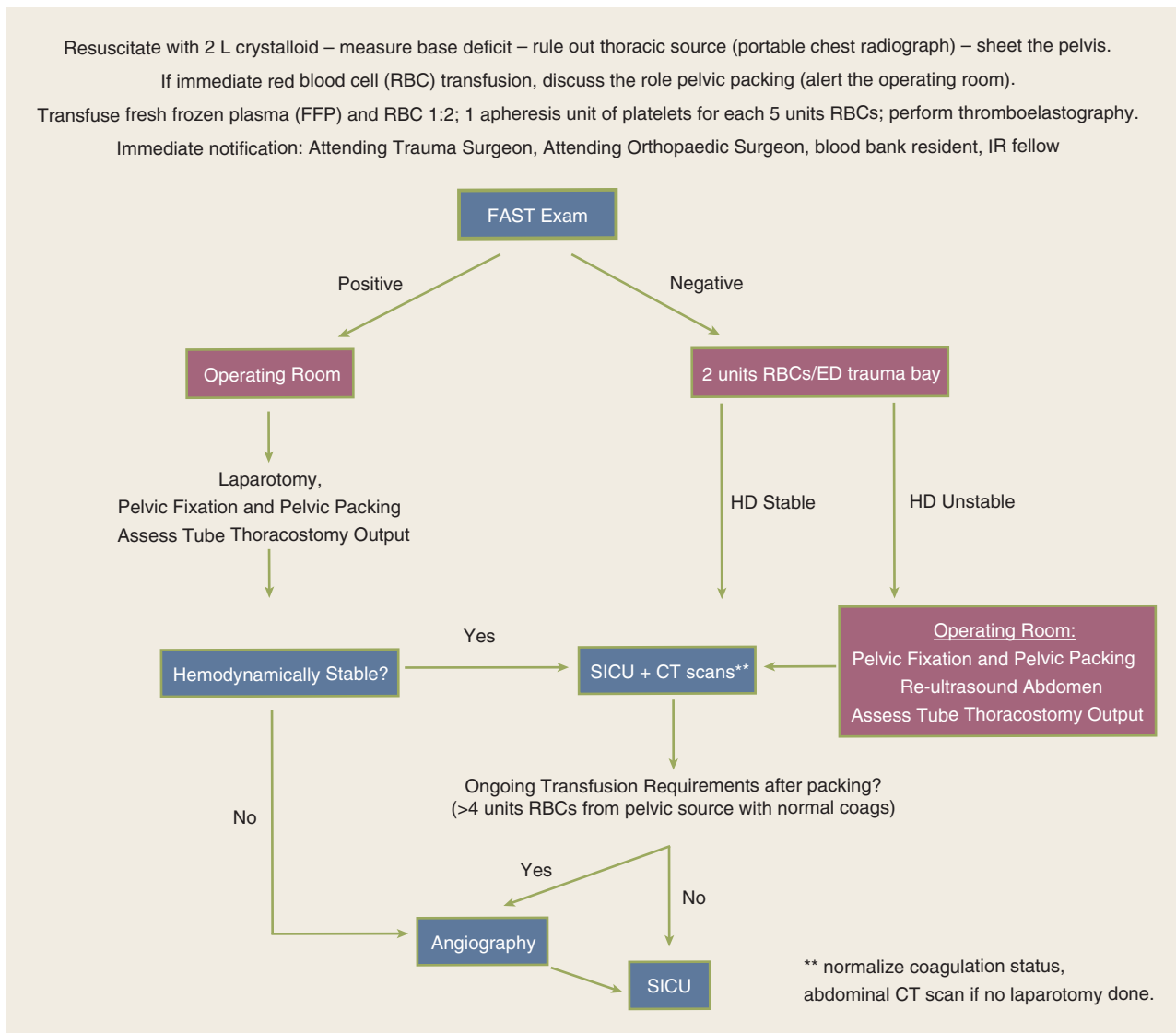


Figure 7-69. Management algorithm for patients with pelvic fractures with hemodynamic instability. CT = computed tomography; ED = emergency department; FAST = focused abdominal sonography for trauma; HD = hemodynamic; PLT = platelets; PRBCs = packed red blood cells; SICU = surgical intensive care unit.

among clinicians on management. Current management algorithms in the United States incorporate variable time frames for bony stabilization and fixation, as well as hemorrhage control by preperitoneal pelvic packing and/or angioembolization. Early institution of a multidisciplinary approach with the involvement of trauma surgeons, orthopedic surgeons, interventional radiologists, the director of the blood bank, and anesthesiologists is imperative due to high associated mortality rates (Fig. 7-69).

Evaluation in the ED focuses on identification of injuries mandating operative intervention (e.g., massive hemothorax, ruptured spleen) and injuries related to pelvic fracture that alter management (e.g., injuries to the iliac artery). Immediate temporary stabilization with sheeting of the pelvis or application of commercially available compression devices should be performed. In high risk patients, (e.g. autopedestrian accident) with profound shock, this should be done before radiographic confirmation. If the patient's primary source of bleeding is the fracture-related hematoma, several options exist for hemorrhage control.

Because 85% of bleeding due to pelvic fractures is venous or bony in origin the authors advocate immediate external fixation and preperitoneal pelvic packing.^{124,125} Anterior external fixation decreases pelvic volume, which promotes tamponade of venous bleeding and prevents secondary hemorrhage from the shifting of bony elements. Pelvic packing, in which six laparotomy pads (four in children) are placed directly into the paravesical space through a small suprapubic incision, provides tamponade for the bleeding (Fig. 7-70). Pelvic packing also eliminates the often difficult decision by the trauma surgeon: OR vs. interventional radiology? All patients can be rapidly transported to the OR and packing can be accomplished in under 30 minutes. In the authors' experience, this results in hemodynamic stability and abrupt cessation of the need for ongoing blood transfusion in the majority of cases.¹²⁵ Patients also can undergo additional procedures such as laparotomy, thoracotomy, external fixation of extremity fractures, open fracture débridement, or craniotomy. Currently, angiography is reserved for patients with evidence of

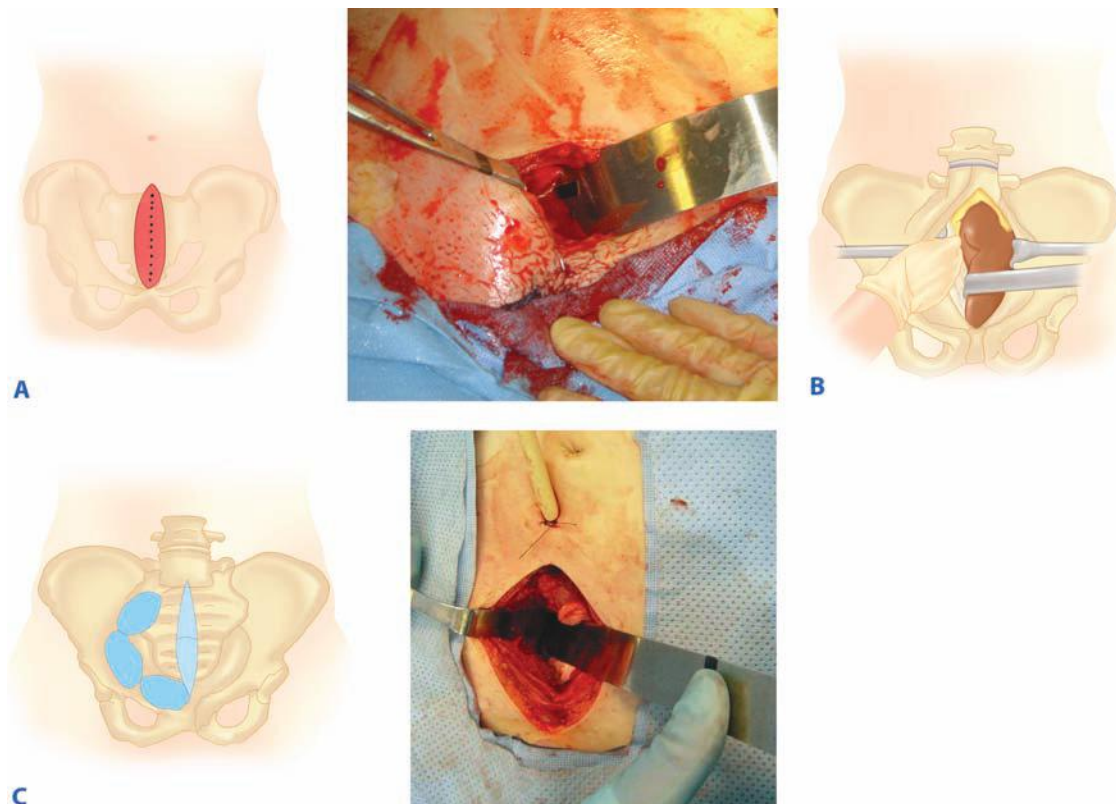


Figure 7-70. **A.** Pelvic packing is performed through a 6- to 8-cm midline incision made from the pubic symphysis cephalad, with division of the midline fascia. **B.** The pelvic hematoma often dissects the preperitoneal and paravesical space down to the presacral region, which facilitates packing; alternatively, blunt digital dissection opens the preperitoneal space for packing. **C.** Three standard surgical laparotomy pads are placed on each side of the bladder, deep within the preperitoneal space; the fascia is closed with an O polydioxanone monofilament suture and the skin with staples.

ongoing pelvic bleeding after admission to the SICU (>4 units of RBCs in the first 12 postoperative hours after the coagulopathy is corrected). Patients undergo standard posttrauma resuscitative SICU care, and the pelvic packs are removed within 48 hours, a time frame chosen empirically based on the authors' experience with liver packing. The authors elect to repack the patient's pelvis if there is persistent oozing and perform serial washouts of the preperitoneal space if it appears infected.

Another clinical challenge is the open pelvic fracture. In many instances the wounds are located in the perineum, and the risk of pelvic sepsis and osteomyelitis is high. To reduce the risk of infection, performance of a diverting sigmoid colectomy is recommended. The pelvic wound is manually débrided and then irrigated daily with a high-pressure pulsatile irrigation system until granulation tissue covers the wound. The wound is then left to heal by secondary intention with a wound vacuum-assisted wound closure (VAC) device.

Extremity Vascular Injuries, Fractures, and Compartment Syndromes

Patients with injured extremities often require a multidisciplinary approach with involvement of trauma, orthopedic, and plastic surgeons to address vascular injuries, fractures, soft tissue injuries, and compartment syndromes. Immediate stabilization of fractures or unstable joints is done in the ED using Hare traction, knee immobilizers, or plaster splints. In patients with open fractures the wound should be covered with povidone iodine (Betadine)-soaked gauze and antibiotics administered.

Options for fracture fixation include external fixation or open reduction and internal fixation with plates or intramedullary nails. Vascular injuries, either isolated or in combination with fractures, require emergent repair. Common combined injuries include clavicle/first rib fractures and subclavian artery injuries, dislocated shoulder/proximal humeral fractures and axillary artery injuries, supracondylar fractures/elbow dislocations and brachial artery injuries, femur fracture and superficial femoral artery injuries, and knee dislocation and popliteal vessel injuries. On-table angiography in the OR facilitates rapid intervention and is warranted in patients with evidence of limb threat at ED arrival. Arterial access for on-table lower extremity angiography can be obtained percutaneously at the femoral vessels with a standard arterial catheter, via femoral vessel exposure and direct cannulation, or with superficial femoral artery (SFA) exposure just above the medial knee. Controversy exists regarding which should be done first, fracture fixation or arterial repair. The authors prefer placement of temporary intravascular shunts first with arterial occlusions to minimize ischemia during fracture treatment, with definitive vascular repair following. Rarely, immediate amputation may be considered due to the severity of orthopedic and neurovascular injuries. This is particularly true if primary nerve transection is present in addition to fracture and arterial injury.¹²⁶ Collaborative decision making by the trauma, orthopedic, and plastic/reconstructive team is essential.

Operative intervention for vascular injuries should follow standard principles of repair (see "Vascular Repair Techniques"). For subclavian or axillary artery repairs, 6-mm PTFE

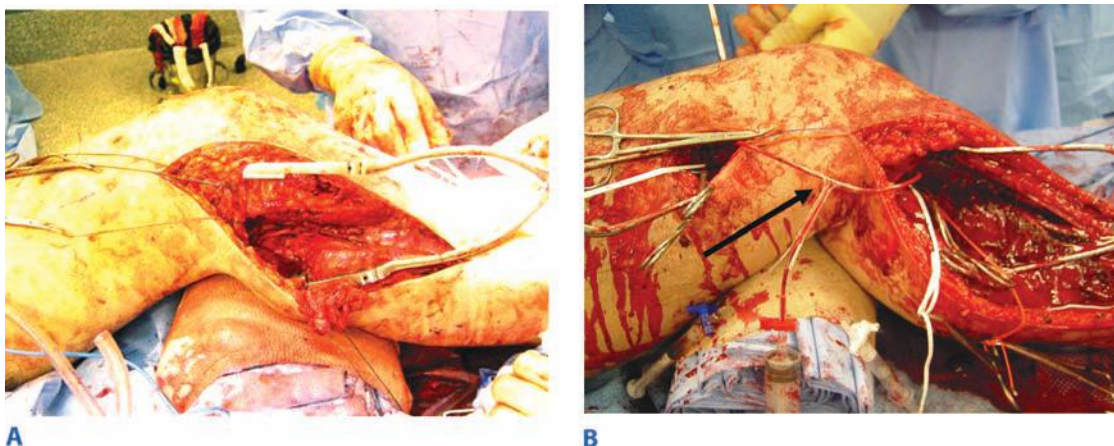


Figure 7-71. **A.** The popliteal space is commonly accessed using a single medial incision (the detached semitendinosus, semimembranosus, and gracilis muscles are identified by different suture types). **B.** Alternatively, a medial approach with two incisions may be used. Insertion of a Pruitt-Inahara shunt (*arrow*) provides temporary restoration of blood flow, which prevents ischemia during fracture treatment.

graft and RSVG are used. Because associated injuries of the brachial plexus are common, a thorough neurologic examination of the extremity is mandated before operative intervention. Operative approach for a brachial artery injury is via a medial upper extremity longitudinal incision; proximal control may be obtained at the axillary artery, and an S-shaped extension through the antecubital fossa provides access to the distal brachial artery. The injured vessel segment is excised, and an end-to-end interposition RSVG graft is performed. Upper extremity fasciotomy is rarely required unless the patient manifests preoperative neurologic changes or diminished pulse upon revascularization, or the time to operative intervention is extended. For SFA injuries, external fixation of the femur typically is performed, followed by end-to-end RSVG of the injured SFA segment. Close monitoring for calf compartment syndrome is mandatory. Preferred access to the popliteal space for an acute injury is the medial one-incision approach with detachment of the semitendinosus, semimembranosus, and gracilis muscles (Fig. 7-71). Another option is a medial approach with two incisions using a longer RSVG, but this requires interval ligation of the popliteal artery and geniculate branches. Rarely, with open wounds a straight posterior approach with an S-shaped incision can be used. If the patient has an associated popliteal vein injury, this should be repaired first with a PTFE interposition graft while the artery is shunted. For an isolated popliteal artery injury, RSVG is performed with an end-to-end anastomosis. Compartment syndrome is common, and presumptive four-compartment fasciotomies are warranted in patients with combined arterial and venous injury. Once the vessel is repaired and restoration of arterial flow documented, completion angiography should be done in the OR if there is no palpable distal pulse. Vasoparalysis with verapamil, nitroglycerin, and papaverine may be used to treat vasoconstriction (Table 7-11).

Compartment syndromes, which can occur anywhere in the extremities, involve an acute increase in pressure inside a closed space, which impairs blood flow to the structures within. Causes of compartment syndrome include arterial hemorrhage into a compartment, venous ligation or thrombosis, crush injuries, and reperfusion injury. In conscious patients, pain is the prominent symptom, and active or passive motion of muscles in the involved compartment increases the pain. Paresthesias may

Table 7-11

Arterial vasospasm treatment guideline

Step 1: Intra-arterial alteplase (tissue plasminogen activator) 5 mg/20 mL bolus If spasm continues, proceed to step 2.
Step 2: Intra-arterial nitroglycerin 200 µg/20 mL bolus Repeat same dose once as needed. If spasm continues, proceed to step 3.
Step 3: Inter-arterial verapamil 10 mg/10 mL bolus If spasm continues, proceed to step 4.
Step 4: Inter-arterial papaverine drip 60 mg/50 mL given over 15 min

also be described. In the lower extremity, numbness between the first and second toes is the hallmark of early compartment syndrome in the exquisitely sensitive anterior compartment and its enveloped deep peroneal nerve. Progression to paralysis can occur, and loss of pulses is a late sign. In comatose or obtunded patients, the diagnosis is more difficult to secure. In patients with a compatible history and a tense extremity, compartment pressures should be measured with a hand-held Stryker device. Fasciotomy is indicated in patients with a gradient of <35 mm Hg (gradient = diastolic pressure – compartment pressure), ischemic periods of >6 hours, or combined arterial and venous injuries. The lower extremity is most frequently involved, and compartment release is performed using a two-incision, four-compartment fasciotomy (Fig. 7-72). Of note, the soleus muscle must be detached from the tibia to decompress the deep flexor compartment.

SURGICAL INTENSIVE CARE MANAGEMENT

Postinjury Resuscitation

ICU management of the trauma patient, either with direct admission from the ED or after emergent operative intervention, is considered in distinct phases, because there are differing goals

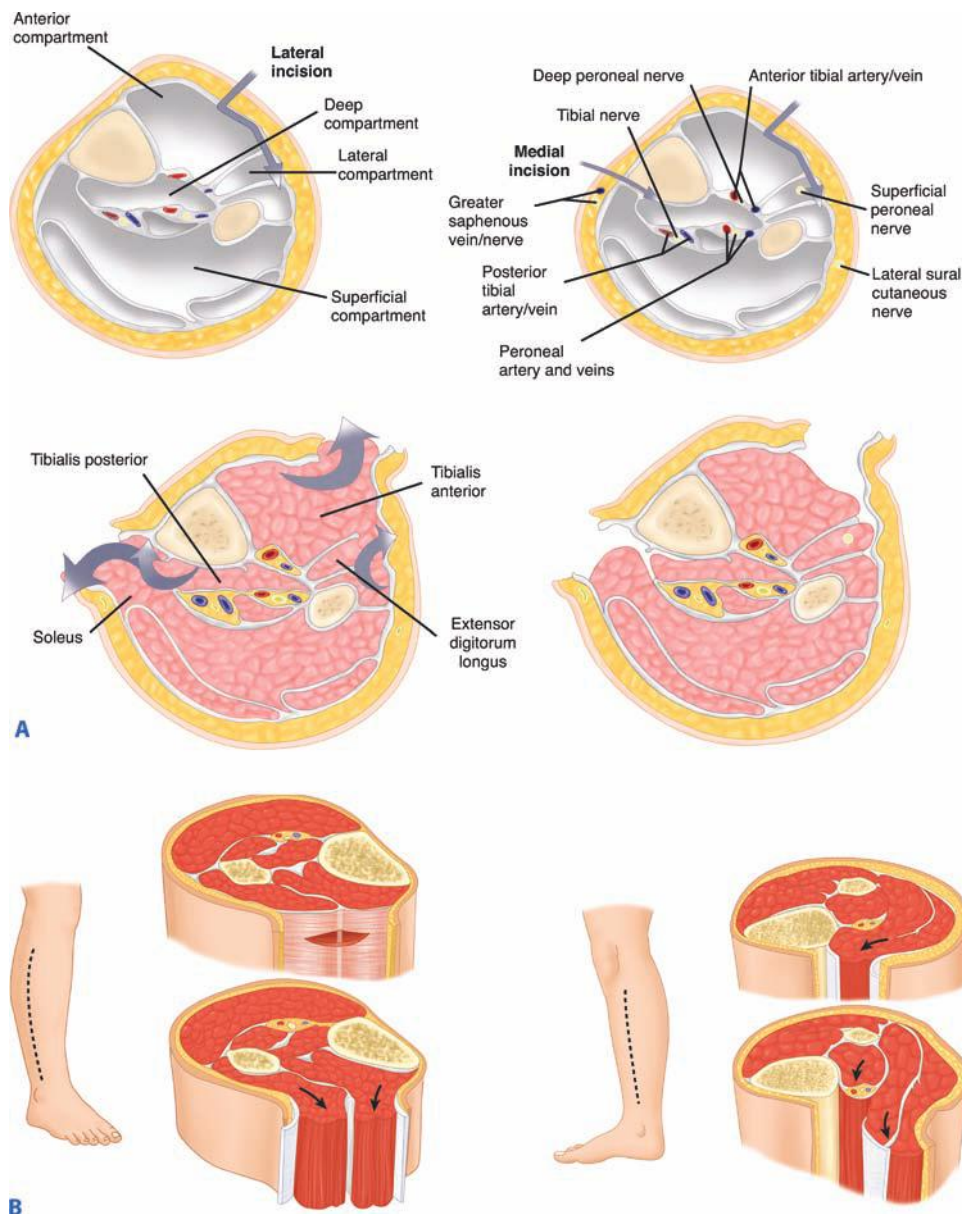


Figure 7-72. **A.** The anterior and lateral compartments are approached from a lateral incision, with identification of the fascial raphe between the two compartments. Care must be taken to avoid the superficial peroneal nerve running along the raphe. **B.** To decompress the deep flexor compartment, which contains the tibial nerve and two of the three arteries to the foot, the soleus muscle must be detached from the tibia.

and priorities. The period of acute resuscitation, typically lasting for the first 12 to 24 hours after injury, combines several key principles: optimizing tissue perfusion, ensuring normothermia, and restoring coagulation. There are a multitude of management algorithms aimed at accomplishing these goals, the majority of which involve goal-directed resuscitation with initial volume loading to attain adequate preload, followed by judicious use of inotropic agents or vasopressors.¹²⁷ Although the optimal hemoglobin level remains debated, during shock resuscitation a hemoglobin level of >10 g/dL is generally accepted to optimize hemostasis and ensure adequate oxygen delivery. After the first 24 hours of resuscitation, a more judicious transfusion trigger of a hemoglobin level of <7 g/dL in the euvoletic patient limits the adverse inflammatory effects of stored RBCs. The resuscitation of the severely injured trauma patient may require a considerable amount of crystalloid resuscitation, but recent trends have focused on limiting crystalloid loading. Although early colloid administration is appealing, evidence to date does not support this concept. In fact, optimizing crystalloid administra-

tion is a challenging aspect of early care (i.e., balancing cardiac performance against generation of an abdominal compartment syndrome and generalized tissue edema).

Invasive monitoring with pulmonary artery catheters is controversial but may be a necessary adjunct in occasional patients with multiple injuries who require advanced inotropic support. Not only do such devices allow minute-to-minute monitoring of the patient, but the added information on the patient's volume status, cardiac function, peripheral vascular tone, and metabolic response to injury permits appropriate therapeutic intervention. With added information on the patient's cardiac function, cardiac indices and oxygen delivery become important variables in the ongoing ICU management. Resuscitation to values of >500 mL/min per square meter for the oxygen delivery index and >3.8 L/min per square meter for the cardiac index are the goals.¹³³ Pulmonary artery catheters also enable the physician to monitor response to vasoactive agents. Although norepinephrine is the agent of choice for patients with low systemic vascular resistance who are unable to maintain a mean arterial

pressure of >60 mm Hg, patients may have an element of myocardial dysfunction requiring inotropic support. The role of relative adrenal insufficiency is another controversial area.

Optimal early resuscitation is mandatory and determines when the patient can undergo definitive diagnosis as well as when the patient can be returned to the OR after initial damage control surgery. Specific goals of resuscitation before repeated “semielective” transport include a core temperature of >35°C (95°F), base deficit of <6 mmol/L, and normal coagulation indices. Although correction of metabolic acidosis is desirable, how quickly this should be accomplished requires careful consideration. Adverse sequelae of excessive crystalloid resuscitation include increased intracranial pressure, worsening pulmonary edema, and intra-abdominal visceral and retroperitoneal edema resulting in secondary abdominal compartment syndrome. Therefore, it should be the overall trend of the resuscitation rather than a rapid reduction of the base deficit that is the goal. The goal is to normalize lactate within 24 hours.

In general, wounds sustained from trauma should be examined daily for progression of healing and signs of infection. Complex soft tissue wounds of the abdomen, such as degloving injuries after blunt trauma (termed *Morel-Lavallee lesions*), shotgun wounds, and other destructive blast injuries, are particularly difficult to manage. Following initial débridement of devitalized tissue, wound care includes wet-to-dry dressing changes twice daily or application of a VAC device. Repeated operative débridement may be necessary, and early involvement of the reconstructive surgery service for possible flap coverage is advised. Midline laparotomy wounds are inspected 48 hours postoperatively by removing the sterile surgical dressing. If an ileostomy or colostomy is required, one should inspect it daily to ensure that it is viable. If the patient develops high-grade fever, the wound should be inspected sooner to exclude an early necrotizing infection. If a wound infection is identified—as evidenced by erythema, pain along the wound, or purulent drainage—the wound should be widely opened by removing skin staples. After ensuring that the midline fascia is intact with digital palpation, the wound is initially managed with wet-to-dry dressing changes. The most common intra-abdominal complications are anastomotic failure and abscess. The choice between percutaneous and operative therapy is based on the location, timing, and extent of the collection.

Abdominal Compartment Syndrome

The abdominal compartment syndrome is classified as pathologic intra-abdominal hypertension due to intra-abdominal injury (primary) or splanchnic reperfusion after massive resuscitation (secondary). Secondary abdominal compartment syndrome may result from any condition requiring extensive crystalloid resuscitation, including extremity trauma, chest trauma, or even postinjury sepsis. The sources of increased intra-abdominal pressure include gut edema, ascites, bleeding, and packs. A diagnosis of intra-abdominal hypertension cannot reliably be made by physical examination; therefore, it is obtained by measuring the intraperitoneal pressure. The most common technique is to measure the patient’s bladder pressure. Fifty milliliters of saline is instilled into the bladder via the aspiration port of the Foley catheter with the drainage tube clamped, and a three-way stopcock and water manometer is placed at the level of the pubic symphysis. Bladder pressure is then measured on the manometer in centimeters of water (Table 7-12) and correlated with the physiologic impact of abdominal compartment

Table 7-12

Abdominal compartment syndrome grading system

GRADE	BLADDER PRESSURE	
	mmHg	cm H ₂ O
I	10–15	13–20
II	16–25	21–35
III	26–35	36–47
IV	>35	>48

syndrome. Conditions in which the bladder pressure is unreliable include bladder rupture, external compression from pelvic packing, neurogenic bladder, and adhesive disease.

Increased abdominal pressure affects multiple organ systems (Fig. 7-73). Abdominal compartment syndrome, as noted earlier, is defined as intra-abdominal hypertension sufficient to produce physiologic deterioration and frequently manifests via such end-organ sequelae as decreased urine output, increased pulmonary inspiratory pressures, decreased cardiac preload, and increased cardiac afterload. Because any of these clinical symptoms of abdominal compartment syndrome may be attributed to the primary injury, a heightened awareness of this syndrome must be maintained. Organ failure can occur over a wide range of recorded bladder pressures. Generally, no specific bladder pressure prompts therapeutic intervention, except when the pressure is >35 mm Hg. Rather, emergent decompression is carried out when intra-abdominal hypertension reaches a level at which end-organ dysfunction occurs. Mortality is directly affected by the timing of decompression, with 60% mortality in patients undergoing presumptive decompression, 70% mortality in patients with a delay in decompression, and nearly uniform mortality in those not undergoing decompression. Usually decompression is performed operatively, either in the ICU if the patient is hemodynamically unstable or in the OR. ICU bedside laparotomy is easily accomplished, avoids transport of hemodynamically compromised patients, and requires minimal equipment (e.g., scalpel, suction device, cautery, and dressings for temporary abdominal closure). In patients with significant intra-abdominal fluid as the primary component of abdominal compartment syndrome, rather than bowel or retroperitoneal edema, decompression can be accomplished effectively via a percutaneous drain. This method is particularly applicable for nonoperative management of major liver injuries. These patients are identified by bedside ultrasound, and the morbidity of a laparotomy is avoided. When operative decompression is required with egress of the abdominal contents, temporary coverage is obtained using a subfascial 45 × 60 cm sterile drape and Ioban application (see Fig. 7-50).

The performance of damage control surgery and recognition of abdominal compartment syndrome have dramatically improved patient survival, but at the cost of an open abdomen. Several management points deserve attention. Despite having a widely open abdomen, patients can develop recurrent abdominal compartment syndrome, which increases their morbidity and mortality; therefore, bladder pressure should be monitored every 4 hours, with significant increases in pressures alerting the clinician to the possible need for repeat operative

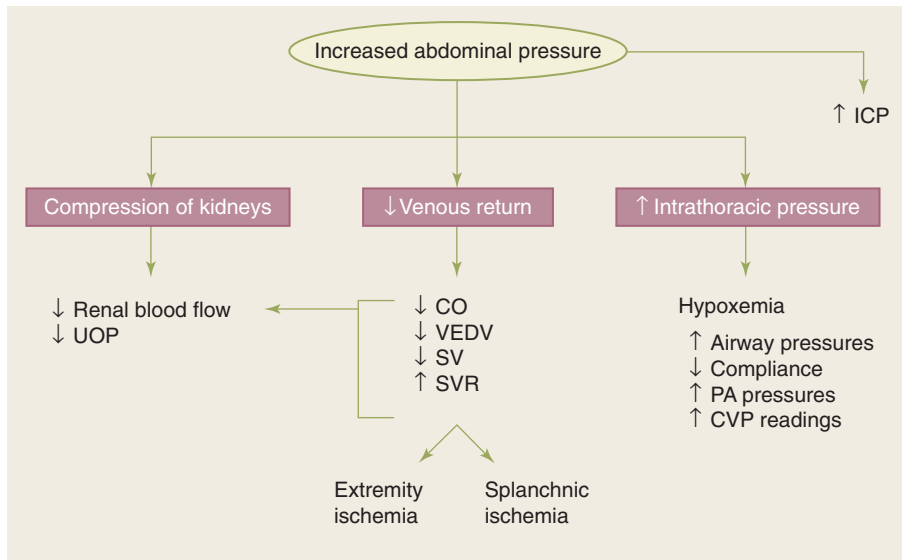


Figure 7-73. Abdominal compartment syndrome is defined by the end organ sequelae of intra-abdominal hypertension. CO = cardiac output; CVP = central venous pressure; ICP = intracranial pressure; PA = pulmonary artery; SV = stroke volume; SVR = systemic vascular resistance; UOP = urine output; VEDV = ventricular end diastolic volume.

decompression. Patients with an open abdomen lose between 500 and 2500 mL per day of abdominal effluent. Appropriate volume compensation for this albumin-rich fluid remains controversial, with regard to both the amount administered (replacement based on clinical indices vs. routine ½ mL replacement for every milliliter lost) as well as the type of replacement (crystalloid vs. colloid).

Following resuscitation and management of specific injuries, the goal of the operative team is to close the abdomen as quickly as possible. Multiple techniques have been introduced to obtain fascial closure of the open abdomen to minimize morbidity and cost of care. Historically, for patients who could not be closed at repeat operation, approximation of the fascia with mesh (prosthetic or biologic) was used, with planned reoperation. Another option was split-thickness skin grafts applied directly to the exposed bowel for coverage; removal of the skin grafts was planned 9 to 12 months after the initial surgery, with definitive repair of the hernia by component separation. However, delayed abdominal wall reconstruction was resource intensive, with considerable patient morbidity. The advent of VAC technology has revolutionized fascial closure. The authors currently use a sequential closure technique with the wound VAC device that is based on constant fascial tension and return to the OR every 48 hours until closure is complete (Fig. 7-74).¹²⁸ The authors' success rate with this approach exceeds 95%. This is important because among patients not attaining fascial closure, 20% suffer GI tract complications that prolong their hospital course. These include intra-abdominal abscess, enteric fistula, and bowel perforations (Fig. 7-75). Management requires frequent operative or percutaneous drainage of abscesses, control of fistulas, and prolonged nutritional support.

SPECIAL POPULATIONS

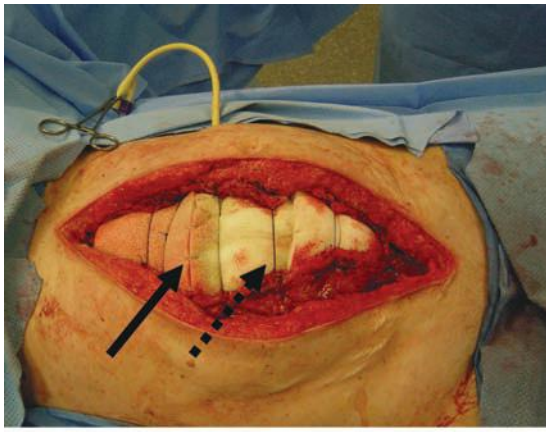
Pregnant Patients

During pregnancy, 7% of women are injured. Motor vehicle collisions and falls are the leading causes of injury, accounting for 70% of cases. Fetal death after trauma most frequently occurs after motor vehicle collisions, but only 11% of fetal deaths are

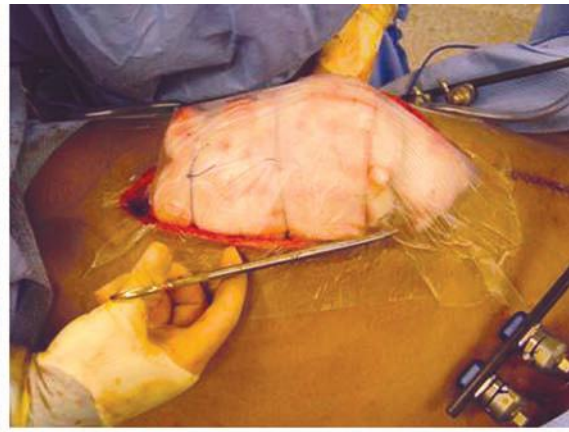
due to the death of the mother; therefore, early trauma resuscitation and management is directed not only at the mother but also at the fetus. Domestic violence is also common, affecting between 10% and 30% of pregnant women and resulting in fetal mortality of 5%.

Pregnancy results in physiologic changes that may impact postinjury evaluation (Table 7-13). Heart rate increases by 10 to 15 beats per minute during the first trimester and remains elevated until delivery. Blood pressure diminishes during the first two trimesters due to a decrease in systemic vascular resistance and rises again slightly during the third trimester (mean values: first = 105/60, second = 102/55, third = 108/67). Intravascular volume is increased by up to 8 L, which results in a relative anemia but also a relative hypervolemia. Consequently a pregnant woman may lose 35% of her blood volume before exhibiting signs of shock. Pregnant patients have an increase in tidal volume and minute ventilation but a decreased functional residual capacity; this results in a diminished PCO_2 and respiratory alkalosis. Also, pregnant patients may desaturate more rapidly, particularly in the supine position and during intubation. Supplemental oxygen is always warranted in the trauma patient but is particularly critical in the injured pregnant patient, because the oxygen dissociation curve is shifted to the left for the fetus compared to the mother (i.e., small changes in maternal oxygenation result in larger changes for the fetus because the fetus is operating in the steep portions of the dissociation curve). Anatomic changes contribute to these pulmonary functional alterations and are relevant in terms of procedures. With the gravid uterus enlarged, DPL should be performed in a supra-umbilical site with the catheter directed cephalad. In addition, the upward pressure on the diaphragm calls for caution when placing a thoracostomy tube; standard positioning may result in an intra-abdominal location or perforation of the diaphragm.

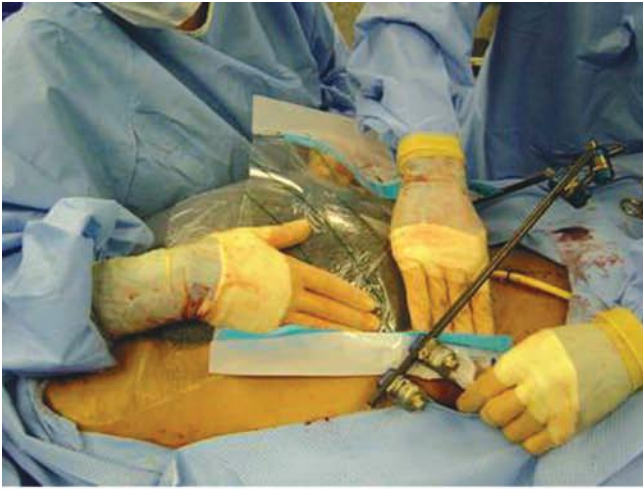Other physiologic changes during pregnancy affect the GI, renal, and hematologic systems. The lower esophageal sphincter has decreased competency, which increases the risk for aspiration. Liver function test values increase, with the alkaline phosphatase level nearly doubling. The high levels of progesterone impair gallbladder contractions, which results in bile stasis and an increased incidence of gallstone formation; this may not



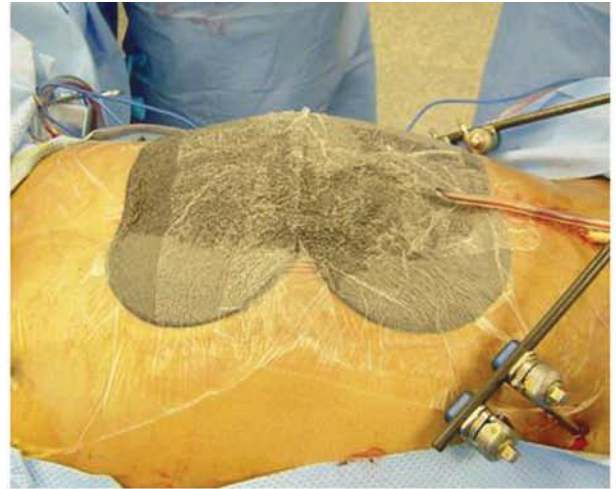
A



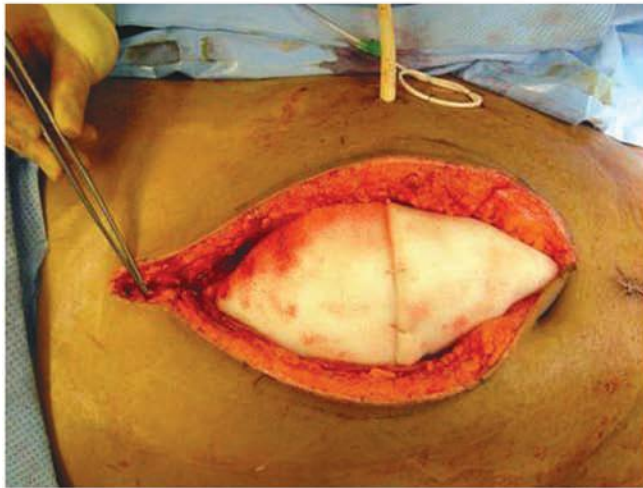
B



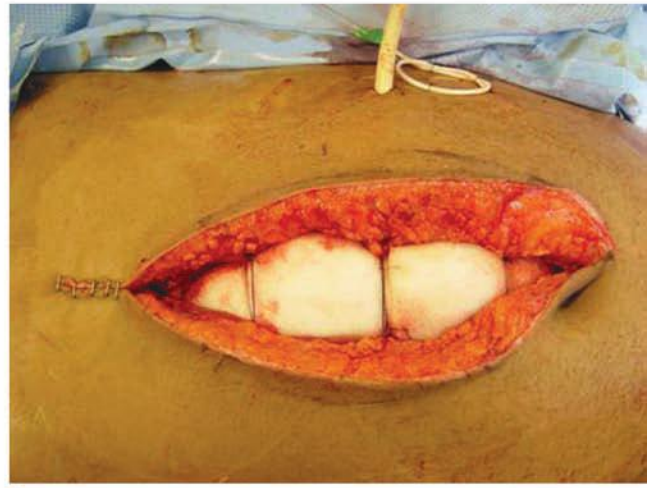
C



D

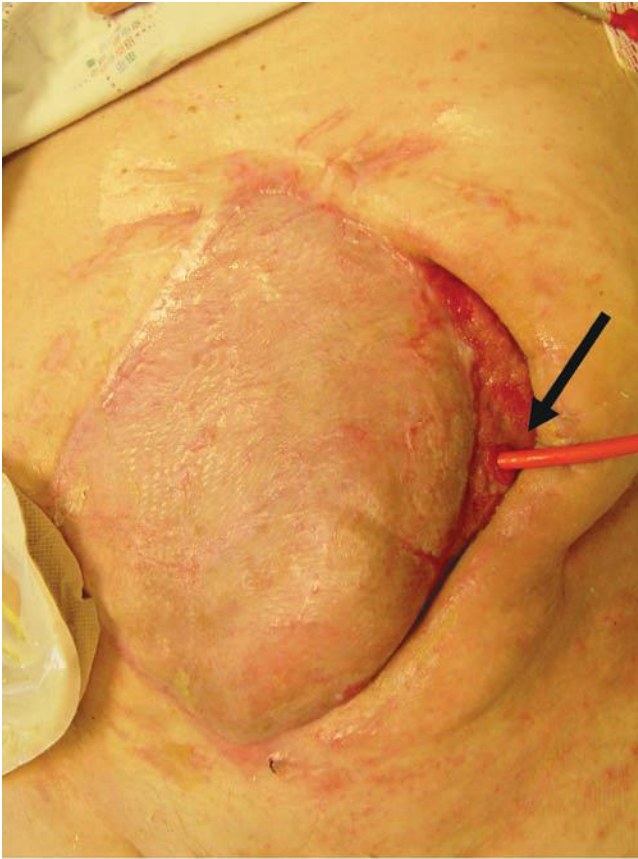

E

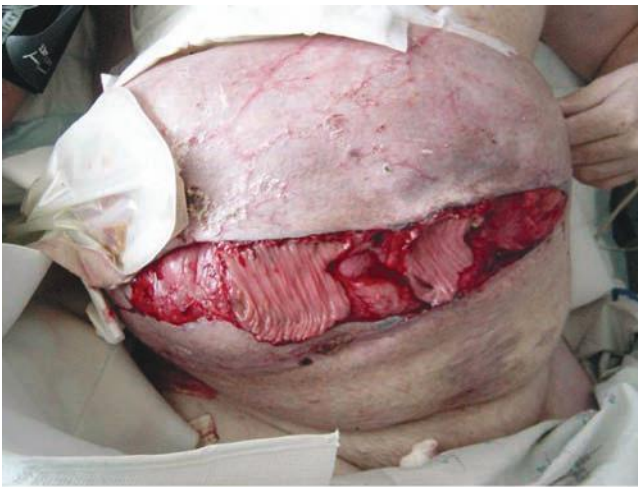

F

Figure 7-74. The authors' sequential closure technique for the open abdomen. **A.** Multiple white sponges (*solid arrow*), stapled together, are placed on top of the bowel underneath the fascia. Interrupted No. 1 polydioxanone sutures are placed approximately 5 cm apart (*dashed arrow*), which puts the fascia under moderate tension over the white sponge. **B.** After the sticky clear plastic vacuum-assisted closure (VAC) dressing is placed over the white sponges and adjacent 5 cm of skin, the central portion is removed by cutting along the wound edges. **C** and **D.** Black VAC sponges are placed on top of the white sponges and plastic-protected skin with standard occlusive dressing and suction. **E.** On return to the operating room (OR) 48 hours later, fascial sutures are placed from both the superior and inferior directions until tension precludes further closure; skin is closed over the fascial closure with skin staples. **F.** White sponges (fewer in number) are again applied and fascial retention sutures are placed with planned return to the OR in 48 hours.



A



B

Figure 7-75. Complications after split-thickness skin graft closure of the abdomen include enterocutaneous fistulas (intubated here with a red rubber catheter) (**A**; *arrow*) and rupture of the graft with exposure of the bowel mucosa (**B**).

affect the trauma bay evaluation but becomes important in a prolonged ICU stay. Plasma albumin level decreases from a normal of around 4.3 g/dL to an average of 3.0 g/dL. Renal blood flow increases by 30% during pregnancy, which causes a decrease in serum level of blood urea nitrogen and creatinine. The uterus may also compress the ureters and bladder, causing hydronephrosis and hydroureter. Finally, as noted earlier there is a relative anemia during pregnancy, but a hemoglobin level of <11 g/dL

Table 7-13

Physiologic effects of pregnancy

Cardiovascular

- Increase in heart rate by 10–15 bpm
- Decreased systemic vascular resistance resulting in:
 - (a) Increased intravascular volume
 - (b) Decreased blood pressure during the first two trimesters

Pulmonary

- Elevated diaphragm
- Increased tidal volume
- Increased minute ventilation
- Decreased functional residual capacity

Hematopoietic

- Relative anemia
- Leukocytosis
- Hypercoagulability
 - (a) Increased levels of factors VII, VIII, IX, X, XII
 - (b) Decreased fibrinolytic activity

Other

- Decreased competency of lower esophageal sphincter
- Increased enzyme levels on liver function tests
- Impaired gallbladder contractions
- Decreased plasma albumin level
- Decreased blood urea nitrogen and creatinine levels
- Hydronephrosis and hydroureter

is considered abnormal. Additional hematologic changes include a moderate leukocytosis (up to 20,000 mm^3) and a relative hypercoagulable state due to increased levels of factors VII, VIII, IX, X, and XII and decreased fibrinolytic activity.

During evaluation in the ED, the primary and secondary surveys commence, with mindfulness that the mother always receives priority while conditions are still optimized for the fetus.¹²⁹ This management includes provision of supplemental oxygen (to prevent maternal and fetal hypoxia), aggressive fluid resuscitation (the hypervolemia of pregnancy may mask signs of shock), and placement of the patient in the left lateral decubitus position (or tilting of the backboard to the left) to avoid caval compression. Assessment of the fetal heart rate is the most valuable information regarding fetal viability. Fetal monitoring should be performed with a cardiotocographic device that measures both contractions and fetal heart tones (FHTs). Because change in heart rate is the primary response of the fetus to hypoxia or hypotension, anything above an FHT of 160 is a concern, whereas bradycardia (FHT of <120) is considered fetal distress. Ideally, if possible, a member of the obstetrics team should be present during initial evaluation to perform a pelvic examination using a sterile speculum. Vaginal bleeding can signal early cervical dilation and labor, abruptio placentae, or placenta previa. Amniotic sac rupture can result in prolapse of the umbilical cord with fetal compromise. Strong contractions are associated with true labor and should prompt consideration of delivery and resuscitation of the neonate. Focused prenatal history taking should elicit a history of pregnancy-induced hypertension, gestational diabetes, congenital

heart disease, preterm labor, or placental abnormalities. Asking the patient when the baby first moved and if she is currently experiencing movement of the fetus is important. Determining fetal age is key for considerations of viability. Gestational age may be estimated by noting fundal height, with the fundus approximating the umbilicus at 20 weeks and the costal margin at 40 weeks. Discrepancy in dates and size may be due to uterine rupture or hemorrhage.

Initial evaluation for abdominopelvic trauma in pregnant patients should proceed in the standard manner. Ultrasound (FAST) of the abdomen should evaluate the four windows (pericardial, right and left upper quadrant, and bladder) and additionally assess FHTs, fetal movement, and sufficiency of amniotic fluid. DPL can be performed in pregnant women via a supraumbilical, open technique. Trauma radiography of pregnant patients presents a conundrum. Radiation damage has three distinct phases of damage and effect: preimplantation, during the period of organogenesis from 3 to 16 weeks, and after 16 weeks. Generally, it is accepted that “safe” doses of radiation from radiography are <5 rad.¹³⁰ A chest radiograph results in a dose of 0.07 mrad; CT scan of the chest, <1 rad; and CT scan of the abdomen, 3.5 rad. It is important, therefore, to limit radiographs to those that are essential and to shield the pelvis with a lead apron when possible. If clinically warranted, however, a radiograph should be obtained.

The vast majority of injuries are treated similarly whether the patient is pregnant or not. Following standard protocols for nonoperative management of blunt trauma avoids the risks associated with general anesthesia. A particular challenge in the pregnant trauma patient is a major pelvic fracture. Because uterine and retroperitoneal veins may dilate to 60 times their original size, hemorrhage from these vessels may be torrential. Fetal loss may be related to both maternal shock and direct injury to the uterus or fetal head. Penetrating injuries in this patient population also carry a high risk. The gravid uterus is a large target, and any penetrating injury to the abdomen may result in fetal injury depending on trajectory and uterine size. Gunshot wounds to the abdomen are associated with a 70% injury rate to the uterus and 35% mortality rate of the fetus. If the bullet traverses the uterus and the fetus is viable, cesarean section should be performed. On the other hand, stab wounds do not often penetrate the thick wall of the uterus. Indications for emergent cesarean section include: (a) severe maternal shock or impending death (if the fetus is delivered within 5 minutes, survival is estimated at 70%), (b) uterine injury or significant fetal distress (anticipated survival rates of >70% if FHTs are present and fetal gestational age is >28 weeks).¹³¹

Any patient with a viable pregnancy should be monitored after trauma, with the length of monitoring determined by the injury mechanism and patient physiology. Patients who are symptomatic, defined by the presence of uterine irritability or contractions, abdominal tenderness, vaginal bleeding, or blood pressure instability, should be monitored in the hospital for at least 24 hours. In addition, patients at high risk for fetal loss (those experiencing vehicle ejection or involved in motorcycle or pedestrian collisions and those with maternal tachycardia, Injury Severity Score of >9, gestational period of >35 weeks, or history of prior assault) also warrant careful monitoring.¹³² Patients without these risk factors who are asymptomatic can be monitored for 6 hours in the ED and sent home if no problems develop. They should be counseled regarding warning signs that mandate prompt return to the ED.

Geriatric Patients

Elderly trauma patients (>65 years of age) are hospitalized twice as often as those in any other age group, and this population accounts for one quarter of all trauma admissions. Although the physiology of aging separates older trauma patients from the younger generation (Table 7-14), treatment must remain individualized (some octogenarians look and physiologically act 50 years old, whereas others appear closer to 100 years). No chronologic age is associated with a higher morbidity or mortality, but a patient’s comorbidities do impact the individual’s postinjury course and outcome. For example, recognition that a patient is taking beta blockers affects the physician’s evaluation of vital signs in the ED and impacts treatment course in the ICU. Early monitoring of arterial blood gas values will identify occult shock. A base deficit of >6 mmol/L is associated with a twofold higher risk of mortality in patients over the age of 55 than in younger patients (67% vs. 30%).¹³³

Although the published literature on geriatric traumatic brain injury is relatively sparse and uncontrolled with regard to management, some interesting points are noted. First, outcomes are worse in this age group than in their younger counterparts. Based on data from the Traumatic Coma Databank, mortality in patients with severe head injury more than doubles after the age of 55. Moreover, 25% of patients with a normal GCS score of 15 had intracranial bleeding, with an associated mortality of 50%.¹²³ Just as there is no absolute age that predicts outcome, admission GCS score is a poor predictor of individual outcome.

Table 7-14

Physiologic effects of aging

Cardiovascular

Increased prevalence of heart disease

Fatty deposition in the myocardium, resulting in:

- (a) Progressive stiffening and loss of elasticity
- (b) Diminished stroke volume, systolic contraction, and diastolic relaxation

Decrease in cardiac output of 0.5% per year

Atherosclerotic disease that limits cardiac response to stress

Increased risk of coronary ischemia

Thickening and calcification of the cardiac valves, which results in valvular incompetence

Pulmonary

Loss of compliance

Progressive loss of alveolar size and surface area

Air trapping and atelectasis

Intracranial

Loss of cerebral volume, resulting in:

- (a) Increased risk of tearing of bridging veins with smaller injuries
- (b) Accumulation of a significant amount of blood before symptoms occur

Senescence of the senses

Other

Decline in creatinine clearance by 80%–90%

Osteoporosis, which causes a greater susceptibility to fractures

Therefore, the majority of trauma centers advocate an initial aggressive approach with re-evaluation at the 72-hour mark to determine subsequent care.

One of the most common sequelae of blunt thoracic trauma is rib fractures. In the aging population, perhaps due to osteoporosis, less force is required to cause a fracture. In fact, in one study, 50% of patients >65 years old sustained rib fractures from a fall of <6 ft, compared with only 1% of patients <65 years of age. Concurrent pulmonary contusion is noted in up to 35% of patients, and pneumonia complicates the injuries in 10% to 30% of patients with rib fractures, not surprisingly leading to longer ICU stays.^{135,136} Additionally, mortality increases linearly with the number of rib fractures. Patients who sustain more than six rib fractures have pulmonary morbidity rates of >50% and overall mortality rates of >20%.

Chronologic age is not the best predictor of outcome, but the presence of pre-existing conditions, which affect a patient's physiologic age, is associated with increased mortality rates. Injury Severity Score is probably the best overall predictor of patient outcome in the elderly; however, for any given individual its sensitivity may not be precise, and there is a time delay in obtaining sufficient information to calculate the final score. In addition to pre-existing conditions and severity of injury, the occurrence of complications compounds the risk for mortality.

Pediatric Patients

Twenty million children, or almost one in four children, are injured each year, with an associated cost of treating the injured child of \$16 billion per year. Injury is the leading cause of death among children over the age of 1 year, with 15,000 to 25,000 pediatric deaths per year. Disability after traumatic injury is more devastating, with rates 3 to 10 times that of the death rate. Pediatric trauma involves different mechanisms, different constellations of injury, and the potential for long-term problems related to growth and development. As with adult trauma, over 85% of pediatric trauma has a blunt mechanism, with boys injured twice as often as girls.¹³⁷ Falls are the most common cause of injury in infants and toddlers. In children, bicycle mishaps are the most common cause of severe injury, whereas motor vehicle-related injury predominates in adolescence. Although unintentional injuries are by far the most common type of injuries in childhood, the number of intentional injuries, such as firearm-related injury and child abuse, is increasing.

ED preparation for the pediatric trauma patient includes assembling age-appropriate equipment (e.g., intubation equipment; IV catheters, including intraosseous needles and 4F single-lumen lines), laying out the Broselow Pediatric Emergency Tape (which allows effective approximation of the patient's weight, medication doses, size of endotracheal tube, and chest tube size), and turning on heat lamps. Upon the pediatric patient's arrival, the basic tenets of the ABCs apply, with some caveats. In children, the airway is smaller and more cephalad in position compared with that of adults, and in children younger than 10 years, the larynx is funnel shaped rather than cylindrical as in adults. Additionally, the child's tongue is much larger in relation to the oropharynx. Therefore, a small amount of edema or obstruction can significantly reduce the diameter of the airway (thus increasing the work of breathing), and the tongue may posteriorly obstruct the airway, causing intubation to be difficult. During intubation, a Miller (straight) blade rather than a Macintosh (curved) blade may be more effective due to the acute angle of the cephalad, funnel-shaped larynx. Administration

of atropine before rapid-sequence intubation will prevent bradycardia. Adequate ventilation is critical, because oxygen consumption in infants and young children is twice that in adults; onset of hypoxemia, followed by cardiac arrest, may be precipitous. Because gastric distension can inhibit adequate ventilation, placement of a nasogastric tube may facilitate effective gas exchange. Approximately one third of preventable deaths in children are related to airway management; therefore, if airway control cannot be obtained using a standard endotracheal method, surgical establishment of an airway should be considered. In children older than 11 years, standard cricothyroidotomy is performed. Due to the increased incidence of subglottic stenosis in younger patients, needle cricothyroidotomy with either a 14- or 16-gauge catheter is advocated, although it is rarely used. Alternatively, tracheostomy may be performed. In children, the standard physiologic response to hypovolemia is peripheral vasoconstriction and reflex tachycardia; this may mask significant hemorrhagic injury, because children can compensate for up to a 25% loss of circulating blood volume with minimal external signs. "Normal" values for vital signs should not necessarily make one feel more secure about the child's volume status. Volume restoration is based on the child's weight; two to three boluses of 20 mL/kg of crystalloid is appropriate.

After initial evaluation based on the trauma ABCs, identification and management of specific injuries proceeds. Acute traumatic brain injury is the most common cause of death and disability in any pediatric age group. Although falls are the most common mechanism overall, severe brain injury most often is due to child abuse (in children <2 years) or motor vehicle collisions (in those >2 years). Head CT should be performed to determine intracranial pathology, followed by skull radiography to diagnose skull fractures. As in adults, CPP is monitored, and appropriate resuscitation is critical to prevent the secondary insults of hypoxemia and hypovolemia. Although some data indicate that the pediatric brain recovers from traumatic injury better than the adult brain, this advantage may be eliminated if hypotension is allowed to occur.

As is true in adults, the vast majority of thoracic trauma is also blunt. However, because a child's skeleton is not completely calcified, it is more pliable. Significant internal organ damage may occur without overlying bony fractures. For example, adult patients with significant chest trauma have a 70% incidence of rib fractures, whereas only 40% of children with significant chest trauma do. Pneumothorax is treated similarly in the pediatric population; patients who are asymptomatic with a pneumothorax of <15% are admitted for observation, whereas those who have a pneumothorax of >15% or who require positive pressure ventilation undergo tube decompression. Presence of a hemothorax in this age group may be particularly problematic, because the child's chest may contain his or her entire blood volume. If the chest tube output is initially 20% of the patient's blood volume (80 mL/kg) or is persistently >1 to 2 mL/kg per hour, thoracotomy should be considered. Aortic injuries are rare in children, and tracheobronchial injuries are more amenable to nonoperative management. Thoracic injuries are second only to brain injuries as the main cause of death according to the National Pediatric Trauma Registry; however, the overall mortality rate of 15% correlates with the levels in many adult studies.

The evaluation for abdominal trauma in the pediatric patient is similar to that in the adult. FAST is valid in the pediatric

age group to detect intra-abdominal fluid.¹³⁸ The mechanism of injury often correlates with specific injury patterns. A child sustaining a blow to the epigastrium (e.g., hitting the handlebars during a bike accident) should be evaluated for a duodenal hematoma and/or a pancreatic transection. After a motor vehicle collision in which the patient was wearing a passenger restraint, injuries comprising the “lap belt complex” or “seat belt syndrome” (i.e., abdominal wall contusion, small bowel perforation, flexion-distraction injury of the lumbar spine, diaphragm rupture, and occasionally abdominal aortic dissection) may exist. Nonoperative management of solid organ injuries, first used in children, is the current standard of care in the hemodynamically stable patient. If the patient shows clinical deterioration or hemodynamic lability, has a hollow viscus injury, or requires >40 mL/kg of packed RBCs, continued nonoperative management is not an option. Success rates of nonoperative management approach 95%, with an associated 10% to 23% transfusion rate. Blood transfusion rates, however, are significantly lower in patients managed nonoperatively than in patients undergoing operation (13% vs. 44%).¹³⁹

REFERENCES

Entries highlighted in bright blue are key references.

1. Minino AM, Heron MP, Murphy SL, et al. Deaths: final data for 2004. *Natl Vital Stat Rep.* 55, August 21, 2007; 55(19): 1-120. Available at http://www.cdc.gov/nchs/data/nvsr/nvsr55/nvsr55_19.pdf [accessed October 29, 2012].
2. National Center for Injury Prevention and Control: *CDC Injury Fact Book*. Atlanta: Centers for Disease Control and Prevention, November 2006. Available at http://www.cdc.gov/ncipc/fact_book/InjuryBook2006.pdf [accessed October 29, 2012].
3. Esposito TJ and Brasel KJ. Epidemiology. Mattox KL, Moore EE, Feliciano DV (eds): *Trauma*, 7th ed. New York: McGraw-Hill, 2013.
4. Eastman AB. Wherever the dart lands: toward the ideal trauma system. *J Am Coll Surg.* 2010;211(2):153-168.
5. MacKenzie EJ, Rivara FP, Jurkovich GJ, et al. A national evaluation of the effect of trauma-center care on mortality. *N Engl J Med.* 2006;354(4):366-378.
6. **American College of Surgeons: *Advanced Trauma Life Support*, 9th ed. Chicago: American College of Surgeons, 2012.**
7. Haut ER, Kalish BT, Efron DT, et al. Spine immobilization in penetrating trauma: more harm than good? *J Trauma.* 2010;68(1):115-120.
8. Lustenberger T, Talving P, Lam L, et al. Unstable cervical spine fracture after penetrating neck injury: a rare entity in an analysis of 1,069 patients. *J Trauma.* 2011;70(4):870-872.
9. Sakles JC, Mosier JM, Chiu S, Keim SM. Tracheal intubation in the emergency department: a comparison of GlideScope® video laryngoscopy to direct laryngoscopy in 822 intubations. *J Emerg Med.* 2012;42(4):400-405.
10. Inaba K, Ives C, McClure K, et al. Radiologic evaluation of alternative sites for needle decompression of tension pneumothorax. *Arch Surg.* 2012;147(9):813-818.
11. Carretta A, Melloni G, Bandiera A, Negri G, Voci C, Zannini P. Conservative and surgical treatment of acute posttraumatic tracheobronchial injuries. *World J Surg.* 2011;35(11):2568-2574.
12. Gómez-Caro A, Ausín P, Moradiellos FJ, et al. Role of conservative medical management of tracheobronchial injuries. *J Trauma.* 2006;61(6):1426-1434.
13. Demetriades D, Chan LS, Bhasin P, et al. Relative bradycardia in patients with traumatic hypotension. *J Trauma.* 1998;45(3):534-539.
14. Voigt J, Waltzman M, Lottenberg L. Intraosseous vascular access for in-hospital emergency use: a systematic clinical review of the literature and analysis. *Pediatr Emerg Care.* 2012;28(2):185-199.
15. Weiser G, Hoffmann Y, Galbraith R, Shavit I. Current advances in intraosseous infusion - a systematic review. *Resuscitation.* 2012;83(1):20-26.
16. Callahan M. Pericardiocentesis in traumatic and nontraumatic cardiac tamponade. *Ann Emerg Med.* 1984;13(10):924-945.
17. Burlew CC, Moore EE, Moore FA, et al. Western trauma association critical decisions in Trauma: resuscitative thoracotomy. *J Trauma*, in press.
18. Moore EE, Knudson MM, Burlew CC, et al. WTA Study Group. Defining the limits of resuscitative emergency department thoracotomy: a contemporary Western Trauma Association perspective. *J Trauma.* 2011;70(2):334-339.
19. Ouellet JF, Roberts DJ, Tiruta C, et al. Admission base deficit and lactate levels in Canadian patients with blunt trauma: are they useful markers of mortality? *J Trauma Acute Care Surg.* 2012;72(6):1532-1535.
20. Callaway DW, Shapiro NI, Donnino MW, Baker C, Rosen CL. Serum lactate and base deficit as predictors of mortality in normotensive elderly blunt trauma patients. *J Trauma* 2009;66(4):1040-1044.
21. Kliegel A, Losert H, Sterz F, et al. Serial lactate determinations for prediction of outcome after cardiac arrest. *Medicine (Baltimore)* 2004;83(5):274-279.
22. Cohn SM, Nathens AB, Moore FA, et al. Tissue oxygen saturation predicts the development of organ dysfunction during traumatic shock resuscitation. *J Trauma.* 2007;62:44-54.
23. Clancy K, Velopoulos C, Bilaniuk JW, et al. Screening for blunt cardiac injury: An Eastern Association for the Surgery of Trauma practice management guideline. *J Trauma Acute Care Surg.* 2012;73:S301-S306.
24. Velmahos GC, Karaïskakis M, Salim A, et al. Normal electrocardiography and serum troponin I levels preclude the presence of clinically significant blunt cardiac injury. *J Trauma.* 2003;54(1):45-50.
25. Ferrada P, Murthi S, Anand RJ, Bochicchio GV, Scalea T. Transthoracic focused rapid echocardiographic examination: real-time evaluation of fluid status in critically ill trauma patients. *J Trauma.* 2011;70:56-62.
26. Arntfield RT, Millington SJ. Point of care cardiac ultrasound applications in the emergency department and intensive care unit—a review. *Curr Cardiol Rev.* 2012;8(2):98-108.
27. Dolich MO, McKenney MG, Varela JE, et al. 2,576 ultrasounds for blunt abdominal trauma. *J Trauma.* 2001; 50: 108-112.
28. Sondeen JL, Coppes VG, Holcomb JB. Blood pressure at which rebleeding occurs after resuscitation in swine with aortic injury. *J Trauma.* 2003; 54(Suppl):S110-S117.
29. **Brain Trauma Foundation, American Association of Neurological Surgeons, Congress of Neurological Surgeons: *Guidelines for the management of severe traumatic brain injury.* *J Neurotrauma* 24(Suppl):S1, 2007.**
30. Ryb GE, Dischinger PC, Kufera JA, et al. Delta V, principal direction of force, and restraint use contributions to motor vehicle crash mortality. *J Trauma.* 2007;63:1000-1005.
31. Ivascu FA, Howells GA, Junn FS, Bair HA, Bendick PJ, Janczyk RJ. Predictors of mortality in trauma patients with intracranial hemorrhage on preinjury aspirin or clopidogrel. *J Trauma.* 2008;65(4):785-788.
32. Moore MM, Pasquale MD, Badellino M. Impact of age and anticoagulation: need for neurosurgical intervention in trauma patients with mild traumatic brain injury. *J Trauma Acute Care Surg.* 2012;73(1):126-130.
33. Diaz JJ Jr., Aulino JM, Collier B, et al. The early work-up for isolated ligamentous injury of the cervical spine: Does does

- computed tomography scan have a role? *J Trauma*. 2005; 59:897-903.
34. Sekharan J, Dennis JW, Veldenz HC, et al. Continued experience with physical examination alone for evaluation and management of penetrating zone 2 neck injuries: Results results of 145 cases. *J Vasc Surg*. 2000;32:483-489.
 35. Inaba K, Branco BC, Menaker J, et al. Evaluation of multi-detector computed tomography for penetrating neck injury: a prospective multicenter study. *J Trauma Acute Care Surg*. 2012;72:576-583.
 36. Fabian TC, Richardson JD, Croce MA, et al. Prospective study of blunt aortic injury: multicenter trial of the American Association for the Surgery of Trauma. *J Trauma Trauma*. 1997;42:374-380.
 37. Dyer DS, Moore EE, Ilke DN, et al. Thoracic aortic injury: how predictive is mechanism and is chest computed tomography a reliable screening tool? A prospective study of 1,561 patients. *J Trauma*. 2000;48:673-682.
 38. Siegel JH, Smith JA, Siddiqi SQ. Change in velocity and energy dissipation on impact in motor vehicle crashes as a function of the direction of crash: key factors in the production of thoracic aortic injuries, their pattern of associated injuries and patient survival. A Crash Injury Research Engineering Network (CIREN) study. *J Trauma* 2004;57(4):760-777.
 39. Flowers JL, Graham SM, Ugarte MA, et al. Flexible endoscopy for the diagnosis of esophageal trauma. *J Trauma*. 1996; 40:261-265.
 40. Cox CS Jr., Allen GS, Fischer RP, et al. Blunt vs. penetrating subclavian artery injury: Presentation, injury pattern, and outcome. *J Trauma* .1999;46:445-449.
 41. Demetriades D, Hadjizacharia P, Constantinou C, et al. Selective nonoperative management of penetrating abdominal solid organ injuries. *Ann Surg*. 2006; 244:620-628.
 42. Biffi WL, Cothren CC, Brasel KJ, et al. A prospective observational multicenter study of the optimal management of patients with anterior abdominal stab wounds. *J Trauma*. 2008; 64:250.
 43. Biffi WL, Kaups KL, Pham TN, et al. Validating the Western Trauma Association algorithm for managing patients with anterior abdominal stab wounds: a Western Trauma Association multicenter trial. *J Trauma*. 2011;71(6):1494-1502.
 44. Ochsner MG, Knudson MM, Pachter HL, et al. Significance of minimal or no intraperitoneal fluid visible on CT scan associated with blunt liver and splenic injuries: A multicenter analysis. *J Trauma*. 2000; 49:505-510.
 45. Yu J, Fulcher AS, Turner MA, Cockrell C, Halvorsen RA. Blunt bowel and mesenteric injury: MDCT diagnosis. *Abdom Imaging*. 2011;36(1):50-61.
 46. LeBedis CA, Anderson SW, Soto JA. CT imaging of blunt traumatic bowel and mesenteric injuries. *Radiol Clin North Am*. 2012;50(1):123-136.
 47. Fox N, Rajani RR, Bokhari F, et al. Evaluation and management of penetrating lower extremity arterial trauma: an Eastern Association for the Surgery of Trauma practice management guideline. *J Trauma Acute Care Surg*. 2012;73:S315-S320.
 48. Burch JM, Franciose RJ, Moore EE, et al. Single-layer continuous vs. two-layer interrupted intestinal anastomosis—a prospective randomized study. *Ann Surg*. 2000; 231:832-837.
 49. Moore EE. Thomas G. Orr Memorial Lecture. Staged laparotomy for the hypothermia, acidosis, and coagulopathy syndrome. *Am J Surg*. 1996;172:405-410.
 50. Gonzalez E, Pieracci FM, Moore EE, Kashuk JL. Coagulation abnormalities in the trauma patient: the role of point-of-care thromboelastography. *Semin Thromb Hemost*. 2010;36:723-737.
 51. Cohen MJ, Call M, Nelson M, et al. Critical role of activated protein C in early coagulopathy and later organ failure, infection and death in trauma patients. *Ann Surg*. 2012;255(2): 379-385.
 52. Cotton BA, Harvin JA, Kostousou V, et al. Hyperfibrinolysis at admission is an uncommon but highly lethal event associated with shock and prehospital fluid administration. *J Trauma Acute Care Surg*. 2012;73(2):365-370.
 53. Hebert PC, Wells G, Blajchman MA, et al. A multicenter, randomized, controlled clinical trial of transfusion requirements in critical care. *New Engl J Med*. 1999; 340:409-417.
 54. West MA, Shapiro MB, Nathens AB, et al. Inflammation and the host response to injury, a large-scale collaborative project: Patient-oriented research core-standard operating procedures for clinical care. IV. Guidelines for transfusion in the trauma patient. *J Trauma*. 2006; 61:436-439.
 55. Toy P, Popovsky MA, Abraham E, et al. Transfusion-related acute lung injury: definition and review. *Crit Care Med*. 2005; 33:721-726.
 56. Moore FA, Moore EE, Sauaia A. Blood transfusion: an independent risk factor for postinjury multiple organ failure. *Arch Surg*. 1997;132:620-624.
 57. Kashuk JL, Moore EE, Sauaia A, et al. Postinjury life-threatening coagulopathy: is 1:1 fresh frozen plasma: packed red blood cells the answer? *J Trauma*. 2008;65:261-270.
 58. Davenport R, Curry N, Manson J, et al. Hemostatic effects of fresh frozen plasma may be maximal at red cell ratios of 1:2. *J Trauma*. 2011;70(1):90-95.
 59. Stanworth SJ, Morris TP, Gaarder C, et al. Reappraising the concept of massive transfusion in trauma. *Crit Care*. 2010;14(6):R239.
 60. Dzik WH, Blajchman MA, Fergusson D, et al. Clinical review: Canadian National Advisory Committee on Blood and Blood Products—Massive transfusion consensus conference 2011: report of the panel. *Crit Care*. 2011;15(6):242.
 61. Menaker J, Stein DM, Scalea TM. Incidence of early pulmonary embolism after injury. *J Trauma*. 2007; 63:620-624.
 62. Prager M, Polterauer P, Böhmig HJ, et al. Collagen vs. gelatin-coated Dacron vs. stretch polytetrafluoroethylene in abdominal aortic bifurcation graft surgery: results of a seven-year prospective, randomized multicenter trial. *Surgery*. 2001;130(3):408-414.
 63. Mattox KL. Red River anthology. *J Trauma*. 1997;42(3): 353-368.
 64. Richardson JD, Bergamini TM, Spain DA, et al. Operative strategies for management of abdominal aortic gunshot wounds. *Surgery*. 1996;120(4):667-671.
 65. Cosgriff N, Moore EE, Sauaia A, Kenny-Moynihan M, Burch JM, Galloway B. Predicting life-threatening coagulopathy in the massively transfused trauma patient: hypothermia and acidosis revisited. *J Trauma*. 1997;42(5):857-861.
 66. Maegele M, Spinella PC, Schöchl H. The acute coagulopathy of trauma: mechanisms and tools for risk stratification. *Shock*. 2012;38(5):450-458.
 67. Nirula R, Millar D, Greene T, et al. Decompressive craniectomy for medical management for refractory intracranial hypertension: An AAST-MITC propensity score analysis. *J Trauma*, in press.
 68. Cooper DJ, Rosenfeld JV, Murray L, et al. DECRA Trial Investigators; Australian and New Zealand Intensive Care Society Clinical Trials Group. Decompressive craniectomy in diffuse traumatic brain injury. *N Engl J Med*. 2011;364(16):1493-1502.
 69. Rinker C, McMurry F, Groeneweg V, et al. Emergency craniotomy in a rural level III trauma center. *J Trauma*. 1998; 44:984-989.
 70. Hutchison JS, Ward RE, Lacroix J, et al. Hypothermia Pediatric Head Injury Trial Investigators and the Canadian Critical Care Trials Group. Hypothermia therapy after traumatic brain injury in children. *N Engl J Med*. 2008;358(23):2447-2456.
 71. Kramer C, Freeman WD, Hoffman-Snyder C, et al. Therapeutic hypothermia for severe traumatic brain injury: a critically appraised topic. *Neurologist*. 2012;18(3):173-177.

72. Pieracci FM, Moore EE, Beauchamp K, et al. A cost-minimization analysis of phenytoin vs. levetiracetam for early seizure pharmacoprophylaxis after traumatic brain injury. *J Trauma Acute Care Surg.* 2012;72(1):276-281.
73. Cogbill T, Cothren CC, Ahearn MK, et al. Management of severe hemorrhage associated with maxillofacial injuries: a multicenter perspective. *J Trauma.* 2008; 64:250.
74. Bracken MB, Shepard MJ, Holford TR, et al. Administration of methylprednisolone for 24 or 48 hours or tirilazad mesylate for 48 hours in the treatment of acute spinal cord injury. Results of the Third National Acute Spinal Cord Injury Randomized Controlled Trial. National Acute Spinal Cord Injury Study. *JAMA.* 1997;277:1597-1604.
75. Stahel PF, Vanderheiden T, Finn MA. Management strategies for acute spinal cord injury: current options and future perspectives. *Curr Opin Crit Care.* 2012;18(6):651-660.
76. Fehlings MG, Perrin RG: The timing of surgical intervention in the treatment of spinal cord injury: a systematic review of recent clinical evidence. *Spine.* 2006; 31:S28,-S35.
77. Biffi WL, Moore EE, Offner PJ, et al. Blunt carotid arterial injuries: implications of a new grading scale. *J Trauma.* 1999; 47:845-853.
78. Burlew CC, Biffi WL, Moore EE, Barnett CC, Johnson JL, Bensard DD. Blunt cerebrovascular injuries: redefining screening criteria in the era of noninvasive diagnosis. *J Trauma Acute Care Surg.* 2012;72(2):330-335.
79. Cothren CC, Moore EE, Biffi WL, et al. Anticoagulation is the gold standard therapy for blunt carotid injuries to reduce stroke rate. *Arch Surg.* 2004; 139:540-545.
80. Edwards NM, Fabian TC, Claridge JA, et al. Antithrombotic therapy and endovascular stents are effective treatment for blunt carotid injuries: results from long-term followup. *J Am Coll Surg.* 2007; 204:1007-1013.
81. Bladergroen M, Brockman R, Luna G, et al. A twelve-year study of cervicothoracic vascular injuries. *Am J Surg.* 1989;157:483-486.
82. Johnston RH, Wall MJ, Mattox KL. Innominate artery trauma: a thirty-year experience. *J Vasc Surg.* 1993; 17:134-139.
83. Fabian TC, Davis KA, Gavant ML, et al. Prospective study of blunt aortic injury: helical CT is diagnostic and antihypertensive therapy reduces rupture. *Ann Surg.* 1998;227:666.
84. Karmy-Jones R, Nicholls S, Gleason TG. The endovascular approach to acute aortic trauma. *Thorac Surg Clin.* 2007; 17:109-128.
85. Demetriades D, Velmahos GC, Scalea TM, et al. Diagnosis and treatment of blunt thoracic aortic injuries: changing perspectives. *J Trauma.* 2008;64(6):1415-1418.
86. Moore EE, Burch JM, Moore JB. Repair of the torn descending thoracic aorta using the centrifugal pump with partial left heart bypass. *Ann Surg.* 2004; 240:38-43.
87. Wall MJ, Tsai P, Mattox KL. Heart and Thoracic Vascular Injury. Mattox KL, Moore EE, Feliciano DV (eds): *Trauma*, 7th ed. New York: McGraw-Hill, 2013.
88. Jones EL, Burlew CC, Moore EE. BioGlue hemostasis of penetrating cardiac wounds in proximity to the left anterior descending coronary artery. *J Trauma Acute Care Surg.* 2012;72(3):796-798.
89. Cothren CC, Moore EE. Traumatic ventricular septal defect. *Surgery.* 2007;142:776-777.
90. Wall MJ Jr., Hirshberg A, Mattox KL. Pulmonary tractotomy with selective vascular ligation for penetrating injuries to the lung. *Am J Surg.* 1994; 168:665-669.
91. Cothren C, Moore EE, Biffi WL, et al. Lung-sparing techniques are associated with improved outcome compared with anatomic resection for severe lung injuries. *J Trauma* 2002;53:483-487.
92. Cryer HG, Mavroudis C, Yu J, et al. Shock, transfusion, and pneumonectomy. Death is due to right heart failure and increased pulmonary vascular resistance. *Ann Surg.* 1990;212:197-201.
93. Luo L, Yin L, Liu Z, Xiang Z. Posttraumatic pulmonary pseudocyst: Computed tomography findings and management in 33 patients. *J Trauma and Acute Care Surg.* 2012;73(5): 1225-1228.
94. Moore HB, Moore EE, Burlew CC, et al. Western Trauma Association critical decisions in trauma: Management management of parapneumonic effusion. *J Trauma Acute Care Surg.* 2012;73: 1372-1379.
95. de Souza A, Offner PJ, Moore EE, et al. Optimal management of complicated empyema. *Am J Surg.* 2000; 180:507-511.
96. Truitt MS, Murry J, Amos J, et al. Continuous intercostal nerve blockade for rib fractures: ready for primetime? *J Trauma.* 2011;71(6):1548-1552.
97. Kozar RA, Moore FA, Cothren CC, et al. Risk factors for hepatic morbidity following nonoperative management: multicenter study. *Arch Surg.* 2006; 141:451-458.
98. Malhotra AK, Fabian TC, Croce MA, et al. Blunt hepatic injury: a paradigm shift from operative to nonoperative management in the 1990s. *Ann Surg.* 2000;231:804-813.
99. Peitzman AB, Marsh JW. Advanced operative techniques in the management of complex liver injury. *J Trauma Acute Care Surg.* 2012;73(3):765-770.
100. Biffi WL, Moore EE, Franciose RJ. Venovenous bypass and hepatic vascular isolation as adjuncts in the repair of destructive wounds to the retrohepatic inferior vena cava. *J Trauma.* 1998; 45:400-403.
101. Poggetti RS, Moore EE, Moore FA, et al. Balloon tamponade for bilobar transfixing hepatic gunshot wounds. *J Trauma.* 1992; 33:694-697.
102. Delis SG, Bakoyiannis A, Selvaggi G, et al. Liver transplantation for severe hepatic trauma: experience from a single center. *World J Gastroenterol.* 2009;15(13):1641-1644.
103. Lillemoe KD, Melton GB, Cameron JL, et al. Postoperative bile duct strictures: management and outcome in the 1990s. *Ann Surg.* 2000;232:430-441.
104. Pickhardt B, Moore EE, Moore FA, et al. Operative splenic salvage in adults: a decade perspective. *J Trauma.* 1989; 29: 1386-1391.
105. Feliciano DV, Spjut-Patrinely V, Burch JM, et al. Splenorhaphy: the alternative. *Ann Surg.* 1990; 211:569-580.
106. Stassen NA, Bhullar I, Cheng JD, et al. Selective nonoperative management of blunt splenic injury: an Eastern Association for the Surgery of Trauma practice management guideline. *J Trauma and Acute Care Surg.* 2012;73(5):S294-S300.
107. McIntyre LK, Schiff M, Jurkovich GJ. Failure of nonoperative management of splenic injuries: Causes and consequences. *Arch Surg.* 2005;140:563-568.
108. Smith HE, Biffi WL, Majercik SD, et al. Splenic artery embolization: have we gone too far? *J Trauma.* 2006; 61:541-546.
109. Toutouzas KG, Velmahos GC, Kaminski A, et al. Leukocytosis after posttraumatic splenectomy: a physiologic event or sign of sepsis? *Arch Surg.* 2002; 137:924-928.
110. Howdieshell TR, Heffernan D, Dipiro JT. Therapeutic Agents Committee of the Surgical Infection Society. Surgical infection society guidelines for vaccination after traumatic injury. *Surg Infect (Larchmt).* 2006;7(3):275-303.
111. Burch JM, Franciose RJ, Moore EE, et al. Single-layer continuous vs. two-layer interrupted intestinal anastomosis: a prospective randomized trial. *Ann Surg Surg.* 2000;231: 832-837.
112. Todd SR, Kozar RA, Moore FA. Nutrition support in adult trauma patients. *Nutr Clin Pract.* 2006; 21:421-429.
113. Burlew CC, Moore EE, Cuschieri J, et al; the WTA Study Group. Who should we feed? Western Trauma Association multi-institutional study of enteral nutrition in the open abdomen after injury. *J Trauma Acute Care Surg.* 2012;73:1380-1387.

114. Sharpe JP, Magnotti LJ, Weinberg JA, et al. Impact of a defined management algorithm on outcome after traumatic pancreatic injury. *J Trauma Acute Care Surg.* 2012;72:100-105.
115. Vaughn GD, Frazier OH, Graham D, et al. The use of pyloric exclusion in the management of severe duodenal injuries. *Am J Surg.* 1977;134:785.
116. Nelson R, Singer M. Primary repair for penetrating colon injuries. *Cochrane Database Syst Rev* 3:CD002247, 2003.
117. Asensio JA, Britt LD, Borzotta A, et al. Multi-institutional experience with the management of superior mesenteric artery injuries. *J Am Coll Surg.* 2001;193:354-356.
118. Burch JM, Richardson RJ, Martin RR, et al. Penetrating iliac vascular injuries: experience with 233 consecutive patients. *J Trauma.* 1990; 30:1450-1459.
119. Mullins RJ, Lucas CE, Ledgerwood AM. The natural history following venous ligation for civilian injuries. *J Trauma.* 1980;20:737-743.
120. Roth SM, Wheeler JR, Gregory RT, et al. Blunt injury of the abdominal aorta: a review. *J Trauma.* 1997; 42:748-755.
121. Jurkovich GJ, Hoyt DB, Moore FA, et al. Portal triad injuries. *J Trauma.* 1995;39:426-434.
122. Voelzke BB, McAninch JW. Renal gunshot wounds: clinical management and outcome. *J Trauma.* 2009;66(3):593-600.
123. Knudson MM, Harrison PB, Hoyt DB, et al. Outcome after major renovascular injuries: A Western trauma association multicenter report. *J Trauma.* 2000; 49:1116-1122.
124. Cothren CC, Osborn PM, Moore EE, et al: Preperitoneal pelvic packing for hemodynamically unstable pelvic fractures: A paradigm shift. *J Trauma.* 62:834-839.
125. Burlew CC, Moore EE, Smith WR, et al. Preperitoneal pelvic packing/external fixation with secondary angioembolization: optimal care for life-threatening hemorrhage from unstable pelvic fractures. *J Am Coll Surg.* 2011;212(4):628-635.
126. Bosse MJ, MacKenzie EJ, Kellam JF, et al. An analysis of outcomes of reconstruction or amputation of leg-threatening injuries. *N Engl J Med.* 2002;347:1924-1931.
127. Moore FA, McKinley BA, Moore EE, et al. Inflammation and the Host Response to Injury, a large-scale collaborative project: patient-oriented research core—standard operating procedures for clinical care. III. Guidelines for shock resuscitation. *J Trauma,* 2006;61:82-89.
128. Burlew CC, Moore EE, Biffl WL, Bensard DD, Johnson JL, Barnett CC. One hundred percent fascial approximation can be achieved in the postinjury open abdomen with a sequential closure protocol. *J Trauma Acute Care Surg.* 2012;72(1):235-241.
129. Sela HY, Weiniger CF, Hersch M, Smueloff A, Laufer N, Einav S. The pregnant motor vehicle accident casualty: adherence to basic workup and admission guidelines. *Ann Surg.* 2011;254(2):346-352.
130. ACOG Committee on Obstetric Practice: ACOG Committee Opinion. Number 299, September 2004. Guidelines for diagnostic imaging during pregnancy. *Obstet Gynecol* 2004;104:647-651.
131. Morris JA, Rosenbower TJ, Jurkovich GJ, et al: . Infant survival after cesarean section for trauma. *Ann Surg.* 1996;223:481-488.
132. Curet MJ, Schermer CR, Demarest GB, et al. Predictors of outcome in trauma during pregnancy: Identification of patients who can be monitored for less than 6 hours. *J Trauma.* 2000;49:18-24.
133. Davis JW, Kaups KL. Base deficit in the elderly: a marker of severe injury and death. *J Trauma.* 1998; 45:873-877.
134. Reynolds FD, Dietz PA, Higgins D, et al. Time to deterioration of the elderly, anticoagulated, minor head injury patient who presents without evidence of neurologic abnormality. *J Trauma.* 2003;54:492-496.
135. Bulger EM, Arneson MA, Mock CN, et al. Rib fractures in the elderly. *J Trauma* 2000;48:1040-1046.
136. Bergeron E, Lavoie A, Clas D, et al. Elderly trauma patients with rib fractures are at greater risk of death and pneumonia. *J Trauma.* 2003;54:478-485.
137. Tepas JJ. The national pediatric trauma registry: a legacy of commitment to control childhood injury. *Semin Pediatr Surg.* 2004;13:126-132.
138. Partrick DA, Bensard DD, Moore EE, et al. Ultrasound is an effective triage tool to evaluate blunt abdominal trauma in the pediatric population. *J Trauma.* 1998;45:57-63.
139. Partrick DA, Bensard DD, Moore EE, et al. Nonoperative management of solid organ injuries in children results in decreased blood utilization. *J Pediatr Surg.* 1999;34:1695-1699.

8 chapter

Burns

Jonathan Friedstat, Fred W. Endorf,
and Nicole S. Gibran

Background	227	Transfusion	231	Surgery	233
Initial Evaluation	227	Inhalation Injury and Ventilator Management	231	Wound Coverage	234
Classification of Burns	228	Treatment of the Burn Wound	232	Rehabilitation	235
Burn Depth	229	Nutrition	232	Prevention	235
Prognosis	230	Complications in Burn Care	233	Radiation Burns	235
Resuscitation	230			Future Areas of Study	236

Surgical care of the burned patient has evolved into a specialized field incorporating the interdisciplinary skills of burn surgeons, nurses, therapists, and other healthcare specialists. However, recent mass casualty events have been a reminder that healthcare systems may be rapidly pressed to care for large numbers of burn patients. Naturally, general surgeons may be at the forefront in these events, so it is crucial that they are comfortable with the care of burned patients and well equipped to provide standard of care.

BACKGROUND

Burn injury historically carried a poor prognosis. With advances in fluid resuscitation¹ and the advent of early excision of the burn wound,² survival has become an expectation even for patients with severe burns. Continued improvements in critical care and progress in skin bioengineering herald a future in which functional and psychological outcomes are equally important as survival alone. With this shift in priority, the American Burn Association (ABA) has emphasized referral to specialized burn centers after early stabilization. Specific criteria should guide transfer of patients with more complex injuries or other medical needs to a burn center (Table 8-1). The ABA has published standards of care³ and created a verification process to ensure that burn centers meet those standards.⁴ Because of increased prehospital safety measures, burn patients are being transferred longer distances to receive definitive care at regional burn centers⁵; recent data from one burn center with a particularly wide catchment area confirmed that even transport times averaging 7 hours did not affect the long-term outcomes of burn patients.⁶

INITIAL EVALUATION

Initial evaluation of the burned patient involves four crucial assessments: airway management, evaluation of other injuries, estimation of burn size, and diagnosis of CO and cyanide poisoning. With direct thermal injury to the upper airway or smoke inhalation, rapid and severe airway edema is a potentially lethal threat. Anticipating the need for intubation and establishing an

early airway are critical. Perioral burns and singed nasal hairs are signs that the oral cavity and pharynx should be further evaluated for mucosal injury, but these physical findings alone do not indicate an upper airway injury. Signs of impending respiratory compromise may include a hoarse voice, wheezing, or stridor; subjective dyspnea is a particularly concerning symptom and should trigger prompt elective endotracheal intubation. In patients with combined multiple trauma, especially oral trauma, nasotracheal intubation may be useful but should be avoided if oral intubation is safe and easy.

Burned patients should be first considered trauma patients, especially when details of the injury are unclear. A primary survey should be conducted in accordance with Advanced Trauma Life Support guidelines. Concurrently with the primary survey, large-bore peripheral intravenous (IV) catheters should be placed and fluid resuscitation should be initiated; for a burn larger than 40% total body surface area (TBSA), two large-bore IVs are ideal. IV placement through burned skin is safe and effective but requires attention to securing the catheters. Central venous access may provide useful information as to volume status and be useful in severely burned patients. Rarely, IV resuscitation is indicated in patients with burns smaller than 15% who can usually hydrate orally. Pediatric patients with burns larger than 15% may require intraosseous access in emergent situations if venous access cannot be attained. An early and comprehensive secondary survey must be performed on all burn patients, but especially those with a history of associated trauma such as with a motor vehicle collision. Also, patients from structural fires in which the manner of egress is not known should be carefully evaluated for injuries from a possible jump or fall. Urgent radiology studies, such as a chest x-ray, should be performed in the emergency department, but nonurgent skeletal evaluation (i.e., extremity x-rays) can be done in the intensive care unit (ICU) to avoid hypothermia and delays in burn resuscitation. Hypothermia is a common prehospital complication that contributes to resuscitation failure. Patients should be wrapped with clean blankets in transport. Cooling blankets should be avoided in patients with moderate or large (>20% TBSA) burns.

Key Points

- 1▶ Follow American Burn Association criteria for transfer of a patient to a regional burn center.
- 2▶ Never administer prophylactic antibiotics other than tetanus vaccination.
- 3▶ Early excision and grafting of full-thickness and deep partial-thickness burns improve outcomes.

- 4▶ Intravenous fluid resuscitation for patients with burns greater than 20% of total body surface area (children with burns >15% of total body surface area) should be titrated to mean arterial pressure (MAP) greater than 60 mmHg and urine output greater than 30 mL/h.

Patients with acute burn injuries should never receive prophylactic antibiotics. This intervention has been clearly demonstrated to promote development of fungal infections and resistant organism and was abandoned in the mid-1980s. A tetanus booster should be administered in the emergency room.

The importance of pain management for these patients has been widely recognized over the past 25 years. However, we must also consider treatment of long-term anxiety. Therefore, it is important to administer an anxiolytic such as a benzodiazepine with the initial narcotics.

Most burn resuscitation formulas estimate fluid requirements using the burn size as a percentage of TBSA (%TBSA). The “rule of nines” is a crude but quick and effective method of estimating burn size (Fig. 8-1). In adults, the anterior and posterior trunk each account for 18%, each lower extremity is 18%, each upper extremity is 9%, and the head is 9%. In children under 3 years old, the head accounts for a larger relative surface area and should be taken into account when estimating burn size. Diagrams such as the Lund and Browder chart give a more accurate accounting of the true burn size in children. The importance of an accurate burn size assessment cannot be overemphasized. Superficial or first-degree burns should not be included when calculating the %TBSA, and thorough cleaning of soot and debris is mandatory to avoid confusing

soiled skin with burns. Examination of referral data suggests that physicians inexperienced with burns tend to overestimate the size of small burns and underestimate the size of large burns, with potentially detrimental effects on pretransfer resuscitation.⁷

An important contributor to early mortality in burn patients is carbon monoxide (CO) poisoning resulting from smoke inhalation. The affinity of CO for hemoglobin is approximately 200 to 250 times more than that of oxygen, which decreases the levels of normal oxygenated hemoglobin and can quickly lead to anoxia and death.⁸ Unexpected neurologic symptoms should raise the level of suspicion, and an arterial carboxyhemoglobin level must be obtained because pulse oximetry can be falsely elevated. Administration of 100% oxygen is the gold standard for treatment of CO poisoning and reduces the half-life of CO from 250 minutes in room air to 40 to 60 minutes on 100% oxygen.⁹ Some authors have proposed hyperbaric oxygen as an adjunctive therapy for CO poisoning.¹⁰ However, the data are mixed regarding the success of hyperbaric oxygen, and its associated logistical difficulties and complications have limited its usefulness for patients with moderate or large burns.^{11,12} Patients who sustain a cardiac arrest as a result of their CO poisoning have an extremely poor prognosis regardless of the success of initial resuscitation attempts.¹³ Hydrogen cyanide toxicity may also be a component of smoke inhalation injury. Afflicted patients may have a persistent lactic acidosis or ST elevation on electrocardiogram (ECG).¹⁴ Cyanide inhibits cytochrome oxidase, which is required for oxidative phosphorylation.¹⁵ Treatment consists of sodium thiosulfate, hydroxocobalamin, and 100% oxygen. Sodium thiosulfate works by transforming cyanide into a nontoxic thiocyanate derivative, but it works slowly and is not effective for acute therapy. Hydroxocobalamin quickly complexes with cyanide, is excreted by the kidney, and is recommended for immediate therapy.⁹ In the majority of patients, the lactic acidosis will resolve with ventilation, and sodium thiosulfate treatment becomes unnecessary.¹⁶

Table 8-1

Guidelines for referral to a burn center

Partial-thickness burns greater than 10% TBSA
Burns involving the face, hands, feet, genitalia, perineum, or major joints
Third-degree burns in any age group
Electrical burns, including lightning injury
Chemical burns
Inhalation injury
Burn injury in patients with complicated pre-existing medical disorders
Patients with burns and concomitant trauma in which the burn is the greatest risk. If the trauma is the greater immediate risk, the patient may be stabilized in a trauma center before transfer to a burn center.
Burned children in hospitals without qualified personnel for the care of children
Burn injury in patients who will require special social, emotional, or rehabilitative intervention

TBSA = total body surface area.

CLASSIFICATION OF BURNS

Burns are commonly classified as thermal, electrical, or chemical burns, with thermal burns consisting of flame, contact, or scald burns. Flame burns are not only the most common cause for hospital admission of burns, but also have the highest mortality. This is primarily related to their association with structural fires and the accompanying inhalation injury and/or CO poisoning.¹⁷

Electrical burns make up only 4% of U.S. hospital admissions but have special concerns including the potential for cardiac arrhythmias and compartment syndromes with concurrent rhabdomyolysis. A baseline ECG is recommended in all patients

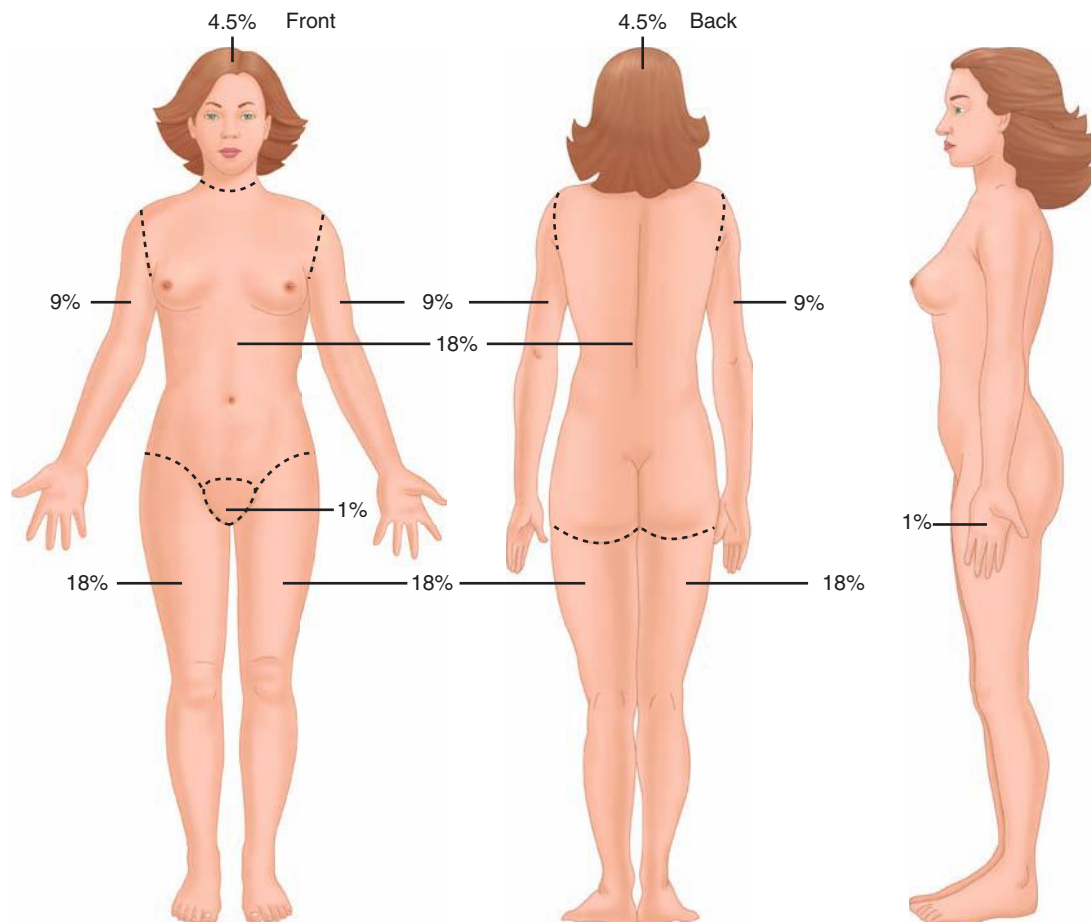


Figure 8-1. The “rule of nines” can be used as a quick reference for estimating a patient’s burn size by dividing the body into regions to which total body surface area is allocated in multiples of nine.

with an electrical injury, and a normal ECG in a low-voltage injury may preclude hospital admission. Because compartment syndrome and rhabdomyolysis are common in high-voltage electrical injuries, vigilance must be maintained for neurologic or vascular compromise, and fasciotomies should be performed even in cases of moderate clinical suspicion. Long-term neurologic and visual symptoms are not uncommon with high-voltage electrical injuries, and ophthalmologic and neurologic consultation should be obtained to better define a patient’s baseline function.¹⁸

Chemical burns are less common but potentially severe burns. The most important components of initial therapy are careful removal of the toxic substance from the patient and irrigation of the affected area with water for a minimum of 30 minutes, except in cases of concrete powder or powdered forms of lye, which should be swept from the patient to avoid activating the aluminum hydroxide with water. The offending agents in chemical burns can be systemically absorbed and may cause specific metabolic derangements. Formic acid has been known to cause hemolysis and hemoglobinuria, and hydrofluoric acid causes hypocalcemia. Hydrofluoric acid is a particularly common offender due to its widespread industrial uses. Calcium-based therapies are the mainstay of treating hydrofluoric acid burns, with topical application of calcium gluconate onto wounds¹⁹ and IV administration of calcium gluconate for systemic symptoms. Intra-arterial calcium gluconate infusion provides effective treatment of progressive tissue injury and intense pain.^{20,21} Patients undergoing intra-arterial therapy need

continuous cardiac monitoring. Persistent refractory hypocalcemia with electrocardiac abnormalities may signal the need for emergent excision of the burned areas.

BURN DEPTH

Based on the original burn depth classification by Dupuytren in 1832,²² burn wounds are commonly classified as superficial (first-degree), partial-thickness (second-degree), full-thickness (third-degree), and fourth-degree burns, which affect underlying soft tissue. Partial-thickness burns are classified as either superficial or deep partial-thickness burns by depth of involved dermis. Clinically, first-degree burns are painful but do not blister, second-degree burns have dermal involvement and are extremely painful with weeping and blisters, and third-degree burns are leathery, painless, and nonblanching. Jackson described three zones of tissue injury following burn injury.²³ The zone of coagulation is the most severely burned portion and is typically in the center of the wound. As the name implies, the affected tissue is coagulated and sometimes frankly necrotic, much like a third- or fourth-degree burn, and will need excision and grafting. Peripheral to that is a zone of stasis, with variable degrees of vasoconstriction and resultant ischemia, much like a second-degree burn. Appropriate resuscitation and wound care may help prevent conversion to a deeper wound, but infection or suboptimal perfusion may result in an increase in burn depth. This is clinically relevant because many superficial partial-thickness burns will heal with expectant management, and the

3▶ majority of deep partial-thickness burns require excision and skin grafting. The last area of a burn is called the zone of hyperemia, which will heal with minimal or no scarring and is most like a superficial or first-degree burn.

Unfortunately, even experienced burn surgeons have limited ability to accurately predict the healing potential of partial-thickness burns soon after injury; one reason is that burn wounds evolve over the 48 to 72 hours after injury. Numerous techniques have been developed with the idea that better early prediction of burn depth will expedite appropriate surgical decision making. One of the most effective ways to determine burn depth is full-thickness biopsy, but this has several limitations; not only is the procedure painful and potentially scarring, but accurate interpretation of the histopathology requires a specialized pathologist and may have slow turnaround times.²⁴ Laser Doppler can measure skin perfusion to predict burn depth with a positive predictive value of up to 80% in some studies.^{25,26} Noncontact ultrasound has been postulated as a painless modality to predict nonhealing wounds and has the advantage of easily performed serial measurements.²⁷ Unfortunately, none of these newer therapies have proven adequately superior to justify their cost and as yet have not substituted serial examination by experienced burn surgeons.

PROGNOSIS

The Baux score (mortality risk equals age plus %TBSA) was used for many years to predict mortality in burns. Analysis of multiple risk factors for burn mortality has validated age and %TBSA as the strongest predictors of mortality.²⁸ Advancements in burn care have lowered overall mortality to the point that the Baux score may no longer be accurate. However, age and burn size, as well as inhalation injury, continue to be the most robust indicators for burn mortality.²⁹ Age even as a single variable strongly predicts mortality in burns,³⁰ and in-hospital mortality in elderly burn patients is a function of age regardless of other comorbidities.³¹ In nonelderly patients, comorbidities such as preinjury human immunodeficiency virus (HIV), metastatic cancer, and kidney or liver disease may influence mortality and length of stay.³² A recent large database study of 68,661 burn patients found that the variables with the highest predictive value for mortality were age, %TBSA, inhalation injury, coexistent trauma, and pneumonia.³³

RESUSCITATION

A myriad of formulas exist for calculating fluid needs during burn resuscitation, suggesting that no one formula benefits all patients. The most commonly used formula, the Parkland or Baxter formula, consists of 3 to 4 mL/kg/% burn of lactated Ringer's, of which half is given during the first 8 hours after burn and the remaining half is given over the subsequent 16 hours. The concept behind continuous fluid requirements is simple. The burn (and/or inhalation injury) drives an inflammatory response that leads to capillary leak; as plasma leaks into the extravascular space, crystalloid administration maintains the intravascular volume. Therefore, if a patient receives a large fluid bolus in a prehospital setting or emergency department, that fluid has likely leaked into the interstitium and the patient still requires ongoing burn resuscitation according to the estimates. Continuation of fluid volumes should depend on the time since injury, urine output, and mean arterial pressure (MAP). As the leak closes, the patient will require less volume to maintain these two resuscitation endpoints. Children under 20 kg have the

additional requirement that they do not have sufficient glycogen stores to maintain an adequate glucose level in response to the inflammatory response. Specific pediatric formulas have been described, but the simplest approach is to deliver a weight-based maintenance IV fluid with glucose supplementation in addition to the calculated resuscitation fluid with lactated Ringer's.

It is important to remember that any formula for burn resuscitation is merely a guideline, and fluid must be titrated based on appropriate measures of adequate resuscitation. A number of parameters are widely used to gauge burn resuscitation, but the most common remain the simple outcomes of blood pressure and urine output. As in any critically ill patient, a target

4▶ MAP of 60 mmHg ensures optimal end-organ perfusion. Goals for urine output should be 30 mL/h in adults and 1 to 1.5 mL/kg/h in pediatric patients. Because blood pressure and urine output may not correlate perfectly with true tissue perfusion, the search continues for other adjunctive parameters that may more accurately reflect adequate resuscitation. Some centers have found serum lactate to be a better predictor of mortality in severe burns,^{34,35} and others have found that base deficit predicts eventual organ dysfunction and mortality.^{36,37} Because burned patients with normal blood pressure and serum lactate levels may have compromised gastric mucosal perfusion, continuous measurement of mucosal pH with its logistical difficulties has garnered limited popularity.^{38,39} Invasive monitoring with pulmonary artery catheters typically results in significant excessive fluid administration without improved cardiac output or preload measurements; use of invasive monitoring seems to have variable effects on long-term outcomes.⁴⁰

Actual administered fluid volumes typically exceed volumes predicted by standard formulas.⁴¹ One survey of burn centers showed that 58% of patients end up getting more fluids than would be predicted by Baxter's formula.⁴² Comparison of modern-day patients with historical controls shows that over-resuscitation may be a relatively recent trend.⁴³ One theory is that increased opioid analgesic use results in peripheral vasodilation and hypotension and the need for greater volumes of bloused resuscitative fluids.⁴⁴ A classic study by Navar et al showed that burned patients with inhalation injury required an average of 5.76 mL/kg/% burn, vs. 3.98 mL/kg/% burn for patients without inhalation injury, and this has been corroborated by subsequent studies.^{45,46} Prolonged mechanical ventilation may also play a role in increased fluid needs.⁴⁷ A recent multicenter study found that age, weight, %TBSA, and intubation on admission were significant predictors of more fluid delivery during the resuscitation period. Those patients receiving higher fluid volumes were at increased risk of complications and death.⁴⁸ Common complications include abdominal compartment syndrome, extremity compartment syndrome, intraocular compartment syndrome, and pleural effusions. Monitoring bladder pressures can provide valuable information about development of intra-abdominal hypertension.

The use of colloid as part of the burn resuscitation has generated much interest over the years. In late resuscitation when the capillary leak has closed, colloid administration may decrease overall fluid volumes and potentially may decrease associated complications such as intra-abdominal hypertension.⁴⁹ However, albumin use has never been shown to improve outcomes in burn patients and has controversial effects on mortality in critically ill patients.^{50,51} Attempts to minimize fluid volumes in burn resuscitation have included study of hypertonic solutions, which appear to transiently decrease initial resuscitation volumes, with the downside of causing hyperchloremic acidosis.⁵²

Other adjuncts are being increasingly used during initial burn resuscitation. High-dose ascorbic acid (vitamin C) may decrease fluid volume requirements and ameliorate respiratory embarrassment during resuscitation.⁵³ Plasmapheresis may also decrease fluid requirements in patients who require higher volumes than predicted to maintain adequate urine output and MAP. It is postulated that plasmapheresis may filter out inflammatory mediators, thus decreasing ongoing vasodilation and capillary leak.⁵⁴

One recent adjunct that has found increasing utility in other surgical ICUs has been the application of bedside thoracic ultrasound.⁵⁵ Ultrasound offers the potential to make rapid, noninvasive assessments during acute changes in clinical condition. For burn patients, bedside ultrasonography may be indicated for evaluation of volume status, gross assessment of cardiac function, and diagnosis of pneumothorax. Determining patient cardiac function and volume status may guide fluid resuscitation. Cardiac function can be evaluated with three common heart views: the parasternal long axis, parasternal short axis, and apical four-chamber views.⁵⁶ Volume status can be estimated by examination of cardiac function, evaluation of the inferior vena cava (IVC) diameter, and changes with respiration. Ultrasound also allows timely diagnosis of pneumothorax.⁵⁷ A high-frequency probe with an adequate window between ribs permits identification of lung parenchyma against the chest wall. A pneumothorax appears as a transition on ultrasound between lung parenchyma, which has a heterogeneous appearance, and air, which has a hypoechoic appearance. Further studies are warranted to identify indications for the use of ultrasound in burned patients.

TRANSFUSION

The role of blood transfusion in critically injured patients has undergone a reevaluation in recent years.^{58,59} Blood transfusions are considered to be immunosuppressive, which is one explanation for the common responses seen to blood transfusions, such as increased infection and shorter time to recurrence after oncologic surgery.⁶⁰ A large multicenter study of blood transfusions in burn patients found that increased numbers of transfusions were associated with increased infections and higher mortality in burn patients, even when correcting for burn severity.⁶¹ A follow-up study implanting a restrictive transfusion policy in burned children showed that a hemoglobin threshold of 7 g/dL had no more adverse outcomes vs. a traditional transfusion trigger of 10 g/dL. In addition, costs incurred to the institution were significantly less.⁶² These data, in concert with other reported complications such as transfusion-related lung injury,⁶³ have led to recommendations that blood transfusions be used only when there is an apparent physiologic need. Attempts to minimize blood transfusion in nonburned critically ill patients have led to use of erythropoietin by some centers. However, burn patients often have elevated erythropoietin levels, and a randomized study in burn patients showed that recombinant human erythropoietin did not effectively prevent anemia or decrease the number of transfusions given.⁶⁴

INHALATION INJURY AND VENTILATOR MANAGEMENT

Inhalation injuries are commonly seen in tandem with burn injuries and are known to increase mortality in burned patients.⁶⁵ Smoke inhalation is present in as many as 35% of hospitalized burn patients and may triple the hospital stay compared to

isolated burn injuries.⁶⁶ The combination of burns, inhalation injury, and pneumonia increases mortality by up to 60% over burns alone.⁶⁷ Subsequent development of the adult respiratory distress syndrome (ARDS) is common in these patients and may be caused in part by recruitment of alveolar leukocytes with an enhanced endotoxin-activated cytokine response.⁶⁸ When ARDS complicates burns and inhalation injury, mortality approaches 66%; in one study, patients with burns $\geq 60\%$ TBSA in combination with inhalation injury and ARDS had 100% mortality.⁶⁹

Smoke inhalation causes injury in two ways: by direct heat injury to the upper airways and inhalation of combustion products into the lower airways. Direct injury to the upper airway causes airway swelling that typically leads to maximal edema in the first 24 to 48 hours after injury and often requires a short course of endotracheal intubation for airway protection. Combustion products found in smoke, most commonly from synthetic substances in structural fires, cause lower airway injury. These irritants cause direct mucosal injury, which in turn leads to mucosal sloughing, edema, reactive bronchoconstriction, and finally obstruction of the lower airways. Injury to both the epithelium and pulmonary alveolar macrophages causes release of prostaglandins, chemokines, and other inflammatory mediators; neutrophil migration; increased tracheobronchial blood flow; and finally increased capillary permeability. All of these components of acute lung injury increase the risk of pneumonia and ARDS following an inhalation injury.

The physiologic effects of smoke inhalation are numerous. Inhalation injury decreases lung compliance⁷⁰ and increases airway resistance work of breathing.⁷¹ Inhalation injury in the presence of burns also increases overall metabolic demands.⁷² The most common physiologic derangement seen with inhalation injury is increased fluid requirement during resuscitation. Since severe inhalation injury may result in mucosal sloughing with obstruction of smaller airways, bronchoscopy findings including carbon deposits, erythema, edema, bronchorrhea, and a hemorrhagic appearance may be useful for staging inhalation injury. Furthermore, bronchoalveolar lavage within 24 hours after an inhalation injury demonstrates a high rate of positive quantitative cultures,⁷³ suggesting that pneumonia develops soon after the acute lung injury. Because bronchoscopy is an invasive test, attempts have been made to utilize other diagnostic modalities, such as thoracic computed tomography (CT) scans⁷⁴ and xenon ventilation-perfusion scanning.⁷⁵ Decreased $\text{PaO}_2:\text{FiO}_2$ ratio (<200) on admission may not only predict inhalation injury but also indicate increased fluid needs more accurately than bronchoscopic grading of the severity of inhalation.⁷⁶

Treatment of inhalation injury consists primarily of supportive care. Aggressive pulmonary toilet and routine use of nebulized bronchodilators such as albuterol are recommended. Nebulized *N*-acetylcysteine is an antioxidant free radical scavenger designed to decrease the toxicity of high oxygen concentrations. Aerosolized heparin aims to prevent formation of fibrin plugs and decrease the formation of airway casts. These agents seem to improve pulmonary toilet but have no demonstrated effect on mortality.⁷⁷ Aerosolized tissue plasminogen activator⁷⁸ and recombinant human antithrombin⁷⁹ have shown promise in sheep models, but have not yet seen widespread clinical use. Administration of intrabronchial surfactant has been used as a salvage therapy in patients with severe burns and inhalation injury.⁸⁰ Inhaled nitric oxide may also be useful as a last effort in burn patients with severe lung injury who are failing other means of ventilatory support.⁸¹ The use of steroids has traditionally

been avoided due to worse outcomes in burn patients,⁸² but new promising data in late ARDS have prompted scientific review of steroid use.⁸³

New ventilator strategies have contributed to the improved mortality with ARDS. Although ARDS still contributes to mortality in burn patients, treatments have improved so that mortality is primarily from multisystem organ failure rather than isolated respiratory causes.⁸⁴ The ARDS Network Study finding that low tidal volume (6 cc/kg) or “lung-protective ventilation” had a 22% lower mortality than patients with traditional tidal volumes (12 cc/kg)⁸⁵ has dramatically changed the management of patients with acute lung injury. A similar approach had previously been shown to improve outcomes in pediatric burn patients.⁸⁶ In patients with refractory hypoxemia despite lung-protective ventilation, prone positioning may improve oxygenation but has not shown a definitive effect on mortality.⁸⁷ No specific studies have examined prone positioning in burned patients, and caution must be used in patients with facial burns who are already at risk for loss of the endotracheal tube. High-frequency percussive ventilation (HFPV) has shown early promise in patients with inhalation injury.⁸⁸ One study showed notable decreases in both morbidity and mortality with HFPV, especially in patients with burns less than 40% TBSA and inhalation injury.⁸⁹ A related technique is high-frequency oscillatory ventilation, which has been used primarily as a salvage modality in patients refractory to more conventional measures.⁹⁰ Extracorporeal membrane oxygenation (ECMO) is typically reserved for salvage situations, and experience with this modality is limited to small numbers of patients.⁹¹ A promising area of future study may be arteriovenous carbon dioxide removal, a technique that has proven superior to both low tidal volume ventilation and HFPV in a sheep model but has not yet transitioned from bench to bedside.⁹²

TREATMENT OF THE BURN WOUND

Multitudes of topical therapies exist for the treatment of burn wounds. Silver sulfadiazine is one of the most widely used in clinical practice. Silver sulfadiazine has a wide range of antimicrobial activity, primarily as prophylaxis against burn wound infections rather than treatment of existing infections. It has the added benefits of being inexpensive and easily applied and has soothing qualities. It is not significantly absorbed systemically and thus has minimal metabolic derangements. Silver sulfadiazine has a reputation for causing neutropenia, but this association is more likely due to neutrophil margination from the inflammatory response. True allergic reactions to the sulfa component of silver sulfadiazine are rare, and at-risk patients can have a small test patch applied to identify a burning sensation or rash. Silver sulfadiazine destroys skin grafts and is contraindicated on burns or donor sites in proximity to newly grafted areas. Also, silver sulfadiazine may retard epithelial migration in healing partial-thickness wounds.

Mafenide acetate, either in cream or solution form, is an effective topical antimicrobial. It is effective even in the presence of eschar and can be used in both treating and preventing wound infections; the solution formulation is an excellent antimicrobial for fresh skin grafts. Use of mafenide acetate may be limited by pain with application to partial-thickness burns. Mafenide is absorbed systemically, and a major side effect is metabolic acidosis resulting from carbonic anhydrase inhibition.

Silver nitrate has broad-spectrum antimicrobial activity as a topical solution. The solution used must be dilute (0.5%), and

prolonged topical application leads to electrolyte extravasation with resulting hyponatremia. A rare complication is methemoglobinemia. Although inexpensive, silver nitrate solution causes black stains, and laundry costs may offset any fiscal benefit to the hospital. Increasingly, Dakin’s solution (0.5% sodium hypochlorite solution) is being used as an inexpensive topical antimicrobial.

For smaller burns or larger burns that are nearly healed, topical ointments such as bacitracin, neomycin, and polymyxin B can be used. These are also useful for superficial partial-thickness facial burns as they can be applied and left open to air without dressing coverage. Meshed skin grafts in which the interstices are nearly closed are another indication for use of these agents, preferably with greasy gauze to help retain the ointment in the affected area. All three have been reported to cause nephrotoxicity and should be used sparingly in large burns. The recent media fascination with methicillin-resistant *Staphylococcus aureus* (MRSA) has led to widespread use by community practitioners of mupirocin for new burns. Unless the patient has known risk factors for MRSA, mupirocin should only be used in culture-positive burn wound infections to prevent emergence of further resistance.

Silver-impregnated dressings such as Acticoat (Smith & Nephew, London, United Kingdom), Aquacel Ag (Convatec, Princeton, NJ), and Mepilex Ag (Mölnlycke Health Care US, LLC, Norcross, GA) are increasingly being used for donor sites, skin grafts, and partial-thickness burns. These may be more comfortable for the patient, reduce the number of dressing changes, and shorten hospital length of stay, but they do limit serial wound examinations. Biologic membranes such as Biobrane (Dow-Hickham, Sugarland, TX) provide a prolonged barrier under which wounds may heal. Because of the occlusive nature of these dressings, these are typically used only on fresh superficial partial-thickness burns that are clearly not contaminated.

NUTRITION

Nutritional support may be more important in patients with large burns than in any other patient population. Not only does adequate nutrition play a role in acute issues such as immune responsiveness, but the hypermetabolic response in burn injury may raise baseline metabolic rates by as much as 200%.⁹³ This can lead to catabolism of muscle proteins and decreased lean body mass that may delay functional recovery.⁹⁴ Early enteral feeding for patients with burns larger than 20% TBSA is safe and may reduce loss of lean body mass,⁹⁵ slow the hypermetabolic response,⁹⁶ and result in more efficient protein metabolism.⁹⁷ If the enteral feeds are started within the first few hours after admission, gastric ileus can be avoided. Adjuncts such as metoclopramide promote gastrointestinal motility; if other measures for gastric feeding are unsuccessful, advancing the tube into the small bowel with nasojejunal feeding can be attempted.⁹⁸ In endotracheally intubated patients, trips to the operating room do not necessitate holding enteral feedings.⁹⁹ Immune-modulating supplements such as glutamine may decrease infectious complications and mortality in burn patients,¹⁰⁰ likely via prevention of T-cell suppression in mesenteric lymph nodes.¹⁰¹

Calculating the appropriate caloric needs of the burn patient can be challenging. A commonly used formula in non-burned patients is the Harris-Benedict equation, which calculates caloric needs using factors such as gender, age, height, and weight. This formula uses an activity factor for specific injuries,

and for burns, the basal energy expenditure is multiplied by two. The Harris-Benedict equation may be inaccurate in burns of less than 40% TBSA, and in these patients, the Curreri formula may be more appropriate. This formula estimates caloric needs to be 25 kcal/kg/d plus 40 kcal/%TBSA/d. Indirect calorimetry can also be used to calculate resting energy expenditure, but in burn patients, a “metabolic cart” has not been documented to be more beneficial than the predictive equations.¹⁰² Titrating caloric needs closely is important, because overfeeding patients will lead to storage of fat instead of muscle anabolism.¹⁰³

Modifying the hypermetabolic response is an area of intense study with several recent findings. β -Blocker use in pediatric patients decreases heart rate and resting energy expenditure and abrogates protein catabolism, even in long-term use.¹⁰⁴ There may be benefits to β -blockade in adult patients,¹⁰⁵ and many centers use β -blockers routinely in the adult population with limited safety and efficacy data. The anabolic steroid oxandrolone has been extensively studied in pediatric patients as well, and has demonstrated improvements in lean body mass and bone density in severely burned children.¹⁰⁶ The weight gain and functional improvements seen with oxandrolone may persist even after stopping administration of the drug.¹⁰⁷ A recent double-blind, randomized study of oxandrolone showed decreased length of stay, improved hepatic protein synthesis, and no adverse effects on endocrine function, although the authors noted a rise in transaminases with unclear clinical significance.¹⁰⁸ Intensive insulin therapy in critically ill patients has shown benefit, presumably from avoidance of hyperglycemia.¹⁰⁹ However, in burn patients, the insulin itself may have a metabolic benefit, with improvements in lean body mass and amelioration of the inflammatory response to burn injury.^{110,111} Oral hypoglycemic agents such as metformin also help to avoid hyperglycemia and may contribute to prevention of muscle catabolism.¹¹²

COMPLICATIONS IN BURN CARE

There are several complications commonly associated with treatment of burn patients. Though not always avoidable, maintaining vigilance for typical complications and using appropriate techniques for prevention may limit the frequency and severity of complications. Ventilator-associated pneumonia, as in all critically ill patients, is a significant problem in burned patients. However, it is so common in patients with inhalation injury that a better nomenclature may be postinjury pneumonia. Unfortunately, commonly used scores in critical illness such as the Clinical Pulmonary Infection Score (CPIS) have not been shown to be reliable in burn patients. Quantitative bronchoscopic cultures in the setting of clinical suspicion of pneumonia should guide treatment of pneumonia.¹¹³ Simple measures such as elevating the head of the bed and maintaining excellent oral hygiene and pulmonary toilet are recommended to help decrease the risk of postinjury pneumonia. There is some question as to whether early tracheostomy decreases infectious morbidity in burn patients and whether it improves long-term outcomes. There do not seem to be any major differences in the rates of pneumonia with early tracheostomy, though there may be reduced development of subglottic stenosis compared with prolonged endotracheal intubation.^{114,115} Practical considerations such as protection of facial skin grafts may influence the decision for tracheostomy placement. One major consideration in deciding whether to perform a tracheostomy has been the presence of eschar at the insertion site, which complicates

tracheostomy site care and increases the risk of airway infection. Bedside percutaneous dilatational tracheostomy is a facile method for performing tracheostomy and is reported to be as safe as open tracheostomy in the burn population.¹¹⁶

Massive resuscitation of burned patients may lead to an abdominal compartment syndrome characterized by increased airway pressures with hypoventilation, and decreased urine output and hemodynamic compromise. Decompressive laparotomy is the standard of care for refractory abdominal compartment syndrome but carries an especially poor prognosis in burn patients.¹¹⁷ Adjunctive measures such as minimizing fluid, performing torso escharotomies, decreasing tidal volumes, and chemical paralysis should be initiated before resorting to decompressive laparotomy. Patients undergoing massive resuscitation also develop elevated intraocular pressures and may require lateral canthotomy.¹¹⁸

Deep vein thrombosis (DVT) has been commonly believed to be a rare phenomenon in burned patients, and there is a paucity of controlled studies regarding heparin prophylaxis in this population.¹¹⁹ However, recent data show that up to 25% of burn patients develop DVT, and fatal pulmonary emboli have been reported in burn patients.^{120,121} A large retrospective study in patients with routine prophylaxis found DVT in only 0.25% of patients and reported no bleeding complications.¹²² Thus, it appears that heparin prophylaxis is safe in burn patients and may help prevent thrombotic complications.

Unfortunately, the use of both prophylactic and therapeutic heparin may be associated with heparin-associated thrombocytopenia (HIT). One study of HIT in burn patients showed an incidence of 1.6% in heparinized burn patients. Thrombotic complications included DVT, pulmonary embolus, and even arterial thrombosis requiring limb amputation. Nonheparin anticoagulation for HIT commonly caused bleeding complications requiring transfusion.¹²³ Although rare, a high index of suspicion for HIT should be maintained in thrombocytopenic burn patients, particularly if the platelet counts drop at hospital days 7 to 10.

Burn patients often require central venous access for fluid resuscitation and hemodynamic monitoring. Because of the anatomic relation of their burns to commonly used access sites, burn patients may be at higher risk for catheter-related bloodstream infections. The 2009 Centers for Disease Control and Prevention National Healthcare Safety Network report (<http://www.cdc.gov/nhsn/dataStat.html>) indicates that American burn centers have higher infectious complication rates than any other ICUs. Because burn patients may commonly exhibit leukocytosis with a documented bloodstream infection, practice has been to rewire lines over a guide wire and to culture the catheter tip. However, this may increase the risk of catheter-related infections in burned patients, and a new site should be used if at all possible.¹²⁴

SURGERY

Full-thickness burns with a rigid eschar can form a tourniquet effect as the edema progresses, leading to compromised venous outflow and eventually arterial inflow. The resulting compartment syndrome is most common in circumferential extremity burns, but abdominal and thoracic compartment syndromes also occur. Warning signs of impending compartment syndrome may include paresthesias, pain, decreased capillary refill, and progression to loss of distal pulses; in an intubated patient,

the surgeon should anticipate the compartment syndrome and perform frequent neurovascular evaluations. Abdominal compartment syndrome should be suspected with decreased urine output, increased ventilator airway pressures, and hypotension. Hypoventilation, increased airway pressures, and hypotension may also characterize thoracic compartment syndrome. Escharotomies are rarely needed within the first 8 hours following injury and should not be performed unless indicated because of the terrible aesthetic sequelae. When indicated, they are usually performed at the bedside, preferably with electrocautery to minimize blood loss. Extremity incisions are made on the lateral and medial aspects of the limbs in an anatomic position and may extend onto thenar and hypothenar eminences of the hand. Digital escharotomies do not usually result in any meaningful salvage of functional tissue and are not recommended. Inadequate perfusion despite proper escharotomies may indicate the need for fasciotomy, but this procedure should not be routinely performed as part of the eschar release. Thoracic escharotomies should be placed along the anterior axillary lines with bilateral subcostal and subclavicular extensions. Extension of the anterior axillary incisions down the lateral abdomen typically will allow adequate release of abdominal eschar.

The strategy of early excision and grafting in burned patients revolutionized survival outcomes in burn care. Not only did it improve mortality, but early excision also decreased reconstruction surgery, hospital length of stay, and costs of care.^{125,126} Once the initial resuscitation is complete and the patient is hemodynamically stable, attention should be turned to excising the burn wound. Burn excision and wound coverage should ideally start within the first several days, and in larger burns, serial excisions can be performed as patient condition allows. Excision is performed with repeated tangential slices using a Watson or Goulian blade until viable, diffusely bleeding tissue remains. It is appropriate to leave healthy dermis, which will appear white with punctate areas of bleeding. Excision to fat or fascia may be necessary in deeper burns. The downside of tangential excision is a high blood loss, though this may be ameliorated using techniques such as instillation of an epinephrine tumescence solution underneath the burn. Pneumatic tourniquets are helpful in extremity burns, and compresses soaked in a dilute epinephrine solution are necessary adjuncts after excision. A fibrinogen and thrombin spray sealant (Tisseel Fibrin Sealant; Baxter, Deerfield, IL) also has beneficial effects on both hemostasis and graft adherence to the wound bed. The use of these techniques has markedly decreased the number of blood transfusions given during burn surgery.¹²⁷ For patients with clearly deep burns and concern for excessive blood loss, fascial excision may be employed. In this technique, electrocautery is used to excise the burned tissue and the underlying subcutaneous tissue down to muscle fascia. This technique markedly decreases blood loss but results in a cosmetically inferior appearance due to the loss of subcutaneous tissue. For excision of burns in difficult anatomic areas such as the face, eyelids, or hands, a pressurized water dissector may offer more precision but is time consuming, has a steep learning curve, and is expensive.¹²⁸

WOUND COVERAGE

Since full-thickness burns are impractical for most burn wounds, split-thickness sheet autografts harvested with a power dermatome make the most durable wound coverings and have a decent cosmetic appearance. In larger burns, meshed

autografted skin provides a larger area of wound coverage. This also allows drainage of blood and serous fluid to prevent accumulation under the skin graft with subsequent graft loss. Areas of cosmetic importance such as the face, neck, and hands should be grafted with nonmeshed sheet grafts to ensure optimal appearance and function. Unfortunately, even extensive meshing of skin grafts in patients with limited donor sites may not provide adequate amounts of skin. Options for temporary wound coverage include human cadaveric allograft, which is incorporated into the wound but is rejected by the immune system and must be eventually replaced. This allows temporary biologic wound coverage until donor sites heal enough so that they may be reharvested. Xenograft appears to function as well as allograft for temporary wound coverage and is considerably less expensive.

The search for a perfect permanent synthetic skin substitute remains elusive. Integra (Integra LifeSciences Corporation, Plainsboro, NJ) is a bilayer product with a porous collagen-chondroitin 6-sulphate inner layer that is attached to an outer silastic sheet, which helps prevent fluid loss and infection as the inner layer becomes vascularized, creating an artificial neodermis. At approximately 2 weeks after placement, the silastic layer can be removed and a thin autograft can be placed over the neodermis. This results in faster healing of the more superficial donor sites and seems to be associated with hypertrophic scarring and improved joint function.¹²⁹ Alloderm (LifeCell Corporation, The Woodlands, TX) is another dermal substitute consisting of cryopreserved acellular human dermis. This must also be used in combination with thin split-thickness skin grafts.¹³⁰

Epidermal skin substitutes such as cultured epithelial autografts are an option in patients with massive burns and very limited donor sites.¹³¹ Their clinical use has been limited by a long turnaround time for culturing, as well as the fragility of the cultured skin, which creates great difficulty with intraoperative handling and graft take. There are promising developments in skin culturing techniques and engineered skin development, but no other products are Food and Drug Administration approved and commercially available.¹³²

Thighs make convenient anatomic donor sites; they are easily harvested and relatively hidden from an aesthetic standpoint. The thicker skin of the back is useful in older patients, who have thinner skin elsewhere and may have difficulty with healing of donor sites. The buttocks are an excellent donor site in infants and toddlers; silver sulfadiazine can be applied to the donor site with a diaper as coverage. The scalp is also an excellent donor site; the skin is thick and the many hair follicles allow rapid healing, with the added advantage of being completely hidden once hair regrows. Epinephrine tumescence is necessary for harvesting the scalp, for both hemostasis of this hypervascular area and also to create a smooth contoured surface for harvesting.

The list of commonly used donor site dressings is long and includes simple transparent films to hydrocolloids, petrolatum gauzes, and silver-impregnated dressings. Donor sites close to fresh grafts may be dressed with a porous nonadherent gauze, and both the donors and grafts are soaked with an antimicrobial solution. Principals behind choosing a dressing should balance ease of care, comfort, infection control, and cost. The choice of donor site dressing is largely institution dependent, and few data support the clear superiority of any single treatment plan.

REHABILITATION

Rehabilitation is an integral part of the clinical care plan for the burn patient and should be initiated on admission. Immediate and ongoing physical and occupational therapy is mandatory to prevent functional loss. Patients who are unable to actively participate should have passive range of motion done at least twice a day. This includes patients with burns over joints, such as with hand burns. Patients should be taught exercises they can do themselves to maintain full range of motion. Patients with foot and extremity burns should be instructed to walk independently without crutches or other assistive devices to prevent extremity swelling, desensitize the burned areas, and prevent disuse atrophy; when patients are not ambulating, they must elevate the affected extremity to minimize swelling. If postoperative immobilization is used for graft protection, the graft should be evaluated early and at frequent intervals so that active exercise can be resumed at the earliest possible occasion. The transition to outpatient care should also include physical and occupational therapy, with introduction of exercises designed to accelerate return to activities of daily living as well as specific job-related tasks. Tight-fitting pressure garments provide vascular support in burns that are further along in the healing process. Whether they prevent hypertrophic scar formation has been long debated. However, they do provide vascular support that many patients find more comfortable.

Once patients have recovered from their acute burns, many face management of the hypertrophic burn scars. In patients with healed burns or donor sites, hypertrophic scar-related morbidity includes pruritus, erythema, pain, thickened tight skin, and even contractures. Within these scars, there is believed to be an increased inflammatory response that has increased neovascularization, abundant collagen production, and abnormal extracellular matrix structure. Treatment for these scars has included nonsurgical therapies such as compression garments, silicone gel sheeting, massage, physical therapy, and corticosteroid. Surgical excision and scar revision represent more invasive scar management approaches that are often necessary for functional and aesthetic recovery.

Laser-based therapies provide additional treatment options for symptomatic hypertrophic scars. Two of the most common ones are the pulsed dye laser (PDL) and the ablative carbon dioxide (CO₂) laser. The PDL causes photothermolysis of hemoglobin, resulting in coagulative necrosis.¹³³ It obliterates small capillaries close to the skin and has had success treating congenital, cutaneous vascular malformations. The CO₂ laser has been used for treatment of acne and recently has been gaining increasing acceptance for its use to treat hypertrophic burn scars.¹³⁴ It works by ablating microscopic columns of tissue to flatten scars and is also believed to stimulate matrix metalloproteinases and other signaling pathways to induce collagen reorganization. Lasers are believed to help with scar remodeling and collagen reorganization. Outpatient and office-based treatment sessions are tolerated well by most patients. There is wide practice variation on when to start therapy and the number of treatments, but the literature has general support for starting treatment at 6 to 12 months and offering three treatments. More research is needed to determine the full potential of laser therapy to provide burn survivors a less invasive treatment of hypertrophic scars with improved symptoms and quality of life.

Psychological rehabilitation is equally important in the burn patient. Depression, posttraumatic stress disorder, concerns about image, and anxiety about returning to society constitute

predictable barriers to progress in both the inpatient and outpatient setting. Psychological distress occurs in as many as 34% of burn patients and persists in severity long after discharge.¹³⁵ Despite this, many patients will be able to quickly return to work or school, and goals should be set accordingly. The return to school for pediatric patients is actually very prompt, averaging about 10 days after discharge. However, further study is needed to determine whether attendance and performance suffer despite early re-entry to school.¹³⁶ The involvement of clinical psychologists and psychiatrists is invaluable in providing guidance and coping techniques to lessen the significant psychological burden of burn injury.

PREVENTION

Despite many areas of progress in prevention, burns continue to be a common source of injury. Some successful initiatives have included community-based interventions targeting simple home safety measures. Smoke alarms are known to decrease mortality from structural fires, but not all homes are equipped with proper smoke alarms, particularly in low-income households. Mandatory smoke alarm installation via community initiatives can be successful, but seems to be contingent on close long-term follow-up to ensure proper maintenance and function.^{137,138} Regulation of hot water heater temperatures has had some success and may be even more effective in conjunction with community-based programs emphasizing education and in-home inspections.^{139,140}

RADIATION BURNS

Interest in mass burn casualty disaster planning invariably includes a discussion of radiation burns. The 1945 nuclear bombing on Hiroshima and Nagasaki provided several important lessons for healthcare providers. First, the proximity to the detonated bomb directly impacted mortality. The fatality rate at 0.6 miles from ground zero was 86%, decreased to 27% at 0.6 to 1.6 miles, and was 2% for patients 1.6 to 3.1 miles away. Over 122,338 individuals died in Hiroshima, and 68,000 of these deaths occurred in the first 20 days. Of the survivors, 79,130 people were injured and 118,613 remain uninjured. Estimates of the injuries at Hiroshima suggest that 90% of patients had burns, 83% sustained traumatic injuries, and 37% had radiation injuries.^{141,142}

The mechanism of the explosion explains how radioactive material is distributed. A 20-kiloton nuclear device generates 180 mph winds 0.8 miles from the epicenter. The explosion results in a direct pressure wave and an indirect wind drag. The direct pressure can destroy windows and buildings, rupture eardrums, and cause pulmonary contusions, pneumothoraces, and hemothoraces. Radiation travels linearly, resulting in varying degree of burns depending on the distance from ground zero and time of exposure. A fireball at detonation sends radioactive material into the air and follows wind patterns settling to the ground in a predictable pattern. Thermal injuries near ground zero result in 100% fatalities due to incineration.^{141,142}

Radioactive material results in both acute injury from immediate exposure and more prolonged injury from delayed exposure to radioactive fallout or contamination. When a 10-kiloton nuclear bomb is detonated, people at a distance 0.7 miles from ground zero absorb 4.5 Gy. At 60 days, the medial lethal radiation dose (LD₅₀) is 3.5 Sv; with aggressive medical

care, this dose might be doubled to nearly 7 Sv. To put this in context, radiation exposure from a diagnostic CT of the chest or abdomen is 5 mSv, and the average annual background absorbed radiation dose is 3.6 mSv. Radiation is known to impact several organ systems and result in several syndromes based on increasing exposure doses. These syndromes include hematologic (1–8 Sv exposure), gastrointestinal (8–30 Sv exposure), and cardiovascular/neurologic syndromes (>30 Sv exposure), with the latter two being nonsurvivable.¹⁴¹⁻¹⁴³

After initial evaluation and decontamination by removing clothing, a useful way to estimate exposure is by determining the time to emesis. Patients who do not experience emesis within 4 hours of exposure are unlikely to have severe clinical effects. Emesis within 2 hours suggests a dose of at least 3 Sv, and emesis within 1 hour suggests at least 4 Sv. The hematologic system follows a similar dose-dependent temporal pattern for predicting radiation exposure, mortality, and treatment. These have been determined based on the Armed Forces Radiobiology Research Institute's Biodosimetry Assessment Tool, which can be downloaded from www.afri.usuhs.mil.

The combination of radiation exposure and burn wounds has the potential to increase mortality compared with traditional burns. Early closure of wounds before radiation depletes circulating lymphocytes may be needed for wound healing (which occurs within 48 hours). Also, in radiation injuries combined with burn or trauma, laboratory lymphocyte counts may be unreliable.¹⁴¹⁻¹⁴⁴ A significant difference between burn/traumatic injuries and radiation injures is that burn/traumatic injuries can result in higher mortality when not treated within hours.

Decontamination and triage are vital to maximize the number of survivors. Initial decontamination requires removal of clothing and washing wounds with water. Irrigation fluid should be collected to prevent radiation spread into the water supply. Work by many professional organizations, including the ABA, has focused on nationwide triage for disasters and will be vital to save as many lives as possible. Yet, it is likely that expectant or comfort care could be offered to more patients than typically seen in civilian hospitals, due to resource availability after the disaster.

FUTURE AREAS OF STUDY

It has long been anecdotally noted that two patients of similar ages and burn size may have very divergent responses to their burn injuries. Attention is being increasingly turned to identifying genetic differences among burn patients and how they affect response to injury. Specific allele variants have been linked with increased mortality in burned patients.¹⁴⁵ It may be that genetic differences may predispose burn patients to severe sepsis,¹⁴⁶ perhaps by downregulating the immune response.¹⁴⁷ The Inflammation and the Host Response to Injury trial was a prospective, multicenter, federally funded study that aimed to define specific genetic pathways that differ in the response to both burns and traumatic injury.¹⁴⁸ Blood and tissue samples from a strictly defined patient population were analyzed using gene arrays to determine whether differential expression in certain genetic pathways affects clinical outcomes.¹⁴⁹ Although data from this study are still being analyzed, some interesting findings suggest that sepsis, trauma, and burn patients share common gene expression patterns, starting early after injury. These genes can upregulate proinflammatory pathways as well as disrupt antigen presentation pathways. A better understanding of these common genomic responses may allow for the targeted treatment

of immunologic and signal pathways to help improve patient survival from burn injuries.

With the dramatic progress in improving survival following a major burn injury during the twentieth century, understanding and addressing functional and psychological outcomes is critical to the well-being of burn survivors. Since 1993, the National Institute of Disability and Rehabilitation Research has funded four burn model systems to identify long-term sequelae of burn injuries and to develop ways to improve outcomes for survivors. Ongoing outcome studies are crucial for dismantling barriers that our patients face in returning to their communities and to the workplace or to school.

REFERENCES

Entries highlighted in bright blue are key references.

- 1. Baxter CR, Shires T. Physiological response to crystalloid resuscitation of severe burns. *Ann N Y Acad Sci.* 1968;150:874.**
2. Janzekovic Z. A new concept in the early excision and immediate grafting of burns. *J Trauma.* 1970;10(12):1103-1108.
3. Practice Guidelines for Burn Care. *J Burn Care Rehabil.* 2001;22:1S.
4. Supple KG, Fiala SM, Gamelli RL. Preparation for burn center verification. *J Burn Care Rehabil.* 1997;18:58-60.
5. Klein, MB, Kramer CB, Nelson J, et al. Geographic access to burn center hospitals. *JAMA.* 2009;302(16):1774-1781.
- 6. Klein MB, Nathens AB, Emerson D, et al. An analysis of the long-distance transport of burn patients to a regional burn center. *J Burn Care Res.* 2007;28(1):49-55.**
7. Freiburg C, Igneri P, Sartorelli K, et al. Effects of differences in percent total body surface area estimation on fluid resuscitation of transferred burn patients. *J Burn Care Res.* 2007;28(1):42-48.
8. Prien T, Traber DL. Toxic smoke compounds and inhalation injury: a review. *Burns Incl Therm Inj.* 1988;14:451-460.
9. Crapo RO. Smoke-inhalation injuries. *JAMA.* 1981;246:1694-1696.
10. Hampson NB, Mathieu D, Piantadosi CA, et al. Carbon monoxide poisoning: interpretation of randomized clinical trials and unresolved treatment issues. *Undersea Hyperb Med.* 2001;28:157.
11. Juurlink DN, Stanbrook MB, McGuigan MA. Hyperbaric oxygen for carbon monoxide poisoning. *Cochrane Database Syst Rev.* 2000;2:CD002041.
12. Grube BJ, Marvin JA, Heimbach DM. Therapeutic hyperbaric oxygen: help or hindrance in burn patients with carbon monoxide poisoning? *J Burn Care Rehabil.* 1988;9:249.
13. Hampson NB, Zmaeff JL. Outcome of patients experiencing cardiac arrest with carbon monoxide poisoning treated with hyperbaric oxygen. *Ann Emerg Med.* 2001;38:36.
14. Becker CE. The role of cyanide in fires. *Vet Hum Toxicol.* 1985;27:487-490.
15. Charnock EL, Meehan JJ. Postburn respiratory injuries in children. *Pediatr Clin N Am.* 1980;27:661-676.
16. Barillo DJ, Goode R, Esch V. Cyanide poisoning in victims of fire: analysis of 364 cases and review of the literature. *J Burn Care Rehabil.* 1994;15(1):46-57.
17. American Burn Association. Burn incidence and treatment in the US: 2007 fact sheet. Available at http://www.ameriburn.org/resources_factsheet.php. Accessed January 6, 2008.
18. Arnoldo B, Klein M, Gibran NS. Practice guidelines for the management of electrical injuries. *J Burn Care Res.* 2006;27(4):439-447.
19. Chick LR, Borah G. Calcium carbonate gel therapy for hydrofluoric acid burns of the hand. *Plast Reconstr Surg.* 1990;86(5):935-940.

20. Hatzifotis M, Williams A, Muller M, et al. Hydrofluoric acid burns. *Burns*. 2004;30(2):156-159.
21. Dunser MW, Ohlbauer M, Rieder J, et al. Critical care management of major hydrofluoric acid burns: a case report, review of the literature, and recommendations for therapy. *Burns*. 2004;30(4):391-398.
22. Dupuytren G, Doane AS. *Clinical Lectures on Surgery: Delivered at Hotel Dieu*. Boston: Carter, Hendee; 1832.
23. Jackson D. The diagnosis of the depth of burning. *J Br Surg*. 1953; 40:588-596.
24. Watts AM, Tyler MP, Perry ME, et al. Burn depth and its histological measurement. *Burns*. 2001;27(2):154-160.
25. Bray R, Forrester K, Leonard C, et al. Laser Doppler imaging of burn scars: a comparison of wavelength and scanning methods. *Burns*. 2003;29(3):199-206.
26. Mileski WJ, Atilas L, Purdue G, et al. Serial measurements increase the accuracy of laser Doppler assessment of burn wounds. *J Burn Care Rehabil*. 2003;24:187-191.
27. Iraniha S, Cinat ME, VanderKam VM, et al. Determination of burn depth with noncontact ultrasonography. *J Burn Care Rehabil*. 2000;21(4):333-338.
28. Zawacki BE, Azen SP, Imbus SH, et al. Multifactorial probit analysis of mortality in burn patients. *Ann Surg*. 1979; 189:1-5.
29. Ryan CM, Schoenfeld DA, Thorpe WP, et al. Objective estimates of the probability of death from burn injuries. *N Engl J Med*. 1998;362:366.
30. Moreau AR, Westfall PH, Cancio LC, et al. Development and validation of an age-risk score for mortality prediction after thermal injury. *J Trauma*. 2005;58(5):967-972.
31. Mandell SP, Pham T, Klein MB. Repeat hospitalization and mortality in older adult burn patients. *J Burn Care Res*. 2013;34(1):e36-41.
32. Thombs BD, Singh VA, Halonen J, et al. The effects of preexisting medical comorbidities on mortality and length of hospital stay in acute burn injury: evidence from a national sample of 31,338 adult patients. *Ann Surg*. 2007;245(4):629-634.
33. McGwin G, George RL, Cross JM, et al. Improving the ability to predict mortality among burn patients. *Burns*. 2008;34(3):320-327.
34. Jeng JC, Jablonski K, Bridgeman A, et al. Serum lactate, not base deficit, rapidly predicts survival after major burns. *Burns*. 2002;28(2):161-166.
35. Cochrane A, Edelman LS, Saffle JR, et al. The relationship of serum lactate and base deficit in burn patients to mortality. *J Burn Care Res*. 2007;28(2):231-240.
36. Cartotto R, Choi J, Gomez M, et al. A prospective study on the implications of a base deficit during fluid resuscitation. *J Burn Care Rehabil*. 2003;24(2):75-84.
37. Andel D, Kamolz LP, Roka J, et al. Base deficit and lactate: early predictors of morbidity and mortality in patients with burns. *Burns*. 2007;33(8):973-978.
38. Venkatesh B, Meacher R, Muller MJ, et al. Monitoring tissue oxygenation during resuscitation of major burns. *J Trauma*. 2001;50(3):485-494.
39. Lorente JA, Ezpleta A, Esteban A, et al. Systemic hemodynamics, gastric intramucosal PCO₂ changes, and outcome in critically ill burn patients. *Crit Care Med*. 2000;28(6): 1728-1735.
40. Holm C, Mayr M, Tegeler J, et al. A clinical randomized study on the effects of invasive monitoring on burn shock resuscitation. *Burns*. 2004;30(8):798-807.
41. Cartotto RC, Innes M, Musgrave MA, et al. How well does the Parkland formula estimate actual fluid resuscitation volumes? *J Burn Care Rehabil*. 2002;23(4):258-265.
42. Engrav LH, Colescott PL, Kemalyan N, et al. **A biopsy of the use of the Baxter formula to resuscitate burns or do we do it like Charlie did it?** *J Burn Care Rehabil*. 2000;21(2):91-95.
43. Friedrich JB, Sullivan SR, Engrav LH, et al. **Is supra-Baxter resuscitation in burn patients a new phenomenon?** *Burns*. 2004;30(5):464-466.
44. Sullivan SR, Friedrich JB, Engrav LH, et al. "Opioid creep" is real and may be the cause of "fluid creep." *Burns*. 2004;30(6):583-590.
45. Navar PD, Saffle JR, Warden GD. Effect of inhalation injury on fluid resuscitation requirements after thermal injury. *Am J Surg*. 1985;150(6):716-720.
46. Dai NT, Chen TM, Cheng TY, et al. The comparison of early fluid therapy in extensive flame burns between inhalation and noninhalation injuries. *Burns*. 1998;24(7):671-675.
47. Cancio LC, Chavez S, Alvarado-Ortega M, et al. Predicting increased fluid requirements during the resuscitation of thermally injured patients. *J Trauma*. 2004;56(2):404-414.
48. Klein MB, Hayden D, Elson C, et al. The association between fluid administration and outcome following major burn: a multicenter study. *Ann Surg*. 2007;245(4):622-628.
49. O'Mara MS, Slater H, Goldfarb IW, et al. A prospective, randomized evaluation of intra-abdominal pressures with crystalloid and colloid resuscitation in burn patients. *J Trauma*. 2005;58(5):1011-1018.
50. Cochrane A, Morris SE, Edelman LS, et al. Burn patient characteristics and outcomes following resuscitation with albumin. *Burns*. 2007;33(1):25-30.
51. Perel P, Roberts I. Colloids versus crystalloids for fluid resuscitation in critically ill patients. *Cochrane Database Syst Rev*. 2007;4:CD000567.
52. Kinsky MP, Milner SM, Button B, et al. Resuscitation of severe thermal injury with hypertonic saline dextran: effects on peripheral and visceral edema in sheep. *J Trauma*. 2000;49(5):844-853.
53. Tanaka H, Matsuda T, Miyagantani Y, et al. Reduction of resuscitation fluid volumes in severely burned patients using ascorbic acid administration: a randomized, prospective study. *Arch Surg*. 2000;135(3):326-331.
54. Warden GD, Stratta RJ, Saffle JR, et al. Plasma exchange therapy in patients failing to resuscitate from burn shock. *J Trauma*. 1983;23:945.
55. Cannon JW, Chung KK, King DR. Advanced technologies in trauma critical care management. *Surg Clin North Am*. 2012;92(4):903-923.
56. Gunst M, Sperry J, Ghaemmaghami V, et al. Bedside echocardiographic assessment for trauma/critical care: the BEAT exam. *J Am Coll Surg*. 2008;207(3):e1-3.
57. Yarmus L, Feller-Kopman D. Pneumothorax in the critically ill patient. *Chest*. 2012;141(4):1098-1105.
58. Callcut RA, Cotton BA, Muskat P, et al. Defining when to initiate massive transfusion: a validation study of individual massive transfusion triggers in PROMMTT patients. *J Trauma Acute Care Surg*. 2013;74(1):59-68.
59. Brown LM, Aro SO, Cohen MJ, et al. A high fresh frozen plasma: packed red blood cell transfusion ratio decreases mortality in all massively transfused trauma patients regardless of admission international normalized ratio. *J Trauma*. 2011;71(2 Suppl 3):S358-S363.
60. Benson D, Barnett CC Jr. Perioperative blood transfusions promote pancreas cancer progression. *J Surg Res*. 2011;166(2):275-279.
61. Palmieri TL, Caruso DM, Foster KN, et al. Effect of blood transfusion on outcome after major burn injury: a multicenter study. *Crit Care Med*. 2006;34(6):1602-1607.
62. Palmieri TL, Lee T, O'Mara MS, et al. Effects of a restrictive blood transfusion policy on outcomes in children with burn injury. *J Burn Care Res*. 2007;28(1):65-70.
63. Higgins S, Fowler R, Callum J, et al. Transfusion-related acute lung injury in patients with burns. *J Burn Care Res*. 2007;28(1):56-64.

64. Still JM Jr, Belcher K, Law EJ, et al. A double-blinded prospective evaluation of recombinant human erythropoietin in acutely burned patients. *J Trauma*. 1995;38(2):233-236.
65. Muller MJ, Pegg SP, Rule MR. Determinants of death following burn injury. *Br J Surg*. 2001;88:583.
66. Tredget EE, Shankowsky HA, Taerum TV, et al. The role of inhalation injury in burn trauma. A Canadian experience. *Ann Surg*. 1990;212(6):720-727.
67. Shirani KZ, Pruitt BA, Mason AD. The influence of inhalation injury and pneumonia on burn mortality. *Ann Surg*. 1987;205(1):82-87.
68. Wright MJ, Murphy JT. Smoke inhalation enhances early alveolar leukocyte responsiveness to endotoxin. *J Trauma*. 2005;59(1):64-70.
69. Darling GE, Keresteci MA, Ibanez D, et al. Pulmonary complications in inhalation injuries with associated cutaneous burn. *J Trauma*. 1996;40(1):83-89.
70. Jones WG, Barie PS, Madden M, et al. The use of compliance in predicting early mortality after inhalation injury. *Curr Surg*. 1988;45(4):309-312.
71. Mlcak R, Cortiella J, Desai M, et al. Lung compliance, airway resistance, and work of breathing in children after inhalation injury. *J Burn Care Rehabil*. 1997;18(6):531-534.
72. Demling R, Lalonde C, Youn YK, et al. Effect of graded increases in smoke inhalation injury on the early systemic response to a body burn. *Crit Care Med*. 1995;23(1):171-178.
73. Mosier MJ, Gamelli RL, Halerz MM, et al. Microbial contamination in burn patients undergoing urgent intubation as part of their early airway management. *J Burn Care Res*. 2008;29(2):304-310.
74. Gore MA, Joshi AR, Nagarajan G, et al. Virtual bronchoscopy for diagnosis of inhalation injury in burnt patients. *Burns*. 2004;30:165-168.
75. Schall GL, McDonald HD, Carr LB, et al. Xenon ventilation-perfusion lung scans: the early diagnosis of inhalation injury. *JAMA*. 1978;240:2441.
76. Endorf F, Gamelli RL. Inhalation injury, pulmonary perturbations, and fluid resuscitation. *J Burn Care Res*. 2007;28(1):80-83.
77. Ramzy PI, Barret JP, Herndon DN. Thermal injury. *Crit Care Clin*. 1999;15(2):333-352.
78. Enkhbaatar P, Murakami K, Cox R, et al. Aerosolized tissue plasminogen inhibitor improves pulmonary function in sheep with burn and smoke inhalation. *Shock*. 2004;22(1):70-75.
79. Murakami K, McGuire R, Cox RA, et al. Recombinant antithrombin attenuates pulmonary inflammation following smoke inhalation and pneumonia in sheep. *Crit Care Med*. 2003;31(2):577-583.
80. Pallua N, Warbanow K, Noah EM, et al. Intrabronchial surfactant application in cases of inhalation injury: first results from patients with severe burns and ARDS. *Burns*. 1998;24(3):197-206.
81. Sheridan RL, Zapol WM, Ritz RH, et al. Low-dose inhaled nitric oxide in acutely burned children with profound respiratory failure. *Surgery*. 1999;126:856.
82. Moylan JA, Alexander LG Jr. Diagnosis and treatment of inhalation injury. *World J Surg*. 1978;2:185-191.
83. Thompson BT. Glucocorticoids and acute lung injury. *Crit Care Med*. 2003;31:S253.
84. Hollingsed TC, Saffle JR, Barton RG, et al. Etiology and consequences of respiratory failure in thermally injured patients. *Am J Surg*. 1993;166:592.
85. Ventilation with lower tidal volumes as compared with traditional tidal volumes for acute lung injury and the acute respiratory distress syndrome. The Acute Respiratory Distress Syndrome Network. *N Engl J Med*. 2000;342:1301.
86. Sheridan RL, Kacmarek RM, McEttrick MM, et al. Permissive hypercapnia as a ventilatory strategy in burned children: effect on barotrauma, pneumonia, and mortality. *J Trauma*. 1995;39:854.
87. Venet C, Guyomarch S, Migeot C, et al. The oxygenation variations related to prone positioning during mechanical ventilation: a clinical comparison between ARDS and non-ARDS hypoxemic patients. *Intensive Care Med*. 2001;27:1352.
88. Reper P, Van Bos R, Van Loey K, et al. High frequency percussive ventilation in burn patients: hemodynamics and gas exchange. *Burns*. 2003;29:603.
89. Hall JJ, Hunt JL, Arnoldo BD, et al. Use of high-frequency percussive ventilation in inhalation injuries. *J Burn Care Res*. 2007;28(3):396-400.
90. Cartotto R, Ellis S, Gomez M, et al. High frequency oscillatory ventilation in burn patients with the acute respiratory distress syndrome. *Burns*. 2004;30:453-463.
91. Patton ML, Simone MR, Kraut JD, et al. Successful utilization of ECMO to treat an adult burn patient with ARDS. *Burns*. 1998;24:566.
92. Schmalstieg FC, Keeney SE, Rudloff HE, et al. Arteriovenous CO2 removal improves survival compared to high frequency percussive and low tidal volume ventilation in a smoke/burn sheep acute respiratory distress syndrome model. *Ann Surg*. 2007;246(3):512-521; discussion 521-523.
93. Hart DW, Wolf SE, Mlcak R, et al. Persistence of muscle catabolism after severe burn. *Surgery*. 2000;128(2):312-319.
94. Hart DW, Wolf SE, Chinkes DL, et al. Determinants of skeletal muscle catabolism after severe burn. *Ann Surg*. 2000;232(4):455-465.
95. Gottschlich MM, Jenkins ME, Mayes T, et al. The 2002 clinical research award: an evaluation of the safety of early vs. delayed enteral support and effects on clinical, nutritional, and endocrine outcomes after severe burns. *J Burn Care Rehabil*. 2002;23(6):401-415.
96. Hart DW, Wolf SE, Chinkes DL, et al. Effects of early excision and aggressive enteral feeding on hypermetabolism, catabolism, and sepsis after severe burn. *J Trauma*. 2003;54(4):755-764.
97. Jeschke MG, Herndon DN, Ebener C, et al. Nutritional intervention high in vitamins, protein, amino acids, and (omega)3 fatty acids improves protein metabolism during the hypermetabolic state after thermal injury. *Arch Surg*. 2001;136(11):1301-1306.
98. Sefton EJ, Boulton-Jones JR, Anderton D, et al. Enteral feeding in patients with major burn injury: the use of nasojejunal feeding after the failure of nasogastric feeding. *Burns*. 2002;28(4):386-390.
99. Jenkins ME, Gottschlich MM, Warden GD. Enteral feeding during operative procedures in thermal injuries. *J Burn Care Rehabil*. 1994;15:199.
100. Garrel D, Patenaude J, Nedelec B, et al. Decreased mortality and infectious morbidity in adult burn patients given enteral glutamine supplements: a prospective, controlled, randomized clinical trial. *Crit Care Med*. 2003;31(10):2444-2449.
101. Choudry MA, Haque F, Khan M, et al. Enteral nutritional supplementation prevents mesenteric lymph node T-cell suppression in burn injury. *Crit Care Med*. 2003;31(6):1764-1770.
102. Liusuwan RA, Palmieri TL, Kinoshita L, et al. Comparison of measured resting energy expenditure vs. predictive equations in pediatric burn patients. *J Burn Care Rehabil*. 2005;26(6):464-470.
103. Hart DW, Wolf SE, Herndon DN, et al. Energy expenditure and caloric balance after burn: increased feeding leads to fat rather than lean mass accretion. *Ann Surg*. 2002;235(1):152-161.
104. Herndon DN, Hart DW, Wolf SE, et al. Reversal of catabolism by beta-blockade after severe burns. *N Engl J Med*. 2001;345(17):1223-1229.
105. Arbabi S, Ahrens KS, Wahl WL, et al. Beta-blocker use is associated with improved outcomes in adult burn patients. *J Trauma*. 2004;56(2):265-269; discussion 269-271.

106. Murphy KD, Thomas S, Mlcak RP, et al. Effects of long-term oxandrolone administration in severely burned children. *Surgery*. 2004;136(2):219-224.
107. Demling RH, DeSanti L. Oxandrolone induced lean mass gain during recovery from severe burns is maintained after discontinuation of the anabolic steroid. *Burns*. 2003;29:793.
108. Jeschke MG, Finnerty CC, Suman OE, et al. The effect of oxandrolone on the endocrinologic, inflammatory, and hypermetabolic responses during the acute phase postburn. *Ann Surg*. 2007;246(3):351-360; discussion 360-362.
109. Van den Berghe G, Wouters P, Weekers F, et al. Intensive insulin therapy in critically ill patients. *N Engl J Med*. 2001;345:1359-1367.
110. Thomas SJ, Morimoto K, Herndon DN, et al. The effect of prolonged euglycemic hyperinsulinemia on lean body mass after severe burn. *Surgery*. 2002;132(2):341-347.
111. Jeschke MG, Klein D, Herndon DN. Insulin treatment improves the systemic inflammatory reaction to severe trauma. *Ann Surg*. 2004;239(4):553-560.
112. Gore DC, Wolf SE, Sanford A, et al. Influence of metformin on glucose intolerance and muscle catabolism following severe burn injury. *Ann Surg*. 2005;241(2):334-342.
113. Pham TN, Neff MJ, Simmons JM, et al. The clinical pulmonary infection score poorly predicts pneumonia in patients with burns. *J Burn Care Res*. 2007;28(1):76-79.
114. Barret JP, Desai MH, Herndon DN. Effects of tracheostomies on infection and airway complications in pediatric burn patients. *Burns*. 2000;26:190.
115. Saffle JR, Morris SE, Edelman L. Early tracheostomy does not improve outcome in burn patients. *J Burn Care Rehabil*. 2002;23:431.
116. Gravvanis AI, Tsoutsos DA, Iconomou TG, et al. Percutaneous vs. conventional tracheostomy in burned patients with inhalation injury. *World J Surg*. 2005;29(12):1571-1575.
117. Hershberger RC, Hunt JL, Arnoldo BD, Purdue GF. Abdominal compartment syndrome in the severely burned patient. *J Burn Care Res*. 2007;28(5):708-714.
118. Sullivan SR, Ahmadi AJ, Singh CN, et al. Elevated orbital pressure: another untoward effect of massive resuscitation after burn injury. *J Trauma*. 2006;60(1):72-76.
119. Faucher LD, Conlon KM. Practice guidelines for deep venous thrombosis prophylaxis in burns. *J Burn Care Res*. 2007;28(5):661-663.
120. Wibbenmeyer LA, Hoballah JJ, Amelon MJ, et al. The prevalence of venous thromboembolism of the lower extremity among thermally injured patients determined by duplex sonography. *J Trauma*. 2003;55:1162-1167.
121. Wahl WL, Brandt MM, Ahrns KS, et al. Venous thrombosis incidence in burn patients: preliminary results of a prospective study. *J Burn Care Rehabil*. 2002;23:97.
122. Fecher AM, O'Mara MS, Goldfarb IW, et al. Analysis of deep vein thrombosis in burn patients. *Burns*. 2004;30(6):591-593.
123. Scott JR, Klein MB, Gernsheimer T, et al. Arterial and venous complications of heparin-induced thrombocytopenia in burn patients. *J Burn Care Res*. 2007;28(1):71-75.
124. O'Mara MS, Reed NL, Palmieri TL, et al. Central venous catheter infections in burn patients with scheduled catheter exchange and replacement. *J Surg Res*. 2007;142(2):341-350.
125. Engrav LH, Heimbach DM, Reus JL, et al. Early excision and grafting vs. nonoperative treatment of burns of indeterminate depth: a randomized prospective study. *J Trauma*. 1983;23:1001-1004.
126. Thompson P, Herndon DN, Abston S, et al. Effect of early excision on patients with major thermal injury. *J Trauma*. 1987;27(2):205-207.
127. Sheridan RL, Tompkins RG. What's new in burns and metabolism. *J Am Coll Surg*. 2004;198(2):243-263.
128. Klein MB, Hunter S, Heimbach DM, et al. The Versajet water dissector: a new tool for tangential excision. *J Burn Care Rehabil*. 2005;26(6):483-487.
129. Jones I, Currie L, Martin R. A guide to biological skin substitutes. *Br J Plast Surg*. 2002;55(3):185-193.
130. Kearney JN. Clinical evaluation of skin substitutes. *Burns*. 2001;27(5):545-551.
131. Compton CC, Gill JM, Bradford DA, et al. Skin regenerated from cultured epithelial autografts on full-thickness burn wounds from 6 days to 5 years after grafting. A light, electron microscopic and immunohistochemical study. *Lab Invest*. 1989;60(5):600-612.
132. Boyce ST, Kagan RJ, Yakuboff KP, et al. Cultured skin substitutes reduce donor skin harvesting for closure of excised, full-thickness burns. *Ann Surg*. 2002;235(2):269-279.
133. Parrett BM, Donelan MB. Pulsed dye laser in burn scars: current concepts and future directions. *Burns*. 2010;36(4):443-449.
134. Cho SB, Lee SJ, Chung WS, et al. Treatment of burn scar using a carbon dioxide fractional laser. *J Drugs Dermatol*. 2010;9(2):173-175.
135. Carniol PJ, Meshkov L, Grunebaum LD. Laser treatment of facial scars. *Curr Opin Otolaryngol Head Neck Surg*. 2011;19(4):283-288.
136. Christiansen M, Carrougher GJ, Engrav LH, et al. Time to school re-entry after burn injury is quite short. *J Burn Care Res*. 2007;28(3):478-481; discussion 482-483.
137. Ballesteros MF, Jackson ML, Martin MW. Working toward the elimination of residential fire deaths: The Centers for Disease Control and Prevention's Smoke Alarm Installation and Fire Safety Education (SAIFE) Program. *J Burn Care Rehabil*. 2005;26(5):434-439.
138. DiGuiseppi C, Roberts I, Wade A, et al. Incidence of fires and related injuries after giving out free smoke alarms: cluster randomised controlled trial. *Br Med J*. 2002;325:995-998.
139. Fallat ME, Rengers SJ. The effect of education and safety devices on scald burn prevention. *J Trauma*. 1993;34:560-564.
140. Cagle KM, Davis JW, Dominic W, et al. Results of a focused scald-prevention program. *J Burn Care Res*. 2006;27:859-863.
141. Wolbarst AB, Wiley AL Jr, Nemhauser JB, et al. Medical response to a major radiologic emergency: a primer for medical and public health practitioners. *Radiology*. 2010;254(3):660-677.
142. Flynn DF, Goans RE. Nuclear terrorism: triage and medical management of radiation and combined-injury casualties. *Surg Clin North Am*. 2006;86(3):601-636.
143. DiCarlo AL, Maher C, Hick JL, et al. Radiation injury after a nuclear detonation: medical consequences and the need for scarce resources allocation. *Disaster Med Public Health Prep*. 2011;5(Suppl 1):S32-S44.
144. Palmer JL, Deburghraeve CR, Bird MD, et al. Development of a combined radiation and burn injury model. *J Burn Care Res*. 2011;32(2):317-323.
145. Barber RC, Aragaki CC, Chang LY, et al. CD14-159 C allele is associated with increased risk of mortality after burn injury. *Shock*. 2007;27(3):232-237.
146. Barber RC, Chang LY, Arnoldo BD, et al. Innate immunity SNPs are associated with risk for severe sepsis after burn injury. *Clin Med Res*. 2006;4(4):250-255.
147. Moore CB, Medina MA, van Deventer HW, et al. Downregulation of immune signaling genes in patients with large surface burn injury. *J Burn Care Res*. 2007;28(6):879-887.
148. Xiao W, Mindrinos MN, Seok J, et al. Inflammation and host response to injury large-scale collaborative research program. A genomic storm in critically injured humans. *J Exp Med*. 2011;208(13):2581-2590.
149. Klein MB, Silver G, Gamelli RL, et al. Inflammation and the Host Response to Injury Investigators. Inflammation and the host response to injury: an overview of the multicenter study of the genomic and proteomic response to burn injury. *J Burn Care Res*. 2006;27(4):448-451.

This page intentionally left blank

9 chapter

Wound Healing

Adrian Barbul, David T. Efron, and
Sandra L. Kavalukas

History of Wound Healing	241	Heritable Diseases of Connective Tissue	246	Nerve / 251	
Phases of Wound Healing	241	Ehlers-Danlos Syndrome / 246		Fetal Wound Healing / 251	
Hemostasis and Inflammation / 242		Marfan's Syndrome / 246		Classification of Wounds	252
Proliferation / 244		Osteogenesis Imperfecta / 248		Factors Affecting Wound Healing / 252	
Matrix Synthesis / 244		Epidermolysis Bullosa / 248		Chronic Wounds / 259	
Maturation and Remodeling / 245		Acrodermatitis Enteropathica / 249		Excess Healing	261
Epithelialization / 245		Healing in Specific Tissues	249	Treatment of Wounds	264
Role of Growth Factors in Normal Healing / 246		Gastrointestinal Tract / 249		Local Care / 264	
Wound Contraction / 246		Bone / 249		Antibiotics / 265	
		Cartilage / 251		Dressings / 265	
		Tendon / 251		Skin Replacements / 266	

HISTORY OF WOUND HEALING

The earliest accounts of wound healing date back to about 2000 B.C., when the Sumerians employed two modes of treatment: a spiritual method consisting of incantations, and a physical method of applying poultice-like materials to the wound. The Egyptians were the first to differentiate between infected and diseased wounds compared to noninfected wounds. The 1650 B.C. Edwin Smith Surgical Papyrus, a copy of a much older document, describes at least 48 different types of wounds. A later document (Ebers Papyrus, 1550 B.C.) relates the use of concoctions containing honey (antibacterial properties), lint (absorbent properties), and grease (barrier) for treating wounds. These same properties are still considered essential in contemporary daily wound management.

The Greeks, equipped with the knowledge bequeathed by the Egyptians, went even further and classified wounds as acute or chronic in nature. Galen of Pergamum (120–201 A.D.), appointed as the doctor to the Roman gladiators, had an enormous number of wounds to deal with following gladiatorial combats. He emphasized the importance of maintaining a moist environment to ensure adequate healing. It took almost 19 centuries for this important concept to be proven scientifically, when it was shown that the epithelialization rate increases by 50% in a moist wound environment when compared to a dry wound environment.¹

The next major stride in the history of wound healing was the discovery of antiseptics and their importance in reducing wound infections. Ignaz Philipp Semmelweis, a Hungarian obstetrician (1818–1865), noted that the incidence of puerperal fever was much lower if medical students, following cadaver-dissection class and prior to attending childbirth, washed their hands with soap and hypochlorite. Louis Pasteur (1822–1895) was instrumental in dispelling the theory of spontaneous

generation of germs and proving that germs existed in and were always introduced from the environment. Joseph Lister probably made one of the most significant contributions to wound healing. On a visit to Glasgow, Scotland, Lister noted that some areas of the city's sewer system were less murky than the rest. He discovered that the water from pipes that were dumping waste containing carbolic acid (phenol) was clear. In 1865, Lister began soaking his surgical instruments in phenol and spraying the operating rooms, reducing the postoperative mortality rates from 50% to 15%. After attending an impressive lecture by Lister in 1876, Robert Wood Johnson left the meeting and began 10 years of research that would ultimately result in the production of an antiseptic dressing in the form of cotton gauze impregnated with iodoform. Since then, several other materials have been used to impregnate cotton gauze to achieve antiseptics.

The 1960s and 1970s led to the development of polymeric dressings. These polymeric dressings can be custom made to specific parameters, such as permeability to gases (occlusive vs. semioclusive), varying degrees of absorbency, and different physical forms. Due to the ability to customize, the available range of materials that aid in wound care has grown exponentially to include an ever-expanding variety. Currently, the practice of wound healing encompasses manipulation and/or use of, among others, inflammatory cytokines, growth factors, and bioengineered tissue. It is the combination of all these modalities that enables optimal wound healing.

PHASES OF WOUND HEALING

As noted by John Hunter (1728–1793), a keen observer of biologic phenomena, “. . . the injury alone has in all cases a tendency to produce the disposition and the means of a cure.”² Normal wound healing follows a predictable pattern that can be divided into overlapping phases defined by characteristic

Key Points

- 1▶ Wound healing is a complex cellular and biochemical cascade that leads to restitution of integrity and function.
- 2▶ Although individual tissues may have unique healing characteristics, all tissues heal by similar mechanisms, and the process undergoes phases of inflammation, cellular migration, proliferation, matrix deposition, and remodeling.
- 3▶ Factors that impede normal healing include local, systemic, and technical conditions that the surgeon must take into account.
- 4▶ Clinically, excess healing can be as significant a problem as impaired healing; genetic, technical, and local factors play a major role.
- 5▶ Optimal outcome of acute wounds relies on complete evaluation of the patient and of the wound and application of best practices and techniques.

cellular populations and biochemical activities: (a) hemostasis and inflammation, (b) proliferation, and (c) maturation and remodeling. An approximate timeline of these events is depicted in Fig. 9-1. This sequence of events is fluid and overlapping, and in most circumstances spans the time from injury to resolution of acute wounds. All wounds need to progress through this series of cellular and biochemical events that

characterizes the phases of healing in order to successfully re-establish tissue integrity.

Hemostasis and Inflammation

Hemostasis precedes and initiates inflammation with the ensuing release of chemotactic factors from the wound site (Fig. 9-2A). Wounding by definition disrupts tissue integrity, leading to

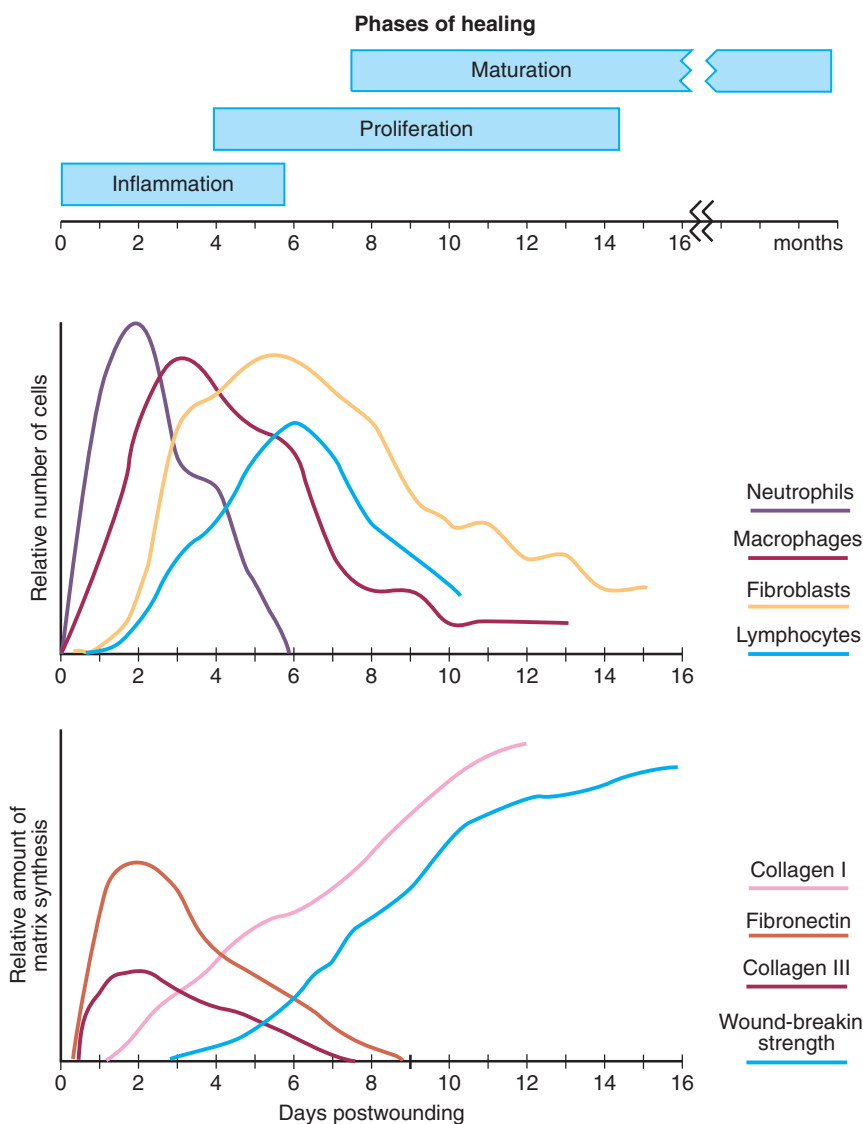


Figure 9-1. The cellular, biochemical, and mechanical phases of wound healing.

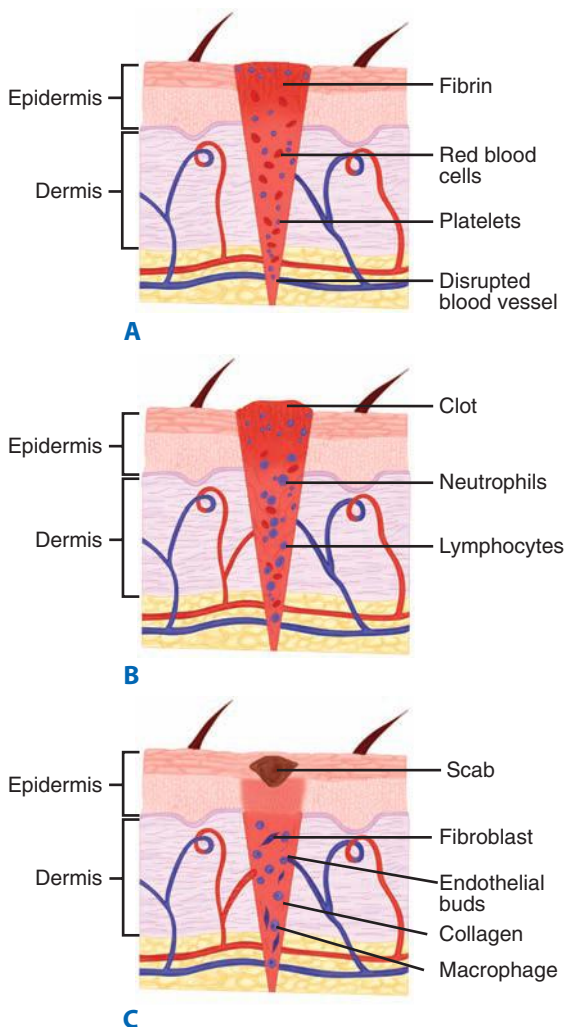


Figure 9-2. The phases of wound healing viewed histologically. **A.** The hemostatic/inflammatory phase. **B.** Latter inflammatory phases reflecting infiltration by mononuclear cells and lymphocytes. **C.** The proliferative phase, with associated angiogenesis and collagen synthesis.

division of blood vessels and direct exposure of extracellular matrix to platelets. Exposure of subendothelial collagen to platelets results in platelet aggregation, degranulation, and activation of the coagulation cascade. Platelet α granules release a number of wound-active substances, such as platelet-derived growth factor (PDGF), transforming growth factor- β (TGF- β), platelet-activating factor (PAF), fibronectin, and serotonin. In addition to achieving hemostasis, the fibrin clot serves as scaffolding for the migration into the wound of inflammatory cells such as polymorphonuclear leukocytes (PMNs, neutrophils) and monocytes.

Cellular infiltration after injury follows a characteristic, predetermined sequence (see Fig. 9-1). PMNs are the first infiltrating cells to enter the wound site, peaking at 24 to 48 hours. Increased vascular permeability, local prostaglandin release, and the presence of chemotactic substances such as complement factors, interleukin-1 (IL-1), tumor necrosis factor- α (TNF- α), TGF- β , platelet factor 4, or bacterial products all stimulate neutrophil migration.

The postulated primary role of neutrophils is phagocytosis of bacteria and tissue debris. PMNs are also a major source of cytokines early during inflammation, especially TNF- α ³ which may have a significant influence on subsequent angiogenesis and

collagen synthesis (see Fig. 9-2B). PMNs also release proteases such as collagenases, which participate in matrix and ground substance degradation in the early phase of wound healing. Other than their role in limiting infections, these cells do not appear to play a role in collagen deposition or acquisition of mechanical wound strength. On the contrary, neutrophil factors have been implicated in delaying the epithelial closure of wounds.⁴

The second population of inflammatory cells that invades the wound consists of macrophages, which are recognized as being essential to successful healing.⁵ Derived from circulating monocytes, macrophages achieve significant numbers in the wound by 48 to 96 hours postinjury and remain present until wound healing is complete.

Macrophages, like neutrophils, participate in wound débridement via phagocytosis and contribute to microbial stasis via oxygen radical and nitric oxide synthesis (see Fig. 9-2B,C). The macrophage's most pivotal function is activation and recruitment of other cells via mediators such as cytokines and growth factors, as well as directly by cell-cell interaction and intercellular adhesion molecules (ICAM). By releasing such mediators as TGF- β , vascular endothelial growth factor (VEGF), insulin-like growth factor (IGF), epithelial growth factor (EGF), and lactate, macrophages regulate cell proliferation, matrix synthesis, and angiogenesis.^{6,7} Macrophages also play a significant role in regulating angiogenesis and matrix deposition and remodeling (Table 9-1).

T lymphocytes comprise another population of inflammatory/immune cells that routinely invades the wound. Less numerous than macrophages, T-lymphocyte numbers peak at about 1 week postinjury and truly bridge the transition from the inflammatory to the proliferative phase of healing. Though known to be essential to wound healing, the role of lymphocytes in wound healing is not fully defined.⁸ A significant body of

Table 9-1

Macrophage activities during wound healing

ACTIVITY	MEDIATORS
Phagocytosis	Reactive oxygen species Nitric oxide
Débridement	Collagenase, elastase
Cell recruitment and activation	Growth factors: PDGF, TGF- β , EGF, IGF Cytokines: TNF- α , IL-1, IL-6 Fibronectin
Matrix synthesis	Growth factors: TGF- β , EGF, PDGF Cytokines: TNF- α , IL-1, IFN- γ Enzymes: arginase, collagenase Prostaglandins Nitric oxide
Angiogenesis	Growth factors: FGF, VEGF Cytokines: TNF- α Nitric oxide

EGF = epithelial growth factor; FGF = fibroblast growth factor; IGF = insulin-like growth factor; IFN- γ = interferon- γ ; IL = interleukin; PDGF = platelet-derived growth factor; TGF- β = transforming growth factor- β ; TNF- α = tumor necrosis factor- α ; VEGF = vascular endothelial growth factor.

data supports the hypothesis that T lymphocytes play an active role in the modulation of the wound environment. Depletion of most wound T lymphocytes decreases wound strength and collagen content,⁹ while selective depletion of the CD8⁺ suppressor subset of T lymphocytes enhances wound healing. However, depletion of the CD4⁺ helper subset has no effect.¹⁰ Lymphocytes also exert a downregulating effect on fibroblast collagen synthesis by cell-associated interferon (IFN)- γ , TNF- α , and IL-1. This effect is lost if the cells are physically separated, suggesting that extracellular matrix synthesis is regulated not only via soluble factors but also by direct cell-cell contact between lymphocytes and fibroblasts.¹¹

Proliferation

The proliferative phase is the second phase of wound healing and roughly spans days 4 through 12 (see Fig. 9-2C). It is during this phase that tissue continuity is re-established. Fibroblasts and endothelial cells are the last cell populations to infiltrate the healing wound, and the strongest chemotactic factor for fibroblasts is PDGF.^{12,13} Upon entering the wound environment, recruited fibroblasts first need to proliferate, and then become activated, to carry out their primary function of matrix synthesis remodeling. This activation is mediated mainly by the cytokines and growth factors released from wound macrophages.

Fibroblasts isolated from wounds synthesize more collagen than nonwound fibroblasts, they proliferate less, and they actively carry out matrix contraction. Although it is clear that the cytokine-rich wound environment plays a significant role in this phenotypic alteration and activation, the exact mediators are only partially characterized.^{14,15} Additionally, lactate, which accumulates in significant amounts in the wound environment over time (~10 mmol), is a potent regulator of collagen synthesis through a mechanism involving adenosine diphosphate (ADP)-ribosylation.^{16,17}

Endothelial cells also proliferate extensively during this phase of healing. These cells participate in the formation of new capillaries (angiogenesis), a process essential to successful wound healing. Endothelial cells migrate from intact venules close to the wound. Their migration, replication, and new capillary tubule formation is under the influence of such cytokines and growth factors as TNF- α , TGF- β , and VEGF. Although many cells produce VEGF, macrophages represent a major source in the healing wound, and VEGF receptors are located specifically on endothelial cells.^{18,19}

Matrix Synthesis

Biochemistry of Collagen. Collagen, the most abundant protein in the body, plays a critical role in the successful completion of adult wound healing. Its deposition, maturation, and subsequent remodeling are essential to the functional integrity of the wound.

Although there are at least 18 types of collagen described, the main ones of interest to wound repair are types I and III. Type I collagen is the major component of extracellular matrix in skin. Type III, which is also normally present in skin, becomes more prominent and important during the repair process.

Biochemically, each chain of collagen is composed of a glycine residue in every third position. The second position in the triplet is made up of proline or lysine during the translation process. The polypeptide chain that is translated from mRNA contains approximately 1000 amino acid residues and is called *procollagen*. Release of procollagen into the endoplasmic

reticulum results in the hydroxylation of proline to hydroxyproline and of lysine to hydroxylysine by specific hydroxylases (Fig. 9-3). Prolyl hydroxylase requires oxygen and iron as cofactors, α -ketoglutarate as co-substrate, and ascorbic acid (vitamin C) as an electron donor. In the endoplasmic reticulum, the procollagen chain is also glycosylated by the linking of galactose and glucose at specific hydroxylysine residues. These steps of hydroxylation and glycosylation alter the hydrogen bonding forces within the chain, imposing steric changes that force the procollagen chain to assume an α -helical configuration.

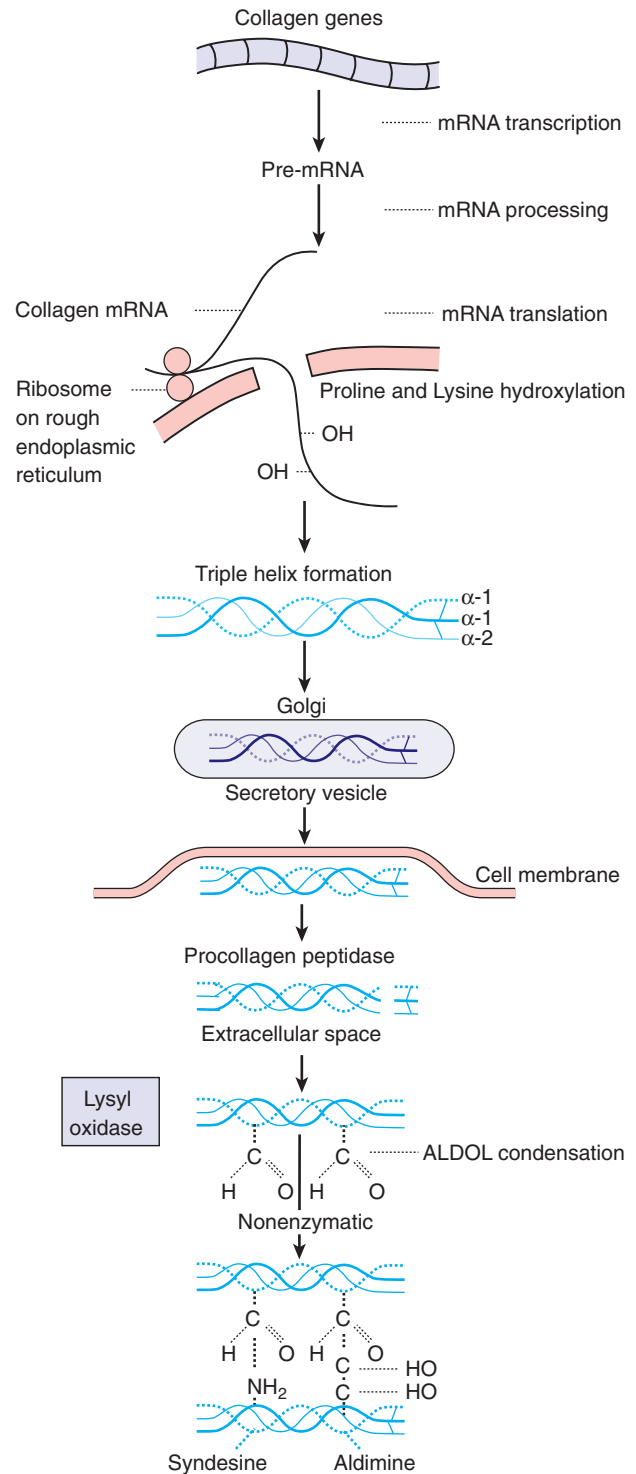


Figure 9-3. The steps of collagen synthesis. mRNA = messenger RNA.

Three α -helical chains entwine to form a right-handed superhelical structure called *procollagen*. At both ends, this structure contains nonhelical peptide domains called *registration peptides*. Although initially joined by weak, ionic bonds, the procollagen molecule becomes much stronger by the covalent cross-linking of lysine residues.

Extracellularly, the nonhelical registration peptides are cleaved by a procollagen peptidase, and the procollagen strands undergo further polymerization and cross-linking. The resulting collagen monomer is further polymerized and cross-linked by the formation of intra- and intermolecular covalent bonds.

Collagen synthesis, as well as posttranslational modifications, are highly dependent on systemic factors such as an adequate oxygen supply; the presence of sufficient nutrients (amino acids and carbohydrates) and cofactors (vitamins and trace metals); and the local wound environment (vascular supply and lack of infection). Addressing these factors and reversing nutritional deficiencies can optimize collagen synthesis and deposition.

Proteoglycan Synthesis. Glycosaminoglycans comprise a large portion of the “ground substance” that makes up granulation tissue. Rarely found free, they couple with proteins to form proteoglycans. The polysaccharide chain is made up of repeating disaccharide units composed of glucuronic or iduronic acid and a hexosamine, which is usually sulfated. The disaccharide composition of proteoglycans varies from about 10 units in the case of heparan sulfate to as much as 2000 units in the case of hyaluronic acid.

The major glycosaminoglycans present in wounds are dermatan and chondroitin sulfate. Fibroblasts synthesize these compounds, increasing their concentration greatly during the first 3 weeks of healing. The interaction between collagen and proteoglycans is being actively studied. It is thought that the assembly of collagen subunits into fibrils and fibers is dependent upon the lattice provided by the sulfated proteoglycans. Furthermore, it appears that the extent of sulfation is critical in determining the configuration of the collagen fibrils. As scar collagen is deposited, the proteoglycans are incorporated into the collagen scaffolding. However, with scar maturation and collagen remodeling, the content of proteoglycans gradually diminishes.

Maturation and Remodeling

The maturation and remodeling of the scar begins during the fibroplastic phase and is characterized by a reorganization of previously synthesized collagen. Collagen is broken down by matrix metalloproteinases (MMPs), and the net wound collagen content is the result of a balance between collagenolysis and collagen synthesis. There is a net shift toward collagen synthesis and eventually the re-establishment of extracellular matrix composed of a relatively acellular collagen-rich scar.

Wound strength and mechanical integrity in the fresh wound are determined by both the quantity and quality of the newly deposited collagen. The deposition of matrix at the wound site follows a characteristic pattern: fibronectin and collagen type III constitute the early matrix scaffolding; glycosaminoglycans and proteoglycans represent the next significant matrix components; and collagen type I is the final matrix. By several weeks postinjury, the amount of collagen in the wound reaches a plateau, but the tensile strength continues to increase for several more months.²⁰ Fibril formation and fibril cross-linking result in decreased collagen solubility, increased strength, and increased resistance to enzymatic degradation of the collagen matrix. Fibrillin, a glycoprotein secreted by fibroblasts, is essential for the formation of elastic fibers found in connective tissue.

Scar remodeling continues for many (6 to 12) months postinjury, gradually resulting in a mature, avascular, and acellular scar. The mechanical strength of the scar never achieves that of the uninjured tissue.

There is a constant turnover of collagen in the extracellular matrix, both in the healing wound as well as during normal tissue homeostasis. Collagenolysis is the result of collagenase activity, a class of MMPs that require activation. Both collagen synthesis and lysis are strictly controlled by cytokines and growth factors. Some factors affect both aspects of collagen remodeling. For example, TGF- β increases new collagen transcription and also decreases collagen breakdown by stimulating synthesis of tissue inhibitors of metalloproteinase.²¹ This balance of collagen deposition and degradation is the ultimate determinant of wound strength and integrity.

Epithelialization

While tissue integrity and strength are being re-established, the external barrier must also be restored. This process is characterized primarily by proliferation and migration of epithelial cells adjacent to the wound (Fig. 9-4). The process begins within 1 day of injury and is seen as thickening of the epidermis at the wound edge. Marginal basal cells at the edge of the wound lose their firm attachment to the underlying dermis, enlarge, and begin to migrate across the surface of the provisional matrix. Fixed basal cells in a zone near the cut edge undergo a series of rapid mitotic divisions, and these cells appear to migrate by moving over one another in a leapfrog fashion until the defect is covered.²²

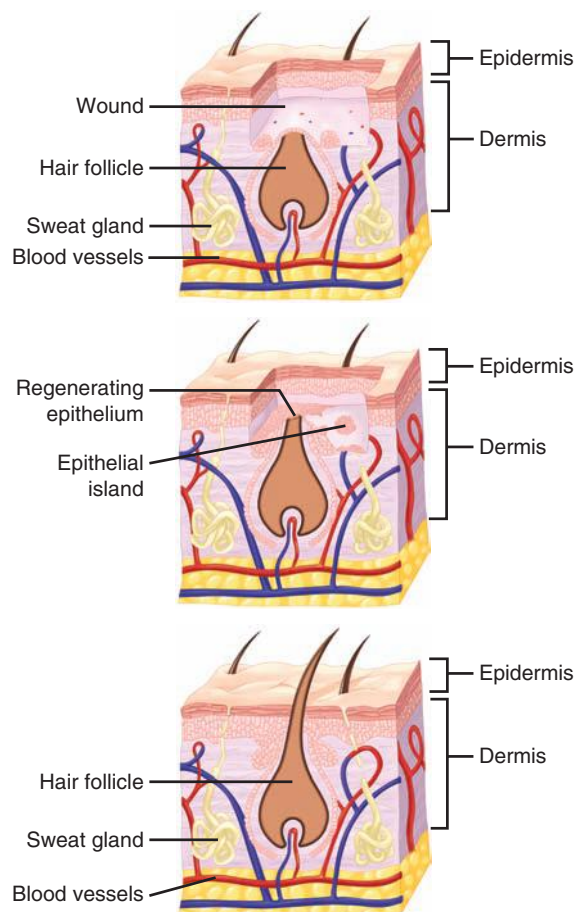


Figure 9-4. The healing by epithelialization of superficial cutaneous wounds.

Once the defect is bridged, the migrating epithelial cells lose their flattened appearance, become more columnar in shape, and increase their mitotic activity. Layering of the epithelium is re-established, and the surface layer eventually keratinizes.²³

Re-epithelialization is complete in less than 48 hours in the case of approximated incised wounds, but may take substantially longer in the case of larger wounds, where there is a significant epidermal/dermal defect. If only the epithelium and superficial dermis are damaged, such as occurs in split-thickness skin graft donor sites or in superficial second-degree burns, then repair consists primarily of re-epithelialization with minimal or no fibroplasia and granulation tissue formation. The stimuli for re-epithelialization remain incompletely defined; however, it appears that the process is mediated by a combination of a loss of contact inhibition; exposure to constituents of the extracellular matrix, particularly fibronectin; and cytokines produced by immune mononuclear cells.^{24,25} In particular EGF, TGF- β , basic fibroblast growth factor (bFGF), PDGF, and IGF-1 have been shown to promote epithelialization.

Role of Growth Factors in Normal Healing

Growth factors and cytokines are polypeptides produced in normal and wounded tissue that stimulate cellular migration, proliferation, and function. They often are named for the cells from which they were first derived (e.g., platelet-derived growth factor, PDGF) or for their initially identified function (e.g., fibroblast growth factor, FGF). These names are often misleading because growth factors have been demonstrated to have multiple functions. Most growth factors are extremely potent and produce significant effects in nanomolar concentrations.

They may act in an autocrine manner (where the growth factor acts on the cell producing it), a paracrine manner (by release into the extracellular environment, where it acts on the immediately neighboring cells), or in an endocrine manner (where the effect of the substance is distant to the site of release, and the substance is carried to the effector site through the blood stream). The timing of release may be as important as concentration in determining the effectiveness of growth factors. As these polypeptides exert their effects by cell-surface receptor binding, the appropriate receptor on the responding cells must be present at the time of release in order for the biologic effect to occur. Table 9-2 summarizes the principal growth factors found in healing wounds and their known effects on cells participating in the healing process. Growth factors have divergent actions on different cells; they can be chemoattractive to one cell type while stimulating replication of a different cell type. Little is known about the ratio of growth factor concentrations, which may be as important as the absolute concentration of individual growth factors.

Growth factors act on cells via surface receptor binding. Various receptor types have been described, such as ion channels, G-protein linked, or enzyme linked. The response elicited in the cell is usually one of phosphorylation or dephosphorylation of second-messenger molecules through the action of phosphatases or kinases, resulting in activation or deactivation of proteins in the cytosol or nucleus of the target cell. Phosphorylation of nuclear proteins is followed by the initiation of transcription of target genes.²⁶ The signal is stopped by internalization of the receptor-ligand complex.

Wound Contraction

All wounds undergo some degree of contraction. For wounds that do not have surgically approximated edges, the area of the wound will be decreased by this action (healing by secondary intention);

the shortening of the scar itself results in contracture. The myofibroblast has been postulated as being the major cell responsible for contraction, and it differs from the normal fibroblast in that it possesses a cytoskeletal structure. Typically this cell contains α -smooth muscle actin in thick bundles called *stress fibers*, giving myofibroblasts contractile capability.²⁷ The α -smooth muscle actin is undetectable until day 6, and then is increasingly expressed for the next 15 days of wound healing.²⁸ After 4 weeks, this expression fades and the cells are believed to undergo apoptosis.²⁹ A puzzling point is that the identification of myofibroblasts in the wound does not correspond directly to the initiation of wound contraction, which starts almost immediately after injury.

Fibroblasts placed in a collagen lattice in vitro actively move in the lattice and contract it without expressing stress fibers. It is postulated that the movement of cells with concomitant reorganization of the cytoskeleton is responsible for contraction.³⁰

HERITABLE DISEASES OF CONNECTIVE TISSUE

Heritable diseases of connective tissue consist of a group of generalized, genetically determined, primary disorders of one of the elements of connective tissue: collagen, elastin, or mucopolysaccharide. Five major types, Ehlers-Danlos syndrome, Marfan's syndrome, osteogenesis imperfecta, epidermolysis bullosa, and acrodermatitis enteropathica, will be discussed, as each provides unique challenges to the surgeon.

Ehlers-Danlos Syndrome

Ehlers-Danlos syndrome (EDS) is a group of 10 disorders that present as a defect in collagen formation. Over half of the affected patients manifest genetic defects encoding alpha chains of collagen type V, causing it to be either quantitatively or structurally defective. These changes lead to "classic" EDS with phenotypic findings that include thin, friable skin with prominent veins, easy bruising, poor wound healing, atrophic scar formation, recurrent hernias, and hyperextensible joints. Gastrointestinal problems include bleeding, hiatal hernia, intestinal diverticulae, and rectal prolapse. Small blood vessels are fragile, making suturing difficult during surgery. Large vessels may develop aneurysms, varicosities, or arteriovenous fistulas or may spontaneously rupture.³¹⁻³³ Table 9-3 presents a description of EDS subtypes including a recently recognized autosomal recessive form characterized by tenascin-X deficiency. The defect is a quantitative loss of protein, resulting in phenotypic changes similar to those observed in other types of EDS.

EDS must be considered in every child with recurrent hernias and coagulopathy, especially when accompanied by platelet abnormalities and low coagulation factor levels. Inguinal hernias in these children resemble those seen in adults. Great care should be taken to avoid tearing the skin and fascia. The transversalis fascia is thin, and the internal ring is greatly dilated. An adult-type repair with the use of mesh or felt may result in a lower incidence of recurrence.³⁴

The biochemical changes and phenotypic manifestation of the disease represent a major challenge to the surgeon. Dermal wounds should be closed in two layers, approximated with the sutures under tension, and the stitches should be left in place twice as long as usual. In addition, external fixation with adhesive tape can help reinforce the scar and prevent stretching.³⁵

Marfan's Syndrome

Patients with Marfan's syndrome have tall stature, arachnodactyly, lax ligaments, myopia, scoliosis, pectus excavatum, and aneurysm

Table 9-2

Growth factors participating in wound healing

GROWTH FACTOR	WOUND CELL ORIGIN	CELLULAR AND BIOLOGIC EFFECTS
PDGF	Platelets, macrophages, monocytes, smooth muscle cells, endothelial cells	Chemotaxis: fibroblasts, smooth muscle, monocytes, neutrophils Mitogenesis: fibroblasts, smooth muscle cells Stimulation of angiogenesis Stimulation of collagen synthesis Enhance re-epithelialization Modulate tissue remodeling
FGF	Fibroblasts, endothelial cells, keratinocytes, smooth muscle cells, chondrocytes	Stimulation of angiogenesis (by stimulation of endothelial cell proliferation and migration) Mitogenesis: mesoderm and neuroectoderm
HGF	Fibroblasts	Stimulates fibroblasts, keratinocytes, chondrocytes, myoblasts Suppresses inflammation, granulation tissue formation, angiogenesis, re-epithelialization
Keratinocyte growth factor	Keratinocytes, fibroblasts	Significant homology with FGF; stimulates keratinocytes
EGF	Platelets, macrophages, monocytes (also identified in salivary glands, duodenal glands, kidney, and lacrimal glands)	Stimulates proliferation and migration of all epithelial cell types
TGF- α	Keratinocytes, platelets, macrophages	Homology with EGF; binds to EGF receptor Mitogenic and chemotactic for epidermal and endothelial cells
TGF- β (three isoforms: β 1, β 2, β 3)	Platelets, T lymphocytes, macrophages, monocytes, neutrophils, fibroblasts, keratinocytes	Stimulates angiogenesis Stimulates leukocyte chemotaxis TGF- β 1 stimulates wound matrix production (fibronectin, collagen glycosaminoglycans); regulation of inflammation TGF- β 3 inhibits scar formation
Insulin-like growth factors (IGF-1, IGF-2)	Platelets (IGF-1 in high concentrations in liver; IGF-2 in high concentrations in fetal growth); likely the effector of growth hormone action	Promote protein/extracellular matrix synthesis Increase membrane glucose transport
Vascular endothelial growth factor	Macrophages, fibroblasts, endothelial cells, keratinocytes	Mitogen for endothelial cells (not fibroblasts) Stimulates angiogenesis Proinflammatory
IL-1	Macrophages, leukocytes, keratinocytes, fibroblasts	Proinflammatory Stimulates angiogenesis, re-epithelialization, tissue remodeling
IL-4	Leukocytes	Enhances collagen synthesis
IL-6	Fibroblasts, endothelial cells, macrophages, keratinocytes	Stimulates inflammation, angiogenesis, re-epithelialization, collagen deposition, tissue remodeling
Activin	Keratinocytes, fibroblasts	Stimulates granulation tissue formation, keratinocyte differentiation, re-epithelialization
Angiopoietin-1/-2 CX3CL1	Endothelial cells Macrophages, endothelial cells	Stimulates angiogenesis Stimulates inflammation, angiogenesis, collagen deposition
Granulocyte-macrophage colony-stimulating factor	Macrophage/monocytes, endothelial cells, fibroblasts	Stimulates macrophage differentiation/proliferation

CX3CL1 = chemokine (C-X3-C motif) ligand; EGF = epidermal growth factor; FGF = fibroblast growth factor; HGF = hepatocyte growth factor; IL = interleukin; PDGF = platelet-derived growth factor; TGF = transforming growth factor.

Table 9-3

Clinical, genetic, and biochemical aspects of Ehlers-Danlos subtypes

TYPE	CLINICAL FEATURES	INHERITANCE	BIOCHEMICAL DEFECT
I	Skin: soft, hyperextensible, easy bruising, fragile, atrophic scars; hypermobile joints; varicose veins; premature births	AD	Not known
II	Similar to type I, except less severe	AD	Not known
III	Skin: soft, not hyperextensible, normal scars; small and large joint hypermobility	AD	Not known
IV	Skin: thin, translucent, visible veins, normal scarring, no hyperextensibility; no joint hypermobility; arterial, bowel, and uterine rupture	AD	Type III collagen defect
V	Similar to type II	XLR	Not known
VI	Skin: hyperextensible, fragile, easy bruising; hypermobile joints; hypotonia; kyphoscoliosis	AR	Lysyl hydroxylase deficiency
VII	Skin: soft, mild hyperextensibility, no increased fragility; extremely lax joints with dislocations	AD	Type I collagen gene defect
VIII	Skin: soft, hyperextensible, easy bruising, abnormal scars with purple discoloration; hypermobile joints; generalized periodontitis	AD	Not known
IX	Skin: soft, lax; bladder diverticula and rupture; limited pronation and supination; broad clavicle; occipital horns	XLR	Lysyl oxidase defect with abnormal copper use
X	Similar to type II with abnormal clotting studies	AR	Fibronectin defect
TNx	Hypermobility joints, skin fragility	AR	Absence of tenascin X protein

AD = autosomal dominant; AR = autosomal recessive; XLR = X-linked recessive.

Source: Reproduced and updated with permission from Phillips et al.³¹ Copyright © Elsevier.

of the ascending aorta. Patients who suffer from this syndrome also are prone to hernias. Surgical repair of a dissecting aneurysm is difficult, as the soft connective tissue fails to hold sutures. Skin may be hyperextensible but shows no delay in wound healing.^{36,37}

The genetic defect associated with Marfan's syndrome is a mutation in the *FBNI* gene, which encodes for fibrillin. Previously, it was thought that structural alteration of the microfibrillar system was responsible for the phenotypic changes seen with the disease. However, recent research indicates an intricate role that *FBNI* gene products play in TGF- β signaling. These extracellular matrix molecules normally bind and regulate TGF- β signaling; abnormal *FBNI* gene function may cause an increase in TGF- β signaling, particularly in the aortic wall.³⁸

Osteogenesis Imperfecta

Patients with osteogenesis imperfecta (OI) have brittle bones, osteopenia, low muscle mass, hernias, and ligament and joint laxity. OI is a result of a mutation in type I collagen. Mutations in prolidase, an enzyme responsible for cleaving c-terminal proline and hydroxyproline, may have a role in the disease. There are four major OI subtypes with mild to lethal manifestations. Patients experience dermal thinning and increased bruisability. Scarring is normal, and the skin is not hyperextensible. Surgery can be successful but difficult in these patients, as the bones fracture easily under minimal stress.^{31,34} Table 9-4 lists the various features associated with the clinical subtypes of OI.

Epidermolysis Bullosa

Epidermolysis bullosa (EB) is classified into four major subtypes: EB simplex, junctional EB, dystrophic EB, and Kindler's syndrome. The first three are determined by location in various

skin layers; the last can present as multiple blisters throughout different layers of skin. There are identified genetic defects for each subtype, but the overall phenotype is remarkably similar. The disease manifestations include impairment in tissue adhesion within the epidermis, basement membrane, or dermis, resulting in tissue separation and blistering with minimal trauma. Characteristic features of EB are blistering and ulceration. The recessively inherited dystrophic type is characterized by defects in the *COL7A1* gene, encoding type 7 collagen, important for connecting the epidermis to the dermis, and therefore phenotypically resulting in blistering.³⁹ Management of nonhealing

Table 9-4

Osteogenesis imperfecta: clinical and genetic features

TYPE	CLINICAL FEATURES	INHERITANCE
I	Mild bone fragility, blue sclera	Dominant
II	"Prenatal lethal"; crumpled long bones, thin ribs, dark blue sclera	Dominant
III	Progressively deforming; multiple fractures; early loss of ambulation	Dominant/recessive
IV	Mild to moderate bone fragility; normal or gray sclera; mild short stature	Dominant

Source: Reproduced with permission from Phillips et al.³¹ Copyright © Elsevier.

wounds in patients with EB is a challenge, as their nutritional status is compromised because of oral erosions and esophageal obstruction. Surgical interventions include esophageal dilatation and gastrostomy tube placement. Dermal incisions must be meticulously placed to avoid further trauma to skin.^{34,40} The skin requires nonadhesive pads covered by a “bulky” dressing to avoid blistering.

Acrodermatitis Enteropathica

Acrodermatitis enteropathica (AE) is an autosomal recessive disease of children that causes an inability to absorb sufficient zinc from breast milk or food. The AE mutation affects zinc uptake in the intestine by preventing zinc from binding to the cell surface and its translocation into the cell. Recently, the genetic defect has been localized on chromosome 8q24.3 identified as the *SLC39A4* gene, expressed in the intestinal lumen and upregulated based on zinc stores.⁴¹ Zinc deficiency is associated with impaired granulation tissue formation, as zinc is a necessary cofactor for DNA polymerase and reverse transcriptase, and its deficiency may impair healing due to inhibition of cell proliferation.

AE is characterized by impaired wound healing as well as erythematous pustular dermatitis involving the extremities and the areas around the bodily orifices. Diagnosis is confirmed by the presence of an abnormally low blood zinc level (>100 mg/dL). Oral supplementation with 100 to 400 mg zinc sulfate orally per day is curative for impaired healing.^{42,43}

HEALING IN SPECIFIC TISSUES

Gastrointestinal Tract

Healing of full-thickness injury to the gastrointestinal (GI) tract remains an unresolved clinical issue. Healing of full-thickness GI wounds begins with a surgical or mechanical reapposition of the bowel ends, which is most often the initial step in the repair process. Sutures or staples are principally used, although various other means such as buttons, plastic tubes, and various wrappings have been attempted with variable success. Failure of healing results in dehiscence, leaks, and fistulas, which carry significant morbidity and mortality. Conversely, excessive healing can be just as troublesome, resulting in stricture formation and stenosis of the lumen. Repair of the GI tract is vital to restoring the integrity of the luminal structure and to the resumption of motor, absorptive, and barrier functions.

The gross anatomic features of the GI tract are remarkably constant throughout most of its length. Within the lumen, the epithelium is supported by the lamina propria and underlying muscularis mucosa. The submucosa lies radially and circumferentially outside of these layers, is comprised of abundant collagenous and elastic fibers, and supports neural and vascular structures. Further toward the peritoneal surface of the bowel are the inner and outer muscle layers and ultimately a peritoneal extension, the serosa. The submucosa is the layer that imparts the greatest tensile strength and greatest suture-holding capacity, a characteristic that should be kept in mind during surgical repair of the GI tract. Additionally, serosal healing is essential for quickly achieving a watertight seal from the luminal side of the bowel. The importance of the serosa is underscored by the significantly higher rates of anastomotic failure observed clinically in segments of bowel that are extraperitoneal and lack serosa (i.e., the esophagus and rectum).

Injuries to all parts of the GI tract undergo the same sequence of healing as cutaneous wounds. However, there are some significant differences (Table 9-5). Mesothelial (serosal) and mucosal healing can occur without scarring. The early integrity of the anastomosis is dependent on formation of a fibrin seal on the serosal side, which achieves watertightness, and on the suture-holding capacity of the intestinal wall, particularly the submucosal layer. There is a significant decrease in marginal strength during the first week due to an early and marked collagenolysis. The lysis of collagen is carried out by collagenase derived from neutrophils, macrophages, and intraluminal bacteria. Recently, it has been shown that strains of *Pseudomonas aeruginosa* undergo phenotypic shifts characterized by higher collagenase secretion in an injured/anastomosed bowel environment.⁴⁴ Collagenase activity occurs early in the healing process, and during the first 3 to 5 days, collagen breakdown far exceeds collagen synthesis. The integrity of the anastomosis represents equilibrium between collagen lysis, which occurs early, and collagen synthesis, which takes a few days to initiate (Fig. 9-5). Collagenase is expressed postinjury in all segments of the GI tract, but it is much more marked in the colon compared to the small bowel. Collagen synthesis in the GI tract is carried out by both fibroblasts and smooth muscle cells. Colon fibroblasts produce greater amounts of collagen than skin fibroblasts, reflecting different phenotypic features, as well as different responses to cytokines and growth factors among these different fibroblast populations. Ultimate anastomotic strength is not always related to the absolute amount of collagen, and the structure and arrangement of the collagen matrix may be more important.⁴⁵

Technical Considerations. Traditional teaching holds that in order for an anastomosis to heal without complications it must be tension-free, have an adequate blood supply, receive adequate nutrition, and be free of sepsis. Although sound principles for all wound healing, there are several considerations unique to anastomotic healing. From a technical viewpoint, the ideal method of suturing two ends of bowel together has not yet been identified. Although debate exists concerning methods of creating an anastomosis, clinically there has been no convincing evidence that a given technique has any advantage over another (i.e., hand-sutured vs. stapled, continuous vs. interrupted sutures, absorbable vs. nonabsorbable sutures, or single- vs. two-layer closure). A recent meta-analysis revealed that stapled ileocolic anastomoses have fewer leak rates than hand-constructed ones, but no data on colo-colic or small bowel anastomoses have been offered yet.⁴⁶ It is known, however, that hand-sutured everting anastomoses are at greater risk of leakage and cause greater adhesion formation, but have a lower incidence of stenosis. Because no overall definite superiority of any one method exists, it is recommended that surgeons be familiar with several techniques and apply them as circumstances dictate.

The amount of intravenous fluid administered perioperatively affects many aspects of recovery from colonic surgery; experimental and clinical data show that anastomotic healing may be adversely affected by overzealous fluid administration, which results in fluid accumulation in the third space, increased abdominal pressure, and tissue edema, all of which can compromise blood flow in the small vessels at the healing edge.^{47,48}

Bone

Following any type of injury to bone, several changes take place at the site of injury to restore structural and functional integrity. Most of the phases of healing resemble those observed

Table 9-5

Comparison of wound healing in the gastrointestinal tract and skin

		GI TRACT	SKIN
Wound environment	pH	Varies throughout GI tract in accordance with local exocrine secretions	Usually constant except during sepsis or local infection
	Microorganisms	Aerobic and anaerobic, especially in the colon and rectum; problematic if they contaminate the peritoneal cavity	Skin commensals rarely cause problems; infection usually results from exogenous contamination or hematogenous spread
	Shear stress	Intraluminal bulk transit and peristalsis exert distracting forces on the anastomosis	Skeletal movements may stress the suture line but pain usually acts as a protective mechanism preventing excess movement
	Tissue oxygenation	Dependent on intact vascular supply and neocapillary formation	Circulatory transport of oxygen as well as diffusion
Collagen synthesis	Cell type	Fibroblasts and smooth muscle cells	Fibroblasts
	Lathyrogens	D-Penicillamine has no effect on collagen cross-linking	Significant inhibition of cross-linking with decreased wound strength
	Steroids	Contradictory evidence exists concerning their negative effect on GI healing; increased abscess in the anastomotic line may play a significant role	Significant decrease in collagen accumulation
Collagenase activity	—	Increased presence throughout GI tract after transection and reanastomosis; during sepsis excess enzyme may promote dehiscence by decreasing suture-holding capacity of tissue	Not as significant a role in cutaneous wounds
Wound strength	—	Rapid recovery to preoperative level.	Less rapid than GI tissue
Scar formation	Age	Definite scarring seen in fetal wound sites	Usually heals without scar formation in the fetus

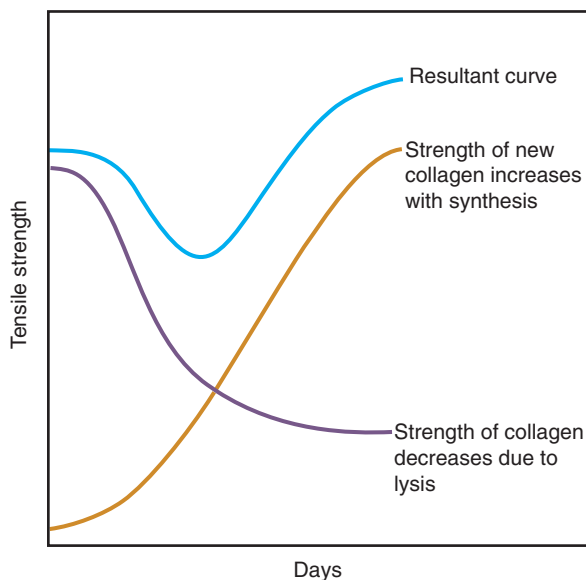


Figure 9-5. Diagrammatic representation of the concept of GI wound healing as a fine balance between collagen synthesis and collagenolysis. The “weak” period when collagenolysis exceeds collagen synthesis can be prolonged or exacerbated by any factors that upset the equilibrium. (Reproduced with permission from Hunt TK, Van Winkle W Jr. *Wound healing: normal repair*. In: Dunphy JE, ed. *Fundamentals of Wound Management in Surgery*. New York: Chirurgecom, Inc.; 1976:29.)

in dermal healing, but some notable individual characteristics apply to bone injuries. The initial stage of hematoma formation consists of an accumulation of blood at the fracture site, which also contains devitalized soft tissue, dead bone, and necrotic marrow. The next stage accomplishes the liquefaction and degradation of nonviable products at the fracture site. The normal bone adjacent to the injury site can then undergo revascularization, with new blood vessels growing into the fracture site. This is similar to the formation of granulation tissue in soft tissue. The symptoms associated with this stage are characteristic of inflammation, with clinical evidence of swelling and erythema.

Three to 4 days following injury, soft tissue forms a bridge between the fractured bone segments in the next stage (soft callus stage). This soft tissue is deposited where neovascularization has taken place and serves as an internal splint, preventing damage to the newly laid blood vessels and achieving a fibrocartilaginous union. The soft callus is formed externally along the bone shaft and internally within the marrow cavity. Clinically, this phase is characterized by the end of pain and inflammatory signs.

The next phase (hard callus stage) consists of mineralization of the soft callus and conversion to bone. This may take up to 2 to 3 months and leads to complete bony union. The bone is now considered strong enough to allow weight bearing and will appear healed on radiographs. This stage is followed by the remodeling phase, in which the excessive callus is reabsorbed and the marrow cavity is recanalized. This remodeling allows for the correct transmission of forces and restores the contours of the bone.

As in dermal healing, the process of osseous union is mediated by soluble growth factors and cytokines. The most extensively studied group is the bone morphogenic proteins (BMPs), which belong to the TGF- β superfamily. By stimulating the differentiation of mesenchymal cells into chondroblasts and osteoblasts, BMPs directly affect bone and cartilage repair. Other growth factors such as PDGF, TGF- β , TNF- α , and bFGF also participate in bony repair by mediating the inflammatory and proliferative phases of healing.

Cartilage

Cartilage consists of cells (chondrocytes) surrounded by an extracellular matrix made up of several proteoglycans, collagen fibers, and water. Unlike bone, cartilage is very avascular and depends on diffusion for transmittal of nutrients across the matrix. Additionally, the hypervascular perichondrium contributes substantially to the nutrition of the cartilage. Therefore, injuries to cartilage may be associated with permanent defects due to the meager and tenuous blood supply.

The healing response of cartilage depends on the depth of injury. In a superficial injury, there is disruption of the proteoglycan matrix and injury to the chondrocytes. There is no inflammatory response, but an increase in synthesis of proteoglycan and collagen dependent entirely on the chondrocyte. Unfortunately, the healing power of cartilage is often inadequate, and overall regeneration is incomplete. Therefore, superficial cartilage injuries are slow to heal and often result in persistent structural defects.

In contrast to superficial injuries, deep injuries involve the underlying bone and soft tissue. This leads to the exposure of vascular channels of the surrounding damaged tissue that may help in the formation of granulation tissue. Hemorrhage allows for the initiation of the inflammatory response and the subsequent mediator activation of cellular function for repair. As the granulation tissue is laid down, fibroblasts migrate toward the wound and synthesize fibrous tissue that undergoes chondrification. Gradually, hyaline cartilage is formed, which restores the structural and functional integrity of the injured site.

Tendon

Tendons and ligaments are specialized structures that link muscle and bone, and bone and bone, respectively. They consist of parallel bundles of collagen interspersed with spindle cells. Tendons and ligaments can be subjected to a variety of injuries, such as laceration, rupture, and contusion. Due to the mobility of the underlying bone or muscles, the damaged ends usually separate. Tendon and ligament healing progresses in a similar fashion as in other areas of the body (i.e., through hematoma formation, organization, laying down of reparative tissue, and scar formation). Matrix is characterized by accumulation of type I and III collagen along with increased water, DNA, and glycosaminoglycan content. As the collagen fibers are organized, transmission of forces across the damaged portion can occur. Restoration of the mechanical integrity may never be equal to that of the undamaged tendon.

Tendon vasculature has a clear effect on healing. Hypovascular tendons tend to heal with less motion and more scar formation than tendons with better blood supply. The specialized cells, tenocytes, are metabolically very active and retain a large regenerative potential, even in the absence of vascularity. Cells on the tendon surface are identical to those within the sheath and play a role in tendon healing as well.

Nerve

Nerve injuries are very common, with an estimated 200,000 repairs performed every year in the United States. Peripheral nerves are a complex arrangement of axons, nonneuronal cells, and extracellular elements. There are three types of nerve injuries: neurapraxia (focal demyelination), axonotmesis (interruption of axonal continuity but preservation of Schwann cell basal lamina), and neurotmesis (complete transection). Following all types of injury, the nerve ends progress through a predictable pattern of changes involving three crucial steps: (a) survival of axonal cell bodies; (b) regeneration of axons that grow across the transected nerve to reach the distal stump; and (c) migration and connection of the regenerating nerve ends to the appropriate nerve ends or organ targets.

Phagocytes remove the degenerating axons and myelin sheath from the distal stump (Wallerian degeneration). Regenerating axonal sprouts extend from the proximal stump and probe the distal stump and the surrounding tissues. Schwann cells ensheath and help in remyelinating the regenerating axons. Functional units are formed when the regenerating axons connect with the appropriate end targets. Several factors play a role in nerve healing, such as growth factors, cell adhesion molecules, and nonneuronal cells and receptors. Growth factors include nerve growth factor, brain-derived neurotrophic factor, basic and acidic fibroblastic growth factors, and neuroleukin. Cell adhesion molecules involved in nerve healing include nerve adhesion molecule, neuron-glia adhesion molecule, myelin adhesion glycoprotein, and N-cadherin. This complex interplay of growth factors and adhesion molecules helps in nerve regeneration.

Fetal Wound Healing

The main characteristic that distinguishes the healing of fetal wounds from that of adult wounds is the lack of scar formation. Understanding how fetal wounds achieve integrity without evidence of scarring holds promise for the possible manipulation of unwanted fibrosis or excessive scar formation in adults.

Although early fetal healing is characterized by the absence of scarring and resembles tissue regeneration, there is a phase of transition during gestational life when a more adult-like healing pattern emerges. This so-called “transition wound” occurs at the beginning of the third trimester, and during this period, there is scarless healing; however, there is a loss of the ability to regenerate skin appendages.⁴⁹ Eventually a classic, adult-patterned healing with scar formation occurs exclusively, although overall healing continues to be faster than in adults.

There are a number of characteristics that may influence the differences between fetal and adult wounds. These include wound environment, inflammatory responses, differential growth factor profiles, and wound matrix.

Wound Environment. The fetus is bathed in a sterile, temperature-stable fluid environment, although this alone does not explain the observed differences. Experiments have demonstrated that scarless healing may occur outside of the amniotic fluid environment, and conversely, scars can form in utero.^{50,51}

Inflammation. The extent and robustness of the inflammatory response correlates directly with the amount of scar formation in all healing wounds. Reduced fetal inflammation due to the immaturity of the fetal immune system may partially explain the lack of scarring observed. Not only is the fetus neutropenic, but fetal wounds contain lower numbers of PMNs and macrophages.⁵²

Growth Factors. Fetal wounds are notable for the absence of TGF- β , which may have a significant role in scarring. Conversely, blocking TGF- β 1 or TGF- β 2 using neutralizing antibodies considerably reduces scar formation in adult wounds. Exogenous application of TGF- β 3 downregulates TGF- β 1 and TGF- β 2 levels at the wound site with a resultant reduction in scarring.⁵³ Thus, the balance between the concentration and/or activity of TGF- β isoforms may be important for regulating scar production.

Wound Matrix. The fetal wound is characterized by excessive and extended hyaluronic acid production, a high-molecular-weight glycosaminoglycan that is produced primarily by fibroblasts. Although adult wounds also produce hyaluronic acid, its synthesis is sustained only in the fetal wound. Components of amniotic fluid, most specifically fetal urine, have a unique ability to stimulate hyaluronic acid production.⁵⁴ Fetal fibroblasts produce more collagen than adult fibroblasts, and the increased level of hyaluronic acid may aid in the orderly organization of collagen. As a result of these findings, hyaluronic acid is used topically to enhance healing and to inhibit postoperative adhesion formation.⁵⁵ The collagen pattern of fetal wounds is reticular in nature and resembles surrounding tissue, while adult patterns express large bundles of parallel collagen fibrils oriented perpendicular to the surface.⁵⁶

CLASSIFICATION OF WOUNDS

Wounds are classified as either acute or chronic. Acute wounds heal in a predictable manner and time frame. The process occurs with few, if any, complications, and the end result is a well-healed wound. Surgical wounds can heal in several ways. An incised wound that is clean and closed by sutures is said to heal by primary intention. Often, because of bacterial contamination or tissue loss, a wound will be left open to heal by granulation tissue formation and contraction; this constitutes healing by secondary intention. Delayed primary closure, or healing by tertiary intention, represents a combination of the first two, consisting of the placement of sutures, allowing the wound to stay open for a few days, and the subsequent closure of the sutures (Fig. 9-6).

The healing spectrum of acute wounds is broad (Fig. 9-7). In examining the acquisition of mechanical integrity and strength during healing, the normal process is characterized by a constant and continual increase that reaches a plateau at some point postinjury. Wounds with delayed healing are characterized by decreased wound-breaking strength in comparison to wounds that heal at a normal rate; however, they eventually achieve the same integrity and strength as wounds that heal normally. Conditions such as nutritional deficiencies, infections, or severe trauma cause delayed healing, which reverts to normal with correction of the underlying pathophysiology. Impaired healing is characterized by a failure to achieve mechanical strength equivalent to normally healed wounds. Patients with compromised immune systems such as those with diabetes, chronic steroid usage, or tissues damaged by radiotherapy are prone to this type of impaired healing. The surgeon must be aware of these situations and exercise great care in the placement of incision and suture selection, postoperative care, and adjunctive therapy to maximize the chances of healing without supervening complications.

Normal healing is affected by both systemic and local factors (Table 9-6). The clinician must be familiar with these factors and should attempt to counteract their deleterious effects. Complications occurring in wounds with higher risk can lead to failure of healing or the development of chronic, nonhealing wounds.

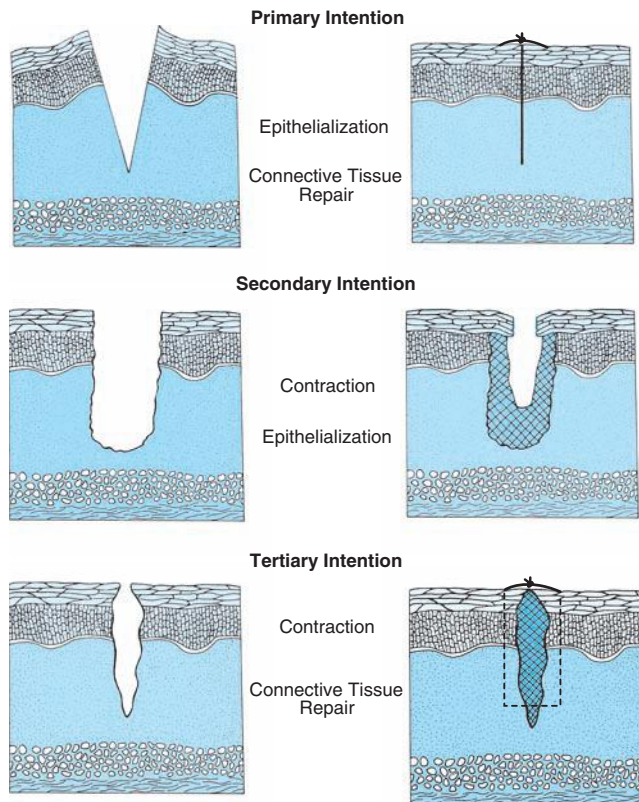


Figure 9-6. Different clinical approaches to the closure and healing of acute wounds.

Factors Affecting Wound Healing

Advanced Age. Most surgeons believe that aging produces intrinsic physiologic changes that result in delayed or impaired wound healing. Clinical experience with elderly patients tends to support this belief. Studies of hospitalized surgical patients show a direct correlation between older age and poor wound healing outcomes such as dehiscence and incisional hernia.^{57,58}

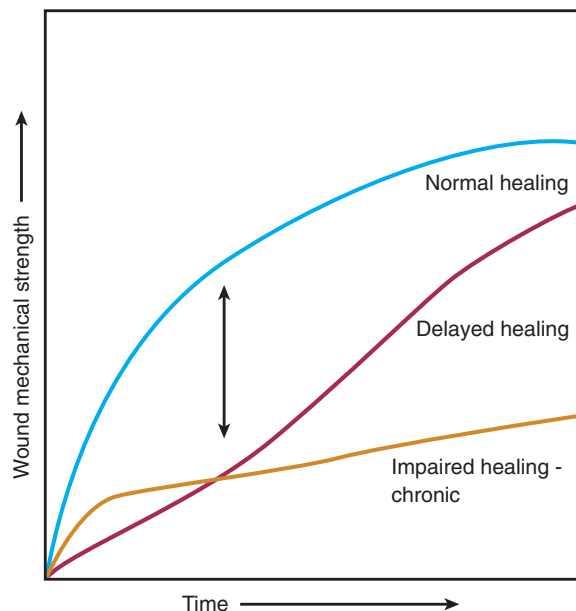


Figure 9-7. The acquisition of wound mechanical strength over time in normal, delayed, and impaired healing.

Table 9-6

Factors affecting wound healing

Systemic

Age
Nutrition
Trauma
Metabolic diseases
Immunosuppression
Connective tissue disorders
Smoking

Local

Mechanical injury
Infection
Edema
Ischemia/necrotic tissue
Topical agents
Ionizing radiation
Low oxygen tension
Foreign bodies

However, these statistics fail to take into account underlying illnesses or diseases as a possible source of impaired wound healing in the elderly. The increased incidence of cardiovascular disease, metabolic diseases (diabetes mellitus, malnutrition, and vitamin deficiencies), and cancer, and the widespread use of drugs that impair wound healing may all contribute to the higher incidence of wound problems in the elderly. However, more recent clinical experience suggests that major operative interventions can be accomplished safely in the elderly.

The results of animal studies regarding the effects of aging on wound healing have yielded contradictory results. In healthy human volunteers, there was a significant delay of 1.9 days in the epithelialization of superficial skin defects in those older than 70 years of age when compared to younger volunteers.⁵⁹ In the same volunteers, using a micro-model of fibroplasia, no difference in DNA or hydroxyproline wound accumulation could be demonstrated between the young and elderly groups; however, the young volunteers had a significantly higher amount of total α -amino nitrogen in their wounds, a reflection of total protein content of the wound. Thus, although wound collagen synthesis does not seem to be impaired with advanced age, noncollagenous protein accumulation at wounded sites is decreased with aging, which may impair the mechanical properties of scarring in elderly patients.

Hypoxia, Anemia, and Hypoperfusion. Low oxygen tension has a profoundly deleterious effect on all aspects of wound healing. Fibroplasia, although stimulated initially by the hypoxic wound environment, is significantly impaired by local hypoxia. Optimal collagen synthesis requires oxygen as a cofactor, particularly for the hydroxylation steps. Increasing subcutaneous oxygen tension levels by increasing the fraction of inspired oxygen (F_{iO_2}) of inspired air for brief periods during and immediately following surgery results in enhanced collagen deposition and in decreased rates of wound infection after elective surgery.⁶⁰⁻⁶²

Major factors affecting local oxygen delivery include hypoperfusion either for systemic reasons (low volume or cardiac failure) or due to local causes (arterial insufficiency, local vasoconstriction, or excessive tension on tissues). The level of vasoconstriction of the subcutaneous capillary bed is exquisitely

responsive to fluid status, temperature, and hyperactive sympathetic tone as is often induced by postoperative pain. Correction of these factors can have a remarkable influence on wound outcome, particularly on decreasing wound infection rates.⁶¹⁻⁶³ Mild to moderate normovolemic anemia does not appear to adversely affect wound oxygen tension and collagen synthesis, unless the hematocrit falls below 15%.⁶³

Steroids and Chemotherapeutic Drugs. Large doses or chronic usage of glucocorticoids reduce collagen synthesis and wound strength.⁶⁴ The major effect of steroids is to inhibit the inflammatory phase of wound healing (angiogenesis, neutrophil and macrophage migration, and fibroblast proliferation) and the release of lysosomal enzymes. The stronger the anti-inflammatory effect of the steroid compound used, the greater the inhibitory effect on wound healing. Steroids used after the first 3 to 4 days postinjury do not affect wound healing as severely as when they are used in the immediate postoperative period. Therefore, if possible, their use should be delayed, or alternatively, forms with lesser anti-inflammatory effects should be administered.

In addition to their effect on collagen synthesis, steroids also inhibit epithelialization and contraction and contribute to increased rates of wound infection, regardless of the time of administration.⁶⁴ Steroid-delayed healing of cutaneous wounds can be stimulated to epithelialize by topical application of vitamin A.^{64,65} Collagen synthesis of steroid-treated wounds also can be stimulated by vitamin A.

All chemotherapeutic antimetabolite drugs adversely affect wound healing by inhibiting early cell proliferation and wound DNA and protein synthesis, all of which are critical to successful repair. Delay in the use of such drugs for about 2 weeks postinjury appears to lessen the wound healing impairment.⁶⁶ Extravasation of most chemotherapeutic agents is associated with tissue necrosis, marked ulceration, and protracted healing at the affected site.⁶⁷

Metabolic Disorders. Diabetes mellitus is the best known of the metabolic disorders contributing to increased rates of wound infection and failure.⁶⁸ Uncontrolled diabetes results in reduced inflammation, angiogenesis, and collagen synthesis. Additionally, the large- and small-vessel disease that is the hallmark of advanced diabetes contributes to local hypoxemia. Defects in granulocyte function, capillary ingrowth, and fibroblast proliferation all have been described in diabetes. Obesity, insulin resistance, hyperglycemia, and diabetic renal failure contribute significantly and independently to the impaired wound healing observed in diabetics.⁶⁹ In wound studies on experimental diabetic animals, insulin restores collagen synthesis and granulation tissue formation to normal levels if given during the early phases of healing.⁷⁰ In clean, noninfected, and well-perfused experimental wounds in human diabetic volunteers, type 1 diabetes mellitus was noted to decrease wound collagen accumulation in the wound, independent of the degree of glycemic control. Type 2 diabetic patients showed no effect on collagen accretion when compared to healthy, age-matched controls.⁷¹ Furthermore, the diabetic wound appears to be lacking in sufficient growth factor levels, which signal normal healing. It remains unclear whether decreased collagen synthesis or an increased breakdown due to an abnormally high proteolytic wound environment is responsible.

Careful preoperative correction of blood sugar levels improves the outcome of wounds in diabetic patients. Increasing the inspired oxygen tension, judicious use of antibiotics, and

correction of other coexisting metabolic abnormalities all can result in improved wound healing.

Uremia also has been associated with disordered wound healing. Experimentally, uremic animals demonstrate decreased wound collagen synthesis and breaking strength. The contribution of uremia alone to this impairment, rather than that of associated malnutrition, is difficult to assess.⁶⁹ The clinical use of dialysis to correct the metabolic abnormalities and nutritional restoration should impact greatly on the wound outcome of such patients.

Obesity is the largest growing public health problem in the United States and the world. Over 60% of Americans are overweight or obese. Uncomplicated obesity (i.e., in the absence of comorbid conditions such as cardiovascular disease, diabetes, or respiratory insufficiency) has by itself significant deleterious effects on wound healing. Visceral adiposity is active metabolically and immunologically and, through generation of proinflammatory cytokines and adipokines, leads to the development of the metabolic syndrome. Many of these molecules have effects on cells participating in the healing response. In nondiabetic obese rodents, wounds are mechanically weaker, and there is less dermal and reparative scar collagen. Pre-adipocytes infiltrate the dermis, and although they can evolve into fibroblasts, their regulatory mechanisms appear different from those of dermal or wound fibroblasts. Many studies indicate that obese patients have high rates of perioperative complications, with estimates as high as 30% for wound dehiscence, 17% for surgical site infections, 30% for incisional hernias, 19% for seromas, 13% for hematomas, and 10% for fat necrosis.⁷²⁻⁷⁴ Increased subcutaneous fat was associated with a 10-fold increased risk of surgery-related complications including anastomotic leaks, abdominal collection, and wound infections.⁷⁵ In many studies, obesity is a constant and major risk factor for hernia formation and recurrence after repair. The mechanism by which obesity impairs wound healing awaits complete delineation.

Nutrition. The importance of nutrition in the recovery from traumatic or surgical injury has been recognized by clinicians since the time of Hippocrates. Poor nutritional intake or lack of individual nutrients significantly alters many aspects of wound healing. The clinician must pay close attention to the nutritional status of patients with wounds, since wound failure or wound infections may be no more than a reflection of poor nutrition. Although the full interaction of nutrition and wound healing is still not fully understood, efforts are being made to develop wound-specific nutritional interventions and institute the pharmacologic use of individual nutrients as modulators of wound outcomes.

Experimental rodents fed either a 0% or 4% protein diet have impaired collagen deposition with a secondary decrease in skin and fascial wound-breaking strength and increased wound infection rates. Induction of energy-deficient states by providing only 50% of the normal caloric requirement leads to decreased granulation tissue formation and matrix protein deposition in rats. Acute fasting in rats markedly impairs collagen synthesis while decreasing procollagen mRNA.⁷⁶

Clinically, it is extremely rare to encounter pure energy or protein malnutrition, and the vast majority of patients exhibit combined protein-energy malnutrition. Such patients have diminished hydroxyproline accumulation (an index of collagen deposition) into subcutaneously implanted polytetrafluoroethylene tubes when compared to normally nourished patients (Fig. 9-8). Furthermore, malnutrition correlates clinically with enhanced rates of wound complications and increased wound failure

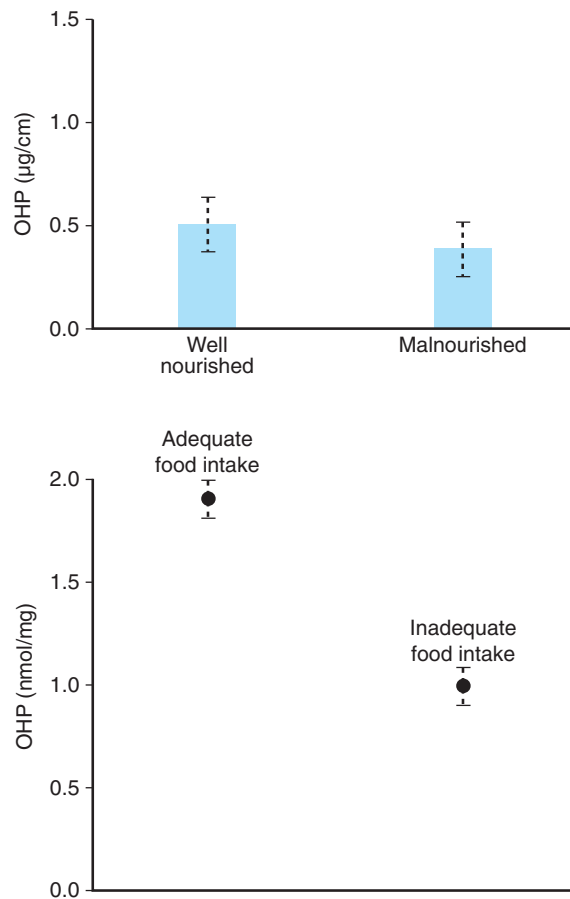


Figure 9-8. Effect of malnutrition on collagen deposition in experimental human wounds. OHP = hydroxyproline.

following diverse surgical procedures. This reflects impaired healing response as well as reduced cell-mediated immunity, phagocytosis, and intracellular killing of bacteria by macrophages and neutrophils during protein-calorie malnutrition.⁷⁶

Two additional nutrition-related factors warrant discussion. First, the degree of nutritional impairment need not be long-standing in humans, as opposed to the experimental situation. Thus patients with brief preoperative illnesses or reduced nutrient intake in the period immediately preceding the injury or operative intervention will demonstrate impaired fibroplasias.^{77,78} Second, brief and not necessarily intensive nutritional intervention, either via the parenteral or enteral route, can reverse or prevent the decreased collagen deposition noted with malnutrition or with postoperative starvation.⁷⁹

The possible role of single amino acids in enhanced wound healing has been studied for the last several decades. Arginine appears most active in terms of enhancing wound fibroplasia. Arginine deficiency results in decreased wound-breaking strength and wound-collagen accumulation in chow-fed rats. Rats that are given 1% arginine HCl supplementation, and therefore are not arginine-deficient, have enhanced wound-breaking strength and collagen synthesis when compared to chow-fed controls.⁸⁰ Studies have been carried out in healthy human volunteers to examine the effect of arginine supplementation on collagen accumulation. Young, healthy, human volunteers (aged 25–35 years) were found to have significantly increased wound-collagen deposition following oral supplementation with either 30 g of arginine aspartate (17 g of

free arginine) or 30 g of arginine HCl (24.8 g of free arginine) daily for 14 days.⁸¹ In a study of healthy older humans (aged 67–82 years), daily supplements of 30 g of arginine aspartate for 14 days resulted in significantly enhanced collagen and total protein deposition at the wound site when compared to controls given placebos. There was no enhanced DNA synthesis present in the wounds of the arginine-supplemented subjects, suggesting that the effect of arginine is not mediated by an inflammatory mode of action.⁸² In this and later studies, arginine supplementation, whether administered orally or parenterally, had no effect on the rate of epithelialization of a superficial skin defect. This further suggests that the main effect of arginine on wound healing is to enhance wound collagen deposition. Recently, a dietary supplemental regimen of arginine, β -hydroxy- β -methyl butyrate, and glutamine was found to significantly and specifically enhance collagen deposition in elderly, healthy human volunteers when compared to an isocaloric, isonitrogenous supplement (Fig. 9-9).⁸³ As increases in breaking strength during the first weeks of healing are directly related to new collagen synthesis, arginine supplementation may result in an improvement in wound strength as a consequence of enhanced collagen deposition.

The vitamins most closely involved with wound healing are vitamin C and vitamin A. Scurvy or vitamin C deficiency leads to a defect in wound healing, particularly via a failure in collagen synthesis and cross-linking. Biochemically, vitamin C is required for the conversion of proline and lysine to hydroxyproline and hydroxylysine, respectively. Vitamin C deficiency has also been associated with an increased incidence of wound infection, and if wound infection does occur, it tends to be more severe. These effects are believed to be due to an associated impairment in neutrophil function, decreased complement activity, and decreased walling-off of bacteria secondary to insufficient collagen deposition. The recommended dietary allowance is 60 mg daily. This provides a considerable safety margin for most

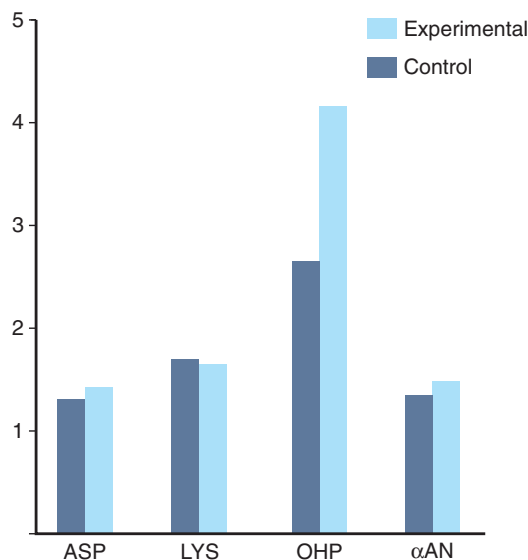


Figure 9-9. Ratios of 14-day to 7-day values for aspartate (ASP), hydroxyproline (OHP), lysine (LYS), and α -amino nitrogen (α AN) in volunteers given dietary supplements of arginine, β -hydroxy- β -methylbutyrate, and glutamine. * $P < .05$. (Reproduced with permission from Williams JZ, Abumrad NN, Barbul A. Effect of a specialized amino acid mixture on human collagen deposition. *Ann Surg.* 2002;236:369.)

healthy nonsmokers. In severely injured or extensively burned patients, this requirement may increase to as high as 2 g daily. There is no evidence that excess vitamin C is toxic; however, there is no evidence that supertherapeutic doses of vitamin C are of any benefit.⁸⁴

Vitamin A deficiency impairs wound healing, while supplemental vitamin A benefits wound healing in nondeficient humans and animals. Vitamin A increases the inflammatory response in wound healing, probably by increasing the lability of lysosomal membranes. There is an increased influx of macrophages, with an increase in their activation and increased collagen synthesis. Vitamin A directly increases collagen production and epidermal growth factor receptors when it is added in vitro to cultured fibroblasts. As mentioned before, supplemental vitamin A can reverse the inhibitory effects of corticosteroids on wound healing. Vitamin A also can restore wound healing that has been impaired by diabetes, tumor formation, cyclophosphamide, and radiation. Serious injury or stress leads to increased vitamin A requirements. In the severely injured patient, supplemental doses of vitamin A have been recommended. Doses ranging from 25,000 to 100,000 IU per day have been advocated.

The connections between specific minerals and trace elements and deficits in wound healing are complex. Frequently, deficiencies are multiple and include macronutrient deficiencies. As with some of the vitamins described earlier, the specific trace element may function as a cofactor or part of an enzyme that is essential for homeostasis and wound healing. Clinically, preventing deficiencies is often easier to accomplish than diagnosing them.

Zinc is the most well-known element in wound healing and has been used empirically in dermatologic conditions for centuries. It is essential for wound healing in animals and humans. There are over 150 known enzymes for which zinc is either an integral part or an essential cofactor, and many of these enzymes are critical to wound healing.⁸⁵ With zinc deficiency, there is decreased fibroblast proliferation, decreased collagen synthesis, impaired overall wound strength, and delayed epithelialization. These defects are reversed by zinc supplementation. To date, no study has shown improved wound healing with zinc supplementation in patients who are not zinc deficient.⁸⁶

Infections. Wound infections continue to represent a major medical problem, both in terms of how they affect the outcome of surgical procedures (surgical site infections), and for their impact on the length of hospital stay and medical costs.⁸⁷ Many otherwise successful surgical operations fail because of the development of wound infections. The occurrence of infections is of major concern when implants are used, and their occurrence may lead to the removal of the prosthetic material, thus subjecting the patient to further operations and severe risk of morbidity and mortality. Infections can weaken an abdominal closure or hernia repair and result in wound dehiscence or recurrence of the hernia. Cosmetically, infections can lead to disfiguring, unsightly, or delayed closures.

Exhaustive studies have been undertaken that examine the appropriate prophylactic treatment of operative wounds. Bacterial contaminants normally present on skin are prevented from entry into deep tissues by intact epithelium. Surgery breaches the intact epithelium, allowing bacteria access to these tissues and the bloodstream. Antibiotic prophylaxis is most effective when adequate concentrations of antibiotic are present in the tissues at the time of incision, and assurance of adequate preoperative antibiotic dosing and timing has become a significant

hospital performance measure.⁸⁸ Addition of antibiotics after operative contamination has occurred clearly is ineffective in preventing postoperative wound infections.

Studies that compare operations performed with and without antibiotic prophylaxis demonstrate that class II, III, and IV procedures (see below) treated with appropriate prophylactic antibiotics have only one third the wound infection rate of previously reported untreated series.⁸⁹ More recently, repeat dosing of antibiotics has been shown to be essential in decreasing postoperative wound infections in operations with durations exceeding the biochemical half-life ($t_{1/2}$) of the antibiotic or in which there is large-volume blood loss and fluid replacement.^{90,91} In lengthy cases, those in which prosthetic implants are used, or when unexpected contamination is encountered, additional doses of antibiotic may be administered for 24 hours postoperatively.

Selection of antibiotics for use in prophylaxis should be tailored to the type of surgery to be performed, operative contaminants that might be encountered during the procedure, and the profile of resistant organisms present at the institution where the surgery is performed. The continuing widespread appearance of methicillin-resistant *Staphylococcus aureus* (MRSA), and vancomycin-resistant enterococci (VRE) has significantly restricted the selection of these agents for routine use. Surgery-specific treatment guidelines are provided in Table 9-7.⁹⁰

Patients with prosthetic heart valves or any implanted vascular or orthopedic prostheses should receive antibiotic prophylaxis prior to any procedure in which significant bacteremia is anticipated. Dental procedures require prophylaxis with broad-spectrum penicillins or amoxicillin, while urologic instrumentation should be pretreated with a second-generation cephalosporin. Patients with prostheses who undergo gastrointestinal surgery should receive anaerobic coverage combined with a cephalosporin. Nasal screening and decolonization for *Staphylococcus aureus* carriers is recommended for selected procedures (i.e., cardiac, orthopedic, neurosurgical procedures with implants).

The incidence of wound infection is about 5% to 10% nationwide and has not changed during the last few decades. Quantitatively, it has been shown that if the wound is contaminated with $>10^5$ microorganisms, the risk of wound infection is markedly increased, but this threshold may be much lower in the presence of foreign materials. The source of pathogens for the infection is usually the endogenous flora of the patient's skin, mucous membranes, or from hollow organs. The most common organisms responsible for wound infections in order of frequency are *Staphylococcus* species, coagulase-negative *Streptococcus*, enterococci, and *Escherichia coli*. The incidence of wound infection bears a direct relationship to the degree of contamination that occurs during the operation from the disease process itself (clean—class I, clean contaminated—class II, contaminated—class III, and dirty—class IV). Many factors contribute to the development of postoperative wound infections. Most surgical wound infections become apparent within 7 to 10 days postoperatively, although a small number manifest years after the original operative intervention. With the hospital stay becoming shorter and shorter, many infections are detected in the outpatient setting, leading to underreporting of the true incidence of wound infections absent intensive surveillance. There has been much debate about the actual definition of wound infection. The narrowest definition would include wounds that drain purulent material with bacteria identified on culture. The more broad definition would include all wounds

draining pus, whether or not the bacteriologic studies are positive; wounds that are opened by the surgeon; and wounds that the surgeon considers infected.⁹²

Anatomically, wound infections can be classified as superficial incisional, deep incisional, and organ/space wound infections, involving fascia, muscle, or the abdominal cavity. About three fourths of all wound infections are superficial, involving skin and subcutaneous tissue only. Clinical diagnosis is easy when a postoperative wound looks edematous and erythematous and is tender. Often the presentation is more subtle, and development of postoperative fever, usually low-grade; development of a mild and unexplained leukocytosis; or the presence of undue incisional pain should direct attention to the wound. Inspection of the wound is most useful in detecting subtle edema around the suture or staple line, manifested as a waxy appearance of the skin, which characterizes the early phase of infection. If a wound infection is suspected, several stitches or staples around the most suspicious area should be removed with insertion of a cotton-tipped applicator into the subcutaneous area to open a small segment of the incision. This causes minimal if any discomfort to the patient. Presence of pus mandates further opening of the subcutaneous and skin layers to the full extent of the infected pocket. Samples should be taken for aerobic and anaerobic cultures, with very few patients requiring antibiotic therapy. Patients who are immunosuppressed (diabetics and those on steroids or chemotherapeutic agents), who have evidence of tissue penetration or systemic toxicity, or who have had prosthetic devices inserted (vascular grafts, heart valves, artificial joints, or mesh) should be treated with systemic antibiotics.⁹²

Deep wound infections arise immediately adjacent to the fascia, either above or below it, and often have an intra-abdominal component. Most intra-abdominal infections do not, however, communicate with the wound. Deep infections present with fever and leukocytosis. The incision may drain pus spontaneously, or the intra-abdominal extension may be recognized following the drainage of what was thought to be a superficial wound infection, but pus draining between the fascial sutures will be noted. Sometimes wound dehiscence will occur.

The most dangerous of the deep infections is necrotizing fasciitis. It results in high mortality, particularly in the elderly. This is an invasive process that involves the fascia and leads to secondary skin necrosis. Pathophysiologically, it is a septic thrombosis of the vessels between the skin and the deep layers. The skin demonstrates hemorrhagic bullae and subsequent frank necrosis, with surrounding areas of inflammation and edema. The fascial necrosis is usually wider than the skin involvement or than the surgeon estimates on clinical grounds. The patient is toxic and has high fever, tachycardia, and marked hypovolemia, which if uncorrected, progresses to cardiovascular collapse. Bacteriologically, this is a mixed infection, and samples should be obtained for Gram stain smears and cultures to aid in diagnosis and treatment. As soon as bacteriologic studies have been obtained, high-dose penicillin treatment needs to be started (20–40 million U/d intravenously) due to concern over the presence of *Clostridia perfringens* and other related species; broad-spectrum antibiotics should be added and the regimen modified based on culture results. Cardiovascular resuscitation with electrolyte solutions, blood, and/or plasma is carried out as expeditiously as possible prior to induction of anesthesia. The aim of surgical treatment is thorough removal of all necrosed skin and fascia. If viable skin overlies necrotic fascia, multiple longitudinal skin incisions can be made to allow for excision of the devitalized fascia.

Table 9-7

Antimicrobial prophylaxis for surgery

NATURE OF OPERATION	COMMON PATHOGENS	RECOMMENDED ANTIMICROBIALS	ADULT DOSAGE BEFORE SURGERY ¹
Cardiac	<i>Staphylococcus aureus</i> , <i>S. epidermidis</i>	Cefazolin <i>or</i> Cefuroxime <i>or</i> Vancomycin ⁴	1–2 g IV ^{2,3} 1.5 g IV ³ 1 g IV
Gastrointestinal			
esophageal/gastroduodenal	Enteric gram-negative bacilli, gram-positive cocci	High risk ⁵ only: cefazolin ⁶	1–2 g IV ²
Biliary tract	Enteric gram-negative bacilli, enterococci, clostridia	High risk ⁷ only: cefazolin ^{6,8}	1–2 g IV ²
Colorectal	Enteric gram-negative bacilli, anaerobes, enterococci	Oral: neomycin + erythromycin base ⁹ <i>or</i> metronidazole ⁹ Parenteral: cefoxitin ⁶ <i>or</i> Cefotetan ⁶ Cefazolin + Metronidazole ⁶ <i>or</i> Ampicillin/sulbactam	—see note 9 1–2 g IV 1–2 g IV 1–2 g IV ² 0.5 g IV 3 g IV
Appendectomy, nonperforated ¹¹	Same as for colorectal	Cefoxitin ⁶ <i>or</i> cefotetan ⁶ <i>or</i> Cefazolin ⁶ + Metronidazole	1–2 g IV 1–2 g IV ² 0.5 g IV
Genitourinary			
Cystoscopy alone	Enteric gram-negative bacilli, enterococci	High risk only ¹² : ciprofloxacin ¹⁰ <i>or</i> Trimethoprim-sulfamethoxazole	500 mg PO <i>or</i> 400 mg IV 1 DS tablet
Cystoscopy with manipulation <i>or</i> upper tract instrumentation ¹³	Enteric gram-negative bacilli, enterococci	Ciprofloxacin ¹⁰ <i>or</i> Trimethoprim-sulfamethoxazole	500 mg PO <i>or</i> 400 mg IV 1 DS tablet
Open <i>or</i> laparoscopic surgery ¹⁴	Enteric gram-negative bacilli, enterococci	Cefazolin ⁶	1–2 g IV ²
Gynecologic and obstetric			
Vaginal, abdominal, <i>or</i> laparoscopic hysterectomy	Enteric gram-negative bacilli, anaerobes, group B streptococci, enterococci	Cefazolin ⁶ <i>or</i> cefoxitin ⁶ <i>or</i> cefotetan ⁶ <i>or</i> Ampicillin/sulbactam ^{6,10}	1–2 g IV ² 3 g IV
Cesarean section	Same as for hysterectomy	Cefazolin ⁶	1–2 g IV ²
Abortion, surgical	Same as for hysterectomy	Doxycycline	300 mg PO ¹⁵
Head and neck surgery			
Incisions through oral <i>or</i> pharyngeal mucosa	Anaerobes, enteric gram-negative bacilli, <i>S. aureus</i>	Clindamycin <i>or</i> Cefazolin + Metronidazole <i>or</i> Ampicillin/sulbactam ¹⁰	600–900 mg IV 1–2 g IV ² 0.5 g IV 3 g IV
Neurosurgery	<i>S. aureus</i> , <i>S. epidermidis</i>	Cefazolin	1–2 g IV ²
Ophthalmic	<i>S. epidermidis</i> , <i>S. aureus</i> , streptococci, enteric gram-negative bacilli, <i>Pseudomonas</i> spp.	Gentamicin, tobramycin, ciprofloxacin, gatifloxacin, levofloxacin, moxifloxacin, ofloxacin <i>or</i> neomycin-gramicidin-polymyxin B <i>OR</i> cefazolin	Multiple drops topically over 2 to 24 hours 100 mg subconjunctivally
Orthopedic	<i>S. aureus</i> , <i>S. epidermidis</i>	Cefazolin ¹⁶ <i>or</i> Vancomycin ^{2,16}	1–2 g IV ² , 1 g IV
Thoracic (noncardiac)	<i>S. aureus</i> , <i>S. epidermidis</i> , streptococci, enteric gram-negative bacilli	Cefazolin <i>or</i> Ampicillin/sulbactam ¹⁰ <i>or</i> Vancomycin ⁴	1–2 g IV ² 3 g IV 1 g IV

Table 9-7

Antimicrobial prophylaxis for surgery

NATURE OF OPERATION	COMMON PATHOGENS	RECOMMENDED ANTIMICROBIALS	ADULT DOSAGE BEFORE SURGERY ¹
Vascular Arterial surgery involving a prosthesis, the abdominal aorta, or a groin incision	<i>S. aureus</i> , <i>S. epidermidis</i> , enteric gram-negative bacilli	Cefazolin <i>or</i> Vancomycin ⁴	1–2 g IV ² 1 g IV
Lower extremity amputation for ischemia	<i>S. aureus</i> , <i>S. epidermidis</i> , enteric gram-negative bacilli, clostridia	Cefazolin <i>or</i> Vancomycin ⁴	1–2 g IV ² 1 g IV

¹Parenteral prophylactic antimicrobials can be given as a single IV dose begun within 60 min before the operation. For prolonged operations (>3 h) or those with major blood loss, or in patients with extensive burns, additional intraoperative doses should be given at intervals 1–2 times the half-life of the drug (ampicillin/sulbactam q2 h, cefazolin q4 h, cefuroxime q4 h, cefoxitin q2 h, clindamycin q6 h, vancomycin q12 h) for the duration of the procedure in a patient with normal renal function. If vancomycin or a fluoroquinolone is used, the infusion should be started 60–120 min before the initial incision to minimize the possibility of an infusion reaction close to the time of induction of anesthesia and to have adequate tissue levels at the time of incision.

²The recommended dose of cefazolin is 1 g for patients who weigh 80 kg and 2 g for those >80 kg. Morbidly obese patients may need higher doses.

³Some experts recommend an additional dose when patients are removed from bypass during open heart surgery.

⁴Vancomycin can be used in hospitals in which methicillin-resistant *Staphylococcus aureus* (MRSA) and *S. epidermidis* are a frequent cause of postoperative wound infection, in patients previously colonized with MRSA, or for those who are allergic to penicillin or cephalosporins. Rapid IV administration may cause hypotension, which could be especially dangerous during induction of anesthesia. Even when the drug is given over 60 min, hypotension may occur; treatment with diphenhydramine (Benadryl and others) and further slowing of the infusion rate may be helpful. Some experts would give 15 mg/kg of vancomycin to patients weighing more than 75 kg up to a maximum of 1.5 g with a slower infusion rate (90 min for 1.5 g). For procedures in which gram-negative bacilli are common pathogens, many experts would add another drug such as an aminoglycoside (gentamicin, tobramycin, or amikacin), aztreonam, or a fluoroquinolone.

⁵Morbid obesity, GI obstruction, decreased gastric acidity or gastrointestinal motility, gastric bleeding, malignancy or perforation, or immunosuppression.

⁶For patients allergic to penicillin and cephalosporins, clindamycin or vancomycin with either gentamicin, ciprofloxacin, levofloxacin, or aztreonam is a reasonable alternative. Fluoroquinolones should not be used for prophylaxis in cesarean section.

⁷Age >70 y, acute cholecystitis, nonfunctioning gallbladder, obstructive jaundice, or common duct stones.

⁸Cefotetan, cefoxitin, and ampicillin/sulbactam are reasonable alternatives.

⁹In addition to mechanical bowel preparation, 1 g of neomycin plus 1 g of erythromycin at 1 P.M., 2 P.M., and 11 P.M. or 2 g of neomycin plus 2 g of metronidazole at 7 P.M. and 11 P.M. the day before an 8 A.M. operation.

¹⁰Due to increasing resistance of *E. coli* to fluoroquinolones and ampicillin/sulbactam, local sensitivity profiles should be reviewed prior to use.

¹¹For a ruptured viscus, therapy is often continued for about 5 d.

¹²Urine culture positive or unavailable, preoperative catheter, transrectal prostate biopsy, or placement of prosthetic material.

¹³Shock wave lithotripsy, ureteroscopy.

¹⁴Including percutaneous renal surgery, procedures with entry into the urinary tract, and those involving implantation of a prosthesis. If manipulation of bowel is involved, prophylaxis is given according to colorectal guidelines.

¹⁵Divided into 100 mg before procedure and 200 mg after.

¹⁶If a tourniquet is to be used in the procedure, the entire dose of antibiotic must be infused prior to its inflation.

Source: Reprinted with special permission from *Treatment Guidelines from The Medical Letter*, October 2012; Vol. 10(122):73. www.medicalletter.org.

Although removal of all necrotic tissue is the goal of the first surgical intervention, the distinction between necrotic and simply edematous tissue often is difficult. Careful inspection every 12 to 24 hours will reveal any new necrotic areas, and these need further débridement and excision. When all necrotic tissue has been removed and the infection has been controlled, the wounds may be covered with homo- or xenografts until definitive reconstruction and autografting can take place.

The mere presence of bacteria in an open wound, either acute or chronic, does not constitute an infection, because large numbers of bacteria can be present in the normal situation. In addition, the bacteria identified by cultures may not be representative of the bacteria causing the actual wound infection. There seems to be confusion as to what exactly constitutes wound infection. For purposes of clarity, we have to differentiate between contamination, colonization, and infection. *Contamination* is the presence of bacteria without multiplication, *colonization* is multiplication without host response, and *infection* is the presence of host response in reaction to deposition and multiplication of bacteria. The presence of a host response helps to differentiate between infection and colonization as seen in chronic wounds. The host response that helps in diagnosing wound infection comprises cellulitis, abnormal

discharge, delayed healing, change in pain, abnormal granulation tissue, bridging, and abnormal color and odor.

As discussed previously, neutrophils play a major role in preventing wound infections. Chronic granulomatous disease (CGD) comprises a genetically heterogeneous group of diseases in which the reduced nicotinamide adenine dinucleotide phosphate (NADPH)-dependent oxidase enzyme is deficient. This defect impairs the intracellular killing of microorganisms, leaving the patient liable to infection by bacteria and fungi. Afflicted patients have recurrent infections and form granulomas, which can lead to obstruction of the gastric antrum and genitourinary tracts and poor wound healing. Surgeons become involved when the patient develops infectious or obstructive complications.

The nitroblue tetrazolium (NBT) reduction test is used to diagnose CGD. Normal neutrophils can reduce this compound, while neutrophils from affected patients do not, facilitating the diagnosis via a colorimetric test. Clinically, patients develop recurrent infections such as pneumonia, lymphadenitis, hepatic abscess, and osteomyelitis. Organisms most commonly responsible are *Staphylococcus aureus*, *Aspergillus*, *Klebsiella*, *Serratia*, or *Candida*. When CGD patients require surgery, a preoperative pulmonary function test should be considered since they are

predisposed to obstructive and restrictive lung disease. Wound complications, mainly infection, are common. Sutures should be removed as late as possible since the wounds heal slowly. Abscess drains should be left in place for a prolonged period until the infection is completely resolved.⁹³

Hyperglycemia has been shown to be a significant risk factor of postoperative infections.⁹⁴ Tight blood glucose control, beginning preoperatively and continued into the operating room and beyond, has been associated with significant reduction in infectious complications, in particular following cardiac surgery.^{95,96} Too tight of a glycemic control (80–100 mg/dL) appears to be associated with more complications and is as effective, if not less than, moderate control (120–180 mg/dL).^{97,98}

Another host factor that has been implicated in the development of superficial surgical site infection relates to the state of the subcutaneous capillary bed. Thomas K. Hunt had shown through several decades of work that this capillary bed is exquisitely sensitive to hypovolemia,⁹⁹ hypothermia,¹⁰⁰ and stress, leading to rapid vasoconstriction with secondary impaired oxygen delivery and increased rates of infection.⁶¹ Maintenance of euolemia, core temperature above 36 to 36.5°C, and pain control have all been shown singly and additively to reduce rates of wound infections.⁶³ Another suggestion has been to increase inspired FiO_2 to 0.8 for the duration of the operation and in the immediate postoperative period, as a means of increasing subcutaneous tissue oxygen delivery. Although successful in most studies,^{62,101} there have also been negative results from such a single approach¹⁰²; this suggests that addressing volume, temperature, pain control, and oxygen delivery in concert may be the more fruitful approach to reduce surgical wound infections.

Chronic Wounds

Chronic wounds are defined as wounds that have failed to proceed through the orderly process that produces satisfactory anatomic and functional integrity or that have proceeded through the repair process without producing an adequate anatomic and functional result. The majority of wounds that have not healed in 3 months are considered chronic. *Skin ulcers*, which usually occur in traumatized or vascular compromised soft tissue, are also considered chronic in nature, and proportionately are the major component of chronic wounds. In addition to the factors discussed earlier that can delay wound healing, other causative mechanisms may also play a role in the etiology of chronic wounds. Repeated trauma, poor perfusion or oxygenation, and/or excessive inflammation contribute to the causation and the perpetuation of the chronicity of wounds.

Unresponsiveness to normal regulatory signals also has been implicated as a predictive factor of chronic wounds. This may come about as a failure of normal growth factor synthesis,¹⁰³ and thus an increased breakdown of growth factors within a wound environment that is markedly proteolytic because of overexpression of protease activity or a failure of the normal antiprotease inhibitor mechanisms.¹⁰⁴ Fibroblasts from chronic wounds also have been found to have decreased proliferative potential, perhaps because of senescence¹⁰⁵ or decreased expression of growth factor receptors.¹⁰⁶ Chronic wounds occur due to various etiologic factors, and several of the most common are discussed later.

Malignant transformation of chronic ulcers can occur in any long-standing wound (Marjolin's ulcer). Any wound that does not heal for a prolonged period of time is prone to malignant transformation. Malignant wounds are differentiated clinically from nonmalignant wounds by the presence of overturned

wound edges (Fig. 9-10). In patients with suspected malignant transformations, biopsy of the wound edges must be performed to rule out malignancy. Cancers arising de novo in chronic wounds include both squamous and basal cell carcinomas.

Ischemic Arterial Ulcers. These wounds occur due to a lack of blood supply and are painful at presentation. They usually are associated with other symptoms of peripheral vascular disease, such as intermittent claudication, rest pain, night pain, and color or trophic changes. These wounds commonly are present at the most distal portions of the extremities such as the interdigital clefts, although more proximal locations are also encountered. On examination, there may be diminished or absent pulses with decreased ankle-brachial index and poor formation of granulation tissue. Other signs of peripheral ischemia, such as dryness of skin, hair loss, scaling, and pallor can be present. The wound itself usually is shallow with smooth margins, and a pale base and surrounding skin may be present. The management of these wounds is two-pronged and includes revascularization and wound care.¹⁰⁷ Nonhealing of these wounds is the norm unless successful revascularization is performed. After establishing adequate blood supply, most such wounds progress to heal satisfactorily.

A strategy of prevention is extremely important in the approach to patients with limb ischemia. In bedridden patients, especially those who are sedated (in the intensive care unit), demented, or with peripheral neural compromise (neuropathy or paraplegia), pressure ulcers develop rapidly and often unnecessarily. Removal of restrictive stockings (in patients with critical ischemia), frequent repositioning, and surveillance are vital to preventing these ulcers.¹⁰⁸

Venous Stasis Ulcers. Although there is unanimous agreement that venous ulcers are due to venous stasis and hydrostatic back pressure, there is less consensus as to what are the exact pathophysiologic pathways that lead to ulceration and impaired healing. On the microvascular level, there is alteration and distention of the dermal capillaries with leakage of fibrinogen into the tissues; polymerization of fibrinogen into fibrin cuffs leads to perivascular cuffing that can impede oxygen exchange, thus contributing to ulceration. These same fibrin cuffs and the leakage of macromolecules such as fibrinogen and α_2 -macroglobulin trap growth factors and impede wound healing.¹⁰³ Another hypothesis suggests that neutrophils adhere to the capillary endothelium and cause plugging with diminished dermal blood flow. Venous hypertension and capillary damage lead to extravasation of hemoglobin. The products of this breakdown are irritating and cause pruritus and skin damage. The resulting brownish pigmentation of skin combined with the loss of subcutaneous fat produces characteristic changes called lipodermatosclerosis. Regardless of the pathophysiologic mechanisms, the clinically characteristic picture is that of an ulcer that fails to re-epithelialize despite the presence of adequate granulation tissue.

Venous stasis occurs due to the incompetence of either the superficial or deep venous systems. Chronic venous ulcers usually are due to the incompetence of the deep venous system and are commonly painless. Stasis ulcers tend to occur at the sites of incompetent perforators, the most common being above the medial malleolus, over Cockett's perforator. Upon examination, the typical location combined with a history of venous incompetence and other skin changes is diagnostic. The wound usually is shallow with irregular margins and pigmented surrounding skin.

The cornerstone of treatment of venous ulcers is compression therapy, although the best method to achieve it remains

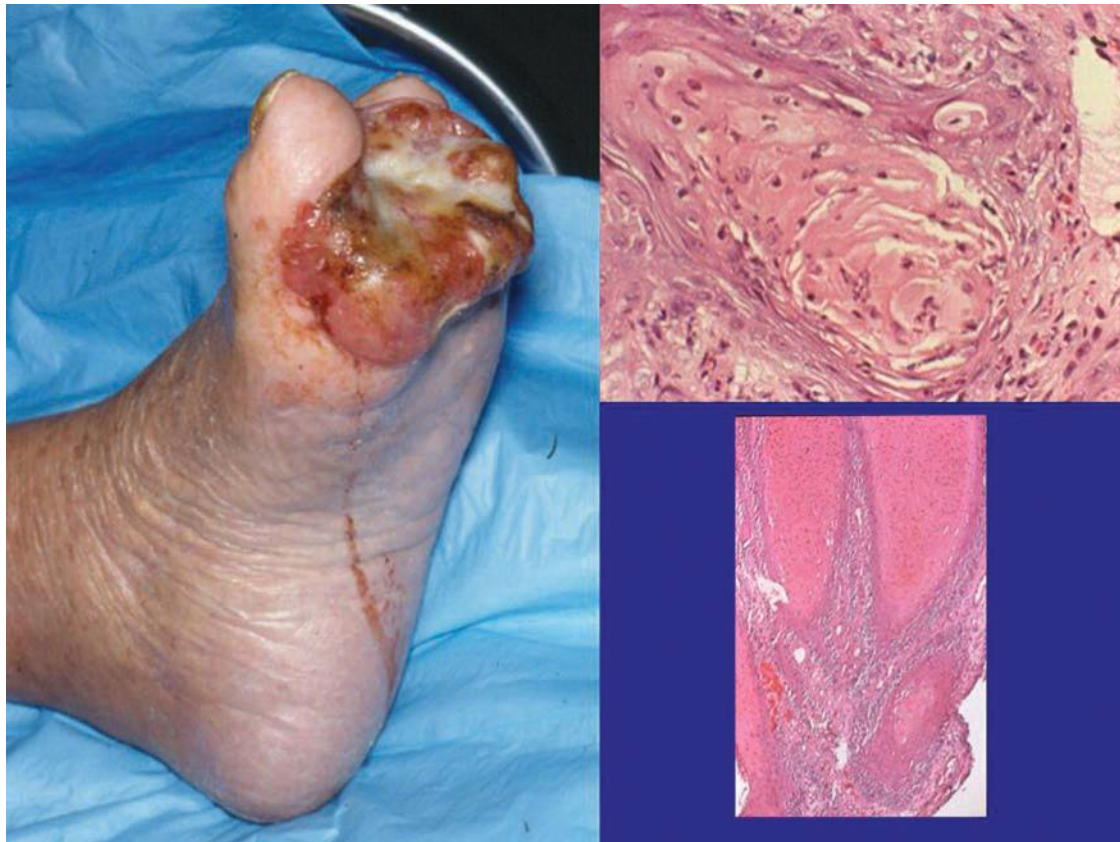

Figure 9-10. Typical appearance of the malignant transformation of a long-standing chronic wound. (Photos used with permission by Dr. Robert S. Kirsner, University of Miami.)

controversial. Compression can be accomplished via rigid or flexible means. The most commonly used method is the rigid, zinc oxide-impregnated, nonelastic bandage. Others have proposed a four-layered bandage approach as a more optimal method of obtaining graduated compression.¹⁰⁹ Wound care in these patients focuses on maintaining a moist wound environment, which can be achieved with hydrocolloids. Other, more modern approaches include use of vasoactive substances and growth factor application, as well as the use of skin substitutes. Recently, sprayed allogeneic keratinocytes and fibroblasts plus four-layer bandages have been shown to hasten healing when compared to compression alone.¹¹⁰ Most venous ulcers can be healed with perseverance and by addressing the venous hypertension.¹⁰⁹ Unfortunately, recurrences are frequent despite preventative measures, largely because of patients' lack of compliance.¹¹¹

Diabetic Wounds. Ten percent to 25% of diabetic patients run the risk of developing ulcers. There are approximately 50,000 to 60,000 amputations performed in diabetic patients each year in the United States. The major contributors to the formation of diabetic ulcers include neuropathy, foot deformity, and ischemia. It is estimated that 60% to 70% of diabetic ulcers are due to neuropathy, 15% to 20% are due to ischemia, and another 15% to 20% are due to a combination of both. The neuropathy is both sensory and motor and is secondary to persistently elevated glucose levels. The loss of sensory function allows unrecognized injury to occur from ill-fitting shoes, foreign bodies, or other trauma. The motor neuropathy or Charcot's foot leads to collapse or dislocation of the interphalangeal or metatarsophalangeal joints, causing pressure on

areas with little protection. There is also severe micro- and macrovascular circulatory impairment.

Once ulceration occurs, the chances of healing are poor. The treatment of diabetic wounds involves local and systemic measures.¹¹² Achievement of adequate blood sugar levels is very important. Most diabetic wounds are infected, and eradication of the infectious source is paramount to the success of healing. Treatment should address the possible presence of osteomyelitis and should employ antibiotics that achieve adequate levels both in soft tissue and bone. Wide débridement of all necrotic or infected tissue is another cornerstone of treatment. Off-loading of the ulcerated area by using specialized orthotic shoes or casts allows for ambulation while protecting the fragile wound environment. Topical application of PDGF and granulocyte-macrophage colony-stimulating factor has met with limited but significant success in achieving closure.¹¹³ The application of engineered skin allograft substitutes, although expensive, also has shown some significant success.¹¹⁴ Prevention and specifically foot care play an important role in the management of diabetics.¹¹⁵

Decubitus or Pressure Ulcers. The incidence of pressure ulcers ranges from 2.7% to 9% in the acute care setting, in comparison to 2.4% to 23% in long-term care facilities. A pressure ulcer is a localized area of tissue necrosis that develops when soft tissue is compressed between a bony prominence and an external surface. Excessive pressure causes capillary collapse and impedes the delivery of nutrients to body tissues. Pressure ulcer formation is accelerated in the presence of friction, shear forces, and moisture. Other contributory factors in the pathogenesis of pressure ulcers include immobility, altered activity

levels, altered mental status, chronic conditions, and altered nutritional status. The four stages of pressure ulcer formation are as follows: stage I, nonblanching erythema of intact skin; stage II, partial-thickness skin loss involving epidermis or dermis or both; stage III, full-thickness skin loss, but not through the fascia; and stage IV, full-thickness skin loss with extensive involvement of muscle and bone.

The treatment of established pressure ulcers is most successful when carried out in a multidisciplinary manner by involving wound care teams consisting of physicians, nurses, dietitians, physical therapists, and nutritionists. Care of the ulcer itself comprises débridement of all necrotic tissue, maintenance of a favorable moist wound environment that will facilitate healing, relief of pressure, and addressing host issues such as nutritional, metabolic, and circulatory status. Débridement is most efficiently carried out surgically, but enzymatic proteolytic preparations and hydrotherapy also are used. The wound bed should be kept moist by employing dressings that absorb secretions but do not desiccate the wound.¹¹⁶ Operative repair, usually involving flap rotation, has been found to be useful in obtaining closure. Unfortunately, recurrence rates are extremely high, owing to the population at risk and the inability to fully address the causative mechanisms.¹¹⁷

EXCESS HEALING

Clinically, excess healing can be as significant as wound failure. It is likely that more operative interventions are required for correction of the morbidity associated with excessive healing than are required for wound failure. The clinical manifestations of exuberant healing are protean and differ in the skin (mutilating or debilitating scars, burn contractions), tendons (frozen repairs), the GI tract (strictures or stenoses), solid organs (cirrhosis, pulmonary fibrosis), or the peritoneal cavity (adhesive disease).

Hypertrophic scars (HTSs) and keloids represent an overabundance of fibroplasia in the dermal healing process. HTSs rise above the skin level but stay within the confines of the original wound and often regress over time. Keloids rise above the skin level as well, but extend beyond the border of the original wound and rarely regress spontaneously (Fig. 9-11). Both HTSs and keloids occur after trauma to the skin and may be tender, pruritic, and cause a burning sensation. Keloids are 15 times more common in darker-pigmented ethnicities, with individuals of African, Spanish, and Asian ethnicities being especially susceptible. Men and women are equally affected. Genetically, the predilection to keloid formation appears to be autosomal dominant with incomplete penetration and variable expression.^{117,118}

HTSs usually develop within 4 weeks after trauma. The risk of HTS increases if epithelialization takes longer than 21 days, independent of site, age, and race. Rarely elevated more than 4 mm above the skin level, HTSs stay within the boundaries of the wound. They usually occur across areas of tension and flexor surfaces, which tend to be at right angles to joints or skin creases. The lesions are initially erythematous and raised and over time may evolve into pale, flatter scars.

Keloids can result from surgery, burns, skin inflammation, acne, chickenpox, zoster, folliculitis, lacerations, abrasions, tattoos, vaccinations, injections, insect bites, or ear piercing, or may arise spontaneously. Keloids tend to occur 3 months to years after the initial insult, and even minor injuries can result in large lesions. They vary in size from a few millimeters to large,

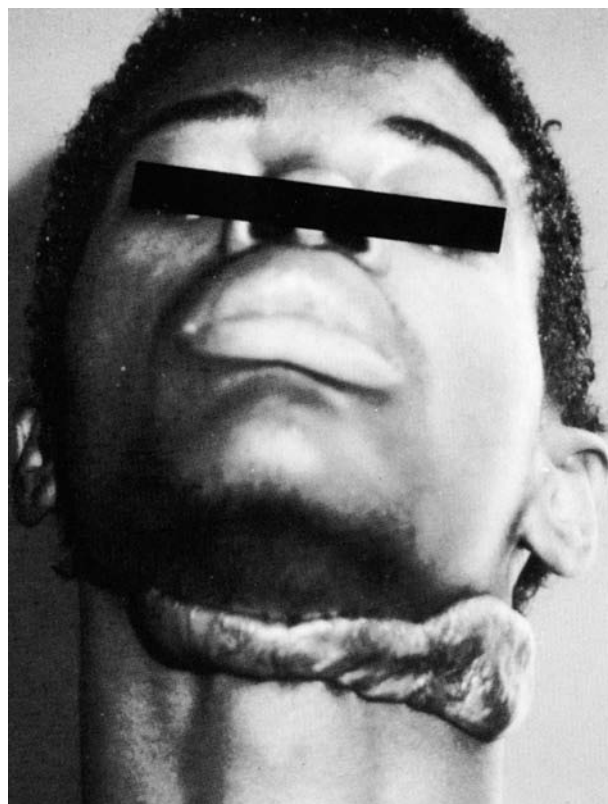


Figure 9-11. Recurrent keloid on the neck of a 17-year-old patient that had been revised several times. (Reproduced with permission from Murray JC, Pinnell SR. *Keloids and excessive dermal scarring*. In: Cohen IK, Diegelmann RF, Lindblad WJ, eds. *Wound Healing: Biochemical and Clinical Aspects*. Philadelphia: WB Saunders; 1993. Copyright Elsevier.)

pedunculated lesions with a soft to rubbery or hard consistency. While they project above surrounding skin, they rarely extend into underlying subcutaneous tissues. Certain body sites have a higher incidence of keloid formation, including the skin of the earlobe as well as the deltoid, presternal, and upper back regions. They rarely occur on eyelids, genitalia, palms, soles, or across joints. Keloids rarely involute spontaneously, and surgical intervention can lead to recurrence, often with a worse result (Table 9-8).

Histologically, both HTSs and keloids demonstrate increased thickness of the epidermis with an absence of rete ridges. There is an abundance of collagen and glycoprotein deposition. Normal skin has distinct collagen bundles, mostly parallel to the epithelial surface, with random connections between bundles by fine fibrillar strands of collagen. In HTS, the collagen bundles are flatter and more random, and the fibers are in a wavy pattern. In keloids, the collagen bundles are virtually nonexistent, and the fibers are connected haphazardly in loose sheets with a random orientation to the epithelium. The collagen fibers are larger and thicker, and myofibroblasts are generally absent.¹¹⁹

Keloidal fibroblasts have normal proliferation parameters but synthesize collagen at a rate 20 times greater than that observed in normal dermal fibroblasts, and 3 times higher than fibroblasts derived from HTS. Abnormal amounts of extracellular matrix such as fibronectin, elastin, and proteoglycans also are produced. The synthesis of fibronectin, which promotes clot generation, granulation tissue formation, and re-epithelialization,

TABLE 9-8

Characteristics of keloids and hypertrophic scars

	KELOID	HYPERTROPHIC SCAR
Incidence	Rare	Frequent
Ethnic groups	African American, Asian, Hispanic	No predilection
Prior injury	Yes	Yes
Site predilection	Neck, chest, ear lobes, shoulders, upper back	Anywhere
Genetics	Autosomal dominant with incomplete penetration	No
Timing	Symptom-free interval; may appear years after injury	4–6 weeks postinjury
Symptoms	Pain, pruritus, hyperesthesia, growth beyond wound margins	Raised, some pruritus, respects wound confines
Regression	No	Frequent spontaneous
Contracture	Rare	Frequent
Histology	Hypocellular, thick, wavy collagen fibers in random orientation	Parallel orientation of collagen fibers

decreases during the normal healing process; however, production continues at high levels for months to years in HTSs and keloids. This perturbed synthetic activity is mediated by altered growth factor expression. TGF- β expression is higher in HTS, and both HTS- and keloid-derived fibroblasts respond to lower concentrations of TGF- β than do normal dermal fibroblasts. HTSs also express increased levels of insulin-like growth factor-1, which reduces collagenase mRNA activity and increases mRNA for types I and II procollagen.¹²⁰ Keloid fibroblasts have enhanced expression of TGF- β 1 and TGF- β 2, VEGF, and plasminogen activator inhibitor-1 and an increased number of PDGF receptors; they also have upregulated antiapoptotic gene expression, which can be differentially expressed within different areas of the same scar.

The underlying mechanisms that cause HTSs and keloids are not known. The immune system appears to be involved in the formation of both HTSs and keloids, although the exact relationship is unknown. Much is inferred from the presence of various immune cells in HTSs and keloids. For example, in both HTSs and keloids, keratinocytes express human leukocyte antigen (HLA)-2 and ICAM-1 receptors, which are absent in normal scar keratinocytes. Keloids also have increased deposition of immunoglobulins IgG, IgA, and IgM, and their formation correlates with serum levels of IgE. Antinuclear antibodies against fibroblasts, epithelial cells, and endothelial cells are found in keloids, but not HTSs. HTSs have higher T lymphocyte and Langerhans cell contents. There is also a larger number of mast cells present in both HTSs and keloids compared to normal scars. Another recently described cell population is the fibrocyte, a leukocyte subpopulation derived from peripheral mononuclear cells. Present in large numbers at the site of excess scarring, fibrocytes can stimulate fibroblast numbers and collagen synthesis. They also generate large numbers of cytokines, growth factors, and extracellular matrix proteins, which are characteristically upregulated in keloid tissue. Other mechanisms that may cause abnormal scarring include mechanical tension (although keloids often occur in areas of minimal tension) and prolonged irritation and/or inflammation that may lead to the generation of abnormal concentrations of profibrotic cytokines.

Treatment goals include restoration of function to the area, relief of symptoms, and prevention of recurrence. Many patients

seek intervention due to cosmetic concerns. Because the underlying mechanisms causing keloids and HTSs remain unknown, many different modalities of treatment have been used without consistent success.¹²¹

Excision alone of keloids is subject to a high recurrence rate, ranging from 45% to 100%. Inclusion of the dermal advancing edge that characterizes keloids, use of incisions in skin tension lines, and tension-free closure all have been proposed to decrease recurrence rates. There are fewer recurrences when surgical excision is combined with other modalities such as intralesional corticosteroid injection, topical application of silicone sheets, or the use of radiation or pressure. Surgery is recommended for debulking large lesions or as second-line therapy when other modalities have failed. Silicone application is relatively painless and should be maintained for 24 hours a day for about 3 months to prevent rebound hypertrophy. It may be secured with tape or worn beneath a pressure garment. The mechanism of action is not understood, but increased hydration of the skin, which decreases capillary activity, inflammation, hyperemia, and collagen deposition, may be involved. Silicone is more effective than other occlusive dressings and is an especially good treatment for children and others who cannot tolerate the pain involved in other modalities.¹⁰²

Intralesional corticosteroid injections decrease fibroblast proliferation, collagen and glycosaminoglycan synthesis, the inflammatory process, and TGF- β levels. When used alone, however, there is a variable rate of response and recurrence; therefore, steroids are recommended as first-line treatment for keloids and second-line treatment for HTSs if topical therapies have failed. Intralesional injections are more effective on younger scars. They may soften, flatten, and give symptomatic relief to keloids, but they cannot make the lesions disappear and they cannot narrow wide HTSs. Success is enhanced when used in combination with surgical excision. Serial injections every 2 to 3 weeks are required. Complications include skin atrophy, hypopigmentation, telangiectasias, necrosis, and ulceration.

Although radiation destroys fibroblasts, it has variable, unreliable results and produces poor results, with 10% to 100% recurrence when used alone. It is more effective when combined with surgical excision. The timing, duration, and dosage for radiation therapy are still controversial, but doses ranging from

1500 to 2000 rads appear effective. Given the risks of hyperpigmentation, pruritus, erythema, paresthesias, pain, and possible secondary malignancies, radiation should be reserved for adults with scars resistant to other modalities.

Pressure aids collagen maturation, flattens scars, and improves thinning and pliability. It reduces the number of cells in a given area, possibly by creating ischemia, which decreases tissue metabolism and increases collagenase activity. External compression is used to treat HTSs, especially after burns. Therapy must begin early, and a pressure between 24 and 30 mmHg must be achieved in order to exceed capillary pressure, yet preserve peripheral blood circulation. Garments should be worn for 23 to 24 hours a day for up to 1 or more years to avoid rebound hypertrophy. Scars older than 6 to 12 months respond poorly.

Topical retinoids also have been used as treatment for both HTSs and keloids, with reported responses of 50% to 100%. Intralesional injections of IFN- γ , a cytokine released by T lymphocytes, reduce collagen types I, II, and III by decreasing mRNA and possibly by reducing levels of TGF- β . As monotherapy, IFN- γ has failed because of high recurrence rates due to resistance to repeated injections. More recently, imiquimod, an immunomodulator that induces IFN- γ and other cytokines at the site of application, has been recommended following excision. Intralesional injections of chemotherapeutic agents such as 5-fluorouracil have been used both alone and in combination with steroids. The use of bleomycin or mitomycin C has been reported to achieve some success in older scars resistant to steroids.

Peritoneal Scarring. Peritoneal adhesions are fibrous bands of tissues formed between organs that are normally separated and/or between organs and the internal body wall. Most intra-abdominal adhesions are a result of peritoneal injury, either by a prior surgical procedure or due to intra-abdominal infection. Postmortem examinations demonstrate adhesions in 67% of patients with prior surgical procedures and in 28% with a history of intra-abdominal infection. Intra-abdominal adhesions are the most common cause (65%–75%) of small bowel obstruction, especially in the ileum. Operations in the lower abdomen have a higher chance of producing small bowel obstruction. Following rectal surgery, left colectomy, or total colectomy, there is an 11% chance of developing small bowel obstruction within 1 year, and this rate increases to 30% by 10 years. Adhesions also are a leading cause of secondary infertility in women and can cause substantial abdominal and pelvic pain. Adhesions account for 2% of all surgical admissions and 3% of all laparotomies in general surgery.¹²²

Adhesions form when the peritoneal surface is damaged due to surgery, thermal or ischemic injury, inflammation, or foreign body reaction. The injury disrupts the protective mesothelial cell layer lining the peritoneal cavity and the underlying connective tissue. The injury elicits an inflammatory response consisting of hyperemia, fluid exudation, release and activation of white blood cells and platelets in the peritoneal cavity, activation of inflammatory cytokines, and the onset of the coagulation and complement cascades. Fibrin deposition occurs between the damaged but opposed serosal surfaces. These filmy adhesions often are transient and degraded by proteases of the fibrinolytic system, with restoration of the normal peritoneal surface. If insufficient fibrinolytic activity is present, permanent fibrous adhesions will form by collagen deposition within 1 week of the injury (Fig. 9-12).

Extensive research has been done on the effect of surgery and peritonitis on the fibrinolytic and inflammatory cascades

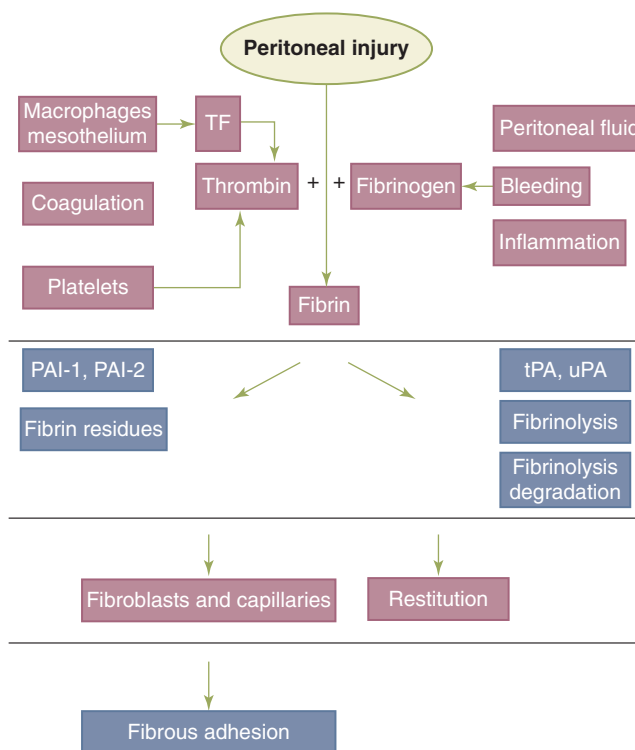


Figure 9-12. Fibrin formation and degradation in peritoneal tissue repair and adhesion formation. PAI-1, PAI-2 = types 1 and 2 plasminogen activator inhibitor; TF = tissue factor; tPA = tissue plasminogen activator; uPA = urokinase plasminogen activator.

within the peritoneal cavity. During normal repair, fibrin is principally degraded by the fibrinolytic protease plasmin, which is derived from inactive plasminogen through the action of two plasminogen activators (PA): tissue-type plasminogen activator (tPA) and urokinase-type plasminogen activator (uPA). Fibrinolytic activity in peritoneal fluid is reduced after abdominal surgery due to initial decreases in tPA levels and later to increases in plasminogen activator inhibitor-1 (PAI-1), which are induced by various cytokines, including TNF- α , IL-1, and interleukin-6 (IL-6).¹²³

There are two major strategies for adhesion prevention or reduction. Surgical trauma is minimized within the peritoneum by careful tissue handling, avoiding desiccation and ischemia, and spare use of cautery, laser, and retractors. Fewer adhesions form with laparoscopic surgical techniques due to reduced tissue trauma. The second major advance in adhesion prevention has been the introduction of barrier membranes and gels, which separate and create barriers between damaged mesothelial surfaces, allowing for adhesion-free healing. Currently, only three products are Food and Drug Administration (FDA) approved for reducing adhesion formation: Interceed[®] (oxidized regenerated cellulose, indicated only in pelvic surgery), Sefrafilm[®] (a film composed of hyaluronic acid and carboxymethylcellulose) that is usually applied below the incision, and Adept[®] (4% icodextrin, a corn starch derivative in electrolyte solution, also for use mainly in pelvic surgery). However, use of these substances directly over bowel anastomoses is contraindicated due to an elevated risk of leak.¹²⁴ There have been innumerable studies investigating different molecules in hopes of preventing adhesion formation, but most of the success is limited to animal models, and clinically significant results in humans have yet to be achieved.

Local Care (Fig. 9-13)

Management of acute wounds begins with obtaining a careful history of the events surrounding the injury. The history is followed by a meticulous examination of the wound. Examination should assess the depth and configuration of the wound, the extent of nonviable tissue, and the presence of foreign bodies and other contaminants. Examination of the wound

5► may require irrigation and débridement of the edges of the wound and is facilitated by use of local anesthesia. Antibiotic administration and tetanus prophylaxis may be needed, and planning the type and timing of wound repair should take place.

After completion of the history, examination, and administration of tetanus prophylaxis, the wound should be meticulously anesthetized. Lidocaine (0.5%–1%) or bupivacaine (0.25%–0.5%) combined with a 1:100,000 to 1:200,000 dilution of epinephrine provides satisfactory anesthesia and hemostasis. Epinephrine should not be used in wounds of the fingers, toes, ears, nose, or penis, due to the risk of tissue necrosis secondary to terminal arteriole vasospasm in these structures. Injection of these anesthetics can result in significant initial patient discomfort, and this can be minimized by slow injection, infiltration of the subcutaneous tissues, and buffering the solution with sodium bicarbonate. Care must be observed in calculating the maximum dosages of lidocaine or bupivacaine in order to avoid toxicity-related side effects.

Irrigation to visualize all areas of the wound and remove foreign material is best accomplished with normal saline (without additives). High-pressure wound irrigation is more effective in achieving complete débridement of foreign material and nonviable tissues. Iodine, povidone-iodine, hydrogen peroxide, and organically based antibacterial preparations have all been shown to impair wound healing due to injury to wound neutrophils and macrophages, and thus should not be used. All hematomas present within wounds should be carefully evacuated and any remaining bleeding sources controlled with ligature or cautery. If the injury has resulted in the formation of a marginally viable flap of skin or tissue, this should be resected or revascularized prior to further wound repair and closure.

After the wound has been anesthetized, explored, irrigated, and débrided, the area surrounding the wound should be cleaned, inspected, and the surrounding hair clipped. The area surrounding the wound should be prepared with povidone iodine, chlorhexidine, or similar bacteriostatic solutions and draped with sterile towels. Having ensured hemostasis and adequate débridement of nonviable tissues and removal of any remaining foreign bodies, irregular, macerated, or beveled wound edges should be débrided in order to provide a fresh edge for reapproximation. Although plastic surgical techniques such as W- or Z-plasty are seldom recommended for acute wounds, great care must be taken to realign wound edges properly. This is particularly important for wounds that cross the vermilion border, eyebrow, or hairline. Initial sutures that realign the edges of these different tissue types will speed and greatly enhance the aesthetic outcome of the wound repair.

In general, the smallest suture required to hold the various layers of the wound in approximation should be selected in order to minimize suture-related inflammation. Nonabsorbable or slowly absorbing monofilament sutures are most suitable for approximating deep fascial layers, particularly in the abdominal wall. Subcutaneous tissues should be closed with braided absorbable sutures, with care to avoid placement of sutures in fat. Although traditional teaching in wound closure has emphasized multiple-layer closures, additional layers of suture closure are associated with increased risk of wound infection, especially when placed in fat. Drains may be placed in areas at risk of forming fluid collections.

In areas of significant tissue loss, rotation of adjacent musculocutaneous flaps may be required to provide sufficient tissue mass for closure. These musculocutaneous flaps may be based on intrinsic blood supply or may be moved from distant sites as free flaps and anastomosed into the local vascular bed. In areas with significant superficial tissue loss, split-thickness skin grafting (placed in a delayed manner to assure an adequate tissue bed) may be required and will speed formation of an intact epithelial barrier to fluid loss and infection. Split-thickness skin grafts are readily obtained using manual or mechanical dermatomes, and the grafts may be “meshed” in order to increase the surface area of their coverage. It is essential to ensure hemostasis

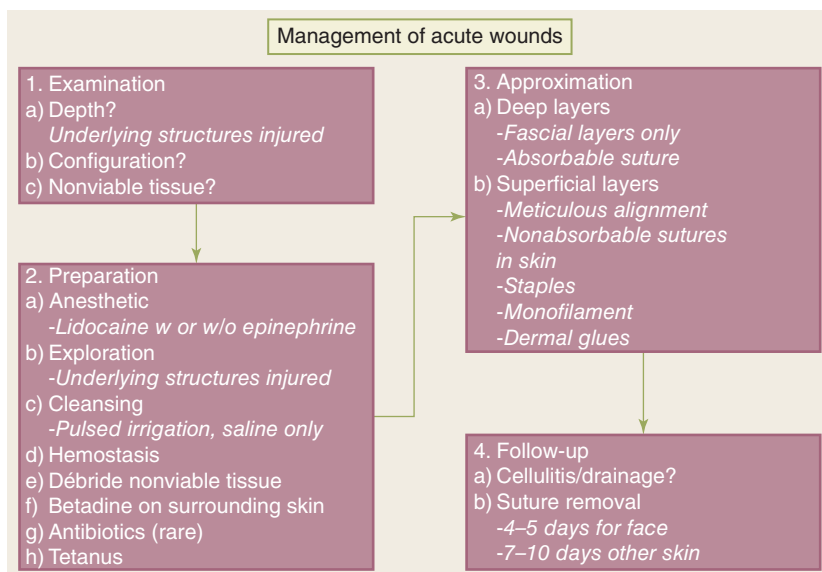


Figure 9-13. Algorithm for management of acute wounds.

of the underlying tissue bed prior to placement of split-thickness skin grafts, as the presence of a hematoma below the graft will prevent the graft from taking, resulting in sloughing of the graft. In acute, contaminated wounds with skin loss, use of porcine skin xenografts or skin cadaveric allografts is prudent until the danger of infection passes.

After closing deep tissues and replacing significant tissue deficits, skin edges should be reapproximated for cosmesis and to aid in rapid wound healing. Skin edges may be quickly reapproximated with stainless steel staples or nonabsorbable monofilament sutures. Care must be taken to remove these from the wound prior to epithelialization of the skin tracts where sutures or staples penetrate the dermal layer. Failure to remove the sutures or staples prior to 7 to 10 days after repair will result in a cosmetically inferior wound. Where wound cosmesis is important, the above problems may be avoided by placement of buried dermal sutures using absorbable braided sutures. This method of wound closure allows for a precise reapproximation of wound edges and may be enhanced by application of wound closure tapes to the surface of the wound. Intradermal absorbable sutures do not require removal. Use of skin tapes alone is only recommended for closure of the smallest superficial wounds. Larger wounds generate sufficient lateral tension that the epithelial edges either separate or curl upward under the tapes, resulting in inadequate epithelial apposition and poor cosmesis.

The development of octyl-cyanoacrylate tissue glues have shown new promise for the management of simple, linear wounds with viable skin edges. These new glues are less prone to brittleness and have superior burst-strength characteristics. Studies have shown them to be suitable for use in contaminated situations without significant risk of infection. When used in the above types of wounds, these glues appear to provide superb cosmetic results and result in significantly less trauma than sutured repair, particularly when used in pediatric patients.

Antibiotics

Antibiotics should be used only when there is an obvious wound infection. Most wounds are contaminated or colonized with bacteria. The presence of a host response constitutes an infection and justifies the use of antibiotics. Signs of infection to look for include erythema, cellulitis, swelling, and purulent discharge. Indiscriminate use of antibiotics should be avoided to prevent emergence of multidrug-resistant bacteria.

Antibiotic treatment of acute wounds must be based on organisms suspected to be found within the infected wound and the patient's overall immune status. When a single specific organism is suspected, treatment may be commenced using a single antibiotic. Conversely, when multiple organisms are suspected, as with enteric contamination or when a patient's immune function is impaired by diabetes, chronic disease, or medication, treatment should commence with a broad-spectrum antibiotic or several agents in combination. Lastly, the location of the wound and the quality of tissue perfusion to that region will significantly impact wound performance after injury. Antibiotics also can be delivered topically as part of irrigations or dressings, although their efficacy is questionable.

Dressings

The main purpose of wound dressings is to provide the ideal environment for wound healing. The dressing should facilitate the major changes taking place during healing to produce an optimally

Table 9-9

Desired characteristics of wound dressings

Promote wound healing (maintain moist environment)
Conformability
Pain control
Odor control
Nonallergenic and nonirritating
Permeability to gas
Safety
Nontraumatic removal
Cost-effectiveness
Convenience

healed wound. Although the ideal dressing still is not a clinical reality, technological advances are promising (Table 9-9).

Covering a wound with a dressing mimics the barrier role of epithelium and prevents further damage. In addition, application of compression provides hemostasis and limits edema. Occlusion of a wound with dressing material helps healing by controlling the level of hydration and oxygen tension within the wound. It also allows transfer of gases and water vapor from the wound surface to the atmosphere. Occlusion affects both the dermis and epidermis, and it has been shown that exposed wounds are more inflamed and develop more necrosis than covered wounds. Occlusion also helps in dermal collagen synthesis and epithelial cell migration and limits tissue desiccation. Since it may enhance bacterial growth, occlusion is contraindicated in infected and/or highly exudative wounds.

Dressings can be classified as primary or secondary. A primary dressing is placed directly on the wound and may provide absorption of fluids and prevent desiccation, infection, and adhesion of a secondary dressing. A secondary dressing is one that is placed on the primary dressing for further protection, absorption, compression, and occlusion. Many types of dressings exist and are designed to achieve certain clinically desired endpoints.

Absorbent Dressings. Accumulation of wound fluid can lead to maceration and bacterial overgrowth. Ideally, the dressing should absorb without getting soaked through, as this would permit bacteria from the outside to enter the wound. The dressing must be designed to match the exudative properties of the wound and may include cotton, wool, and sponge.

Nonadherent Dressings. Nonadherent dressings are impregnated with paraffin, petroleum jelly, or water-soluble jelly for use as nonadherent coverage. A secondary dressing must be placed on top to seal the edges and prevent desiccation and infection.

Occlusive and Semioclusive Dressings. Occlusive and semioclusive dressings provide a good environment for clean, minimally exudative wounds. These film dressings are waterproof and impervious to microbes but permeable to water vapor and oxygen.

Hydrophilic and Hydrophobic Dressings. These dressings are components of a composite dressing. Hydrophilic dressing aids in absorption, whereas a hydrophobic dressing is waterproof and prevents absorption.

Hydrocolloid and Hydrogel Dressings. Hydrocolloid and hydrogel dressings attempt to combine the benefits of occlusion and absorbency. Hydrocolloids and hydrogels form complex

structures with water, and fluid absorption occurs with particle swelling, which aids in atraumatic removal of the dressing. Absorption of exudates by the hydrocolloid dressing leaves a yellowish-brown gelatinous mass after dressing removal that can be washed off. Hydrogel is a cross-linked polymer that has high water content. Hydrogels allow a high rate of evaporation without compromising wound hydration, which makes them useful in burn wound treatment.

Alginates. Alginates are derived from brown algae and contain long chains of polysaccharides containing mannuronic and glucuronic acid. The ratios of these sugars vary with the species of algae used, as well as the season of harvest. Processed as the calcium form, alginates turn into soluble sodium alginate through ion exchange in the presence of wound exudates. The polymers gel, swell, and absorb a great deal of fluid. Alginates are being used when there is skin loss, in open surgical wounds with medium exudation, and on full-thickness chronic wounds.

Absorbable Materials. Absorbable materials are mainly used within wounds as hemostats and include collagen, gelatin, oxidized cellulose, and oxidized regenerated cellulose.

Medicated Dressings. Medicated dressings have long been used as a drug-delivery system. Agents delivered in the dressings include benzoyl peroxide, zinc oxide, neomycin, and bacitracin-zinc. These agents have been shown to increase epithelialization by 28%.

The type of dressing to be used depends on the amount of wound drainage. A nondraining wound can be covered with semioclusive dressing. Drainage of less than 1 to 2 mL/d may require a semioclusive or absorbent nonadherent dressing. Moderately draining wounds (3–5 mL/d) can be dressed with a nonadherent primary layer plus an absorbent secondary layer plus an occlusive dressing to protect normal tissue. Heavily draining wounds (>5 mL/d) require a similar dressing as moderately draining wounds, but with the addition of a highly absorbent secondary layer.

Mechanical Devices. Mechanical therapy augments and improves on certain functions of dressings, in particular the absorption of exudates and control of odor. The vacuum-assisted closure (VAC) system assists in wound closure by applying localized negative pressure to the surface and margins of the wound. The negative-pressure therapy is applied to a special foam dressing cut to the dimensions of the wound and positioned in the wound cavity or over a flap or graft. The continuous negative pressure is very effective in removing exudates from the wound. This form of therapy has been found to be effective for chronic open wounds (diabetic ulcers and stages III and IV pressure ulcers), acute and traumatic wounds,¹²⁵ flaps and grafts, and subacute wounds (i.e., dehisced incisions), although more randomized trials need to be carried out to confirm efficacy.

Skin Replacements

All wounds require coverage in order to prevent evaporative losses and infection and to provide an environment that promotes healing. Both acute and chronic wounds may demand use of skin replacement, and several options are available.

Conventional Skin Grafts. Skin grafts have long been used to treat both acute and chronic wounds. Split- (partial-) thickness grafts consist of the epidermis plus part of the dermis, whereas full-thickness grafts retain the entire epidermis and dermis. Autologous grafts (autografts) are transplants from one site on the body to another; allogeneic grafts (allografts, homografts)

are transplants from a living nonidentical donor or cadaver to the host; and xenogeneic grafts (heterografts) are taken from another species (e.g., porcine). Split-thickness grafts require less blood supply to restore skin function. The dermal component of full-thickness grafts lends mechanical strength and resists wound contraction better, resulting in improved cosmesis. Allogeneic and xenogeneic grafts require the availability of tissue, are subject to rejection, and may contain pathogens.

The use of skin grafts or bioengineered skin substitutes and other innovative treatments (e.g., topically applied growth factors, systemic agents, and gene therapy) cannot be effective unless the wound bed is adequately prepared. This may include débridement to remove necrotic or fibrinous tissue, control of edema, revascularization of the wound bed, decreasing the bacterial burden, and minimizing or eliminating exudate. Temporary placement of allografts or xenografts may be used to prepare the wound bed.

Skin Substitutes. Originally devised to provide coverage of extensive wounds with limited availability of autografts, skin substitutes also have gained acceptance as natural dressings. Manufactured by tissue engineering, they combine novel materials with living cells to provide functional skin substitutes, providing a bridge between dressings and skin grafts.

Skin substitutes have theoretical advantages of being readily available and not requiring painful harvest, and they may be applied freely or with surgical suturing. In addition, they promote healing, either by stimulating host cytokine generation or by providing cells that may also produce growth factors locally. Their disadvantages include limited survival, high cost, and the need for multiple applications (Table 9-10). Allografting, albeit with a very thin graft, may at times be required to accomplish complete coverage.

A variety of skin substitutes are available, each with its own set of advantages and disadvantages; however, the ideal skin substitute has yet to be developed (Table 9-11). The development of the newer composite substitutes, which provide both the dermal and epidermal components essential for permanent skin replacement, may represent an advance toward that goal. The acellular (e.g., native collagen or synthetic material) component acts as a scaffold, promotes cell migration and growth, and activates tissue regeneration and remodeling. The cellular elements re-establish lost tissue and associated function, synthesize extracellular matrix components, produce essential mediators such as cytokines and growth factors, and promote proliferation and migration.

Cultured epithelial autografts (CEAs) represent expanded autologous or homologous keratinocytes. CEAs are expanded from a biopsy of the patient's own skin, will not be rejected,

Table 9-10

Desired features of tissue-engineered skin

Rapid re-establishment of functional skin (epidermis/dermis)
Receptive to body's own cells (e.g., rapid "take" and integration)
Graftable by a single, simple procedure
Graftable on chronic or acute wounds
Engraftment without use of extraordinary clinical intervention (i.e., immunosuppression)

Table 9-11

Advantages and disadvantages of various bioengineered skin substitutes

SKIN SUBSTITUTE	ADVANTAGES	DISADVANTAGES
Cultured allogeneic keratinocyte graft	No biopsy needed “Off the shelf” availability Provides wound coverage Promotes healing	Unstable Does not prevent wound contracture Inadequate cosmesis Possibility of disease transmission Fragile
Bioengineered dermal replacement	Prevents contracture Good prep for graft application	Limited ability to drive re-epithelialization Largely serves as temporary dressing
Cultured bilayer skin equivalent	More closely mimics normal anatomy Does not need secondary procedure Easily handled Can be sutured, meshed, etc.	Cost Short shelf life True engraftment questionable

and can stimulate re-epithelialization as well as the growth of underlying connective tissue. Keratinocytes harvested from a biopsy roughly the size of a postage stamp are cultured with fibroblasts and growth factors and grown into sheets that can cover large areas and give the appearance of normal skin. Until the epithelial sheets are sufficiently expanded, the wound must be covered with an occlusive dressing or a temporary allograft or xenograft. The dermis regenerates very slowly, if at all, for full-thickness wounds, because the sheets are very fragile, are difficult to work with, are susceptible to infection, and do not resist contracture well, leading to poor cosmetic results.

CEAs are available from cadavers, unrelated adult donors, or neonatal foreskins. Fresh or cryopreserved cultured allogeneic keratinocytes can be left in place long enough to be superseded by multiplying endogenous skin cells because, unlike allografts containing epidermal Langerhans cells, they do not express major histocompatibility antigens. Cryopreserved CEAs are readily available “off the shelf,” and provide growth factors that may aid healing. However, like autologous keratinocyte sheets, the grafts lack the strength provided by a dermal component and pose a risk of disease transmission.

Viable fibroblasts can be grown on bioabsorbable or non-bioabsorbable meshes to yield living dermal tissue that can act as a scaffold for epidermal growth. Fibroblasts stimulated by growth factors can produce type I collagen and glycosaminoglycans (e.g., chondroitin sulfates), which adhere to the wound surface to permit epithelial cell migration, as well as adhesive ligands (e.g., the matrix protein fibronectin), which promote cell adhesion. This approach has the virtue of being less time-consuming and expensive than culturing keratinocyte sheets. There are a number of commercially available, bioengineered dermal replacements approved for use in burn wound treatment as well as other indications.

Bioengineered skin substitutes have evolved from keratinocyte monolayers to dermal equivalents to split-thickness products with a pseudo-epidermis, and most recently, to products containing both epidermal and dermal components that resemble the three-dimensional structure and function of normal skin (see Table 9-11). Indicated for use with standard compression therapy in the treatment of venous insufficiency ulcers and for the treatment of neuropathic diabetic foot ulcers, these bilayered skin equivalents also are being used in a variety of wound care settings.

Growth Factor Therapy. As discussed previously, it is believed that nonhealing wounds result from insufficient or inadequate growth factors in the wound environment. A simplistic solution would be to flood the wound with single or multiple growth factors in order to “jump-start” healing and re-epithelialization. Although there is a large body of work demonstrating the effects of growth factors in animals, translation of these data into clinical practice has met with limited success. Growth factors for clinical use may be either recombinant or homologous/autologous. Autologous growth factors are harvested from the patient’s own platelets, yielding an unpredictable combination and concentration of factors, which are then applied to the wound. This approach allows treatment with patient-specific factors at an apparently physiologic ratio of growth factor concentrations. Disappointingly, a recent meta-analysis failed to demonstrate any value for autologous platelet-rich plasma in the treatment of chronic wounds.¹²⁶ Recombinant molecular biologic means permit the purification of high concentrations of individual growth factors. Current FDA-approved formulations, as well as those used experimentally, deliver concentrations approximately 10^3 times higher than those observed physiologically.

At present, only platelet-derived growth factor BB (PDGF-BB) is currently approved by the FDA for treatment of diabetic foot ulcers. Application of recombinant human PDGF-BB in a gel suspension to these wounds increases the incidence of total healing and decreases healing time. Several other growth factors have been tested clinically and show some promise, but currently none are approved for use. A great deal more needs to be discovered about the concentration, temporal release, and receptor cell population before growth factor therapy is to make a consistent impact on wound healing.

Gene or Cell Therapy. Given the disappointing results from the application of purified growth factors onto wounds, the possible therapeutic potential of gene therapy has been recognized and studied. Direct access to the open wound bed, which characterizes almost all chronic wounds, has facilitated this therapy. Gene delivery to wounds includes traditional approaches such as viral vectors and plasmid delivery or, more recently, electroporation and microseeding.

Although a variety of genes expressing interleukin-8, PDGF, IGF-1, keratinocyte growth factor, and laminin-5 have

been successfully delivered to wounds in both animal and human models, the effects have been modest and specific to unique wound situations. Delivering *extra* genes into the wound bed presents the challenge of expression of the necessary signals to turn the genes on and off at appropriate times so that dysregulated, hypertrophic, and abnormal healing does not occur. Elaborate systems have been created for topical use as on/off switches for genes. The more important question is which genes to express, in what temporal sequence, and in what regions of the wound bed, as it is unlikely that a single gene coding for one protein can significantly affect overall healing. There is growing consensus that delivery of genes is not going to represent the universal solution. Although gene therapy replaces missing or defective genes, most acute wounds already have and express the necessary genes for successful healing and the wound environment produces signals adequate to the activation of these genes. What, if any, are the deficiencies in gene expression or activity in failed wounds is unknown.

Another approach is to deliver multiple genes coding for proteins that can act synergistically and even in a timed sequence, as would occur during normal healing. This would involve the use of activated cells that participate in the healing sequence that could be delivered in an activated state to the wound environment. Use of mesenchymal stem cells as a delivery vector for many genes simultaneously is the latest such approach. The feasibility of applying bone marrow-derived, umbilical cord-derived, adipose-derived, and epidermal stem cells that can differentiate into various cells that participate in the wound healing response also has been documented. These cells, as part of their differentiation and activation in the wound, have been shown to produce a variety of growth factors including VEGF, PDGF, bFGF, and MMP-9. The challenges remain how to maintain the viability and activity of the transplanted cells, how to document that the observed effects are due to the delivered cells, and what are the mechanisms necessary for regulating or ending their activity.

REFERENCES

Entries highlighted in bright blue are key references.

1. Winter GD. Formation of the scab and the rate of epithelialisation of superficial wounds in the skin of the young domestic pig. *Nature*. 1962;193:293.
2. Gulliver G, ed. *The Works of John Hunter*. London: Longman; 1837.
3. Feiken E, Romer J, Eriksen J, et al. Neutrophils express tumor necrosis factor-alpha during mouse skin wound healing. *J Invest Dermatol*. 1995;105:120.
4. Dovi JV, He L-K, DiPietro LA. Accelerated wound closure in neutrophil-depleted mice. *J Leukoc Biol*. 2003;73:448.
5. Leibovich SJ, Ross R. The role of the macrophage in wound repair. A study with hydrocortisone and antimacrophage serum. *Am J Pathol*. 1975;78:71.
6. DiPietro LA. Wound healing: the role of the macrophage and other immune cells. *Shock*. 1995;4:233.
7. Zabel DD, Feng JJ, Scheuenstuhl H, et al. Lactate stimulation of macrophage-derived angiogenic activity is associated with inhibition of poly(ADP-ribose) synthesis. *Lab Invest*. 1996;74:644.
8. Schäffer MR, Barbul A. Lymphocyte function in wound healing and following injury. *Br J Surg*. 1998;85:444.
9. Efron JE, Frankel HL, Lazarou SA, et al. Wound healing and T-lymphocytes. *J Surg Res*. 1990;48:460.
10. Barbul A, Breslin RJ, Woodyard JP, et al. The effect of in vivo T helper and T suppressor lymphocyte depletion on wound healing. *Ann Surg*. 1989;209:479.
11. Rezzonico R, Burger D, Dayer JM. Direct contact between T lymphocytes and human dermal fibroblasts or synoviocytes down-regulates types I and III collagen production via cell-associated cytokines. *J Biol Chem*. 1998;273:18720.
12. Grotendorst GR. Chemoattractants and growth factors. In: Cohen K, Diegelmann RF, Lindblad WJ, eds. *Wound Healing, Biochemical and Clinical Aspects*. Philadelphia: WB Saunders; 1992:237.
13. Bonner JC, Osornio-Vargas AR, Badgett A, et al. Differential proliferation of rat lung fibroblasts induced by the platelet-derived growth factor-AA, -AB, and -BB isoforms secreted by rat alveolar macrophages. *Am J Respir Cell Mol Biol*. 1991; 5:539.
14. Pricolo VE, Caldwell MD, Mastrofrancesco B, et al. Modulatory activities of wound fluid on fibroblast proliferation and collagen synthesis. *J Surg Res*. 1990;48:534.
15. Regan MC, Kirk SJ, Wasserkrug HL, et al. The wound environment as a regulator of fibroblast phenotype. *J Surg Res*. 1991;50:442.
16. Gimbel ML, Hunt TK, Hussain MZ. Lactate controls collagen gene promoter activity through poly-ADP-ribosylation. *Surg Forum*. 2000;51:26.
17. Ghani QP, Hussain MZ, Hunt TK. Control of procollagen gene transcription and prolyl hydroxylase activity by poly(ADP-ribose). In: Poirier G, Moreaer A, eds. *ADP-Ribosylation Reactions*. New York: Springer-Verlag; 1992:111.
18. Xiong M, Elson G, Legarda D, et al. Production of vascular endothelial growth factor by murine macrophages: regulation by hypoxia, lactate, and the inducible nitric oxide synthase pathway. *Am J Pathol*. 1998;153:587.
19. Ferrara N, Davis-Smith T. The biology of vascular endothelial growth factor. *Endocrine Rev*. 1997;18:4.
20. Levenson SM, Geever EF, Crowley LV, et al. The healing of rat skin wounds. *Ann Surg*. 1965;161:293.
21. Zhou LJ, Ono I, Kaneko F. Role of transforming growth factor-beta 1 in fibroblasts derived from normal and hypertrophic scarred skin. *Arch Dermatol Res*. 1997;289:645.
22. Stenn KS, Depalma L. Re-epithelialization. In: Clark RAF, Hensen PM, eds. *The Molecular and Cellular Biology of Wound Repair*. New York: Plenum; 1988:321.
23. Johnson FR, McMinn RMH. The cytology of wound healing of the body surface in mammals. *Biol Rev*. 1960;35:364.
24. Woodley DT, Bachman PM, O'Keefe EJ. The role of matrix components in human keratinocyte re-epithelialization. In: Barbul A, Caldwell MD, Eaglstein WH, et al, eds. *Clinical and Experimental Approaches to Dermal and Epidermal Repair. Normal and Chronic Wounds*. New York: Wiley-Liss; 1991:129.
25. Lynch SE. Interaction of growth factors in tissue repair. In: Barbul A, Caldwell MD, Eaglstein WH, et al, eds. *Clinical and Experimental Approaches to Dermal and Epidermal Repair. Normal and Chronic Wounds*. New York: Wiley-Liss; 1991:341.
26. Jans DA, Hassan G. Nuclear targeting by growth factors, cytokines, and their receptors: a role in signaling? *Bioassays*. 1998;20:400.
27. Schmitt-Graff A, Desmouliere A, Gabbiani G. Heterogeneity of myofibroblast phenotypic features: an example of fibroblastic cell plasticity. *Virchows Arch*. 1994;425:3.
28. Darby I, Skalli O, Gabbiani G. Alpha-smooth muscle actin is transiently expressed by myofibroblasts during experimental wound healing. *Lab Invest*. 1990;63:21.
29. Desmouliere A, Redard M, Darby I, et al. Apoptosis mediates the decrease in cellularity during the transition between granulation tissue and scar. *Am J Pathol*. 1995;146:56.

30. Ehrlich HP. Wound closure: evidence of cooperation between fibroblasts and collagen matrix. *Eye*. 1988;2:149.
31. Phillips C, Wenstrup RJ. Biosynthetic and genetic disorders of collagen. In: Cohen IK, Diegelmann RF, Lindblad WJ, eds. *Wound Healing Biochemical and Clinical Aspects*. Philadelphia: WB Saunders; 1992:152.
32. Sidhu-Malik NK, Wenstrup RJ. The Ehlers-Danlos syndromes and Marfan syndrome: inherited diseases of connective tissue with overlapping clinical features. *Semin Dermatol*. 1995;14:40.
33. Woolley MM, Morgan S, Hays DM. Heritable disorders of connective tissue. Surgical and anesthetic problems. *J Pediatr Surg*. 1967;2:325.
34. McEntyre RL, Raffensperger JG. Surgical complications of Ehlers-Danlos syndrome in children. *J Pediatr Surg*. 1977;13:531.
35. Malfait F, Wenstrup RJ, DePaepe AD. Clinical and genetic aspects of Ehlers-Danlos syndrome, classic type. *Genetics Med*. 2010;12:597.
36. Hunt TK. Disorders of wound healing. *World J Surg*. 1980;4:271.
37. Anonymous. Heritable disorders of connective tissue. *JAMA*. 1973;224(5 Suppl):774.
38. le Goff C, Cormier-Daire V. From tall to short: the role of TGF- β signaling in growth and its disorders. *Am J Med Genetics Part C (Semin Med Genetics)*. 2012;160C:145.
39. Knaup J, Verwanger T, Gruber C, et al. Epidermolysis bullosa: a group of skin disease with different causes but commonalities in gene expression. *Exp Dermatol*. 2012;21:527.
40. Carter DM, Lin AN. Wound healing and epidermolysis bullosa. *Arch Dermatol*. 1988;124:732.
41. Coromilas A, Brandling-Bennett H, Morel K, et al. Novel SLC39A4 mutation in acrodermatitis enteropathica. *Pediatr Dermatol*. 2011;28:697.
42. Kruse-Jarres JD. Pathogenesis and symptoms of zinc deficiency. *Am Clin Lab*. 2001;20:17.
43. Okada A, Takagi Y, Nezu R, et al. Zinc in clinical surgery—a research review. *Jpn J Surg*. 1990;20:635.
44. Olivas A, Shogan B, Valuckaite V, et al. Intestinal tissues induce an SNP mutation in *Pseudomonas aeruginosa* that enhances its virulence: possible role in anastomotic leak. *PLOS One*. 2012;7(8):e44326.
45. Thornton FJ, Barbul A. Healing in the gastrointestinal tract. *Surg Clin North Am*. 1997;77:549.
46. Choy PYG, Bissett IP, Docherty JG, Parry BR, Merrie AEH. Stapled versus handsewn methods for ileocolic anastomoses. *Cochrane Database Syst Rev*. 2007;3:CD004320.
47. Marjanovic G, Vilain C, Juettner E, et al. Impact of different crystalloid volume regimens on anastomotic stability. *Ann Surg*. 2009;249:181-185.
48. Schnuriger B, Inaba K, Wu T, et al. Crystalloids after primary colon resection and anastomosis at initial trauma laparotomy: excessive volumes are associated with anastomotic leakage. *J Trauma*. 2011;70:603-610.
49. Lorenz PH, Whitby DJ, Longaker MT, et al. Fetal wound healing. The ontogeny of scar formation in the non-human primate. *Ann Surg*. 1993;217:391.
50. Longaker MT, Whitby DJ, Ferguson MWJ, et al. Adult skin wounds in the fetal environment heal with scar formation. *Ann Surg*. 1994;219:65.
51. Lorenz HP, Longaker MT, Perkocha LA, et al. Scarless wound repair: a human fetal skin model. *Development*. 1992;114:253.
52. Adzick NS, Harrison MR, Glick PL, et al. Comparison of fetal, newborn and adult rabbit wound healing by histologic, enzyme-histochemical and hydroxyproline determinations. *J Pediatr Surg*. 1991;20:315.
53. Shah M, Foreman DM, Ferguson MWJ. Neutralizing antibody to TGF- β 1,2 reduces cutaneous scarring in adult rodents. *J Cell Sci*. 1994;107:1137.
54. Longaker MT, Adzick NS. The biology of fetal wound healing: a review. *Plast Reconstr Surg*. 1990;87:788.
55. Seeger JM, Kaelin LD, Staples EM, et al. Prevention of post-operative pericardial adhesions using tissue-protective solutions. *J Surg Res*. 1997;68:63.
56. Longaker MT, Whitby DJ, Adzick NS, et al. Studies in fetal wound healing. VI: Second and early third trimester fetal wounds demonstrate rapid collagen deposition without scar formation. *J Pediatr Surg*. 1990;25:63.
57. Halasz NA. Dehiscence of laparotomy wounds. *Am J Surg*. 1968;116:210.
58. Mendoza CB, Postlethwait RW, Johnson WD. Incidence of wound disruption following operation. *Arch Surg*. 1970;101:396.
59. Holt D, Kirk SJ, Regan MC, et al. Effect of age on wound healing in healthy humans. *Surgery*. 1992;112:293.
60. Jonson K, Jensen JA, Goodson WH III, et al. Tissue oxygenation, anemia, and perfusion in relation to wound healing in surgical patients. *Ann Surg*. 1991;214:605.
61. Hopf HW, Hunt TK, West JM, et al. Wound tissue oxygen tension predicts the risk of wound infection in surgical patients. *Arch Surg*. 1997;132:997.
62. Greif R, Akca O, Horn EP, et al. Supplemental perioperative oxygen to reduce the incidence of surgical-wound infection. Outcomes Research Group. *N Engl J Med*. 2000;342:161.
63. Kurz A, Sessler D, Leonhardt R. Perioperative normothermia to reduce the incidence of surgical-wound infection and shorten hospitalization. *N Engl J Med*. 1996;334:1209.
64. Ehrlich HP, Hunt TK. Effects of cortisone and vitamin A on wound healing. *Ann Surg*. 1968;167:324.
65. Anstead GM. Steroids, retinoids, and wound healing. *Adv Wound Care*. 1998;11:277.
66. Ferguson MK. The effect of antineoplastic agents on wound healing. *Surg Gynecol Obstet*. 1982;154:421.
67. Larson DL. Alterations in wound healing secondary to infusion injury. *Clin Plast Surg*. 1990;17:509.
68. Cruse PJE, Foord RA. A prospective study of 23,649 surgical wounds. *Arch Surg*. 1973;107:206.
69. Yue DK, McLennan S, Marsh M, et al. Effects of experimental diabetes, uremia, and malnutrition on wound healing. *Diabetes*. 1987;36:295.
70. Goodson WH III, Hunt TK. Studies of wound healing in experimental diabetes mellitus. *J Surg Res*. 1977;22:221.
71. Black E, Vibe-Petersen J, Jorgensen LN, et al. Decrease in collagen deposition in wound repair in type I diabetes independent of glycemic control. *Arch Surg*. 2003;138:34.
72. Spiliotis J, Tsiveriotis K, Datsis AD, et al. Wound dehiscence is still a problem in the 21st century: a retrospective study. *World J Emerg Surg*. 2009;4:12.
73. Coon D, Gusenoff JA, Kannan N, et al. Body mass and surgical complications in the postbariatric reconstructive patient: analysis of 511 cases. *Ann Surg*. 2009;249:397-401.
74. Arthurs ZM, Cuadrado D, Sohn V, et al. Post-bariatric panniculectomy: pre-panniculectomy body mass index impacts the complication profile. *Am J Surg*. 2007;193:567-570.
75. Tsukada K, Miyazaki T, Kato H, et al. Body fat accumulation and postoperative complications after abdominal surgery. *Am Surg*. 2004;70:347-351.
76. Williams JZ, Barbul A. Nutrition and wound healing. *Surg Clin North Am*. 2003;83:571.
77. Goodson WH, Jensen JA, Gramja-Mena L, et al. The influence of a brief preoperative illness on postoperative healing. *Ann Surg*. 1987;205:250.

78. Winsor JA, Knight GS, Hill GL. Wound healing in surgical patients: recent food intake is more important than nutritional status. *Br J Surg*. 1988;75:135.
79. Haydock DA, Hill GL. Improved wound healing response in surgical patients receiving intravenous nutrition. *Br J Surg*. 1987;74:320.
80. Seifter E, Rettura G, Barbul A, et al. Arginine: an essential amino acid for injured rats. *Surgery*. 1978;84:224.
81. Barbul A, Lazarou S, Efron DT, et al. Arginine enhances wound healing in humans. *Surgery*. 1990;108:331.
82. Kirk SJ, Regan MC, Holt D, et al. Arginine stimulates wound healing and immune function in aged humans. *Surgery*. 1993;114:155.
83. Williams JZ, Abumrad NN, Barbul A. Effect of a specialized amino acid mixture on human collagen deposition. *Ann Surg*. 2002;236:369.
84. Levenson SM, Seifter E, VanWinkle W. Nutrition. In: Hunt TK, Dunphy JE, eds. *Fundamentals of Wound Management in Surgery*. New York: Appleton-Century-Crofts; 1979:286.
85. Jeejeebhoy KN, Cheong WK. Essential trace metals: deficiencies and requirements. In: Fischer JE, ed. *Nutrition and Metabolism in the Surgical Patient*. Boston: Little, Brown and Company; 1996:295.
86. Wilkinson EAJ, Hawke CI. Oral zinc for arterial and venous ulcers (Cochrane Review), in *The Cochrane Library*, 1:2002. Oxford: Update Software.
87. Robson MC. Wound infection: a failure of wound healing caused by an imbalance of bacteria. *Surg Clin North Am*. 1997;77:637.
88. Birkmeyer NJO, Birkmeyer JD. Strategies for improving surgical quality: should payers reward excellence or effort? *N Engl J Med*. 2006;354:864.
89. Classen DC, Evans RS, Pestotnik SL, et al. The timing of prophylactic administration of antibiotics and the risk of surgical-wound infection. *N Engl J Med*. 1992;326:281.
90. Anonymous. Antimicrobial prophylaxis for surgery. *Med Letter*. 2012;10:73.
91. Gupta N, Kaul-Gupta R, Carstens MM, et al. Analyzing prophylactic antibiotic administration in procedures lasting more than four hours: are published guidelines being followed? *Am Surg*. 2003;69:669.
92. Arnold MA, Barbul A. Surgical site infections. In: Cameron JL, ed. *Current Surgical Therapy*. 9th ed. St. Louis: Mosby-Elsevier; 2008:1152-1160.
93. Liese JG, Jenrossek V, Jansson A, et al. Chronic granulomatous disease in adults. *Lancet*. 1996;347:220.
94. Ramos M, Khalpey Z, Lipsitz S, et al. Relationship of perioperative hyperglycemia and postoperative infections in patients who undergo general and vascular surgery. *Ann Surg*. 2008;248:585-591.
95. Van den Berghe G, Wouters P, Weekers P, et al. Intensive insulin therapy in critically ill patients. *N Engl J Med*. 2001;345:1359-1367.
96. Lazar HL, Chipkin SR, Fitzgerald CA, et al. Tight glycaemic control in diabetic coronary artery bypass graft patients improves perioperative outcomes and decreases recurrent ischemic events. *Circulation*. 2004;109:1497-1502.
97. Gandhi GY, Nuttall GA, Abel MD, et al. Intensive intraoperative insulin therapy versus conventional glucose management during cardiac surgery: a randomized trial. *Ann Int Med*. 2007;146:233-243.
98. Lazar HL, McDonnell MM, Chipkin S, et al. Effects of aggressive versus moderate glycaemic control on clinical outcomes in diabetic coronary artery bypass patients. *Ann Surg*. 2011;254:458-463.
99. Gottrup F, Firmin R, Rabkin J, et al. Directly measured tissue oxygen tension and arterial oxygen tension assess tissue perfusion. *Crit Care Med*. 1987;15:1030-1036.
100. Sheffield CW, Sessler DI, Hopf HW, et al. Centrally and locally mediated thermoregulatory responses alter subcutaneous oxygen tension. *Wound Repair Regen*. 1996;4:339-345.
101. Maragakis LL, Cosgrove SE, Martinez EA, et al. Intraoperative fraction of inspired oxygen is a modifiable risk factor for surgical site infection after spinal surgery. *Anesthesiology*. 2009;110:556-562.
102. Meyhoff C, Weyerslev J, Jorgensen LN, et al. Effect of high perioperative oxygen fraction on surgical site infection and pulmonary complications after abdominal surgery: the PROXI Randomized Clinical Trial. *JAMA*. 2009;302:1543-1550.
103. Falanga V, Eaglstein WH. The "trap" hypothesis of venous ulceration. *Lancet*. 1993;341:1006.
104. Lobmann R, Ambrosch A, Schultz G, et al. Expression of matrix-metalloproteinases and their inhibitors in the wounds of diabetic and non-diabetic patients. *Diabetologia*. 2002;45:1011.
105. Stanley A, Osler T. Senescence and the healing rates of venous ulcers. *J Vasc Surg*. 2001;33:1206.
106. Kim BC, Kim HT, Park SH, et al. Fibroblasts from chronic wounds show altered TGF- β -signaling and decreased TGF- β type II receptor expression. *J Cell Physiol*. 2003;195:331.
107. Hopf HW, Ueno C, Aslam R, et al. Guidelines for the treatment of arterial insufficiency ulcers. *Wound Repair Regen*. 2006;14:693.
108. Hopf HW, Ueno C, Aslam R, et al. Guidelines for the prevention of lower extremity arterial ulcers. *Wound Repair Regen*. 2008;16:175.
109. Robson MC, Cooper DM, Aslam R, et al. Guidelines for the treatment of venous ulcers. *Wound Repair Regen*. 2006;14:649.
110. Kirsner RS, Marston WA, Snyder RJ, et al. Sprayed-applied cell therapy with human allogeneic fibroblasts and keratinocytes for treatment of chronic venous leg ulcers: a phase 2, multicenter, double-blind, randomized, placebo-controlled trial. *Lancet*. 2012;380:977-985.
111. Robson MC, Cooper DM, Aslam R, et al. Guidelines for the prevention of venous ulcers. *Wound Repair Regen*. 2008;16:147.
112. Steed DL, Attinger C, Colaizzi T, et al. Guidelines for treatment of diabetic ulcers. *Wound Repair Regen*. 2006;14:680.
113. Jeffcoate WJ, Harding KG. Diabetic foot ulcers. *Lancet*. 2003;361:1545.
114. Steed DL, Attinger C, Brem H, et al. Guidelines for the prevention of diabetic ulcers. *Wound Repair Regen*. 2008;16:169.
115. Whitney J, Phillips L, Aslam R, et al. Guidelines for the treatment of pressure ulcers. *Wound Repair Regen*. 2006;14:663.
116. Stechmiller JK, Cowan L, Whitney J, et al. Guidelines for the prevention of pressure ulcers. *Wound Repair Regen*. 2008;16:151.
117. Niessen FB, Spauwen PH, Schalkwijk J, et al. On the nature of hypertrophic scars and keloids: a review. *Plast Reconstr Surg*. 1999;104:1435.
118. Marneros AG, Norris JE, Olsen BR, et al. Clinical genetics of familial keloids. *Arch Dermatol*. 2001;137:1429.
119. Gauglitz GG, Korting HC, Pavicic T, et al. Hypertrophic scarring and keloids: pathomechanisms and current and emerging treatment strategies. *Mol Med*. 2011;17:113-125.
120. Butler PD, Longaker MT, Yang GP. Current progress in keloid research and treatment. *J Am Coll Surg*. 2008;206:731.

121. Mustoe TA. Evolution of silicone therapy and mechanism of action in scar management. *Aesthetic Plast Surg.* 2008;32:82.
122. Dijkstra FR, Nieuwenhuijzen M, Reijnen MM, et al. Recent clinical developments in pathophysiology, epidemiology, diagnosis and treatment of intra-abdominal adhesions. *Scand J Gastroenterol Suppl.* 2000;232:52.
123. Cheong YC, Laird SM, Shellton JB, et al. The correlation of adhesions and peritoneal fluid cytokine concentrations: a pilot study. *Hum Reprod.* 2002;17:1039.
124. Zeng Q, Yu Z, You J, Zhang Q. Efficacy and safety of Seprafilm for preventing postoperative abdominal adhesion: systematic review and meta-analysis. *World J Surg.* 2007;31:2125.
125. Armstrong DG, Lavery L. Negative pressure wound therapy after partial diabetic foot amputation: a multicentre, randomised controlled trial. *Lancet.* 2005;366:1704.
126. Martinez-Zapata MJ, Marti-Carvajal AJ, Sola I, et al. Autologous platelet-rich plasma for treating chronic wounds. *Cochrane Database Syst Rev.* 2012;10:CD006899.

This page intentionally left blank

10 chapter

Oncology

Funda Meric-Bernstam and
Raphael E. Pollock

Oncology and Surgical Practice	273		
Epidemiology	274		
Basic Principles of Cancer Epidemiology / 274			
Cancer Incidence and Mortality in the United States / 274			
Global Statistics on Cancer Incidence and Mortality / 275			
Cancer Biology	277		
Hallmarks of Cancer / 277			
Cell Proliferation and Transformation / 277			
Cancer Initiation / 278			
Cell-Cycle Dysregulation in Cancer / 279			
Oncogenes / 279			
Alterations in Apoptosis in Cancer Cells / 281			
Autophagy in Cancer Cells / 283			
Cancer Invasion / 283			
Angiogenesis / 283			
Metastasis / 284			
Epithelial-Mesenchymal Transition / 285			
Cancer Stem Cells / 285			
Cancer Etiology	285		
Cancer Genomics / 285			
Tumor Heterogeneity and Molecular Evolution / 287			
Genes Associated with Hereditary Cancer Risk / 287			
		<i>BRCA1, BRCA2, and Hereditary Breast-Ovarian Cancer / 291</i>	
		APC Gene and Familial Adenomatous Polyposis / 291	
		PTEN and Cowden Disease / 292	
		RET Proto-Oncogene and Multiple Endocrine Neoplasia Type 2 / 293	
		Chemical Carcinogens / 293	
		Physical Carcinogens / 293	
		Viral Carcinogens / 295	
		Cancer Risk Assessment	296
		Cancer Screening	297
		Cancer Diagnosis	299
		Cancer Staging	300
		Tumor Markers	301
		Prognostic and Predictive Tissue Markers / 301	
		Serum Markers / 302	
		Circulating Tumor Cells / 303	
		Bone Marrow Micrometastases / 304	
		Surgical Approaches to Cancer Therapy	304
		Multidisciplinary Approach to Cancer / 304	
		Surgical Management of Primary Tumors / 304	
		Surgical Management of the Regional Lymph Node Basin / 305	
		Surgical Management of Distant Metastases / 306	
		Chemotherapy	306
		Clinical Use of Chemotherapy / 306	
		Principles of Chemotherapy / 307	
		Anticancer Agents / 307	
		Combination Chemotherapy / 307	
		Drug Toxicity / 308	
		Administration of Chemotherapy / 308	
		Hormonal Therapy	308
		Targeted Therapy	309
		Immunotherapy	309
		Gene Therapy	312
		Mechanisms of Intrinsic and Acquired Drug Resistance	312
		Radiation Therapy	313
		Physical Basis of Radiation Therapy / 313	
		Biologic Basis of Radiation Therapy / 313	
		Radiation Therapy Planning / 314	
		Side Effects / 314	
		Cancer Prevention	314
		Trends in Oncology	316
		Cancer Screening and Diagnosis / 316	
		Surgical Therapy / 316	
		Systemic Therapy / 316	

ONCOLOGY AND SURGICAL PRACTICE

As the population ages, oncology is becoming a larger portion of surgical practice. The surgeon often is responsible for the initial diagnosis and management of solid tumors. Knowledge of cancer epidemiology, etiology, staging, and natural history is required for initial patient assessment, as well as to determination of the optimal surgical therapy.

Modern cancer therapy is multidisciplinary, involving the coordinated care of patients by surgeons, medical oncologists, radiation oncologists, reconstructive surgeons, pathologists, radiologists, and primary care physicians. *Primary* (or **1▶** *definitive*) *surgical therapy* refers to en bloc resection of tumor with adequate margins of normal tissues and regional lymph nodes as necessary. *Adjuvant therapy* refers to radiation therapy and systemic therapies, including chemotherapy,

immunotherapy, hormonal therapy, and, increasingly, biologic therapy. The primary goal of surgical and radiation therapy is local and regional control. On the other hand, the primary goal of systemic therapy is systemic control by treatment of distant foci of subclinical disease to prevent distant recurrence. Surgeons must be familiar with adjuvant therapies to coordinate multidisciplinary care and to determine the best sequence of therapy.

Recent advances in molecular biology are revolutionizing medicine. New information is being translated rapidly into clinical use, with the development of new prognostic and predictive markers and new biologic therapies. Increasingly cancer therapy is getting personalized, incorporating information about each patient's tumor characteristics, patient's own genome, as well as host immune responses and tumor microenvironment, into clinical decision-making. It is therefore essential that surgeons

Key Points

- 1▶ Modern cancer therapy is multidisciplinary, involving coordinated care by surgeons, medical oncologists, radiation oncologists, reconstructive surgeons, pathologists, radiologists, and primary care physicians.
- 2▶ Understanding cancer biology is essential to successfully implement personalized cancer therapy.
- 3▶ The following alterations are critical for malignant cancer growth: self-sufficiency of growth signals, insensitivity to growth-inhibitory signals, evasion of apoptosis, potential for limitless replication, angiogenesis, invasion and metastasis. Reprogramming of energy metabolism and evading immune destruction.

understand the principles of molecular oncology to appropriately interpret these new contributions and incorporate them into practice.

EPIDEMIOLOGY

Basic Principles of Cancer Epidemiology

The term *incidence* refers to the number of new cases occurring. Incidence is usually expressed as the number of new cases per 100,000 persons per year. *Mortality* refers to the number of deaths occurring and is expressed as the number of deaths per 100,000 persons per year. Incidence and mortality data are usually available through cancer registries. Mortality data are also available as public records in many countries where deaths are registered as vital statistics, often with the cause of death. In areas where cancer registries do not exist, mortality data are used to extrapolate incidence rates. These numbers are likely to be less accurate than registry data, as the relationship between incidence and cause-specific death is likely to vary significantly among countries owing to the variation in health care delivery.

The incidence of cancer varies by geography. This is due in part to genetic differences and in part to differences in environmental and dietary exposures. Epidemiologic studies that monitor trends in cancer incidence and mortality have tremendously enhanced our understanding of the etiology of cancer. Furthermore, analysis of trends in cancer incidence and mortality allows us to monitor the effects of different preventive and screening measures, as well as the evolution of therapies for specific cancers.

The two types of epidemiologic studies that are conducted most often to investigate the etiology of cancer and the effect of prevention modalities are cohort studies and case-control studies. Cohort studies follow a group of people who initially do not have a disease over time and measure the rate of development of a disease. In cohort studies, a group that is exposed to a certain environmental factor or intervention usually is compared to a group that has not been exposed (e.g., smokers vs. nonsmokers). Case-control studies compare a group of patients affected with a disease to a group of individuals without the disease for a given exposure. The results are expressed in terms of an odds ratio, or relative risk. A relative risk <1 indicates a protective effect of the exposure, whereas a relative risk >1 indicates an increased risk of developing the disease with exposure.

Cancer Incidence and Mortality in the United States

In the year 2013, it is estimated that 1.6 million new cancer cases will be diagnosed in the United States, excluding carcinoma in situ of any site except bladder, and excluding basal cell and squamous cell carcinomas of the skin.¹ In addition,

64,640 cases of carcinoma in situ of the breast, and 61,300 of melanoma in situ are expected.¹

It is estimated that in 2013 estimated 580,350 people will die of cancer in the United States, corresponding to about 1600 deaths per day.¹ The estimated new cancer cases and deaths by cancer type are shown in Table 10-1.¹ The most common causes of cancer death in men are cancers of the lung and bronchus, prostate, and colon and rectum; in women, cancers are of the lung and bronchus, breast, and colon and rectum.¹ These four cancers account for almost half (48%) of total cancer deaths among men and women.

The annual age-adjusted cancer incidence rates among males and females for selected cancer types are shown in Fig. 10-1.¹ Incidence rates are declining for most cancer sites, but they are increasing among both men and women for melanoma of the skin, cancers of the liver and thyroid (Fig. 10-2).¹ Incidence rates are decreasing for all four major cancer sites except for breast cancer in women. Age-adjusted incidence rate of breast cancer started to decrease from 2001 to 2004.² This decrease in breast cancer incidence has at least temporally been associated with the first report of the Women's Health Initiative, which documented an increased risk of coronary artery disease and breast cancer with the use of hormone replacement therapy; this was followed by a drop in the use of hormone replacement therapy by postmenopausal women in the United States.² Unfortunately after this initial drop, breast cancer incidence has remained relatively stable from 2005 to 2009.

Declines in colorectal cancer incidence have been mainly attributed to increased screening that allows for removal of precancerous polyps. Prostate cancer rates rapidly increased and decreased between 1995 and 1998. These trends are thought to be attributable to increased use of prostate-specific antigen (PSA) screening.³ Although analysis now suggest prostate cancer incidence has declined steadily by 1.9% per year from 2000 to 2009, annual rates fluctuate likely reflecting variations in screening.

Differences in lung cancer incidence patterns between women and men are thought to reflect historical differences in tobacco use. Differences in smoking prevalence is also thought to contribute to regional differences in lung cancer incidence. Lung cancer incidence is fourfold higher in Kentucky which has the highest smoking prevalence, compared with Utah, that has the lowest smoking prevalence (128 vs. 34 lung cancer cases per 100,000 men).¹

The 5-year survival rates for selected cancers are listed in Table 10-2. From 2005 to 2009, cancer death rates decreased by 1.8% per year in males and by 1.5% per year in females.¹ These declines in mortality have been consistent in the past decade, and larger than what was observed in the previous decade.³ Over the past two decades, death rates have decreased from their peak by more than 30% for colorectal cancer, female breast cancer,

Table 10-1

Estimated new cancer cases and deaths, United States, 2013^a

	ESTIMATED NEW CASES	ESTIMATED DEATHS		ESTIMATED NEW CASES	ESTIMATED DEATHS
All cancers	1,660,290	580,350	Genital system	339,810	58,480
Oral cavity and pharynx	41,380	7,890	Uterine cervix	12,340	4,030
Digestive system	290,200	144,570	Uterine corpus	49,560	8,190
Esophagus	17,990	15,210	Ovary	22,240	14,030
Stomach	21,600	10,990	Vulva	4,700	990
Small intestine	8,810	1,170	Vagina and other genital, female	2,890	840
Colon and rectum	142,820	50,830	Prostate	238,590	29,720
Anus, anal canal, and anorectum	7,060	880	Testis	7,920	370
Liver and intrahepatic bile duct	30,640	21,670	Penis and other genital, male	1,570	310
Gallbladder and other biliary	10,310	3,230	Urinary system	140,430	29,790
Pancreas	45,220	38,460	Urinary bladder	72,570	15,210
Other digestive organs	5,750	2,130	Kidney and renal pelvis	65,150	13,680
Respiratory system	246,210	163,890	Ureter and other urinary organs	2,710	900
Larynx	12,260	3,630	Eye and orbit	2,800	320
Lung and bronchus	228,190	159,480	Brain and other nervous system	23,130	14,080
Other respiratory organs	5,760	780	Endocrine system	62,710	2,770
Bones and joints	3,010	1,440	Thyroid	60,220	1,850
Soft tissue (including heart)	11,410	4,390	Other endocrine	2,490	920
Skin (excluding basal and squamous)	82,770	12,650	Lymphoma	79,030	20,200
Melanoma	76,690	9,480	Multiple myeloma	22,350	10,710
Other nonepithelial	6,080	3,170	Leukemia	48,610	23,720
Breast	234,580	40,030	Other and unspecified primary sites^b	31,860	45,420

^aExcludes basal and squamous cell skin cancers and in situ carcinomas except those of urinary bladder.

^bMore deaths than cases suggest lack of specificity in recording underlying causes of death on death certificate.

Source: Modified with permission from John Wiley and Sons: Siegel R et al. *Cancer statistics, 2013*. CA: a cancer journal for clinicians. 2013;63:11. © 2013 American Cancer Society, Inc.

male lung cancer and more than 40% for prostate cancer. The decrease in lung cancer death rates in men is thought to be due to a decrease in tobacco use, whereas the decreases in death rates from breast, colorectal cancer, and prostate cancer reflect advances in early detection and treatment.



Global Statistics on Cancer Incidence and Mortality

The five most common cancers for men worldwide are lung, prostate, colorectal cancer, stomach, liver, and for women are breast, colorectal, cervix, lung, and stomach.⁴ Notably, for several cancer types there is wide geographical variability in cancer incidence (Fig. 10-3). The mortality rates for different cancers also vary significantly among countries. This is attributable not only to variations in incidence but also to variations in survival after a cancer diagnosis. The survival rates are influenced by treatment patterns as well as by variations in cancer screening practices, which affect the stage of cancer at diagnosis. For example, the 5-year survival rate for stomach cancer is much higher in Japan, where the cancer incidence is high enough to

warrant mass screening, which is presumed to lead to earlier diagnosis. In the case of prostate cancer, on the other hand, the mortality rates diverge much less than the incidence rates among countries. Survival rates for prostate cancer are much higher in North America than in developing countries.⁵ It is possible that the extensive screening practices in the United States allow discovery of cancers at an earlier, more curable stage; however, it is also possible that this screening leads to discovery of more latent, less biologically aggressive cancers, which may not have caused death even if they had not been identified.

About one million new cases of stomach cancer were estimated to have occurred in 2008 (988,000 cases, 7.8% of the total), making it the fourth most common malignancy in the world, behind cancers of the lung, breast, and colorectal cancer. The incidence of stomach cancer varies significantly among different regions of the world. The difference in risk by country is presumed to be primarily due to differences in dietary factors. The risk is increased by high consumption of preserved salted foods such as meats and pickles, and decreased by high intake of fruits and vegetables.⁵ There also is some international variation

Estimated new cases*

		Males		Females			
Prostate	238,590	28%			Breast	232,340	29%
Lung & bronchus	118,080	14%			Lung & bronchus	110,110	14%
Colorectum	73,680	9%			Colorectum	69,140	9%
Urinary bladder	54,610	6%			Uterine corpus	49,560	6%
Melanoma of the skin	45,060	5%			Thyroid	45,310	6%
Kidney & renal pelvis	40,430	5%			Non-Hodgkin lymphoma	32,140	4%
Non-Hodgkin lymphoma	37,600	4%			Melanoma of the skin	31,630	4%
Oral cavity & pharynx	29,620	3%			Kidney & renal pelvis	24,720	3%
Leukemia	27,880	3%			Pancreas	22,480	3%
Pancreas	22,740	3%			Ovary	22,240	3%
All Sites	854,790	100%	All Sites	805,500	100%		

Estimated deaths



		Males		Females			
Lung & bronchus	87,260	28%			Lung & bronchus	72,220	26%
Prostate	29,720	10%			Breast	39,620	14%
Colorectum	26,300	9%			Colorectum	24,530	9%
Pancreas	19,480	6%			Pancreas	18,980	7%
Liver & intrahepatic bile duct	14,890	5%			Ovary	14,030	5%
Leukemia	13,660	4%			Leukemia	10,060	4%
Esophagus	12,220	4%			Non-Hodgkin lymphoma	8,430	3%
Urinary bladder	10,820	4%			Uterine corpus	8,190	3%
Non-Hodgkin's lymphoma	10,590	3%			Liver & intrahepatic bile duct	6,780	2%
Kidney & renal pelvis	8,780	3%			Brain & other nervous system	6,150	2%
All Sites	306,920	100%	All Sites	271,430	100%		

Figure 10-1. Ten leading cancer types with the estimated new cancer cases and deaths by sex in the United States, 2013. *Excludes basal and squamous cell skin cancers and in situ carcinomas except those of the urinary bladder. Estimates are rounded to the nearest 10 (Modified with permission from John Wiley and Sons: Siegel R et al. Cancer statistics, 2013. CA: a cancer journal for clinicians. 2013;63:11. © 2013 American Cancer Society, Inc.)

in the incidence of infection with *Helicobacter pylori*, which is known to play a major role in gastric cancer development.⁵ Fortunately, a steady decline is being observed in the incidence and mortality rates of gastric cancer. This may be related to improvements in preservation and storage of foods as well as due to changes in the prevalence of *H. pylori*.⁵ More than 70% of cases (713,000 cases) occur in developing countries, and half the cases in the world occur in Eastern Asia (mainly in China).⁴ Age-standardized incidence rates are about twice as high for men as for women, ranging from 3.9 in Northern Africa to 42.4 in Eastern Asia for men, and from 2.2 in Southern Africa to 18.3 in Eastern Asia for women. Stomach cancer is the second leading cause of cancer death in both sexes worldwide.

Overall, the incidence of breast cancer is rising in most countries. Incidence varies from 19.3 per 100,000 women in Eastern Africa to 89.7 per 100,000 women in Western Europe, and are high in developed regions of the world (except Japan) and low in most of the developing regions.⁴ Although breast cancer has been linked to cancer susceptibility genes, mutations in these genes account for only 5% to 10% of breast tumors, which suggests that the wide geographic variations in breast cancer incidence are not due to geographic variations in the prevalence of these genes. Most of the differences, therefore, are attributed to differences in reproductive factors, diet, alcohol,

obesity, physical activity, and other environmental differences. Indeed, breast cancer risk increases significantly in females who have migrated from Asia to America.⁵ The range of breast cancer mortality rates is much less (approximately 6 to 19 per 100,000) because of the more favorable survival of breast cancer in developed regions. As a result, breast cancer ranks as the fifth cause of death from cancer overall (458,000 deaths), but it is still the most frequent cause of cancer death in women in both developing (269,000 deaths, 12.7% of total) and developed regions (estimated 189,000 deaths).⁴

There is a 25-fold variation in colon cancer incidence worldwide.⁵ The incidence of colon and rectal cancer is higher in developed countries than in developing countries. The incidence rates are highest in North America, Australia and New Zealand, and Western Europe, and especially in Japanese men.⁵ In contrast, the incidence is relatively low in North Africa, South America, and eastern, Southeastern, and Western Asia. These geographic differences are thought to reflect environmental exposures and are presumed to be related mainly to dietary differences in consumption of animal fat, meat, and fiber.⁵

Worldwide liver cancer is the fifth most common cancer in men (523,000 cases, 7.9% of the total) and the seventh in women (226,000 cases, 6.5% of the total). Almost 85% of liver cancer cases occur in developing countries, and particularly in men.⁴

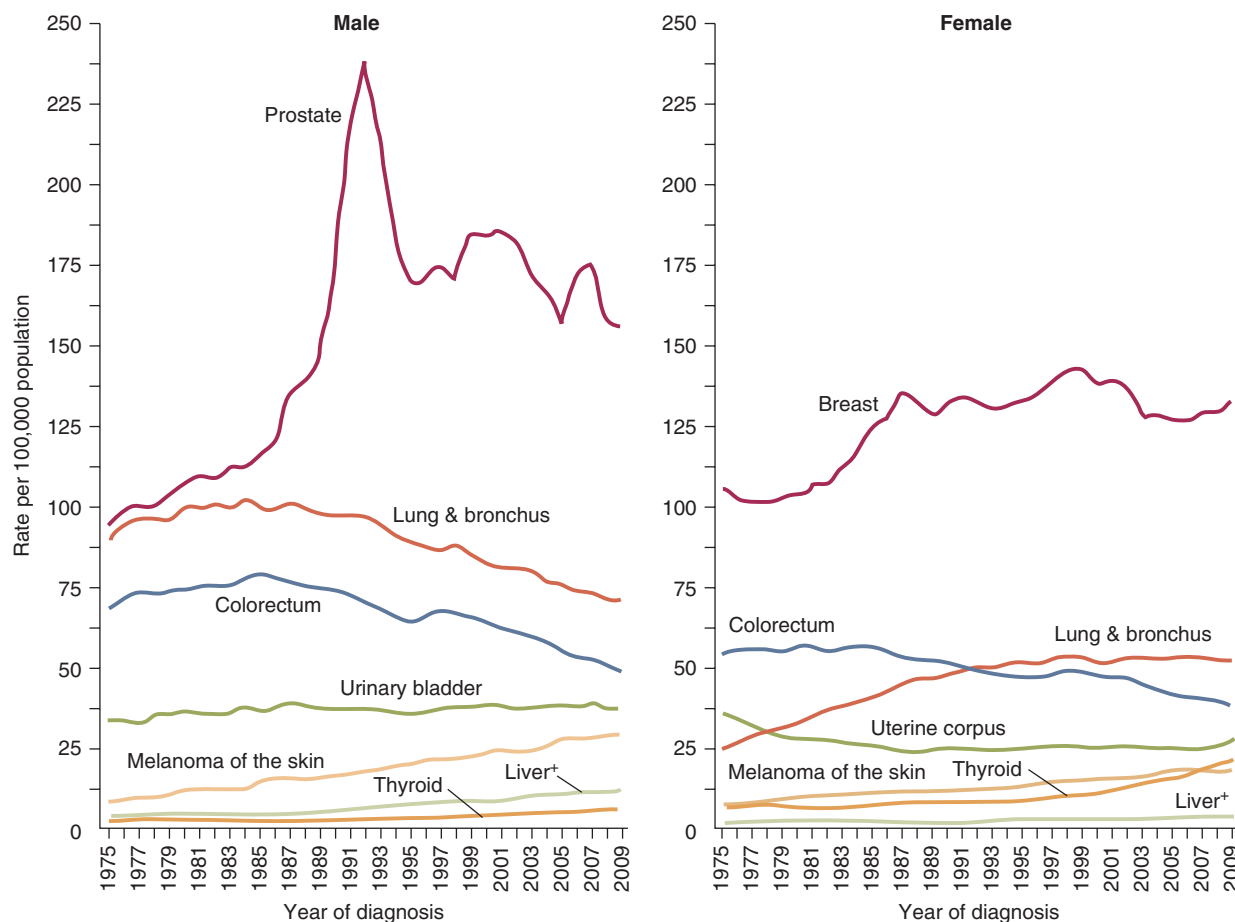


Figure 10-2. Trends in cancer incidence rates for selected cancer by sex among males and females for selected cancer types, United States, 1975 to 2009. Rates are age adjusted to the 2000 U.S. standard population. (Modified with permission from John Wiley and Sons: Siegel R et al. Cancer statistics, 2013. CA: a cancer journal for clinicians. 2013;63:11. © 2013 American Cancer Society, Inc.)¹

*Liver includes intrahepatic bile duct

The overall sex ratio male:female is 2:4. The regions of high incidence are Eastern and Southeastern Asia, Middle and Western Africa, as well as Melanesia and Micronesia/Polynesia (particularly in men). Low rates are estimated in developed regions, with the exception of Southern Europe. There were an estimated 694,000 deaths from liver cancer in 2008 (477,000 in men, 217,000 in women), and because of its high fatality (overall ratio of mortality to incidence of 0.93), liver cancer is the third most common cause of death from cancer worldwide. The geographical distribution of the mortality rates is similar to that observed for incidence. Worldwide, the major risk factors for liver cancer are infection with hepatitis B and C viruses and consumption of foods contaminated with aflatoxin. Hepatitis B immunization in children has recently been shown to reduce the incidence of liver cancer.⁵

In summary, the incidence rates of many common cancers vary widely by geography. This is due in part to genetic differences, including racial and ethnic differences. It is due also in part to differences in environmental and dietary exposures, factors that can potentially be altered. Therefore, establishment of regional and international databases is critical to improving our understanding of the etiology of cancer and will ultimately assist in the initiation of targeted strategies for global cancer prevention. Furthermore, the monitoring of cancer mortality rates and 5-year cancer-specific survival rates will identify regions where there are inequities of health care, so that access to health care can be facilitated and guidelines for treatment can be established.

CANCER BIOLOGY

Hallmarks of Cancer

Although there are >100 types of cancer, it has been proposed that there are six essential alterations in cell physiology that dictate malignant growth: self-sufficiency of growth signals, insensitivity to growth-inhibitory signals, evasion of apoptosis (programmed cell death), potential for limitless replication, angiogenesis, and invasion and metastasis.⁶ Recently two additional hallmarks have emerged—reprogramming of energy metabolism and evading immune destruction.⁷ These hallmarks of cancer are being pursued as targets for cancer therapy (Figure 10-4).

Cell Proliferation and Transformation

In normal cells, cell growth and proliferation are under strict control. In cancer cells, cells become unresponsive to normal growth controls, which leads to uncontrolled growth and proliferation. Human cells require several genetic changes for neoplastic transformation. Cell type-specific differences also exist for tumorigenic transformation. Abnormally proliferating, transformed cells outgrow normal cells in the culture dish (i.e., in vitro) and commonly display several abnormal characteristics.⁸ These include loss of contact inhibition (i.e., cells continue to proliferate after a confluent monolayer is formed); an altered appearance and poor adherence to other cells or to the substratum; loss of anchorage dependence for growth; immortalization;

Table 10-2

Five-year relative survival rates adjusted to normal life expectancy by year of diagnosis, United States, 1975–2008

CANCER TYPE	RELATIVE 5-YEAR SURVIVAL RATES (%)		
	1975–1977	1987–1989	2002–2008
All cancers	49	56	68
Brain	22	29	35
Breast (female)	75	84	90
Uterine cervix	69	70	69
Colon	51	61	65
Uterine corpus	87	83	83
Esophagus	5	10	19
Hodgkin's disease	72	79	87
Kidney	50	57	72
Larynx	66	66	63
Leukemia	34	43	58
Liver	3	5	16
Lung and bronchus	12	13	17
Melanoma of the skin	82	88	93
Multiple myeloma	25	28	43
Non-Hodgkin's lymphoma	47	51	71
Oral cavity	53	54	65
Ovary	36	38	43
Pancreas	2	4	6
Prostate	68	83	100
Rectum	48	58	68
Stomach	15	20	28
Testis	83	95	96
Thyroid	92	95	98
Urinary bladder	73	79	80

Source: Modified with permission from John Wiley and Sons: Siegel R et al. *Cancer statistics, 2013*. CA: a cancer journal for clinicians. 2013;63:11. © 2013 American Cancer Society, Inc.

and gain of tumorigenicity (i.e., the ability to give rise to tumors when injected into an appropriate host).

Cancer Initiation

Tumorigenesis is proposed to have three steps: initiation, promotion, and progression. Initiating events such as gain of function of genes known as *oncogenes* or loss of function of genes known as *tumor-suppressor genes* may lead a single cell to acquire a distinct growth advantage. Although tumors usually arise from a single cell or clone, it is thought that sometimes not a single cell but rather a large number of cells in a target organ may have undergone the initiating genetic event. Thus, many normal-appearing cells may have an increased malignant potential. This is referred to as a *field effect*. The initiating events are usually genetic and occur as deletions of tumor-suppressor genes or amplification or mutation of oncogenes. Subsequent events can lead to accumulations of additional deleterious mutations in the clone.

Cancer is thought to be a disease of clonal progression as tumors arise from a single cell and accumulate mutations that

confer on the tumor an increasingly aggressive behavior. Most tumors go through a progression from benign lesions to in situ tumors to invasive cancers (e.g., atypical ductal hyperplasia to ductal carcinoma in situ to invasive ductal carcinoma of the breast). Fearon and Vogelstein proposed the model for colorectal tumorigenesis presented in Fig. 10-5.⁹ Colorectal tumors arise from the mutational activation of oncogenes coupled with mutational inactivation of tumor-suppressor genes, the latter being the predominant change.⁹ Mutations in at least four or five genes are required for formation of a malignant tumor, while fewer changes suffice for a benign tumor. Although genetic mutations often occur in a preferred sequence, a tumor's biologic properties are determined by the total accumulation of its genetic changes.

Gene expression is a multistep process that starts from transcription of a gene into messenger ribonucleic acid (mRNA) and then translation of this sequence into the functional protein. There are several controls at each level. In addition to alterations at the genome level (e.g., amplifications of a gene), alterations

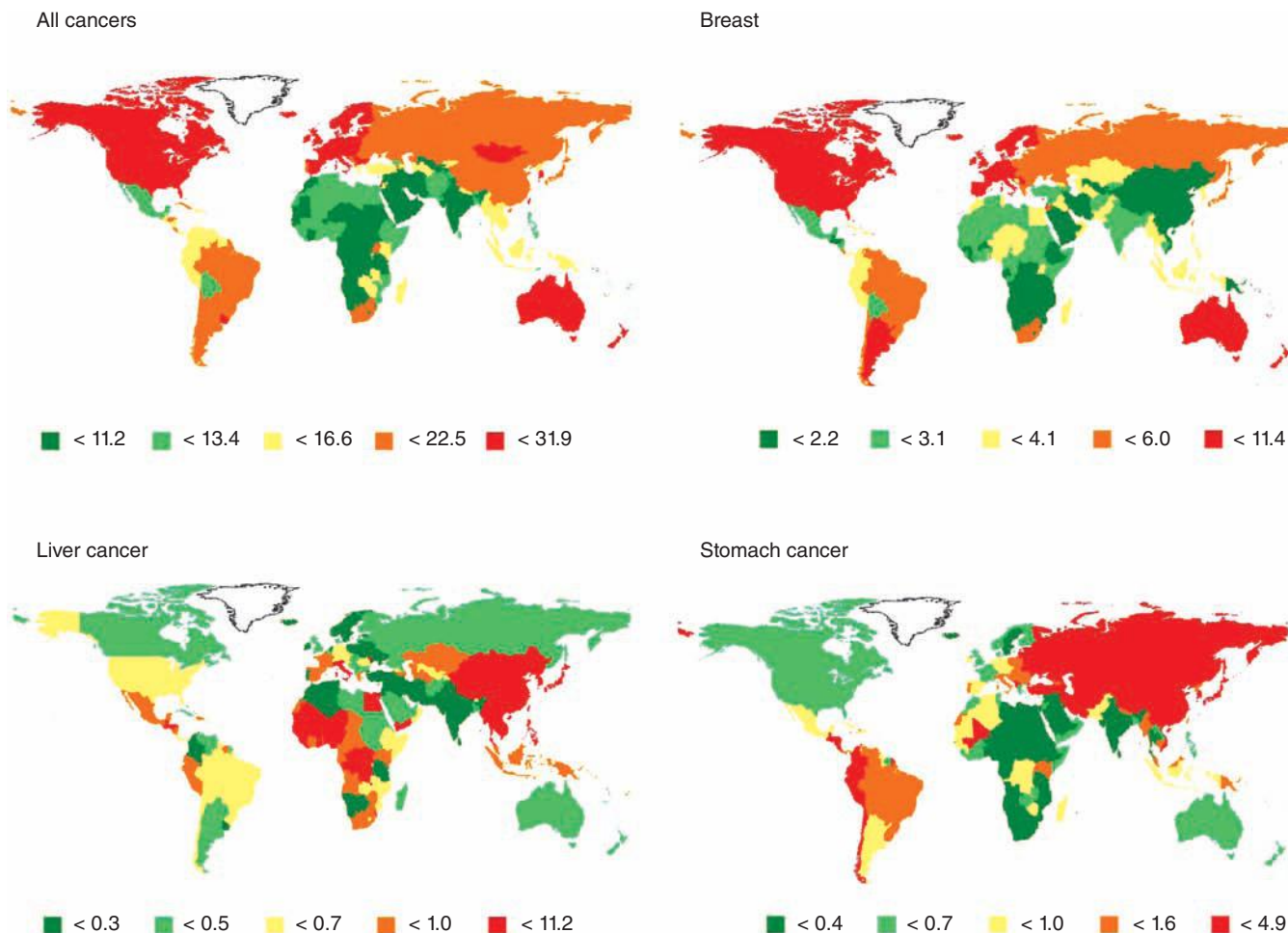


Figure 10-3. Estimated cancer incidence worldwide in 2008. Age-standardized incidence rates per 100,000 for all cancers (upper left), breast cancer (upper right), liver cancer (lower left), and stomach cancer (lower right). (Modified with permission from Ferlay, IARC)⁴

at the transcription level (e.g., methylation of the DNA leading to transcriptional silencing) or at the level of mRNA processing, mRNA stability, mRNA translation, or protein stability, all can alter the levels of critical proteins and thus contribute to tumorigenesis. Alternatively, changes in the genomic sequence can lead to a mutated product with altered function.

Cell-Cycle Dysregulation in Cancer

The proliferative advantage of tumor cells is a result of their ability to bypass quiescence. Cancer cells often show alterations in signal transduction pathways that lead to proliferation in response to external signals. Mutations or alterations in the expression of cell-cycle proteins, growth factors, growth factor receptors, intracellular signal transduction proteins, and nuclear transcription factors all can lead to disturbance of the basic regulatory mechanisms that control the cell cycle, allowing unregulated cell growth and proliferation.

The cell cycle is divided into four phases (Fig. 10-6).¹⁰ During the synthetic or S phase, the cell generates a single copy of its genetic material, whereas in the mitotic or M phase, the cellular components are partitioned between two daughter cells. The G_1 and G_2 phases represent gap phases during which the cells prepare themselves for completion of the S and M phases, respectively. When cells cease proliferation, they exit the cell cycle and enter the quiescent state referred to as G_0 . In human tumor cell-cycle regulators like INK4A, INK4B, and KIP1 are

frequently mutated or altered in expression. These alterations underscore the importance of cell-cycle regulation in the prevention of human cancers.

Oncogenes

Normal cellular genes that contribute to cancer when abnormal are called *oncogenes*. The normal counterpart of such a gene is referred to as a *proto-oncogene*. Oncogenes are usually designated by three-letter abbreviations, such as *myc* or *ras*. Oncogenes are further designated by the prefix “v-” for virus or “c-” for cell or chromosome, corresponding to the origin of the oncogene when it was first detected. Proto-oncogenes can be activated (show increased activity) or overexpressed (expressed at increased protein levels) by translocation (e.g., *abl*), promoter insertion (e.g., *c-myc*), mutation (e.g., *ras*), or amplification (e.g., *HER2/neu*). More than 100 oncogenes have been identified.

Oncogenes may be growth factors (e.g., platelet-derived growth factor), growth factor receptors (e.g., *HER2*), intracellular signal transduction molecules (e.g., *ras*), nuclear transcription factors (e.g., *c-myc*), or other molecules involved in the regulation of cell growth and proliferation. Growth factors are ubiquitous proteins that are produced and secreted by cells locally and that stimulate cell proliferation by binding specific cell-surface receptors on the same cells (autocrine stimulation) or on neighboring cells (paracrine stimulation). Persistent overexpression

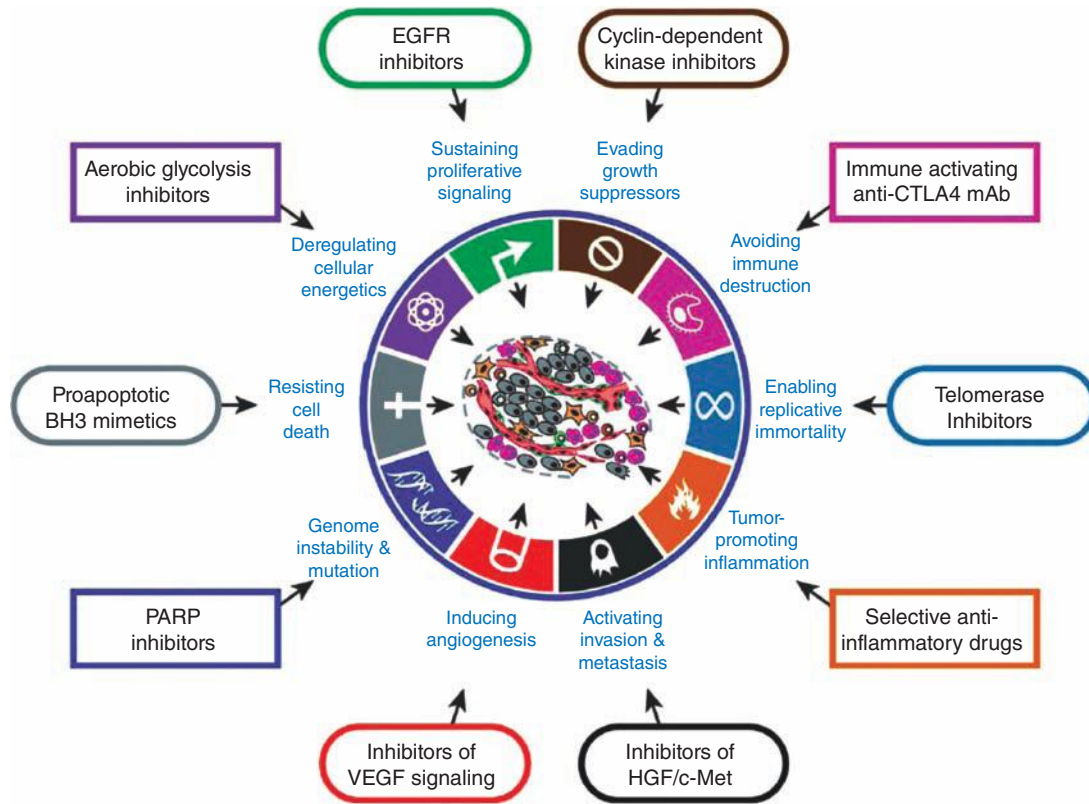


Figure 10-4. Hallmarks of cancer and their therapeutic implications. Drugs that interfere with each of the acquired capabilities necessary for tumor growth and progression are in clinical trials and in some cases approved for clinical use in treating forms of human cancer. The drugs listed are illustrative examples. (Modified with permission from Hanahan et al. Copyright Elsevier.)⁷

of growth factors can lead to uncontrolled autostimulation and neoplastic transformation. Alternatively, growth factor receptors can be aberrantly activated (turned on) through mutations or overexpressed (continually presenting cells with growth-stimulatory signals, even in the absence of growth factors), which leads cells to respond as if growth factor levels are altered. The growth-stimulating effect of growth factors and other mitogens is mediated through postreceptor signal transduction molecules.

These molecules mediate the passage of growth signals from the outside to the inside of the cell and then to the cell nucleus, initiating the cell cycle and DNA transcription. Aberrant activation or expression of cell-signaling molecules, cell-cycle molecules, or transcription factors may play an important role in neoplastic transformation. Protein tyrosine kinases account for a large portion of known oncogenes. One of the best-studied oncogenes, *HER2* is discussed as an example later.

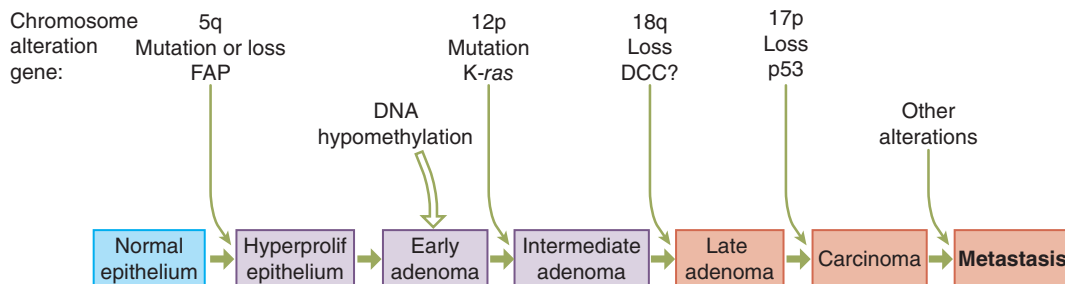


Figure 10-5. A genetic model for colorectal tumorigenesis. Tumorigenesis proceeds through a series of genetic alterations involving oncogenes and tumor-suppressor genes. In general, the three stages of adenomas represent tumors of increasing size, dysplasia, and villous content. Individuals with familial adenomatous polyposis (FAP) inherit a mutation on chromosome arm 5q. In tumors arising in individuals without polyposis, the same region may be lost or mutated at a relatively early stage of tumorigenesis. A *ras* gene mutation (usually *K-ras*) occurs in one cell of a pre-existing small adenoma which, through clonal expansion, produces a larger and more dysplastic tumor. The chromosome arms most frequently deleted include 5q, 17p, and 18q. Allelic deletions of chromosome arms 17p and 18q usually occur at a later stage of tumorigenesis than do deletions of chromosome arm 5q or *ras* gene mutations. The order of these changes varies, however, and accumulation of these changes, rather than their order of appearance, seems most important. Tumors continue to progress once carcinomas have formed, and the accumulated chromosomal alterations correlate with the ability of the carcinomas to metastasize and cause death. DCC = deleted in colorectal cancer gene. (Modified with permission from Fearon et al. Copyright Elsevier.)⁹

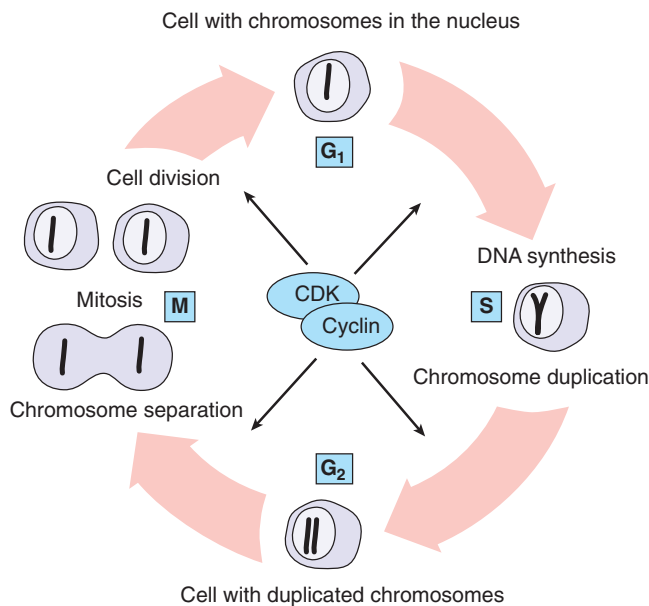


Figure 10-6. Schematic representation of the phases of the cell cycle. Mitogenic growth factors can drive a quiescent cell from G_0 into the cell cycle. Once the cell cycle passes beyond the restriction point, mitogens are no longer required for progression into and through S phase. The DNA is replicated in S phase, and the chromosomes are condensed and segregated in mitosis. In early G_1 phase, certain signals can drive a cell to exit the cell cycle and enter a quiescent phase. Cell-cycle checkpoints have been identified in G_1 , S, G_2 , and M phases. CDK = cyclin-dependent kinase. (Adapted from Kastan *et al*)¹⁰

HER2, also known as *neu* or *c-erbB-2*, is a member of the epidermal growth factor receptor (EGFR) family and is one of the best-characterized tyrosine kinases. Unlike other receptor tyrosine kinases, *HER2/neu* does not have a direct soluble ligand. It plays a key role in signaling, however, because it is the preferred partner in heterodimer formation with all the other EGFR family members (*EGFR/c-erbB-1*, *HER2/c-erbB-3*, and *HER3/c-erbB-4*), which bind at least 30 ligands, including epidermal growth factor (EGF), transforming growth factor α (TGF α), heparin-binding EGF-like growth factor, amphiregulin, and heregulin.¹¹ Heterodimerization with *HER2* potentiates recycling of receptors rather than degradation, enhances signal potency and duration, increases affinity for ligands, and increases catalytic activity.¹¹

HER2 can interact with different members of the HER family and activate mitogenic and antiapoptotic pathways (Fig. 10-7). The specificity and potency of the intracellular signals are affected by the identity of the ligand, the composition of the receptors, and the phosphotyrosine-binding proteins associated with the erbB molecules. The Ras- and Shc-activated mitogen-activated protein kinase (MAPK) pathway is a target of all erbB ligands, which increase the transcriptional activity of early response genes such as *c-myc*, *c-fos*, and *c-jun*.¹² MAPK-independent pathways such as the phosphoinositide-3 kinase (PI3K) pathway also are activated by most erbB dimers, although the potency and kinetics of activation may differ. Stimulation of the PI3K pathway through *HER2* signaling also can lead to activation of survival molecule Akt, which suppresses apoptosis through multiple mechanisms. The critical role of *HER2* in cancer biology has been leveraged for therapeutics, leading to several *HER2*-targeted drugs with different mechanism of action

approved by the Food and Drug Administration (FDA): monoclonal antibodies trastuzumab and pertuzumab, small molecule inhibitor lapatinib, and antibody-drug conjugate ado-trastuzumab emtansine.

The mutant rat *neu* gene was first recognized as an oncogene in neuroblastomas from carcinogen-treated rats.¹³ The *HER2* gene is frequently amplified and the protein overexpressed in many cancers, including breast, ovarian, lung, gastric, and oral cancers. Overexpression of *HER2* results in ligand-independent activation of *HER2* kinase, which leads to mitogenic signaling. *HER2* overexpression is associated with increased cell proliferation and anchorage-independent growth as well as resistance to proapoptotic stimuli. Further, overexpression of *HER2* increases cell migration and upregulates the activities of matrix metalloproteinases (MMPs) and in vitro invasiveness. In animal models, *HER2* increases tumorigenicity, angiogenesis, and metastasis. These results all suggest that *HER2* plays a key role in cancer biology. More recently *HER2* mutations have also been reported in human cancer. *HER2* mutations have been detected in 2% to 4% of nonsmall cell lung cancer.¹⁴⁻¹⁷ In frame insertions within exon 20 has been the most commonly reported mutation. *HER2* mutations are more common in nonsmokers and are nonoverlapping with other oncogenic mutations in lung cancer (e.g., EGFR and Ras). Data from 8 breast cancer genome-sequencing projects identified 25 patients with *HER2* somatic mutations in cancers lacking *HER2* gene amplification.¹⁸ Seven of 13 mutations were functionally characterized and found to be activating mutations. All of these mutations were sensitive to the irreversible kinase inhibitor, neratinib. A prospective, multi-institutional clinical trial has been launched to screen patients with stage IV breast cancer for *HER2* somatic mutations and determine the clinical outcome of treating them with *HER2*-targeted therapy.

Alterations in Apoptosis in Cancer Cells

Apoptosis is a genetically regulated program to dispose of cells. Cancer cells must avoid apoptosis if tumors are to arise. The growth of a tumor mass is dependent not only on an increase in proliferation of tumor cells but also on a decrease in their apoptotic rate. Apoptosis is distinguished from necrosis because it leads to several characteristic changes. In early apoptosis, the changes in membrane composition lead to extracellular exposure of phosphatidylserine residues, which avidly bind annexin, a characteristic that is used to discriminate apoptotic cells in laboratory studies. Late in apoptosis there are characteristic changes in nuclear morphology, such as chromatin condensation, nuclear fragmentation, and DNA laddering, as well as membrane blebbing. Apoptotic cells are then engulfed and degraded by phagocytic cells. The effectors of apoptosis are a family of proteases called *caspases* (cysteine-dependent and aspartate-directed proteases). The initiator caspases (e.g., 8, 9, and 10), which are upstream, cleave the downstream executioner caspases (e.g., 3, 6, and 7) that carry out the destructive functions of apoptosis.

Two principal molecular pathways signal apoptosis by cleaving the initiator caspases with the potential for crosstalk: the mitochondrial pathway and the death receptor pathway. In the mitochondrial (or intrinsic) pathway, death results from the release of cytochrome c from the mitochondria. Cytochrome c, procaspase 9, and apoptotic protease activating factor 1 (Apaf-1) form an enzyme complex, referred to as the *apoptosome*, that activates the effector caspases. In addition to these proteins,

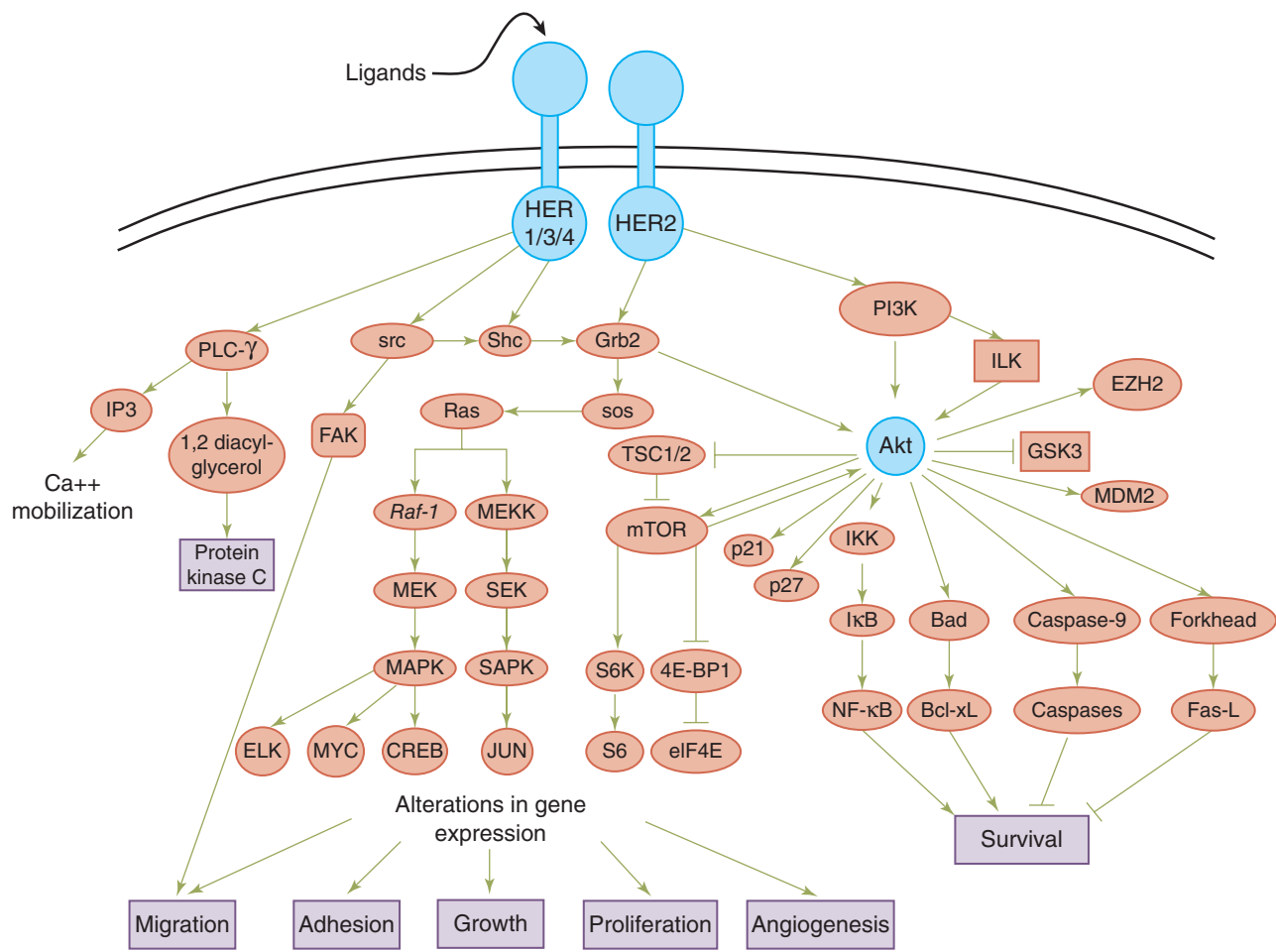


Figure 10-7. The HER2 signaling pathway. HER2 can interact with different members of the HER family and activate mitogenic and antiapoptotic pathways. 4E-BP1= eIF4E binding protein 1; CREB = cyclic adenosine monophosphate element binding; eIF4E = eukaryotic initiation factor 4E; EZH = enhancer of zeste homolog; FAK = focal adhesion kinase; Fas-L = Fas ligand; GSK3 = glycogen synthase kinase-3; HER = human epidermal growth receptor; IKK = I κ B kinase; ILK = integrin-linked kinase; IP3 = inositol triphosphate; I κ B = inhibitor of NF- κ B; MAPK = mitogen-activated protein kinase; MDM2 = mouse double minute 2 homologue; MEK = mitogen-activated protein/extracellular signal regulated kinase kinase; MEKK = MEK kinase; mTOR = mammalian target of rapamycin; NF- κ B = nuclear factor κ B; PI3K = phosphoinositide-3 kinase; PLC- γ = phospholipase C γ ; SAPK = stress-activated protein kinase; SEK = SAPK/extracellular signal regulated kinase kinase; TSC = tuberous sclerosis complex. (Modified with permission from Meric-Bernstam et al.)¹⁷¹

the mitochondria contain other proapoptotic proteins such as second mitochondria-derived activator of caspase/direct inhibitor of apoptosis-binding protein with low pI (Smac/DIABLO). The mitochondrial pathway can be stimulated by many factors, including DNA damage, reactive oxygen species, or the withdrawal of survival factors. The permeability of the mitochondrial membrane determines whether the apoptotic pathway will proceed. The Bcl-2 family of regulatory proteins includes both proapoptotic proteins (e.g., Bax, BAD, and Bak) and antiapoptotic proteins (e.g., Bcl-2 and Bcl-xL). The activity of the Bcl-2 proteins is centered on the mitochondria, where they regulate membrane permeability. Growth factors promote survival signaling through the PI3K/Akt pathway, which phosphorylates and inactivates proapoptotic BAD. In contrast, growth factor withdrawal may promote apoptosis through signaling by unphosphorylated BAD. The heat shock proteins, including Hsp70 and Hsp27, are also involved in inhibition of downstream apoptotic pathways by blocking formation of the apoptosome complex and inhibiting release of cytochrome c from the mitochondria.¹⁹

The second principal apoptotic pathway is the death receptor pathway, sometimes referred to as the *extrinsic pathway*.

Cell-surface death receptors include Fas/APO1/CD95, tumor necrosis factor receptor 1, and KILL-ER/DR5, which bind their ligands Fas-L, tumor necrosis factor (TNF), and TNF-related apoptosis-inducing ligand (TRAIL), respectively. When the receptors are bound by their ligands, they form a death-inducing signaling complex (DISC). At the DISC, procaspase 8 and procaspase 10 are cleaved, yielding active initiator caspases.²⁰ The death receptor pathway may be regulated at the cell surface by the expression of “decoy” receptors for Fas (DcR3) and TRAIL (TRID and TRUND). The decoy receptors are closely related to the death receptors but lack a functional death domain; therefore, they bind death ligands but do not transmit a death signal. Another regulatory group is the FADD-like interleukin-1 protease-inhibitory proteins (FLIPs). FLIPs have homology to caspase 8; they bind to the DISC and inhibit the activation of caspase 8. Finally, inhibitors of apoptosis proteins (IAPs) block caspase 3 activation and have the ability to regulate both the death receptor and the mitochondrial pathway.

In human cancers, aberrations in the apoptotic program include increased expression of Fas and TRAIL decoy receptors; increased expression of antiapoptotic Bcl-2; increased expression

of the IAP-related protein survivin; increased expression of c-FLIP; mutations or downregulation of proapoptotic Bax, caspase 8, APAF1, XAF1, and death receptors CD95, TRAIL-R1, and TRAIL-R2; alterations of the p53 pathway; overexpression of growth factors and growth factor receptors; and activation of the PI3K/Akt survival pathway.²⁰

Autophagy in Cancer Cells

Autophagy (self-eating) is a major cellular pathway for protein and organelle turnover. This process helps maintain a balance between anabolism and catabolism for normal cell growth and development. Inability to activate autophagy in response to nutrient deprivation, or constitutive activation of autophagy in response to stress, can lead to cell death; thus autophagy is sometimes referred to as a second form of programmed cell death. Autophagy plays an essential role during starvation, cellular differentiation, cell death, and aging. Autophagy is also involved in the elimination of cancer cells by triggering a nonapoptotic cell death program, which suggests a negative role in tumor development. Mouse models that are heterozygotes for the beclin 1 gene, an important gene for autophagy, have altered autophagic response and show a high incidence of spontaneous tumors, which establishes a role for autophagy in tumor suppression.²¹ This also suggests that mutations in other genes operating in this pathway may contribute to tumor formation through deregulation of autophagy. However, autophagy also acts as a stress response mechanism to protect cancer cells from low nutrient supply or therapeutic insults. Studies on the molecular determinants of autophagy are ongoing to determine whether autophagy can be modulated for therapeutic purposes.

Cancer Invasion

A feature of malignant cells is their ability to invade the surrounding normal tissue. Tumors in which the malignant cells appear to lie exclusively above the basement membrane are referred to as *in situ cancer*, whereas tumors in which the malignant cells are demonstrated to breach the basement membrane, penetrating into surrounding stroma, are termed *invasive cancer*. The ability to invade involves changes in adhesion, initiation of motility, and proteolysis of the extracellular matrix (ECM).

Cell-to-cell adhesion in normal cells involves interactions between cell-surface proteins. Calcium adhesion molecules of the cadherin family (E-cadherin, P-cadherin, and N-cadherin) are thought to enhance the cells' ability to bind to one another and suppress invasion. Migration occurs when cancer cells penetrate and attach to the basal matrix of the tissue being invaded; this allows the cancer cell to pull itself forward within the tissue. Attachment to glycoproteins of the ECM such as fibronectin, laminin, and collagen is mediated by tumor cell integrin receptors. Integrins are a family of glycoproteins that form heterodimeric receptors for ECM molecules. The integrins can form at least 25 distinct pairings of their α and β subunits, and each pairing is specific for a unique set of ligands. In addition to regulating cell adhesion to the ECM, integrins relay molecular signals regarding the cellular environment that influence shape, survival, proliferation, gene transcription, and migration.

Factors that are thought to play a role in cancer cell motility include autocrine motility factor, autotaxin, scatter factor (also known as *hepatocyte growth factor*), TGF α , EGF, and insulin-like growth factors.

Serine, cysteine, and aspartic proteinases and MMPs have all been implicated in cancer invasion. Urokinase and tissue

plasminogen activators (uPA and tPA) are serine proteases that convert plasminogen into plasmin. Plasmin, in return, can degrade several ECM components. Plasmin also may activate MMPs. uPA has been more closely correlated with tissue invasion and metastasis than tPA. Plasminogen activator inhibitors 1 and 2 (PAI-1 and PAI-2) are produced in tissues and counteract the activity of plasminogen activators.

MMPs comprise a family of metal-dependent endopeptidases. Upon activation, MMPs degrade a variety of ECM components. Although MMPs often are referred to by their common names, which reflect the ECM component for which they have specificity, a sequential numbering system has been adopted for standardization. For example, collagenase-1 is now referred to as *MMP-1*. The MMPs are further classified as secreted and membrane-type MMPs. Most of the MMPs are synthesized as inactive zymogens (pro-MMP) and are activated by proteolytic removal of the propeptide domain outside the cell by other active MMPs or serine proteinases.

MMPs are upregulated in almost every type of cancer. Some of the MMPs are expressed by cancer cells, whereas others are expressed by the tumor stromal cells. Experimental models have demonstrated that MMPs promote cancer progression by increasing cancer cell growth, migration, invasion, angiogenesis, and metastasis. MMPs exert these effects by cleaving not only structural components of the ECM but also growth factor-binding proteins, growth factor precursors, cell adhesion molecules, and other proteinases. The activity of MMPs is regulated by their endogenous inhibitors and tissue inhibitors of MMPs (TIMP-1, TIMP-2, TIMP-3, and TIMP-4).

Angiogenesis

Angiogenesis is the establishment of new blood vessels from a pre-existing vascular bed. This neovascularization is essential for tumor growth and metastasis. Tumors develop an angiogenic phenotype as a result of accumulated genetic alterations and in response to local selection pressures such as hypoxia. Many of the common oncogenes and tumor-suppressor genes have been shown to play a role in inducing angiogenesis.

In response to the angiogenic switch, pericytes retract and the endothelium secretes several growth factors such as basic fibroblast growth factor, platelet-derived growth factor (PDGF), and insulin-like growth factor. The basement membrane and stroma around the capillary are proteolytically degraded, a process that is mediated in most part by uPA. The endothelium then migrates through the degraded matrix, initially as a solid cord and later forming lumina. Finally, sprouting tips anastomose to form a vascular network surrounded by a basement membrane.

Angiogenesis is mediated by factors produced by various cells, including tumor cells, endothelial cells, stromal cells, and inflammatory cells. The first proangiogenic factor was identified by Folkman and colleagues in 1971.²² Since then, several other factors have been shown to be proangiogenic or antiangiogenic. Of the angiogenic stimulators, the best studied are the vascular endothelial growth factors (VEGFs). The VEGF family consists of six growth factors (VEGF-A, VEGF-B, VEGF-C, VEGF-D, VEGF-E, and placental growth factor) and three receptors (VEGFR1 or Flt-1, VEGFR2 or KDR/FLK-1, and VEGFR3 or Flt-4).²³ Neuropilin 1 and 2 also may act as receptors for VEGF.²⁴ VEGF is induced by hypoxia and by different growth factors and cytokines, including EGF, PDGF, TNF- α , TGF β , and interleukin-1 β . VEGF has various functions, including increasing vascular permeability, inducing endothelial cell

proliferation and tube formation, and inducing endothelial cell synthesis of proteolytic enzymes such as uPA, PAI-1, urokinase plasminogen activator receptor, and MMP-1. Furthermore, VEGF may mediate blood flow by its effects on the vasodilator nitric oxide and act as an endothelial survival factor, thus protecting the integrity of the vasculature. The proliferation of new lymphatic vessels, lymphangiogenesis, is also thought to be controlled by the VEGF family. Signaling in lymphatic cells is thought to be modulated by VEGFR3.²⁵ Experimental studies with VEGF-C and VEGF-D have shown that they can induce tumor lymphangiogenesis and direct metastasis via the lymphatic vessels and lymph nodes.^{25, 26}

PDGFs A, B, C, and D also play important roles in angiogenesis. PDGFs cannot only enhance endothelial cell proliferation directly but also upregulate VEGF expression in vascular smooth muscle cells, promoting endothelial cell survival via a paracrine effect.²³ The angiopoietins angiopoietin-1 and angiopoietin-2 (Ang-1 and Ang-2), in return, are thought to regulate blood vessel maturation. Ang-1 and Ang-2 both bind angiopoietin-1 receptor (also known as tyrosine-protein kinase receptor TIE-2), but only the binding of Ang-1 activates signal transduction; thus Ang-2 is an Ang-1 antagonist. Ang-1, via the Tie-2 receptor, induces remodeling and stabilization of blood vessels. Upregulation of Ang-2 by hypoxic induction of VEGF inhibits Ang-1-induced Tie-2 signaling, which results in destabilization of vessels and makes endothelial cells responsive to angiogenic

signals, thus promoting angiogenesis in the presence of VEGF. Therefore the balance between these factors determines the angiogenic capacity of a tumor.

Tumor angiogenesis is regulated by several factors in a coordinated fashion. In addition to upregulation of proangiogenic molecules, angiogenesis also can be encouraged by suppression of naturally occurring inhibitors. Such inhibitors of angiogenesis include thrombospondin 1 and angiostatin. Angiogenesis is a prerequisite not only for primary tumor growth but also for metastasis. Angiogenesis in the primary tumor, as determined by microvessel density, has been demonstrated to be an independent predictor of distant metastatic disease and survival in several cancers. Expression of angiogenic factors such as VEGFs has had prognostic value in many studies. These findings further emphasize the importance of angiogenesis in cancer biology.

Metastasis

Metastases arise from the spread of cancer cells from the primary site and the formation of new tumors in distant sites. The metastatic process consists of a series of steps that need to be completed successfully (Fig. 10-8).²⁷ First, the primary cancer must develop access to the circulation through either the blood circulatory system or the lymphatic system. After the cancer cells are shed into the circulation, they must survive. Next, the circulating cells lodge in a new organ and extravasate into the

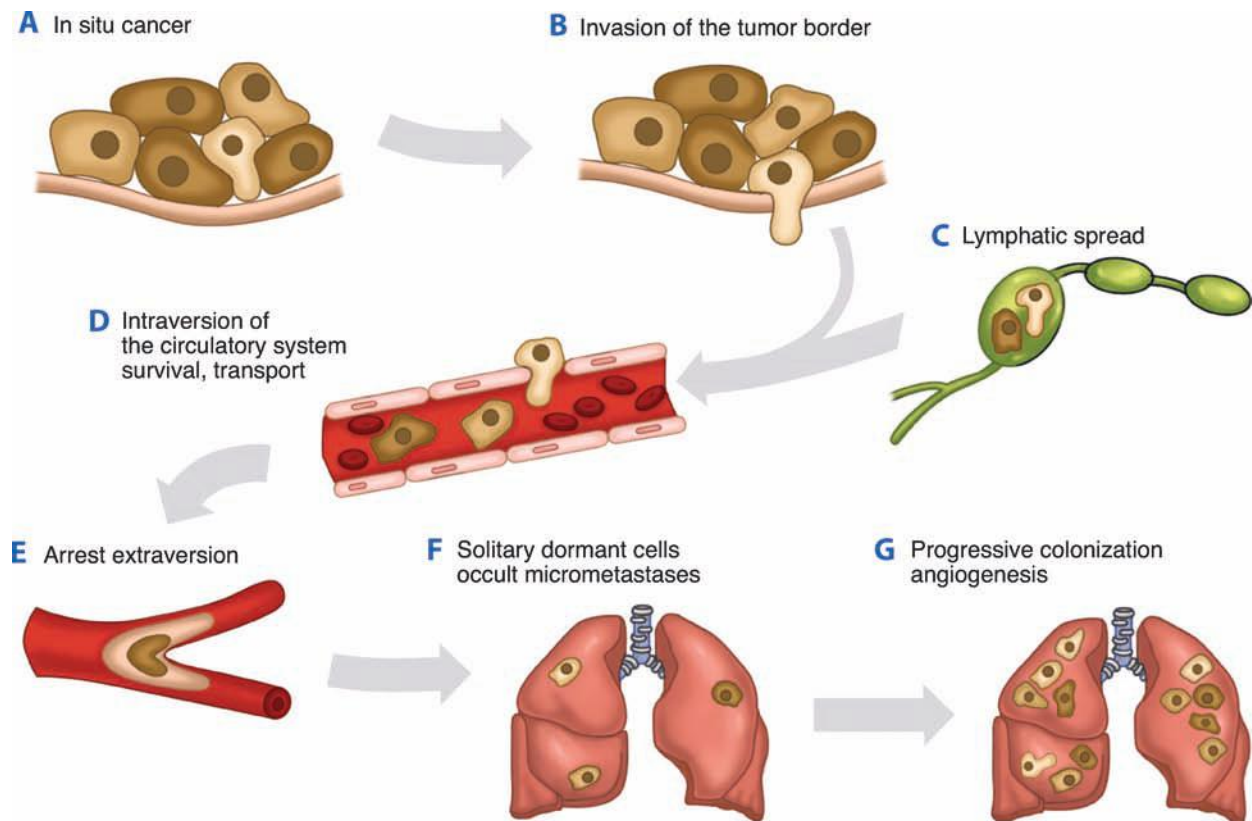


Figure 10-8. A schematic representation of the metastatic process. **A.** The metastatic process begins with an in situ cancer surrounded by an intact basement membrane. **B.** Invasion requires reversible changes in cell-cell and cell-extracellular matrix adherence, destruction of proteins in the matrix and stroma, and motility. **C.** Metastasizing cells can enter the circulation via the lymphatics. **D.** They can also directly enter the circulation. **E.** Intravascular survival of the tumor cells and extravasation of the circulatory system follow. **F.** Metastatic single cells can colonize sites and remain dormant for years as occult micrometastases. **G.** Subsequent progression and neovascularization leads to clinically detectable metastases and progressively growing, angiogenic metastases. (Adapted by permission from Macmillan Publishers Ltd. Steeg PS. *Metastasis suppressors alter the signal transduction of cancer cells.* Nat Rev Cancer. 2003;3:55. Copyright © 2003.)²⁷

new tissue. Next, the cells need to initiate growth in the new tissue and eventually establish vascularization to sustain the new tumor. Overall, metastasis is an inefficient process, although the initial steps of hematogenous metastasis (the arrest of tumor cells in the organ and extravasation) are believed to be performed efficiently. Only a small subset of cancer cells is then able to initiate micrometastases, and an even smaller portion goes on to grow into macrometastases.

Metastases can sometimes arise several years after the treatment of primary tumors. For example, although most breast cancer recurrences occur within the first 10 years after the initial treatment and recurrences are rare after 20 years, breast cancer recurrences have been reported decades after the original tumor. This phenomenon is referred to as *dormancy*, and it remains one of the biggest challenges in cancer biology. Persistence of solitary cancer cells in a secondary site such as the liver or bone marrow is one possible contributor to dormancy.²⁸ Another explanation of dormancy is that cells remain viable in a quiescent state and then become reactivated by a physiologically perturbing event. Interestingly, primary tumor removal has been proposed to be a potentially perturbing factor.²⁹ An alternate explanation is that cells establish preangiogenic metastases in which they continue to proliferate but that the proliferative rate is balanced by the apoptotic rate. Therefore, when these small metastases acquire the ability to become vascularized, substantial tumor growth can be achieved at the metastatic site, leading to clinical detection.

Several types of tumors metastasize in an organ-specific pattern. One explanation for this is mechanical and is based on the different circulatory drainage patterns of the tumors. When different tumor types and their preferred metastasis sites were compared, 66% of organ-specific metastases were explained on the basis of blood flow alone. The other explanation for preferential metastasis is what is referred to as the “*seed and soil*” theory, the dependence of the seed (the cancer cell) on the soil (the secondary organ). According to this theory, once cells have reached a secondary organ, their growth efficiency in that organ is based on the compatibility of the cancer cell’s biology with its new microenvironment. For example, breast cancer cells may grow more efficiently in bone than in some other organs because of favorable molecular interactions that occur in the bone microenvironment. The ability of cancer cells to grow in a specific site likely depends on features inherent to the cancer cell, features inherent to the organ, and the interplay between the cancer cell and its microenvironment.³⁰

Many of the oncogenes discovered to date, such as *HER2* and *ras*, are thought to potentiate not only malignant transformation but also one or more of the steps required in the metastatic process. Experimental models have suggested a role for several molecules, including RhoC, osteopontin and interleukin-11, and Twist, in tumor metastasis. Metastasis also may involve the loss of metastasis-suppressor genes. Laboratory work involving cancer cell lines that have been selected to have a higher metastatic potential have led to the realization that these more highly metastatic cells have a different gene expression profile than their less metastatic parental counterparts. This in turn has led to the currently held belief that the ability of a primary tumor to metastasize may be predictable by analysis of its gene expression profile. Indeed, several studies have recently focused on identifying a gene expression profile or a molecular signature that is associated with metastasis. It has been shown that such a gene expression profile can be used to predict the probability that the

patient will remain free of distant metastasis.³¹ This suggests that the metastatic potential of a tumor is already predetermined by the genetic alterations that the cancer cells acquire early in tumorigenesis. Notably, this hypothesis differs from the multistep tumorigenesis theory in that the ability to metastasize is considered an inherent quality of the tumor from the beginning. It is assumed that metastasis develops not from a few rare cells in the primary tumor that acquire the ability to metastasize but that all cells in tumors with such molecular signatures develop the ability to metastasize. The reality probably lies in between since some early genetic changes detectable in the entire tumor can give tumors an advantage in the metastatic process, whereas additional genetic changes can give a clone of cells additional advantages, thus allowing them to succeed in metastasis.

Epithelial-Mesenchymal Transition

A regulatory program referred to as epithelial-mesenchymal transition (EMT) is a fundamental event in morphogenesis. During EMT epithelial cells are converted to migratory and invasive cells.³² EMT, has also been implicated as the mechanism through which epithelial cells acquire the ability to migrate, invade, resist apoptosis and metastasize. EMT is a developmental process, and a set of pleiotropically acting transcriptional factors, including Snail, Twist, Slug, and Zeb1/2 orchestrate EMT. Several of these transcription factors can directly repress E-cadherin gene expression, depriving cancer cells of this key suppressor of motility and invasiveness. It has been proposed that the process of invasion and metastases requires significant plasticity, suggesting that EMT is required for invasion, intravasation and extravasation, and suppression of EMT regulators (and consequently EMT reversion, or MET) is required for metastatic outgrowth.³³⁻³⁵

Cancer Stem Cells

Stem cells are cells that have the ability to perpetuate themselves through self-renewal and to generate mature cells of a particular tissue through differentiation.³⁶ It has recently been proposed that stem cells themselves may be the target of transformation. It was first documented for leukemia and multiple myeloma that only a small subset of cancer cells is capable of extensive proliferation. It has subsequently also been shown for many solid cancers that only a small proportion of cells is clonogenic in culture and in vivo. In leukemia and multiple myeloma only a small subset of cancer cells is capable of extensive proliferation. Similarly, in many solid tumor types only a small proportion of cells is clonogenic in culture and in vivo. If indeed tumor growth and metastasis are driven by a small population of cancer stem cells, this may alter our current approaches to cancer therapy. Currently available drugs can shrink metastatic tumors but often cannot eradicate them. The failure of these treatments usually is attributed to the acquisition of drug resistance by the cancer cells; however, the cancer stem cell hypothesis raises the possibility that existing therapies may simply fail to kill cancer stem cells effectively. Therapeutic approaches targeting stem cells specifically are under study.

CANCER ETIOLOGY

Cancer Genomics

One widely held opinion is that cancer is a genetic disease that arises from an accumulation of genomic alterations that leads to the selection of cells with increasingly aggressive behavior. These alterations may lead either to a gain of function by oncogenes

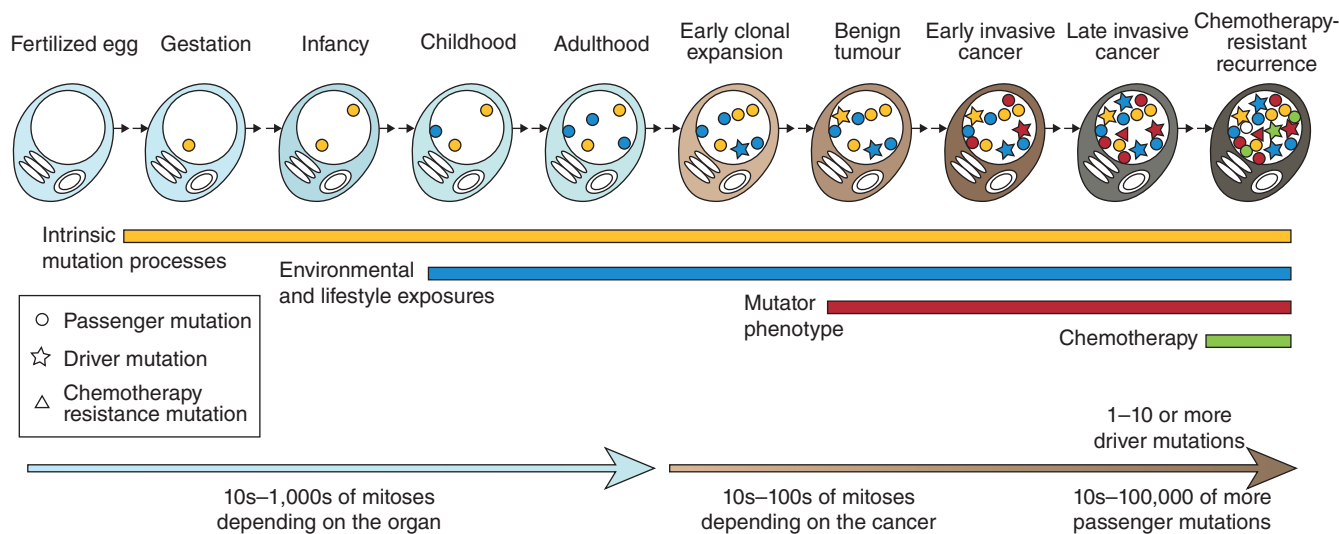


Figure 10-9. Accumulation of somatic mutations acquired by the cancer cell. Mutations may be acquired while the cell lineage is phenotypically normal, reflecting intrinsic mutations acquired during normal cell division as well as the effects of exogenous mutagens. Other processes such as example DNA repair defects may contribute to the mutational burden. Passenger mutations do not have any effect on the cancer cell, but driver mutations cause clonal expansion. Relapse after chemotherapy can be associated with resistance mutations that may predate the initiation of treatment. (Adapted by permission from Macmillan Publishers Ltd. Stratton MR, Campbell PJ, Futreal PA. *The cancer genome*. Nature. 2009;458:719. Copyright © 2009.)³⁷

or to a loss of function by tumor-suppressor genes. These acquired gene alterations are termed somatic mutations to distinguish them from germline mutations that are inherited from parents and transmitted to offspring. Somatic mutations in a cancer genome may consist of several classes of DNA sequence changes. These include substitutions of one base by another; insertions or deletions of small or large segments of DNA; rearrangements, in which the DNA sequence has been broken and then rejoined to another DNA segment; copy number losses that may result in complete absence of a DNA sequence and copy number gains from the two copies present in the normal diploid genome.

Somatic mutations in a cancer cell genome have accumulated over the lifetime of the patient (Fig. 10-9).³⁷ DNA in normal cells is continuously damaged by internal and external mutagens. Most of this damage is repaired; however, a small fraction may remain as fixed mutations. Mutation rates increase in the presence of substantial exogenous mutagenic exposures, such as tobacco carcinogens or various forms of radiation, including ultraviolet light. These exposures are associated with increased rates of lung and skin cancer, respectively, and somatic mutations within such cancers often exhibit the distinctive mutational signatures known to be associated with the mutagen.³⁸ The rates of somatic mutations are also increased in several rare inherited diseases, such as Fanconi anemia, ataxia telangiectasia, and xeroderma pigmentosum, which are associated with increased risks of cancer.^{39, 40} The rest of the somatic mutations in a cancer cell have been acquired after the cancer cell already shows phenotypic evidence of neoplastic change. Whether the somatic mutation rate is always higher during this part of the lineage is controversial. This is clearly the case for some cancers. For instance, colorectal and endometrial cancers with defective DNA mismatch repair due to abnormalities in genes such as *MLH1* and *MSH2*, exhibit increased rates of single nucleotide changes and small insertions/deletions at polynucleotide tract.⁴¹ These tumor types are often referred to as “mutator phenotypes.”

To date about 300 genes that have been reported to be mutated and causally implicated in cancer development.⁴² Ninety percent of cancer genes show somatic mutations in cancer, 20% show germline mutations, and 10% show both. The most common class of genomic alterations among the known cancer genes is a chromosomal translocation that creates a chimeric gene. Many more cancer genes have been found in leukemias, lymphomas, and sarcomas than in other types of cancer; and these genes are usually altered by chromosomal translocation. The most common cancer genes are protein kinases. Several domains that are involved in DNA binding and transcriptional regulation are also common in proteins encoded by cancer genes. Somatic mutations in a cancer genome may be classified according to its consequences for cancer development. “Driver” mutations confer a growth advantage to the cells carrying them and have been positively selected during the evolution of the cancer. The remainder of mutations are “bystanders” or “passengers” that do not confer growth advantage. It is likely that most somatic mutations are passenger mutations. Each tumor may have dozens to hundreds of genomic alterations, making it critical to determine which alterations are indeed drivers, and potentially better therapeutic targets.

There are several ongoing large scale studies to characterize and catalogue genomic alterations in different cancer types, including the Cancer Genome Project at the Sanger Institute, United Kingdom, and The Cancer Genome Atlas project (TCGA). There are also increasing number of publically accessible resources, including COSMIC (<http://www.sanger.ac.uk/cosmic>), which curates comprehensive information on somatic mutations in human cancer.⁴³ These resources are being utilized to determine the most common genomic alterations in common tumor types. This information is being integrated into clinical practice in many tumor types, such as lung cancer, where molecular drivers are being chosen taking into consideration in systemic therapy selection (Fig. 10-10).

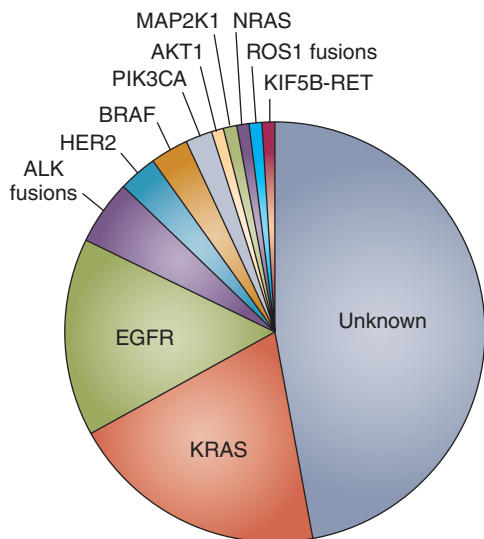


Figure 10-10. Molecular subsets of lung adenocarcinoma. Pie chart shows the percentage of tumors with each potentially actionable alteration. (Adapted by permission from Macmillan Publishers Ltd. Pao W, Hutchinson KE. Chipping away at the lung cancer genome. *Nat Med.* 2012;18:349. Copyright © 2012.)¹⁷²

Tumor Heterogeneity and Molecular Evolution

There is increasing recognition that tumors are heterogeneous; this represents an important challenge to utilizing genomic alterations to personalize cancer therapy (Fig. 10-11).⁴⁴ First, there is significant intertumoral heterogeneity, such that patients with tumors that seem similar histologically, may differ in genomic alterations and in malignant potential.⁴⁵⁻⁴⁷ Second, during cancer progression, subclones frequently arise, resulting in differences in the proportion and pattern of genomic alterations between the primary tumor and the metastases or local-regional recurrences.⁴⁴ Third, there may also be significant intratumoral heterogeneity, with spatially separated heterogeneous somatic mutations and chromosomal imbalances.⁴⁸ Such spatial heterogeneity of subclones within the primary tumor or metastases provides an additional challenge, as it has been proposed that

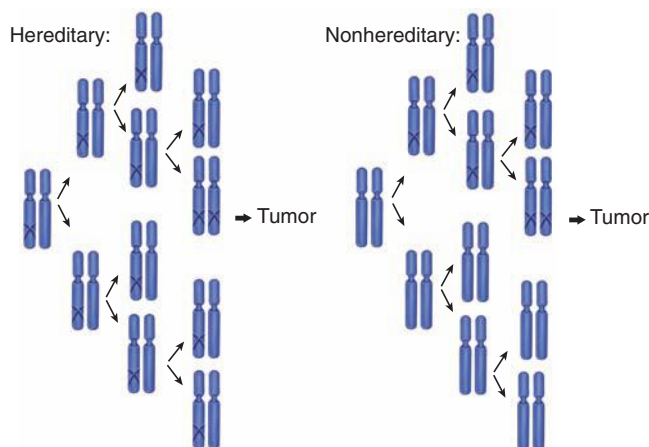


Figure 10-11. “Two-hit” tumor formation in both hereditary and nonhereditary cancers. A “one-hit” clone is a precursor to the tumor in nonhereditary cancer, whereas all cells are one-hit clones in hereditary cancer. (Adapted by permission from Macmillan Publishers Ltd. Knudson AG. Two genetic hits (more or less) to cancer. *Nat Rev Cancer.* 2001;1:157. Copyright © 2001.)⁵¹

sequencing of a biopsy specimen or only a portion of the tumor could miss therapeutically relevant genomic alterations. The genomic alterations found in a tumor can also change under the selective pressure of a targeted therapy, adding to the challenge of implementing genomically-informed personalized therapy.

Genes Associated with Hereditary Cancer Risk

Most of our information on human cancer genes has been gained from hereditary cancers. In the case of hereditary cancers, the individual carries a particular germline mutation in every cell. To date, over 70 genes have been associated with hereditary cancers (Table 10-3).⁴² A few of these hereditary cancer genes are oncogenes, but most are tumor-suppressor genes. Although hereditary cancer syndromes are rare, somatic mutations that occur in sporadic cancer have been found to disrupt the cellular pathways altered in hereditary cancer syndromes, which suggests that these pathways are critical to normal cell growth, cell cycle, and proliferation.

The following factors may suggest the presence of a hereditary cancer⁴⁹:

1. Tumor development at a much younger age than usual
2. Presence of bilateral disease
3. Presence of multiple primary malignancies
4. Presentation of a cancer in the less affected sex (e.g., male breast cancer)
5. Clustering of the same cancer type in relatives
6. Occurrence of cancer in association with other conditions such as mental retardation or pathognomonic skin lesions

It is crucial that all surgeons caring for cancer patients be aware of hereditary cancer syndromes, because a patient’s genetic background has significant implications for patient counseling, planning of surgical therapy, and cancer screening and prevention. Some of the more commonly encountered hereditary cancer syndromes are discussed here.

rb1 Gene. The retinoblastoma gene *rb1* was the first tumor suppressor to be cloned. The *rb1* gene product, the Rb protein, is a regulator of transcription that controls the cell cycle, differentiation, and apoptosis in normal development.⁵⁰ Retinoblastoma has long been known to occur in hereditary and nonhereditary forms. Interestingly, although most children with an affected parent develop bilateral retinoblastoma, some develop unilateral retinoblastoma. Furthermore, some children with an affected parent are not affected themselves but then have an affected child, which indicates that they are *rb1* mutation carriers. These findings led to the theory that a single mutation is not sufficient for tumorigenesis. Alfred Knudson hypothesized that hereditary retinoblastoma involves two mutations, of which one is germline and one somatic, whereas nonhereditary retinoblastoma is due to two somatic mutations (Fig. 10-12).⁵¹ Thus, both hereditary and nonhereditary forms of retinoblastoma involve the same number of mutations, a hypothesis known as Knudson’s “two-hit” hypothesis. A “hit” may be a point mutation, a chromosomal deletion referred to as *allelic loss*, or a loss of heterozygosity, or silencing of an existing gene.

p53 and Li-Fraumeni Syndrome. Li-Fraumeni syndrome (LFS) was first defined on the basis of observed clustering of malignancies, including early-onset breast cancer, soft tissue sarcomas, brain tumors, adrenocortical tumors, and leukemia.⁵² Criteria for classic LFS in an individual (the proband) include:

Table 10-3

Selected genes associated with hereditary cancer

SYMBOL	NAME	TUMOR TYPES (GERMLINE MUTATIONS)	CANCER SYNDROME
ALK	anaplastic lymphoma kinase (Ki-1)	Neuroblastoma	Familial neuroblastoma
APC	adenomatous polyposis of the colon gene	Colorectal, pancreatic, desmoid, hepatoblastoma, glioma, other CNS	Adenomatous polyposis coli; Turcot syndrome
ATM	ataxia telangiectasia mutated	Leukemia, lymphoma, medulloblastoma, glioma	Ataxia-telangiectasia
BLM	Bloom Syndrome	Leukemia, lymphoma, skin squamous cell, other cancers	Bloom Syndrome
BMPR1A	bone morphogenetic protein receptor, type IA	Gastrointestinal polyps	Juvenile polyposis
BRCA1	familial breast/ovarian cancer gene 1	Breast, ovarian	Hereditary breast/ovarian cancer
BRCA2	familial breast/ovarian cancer gene 2	Breast, ovarian, pancreatic	Hereditary breast/ovarian cancer
BRIP1	BRCA1 interacting protein C-terminal helicase 1	AML, leukemia, breast	Fanconi anaemia J, breast cancer susceptibility
BUB1B	BUB1 budding uninhibited by benzimidazoles 1 homolog beta (yeast)	Rhabdomyosarcoma	Mosaic variegated aneuploidy
CDH1	cadherin 1, type 1, E-cadherin (epithelial) (ECAD)	Gastric, lobular cancer	Familial gastric carcinoma
CDK4	cyclin-dependent kinase 4	Melanoma	Familial malignant melanoma
CDKN2A	cyclin-dependent kinase inhibitor 2A (p16(INK4a)) gene	Melanoma, pancreatic	Familial malignant melanoma
CDKN2a(p14)	cyclin-dependent kinase inhibitor 2A- p14ARF protein	Melanoma, pancreatic	Familial malignant melanoma
CHEK2	CHK2 checkpoint homolog (<i>S. pombe</i>)	Breast	Familial breast cancer
CYLD	familial cylindromatosis gene	Cylindroma	Familial cylindromatosis
DDB2	damage-specific DNA binding protein 2	Skin basal cell, skin squamous cell, melanoma	Xeroderma pigmentosum (E)
DICER1	dicer 1, ribonuclease type III	Pleuropulmonary blastoma	Familial Pleuropulmonary Blastoma
EGFR	epidermal growth factor receptor (erythroblastic leukemia viral (v-erb-b) oncogene homolog, avian)	NSCLC	Familial lung cancer
ERCC2, 3, 4, 5	excision repair cross-complementing rodent repair deficiency, complementation group	Skin basal cell, skin squamous cell, melanoma	Xeroderma pigmentosum (D, B, F, G))
EXT1	multiple exostoses type 1 gene	exostoses, osteosarcoma	exostoses, osteosarcoma
FANCA, C, D2, E, F, G	Fanconi anemia, complementation group	AML, leukemia	Fanconi anaemia A, C, D2, E, F, G
FH	fumarate hydratase	leiomyomatosis, renal	Hereditary leiomyomatosis and renal cell cancer
GPC3	glypican 3	Wilms' tumor	Simpson-Golabi-Behmel syndrome
HRAS	v-Ha-ras Harvey rat sarcoma viral oncogene homolog	v-Ha-ras Harvey rat sarcoma viral oncogene homolog	Costello syndrome
HRPT2	Hyperparathyroidism 2 (parafibromin)	parathyroid adenoma, multiple ossifying jaw fibroma	Hyperparathyroidism-jaw tumor syndrome
KIT	v-kit Hardy-Zuckerman 4 feline sarcoma viral oncogene homolog	GIST, epithelioma	Familial gastrointestinal stromal tumor

Table 10-3

Selected genes associated with hereditary cancer (continued)

SYMBOL	NAME	TUMOR TYPES (GERMLINE MUTATIONS)	CANCER SYNDROME
MADH4	Homolog of <i>Drosophila</i> Mothers Against Decapentaplegic 4 gene	Gastrointestinal polyps	Juvenile polyposis
MEN1	multiple endocrine neoplasia type 1 gene	Parathyroid adenoma, pituitary adenoma, pancreatic islet cell, carcinoid	Parathyroid adenoma, pituitary adenoma, pancreatic islet cell, carcinoid
MLH1	<i>E. coli</i> MutL homolog gene	Colorectal, endometrial, ovarian, CNS	Hereditary nonpolyposis colorectal cancer, Turcot syndrome
MPL	myeloproliferative leukemia virus oncogene, thrombopoietin receptor	MPD	Familial essential thrombocythemia
MSH2	mutS homolog 2 (<i>E. coli</i>)	colorectal, endometrial, ovarian	Hereditary non-polyposis colorectal cancer
MSH6	mutS homolog 6 (<i>E. coli</i>)	colorectal, endometrial, ovarian	Hereditary non-polyposis colorectal cancer
MUTYH	mutY homolog (<i>E. coli</i>)	Colorectal	Adenomatous polyposis coli
NBS1	Nijmegen breakage syndrome 1 (nibrin)	NHL, glioma, medulloblastoma, rhabdomyosarcoma	Nijmegen breakage syndrome
NF1	neurofibromatosis type 1 gene	Neurofibroma, glioma	Neurofibromatosis type 1
NF2	neurofibromatosis type 2 gene	Meningioma, acoustic neuroma	Neurofibromatosis type 2
PALB2	partner and localizer of BRCA2	Wilms tumor, medulloblastoma, AML, breast	Fanconi anaemia N, breast cancer susceptibility
PHOX2B	paired-like homeobox 2b	Neuroblastoma	Familial neuroblastoma
PMS1	PMS1 postmeiotic segregation increased 1 (<i>S. cerevisiae</i>)	Colorectal, endometrial, ovarian	Hereditary non-polyposis colorectal cancer
PMS2	PMS2 postmeiotic segregation increased 2 (<i>S. cerevisiae</i>)	Colorectal, endometrial, ovarian, medulloblastoma, glioma	Hereditary nonpolyposis colorectal cancer, Turcot syndrome
PRKAR1A	protein kinase, cAMP-dependent, regulatory, type I, alpha (tissue specific extinguisher 1)	Myxoma, endocrine, papillary thyroid	Carney complex
PTCH	Homolog of <i>Drosophila</i> Patched gene	Skin basal cell, medulloblastoma	Nevoid Basal Cell Carcinoma Syndrome
PTEN	phosphatase and tensin homolog gene	Hamartoma, glioma, prostate, endometrial	Cowden Syndrome, Bannayan-Riley-Ruvalcaba syndrome
RB1	retinoblastoma gene	Retinoblastoma, sarcoma, breast, small cell lung	Familial retinoblastoma
RECQL4	RecQ protein-like 4	Osteosarcoma, skin basal and squamous cell	Rothmund-Thompson Syndrome
RET	ret proto-oncogene	Medullary thyroid, papillary thyroid, pheochromocytoma	Multiple endocrine neoplasia 2A/2B
SBDS	Shwachman-Bodian-Diamond syndrome protein	AML, MDS	Schwachman-Diamond syndrome
SDH5	chromosome 11 open reading frame 79	Paraganglioma	Familial paraganglioma
SHD, B, D	succinate dehydrogenase complex	Paraganglioma, pheochromocytoma	Familial paraganglioma

(Continued)

Table 10-3

Selected genes associated with hereditary cancer (continued)

SYMBOL	NAME	TUMOR TYPES (GERMLINE MUTATIONS)	CANCER SYNDROME
SMARCB1	SWI/SNF related, matrix associated, actin dependent regulator of chromatin, subfamily b, member 1	Malignant rhabdoid	Rhabdoid predisposition syndrome
STK11	serine/threonine kinase 11 gene (LKB1)	Jejunal hamartoma, ovarian, testicular, pancreatic	Peutz-Jeghers syndrome
SUFU	suppressor of fused homolog (<i>Drosophila</i>)	Medulloblastoma	Medulloblastoma predisposition
TCF1	transcription factor 1, hepatic (HNF1)	Hepatic adenoma, hepatocellular carcinoma	Familial Hepatic Adenoma
TP53	tumor protein p53	Breast, sarcoma, adrenocortical carcinoma, glioma, multiple other tumor types	Li-Fraumeni syndrome
TSC1	tuberous sclerosis 1 gene	Hamartoma, renal cell	Tuberous sclerosis 1
TSC2	tuberous sclerosis 2 gene	Hamartoma, renal cell	Tuberous sclerosis 2
TSHR	thyroid stimulating hormone receptor	Thyroid adenoma	
VHL	von Hippel-Lindau syndrome gene	Renal, hemangioma, pheochromocytoma	von Hippel-Lindau syndrome
WRN	Werner syndrome (RECQL2)	Osteosarcoma, meningioma, others	Werner Syndrome
WT1	Wilms' tumor 1 gene	Wilms'	Denys-Drash syndrome, Frasier syndrome, Familial Wilms tumor
XPA, C	xeroderma pigmentosum, complementation group	Skin basal cell, skin squamous cell, melanoma	Xeroderma pigmentosum (A C)

A, amplification; **AEL**, acute eosinophilic leukemia; **AL**, acute leukemia; **ALCL**, anaplastic large-cell lymphoma; **ALL**, acute lymphocytic leukemia; **AML**, acute myelogenous leukemia; **AML***, acute myelogenous leukemia (primarily treatment associated); **APL**, acute promyelocytic leukemia; **B-ALL**, B-cell acute lymphocytic leukaemia; **B-CLL**, B-cell Lymphocytic leukemia; **B-NHL**, B-cell Non-Hodgkin Lymphoma; **CLL**, chronic lymphatic leukemia; **CML**, chronic myeloid leukemia; **CMML**, chronic myelomonocytic leukemia; **CNS**, central nervous system; **D**, large deletion; **DFSP**, dermatofibrosarcoma protuberans; **DLBL**, diffuse large B-cell lymphoma; **DLCL**, diffuse large-cell lymphoma; **Dom**, dominant; **E**, epithelial; **F**, frameshift; **GIST**, gastrointestinal stromal tumour; **JMML**, juvenile myelomonocytic leukemia; **L**, leukaemia/lymphoma; **M**, mesenchymal; **MALT**, mucosa-associated lymphoid tissue lymphoma; **MDS**, myelodysplastic syndrome; **Mis**, Missense; **MLCLS**, mediastinal large cell lymphoma with sclerosis; **MM**, multiple myeloma; **MPD**, Myeloproliferative disorder; **N**, nonsense; **NHL**, non-Hodgkin lymphoma; **NK/T**, natural killer T cell; **NSCLC**, non small cell lung cancer; **O**, other; **PMBL**, primary mediastinal B-cell lymphoma; **pre-B All**, pre-B-cell acute lymphoblastic leukaemia; **Rec**, recessive; **S**, splice site; **T**, translocation; **T-ALL**, T-cell acute lymphoblastic leukemia; **T-CLL**, T-cell chronic lymphocytic leukaemia; **TGCT**, testicular germ cell tumour; **T-PLL**, T cell prolymphocytic leukemia

Source: Adapted by permission from Macmillan Publishers Ltd. Futreal PA et al. A census of human cancer genes. Nat Rev Cancer. 2004;4:177. Copyright © 2004.

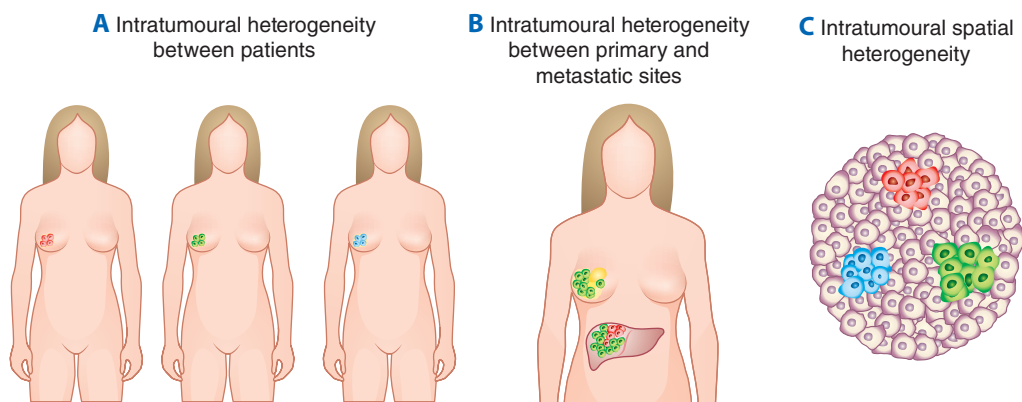


Figure 10-12. Tumor heterogeneity. **A.** Patients with tumors with similar histologies may differ in genetic mutation status and other molecular features **B.** Cells within the primary tumor can acquire or lose genomic alterations in metastatic sites. **C.** Intratumoural spatial heterogeneity: common initiating genomic events usually exist in all tumor cells but additional spatially separated heterogeneous somatic mutations or copy number changes may accumulate. (Adapted with permission from Meric-Bernstam and Mills)⁴⁴

(a) a bone or soft tissue sarcoma when younger than 45 years, (b) a first-degree relative with cancer before age 45 years, and (c) another first- or second-degree relative with either a sarcoma diagnosed at any age or any cancer diagnosed before age 45 years.⁵³ Approximately 70% of LFS families have been shown to have germline mutations in the tumor-suppressor gene p53.⁵⁴ Breast carcinoma, soft tissue sarcoma, osteosarcoma, brain tumors, adrenocortical carcinoma, Wilms' tumor, and phyllodes tumor of the breast are strongly associated; pancreatic cancer is moderately associated; and leukemia and neuroblastoma are weakly associated with germline p53 mutations.⁵⁵ Mutations of p53 have not been detected in approximately 30% of LFS families, and it is hypothesized that genetic alterations in other proteins interacting with p53 function may play a role in these families.

Of the known genes in human cancer, p53 is the most commonly mutated. The p53 protein regulates cell-cycle progression as well as apoptotic cell death as part of stress response pathways after exposure to ionizing or ultraviolet (UV) irradiation, chemotherapy, acidosis, growth factor deprivation, or hypoxia. When cells are exposed to stressors, p53 acts as a transcription factor for genes that induce cell-cycle arrest or apoptosis. A majority of p53 mutations are found within a central DNA recognition motif and disrupt DNA binding by p53. Families with germline missense mutations in the DNA-binding domain show a more highly penetrant phenotype than families with other p53 mutations.⁵⁶ Furthermore, proband cancers are linked with significantly younger age at diagnosis in patients with missense mutations in the DNA-binding domain.⁵⁶

BRCA1, BRCA2, and Hereditary Breast-Ovarian Cancer

Syndromes. It is estimated that 5% to 10% of breast cancers are hereditary. Of women with early-onset breast cancer (aged 40 years or younger), nearly 10% have a germline mutation in one of the breast cancer genes *BRCA1* or *BRCA2*.⁵⁷ Mutation carriers are more prevalent among women who have a first- or second-degree relative with premenopausal breast cancer or ovarian cancer at any age. The likelihood of a *BRCA* mutation is higher in patients who belong to a population in which founder mutations may be prevalent, such as in the Ashkenazi Jewish population. For a female *BRCA1* mutation carrier, the cumulative risks of developing breast cancer and ovarian cancer by age 70 have been estimated to be 87% and 44%, respectively.⁵⁸ The cumulative risks of breast cancer and ovarian cancer by age 70 in families with *BRCA2* mutation have been estimated to be 84% and 27%, respectively.⁵⁹ Although male breast cancer can occur with either *BRCA1* or *BRCA2* mutation, the majority of families (76%) with both male and female breast cancer have mutations in *BRCA2*.⁵⁹ Besides breast and ovarian cancer, *BRCA1* and *BRCA2* mutations may be associated with increased risks for several other cancers. *BRCA1* mutations confer a fourfold increased risk for colon cancer and threefold increased risk for prostate cancer.⁵⁸ *BRCA2* mutations confer a fivefold increased risk for prostate cancer, sevenfold in men younger than 65 years.⁶⁰ Furthermore, *BRCA2* mutations confer a fivefold increased risk for gallbladder and bile duct cancers, fourfold increased risk for pancreatic cancer, and threefold increased risk for gastric cancer and malignant melanoma.⁶⁰

BRCA1 was the first breast cancer susceptibility gene identified and has been mapped to 17q21. *BRCA2*, mapped to 13q12.3, was reported shortly afterward. *BRCA1* and *BRCA2*

encode large nuclear proteins, 208 kDa and 384 kDa, respectively, that have been implicated in processes fundamental to all cells, including DNA repair and recombination, checkpoint control of the cell cycle, and transcription.⁶¹ Although early studies suggested that the two proteins function together as a complex, subsequent data demonstrated that they have distinct functions.^{62, 63} In fact, breast cancers arising from *BRCA1* or *BRCA2* mutations are different at the molecular level and have been found to have distinct gene expression profiles.⁶⁴ *BRCA1*-associated tumors are more likely to be estrogen receptor negative, whereas *BRCA2*-associated tumors are more likely to be estrogen receptor positive. Currently, studies are ongoing to determine whether *BRCA1* and *BRCA2* status can be used to guide systemic therapy choices for breast cancer.

APC Gene and Familial Adenomatous Polyposis

Patients affected with familial adenomatous polyposis (FAP) characteristically develop hundreds to thousands of polyps in the colon and rectum. The polyps usually appear in adolescence and, if left untreated, progress to colorectal cancer. FAP is associated with benign extracolonic manifestations that may be useful in identifying new cases, including congenital hypertrophy of the retinal pigment epithelium, epidermoid cysts, and osteomas. In addition to colorectal cancer, patients with FAP are at risk for upper intestinal neoplasms (gastric and duodenal polyps, duodenal and periampullary cancer), hepatobiliary tumors (hepatoblastoma, pancreatic cancer, and cholangiocarcinoma), thyroid carcinomas, desmoid tumors, and medulloblastomas.

The product of the adenomatous polyposis coli tumor-suppressor gene (*APC*) plays an important role in cell-cell interactions, cell adhesion, regulation of β -catenin, and maintenance of cytoskeletal microtubules. Alterations in *APC* lead to dysregulation of several physiologic processes that govern colonic epithelial cell homeostasis, including cell-cycle progression, migration, differentiation, and apoptosis. Mutations in the *APC* have been identified in FAP and in 80% of sporadic colorectal cancers.⁶⁵ Furthermore, *APC* mutations are the earliest known genetic alterations in colorectal cancer progression, which emphasizes its importance in cancer initiation. The germline mutations in *APC* may arise from point mutations, insertions, or deletions that lead to a premature stop codon and a truncated, functionally inactive protein. The risk of developing specific manifestations of FAP is correlated with the position of the *APC* mutations, a phenomenon referred to as *genotype-phenotype correlation*. For example, desmoids usually are associated with mutations between codons 1403 and 1578.^{66, 67} Mutations in the extreme 5' or 3' ends of *APC*, or in the alternatively spliced region of exon 9, are associated with an attenuated version of FAP. Better understanding of the genotype-phenotype correlations may assist in patient counseling and therapeutic planning.

Mismatch Repair Genes and Hereditary Nonpolyposis Colorectal Cancer.

Hereditary nonpolyposis colorectal cancer (HNPCC), also referred to as *Lynch syndrome*, is an autosomal dominant hereditary cancer syndrome that predisposes to a wide spectrum of cancers, including colorectal cancer without polyposis. Some have proposed that HNPCC consists of at least two syndromes: Lynch syndrome 1, which entails hereditary predisposition for colorectal cancer with early age of onset (approximately age 44 years) and an excess of synchronous and metachronous colonic cancers; and Lynch syndrome 2, featuring a similar colonic phenotype accompanied by a high risk

Table 10-4

Revised criteria for hereditary nonpolyposis colon cancer (HNPCC) (Amsterdam criteria II)

Three or more relatives with an HNPCC-associated cancer (colorectal cancer, endometrial cancer, cancer of the small bowel, ureter, or renal pelvis), one of whom is a first-degree relative of the other two
 At least two successive generations affected
 At least one case diagnosed before age 50 y
 Familial adenomatous polyposis excluded
 Tumors verified by pathologic examination

Source: Modified with permission from Vasen et al. Copyright Elsevier.⁶⁹

for carcinoma of the endometrium, transitional cell carcinoma of the ureter and renal pelvis, and carcinomas of the stomach, small bowel, ovary, and pancreas.⁶⁸ The diagnostic criteria for HNPCC are referred to as the *Amsterdam criteria*, or the *3-2-1-0 rule*. The classic Amsterdam criteria were revised to include other HNPCC-related cancers (Table 10-4).⁶⁹ These criteria are met when three or more family members have histologically verified, HNPCC-associated cancers (one of whom is a first-degree relative of the other two), two or more generations are involved, at least one individual was diagnosed before age 50 years, and no individuals have FAP.⁶⁹

During DNA replication, DNA polymerases may introduce single nucleotide mismatches or small insertion or deletion loops. These errors are corrected through a process referred to as *mismatch repair*. When mismatch repair genes are inactivated, DNA mutations in other genes that are critical to cell growth and proliferation accumulate rapidly. In HNPCC, germline mutations have been identified in several genes that play a key role in DNA nucleotide mismatch repair: *hMLH1* (human mutL homologue 1), *hMSH2* (human mutS homologue 2), *hMSH6*, and *hPMS1* and *hPMS2* (human post-meiotic segregation 1 and 2), of which *hMLH1* and *hMSH2* are the most common.⁷⁰⁻⁷⁵ The hallmark of HNPCC is microsatellite instability, which occurs on the basis of unrepaired mismatches and small insertion or deletion loops. Microsatellite instability can be tested by comparing the DNA of a patient's tumor with DNA from adjacent normal epithelium, amplifying the DNA with polymerase chain reaction (PCR) using a standard set of markers, comparing the amplified genomic DNA sequences, and classifying the degree of microsatellite instability as high, low, or stable. Such microsatellite instability testing may help select patients who are more likely to have germline mutations.

PTEN and Cowden Disease

Somatic deletions or mutations in the tumor-suppressor gene *PTEN* (phosphatase and tensin homologue deleted on chromosome 10) have been observed in a number of glioma breast, prostate, and renal carcinoma cell lines and several primary tumor specimens.⁷⁶

PTEN encodes a 403-amino-acid protein, tyrosine phosphatase. *PTEN* negatively controls the PI3K signaling pathway for the regulation of cell growth and survival by dephosphorylating

phosphoinositol 3,4,5-triphosphate; thus mutation of *PTEN* leads to constitutive activation of the PI3K/Akt signaling pathway. The “hot spot” for *PTEN* mutations has been identified in exon 5. Forty-three percent of CD mutations have been identified in this exon, which contains the tyrosine phosphatase core domain. This suggests that the *PTEN* catalytic activity is vital for its biologic function. *PTEN* was identified as the susceptibility gene for the autosomal dominant syndrome Cowden disease (CD) or multiple hamartoma syndrome.⁷⁷ Trichilemmomas, benign tumors of the hair follicle infundibulum, and mucocutaneous papillomatosis are pathognomonic of CD. Other common features include thyroid adenomas and multinodular goiters, breast fibroadenomas, and hamartomatous GI polyps. The diagnosis of CD is made when an individual or family has a combination of pathognomonic major and/or minor criteria proposed by the International Cowden Consortium.⁷⁸ CD is associated with an increased risk of breast and thyroid cancers. Breast cancer develops in 25% to 50% of affected women.⁷⁸

p16 and Hereditary Malignant Melanoma. The gene p16, also known as *INK4A*, *CDKN1*, *CDKN2A*, and *MTS1*, is a tumor suppressor that acts by binding CDK4 and CDK6 and inhibiting the catalytic activity of the CDK4-CDK6/cyclin D complex that is required for phosphorylation of Rb and subsequent cell-cycle progression. Studies suggest that germline mutations in p16 can be found in 20% of melanoma-prone families.⁷⁹ Mutations in p16 that alter its ability to inhibit the catalytic activity of the CDK4-CDK6/cyclin D complex not only increase the risk of melanoma by 75-fold but also increase the risk of pancreatic cancer by 22-fold.⁸⁰ Interestingly, p16 mutations that do not appear to alter its function increase the risk of melanoma by 38-fold and do not increase the risk of pancreatic cancer.⁸⁰ Genomic characterization of primary tumors has revealed that p16 is inactivated through point mutation, promoter methylation, or deletion in a significant portion of sporadic tumors, including cancers of the pancreas, esophagus, head and neck, stomach, breast, and colon, as well as melanomas.

E-cadherin and Hereditary Diffuse Gastric Cancer. E-cadherin is a cell adhesion molecule that plays an important role in normal architecture and function of epithelial cells. The adhesive function of E-cadherin is dependent on interaction of its cytoplasmic domain with β - and γ -catenins and may be regulated by phosphorylation of β -catenin.

Hereditary diffuse gastric carcinoma is an autosomal dominant cancer syndrome that results from germline mutations in the E-cadherin gene, *CDH1*. Carriers of *CDH1* mutations have a 70% to 80% chance of developing gastric cancer.⁸¹ Furthermore, mutations of *CDH1* have been described in sporadic cancers of the ovary, endometrium, breast, and thyroid. However, frequent mutations have been identified in only two particular tumors: diffuse gastric carcinomas and lobular breast carcinomas. Invasive lobular breast carcinomas often show inactivating mutations in combination with a loss of heterozygosity of the wild-type *CDH1* allele.⁸² Interestingly, in gastric carcinomas the predominant mutations are exon skipping causing in-frame deletions, whereas most mutations identified in lobular breast cancers are premature stop codons; this suggests a genotype-phenotype correlation.

RET Proto-Oncogene and Multiple Endocrine Neoplasia Type 2

The *RET* (rearranged during transfection) gene encodes for a transmembrane receptor tyrosine kinase that plays a role in proliferation, migration, and differentiation of cells derived from the neural crest. Gain-of-function mutations in the *RET* gene are associated with medullary thyroid carcinoma in isolation or multiple endocrine neoplasia type 2 (MEN2) syndromes. MEN2A is associated with medullary thyroid carcinoma and pheochromocytoma (in 50%) or parathyroid adenoma (in 20%), whereas MEN2B is associated with medullary thyroid carcinoma, marfanoid habitus, mucosal neuromas, and ganglioneuromatosis.⁸³ *RET* mutations lead to uncontrolled growth of the thyroid C cells, and in familial medullary cancer, C-cell hyperplasia progresses to bilateral, multicentric medullary thyroid cancer. Mutations in the *RET* gene have also been identified in half of sporadic medullary thyroid cancers.

Genetic Modifiers of Risk. Individuals carrying identical germline mutations vary in regard to cancer penetrance (whether cancer will develop or not) and cancer phenotype (the tissues involved). It is thought that this variability may be due to environmental influences or, if genetic, to genetic modifiers of risk. Similarly, genetic modifiers of risk also can play a role in determining whether an individual will develop cancer after exposure to carcinogens.

Chemical Carcinogens

The first report indicating that cancer could be caused by environmental factors was by John Hill, who in 1761 noted the association between nasal cancer and excessive use of tobacco snuff.⁸⁴ Currently, approximately 60% to 90% of cancers are thought to be due to environmental factors. Any agent that can contribute to tumor formation is referred to as a *carcinogen* and can be a chemical, physical, or viral agent. Chemicals are classified into three groups based on how they contribute to tumor formation. The first group of chemical agents, the genotoxins, can initiate carcinogenesis by causing a mutation. The second group, the cocarcinogens, by themselves cannot cause cancer but potentiate carcinogenesis by enhancing the potency of genotoxins. The third group, tumor promoters, enhances tumor formation when given after exposure to genotoxins.

The International Agency for Research on Cancer (IARC) maintains a registry of human carcinogens that is available through the World Wide Web (<http://www.iarc.fr>). The compounds are categorized into five groups based on an analysis of epidemiologic studies, animal models, and short-term mutagenesis tests. Group 1 contains what are considered to be proven human carcinogens, based on formal epidemiologic studies among workers who were exposed for long periods (several years) to the chemicals.⁸⁵ Group 2A contains what are considered to be probable human carcinogens. Suggestive epidemiologic evidence exists for compounds in this group, but the data are insufficient to establish causality. There is evidence of carcinogenicity, however, from animal studies carried out under conditions relevant to human exposure. Group 2B contains what are considered to be possible carcinogens, because these substances are associated with a clear statistically and biologically significant increase in the incidence of malignant tumors in more than one animal species or strain. Group 3 agents are not classifiable, and Group 4 agents are probably not carcinogenic to humans.

Selected substances that have been classified as proven carcinogens (group 1) by the IARC in an expert panel review in 2009 are listed in Table 10-5.⁸⁶

Physical Carcinogens

Physical carcinogenesis can occur through induction of inflammation and cell proliferation over a period of time or through exposure to physical agents that induce DNA damage. Foreign bodies can cause chronic irritation that can expose cells to carcinogenesis due to other environmental agents. In animal models, for example, subcutaneous implantation of a foreign body can lead to the development of tumors that have been attributed to chronic irritation from the foreign objects. In humans, clinical scenarios associated with chronic irritation and inflammation such as chronic nonhealing wounds, burns, and inflammatory bowel syndrome have all been associated with an increased risk of cancer. *H. pylori* infection is associated with gastritis and gastric cancer, and thus, its carcinogenicity may be considered physical carcinogenesis. Infection with the liver fluke *Opisthorchis viverrini* similarly leads to local inflammation and cholangiocarcinoma.

The induction of lung and mesothelial cancers by asbestos fibers and nonfibrous particles such as silica are other examples of foreign body-induced physical carcinogenesis.⁸⁷ Animal experiments have demonstrated that the dimensions and durability of the asbestos and other fibrous minerals are the key determinants of their carcinogenicity.⁸⁸ Short fibers can be inactivated by phagocytosis, whereas long fibers (>10 μm) are cleared less effectively and are encompassed by proliferating epithelial cells. The long fibers support cell proliferation and have been shown to preferentially induce tumors. Asbestos-associated biologic effects also may be mediated through reactive oxygen and nitrogen species. Furthermore, an interaction occurs between asbestos and silica and components of cigarette smoke. Polycyclic aromatic hydrocarbons (PAHs) in cigarette smoke are metabolized by epithelial cells and form DNA adducts. If PAH is coated on asbestos, PAH uptake is increased.⁸⁷ Both PAH and asbestos impair lung clearance, potentially increasing uptake further. Therefore, physical carcinogens may be synergistic with chemical carcinogens.

Radiation is the best-known agent of physical carcinogens and is classified as ionizing radiation (X-rays, gamma rays, and alpha and beta particles) or nonionizing radiation (UV). The carcinogenic potential of ionizing radiation was recognized soon after Wilhelm Conrad Roentgen's discovery of X-rays in 1895. Within the next 20 years, a large number of radiation-related skin cancers were reported. Long-term follow-up of survivors of the atomic bombing of Hiroshima and Nagasaki revealed that virtually all tissues exposed to radiation are at risk for cancer.

Radiation can induce a spectrum of DNA lesions that includes damage to the nucleotide bases and cross-linking, and DNA single- and double-strand breaks (DSBs). Misrepaired DSBs are the principal lesions of importance in the induction of chromosomal abnormalities and gene mutations. DSBs in irradiated cells are repaired primarily by a nonhomologous end-joining process, which is error prone; thus, DSBs facilitate the production of chromosomal rearrangements and other large-scale changes such as chromosomal deletions. It is thought that radiation may initiate cancer by inactivating tumor-suppressor genes. Activation of oncogenes appears to play a lesser role in radiation carcinogenesis.

Table 10-5

Group 1 chemical carcinogens and evidence for carcinogenicity in humans and for genotoxicity as the main mechanism

	TUMOR SITES OR TYPES WITH SUFFICIENT EVIDENCE IN HUMANS	EVIDENCE OF GENOTOXICITY AS THE MAIN MECHANISM
4-Aminobiphenyl	Urinary bladder	Strong
Benzidine	Urinary bladder	Strong
Dyes metabolized to benzidine	..	Strong*
4,4'-Methylenebis(2-chloroaniline)	..	Strong*
2-Naphthylamine	Urinary bladder	Strong
Ortho-toluidine	Urinary bladder	Moderate
Auramine production	Urinary bladder	Weak/lack of data†
Magenta production	Urinary bladder	Weak/lack of data†
Benzo[α]pyrene	..	Strong*
Soot (chimney sweeping)	Skin, lung	Moderate
Coal gasification	Lung	Strong
Coal-tar distillation	Skin	Strong
Coke production	Lung	Strong
Coal-tar pitches (paving, roofing)	Lung	Strong
Aluminum production	Lung, urinary bladder	Weak/moderate†‡
Aflatoxins	Hepatocellular carcinoma	Strong
Benzene	ANLL	Strong
Bis(chloromethyl)ether/ chloromethyl methylether	Lung	Moderate/strong
1,3-Butadiene	Haematolymphatic organs	Strong
Dioxin (2,3,7,8-TCDD)	All cancers combined**	See text§
2,3,4,7,8-Pentachlorodibenzofuran	..	See text*§
3,3',4,4',5-Pentachlorobiphenyl (PCB-126)	..	See text*§
Ethylene oxide	..	Strong*
Formaldehyde	Nasopharynx Leukemia**	Strong Moderate
Sulfur mustard	Lung	Strong
Vinyl chloride	Hepatic angiosarcoma, hepatocellular carcinoma	Strong
Iron and steel founding	Lung	Weak/moderate
Isopropyl alcohol manufacture using strong acids	Nasal cavity	Weak/lack of data
Mineral oils	Skin	Weak/lack of data
Occupational exposure as a painter	Lung, urinary bladder, pleural mesothelioma	Strong‡
Rubber-manufacturing industry	Leukaemia, lymphoma**, urinary bladder, lung**, stomach**	Strong‡
Shale oils	Skin	Weak/lack of data
Strong inorganic acid mists	Larynx	Weak/lack of data

ANLL, acute non-lymphocytic leukaemia; ALL, acute lymphocytic leukaemia; CLL, chronic lymphocytic leukaemia; MM, multiple myeloma; NHL, non-Hodgkin lymphoma; STS, soft-tissue sarcoma.

*Agents classified in Group 1 on the basis of mechanistic information.

†Weak evidence in workers, but strong evidence for some chemicals in this industry.

‡Due to the diversity and complexity of these exposures, other mechanisms may also be relevant.

§Strong evidence for an aryl hydrocarbon receptor (AhR)-mediated mechanism.

¶Particularly myeloid leukemia.

||After maternal exposure (before or during pregnancy, or both).

**New epidemiological findings.

Source: Adapted from Baan et al 2009. Copyright Elsevier.⁸⁶

Although it has been assumed that the initial genetic events induced by radiation constitute direct mutagenesis from radiation, other indirect effects may contribute to carcinogenesis. For example, radiation induces genomic instability in cells that persists for at least 30 generations after irradiation. Therefore, even if cells do not acquire mutations at initial irradiation, they remain at risk for developing new mutations for several generations. Moreover, even cells that have not been directly irradiated appear to be at risk, a phenomenon referred to as the *bystander effect*.

Nonionizing UV radiation is a potent DNA-damaging agent and is known to induce skin cancer in experimental animals. Most nonmelanoma human skin cancers are thought to be induced by repeated exposure to sunlight, which leads to a series of mutations that allow the cells to escape normal growth control. Patients with inherited xeroderma pigmentosum lack one or more DNA repair pathways, which confers susceptibility to UV-induced cancers, especially on sun-exposed body parts. Patients with ataxia telangiectasia mutated syndrome also have a radiation-sensitive phenotype.

Viral Carcinogens

One of the first observations that cancer may be caused by transmissible agents was by Peyton Rous in 1910 when he demonstrated that cell-free extracts from sarcomas in chickens could transmit sarcomas to other animals injected with these extracts.⁸⁹ This was subsequently discovered to represent viral transmission of cancer by the Rous sarcoma virus. At present, several human viruses are known to have oncogenic properties, and several have been causally linked to human cancers (Table 10-6).⁸⁵ It is estimated that 15% of all human tumors worldwide are caused by viruses.⁹⁰

Viruses may cause or increase the risk of malignancy through several mechanisms, including direct transformation, expression of oncogenes that interfere with cell-cycle checkpoints or DNA repair, expression of cytokines or other growth factors, and alteration of the immune system. Oncogenic viruses may be RNA or DNA viruses. Oncogenic RNA viruses are retroviruses and contain a reverse transcriptase. After the viral infection, the single-stranded RNA viral genome is transcribed into a double-stranded DNA copy, which is then integrated into the chromosomal DNA of the cell. Retroviral infection of the cell is permanent; thus, integrated DNA sequences remain in the host chromosome. Oncogenic transforming retroviruses carry oncogenes derived from cellular genes. These cellular genes, referred to as *proto-oncogenes*, usually are involved in mitogenic signaling and growth control, and include protein kinases, G proteins, growth factors, and transcription factors (Table 10-7).⁹⁰

Integration of the provirus upstream of a proto-oncogene may produce chimeric virus-cell transcripts and recombination during the next round of replication that could lead to incorporation of the cellular gene into the viral genome.⁹⁰ Then again, many retroviruses do not possess oncogenes but can cause tumors in animals regardless. This occurs by integration of the provirus near a normal cellular proto-oncogene and activation of the expression of these genes by the strong promoter and enhancer sequences in the integrated viral sequence.

Unlike the oncogenes of the RNA viruses, those of the DNA tumor viruses are viral, not cellular, in origin. These genes are required for viral replication using the host cell machinery. In permissive hosts, infection with an oncogenic DNA virus may result in a productive lytic infection, which leads to cell death and the release of newly formed viruses. In nonpermissive cells, the viral DNA can be integrated into the cellular chromosomal DNA, and some of the early viral genes can be synthesized persistently, which leads to transformation of cells to a neoplastic state. The binding of viral oncoproteins to cellular tumor-suppressor proteins p53 and Rb is fundamental to the carcinogenesis induced by most DNA viruses, although some target different cellular proteins.

Like other types of carcinogenesis, viral carcinogenesis is a multistep process. Some retroviruses contain two cellular oncogenes, rather than one, in their genome and are more rapidly tumorigenic than single-gene transforming retroviruses, which emphasizes the cooperation between transforming genes. Furthermore, some viruses encode genes that suppress or delay apoptosis.

Although immunocompromised individuals are at elevated risk, most patients infected with oncogenic viruses do not develop cancer. When cancer does develop, it usually occurs several years after the viral infection. It is estimated, for example, that the risk of hepatocellular carcinoma (HCC) among individuals infected with hepatitis C virus is 1% to 3% after 30 years.⁹¹ There may be synergy between various environmental factors and viruses in carcinogenesis.

Recognition of a viral origin for some tumors has led to the pursuit of vaccination as a preventive strategy. The use of childhood hepatitis B vaccination has already translated into a decrease in liver cancer incidence in the Far East.⁵ Similarly, it is recognized that cervical cancer and its obligate precursors, cervical intraepithelial neoplasia grades 2 and 3, and adenocarcinoma in situ, are caused by oncogenic human papillomavirus (HPV); administration of HPV vaccine to HPV-naïve women,

Table 10-6

Selected viral carcinogens^a

VIRUS	PREDOMINANT TUMOR TYPE ^b
Epstein-Barr virus	Burkitt's lymphoma
	Hodgkin's disease
	Immunosuppression-related lymphoma
	Sinonasal angiocentric T-cell lymphoma
	Nasopharyngeal carcinoma
Hepatitis B virus	Hepatocellular carcinoma
Hepatitis C virus	Hepatocellular carcinoma
HIV type 1	Kaposi's sarcoma
	Non-Hodgkin's lymphoma
Human papillomavirus 16 and 18	Cervical cancer
	Anal cancer
Human T-cell lymphotropic viruses	Adult T-cell leukemia/lymphoma

^aData based on information in the International Agency for Research on Cancer monographs.⁸⁵

^bOnly tumor types for which causal relationships are established are listed. Other cancer types may be linked to the agents with a lower frequency or with insufficient data to prove causality.

Table 10-7

Selected cellular oncogenes in retroviruses

ONCOGENE	VIRUS NAME	ORIGIN	PROTEIN PRODUCT
<i>abl</i>	Abelson murine leukemia virus	Mouse	Tyrosine kinase
<i>fes</i>	ST feline sarcoma virus	Cat	Tyrosine kinase
<i>fps</i>	Fujinami sarcoma virus	Chicken	Tyrosine kinase
<i>src</i>	Rous sarcoma virus	Chicken	Tyrosine kinase
<i>erbB</i>	Avian erythroblastosis virus	Chicken	Epidermal growth factor receptor
<i>fms</i>	McDonough feline sarcoma virus	Cat	Colony-stimulating factor receptor
<i>kit</i>	Hardy-Zuckerman 4 feline sarcoma virus	Cat	Stem cell factor receptor
<i>mil</i>	Avian myelocytoma virus	Chicken	Serine/threonine kinase
<i>mos</i>	Moloney murine sarcoma virus	Mouse	Serine/threonine kinase
<i>raf</i>	Murine sarcoma virus 3611	Mouse	Serine/threonine kinase
<i>sis</i>	Simian sarcoma virus	Monkey	Platelet-derived growth factor
<i>H-ras</i>	Harvey murine sarcoma virus	Rat	GDP/GTP binding
<i>K-ras</i>	Kirsten murine sarcoma virus	Rat	GDP/GTP binding
<i>erbA</i>	Avian erythroblastosis virus	Chicken	Transcription factor (thyroid hormone receptor)
<i>ets</i>	Avian myeloblastosis virus E26	Chicken	Transcription factor
<i>fos</i>	FBJ osteosarcoma virus	Mouse	Transcription factor (AP1 component)
<i>jun</i>	Avian sarcoma virus 17	Chicken	Transcription factor (AP1 component)
<i>myb</i>	Avian myeloblastosis virus	Chicken	Transcription factor
<i>myc</i>	MC29 myelocytoma virus	Chicken	Transcription factor (NF- κ B family)

AP1, activator protein 1; **FBJ**, Finkel-Biskis-Jinkins; **GDP**, guanosine diphosphate; **GTP**, guanosine triphosphate; **NF- κ B**, nuclear factor κ B.

Source: Modified from Butel JS. Viral carcinogenesis: revelation of molecular mechanisms and etiology of human disease. *Carcinogenesis*. 2000;21:405. By permission of Oxford University Press.

substantially reduces the incidence of HPV16/18-related cervical precancers and cervical cancer.⁹² The American Cancer Society now recommends routine HPV vaccination principally for females aged 11 to 12 years, but also for females aged 13 to 18 years to “catch up” those who missed the opportunity to be vaccinated or who need to complete the vaccination series.⁹³

CANCER RISK ASSESSMENT

Cancer risk assessment is an important part of the initial evaluation of any patient. A patient’s cancer risk not only is an important determinant of cancer screening recommendations but also may alter how aggressively an indeterminate finding will be pursued for diagnosis. A “probably benign” mammographic lesion, for example, defined as one with <2% probability of malignancy (American College of Radiology category III) is usually managed with a 6-month follow-up mammogram in a patient at baseline cancer risk, but obtaining a tissue diagnosis may be preferable in a patient at high risk for breast cancer.⁹⁴

Cancer risk assessment starts with taking a complete history that includes history of environmental exposures to potential carcinogens and a detailed family history. Risk assessment for breast cancer, for example, includes obtaining a family history to determine whether another member of the family is known to carry a breast cancer susceptibility gene; whether there is familial clustering of breast cancer, ovarian cancer, thyroid cancer, sarcoma, adrenocortical carcinoma, endometrial cancer,

brain tumors, dermatologic manifestations, leukemia, or lymphoma; and whether the patient is from a population at increased risk, such as individuals of Ashkenazi Jewish descent. Patients who have a family history suggestive of a cancer susceptibility syndrome such as hereditary breast-ovarian syndrome, LFS, or CD would benefit from genetic counseling and possibly genetic testing.

There are several models that can estimate risk based on complex family histories and assist clinicians in estimating breast cancer risk or the likelihood that a BRCA mutation is present, including the Claus model, Tyrer-Cuzick model, BRCAPRO model, and the Breast and Ovarian Analysis of Disease Incidence and Carrier Estimation Algorithm (BOADICEA) model.⁹⁵⁻⁹⁸ Patients who do have a strong hereditary component of risk can be evaluated on the basis of their age, race, personal history, and exposures. One of the most commonly used models for risk assessment in breast cancer is the Gail model.⁹⁹ Gail and colleagues analyzed the data from 2852 breast cancer cases and 3146 controls from the Breast Cancer Detection and Demonstration Project, a mammography screening project conducted in the 1970s, and developed a model for projecting breast cancer incidence. The model uses risk factors such as an individual’s age, age at menarche, age at first live birth, number of first-degree relatives with breast cancer, number of previous breast biopsy specimens, and whether the biopsy specimen results revealed atypical ductal hyperplasia (Table 10-8).⁹⁹ This model has led to the development of a

Table 10-8

Assessment of risk for invasive breast cancer

RISK FACTOR	RELATIVE RISK (%)
Age at menarche (years)	
>14	1.00
12–13	1.10
<12	1.21
Age at first live birth (years)	
Patients with no first-degree relatives with cancer	
<20	1.00
20–24	1.24
25–29 or nulliparous	1.55
≥30	1.93
Patients with one first degree-relative with cancer	
<20	1.00
20–24	2.64
25–29 or nulliparous	2.76
≥30	2.83
Patients with ≥2 first-degree relatives with cancer	
<20	6.80
20–24	5.78
25–29 or nulliparous	4.91
≥30	4.17
Breast biopsies (number)	
Patients aged <50 y at counseling	
0	1.00
1	1.70
≥2	2.88
Patients aged ≥50 y at counseling	
0	1.00
1	1.27
≥2	1.62
Atypical hyperplasia	
No biopsies	1.00
At least 1 biopsy, no atypical hyperplasia	0.93
No atypical hyperplasia, hyperplasia status unknown for at least 1 biopsy	1.00
Atypical hyperplasia in at least 1 biopsy	1.82

Source: Modified from Gail MH et al.⁹⁹

breast cancer risk assessment tool, which is available on the World Wide Web.¹⁰⁰ This tool incorporates the risk factors used in the Gail model, as well as race and ethnicity, and allows a health professional to project a woman's individualized estimated risk for invasive breast cancer over a 5-year period

and over her lifetime (to age 90 years). Notably, these risk projections assume that the woman is undergoing regular clinical breast examinations and screening mammograms. Also of note is that this program underestimates the risk for women who have already had a diagnosis of invasive or noninvasive breast cancer and does not take into account specific genetic predispositions such as mutations in *BRCA1* or *BRCA2*. However, risk assessment tools such as this have been validated and are now in widespread clinical use. Similar models are in development or are being validated for other cancers. For example, a lung cancer risk prediction model, which includes age, sex, asbestos exposure history, and smoking history, has been found to predict risk of lung cancer.¹⁰¹ There is now growing interest in using each individual's genotype, such as presence or absence of single nucleotide polymorphisms which each may confer low or intermediate cancer risk. Risk models that include biological as well as environmental factors may accurately predict cancer risk, providing better guidance as to which patients should undergo more intensive screening (e.g., screening with magnetic resonance imaging of the breast, computerized tomography screening of the lung), and should be considered for preventive strategies.

CANCER SCREENING

Early detection is the key to success in cancer therapy. Screening for common cancers using relatively noninvasive tests is expected to lead to early diagnosis, allow more conservative surgical therapies with decreased morbidity, and potentially improve surgical cure rates and overall survival rates. Key factors that influence screening guidelines are how prevalent the cancer is in the population, what risk is associated with the screening measure, and whether early diagnosis actually affects outcome. The value of a widespread screening measure is likely to go up with the prevalence of the cancer in a population, which often determines the age cutoffs for screening and explains why screening is done only for common cancers. The risks associated with the screening measure are a significant consideration, especially with more invasive screening measures such as colonoscopy. The consequences of a false-positive screening test result also need to be considered. For example, when 1000 screening mammograms are taken, only 2 to 4 new cases of cancer will be identified; this number is slightly higher (6 to 10 prevalent cancers per 1000 mammograms) for initial screening mammograms.¹⁰² However, as many as 10% of screening mammograms may be potentially suggestive of an abnormality, which requires further imaging (i.e., a 10% recall rate). Of those women with abnormal mammogram findings, only 5% to 10% will be determined to have a breast cancer. Among women for whom biopsy specimen is recommended, 25% to 40% will have a breast cancer. A false-positive screening result is likely to induce significant emotional distress in patients, leads to unnecessary biopsy specimens, and has cost implications for the health care system.

The 2013 American Cancer Society guidelines for the early detection of cancer are listed in Table 10-9.⁹³ These guidelines are updated periodically to incorporate emerging technologies and new data on the efficacy of screening measures. Besides the American Cancer Society, several other professional bodies make recommendations for screening. Although the screening guidelines differ somewhat, most organizations do not emphasize one screening strategy as superior to another, but all emphasize the importance of age-appropriate screening.

Table 10-9

American Cancer Society recommendations for early detection of cancer in average-risk, asymptomatic individuals

CANCER SITE	POPULATION	TEST OR PROCEDURE	FREQUENCY
Breast	Women, aged ≥ 20 y	BSE	It is acceptable for women to choose not to do BSE or to do BSE regularly (monthly) or irregularly. Beginning in their early 20s, women should be told about the benefits and limitations of BSE. Whether a woman ever performs BSE, the importance of prompt reporting of any new breast symptoms to a health professional should be emphasized. Women who choose to do BSE should receive instruction and have their technique reviewed on the occasion of a periodic health examination.
		CBE	For women in their 20s and 30s, it is recommended that CBE be part of a periodic health examination, preferably at least every 3 y. Asymptomatic women aged ≥ 40 y should continue to receive a CBE as part of a periodic health examination, preferably annually.
		Mammography	Begin annual mammography at age 40 y. ^a
Cervix	Woman, aged 21–65 y	Pap test and HPV DNA test	Cervical cancer screening should begin at age 21 y. For women aged 21–29 y, screening should be done every 3 y with conventional or liquid-based Pap tests. For women aged 30–65 y, screening should be done every 5 y with both the HPV test and the Pap test (preferred), or every 3 y with the Pap test alone (acceptable). Women aged >65 y who have had ≥ 3 consecutive negative Pap tests or ≥ 2 consecutive negative HPV and Pap tests within the last 10 y, with the most recent test occurring within the last 5 y, and women who have had a total hysterectomy should stop cervical cancer screening. Women at any age should not be screened annually by any screening method.
Colorectal	Men and women aged ≥ 50 y	FOBT with at least 50% test sensitivity for cancer, or FIT with at least 50% test sensitivity for cancer, or	Annual, starting at age 50 y. Testing at home with adherence to manufacturer's recommendation for collection techniques and number of samples is recommended. FOBT with the single stool sample collected on the clinician's fingertip during a DRE in the healthcare setting is not recommended. Guaiac-based toilet bowl FOBT tests also are not recommended. In comparison with guaiac-based tests for the detection of occult blood, immunochemical tests are more patient-friendly, and are likely to be equal or better insensitivity and specificity. There is no justification for repeating FOBT in response to an initial positive finding.
		Stool DNA test ^b , or	Interval uncertain, starting at age 50 y.
		FSIG, or	Every 5 y, starting at age 50 y. FSIG can be performed alone, or consideration can be given to combining FSIG performed every 5 y with a highly sensitive guaiac-based FOBT or FIT performed annually.
		DCBE, or	Every 5 y, starting at age 50 y.
		Colonoscopy	Every 10 y, starting at age 50 y.
		CT colonography	Every 5 yr, starting at age 50 y.
Endometrial	Women, at menopause		At the time of menopause, women at average risk should be informed about the risks and symptoms of endometrial cancer and strongly encouraged to report any unexpected bleeding or spotting to their physicians.

Table 10-9

American Cancer Society recommendations for early detection of cancer in average-risk, asymptomatic individuals (continued)

CANCER SITE	POPULATION	TEST OR PROCEDURE	FREQUENCY
Lung	Current or former smokers aged 50–74 in good health with at least a 30 pack-year history	LDCT	Clinicians with access to high-volume, high-quality lung cancer screening and treatment centers should initiate a discussion about lung cancer screening with apparently healthy patients aged 55–74 y who have at least a 30 pack-y smoking history, and who currently smoke or have quit within the past 15 y. A process of informed and shared decision-making with a clinician related to the potential benefits, limitations, and harms associated with screening for lung cancer with LDCT should occur before any decision is made to initiate lung cancer screening. Smoking cessation counseling remains a high priority for clinical attention in discussions with current smokers, who should be informed of their continuing risk of lung cancer. Screening should not be viewed as an alternative to smoking cessation.
Prostate	Men, aged ≥ 50 y	DRE and PSA	Men who have at least a 10-y life expectancy should have an opportunity to make an informed decision with their health care provider about whether to be screened for prostate cancer, after receiving information about the potential benefits, risks, and uncertainties associated with prostate cancer screening. Prostate cancer screening should not occur without an informed decision-making process.
Cancer-related checkup	Men and women aged ≥ 20 y		On the occasion of a periodic health examination, the cancer-related checkup should include examination for cancers of the thyroid, testicles, ovaries, lymph nodes, oral cavity, and skin, as well as health counseling about tobacco, sun exposure, diet and nutrition, risk factors, sexual practices, and environmental and occupational exposures.

ACS, American Cancer Society; **BSE**, breast self-examination; **CBE**, clinical breast examination; **Pap**, Papanicolaou; **HPV**, human papillomavirus; **FOBT**, fecal occult blood test; **FIT**, fecal immunochemical test; **DRE**, digital rectal examination; **FSIG**, flexible sigmoidoscopy; **DCBE**, double-contrast barium enema; **CT**, computed tomography; **LDCT**, low-dose helical CT; **PSA**, prostate-specific antigen.

^aBeginning at age 40 y, annual CBE should ideally be performed prior to mammography.

^bThe stool DNA test approved for colorectal cancer screening in 2008 is no longer commercially available. New stool DNA tests are presently undergoing evaluation and may become available at some future time.

Source: Modified with permission from John Wiley and Sons: Smith RA et al. Cancer screening in the United States, 2013: a review of current American Cancer Society guidelines, current issues in cancer screening, and new guidance on cervical cancer screening and lung cancer screening. *CA: a cancer journal for clinicians*. 2013;63:87. © 2013 American Cancer Society, Inc.

Screening guidelines are developed for the general baseline-risk population. These guidelines need to be modified for patients who are at high risk. For example, more intensive colorectal cancer screening is recommended for individuals at increased risk because of a history of adenomatous polyps, a personal history of colorectal cancer, a family history of either colorectal cancer or colorectal adenomas diagnosed in a first-degree relative before age 60 years, a personal history of inflammatory bowel disease of significant duration, or a family history or genetic test result indicating FAP or HNPCC. For some diseases, in higher risk populations, both the screening modality and the screening intensity may be altered. For example, breast magnetic resonance imaging is recommended as an adjunct to mammography for breast cancer screening in BRCA mutation carriers, first-degree relatives of carriers, and women with a lifetime breast cancer risk of 20% to 25% or higher.¹⁰³

More recently, the National Lung Screening Trial demonstrated a 20% reduction in lung cancer deaths in adults aged 55 to 74 years who were at high risk of lung cancer and randomized

to low-dose helical computed tomography (LDCT) screening compared with screening with annual CXR.¹⁰⁴ In 2013, the American Cancer Society updated their lung cancer screening recommendations to emphasize that clinicians with access to high-volume, high-quality lung cancer screening and treatment centers should ascertain the smoking history of their patients 55 to 74 years of age, and should discuss lung cancer screening with those who have at least a 30 pack-year smoking history, currently smoke, or have quit within the past 15 years, and who are in relatively good health.¹⁰⁵ It is recommended that this discussion include the benefits, uncertainties, and harms associated with screening for lung cancer with LDCT.

CANCER DIAGNOSIS

The definitive diagnosis of solid tumors is obtained by performing a biopsy specimen of the lesion. Biopsy findings determine the tumor histology and grade and thus, assist in definitive therapeutic planning. Biopsy specimens of mucosal lesions usually are

obtained endoscopically (e.g., via colonoscope, bronchoscope, or cystoscope). Lesions that are easily palpable, such as those of the skin, can either be excised or sampled by punch biopsy specimen. Deep-seated lesions can be localized with computed tomographic (CT) scan or ultrasound guidance for biopsy specimen.

A sample of a lesion can be obtained with a needle or with an open incisional or excisional biopsy specimen. Fine-needle aspiration is easy and relatively safe, but has the disadvantage of not giving information on tissue architecture. For example, fine-needle aspiration biopsy specimen of a breast mass can make the diagnosis of malignancy but cannot differentiate between an invasive and noninvasive tumor. Therefore core-needle biopsy specimen is more advantageous when the histologic findings will affect the recommended therapy. Core biopsy specimen, like fine-needle aspiration, is relatively safe and can be performed either by direct palpation (e.g., a breast mass or a soft tissue mass) or can be guided by an imaging study (e.g., stereotactic core biopsy specimen of the breast). Core biopsy specimens, like fine-needle aspirations, have the disadvantage of introducing sampling error. For example, 19% to 44% of patients with a diagnosis of atypical ductal hyperplasia based on core biopsy specimen findings of a mammographic abnormality are found to have carcinoma upon excision of the lesion.¹⁰⁶ It is crucial to ensure that the histologic findings are consistent with the clinical scenario and to know the appropriate interpretation of each histologic finding. A needle biopsy specimen for which the report is inconsistent with the clinical scenario should be either repeated or followed by an open biopsy specimen.

Open biopsy specimens have the advantage of providing more tissue for histologic evaluation and the disadvantage of being an operative procedure. Incisional biopsy specimens are reserved for very large lesions in which a definitive diagnosis cannot be made by needle biopsy specimen. Excisional biopsy specimens are performed for lesions for which either core biopsy specimen is not possible or the results are nondiagnostic. Excisional biopsy specimens should be performed with curative intent, that is, by obtaining adequate tissue around the lesion to ensure negative surgical margins. Marking of the orientation of the margins by sutures or clips by the surgeon and inking of the specimen margins by the pathologist will allow for determination of the surgical margins and will guide surgical re-excision if one or more of the margins are positive for microscopic tumor or are close. The biopsy specimen incision should be oriented to allow for excision of the biopsy specimen scar if repeat operation is necessary. Furthermore, the biopsy specimen incision should directly overlie the area to be removed rather than tunneling from another site, which runs the risk of contaminating a larger field. Finally, meticulous hemostasis during a biopsy specimen is essential, because a hematoma can lead to contamination of the tissue planes and can make subsequent follow-up with physical examinations much more challenging.

CANCER STAGING

Cancer staging is a system used to describe the anatomic extent of a malignant process in an individual patient. Staging systems may incorporate relevant clinical prognostic factors such as tumor size, location, extent, grade, and dissemination to regional lymph nodes or distant sites. Accurate staging is essential in designing an appropriate treatment regimen for an individual patient. Staging of the lymph node basin is considered a standard part of primary surgical therapy for most surgical procedures and

is discussed later in this chapter. Cancer patients who are considered to be at high risk for distant metastasis usually undergo a preoperative staging work-up. This involves a set of imaging studies of sites of preferential metastasis for a given cancer type. For a patient with breast cancer, for example, a staging work-up would include a chest radiograph, bone scan, and liver ultrasound, or CT scan of the abdomen to evaluate for lung, bone, and liver metastases, respectively. A distant staging work-up usually is performed only for patients likely to have metastasis based on the characteristics of the primary tumor; for example, a staging work-up for a patient with ductal carcinoma in situ of the breast or a small invasive breast tumor is likely to be low yield and not cost effective.

Recently there also is interest in using molecular imaging with positron emission tomography (PET) scanning, or PET/CT, for cancer staging. Most commonly PET scanning is performed with fluorine 18 incorporated into fluorodeoxyglucose (FDG). FDG PET assesses the rate of glycolysis. FDG uptake is increased in most malignant tissues but also in benign pathologic conditions such as inflammatory disorders, trauma, infection, and granulomatous disease. It may be especially useful in the staging and management of lymphoma, lung cancer, and colorectal cancer. The role of PET in evaluating many other cancers is evolving, and additional molecular tracers, such as 3'-deoxy-3'-¹⁸F-fluorothymidine, used to assess proliferation, are being actively pursued.

Standardization of staging systems is essential to allow comparison of results from different studies from different institutions and worldwide. The staging systems proposed by the American Joint Committee on Cancer (AJCC) and the Union Internationale Contre le Cancer (International Union Against Cancer, or UICC) are among the most widely accepted staging systems. Both the AJCC and the UICC have adopted a shared tumor, node, and metastasis (TNM) staging system that defines the cancer in terms of the anatomic extent of disease and is based on assessment of three components: the size of the primary tumor (T), the presence (or absence) and extent of nodal metastases (N), and the presence (or absence) and extent of distant metastases (M).

The TNM staging applies only to tumors that have been microscopically confirmed to be malignant. Standard TNM staging (clinical and pathologic) is completed at initial diagnosis. Clinical staging (cTNM or TNM) is based on information gained up until the initial definitive treatment. Pathologic staging (pTNM) includes clinical information and information obtained from pathologic examination of the resected primary tumor and regional lymph nodes. Other classifications, such as retreatment staging (rTNM) or autopsy staging (aTNM), should be clearly identified as such.

The clinical measurement of tumor size (T) is the one judged to be the most accurate for each individual case based on physical examination and imaging studies. For example, in breast cancer the size of the tumor could be obtained from a physical examination, mammogram, or ultrasound, and the tumor size is based only on the invasive component.

If even one lymph node is involved by tumor, the N component is at least N1. For many solid tumor types, simply the absence or presence of lymph node involvement is recorded, and the tumor is categorized either as N0 or N1. For other tumor types, the number of lymph nodes involved, the size of the lymph nodes or the lymph node metastasis, or the regional lymph node basin involved also has been shown to have prognostic value.

In these cancers, the designations N1, N2, and N3 suggest an increasing abnormality of lymph nodes based on size, characteristics, and location. NX indicates that the lymph nodes cannot be fully assessed.

Cases in which there is no distant metastasis are designated M0, cases in which one or more distant metastases are detected are designated M1, and cases in which the presence of distant metastasis cannot be assessed are designated MX. In clinical practice, negative findings on clinical history and examination are sufficient to designate a case as M0. However, in clinical trials, routine follow-up often are performed to standardize the detection of distant metastases.

The practice of dividing cancer cases into groups according to stage is based on the observation that the survival rates are higher for localized (lower-stage) tumors than for tumors that have extended beyond the organ of origin. Therefore, staging assists in selection of therapy, estimation of prognosis, evaluation of treatments, and exchange of information among treatment centers. Notably, the AJCC regularly updates its staging system to incorporate advances in prognostic technology to improve the predictive accuracy of the TNM system. Therefore it is important to know which revision of a staging system is being used when evaluating studies.

TUMOR MARKERS

Prognostic and Predictive Tissue Markers

Tumor markers are substances that can be detected in higher than normal amounts in the serum, urine, or tissues of patients with certain types of cancer. Tumor markers are produced either by the cancer cells themselves or by the body in a response to the cancer.

Over the past decade, there has been an especially high interest in identifying tissue tumor markers that can be used as prognostic or predictive markers. Although the terms *prognostic marker* and *predictive marker* are sometimes used interchangeably, the term *prognostic marker* generally is used to describe molecular markers that predict disease-free survival, disease-specific survival, and overall survival, whereas the term *predictive marker* often is used in the context of predicting response to certain therapies.

The goal is to identify prognostic markers that can give information on prognosis independent of other clinical characteristics and therefore can provide information to supplement the projections based on clinical presentation. This would allow practitioners to further classify patients as being at higher or lower risk within clinical subgroups and to identify patients who may benefit most from adjuvant therapy. For example, ideal prognostic tumor markers would be able to help determine which patients with node-negative breast cancer are at higher risk of relapse so that adjuvant systemic therapy could be given only to that group. However, although a large number of studies have identified potential novel prognostic markers, most have not been tested with enough vigor to be shown to be of clinical utility. In the 2007 American Society of Clinical Oncology (ASCO) guidelines, it was decided that level of uPA/PAI-1 measured by enzyme-linked immunosorbent assay could be used to determine prognosis in cases of newly diagnosed node-negative breast cancer.¹⁰⁷ In contrast, the data for many other markers, including DNA content, proportion of tumor cells in S phase, Ki-67, cyclin E, p27, p21, thymidine kinase, topoisomerase II, HER2, p53, and cathepsin D, were felt to be insufficient to support their use in the management of breast cancer patients.¹⁰⁷ Similarly, in the 2006 ASCO GI tumor guidelines,

the data were felt to be insufficient to recommend the routine use of p53, *ras*, thymidine synthase, dihydropyrimidine dehydrogenase, thymidine phosphorylase, microsatellite instability, 18q loss of heterozygosity, or deleted-in-colon-cancer protein in the management of patients with colorectal cancer.¹⁰⁸

Predictive markers are markers that can prospectively identify patients who will benefit from a certain therapy. For example in breast cancer, estrogen receptor (ER) and *HER2* assessment can identify patients who can benefit from antiestrogen therapies (e.g., tamoxifen) and anti-*HER2* targeted therapies (e.g., trastuzumab), respectively, and the 2007 ASCO guidelines recommend that these markers be routinely assessed.¹⁰⁷ High-throughput techniques such as transcriptional profiling allow for assessment of the relative mRNA levels of thousands of genes simultaneously in a given tumor using microarray technology. With the advent of such molecular profiling technologies, researchers have focused on identifying expression profiles that are prognostic for different cancer types. For breast cancer, although many such multiparameter tests are under development, few have reached the large-scale validation stage.¹⁰⁹ In 2007, ASCO guidelines suggested that one of these, the *Oncotype DX* assay, can be used to predict recurrence in women with node-negative, ER-positive breast cancer who are treated with tamoxifen.¹⁰⁷ *Oncotype DX* is a quantitative reverse-transcriptase polymerase chain reaction (RT-PCR) test that used paraffin-fixed tissue. A 21-gene recurrence score (RS) is generated based on the expression of 16 cancer genes and 5 reference genes. The levels of expression are used to derive an RS that ranges from 0 to 100, using a prospectively defined mathematical algorithm. This novel quantitative approach to the evaluation of the best-known molecular pathways in breast cancer has produced impressive results. Use of this multigene assay to predict recurrence was validated in the National Surgical Adjuvant Breast and Bowel Project (NSABP) B-14 trial, in which ER-positive, node-negative patients had received tamoxifen.¹¹⁰ By multivariate Cox proportional analysis, RS was found to be independently associated with recurrence risk, with a hazard ratio of 3.21 (95% confidence interval of 2.23 to 4.65, $P < .001$). The RS was indeed able to stratify patients by freedom from distant recurrence (Fig. 10-13).¹¹⁰ The Trial Assessing Individualized

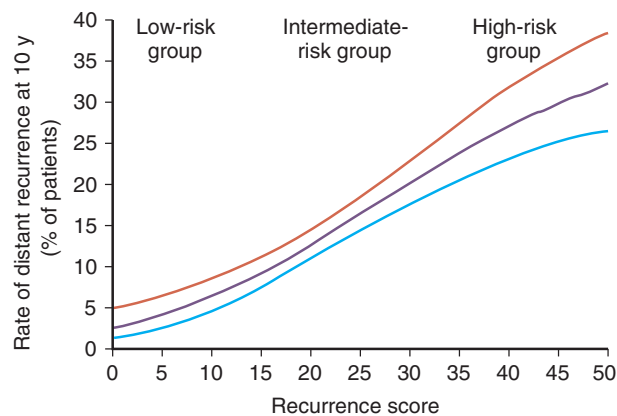


Figure 10-13. Distant recurrence as a continuous function of the recurrence score derived from tumor levels of expression of 21 genes. (From Paik S, et al: A multigene assay to predict recurrence of tamoxifen-treated, node-negative breast cancer. *N Engl J Med.* 2004;351:281. Copyright © 2004 Massachusetts Medical Society. Reprinted with permission from Massachusetts Medical Society.)¹¹⁰

Options for Treatment for breast cancer (TAILORx) is evaluating the utility of *Oncotype DX* for predicting prognosis in patients with ER-positive, node-negative tumors and will focus on women with intermediate RS scores in whom the role of chemotherapy is unclear. Several other multigene predictors for breast cancer are available including MammaPrint, a gene expression profiling platform assessing a 70-gene transcriptional signature.¹¹¹ This assay was approved by the Food and Drug Administration (FDA) in February 2007. The usefulness of this assay in making therapy-related decisions is being tested prospectively in a large-scale study, the Microarray in Node-Negative Disease May Avoid Chemotherapy (MINDACT) trial.

Multigene profiles to predict prognosis are in development or in validation phases for many other solid tumor types, including lung cancer, ovarian cancer, pancreatic cancer, colorectal cancer, and melanoma. Gene signatures and genomic alterations also are being studied for their ability to predict response to specific chemotherapy regimens or targeted therapies. Many of these multigene marker sets will likely be incorporated into clinical practice in the years to come.

Serum Markers

Serum markers are under active investigation because they may allow early diagnosis of a new cancer or may be used to follow cancer response to therapy or monitor for recurrence. Unfortunately, identification of serum markers of clinical value has been challenging. Many of the tumor markers proposed so far have had low sensitivities and specificities.¹⁰⁹ Tumor marker levels may not be elevated in all patients with cancer, especially in the early stages, when a serum marker would be most useful for diagnosis. Therefore when a tumor marker is used to monitor recurrence, it is important to be certain that the level of the tumor marker was elevated before primary therapy. Moreover, tumor marker levels can be elevated in benign conditions. Many tumor markers are not specific for a certain type of cancer and can be elevated with more than one type of tumor. Since there may be significant laboratory variability, it is important to obtain serial results from the same laboratory. In spite of these many clinical limitations, several serum markers are in clinical use. A few of the commonly measured serum tumor markers are discussed in the following sections.

Prostate-Specific Antigen. Prostate-specific antigen (PSA) is an androgen-regulated serine protease produced by the prostate epithelium. PSA is normally present in low concentrations in the blood of all adult males. PSA levels may be elevated in the blood of men with benign prostate conditions such as prostatitis and benign prostatic hyperplasia, as well as in men with prostate cancer. PSA levels have been shown to be useful in evaluating the effectiveness of prostate cancer treatment and monitoring for recurrence after therapy. In monitoring for recurrence, a trend of increasing levels is considered more significant than a single absolute elevated value.

Although PSA has been widely used for prostate cancer screening, the utility of PSA screening remains controversial. There is concern that the number of men who avoid dying from prostate cancer due to screening is small, while the harms related to the treatment of screen-detected cancers, including incontinence and erectile dysfunction are at least moderate. In 2012, the US Preventive Services Task Force concluded with moderate certainty that the harms of PSA testing outweigh the benefits and on that basis recommended against PSA-based screening

for all men.¹¹² In 2010, the American Cancer Society updated its guidelines for the early detection of prostate cancer to state that men who have at least a 10-year life expectancy should have an opportunity to make an informed decision with their health care provider about whether to be screened for prostate cancer with digital rectal exam and serum PSA, after receiving information about the benefits, risks, and uncertainties associated with prostate cancer screening;¹¹³ this recommendation was reinforced in their 2013 guidelines.⁹³

Carcinoembryonic Antigen. Carcinoembryonic antigen (CEA) is a glycoprotein found in the embryonic endodermal epithelium. Elevated CEA levels have been detected in patients with primary colorectal cancer as well as in patients with breast, lung, ovarian, prostate, liver, and pancreatic cancer. Levels of CEA also may be elevated in benign conditions, including diverticulitis, peptic ulcer disease, bronchitis, liver abscess, and alcoholic cirrhosis, especially in smokers and in elderly persons.

CEA measurement is most commonly used in the management of colorectal cancer. However, the appropriate use of CEA testing in patients with colorectal cancer has been debated. Use of CEA level as a screening test for colorectal cancer is not recommended. CEA levels may be useful if obtained preoperatively and postoperatively in patients with a diagnosis of colorectal cancer. Preoperative elevation of CEA level is an indicator of poor prognosis. However, the 2007 ASCO clinical practice guidelines state that the data are insufficient to support the use of CEA to determine whether to give a patient adjuvant therapy; the data are stronger for the use of CEA for monitoring for postoperative recurrence.¹⁰⁷ CEA measurement is the most cost-effective approach for detecting metastasis, with 64% of recurrences being detected first by an elevation in CEA level. Therefore, in cases in which the patient would be a candidate for resection of recurrent colorectal cancer or systemic therapy, the 2006 ASCO guidelines recommend that postoperative CEA testing be performed every 3 months in patients with stage II or III disease for at least 3 years.¹⁰⁸ CEA is the marker of choice for monitoring metastatic colorectal cancer during systemic therapy.¹⁰⁸

There is also interest in using CEA levels for monitoring patients with breast cancer. However, the 2007 ASCO guidelines state that the routine use of CEA for screening, diagnosis, staging, or surveillance of breast cancer is not recommended because available data are insufficient.¹⁰⁷ For monitoring patients during active therapy, CEA can be used in conjunction with diagnostic imaging and history and physical examination.¹⁰⁷ In the absence of measurable disease, an increase in CEA level may be taken to indicate treatment failure. However, caution is advised when interpreting rising levels in the first 4 to 6 weeks of therapy.¹⁰⁷

Alpha-Fetoprotein. Alpha-fetoprotein (AFP) is a glycoprotein normally produced by a developing fetus. AFP levels decrease soon after birth in healthy adults. An elevated level of AFP suggests the presence of either primary liver cancer or a germ cell tumor of the ovary or testicle. Rarely, other types of cancer such as gastric are associated with an elevated AFP level. Benign conditions that can cause elevations of AFP include cirrhosis, hepatic necrosis, acute hepatitis, chronic active hepatitis, ataxia-telangiectasia, Wiskott-Aldrich syndrome, and pregnancy.¹¹⁴

The sensitivity of an elevated AFP level for detecting HCC is approximately 60%. AFP is considered to be sensitive

and specific enough to be used for screening for HCC in high-risk populations. Current consensus recommendations are to screen healthy hepatitis B virus carriers with annual or semi-annual measurement of AFP level and to screen carriers with cirrhosis or chronic hepatitis and patients with cirrhosis of any etiology with twice-yearly measurement of AFP level and liver ultrasonography.¹¹⁵ Although AFP testing has been used widely for a long time, its efficacy in early diagnosis of HCC is limited. With improvements in imaging technology, a larger proportion of patients diagnosed with HCC are now AFP seronegative.

Cancer Antigen 19-9. Cancer antigen 19-9 (CA 19-9) is a tumor-related antigen that was originally defined by a monoclonal antibody produced by a hybridoma prepared from murine spleen cells immunized with a human colorectal cancer cell line.¹⁰⁸ The data are insufficient to recommend use of CA 19-9 for screening, diagnosis, surveillance, or monitoring of therapy for colon cancer.¹⁰⁸ Based on the 2006 ASCO guidelines, there are also insufficient data to recommend use of CA 19-9 for screening, diagnosis, or determination of the operability of pancreatic cancer.¹⁰⁸ However, for patients with locally advanced or metastatic cancer receiving active therapy, CA 19-9 can be measured at the start of therapy and every 1 to 3 months while therapy is given; elevations in serial CA 19-9 levels may indicate progressive disease and should be confirmed by additional studies.¹⁰⁸

Cancer Antigen 15-3. Cancer antigen 15-3 (CA 15-3) is an epitope of a large membrane glycoprotein encoded by the *MUC1* gene that tumor cells shed into the bloodstream. The CA 15-3 epitope is recognized by two monoclonal antibodies in a sandwich radioimmunoassay. CA 15-3 levels are most useful in following the course of treatment in women diagnosed with advanced breast cancer. CA 15-3 levels are infrequently elevated in early-stage breast cancer. CA 15-3 levels can be increased in benign conditions such as chronic hepatitis, tuberculosis, sarcoidosis, pelvic inflammatory disease, endometriosis, systemic lupus erythematosus, pregnancy, and lactation, and in other types of cancer such as lung, ovarian, endometrial, and GI cancers.

The sensitivity of CA 15-3 is higher for metastatic disease, and in these cases studies have shown sensitivity to be between 54% and 87%, with specificity as high as 96%. This has led to interest in using CA 15-3 for monitoring patients with advanced breast cancer for recurrence. Elevated CA 15-3 levels have been reported before relapse in 54% of patients, with a lead time of 4.2 months. Therefore, detection of elevated CA 15-3 levels during follow-up should prompt evaluation for recurrent disease. However, 6% to 8% of patients without recurrence will have elevated CA 15-3 levels that require evaluation. Furthermore, monitoring with the use of CA 15-3 levels has shown no demonstrated impact on survival. Therefore, the 2007 ASCO guidelines state that the routine use of CA 15-3 for screening, diagnosis, staging, or surveillance of breast cancer is not recommended because available data are insufficient.¹⁰⁷ For monitoring patients during active therapy, CA 15-3 can be used in conjunction with diagnostic imaging and history and physical examination.¹⁰⁷ In the absence of measurable disease, an increase may be interpreted to indicate treatment failure. However, caution is advised when interpreting rising levels in the first 4 to 6 weeks of therapy.¹⁰⁷

Cancer Antigen 27-29. The MUC-1 gene product in the serum may be quantitated by using radioimmunoassay with a monoclonal antibody against the cancer antigen 27-29 (CA 27-29). CA 27-29 levels can be elevated in breast cancer as well

as in cancers of the colon, stomach, kidney, lung, ovary, pancreas, uterus, and liver. First-trimester pregnancy, endometriosis, benign breast disease, kidney disease, and liver disease also may be associated with elevated CA 27-29 levels.

CA 27-29 has been reported to have a sensitivity of 57%, a specificity of 98%, a positive predictive value of 83%, and a negative predictive value of 93% in detecting breast cancer recurrences.¹¹⁶ Although CA 27-29 has been found to predict recurrence an average of 5.3 months before other symptoms or tests, testing of CA 27-29 levels has not been demonstrated to affect disease-free and overall survival rates.^{116, 117} Therefore, the 2007 ASCO guidelines state that, as with CA 15-3, the routine use of CA 27-29 for screening, diagnosis, staging, or surveillance of breast cancer is not recommended because available data are insufficient.¹⁰⁷ CA 27-29 levels can be used together with diagnostic imaging and history and physical examination to monitor patients during active therapy.¹⁰⁷ When no measurable disease is present, an increase in level may be considered to indicate treatment failure. However, rising levels in the first 4 to 6 weeks of therapy should be interpreted with caution.¹⁰⁷

Circulating Tumor Cells

Circulating tumor cells (CTCs) are cells present in the blood that possess antigenic or genetic characteristics of a specific tumor type.¹⁰⁷ One CTC detection methodology is capture and quantitation of CTCs with immunomagnetic beads coated with antibody specific for cell-surface, epithelial, or cancer antigens. Another methodology used to detect cancer cells in the peripheral blood is RT-PCR. It has been suggested that measurement of CTCs can be an effective tool for selecting patients who have a high risk of relapse and for monitoring efficacy of cancer therapy.

CTCs have probably been most extensively studied in breast cancer.¹⁰⁷ The most promising data come from the use of CTC measures in metastatic breast cancer. In a prospective multicenter trial, the number of CTCs (≥ 5 CTCs vs. < 5 CTCs per 7.5 mL of whole blood) before treatment of metastatic breast cancer was an independent predictor of progression-free and overall survival rates.¹¹⁸ The presence of > 5 CTCs after the first course of therapy predicted lack of response to treatment. This technology, known as *CellSearch*, has been approved by the FDA for clinical use. Further, in a recent single institutional study, detection of one or more CTCs in Stage I-III breast cancer patients was associated with both decreased progression-free survival and overall survival.¹¹⁹

However, there is limited data to prove that the use of CTC testing leads to improved survival or improved quality of life; thus the ASCO 2007 guidelines update did not recommend the use of CTC measurement in any clinical setting.¹⁰⁷ The clinical utility of measuring CTC response to initial therapy is now being tested prospectively in a multicenter clinical trial. The use of CTC levels as a tool in treating many other types of tumor is also under active investigation.

The prognostic implications of detection of CTCs by RT-PCR have been intensively studied for melanoma. In the recent multicenter Sunbelt Melanoma Trial, serial RT-PCR was performed on peripheral blood samples using four markers—tyrosinase, melanoma antigen reacting to T cell (MART-1), melanoma antigen 3 (MAGE3), and gp 100—to detect occult melanoma cells in the bloodstream.¹²⁰ Although there were no differences in survival between patients in whom at least one marker was detected and those in whom no markers were

detected, the disease-free survival and distant disease-free survival were worse for patients in whom more than one marker was detected at any time during follow-up.¹²⁰ The detection of occult cancer cells with RT-PCR remains investigational, however, and is not used to direct therapy for melanoma and other cancer types at this time.

Bone Marrow Micrometastases

Micrometastatic disease in the bone marrow, also referred to as *minimal residual disease*, also is being investigated as a potential prognostic marker. Bone marrow micrometastatic disease usually is detected by staining bone marrow aspirates with monoclonal antibodies to cytokeratin, but other methodologies such as flow cytometry and RT-PCR are being explored. Breast cancer patients with bone marrow micrometastasis have larger tumors, tumors with a higher histologic grade, more lymph node metastases, and more hormone receptor-negative tumors than patients without bone marrow micrometastasis. In 4700 patients with stage I, II, or III breast cancer, micrometastasis was a significant prognostic factor associated with poor overall survival, breast cancer-specific survival, disease-free survival, and distant disease-free survival during a 10-year observation period.¹²¹ Recently, in the American College of Surgeons Oncology Group Z0010 trial enrolled women with clinical T1 to T2N0M0 invasive breast carcinoma in a prospective observational study to determine the association between survival and metastases detected by immunochemical staining of bone marrow specimens from patients with early-stage breast cancer.¹²² Of 3413 bone marrow specimens examined by immunocytochemistry, only 104 (3.0%) were positive for tumor. Bone marrow involvement was associated with a decreased overall survival but this association was not significant on multivariable analysis. The prognostic implication of bone marrow involvement is also being studied by the National Surgical Adjuvant Breast and Bowel Project Protocol BP-59.

At this time the routine use of bone marrow testing is not recommended.¹⁰⁷ Ongoing clinical trials are evaluating the role of routine assessment of bone marrow status in the care of patients with early and advanced breast cancer. The utility of assessment of bone marrow micrometastasis is also being evaluated in other tumor types, including gastric, esophageal, colorectal, lung, cervical, and ovarian cancer.¹²³

SURGICAL APPROACHES TO CANCER THERAPY

Multidisciplinary Approach to Cancer

Although surgery is an effective therapy for most solid tumors, patients who die from cancer usually die of metastatic disease. Therefore, to improve patient survival rates, a multimodality approach, including systemic therapy and radiation therapy is key for most tumors. It is important that surgeons involved in cancer care not only know the techniques for performing a cancer operation but also know the alternatives to surgery and be well versed in reconstructive options. It is also crucial that the surgeon be familiar with the indications for and complications of preoperative and postoperative chemotherapy and radiation therapy. Although the surgeon may not be delivering these other therapies, as the first physician to see a patient with a cancer diagnosis, he or she is ultimately responsible for initiating the appropriate consultations. For this reason, the surgeon often is responsible for determining the most appropriate adjuvant

therapy for a given patient as well as the best sequence for therapy. In most instances, a multidisciplinary approach beginning at the patient's initial presentation is likely to yield the best result.

Surgical Management of Primary Tumors

The goal of surgical therapy for cancer is to achieve oncologic cure. A curative operation presupposes that the tumor is confined to the organ of origin or to the organ and the regional lymph node basin. Patients in whom the primary tumor is not resectable with negative surgical margins are considered to have inoperable disease. The operability of primary tumors is best determined before surgery with appropriate imaging studies that can define the extent of local-regional disease. For example, a preoperative thin-section CT scan is obtained to determine resectability of pancreatic cancer, which is based on the absence of extrapancreatic disease, the absence of tumor extension to the superior mesenteric artery and celiac axis, and a patent superior mesenteric vein-portal vein confluence.¹²⁴ Disease involving multiple distant metastases is deemed inoperable because it is usually not curable with surgery of the primary tumor. Therefore patients who are at high risk of having distant metastasis should undergo a staging work-up before surgery for the primary tumor. On occasion, primary tumors are resected in these patients for palliative reasons, such as improving the quality of life by alleviating pain, infection, or bleeding. An example of this is toilet mastectomies for large ulcerated breast tumors. Patients with limited metastases from a primary tumor on occasion are considered surgical candidates if the natural history of isolated distant metastases for that cancer type is favorable or the potential complications associated with leaving the primary tumor intact are significant.

In the past it was presumed that the more radical the surgery, the better the oncologic outcome would be. Over the past three decades, this has been recognized as not necessarily being true, which has led to more conservative operations, with wide local excisions replacing compartmental resections of sarcomas, and partial mastectomies, skin-sparing mastectomies, and breast-conserving therapies replacing radical mastectomies for breast cancer. The uniform goal for all successful oncologic operations seems to be achieving widely negative margins with no evidence of macroscopic or microscopic tumor at the surgical margins. The importance of negative surgical margins for local tumor control and/or survival has been documented for many tumor types, including sarcoma, breast cancer, pancreatic cancer, and rectal cancer. Thus it is clear that every effort should be made to achieve microscopically negative surgical margins. Inking of the margins, orientation of the specimen by the surgeon, and immediate gross evaluation of the margins by a pathologist using frozen-section analysis when necessary may assist in achieving negative margins at the first operation. In the end, although radiation therapy and systemic therapy can assist in decreasing local recurrence rates in the setting of positive margins, adjuvant therapy cannot substitute for adequate surgery.

Although it is clear that the surgical gold standard is negative surgical margins, the appropriate surgical margins for optimal local control are controversial for many cancer types. In contrast, in melanoma the optimal margin width for any tumor depth has been better defined, owing to the systematic study of this question in randomized clinical trials.^{125, 126} Although such randomized studies may not be possible for all tumor types, it

is important to determine optimum surgical margins for each cancer type so that adjuvant radiation and systemic therapy can be offered to patients deemed to be at increased risk for local treatment failure. There are also ongoing studies on approaches to assess margins intraoperatively, to allow immediate intraoperative reexcisions as needed, and maximizing local control.

Surgical Management of the Regional Lymph Node Basin

Most neoplasms have the ability to metastasize via the lymphatics. Therefore, most oncologic operations have been designed to remove the primary tumor and draining lymphatics en bloc. This type of operative approach usually is undertaken when the lymph nodes draining the primary tumor site lie adjacent to the tumor bed, as is the case for colorectal cancers and gastric cancers. For tumors in which the regional lymph node basin is not immediately adjacent to the tumor (e.g., melanomas), lymph node surgery can be performed through a separate incision. Unlike most carcinomas, soft tissue sarcomas rarely metastasize to the lymph nodes (<5%); therefore lymph node surgery usually is not necessary.

It is generally accepted that a formal lymphadenectomy is likely to minimize the risk of regional recurrence of most cancers. For example, the introduction of total mesorectal excision of rectal cancer has been associated with a large decline in local-regional recurrence, and this procedure has become the new standard of operative management.¹²⁷ On the other hand, there have been two opposing views regarding the role of lymphadenectomy in survival of cancer patients. The traditional Halsted view states that lymphadenectomy is important for staging and survival. The opposing view counters that cancer is systemic at inception and that lymphadenectomy, although useful for staging, does not affect survival. For most cancers, involvement of the lymph nodes is one of the most significant prognostic factors. Interestingly, in some studies removal of a larger number of lymph nodes has been found to be associated with an improved overall survival rate for many tumors, including breast cancer, colon cancer, and lung cancer. Although this seems to support the Halsted theory that more extensive lymphadenectomy yielding of nodes reduces the risk of regional recurrence, there may be alternative explanations for the same finding. For example, the surgeon who performs a more extensive lymphadenectomy may obtain wider margins around the tumor or even provide

better overall care, such as ensuring that patients receive the appropriate adjuvant therapy or undergo a more thorough staging work-up. Alternatively, the pathologist may perform a more thorough examination, identifying more nodes and more accurately staging the nodes. The effect of appropriate staging on survival is twofold. Patients with nodal metastases may be offered adjuvant therapy, which improves their survival chances. Further, the improved staging can improve perceived survival rates through a “Will Rogers effect”; that is, identification of metastases that had formerly been silent and unidentified leads to stage migration and thus to a perceived improvement in chances of survival. Clearly the impact of lymphadenectomy on survival will not be easily resolved.

Surgical management of the clinically negative regional lymph node basin has evolved with the introduction of lymphatic mapping technology (Fig. 10-14).¹²⁸ Lymphatic mapping and sentinel lymph node biopsy specimen were first reported in 1977 by Cabanas for penile cancer.¹²⁹ Now, sentinel node biopsy specimen is the standard of care for the management of melanoma and breast cancer. Moreover, the utility of sentinel node biopsy specimen in other cancer types is being explored.

The first node to receive drainage from the tumor site is termed the sentinel node. This node is the node most likely to contain metastases, if metastases to that regional lymph node basin are present. The goal of lymphatic mapping and sentinel lymph node biopsy specimen is to identify and remove the lymph node most likely to contain metastases in the least invasive fashion. The practice of sentinel lymph node biopsy specimen followed by regional lymph node dissection for selected patients with a positive sentinel lymph node avoids the morbidity of lymph node dissections in patients with negative nodes. An additional advantage of the sentinel lymph node technique is that it directs attention to a single node, which allows more careful analysis of the lymph node most likely to have a positive yield and increases the accuracy of nodal staging. Two criteria are used to assess the efficacy of a sentinel lymph node biopsy specimen: the sentinel lymph node identification rate and the false-negative rate. The sentinel lymph node identification rate is the proportion of patients in whom a sentinel lymph node was identified and removed among all patients undergoing an attempted sentinel lymph node biopsy specimen. The false-negative rate is the proportion of patients with regional lymph node metastases in whom the sentinel lymph node was found

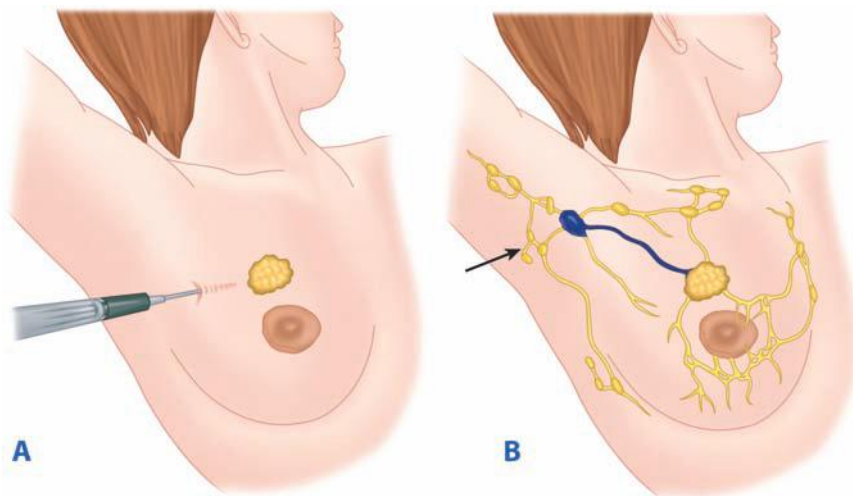


Figure 10-14. Lymphatic mapping and sentinel lymph node biopsy specimen for breast cancer. **A.** Peritumoral injection of blue dye. **B.** Blue dye draining into the sentinel lymph node. (Modified with permission from Meric F, Hunt KK. With kind permission from Springer Science and Business Media.)¹²⁸

to be negative. False-negative biopsy specimen results may be due to identifying the wrong node or to missing the sentinel node (i.e., surgical error) or they may be due to the cancer cells' establishing metastases not in the first node encountered but in a second-echelon node (i.e., biologic variation). Alternatively, false-negative biopsy specimen results may be due to inadequate histologic evaluation of the lymph node. The false-negative rates for sentinel lymph node biopsy specimen in study series range between 0% and 11%. Both increases in the identification rate and decreases in the false-negative rate have been observed as surgeons gain experience with the technique.

Lymphatic mapping is performed by using isosulfan blue dye, technetium-labeled sulfur colloid or albumin, or a combination of both techniques to detect sentinel nodes. The combination of blue dye and technetium has been reported to improve the capability of detecting sentinel lymph nodes. The nodal drainage pattern usually is determined with a preoperative lymphoscintigram, and the "hot" and/or blue nodes are identified with the assistance of a gamma probe and careful nodal basin exploration. Careful manual palpation is a crucial part of the procedure to minimize the false-negative rate.

The nodes are evaluated with serial sectioning, hematoxylin and eosin staining, and immunohistochemical analysis with S-100 protein and homatropine methylbromide staining for melanoma and cytokeratin staining for breast cancer. The utility of molecular techniques such as RT-PCR to assess the sentinel nodes is still being explored.

The nodes are evaluated with serial sectioning, hematoxylin and eosin staining, and immunohistochemical analysis with S-100 protein and homatropine methylbromide staining for melanoma and cytokeratin staining for breast cancer. The utility of molecular techniques such as RT-PCR to assess the sentinel nodes is still being explored.

Another area of active investigation is the prognostic value of minimal nodal involvement. For example, in breast cancer, nodes with isolated tumor cell deposits of <0.2 mm (also called *nanometastasis*) are considered to be N0 by the sixth edition of the AJCC staging manual. However, some retrospective studies have suggested that even this amount of nodal disease burden has negative prognostic implications.¹³⁰ Molecular ultrastaging with RT-PCR for patients with node-negative disease was assessed in a prospective multicenter trial and was found not to be prognostic in malignant melanoma.¹²⁰ However, a recent meta-analysis of 22 studies enrolling 4019 patients found that PCR positivity was associated with worse overall and disease-free survival.¹³¹ Further study of the utility of ultrastaging of nodes in breast cancer, melanoma, and several other tumor types is ongoing.

Until recently, in breast cancer management, when sentinel node mapping revealed a positive sentinel node, this was followed by a completion axillary lymph node dissection. Recently results of the American College of Surgeons Oncology Group Z0011 trial, challenged this practice. ACOSOG Z11 was a phase 3 multicenter noninferiority trial conducted to determine the effects of complete axillary lymph node dissection on survival of patients with sentinel lymph node metastasis of breast cancer.¹²² Patients were women with clinical T1-T2 invasive breast cancer, no palpable adenopathy, and 1 to 2 SLNs containing metastases identified by frozen section, touch preparation, or hematoxylin-eosin staining on permanent section. All patients underwent breast-conserving surgery and tangential whole-breast irradiation. Those with sentinel node metastases identified by sentinel node biopsy specimen were randomized to undergo axillary lymph node dissection or no further axillary treatment. At a median follow-up of 6.3 years, 5-year overall survival was 91.8% (95% confidence interval [CI], 89.1%–94.5%) with axillary lymph node dissection and 92.5% (95% CI, 90.0%–95.1%) with sentinel node alone. The 5-year disease-free survival was 82.2% (95% CI, 78.3%–86.3%) with

axillary lymph node dissection, and 83.9% (95% CI, 80.2%–87.9%) with sentinel node alone. Thus ACOSOGZ11 demonstrated that among breast cancer patients with limited sentinel node metastasis treated with breast conservation and systemic therapy, the use of sentinel node alone compared with axillary lymph node dissection did not result in inferior survival. This study challenges the traditional surgical dictum of regional management, and has led to a selective utilization of completion axillary lymph node dissection in breast cancer patients undergoing breast conservation. The role of completion lymph node dissections in melanoma is under investigation.

Surgical Management of Distant Metastases

The treatment of a patient with distant metastases depends on the number and sites of metastases, the cancer type, the rate of tumor growth, the previous treatments delivered and the responses to these treatments, and the patient's age, physical condition, and desires. Although once a tumor has metastasized it usually is not curable with surgical therapy, such therapy has resulted in cure in selected cases with isolated metastases to the liver, lung, or brain.

Patient selection is the key to the success of surgical therapy for distant metastases. The cancer type is a major determinant in surgical decision making. A liver metastasis from a colon cancer is more likely to be an isolated and thus resectable lesion than a liver metastasis from a pancreatic carcinoma. The growth rate of the tumor also plays an important role and can be determined in part by the disease-free interval and the time between treatment of the primary tumor and detection of the distant recurrence. Patients with longer disease-free intervals have a higher survival rate after surgical metastasectomy than those with a short disease-free interval. Similarly, patients who have synchronous metastases (metastases diagnosed at the initial cancer diagnosis) do worse after metastasectomy than patients who develop metachronous metastases (metastasis diagnosed after a disease-free interval). The natural history of metastatic disease is so poor for some tumors (e.g., pancreatic cancer) that there is no role at this time for surgical metastasectomy. In cancers with a more favorable outlook, observation for several weeks or months, potentially with initial treatment with systemic therapy, can allow the surgeon to monitor for metastases at other sites.

In curative surgery for distant metastases, as with surgery for primary tumors, the goal is to resect the metastases with negative margins. In patients with hepatic metastases that are unresectable because their location near intrahepatic blood vessels precludes a margin-negative resection, or because they are multifocal or hepatic function is inadequate, tumor ablation with cryotherapy or radiofrequency ablation is an alternative.^{132, 133} Curative resections or ablative procedures should be attempted only if the lesions are accessible and the procedure can be performed safely.

CHEMOTHERAPY

Clinical Use of Chemotherapy

In patients with documented distant metastatic disease, chemotherapy is usually the primary modality of therapy. The goal of therapy in this setting is to decrease the tumor burden, thus prolonging survival. It is rare to achieve cure with chemotherapy for metastatic disease for most solid tumors. Chemotherapy administered to a patient who is at high risk for distant recurrence but has no evidence of distant disease is referred to as

adjuvant chemotherapy. The goal of adjuvant chemotherapy is eradication of micrometastatic disease, with the intent of decreasing relapse rates and improving survival rates.

Adjuvant therapy can be administered after surgery (postoperative chemotherapy) or before surgery (preoperative chemotherapy, neoadjuvant chemotherapy, or induction therapy). A portion or all of the planned adjuvant chemotherapy can be administered before the surgical removal of the primary tumor. Preoperative chemotherapy has three potential advantages. The first is that preoperative regression of tumor can facilitate resection of tumors that were initially inoperable or allow more conservative surgery for patients whose cancer was operable to begin with. In the NSABP B-18 project, for example, women were randomly assigned to receive adjuvant doxorubicin and cyclophosphamide preoperatively or postoperatively. More patients treated before surgery than after surgery underwent breast-conserving surgery (68% vs. 60%).¹³⁴ The second advantage of preoperative chemotherapy is the treatment of micrometastases without the delay of postoperative recovery. The third advantage is the ability to assess a cancer's response to treatment clinically, after a number of courses of chemotherapy, and pathologically, after surgical resection. This is especially important if alternative treatment regimens are available to be offered to patients whose disease responded inadequately. Molecular characterization of the residual disease may also give insight into mechanisms of chemoresistance and possible therapeutic targets.

There are some potential disadvantages to preoperative chemotherapy, however. Although disease progression while the patient is receiving preoperative chemotherapy is rare in chemotherapy-sensitive tumors such as breast cancer, it is more frequent in relatively chemotherapy-resistant tumors such as sarcomas.¹³⁵ Thus, patient selection is critical to ensure that the opportunity to treat disease surgically is not lost by giving preoperative chemotherapy. Often, rates of postoperative wound infection, flap necrosis, and delays in postoperative adjuvant therapy do not differ between patients who are treated with preoperative chemotherapy and patients who are treated with surgery first. However, preoperative chemotherapy can introduce special challenges to tumor localization, margin analysis, lymphatic mapping, and pathologic staging.

Response to chemotherapy is monitored clinically with imaging studies as well as physical examinations. Response usually is defined as complete response, partial response, stable disease, or progression. Response generally is assessed using the Response Evaluation Criteria in Solid Tumors (RECIST) criteria.¹³⁶ Objective tumor response assessment is critical, because tumor response is used as a prospective endpoint in clinical trials and tumor response is a guide to clinicians regarding continuation of current therapy.

Principles of Chemotherapy

Chemotherapy destroys cells by first-order kinetics, which means that with the administration of a drug a constant percentage of cells is killed, not a constant number of cells. If a patient with 10^{12} tumor cells is treated with a dose that results in 99.9% cell kill (3-log cell kill), the tumor burden will be reduced from 10^{12} to 10^9 cells (or 1 kg to 1 g). If the patient is re-treated with the same drug, which theoretically could result in another 3-log cell kill, the cells would decrease in number from 10^9 to 10^6 (1 g to 1 mg) rather than being eliminated totally.

Chemotherapeutic agents can be classified according to the phase of the cell cycle during which they are effective.

Cell-cycle phase-nonspecific agents (e.g., alkylating agents) have a linear dose-response curve, such that the fraction of cells killed increases with the dose of the drug.¹³⁷ In contrast, the cell-cycle phase-specific drugs have a plateau with respect to cell killing ability, and cell kill will not increase with further increases in drug dose.

Anticancer Agents

Alkylating Agents. Alkylating agents are cell-cycle-nonspecific agents, that is, they are able to kill cells in any phase of the cell cycle. They act by cross-linking the two strands of the DNA helix or by causing other direct damage to the DNA. The damage to the DNA prevents cell division and, if severe enough, leads to apoptosis. The alkylating agents are composed of three main subgroups: classic alkylators, nitrosoureas, and miscellaneous DNA-binding agents (Table 10-10).

Antitumor Antibiotics. Antitumor antibiotics are the products of fermentation of microbial organisms. Like the alkylating agents, these agents are cell-cycle nonspecific. Antitumor antibiotics damage the cell by interfering with DNA or RNA synthesis, although the exact mechanism of action may differ by agent.

Antimetabolites. Antimetabolites are generally cell-cycle-specific agents that have their major activity during the S phase of the cell cycle and have little effect on cells in G_0 . These drugs are most effective, therefore, in tumors that have a high growth fraction. Antimetabolites are structural analogues of naturally occurring metabolites involved in DNA and RNA synthesis. Therefore, they interfere with normal synthesis of nucleic acids by substituting for purines or pyrimidines in the metabolic pathway to inhibit critical enzymes in nucleic acid synthesis. The antimetabolites include folate antagonists, purine antagonists, and pyrimidine antagonists.

Plant Alkaloids. Plant alkaloids are derived from plants such as the periwinkle plant, *Vinca rosea* (e.g., vincristine, a vinca alkaloid), or the root of American mandrake, *Podophyllum peltatum* (e.g., etoposide, a podophyllotoxin).¹³⁷ Vinca alkaloids affect the cell by binding to tubulin in the S phase. This blocks microtubule polymerization, which results in impaired mitotic spindle formation in the M phase. Taxanes such as paclitaxel, on the other hand, cause excess polymerization and stability of microtubules, which blocks the cell cycle in mitosis. The epipodophyllotoxins act to inhibit a DNA enzyme called *topoisomerase II* by stabilizing the DNA-topoisomerase II complex. This results in an inability to synthesize DNA, and thus the cell cycle is stopped in the G_1 phase.¹³⁷

Combination Chemotherapy

Combination chemotherapy may provide greater efficacy than single-agent therapy by three mechanisms: (a) it provides maximum cell kill within the range of toxicity for each drug that can be tolerated by the host, (b) it offers a broader range of coverage of resistant cell lines in a heterogeneous population, and (c) it prevents or delays the emergence of drug-resistant cell lines.¹³⁷ When combination regimens are devised, drugs known to be active as single agents usually are selected. Drugs with different mechanisms of action are combined to allow for additive or synergistic effects. Combining cell-cycle-specific and cell-cycle-nonspecific agents may be especially advantageous. Drugs with differing dose-limiting toxic effects are combined to allow for

Table 10-10

Classification of chemotherapeutic agents

Alkylating agents*Classic alkylating agents*

Busulfan
 Chlorambucil
 Cyclophosphamide
 Ifosfamide
 Mechlorethamine (nitrogen mustard)
 Melphalan
 Mitomycin C
 Triethylene thiophosphoramide (thiotepa)

Nitrosoureas

Carmustine (BCNU)
 Lomustine (CCNU)
 Semustine (MeCCNU)
 Streptozocin

Miscellaneous DNA-binding agents

Carboplatin
 Cisplatin
 Dacarbazine (DTIC)
 Hexamethylmelamine
 Procarbazine

Antitumor antibiotics

Bleomycin
 Dactinomycin (actinomycin D)
 Daunorubicin
 Doxorubicin
 Idarubicin
 Plicamycin (mithramycin)

Antimetabolites

Folate analogues
 Methotrexate

Purine analogues

Azathioprine
 Mercaptopurine
 Thioguanine
 Cladribine (2-chlorodeoxyadenosine)
 Fludarabine
 Pentostatin

Pyrimidine analogues

Capecitabine
 Cytarabine
 Floxuridine
 Gemcitabine

Ribonucleotide reductase inhibitors

Hydroxyurea

Plant alkaloids*Vinca alkaloids*

Vinblastine
 Vincristine
 Vindesine
 Vinorelbine

Epipodophyllotoxins

Etoposide
 Teniposide

Taxanes

Paclitaxel
 Docetaxel

Miscellaneous agents

Asparaginase
 Estramustine
 Mitotane

each drug to be given at therapeutic doses. Drugs with different patterns of resistance are combined whenever possible to minimize cross-resistance. The treatment-free interval between cycles is kept to the shortest possible time that will allow for recovery of the most sensitive normal tissue.

Drug Toxicity

Tumors are more susceptible than normal tissue to chemotherapeutic agents, in part because they have a higher proportion of dividing cells. Normal tissues with a high growth fraction, such as the bone marrow, oral and intestinal mucosa, and hair follicles, are also sensitive to chemotherapeutic effects. Therefore, treatment with chemotherapeutic agents can produce toxic effects such as bone marrow suppression, stomatitis, ulceration of the GI tract, and alopecia. Toxic effects usually are graded from 0 to 4 on the basis of World Health Organization standard criteria.¹³⁸ Significant drug toxicity may necessitate a dosage reduction. A toxic effect requiring a dose modification or change in dose intensity is referred to as a dose-limiting toxic effect. Because maintaining dose intensity is important to preserve as high a tumor cell kill as possible, several supportive strategies have been developed, such as administration of colony-stimulating factors and erythropoietin to treat poor bone marrow reserve and administration of cytoprotectants such as mesna and amifostine to prevent renal dysfunction.

Administration of Chemotherapy

Chemotherapy usually is administered systemically (IV, IM, SC, or PO). Systemic administration treats micrometastases at widespread sites and prevents systemic recurrence. However, it increases the drug's toxicity to a wide range of organs throughout the body. One method to minimize systemic toxicity while enhancing target organ delivery of chemotherapy is regional administration of chemotherapy. Many of these approaches require surgical access, such as intrahepatic delivery of chemotherapy for hepatic carcinomas or metastatic colorectal cancer using a hepatic artery infusion pump, limb perfusion for extremity melanoma and sarcoma, and intraperitoneal hyperthermic perfusion for pseudomyxoma peritonei. Alternately, percutaneous access may be utilized, such as limb infusion with percutaneously placed catheters.

HORMONAL THERAPY

Some tumors, most notably breast and prostate cancers, originate from tissues whose growth is under hormonal control. The first attempts at hormonal therapy were through surgical ablation of the organ producing the hormones involved, such as oophorectomy for breast cancer. Currently, hormonal anti-cancer agents include androgens, antiandrogens, antiestrogens, estrogens, glucocorticoids, gonadotropin inhibitors, progestins,

aromatase inhibitors, and somatostatin analogues. Hormones or hormone-like agents can be administered to inhibit tumor growth by blocking or antagonizing the naturally occurring substance, such as with the estrogen antagonist tamoxifen. Other substances that block the synthesis of the natural hormone can be administered as alternatives. Aromatase inhibitors, for example, block the peripheral conversion of endogenous androgens to estrogens in postmenopausal women. Hormonal therapy provides a highly tumor-specific form of therapy in sensitive tissues. In breast cancer, estrogen and progesterone receptor status is used to predict the success of hormonal therapy. Androgen receptor is also being pursued as a therapeutic target for breast cancer treatment.

TARGETED THERAPY

Over the past decade, increased understanding of cancer biology has fostered the emerging field of molecular therapeutics. The basic principle of molecular therapeutics is to exploit the molecular differences between normal cells and cancer cells to develop targeted therapies. Thus targeted therapies usually are directed at the processes involved in tumor growth rather than directly targeting the tumor cells. The ideal molecular target would be exclusively expressed in the cancer cells, be the driving force of the proliferation of the cancer cells, and be critical to their survival. A large number of molecular targets are currently being explored, both preclinically and in clinical trials. The major groups of targeted therapy agents are inhibitors of growth factor receptors, inhibitors of intracellular signal transduction, cell-cycle inhibitors, apoptosis-based therapies, and antiangiogenic compounds.

Protein kinases have come to the forefront as attractive therapeutic targets with the success of imatinib mesylate (Gleevec) in treating chronic myelogenous leukemia and GI stromal tumors, and trastuzumab (Herceptin) in treating breast cancer, and vemurafenib in treating melanoma. These drugs work by targeting bcr-abland c-kit (imatinib) and HER2 and Braf, respectively. For example, recently a phase III randomized trial demonstrated that, compared with dacarbazine, standard of care chemotherapy option for patients with metastatic melanoma with a V600E BRAF mutation, the BRAF inhibitor vemurafenib led to significantly higher response rates (48% vs. 5%).¹³⁹ At 6 months, overall survival was 84% (95% CI, 78 to 89) in the vemurafenib group and 64% (95% CI, 56 to 73) in the dacarbazine group. The hazard ratio for tumor progression in the vemurafenib group was 0.26 (95% CI, 0.20 to 0.33; $P < 0.001$). The estimated median progression-free survival was 5.3 months in the vemurafenib group and 1.6 months in the dacarbazine group. This trial highlights the fact that in at least some tumor types targeted therapies that inhibit a genomic alteration that is a driver is likely to be more effective than an unselected therapeutic option.

Sequencing of the human genome has revealed approximately 500 protein kinases. Several tyrosine kinases have been shown to have oncogenic properties and many other protein kinases have been shown to be aberrantly activated in cancer cells.⁹⁰ Therefore, protein kinases involved in these aberrantly activated pathways are being aggressively pursued in molecular therapeutics. Potential targets like HER2 can be targeted via different strategies, such as transcriptional downregulation, targeting of mRNA, RNA inhibition, antisense strategies, direct inhibition of protein activity, and induction of immunity against the protein.

Most of the compounds in development are monoclonal antibodies like trastuzumab or small-molecule kinase inhibitors like imatinib or vemurafenib. Some other agents, such as sunitinib, are multi-targeted kinase inhibitors. Selected FDA-approved targeted therapies are listed in Table 10-11. Many of the promising pathways, such as the PI3K/Akt/mTOR pathway are being pursued as therapeutic targets with several drugs in development, targeting different aspects of the pathway (Fig. 10-15).¹⁴⁰

Development of molecularly targeted agents for clinical use presents several unique challenges. Once an appropriate compound is identified and confirmed to have activity in pre-clinical testing, predictive markers for activity in the preclinical setting must be defined. Expression of a target may not be sufficient to predict response, because the pathway of interest may not be activated or critical to the cancer's survival. Although in traditional phase I trials the goal is to identify the maximum tolerated dosage, the maximum dosage of biologic agents may not be necessary to achieve the desired biologic effect. Thus assays to verify modulation of the target need to be developed to determine at what dosage the desired effect is achieved. When phase II and III clinical trials are initiated, biomarker modulation studies should be integrated into the trial to determine whether clinical response correlates with target modulation and thus to identify additional parameters that impact response. Rational dose selection and limitation of study populations to patients most likely to respond to the molecular therapy as determined by predictive markers are most likely to lead to successful clinical translation of a product. Finally, most biologic agents are cytostatic, not cytotoxic. Thus rational combination therapy mixing new biologic agents with either established chemotherapeutic agents that have synergy or with other biologic agents is more likely to lead to cancer cures.

IMMUNOTHERAPY

The aim of immunotherapy is to induce or potentiate inherent antitumor immunity that can destroy cancer cells. Central to the process of antitumor immunity is the ability of the immune system to recognize tumor-associated antigens present on human cancers and to direct cytotoxic responses through humoral or T-cell-mediated immunity. Overall, T-cell-mediated immunity appears to have the greater potential of the two for eradicating tumor cells. T cells recognize antigens on the surfaces of target cells as small peptides presented by class I and class II MHC molecules.

Several antitumor strategies are under investigation. One approach to antitumor immunity is nonspecific immunotherapy, which stimulates the immune system as a whole through administration of bacterial agents or their products, such as bacille Calmette-Guérin. This approach is thought to activate the effectors of antitumor response such as natural killer cells and macrophages, as well as polyclonal lymphocytes.¹⁴¹ Another approach to nonspecific immunotherapy is systemic administration of cytokines such as interleukin-2, interferon- α , and interferon- γ . Interleukin-2 stimulates proliferation of cytotoxic T lymphocytes and maturation of effectors such as natural killer cells into lymphokine-activated killer cells. Interferons, on the other hand, exert antitumor effects directly by inhibiting tumor cell proliferation and indirectly by activating host immune cells, including macrophages, dendritic cells, and natural killer cells, and by enhancing human leukocyte antigen (HLA) class I expression on tumor cells.¹⁴¹

Table 10-11

Selected FDA-approved targeted therapies

GENERIC NAME	TRADE NAME	TARGET	FDA-APPROVED INDICATIONS
Ado-trastuzumab emtansine	Kadcyla	HER2	Breast cancer
Axitinib	Inlyta	KIT, FDGFR β , VEGFR1/2/3	RCC
Bevacizumab	Avastin	VEGF	Colorectal cancer, lung cancer, glioblastoma, NSCLC RCC
Bosutinib	Bosulif	ABL	CML(Philadelphia chromosome+)
Cabozantinib	Cometriq	FLT3, KIT, MET, RET, VEGFR2	Medullary thyroid cancer
Cetuximab	Erbix	EGFR	Colorectal cancer (<i>KRAS</i> wild-type) Squamous cell cancer of the head and neck
Dasatinib	Sprycel	ABL, src family, KIT, EPHA2, PDGFR- β	CML
Erlotinib	Tarceva	EGFR	NSCLC, Pancreatic cancer
Everolimus	Afinitor	mTOR	PNET, RCC, Breast cancer. Nonresectable subependymal giant cell astrocytoma associated with tuberous sclerosis
Gefitinib	Iressa	EGFR	NSCLC with known/previous benefit from gefitinib (limited approval)
Imatinib	Gleevec	KIT, ABL, PDGFR	CML, GIST (KIT+), Dermatofibrosarcoma protuberans
Lapatinib	Tykerb	EGFR and HER2	Breast cancer (<i>HER2</i> +))
Nilotinib	Tasigna	ABL	CML (Philadelphia chromosome+)
Panitumumab	Vectibix	EGFR	Colorectal cancer (<i>KRAS</i> wild type)
Pazopanib	Votrient	VEGFR, PDGFR, KIT	RCC
Pertuzumab	Perjeta	HER2	Breast cancer (<i>HER</i> +))
Ponatinib	Iclusig	ABL, FGFR1-3, FLT3, VEGFR2	CML, ALL (Philadelphia chromosome+)
Regorafenib	Stivarga	KIT, PDGFR β , RAF, RET, VEGFR1/2/3	Colorectal cancer, GIST
Sorafenib	Nexavar	VEGFR, PDGFR, KIT, RAF	HCC RCC
Sunitinib	Sutent	VEGFR PDGFR KIT, Flt-3, RET	GIST, RCC, PNET
Temsirolimus	Torisel	mTOR	RCC
Trastuzumab	Herceptin	HER2	Breast cancer (<i>HER2</i> +)) Gastric cancer (<i>HER2</i> +))
Vandetanib	Caprelsa	EGFR, RET, VEGFR2	Medullary thyroid cancer
Vemurafenib	Zelboraf	BRAF	Melanoma (<i>BRAF V600E</i> mutant)

CML, chronic myelogenous leukemia; **EGFR**, epidermal growth factor receptor; **EPHA2**, ephrin A2; **FDA**, Food and Drug Administration; **Flt-3**, fms-related tyrosine kinase 3; **GIST**, GI stromal tumor; **HCC**, Hepatocellular cancer, **HER2**, human epidermal growth factor receptor 2; **mTOR**, mammalian target of rapamycin; **NSCLC**, non-small cell lung cancer, **PDGF**, platelet-derived growth factor; **PDGFR**, platelet-derived growth factor receptor; **PNET**, Pancreatic neuroendocrine tumor, **RCC**, renal cell carcinoma; **RET**, rearranged during transfection; **VEGF**, vascular endothelial growth factor; **VEGFR**, vascular endothelial growth factor receptor.

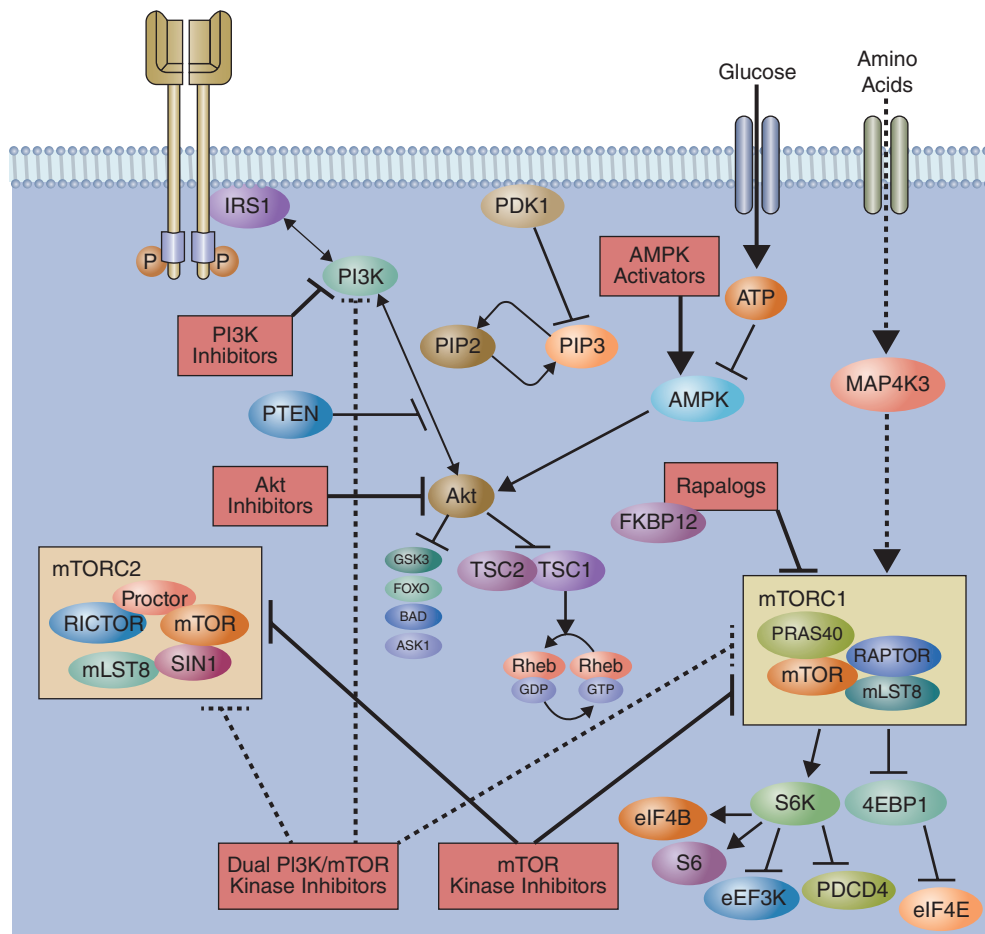


Figure 10-15. Targeting PI3K/Akt/mTOR signaling. This central pathway is altered in many tumor types and is being pursued as a therapeutic target through development of numerous pathway inhibitors targeting PI3K, Akt, mTOR, dual inhibitors as well as several upstream and downstream regulators. (Modified with permission from McAuliffe et al. Copyright Elsevier.)¹⁴⁰

Antigen-specific immunotherapy can be active, as is achieved through antitumor vaccines, or passive. In passive immunotherapy, antibodies to specific tumor-associated antigens can be produced by hybridoma technique and then administered to patients whose cancers express these antigens, inducing antibody-dependent cellular cytotoxicity.

The early attempts at vaccination against cancers used allogeneic cultured cancer cells, including irradiated cells, cell lysates, and shed antigens isolated from tissue culture supernatants. An alternate strategy is the use of autologous tumor vaccines. These have the potential advantage of being more likely to contain antigens relevant for the individual patient but have the disadvantage of requiring a large amount of tumor tissue for preparation, which restricts eligibility of patients for this modality. Strategies to enhance immunogenicity of tumor cells include the introduction of genes encoding cytokines or chemokines, and fusion of the tumor cells to allogeneic MHC class II-bearing cells.¹⁴² Alternatively, heat shock proteins derived from a patient's tumor can be used, because heat shock protein peptide complexes are readily taken up by dendritic cells for presentation to T cells.¹⁴²

Identification of tumor antigens has made it possible to perform antigen-specific vaccination. For example in the case of melanoma, several antigens have been identified that can be recognized by both CD8⁺ cytotoxic T cells and CD4⁺ helper T cells, including MART-1, gp 100, MAGE1, tyrosinase, TRP-1, TRP-2, and NY-ESO-1.¹⁴³ Antigens tested usually are

overexpressed or mutated in cancer cells. Tissue specificity and immunogenicity are important determinants in choosing an appropriate target. Vaccines directed at defined tumor antigens aim to combine selected tumor antigens and appropriate routes for delivering these antigens to the immune system to optimize antitumor immunity.¹⁴⁴ Several different vaccination approaches are under study, including tumor cell-based vaccines, peptide-based vaccines, recombinant virus-based vaccines, DNA-based vaccines, and dendritic cell vaccines.

In adoptive transfer, antigen-specific effector cells (i.e., cytotoxic T lymphocytes) or antigen-nonspecific effector cells (i.e., natural killer cells) can be transferred to a patient. These effector cells can be obtained from the tumor (tumor-infiltrating lymphocytes) or the peripheral blood.

Clinical experience in patients with metastatic disease has shown objective tumor responses to a variety of immunotherapeutic modalities. It is thought, however, that the immune system is overwhelmed with the tumor burden in this setting, and thus adjuvant therapy may be preferable, with immunotherapy reserved for decreasing tumor recurrences. Trials to date suggest that immunotherapy is a potentially useful approach in the adjuvant setting. How to best select patients for this approach and how to integrate immunotherapy with other therapies are not well understood for most cancer types.

Tolerance to self-antigens expressed in tumors is a limitation in generating antitumor responses.¹⁴⁵ Recently, several

pathways that modulate tolerance and approaches to manipulating these pathways have been identified: pathways that activate professional antigen-presenting cells such as Toll-like receptors, growth factors, and the CD40 pathway; cytokines to enhance immunoactivation; and pathways that inhibit T-cell inhibitory signals or Tregs.¹⁴⁵

A new strategy being actively explored involves the use of cytotoxic T-lymphocyte antigen 4 (CTLA-4). CTLA-4 exists on the surfaces of T cells and has a homeostatic immunosuppressive function, downregulating the response of T cells to stimuli.¹⁴⁶

In a recent phase 3 study, ipilimumab—which blocks CTLA-4, was administered with or without glycoprotein 100 (gp100) peptide vaccine and was compared with gp100 alone in HLA-A*0201-positive patients with previously treated metastatic melanoma. The median overall survival was significantly longer for patients receiving ipilimumab with or without gp100, compared with patients who receiving gp100.¹⁴⁷ In another Phase III trial, ipilimumab in combination with dacarbazine, compared with dacarbazine plus placebo, improved overall survival in patients with previously untreated metastatic melanoma.¹⁴⁸ Anti-CTLA-4 antibodies are under study for use in melanoma as well as several other cancer types as single agents, in combination with targeted therapies, interleukin-2, chemotherapy, or peptide vaccines.¹⁴⁶

Programmed death ligand 1 (PD-L1) is a 40kDa type 1 transmembrane protein that is thought to play an important role in suppressing the immune system. PD-L1 binds to its receptor, PD-1, which is found on activated T cells, B cells, and myeloid cells. The PD1/PDL1 pathway is increasingly recognized as a key contributor to tumor-mediated immune suppression. Thus both anti-PD1 and anti-PD-L1 strategies are actively being pursued for cancer therapy.

GENE THERAPY

Gene therapy is being pursued as a possible approach to modifying the genetic program of cancer cells as well as treating metabolic diseases. The field of cancer gene therapy uses a variety of strategies, ranging from replacement of mutated or deleted tumor-suppressor genes to enhancement of immune responses to cancer cells.¹⁴⁹ Indeed, in preclinical models, approaches such as replacement of tumor-suppressor genes leads to growth arrest or apoptosis. However, the translation of these findings into clinically useful tools presents special challenges.

One of the main difficulties in getting gene therapy technology from the laboratory to the clinic is the lack of a perfect delivery system. An ideal vector would be administered through a noninvasive route and would transduce all of the cancer cells and none of the normal cells. Furthermore, the ideal vector would have a high degree of activity, that is, it would produce an adequate amount of the desired gene product to achieve target cell kill. Unlike genetic diseases in which delivery of the gene of interest into only a portion of the cells may be sufficient to achieve clinical effect, cancer requires either that the therapeutic gene be delivered to all of the cancer cells or that a therapeutic effect be achieved on nontransfected cells as well as transfected cells through a bystander effect. But then, treatment of a metabolic disease requires prolonged gene expression, whereas transient expression may be sufficient for cancer therapy.

Several vector systems are under study for gene therapy; however, none is considered ideal. One of the promising approaches to increase the number of tumor cells transduced is the use of a replication-competent virus like a parvovirus,

human reovirus, or vesicular stomatitis virus that selectively replicates within malignant cells and lyses them more efficiently than it does normal cells. Another strategy for killing tumor cells with suicide genes exploits tumor-specific expression elements, such as the MUC-1, PSA, CEA, or VEGF promoters, that can be used to achieve tissue-specific or tumor-specific expression of the desired gene.

Because the goal in cancer therapy is to eradicate systemic disease, optimization of delivery systems is the key to success for gene therapy strategies. Gene therapy is likely to be most successful when combined with standard therapies, but it will provide the advantage of customization of therapy based on the molecular status of an individual's tumor.

MECHANISMS OF INTRINSIC AND ACQUIRED DRUG RESISTANCE

Several tumor factors influence tumor cell kill. Tumors are heterogeneous, and, according to the Goldie-Coldman hypothesis, tumor cells are genetically unstable and tend to mutate to form different cell clones. This has been used as an argument for giving chemotherapy as soon as possible in treatment to reduce the likelihood that resistant clones will emerge. Tumor size is another important variable. Large tumor, may have greater heterogeneity, although heterogeneity may also differ based on biological subtype. Moreover, according to the Gompertzian model, cancer cells initially grow rapidly (exponential growth phase), then the growth slows down owing to hypoxia and decreased nutrient supply. Because of the larger proportion of cells dividing, smaller tumors may be more chemosensitive.

Multiple mechanisms of systemic therapy resistance have been identified (Table 10-12).¹⁵⁰ Cells may exhibit reduced sensitivity to drugs by virtue of their cell-cycle distribution. For example, cells in the G₀ phase are resistant to drugs active in the S phase. This phenomenon of “kinetic resistance” usually is temporary, and if the drug level can be maintained, all cells will eventually pass through the vulnerable phase of the cell cycle.¹³⁷ Alternatively, tumor cells may exhibit “pharmacologic resistance,” in which the failure to kill cells is due to insufficient drug concentration. This may occur when tumor cells are located in sites where effective drug concentrations are difficult to achieve (such as the central nervous system) or can be due to enhanced metabolism of the drug after its administration, decreased conversion of the drug to its active form, or decrease in the intracellular drug level caused by increased removal of the drug from the cell associated with enhanced expression of P-glycoprotein, the protein product of multidrug resistance gene 1. Other mechanisms of resistance include decreased affinity of the target enzyme for the drug, altered amount of the target enzyme, or enhanced repair of the drug-induced defect. For drug-sensitive cancers, another factor limiting optimal killing is improper dosing. A dose reduction of 20% because of drug toxicity can lead to a decline in the cure rate by as much as 50%.¹³⁷ Furthermore, a twofold increase in dose can be associated with a tenfold (1 log) increase in tumor cell kill.

Cancer cells demonstrate adaptive responses to targeted therapy, like activating alternate pathways of survival; thus these alterations may blunt therapeutic efficacy. Cancer cells also acquire resistance upon prolonged treatment with targeted therapy through a variety of mechanisms. One mechanism is through the loss of the target. For example, this was observed in a study of patients with *HER2*-positive breast cancer patients

Table 10-12

General mechanisms of drug resistance**Cellular and biochemical mechanisms**

- Decreased drug accumulation
 - Decreased drug influx
 - Increased drug efflux
 - Altered intracellular trafficking of drug
- Decreased drug activation
- Increased inactivation of drug or toxic intermediate
- Increased repair of drug-induced damage to:
 - DNA
 - Protein
 - Membranes
- Alteration of drug targets (quantitatively or qualitatively)
- Alteration of cofactor or metabolite levels
- Alteration of gene expression
 - DNA mutation, amplification, or deletion
 - Altered transcription, posttranscription processing, or translation
 - Altered stability of macromolecules

Mechanisms relevant in vivo

- Pharmacologic and anatomic drug barriers (tumor sanctuaries)
- Host-drug interactions
 - Increased drug inactivation by normal tissues
 - Decreased drug activation by normal tissues
 - Relative increase in normal tissue drug sensitivity (toxicity)

Host-tumor interactions

Source: Modified with permission from Morrow et al.¹⁵⁰

who were treated with neoadjuvant trastuzumab-based chemotherapy.¹⁵¹ Post-neoadjuvant treatment, a third of the samples from patients who did not have a complete pathologic response displayed loss of the *HER2* amplification that had been present in their pretreatment-biopsy specimens¹⁵¹. Another means by which cancers develop resistance is the acquisition of additional genomic aberrations. In lung cancer, a second mutation in EGFR (T790M) and MET amplification have been described as two main mechanisms of drug resistance to EGFR inhibitors erlotinib and gefitinib.¹⁵²⁻¹⁵⁴ Other mechanisms like novel genetic changes, including *HER2* and EGFR amplification, *PIK3CA* mutations, and markers of epithelial-to-mesenchymal transition have also been reported in EGFR inhibitor resistant lung.^{155, 156} Analysis of metastases from patients with colorectal cancer who developed resistance to cetuximab or panitumumab showed the emergence of KRAS amplification in one sample and acquisition of secondary KRAS mutations in 60% of the cases.¹⁵⁷ These studies emphasize the utility of repeat tumor biopsy specimens at the time of relapse or progression to identify mechanisms of resistance and best combinatorial therapies.

RADIATION THERAPY**Physical Basis of Radiation Therapy**

Ionizing radiation is energy strong enough to remove an orbital electron from an atom. This radiation can be electromagnetic, like a high-energy photon, or particulate, such as an electron, proton, neutron, or alpha particle. Radiation therapy is delivered primarily as

high-energy photons (gamma rays and X-rays) and charged particles (electrons). Gamma rays are photons that are released from the nucleus of a radioactive atom. X-rays are photons that are created electronically, such as with a clinical linear accelerator. Currently, high-energy radiation is delivered to tumors primarily with linear accelerators. X-rays traverse the tissue, depositing the maximum dose beneath the surface, and thus spare the skin. Electrons are used to treat superficial skin lesions, superficial tumors, or surgical beds to a depth of 5 cm. Gamma rays typically are produced by radioactive sources used in brachytherapy.

The dose of radiation absorbed correlates with the energy of the beam. The basic unit is the amount of energy absorbed per unit of mass (joules per kilogram) and is known as a *gray* (Gy). One gray is equivalent to 100 rads, the unit of radiation measurement used in the past.

Biologic Basis of Radiation Therapy

Radiation deposition results in DNA damage manifested by single- and double-strand breaks in the sugar phosphate backbone of the DNA molecule.¹⁵⁸ Cross-linking between the DNA strands and chromosomal proteins also occurs. The mechanism of DNA damage differs by the type of radiation delivered. Electromagnetic radiation is indirectly ionizing through short-lived hydroxyl radicals produced primarily by the ionization of cellular hydrogen peroxide (H₂O₂).¹⁵⁸ Protons and other heavy particles are directly ionizing and directly damage DNA.

Radiation damage is manifested primarily by the loss of cellular reproductive integrity. Most cell types do not show signs of radiation damage until they attempt to divide, so slowly proliferating tumors may persist for months and appear viable. Some cell types, however, undergo apoptosis.

The extent of DNA damage after radiation exposure is dependent on several factors. The most important of these is cellular oxygen. Hypoxic cells are significantly less radiosensitive than aerated cells. Because the presence of oxygen is thought to prolong the half-life of free radicals produced by the interaction of X-rays and cellular H₂O₂, indirectly ionizing radiation is less efficacious in tumors with areas of hypoxia.¹⁵⁸ In contrast, radiation damage from directly ionizing radiation is independent of cellular oxygen levels.

The extent of DNA damage from indirectly ionizing radiation is dependent on the phase of the cell cycle. The most radiation-sensitive phases are G₂ and M, whereas G₁ and late S phases are less sensitive. Thus irradiation of a population of tumor cells results in killing of a greater proportion of cells in G₂ and M phases. However, delivery of radiation in divided doses, a concept referred to as *fractionation*, allows the surviving G₁ and S phase cells to progress to more sensitive phases, a process referred to as *reassortment*. In contrast to DNA damage after indirectly ionizing radiation, that after exposure to directly ionizing radiation is less dependent on the cell-cycle phase.¹⁵⁹

Several chemicals can modify the effects of ionizing radiation. These include hypoxic cell sensitizers such as metronidazole and misonidazole, which mimic oxygen and increase cell kill of hypoxic cells.¹⁵⁸ A second category of radiation sensitizers are the thymidine analogues iododeoxyuridine and bromodeoxyuridine. These molecules are incorporated into the DNA in place of thymidine and render the cells more susceptible to radiation damage; however, they are associated with considerable acute toxicity. Several other chemotherapeutic agents sensitize cells to radiation through various mechanisms, including

Radiation Therapy Planning

Radiation therapy is delivered in a homogeneous dose to a well-defined region that includes tumor and/or surrounding tissue at risk for subclinical disease. The first step in planning is to define the target to be irradiated as well as the dose-limiting organs in the vicinity.¹⁶⁰ Treatment planning includes evaluation of alternative treatment techniques, which is done through a process referred to as *simulation*. Once the beam distribution that will best achieve homogeneous delivery to the target volume and minimize the dose to the normal tissue is determined, immobilization devices and markings or tattoos on the patient's skin are used to ensure that each daily treatment is given in the same way. Conventional fractionation is 1.8 to 2 Gy/d, administered 5 days each week for 3 to 7 weeks.

Radiation therapy may be used as the primary modality for palliation in certain patients with metastatic disease, primarily patients with bony metastases. In these cases, radiation is recommended for symptomatic metastases only. However, lytic metastases in weight-bearing bones such as the femur, tibia, or humerus also are considered for irradiation. Another circumstance in which radiation therapy might be appropriate is spinal cord compression due to metastases to the vertebral body that extend posteriorly to the spinal canal.

The goal of adjuvant radiation therapy is to decrease local-regional recurrence rates. Adjuvant radiation therapy can be given before surgery, after surgery, or, in selected cases, during surgery. Preoperative radiation therapy has several advantages. It may minimize seeding of the tumor during surgery and it allows for smaller treatment fields because the operative bed has not been contaminated with tumor cells. Also, radiation therapy for inoperable tumors may achieve adequate reduction to make them operable. The disadvantages of preoperative therapy are an increased risk of postoperative wound healing problems and the difficulty in planning subsequent radiation therapy in patients who have positive surgical margins. If radiation therapy is given postoperatively, it is usually given 3 to 4 weeks after surgery to allow for wound healing. The advantage of postoperative radiation therapy is that the surgical specimen can be evaluated histologically and radiation therapy can be reserved for patients who are most likely to benefit from it. Further, the radiation therapy can be modified on the basis of margin status. The disadvantages of postoperative radiation therapy are that the volume of normal tissue requiring irradiation may be larger owing to surgical contamination of the tissue planes and that the tumor may be less sensitive to radiation owing to poor oxygenation. Postlaparotomy adhesions may decrease the mobility of the small bowel loops, increasing the risk for radiation injury in abdominal or pelvic irradiation. Given the potential advantages and disadvantages of both approaches, the roles of preoperative and postoperative radiation therapy are being actively evaluated and compared for many cancer types.

Another mode of postoperative radiation therapy is brachytherapy. In brachytherapy, unlike in external beam therapy, the radiation source is in contact with the tissue being irradiated. The radiation source may be cesium, gold, iridium, or radium. Brachytherapy is administered via temporary or permanent delivery implants such as needles, seeds, or catheters. Temporary brachytherapy catheters are placed either during open surgery or percutaneously soon after surgery. The implants

are loaded interstitially, and treatment usually is given postoperatively for a short duration, such as 1 to 3 days. Although brachytherapy has the disadvantages of leaving scars at the catheter insertion site and requiring special facilities for inpatient brachytherapy the advantage of patient convenience owing to the shorter treatment duration, has made intracavitary treatment approaches very popular for the treatment of breast cancer.

Another short delivery approach is intraoperative radiotherapy (IORT), often used in combination with external beam therapy. The oncologic consequences of the limited treatment volume and duration associated with brachytherapy and IORT are not well understood. Accelerated partial breast irradiation with interstitial brachytherapy, intracavitary brachytherapy (MammoSite), IORT, and three-dimensional conformal external beam radiotherapy is being compared with whole breast irradiation in an intergroup phase III trial (NSABP B-39/Radiation Therapy Oncology Group 0413). Several additional studies of adjuvant IORT also are ongoing internationally. There has also been increasing interest in utilizing intensity-modulated radiation therapy (IMRT). IMRT is a complex technique for the delivery of radiation therapy preferentially to target structures while minimizing doses to adjacent normal critical structures.¹⁶¹ It is widely utilized for the treatment of a variety of tumor types, including the central nervous system, head and neck, breast, prostate, gastrointestinal tract, and gynecologic organs, as well as in patients where previous radiation therapy has been delivered.

It is thought that chemotherapy given concurrently with radiation improves survival rates. Chemotherapy before radiation has the advantage of reducing the tumor burden, which facilitates radiation therapy. On the other hand, some chemotherapy regimens, when given concurrently with radiation, may sensitize the cells to radiation therapy. Chemoradiation is being pursued in many tumor types, including rectal cancer, pancreatic cancer, and esophageal cancer.¹⁶²⁻¹⁶⁴ In a recent Cochrane review of six randomized controlled trials, it was demonstrated that in patients T3/4 rectal cancer, chemoradiation was associated with a significantly lower local recurrence rate compared with radiation therapy alone (OR 0.56, 95% CI 0.42-0.75, $P < 0.0001$), but was not associated with improved survival.¹⁶²

Side Effects

Both tumor and normal tissue have radiation dose-response relationships that can be plotted as a sigmoidal curve (Fig. 10-16).¹⁶⁰ A minimum dose of radiation must be given before any response is seen. The response to radiation then increases slowly with an increase in dose. At a certain dose level the curves become exponential, with increases in tumor response and normal tissue toxicity with each incremental dose increase. The side effects of radiation therapy can be acute, occurring during or 2 to 3 weeks after therapy, or chronic, occurring weeks to years after therapy. The side effects depend on the tissue included in the target volume. Some of the major acute and chronic sequelae of radiation are summarized in Table 10-13.^{160, 165} In addition to these effects, a small increase in the risk for secondary malignancies is attributable to radiation therapy.

CANCER PREVENTION

The truth of the old axiom, "An ounce of prevention is worth a pound of cure" is being increasingly recognized in oncology. Cancer prevention can be divided into three categories: (a) primary prevention (i.e., prevention of initial cancers in healthy

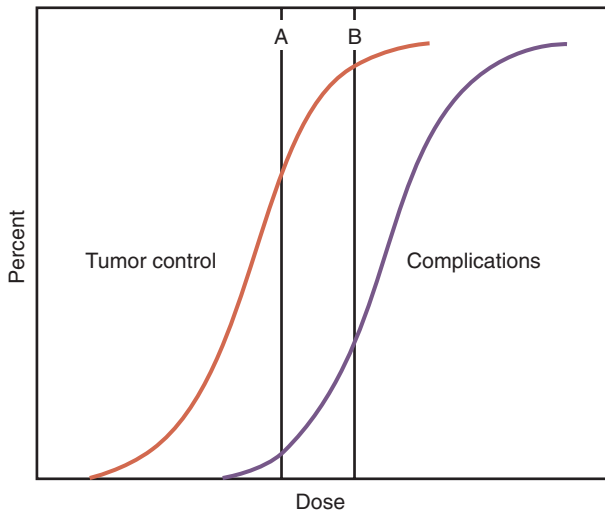


Figure 10-16. The probability of tumor control and of complications at different radiation doses. **A.** At lower doses, the probability of complications is low, with a moderate chance of tumor control. **B.** Increasing the dose may gain a higher chance of tumor control at the price of significantly higher complication risks. (Modified with permission from Eisbruch A, Lichter AS. With kind permission from Springer Science and Business Media.)¹⁶⁰

individuals), (b) secondary prevention (i.e., prevention of cancer in individuals with premalignant conditions), and (c) tertiary prevention (i.e., prevention of second primary cancers in patients cured of their initial disease).

The systemic or local administration of therapeutic agents to prevent the development of cancer, called *chemoprevention*, is being actively explored for several cancer types. In breast cancer, the NSABP Breast Cancer Prevention Trial demonstrated that tamoxifen administration reduces the risk of breast cancer by one half and reduces the risk of estrogen receptor-positive tumors by 69% in high-risk patients.¹⁶⁶ Therefore, tamoxifen has been approved by the FDA for breast cancer chemoprevention.

The subsequent NSABP P-2 trial demonstrated that raloxifene is as effective as tamoxifen in reducing the risk of invasive breast cancer and is associated with a lower risk of thromboembolic events and cataracts but a non-statistically significant higher risk of noninvasive breast cancer; these findings led the FDA to approve raloxifene for prevention as well. Several other agents are also under investigation.¹⁶⁷ Celecoxib has been shown to reduce polyp number and polyp burden in patients with FAP, which led to its approval by the FDA for these patients. In head and neck cancer, 13-*cis*-retinoic acid has been shown both to reverse oral leukoplakia and to reduce second primary tumor development.^{168, 169} Thus, the chemoprevention trials completed so far have demonstrated success in primary, secondary, and tertiary prevention. Although the successes of these chemoprevention studies are impressive, much remains to be done over the next few years to improve patient selection and decrease therapy-related toxic effects. It is important for surgeons to be aware of these preventive options, because they are likely to be involved in the diagnosis of premalignant and malignant conditions and will be the ones to counsel patients about their chemopreventive options.

In selected circumstances, the risk of cancer is high enough to justify surgical prevention. These high-risk settings include hereditary cancer syndromes such as hereditary breast-ovarian cancer syndrome, hereditary diffuse gastric cancer, multiple endocrine neoplasia type 2, FAP, and hereditary nonpolyposis colorectal cancer, as well as some nonhereditary conditions such as chronic ulcerative colitis. Most prophylactic surgeries are large ablative surgeries (e.g., bilateral risk-reducing mastectomy or total proctocolectomy). Therefore, it is important that the patient be completely informed about potential surgical complications as well as long-term lifestyle consequences. Further, the conservative options of close surveillance and chemoprevention need to be discussed. The patient's cancer risk needs to be assessed accurately and implications for survival discussed. Ultimately, the decision to proceed with surgical prevention should be individualized and made with caution.

Table 10-13

Local effects of radiation

ORGAN	ACUTE CHANGES	CHRONIC CHANGES
Skin	Erythema, wet or dry desquamation, epilation	Telangiectasia, subcutaneous fibrosis, ulceration
GI tract	Nausea, diarrhea, edema, ulceration, hepatitis	Stricture, ulceration, perforation, hematochezia
Kidney	—	Nephropathy, renal insufficiency
Bladder	Dysuria	Hematuria, ulceration, perforation
Gonads	Sterility	Atrophy, ovarian failure
Hematopoietic tissue	Lymphopenia, neutropenia, thrombocytopenia	Pancytopenia
Bone	Epiphyseal growth arrest	Necrosis
Lung	Pneumonitis	Pulmonary fibrosis
Heart	—	Pericarditis, vascular damage
Upper aerodigestive tract	Mucositis, xerostomia, anosmia	Xerostomia, dental caries
Eye	Conjunctivitis	Cataract, keratitis, optic nerve atrophy
Nervous system	Cerebral edema	Necrosis, myelitis

Cancer Screening and Diagnosis

It is clear that the practice of oncology will change dramatically over the next few decades, because our understanding of the molecular basis of cancer and available technologies are evolving rapidly. One of the critical changes expected is earlier detection of cancers. With improvements in available imaging modalities and development of newer functional imaging techniques, it is likely that many tumors will be detected at earlier, more curable stages in the near future.

Another area of rapid development is the identification of serum markers. High-throughput technologies such as matrix-assisted laser desorption ionization time-of-flight mass spectroscopy and liquid chromatography ion-spray tandem mass spectroscopy have revolutionized the field of proteomics and are now being used to compare the serum protein profiles of patients with cancer with those of individuals without cancer. Identification of unique proteins as well as unique proteomic profiles for most cancer types is being pursued actively by many researchers and, if successful, could dramatically enhance our ability to detect cancers early.¹⁷⁰ In addition, there is greater interest placed in leveraging circulating free DNA as a potential approach for cancer screening.

Surgical Therapy

The current trend in surgery is toward more conservative resections. With earlier identification of tumors, more conservative operations may be possible. The goal, however, is always to remove the tumor en bloc with wide negative margins. Another interesting area being explored is the destruction of tumors by techniques such as radiofrequency ablation, cryoablation, and heat-producing technologies like lasers, microwaves, or focused ultrasound. Pilot studies have demonstrated that radiofrequency ablation is effective for destruction of small primary breast cancers. Although this approach remains experimental and potentially of limited applicability because of the need for expertise in breast imaging, the development of imaging technologies that can accurately map the extent of cancer cells, these types of noninvasive interventions are likely to come to the forefront. However, use of these techniques will be limited to treatment of cancers not involving hollow viscera.

The debate over how to manage the regional lymph node basins for certain cancer types continues. With an increasing understanding of the metastatic process, surgeons may be able to stratify patients on the basis of the likelihood that their disease will spread metastatically, based on the gene expression profile of their primary tumors, and offer regional therapy accordingly. There is also a growing interest in minimally invasive surgical treatments for a variety of cancer types.

Systemic Therapy

The current trend in systemic therapy is toward individualized therapy. It is now presumed that all cancers of a certain cell origin are the same. Thus all patients are offered the same systemic therapy. Not all patients respond to these therapies; however, this emphasizes the biologic variability within the tumor groups. Therefore, the intent is to determine the underlying biology of each tumor to tailor therapy accordingly. Genomic, transcriptional, and proteomic profiling approaches are being used to identify molecular signatures that correlate with response to certain agents. It is likely that in the near future all tumors can be

tested and treatments individualized. Patients who will respond to conventional therapies can be treated with these regimens, whereas patients who will not respond will not, which spares them the toxicity. Instead, the latter patients can be offered novel therapies. Furthermore, with emerging biologic therapies, it is likely that patients may be given a combination of biologic therapies that specifically target the alterations in their own tumors. Patients can be genotyped for critical alleles that may affect drug metabolism and thus, may influence the efficacy as well as the side effect of the drugs given. Finally, stratification of patients by gene expression profile for prognosis may assist in determining which patients are at higher risk of relapse, so that patients whose tumors have less aggressive biologic characteristics can be spared further therapy.

REFERENCES

Entries highlighted in bright blue are key references.

1. Siegel R, Naishadham D, Jemal A. **Cancer statistics, 2013.** *CA Cancer J Clin.* 2013;**63**:11-30.
2. Ravdin PM, Cronin KA, Howlader N, et al. The decrease in breast-cancer incidence in 2003 in the United States. *NEngl JMed.* 2007;**356**:1670-1674.
3. Jemal A, Siegel R, Ward E, et al. Cancer statistics, 2008. *CA Cancer J Clin.* 2008;**58**:71-96.
4. Ferlay J, Shin HR, Bray F, Forman D, Mathers C, Parkin DM. **GLOBOCAN 2008 v2.0, Cancer Incidence and Mortality Worldwide: IARC CancerBase No. 10 [Internet]. Lyon, France: International Agency for Research on Cancer; 2010. Available at: <http://globocan.iarc.fr>. Accessed March 1, 2013.**
5. Parkin DM, Bray F, Ferlay J, Pisani P. Global cancer statistics, 2002. *CA Cancer J Clin.* 2005;**55**:74-108.
6. Hanahan D, Weinberg RA. The hallmarks of cancer. *Cell.* 2000;**100**:57-70.
7. Hanahan D, Weinberg RA. Hallmarks of cancer: the next generation. *Cell.* 2011;**144**:646-674.
8. Pelengaris S, Khan M, Evan G. c-MYC: more than just a matter of life and death. *Nat Rev Cancer.* 2002;**2**:764-776.
9. Fearon ER, Vogelstein B. **A genetic model for colorectal tumorigenesis.** *Cell.* 1990;**61**:759-767.
10. Kastan M, Skapek S. Molecular biology of cancer: the cell cycle. In: DeVita V, Hellman S, Rosenberg S, eds. *Cancer: Principles and Practice of Oncology.* 7th ed: Lippincott Williams & Wilkins; 2005.
11. Eccles SA. The role of c-erbB-2/HER2/neu in breast cancer progression and metastasis. *J Mammary Gland Biol Neoplasia.* 2001;**6**:393-406.
12. Wang SC, Hung MC. HER2 overexpression and cancer targeting. *Semin Oncol.* 2001;**28**:115-124.
13. Schechter AL, Stern DF, Vaidyanathan L, et al. The neu oncogene: an erb-B-related gene encoding a 185,000-Mr tumour antigen. *Nature.* 1984;**312**:513-516.
14. Arcila ME, Chaft JE, Nafa K, et al. Prevalence, clinicopathologic associations, and molecular spectrum of ERBB2 (HER2) tyrosine kinase mutations in lung adenocarcinomas. *Clinical cancer research: an official Journal of the American Association for Cancer Research.* 2012;**18**:4910-4918.
15. Wang SE, Narasanna A, Perez-Torres M, et al. HER2 kinase domain mutation results in constitutive phosphorylation and activation of HER2 and EGFR and resistance to EGFR tyrosine kinase inhibitors. *Cancer Cell.* 2006;**10**:25-38.
16. Li D, Ambrogio L, Shimamura T, et al. BIBW2992, an irreversible EGFR/HER2 inhibitor highly effective in preclinical lung cancer models. *Oncogene.* 2008;**27**:4702-4711.
17. Shimamura T, Ji H, Minami Y, et al. Non-small-cell lung cancer and Ba/F3 transformed cells harboring the ERBB2

- G776insV_G/C mutation are sensitive to the dual-specific epidermal growth factor receptor and ERBB2 inhibitor HKI-272. *Cancer Res.* 2006;66:6487-6491.
18. Bose R, Kavuri SM, Searleman AC, et al. Activating HER2 mutations in HER2 gene amplification negative breast cancer. *Cancer Discov.* 2013;3:224-237.
 19. Kim R, Tanabe K, Uchida Y, Emi M, Inoue H, Toge T. Current status of the molecular mechanisms of anticancer drug-induced apoptosis. The contribution of molecular-level analysis to cancer chemotherapy. *Cancer ChemotherPharmacol.* 2002;50:343-352.
 20. Igney FH, Krammer PH. Death and anti-death: tumour resistance to apoptosis. *Nat Rev Cancer.* 2002;2:277-288.
 21. Yu EW, Koshland DE Jr. Propagating conformational changes over long (and short) distances in proteins. *Proc Natl AcadSciUSA.* 2001;98:9517-520.
 22. Folkman J, Merler E, Abernathy C, Williams G. Isolation of a tumor factor responsible for angiogenesis. *J ExpMed.* 1971;133:275-288.
 23. McCarty MF, Liu W, Fan F, et al. Promises and pitfalls of anti-angiogenic therapy in clinical trials. *Trends Mol Med.* 2003;9:53-58.
 24. Soker S, Takashima S, Miao HQ, Neufeld G, Klagsbrun M. Neuropilin-1 is expressed by endothelial and tumor cells as an isoform-specific receptor for vascular endothelial growth factor. *Cell.* 1998;92:735-745.
 25. Stacker SA, Achen MG, Jussila L, Baldwin ME, Alitalo K. Lymphangiogenesis and cancer metastasis. *Nat Rev Cancer.* 2002;2:573-583.
 26. He Y, Kozaki K, Karpanen T, et al. Suppression of tumor lymphangiogenesis and lymph node metastasis by blocking vascular endothelial growth factor receptor 3 signaling. *J Natl Cancer Inst.* 2002;94:819-825.
 27. Steeg PS. Metastasis suppressors alter the signal transduction of cancer cells. *Nat Rev Cancer.* 2003;3:55-63.
 28. Naumov GN, MacDonald IC, Weinmeister PM, et al. Persistence of solitary mammary carcinoma cells in a secondary site: a possible contributor to dormancy. *Cancer Res.* 2002;62:2162-2168.
 29. Demicheli R. Tumour dormancy: findings and hypotheses from clinical research on breast cancer. *Semin Cancer Biol.* 2001;11:297-306.
 30. Chambers AF, Groom AC, MacDonald IC. Dissemination and growth of cancer cells in metastatic sites. *Nat Rev Cancer.* 2002;2:563-572.
 31. van de Vijver MJ, He YD, van't Veer LJ, et al. A gene-expression signature as a predictor of survival in breast cancer. *N Engl J Med.* 2002;347:1999-2009.
 32. De Craene B, Bex G. Regulatory networks defining EMT during cancer initiation and progression. *Nat Rev Cancer.* 2013;13:97-110.
 33. Alderton GK. Metastasis: epithelial to mesenchymal and back again. *Nat RevCancer.* 2013;13:3.
 34. Ocana OH, Corcoles R, Fabra A, et al. Metastatic colonization requires the repression of the epithelial-mesenchymal transition inducer Prrx1. *Cancer Cell.* 2012;22:709-724.
 35. Tsai JH, Donaher JL, Murphy DA, Chau S, Yang J. Spatio-temporal regulation of epithelial-mesenchymal transition is essential for squamous cell carcinoma metastasis. *Cancer Cell.* 2012;22:725-736.
 36. Reya T, Morrison SJ, Clarke MF, Weissman IL. Stem cells, cancer, and cancer stem cells. *Nature.* 2001;414:105-111.
 37. Stratton MR, Campbell PJ, Futreal PA. The cancer genome. *Nature.* 2009;458:719-724.
 38. Olivier M, Hussain SP, Caron de Fromentel C, Hainaut P, Harris CC. TP53 mutation spectra and load: a tool for generating hypotheses on the etiology of cancer. *IARC Sci Publ.* 2004:247-270.
 39. Kennedy RD, D'Andrea AD. DNA repair pathways in clinical practice: lessons from pediatric cancer susceptibility syndromes. *J Clin Oncol.* 2006;24:3799-3808.
 40. Hanks S, Rahman N. Aneuploidy-cancer predisposition syndromes: a new link between the mitotic spindle checkpoint and cancer. *Cell Cycle.* 2005;4:225-227.
 41. Lengauer C, Kinzler KW, Vogelstein B. Genetic instabilities in human cancers. *Nature.* 1998;396:643-649.
 42. Futreal PA, Coin L, Marshall M, et al. A census of human cancer genes. *Nat Rev Cancer.* 2004;4:177-183.
 43. Forbes SA, Tang G, Bindal N, et al. COSMIC (the Catalogue of Somatic Mutations in Cancer): a resource to investigate acquired mutations in human cancer. *Nucleic Acids Res.* 2010;38:D652-D657.
 44. Meric-Bernstam F, Mills GB. Overcoming implementation challenges of personalized cancer therapy. *Nat Rev Clin Oncol.* 2012;9:542-548.
 45. Perou CM, Sorlie T, Eisen MB, et al. Molecular portraits of human breast tumours. *Nature.* 2000;406:747-752.
 46. Sorlie T, Tibshirani R, Parker J, et al. Repeated observation of breast tumor subtypes in independent gene expression data sets. *Proc Natl Acad Sciences USA.* 2003;100:8418-8423.
 47. Sorlie T, Perou CM, Tibshirani R, et al. Gene expression patterns of breast carcinomas distinguish tumor subclasses with clinical implications. *Proc Natl AcadSciences USA.* 2001;98:10869-10874.
 48. Gerlinger M, Rowan AJ, Horswell S, et al. Intratumor heterogeneity and branched evolution revealed by multiregion sequencing. *N Engl J Med.* 2012;366:883-892.
 49. Vahteristo P, Tamminen A, Karvinen P, et al. p53, CHK2, and CHK1 genes in Finnish families with Li-Fraumeni syndrome: further evidence of CHK2 in inherited cancer predisposition. *Cancer Res.* 2001;61:5718-5722.
 50. DiCiommo D, Gallie BL, Bremner R. Retinoblastoma: the disease, gene and protein provide critical leads to understand cancer. *Semin Cancer Biol.* 2000;10:255-269.
 51. Knudson AG. Two genetic hits (more or less) to cancer. *Nat Rev Cancer.* 2001;1:157-162.
 52. Li FP, Fraumeni JF Jr. Soft-tissue sarcomas, breast cancer, and other neoplasms. A familial syndrome? *Ann Intern Med.* 1969;71:747-752.
 53. Li FP, Fraumeni JF Jr., Mulvihill JJ, et al. A cancer family syndrome in twenty-four kindreds. *Cancer Res.* 1988;48:5358-5362.
 54. Birch JM, Hartley AL, Tricker KJ, et al. Prevalence and diversity of constitutional mutations in the p53 gene among 21 Li-Fraumeni families. *Cancer Res.* 1994;54:1298-1304.
 55. Birch JM, Alston RD, McNally RJ, et al. Relative frequency and morphology of cancers in carriers of germline TP53 mutations. *Oncogene.* 2001;20:4621-4628.
 56. Birch JM, Blair V, Kelsey AM, et al. Cancer phenotype correlates with constitutional TP53 genotype in families with the Li-Fraumeni syndrome. *Oncogene.* 1998;17:1061-1068.
 57. Loman N, Johannsson O, Kristoffersson U, Olsson H, Borg A. Family history of breast and ovarian cancers and BRCA1 and BRCA2 mutations in a population-based series of early-onset breast cancer. *J Natl Cancer Inst.* 2001;93:1215-1223.
 58. Ford D, Easton DF, Bishop DT, Narod SA, Goldgar DE. Risks of cancer in BRCA1-mutation carriers. Breast Cancer Linkage Consortium. *Lancet.* 1994;343:692-695.
 59. Ford D, Easton DF, Stratton M, et al. Genetic heterogeneity and penetrance analysis of the BRCA1 and BRCA2 genes in breast cancer families. The Breast Cancer Linkage Consortium. *Am J Hum Genet.* 1998;62:676-689.
 60. The Breast Cancer Linkage Consortium. Cancer risks in BRCA2 mutation carriers. *J Natl Cancer Inst.* 1999;91:1310-1316.
 61. Venkitaraman AR. Cancer susceptibility and the functions of BRCA1 and BRCA2. *Cell.* 2002;108:171-182.

62. Liu Y, West SC. Distinct functions of BRCA1 and BRCA2 in double-strand break repair. *Breast Cancer Res.* 2002;4:9-13.
63. Venkitaraman AR. Functions of BRCA1 and BRCA2 in the biological response to DNA damage. *J Cell Sci.* 2001;114:3591-3598.
64. Hedenfalk I, Duggan D, Chen Y, et al. Gene-expression profiles in hereditary breast cancer. *N Engl J Med.* 2001;344:539-548.
65. Sieber OM, Tomlinson IP, Lamlum H. The adenomatous polyposis coli (APC) tumour suppressor—genetics, function and disease. *Mol Med Today.* 2000;6:462-469.
66. Caspari R, Olschwang S, Friedl W, et al. Familial adenomatous polyposis: desmoid tumours and lack of ophthalmic lesions (CHRPE) associated with APC mutations beyond codon 1444. *Hum Mol Genet.* 1995;4:337-340.
67. Davies DR, Armstrong JG, Thakker N, et al. Severe Gardner syndrome in families with mutations restricted to a specific region of the APC gene. *Am J Hum Genet.* 1995;57:1151-1158.
68. Lynch HT, Smyrk TC, Watson P, et al. Genetics, natural history, tumor spectrum, and pathology of hereditary nonpolyposis colorectal cancer: an updated review. *Gastroenterology.* 1993;104:1535-1549.
69. Vasen HF, Watson P, Mecklin JP, Lynch HT. New clinical criteria for hereditary nonpolyposis colorectal cancer (HNPCC, Lynch syndrome) proposed by the International Collaborative group on HNPCC. *Gastroenterology.* 1999;116:1453-1456.
70. Leach FS, Nicolaides NC, Papadopoulos N, et al. Mutations of a mutS homolog in hereditary nonpolyposis colorectal cancer. *Cell.* 1993;75:1215-1225.
71. Fishel R, Lescoe MK, Rao MR, et al. The human mutator gene homolog MSH2 and its association with hereditary nonpolyposis colon cancer. *Cell.* 1993;75:1027-1038.
72. Miyaki M, Konishi M, Tanaka K, et al. Germline mutation of MSH6 as the cause of hereditary nonpolyposis colorectal cancer. *Nat Genet.* 1997;17:271-272.
73. Bronner CE, Baker SM, Morrison PT, et al. Mutation in the DNA mismatch repair gene homologue hMLH1 is associated with hereditary non-polyposis colon cancer. *Nature.* 1994;368:258-261.
74. Papadopoulos N, Nicolaides NC, Wei YF, et al. Mutation of a mutL homolog in hereditary colon cancer. *Science.* 1994;263:1625-1629.
75. Nicolaides NC, Papadopoulos N, Liu B, et al. Mutations of two PMS homologues in hereditary nonpolyposis colon cancer. *Nature.* 1994;371:75-80.
76. Steck PA, Pershouse MA, Jasser SA, et al. Identification of a candidate tumour suppressor gene, MMAC1, at chromosome 10q23.3 that is mutated in multiple advanced cancers. *Nat Genet.* 1997;15:356-362.
77. Liaw D, Marsh DJ, Li J, et al. Germline mutations of the PTEN gene in Cowden disease, an inherited breast and thyroid cancer syndrome. *Nat Genet.* 1997;16:64-67.
78. Eng C. Will the real Cowden syndrome please stand up: revised diagnostic criteria. *J Med Genet.* 2000;37:828-830.
79. Greene MH. The genetics of hereditary melanoma and nevi. 1998 update. *Cancer.* 1999;86:2464-2477.
80. Goldstein AM, Fraser MC, Struewing JP, et al. Increased risk of pancreatic cancer in melanoma-prone kindreds with p16INK4 mutations. *N Engl J Med.* 1995;333:970-974.
81. Fitzgerald RC, Caldas C. E-cadherin mutations and hereditary gastric cancer: prevention by resection? *Dig Dis.* 2002;20:23-31.
82. Bex G, Van Roy F. The E-cadherin/catenin complex: an important gatekeeper in breast cancer tumorigenesis and malignant progression. *Breast Cancer Res.* 2001;3:289-293.
83. Alsanea O, Clark OH. Familial thyroid cancer. *Curr Opin Oncol.* 2001;13:44-51.
84. Redmond DE Jr. Tobacco and cancer: the first clinical report, 1761. *N Engl J Med.* 1970;282:18-23.
85. <http://monographs.iarc.fr/ENG/Classification/index.php>: IARC Monographs on the Evaluation of Carcinogenic Risks to Humans, Complete List of Agents Evaluated and Their Classification, International Agency for Research on Cancer (IARC). Accessed January 16, 2008.
86. Baan R, Grosse Y, Straif K, et al. A review of human carcinogens—Part F: chemical agents and related occupations. *Lancet Oncol.* 2009;10:1143-1144.
87. Timblin C, Janssen-Heininger Y, Mossman B. Physical agents in human carcinogenesis. In: Coleman W, Tsongalis G, eds. *The Molecular Basis of Human Cancer.* Totowa, NJ: Humana Press; 2002:223.
88. Stanton MF, Layard M, Tegeris A, et al. Relation of particle dimension to carcinogenicity in amphibole asbestoses and other fibrous minerals. *J Natl Cancer Inst.* 1981;67:965-975.
89. Rous P. A transmissible avian neoplasm. (Sarcoma of the common fowl) by Peyton Rous, M.D., *Experimental Medicine for Sept. 1, 1910*, vol. 12, pp. 696-705. *J Exp Med.* 1979;150:738-753.
90. Butel JS. Viral carcinogenesis: revelation of molecular mechanisms and etiology of human disease. *Carcinogenesis.* 2000;21:405-426.
91. El-Serag HB. Hepatocellular carcinoma and hepatitis C in the United States. *Hepatology.* 2002;36:S74-S83.
92. Ault KA. Effect of prophylactic human papillomavirus L1 virus-like-particle vaccine on risk of cervical intraepithelial neoplasia grade 2, grade 3, and adenocarcinoma in situ: a combined analysis of four randomised clinical trials. *Lancet.* 2007;369:1861-1868.
93. Smith RA, Brooks D, Cokkinides V, Saslow D, Brawley OW. **Cancer screening in the United States, 2013: A review of current American Cancer Society guidelines, current issues in cancer screening, and new guidance on cervical cancer screening and lung cancer screening.** *CA Cancer J Clin.* 2013;63:87-105.
94. Whitman G, Stelling C. Stereotactic core needle biopsy of breast lesions: Experience at the University of Texas M. D. Anderson Cancer Center. In: Singletary S, ed. *Breast Cancer.* New York Springer-Verlag; 1999:4.
95. Claus EB, Risch N, Thompson WD. Autosomal dominant inheritance of early-onset breast cancer. Implications for risk prediction. *Cancer.* 1994;73:643-651.
96. Tyrer J, Duffy SW, Cuzick J. A breast cancer prediction model incorporating familial and personal risk factors. *Stat Med.* 2004;23:1111-1130.
97. Berry DA, Iversen ES, Jr, Gudbjartsson, et al. BRCAPRO validation, sensitivity of genetic testing of BRCA1/BRCA2, and prevalence of other breast cancer susceptibility genes. *J Clin Oncol.* 2002;20:2701-2712.
98. Antoniou AC, Pharoah PP, Smith P, Easton DF. The BOADICEA model of genetic susceptibility to breast and ovarian cancer. *Br J Cancer.* 2004;91:1580-1590.
99. Gail MH, Brinton LA, Byar DP, et al. Projecting individualized probabilities of developing breast cancer for white females who are being examined annually. *J Natl Cancer Inst.* 1989;81:1879-1886.
100. <http://www.cancer.gov/bcrisktool>: Breast Cancer Risk Assessment Tool, National Cancer Institute. Accessed December 26, 2008.
101. Bach PB, Kattan MW, Thornquist MD, et al. Variations in lung cancer risk among smokers. *J Natl Cancer Inst.* 2003;95:470-478.
102. Bassett L, Hendrick R, Bassford T. Quality determinants of mammography. In: Agency for Health Care Policy and Research PHS, ed. *Clinical Practice Guideline No 13.* Rockville, HHS, US; 1994.
103. Saslow D, Boetes C, Burke W, et al. American Cancer Society guidelines for breast screening with MRI as an adjunct to mammography. *Cancer J Clin.* 2007;57:75-89.
104. Aberle DR, Adams AM, Berg CD, et al. Reduced lung-cancer mortality with low-dose computed tomographic screening. *N Engl J Med.* 2011;365:395-409.

105. Wender R, Fontham ET, Barrera E, Jr., et al. American Cancer Society lung cancer screening guidelines. *Cancer J Clin.* 2013;63:106-117.
106. Jacobs TW, Connolly JL, Schnitt SJ. Nonmalignant lesions in breast core needle biopsies: to excise or not to excise? *Am J Surg Pathol.* 2002;26:1095-1110.
107. Harris L, Fritsche H, Mennel R, et al. American Society of Clinical Oncology 2007 update of recommendations for the use of tumor markers in breast cancer. *J Clin Oncol.* 2007;25:5287-5312.
108. Locker GY, Hamilton S, Harris J, et al. ASCO 2006 update of recommendations for the use of tumor markers in gastrointestinal cancer. *J Clin Oncol.* 2006;24:5313-5327.
109. Way BA, Kessler G. Tumour marker overview. *Lab Med Newsletter.* 1996;4:1-7.
110. Paik S, Shak S, Tang G, et al. A multigene assay to predict recurrence of tamoxifen-treated, node-negative breast cancer. *N Engl J Med.* 2004;351:2817-2826.
111. van 't Veer LJ, Dai H, van de Vijver MJ, et al. Gene expression profiling predicts clinical outcome of breast cancer. *Nature.* 2002;415:530-536.
112. Moyer VA. Screening for prostate cancer: U.S. Preventive Services Task Force recommendation statement. *Ann Intern Med.* 2012;157:120-134.
113. Wolf AM, Wender RC, Etzioni RB, et al. American Cancer Society guideline for the early detection of prostate cancer: update 2010. *Cancer J Clin.* 2010;60:70-98.
114. <http://www.labcorp.com/datasets/labcorp/html/chapter/mono/ri000600.htm>: Alpha-Fetoprotein (AFP), Serum, Tumor Marker (Serial Monitor), Laboratory Corporation of America. Accessed December 26, 2008.
115. Nguyen MH, Keeffe EB. Screening for hepatocellular carcinoma. *J Clin Gastroenterol.* 2002;35:S86-S91.
116. Chan DW, Beveridge RA, Muss H, et al. Use of Truquant BR radioimmunoassay for early detection of breast cancer recurrence in patients with stage II and stage III disease. *J Clin Oncol.* 1997;15:2322-2328.
117. Outcomes of cancer treatment for technology assessment and cancer treatment guidelines. American Society of Clinical Oncology. *J Clin Oncol.* 1996;14:671-679.
118. Cristofanilli M, Budd GT, Ellis MJ, et al. Circulating tumor cells, disease progression, and survival in metastatic breast cancer. *N Engl J Med.* 2004;351:781-791.
119. Lucci A, Hall CS, Lodhi AK, et al. Circulating tumour cells in non-metastatic breast cancer: a prospective study. *Lancet Oncol.* 2012;13:688-695.
120. Scoggins CR, Ross MI, Reintgen DS, et al. Prospective multi-institutional study of reverse transcriptase polymerase chain reaction for molecular staging of melanoma. *J Clin Oncol.* 2006;24:2849-2857.
121. Braun S, Vogl FD, Naume B, et al. A pooled analysis of bone marrow micrometastasis in breast cancer. *N Engl J Med.* 2005;353:793-802.
122. Giuliano AE, Hawes D, Ballman KV, et al. Association of occult metastases in sentinel lymph nodes and bone marrow with survival among women with early-stage invasive breast cancer. *JAMA.* 2011;306:385-393.
123. Janni W, Rack B, Lindemann K, Harbeck N. Detection of micrometastatic disease in bone marrow: is it ready for prime time? *Oncologist.* 2005;10:480-492.
124. Grau A, Spitz F, Bouvet M. Pancreatic adenocarcinoma. In: Feig B, Berger D, Fuhrman G, eds. *The M D Anderson Surgical Oncology Handbook.* Philadelphia Lippincott Williams & Wilkins; 2003:303.
125. Balch CM, Soong SJ, Smith T, et al. Long-term results of a prospective surgical trial comparing 2 cm vs. 4 cm excision margins for 740 patients with 1-4 mm melanomas. *Ann Surg Oncol.* 2001;8:101-108.
126. Moore HG, Riedel E, Minsky BD, et al. Adequacy of 1-cm distal margin after restorative rectal cancer resection with sharp mesorectal excision and preoperative combined-modality therapy. *Ann Surg Oncol.* 2003;10:80-85.
127. Kapiteijn E, van de Velde CJ. The role of total mesorectal excision in the management of rectal cancer. *Surg Clin North Am.* 2002;82:995-1007.
128. Meric F, Hunt KK. Surgical options for breast cancer. In: Hunt KK, Robb GL, Strom EA, Ueno NT, eds. *M D Anderson Cancer Care Series-Breast Cancer.* New York Springer-Verlag; 2001:187-222.
129. Cabanas RM. An approach for the treatment of penile carcinoma. *Cancer.* 1977;39:456-466.
130. Querzoli P, Pedriali M, Rinaldi R, et al. Axillary lymph node nanometastases are prognostic factors for disease-free survival and metastatic relapse in breast cancer patients. *Clin Cancer Res.* 2006;12:6696-6701.
131. Mocellin S, Pilati P, Lise M, Nitti D. Meta-analysis of hepatic arterial infusion for unresectable liver metastases from colorectal cancer: the end of an era? *J Clin Oncol.* 2007;25:5649-5654.
132. Pearson AS, Izzo F, Fleming RY, et al. Intraoperative radiofrequency ablation or cryoablation for hepatic malignancies. *Am J Surg.* 1999;178:592-599.
133. Curley SA, Izzo F. Radiofrequency ablation of primary and metastatic hepatic malignancies. *Int J Clin Oncol.* 2002;7:72-81.
134. Fisher B, Bryant J, Wolmark N, et al. Effect of preoperative chemotherapy on the outcome of women with operable breast cancer. *J Clin Oncol.* 1998;16:2672-2685.
135. Meric F, Hess KR, Varma DG, et al. Radiographic response to neoadjuvant chemotherapy is a predictor of local control and survival in soft tissue sarcomas. *Cancer.* 2002;95:1120-1126.
136. Therasse P, Arbuck SG, Eisenhauer EA, et al. New guidelines to evaluate the response to treatment in solid tumors. European Organization for Research and Treatment of Cancer, National Cancer Institute of the United States, National Cancer Institute of Canada. *J Natl Cancer Inst.* 2000;92:205-216.
137. Page R. Principles of Chemotherapy. In: Pazdur R, Hoskins W, Coia L, eds. *Cancer Management: A Multidisciplinary Approach.* Melville PRR Inc; 2001:21.
138. Miller AB, Hoogstraten B, Staquet M, Winkler A. Reporting results of cancer treatment. *Cancer.* 1981;47:207-214.
139. Chapman PB, Hauschild A, Robert C, et al. Improved survival with vemurafenib in melanoma with BRAF V600E mutation. *N Engl J Med.* 2011;364:2507-2516.
140. McAuliffe PF, Meric-Bernstam F, Mills GB, Gonzalez-Angulo AM. Deciphering the role of PI3K/Akt/mTOR pathway in breast cancer biology and pathogenesis. *Clin Breast Cancer.* 2010;10 Suppl 3:S59-S65.
141. Mocellin S, Rossi CR, Lise M, Marincola FM. Adjuvant immunotherapy for solid tumors: from promise to clinical application. *Cancer Immunol Immunother.* 2002;51:583-595.
142. Perales MA, Wolchok JD. Melanoma vaccines. *Cancer Invest.* 2002;20:1012-1026.
143. Lizee G, Cantu MA, Hwu P. Less yin, more yang: confronting the barriers to cancer immunotherapy. *Clin Cancer Res.* 2007;13:5250-5255.
144. Dermime S, Armstrong A, Hawkins RE, Stern PL. Cancer vaccines and immunotherapy. *Br Med Bull.* 2002;62:149-162.
145. Berinstein NL. Enhancing cancer vaccines with immunomodulators. *Vaccine.* 2007;25 Suppl 2:B72-B88.
146. Cranmer LD, Hersh E. The role of the CTLA4 blockade in the treatment of malignant melanoma. *Cancer Invest.* 2007;25:613-631.
147. Hodi FS, O'Day SJ, McDermott DF, et al. Improved survival with ipilimumab in patients with metastatic melanoma. *The N Engl J Med.* 2010;363:711-723.
148. Robert C, Thomas L, Bondarenko I, et al. Ipilimumab plus dacarbazine for previously untreated metastatic melanoma. *N Engl J Med.* 2011;364:2517-2526.

149. Cusack JC, Jr., Tanabe KK. Introduction to cancer gene therapy. *Surg Oncol Clin N Am*. 2002;11:497-519.
150. Morrow C, Cowan K. Drug resistance and its clinical circumvention. In: Bast R, Kufe D, Pollock R, eds. *Cancer Medicine*. Hamilton: B.C. Decker, Inc; 2000:539.
151. Mittendorf EA, Wu Y, Scaltriti M, et al. Loss of HER2 amplification following trastuzumab-based neoadjuvant systemic therapy and survival outcomes. *Clin Cancer Res* 2009;15:7381-7388.
152. Pao W, Miller VA, Politi KA, et al. Acquired resistance of lung adenocarcinomas to gefitinib or erlotinib is associated with a second mutation in the EGFR kinase domain. *PLoS Med*. 2005;2:e73.
153. Engelman JA, Zejnullahu K, Mitsudomi T, et al. MET amplification leads to gefitinib resistance in lung cancer by activating ERBB3 signaling. *Science*. 2007;316:1039-1043.
154. Bean J, Brennan C, Shih JY, et al. *MET* amplification occurs with or without *T790M* mutations in *EGFR* mutant lung tumors with acquired resistance to gefitinib or erlotinib. *Proc Natl Acad Sci USA*. 2007;104:20932-20937.
155. Sequist LV, Waltman BA, Dias-Santagata D, et al. Genotypic and histological evolution of lung cancers acquiring resistance to EGFR inhibitors. *Sci Transl Med*. 2011;3:75ra26.
156. Takezawa K, Pirazzoli V, Arcila ME, et al. HER2 amplification: a potential mechanism of acquired resistance to EGFR inhibition in EGFR-mutant lung cancers that lack the second-site EGFR T790M mutation. *Cancer Discov*. 2012;2:922-933.
157. Misale S, Yaeger R, Hobor S, et al. Emergence of KRAS mutations and acquired resistance to anti-EGFR therapy in colorectal cancer. *Nature*. 2012;486:532-536.
158. Mundt A, Roeske J, Weichelbaum R. Principles of Radiation Oncology. In: Bast R, Kuff D, Pollock R, eds. *Cancer Medicine*. Hamilton B.C. Decker Inc; 2000:465.
159. Raju MR, Carpenter SG. A heavy particle comparative study. Part IV: acute and late reactions. *Br J Radiol*. 1978;51:720-727.
160. Eisbruch A, Lichter AS. What a surgeon needs to know about radiation. *Ann Surg Oncol*. 1997;4:516-522.
161. Hartford AC, Galvin JM, Beyer DC, et al. American College of Radiology (ACR) and American Society for Radiation Oncology (ASTRO) Practice Guideline for Intensity-modulated Radiation Therapy (IMRT). *Am J Clin Oncol*. 2012;35:612-617.
162. McCarthy K, Pearson K, Fulton R, Hewitt J. Pre-operative chemoradiation for non-metastatic locally advanced rectal cancer. *Cochrane Database Syst Rev*. 2012;12:CD008368.
163. Evans DB, Varadhachary GR, Crane CH, et al. Preoperative gemcitabine-based chemoradiation for patients with resectable adenocarcinoma of the pancreatic head. *J Clin Oncol*. 2008;26:3496-3502.
164. Courrech Staal EF, Aleman BM, Boot H, van Velthuysen ML, van Tinteren H, van Sandick JW. Systematic review of the benefits and risks of neoadjuvant chemoradiation for oesophageal cancer. *BrJSurg*. 2010;97:1482-1496.
165. Daly J, Bertagnolli M, DeCosse J. Oncology. In: Schwartz S, Spencer F, Galloway A, eds. *Principles of Surgery*. New York: McGraw-Hill; 1999:297.
166. Fisher B, Costantino JP, Wickerham DL, et al. Tamoxifen for prevention of breast cancer: report of the National Surgical Adjuvant Breast and Bowel Project P-1 Study. *J Natl Cancer Inst*. 1998;90:1371-1388.
167. Vogel VG, Costantino JP, Wickerham DL, et al. Effects of tamoxifen vs raloxifene on the risk of developing invasive breast cancer and other disease outcomes: the NSABP Study of Tamoxifen and Raloxifene (STAR) P-2 trial. *JAMA*. 2006;295:2727-2741.
168. Lippman SM, Batsakis JG, Toth BB, et al. Comparison of low-dose isotretinoin with beta carotene to prevent oral carcinogenesis. *N Engl J Med*. 1993;328:15-20.
169. Hong WK, Lippman SM, Itri LM, et al. Prevention of second primary tumors with isotretinoin in squamous-cell carcinoma of the head and neck. *N Engl J Med*. 1990;323:795-801.
170. Sidransky D. Emerging molecular markers of cancer. *Nat Rev Cancer*. 2002;2:210-219.
171. Meric-Bernstam F, Hung MC. Advances in targeting human epidermal growth factor receptor-2 signaling for cancer therapy. *Clin Cancer Res*. 2006;12:6326-6330.
172. Pao W, Hutchinson KE. Chipping away at the lung cancer genome. *Nat Med*. 2012;18:349-351.

11 chapter

Transplantation

Angelika C. Gruessner, Tun Jie, Klearchos Papas,
Marian Porubsky, Abbas Rana, M. Cristy Smith,
Sarah E. Yost, David L. Dunn, and Rainer W.G. Gruessner

Background	321	Ecuzimab / 329	Islet versus Pancreas Transplants / 344		
Definitions	321	Infections and Malignancies	329	Islet Transplantation	344
History	322	Infections / 329		Liver Transplantation	345
Transplant Immunobiology	323	Malignancies / 330		History / 345	
Transplant Antigens	324	Organ Procurement and Preservation	330	Indications / 346	
Allorecognition and Lymphocyte Activation	324	Deceased Donors / 330		Recipient Selection / 347	
Clinical Rejection	324	Living Donors / 332		Contraindications / 348	
Hyperacute / 324		Organ Preservation / 332		Surgical Procedure / 348	
Acute / 324		Kidney Transplantation	334	Pediatric Transplants / 349	
Chronic / 324		Introduction / 334		Deceased Donor Split-Liver Transplants / 349	
Clinical Immunosuppression	324	Pretransplant Evaluation / 334		Living Donor Transplants / 349	
Induction	325	Medical Evaluation / 335		Postoperative Care / 349	
Depleting Antibodies / 325		Surgical Evaluation / 336		Evaluation of Graft Function / 351	
Nondepleting Antibodies / 325		Recipient Operation / 336		Complications / 351	
Maintenance	325	Grafts with Multiple Renal Arteries / 337		Intestine and Multivisceral Transplantation	352
Corticosteroids / 325		En Bloc Grafts / 338		Indications and Recipient Selection / 352	
Azathioprine / 326		Perioperative Care / 338		Surgical Procedure / 352	
Mycophenolate Mofetil / 326		Results / 339		Postoperative Care / 353	
Sirolimus / 327		Pancreas Transplantation	340	Heart and Lung Transplantation	354
Cyclosporine / 328		Donor Operation / 340		History / 354	
Tacrolimus / 328		Back Table Preparation of the Pancreas Graft / 341		Heart Transplants / 355	
Belatacept / 328		Recipient Operation / 341		Lung Transplants / 356	
Humoral Rejection	328	Complications / 343		Heart-Lung Transplants / 358	
Rituximab / 328		Living Donor Pancreas Transplants / 343		Xenotransplants	358
Bortezomib / 329		Results / 344			

BACKGROUND

Organ transplantation is a relatively novel field of medicine that has made significant progress since the second half of the twentieth century. Advances in surgical technique and a better understanding of immunology are the two main reasons that transplants have evolved from experimental procedures, just several decades ago, to a widely accepted treatment today for patients with end-stage organ failure. Throughout the world, for a variety of indications, kidney, liver, pancreas, intestine, heart, and lung transplants are now the current standard of care.

But the success of transplantation has created new challenges. A better understanding of the pathophysiology of end-stage organ failure as well as advances in critical care medicine and in the treatment of various diseases led to expanding the criteria for, and decreasing the contraindications to, transplants.

As a result, the discrepancy between the ever-growing number of patients awaiting a transplant and the limited number of organs available is one of the biggest challenges (Fig. 11-1). In 2009 alone, according to the United Network for Organ Sharing (UNOS), about 105,000 patients in the United States were awaiting a transplant, yet the number of transplants performed was only about 28,000 (Fig. 11-2).

DEFINITIONS

In addition to being the overall name of this relatively new field of medicine, *transplantation* is the process of transferring an organ, tissue, or cell from one place to another. An *organ transplant* is a surgical procedure in which a failing organ is replaced by a functioning one. The organ is transplanted either orthotopically (implanted in the same anatomic location in the recipient as it was in the donor) or heterotopically (implanted in

Key Points

- 1▶ The field of transplantation has made tremendous advances in the last 50 years, mainly due to refinements in surgical technique and development of effective immunosuppressive medications.
- 2▶ Although immunosuppressive medications are essential for transplantation, they are associated with significant short- and long-term morbidity.
- 3▶ Opportunistic infections can be significantly lowered by the use of appropriate antimicrobial agents.
- 4▶ Kidney transplantation represents the treatment of choice for almost all patients with end-stage renal disease. The gap between demand (patients on the waiting list) and supply (available kidneys) continues to widen.
- 5▶ Pancreas transplantation represents the most reliable way to achieve euglycemia in patients with poorly controlled diabetes.
- 6▶ The results of islet transplantation continue to improve but still trail those of pancreas transplantation.
- 7▶ Liver transplantation has become the standard of care for many patients with end-stage liver failure and/or liver cancer.

another anatomic location). Orthotopic transplants require the removal of the diseased organ (heart, lungs, liver, or intestine); in heterotopic transplants, the diseased organ is kept in place (kidney, pancreas).

According to the degree of immunologic similarity between the donor and recipient, transplants are divided into three main categories: (a) An *autotransplant* is the transfer of cells, tissue, or an organ from one part of the body to another part in the same person, so no immunosuppression is required. This type of transplant includes skin and vein, bone, cartilage, nerve, and islet cell transplants. (b) An *allograft* is the transfer of cells, tissue, or an organ from one person to another of the same species. The immune system of the recipient recognizes the donated organ as a foreign body, so immunosuppression is required in order to avoid rejection. (c) A *xenograft* is the transfer of cells, tissue, or an organ from one organism to another from a different species. To date, animal-to-human transplants are still experimental procedures, given the very complex immunologic and infectious issues that have yet to be solved.

HISTORY

Over the centuries, multiple references to transplantation can be found in the literature. Yet transplantation as a recognized scientific and medical field began to emerge only in the middle of the twentieth century. Two major events preceded the rise of transplantation.

First, the surgical technique of the vascular anastomosis was developed by French surgeon Alexis Carrel.¹ This led to increased transplant activity, especially in animal models. Russian surgeon Yu Yu Voronoy was the first to report a series of human-to-human kidney transplants in the 1940s.² But the outcomes were dismal, mainly because of the lack of understanding of the underlying immunologic processes.

Second, the findings of British scientist Sir Peter B. Medawar in the 1940s were also key.³ In his work with skin grafts in animal models and in human burn patients, he learned that the immune system plays a crucial role in the failure of skin grafts. His research led to a better understanding of the immune system and is considered to be the birth of transplant immunobiology.

The first human transplant with long-term success was performed by Joseph Murray in Boston, Massachusetts, in 1954.⁴ Because it was a living related kidney transplant between identical twins, no immunosuppression was required; the recipient lived for another 8 years before he died of issues unrelated to the transplanted kidney. Other centers performed similar transplants and could reproduce the good results.

Ultimately, attempts were made to perform kidney transplants between nonidentical individuals. For immunosuppression, total-body radiation and an anticancer agent called 6-mercaptopurine were used; given the profound toxicity of both those methods of immunosuppression, results were discouraging. A breakthrough was achieved in the early 1960s with

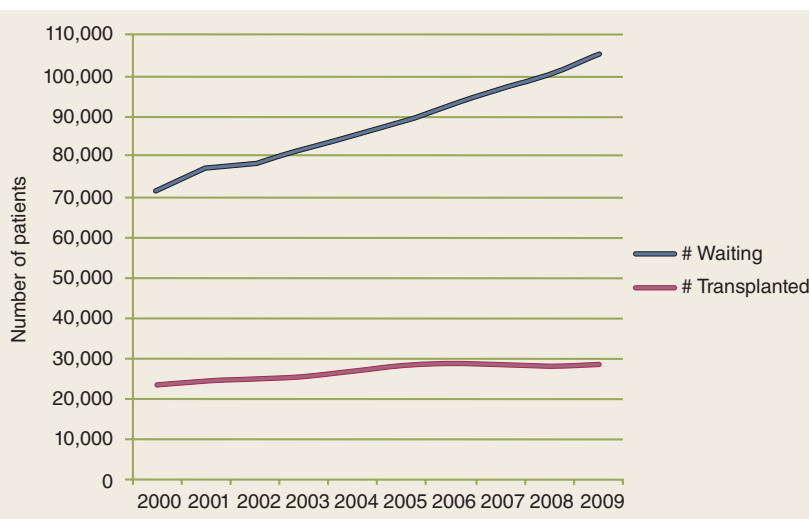


Figure 11-1. Patients on the waiting list and the number of organ transplants performed, 2000 to 2009. (U.S. data from the Scientific Registry of Transplant Recipients Annual Report, <http://srrt.org>)

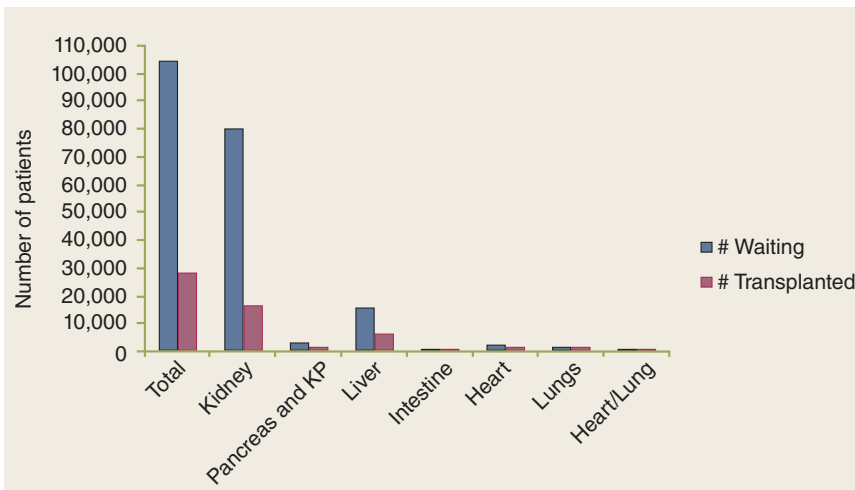


Figure 11-2. Patients on the waiting list and the number of organ transplants performed, 2009. KP = kidney and pancreas. (U.S. data from the Scientific Registry of Transplant Recipients Annual Report, <http://srtr.org>)

the introduction of maintenance immunosuppression through a combination of corticosteroids and a less toxic derivative of 6-mercaptopurine, azathioprine.^{5,6}

Increasing experience with kidney transplants and the better results achieved with maintenance immunosuppression paved the way for the era of extrarenal transplants (Table 11-1). In 1963, the first liver transplant was performed by Thomas Starzl in Denver, Colorado, and the first lung transplant was performed by James Hardy in Jackson, Mississippi. In 1966, the first pancreas transplant was performed by William Kelly and Richard Lillehei in Minneapolis, Minnesota. In 1967, the first successful heart transplant was performed by Christiaan Barnard in Cape Town, South Africa. The early years of transplantation were marked by high mortality, mainly because of irreversible rejection. Dramatic changes occurred with the further development of immunosuppression. The groundbreaking event was the introduction of the first anti-T lymphocyte (T cell) drug, cyclosporine, in the early 1980s.⁷ Since then, with an even better understanding of immunologic processes, many other drugs have been introduced that target specific pathways of rejection. As a result, rejection rates have decreased substantially, allowing a 1-year graft survival rate in excess of 80% in all types of transplants.

The gradual increase in the organ shortage led to innovative surgical techniques. For example, deceased donor split-liver

transplants and living donor liver transplants have helped expand the liver donor pool. Similarly, living donor intestine and pancreas techniques have been developed. The evolution of donor nephrectomy from an open to a minimally invasive procedure (laparoscopic or robotic) has helped increase the pool of living kidney donors.

TRANSPLANT IMMUNOBIOLOGY

The outcomes of early transplants were unsatisfactory. The limiting factor was the lack of understanding of immunologic processes. Irreversible rejection was the reason for graft loss in the vast majority of recipients. A better understanding of transplant immunobiology led to significant improvements in patient and graft survival rates.^{8,9} The immune system is designed as a defense system to protect the body from foreign pathogens, such as viruses, bacteria, and fungi, but it also acts to reject transplanted cells, tissues, and organs, recognizing them as foreign. It mediates other complex processes as well, such as the body's response to trauma or to tumor growth. No matter what the pathogen is, the immune system recognizes it as a foreign antigen and triggers a response that eventually leads either to death or to rejection of the pathogen.

Table 11-1

Transplant history

ORGAN	YEAR	SURGEON	LOCATION
Kidney	1954	Joseph E. Murray	Boston, MA
Liver	1963	Thomas E. Starzl	Denver, CO
Lung	1963	James D. Hardy	Jackson, MS
Pancreas	1966	Richard C. Lillehei	Minneapolis, MN
Heart	1967	Christiaan N. Barnard	Cape Town, South Africa
Small intestine	1967	Richard C. Lillehei	Minneapolis, MN
Heart/lung	1981	Bruce Reitz	Stanford, CA
Multivisceral	1989	Thomas E. Starzl	Pittsburgh, PA

Transplants between genetically nonidentical persons lead to recognition and rejection of the organ by the recipient's immune system, if no intervention is undertaken. The main antigens responsible for this process are part of the major histocompatibility complex (MHC). In humans, these antigens make up the human leukocyte antigen (HLA) system. The antigen-encoding genes are located on chromosome 6. Two major classes of HLA antigens are recognized. They differ in their structure, function, and tissue distribution. Class I antigens (HLA-A, HLA-B, and HLA-C) are expressed by all nucleated cells. Class II antigens (HLA-DR, HLA-DP, and HLA-DQ) are expressed by antigen-presenting cells (APCs) such as B lymphocytes, dendritic cells, macrophages, and other phagocytic cells.

The principal function of HLA antigens is to present the fragments of foreign proteins to T lymphocytes. This leads to recognition and elimination of the foreign antigen with great specificity. HLA molecules play a crucial role in transplant recipients as well. They can trigger rejection of a graft via two different mechanisms. The most common mechanism is cellular rejection, in which the damage is done by activated T lymphocytes. The process of activation and proliferation is triggered by exposure of T lymphocytes to the donor's HLA molecules. The other mechanism is humoral rejection, in which the damage is done by circulating antibodies against the donor's HLA molecules. The donor-specific antibodies can be present either pretransplant, due to previous exposure (because of a previous transplant, pregnancy, blood transfusion, or immunization), or posttransplant. After binding to the donor's HLA molecules, the complement cascade is activated, leading to cellular lysis.

ALLORECOGNITION AND LYMPHOCYTE ACTIVATION

The immune system of each person is designed to discriminate between self and nonself cells and tissues. This process is called allorecognition, with T cells playing the crucial role. The recognition of foreign HLA antigens by the recipient's T cells may occur by either a direct or an indirect pathway. Direct recognition occurs when the recipient's T cells are activated by direct interaction with the donor's HLA molecules. Indirect recognition occurs when the recipient's T cells are activated by interaction with APCs that have processed and presented the foreign antigen. The foreign antigen can be shed from the graft into the circulation, or it can be identified by the APCs in the graft itself.

Independent of the pathway of foreign HLA antigen presentation, the ensuing activation of T cells is similar. A two-signal model, T-cell activation begins with the engagement of the T-cell receptor (TCR)/CD3 complex with the foreign molecule. This interaction causes transmission of the signal into the cell, named signal 1. However, this signal alone is not sufficient to activate the T cell. An additional costimulatory signal is required, named signal 2. Two well-characterized costimulatory interactions are the CD40/CD154 and B7/CD28 pathways. The "master switch" is turned on by the interaction of CD40 protein with APCs, along with the interaction of CD154 protein with T cells; this ligation induces the upregulation of other costimulatory molecules. Transmission of signal 1 and signal 2 into the cell nucleus leads to upregulation of the transcription of genes for several cytokines, including the T-cell growth factor interleukin-2 (IL-2). In turn, IL-2 activates a number of pathways, leading to proliferation and

differentiation of T cells. Rejection is a result of an attack of activated T cells on the transplanted organ.

Although T-cell activation is the main culprit in rejection, B-cell activation and subsequent antibody production also play a role. After the foreign HLA antigen is processed by B cells, it interacts with activated helper T cells, leading to differentiation of B cells into plasma cells and subsequently to their proliferation and antibody production.

CLINICAL REJECTION

Graft rejection is due to a complex interaction of different parts of the immune system, including B and T lymphocytes, APCs, and cytokines. The end result is graft damage caused by inflammatory injury. According to its onset and pathogenesis, rejection is divided into three main types: *hyperacute*, *acute*, and *chronic* (each described in the following sections).

Hyperacute

Hyperacute rejection, a very rapid type of rejection, results in irreversible damage and graft loss within minutes to hours after organ reperfusion. It is triggered by preformed antibodies against the donor's HLA or ABO blood group antigens. These antibodies activate a series of events that result in diffuse intravascular coagulation, causing ischemic necrosis of the graft. Fortunately, pretransplant blood group typing and cross-matching (in which the donor's cells are mixed with the recipient's serum, and then destruction of the cells is observed) have virtually eliminated the incidence of hyperacute rejection.

Acute

Acute rejection, the most common type of rejection, usually occurs within a few days or weeks posttransplant. According to the mechanism involved, it is further divided into cellular (T-cell-mediated) rejection, humoral (antibody-mediated) rejection, or a combination of both. The diagnosis is based on the results of biopsies of the transplanted organ, special immunologic stains, and laboratory tests (such as elevated creatinine levels in kidney transplant recipients, elevated liver function values in liver transplant recipients, and elevated levels of glucose, amylase, and lipase in pancreas transplant recipients).

Chronic

Chronic rejection is a slow type of rejection. It can manifest within the first year posttransplant, but most often progresses gradually over several years. The mechanism is not well understood, but the pathologic changes eventually lead to fibrosis and loss of graft function. With advances in immunosuppression, this relatively rare form of rejection is becoming more common.

CLINICAL IMMUNOSUPPRESSION

A successful transplant is a balance between the recipient's immune response, the donor's allograft, and pharmacologic immunosuppression. Immunosuppressive regimens are very

2► important to graft and patient survival posttransplant. Immunosuppression has evolved from the use of azathioprine and steroids in the 1960s and 1970s to the development, in the 1980s, of cyclosporine, which increased allograft survival.^{10,11} The introduction of tacrolimus and mycophenolate mofetil (MMF) in the 1990s further changed the field of transplantation, enabling a variety of combinations to be used for immunosuppression (Table 11-2).

Table 11-2

Immunosuppressive drugs by grouping**Immunophilin binders**

- Calcineurin inhibitors
 - Cyclosporine
 - Tacrolimus
- Noninhibitors of calcineurin
 - Sirolimus

Antimetabolites

- Inhibitors of de novo purine synthesis
 - Azathioprine
 - Mycophenolate mofetil

Biologic immunosuppression

- Polyclonal antibodies
 - Atgam
 - Antithymocyte immunoglobulin
- Monoclonal antibodies
 - Muromonab-CD3
 - Basiliximab
 - Belatacept
 - Alemtuzumab
 - Rituximab
 - Bortezomib
 - Eculizumab

Other

- Corticosteroids

Immunosuppressants usually are used in multidrug regimens, aimed at increasing efficacy by targeting multiple pathways to lower the immune response and to decrease the toxicity of individual agents. Certain regimens may involve withdrawal, avoidance, or minimization of certain classes of drugs. Transplant centers generally institute their immunosuppressive protocols based on experience, risk profiles, cost considerations, and outcomes. Immunosuppression is delivered in two phases: induction (starting immediately posttransplant, when the risk of rejection is highest) and maintenance (usually starting within days posttransplant and continuing for the life of the recipient or graft). Thus, the level of immunosuppression is highest in the first 3 to 6 months posttransplant; during this time, prophylaxis against various bacterial, viral, or even antifungal opportunistic infections is also given.^{12,13}

A conventional immunosuppressive protocol might include (a) induction with anti-T-lymphocyte–depleting or nondepleting antibodies and (b) maintenance with calcineurin inhibitors, antiproliferative agents, and corticosteroids. Characteristics of the most common immunosuppressive agents are listed in Table 11-3.

INDUCTION

Induction includes the use of depleting (polyclonal) antibodies or nondepleting antibodies within the first month posttransplant. Studies have shown that induction with antibody regimens may prevent acute rejection, potentially leading to improved graft survival and the use of less maintenance immunosuppression.

Depleting Antibodies

Rabbit antithymocyte globulin (Thymoglobulin) is a purified gamma globulin obtained by immunizing rabbits with human

thymocytes. Atgam, which has largely been replaced by Thymoglobulin, is a purified gamma globulin obtained by immunizing horses with human thymocytes. These agents contain antibodies to T cells and B lymphocytes (B cells), integrins, and other adhesion molecules, thereby resulting in rapid depletion of peripheral lymphocytes. Typically, the total dose of Thymoglobulin is roughly 6 mg/kg, a dose that has been shown to confer adequate lymphocyte depletion and better allograft survival. Doses of 3 mg/kg may not effectively prevent acute rejection, but more doses and prolonged duration increase the risk of infection and the potential occurrence of lymphoma. Thymoglobulin administration causes a cytokine release syndrome, so premedications (acetaminophen and diphenhydramine) are usually given. The principal side effects of Thymoglobulin include fever, chills, arthralgias, thrombocytopenia, leukopenia, and an increased incidence of a variety of infections.^{14,15}

Nondepleting Antibodies

Basiliximab (Simulect) is an anti-CD25 monoclonal antibody. The alpha subunit of the IL-2 receptor, also known as *Tac* or *CD25*, is found exclusively on activated T cells. Blockade of this component by monoclonal antibody selectively prevents IL-2–induced T-cell activation. No lymphocyte depletion occurs with basiliximab; it is not designed to be used to treat acute rejection. Its selectivity in blocking IL-2–mediated responses makes it a powerful induction agent without the added risks of infections, malignancies, or other major side effects. Currently, basiliximab is the only available anti-CD25 monoclonal antibody approved for clinical use. Usually, it is followed by the use of calcineurin inhibitors, corticosteroids, and MMF as maintenance immunosuppression.¹⁶

Alemtuzumab (Campath), another anti-CD52 monoclonal antibody, was initially used to treat chronic lymphocytic leukemia. The use of alemtuzumab has grown in the field of transplantation, given its profound lymphocyte-depleting effects. It causes cell death by complement-mediated cytotoxicity, antibody-mediated cytotoxicity, and apoptosis. One dose alone (30 mg) depletes 99% of lymphocytes. Monocyte recovery can be seen at 3 months posttransplant; B-cell recovery at 12 months; and T-cell recovery, albeit only to 50% of baseline, at 36 months. Alemtuzumab causes a significant cytokine release reaction and often requires premedications (steroids and antihistamines). Because of the long-lasting T-cell depletion, the risks of infection and posttransplant lymphoproliferative disorder remain. Currently, alemtuzumab is available only through a limited distribution program, not through commercial medication distributors.^{17,18}

MAINTENANCE**Corticosteroids**

Corticosteroids have had a role in immunosuppression since the beginning of the field of transplantation. Despite numerous attempts to limit or discontinue their use, they remain an integral component of most immunosuppressive protocols, for both induction and maintenance. Moreover, they are often the first-line agents in the treatment of acute rejection. Steroids bind to glucocorticoid-responsive elements in DNA that prevent the transcription of cytokine genes and cytokine receptors. In addition, steroids have an impact on lymphocyte depletion, on decreases in cell-mediated immunity, and on T-cell activation of many phases of rejection.

Table 11-3

Summary of the main immunosuppressive drugs

DRUG	MECHANISM OF ACTION	ADVERSE EFFECTS	CLINICAL USES	DOSAGE
Cyclosporine (CSA)	Binds to cyclophilin Inhibits calcineurin and IL-2 synthesis	Nephrotoxicity Tremor Hypertension Hirsutism	Improved bioavailability of microemulsion form	Oral dose 5 mg/kg per day (given in two divided doses)
Tacrolimus (FK506)	Binds to FKBP Inhibits calcineurin and IL-2 synthesis	Nephrotoxicity Hypertension Neurotoxicity GI toxicity (nausea, diarrhea)	Improved patient and graft survival in (liver) primary immunosuppression and rescue therapy Used as mainstay of maintenance protocols	IV 0.015 mg/kg per day as continuous infusion PO 0.05 mg/kg per day (given every 12 h)
Mycophenolate mofetil	Antimetabolite Inhibits enzyme necessary for de novo purine synthesis	Leukopenia GI toxicity	Effective for primary immunosuppression in combination with tacrolimus	1 g bid PO
Sirolimus	Inhibits lymphocyte effects driven by IL-2 receptor	Thrombocytopenia Increased serum cholesterol/LDL Poor wound healing	May allow early withdrawal of steroids and decreased calcineurin doses	2–4 mg/d, adjusted to trough drug levels
Corticosteroids	Multiple actions Anti-inflammatory Inhibits lymphokine production	Cushingoid state Glucose intolerance Osteoporosis	Used in induction, maintenance, and treatment of acute rejection	Varies from milligrams to several grams per day Maintenance doses, 5–10 mg/d
Azathioprine	Antimetabolite Interferes with DNA and RNA synthesis	Thrombocytopenia Neutropenia Liver dysfunction	Used in maintenance protocols or if intolerance to mycophenolate mofetil	1–3 mg/kg per day for maintenance
Belatacept	T-cell blocker	Increased risk of bacterial infections	New drug for maintenance immunosuppression in renal transplants only	5–10 mg/kg per day infusion

FKBP = FK506-binding protein; GI = gastrointestinal; IL = interleukin; IV = intravenous; LDL = low-density lipoprotein; PO = oral

Nonetheless, the numerous adverse effects of steroid therapy contribute significantly to morbidity in transplant recipients.¹⁹ Common side effects include acne, increased appetite and associated weight gain, mood changes, diabetes, hypertension, and impaired wound healing.

One of the most common maintenance immunosuppressive regimens consists of triple-drug therapy: prednisone, a calcineurin inhibitor, and an antimetabolite. Large doses of steroids are usually given perioperatively and in the immediate postoperative period. Protocols vary by center, but the steroid dose is usually tapered to an adult dose of roughly 5 to 15 mg daily, or completely stopped at some point. Steroids are substrates for CYP3A4, CYP3A5, and P-glycoprotein pathways where drug interactions might need to be monitored.^{20,21}

Azathioprine

An antimetabolite, azathioprine (AZA) is converted to 6-mercaptopurine and inhibits both the de novo purine synthesis and salvage purine synthesis. AZA decreases T-lymphocyte activity and decreases antibody production. It has been used in transplant recipients for more than 40 years, but became an adjunctive agent after the introduction of cyclosporine. With the development of newer agents such as MMF, the use of AZA has

decreased significantly. However, it is preferred in recipients who are considering conceiving a child, because MMF is teratogenic in females and can cause birth defects. AZA might be an option for recipients who cannot tolerate the gastrointestinal (GI) side effects of MMF.

The most significant side effect of AZA, often dose-related, is bone marrow suppression. Leukopenia is often reversible with dose reduction or temporary cessation of the drug. Other significant side effects include hepatotoxicity, pancreatitis, neoplasia, anemia, and pulmonary fibrosis. Its most significant drug interaction is with allopurinol, which blocks AZA's metabolism, increasing the risk of pancytopenia. Recommendations are to not use AZA and allopurinol together, or if doing so is unavoidable, to decrease the dose of AZA by 75%.²²

Mycophenolate Mofetil

Approved in May 1995 by the U.S. Food and Drug Administration (FDA) for preventing acute rejection after kidney transplants, MMF has now been incorporated into routine maintenance regimens after many solid organ transplants. Mycophenolate is the prodrug of mycophenolate acid, derived from *Penicillium* fungi. Mycophenolate acid is an inhibitor of inosine monophosphate dehydrogenase (IMPDH) involved in

the de novo pathway of purine synthesis.²³ MMF is available in capsules (250 and 500 mg); the starting dose is 1 g twice daily. In hopes of decreasing the GI side effects, an enteric-coated formulation called Myfortic was developed; its benefits have not been clearly demonstrated in studies, but in some conversion studies, patients did report less GI intolerance. The pharmacokinetics of MMF are complex; mycophenolic acid (MPA) levels are not routinely performed at most transplant centers. Studies have shown that MPA levels and the incidence of rejection are not significantly correlated.²⁴ The most common side effects of MMF are GI in nature, most commonly diarrhea, nausea, dyspepsia, and bloating. Esophagitis and gastritis occur in roughly 5% of recipients and may represent a cytomegalovirus (CMV) or herpesvirus family infection. The other important side effects are leukopenia, anemia, and thrombocytopenia (Table 11-4). Leukopenia can sometimes be reversed by lowering the MMF dose and discontinuing other agents like valganciclovir. MMF does not have any significant drug interactions, but clinicians should be careful to avoid

additive toxicities with other medications that might lead to leukopenia and thrombocytopenia.

Sirolimus

The first mammalian target of rapamycin (mTOR) inhibitors to enter clinical use was sirolimus (Rapamune). A key regulatory kinase, mTOR changes cells from the G1 to S phase in the cell cycle, in response to proliferation signals provided by cytokines like IL-2. The mTOR inhibitors bind to FK506-binding protein (FKBP), and the sirolimus-FKBP complex binds to mTOR. Sirolimus also inhibits proliferation of vascular smooth muscle cells, possibly easing the vasculopathy and progressive fibrosis that can affect allografts. Sirolimus is a substrate for CYP3A4/4 and has many significant drug interactions (see Table 11-4).

To date, sirolimus has been used in a variety of combinations for maintenance immunosuppression, alone or in conjunction with one of the calcineurin inhibitors. In such combinations, sirolimus usually is used to help withdraw, or completely avoid the use of, steroids. It also has been used as an alternative to

Table 11-4

Side effects and drug interactions of the main immunosuppressive drugs

	COMMON SIDE EFFECTS	OTHER MEDICATIONS THAT INCREASE BLOOD LEVELS	OTHER MEDICATIONS THAT DECREASE BLOOD LEVELS	OTHER MEDICATIONS THAT POTENTIATE TOXICITY
Cyclosporine (CSA)	Hypertension, nephrotoxicity, hirsutism, neurotoxicity, gingival hyperplasia, hypomagnesemia, hyperkalemia	Verapamil, diltiazem, clarithromycin, azithromycin, erythromycin, azole antifungals, protease inhibitors, grapefruit juice	Isoniazid, carbamazepine, phenobarbital, phenytoin, rifampin, St. John's Wort	Nephrotoxicity: ganciclovir, aminoglycosides, NSAIDs, ACE-Is, and ARBs
Tacrolimus (FK506)	Hypertension, nephrotoxicity, alopecia, hyperglycemia, neurotoxicity, hypomagnesemia, hyperkalemia	Verapamil, diltiazem, clarithromycin, azithromycin, erythromycin, azole antifungals, protease inhibitors, grapefruit juice	Isoniazid, carbamazepine, phenobarbital, phenytoin, rifampin, St. John's wort	Nephrotoxicity: ganciclovir, aminoglycosides, NSAIDs, ACE-Is, and ARBs
Sirolimus	Thrombocytopenia and neutropenia, elevated cholesterol, extremity edema, impaired wound healing	Verapamil, diltiazem, clarithromycin, azithromycin, erythromycin, azole antifungals, protease inhibitors, grapefruit juice	Isoniazid, carbamazepine, phenobarbital, phenytoin, rifampin, St. John's wort	—
Mycophenolate mofetil	Leukopenia, thrombocytopenia, GI upset	—	Cholestyramine, antacids	Bone marrow suppression: valganciclovir, ganciclovir, TMP-SMX
Corticosteroids	Hyperglycemia, osteoporosis, cataracts, myopathy, weight gain	—	—	—
Azathioprine	Leukopenia, anemia, thrombocytopenia, neoplasia, hepatitis, cholestasis	—	—	Bone marrow suppression: allopurinol, sulfonamides

ACE-I = angiotensin-converting enzyme inhibitor; ARB = angiotensin receptor blocker; NSAID = nonsteroidal anti-inflammatory drug; TMP-SMX = trimethoprim-sulfamethoxazole

tacrolimus or cyclosporine, in a calcineurin-sparing protocol. One of the most significant side effects of sirolimus is hypertriglyceridemia, a condition that may be resistant to statins and fibrates. Impaired wound healing (immediately posttransplant in particular), thrombocytopenia, leukopenia, and anemia also are associated with sirolimus, and these problems are exacerbated when it is used in combination with MMF.^{25,26}

Cyclosporine

The introduction of cyclosporine in the early 1980s dramatically altered the field of transplantation by significantly improving outcomes after kidney transplantation. Cyclosporine binds with its cytoplasmic receptor protein, cyclophilin, which subsequently inhibits the activity of calcineurin, thereby decreasing the expression of several critical T-cell activation genes, the most important being for IL-2. As a result, T-cell activation is suppressed.²⁷

Many formulations of cyclosporine exist, so it is important to know which one the transplant recipient is taking. Sandimmune, an older, oil-based formulation, has poor bioavailability and variable absorption. The newer formulations, Gengraf and Neoral, are microemulsified with improved bioavailability. Cyclosporine can be given intravenously or orally to maintain trough levels of 250 to 350 ng/mL for the first 3 months posttransplant; then it can be tapered to 150 to 250 ng/mL.²⁸

The metabolism of cyclosporine is via the cytochrome P450 system, resulting in many significant drug interactions (see Table 11-4). Calcineurin inhibitors are nephrotoxic and constrict the afferent arteriole in a dose-dependent, reversible manner (Table 11-5). They also can cause hyperkalemia and hypomagnesemia. Several neurologic complications, including headaches, tremor, and seizures, also have been reported.²⁹

Cyclosporine has several undesirable cosmetic effects, including hirsutism and gingival hyperplasia. It is associated with a higher incidence of hypertension and hyperlipidemia than is tacrolimus.

Tacrolimus

The calcineurin inhibitor tacrolimus (Prograf) is now the backbone of most immunosuppressive regimens. Tacrolimus

acts by binding FKBP, causing roughly 10 to 100 times more potent inhibition of IL-2 production than cyclosporine (which acts by binding cyclophilins). It can be given intravenously, orally, or sublingually to maintain trough levels of 8 to 12 ng/mL for the first 3 months posttransplant; then it can be tapered to 6 to 10 ng/mL.

The metabolism of tacrolimus is via the cytochrome P450 system, resulting in many significant drug interactions (see Table 11-4).

Tacrolimus causes a higher incidence of new-onset diabetes posttransplant than does cyclosporine. Other side effects include alopecia, nephrotoxicity, neurotoxicity, hypertension, hyperkalemia, hypomagnesemia, and an increased incidence of certain types of infection.³⁰

Belatacept

The best-characterized pathway of T-cell costimulation includes CD28; its homologue, the cytotoxic T-lymphocyte-associated protein 4 (CTLA4); and their ligands, CD80 and CD86. Belatacept (also known as LEA29Y) was developed through two amino acid substitutions to abatacept (also known as CTLA4-Ig), a fusion protein consisting of the extracellular domain of CTLA4 and the Fc domain of immunoglobulin G (IgG). It is a high-avidity molecule with slower dissociation rates.

Recent trials have compared the use of belatacept vs. a standard cyclosporine protocol in recipients of living donor, deceased donor, and extended-criteria donor kidneys. Belatacept was not inferior to cyclosporine in both patient and allograft survival rates, but was associated with a higher rate of biopsy-proven acute cellular rejection.

In terms of adverse effects, belatacept differs from standard calcineurin-based regimens because of an increased risk of posttransplant lymphoproliferative disorder (PTLD); the greatest risk is in recipients who are Epstein-Barr virus (EBV)-seronegative pretransplant. The FDA recommends the use of belatacept only in seropositive recipients. Studies in liver transplant recipients were halted early because of increased mortality rates.

However, belatacept does have a lower incidence of cardiovascular risk factors including metabolic lipid disorders, hypertension, neurotoxicity, glucose abnormalities, and adverse cosmetic effects. Except for the increased risk of malignancy, the more favorable adverse effect profile of belatacept and its convenient monthly dosing schedule may make it an attractive option for maintenance of immunosuppression, possibly improving compliance.^{31,32}

HUMORAL REJECTION

Rituximab

A chimeric anti-CD20 (anti-B cell) monoclonal antibody, rituximab is currently FDA approved for treating lymphoma. The CD20 antigen is expressed early in the B-cell cycle but is absent on mature plasma cells. The variable region binds to CD20 through three different mechanisms: (a) antibody-dependent cell cytotoxicity, (b) complement-dependent cell killing, and (c) induction of apoptotic cell death. The use of rituximab has grown to include the treatment of antibody-mediated rejection and use in desensitization protocols. Studies so far have been small, with rituximab usually used in conjunction with plasmapheresis, steroids, and intravenous immunoglobulin (IVIG).³³⁻³⁵

Table 11-5

Drug interactions and side effects associated with calcineurin inhibitors

INTERACTIONS	MEDICATIONS
Inhibition of metabolism	Clarithromycin, erythromycin, azole antifungals, diltiazem, verapamil, nicardipine, amiodarone, grapefruit juice, ritonavir, azithromycin
Induction of metabolism	Nevirapine, rifampin, St. John's wort, carbamazepine, phenobarbital, phenytoin, caspofungin
Hyperkalemia	Potassium-sparing diuretics, angiotensin-converting enzyme inhibitors (ACE-Is), angiotensin receptor blockers (ARBs), β -blockers, trimethoprim-sulfamethoxazole
Nephrotoxicity	Nonsteroidal anti-inflammatory drugs, aminoglycosides, amphotericin, ACE-Is, ARBs

Bortezomib

A proteasome inhibitor, bortezomib is FDA approved for treating multiple myeloma. It can directly target plasma cells. Traditional treatments have been successful in removing antibodies, inhibiting antibody activity, or lowering antibody production; however, targeting mature antibody production in plasma cells has not met with success. Bortezomib has been shown to cause apoptosis of normal plasma cells, thereby decreasing alloantibody production in sensitized patients. Several case reports and series have described the use of bortezomib for the treatment of antibody-mediated rejection and in desensitization protocols.^{34,36,37}

Eculizumab

A humanized monoclonal antibody with high affinity for C5, eculizumab is a first-in-class, FDA-approved agent for treating paroxysmal nocturnal hemoglobinuria and hemolytic uremic syndrome. It blocks the activation of the terminal complement cascade. Most antibody-mediated rejection episodes are associated with early complement activation as evidenced on renal transplant biopsies by the presence of C4d+ staining of the peritubular capillaries. Given its highly selective mechanism of action, this agent is predicted to be useful to treat antibody-mediated rejection and to desensitize patients pretransplant. However, its serious adverse effects include an increased risk of infections, especially due to encapsulated bacteria such as *Neisseria meningitidis*. Patients should be immunized with meningococcal vaccine at least 2 weeks before the administration of eculizumab.^{34,38,39}

INFECTIONS AND MALIGNANCIES

Advances in immunosuppression have led to improved graft survival rates. However, the growing population of immunosuppressed patients, in turn, has led to an increased incidence of opportunistic infections and malignancies. Such posttransplant complications have become important barriers to long-term disease-free survival.

Infections

Transplant recipients are predisposed to a variety of infections. Immunosuppression is the obvious reason. Moreover, such patients have already endured end-stage organ disease pretransplant and then the stress of an invasive transplant operation. Posttransplant, they continue to have significant comorbid conditions.

Early. Early infections (i.e., infections occurring within 1 month posttransplant) can be due to a wide spectrum of pathogens (bacterial, viral, and fungal). In the immediate postoperative period, recipients are significantly compromised from the stress of the operation, from induction immunosuppression, and often from initially impaired graft function. Infections during this period can be devastating.

It is imperative to differentiate between medical and surgical infections. Surgical infections are the most common and require expedient surgical intervention. Typical examples include generalized peritonitis, intra-abdominal abscesses, and wound infections.

In liver and pancreas recipients, surgical infections are most severe. The incidence of intra-abdominal infections is decreasing, but they remain a significant problem: they are the second most common reason (after vascular thrombosis) for graft loss in pancreas recipients.

Lengthy operations with significant blood loss, prolonged warm and cold ischemic times, and spillage of contaminated fluid (bile, urine, or bowel contents) predispose patients to intra-abdominal infections. Other prominent risk factors are the high level of induction immunosuppression immediately posttransplant and anastomotic leaks. Furthermore, pretransplant infections can re-emerge or worsen.

The signs and symptoms of intra-abdominal infections are those of peritonitis: fever, hypotension, ileus, and abdominal pain, although the latter can be masked by immunosuppression. Treatment entails a prompt return to the operating room. Intra-abdominal infections are usually polymicrobial, involving several bacterial and fungal species. Common bacterial isolates include *Escherichia coli*, as well as *Enterococcus*, *Klebsiella*, and *Pseudomonas* species. Common fungal isolates are *Candida albicans*, *Candida krusei*, and *Candida glabrata*. Localized infections or abscesses can be treated with percutaneous drainage and antibiotics.

Medical infections include respiratory, urinary tract, and bloodstream infections. Medical treatment should also be aggressive, often including empiric antibiotics and antifungal medications even before culture results are available. Recipients of organs from infected donors should be treated per the results of donor culture speciation and the antibiotic sensitivity profile.

Late. Late infections primarily are due to chronic immunosuppression, specifically the depression of cell-mediated immunity that renders recipients susceptible to viruses, fungi, and parasites.

Members of the herpesvirus group are the most common etiologic agents of viral infections posttransplantation, with herpes simplex virus (HSV), CMV, and EBV being the most prominent. Pretransplant exposure to viruses may confer immunity. Recipients who are seronegative for HSV, CMV, and/or EBV have a higher incidence of posttransplant infections, especially if they receive donor allografts from seropositive donors.

CMV is a latent infection that can be transmitted to seronaive recipients by donor organs from seropositive individuals, can reactivate during immunosuppression, or both. Infections usually occur 3 to 6 months posttransplant or during treatment for rejection. The incidence of CMV has been greatly reduced with 12-week acyclovir prophylaxis.⁴⁰ CMV infections range from an asymptomatic or mild flu-like syndrome to tissue-invasive disease resulting in pneumonitis, hepatitis, and GI ulcerations. Symptomatic infections and all tissue-invasive CMV disease should be treated with intravenous (IV) ganciclovir, a reduction in immunosuppression, or both, although successful treatment of mild to moderate rejection and concurrent mild to moderate CMV disease has been described.

EBV infections range from a mild mononucleosis syndrome to severe hepatitis and highly morbid PTLD. PTLD ranges from a localized tumor to a progressive, diffuse infiltration of various organs including the brain. It results from the proliferation of EBV-positive B cells in immunosuppressed patients. The main risk factors are a high degree of immunosuppression and a predisposing EBV serostatus (seronaive recipient, seropositive donor). Among patients with early lesions, the first line of treatment is to reduce immunosuppression. For those with more advanced PTLD, rituximab is used.

After 6 months posttransplant, the risk of invasive fungal infections is closely associated with environmental exposures. *Blastomyces dermatitidis* grows in moist soil in the Midwest and Southeast regions of the United States. Diagnosis is confirmed by biopsy; the preferred treatment is IV amphotericin B.

Coccidioides immitis can cause invasive coccidioidomycosis after inhalation of aerosolized infectious particles. It is endemic in the Southwest, Northern Mexico, and various parts of Central and South America. This infection can be resilient and difficult to treat. The first line of treatment is high-dose amphotericin B.

Histoplasma capsulatum is found in chicken and bat droppings in the Ohio River and Mississippi River valleys. Dissemination is commonplace; up to a quarter of patients have central nervous system (CNS) involvement. Treatment consists of prolonged (3 to 13 months) administration of oral itraconazole.

Opportunistic infections with *Aspergillus*, *Cryptococcus*, *Mucor*, and *Rhizopus* species are rare but can cause serious infections. Patients with invasive *Candida* or *Aspergillus* infections have a 20% mortality rate. Prophylaxis with fluconazole has been shown to reduce invasive fungal infections in liver recipients.⁴¹

Pneumocystis jiroveci (also known as PCP) is ubiquitous and can cause pulmonary disease in immunocompromised patients. However, trimethoprim-sulfamethoxazole (TMP-SMX) is effective prophylaxis against PCP, and daily, lifelong administration has virtually eliminated this infection among transplant recipients.

Malignancies

Chronic immunosuppression increases the risk of developing certain types of malignancies. The most extensive data, from a cohort study involving more than 175,000 solid organ transplant recipients, showed that 10,656 of them developed malignancies. The standardized incidence ratio was 2.10 (as compared with the general population). Recipients had at least a fivefold increase (as compared with the general population) in these types of malignancies: Kaposi's sarcoma, nonmelanoma skin cancer, non-Hodgkin's lymphoma, and cancer of the liver, anus, vulva, and lip. In addition, recipients had a statistically significant increase (as compared with the general population) in melanoma, Hodgkin's lymphoma, and cancer of the lung, kidney, colon, rectum, and pancreas.⁴²

ORGAN PROCUREMENT AND PRESERVATION

Organ procurement is a key element in organ transplantation. Currently, 58 organ procurement organizations (OPOs) exist in the United States, all members of the Organ Procurement and Transplantation Network (OPTN), which is a federally mandated network created by and overseen by UNOS. Each OPO is responsible for evaluating and procuring deceased donor organs for transplantation in a specific geographic region. Hospitals receiving any type of federal reimbursement for their services (whether transplant-related or not) are required to report all deaths to their OPO in a timely manner. Each OPO then determines the medical suitability of the deceased for organ donation; requests consent for donation from family members; if consent is given, contacts the OPTN to analyze and identify potential recipients whose HLA antigens most closely match those of the donor; and arranges for the recovery and transport of any donated organs.

Strategies to increase organ donation and utilization have been successfully implemented in the last 10 years. The nationwide "Organ Donation Breakthrough Collaborative," sponsored by the U.S. Department of Health and Human Services in 2003, brought the OPOs and transplant communities into a single

concerted program to develop best practices guidelines. However, a severe donor shortage remains. The number of living organ donors peaked in 2007 and has declined since.

Alternative options include tissue engineering and stem cell research, but those fields are in their infancy in terms of producing fully functional and vascularized human organs. With the development of genetic knockout pigs, xenotransplantation still shows promise, but two problems in particular—immunologic barriers and xenosis (also known as zoonosis) of endogenous porcine retroviruses—have yet to be satisfactorily addressed.

Today, the gap between patients waiting for organ transplants and the number of organs available continues to widen. More than 110,000 patients are on the waiting list for solid organ transplants, but only 28,456 transplants were performed in 2011.

Deceased Donors

Most transplants today utilize organs from deceased donors. Formerly, death was determined by the cessation of both cardiac and respiratory function.

Donation after Brain Death. In 1968, the concept of "irreversible coma" was introduced by an ad hoc committee report at Harvard Medical School; that concept was pivotal to the final acceptance, in 1981, of "brain death" as a legal definition in the United States. The legal language states that the declaration of brain death should be in accordance with acceptable medical standards, but does not specify clinical methodology. It is customary for hospitals to establish their own policies to declare brain death, according to their standards of care and local regulations.

Typically, brain death is defined as the irreversible cessation of brain function, including the brainstem. The presence of medical conditions that mimic brain death—such as drug overdose, medication side effects, severe hypothermia, hypoglycemia, induced coma, and chronic vegetative state—need to be excluded. The latest evidence-based guideline on determining brain death in adults reaffirmed the validity of current clinical practice.⁴³ Briefly, the clinical diagnosis of brain death consists of four essential steps: (a) establishment of the proximate cause of the neurologic insult; (b) clinical examinations to determine coma, absence of brainstem reflexes, and apnea; (c) utilization of ancillary tests, such as electroencephalography (EEG), cerebral angiography, or nuclear scans, in patients who do not meet clinical criteria; and (d) appropriate documentation. A similar guideline on determining brain death in pediatric patients was recently developed.⁴⁴

Once the diagnosis of brain death has been established, the local OPO assumes the care of the potential donor and initiates the process of donor evaluation and organ donation, and the potential donor is screened for contraindications to donation. The medical history and social history are obtained from the available family members. A battery of tests, including serologic or molecular detection of human immunodeficiency virus (HIV) and viral hepatitis, are performed. The exact medical conditions that preclude donation vary; nonetheless, in the United States, infections and other medical conditions that determine eligibility are dictated by UNOS bylaws and routinely reviewed and updated.

The OPO focuses on preserving organ function and optimizing peripheral oxygen delivery until organ procurement commences.⁴⁵ In all deceased donors, core temperature, systemic arterial blood pressure, arterial oxygen saturation, and urine output must be determined routinely and frequently. Arterial blood gases, serum electrolytes, blood urea nitrogen,

serum creatinine, liver enzyme, hemoglobin, and coagulation tests need to be monitored regularly. In all brain-dead donors, elevated intracranial pressure triggers a compensatory catecholamine response to maintain cerebral perfusion pressure. Ischemic injury to the spinal cord and the sympathetic system may lead to a profound vasodilation. As a result, brain-dead donors frequently have severe hemodynamic and metabolic derangements, so aggressive monitoring and intervention are required to prevent loss of precious organs.

Previous studies of deceased donor care focused on organ-specific resuscitation protocols that resulted in only marginal gains in the number of organs transplanted. The latest developments center on multisystem protocols to increase the number of organs transplanted per donor (OTPD).^{46,47} The goals are to maintain a core temperature between 36.0 and 37.5°C, a mean arterial pressure >70 mmHg or a systolic pressure >100 mmHg, and a hemoglobin level between 7 and 10 g/dL; hormonal therapy and aggressive treatment of arrhythmias and metabolic derangements are also called for.⁴⁷

Surgical Technique. Procurement of multiple organs (heart, lungs, kidney, liver, pancreas, and/or small bowel), or multivisceral procurement, was first described by the Pittsburgh group in 1987.⁴⁸ Since then, most centers have incorporated changes, especially with regard to the timing and location of dissection and flushing.^{49,50} The basic steps involve a long incision to provide wide exposure of all thoracic and abdominal organs (Fig. 11-3). A Cattell-Braasch maneuver (complete mobilization of the distal small bowel, right colon, and duodenum) is performed to allow for identification of the distal aorta, iliac bifurcation, and distal inferior vena cava (IVC). The infrarenal aorta is the site for inserting the cannula that will allow for flushing of the organs with cold preservation solution. Sometimes, division of the inferior mesenteric artery is necessary to facilitate the exposure of the distal aorta. The third portion of the duodenum is retracted cephalad to expose the root of the superior mesenteric artery (SMA). Limited dissection is performed at the root of the SMA, which is encircled with a vessel loop to enable its temporary occlusion at the time of flushing, thus reducing the incidence of overperfusion injury to the pancreas.

A large anomalous or replaced right hepatic artery typically rises from the SMA, and this should be identified and

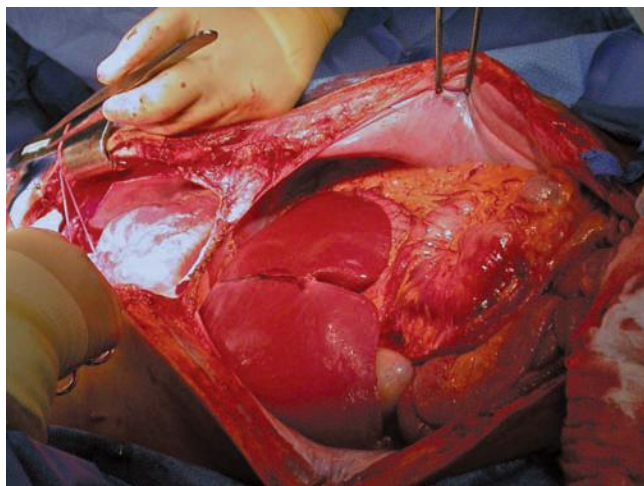


Figure 11-3. Exposure for thoracic and abdominal organ procurement.

preserved. Lateral to the SMA is the inferior mesenteric vein (IMV), which can be cannulated for portal flushing. Dissection of the hepatic hilum and the pancreas should be limited to the common hepatic artery (CHA), and branches of the CHA (e.g., splenic, left gastric, and gastroduodenal arteries) are exposed. The gastrohepatic ligament is carefully examined to preserve a large anomalous or replaced left hepatic artery, if present. The supraceliac aorta can be exposed by dividing the left triangular ligament of the liver and the gastrohepatic ligament.

The common bile duct is transected at the superior margin of the head of the pancreas. The gallbladder is incised and flushed with ice-cold saline to clear the bile and sludge. If the pancreas is to be procured, the duodenum is flushed with antimicrobial solution. Before the cannulation of the distal aorta, systemic heparinization (300 units/kg) is administered. The supraceliac aorta is clamped; cold preservation fluid is infused via the aortic (systemic) and IMV (portal) cannulas. The thoracic organs, liver, pancreas, and kidneys are then removed.

Donation after Cardiac Death. Given the severe shortage of donor organs, donation after cardiac death (DCD)—also known as donation by non-heart-beating donors (NHBDs)—was reintroduced to the transplant community in the 1990s.⁵¹ The category of DCD (Maastricht classification) was initially proposed at an international workshop and is now widely adopted for organ procurement.⁵² Currently, most NHBDs in the United States meet Maastricht classification III; that is, they have suffered a devastating injury with no chance of a meaningful recovery but do not meet the criteria for brain death. After consent for donation is obtained from the next of kin, the donor's life support is removed. After the cessation of cardiac and respiratory function, organ procurement commences. DCD procurement protocols vary between states; religious and cultural differences need to be taken into consideration. The surgical team must be familiar with, and respect, the local protocol.

With cardiac death (as opposed to brain death), warm ischemic injury to organs can occur during the period between circulatory cessation and rapid core cooling through perfusion of preservation solution. However, the difference in long-term outcomes is negligible for recipients of organs from either type of donor. Still, a significant percentage of liver grafts procured after cardiac death, especially those with more than 25 minutes of warm ischemic time, develop devastating ischemic cholangiopathy and fail.⁵³

A new development to minimize ischemic injury to organs procured after cardiac death has been the application of extracorporeal membrane oxygenation (ECMO). With ECMO, DCD differs in two key ways: (a) cannulation occurs *before* withdrawal of life support and (b) organs are perfused via ECMO with warm oxygenated blood *after* declaration of cardiac death. The initial experience with organs procured using ECMO has been encouraging.

Surgical Technique. Surgeons who perform multiple organ retrieval should be familiar and experienced with the super-rapid technique described by the Pittsburgh group.⁵⁴ Preferably, NHBDs undergo withdrawal of life support in the operating room *after* the surgical site is prepped and draped, as soon as the surgical team is ready. Alternatively, the NHBD is transported to the operating room after declaration of cardiac death.

A midline incision is used to rapidly gain entry into the abdominal cavity. An assistant retracts the small bowel and the sigmoid colon laterally, so that the bifurcation of the aorta can

be easily identified on the left side of the vertebral column. A short segment of the distal aorta is dissected out from the retroperitoneum. A moist umbilical tape is passed around the aorta, which is used to secure a cannula. The distal aorta is clamped. Next, a cannula is passed cephalad through an aortotomy and secured. Flushing with cold preservation solution is started at once, followed by cross-clamping the aorta proximally (thoracic aorta) and venting through the vena cava. The portal flush is then instituted.

The rest of the procedure is similar to procurement after brain death, with two noticeable differences. First, to avoid injury to a large anomalous or replaced left hepatic artery, the gastrohepatic ligament and the left gastric artery are separated from the stomach at the lesser curvature. Second, to avoid injury to a large anomalous or replaced right hepatic artery, the SMA is examined before it is divided. If the pancreas is not procured, a common aortic patch encompassing both the SMA and the celiac artery can be procured with the liver.

Living Donors

The maxim of medical ethics is “*primum non nocere*” (above all, do no harm), and for that reason, living organ donation presents unique ethical and legal challenges. Performing potentially harmful operations to remove organs from healthy individuals seems, at first glance, to contradict that maxim. But in fact, the ethical framework of living organ donation rests on three guiding principles respected in all discussions of medical practice: *benevolence* to the recipient, *nonmaleficence* to the donor, and the donor’s *right to autonomy*.⁵⁵ In order to achieve optimal outcomes (the common good), transplant professionals should focus on maximizing the benefits for the recipient and minimizing the damage to the donor. The Uniform Anatomical Gift Act adopted by all states in the United States (with slight variations) provides the legal framework for competent adult living donors to decide whether or not to donate. It is the fiduciary duty of transplant professionals to explain the risks of organ donation. Any decision to donate should be uncoerced, and no enticements should be offered.

The use of living donors offers numerous advantages for recipients in need. First and foremost is the availability of lifesaving organs for those who would otherwise succumb to the progression of their end-stage disease. In certain parts of the world, such as East Asia, the concept of brain death and the use of deceased donors conflict with the prevailing culture or religion. Even in countries where the use of deceased donors is accepted, the use of living donors may significantly shorten the waiting time for recipients. A shorter waiting time generally implies a healthier recipient—one whose body has not been ravaged by prolonged end-stage organ failure. Moreover, with the use of living donors, transplants are planned (rather than emergency) procedures, allowing for better preoperative preparation of the recipient. Receiving an organ from a closely matched relative may also have immunologic benefits. And long-term results may be superior with the use of living donors, as is certainly the case with kidney transplants.

The major disadvantage is the risk to the living donor. Medically, there is no possibility of benefit to the donor, only the potential for harm. The risk of death associated with donation depends on the organ being removed. For a nephrectomy, the estimated mortality risk is less than 0.05%; for a partial hepatectomy, about 0.2%. The risk of surgical and medical complications also depends on the procedure being performed.

In addition, long-term complications may be associated with a partial loss of organ function after donation. The guiding principle should be minimization of risk to the donor. All potential risks must be carefully explained to the potential donor, and written informed consent must be obtained.⁵⁶

Surgical Technique. The kidney, the first organ to be transplanted from living donors, is still the most common organ donated by these individuals. The donor’s left kidney is usually preferable because of the long vascular pedicle. Use of living donor kidneys with multiple renal arteries should be avoided, in order to decrease the complexity of the vascular reconstruction and to help avoid graft thrombosis. Most donor nephrectomies are now performed via minimally invasive techniques, that is, laparoscopically, whether hand-assisted or not. With laparoscopic techniques, an intraperitoneal approach is most common: it involves mobilizing the colon, isolating the ureter and renal vessels, mobilizing the kidney, dividing the renal vessels and the distal ureter[C6], and removing the kidney (Fig. 11-4). Extensive dissection around the ureter should be avoided, and the surgeon should strive to preserve as much length of the renal artery and vein as possible.

Liver transplants with living donors are not as commonly performed, given the significantly higher rates of donor mortality and morbidity. Initially, only adult donors for pediatric recipients were selected, but now, living donor liver transplants also involve adult donors for adult recipients. In dual graft living donor liver transplants, segmental grafts from two living donors augment the recipient’s graft size.⁵⁷ The donor hepatectomy is similar to a major lobar hepatectomy, except that it is important to preserve the integrity of the vascular structure until graft resection (Fig. 11-5).

Living donor transplants of organs other than the kidney and liver are fairly uncommon, but certain centers do perform such transplants. Living donor pancreas transplants involve performing a distal pancreatectomy, with the graft consisting of the body and tail of the pancreas; vascular inflow and outflow are provided by the splenic artery and splenic vein. Living donor intestinal transplants usually involve removal of about 200 cm of the donor’s ileum, with inflow and outflow provided by the ileocolic vessels. Living donor lung transplants involve removal of one lobe of one lung from each of two donors; both grafts are then transplanted into the recipient.

Organ Preservation

The development and continuing refinement of organ preservation methods have completely revolutionized the transplant field. Extending the time that organs can be safely stored after procurement has enabled better organ utilization and better recipient outcomes.^{58,59} Hypothermia and pharmacologic inhibition are the two most frequent methods. Both slow—yet cannot completely shut down—the removed organ’s metabolic activity, so both have adverse effects, such as cellular swelling and degradation. Cold storage solutions were introduced to mitigate some of the adverse effects of hypothermia or pharmacologic inhibition alone. Such solutions help prevent cellular swelling and the loss of cellular potassium.

One, and perhaps the most effective, preservation solution was developed at the University of Wisconsin and remains in wide use.⁶⁰ Its ingredients include lactobionate (which helps prevent cellular swelling and reperfusion injury), raffinose, and hydroxyethyl starch (which helps reduce swelling of endothelial

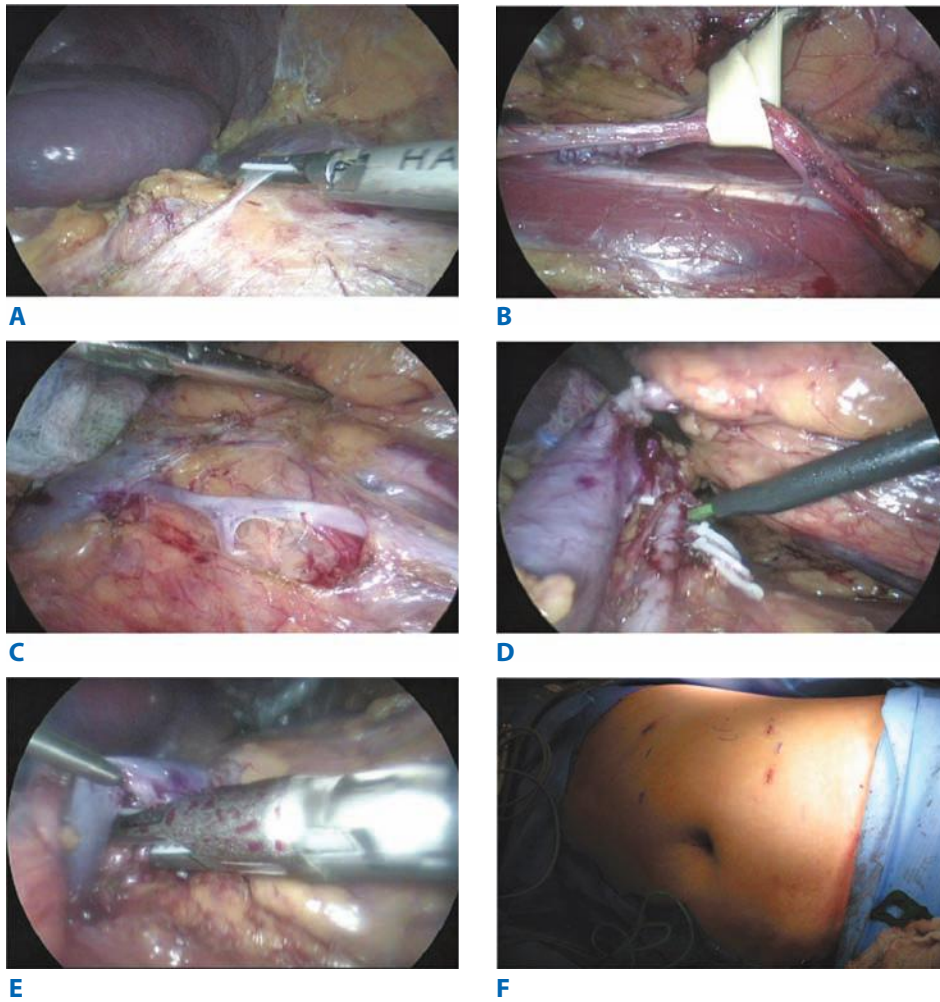


Figure 11-4. Laparoscopic left donor nephroureterectomy. **A.** Takedown of splenic flexure of colon to expose the left renal hilum. **B.** Dissection of left ureter off the psoas muscle. **C.** Dissection of left renal vein and gonadal vein. Left ureter seen lateral to the dissection. **D.** Dissection of left renal artery. Lumbar veins clipped and divided. **E.** Endo-TA stapler transection of the left renal artery. **F.** Placement of ports and Pfannenstiel incision for the donor kidney extraction.

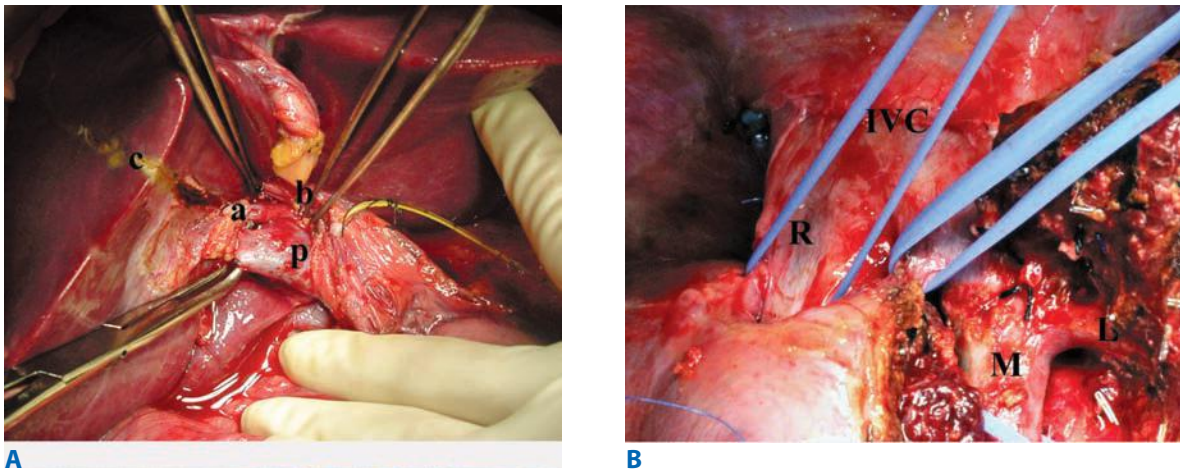


Figure 11-5. Donor hepatectomy (right hepatectomy). **A.** The liver parenchymal transection line (c, the Cantlie line) marked with cautery. Right portal vein (p) and right hepatic artery (a) isolated. b = bile duct. Cystic duct was cannulated for intraoperative cholangiography. **B.** Exposure of hepatic veins after transection of the parenchyma. IVC = inferior vena cava; L = left hepatic vein; M = middle hepatic vein; R = right hepatic vein

cells, thereby decreasing edema). Histidine-tryptophan-ketoglutarate solution is also currently in wide use.⁶¹

Despite enhancements in preservation methods, the amount of time that an organ can be safely stored remains relatively short (hours, not days), particularly with organs from marginal donors. Among kidney recipients, delayed graft function becomes significantly more frequent after cold ischemic times of more than 24 hours, necessitating temporary dialysis, which is associated with increased risks of graft loss and higher costs.⁶² Among liver recipients, primary nonfunction and biliary complications ensue after prolonged cold ischemic times. In the case of heart and lung recipients, ischemic times should be under 6 hours. All of those times assume the use of normal donors.

There is revived interest in the use of the pulsatile perfusion pump, a kidney graft preservation method that has been available for more than 40 years.⁶³ With the increasing shortage of available donor organs and the rise in the use of organs after cardiac death, the pulsatile perfusion pump is garnering renewed enthusiasm as an adjunct method of preservation, even for donor organs other than kidneys.^{64,65}

KIDNEY TRANSPLANTATION

Introduction

Ullman reported the first attempted human kidney transplant in 1902.⁶⁶ For the next 50 years, sporadic attempts all ended in either technical failure or in graft failure from rejection. Joseph Murray performed the first successful kidney transplant in 1954, an epochal event in the history of organ transplantation. In that first case, the immunologic barrier was circumvented by transplanting a kidney between identical twins.⁶⁷ For his pivotal contribution, Murray shared the Nobel Prize in Physiology or Medicine in 1990 with E. Donnall Thomas for their discoveries concerning “organ and cell transplantation in the treatment of human disease.”

The introduction of AZA (Imuran) in 1960 marked the beginning of a new era in kidney transplantation. With the combination of steroids and AZA for maintenance immunosuppression, the 1-year graft survival rate with a living related donor kidney approached 80%; with a deceased donor kidney, the rate was 65%.⁶⁸ In the ensuing years, major milestones included the introduction of more effective immunosuppressive medications with lower toxicity profiles, such as polyclonal antilymphocyte globulin in the 1970s, cyclosporine in the 1980s, tacrolimus in the 1990s, and biologics in the first decade of the twenty-first century, as previously mentioned.

Parallel to the developments in medical science were the transplant community’s concerted efforts to improve use of healthcare resources. In the United States, the Social Security amendments of 1972 provided Medicare coverage for patients with end-stage renal disease (ESRD). The National Organ Transplant Act of 1984 initiated the process of creating what later became UNOS, an umbrella organization to ensure access to organs by patients in need, to enhance organ procurement and allocation, and to improve posttransplant outcomes. This infrastructure later became the blueprint for other countries to follow. As a result, organ transplantation is the most transparent field of medicine. Data such as transplant center performance are readily available on public websites; penalties for violation of regulations and for underperformance often result in transplant programs being shut down.

Today, a kidney transplant remains the most definitive and durable renal replacement therapy for patients with ESRD. It offers better survival and improved quality of life and is considerably more cost-effective than dialysis.^{69,70} According to the 2010 Scientific Registry of Transplant Recipients (SRTR) annual report, a total of 84,614 adult patients were on the kidney transplant waiting list, including 33,215 added just that year.⁷¹ Yet in 2009, only 15,964 adult kidney transplants were performed in the United States (9912 with a deceased donor and 6052 with a living donor). Of note, the number of patients added to the kidney transplant waiting list has increased every year, but the number of kidney transplants performed has been declining since 2006. On the positive side, posttransplant outcomes have continued to improve: in 2009, the 1-year graft survival rate with a living donor kidney was 96.5%; with a deceased donor kidney, the rate was 92.0%.

The advantages of a living donor kidney transplant include better posttransplant outcomes, avoidance of prolonged waiting time and dialysis, and the ability to coordinate the donor and recipient procedures in a timely fashion. Living donor kidney recipients enjoy better long-term outcomes, a low incidence of delayed graft function, and reduced risks of posttransplant complications. Furthermore, the elective nature of living donor kidney transplants provides unique opportunities for recipient desensitization treatment if the donor and recipient are ABO-incompatible or if the HLA cross-match results are positive.

Some of the challenges transplant professionals face today are closing the growing gap between supply and demand and thereby reducing the current prolonged waiting times; refining immunosuppressive medications to achieve better outcomes with reduced toxicity; and caring for patients who develop rejection, especially antibody-mediated rejection.

Pretransplant Evaluation

Active infection or the presence of a malignancy, active substance abuse, and poorly controlled psychiatric illness are the few absolute contraindications to a kidney transplant. Studies have demonstrated the overwhelming benefits of kidney transplants in terms of patient survival, quality of life, and cost-effectiveness, so most patients with ESRD are referred for consideration of a kidney transplant. However, to achieve optimal transplant outcomes, the many risks (such as the surgical stress to the cardiovascular system, the development of infections or malignancies with long-term immunosuppression, and the psychosocial and financial impacts on compliance) must be carefully balanced.

Any problems detected during the evaluation of transplant candidates are communicated to their referring physician and/or to a specialist if advanced evaluation and treatment are needed, ultimately improving overall care. Essentially, the pretransplant evaluation is a multifaceted approach to patient education and disease management.

Before the pretransplant medical evaluation begins, kidney transplant candidates are encouraged to attend a group meeting focused on patient education. The meeting is coordinated by a transplant physician or surgeon. The intent is to familiarize patients with the pretransplant evaluation process and with pertinent medical concepts and terms. In an open forum format, important decisions such as type of donor (living vs. deceased) are discussed. The group meeting empowers patients to fully participate in their care and serves as an impetus for a meaningful dialogue with healthcare professionals.

Medical Evaluation

Cardiovascular Disease. Diabetes and hypertension are the leading causes of chronic renal disease. Concomitant cardiovascular disease (CVD) is a common finding in this population. An estimated 30% to 42% of deaths with a functioning kidney graft are due to CVD.^{72,73} Therefore, assessment of the potential kidney transplant candidate's cardiovascular status is an important part of the pretransplant evaluation.

In fact, the American Heart Association and the American College of Cardiology Foundation recently published their expert consensus on CVD evaluation and management for solid organ transplant candidates.⁷⁴ The process should focus on careful screening for the presence of significant cardiac conditions (e.g., angina, valvular disease, and arrhythmias) and for a prior history of congestive heart failure, coronary interventions, or valvular surgery. The perioperative risk assessment is based on patient symptoms and exercise tolerance. For all kidney transplant candidates, a resting 12-lead electrocardiogram (ECG) should be obtained. In addition, in this population, the use of echocardiography to analyze left ventricular function and to assess for pulmonary hypertension is useful.

Stress testing may be considered in patients with no active cardiac condition but with risk factors such as diabetes, hemodialysis for more than 1 year, left ventricular hypertrophy, age greater than 60 years, smoking, hypertension, and dyslipidemia. The utility of noninvasive stress testing (as compared with angiographic studies) for evaluating coronary artery disease is controversial; an additional prognostic marker is the troponin T (cTnT) level.

Malignancies. Because of the long-term use of immunosuppressive medications, transplant recipients are at increased risk for development of malignancies. Untreated and/or active malignancies are absolute contraindications to a transplant (with two exceptions: nonmelanocytic skin cancer and incidental renal cell cancer identified at the time of concurrent nephrectomy [i.e., for polycystic kidney disease] and renal transplantation). For most patients who have undergone treatment of low-grade tumors with a low risk of recurrence (e.g., completely locally excised low-grade squamous cell cancer of the skin, colon cancer in a polyp absent stalk invasion), a wait of at least 2 years after successful treatment is recommended before a kidney transplant can be considered. However, for certain types of tumors, especially at advanced stages or those with a high risk of recurrence (e.g., melanoma, lymphoma, renal cell cancer, breast cancer, colon cancer), a delay of at least 5 years is advisable. According to the Israel Penn International Transplant Tumor Registry, tumor recurrence posttransplant is not infrequent: the recurrence rate is 67% in patients with multiple myeloma, 53% in nonmelanocytic skin cancer, 29% in bladder cancer, and 23% in breast cancer.⁷⁵

Infections. A thorough history of infections and immunizations should be obtained from transplant candidates, who need all recommended age-appropriate vaccinations according to the Centers for Disease Control and Prevention (CDC) guidelines. Ideally, vaccinations should be completed at least 4 to 6 weeks before the kidney transplant takes place. Immunosuppressive medications blunt the immune response and reduce the effectiveness of vaccinations; even more important, with attenuated vaccines, vaccine-derived infections could occur. If a splenectomy is anticipated (e.g., in recipients whose donor is ABO-incompatible or whose HLA cross-match results are positive),

then they should be immunized against encapsulated organisms (such as *Neisseria meningitidis*, *Haemophilus influenzae*, and *Streptococcus pneumoniae*) well in advance of the splenectomy.

Transplant candidates should undergo routine tuberculosis (TB) screening. According to the latest CDC report, in 2011, 3929 TB cases were diagnosed in persons born in the United States and 6546 were diagnosed in foreign-born persons.⁷⁶ Serologic screening combined with a chest roentgenogram for fungal infections such as coccidioidomycosis or histoplasmosis, in patients who either have a history of those infections or are from an endemic area, are recommended. Chronic infections such as osteomyelitis or endocarditis must be fully treated; a suitable waiting period after successful treatment must occur, in order to ensure that relapse does not occur.

Hepatitis can be caused by five different type of viruses, hepatitis virus A, B, C, D, and E, with the first three being the most common. Acute viral hepatitis is a contraindication to a kidney transplant; however, chronic viral hepatitis (most commonly caused by hepatitis B [HBV] or C [HCV]) does not preclude a recipient from undergoing a kidney transplant. In such candidates, obtaining a liver biopsy is essential to assess the disease severity. Recipients infected with HBV should undergo antiviral treatment (e.g., lamivudine) to prevent reactivation and progression of liver disease. Note that HBV is a noncytopathic virus; the liver damage is the result of an immune-mediated process.⁷⁷ Moreover, the presence of normal liver enzymes in patients with HBV antigenemia does not predict the severity of parenchymal damage.

Transplant candidates with chronic HCV infection often have HCV-related glomerulonephritis. As with HBV infection, the clinical presentation and biochemical findings with HCV infection are often unreliable in predicting liver damage. In patients with evidence of cirrhosis, a combined liver-kidney transplant should be considered. In appropriate candidates, pretransplant antiviral treatment with interferon- α may be considered. However, after a kidney transplant, interferon treatment is not recommended, because it may precipitate graft rejection.

Thanks to the excellent outcomes of highly active antiretroviral therapy (HAART), infection with HIV is no longer considered a contraindication to a kidney transplant. Kidney transplant candidates with HIV must have an undetectable HIV viral load and a CD4 lymphocyte count greater than 200/mm³; in addition, they must not have had any opportunistic infection in the previous year.⁷⁸

Latent viral infections such as CMV and EBV are of particular interest, given the risks of reactivation posttransplant and the detrimental effects on graft and patient survival. Knowing the serologic status of CMV and EBV infections helps transplant professionals gauge the risk of immunosuppressive regimens and the impact of the donor's viral status, thereby guiding plans for posttransplant antiviral prophylaxis treatment or, as noted earlier, avoiding transplants between a seropositive donor and a seronegative recipient.

Kidney Disease. The third most common cause of graft loss in kidney transplant recipients is recurrence of glomerular diseases such as focal segmental glomerulosclerosis (FSGS), immunoglobulin A (IgA) nephropathy, hemolytic uremic syndrome, systemic lupus erythematosus, and membranoproliferative glomerulonephritis. FSGS deserves special mention for its frequent occurrence and dramatic presentation of early graft loss. An estimated 30% to 40% of FSGS patients develop recurrent disease posttransplant; of those, up to half eventually

lose their graft.⁷⁹ In recipients with a history of FSGS, posttransplant nephrotic proteinuria should be promptly investigated; if diagnosis is confirmed by kidney biopsy, rescue plasmapheresis should be instituted at once. Adjuvant therapy with rituximab recently has been proposed.⁸⁰

Hypercoagulopathy. Kidney transplant candidates with a history of thrombotic events, repeated miscarriages, or a family history of thrombophilia should be screened for the following coagulopathic disorders: activated protein C resistance ratio, factor V Leiden mutation, factor II 20210 gene mutation, antiphospholipid antibody, lupus anticoagulation, protein C or S deficiency, antithrombin III deficiency, and hyperhomocysteinemia. In recipients at risk for hypercoagulopathy, pediatric kidney grafts should be avoided; so should any kidney allografts with a complex vascular anatomy.⁸¹ A perioperative anticoagulation protocol is recommended in this population.

Surgical Evaluation

Urologic Evaluation. Kidney transplant candidates (pediatric patients, in particular) with chronic kidney disease as a result of congenital or genitourinary abnormalities should undergo a thorough urologic evaluation. A voiding cystourethrogram and a complete lower urinary tract evaluation to rule out outlet obstruction are essential. Indications for a native nephrectomy include chronic pyelonephritis, large polycystic kidneys with loss of intra-abdominal domain, significant vesicoureteral reflux, or uncontrollable renovascular hypertension.

Vascular Evaluation. The potential implant sites for a kidney graft include the recipient's aorta, vena cava, and iliac vessels. Careful physical examination often reveals significant central and/or peripheral vascular disease. Findings such as a pulsatile intra-abdominal mass, diminished or absent peripheral pulse, claudication, rest pain, and tissue loss in lower extremities should be further evaluated by abdominal computed tomography scan or ultrasound, Doppler studies, and/or angiography. With the popularity of endovascular interventions, transplant surgeons should also be familiar with such technology and have detailed anatomic studies of patients with vascular stents.

Immunologic Evaluation. ABO blood typing and HLA typing (HLA-A, -B, and -DR) are required before a kidney transplant. The method of screening for preformed antibodies against HLA antigens (because of prior transplants, blood transfusions, or pregnancies) is evolving. The panel-reactive antibody (PRA) assay is a screening test that examines the ability of serum from a kidney transplant candidate to lyse lymphocytes from a panel of HLA-typed donors. A numeric value, expressed as a percentage, indicates the likelihood of a positive cross-match with a donor. A higher PRA level identifies patients at high risk for a positive cross-match and therefore serves as a surrogate marker to measure the difficulty of finding a suitable donor and the risk of graft rejection.

The latest development in anti-HLA antibody screening is Luminex technology, using HLA-coated fluorescent microbeads and flow cytometry. In theory, this technology pinpoints donor-specific antibodies (DSAs) in the serum of a kidney transplant candidate with a high PRA level. Since all organ donors must undergo HLA typing, a negative cross-match for recipients with a high PRA level can be ensured by avoiding the selection of donors carrying unacceptable antigens (i.e., a virtual cross-match).⁸² Kidney transplant candidate data (including ABO blood types, HLA types, and DSAs) are now entered into a

nationwide central database to facilitate deceased donor kidney allocation, as described earlier.

Psychosocial Evaluation. Psychiatric disorders have been recognized as important contributing factors to poor outcomes posttransplant. Patients with uncontrolled psychiatric disorders are at high risk for noncompliance with treatment, impaired cognitive function, and the development of substance abuse. The psychosocial evaluation is essential to ensure that transplant candidates understand the risks and benefits of the procedure and that they adhere to the lifetime immunosuppressive medication regimen.

Recipient Operation

Kidney allografts usually are transplanted heterotopically. The iliac fossa is recognized as the ideal position because of its proximity to the recipient's bladder and iliac vessels.^{83,84}

Retroperitoneal allograft placement also allows easy access for percutaneous biopsies and interventions for ureteral complications. The right iliac fossa is the preferred site because of its easy access to the recipient's iliac vessels. However, if a pancreas transplant is anticipated in the future or if now failed kidney grafts have been placed at the right iliac fossa, then the left iliac fossa is used for implantation. The current surgical technique for kidney transplants was developed and popularized in the 1950s and 1960s and has changed little since.⁸⁵

A large-bore three-lumen urinary catheter is inserted after the recipient is anesthetized, and it is occluded with a clamp beneath the surgical drapes. Recipients whose native kidneys produce urine will naturally fill up the urinary bladder; those individuals whose kidneys do not will require insufflation of saline prior to creation of the ureteral anastomosis.

Exposure of the operative field starts with a curvilinear skin incision, one to two finger widths above the midline pubic bone and the lateral edge of the rectus sheath. Superiorly, the extension of the incision depends on the recipient's body habitus and the size of the donor kidney. The anterior rectus sheath is incised, medially to laterally, until the lateral edge of the rectus sheath is exposed. The posterior rectus sheath is missing below the arcuate line, thus providing direct access to the extraperitoneal space. The rectus muscle can be easily mobilized medially without being divided. The remainder of the fascial incision is along the lateral edge of the rectus sheath until the desired exposure is achieved (Fig. 11-6).

The retroperitoneal space of the iliac fossa is entered by mobilizing the peritoneum medially. The inferior epigastric vessels, the round ligament (in females), and the spermatic cord and its vasculature (in males) are encountered in this space; the former two structures are divided, while the latter is retracted with a vascular loop. A self-retained retractor is used to expose the surgical field. The iliac vessels should be dissected with great care. To minimize the risk of lymphocele development postoperatively, dissection of the iliac artery should be limited; the intertwining lymphatics around the iliac vessels should be ligated. In general, the donor's renal artery and vein are anastomosed to the recipient's external iliac vessels in an end-to-side fashion (Fig. 11-7). In recipients with a severely calcified iliac artery, the internal iliac artery can be used as an alternative, and in select cases, an endarterectomy must be performed.

After restoring the circulation to the donor's kidney, urinary continuity can be established via several approaches. The approach chosen depends on such factors as the length of the donor ureter and a recipient history of bladder surgery, native

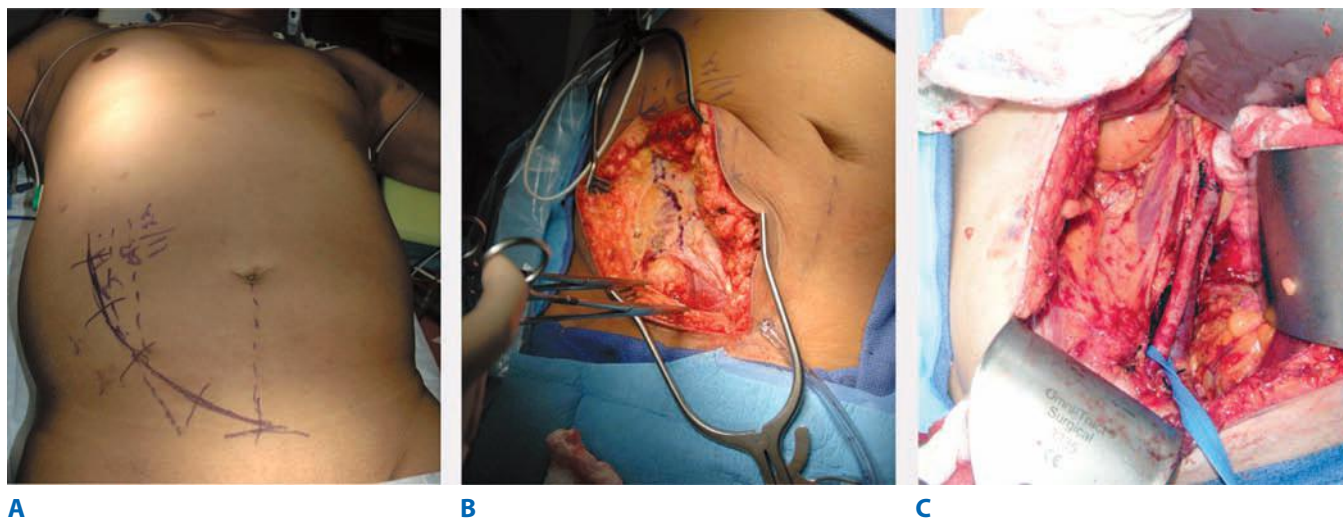


Figure 11-6. Incision and exposure for kidney transplant. **A.** Mark for the skin incision. **B.** Anterior rectus sheath incised obliquely. The abdominal muscle transected lateral to the rectus muscle. **C.** External iliac artery and vein dissected.

nephrectomy, or pelvic radiation. The two most common procedures to restore urinary continuity are the Leadbetter-Politano and a modification of the Lich (e.g., extravesical) ureteroneocystostomy, which actually was designed to avoid ureteral reimplantation.

During the former procedure, a large cystostomy is created in the dome of the bladder, and the donor ureter is brought through a lateral and somewhat inferior 1-cm submucosal tunnel into the bladder, the end of which is spatulated and then sewn in place without tension with interrupted absorbable sutures placed through the mucosa and submucosa on the inside of the bladder.

An extravesical ureteroneocystostomy is performed by careful dissection of a 1-cm portion of the muscular layers on the anterolateral portion of the bladder until a “bubble” of mucosa is exposed. The donor ureter is spatulated in a diamond-shaped fashion, the bladder mucosa is incised, absorbable interrupted sutures are placed in four quadrants, and a mucosa-to-mucosa anastomosis is created using running absorbable sutures with a temporary ureteral stent in place of the first three-quarters of

the anastomosis. The muscular layers of the bladder are then carefully approximated over the anastomosis to prevent reflux.

The decision to place a ureteral stent depends on the surgeon, who must try to balance the risk of infectious complications with the possible technical complications of a ureteral anastomosis, but in general, this is not required except during the rarely performed donor ureter to recipient ureter anastomosis or in the case of a pediatric kidney transplant. Fixation of the donor’s kidneys is not necessary, except in the case of small kidneys (usually from a pediatric donor) or en bloc kidneys.

Grafts with Multiple Renal Arteries

In 10% to 30% of donor kidneys, multiple renal arteries are encountered. Unless kidney transplant candidates have hypercoagulopathy, grafts with multiple renal arteries fare as well as those with single vessels.⁸⁶ Vascular reconstruction options include implanting the donor’s arteries separately, reconstructing the multiple arteries into a common channel, or combining multiple arteries into a common Carrel patch (Fig. 11-8).

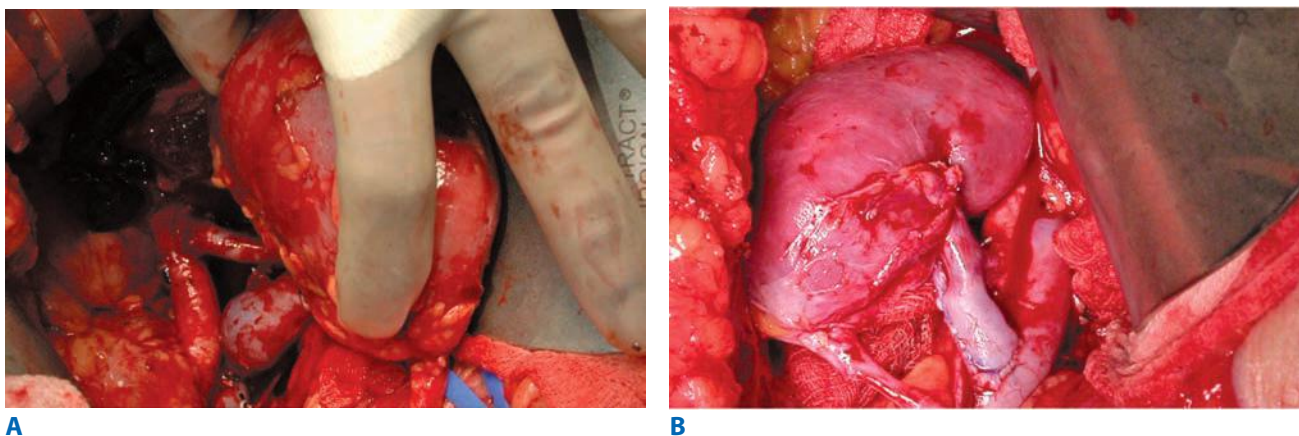


Figure 11-7. Vascular anastomoses of kidney transplant. **A.** Arterial anastomosis: donor renal artery with Carrel patch to recipient external iliac artery, end-to-side. **B.** Venous anastomosis: donor renal vein with caval extension conduit to recipient external iliac vein, end-to-side.

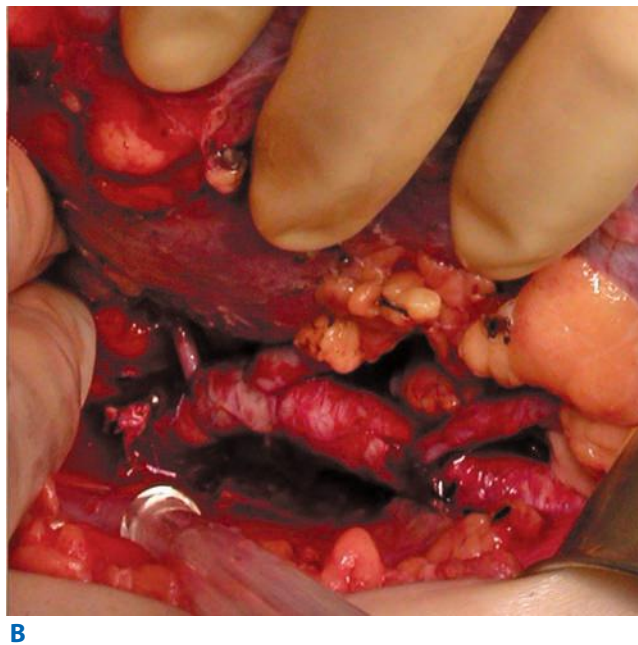
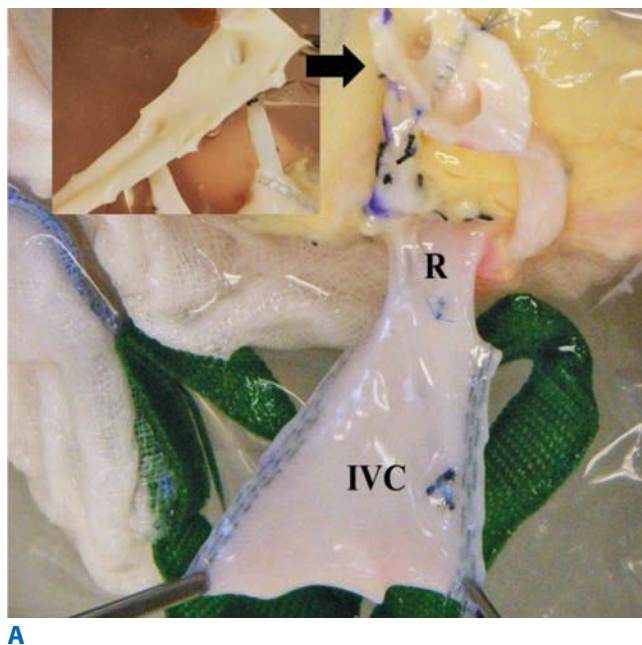


Figure 11-8. Arterial and venous reconstruction. **A.** Two renal arteries combined into a single Carrel patch (arrow). Right renal vein extension conduit constructed with stapled caval patch. IVC = inferior vena cava; R = right renal vein. **B.** Three renal arteries anastomosed to external iliac artery separately.

En Bloc Grafts

Debate persists about whether to implant kidneys obtained from young donors (<5 years or whose body weight is under 20 kg) as a single en bloc unit into one recipient or separately into two recipients. The underlying issues are the shortage of donor organs, the complexity of the surgical procedure, the risks of graft thrombosis, ureteral complications, and long-term outcomes.

In en bloc kidney transplants, the donor aorta and vena cava are used as the vascular inflow and outflow conduits. Therefore, reconstruction of the en bloc graft pretransplant is key to a successful transplant. The donor's suprarenal vena cava and aorta are oversewn. The lumbar branches of the cava and aorta are ligated. Dissection around the renal hilum should be avoided. The orientation of the cava and aorta should be

clearly marked, in order to avoid torsion of the anastomosis. If the color of the two kidneys looks different after reperfusion, repositioning should be attempted to rule out vascular torsion; fixation of the en bloc kidneys to the retroperitoneum is often necessary. The donor's ureters are implanted to the recipient's bladder, either as two separate anastomoses or as a common patch (Fig. 11-9). Only a handful of centers have performed en bloc kidney transplants, but the long-term outcomes are encouraging.^{87,88}

Perioperative Care

Preoperatively, a thorough history and physical examination should be performed. Any changes in transplant candidates' recent medical history should be investigated in great detail.

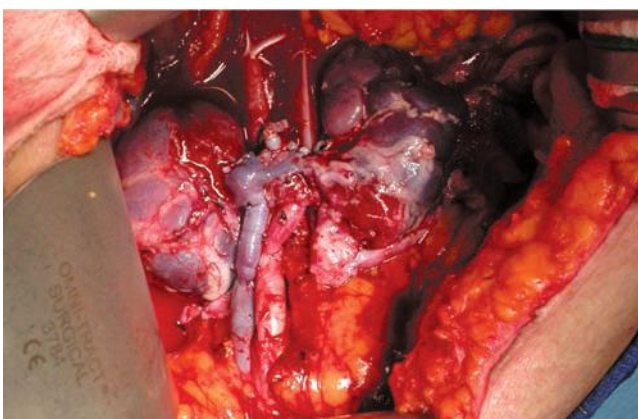
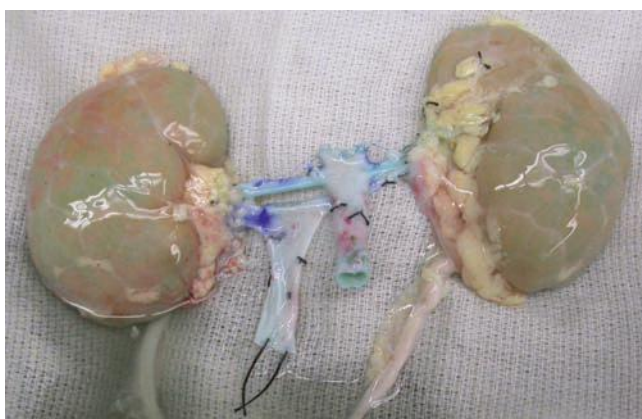

Figure 11-9. En bloc kidney transplant (3-month-old donor kidneys). **A.** En bloc kidneys benched. Vascular integrity tested with methylene blue (blue hue look of the kidneys). **B.** En bloc kidneys transplanted in to a 62-year-old woman. Donor aorta anastomosed to recipient's external iliac artery; donor cava, to recipient's external iliac vein.

In those recipients with a historically negative PRA level who have recently undergone blood transfusions, a prospective tissue cross-match is necessary to avoid graft rejection. Electrolyte panels should be checked. Emergency dialysis may be necessary for transplant candidates experiencing hyperkalemia or fluid overload.

For dialysis-dependent transplant candidates, the catheter sites should be examined preoperatively to rule out infections. Vascular access for hemodialysis is essential to avoid complications related to posttransplant acute tubular necrosis (ATN). Vascular evaluation is mandatory; any changes in results should be investigated by appropriate imaging studies.

As is routine for other major surgical procedures, transplant candidates should preoperatively undergo a chest x-ray, a 12-lead ECG, blood typing, cross-match tests, and prophylaxis against surgical site infection (by administration of a nonnephrotoxic antibiotic with activity against both common skin microflora and gram-negative pathogens); candidates should receive nothing to eat or drink.

Intraoperatively, transplant recipients should be kept well-hydrated to avoid ATN and should receive heparin prior to vascular occlusion. Before reperfusion of the transplanted kidney, the desired central venous pressure should be maintained at around 10 mmHg, and the systolic blood pressure should be above 120 mmHg. In pediatric recipients of an adult graft, a superphysiologic condition may be necessary to avoid ATN or graft thrombosis. Mannitol often is administered before reperfusion as a radical scavenger and diuretic agent, and a diuretic such as furosemide is administered as well.

Postoperatively, the guiding principles for the care of kidney transplant recipients are the same as for other surgical patients. The crucial elements include hemodynamic stability and fluid and electrolyte balance. To achieve a euvolemic state, the recipient's urine output is replaced with either an equal or a reduced volume of IV fluid on an hourly basis, depending on the medical status. In recipients undergoing brisk diuresis, aggressive replacement of electrolytes (including calcium, magnesium, and potassium) may be necessary. In recipients experiencing ATN, fluid overload, or hyperkalemia, however, fluid restriction, treatment for hyperkalemia, and even hemodialysis may be necessary.

Hypotension is an unusual event immediately posttransplant. The differential diagnoses include hypovolemia, vasodilation, and myocardial infarction with cardiac failure. Immediate action should be taken to avoid life-threatening complications. Posttransplant hypertension can be mediated by catecholamines, fluid overload, or immunosuppressive agents.

Postoperatively, urine output is used as a surrogate marker to monitor graft function. Among recipients whose native kidneys produce significant amounts of urine, normal or increased urine output can be misleading; for them, serum blood urea nitrogen and creatinine levels are more reliable indicators of kidney graft function.

Suddenly decreased or minimal urine output requires immediate attention. A change in volume status is the most common cause, but other culprits include blockage of the urinary catheter, urinary leak, vascular thrombosis, hypotension, drug-related nephrotoxicity, ATN, and rejection (all of which must be thoroughly investigated). Diagnostic studies such as Doppler ultrasound, nuclear renograms, or biopsies should be considered.

Postoperative bleeding is an uncommon event after a kidney transplant. Recipients on anticoagulation or antiplatelet

treatments are at increased risk. Signs and symptoms (such as an expanding hematoma over the surgical site, increased pain over the graft, a falling hemoglobin level, hypotension, and tachycardia) should arouse suspicion of hemorrhage. Doppler ultrasound is useful to establish the underlying cause. Surgical exploration seldom is required, because the accumulated hematoma tamponades the bleed. Indications for surgical exploration include ongoing transfusion requirement, hemodynamic instability, and graft dysfunction from hematoma compression. For recipients on anticoagulation or antiplatelet treatments, the threshold for surgical exploration is lower. Small unligated vessels at the donor's renal hilum or recipient's retroperitoneum are likely sources of bleeding.

One of the most devastating postoperative complications in kidney recipients is graft thrombosis. It is rare, occurring in fewer than 1% of recipients. The recipient risk factors include a history of recipient hypercoagulopathy and severe peripheral vascular disease; donor-related risk factors include the use of en bloc or pediatric donor kidneys, procurement damage, technical factors such as intimal dissection or torsion of vessels, and hyperacute rejection. Graft thrombosis usually occurs within the first several days posttransplant. Acute cessation of urine output in recipients with brittle posttransplant diuresis and the sudden onset of hematuria or graft pain should arouse suspicion of graft thrombosis. Doppler ultrasound may help confirm the diagnosis. In cases of graft thrombosis, an urgent thrombectomy is indicated; however, it rarely results in graft salvage.

Urologic complications are seen in up to 5% of recipients. The cause is often related to ureteral ischemia, damage during procurement of the donor's distal ureter, or technical errors. Symptoms of urine leak include fever, pain, swelling at the graft site, increased creatinine level, decreased urine output, and cutaneous urinary drainage. Diagnosis can be confirmed by a combination of ultrasound, nuclear renography, drainage of perinephric fluid collection, and comparison of serum and fluid creatinine levels. Depending on the location and volume of the urine leak, satisfactory results can be achieved by surgical exploration and repair or by percutaneous placement of a nephrostomy and ureteral stenting.

Early urinary obstruction can be due to edema, blood clots, torsion of the ureter, or compression from a hematoma. Late urinary obstruction is often related to ischemia. The appearance of hydronephrosis on ultrasound is a good initial indicator. Treatment includes percutaneous placement of a nephrostomy and ureteral stenting. If transluminal intervention fails, surgical intervention (such as ureteral reimplantation or a ureteropyelostomy) can be undertaken.

Results

A kidney transplant remains the most common solid organ transplant in the world today. With the introduction of induction immunosuppressive therapy and ever-improving, less toxic immunosuppressive medications, posttransplant outcomes have become better and better. According to a recent analysis of more than 250,000 U.S. adult kidney transplant recipients, the actual half-life (50% graft survival) of a deceased donor kidney was 6.6 years in 1989, 8 years in 1995, and 8.8 years in 2005. Interestingly, during that same period—though with a much better overall outcome—the half-life of a living donor kidney has essentially remained the same: 11.4 years in 1989 and 11.9 years in 2005.⁸⁹

The biggest improvements have been in the reduction of 1-year graft failure. With a deceased donor kidney, the 1-year graft failure rate dropped from 20% in 1989 to less than 7% in 2009; with a living donor kidney, the rate dropped from 8.5% in 1989 to less than 3% in 2009.⁸⁹ Furthermore, steroid-free protocols⁹⁰ and calcineurin-free protocols⁹¹ have been validated and implemented in the last two decades, further reducing medication-related side effects and vastly improving the quality of life for tens of thousands of recipients.

Currently, the most common cause of graft loss is recipient death (usually from cardiovascular causes) with a functioning graft. The second most common cause is chronic allograft nephropathy; characterized by a slow, unrelenting deterioration of graft function, it likely has multiple causes (both immunologic and nonimmunologic).^{92,93} The graft failure rate due to complications related to surgical technique has remained at about 2%.

PANCREAS TRANSPLANTATION

A successful pancreas transplant is currently the only definitive long-term treatment for patients with insulin-dependent diabetes mellitus (IDDM) that (a) restores normal glucose hemostasis without exposing patients to the risk of severe hypoglycemia and (b) prevents, halts, or reverses the development or progression of secondary complications of diabetes.⁹⁴

Given its vast medical, social, and financial implications, diabetes mellitus is a huge burden to patients and to society as a whole. An estimated 10% to 15% of the U.S. population is affected by it; of all diabetic patients, 10% have early-onset disease. In the United States, diabetes mellitus is the most common cause of end-stage kidney disease, blindness, impotence, major limb amputations, and coronary or peripheral vascular bypass procedures. It is one of the most common causes of death, along with myocardial infarction and stroke. Diabetes significantly decreases not only the quality of life but also life expectancy.

Despite improvements in exogenous insulin administration (including the use of devices such as insulin pumps), wide fluctuations in glucose levels and the risk of hypoglycemic episodes are common. The Diabetes Control and Complications Trial (DCCT) demonstrated in the late 1990s that intensive insulin therapy may slow the rate of secondary complications of diabetes—yet at the expense of (life-threatening) iatrogenic hypoglycemia. The annual mortality rate of patients with insulin-induced inadvertent hypoglycemia is estimated to be as high as 2% to 3%.

Since the first pancreas transplant in December 1966, performed by William Kelly and Richard Lillehei at the University of Minnesota, more than 25,000 pancreas transplants in the United States and more than 10,000 pancreas transplants from all over the world have been reported to the International Pancreas Transplant Registry (IPTR), which is maintained at the University of Arizona.^{94,95}

Pancreas transplants are performed in three recipient categories:

- *Simultaneous pancreas and kidney (SPK) transplant in diabetic and uremic patients.* Almost 80% of pancreas transplants are performed in this category. The recipient is already obligated to lifelong immunosuppressive therapy, due to the need for a kidney transplant, so only the surgical risk of a pancreas transplant is added. A successful SPK

transplant renders the recipient dialysis-free and insulin-independent.

- *Pancreas after kidney (PAK) transplant in diabetic and posturemic patients.* Approximately 15% of all pancreas transplants fall into this category. These patients previously underwent a kidney transplant with either a living or deceased donor, but are candidates for a subsequent pancreas transplant because of poor glucose control or because of progression of secondary diabetic complications (which may include the development of diabetic nephropathy in the transplanted kidney).
- *Pancreas transplant alone (PTA) in nonuremic patients with brittle diabetes mellitus.* Only about 8% of all pancreas transplants are in this category. These patients have not yet developed advanced diabetic nephropathy, but their glucose levels are extremely labile despite best efforts to control it. Because of the lifelong need for immunosuppressive therapy, the surgical risk has to be balanced with the medical risks of brittle diabetes (e.g., frequent episodes of hypoglycemia and hypoglycemic unawareness).

In SPK recipients, a plethora of literature exists that demonstrates significant improvements in secondary diabetic complications (across all organ systems) posttransplant. Improvements have been reported in diabetic nephropathy, neuropathy (autonomic and peripheral), micro- and macrovascular disease, retinopathy, gastroparesis, and other secondary complications.⁹⁶ Currently, more than 1000 pancreas transplants are performed annually in the United States, with the goal of conferring the following benefits: excellent glucose control (similar to that of a functioning native pancreas), prevention or improvement of secondary diabetic complications, and increased quality of life and life expectancy. In addition, pancreas transplants can be successfully performed in patients who have undergone a total pancreatectomy for benign disease (such as chronic pancreatitis) to treat both endocrine and exocrine deficiency after surgery.⁹⁷

Donor Operation

The general criteria for selecting deceased donors for pancreas procurement are similar to those for other solid organs; a history of type 1 diabetes mellitus obviously is a contraindication. Relative contraindications include previous pancreatic procedure(s), as well as pancreatic disorders, such as chronic pancreatitis and intraductal papillary mucinous neoplasm. Hyperglycemia in itself is not a contraindication to pancreas procurement, because its cause in brain-dead donors usually is severe insulin resistance, which is rarely observed in recipients.

In light of better anatomic understanding and improved surgical skills, all three abdominal organs that share a common blood supply (pancreas, liver, and intestine) can be procured at the same time and transplanted into three different recipients (Fig. 11-10). During pancreas procurement, a “no-touch” technique of the gland is preferred; dissection of the pancreas is carried out in a way that avoids direct manipulation of the organ such that simultaneous procurement of the spleen, duodenum, and surrounding connective tissues occurs.

In contrast to the liver and kidneys, the pancreas should not be extensively flushed at the end of the procurement. To minimize the amount of preservation fluid that reaches the pancreas, the splenic artery and SMA can be temporarily clamped at their origin from the aorta. Usually, the celiac axis with an

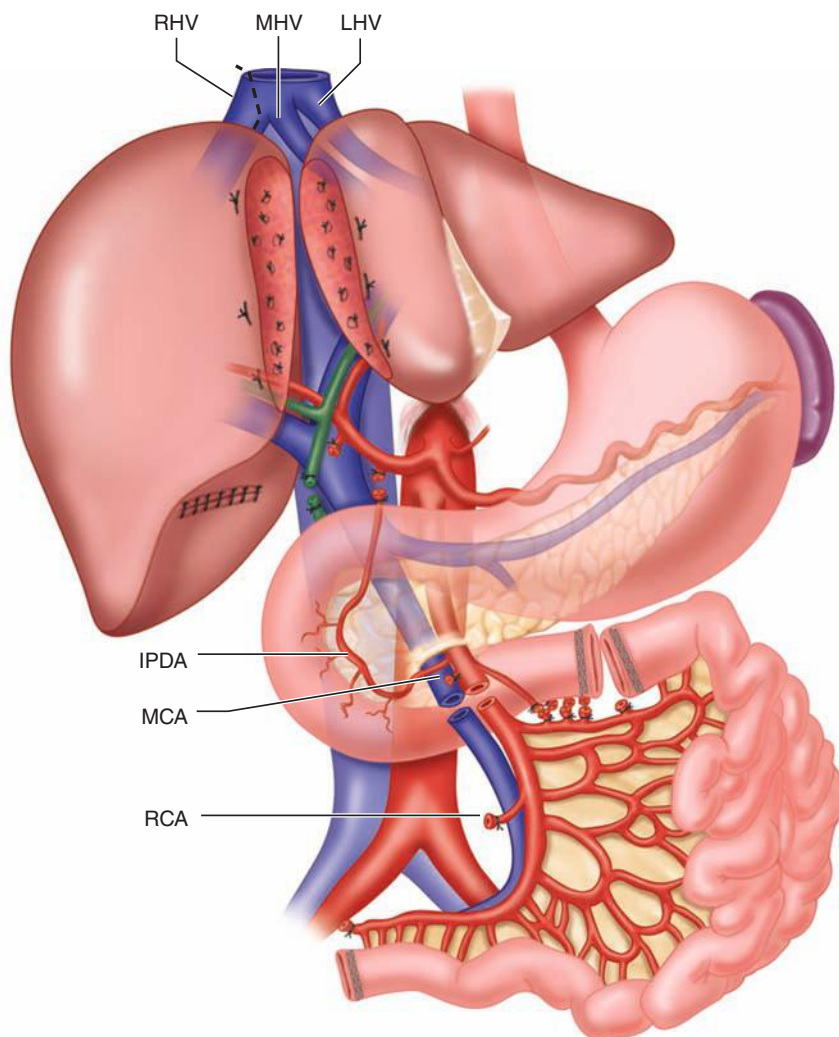


Figure 11-10. Simultaneous pancreas, in situ split-liver, and intestine procurement. IPDA = inferior pancreaticoduodenal artery; LHV = left hepatic vein; MCA = middle cerebral artery; MHV = middle hepatic vein; RCA = right coronary artery; RHV = right hepatic vein. (Reproduced from Gruessner RWG, Sutherland DER, eds. *Transplantation of the Pancreas*. New York: Springer, 2004; Color Plate VI, Figure 8.1.3.11. With kind permission of Springer Science + Business Media.)

aortic Carrel patch is retained with the liver. The splenic artery is divided close to its origin and is retained with the pancreas. The SMA is also procured with an aortic Carrel patch and is retained with the pancreas.

In case of a replaced or aberrant right hepatic artery, this first branch off of the SMA is carefully dissected out from the posterior surface of the pancreas. A replaced or aberrant right hepatic artery does not transverse the pancreas and is not a contraindication to combined pancreas and liver procurement. But with this anatomic variant, an aortic Carrel patch with the proximal SMA and replaced or aberrant right hepatic artery remains with the liver; the distal SMA with the inferior pancreaticoduodenal artery remains with the pancreas.

In the relatively rare event that the liver is not procured, then neither the splenic nor the gastroduodenal arteries need to be divided at their respective takeoff; the donor's celiac axis and the SMA are included on a common Carrel patch. This technique allows a single arterial anastomosis to be performed in the recipient without reconstruction. At the end of the procurement, the pancreas is attached to the spleen, duodenum, and proximal jejunum, which is stapled at both ends.⁹⁸

Back Table Preparation of the Pancreas Graft

Back table preparation of the pancreas graft consists of four steps: (a) removal of the spleen; (b) shortening, restapling, and/

or suture reinforcement of the mesenteric root; (c) trimming of any excess distal and proximal duodenum, along with reinforcement of the proximal staple line; and (d) arterial reconstruction.

Back table preparation is carried out in a basin filled with chilled preservation solution. The most common technique to create a single arterial inflow to the pancreas graft is the "Y-graft" reconstruction, using a resected segment of the donor iliac artery bifurcation. In this technique, the donor external iliac artery is anastomosed end-to-end to the donor SMA, and the donor internal iliac artery is anastomosed end-to-end to the splenic artery (Fig. 11-11). This procedure allows the donor common iliac artery to be anastomosed as a single vessel to the recipient's common iliac artery. For venous outflow, the portal vein is kept relatively short, in order to avoid the risk of venous thrombosis by kinking or impingement.⁹⁸

Recipient Operation

Over the years, different surgical techniques have been described for (a) the management of exocrine pancreatic secretions and (b) the type of venous drainage. For the secretions, the two most common techniques are drainage of the duodenal segment to the bladder (bladder drainage) or to the small bowel (enteric drainage) (Figs. 11-12 and 11-13). For venous drainage, systemic venous drainage is preferred over portal venous drainage.

The pancreas graft is usually placed intra-abdominally and preferably on the right side, because the iliac vessels are in a more

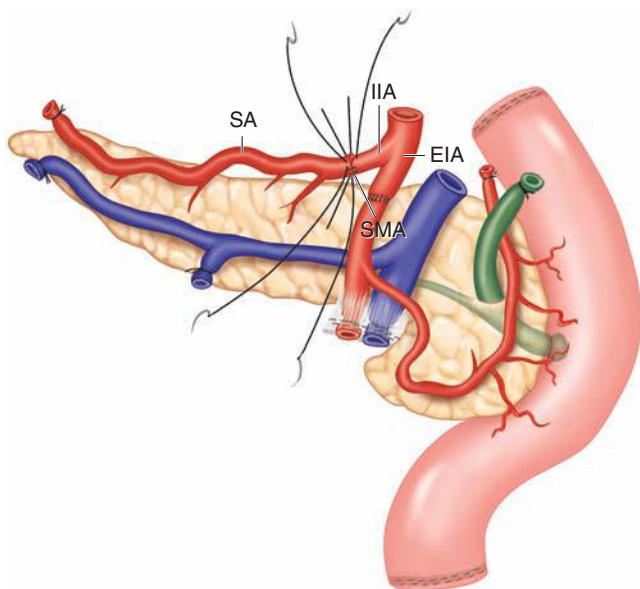


Figure 11-11. Posterior view of the pancreas graft with Y-graft reconstruction. EIA = external iliac artery; IIA = internal iliac artery; SA = splenic artery; SMA = superior mesenteric artery. (Reproduced from Gruessner RWG, Sutherland DER, eds. *Transplantation of the Pancreas*. New York: Springer, 2004; Color Plate VII, Figure 8.1.3.13[B]. With kind permission of Springer Science + Business Media.)

shallow position on the right than on the left side; moreover, the vessels are already appropriately aligned for the vascular anastomoses (i.e., a lateral position for the common iliac vein, a medial position for the common iliac artery). Venous and arterial anastomoses are performed end-to-side. After restoration of

blood flow to the graft, hemostasis must be meticulously maintained. Because the donor portal vein purposely is kept short, ligation and transection of all of the recipient's internal iliac vein branches are frequently performed, in order to prevent tension on the venous anastomosis. The pancreas usually is placed with the pancreatic head and duodenum pointing caudally.

Bladder drainage is performed using either a hand-sewn or a stapled anastomosis in which the antimesenteric side of the donor duodenum is sewn to the superior portion of the dome of the bladder. The stapled technique requires that a circular cutting stapler be inserted through the open distal end of the donor duodenum, which is subsequently closed. Bladder drainage has two main advantages. First, rejection of the exocrine pancreas precedes rejection of the endocrine pancreas by 5 to 7 days. Amylase levels are measured routinely in the recipient's urine. With bladder drainage, antirejection treatment can successfully be implemented when the recipient is still normoglycemic and only hypoamylasuric. In the absence of hyperglycemia, more than 90% of pancreas rejection episodes are reversible. Second, bladder drainage avoids the bacterial contamination that occurs with enteric drainage. If an anastomotic leak occurs, it is easier to treat, because the infection usually remains localized to the right lower quadrant.

Enteric drainage is more physiologic and has advantages as well. The antimesenteric side of the donor's duodenum is anastomosed to the antimesenteric portion of the recipient's jejunum in a side-to-side fashion. The enteric anastomosis can also involve a defunctionalized Roux-en-Y loop, which minimizes the potential complications if an enteric leak occurs.⁹⁸ Currently, in the United States, more than 80% of all pancreas transplants are performed with enteric drainage for the exocrine pancreatic secretions, and more than 90% employ systemic venous drainage.⁹⁵

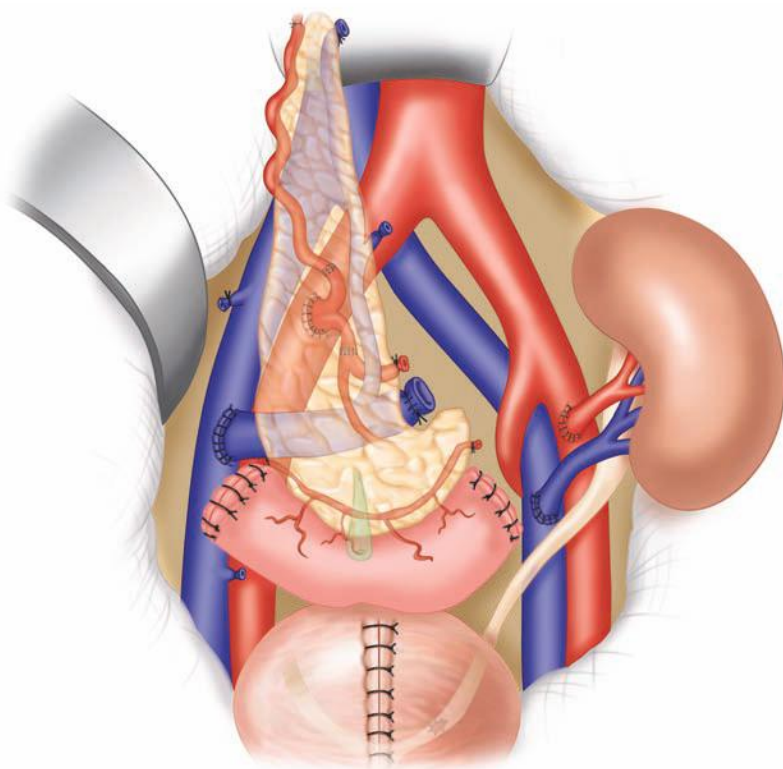


Figure 11-12. Whole-organ transplant with systemic vein and bladder exocrine drainage. (Reproduced from Gruessner RWG, Sutherland DER, eds. *Transplantation of the Pancreas*. New York: Springer, 2004; Color Plate XIV, Figure 8.2.2.2[B]. With kind permission of Springer Science + Business Media.)

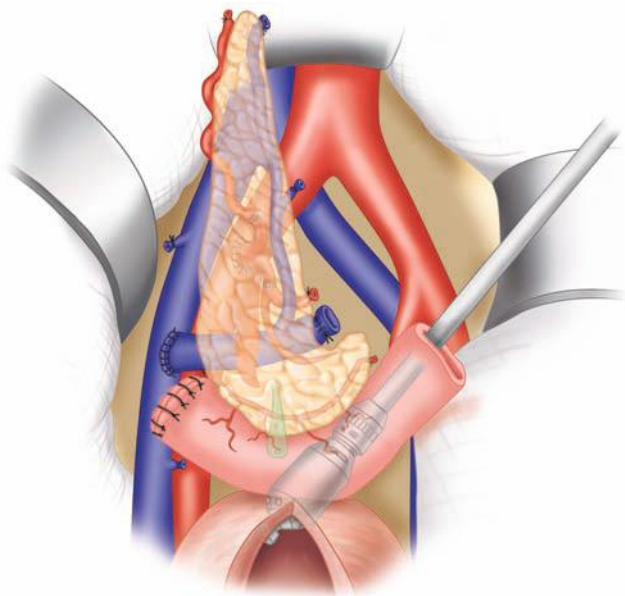


Figure 11-13. Whole-organ transplant with systemic vein and enteric exocrine drainage. (Reproduced from Gruessner RWG, Sutherland DER, eds. *Transplantation of the Pancreas*. New York: Springer, 2004; Color Plate XIV, Figure 8.2.2.2[A]. With kind permission of Springer Science + Business Media.)

Complications

The technical complication rate for pancreas transplants is higher than for any other solid organ transplant. Four factors contribute to the high surgical complication rate⁹⁹: (a) the nature of the organ itself with inherent organ-specific surgical complications (e.g., pancreatitis, abscesses, necrosis, fistulas, and pseudocysts) and its low blood flow (which significantly increases the risk of thrombosis, as compared with a kidney or liver transplant); (b) the risk of a leak or infection after connecting two hollow viscera (the duodenum and either the bladder or small intestine); (c) the increased incidence of rejection episodes, because the pancreas is one of the most immunogenic solid organs; and (d) the underlying disease of diabetes mellitus, predisposing patients not only to infections but also to cardiovascular and other complications.

The most common surgical complications are thrombosis (an incidence of 5%–15%), intra-abdominal abscesses (5%–10%), and bleeding (6%–8%). Other pancreas-specific complications include graft pancreatitis (frequently due to procurement or reperfusion injury), pancreatic fistulas, and pancreatic pseudocysts. Anastomotic leaks do not always require a graft pancreatectomy, but arterial pseudoaneurysms, arteriovenous fistulas, and wound dehiscence may. Bleeding frequently requires relaparotomy.

Thrombosis usually occurs within the first week posttransplant. It manifests as a sudden increase in insulin requirements or as a sharp drop in urinary amylase levels. Venous thrombosis, which is more common than arterial thrombosis, is associated with distinct clinical symptoms, including a swollen and tender graft, hematuria, lower extremity edema, and deep vein thrombosis, the latter two occurring ipsilaterally. Arterial thrombosis is less symptomatic and may not initially cause pain; its diagnosis is usually confirmed by Doppler ultrasonography. Surgical exploration in recipients with thrombosis usually requires a graft pancreatectomy.

With the advent of advanced interventional radiologic procedures to drain intra-abdominal abscesses, the reoperation rate has markedly decreased. Pancreas transplant recipients are usually kept on broad-spectrum antimicrobial agents for the first 7 days posttransplant.

The most common nonsurgical complication posttransplant is rejection. The incidence of rejection is about 30% within the first year. The diagnosis is usually based on an increase in serum amylase and lipase levels and, in bladder-drained recipients, a decrease in urinary amylase levels. A sustained drop in urinary amylase levels greater than 25% from baseline should prompt a pancreas graft biopsy to rule out rejection. In enteric-drained recipients, one must rely on serum amylase and lipase levels only. Other signs and symptoms of rejection include tenderness over the graft, unexplained fever, and hyperglycemia, which usually is a late finding; fewer than 5% of all rejection episodes can be reversed in its presence. The diagnosis of rejection should be confirmed by a percutaneous pancreas graft biopsy.

Other nonsurgical complications include infections with CMV, HCV, or extra-abdominal bacteria or fungi; malignancies, such as PTLD; and, rarely, graft-versus-host disease. For such complications, the diagnosis and treatment are similar to what is recommended after other solid organ transplants.

Bladder-drained pancreas recipients may experience an array of unique urologic complications. Usually the result of the irritating nature of pancreatic enzymes on the urothelium in the bladder and urethra, these urologic complications can lead to cystitis, hematuria, and dysuria. With the loss of bicarbonate from pancreatic secretions, dehydration and metabolic acidosis are not uncommon. Many of these complications are chronic, such that approximately 20% to 30% of all bladder-drained recipients require conversion to enteric drainage within the first 5 years posttransplant.¹⁰⁰

Living Donor Pancreas Transplants

Pancreas transplants using living donors also can be performed safely and successfully in select donors and recipients. Since 1979, about 150 such transplants have been performed worldwide, with 1-year graft survival rates in excess of 85% over the last decade. A meticulous donor evaluation using standard criteria remains key to a low donor metabolic and surgical complication rate. The concept of procuring the distal pancreas from a living donor is based on the observation that patients with benign or malignant pancreatic disorders can undergo a distal hemipancreatectomy without any serious change in endocrine function.

Living donor pancreas transplants are ideal for patients with an identical twin, but other relatives can be suitable donors as well. In particular, patients with high PRA levels should be considered for a living donor transplant.

Living donor pancreas transplants decrease the number of deaths of diabetic patients on the waiting list, help overcome the organ shortage, reduce mortality and morbidity, and improve the quality of life for patients with debilitating side effects of diabetes. The use of living donors also reduces the risk of graft rejection, as compared with the use of deceased donors. Yet living donor pancreas transplants remain relatively rare, performed under very selective circumstances. In terms of surgical technique, the donor splenic artery and vein are anastomosed to the recipient's external iliac artery and vein in an end-to-side fashion, and exocrine drainage can occur via an anastomosis

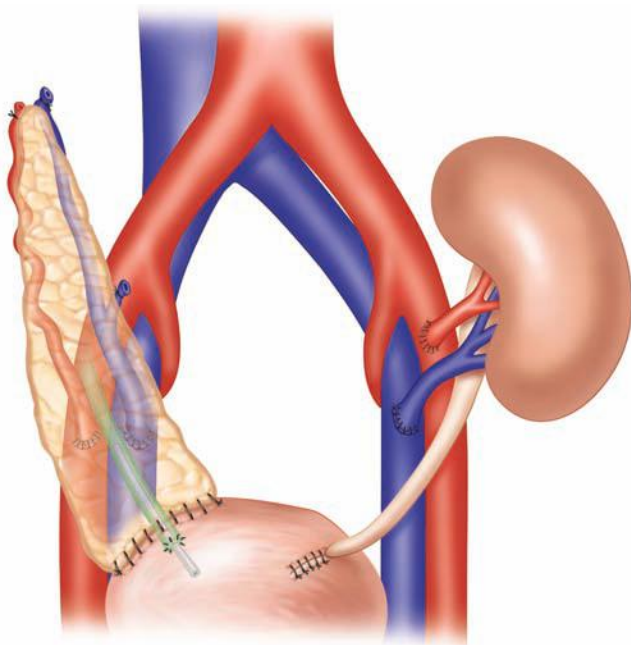


Figure 11-14. Segmental transplant with systemic vein and bladder exocrine drainage. The donor splenic artery and splenic vein are anastomosed end-to-side to the recipient's external iliac artery and vein. The splenic artery anastomosis is lateral and proximal to the splenic vein anastomosis. A two-layer ductocystostomy is constructed. (Reproduced from Gruessner RWG, Sutherland DER, eds. *Transplantation of the Pancreas*. New York: Springer, 2004; Color Plate XVI, Figure 8.2.2.4. With kind permission of Springer Science + Business Media.)

of the pancreatic duct and transected end of the pancreas to the bladder or bowel¹⁰¹ (Fig. 11-14).

Results

As of December 2010, more than 35,000 pancreas transplants had been reported to the IPTR: more than 25,000 transplants in the United States and more than 10,000 in other countries. According to IPTR data, recipient age at the time of the transplant has increased significantly, and so has the number of transplants for patients with type 2 diabetes. The trend over time has been toward stricter donor criteria, with a concentration on younger donors, preferably trauma victims, and on short pancreas graft preservation time.

Drainage techniques have changed over time, too: enteric drainage of exocrine pancreatic secretions is now predominant, in combination with systemic drainage of the venous effluent of the pancreas graft. Immunosuppressive protocols have developed toward antibody induction therapy, followed by administration of tacrolimus and MMF for maintenance. Steroid avoidance has increased over time in all three recipient categories.

These changes have led to improved patient and graft survival rates. In all three recipient categories, early technical graft loss rates have decreased significantly to about 8%. Likewise, the 1-year immunologic graft loss rate has also decreased, ranging from 2% to 6%. The 1-year patient survival rates now exceed 90% in all three recipient categories. The highest 1-year pancreas graft survival rate is in SPK recipients: 86% for the pancreas and 93% for the kidney. The 1-year pancreas graft survival rate is 80% in PAK recipients and 78% in PTA recipients.

Significant improvements have been noted not only in 1-year pancreas graft function but also in long-term success rates. The most recent 5-, 10-, and 20-year pancreas graft function rates are 80%, 68%, and 45% for SPK recipients; 62%, 46%, and 16% for PAK recipients; and 59%, 39%, and 12% for PTA recipients, respectively. The quality of the deceased donor graft is of paramount importance. The use of anti-T-cell induction therapy has had a significant impact on long-term graft survival, specifically in PTA recipients.

IPTR data show significant improvements in patient survival and pancreas graft function rates since the inception of UNOS, over a course of 24 years.^{92,95,99,102} Clearly, pancreas transplants now offer excellent outcomes for patients with IDDM.

Islet vs. Pancreas Transplants

Pancreas transplants are frequently compared with islet transplants, which are less invasive and, therefore, more appealing. It is important to emphasize that these two types of transplants are not mutually exclusive but rather complementary. The results of islet transplants have improved over the past decade, but overall islet graft function, specifically long-term function, still significantly trails overall pancreas graft function.¹⁰³ Islet trans-

plants involve pancreas procurement (as described earlier) and then separation of islets from the exocrine pancreatic tissues using proteolytic enzymes (as described later). The human pancreas contains about one million islets, of which half are lost during the isolation process. About 10,000 islets per kilogram of body weight are needed to achieve insulin independence when transplanted into the liver. Frequently, one donor pancreas does not suffice; in fact, up to four donor pancreases have been used for one islet recipient.

Because of the relatively disappointing long-term outcomes, insurance providers in the United States do not provide reimbursement for islet transplants. Transplant centers with both pancreas and islet transplant programs follow an algorithm that favors islet transplants in patients with a high surgical risk and pancreas transplants in patients with a low surgical risk. Although solitary donor pancreases are not in short supply, only one donor pancreas is required for a successful pancreas transplant; in contrast, two to four donor pancreases are commonly used for one islet recipient with less favorable long-term outcomes.

Of note, the primary goal of current islet transplant trials is not insulin independence but rather a reduction in the incidence and severity of hypoglycemic events, a reduction in exogenous insulin requirements, and an amelioration of hemoglobin A_{1c} levels. Islet transplants rarely maintain long-term insulin independence. A recent study showed a higher rate of insulin independence in PTA recipients than in recipients of an islet transplant alone, despite the use of up to three donor pancreases in each of the islet recipients.¹⁰⁴ Until islet transplant results significantly improve and include long-term insulin independence, a pancreas transplant remains the treatment of choice for β -cell replacement therapy in patients with IDDM.

ISLET TRANSPLANTATION

Transplanting islets of Langerhans isolated from deceased donor pancreases is an appealing option for patients with type 1 diabetes. An islet transplant involves the procurement of a donor pancreas and its transportation to a specialized islet

isolation facility, where the pancreas is enzymatically digested; then, the islets are purified from the rest of the digested pancreas using density gradients. The purified islets are then cultured and evaluated for their identity, viability, and potency, before being infused into the portal vein of a diabetic recipient. When the procedure is successful, these islet cells engraft into the recipient and secrete insulin, providing excellent moment-to-moment control of blood glucose, as is seen with a whole-pancreas transplant.

A successful islet transplant offers advantages over exogenous insulin injections—advantages that are similar to those of a whole-pancreas transplant. These advantages include restoring β -cell secretory capacity, improving glucose counterregulation, restoring hypoglycemia awareness, providing perfect or near-perfect glucose homeostasis, and, potentially, preventing secondary diabetic complications.

Unlike a whole-pancreas transplant, an islet transplant does not involve a major surgical procedure with its associated mortality and morbidity. Instead, it can generally be performed as an outpatient procedure using percutaneous catheter-based therapy to cannulate a branch of the portal vein, with minimal recovery time for the recipient. Potential complications associated with islet injection include portal hypertension, portal vein thrombosis, hepatic abscesses, and bacteremia. Theoretically, islet transplants could have wider application (as compared with current practice and with whole-pancreas transplants), given the significantly lower surgical risk, the relatively small tissue volume transplanted, and the potential for islet immunomodulation or immunoisolation, which could minimize or eliminate the need for immunosuppression.

The first reported attempt at an islet transplant was in 1893 by Watson-Williams and Harsant: they transplanted a sheep's minced pancreas into the subcutaneous tissue of a young boy with ketoacidosis.¹⁰⁵ The discovery of insulin may have reduced interest in islet transplants as a treatment for diabetes, at least until the realization that insulin could not provide perfect glycemic control and that, therefore, patients ultimately suffered devastating secondary complications. Several milestones ensued: the first whole-pancreas transplants,¹⁰⁶ early success with rodent islet transplants,¹⁰⁷ and then, in the 1970s, human islet autotransplants after pancreatectomy, in order to address the intractable pain associated with chronic pancreatitis, by Sutherland, Najarian, and colleagues in Minnesota.¹⁰⁸

Until recently, attempts to extend those trailblazing findings of clinical islet autotransplants to clinical islet allotransplants in patients with type 1 diabetes met with generally very poor success. For example, in 1995, a report of the International Islet Transplant Registry indicated that of 270 recipients, only 5% were insulin-independent at 1 year posttransplant.

In 2000, Shapiro and colleagues reported the results of the Edmonton protocol, which enabled consistent diabetes reversal and short-term (<1 year) insulin independence.¹⁰⁹⁻¹¹¹ The Edmonton protocol prescribed transplanting a large number of freshly isolated islets (>10,000 islet equivalents per kilogram body weight, typically requiring the use of two to four pancreases) with a specialized “islet-sparing,” steroid-free immunosuppressive protocol consisting of low-dose tacrolimus, sirolimus, and IL-2 receptor antibody induction. Those results were replicated at other experienced transplant centers,^{112,113} but the rates of long-term (>5 year) insulin independence remained poor, well below those of whole-pancreas transplants.¹¹⁴ Still, despite the low rates of long-term insulin independence, most

islet recipients were C-peptide positive and retained hypoglycemia awareness, indicating residual islet function and benefit. In fact, at 9 years posttransplant, 15% remained insulin-independent, and 73% had hypoglycemia awareness and corrected hemoglobin A_{1c} levels.¹¹⁵

In the mid-2000s, new trials began with the goal of establishing protocols that enable insulin independence, using islets from a single donor pancreas; the results were good, especially with strict donor and recipient selection.^{116,117} In the most experienced centers, long-term rates of diabetes reversal are now about 50% at 5 years posttransplant. The reasons include refinements in pancreas preservation, islet isolation, and culture protocols, as well as the use of newer induction immunosuppressive agent combinations, such as a T-cell–depleting antibody (anti-CD3 antibody, alemtuzumab, or antithymocyte globulin) and a tumor necrosis factor-alpha (TNF- α) inhibitor (etanercept or infliximab). Presumably, viable β -cell mass is now preserved, both pre and posttransplant.¹¹⁶⁻¹²⁰ Thus, islet transplant results are approaching those of whole-pancreas transplants; however, because islets from more than one pancreas are typically needed, those results cannot be directly compared with the results of whole-pancreas transplants.^{121,122}

In the United States, an islet transplant is still officially deemed an experimental procedure. In contrast, since 2001, it has been considered a standard of care and is fully reimbursed in Canada and, more recently, in the United Kingdom, Sweden, Switzerland, France, and Italy as well. Worldwide, since 2000, more than 750 patients with diabetes have undergone an islet transplant, and 80 ongoing trials have enrolled up to 1500 islet recipients.¹¹⁸ One of the U.S. trials (a multicenter phase 3 registration trial sponsored by the National Institutes of Health) aims to collect the necessary data for submitting a biological license application (BLA) to the FDA. A successful BLA would open the road for islet transplants to become a standard of care and thus reimbursable by the Centers for Medicare and Medicaid Services.

The full potential of islet transplants remains to be realized, but the future is exciting. As the latest improvements in pancreas preservation, islet isolation and purification, islet culture, and islet immunoisolation are implemented clinically, the hope is that sustained insulin independence will become consistently possible with a single pancreas donor and without the need for systemic immunosuppression.

LIVER TRANSPLANTATION

The first attempts at liver transplants in the late 1960s through the 1980s were largely experimental endeavors, with a 1-year survival rate of only 30%. But breakthroughs in immunosuppression, surgical technique, organ preservation, anesthesia, and critical care have improved that rate to approximately 85% today. Liver transplants remain daunting, especially in the face of an organ shortage that results in sicker potential candidates. Unfortunately, the perioperative mortality rate and the 1-year mortality rate are among the highest of any surgical operation currently performed.

History

The first experimental liver transplants in dogs are often attributed to C. Stuart Welch in 1955 and then Jack Cannon in 1956. However, current scholarship reveals that Vittorio Staudacher first described the technique in 1952.¹²³ A series of canine

experiments followed, which refined the surgical technique to ensure perioperative survival.

The next obstacle—immunologic rejection—was addressed by drug immunosuppression with AZA and prednisone. The first human liver transplant trials started in 1963 with Thomas Starzl, but a series of deaths led to a voluntary moratorium for 3.5 years. With the resumption of clinical transplants in 1967, Starzl performed the first successful liver transplant. Still, for the next decade, survival rates were dismal: only 20% of the 170 liver transplant recipients in Starzl's program at the University of Colorado survived more than 5 years.¹²⁴

Several innovations dramatically improved outcomes. The advent of better immunosuppressive drugs was instrumental. In 1978, cyclosporine was introduced clinically in England. It was soon combined with prednisone to great effect. The arrival of tacrolimus in the 1990s further improved graft survival.

Technical advances were also significant. Donor procurement techniques and cold organ preservation protocols were standardized, and the recipient operation was also refined. Choledochocholedestomy or choledochojejunostomy to a Roux-en-Y limb became standard and significantly decreased the frequency of biliary complications. Innovations, including living donor liver transplants and deceased donor split-liver transplants, enabled more pediatric recipients to be transplanted. Improvements in portosystemic shunting and perioperative critical care also were contributory.

Indications

In general, any form of irreversible liver disease is an indication **7▶** for a liver transplant. Chronic alcoholic disease and HCV are the most common indications in the United States. An extensive list of acute and chronic diseases of the liver that are treatable by a liver transplant is provided in Table 11-6.

Offering transplants to alcoholic patients has always drawn some opposition, because of the perception of it being a self-inflicted illness, as well as concerns about recidivism and the recipient's possible inability to maintain postoperative immunosuppression and care. Yet studies have shown that such patients have excellent outcomes and that liver transplants for them are cost-effective.¹²⁵⁻¹²⁷ Because patients who drink 4 to 8 ounces of liquor daily for 10 to 15 years have an increased risk of developing cirrhosis, the general requirement for acceptance as a transplant candidate is 6 months of abstinence. Furthermore, most transplant centers recommend rehabilitation and Alcoholics Anonymous programs.

Transplants for HCV have yielded worse outcomes than transplants for other diseases.¹²⁸ The reason is the universal recurrence of the virus posttransplant. Viral levels reach pretransplant levels as early as 72 hours posttransplant.¹²⁹ The course of the viral infection is often accelerated posttransplant: 10% to 20% of recipients develop cirrhosis after just 5 years.¹³⁰ Studies have suggested that use of older donors may increase the chance of aggressive recurrence.¹³¹ The best method to prevent recurrence would be to eradicate the infection pretransplant, but doing so is not always possible because patients with decompensated cirrhosis often cannot tolerate treatment. Once recurrence occurs, treatment methods are limited. One study found that pegylated interferon and ribavirin therapy achieved a sustained viral response in 44% of patients.¹³²

A substantial number of patients undergo liver transplants for cholestatic disorders. Primary biliary cirrhosis, an autoimmune disease, is characterized by damage to the intralobular bile

Table 11-6

Diseases amenable to treatment by a liver transplant

Autoimmune liver diseases
Autoimmune hepatitis
Primary biliary cirrhosis
Primary sclerosing cholangitis
Congenital
Biliary atresia
Viral hepatitis
Hepatitis B
Hepatitis C
Alcoholic liver disease
Metabolic diseases
α_1 -Antitrypsin deficiency
Cystic fibrosis
Hemochromatosis
Tyrosinemia
Wilson's disease
Hepatic malignancy
Hepatocellular carcinoma
Neuroendocrine tumor metastatic to liver
Fulminant hepatic failure
Other
Alagille syndrome
Cryptogenic cirrhosis
Budd-Chiari syndrome
Polycystic liver disease
Amyloidosis

ducts that progresses to liver cirrhosis. Trends toward earlier treatment may explain the slight decrease in liver transplants for this disorder.¹³³ Posttransplant outcomes in patients with this disorder have been excellent, with many centers achieving 1-year survival rates of 90% to 95%. Recurrence is relatively uncommon: a large series reported a 30% recurrence rate at 10 years posttransplant.¹³⁴

The second most common cholestatic disorder among liver transplant candidates is primary sclerosing cholangitis. It is characterized by inflammation and fibrosis of large intra- and extrahepatic biliary ducts; 70% of such patients also have inflammatory bowel disease. Recurrent cholangitis is common and increases mortality rates beyond what would be expected on the basis of laboratory values. On behalf of such patients, appeals can often be made for priority in allocation to the UNOS regional review boards. Posttransplant outcomes for such patients have been excellent. Primary sclerosing cholangitis is a significant risk factor for cholangiocarcinoma, so annual screenings (including imaging and measurement of serum CA 19-9 levels) should be carried out. Recurrence is fairly uncommon: studies have reported a recurrence rate of up to 20% at 10 years posttransplant.¹³⁵

Progressive metabolic disorders also are treatable with liver transplants. Hemochromatosis, an inherited disorder, results in excessive intestinal iron absorption. Iron deposition can cause cirrhosis and severe cardiomyopathy. Careful cardiac evaluation is necessary pretransplant.

Another metabolic disorder, α_1 -antitrypsin deficiency, is characterized by insufficient levels of a protease inhibitor,

resulting in early-onset emphysema and cirrhosis. Careful pulmonary evaluation is necessary pretransplant.

Wilson's disease, an autosomal recessive disorder characterized by impaired cellular copper transport, leads to copper accumulation in the liver, brain, and cornea. Patients can develop significant neurologic complications and cirrhosis. Several reports suggest improvement of neurologic deficiencies posttransplant.^{136,137}

Transplants can also be performed in patients with hepatic malignancies, but only in accordance with strict criteria. Hepatocellular carcinoma (HCC), a complication of cirrhosis, is the most common type of hepatic malignancy. Resection is the first line of treatment if possible, but often, cirrhosis is too advanced. If the tumor meets the Milan criteria, a liver transplant can be performed. These criteria were established by a landmark paper in 1996 showing that patients with a single tumor under 5 cm in diameter, or with three tumors under 3 cm in diameter, in the absence of vascular invasion, had a 4-year survival rate of 85%.¹³⁸ Patients with such tumors receive exception points, based on their UNOS region, allowing for a timely transplant before their tumors spread.

Transplants for cholangiocarcinoma are still in the experimental stages but may be performed if the center has an experimental protocol in place. The Mayo Clinic protocol, which uses neoadjuvant therapy and strict exclusion criteria, has resulted in a 5-year survival rate of 82%.¹³⁹

Acute fulminant hepatic failure also is an indication for a liver transplant; in fact, such patients are the highest priority for the next available liver in their UNOS region. This devastating illness is defined by acute and severe liver injury with impaired synthetic function and encephalopathy in a person who had normal liver function. It is often caused by acetaminophen overdose; acute fulminant viral hepatitis A, B, and E; other viral infections; drug toxicity; ingestion of *Amanita* mushrooms; acute fatty liver of pregnancy; or Wilson's disease. A significant number of patients will recover with supportive care. The difficulty lies in predicting who will *not* recover and therefore would benefit from a liver transplant. The King's College criteria were developed for this purpose: patients with acetaminophen-induced disease, a pH <7.3 or grade III/IV encephalopathy, a prothrombin time >100 seconds, and serum creatinine >3.4 mg/dL meet those criteria.¹⁴⁰ Management of acute liver failure is very intensive. Such patients suffer from severe coagulopathy, hypoglycemia, lactic acidosis, and renal dysfunction. They are susceptible to infections, which are frequently overwhelming. Cerebral edema, a serious complication of acute liver failure, is a leading cause of death from brain herniation. Intracranial pressure monitoring and serial imaging are often necessary; if a patient develops irreversible brain damage, a transplant is not performed.

Recipient Selection

The diagnosis of cirrhosis itself is not an indication for a transplant. Patients may have compensated cirrhosis for years such that the traditional indication for a transplant is decompensated cirrhosis, manifested by hepatic encephalopathy, ascites, spontaneous bacterial peritonitis, portal hypertensive bleeding, and hepatorenal syndrome (each described below).

Hepatic encephalopathy is an altered neuropsychiatric state caused by metabolic abnormalities resulting from liver failure. The early stages result in sleep disturbances and depression. As the liver disease progresses, patients can become somnolent

and confused and, in the end stages, comatose. Ammonia is produced by enterocytes from glutamine and from colonic bacterial catabolism, and the use of serum ammonia levels as a marker of encephalopathy is controversial because a variety of factors can influence levels. Hyperammonemia suggests worsening liver function and bypass of portal blood flow around the liver. GI bleeding and infection can exacerbate hepatic encephalopathy.

Ascites (the accumulation of fluid in the abdominal cavity) that is caused by cirrhosis is a transudate with a high serum-ascites gradient (>1.1 g/dL). Associated with portal hypertension, it is treated initially with sodium restriction and diuretics. Refractory ascites necessitates large-volume paracentesis and eventually a transjugular intrahepatic portosystemic shunt (TIPS). Contraindications to TIPS placement include significant hepatic encephalopathy, advanced liver disease, congestive heart failure, renal insufficiency, and severe pulmonary hypertension.¹⁴¹

Spontaneous bacterial peritonitis, an infection of the ascitic fluid without an evident intra-abdominal source, is characterized by fever, abdominal pain, and an ascitic fluid polymorphonuclear count ≥ 250 cell/mm³ on paracentesis. The first line of empiric treatment is with a third-generation cephalosporin because the majority of cases are caused by aerobic gram-negative microbes such as *E. coli*, although Gram stain and culture results should be used to guide therapy.

Portal hypertensive bleeding can be a devastating event for patients with cirrhosis. Each bleeding event carries a 30% mortality rate and accounts for a third of all deaths related to cirrhosis. Only 50% of bleeding events cease spontaneously, so treatment must be expedient. The initial medical treatment is with vasopressin and octreotide. The initial intervention is endoscopy with sclerotherapy and band ligation of bleeding varices. If those initial attempts fail, more aggressive treatment is necessary with a balloon tamponade (using a Sengstaken-Blakemore tube) and with emergent TIPS placement. The last line of treatment is emergency surgery to place a portosystemic shunt, transect the esophagus, or devascularize the gastroesophageal junction (Sugiura procedure). Preventing variceal bleeding is essential and can be achieved, with some success, using β -blockers.

Hepatorenal syndrome is a form of acute renal failure that develops as liver disease worsens. The etiology is unclear, but splanchnic vasodilation from portal hypertension and increased production of circulating vasodilators result in a decline in renal perfusion. Characterized by oliguria (<500 mL of urine/day) and low urine sodium levels (<10 mEq/L), hepatorenal syndrome is often reversed by a liver transplant, even after dialysis dependence. Pretransplant, other causes of renal failure need to be excluded, including ATN, drug nephrotoxicity, and chronic renal disease. The initial medical therapy includes octreotide, midodrine, and vasopressin analogs, but the syndrome often progresses to dialysis dependence.

The Model for End-Stage Liver Disease (MELD) was originally developed to assess risk for TIPS placement.¹⁴² Later analysis revealed it to be an excellent model to predict survival among patients with cirrhosis, especially those on the waiting list for a liver transplant.¹⁴³ In 2002, liver graft allocation was restructured to be based on the MELD score.

Although the historic indication for a liver transplant is decompensated cirrhosis, a landmark analysis comparing waiting list mortality with posttransplant mortality established that a minimum MELD score of 18 is necessary to have a survival benefit posttransplant. A MELD score between 15 and 18 does

not confer a survival advantage, but a transplant may be justified if the patient has significant morbidity from cirrhosis.¹⁴⁴

Acute liver failure itself is an indication for a liver transplant. To qualify for Status 1 (first priority for a donor liver within the UNOS region), the transplant candidate must meet the following criteria: (a) onset of hepatic encephalopathy within 8 weeks after the first symptoms of liver disease; (b) absence of pre-existing liver disease; and (c) ventilator dependence, dialysis, or an international normalized ratio (INR) >2.0.

Contraindications

In general terms, contraindications to a liver transplant include insufficient cardiopulmonary reserve, uncontrolled malignancy or infection, and refractory noncompliance. Older age is only a relative contraindication: carefully selected recipients over the age of 70 years can achieve satisfactory outcomes.¹⁴⁵

Patients with reduced cardiopulmonary reserve are unlikely to survive a liver transplant. Candidates should have a normal ejection fraction. If coronary arterial disease is present, they should undergo revascularization pretransplant. Severe chronic obstructive pulmonary disease (COPD) with oxygen dependence is a contraindication. Severe pulmonary hypertension with a mean pulmonary artery pressure greater than 35 mmHg that is refractory to medical therapy is also a contraindication. Candidates with pulmonary hypertension should be evaluated with a right heart catheterization.

For candidates with alcoholic liver disease, few reliable predictors of posttransplant relapse exist.¹⁴⁶ Most centers require 6 months of abstinence from drugs and alcohol. Insurance companies often make more stringent demands, including random drug screening and 1 year of abstinence.

Uncontrolled infections pretransplant are a substantial risk posttransplant when the patient becomes significantly immunosuppressed. Fungal and multidrug-resistant bacterial infections are relative contraindications. Some centers require an extended period of treatment and documented eradication pretransplant. HIV infection is a relative contraindication; some centers have strict protocols that exclude patients with a history of acquired immunodeficiency syndrome (AIDS)-related illnesses as well as those who are coinfecting with HCV.

Ideally, patients with a history of malignancy (with the exception of HCC) should be cured of the cancer pretransplant. In most cases, this means eradication, completion of curative therapy, and absence of recurrence over a certain period of time, which varies by the tumor type, but can be up to 5 years or longer for aggressive tumors (see earlier Malignancy section).

Surgical Procedure

A liver transplant is among the most extensive operations performed, and it can be associated with considerable blood loss. A bilateral subcostal incision with midline extension is used. Mechanical retraction spreads the rib cage to allow access. The ligamentous attachments of the liver are dissected free. The vascular structures are isolated, including the suprahepatic and infrahepatic vena cava, the portal vein, and hepatic artery (Fig. 11-15). The bile duct, portal structures, and vena cava are divided, completing the hepatectomy (Fig. 11-16)—often the bloodiest and most difficult part of the operation, particularly in the presence of extensive varices and severe coagulopathy.

After the liver is removed, the anhepatic phase begins. This phase is characterized by the absence of inferior vena caval return to the heart and by portal congestion due to clamping of the

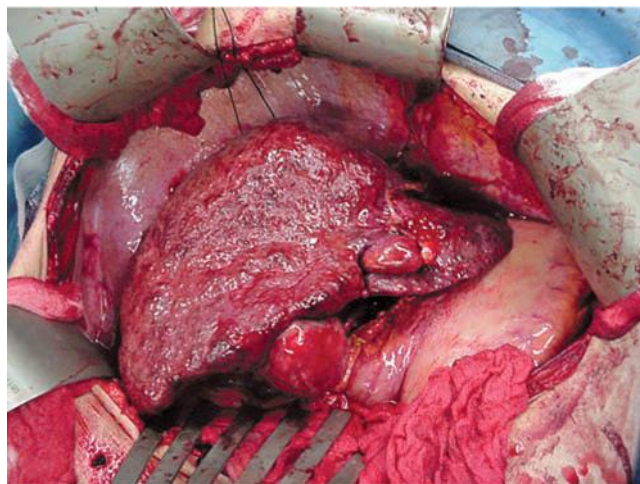


Figure 11-15. Cirrhotic liver immobilized in preparation for complete hepatectomy.

portal vein. Significant hemodynamic instability and increased variceal bleeding can occur. Patients who are unable to tolerate this phase can be placed on venovenous bypass, with cannulas drawing blood from the IVC via the femoral vein and via the portal vein, returning it to the systemic circulation via the subclavian vein. Venovenous bypass itself can cause complications, including air embolism, thromboembolism, and trauma to the cannulated vessels.

The donor liver is placed in the orthotopic position. The suprahepatic vena caval anastomosis is performed first in an end-to-end fashion, followed by the infrahepatic vena caval and portal anastomosis, both also end-to-end. The liver is then reperfused, often leading to a period of hemodynamic instability and cardiac arrhythmias due to the release of byproducts of ischemia from the donor liver. Coagulopathy also can worsen because of these byproducts as well as fibrinolysis.

The arterial anastomosis between the donor common hepatic or celiac trunk is most often performed with the recipient CHA in an end-to-end fashion. Of course, many variations are possible. After arterial reperfusion, the bile duct anastomosis

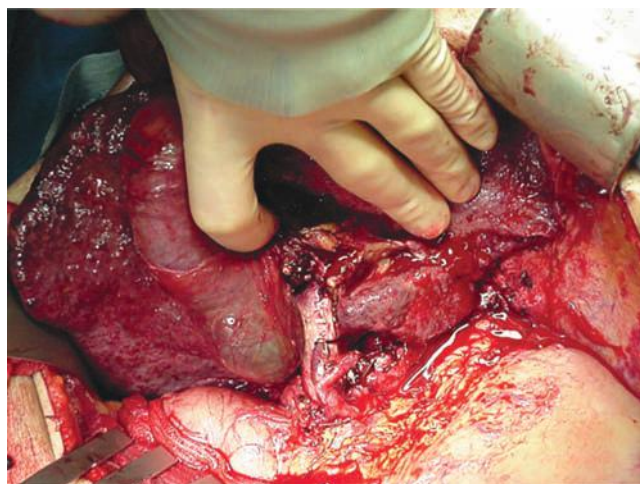


Figure 11-16. Isolation and division of the hilar structures to diseased liver—hepatic artery, portal vein, and common bile duct.

is performed between the donor and recipient common ducts, also in an end-to-end fashion. If necessary for technical reasons, the recipient common duct can be joined to a Roux-en-Y limb. Some surgeons choose to insert a T-tube or place internal stents in the common bile duct to protect the anastomosis.

The piggyback technique is a common variation of the standard technique. The recipient's IVC is preserved by carefully dissecting off the posterior aspect of the liver. This added dissection is a disadvantage of this variation, often increasing hepatectomy time and blood loss. The recipient's liver is removed by dividing it at the confluence of the hepatic veins. The preserved IVC is an advantage of this variation, allowing venous return from the lower body to the heart during the anhepatic phase and improving renal perfusion. No randomized studies, however, have demonstrated the superiority of the piggyback technique over the standard technique.

Pediatric Transplants

Outcomes after pediatric liver transplants are among the best after any type of transplant, with a 1-year survival rate of 90%. The most common indication is biliary atresia. After diagnosis is confirmed, a Kasai procedure is promptly carried out: a Roux-en-Y loop of bowel is directly anastomosed to the hilum of the liver. The Kasai procedure often allows time for the children to grow in size, reducing the risk of a transplant when it is required, as it eventually is in 75% of such children.

The other common indication for a pediatric liver transplant is a metabolic disorder, such as α_1 -antitrypsin deficiency, tyrosine metabolism deficiencies, and primary oxalosis. Since the MELD score was developed for adults, pediatric liver allocation is based on an analogous model, the Pediatric End-Stage Liver Disease (PELD) score, which incorporates bilirubin levels, INR, albumin levels, age, and growth failure.

The surgical procedure is similar to the adult procedure. Graft implantation is more challenging, given the pediatric recipient's smaller vascular structures. As a result, surgical complications are much more common in pediatric recipients. Hepatic artery thrombosis is about three times more common. Donor size matching is very important in the pediatric population and often limits the donor pool for pediatric recipients. To address this issue, deceased donor split-liver transplants and living donor transplants (both described in the following sections) have been developed.

Deceased Donor Split-Liver Transplants

A deceased donor allograft can be split into two grafts, most frequently into a left lateral segment for a child and an extended right segment for an adult (Fig. 11-17). It can be done *in vivo* (during the donor operation) or *ex vivo* (on the back table after the donor liver is removed). Both techniques have similar outcomes. Increased morbidity is associated with splitting allografts, whether for adult or pediatric recipients; however, the technique is justified given the donor shortage and has been important for improving access to transplants for pediatric recipients.¹⁴⁷

Living Donor Transplants

Donation by an adult living donor to an adult recipient requires either the right or left lobe of the liver (Fig. 11-18). Donation by an adult living donor to a pediatric recipient requires the left lateral lobe (Fig. 11-19). Donor safety is paramount. The donor operation has a 0.2% mortality rate and significant morbidity rates, including rehospitalization (8.5%), bile leak or stricture

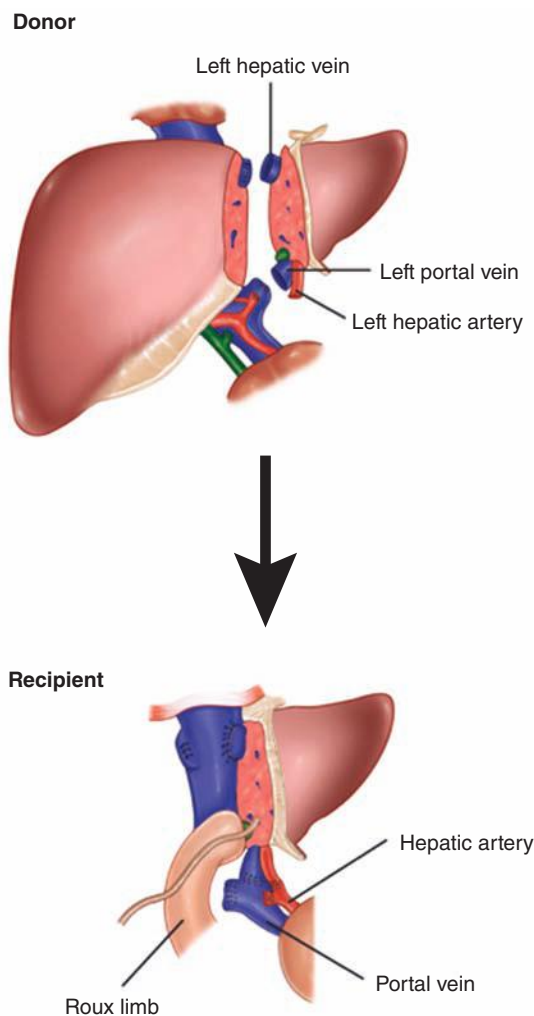


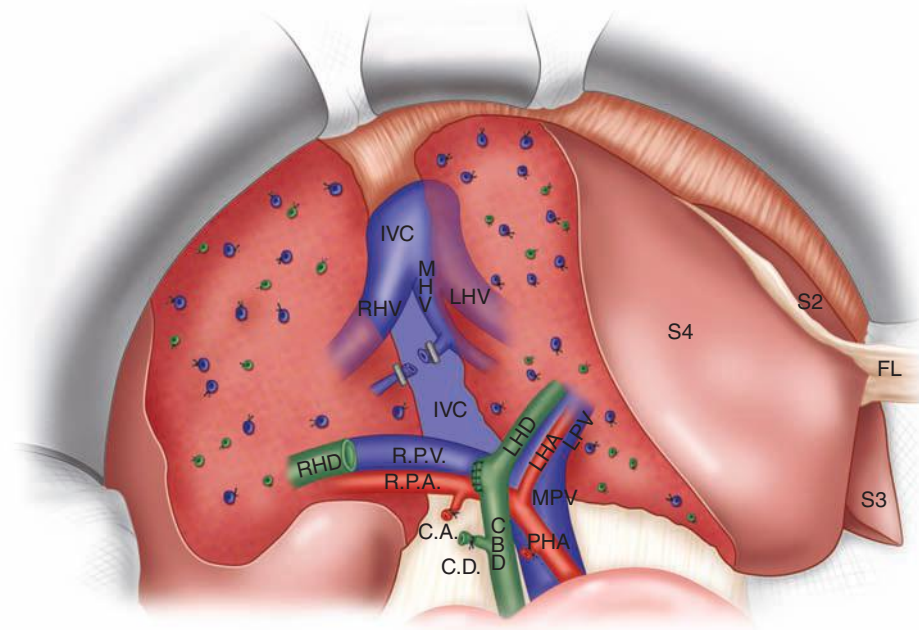
Figure 11-17. Donor and recipient procedure for living donor liver transplant into a pediatric recipient.

(6.0%), reoperation (4.5%), and major postoperative infections (1.1%).¹⁴⁸ Careful donor selection is vital. Potential donors should be medically and psychologically healthy, their hepatic anatomy should be amenable to donation, and absolutely no coercion can occur. A separate donor team should serve as the donor advocate and thoroughly explain all risks.

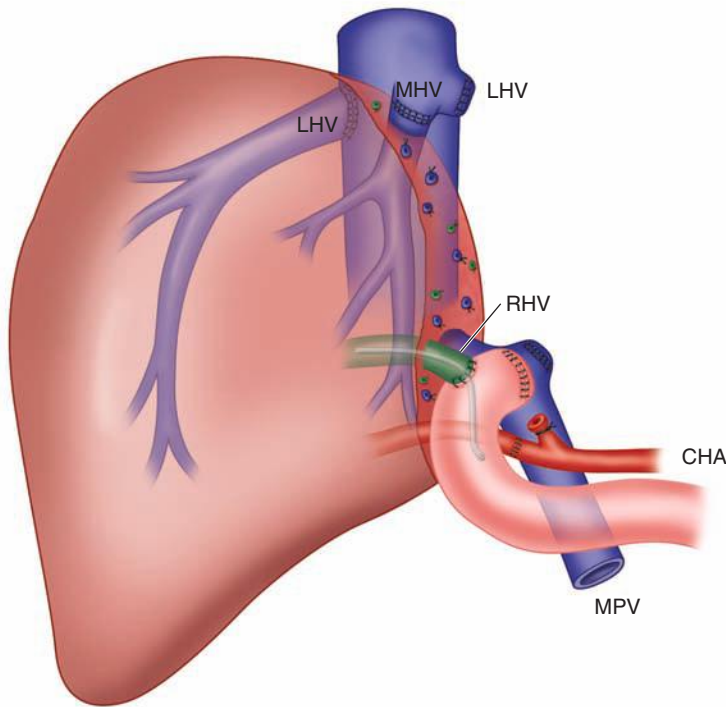
Careful recipient selection is essential. Transplant candidates also must qualify for a deceased donor liver transplant, because a significant number of living donor transplant recipients will eventually require a retransplant. Transplant candidates should be medically fit enough to withstand the rigors of the operation and of the postoperative course with a partial graft. An absolute contraindication is a critical illness: the limited success of such transplants does not justify the risks to the living donor. The obvious advantages of a living donor transplant are that it can be done expediently (avoiding the waiting list mortality associated with candidates for a deceased donor transplant) and that it can be planned.

Postoperative Care

A liver transplant imposes significant trauma on the major organ systems. Immediately posttransplant, the first goal is to stabilize those systems. Acid-base equilibrium and hemodynamic stability are often difficult to maintain but are essential.



A



B

Figure 11-18. A. Hepatic transection completed for right lobe removal. CA = cystic artery; CBD = common bile duct; CD = cystic duct; FL = falciform ligament; IVC = inferior vena cava; LHD = left hepatic duct; LHV = left hepatic vein; MHV = middle hepatic vein; MPV = main portal vein; PHA = proper hepatic artery; RHA = right hepatic artery; RHV = right hepatic vein; RPV = right portal vein; S2, S3, S4 = segments 2, 3, and 4. B. Implantation of the donor right lobe with the MHV. CHA = common hepatic artery. (Reproduced with permission from Gruessner RWG, Benedetti E, eds. *Living Donor Organ Transplantation*. New York: McGraw-Hill, 2008. © 2008 by The McGraw-Hill Companies, Inc.)

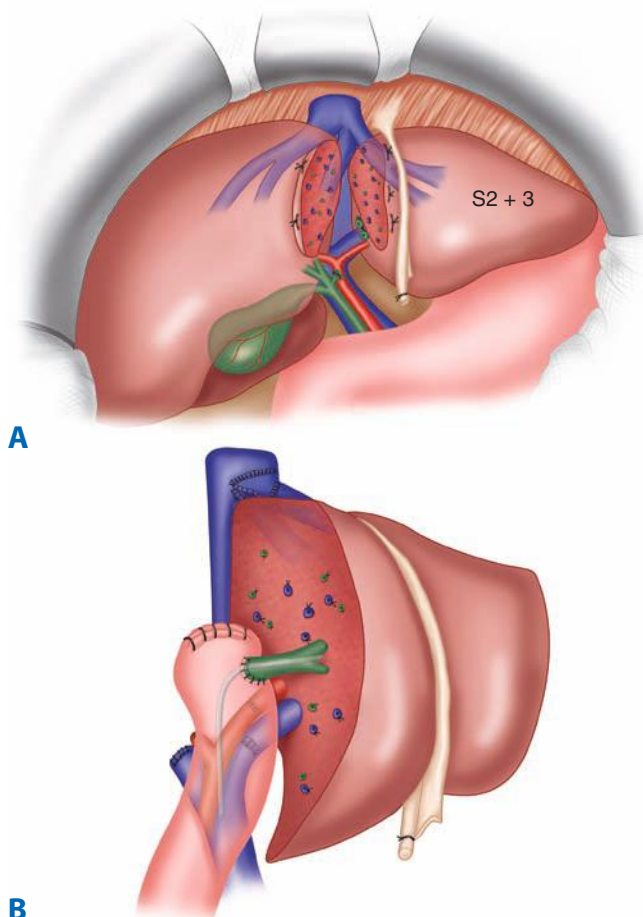


Figure 11-19. **A.** Hepatic transection completed for removal of left lateral segments (S2 and S3). Bile ducts to segments 2 and 3 divided; vascular structures still intact. **B.** Implantation of the donor left lobe. (Reproduced with permission from Gruessner RWG, Benedetti E, eds. *Living Donor Organ Transplantation*. New York: McGraw-Hill, 2008. © 2008 by The McGraw-Hill Companies, Inc.)

Periods of hypotension can increase the risk of hepatic artery thrombosis. Careful attention needs to be paid to ongoing bleeding. Appropriate hemoglobin levels should be maintained. Ongoing bleeding mandates a return trip to the operating room; the rate of reoperation can be as high as 25% among high-risk patients. Transfusion of platelets and fresh frozen plasma must be done prudently, because theoretically their administration can increase the risk of hepatic artery thrombosis. Graft function should be evaluated frequently; if it is impaired, an ultrasound is urgently required to assess for the presence of vascular complications.

Evaluation of Graft Function

Evaluation of the graft begins in the operating room. Its appearance overall, any swelling, and the quantity and quality of bile production after reperfusion can help assess function. In the intensive care unit, hemodynamic stability, correction of coagulopathy, euglycemia, successful temperature regulation, clearance of lactic acid, and restoration of neurologic status

are all signs of a functioning graft, even before the first set of liver function test results are obtained. Transaminases usually peak by postoperative day 2. An aspartate transaminase (AST) level greater than 2500 IU/L is suggestive of significant injury. Cholestasis usually peaks from postoperative day 7 to 12. The INR should improve shortly after reperfusion.

In 3% to 4% of patients undergoing a liver transplant, the graft does not function for any identifiable reason, a condition termed primary nonfunction; in such cases, a retransplant is the only option. Some studies suggest that a peak AST level of 5000 IU/L may be predictive of primary nonfunction.¹⁴⁹⁻¹⁵¹ Factors associated with primary nonfunction include donor macrosteatosis, prolonged cold and warm ischemic times, and prolonged donor hospital stay.¹⁵¹

Complications

Vascular complications occur in about 8% to 12% of recipients and include thrombosis, stenosis, and pseudoaneurysm formation.

The most common vascular complication is hepatic artery thrombosis. Recent reviews suggest that its incidence is between 1.6% and 4%¹⁵²; the mortality rate is 50%, even after definitive therapy.¹⁵³ Early presentation can be quite dramatic, with fulminant hepatic necrosis, primary nonfunction, transaminitis, or fever. Late presentation, however, can be asymptomatic or subtle, with cholangitis, bile leak, mild transaminitis, hepatic abscesses, or failure to thrive. Diagnostic imaging with ultrasound has more than 90% sensitivity and specificity. If hepatic artery thrombosis is identified, urgent re-exploration is needed. A thrombectomy or revision of an anastomosis may be successful, but with significant hepatic necrosis, a retransplant is necessary.

Thrombosis of the portal vein is very uncommon. Signs of early thrombosis include liver dysfunction, ascites, and variceal bleeding. Upon diagnosis, an operative thrombectomy should be attempted.

Biliary complications remain the Achilles' heel of liver transplantation, affecting 10% to 35% of these organ recipients. Signs include fever and abdominal pain, with bilious drainage from surgical drains. Diagnosis is made with cholangiography.

Complications manifest themselves as leaks or strictures. Leaks require a reoperation and surgical correction, whereas strictures can most often be managed with radiologic or endoscopic interventions. Two common reconstructions are choledochostomy and choledochojejunostomy. Some centers also routinely use T-tube stents or internal stents. Consensus has not been reached as to which reconstruction technique is superior. Early infectious complications are often associated with initial graft function and pretransplant risk factors. Intra-abdominal infections should raise concerns of a possible bile leak. Fungal infections are often associated with poor graft function. Given the immunosuppressed and compromised state of liver recipients, early infectious complications can be devastating.

The types of opportunistic infections that occur in liver transplant recipients are similar to those that occur in other types of solid organ transplant recipients and are due to suppression of cell-mediated immunity by chronic immunosuppressive drug administration.

Acute rejection occurs in approximately 20% of liver recipients. The first line of treatment is with a high dose of a corticosteroid, which is usually effective; if not, antilymphocyte therapy is initiated. Rejection of the liver (unlike other transplanted organs) does not adversely affect patient or graft

survival rates. Maintenance immunosuppression consists of a corticosteroid, tacrolimus, and mycophenolate.

INTESTINE AND MULTIVISCERAL TRANSPLANTATION

After the introduction of long-term total parenteral nutrition (TPN) in the late 1970s and the early success of liver, kidney, and heart transplants, the first attempts at intestine transplants were made. Over the first two decades, the results were dismal. But the introduction of the immunosuppressive drug tacrolimus in the late 1980s led to significant improvement in graft and patient survival rates. Nonetheless, intestine transplants remain the least frequently performed of all transplants, with the lowest graft survival rates.

The main obstacle is the high immunogenicity of the intestine, caused by its abundant lymphoid tissue. High levels of immunosuppression are needed, yet the rejection rate is still high. The microbial colonization of the intestine confers the risk of translocation of pathogenic microorganisms into the recipient's circulation, causing severe systemic infections. Through the first decade of the twenty-first century, the survival of patients on long-term TPN was superior to the survival of intestine transplant recipients, so a transplant was considered only as rescue therapy for patients with life-threatening TPN-related complications.

Over the last several years, improvements in surgical techniques, in perioperative and postoperative care, and particularly in immunosuppressive protocols have led to significantly better patient and graft survival rates posttransplant.¹⁵⁴ Recent data indicate that survival rates after an intestine transplant often are better than, or at least similar to, survival rates among patients receiving chronic TPN in the home setting.¹⁵⁵ Today, an intestine or multivisceral transplant is recognized as a feasible treatment.

Indications and Recipient Selection

An intestine transplant is indicated for patients with irreversible intestine failure in combination with TPN failure. The definition of intestine failure does not specify the exact length of the remaining intestine. Intestine failure is typically multifactorial. Variables include what part of the small intestine is absent, whether or not the ileocecal valve is present, whether or not the patient underwent an ostomy, and how long the remaining colon is. TPN failure is defined as significant biochemical or pathologic evidence of liver injury, loss of central vein access with thrombosis of at least two central veins, frequent indwelling catheter infection or a single episode of fungal infection, and recurrent episodes of severe dehydration despite IV fluid supplementation.

Indications for a transplant differ between the adult and pediatric population. The leading causes of intestine failure are summarized in Table 11-7. The disease involvement of organs other than the intestine dictates the extent of the operation required. Liver failure is often seen in patients on long-term TPN. If pathologic or biochemical evidence of severe liver damage is combined with signs of portal hypertension, then a combined liver-intestine transplant is the treatment of choice. However, a multivisceral transplant (liver, pancreas, stomach, duodenum, and/or small intestine) might be necessary among children who suffer diffuse intestinal dysmotility syndromes and adults who develop diffuse portomesenteric thrombosis, extensive intra-abdominal desmoid disease encasing the main

Table 11-7

Leading causes of intestine failure

CHILDREN	ADULTS
Gastroschisis	Visceral ischemia secondary to SMA/SMV thrombosis
Midgut volvulus	Crohn's disease
Intestinal atresia	Trauma
Necrotizing enterocolitis	Mesenteric desmoid tumors
Microvillus involution disease	Radiation enteritis
Hirschsprung's disease	Massive resection secondary to tumors
Crohn's disease	Chronic intestinal pseudo-obstruction
Pseudo-obstruction	Autoimmune enteropathy

SMA = superior mesenteric artery; SMV = superior mesenteric vein

visceral vascular structures with concurrent short gut syndrome, or massive abdominal trauma.

Surgical Procedure

For both the donor and recipient surgery, the key decision is which organs will be transplanted.¹⁵⁶ For an isolated intestine transplant, the blood supply is based on the arterial inflow from the SMA and on the venous outflow from the superior mesenteric vein (SMV). Both vessels are isolated at the root of the mesentery.

For a combined liver-intestine transplant, the blood supply is based on the arterial inflow from the celiac axis and SMA, which are procured en bloc with an aortic patch. The liver, duodenum, pancreas, and small intestine—because of their close anatomic relationship—are procured en bloc. If the hepatoduodenal ligament is left intact, no biliary reconstruction is necessary, which virtually eliminates the risk of postoperative biliary complications.¹⁵⁷ Because the entire splanchnic system drains into the liver, venous drainage is achieved by anastomosis of the hepatic veins to the recipient's vena cava.

For both an isolated intestine transplant and a combined liver-intestine transplant, the proximal transection of the GI tract occurs at the first portion of the duodenum. For a multivisceral transplant, the stomach is part of the graft; hence, the transection of the GI tract occurs at the distal esophagus. Figs. 11-20 to 11-22 show these three main types of transplants.

The vast majority of intestine transplants use a deceased donor organ. However, advances in surgical techniques have made the use of living donors a feasible alternative for either an isolated intestine transplant or a combined liver-intestine transplant. With a living donor, the donor operation is slightly different: for an isolated intestine transplant, 150 to 200 cm of the donor's ileum, on a vascular pedicle comprising the ileocolic artery and vein, are used¹⁵⁸ (Fig. 11-23); for a combined liver-intestine transplant, performed almost exclusively for pediatric recipients, segments II and III of the donor's liver are used, in addition to the intestine (Fig. 11-24).

Similarly, the recipient operation also varies by the organs transplanted. Generally, the recipient's infrarenal aorta is used to

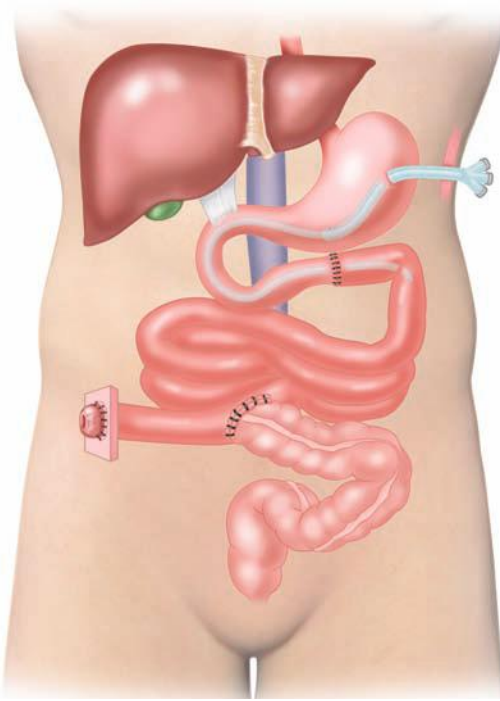


Figure 11-20. Isolated intestine transplant.

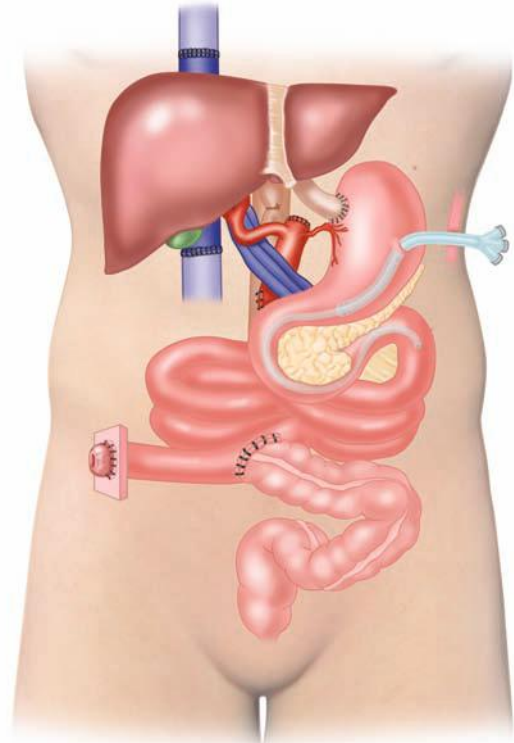


Figure 11-22. Multivisceral transplant.

achieve the arterial inflow to the graft. For an isolated intestine transplant, venous drainage is achieved via systemic or portomesenteric drainage; for a combined liver-intestine transplant or a multivisceral transplant, venous drainage is achieved via the hepatic veins. Systemic venous drainage, given its lesser technical difficulty, is preferred over portomesenteric drainage. The diversion of splanchnic flow into the systemic venous circulation

can cause several metabolic abnormalities, but no hard evidence shows any negative impact clinically on the recipient.

After the organs are perfused, the continuity of the recipient's GI tract is restored, which includes the placement of a gastrostomy or jejunostomy feeding tube and an ileostomy. In the early postoperative period, the ileostomy enables regular endoscopic surveillance and biopsy of the intestinal mucosa. Once the recipient recovers, the ileostomy can be taken down.

The last, but often the most difficult, part of the recipient operation is abdominal wall closure. It is especially challenging in intestine transplant recipients because they have usually undergone multiple previous procedures, resulting in many scars, ostomies, feeding tubes, and the loss of abdominal domain. To provide sufficient coverage of the transplanted organs, the use of prosthetic mesh often is necessary.

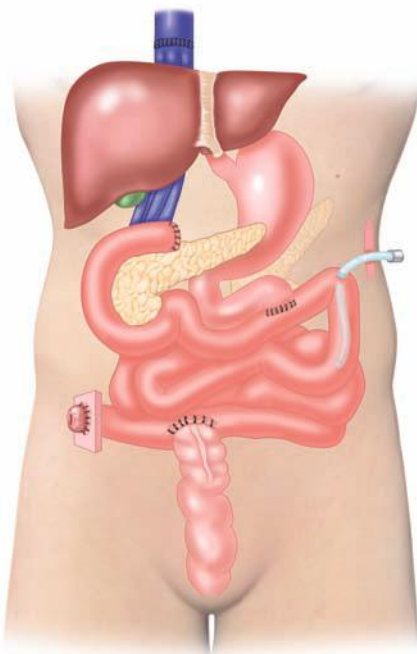


Figure 11-21. Combined liver-intestine transplant.

Postoperative Care

Initial postoperative care for intestine transplant recipients does not significantly differ from that for other organ transplant recipients. In the intensive care unit, each recipient's cardiovascular, pulmonary, and renal function is closely monitored; aggressive resuscitation with fluid, electrolytes, and blood products is performed. Broad-spectrum antibiotics are an integral component of care.

Of all solid organ transplants, intestine transplants have the highest rate of rejection. With intestine transplants, no serologic marker of rejection is available, so frequent biopsies and histologic evaluation of the intestinal mucosa are of utmost importance. Rejection leads to structural damage of the intestinal mucosa. Translocation of endoluminal pathogens into the circulation can cause systemic infections.

Thanks to the introduction of new immunosuppressive protocols, the rejection rates and the overall patient and graft

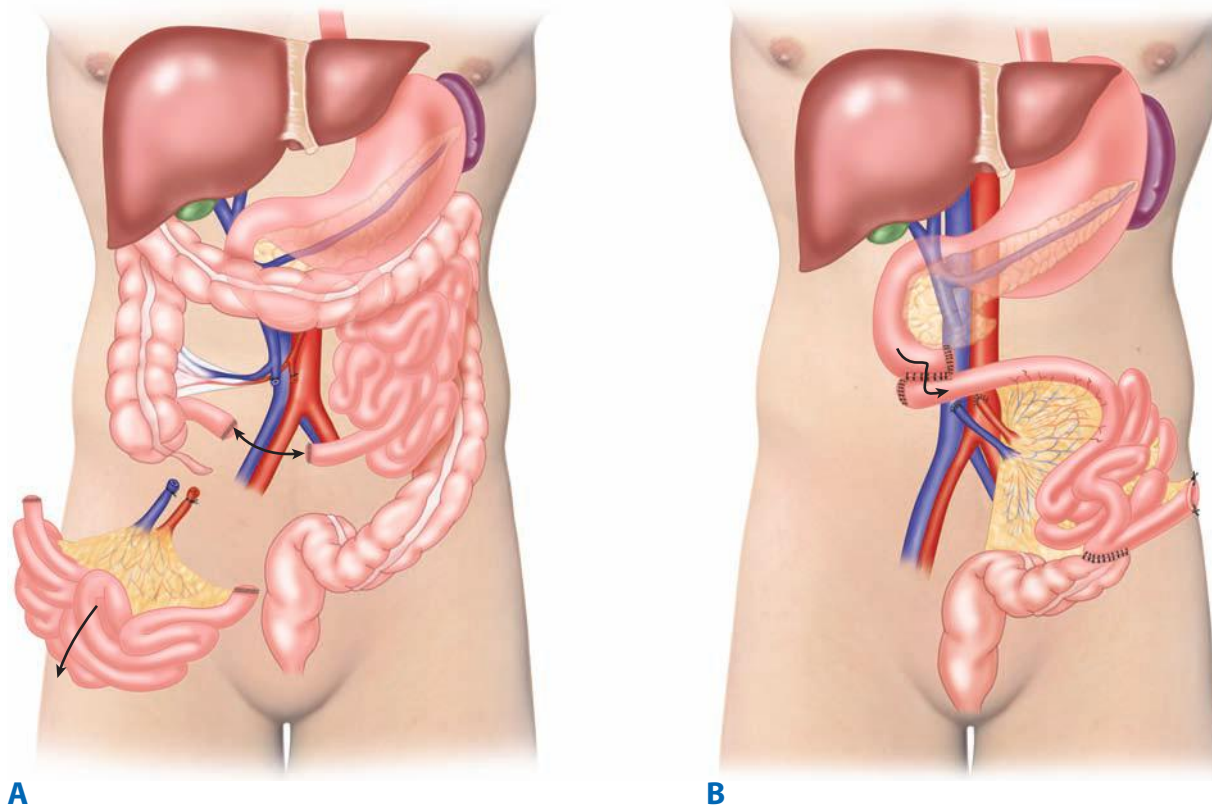


Figure 11-23. **A.** Donor operation. About 180 to 200 cm of distal ileum on a vascular pedicle comprising the ileocolic artery and vein are removed. **B.** Recipient operation. The donor's ileocolic artery and vein (or the terminal branches of the donor's superior mesenteric artery and vein) are anastomosed end-to-side to the recipient's infrarenal aorta and vena cava. (Reproduced with permission from Gruessner RWG, Benedetti E, eds. *Living Donor Organ Transplantation*. New York: McGraw-Hill, 2008. © 2008 by The McGraw-Hill Companies, Inc.)

survival rates have improved significantly. Variations between the protocols exist, but the general concept is to induce immunosuppression with polyclonal T-cell antibody and high doses of a corticosteroid, followed by maintenance doses of corticosteroids and the calcineurin inhibitor tacrolimus.

Immediately posttransplant, recipients are maintained on TPN. Enteral nutrition is initiated as early as possible, but is advanced very cautiously. It can take several weeks for the transplanted intestine to achieve structural integrity and functionality and for the recipient to tolerate the full strength of tube feeds.

Despite all the recent advances, the complication rate posttransplant remains high. The most common complications include intra-abdominal abscesses, enteric leaks, intra-abdominal sepsis, the need for a reoperation, graft thrombosis, life-threatening bleeding, and central line problems. Immunosuppression-specific complications include rejection, PTLD, graft-versus-host disease (GVHD), infections, and malignancies. Tailoring the recipient's immunosuppression plays a critical role in preventing these complications: a low level of immunosuppression leads to graft rejection, but too much confers a high risk of infectious complications, PTLD, and, less commonly, GVHD—all of which are associated with a significantly increased risk of graft failure and mortality.

The long-term results of intestine transplants have improved significantly, even though they still remain inferior to the results of other abdominal organ transplants.^{159,160}

HEART AND LUNG TRANSPLANTATION

History

The first successful heterotopic heart transplant, in an animal model, was performed by Carrel and Guthrie in 1905.¹⁶¹ Subsequent progress with cardiopulmonary bypass and immunologic modulation facilitated the first successful adult human heart transplant, performed by Christiaan Barnard in 1967 in Cape Town, South Africa.¹⁶² However, it was Norman Shumway at Stanford who persisted with heart transplants, in the face of disappointing patient outcomes at a number of early centers. Thanks to the diligence of Shumway and colleagues in perfecting heart transplant techniques, along with the development, by Caves, of endomyocardial biopsy as a method of allograft rejection surveillance, human heart transplants began to reappear in the 1980s as a viable solution to end-stage heart failure. By 1981, the introduction of cyclosporin A finally created the necessary clinical immunologic modulation necessary to make long-term survival of heart recipients a reality.¹⁶¹

Lung transplants have a similar history. In the 1950s, Metras in France and Hardin and Kittle in the United States performed canine lung transplants, demonstrating that meticulous anastomotic technique could produce normal pulmonary pressures. Hardy performed the first human lung transplant in 1963, although the patient lived only 18 days. The first successful long-term lung transplant was performed in 1983 in Toronto. These early lung recipients, however, were plagued

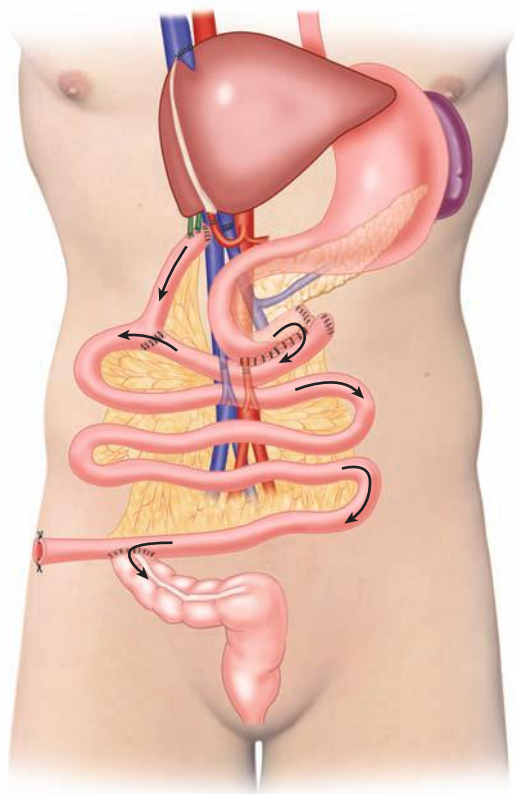


Figure 11-24. Recipient operation. For a combined living donor liver-intestine transplant in a pediatric recipient, liver segments 2 and 3 are implanted in standard fashion (the donor's left hepatic vein to the recipient's vena cava, the donor's left hepatic artery to the recipient's proper or common hepatic artery, the donor's left portal vein branch to the recipient's portal vein trunk). The donor's ileocolic artery and vein are anastomosed to the recipient's infrarenal aorta and cava. In the recipient, a duodenum-to-donor ileum anastomosis and a distal Bishop-Coop ileostomy are constructed to re-establish bowel continuity. A very short Roux-en-Y loop (10 to 20 cm) is anastomosed to the donor's bile duct(s). (*Reproduced with permission from Gruessner RWG, Benedetti E, eds. Living Donor Organ Transplantation. Color Plates, Figure IN-6. New York: McGraw-Hill, 2008. © 2008 by The McGraw-Hill Companies, Inc.*)

by infection, rejection, and, most significantly, bronchial anastomotic dehiscence. Cooper and colleagues soon determined that the high-dose corticosteroids used for immunosuppression were responsible for the frequent occurrence of dehiscence. The combination of high-dose corticosteroids and ischemic donor bronchi was deadly to lung recipients. Cooper, Morgan, and colleagues showed that the bronchial anastomosis could be protected by wrapping it with a vascular omental pedicle, which not only provided neovascularity but also offered a buttress against any partial dehiscence.¹⁶³

Once cyclosporine became available for lung recipients, corticosteroid doses could be quickly tapered and stopped; cyclosporine poses no danger to the integrity of the bronchial anastomosis. In fact, the introduction of cyclosporine allowed the success of the first combined heart-lung transplant at Stanford in 1981 (after unsuccessful attempts by Cooley in 1969, Lillehei in 1970, and Barnard in 1981, all of whom used only high-dose corticosteroids for immunosuppression). The 1980s marked the start of the modern age of thoracic transplants.

Heart Transplants

Indications. The most common diagnosis leading to a heart transplant is ischemic dilated cardiomyopathy, which stems from coronary artery disease, followed by idiopathic dilated myopathy and congenital heart disease. About 3000 patients are added to the waiting list each year.

Evaluation. Pretransplant, both candidates and potential donors are evaluated to ensure their suitability for the procedure. Transplant candidates undergo echocardiography, right and left heart catheterization, evaluation for any undiagnosed malignancies, laboratory testing to assess the function of other organs (such as the liver, kidneys, and endocrine system), a dental examination, psychosocial evaluation, and appropriate screening (such as mammography, colonoscopy, and prostate-specific antigen testing). Once the evaluation is complete, the selection committee determines, at a multidisciplinary conference, whether or not a heart transplant is needed and is likely to be successful. Transplant candidates who meet all of the center's criteria are added to the waiting list, according to the UNOS criteria, which are based on health status.

Once a potential deceased donor is identified, the surgeon reviews the status report and screening examination results. The donor is initially matched to the recipient per the recipient's status on the UNOS waiting list, the size match, and the blood type. Results of the donor's serologic testing, echocardiography, chest x-ray, hemodynamic testing, and possibly coronary artery evaluation are assessed, in order to determine whether or not the donor's heart can withstand up to 4 hours of cold ischemic time during procurement, transport, and surgery.

Procedure. Heart transplants are most often performed orthotopically (Fig. 11-25). The recipient's native heart is removed,

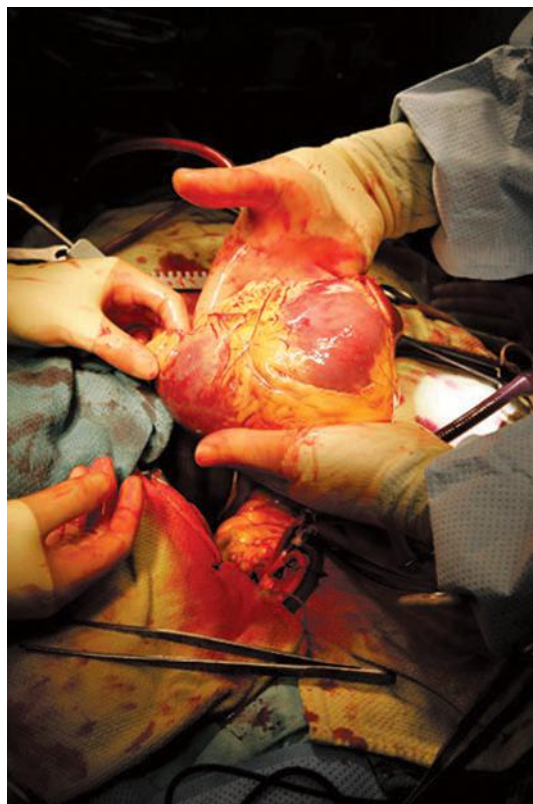


Figure 11-25. A donor's heart brought forward for anastomosis.

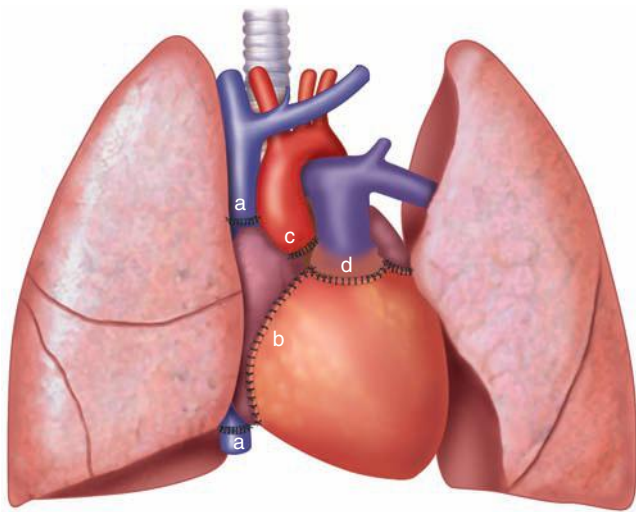


Figure 11-26. Suture lines for bicaval anastomosis (a), biatrial anastomosis (b), aortic anastomosis (c), and pulmonary artery anastomosis (d).

leaving the superior vena cava, the IVC, the left atrial cuff, the aorta, and the pulmonary artery in situ, in order to allow for anastomosis of the donor's heart. Usually the left atrial cuff is anastomosed first, providing left heart inflow. Right heart inflow is achieved using a bicaval technique, by directly sewing the donor's superior vena cava and IVC to the recipient's venae cavae or by creating an anastomosis of the right atrium to a right atrial cuff. The donor's main pulmonary artery is connected to the recipient's pulmonary artery, and finally, the aortic anastomosis is completed (Fig. 11-26).

Once the cross-clamp is removed, the heart is allowed to receive circulation from the recipient and begins to function normally. Inotropic support with isoproterenol, dobutamine, or epinephrine is often required for 3 to 5 days, in order to support recovery from the cold ischemia.¹⁶⁴

On rare occasions, a heterotopic or "piggyback" heart can be transplanted, leaving the native heart in place. But this scenario is becoming very uncommon with the increasing use of mechanical circulatory support for single-ventricle failure.

Posttransplant Care. Patient survival rates for heart recipients differ slightly after primary transplants vs. retransplants. After primary transplants, the patient survival rates at 1, 3, and 5 years are 87%, 79%, and 72%, respectively; after retransplants, the rates are 82%, 67%, and 58%.¹⁶⁵ An increasing number of heart recipients have now survived more than 15 to 20 years with their first graft, especially those with no significant history of either cellular or antibody-mediated rejection.

Heart recipients must be monitored for both early and late complications. Early complications include primary graft dysfunction, acute cellular or antibody-mediated rejection, right heart failure secondary to pulmonary hypertension, and infection. Hemodynamic values are monitored to assess early graft function; pharmacologic and sometimes mechanical support is instituted if needed.

The goal of immunosuppression is to prevent rejection, which is assessed by immunosuppressive levels and, early on, by endomyocardial biopsy. Both T-cell-mediated (cellular) and B-cell-mediated (antibody-mediated) rejection are monitored.

Most of the immunosuppression used is aimed at T cells; however, if the recipient has many preformed antibodies or develops donor-specific antibodies, other strategies (such as plasmapheresis or rituximab) are used to reduce the antibody load. Immunosuppressive regimens can vary by center, but most often consist of three categories of medications: a calcineurin inhibitor (usually tacrolimus or cyclosporine), an antiproliferative agent (MMF or AZA), and a corticosteroid (prednisone). Other immunosuppressive agents can be used, depending on the needs of individual recipients.

Recipients are also assessed for any infections, with visual inspection of wound healing and with monitoring of the complete blood count and cultures as needed. Other common early sequelae include drug-induced nephrotoxicity, glucose intolerance, hypertension, hyperlipidemia, osteoporosis, malignancies, and biliary disease.

Late complications include acquired transplant vasculopathy, progressive renal failure, and, most commonly, malignancies, especially skin cancer and PTLD. Accelerated coronary artery disease is the third most common cause of death post-transplant (after infections and acute rejection) and the most common cause after the first year. Coronary artery disease can begin to develop as early as 1 year posttransplant. Its pathogenesis is unknown, but it is believed to be immunologic. Because of these late complications, most transplant centers continue to perform screening tests and recipient examinations at least annually after the first year.

Lung Transplants

Indications. The indications for a lung transplant include congenital disease, emphysema, COPD, cystic fibrosis, idiopathic pulmonary fibrosis, primary pulmonary hypertension, α_1 -antitrypsin deficiency, and the need for a retransplant after primary graft failure. Each year in the United States, about 1600 patients are added to the waiting list; nearly a third of them have COPD and/or emphysema. The next most common diagnosis among patients on the waiting list is cystic fibrosis. A lung allocation score (LAS) was instituted in 2005. The average lung transplant candidate requires oxygen (often 4 L/min or more at rest) and has an extensively compromised quality of life, as documented by the results of pulmonary function and 6-minute walk tests.

Evaluation. Evaluation for a lung transplant is very similar to evaluation for a heart transplant, except that lung transplant candidates undergo more extensive pulmonary function testing, a 6-minute walk test, chest computed tomography, ventilation-perfusion (V-Q) scanning, and arterial blood gas assessment. In addition, all lung transplant candidates must have adequate cardiac function and must meet psychosocial requirements.

Potential lung donors are also screened for blood type and size match. Larger lungs are accepted for COPD patients; smaller lungs are chosen for the restricted chest cavity of fibrotic patients. Donors should have a partial pressure of oxygen in arterial blood (P_{aO_2}) value >300 mmHg on a fraction of inspired oxygen (F_{iO_2}) of 100% and a positive end-expiratory pressure (PEEP) value of 5. Ideally, donors will have normal chest x-ray results, but exceptions for isolated abnormalities that will not affect subsequent graft function can be made. Living donors can donate a single lobe to a smaller recipient, such as a child. Single-lung transplants are common in many centers and can

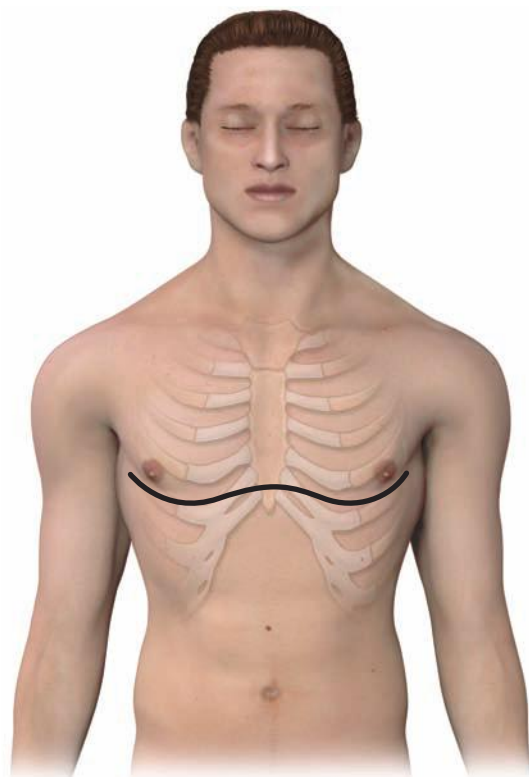


Figure 11-27. Clamshell incision. Bronchial anastomosis with ligated pulmonary arteries and veins.

serve to increase the availability of lungs for multiple recipients. Newer concepts, such as “lung in the box” extracorporeal lung perfusion and stem cell technologies, may further improve the availability of donor lungs by optimizing the use of otherwise marginal grafts.

Procedure. Lung transplants can be done either as (a) single-lung transplants (to either side via thoracotomy) or as (b) sequential bilateral-lung transplants (via bilateral thoracotomies or via a single clamshell incision that divides the sternum; Fig. 11-27). They can be done absent extracorporeal mechanical cardiopulmonary perfusion (bypass), with the lung with the worst function (as predicted by preoperative ventilation and perfusion scanning) transplanted first. Despite careful surgical technique and excellent anesthesia, the poor pulmonary reserve of some lung recipients may require the institution of cardiopulmonary bypass to complete the transplant. Bypass is initiated through the chest by direct cardiac cannulation or peripherally via the femoral vessels.

Once the thoracotomy is made, a recipient pneumonectomy is performed with care, in order to avoid injury to the phrenic or recurrent laryngeal nerves. The pulmonary veins and main pulmonary artery are encircled outside the pericardium. At this point, once the main pulmonary vessels are occluded, the need for cardiopulmonary bypass can be assessed. The vessels and bronchus are ligated; the donor’s lung is prepared and brought to the table wrapped in cold iced gauze, in order to extend the cold preservation time. The bronchial anastomosis (Fig. 11-28) is performed first and then covered with peribronchial tissue or pericardium. The pulmonary artery and, finally, the vein are anastomosed. The lung is then deaired before the

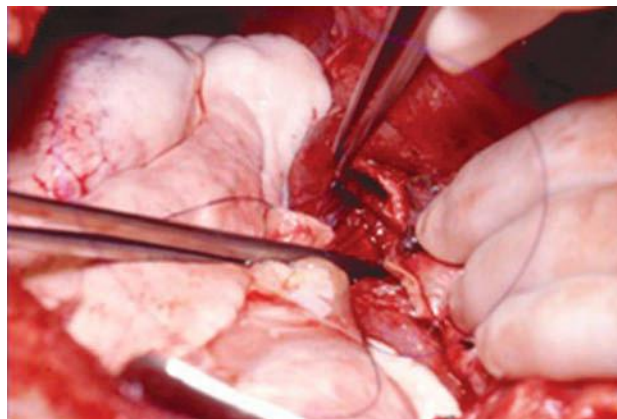


Figure 11-28. Bronchial anastomosis.

final anastomotic suture is tightened, with gentle lung insufflation. All clamps are removed, and the lung is aerated. At least two chest tubes are left in place. After the transplant is complete, a bronchoscopy is performed to clear the airway of blood and secretions.

Posttransplant Care. Patient survival rates for lung recipients vary significantly after primary vs. redo transplants. After primary transplants, the patient survival rates at 1, 3, and 5 years are 83%, 62%, and 46%, respectively; after retransplants, the rates are 64%, 38%, and 28%.

Postoperative care of lung recipients can be very labor-intensive. These patients require meticulous ventilator management, in order to maintain F_{iO_2} at a minimum and to keep P_{aO_2} at 70 mmHg. Most patients are extubated within the first 24 to 48 hours. Recipients can require multiple bronchoscopies for both airway management and surveillance biopsies. Diuretics are used generously to counteract any positive fluid balance from the operation and to help with pulmonary recovery.

Early complications include technical complications, graft dysfunction, infections, and rejection. Technical complications often involve stenosis of one or more anastomoses leading to graft dysfunction. Bronchoscopy, V-Q scanning, echocardiography, and radiologic imaging are useful in identifying the causes of graft dysfunction. In up to 20% of recipients, primary early graft dysfunction can occur with no obvious cause. Such dysfunction may be due to some pathology from the donor, perhaps an unknown aspiration, infection, or contusion; or it could result from poor graft preservation at the time of organ procurement. In the intensive care unit, aggressive ventilator and pharmacologic management can help, but recipients can nonetheless progress to the need for mechanical support in the form of ECMO. Infections are treated with appropriate antibiotics, which can be challenging in patients with cystic fibrosis and a history of multidrug-resistant organisms. Rejection is monitored by biopsies and treated as needed.

Late complications include airway complications, such as strictures and, rarely, dehiscence, bronchiolitis obliterans, and malignancies. Strictures are treated with bronchoscopic dilation and intervention. Bronchiolitis obliterans often is a sequela of chronic rejection, but can be due to aspiration, chronic infections, or various other causes. In recipients with a progressive fall in their forced expiratory volume in 1 second (FEV_1), bronchiolitis obliterans is suspected. All recipients should be taught to perform microspirometry at home as a screening

tool posttransplant. Biopsies are performed to confirm the diagnosis of any complication and, if possible, the cause. Despite aggressive screening and treatment, more than 50% of recipients will develop graft dysfunction. Most if not all of the sequelae of chronic immunosuppression that occur in lung transplant recipients are similar to those occurring in other groups of solid organ transplants.

Heart-Lung Transplants

Every year in the United States, 30 to 50 patients are added to the list of patients waiting to receive a simultaneous heart-lung transplant. The most common diagnosis is idiopathic pulmonary fibrosis, followed by primary pulmonary hypertension. Heart-lung candidates are often younger than their single-organ counterparts. The patient survival rates at 1, 3, and 5 years are 66%, 48%, and 39%, respectively. Often, lung complications ultimately lead to graft failure. The immunosuppression is the same as that for single thoracic organ recipients, with emphasis on weaning the patient off corticosteroids as early as possible.

XENOTRANSPLANTS

Xenotransplants (i.e., cross-species transplants of organs, tissues, or cells) have immense, yet untapped, potential to solve the critical shortage of available grafts. A primary hurdle is the formidable immunologic barrier between species, especially with vascularized whole organs.¹⁶⁶⁻¹⁷⁰ Other problems include the potential risk of transmitting infections (known as zoonoses or xenoses) and the ethical problems of using animals for widespread human transplants, even though great progress has been made in the past few years in efforts to overcome these problems.¹⁶⁶⁻¹⁷²

Pigs are generally accepted as the most likely donor species for xenotransplants into human beings.¹⁷³ Pigs would also be easier to raise on a large-scale basis. Guidelines for raising pigs in specialized facilities designated as pathogen-free have been established; in anticipation of clinical trials, such facilities have already been created and populated.^{171,172}

The immunologic barrier in pig-to-human xenotransplants is highly complex, but generally involves four subtypes of rejection.¹⁶⁶ The first is hyperacute rejection (HAR), which is mediated by the presence of natural (preformed) xenoantibodies in humans. These antibodies bind to antigens found mainly on the vascular endothelial cells of porcine donor organs, leading to complement activation, intravascular coagulation, and rapid graft ischemia soon after the transplant. The second subtype is acute humoral xenograft rejection (AHXR), a delayed form of antibody-mediated rejection seen in pig-to-nonhuman-primate transplants after steps to prevent HAR—steps such as depletion of anti-pig antibodies or complement from nonhuman primates' serum. Alternative names for AHXR include acute vascular rejection or delayed xenograft rejection. The third subtype is an acute cellular rejection process (similar to the classic T-cell-mediated acute rejection seen in allograft recipients). The fourth subtype is chronic rejection in grafts that survive for more than a few weeks (similar to the chronic rejection seen in long-surviving allograft recipients, with features of chronic vasculopathy).

Many different options are being tested to overcome this immunologic barrier, including the genetic engineering of pigs, the use of agents to inhibit platelet aggregation and complement

activation, and the administration of powerful immunosuppressive drugs.¹⁶⁶⁻¹⁷³

During the first decade of the twenty-first century, the field of whole-organ xenotransplantation progressed significantly, thanks to the increasing availability of genetically engineered pigs and new immunosuppressive protocols. At a recent symposium organized by the International Xenotransplantation Association, data presented demonstrated extended survival time of porcine solid organs in nonhuman primates: from about 30 days to an average of 60 days and even up to 250 days (depending on the model).^{166,169,174,175} However, clinical application is still limited by thrombotic microangiopathy and consumptive coagulopathy; novel methods to prevent those complications will be required for further progress.

Cellular xenotransplants have made great strides and are currently in the early stages of clinical trials. Porcine islet xenotransplants are the most advanced form; five independent groups have now demonstrated survival and function of porcine islets in nonhuman primates for more than 100 days.^{166,175-181} For the clinical trials, cost-benefit models have been developed, and the regulatory framework has been established.^{170-172,178} One trial of particular interest involves transplanting encapsulated porcine islets without immunosuppression.¹⁷⁹ Early results are encouraging. But the efficacy of that approach may be limited until further genetic engineering enables proper oxygenation and nourishment of islet grafts, thereby supporting their viability and function.

The future of xenotransplantation is exciting. Continued active research will focus on further genetic engineering of pigs, newer immunosuppressive drugs, and tissue engineering approaches that will minimize or eliminate the need for immunosuppression. Given recent progress, routine clinical application of cellular xenotransplants is likely within the next decade.

REFERENCES

Entries highlighted in bright blue are key references.

1. Carrel A. The surgery of blood vessels, etc. *B Johns Hopkins Hosp* 1907;18:18-28.
2. Hamilton D, Reid, WA. Yu Yo Voronoy and the first human kidney allograft. *Surg Gynecol Obstet*. 1984;159(3):289-294.
3. Medawar PB. Immunity to homologous grafted skin; the suppression of cell division in grafts transplanted to immunized animals. *Br J Exp Pathol*. 1946;27:9-14.
4. Merrill JP, Murray J, Harrison JH. Successful homotransplantation of the human kidney between identical twins. *JAMA*. 1956;160(4):277-282.
5. Murray JE, Merrill J, Harrison JH, et al. Prolonged survival of human-kidney homografts by immunosuppressive drug therapy. *N Engl J Med*. 1963;268:1315-1323.
6. Starzl TE, Waddell WR, Marchioro TL. Reversal of rejection in human renal homografts with subsequent development of homograft tolerance. *Surg Gynecol Obstet*. 1963;117(4):385.
7. Calne RY, Rolles K, Thiru S, et al. Cyclosporin A initially as the only immunosuppressant in 34 recipients of cadaveric organs: 32 kidneys, 2 pancreases, and 2 livers. *Lancet*. 1979;2(8151):1033-1036.
8. Hall BM, Dorsch S, Roser B. Cellular basis of allograft-rejection in vivo. 1. Cellular requirements for 1st set rejection of heart grafts. *J Exp Med*. 1978;148(4):878-889.
9. Hall BM, Dorsch S, Roser B. Cellular basis of allograft-rejection in vivo. 2. Nature of memory cells mediating second set heart graft rejection. *J Exp Med*. 1978;148(4):890-902.

10. Hariharan S, Johnson CP, Bresnahan BA, et al. Improved graft survival after renal transplantation in the United States, 1988 to 1996. *N Engl J Med.* 2000;342(9):605-612.
11. Cicciarelli J. Cyclosporine and trends in kidney transplantation. *Clin Transpl.* 1986;6:223-320.
12. Meier-Kriesche HU, Li S, Gruessner RW, et al. Immunosuppression: evolution in practice and trends, 1994-2004. *Am J Transplant.* 2006;6(5 Pt 2):1111-1131.
13. Halloran PF. Immunosuppressive drugs for kidney transplantation. *N Engl J Med.* 2004;351(26):2715-2729.
14. Zand MS, Vo T, Huggins J, et al. Polyclonal rabbit antithymocyte globulin triggers B-cell and plasma cell apoptosis by multiple pathways. *Transplantation.* 2005;79(11):1507-1515.
15. Brennan DC, Daller JA, Lake KD, Cibrik D, Del Castillo D. Rabbit antithymocyte globulin versus basiliximab in renal transplantation. *N Engl J Med.* 2006;355(19):1967-1977.
16. Vega O, Cardenas G, Correa-Rotter R, Alberu J, Morales-Buenrostro LE. Basiliximab vs. limited dose daclizumab (2 mg/kg) administered in single or two separated doses in kidney transplantation. *Rev Invest Clin.* 2008;60(2):82-86.
17. Kirk AD, Hale DA, Mann RB, et al. Results from a human renal allograft tolerance trial evaluating the humanized CD52-specific monoclonal antibody alemtuzumab (CAMP-1H). *Transplantation.* 2003;76(1):120-129.
18. Agarwal A, Shen LY, Kirk AD. The role of alemtuzumab in facilitating maintenance immunosuppression minimization following solid organ transplantation. *Transpl Immunol.* 2008;20(1-2):6-11.
19. Fryer JP, Granger DK, Leventhal JR, et al. Steroid-related complications in the cyclosporine era. *Clin Transplant.* 1994; 8:224.
20. Humar A, Crotteau S, Gruessner A, et al. Steroid minimization in liver transplant recipients: impact on hepatitis C recurrence and posttransplant diabetes. *Clin Transplant.* 2007;21:526.
21. Matas AJ, Kandaswamy R, Gillingham KJ, et al. Prednisone-free maintenance immunosuppression—a 5-year experience. *Am J Transplant.* 2005;5:2473.
22. Elion GB. The George Hitchings and Gertrude Elion Lecture. The pharmacology of azathioprine. *Ann N Y Acad Sci.* 1993;685:400-407.
23. Remuzzi G, Lesti M, Gotti E, et al. Mycophenolate mofetil versus azathioprine for prevention of acute rejection in renal transplantation (MYSS): a randomized trial. *Lancet.* 2004;364:503.
24. Bolin P, Tanriover B, Zibari GB, et al. Improvement in 3-month patient-reported gastrointestinal symptoms after conversion from mycophenolate mofetil to enteric-coated mycophenolate sodium in renal transplant patients. *Transplantation.* 2007;84(11):1443-1451.
25. Kaplan B, Schold J, Srinivas T, et al. Effect of sirolimus withdrawal in patients with deteriorating renal function. *Am J Transpl.* 2004;4(10):1709-1712.
26. Larson TS, Dean PG, Stegall MD, et al. Complete avoidance of calcineurin inhibitors in renal transplantation: a randomized trial comparing sirolimus and tacrolimus. *Am J Transplant.* 2006;6:514.
27. Burke JF, Pirsch JD, Ramos EL, et al. Long-term efficacy and safety of cyclosporine in renal transplant recipients. *N Engl J Med.* 1994;331:358.
28. Calne RY, Rolles K, White DJG, et al. Cyclosporin A initially as the only immunosuppressant in 34 recipients of cadaveric organs. *Lancet.* 1979;2:1033.
29. Sweny P, Farrington K, Younis F, et al. Sixteen months experience with cyclosporin A in human kidney transplantation. *Transplant Proc.* 1981;13:365.
30. Mihatsch MJ, Kyo M, Morozumi K, et al. The side-effects of cyclosporine-A and tacrolimus. *Clin Nephrol.* 1998;49(6):356-363.
31. Larsen CP, Pearson TC, Adams AB, et al. Rational development of LEA29Y (belatacept), a high-affinity variant of CTLA4-Ig with potent immunosuppressive properties. *Am J Transplant.* 2005;5:443.
32. Vincenti F, Larsen C, Durrback A, et al. Costimulation blockade with belatacept in renal transplantation. *N Engl J Med.* 2005;353:770.
33. Pescovitz MD. Rituximab, an anti-cd20 monoclonal antibody: history and mechanism of action. *Am J Transplant.* 2006;6:859.
34. Blume OR, Yost SE, Kaplan B. Antibody-mediated rejection: pathogenesis, prevention, treatment, and outcomes. *J Transplant.* 2012:201754.
35. Becker YT, Becker BN, Pirsch JD, Sollinger HW. Rituximab as treatment for refractory kidney transplant rejection. *Am J Transplant.* 2004;4:996.
36. Perry DK, Burns JM, Pollinger HS, et al. Proteasome inhibition causes apoptosis of normal human plasma cells preventing alloantibody production. *Am J Transplant.* 2009; 9:201.
37. Everly MJ, Everly JJ, Susskind B, et al. Bortezomib provides effective therapy for antibody- and cell-mediated acute rejection. *Transplantation.* 2008;86:1754.
38. Lock JE, Magro CM, Singer AL, et al. The use of antibody to complement protein C5 for salvage treatment of severe antibody-mediated rejection. *Am J Transplant.* 2011;24:e61.
39. Stegall MD, Diwan T, Raghavaiah S, et al. Terminal complement inhibition decreases antibody-mediated rejection in sensitized renal transplant recipients. *Am J Transplant.* 2011; 11:2405.
40. Hodson EM, Jones CA, Webster AC, et al. Antiviral medications to prevent cytomegalovirus disease and early death in recipients of solid-organ transplants: a systemic review of randomized controlled trials. *Lancet.* 2005;365(9477): 2105-2115.
41. Playford EG, Webster AC, Sorell TC, Craig JC. Antifungal agents for preventing fungal infections in solid organ transplant recipients. *Cochrane Database Syst Rev.* 2004;3: CD004291.
42. Engels EA, Pfeiffer RM, Fraumeni JF Jr., et al. Spectrum of cancer risk among US solid organ transplant recipients. *JAMA.* 2011;306(17):1891-1901.
43. Wijdicks EFM, Varelas PN, Gronseth GS, et al. Evidence-based guideline update: determining brain death in adults. Report of the Quality Standards Subcommittee of the American Academy of Neurology. *Neurology.* 2010;74(23):1911-1918.
44. Nakagawa TA, Ashwal S, Mathur M, et al. Guidelines for the determination of brain death in infants and children: an update of the 1987 Task Force Recommendations—Executive Summary. *Ann Neurol.* 2012;71(4):573-585.
45. Delgado DH, Rao V, Ross HJ. Donor management in cardiac transplantation. *Can J Cardiol.* 2002;18(11):1217-1223.
46. Malinoski DJ, Daly MC, Patel MS, et al. Achieving donor management goals before deceased donor procurement is associated with more organs transplanted per donor. *J Trauma.* 2011;71(4):990-995.
47. Shemie SD, Ross H, Pagliarello J, et al. Organ donor management in Canada: recommendations of the forum on Medical Management to Optimize Donor Organ Potential. *Can Med Assoc J.* 2006;174(6):S13-S30.
48. Starzl TE, Miller C, Broznick B, et al. An improved technique for multiple organ harvesting. *Surg Gynecol Obstet.* 1987;165(4):343-348.
49. Abu-Elmagd K, Fung J, Bueno J, et al. Logistics and technique for procurement of intestinal, pancreatic, and hepatic grafts from the same donor. *Ann Surg.* 2000;232(5): 680-687.
50. Boggi U, Vistoli F, Del Chiaro M, et al. A simplified technique for the en bloc procurement of abdominal organs that

- is suitable for pancreas and small-bowel transplantation. *Surgery*. 2004;135(6):629-641.
51. Cho YW, Terasaki PI, Cecka JM. High kidney graft survival rates using non-heart-beating trauma donors. *Transplant Proc*. 1998;30(7):3795-3796.
 52. Kootstra G, Daemen JHC, Oomen APA. Categories of non-heart-beating donors. *Transplant Proc*. 1995;27(5):2893-2894.
 53. Jay CL, Lyuksemburg V, Ladner DP, et al. Ischemic cholangiopathy after controlled donation after cardiac death liver transplantation a meta-analysis. *Ann Surg*. 2011;253(2):259-264.
 54. Casavilla A, Ramirez C, Shapiro R, et al. Liver and kidney transplantation from non-heart beating donors: the Pittsburgh experience. *Transplant Proc*. 1995;27(1):710-712.
 55. Reese PP, Caplan AL, Kesselheim AS, et al. Creating a medical, ethical, and legal framework for complex living kidney donors. *Clin J Am Soc Nephrol*. 2006;1(6):1148-1153.
 56. Barr ML, Belghiti J, Villamil FG, et al. A report of the Vancouver forum on the care of the live organ donor: lung, liver, pancreas, and intestine data and medical guidelines. *Transplantation*. 2006;81(10):1373-1385.
 57. Jeon H, Lee SG. Living donor liver transplantation. *Curr Opin Organ Transplant*. 2010;15(3):283-287.
 58. St. Peter SD, Imber CJ, Friend PJ. Liver and kidney preservation by perfusion. *Lancet*. 2002;359(9306):604-613.
 59. Van der Werf WJ, D'Alessandro AM, Hoffmann RM, et al. Procurement, preservation, and transport of cadaver kidneys. *Surg Clin North Am*. 1998;78(1):41.
 60. Dalessandro AM, Southard JH, Love RB, et al. Organ preservation. *Surg Clin North Am*. 1994;74(5):1083.
 61. Feng L, Zhao N, Yao X, et al. Histidine-tryptophan-ketoglutarate solution vs. University of Wisconsin solution for liver transplantation: a systematic review. *Liver Transplant*. 2007;13(8):1125-1136.
 62. Siedlecki A, Irish W, Brennan DC. Delayed graft function in the kidney transplant. *Am J Transplant*. 2011;11(11):2279-2296.
 63. Sterling WA, Pierce JC, Lee HM, et al. Comparison of methods of preservation of cadaver kidneys. *Transplant Proc*. 1972;4(4):621-623.
 64. Leeser DB, Bingaman AW, Poliakova L, et al. Pulsatile pump perfusion of pancreata before human islet cell isolation. *Transplant Proc*. 2004;36(4):1050-1051.
 65. van der Plaats A, Maathuis MHJ, Hart NAT, et al. The Groningen hypothermic liver perfusion pump: functional evaluation of a new machine perfusion system. *Ann Biomed Engineer*. 2006;34(12):1924-1934.
 66. Ullman E. Tissue and organ transplantation. *Ann Surg*. 1914;60:195-219.
 67. Murray JE, Hills W. The first successful organ transplants in man. *J Am Coll Surg*. 2005;200(1):5-9.
 68. Murray JE. The 50th anniversary of the first successful human organ transplant. *Revista De Investigacion Clinica*. 2005;57(2):118-119.
 69. Wolfe RA, Ashby VB, Milford EL, et al. Comparison of mortality in all patients on dialysis, patients on dialysis awaiting transplantation, and recipients of a first cadaveric transplant. *N Engl J Med*. 1999;341(23):1725-1730.
 70. Wyld M, Morton RL, Hayen A, et al. A systematic review and meta-analysis of utility-based quality of life in chronic kidney disease treatments. *PLoS Med*. 2012;9(9):e1001307.
 71. Scientific Registry of Transplant Recipients. http://srrt.transplant.hrsa.gov/annual_reports/2010/chapter_index.htm.
 72. Ojo AO, Hanson JA, Wolfe RA, et al. Long-term survival in renal transplant recipients with graft function. *Kidney Int*. 2000;57(1):307-313.
 73. Kahwaji J, Bunnapradist S, Hsu JW, et al. Cause of death with graft function among renal transplant recipients in an integrated healthcare system. *Transplantation*. 2011;91(2):225-230.
 74. Lentine KL, Costa SP, Weir MR, et al. Cardiac disease evaluation and management among kidney and liver transplantation candidates: a scientific statement from the American Heart Association and the American College of Cardiology Foundation: endorsed by the American Society of Transplant Surgeons, American Society of Transplantation, and National Kidney Foundation. *Circulation*. 2012;126(5):617-663.
 75. Penn I. Evaluation of transplant candidates with pre-existing malignancies. *Ann Transplant*. 1997;2(4):14-17.
 76. Trends in tuberculosis—United States, 2011. *MMWR Morb Mortal Wkly Rep*. 2012;61(11):181-185.
 77. Chisari FV, Ferrari C. Hepatitis B virus immunopathogenesis. *Annu Rev Immunol*. 1995;13:29-60.
 78. Harbell J, Fung J, Nissen N, et al. Surgical complications in 275 HIV-infected liver and/or kidney transplantation recipients. *Surgery*. 2012;152(3):376-381.
 79. Fine RN. Recurrence of nephrotic syndrome/focal segmental glomerulosclerosis following renal transplantation in children. *Pediatr Nephrol*. 2007;22(4):496-502.
 80. Araya CE, Dharnidharka VR. The factors that may predict response to rituximab therapy in recurrent focal segmental glomerulosclerosis: a systematic review. *J Transplant*. 2011;2011:374213.
 81. Pham PT, Pham PA, Pham PC, et al. Evaluation of adult kidney transplant candidates. *Semin Dial*. 2010;23(6):595-605.
 82. Taylor CJ, Kosmoliaptis V, Summers DM, et al. Back to the future: application of contemporary technology to long-standing questions about the clinical relevance of human leukocyte antigen-specific alloantibodies in renal transplantation. *Hum Immunol*. 2009;70(8):563-568.
 83. Hume DM, Merrill JP, Miller BF, et al. Experiences with renal homotransplantation in the human: report of 9 cases. *J Clin Invest*. 1955;34(2):327-382.
 84. Murray JE, Merrill JP, Harrison JH. Kidney transplantation between 7 pairs of identical twins. *Ann Surg*. 1958;148(3):343-359.
 85. Starzl TE, Marchioro TL, Dickinson TC, et al. Technique of renal homotransplantation: experience with 42 cases. *Arch Surg*. 1964;89(1):87-104.
 86. Ghazanfar A, Tavakoli A, Zaki MR, et al. The outcome of living donor renal transplants with multiple renal arteries; a large cohort study with a mean follow-up period of 10 years. *Transplant Proc*. 2010;42:1654.
 87. Laurence JM, Sandroussi C, Lam VWT, et al. Utilization of small pediatric donor kidneys: a decision analysis. *Transplantation*. 2011;91(10):1110-1113.
 88. Lau KK, Berg GM, Schjoneman YG, et al. Pediatric en bloc kidney transplantation into pediatric recipients. *Pediatr Transplant*. 2010;14(1):100-104.
 89. Lamb KE, Lodhi S, Meier-Kriesche HU. Long-term renal allograft survival in the United States: a critical reappraisal. *Am J Transplant*. 2011;11(3):450-462.
 90. Rizzari MD, Suszynski TM, Gillingham KJ, et al. Ten-year outcome after rapid discontinuation of prednisone in adult primary kidney transplantation. *Clin J Am Soc Nephrol*. 2012;7(3):494-503.
 91. Vincenti F, Larsen CP, Alberu J, et al. Three-year outcomes from BENEFIT, a randomized, active-controlled, parallel-group study in adult kidney transplant recipients. *Am J Transplant*. 2012;12(1):210-217.
 92. Massy ZA, Guijarro C, Wiederkehr MR, et al. Chronic renal allograft rejection: immunologic and nonimmunologic risk factors. *Kidney Int*. 1996;49(2):518-524.

93. Traynor C, Jenkinson A, Williams Y, et al. Twenty-year survivors of kidney transplantation. *Am J Transplant.* 2012;12:3289.
94. Sutherland ER, Gruessner RWG. History of pancreas transplantation (Chapter 4). In: Gruessner RWG, Sutherland DER, eds. *Transplantation of the Pancreas.* New York: Springer-Verlag; 2004:39-68.
95. Gruessner AC. **2011 update on pancreas transplantation: comprehensive trend analysis of 25,000 cases followed up over the course of twenty-four years at the International Pancreas Transplant Registry (IPTR).** *Rev Diabet Stud.* 2011;8:6-16.
96. Effects of pancreas transplantation on secondary complications of diabetes (Chapter 16). In: Gruessner RWG, Sutherland DER, eds. *Transplantation of the Pancreas.* New York: Springer-Verlag; 2004:455-508.
97. Gruessner RW, Sutherland DE, Drangstveit MB, Kandaswamy R, Gruessner AC. Pancreas allotransplants in patients with a previous total pancreatectomy for chronic pancreatitis. *J Am Coll Surg.* 2008;206:458-465.
98. Surgical aspects of pancreas transplantation (Chapter 8). In: Gruessner RWG, Sutherland DER, eds. *Transplantation of the Pancreas.* New York: Springer-Verlag; 2004:111-178.
99. Sutherland DER, Zamir GA, Brayman KL. Transplantation of the pancreas. In: Cameron JL, Cameron AM, eds. *Current Surgical Therapy.* 10th ed. New York: Elsevier Saunders; 2011:460-471.
100. Postoperative management (Chapter 9). In: Gruessner RWG, Sutherland DER, eds. *Transplantation of the Pancreas.* New York: Springer-Verlag; 2004:179-266.
101. Pancreas transplantation (Section II). In: Gruessner RWG, Benedetti E, eds. *Living Donor Organ Transplantation.* New York: McGraw-Hill; 2008:369-437.
102. Gruessner AC, Sutherland DER, Gruessner RWG. Long-term outcome after pancreas transplantation. *Curr Opin Transplant.* 2012;17:100-105.
103. Shapiro AM, Ricordi C, Hering BJ. **International trial of the Edmonton protocol for islet transplantation.** *N Engl J Med.* 2006;355:1318-1330.
104. Maffi P, Scavini M, Soggi C, et al. Risks and benefits of transplantation in the cure of type 1 diabetes; whole pancreas versus islet transplantation. A single center study. *Rev Diabet Stud.* 2011;8:44-50.
105. Williams PW. Notes on diabetes treated with extract and by grafts of sheep's pancreas. *Br Med J.* 1894;1303-1304.
106. Kelly WD, Lillehei RC, Merkel FK, et al. Allotransplantation of the pancreas and duodenum along with the kidney in diabetic nephropathy. *Surgery.* 1967;61(6):827-837.
107. Ballinger WF, Lacy PE. Transplantation of intact pancreatic islets in rats. *Surgery.* 1972;72:175-186.
108. Najarian JS, Sutherland DE, Baumgartner D, et al. Total or near total pancreatectomy and islet autotransplantation for treatment of chronic pancreatitis. *Ann Surg.* 1980;192(4):526-542.
109. Shapiro AM, Lakey JR, Ryan EA, et al. Islet transplantation in seven patients with type 1 diabetes mellitus using a glucocorticoid-free immunosuppressive regimen. *N Engl J Med.* 2000;343(4):230-238.
110. Ryan EA, Lakey JR, Paty BW, et al. Successful islet transplantation: continued insulin reserve provides long-term glycemic control. *Diabetes.* 2002;51(7):2148-2157.
111. Ryan EA, Lakey JR, Rajotte RV, et al. Clinical outcomes and insulin secretion after islet transplantation with the Edmonton protocol. *Diabetes.* 2001;50(4):710-719.
112. Shapiro AM, Ricordi C, Hering B. Edmonton's islet success has indeed been replicated elsewhere. *Lancet.* 2003;362(9391):1242.
113. Shapiro AM, Ricordi C, Hering BJ, et al. International trial of the Edmonton protocol for islet transplantation. *N Engl J Med.* 2006;355(13):1318-1330.
114. Ryan EA, Paty BW, Senior PA, et al. Five-year follow-up after clinical islet transplantation. *Diabetes.* 2005;54(7):2060-2069.
115. McCall M, James Shapiro AM. Update on islet transplantation. *Cold Spring Harb Perspect Med.* 2012;2(7):1-16.
116. Markmann JF, Deng S, Huang X, et al. Insulin independence following isolated islet transplantation and single islet infusions. *Ann Surg.* 2003;237(6):741-749.
117. Hering BJ, Kandaswamy R, Ansite JD, et al. Single-donor, marginal-dose islet transplantation in patients with type 1 diabetes. *JAMA.* 2005;293(7):830-835.
118. Shapiro AM. Strategies toward single-donor islets of Langerhans transplantation. *Curr Opin Organ Transplant.* 2011;16(6):627-631.
119. Bellin MD, Kandaswamy R, Parkey J, et al. Prolonged insulin independence after islet allotransplants in recipients with type 1 diabetes. *Am J Transplant.* 2008;8(11):2463-2470.
120. Bellin MD, Barton FB, Heitman A, et al. Potent induction immunotherapy promotes long-term insulin independence after islet transplantation in type 1 diabetes. *Am J Transplant.* 2012;12(6):1576-1583.
121. Rickels MR. Recovery of endocrine function after islet and pancreas transplantation. *Curr Diabet Rep.* 2012;12:587-596.
122. Barton FB, Rickels MR, Alejandro R, et al. Improvement in outcomes of clinical islet transplantation: 1999-2010. *Diabetes Care.* 2012;35(7):1436-1445.
123. Busuttil RW, De Carlis LG, Mihaylov PV, Gridelli B, Fassati LR, Starzl TE. The first report of orthotopic liver transplantation in the Western world. *Am J Transplant.* 2012;12(6):1385-1387.
124. Starzl TE, Demetris AJ, Trucco M, et al. **Cell migration and chimerism after whole-organ transplantation: the basis of graft acceptance.** *Hepatology.* 1993;17(6):1127-1152.
125. Cohen C, Benjamin M. Alcoholics and liver transplantation. The Ethics and Social Impact Committee of the Transplant and Health Policy Center. *JAMA.* 1991;265(10):1299-1301.
126. Lucey MR. Liver transplantation in patients with alcoholic liver disease. *Liver Transplant.* 2011;17(7):751-759.
127. Longworth L, Young T, Buxton MJ, et al. Midterm cost-effectiveness of the liver transplantation program of England and Wales for three disease groups. *Liver Transplant.* 2003;9(12):1295-1307.
128. Charlton M, Ruppert K, Belle SH, et al. Long-term results and modeling to predict outcomes in recipients with HCV infection: results of the NIDDK liver transplantation database. *Liver Transplant.* 2004;10(9):1120-1130.
129. Garcia-Retortillo M, Forns X, Feliu A, et al. Hepatitis C virus kinetics during and immediately after liver transplantation. *Hepatology.* 2002;35(3):680-687.
130. Berenguer M, Prieto M, Rayon JM, et al. Natural history of clinically compensated hepatitis C virus-related graft cirrhosis after liver transplantation. *Hepatology.* 2000;32(4 Pt 1):852-858.
131. Lakey JR, Shorr JS, Steffen BJ, Chu AH, Gordon RD, Wiesner RH. Differential effects of donor age in liver transplant recipients infected with hepatitis B, hepatitis C, and without viral hepatitis. *Am J Transplant.* 2005;5(3):549-557.
132. Neff GW, Montalbano M, O'Brien CB, et al. Treatment of established recurrent hepatitis C in liver-transplant recipients with pegylated interferon-alfa-2b and ribavirin therapy. *Transplantation.* 2004;78(9):1303-1307.
133. Lee J, Belanger A, Doucette JT, Stanca C, Friedman S, Bach N. Transplantation trends in primary biliary cirrhosis. *Clin Gastroenterol Hepatol.* 2007;5(11):1313-1315.

134. Liermann Garcia RF, Evangelista Garcia C, McMaster P, Neuberger J. Transplantation for primary biliary cirrhosis: retrospective analysis of 400 patients in a single center. *Hepatology*. 2001;33(1):22-27.
135. Campsen J, Zimmerman MA, Trotter JF, et al. Clinically recurrent primary sclerosing cholangitis following liver transplantation: a time course. *Liver Transplant*. 2008;14(2):181-185.
136. Schilsky ML, Scheinberg IH, Sternlieb I. Liver transplantation for Wilson's disease: indications and outcome. *Hepatology*. 1994;19(3):583-587.
137. Medici V, Mirante VG, Fassati LR, et al. Liver transplantation for Wilson's disease: the burden of neurological and psychiatric disorders. *Liver Transplant*. 2005;11(9):1056-1063.
138. Mazzaferro V, Regalia E, Doci R, et al. Liver transplantation for the treatment of small hepatocellular carcinomas in patients with cirrhosis. *N Engl J Med*. 1996;334(11):693-699.
139. Heimbach JK, Haddock MG, Alberts SR, et al. Transplantation for hilar cholangiocarcinoma. *Liver Transplant*. 2004;10(10 Suppl 2):S65-S68.
140. O'Grady JG, Alexander GJ, Hayllar KM, Williams R. Early indicators of prognosis in fulminant hepatic failure. *Gastroenterology*. 1989;97(2):439-445.
141. Boyer TD, Haskal ZJ. The role of transjugular intrahepatic portosystemic shunt (TIPS) in the management of portal hypertension: update 2009. *Hepatology*. 2010;51(1):306.
142. Kamath PS, Wiesner RH, Malinchoc M, et al. A model to predict survival in patients with end-stage liver disease. *Hepatology*. 2001;33(2):464-470.
143. Wiesner R, Edwards E, Freeman R, et al. Model for end-stage liver disease (MELD) and allocation of donor livers. *Gastroenterology*. 2003;124(1):91-96.
144. Merion RM, Schaubel DE, Dykstra DM, Freeman RB, Port FK, Wolfe RA. The survival benefit of liver transplantation. *Am J Transplant*. 2005;5(2):307-313.
145. Safdar K, Neff GW, Montalbano M, et al. Liver transplant for the septuagenarians: importance of patient selection. *Transplant Proc*. 2004;36(5):1445-1448.
146. Bellamy CO, DiMartini AM, Ruppert K, et al. Liver transplantation for alcoholic cirrhosis: long term follow-up and impact of disease recurrence. *Transplantation*. 2001;72(4):619-626.
147. Vagefi PA, Parekh J, Ascher NL, Roberts JP, Freise CE. Outcomes with split liver transplantation in 106 recipients: the University of California, San Francisco, experience from 1993 to 2010. *Arch Surg*. 2011;146(9):1052-1059.
148. Brown RS Jr., Russo MW, Lai M, et al. A survey of liver transplantation from living adult donors in the United States. *N Engl J Med*. 2003;348(9):818-825.
149. Bilzer M, Gerbes AL. Preservation injury of the liver: mechanisms and novel therapeutic strategies. *J Hepatol*. 2000;32(3):508-515.
150. Jaeschke H. Preservation injury: mechanisms, prevention, and consequences. *J Hepatol*. 1996;25(5):774-780.
151. Serracino-Inglott F, Habib NA, Mathie RT. Hepatic ischemia-reperfusion injury. *Am J Surg*. 2001;181(2):160-166.
152. Drazan K, Shaked A, Olthoff KM, et al. Etiology and management of symptomatic adult hepatic artery thrombosis after orthotopic liver transplantation (OLT). *Am Surg*. 1996;62(3):237-240.
153. Tzakis AG, Gordon RD, Shaw BW Jr., Iwatsuki S, Starzl TE. Clinical presentation of hepatic artery thrombosis after liver transplantation in the cyclosporine era. *Transplantation*. 1985;40(6):667-671.
154. Grant D, Abu-Elmagd K, Reyes J, et al. 2003 report of the intestine transplant registry: a new era has dawned. *Ann Surg*. 2005;241(4):607-613.
155. Abu-Elmagd K, Mazariegos G, Bond G, et al. Intestinal transplantation: current status and future considerations. *Am J Gastroenterol*. 2006;101(9):S145-S146.
156. Yersiz H, Renz JF, Hisatake GM, et al. Multivisceral and isolated intestinal procurement techniques. *Liver Transplant*. 2003;9(8):881-886.
157. Bueno J, Abu-Elmagd K, Mazariegos G, Madariaga J, Fung J, Reyes J. Composite liver-small bowel allografts with preservation of donor duodenum and hepatic biliary system in children. *J Pediatr Surg*. 2000;35(2):291-295; discussion 95-96.
158. Farmer DG, McDiarmid SV, Edelstein S, et al. Improved outcome after intestinal transplantation at a single institution over 12 years. *Transplant Proc*. 2004;36(2):303-304.
159. Tzakis AG, Kato T, Levi DM, et al. 100 multivisceral transplants at a single center. *Ann Surg*. 2005;242(4):480-490; discussion 91-93.
160. Gruessner RWG, Sharp HL. Living related intestinal transplantation: first report of a standardized surgical technique. *Transplant*. 1997;64:1605-1607.
161. Kouchoukos NT, Blackstone EH, Doty DB. Heart failure. In: Kouchoukos NT, Blackstone EH, Doty DB, et al, eds. *Cardiac Surgery*. 3rd ed. New York: Kirklin/Barratt-Boyes; 2003:1725.
162. First human heart transplant. The History Channel website. Retrieved October 15, 2012, from <http://www.history.com/this-day-in-history/first-human-heart-transplant>.
163. Meyers BF, Patterson GA, Haverich A, Harringer W. Lung transplantation, heart-lung transplantation. In: Pearson FG, Cooper JD, Deslauriers J, et al, eds. *Thoracic Surgery*. 2nd ed. New York: Churchill-Livingston; 2002:1085-1131.
164. Costanzo MR, Dipchand A, Starling R, et al. The International Society of Heart and Lung Transplantation Guidelines for care of heart transplant recipients. *J Heart Lung Transplant*. 2010;29(8):914-956.
165. National Transplant Data. UNOS/HRSA website. Retrieved October 12, 2012, from <http://www.optn.transplant.hrsa.gov/latestData>.
166. Esker B, Cooper DKC. Overcoming the barriers to xenotransplantation: prospects for the future. *Exp Rev Clin Immunol*. 2010;6(2):219-230.
167. Schuurman HJ. Xenotransplantation: from the lab to the clinic: Sunrise Symposium at the XXIII International Congress of the Transplantation Society, Vancouver, Canada, August 2010. *Clin Transplant*. 2011;25(4):E415-E421.
168. Dooldeniya MD, Warrens AN. Xenotransplantation: where are we today? *J R Soc Med*. 2003;96:111.
169. Thompson P, Badell IR, Lowe M, et al. Alternative immunomodulatory strategies for xenotransplantation: CD40/154 pathway-sparing regimens promote xenograft survival. *Am J Transplant*. 2012;12(7):1765-1775.
170. Hering BJ, Cooper DKC, Cozzi E, et al. The International Xenotransplantation Association consensus statement on conditions for undertaking clinical trials of porcine islet products in type I diabetes: executive summary. *Xenotransplantation*. 2009;16:196-202.
171. Schuurman HJ. Regulatory aspects of pig-to-human islet transplantation. *Xenotransplantation*. 2008;15(2):116-120.
172. Schuurman HJ. The International Xenotransplantation Association consensus statement on conditions for undertaking clinical trials of porcine islet products in type 1 diabetes—chapter 2: Source pigs. *Xenotransplantation*. 2009;16(4):215-222.
173. Dorling A. Clinical xenotransplantation: pigs might fly? *Am J Transplant*. 2002;2:695.
174. Greenstein JL, Schuurman H-J. Solid organ xenotransplantation: progress, promise, and regulatory issues. *J Comm Bio-tech*. 2001;8:15-29.

175. Thompson P, Badell IR, Lowe M, et al. Islet xenotransplantation using gal-deficient neonatal donors improves engraftment and function. *Am J Transplant*. 2011;11:2593-2602.
176. Rood PPM, Cooper DKC. Islet xenotransplantation: are we really ready for clinical trials? *Am J Transplant*. 2006;6(6):1269-1274.
177. Mihalicz D, Rajotte R, Rayat G. Porcine islet xenotransplantation for the treatment of type I diabetes. In: *Type I Diabetes: Pathogenesis, Genetics and Immunotherapy*. New York: InTech; 2011:479-502.
178. Beckwith J, Nyman JA, Flanagan B, et al. A health-economic analysis of porcine islet xenotransplantation. *Xenotransplantation*. 2010;17:233-242.
179. Elliot RB, Living Cell Technologies, Ltd. Towards xenotransplantation of pig islets in the clinic. *Curr Opin Organ Transplant*. 2011;16(2):195-200.
180. Marigliano M, Bertera S, Grupillo M, et al. Pig-to-nonhuman primate pancreatic islet xenotransplantation: an overview. *Curr Diab Rep*. 2011;11(5):402-412.
181. Dufrane D, Gianello P. Pig islet for xenotransplantation in human: structural and physiological compatibility for human clinical application. *Transplant Rev (Orlando)*. 2012;26:183-188.

This page intentionally left blank

12

chapter

Patient Safety

Catherine L. Chen, Michol A. Cooper,
Mark L. Shapiro, Peter B. Angood, and Martin
A. Makary

Background	365	Comprehensive Unit-Based Safety Program	372	Surgical Counts / 378	
The Science of Patient Safety	365	Measuring Quality in Surgery	373	Wrong-Site Surgery / 378	
High Reliability Organizations / 365		Agency For Healthcare Research and Quality Patient Safety Indicators / 373		The Joint Commission Universal Protocol To Ensure Correct Surgery / 378	
The Institute Of Medicine Report / 366		The Surgical Care Improvement Project Measures / 374		Transparency in Healthcare	379
The Conceptual Model / 366		National Surgical Quality Improvement Program / 374		Risk Management	380
Creating a Culture of Safety	368	The Leapfrog Group / 375		The Importance Of Communication in Managing Risk / 380	
Assessing An Organization's Safety Culture / 368		World Health Organization "Safe Surgery Saves Lives" Initiative / 375		Complications	380
Teamwork and Communication	368	National Quality Forum / 376		Complications in Minor Procedures / 380	
Measuring Teamwork / 369		"Never Events" in Surgery	376	Organ System Complications / 383	
Communication Tools	370	Retained Surgical Items / 377		Wounds, Drains, And Infection / 389	
Operating Room Briefings / 370				Nutritional And Metabolic Support Complications / 391	
Operating Room Debriefings / 370				Problems With Thermoregulation / 393	
Sign Outs / 371					
Implementation / 372					

BACKGROUND

Patient harm due to medical mistakes can be catastrophic, resulting in high-profile consequences for the patient, surgeon, and institution. A single error can even destroy a surgeon's career. While mistakes are inherent to human nature, it is becoming more recognized that many mistakes are preventable.

1▶ Patient safety is a science that promotes the use of evidence-based medicine and local wisdom to minimize the impact of human error on quality patient care. Wrong-site/wrong-procedure surgeries, retained sponges, unchecked blood transfusions, mismatched organ transplants, and overlooked allergies are all examples of potentially catastrophic events that can be prevented by implementing safer hospital systems. This chapter provides an overview of the modern-day field of patient safety by reviewing key measures of safety and quality, components of culture, interventions and tools, and risk management strategies in surgery.

THE SCIENCE OF PATIENT SAFETY

Medicine is considered a high-risk system with a high error rate, but these two characteristics are not always correlated. Other high-risk industries have managed to maintain an impeccably low error rate. For example, one of the highest risk systems in existence today, the U.S. Navy's nuclear submarine program, has an unmatched safety record.

Much of the credit for their safety record is due to the culture of the nuclear submarine program, with its insistence

on individual ownership, responsibility, attention to detail, professionalism, moral integrity, and mutual respect. These characteristics have created the cultural context necessary for high-quality communications under high-risk, high-stress conditions. Each reactor operator is aware of what is going on at all times and is responsible for understanding the implications and possible consequences of any action. Communication flows freely between crewmen and officers, and information about any mistakes that occur are dispersed rapidly through the entire system so that other workers can learn how to prevent similar mistakes in the future.¹

High Reliability Organizations

The nuclear submarine program is an example of an organization that has achieved the distinction of being considered a "high reliability organization." High reliability organization theory recognizes that there are certain high-risk industries and organizations that have achieved very low accident and error rates compared to what would be expected given the inherent risks involved in their daily operations. Other high reliability industries and organizations include aircraft carrier flight decks, nuclear power plants, and the Federal Aviation Administration's air traffic control system. In fact, one reason why nuclear power plants have such an excellent reliability record may be that their operators are often former naval submarine officers whose previous experience and training within one highly reliable organization are easily transferable to other organizations.¹

One of the assumptions underlying the science of high reliability organizations is that humans who operate and manage

Key Points

- 1▶ Patient harm due to medical mistakes can be catastrophic and, in some cases, result in high-profile consequences not only for the patient, but also for the surgeon and institution.
- 2▶ Patient safety is a science that promotes the use of evidence-based medicine and common sense improvements in an attempt to minimize the impact of human error on the routine delivery of services.
- 3▶ The structure-process-outcome framework within the context of an organization's culture helps to clarify how risks and hazards embedded within the organization's structure may potentially lead to error and injure or harm patients.
- 4▶ Poor communication contributes to approximately 60% of the sentinel events reported to The Joint Commission.
- 5▶ Operating room briefings are team discussions of critical issues and potential hazards that can improve the safety of the operation and have been shown to improve operating room culture and decrease operating room delays.
- 6▶ National Quality Forum surgical "never events" include retained surgical items, wrong-site surgery, and death on the day of surgery of a normal healthy patient (American Society of Anesthesiologists Class 1).
- 7▶ Patient rapport is the most important determinant of malpractice claims against a surgeon.

complex systems are themselves not sufficiently complex to sense and anticipate the problems generated by the system.² This introduces another important idea undergirding the science of patient safety: the concept of normal accident theory. Instead of attributing accidents to individual error, this theory states that accidents are intrinsic to high-volume activities and even inevitable in some settings. Accidents should not be used merely to identify and punish the person at fault, but should be seen as a systems problem and addressed at a broader level. As Reason states, even the "best people can make the worst errors as a result of latent conditions."²

High-risk systems, as defined by Perrow in 1984¹:

- Have the potential to create a catastrophe, loosely defined as an event leading to loss of human or animal life, despoiling of the environment, or some other situation that gives rise to the sense of "dread."
- Are complex, in that they have large numbers of highly interdependent subsystems with many possible combinations that are nonlinear and poorly understood.
- Are tightly coupled, so that any perturbation in the system is transmitted rapidly between subsystems with little attenuation.

However, high reliability organization theory suggests that proper oversight of people, processes, and technology can handle complex and hazardous activities and keep error rates acceptably low.² Studies of multiple high reliability organizations show that they share the following common characteristics²:

- People are supportive of one another.
- People trust one another.
- People have friendly, open relationships emphasizing credibility and attentiveness.
- The work environment is resilient and emphasizes creativity and goal achievement, providing strong feelings of credibility and personal trust.

Developing these characteristics is an important step toward achieving a low error rate in any organization. For this reason, safety culture is a measure used by hospitals nationwide to improve outcomes and is increasingly recognized as a metric of hospital quality.

The Institute of Medicine Report

Although healthcare as a whole can be considered a high-risk system, it is far from a high reliability organization. This fact was brought to light in the Institute of Medicine's report "To Err Is Human: Building a Safer Health System," which was published in 2000.³ A landmark document in raising awareness of the magnitude of the problem of medical mistakes, the report is the most frequently cited document in the medical literature in recent years.⁴ The Institute of Medicine (IOM) report shocked the healthcare community by concluding that between 44,000 and 98,000 deaths and over 1 million injuries occurred each year in American hospitals due to medical error. In fact, the number of deaths attributed to medical error is the aviation equivalent of one jumbo jet crash per day. As this report was disseminated, awareness about medical errors increased, and physicians and other health providers began speaking openly about mistakes and the difficulties they face when dealing with them.

The IOM report brought much-needed attention to the field of patient safety. In addition, it standardized the language used to describe errors in medicine, defining important terms for future research and quality improvement (Table 12-1). Following its publication, interest in patient safety research and programs increased exponentially. In an effort to improve patient safety, health services researchers began to collaborate with scientists from other disciplines, such as human factors engineering, psychology, and informatics to develop innovative solutions to longstanding safety problems. The discussion around patient safety also became more personalized by highlighting the stories of individual patients who had died from medical errors. Most importantly, the report transformed the conversation about patient safety from blaming individuals for errors to improving the systems that allow them to take place (Case 12-1).⁵

The Conceptual Model

The Donabedian model of measuring quality identifies three main types of improvements: changes to structure, process, and outcome (Fig. 12-1).⁶ **Structure** refers to the physical and organizational tools, equipment, and policies that improve safety. Structural measures ask, "Do the right tools, equipment, and policies exist?" **Process** is the application of these tools, equipment, and policies/procedures to patients (good practices

Table 12-1

Types of medical error

Adverse event

- Injury caused by medical management rather than the underlying condition of the patient
- Prolongs hospitalization, produces a disability at discharge, or both
- Classified as preventable or unpreventable

Negligence

- Care that falls below a recognized standard of care
- Standard of care is considered to be care a reasonable physician of similar knowledge, training, and experience would use in similar circumstances

Near miss

- An error that does not result in patient harm
- Analysis of near misses provides the opportunity to identify and remedy system failures before the occurrence of harm

Sentinel event

- An unexpected occurrence involving death or serious physical or psychological injury
- The injury involves loss of limb or function
- This type of event requires immediate investigation and response
- Other examples
 - Hemolytic transfusion reaction involving administration of blood or blood products having major blood group incompatibilities
 - Wrong-site, wrong-procedure, or wrong-patient surgery
 - A medication error or other treatment-related error resulting in death
 - Unintentional retention of a foreign body in a patient after surgery

Source: From Woreta et al,⁵⁰ with permission.

Case 12-1 Systems change resulting from medical error

Libby Zion was an 18-year-old woman who died after being admitted to the New York Hospital with fever and agitation on the evening of October 4, 1984. Her father, Sidney Zion, a lawyer and columnist for the *N.Y. Daily News*, was convinced that his daughter's death was due to inadequate staffing and overworked physicians at the hospital and was determined to bring about changes to prevent other patients from suffering as a result of the teaching hospital system. Due to his efforts to publicize the circumstances surrounding his daughter's death, Manhattan District Attorney Robert Morgenthau agreed to let a grand jury consider murder charges. Although the hospital was not indicted, in May 1986, a grand jury issued a report strongly criticizing "the supervision of interns and junior residents at a hospital in NY County."

As a result, New York State Health Commissioner David Axelrod convened a panel of experts headed by Bertrand M. Bell, a primary care physician at Albert Einstein College of Medicine who had long been critical of the lack of supervision of physicians-in-training, to evaluate the training and supervision of doctors in New York State. The Bell Commission recommended that residents work no more than 80 hours per week and no more than 24 consecutive hours per shift, and that a senior physician needed to be physically present in the hospital at all times. These recommendations were adopted by New York State in 1989. In 2003, the Accreditation Council on Graduate Medical Education followed by mandating that all residency training programs adhere to the reduced work hour schedule.

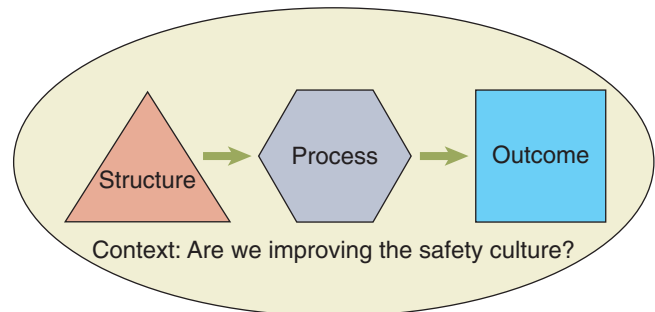


Figure 12-1. Donabedian model for measuring quality. (From Makary et al,⁶ with permission.)

and evidence-based medicine). Process measures ask, "Are the right tools, policies, and equipment being used?" *Outcome* is the result on patients. Outcome measures ask, "How often are patients harmed?" In this model, structure (how care is organized) plus process (what we do) influences patient outcomes (the results achieved).⁷

The structure, process, and outcome components of quality measurement all occur within the context of an organization's overall *culture*. The local culture impacts all aspects of the delivery of care because it affects how front-line personnel understand and deliver safe patient care. In fact, culture (collective attitudes and beliefs of caregivers) is increasingly being recognized to be the fourth measurable component to the structure-process-outcome model. This recognition is based on growing evidence that local culture is linked to a variety of important clinical outcomes.⁷ For any new patient safety initiative to be deemed successful, any change in structure or process must lead to a corresponding positive change in patient outcomes.⁸

Culture is to an organization what personality is to the individual—a hidden, yet unifying theme that provides meaning, direction, and mobilization.² Organizations with effective safety cultures share a constant commitment to safety as a top-level priority that permeates the entire organization. These organizations frequently share the following characteristics⁹:

- An acknowledgment of the high-risk, error-prone nature of an organization's activities
- A nonpunitive environment where individuals are able to report errors or close calls without fear of punishment or retaliation
- An expectation of collaboration across ranks to seek solutions to vulnerabilities
- A willingness on the part of the organization to direct resources to address safety concerns

Traditional surgical culture stands almost in direct opposition to the values upheld by organizations with effective safety cultures for several reasons. Surgeons are less likely to acknowledge their propensity to make mistakes or to admit these mistakes to others.¹⁰ Surgeons tend to minimize the effect of stress on their ability to make decisions.¹¹ The surgical culture, especially in the operating room (OR), is traditionally rife with hierarchy. Intimidation of other OR personnel by surgeons was historically accepted as the norm. This can prevent nurses and other OR staff from pointing out potential errors or mistakes. Moreover, this culture is not limited to the OR. In the intensive care unit (ICU), when compared to physicians, nurses reported more difficulty speaking up, disagreements were not appropriately resolved, and decisions were made without adequate input.¹² In addition, the field of medicine strongly values professional autonomy, which frequently promotes individualism over cooperation, often to the detriment of patient care.¹³ Finally, patient safety, although often viewed as important, is seldom promoted from an organizational priority to an organizational value. Organizations often do not feel the need to devote resources to overhauling their patient safety systems as long as they perceive their existing processes to be adequate. It often takes a high-profile sentinel event to motivate leaders to commit the necessary time and resources to improving patient safety within their organization, as exemplified by the Dana-Farber Institute in the aftermath of Betsy Lehman's death (Case 12-2).

Assessing an Organization's Safety Culture

Efforts to foster cultural change within an organization with regard to patient safety have been limited in the past by the inability to measure the impact of any given intervention. However, studies have shown that employee attitudes about culture are associated with error reduction behaviors in aviation and with patient outcomes in ICUs. The Safety Attitudes Questionnaire (SAQ) is a validated survey instrument that can be used to measure culture in a healthcare setting.⁶ Adapted from two safety tools used in aviation, the Flight Management Attitudes Questionnaire and its predecessor, the Cockpit Management Attitudes Questionnaire, the SAQ consists of a series of questions measuring six domains: teamwork climate, safety climate, job satisfaction, perception of management, stress recognition, and working conditions.

The safety climate scale portion of the questionnaire consists of the following seven items:

Case 12-2 High-profile sentinel event

On December 3, 1994, Betsy Lehman, a *Boston Globe* health columnist, died as a result of receiving four times the intended dose of chemotherapy for breast cancer. Remarkably, 2 days later, Maureen Bateman, a teacher being treated for cancer, also received a chemotherapy overdose and suffered irreversible heart damage. After investigating the medication errors, the prescribing doctor, three druggists, and 15 nurses were disciplined by state regulators. The hospital was sued by the two women's families and by one of the doctors disciplined.

As a result of this widely publicized event, the Dana-Farber Cancer Institute invested more than \$11 million to overhaul their safety programs, including providing new training for their employees and giving doctors more time to meet with patients. The hospital adopted a full disclosure policy so that patients would be informed anytime a mistake had affected their care. Dana-Farber also started a patient committee providing advice and feedback on ways to improve care at the hospital.

- I am encouraged by my colleagues to report any patient safety concerns I may have.
- The culture in this clinical area makes it easy to learn from the mistakes of others.
- Medical errors are handled appropriately in this clinical area.
- I know the proper channels to direct questions regarding patient safety in this clinical area.
- I receive appropriate feedback about my performance.
- I would feel safe being treated here as a patient.
- In this clinical area, it is difficult to discuss mistakes.

Although perceptions of teamwork climate can differ as a function of one's role in the OR, perceptions of safety climate are relatively consistent across OR providers in a given hospital. Validated in over 500 hospitals, the SAQ is used to establish benchmark safety culture scores by healthcare worker type, department, and hospital. Using this survey, hospitals can compare culture between different types of healthcare workers within a department as well as culture between departments throughout the institution. Scores can be compared to those of other participating institutions to compare safety climates. This allows hospitals to participate with one another to implement programs to improve safety culture. In addition, scores are used to evaluate the effectiveness of safety interventions by comparing the SAQ safety climate scores after implementation to baseline scores.

Strong teamwork is at the core of any effective organization and is a key element to ensuring patient safety in the OR. Teamwork is dependent on the underlying culture and patterns of communication. The ability for all team members, to "speak up" about patient safety concerns is one of the most important elements of creating a culture of patient safety.

TEAMWORK AND COMMUNICATION

According to The Joint Commission, communication breakdown is one of the top three root causes of sentinel events such as wrong-site surgery (Fig. 12-2). Poor communication contributed to over 60% of sentinel events reported to The Joint

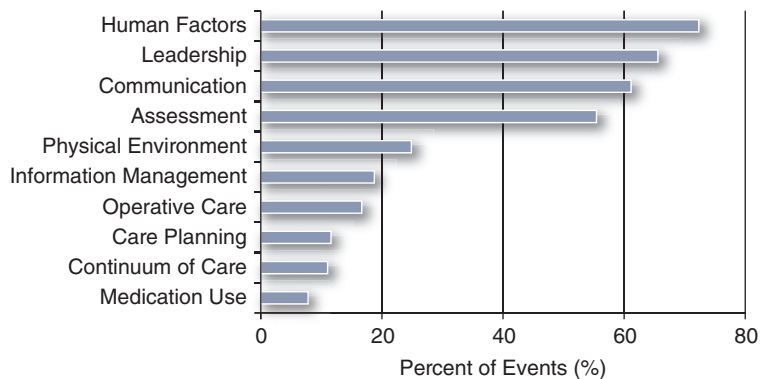


Figure 12-2. Root causes of sentinel events 2004 to 2012. (From Makary et al,¹⁷ with permission from Elsevier. ©2006 by the American College of Surgeons.)

4▶ Commission in 2011.¹⁴ Good communication is an essential component of teamwork and is especially important in the OR, one of the most complex work environments in healthcare.

Within the realm of patient care, there are enormous amounts of information being exchanged between healthcare providers on a daily basis. Much of this information, if prioritized correctly, has the potential to prevent unintended medical errors and serious harm to patients. The importance of good communication in preventing medical errors is undeniable; however, it is difficult to achieve. The traditional surgical hierarchy can prevent OR personnel from sharing important patient data and expressing safety concerns. One perioperative field study showed a 30% rate of communication failure in the OR, with 36% of these breakdowns having a substantial impact on patient safety.¹⁵

In addition to overcoming the cultural barrier to better teamwork and communication, The prospective study by Christian and associates of patient safety in the OR demonstrated that the standard workflow of the OR itself presents many opportunities for the loss or degradation of critical information.¹⁶ Hand-offs of patient care from the OR to other locations or providers are particularly prone to information loss, which has been demonstrated in other clinical settings. Hand-offs and auxiliary tasks, such as the surgical count, frequently take place during critical portions of the case and place competing demands on provider attention from primary patient-centered activities. Communication between the surgeon and pathologist also is vulnerable, because the communication often occurs through secondary messengers such as nurses or technicians. This information loss can lead to delays, overuse of staff and resources, uncertainty in clinical decision making and planning, and oversights in patient preparation.

Measuring Teamwork

Research in commercial aviation has demonstrated a strong correlation between better teamwork and improved safety performance. Cockpit crew members' reluctance to question a captain's judgment has been identified as a root cause of aviation accidents. Good attitudes about teamwork are associated with error-reduction behaviors in aviation, improved patient outcomes in ICUs, and decreased nurse turnover in the OR. It is also associated with higher job satisfaction ratings and less sick time taken from work.

The SAQ can be used to measure teamwork and provide benchmarks for departments or hospitals seeking to measure and improve their teamwork climate.¹⁷ The SAQ teamwork

scores are responsive to interventions that aim to improve teamwork among operating teams, such as the implementation of ICU checklists, executive walk rounds, and preoperative briefing team discussions. The communication and collaboration sections of the SAQ reflect OR caregiver views on teamwork and can be used to distinguish meaningful interventions from impractical and ineffective programs.

In a survey of OR personnel across 60 hospitals, the SAQ identified substantial differences in the perception of teamwork in the OR depending on one's role. Physicians frequently rated the teamwork of others as good, while nurses at the same institutions perceived teamwork as poor (Fig. 12-3). Similar discrepancies have been found in ICUs. These discrepancies can be attributed to differences in the communication skills that are valued by surgeons and nurses. For example, nurses describe good collaboration as having their input respected, while physicians describe good collaboration as having nurses who can anticipate their needs and follow instructions. Efforts to improve the communication that takes place between physicians and nurses can directly improve the perception of teamwork and collaboration by the OR team (Table 12-2). Empowering well-respected surgeons to promote principles of teamwork and communication can go a long way toward transforming attitudinal and behavioral changes in fellow physicians as well as other members of the surgical team. Surgeons are increasingly encouraging the respectful and timely voicing of concerns of OR personnel.

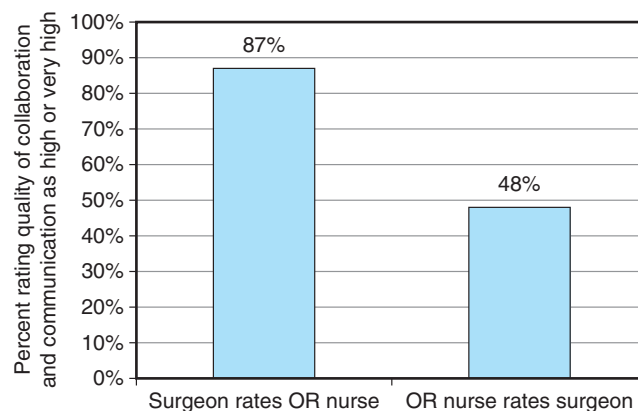


Figure 12-3. Differences in teamwork perceptions between surgeons and operating room (OR) nurses. (From Makary et al,¹⁷ with permission. Copyright Elsevier.)

Table 12-2

Percentage of operating room caregivers reporting a high or very high level of collaboration with other members of the operating room team

CAREGIVER POSITION PERFORMING RATING	CAREGIVER POSITION BEING RATED			
	SURGEON	ANESTHESIOLOGIST	NURSE	CRNA
Surgeon	85	84	88	87
Anesthesiologist	70	96	89	92
Nurse	48	63	81	68
CRNA	58	75	76	93

The best teamwork scores were recorded by anesthesiologists when they rated their teamwork with other anesthesiologists (“high” or “very high” 96% of the time). The lowest teamwork ratings were recorded by nurses when they rated their teamwork with surgeons (“high” or “very high” 48% of the time). CRNA = certified registered nurse anesthetist.

Source: From Makary et al,¹⁷ with permission from Elsevier. ©2006 by the American College of Surgeons.

COMMUNICATION TOOLS

High reliability organizations such as aviation frequently use tools such as prompts, checks, standard operating protocols, and communication interventions such as team briefings and debriefings. These tools identify and mitigate hazards and allow an organization to complete tasks more efficiently. They also foster a culture of open communication and speaking up if a

5▶ team member senses a safety concern. Safety checks and standardized team discussions serve as prompts to help “engineer out” human error, providing quality assurance and improving information flow. They also can prevent errors related to omissions, which are more likely to occur when there is information overload, multiple steps in a process, repetitions in steps, and planned departures from routine processes, and when there are other interruptions and distractions present while the process is being executed. These same interventions have been shown to improve patient safety in ORs and ICUs.^{18,19}

Operating Room Briefings

Preoperative briefings and checklists, when used appropriately, help to facilitate transfer of information between team members (Table 12-3). A briefing, or checklist, is any preprocedure discussion of requirements, needs, and special issues of the procedure. Briefings often are locally adapted to the specific needs of the specialty. They have been associated with an improved safety culture, including increased awareness of wrong-site/wrong-procedure errors, early reporting of equipment problems, reduced operational costs and fewer unexpected delays. In one

study, 30.9% of OR personnel reported a delay before the institution of OR briefings, and only 23.3% reported delays after briefings were instituted.²⁰ OR briefings are increasingly being used to ensure evidence-based measures, such as the appropriate administration of preoperative antibiotics and deep vein thrombosis (DVT) prophylaxis, are used. Briefings allow personnel to discuss potential problems, before they become a “near miss” or cause actual harm.

The World Health Organization (WHO) has recently developed a comprehensive perioperative checklist as a primary intervention of the “Safe Surgery Saves Lives” program—an effort to reduce surgical deaths across the globe (Fig. 12-4).²¹ The WHO checklist includes prompts to ensure that infection prevention measures are followed, potential airway complications are precluded (e.g., anesthesia has necessary equipment and assistance for a patient with a difficult airway), and the groundwork for effective surgical teamwork is established (e.g., proper introductions of all OR personnel). Aspects of The Joint Commission’s preprocedure “Universal Protocol” (or “time-out”) also are included in the checklist (e.g., checks to ensure operation performed on correct patient and correct site).

Operating Room Debriefings

Postprocedural debriefings improve patient safety by allowing for discussion and reflection on causes for errors and critical incidents that occurred during the case. Errors or critical incidents are regarded as learning opportunities rather than cause for punishment. During the debriefing, the team also can discuss what went well during the case and designate a point person to follow up on any proposed actions that result from the discussion. In addition, most debriefings include a verification of the sponge, needle, and instrument counts and confirmation of the correct labeling of the surgical specimen.

Errors in surgical specimen labeling have not received as much attention as incorrect sponge or instrument counts as an indicator of the quality of communication in the OR. However, an error in communication or during the hand-off process increases the risk of mislabeling a surgical specimen before its arrival in a pathology laboratory. In one study, this type of identification error occurred in 4.3 per 1000 surgical specimens, which implies an annualized rate of occurrence of 182 mislabeled

Table 12-3

Five-point operating room briefing

- What are the **names and roles** of the team members?
- Is the correct patient/procedure confirmed? (The Joint Commission Universal Protocol [**TIME-OUT**])
- Have **antibiotics** been given? (if appropriate)
- What are the **critical steps** of the procedure?
- What are the **potential problems** for the case?

Source: From Makary et al,¹⁹ with permission from Elsevier. ©2007 by the American College of Surgeons.

Surgical Safety Checklist

World Health Organization

Patient Safety
A World Alliance for Safer Health Care

Before induction of anaesthesia

(with at least nurse and anaesthetist)

Before skin incision

(with nurse, anaesthetist and surgeon)

Before patient leaves operating room

(with nurse, anaesthetist and surgeon)

Has the patient confirmed his/her identity, site, procedure, and consent?

Yes

Is the site marked?

Yes
 Not applicable

Is the anaesthesia machine and medication check complete?

Yes

Is the pulse oximeter on the patient and functioning?

Yes

Does the patient have a:

Known allergy?

No
 Yes

Difficult airway or aspiration risk?

No
 Yes, and equipment/assistance available

Risk of >500ml blood loss (7ml/kg in children)?

No
 Yes, and two IVs/central access and fluids planned

Confirm all team members have introduced themselves by name and role.

Confirm the patient's name, procedure, and where the incision will be made.

Has antibiotic prophylaxis been given within the last 60 minutes?

Yes
 Not applicable

Anticipated Critical Events

To Surgeon:

What are the critical or non-routine steps?
 How long will the case take?
 What is the anticipated blood loss?

To Anaesthetist:

Are there any patient-specific concerns?

To Nursing Team:

Has sterility (including indicator results) been confirmed?
 Are there equipment issues or any concerns?

Is essential imaging displayed?

Yes
 Not applicable

Nurse Verbally Confirms:

The name of the procedure
 Completion of instrument, sponge and needle counts
 Specimen labelling (read specimen labels aloud, including patient name)
 Whether there are any equipment problems to be addressed

To Surgeon, Anaesthetist and Nurse:

What are the key concerns for recovery and management of this patient?

This checklist is not intended to be comprehensive. Additions and modifications to fit local practice are encouraged. Revised 1 / 2009 © WHO, 2009

Figure 12-4. World Health Organization surgical safety checklist. (Reproduced with permission from World Health Organization *Safe Surgery Saves Lives*. Available at: <http://www.who.int/patientsafety/safesurgery/en/>. Accessed November 8, 2012.)

specimens per year (Fig. 12-5).²² Errors involving specimen identification can result in delays in care, the need for an additional biopsy or therapy, failure to use appropriate therapy, or therapy administered to the wrong body site, side, or patient. These system failures can lead to significant harm to the patient, costs to the institution, and distrust by a community. Given the frequency of occurrence and the feasibility and validity of measuring them, mislabeled surgical specimens may serve as a useful indicator of patient safety, and should be included in any postprocedural debriefing checklist.

Sign Outs

In healthcare, information frequently passes to covering providers without prioritizing potential concerns. This makes sign outs a very vulnerable process of care, which can lead to catastrophic events.

The term *sign out* can refer to either the verbal or written communication of patient information to familiarize oncoming physicians about patients who will be under their care. Sign outs should occur whenever a patient's care setting or provider is changing. When performed well, sign outs help to ensure the

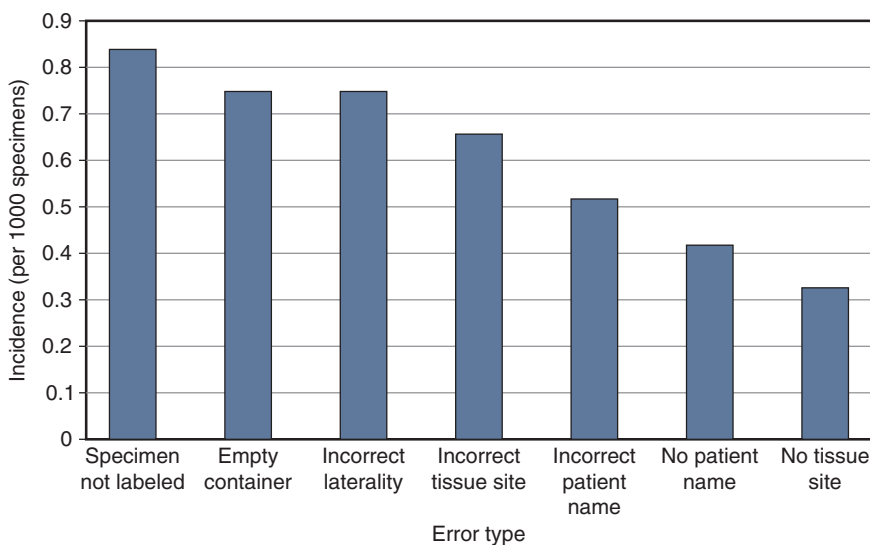


Figure 12-5. Incidence of identification errors observed per 1000 specimens (n = 21,351). (From Makary et al,²² with permission. Copyright Elsevier.)

Case 12-3 Inadequate sign out leading to medical error

Josie King was an 18-month-old child who was admitted to Johns Hopkins Hospital in January of 2001 for first- and second-degree burns. She spent 10 days in the pediatric intensive care unit and was well on her way to recovery. She was transferred to an intermediate care floor with the expectation that she would be sent home in a few days.

The following week, her central line was removed, but nurses would not allow Josie to drink anything by mouth. Around 1 P.M. the next day, a nurse came to Josie's bedside with a syringe of methadone. Although Josie's mother told the nurse that there was no order for narcotics, the nurse insisted that the orders had been changed and administered the drug. Josie's heart stopped, and her eyes became fixed. She was moved to the pediatric intensive care unit and placed on life support. Two days later, on February 22, 2001, she died from severe dehydration.

After her death, Josie's parents, Sorrel and Jay King, were motivated to work with leaders at Johns Hopkins to ensure that no other family would have to endure the death of a child due to medical error. They later funded the Josie King Patient Safety Program and an academic scholarship in the field of safety.

transfer of pertinent information. However, previous studies have shown the hand-off process to be variable, unstructured, and prone to error. Common categories of communication failure during sign outs include content omissions, such as failure to mention active medical problems, and failures in the actual communication process, such as leaving illegible or unclear notes (Case 12-3).²³ These failures lead to confusion and uncertainty by the covering physician during patient care decisions, resulting in the delivery of inefficient and suboptimal care.

The use of more structured verbal communication such as the Situational Debriefing Model, otherwise known as *SBAR* (situation, background, assessment, and recommendation), used by the U.S. Navy, can be applied to healthcare to improve the communication of critical information in a timely and orderly fashion.²³ In addition, all sign outs should begin with the statement, "In this patient, I am most concerned about . . ." to signal to the healthcare provider on the receiving end the most important safety concerns regarding that specific patient.

Implementation

Tools such as checklists, sign outs, briefings, and debriefings improve communication between healthcare providers and create a safer patient environment (Fig. 12-6). Although their use in healthcare is still highly variable, specialties that

have incorporated them, such as intensive care and anesthesia, have made impressive strides in patient safety. Currently, communication breakdowns, information loss, hand off, multiple competing tasks, and high workload are considered "annoying but accepted features" of the perioperative environment.¹⁷ As physician attitudes toward errors, stress, and teamwork in medicine become more favorable toward the common goals of reducing error and improving teamwork and communication, medicine will likely achieve many of the milestones in safety that high-reliability industries such as aviation have already accomplished.

COMPREHENSIVE UNIT-BASED SAFETY PROGRAM

As medical care and hospitals continue to expand, the care that is provided to patients is becoming more fragmented. This fragmentation makes communication more difficult and opportunities for medical errors more common. These problems require common sense solutions, often necessitating a change in the way that care is delivered on the local level. Unit-based meetings to discuss processes that are potentially dangerous for patients can quickly bring danger areas out into the open.

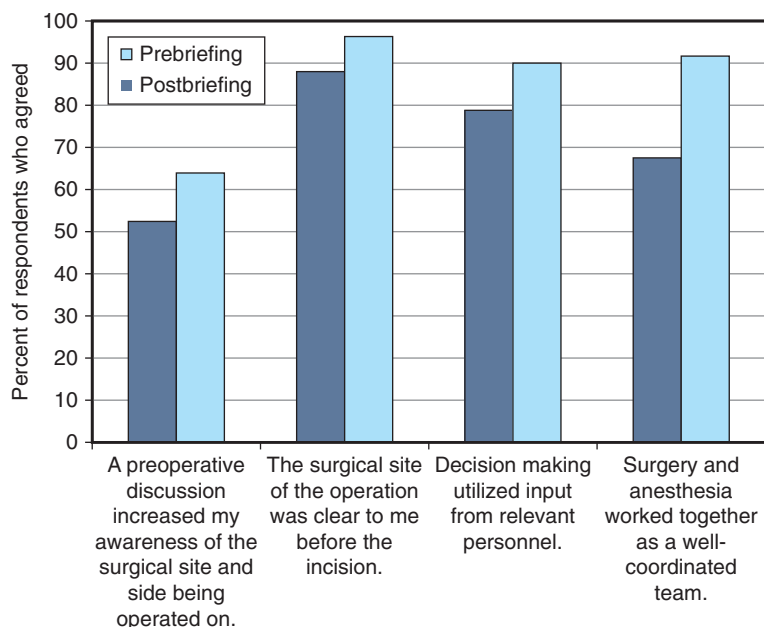


Figure 12-6. Impact of operating room briefings on teamwork and communication. (From Makary et al,¹⁹ with permission from Elsevier. ©2007 by the American College of Surgeons.)

These meetings should be held on a regular basis and bring together a multidisciplinary team of physicians, nurses, technicians, social workers, and other staff who can each voice their concerns about safety hazards in their area. This enables all aspects of patient care to be addressed and improved continuously, thereby streamlining and improving patient care.²⁴

The implementation of the Comprehensive Unit-Based Safety Program (CUSP) involves measurement of a unit's safety culture prior to starting the program and inclusion of hospital management from the start. Having management involved allows for more efficient allocation of resources and allows them to better understand the problems faced by front-line providers. Once CUSP is in place, changes can be made using local wisdom to advance patient care.²⁴ The impact of changes made using CUSP can be measured using both patient outcomes and safety culture data.

Implementation of CUSP has been associated with improved patient outcomes including decreased surgical site infections. In a 2-year study of colorectal patients, where the first year was pre-CUSP implementation and the second year was post-CUSP implementation, there was a 33% decrease in the surgical site infection rate after CUSP.²⁵ In this study, the CUSP group met monthly and came up with a list of interventions based on their experience with these cases, including standardization of skin preparation and warming of patients in the preanesthesia area. This study showed that CUSP can be highly effective in ameliorating patient harm and improving patient care.

MEASURING QUALITY IN SURGERY

Despite the newfound focus on patient safety in surgery and the number of initiatives being undertaken by many organizations to improve their safety culture, there are few tools to actually measure whether these efforts actually are effective in reducing the number of errors. Several agencies and private groups have developed criteria to evaluate quality and safety within hospitals.

Agency for Healthcare Research and Quality Patient Safety Indicators

The Agency for Healthcare Research and Quality (AHRQ) was created in 1989 as a Public Health Service agency in the Department of Health and Human Services. Its mission is to improve the quality, safety, efficiency, and effectiveness of healthcare for all Americans. Nearly 80% of the AHRQ's budget is awarded as grants and contracts to researchers at universities and other research institutions across the country. The AHRQ sponsors and conducts research that provides evidence-based information on healthcare outcomes, quality, cost, use, and access. It has advocated the use of readily available hospital inpatient administrative data to measure healthcare quality. The information helps healthcare decision makers make more informed decisions and improve the quality of healthcare services.²⁶

One of the major contributions of the AHRQ is a set of Patient Safety Indicators (PSIs), initially released in 2003 and revised in 2010. PSIs are a tool to help health system leaders identify potential adverse events occurring during hospitalization. Developed after a comprehensive literature review, analysis of International Classification of Diseases, Ninth Revision, Clinical Modification (ICD-9-CM) codes, review by a clinician panel, implementation of risk adjustment, and

Table 12-4

Agency for Healthcare Research and Quality patient safety indicators

Provider-level patient safety indicators

- Complications of anesthesia
- Death in low mortality diagnosis-related groups
- Decubitus ulcer
- Failure to rescue
- Foreign body left in during procedure
- Iatrogenic pneumothorax
- Selected infections due to medical care
- Postoperative hip fracture
- Postoperative hemorrhage or hematoma
- Postoperative physiologic and metabolic derangements
- Postoperative respiratory failure
- Postoperative pulmonary embolism or deep vein thrombosis
- Postoperative sepsis
- Postoperative wound dehiscence in abdominopelvic surgical patients
- Accidental puncture and laceration
- Transfusion reaction
- Birth trauma—injury to neonate
- Obstetric trauma—vaginal delivery with instrument
- Obstetric trauma—vaginal delivery without instrument
- Obstetric trauma—cesarean delivery

Area-level patient safety indicators

- Foreign body left in during procedure
- Iatrogenic pneumothorax
- Selected infections due to medical care
- Postoperative wound dehiscence in abdominopelvic surgical patients
- Accidental puncture and laceration
- Transfusion reaction
- Postoperative hemorrhage or hematoma

Source: From Agency for Healthcare Research and Quality²⁷

empirical analyses, these 27 indicators provide information on potential in-hospital complications and adverse events following surgeries, procedures, and childbirth (Table 12-4).

Provider-level indicators provide a measure of the potentially preventable complications for patients who received their initial care and the complication of care within the same hospitalization. They include only those cases where a secondary diagnosis code flags a potentially preventable complication. Area-level indicators capture all cases of the potentially preventable complications that occur in a given area (e.g., metropolitan area or county), either during their initial hospitalization or resulting in subsequent hospitalization.²⁷

Currently, PSIs are considered indicators, not definitive measures, of patient safety concerns. They can identify potential safety problems that merit further investigation. They also can be used to better prioritize and evaluate local and national initiatives, and even as benchmarks for tracking progress in patient safety. In the future, further growth in electronic health data will make administrative data based tools like the PSIs more useful.²⁸

The Surgical Care Improvement Project Measures

The Surgical Care Improvement Project (SCIP) was established in 2003 by a national partnership of organizations committed to improving surgical care by reducing surgical complications. The steering committee is comprised of groups such as the Centers for Medicare and Medicaid Services, the American Hospital Association, Centers for Disease Control and Prevention (CDC), Institute for Healthcare Improvement, The Joint Commission, and others.

The incidence of postoperative complications ranges from 6% for patients undergoing noncardiac surgery to more than 30% for patients undergoing high-risk surgery. Common postoperative complications include surgical site infections (SSIs), myocardial infarction, postoperative pneumonia, and thromboembolic complications. Patients who experience postoperative complications have increased hospital length of stay (3–11 days longer than those without complications), increased hospital costs (ranging from \$1398 for an infectious complication to \$18,310 for a thromboembolic event), and increased mortality (median patient survival decreases by up to 69%).²⁹

Despite well-established evidence that many of these adverse events are preventable, failure to comply with standards of care known to prevent them results in unnecessary harm to a large number of patients. SCIP has identified three broad areas within surgery where potential complications have a high incidence and cost and there is a significant opportunity for prevention: SSIs, venous thromboembolism, and adverse cardiac events. The SCIP measures aim to reduce the incidence of these events during the perioperative period by advocating the use of proven process and outcome measures. These process and outcome measures are detailed in Table 12-5.

SSIs account for 14% to 16% of all hospital-acquired infections and are a common complication of care, occurring in 2% to 5% of patients after clean extra-abdominal operations and up to 20% of patients undergoing intra-abdominal procedures. By implementing steps to reduce SSIs, hospitals could recognize a savings of \$3152 and reduction in extended length of stay by 7 days on each patient developing an infection.³⁰

Adverse cardiac events occur in 2% to 5% of patients undergoing noncardiac surgery and as many as 34% of patients undergoing vascular surgery. Certain perioperative cardiac events, such as myocardial infarction, are associated with a mortality rate of 40% to 70% per event, prolonged hospitalization, and higher costs. Appropriately administered β -blockers reduce perioperative ischemia, especially in at-risk patients. It has been found that nearly half of the fatal cardiac events could be preventable with β -blocker therapy.³⁰

DVT occurs after approximately 25% of all major surgical procedures performed without prophylaxis, and pulmonary embolism (PE) occurs after 7%. Despite the well-established efficacy and safety of preventive measures, studies show that prophylaxis often is underused or used inappropriately. Both low-dose unfractionated heparin and low molecular weight heparin have similar efficacy in DVT and PE prevention. Prophylaxis using low-dose unfractionated heparin has been shown to reduce the incidence of fatal PEs by 50%.³⁰

The SCIP effort provides an infrastructure and guidelines for data collection and quality improvement on a national scale. By achieving high levels of compliance with evidence-based practices to reduce SSIs, venous thromboembolism events, and perioperative cardiac complications, the potential number of

Table 12-5

The Surgical Care Improvement Project measures

Process of care performance measures

Infection

- Prophylactic antibiotic received within 1 h before surgical incision
- Prophylactic antibiotic selection for surgical patients
- Prophylactic antibiotics discontinued within 24 h after surgery end time (48 h for cardiac patients)
- Cardiac surgery patients with controlled 6 A.M. postoperative serum glucose
- Surgery patients with appropriate hair removal
- Colorectal surgery patients with immediate postoperative normothermia

Venous thromboembolism

- Surgery patients with recommended venous thromboembolism prophylaxis ordered
- Surgery patients who received appropriate venous thromboembolism prophylaxis within 24 h before surgery to 24 h after surgery

Cardiac events

- Surgery patients on a β -blocker prior to arrival who received a β -blocker during the perioperative period

Proposed outcome measures

Infection

- Postoperative wound infection diagnosed during index hospitalization

Venous thromboembolism

- Intra- or postoperative pulmonary embolism diagnosed during index hospitalization and within 30 d of surgery
- Intra- or postoperative deep vein thrombosis diagnosed during index hospitalization and within 30 d of surgery

Cardiac events

- Intra- or postoperative acute myocardial infarction diagnosed during index hospitalization and within 30 d of surgery

Global measures

- Mortality within 30 d of surgery
- Readmission within 30 d of surgery

Source: From Surgical Care Improvement Project,³⁰ with permission.

lives saved in the Medicare patient population alone exceeds 13,000 annually.²⁹

National Surgical Quality Improvement Program

The National Surgical Quality Improvement Program (NSQIP) is a measurement program that allows hospitals to sample their rates of postoperative events and compare them to similar hospitals. Created by the Veterans Health Administration (VA) in 1991, NSQIP has been credited with measuring and improving morbidity and mortality outcomes at the VA, reducing 30-day mortality rate after major surgery by 31%, and 30-day postoperative morbidity by 45% in its first decade.³¹ Beta testing at 18 non-VA sites from 2001 to 2004 demonstrated the feasibility and utility of the program in the private sector. The program was subsequently expanded to the private sector in 2004 when the American College of Surgeons endorsed the program and encouraged hospital participation to measure and evaluate outcomes on

a large scale. A study of 118 hospitals participating in NSQIP between 2005 to 2007 showed that 82% of hospitals decreased their complication rates, and there was a decrease in morbidity of 11% and mortality of 17% annually per hospital.³² Currently, over 400 private-sector U.S. hospitals participate in the program.

NSQIP uses a risk-adjusted ratio of the observed to expected outcome (focusing primarily on 30-day morbidity and mortality) to compare the performance of participating hospitals with their peers. The data the program has compiled also can be used to conduct observational studies using prospectively collected information on more than 1.5 million patients and operations. The expansion of NSQIP to the private sector has helped shift the focus from merely preventing the provider errors and sentinel events highlighted by the IOM publication “To Err Is Human” to the larger goal of preventing all adverse postoperative outcomes.

Several insights about patient safety have arisen as a result of NSQIP. First, safety is indistinguishable from overall quality of surgical care and should not be addressed separately. Defining quality in terms of keeping a patient safe from adverse outcomes allows the NSQIP data to be used to assess and improve quality of care by making improvements in patient safety. In other words, prevention of errors is synonymous with the reduction of adverse outcomes and can be used as a reliable quality measure. Second, during an episode of surgical care, adverse outcomes, and hence, patient safety, are primarily determined by the quality of the systems of care. Errors in hospitals with higher than expected observed to expected outcomes ratios are more likely to be from system errors than from provider incompetence. This underscores the importance of adequate communication, coordination, and teamwork in achieving quality surgical care. Finally, reliable comparative outcomes data are imperative for the identification of system problems. Risk-adjusted rates of adverse outcomes must be compared with those at peer institutions to appreciate more subtle system errors that lead to adverse outcomes to prompt changes in the quality of an institution’s processes and structures.

The Leapfrog Group

One of the largest efforts to standardize evidence-based medicine in the United States is led by The Leapfrog Group, an alliance of large public and private healthcare purchasers representing more than 37 million individuals across the United States. This healthcare consortium was founded in 2000 with the aim to exert their combined leverage toward improving nationwide standards of healthcare quality, optimizing patient outcomes, and ultimately lowering healthcare costs. The Leapfrog Group’s strategy to achieve these goals is through providing patient referral, financial incentives, and public recognition for hospitals that practice or implement evidence-based healthcare standards.

The healthcare quality and safety practices (leaps) that Leapfrog initially identified to measure healthcare standards were hospital use of computerized physician order entry systems, 24-hour ICU physician staffing, and evidence-based hospital referral (EBHR) standards for five high-risk operations.³³ In 2010, after the National Quality Forum (NQF) released its updated Safe Practices for Better Healthcare, Leapfrog added a safe practices leap, which includes eight practices from the NQF report.³⁴

Leapfrog collects data on these practices through administration of an ongoing, voluntary, web-based hospital quality and safety survey. This survey is conducted in 41 regions that cover over half of the U.S. population and 62% of all hospital beds in the country. In 2011, more than 1200 urban, suburban,

Table 12-6

Recommended annual volumes: hospitals and surgeons

1. Coronary artery bypass graft	≥450/100
2. Percutaneous coronary intervention	≥400/75
3. Abdominal aortic aneurysm repair	≥50/22
4. Aortic valve replacement	≥120/22
5. Pancreatic resection	≥11/2
6. Esophagectomy	≥13/2
7. Bariatric surgery	>100/20

Source: From The Leapfrog Group,³⁴ with permission.

and rural hospitals participated in the survey. Leapfrog asks for information on eight high-risk conditions or procedures, including coronary artery bypass graft, percutaneous coronary intervention, abdominal aortic aneurysm (AAA) repair, pancreatic resection, and esophagectomy. These procedures were chosen because evidence exists that adherence to certain process measures can dramatically improve the outcomes of these procedures. In addition, more than 100 studies also have demonstrated that better results are obtained at high-volume hospitals when undergoing cardiovascular surgery, major cancer resections, and other high-risk procedures. Hospitals fulfilling the EBHR Safety Standard are expected to meet the hospital and surgeon volume criteria shown in Table 12-6. Hospitals that do not meet these criteria but adhere to the Leapfrog-endorsed process measures for coronary artery bypass graft surgery, percutaneous coronary intervention, AAA repair, and care for high-risk neonates, receive partial credit toward fulfilling the EBHR Safety Standard. Leapfrog purchasers work to recognize and reward hospitals that provide care for their enrollees who meet EBHR standards.³²

In a recent study, Brooke and associates analyzed whether achieving Leapfrog’s established evidence-based standards for AAA repair, including meeting targets for case volume and perioperative β -blocker usage, correlated with improved patient outcomes over time.³³ After controlling for differences in hospital and patient characteristics, hospitals that implemented a policy for perioperative β -blocker usage had an estimated 51% reduction in mortality following open AAA repair cases. Among 111 California hospitals in which endovascular AAA repair was performed, in-hospital mortality was reduced by an estimated 61% over time among hospitals meeting Leapfrog case volume standards, although this result was not statistically significant. These results suggest that hospital compliance with Leapfrog standards for elective AAA repair is an effective means to help improve in-hospital mortality outcomes over time and support further efforts aimed at standardizing patient referral to hospitals that comply with evidence-based medicine standards for other surgical procedures.

The newest effort of the Leapfrog group is to promote transparency of hospital outcomes using a safety scorecard. This information can be viewed at hospitalsafetyscore.org.

World Health Organization “Safe Surgery Saves Lives” Initiative

In October 2004, the WHO launched a global initiative to strengthen healthcare safety and monitoring systems by creating the World Alliance for Patient Safety. As part of the group’s efforts to improve patient safety, the alliance implemented a

series of safety campaigns that brought together experts in specific problem areas through individual Global Patient Safety Challenges. The second Global Patient Safety Challenge focuses on improving the safety of surgical care. The main goal of the campaign, called *Safe Surgery Saves Lives*, is to reduce surgical deaths and complications through the universal adaptation of a comprehensive perioperative surgical safety checklist in ORs worldwide. In addition to the checklist, the WHO defined a set of uniform measures for national and international surveillance of surgical care to better assess the quantity and quality of surgical care being delivered worldwide.²¹ At the population level, metrics include the number of surgeon, anesthesia, and nurse providers per capita, the number of ORs per capita, and overall surgical case volumes and mortality rates. At the hospital level, metrics include safety improvement structures and a surgical “Apgar score,” a validated method of prognosticating patient outcomes based on intraoperative events (i.e., hypotension, tachycardia, blood loss).³⁵

National Quality Forum

The National Quality Forum (NQF) is a coalition of health-care organizations that has worked to develop and implement a national strategy for healthcare quality measurement and reporting. Their mission is to improve the quality of American healthcare by setting national priorities and goals for performance improvement, endorsing national consensus standards for measuring and publicly reporting on performance, and promoting the attainment of national goals through education and outreach programs.

One of the major contributions of the NQF is the development of a list of Serious Reportable Events, which are frequently referred to as “*never events*.”³⁶ According to the NQF, “never events” are errors in medical care that are clearly identifiable, preventable, and serious in their consequences for patients and that indicate a real problem in the safety and credibility of a healthcare facility. Examples of “never events” include surgery performed on the wrong body part; a foreign body left in a patient after surgery; a mismatched blood transfusion; a major medication error; a severe “pressure ulcer” acquired in the hospital; and preventable postoperative deaths (Table 12-7). Criteria for inclusion as a “never event” are listed below. The event must be:

- Unambiguous (i.e., the event must be clearly identifiable and measurable, and thus feasible to include in a reporting system);
- Usually preventable, with the recognition that some events are not always avoidable, given the complexity of healthcare;

Table 12-7

Surgical “never events”

- Surgery performed on the wrong body part
- Surgery performed on the wrong patient
- Wrong surgical procedure performed on a patient
- Unintended retention of a foreign object in a patient after surgery or other procedure
- Intraoperative or immediately postoperative death in an ASA Class 1 patient

ASA = American Society of Anesthesiologists.
Source: From National Quality Forum,³⁶ with permission.

Case 12-4 Surgical “never event”

In 2002, Mike Hurewitz, a reporter for *The Times Union* of Albany, suddenly began vomiting blood 3 days after donating part of his liver to his brother while recovering on a hospital floor in which 34 patients were being cared for by one first-year resident. He aspirated and died immediately with no other physician available to assist the overworked first-year resident.

Recognized for its advances in the field of liver transplantation, at the time, Mount Sinai Hospital was performing more adult-to-adult live-donor operations than any other hospital in the country. But the program was shut down by this event. Mount Sinai was held accountable for inadequate care and was banned from performing any live-donor adult liver transplants for more than 1 year. Of the 92 complaints investigated by the state, 75 were filed against the liver transplant unit, with 62 involving patient deaths. The state concluded that most of the 33 serious violations exhibited by the hospital occurred within the liver transplant unit.

As a result of the investigation, Mount Sinai revamped many of the procedures within its transplant unit. Among the changes, first-year residents no longer staffed the transplant service, two healthcare practitioners physically present in the hospital oversaw the transplant unit at all times, and any page coming from the transplant unit had to be answered within 5 minutes of the initial call. In addition, nurses monitored patients’ vital signs more closely after surgery, transplant surgeons were required to make postoperative visits to both organ donor and recipient, and each registered nurse was assigned to four patients, rather than six or seven. The death also led New York to become the first state to develop guidelines for treating live organ donors. Finally, Mike Hurewitz’s widow became a patient safety advocate, urging stricter controls on live donor programs.

- Serious, resulting in death or loss of a body part, disability, or more than transient loss of a body function; and
- Any one of the following:
 - Adverse, and/or
 - Indicative of a problem in a healthcare facility’s safety systems, and/or
 - Important for public credibility or public accountability.

These events are not a reasonable medical risk of undergoing surgery that the patient must accept but medical errors that should never happen (Case 12-4). The occurrence of any of these events signals that an organization’s patient safety culture or processes have defects that need to be evaluated and corrected (Table 12-8).

“NEVER EVENTS” IN SURGERY

Never events are errors in medical care that are clearly identifiable, preventable, and serious in their consequences for patients and that indicate a real problem in the safety and credibility of a healthcare facility.³⁶ Despite widespread agreement that surgical never events are preventable and despite several national and local programs being launched to decrease them, never events are still a significant problem. A study from Mehtsun

Table 12-8

Four patient events that advanced the modern field of patient safety

PATIENT	INSTITUTION	YEAR	EVENT	ROOT CAUSE	OUTCOME
Libby Zion	New York Hospital, New York, NY	1984	Missed allergy to Demerol	Physician fatigue	Bell Commission shortened resident work hours
Betsy Lehman	Dana-Farber Cancer Institute, Boston, MA	1994	Chemotherapy overdose	Lack of medication checks and triggers	Fired doctor, three pharmacists, 15 nurses; overhauled safety program
Josie King	Johns Hopkins Hospital, Baltimore, MD	2001	Severe dehydration	Poor communication	Increased safety research funding
Mike Hurewitz	Mt. Sinai Hospital, New York, NY	2002	Inadequate postoperative care	Inadequate supervision	Transplant program shut down until better patient safety safeguards implemented

and colleagues showed that from October 1990 to October 2010, nationwide there were 9744 paid malpractice claims for never events. Of these, mortality was reported in 6.6%, permanent injury in 33%, and temporary injury in 59%. The cost of the never events totaled \$1.3 billion. Also, of physicians who were named in a surgical never event claim, 12.4% were named in a future never events claim.³⁷ Another study in 2010 by The Joint Commission found that wrong-site surgery occurs 40 times per week nationwide.³⁸ Future directions for decreasing these problems include public reporting of never events by hospitals to increase hospital accountability, more formal training in teamwork, and CUSP programs in hospitals that have higher rates of never events to help elucidate the root cause.

Retained Surgical Items

A retained surgical item refers to any surgical item found to be inside a patient after he or she has left the OR, thus requiring a second operation to remove the item.³⁹ Estimates of retained foreign bodies in surgical procedures range from one case per 8000 to 18,000 operations, corresponding to one case or more each year for a typical large hospital or approximately 1500 cases per year in the United States.⁴⁰ This estimate is based on an analysis of malpractice claims and is likely to underestimate the true incidence. The risk of having a retained surgical item increases during emergency surgery, when there are unplanned changes in procedure (due to new diagnoses encountered in the OR), and in patients with higher body mass index (Table 12-9).⁴⁰

The most common retained surgical item is a surgical sponge, but other items, such as surgical instruments and needles, can also be inadvertently left inside a patient after

an operation. Retained surgical sponges are commonly discovered as an incidental finding on a routine postoperative radiograph, but also have been discovered in patients presenting with a mass or abdominal pain. Patients with sponges that were originally left in an intracavitary position (such as inside the chest or abdomen) also can present with complications such as abscess, erosion through the skin, fistula formation, bowel obstruction, hematuria, or the development of a new, tumor-like lesion.

Retained surgical needles usually are discovered incidentally, and reports of retained needles are uncommon. Retained surgical needles have not been reported to cause injury in the same way that nonsurgical needles (e.g., sewing needles, hypodermic needles) have been reported to perforate bowel or lodge in vessels and migrate. However, there have been reports of chronic pelvic pain and ocular irritation caused by retained surgical needles. A study of plain abdominal radiographs in pigs has demonstrated that medium- to large-size needles can easily be detected. The decision to remove these retained needles depends on symptoms and patient preference. Needles smaller than 13 mm have been found to be undetectable on plain radiograph in several studies, have not been shown to cause injury to vessels or visceral organs, and can probably be left alone.

Although the actual incidence of retained surgical instruments is unknown, they are retained with far less frequency than surgical sponges. The initial presentation of a retained surgical instrument is most commonly pain in the surgical site or the sensation of a mass of fullness after a surgical procedure that leads to the discovery of a metallic object on a radiographic study. Commonly retained instruments include the malleable and “FISH” instrument that are used to protect the viscera when closing abdominal surgery.

A retained surgical foreign body should be included in the differential diagnosis of any postoperative patient who presents with pain, infection, a palpable mass, or a radiopaque structure on imaging. The diagnosis can usually be made using a computed tomographic (CT) scan, and this is often the only test needed. If a retained surgical item is identified in the setting of an acute clinical presentation, the treatment usually is removal of the item. However, if the attempt to remove the retained surgical item can potentially cause more harm than the item itself, as in the case of a needle or a small part of a surgical item, then removal is occasionally not recommended. Retained surgical sponges should always be removed.

Table 12-9

Risk factors for retained surgical sponges

- Emergency surgery
- Unplanned changes in procedure
- Patient with higher body mass index
- Multiple surgeons involved in same operation
- Multiple procedures performed on same patient
- Involvement of multiple operating room nurses/staff members
- Case duration covers multiple nursing “shifts”

The American College of Surgeons and the Association of Perioperative Registered Nurses, in addition to The Joint Commission, have issued guidelines to try to prevent the occurrence of retained surgical items. Current recommendations include the use of standard counting procedures, performing a thorough wound exploration before closing a surgical site, and using only x-ray–detectable items in the surgical wound. These organizations also strongly endorse the completion of a postoperative debriefing after every operation. An x-ray at the completion of an operation is encouraged if there is any concern for a foreign body based on confusion regarding the counts by even a single member of the OR team or in the presence of a risk factor.

Surgical Counts

The benefit of performing surgical counts to prevent the occurrence of retained surgical items is controversial. The increased risk of a retained surgical item during emergency surgery in the study by Gawande and colleagues appeared to be related to bypassing the surgical count in many of these cases.⁴⁰ However, in another study, the “falsely correct count,” in which a count is performed and declared correct when it is actually incorrect, occurred in 21% to 100% of cases in which a retained surgical item was found.³⁹ This type of count was the most common circumstance encountered in all retained surgical item cases, which suggests that performing a surgical count in and of itself does not prevent this error from taking place. The counting protocol also imposes significant demands on the nursing staff and distracts them from focusing on other primarily patient-centered tasks, often during critical portions of the case.¹⁶

A retained surgical item can occur even in the presence of a known incorrect count. This event is usually a result of poor communication in which a surgeon will dismiss the incorrect count and/or fail to obtain a radiograph before the patient leaves the OR. Having stronger institutional policies in place in case of an incorrect count (such as requiring a mandatory radiograph while the patient is still in the OR) can avoid conflict among caregivers and mitigate the likelihood of a retained surgical item occurring as a result of a known incorrect count.

Although there is no single tool to prevent all errors, the development of multiple lines of defense to prevent retained surgical items and universally standardizing and adhering to OR safety protocols by all members of the surgical team will help reduce the incidence of this never event.⁴¹ Surgeons should take the lead in the prevention of retained surgical items by avoiding the use of small or nonradiologically detectable sponges in large cavities, performing a thorough wound inspection before closing any surgical incision, and having a vested interest in the counting procedure performed by nursing staff. The value of routine radiography to prevent a retained surgical item in emergency cases or when major procedures involving multiple surgical teams are being performed is becoming more apparent.

The widely accepted legal doctrine when a foreign body is erroneously left in a patient is that the mere presence of the item in the plaintiff's body indicates that the patient did not receive proper surgical care. The characteristics of the surgeon and their style, bedside manner, honesty, and confidence demonstrated in the management of the case can go a long way in averting a lawsuit or mitigating damages.

Wrong-Site Surgery

Wrong-site surgery is any surgical procedure performed on the wrong patient, wrong body part, wrong side of the body, or wrong level of a correctly identified anatomic site. It is difficult

to determine the true incidence of wrong-site surgery for several reasons. First, there is no standard definition for what constitutes wrong-site surgery among various healthcare organizations. Another factor is that wrong-site surgery is underreported by healthcare providers. Finally, the total number of potential opportunities for each type of wrong-site error is unknown. However, various studies show incidences ranging from one in 112,994 cases to one in 15,500 cases.⁴² The Washington University School of Medicine suggests a rate of one in 17,000 operations, which adds up to approximately 4000 wrong-site surgeries in the United States each year. If these numbers are correct, wrong-site surgery is the third most frequent life-threatening medical error in the United States.⁴³

Several states now require mandatory reporting of all wrong-site surgery events, including near misses. These data provide some insight into the number of actual errors compared to the number of potential opportunities to perform wrong-site surgery. Of the 427 reports of wrong-site surgery submitted from June 2004 through December 2006 to the Pennsylvania Patient Safety Reporting System, more than 40% of the errors actually reached the patient, and nearly 20% involved completion of a wrong-site procedure.⁴²

The risk of performing wrong-site surgery increases when there are multiple surgeons involved in the same operation or multiple procedures are performed on the same patient, especially if the procedures are scheduled or performed on different areas of the body.⁴³ Time pressure, emergency surgery, abnormal patient anatomy, and morbid obesity are also thought to be risk factors.⁴³ Communication errors are the root cause in more than 70% of the wrong-site surgeries reported to The Joint Commission.⁴² Other risk factors include receiving an incomplete preoperative assessment; having inadequate procedures in place to verify the correct surgical site; or having an organizational culture that lacks teamwork or reveres the surgeon as someone whose judgment should never be questioned.⁴²

There is a one in four chance that surgeons who work on symmetric anatomic structures will be involved in a wrong-site error sometime during their careers.⁴³ The specialties most commonly involved in reporting wrong-site surgeries according to The Joint Commission are orthopedic/podiatric surgery (41%), general surgery (20%), neurosurgery (14%), urology (11%), and maxillofacial, cardiovascular, otolaryngology, and ophthalmology (14%).⁴² Most errors involved symmetric anatomic structures: lower extremities (30%), head/neck (24%), and genital/urinary/pelvic/groin (21%).³⁸ Although orthopedic surgery is the most frequently involved, this may be due to the higher volume of cases performed as well as the increased opportunity for lateralization errors inherent in the specialty. In addition, because the American Academy of Orthopaedic Surgeons has historically tried as a professional organization to reduce wrong-site operations, orthopedic surgeons may be more likely to report these events when they do occur.⁴³

The Joint Commission Universal Protocol to Ensure Correct Surgery

The movement to eliminate wrong-site surgery began among professional orthopedic societies in the mid-1990s, when both the Canadian Orthopaedic Association and the American Academy of Orthopaedic Surgeons issued position statements and embarked on educational campaigns to prevent the occurrence of wrong-site surgery within their specialty.⁴³ Other organizations that issued position statements advocating for the

elimination of wrong-site surgery include the North American Spine Society, the American Academy of Ophthalmology, the Association of Perioperative Registered Nurses, and the American College of Surgeons. After issuing a review of wrong-site surgery in their Sentinel Event Alert in 1998, The Joint Commission made the elimination of wrong-site surgery one of their first National Patient Safety Goals in 2003 and adopted a universal protocol for preventing wrong-site, wrong-procedure, and wrong-person surgery in 2004. The protocol has been endorsed by more than 50 professional associations and organizations.

A preoperative “time-out” or “pause for the cause” to confirm the patient, procedure, and site to be operated on before incision was recommended by The Joint Commission and is now mandatory for all ORs in the United States. Elements of the protocol include the following:

- Verifying the patient’s identity
- Marking the surgical site
- Using a preoperative site verification process such as a checklist
- Confirming the availability of appropriate documents and studies before the start of a procedure
- Taking a brief time-out immediately before skin incision, in which all members of the surgical team actively communicate and provide oral verification of the patient’s identity, surgical site, surgical procedure, administration of preoperative medications, and presence of appropriate medical records, imaging studies, and equipment
- Monitoring compliance with protocol recommendations

Focusing on individual process components of the universal protocol, such as surgical site marking or the time-out, is not enough to prevent wrong-site surgery. Over a 30-month period in Pennsylvania, 21 wrong-side errors occurred despite the proper use of time-out procedures, with 12 of these errors resulting in complete wrong-side procedures. During the same period, correct site markings failed to prevent another 16 wrong-site surgeries, of which six were not recognized until after the procedure had been completed.⁴³

Site verification begins with the initial patient encounter by the surgeon, continues throughout the preoperative verification process and during multiple critical points in the OR, and requires the active participation of the entire operating team, especially the surgeon and anesthesia provider. Based on a recent review of malpractice claims, two thirds of wrong-site operations could have been prevented by a site-verification protocol.⁴⁴

Despite the proliferation of wrong-site protocols in the last decade, their effectiveness is difficult to measure as the incidence of wrong-site surgery is too rare to measure as a rate. Interestingly, the number of sentinel events reported to The Joint Commission has not changed significantly since the widespread implementation of the Universal Protocol in 2004.⁴³ This could be due to an increase in reporting rather than an actual increase in the incidence of wrong-site surgery.

The legal treatment of wrong-site surgery is similar to that of surgical items erroneously left in a patient: the mere fact that it occurred indicates that the patient did not receive proper surgical care. A malpractice claim may lead to a settlement or award on verdict in the six- or seven-figure range in 2011 U.S. dollars.³⁷

Ultimately, the occurrence of retained surgical items or wrong-site surgery is a reflection of the quality of professional communication between caregivers and the degree of

Table 12-10

Best practices for operating room safety

- Conduct The Joint Commission Universal Protocol (“time-out”) to prevent wrong-site surgery.
- Perform an operating room briefing (checklist) to identify and mitigate hazards early.
- Promote a culture of speaking up about safety concerns.
- Use a screening x-ray to detect foreign bodies in high-risk cases.
- Begin patient sign-outs with the most likely immediate safety hazard.

Source: Reproduced with permission from Michaels RK, et al. Achieving the National Quality Forum’s “Never Events”: Prevention of wrong site, wrong procedure, and wrong patient operations. *Ann Surg* 245:526, 2007.

teamwork among the members of the operating team. In addition to standardizing procedures like the surgical count, instituting mandatory postoperative radiographs in the presence of a known miscount, and reforming the processes of patient identification and site verification, organizations should also strive to create a culture of safety, create independent and redundant checks for key processes, and create a system in which caregivers can learn from their mistakes (Table 12-10).⁴⁵

TRANSPARENCY IN HEALTHCARE

Despite a large increase in data being collected about patient safety and harm, much of it is not available to the public or other hospitals. This lack of transparency allows some hospitals to continue to practice outdated medicine and, in some cases, puts patients at a higher risk of serious complications. In a study by Mark Chassin, the health commissioner of New York State, having hospitals publicly disclose their mortality rates for coronary artery bypass graft (CABG) procedures resulted in a 41% decline in mortality from CABGs statewide.⁴⁶ In this study, when CABG mortality data were initially made public, there was a wide range in cardiac surgery-related mortality from 1% to 18%, depending on the hospital; the standard of care is 2%. The reasons for higher mortality in the poorly performing hospitals ranged from poor communication between care teams to one rogue surgeon operating when the surgeon should not have been. The consequence of making this data transparent was that the hospitals held multidisciplinary, CUSP-like meetings, where as a team they decided on the measures to implement for improvement. Through this, over the next year, most hospitals decreased their mortality rate to below 2%. Even the hospital that had an 18% mortality rate decreased it to 7% within 3 years and 1.7% over the next several years.

Transparency in healthcare is becoming central to the healthcare quality discussion. A new SCIP core measure is publishing practitioner performance, and all Leapfrog survey results are published online where other hospitals and the public can see them. Additionally, different large medical societies, including the Society for Thoracic Surgery (STS), are encouraging and rewarding practitioners and hospitals that are transparent with their outcomes. Making hospital outcomes transparent makes hospitals accountable to the public for their outcomes and, in the case of New York, caused a radical improvement in the quality of care provided to patients. It also empowers patients by making them better informed about which hospital they choose for their care, which will further incentivize hospitals to improve.

Between one half and two thirds of hospital-wide adverse events are attributable to surgical care. Most surgical errors occur in the OR and are technical in nature. Surgical complications and adverse outcomes have previously been linked to lack of surgeon specialization, low hospital volume, communication breakdowns, fatigue, surgical residents and trainees, and numerous other factors.⁴⁷

However, poor surgical outcomes are not necessarily correlated with a surgeon's level of experience in performing a certain procedure. In one study, three fourths of the technical errors that occurred in a review of malpractice claims data involved fully trained and experienced surgeons operating within their area of expertise, and 84% occurred in routine operations that do not require advanced training. Rather than surgeon expertise, these errors likely occurred due to situations complicated by patient comorbidity, complex anatomy, repeat surgery, or equipment problems (Table 12-11). Because these errors occurred during routine operations, previous suggestions to limit the performance of high-complexity operations using selective referral, regionalization, or limitation of privileging may not actually be effective in reducing the incidence of technical error among surgical patients.⁴⁷

In any event, although there has been much emphasis on reducing the prevalence of surgical technical errors as a way of improving surgical care, a technical error in the OR may not be the most important indicator of whether a surgeon will be sued by a patient. Recent studies point to the importance of a surgeon's communication skills in averting malpractice litigation. In the American College of Surgeons' Closed Claims Study, although intraoperative organ injuries occurred in 40% of patients, a surgical technical misadventure was the most deficient component of care in only 12% of patients. In fact, communication and practice pattern violations were the most common deficiency in care for one third of patients in the Closed Claims Study who received the expected standard of surgical care.⁴⁸

The Importance of Communication in Managing Risk

The manner and tone in which a physician communicates is potentially more important to avoiding a malpractice claim than the actual content of the dialogue. For example, a physician relating to a patient in a "negative" manner may trigger litigious feelings when there is a bad result, whereas a physician relating in a "positive" manner may not. Expressions of dominance, in which the voice tone is deep, loud, moderately fast, unaccented, and clearly articulated, may communicate a lack of empathy and understanding for the patient, whereas concern or anxiety in the surgeon's voice is often positively related to expressing concern

and empathy. General and orthopedic surgeons whose tone of voice was judged to be more dominant were more likely to have been sued than those who sounded less dominant.⁴⁹

When significant medical errors do occur, physicians have an ethical and professional responsibility to immediately disclose them to patients. Failure to disclose errors to patients undermines public confidence in medicine and can create legal liability related to fraud. Physicians' fear of litigation represents a major barrier to error disclosure. However, when handled appropriately, immediate disclosure of errors frequently leads to improved patient rapport, improved satisfaction, and fewer malpractice claims.⁵⁰ In fact, rapport is the most important factor in determining whether a lawsuit is filed against a physician.

In 1987, the Department of Veterans Affairs Hospital in Lexington, Kentucky, implemented the nation's first formal apology and medical error full disclosure program, which called for the hospital and its doctors to work with patients and their families to settle a case. As a result, the hospital improved from having one of the highest malpractice claims totals in the VA system to being ranked among the lowest quartile of a comparative group of similar hospitals for settlement and litigation costs over a 7-year period. Its average payout in 2005 was \$16,000 per settlement, vs. the national VA average of \$98,000 per settlement, and only two lawsuits went to trial during a 10-year period. As a result of the success of this program, the Department of Veteran Affairs expanded the program to all VA hospitals nationwide in October 2005. This model also was replicated at the University of Michigan Health System with similar results. Its full-disclosure program cut the number of pending lawsuits by one half and reduced litigation costs per case from \$65,000 to \$35,000, saving the hospital approximately \$2 million in defense litigation bills each year. In addition, University of Michigan doctors, patients, and lawyers are happier with this system. The cultural shift toward honesty and openness also has led to the improvement of systems and processes to reduce medical errors, especially repeat medical errors.⁵¹

With regard to risk management, the importance of good communication by surgeons and other care providers cannot be overemphasized. Whether alerting other members of the care team about a patient's needs, openly discussing concerns the patient and/or family might have, or disclosing the cause of a medical error, open communication with all parties involved can reduce anger and mistrust of the medical system; the frequency, morbidity, and mortality of preventable adverse events; and the likelihood of litigation.

COMPLICATIONS

Despite the increased focus on improving patient safety and minimizing medical errors, it is impossible to eliminate human error entirely. Individual errors can cause minor or major complications during or after a surgical procedure. Although these types of errors may not be publicized as much as wrong-site surgery or a retained surgical item, they can still lead to surgical complications that prolong the course of illness, lengthen hospital stay, and increase morbidity and mortality rates.

Complications in Minor Procedures

Central Venous Access Catheters. Complications of central venous access catheters are common. Improvements in ultrasound technology and mass education surrounding the use and

Table 12-11

Common causes of lawsuits in surgery

- Positional nerve injury
- Common bile duct injury
- Failure to diagnose or delayed diagnosis
- Failure to treat, delayed treatment, or wrong treatment
- Inadequate documentation
- Inappropriate surgical indication
- Failure to call a specialist
- Cases resulting in amputation/limb loss

techniques in ultrasonography have led to increased employment and enthusiasm for its use in central venous catheter placement. Numerous institutions have recently begun to mandate use of ultrasound for placement of all central venous lines. Anecdotally, many subclavian catheters have been alternatively placed at the internal jugular position due to a perceived benefit of decreasing complications. Literature exists that there is some merit to this; however, one should proceed with caution as the decrease in pneumothoraces may not be balanced by the increase in line infections as the neck is difficult to keep the site clean and the dressing intact. Steps to decrease complications include the following:

- Ensure that central venous access is indicated.
- Experienced personnel should insert the catheter or should supervise the insertion.
- Use proper positioning and sterile technique.
- Ultrasound is recommended for internal jugular vein insertion.
- All central venous catheters should be assessed on a daily basis and should be exchanged only for specific indications (not as a matter of routine).
- All central catheters should be removed as soon as possible.

Common complications of central venous access include the following.

Pneumothorax Occurrence rates from both subclavian and internal jugular vein approaches are 1% to 6%. Prevention requires proper positioning of the patient and correct insertion technique. A postprocedure chest x-ray is mandatory to confirm the presence or absence of a pneumothorax, regardless of whether a pneumothorax is suspected. Pneumothorax rates are higher among the inexperienced but occur with experienced operators as well. If the patient is stable, and the pneumothorax is small (<15%), close expectant observation may be adequate. If the patient is symptomatic, a thoracostomy tube should be placed. Occasionally, pneumothorax will occur as late as 48 to 72 hours after central venous access attempts. This usually creates sufficient compromise that a tube thoracostomy is required.

Arrhythmias Arrhythmias result from myocardial irritability secondary to guidewire placement and usually resolve when the catheter or guidewire is withdrawn from the right heart. Prevention requires electrocardiogram (ECG) monitoring whenever possible during catheter insertion and rapid recognition when a new arrhythmia begins.

Arterial Puncture Inadvertent puncture or laceration of an adjacent artery with bleeding can occur, but the majority will resolve with direct pressure on or near the arterial injury site. Rarely will angiography, stent placement, or surgery be required to repair the puncture site, but close observation and a chest x-ray are indicated. Ultrasound guided insertion has not mitigated this complication, but may decrease the incidence of arterial puncture. Ultrasound has also been shown to decrease the number of attempts and the time it takes to complete insertion.

Lost Guidewire A guidewire or catheter that inadvertently migrates further into the vascular space away from the insertion site can be readily retrieved with interventional angiography techniques. A prompt chest x-ray and close monitoring of the patient until retrieval are indicated.

Air Embolus Although estimated to occur in only 0.2% to 1% of patients, an air embolism can be dramatic and fatal. If an

embolus is suspected, the patient should immediately be placed into a left lateral decubitus Trendelenburg position, so the entrapped air can be stabilized within the right ventricle. Auscultation over the precordium may reveal a “crunching” noise, but a portable chest x-ray will help confirm the diagnosis. Aspiration via a central venous line accessing the heart may decrease the volume of gas in the right side of the heart and minimize the amount traversing into the pulmonary circulation. Subsequent recovery of intracardiac and intrapulmonary air may require open surgical or angiographic techniques. Treatment may prove futile if the air bolus is larger than 50 mL, however.

Pulmonary Artery Rupture Flow-directed, pulmonary artery (“Swan-Ganz”) catheters can cause pulmonary artery rupture due to excessive advancement of the catheter into the pulmonary circulation. There usually is a sentinel bleed with coughing noted when a pulmonary artery catheter balloon is inflated, followed by uncontrolled hemoptysis. Reinflation of the catheter balloon is the initial step in management, followed by immediate airway intubation with mechanical ventilation, an urgent portable chest x-ray, and notification of the OR that an emergent thoracotomy may be required. If there is no further bleeding after the balloon is reinflated, the x-ray shows no significant consolidation of lung fields from ongoing bleeding, and the patient is easily ventilated, then a conservative nonoperative approach may be considered. However, more typically a pulmonary angiogram with angioembolization or vascular stenting is required. Hemodynamically unstable patients rarely survive because of the time needed to initiate and perform interventional procedures or a thoracotomy and to identify the ruptured branch of the pulmonary artery.

Central Venous Line Infection The CDC reports mortality rates of 12% to 25% when a central venous line infection becomes systemic, with a cost of approximately \$25,000 per episode.⁵²⁻⁵⁴ The CDC does not recommend routine central line changes, but when the clinical suspicion is high, the site of venous access must be changed. Nearly 15% of hospitalized patients will acquire central venous line sepsis. In many instances, once an infection is recognized as central line sepsis, removing the line is adequate. *Staphylococcus aureus* infections, however, present a unique problem because of the potential for metastatic seeding of bacterial emboli. The required treatment is 4 to 6 weeks of tailored antibiotic therapy. Using a checklist when inserting central venous catheters has been shown to significantly decrease rates of line infections.⁵⁵ Following a checklist strategy and close monitoring of catheters has resulted in significant reductions in infection rates for numerous institutions and many are now reporting zero annual infection rates.

Arterial Lines. Arterial lines are placed to facilitate arterial blood gas sampling and hemodynamic monitoring. The use of ultrasound to assist in placement of these catheters has become commonplace and markedly reduces the number of attempts and time for insertion completion.

Arterial access requires a sterile Seldinger technique, and a variety of arteries are used, including the radial, femoral, brachial, axillary, dorsalis pedis, or superficial temporal arteries. Although complications occur less than 1% of the time, they can be catastrophic. Complications include thrombosis, bleeding, hematoma, arterial spasm (nonthrombotic pulselessness), and infection. Thrombosis or embolization of an extremity arterial catheter can result in the loss of a digit, hand, or foot, and the risk is nearly the same for both femoral and radial cannulation.

Thrombosis with distal tissue ischemia is treated with anticoagulation, but occasionally surgical intervention is required. Pseudoaneurysms and arteriovenous fistulae can also occur.

Endoscopy and Bronchoscopy. The principal risk of gastrointestinal (GI) endoscopy is perforation. Perforations occur in 1:10,000 patients with endoscopy alone, but have a higher incidence rate when biopsies are performed (up to 10%). This increased risk is due to complications of intubating a GI diverticulum (either esophageal or colonic), or from the presence of weakened or inflamed tissue in the intestinal wall (e.g., diverticulitis, glucocorticoid use, or inflammatory bowel disease).

Patients will usually complain of diffuse abdominal pain shortly after the procedure, and then progress with worsening abdominal discomfort and peritonitis on examination. In obtunded or elderly patients, a change in clinical status may take 24 to 48 hours. Radiologic studies to look for free intraperitoneal air, retroperitoneal air, or a pneumothorax are diagnostic. Open or laparoscopic exploration locates the perforation and allows repair and local decontamination of the surrounding tissues.

The occasional patient who may be a candidate for non-operative management is one in whom perforation arises during an elective, bowel-prepped endoscopy and who does not have significant pain or clinical signs of infection. These patients must be closely observed in a monitored setting, on strict dietary restriction and broad-spectrum antibiotics.

Complications of bronchoscopy include bronchial plugging, hypoxemia, pneumothorax, lobar collapse, and bleeding. When diagnosed in a timely fashion, they are rarely life threatening. Bleeding usually resolves spontaneously and rarely requires surgery, but may require repeat endoscopy for thermo-coagulation or fibrin glue application. The presence of a pneumothorax necessitates placement of a thoracostomy tube when significant deoxygenation occurs or the pulmonary mechanics are compromised. Lobar collapse or mucous plugging usually responds to aggressive pulmonary toilet, but occasionally requires repeat bronchoscopy. If biopsies have been performed, the risk for these complications increases.

Tracheostomy. Tracheostomy facilitates weaning from a ventilator, may decrease length of ICU or hospital stay, and improves pulmonary toilet. Tracheostomies are performed open, percutaneously, with or without bronchoscopy, and with or without Doppler guidance. Arguments for percutaneous tracheostomy largely side with efficiency and cost containment over open tracheostomy. A recent literature review examining early (<3–7 days) vs. late (>14 days) tracheostomy demonstrates little difference in outcomes but does demonstrate greater patient comfort in those patients with tracheostomy than those with an endotracheal tube. Complications and outcomes between the two different methods remain largely equivalent.

Recent studies do not support obtaining a routine chest x-ray after percutaneous or open tracheostomy.^{56,57} However, significant lobar collapse can occur from copious tracheal secretions or mechanical obstruction. The most dramatic complication of tracheostomy is tracheoinnominate artery fistula (TIAF) (Fig. 12-7).^{58,59} This occurs rarely (~0.3%) but carries a 50% to 80% mortality rate. TIAFs can occur as early as 2 days or as late as 2 months after tracheostomy. A sentinel bleed occurs in 50% of TIAF cases, followed by a large-volume bleed. Should a TIAF be suspected, the patient should be transported immediately to the OR for fiberoptic evaluation. If needed, remove the tracheostomy and place a finger through the tracheostomy site to apply direct pressure anteriorly for compression of

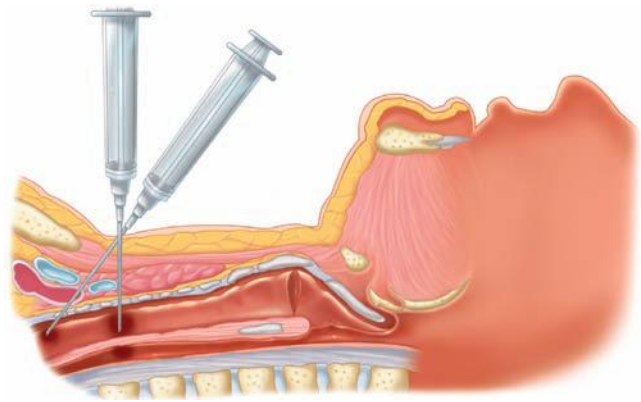


Figure 12-7. This illustration depicts improper positioning of the percutaneous needle. It is possible to access the innominate artery via the trachea, thus placing the patient at risk for early tracheoinnominate artery fistula.

the innominate artery while preparation for a more definitive approach is organized.

Percutaneous Endogastrostomy. A misplaced percutaneous endogastrostomy (PEG) tube may lead to intra-abdominal sepsis with peritonitis and/or an abdominal wall abscess with necrotizing fasciitis. As in other minor procedures, the initial placement technique must be fastidious to avoid complications. Transillumination of the abdomen may decrease the risk for error, but this is unsubstantiated in the literature. Inadvertent colotomies, intraperitoneal placement of the tube and subsequent leakage of tube feeds with peritonitis, and abdominal wall abscesses require surgery to correct the complications and to replace the PEG with an alternate feeding tube, usually a jejunostomy.

A dislodged or prematurely removed PEG tube should be replaced as early as possible after dislodgment because the gastrostomy site closes rapidly. A contrast x-ray (sinogram) should be performed to confirm the tube's intragastric position before feeding. If there is uncertainty of the tube location, conversion to an open tube placement procedure is required.

Tube Thoracostomy. Chest tube insertion is performed for pneumothorax, hemothorax, pleural effusions, or empyema. In most patients, a chest tube can be easily placed with a combination of local analgesia and light conscious sedation. Common complications include inadequate analgesia or sedation, incomplete penetration of the pleura with formation of a subcutaneous track for the tube, lacerations to the lung or diaphragm, intraperitoneal placement of the tube through the diaphragm, and bleeding related to these various lacerations or injury to pleural adhesions. Additional problems include slippage of the tube out of position or mechanical problems related to the drainage system. In patients with bullous disease, there can be significant intrapleural scarring and it can be easy to mistakenly place the chest tube into a bullae. All of these complications can be avoided with proper initial insertion techniques, plus a daily review of the drainage system and follow-up radiographs. Tube removal can create a residual pneumothorax if the patient does not maintain positive intrapleural pressure by Valsalva's maneuver during tube removal and dressing application.

Complications of Angiography. Intramural dissection of a cannulated artery can lead to complications such as ischemic stroke from a carotid artery dissection or occlusion, mesenteric ischemia from dissection of the superior mesenteric artery,

or a more innocuous finding of “blue toe syndrome” from a dissected artery in a peripheral limb. Invasive or noninvasive imaging studies confirm the suspected problem. The severity of ischemia and extent of dissection determine if anticoagulation therapy or urgent surgical exploration is indicated.

Bleeding from a vascular access site usually is obvious, but may not be visible when the blood loss is tracking into the retroperitoneal tissue planes after femoral artery cannulation. These patients can present with hemorrhagic shock; an abdominopelvic CT scan delineates the extent of bleeding along the retroperitoneum. Initial management is direct compression at the access site and resuscitation as indicated. Urgent surgical exploration may be required to control the bleeding site and evacuate larger hematomas.

Renal complications of angiography occur in 1% to 2% of patients. Contrast nephropathy is a temporary and preventable complication of radiologic studies such as CT, angiography, and/or venography. Intravenous (IV) hydration before and after the procedure is the most efficient method for preventing contrast nephropathy. Nonionic contrast also may be of benefit in higher-risk patients. Close communication between providers is often required to resolve the priorities in care as well as to balance the risks versus benefits of renal protection when managing patients in need of angiographic procedures.

Complications of Biopsies. Lymph node biopsies have direct and indirect complications that include bleeding, infection, lymph leakage, and seromas. Measures to prevent direct complications include proper surgical hemostasis, proper skin preparation, and a single preoperative dose of antibiotic to cover skin flora 30 to 60 minutes before incision. Bleeding at a biopsy site usually can be controlled with direct pressure. Infection at a biopsy site will appear 5 to 10 days postoperatively and may require opening of the wound to drain the infection. Seromas or lymphatic leaks resolve with aspiration of seromas and the application of pressure dressings, but may require repeated treatments or even placement of a vacuum drain.

Organ System Complications

Neurologic System. Neurologic complications that occur after surgery include motor or sensory deficits and mental status changes. Peripheral motor and sensory deficits are often due

to neurapraxia secondary to improper positioning and/or padding during operations. Treatment is largely clinical observation, and the majority of deficits resolve spontaneously within 1 to 3 months.

Direct injury to nerves during a surgical intervention is a well-known complication of several specific operations, including superficial parotidectomy (facial nerve), carotid endarterectomy (hypoglossal nerve), thyroidectomy (recurrent laryngeal nerve), prostatectomy (nervi erigentes), inguinal herniorrhaphy (ilioinguinal nerve), and mastectomy (long thoracic and thoracodorsal nerves). The nerve injury may be a stretch injury or an unintentionally severed nerve. In addition to loss of function, severed nerves can result in a painful neuroma that may require subsequent surgery.

Mental status changes in the postoperative patient can have numerous causes (Table 12-12). Mental status changes must be continually assessed. A noncontrast CT scan should be used early to detect new or evolving intracranial causes.

Atherosclerotic disease increases the risk for intraoperative and postoperative stroke (cerebrovascular accident). Postoperatively, hypotension and hypoxemia are the most likely causes of a cerebrovascular accident. Neurologic consultation should be obtained immediately to confirm the diagnosis. Management is largely supportive and includes adequate intravascular volume replacement plus optimal oxygen delivery. Advents in interventional radiology by radiologists and vascular and neurologic surgeons have proven successful alternatives in patients requiring diagnostic and therapeutic care in the immediate and acute postoperative period. Catheter-directed therapy with anticoagulants such as the kinases and tissue plasminogen activator (tPA) has potential benefit in postoperative thrombosis where reoperation carries significant risk. In addition, endoluminal stents with drug-eluting stents (DESs) or non-DESs have been used with some degree of success. DESs do require systemic antiplatelet therapy due to the alternative coagulation pathway. Duration of antiplatelet therapy of 1 year is routine.

Eyes, Ears, and Nose. Corneal abrasions are unusual, but are due to inadequate protection of the eyes during anesthesia. Overlooked contact lenses in patients occasionally may cause conjunctivitis.

Table 12-12

Common causes of mental status changes

ELECTROLYTE IMBALANCE	TOXINS	TRAUMA	METABOLIC	MEDICATIONS
Sodium	Ethanol	Closed head injury	Thyrotoxicosis	Aspirin
Magnesium	Methanol	Pain	Adrenal insufficiency	β-Blockers
Calcium	Venoms and poisons	Shock	Hypoxemia	Narcotics
Inflammation	Ethylene glycol	Psychiatric	Acidosis	Antiemetics
Sepsis	Carbon monoxide	Dementia	Severe anemia	MAOIs
AIDS		Depression	Hyperammonemia	TCA
Cerebral abscess		ICU psychosis	Poor glycemic control	Amphetamines
Meningitis		Schizophrenia	Hypothermia	Antiarrhythmics
Fever/hyperpyrexia			Hyperthermia	Corticosteroids, anabolic steroids

AIDS = acquired immunodeficiency syndrome; ICU = intensive care unit; MAOI = monoamine oxidase inhibitor; TCA = tricyclic antidepressant.

Persistent epistaxis can occur after nasogastric tube placement or removal, and nasal packing is the best treatment option if prolonged persistent direct pressure on the external nares fails. Anterior and posterior nasal gauze packing with balloon tamponade, angioembolization, and fibrin glue placement may be required in refractory cases. The use of antibiotics for posterior packing is controversial.

External otitis and otitis media occasionally occur postoperatively. Patients complain of ear pain or decreased hearing, and treatment includes topical antibiotics and nasal decongestion for symptomatic improvement.

Ototoxicity due to aminoglycoside administration occurs in up to 10% of patients, and is often irreversible. Vancomycin-related ototoxicity occurs about 3% of the time when used alone, and as often as 6% when used with other ototoxic agents.^{60,61}

Vascular Problems of the Neck. Complications of carotid endarterectomy include central or regional neurologic deficits or bleeding with an expanding neck hematoma. An acute change in mental status or the presence of localized neurologic deficit requires an immediate return to the OR. An expanding hematoma may warrant emergent airway intubation and subsequent transfer to the OR for control of hemorrhage. Intraoperative anticoagulation with heparin during carotid surgery makes bleeding a postoperative risk. Other complications include arteriovenous fistulae, pseudoaneurysms, and infection, all of which are treated surgically.

Intraoperative hypotension during manipulation of the carotid bifurcation can occur and is related to increased tone from baroreceptors that reflexly cause bradycardia. Should hypotension occur when manipulating the carotid bifurcation, an injection of 1% lidocaine solution around this structure should attenuate this reflexive response.

The most common delayed complication following carotid endarterectomy remains myocardial infarction. The possibility of a postoperative myocardial infarction should be considered as a cause of labile blood pressure and arrhythmias in high-risk patients.

Thyroid and Parathyroid Glands. Surgery of the thyroid and parathyroid glands can result in hypocalcemia in the immediate postoperative period. Manifestations include ECG changes (shortened P-R interval), muscle spasm (tetany, Chvostek's sign, and Trousseau's sign), paresthesias, and laryngospasm. Treatment includes calcium gluconate infusion and, if tetany ensues, chemical paralysis with intubation. Maintenance treatment is thyroid hormone replacement (after thyroidectomy) in addition to calcium carbonate and vitamin D.

Recurrent laryngeal nerve (RLN) injury occurs in less than 5% of patients. Of those with injury, approximately 10% are permanent. Dissection near the inferior thyroid artery is a common area for RLN injury. At the conclusion of the operation, if there is suspicion of an RLN injury, direct laryngoscopy is diagnostic. The cord on the affected side will be in the paramedian position. With bilateral RLN injury, the chance of a successful extubation is poor. If paralysis of the cords is not permanent, function may return 1 to 2 months after injury. Permanent RLN injury can be treated by various techniques to stent the cords in a position of function.

Superior laryngeal nerve injury is less debilitating, as the common symptom is loss of projection of the voice. The glottic aperture is asymmetrical on direct laryngoscopy, and management is limited to clinical observation.

Respiratory System. Surgical complications that put the respiratory system in jeopardy are not confined to technical errors. Malnutrition, inadequate pain control, inadequate mechanical ventilation, inadequate pulmonary toilet, and aspiration can cause serious pulmonary problems.

Pneumothorax can occur from central line insertion during anesthesia or from a diaphragmatic injury during an abdominal procedure. Hypotension, hypoxemia, and tracheal deviation away from the affected side may be present. A tension pneumothorax can cause complete cardiovascular collapse. Treatment is by needle thoracostomy, followed by tube thoracostomy. The chest tube is inserted at the fifth intercostal space in the anterior axillary line. The anterior chest wall is up to 1 cm thicker than the lateral chest wall, so needle decompression is more effective in the lateral position. Attempted prehospital needle decompression in the traditional anterior position results in only 50% needle entry into the thoracic cavity.

Hemothoraces should be evacuated completely. Delay in evacuation of a hemothorax leaves the patient at risk for empyema and entrapped lung. If evacuation is incomplete with tube thoracostomy, video-assisted thoracoscopy or open evacuation and pleurodesis may be required.

Pulmonary atelectasis results in a loss of functional residual capacity (FRC) of the lung and can predispose to pneumonia. Poor pain control in the postoperative period contributes to poor inspiratory effort and collapse of the lower lobes in particular. The prevention of atelectasis is facilitated by sitting the patient up as much as possible, early ambulation, and adequate pain control. An increase in FRC by 700 mL or more can be accomplished by sitting patients up to greater than 45°. For mechanically ventilated patients, simply placing the head of the bed at 30 to 45° elevation and delivering adequate tidal volumes (8–10 mL/kg) improves pulmonary outcomes.

Patients with inadequate pulmonary toilet are at increased risk for bronchial plugging and lobar collapse. Patients with copious and tenacious secretions develop these plugs most often, but foreign bodies in the bronchus can be the cause of lobar collapse as well. The diagnosis of bronchial plugging is based on chest x-ray and clinical suspicion with acute pulmonary decompensation with increased work of breathing and hypoxemia. Fiberoptic bronchoscopy can be useful to clear mucous plugs and secretions.

Aspiration complications include pneumonitis and pneumonia. The treatment of pneumonitis is similar to that for acute respiratory distress syndrome (see later in this section) and includes oxygenation with general supportive care. Antibiotics are not indicated. Hospitalized patients who develop aspiration pneumonitis have a mortality rate as high as 70% to 80%. Early, aggressive, and repeated bronchoscopy for suctioning of aspirated material from the tracheobronchial tree will help minimize the inflammatory reaction of pneumonitis and facilitate improved pulmonary toilet. Forced diuresis to overcome anasarca and over-resuscitation remains controversial and unsubstantiated. Complications of forced diuresis include electrolyte disturbances, replacement of those electrolytes, metabolic alkalosis, hypotension, and acute kidney injury.

Pneumonia is the second most common nosocomial infection and is the most common infection in ventilated patients. Ventilator-associated pneumonia (VAP) occurs in 15% to 40% of ventilated ICU patients, with a probability rate of 5% per day, up to 70% at 30 days. The 30-day mortality rate of nosocomial pneumonia can be as high as 40% and depends on the

microorganisms involved and the timeliness of initiating appropriate antimicrobials Protocol-driven approaches for prevention and treatment of VAP are recognized as beneficial in managing these difficult infectious complications.

Once the diagnosis of pneumonia is suspected (an abnormal chest x-ray, fever, productive cough with purulent sputum, and no other obvious fever sources), it is invariably necessary to initially begin treatment with broad-spectrum antibiotics until proper identification, colony count ($\geq 100,000$ colony-forming units [CFU]), and sensitivity of the microorganisms are determined.⁶² The spectrum of antibiotic coverage should be narrowed as soon as the culture sensitivities are determined. Double-coverage antibiotic strategy for the two pathogens, *Pseudomonas* and *Acinetobacter* spp., may be appropriate if the local prevalence of these particularly virulent organisms is high. One of the most helpful tools in treating pneumonia and other infections is the tracking of a medical center's antibiogram every 6 to 12 months.⁶³

Epidural analgesia decreases the risk of perioperative pneumonia. This method of pain control improves pulmonary toilet and the early return of bowel function; both have a significant impact on the potential for aspiration and for acquiring pneumonia. The routine use of epidural analgesia results in a lower incidence of pneumonia than patient-controlled analgesia.⁶⁴

Acute lung injury (ALI) was a diagnosis applied to patients with similar findings to those with acute respiratory distress syndrome (ARDS). The Berlin definition of ARDS developed by the American-European Consensus Conference of 2012 effectively not only simplifies the definition of ARDS, but eliminates the term ALI from critical care vernacular. ARDS is now classified by partial pressure of oxygen in arterial blood (P_{aO_2})/fraction of inspired oxygen (F_{iO_2}) ratios as mild (300–201 mmHg), moderate (200–101 mmHg), and severe (<100 mmHg). Elements of modification of the definition include the following: less than 7 days of onset; removal of pulmonary artery occlusion pressure; and clinical judgment for characterizing hydrostatic pulmonary edema is acceptable, unless risk factors for ARDS have been eliminated, in which case objective analysis is necessary.^{65–68}

The definition of ARDS traditionally included five criteria (Table 12-13). The multicenter ARDS Research Network (ARDSnet) research trial demonstrated improved clinical outcomes for ARDS patients ventilated at tidal volumes of only 5 to 7 mL/kg.⁶⁹ This strategy is no longer prescribed solely for patients with ARDS, but is also recommended for patients with normal pulmonary physiology as well who are intubated for reasons other than acute respiratory failure. The beneficial effects of positive end-expiratory pressure (PEEP) for ARDS were confirmed in this study as well. The maintenance of PEEP during ventilatory support is determined based on blood gas analysis, pulmonary mechanics, and requirements for supplemental oxygen. As gas exchange improves with resolving ARDS, the initial step in decreasing ventilatory support should be to decrease the levels of supplemental oxygen first, and then to slowly bring the PEEP levels back down to minimal levels.⁷⁰ This is done to minimize the potential for recurrent alveolar collapse and a worsening gas exchange.

Not all patients can be weaned easily from mechanical ventilation. When the respiratory muscle energy demands are not balanced or there is an ongoing active disease state external to the lungs, patients may require prolonged ventilatory support.

Table 12-13

Inclusion criteria for the acute respiratory distress syndrome

Acute onset	
Predisposing condition	
$P_{aO_2} : F_{iO_2} < 200$ (regardless of positive end-expiratory pressure)	
Bilateral infiltrates	
Pulmonary artery occlusion pressure <18 mmHg	
No clinical evidence of right heart failure	
F_{iO_2} = fraction of inspired oxygen; P_{aO_2} = partial pressure of arterial oxygen	

Protocol-driven ventilator weaning strategies are successful and have become part of the standard of care. The use of a weaning protocol for patients on mechanical ventilation greater than 48 hours reduces the incidence of VAP and the overall length of time on mechanical ventilation. Unfortunately, there is still no reliable way of predicting which patient will be successfully extubated after a weaning program, and the decision for extubation is based on a combination of clinical parameters and measured pulmonary mechanics.⁷¹ The Tobin Index (frequency [breaths per minute]/tidal volume [L]), also known as the *rapid shallow breathing index*, is perhaps the best negative predictive instrument.⁷² If the result equals less than 105, then there is nearly a 70% chance the patient will pass extubation. If the score is greater than 105, the patient has an approximately 80% chance of failing extubation. Other parameters such as the negative inspiratory force, minute ventilation, and respiratory rate are used, but individually have no better predictive value than the rapid shallow breathing index.⁷³

Malnutrition and poor nutritional support may adversely affect the respiratory system. The respiratory quotient (RQ), or respiratory exchange ratio, is the ratio of the rate of carbon dioxide (CO_2) produced to the rate of oxygen uptake ($RQ = V_{CO_2} / \dot{V}_{O_2}$). Lipids, carbohydrates, and protein have differing effects on CO_2 production. Patients consuming a diet of mostly carbohydrates have an RQ of 1 or greater. The RQ for a diet of mostly lipids is closer to 0.7, and that for a diet of mostly protein is closer to 0.8. Ideally, an RQ of 0.75 to 0.85 suggests adequate balance and composition of nutrient intake. An excess of carbohydrate may negatively affect ventilator weaning because of the abnormal RQ due to higher CO_2 production and altered pulmonary gas exchange.

Although not without risk, tracheostomy decreases the pulmonary dead space and provides for improved pulmonary toilet. When performed before the tenth day of ventilatory support, tracheostomy may decrease the incidence of VAP, the overall length of ventilator time, and the number of ICU patient days.

The occurrence of PE is probably underdiagnosed. Its etiology is thought to stem from DVT. This concept, however, has recently been questioned from Spaniolas et al.⁷⁴ The diagnosis of PE is made when a high degree of clinical suspicion for PE leads to imaging techniques such as ventilation:perfusion nuclear scans or CT pulmonary angiogram. Clinical findings include elevated central venous pressure, hypoxemia, shortness of breath, hypocarbia secondary to tachypnea, and right heart strain on ECG. Ventilation:perfusion nuclear scans are often

indeterminate in patients who have an abnormal chest x-ray and are less sensitive than a CT angiogram or pulmonary angiogram for diagnosing PE. The pulmonary angiogram remains the gold standard for diagnosing PE, but spiral CT angiogram has become an alternative method because of its relative ease of use and reasonable rates of diagnostic accuracy. For cases without clinical contraindications to therapeutic anticoagulation, patients should be empirically started on heparin infusion until the imaging studies are completed if the suspicion of a PE is high.

Sequential compression devices on the lower extremities and low-dose subcutaneous heparin or low molecular weight heparinoid administration are routinely used to prevent DVT and, by inference, the risk of PE. Neurosurgical and orthopedic patients have higher rates of PE, as do obese patients and those at prolonged bed rest.

When anticoagulation is contraindicated, or when a known clot exists in the inferior vena cava (IVC), decreasing risk for PE includes insertion of an IVC filter. The Greenfield filter has been most widely studied, and it has a failure rate of less than 4%. Newer devices include those with nitinol wire that expands with body temperature and retrievable filters. Retrievable filters, however, must be considered as permanent. In most studies, the actual retrievable rate only reached about 20%. Some studies recognize the benefit of automated reminders and diligence of outlying patient follow-up, where higher retrieval rates have been achieved.⁷⁵ Patients with spinal cord injury and multiple long-bone or pelvic fractures frequently receive IVC filters, and there appears to be a low, but not insignificant, long-term complication rate with their use. However, IVC filters do not prevent PEs that originate from DVTs of the upper extremities.

Cardiac System. Arrhythmias are often seen preoperatively in elderly patients but may occur postoperatively in any age group. Atrial fibrillation is the most common arrhythmia⁷⁶ and occurs between postoperative days 3 to 5 in high-risk patients. This is typically when patients begin to mobilize their interstitial fluid into the vascular fluid space. Contemporary evidence suggests that rate control is more important than rhythm control for atrial fibrillation.^{77,78} The first-line treatment includes β -blockade and/or calcium channel blockade. β -Blockade must be used judiciously, because hypotension, as well as withdrawal from β -blockade with rebound hypertension, is possible. Calcium channel blockers are an option if β -blockers are not tolerated by the patient, but caution must be exercised in those with a history of congestive heart failure. Although digoxin is still a standby medication, it has limitations due to the need for optimal dosing levels. Cardioversion may be required if patients become hemodynamically unstable and the rhythm cannot be controlled.

Ventricular arrhythmias and other tachyarrhythmias may occur in surgical patients as well. Similar to atrial rhythm problems, these are best controlled with β -blockade, but the use of other antiarrhythmics or cardioversion may be required if patients become hemodynamically unstable.

Cardiac ischemia is a cause of postoperative mortality. Acute myocardial infarction (AMI) can present insidiously, or it can be more dramatic with the classic presentation of shortness of breath, severe angina, and sudden cardiogenic shock. The workup to rule out an AMI includes an ECG and cardiac enzyme measurements. The patient should be transferred to a monitored (telemetry) floor. Morphine, supplemental oxygen, nitroglycerine, and aspirin (MONA) are the initial therapeutic maneuvers for those being investigated for AMI.

Gastrointestinal System. Surgery of the esophagus is potentially complicated because of its anatomic location and blood supply. Nutritional support strategies should be considered for esophageal resection patients to maximize the potential for survival. The two primary types of esophageal resection performed are the transhiatal resection and the transthoracic (Ivor-Lewis) resection.⁷⁹ The transhiatal resection has the advantage that a formal thoracotomy incision is avoided. However, dissection of the esophagus is blind, and anastomotic leaks occur more than with other resections. However, when a leak does occur, simple opening of the cervical incision and draining the leak is all that is usually required.

The transthoracic Ivor-Lewis resection includes an esophageal anastomosis performed in the chest near the level of the azygos vein. These have lower leak rates, but leaks result in mediastinitis and can be difficult to control. The reported mortality is about 50% with an anastomotic leak, and the overall mortality is about 5%, which is similar to transhiatal resection.

Postoperative ileus is related to dysfunction of the neural reflex axis of the intestine. Excessive narcotic use may delay return of bowel function. Epidural anesthesia results in better pain control, and there is an earlier return of bowel function and a shorter length of hospital stay. The limited use of nasogastric tubes and the initiation of early postoperative feeding are associated with an earlier return of bowel function.⁸⁰ The use of chewing gum and other oral stimulants to minimize ileus remains controversial.

Pharmacologic agents commonly used to stimulate bowel function include metoclopramide and erythromycin. Metoclopramide's action is limited to the stomach and duodenum, and it may help primarily with gastroparesis. Erythromycin is a motilin agonist that works throughout the stomach and bowel. Several studies demonstrate significant benefit from the administration of erythromycin in those suffering from an ileus.⁸¹ Alvimopan, a newer agent and a mu-opioid receptor antagonist, has shown some promise in many studies for earlier return of gut function and subsequent reduction in length of stay.^{82,83} Neostigmine has been used in refractory pan-ileus patients (Ogilvie's syndrome) with some degree of success. It is recommended for patients receiving this type of therapy to be in a monitored unit.^{84,0}

Small bowel obstruction occurs in less than 1% of early postoperative patients. When it does occur, adhesions are usually the cause. Internal and external hernias, technical errors, and infections or abscesses are also causative. Hyaluronidase is a mucolytic enzyme that degrades connective tissue, and the use of a methylcellulose form of hyaluronidase, Sefrafilm, has been shown to result in a 50% decrease in adhesion formation in some patients.^{85,86} This should translate into a lower occurrence of postoperative bowel obstruction, but this has yet to be proven.

Fistulae are the abnormal communication of one structure to an adjacent structure or compartment and are associated with extensive morbidity and mortality. Common causes for fistula formation are summarized in the mnemonic FRIENDS (Foreign body, Radiation, Ischemia/Inflammation/Infection, Epithelialization of a tract, Neoplasia, Distal obstruction, and Steroid use). Postoperatively, they are most often caused by infection or obstruction leading to an anastomotic leak. The cause of the fistula must be recognized early, and treatment may include nonoperative management with observation and nutritional support, or a delayed operative management strategy that also includes nutritional support and wound care.

GI bleeding can occur perioperatively (Table 12-14). Technical errors such as a poorly tied suture, a nonhemostatic

Table 12-14

Common causes of upper and lower gastrointestinal (GI) hemorrhage

UPPER GI BLEED	LOWER GI BLEED
Erosive esophagitis	Angiodysplasia
Gastric varices	Radiation proctitis
Esophageal varices	Hemangioma
Dieulafoy's lesion	Diverticulosis
Aortoduodenal fistula	Neoplastic diseases
Mallory-Weiss tear	Trauma
Peptic ulcer disease	Vasculitis
Trauma	Hemorrhoids
Neoplastic disease	Aortoenteric fistula Intussusception Ischemic colitis Inflammatory bowel disease Postprocedure bleeding

staple line, or a missed injury can all lead to postoperative intestinal bleeding.^{87,88} The source of bleeding is in the upper GI tract about 85% of the time and is usually detected and treated endoscopically. Surgical control of intestinal bleeding is required in up to 40% of patients.⁸⁹

When patients in the ICU have a major bleed from stress gastritis, the mortality risk is as high as 50%. It is important to keep the gastric pH greater than 4 to decrease the overall risk for stress gastritis in patients mechanically ventilated for 48 hours or greater and patients who are coagulopathic.⁹⁰ Proton pump inhibitors, H₂-receptor antagonists, and intragastric antacid installation are all effective measures. However, patients who are not mechanically ventilated or who do not have a history of gastritis or peptic ulcer disease should not be placed on gastritis prophylaxis postoperatively because it carries a higher risk of causing pneumonia.

Hepatobiliary-Pancreatic System. Complications involving the hepatobiliary system are usually due to technical errors. Laparoscopic cholecystectomy has become the standard of care for cholecystectomy, but common bile duct injury remains a nemesis of this approach. Intraoperative cholangiography has not been shown to decrease the incidence of common bile duct injuries because the injury to the bile duct usually occurs before the cholangiogram.^{91,92} Early recognition and immediate repair of an injury are important, because delayed bile duct leaks often require a more complex repair.

Ischemic injury due to devascularization of the common bile duct has a delayed presentation days to weeks after an operation. Endoscopic retrograde cholangiopancreatography (ERCP) demonstrates a stenotic, smooth common bile duct, and liver function studies are elevated. The recommended treatment is a Roux-en-Y hepaticojejunostomy.

A bile leak due to an unrecognized injury to the ducts may present after cholecystectomy as a biloma. These patients may present with abdominal pain and hyperbilirubinemia. The diagnosis of a biliary leak can be confirmed by CT scan, ERCP, or radionuclide scan. Once a leak is confirmed, a retrograde biliary stent and external drainage are the treatment of choice.

Hyperbilirubinemia in the surgical patient can be a complex problem. Cholestasis makes up the majority of causes for hyperbilirubinemia, but other mechanisms of hyperbilirubinemia include reabsorption of blood (e.g., hematoma from trauma), decreased bile excretion (e.g., sepsis), increased unconjugated bilirubin due to hemolysis, hyperthyroidism, and impaired excretion due to congenital abnormalities or acquired disease. Errors in surgery that cause hyperbilirubinemia largely involve missed or iatrogenic injuries.

The presence of cirrhosis predisposes to postoperative complications. Abdominal or hepatobiliary surgery is problematic in the cirrhotic patient. Ascites leak in the postoperative period can be an issue when any abdominal operation has been performed. Maintaining proper intravascular oncotic pressure in the immediate postoperative period can be difficult, and resuscitation should be maintained with crystalloid solutions. Prevention of renal failure and the management of the hepatorenal syndrome can be difficult, as the demands of fluid resuscitation and altered glomerular filtration become competitive. Spironolactone with other diuretic agents may be helpful in the postoperative care. These patients often have a labile course, and bleeding complications due to coagulopathy are common. The operative mortality in cirrhotic patients is 10% for Child class A, 30% for Child class B, and 82% for Child class C patients.⁹³

Pyogenic liver abscess occurs in less than 0.5% of adult admissions, due to retained necrotic liver tissue, occult intestinal perforations, benign or malignant hepatobiliary obstruction, sepsis, and hepatic arterial occlusion. The treatment is long-term antibiotics with percutaneous drainage of large abscesses.

Pancreatitis can occur following injection of contrast during cholangiography and ERCP. These episodes range from a mild elevation in amylase and lipase with abdominal pain, to a fulminant course of pancreatitis with necrosis requiring surgical débridement. Traumatic injuries to the pancreas can occur during surgical procedures on the kidneys, GI tract, and spleen most commonly. Treatment involves serial CT scans and percutaneous drainage to manage infected fluid and abscess collections; sterile collections should not be drained because drain placement can introduce infection. A pancreatic fistula may respond to antisecretory therapy with a somatostatin analogue. Management of these fistulae initially includes ERCP with or without pancreatic stenting, percutaneous drainage of any fistula fluid collections, total parenteral nutrition (TPN) with bowel rest, and repeated CT scans. The majority of pancreatic fistulae will eventually heal spontaneously.

Renal System. Renal failure can be classified as prerenal failure, intrinsic renal failure, and postrenal failure. Postrenal failure, or obstructive renal failure, should always be considered when low urine output (oliguria) or anuria occurs. The most common cause is a misplaced or clogged urinary catheter. Other, less common causes to consider are unintentional ligation or transection of ureters during a difficult surgical dissection (e.g., colon resection for diverticular disease) or a large retroperitoneal hematoma (e.g., ruptured aortic aneurysm).

Oliguria is initially evaluated by flushing the urinary catheter using sterile technique. Urine electrolytes should also be measured (Table 12-15). A hemoglobin and hematocrit level should be checked immediately. Patients in compensated shock from acute blood loss may manifest anemia and end-organ malperfusion as oliguria.

Acute tubular necrosis (ATN) carries a mortality risk of 25% to 50% due to the many complications that can cause, or result from, this insult. When ATN is due to poor inflow

Table 12-15

Urinary electrolytes associated with acute renal failure and their possible etiologies

	FE _{Na}	OSMOLARITY	UR _{Na}	ETIOLOGY
Prerenal	<1	>500	<20	CHF, cirrhosis
Intrinsic failure	>1	<350	>40	Sepsis, shock

CHF = congestive heart failure; FE_{Na} = fractional excretion of sodium; UR_{Na} = urinary excretion of sodium.

(prerenal failure), the remedy begins with IV administration of crystalloid or colloid fluids as needed. If cardiac insufficiency is the problem, the optimization of vascular volume is achieved first, followed by inotropic agents, as needed. Intrinsic renal failure and subsequent ATN are often the result of direct renal toxins. Aminoglycosides, vancomycin, and furosemide, among other commonly used agents, contribute directly to nephrotoxicity. Contrast-induced nephropathy usually leads to a subtle or transient rise in creatinine. In patients who are volume depleted or have poor cardiac function, contrast nephropathy may permanently impair renal function.⁹⁴⁻⁹⁷

The treatment of renal failure due to myoglobinuria has shifted away from the use of sodium bicarbonate for alkalinizing the urine, to merely maintaining brisk urine output of 100 mL/h with crystalloid fluid infusion. Mannitol and furosemide are not recommended. Patients who do not respond to resuscitation are at risk for needing renal replacement therapy. Fortunately, most of these patients eventually recover from their renal dysfunction.

Musculoskeletal System. A compartment syndrome can develop in any compartment of the body. Compartment syndrome of the extremities generally occurs after a closed fracture. The injury alone may predispose the patient to compartment syndrome, but aggressive fluid resuscitation can exacerbate the problem. Pain with passive motion is the hallmark of compartment syndrome, and the anterior compartment of the leg is usually the first compartment to be involved. Confirmation of the diagnosis is obtained by direct pressure measurement of the individual compartments. If the pressures are greater than 20 to 25 mmHg in any of the compartments, then a four-compartment fasciotomy is considered. Compartment syndrome can be due to ischemia-reperfusion injury, after an ischemic time of 4 to 6 hours. Renal failure (due to myoglobinuria), tissue loss, and a permanent loss of function are possible results of untreated compartment syndrome.

Decubitus ulcers are preventable complications of prolonged bed rest due to traumatic paralysis, dementia, chemical paralysis, or coma. Unfortunately, they are still occurring despite extensive research and clinical initiatives that demonstrate successful prevention strategies. Ischemic changes in the microcirculation of the skin can be significant after 2 hours of sustained pressure. Routine skin care and turning of the patient help ensure a reduction in skin ulceration. This can be labor intensive, and special mattresses and beds are available to help. The treatment of a decubitus ulcer in the noncoagulopathic patient is surgical débridement. Once the wound bed has a viable granulation base without an excess of fibrinous debris, a vacuum-assisted closure dressing can be applied. Wet to moist

dressings with frequent dressing changes is the alternative and is labor intensive. Expensive topical enzyme preparations are also available. If the wounds fail to respond to these measures, soft tissue coverage by flap is considered.

Contractures are the result of muscle disuse. Whether from trauma, amputation, or vascular insufficiency, contractures can be prevented by physical therapy and splinting. If not attended to early, contractures will prolong rehabilitation and may lead to further wounds and wound healing issues. Depending on the functional status of the patient, contracture releases may be required for long-term care.

Hematologic System. The transfusion guideline of maintaining the hematocrit level in all patients at greater than 30% is no longer valid. Only patients with symptomatic anemia, who have significant cardiac disease, or who are critically ill and require increased oxygen-carrying capacity to adequately perfuse end organs require higher levels of hemoglobin. Other than these select patients, the decision to transfuse should generally not occur until the hemoglobin level reaches 7 mg/dL or the hematocrit reaches 21%.

Transfusion reactions are common complications of blood transfusion. These can be attenuated with a leukocyte filter, but not completely prevented. The manifestations of a transfusion reaction include simple fever, pruritus, chills, muscle rigidity, and renal failure due to myoglobinuria secondary to hemolysis. Discontinuing the transfusion and returning the blood products to the blood bank is an important first step, but administration of antihistamine and possibly steroids may be required to control the reaction symptoms. Severe transfusion reactions are rare but can be fatal.

Infectious complications in blood transfusion range from cytomegalovirus transmission, which is benign in the nontransplant patient, to human immunodeficiency virus (HIV) infection, to passage of the hepatitis viruses (Table 12-16).

Patients on warfarin (Coumadin) who require surgery can have anticoagulation reversal by administration of fresh-frozen plasma. Each unit of fresh frozen plasma contains 200 to 250 mL of plasma and includes one unit of coagulation factor per milliliter of plasma.

Thrombocytopenia may require platelet transfusion for a platelet count less than 20,000/mL when invasive procedures are performed, or when platelet counts are low and ongoing bleeding from raw surface areas persists. One unit of platelets will increase the platelet count by 5000 to 7500 per mL in adults. It is important to delineate the cause of the low platelet count.

Table 12-16

Rate of viral transmission in blood product transfusions^a

HIV	1:1.9 million
HBV ^b	1:137,000
HCV	1:1 million

^aPost-nucleic acid amplification technology (1999). Earlier rates were erroneously reported higher due to lack of contemporary technology.

^bHBV is reported with pre-nucleic acid amplification technology. Statistical information is unavailable with post-nucleic acid amplification technology at this writing.

Note that bacterial transmission is 50 to 250 times higher than viral transmission per transfusion.

HBV = hepatitis B virus; HCV = hepatitis C virus.

Usually there is a self-limiting or reversible condition such as sepsis. Rarely, it is due to heparin-induced thrombocytopenia I and II. Complications of heparin-induced thrombocytopenia II can be serious because of the diffuse thrombogenic nature of the disorder. Simple precautions to limit this hypercoagulable state include saline solution flushes instead of heparin solutions and limiting the use of heparin-coated catheters. The treatment is anticoagulation with synthetic agents such as argatroban.

For patients with uncontrollable bleeding due to disseminated intravascular coagulopathy (DIC), a potentially useful drug is factor VIIa, but its use should be judicious.⁹⁸⁻¹⁰⁰ Originally used in hepatic trauma and obstetric emergencies, this agent was lifesaving in some circumstances. The CONTROL Trial,¹⁰¹ however, has largely decreased overuse of this agent because investigators demonstrated no benefit over simple factor replacement in severely coagulopathic patients. Factor VIIa use may also be limited due to its potential thrombotic complications. For some situations, the combination of ongoing, nonsurgical bleeding and renal failure can occasionally be successfully treated with desmopressin.

In addition to classic hemophilia, other inherited coagulation factor deficiencies can be difficult to manage in surgery. When required, transfusion of appropriate replacement products is coordinated with the regional blood bank center before surgery. Other blood dyscrasias seen by surgeons include hypercoagulopathic patients. Those who carry congenital anomalies such as the most common factor V Leiden deficiency, as well as protein C and S deficiencies, are likely to form thromboses if inadequately anticoagulated, and these patients should be managed in conjunction with a hematologist.

Abdominal Compartment Syndrome. Multisystem trauma, thermal burns, retroperitoneal injuries, and surgery related to the retroperitoneum are the major initial causative factors that may lead to abdominal compartment syndrome (ACS). Ruptured AAA, major pancreatic injury and resection, or multiple intestinal injuries are also examples of clinical situations in which a large volume of IV fluid resuscitation puts these patients at risk for intra-abdominal hypertension. Manifestations of ACS typically include progressive abdominal distention followed by increased peak airway ventilator pressures, oliguria followed by anuria, and an insidious development of intracranial hypertension.¹⁰² These findings are related to elevation of the diaphragm and inadequate venous return from the vena cava or renal veins secondary to the transmitted pressure on the venous system.

Measurement of abdominal pressures is easily accomplished by transducing bladder pressures from the urinary catheter after instilling 100 mL of sterile saline into the urinary bladder.¹⁰³ A pressure greater than 20 mmHg constitutes intra-abdominal hypertension, but the diagnosis of ACS requires intra-abdominal pressure greater than 25 to 30 mmHg, with at least one of the following: compromised respiratory mechanics and ventilation, oliguria or anuria, or increasing intracranial pressures.¹⁰⁴⁻¹⁰⁶

The treatment of ACS is to open any recent abdominal incision to release the abdominal fascia or to open the fascia directly if no abdominal incision is present. Immediate improvement in mechanical ventilation pressures, intracranial pressures, and urine output is usually noted. When expectant management for ACS is considered in the OR, the abdominal fascia should be left open and covered under sterile conditions (e.g., a vacuum-assisted open abdominal wound closure system) with plans made for a second-look operation and delayed fascial closure.

Patients with intra-abdominal hypertension should be monitored closely with repeated examinations and measurements of bladder pressure, so that any further deterioration is detected and operative management can be initiated. Left untreated, ACS may lead to multiple system end-organ dysfunction or failure and has a high mortality.

Abdominal wall closure should be attempted every 48 to 72 hours until the fascia can be reapproximated. If the abdomen cannot be closed within 5 to 7 days following release of the abdominal fascia, a large incisional hernia is the net result. A variety of surgical options have evolved for prevention and closure of the resultant hernias, but no standard approach has yet evolved.

Wounds, Drains, and Infection

Wound (Surgical Site) Infection. No prospective, randomized, double-blind, controlled studies exist that demonstrate antibiotics used beyond 24 hours in the perioperative period prevent infections. Prophylactic use of antibiotics should simply not be continued beyond this time. Irrigation of the operative field and the surgical wound with saline solution has shown benefit in controlling wound inoculum.¹⁰⁷ Irrigation with an antibiotic-based solution has not demonstrated significant benefit in controlling postoperative infection.

Antibacterial-impregnated polyvinyl placed over the operative wound area for the duration of the surgical procedure has not been shown to decrease the rate of wound infection.¹⁰⁸⁻¹¹² Although skin preparation with 70% isopropyl alcohol has the best bactericidal effect, it is flammable and could be hazardous when electrocautery is used. The contemporary formulas of chlorhexidine gluconate with isopropyl alcohol remain more advantageous.¹¹³⁻¹¹⁵

There is a difference between wound colonization and infection. Overtreating colonization is just as injurious as undertreating infection. The strict definition of wound (soft tissue) infection is more than 10^5 CFU per gram of tissue. This warrants expeditious and proper antibiotic/antifungal treatment.^{63,116} Often, however, clinical signs raise enough suspicion that the patient is treated before a confirmatory culture is undertaken. The clinical signs of wound infection include *rubor*, *tumor*, *calor*, and *dolor* (redness, swelling, heat, and pain). Once the diagnosis of wound infection has been established, the most definitive treatment remains open drainage of the wound. The use of antibiotics for wound infection treatment should be limited.¹¹⁷⁻¹²⁰

One type of wound dressing/drainage system that is gaining popularity is the vacuum-assisted closure dressing. The principle of the system is to decrease local wound edema and to promote healing through the application of a sterile dressing that is then covered and placed under controlled suction for a period of 2 to 4 days at a time. Although costly, the benefits are frequently dramatic and may offset the costs of nursing care, frequent dressing changes, and operative wound débridement.

Drain Management. The four indications for applying a surgical drain are:

- To collapse surgical dead space in areas of redundant tissue (e.g., neck and axilla)
- To provide focused drainage of an abscess or grossly infected surgical site
- To provide early warning notice of a surgical leak (either bowel contents, secretions, urine, air, or blood)—the so-called *sentinel drain*
- To control an established fistula leak

Open drains are often used for large contaminated wounds such as perirectal or perianal fistulas and subcutaneous abscess cavities. They prevent premature closure of an abscess cavity in a contaminated wound. More commonly, surgical sites are drained by closed suction drainage systems, but data do not support closed suction drainage to “protect an anastomosis” or to “control a leak” when placed at the time of surgery. Closed suction devices can exert a negative pressure of 70 to 170 mmHg at the level of the drain; therefore, the presence of this excess suction may call into question whether an anastomosis breaks down on its own or whether the drain creates a suction injury that promotes leakage (Fig. 12-8).¹²¹

On the other hand, CT- or ultrasound-guided placement of percutaneous drains is now the standard of care for abscesses, loculated infections, and other isolated fluid collections such as pancreatic leaks. The risk of surgery is far greater than the placement of an image-guided drain.

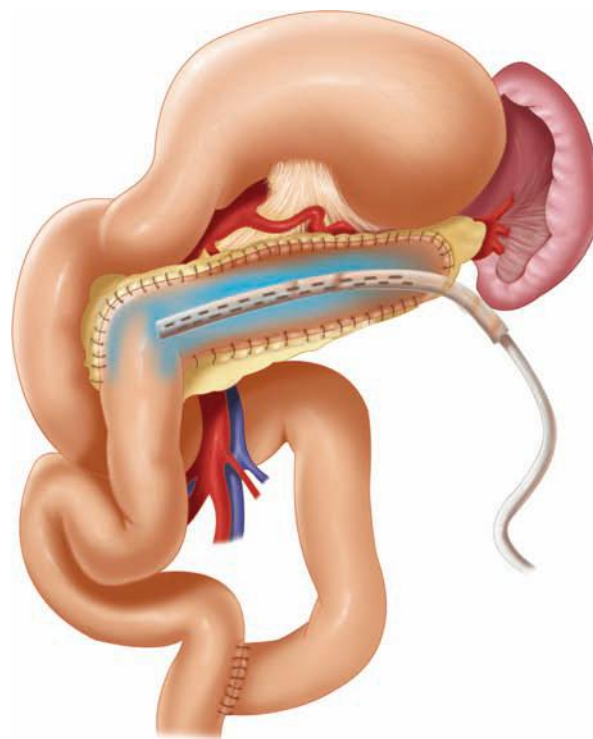
The use of antibiotics when drains are in place is often unnecessary as the drain provides direct source control. Twenty-four to 48 hours of antibiotic use after drain placement is prophylactic, and after this period, only specific treatment of positive cultures should be performed, to avoid increased drug resistance and superinfection.

Urinary Catheters. Several complications of urinary catheters can occur that lead to an increased length of hospital stay and morbidity. In general, use of urinary catheters should be minimized and every opportunity to expeditiously remove them should be encouraged. If needed, it is recommended that the catheter be inserted its full length up to the hub and that urine flow is established before the balloon is inflated, because misplacement of the catheter in the urethra with premature inflation of the balloon can lead to tears and disruption of the urethra.

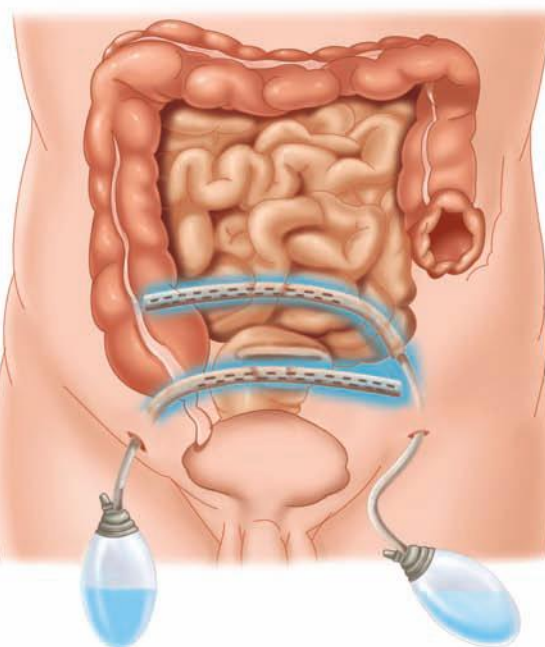
Enlarged prostatic tissue can make catheter insertion difficult, and a catheter coudé may be required. If this attempt is also unsuccessful, then a urologic consultation for endoscopic placement of the catheter may be required to prevent harm to the urethra. For patients with urethral strictures, filiform-tipped catheters and followers may be used, but these can potentially cause bladder injury. If endoscopic attempts fail, the patient may require a percutaneously placed suprapubic catheter to obtain decompression of the bladder. Follow-up investigations of these patients are recommended so definitive care of the urethral abnormalities can be pursued.

The most frequent nosocomial infection is urinary tract infection (UTI). These infections are classified into complicated and uncomplicated forms. The uncomplicated type is a UTI that can be treated with outpatient antibiotic therapy. The complicated UTI usually involves a hospitalized patient with an indwelling catheter whose UTI is diagnosed as part of a fever workup. The interpretation of urine culture results of less than 100,000 CFU/mL is controversial. Before treating such a patient, one should change the catheter and then repeat the culture to see if the catheter was simply colonized with organisms. Cultures with more than 100,000 CFU/mL should be treated with the appropriate antibiotics and the catheter changed or removed as soon as possible. Undertreatment or misdiagnosis of a UTI can lead to urosepsis and septic shock.

Recommendations are mixed on the proper way to treat *Candida albicans* fungal bladder infections. Continuous bladder washings with fungicidal solution for 72 hours have been recommended, but this is not always effective. Replacement of the urinary catheter and a course of fluconazole are appropriate



A



B

Figure 12-8. This illustration demonstrates typical intraoperative placement of closed suction devices in pancreatic or small bowel surgery, where there may be an anastomosis. At negative pressures of 70 to 170 mmHg, these devices may actually encourage anastomotic leaks and not prevent them or become clogged by them.

treatments, but some infectious disease specialists claim that *C. albicans* in the urine may serve as an indication of fungal infection elsewhere in the body. If this is the case, then screening cultures for other sources of fungal infection should be performed whenever a fungal UTI is found.

Empyema. One of the most debilitating infections is an empyema, or infection of the pleural space. Frequently, an

overwhelming pneumonia is the source of an empyema, but a retained hemothorax, systemic sepsis, esophageal perforation from any cause, and infections with a predilection for the lung (e.g., tuberculosis) are potential etiologies as well. The diagnosis is confirmed by chest x-ray or CT scan, followed by aspiration of pleural fluid for bacteriologic analysis. Gram's stain, lactate dehydrogenase, protein, pH, and cell count are obtained, and broad-spectrum antibiotics are initiated while the laboratory studies are performed. Once the specific organisms are confirmed, anti-infective agents are tailored appropriately. Placement of a thoracostomy tube is needed to evacuate and drain the infected pleural fluid, but depending on the specific nidus of infection, video-assisted thoracoscopy may also be helpful for irrigation and drainage of the infection. Refractory empyemas require specialized surgical approaches.

Abdominal Abscesses. Postsurgical intra-abdominal abscesses can present with vague complaints of intermittent abdominal pain, fever, leukocytosis, and a change in bowel habits. Depending on the type and timing of the original procedure, the clinical assessment of these complaints is sometimes difficult, and a CT scan is usually required. When a fluid collection within the peritoneal cavity is found on CT scan, antibiotics and percutaneous drainage of the collection is the treatment of choice. Initial antibiotic treatment is usually with broad-spectrum antibiotics such as piperacillin-tazobactam or imipenem. Should the patient exhibit signs of peritonitis and/or have free air on x-ray or CT scan, then re-exploration should be considered.

For patients who present primarily (i.e., not postoperatively) with the clinical and radiologic findings of an abscess but are clinically stable, the etiology of the abscess must be determined. A plan for drainage of the abscess and decisions about further diagnostic studies with consideration of the timing of any definitive surgery all need to be balanced. This can be a complex set of decisions, depending on the etiology (e.g., appendicitis or diverticulitis), but if the patient exhibits signs of peritonitis, urgent surgical exploration should be performed.

Necrotizing Fasciitis. Postoperative infections that progress to the fulminant soft tissue infection known as *necrotizing fasciitis* are uncommon. Group A streptococcal (M types 1, 3, 12, and 28) soft tissue infections, as well as infections with *Clostridium perfringens* and *C. septicum*, carry a mortality of 30% to 70%. Septic shock can be present, and patients can become hypotensive less than 6 hours following inoculation. Manifestations of a group A *Streptococcus pyogenes* infection in its most severe form include hypotension, renal insufficiency, coagulopathy, hepatic insufficiency, ARDS, tissue necrosis, and erythematous rash.

These findings constitute a surgical emergency, and the mainstay of treatment remains wide débridement of the necrotic tissue to the level of bleeding, viable tissue. A gray serous fluid at the level of the necrotic tissue is usually noted, and as the infection spreads, thrombosed blood vessels are noted along the tissue planes involved with the infection. Typically, the patient requires serial trips to the OR for wide débridement until the infection is under control. Antibiotics are an important adjunct to surgical débridement, and broad-spectrum coverage should be used because these infections may be polymicrobial (i.e., so-called *mixed-synergistic infections*). *S. pyogenes* is eradicated with penicillin, and it should still be used as the initial drug of choice.

Table 12-17

Mortality associated with patients exhibiting two or more criteria for systemic inflammatory response syndrome (SIRS)

PROGNOSIS	MORTALITY (%)
2 SIRS criteria	5
3 SIRS criteria	10
4 SIRS criteria	15–20

Systemic Inflammatory Response Syndrome, Sepsis, and Multiple-Organ Dysfunction Syndrome. The systemic inflammatory response syndrome (SIRS) and the multiple-organ dysfunction syndrome (MODS) carry significant mortality risks (Table 12-17). Specific criteria have been established for the diagnosis of SIRS (Table 12-18), but two criteria are not required for the diagnosis of SIRS: lowered blood pressure and blood cultures positive for infection. SIRS is the result of proinflammatory cytokines related to tissue malperfusion or injury. The dominant cytokines implicated in this process include interleukin (IL)-1, IL-6, and tissue necrosis factor (TNF). Other mediators include nitric oxide, inducible macrophage-type nitric oxide synthase, and prostaglandin I₂.

Sepsis is categorized as sepsis, severe sepsis, and septic shock. Sepsis is SIRS plus infection. Severe sepsis is sepsis plus signs of cellular hypoperfusion or end-organ dysfunction. Septic shock is sepsis plus hypotension after adequate fluid resuscitation.

MODS is the culmination of septic shock and multiple end-organ failure.¹²² Usually there is an inciting event (e.g., perforated sigmoid diverticulitis), and as the patient undergoes resuscitation, he or she develops cardiac hypokinesia and oliguric or anuric renal failure, followed by the development of ARDS and eventually septic shock with death.

The international Surviving Sepsis Campaign (<http://www.sccm.org/Documents/SSC-Guidelines.pdf>) continues to demonstrate the importance of early recognition and initiation of specific treatment guidelines for optimal management of sepsis. Management of SIRS/MODS includes aggressive global resuscitation and support of end-organ perfusion, correction of the inciting etiology, control of infectious complications, and management of iatrogenic complications.¹²³⁻¹²⁵ Drotrecogin- α , or recombinant activated protein C, appears to specifically counteract the cytokine cascade of SIRS/MODS, but its use is still limited.^{126,127} Other adjuncts for supportive therapy include

Table 12-18

Inclusion criteria for the systemic inflammatory response syndrome

Temperature >38°C or <36°C (>100.4°F or <96.8°F)
Heart rate >90 beats/min
Respiratory rate >20 breaths/min or PaCO ₂ <32 mmHg
White blood cell count <4000 or >12,000 cells/mm ³ or >10% immature forms

PaCO₂ = partial pressure of arterial carbon dioxide.

tight glucose control, low tidal volumes in ARDS, vasopressin in septic shock, and steroid replacement therapy.

Nutritional and Metabolic Support Complications

Nutrition-Related Complications. A basic principle is to use enteral feeding whenever possible, but complications can intervene such as aspiration, ileus, and to a lesser extent, sinusitis. There is no difference in aspiration rates when a small-caliber feeding tube is placed post-pyloric or if it remains in the stomach. Patients who are fed via nasogastric tubes are at risk for aspiration pneumonia, because these relatively large-bore tubes stent open the gastroesophageal junction, creating the possibility of gastric reflux. The use of enteric and gastric feeding tubes obviates complications of TPN, such as pneumothorax, line sepsis, upper extremity DVT, and the related expense. There is growing evidence to support the initiation of enteral feeding in the early postoperative period, before the return of bowel function, where it is usually well tolerated.

In patients who have had any type of nasal intubation who are having high, unexplained fevers, sinusitis must be entertained as a diagnosis. CT scan of the sinuses is warranted, followed by aspiration of sinus contents so the organism(s) are appropriately treated.

Patients who have not been enterally fed for prolonged periods secondary to multiple operations, those who have had enteral feeds interrupted for any other reason, or those with poor enteral access are at risk for the refeeding syndrome, which is characterized by severe hypophosphatemia and respiratory failure. Slow progression of the enteral feeding administration rate can avoid this complication.

Common TPN problems are mostly related to electrolyte abnormalities that may develop. These electrolyte errors include deficits or excesses in sodium, potassium, calcium, magnesium, and phosphate. Acid-base abnormalities can also occur with the improper administration of acetate or bicarbonate solutions.

The most common cause for hypernatremia in hospitalized patients is underresuscitation, and conversely, hyponatremia is most often caused by fluid overload. Treatment for hyponatremia is fluid restriction in mild or moderate cases and the administration of hypertonic saline for severe cases. An overly rapid correction of the sodium abnormality may result in central pontine myelinolysis, which results in a severe neurologic deficit. Treatment for hyponatremic patients includes fluid restriction to correct the free water deficit by 50% in the first 24 hours. An overcorrection of hyponatremia can result in severe cerebral edema, a neurologic deficit, or seizures.

Glycemic Control. In 2001, Van den Berghe and colleagues demonstrated that tight glycemic control by insulin infusion is associated with a 50% reduction in mortality in the critical care setting.¹²⁸ This prospective, randomized, controlled trial of 1500 patients had two study arms: the intensive-control arm, where the serum glucose was maintained between 80 and 110 mg/dL with insulin infusion; and the control arm, where patients received an insulin infusion only if blood glucose was greater than 215 mg/dL, but serum glucose was then maintained at 180 to 200 mg/dL.

The tight glycemic control group had an average serum glucose level of 103 mg/dL, and the average glucose level in the control group was 153 mg/dL. Hypoglycemic episodes (glucose <40 mg/dL) occurred in 39 patients in the tightly controlled group, while the control group had episodes in six patients.

The overall mortality was reduced from 8% to 4.6%, but the mortality of those patients whose ICU stay lasted longer than 5 days was reduced from 20% to 10%. Secondary findings included an improvement in overall morbidity, a decreased percentage of ventilator days, less renal impairment, and a lower incidence of bloodstream infections. These findings have been corroborated by subsequent similar studies, and the principal benefit appears to be a greatly reduced incidence of nosocomial infections and sepsis. It is not known whether the benefits are due to strict euglycemia, to the anabolic properties of insulin, or both, but the maintenance of strict euglycemia between 140 and 180 mg/dL appears to be a powerful therapeutic strategy.¹²⁸⁻¹³⁰ A number of studies followed this sentinel publication of tight glycemic control. NICE-SUGAR¹³¹ and COITSS¹³² revisited the Van den Berghe study and found that the glycemic goals found initially to improve outcomes in critically ill patients were now found to be associated with a higher mortality when glucose was kept below 180 mg/dL, due to an increase in incidents of hypoglycemia. When targeted goals of 180 mg/dL are achieved, less occurrences of hypoglycemia have been documented and improved survivorship has been achieved. In addition, some studies find no relationship between glycemic control and improved outcomes. Thus, glycemic control in the critically ill still remains unclear and elusive at best.^{133,134} Part of the difficulty in achieving “tight glycemic control” is the necessity for frequent (every 1–2 hours) blood glucose determinations. When this is performed, glycemic control is enhanced and hypoglycemia is avoided.

Metabolism-Related Complications. “Stress dose steroids” have been advocated for the perioperative treatment of patients on corticosteroid therapy, but recent studies strongly discourage the use of supraphysiologic doses of steroids when patients are on low or maintenance doses (e.g., 5–15 mg) of prednisone daily. Parenteral glucocorticoid treatment need only replicate physiologic replacement steroids in the perioperative period. When patients are on steroid replacement doses equal to or greater than 20 mg per day of prednisone, it may be appropriate to administer additional glucocorticoid doses for no more than 2 perioperative days.¹³⁵⁻¹³⁷

Adrenal insufficiency may be present in patients with a baseline serum cortisol less than 20 µg/dL. A rapid provocative test with synthetic adrenocorticotropic hormone may confirm the diagnosis. After a baseline serum cortisol level is drawn, 250 µg of cosyntropin is administered. At exactly 30 and 60 minutes following the dose of cosyntropin, serum cortisol levels are obtained. There should be an incremental increase in the cortisol level of between 7 and 10 µg/dL for each half hour. If the patient is below these levels, a diagnosis of adrenal insufficiency is made, and glucocorticoid and mineralocorticoid administration is then warranted. Mixed results are common, but the complication of performing major surgery on an adrenally insufficient patient is sudden or profound hypotension that is not responsive to fluid resuscitation.¹²³

Thyroid hormone abnormalities usually consist of previously undiagnosed thyroid abnormalities. Hypothyroidism and the so-called *sick-euthyroid syndrome* are more commonly recognized in the critical care setting. When surgical patients are not progressing satisfactorily in the perioperative period, screening for thyroid abnormalities should be performed. If the results show mild to moderate hypothyroidism, then thyroid replacement should begin immediately and thyroid function studies should be monitored closely. All patients should

be reassessed after the acute illness has subsided regarding the need for chronic thyroid replacement therapy.

Problems with Thermoregulation

Hypothermia. Hypothermia is defined as a core temperature less than 35°C (95°F) and is divided into subsets of mild (35–32°C [95–89.6°F]), moderate (32–28°C [89.6–82.4°F]), and severe (<28°C [<82.4°F]) hypothermia. Shivering, the body's attempt to reverse the effects of hypothermia, occurs between 37 and 31°C (98.6 and 87.8°F), but ceases at temperatures below 31°C (87.8°F). Patients who are moderately hypothermic are at higher risk for complications than are those who are more profoundly hypothermic.

Hypothermia creates a coagulopathy that is related to platelet and clotting cascade enzyme dysfunction. This triad of metabolic acidosis, coagulopathy, and hypothermia is commonly found in long operative cases and in patients with blood dyscrasias. The enzymes that contribute to the clotting cascade and platelet activity are most efficient at normal body temperatures; therefore all measures must be used to reduce heat loss intraoperatively.¹³⁸

The most common cardiac abnormality is the development of arrhythmias when body temperature drops below 35°C (95°F). Bradycardia occurs with temperatures below 30°C (86°F). It is well known that hypothermia may induce CO₂ retention, resulting in respiratory acidosis. Renal dysfunction of hypothermia manifests itself as a paradoxical polyuria and is related to an increased glomerular filtration rate, as peripheral vascular constriction creates central shunting of blood. This is potentially perplexing in patients who are undergoing resuscitation for hemodynamic instability, because the brisk urine output provides a false sense of an adequate intravascular fluid volume.

Induced peripheral hypothermia for hyperpyrexia due to infection (not to include neurologic or cardiac disease) is likely deleterious and does not appear to be beneficial. Placing cooling blankets on or under the patient or ice packs in the axillae or groin may be effective in cooling the skin, and when this occurs, a subsequent feedback loop triggers the hypothalamus to raise the internally regulated set point, thus raising core temperature even higher. This paradoxical reaction may be why outcomes for those who feel the need to treat a fever in the ICU by cooling the skin and arguably the core have worse outcomes. Cooling core temperatures can be achieved reliably with catheter-directed therapy with commercially available devices. Whether this is a worthwhile practice or not may be controversial. Poor data exist in support of treating fevers lower than 42°C in any fashion.^{133,134,139-142}

Adult trauma patients who underwent induced hypothermia had poor outcomes in a recent investigation, and thus, this remains a procedure to be avoided. In a similar vein, pediatric patients who were induced did not show any improvement, and therefore, induced hypothermia is not recommended. Complications with induced hypothermia include, but are not limited to, hypokalemia, diuresis, DVT (due to catheter-related vein injury), arrhythmias, shivering, undiagnosed catheter-related bloodstream infection, and bacteremia.¹⁴³⁻¹⁴⁶

Neurologic dysfunction is inconsistent in hypothermia, but a deterioration in reasoning and decision-making skills progresses as body temperature falls, and profound coma (and a flat electroencephalogram) occurs as the temperature drops below 30°C (86°F). The diagnosis of hypothermia is important,

Table 12-19

Common causes of elevated temperature in surgical patients

HYPERTHERMIA	HYPERPYREXIA
Environmental	Sepsis
Malignant hyperthermia	Infection
Neuroleptic malignant syndrome	Drug reaction
Thyrotoxicosis	Transfusion reaction
Pheochromocytoma	Collagen disorders
Carcinoid syndrome	Factitious syndrome
Iatrogenic	Neoplastic disorders
Central/hypothalamic responses	
Pulmonary embolism	
Adrenal insufficiency	

so accurate measurement techniques are required to get a true core temperature.

Methods used to warm patients include warm air circulation over the patient and heated IV fluids, and more aggressive measures such as bilateral chest tubes with warm solution lavage, intraperitoneal rewarming lavage, and extracorporeal membrane oxygenation. A rate of temperature rise of 2 to 4°C/h (3.6–7.2°F/h) is considered adequate, but the most common complication for nonbypass rewarming is arrhythmia with ventricular arrest.

Hyperthermia. Hyperthermia is a core temperature greater than 38.6°C (101.5°F) and has a host of etiologies (Table 12-19).¹⁴⁷ Hyperthermia can be environmentally induced (e.g., summer heat with inability to dissipate heat or control exposure), iatrogenically induced (e.g., heat lamps and medications), endocrine in origin (e.g., thyrotoxicosis), or neurologically induced (i.e., hypothalamic).

Malignant hyperthermia occurs after exposure to agents such as succinylcholine and some halothane-based inhalational anesthetics. The presentation is dramatic, with rapid onset of increased temperature, rigors, and myoglobinuria related to myonecrosis. Medications must be discontinued immediately and dantrolene administered (2.5 mg/kg every 5 minutes) until symptoms subside. Aggressive cooling methods are also implemented, such as an alcohol bath, or packing in ice. In cases of severe malignant hyperthermia, the mortality rate is nearly 30%.

Thyrotoxicosis can occur after surgery due to undiagnosed Graves' disease. Hyperthermia (>40°C [104°F]), anxiety, copious diaphoresis, congestive heart failure (present in about one fourth of episodes), tachycardia (most commonly atrial fibrillation), and hypokalemia (up to 50% of patients) are hallmarks of the disease. The treatment of thyrotoxicosis includes glucocorticoids, propylthiouracil, β-blockade, and iodide (Lugol's solution) delivered in an emergent fashion. As the name suggests, these patients are usually toxic and require supportive measures as well. Acetaminophen, the cooling modalities noted in the previous paragraph, and vasoactive agents often are indicated.

Entries highlighted in bright blue are key references.

1. Bierly PE III, Spender JC. Culture and high reliability organizations: the case of the nuclear submarine. *J Manage.* 1995;21:639.
2. Ruchlin HS, Dubbs NL, Callahan MA. The role of leadership in instilling a culture of safety: lessons from the literature. *J Healthcare Mgmt.* 2004;49:47.
3. **Kohn KT, Corrigan JM, Donaldson MS. *To Err Is Human: Building a Safer Health System.* Washington, DC: National Academy Press; 1999.**
4. Hindle D, Braithwaite J, Iedema R. *Patient Safety Research: A Review of the Technical Literature.* Sydney, Australia: Centre for Clinical Governance Research, University of South Wales; 2005:8.
5. Stelfox HT, Palmisani S, Scurlack C, et al. The “To Err Is Human” report and the patient safety literature. *Qual Saf Health Care.* 2006;15:174.
6. Makary MA, Sexton JB, Freischlag JA, et al. Patient safety in surgery. *Ann Surg.* 2006;243:628.
7. Berenholtz SM, Pronovost PJ. Monitoring patient safety. *Crit Care Clin* 2007;23:659.
8. Baker DP, Gustafson S, Beaubien J, et al. Medical team training. In: *Medical Teamwork and Patient Safety: The Evidence-Based Relation. Literature Review.* AHRQ Publication No. 05-0053. Rockville, MD: Agency for Healthcare Research and Quality; April 2005. Available at: <http://www.ahrq.gov/qual/medteam/medteam4.htm>. Accessed November 13, 2012.
9. Pizzi LT, Goldfarb NI, Nash DB. Promoting a culture of safety. In: *Making Health Care Safer: A Critical Analysis of Patient Safety Practices. Evidence Report/Technology Assessment: Number 43.* AHRQ Publication No. 01-E058. Rockville, MD: Agency for Healthcare Research and Quality; July 2001. Available at: <http://www.ahrq.gov/clinic/ptsafety/chap40.htm>. Accessed November 12, 2012.
10. Chan DK, Gallagher TH, Reznick R, et al. How surgeons disclose medical errors to patients: a study using standardized patients. *Surgery.* 2005;138:851.
11. Sexton JB, Thomas EJ, Helmreich RL. Error, stress, and teamwork in medicine and aviation: cross sectional surveys. *BMJ.* 2000;320:745.
12. Thomas EJ, Sexton JB, Helmreich RL. Discrepant attitudes about teamwork among critical care nurses and physicians. *Crit Care Med.* 2003;31:956.
13. Amalberti R, Auroy Y, Berwick D, et al. Five system barriers to achieving ultrasafe health care. *Ann Intern Med.* 2005;142:756.
14. The Joint Commission. Sentinel Event Statistics. Available at: <http://www.jointcommission.org/SentinelEvents/Statistics>. Accessed November 8, 2012.
15. Lingard L, Espin S, Whyte S, et al. Communication failures in the operating room: an observational classification of recurrent types and effects. *Qual Saf Health Care.* 2004;13:330.
16. **Christian CK, Gustafson ML, Roth EM, et al. A prospective study of patient safety in the operating room. *Surgery.* 2006;139:159.**
17. **Makary MA, Sexton JB, Freischlag JA, et al. Operating room teamwork among physicians and nurses: teamwork in the eye of the beholder. *J Am Coll Surg.* 2006;202:746.**
18. Pronovost PJ, Berenholtz SM, Goeschel CA, et al. Creating high reliability in health care organizations. *Health Serv Res.* 2006;41:1599.
19. **Makary MA, Mukherjee A, Sexton JB, et al. Operating room briefings and wrong-site surgery. *J Am Coll Surg.* 2007;204:236.**
20. Nundy S, Mukherjee A, Sexton JB, et al. Impact of pre-operative briefings on operating room delays. *Arch Surg.* 2008;143:1068.
21. World Health Organization. *Guidelines for Safe Surgery.* Geneva, Switzerland: World Health Organization; 2009.
22. Makary MA, Epstein J, Pronovost PJ, et al. Surgical specimen identification errors: a new measure of quality in surgical care. *Surgery.* 2007;141:450.
23. Arora V, Johnson J, Lovinger D, et al. Communication failures in patient sign-out and suggestions for improvement: a critical incident analysis. *Qual Saf Health Care.* 2005;14:401.
24. Cooper M, Makary M. A comprehensive unit-based safety (CUSP) in surgery: improving quality through transparency. *Surg Clin North Am.* 2012;92(1):51-63.
25. **Wick ED, Hobson DB, Bennett JL, et al. Implementation of a surgical comprehensive unit-based safety program to reduce surgical site infections. *J Am Coll Surg.* 2012;215(2):193-200.**
26. Agency for Healthcare Research and Quality. *AHRQ Profile: Quality Research for Quality Healthcare.* AHRQ Publication No. 00-P005. Rockville, MD: Agency for Healthcare Research and Quality; March 2001. Available at: <http://www.ahrq.gov/about/profile.htm>. Accessed November 2, 2012.
27. Agency for Healthcare Research and Quality. *Patient Safety Indicators Overview. AHRQ Quality Indicators.* Rockville, MD: Agency for Healthcare Research and Quality; February 2006. Available at: http://www.qualityindicators.ahrq.gov/psi_overview.htm. Accessed November 10, 2012.
28. Zhan C, Miller MR. Administrative data based patient safety research: a critical review. *Qual Saf Health Care.* 2003;12:58.
29. Bratzler DW. The Surgical Infection Prevention and Surgical Care Improvement Projects: promises and pitfalls. *Am Surg.* 2006;72:110.
30. The Joint Commission. SCIP Target Areas. Available at: http://www.jointcommission.org/surgical_care_improvement_project/. Accessed November 1, 2012.
31. Khuri SF. Safety, quality, and the National Surgical Quality Improvement Program. *Am Surg.* 2006;72:994.
32. Hall BL, Hamilton BH, Richards K, Bilimoria KY, Cohen ME, Ko CY. Does surgical quality improve in the American College of Surgeons National Surgical Quality Improvement Program: an evaluation of all participating hospitals. *Ann Surg.* 2009;250(3):363-376.
33. Brooke BS, Perler BA, Dominic F, et al. California hospitals meeting Leapfrog quality standards for abdominal aortic aneurysm repair. *J Vasc Surg* 2008;47:1155.
34. The Leapfrog Group. Available at: http://www.leapfroggroup.org/56440/leapfrog_hospital_survey_copy/leapfrog_safety_practices/evidence-based_hospital_referral. Accessed November 7, 2010.
35. Gawande AA, Kwaan MR, Regenbogen SE, et al. An Apgar score for surgery. *J Am Coll Surg.* 2007;204:201.
36. *Serious Reportable Events in Healthcare 2011 Update: A Consensus Report.* Washington, DC: National Quality Forum; 2011.
37. Mehtsun W, Ibrahim A, Pronovost P, Diener-West M, Makary M. Surgical never events: cost and outcome for patients and providers. *Surgery.* 2013;153(4):465-472.
38. Crane M. Wrong-site surgery occurs 40 times a week. *Medscape Medical News;* 2011. Available at: <http://www.medscape.com/viewarticle/745581>. Accessed September 17, 2013.
39. Gibbs VC, Coakley FD, Reines HD. Preventable errors in the operating room: retained foreign bodies after surgery—Part 1. *Curr Probl Surg.* 2007;44:281.
40. Gawande AA, Studdert DM, Orav EJ, et al. Risk factors for retained instruments and sponges after surgery. *N Engl J Med.* 2003;34:229.
41. Lincourt AE, Harrell A, Cristiano J, et al. Retained foreign bodies after surgery. *J Surg Res.* 2007;138:170.
42. Doing the “right” things to correct wrong-site surgery. *Pennsylvania Patient Safety Reporting System (PA-PSRS) Patient Safety Advisory.* 2007;4:1.

43. Clarke JR, Johnston J, Finley ED. Getting surgery right. *Ann Surg.* 2007;246:395.
44. Kwaan MR, Studdert DM, Zinner MJ, et al. Incidence, patterns, and prevention of wrong-site surgery. *Arch Surg.* 2006;141:353.
45. Michaels RK, Makary MA, Dahab Y, et al. Achieving the National Quality Forum's "never events": prevention of wrong site, wrong procedure, and wrong patient operations. *Ann Surg.* 2007;245:526.
46. Chassin MR. Achieving and sustaining improved quality: lessons from New York state and cardiac surgery. *Health Aff.* 2002;21(4):40-51.
47. Regenbogen SE, Greenberg CC, Studdert DM, et al. Patterns of technical error among surgical malpractice claims: an analysis of strategies to prevent injury to surgical patients. *Ann Surg.* 2007;246:705.
48. Griffen FD, Stephens LS, Alexander JB, et al. The American College of Surgeons' closed claims study: new insights for improving care. *J Am Coll Surg.* 2007;204:561.
49. Ambady N, LaPlante D, Nguyen T, et al. Surgeons' tone of voice: a clue to malpractice history. *Surgery.* 2002;132:5.
50. Woreta TA, Makary MA. Patient safety. In: Makary M, ed. *General Surgery Review.* Washington, DC: Ladner-Drysdale; 2008:553.
51. Wojcieszak D, Banja J, Houk C. The Sorry Works! Coalition: making the case for full disclosure. *Jt Comm J Qual Patient Saf.* 2006;32:344.
52. Veenstra DL, Saint S, Sullivan SD. Cost-effectiveness of antiseptic-impregnated central venous catheters for the prevention of catheter-related bloodstream infection. *JAMA.* 1999;282:554.
53. O'Grady NP, Alexander M, Dellinger EP, et al. Guidelines for the prevention of intravascular catheter-related infections. *Am J Infect Control.* 2002;30:476.
54. Stoiser B, Kofler J, Staudinger T, et al. Contamination of central venous catheters in immunocompromised patients: a comparison between two different types of central venous catheters. *J Hosp Infect.* 2002;50:202.
55. Berenholtz S, Pronovost P, Lipsett P, et al. Eliminating catheter-related bloodstream infections in the intensive care unit. *Crit Care Med.* 2004;32:2014.
56. Tyroch AH, Kaups K, Lorenzo M, et al. Routine chest radiograph is not indicated after open tracheostomy: a multicenter perspective. *Am Surg.* 2002;68:80.
57. Datta D, Onyirimba F, McNamee MJ. The utility of chest radiographs following percutaneous dilatational tracheostomy. *Chest.* 2003;123:1603.
58. Gelman JJ, Aro M, Weiss SM. Tracheo-innominate artery fistula. *J Am Coll Surg.* 1994;179:626.
59. Keceligil HT, Erk MK, Kolbakir F, et al. Tracheoinnominate artery fistula following tracheostomy. *Cardiovasc Surg.* 1995;3:509.
60. Rybak MJ, Abate BJ, Kang SL, et al. Prospective evaluation of the effect of an aminoglycoside dosing regimen on rates of observed nephrotoxicity and ototoxicity. *Antimicrob Agents Chemother.* 1999;43:1549.
61. Sandur S, Stoller JK. Pulmonary complications of mechanical ventilation. *Clin Chest Med.* 1999;20:223.
62. Salem M, Tainsh RE, Bromberg J, et al. Perioperative glucocorticoid coverage: a reassessment 42 years after emergence of a problem. *Ann Surg.* 1994;219:416.
63. Hughes MG, Evans HL, Chong TW, et al. Effect of an intensive care unit rotating empiric antibiotic schedule on the development of hospital-acquired infections on the non-intensive care unit ward. *Crit Care Med.* 2004;32:53.
64. Horn SD, Wright HL, Couperus JJ, et al. Association between patient-controlled analgesia pump use and postoperative surgical site infection in intestinal surgery patients. *Surg Infect (Larchmt).* 2002;3:109.
65. Ferguson ND, Fan E, Camporota L, et al. The Berlin definition of ARDS: an expanded rationale, justification, and supplementary material. *Intensive Care Med.* 2012;38(10):1573-1582.
66. Villar J, Kacmarek RM. The American-European Consensus Conference definition of the acute respiratory distress syndrome is dead, long live positive end-expiratory pressure! *Med Intensiva.* 2012;36(8):571-575.
67. ARDS Definition Task Force, Ranieri VM, Rubenfeld GD, et al. Acute respiratory distress syndrome: the Berlin Definition. *JAMA.* 2012;307(23):2526-2533.
68. Thille AW, Esteban A, Fernández-Segoviano P, et al. Comparison of the Berlin definition for acute respiratory distress syndrome with autopsy. *Am J Respir Crit Care Med.* 2013;187(7):761-767.
69. The Acute Respiratory Distress Syndrome Network. Ventilation with lower tidal volumes as compared with traditional tidal volumes for acute lung injury and the acute respiratory distress syndrome. *N Engl J Med.* 2000;342:1301.
70. Valente Barbas CS. Lung recruitment maneuvers in acute respiratory distress syndrome and facilitating resolution. *Crit Care Med.* 2003;31:S265.
71. Singh JM, Stewart TE. High-frequency mechanical ventilation principles and practices in the era of lung-protective ventilation strategies. *Respir Care Clin North Am.* 2002;8:247.
72. Yang KL, Tobin MJ. A prospective study of indexes predicting the outcome of trials of weaning from mechanical ventilation. *N Engl J Med.* 1991;324:1445.
73. Epstein SK. Etiology of extubation failure and the predictive value of the rapid shallow breathing index. *Am J Respir Crit Care Med.* 1995;152:545.
74. Spaniolas K, Velmahos GC, Wicky S, et al. Is upper extremity deep venous thrombosis underdiagnosed in trauma patients? *Am Surg.* 2008;74(2):124-128.
75. Dabbagh O, Nagam N, Chitima-Matsiga R, et al. Retrievable inferior vena cava filters are not getting retrieved: where is the gap? *Thromb Res.* 2010;126(6):493-497.
76. Falk RH. Atrial fibrillation. *N Engl J Med.* 2001;344:1067.
77. Van Gelder IC, Hagens VE, Bosker HA, et al. A comparison of rate control and rhythm control in patients with recurrent persistent atrial fibrillation. *N Engl J Med.* 2002;347:1834.
78. Wyse DG, Waldo AL, DiMarco JP, et al. A comparison of rate control and rhythm control in patients with atrial fibrillation. *N Engl J Med.* 2002;347:1825.
79. Franklin RH. Ivor Lewis Lecture, 1975. The advancing frontiers of oesophageal surgery. *Ann R Coll Surg Engl.* 1977;59:284.
80. Stewart BT, Woods RJ, Collopy BT, et al. Early feeding after elective open colorectal resections: a prospective randomized trial. *Aust N Z J Surg.* 1998;68:125.
81. Asao T, Kuwano H, Nakamura J, et al. Gum chewing enhances early recovery from postoperative ileus after laparoscopic colectomy. *J Am Coll Surg.* 2002;195:30.
82. Kelley SR, Wolff BG, Lovely JK, Larson DW. Fast-track pathway for minimally invasive colorectal surgery with and without alvimopan (Entereg)(TM): which is more cost-effective? *Am Surg.* 2013;79(6):630-633.
83. Wang S, Shah N, Philip J, et al. Role of alvimopan (entereg) in gastrointestinal recovery and hospital length of stay after bowel resection. *P T.* 2012;37(9):518-525.
84. Elsner JL, Smith JM, Ensor CR. Intravenous neostigmine for postoperative acute colonic pseudo-obstruction. *Ann Pharmacother.* 2012;46(3):430-435.
85. Tang CL, Seow-Choen F, Fook-Chong S, et al. Bioresorbable adhesion barrier facilitates early closure of the defunctioning ileostomy after rectal excision: a prospective, randomized trial. *Dis Colon Rectum.* 2003;46:1200.
86. Beck DE, Cohen Z, Fleshman JW, et al. A prospective, randomized, multicenter, controlled study of the safety of

- Septrafilm adhesion barrier in abdominopelvic surgery of the intestine. *Dis Colon Rectum*. 2003;46:1310.
87. Smoot RL, Gostout CJ, Rajan E, et al. Is early colonoscopy after admission for acute diverticular bleeding needed? *Am J Gastroenterol*. 2003;98:1996.
 88. Sorbi D, Gostout CJ, Peura D, et al. An assessment of the management of acute bleeding varices: a multicenter prospective member-based study. *Am J Gastroenterol*. 2003;98:2424.
 89. Domschke W, Lederer P, Lux G. The value of emergency endoscopy in upper gastrointestinal bleeding: review and analysis of 2014 cases. *Endoscopy*. 1983;15:126.
 90. Cash BD. Evidence-based medicine as it applies to acid suppression in the hospitalized patient. *Crit Care Med*. 2002;30:S373.
 91. Lidwig K, Bernhardt J, Steffen H, et al. Contribution of intraoperative cholangiography to incidence and outcome of common bile duct injuries during laparoscopic cholecystectomy. *Surg Endosc*. 2002;16:1098.
 92. Flum DR, Dellinger EP, Cheadle A, et al. Intraoperative cholangiography and risk of common bile duct injury during cholecystectomy. *JAMA*. 2003;289:1639.
 93. Yoon YH, Hsiao-ye Y, Grant BF, et al. Liver cirrhosis mortality in the United States, 1970-98. Surveillance Report No. 57. Rockville, MD: National Institute on Alcohol Abuse and Alcoholism; December 2001.
 94. Solomon R, Werner C, Mann D, et al. Effects of saline, mannitol, and furosemide to prevent acute decreases in renal function induced by radiocontrast agents. *N Engl J Med*. 1994;331:1416.
 95. Stevens MA, McCullough PA, Tobin KJ, et al. A prospective randomized trial of prevention measures in patients at high risk for contrast nephropathy: results of the P.R.I.N.C.E. study. Prevention of Radiocontrast Induced Nephropathy Clinical Evaluation. *J Am Coll Cardiol*. 1999;33:403.
 96. Birck R, Krzossok S, Markowitz F, et al. Acetylcysteine for prevention of contrast nephropathy: meta-analysis. *Lancet*. 2003;362:598.
 97. Baker CS, Wragg A, Kumar S, et al. A rapid protocol for the prevention of contrast-induced renal dysfunction: the RAPPID study. *J Am Coll Cardiol*. 2003;41:2114.
 98. Laffan M, O'Connell NM, Perry DJ, et al. Analysis and results of the recombinant factor VIIa extended-use registry. *Blood Coagul Fibrinolysis*. 2003;14:S35.
 99. Hedner U. Dosing with recombinant factor VIIa based on current evidence. *Semin Hematol*. 2004;41:35.
 100. Midathada MV, Mehta P, Waner M, et al. Recombinant factor VIIa in the treatment of bleeding. *Am J Clin Pathol*. 2004;121:124.
 101. Dutton RP, Parr M, Tortella BJ, et al. Recombinant activated factor VII safety in trauma patients: results from the CONTROL trial. *J Trauma*. 2011;71(1):12-19.
 102. Bloomfield GL, Dalton JM, Sugerma HJ, et al. Treatment of increasing intracranial pressure secondary to the acute abdominal compartment syndrome in a patient with combined abdominal and head trauma. *J Trauma*. 1995;39:1168.
 103. Kron I, Harman PK, Nolan SP. The measurement of intra-abdominal pressure as a criterion for abdominal re-exploration. *Ann Surg*. 1984;199:28.
 104. Ivatury RR, Porter JM, Simon RJ, et al. Intra-abdominal hypertension after life-threatening penetrating abdominal trauma: prophylaxis, incidence, and clinical relevance to gastric mucosal pH and abdominal compartment syndrome. *J Trauma*. 1998;44:1016.
 105. Ivatury RR, Sugerma HJ, Peitzman AB. Abdominal compartment syndrome: recognition and management. *Adv Surg*. 2001;35:251.
 106. Saggi BH, Sugerma HJ, Ivatury RR, et al. Abdominal compartment syndrome. *J Trauma*. 1998;45:597.
 107. Anglen J, Apostoles PS, Christensen G, et al. Removal of surface bacteria by irrigation. *J Orthop Res*. 1966;14:251.
 108. Lewis DA, Leaper DJ, Speller DC. Prevention of bacterial colonization of wounds at operation: comparison of iodine-impregnated ("Ioban") drapes with conventional methods. *J Hosp Infect*. 1984;5:431.
 109. O'Rourke E, Runyan D, O'Leary J, et al. Contaminated iodophor in the operating room. *Am J Infect Control*. 2003;31:255.
 110. Ostrander RV, Brage ME, Botte MJ. Bacterial skin contamination after surgical preparation in foot and ankle surgery. *Clin Orthop*. 2003;406:246.
 111. Ghogawala Z, Furtado D. In vitro and in vivo bactericidal activities of 10%, 2.5%, and 1% povidone-iodine solution. *Am J Hosp Pharm*. 1990;47:1562.
 112. Anderson RL, Vess RW, Carr JH. Investigations of intrinsic *Pseudomonas cepacia* contamination in commercially manufactured povidone-iodine. *Infect Control Hosp Epidemiol*. 1991;12:297.
 113. Birnbach DJ, Meadows W, Stein DJ, et al. Comparison of povidone iodine and DuraPrep, an iodophor-in-isopropyl alcohol solution, for skin disinfection prior to epidural catheter insertion in parturients. *Anesthesiology*. 2003;98:164.
 114. Moen MD, Noone MG, Kirson I. Povidone-iodine spray technique versus traditional scrub-paint technique for preoperative abdominal wall preparation. *Am J Obstet Gynecol*. 2002;187:1434; discussion 1436.
 115. Strand CL, Wajsbort RR, Sturmman K. Effect of iodophor vs iodine tincture skin preparation on blood culture contamination rate. *JAMA*. 1993;269:1004.
 116. Paterson DL, Ko WC, Von Gottberg A, et al. International prospective study of *Klebsiella pneumoniae* bacteremia: implications of extended-spectrum beta-lactamase production in nosocomial infections. *Ann Intern Med*. 2004;140:26.
 117. Wittmann DH, Schein M. Let us shorten antibiotic prophylaxis and therapy in surgery. *Am J Surg*. 1966;172:26S.
 118. Dellinger EP. Duration of antibiotic treatment in surgical infections of the abdomen. Undesired effects of antibiotics and future studies. *Eur J Surg Suppl*. 1996;576:29; discussion 31.
 119. Fry DE. Basic aspects of and general problems in surgical infections. *Surg Infect (Larchmt)*. 2001;2(Suppl 1):S3.
 120. Barie PS. Modern surgical antibiotic prophylaxis and therapy—less is more. *Surg Infect (Larchmt)*. 2000;1:23.
 121. Grobmyer SR, Graham D, Brennan MF, et al. High-pressure gradients generated by closed-suction surgical drainage systems. *Surg Infect (Larchmt)*. 2002;3:245.
 122. Power DA, Duggan J, Brady HR. Renal-dose (low-dose) dopamine for the treatment of sepsis-related and other forms of acute renal failure: ineffective and probably dangerous. *Clin Exp Pharmacol Physiol Suppl*. 1999;26:S23.
 123. Vincent JL, Abraham E, Annane D, et al. Reducing mortality in sepsis: new directions. *Crit Care*. 2002;6(Suppl 3):S1.
 124. Malay MB, Ashton RC Jr., Landry DW, et al. Low-dose vasopressin in the treatment of vasodilatory septic shock. *J Trauma*. 1999;47:699; discussion 703.
 125. Annane D, Sebille V, Charpentier C, et al. Effect of treatment with low doses of hydrocortisone and fludrocortisone on mortality in patients with septic shock. *JAMA*. 2002;288:862.
 126. Dhainaut JF, Laterre PF, LaRosa SP, et al. The clinical evaluation committee in a large multicenter phase 3 trial of drotrecogin alfa (activated) in patients with severe sepsis (PROWESS): role, methodology, and results. *Crit Care Med*. 2003;31:2291; comment 2405.
 127. Betancourt M, McKinnon PS, Massanari RM, et al. An evaluation of the cost effectiveness of drotrecogin alfa (activated) relative to the number of organ system failures. *Pharmacoeconomics*. 2003;21:1331.

128. Van den Berghe G, Wouters P, Weekers F, et al. Intensive insulin therapy in the critically ill patients. *N Engl J Med.* 2001;345:1359.
129. Finney SJ, Zekveld C, Elia A, et al. Glucose control and mortality in critically ill patients. *JAMA.* 2003;290:2041.
130. Furnary AP, Gao G, Grunkemeier GL, et al. Continuous insulin infusion reduces mortality in patients with diabetes undergoing coronary artery bypass grafting. *J Thorac Cardiovasc Surg.* 2003;125:1007.
131. NICE-SUGAR Study Investigators, Finfer S, Chittock DR, et al. Intensive versus conventional glucose control in critically ill patients. *N Engl J Med.* 2009;360(13):1283-1297.
132. COITSS Study Investigators, Annane D, Cariou A, et al. Corticosteroid treatment and intensive insulin therapy for septic shock in adults: a randomized controlled trial. *JAMA.* 2010;303(4):341-348.
133. Saberi F, Heyland D, Lam M, et al. Prevalence, incidence, and clinical resolution of insulin resistance in critically ill patients: an observational study. *JPEN J Parenter Enteral Nutr.* 2008;32(3):227-235.
134. Arabi YM, Dabbagh OC, Tamim HM, et al. Intensive versus conventional insulin therapy: a randomized controlled trial in medical and surgical critically ill patients. *Crit Care Med.* 2008;36(12):3190-3197.
135. La Rochelle GE Jr., La Rochelle AG, Ratner RE, et al. Recovery of the hypothalamic-pituitary-adrenal axis in patients with rheumatic diseases receiving low-dose prednisone. *Am J Med.* 1993;95:258.
136. Bromberg JS, Alfrey EJ, Barker CF, et al. Adrenal suppression and steroid supplementation in renal transplant recipients. *Transplantation.* 1991;51:385.
137. Freidman RJ, Schiff CF, Bromberg JS. Use of supplemental steroids in patients having orthopaedic operations. *J Bone Joint Surg.* 1995;77:1801.
138. Kempainen RR, Brunette DD. The evaluation and management of accidental hypothermia. *Respir Care.* 2004;49:192.
139. Niven DJ, Stelfox HT, Léger C, et al. Assessment of the safety and feasibility of administering antipyretic therapy in critically ill adults: a pilot randomized clinical trial. *J Crit Care.* 2013;28(3):296-302.
140. Schortgen F, Clabault K, Katsahian S, et al. Fever control using external cooling in septic shock: a randomized controlled trial. *Am J Respir Crit Care Med.* 2012;185(10):1088-1095.
141. Hoedemaekers CW, Ezzahti M, Gerritsen A, et al. Comparison of cooling methods to induce and maintain normo- and hypothermia in intensive care unit patients: a prospective intervention study. *Crit Care (London).* 2007;11(4):R91.
142. O'Donnell J, Axelrod P, Fisher C, et al. Use and effectiveness of hypothermia blankets for febrile patients in the intensive care unit. *Clin Infect Dis.* 1997;24(6):1208-1213.
143. Adelson PD, Wisniewski SR, Beca J, et al. Comparison of hypothermia and normothermia after severe traumatic brain injury in children (Cool Kids): a phase 3, randomised controlled trial. *Lancet Neurol.* 2013;12(6):546-553.
144. Georgiou AP, Manara AR. Role of therapeutic hypothermia in improving outcome after traumatic brain injury: a systematic review. *Br J Anaesth.* 2013;110(3):357-367.
145. Peterson K, Carson S, Carney N. Hypothermia treatment for traumatic brain injury: a systematic review and meta-analysis. *J Neurotrauma.* 2008;25(1):62-71.
146. Schulman CI, Namias N, Doherty J, et al. The effect of antipyretic therapy upon outcomes in critically ill patients: a randomized, prospective study. *Surg Infect.* 2005;6(4):369-375.
147. O'Donnell J, Axelrod P, Fisher C, et al. Use and effectiveness of hypothermia blankets for febrile patients in the intensive care unit. *Clin Infect Dis.* 1977;24:1208.

This page intentionally left blank

13 chapter

Physiologic Monitoring of the Surgical Patient

Louis H. Alarcon and Mitchell P. Fink

Introduction	399	Measurement of Cardiac Output by Thermodilution / 403	Urine Output / 410	
Arterial Blood Pressure	400	Mixed Venous Oximetry / 404	Bladder Pressure / 411	
Noninvasive Measurement of Arterial Blood Pressure / 400		Effect of Pulmonary Artery Catheterization on Outcome / 405	Neurologic Monitoring	411
Invasive Monitoring of Arterial Blood Pressure / 401		Minimally Invasive Alternatives to the Pulmonary Artery Catheter / 407	Intracranial Pressure / 411	Electroencephalogram and Evoked Potentials / 411
Electrocardiographic Monitoring	401	Respiratory Monitoring	Transcranial Doppler	
Cardiac Output and Related Parameters	402	Arterial Blood Gases / 409	Ultrasonography / 411	
Determinants of Cardiac Performance / 402		Determinants of Oxygen Delivery / 409	Jugular Venous Oximetry / 412	
Placement of the Pulmonary Artery Catheter / 402		Peak and Plateau Airway Pressure / 409	Transcranial Near-Infrared Spectroscopy / 412	
Hemodynamic Measurements / 403		Pulse Oximetry / 410	Brain Tissue Oxygen Tension / 412	
		Capnometry / 410	Conclusions	412
		Renal Monitoring		

INTRODUCTION

The Latin verb *monere*, which means “to warn, or advise” is the origin for the English word *monitor*. In modern medical practice, patients undergo monitoring to detect pathologic variations in physiologic parameters, providing advanced warning of impending deterioration in the status of one or more organ systems. The intended goal of this endeavor is to allow the clinician to take appropriate actions in a timely fashion to prevent or ameliorate the physiologic derangement. Furthermore, physiologic monitoring is used not only to warn, but also to titrate therapeutic interventions, such as fluid resuscitation or the infusion of vasoactive or inotropic drugs. The intensive care unit (ICU) and operating room are the two locations where the most advanced monitoring capabilities routinely are employed in the care of critically ill patients.

In the broadest sense, physiologic monitoring encompasses a spectrum of endeavors, ranging in complexity from the routine and intermittent measurement of the classic vital signs (i.e., temperature, heart rate, arterial blood pressure, and respiratory rate) to the continuous recording of the oxidation state of cytochrome oxidase, the terminal element in the mitochondrial electron transport chain. The ability to assess clinically relevant parameters of tissue and organ status and employ this knowledge to improve patient outcomes represents the “holy grail” of critical care medicine. Unfortunately, consensus often is lacking regarding the most appropriate parameters to monitor in order to achieve this goal. Furthermore, making an inappropriate therapeutic decision

due to inaccurate physiologic data or misinterpretation of good data can lead to a worse outcome than having no data at all.

1► Of the highest importance is the integration of physiologic data obtained from monitoring into a coherent and evidenced-based treatment plan. Current technologies available to assist the clinician in this endeavor are summarized in this chapter. Also presented is a brief look at emerging techniques that may soon enter into clinical practice.

In essence, the goal of hemodynamic monitoring is to ensure that the flow of oxygenated blood through the microcirculation is sufficient to support aerobic metabolism at the cellular level. In general, mammalian cells cannot store oxygen for subsequent use in oxidative metabolism, although a relatively tiny amount is stored in muscle tissue as oxidized myoglobin. Thus, aerobic synthesis of adenosine triphosphate (ATP), the energy “currency” of cells, requires the continuous delivery of oxygen by diffusion from hemoglobin in red blood cells to the oxidative machinery within mitochondria. Delivery of oxygen to mitochondria may be insufficient for several reasons. For example, cardiac output, hemoglobin concentration of blood, or the oxygen content of arterial blood each can be inadequate for independent reasons. Alternatively, despite adequate cardiac output, perfusion of capillary networks can be impaired as a consequence of dysregulation of arteriolar tone, microvascular thrombosis, or obstruction of nutritive vessels by sequestered leukocytes or platelets. Hemodynamic monitoring that does not take into account all of these factors will portray an incomplete and perhaps misleading picture of cellular physiology.

Key Points

1► The delivery of modern critical care is predicated on the ability to monitor a large number of physiologic variables and formulate evidenced-based therapeutic strategies to manage these variables. Technological advances in monitoring have at least a theoretical risk of exceeding our ability to understand the clinical implications of the derived information. This could result in the use of monitoring data to make inappropriate clinical decisions. Therefore, the implementation of any new monitoring technology must take into account the relevance and accuracy of the data obtained, the risks to the patient, as

well as the evidence supporting any intervention directed at correcting the detected abnormality.

2► The routine use of invasive monitoring devices, specifically the pulmonary artery catheter, must be questioned in light of the available evidence which does not demonstrate a clear benefit to its widespread use in various populations of critically ill patients. The future of physiologic monitoring will be dominated by the application of noninvasive and highly accurate devices which guide evidenced-based therapy.

Under normal conditions when the supply of oxygen is plentiful, aerobic metabolism is determined by factors other than the availability of oxygen. These factors include the hormonal milieu and mechanical workload of contractile tissues. However, in pathologic circumstances when oxygen availability is inadequate, oxygen utilization (VO_2) becomes dependent upon oxygen delivery (DO_2). The relationship of VO_2 to DO_2 over a broad range of DO_2 values is commonly represented as two intersecting straight lines. In the region of higher DO_2 values, the slope of the line is approximately zero, indicating that VO_2 is largely independent of DO_2 . In contrast, in the region of low DO_2 values, the slope of the line is nonzero and positive, indicating that VO_2 is supply-dependent. The region where the two lines intersect is called *the point of critical oxygen delivery* (DO_{2crit}), and represents the transition from supply-independent to supply-dependent oxygen uptake. Below a critical threshold of oxygen delivery, increased oxygen extraction cannot compensate for the delivery deficit; hence, oxygen consumption begins to decrease. The slope of the supply-dependent region of the plot reflects the maximal oxygen extraction capability of the vascular bed being evaluated.

The subsequent sections will describe the techniques and utility of monitoring various physiologic parameters.

ARTERIAL BLOOD PRESSURE

The pressure exerted by blood in the systemic arterial system, commonly referred to as “*blood pressure*,” is a cardinal parameter measured as part of the hemodynamic monitoring of patients. Extremes in blood pressure are either intrinsically deleterious or are indicative of a serious perturbation in normal physiology. Arterial blood pressure is a complex function of both cardiac output and vascular input impedance. Thus, inexperienced clinicians may assume that the presence of a normal blood pressure is evidence that cardiac output and tissue perfusion are adequate. This assumption frequently is incorrect and is the reason why some critically ill patients may benefit from forms of hemodynamic monitoring in addition to measurement of arterial pressure.

Blood pressure can be determined directly by measuring the pressure within the arterial lumen or indirectly using a cuff around an extremity. When the equipment is properly set up and calibrated, direct intra-arterial monitoring of blood pressure provides accurate and continuous data. Additionally, intra-arterial catheters provide a convenient way to obtain samples of blood for measurements of arterial blood gases and other laboratory

studies. Despite these advantages, intra-arterial catheters are invasive devices and occasionally are associated with serious complications.

Noninvasive Measurement of Arterial Blood Pressure

Both manual and automated means for the noninvasive determination of blood pressure use an inflatable sphygmomanometer cuff to increase pressure around an extremity, and a means for detecting the presence or absence of arterial pulsations. Several methods exist for this purpose. The time-honored approach is the auscultation of the Korotkoff sounds, which are heard over an artery distal to the cuff as the cuff is deflated from a pressure higher than systolic pressure to one less than diastolic pressure. *Systolic pressure* is defined as the pressure in the cuff when tapping sounds are first audible. *Diastolic pressure* is the pressure in the cuff when audible pulsations first disappear.

Another means for pulse detection when measuring blood pressure noninvasively depends upon the detection of oscillations in the pressure within the bladder of the cuff. This approach is simple, and unlike auscultation, can be performed even in a noisy environment (e.g., a busy emergency room). Unfortunately, this approach is neither accurate nor reliable. Other methods, however, can be used to reliably detect the reappearance of a pulse distal to the cuff and thereby estimate systolic blood pressure. Two excellent and widely available approaches for pulse detection are use of a Doppler stethoscope (reappearance of the pulse produces an audible amplified signal) or a pulse oximeter (reappearance of the pulse is indicated by flashing of a light-emitting diode).

A number of automated devices are capable of repetitively measuring blood pressure noninvasively. Some of these devices measure pressure oscillations in the inflatable bladder encircling the extremity to detect arterial pulsations as pressure in the cuff is gradually lowered from greater than systolic to less than diastolic pressure. Other automated noninvasive devices use a piezoelectric crystal positioned over the brachial artery as a pulse detector. The accuracy of these devices is variable, and often dependent on the size mismatch between the arm circumference and the cuff size.¹ If the cuff is too narrow (relative to the extremity), the measured pressure will be artifactually elevated. Therefore, the width of the cuff should be approximately 40% of its circumference.

Another noninvasive approach for measuring blood pressure relies on a technique called *photoplethysmography*. This

method is capable of providing continuous information, since systolic and diastolic blood pressures are recorded on a beat-to-beat basis. Photoplethysmography uses the transmission of infrared light to estimate the amount of hemoglobin (directly related to the volume of blood) in a finger placed under a servo-controlled inflatable cuff. A feedback loop controlled by a microprocessor continually adjusts the pressure in the cuff to maintain the blood volume of the finger constant. Under these conditions, the pressure in the cuff reflects the pressure in the digital artery. The measurements obtained using photoplethysmography generally agree closely with those obtained by invasive monitoring of blood pressure.² However, these readings may be less accurate in patients with hypotension or hypothermia.

Invasive Monitoring of Arterial Blood Pressure

Direct and continuous monitoring of arterial pressure in critically ill patients may be performed by using fluid-filled tubing to connect an intra-arterial catheter to an external strain-gauge transducer. The signal generated by the transducer is electronically amplified and displayed as a continuous waveform by an oscilloscope. Digital values for systolic and diastolic pressure also are displayed. Mean pressure, calculated by electronically averaging the amplitude of the pressure waveform, also can be displayed. The fidelity of the catheter-tubing-transducer system is determined by numerous factors, including the compliance of the tubing, the surface area of the transducer diaphragm, and the compliance of the diaphragm. If the system is underdamped, then the inertia of the system, which is a function of the mass of the fluid in the tubing and the mass of the diaphragm, causes overshoot of the points of maximum positive and negative displacement of the diaphragm during systole and diastole, respectively. Thus, in an underdamped system, systolic pressure will be overestimated and diastolic pressure will be underestimated. In an overdamped system, displacement of the diaphragm fails to track the rapidly changing pressure waveform, and systolic pressure will be underestimated and diastolic pressure will be overestimated. It is important to note that even in an underdamped or over-damped system, mean pressure will be accurately recorded, provided the system has been properly calibrated. For these reasons, when using direct measurement of intra-arterial pressure to monitor patients, clinicians should make clinical decisions based primarily on the measured mean arterial blood pressure.

The radial artery at the wrist is the site most commonly used for intra-arterial pressure monitoring. Other sites include the femoral and axillary artery. It is important to recognize, however, that measured arterial pressure is determined in part by the site where the pressure is monitored. Central (i.e., aortic) and peripheral (e.g., radial artery) pressures typically are different as a result of the impedance and inductance of the arterial tree. Systolic pressures typically are higher and diastolic pressures are lower in the periphery, whereas mean pressure is approximately the same in the aorta and more distal sites.

Distal ischemia is an uncommon complication of intra-arterial catheterization. The incidence of thrombosis is increased when larger-caliber catheters are employed and when catheters are left in place for an extended period of time. The incidence of thrombosis can be minimized by using a 20-gauge (or smaller) catheter in the radial artery and removing the catheter as soon as feasible. The risk of distal ischemic injury can be reduced by ensuring that adequate collateral flow is present prior to

catheter insertion. At the wrist, adequate collateral flow can be documented by performing a modified version of the Allen test, wherein the artery to be cannulated is digitally compressed while using a Doppler stethoscope to listen for perfusion in the palmar arch vessels.

Another potential complication of intra-arterial monitoring is retrograde embolization of air bubbles or thrombi into the intracranial circulation. In order to minimize this risk, care should be taken to avoid flushing arterial lines when air is present in the system, and only small volumes of fluid (less than 5 mL) should be employed for this purpose. Catheter-related infections can occur with any intravascular monitoring device. However, catheter-related bloodstream infection is a relatively uncommon complication of intra-arterial lines used for monitoring, occurring in 0.4% to 0.7% of catheterizations.³ The incidence increases with longer duration of arterial catheterization.

ELECTROCARDIOGRAPHIC MONITORING

The electrocardiogram (ECG) records the electrical activity associated with cardiac contraction by detecting voltages on the body surface. A standard 3-lead ECG is obtained by placing electrodes that correspond to the left arm (LA), right arm (RA), and left leg (LL). The limb leads are defined as lead I (LA-RA), lead II (LL-RA), and lead III (LL-LA). The ECG waveforms can be continuously displayed on a monitor, and the devices can be set to sound an alarm if an abnormality of rate or rhythm is detected. Continuous ECG monitoring is widely available and applied to critically ill and perioperative patients. Monitoring of the ECG waveform is essential in patients with acute coronary syndromes or blunt myocardial injury, because dysrhythmias are the most common lethal complication. In patients with shock or sepsis, dysrhythmias can occur as a consequence of inadequate myocardial oxygen delivery or as a complication of vasoactive or inotropic drugs used to support blood pressure and cardiac output. Dysrhythmias can be detected by continuously monitoring the ECG tracing, and timely intervention may prevent serious complications. With appropriate computing hardware and software, continuous ST-segment analysis also can be performed to detect ischemia or infarction.

Additional information can be obtained from a 12-lead ECG, which is essential for patients with potential myocardial ischemia or to rule out cardiac complications in other acutely ill patients. Continuous monitoring of the 12-lead ECG is now available and is proving to be beneficial in certain patient populations. In a study of 185 vascular surgical patients, continuous 12-lead ECG monitoring was able to detect transient myocardial ischemic episodes in 20.5% of the patients.⁴ This study demonstrated that the precordial lead V₄, which is not routinely monitored on a standard 3-lead ECG, is the most sensitive for detecting perioperative ischemia and infarction. To detect 95% of the ischemic episodes, two or more precordial leads were necessary. Thus, continuous 12-lead ECG monitoring may provide greater sensitivity than 3-lead ECG for the detection of perioperative myocardial ischemia, and may become standard for monitoring high-risk surgical patients.

Currently, there is considerable interest in using computerized approaches to analyze ECG waveforms and patterns to uncover hidden information that can be used to predict sudden cardiac death or the development of serious dysrhythmias. ECG patterns of interest include repetitive changes in the morphology of the T-wave [T-wave alternans (TWA)]⁵ and heart rate variability.⁶

Integrated monitoring systems employ software that integrates vital signs to produce a single-parameter index which allows early detection of physiologic perturbations. The input variables include noninvasive measurements of heart rate, respiratory rate, blood pressure, blood oxygen saturation via pulse oximetry (SpO_2), and temperature. The software uses sophisticated algorithms refined in an iterative fashion to develop a probabilistic model of normality, previously developed from a representative sample patient training set. Variance from these data set are used to evaluate the probability that the patient-derived vital signs are within the normal range. An abnormal index can occur while no single vital sign parameter is outside the range of normal if their combined patterns are consistent with known instability patterns. Employing such an integrated monitoring system in step-down unit patients has been shown to be a sensitive method to detect early physiologic abnormalities that may precede hemodynamic instability.⁷

CARDIAC OUTPUT AND RELATED PARAMETERS

Bedside catheterization of the pulmonary artery was introduced into clinical practice in the 1970s. Although the pulmonary artery catheter (PAC) initially was used primarily to manage patients with cardiogenic shock and other acute cardiac diseases, indications for this form of invasive hemodynamic monitoring gradually expanded to encompass a wide variety of clinical conditions. Clearly, many clinicians believe that information valuable for the management of critically ill patients is afforded by having a PAC in place. However, unambiguous data in support of this view are scarce, and several studies suggest that bedside PAC may not benefit most critically ill patients, and in fact lead to some serious complications (see next).

Determinants of Cardiac Performance

Preload. Starling's law of the heart states that the force of muscle contraction depends on the initial length of the cardiac fibers. Using terminology that derives from early experiments using isolated cardiac muscle preparations, preload is the stretch of ventricular myocardial tissue just prior to the next contraction. Thus, cardiac preload is determined by end-diastolic volume (EDV). For the right ventricle, central venous pressure (CVP) approximates right ventricular end-diastolic pressure (EDP). For the left ventricle, pulmonary artery occlusion pressure (PAOP), which is measured by transiently inflating a balloon at the end of a pressure monitoring catheter positioned in a small branch of the pulmonary artery, approximates left ventricular end-diastolic pressure. The presence of atrioventricular valvular stenosis may alter this relationship.

Clinicians frequently use EDP as a surrogate for EDV, but EDP is determined not only by volume but also by the diastolic compliance of the ventricular chamber. Ventricular compliance is altered by various pathologic conditions and pharmacologic agents. Furthermore, the relationship between EDP and true preload is not linear, but rather is exponential.

Afterload. Afterload is another term derived from *in vitro* experiments using isolated strips of cardiac muscle, and is defined as the force resisting fiber shortening once systole begins. Several factors comprise the *in vivo* correlate of ventricular afterload, including ventricular intracavitary pressure, wall thickness, chamber radius, and chamber geometry. Since these factors are difficult to assess clinically, afterload is commonly approximated by calculating systemic vascular resistance, defined as mean arterial pressure (MAP) divided by cardiac output.

Contractility. Contractility is defined as the inotropic state of the myocardium. Contractility is said to increase when the force of ventricular contraction increases at constant preload and afterload. Clinically, contractility is difficult to quantify, because virtually all of the available measures are dependent to a certain degree on preload and afterload. If pressure-volume loops are constructed for each cardiac cycle, small changes in preload and/or afterload will result in shifts of the point defining the end of systole. These end-systolic points on the pressure vs. volume diagram describe a straight line, known as the *end-systolic pressure-volume line*. A steeper slope of this line indicates greater contractility.

Placement of the Pulmonary Artery Catheter

In its simplest form, the pulmonary artery catheter (PAC) has four channels. One channel terminates in a balloon at the tip of the catheter. The proximal end of this channel is connected to a syringe to permit inflation of the balloon with air (saline should never be used). Prior to insertion of the PAC, the integrity of the balloon should be verified by inflating it. In order to minimize the risk of vascular or ventricular perforation by the relatively inflexible catheter, it also is important to verify that the inflated balloon extends just beyond the tip of the device. A second channel in the catheter contains wires that are connected to a thermistor located near the tip of the catheter. At the proximal end of the PAC, the wires terminate in a fitting that permits connection to appropriate hardware for the calculation of cardiac output using the thermodilution technique (see next). The final two channels are used for pressure monitoring and the injection of the thermal indicator for determinations of cardiac output. One of these channels terminates at the tip of the catheter. The other terminates 20 cm proximal to the tip.

Placement of a PAC requires access to the central venous circulation. Such access can be obtained at a variety of sites, including the antecubital, femoral, jugular, and subclavian veins. Percutaneous placement through either the jugular or subclavian vein generally is preferred. Right internal jugular vein cannulation carries the lowest risk of complications, and the path of the catheter from this site into the right atrium is straight. In the event of inadvertent arterial puncture, local pressure is significantly more effective in controlling bleeding from the carotid artery compared to the subclavian artery. Nevertheless, it is more difficult to keep occlusive dressings in place on the neck than in the subclavian fossa. Furthermore, the anatomic landmarks in the subclavian position are quite constant, even in patients with anasarca or massive obesity; the subclavian vein always is attached to the deep (concave) surface of the clavicle. In contrast, the appropriate landmarks to guide jugular venous cannulation are sometimes difficult to discern in obese or very edematous patients. However, ultrasonic guidance, which should be used routinely, has been shown to facilitate bedside jugular venipuncture.⁸

Cannulation of the vein normally is performed percutaneously, using the Seldinger technique. A small-bore needle is inserted through the skin and subcutaneous tissue into the vein. After documenting return of venous blood, a guidewire with a flexible tip is inserted through the needle into the vein and the needle is withdrawn. A dilator/introducer sheath is passed over the wire, and the wire and the dilator are removed. The proximal terminus of the distal port of the PAC is connected through low-compliance tubing to a strain-gauge transducer, and the tubing-catheter system is flushed with fluid. While constantly

observing the pressure tracing on an oscilloscope, the PAC is advanced with the balloon deflated until respiratory excursions are observed. The balloon is then inflated, and the catheter advanced further (“floated”), while monitoring pressures sequentially in the right atrium and right ventricle en route to the pulmonary artery. The pressure waveforms for the right atrium, right ventricle, and pulmonary artery are each characteristic. The catheter is advanced out into the pulmonary artery until a damped tracing indicative of the “wedged” position is obtained. The balloon is then deflated, taking care to ensure that a normal pulmonary arterial tracing is again observed on the monitor; leaving the balloon inflated can increase the risk of pulmonary infarction or perforation of the pulmonary artery. Unnecessary measurements of the pulmonary artery occlusion pressure are discouraged as rupture of the pulmonary artery may occur.

Hemodynamic Measurements

Even in its simplest embodiment, the PAC is capable of providing clinicians with a remarkable amount of information about the hemodynamic status of patients. Additional information may be obtained if various modifications of the standard PAC are employed. By combining data obtained through use of the PAC with results obtained by other means (i.e., blood hemoglobin concentration and oxyhemoglobin saturation), derived estimates of systemic oxygen transport and utilization can be calculated. Direct and derived parameters obtainable by bedside pulmonary arterial catheterization are summarized in Table 13-1. The equations used to calculate the derived parameters are summarized in Table 13-2. The approximate normal ranges for a number of these hemodynamic parameters (in adults) are shown in Table 13-3.

Table 13-1

Directly Measured and Derived Hemodynamic Data Obtainable by Bedside Pulmonary Artery Catheterization

STANDARD PAC	PAC WITH ADDITIONAL FEATURE(S)	DERIVED PARAMETERS
CVP	S $\bar{v}O_2$ (continuous)	SV (or SVI)
PAP	Q_T or Q_T^* (continuous)	SVR (or SVRI)
PAOP	RVEF	PVR (or PVRI)
S $\bar{v}O_2$ (intermittent)		RVEDV
Q_T or Q_T^* (intermittent)		$\dot{b}O_2$ $\bar{v}O_2$ ER Q_S/Q_T

CVP = mean central venous pressure; $\dot{b}O_2$ = systemic oxygen delivery; ER = systemic oxygen extraction ratio; PAOP = pulmonary artery occlusion (wedge) pressure; PAP = pulmonary artery pressure; PVR = pulmonary vascular resistance; PVRI = pulmonary vascular resistance index; Q_S/Q_T = fractional pulmonary venous admixture (shunt fraction); Q_T = cardiac output; Q_T^* = cardiac output indexed to body surface area (cardiac index); RVEDV = right ventricular end-diastolic volume; RVEF = right ventricular ejection fraction; SV = stroke volume; SVI = stroke volume index; S $\bar{v}O_2$ = fractional mixed venous (pulmonary artery) hemoglobin saturation; SVR = systemic vascular resistance; SVRI = systemic vascular resistance index; $\bar{v}O_2$ = systemic oxygen utilization.

Table 13-2

Formulas for calculation of hemodynamic parameters that can be derived by using data obtained by pulmonary artery catheterization

Q_T^* (L·min⁻¹·m⁻²) = Q_T /BSA, where BSA is body surface area (m²)
 SV (mL) = Q_T /HR, where HR is heart rate (min⁻¹)
 SVR (dyne·sec·cm⁻⁵) = [(MAP – CVP) × 80] / Q_T , where MAP is mean arterial pressure (mm Hg)
 SVRI (dyne·sec·cm⁻⁵·m⁻²) = [(MAP – CVP) × 80] / Q_T^*
 PVR (dyne·sec·cm⁻⁵) = [(PAP – PAOP) × 80] / Q_T , where PAP is mean pulmonary artery pressure
 PVRI (dyne·sec·cm⁻⁵·m⁻²) = [(PAP – PAOP) × 80] / Q_T^*
 RVEDV (mL) = SV/RVEF
 $\dot{b}O_2$ (mL·min⁻¹·m⁻²) = Q_T^* × CaO₂ × 10, where CaO₂ is arterial oxygen content (mL/dL)
 $\bar{v}O_2$ (mL·min⁻¹·m⁻²) = Q_T^* × (CaO₂ – C $\bar{v}O_2$) × 10, where C $\bar{v}O_2$ is mixed venous oxygen content (mL/dL)
 CaO₂ = (1.36 × Hgb × SaO₂) + (0.003 + PaO₂), where Hgb is hemoglobin concentration (g/dL), SaO₂ is fractional arterial hemoglobin saturation, and PaO₂ is the partial pressure of oxygen in arterial blood
 C $\bar{v}O_2$ = (1.36 × Hgb × S $\bar{v}O_2$) + (0.003 + P $\bar{v}O_2$), where P $\bar{v}O_2$ is the partial pressure of oxygen in pulmonary arterial (mixed venous) blood
 Q_S/Q_T = (CCO₂ – CaO₂) / (CCO₂ – C $\bar{v}O_2$), where C $\bar{v}O_2$ (mL/dL) is the content of oxygen in pulmonary end capillary blood
 CCO₂ = (1.36 × Hgb) + (0.003 + PAO₂), where PAO₂ is the alveolar partial pressure of oxygen
 PAO₂ = [FiO₂ × (P_B – PH_{2O})] – PaCO₂/RQ, where FiO₂ is the fractional concentration of inspired oxygen, P_B is the barometric pressure (mm Hg), P_{H_{2O}} is the water vapor pressure (usually 47 mm Hg), PaCO₂ is the partial pressure of carbon dioxide in arterial blood (mm Hg), and RQ is respiratory quotient (usually assumed to be 0.8)

C $\bar{v}O_2$ = central venous oxygen pressure; CVP = mean central venous pressure; $\dot{b}O_2$ = systemic oxygen delivery; PAOP = pulmonary artery occlusion (wedge) pressure; PVR = pulmonary vascular resistance; PVRI = pulmonary vascular resistance index; Q_S/Q_T = fractional pulmonary venous admixture (shunt fraction); Q_T = cardiac output; Q_T^* = cardiac output indexed to body surface area (cardiac index); RVEDV = right ventricular end-diastolic volume; RVEF = right ventricular ejection fraction; SV = stroke volume; SVI = stroke volume index; S $\bar{v}O_2$ = fractional mixed venous (pulmonary artery) hemoglobin saturation; SVR = systemic vascular resistance; SVRI = systemic vascular resistance index; $\bar{v}O_2$ = systemic oxygen utilization.

Measurement of Cardiac Output by Thermodilution

Before the development of the PAC, determining cardiac output (Q_T) at the bedside required careful measurements of oxygen consumption (Fick method) or spectrophotometric determination of indocyanine green dye dilution curves. Measurements of Q_T using the thermodilution technique are simple and reasonably accurate. The measurements can be performed repetitively and the principle is straightforward. If a bolus of an indicator is rapidly and thoroughly mixed with a moving fluid upstream from a detector, then the concentration of the indicator at the detector will increase sharply and then exponentially diminish back

Table 13-3

Approximate normal ranges for selected hemodynamic parameters in adults

PARAMETER	NORMAL RANGE
CVP	0–6 mm Hg
Right ventricular systolic pressure	20–30 mm Hg
Right ventricular diastolic pressure	0–6 mm Hg
PAOP	6–12 mm Hg
Systolic arterial pressure	100–130 mm Hg
Diastolic arterial pressure	60–90 mm Hg
MAP	75–100 mm Hg
Q_T	4–6 L/min
Q_T^*	2.5–3.5 L·min ⁻¹ ·m ⁻²
SV	40–80 mL
SVR	800–1400 dyne·sec·cm ⁻⁵
SVRI	1500–2400 dyne·sec·cm ⁻⁵ ·m ⁻²
PVR	100–150 dyne·sec·cm ⁻⁵
PVRI	200–400 dyne·sec·cm ⁻⁵ ·m ⁻²
Ca _{O₂}	16–22 mL/dL
Cv _{O₂}	~15 mL O ₂ /dL blood
$\dot{V}O_2$	400–660 mL·min ⁻¹ ·m ⁻²
$\bar{V}O_2$	115–165 mL·min ⁻¹ ·m ⁻²

Ca_{O₂} = arterial oxygen content; Cv_{O₂} = central venous oxygen pressure; CVP = mean central venous pressure; $\dot{V}O_2$ = systemic oxygen delivery; MAP = mean arterial pressure; PAOP = pulmonary artery occlusion (wedge) pressure; PVR = pulmonary vascular resistance; PVRI = pulmonary vascular resistance index; Q_T = cardiac output; Q_T^* = cardiac output indexed to body surface area (cardiac index); SV = stroke volume; SVI = stroke volume index; SVR = systemic vascular resistance; SVRI = systemic vascular resistance index; $\bar{V}O_2$ = systemic oxygen utilization.

to zero. The area under the resulting time-concentration curve is a function of the volume of indicator injected and the flow rate of the moving stream of fluid. Larger volumes of indicator result in greater areas under the curve, and faster flow rates of the mixing fluid result in smaller areas under the curve. When Q_T is measured by thermodilution, the indicator is heat and the detector is a temperature-sensing thermistor at the distal end of the PAC. The relationship used for calculating Q_T is called the Stewart-Hamilton equation:

$$Q_T = [V \times (T_B - T_I) \times K_1 \times K_2] / \int T_B(t) dt$$

where V is the volume of the indicator injected, T_B is the temperature of blood (i.e., core body temperature), T_I is the temperature of the indicator, K_1 is a constant that is the function of the specific heats of blood and the indicator, K_2 is an empirically derived constant that accounts for several factors (the dead space volume of the catheter, heat lost from the indicator as it traverses the catheter, and the injection rate of the indicator), and $\int T_B(t) dt$ is the area under the time-temperature curve. In clinical practice, the Stewart-Hamilton equation is solved by a microprocessor.

Determination of cardiac output by the thermodilution method is generally quite accurate, although it tends to systematically overestimate Q_T at low values. Changes in blood temperature and Q_T during the respiratory cycle can influence the measurement. Therefore, results generally should be recorded as the mean of two or three determinations obtained at random points in the respiratory cycle. Using cold injectate widens the difference between T_B and T_I and thereby increases signal-to-noise ratio. Nevertheless, most authorities recommend using room temperature injectate (normal saline or 5% dextrose in water) to minimize errors resulting from warming of the fluid as it transferred from its reservoir to a syringe for injection.

Technologic innovations have been introduced that permit continuous measurement of Q_T by thermodilution. In this approach, thermal transients are not generated by injecting a bolus of a cold indicator, but rather by heating the blood with a tiny filament located on the PAC upstream from the thermistor. By correlating the amount of current supplied to the heating element with the downstream temperature of the blood, it is possible to estimate the average blood flow across the filament and thereby calculate Q_T . Based upon the results of several studies, continuous determinations of Q_T using this approach agree well with data generated by conventional measurements using bolus injections of a cold indicator.⁹ Information is lacking regarding the clinical value of being able to monitor Q_T continuously.

Mixed Venous Oximetry

The Fick equation can be written as $Q_T = \dot{V}O_2 / (Ca_{O_2} - CVO_2)$, where Ca_{O_2} is the content of oxygen in arterial blood and CVO_2 is the content of oxygen in mixed venous blood. The Fick equation can be rearranged as follows: $CVO_2 = Ca_{O_2} - \dot{V}O_2 / Q_T$. If the small contribution of dissolved oxygen to CVO_2 and Ca_{O_2} is ignored, the rearranged equation can be rewritten as $SVO_2 = \bar{S}a_{O_2} - \dot{V}O_2 / (Q_T \times Hgb \times 1.36)$, where SVO_2 is the fractional saturation of hemoglobin in mixed venous blood, $\bar{S}a_{O_2}$ is the fractional saturation of hemoglobin in arterial blood, and Hgb is the concentration of hemoglobin in blood. Thus it can be seen that SVO_2 is a function of $\dot{V}O_2$ (i.e., metabolic rate), Q_T , $\bar{S}a_{O_2}$, and Hgb . Accordingly, subnormal values of SVO_2 can be caused by a decrease in Q_T (due, for example, to heart failure or hypovolemia), a decrease in $\bar{S}a_{O_2}$ (due, for example, to intrinsic pulmonary disease), a decrease in Hgb (i.e., anemia), or an increase in metabolic rate (due, for example, to seizures or fever). With a conventional PAC, measurements of SVO_2 require aspirating a sample of blood from the distal (i.e., pulmonary arterial) port of the catheter and injecting the sample into a blood gas analyzer. Therefore for practical purposes, measurements of SVO_2 can be performed only intermittently.

By adding a fifth channel to the PAC, it has become possible to monitor SVO_2 continuously. The fifth channel contains two fiber-optic bundles, which are used to transmit and receive light of the appropriate wavelengths to permit measurements of hemoglobin saturation by reflectance spectrophotometry. Continuous SVO_2 devices provide measurements of SVO_2 that agree quite closely with those obtained by conventional analyses of blood aspirated from the pulmonary artery. Despite the theoretical value of being able to monitor SVO_2 continuously, data are lacking to show that this capability favorably improves outcomes. In a prospective, observational study of 3265 patients undergoing cardiac surgery with either a standard PAC or a PAC with continuous SVO_2 monitoring, the oximetric catheter was associated with fewer arterial blood gas and thermodilution cardiac output determinations, but no difference in patient

outcome.¹⁰ Since pulmonary artery catheters that permit continuous monitoring of SVO_2 are more expensive than conventional PACs, the routine use of these devices cannot be recommended.

The saturation of oxygen in the right atrium or superior vena cava ($ScVO_2$) correlates closely with SVO_2 over a wide range of conditions,¹¹ although the correlation between $ScVO_2$ and SVO_2 has been questioned under certain conditions (e.g., septic shock).¹² Since measurement of $ScVO_2$ requires placement of a central venous catheter rather than a PAC, it is somewhat less invasive and easier to carry out. By using a central venous catheter equipped to permit fiber-optic monitoring of $ScVO_2$, it may be possible to titrate the resuscitation of patients with shock using a less invasive device than the PAC.^{11,13} The Surviving Sepsis Campaign international guidelines for the management of severe sepsis and septic shock recommends that during the first 6 hours of resuscitation, the goals of initial resuscitation of sepsis-induced hypoperfusion should include all of the following: CVP 8–12 mm Hg, MAP \geq 65 mm Hg, urine output \geq 0.5 mL/kg/h, $ScVO_2$ of 70% or SVO_2 of 65%.¹⁴

Effect of Pulmonary Artery Catheterization on Outcome

Despite initial enthusiasm for using the PAC in the management of critically-ill patients, several studies have failed to show improved outcomes with their use. Connors and colleagues reported results of a major observational study evaluating the

value of PAC in critically ill patients.¹⁵ These researchers compared two groups of patients: those who did and those who did not undergo placement of a PAC during their first 24 hours of ICU care. The investigators recognized that the value of their intended analysis was completely dependent on the robustness of their methodology for case-matching, because sicker patients (i.e., those at greater risk of mortality based upon the severity of their illness) were presumably more likely to undergo pulmonary artery catheterization. Accordingly, the authors used sophisticated statistical methods for generating a cohort of study (i.e., PAC) patients, each one having a paired control matched carefully for severity of illness. Connors et al concluded that placement of a pulmonary artery catheter during the first 24 hours of stay in an ICU is associated with a significant increase in the risk of mortality, even when statistical methods are used to account for severity of illness.¹⁵

A number of prospective, randomized controlled trials of PAC are summarized in Table 13-4. The study by Pearson et al was underpowered with only 226 patients enrolled.¹⁶ In addition, the attending anesthesiologists were permitted to exclude patients from the CVP group at their discretion; thus, randomization was compromised. The study by Tuman et al was large (1094 patients were enrolled), but different anesthesiologists were assigned to the different groups.¹⁷ Furthermore, 39 patients in the CVP group underwent placement of a PAC because of hemodynamic complications. All of the individual

Table 13-4

Summary of randomized, prospective clinical trials comparing pulmonary artery catheter with central venous pressure monitoring

AUTHOR	STUDY POPULATION	GROUPS	OUTCOMES
Pearson et al ¹⁶	“Low risk” patients undergoing cardiac or vascular surgery	CVP catheter (group 1); PAC (group 2); PAC with continuous $S\bar{v}O_2$ readout (group 3)	No differences among groups for mortality or length of ICU stay; significant differences in costs (group 1 < group 2 < group 3)
Tuman et al ¹⁷	Cardiac surgical patients	PAC; CVP	No differences between groups for mortality, length of ICU stay, or significant noncardiac complications
Bender et al ¹⁸	Vascular surgery patients	PAC; CVP	No differences between groups for mortality, length of ICU stay, or length of hospital stay
Valentine et al ¹⁹	Aortic surgery patients	PAC + hemodynamic optimization in ICU night before surgery; CVP	No differences between groups for mortality or length of ICU stay; significantly higher incidence of postoperative complications in PAC group
Sandham et al ²⁰	“High risk” major surgery	PAC; CVP	No differences between groups for mortality, length of ICU stay; increased incidence of pulmonary embolism in PAC group
Harvey S, et al ²¹	Medical and surgical ICU patients	PAC vs. no PAC, with option for alternative CO measuring device in non-PAC group	No differences in hospital mortality between the 2 groups, increased incidence of complications in the PAC group
Binanay, et al ²³	Patients with CHF	PAC vs. no PAC	No difference in hospital mortality between the 2 groups, increased incidence of adverse events in the PAC group
Wheeler, et al ²⁴	Patients with ALI	PAC vs. CVC with a fluid and inotropic management protocol	No difference in ICU or hospital mortality, or incidence of organ failure between the 2 groups; increased incidence of adverse events in the PAC group

ALI = acute lung injury, CHF = congestive heart failure, CO = cardiac output, CVC = central venous catheter, ICU = intensive care unit, PAC = pulmonary artery catheter, = $S\bar{v}O_2$ fractional mixed venous (pulmonary artery) hemoglobin saturation.

single-institution studies of vascular surgery patients were relatively underpowered, and all excluded at least certain categories of patients (e.g., those with a history of recent myocardial infarction).^{18,19}

In the largest randomized controlled trial of the PAC, Sandham et al randomized nearly 2000 American Society of Anesthesiologists (ASAs) class III and IV patients undergoing major thoracic, abdominal, or orthopedic surgery to placement of a PAC or CVP catheter.²⁰ In the patients assigned to receive a PAC, physiologic goal-directed therapy was implemented by protocol. There were no differences in mortality at 30 days, 6 months, or 12 months between the two groups, and ICU length of stay was similar. There was a significantly higher rate of pulmonary emboli in the PAC group (0.9% vs. 0%). This study has been criticized because most of the patients enrolled were not in the highest risk category.

In the “PAC-Man” trial, a multicenter, randomized trial in 65 United Kingdom hospitals, over 1000 ICU patients were managed with or without a PAC.²¹ The specifics of the clinical management were then left up to the treating clinicians. There was no difference in hospital mortality between the 2 groups (with PAC 68% vs. without PAC 66%, $p = 0.39$). However, a 9.5% complication rate was associated with the insertion or use of the PAC, although none of these complications were fatal. Clearly, these were critically ill patients, as noted by the high hospital mortality rates. Supporters of the PAC use cite methodology problems with this study, such as loose inclusion criteria and the lack of a defined treatment protocol.

A meta-analysis of 13 randomized studies of the PAC included over 5000 patients was published in 2005.²² A broad spectrum of critically ill patients was included in these heterogeneous trials, and the hemodynamic goals and treatment strategies varied. While the use of the PAC was associated with an increased use of inotropes and vasodilators, there were no differences in mortality or hospital length of stay between the patients managed with a PAC and those managed without a PAC.

The ESCAPE trial (which was one of the studies included in the previous meta-analysis)²³ evaluated 433 patients with severe or recurrent congestive heart failure (CHF) admitted to the ICU. Patients were randomized to management by clinical assessment and a PAC or clinical assessment without a PAC. The goal in both groups was resolution of CHF, with additional PAC targets of a pulmonary capillary occlusion pressure of 15 mm Hg and a right atrial pressure of 8 mm Hg. There was no formal treatment protocol, but inotropic support was discouraged. Substantial reduction in symptoms, jugular venous pressure, and edema was noted in both groups. There was no significant difference in the primary end point of days alive and out of the hospital during the first 6 months, or hospital mortality (PAC 10% vs. without PAC 9%). Adverse events were more common among patients in the PAC group (21.9% vs. 11.5%; $P = 0.04$).

Finally, the Fluids and Catheters Treatment Trial (FACTT) conducted by the Acute Respiratory Distress Syndrome (ARDS) Clinical Trials Network was published in 2006.²⁴ The risks and benefits of PAC compared with central venous catheters (CVC) were evaluated in 1000 patients with acute lung injury. Patients were randomly assigned to receive either a PAC or a CVC to guide management for 7 days via an explicit protocol. Patients also were randomly assigned to a conservative or liberal fluid strategy in a 2×2 factorial design (outcomes based on the fluid management strategy were published separately). Mortality during the first 60 days was similar in the PAC and CVC

groups (27% and 26%, respectively; $P = 0.69$). The duration of mechanical ventilation and ICU length of stay also were not influenced by the type of catheter used. The type of catheter employed did not affect the incidence of shock, respiratory or renal failure, ventilator settings, or requirement for hemodialysis or vasopressors. There was a 1% rate of crossover from CVC-guided therapy to PAC-guided therapy. The type of catheter used did not affect the administration of fluids or diuretics, and the net fluid balance was similar in the two groups. The PAC group had approximately twice as many catheter-related adverse events (mainly arrhythmias).

Few subjects in critical care medicine have historically generated more emotional responses among experts in the field than the use of the PAC. As these studies demonstrate, it is not possible to show that therapy directed by use of the PAC saves lives when it is evaluated in a large population of patients. Certainly, given the available evidence, routine use of the PAC cannot be justified. Whether selective use of the device in a few relatively uncommon clinical situations is warranted or valuable remains a controversial issue. Consequently, a marked decline in the use of the PAC from 5.66 per 1000 medical admissions in 1993 to 1.99 per 1000 medical admissions in 2004 has been seen.²⁵ Based upon the results and exclusion criteria in these prospective randomized trials, reasonable criteria for perioperative monitoring without use of a PAC are presented in Table 13-5.

One of the reasons for using a PAC to monitor critically ill patients is to optimize cardiac output and systemic oxygen delivery. Defining what constitutes the optimum cardiac output, however, has proven to be difficult. A number of randomized trials evaluating the effect on outcome of goal-directed compared to conventional hemodynamic resuscitation have been published. Some studies provide support for the notion that interventions designed to achieve supraphysiologic goals for DO_2 , VO_2 , and Q_T improve outcome.^{26,27} However, other published studies do not support this view, and a meta-analysis concluded that interventions designed to achieve supraphysiological goals for oxygen transport do not significantly reduce mortality rates in critically ill patients.^{28,29} At this time, supraphysiological resuscitation of patients in shock cannot be endorsed.

There is no simple explanation for the apparent lack of effectiveness of pulmonary artery catheterization, although several concurrent possibilities exist. First, even though bedside pulmonary artery catheterization is quite safe, the procedure

Table 13-5

Suggested criteria for perioperative monitoring without use of a pulmonary artery catheter in patients undergoing cardiac or major vascular surgical procedures

- No anticipated need for suprarenal or supraceliac aortic cross-clamping
- No history of myocardial infarction during 3 months prior to operation
- No history of poorly compensated congestive heart failure
- No history of coronary artery bypass graft surgery during 6 weeks prior to operation
- No history of ongoing symptomatic mitral or aortic valvular heart disease
- No history of ongoing unstable angina pectoris

is associated with a finite incidence of serious complications, including ventricular arrhythmias, catheter-related sepsis, central venous thrombosis, pulmonary arterial perforation, and pulmonary embolism.²⁰ The adverse effects of these complications on outcome may equal or even outweigh any benefits associated with using a PAC to guide therapy. Second, the data generated by the PAC may be inaccurate, leading to inappropriate therapeutic interventions. Third, the measurements, even if accurate, may often be misinterpreted.²⁹ Furthermore, the current state of understanding is primitive when it comes to deciding what is the best management for certain hemodynamic disturbances, particularly those associated with sepsis or septic shock. Taking all of this into consideration, it may be that interventions prompted by measurements obtained with a PAC are actually harmful to patients. As a result, the marginal benefit now available by placing a PAC may be quite small. Less invasive modalities are available that may provide clinically useful hemodynamic information.

It may be true that aggressive hemodynamic resuscitation of patients, guided by various forms of monitoring, is valuable only during certain critical periods, such as the first few hours after presentation with septic shock or during surgery. For example, Rivers and colleagues reported that survival of patients with septic shock is significantly improved when resuscitation in the emergency department is guided by a protocol that seeks to keep ScVO₂ greater than 70%.¹³ Similarly, a study using an ultrasound-based device (see Doppler Ultrasonography below) to assess cardiac filling and SV showed that maximizing SV intraoperatively results in fewer postoperative complications and shorter hospital length of stay.³⁰

Minimally Invasive Alternatives to the Pulmonary Artery Catheter

Because of the cost, risks and questionable benefit associated with bedside pulmonary artery catheterization, there has been interest in the development of practical means for less invasive monitoring of hemodynamic parameters. Several approaches have been developed, which have achieved variable degrees of success. None of these methods render the standard thermodilution technique of the pulmonary artery catheter obsolete. However, these strategies may contribute to improvements in the hemodynamic monitoring of critically ill patients.

Doppler Ultrasonography. When ultrasonic sound waves are reflected by moving erythrocytes in the bloodstream, the frequency of the reflected signal is increased or decreased, depending on whether the cells are moving toward or away from the ultrasonic source. This change in frequency is called the *Doppler shift*, and its magnitude is determined by the velocity of the moving red blood cells. Therefore, measurements of the Doppler shift can be used to calculate red blood cell velocity. With knowledge of both the cross-sectional area of a vessel and the mean red blood cell velocity of the blood flowing through it, one can calculate blood flow rate. If the vessel in question is the aorta, then Q_T can be calculated as:

$$Q_T = HR \times A \times \int V(t)dt$$

where A is the cross-sectional area of the aorta and $\int V(t)dt$ is the red blood cell velocity integrated over the cardiac cycle.

Two approaches have been developed for using Doppler ultrasonography to estimate Q_T. The first approach uses an ultrasonic transducer, which is positioned manually in the suprasternal notch and focused on the root of the aorta.

Aortic cross-sectional area can be estimated using a nomogram, which factors in age, height, and weight, back-calculated if an independent measure of Q_T is available, or by using two-dimensional transthoracic or transesophageal ultrasonography. While this approach is completely noninvasive, it requires a highly-skilled operator in order to obtain meaningful results, and is laborintensive. Moreover, unless Q_T measured using thermodilution is used to back-calculate aortic diameter, accuracy using the suprasternal notch approach is not acceptable. Accordingly, this method is useful only for obtaining very intermittent estimates of Q_T, and has not been widely adopted by clinicians.

A second more promising, albeit more invasive, approach has been introduced. In this method blood flow velocity is continuously monitored in the descending thoracic aorta using a continuous-wave Doppler transducer introduced into the esophagus. The probe is connected to a monitor, which continuously displays the blood flow velocity profile in the descending aorta as well as the calculated Q_T. In order to maximize the accuracy of the device, the probe position must be adjusted to obtain the peak velocity in the aorta. In order to transform blood flow in the descending aorta into Q_T, a correction factor is applied that is based on the assumption that only 70% of the flow at the root of the aorta is still present in the descending thoracic aorta. A meta-analysis of the available data show a good correlation between cardiac output estimates obtained by trans-esophageal Doppler and PAC in critically-ill patients.³¹ The ultrasonic device also calculates a derived parameter termed *flow time corrected* (FTc), which is the systolic flow time in the descending aorta corrected for heart rate. FTc is a function of preload, contractility, and vascular input impedance. Although it is not a pure measure of preload, Doppler-based estimates of SV and FTc have been used successfully to guide volume resuscitation in high-risk surgical patients undergoing major operations.³⁰

Impedance Cardiography. The impedance to flow of alternating electrical current in regions of the body is commonly called *bioimpedance*. In the thorax, changes in the volume and velocity of blood in the thoracic aorta lead to detectable changes in bioimpedance. The first derivative of the oscillating component of thoracic bioimpedance (dZ/dt) is linearly related to aortic blood flow. On the basis of this relationship, empirically derived formulas have been developed to estimate SV, and subsequently Q_T, noninvasively. This methodology is called *impedance cardiography*. The approach is attractive because it is noninvasive, provides a continuous readout of Q_T, and does not require extensive training. Despite these advantages, measurements of Q_T obtained by impedance cardiography are not sufficiently reliable to be used for clinical decision making and have poor correlation with thermodilution.³²

Because of the limitations of bioimpedance devices, a newer approach for processing the impedance signal was developed and commercialized. This approach is based on the recognition that the impedance signal has two components: amplitude and phase. Whereas the amplitude of the thoracic impedance signal is determined by all of the components of the thoracic cavity (bone, blood, muscle and other soft tissues), phase shifts are determined entirely by pulsatile flow. The vast majority of pulsatile flow is related to blood moving within the aorta. Therefore, the “bioreactance” signal correlates closely with aortic flow, and cardiac output determined using this approach agrees closely with cardiac output measured using conventional indicator dilution techniques.³³

Pulse Contour Analysis. Another method for determining cardiac output is an approach called *pulse contour analysis* for estimating SV on a beat-to-beat basis. The mechanical properties of the arterial tree and SV determine the shape of the arterial pulse waveform. The pulse contour method of estimating Q_T uses the arterial pressure waveform as an input for a model of the systemic circulation in order to determine beat-to-beat flow through the circulatory system. The parameters of resistance, compliance, and impedance are initially estimated based on the patient's age and sex, and subsequently can be refined by using a reference standard measurement of Q_T . The reference standard estimation of Q_T is obtained periodically using the indicator dilution approach by injecting the indicator into a central venous catheter and detecting the transient increase in indicator concentration in the blood using an arterial catheter. In one commercially available embodiment of this approach, the lithium ion (Li^+) is the indicator used for the periodic calibrations of the device. The lithium carbonate indicator can be injected into a peripheral vein, and the doses do not exert pharmacologically relevant effects in adult patients. The Li^+ indicator dilution method has shown to be at least as reliable as other thermodilution methods over a broad range of CO in a variety of patients.³³ In another commercially available system, a conventional bolus of cold fluid is used as the indicator for calibration. The thermodilution-based calibration requires central venous catheterization, although the temperature change is detected in a transpulmonary fashion (i.e., in a peripheral artery).

Measurements of Q_T based on pulse contour monitoring using these two approaches are comparable in accuracy to standard PAC thermodilution methods, but are less invasive since transcatheterization is not needed.³⁴ Using on-line pressure waveform analysis, the computerized algorithms can calculate SV, Q_T , systemic vascular resistance, and an estimate of myocardial contractility, (i.e., the rate of rise of the arterial systolic pressure [dP/dT]). The use of pulse contour analysis has been applied using noninvasive photoplethysmographic measurements of arterial pressure. However, the accuracy of this technique has been questioned and its clinical utility remains to be determined.³⁵

One commercially available device, which can be used for estimating cardiac output, does not require external calibration. Instead, the relationship between pulse pressure and stroke volume is determined using a proprietary algorithm that uses biometric data, such as age, gender, and height, as inputs. Although this methodology is gaining fairly wide acceptance in critical care medicine, reported accuracy (in comparison to "gold standard" approaches) is not very good.³³

Partial Carbon Dioxide Rebreathing. Partial carbon dioxide (CO_2) rebreathing uses the Fick principle to estimate Q_T noninvasively. By intermittently altering the dead space within the ventilator circuit via a rebreathing valve, changes in CO_2 production (V_{CO_2}) and end-tidal CO_2 (ETCO_2) are used to determine cardiac output using a modified Fick equation ($Q_T = \Delta V_{\text{CO}_2} / \Delta \text{ETCO}_2$). Commercially available devices use this Fick principle to calculate Q_T using intermittent partial CO_2 rebreathing through a disposable rebreathing loop. These devices consist of a CO_2 sensor based on infrared light absorption, an airflow sensor, and a pulse oximeter. Changes in intrapulmonary shunt and hemodynamic instability impair the accuracy of Q_T estimated by partial CO_2 rebreathing. Continuous in-line pulse oximetry and inspired fraction of inspired O_2 (FiO_2) are used to estimate shunt fraction to correct Q_T .

Some studies of the partial CO_2 rebreathing approach suggest that this technique is not as accurate as thermodilution, the gold standard for measuring Q_T .^{34,36} However, other studies suggest that the partial CO_2 rebreathing method for determination of Q_T compares favorably to measurements made using a PAC in critically ill patients.³⁷

Transesophageal Echocardiography. Transesophageal echocardiography (TEE) has made the transition from operating room to intensive care unit. TEE requires that the patient be sedated and usually intubated for airway protection. Using this powerful technology, global assessments of LV and RV function can be made, including determinations of ventricular volume, EF, and Q_T . Segmental wall motion abnormalities, pericardial effusions, and tamponade can be readily identified with TEE. Doppler techniques allow estimation of atrial filling pressures. The technique is somewhat cumbersome and requires considerable training and skill in order to obtain reliable results. Recently, a TEE probe has been introduced into practice that is small enough in diameter that it can be left in place for as long as 72 hours. While only limited data are currently available with this probe, it seems like it will be a useful cardiac monitoring tool for use in selected, patients with complex problems.

Assessing Preload Responsiveness. Although pulse contour analysis or partial CO_2 rebreathing may be able to provide estimates of SV and Q_T , these approaches alone can offer little or no information about the adequacy of preload. Thus, if Q_T is low, some other means must be employed to estimate preload. Many clinicians assess the adequacy of cardiac preload by determining CVP or PAOP. However, neither CVP nor PAOP correlate well with the true parameter of interest, left ventricular end-diastolic volume (LVEDV).³⁸ Extremely high or low CVP or PAOP results are informative, but readings in a large middle zone (i.e., 5–20 mm Hg) are less useful. Furthermore, changes in CVP or PAOP fail to correlate well with changes in stroke volume.^{37,39} Echocardiography can be used to estimate LVEDV, but this approach is dependent on the skill and training of the individual using it, and isolated measurements of LVEDV fail to predict the hemodynamic response to alterations in preload.⁴⁰

When intrathoracic pressure increases during the application of positive airway pressure in mechanically ventilated patients, venous return decreases, and as a consequence, left ventricular stroke volume (LVS_V) also decreases. Therefore, pulse pressure variation (PPV) during a positive pressure episode can be used to predict the responsiveness of cardiac output to changes in preload.^{39,41} PPV is defined as the difference between the maximal pulse pressure and the minimum pulse pressure divided by the average of these two pressures. This approach has been validated by comparing PPV, CVP, PAOP, and systolic pressure variation as predictors of preload responsiveness in a cohort of critically ill patients. Patients were classified as being "preload responsive" if their cardiac index [$Q_T/\text{Body Surface Area (BSA)}$] increased by at least 15% after rapid infusion of a standard volume of intravenous fluid.⁴² Receiver-operating characteristic (ROC) curves demonstrated that PPV was the best predictor of preload responsiveness. Although atrial arrhythmias can interfere with the usefulness of this technique, PPV remains a useful approach for assessing preload responsiveness in most patients because of its simplicity and reliability.⁴⁰

Near-infrared Spectroscopic Measurement of Tissue Hemoglobin Oxygen Saturation. Near-infrared spectroscopy (NIRS) allows continuous, noninvasive measurement of tissue

hemoglobin oxygen saturation (StO₂) using near-infrared wavelengths of light (700–1000 nm). This technology is based on Beer's law, which states that the transmission of light through a solution with a dissolved solute decreases exponentially as the concentration of the solute increases. In mammalian tissue, three compounds change their absorption pattern when oxygenated: cytochrome aa3, myoglobin, and hemoglobin. Because of the distinct absorption spectra of oxyhemoglobin and deoxyhemoglobin, Beer's law can be used to detect their relative concentrations within tissue. Thus, the relative concentrations of the types of hemoglobin can be determined by measuring the change in light intensity as it passes through the tissue. Since about 20% of blood volume is intra-arterial and the StO₂ measurements are taken without regard to systole or diastole, spectroscopic measurements are primarily indicative of the venous oxyhemoglobin concentration.

NIRS has been evaluated to assess the severity of traumatic shock in animal models and in trauma patients. Studies have shown that peripheral muscle StO₂, as determined by NIRS, is as accurate as other end points of resuscitation (i.e., base deficit, mixed venous oxygen saturation) in a porcine model of hemorrhagic shock.⁴³ Continuously-measured StO₂ has been evaluated in blunt trauma patients as a predictor of the development of multiple organ dysfunction syndrome (MODS) and mortality.⁴⁴ Exactly 383 patients were studied at seven level 1 trauma centers. StO₂ was monitored for 24 hours after admission along with vital signs and other endpoints of resuscitation, such as base deficit (BD). Minimum StO₂ (using a minimum StO₂ ≤ 75% as a cutoff) had a similar sensitivity and specificity in predicting the development of MODS as BD ≥ 6 mEq/L. StO₂ and BD were also comparable in predicting mortality. Thus, NIRS-derived muscle StO₂ measurements perform similarly to BD in identifying poor perfusion and predicting the development of MODS or death after severe torso trauma, yet have the additional advantages of being continuous and noninvasive. Ongoing prospective studies will help determine the clinical utility of continuous monitoring of StO₂ in clinical scenarios such as trauma, hemorrhagic shock, and sepsis.

RESPIRATORY MONITORING

The ability to monitor various parameters of respiratory function is of utmost importance in critically ill patients. Many of these patients require mechanical ventilation. Monitoring of their respiratory physiology is necessary to assess the adequacy of oxygenation and ventilation, guide weaning and liberation from mechanical ventilation, and detect adverse events associated with respiratory failure and mechanical ventilation. These parameters include gas exchange, neuromuscular activity, respiratory mechanics, and patient effort.

Arterial Blood Gases

Blood gas analysis may provide useful information when caring for patients with respiratory failure. However, even in the absence of respiratory failure or the need for mechanical ventilation, blood gas determinations also can be valuable to detect alterations in acid-base balance due to low Q_T, sepsis, renal failure, severe trauma, medication or drug overdose, or altered mental status. Arterial blood can be analyzed for pH, Po₂, Pco₂, HCO₃⁻ concentration and calculated base deficit. When indicated, carboxyhemoglobin and methemoglobin levels

also can be measured. In recent years, efforts have been made to decrease the unnecessary use of arterial blood gas analysis. Serial arterial blood gas determinations are not necessary for routine weaning from mechanical ventilation in the majority of postoperative patients.

Most bedside blood gas analyses still involve removal of an aliquot of blood from the patient, although continuous bedside arterial blood gas determinations are now possible without sampling via an indwelling arterial catheter that contains a biosensor. In studies comparing the accuracy of continuous arterial blood gas and pH monitoring with a conventional laboratory blood gas analyzer, excellent agreement between the two methods has been demonstrated.⁴⁵ Continuous monitoring can reduce the volume of blood loss due to phlebotomy and dramatically decrease the time necessary to obtain blood gas results. Continuous monitoring, however, is expensive and is not widely employed.

Determinants of Oxygen Delivery

The primary goal of the cardiovascular and respiratory systems is to deliver oxygenated blood to the tissues. DO₂ is dependent to a greater degree on the oxygen saturation of hemoglobin (Hgb) in arterial blood (Sao₂) than on the partial pressure of oxygen in arterial blood (Pao₂). DO₂ also is dependent on Q_T and Hgb. Dissolved oxygen in blood, which is proportional to the PaO₂, makes only a negligible contribution to DO₂, as is apparent from the equation:

$$DO_2 = Q_T \times [(Hgb \times Sao_2 \times 1.36) + (Pao_2 \times 0.0031)]$$

Sao₂ in mechanically ventilated patients depends on the mean airway pressure, the fraction of inspired oxygen (Fio₂), and SVO₂. Thus, when Sao₂ is low, the clinician has only a limited number of ways to improve this parameter. The clinician can increase mean airway pressure by increasing positive-end expiratory pressure (PEEP) or inspiratory time. Fio₂ can be increased to a maximum of 1.0 by decreasing the amount of room air mixed with the oxygen supplied to the ventilator. SVO₂ can be increased by increasing Hgb or Q_T or decreasing oxygen utilization (e.g., by administering a muscle relaxant and sedation).

Peak and Plateau Airway Pressure

Airway pressures routinely are monitored in mechanically ventilated patients. The peak airway pressure measured at the end of inspiration (P_{peak}) is a function of the tidal volume, the resistance of the airways, lung/chest wall compliance, and peak inspiratory flow. The airway pressure measured at the end of inspiration when the inhaled volume is held in the lungs by briefly closing the expiratory valve is termed *the plateau airway pressure* (P_{plateau}). As a static parameter, plateau airway pressure is independent of the airway resistance and peak airway flow, and is related to the lung/chest wall compliance and delivered tidal volume. Mechanical ventilators monitor P_{peak} with each breath and can be set to trigger an alarm if the P_{peak} exceeds a predetermined threshold. P_{plateau} is not measured routinely with each delivered tidal volume, but rather is measured intermittently by setting the ventilator to close the exhalation circuit briefly at the end of inspiration and record the airway pressure when airflow is zero.

If both P_{peak} and P_{plateau} are increased (and tidal volume is not excessive), then the underlying problem is a decrease in the compliance in the lung/chest wall unit. Common causes of this problem include pneumothorax, hemothorax, lobar atelectasis, pulmonary edema, pneumonia, acute respiratory distress

syndrome (ARDS), active contraction of the chest wall or diaphragmatic muscles, abdominal distention, and intrinsic PEEP, such as occurs in patients with bronchospasm and insufficient expiratory times. When P_{peak} is increased but P_{plateau} is relatively normal, the primary problem is an increase in airway resistance, such as occurs with bronchospasm, use of a small-caliber endotracheal tube, or kinking or obstruction of the endotracheal tube. A low P_{peak} also should trigger an alarm, as it suggests a discontinuity in the airway circuit involving the patient and the ventilator.

Ventilator-induced lung injury (VILI) is now an established clinical entity of great relevance to the care of critically ill patients. Excessive airway pressure and tidal volume adversely affect pulmonary and possibly systemic responses to critical illness. Subjecting the lung parenchyma to excessive pressure, known as *barotrauma*, can result in parenchymal lung injury, diffuse alveolar damage similar to ARDS, and pneumothorax, and can impair venous return and therefore limit cardiac output. Lung-protective ventilation strategies have been developed to prevent the development of VILI and improve patient outcomes. In a large, multicenter randomized trial of patients with ARDS from a variety of etiologies, limiting plateau airway pressure to less than 30 cm H₂O and tidal volume to less than 6 mL/kg of ideal body weight reduced 28-day mortality by 22% relative to a ventilator strategy that used a tidal volume of 12 mL/kg.⁴⁶ For this reason, monitoring of plateau pressure and using a low tidal volume strategy in patients with ARDS is now the standard of care. Recent data also suggest that a lung-protective ventilation strategy is associated with improved clinical outcomes in ventilated patients without ARDS.⁴⁷

Pulse Oximetry

The pulse oximeter is a microprocessor-based device that integrates oximetry and plethysmography to provide continuous noninvasive monitoring of the oxygen saturation of arterial blood (Sao_2). It is considered one of the most important and useful technologic advances in patient monitoring. Continuous, noninvasive monitoring of arterial oxygen saturation is possible using light-emitting diodes and sensors placed on the skin. Pulse oximetry employs two wavelengths of light (i.e., 660 nm and 940 nm) to analyze the pulsatile component of blood flow between the light source and sensor. Because oxyhemoglobin and deoxyhemoglobin have different absorption spectra, differential absorption of light at these two wavelengths can be used to calculate the fraction of oxygen saturation of hemoglobin. Under normal circumstances, the contributions of carboxyhemoglobin and methemoglobin are minimal. However, if carboxyhemoglobin levels are elevated, the pulse oximeter will incorrectly interpret carboxyhemoglobin as oxyhemoglobin and the arterial saturation displayed will be falsely elevated. When the concentration of methemoglobin is markedly increased, the Sao_2 will be displayed as 85%, regardless of the true arterial saturation.⁴⁸ The accuracy of pulse oximetry begins to decline at Sao_2 values less than 92%, and tends to be unreliable for values less than 85%.⁴⁹

Several studies have assessed the frequency of arterial oxygen desaturation in hospitalized patients and its effect on outcome. Monitoring pulse oximetry in surgical patients is associated with a reduction in unrecognized deterioration, rescue events and transfers to the ICU.⁵⁰ Because of its clinical relevance, ease of use, noninvasive nature, and cost-effectiveness, pulse oximetry has become a routine monitoring strategy in

patients with respiratory disease, intubated patients, and those undergoing surgical intervention under sedation or general anesthesia. Pulse oximetry is especially useful in the titration of Fio_2 and PEEP for patients receiving mechanical ventilation, and during weaning from mechanical ventilation. The widespread use of pulse oximetry has decreased the need for arterial blood gas determinations in critically ill patients.

Capnometry

Capnometry is the measurement of carbon dioxide in the airway throughout the respiratory cycle. Capnometry is most commonly measured by infrared light absorption. CO_2 absorbs infrared light at a peak wavelength of approximately 4.27 μm . Capnometry works by passing infrared light through a sample chamber to a detector on the opposite side. More infrared light passing through the sample chamber (i.e., less CO_2) causes a larger signal in the detector relative to the infrared light passing through a reference cell. Capnometric determination of the partial pressure of CO_2 in end-tidal exhaled gas (PETCO_2) is used as a surrogate for the partial pressure of CO_2 in arterial blood (Paco_2) during mechanical ventilation. In healthy subjects, PETCO_2 is about 1 to 5 mm Hg less than Paco_2 .⁵¹ Thus, PETCO_2 can be used to estimate Paco_2 without the need for blood gas determination. However, changes in PETCO_2 may not correlate with changes in Paco_2 during a number of pathologic conditions (see next).

Capnography allows the confirmation of endotracheal intubation and continuous assessment of ventilation, integrity of the airway, operation of the ventilator, and cardiopulmonary function. Capnometers are configured with either an in-line sensor or a sidestream sensor. The sidestream systems are lighter and easy to use, but the thin tubing that samples the gas from the ventilator circuit can become clogged with secretions or condensed water, preventing accurate measurements. The in-line devices are bulky and heavier, but are less likely to become clogged. Continuous monitoring with capnography has become routine during surgery under general anesthesia and for some intensive care patients. A number of situations can be promptly detected with continuous capnography. A sudden reduction in PETCO_2 suggests either obstruction of the sampling tubing with water or secretions, or a catastrophic event such as loss of the airway, airway disconnection or obstruction, ventilator malfunction, or a marked decrease in Q_T . If the airway is connected and patent and the ventilator is functioning properly, then a sudden decrease in PETCO_2 should prompt efforts to rule out cardiac arrest, massive pulmonary embolism, or cardiogenic shock. PETCO_2 can be persistently low during hyperventilation or with an increase in dead space such as occurs with pulmonary embolization (even in the absence of a change in Q_T). Causes of an increase in PETCO_2 include reduced minute ventilation or increased metabolic rate.

RENAL MONITORING

Urine Output

Bladder catheterization with an indwelling catheter allows the monitoring of urine output, usually recorded hourly by the nursing staff. With a patent Foley catheter, urine output is a gross indicator of renal perfusion. The generally accepted normal urine output is 0.5 mL/kg per hour for adults and 1 to 2 mL/kg per hour for neonates and infants. Oliguria may reflect inadequate renal artery perfusion due to hypotension, hypovolemia, or low Q_T . Low urine flow also can be a sign of intrinsic renal

dysfunction. It is important to recognize that normal urine output does not exclude the possibility of impending renal failure.

Bladder Pressure

The triad of oliguria, elevated peak airway pressures, and elevated intra-abdominal pressure is known as the abdominal compartment syndrome (ACS). This syndrome, first described in patients after repair of ruptured abdominal aortic aneurysm, is associated with interstitial edema of the abdominal organs, resulting in elevated intra-abdominal pressure (IAP). When IAP exceeds venous or capillary pressures, perfusion of the kidneys and other intra-abdominal viscera is impaired. Oliguria is a cardinal sign. While the diagnosis of ACS is a clinical one, measuring IAP is useful to confirm the diagnosis. Ideally, a catheter inserted into the peritoneal cavity could measure IAP to substantiate the diagnosis. In practice, transurethral bladder pressure measurement reflects IAP and is most often used to confirm the presence of ACS. After instilling 50 to 100 mL of sterile saline into the bladder via a Foley catheter, the tubing is connected to a transducing system to measure bladder pressure. Intra-abdominal hypertension is defined as an IAP ≥ 12 mm Hg recorded on three standard measurements conducted 4 to 6 hours apart, while the diagnosis of ACS is the presence of an IAP ≥ 20 mm Hg recorded by three measurements 1 to 6 hours apart.^{52,60} Less commonly, gastric or inferior vena cava pressures can be monitored with appropriate catheters to detect elevated intra-abdominal pressures.

NEUROLOGIC MONITORING

Intracranial Pressure

Because the brain is rigidly confined within the bony skull, cerebral edema or mass lesions increase intracranial pressure (ICP). Monitoring of ICP currently is recommended in patients with severe traumatic brain injury (TBI), defined as a Glasgow Coma Scale (GCS) score less than or equal to 8 with an abnormal CT scan, and in patients with severe TBI and a normal CT scan if two or more of the following are present: age greater than 40 years, unilateral or bilateral motor posturing, or systolic blood pressure less than 90 mm Hg.⁵³ ICP monitoring also is indicated in patients with acute subarachnoid hemorrhage with coma or neurologic deterioration, intracranial hemorrhage with intraventricular blood, ischemic middle cerebral artery stroke, fulminant hepatic failure with coma and cerebral edema on CT scan, and global cerebral ischemia or anoxia with cerebral edema on CT scan. The goal of ICP monitoring is to ensure that cerebral perfusion pressure (CPP) is adequate to support perfusion of the brain. CPP is equal to the difference between MAP and ICP: $CPP = MAP - ICP$.

One type of ICP measuring device, the ventriculostomy catheter, consists of a fluid-filled catheter inserted into a cerebral ventricle and connected to an external pressure transducer. This device permits measurement of ICP, but also allows drainage of cerebrospinal fluid (CSF) as a means to lower ICP and sample CSF for laboratory studies. Other devices locate the pressure transducer within the central nervous system and are used only to monitor ICP. These devices can be placed in the intraventricular, parenchymal, subdural, or epidural spaces. Ventriculostomy catheters are the accepted standard for monitoring ICP in patients with TBI due to their accuracy, ability to drain CSF, and low complication rate. The associated complications include infection (5%), hemorrhage (1.1%), catheter

malfunction or obstruction (6.3%–10.5%), and malposition with injury to cerebral tissue.⁵⁴

The purpose of ICP monitoring is to detect and treat abnormal elevations of ICP that may be detrimental to cerebral perfusion and function. In TBI patients, ICP >20 mm Hg is associated with unfavorable outcomes.⁵⁵ However, few studies have shown that treatment of elevated ICP improves clinical outcomes in human trauma patients. In a randomized, controlled, double-blind trial, Eisenberg and colleagues demonstrated that maintaining ICP less than 25 mm Hg in patients without craniectomy and less than 15 mm Hg in patients with craniectomy is associated with improved outcome.⁵⁶ In patients with low CPP, therapeutic strategies to correct CPP can be directed at increasing MAP, decreasing ICP, or both. While it has been recommended that CPP be maintained between 50 and 70 mm Hg, the evidence to support this recommendation is not overly compelling.⁵⁷ Furthermore, a retrospective cohort study of patients with severe TBI found that ICP/CPP-targeted neuro-intensive care was associated with prolonged mechanical ventilation and increased therapeutic interventions, without evidence for improved outcome in patients who survive beyond 24 hours.⁵⁸

Electroencephalogram and Evoked Potentials

Electroencephalogram offers the capacity to monitor global neurologic electrical activity, while evoked potential monitoring can assess pathways not detected by the conventional EEG. Continuous EEG (CEEG) monitoring in the intensive care unit (ICU) permits ongoing evaluation of cerebral cortical activity. It is especially useful in obtunded and comatose patients. CEEG also is useful for monitoring of therapy for status epilepticus and detecting early changes associated with cerebral ischemia. CEEG can be used to adjust the level of sedation, especially if high-dose barbiturate therapy is being used to manage elevated ICP. Somatosensory and brain stem evoked potentials are less affected by the administration of sedatives than is the EEG. Evoked potentials are useful for localizing brain stem lesions or proving the absence of such structural lesions in cases of metabolic or toxic coma. They also can provide prognostic data in posttraumatic coma.

An advance in EEG monitoring is the use of the bispectral index (BIS) to titrate the level of sedative medications. While sedative drugs are usually titrated to the clinical neurologic examination, the BIS device has been used in the operating room to continuously monitor the depth of anesthesia. The BIS is an empirical measurement statistically derived from a database of over 5000 EEGs.⁵⁹ The BIS is derived from bifrontal EEG recordings and analyzed for burst suppression ratio, relative alpha:beta ratio, and bicoherence. Using a multivariate regression model, a linear numeric index (BIS) is calculated, ranging from 0 (isoelectric EEG) to 100 (fully awake). Its use has been associated with lower consumption of anesthetics during surgery and earlier awakening and faster recovery from anesthesia.⁶⁰ The BIS also has been validated as a useful approach for monitoring the level of sedation for ICU patients, using the revised Sedation-Agitation Scale as a gold standard.⁶¹

Transcranial Doppler Ultrasonography

This modality provides a noninvasive method for evaluating cerebral hemodynamics. Transcranial Doppler (TCD) measurements of middle and anterior cerebral artery blood flow velocity are useful for the diagnosis of cerebral vasospasm after subarachnoid hemorrhage. Qureshi et al demonstrated that an increase in the middle cerebral artery mean flow velocity as

assessed by TCD is an independent predictor of symptomatic vasospasm in a prospective study of patients with aneurysmal subarachnoid hemorrhage.⁶² In addition, while some have proposed using TCD to estimate ICP, studies have shown that TCD is not a reliable method for estimating ICP and CPP, and currently cannot be endorsed for this purpose.⁶³ TCD also is useful to confirm the clinical examination for determining brain death in patients with confounding factors such as the presence of CNS depressants or metabolic encephalopathy.

Jugular Venous Oximetry

When the arterial oxygen content, hemoglobin concentration, and the oxyhemoglobin dissociation curve are constant, changes in jugular venous oxygen saturation (SjO_2) reflect changes in the difference between cerebral oxygen delivery and demand. Generally, a decrease in SjO_2 reflects cerebral hypoperfusion, whereas an increase in SjO_2 indicates the presence of hyperemia. SjO_2 monitoring cannot detect decreases in regional cerebral blood flow if overall perfusion is normal or above normal. This technique requires the placement of a catheter in the jugular bulb, usually via the internal jugular vein. Catheters that permit intermittent aspiration of jugular venous blood for analysis or continuous oximetry catheters are available.

Low SjO_2 is associated with poor outcomes after TBI.⁶⁴ Nevertheless, the value of monitoring SjO_2 remains unproven. If it is employed, it should not be the sole monitoring technique, but rather should be used in conjunction with ICP and CPP monitoring. By monitoring ICP, CPP, and SjO_2 , early intervention with volume, vasopressors, and hyperventilation has been shown to prevent ischemic events in patients with TBI.⁶⁵

Transcranial Near-Infrared Spectroscopy

Transcranial near-infrared spectroscopy (NIRS) is a noninvasive continuous monitoring method to determine cerebral oxygenation. It employs technology similar to that of pulse oximetry to determine the concentrations of oxy- and deoxyhemoglobin with near-infrared light and sensors, and takes advantage of the relative transparency of the skull to light in the near-infrared region of the spectrum. Continuous monitoring of cerebral perfusion via transcranial NIRS may provide a method to detect early cerebral ischemia in patients with traumatic brain injury.⁶⁶ Nevertheless, this form of monitoring remains largely a research tool at the present time.

Brain Tissue Oxygen Tension

While the standard of care for patients with severe TBI includes ICP and CPP monitoring, this strategy does not always prevent secondary brain injury. Growing evidence suggests that monitoring local brain tissue oxygen tension ($PbtO_2$) may be a useful adjunct to ICP monitoring in these patients. Normal values for $PbtO_2$ are 20 to 40 mm Hg, and critical levels are 8 to 10 mm Hg. A recent clinical study sought to determine whether the addition of a $PbtO_2$ monitor to guide therapy in severe traumatic brain injury was associated with improved patient outcomes.⁶⁷ Twenty-eight patients with severe traumatic brain injury (GCS score ≤ 8) were enrolled in an observational study at a level I trauma center. These patients received invasive ICP and $PbtO_2$ monitoring and were compared with 25 historical controls matched for age, injuries, and admission GCS score that had undergone ICP monitoring alone. Goals of therapy in both groups included maintaining an ICP < 20 mm Hg and a CPP > 60 mm Hg. Among patients with $PbtO_2$ monitoring,

therapy also was directed at maintaining $PbtO_2 > 25$ mm Hg. The groups had similar mean daily ICP and CPP levels. The mortality rate in the historical controls treated with standard ICP and CPP management was 44%. Mortality was significantly lower in the patients who had therapy guided by $PbtO_2$ monitoring in addition to ICP and CPP (25%; $P < 0.05$). The benefits of $PbtO_2$ monitoring may include the early detection of brain tissue ischemia despite normal ICP and CPP. In addition, $PbtO_2$ -guided management may reduce potential adverse effects associated with therapies to maintain ICP and CPP.

CONCLUSIONS

Modern intensive care is predicated by the need and ability to continuously monitor a wide range of physiologic parameters. This capability has dramatically improved the care of critically ill patients and advanced the development of the specialty of critical care medicine. In some cases, the technological ability to measure such variables has surpassed our understanding of the significance or the knowledge of the appropriate intervention to ameliorate such pathophysiologic changes. In addition, the development of less invasive monitoring methods has been promoted by the recognition of complications associated with invasive monitoring devices. The future portends the continued development of noninvasive monitoring devices along with their application in an evidenced-based strategy to guide rational therapy.

REFERENCES

Entries highlighted in bright blue are key references.

1. Bur A, Herkner H, Vlcek M, et al. Factors influencing the accuracy of oscillometric blood pressure measurement in critically ill patients. *Crit Care Med.* 2003;31(3):793-799.
2. Fischer MO, Avram R, Carjaliu I, et al. Non-invasive continuous arterial pressure and cardiac index monitoring with Nexfin after cardiac surgery. *Br J Anaesth.* 2012;109(4):514-521.
3. Traore O, Liotier J, Souweine B. Prospective study of arterial and central venous catheter colonization and of arterial- and central venous catheter-related bacteremia in intensive care units. *Crit Care Med.* 2005;33(6):1276-1280.
4. Landesberg G, Mosseri M, Wolf Y, Vesselov Y, Weissman C. Perioperative myocardial ischemia and infarction: identification by continuous 12-lead electrocardiogram with online ST-segment monitoring. *Anesthesiology.* 2002;96(2):264-270.
5. Yu H, Pi-Hua F, Yuan W, et al. Prediction of sudden cardiac death in patients after acute myocardial infarction using T-wave alternans: a prospective study. *J Electrocardiol.* 2012;45(1):60-65.
6. Chen WL, Tsai TH, Huang CC, Chen JH, Kuo CD. Heart rate variability predicts short-term outcome for successfully resuscitated patients with out-of-hospital cardiac arrest. *Resuscitation.* 2009;80(10):1114-1118.
7. Hravnak M, Edwards L, Clontz A, et al. Defining the incidence of cardiorespiratory instability in patients in step-down units using an electronic integrated monitoring system. *Arch Intern Med.* 2008;168(12):1300-1308.
8. Hayashi H, Amano M. Does ultrasound imaging before puncture facilitate internal jugular vein cannulation? Prospective randomized comparison with landmark-guided puncture in ventilated patients. *J Cardiothorac Vasc Anesth.* 2002;16(5):572-575.
9. Mihm FG, Gettinger A, Hanson CW III, et al. A multicenter evaluation of a new continuous cardiac output pulmonary artery catheter system. *Crit Care Med.* 1998;26(8):1346-1350.
10. London MJ, Moritz TE, Henderson WG, et al. Standard versus fiberoptic pulmonary artery catheterization for cardiac surgery

- in the Department of Veterans Affairs: a prospective, observational, multicenter analysis. *Anesthesiology*. 2002;96(4):860-870.
11. Rivers EP, Ander DS, Powell D. Central venous oxygen saturation monitoring in the critically ill patient. *Curr Opin Crit Care*. 2001;7(3):204-211.
 12. Varpula M, Karlsson S, Ruokonen E, Pettila V. Mixed venous oxygen saturation cannot be estimated by central venous oxygen saturation in septic shock. *Intens Care Med*. 2006;32(9):1336-1343.
 13. Rivers E, Nguyen B, Havstad S, et al. Early goal-directed therapy in the treatment of severe sepsis and septic shock. *N Engl J Med*. 2001;345(19):1368-1377.
 14. Dellinger RP, Levy MM, Rhodes A, et al. Surviving sepsis campaign: international guidelines for management of severe sepsis and septic shock. *Crit Care Med*. 2013;41(2):580-637.
 15. Connors AF Jr., Speroff T, Dawson NV, et al. The effectiveness of right heart catheterization in the initial care of critically ill patients. SUPPORT Investigators. *JAMA*. 1996;276(11):889-897.
 16. Pearson KS, Gomez MN, Moyers JR, Carter JG, Tinker JH. A cost/benefit analysis of randomized invasive monitoring for patients undergoing cardiac surgery. *Anesth Analg*. 1989;69(3):336-341.
 17. Tuman KJ, McCarthy RJ, Spiess BD, et al. Effect of pulmonary artery catheterization on outcome in patients undergoing coronary artery surgery. *Anesthesiology*. 1989;70(2):199-206.
 18. Bender JS, Smith-Meek MA, Jones CE. Routine pulmonary artery catheterization does not reduce morbidity and mortality of elective vascular surgery: results of a prospective, randomized trial. *Ann Surg*. 1997;226(3):229-236.
 19. Valentine RJ, Duke ML, Inman MH, et al. Effectiveness of pulmonary artery catheters in aortic surgery: a randomized trial. *J Vasc Surg*. 1998;27(2):203-211; discussion 11-2.
 20. Sandham JD, Hull RD, Brant RF, et al. A randomized, controlled trial of the use of pulmonary-artery catheters in high-risk surgical patients. *N Engl J Med*. 2003;348(1):5-14.
 21. Harvey S, Harrison DA, Singer M, et al. Assessment of the clinical effectiveness of pulmonary artery catheters in management of patients in intensive care (PAC-Man): a randomised controlled trial. *Lancet*. 2005;366(9484):472-477.
 22. Shah MR, Hasselblad V, Stevenson LW, et al. Impact of the pulmonary artery catheter in critically ill patients: meta-analysis of randomized clinical trials. *JAMA*. 2005;294(13):1664-1670.
 23. Binanay C, Califf RM, Hasselblad V, et al. Evaluation study of congestive heart failure and pulmonary artery catheterization effectiveness: the ESCAPE trial. *JAMA*. 2005;294(13):1625-1633.
 24. National Heart Lung, Blood Institute Acute Respiratory Distress Syndrome (ARDS) Clinical Trials Network, Wheeler AP, et al. Pulmonary-artery versus central venous catheter to guide treatment of acute lung injury. *N Engl J Med*. 2006;354(21):2213-2224.
 25. Wiener RS, Welch HG. Trends in the use of the pulmonary artery catheter in the United States, 1993-2004. *JAMA*. 2007;298(4):423-429.
 26. Shoemaker WC, Appel PL, Kram HB, Waxman K, Lee TS. Prospective Trial of Supranormal Values of Survivors as Therapeutic Goals in High-Risk Surgical Patients. *Chest*. 1988;94(6):1176-1186.
 27. Bishop MH, Shoemaker WC, Appel PL, et al. Prospective, randomized trial of survivor values of cardiac index, oxygen delivery, and oxygen consumption as resuscitation endpoints in severe trauma. *J Trauma*. 1995;38(5):780-787.
 28. Heyland DK, Cook DJ, King D, Kernerman P, Brun-Buisson C. Maximizing oxygen delivery in critically ill patients: a methodologic appraisal of the evidence. *Crit Care Med*. 1996;24(3):517-524.
 29. Alia I, Esteban A, Gordo F, et al. A randomized and controlled trial of the effect of treatment aimed at maximizing oxygen delivery in patients with severe sepsis or septic shock. *Chest*. 1999;115(2):453-461.
 30. Gan TJ, Soppitt A, Maroof M, et al. Goal-directed intraoperative fluid administration reduces length of hospital stay after major surgery. *Anesthesiology*. 2002;97(4):820-826.
 31. Dark PM, Singer M. The validity of trans-esophageal Doppler ultrasonography as a measure of cardiac output in critically ill adults. *Intensive Care Med*. 2004;30(11):2060-2066.
 32. Imhoff M, Lehner JH, Lohlein D. Noninvasive whole-body electrical bioimpedance cardiac output and invasive thermodilution cardiac output in high-risk surgical patients. *Crit Care Med*. 2000;28(8):2812-2818.
 33. Marik PE. Noninvasive cardiac output monitors: a state-of-the-art review. *J Cardiothorac Vasc Anesth*. 2013;27(1):121-134.
 34. Mielck F, Buhre W, Hanekop G, et al. Comparison of continuous cardiac output measurements in patients after cardiac surgery. *J Cardiothorac Vasc Anesth*. 2003;17(2):211-216.
 35. Remmen JJ, Aengevaeren WR, Verheugt FW, et al. Finapres arterial pulse wave analysis with Modelflow is not a reliable non-invasive method for assessment of cardiac output. *Clin Sci (Lond)*. 2002;103(2):143-149.
 36. van Heerden PV, Baker S, Lim SI, Weidman C, Bulsara M. Clinical evaluation of the non-invasive cardiac output (NICO) monitor in the intensive care unit. *Anaesth Intensive Care*. 2000;28(4):427-430.
 37. Odenstedt H, Stenqvist O, Lundin S. Clinical evaluation of a partial CO₂ rebreathing technique for cardiac output monitoring in critically ill patients. *Acta Anaesthesiol Scand*. 2002;46(2):152-159.
 38. Godje O, Peyerl M, Seebauer T, et al. Central venous pressure, pulmonary capillary wedge pressure, and intrathoracic blood volumes as preload indicators in cardiac surgery patients. *Eur J Cardiothorac Surg*. 1998;13(5):533-539.
 39. Pinsky MR, Teboul JL. Assessment of indices of preload and volume responsiveness. *Curr Opin Crit Care*. 2005;11(3):235-239.
 40. Gunn SR, Pinsky MR. Implications of arterial pressure variation in patients in the intensive care unit. *Curr Opin Crit Care*. 2001;7(3):212-217.
 41. Mesquida J, Kim HK, Pinsky MR. Effect of tidal volume, intrathoracic pressure, and cardiac contractility on variations in pulse pressure, stroke volume, and intrathoracic blood volume. *Intensive Care Med*. 2011;37(10):1672-1679.
 42. Michard F, Boussat S, Chemla D, et al. Relation between respiratory changes in arterial pulse pressure and fluid responsiveness in septic patients with acute circulatory failure. *Am J Respir Crit Care Med*. 2000;162(1):134-138.
 43. Crookes BA, Cohn SM, Burton EA, Nelson J, Proctor KG. Noninvasive muscle oxygenation to guide fluid resuscitation after traumatic shock. *Surgery*. 2004;135(6):662-670.
 44. Cohn SM, Nathens AB, Moore FA, et al. Tissue oxygen saturation predicts the development of organ dysfunction during traumatic shock resuscitation. *J Trauma*. 2007;62(1):44-54; discussion 54-5.
 45. Haller M, Kilger E, Briegel J, Forst H, Peter K. Continuous intra-arterial blood gas and pH monitoring in critically ill patients with severe respiratory failure: a prospective, criterion standard study. *Crit Care Med*. 1994;22(4):580-587.
 46. Ventilation with lower tidal volumes as compared with traditional tidal volumes for acute lung injury and the acute respiratory distress syndrome. The Acute Respiratory Distress Syndrome Network. *N Engl J Med*. 2000;342(18):1301-1308.
 47. Serpa Neto A, Cardoso SO, Manetta JA, et al. Association between use of lung-protective ventilation with lower tidal volumes and clinical outcomes among patients without acute respiratory distress syndrome: a meta-analysis. *JAMA*. 2012;308(16):1651-1659.

48. Tremper KK. Pulse oximetry. *Chest*. 1989;95(4):713-715.
49. Shoemaker WC, Belzberg H, Wo CCJ, et al. Multicenter study of noninvasive monitoring systems as alternatives to invasive monitoring of acutely ill emergency patients. *Chest*. 1998;114(6):1643-1652.
50. Taenzer AH, Pyke JB, McGrath SP, Blike GT. Impact of pulse oximetry surveillance on rescue events and intensive care unit transfers: a before-and-after concurrence study. *Anesthesiology*. 2010;112(2):282-287.
51. Jubran A, Tobin MJ. Monitoring during mechanical ventilation. *Clin Chest Med*. 1996;17(3):453-473.
52. Sugrue M. Abdominal compartment syndrome. *Curr Opin Crit Care*. 2005;11(4):333-338.
53. Brain Trauma F, American Association of Neurological S, Congress of Neurological S, et al. Guidelines for the management of severe traumatic brain injury. VI. Indications for intracranial pressure monitoring. *J Neurotrauma*. 2007;24 Suppl: 1S37-1S44.
54. Brain Trauma F, American Association of Neurological S, Congress of Neurological S, et al. Guidelines for the management of severe traumatic brain injury. VII. Intracranial pressure monitoring technology. *J Neurotrauma*. 2007;24 Suppl: 1S45-1S54.
55. Juul N, Morris GF, Marshall SB, Marshall LF. Intracranial hypertension and cerebral perfusion pressure: influence on neurological deterioration and outcome in severe head injury. The Executive Committee of the International Selfotel Trial. *J Neurosurg*. 2000;92(1):1-6.
56. Eisenberg HM, Frankowski RF, Contant CF, Marshall LF, Walker MD. High-dose barbiturate control of elevated intracranial pressure in patients with severe head injury. *J Neurosurg*. 1988;69(1):15-23.
57. Brain Trauma F, American Association of Neurological S, Congress of Neurological S, et al. Guidelines for the management of severe traumatic brain injury. IX. Cerebral perfusion thresholds. *J Neurotrauma*. 2007;24 Suppl: 1S59-1S64.
58. Cremer OL, van Dijk GW, van Wensen E, et al. Effect of intracranial pressure monitoring and targeted intensive care on functional outcome after severe head injury. *Crit Care Med*. 2005;33(10):2207-2213.
59. Sigl JC, Chamoun NG. An introduction to bispectral analysis for the electroencephalogram. *J Clin Monit*. 1994;10(6):392-404.
60. Gan TJ, Glass PS, Windsor A, et al. Bispectral index monitoring allows faster emergence and improved recovery from propofol, alfentanil, and nitrous oxide anesthesia. BIS Utility Study Group. *Anesthesiology*. 1997;87(4):808-815.
61. Simmons LE, Riker RR, Prato BS, Fraser GL. Assessing sedation during intensive care unit mechanical ventilation with the Bispectral Index and the Sedation-Agitation Scale. *Crit Care Med*. 1999;27(8):1499-1504.
62. Qureshi AI, Sung GY, Razumovsky AY, et al. Early identification of patients at risk for symptomatic vasospasm after aneurysmal subarachnoid hemorrhage. *Crit Care Med*. 2000;28(4):984-990.
63. Czosnyka M, Matta BF, Smielewski P, Kirkpatrick PJ, Pickard JD. Cerebral perfusion pressure in head-injured patients: a noninvasive assessment using transcranial Doppler ultrasonography. *J Neurosurg*. 1998;88(5):802-808.
64. Feldman Z, Robertson CS. Monitoring of cerebral hemodynamics with jugular bulb catheters. *Crit Care Clin*. 1997;13(1):51-77.
65. Vigue B, Ract C, Benayed M, et al. Early SjvO₂ monitoring in patients with severe brain trauma. *Intens Care Med*. 1999;25(5):445-451.
66. Murkin JM, Arango M. Near-infrared spectroscopy as an index of brain and tissue oxygenation. *Br J Anaesth*. 2009;103 Suppl: i13-li13.
67. Stiefel MF, Spiotta A, Gracias VH, et al. Reduced mortality rate in patients with severe traumatic brain injury treated with brain tissue oxygen monitoring. *J Neurosurg*. 2005;103(5):805-811.

14 chapter

Minimally Invasive Surgery, Robotics, Natural Orifice Transluminal Endoscopic Surgery, and Single-Incision Laparoscopic Surgery

Donn H. Spight, John G. Hunter, and Blair A. Jobe

Introduction	415	Extraperitoneal Surgery / 422	Single-Incision Laparoscopic Surgery / 433
Historical Background	415	Hand-Assisted Laparoscopic Access / 423	Special Considerations 435
Physiology and Pathophysiology of Minimally Invasive Surgery	417	Natural Orifice Transluminal Endoscopic Surgery Access / 423	Pediatric Laparoscopy / 435
Laparoscopy / 417		Single-Incision Laparoscopic Surgery Access / 423	Laparoscopy during Pregnancy / 435
Thoracoscopy / 419		Port Placement / 424	Minimally Invasive Surgery and Cancer Treatment / 436
Extracavitary Minimally Invasive Surgery / 419		Imaging Systems / 425	Considerations in the Elderly and Infirm / 436
Anesthesia / 419		Energy Sources for Endoscopic and Endoluminal Surgery / 426	Cirrhosis and Portal Hypertension / 436
The Minimally Invasive Team / 419		Instrumentation / 429	Economics of Minimally Invasive Surgery / 436
Room Setup and the Minimally Invasive Suite / 420		Robotic Surgery / 429	Education and Skill Acquisition / 437
Patient Positioning / 420		Endoluminal and Endovascular Surgery / 431	Telementoring / 437
General Principles of Access / 421		Natural Orifice Transluminal Endoscopic Surgery / 432	Innovation and Introduction of New Procedures / 437
Laparoscopic Access / 421			
Access for Subcutaneous and			

INTRODUCTION

Minimally invasive surgery describes an area of surgery that crosses all traditional disciplines, from general surgery to neurosurgery. It is not a discipline unto itself, but more a philosophy of surgery, a way of thinking. Minimally invasive surgery is a means of performing major operations through small incisions, often using miniaturized, high-tech imaging systems, to minimize the trauma of surgical exposure. Some believe that the term *minimal access surgery* more accurately describes the small incisions generally necessary to gain access to surgical sites in high-tech surgery, but John Wickham's term *minimally invasive surgery* (MIS) is widely used because it describes the paradox of postmodern high-tech surgery—small holes, big operations.

Robotic surgery today is practiced using a single platform (Intuitive, Inc., Sunnyvale, CA) and should better be termed *computer-enhanced surgery* because the term *robotics* assumes autonomous action that is not a feature of the da Vinci robotic system. Instead, the da Vinci robot couples an ergonomic workstation that features stereoptic video imaging and intuitive micromanipulators (surgeon side) with a set of arms delivering specialized laparoscopic instruments enhanced with more degrees of freedom than are allowed by laparoscopic surgery alone (patient side). A computer between the surgeon side and patient side removes surgical tremor and scales motion to allow precise microsurgery, which is helpful for microdissection and difficult anastomoses.

Single-incision laparoscopic surgery (SILS), also called laparoendoscopic single-site surgery (LESS), is a recent addition to the armamentarium of the minimally invasive surgeon.

As public awareness has grown, so too has its spread outside of larger institutions. SILS challenges the well-established paradigm of standard laparoscopic surgery by placing multiple trocars within the fascia at the umbilicus or through a single multichannel trocar at the umbilicus. The manipulation of tightly spaced instruments across the fulcrum of the abdominal wall requires that the surgeon either operate in a crossed hands fashion or use specialized curved instruments to avoid clashing outside the body while working intra-abdominally. The primary advantage of SILS is the reduction to one surgical scar. Greater efficacy, safety, and cost savings have yet to be fully elucidated in the increasing number of procedures that are being attempted in this manner. The advent of a robotic SILS platform now enables the computer reassignment of the surgeon's hands, thus eliminating the difficult ergonomic challenges making the technique far more accessible.

Natural orifice transluminal endoscopic surgery (NOTES) is an extension of interventional endoscopy. Using the mouth, anus, vagina, and urethra (natural orifices), flexible endoscopes are passed through the wall of the esophagus, stomach, colon, bladder, or vagina entering the mediastinum, the pleural space, or the peritoneal cavity. The advantage of this method of minimal access is principally the elimination of the scar associated with laparoscopy or thoracoscopy. Other advantages have yet to be elucidated, including pain reduction, need for hospitalization, and cost savings.

HISTORICAL BACKGROUND

Although the term *minimally invasive surgery* is relatively recent, the history of its component parts is nearly 100 years old. What is considered the newest and most popular variety

Key Points

- 1▶ Minimally invasive surgery describes a philosophical approach to surgery in which access trauma is minimized without compromising the quality of the surgical procedure.
- 2▶ The carbon dioxide pneumoperitoneum used for laparoscopy induces some unique pathophysiologic consequences.
- 3▶ Robotic surgery has been most valuable in the pelvis for performance of minimally invasive prostatectomy and gynecologic and fertility procedures.
- 4▶ Natural orifice transluminal endoscopic surgery represents a new opportunity to develop truly scar-free surgery.
- 5▶ Single-incision laparoscopic surgery reduces the amount of abdominal wall trauma but presents unique challenges to the traditional tenets of laparoscopic ergonomics.
- 6▶ Laparoscopy during pregnancy is best performed in the second trimester and is safe if appropriate monitoring is performed.
- 7▶ Laparoscopic surgery for cancer is also appropriate if good tissue handling techniques are maintained.
- 8▶ Training for laparoscopy requires practice outside of the operating room in a simulation laboratory.

of MIS, laparoscopy, is, in fact, the oldest. Primitive laparoscopy, placing a cystoscope within an inflated abdomen, was first performed by Kelling in 1901.¹ Illumination of the abdomen required hot elements at the tip of the scope and was dangerous. In the late 1950s, Hopkins described the rod lens, a method of transmitting light through a solid quartz rod with no heat and little light loss.¹ Around the same time, thin quartz fibers were discovered to be capable of trapping light internally and conducting it around corners, opening the field of fiber optics and allowing the rapid development of flexible endoscopes.^{2,3} In the 1970s, the application of flexible endoscopy grew faster than that of rigid endoscopy except in a few fields such as gynecology and orthopedics.⁴ By the mid-1970s, rigid and flexible endoscopes made a rapid transition from diagnostic instruments to therapeutic ones. The explosion of video-assisted surgery in the past 20 years was a result of the development of compact, high-resolution, charge-coupled devices (CCDs) that could be mounted on the internal end of flexible endoscopes or on the external end of a Hopkins telescope. Coupled with bright light sources, fiber-optic cables, and high-definition video monitors, the videoendoscope has changed our understanding of surgical anatomy and reshaped surgical practice.

Flexible endoscopic imaging started in the 1960s with the first bundling of many quartz fibers into bundles, one for illumination and one for imaging. The earliest upper endoscopes revolutionized the diagnosis and treatment of gastroesophageal reflux and peptic ulcer disease and made possible early detection of upper and lower gastrointestinal (GI) cancer at a stage that could be cured. The first endoscopic surgical procedure was the colonoscopic polypectomy, developed by Shinya and Wolfe, two surgeons from New York City. The percutaneous endoscopic gastrostomy (PEG) invented by Gauderer and Ponsky may have been the first NOTES procedure, reported in 1981.⁵ Endoscopic pancreatic pseudocyst drainage is thought to be the next NOTES procedure developed; however, there was little energy and money put into the development of NOTES until a number of gastroenterologists claimed the ability to remove the gallbladder with a flexible endoscope, using a transgastric technique. With this pronouncement, the surgical community took notice and seized the momentum for NOTES research and development. Today most intra-abdominal NOTES procedures remain within the realm of research or incorporate a hybrid laparoscopic technique outside of highly specialized centers. Clinically the

transvaginal approach has been studied the most extensively. Evaluation of 551 female patients from the German NOTES registry has shown conversion and complication rates similar to conventional laparoscopic surgery for cholecystectomy and appendectomy procedures.⁶ Endoscopic mucosal resection (EMR) of early-stage esophageal and gastric lesions has revolutionized the management of these malignancies. The peroral endoscopic myotomy (POEM) procedure for achalasia is showing clinical efficacy and gaining popularity.

As the race to minimize the size and increase the functionality of laparoscopic instruments progressed, the notion of using fewer access points to accomplish the same operations resulted in the development of *single-incision laparoscopic surgery* (SILS), synonymously termed *laparoendoscopic single-site surgery* (LESS). Viewed as a progression of laparoscopic surgery, SILS has recently garnered greater enthusiasm over its transvisceral NOTES counterpart.⁷ Currently the single-incision technique is used regularly across a wide variety of surgical areas including general, urologic, gynecologic, colorectal, and bariatric surgery.⁸ Although optical imaging produced the majority of MIS procedures, other (traditionally radiologic) imaging technologies allowed the development of innovative procedures in the 1970s. Fluoroscopic imaging allowed the adoption of percutaneous vascular procedures, the most revolutionary of which was balloon angioplasty. Balloon-based procedures spread into all fields of medicine used to open up clogged lumens with minimal access. Stents were then developed that were used in many disciplines to keep the newly ballooned segment open. The culmination of fluoroscopic balloon and stent proficiency is exemplified by the transvenous intrahepatic portosystemic shunt and by the aortic stent graft, which has nearly replaced open elective abdominal aortic aneurysm repair.

MIS procedures using ultrasound imaging have been limited to fairly crude exercises, such as fragmenting kidney stones and freeing liver tumors, because of the relatively low resolution of ultrasound devices. Newer, high-resolution ultrasound methods with high-frequency crystals may act as a guide while performing minimally invasive resections of individual layers of the intestinal wall.

Axial imaging, such as computed tomography (CT), has allowed the development of an area of MIS that often is not recognized because it requires only a CT scanner and a long needle. CT-guided drainage of abdominal fluid collections and percutaneous biopsy of abnormal tissues are minimally invasive

means of performing procedures that previously required a celiotomy. CT-guided percutaneous radiofrequency (RF) ablation has emerged as a useful treatment for primary and metastatic liver tumors. This procedure also is performed laparoscopically under ultrasound guidance.⁹

A powerful, noninvasive method of imaging that will allow the development of the least invasive—and potentially noninvasive—surgery is magnetic resonance imaging (MRI). MRI is an extremely valuable diagnostic tool, but it is only slowly coming to be of therapeutic value. One obstacle to the use of MRI for MIS is that image production and refreshment of the image as a procedure progresses are slow. Another is that all instrumentation must be nonmetallic when working with the powerful magnets of an MRI scanner. Moreover, MRI magnets are bulky and limit the surgeon's access to the patient. Open magnets have been developed that allow the surgeon to stand between two large MRI coils, obtaining access to the portion of the patient being scanned. The advantage of MRI, in addition to the superb images produced, is that there is no radiation exposure to patient or surgeon. Some neurosurgeons are accumulating experience using MRI to perform frameless stereotactic surgery.

Robotic surgery has been dreamed about for some time, and many science fiction–like devices have been developed over the years to provide mechanical assistance for the surgeon. The first computer-assisted robot was designed to accurately drill femoral shaft bone for wobble-free placement of hip prostheses. Although the concept was appealing, the robot proved no better than a skilled orthopedic surgeon and was a good deal slower. Following this, the first and only two commercially successful robots for laparoscopic surgery were developed in California. Computer Motion, founded by Yulun Wang in Santa Barbara, used National Science Foundation funds to create a mechanical arm, the Aesop robot, which held and moved the laparoscope with voice, foot, or hand control. In Northern California, a master-slave system first developed for surgery on the multinational space station by Philip Green was purchased by Fred Moll and Lonnie Smith, and then reengineered with the surgeon in mind to create a remarkably intuitive computer-enhanced surgical platform. The company, Intuitive Surgical, was aptly named, and their primary product, the da Vinci robot, is currently the only major robotic platform on the market. Although eschewed by many experienced laparoscopists, the da Vinci achieved a toehold among many skilled surgeons who found that the robot could facilitate MIS procedures that were difficult with standard laparoscopic procedures. The latest iteration of the da Vinci platform released in 2009 features high-definition, three-dimensional vision and a dual-console capability allowing greater visualization, assistance, and instruction capabilities.

PHYSIOLOGY AND PATHOPHYSIOLOGY OF MINIMALLY INVASIVE SURGERY

Even with the least invasive of the MIS procedures, physiologic changes occur. Many minimally invasive procedures require minimal or no sedation, and there are few adverse consequences to the cardiovascular, endocrinologic, or immunologic systems. The least invasive of such procedures include stereotactic biopsy of breast lesions and flexible GI endoscopy. Minimally invasive procedures that require general anesthesia have a greater physiologic impact because of the

anesthetic agent, the incision (even if small), and the induced pneumoperitoneum.

Laparoscopy

The unique feature of laparoscopic surgery is the need to lift the abdominal wall from the abdominal organs. Two methods have been devised for achieving this.¹⁰ The first, used by most surgeons, is a pneumoperitoneum. Throughout the early twentieth century, intraperitoneal visualization was achieved by inflating the abdominal cavity with air, using a sphygmomanometer bulb.¹¹ The problem with using air insufflation is that nitrogen is poorly soluble in blood and is slowly absorbed across the peritoneal surfaces. Air pneumoperitoneum was believed to be more painful than nitrous oxide (N₂O) pneumoperitoneum, but less painful than carbon dioxide (CO₂) pneumoperitoneum.

2► Subsequently, CO₂ and N₂O were used for inflating the abdomen. N₂O had the advantage of being physiologically inert and rapidly absorbed. It also provided better analgesia for laparoscopy performed under local anesthesia when compared with CO₂ or air.¹² Despite initial concerns that N₂O would not suppress combustion, controlled clinical trials have established its safety within the peritoneal cavity.¹³ In addition, N₂O has been shown to reduce the intraoperative end-tidal CO₂ and minute ventilation required to maintain homeostasis when compared to CO₂ pneumoperitoneum.¹³ The effect of N₂O on tumor biology and the development of port site metastasis are unknown. As such, caution should be exercised when performing laparoscopic cancer surgery with this agent. Finally, the safety of N₂O pneumoperitoneum in pregnancy has yet to be elucidated.

The physiologic effects of CO₂ pneumoperitoneum can be divided into two areas: (a) gas-specific effects and (b) pressure-specific effects (Fig. 14-1). CO₂ is rapidly absorbed across the peritoneal membrane into the circulation. In the circulation, CO₂ creates a respiratory acidosis by the generation of carbonic acid.¹⁴ Body buffers, the largest reserve of which lies in bone, absorb CO₂ (up to 120 L) and minimize the development of hypercarbia or respiratory acidosis during brief endoscopic procedures.¹⁴ Once the body buffers are saturated, respiratory acidosis develops rapidly, and the respiratory system assumes the burden of keeping up with the absorption of CO₂ and its release from these buffers.

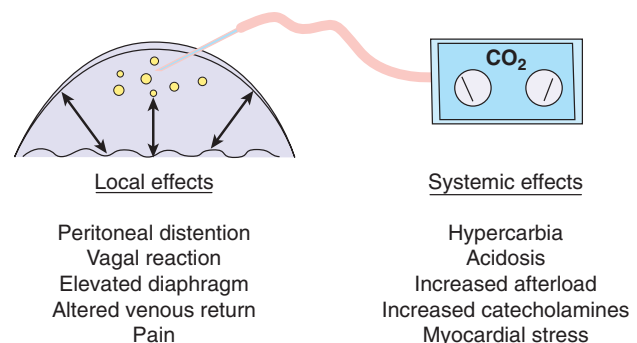


Figure 14-1. Carbon dioxide gas insufflated into the peritoneal cavity has both local and systemic effects that cause a complex set of hemodynamic and metabolic alterations. (Reproduced with permission from Hunter JG, ed. *Bailliere's Clinical Gastroenterology Laparoscopic Surgery*. London/Philadelphia: Bailliere Tindall; 1993:758. Copyright Elsevier.)

In patients with normal respiratory function, this is not difficult; the anesthesiologist increases the ventilatory rate or vital capacity on the ventilator. If the respiratory rate required exceeds 20 breaths per minute, there may be less efficient gas exchange and increasing hypercarbia.¹⁵ Conversely, if vital capacity is increased substantially, there is a greater opportunity for barotrauma and greater respiratory motion-induced disruption of the upper abdominal operative field. In some situations, it is advisable to evacuate the pneumoperitoneum or reduce the intra-abdominal pressure to allow time for the anesthesiologist to adjust for hypercarbia.¹⁶ Although mild respiratory acidosis probably is an insignificant problem, more severe respiratory acidosis leading to cardiac arrhythmias has been reported.¹⁷ Hypercarbia also causes tachycardia and increased systemic vascular resistance, which elevates blood pressure and increases myocardial oxygen demand.^{14,17}

The pressure effects of the pneumoperitoneum on cardiovascular physiology also have been studied. In the hypovolemic individual, excessive pressure on the inferior vena cava and a reverse Trendelenburg position with loss of lower extremity muscle tone may cause decreased venous return and decreased cardiac output.^{14,18} This is not seen in the normovolemic patient. The most common arrhythmia created by laparoscopy is bradycardia. A rapid stretch of the peritoneal membrane often causes a vagovagal response with bradycardia and, occasionally, hypotension.¹⁹ The appropriate management of this event is desufflation of the abdomen, administration of vagolytic agents (e.g., atropine), and adequate volume replacement.²⁰

With the increased intra-abdominal pressure compressing the inferior vena cava, there is diminished venous return from the lower extremities. This has been well documented in the patient placed in the reverse Trendelenburg position for upper abdominal operations. Venous engorgement and decreased venous return promote venous thrombosis.^{21,22} Many series of advanced laparoscopic procedures in which deep venous thrombosis (DVT) prophylaxis was not used demonstrate the frequency of pulmonary embolus. This usually is an avoidable complication with the use of sequential compression stockings, subcutaneous heparin, or low molecular weight heparin.^{20,23} In short-duration laparoscopic procedures, such as appendectomy, hernia repair, or cholecystectomy, the risk of DVT may not be sufficient to warrant extensive DVT prophylaxis.

The increased pressure of the pneumoperitoneum is transmitted directly across the paralyzed diaphragm to the thoracic cavity, creating increased central venous pressure and increased filling pressures of the right and left sides of the heart. If the intra-abdominal pressures are kept under 20 mmHg, the cardiac output usually is well maintained.²²⁻²⁴ The direct effect of the pneumoperitoneum on increasing intrathoracic pressure increases peak inspiratory pressure, pressure across the chest wall, and also, the likelihood of barotrauma. Despite these concerns, disruption of blebs and consequent pneumothoraces are rare after uncomplicated laparoscopic surgery.²⁴ Pneumothoraces occurring with laparoscopic esophageal surgery may be very significant. The pathophysiology and management are discussed at the end of this section. Increased intra-abdominal pressure decreases renal blood flow, glomerular filtration rate, and urine output. These effects may be mediated by direct pressure on the kidney and the renal vein.^{25,26} The secondary effect of decreased renal blood flow is to increase plasma renin release, thereby increasing sodium retention. Increased circulating antidiuretic hormone levels also are found during the

pneumoperitoneum, increasing free water reabsorption in the distal tubules.²⁷ Although the effects of the pneumoperitoneum on renal blood flow are immediately reversible, the hormonally mediated changes such as elevated antidiuretic hormone levels decrease urine output for up to 1 hour after the procedure has ended. Intraoperative oliguria is common during laparoscopy, but the urine output is not a reflection of intravascular volume status; intravenous (IV) fluid administration during an uncomplicated laparoscopic procedure should not be linked to urine output. Because insensible fluid losses through the open abdomen are eliminated with laparoscopy, the need for supplemental fluid during a laparoscopic surgical procedure should only keep up with venous pooling in the lower limbs, third-space losses into the bowel, and blood loss, which is generally less than occurs with an equivalent open operation.

The hemodynamic and metabolic consequences of pneumoperitoneum are well tolerated by healthy individuals for a prolonged period and by most individuals for at least a short period. Difficulties can occur when a patient with compromised cardiovascular function is subjected to a long laparoscopic procedure. It is during these procedures that alternative approaches should be considered or insufflation pressure reduced. Alternative gases that have been suggested for laparoscopy include the inert gases helium, neon, and argon. These gases are appealing because they cause no metabolic effects, but are poorly soluble in blood (unlike CO₂ and N₂O) and are prone to create gas emboli if the gas has direct access to the venous system.²² Gas emboli are rare but serious complications of laparoscopic surgery.^{23,28} They should be suspected if hypotension develops during insufflation. Diagnosis may be made by listening (with an esophageal stethoscope) for the characteristic “mill wheel” murmur. The treatment of gas embolism is to place the patient in a left lateral decubitus position with the head down to trap the gas in the apex of the right ventricle.²³ A rapidly placed central venous catheter then can be used to aspirate the gas out of the right ventricle.

In some situations, minimally invasive abdominal surgery should be performed without insufflation. This has led to the development of an abdominal lift device that can be placed through a 10- to 12-mm trocar at the umbilicus.²⁹ These devices have the advantage of creating little physiologic derangement, but they are bulky and intrusive. The exposure and working room offered by lift devices also are inferior to those accomplished by pneumoperitoneum. Lifting the anterior abdominal wall reduces space available laterally and thereby displaces the bowel medially and anteriorly into the operative field. A pneumoperitoneum, with its well-distributed intra-abdominal pressure, provides better exposure. Abdominal lift devices also cause more postoperative pain, but they do allow the performance of MIS with standard (nonlaparoscopic) surgical instruments.

Endocrine responses to laparoscopic surgery are not always intuitive. Serum cortisol levels after laparoscopic operations are often higher than after the equivalent operation performed through an open incision.³⁰ The greatest difference between the endocrine response of open and laparoscopic surgery is the more rapid equilibration of most stress-mediated hormone levels after laparoscopic surgery. Immune suppression also is less after laparoscopy than after open surgery. There is a trend toward more rapid normalization of cytokine levels after a laparoscopic procedure than after the equivalent procedure performed by celiotomy.³¹

Transhiatal mobilization of the distal esophagus is commonly performed as a component of many laparoscopic upper

abdominal procedures. If there is compromise of the mediastinal pleura with resultant CO₂ pneumothorax, the defect should be enlarged so as to prevent a tension pneumothorax. Even with such a strategy, tension pneumothorax may develop, as mediastinal structures may seal the hole during inspiration, allowing the chest to fill during expiration. In addition to enlargement of the hole, a thoracostomy tube (chest tube) should be placed across the breach into the abdomen with intra-abdominal pressures reduced below 8 mmHg, or a standard chest tube may be placed. When a pneumothorax occurs with laparoscopic Nissen fundoplication or Heller myotomy, it is preferable to place an 18-French red rubber catheter with multiple side holes cut out of the distal end across the defect. At the end of the procedure, the distal end of the tube is pulled out a 10-mm port site (as the port is removed), and the pneumothorax is evacuated to a primitive water seal using a bowl of sterile water or saline. During laparoscopic esophagectomy, it is preferable to leave a standard chest tube, as residual intra-abdominal fluid will tend to be siphoned through the defect postoperatively, if the tube is removed at the end of the case.

Thoracoscopy

The physiology of thoracic MIS (thoracoscopy) is different from that of laparoscopy. Because of the bony confines of the thorax, it is unnecessary to use positive pressure when working in the thorax.³² The disadvantages of positive pressure in the chest include decreased venous return, mediastinal shift, and the need to keep a firm seal at all trocar sites. Without positive pressure, it is necessary to place a double-lumen endotracheal tube so that the ipsilateral lung can be deflated when the operation starts. By collapsing the ipsilateral lung, working space within the thorax is obtained. Because insufflation is unnecessary in thoracoscopic surgery, it can be beneficial to use standard instruments via extended port sites in conjunction with thoracoscopic instruments. This approach is particularly useful when performing advanced procedures such as thoracoscopic anatomic pulmonary resection.

Extracavitary Minimally Invasive Surgery

Many MIS procedures create working spaces in extrathoracic and extraperitoneal locations. Laparoscopic inguinal hernia repair usually is performed in the anterior extraperitoneal Retzius space.^{33,34} Laparoscopic nephrectomy often is performed with retroperitoneal laparoscopy. Endoscopic retroperitoneal approaches to pancreatic necrosectomy have seen some limited use.³⁵ Lower extremity vascular procedures and plastic surgical endoscopic procedures require the development of working space in unconventional planes, often at the level of the fascia, sometimes below the fascia, and occasionally in nonanatomic regions.³⁶ Some of these techniques use insufflation of gas, but many use balloon inflation to develop the space, followed by low-pressure gas insufflation or lift devices to maintain the space (Fig. 14-2). These techniques produce fewer and less severe adverse physiologic consequences than does the pneumoperitoneum, but the insufflation of carbon dioxide into extraperitoneal locations can spread widely, causing subcutaneous emphysema and metabolic acidosis.

Anesthesia

Proper anesthesia management during laparoscopic surgery requires a thorough knowledge of the pathophysiology of the CO₂ pneumoperitoneum.²⁰ The laparoscopic surgeon can

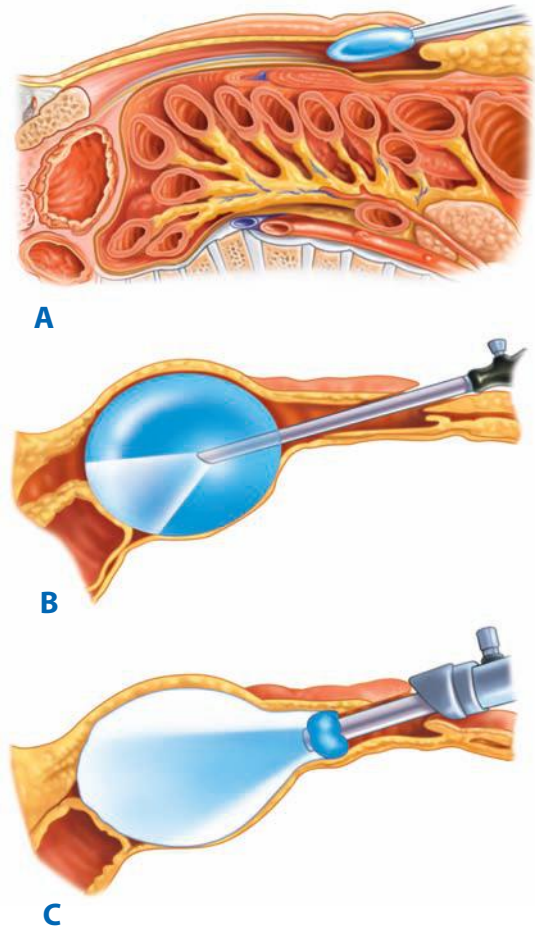


Figure 14-2. Balloons are used to create extra-anatomic working spaces. In this example (A through C), a balloon is introduced into the space between the posterior rectus sheath and the rectus abdominal muscle. The balloon is inflated in the preperitoneal space to create working room for extraperitoneal endoscopic hernia repair.

influence cardiovascular performance by reducing or removing the CO₂ pneumoperitoneum. Insensible fluid losses are negligible, and therefore, IV fluid administration should not exceed that necessary to maintain circulating volume. MIS procedures are often outpatient procedures, so short-acting anesthetic agents are preferable. Because the factors that require hospitalization after laparoscopic procedures include the management of nausea, pain, and urinary retention, the anesthesiologist should minimize the use of agents that provoke these conditions and maximize the use of medications that prevent such problems. Critical to the anesthesia management of these patients is the use of nonnarcotic analgesics (e.g., ketorolac) when hemostasis allows it and the liberal use of antiemetic agents, including ondansetron and steroids.

The Minimally Invasive Team

From the beginning, the tremendous success of MIS was founded on the understanding that a team approach was necessary. The many laparoscopic procedures performed daily range from basic to advanced complexity, and require that the surgical team have an intimate understanding of the operative conduct (Table 14-1). Minimally invasive procedures require complicated and fragile equipment that demands constant maintenance. In addition, multiple intraoperative adjustments to the equipment, camera, insufflator, monitors, and patient/surgeon

Table 14-1

Laparoscopic surgical procedures

BASIC	ADVANCED	
Appendectomy	Nissen fundoplication	Lymph node dissection
Cholecystectomy	Heller myotomy	Robotics
Hernia repair	Gastrectomy	Stereo imaging
	Esophagectomy	Telemedicine
	Enteral access	Laparoscopy-assisted procedures
	Bile duct exploration	Hepatectomy
	Colectomy	Pancreatectomy
	Splenectomy	Prostatectomy
	Adrenalectomy	Hysterectomy
	Nephrectomy	

position are made during these procedures. As such, a coordinated team approach is mandated to ensure patient safety and excellent outcomes. More and more, flexible endoscopes are used to guide or provide quality control for laparoscopic procedures. As NOTES, SILS, and robotic surgery penetrate the operative theatre, hybrid procedures (laparoscopy and endoscopy) and complicated robotics cases will require a nursing staff capable of maintaining flexible endoscopes and understanding the operation of sophisticated technology.

A typical MIS team may consist of a laparoscopic surgeon and an operating room (OR) nurse with an interest in laparoscopic and endoscopic surgery. Adding dedicated assistants and circulating staff with an intimate knowledge of the equipment will add to and enhance the team nucleus. Studies have demonstrated that having a designated laparoscopic team increases the efficiency and safety of laparoscopic surgery, which is translated into a benefit for patient and hospital.³⁷

Room Setup and the Minimally Invasive Suite

Nearly all MIS, whether using fluoroscopic, ultrasound, or optical imaging, incorporates a video monitor as a guide. Occasionally, two images are necessary to adequately guide the operation, as in procedures such as endoscopic retrograde cholangiopancreatography, laparoscopic common bile duct exploration, and laparoscopic ultrasonography. When two images are necessary, the images should be displayed on two adjacent video monitors or projected on a single screen with a picture-in-picture effect. The video monitor(s) should be set across the operating table from the surgeon. The patient should be interposed between the surgeon and the video monitor; ideally, the operative field also lies between the surgeon and the monitor. In pelviscopic surgery, it is best to place the video monitor at the patient's feet, and in laparoscopic cholecystectomy, the monitor is placed at the 10 o'clock position (relative to the patient) while the surgeon stands on the patient's left at the 4 o'clock position. The insufflating and patient-monitoring equipment ideally also is placed across the table from the surgeon, so that the insufflating pressure and the patient's vital signs and end-tidal CO₂ tension can be monitored.

The development of the minimally invasive surgical suite has been a tremendous contribution to the field of laparoscopy

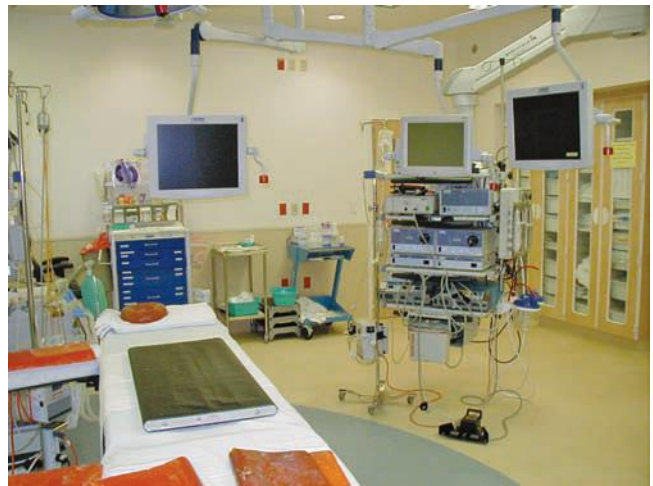

Figure 14-3. An example of a typical minimally invasive surgery suite. All core equipment is located on easily movable consoles.

in that it has facilitated the performance of advanced procedures and techniques (Fig. 14-3). By having the core equipment (monitors, insufflators, and imaging equipment) located within mobile, ceiling-mounted consoles, the surgery team is able to accommodate and make small adjustments rapidly and continuously throughout the procedure. The specifically designed minimally invasive surgical suite serves to decrease equipment and cable disorganization, ease the movements of operative personnel around the room, improve ergonomics, and facilitate the use of advanced imaging equipment such as laparoscopic ultrasound.³⁸ Although having a minimally invasive surgical suite available is very useful, it is not essential to successfully carry out advanced laparoscopic procedures.

Patient Positioning

Patients usually are placed in the supine position for laparoscopic surgery. When the operative field is the gastroesophageal junction or the left lobe of the liver, it is easiest to operate from between the legs. The legs may be elevated in Allen stirrups or abducted on leg boards to achieve this position. When pelvic procedures are performed, it usually is necessary to place the legs in Allen stirrups to gain access to the perineum. A lateral decubitus position with the table flexed provides the best access to the retroperitoneum when performing nephrectomy or adrenalectomy. For laparoscopic splenectomy, a 45° tilt of the patient provides excellent access to the lesser sac and the lateral peritoneal attachments to the spleen. For thoracoscopic surgery, the patient is placed in the lateral position with table flexion to open the intercostal spaces and the distance between the iliac crest and costal margin (Fig. 14-4). Additional consideration must be made in robotic operations to position the patient appropriately before starting. Clashing of the robotic arms with surrounding equipment or each other can occur if not positioned correctly. Once the robot is docked to the patient, the bed cannot be moved without undocking.

When the patient's knees are to be bent for extended periods or the patient is going to be placed in a reverse Trendelenburg position for more than a few minutes, DVT prophylaxis should be used. Sequential compression of the lower extremities during prolonged (>90 minutes) laparoscopic procedures increases venous return and provides inhibition of thromboplastin activation.

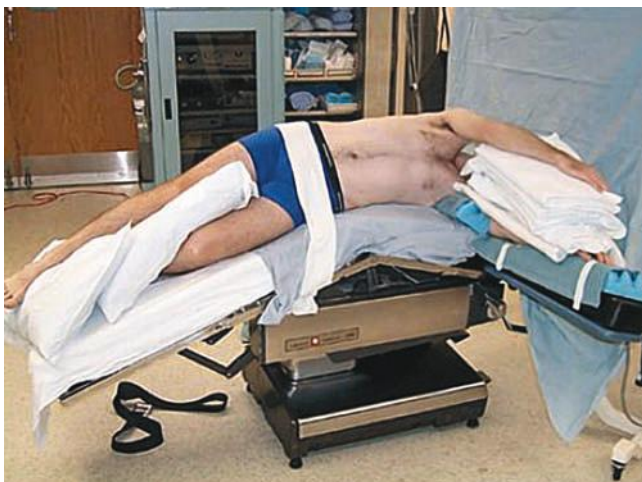

Figure 14-4. Proper padding and protection of pressure points is an essential consideration in laparoscopic and thoracoscopic approaches. In preparation for thoracoscopy, this patient is placed in left lateral decubitus position with the table flexed, which serves to open the intercostal spaces and increase the distance between the iliac crest and the inferior costal margin.

General Principles of Access

The most natural ports of access for MIS and NOTES are the anatomic portals of entry and exit. The nares, mouth, urethra, and anus are used to access the respiratory, GI, and urinary systems. The advantage of using these points of access is that no incision is required. The disadvantages lie in the long distances between the orifice and the region of interest. For NOTES procedures, the vagina may serve as another point of access, entering the abdomen via the posterior cul-de-sac of the pelvis. Similarly, the peritoneal cavity may be reached through the side wall of the stomach or colon.

Access to the vascular system may be accomplished under local anesthesia by cutting down and exposing the desired

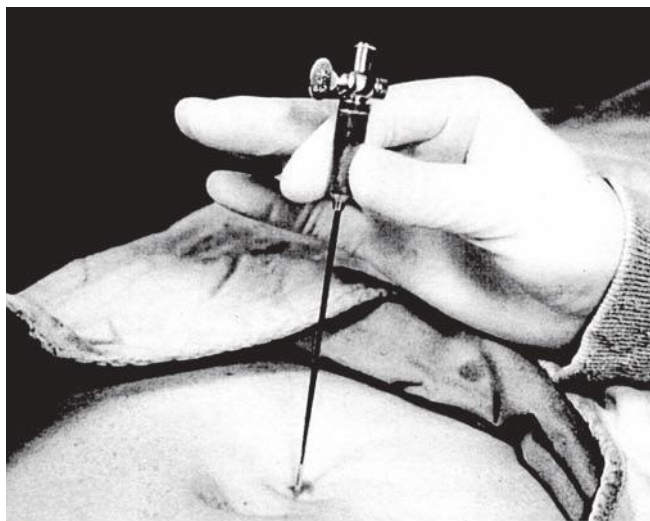
vessel, usually in the groin. Increasingly, vascular access is obtained with percutaneous techniques using a small incision, a needle, and a guidewire, over which are passed a variety of different-sized access devices. This approach, known as the Seldinger technique, is most frequently used by general surgeons for placement of Hickman catheters, but also is used to gain access to the arterial and venous system for performance of minimally invasive procedures. Guidewire-assisted, Seldinger-type techniques also are helpful for gaining access to the gut for procedures such as PEG, for gaining access to the biliary system through the liver, and for gaining access to the upper urinary tract.

In thoracoscopic surgery, the access technique is similar to that used for placement of a chest tube. In these procedures, general anesthesia and single lung ventilation are essential. A small incision is made over the top of a rib and, under direct vision, carried down through the pleura. The lung is collapsed, and a trocar is inserted across the chest wall to allow access with a telescope. Once the lung is completely collapsed, subsequent access may be obtained with direct puncture, viewing all entry sites through the videoendoscope. Because insufflation of the chest is unnecessary, simple ports that keep the small incisions open are all that is required to allow repeated access to the thorax.

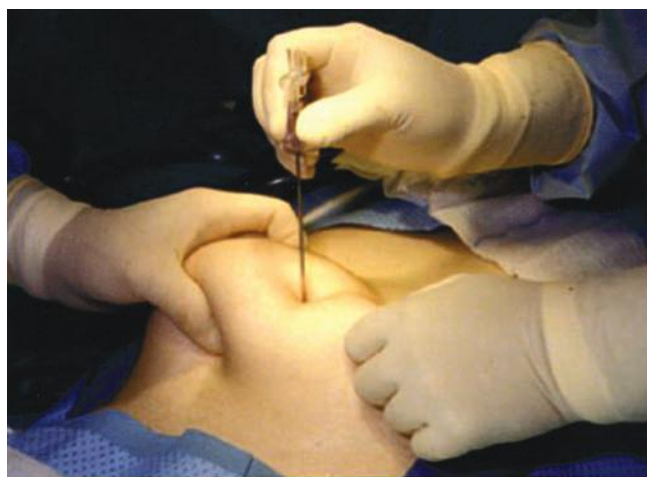Laparoscopic Access

The requirements for laparoscopy are more involved, because the creation of a pneumoperitoneum requires that instruments of access (trocars) contain valves to maintain abdominal inflation.

Two methods are used for establishing abdominal access during laparoscopic procedures.^{39,40} The first, direct puncture laparoscopy, begins with the elevation of the relaxed abdominal wall with two towel clips or a well-placed hand. A small incision is made in the umbilicus, and a specialized spring-loaded (Veress) needle is placed in the abdominal cavity (Fig. 14-5). With the Veress needle, two distinct pops are felt as the surgeon passes the needle through the abdominal wall fascia and the peritoneum. The umbilicus usually is selected as the preferred



A



B

Figure 14-5. **A.** Insufflation of the abdomen is accomplished with a Veress needle held at its serrated collar with a thumb and forefinger. **B.** Because the linea alba is fused to the umbilicus, the abdominal wall is grasped with fingers or penetrating towel clip to elevate the abdominal wall away from the underlying structures.



Figure 14-6. It is essential to be able to interpret the insufflator pressure readings and flow rates. These readings indicate proper intraperitoneal placement of the Veress needle.

point of access because, in this location, the abdominal wall is quite thin, even in obese patients. The abdomen is inflated with a pressure-limited insufflator. CO₂ gas usually is used, with maximal pressures in the range of 14 to 15 mmHg. During the process of insufflation, it is essential that the surgeon observe the pressure and flow readings on the monitor to confirm an intraperitoneal location of the Veress needle tip (Fig. 14-6). Laparoscopic surgery can be performed under local anesthesia, but general anesthesia is preferable. Under local anesthesia, N₂O is used as the insufflating agent, and insufflation is stopped after 2 L of gas is insufflated or when a pressure of 10 mmHg is reached.

After peritoneal insufflation, direct access to the abdomen is obtained with a 5- or 10-mm trocar. The critical issues for safe direct-puncture laparoscopy include the use of a vented stylet for the trocar, or a trocar with a safety shield or dilating tip. The trocar must be pointed away from the sacral promontory and the great vessels.⁴¹ Patient position should be surveyed before trocar placement to ensure a proper trajectory. For performance of laparoscopic cholecystectomy, the trocar is angled toward the right upper quadrant.

Occasionally, the direct peritoneal access (Hasson) technique is advisable.⁴² With this technique, the surgeon makes a small incision just below the umbilicus and under direct vision locates the abdominal fascia. Two Kocher clamps are placed on the fascia, and with curved Mayo scissors, a small incision is made through the fascia and underlying peritoneum. A finger is placed into the abdomen to make sure that there is no adherent bowel. A sturdy suture is placed on each side of the fascia and secured to the wings of a specialized trocar, which is then passed directly into the abdominal cavity (Fig. 14-7). Rapid insufflation can make up for some of the time lost with the initial dissection. This technique is preferable for the abdomen of patients who have undergone previous operations in which small bowel may be adherent to the undersurface of the abdominal wound. The close adherence of bowel to the peritoneum in the previously operated abdomen does not eliminate the possibility of intestinal injury but should make great vessel injury extremely unlikely. Because of the difficulties in visualizing the abdominal region immediately adjacent to the primary trocar, it is recommended that the telescope be passed through a

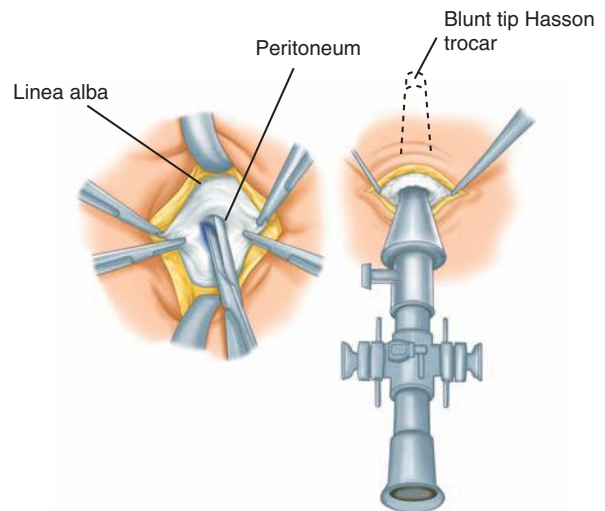


Figure 14-7. The open laparoscopy technique involves identification and incision of the peritoneum, followed by the placement of a specialized trocar with a conical sleeve to maintain a gas seal. Specialized wings on the trocar are attached to sutures placed through the fascia to prevent loss of the gas seal.

secondary trocar to inspect the site of initial abdominal access.⁴⁰ Secondary punctures are made with 5- and 10-mm trocars. For safe access to the abdominal cavity, it is critical to visualize all sites of trocar entry.^{41,42} At the completion of the operation, all trocars are removed under direct vision, and the insertion sites are inspected for bleeding. If bleeding occurs, direct pressure with an instrument from another trocar site or balloon tamponade with a Foley catheter placed through the trocar site generally stops the bleeding within 3 to 5 minutes. When this is not successful, a full-thickness abdominal wall suture has been used successfully to tamponade trocar site bleeding.

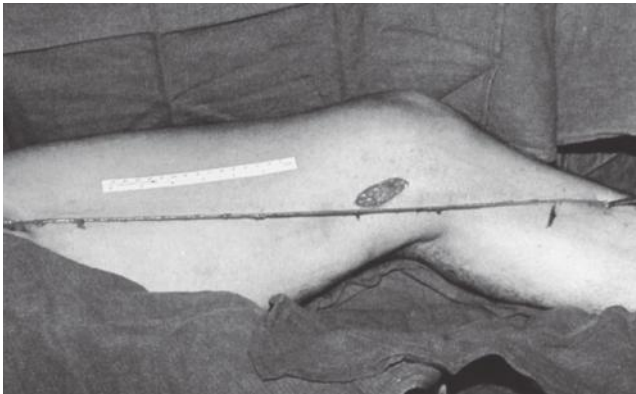
It is generally agreed that 5-mm trocars need no site suturing. Ten-millimeter trocars placed off the midline and above the transverse mesocolon do not require repair. Conversely, if the fascia has been dilated to allow the passage of the gallbladder or other organ, it should be repaired at the fascial level with interrupted sutures. The port site may be closed with suture delivery systems similar to crochet needles enabling mass closure of the abdominal wall. This is especially helpful in obese patients where direct fascial closure may be challenging, through a small skin incision. Failure to close lower abdominal trocar sites that are 10 mm in diameter or larger can lead to an incarcerated hernia.

Access for Subcutaneous and Extraperitoneal Surgery

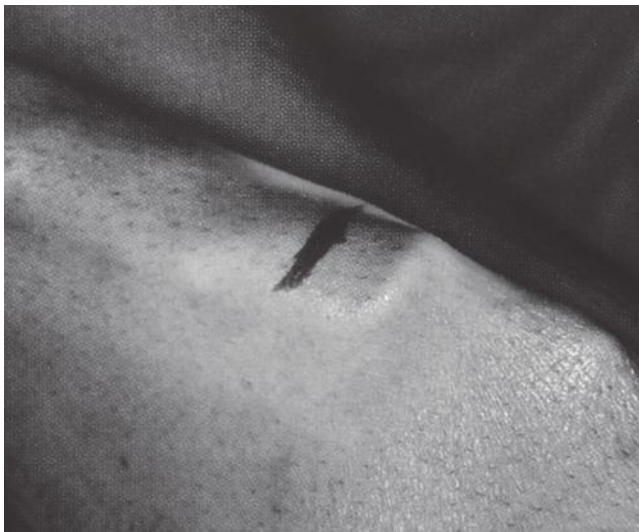There are two methods for gaining access to nonanatomic spaces. For retroperitoneal locations, balloon dissection is effective. This access technique is appropriate for the extraperitoneal repair of inguinal hernias and for retroperitoneal surgery for adrenalectomy, nephrectomy, lumbar discectomy, pancreatic necrosectomy, or para-aortic lymph node dissection.^{43,44} The initial access to the extraperitoneal space is performed in a way similar to direct puncture laparoscopy, except that the last layer (the peritoneum) is not traversed. Once the transversalis fascia has been punctured, a specialized trocar with a balloon on the end is introduced. The balloon is inflated in the extraperitoneal space to create a working chamber. The balloon then is deflated

and a Hasson trocar is placed. An insufflation pressure of 10 mmHg usually is adequate to keep the extraperitoneal space open for dissection and will limit subcutaneous emphysema. Higher gas pressures force CO₂ into the soft tissues and may contribute to hypercarbia. Extraperitoneal endosurgery provides less working space than laparoscopy but eliminates the possibility of intestinal injury, intestinal adhesion, herniation at the trocar sites, and ileus. These issues are important for laparoscopic hernia repair because extraperitoneal approaches prevent the small bowel from sticking to the prosthetic mesh.³⁴

Subcutaneous surgery has been most widely used in cardiac, vascular, and plastic surgery.³⁶ In cardiac surgery, subcutaneous access has been used for saphenous vein harvesting, and in vascular surgery for ligation of subfascial perforating veins (Linton procedure). With minimally invasive techniques, the entire saphenous vein above the knee may be harvested through a single incision (Fig. 14-8).^{45,46} Once the saphenous vein is



A



B

Figure 14-8. A. With two small incisions, virtually the entire saphenous vein can be harvested for bypass grafting. B. The lighted retractor in the subcutaneous space during saphenous vein harvest is seen illuminating the skin. (Reproduced with permission of Taylor & Francis, LLC from Jones GE, Eaves FE III, Howell RL, et al. Harvest of muscle, nerve, fascia, and vein. In: Bostwick J III, Eaves FE III, Nahai F, eds. Endoscopic Plastic Surgery. St Louis: Quality Medical Publishing, Inc.; 1995:542. Permission conveyed through Copyright Clearance Center, Inc.)

located, a long retractor that holds a 5-mm laparoscope allows the coaxial dissection of the vein and coagulation or clipping of each side branch. A small incision above the knee also can be used to ligate perforating veins in the lower leg.

Subcutaneous access also is used for plastic surgery procedures.⁴⁶ Minimally invasive approaches are especially well suited to cosmetic surgery, in which attempts are made to hide the incision. It is easier to hide several 5-mm incisions than one long incision. The technique of blunt dissection along fascial planes combined with lighted retractors and endoscope-holding retractors is most successful for extensive subcutaneous surgery. Some prefer gas insufflation of these soft tissue planes. The primary disadvantage of soft tissue insufflation is that subcutaneous emphysema can be created.

Hand-Assisted Laparoscopic Access

Hand-assisted laparoscopic surgery is thought to combine the tactile advantages of open surgery with the minimal access of laparoscopy and thoracoscopy. This approach commonly is used to assist with difficult cases before conversion to celiotomy is necessary. Additionally, hand-assisted laparoscopic surgery is used to help surgeons negotiate the steep learning curve associated with advanced laparoscopic procedures.⁴⁷ This technology uses an entryway for the hand that preserves the pneumoperitoneum and enables laparoscopic visualization in combination with the use of minimally invasive instruments (Fig. 14-9). Formal investigation of this modality has been limited primarily to case reports and small series and has focused primarily on solid organ and colon surgery.

Intraperitoneal, intrathoracic, and retroperitoneal access for robotic surgery adheres to the principles of laparoscopic and thoracoscopic access; however, the port size for the primary puncture is 12 mm to allow placement of the stereo laparoscope. Remaining trocars are 8 mm.

Natural Orifice Transluminal Endoscopic Surgery Access

Multiple studies have shown safety in the performance of NOTES procedures. Transvaginal, transvesicle, transanal, transcolonic, transgastric, and transoral approaches have all been attempted with varying success. The ease of decontamination, entry, and closure of these structures create variable challenges. The transvaginal approach for resection of the uterus has been employed for many years by gynecologists and has been modified by laparoscopists with great success. Extraction of the gallbladder, kidney, bladder, large bowel, and stomach can be performed via the vagina. The esophagus can be traversed to enter the mediastinum. Leaving the orifice or organ of entry with an endoscope requires the use of an endoscopic needle knife followed by submucosal tunneling or direct puncture and balloon dilation (Fig. 14-10). Closure has been performed using endoscopic clips or sutures with advanced endoscopic platforms.

Single-Incision Laparoscopic Surgery Access

There is no standardized approach for SILS, and access techniques vary by surgeon preference. Traditionally, a single skin incision is made directly through the umbilical scar ranging from 1 to 3 cm. Through this single incision, multiple low-profile trocars can be placed separately into the fascia to allow insufflation, camera, and working instruments. The advantage of this technique is that conventional laparoscopic tools can be employed. The disadvantage becomes apparent when an extraction site

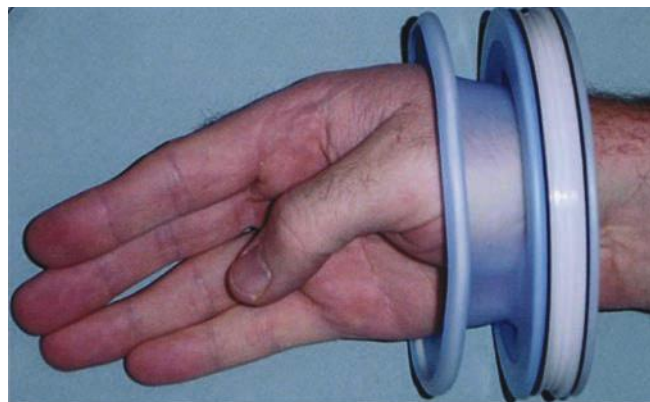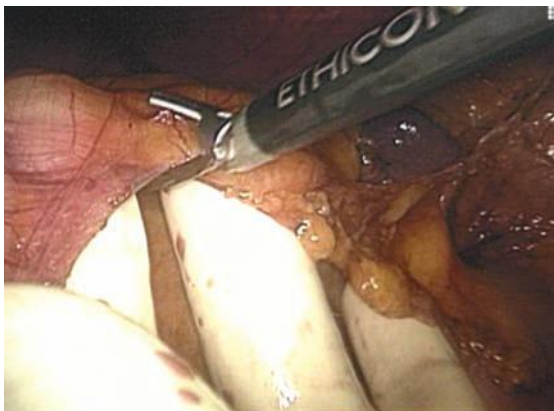


Figure 14-9. This is an example of hand-assisted laparoscopic surgery during left colectomy. The surgeon uses a hand to provide retraction and counter tension during mobilization of the colon from its retroperitoneal attachments, as well as during division of the mesocolon. This technique is particularly useful in the region of the transverse colon.

is needed. A variety of specialized multilumen trocars are on the market that can be placed through the umbilical ring⁴⁸ (Fig. 14-11A,B). The advantages of these devices include faster access, improved safety, minimization of air leaks, and platform-derived instrument triangulation. The major disadvantage is cost.

Port Placement

Trocar for the surgeon's left and right hand should be placed at least 10 cm apart. For most operations, it is possible to orient the telescope between these two trocars and slightly back from them. The ideal trocar orientation creates an equilateral triangle

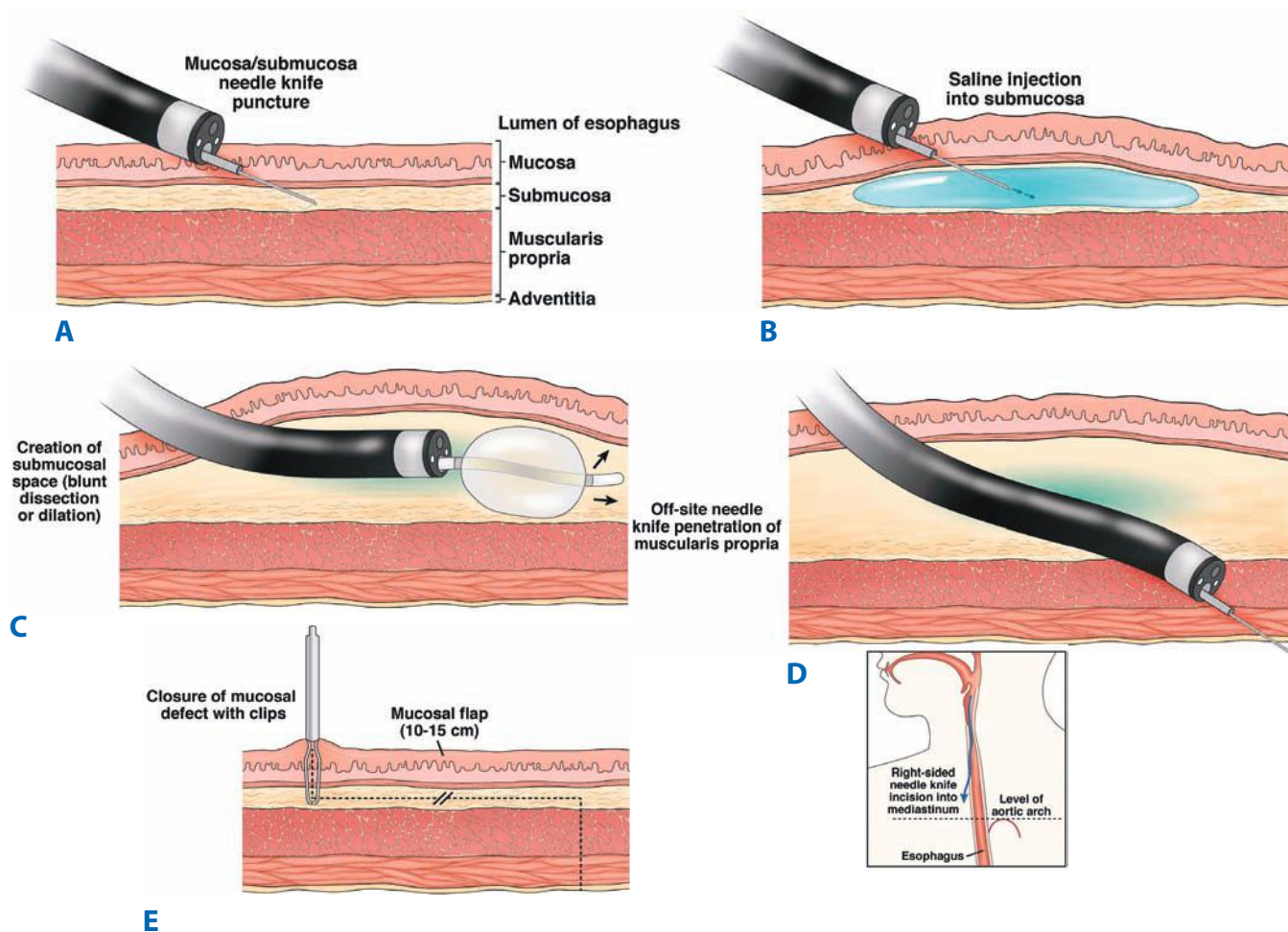


Figure 14-10. Submucosal tunnel technique for transesophageal mediastinoscopy. (Reproduced with permission from Khashab MA, Kalloo AN. NOTES: current status and new horizons. *Gastroenterology*. 2012;142:704-710. © 2012 by the AGA Institute.)

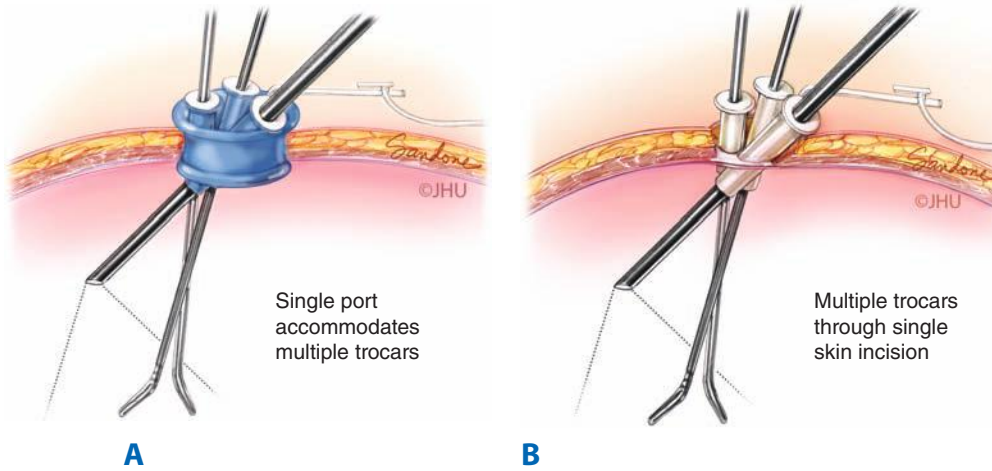


Figure 14-11. **A.** Specialized multilumen trocars can facilitate instrument placement. **B.** For single-incision laparoscopic surgery, multiple fascial punctures can be performed via a single skin incision. (Illustration by Corinne Sandone. © 2014 JHU. Reprinted with permission.)

between the surgeon's right hand, left hand, and the telescope, with 10 to 15 cm on each leg. If one imagines the target of the operation (e.g., the gallbladder or gastroesophageal junction) oriented at the apex of a second equilateral triangle built on the first, these four points of reference create a diamond (Fig. 14-12). The surgeon stands behind the telescope, which provides optimal ergonomic orientation but frequently requires that a camera operator (or mechanical camera holder) reach between the surgeon's hands to guide the telescope. SILS is challenging for even the experienced laparoscopist because it violates most of the aforementioned ergonomic principles. Having only a single point of entry into the abdominal cavity creates an inherently crowded port and hand position. The inability to space trocars severely limits the ability to triangulate the left and right hand instruments. As a result, the surgeon must often work in a crossed hands fashion (Fig. 14-13). Additionally, the axis of the camera view is often in line with the working instruments, making visualization difficult without a deflectable tip laparoscope.

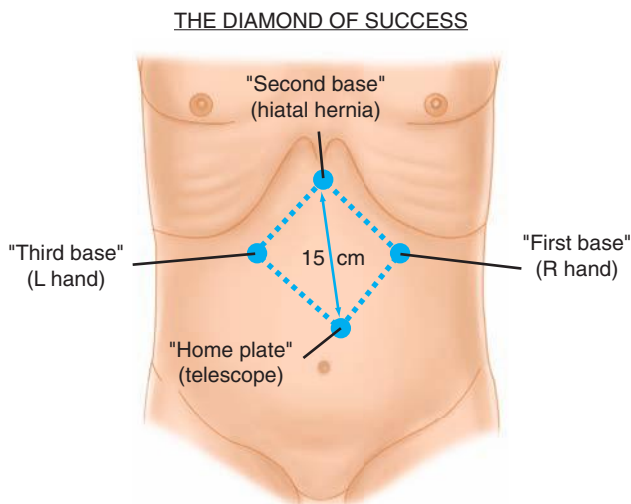


Figure 14-12. The diamond configuration created by placing the telescope between the left and the right hand, recessed from the target by about 15 cm. The distance between the left and the right hand is also ideally 10 to 15 cm. In this "baseball diamond" configuration, the surgical target occupies the second base position.

The position of the operating table should permit the surgeon to work with both elbows in at the sides, with arms bent 90° at the elbow.⁴⁹ It usually is necessary to alter the operating table position with left or right tilt with the patient in the Trendelenburg or reverse Trendelenburg position, depending on the operative field.^{50,51}

Imaging Systems

Two methods of videoendoscopic imaging are widely used. Both methods use a camera with a CCD, which is an array of photosensitive sensor elements (pixels) that convert the incoming light intensity to an electric charge. The electric charge is subsequently converted into a black-and-white image.⁵²

With videoendoscopy, the CCD chip is placed on the internal end of a long, flexible endoscope. With older flexible endoscopes, thin quartz fibers are packed together in a bundle, and the CCD camera is mounted on the external end of the endoscope. Most standard GI endoscopes have the CCD chip at the distal

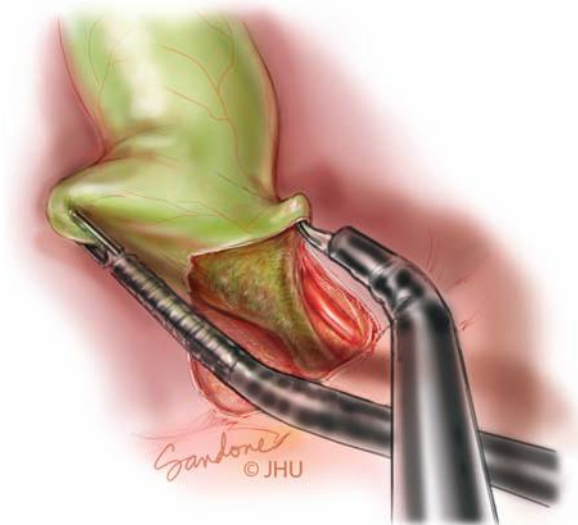


Figure 14-13. The single point of abdominal entry for trocars often requires that the surgeon work in a crossed hands fashion. (Illustration by Corinne Sandone. © 2014 JHU. Reprinted with permission.)

end, but small, delicate choledochoscopes and nephroscopes are equipped with fiber-optic bundles.⁵³ Distally mounted CCD chips were developed for laparoscopy as well but remain very expensive and therefore have not become as widely used.

Video cameras come in two basic designs. Nearly all laparoscopic cameras contain a red, green, and blue input, and are identical to the color cameras used for television production.⁵² An additional feature of many video cameras is digital enhancement. Digital enhancement detects edges, areas where there are drastic color or light changes between two adjacent pixels.⁵⁴ By enhancing this difference, the image appears sharper and surgical resolution is improved. New laparoscopic cameras contain a high-definition (HD) chip, which increases the lines of resolution from 480 to 1080 lines. To enjoy the benefit of the clarity of HD video imaging, HD monitors also are necessary.

Priorities in a video imaging system for MIS are illumination first, resolution second, and color third. Without the first two attributes, video surgery is unsafe. Illumination and resolution are as dependent on the telescope, light source, and light cable as on the video camera used. Imaging for laparoscopy, thoracoscopy, and subcutaneous surgery uses a rigid metal telescope, usually 30 cm in length. Longer telescopes are available for obese patients and for reaching the mediastinum and deep in the pelvis from a periumbilical entry site. The standard telescope contains a series of quartz optical rods and focusing lenses.⁵⁵ Telescopes vary in size from 2 to 12 mm in diameter. Because light transmission is dependent on the cross-sectional area of the quartz rod, when the diameter of a rod/lens system is doubled, the illumination is quadrupled. Little illumination is needed in highly reflective, small spaces such as the knee, and a very small telescope will suffice. When working in the abdominal cavity, especially if blood is present, the full illumination of a 10-mm telescope usually is necessary.

Rigid telescopes may have a flat or angled end. The flat end provides a straight view (0°), and the angled end provides an oblique view (30° or 45°).⁵² Angled telescopes allow greater flexibility in viewing a wider operative field through a single trocar site (Fig. 14-14A); rotating an angled telescope changes the field of view. The use of an angled telescope has distinct advantages for most videoendoscopic procedures, particularly in visualizing the common bile duct during laparoscopic



Figure 14-14. A. The laparoscope tips come in a variety of angled configurations. All laparoscopes have a 70° field of view. A 30° -angled scope enables the surgeon to view this field at a 30° angle to the long axis of the scope.

cholecystectomy or visualizing the posterior esophagus or the tip of the spleen during laparoscopic fundoplication. Flexible tip laparoscopes offer even greater optical freedom.

Light is delivered to the endoscope through a fiber-optic light cable. These light cables are highly inefficient, losing $>90\%$ of the light delivered from the light source. Extremely bright light sources (300 watts) are necessary to provide adequate illumination for laparoscopic surgery.

The quality of the videoendoscopic image is only as good as the weakest component in the imaging chain (Fig. 14-15). Therefore, it is important to use a video monitor that has a resolution equal to or greater than the camera being used.⁵⁵ Resolution is the ability of the optical system to distinguish between line pairs. The larger the number of line pairs per millimeter, the sharper and more detailed the image. Most high-resolution monitors have up to 700 horizontal lines. HD television can deliver up to eight times more resolution than standard monitors; when combined with digital enhancement, a very sharp and well-defined image can be achieved.^{52,55} A heads-up display is a high-resolution liquid crystal monitor that is built into eyewear worn by the surgeon.⁵⁶ This technology allows the surgeon to view the endoscopic image and operative field simultaneously. The proposed advantages of heads-up display include a high-resolution monocular image, which affords the surgeon mobility and reduces vertigo and eyestrain. However, this technology has not yet been widely adopted.

Interest in three-dimensional (3-D) laparoscopy has waxed and waned. 3-D laparoscopy provides the additional depth of field that is lost with two-dimensional endosurgery and improves performance of novice laparoscopists performing complex tasks of dexterity, including suturing and knot tying.⁵⁷ The advantages of 3-D systems are less obvious to experienced laparoscopists. Additionally, because 3-D systems require the flickering of two similar images, which are resolved with special glasses, the images' edges become fuzzy and resolution is lost. The optical accommodation necessary to rectify these slightly differing images is tiring and may induce headaches when one uses these systems for a long period of time. The da Vinci robot uses a specialized laparoscope with two optical bundles on opposite sides of the telescope. A specialized binocular eyepiece receives input from two CCD chips, each capturing the image from one of the two quartz rod lens systems, thereby creating true 3-D imaging without needing to employ active or passive technologies that have made 3-D laparoscopy so disappointing.

Single-incision laparoscopy presents new challenges to visualization of the operative field. In the traditional laparoscope, the light source enters the scope at a 90° angle. That position coupled with a bulky scope handle creates crowding in an already limited space. Additionally, because the scope and instruments enter the abdomen at the same point, an adequate perspective is often unobtainable even with a 30° scope. The advent of increased length laparoscopes with lighting coming from the end and a deflectable tip now allows the surgeon to re-create a sense of internal triangulation with little compromise externally. The ability to move the shaft of the scope off line while maintaining the same image provides a greater degree of freedom for the working ports.

Energy Sources for Endoscopic and Endoluminal Surgery

Many MIS procedures use conventional energy sources, but the benefits of bloodless surgery to maintain optimal visualization

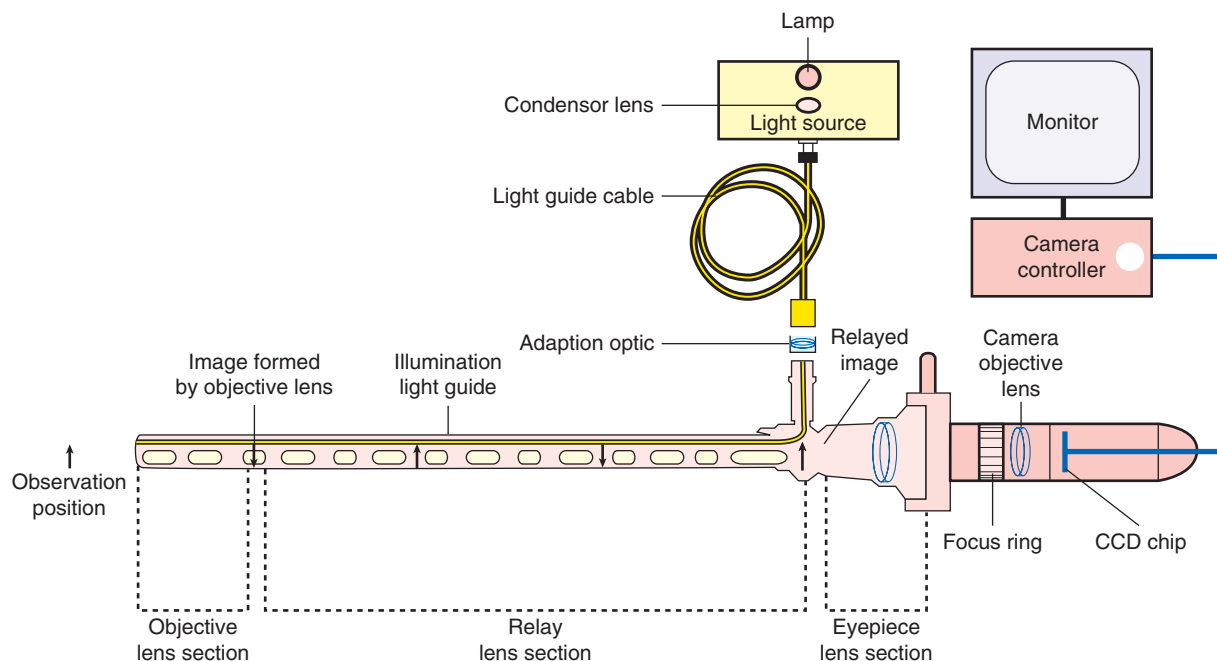


Figure 14-15. The Hopkins rod lens telescope includes a series of optical rods that effectively transmit light to the eyepiece. The video camera is placed on the eyepiece to provide the working image. The image is only as clear as the weakest link in the image chain. CCD = charge-coupled device. (Reproduced with permission from Prescher et al.⁵² Copyright Elsevier.)

have spawned new ways of applying energy. The most common energy source is RF electro-surgery using an alternating current with a frequency of 500,000 cycles/s (Hz). Tissue heating progresses through the well-known phases of coagulation (60°C [140°F]), vaporization and desiccation (100°C [212°F]), and carbonization (>200°C [392°F]).⁵⁸

The two most common methods of delivering RF electro-surgery are with monopolar and bipolar electrodes. With monopolar electro-surgery, a remote ground plate on the patient's leg or back receives the flow of electrons that originate at a point source, the surgical electrode. A fine-tipped electrode causes a high current density at the site of application and rapid tissue heating. Monopolar electro-surgery is inexpensive and easy to modulate to achieve different tissue effects.⁵⁹ A short-duration, high-voltage discharge of current (coagulation current) provides extremely rapid tissue heating. Lower-voltage, higher-wattage current (cutting current) is better for tissue desiccation and vaporization. When the surgeon desires tissue division with the least amount of thermal injury and least coagulation necrosis, a cutting current is used.

With bipolar electro-surgery, the electrons flow between two adjacent electrodes. The tissue between the two electrodes is heated and desiccated. There is little opportunity for tissue cutting when bipolar current is used alone, but the ability to coapt the electrodes across a vessel provides the best method of small-vessel coagulation without thermal injury to adjacent tissues⁶⁰ (Fig. 14-16). Advanced laparoscopic device manufacturers have leveraged the ability to selectively use bipolar energy and combined it with compressive force and a controllable blade to create a number of highly functional dissection and vessel-sealing tools.

To avoid thermal injury to adjacent structures, the laparoscopic field of view must include all uninsulated portions of the electro-surgical electrode. In addition, the integrity of the

insulation must be maintained and assured. Capacitive coupling occurs when a plastic trocar insulates the abdominal wall from the current; in turn, the current is bled off of a metal sleeve or laparoscope into the viscera⁵⁴ (Fig. 14-17A). This may result in thermal necrosis and a delayed fecal fistula. Another potential mechanism for unrecognized visceral injury may occur with the direct coupling of current to the laparoscope and adjacent bowel⁵⁸ (Fig. 14-17B).

Another method of delivering RF electro-surgery is argon beam coagulation. This is a type of monopolar electro-surgery in which a uniform field of electrons is distributed across a tissue surface by the use of a jet of argon gas. The argon gas jet distributes electrons more evenly across the surface than does spray




Figure 14-16. An example of bipolar coagulation devices. The flow of electrons passes from one electrode to the other, and the intervening tissue is heated and desiccated.

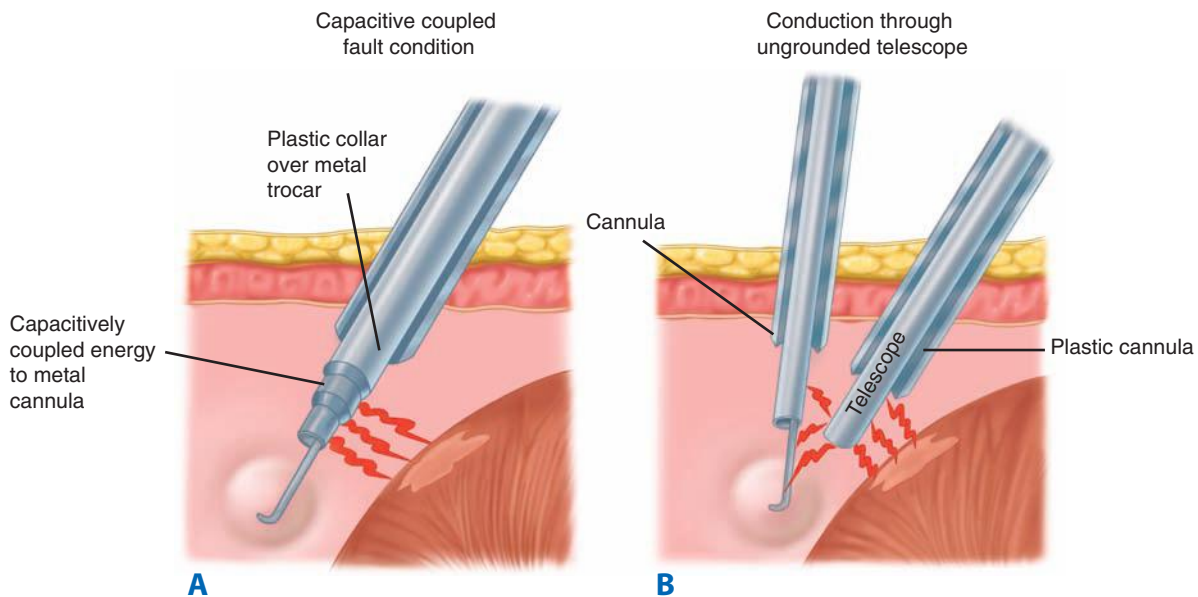


Figure 14-17. A. Capacitive coupling occurs as a result of high current density bleeding from a port sleeve or laparoscope into adjacent bowel. B. Direct coupling occurs when current is transmitted directly from the electrode to a metal instrument or laparoscope, and then into adjacent tissue. (Reproduced with permission from Odell.⁵⁸)

electrofulguration. This technology has its greatest application for coagulation of diffusely bleeding surfaces such as the cut edge of liver or spleen. It is of less value in laparoscopic procedures because the increased intra-abdominal pressures created by the argon gas jet can increase the chances of a gas embolus. It is paramount to vent the ports and closely monitor insufflation pressure when using this source of energy within the context of laparoscopy.

With endoscopic endoluminal surgery, RF alternating current in the form of a monopolar circuit represents the mainstay for procedures such as snare polypectomy, sphincterotomy, lower esophageal sphincter ablation, and biopsy.^{61,62} A grounding (return) electrode is necessary for this form of energy. Bipolar electrocoagulation is used primarily for thermal hemostasis. The electro-surgical generator is activated by a foot pedal so the endoscopist may keep both hands free during the endoscopic procedure.

Gas, liquid, and solid-state lasers have been available for medical application since the mid-1960s.⁶³ The CO₂ laser (wavelength 10.6 μm) is most appropriately used for cutting and superficial ablation of tissues. It is most helpful in locations unreachable with a scalpel such as excision of vocal cord granulomas. The CO₂ laser beam must be delivered with a series of mirrors and is therefore somewhat cumbersome to use. The next most popular laser is the neodymium yttrium-aluminum garnet (Nd:YAG) laser. Nd:YAG laser light is 1.064 μm (1064 nm) in wavelength. It is in the near-infrared portion of the spectrum and, like CO₂ laser light, is invisible to the naked eye. A unique feature of the Nd:YAG laser is that 1064-nm light is poorly absorbed by most tissue pigments and therefore travels deep into tissue.⁶⁴ Deep tissue penetration provides deep tissue heating (Fig. 14-18). For this reason, the Nd:YAG laser is capable of the greatest amount of tissue destruction with a single application.⁶³ Such capabilities make it the ideal laser for destruction of large fungating tumors of the rectosigmoid, tracheobronchial tree, or esophagus. A disadvantage is that the deep tissue heating may cause perforation of a hollow viscus.

When it is desirable to coagulate flat lesions in the cecum, a different laser should be chosen. The frequency-doubled Nd:YAG laser, also known as the KTP laser (potassium thionyl phosphate crystal is used to double the Nd:YAG frequency), provides 532-nm light. This is in the green portion of the spectrum, and at this wavelength, selective absorption by red pigments in tissue (such as hemangiomas and arteriovenous malformations) is optimal. The depth of tissue heating is intermediate, between those of the CO₂ and the Nd:YAG lasers. Coagulation (without vaporization) of superficial vascular lesions can be obtained without intestinal perforation.⁶⁴

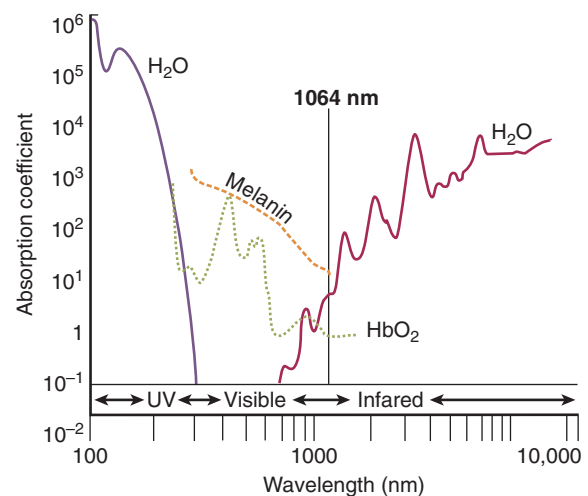


Figure 14-18. This graph shows the absorption of light by various tissue compounds (water, melanin, and oxyhemoglobin) as a function of the wavelength of the light. The nadir of the oxyhemoglobin and melanin curves is close to 1064 nm, the wavelength of the neodymium yttrium-aluminum garnet laser. (Reproduced with permission from Hunter JG, Sackier JM, eds. Minimally Invasive Surgery. New York: McGraw-Hill; 1993:28.)

In flexible GI endoscopy, the CO₂ and Nd:YAG lasers have largely been replaced by heater probes and endoluminal stents. The heater probe is a metal ball that is heated to a temperature (60–100°C [140°–212°F]) that allows coagulation of bleeding lesions without perforation.

Photodynamic therapy is a palliative treatment for obstructing cancers of the GI tract.⁶⁵ Patients are given an IV dose of porfimer sodium, which is a photosensitizing agent that is taken up by malignant cells. Two days after administration, the drug is endoscopically activated using a laser. The activated porfimer sodium generates oxygen free radicals, which kill the tumor cells. The tumor is later endoscopically débrided. The use of this modality for definitive treatment of early cancers is in experimental phases and has yet to become established.

A unique application of laser technology provides extremely rapid discharge (<10⁻⁶ s) of large amounts of energy (>10³ volts). These high-energy lasers, of which the pulsed dye laser has seen the most clinical use, allow the conversion of light energy to mechanical disruptive energy in the form of a shock wave. Such energy can be delivered through a quartz fiber, and with rapid repetitive discharges, can provide sufficient shock-wave energy to fragment kidney stones and gallstones.⁶⁶ Shock waves also may be created with miniature electric spark-plug discharge systems known as electrohydraulic lithotriptors. These devices also are inserted through thin probes for endoscopic application. Lasers have the advantage of pigment selectivity, but electrohydraulic lithotriptors are more popular because they are substantially less expensive and are more compact.

Methods of producing shock waves or heat with ultrasonic energy are also of interest. Extracorporeal shockwave lithotripsy creates focused shock waves that intensify as the focal point of the discharge is approached. When the focal point is within the body, large amounts of energy are capable of fragmenting stones. Slightly different configurations of this energy can be used to provide focused internal heating of tissues. Potential applications of this technology include the ability to noninvasively produce sufficient internal heating to destroy tissue without an incision.

A third means of using ultrasonic energy is to create rapidly oscillating instruments that are capable of heating tissue with friction; this technology represents a major step forward in energy technology.⁶⁷ An example of its application is the laparoscopic coagulation shears device (Harmonic Scalpel), which is capable of coagulating and dividing blood vessels by first occluding them and then providing sufficient heat to weld the blood vessel walls together and to divide the vessel. This non-electric method of coagulating and dividing tissue with a minimal amount of collateral damage has facilitated the performance of numerous endosurgical procedures.⁶⁸ It is especially useful in the control of bleeding from medium-sized vessels that are too big to manage with monopolar electrocautery and require bipolar desiccation followed by cutting.

Instrumentation

Hand instruments for MIS usually are duplications of conventional surgical instruments made longer, thinner, and smaller at the tip. It is important to remember that when grasping tissue with laparoscopic instruments, a greater force is applied over a smaller surface area, which increases the risk for perforation or injury.⁶⁹

Certain conventional instruments such as scissors are easy to reproduce with a diameter of 3 to 5 mm and a length of 20 to 45 cm, but other instruments such as forceps and clamps cannot

provide remote access. Different configurations of graspers were developed to replace the various configurations of surgical forceps and clamps. Standard hand instruments are 5 mm in diameter and 30 cm in length, but smaller and shorter hand instruments are now available for pediatric surgery, for microlaparoscopic surgery, and for arthroscopic procedures.⁶⁹ A unique laparoscopic hand instrument is the monopolar electrical hook. This device usually is configured with a suction and irrigation apparatus to eliminate smoke and blood from the operative field. The monopolar hook allows tenting of tissue over a bare metal wire with subsequent coagulation and division of the tissue.

Instrumentation for NOTES is still evolving, but many long micrograspers, microscissors, electrocautery adapters, suturing devices, clip applicators, and visceral closure devices are in design and application. These instruments often require an entirely different endoscopic platform requiring manipulation by a surgeon and assistant to accomplish complex maneuvers. Techniques such as mucosotomy, hydrodissection, and clip application require specialized training. The sheer size of the instrumentation often requires an overtube to allow easy exchange throughout the procedure. Instrumentation for SILS seeks to restore the surgeon's ability to triangulate the left and right hands through variation in length, mechanical articulation, or curved design. Additionally, a lower profile camera head helps reduce the instrument crowding that occurs at the single point of abdominal entry.

Robotic Surgery

The term robot defines a device that has been programmed to perform specific tasks in place of those usually performed by people. The devices that have earned the title "surgical robots" would be more aptly termed computer-enhanced surgical devices, as they are controlled entirely by the surgeon for the purpose of improving performance. The first computer-assisted surgical device was the laparoscopic camera holder (Aesop, Computer Motion, Goleta, CA), which enabled the surgeon to maneuver the laparoscope either with a hand control, foot control, or voice activation. Randomized studies with such camera holders demonstrated a reduction in operative time, steadier image, and a reduction in the number of required laparoscope cleanings.⁷⁰ This device had the advantage of eliminating the need for a human camera holder, which served to free valuable OR personnel for other duties. This technology has now been eclipsed by simpler systems using passive positioning of the camera with a mechanical arm, but the benefits of a steadier image and fewer members of the OR team remain.

The major revolution in robotic surgery was the development of a master-slave surgical platform that returned the wrist to laparoscopic surgery and improved manual dexterity by developing an ergonomically comfortable work station, with 3-D imaging, tremor elimination, and scaling of movement (e.g., large, gross hand movements can be scaled down to allow suturing with microsurgical precision) (Fig. 14-19). The most recent iteration of the robotic platform features a second console slave enabling greater assisting and teaching opportunities. The surgeon is physically separated from the operating table, and the working arms of the device are placed over the patient (Fig. 14-20). An assistant remains at the bedside and changes the instruments as needed, providing retraction as needed to facilitate the procedure. The robotic platform (da Vinci, Intuitive Surgical, Sunnyvale, CA) was initially greeted with

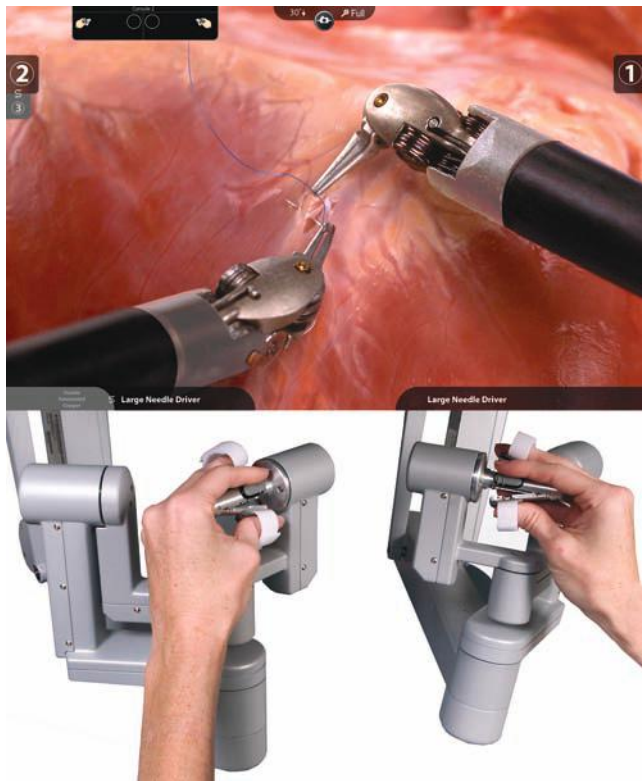


Figure 14-19. Robotic instruments and hand controls. The surgeon is in a sitting position, and the arms and wrists are in an ergonomic and relaxed position.

some skepticism by expert laparoscopists, as it was difficult to prove additional value for operations performed with the da Vinci robot. Not only were the operations longer and the equipment more expensive, but additional quality could not be demonstrated. Two randomized controlled trials compared robotic and conventional laparoscopic approaches to Nissen fundoplication.^{71,72} In both of these trials, the operative time was longer for robotic surgery, and there was no difference in ultimate outcome. Similar results were achieved for laparoscopic cholecystectomy.⁷³ Nevertheless, the increased dexterity provided by the da Vinci robot convinced many surgeons and health administrators that robotic platforms were worthy of investment, for marketing purposes if for no other reason. The success story for computer-enhanced surgery with the da Vinci started with cardiac surgery and migrated to the pelvis. Mitral valve surgery, performed with right thoracoscopic access, became one of the more popular procedures performed with the robot.⁷⁴

To date, a myriad of publications have demonstrated success performing procedures from thyroidectomies to colectomies with total mesorectal excision. Almost any procedure performed laparoscopically has been attempted robotically, although true advantage is demonstrated only very sparingly. In most cases, increased cost and operative time challenge the notion of “better.”

The tidal wave of enthusiasm for robotic surgery came when most minimally invasive urologists declared robotic prostatectomy to be preferable to laparoscopic and open prostatectomy.⁷⁵ The great advantage—it would appear—of robotic

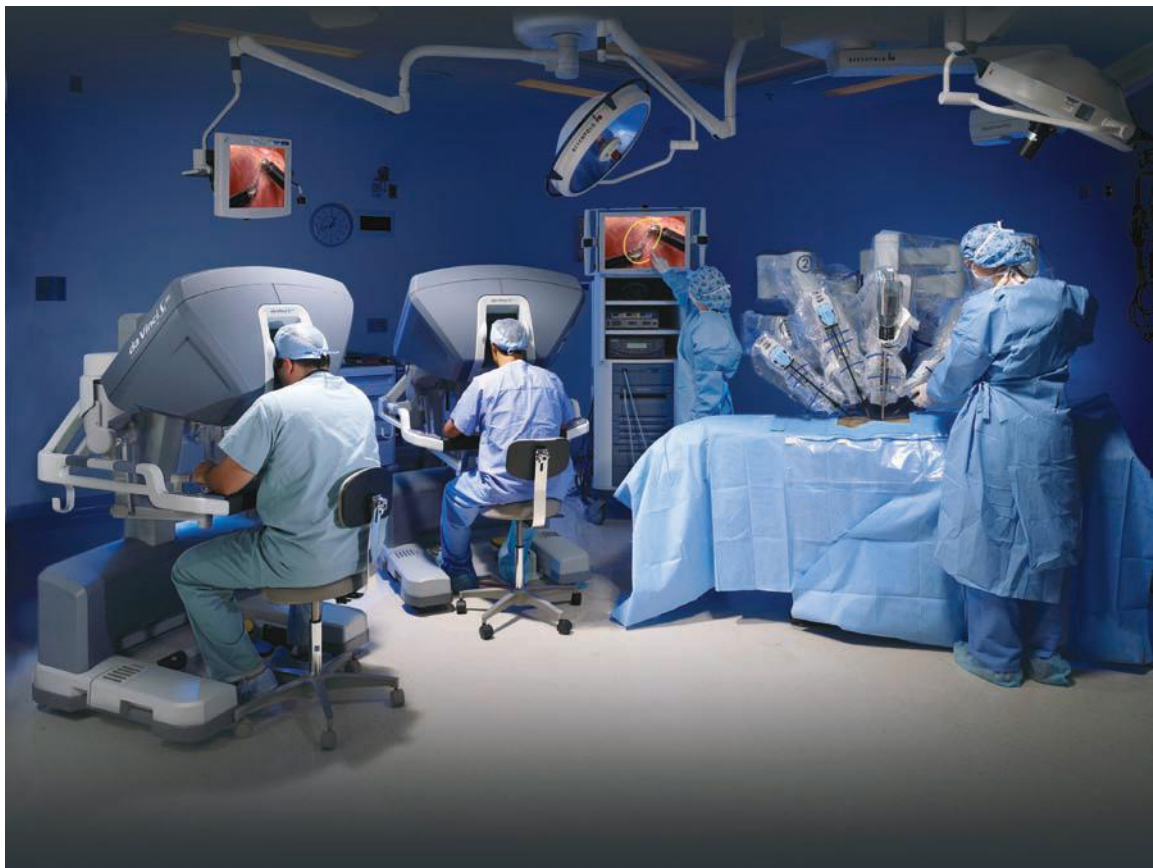

Figure 14-20. Room setup and position of surgeon and assistant for robotic surgery. (©2013 Intuitive Surgical, Inc. Reprinted with permission.)

prostatectomy is the ability to visualize and spare the pelvic nerves responsible for erectile function. In addition, the creation of the neocystourethrotomy, following prostatectomy, was greatly facilitated by needle holders and graspers with a wrist in them. Female pelvic surgery with the da Vinci robot is also reaching wide appeal. The magnified imaging provided makes this approach ideal for microsurgical tasks such as reanastomosis of the Fallopian tubes.

The final frontier for computer-enhanced surgery is the promise of telesurgery, in which the surgeon is a great distance from the patient (e.g., combat or space). This application has rarely been used, as the safety provided by having the surgeon at bedside cannot be sacrificed to prove the concept. However, remote laparoscopic cholecystectomy has been performed when a team of surgeons located in New York performed a cholecystectomy on a patient located in France.⁷⁶

Endoluminal and Endovascular Surgery

The fields of vascular surgery, interventional radiology, neuroradiology, gastroenterology, general surgery, pulmonology, and urology all encounter clinical scenarios that require the urgent restoration of luminal patency. Based on this need, fundamental techniques have been pioneered that are applicable to all specialties and virtually every organ system. As a result, all minimally invasive surgical procedures, from coronary artery angioplasty to palliation of pancreatic malignancy, involve the use of access devices, catheters, guidewires, balloon dilators, stents, and other devices (e.g., lasers, atherectomy catheters) that are capable of opening up the occluded biologic cylinder⁷⁷ (Table 14-2). Endoluminal balloon dilators may be inserted through an endoscope, or they may be fluoroscopically guided. Balloon dilators all have low compliance—that is, the balloons do not stretch as the pressure within the balloon is increased. The high pressures achievable in the balloon create radial expansion of the narrowed vessel or orifice, usually disrupting

the atherosclerotic plaque, the fibrotic stricture, or the muscular band (e.g., esophageal achalasia).⁷⁸

Once the dilation has been attained, it is frequently beneficial to hold the lumen open with a stent.⁷⁹ Stenting is particularly valuable in treating malignant lesions and atherosclerotic occlusions or aneurysmal disease (Fig. 14-21). Stenting is also of value to seal leaky cylinders, including aortic dissections, traumatic vascular injuries, leaking GI anastomoses, and fistulas. Stenting usually is not applicable for long-term management of benign GI strictures except in patients with limited life expectancy (Fig. 14-22).⁷⁹⁻⁸¹

A variety of stents are available that are divided into six basic categories: plastic stents, metal stents, drug-eluting stents (to decrease fibrovascular hyperplasia), covered metal stents, anchored stent grafts, and removable covered plastic stents⁸⁰ (Fig. 14-23). Plastic stents came first and are used widely as endoprotheses for temporary bypass of obstructions in the biliary or urinary systems. Metal stents generally are delivered over a balloon and expanded with the balloon to the desired size. These metal stents usually are made of titanium or nitinol and are still used in coronary stenting. A chemotherapeutic agent

Table 14-2

Modalities and techniques of restoring luminal patency

MODALITY	TECHNIQUE
Core out	Photodynamic therapy Laser Coagulation Endoscopic biopsy forceps Chemical Ultrasound
Fracture	Ultrasound Endoscopic biopsy Balloon
Dilate	Balloon Bougie Angioplasty Endoscope
Bypass	Transvenous intrahepatic portosystemic shunt Surgical (synthetic or autologous conduit)
Stent	Self-expanding metal stent Plastic stent

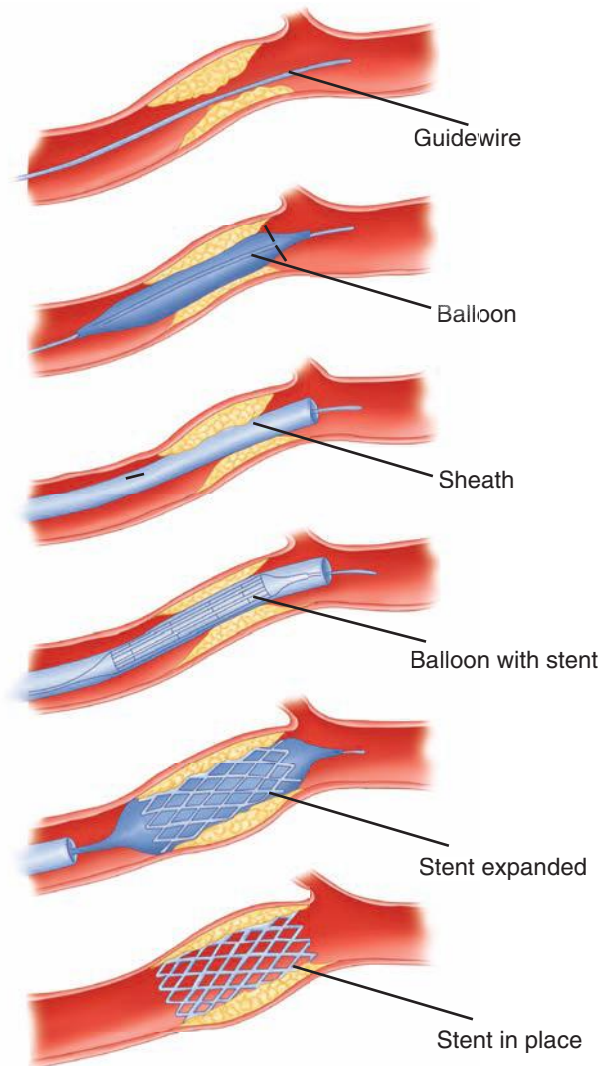
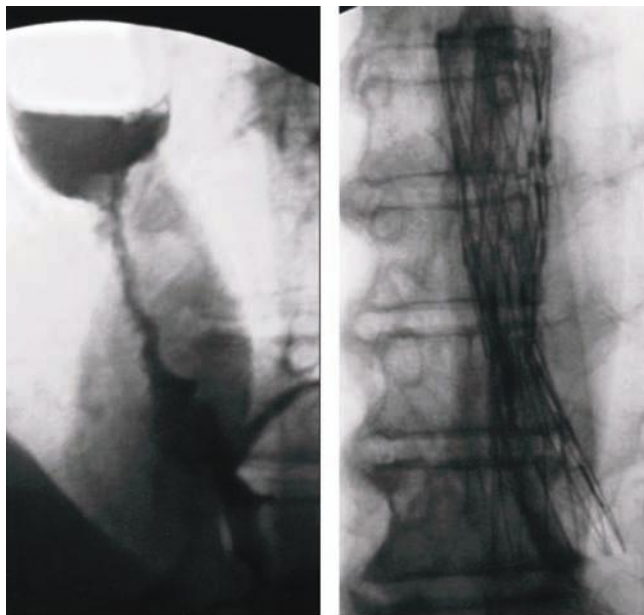


Figure 14-21. The deployment of a metal stent across an isolated vessel stenosis is illustrated. (Reproduced with permission from Hunter JG, Sackier JM, eds. *Minimally Invasive Surgery*. New York: McGraw-Hill; 1993:235.)



A **B**
Figure 14-22. This is an esophagram in a patient with severe dysphagia secondary to advanced esophageal cancer (**A**) before and (**B**) after placement of a covered self-expanding metal stent.

was added to coronary stents several years ago to decrease endothelial proliferation. These drug-eluting stents provide greater long-term patency but require long-term anticoagulation with antiplatelet agents to prevent thrombosis.⁸² Coated




Figure 14-23. Covered self-expanding metal stents. These devices can be placed fluoroscopically or endoscopically.

metal stents are used to prevent tissue ingrowth. Ingrowth may be an advantage in preventing stent migration, but such tissue ingrowth may occlude the lumen and cause obstruction anew. This is a particular problem when stents are used for palliation of GI malignant growth and may be a problem for the long-term use of stents in vascular disease. Filling the interstices with Silastic or other materials may prevent tumor ingrowth but also makes stent migration more likely. In an effort to minimize stent migration, stents have been incorporated with hooks and barbs at the proximal end of the stent to anchor it to the wall of the vessel. Endovascular stenting of aortic aneurysms has nearly replaced open surgery for this condition. Lastly, self-expanding plastic stents have been developed as temporary devices to be used in the GI tract to close internal fistulas and bridge leaking anastomoses.

Natural Orifice Transluminal Endoscopic Surgery

The use of the flexible endoscope to enter the GI, urinary, or reproductive tracts and then traverse the wall of the structure to enter the peritoneal cavity, the mediastinum, or the chest has strong appeal to patients wishing to avoid scars and pain caused by abdominal wall trauma. In truth, transluminal surgery **4▶** has been performed in the stomach for a long time, either from the inside out (e.g., percutaneous, PEG, and transgastric pseudocyst drainage) or from the outside in (e.g., laparoscopic assisted intragastric tumor resection). The catalyzing events for NOTES were the demonstration that a porcine gallbladder could be removed with a flexible endoscope passed through the wall of the stomach and then removed through the mouth, and the demonstration in a series of 10 human cases from India of the ability to perform transgastric appendectomy. Since that time, a great deal of money has been invested by endoscopic and MIS companies to help surgeons and gastroenterologists explore this new territory. Systemic inflammatory markers such as C-reactive protein, tumor necrosis factor- α , interleukin (IL)- 1β , and IL-6 have been shown to be similar in transgastric and transcolonic NOTES when compared to laparoscopy in porcine models.⁸³ Concerns about the safety of transluminal access and limitations in equipment remain the greatest barriers to expansion. To date, the most headline-grabbing procedures have been the transvaginal and transgastric removal of the gallbladder⁸⁴⁻⁸⁶ (Fig. 14-24). To ensure safety, all human cases thus far have involved laparoscopic assistance to aid in retraction and ensure adequate closure of the stomach or vagina. To date, thousands of transvaginal and transgastric procedures have been performed internationally, with two large registries demonstrating noninferiority to conventional laparoscopy.⁸⁷ The fact that the vast majority of these procedures are being done transvaginally creates an obvious limitation in applicability.

The rapid growth of endoscopic technology catalyzed by NOTES has already spun off new technologies capable of performing a wide variety of endoscopic surgical procedures from EMR, to ablation of Barrett's esophagus, to creation of competent antireflux valves in patients with gastroesophageal reflux disease.

POEM has shown promise as a NOTES treatment for esophageal achalasia.⁸⁸ In this procedure, a 1.5- to 2-cm mucosotomy is created within the anterior esophagus 10 cm proximal to the gastroesophageal junction. A submucosal tunnel is then created using a combination of electrocautery, hydrodissection, and carbon dioxide insufflation. The scope is advanced

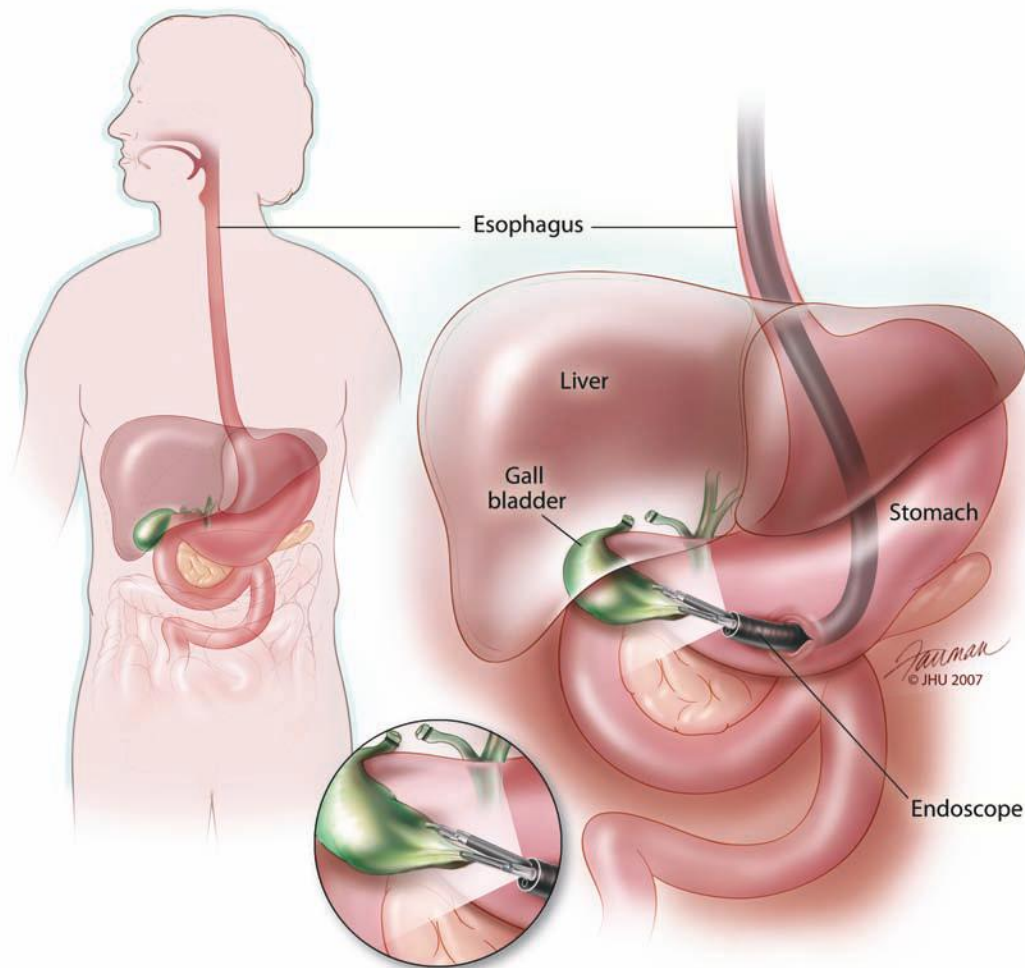


Figure 14-24. Transgastric cholecystectomy using natural orifice transluminal endoscopic surgery technology and one to three laparoscopic ports has been performed occasionally in several locations around the world. (Illustration by Jennifer Fairman. © 2007 JHU. Reprinted with permission.)

beyond the gastroesophageal junction, and a circular myotomy is performed avoiding disruption of the longitudinal fibers. The mucosotomy is then closed using endoscopic clips (Fig. 14-25). Over 1000 clinical POEM cases have been performed worldwide. Data from expert NOTES surgeons suggest that this selective myotomy avoids abdominal trauma and minimally disrupts the normal anatomic characteristics of the gastroesophageal junction while providing significant relief of symptoms.⁸⁹ Randomized clinical trials and long-term follow-up need to be performed to further evaluate efficacy.

Although this application is still considered experimental, there is little doubt that when equivalent operations can be performed with less pain, fewer scars, and less disability, patients will flock to it. NOTES procedures are associated with an increased mental workload and significant learning curve for even experienced surgical endoscopists. Surgeons should engage only when they can perform these procedures with the safety and efficacy demanded by our profession.

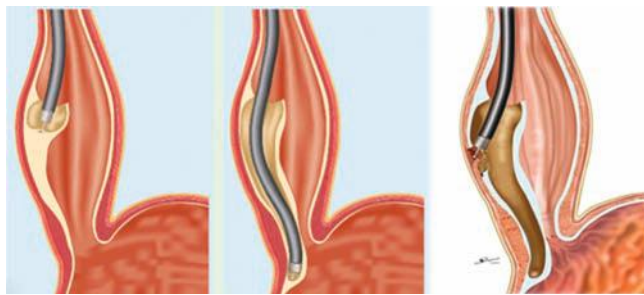
Single-Incision Laparoscopic Surgery

As a surgical technique, SILS seems to be a natural progression from conventional laparoscopic surgery. As surgeons sought to reduce the number and size of abdominal wall trocars and NOTES procedures necessitated laparoscopic surveillance, the

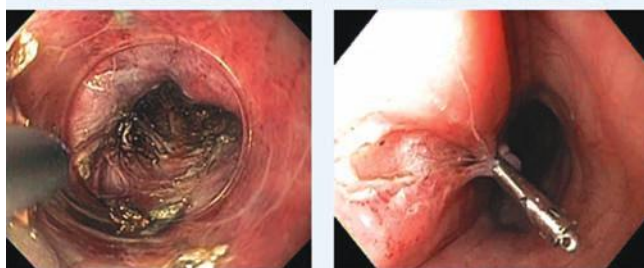
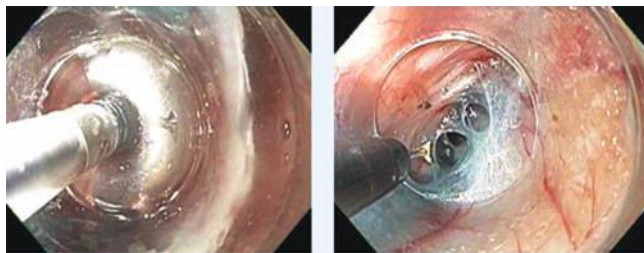
idea of a hybridization took off. An incision in the umbilicus, a preexisting scar, is thought to be less painful, have fewer wound complications, lead to quicker return to activity, and have a better cosmetic appearance than conventional laparoscopy. Perhaps one of the earliest examples of SILS is the application of laparoscopic instrumentation to resect lesions in the rectum or sigmoid colon. Using the anus as the portal of entry, transanal endoscopic microsurgery (TEMS) employs a specialized multichannel trocar to reach lesions located 8 to 18 cm away from the anal verge (Fig. 14-26).

More deformable versions of these complex trocars have been developed with features to allow insufflation and be amenable to maintaining a seal within the natural orifice of the umbilicus (see Fig. 14-11). Ports typically contain three or four channels. The latter often affords the ability to place a dedicated retractor.

There are many challenges faced by the operating surgeon in SILS procedures. These include crowded trocar placement, a lack of triangulation of left and right hand instruments, **5▶** frequent crossing or clashing of instruments, limited visualization, and limited retraction ability. These challenges are mitigated by surgeon experience and the development of specialized instruments. Articulating or curved instruments of varying lengths and an extended length can improve working space.



A



B

Figure 14-25. **A.** Peroral endoscopic esophageal myotomy for the treatment of achalasia. **B.** Serial images showing overtube in submucosal tunnel, using needle knife to divide circular muscle fibers of esophagus, and closure of myotomy with clips. (**A.** From Inoue H, Minami H, Kobayashi Y, et al. *Peroral endoscopic myotomy (POEM) for esophageal achalasia*. *Endoscopy*. 2010;42:265-271. Thieme. **B.** From Rieder E, Dunst CM, Kastenmeier AS, et al. *Development and technique of peroral endoscopic myotomy (POEM) for achalasia*. *Eur Surg*. 2011;43/3:140-145. With kind permission from Springer Science + Business Media.)

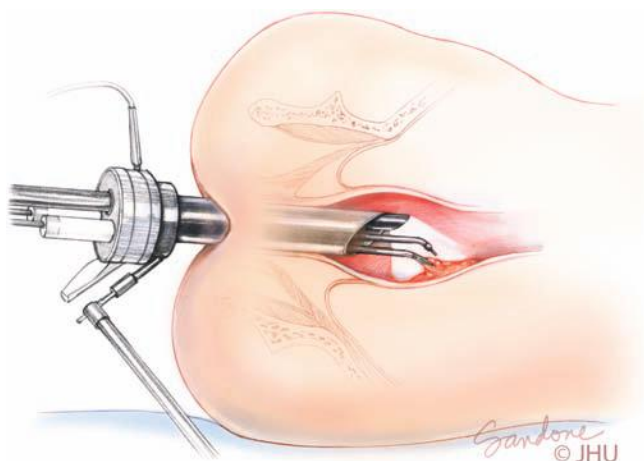


Figure 14-26. Transanal endoscopic microsurgery scope. (Illustration by Corinne Sandone. © 2014 JHU. Reprinted with permission.)

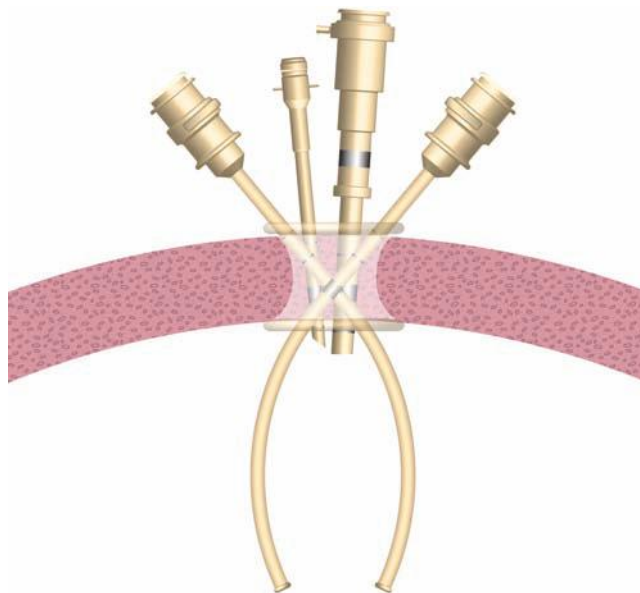


Figure 14-27. Example of curved instruments used in single-incision laparoscopic surgery. (©2013 Intuitive Surgical, Inc. Reprinted with permission.)

Curved instruments are typically reusable and offer less clutter than their more sophisticated counterparts, providing some cost reduction (Fig. 14-27). A low-profile HD scope with or without a deflectable tip can improve visualization greatly. Even with such instrumentation, the learning curve is very steep, particularly when the surgeon is forced to work in a cross-handed technique. The accomplished SILS surgeon will possess a tool bag of innovative strategies to retract structures like the gallbladder away from the operative field. These tricks may range from the use of percutaneous needlescopic instruments to the application of transfascial sutures. Expert consensus recommendations for efficient SILS are shown in Tables 14-3 and 14-4.⁸ When performing SILS procedures, it is imperative to follow proven tenets of operative conduct such as visualizing the “critical view” of safety in a laparoscopic cholecystectomy. As safety should always be the paramount concern, the addition of extra trocars or conversion to traditional laparoscopy should not be considered a failure.

Contraindications include those true of traditional laparoscopy. Relative contraindications include previous surgery and high body mass index (BMI). Patients with a high BMI or

Table 14-3

Expert panel recommendations for accomplishing single-incision laparoscopic surgery efficiently

Multichannel port preferably to be placed intraumbilically, but an extraumbilical approach can be used in certain cases
 Extra ports should be used where there is a clinical need
 When applicable, sutures can be useful for added retraction
 Closure should be accomplished using sutures of absorbable material placed either continuously or interrupted
 Skin should be closed with absorbable sutures or glue

Source: Ahmed I, Cianco F, Ferrar V, et al. Current status of single-incision laparoscopic surgery: European experts' views. *Surg Laparosc Endosc Percutan Tech*. 2012;22(3):194-199.

Table 14-4

Expert panel recommendations for single-incision laparoscopic surgery equipment and instrumentation

RECOMMENDED EQUIPMENT/ INSTRUMENTATION	BENEFIT TO SURGEON
Slimline instruments with low-profile design	Reduces internal and external clashing
Varied-length instruments	Reduces extracorporeal clashing
Longer instruments	Advantageous for reaching the surgical field
Articulating (or prebent) instruments	Restore triangulation
Small-diameter, low-profile angle scope	Reduces clashing by providing additional space
High-definition camera	Achieves high-quality images for intraoperative visualization

Source: Ahmed I, Cianco F, Ferrar V, et al. Current status of single-incision laparoscopic surgery: European experts' views. *Surg Laparosc Endosc Percutan Tech.* 2012;22(3):194-199.

central obesity can pose a challenge because the umbilicus may be located far from operative target. Size and morphology of the target organ should always be considered when doing SILS.

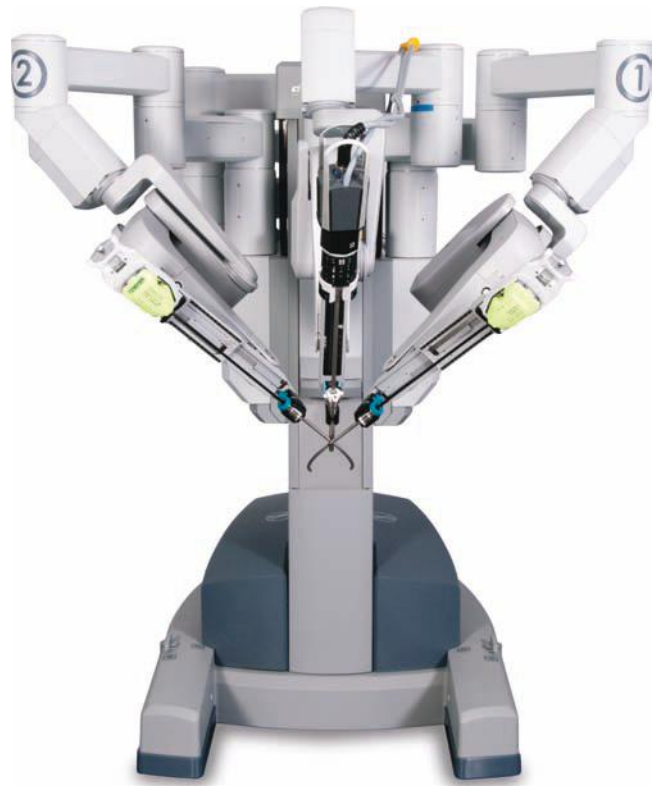Many studies have demonstrated equivalency to standard laparoscopic procedures regarding intraoperative and postoperative complications. However, it is questionable what the full benefit of the dramatic reduction in ergonomics and the increase in complexity provide beyond an improved cosmetic appearance. This is in large part due to the already improved benefits of laparoscopic surgery.

A meta-analysis performed by Ahmed and colleagues in 2010 found the conversion rate from SILS to conventional laparoscopy to be 0% to 24% for cholecystectomies, 0% to 41% for appendectomies, and 0% to 33% for nephrectomies.⁹⁰ The most common complications were intra-abdominal abscesses and wound infections. The recently released robotics application may provide the bridge necessary to bypass the significant technical skills learning curve required to operate through a single site (Fig. 14-28).

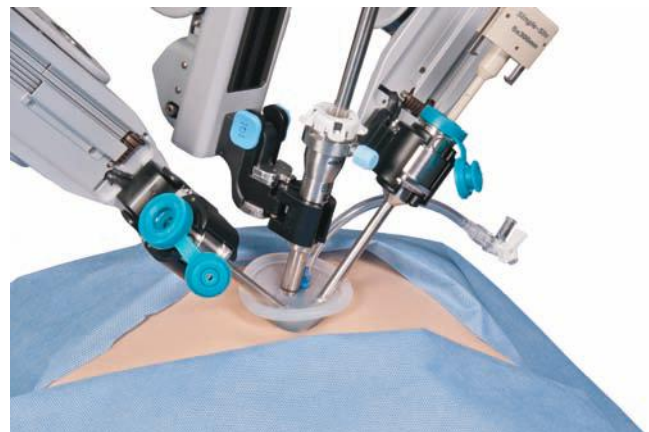
SPECIAL CONSIDERATIONS

Pediatric Laparoscopy

The advantages of MIS in children may be more significant than in the adult population. MIS in the adolescent is little different from that in the adult, and standard instrumentation and trocar positions usually can be used. However, laparoscopy in the infant and young child requires specialized instrumentation. The instruments are shorter (15–20 cm), and many are 3 mm in diameter rather than 5 mm. Because the abdomen of the child is much smaller than that of the adult, a 5-mm telescope provides sufficient illumination for most operations. The development of 5-mm clippers and bipolar devices has obviated the need for 10-mm trocars in pediatric laparoscopy.⁹¹ Because



A



B

Figure 14-28. A and B. Robotic single-incision surgery platform. (©2013 Intuitive Surgical, Inc. Reprinted with permission.)

the abdominal wall is much thinner in infants, a pneumoperitoneum pressure of 8 mmHg can provide adequate exposure. DVT is rare in children, so prophylaxis against thrombosis probably is unnecessary. A wide variety of pediatric surgical procedures are frequently performed with MIS access, from pull-through procedures for colonic aganglionosis (Hirschsprung's disease) to repair of congenital diaphragmatic hernias.⁹²

Laparoscopy during Pregnancy

Concerns about the safety of laparoscopic cholecystectomy or appendectomy in the pregnant patient have been thoroughly investigated and are readily managed. Access to the abdomen in the pregnant patient should take into consideration the height of the uterine fundus, which reaches the umbilicus at

6► 20 weeks. In order not to damage the uterus or its blood supply, most surgeons feel that the open (Hasson) approach should be used in favor of direct puncture laparoscopy. The patient should be positioned slightly on the left side to avoid compression of the vena cava by the uterus. Because pregnancy poses a risk for thromboembolism, sequential compression devices are essential for all procedures. Fetal acidosis induced by maternal hypercarbia also has been raised as a concern. The arterial pH of the fetus follows the pH of the mother linearly; and therefore, fetal acidosis may be prevented by avoiding a respiratory acidosis in the mother.⁹³ The pneumoperitoneum pressure induced by laparoscopy is not a safety issue either as it has been proved that mid-pregnancy uterine contractions provide a much greater pressure in utero than a pneumoperitoneum of 15 mmHg. More than 100 cases of laparoscopic cholecystectomy in pregnancy have been reported with uniformly good results.⁹⁴ The operation should be performed during the second trimester of pregnancy if possible. Protection of the fetus against intraoperative x-rays is imperative. Some believe it advisable to track fetal pulse rates with a transvaginal ultrasound probe; however, the significance of fetal tachycardia or bradycardia is a bit unclear in the second trimester of pregnancy. To be prudent, however, heart rate decelerations reversibly associated with pneumoperitoneum creation might signal the need to convert to open cholecystectomy or appendectomy.

Minimally Invasive Surgery and Cancer Treatment

MIS techniques have been used for many decades to provide palliation for the patient with an obstructive cancer. Laser treatment, intracavitary radiation, stenting, and dilation are outpatient techniques that can be used to reestablish the continuity of an obstructed esophagus, bile duct, ureter, or airway. MIS techniques also have been used in the staging of cancer. Mediastinoscopy is still used occasionally before thoracotomy to assess the status of the mediastinal lymph nodes. Laparoscopy also is used to assess the liver in patients being evaluated for pancreatic, gastric, or hepatic resection. New technology and greater surgical skills allow for accurate minimally invasive staging of cancer.⁹⁵ Occasionally, it is appropriate to perform palliative measures (e.g., laparoscopic gastrojejunostomy to bypass a pancreatic cancer) at the time of diagnostic laparoscopy if diagnostic findings preclude attempts at curative resection.

Initially controversial, the role of MIS to provide a safe curative treatment of cancer has proven to be no different from the principles of open surgery. All gross and microscopic tumor should be removed (an R0 resection), and an adequate lymphadenectomy should be performed to allow accurate staging. Generally, this number has been 10 to 15 lymph nodes, although there is still debate as to the value of more extensive lymphadenectomy. All of the major abdominal cancer operations have been performed with laparoscopy. Of the three major cancer resections of GI cancer (liver lobe, pancreatic head, and esophagus), only esophagectomy is routinely performed by a fair number of centers.^{96,97} Laparoscopic hepatectomy has attracted a loyal following, and distal pancreatectomy frequently is performed with laparoscopic access. In Japan, laparoscopic-assisted gastrectomy has become quite popular for early gastric cancer, an epidemic in Japan far exceeding that of colon cancer in North America and Northern Europe. The most common cancer operation performed laparoscopically is segmental colectomy, which has proven itself safe and efficacious in a multicenter controlled randomized trial.⁹⁸

7►

Considerations in the Elderly and Infirm

Laparoscopic cholecystectomy has made possible the removal of a symptomatic gallbladder in many patients previously thought to be too elderly or too ill to undergo a laparotomy. Older patients are more likely to require conversion to celiotomy because of disease chronicity.⁹⁸

Operations on these patients require close monitoring of anesthesia. The intraoperative management of these patients may be more difficult with laparoscopic access than with open access. The advantage of MIS lies in what happens after the operation. Much of the morbidity of surgery in the elderly is a result of impaired mobility. In addition, pulmonary complications, urinary tract sepsis, DVT, pulmonary embolism, congestive heart failure, and myocardial infarction often are the result of improper fluid management and decreased mobility. By allowing rapid and early mobilization, laparoscopic surgery has made possible the safe performance of procedures in the elderly and infirm.

Cirrhosis and Portal Hypertension

Patients with hepatic insufficiency pose a significant challenge for any type of surgical intervention.⁹⁹ The ultimate surgical outcome in this population relates directly to the degree of underlying hepatic dysfunction.¹⁰⁰ Often, this group of patients has minimal reserve, and the stress of an operation will trigger complete hepatic failure or hepatorenal syndrome. These patients are at risk for major hemorrhage at all levels, including trocar insertion, operative dissection in a field of dilated veins, and secondary to an underlying coagulopathy. Additionally, ascitic leak from a port site may occur, leading to bacterial peritonitis. Therefore, a watertight port site closure should be carried out in all patients.

It is essential that the surgeon be aware of the severity of hepatic cirrhosis as judged by a Model of End-Stage Liver Disease (MELD) score or Child's classification. Additionally, the presence of portal hypertension is a relative contraindication to laparoscopic surgery until the portal pressures are reduced with portal decompression. For example, if a patient has an incarcerated umbilical hernia and ascites, a preoperative paracentesis or transjugular intrahepatic portosystemic shunt procedure in conjunction with aggressive diuresis may be considered. Because these patients commonly are intravascularly depleted, insufflation pressures should be reduced to prevent a decrease in cardiac output, and minimal amounts of Na⁺-sparing IV fluids should be given.

Economics of Minimally Invasive Surgery

Minimally invasive surgical procedures reduce the costs of surgery most when length of hospital stay can be shortened and return to work is quickened. For example, shorter hospital stays can be demonstrated in laparoscopic cholecystectomy, Nissen fundoplication, splenectomy, and adrenalectomy. Procedures such as inguinal herniorrhaphy that are already performed as outpatient procedures are less likely to provide cost savings. Procedures that still require a 4- to 7-day hospitalization, such as laparoscopy-assisted colectomy, are less likely to deliver a lower bottom line than their open surgery counterparts. Nonetheless, with responsible use of disposable instrumentation and a commitment to the most effective use of the inpatient setting, most laparoscopic procedures can be made less expensive than their conventional equivalents.

Education and Skill Acquisition

Historically, surgeons in training (residents, registrars, and fellows) acquired their skills in minimally invasive techniques through a series of operative experiences of graded complexity. This training occurred on patients. Although such a paradigm did not compromise patient safety, learning in the OR is costly. In addition, the recent worldwide constraint placed on resident work hours makes it attractive to teach laparoscopic skills outside of the OR.

Skills labs started at nearly every surgical training center in the 1990s with low fidelity box-type trainers. These were rudimentary simulated abdominal cavities with a video camera, monitor, trocars, laparoscopic instruments, and target models. These targets were often as simple as a pegboard and rubber rings, or a latex drain to practice suturing and knot tying. Virtual reality training devices present a unique opportunity to improve and enhance experiential learning in endoscopy and laparoscopy for all surgeons. This technology has the advantage of enabling objective measurement of psychomotor skills, which can be used to determine progress in skill acquisition and, ultimately, technical competency.¹⁰¹ Several of these devices have been validated as a means of measuring proficiency in skill performance. More importantly, training on virtual reality platforms has proven to translate to improved operative performance in randomized trials.^{102,103} Currently surgical skills labs are mandatory for Residency Review Committee credentialing.

8▶ Successful completion of the Fundamentals of Laparoscopic Surgery (FLS) technical and cognitive examination became a mandatory prerequisite for the American Board of Surgery qualification examination in general surgery in 2010. In the future, institutions may require simulator training to the expert level as a prerequisite for performance of laparoscopic procedures in the OR. The Fundamental of Endoscopic Surgery (FES) and Fundamentals of Robotic Surgery (FRS) high stakes exams are both on the horizon for future surgical trainees. The American College of Surgeons has taken a leadership position in accrediting skills labs across the world as American College of Surgeons–accredited educational institutes.

Telementoring

In response to the Institute of Medicine's call for the development of unique technologic solutions to deliver health care to rural and underserved areas, surgeons are beginning to explore the feasibility of telementoring. Teleconsultation or telementoring

is two-way audio and visual communication between two geographically separated providers. This communication can take place in the office setting or directly in the OR when complex scenarios are encountered. Although local communication channels may limit its performance in rural areas, the technology is available and currently is being used, especially in states and provinces with large geographically remote populations.¹⁰³

Innovation and Introduction of New Procedures

The revolution in minimally invasive general surgery, which occurred in 1990, created ethical challenges for the profession. The problem was this: If competence is gained from experience, how was the surgeon to climb the competence curve (otherwise known as the learning curve) without injuring patients? If it was indeed impossible to achieve competence without making mistakes along the way, how should one effectively communicate this to patients such that they understand the weight of their decisions? Even more fundamentally important is determining the path that should be followed before one recruits the first patient for a new procedure.

Although procedure development is fundamentally different than drug development (i.e., there is great individual variation in the performance of procedures, but no difference between one tablet and the next), adherence to a process similar to that used to develop a new drug is a reasonable path for a surgical innovator. At the outset, the surgeon must identify the problem that is not solved with current surgical procedures. For example, although the removal of a gallbladder through a Kocher incision is certainly effective, it creates a great deal of disability, pain, and scarification. As a result of those issues, many patients with very symptomatic biliary colic delayed operation until life-threatening complications occurred. Clearly, there was a need for developing a less invasive approach (Fig. 14-29).

Once the opportunity has been established, the next step involves a search through other disciplines for technologies and techniques that might be applied. Again, this is analogous to the drug industry, where secondary drug indications have often turned out to be more therapeutically important than the primary indication for drug development. The third step is *in vivo* studies in the most appropriate animal model. These types of studies are controversial because of the resistance to animal experimentation, and yet without such studies, many humans would be

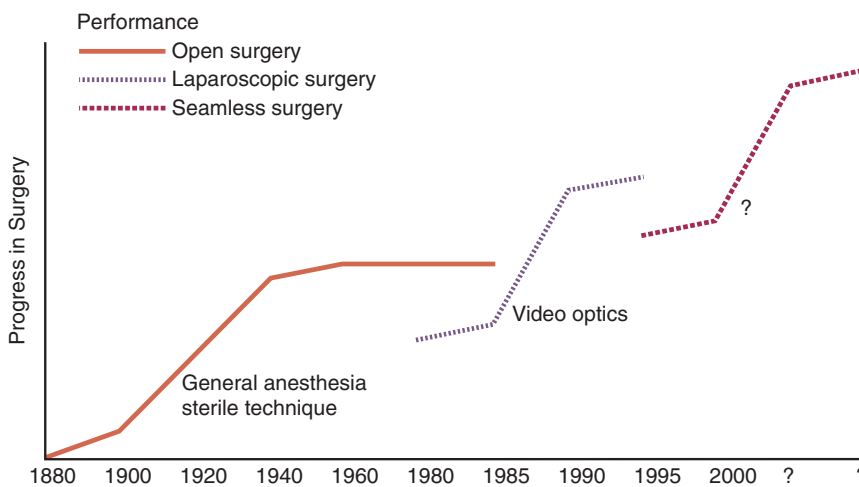


Figure 14-29. The progress of general surgery can be reflected by a series of performance curves. General anesthesia and sterile technique allowed the development of maximally invasive open surgery over the last 125 years. Video optics allowed the development of minimally invasive surgery over the last 25 years. Noninvasive (seamless) surgery will result when a yet undiscovered transformational event allows surgery to occur without an incision, and perhaps without anesthesia.

injured or killed during the developmental phase of medical drugs, devices, and techniques. These steps often are called the preclinical phase of procedure development.

The decision as to when such procedures are ready to come out of the lab is a difficult one. Put simply, the procedure should be reproducible, provide the desired effect, and not have serious side effects. Once these three criteria are reached, the time for human application has arrived. Before the surgeon discusses the new procedure with patients, it is important to achieve full institutional support. Involvement of the medical board, the chief of the medical staff, and the institutional review board is essential before commencing on a new procedure. These bodies are responsible for the use of safe, high-quality medical practices within their institution, and they will demand that great caution and all possible safeguards are in place before proceeding.

The dialogue with the patient who is to be first must be thorough, brutally honest, and well documented. The psychology that allows a patient to decide to be first is quite interesting, and may, under certain circumstances, require psychiatric evaluation. Certainly if a dying cancer patient has a chance with a new drug, this makes sense. Similarly, if the standard surgical procedure has a high attendant morbidity and the new procedure offers a substantially better outcome, the decision to be first is understandable. On the other hand, when the benefits of the new approach are small and the risks are largely unknown, a more complete psychological profile may be necessary before proceeding.

For new surgical procedures, it generally is wise to assemble the best possible operative team, including a surgeon experienced with the old technique, and assistants who have participated in the earlier animal work. This initial team of experienced physicians and nurses should remain together until full competence with the procedure is attained. This may take 10 procedures, or it may take 50 procedures. The team will know that it has achieved competence when the majority of procedures take the same length of time and the team is relaxed and sure of the flow of the operation. This will complete phase I of the procedure development.

In phase II, the efficacy of the procedure is tested in a non-randomized fashion. Ideally, the outcome of new techniques must be as good as or better than the procedure that is being replaced. This phase should occur at several medical centers to prove that good outcomes are achievable outside of the pioneering institution. These same requirements may be applied to the introduction of new technology into the OR. The value equation requires that the additional measurable procedure quality exceeds the additional measurable cost to the patient or healthcare system. In phase III, a randomized trial pits the new procedure against the old.

Once the competence curve has been climbed, it is appropriate for the team to engage in the education of others. During the ascension of the competence curve, other learners in the institution (i.e., surgical residents) may not have the opportunity to participate in the first case series. Although this may be difficult for them, the best interest of the patient must be put before the education of the resident.

The second stage of learning occurs when the new procedure has proven its value and a handful of experts exist, but the majority of surgeons have not been trained to perform the new procedure. In this setting, it is relatively unethical for surgeons to forge ahead with a new procedure in humans as if they had spent the same amount of time in intensive study that the

first team did. The fact that one or several surgical teams were able to perform an operation does not ensure that all others with the same medical degrees can perform the operation with equal skill. It behooves the learners to contact the experts and request their assistance to ensure an optimal outcome at the new center. Although it is important that the learners contact the experts, it is equally important that the experts be willing to share their experience with their fellow professionals. As well, the experts should provide feedback to the learners as to whether they feel the learners are equipped to forge ahead on their own. If not, further observation and assistance from the experts are required. Although this approach may sound obvious, it is fraught with difficulties. In many situations, ego, competitiveness, and monetary concerns have short-circuited this process and led to poor patient outcomes. To a large extent, MIS has recovered from the black eye it received early in development, when inadequately trained surgeons caused an excessive number of significant complications.

If innovative procedures and technologies are to be developed and applied without the mistakes of the past, surgeons must be honest when they answer these questions: Is this procedure safe? Would I consider undergoing this procedure if I developed a surgical indication? Is the procedure as good as or better than the procedure it is replacing? Do I have the skills to apply this procedure safely and with equivalent results to the more experienced surgeon? Answering these questions in the affirmative should be a professional obligation. A negative response should motivate the surgeon to seek an alternative procedure or outside assistance before subjecting a patient to the new procedure.

REFERENCES

Entries highlighted in bright blue are key references.

- Hopkins HH. Optical principles of the endoscope. In: Berci G, ed. *Endoscopy*. New York: Appleton-Century-Crofts; 1976:3.
- Katzir A. Optical fibers in medicine. *Sci Am*. 1989;260:120.
- Hirschowitz BI. A personal history of the fiberscope. *Gastroenterology*. 1979;76:864.
- Veritas TF. Coelioscopy: a synthesis of Georg Kelling's work with insufflation, endoscopy, and luft tamponade. In: Litynski GS, ed. *Highlights in the History of Laparoscopy*. Frankfurt/Main: Barbara Bernert Verlag; 1996:3.
- Ponsky JL, Gauderer MW. Percutaneous endoscopic gastrostomy: a nonoperative technique for feeding gastrostomy. *Gastrointest Endosc*. 1981;27:9.
- Lehman KS, Ritz JP, Wibmer A, et al. The German registry for natural orifice transluminal endoscopic surgery: the report of the first 551 patients. *Ann Surg*. 2010;252:263-270.
- Autorino R, White WM, Gettman MT, et al. Public perception of "scarless" surgery: a critical analysis of the literature. *Urology*. 2012;80:495-502.
- Ahmed I, Cianco F, Ferrar V, et al. Current status of single-incision laparoscopic surgery: European experts' views. *Surg Laparosc Endosc Percutan Tech*. 2012;22(3):194-199.
- Wood BJ, Ramkaransingh JR, Fogo T, et al. Percutaneous tumor ablation with radiofrequency. *Cancer*. 2002;94:443.
- Smith RS, Fry WR, Tsoi EK, et al. Gasless laparoscopy and conventional instruments: the next phase of minimally invasive surgery. *Arch Surg*. 1993;128:1102.
- Litynski GS. *Highlights in the History of Laparoscopy*. Frankfurt/Main: Barbara Bernert Verlag; 1996:78.

12. Hunter JG, Staheli J, Oddsdottir M, et al. Nitrous oxide pneumoperitoneum revisited: is there a risk of combustion? *Surg Endosc.* 1995;9:501.
13. Tsereteli Z, Terry ML, Bowers S, et al. Prospective randomized clinical trial comparing nitrous oxide and carbon dioxide pneumoperitoneum for laparoscopic surgery. *J Am Coll Surg.* 2002;195:173.
14. Callery MP, Soper NJ. **Physiology of the pneumoperitoneum.** In: Hunter JG, ed. *Baillière's Clinical Gastroenterology: Laparoscopic Surgery.* London/Philadelphia: Baillière Tindall; 1993:757.
15. Ho HS, Gunther RA, Wolfe B. Intraperitoneal carbon dioxide insufflation and cardiopulmonary functions. *Arch Surg.* 1992;127:928.
16. Wittgen CM, Andrus CH, Fitzgerald S, et al. Analysis of the hemodynamic and ventilatory effects of laparoscopic cholecystectomy. *Arch Surg.* 1991;126:997.
17. Cullen DJ, Eger EI. Cardiovascular effects of carbon dioxide in man. *Anesthesiology.* 1974;41:345.
18. Cunningham AJ, Turner J, Rosenbaum S, et al. Transoesophageal echocardiographic assessment of haemodynamic function during laparoscopic cholecystectomy. *Br J Anaesth.* 1993;70:621.
19. Harris MNE, Plantevin OM, Crowther A, et al. Cardiac arrhythmias during anaesthesia for laparoscopy. *Br J Anaesth.* 1984;56:1213.
20. Borten M, Friedman EA. Choice of anaesthesia. In: *Laparoscopic Complications: Prevention and Management.* Toronto: BC Decker; 1986:173.
21. Jorgenson JO, Hanel K, Lalak NJ, et al. Thromboembolic complications of laparoscopic cholecystectomy (letter). *Br Med J.* 1993;306:518.
22. Ho HS, Wolfe BM. The physiology and immunology of endosurgery. In: Toouli JG, Gossot D, Hunter JG, eds. *Endosurgery.* New York/London: Churchill-Livingstone; 1996:163.
23. Sackier JM, Nibhanupudy B. The pneumoperitoneum-physiology and complications. In: Toouli JG, Gossot D, Hunter JG, eds. *Endosurgery.* New York/London: Churchill-Livingstone; 1996:155.
24. Kashtan J, Green JF, Parsons EQ, et al. Hemodynamic effects of increased abdominal pressure. *J Surg Res.* 1981;30:249.
25. McDougall EM, Monk TG, Wolf JS Jr, et al. The effect of prolonged pneumoperitoneum on renal function in an animal model. *J Am Coll Surg.* 1996;182:317.
26. Lindberg F, Bergqvist D, Bjorck M, et al. Renal hemodynamics during carbon dioxide pneumoperitoneum: an experimental study in pigs. *Surg Endosc.* 2003;17:480.
27. Hazebroek EJ, de Vos tot Nederveen Cappel R, Gommers D, et al. Antidiuretic hormone release during laparoscopic donor nephrectomy. *Arch Surg.* 2002;137:600; discussion 605.
28. Ostman PL, Pantle-Fisher FH, Fanre EA, et al. Circulatory collapse during laparoscopy. *J Clin Anesth.* 1990;2:129.
29. Alijani A, Cuschieri A. Abdominal wall lift systems in laparoscopic surgery: gasless and low-pressure systems. *Semin Laparosc Surg.* 2001;8:53.
30. Ozawa A, Konishi F, Nagai H, et al. Cytokine and hormonal responses in laparoscopic-assisted colectomy and conventional open colectomy. *Surg Today.* 2000;30:107.
31. Burpee SE, Kurian M, Murakame Y, et al. The metabolic and immune response to laparoscopic versus open liver resection. *Surg Endosc.* 2002;16:899.
32. Gossot D. Access modalities for thoracoscopic surgery. In: Toouli JG, Gossot D, Hunter JG, eds. *Endosurgery.* New York/London: Churchill-Livingstone; 1996:743.
33. Memon MA, Cooper NJ, Memon B, et al. Meta-analysis of randomized clinical trials comparing open and laparoscopic inguinal hernia repair. *Br J Surg.* 2003;90:1479.
34. Himpens J. Laparoscopic preperitoneal approach to the inguinal hernia. In: Toouli JG, Gossot D, Hunter JG, eds. *Endosurgery.* New York/London: Churchill-Livingstone; 1996:949.
35. Horvath KD, Kao LS, Wherry KL, et al. A technique for laparoscopic-assisted percutaneous drainage of infected pancreatic necrosis and pancreatic abscess. *Surg Endosc.* 2001;15:1221.
36. Eaves FF. Basics of endoscopic plastic surgery. In: Bostwick J, Eaves FF, Nahai F, eds. *Endoscopic Plastic Surgery.* St Louis: Quality Medical Publishing; 1995:59.
37. Kenyon TA, Lenker MP, Bax TW, et al. **Cost and benefit of the trained laparoscopic team. A comparative study of a designated nursing team vs. a nontrained team.** *Surg Endosc.* 1997;11:812.
38. Herron DM, Gagner M, Kenyon TL, et al. The minimally invasive surgical suite enters the 21st century. A discussion of critical design elements. *Surg Endosc.* 2001;15:415.
39. Byron JW, Markenson G, Miyazawa K. A randomised comparison of Veress needle and direct insertion for laparoscopy. *Surg Gynecol Obstet.* 1993;177:259.
40. Fletcher DR. Laparoscopic access. In: Toouli JG, Gossot D, Hunter JG, eds. *Endosurgery.* New York/London: Churchill-Livingstone; 1996:189.
41. Hanney RM, Alle KM, Cregan PC. Major vascular injury and laparoscopy. *Aust N Z J Surg.* 1995;65:533.
42. Catarci M, Carlini M, Gentileschi P, et al. Major and minor injuries during the creation of pneumoperitoneum. A multicenter study on 12,919 cases. *Surg Endosc.* 2001;15:566.
43. Siperstein AE, Berber E, Engle KL, et al. Laparoscopic posterior adrenalectomy: technical considerations. *Arch Surg.* 2000;135:967.
44. Vasilev SA, McGonigle KF. Extraperitoneal laparoscopic para-aortic lymph node dissection. *Gynecol Oncol.* 1996;61:315.
45. Schurr UP, Lachat ML, Reuthebuch O, et al. Endoscopic saphenous vein harvesting for CABG—a randomized prospective trial. *Thorac Cardiovasc Surg.* 2002;50:160.
46. Lumsden AB, Eaves FF. Vein harvest. In: Bostwick J, Eaves FF, Nahai F, eds. *Endoscopic Plastic Surgery.* St. Louis: Quality Medical Publishing; 1995:535.
47. Targarona EM, Gracia E, Rodriguez M, et al. Hand-assisted laparoscopic surgery. *Arch Surg.* 2003;138:138.
48. **Ross S, Rosemurgy A, Albrink M, et al. Consensus statement of the consortium for LESS cholecystectomy.** *Surg Endosc.* 2012;26:2711-2716.
49. Berquer R, Smith WD, Davis S. An ergonomic study of the optimum operating table height for laparoscopic surgery. *Surg Endosc.* 2002;16:416.
50. Berguer R, Smith WD, Chung YH. Performing laparoscopic surgery is significantly more stressful for the surgeon than open surgery. *Surg Endosc.* 2001;15:1204.
51. Emam TA, Hanna G, Cuschieri A. Ergonomic principles of task alignment, visual display, and direction of execution of laparoscopic bowel suturing. *Surg Endosc.* 2002;16:267.
52. Prescher T. Video imaging. In: Toouli JG, Gossot D, Hunter JG, eds. *Endosurgery.* New York/London: Churchill-Livingstone; 1996:41.
53. Margulies DR, Shabot MM. Fiberoptic imaging and measurement. In: Hunter JG, Sackier JM, eds. *Minimally Invasive Surgery.* New York: McGraw-Hill; 1993:7.
54. Wenzl R, Lehner R, Holzer A, et al. Improved laparoscopic operating techniques using a digital enhancement video system. *J Am Assoc Gynecol Laparosc.* 1998;5:175.
55. Berci G, Paz-Partlow M. Videoendoscopic technology. In: Toouli JG, Gossot D, Hunter JG, eds. *Endosurgery.* New York/London: Churchill-Livingstone; 1996:33.

56. Levy ML, Day JD, Albuquerque F, et al. Heads-up intraoperative endoscopic imaging: a prospective evaluation of techniques and limitations. *Neurosurgery*. 1997;40:526.
57. Taffinder N, Smith SG, Huber J, et al. The effect of a second-generation 3D endoscope on the laparoscopic precision of novices and experienced surgeons. *Surg Endosc*. 1999;13:1087.
58. Odell RC. Laparoscopic electrosurgery. In: Hunter JG, Sackier JM, eds. *Minimally Invasive Surgery*. New York: McGraw-Hill; 1993:33.
59. Voyels CR, Tucker RD. Education and engineering solutions for potential problems with laparoscopic monopolar electrosurgery. *Am J Surg*. 1992;164:57.
60. Blanc B, d'Ercole C, Gaiato ML, et al. Cause and prevention of electrosurgical injuries in laparoscopy. *J Am Coll Surg*. 1994;179:161.
61. Tucker RD. Principles of electrosurgery. In: Sivak MV, ed. *Gastroenterologic Endoscopy*. 2nd ed. Philadelphia: WB Saunders; 2000:125.
62. Barlow DE. Endoscopic application of electrosurgery: a review of basic principles. *Gastrointest Endosc*. 1982;28:73.
63. Trus TL, Hunter JG. Principles of laser physics and tissue interaction. In: Toouli JG, Gossot D, Hunter JG, eds. *Endosurgery*. New York/London: Churchill-Livingstone; 1996:103.
64. Bass LS, Oz MC, Trokel SL, et al. Alternative lasers for endoscopic surgery: comparison of pulsed thulium-holmium-chromium:YAG with continuous-wave neodymium:YAG laser for ablation of colonic mucosa. *Lasers Surg Med*. 1991;11:545.
65. Greenwald BD. Photodynamic therapy for esophageal cancer. *Chest Surg Clin North Am*. 2000;10:625.
66. Hunter JG, Bruhn E, Godman G, et al. Reflectance spectroscopy predicts safer wavelengths for pulsed laser lithotripsy of gallstones (abstract). *Gastrointest Endosc*. 1991;37:273.
67. Amaral JF, Chrostek C. Comparison of the ultrasonically activated scalpel to electrosurgery and laser for laparoscopic surgery. *Surg Endosc*. 1993;7:141.
68. Huscher CG, Liriei MM, Di Paola M, et al. Laparoscopic cholecystectomy by ultrasonic dissection without cystic duct and artery ligation. *Surg Endosc*. 2003;17:442.
69. Jobe BA, Kenyon T, Hansen PD, et al. Mini-laparoscopy: current status, technology and future applications. *Minim Invasive Ther Allied Technol*. 1998;7:201.
70. Aiono S, Gilbert JM, Soim B, et al. Controlled trial of the introduction of a robotic camera assistant (EndoAssist) for laparoscopic cholecystectomy. *Surg Endosc*. 2002;16:1267.
71. Melvin WS, Needleman BJ, Krause KR, et al. Computer-enhanced vs. standard laparoscopic anti-reflux surgery. *J Gastrointest Surg*. 2002;6:11.
72. Costi R, Himpens J, Bruyns J, et al. Robotic fundoplication: from theoretic advantages to real problems. *J Am Coll Surg*. 2003;197:500.
73. Ruurda JP, Broeders IA, Simmermacher RP, et al. Feasibility of robot-assisted laparoscopic surgery: an evaluation of 35 robot-assisted laparoscopic cholecystectomies. *Surg Laparosc Endosc Percutan Tech*. 2002;12:41.
74. Rodriguez E, Nifong LW, Chu MW, et al. Robotic mitral valve repair for anterior leaflet and bileaflet prolapsed. *Ann Thorac Surg*. 2008;85:438; discussion 444.
75. Menon M, Tewari A, Baize B, et al. Prospective comparison of radical retropubic prostatectomy and robot-assisted anatomic prostatectomy: the Vattikuti Urology Institute experience. *Urology*. 2002;60:864.
76. Marescaux J, Leroy J, Gagner M, et al. Transatlantic robot-assisted telesurgery. *Nature*. 2001;413:379.
77. Fleischer DE. Stents, clogology, and esophageal cancer. *Gastrointest Endosc*. 1996;43:258.
78. Foutch P, Sivak M. Therapeutic endoscopic balloon dilatation of the extrahepatic biliary ducts. *Am J Gastroenterol*. 1985;80:575.
79. Hoepffner N, Foerster EC, Högemann B, et al. Long-term experience in wall stent therapy for malignant choledochostenosis. *Endoscopy*. 1994;26:597.
80. Kozarek RA, Ball TJ, Patterson D. Metallic self-expanding stent application in the upper gastrointestinal tract: caveats and concerns. *Gastrointest Endosc*. 1992;38:1.
81. Anderson JR, Sorenson SM, Kruse A, et al. Randomized trial of endoscopic endoprosthesis versus operative bypass in malignant obstructive jaundice. *Gut*. 1989;30:1132.
82. Ruygrok PN, Sim KH, Chan C, et al. Coronary intervention with a heparin-coated stent and aspirin only. *J Invasive Cardiol*. 2003;15:439.
83. Hucl T, Benes M, Kocik M, et al. Comparison of inflammatory response to transgastric and transcolonic NOTES. *Gastrointest Endosc*. 2012;75(4 Suppl):AB272.
84. Bessler M, Stevens PD, Milone L, et al. Transvaginal laparoscopic cholecystectomy: laparoscopically assisted. *Surg Endosc*. 2008;22:1715.
85. Marescaux J, Dallemagne B, Perretta S, et al. Surgery without scars: report of transluminal cholecystectomy in a human being. *Arch Surg*. 2007;142:823; discussion 826.
86. Bessler M, Stevens PD, Milone L, et al. Transvaginal laparoscopic cholecystectomy: laparoscopically assisted. *Surg Endosc*. 2008;22:1715.
87. Khashab MA, Kalloo AN. NOTES: current status and new horizons. *Gastroenterology*. 2012;142:704-710.
88. Inoue H, Minami H, Kobayashi Y, et al. Peroral endoscopic myotomy (POEM) for esophageal achalasia. *Endoscopy*. 2010;42:265-271.
89. Kurian AA, Dunst CM, Sharata A, Bhayani NH, Reavis KM, Swanstom LL. Peroral endoscopic esophageal myotomy: defining the learning curve. *Gastrointest Endosc*. 2013;12:S5016-S5107.
90. Ahmed K, Wang TT, Patel VM, et al. The role of single incision laparoscopic surgery in abdominal and pelvic surgery: a systematic review. *Surg Endosc*. 2010;25:378-396.
91. Georgeson KE. Pediatric laparoscopy. In: Toouli JG, Gossot D, Hunter JG, eds. *Endosurgery*. New York/London: Churchill-Livingstone; 1996:929.
92. Holcomb GW. Diagnostic laparoscopy: equipment, technique, and special concerns in children. In: Holcomb GW, ed. *Pediatric Endoscopic Surgery*. Norwalk: Appleton & Lange; 1993:9.
93. Hunter JG, Swanstrom LL, Thornburg K. Carbon dioxide pneumoperitoneum induces fetal acidosis in a pregnant ewe model. *Surg Endosc*. 1995;9:272.
94. Morrell DG, Mullins JR, Harrison P. Laparoscopic cholecystectomy during pregnancy in symptomatic patients. *Surgery*. 1992;112:856.
95. Callery MP, Strasberg SM, Doherty GM, et al. Staging laparoscopy with laparoscopic ultrasonography: optimizing resectability in hepatobiliary and pancreatic malignancy. *J Am Coll Surg*. 1997;185:33.
96. Luketich JD, Alvelo-Rivera M, Buenaventura PO, et al. Minimally invasive esophagectomy: outcomes in 222 patients. *Ann Surg*. 2003;238:486; discussion 494.
97. Fleshman J, Sargent DJ, Green E, for the Clinical Outcomes of Surgical Therapy Study Group. Laparoscopic colectomy for cancer is not inferior to open surgery based on 5-year data from the COST Study Group trial. *Ann Surg*. 2007;246:655; discussion 662.
98. Fried GM, Clas D, Meakins JL. Minimally invasive surgery in the elderly patient. *Surg Clin North Am*. 1994;74:375.

99. Borman PC, Terblanche J. Subtotal cholecystectomy: for the difficult gallbladder in portal hypertension and cholecystitis. *Surgery*. 1985;98:1.
100. Litwin DWM, Pham Q. Laparoscopic surgery in the complicated patient. In: Eubanks WS, Swanstrom LJ, Soper NJ, eds. *Mastery of Endoscopic and Laparoscopic Surgery*. Philadelphia: Lippincott, Williams & Wilkins; 2000:57.
101. Gallagher AG, Smith CD, Bowers SP, et al. Psychomotor skills assessment in practicing surgeons experienced in performing advanced laparoscopic procedures. *J Am Coll Surg*. 2003;197:479.
102. Seymour NE, Gallagher AG, Roman SA, et al. Virtual reality training improves operating room performance: results of a randomized, double-blinded study. *Ann Surg*. 2002;236:458; discussion 463.
103. Anvari M. Telesurgery: remote knowledge translation in clinical surgery. *World J Surg*. 2007;31:1545.

This page intentionally left blank

15 chapter

Molecular and Genomic Surgery

Xin-Hua Feng, Xia Lin, Juehua Yu, John Nemunaitis, and F. Charles Brunicardi

Overview of Molecular Cell Biology

443

Basic Concepts of Molecular Research / 443
Molecular Approaches to Surgical Research / 444

Fundamentals of Molecular and Cell Biology

444

DNA and Heredity / 444

Gene Regulation / 446
Human Genome / 449
Cell Cycle and Apoptosis / 450
Signal Transduction Pathways / 450
Gene Therapy and Molecular Drugs in Cancer / 453
Stem Cell Research / 456
The Atomic Theory of Disease / 456

Technologies of Molecular and Cell Biology

456

DNA Cloning / 456
Detection of Nucleic Acids and Proteins / 457
Cell Manipulations / 462
Genetic Manipulations / 463
Personalized Genomic Medicine and Surgery / 463

OVERVIEW OF MOLECULAR CELL BIOLOGY

The beginning of modern medicine can be traced back to centuries ago when physicians and scientists began studying human anatomy from cadavers in morgues and animal physiology following hunting expeditions. Gradually, from the study of animals and plants in greater detail and the discovery of microbes, scientific principles governing life lead to the emergence of the biological sciences. As biological science developed and expanded, scientists and physicians began to utilize the principles of biological sciences to solve challenges of human diseases while continuing to explore the fundamentals of life in greater detail. With ever-evolving state-of-the-art scientific tools, our understanding of how cells, tissues, organs, and entire organisms function, down to the level of molecular and subatomic structure, has resulted in modern biology with an enormous impact on modern healthcare and the discovery of amazing treatments for disease at an exponential pace. Significant progress has been made in molecular studies of organ development, cell signaling, and gene regulation. The advent of recombinant DNA technology, polymerase chain reaction (PCR) techniques, and next-generation genomic sequencing, which resulted in the sequencing of the human genome, holds the potential to have a transformational influence on healthcare and society this century by not only broadening our understanding of the pathophysiology of disease, but also by bringing about necessary changes in personalized medicine.

Today's practicing surgeons are becoming increasingly aware that many modern surgical procedures rely on the information gained through molecular research (i.e., personalized surgery). Genomic information, such as deleterious *BRCA* and *RET* proto-oncogene mutations, is being used to help direct prophylactic procedures to remove potentially harmful tissues before they do damage to patients. Molecular engineering has led to cancer-specific gene therapy that could serve in the near future as a more effective adjunct to surgical debulking of tumors than radiation or chemotherapy, so surgeons will benefit

from a clear introduction to how basic biochemical and biological principles relate to the developing area of molecular biology. This chapter reviews the current information on modern molecular biology for the surgical community.

Basic Concepts of Molecular Research

The modern era of molecular biology, which has been mainly concerned with how genes govern cell activity, began in 1953 when James D. Watson and Francis H. C. Crick made one of the greatest scientific discoveries by deducing the double-helical structure of deoxyribonucleic acid (DNA).^{1,2} The year 2003 marked the 50th anniversary of this great discovery. In the same year, the Human Genome Project completed with sequencing approximately 20,000 to 25,000 genes and 3 billion base pairs in human DNA.³ Before 1953, one of the most mysterious aspects of biology was how genetic material was precisely duplicated from one generation to the next. Although DNA had been implicated as genetic material, it was the base-paired structure of DNA that provided a logical interpretation of how a double helix could “unzip” to make copies of itself. This DNA synthesis, termed *replication*, immediately gave rise to the notion that a template was involved in the transfer of information between generations, and thus confirmed the suspicion that DNA carried an organism's hereditary information.

Within cells, DNA is packed tightly into chromosomes. One important feature of DNA as genetic material is its ability to encode important information for all of a cell's functions (Fig. 15-1). Based on the principles of base complementarity, scientists also discovered how information in DNA is accurately transferred into the protein structure. DNA serves as a template for RNA synthesis, termed *transcription*, including messenger RNA (mRNA, or the protein-encoding RNA), ribosomal RNA (rRNA), and transfer RNA (tRNA). mRNA carries the information from DNA to make proteins, termed *translation*, with the assistance of rRNA and tRNA. Each of these steps is precisely controlled in such a way that genes are properly expressed in each cell at a specific time and location. In recent years, new

Key Points

- 1▶ Biological sciences developed drastically in last 60 years after the uncovering of DNA structure by Watson and Crick
- 2▶ The completion of the human genome sequence in 2003 represents a great milestone in modern science.
- 3▶ The technology emerging from molecular and cellular biology has revolutionized the understanding of disease and will radically transform the practice of surgery.
- 4▶ The use of genetically modified mouse models and cell lines using gene therapy and RNA interference therapy has greatly

- 5▶ contributed to the understanding of the molecular basis for human diseases and targeted therapies.
- 5▶ The sequencing of each individual's genome has the potential to improve the predication, prevention, and targeted treatment of disease, resulting in personalized medicine and surgery.
- 6▶ The use of functional genomics and modern molecular analysis will facilitate the discovery of actionable genes to guide choice of care.

classes of noncoding RNAs (ncRNA), for example, microRNA (or miRNA), Piwi-interacting RNA (or piRNA), and long intergenic noncoding RNA (or lincRNA), have been identified. Although the number of ncRNAs encoded in the human genome is unknown and a lot of ncRNAs have not been validated for their functions, ncRNAs have been associated to regulate gene expression through posttranscriptional gene regulation such as mRNA degradation or epigenetic regulation such as chromatin structure modification and DNA methylation induction.⁴ Consequently, the differential gene activity in a cell determines its actions, properties, and functions.

Molecular Approaches to Surgical Research

Rapid advances in molecular and cellular biology over the past half century have revolutionized the understanding of disease and will radically transform the practice of surgery. In the future, molecular techniques will be increasingly applied to surgical disease and will lead to new strategies for the selection and implementation of operative therapy. Surgeons should be familiar with the fundamental principles of molecular and cellular biology so that emerging scientific breakthroughs can be translated into improved care of the surgical patient.

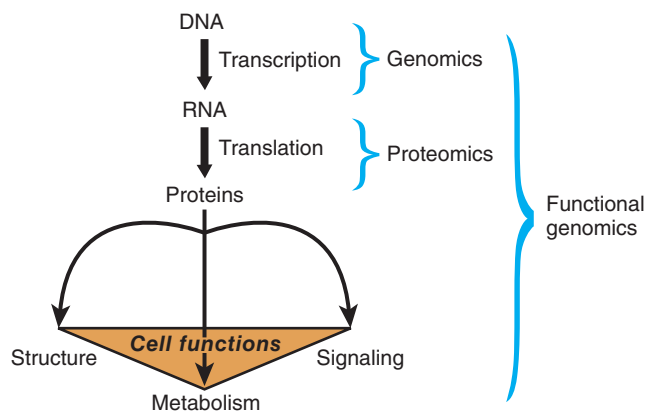


Figure 15-1. The flow of genetic information from DNA to protein to cell functions. The process of transmission of genetic information from DNA to RNA is called *transcription*, and the process of transmission from RNA to protein is called *translation*. Proteins are the essential controlling components for cell structure, cell signaling, and metabolism. *Genomics* and *proteomics* are the study of the genetic composition of a living organism at the DNA and protein level, respectively. The study of the relationship between genes and their cellular functions is called *functional genomics*.

The greatest advances in the field of molecular biology have been in the areas of analysis and manipulation of DNA.¹ Since Watson and Crick's discovery of DNA structure, an intensive effort has been made to unlock the deepest biologic secrets of DNA. Among the avalanche of technical advances, one discovery in particular has drastically changed the world of molecular biology: the uncovering of the enzymatic and microbiologic techniques that produce recombinant DNA. Recombinant DNA technology involves the enzymatic manipulation of DNA and, subsequently, the cloning of DNA. DNA molecules are cloned for a variety of purposes including safeguarding DNA samples, facilitating sequencing, generating probes, and expressing recombinant proteins in one or more host organisms. DNA can be produced by a number of means, including restricted digestion of an existing vector, PCR, and cDNA synthesis. As DNA cloning techniques have developed over the last quarter century, researchers have moved from studying DNA to studying the functions of proteins, and from cell and animal models to molecular therapies in humans. Expression of recombinant proteins provides a method for analyzing gene regulation, structure, and function. In recent years, the uses for recombinant proteins have expanded to include a variety of new applications, including gene therapy and biopharmaceuticals. The basic molecular approaches for modern surgical research include DNA cloning, cell manipulation, disease modeling in animals, and clinical trials in human patients.

FUNDAMENTALS OF MOLECULAR AND CELL BIOLOGY

DNA and Heredity

DNA forms a right-handed, double-helical structure that is composed of two antiparallel strands of unbranched polymeric deoxyribonucleotides linked by phosphodiester bonds between the 5' carbon of one deoxyribose moiety to the 3' carbon of the next (Fig. 15-2). DNA is composed of four types of deoxyribonucleotides: adenine (A), cytosine (C), guanine (G), and thymine (T). The nucleotides are joined together by phosphodiester bonds. In the double-helical structure deduced by Watson and Crick, the two strands of DNA are complementary to each other. Because of size, shape, and chemical composition, A always pairs with T, and C with G, through the formation of hydrogen bonds between complementary bases that stabilize the double helix.

Recognition of the hereditary transmission of genetic information is attributed to the Austrian monk, Gregor Mendel. His seminal work, ignored upon publication until its rediscovery in 1900, established the laws of segregation and of independent

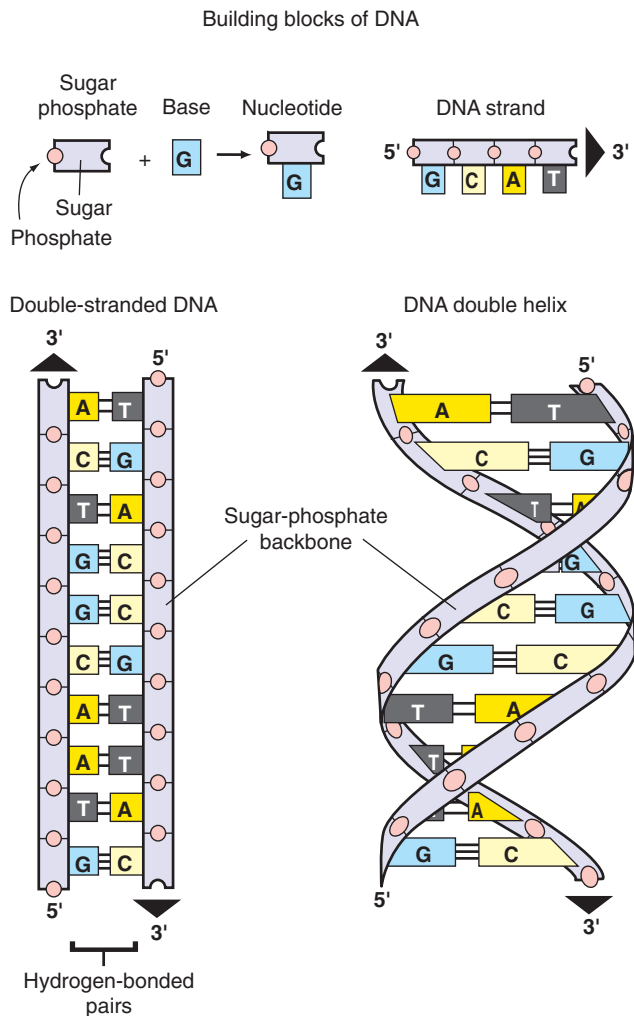


Figure 15-2. Schematic representation of a DNA molecule forming a double helix. DNA is made of four types of nucleotides, which are linked covalently into a DNA strand. A DNA molecule is composed of two DNA strands held together by hydrogen bonds between the pair bases. The arrowheads at the ends of the DNA strands indicate the polarities of the two strands, which run antiparallel to each other in the DNA molecule. The diagram at the bottom left of the figure shows the DNA molecule straightened out. In reality, the DNA molecule is twisted into a double helix, of which each turn of DNA is made up of 10.4 nucleotide pairs, as shown on the right. (Republished with permission of Garland Publishing, Inc. from Alberts B, Johnson A, Lewis J, et al. *Molecular Biology of the Cell*, 5th ed. New York: Garland Science; 2008. Permission conveyed through Copyright Clearance Center, Inc.)

assortment. These two principles established the existence of paired elementary units of heredity and defined the statistical laws that govern them.⁵ DNA was isolated in 1869, and a number of important observations of the inherited basis of certain diseases were made in the early part of the twentieth century. Although today it appears easy to understand how DNA replicates, before the 1950s, the idea of DNA as the primary genetic material was not appreciated. The modern era of molecular biology began in 1944 with the demonstration that DNA was the substance that carried genetic information. The first experimental evidence that DNA was genetic material came from simple transformation experiments conducted in the 1940s using *Streptococcus pneumoniae*. One strain of the bacteria could be converted into another by incubating it with DNA from the other,

just as the treatment of the DNA with deoxyribonuclease would inactivate the transforming activity of the DNA. Similarly, in the early 1950s, before the discovery of the double-helical structure of DNA, the entry of viral DNA and not the protein into the host bacterium was believed to be necessary to initiate infection by the bacterial virus or bacteriophage. Key historical events concerning genetics are outlined in Table 15-1.

Table 15-1

Historical events in genetics and molecular biology

YEAR	INVESTIGATOR	EVENT
1865	Mendel	Laws of genetics established
1869	Miescher	DNA isolated
1905	Garrod	Human inborn errors of metabolism
1913	Sturtevant	Linear map of genes
1927	Muller	X-rays cause inheritable genetic damage
1928	Griffith	Transformation discovered
1941	Beadle and Tatum	“One gene, one enzyme” concept
1944	Avery, MacLeod, McCarty	DNA as material of heredity
1950	McClintock	Existence of transposons confirmed
1953	Watson and Crick	Double-helical structure of DNA
1957	Benzer and Kornberg	Recombination and DNA polymerase
1966	Nirenberg, Khorana, Holley	Genetic code determined
1970	Temin and Baltimore	Reverse transcriptase
1972	Cohen, Boyer, Berg	Recombinant DNA technology
1975	Southern	Transfer of DNA fragments from sizing gel to nitrocellulose (Southern blot)
1977	Sanger, Maxim, Gilbert	DNA sequencing methods
1982	—	GenBank database established
1985	Mullis	Polymerase chain reaction
1986	—	Automated DNA sequencing
1989	Collins	Cystic fibrosis gene identified by positional cloning and linkage analysis
1990	—	Human Genome Project initiated
1997	Roslin Institute	Mammalian cloning (Dolly)
2001	IHGSC and Celera Genomics	Draft versions of human genome sequence published
2003	—	Human Genome Project completed

IHGSC = International Human Genome Sequencing Consortium.

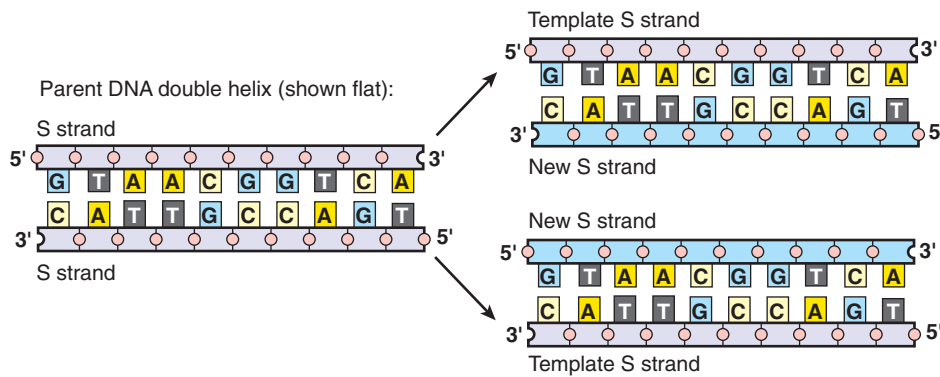


Figure 15-3. DNA replication. As the nucleotide A only pairs with T, and G with C, each strand of DNA can determine the nucleotide sequence in its complementary strand. In this way, double-helical DNA can be copied precisely. (Reprinted with permission of Garland Publishing, Inc. from Alberts B, Johnson A, Lewis J, et al. *Molecular Biology of the Cell*, 5th ed. New York: Garland Science; 2008. Permission conveyed through Copyright Clearance Center, Inc.)

For cells to pass on the genetic material (DNA) to each progeny, the amount of DNA must be doubled. Watson and Crick recognized that the complementary base-pair structure of DNA implied the existence of a template-like mechanism for the copying of genetic material.¹ The transfer of DNA material from the mother cell to daughter cells takes place during somatic cell division (also called *mitosis*). Before a cell divides, DNA must be precisely duplicated. During replication, the two strands of DNA separate, and each strand creates a new complementary strand by precise base-pair matching (Fig. 15-3). The two, new, double-stranded DNAs carry the same genetic information, which can then be passed on to two daughter cells. Proofreading mechanisms ensure that the replication process occurs in a highly accurate manner. The fidelity of DNA replication is absolutely crucial to maintaining the integrity of the genome from generation to generation. However, mistakes can still occur during this process, resulting in *mutations*, which may lead to a change of the DNA's encoded protein and, consequently, a change of the cell's behavior. The reliable dependence of many features of modern organisms on subtle changes in genome is linked to Mendelian inheritance and also contributes to the processes of Darwinian evolution. In addition, massive changes, so-called *genetic instability*, can occur in the genome of somatic cells such as cancer cells.

Gene Regulation

Living cells have the necessary machinery to enzymatically transcribe DNA into RNA and translate the mRNA into protein. This machinery accomplishes the two major steps required for gene expression in all organisms: transcription and translation (Fig. 15-4). However, gene regulation is far more complex, particularly in eukaryotic organisms. For example, many gene transcripts must be spliced to remove the intervening sequences. The sequences that are spliced off are called *introns*, which appear to be useless, but in fact may carry some regulatory information. The sequences that are joined together, and are eventually translated into protein, are called *exons*. Additional regulation of gene expression includes modification of mRNA, control of mRNA stability, and its nuclear export into cytoplasm (where it is assembled into ribosomes for translation). After mRNA is translated into protein, the levels and functions of the proteins can be further regulated posttranslationally. However, the following sections will mainly focus on gene regulation at transcriptional and translational levels.

Transcription. Transcription is the enzymatic process of RNA synthesis from DNA.⁶ In bacteria, a single RNA polymerase carries out all RNA synthesis, including that of mRNA, rRNA, and tRNA. Transcription often is coupled with translation in such a way that an mRNA molecule is completely accessible to

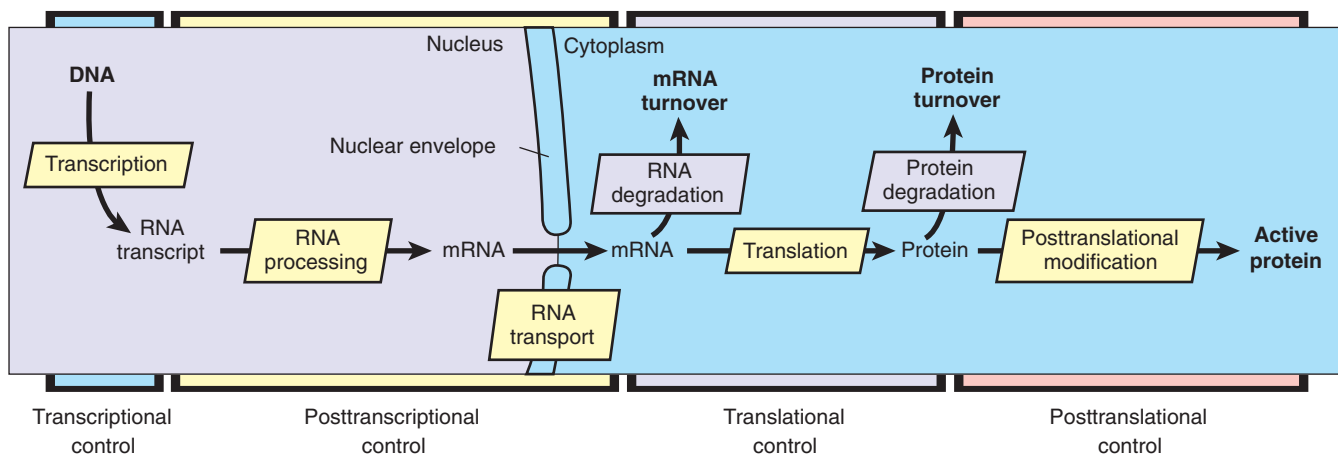


Figure 15-4. Four major steps in the control of eukaryotic gene expression. Transcriptional and posttranscriptional control determine the level of messenger RNA (mRNA) that is available to make a protein, while translational and posttranslational control determine the final outcome of functional proteins. Note that posttranscriptional and posttranslational controls consist of several steps.

ribosomes, and bacterial protein synthesis begins on an mRNA molecule even while it is still being synthesized. Therefore, a discussion of gene regulation with a look at the simpler prokaryotic system precedes that of the more complex transcription and posttranscriptional regulation of eukaryotic genes.

Transcription in Bacteria Initiation of transcription in prokaryotes begins with the recognition of DNA sequences by RNA polymerase. First, the bacterial RNA polymerase catalyzes RNA synthesis through loose binding to any region in the double-stranded DNA and then through specific binding to the *promoter* region with the assistance of accessory proteins called σ factors (sigma factors). A promoter region is the DNA region upstream of the transcription initiation site. RNA polymerase binds tightly at the promoter sites and causes the double-stranded DNA structure to unwind. Consequently, few nucleotides can be base-paired with the DNA template to begin transcription. Once transcription begins, the σ factor is released. The growing RNA chain may begin to peel off as the chain elongates. This occurs in such a way that there are always about 10 to 12 nucleotides of the growing RNA chains that are base-paired with the DNA template.

The bacterial promoter contains a region of about 40 bases that include two conserved elements called *-35 region* and *-10 region*. The numbering system begins at the initiation site, which is designated +1 position, and counts backward (in negative numbers) on the promoter and forward on the transcribed region. Although both regions on different promoters are not the same sequences, they are fairly conserved and very similar. This conservation provides the accurate and rapid initiation of transcription for most bacterial genes. It is also common in bacteria that one promoter serves to transcribe a series of clustered genes, called an *operon*. A single transcribed mRNA contains a series of coding regions, each of which is later independently translated. In this way, the protein products are synthesized in a coordinated manner. Most of the time, these proteins are involved in the same metabolic pathway, thus demonstrating that the control by one operon is an efficient system. After initiation of transcription, the polymerase moves along the DNA to elongate the chain of RNA, although at a certain point, it will stop. Each step of RNA synthesis, including initiation, elongation, and termination, will require the integral functions of RNA polymerase as well as the interactions of the polymerase with regulatory proteins.

Transcription in Eukaryotes Transcription mechanisms in eukaryotes differ from those in prokaryotes. The unique features of eukaryotic transcription are as follows: (a) Three separate RNA polymerases are involved in eukaryotes: RNA polymerase I transcribes the precursor of 5.8S, 18S, and 28S rRNAs; RNA polymerase II synthesizes the precursors of mRNA as well as microRNA; and RNA polymerase III makes tRNAs and 5S rRNAs. (b) In eukaryotes, the initial transcript is often the precursor to final mRNAs, tRNAs, and rRNAs. The precursor is then modified and/or processed into its final functional form. RNA splicing is one type of processing to remove the noncoding introns (the region between coding exons) on an mRNA. (c) In contrast to bacterial DNA, eukaryotic DNA often is packaged with histone and nonhistone proteins into chromatin. Transcription will only occur when the chromatin structure changes in such a way that DNA is accessible to the polymerase. (d) RNA is made in the nucleus and transported into cytoplasm, where translation occurs. Therefore, unlike bacteria, eukaryotes undergo uncoupled transcription and translation.

Eukaryotic gene transcription also involves the recognition and binding of RNA polymerase to the promoter DNA. However, the interaction between the polymerase and DNA is far more complex in eukaryotes than in prokaryotes. Because the majority of studies have been focused on the regulation and functions of proteins, this chapter primarily focuses on how protein-encoding mRNA is made by RNA polymerase II.

Translation. DNA directs the synthesis of RNA; RNA in turn directs the synthesis of proteins. Proteins are variable-length polypeptide polymers composed of various combinations of 20 different amino acids and are the working molecules of the cell. The process of decoding information on mRNA to synthesize proteins is called *translation* (see Fig. 15-1). Translation takes place in ribosomes composed of rRNA and ribosomal proteins. The numerous discoveries made during the 1950s made it easy to understand how DNA replication and transcription involve base-pairing between DNA and DNA or DNA and RNA. However, at that time, it was still impossible to comprehend how mRNA transfers the information to the protein-synthesizing machinery. The genetic information on mRNA is composed of arranged sequences of four bases that are transferred to the linear arrangement of 20 amino acids on a protein. Amino acids are characterized by a central carbon unit linked to four side chains: an amino group ($-\text{NH}_2$), a carboxy group ($-\text{COOH}$), a hydrogen, and a variable ($-\text{R}$) group. The amino acid chain is assembled via peptide bonds between the amino group of one amino acid and the carboxy group of the next. Because of this decoding, the information carried on mRNA relies on tRNA. Translation involves all three RNAs. The precise transfer of information from mRNA to protein is governed by *genetic code*, the set of rules by which codons are translated into an amino acid (Table 15-2). A *codon*, a triplet of three bases, codes for one amino acid. In this case, random combinations of the four bases form $4 \times 4 \times 4$, or 64 codes. Because 64 codes are more than enough for 20 amino acids, most amino acids are coded by more than one codon. The start codon is AUG, which also corresponds to methionine; therefore, almost all proteins begin with this amino acid. The sequence of nucleotide triplets that follows the start codon signal is termed the *reading frame*. The codons on mRNA are sequentially recognized by tRNA adaptor proteins. Specific enzymes termed *aminoacyl-tRNA synthetases* link a specific amino acid to a specific tRNA. The translation of mRNA to protein requires the ribosomal complex to move stepwise along the mRNA until the initiator methionine sequence is identified. In concert with various protein initiator factors, the methionyl-tRNA is positioned on the mRNA and protein synthesis begins. Each new amino acid is added sequentially by the appropriate tRNA in conjunction with proteins called *elongation factors*. Protein synthesis proceeds in the amino-to-carboxy-terminus direction.

The biologic versatility of proteins is astounding. Among many other functions, proteins serve as enzymes that catalyze critical biochemical reactions, carry signals to and from the extracellular environment, and mediate diverse signaling and regulatory functions in the intracellular environment. They also transport ions and various small molecules across plasma membranes. Proteins make up the key structural components of cells and the extracellular matrix and are responsible for cell motility. The unique functional properties of proteins are largely determined by their structure (Fig. 15-5).

Regulation of Gene Expression. The human organism is made up of a myriad of different cell types that, despite their vastly

Table 15-2

The genetic code

		SECOND BASE IN CODON													
		U			C			A			G				
First Base in Codon	U	UUU	Phe	[F]	UCU	Ser	[S]	UAU	Tyr	[Y]	UGU	Cys	[C]	U	Third Base in Codon
	C	UUC	Phe	[F]	UCC	Ser	[S]	UAC	Tyr	[Y]	UGC	Cys	[C]	C	
A	UUA	Leu	[L]	UCA	Ser	[S]	UAA	STOP	—	UGA	STOP	—	A		
G	UUG	Leu	[L]	UCG	Ser	[S]	UAG	STOP	—	UGG	Trp	[W]	G		
U	CUU	Leu	[L]	CCU	Pro	[P]	CAU	His	[H]	CGU	Arg	[R]	U		
C	CUC	Leu	[L]	CCC	Pro	[P]	CAC	His	[H]	CGC	Arg	[R]	C		
A	CUA	Leu	[L]	CCA	Pro	[P]	CAA	Gln	[Q]	CGA	Arg	[R]	A		
G	CUG	Leu	[L]	CCG	Pro	[P]	CAG	Gln	[Q]	CGG	Arg	[R]	G		
U	AUU	Ile	[I]	ACU	Thr	[T]	AAU	Asn	[N]	AGU	Ser	[S]	U		
C	AUC	Ile	[I]	ACC	Thr	[T]	AAC	Asn	[N]	AGC	Ser	[S]	C		
A	AUA	Ile	[I]	ACA	Thr	[T]	AAA	Lys	[K]	AGA	Arg	[R]	A		
G	AUG	Met	[M]	ACG	Thr	[T]	AAG	Lys	[K]	AGG	Arg	[R]	G		
U	GUU	Val	[V]	GCU	Ala	[A]	GAU	Asp	[D]	GGU	Gly	[G]	U		
C	GUC	Val	[V]	GCC	Ala	[A]	GAC	Asp	[D]	GGC	Gly	[G]	C		
A	GUA	Val	[V]	GCA	Ala	[A]	GAA	Glu	[E]	GGA	Gly	[G]	A		
G	GUG	Val	[V]	GCG	Ala	[A]	GAG	Glu	[E]	GGG	Gly	[G]	G		

A = adenine; C = cytosine; G = guanine; U = uracil; Ala = alanine; Arg = arginine; Asn = asparagine; Asp = aspartic acid; Cys = cysteine; Glu = glutamic acid; Gln = glutamine; Gly = glycine; His = histidine; Ile = isoleucine; Leu = leucine; Lys = lysine; Met = methionine; Phe = phenylalanine; Pro = proline; Ser = serine; Thr = threonine; Trp = tryptophan; Tyr = tyrosine; Val = valine. Letter in [] indicates single letter code for amino acid.

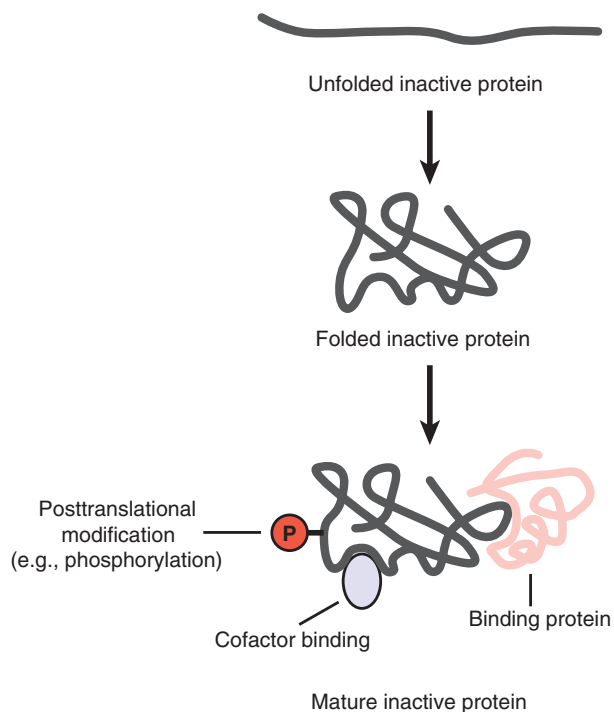


Figure 15-5. Maturation of a functional protein. Although the linear amino acid sequence of a protein often is shown, the function of a protein also is controlled by its correctly folded three-dimensional structure. In addition, many proteins also have covalent posttranslational modifications such as phosphorylation or noncovalent binding to a small molecule or a protein.

different characteristics, contain the same genetic material. This cellular diversity is controlled by the *genome* and accomplished by tight regulation of gene expression. This leads to the synthesis and accumulation of different complements of RNA and, ultimately, to the proteins found in different cell types. For example, muscle and bone express different genes or the same genes at different times. Moreover, the choice of which genes are expressed in a given cell at a given time depends on signals received from its environment. There are multiple levels at which gene expression can be controlled along the pathway from DNA to RNA to protein (see Fig. 15-4). *Transcriptional control* refers to the mechanism for regulating when and how often a gene is transcribed. Splicing of the primary RNA transcript (*RNA processing control*) and selection of completed mRNAs for nuclear export (*RNA transport control*) represent additional potential regulatory steps. The mRNAs in the cytoplasm can be selectively translated by ribosomes (*translational control*) or selectively stabilized or degraded (*mRNA degradation control*). Finally, the resulting proteins can undergo selective activation, inactivation, or compartmentalization (*protein activity control*).

Because a large number of genes are regulated at the transcriptional level, regulation of gene transcripts (i.e., mRNA) often is referred to as *gene regulation* in a narrow definition. Each of the steps during transcription is properly regulated in eukaryotic cells. Because genes are differentially regulated from one another, one gene can be differentially regulated in different cell types or at different developmental stages. Therefore, gene regulation at the level of transcription is largely context

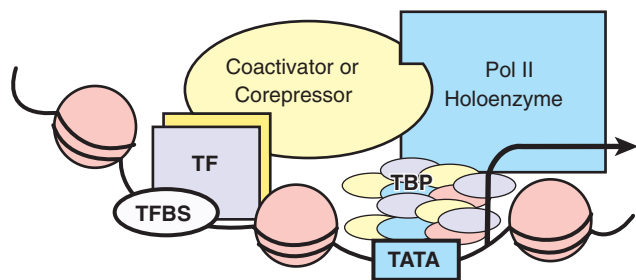


Figure 15-6. Transcriptional control by RNA polymerase. DNA is packaged into a chromatin structure. TATA = the common sequence on the promoter recognized by TBP and polymerase II holoenzyme; TBP = TATA-binding protein and associated factors; TF = hypothetical transcription factor; TFBS = transcription factor binding site; ball-shaped structures = nucleosomes. Coactivator or corepressor is a factor linking the TF with the Pol II complex.

dependent. However, there is a common scheme that applies to transcription at the molecular level (Fig. 15-6). Each gene promoter possesses unique sequences called *TATA boxes* that can be recognized and bound by a large complex containing RNA polymerase II, forming the basal transcription machinery. Usually located upstream of the TATA box (but sometimes longer distances) are a number of regulatory sequences referred to as *enhancers* that are recognized by regulatory proteins called *transcription factors*. These transcription factors specifically bind to the enhancers, often in response to environmental or developmental cues, and cooperate with each other and with basal transcription factors to initiate transcription. Regulatory sequences that negatively regulate the initiation of transcription also are present on the promoter DNA. The transcription factors that bind to these sites are called *repressors*, in contrast to the *activators* that activate transcription. The molecular interactions between transcription factors and promoter DNA, as well as between the cooperative transcription factors, are highly regulated and context-dependent. Specifically, the recruitment of transcription factors to the promoter DNA occurs in response to physiologic signals. A number of structural motifs in these DNA-binding transcription factors facilitate this recognition and interaction. These include the helix-turn-helix, the homeodomain motif, the zinc finger, the leucine zipper, and the helix-loop-helix motifs.

Human Genome

Genome is a collective term for all genes present in one organism. The human genome contains DNA sequences of 3 billion base pairs, carried by 23 pairs of chromosomes. The human genome has an estimated 25,000 to 30,000 genes, and overall, it is 99.9% identical in all people.^{7,8} Approximately 3 million locations where single-base DNA differences exist have been identified and termed *single nucleotide polymorphisms*. Single nucleotide polymorphisms may be critical determinants of human variation in disease susceptibility and responses to environmental factors.

The completion of the human genome sequence in 2003 represented another great milestone in modern science. The Human Genome Project created the field of *genomics*, which is the study of genetic material in detail (see Fig. 15-1). The medical field is building on the knowledge, resources, and technologies emanating from the human genome to further the

understanding of the relationship of the genes and their mutations to human health and disease. This expansion of genomics into human health applications resulted in the field of genomic medicine.

3▶ The emergence of genomics as a science will transform the practice of medicine and surgery in this century. This breakthrough has allowed scientists the opportunity to gain remarkable insights into the lives of humans. Ultimately, the goal is to use this information to develop new ways to treat, cure, or even prevent the thousands of diseases that afflict humankind. In the twenty-first century, work will begin to incorporate the information embedded in the human genome sequence into surgical practices. By doing so, the genomic information can be used for diagnosing and predicting disease and disease susceptibility. Diagnostic tests can be designed to detect errant genes in patients suspected of having particular diseases or of being at risk for developing them. Furthermore, exploration into the function of each human gene is now possible, which will shed light on how faulty genes play a role in disease causation. This knowledge also makes possible the development of a new generation of therapeutics based on genes. Drug design is being revolutionized as researchers create new classes of medicines based on a reasoned approach to the use of information on gene sequence and protein structure function rather than the traditional trial-and-error method. Drugs targeted to specific sites in the body promise to have fewer side effects than many of today's medicines. Finally, other applications of genomics will involve the transfer of genes to replace defective versions or the use of gene therapy to enhance normal functions such as immunity.

Proteomics refers to the study of the structure and expression of proteins as well as the interactions among proteins encoded by a human genome (see Fig. 15-1).⁹ A number of Internet-based repositories for protein sequences exist, including Swiss-Prot (<http://www.expasy.ch>). These databases allow comparisons of newly identified proteins with previously characterized sequences to allow prediction of similarities, identification of splice variants, and prediction of membrane topology and posttranslational modifications. Tools for proteomic profiling include two-dimensional gel electrophoresis, time-of-flight mass spectrometry, matrix-assisted laser desorption/ionization, and protein microarrays. *Structural proteomics* aims to describe the three-dimensional structure of proteins that is critical to understanding function. *Functional genomics* seeks to assign a biochemical, physiologic, cell biologic, and/or developmental function to each predicted gene. An ever-increasing arsenal of approaches, including transgenic animals, RNA interference (RNAi), and various systematic mutational strategies, will allow dissection of functions associated with newly discovered genes. Although the potential of this field of study is vast, it is in its early stages.

It is anticipated that a genomic and proteomic approach to human disease will lead to a new understanding of pathogenesis that will aid in the development of effective strategies for early diagnosis and treatment.¹⁰ For example, identification of altered protein expression in organs, cells, subcellular structures, or protein complexes may lead to development of new biomarkers for disease detection. Moreover, improved understanding of how protein structure determines function will allow rational identification of therapeutic targets, and thereby not only accelerate drug development, but also lead to new strategies to evaluate therapeutic efficacy and potential toxicity.⁹

Cell Cycle and Apoptosis

Every organism is composed of many different cell types at different developmental stages. Some cell types continue to grow, while some cells stop growing after a developmental stage or resume growth after a break. For example, embryonic stem cells grow continuously, while nerve cells and striated muscle cells stop dividing after maturation. Cell cycle is the process for every cell including DNA replication and protein synthesis, DNA segregation in half, and package DNA and protein in two newly formed cells to enable passage of identical genetic information from one parental cell to two daughter cells. Thus, the cell cycle is the fundamental mechanism to maintain tissue homeostasis. A cell cycle comprises four periods: G_1 (first gap phase before DNA synthesis), S (synthesis phase when DNA replication occurs), G_2 (the gap phase before mitosis), and M (mitosis, the phase when two daughter cells with identical DNA are generated) (Fig. 15-7). After a full cycle, the daughter cells enter G_1 again, and when they receive appropriate signals, undergo another cycle, and so on. The machinery that drives cell cycle progression is made up of a group of enzymes called *cyclin-dependent kinases* (CDKs). Cyclin expression fluctuates during the cell cycle, and cyclins are essential for CDK activities and form complexes with CDK. The cyclin A/CDK1 and cyclin B/CDK1 drive the progression for the M phase, while cyclin A/CDK2 is the primary S phase complex. Early G_1 cyclin D/CDK4/6 or late G_1 cyclin E/CDK2 controls the G_1 -S transition. There also are negative regulators for CDK termed *CDK inhibitors*, which inhibit the assembly or activity of the cyclin-CDK complex. Expression of cyclins and CDK inhibitors often is regulated by developmental and environmental factors.

The cell cycle is connected with signal transduction pathways as well as gene expression. Although the S and M phases rarely are subjected to changes imposed by extracellular signals, the G_1 and G_2 phases are the primary periods when cells decide

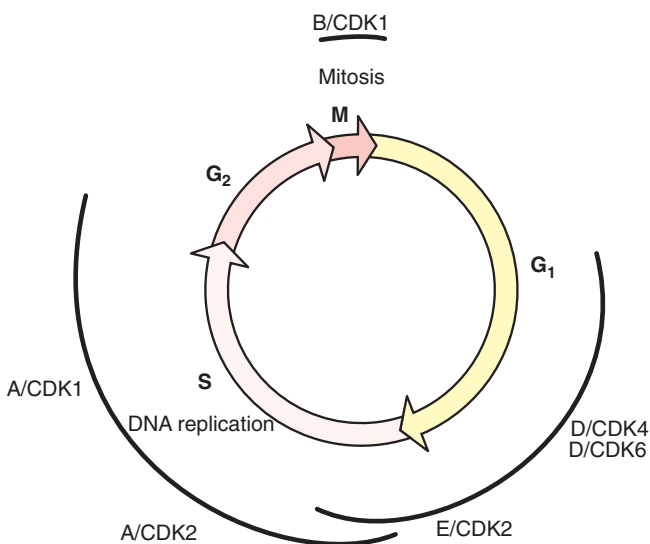


Figure 15-7. The cell cycle and its control system. M is the mitosis phase, when the nucleus and the cytoplasm divide; S is the phase when DNA is duplicated; G_1 is the gap between M and S; G_2 is the gap between S and M. A complex of cyclin and cyclin-dependent kinase (CDK) controls specific events of each phase. Without cyclin, CDK is inactive. Different cyclin/CDK complexes are shown around the cell cycle. A, B, D, and E stand for cyclin A, cyclin B, cyclin D, and cyclin E, respectively.

whether or not to move on to the next phase. During the G_1 phase, cells receive green- or red-light signals, S phase entry or G_1 arrest, respectively. Growing cells proliferate only when supplied with appropriate mitogenic growth factors. Cells become committed to entry of the cell cycle only toward the end of G_1 . Mitogenic signals stimulate the activity of early G_1 CDKs (e.g., cyclin D/CDK4) that inhibit the activity of pRb protein and activate the transcription factor called *E2F* to induce the expression of batteries of genes essential for G_1 -S progression. Meanwhile, cells also receive antiproliferative signals such as those from tumor suppressors. These antiproliferative signals also act in the G_1 phase to stop cells' progress into the S phase by inducing CKI production. For example, when DNA is damaged, cells will repair the damage before entering the S phase. Therefore, G_1 contains one of the most important checkpoints for cell cycle progression. If the analogy is made that CDK is to a cell as an engine is to a car, then cyclins and CKI are the gas pedal and brake, respectively. Accelerated proliferation or improper cell cycle progression with damaged DNA would be disastrous. Genetic gain-of-function mutations in oncogenes (that often promote expression or activity of the cyclin/CDK complex) or loss-of-function mutations in tumor suppressor (that stimulate production of CKI) are causal factors for malignant transformation.

In addition to cell cycle control, cells use genetically programmed mechanisms to kill cells. This cellular process, called *apoptosis* or *programmed cell death*, is essential for the maintenance of tissue homeostasis (Fig. 15-8).

Normal tissues undergo proper apoptosis to remove unwanted cells, those that have completed their jobs or have been damaged or improperly proliferated. Apoptosis can be activated by many physiologic stimuli such as death receptor signals (e.g., Fas or cytokine tumor necrosis factor), growth factor deprivation, DNA damage, and stress signals. Two major pathways control the biochemical mechanisms governing apoptosis: the death receptor and mitochondrial. However, recent advances in apoptosis research suggest an interconnection of the two pathways. What is central to the apoptotic machinery is the activation of a cascade of proteinases called caspases. Similarly to CDK in the cell cycle, activities and expression of caspases are well controlled by positive and negative regulators. The complex machinery of apoptosis must be tightly controlled. Perturbations of this process can cause neoplastic transformation or other diseases.

Signal Transduction Pathways

Gene expression in a genome is controlled in a temporal and spatial manner, at least in part by signaling pathways.¹¹ A signaling pathway generally begins at the cell surface and, after a signaling relay by a cascade of intracellular effectors, ends up in the nucleus (Fig. 15-9). All cells have the ability to sense changes in their external environment. The bioactive substances to which cells can respond are many and include proteins, short peptides, amino acids, nucleotides/nucleosides, steroids, retinoids, fatty acids, and dissolved gases. Some of these substances are lipophilic and thereby can cross the plasma membrane by diffusion to bind to a specific target protein within the cytoplasm (intracellular receptor). Other substances bind directly with a transmembrane protein (cell-surface receptor). Binding of ligand to receptor initiates a series of biochemical reactions (*signal transduction*) typically involving protein-protein interactions and the transfer of high-energy phosphate groups, leading to various cellular end responses.

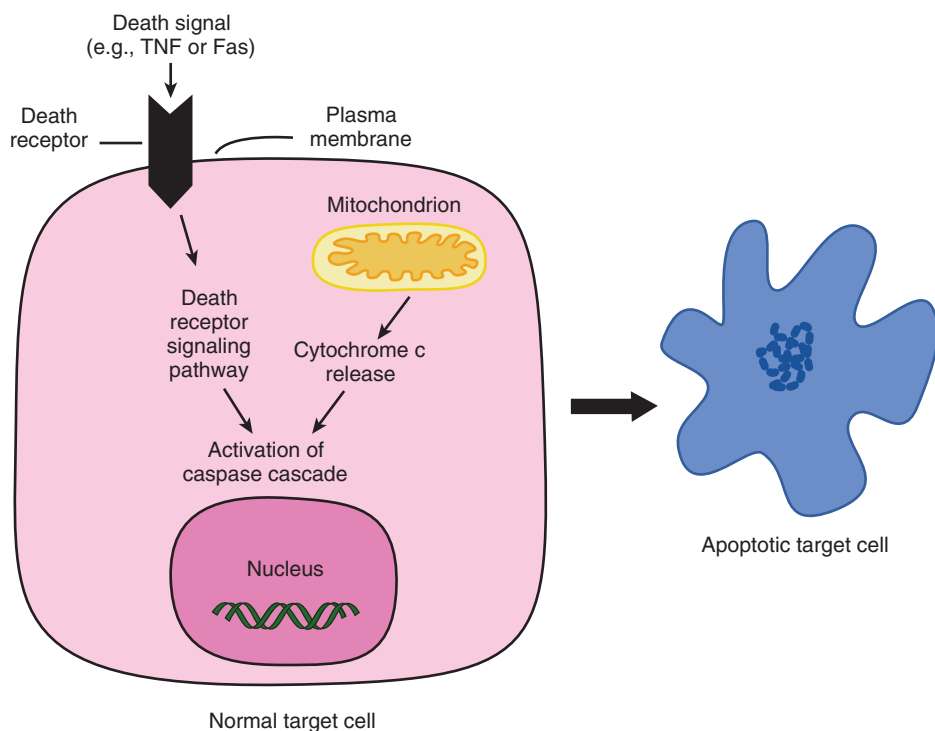


Figure 15-8. A simplified view of the apoptosis pathways. Extracellular death receptor pathways include the activation of Fas and tumor necrosis factor (TNF) receptors, and consequent activation of the caspase pathway. Intracellular death pathway indicates the release of cytochrome c from mitochondria, which also triggers the activation of the caspase cascade. During apoptosis, cells undergo DNA fragmentation and nuclear and cell membrane breakdown, and are eventually digested by other cells.

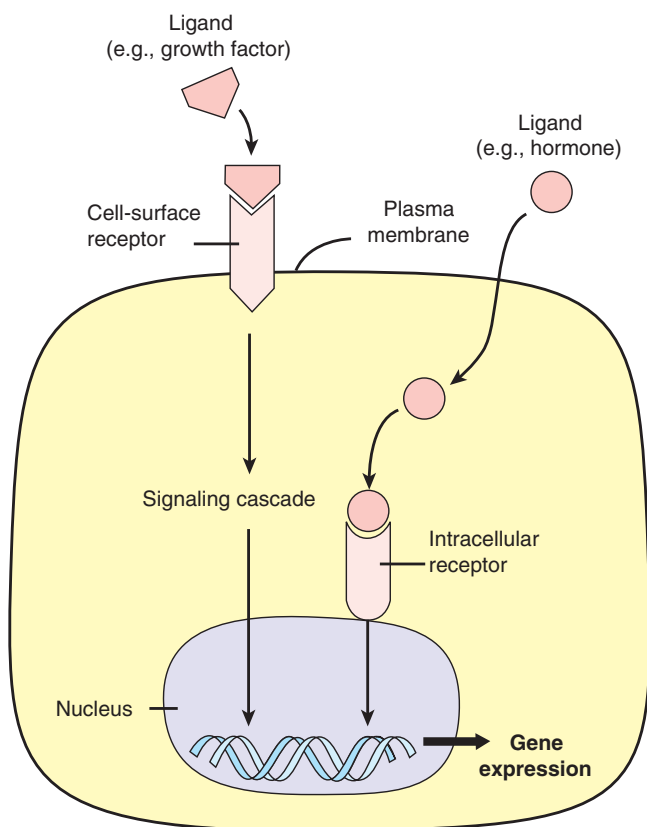


Figure 15-9. Cell-surface and intracellular receptor pathways. Extracellular signaling pathway: Most growth factors and other hydrophilic signaling molecules are unable to move across the plasma membrane and directly activate cell-surface receptors such as G-protein-coupled receptors and enzyme-linked receptors. The receptor serves as the receiver, and in turn activates the downstream signals in the cell. Intracellular signaling pathway: Hormones or other diffusible molecules enter the cell and bind to the intracellular receptor in the cytoplasm or in the nucleus. Either extracellular or intracellular signals often reach the nucleus to control gene expression.

Control and specificity through simple protein-protein interactions—referred to as *adhesive interactions*—is a common feature of signal transduction pathways in cells.¹² Signaling also involves catalytic activities of signaling molecules, such as protein kinases/phosphatases, that modify the structures of key signaling proteins. Upon binding and/or modification by upstream signaling molecules, downstream effectors undergo a conformational (allosteric) change and, consequently, a change in function. The signal that originates at the cell surface and is relayed by the cytoplasmic proteins often ultimately reaches the transcriptional apparatus in the nucleus. It alters the DNA binding and activities of transcription factors that directly turn genes on or off in response to the stimuli. Abnormal alterations in signaling activities and capacities in otherwise normal cells can lead to diseases such as cancer.

Advances in biology in the last two decades have dramatically expanded the view on how cells are wired with signaling pathways. In a given cell, many signaling pathways operate simultaneously and crosstalk with one another. A cell generally may react to a hormonal signal in a variety of ways: (a) by changing its metabolite or protein, (b) by generating an electric current, or (c) by contracting. Cells continually are subject to multiple input signals that simultaneously and sequentially activate multiple receptor- and non-receptor-mediated signal transduction pathways, which form a signaling network. Although the regulators responsible for cell behavior are rapidly identified as a result of genomic and proteomic techniques, the specific functions of the individual proteins, how they assemble, and the networks that control cellular behavior remain to be defined. An increased understanding of cell regulatory pathways—and how they are disrupted in disease—will likely reveal common themes based on protein interaction domains that direct associations of proteins with other polypeptides, phospholipids, nucleic acids, and other regulatory molecules. Advances in the understanding of signaling networks will require methods of investigation that move beyond traditional “linear” approaches into

medical informatics and computational biology. The bewildering biocomplexity of such networks mandates multidisciplinary and transdisciplinary research collaboration. The vast amount of information that is rapidly emerging from genomic and proteomic data mining will require the development of new modeling methodologies within the emerging disciplines of medical mathematics and physics.

Signaling pathways often are grouped according to the properties of signaling receptors. Many hydrophobic signaling molecules are able to diffuse across plasma membranes and directly reach specific cytoplasmic targets. Steroid hormones, thyroid hormones, retinoids, and vitamin D are examples that exert their activity upon binding to structurally related receptor proteins that are members of the *nuclear hormone receptor superfamily*. Ligand binding induces a conformational change that enhances transcriptional activity of these receptors. Most extracellular signaling molecules interact with transmembrane protein receptors that couple ligand binding to intracellular signals, leading to biologic actions.

There are three major classes of cell-surface receptors: *transmitter-gated ion channels*, *seven-transmembrane G-protein-coupled receptors (GPCRs)*, and *enzyme-linked receptors*. The superfamily of GPCRs is one of the largest families of proteins, representing over 800 genes of the human genome. Members of this superfamily share a characteristic seven-transmembrane configuration. The ligands for these receptors are diverse and include hormones, chemokines, neurotransmitters, proteinases, inflammatory mediators, and even sensory signals such as odorants and photons. Most GPCRs signal through *heterotrimeric G proteins*, which are guanine-nucleotide regulatory complexes. Thus the receptor serves as the receiver, the G protein serves as the transducer, and the enzyme serves as the effector arm. *Enzyme-linked receptors* possess an extracellular ligand-recognition domain and a cytosolic domain that either has intrinsic enzymatic activity or directly links with an enzyme. Structurally, these receptors usually have only one transmembrane-spanning domain. Of at least five forms of enzyme-linked receptors classified by the nature of the enzyme activity to which they are coupled, the growth factor receptors such as tyrosine kinase receptor or serine/threonine kinase receptors mediate diverse cellular events including cell growth, differentiation, metabolism, and survival/apoptosis. Dysregulation (particularly mutations) of these receptors is thought to underlie conditions of abnormal cellular proliferation in the context of cancer. The following sections will further review two examples of growth factor signaling pathways and their connection with human diseases.

Insulin Pathway and Diabetes.¹³ The discovery of insulin in the early 1920s is one of the most dramatic events in the treatment of human disease. *Insulin* is a peptide hormone that is secreted by the β -cell of the pancreas. Insulin is required for the growth and metabolism of most mammalian cells, which contain cell-surface insulin receptors (InsR). Insulin binding to InsR activates the kinase activity of InsR. InsR then adds phosphoryl groups, a process referred to as *phosphorylation*, and subsequently activates its immediate intracellular effector, called *insulin receptor substrate (IRS)*. IRS plays a central role in coordinating the signaling of insulin by activating distinct signaling pathways, the PI3K-Akt pathway and MAPK pathway, both of which possess multiple protein kinases that can control transcription, protein synthesis, and glycolysis (Fig. 15-10).

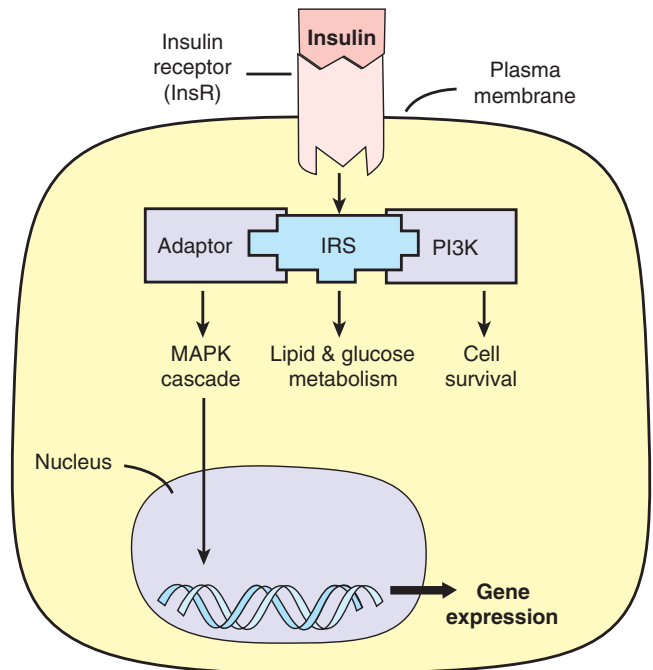


Figure 15-10. Insulin-signaling pathway. Insulin is a peptide growth factor that binds to and activates the heterotetrameric receptor complex (InsR). InsR possesses protein tyrosine kinase activity and is able to phosphorylate the downstream insulin receptor substrate (IRS). Phosphorylated IRS serves as a scaffold and controls the activation of multiple downstream pathways for gene expression, cell survival, and glucose metabolism. Inactivation of the insulin pathway can lead to type 2 diabetes.

The primary physiologic role of insulin is in glucose homeostasis, which is accomplished through the stimulation of glucose uptake into insulin-sensitive tissues such as fat and skeletal muscle. Defects in insulin synthesis/secretion and/or responsiveness are major causal factors in diabetes, one of the leading causes of death and disability in the United States, affecting an estimated 16 million Americans. Type 2 diabetes accounts for about 90% of all cases of diabetes. Clustering of type 2 diabetes in certain families and ethnic populations points to a strong genetic background for the disease. More than 90% of affected individuals have insulin resistance, which develops when the body is no longer able to respond correctly to insulin circulating in the blood. Although relatively little is known about the biochemical basis of this metabolic disorder, it is clear that the insulin-signaling pathways malfunction in this disease. It is also known that genetic mutations in the InsR or IRS cause type 2 diabetes, although which one is not certain. The majority of type 2 diabetes cases may result from defects in downstream-signaling components in the insulin-signaling pathway. Type 2 diabetes also is associated with declining β -cell function, resulting in reduced insulin secretion; these pathways are under intense study. A full understanding of the basis of insulin resistance is crucial for the development of new therapies for type 2 diabetes. Furthermore, apart from type 2 diabetes, insulin resistance is a central feature of several other common human disorders, including atherosclerosis and coronary artery disease, hypertension, and obesity.

Transforming Growth Factor- β (TGF- β) Pathway and Cancers.¹⁴ Growth factor signaling controls cell growth, differentiation, and apoptosis. Although insulin and many mitogenic

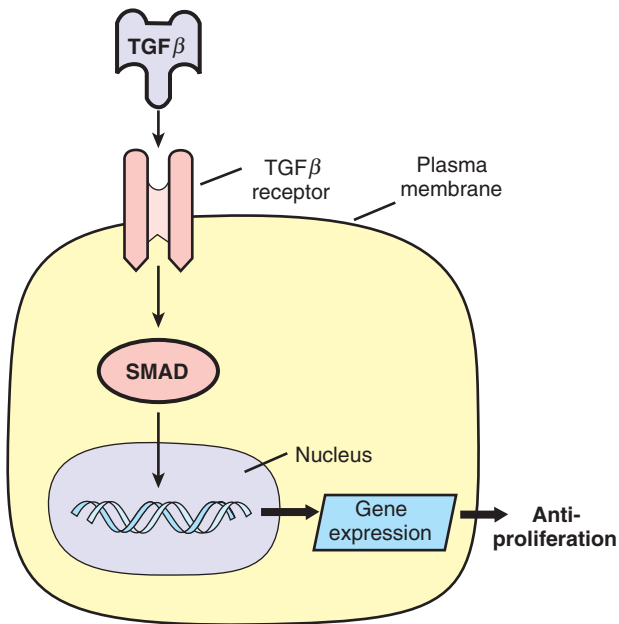


Figure 15-11. TGF- β signaling pathway. The TGF- β family has at least 29 members encoded in the human genome. They are also peptide growth factors. Each member binds to a heterotetrameric complex consisting of a distinct set of type I and type II receptors. TGF- β receptors are protein serine/threonine kinases and can phosphorylate the downstream substrates called *SMAD* proteins. Phosphorylated SMADs are directly transported into the nucleus, where they bind to the DNA and regulate gene expression that is responsible for inhibition of cell proliferation. Inactivation of the TGF- β pathway through genetic mutations in the TGF- β receptors or SMADs is frequent in human cancer, leading to the uncontrolled proliferation of cancer cells.

growth factors promote cell proliferation, some growth factors and hormones inhibit cell proliferation. TGF- β is one of them. The balance between mitogens and TGF- β plays an important role in controlling the proper pace of cell cycle progression. The growth inhibition function of TGF- β signaling in epithelial cells plays a major role in maintaining tissue homeostasis.

The TGF- β superfamily comprises a large number of structurally related growth and differentiation factors that act through a receptor complex at the cell surface (Fig. 15-11). The complex consists of transmembrane serine/threonine kinases. The receptor signals through activation of heterotrimeric complexes of intracellular effectors called SMADs (which are contracted from homologous *Caenorhabditis elegans* Sma and *Drosophila* Mad, two evolutionarily conserved genes for TGF- β signaling). Upon phosphorylation by the receptors, SMAD complexes translocate into the nucleus, where they bind to gene promoters and cooperate with specific transcription factors to regulate the expression of genes that control cell proliferation and differentiation. For example, TGF- β strongly induces the transcription of a gene called *p15^{INK4B}* (a type of CKI) and, at the same time, reduces the expression of many oncogenes such as *c-Myc*. The outcome of the altered gene expression leads to the inhibition of cell cycle progression. Meanwhile, the strength and duration of TGF- β signaling is fine-tuned by a variety of positive or negative modulators, including protein phosphatases. Therefore, controlled activation of TGF- β signaling is an intrinsic mechanism for cells to ensure controlled proliferation.

Resistance to TGF- β 's anticancer action is one hallmark of human cancer cells. TGF- β receptors and SMADs are identified as tumor suppressors. The TGF- β signaling circuit can be disrupted in a variety of ways and in different types of human tumors. Some lose TGF- β responsiveness through downregulation or mutations of their TGF- β receptors. The cytoplasmic SMAD4 protein, which transduces signals from ligand-activated TGF- β receptors to downstream targets, may be eliminated through mutation of its encoding gene. The locus encoding cell cycle inhibitor *p15^{INK4B}* may be deleted. Alternatively, the immediate downstream target of its actions, cyclin-dependent kinase 4 (CDK4), may become unresponsive to the inhibitory actions of *p15^{INK4B}* because of mutations that block *p15^{INK4B}* binding. The resulting cyclin D/CDK4 complexes constitutively inactivate tumor suppressor pRb by hyperphosphorylation. Finally, functional pRb, the end target of this pathway, may be lost through mutation of its gene. For example, in pancreatic and colorectal cancers, 100% of cells derived from these cancers carry genetic defects in the TGF- β signaling pathway. Therefore, the antiproliferative pathway converging onto pRb and the cell division cycle is, in one way or another, disrupted in a majority of human cancer cells. Besides cancer, dysregulation of TGF- β signaling also has been associated with other human diseases such as Marfan's syndrome and thoracic aortic aneurysm.

Gene Therapy and Molecular Drugs in Cancer

Modern advances in the use of molecular biology to manipulate genomes have greatly contributed to the understanding of the molecular basis for how cells live, die, or differentiate. Given the fact that human diseases arise from improper changes in the genome, the continuous understanding of how the genome functions will make it possible to tailor medicine on an individual basis. Although significant hurdles remain, the course toward therapeutic application of molecular biology already has been mapped out by many proof-of-principle studies in the literature. In this section, cancer is used as an example to elaborate some therapeutic applications of molecular biology. Modern molecular medicine includes gene therapy and molecular drugs that target genes or gene products that wire human cells.

Cancer is a complex disease, involving uncontrolled growth and spread of tumor cells (Fig. 15-12). Cancer development depends on the acquisition and selection of specific characteristics that set the tumor cell apart from normal somatic cells. Cancer cells have defects in regulatory circuits that govern normal cell proliferation and homeostasis. Many lines of evidence indicate that tumorigenesis in humans is a multistep process and that these steps reflect genetic alterations that drive the progressive transformation of normal human cells into highly malignant derivatives. The genomes of tumor cells are invariably altered at multiple sites, having suffered disruption through lesions as subtle as point mutations and as obvious as changes in chromosome complement. A succession of genetic changes, each conferring one or another type of growth advantage, leads to the progressive conversion of normal human cells into cancer cells.

Cancer research in the past 20 years has generated a rich and complex body of knowledge, revealing cancer to be a disease involving dynamic changes in the genome. The causes of cancer include genetic predisposition, environmental influences, infectious agents, and aging. These transform normal cells into cancerous ones by derailing a wide spectrum of regulatory pathways including signal transduction pathways, cell

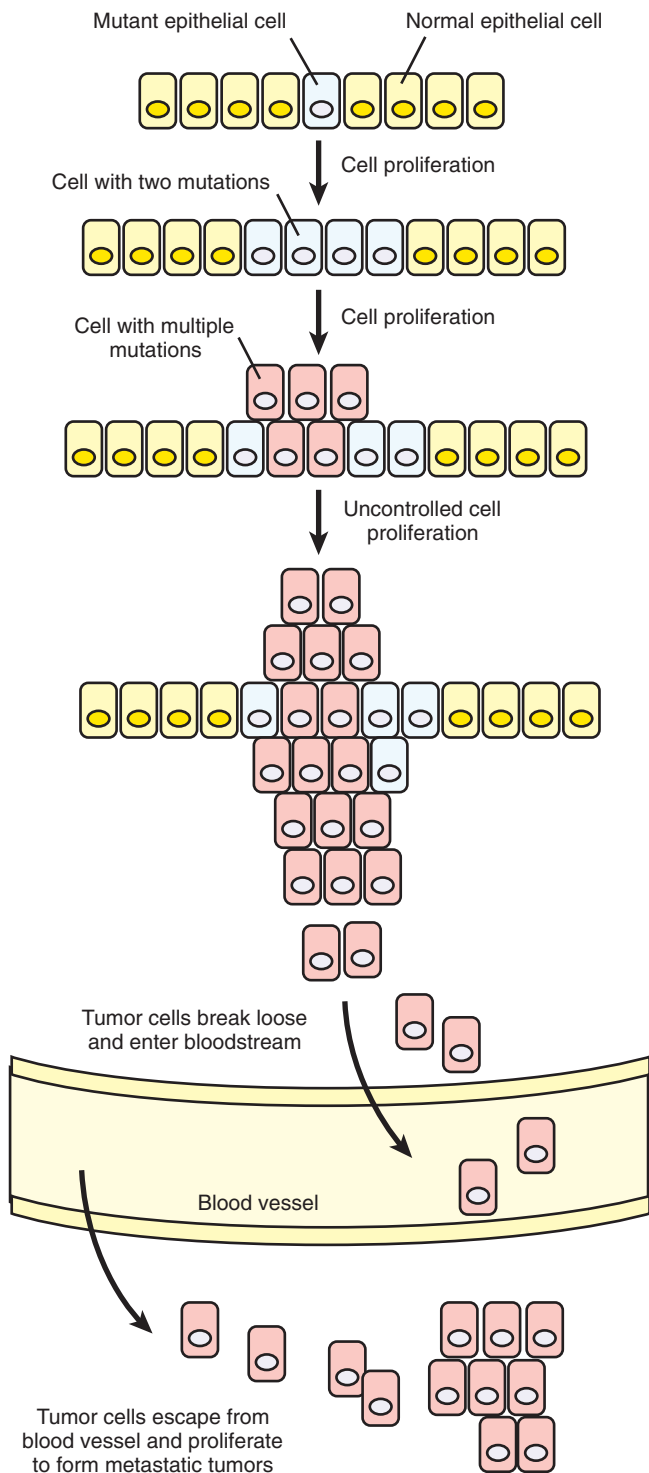


Figure 15-12. Tumor clonal evolution and metastasis. A tumor develops from mutant cells with multiple genetic mutations. Through repeated alterations in the genome, mutant epithelial cells are able to develop into a cluster of cells (called a *tumor clone*) that proliferates in an uncontrollable fashion. Further changes in the tumor cells can transform the tumor cells into a population of cells that can enter the blood vessels and repopulate in a new location.

cycle machinery, or apoptotic pathways.^{15,16} The early notion that cancer was caused by mutations in genes critical for the control of cell growth implied that genome stability is important for preventing oncogenesis. There are two classes of cancer genes in which alteration has been identified in human and

animal cancer cells: oncogenes, with dominant gain-of-function mutations, and tumor suppressor genes, with recessive loss-of-function mutations. In normal cells, oncogenes promote cell growth by activating cell cycle progression, whereas tumor suppressors counteract oncogenes' functions. Therefore, the balance between oncogenes and tumor suppressors maintains a well-controlled state of cell growth.

During the development of most types of human cancer, cancer cells can break away from primary tumor masses, invade adjacent tissues, and hence travel to distant sites where they form new colonies. This spreading process of tumor cells, called *metastasis*, is the cause of 90% of human cancer deaths. Metastatic cancer cells that enter the bloodstream can reach virtually all tissues of the body. Bones are one of the most common places for these cells to settle and start growing again. Bone metastasis is one of the most frequent causes of pain in people with cancer. It also can cause bones to break and create other symptoms and problems for patients.

The progression in the knowledge of cancer biology has been accelerating in recent years. All of the scientific knowledge acquired through hard work and discovery has made it possible for cancer treatment and prevention. As a result of explosive new discoveries, some modern treatments were developed. The success of these therapies, together with traditional treatments such as surgical procedures, is further underscored by the fact that in 2002 the cancer rate was reduced in the United States. Current approaches to the treatment of cancer involve killing cancer cells with toxic chemicals, radiation, or surgery. Alternatively, several new biologic- and gene-based therapies are aimed at enhancing the body's natural defenses against invading cancers. Understanding the biology of cancer cells has led to the development of designer therapies for cancer prevention and treatment. Gene therapy, immune system modulation, genetically engineered antibodies, and molecularly designed chemical drugs are all promising fronts in the war against cancer.

Immunotherapy. The growth of the body is controlled by many natural signals through complex signaling pathways. Some of these natural agents have been used in cancer treatment and have been proven effective for fighting several cancers through the clinical trial process. These naturally occurring biologic agents, such as interferons, interleukins, and other cytokines, can now be produced in the laboratory. These agents, as well as the synthetic agents that mimic the natural signals, are given to patients to influence the natural immune response agents either by directly altering the cancer cell growth or by acting indirectly to help healthy cells control the cancer. One of the most exciting applications of immunotherapy has come from the identification of certain tumor targets called *antigens* and the aiming of an antibody at these targets. This was first used as a means of localizing tumors in the body for diagnosis and was more recently used to attack cancer cells. Trastuzumab (Herceptin) is an example of such a drug.¹⁷ Trastuzumab is a monoclonal antibody that neutralizes the mitogenic activity of cell-surface growth factor receptor HER-2, which is overexpressed in approximately 25% of breast cancers. HER-2–overexpressing tumors tend to grow faster and generally are more likely to recur than tumors that do not overproduce HER-2. Trastuzumab is designed to attack cancer cells that overexpress HER-2 by slowing or preventing the growth of these cells, resulting in increased survival of HER-2–positive breast cancer patients. Another significant example is the administration of interleukin-2 (IL-2) to patients with metastatic melanoma or kidney cancer, which has been

shown to mediate the durable regression of metastatic cancer. IL-2, a cytokine produced by human helper T lymphocytes, has a wide range of immune regulatory effects, including the expansion of lymphocytes following activation by a specific antigen. Although IL-2 has no direct impact on cancer cells, the impact of IL-2 on cancers *in vivo* derives from its ability to expand lymphocytes with antitumor activity. The expanded lymphocyte pool enables recognition of the antigen on cancer cells. Thus, the molecular identification of cancer antigens has opened new possibilities for the development of effective immunotherapies for patients with cancer. Clinical studies using immunization with peptides derived from cancer antigens have shown that high levels of lymphocytes with antitumor activity can be produced in cancer-bearing patients. Highly avid antitumor lymphocytes can be isolated from immunized patients and grown *in vitro* for use in cell-transfer therapies.

Chemotherapy. The primary function of anticancer chemicals is to block different steps involved in cell growth and replication. These chemicals often block a critical chemical reaction in a signal transduction pathway or during DNA replication or gene expression. For example, STI571, also known as *Gleevec*, is one of the first molecularly targeted drugs based on the changes that cancer causes in cells.¹⁸ STI571 offers promise for the treatment of chronic myeloid leukemia (CML) and may soon surpass interferon- γ as the standard treatment for the disease. In CML, STI571 is targeted at the Bcr-Abl kinase, an activated oncogene product in CML (Fig. 15-13). Bcr-Abl is an overly activated protein kinase resulting from a specific genetic abnormality generated by chromosomal translocation that is found in the cells of patients with CML. STI571-mediated inhibition of Bcr-Abl kinase activity not only prevents cell growth of Bcr-Abl-transformed leukemic cells, but also induces apoptosis. Clinically, the drug quickly corrects the blood cell abnormalities caused by the leukemia in a majority of patients, achieving a complete disappearance of the leukemic blood cells and the return of normal blood cells. Additionally, the drug appears to have some effect on other cancers including certain brain tumors and gastrointestinal (GI) stromal tumors, a very rare type of stomach cancer.

Gene Therapy. Gene therapy is an experimental treatment that involves genetically altering a patient's own tumor cells or lymphocytes (cells of the immune system, some of which can attack cancer cells). For years, the concept of gene therapy has held promise as a new, potentially potent weapon to attack cancer. Although a rapid progression in the understanding of

the molecular and clinical aspects of gene therapy has been witnessed in the past decade, gene therapy treatment has not yet been shown to be superior to standard treatments in humans.

Several problems must be resolved to transform it into a clinically relevant form of therapy. The major issues that limit its translation to the clinic are improving the selectivity of tumor targeting, improving the delivery to the tumor, and the enhancement of the transduction rate of the cells of interest. In most gene therapy trials for malignant diseases, tumors can be accessed and directly injected (*in situ* gene therapy). The *in situ* gene therapy also offers a better distribution of the vector virus throughout the tumor. Finally, a combination of gene therapy strategies will be more effective than the use of a single gene therapy system. An important aspect of effective gene therapy involves the choice of appropriate genes for manipulation. Genes that promote the production of messenger chemicals or other immune-active substances can be transferred into the patient's cells. These include genes that inhibit cell cycle progression, induce apoptosis, enhance host immunity against cancer cells, block the ability of cancer cells to metastasize, and cause tumor cells to undergo suicide. Recent development of RNAi technology, which uses a loss-of-function approach to block gene functions, ensures a new wave of hopes for gene therapy. Nonetheless, gene therapy is still experimental and is being studied in clinical trials for many different types of cancer. The mapping of genes responsible for human cancer is likely to provide new targets for gene therapy in the future. The preliminary results of gene therapy for cancer are encouraging, and as advancements are made in the understanding of the molecular biology of human cancer, the future of this rapidly developing field holds great potential for treating cancer.

It is noteworthy that the use of multiple therapeutic methods has proven more powerful than a single method. The use of chemotherapy after surgery to destroy the few remaining cancerous cells in the body is called *adjuvant* therapy. Adjuvant therapy was first tested and found to be effective in breast cancer. It was later adopted for use in other cancers. A major discovery in chemotherapy is the advantage of multiple chemotherapeutic agents (known as *combination* or *cocktail chemotherapy*) over single agents. Some types of fast-growing leukemias and lymphomas (tumors involving the cells of the bone marrow and lymph nodes) responded extremely well to combination chemotherapy, and clinical trials led to gradual improvement of the drug combinations used. Many of these tumors can be cured today by combination chemotherapy. As

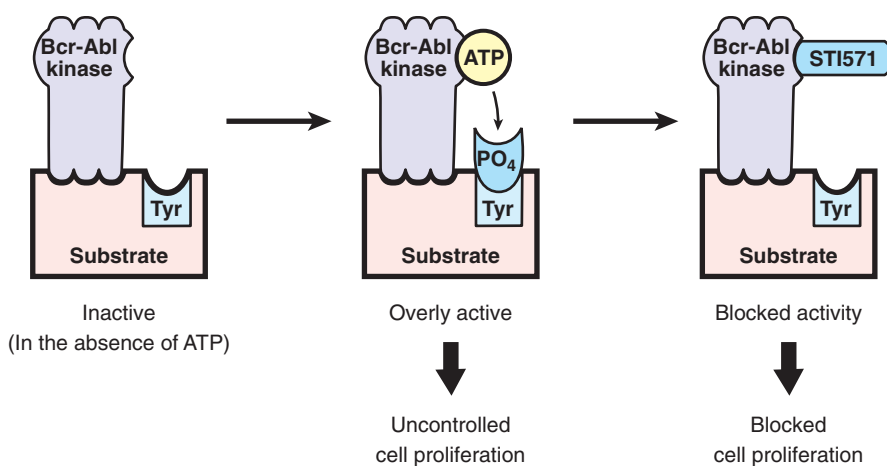


Figure 15-13. Mechanism of STI571 as a molecular drug. Bcr-Abl is an overly activated oncogene product resulting from a specific genetic abnormality generated by chromosomal translocation that is found in cells of patients with chronic myeloid leukemia. Bcr-Abl is an activated protein kinase and thus requires adenosine triphosphate (ATP) to phosphorylate substrates, which in turn promote cell proliferation. STI571 is a small molecule that competes with the ATP-binding site and thus blocks the transfer of phosphoryl group to substrate. PO₄ = phosphate; Tyr = tyrosine.

cancer cells carry multiple genetic defects, the use of combination chemotherapy, immunotherapy, and gene therapies may be more effective in treating cancers.

Stem Cell Research

Stem cell biology represents a cutting-edge scientific research field with potential clinical applications.¹⁹ It may have an enormous impact on human health by offering hope for curing human diseases such as diabetes mellitus, Parkinson's disease, neurologic degeneration, and congenital heart disease. Stem cells are endowed with two remarkable properties (Fig. 15-14). First, stem cells can proliferate in an undifferentiated but pluripotent state and, as a result, can self-renew. Second, they have the ability to differentiate into many specialized cell types. There are two groups of stem cells: embryonic stem (ES) cells and adult stem cells. Human ES cells are derived from early preimplantation embryos called *blastocysts* (5 days postfertilization) and are capable of generating all differentiated germ layers in the body—ectoderm, mesoderm, and endoderm—and therefore are considered pluripotent. Adult stem cells are present in and can be isolated from adult tissues. They often are tissue specific and only can generate the cell types comprising a particular tissue in the body; therefore, they are considered multipotent. However, in some cases, they can transdifferentiate into cell types found in other tissues, called transdifferentiation. For example, hematopoietic stem cells are adult stem cells. They reside in bone marrow and are capable of generating all cell types of the blood and immune system.

Stem cells can be grown in culture and be induced to differentiate into a particular cell type, either *in vitro* or *in vivo*. With the recent and continually increasing improvement in culturing stem cells, scientists are beginning to understand the molecular mechanisms of stem cell self-renewal and differentiation in response to environmental cues. It is believed that discovery of the signals that control self-renewal vs. differentiation will be extremely important for the therapeutic use of stem cells in treating disease. It is possible that success in the study of the changes in signal transduction pathways in stem cells will lead to the development of therapies to replace diseased or damaged cells in the body using stem cell derivatives. Recently, stem cell research has been transformed by the discovery from the Shinya Yamanaka group and the James Thomson group, who have found that a simple genetic manipulation can reprogram adult differentiated cells back into pluripotent stem cells.^{20,21} This exciting discovery not only bypasses the ethical issues of

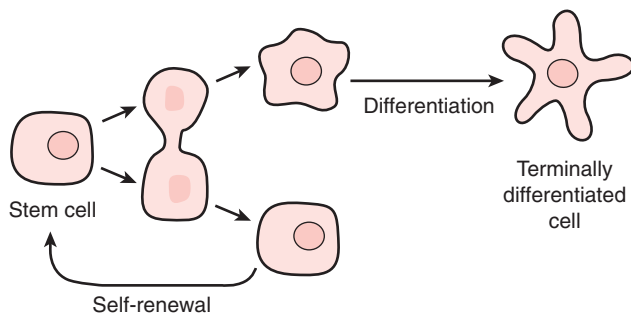


Figure 15-14. Stem cells. A stem cell is capable of self-renewal (unlimited cell cycle) and differentiation (becoming nondividing cells with specialized functions). Differentiating stem cells often undergo additional cell divisions before they become fully mature cells that carry out specific tissue functions.

using early embryos to generate ES cells, but also ensures a potentially limitless source of patient-specific stem cells for tissue engineering and regenerative medicine.

The Atomic Theory of Disease²²

The staggering advances in anatomy, physiology, and molecular biology over the past centuries have led us to our current state in which the atom is now the anatomy of the twenty-first century. As 99% of the body is composed of six elements (oxygen, carbon, hydrogen, nitrogen, calcium, and phosphorus), the next great advance in medicine will be bridging the subatomic, molecular, and genomic levels by forming an atomic theory of disease, which states that alterations in the composition of subatomic particles are the root cause of disease. The atomic theory of disease would include genetic alterations at the atomic/subatomic level that are akin to single nucleotide polymorphisms (SNPs), in which alleles for a gene differ on the exact nucleotide in a single location, which can change the ultimate protein structure. This can lead to subtle changes in function or dramatic results that cause pathology. We hypothesize that on a subatomic level, there could potentially be polymorphisms as well, in which there are subtle changes in the sea of subatomic particles. Isotopes, discovered 100 years ago, would fall into this category of subatomic polymorphism, as they differ in the number of neutrons present in the atom. Differences in other particles may not change the mass of the atom, but may alter some of the characteristics of the atom.

A known example of a change in the subatomic milieu of an element leading to a disease process is that of methemoglobinemia, a disorder characterized by an overabundance of methemoglobin. Methemoglobin contains an oxidized form of iron (carrying an extra electron), as opposed to the reduced form in normal hemoglobin. This results in a shift in the oxygen-hemoglobin dissociation curve to the left, causing hypoxia. Methemoglobinemia can be congenital, due to a defect in an enzyme that normally reduces methemoglobin back to hemoglobin, or acquired, caused by breakdown products of drugs that can oxidize hemoglobin. Although there is less than 1% of methemoglobin normally present in human tissues, affecting local blood flow and inflammation through its effects on nitric oxide and heme, large quantities can lead to respiratory failure and death.

TECHNOLOGIES OF MOLECULAR AND CELL BIOLOGY

DNA Cloning

Since the advent of recombinant DNA technology three decades ago, hundreds of thousands of genes have been identified. Recombinant DNA technology is the technology that uses advanced enzymatic and microbiologic techniques to manipulate DNA.²³ Pure pieces of any DNA can be inserted into bacteriophage DNA or other carrier DNA such as plasmids to produce recombinant DNA in bacteria. In this way, DNA can be reconstructed, amplified, and used to manipulate the functions of individual cells or even organisms. This technology, often referred to as *DNA cloning*, is the basis of all other DNA analysis methods. It is only with the awesome power of recombinant DNA technology that the completion of the Human Genome Project was possible. It also has led to the identification of the entire gene complements of organisms such as viruses, bacteria, worms, flies, and plants.

Molecular cloning refers to the process of cloning a DNA fragment of interest into a DNA vector that ultimately

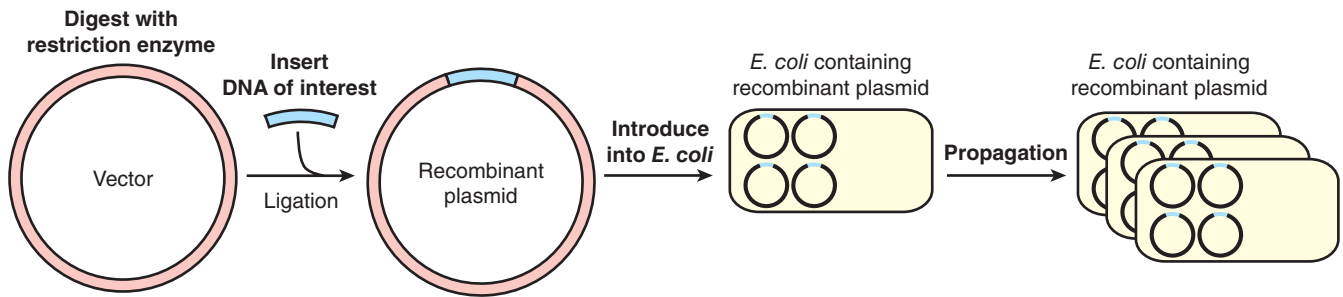


Figure 15-15. Generation of recombinant DNA. The vector is a circular DNA molecule that is capable of replicating in *Escherichia coli* cells. Insert DNA (often your favorite gene) is ligated to the vector after ends of both DNA are properly treated with restriction enzymes. Ligated DNA (i.e., the recombinant plasmid DNA) is then transformed into *E. coli* cells, where it replicates to produce recombinant progenies. *E. coli* cells carrying the recombinant plasmid can be propagated to yield large quantities of plasmid DNA.

is delivered into bacterial or mammalian cells or tissues^{24,25} (Fig. 15-15). This represents a very basic technique that is widely used in almost all areas of biomedical research. DNA vectors often are called *plasmids*, which are extrachromosomal molecules of DNA that vary in size and can replicate and be transmitted from bacterial cell to cell. Plasmids can be propagated either in the cytoplasm or after insertion, as part of the bacterial chromosome in *Escherichia coli*. The process of molecular cloning involves several steps of manipulation of DNA. First, the vector plasmid DNA is cleaved with a restriction enzyme to create compatible ends with the foreign DNA fragment to be cloned. The vector and the DNA fragment are then joined *in vitro* by a DNA ligase. Alternatively, DNA cloning can be simply done through the so-called *Gateway Technology* that allows for the rapid and efficient transfer of DNA fragments between different cloning vectors while maintaining reading frame and orientation, without the use of restriction endonucleases and DNA ligase. The technology, which is based on the site-specific recombination system of bacteriophage λ , is simple, fast, robust, and automatable and thus compatible for high-throughput DNA cloning.

Finally, the ligation product or the Gateway reaction product is introduced into competent host bacteria; this procedure is called *transformation*, which can be done by either calcium/heat shock or electroporation. Precautions must be taken in every step of cloning to generate the desired DNA construct. The vector must be correctly prepared to maximize the creation of recombinants; for example, it must be enzymatically treated to prevent self-ligation. Host bacteria must be made sufficiently competent to permit the entry of recombinant plasmids into cells. The selection of desired recombinant plasmid-bearing *E. coli* normally is achieved by the property of drug resistance conferred by the plasmid vectors. The plasmids encoding markers provide specific resistance to (i.e., the ability to grow in the presence of) antibiotics such as ampicillin, kanamycin, and tetracycline. The foreign component in the plasmid vector can be a mammalian expression cassette, which can direct expression of foreign genes in mammalian cells. The resulting plasmid vector can be amplified in *E. coli* to prepare large quantities of DNA for its subsequent applications such as transfection, gene therapy, transgenics, and knockout mice.

Detection of Nucleic Acids and Proteins

Southern Blot Hybridization. Southern blotting refers to the technique of transferring DNA fragments from an electrophoresis gel to a membrane support and the subsequent analysis of the fragments by hybridization with a radioactively or

chemiluminescently labeled probe (Fig. 15-16).²⁶ Southern blotting is named after E. M. Southern, who in 1975 first described the technique of DNA analysis. It enables reliable and efficient analysis of size-fractionated DNA fragments in an immobilized membrane support. Southern blotting is composed of several steps. It normally begins with the digestion of the DNA samples with appropriate restriction enzymes, which will discriminate wild-type and mutant DNA by size and the separation of DNA samples in an agarose gel by electrophoresis with appropriate DNA size markers, called the DNA ladder. The DNA gel is stained with a dye, usually ethidium

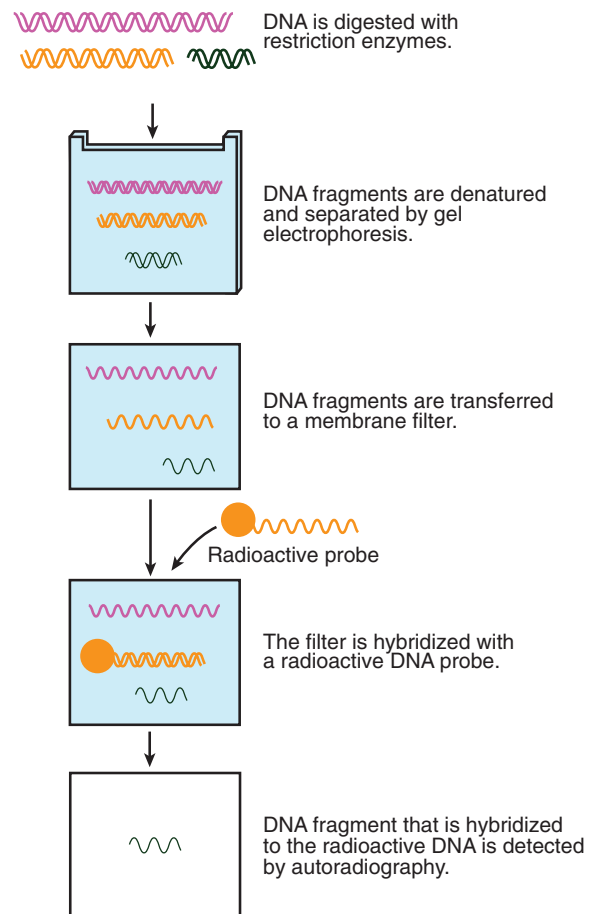


Figure 15-16. Southern blotting. Restriction enzymatic fragments of DNA are separated by agarose gel electrophoresis, transferred to a membrane filter, and then hybridized to a radioactive probe.

bromide, and photographed with a ruler laid alongside the gel so that band positions can later be identified on the membrane. The DNA gel then is treated so the DNA fragments are denatured (i.e., strand separation). The DNA then is transferred onto a nitrocellulose membrane by capillary diffusion or under electricity. After immobilization, the DNA can be subjected to hybridization analysis, enabling bands with sequence similarity to a radioactively or chemiluminescently labeled probe to be identified.

The development of Southern transfer and the associated hybridization techniques made it possible for the first time to obtain information about the physical organization of single and multicopy sequences in complex genomes. The later application of Southern blotting hybridization to the study of restriction fragment length polymorphisms opened up new possibilities such as genetic fingerprinting and prenatal diagnosis of genetic diseases.

Northern Blot Hybridization. Northern blotting refers to the technique of size fractionation of RNA in a gel and the transferring of an RNA sample to a solid support (membrane) in such a manner that the relative positions of the RNA molecules are maintained. The resulting membrane then is hybridized with a labeled probe complementary to the mRNA of interest. Signals generated from detection of the membrane can be used to determine the size and abundance of the target RNA. In principle, Northern blot hybridization is similar to Southern blot hybridization (and hence its name), with the exception that RNA, not DNA, is on the membrane. Although reverse-transcriptase PCR has been used in many applications (described in the next section, Polymerase Chain Reaction), Northern analysis is the only method that provides information regarding mRNA size and has remained a standard method for detection and quantitation of mRNA. The process of Northern hybridization involves several steps, as does Southern hybridization, including electrophoresis of RNA samples in an agarose-formaldehyde gel, transfer to a membrane support, and hybridization to a radioactively labeled DNA probe. Data from hybridization allow quantification of steady-state mRNA levels and, at the same time, provide information related to the presence, size, and integrity of discrete mRNA species. Thus, Northern blot analysis, also termed *RNA gel blot analysis*, commonly is used in molecular biology studies relating to gene expression.

Polymerase Chain Reaction. PCR is an *in vitro* method for the polymerase-directed amplification of specific DNA sequences using two oligonucleotide primers that hybridize to opposite strands and flank the region of interest in the target DNA (Fig. 15-17).²⁷ One cycle of PCR reaction involves template denaturation, primer annealing, and the extension of the annealed primers by DNA polymerase. Because the primer extension products synthesized in one cycle can serve as a template in the next, the number of target DNA copies nearly doubles at each cycle. Thus, a repeated series of cycles result in the exponential accumulation of a specific fragment in which the termini are sharply defined by the 5' ends of the primers. The introduction of the thermostable DNA polymerase (e.g., Taq polymerase) transforms the PCR into a simple and robust reaction. The reaction components (e.g., template, primers, Taq polymerase, 2'-deoxynucleoside 5'-triphosphates, and buffer) could all be assembled and the amplification reaction carried out by simply cycling the temperatures within the reaction tube. The specificity and yield in amplifying a particular

DNA fragment by PCR reaction are affected by the proper setting of the reaction parameters (e.g., enzyme, primer, and Mg²⁺ concentration, as well as the temperature cycling profile). Modifying various PCR parameters to optimize the specificity of amplification yields more homogenous products, even in rare template reactions.

The emergence of the PCR technique has dramatically altered the approach to both fundamental and applied biological problems. The capability of amplifying a specific DNA fragment from a gene or the whole genome greatly advances the study of the gene and its function. It is simple, yet robust, speedy, and most of all, flexible. As a recombinant DNA tool, it underlies almost all of molecular biology. This revolutionary technique enabled the modern methods for the isolation of genes, construction of a DNA vector, introduction of alterations into DNA, and quantitation of gene expression, making it a fundamental cornerstone of genetic and molecular analysis.

Immunoblotting and Immunoprecipitation. Analyses of proteins are primarily carried out by antibody-directed immunologic techniques. For example, Western blotting, also called *immunoblotting*, is performed to detect protein levels in a population of cells or tissues, whereas immunoprecipitation is used to concentrate proteins from a larger pool. Using specific antibodies, microscopic analysis called *immunofluorescence* and *immunohistochemistry* is possible for the subcellular localization and expression of proteins in cells or tissues, respectively.

Immunoblotting refers to the process of identifying a protein from a mixture of proteins (Fig. 15-18). It consists of five steps: (a) sample preparation; (b) electrophoresis (separation of a protein mixture by sodium dodecyl sulfate-polyacrylamide gel electrophoresis); (c) transfer (the electrophoretic transfer of proteins from gel onto membrane support [e.g., nitrocellulose, nylon, or polyvinylidene difluoride]); (d) staining (the subsequent immunodetection of target proteins with specific antibody); and (e) development (colorimetric, chemiluminescent, and recently fluorescent visualization of the antibody-recognized protein). Thus, immunoblotting combines the resolution of gel electrophoresis with the specificity of immunochemical detection. Immunoblotting is a powerful tool used to determine a number of important characteristics of proteins. For example, immunoblotting analysis will determine the presence and the quantity of a protein in a given cellular condition and its relative molecular weight. Immunoblotting also can be used to determine whether posttranslational modification such as phosphorylation has occurred on a protein. Importantly, through immunoblotting analysis, a comparison of the protein levels and modification states in normal vs. diseased tissues is possible.

Immunoprecipitation, another widely used immunochemical technique, is a method that uses antibody to enrich a protein of interest and any other proteins that are associated with it (Fig. 15-19). The principle of the technique lies in the property of a strong and specific affinity between antibodies and their antigens to locate and pull down target proteins in solution. Once the antibody-antigen (target protein) complexes are formed in the solution, they are collected and purified using small agarose beads with covalently attached protein A or protein G. Both protein A and protein G specifically interact with the antibodies, thus forming a large immobilized complex of antibody-antigen bound to beads. The purified protein can then be analyzed by a number of biochemical methods. When immunoprecipitation is combined with immunoblotting, it can

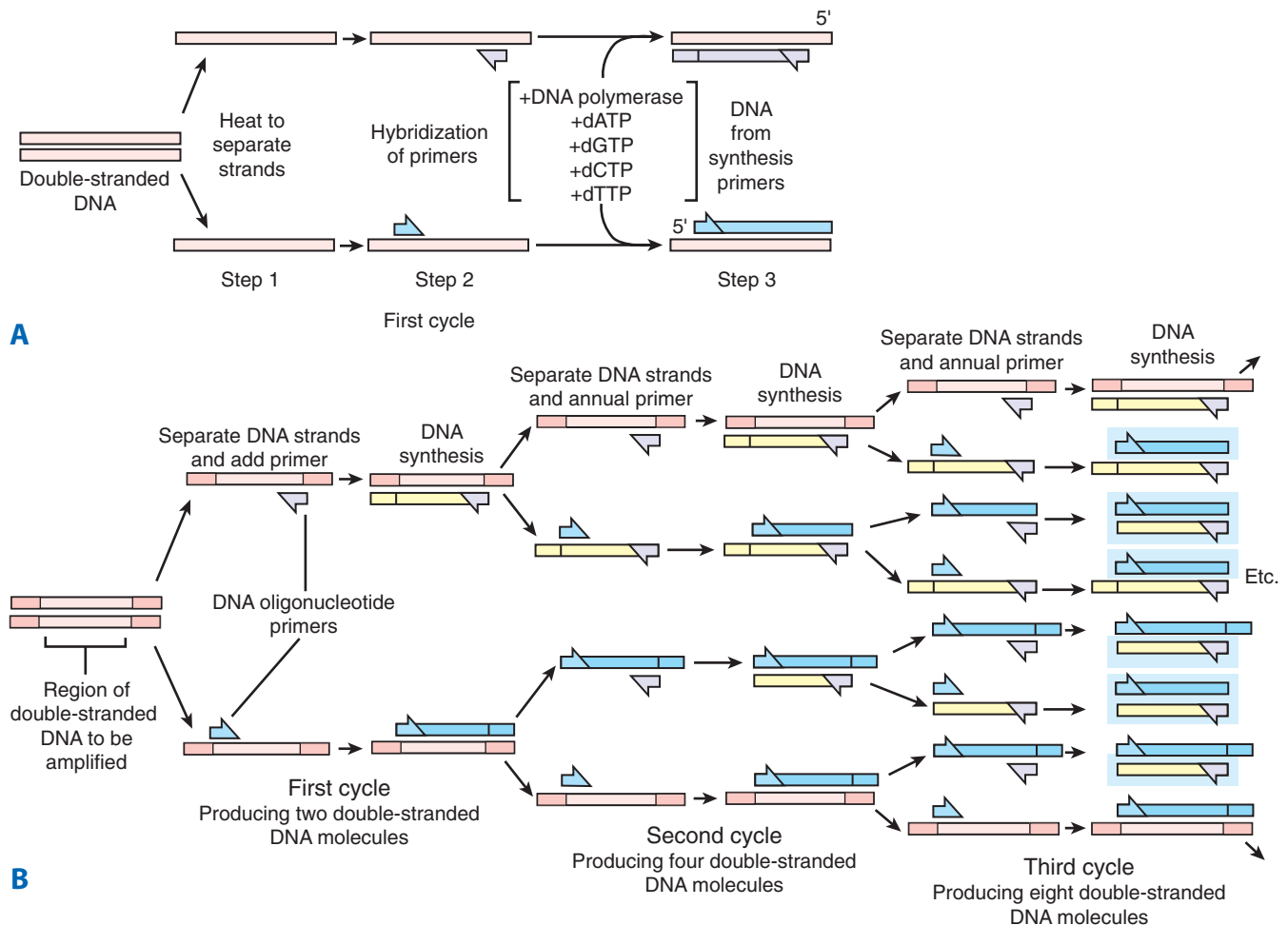


Figure 15-17. Amplification of DNA using the polymerase chain reaction (PCR) technique. Knowledge of the DNA sequence to be amplified is used to design two synthetic DNA oligonucleotides, each complementary to the sequence on one strand of the DNA double helix at opposite ends of the region to be amplified. These oligonucleotides serve as primers for *in vitro* DNA synthesis, which is performed by a DNA polymerase, and they determine the segment of the DNA that is amplified. **A.** PCR starts with a double-stranded DNA, and each cycle of the reaction begins with a brief heat treatment to separate the two strands (*Step 1*). After strand separation, cooling of the DNA in the presence of a large excess of the two primer DNA oligonucleotides allows these primers to hybridize to complementary sequences in the two DNA strands (*Step 2*). This mixture is then incubated with DNA polymerase and the four deoxyribonucleoside triphosphates so that DNA is synthesized, starting from the two primers (*Step 3*). The entire cycle is then begun again by a heat treatment to separate the newly synthesized DNA strands. **B.** As the procedure is performed over and over again, the newly synthesized fragments serve as templates in their turn, and, within a few cycles, the predominant DNA is identical to the sequence bracketed by and including the two primers in the original template. Of the DNA put into the original reaction, only the sequence bracketed by the two primers is amplified because there are no primers attached anywhere else. In the example illustrated in **B**, three cycles of reaction produce 16 DNA chains, eight of which (*boxed in brown*) are the same length as and correspond exactly to one or the other strand of the original bracketed sequence shown at the far left; the other strands contain extra DNA downstream of the original sequence, which is replicated in the first few cycles. After three more cycles, 240 of the 256 DNA chains correspond exactly to the original bracketed sequence, and after several more cycles, essentially all of the DNA strands have this unique length. (*Republished with permission of Garland Publishing, Inc. from Alberts B, Johnson A, Lewis J, et al. Molecular Biology of the Cell, 5th ed. New York: Garland Science; 2008. Permission conveyed through Copyright Clearance Center, Inc.*)

be used for the sensitive detection of proteins in low concentrations, which would otherwise be difficult to detect. Moreover, combined immunoprecipitation and immunoblotting analysis is very efficient in analyzing the protein-protein interactions or determining the posttranslational modifications of proteins. In addition, immunoprecipitated proteins can be used as preparative steps for assays such as intrinsic or associated enzymatic activities. The success of immunoprecipitation is influenced by two major factors: (a) the abundance of the protein in the original preparation and (b) the specificity and affinity of the antibody for this protein.

Recently, *immunoprecipitation* is even used to enrich modified DNA (for example, 5-methylcytosine) for bisulfite

sequencing. Besides proteins of interest, specific antibodies can also be raised against specially modified DNA. Like the protein immunoprecipitation, modified DNA can be pulled down, taking advantage of the specificity and affinity of antibody to antigen.

DNA Microarray. Now that the human genome sequence is completed, the primary focus of biologists is rapidly shifting toward gaining an understanding of how genes function. One of the interesting findings about the human genome is that there are only approximately 25,000 to 30,000 protein-encoding genes. However, it is known that genes and their products function in a complicated and yet orchestrated fashion and that the surprisingly small number of genes from the genome sequence is sufficient to

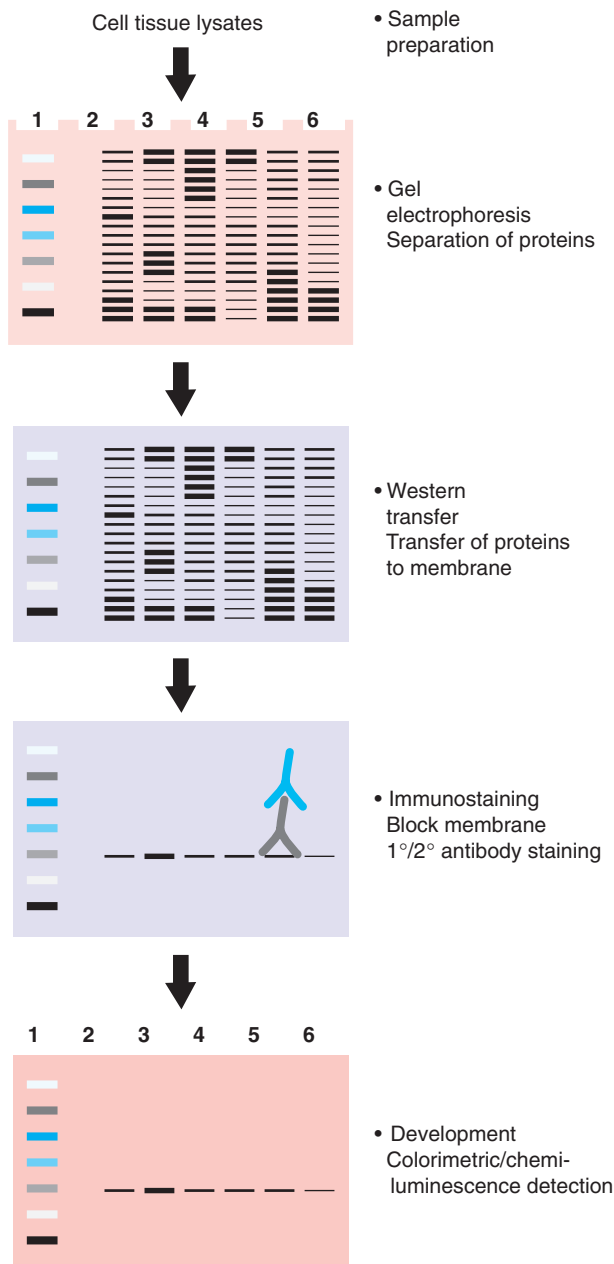


Figure 15-18. Immunoblotting. Proteins are prepared from cells or tissues, separated according to size by sodium dodecyl sulfate-polyacrylamide gel electrophoresis, and transferred to a membrane filter. Detection of a protein of interest can be done by sequential incubation with a primary antibody directed against the protein, and then with an enzyme-conjugated secondary antibody that recognizes the primary antibody. Visualization of the protein is carried out by using colorimetric or luminescent substrates for the conjugated enzyme.

make a human being. Nonetheless, with the tens of thousands of genes present in the genome, traditional methods in molecular biology, which generally work on a one-gene-in-one-experiment basis, cannot generate the whole picture of genome function. In the past several years, a new technology called *DNA microarray* has attracted tremendous interest among biologists as well as clinicians. This technology promises to monitor the whole genome on a single chip so researchers can have a better picture of the interactions among thousands of genes simultaneously.

DNA microarray, also called *gene chip*, *DNA chip*, and *gene array*, refers to large sets of probes of known sequences orderly arranged on a small chip, enabling many hybridization reactions to be carried out in parallel in a small device (Fig. 15-20).²⁸ Like Southern and Northern hybridization, the underlying principle of this technology is the remarkable ability of nucleic acids to form a duplex between two strands with complementary base sequences. DNA microarray provides a medium for matching known and unknown DNA samples based on base-pairing rules and automating the process of identifying the unknowns. Microarrays require specialized robotics and imaging equipment that spot the samples on a glass or nylon substrate, carry out the hybridization, and analyze the data generated. DNA microarrays containing different sets of genes from a variety of organisms are now commercially available, allowing biologists to simply purchase the chips and perform hybridization and data collection. The massive scale of microarray experiments requires the aid of computers. They are used during the capturing of the image of the hybridized target, the conversion of the image into usable measures of the extent of hybridization, and the interpretation of the extent of hybridization into a meaningful measure of the amount of the complementary sequence in the target. Some data-analysis packages are available commercially or can be found in the core facility of certain institutions.

DNA microarray technology has produced many significant results in quite different areas of application. There are two major application forms for the technology: identification of sequence (gene/gene mutation) in multiple regions of a genome and determination of expression level (abundance) of large numbers of genes simultaneously. For example, analysis of genomic DNA detects amplifications and deletions found in human tumors. Differential gene expression analysis also has uncovered networks of genes differentially present in cancers that cannot be distinguished by conventional means. Significantly, recent advancements in next-generation sequencing (e.g., Solexa and 454 technology) have demonstrated the precision and speed to analyze gene expression in any genome.

Next-Generation Sequencing.^{29,30} The recombinant DNA technology greatly impacts the completion of the Human Genome Project due to the invention of shotgun sequencing, which includes breaking the genome DNA into small pieces and randomly cloning those pieces into DNA vectors that are easily sequenced. Based on the overlapping sequence of each clone, computer analysis can be programmed to map and align the DNA sequence that will ultimately cover the whole human genome.

Based on shotgun sequencing, as the sequencing technologies advance, next-generation sequencing has become one of the most powerful tools to analyze DNA mutation, to identify epigenetic modification, and to profile gene expression or ncRNA expression.³¹ The next-generation sequencing process usually includes library construction, sequencing, and data analysis. Take the Illumina next-generation sequencing as an example: DNA are shared or digested into small pieces and then used to generate a DNA library with adapters on both ends of each DNA piece. Then, the DNA library is diluted and loaded on a chamber of a slide, called a *lane*, for cluster amplification. Cycled fluorescent deoxyribonucleotide triphosphates (dNTPs) are then added to the chamber to enable DNA polymerization, resulting in different fluorescent emission representing different dNTP reading on different clusters, into a microscope. The fluorescent

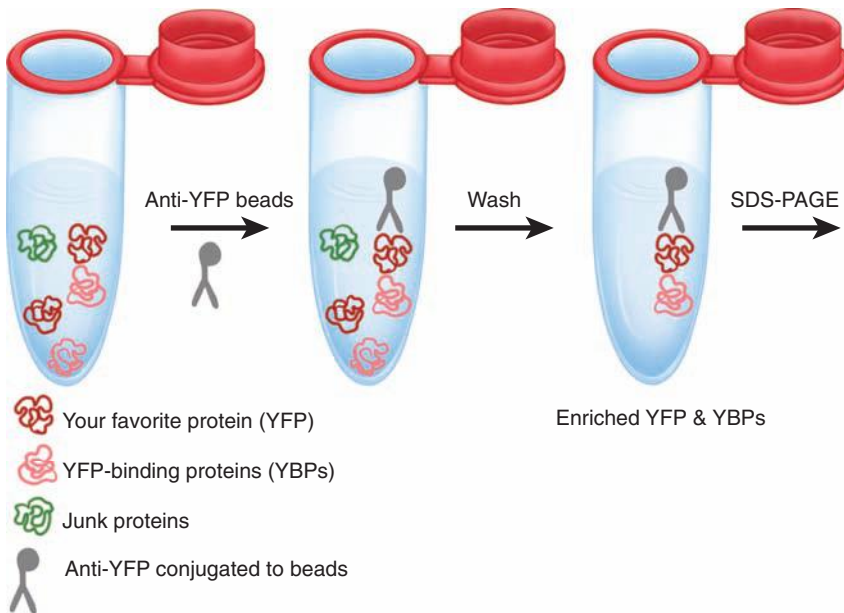


Figure 15-19. Immunoprecipitation. Proteins prepared from cells or tissues can be enriched using an antibody directed against them. The antibody is first conjugated to agarose beads and then incubated with protein mixture. Due to the specific high-affinity interaction between antibody and its antigen (the protein), the antigen-antibody complex can be collected on beads by centrifugation. The immunoprecipitated protein can then be analyzed by immunoblotting. Alternatively, if proteins are radiolabeled in cells or tissues, detection of immunoprecipitated proteins can be achieved by simple sodium dodecyl sulfate-polyacrylamide gel electrophoresis followed by autoradiography.

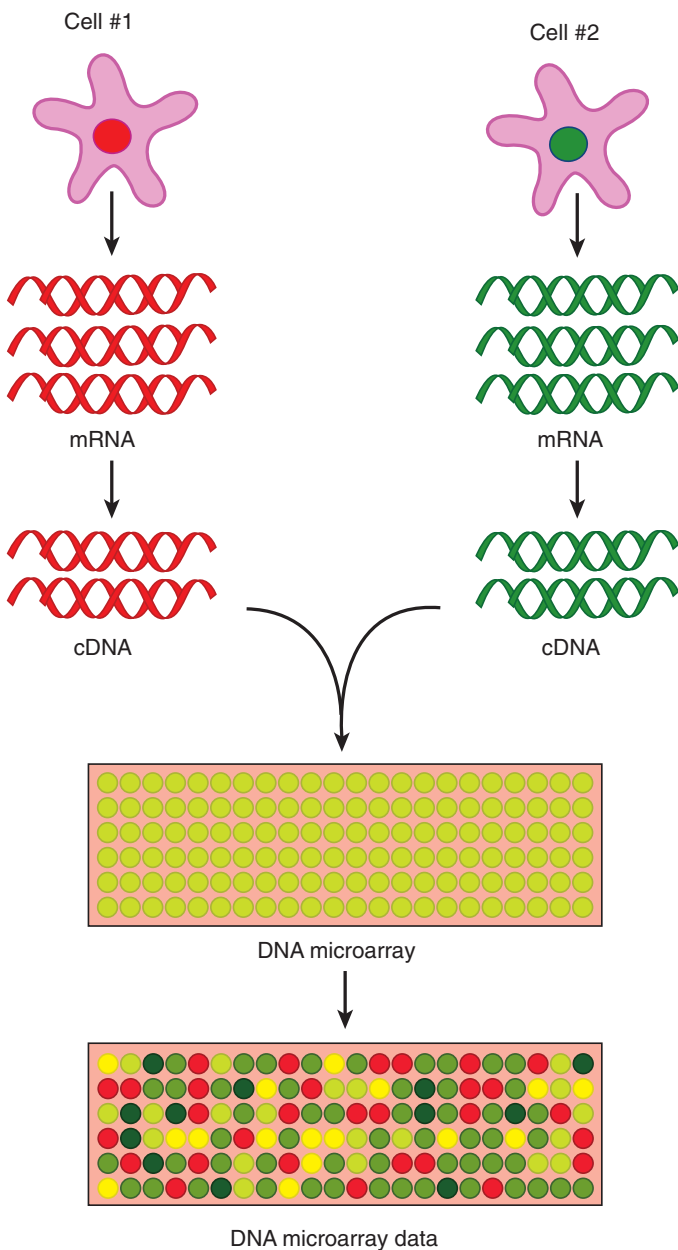


Figure 15-20. DNA microarrays. DNA microarrays, also referred to as *gene chips*, have arrayed oligonucleotides or complementary DNAs (cDNAs) corresponding to tens or hundreds of distinct genes. DNA microarray is used to comparatively analyze gene expression in different cells or tissues. Messenger RNAs (mRNAs) extracted from different sources are converted into cDNAs, which are then labeled with different fluorescent dyes. The two fluorescent cDNA probes are mixed and hybridized to the same DNA microarrays. The ratio of red to green fluorescence at each spot on the chip represents the relative expression of levels of that gene between two different cells. In the example shown in the figure, cDNA from cell #1 is labeled with red fluorescence and that from cell #2 is labeled with green fluorescence. On the microarray, red spots demonstrate that the gene in the cell sample #1 is expressed at a higher level than the corresponding gene in cell sample #2. The green spots indicate that the gene in the cell sample #2 is expressed at a higher level than the corresponding gene in the cell sample #1. Yellow spots represent equal expression of the gene in both cell samples.

signal is transformed into sequencing data that will be aligned and mapped to a standard genome database. The advantages of next-generation sequencing include the following: no necessity of DNA cloning; fast and cost-effective; and a huge amount of data to give a good depth and accuracy of the sequence.

Based on the applications, the most common next-generation sequencing technologies for whole-genome sequencing are whole-genome DNA sequencing, whole-genome bisulfite sequencing (BS-seq), RNA sequencing (RNA-seq), and chromatin immunoprecipitation (ChIP) sequencing (ChIP-seq). Whole-genome DNA sequencing is purely to sequence the DNA sequence of a genome without any preprocessing of the DNA, reflecting any deletions, replications, and mutations within the genomic DNA. BS-seq is commonly used to identify DNA methylation on the genome (5-methylcytosine [5mC]). The process always involves a bisulfite treatment of DNA before library construction, during which the unmethylated cytosine will be transformed to a uracil, resulting in reading as a thymine in data output, whereas 5mC is protected and remains as cytosine in data output. Thus, 5mC and cytosine are distinguished by this way. RNA-seq is usually performed to analyze transcription for the same purpose as performing a microarray. However, RNA-seq is more accurate and provides more information such as splicing variants than traditional microarray. Usually, cDNA that is reversely transcribed from extracted RNA is used to generate libraries. Depending on the needs, mRNA and ncRNA can be enriched in different protocols for RNA extraction. ChIP-seq is always used to map the location of a DNA-binding protein in the genome. Prior to library construction, ChIP is performed to enrich DNA bound by the protein of interest (POI). First, POI and DNA are cross-linked before sonication. Then, a specific antibody is used to pull down POI and attached DNA fragments. After the protein and DNA are reverse cross-linked, DNA will be purified to make the ChIP-seq library.

By using next-generation sequencing technology, any potential mutations in a patient will be scrutinized as well as any defects in epigenetic modification, which will greatly facilitate the diagnosis of patients and personalization of medicine in a fast and economic way.

Cell Manipulations

Cell Culture. Cell culture has become one of the most powerful tools in biomedical laboratories, as cultured cells are being used in a diversity of biologic fields ranging from biochemistry to molecular and cellular biology.³² Through their ability to be maintained *in vitro*, cells can be manipulated by the introduction of genes of interest (cell transfection) and be transferred into *in vivo* biologic receivers (cell transplantation) to study the biologic effect of the interested genes (Fig. 15-21). In the common laboratory settings, cells are cultured either as a monolayer (in which cells grow as one layer on culture dishes) or in suspension.

It is important to know the wealth of information concerning cell culturing before attempting the procedure. For example, conditions of culture will depend on the cell types to be cultured (e.g., origins of the cells such as epithelial or fibroblasts, or primary vs. immortalized/transformed cells). It is also necessary to use cell type-specific culture medium that varies in combination of growth factors and serum concentrations. If primary cells are derived from human patients or animals, some commercial resources have a variety of culture media available for testing. Generally, cells are manipulated in a sterile hood, and the working surfaces are wiped with 70% to 80% ethyl alcohol solution. Cultured cells are usually maintained in a humidified carbon dioxide incubator at 37°C (98.6°F) and need to be examined daily under an inverted microscope to check for possible contamination and confluency (the area cells occupy on the dish). As a general rule, cells should be fed with fresh medium every 2 to 3 days and split when they reach confluency. Depending on the growth rate of cells, the actual time and number of plates required to split cells in two varies from cell line to cell line. Splitting a monolayer requires the detachment of cells from plates by using a trypsin or collagenase treatment, of which concentration and time period vary depending on cell lines. If cultured cells grow continuously in suspension, they are split or subcultured by dilution.

Because cell lines may change their properties when cultured, it is not possible to maintain cell lines in culture indefinitely. Therefore, it is essential to store cells at various time

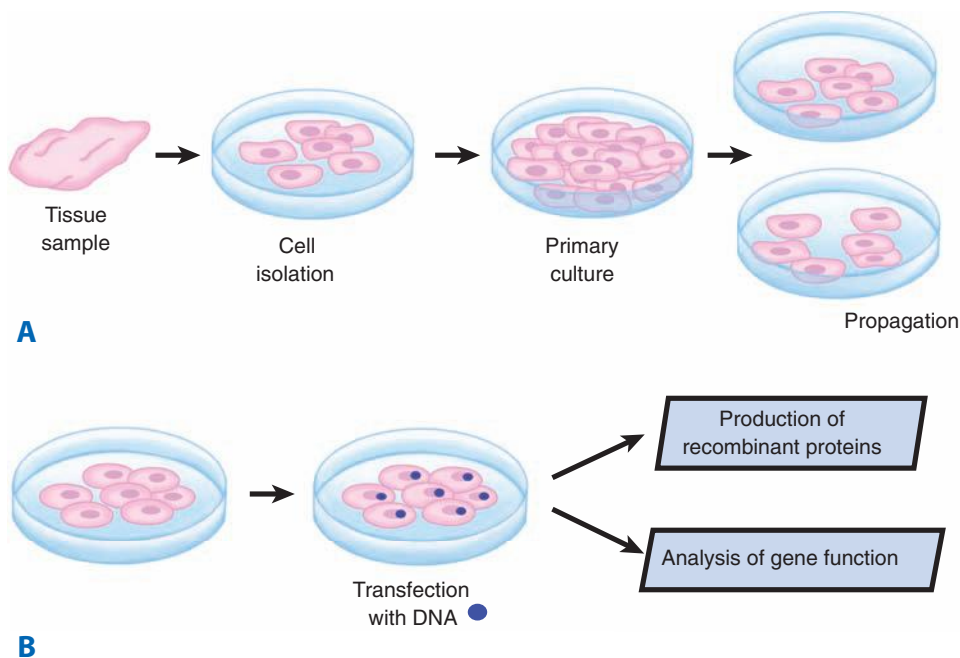


Figure 15-21. Cell culture and transfection. **A.** Primary cells can be isolated from tissues and cultured in medium for a limited period of time. After genetic manipulations to overcome the cell aging process, primary cells can be immortalized into cell lines for long-term culture. **B.** DNA can be introduced into cells to produce recombinant gene products or to analyze the biologic functions of the gene.

passages for future use. The common procedure to use is cryopreservation. The solution for cryopreservation is usually fetal calf serum containing 10% dimethyl sulfoxide or glycerol, stored in liquid nitrogen (-196°C [-320.8°F]) for years of preservation. However, the viability and health of cells when thawed will decrease over time even in liquid nitrogen.

Cell Transfection. Cells are cultured for two reasons: to maintain and to manipulate them (see Fig. 15-21). The transfer of foreign macromolecules, such as nucleic acid, into living cells provides an efficient method for studying a variety of cellular processes and functions at the molecular level. DNA transfection has become an important tool for studying the regulation and function of genes. The cDNA to be expressed should be in a plasmid vector, behind an appropriate promoter working in mammalian cells (e.g., the constitutively active cytomegalovirus promoter or inducible promoter). Depending on the cell type, many ways of introducing DNA into mammalian cells have been developed. Commonly used approaches include calcium phosphate, electroporation, liposome-mediated transfection, the nonliposomal formulation, and the use of viral vectors. These methods have shown variable success when attempting to transfect a wide variety of cells. Transfection can be performed in the presence or absence of serum. It is suggested to test the transfection efficiency of cell lines of interest by comparing transfection with several different approaches. For a detailed transfection protocol, it is best to follow the manufacturer's instructions for the particular reagent. General considerations for a successful transfection depend on several parameters, such as the quality and quantity of DNA and cell culture (type of cell and growth phase). To minimize variations in both of these in transfection experiments, it is best to use cells that are healthy, proliferate well, and are plated at a constant density.

Depending on the transfection method, DNA expression can be transient or stable. Using calcium phosphate and liposome-mediated transfection, after DNA is introduced into the cells, it is normally maintained epigenetically in cells and will be diluted while host cells undergo cell division. Therefore, functional assays should be performed 24 to 72 hours after transfection, also termed *transient transfection*. In many applications, it is important to study the long-term effects of DNA in cells by stable transfection. Thus, electroporation and viral vector are often used in these situations to enable integration of ectopic DNA into the host genome. Stable cell clones can be selected when plasmids carry an antibiotic-resistant marker. In the presence of antibiotics, only those cells that continuously carry the antibiotic-resistant marker (after generations of cell division)

can survive. One application of stable transfection is the generation of transgenic or knockout mouse models, in which the transgene has to be integrated in the mouse genome in the ES cells, followed by microinjection of those transgenic ES cells into blastocysts to generate chimera mice. Stable cells also can be transplanted into host organs to test the effect of transgenic cells *in vivo*.

Genetic Manipulations

Understanding how genes control the growth and differentiation of the mammalian organism has been the most challenging topic of modern research. It is essential for us to understand how genetic mutations and chemicals lead to the pathologic condition of human bodies. The knowledge and ability to change the genetic program will inevitably make a great impact on society and have far-reaching effects on how we think of ourselves.

The mouse has become firmly established as the primary experimental model for studying how genes control mammalian development. Genetically altered mice are powerful tools to study the function and regulation of genes as well as modeling human diseases.³³ The gene function can be studied by creating mutant mice through homologous recombination (gene knockout). A gene of interest (GOI) also can be introduced into the mouse (transgenic mouse) to study its effect on development or diseases. Because mouse models do not precisely represent human biology, genetic manipulations of human somatic or ES cells provide a great means for the understanding of the molecular networks in human cells in addition to mouse models. In all cases, the gene to be manipulated must first be cloned. Gene cloning has been made easy by recombinant DNA technology and the availability of human and mouse genomes (see the Human Genome section). The following section briefly describes the technologies and the principles behind how to combine both mouse genetics and human cell culture in exploring gene function and disease mechanisms.

Transgenic Mice. During the past 20 years, DNA cloning and other techniques have allowed the introduction of new genetic material into the mouse germline. As early as 1980, the first genetic material was successfully introduced into the mouse germline by using pronuclear microinjection of DNA (Fig. 15-22). These animals, called *transgenic*, contain foreign DNA within their genomes. In simple terms, a transgenic mouse is created by the microinjection of ectopic DNA into the one-celled mouse embryo to induce integration, allowing the efficient introduction of cloned genes into the following developing mouse somatic tissues, as well as into the germline.

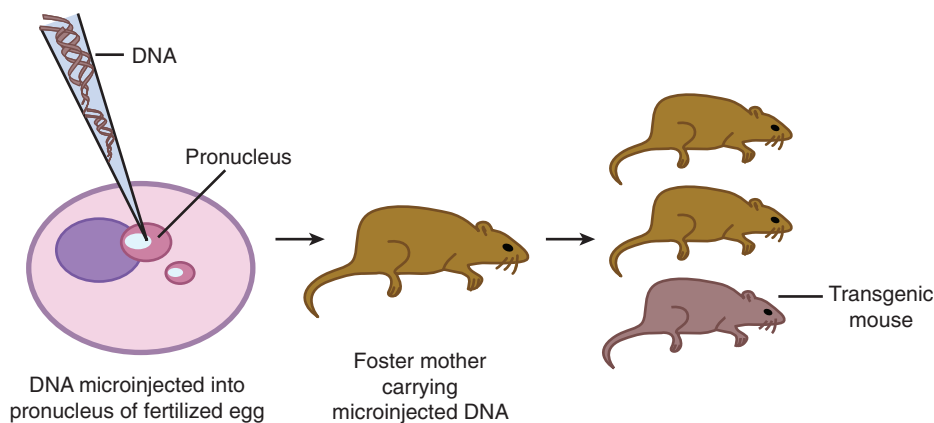


Figure 15-22. Transgenic mouse technology. DNA is microinjected into a pronucleus of a fertilized egg, which is then transplanted into a foster mother. The microinjected egg develops offspring mice. Incorporation of the injected DNA into offspring is indicated by the different coat color of offspring mice.

Designs of a Transgene The transgenic technique has proven to be extremely important for basic investigations of gene regulation, creation of animal models of human disease, and genetic engineering of livestock. The design of a transgene construct is a simple task. Like constructs used in cell transfection, a simple transgene construct consists of a protein-encoding gene and a promoter that precedes it. The most common applications for the use of transgenic mice are similar to those in the cell culture system: (a) to study the functions of proteins encoded by the transgene, (b) to analyze the tissue-specific and developmental-stage-specific activity of a gene promoter, and (c) to generate reporter lines to facilitate biomedical studies. Examples of the first application include overexpression of oncogenes, growth factors, hormones, and other key regulatory genes, as well as genes of viral origins. Overexpression of the transgene normally represents gain-of-function mutations. The tissue distribution or expression of a transgene is determined primarily by *cis*-acting promoter enhancer elements within or in the immediate vicinity of the genes themselves. Thus, controlled expression of the transgene can be made possible by using an inducible or tissue-specific promoter. Furthermore, transgenic mice carrying dominant negative mutations of a regulatory gene also have been generated. For example, a truncated growth factor receptor that can bind to the ligand, but loses its catalytic activity when expressed in mice, can block the growth factor binding to the endogenous protein. In this way, the transgenic mice exhibit a loss of function of phenotype, possibly resembling the knockout of the endogenous gene. The second application of the transgenic expression is to analyze the gene promoter of interest. The gene promoter of interest normally is fused to a reporter gene that encodes β -galactosidase (also called *LacZ*), luciferase, or green fluorescence protein. Chemical staining of *LacZ* activity or detection of chemiluminescence/fluorescence can easily visualize the expression of the reporter gene. The third application originates from the second: when the activity of the promoter is known, a fluorescent reporter gene (such as *GFP*) will be driven by the tissue-specific promoter, therefore labeling a particular type of cells at a particular stage. This application is generally used to isolate a special cell type expressing the *GFP* reporter by fluorescence-activated cell sorting (FACS), as well as lineage-tracing experiments.

Production of Transgenic Mice The success of generating transgenic mice is largely dependent on the proper quality and concentration of the DNA supplied for microinjection. For DNA to be microinjected into mouse embryos, it should be linearized by restriction digestion to increase the chance of proper transgene integration. Concentration of DNA should be accurately determined. Mice that develop from injected eggs often are termed *founder* mice.

Genotyping of Transgenic Mice The screening of founder mice and the transgenic lines derived from the founders is accomplished by determining the integration of the injected gene into the genome. This normally is achieved by performing PCR or Southern blot analysis with a small amount of DNA extracted from the mouse tail. Once a given founder mouse is identified to be transgenic, it will be mated to begin establishing a transgenic line. Usually, for a given gene, more than one transgenic line is generated to assure that the phenotype is due to transgene but not to the interruption of the gene where the transgene integrates into.

Analysis of Phenotype of Transgenic Mice Phenotypes of transgenic mice are dictated by both the expression pattern

and biologic functions of the transgene. Depending on the promoter and the transgene, phenotypes can be predictable or unpredictable. Elucidation of the functions of the transgene-encoded protein *in vitro* often offers some clue to what the protein might function to do *in vivo*. When a constitutively active promoter is used to drive the expression of transgenes, mice should express the gene in every tissue; however, this mouse model may not allow the identification and study of the earliest events in disease pathogenesis. Ideally, the use of tissue-specific or inducible promoter allows one to determine if the pathogenic protein leads to a reversible or irreversible disease process in a cell-autonomous manner. For example, rat insulin promoter can target transgene expression exclusively in the β -cells of pancreatic islets. The phenotype of insulin promoter-mediated transgenic mice is projected to affect the function of human β -cells.

Gene Knockout in Mice. The first recorded knockout mouse was created by Mario R. Capecchi, Sir Martin J. Evans, and Oliver Smithies in 1989. They were awarded the 2007 Nobel Prize in Physiology or Medicine. The isolation and genetic manipulation of mouse ES cells represent one of the most important milestones for modern genetic technologies.³⁴ Several unique properties of ES cells, such as the pluripotency to differentiate into all germ layers in an embryo, including the germline, make them an efficient vehicle to introduce genetic alterations in mice. An important breakthrough from this idea is to generate gene-targeted mutation in mice, first by introducing the targeting vector into the ES cells, allowing selection for successful homologous recombination in a dish, then introducing the selected ES clone into the blastocysts, and finally recovering animals bearing the mutant allele from the germline (Fig. 15-23). This not only makes mouse genetics a powerful approach for addressing important gene functions, but also identifies the mouse as a great system to model human disease.

Targeting Vector The basic concept in building a target vector to knock out a gene is to use two segments of homologous sequence to a GOI that flank a part of the gene essential for functions (e.g., the coding region). In the targeting vector, a positive selectable marker (e.g., the *neo* gene) is placed between the homology arms. Upon the homologous recombination between the arms of the vector and the corresponding genomic regions of the GOI in ES cells, the positive selectable marker will replace the essential segment of the target gene, thus creating a null allele. In addition, a negative selectable marker also can be used alone or in combination with the positive selectable marker, but must be placed outside of the homologous arms to enrich for homologous recombination. To create a conditional knockout (i.e., gene knockout in a spatiotemporal fashion), site-specific recombinases such as the popular cre-loxP system are used. If the consensus loxP sequences that are recognized by cre recombinases are properly designed into targeting loci, controlled expression of the recombinase as a transgene can result in the site-specific recombination at the right time and in the right place (i.e., cell type or tissue). This method, often referred as conditional knockout, is markedly useful to prevent developmental compensations and to introduce null mutations in the adult mouse that would otherwise be lethal. Overall, this cre-loxP system allows for spatial and temporal control over transgene expression and takes advantage of inducers with minimal pleiotropic effects.

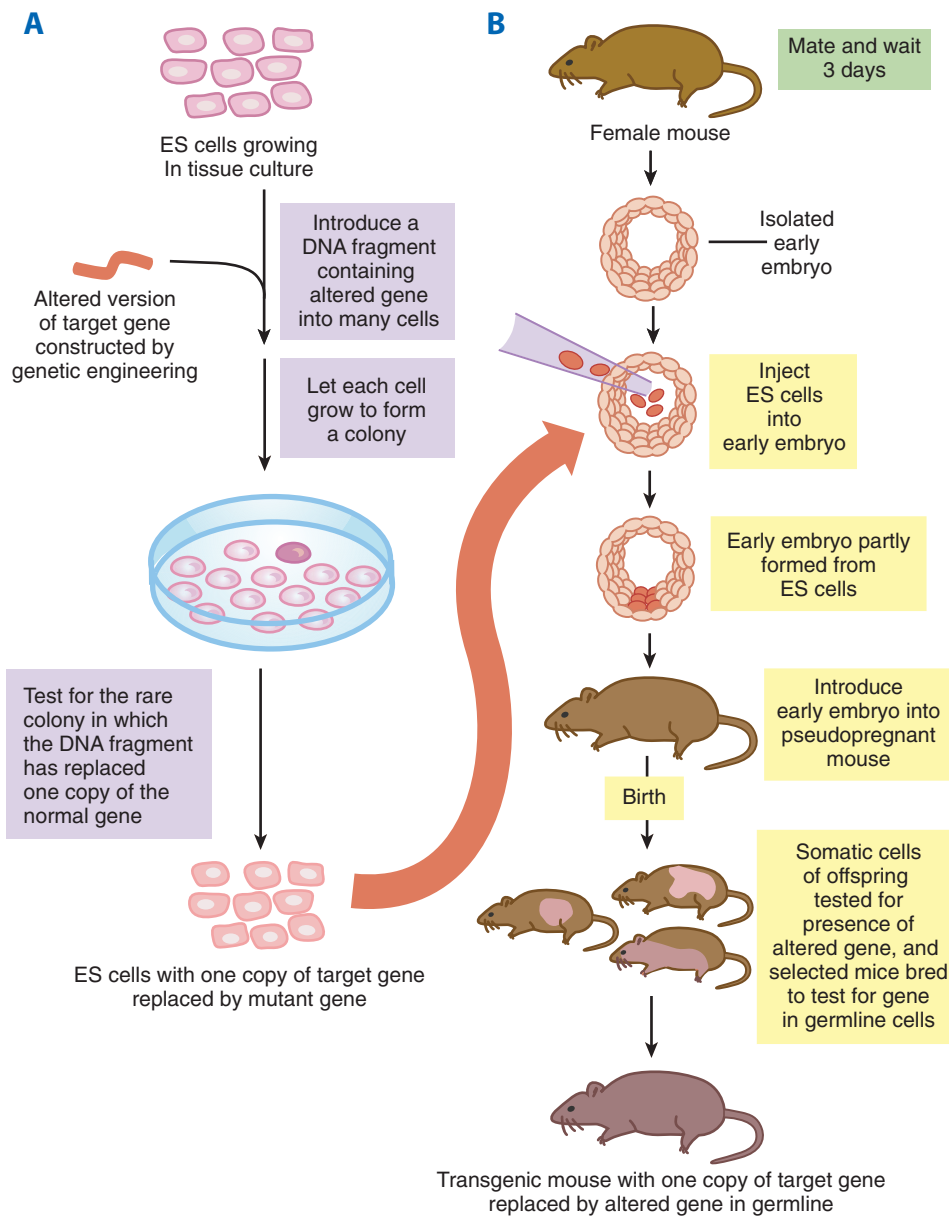


Figure 15-23. Knockout mouse technology. Summary of the procedures used for making gene replacements in mice. In the first step (A), an altered version of the gene is introduced into cultured embryonic stem (ES) cells. Only a few rare ES cells will have their corresponding normal genes replaced by the altered gene through a homologous recombination event. Although the procedure is often laborious, these rare cells can be identified and cultured to produce many descendants, each of which carries an altered gene in place of one of its two normal corresponding genes. In the next step of the procedure (B), these altered ES cells are injected into a very early mouse embryo; the cells are incorporated into the growing embryo, and a mouse produced by such an embryo will contain some somatic cells that carry the altered gene. Some of these mice also will contain germline cells that contain the altered gene. When bred with a normal mouse, some of the progeny of these mice will contain the altered gene in all of their cells. If two such mice are in turn bred (not shown), some of the progeny will contain two altered genes (one on each chromosome) in all of their cells. If the original gene alteration completely inactivates the function of the gene, these mice are known as *knockout mice*. When such mice are missing genes that function during development, they often die with specific defects long before they reach adulthood. These defects are carefully analyzed to help decipher the normal function of the missing gene. (Republished with permission of Garland Publishing, Inc. from Alberts B, Johnson A, Lewis J, et al. *Molecular Biology of the Cell, 5th ed.* New York: Garland Science; 2008. Permission conveyed through Copyright Clearance Center, Inc.)

Introduction of the Targeting Vector into ES Cells ES cell lines can be obtained from other investigators or commercial sources or established from blastocyst-stage embryos. To maintain ES cells at their full developmental potential, optimal growth conditions should be provided in culture. If culture conditions are inappropriate or inadequate, ES cells may acquire genetic lesions or alter their gene expression patterns, and

consequently decrease their pluripotency. Excellent protocols are available in public domains or in mouse facilities in most institutions.

To alter the genome of ES cells, the targeting vector DNA then is transfected into ES cells. Electroporation is the most widely used and the most efficient transfection method for ES cells. Similar procedures for stable cell transfection are used for

selecting ES cells that carry the targeting vector. High-quality, targeting-vector DNA free of contaminating chemicals is first linearized and then electroporated into ES cells. Stable ES cells are selected in the presence of a positive selectable antibiotic drug. After a certain period of time and depending on the type of antibiotics, all sensitive cells die and the resistant cells grow into individual colonies of the appropriate size for subcloning by picking. It is extremely important to minimize the time during which ES cells are in culture between selection and injection into blastocysts. Before injecting the ES cells, DNA is prepared from ES colonies to screen for positive ES cells that exhibit the correct integration or homologous recombination of the targeting vector. Positive ES colonies are then expanded and used for creation of chimeras.

Creation of the Chimera A chimeric organism is one in which cells originate from more than one embryo source. Here, chimeric mice are denoted as those that contain some tissues from the ES cells with an altered genome. When these ES cells give rise to the lineage of the germ layer, the germ cells carrying the altered genome can be passed on to the offspring, thus creating the germline transmission from ES cells. There are two methods for introducing ES cells into preimplantation-stage embryos: injection and aggregation. The injection of embryonic cells directly into the cavity of blastocysts is one of the fundamental methods for generating chimeras, but aggregation chimeras also have become an important alternative for transmitting the ES cell genome into mice. Since every tissue type of a chimera should contain cells from different origins, the mixture of recognizable markers (e.g., coat color) that are specific for each of the donor mouse and ES cells can be used to identify chimeric mice. However, most experimenters probably use existing mouse core facilities already established in some institutions, or contract a commercial vendor for the creation of a chimera.

Genotyping and Phenotyping of Knockout Animals The next step is to analyze whether germline transmission of targeted mutation occurs in mice. DNA from a small amount of tissue from offspring of the chimera is extracted and subjected to genomic PCR or Southern blot DNA hybridization. Positive mice (i.e., those with properly integrated targeting vector into the genome) will be used for the propagation of more knockout mice for phenotype analysis. When the knockout genes are crucial for early embryogenesis, mice often die in utero, an occurrence called *embryonic lethality*. When this happens, only the phenotype of the homozygous (both alleles ablated) knockout mouse embryos and the phenotype of the heterozygous (only one allele ablated) adult mice can be studied. Because most are interested in the phenotype of adult mice, in particular when using mice as disease models, it is recommended to create the conditional knockout using the cre-loxP system so that the GOI can be knocked out at will.

To date, more than 5000 genes have been disrupted by homologous recombination and transmitted through the germline. The phenotypic studies of these mice provide ample information on the functions of these genes in growth and differentiation of organisms and during development of human diseases.

RNA Interference. Although gene ablation in animal models provides an important means to understand the *in vivo* functions of GOI, animal models may not adequately represent human biology. Alternatively, gene targeting can be used to knock out genes in human cells, including human ES cells. Gene targeting in human ES cells by homologous recombination has been extremely low efficiency, although there are more new

techniques emerging aimed at increasing the targeting efficiency. A number of recent advances have made gene targeting in somatic cells as easy as in murine ES cells.³³ However, gene targeting (knocking out both alleles) in somatic cells is a time-consuming process.

Development of RNAi technology in the past few years has provided a more promising approach to understanding the biologic functions of human genes in human cells.³⁵ RNAi is an ancient natural mechanism by which small, double-stranded RNA (dsRNA) acts as a guide for an enzyme complex that destroys complementary RNA and downregulates gene expression in a sequence-specific manner. Although the mechanism by which dsRNA suppresses gene expression is not entirely understood, experimental data provide important insights. In nonmammalian systems such as *Drosophila*, it appears that longer dsRNA is processed into 21–23 nt dsRNA (called *small interfering RNA* or *siRNA*) by an enzyme called *Dicer* containing RNase III motifs. The siRNA apparently then acts as a guide sequence within a multicomponent nuclease complex to target complementary mRNA for degradation. Because long dsRNA induces a potent antiviral response pathway in mammalian cells, short siRNAs are used to perform gene silencing experiments in mammalian cells (Fig. 15-24).

For siRNA studies in mammalian cells, researchers have used two 21-mer RNAs with 19 complementary nucleotides and 3' terminal noncomplementary dimers of thymidine or uridine. The antisense siRNA strand is fully complementary to the mRNA target sequence. Target sequences for an siRNA are identified visually or by software.

The target 19 nucleotides should be compared to an appropriate genome database to eliminate any sequences with significant homology to other genes. Those sequences that appear to be specific to the GOI are the potential siRNA target sites. A few of these target sites are selected for siRNA design. The antisense siRNA strand is the reverse complement of the target sequence. The sense strand of the siRNA is the same sequence as the target mRNA sequence. A deoxythymidine dimer is routinely incorporated at the 3' end of the sense strand siRNA, although it is unknown whether this noncomplementary dinucleotide is important for the activity of siRNAs.

There are two ways to introduce siRNA to knock down gene expression in human cells:

1. RNA transfection: siRNA can be made chemically or using an *in vitro* transcription method. Like DNA oligos, chemically synthesized siRNA oligos can be commercially ordered. However, synthetic siRNA is expensive, and several siRNAs may have to be tried before a particular gene is successfully silenced. *In vitro* transcription provides a more economic approach. Both short and long RNA can be synthesized using bacteriophage RNA polymerase T7, T3, or SP6. In the case of long dsRNAs, RNase such as recombinant *Dicers* will be used to process the long dsRNA into a mixture of 21–23 nt siRNA. siRNA oligos or mixtures can be transfected into a few characterized cell lines such as HeLa (human cervical carcinoma) and 293T cells (human kidney carcinoma). Transfection of siRNA directly into primary cells may be difficult.
2. DNA transfection: Expression vectors for expressing siRNA have been made using RNA polymerase III promoters such as U6 and H1. These promoters precisely transcribe a hairpin structure of dsRNA, which will be processed into siRNA in

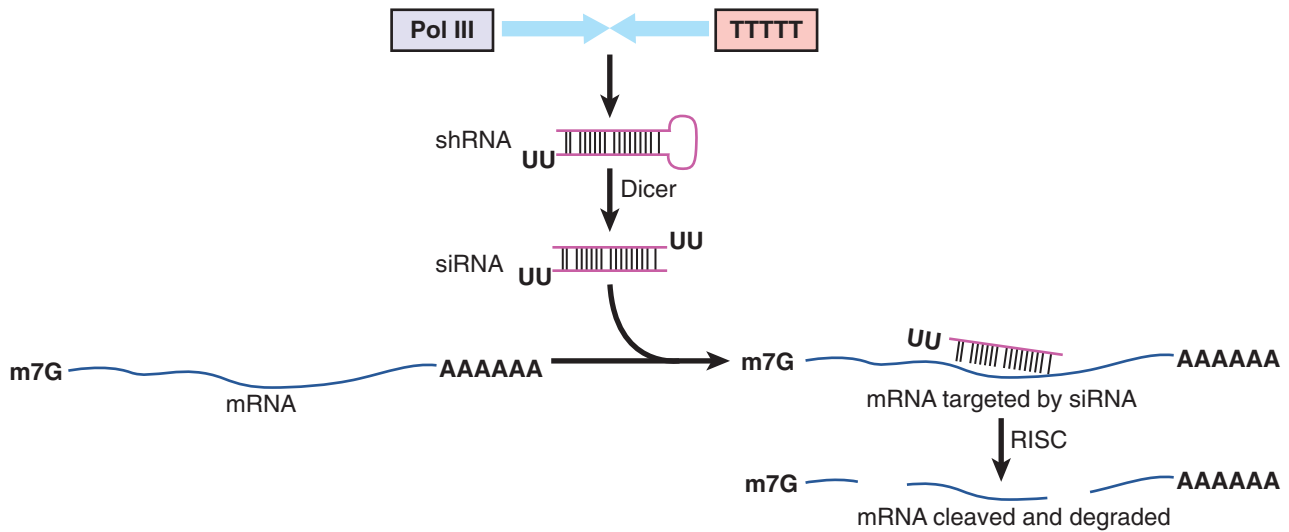


Figure 15-24. RNA interference in mammalian cells. Small interfering RNA (siRNA) can be produced from a polymerase III–driven expression vector. Such a vector first synthesizes a 19–29 nt double-stranded (ds)RNA stem and a loop (labeled as *shRNA* in the figure), and then the RNase complex called *Dicer* processes the hairpin RNA into a small dsRNA (labeled as *siRNA* in the figure). siRNA can be chemically synthesized and directly introduced into the target cell. In the cell, through RNA-induced silencing complex (RISC), siRNA recognizes and degrades target messenger RNAs (mRNAs).

the cell (see Fig. 15-24). Therefore, properly designed DNA oligos corresponding to the desired siRNA will be inserted downstream of the U6 or H1 promoter. There are two advantages of the siRNA expression vectors over siRNA oligos. First, it is easier to transfect DNA into cells. Second, stable populations of cells can be generated that maintain the long-term silencing of target genes. Furthermore, the siRNA expression cassette can be incorporated into a retroviral or adenoviral vector to provide a wide spectrum of applications in gene therapy.

There has been a fast and fruitful development of RNAi tools for *in vitro* and *in vivo* use in mammals. These novel approaches, together with future developments, will be crucial to put RNAi technology to use for effective disease therapy or to exert the awesome power of mammalian genetics. Therefore, the applications of RNAi to human health are enormous. siRNA can be applied as a new tool for sequence-specific regulation of gene expression in functional genomics and biomedical studies. With the availability of the human genome sequences, RNAi approaches hold tremendous promise for unleashing the dormant potential of sequenced genomes.

Practical applications of RNAi will possibly result in new therapeutic interventions. In 2002, the concept of using siRNA in battling infectious diseases and carcinogenesis was proven effective. These include notable successes in blocking replication of viruses, such as HIV, hepatitis B virus, and hepatitis C virus, in cultured cells using siRNA targeted at the viral genome or the human gene encoding viral receptors. RNAi has been shown to antagonize the effects of hepatitis C virus in mouse models. In cancers, silencing of oncogenes such as *c-Myc* or *Ras* can slow down the proliferation rate of cancer cells. Finally, siRNA also has potential applications for some dominant genetic disorders.

The twenty-first century, already heralded as the “century of the gene,” carries great promise for alleviating suffering from disease and improving human health. On the whole, completion

of the human genome blueprint, the promise of gene therapy and molecular therapies, and the existence of stem cells have captured the imagination of the public and the biomedical community. Aside from their potential in curing human diseases, these emerging technologies also have provoked many political, economic, religious, and ethical discussions. As more is discerned about the technologic scientific advances, more attention must also be paid to concerns for their inherent risks and social implications. It is important for surgeons to play a leadership role in the emergence of personalized medicine and surgery, as surgeons have access to the diseased tissues. Surgeons should be establishing collaborations with the genomic and molecular scientists to develop genomic biobanks in order to study the genome and molecular signaling of the disease tissues that will help with an understanding of the underlying cause of an individual’s disease and ultimately lead to effective, targeted therapies. Surgeons must take this enormous opportunity to collaborate with basic and clinical scientists to

5▶ develop the field of personalized genomic medicine and surgery this century.

Bifunctional RNAi Technology.³⁶ Over the last 20 years, the field has worked to define oncogene and nononcogene addiction, discriminate between driver and passenger genes, and appreciate the complexity of complex, robust, network interactions. These insights have led to a preliminary understanding of therapeutically relevant sensitivity and resistance pathway signal patterns requiring *multiple* target modulation. However, this knowledge has not been effectively or reproducibly clinically translated. Clinical response is usually far greater when a combination of single-target molecular therapy is administered. However, it must also be realized that targeting two or more pathways may also increase the toxicity profile, particularly if target specificity is limited. When attempted, off-target toxicity has been demonstrated with combination small-molecule therapy. In contrast, multitargeting bifunctional short hairpin (bi-shRNA) DNA vectors are designed to limit off-target effect given the high specificity for the genes they are designed to target.

Exogenously applied hairpin constructs can be designed to be incorporated into cleavage-dependent RISC or cleavage-independent RISC complexes, or both. The concept of a bifunctional shRNA³⁷ is to increase knockdown efficiency without loss of sequence specificity by engaging both siRNA and miRNA-like (i.e., common biogenic pathway but complementary to target sequence) RISCs, thereby concurrently activating nucleolytic (Ago2-RISC) and nonnucleolytic (Ago1, 3, 4 ± Ago2-RISC) processes.³⁸ Each bi-shRNA contains both a matched stem sequence to promote Ago2-mediated passenger strand cleavage and a second partial mismatched stem sequence for cleavage-independent passenger strand departure. Thus, functionality of the effectors is set by programmed passenger strand guided RISC loading rather than Ago subset distribution in the cancer cell. Both component Ago2 and Ago [1, 2, 4 ± 3] RNAi moieties are fully complementary to the mRNA target sequence. Preliminary data indicate reduced “off-target effects” by shRNA compared with target-identical siRNAs. More than two mismatches in sequences within the target region drastically reduce knockdown effect to undetectable levels (unpublished results). The design process involves in silico scanning of the entire human mRNA RefSeq database to avoid any potential sequence-related “off-target effects.” Published data also indicate persistent susceptibility to shRNA-mediated gene knockdown despite recent evidence of reduced Dicer expression in human cancer cells.³⁹

The first clinical experience with the bi-shRNA platform involved the ex vivo knockdown of furin, a Ca²⁺-dependent, nonredundant proprotein convertase that is essential for proteolytic maturational processing of immunosuppressive TGF-β isoforms (β1 and β2). An autologous whole-cell cancer vaccine, FANGTM (furin-knockdown and GMCSF-augmented),⁴⁰ was produced based on a dual function immunosensitization principle of augmenting tumor antigen expression, presentation, and processing via granulocyte-macrophage colony-stimulating factor (GMCSF) cytokine transgene expression and attenuating secretory immunosuppressive TGF-β. Harvested, autologous cancer cells are transfected with the GMCSF/bi-shRNA^{furin} (FANG) expression plasmid via electroporation. A phase I clinical trial (BB-IND 14205) involving 52 cancer patients was recently completed. Results demonstrated better than 90% knockdown of the bi-shRNA target, furin, and better than 90% knockdown of furin-regulated proteins TGF-β1 and TGF-β2, thereby confirming the mechanistic expectation of this novel RNAi platform. Moreover, predicted extensive GMCSF expression verified our ability to successfully construct multi-cassette vectors with good manufacturing practice techniques fulfilling Food and Drug Administration requirements for clinical testing.

Twenty-seven patients received one or more vaccine dose, and 23 patients achieved stable disease as their best response. No toxic effect was identified. Median survival of the FANGTM-treated patients from time of procurement was 554 days and has not been reached from time of treatment. Expected survival of similar patients is historically less than 1 year. Sequential enzyme-linked immunosorbent spot (ELISPOT) analysis revealed a dramatic and significant increase in immune response from baseline to month 4 in half of the FANGTM-treated patients. Comparison of survival between ELISPOT-positive and ELISPOT-negative patients demonstrated a statistically significant increase in survival from time of procurement ($P = .045$) and time of treatment ($P = .025$).

These phase I study results demonstrated mechanism, safety, and effectiveness of the bi-shRNA technology and clinical functionality of a multitargeting (dual) DNA expression vector. Further utilization of bi-shRNAi technology is under way clinically (targeting STMN1, a microtubule modulation critical to cancer program) and preclinically targeting PDX1⁴¹ (an oncogene-like transcription factor for pancreatic embryogenesis using nonviral nanoparticle delivery mechanisms).⁴²

Personalized Genomic Medicine and Surgery⁴³

Genes determine our susceptibility to diseases and direct our body's response to medicine. Because an individual's genes differ from those of another, the determination of each individual's genome has the potential to improve the predication, prevention, and treatment of disease. Sequencing of individual genomes holds the key to realize this revolution called *personalized genomic medicine and surgery*. Next-generation sequencing, such as Illumina sequencing and 454 pyrosequencing technology, is promising to reduce the time and cost so that genome sequencing can be affordable within healthcare systems. The goal of personalized genomic medicine and surgery is to identify the gene variations in each individual and to target the specific gene variations causing the disease by choosing personalized treatments that effectively work in association with the individual's genomic profile. The importance of surgeons in this transformational field of biomedical science is that surgeons have access to the diseased tissues on a daily basis. Surgeons should partner with the genomic scientists to develop genomic biobanks in order to study the genome of the disease tissues. These discovery studies are rapidly leading to the uncovering of mutations and SNPs that are the underlying cause of an individual's disease and ultimately lead to targeted therapies. Although personalized genomic medicine and surgery holds the potential to revolutionize the practice of modern medicine, there currently exists a gap between our ability to sequence any given individual's genome and how clinicians can apply this information to guide care. There is a rapidly growing list of single genes that are currently guiding care, and these genes are listed as type 1 personalized genes. Examples of these genes are *BRCA1*, **6▶** *RET* proto-oncogene, and *CHD1* mutation, which guide potential use of mastectomy, thyroidectomy, and gastrectomy, respectively; however, the great challenge before the scientific and medical community this century is to learn to use the entire genome to guide personalized care.

REFERENCES

Entries highlighted in bright blue are key references.

1. Watson JD, Crick FH. Molecular structure of nucleic acids: a structure for deoxyribose nucleic acid. *Nature*. 1953;171:737.
2. Alberts B, Johnson A, Lewis J, et al. *Molecular Biology of the Cell*. 4th ed. New York: Garland Science; 2002.
3. International Human Genome Sequencing Consortium. Finishing the euchromatic sequence of the human genome. *Nature*. 2004;431(7011):931-945.
4. ENCODE Project Consortium, Birney E, Stamatoyannopoulos JA, et al. Identification and analysis of functional elements in 1% of the human genome by the ENCODE pilot project. *Nature*. 2007;447(7146):799-816.
5. Mendel G. Versuche über Pflanzen-Hybriden. *Verhandlungen des naturforschenden Vereines, Abhandlungen*. Brünn: 4, 3, 1866.
6. Carey M, Smale ST. *Transcriptional Regulation in Eukaryotes*. New York: Cold Spring Harbor Laboratory Press; 2000.

7. Wolfsberg TG, Wetterstrand KA, Guyer MS, et al. A user's guide to the human genome. *Nat Genet.* 2002;32(Suppl):1-79.
8. U.S. Department of Energy. Genomics and its impact on science and society: the human genome project and beyond. Published online by Human Genome Management Information System (HGMIS). Available at: http://web.ornl.gov/sci/techresources/Human_Genome/publicat/primer2001/primer11.pdf.
9. Simpson RJ. *Proteins and Proteomics*. New York: CSHL Press; 2003.
10. Hanash S. Disease proteomics. *Nature.* 2003;422(6928):226-232.
11. Ptashne M, Gann A. *Genes & Signals*. New York: CSHL Press; 2002.
12. Pawson T, Nash P. Assembly of cell regulatory systems through protein interaction domains. *Science.* 2003;300(5618):445-452.
13. Lizcano JM, Alessi DR. The insulin signalling pathway. *Curr Biol.* 2002;12(7):R236-R238.
14. Feng X-H, Derynck R. Specificity and versatility in TGF-beta signaling through Smads. *Annu Rev Cell Dev Biol.* 2005;21:659-693.
15. Hanahan D, Weinberg RA. The hallmarks of cancer. *Cell.* 2000;100(1):57-70.
16. Hanahan D, Weinberg RA. Hallmarks of cancer: the next generation. *Cell.* 2011;144(5):646-674.
17. McNeil C. Herceptin raises its sights beyond advanced breast cancer. *J Natl Cancer Inst.* 1998;90:882.
18. Druker BJ, Tamura S, Buchdunger E, et al. Effects of a selective inhibitor of the Abl tyrosine kinase on the growth of Bcr-Abl positive cells. *Nat Med.* 1996;2:561.
19. Kiessling AA, Anderson SC. *Human Embryonic Stem Cells: An Introduction to the Science and Therapeutic Potential*. Boston: Jones & Bartlett Pub; 2003.
20. Takahashi K, Tanabe K, Ohnuki M, et al. Induction of pluripotent stem cells from adult human fibroblasts by defined factors. *Cell.* 2007;131(5):861-872.
21. Yu J, Vodyanik MA, Smuga-Otto K, et al. Induced pluripotent stem cell lines derived from human somatic cells. *Science.* 2007;318(5858):1917-1920.
22. Orcutt S. Subatomic medicine and the atomic theory of disease. *Transl Med.* 2012;2:2.
23. Cohen SN, Chang AC, Boyer HW, Helling RB. Construction of biologically functional bacterial plasmids in vitro. *Proc Natl Acad Sci USA.* 1973;70(11):3240-3244.
24. Green MR, Sambrook J. *Molecular Cloning: A Laboratory Manual*. 4th ed. New York: Cold Spring Harbor Laboratory Press; 2012.
25. Ausubel FM, Brent R, Kingston RE, et al. *Current Protocols in Molecular Biology*. 3rd ed. New York: John Wiley & Sons; 1995.
26. Southern EM. Detection of specific sequences among DNA fragments separated by gel electrophoresis. *J Mol Biol.* 1975;98:503.
27. Mullis K, Faloona F, Scharf S, et al. Specific enzymatic amplification of DNA in vitro: the polymerase chain reaction. *Cold Spring Harb Symp Quant Biol.* 1986;51(0):263-273.
28. Bowtell D, Sambrook J. *DNA Microarrays: A Molecular Cloning Manual*. 1st ed. New York: Cold Spring Harbor Laboratory Press; 2002.
29. Caruccio N. Preparation of next-generation sequencing libraries using Nextera™ technology: simultaneous DNA fragmentation and adaptor tagging by in vitro transposition. *Methods Mol Biol.* 2011;733:241-255.
30. Pettersson E, Lundeberg J, Ahmadian A. Generations of sequencing technologies. *Genomics.* 2009;93(2):105-111.
31. Biankin AV, Waddell N, Kassahn KS, et al. Pancreatic cancer genomes reveal aberrations in axon guidance pathway genes. *Nature.* 2012;491(7424):399-405.
32. Bonifacio JS, Dasso M, Harford JB, et al. *Current Protocols in Cell Biology*. New York: John Wiley & Sons; 2003.
33. Nagy A. *Manipulating the Mouse Embryo: A Laboratory Manual*. 3rd ed. New York: Cold Spring Harbor Laboratory Press; 2002.
34. Evans M. Discovering pluripotency: 30 years of mouse embryonic stem cells. *Nat Rev Mol Cell Biol.* 2011;12(10):680-686.
35. Steitz JA. In: Hannon GH, ed. RNAi: A Guide to Gene Silencing. Cold Spring Harbor Laboratory Press. *RNA.* 2004;10(3):350.
36. Rao DD, Senzer N, Wang Z, et al. Bifunctional short hairpin RNA (bi-shRNA): design and pathway to clinical application. *Methods Mol Biol.* 2013;942:259-278.
37. Rao DD, Maples PB, Senzer N, et al. Enhanced target gene knockdown by a bifunctional shRNA: a novel approach of RNA interference. *Cancer Gene Ther.* 2010;17(11):780-791.
38. MacRae IJ, Zhou K, Li F, et al. Structural basis for double-stranded RNA processing by dicer. *Science.* 2006;311(5758):195-198.
39. Senzer N, Rao D, Nemunaitis J. Letter to the editor: does dicer expression affect shRNA processing? *Gene Regul Syst Bio.* 2009;3:103-104.
40. Senzer N, Barve M, Kuhn J, et al. Phase I trial of "bi-shRNAi(furin)/GM-CSF DNA/autologous tumor cell" vaccine (FANG) in advanced cancer. *Mol Ther.* 2012;20(3):679-686.
41. Liu SH, Patel S, Gingras MC, et al. PDX-1: demonstration of oncogenic properties in pancreatic cancer. *Cancer.* 2011;117(4):723-733.
42. Templeton NS, Lasic DD, Frederik PM, et al. Improved DNA: liposome complexes for increased systemic delivery and gene expression. *Nat Biotechnol.* 1997;15(7):647-652.
43. Nemunaitis J, Rao DD, Liu SH, Brunicardi FC. Personalized cancer approach: using RNA interference technology. *World J Surg.* 2011;35(8):1700-1714.

This page intentionally left blank

Part ||

Specific
Considerations

This page intentionally left blank

16 chapter

The Skin and Subcutaneous Tissue

Sajid A. Khan, Jonathan Bank, David H. Song, and Eugene A. Choi

Introduction	473	Thermal Injury / 480	Keratosis / 486
Anatomy and Histology	473	Pressure Injury / 482	Soft Tissue Tumors / 486
Background / 473		Bioengineered Skin Substitutes 482	Neural Tumors / 486
Epidermis / 473		Bacterial Infections of the Skin and Subcutaneous Tissue 483	Malignant Tumors 486
Epidermal Components / 473		Uncomplicated Skin Infections / 483	Basal Cell Carcinoma / 486
Dermis / 475		Complicated Skin Infections / 483	Squamous Cell Carcinoma / 487
Hypodermis (Subcutaneous Fat, Panniculus Adiposus) / 476		Actinomycosis / 484	Melanoma / 488
Inflammatory Conditions	476	Viral Infections with Surgical Implications 485	Merkel Cell Carcinoma / 492
Hidradenitis Suppurativa / 476		Human Papillomavirus Infections / 485	Kaposi's Sarcoma / 492
Pyoderma Gangrenosum / 476		Cutaneous Manifestations of Human Immunodeficiency Virus / 485	Dermatofibrosarcoma Protuberans / 492
Toxic Epidermal Necrolysis and Steven-Johnson Syndrome / 477		Benign Tumors 485	Malignant Fibrous Histiocytoma (Undifferentiated Pleomorphic Sarcoma and Myxofibrosarcoma) / 493
Injuries	477	Hemangioma / 485	Angiosarcoma / 493
Radiation-Induced Injuries / 477		Nevi / 485	Extramammary Paget's Disease / 493
Trauma-Induced Injuries / 478		Cystic Lesions / 486	Conclusion 493
Caustic Injury / 479			

INTRODUCTION

The skin is a complex organ encompassing the body's surface and continuous with the mucous membranes. Accounting for approximately 15% of total body weight, it is the largest organ in the human body. Enabled by an array of tissue and cell types, intact skin protects the body from external insults. However, the skin is also the source of a myriad of pathologies that include inflammatory disorders, mechanical and thermal injuries, infectious diseases, and benign and malignant tumors. The intricacies of this organ and associated pathologies are reasons the skin and subcutaneous tissue remain of great interest and require the attention of various surgical disciplines that include plastic surgery, dermatology, general surgery, and surgical oncology.

ANATOMY AND HISTOLOGY

Background

Components of epithelial, connective, vascular, muscular, and nervous tissue are organized into three histologic layers (epidermis, dermis, and hypodermis), which vary in consistency between various body parts (Fig. 16-1). The thickness of each layer, distribution of dermal appendages, density and type of nerve endings, and melanocyte distribution are just some of the variables that differ by location and purpose. The epidermis and its appendages are of ectodermal origin, whereas the dermis and hypodermis are of mesodermal origin.¹

Epidermis

The epidermis consists of stratified epithelium that undergoes continuous regeneration. Ninety to ninety-five percent of these epithelial cells are ectodermally derived keratinocytes. **1▶** During their differentiation, keratinocytes form flattened, anucleate cells that are ultimately shed from the skin surface. This process results in the formation of distinct cell layers (from deep to superficial): stratum basale (single cell layer), stratum spinosum (5 to 15 cells thick), stratum granulare (1 to 3 cells), and stratum corneum (5 to 10 cells), which is further subdivided into a deep, compact stratum compactum layer and a more superficial, loose stratum disjunctum layer. In the palmoplantar region, an additional layer, the stratum lucidum, can be seen between strata granulare and corneum (see Fig. 16-1). Transit time (keratinization) is approximately 30 days. Epidermal thickness differs between skin regions, ranging from 50 μm on the eyelids to 1 mm on the soles. Interventions such as tissue expansion result in thickening of the epidermis (and thinning of the dermis).

Epidermal Components

Keratinocytes. Basal layer keratinocytes are columnar or cubical cells with a basophilic cytoplasm and large nucleus, and they are aligned with an underlying basement membrane and anchored by hemidesmosomes. Melanosomes are positioned over the nucleus. The cytoplasm includes bundles of filaments comprised of keratin polypeptides; these insert into the desmosomes and contribute to the formation of the cytoskeleton,

Key Points

- 1▶ The epidermis consists of continually regenerating stratified epithelium, and 90% of cells are comprised of ectodermally derived keratinocytes.
- 2▶ Dermal fibers are predominantly made of type I and III collagen in a 4:1 ratio. They are responsible for the mechanical resistance of skin.
- 3▶ *Staphylococcus aureus* is the most common isolate of all skin infections. Impetigo, cellulitis, erysipelas, folliculitis, furuncles, and simple abscesses are examples of uncomplicated infections, whereas deep-tissue infections, extensive cellulitis, necrotizing fasciitis, and myonecrosis are examples of complicated infections.
- 4▶ Hemangiomas arise from benign proliferation of endothelial cells surrounding blood-filled cavities. They most commonly present after birth, rapidly grow during the first year of life, and gradually involute in most cases.
- 5▶ Basal cell carcinoma represents the most common tumor diagnosed in the United States, and the nodular variant is the most common subtype.
- 6▶ Squamous cell carcinoma is the second most common skin cancer, and primary treatment modalities are surgical excision and Moh's microsurgery. Cautery and ablation, cryotherapy, drug therapy, and radiation therapy are alternative treatments.
- 7▶ Tumor thickness, ulceration, and mitotic rate are the most important prognostic indicators of survival in melanoma. If a sentinel node contains metastatic cancer, prognosis is determined by the number of positive nodes, the primary tumor thickness, mitotic rate and ulceration, and the age of the patient.

conferring mechanical resistance to the epidermis as a whole. Other types of intercellular junctions (including gap and adherens junctions) are present as well. Proliferation occurs at this cell layer. Spinosum layer keratinocytes are polygonal, with an eosinophilic cytoplasm. Ultrastructurally, they contain coarse bundles of tonofilaments, cytoplasmic protein found in epithelial cells.

Granular layer keratinocytes are flattened cells, lying parallel to the skin surface, with a diameter of 25 μm ; they contain keratohyalin granules and keratin and lamellar bodies. The latter are involved in the process of desquamation and in the formation of a lipid pericellular coat that acts as a penetration barrier against foreign (hydrophilic) substances.

Corneum layer keratinocytes are highly flattened, hexagonal, eosinophilic cells, containing mainly keratin matrix, that are eventually shed from the skin surface and contribute to the skin's barrier function. The superficial part of eccrine sweat glands and hair follicles are considered part of the epidermis as well. The epithelial cells comprising these units have separate

biologic properties with regard to regeneration, differentiation, and response to various stimuli. Five to ten percent of epidermal cells are nonkeratinocytes, including primarily Langerhans cells, melanocytes, and Merkel cells.

Langerhans Cells. These are mobile, dendritic, antigen-presenting cells present in all stratified epithelia that originate from bone marrow precursors. These cells are capable of uptaking exogenous antigens (by use of Birbeck granules), processing them and presenting them to T cells; they represent 3% to 6% of all cells in the epidermis.²

Melanocytes. Originating from the neural crest, these cells migrate into the epidermis where they produce melanin, the main natural pigment of the skin. They are distributed regularly among basal keratinocytes, at a ratio of 1 melanocyte for every 4 to 10 keratinocytes. Their density reaches 500 to 2000 cells per mm^2 of cutaneous surface, with regional variations (maximal density on genital skin).

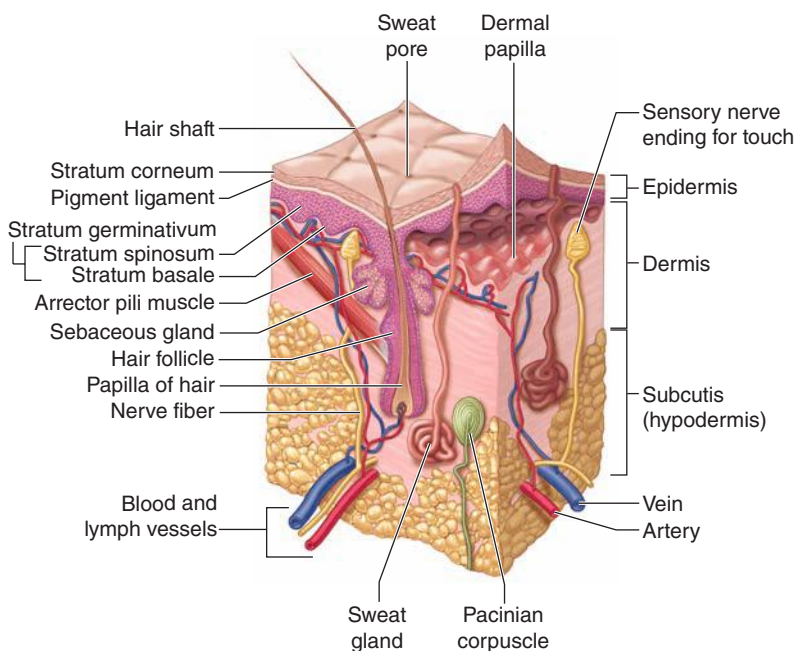


Figure 16-1. Schematic representation of the skin and its appendages. Note that the root of the hair follicle may extend beneath the dermis into the subcutis.

Melanin is produced through the enzymatic activity of tyrosinase on the substrate tyrosine and is then stored in melanosomes; these are transported along the dendritic processes of melanocytes and are eventually transferred to adjacent keratinocytes where they form an umbrella-like cap over the nucleus, protecting it from the effects of ultraviolet (UV) light. Melanocytes express the bcl-2 oncoprotein, S100 protein, and vimentin.

Ethnic variations in pigmentation are due to differences in activity of melanocytes and distribution of melanosomes within the epidermis and not differences in the number of melanocytes.

Merkel Cells. Merkel cells display both neuroendocrine and epithelial features. They function as mechanoreceptors and synapse with dermal sensory axons in the basal layer of the epidermis and the epithelial sheath of hair follicles.

Lymphocytes. The normal human epidermis contains a small percentage (<1%) of lymphocytes, present mainly in the basal layer. They express predominantly a T-memory/effector phenotype.³

Toker Cells. These are cells with a clear cytoplasm and are located within the nipple epidermis in 10% of both males and females. Their role in normal skin and pathology remains poorly understood, but they may be precursors of Paget's cell carcinoma.⁴

Epidermal Appendages. These are specialized epithelial structures, connected to the surface epidermis but located mainly within the dermis and hypodermis. Appendages serve functions that include lubrication, sensation, contractility, and heat loss.

Sweat Glands. Sweat glands are tubular exocrine glands, consisting of a secretory coil and an excretory duct. Eccrine sweat glands are the main sweat glands in humans, playing a vital role in the process of thermoregulation. They are present almost everywhere on the skin (except mucous membranes), with a maximal density over the palms, soles, axillae, and forehead.

Apocrine sweat glands are less abundant in humans and are derived embryologically from the germ cells that produce the pilosebaceous follicle and are, therefore, structurally associated with it. These glands are found in the axillary, anogenital, and nipple regions. They consist of a secretory coil that is larger and more irregular in shape than that of eccrine glands.

A third type of sweat gland was more recently described in the axillary region. The so-called "apoecrine" glands are atrichial glands, opening directly to the skin surface, but their secretory coil is similar to that of apocrine glands and they present during puberty.⁵

Pilosebaceous Follicles. These structures are derived from the epithelial germ layer and lie obliquely in the dermis, with their deepest part reaching the hypodermis. They are present throughout the integument, excluding the glabrous skin (palms, soles) and portions of the genitalia. Their size and morphology are variable (terminal, vellus, lanugo, and intermediary hair). Their growth is cyclic and proceeds through three distinct phases of uneven duration (anagen, catagen, and telogen) during which their histology varies considerably.

Nails. The nails overlie the dorsal aspect of the distal phalanges of the fingers and toes. They consist of three parts: (a) the root, covered by the proximal nail fold, continuous with the lateral nail folds; (b) the nail plate, comprised of hard keratin; and (c) the free edge, overlying the hyponychium, a thickened epidermis. The nail lies on the nail bed, a richly vascular connective

tissue containing numerous arteriovenous shunts. The proximal part of the nail bed is continuous with the nail matrix, responsible for nail growth and adhesion.

Dermis

Architecture. The dermis is a compressible, elastic connective tissue that supports and protects the epidermis, dermal appendages, and neurovascular plexuses. It consists of cells, fibrous molecules, and a ground substance. It turns over continuously, regulated by mechanisms controlling the synthesis and degradation of its protein components. The thickness of the dermis varies considerably with the anatomic location (being much thicker on the back, palms, and soles than on the eyelids).

The papillary (superficial) dermis forms conic upward projections (dermal papillae) alternating with epidermal rete ridges, thus increasing the surface of contact between the dermis and epidermis and allowing for better adhesion between these layers. It contains several cell types (fibroblasts, dermal dendrocytes, and mast cells), vessels, and nerve endings. It is made of collagen fibers arranged in loose bundles and thin elastic fibers stretching perpendicularly to the dermal-epidermal junction. In the distal extremities, dermal papillae contain tactile corpuscles, specialized nerve endings acting as mechanoreceptors. The reticular (deep) dermis is made of coarser collagen bundles, tending to lie parallel to the skin surface. The elastic network is also thicker in this layer. The reticular dermis contains the deep part of cutaneous appendages and vascular and nerve plexuses.

Dermal Fibers. The majority (>90%) of dermal fibers are collagen, predominantly types I and III, which are responsible for the mechanical resistance of the skin. Collagen accounts for 98% of the total mass of dry dermis. Collagen fibers are arranged in bundles that are loose in the papillary dermis and become thicker in the deep dermis. Other collagens found in the dermis include type IV collagen (at the dermo-epidermal junction and in the basement membranes of cutaneous appendages, vessels, muscles, and nerves) and type VII collagen (anchoring fibers of the dermo-epidermal junction).

Elastic fibers are responsible for the retractile properties of the skin due to their ability to stretch to twice their resting length and return to their baseline shape after the deforming force is relieved. In the papillary dermis, they are thin; they become thicker in the reticular dermis, where they tend to run horizontally. By electron microscopy, elastic fibers show variations depending on age and the area studied (sun-exposed or not). They have irregular contours and are made of a central amorphous matrix composed of elastin, an insoluble protein. This core is surrounded by a varying number of microfibrils made of fibrillin. Reticulin fibers consist biochemically of an assembly of thin collagen fibers (types I and III) and fibronectin.

Cells. Fibroblasts are the fundamental cells of the dermis and all connective tissues that synthesize all types of fibers and the ground substance. They appear as spindle-shaped or stellate cells, containing a well-developed rough endoplasmic reticulum. Myofibroblasts are cells derived from fibroblasts, namely during the process of wound healing; they contain myofilaments, visible by electron microscopy, and express (smooth) muscle actin and more rarely desmin.⁶

Dermal dendrocytes represent a heterogeneous population of mesenchymal dendritic cells, recognizable mainly by immunohistochemistry. They are present around capillaries of the papillary dermis, around sweat gland coils, and within the

connective tissue septa of the hypodermis. Dermal dendrocytes complement the immunologically functional cells of the epidermis. Mast cells are mononuclear cells of bone marrow origin, sparsely distributed in the perivascular and periadnexal dermis.

Cutaneous Vasculature. Excluding the epidermis, which is a nonvascular tissue, the skin possesses a rich vascular network that largely exceeds the skin metabolic requirements. This network plays a role in thermoregulation, wound healing, immune reactions, and blood pressure control. Cutaneous vessels belong to the arterial, venous, or lymphatic system; they originate from perforating arteries arising from underlying vessels of the muscles and form two distinct horizontal plexuses that communicate via vessels traversing the dermis vertically. The deep plexus lies close to the dermal-hypodermal junction and provides nutritional arteries to sweat glands and hair follicles. The superficial plexus, derived from terminal arterioles, lies at the interface between the papillary and reticular dermis and provides a vascular loop to every dermal papilla toward the surface (except in the nail bed). This consists of an ascending precapillary arteriole, arterial and venous capillaries forming a hairpin turn, and a descending postcapillary venule (these account for the majority of vessels in the papillary dermis).⁷

Cutaneous Enervation. The skin contains a rich and complex enervation, consisting of an afferent and an efferent limb. The afferent limb is responsible for the perception of eternal stimuli (touch, pressure, vibration, pain, temperature, itch) via a network of sensory myelinated and nonmyelinated fibers, free terminal nerve endings, and tactile corpuscles. The efferent limb is supported by nonmyelinated fibers of the sympathetic system that regulate vasomotricity, sweat secretion, and piloerection.

Hypodermis (Subcutaneous Fat, Panniculus Adiposus)

Fatty tissue is the deepest part of the skin, separating it from the underlying muscle fascia or the periosteum. It plays an important role in thermoregulation, insulation, storage of energy, and protection from mechanical injuries.

The main cells of the hypodermis are the adipocytes—large, rounded cells with a lipid-laden cytoplasm (triglycerides, fatty acids) compressing the nucleus against the cell membrane. Adipocytes are arranged in primary and secondary lobules, the morphology of which varies according to gender and body region. These lobules are separated by connective tissue septa containing cells (fibroblasts, dendrocytes, mast cells), the deepest part of sweat glands, and vessels and nerves contributing to the formation of the corresponding dermal plexuses.

INFLAMMATORY CONDITIONS

Hidradenitis Suppurativa

Hidradenitis suppurativa is a chronic inflammatory disease presenting as painful subcutaneous nodules. Patients experience appreciable physical, psychological, and economical hardship and decreased quality of life when compared to patients who suffer from other chronic dermatologic disease such as psoriasis and alopecia.⁸ It is characterized by multiple abscesses, inter-networking sinus tracts, foul-smelling exudate from draining sinuses, inflammation in the dermis, both atrophic and hypertrophic scars, ulceration, and infection, which may extend deep into the fascia. The diagnosis is made clinically without the need for imaging or laboratory tests. Affected sites are axillary,

inguinal, perineal, mammary, and inframammary areas corresponding to a “milk-line” distribution.

The current pathophysiologic mechanism is that there is follicular occlusion, and not an apocrine disorder as previously believed. Hyperandrogenism does not have a proven role in the disease; poor hygiene, smoking, alcohol consumption, and bacterial involvement are thought to exacerbate rather than initiate the disease process.

Treatment varies depending on disease severity and extent. The majority of patients with early-stage disease (abscesses without significant scarring) respond to topical or systemic antibiotics (clindamycin is first-line therapy). Antiandrogens have an equivocal role in therapy. Application of various anti-inflammatory agents has been successful in limited accounts and with questionable long-term efficacy. With the goal of ablating hair follicles, radiation therapy, radiofrequency ablation, and carbon dioxide (CO₂) laser ablation have been employed, again with less than satisfactory long-term results.⁹⁻¹²

Refractory cases respond best to wide surgical debridement of the affected sites. Recurrence rates tend to be higher in the inframammary and inguino-perineal regions, reaching up to 50%. Primary wound closure after debridement bears a high risk of recurrence and is therefore discouraged. Locoregional flaps, split-thickness skin grafting, and healing by secondary intention are other alternatives. Skin grafting has a faster healing rate compared with secondary wound closure. However, the cost of having a painful donor site and limb immobilization led most patients in one reported study to prefer secondary healing.¹³ Topical antimicrobial creams should be used during the healing process.

Pyoderma Gangrenosum

Pyoderma gangrenosum (PG) is a relatively uncommon non-infectious neutrophilic dermatosis. This disease is commonly associated with inflammatory bowel disease, rheumatoid arthritis, hematologic malignancies, and monoclonal gammopathies. Clinically, the condition is characterized by the presence of sterile pustules, which progress and ulcerate to variable depths and dimensions. The lower extremities are the most commonly affected site, although all other parts of the skin can be involved. Extracutaneous manifestations include the upper airway, eye, genitalia mucosa, lungs, spleen, and muscle. Secondary infection is common. PG is more common in women and peaks in the third to sixth decades of life. Lesion borders are purplish in color with erythematous edges. Five clinical types are identified: ulcerative, pustular, bullous, vegetative, and peristomal. Treatment of this condition is centered on treatment of the inciting disease (i.e., management of Crohn’s disease) and often includes systemic steroids or calcineurin inhibitors. Treatment of PG combines systemic, topical, and surgical modalities. Systemic therapy is instituted in widespread and progressing cases and revolves around anti-inflammatory medications. Calcineurin inhibitors (inhibitors of T-cell activation) and corticosteroids are the mainstay of therapy. Other immunomodulators include sulfa drugs (dapsone), clofazimine, thalidomide, colchicine, azathioprine, cyclophosphamide, and mycophenolate mofetil. Patients with Crohn’s disease and PG treated with infliximab (tumor necrosis factor [TNF]- α inhibitor) and etanercept (TNF- α antagonist) had a marked improvement in their PG.^{14,15} Once ulcers develop, topical antimicrobials should be used to decrease the likelihood of secondary infections. Wound care should be geared toward debridement of purulent exudate

and devitalized tissue, while maintaining a moist environment to facilitate healing. Topical calcineurin inhibitors have been shown to be useful in peristomal PG.¹⁶ Surgical debridement should be used concomitantly with systemic therapy, as the surgical insult may trigger further PG. Wound closure can usually be achieved with split-thickness skin grafting and temporary coverage with allografts or bioengineered skin substitutes.

Toxic Epidermal Necrolysis and Steven-Johnson Syndrome

These inflammatory diseases represent a spectrum of an autoimmune reaction to stimuli such as drugs that result in structural defects in the epidermal-dermal junction. The cutaneous manifestations of toxic epidermal necrolysis syndrome (TENS) follow a prodromal period reminiscent of an upper respiratory tract infection.¹⁷ A symmetrical macular eruption follows starting from the face and trunk and spreading to the extremities. Typically, a Nikolsky sign develops in which lateral pressure causes the epidermis to detach from the basal layer. The macular eruption evolves into blisters, causing an extensive superficial partial-thickness skin injury with exposed dermis (Fig. 16-2). The process progresses for 7 to 10 days; re-epithelialization occurs over 1 to 3 weeks. Mucosal and ocular surfaces may be involved in a similar fashion. Immunosuppressed patients are at higher risk.

TENS historically was considered to be the extreme of a spectrum, with erythema multiforme and Stevens-Johnson syndrome (SJS) being less extensive forms of disease. Currently, erythema multiforme is thought to be a separate entity, related to herpetic and *Mycoplasma pneumoniae* infection. TENS involves more than 30% total body surface area; between 10% and 30% is considered the SJS-TEN overlap syndrome. Prognosis is related to the extent of disease and related primarily to secondary infection and other intensive care unit (ICU)-associated morbidity. With modern-day burn and ICU care, the mortality has declined significantly.¹⁷ The mildest form of the disease is SJS, which clinically presents as second-degree burns appearing as erythema and blisters/bullae of the oropharynx, anoderm, and torso. Less than 10% of total body surface area is involved with this disease. TENS is driven by the same dermo-epidermal structural defects but consists of greater than 30% total body

surface area. In addition to the aforementioned, it affects the mouth, esophagus, small bowel, and colon, resulting in sloughing of mucosa that may present as gastrointestinal bleeding and intestinal malabsorption.¹⁸ It also affects the eyes, genitalia, and other mucosal surfaces.

The drugs most commonly associated with TENS-SJS include aromatic anticonvulsants, sulfonamides, allopurinol, oxicams (nonsteroidal anti-inflammatory drugs), and nevirapine. The pathophysiology of TENS is not completely understood; current theories involve apoptosis due to Fas-mediated mechanisms (a soluble or a membrane-bound protein that causes apoptosis upon activation), granulysin (a proapoptotic protein that permits cell-mediated cytotoxicity), and reactive oxygen species. There appears to be a genetic component, and genetic testing before carbamazepine treatment is recommended in people of Han Chinese ancestry to exclude carriers of HLA-B1502.¹⁹

The two principles of TENS management include early withdrawal of the offending drug and supportive care (i.e., pain control, intravenous fluid, electrolyte repletion, prevention of skin infections, enteral feeds, and possible respiratory support) in a burn unit. Despite drug withdrawal, noxious metabolites may persist. Wound care differs between centers and focuses on debridement of devitalized tissue and coverage with nonadherent dressings. Temporary skin coverage is sometimes needed until re-epithelialization is allowed to progress, reducing the probability of skin infections and dehydration. Coverage can be achieved with biologic dressing (allograft skin), biosynthetic dressings (Biobrane), and antimicrobial dressings (antibiotic or silver-impregnated such as Acticoat). A Wood's lamp examination every 1 hour should be performed to look for corneal sloughing. It should be noted that these diseases should be distinguished from staphylococcal scalded skin syndrome, which clinically appears similar but is a result of exotoxins produced after staphylococcal infections of nasopharynx or otitis media.

Systemic treatment with steroids has fallen out of favor due to increased sepsis rates, prolonged admission, and potentially higher mortality rates. Intravenous immunoglobulin (IVIG) is thought to be a treatment given the presence of anti-Fas antibodies within IVIG. The antagonistic antibodies inhibit Fas-mediated cell apoptosis.²⁰ However, a high variability exists between batches with this regard. There are mixed reports of IVIG treatment efficacy. A 2007 meta-analysis of nine IVIG trials concluded that high-dose IVIG does, in fact, improve survival.²¹ Other treatment protocols include plasmapheresis aimed at decreasing cytokine and drug load, cyclosporine, cyclophosphamide, and anti-TNF- α antibodies.¹⁷

INJURIES

Radiation-Induced Injuries

Radiation-induced injuries can be the result of environmental exposure, industrial/occupational applications, and medical etiologies. Surgeons must be aware of the role radiation plays in oncologic multidisciplinary care. In addition to radiation treatment for cancers such as lymphoma and head and neck squamous cell carcinomas, radiotherapy plays a role in the adjuvant setting either before or after surgical resection in diseases such as rectal, esophageal, and cervical cancers. Although the newer modalities and principles of radiation oncology have allowed for more precise administration of this therapy with theoretically fewer side

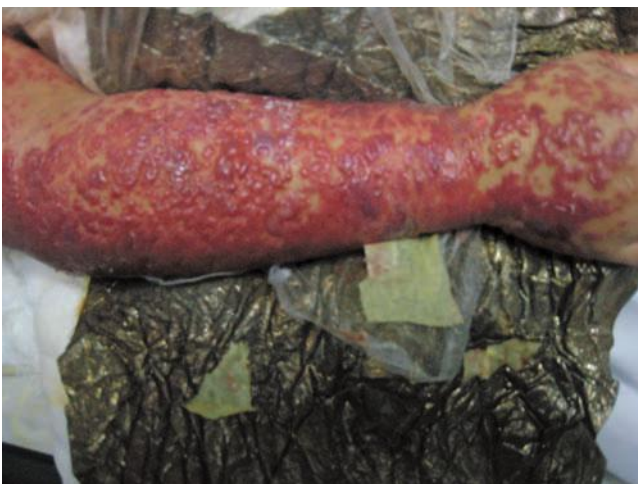

Figure 16-2. Blisters on the forearm of a patient several days after exposure to vancomycin. Note the clear antishear dressing and the dark silver-impregnated antimicrobial dressing (Acticoat™).

effects, there still are complications and clinical entities related to the skin (and deeper viscera) that the surgeon needs to be attuned to.

The replicating basal keratinocytes, hair follicle stem cells, and melanocytes are the most radiosensitive components of the skin. Damage to basal keratinocytes and hair follicle cells causes an immediate burst of free radicals, irreversible double-stranded breaks in nuclear and mitochondrial DNA, and inflammation. The first dose of radiation destroys a percentage of basal keratinocytes, hindering the regenerative capacity of the epidermis; repeated exposures do not allow time for cells to repair.

Acute skin changes are the result of injury to the basal epithelium in the radiated region. Within weeks, this manifests as erythema, edema, and alopecia. As the cells of the skin and subcutaneous tissue undergo repair, permanent hyperpigmentation is clinically apparent. Histologically, the epidermis appears thickened, but the functional integrity is compromised. Severe radiation injury results in complete loss of the epidermis with persistent edema and fibrinous exudate. Re-epithelialization from unaffected wound edges and from recuperating dermal adnexa begins within 10 to 14 days of exposure, provided other parameters are optimized (nutrition, infection, etc.). Chronic changes result from thrombosis and necrosis of capillaries, presenting months to years after the inciting event, ultimately leading to fibrosis and possible ulcers. Chronic skin changes include thinning, hypovascularization, telangiectasia of remaining vessels, ulceration, fibrosis with loss of elasticity, and increased susceptibility to trauma and infection. Chronic radiation skin injury includes delayed ulcers, fibrosis, and telangiectasias that present weeks to years after exposure.

Treatment of minor radiation skin injury consists primarily of maintaining the integrity of remaining skin with moisturizers until recovery of skin adnexa. Management of severe radiation includes surgical excision of damaged tissues as well as control of the typically opiate-resistant pain.

Environmental-induced injuries are from UV radiation and solar-induced skin toxicity and are the most common forms of radiation exposure skin injuries. Radiation reaching the surface of the earth contains infrared (700–2500 nm), visible (400–700 nm), and invisible UV radiation (290–400 nm).²² UVC rays are filtered by the ozone layer of the atmosphere. UVB rays (290–320 nm) and UVA rays (320–400 nm) reach the earth's surface and have cutaneous effects. UVB radiation reaches the earth in relatively low amounts but is highly energetic. UVA rays are lower in energy, but are more abundant, constituting approximately 95% of UV rays reaching the ground. Seasonal, temporal, geo-orbital, and environmental parameters affect solar irradiance. Seventy percent of UVB radiation that reaches the skin is absorbed by the stratum corneum, 20% reaches deeper in the epidermis, and only 10% penetrates the upper part of the dermis. UVA rays are more penetrant, with 20% to 30% reaching the deep dermis. The major chromophores are nucleic acids, aromatic amino acids, and melanin.

Short-term solar radiation effects include erythema and pigmentation. UVB is more effective than UVA in causing a dermal inflammatory response resulting in erythema in a delayed phenomenon, peaking at 6 to 24 hours (dose and skin type dependent). Pigmentation occurs as a result of photo-oxidation of melanin by UVA. Partial fading occurs rapidly within 1 hour after the end of exposure. For higher UVA doses, a stable residual pigmentation is observed after the transient effect. Neomelanization is characterized by a visible brown

pigmentation in UV-exposed skin, which represents an increase in epidermal melanin content. It becomes visible after about 72 hours. An acute erythemogenic dose of UVB is necessary to induce delayed pigmentation; UVA is less effective in tanning and in radiation protection. UVB pigmentation results in a homogeneous tan and UVA protection. However, melanization produced by cumulative UVA exposures appears to be longer lasting than that acquired with UVB exposures.²²

Long-term effects of UV pigmentation can lead to irregular pigmentation and hyperpigmented areas, melasma, postinflammatory pigmentation, and actinic lentigines (sun spots). Radiation damage results from an increase in lysozyme activity, which inhibits the activity of collagenase and elastase and prevents the elastic fibers from proteolysis. The collagen fibril network is impaired and causes an accumulation of an amorphous, elastin-containing material. There is also a loss of collagen and a change in collagen composition (increase in collagen III to collagen I ratio). This structural disarrangement manifests as a loss of firmness and resilience of skin, leading to an older appearance to the skin.

Trauma-Induced Injuries

Mechanical Injury. Skin injuries may occur as a result of penetrating, blunt, and shear forces, or a combination of these. Clean lacerations may be closed primarily after irrigation, debridement, and exploration. Many surgeons will primarily close clean wounds if the injury is treated within 6 hours of the inciting event. However, there is no systematic evidence regarding the timing of closure²³; practitioners are advised to use their judgment. Contaminated or infected wounds should be allowed to heal by secondary intention or delayed primary closure.²⁴

Tangential abrasions should be approached similarly to burns injuries, with management dependent on the depth of the injury incurred. Superficial partial-thickness wounds may be left to heal spontaneously while providing topical antimicrobial prophylaxis or sterile biologic dressings. Deeper wounds may require split-thickness skin grafting to avoid prolonged need for dressing changes and hypertrophic scarring that might result from a prolonged healing period. Degloved skin may be used to provide coverage similar to a skin graft, or as a temporary dressing, provided the wound bed has been cleaned.

Bite Wounds. Accounting for over 4.5 million injuries each year, with many more presumably unreported, seemingly innocuous punctures may lead to severe deep-tissue infections if unrecognized and not treated appropriately.²⁵

Bite bacteriology is influenced by normal mouth flora, as well as the content of the offending animal's food. Early presentation bite wounds yield polymicrobial cultures. Common aerobic bacterial genera include *Pasteurella multocida*, *Streptococcus*, *Staphylococcus*, *Neisseria*, and *Corynebacterium*; anaerobic organisms include *Fusobacterium*, *Porphyromonas*, *Prevotella*, *Propionibacterium*, *Bacteroides*, and *Peptostreptococcus*. *Capnocytophaga canimorsus* bacteria after a dog bite are rare. It appears that immunocompromised patients are most susceptible to this type of infection and its complications. Cultures from an infected bite wound that presents late usually will grow a single organism type. Bacterial load in dog bites is heavily dependent on the content and timing of the last meal and can range between 10³ with a dry meal (biscuits) to 10⁷ within 8 hours of a wet meat meal (Fig. 16-3).²⁶ The bacterial spectrum found in cat bites is very similar to that of dog bites, with a

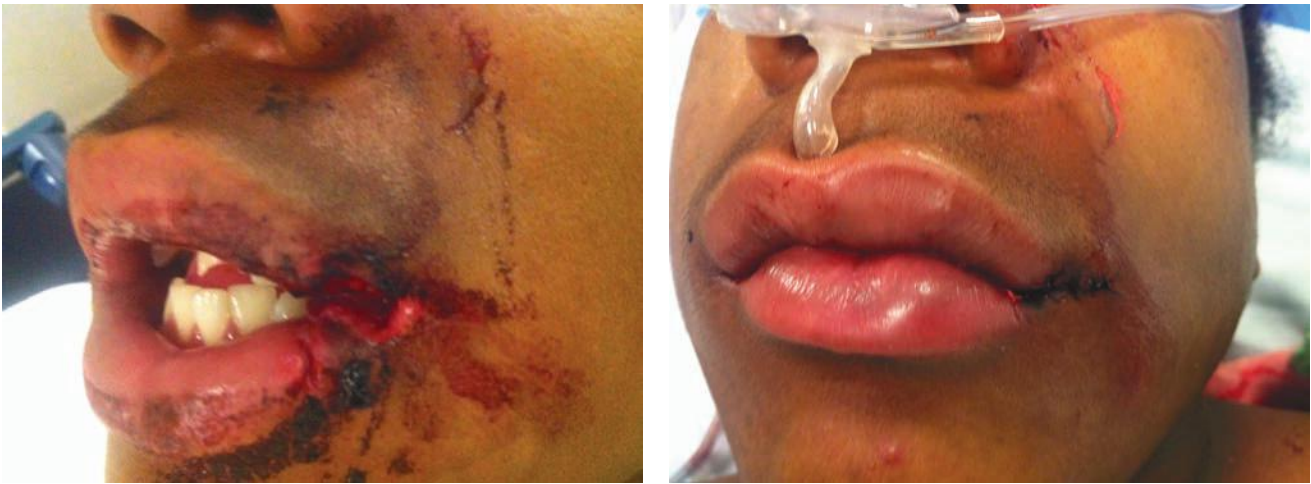

Figure 16-3. A. Dog bite to the face involving the lip and left oral commissure. B. Primary closure following debridement and irrigation. Closure was performed due to aesthetic and functional considerations.

slightly higher prevalence of *Pasteurella* species. Rare infections acquired from cats have been with *Francisella tularensis* (tularemia) and *Yersinia pestis* (human plague).

Bacteria colonizing human bites are those present on the skin or in the mouth. These include the gram-positive aerobic organisms *Staphylococcus aureus*, *Staphylococcus epidermidis*, and *Streptococcus* species, and anaerobes including *Peptococcus* species, *Peptostreptococcus* species, *Bacteroides* species, and *Eikenella corrodens* (facultative anaerobe). Antibiotic coverage must cover gram-positive and anaerobic organisms. A first-generation cephalosporin in combination with penicillin or ampicillin in combination with clavulanic acid provides adequate coverage. Clindamycin is an alternative, but additional coverage for *Eikenella corrodens* should be administered.

Most wounds are amenable to standard wound care protocols. Irrigation (preferably with sterile saline solution) should be performed, although it will reduce surface bacteria only if done with nonpulsatile irrigation. To significantly reduce bacterial load and eliminate particulate debris in the wound, pressure irrigation should be performed. Eighty percent of wounds presenting to the emergency department have a bacterial load under 10^5 , and superficial irrigation will suffice. Larger wounds with signs of infection will require pulse irrigation. Rapid quantitative cultures should be used to guide treatment in wounds with suspected infection. Human bites typically are characterized by higher bacteria load ($>10^5$).

In select cases, bite wounds may be closed primarily, particularly in areas of aesthetic significance such as the face, where secondary intention healing will result in unsightly scarring. This approach should follow initial management as outlined earlier, along with close follow-up to permit early detection of infection.

Rabies in domestic animals in the United States is rare, and the majority of cases are contracted from bat bites. In developing countries, dog bites remain the most common source of rabies. Management of this is beyond the scope of this chapter.

Caustic Injury

Between 2.4% and 10.7% of burns are due to chemical exposure²⁷; however, approximately 30% of burn deaths are related to chemical burns. Damage from chemical burns is related to the concentration, duration, and quantity of acidic or alkaline solution.

Acidic injuries typically cause a more superficial burn pattern due to eschar formation as a result of coagulation necrosis of the skin. This limits subsequent tissue penetration. Exothermic chemical reactions associated with acid burns may cause a combined thermal and chemical injury. Without treatment, this injury will result in erythema and ulcers through the subcutaneous tissue. Injuries related to basic fluids result from liquefactive necrosis starting with fat saponification and result in longer more sustained injuries causing a deeper pattern of injury (Fig. 16-4). Common examples are sodium hydroxide (drain decloggers, paint remover) and calcium hydroxide (cement). This permits further penetration of the unattached molecules, causing further tissue destruction.

The treatment for both types of injuries is based on neutralization of the inciting solution and starts with running distilled water or saline over the affected skin for at least 30 minutes for acidic solutions and 2 hours for alkaline injuries. It should be noted that neutralizing agents do not offer a significant advantage over dilution with water, may delay treatment, and may worsen the injury due to the exothermic reaction that may occur. The clinician observes and treats based on the degree of presentation. Many cases are successfully managed conservatively with topical emollients and oral analgesics, and most cases result in edema, erythema, and induration. If signs of deep second-degree burns develop, local wound care may include debridement, Silvadene, and protective petroleum gauze. In severe cases, injury to the underlying vessels, bones, muscle, and tendon may occur, and these cases may be managed within 24 hours by liposuction through a small catheter and then saline injection. Surgery is indicated for tissue necrosis, uncontrolled pain, or deep-tissue damage. Antibiotics should not be administered unless signs of infection are present.

Injuries that have specific additional treatments include hydrofluoride burns. Hydrofluoride is found in air conditioning cleaners and petroleum refineries. Treatment of hydrofluoride burns should include topical or locally injected calcium gluconate to bind fluoride ions. Intra-arterial calcium gluconate can provide pain relief and preserves arteries from necrosis, whereas intravenous (IV) calcium repletes resorbed calcium stores. Topical calcium carbonate gel and quaternary

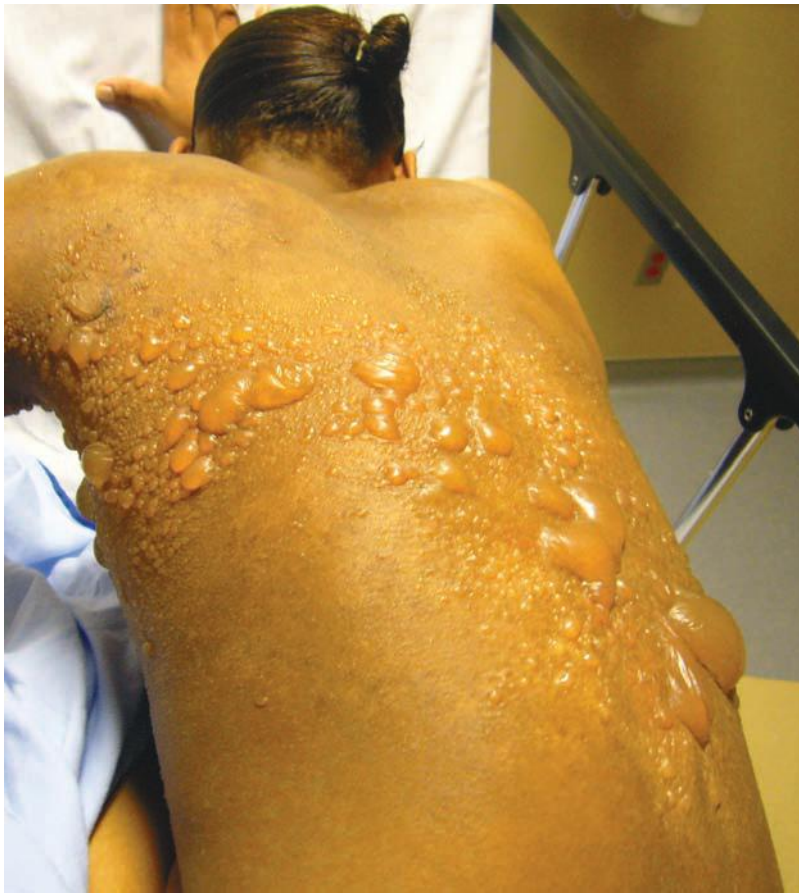

Figure 16-4. Self-inflicted alkali burn with cleaner fluid.

ammonium compounds detoxify fluoride ions. This mitigates the leaching of calcium and magnesium ions by the hydrofluoric acid from the affected tissues and prevents potentially severe hypocalcemia and hypomagnesemia that predispose to cardiac arrhythmias.

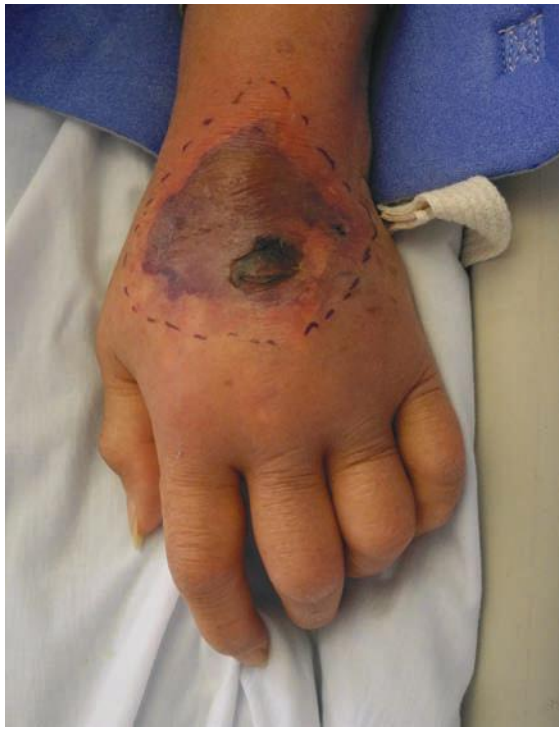IV fluid extravasation results in yet another type of chemical injury and occurs in 0.1% to 0.7% of all cytotoxic drug administrations (Fig. 16-5). The dorsum of the hand is the most common location of this type of injury, predisposing exposure of the extensor tendon. There is a higher risk in patients receiving chemotherapy, and the risk increases dramatically in the pediatric population (11%–58%). Doxorubicin is often the offending agent, and its effects are attributable to direct toxicity resulting in cellular death, perpetuated by release of doxorubicin from cell lysis and failed wound healing. Resultant tissue injury depends on several factors, including solution osmolality, tissue toxicity, vasoconstrictive properties, infusion pressure, and regional anatomic properties.²⁸ Although most extravasations do not culminate in significant injuries, skin and subcutaneous damage is more likely in the critically ill and neonates. This is due, in part, to the type of infusions employed in these patients, the thin skin at the IV site (dorsum of hands and feet), fragility of veins, and the relatively poorly perfused tissue in these locations. Initial presentation may include erythema, blistering, and pain. The true extent of the injury may be beyond the apparent external margins, and this may take days to manifest completely (longer in the case of calcium carbonate infiltrations). Injury to deeper structures should be excluded. Treatment varies from conservative management with limb elevation to saline infiltration (for dilution) and aspiration with liposuction cannula.²⁸ These methods have been shown to be

effective only in the early period following extravasation. Cold or warm compresses should be avoided because they may add a thermal injury component to an area in which thermoregulatory mechanism are impeded due to vasoconstriction, pressure, and inflammation. Surgical intervention includes debridement of devitalized tissue and reconstruction with appropriate technique (i.e., skin substitutes, skin grafting, flaps, or secondary intention). Topical antimicrobial therapy is encouraged until surgery is possible.

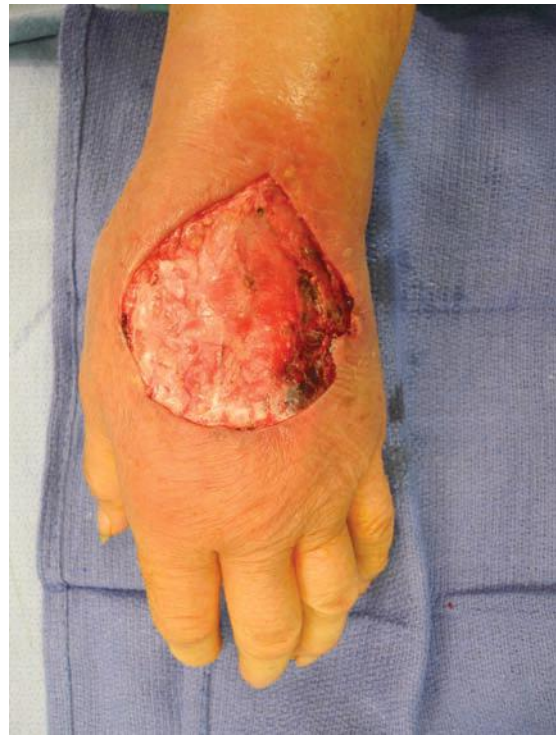Thermal Injury

Exposure of the skin to thermal extremes disrupts its primary function as a barrier to heat loss, evaporation, and microbial invasion. The depth and extent of injury are dependent on the duration and temperature of the exposure. The pathophysiology and management are discussed elsewhere in this book. Briefly, the epicenter of the injury undergoes a varying extent of necrosis (depending on the exposure), otherwise referred to as the zone of coagulation, which is surrounded by the zone of stasis, which has marginal perfusion and questionable viability.²⁹ This is the area of tissue that is most amenable to salvage by appropriate resuscitative and wound management techniques, which would theoretically limit the extent of injury. The outermost area of skin shows characteristics similar to other inflamed tissues and has been designated the zone of hyperemia. The degree of burn corresponds to histologic layers of the affected dermis and correlates with management and prognosis pertaining to timeline of healing and magnitude of scarring (Fig. 16-6).

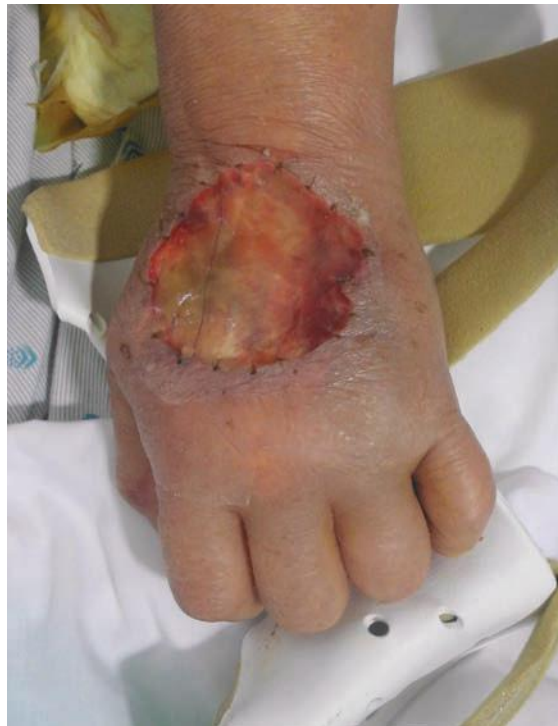Hypothermic skin injury (frostbite) can result from direct cellular damage or the secondary effects of microvascular



A



B



C

Figure 16-5. A. Potassium chloride intravenous infiltrate in a critically ill patient on multiple vasopressors. B. Following operative debridement to paratenon layer. C. Temporary coverage with Integra skin substitute.

thrombosis and subsequent ischemia.³⁰ Freezing of tissue leads to intracellular and extracellular ice formation, intracellular ice formation, cell dehydration and crenation, local electrolyte abnormalities, and disturbances in lipid-protein complexes. With rewarming, the ice melts and damaged cells take up water; affected capillaries leak fluid into the interstitium. Subsequently,

this edema and concomitant inflammatory process result in epidermal blistering and microvasoconstriction, propagating further tissue injury. Treatment includes rapid rewarming to 40 to 42°C, analgesia, debridement of blisters, hydrotherapy, elevation, topical antimicrobials, topical antithromboxanes (aloe vera), and systemic antiprostaglandins (aspirin).

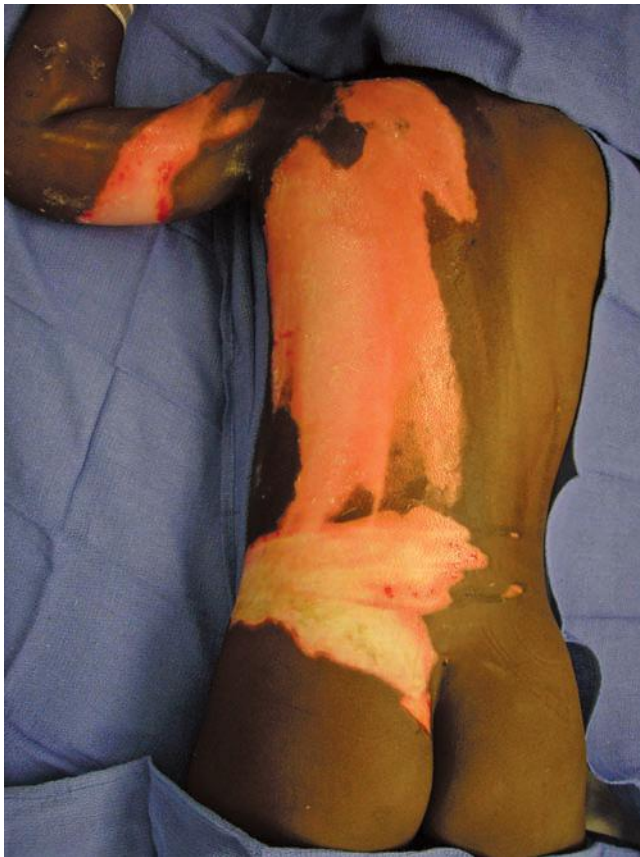
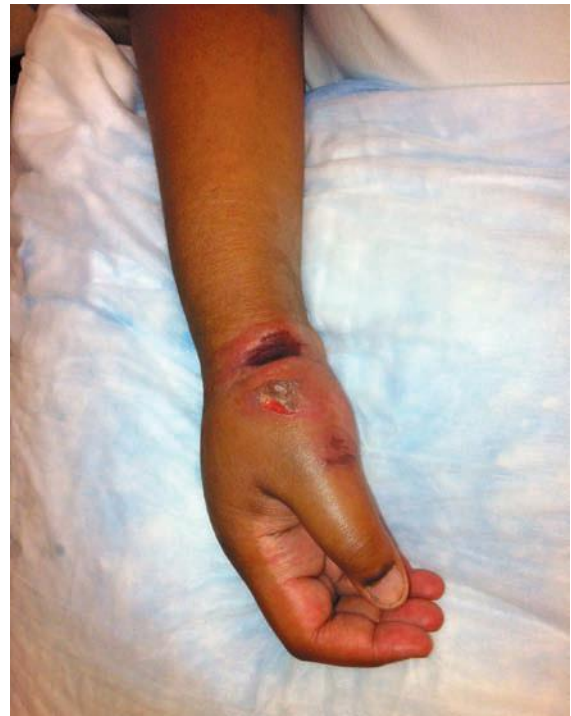
Figure 16-6. Scald burn of upper arm, back, and buttock. Pink areas are superficial partial-thickness burn, whereas whiter areas are deeper burns in the dermis.

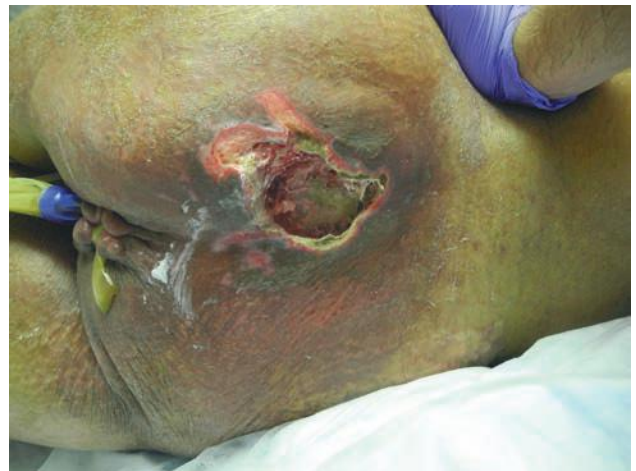Pressure Injury

Tissue pressures that exceed the pressure of the microcirculation (30 mmHg) result in tissue ischemia. Frequent or prolonged ischemic insults will ultimately result in tissue damage (Fig. 16-7). Areas of bony prominence are particularly prone to ischemia, the most common areas being ischial tuberosity (28%), trochanter (19%), sacrum (17%), and heel (9%). Tissue pressures can measure up to 300 mmHg in the ischial region during sitting and 150 mmHg over the sacrum while lying supine.³¹ Muscle is more susceptible than skin to ischemic insult due to its relatively high metabolic demand. Wounds are staged as follows: stage 1, nonblanching erythema over intact skin; stage 2, partial-thickness injury (epidermis or dermis)—blister or crater; stage 3, full-thickness injury extending down to, but not including, fascia and without undermining of adjacent tissue; and stage 4, full-thickness skin injury with destruction or necrosis of muscle, bone, tendon, or joint capsule.

Management principles for pressure sores should include pressure relief (air mattresses and gel cushions for redistribution of pressure), systemic optimization (particularly nutritional support), and wound care.^{32,33} Goals of surgical intervention are drainage of fluid collections, wide debridement of devitalized and scarred tissue, excision of pseudobursa, ostectomy of involved bones, hemostasis, and tension-free closure of dead space with well-vascularized tissue (muscle, musculocutaneous, or fasciocutaneous flaps). Stage 2 and 3 ulcers may be left to heal secondarily after debridement. Subatmospheric pressure wound therapy devices (vacuum-assisted closure) play a role in



A



B

Figure 16-7. **A.** Pressure wound after removal of a poorly padded cast. Stage cannot be determined until debridement but is at least a grade 2 lesion. **B.** Decubitus ulcer of the sacral region, stage 4, to the tendinous and bone layers.

wound management by removing excess interstitial fluid, promoting capillary circulation, decreasing bacterial colonization, increasing vascularity and granulation tissue formation, and contributing to wound size reduction.³⁴

BIOENGINEERED SKIN SUBSTITUTES

Recent work in surgical laboratories has provided surgeons with advancements in bioengineered skin substitutes. Different types of skin substitutes arise from xenograft, autologous, synthetic, and allogeneic sources.³⁵ An example of a xenograft substitute is the porcine dermis Permacol (Tissue Sciences Laboratory), whereas the cultured keratinocyte Epicel (Genzyme Tissue

Repair Corp) grafts represent an autologous substitute. Some examples of synthetic skin substitutes include Biobrane (UDL Laboratories) and Integra (Integra Life Science Corp). Biobrane is a silicon and nylon mesh layer bound with porcine collagen. Integra is a two-layered membrane composed of a silicon layer to maintain hydration and a porous bovine collagen and chondroitin sulfate layer that provides an environment for fibroblasts, macrophages, and capillaries to lay down a vascularized collagen matrix dermal layer. The more superficial silicon layer can be removed, and an autograft can subsequently be applied. AlloDerm (Life Cell) is an allogeneic substitute made of acellular dermal matrix derived from human skin tissue. It provides a matrix for revascularization, incorporating into host tissue, and provides additional strength. In contrast to Integra, it does not provide a dermal matrix to support a skin graft, and thus is not often used as a skin substitute. Several other skin substitutes are also available.

BACTERIAL INFECTIONS OF THE SKIN AND SUBCUTANEOUS TISSUE

In 1998, the Food and Drug Administration (FDA) categorized infections of the skin and skin structures for the purpose of clinical trials. A revision of this categorization in 2010 excluded specific diagnoses such as bite wounds, decubitus ulcers, diabetic foot ulcers, perirectal abscesses, and necrotizing fasciitis. The general division into “uncomplicated” and “complicated” skin infections can be applied to help guide management.³⁶

Staphylococcus aureus is the most common isolate (~44%).³⁷ Other gram-positive bacteria such as *Enterococcus* species (9%), β -hemolytic streptococci (4%), and coagulase-negative staphylococci (3%) are less common. Gram-negative species, including *Pseudomonas aeruginosa* (11%), *Escherichia coli* (7.2%), and *Enterobacter* (5%), *Klebsiella* (4%), and *Serratia* (2%) species, among others, should be considered in

3► complicated infections in patients with diabetes, neutropenia, and cirrhosis.

Uncomplicated Skin Infections

Disease processes included in this category are limited to the epidermis or its appendages and involve a surface area that is less than 75 cm². Impetigo, cellulitis, erysipelas, folliculitis, furuncles, and simple abscesses are included in this category. Folliculitis is an infection of a hair follicle that may progress to a furuncle or a carbuncle (abscess with multiple draining sinuses). Folliculitis and furuncles resolve with adequate hygiene and warm soaks.

Minor primary infections, or a secondarily infected lesion, should be treated with topical ointments such as 2% mupirocin to provide coverage for methicillin-resistant *Staphylococcus aureus* (MRSA). For an uncomplicated furuncle or carbuncle (simple abscess), incision and drainage are sufficient, and antibiotics are not warranted. For nonpurulent, uncomplicated cellulitis β -hemolytic streptococci coverage is recommended (β -lactam such as cephalexin), with MRSA coverage to be added if no response is seen within 48 to 72 hours or in the presence of chills, fevers, expanding erythema, or uncontrolled pain. Dual coverage can be achieved with clindamycin, trimethoprim-sulfamethoxazole, linezolid, or the combination of a tetracycline and a β -lactam. Purulent cellulitis that does not meet criteria for a complicated infection requires MRSA coverage. Need

for empiric coverage for streptococci is unlikely. Clindamycin, trimethoprim-sulfamethoxazole, linezolid, and tetracyclines are options. The infections can be managed on an outpatient basis in the vast majority of cases.

Complicated Skin Infections

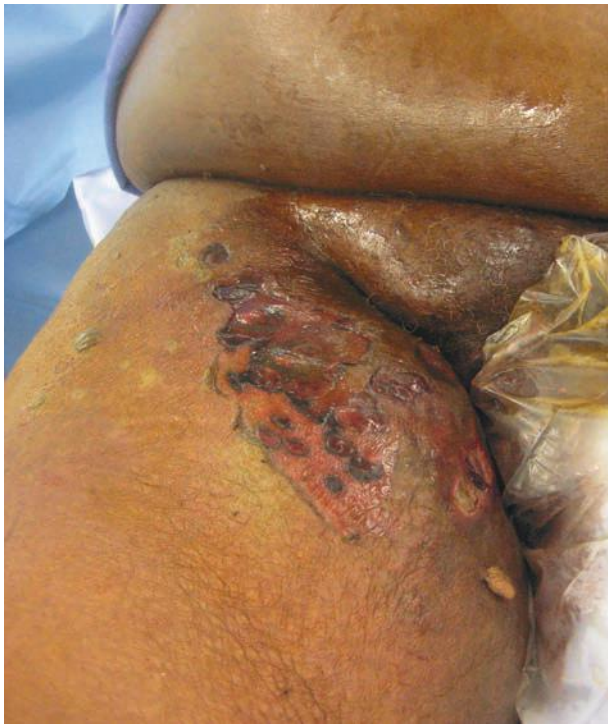Deep-tissue infections (below the dermis), extensive cellulitis, necrotizing fasciitis, and myonecrosis are considered complicated skin infections. A thorough history and exam should be performed to elicit information (e.g., history of trauma, diabetes mellitus, cirrhosis, neutropenia, bites, IV or subcutaneous drug abuse) as well as physical findings such as crepitus (gas-forming organism), fluctuance (abscess), purpura (sepsis in streptococcal infections), bullae (streptococci, *Vibrio vulnificus*), lymphangitis, and signs of a systemic inflammatory response. Aspirated fluid from suspected infected collection should be cultured. Swabs and aspirates in cellulitis have a low yield (10%), whereas tissues cultures may have a higher rate of organism recovery (20%–30%). The utility of computed tomography (CT) or magnetic resonance imaging (MRI) in diagnosing a deep infection is limited and should not delay surgical evaluation and debridement.

Treatment of nonpurulent, complicated cellulitis can begin with a β -lactam, with MRSA coverage added if no response is observed. Empiric MRSA coverage is warranted in all other complicated skin and subcutaneous infections. Vancomycin is the mainstay of therapy, although it is inferior to β -lactams for methicillin-sensitive *Staphylococcus aureus* (MSSA) and has a relatively slow onset of efficacy in vitro. Linezolid, daptomycin, tigecycline, and telavancin are other FDA-approved alternatives for MRSA treatment. Clindamycin is also approved for *S. aureus*; however, resistance may develop, and diarrhea can occur in up to 20% (*Clostridium difficile* related).

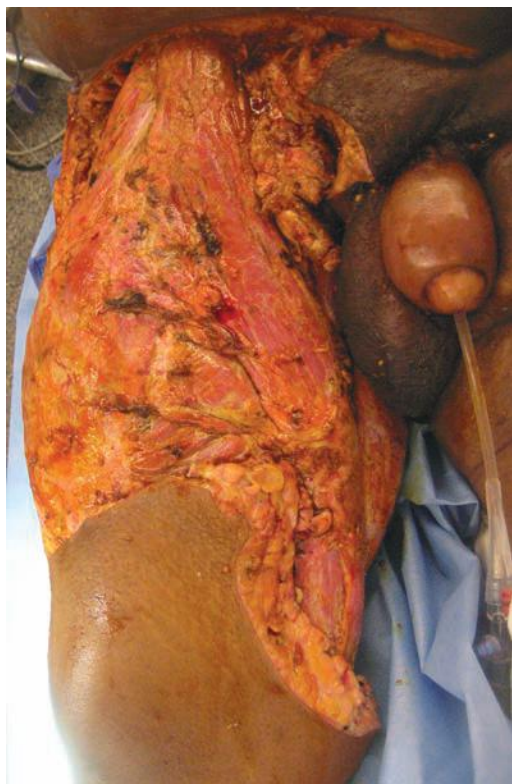Necrotizing infections can manifest with bullae, skin necrosis, pain beyond the margins of erythema, crepitus, gas on imaging, hypotension, or other signs of systemic inflammatory response syndrome (SIRS). These signs are late findings and are frequently absent. Due to substantial morbidity and mortality associated with these infections, the index for suspicion should be high, and the threshold for surgical exploration should be low, particularly in a weakened host, such as diabetic patients, the malnourished, alcoholics, neutropenic or functionally neutropenic patients, cirrhotic patients, renal failure patients, and individuals with peripheral vascular disease.

Common sites of origin are the genitalia, perineum (Fournier’s gangrene), and abdominal wall. Classification is based on the anatomic site, the involved tissue planes (e.g., adipose, fascia, muscle), the offending organisms, and the velocity of the infection. Involvement of the deep fascia (necrotizing fasciitis—deep to the adipose tissue, overlying the muscle) results in a rapidly progressing infection with bacteria spreading along low-resistance tissue planes (Fig. 16-8). Necrotizing myositis primarily involves the muscle but can spread to surrounding tissue as well.

Three types of necrotizing infections can be distinguished based on the organisms involved. Type 1 is the most common, with a polymicrobial source including gram-positive cocci, gram-negative rods, and anaerobes (*Bacteroides* species, *Clostridium perfringens* and *septicum*), occurring in the perineum and trunk of the immunocompromised host. Occasionally an entry site can be identified (incisions, lines, or intestinal perforation), but in 20% to 50% of cases, a risk factor is not



A



B

Figure 16-8. A. Initial presentation of necrotizing soft tissue infection in an obese, diabetic patient. B. Following operative debridement to muscle layer.

identified. Type 2 is a less common, monomicrobial infection with β -hemolytic streptococci or staphylococci (MRSA rising in frequency to 40%). It can be associated with toxic shock and occur in a previously healthy host, typically on the trunk or extremities, with a history of trauma commonly elicited. Type 3

is a rare but fulminant subset resulting from a *V. vulnificus* infection of traumatized skin in sea divers.

Laboratory findings are nonspecific. Leukocytosis, low calcium, and elevated lactate, creatine kinase, and creatinine may be seen. Advanced illness may bring on coagulopathy and acidemia. Blood cultures may or may not be positive. A retrospectively developed scoring system, called the Laboratory Risk Indicator for Necrotizing Fasciitis (LRINEC) score, which includes C-reactive protein (CRP), white blood cell (WBC) count, hemoglobin, plasma sodium, creatinine, and glucose, can be of diagnostic assistance with a high sensitivity and specificity. Tissue samples will demonstrate necrosis, WBC count infiltration, thrombosis, angiitis, and microorganisms.

Management of patients with suspected necrotizing infections should begin with proper patient triage to an ICU for initial evaluation, resuscitation, and treatment. If the diagnosis is clear, operative exploration and debridement should not be delayed. Broad-spectrum IV antibiotics should be started as soon as possible, with vancomycin (for MRSA) in addition to clindamycin or linezolid (to inhibit toxin synthesis) and gram-negative rod coverage (in the form of a third-generation cephalosporin or a quinolone). Surgery is the definitive treatment. Incisions should be made over the involved skin, parallel to neurovascular bundles, extending to and exposing the deep fascia to assess tissue viability. Necrotic tissue will appear dull, gray, and avascular and should be excised. Characteristic “murky dishwasher”-like fluid may be encountered at the affected sites. Borders for debridement are where tissue planes cease to readily separate. Rapid quantitative tissue cultures (if available) and frozen section analysis may help guide the debridement. In Fournier’s gangrene, one should aim to preserve the anal sphincter as well as the testicles (blood supply is independent of the overlying tissue; usually not infected). Revision surgery should be planned (“second look”) within 24 to 48 hours. Adjuncts to surgery include topical antimicrobial creams, subatmospheric pressure wound dressings, and optimization of nutrition. Controversial topics are the role of hyperbaric oxygen (may inhibit infection by creating an oxidative burst, with anecdotally fewer debridements required and improved survival, but the availability is limited) and IVIG (may modulate the immune response to streptococcal superantigens). Wound closure is performed once bacteriologic, metabolic, and nutritional balances are obtained. Mortality ranges from 25% to 40% and is higher in truncal and perineal cases.

Actinomycosis

Actinomycosis should be considered in the differential diagnosis of any acute, subacute, or chronic cutaneous swelling of the head and neck. The cervicofacial form of *Actinomyces* infection is the most common presentation, typically as an acute pyogenic infection in the submandibular or paramandibular area, but infection could be elsewhere in the mandibular and maxillary regions. The primary skin infection may spread to adjacent structures such as the scalp, orbit, ears, and other areas. Oral infection may spread to the hypopharynx, larynx, trachea, salivary glands, and sinuses. Actinomycosis can spread beyond boundaries of tissue planes and may also mimic chronic osteomyelitis. Treatment consists of a combination of penicillin therapy and surgical debridement. Debulking and debriding infected tissue arising from sinus tracts and abscess cavities inhibit actinomycosis growth in most cases.

VIRAL INFECTIONS WITH SURGICAL IMPLICATIONS

Human Papillomavirus Infections

Human papillomaviruses (HPV) are small DNA viruses of the papovavirus family. Over 100 different types have been described and can be classified as cutaneous or mucosal, depending on their tropism. The cutaneous types, HPV-1, -2 and -4, cause common warts, whereas HPV-5 and -8 are associated with epidermodysplasia verruciformis, an extremely rare autosomal recessive genetic disorder of the skin that entails a higher risk of malignant transformation. Mucosal types HPV-6 and -11 have a low malignant potential; lesions induced by HPV-16 and -18 have a higher malignancy potential. Regression of HPV lesions is frequently an immune-mediated, spontaneous event that is exemplified by the persistent and extensive manifestation of this virus in the immune-compromised patient.

Cutaneous manifestations of HPV can vary. Common warts (*verruca vulgaris*) are caused by HPV-1, -2 and -4, with a prevalence of up to 33% in schoolchildren and 3.5% in adults; prevalence is higher in the immunosuppressed patient.³⁸ The hands are the most commonly affected sites. Histologically, nonspecific findings of hyperkeratosis, papillomatosis, and acanthosis are found, as well as the hallmark koilocytes (clear halo around nucleus). Plantar warts occur on the soles of the feet, caused by HPV-1 and -4, commonly at pressure points, and are characterized by a keratotic plug surrounded by a hyperkeratotic ring, with black dots (thrombosed capillaries) on the surface. Plane warts occur on the face, dorsum of hands, and shins. They are caused by HPV-3 and -10 and tend to be multiple, flat-topped lesions with a smooth surface and light brown color. They regress spontaneously. Condyloma acuminatum manifests as multiple exophytic papillomatous lesions in the anogenital area. Sexually transmitted HPV-6 and -11 are responsible for 90% for genital wart cases, although other types have been implicated as well. Giant condyloma acuminatum of Buschke-Lowenstein is a large exophytic, cauliflower-like tumor and is now thought to be a variant of verrucous carcinoma. Epidermodysplasia verruciformis is a form of primary genetic immunodeficiency, rendering patients susceptible to infections with HPV-5 and -8. Recently, a similar clinical picture has been described in human immunodeficiency virus (HIV) and transplant patients.^{39,40} Epidermodysplasia verruciformis presents clinically as multiple flat warts resembling seborrheic keratosis. There is a 30% to 50% risk of squamous cell carcinoma (SCC) transformation.

First-line therapy for single or multiple warts includes topical preparations of salicylic acid, silver nitrate, and glutaraldehyde. If these fail, cryotherapy may be considered. Treatment of recalcitrant lesions includes a variety of therapeutic options aimed at physically destroying the lesions by electrodesiccation, cryoablation, and pulsed dye laser therapy. Additional modalities such as H₂-antagonists and zinc sulfate may have a role in augmenting the immune response and reducing recurrence rates.

Cutaneous Manifestations of Human Immunodeficiency Virus

Skin involvement may result from HIV infection itself or from opportunistic disorders secondary to immune suppression.⁴¹ Primary HIV may manifest as a generalized morbilliform rash. Kaposi's sarcoma may precede the onset of immunosuppression.

During early stages of HIV infection, nonspecific skin changes occur, as well as common disorders with atypical clinical features, including recurrent varicella zoster, hyperkeratotic warts, and seborrheic dermatitis. Condylomata acuminata and verrucae appear early; however, their frequency and severity do not change with disease progression.

Cutaneous manifestations during later stages commonly include chronic herpes simplex virus and cytomegalovirus infections and, to a lesser extent, molluscum contagiosum, which is typically treatable with imiquimod.⁴¹ Mycobacterial infections and mucocutaneous candidiasis also occur. Recurrent and persistent mucocutaneous candidiasis is common in patients with HIV infection. Bacterial infections such as impetigo and folliculitis may be more persistent and widespread.

Malignant lesions such as Kaposi's sarcoma occur in less than 5% of HIV-infected patients in the United States, although the worldwide prevalence in acquired immunodeficiency syndrome (AIDS) patients exceeds 30%. Other cutaneous cancers, particularly basal cell cancer, are becoming more common than Kaposi's sarcoma in patients adhering to highly active antiretroviral therapy (HAART). Approximately 6% of HIV patients will develop a cutaneous malignancy over a 7.5-year period.

With regard to general surgical considerations in HIV patients, contributing related morbidities such as malnutrition, decreased CD4 count, and presence of opportunistic infection may result in delayed and attenuated wound healing capacity.⁴²

BENIGN TUMORS

Hemangioma

▶ Hemangiomas result from benign proliferation of endothelial cells that surround blood-filled cavities. Their natural history most commonly is presentation soon after birth, rapid growth during the first year of life, and gradual involution in more than 90% of cases. Occasionally, their rapid growth directly interferes with the airway, gastrointestinal tract, or musculoskeletal function, and in these select cases, resection is indicated before tumor involution. These tumors may consume a large proportion of cardiac output, resulting in high-output cardiac failure, or may result in a consumptive coagulopathy. In both of these cases, resection is also indicated. Systemic prednisone and interferon- α can impede tumor progression. If these tumors persist into adolescence leaving a cosmetically undesirable telangiectasia, surgical resection may be considered. When surgical resection or debulking is considered, upfront selective embolization can help with planned resection. Finally, some vascular malformations, such as port wine stains of the trigeminal nerve distribution, may prompt the search for a systemic syndrome such as Sturge-Weber syndrome.

Nevi

Overgrowth of melanocytic nevus cells may be found in the epidermis (junctional), partially in the dermis (compound), or completely within the dermis (dermal). They are most commonly acquired, and most involute after migration into the dermis. Congenital nevi are found in less than 1% of neonates, and when characterized as giant congenital nevi, they have up to a 5% chance of developing into a malignant melanoma.^{43,44} The treatment of choice is total excision, and at times, the large wound defect requires serial excisions and local tissue expanders.

Cystic Lesions

There are three types of cutaneous cysts: epidermal, dermoid, and trichilemmal.⁴⁵ All of these benign entities are comprised of epidermis that grows toward the center of the cyst, resulting in central accumulation of keratin to form a cyst. All clinically appear as a white, creamy substance-containing subcutaneous, thin-walled nodule. Epidermal cysts are the most common cutaneous cyst and histologically characterized by mature epidermis complete with granular layer. Trichilemmal cysts are the second most common lesion; they tend to form on the scalp of females, have a distinct odor after rupture, histologically lack a granular layer, and have an outer layer resembling the root sheath of a hair follicle. Dermoid cysts are congenital, found between the forehead to nose tip, and contain squamous epithelium, eccrine glands, and pilosebaceous units, occasionally developing bone, tooth, or nerve tissue. The eyebrow is the most frequent site of presentation. These cysts are commonly asymptomatic but can become inflamed and infected, thus necessitating incision and drainage. After the acute phase subsides, the entire cyst should be removed to prevent recurrence.

Keratosis

Actinic Keratosis. Actinic keratosis is a commonly detected abnormal proliferation of intraepidermal keratinocytes primarily found in fair-skinned individuals. The general behavior of this premalignant lesion is regression, progression, or persistence, and their calculated 10-year potential to transform into SCC is between 6.1% and 10%. In fact, 60% to 65% of SCCs are believed to originate from these precursor lesions.

Seborrheic Keratosis. These premalignant, light-brown lesions with velvet-like texture appear in the sun-exposed skin of older individuals. Histologically, the lesions are characterized by atypical-appearing keratinocytes, and their natural behavior typically is transformation into SCC that rarely metastasizes. Treatment options are excision, fluorouracil, cautery and destruction, and dermabrasion.^{46,47} Interestingly, sudden eruptions of multiple seborrheic keratosis may be associated with other malignancies.

Soft Tissue Tumors

Acrochordons represent hyperplastic cells of the epidermis attached to a fibrous connective tissue stalk. They appear on the trunk, eyelids, and axilla as pedunculated masses and are resected usually for cosmesis.⁴⁸⁻⁵⁰ Dermatofibromas are 1- to 2-cm, soft, solitary nodules consisting of predominantly nonencapsulated whorls of collagen laid down by fibroblasts located on the legs and trunks. These fibromas can be managed nonoperatively, but excision is the treatment of choice.⁴⁸⁻⁵⁰ In rare cases, basal cell carcinomas may develop within the dermatofibromas. Lipomas are the most common subcutaneous neoplasm and have no malignant potential.⁵¹ This soft and fleshy conglomeration of benign adipocytes can be appear almost anywhere on the body, but they are most often found on the trunk and commonly undergo rapid growth. Surgical excision can be considered for symptomatic or large lesions that compromise musculoskeletal function.

Neural Tumors

Benign cutaneous tumors that arise from the nerve sheath are collectively referred to as neural tumors. Dermal neurofibromas are benign neoplasms arising from nerve sheath that appear as fleshy and nontender sessile or pedunculated masses on the

skin. They are most often associated with café-au-lait spots and Lisch nodules in neurofibromatosis type 1 (NF1) disease, also known as von Recklinghausen's disease.^{49,50} Neurilemmomas are discrete nodules consisting of Schwann cells of the peripheral nerve sheath, often causing pain along the distribution of the nerve, and are treated with simple resection. Granular cell tumors are derived from Schwann cells, infiltrate surrounding skeletal muscle, and are resected when symptomatic.^{49,50,52}

MALIGNANT TUMORS

Basal Cell Carcinoma

Basal cell carcinoma (BCC) arises from the basal layer of non-keratinocytes and represents the most common tumor diagnosed in the United States.^{53,54} Annually it accounts for 25% of all diagnosed cancers and 75% of skin cancers.⁵⁵ The primary risk factor for disease development is sun exposure (UVB rays more than UVA rays) particularly during adolescence; however, other factors include immune suppression (i.e., organ transplant recipients, HIV), chemical exposure, and ionizing radiation exposure. BCC can also be a feature of inherited conditions such as xeroderma pigmentosa, unilateral basal cell nevus syndrome, and nevoid BCC syndrome.⁵⁵ The natural behavior of BCC is one of local invasion rather than distant metastasis. Untreated BCC can result in significant morbidity. Thirty percent of cases are found on the nose, and bleeding, ulceration, and itching are often part of the clinical presentation.

The most common form of BCC (60%) is the nodular variant, characterized by raised, pearly pink papules and occasionally a depressed tumor center with raised borders giving the classic "rodent ulcer" appearance. This variant tends to develop in sun-exposed areas of individuals over the age of 60. Superficial BCC accounts for 15% of BCC, is diagnosed at a mean age of 57 years, and typically appears on the trunk as a pink or erythematous plaque with a thin pearly border. The infiltrative form appears on the head and neck in the late 60s with similar clinical appearance to the nodular variant. An important variant to keep in mind is the pigmented variant of nodular BCC because this may be difficult to differentiate from nodular melanoma. Other important subtypes include the morpheaform variant, accounting for 3% of cases and characterized by indistinct borders with a yellow hue, and fibroepithelioma of Pinkus. Histologic subtypes of BCC include nodular and micronodular (50%), superficial (15%), and infiltrative.

Treatment options include Moh's microsurgery, excisional surgery, and cautery and destruction. Moh's microsurgery provides histologic confirmation of excision and maximal conservation of tissue, which is important to keep in mind in cosmetically sensitive areas such as facial lesions. It has also been shown to be cost-effective and associated with low recurrence rates (1%).^{56,57} It is the treatment of choice for morpheaform, poorly delineated, recurrent, and infiltrative BCC, particularly facial lesions. Alternative treatment is excisional surgery with 4-mm margins with extension into subcutaneous tissue, which provides definitive treatment of nonmorpheaform lesions <2 cm in diameter. A common approach used by dermatologists is cautery and destruction, although it should be kept in mind that the results are operator and institution dependent as shown by a study showing inferior results for individuals having the procedure performed at academic training institutions as opposed to experienced private practitioners (local cure 81%

vs. 94%).⁵⁸ This option should only be considered in patients who are not candidates for the more extensive surgical options and for lesions not located in mid-face. Poor surgical candidates and patients without recurrent or morpheaform lesions may be treated with radiation therapy. Radiation also may be used in cases of questionable resection margins or microscopic positive margins after surgery. The practitioner must be aware of the potential consequences of radiation therapy, including poor cosmetic outcomes and future cancer risk.

Six to 12 weeks of imiquimod, an FDA-approved drug and immune modifier, is an option for small-diameter (<2 cm), superficial BCC of the neck, trunk, or extremities, with reported histologic clearance rates of 42% to 76%.⁵⁹⁻⁶³ Topical fluorouracil is another FDA-approved treatment for superficial BCC, and one study of 31 tumors treated daily for 11 weeks showed a 90% histologic clearance rate. Lastly, topical photodynamic therapy has shown some benefit in treatment as well.

It is critical for each patient to have routine annual follow-up that includes full-body skin examinations. Sixty-six percent of recurrences develop within 3 years, and with a few exceptions occurring decades after initial treatment, the remaining recur within 5 years of initial treatment.^{57,64} A second primary BCC may develop after treatment and, in 40% of cases, presents within the first 3 years after treatment.

Squamous Cell Carcinoma

SCC is the second most common skin cancer, accounting for approximately 100,000 cases each year and generally afflicting individuals of lighter skin color. The primary risk factor and driving force for the development of this common cancer is UV exposure; however, other risks include environmental factors such as chemical agents, physical agents (ionizing radiation), psoralen and UVA (PUVA), HPV-16 and -18 infections (immunosuppression), and smoking. Chronic nonhealing wounds, burn scars, and chronic dermatosis are other risk factors, and many darker skin individuals who develop SCC often have a history of one these risk factors (Fig. 16-9). Heritable conditions such as xeroderma pigmentosum, epidermolysis bullosa, and oculocutaneous albinism are predisposing risk factors.

SCC has in situ variants (including Bowen's disease and erythroplasia of Queyrat in situ lesions of the penis) and invasive variants. In situ disease presents as well-delineated pink

papules or plaques, and invasive disease presents as slightly pink or skin-colored, raised plaques. Bleeding of the lesion with minimal trauma is not uncommon, and pain is rare. Most in situ cases grow slowly over time and do not progress to invasive disease, except for Bowen's disease and erythroplasia of Queyrat where the risk of malignant transformation is 3% to 5% and 10%, respectively.⁶⁵

The natural history of invasive disease depends on location and inherent tumor characteristics. For example, lesions associated with chronic inflammation and located at mucocutaneous junctions may metastasize in 10% to 30% of cases, whereas lesions arising in sun-exposed areas without adverse risk factors are less likely to spread and have a better prognosis.⁶⁴ Clinical risk factors for recurrence include presentation with neurologic symptoms, immunosuppression, tumor with poorly defined borders, and tumor that arises at a site of prior radiation. Perineural involvement increases the incidence of local recurrence and lymph node metastasis and has a poorer survival. Other histologic features indicative of aggressive disease include poor differentiation, thickness greater than 4 mm, and adenoid, adenosquamous, and desmoplastic subtypes.⁵⁴

Treatment modalities for SCC include cautery and ablation, cryotherapy, drug therapy including imiquimod, surgical excision, Moh's microsurgery, and radiation therapy. However, cautery and ablation carry the risk of leaving residual tumor behind; in a study of 291 patients with primary in situ lesions treated with cautery and ablation, all but two patients recurred.⁶⁶ This modality is not recommended in dense hair-bearing regions and for tumors extending into subcutaneous tissue.

Surgical excision is the treatment of choice, when feasible. For lesions less than 2 cm in diameter, wide excision with a 4-mm margin for low-grade lesions and a 6-mm margin for high-grade lesions is sufficient. Factors rendering tumors high risk are size >2 cm in diameter and involvement of subcutaneous tissue. Moh's microsurgery is indicated for lesions at sites where cosmesis or function preservation is critical, for poorly differentiated tumors, for invasive lesions, and for verrucous carcinomas. Lower recurrence rates are seen with this modality with primary lesions of the ear or lip, recurrent lesions, primaries with perineural invasion, lesions with diameters >2 cm, and poorly differentiated lesions.^{64,67} It has also found use in nail bed lesions and in those arising in a background of osteomyelitis.

When patients are poor surgical candidates, radiation therapy can play a role in primary modality treatment. It may also act as an adjunct to surgical treatment in cases of lip carcinoma with 30% to 50% involvement, microscopic positive margins, perineural histology, underlying tissue invasion, and multiple recurrences.^{55,68}

The role of lymph node dissection in the setting of SCC is evolving. Regional palpable nodes should be removed along with susceptible regional lymph node basins in patients with SCC in the setting of chronic wounds. Management of lymph node disease involves surgical resection and/or radiation therapy. Patients with parotid disease commonly benefit from a superficial or total parotidectomy (with facial nerve preservation) and adjuvant radiotherapy (60 Gy in 30 fractions). Isolated cervical lymph node involvement without adverse features is managed with follow-up surveillance for patients, which involves skin and regional lymph node examination every 1 to 3 months for the first year after treatment, every 2 to 4 months for the ensuing year, every 4 to 6 months for the next 3 years, and then every 6 to 12 months for the rest of life.⁵⁴

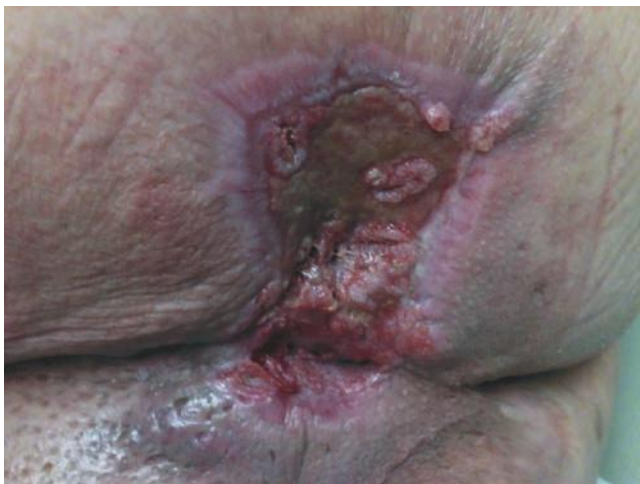

Figure 16-9. Squamous cell carcinoma forming in a chronic wound.

Background. In 2013, an estimated 76,690 individuals were diagnosed with malignant melanoma, accounting for 9480 deaths.^{53,69} The incidence of melanoma is rising faster than most other solid malignancies, and these numbers likely represent an underestimation given the many in situ and thin melanoma cases that are underreported. These tumors primarily arise from melanocytes at the epidermal-dermal junction but may also originate from mucosal surfaces of the oropharynx, nasopharynx, eyes, proximal esophagus, anorectum, and female genitalia. Their pathogenesis is not completely understood, but they are believed to originate from nests of melanocytes that have undergone dysplastic changes.

A well-known environmental risk factor is exposure to solar UV radiation. It was recently reported that greater than 10 tanning bed sessions by adolescents and young adults increased their relative risk of developing melanoma by twofold.⁷⁰ Nonenvironmental risk factors include a personal history of melanoma, which is associated with a 10-fold increase in risk. Individuals with dysplastic nevi have a 10% overall lifetime risk of melanoma, with tumors arising from pre-existing nevi or de novo. Dysplastic nevus syndrome (B-K mole syndrome) has an autosomal dominant transmission with high penetrance and is associated with a nearly 100% lifetime risk in being diagnosed with cutaneous melanoma. Congenital nevi increase risk for melanoma proportionally with size; giant congenital nevi are associated with a 5% to 8% lifetime risk. Five to ten percent of cutaneous melanomas occur in patients with a family history of melanoma, and these individuals have an earlier age of disease onset, commonly express dysplastic nevi, and more commonly have more than one primary lesion. Melanoma development is strongly associated with the p16/CDK4,6/Rb and p14ARF/HMD2/p53 tumor suppressor pathways and the RAF-MEK-ERK and PI3K-Akt oncogenic pathways.⁷¹

Pathogenesis and Clinical Presentation. Melanoma growth most commonly starts as a localized, radial growth phase followed by a vertical growth phase that determines metastatic risk. The subtypes of melanoma include lentigo maligna, superficial spreading, acral lentiginous, mucosal, nodular, polypoid, desmoplastic, amelanotic, and soft tissue. The most common subtype is superficial spreading, accounting for 70% of cases (Fig. 16-10). These melanomas are found anywhere on the body

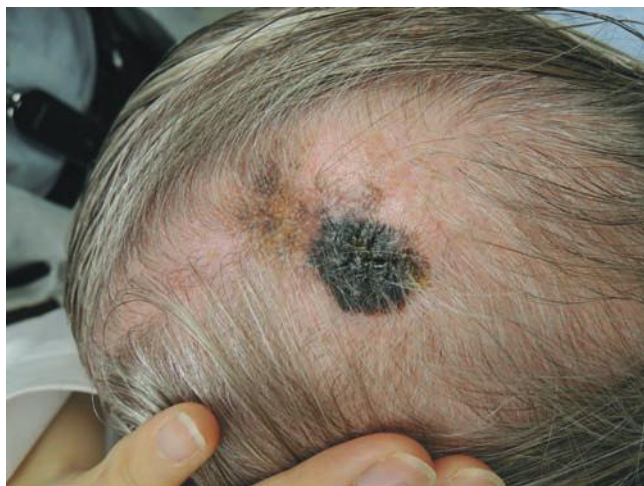

Figure 16-10. Primary cutaneous melanoma seen in the scalp of a 61-year-old male.

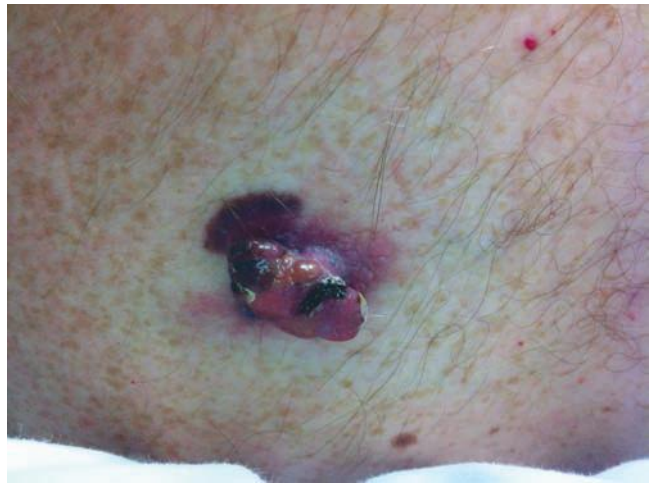

Figure 16-11. Nodular melanoma seen in the leg of a 55-year-old male.

with the exception of the hands and feet. Nodular melanoma accounts for 15% to 30% of melanomas, and this variant is unique in that it begins with a vertical growth phase that partly accounts for its worse prognosis (Fig. 16-11). Lentigo maligna is typically found in older individuals and primarily located in the head and neck region. The acral lentiginous variant accounts for 29% to 72% of melanomas in dark-skinned individuals, is occasionally seen in Caucasians, and is found on palmar, plantar, and subungual surfaces.

Melanoma most commonly manifests as cutaneous disease, and clinical characteristics include an **A**symmetric outline, changing irregular **B**orders, **C**olor variations, **D**iameter greater than 6 mm, and **E**levation (ABCDE). Other key clinical characteristics include a pigmented lesion that has enlarged, ulcerated, or bled. Amelanotic lesions appear as raised pink, purple, or normal-colored skin papules and are often diagnosed late.

Diagnosis and Staging. Workup should begin with a history and physical exam. The entire skin should be checked for synchronous primaries, satellite lesions, and in-transit metastases, and all nodal basins should be examined for lymphadenopathy. Suspicious lesions should undergo excisional biopsy with 1- to 2-mm margins; however, tumors that are large or in a cosmetically or anatomically challenging area can be approached by incisional biopsy, including punch biopsy. Tissue specimen should include full thickness of the lesion and a small section of normal adjacent skin to aid the pathologist in diagnosis. Suspicious lymph nodes should undergo fine-needle aspiration (FNA).

Melanoma is characterized according to the American Joint Committee on Cancer (AJCC) as localized disease (stage I and II), regional disease (stage III), or distant metastatic disease (stage IV). Overall tumor thickness, ulceration, and mitotic rate are the most important prognostic indicators of survival.^{72,73}

If a sentinel node contains metastatic melanoma, the number of positive nodes; thickness, mitotic rate, and ulceration of the primary tumor; and patient age determine prognosis. With clinically positive nodes, the number of positive nodes, primary tumor ulceration, and patient age determine prognosis.⁷⁴ The site of metastasis is strongly associated with prognosis for stage IV disease, and elevated lactate dehydrogenase (LDH) is associated with a worse prognosis.⁷⁵

There is no supporting evidence for chest x-ray or CT in the staging of patients unless there is positive regional lymph node disease (and even in this case, the indications are not so clear).⁴¹ However, high-risk melanoma (i.e., T4b), especially of the lower extremities, may warrant further imaging to stage with modalities such as a positron emission tomography (PET)-CT or CT of the pelvis.⁴¹ In addition, patients with clinically palpable regional lymph nodes are at high risk for distant metastases and should receive additional imaging that includes CT of the chest, abdomen, and pelvis; whole-body PET-CT; or brain MRI.

The sentinel lymph node biopsy (SLNB) technique for melanoma was introduced in 1992 and has become a cornerstone in the management of melanoma, although its role in management continues to be refined. SLNB is a standard staging procedure to evaluate the regional nodes for patients with clinically node-negative malignant melanoma. This technique identifies the first draining lymph node from the primary and has shown excellent accuracy and significantly less morbidity compared to complete resection of nodal basins. The SLNB technique involves preoperative lymphoscintigraphy with intradermal injections of technetium-sulfur colloid to delineate lymphatic drainage and intraoperative intradermal injection of 1 mL of isosulfan or methylene blue dye near the tumor or biopsy site (Figs. 16-12 and 16-13). The radioactive tracer-dye combination allows the sentinel node to be identified in 98% of cases. An incision over the lymph node basin of interest allows nodes to be excised and studied with hematoxylin and eosin and immunohistochemistry (S100, HMB45, and MART-1/Melan-A) staining (Fig. 16-14). Risks of this technique are uncommon but include skin necrosis near the site of injection, anaphylactic shock, lymphedema, surgical site infections, seromas, and hematomas.

Surgical Management of the Primary Tumor and Lymph Nodes. The appropriate excision margin is based on primary tumor depth. Although there are no randomized trials studying margins for melanoma in situ, most surgical oncologists believe

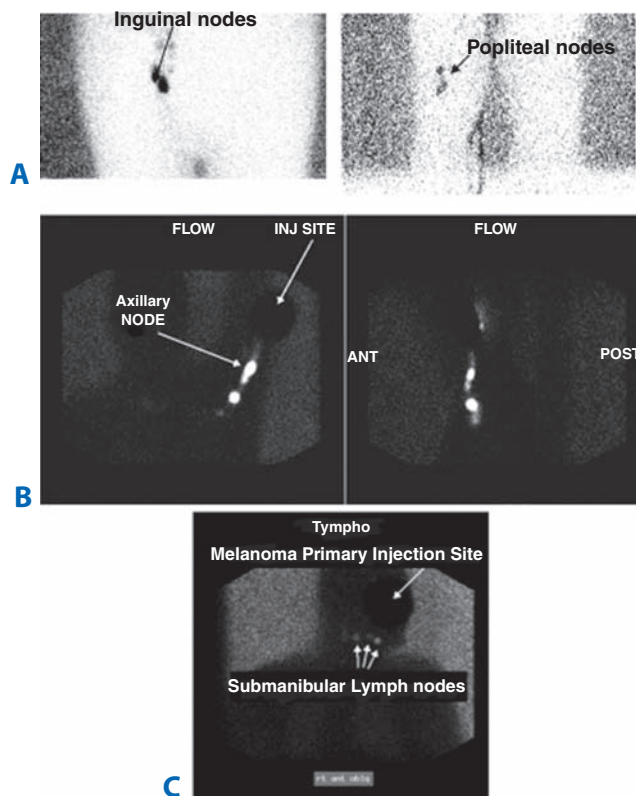


Figure 16-12. After injection of radioactive technetium-99–labeled sulfur colloid tracer at the primary cutaneous melanoma site, sentinel lymph node basins are identified. **A.** Lymphoscintigraphy of 67-year-old male with a malignant melanoma of the right heel; sentinel lymph nodes in both the right popliteal fossa and inguinal region. **B.** Lymphoscintigraphy of 52-year-old male with a malignant melanoma of the posterior right upper arm; sentinel lymph node in the right axillary region. **C.** Lymphoscintigraphy of 69-year-old male with a facial melanoma; sentinel lymph nodes in the submandibular region. ANT = anterior; INJ = injection; POST = posterior.

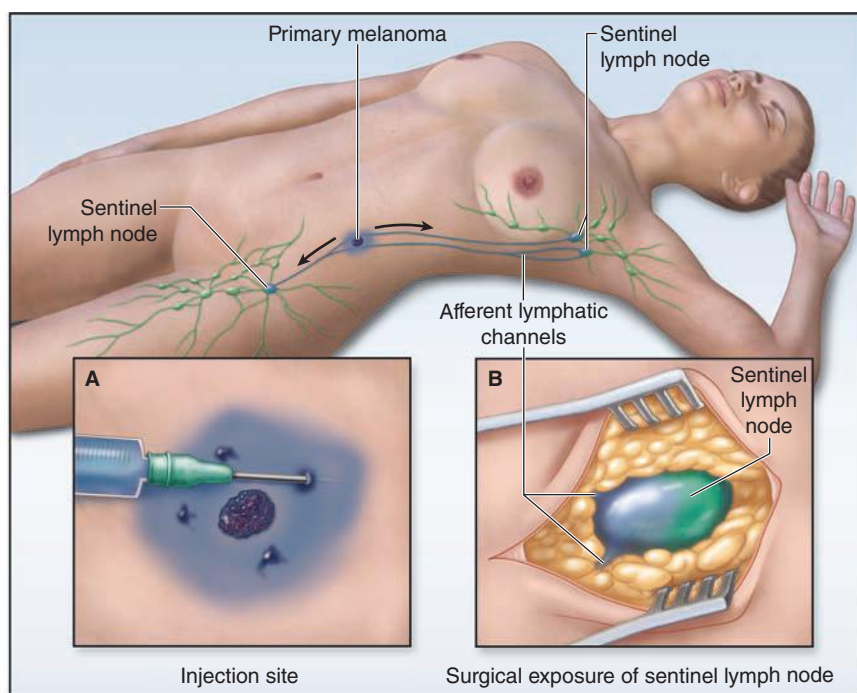


Figure 16-13. Technique of sentinel lymph node biopsy for cutaneous melanoma. After injection of radioactive technetium-99–labeled sulfur colloid tracer at a lower abdominal wall primary cutaneous melanoma site, sentinel lymph node basins are identified. (From Gershenwald JE, Ross MI. Sentinel-lymph node biopsy for cutaneous melanoma. *N Engl J Med.* 2011;364:1738-1745. Copyright © 2011 Massachusetts Medical Society. Reprinted with permission.)

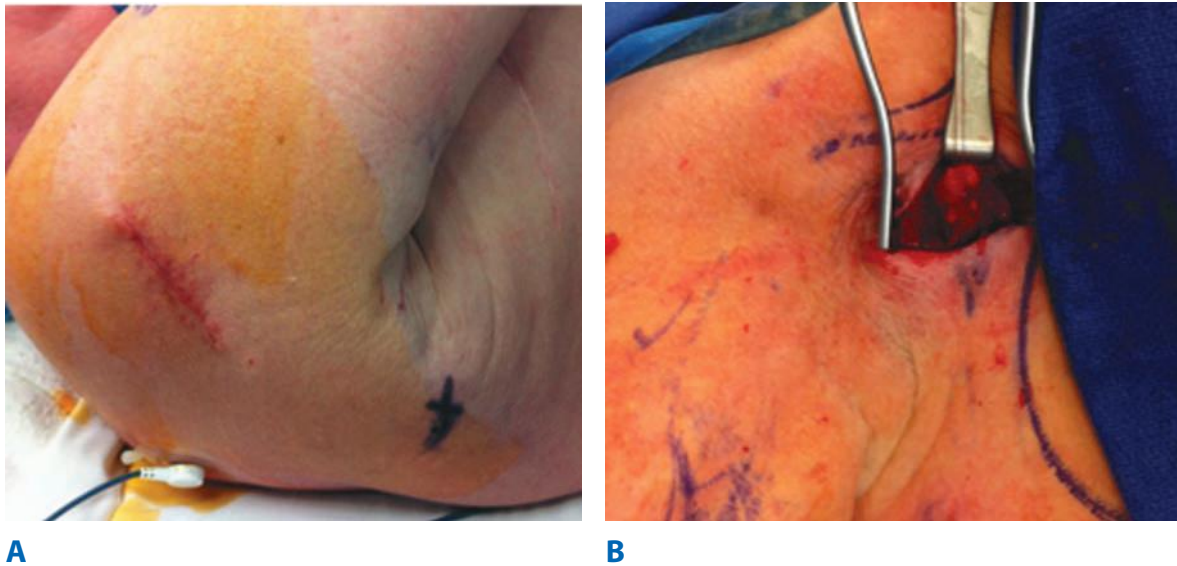


Figure 16-14. Operation of sentinel lymph node biopsy for cutaneous melanoma. After preoperative injection of radioactive technetium-99–labeled sulfur colloid tracer and intraoperative injection of Lymphazurin blue dye around the primary melanoma excision site, the nodal basin of interest is identified. An incision is made directly overlying the lymph node basin in the posterior axillary space. The sentinel lymph nodes are identified and excised.

that margins of 0.5 to 1.0 cm are sufficient. We believe that 1.0-cm margins should be obtained in anatomically feasible areas given the possibility of an incidental finding of a small invasive component in permanent sections. The World Health Organization (WHO) trial by Veronesi and colleagues provided the first prospective randomized controlled trial guiding appropriate margin management.⁷⁶ In this trial, 612 patients with melanoma <2 mm in thickness were randomized to 1- or 3-cm margins. The results demonstrated no difference in overall survival or recurrence-free survival between groups. A trial from the Swedish Melanoma Study Group supported the WHO trial. The Swedish study examined patients with <2-mm thick melanoma who were randomized to 2- or 5-cm margins.⁷⁷ There was no difference in recurrence-free survival (73% vs. 74%; $P = .88$) or overall survival (75% vs. 74%; $P = .77$) between the groups. The Intergroup Melanoma Trial randomized 468 patients with intermediate-thickness melanoma (1–4 mm) to 2- or 4-cm margins of excision.^{78,79} They did not find a significant difference in 10-year overall survival (70% vs. 77%; $P = .074$) or local recurrence (2.1% vs. 2.6%) between the two cohorts. A British trial suggested that there is a limit to how narrow margins can be for melanomas >2 mm thick in showing that 1-cm margins provide worse outcomes compared to 3-cm margins.

Tumors <1 mm thick require 1-cm margins, tumors 1 to 2 mm thick require 1- to 2-cm margins, tumors 2 to 4 mm thick require 2-cm margins, and tumors >4 mm thick require 2-cm margins, although there are no randomized data to support this last point. Technically challenging locations should be treated in a similar fashion. For facial and scalp lesions, advancement flaps usually suffice for closure, as do wedge resections for lesions of the ear helix. When tumors are situated near critical structures (e.g., eye, lip), the best should be done to remove the primary tumor with adequate margins.

SLNBs are recommended for melanomas 1 to 4 mm thick according to the National Comprehensive Cancer Network (NCCN) guideline recommendations.⁴¹ The incidence of regional lymph node metastasis in <1-mm thick melanomas is

5% or less. According to the NCCN guidelines, SLNB may be considered for thin melanoma with adverse features (i.e., >0.75 mm, >1 mitosis per mm, ulcerated), and literature that supports this approach states that SLNB provides prognostic information and is therapeutic for low-volume disease.^{41,80} For tumors that are >4 mm, the incidence of regional lymph node positivity is 35% to 40% and SLNB may provide prognostic information for these thick melanomas.^{81–83}

The role for SLNB is supported by the Multicenter Selective Lymphadenectomy Trial (MSLT)-1, which looked at patients with melanoma 1.5 to 4 mm thick and randomized them to SLNB (and completion lymphadenectomy if positive) vs. no SLNB (and delayed complete lymphadenectomy for recurrent lymph node disease).⁸⁴ SLNBs provided prognostic information but did not affect survival. However, when patients who were lymph node positive only were compared, 5-year overall survival was better if the lymphadenectomy was done at the time of a positive sentinel node vs. when it was delayed until the patients presented with clinical findings. Completion lymphadenectomy is commonly performed for sentinel nodes with metastatic disease, but it has been shown that most of these nodal basins do not have additional disease. Thus, many surgeons do not perform routine completion lymphadenectomy for positive nodes, and data from the MSLT-2 may provide guidance.

Several studies evaluated the indications and benefit for extended lymphadenectomy. Three retrospective studies showed a 12% to 24% improved 5-year overall survival in patients with micrometastasis in elective regional lymphadenectomy specimens compared with patients undergoing therapeutic lymphadenectomy for clinically palpable disease.^{85–87} The last large prospective randomized controlled trial showed a trend toward improved survival in patients with intermediate-thickness (1.5–4 mm) melanomas who underwent immediate elective lymphadenectomy as opposed to nodal observation (77% vs. 73%; $P = .12$).⁸⁸ For patients with clinically evident local regional lymphadenopathy, FNA biopsies can confirm metastatic disease. If metastatic workup including PET-CT excludes

distant disease, resection of the primary melanoma lesion and a completion lymphadenectomy should be performed.

Individuals with face, anterior scalp, and ear primaries who have a positive SLNB should undergo a superficial parotidectomy in addition to a modified radical neck dissection. Patients with positive sentinel nodes in the inguino-femoral nodes should undergo an inguino-femoral lymphadenectomy that includes removal of Cloquet's node. If Cloquet's node is positive or the patient has three or more nodes that contain melanoma metastases, this is an indication for an ilio-obdurator lymphadenectomy.⁴¹

Surgery for Regional and Distant Metastasis. Nonmetastatic, in-transit disease should undergo excision to clear margins when feasible. However, disease not amenable to complete excision derives benefit from isolated limb perfusion (ILP) and isolated limb infusion (ILI) (Fig. 16-15). These two modalities are used to treat regional disease, and their purpose is to administer high doses of chemotherapy, commonly melphalan, to an affected limb while avoiding systemic drug toxicity. ILI was shown to provide a 31% response rate in one study, while hyperthermic ILP provided a 63% complete response rate in an independent study.⁸⁹⁻⁹²

The most common sites of distant metastasis are the lung and liver followed by the brain, gastrointestinal tract, distant skin, and subcutaneous tissue. A limited subset of patients with small-volume, limited distant metastases to the brain, gastrointestinal tract, or distant skin will be cured with resection or gamma knife radiation. Liver metastases are better dealt without surgical resection unless they arise from an ocular primary. Adjuvant therapy after resection of metastatic lesions is not standard of care; however, there are ongoing clinical trials addressing whether drugs and vaccines will be beneficial in this setting.⁵⁵ Surgery may provide palliation for patients with gastrointestinal obstruction, gastrointestinal hemorrhage, and nongastrointestinal hemorrhage. Radiotherapy for symptomatic bony or brain metastases provides palliation in diffuse disease.

Adjuvant and Palliative Therapies. Eastern Cooperative Oncology Group (ECOG) Trials 1684, 1690, and 1694 were prospective randomized controlled trials that demonstrated disease-free survival advantages in patients with melanoma thicker than 4 mm with or without lymph node involvement if they received adjuvant treatment with high-dose interferon (IFN).⁹³⁻⁹⁵

A European Organization for Research and Treatment of Cancer (EORTC) trial also showed recurrence-free survival benefit with pegylated IFN.⁹⁶ It is important to note that IFN therapy is not well tolerated, and the pooled analysis of these trials did not show an improvement in overall survival benefit.

Most patients with metastatic melanoma will not be surgical candidates. Although the medical options for metastatic melanoma have historically been poor, several recent studies have shown promise in drug therapy for metastatic melanoma. BRAF inhibitors (sorafenib), anti-PD1 antibodies, CTLA antibodies (ipilimumab), and high-dose interleukin-2 (IL-2) with and without vaccines have been shown in randomized studies to provide survival benefit in metastatic disease.⁹⁷⁻¹⁰¹ Despite the excitement of recent drugs, surgery will likely play an adjunct role in treating individuals who develop resistance to these drugs over time.

Special Circumstances. Special circumstances of note are melanoma in pregnant women, melanoma of unknown primaries, and noncutaneous melanomas (i.e., ocular). The prognosis of pregnant patients is similar to women who are not pregnant. Extrapolation of studies examining the SLNB technique in pregnant women with breast cancer suggests lymphoscintigraphy may be done safely during pregnancy without risk to the fetus. (Blue dye is contraindicated.) General anesthesia should be avoided during the first trimester, and local anesthetics should be used at this time. It has been suggested by some that after excising the primary tumor during pregnancy, the SLNB may be performed after delivery.

Unknown primary melanoma most commonly presents in lymph nodes (2% of cases and <5% of metastatic presentation). A thorough search for the primary lesion should be sought, including eliciting a history about prior skin lesions, skin procedures (e.g., curettage and electrodesiccation, excision, laser), and review of any prior "benign" pathology. The surgeon should be aware that melanoma is known to spontaneously regress because of an immune response.

Ocular melanoma is the most common noncutaneous disease site, and treatment includes photocoagulation, partial resection, radiation, or enucleation.¹⁰²⁻¹⁰⁴ Ocular melanomas exclusively metastasize to the liver and not regional lymph nodes, and some patients benefit from liver resection. Melanoma of the mucous membranes most commonly presents in

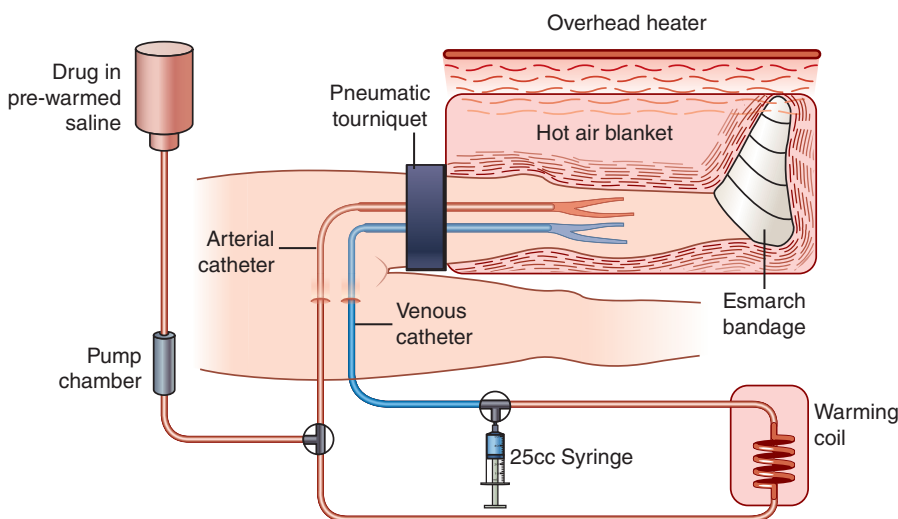


Figure 16-15. Isolated limb infusion. Schematic of isolated limb infusion of lower extremity. (From Testori A, Verhoef C, Kroon HM, et al. *Treatment of melanoma metastasis in a limb by isolated limb perfusion and isolated limb infusion.* J Surg Oncol. 2011;104:397-404. Copyright 2011 John Wiley and Sons. Reprinted with permission.)

the oral cavity, oropharynx, nasopharynx, paranasal sinus, anus, rectum, and female genitalia. Patients with this presentation have a worse prognosis (10% 5-year survival) than individuals with cutaneous melanomas. Management should be excision to negative margins, and radical resections (i.e., abdominoperineal resection) should be avoided because the role of surgery is locoregional control, not cure. Generally speaking, lymph node dissection should be avoided because the benefit is unclear.

Merkel Cell Carcinoma

This is a rare and aggressive neuroendocrine tumor of the skin most commonly found in white men and diagnosed at a mean age of 70 years (Fig. 16-16). Risk factors include UV radiation, PUVA, and immunosuppression. Approximately one in three cases present on the face, with the remainder occurring on sun-exposed skin. A rapidly growing, flesh-colored papule or plaque characterizes the disease. Regional lymph nodes are involved in 30% of patients, and 50% will develop systemic disease (skin, lymph nodes, liver, lung, bone, brain).^{105,106} There are no standardized diagnostic imaging studies for staging, but CT of the chest, abdomen, and pelvis and octreotide scans may provide useful information when clinically indicated.

After examining the entire skin for other lesions, treatment should begin by evaluating the nodal basins. Patients without clinical nodal disease should undergo an SLNB preceding a wide local excision because studies suggest a benefit.¹⁰⁷ In patients with sentinel lymph nodes with metastatic disease, completion lymphadenectomy and/or radiation therapy may follow, and in patients with node-negative disease, observation or

radiation therapy should be considered.¹⁰⁷ SLNB is important for staging and treatment, and the literature suggests that it predicts recurrence and relapse-free survival. Elective lymph node dissection may decrease regional nodal recurrence and in-transit metastases. Patients with clinically positive nodes should have an FNA to confirm disease. If positive, a metastatic staging workup should follow, and if negative, treatment of the primary and nodal basin as managed for sentinel lymph node-positive disease should be considered. A negative FNA and open biopsy-negative disease should be managed by treatment of the primary disease alone. Patients with metastatic disease should be managed according to consensus from a multidisciplinary tumor board.

Important surgical principles for excision of the primary lesion are to excise with wide margins down to fascia and complete circumferential and peripheral deep-margin assessment. Recommended management for margins is 1- to 3-cm margins, and given the rarity of the tumor, there are no randomized trials further defining these margins. Moh's microsurgery may play a role to ensure negative margins. Chemotherapy is commonly used, but there are no data to support a specific regimen or that demonstrate a definitive survival benefit.

Recurrence is common, and one study of 95 patients showed a 47% recurrence, with 80% of recurrences occurring within 2 years and 96% occurring within 5 years.^{108,109} Regional lymph node disease is common, and 70% of patients will have nodal spread within 2 years of disease presentation. Five-year overall survival of head and neck disease in surgically treated patients is between 40% and 68%.

Kaposi's Sarcoma

Kaposi's sarcoma is characterized by the proliferation and inflammation of endothelial-derived spindle cell lesions. There are five major forms of this angioproliferative disorder: classic (Mediterranean), African endemic, HIV-negative men having sex with men (MSM)-associated, AIDS-associated, and immunosuppression-associated; they are all driven by the human herpesvirus (HHV-8).⁶⁸ Kaposi's sarcoma is diagnosed after the fifth decade of life and predominantly found on the skin but can occur anywhere in the body. In North America, the Kaposi's sarcoma herpes virus is transmitted via sexual and nonsexual routes and predominantly affects individuals with compromised immune systems such as those with HIV and transplant recipients on immune-suppressing medications. Clinically, Kaposi's sarcoma appears as multifocal, rubbery blue nodules. Treatment of AIDS-associated Kaposi's sarcoma is with antiviral therapy, and many patients experience a dramatic treatment response.^{110,111} Those individuals who do not respond and have limited mucocutaneous disease may benefit from cryotherapy, photodynamic therapy, radiation therapy, intralesional injections, and topical therapy. Surgical biopsy is important for disease diagnosis, but given the high local recurrence and the fact that Kaposi's sarcoma represents more of a systemic rather than local disease, the benefit of surgery is limited and generally should not be pursued except for palliation.

Dermatofibrosarcoma Protuberans

This rare, low-grade sarcoma of fibroblast origin commonly afflicts individuals during their third decade of life. It has low distant metastatic potential but behaves aggressively locally with finger-like extensions. Tumor depth is the most important prognostic variable. Presentation is characteristically a slow-growing, asymptomatic, violaceous plaque involving the trunk,

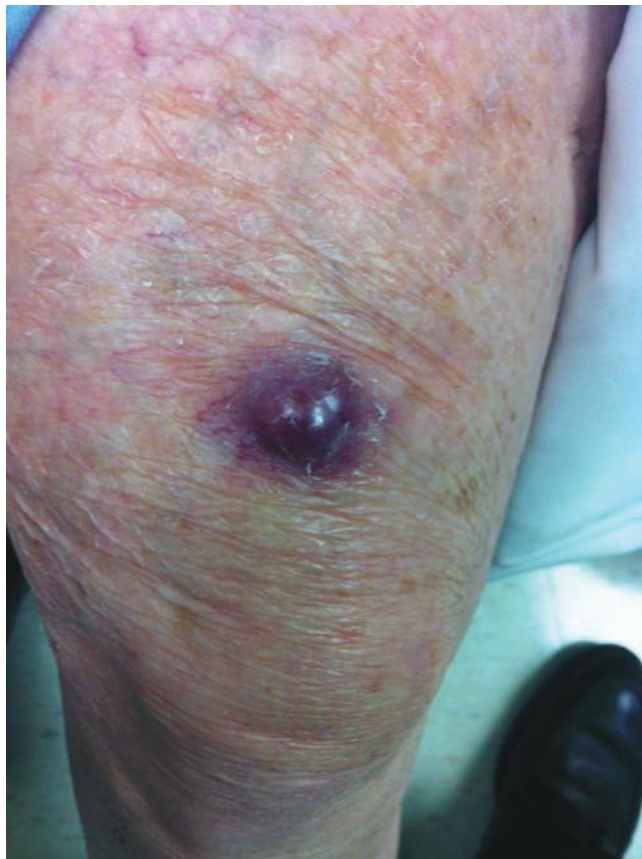


Figure 16-16. Merkel cell carcinoma seen just above the left knee in a 44-year-old female.

head, neck, or extremities. Treatment is wide local excision with 3-cm margins down to deep underlying fascia or Moh's micro-surgery in cosmetically sensitive areas where maximum tissue preservation will benefit.¹¹² No nodal dissection is needed, and both approaches provide similar local control.¹¹³ Some clinicians have used radiation therapy and biologic agents (imatinib) with some success in patients with advanced disease. Local recurrence occurs in 50% to 75% of cases, usually within 3 years of treatment, and thus, clinical follow-up is important. Recurrent tumors should be resected whenever possible.

Malignant Fibrous Histiocytoma (Undifferentiated Pleomorphic Sarcoma and Myxofibrosarcoma)

This uncommon, cutaneous, spindle-cell, soft tissue sarcoma occurs in the extremities, head, and neck of elderly patients. They present as solitary, soft to firm, skin-colored subcutaneous nodules. Complete surgical resection is the treatment of choice, and adjuvant radiation therapy provides local control; patients with positive margins benefit most from this combination. Nevertheless, patients undergoing complete gross resection will experience recurrence in 30% to 35% of cases.⁷¹ Up to 50% of patients may present with distant metastasis, and this is a contraindication to surgical resection.

Angiosarcoma

Angiosarcoma is an uncommon, aggressive cancer that arises from vascular endothelial cells and occurs in four variants, all of which have a poor prognosis.¹¹⁴ The head and neck variant presents in individuals older than 40 years as an ill-defined red patch on the face or scalp, often with satellite lesions and distant metastasis, and has a median survival of 18 to 28 months. Lymphedema-associated angiosarcoma (Stewart-Treves) develops on an extremity ipsilateral to an axillary lymphadenectomy. It appears on the upper, medial arm as a violaceous plaque in an individual with nonpitting edema and has a poor survival. Radiation-induced angiosarcoma occurs 4 to 25 years after radiation therapy for benign (acne) and malignant (i.e., breast cancer) conditions. Finally, the epithelioid variant of angiosarcoma involves the lower extremities and also has a poor prognosis. Surgical excision with wide margins is the treatment of choice for localized disease, but the rate of recurrence is high. Adjuvant radiation therapy can be considered in a multidisciplinary fashion. Cases of extremity disease can be considered for amputation. For widely metastatic disease, chemotherapy and radiation may provide palliation, but these modalities do not prolong overall survival.⁵⁵

Extramammary Paget's Disease

This rare adenocarcinoma of apocrine glands arises in perianal and axillary regions and in genitalia of men and women.¹¹⁵ Clinical presentation is that of erythematous or nonpigmented plaques with an eczema-like appearance that often persist after failed treatment from other therapies. An important characteristic and one that the surgeon must be acutely aware of is the high incidence of concomitant other malignancies with this cutaneous disease. Forty percent of cases are associated with primary gastrointestinal and genitourinary malignancies, and a diligent search should be made after a diagnosis of extramammary Paget's disease is made. Treatment is surgical resection with negative microscopic margins, and adjuvant radiation may provide additional locoregional control.

CONCLUSION

The skin is the largest organ in the human body and is composed of three organized layers that are the source of numerous pathologies. Recognition and management of cutaneous and subcutaneous diseases require an astute clinician to optimize clinical outcomes. Improvements in drugs therapies and health-care practices have helped recovery from skin injuries. Skin and subcutaneous diseases are often managed medically, although surgery frequently complements treatment. Benign tumors are surgical diseases, while malignant tumors are primarily treated surgically, and additional modalities including chemotherapy and radiation therapy are sometimes required. The management of melanoma is at an exciting phase, requiring the coordinated multidisciplinary care of medical oncologists, surgical oncologists, radiation oncologists, dermatopathologists, and plastic and reconstructive surgeons. The advent of new drug therapies will redefine the role of surgery in this disease in the coming years.

REFERENCES

Entries highlighted in bright blue are key references.

1. Kanitakis J. Anatomy, histology, and immunohistochemistry of normal human skin. *Eur J Dermatol.* 2002;12:390-399; quiz 400-401.
2. Girolomoni G, Caux C, Lebecque S, Dezutter-Dambuyant C, Ricciardi-Castagnoli P. Langerhans cells: still a fundamental paradigm for studying the immunobiology of dendritic cells. *Trends Immunol.* 2002;23:6-8.
3. Spetz AL, Strominger J, Groh-Spies V. T cell subsets in normal human epidermis. *Am J Pathol.* 1996;149:665-674.
4. Lundquist K, Kohler S, Rouse RV. Intraepidermal cytokeratin 7 expression is not restricted to Paget cells but is also seen in Toker cells and Merkel cells. *Am J Surg Pathol.* 1999;23:212-219.
5. Sato K, Leidal R, Sato F. Morphology and development of an apoeccrine sweat gland in human axillae. *Am J Physiol.* 1987;252:R166-5180.
6. Eyden B. The myofibroblast: an assessment of controversial issues and a definition useful in diagnosis and research. *Ultrastruct Pathol.* 2001;25:39-50.
7. Braverman IM. The cutaneous microcirculation. *J Invest Dermatol Symp Proc.* 2000;5:3-9.
8. Alikhan A, Lynch PJ, Eisen DB. Hidradenitis suppurativa: a comprehensive review. *J Am Acad Dermatol.* 2009;60:539-61; quiz 62-63.
9. Gold M, Bridges TM, Bradshaw VL, Boring M. ALA-PDT and blue light therapy for hidradenitis suppurativa. *J Drugs Dermatol.* 2004;3:S32-S35.
10. Iwasaki J, Marra DE, Fincher EF, Moy RL. Treatment of hidradenitis suppurativa with a nonablative radiofrequency device. *Dermatol Surg.* 2008;34:114-117.
11. Rivard J, Ozog D. Henry Ford Hospital dermatology experience with Levulan Kerastick and blue light photodynamic therapy. *J Drugs Dermatol.* 2006;5:556-561.
12. Strauss RM, Pollock B, Stables GI, Goulden V, Cunliffe WJ. Photodynamic therapy using aminolaevulinic acid does not lead to clinical improvement in hidradenitis suppurativa. *Br J Dermatol.* 2005;152:803-804.
13. Morgan WP, Harding KG, Hughes LE. A comparison of skin grafting and healing by granulation, following axillary excision for hidradenitis suppurativa. *Ann R Coll Surg Engl.* 1983;65:235-236.
14. Hommes DW, Oldenburg B, van Bodegraven AA, et al. Guidelines for treatment with infliximab for Crohn's disease. *Netherlands J Med.* 2006;64:219-229.

15. Roy DB, Conte ET, Cohen DJ. The treatment of pyoderma gangrenosum using etanercept. *J Am Acad Dermatol*. 2006;54:S128-S134.
16. Khurram Baig M, Marquez H, Noguera JJ, Weiss EG, Wexner SD. Topical tacrolimus (FK506) in the treatment of recalcitrant parastomal pyoderma gangrenosum associated with Crohn's disease: report of two cases. *Colorectal Dis*. 2004;6:250-253.
17. Downey A, Jackson C, Harun N, Cooper A. Toxic epidermal necrolysis: review of pathogenesis and management. *J Am Acad Dermatol*. 2012;66:995-1003.
18. Gerull R, Nelle M, Schaible T. Toxic epidermal necrolysis and Stevens-Johnson syndrome: a review. *Crit Care Med*. 2011;39:1521-1532.
19. Chung WH, Hung SI, Hong HS, et al. Medical genetics: a marker for Stevens-Johnson syndrome. *Nature*. 2004;428:486.
20. French LE, Trent JT, Kerdel FA. Use of intravenous immunoglobulin in toxic epidermal necrolysis and Stevens-Johnson syndrome: our current understanding. *Int Immunopharmacol*. 2006;6:543-549.
21. Trent J, Halem M, French LE, Kerdel F. Toxic epidermal necrolysis and intravenous immunoglobulin: a review. *Semin Cutan Med Surg*. 2006;25:91-93.
22. Battie C, Verschoore M. Cutaneous solar ultraviolet exposure and clinical aspects of photodamage. *Indian J Dermatol Venereol Leprol*. 2012;78(Suppl 1):S9-S14.
23. Eliya MC, Banda GW. Primary closure versus delayed closure for nonbite traumatic wounds within 24 hours post injury. *Cochrane Database Syst Rev*. 2011;9:CD008574.
24. Presutti RJ. Bite wounds. Early treatment and prophylaxis against infectious complications. *Postgrad Med*. 1997;101:243-244, 246-252, 254.
25. Abrahamian FM, Goldstein EJ. Microbiology of animal bite wound infections. *Clin Microbiol Rev*. 2011;24:231-246.
26. Robson M, Krizek T, Heggers J. Biology of surgical infection. *Curr Probl Surg*. 1973:1-62.
27. Hardwicke J, Hunter T, Staruch R, Moiemmen N. Chemical burns—an historical comparison and review of the literature. *Burns*. 2012;38:383-387.
28. Kumar RJ, Pegg SP, Kimble RM. Management of extravasation injuries. *ANZ J Surg*. 2001;71:285-289.
29. Frye KE, Luteran A. *Thermal Burns*. 2nd ed. Philadelphia, PA: Mosby, Elsevier; 2010.
30. Britt LD, Dascombe WH, Rodriguez A. New horizons in management of hypothermia and frostbite injury. *Surg Clin North Am*. 1991;71:345-370.
31. Lindan O, Greenway RM, Piazza JM. Pressure distribution on the surface of the human body. I. Evaluation in lying and sitting positions using a "bed of springs and nails." *Arch Phys Medicine Rehabil*. 1965;46:378-385.
32. Lyder CH. Pressure ulcer prevention and management. *JAMA*. 2003;289:223-226.
33. Cannon BC, Cannon JP. Management of pressure ulcers. *Am J Health Syst Pharm*. 2004;61:1895-1905; quiz 1906-1907.
34. Argenta LC, Morykwas MJ. Vacuum-assisted closure: a new method for wound control and treatment: clinical experience. *Ann Plast Surg*. 1997;38:563-576; discussion 577.
35. Limova M. Active wound coverings: bioengineered skin and dermal substitutes. *Surg Clin North Am*. 2010;90:1237-1255.
36. Rajan S. Skin and soft-tissue infections: classifying and treating a spectrum. *Cleve Clin J Med*. 2012;79:57-66.
37. Moet GJ, Jones RN, Biedenbach DJ, Stilwell MG, Fritsche TR. Contemporary causes of skin and soft tissue infections in North America, Latin America, and Europe: report from the SENTRY Antimicrobial Surveillance Program (1998-2004). *Diagn Microbiol Infect Dis*. 2007;57:7-13.
38. Cardoso JC, Calonje E. Cutaneous manifestations of human papillomaviruses: a review. *Acta Dermatovenereol Alp Panonica Adriat*. 2011;20:145-154.
39. Rogers HD, Macgregor JL, Nord KM, et al. Acquired epidermodysplasia verruciformis. *J Am Acad Dermatol*. 2009;60:315-320.
40. Jacobelli S, Laude H, Carlotti A, et al. Epidermodysplasia verruciformis in human immunodeficiency virus-infected patients: a marker of human papillomavirus-related disorders not affected by antiretroviral therapy. *Arch Dermatol*. 2011;147:590-596.
41. National Comprehensive Cancer Network. *Melanoma, National Comprehensive Cancer Network Clinical Practice Guidelines in Oncology, Melanoma, Version 2.2013*. Fort Washington, PA: National Comprehensive Cancer Network; 2012.
42. Davis PA, Wastell C. A comparison of biomechanical properties of excised mature scars from HIV patients and non-HIV controls. *Am J Surg*. 2000;180:217-222.
43. Kregel S, Hauschild A, Schafer T. Melanoma risk in congenital melanocytic naevi: a systematic review. *Br J Dermatol*. 2006;155:1-8.
44. Schaffer JV. Pigmented lesions in children: when to worry. *Curr Opin Pediatr*. 2007;19:430-440.
45. Satyaprakash AK, Sheehan DJ, Sanguenza OP. Proliferating trichilemmal tumors: a review of the literature. *Dermatol Surg*. 2007;33:1102-1108.
46. Fu W, Cockerell CJ. The actinic (solar) keratosis: a 21st-century perspective. *Arch Dermatol*. 2003;139:66-70.
47. Robins P, Gupta AK. The use of topical fluorouracil to treat actinic keratosis. *Cutis*. 2002;70:4-7.
48. Epstein JH. Photocarcinogenesis, skin cancer, and aging. *J Am Acad Dermatol*. 1983;9:487-502.
49. Luce EA. Oncologic considerations in nonmelanotic skin cancer. *Clin Plast Surg*. 1995;22:39-50.
50. Marks R, Kopf AW. Cancer of the skin in the next century. *Int J Dermatol*. 1995;34:445-447.
51. Mentzel T. Cutaneous lipomatous neoplasms. *Semin Diagn Pathol*. 2001;18:250-257.
52. Sober AJ, Burstein JM. Precursors to skin cancer. *Cancer*. 1995;75:645-650.
53. Jemal A, Siegel R, Xu J, Ward E. Cancer statistics, 2010. *CA Cancer J Clin*. 2010;60:277-300.
54. National Comprehensive Cancer Network. *Basal Cell and Squamous Cell Skin Cancers, National Comprehensive Cancer Network Clinical Practice Guidelines in Oncology, Version 2.2012*. Fort Washington, PA: National Comprehensive Cancer Network; 2012.
55. Reszko A, Wilson LD, Leffell DJ. *Devita, Hellman, Rosenberg's Cancer: Principles and Practice*. 9th ed. Philadelphia, PA: Lippincott Williams & Wilkins; 2011.
56. Rowe DE, Carroll RJ, Day CL Jr. Mohs surgery is the treatment of choice for recurrent (previously treated) basal cell carcinoma. *J Dermatol Surg Oncol*. 1989;15:424-431.
57. Rowe DE, Carroll RJ, Day CL Jr. Long-term recurrence rates in previously untreated (primary) basal cell carcinoma: implications for patient follow-up. *J Dermatol Surg Oncol*. 1989;15:315-328.
58. Kopf AW, Bart RS, Schrage D, Lazar M, Popkin GL. Curettage-electrodesiccation treatment of basal cell carcinomas. *Arch Dermatol*. 1977;113:439-443.
59. Geisse J, Caro I, Lindholm J, Golitz L, Stampone P, Owens M. Imiquimod 5% cream for the treatment of superficial basal cell carcinoma: results from two phase III, randomized, vehicle-controlled studies. *J Am Acad Dermatol*. 2004;50:722-733.
60. Marks R, Gebauer K, Shumack S, et al. Imiquimod 5% cream in the treatment of superficial basal cell carcinoma: results of a multicenter 6-week dose-response trial. *J Am Acad Dermatol*. 2001;44:807-813.
61. Schulze HJ, Cribier B, Requena L, et al. Imiquimod 5% cream for the treatment of superficial basal cell carcinoma: results from a randomized vehicle-controlled phase III study in Europe. *Br J Dermatol*. 2005;152:939-947.

62. Shumack S, Robinson J, Kossard S, et al. Efficacy of topical 5% imiquimod cream for the treatment of nodular basal cell carcinoma: comparison of dosing regimens. *Arch Dermatol.* 2002;138:1165-1171.
63. Vidal D, Matias-Guiu X, Alomar A. Open study of the efficacy and mechanism of action of topical imiquimod in basal cell carcinoma. *Clin Exp Dermatol.* 2004;29:518-525.
64. Rowe DE, Carroll RJ, Day CL Jr. Prognostic factors for local recurrence, metastasis, and survival rates in squamous cell carcinoma of the skin, ear, and lip. Implications for treatment modality selection. *J Am Acad Dermatol.* 1992;26:976-990.
65. Kao GF. Carcinoma arising in Bowen's disease. *Arch Dermatol.* 1986;122:1124-1126.
66. Honeycutt WM, Jansen GT. Treatment of squamous cell carcinoma of the skin. *Arch Dermatol.* 1973;108:670-672.
67. Cassarino DS, Derienzo DP, Barr RJ. Cutaneous squamous cell carcinoma: a comprehensive clinicopathologic classification. Part one. *J Cutan Pathol.* 2006;33:191-206.
68. Ramirez-Amador V, Anaya-Saavedra G, Martinez-Mata G. Kaposi's sarcoma of the head and neck: a review. *Oral Oncol.* 2010;46:135-145.
69. Siegel R, Naishadham D, Jemal A. Cancer statistics, 2012. *CA Cancer J Clin.* 2013;63:11-30.
70. Cust AE, Armstrong BK, Goumas C, et al. Sunbed use during adolescence and early adulthood is associated with increased risk of early-onset melanoma. *Int J Cancer.* 2011;128:2425-2435.
71. Chudnovsky Y, Khavari PA, Adams AE. Melanoma genetics and the development of rational therapeutics. *J Clin Invest.* 2005;115:813-824.
72. Balch CM, Gershenwald JE, Soong SJ, et al. Final version of 2009 AJCC melanoma staging and classification. *J Clin Oncol.* 2009;27:6199-6206.
73. Balch CM, Soong SJ, Gershenwald JE, et al. Prognostic factors analysis of 17,600 melanoma patients: validation of the American Joint Committee on Cancer melanoma staging system. *J Clin Oncol.* 2001;19:3622-3634.
74. Balch CM, Gershenwald JE, Soong SJ, et al. Multivariate analysis of prognostic factors among 2313 patients with stage III melanoma: comparison of nodal micrometastases versus macrometastases. *J Clin Oncol.* 2010;28:2452-2459.
75. Weide B, Elsasser M, Buttner P, et al. Serum markers lactate dehydrogenase and S100B predict independently disease outcome in melanoma patients with distant metastasis. *Br J Cancer.* 2012;107:422-428.
76. Veronesi U, Cascinelli N, Adamus J, et al. **Thin stage I primary cutaneous malignant melanoma. Comparison of excision with margins of 1 or 3 cm.** *N Engl J Med.* 1988;318:1159-1162.
77. Cohn-Cedermark G, Rutqvist LE, Andersson R, et al. Long term results of a randomized study by the Swedish Melanoma Study Group on 2-cm versus 5-cm resection margins for patients with cutaneous melanoma with a tumor thickness of 0.8–2.0 mm. *Cancer.* 2000;89:1495-1501.
78. Balch CM, Soong SJ, Smith T, et al. Long-term results of a prospective surgical trial comparing 2 cm vs. 4 cm excision margins for 740 patients with 1-4 mm melanomas. *Ann Surg Oncol.* 2001;8:101-108.
79. **Balch CM, Urist MM, Karakousis CP, et al. Efficacy of 2-cm surgical margins for intermediate-thickness melanomas (1–4 mm). Results of a multi-institutional randomized surgical trial.** *Ann Surg.* 1993;218:262-267; discussion 267-269.
80. Wright BE, Scheri RP, Ye X, et al. Importance of sentinel lymph node biopsy in patients with thin melanoma. *Arch Surg.* 2008;143:892-899; discussion 899-900.
81. Ferrone CR, Panageas KS, Busam K, Brady MS, Coit DG. Multivariate prognostic model for patients with thick cutaneous melanoma: importance of sentinel lymph node status. *Ann Surg Oncol.* 2002;9:637-645.
82. Gershenwald JE, Mansfield PF, Lee JE, Ross MI. Role for lymphatic mapping and sentinel lymph node biopsy in patients with thick (> or = 4 mm) primary melanoma. *Ann Surg Oncol.* 2000;7:160-165.
83. Gutzmer R, Satzger I, Thoms KM, et al. Sentinel lymph node status is the most important prognostic factor for thick (> or = 4 mm) melanomas. *J Dtsch Dermatol Ges.* 2008;6:198-203.
84. **Morton DL, Cochran AJ, Thompson JF, et al. Sentinel node biopsy for early-stage melanoma: accuracy and morbidity in MSLT-I, an international multicenter trial.** *Ann Surg.* 2005;242:302-311; discussion 311-313.
85. Balch CM, Soong SJ, Murad TM, Ingalls AL, Maddox WA. A multifactorial analysis of melanoma: III. Prognostic factors in melanoma patients with lymph node metastases (stage II). *Ann Surg.* 1981;193:377-388.
86. Callery C, Cochran AJ, Roe DJ, et al. Factors prognostic for survival in patients with malignant melanoma spread to the regional lymph nodes. *Ann Surg.* 1982;196:69-75.
87. Roses DF, Provet JA, Harris MN, Gumpert SL, Dubin N. Prognosis of patients with pathologic stage II cutaneous malignant melanoma. *Ann Surg.* 1985;201:103-107.
88. **Balch CM, Soong S, Ross MI, et al. Long-term results of a multi-institutional randomized trial comparing prognostic factors and surgical results for intermediate thickness melanomas (1.0–4.0 mm). Intergroup Melanoma Surgical Trial.** *Ann Surg Oncol.* 2000;7:87-97.
89. Beasley GM, Caudle A, Petersen RP, et al. A multi-institutional experience of isolated limb infusion: defining response and toxicity in the US. *J Am Coll Surg.* 2009;208:706-715; discussion 715-717.
90. Boesch CE, Meyer T, Waschke L, et al. Long-term outcome of hyperthermic isolated limb perfusion (HILP) in the treatment of locoregionally metastasised malignant melanoma of the extremities. *Int J Hyperthermia.* 2010;26:16-20.
91. Lens MB, Dawes M. Isolated limb perfusion with melphalan in the treatment of malignant melanoma of the extremities: a systematic review of randomised controlled trials. *Lancet Oncol.* 2003;4:359-364.
92. Lindner P, Doubrovsky A, Kam PC, Thompson JF. Prognostic factors after isolated limb infusion with cytotoxic agents for melanoma. *Ann Surg Oncol.* 2002;9:127-136.
93. Kirkwood JM, Ibrahim JG, Sondak VK, et al. High- and low-dose interferon alfa-2b in high-risk melanoma: first analysis of intergroup trial E1690/S9111/C9190. *J Clin Oncol.* 2000;18:2444-2458.
94. Kirkwood JM, Manola J, Ibrahim J, et al. A pooled analysis of Eastern Cooperative Oncology Group and intergroup trials of adjuvant high-dose interferon for melanoma. *Clin Cancer Res.* 2004;10:1670-1677.
95. Kirkwood JM, Strawderman MH, Ernstoff MS, Smith TJ, Borden EC, Blum RH. Interferon alfa-2b adjuvant therapy of high-risk resected cutaneous melanoma: the Eastern Cooperative Oncology Group Trial EST 1684. *J Clin Oncol.* 1996;14:7-17.
96. Eggermont AM, Suci S, Santinami M, et al. Adjuvant therapy with pegylated interferon alfa-2b versus observation alone in resected stage III melanoma: final results of EORTC 18991, a randomised phase III trial. *Lancet.* 2008;372:117-126.
97. Atkins MB, Lotze MT, Dutcher JP, et al. High-dose recombinant interleukin 2 therapy for patients with metastatic melanoma: analysis of 270 patients treated between 1985 and 1993. *J Clin Oncol.* 1999;17:2105-2116.
98. **Chapman PB, Hauschild A, Robert C, et al. Improved survival with vemurafenib in melanoma with BRAF V600E mutation.** *N Engl J Med.* 2011;364:2507-2516.
99. **Hodi FS, O'Day SJ, McDermott DF, et al. Improved survival with ipilimumab in patients with metastatic melanoma.** *N Engl J Med.* 2010;363:711-723.

100. Rosenberg SA, Yang JC, Topalian SL, et al. Treatment of 283 consecutive patients with metastatic melanoma or renal cell cancer using high-dose bolus interleukin 2. *JAMA*. 1994;271:907-913.
101. Smith FO, Downey SG, Klapper JA, et al. Treatment of metastatic melanoma using interleukin-2 alone or in conjunction with vaccines. *Clin Cancer Res*. 2008;14:5610-5618.
102. Albert DM, Ryan LM, Borden EC. Metastatic ocular and cutaneous melanoma: a comparison of patient characteristics and prognosis. *Arch Ophthalmol*. 1996;114:107-108.
103. Inskip PD, Devesa SS, Fraumeni JF Jr. Trends in the incidence of ocular melanoma in the United States, 1974-1998. *Cancer Causes Control*. 2003;14:251-257.
104. Starr OD, Patel DV, Allen JP, McGhee CN. Iris melanoma: pathology, prognosis, and surgical intervention. *Clin Exp Ophthalmol*. 2004;32:294-296.
105. Akhtar S, Oza KK, Wright J. Merkel cell carcinoma: report of 10 cases and review of the literature. *J Am Acad Dermatol*. 2000;43:755-767.
106. Medina-Franco H, Urist MM, Fiveash J, Heslin MJ, Bland KI, Beenken SW. Multimodality treatment of Merkel cell carcinoma: case series and literature review of 1024 cases. *Ann Surg Oncol*. 2001;8:204-208.
107. National Comprehensive Cancer Network. *Merkel Cell Carcinoma, National Comprehensive Cancer Network Clinical Practice Guidelines in Oncology, Version 1.2012*. Fort Washington, PA: National Comprehensive Cancer Network; 2012.
108. Bichakjian CK, Lowe L, Lao CD, et al. Merkel cell carcinoma: critical review with guidelines for multidisciplinary management. *Cancer*. 2007;110:1-12.
109. Ott MJ, Tanabe KK, Gadd MA, et al. Multimodality management of Merkel cell carcinoma. *Arch Surg*. 1999;134:388-392; discussion 92-93.
110. Bower M, Weir J, Francis N, et al. The effect of HAART in 254 consecutive patients with AIDS-related Kaposi's sarcoma. *AIDS*. 2009;23:1701-1706.
111. Martinez V, Caumes E, Gambotti L, et al. Remission from Kaposi's sarcoma on HAART is associated with suppression of HIV replication and is independent of protease inhibitor therapy. *Br J Cancer*. 2006;94:1000-1006.
112. Fields RC, Hameed M, Qin LX, et al. Dermatofibrosarcoma protuberans (DFSP): predictors of recurrence and the use of systemic therapy. *Ann Surg Oncol*. 2011;18:328-336.
113. Meguerditchian AN, Wang J, Lema B, Kraybill WG, Zeitouni NC, Kane JM III. Wide excision or Mohs micrographic surgery for the treatment of primary dermatofibrosarcoma protuberans. *Am J Clin Oncol*. 2010;33:300-303.
114. Requena L, Sanguenza OP. Cutaneous vascular proliferations. Part III. Malignant neoplasms, other cutaneous neoplasms with significant vascular component, and disorders erroneously considered as vascular neoplasms. *J Am Acad Dermatol*. 1998;38:143-175; quiz 176-178.
115. Wagner G, Sachse MM. Extramammary Paget disease: clinical appearance, pathogenesis, management. *J Dtsch Dermatol Ges*. 2011;9:448-454.

17 chapter

The Breast

Kelly K. Hunt, John F.R. Robertson, and
Kirby I. Bland

A Brief History of Breast Cancer Therapy	497	Hormonal and Nonhormonal Risk Factors / 511	Local-Regional Recurrence / 543
Embryology and Functional Anatomy of the Breast	499	Risk Assessment Models / 511	Breast Cancer Prognosis / 544
Embryology / 499		Risk Management / 512	Surgical Techniques In Breast Cancer Therapy
Functional Anatomy / 500		BRCA Mutations / 514	544
Physiology of the Breast	503	Epidemiology and Natural History of Breast Cancer	Excisional Biopsy with Needle Localization / 544
Breast Development and Function / 503		Epidemiology / 517	Sentinel Lymph Node Dissection / 545
Pregnancy, Lactation, and Senescence / 504		Natural History / 518	Breast Conservation / 547
Gynecomastia / 505		Histopathology of Breast Cancer	Mastectomy and Axillary Dissection / 547
Infectious and Inflammatory Disorders of the Breast	506	Carcinoma In Situ / 519	Modified Radical Mastectomy / 548
Bacterial Infection / 506		Invasive Breast Carcinoma / 520	Reconstruction of the Breast and Chest Wall / 549
Mycotic Infections / 506		Diagnosis of Breast Cancer	Nonsurgical Breast Cancer Therapies
Hidradenitis Suppurativa / 506		Examination / 523	550
Mondor's Disease / 507		Imaging Techniques / 523	Radiation Therapy / 550
Common Benign Disorders and Diseases of the Breast	507	Breast Biopsy / 529	Chemotherapy Adjuvant / 550
Aberrations of Normal Development and Involution / 507		Breast Cancer Staging and Biomarkers	Antiestrogen Therapy / 552
Pathology of Nonproliferative Disorders / 508		Breast Cancer Staging / 531	Ablative Endocrine Therapy / 553
Pathology of Proliferative Disorders Without Atypia / 509		Biomarkers / 531	Anti-HER-2/ <i>neu</i> Therapy / 553
Pathology of Atypical Proliferative Diseases / 510		Overview of Breast Cancer Therapy	Special Clinical Situations
Treatment of Selected Benign Breast Disorders and Diseases / 510		In Situ Breast Cancer (Stage 0) / 537	554
Risk Factors for Breast Cancer	511	Early Invasive Breast Cancer (Stage I, IIA, or IIB) / 538	Axillary Lymph Node Metastases in the Setting of an Unknown Primary Cancer / 554
		Advanced Local-Regional Breast Cancer (Stage IIIA or IIIB) / 541	Breast Cancer During Pregnancy / 554
		Internal Mammary Lymph Nodes / 543	Male Breast Cancer / 554
		Distant Metastases (Stage IV) / 543	Phyllodes Tumors / 555
			Inflammatory Breast Carcinoma / 555
			Rare Breast Cancers / 556

A BRIEF HISTORY OF BREAST CANCER THERAPY

Breast cancer has captured the attention of surgeons throughout the ages. The Smith Surgical Papyrus (3000–2500 B.C.) is the earliest known document to refer to breast cancer. The cancer was in a man, but the description encompassed most of the common clinical features. In reference to this cancer, the author concluded, “There is no treatment.”¹ There were few other historical references to breast cancer until the first century. In *De Medicina*, Celsus commented on the value of operations for early breast cancer: “None of these may be removed but the cacoethes (early cancer), the rest are irritated by every method of cure. The more violent the operations are, the more angry they grow.”² In the second century, Galen inscribed his classical clinical observation: “We have often seen in the breast a tumor

exactly resembling the animal the crab. Just as the crab has legs on both sides of his body, so in this disease the veins extending out from the unnatural growth take the shape of a crab's legs. We have often cured this disease in its early stages, but after it has reached a large size, no one has cured it. In all operations we attempt to excise the tumor in a circle where it borders on the healthy tissue.”³

The galenic system of medicine ascribed cancers to an excess of black bile and concluded that excision of a local bodily outbreak could not cure the systemic imbalance. Theories espoused by Galen dominated medicine until the Renaissance. In 1652 Tulp introduced the idea that cancer was contagious when he reported an elderly woman and her housemaid who both developed breast cancer (N. Tulp, *Observationes medicae* 1652).

Key Points

- 1▶ The breast receives its principal blood supply from perforating branches of the internal mammary artery, lateral branches of the posterior intercostal arteries, and branches from the axillary artery, including the highest thoracic, lateral thoracic, and pectoral branches of the thoracoacromial artery.
- 2▶ The axillary lymph nodes usually receive >75% of the lymph drainage from the breast, and the rest flows through the lymph vessels that accompany the perforating branches of the internal mammary artery and enters the parasternal (internal mammary) group of lymph nodes.
- 3▶ Breast development and function are initiated by a variety of hormonal stimuli, with the major trophic effects being modulated by estrogen, progesterone, and prolactin.
- 4▶ Benign breast disorders and diseases are related to the normal processes of reproductive life and to involution, and there is a spectrum of breast conditions that ranges from normal to disorder to disease (aberrations of normal development and involution classification).
- 5▶ To calculate breast cancer risk using the Gail model, a woman's risk factors are translated into an overall risk score by multiplying her relative risks from several categories. This risk score is then compared with an adjusted population risk of breast cancer to determine the woman's individual risk. This model is not appropriate for use in women with a known *BRCA1* or *BRCA2* mutation or women with lobular or ductal carcinoma in situ.
- 6▶ Routine use of screening mammography in women ≥50 years of age reduces mortality from breast cancer by 25%. MRI screening is recommended in women with *BRCA* mutations and may be considered in women with a greater than 20% to 25% lifetime risk of developing breast cancer.
- 7▶ Core-needle biopsy is the preferred method for diagnosis of palpable or nonpalpable breast abnormalities.
- 8▶ When a diagnosis of breast cancer is made, the surgeon should determine the clinical stage, histologic characteristics, and appropriate biomarker levels before initiating local therapy.
- 9▶ Sentinel node dissection is the preferred method for staging of the regional lymph nodes in women with clinically node-negative invasive breast cancer. Axillary dissection may be avoided in women with 1 to 2 positive sentinel nodes who are treated with breast conserving surgery, whole breast radiation and systemic therapy.
- 10▶ Local-regional and systemic therapy decisions for an individual patient with breast cancer are best made using a multidisciplinary treatment approach. The sequencing of therapies is dependent on patient and tumor related factors including breast cancer subtype.

This single incidence was accepted as conclusive evidence and started an idea which persisted into the 20th century among some lay people. The majority of respected surgeons considered operative intervention to be a futile and ill-advised endeavor. The Renaissance and the wars of the 16th and 17th centuries brought developments in surgery, particularly in anatomical understanding. However there were no new theories espoused in relation to cancer. Beginning with Morgagni, surgical resections were more frequently undertaken, including some early attempts at mastectomy and axillary dissection. The 17th century saw the start of the Age of Enlightenment which lasted until the 19th century. In terms of medicine, this resulted in the abandonment of Galen's humoral pathology which was repudiated by Le Dran and the subsequent rise in cellular pathology as espoused by Virchow. Le Dran stated that breast cancer was a local disease that spread by way of lymph vessels to axillary lymph nodes. When operating on a woman with breast cancer, he routinely removed any enlarged axillary lymph nodes.⁴

In the 19th century, Moore, of the Middlesex Hospital, London, emphasized complete resection of the breast for cancer and stated that palpable axillary lymph nodes also should be removed.⁵ In a presentation before the British Medical Association in 1877, Banks supported Moore's concepts and advocated the resection of axillary lymph nodes even when palpable lymphadenopathy was not evident, recognizing that occult involvement of axillary lymph nodes was frequently present. In 1894, Halsted and Meyer reported their operations for treatment of breast cancer.⁶ By demonstrating superior local-regional control rates after radical resection, these surgeons established radical mastectomy as state-of-the-art treatment for that era.

Halsted and Meyer advocated complete dissection of axillary lymph node levels I to III. Both routinely resected the long thoracic nerve and the thoracodorsal neurovascular bundle with the axillary contents. In 1943, Haagensen and Stout described the grave signs of breast cancer, which included: (a) edema of the skin of the breast, (b) skin ulceration, (c) chest wall fixation, (d) an axillary lymph node >2.5 cm in diameter, and (e) fixed axillary lymph nodes. Women with two or more signs had a 42% local recurrence rate and only a 2% five-year disease-free survival rate.⁷ Based on these findings, they declared that women with grave signs were beyond cure by radical surgery. In 1948, Patey and Dyson of the Middlesex Hospital, London, advocated a modified radical mastectomy for the management of advanced operable breast cancer, explaining, "Until an effective general agent for treatment of carcinoma of the breast is developed, a high proportion of these cases are doomed to die."⁸ Their technique included removal of the breast and axillary lymph nodes with preservation of the pectoralis major muscle. They showed that removal of the pectoralis minor muscle allowed access to and clearance of axillary lymph node levels I to III.

During the 1970s, there was a transition from the Halsted radical mastectomy to the modified radical mastectomy as the surgical procedure most frequently used by American surgeons to treat breast cancer. This transition acknowledged that: (a) fewer patients were presenting with advanced local disease with or without the grave signs described by Haagensen, (b) extirpation of the pectoralis major muscle was not essential for local-regional control in stage I and II breast cancer, and (c) neither the modified radical mastectomy nor the Halsted radical mastectomy consistently achieved local-regional control of stage III

breast cancer. Radiation therapy was incorporated into the management of advanced breast cancer and demonstrated improvements in local-regional control. The National Surgical Adjuvant Breast and Bowel Project (NSABP) conducted a randomized trial in the early 1970s to determine the impact of local and regional treatments on survival in operable breast cancer. In the B-04 trial, 1665 women were enrolled and stratified by clinical assessment of the axillary lymph nodes. The clinically node-negative women were randomized into three treatment groups: (a) Halsted radical mastectomy; (b) total mastectomy plus radiation therapy; and (c) total mastectomy alone. Clinically node-positive women were randomized to Halsted radical mastectomy or total mastectomy plus radiation therapy. This trial accrued patients between 1971 and 1974, an era that predated widespread availability of effective systemic therapy for breast cancer and therefore reflect survival associated with local-regional therapy alone. There were no differences in survival between the three groups of node-negative women or between the two groups of node-positive women. These overall survival equivalence patterns have persisted at 25 years of follow-up.⁹

The next major advance in the surgical management of breast cancer was the development of breast conserving surgery. Breast conserving surgery and radium treatment was first reported by Geoffrey Keynes of St Bartholomew's Hospital, London in the British Medical Journal in 1937.¹⁰ Several decades later, the NSABP launched the B-06 trial, a phase III study that randomized 1851 patients to total mastectomy, lumpectomy alone, or lumpectomy with breast irradiation. The results showed no difference in disease-free, distant disease-free, and overall survival among the three groups; however, the omission of radiation therapy resulted in significantly higher rates of ipsilateral breast tumor recurrence in those who received lumpectomy alone.¹¹ The B-06 trial excluded patients who had palpable axillary lymph nodes and those patients randomized to breast conserving surgery had frozen sections performed and if on frozen section the margins were involved the surgeon proceeded to perform a mastectomy but the patient was included in the analysis as though they had a breast conserving operation. Furthermore, in B-06 local in-breast recurrences were regarded as "non-events" in terms of disease-free survival. Both NSABP B-04 and B-06 trials were taken to refute the Halstedian concept that cancer spread throughout a region of the breast to lymphatics and then on to distant sites. Bernard Fisher proposed the "alternative hypothesis" that breast cancer was a systemic disease at diagnosis and that tumor cells had access to both the blood and lymphatic systems and that regional lymph nodes were a marker of systemic disease and not a barrier to the dissemination of cancer cells. He proposed that host factors were important in the development of metastasis and that variations in the local-regional approach to breast cancer were not likely to substantially impact survival. This idea was dominant for a number of years but has been challenged by the Early Breast Cancer Trialists' Collaborative Group overview analysis which reported that "the avoidance of recurrence in a conserved breast avoids about one breast cancer death over the next 15 years for every four such recurrences avoided."¹² Indicating that not all breast cancer is a systemic disease at presentation.

During the 1970s, clinical trials were initiated to determine the value of systemic therapy in the postoperative setting as an adjuvant to surgery. The Early Breast Cancer Trialists' Collaborative Group (EBCTCG) was established in 1985 to coordinate the meta-analysis of data from randomized clinical

trials in order to examine the impact of adjuvant treatments for breast cancer on recurrence and mortality. The EBCTCG overview has demonstrated that anthracycline containing regimens are superior to CMF, and more recently, that the addition of a taxane to an anthracycline-based regimen reduces breast cancer mortality by one third.¹¹ The overview has also demonstrated that tamoxifen is of benefit only in patients with estrogen receptor (ER) positive breast cancer and that tamoxifen may decrease mortality from breast cancer by as much as 50%.¹³ Importantly, the EBCTCG data have shown that proportional reduction in risk was not significantly affected by standard clinical and pathologic factors such as tumor size, ER status, and nodal status.¹⁴ This underscores the importance of stratification of risk in determining adjuvant therapy decisions in order to minimize the toxicities of therapies in those unlikely to benefit, yet realize the substantial benefits gained in local-regional control and survival in those at higher risk.

Many early randomized clinical trials considered all patients similarly in terms of treatment viewing breast cancer as more of a homogeneous disease. Breast cancer has traditionally been defined by pathologic determinants using conventional light microscopy and basic histologic techniques. In the 1980s immunohistochemistry allowed assessment of the expression of individual tumor markers (most commonly proteins) while DNA was initially assessed in terms of its ploidy status. Subsequently, breast cancer specimens have been interrogated at the level of the DNA by labeling genes of interest and allowing fluorescent dyes to quantify the abundance of a particular gene and comparing a large number of genes simultaneously in a single breast cancer specimen. Gene expression arrays have shown that breast cancers cluster according to their intrinsic gene expression patterns into at least five intrinsic subtypes and these intrinsic subtypes correlate with breast cancer outcomes.¹⁵ Breast cancers are now classified by molecular subtypes and these are being used for risk stratification and decision making in terms of local-regional and systemic therapies.

Currently, 50% of American women will consult a surgeon regarding breast disease, 25% will undergo breast biopsy for diagnosis of an abnormality, and 12% will develop some variant of breast cancer. Considerable progress has been made in the integration of surgery, radiation therapy, and systemic therapy to control local-regional disease, enhance survival, and improve the quality of life of breast cancer survivors. Surgeons are traditionally the first physician consulted for breast care and it is critical for them to be well trained in all aspects of the breast from embryologic development, to growth and development, and to benign and malignant disease processes. This will allow the greatest opportunity to achieve optimal outcomes for patients and their families.

EMBRYOLOGY AND FUNCTIONAL ANATOMY OF THE BREAST

Embryology

At the fifth or sixth week of fetal development, two ventral bands of thickened ectoderm (mammary ridges, milk lines) are evident in the embryo.¹⁶ In most mammals, paired breasts develop along these ridges, which extend from the base of the forelimb (future axilla) to the region of the hind limb (inguinal area). These ridges are not prominent in the human embryo and disappear after a short time, except for small portions that may

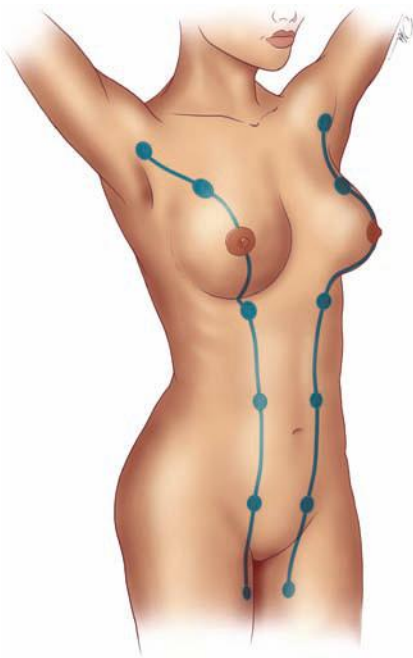

Figure 17-1. The mammary milk line (Visual Art: © 2012.The University of Texas MD Anderson Cancer Center.)

persist in the pectoral region. Accessory breasts (*polymastia*) or accessory nipples (*polythelia*) may occur along the milk line (Fig. 17-1) when normal regression fails. Each breast develops when an ingrowth of ectoderm forms a primary tissue bud in the mesenchyme. The primary bud, in turn, initiates the development of 15 to 20 secondary buds. Epithelial cords develop from the secondary buds and extend into the surrounding mesenchyme. Major (lactiferous) ducts develop, which open into a shallow mammary pit. During infancy, a proliferation of mesenchyme transforms the mammary pit into a nipple. If there is failure of a pit to elevate above skin level, an inverted nipple results. This congenital malformation occurs in 4% of infants. At birth, the breasts are identical in males and females, demonstrating only the presence of major ducts. Enlargement of the breast may be evident and a secretion, historically referred to as *witch's milk*, may be produced. These transitory events occur in response to maternal hormones that cross the placenta.

The breast remains undeveloped in the female until puberty, when it enlarges in response to ovarian estrogen and progesterone, which initiate proliferation of the epithelial and connective tissue elements. However, the breasts remain incompletely developed until pregnancy occurs. Absence of the breast (*amastia*) is rare and results from an arrest in mammary ridge development that occurs during the sixth fetal week. Poland's syndrome consists of hypoplasia or complete absence of the breast, costal cartilage and rib defects, hypoplasia of the subcutaneous tissues of the chest wall, and brachysyndactyly. Breast hypoplasia also may be iatrogenically induced before puberty by trauma, infection, or radiation therapy. *Symmastia* is a rare anomaly recognized as webbing between the breasts across the midline. Accessory nipples (*polythelia*) occur in <1% of infants and may be associated with abnormalities of the urinary tract (renal agenesis and cancer), abnormalities of the cardiovascular system (conduction disturbances, hypertension, congenital heart anomalies), and other conditions (pyloric stenosis, epilepsy, ear

abnormalities, arthrogryposis). Supernumerary breasts may occur in any configuration along the mammary milk line but most frequently occur between the normal nipple location and the symphysis pubis. Turner's syndrome (ovarian agenesis and dysgenesis) and Fleischer's syndrome (displacement of the nipples and bilateral renal hypoplasia) may have polymastia as a component. Accessory axillary breast tissue is uncommon and usually is bilateral.

Functional Anatomy

The breast is composed of 15 to 20 lobes (Fig. 17-2), which are each composed of several lobules.¹⁷ Fibrous bands of connective tissue travel through the breast (Cooper's suspensory ligaments), insert perpendicularly into the dermis, and provide structural support. The mature female breast extends from the level of the second or third rib to the inframammary fold at the sixth or seventh rib. It extends transversely from the lateral border of the sternum to the anterior axillary line. The deep or posterior surface of the breast rests on the fascia of the pectoralis major, serratus anterior, and external oblique abdominal muscles, and the upper extent of the rectus sheath. The retro-mammary bursa may be identified on the posterior aspect of the breast between the investing fascia of the breast and the fascia of the pectoralis major muscles. The axillary tail of Spence extends laterally across the anterior axillary fold. The upper outer quadrant of the breast contains a greater volume of tissue than do the other quadrants. The breast has a protuberant conical form. The base of the cone is roughly circular, measuring 10 to 12 cm in diameter. Considerable variations in the size, contour, and density of the breast are evident among individuals. The nulliparous breast has a hemispheric configuration with distinct flattening above the nipple. With the hormonal stimulation that accompanies pregnancy and lactation, the breast becomes larger and increases in volume and density, whereas with senescence, it assumes a flattened, flaccid, and more pendulous configuration with decreased volume.

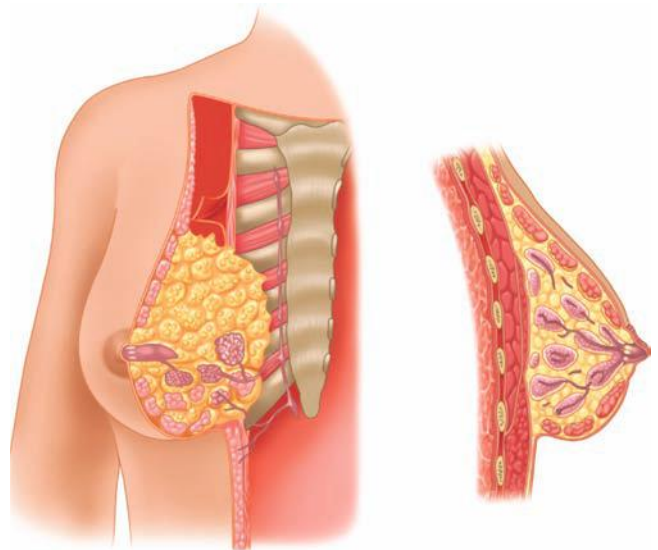


Figure 17-2. Anatomy of the breast. Tangential and cross-sectional (sagittal) views of the breast and associated chest wall. (Reproduced with permission from Romrell LJ, Bland KI. Anatomy of the breast, axilla, chest wall, and related metastatic sites. In: Bland KI, Copeland EMI, eds. *The Breast: Comprehensive Management of Benign and Malignant Diseases*. Philadelphia: Saunders, 2009. Copyright Elsevier.)

Nipple-Areola Complex. The epidermis of the nipple-areola complex is pigmented and is variably corrugated. During puberty, the pigment becomes darker and the nipple assumes an elevated configuration. Throughout pregnancy, the areola enlarges and pigmentation is further enhanced. The areola contains sebaceous glands, sweat glands, and accessory glands, which produce small elevations on the surface of the areola (Montgomery's tubercles). Smooth muscle bundle fibers, which lie circumferentially in the dense connective tissue and longitudinally along the major ducts, extend upward into the nipple, where they are responsible for the nipple erection that occurs with various sensory stimuli. The dermal papilla at the tip of the nipple contains numerous sensory nerve endings and Meissner's corpuscles. This rich sensory innervation is of functional importance, because the sucking of the infant initiates a chain of neurohumoral events that results in milk letdown.

Inactive and Active Breast. Each lobe of the breast terminates in a major (lactiferous) duct (2–4 mm in diameter), which opens through a constricted orifice (0.4–0.7 mm in diameter) into the ampulla of the nipple (see Fig. 17-2). Immediately below the nipple-areola complex, each major duct has a dilated portion (lactiferous sinus), which is lined with stratified squamous epithelium. Major ducts are lined with two layers of cuboidal cells, whereas minor ducts are lined with a single layer of columnar or cuboidal cells. Myoepithelial cells of ectodermal origin reside between the epithelial cells in the basal lamina and contain myofibrils. In the inactive breast, the epithelium is sparse and consists primarily of ductal epithelium (Fig. 17-3). In the early phase of the menstrual cycle, minor ducts are cord-like with small lumina. With estrogen stimulation at the time of ovulation, alveolar epithelium increases in height, duct lumina become more prominent, and some secretions accumulate. When the hormonal stimulation decreases, the alveolar epithelium regresses.

With pregnancy, the breast undergoes proliferative and developmental maturation. As the breast enlarges in response to hormonal stimulation, lymphocytes, plasma cells, and

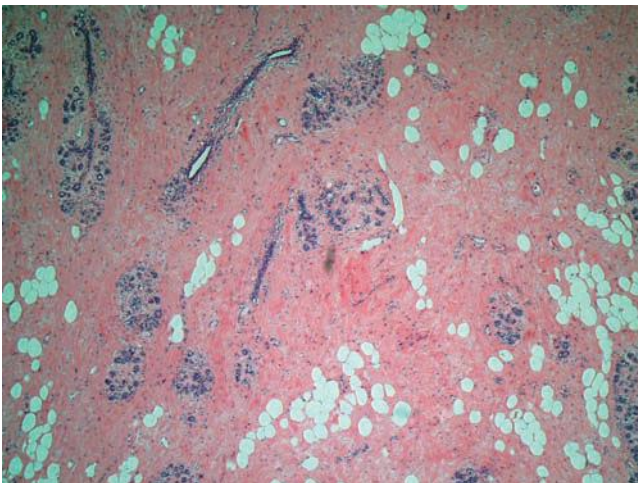


Figure 17-3. Inactive human breast (100x). The epithelium, which is primarily ductal, is embedded in loose connective tissue. Dense connective tissue surrounds the terminal duct lobular units (TDLU). (Photo used with permission of Dr. Sindhu Menon, Consultant Histopathologist & Dr. Rahul Deb, Consultant Histopathologist and Lead Breast Pathologist, Royal Derby Hospital, Derby, UK.)

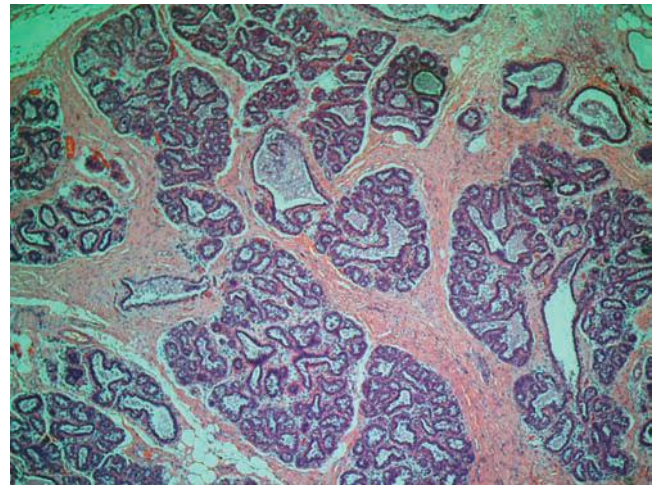


Figure 17-4. Active human breast: pregnancy and lactation (160x). The alveolar epithelium becomes conspicuous during the early proliferative period. The alveolus is surrounded by cellular connective tissue. (Photo used with permission of Dr. Sindhu Menon, Consultant Histopathologist & Dr. Rahul Deb, Consultant Histopathologist and Lead Breast Pathologist, Royal Derby Hospital, Derby, UK.)

eosinophils accumulate within the connective tissues. The minor ducts branch and alveoli develop. Development of the alveoli is asymmetric, and variations in the degree of development may occur within a single lobule (Fig. 17-4). With parturition, enlargement of the breasts occurs via hypertrophy of alveolar epithelium and accumulation of secretory products in the lumina of the minor ducts. Alveolar epithelium contains abundant endoplasmic reticulum, large mitochondria, Golgi complexes, and dense lysosomes. Two distinct substances are produced by the alveolar epithelium: (a) the protein component of milk, which is synthesized in the endoplasmic reticulum (merocrine secretion); and (b) the lipid component of milk (apocrine secretion), which forms as free lipid droplets in the cytoplasm. Milk released in the first few days after parturition is called *colostrum* and has low lipid content but contains considerable quantities of antibodies. The lymphocytes and plasma cells that accumulate within the connective tissues of the breast are the source of the antibody component. With subsequent reduction in the number of these cells, the production of colostrum decreases and lipid-rich milk is released.

Blood Supply, Innervation, and Lymphatics. The breast receives its principal blood supply from: (a) perforating branches of the internal mammary artery; (b) lateral branches of the posterior intercostal arteries; and (c) branches from the axillary artery, including the highest thoracic, lateral thoracic, and pectoral branches of the thoracoacromial artery (Fig. 17-5).

▶ The second, third, and fourth anterior intercostal perforators and branches of the internal mammary artery arborize in the breast as the medial mammary arteries. The lateral thoracic artery gives off branches to the serratus anterior, pectoralis major and pectoralis minor, and subscapularis muscles. It also gives rise to lateral mammary branches. The veins of the breast and chest wall follow the course of the arteries, with venous drainage being toward the axilla. The three principal groups of veins are: (a) perforating branches of the internal thoracic vein, (b) perforating branches of the posterior intercostal veins, and

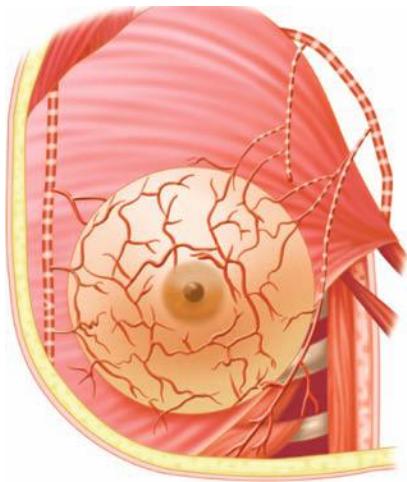


Figure 17-5. Arterial supply to the breast, axilla, and chest wall. (Reproduced with permission from Romrell LJ, Bland KI. Anatomy of the breast, axilla, chest wall, and related metastatic sites. In: Bland KI, Copeland EMI, eds. *The Breast: Comprehensive Management of Benign and Malignant Diseases*. Philadelphia: Saunders, 2009. Copyright Elsevier.)

(c) tributaries of the axillary vein. Batson's vertebral venous plexus, which invests the vertebrae and extends from the base of the skull to the sacrum, may provide a route for breast cancer metastases to the vertebrae, skull, pelvic bones, and central nervous system. Lymph vessels generally parallel the course of blood vessels.

Lateral cutaneous branches of the third through sixth intercostal nerves provide sensory innervation of the breast (lateral mammary branches) and of the anterolateral chest wall. These branches exit the intercostal spaces between slips of the serratus anterior muscle. Cutaneous branches that arise from the cervical plexus, specifically the anterior branches of the supraclavicular nerve, supply a limited area of skin over the upper portion of the breast. The intercostobrachial nerve is the lateral cutaneous branch of the second intercostal nerve and may be visualized during surgical dissection of the axilla. Resection of the intercostobrachial nerve causes loss of sensation over the medial aspect of the upper arm.

The boundaries for lymph drainage of the axilla are not well demarcated, and there is considerable variation in the position of the axillary lymph nodes. The six axillary lymph node groups recognized by surgeons (Figs. 17-6 and 17-7) are: (a) the axillary vein group (lateral), which consists of four to six lymph nodes that lie medial or posterior to the vein and receive most of the lymph drainage from the upper extremity; (b) the external mammary group (anterior or pectoral group), which consists of five to six lymph nodes that lie along the lower border of the pectoralis minor muscle contiguous with the lateral thoracic vessels and receive most of the lymph drainage from the lateral aspect of the breast; (c) the scapular group (posterior or subscapular), which consists of five to seven lymph nodes that lie along the posterior wall of the axilla at the lateral border of the scapula contiguous with the subscapular vessels and receive lymph drainage principally from the lower posterior neck, the posterior trunk, and the posterior shoulder; (d) the central group, which consists of three or four sets of lymph nodes that are

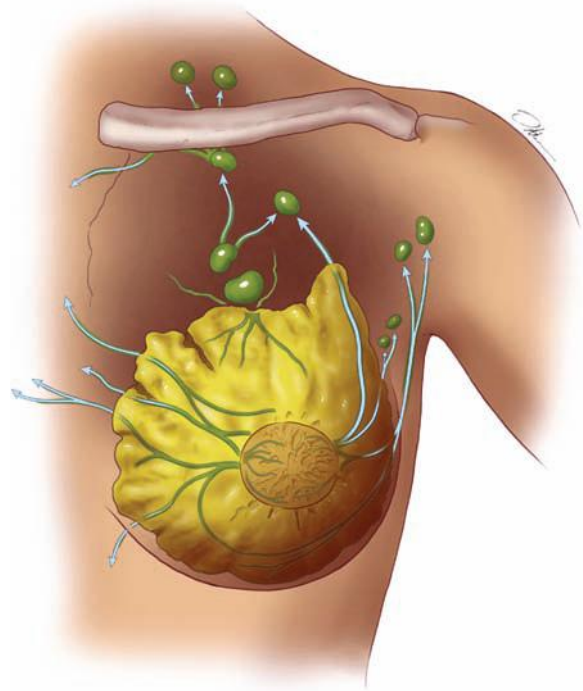


Figure 17-6. Lymphatic pathways of the breast. Arrows indicate the direction of lymph flow. (Visual Art: © 2012. The University of Texas MD Anderson Cancer Center.)

embedded in the fat of the axilla lying immediately posterior to the pectoralis minor muscle and receive lymph drainage both from the axillary vein, external mammary, and scapular groups of lymph nodes, and directly from the breast; (e) the subclavicular

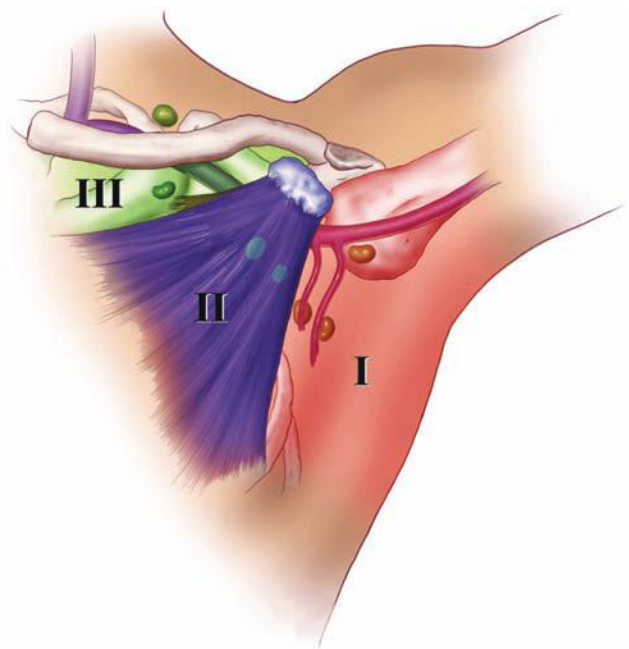


Figure 17-7. Axillary lymph node groups. Level I includes lymph nodes located lateral to the pectoralis minor muscle; level II includes lymph nodes located deep to the pectoralis minor; and level III includes lymph nodes located medial to the pectoralis minor. The axillary vein with its major tributaries and the supraclavicular lymph node group are also illustrated. (Visual Art: © 2012. The University of Texas MD Anderson Cancer Center.)

group (apical), which consists of six to twelve sets of lymph nodes that lie posterior and superior to the upper border of the pectoralis minor muscle and receive lymph drainage from all of the other groups of axillary lymph nodes; and (f) the interpectoral group (Rotter's lymph nodes), which consists of one to four lymph nodes that are interposed between the pectoralis major and pectoralis minor muscles and receive lymph drainage directly from the breast. The lymph fluid that passes through the interpectoral group of lymph nodes passes directly into the central and subclavicular groups.

As indicated in Fig.17-7, the lymph node groups are assigned levels according to their anatomic relationship to the pectoralis minor muscle. Lymph nodes located lateral to or below the lower border of the pectoralis minor muscle are referred to as *level I lymph nodes*, which include the axillary vein, external mammary, and scapular groups. Lymph nodes located superficial or deep to the pectoralis minor muscle are referred to as *level II lymph nodes*, which include the central and interpectoral groups. Lymph nodes located medial to or above the upper border of the pectoralis minor muscle are referred to as *level III lymph nodes*, which consist of the subclavicular group. The plexus of lymph vessels in the breast arises in the interlobular connective tissue and in the walls of the lactiferous ducts and communicates with the subareolar plexus of lymph vessels. Efferent lymph vessels from the breast pass around the lateral edge of the pectoralis major muscle and pierce the clavicopectoral fascia, ending in the external mammary (anterior, pectoral)

group of lymph nodes. Some lymph vessels may travel directly to the subscapular (posterior, scapular) group of lymph nodes. From the upper part of the breast, a few lymph vessels pass directly to the subclavicular (apical) group of lymph nodes. The axillary lymph nodes usually receive >75% of the lymph drainage from the breast. The rest is derived primarily from the medial aspect of the breast, flows through the lymph vessels that accompany the perforating branches of the internal mammary artery, and enters the parasternal (internal mammary) group of lymph nodes.

PHYSIOLOGY OF THE BREAST

Breast Development and Function

Breast development and function are initiated by a variety of hormonal stimuli, including estrogen, progesterone, prolactin, oxytocin, thyroid hormone, cortisol, and growth hormone.^{17,18}

Estrogen, progesterone, and prolactin especially have profound trophic effects that are essential to normal breast development and function. Estrogen initiates ductal development, whereas progesterone is responsible for differentiation of epithelium and for lobular development. Prolactin is the primary hormonal stimulus for lactogenesis in late pregnancy and the postpartum period. It upregulates hormone receptors and stimulates epithelial development. Figure 17-8 depicts the secretion of neurotrophic hormones from the hypothalamus, which

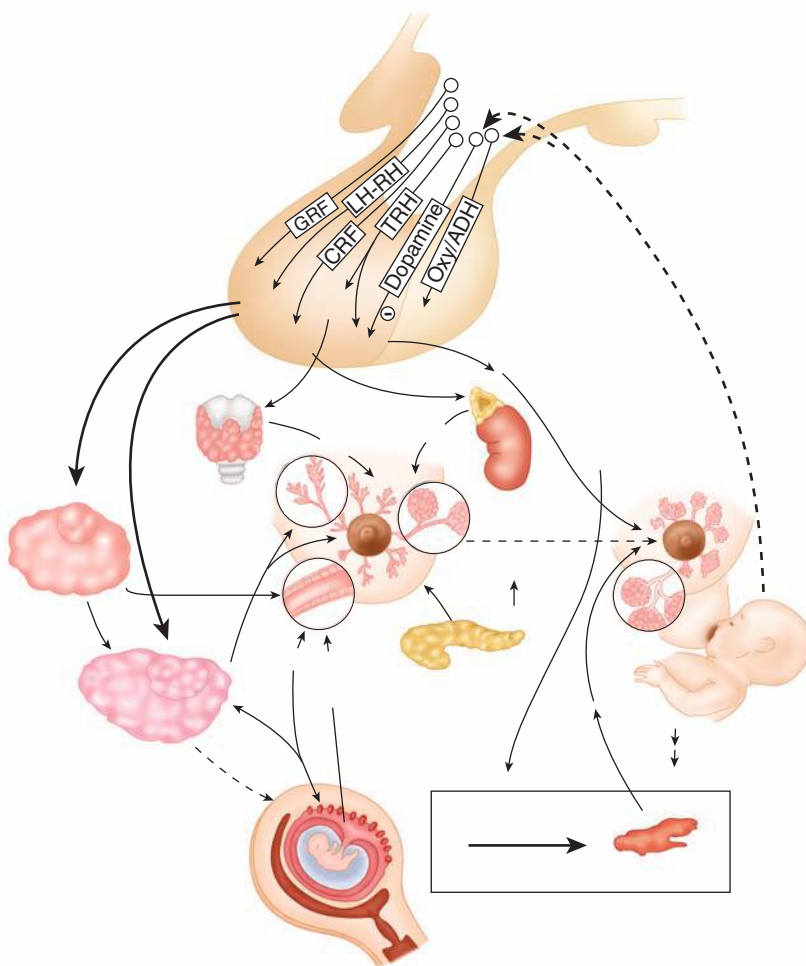


Figure 17-8. Overview of the neuroendocrine control of breast development and function. ADH = antidiuretic hormone; CRF = corticotropin-releasing factor; GRF = growth hormone releasing factor; LH-RH = luteinizing hormone–releasing hormone; Oxy = oxytocin; TRH = thyrotropin-releasing hormone. (Reproduced with permission from Kass R et al. Breast physiology: normal and abnormal development and function. In: Bland KI, Copeland EMI, eds. *The Breast: Comprehensive Management of Benign and Malignant Diseases*. Philadelphia: Saunders, 2009. Copyright Elsevier.)

is responsible for regulation of the secretion of the hormones that affect the breast tissues. The gonadotropins luteinizing hormone (LH) and follicle-stimulating hormone (FSH) regulate the release of estrogen and progesterone from the ovaries. In turn, the release of LH and FSH from the basophilic cells of the anterior pituitary is regulated by the secretion of gonadotropin-releasing hormone (GnRH) from the hypothalamus. Positive and negative feedback effects of circulating estrogen and progesterone regulate the secretion of LH, FSH, and GnRH. These hormones are responsible for the development, function, and maintenance of breast tissues (Fig. 17-9A). In the female neonate, circulating estrogen and progesterone levels decrease after birth and remain low throughout childhood because of the sensitivity of the hypothalamic-pituitary axis to negative feedback from these hormones. With the onset of puberty, there is a decrease in the sensitivity of the hypothalamic-pituitary axis to negative feedback and an increase in its sensitivity to positive feedback from estrogen. These physiologic events initiate

an increase in GnRH, FSH, and LH secretion and ultimately an increase in estrogen and progesterone secretion by the ovaries, leading to establishment of the menstrual cycle. At the beginning of the menstrual cycle, there is an increase in the size and density of the breasts, which is followed by engorgement of the breast tissues and epithelial proliferation. With the onset of menstruation, the breast engorgement subsides and epithelial proliferation decreases.

Pregnancy, Lactation, and Senescence

A dramatic increase in circulating ovarian and placental estrogens and progestins is evident during pregnancy, which initiates striking alterations in the form and substance of the breast (see Fig. 17-9B).¹⁷⁻¹⁹ The breast enlarges as the ductal and lobular epithelium proliferates, the areolar skin darkens, and the accessory areolar glands (Montgomery's glands) become prominent. In the first and second trimesters, the minor ducts branch and develop. During the third trimester, fat droplets accumulate in

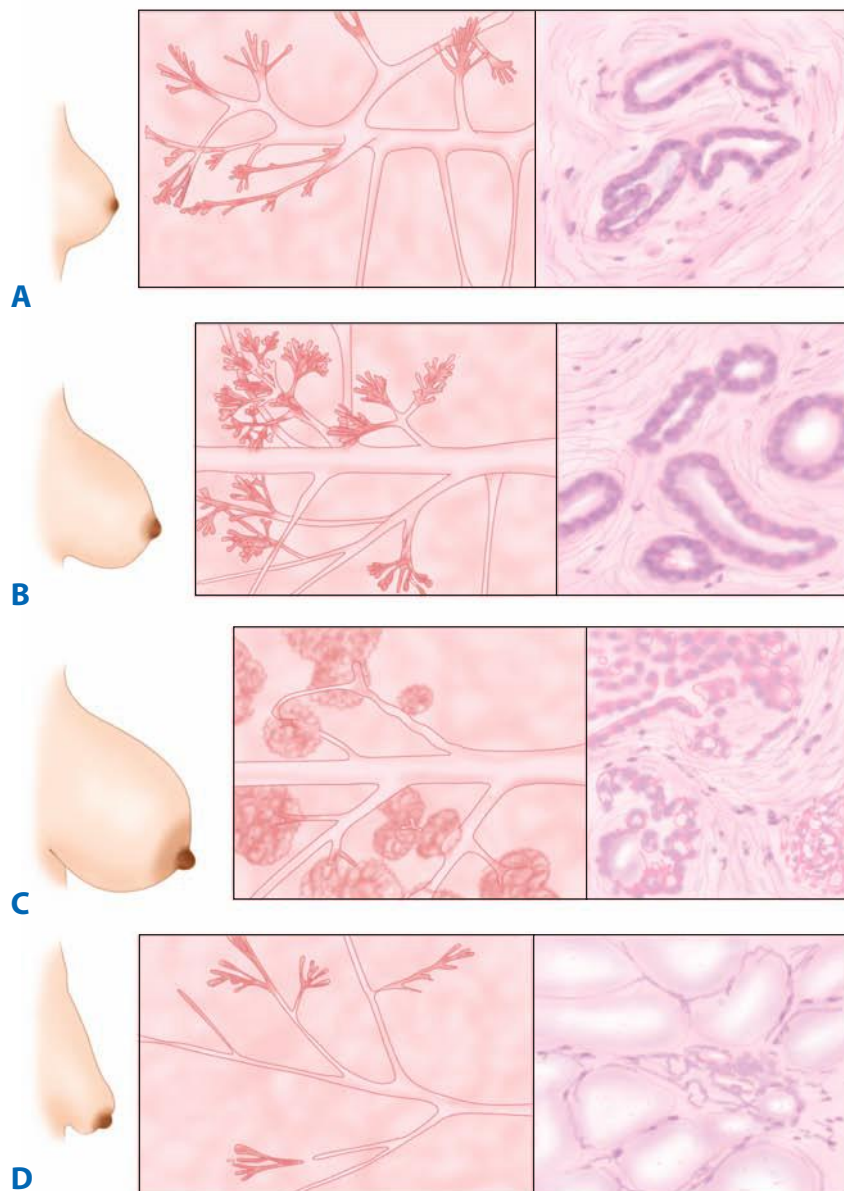


Figure 17-9. The breast at different physiologic stages. The central column contains three-dimensional depictions of microscopic structures. **A.** Adolescence. **B.** Pregnancy. **C.** Lactation. **D.** Senescence.

the alveolar epithelium and colostrum fills the alveolar and ductal spaces. In late pregnancy, prolactin stimulates the synthesis of milk fats and proteins.

After delivery of the placenta, circulating progesterone and estrogen levels decrease, permitting full expression of the lactogenic action of prolactin. Milk production and release are controlled by neural reflex arcs that originate in nerve endings of the nipple-areola complex. Maintenance of lactation requires regular stimulation of these neural reflexes, which results in prolactin secretion and milk letdown. Oxytocin release results from the auditory, visual, and olfactory stimuli associated with nursing. Oxytocin initiates contraction of the myoepithelial cells, which results in compression of alveoli and expulsion of milk into the lactiferous sinuses. After weaning of the infant, prolactin and oxytocin release decreases. Dormant milk causes increased pressure within the ducts and alveoli, which results in atrophy of the epithelium (Fig. 17-9C). With menopause there is a decrease in the secretion of estrogen and progesterone by the ovaries and involution of the ducts and alveoli of the breast. The surrounding fibrous connective tissue increases in density, and breast tissues are replaced by adipose tissues (Fig. 17-9D).

Gynecomastia

Gynecomastia refers to an enlarged breast in the male.²⁰ Physiologic gynecomastia usually occurs during three phases of life: the neonatal period, adolescence, and senescence. Common to each of these phases is an excess of circulating estrogens in relation to circulating testosterone. Neonatal gynecomastia is caused by the action of placental estrogens on neonatal breast tissues, whereas in adolescence, there is an excess of estradiol relative to testosterone, and with senescence, the circulating testosterone level falls, which results in relative hyperestrogenism. In gynecomastia, the ductal structures of the male breast enlarge, elongate, and branch with a concomitant increase in epithelium. During puberty, the condition often is unilateral and typically occurs between ages 12 and 15 years. In contrast, senescent gynecomastia is usually bilateral. In the nonobese male, breast tissue measuring at least 2 cm in diameter must be present before a diagnosis of gynecomastia may be made. Mammography and ultrasonography are used to differentiate breast tissues. Dominant masses or areas of firmness, irregularity, and asymmetry suggest the possibility of a breast cancer, particularly in the older male. Gynecomastia generally does not predispose the male breast to cancer. However, the hypoandrogenic state of Klinefelter's syndrome (XXY), in which gynecomastia is usually evident, is associated with an increased risk of breast cancer. Gynecomastia is graded based on the degree of breast enlargement, the position of the nipple with reference to the inframammary fold and the degree of breast ptosis and skin redundancy: Grade 1: mild breast enlargement without skin redundancy; Grade IIa: moderate breast enlargement without skin redundancy; Grade IIb: moderate breast enlargement with skin redundancy; and Grade 3: marked breast enlargement with skin redundancy and ptosis.

Table 17-1 identifies the pathophysiologic mechanisms that may initiate gynecomastia: estrogen excess states; androgen deficiency states; pharmacologic causes; and idiopathic causes. Estrogen excess results from an increase in the secretion of estradiol by the testicles or by nontesticular tumors, nutritional alterations such as protein and fat deprivation, endocrine disorders (hyperthyroidism, hypothyroidism), and hepatic disease (nonalcoholic and alcoholic cirrhosis). Refeeding gynecomastia

Table 17-1

Pathophysiologic mechanisms of gynecomastia

- I. Estrogen excess states
 - A. Gonadal origin
 1. True hermaphroditism
 2. Gonadal stromal (nongerminal) neoplasms of the testis
 - a. Leydig cell (interstitial)
 - b. Sertoli cell
 - c. Granulosa-theca cell
 3. Germ cell tumors
 - a. Choriocarcinoma
 - b. Seminoma, teratoma
 - c. Embryonal carcinoma
 - B. Nontesticular tumors
 1. Adrenal cortical neoplasms
 2. Lung carcinoma
 3. Hepatocellular carcinoma
 - C. Endocrine disorders
 - D. Diseases of the liver—nonalcoholic and alcoholic cirrhosis
 - E. Nutrition alteration states
- II. Androgen deficiency states
 - A. Senescence
 - B. Hypoandrogenic states (hypogonadism)
 1. Primary testicular failure
 - a. Klinefelter's syndrome (XXY)
 - b. Reifenstein's syndrome
 - c. Rosewater-Gwinup-Hamwi familial gynecomastia
 - d. Kallmann syndrome
 - e. Kennedy's disease with associated gynecomastia
 - f. Eunuchoidal state (congenital anorchia)
 - g. Hereditary defects of androgen biosynthesis
 - h. Adrenocorticotrophic hormone deficiency
 2. Secondary testicular failure
 - a. Trauma
 - b. Orchitis
 - c. Cryptorchidism
 - d. Irradiation
 - C. Renal failure
- III. Pharmacologic causes
- IV. Systemic diseases with idiopathic mechanisms

is related to the resumption of pituitary gonadotropin secretion after pituitary shutdown. Androgen deficiency may initiate gynecomastia. Concurrently occurring with decreased circulating testosterone levels is an elevated level of circulating testosterone-binding globulin, which results in a reduction of free testosterone. This senescent gynecomastia usually occurs in men aged 50 to 70 years. Hypoandrogenic states can be from primary testicular failure or secondary testicular failure. Klinefelter's syndrome (XXY) is an example of primary testicular failure which is manifested by gynecomastia, hypergonadotropic hypogonadism, and azoospermia. Secondary testicular failure may result from trauma, orchitis, and cryptorchidism. Renal failure, regardless of cause, also may initiate gynecomastia.

Pharmacologic causes of gynecomastia include drugs with estrogenic activity (digitalis, estrogens, anabolic steroids, marijuana) or drugs that enhance estrogen synthesis (human chorionic gonadotropin). Drugs that inhibit the action or synthesis of testosterone (cimetidine, ketoconazole, phenytoin, spironolactone, antineoplastic agents, diazepam) also have been implicated. Drugs such as reserpine, theophylline, verapamil, tricyclic antidepressants, and furosemide induce gynecomastia through idiopathic mechanisms.

When gynecomastia is caused by androgen deficiency, then testosterone administration may cause regression. When it is caused by medications, then these are discontinued if possible. When endocrine defects are responsible, then these receive specific therapy. As soon as gynecomastia is progressive and does not respond to other treatments, surgical therapy is considered. Techniques include local excision, liposuction or subcutaneous mastectomy. Attempts to reverse gynecomastia with danazol have been successful, but the androgenic side effects of the drug are considerable.

INFECTIOUS AND INFLAMMATORY DISORDERS OF THE BREAST

Infections in the postpartum period remain proportionately the most common time for breast infections to occur. Infections of the breast unrelated to lactation are proportionately less common, however, are still a relatively common presentation to breast specialists. The latter are classified as intrinsic (secondary to abnormalities in the breast) or extrinsic (secondary to an infection in an adjacent structure, e.g., skin, thoracic cavity) the most common being probably periductal mastitis and infected sebaceous cyst, respectively.

Bacterial Infection

Staphylococcus aureus and *Streptococcus* species are the organisms most frequently recovered from nipple discharge from an infected breast.¹⁷ Typically breast abscesses are seen in staphylococcal infections and present with point tenderness, erythema, and hyperthermia. When these abscesses are related to lactation they usually occur within the first few weeks of breastfeeding. If there is progression of a staphylococcal infection, this may result in subcutaneous, subareolar, interlobular (periductal), and retromammary abscesses (unicentric or multicentric). Previously almost all breast abscesses were treated by operative incision and drainage but now the initial approach is antibiotics and repeated aspiration of the abscess, usually ultrasound guided aspiration.²¹ Operative drainage is now reserved for those cases which don't resolve with repeated aspiration and antibiotic therapy or if there is some other indication for incision and drainage (e.g., thinning or necrosis of the overlying skin). Preoperative ultrasonography is effective in delineating the required extent of the drainage procedure. While staphylococcal infections tend to be more localized and may be situated deep in the breast tissues, streptococcal infections usually present with diffuse superficial involvement. They are treated with local wound care, including application of warm compresses, and the administration of IV antibiotics (penicillins or cephalosporins). Breast infections may be chronic, possibly with recurrent abscess formation. In this situation, cultures are performed to identify acid-fast bacilli, anaerobic and aerobic bacteria, and fungi. Uncommon organisms may be encountered, and long-term antibiotic therapy may be required.

Biopsy of the abscess cavity wall should be considered at the time of incision and drainage to rule out underlying breast cancer in patients where antibiotics and drainage have been ineffective.

Nowadays hospital-acquired puerperal infections of the breast are much less common, but nursing women who present with milk stasis or noninfectious inflammation may still develop this problem. Epidemic puerperal mastitis is initiated by highly virulent strains of methicillin-resistant *S. aureus* that are transmitted via the suckling neonate and may result in substantial morbidity and occasional mortality. Purulent fluid may be expressed from the nipple. In this circumstance, breastfeeding is stopped, antibiotics are started, and surgical therapy is initiated. *Nonepidemic (sporadic) puerperal mastitis* refers to involvement of the interlobular connective tissue of the breast by an infectious process. The patient develops nipple fissuring and milk stasis, which initiates a retrograde bacterial infection. Emptying of the breast using breast suction pumps shortens the duration of symptoms and reduces the incidence of recurrences. The addition of antibiotic therapy results in a satisfactory outcome in >95% of cases.

Zuska's disease, also called *recurrent periductal mastitis*, is a condition of recurrent retroareolar infections and abscesses.^{22,23} Smoking has been implicated as a risk factor for this condition.^{24,25} This syndrome is managed symptomatically by antibiotics coupled with incision and drainage as necessary. Attempts to obtain durable long-term control by wide débridement of chronically infected tissue and/or terminal duct resection have been reported and can be curative but equally can be frustrated by postoperative infections.²⁶

Mycotic Infections

Fungal infections of the breast are rare and usually involve blastomycosis or sporotrichosis.²⁷ Intraoral fungi that are inoculated into the breast tissue by the suckling infant initiate these infections, which present as mammary abscesses in close proximity to the nipple-areola complex. Pus mixed with blood may be expressed from sinus tracts. Antifungal agents can be administered for the treatment of systemic (noncutaneous) infections. This therapy generally eliminates the necessity of surgical intervention, but occasionally drainage of an abscess, or even partial mastectomy, may be necessary to eradicate a persistent fungal infection. *Candida albicans* affecting the skin of the breast presents as erythematous, scaly lesions of the inframammary or axillary folds. Scrapings from the lesions demonstrate fungal elements (filaments and budding cells). Therapy involves the removal of predisposing factors such as maceration and the topical application of nystatin.

Hidradenitis Suppurativa

Hidradenitis suppurativa of the nipple-areola complex or axilla is a chronic inflammatory condition that originates within the accessory areolar glands of Montgomery or within the axillary sebaceous glands.²⁷ Women with chronic acne are predisposed to developing hidradenitis. When located in and about the nipple-areola complex, this disease may mimic other chronic inflammatory states, Paget's disease of the nipple, or invasive breast cancer. Involvement of the axillary skin is often multifocal and contiguous. Antibiotic therapy with incision and drainage of fluctuant areas is appropriate treatment. Excision of the involved areas may be required. Large areas of skin loss may necessitate coverage with advancement flaps or split-thickness skin grafts.

Mondor's Disease

Mondor's disease is a variant of thrombophlebitis that involves the superficial veins of the anterior chest wall and breast.²⁸ In 1939, Mondor described the condition as "string phlebitis," a thrombosed vein presenting as a tender, cord-like structure.²⁹ Frequently involved veins include the lateral thoracic vein, the thoracoepigastric vein, and, less commonly, the superficial epigastric vein. Typically, a woman presents with acute pain in the lateral aspect of the breast or the anterior chest wall. A tender, firm cord is found to follow the distribution of one of the major superficial veins. Rarely, the presentation is bilateral, and most women have no evidence of thrombophlebitis in other anatomic sites. This benign, self-limited disorder is not indicative of a cancer. When the diagnosis is uncertain, or when a mass is present near the tender cord, biopsy is indicated. Therapy for Mondor's disease includes the liberal use of anti-inflammatory medications and application of warm compresses along the symptomatic vein. The process usually resolves within 4 to 6 weeks. When symptoms persist or are refractory to therapy, excision of the involved vein segment may be considered.

COMMON BENIGN DISORDERS AND DISEASES OF THE BREAST

Benign breast disorders and diseases encompass a wide range of clinical and pathologic entities. Surgeons require an in-depth understanding of benign breast disorders and diseases so that clear explanations may be given to affected women, appropriate treatment instituted, and unnecessary long-term follow up avoided.

Aberrations of Normal Development and Involution

The basic principles underlying the aberrations of normal development and involution (ANDI) classification of benign breast conditions are the following: (a) benign breast disorders and diseases are related to the normal processes of reproductive life and to involution; (b) there is a spectrum of breast conditions that ranges from normal to disorder to disease; and (c) the ANDI classification encompasses all aspects of the breast condition, including pathogenesis and the degree of abnormality.³⁰

4► The horizontal component of Table 17-2 defines ANDI along a spectrum from normal, to mild abnormality (disorder), to severe abnormality (disease). The vertical component indicates the period during which the condition develops.

Early Reproductive Years. Fibroadenomas are seen and present symptomatically predominantly in younger women aged 15 to 25 years (Fig. 17-10).³¹ Fibroadenomas usually grow to 1 or 2 cm in diameter and then are stable but may grow to a larger size. Small fibroadenomas (≤ 1 cm in size) are considered normal, whereas larger fibroadenomas (≤ 3 cm) are disorders and giant fibroadenomas (>3 cm) are disease. Similarly, multiple fibroadenomas (more than five lesions in one breast) are very uncommon and are considered disease. It is noted that with the introduction of mammographic screening, asymptomatic fibroadenomas are sometimes found in an older screened population. The precise etiology of adolescent breast hypertrophy is unknown. A spectrum of changes from limited to massive stromal hyperplasia (gigantomastia) is seen. Nipple inversion is a disorder of development of the major

Table 17-2

ANDI classification of benign breast disorders

	NORMAL	DISORDER	DISEASE
Early reproductive years (age 15–25 y)	Lobular development	Fibroadenoma	Giant fibroadenoma
	Stromal development	Adolescent hypertrophy	Gigantomastia
	Nipple eversion	Nipple inversion	Subareolar abscess Mammary duct fistula
Later reproductive years (age 25–40 y)	Cyclical changes of menstruation	Cyclical mastalgia	Incapacitating mastalgia
		Nodularity	
	Epithelial hyperplasia of pregnancy	Bloody nipple discharge	
Involution (age 35–55 y)	Lobular involution	Macrocysts	—
		Sclerosing lesions	
	Duct involution		
	Dilatation	Duct ectasia	Periductal mastitis
	Sclerosis	Nipple retraction	—
	Epithelial turnover	Epithelial hyperplasia	Epithelial hyperplasia with atypia

ANDI = aberrations of normal development and involution.

Source: Reproduced with permission from Hughes LE: Aberrations of normal development and involution (ANDI): A concept of benign breast disorders based on pathogenesis. In: Mansel RE, et al, eds. Hughes, Mansel & Webster's *Benign Disorders and Diseases of the Breast*. London: Saunders, 2009. Copyright Elsevier.

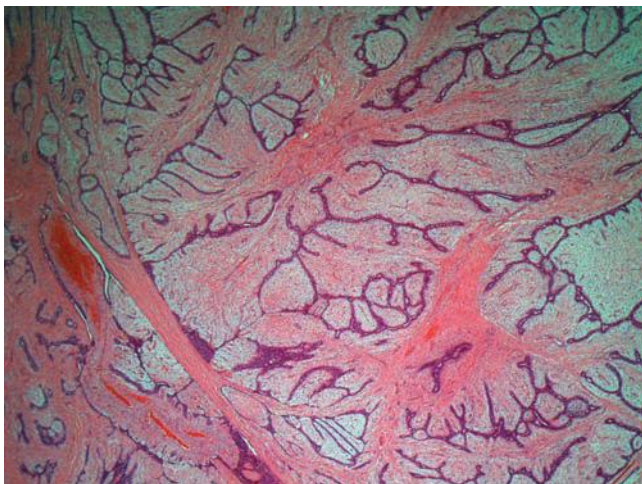


Figure 17-10. Fibroadenoma (40x). These benign tumors are typically well circumscribed and are comprised of both stromal and glandular elements. (Photo used with permission of Dr. Sindhu Menon, Consultant Histopathologist & Dr. Rahul Deb, Consultant Histopathologist and Lead Breast Pathologist, Royal Derby Hospital, Derby, UK.)

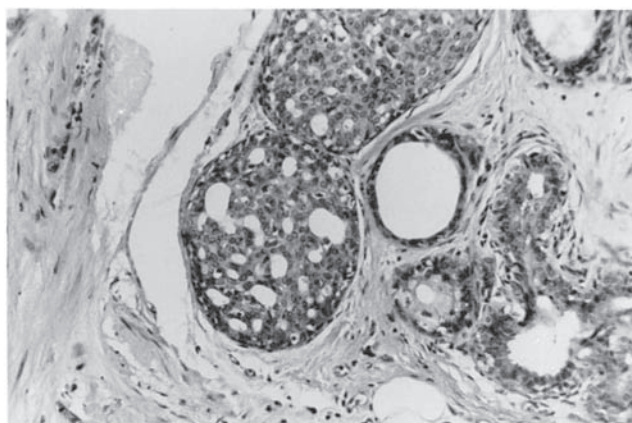
ducts, which prevents normal protrusion of the nipple. Mammary duct fistulas arise when nipple inversion predisposes to major duct obstruction, leading to recurrent subareolar abscess and mammary duct fistula.

Later Reproductive Years. Cyclical mastalgia and nodularity usually are associated with premenstrual enlargement of the breast and are regarded as normal. Cyclical pronounced mastalgia and severe painful nodularity are viewed differently than are physiologic discomfort and lumpiness. Painful nodularity that persists for >1 week of the menstrual cycle is considered a disorder. In epithelial hyperplasia of pregnancy, papillary projections sometimes give rise to bilateral bloody nipple discharge.

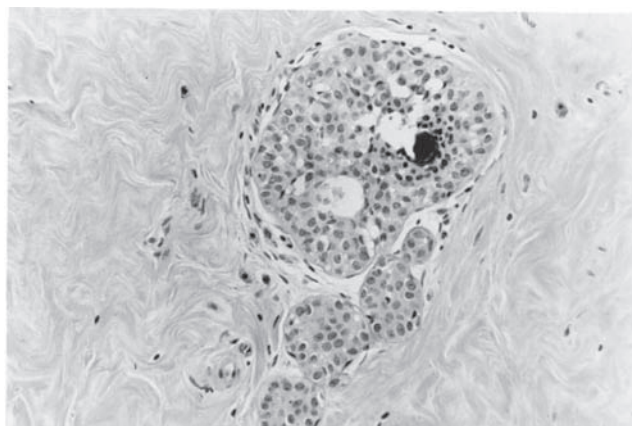
Involution. Involution of lobular epithelium is dependent on the specialized stroma around it. However, an integrated involution of breast stroma and epithelium is not always seen, and disorders of the process are common. When the stroma involutes too quickly, alveoli remain and form microcysts, which are precursors of macrocysts. The macrocysts are common, often subclinical, and do not require specific treatment. Sclerosing adenosis is considered a disorder of both the proliferative and the involutinal phases of the breast cycle. Duct ectasia (dilated ducts) and periductal mastitis are other important components of the ANDI classification. Periductal fibrosis is a sequela of periductal mastitis and may result in nipple retraction. About 60% of women ≥ 70 years of age exhibit some degree of epithelial hyperplasia (Fig. 17-11). Atypical proliferative diseases include ductal and lobular hyperplasia, both of which display some features of carcinoma in situ. Women with atypical ductal or lobular hyperplasia have a fourfold increase in breast cancer risk (Table 17-3).

Pathology of Nonproliferative Disorders

Of paramount importance for the optimal management of benign breast disorders and diseases is the histologic differentiation of benign, atypical, and malignant changes.^{32,33} Determining the clinical significance of these changes is a problem that is compounded by inconsistent nomenclature. The classification



A



B

Figure 17-11. **A.** Ductal epithelial hyperplasia. The irregular intracellular spaces and variable cell nuclei distinguish this process from carcinoma in situ. **B.** Lobular hyperplasia. The presence of alveolar lumina and incomplete distention distinguish this process from carcinoma in situ. (Photos used with permission of Dr. R.L. Hackett.)

Table 17-3

Cancer risk associated with benign breast disorders and in situ carcinoma of the breast

ABNORMALITY	RELATIVE RISK
Nonproliferative lesions of the breast	No increased risk
Sclerosing adenosis	No increased risk
Intraductal papilloma	No increased risk
Florid hyperplasia	1.5 to 2-fold
Atypical lobular hyperplasia	4-fold
Atypical ductal hyperplasia	4-fold
Ductal involvement by cells of atypical ductal hyperplasia	7-fold
Lobular carcinoma in situ	10-fold
Ductal carcinoma in situ	10-fold

Source: Modified from Dupont WD, et al: Risk factors for breast cancer in women with proliferative breast disease. *N Engl J Med* 312:146, 1985.

Table 17-4

Classification of benign breast disorders**Nonproliferative disorders of the breast**

- Cysts and apocrine metaplasia
- Duct ectasia
- Mild ductal epithelial hyperplasia
- Calcifications
- Fibroadenoma and related lesions

Proliferative breast disorders without atypia

- Sclerosing adenosis
- Radial and complex sclerosing lesions
- Ductal epithelial hyperplasia
- Intraductal papillomas

Atypical proliferative lesions

- Atypical lobular hyperplasia
- Atypical ductal hyperplasia

Source: Modified from Consensus Meeting: Is “fibrocystic disease” of the breast precancerous? *Arch Pathol Lab Med.* 1986;110:171.

system originally developed by Page separates the various types of benign breast disorders and diseases into three clinically relevant groups: nonproliferative disorders, proliferative disorders without atypia, and proliferative disorders with atypia (Table 17-4). Nonproliferative disorders of the breast account for 70% of benign breast conditions and carry no increased risk for the development of breast cancer. This category includes cysts, duct ectasia, periductal mastitis, calcifications, fibroadenomas, and related disorders.

Breast macrocysts are an involutional disorder, have a high frequency of occurrence, and are often multiple. Duct ectasia is a clinical syndrome characterized by dilated subareolar ducts that are palpable and often associated with thick nipple discharge. Haagensen regarded duct ectasia as a primary event that led to stagnation of secretions, epithelial ulceration, and leakage of duct secretions (containing chemically irritating fatty acids) into periductal tissue.³⁴ This sequence was thought to produce a local inflammatory process with periductal fibrosis and subsequent nipple retraction. An alternative theory considers periductal mastitis to be the primary process, which leads to weakening of the ducts and secondary dilatation. It is possible that both processes occur and together explain the wide spectrum of problems seen, which include nipple discharge, nipple retraction, inflammatory masses, and abscesses.

Calcium deposits are frequently encountered in the breast. Most are benign and are caused by cellular secretions and debris or by trauma and inflammation. Calcifications that are associated with cancer include microcalcifications, which vary in shape and density and are <0.5 mm in size, and fine, linear calcifications, which may show branching. Fibroadenomas have abundant stroma with histologically normal cellular elements. They show hormonal dependence similar to that of normal breast lobules in that they lactate during pregnancy and involute in the postmenopausal period. Adenomas of the breast are well circumscribed and are composed of benign epithelium with sparse stroma, which is the histologic feature that differentiates them from fibroadenomas. They may be divided into tubular adenomas and lactating adenomas. Tubular adenomas are seen in young nonpregnant women, whereas lactating adenomas are seen during pregnancy or during the postpartum period. Hamartomas are discrete breast tumors that are usually 2 to 4 cm in

diameter, firm, and sharply circumscribed. Adenolipomas consist of sharply circumscribed nodules of fatty tissue that contain normal breast lobules and ducts.

Fibrocystic Disease. The term *fibrocystic disease* is nonspecific. Too frequently, it is used as a diagnostic term to describe symptoms, to rationalize the need for breast biopsy, and to explain biopsy results. Synonyms include fibrocystic changes, cystic mastopathy, chronic cystic disease, chronic cystic mastitis, Schimmelbusch’s disease, mazoplasia, Cooper’s disease, Reclus’ disease, and fibroadenomatosis. *Fibrocystic disease* refers to a spectrum of histopathologic changes that are best diagnosed and treated specifically.

Pathology of Proliferative Disorders Without Atypia

Proliferative breast disorders without atypia include sclerosing adenosis, radial scars, complex sclerosing lesions, ductal epithelial hyperplasia, and intraductal papillomas.^{32,33} Sclerosing adenosis is prevalent during the childbearing and perimenopausal years and has no malignant potential. Histologic changes are both proliferative (ductal proliferation) and involutional (stromal fibrosis, epithelial regression). Sclerosing adenosis is characterized by distorted breast lobules and usually occurs in the context of multiple microcysts, but occasionally presents as a palpable mass. Benign calcifications are often associated with this disorder. Sclerosing adenosis can be managed by observation as long as the imaging features and pathologic findings are concordant. Central sclerosis and various degrees of epithelial proliferation, apocrine metaplasia, and papilloma formation characterize radial scars and complex sclerosing lesions of the breast. Lesions up to 1 cm in diameter are called *radial scars*, whereas larger lesions are called *complex sclerosing lesions*. Radial scars originate at sites of terminal duct branching where the characteristic histologic changes radiate from a central area of fibrosis. All of the histologic features of a radial scar are seen in the larger complex sclerosing lesions, but there is a greater disturbance of structure with papilloma formation, apocrine metaplasia, and occasionally sclerosing adenosis. Distinguishing between a radial scar and invasive breast carcinoma can be challenging based on core needle biopsy sampling. Often the imaging features of a radial scar (which can be quite similar to an invasive cancer) will dictate the need for either a vacuum assisted biopsy or surgical excision in order to exclude the possibility of carcinoma.

Mild ductal hyperplasia is characterized by the presence of three or four cell layers above the basement membrane. Moderate ductal hyperplasia is characterized by the presence of five or more cell layers above the basement membrane. Florid ductal epithelial hyperplasia occupies at least 70% of a minor duct lumen. It is found in >20% of breast tissue specimens, is either solid or papillary, and is associated with an increased cancer risk (see Table 17-3). Intraductal papillomas arise in the major ducts, usually in premenopausal women. They generally are <0.5 cm in diameter but may be as large as 5 cm. A common presenting symptom is nipple discharge, which may be serous or bloody. Grossly, intraductal papillomas are pinkish tan, friable, and usually attached to the wall of the involved duct by a stalk. They rarely undergo malignant transformation, and their presence does not increase a woman’s risk of developing breast cancer (unless accompanied by atypia). However, multiple intraductal papillomas, which occur in younger women and are

less frequently associated with nipple discharge, are susceptible to malignant transformation.

Pathology of Atypical Proliferative Diseases

The atypical proliferative diseases have some of the features of carcinoma in situ but either lack a major defining feature of carcinoma in situ or have the features in less than fully developed form.³⁴ Atypical ductal hyperplasia (ADH) appears similar to low grade ductal carcinoma in situ (DCIS) histologically and is composed of monotonous round, cuboidal, or polygonal cells enclosed by basement membrane with rare mitoses. A lesion will be considered to be ADH if it is up to 2 or 3 mm in size but would be called DCIS if it is larger than 3 mm. The diagnosis can be difficult to establish with core needle biopsy specimen alone and most cases will require excisional biopsy specimen for classification. Individuals with a diagnosis of ADH are at increased risk for development of breast cancer and should be counseled appropriately regarding risk reduction strategies.

In 1978, Haagensen et al described lobular neoplasia, a spectrum of disorders ranging from atypical lobular hyperplasia to lobular carcinoma in situ (LCIS).³⁵ Atypical lobular hyperplasia (ALH) results in minimal distention of lobular units with cells that are similar to those seen in LCIS. The diagnosis of LCIS is made when small monomorphic cells that distend the terminal ductal lobular unit are noted. In cases of LCIS the acini are full and distended while the overall lobular architecture is maintained (Fig. 17-12). Classic LCIS is not associated with a specific mammographic or palpable abnormality but is an incidental finding noted on breast biopsy. There is a variant of LCIS that has been termed *pleomorphic LCIS*. In the case of pleomorphic LCIS, there can be calcifications or other suspicious mammographic changes that dictate the need for biopsy. Classic LCIS is not treated with excision as the patient is at risk for developing invasive breast cancer in either breast and therefore the patient is counseled regarding appropriate risk reduction strategies. Pleomorphic LCIS can be difficult to distinguish from high-grade DCIS and there are some proponents who have suggested that patients with pleomorphic LCIS be

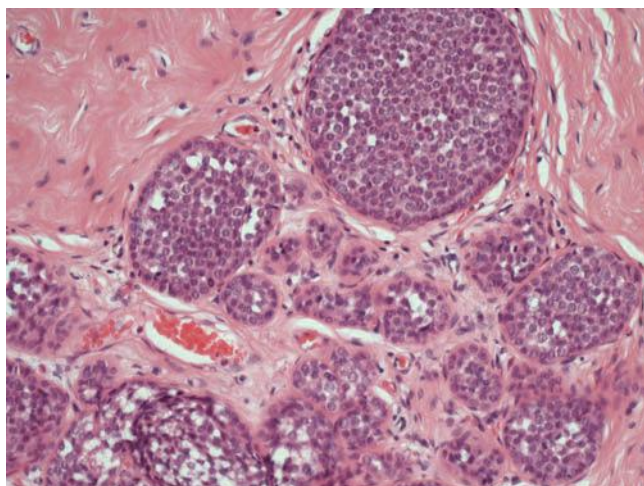


Figure 17-12. Lobular carcinoma in situ (100x). There are small monomorphic cells which distend the terminal duct lobular unit, without necrosis or mitoses. (Photo used with permission of Dr. Sindhu Menon, Consultant Histopathologist & Dr. Rahul Deb, Consultant Histopathologist and Lead Breast Pathologist, Royal Derby Hospital, Derby, UK.)

managed similar to those with DCIS with attention to margins and consideration for radiation therapy in the setting of breast conserving treatment. The use of immunohistochemical staining for E-cadherin can help to discriminate between LCIS and DCIS. In lobular neoplasias, such as ALH and LCIS, there is a lack of E-cadherin expression whereas the majority of ductal lesions will demonstrate E-cadherin reactivity.

Treatment of Selected Benign Breast Disorders and Diseases

Cysts. Because needle biopsy of breast masses may produce artifacts that make mammography assessment more difficult, many multidisciplinary teams prefer to image breast masses before performing either fine needle aspiration or core needle biopsy.^{36,37} In practice, however, the first investigation of palpable breast masses may be a needle biopsy, which allows for the early diagnosis of cysts. A 21-gauge needle attached to a 10-mL syringe is placed directly into the mass, which is fixed by fingers of the nondominant hand. The volume of a typical cyst is 5 to 10 mL, but it may be 75 mL or more. If the fluid that is aspirated is not bloodstained, then the cyst is aspirated to dryness, the needle is removed, and the fluid is discarded, because cytologic examination of such fluid is not cost effective. After aspiration, the breast is carefully palpated to exclude a residual mass. In most cases however imaging has been performed prior to a needle being introduced into the breast and indeed the majority of cysts are now aspirated under ultrasound guidance. If a mass was noted on initial ultrasound or there is a residual mass post-aspiration then a tissue specimen is obtained usually by core biopsy. When cystic fluid is bloodstained, fluid can be sent for cytologic examination. A simple cyst is rarely of concern, but a complex cyst may be the result of an underlying malignancy. A pneumocystogram can be obtained by injecting air into the cyst and then obtaining a repeat mammogram. When this technique is used, the wall of the cyst cavity can be more carefully assessed for any irregularities.

Fibroadenomas. Most fibroadenomas are self-limiting and many go undiagnosed, so a more conservative approach is reasonable. Careful ultrasound examination with core-needle biopsy will provide for an accurate diagnosis. Ultrasonography may reveal specific features that are pathognomonic for fibroadenoma and in a young woman (e.g., under 25 years) where the risk of breast cancer is already very low a core-needle biopsy may not be necessary. In patients where biopsy is performed, the patient is counseled concerning the ultrasound and biopsy results, and surgical excision of the fibroadenoma may be avoided. Cryoablation and ultrasound-guided vacuum assisted biopsy are approved treatments for fibroadenomas of the breast, especially lesions <3 cm. Larger lesions are often still best removed by excision. With short-term follow-up a significant percentage of fibroadenomas will decrease in size and will no longer be palpable.³⁸ However, many will remain palpable, especially those larger than 2 cm.³⁹ Therefore, women should be counseled that the options for treatment include surgical removal, cryoablation, vacuum assisted biopsy, or observation.

Sclerosing Disorders. The clinical significance of sclerosing adenosis lies in its imitation of cancer. On physical examination, it may be confused with cancer, by mammography, and at gross pathologic examination. Excisional biopsy and histologic examination are frequently necessary to exclude the diagnosis of cancer. The diagnostic work-up for radial scars and complex

sclerosing lesions frequently involves stereotactic biopsy. It usually is not possible to differentiate these lesions with certainty from cancer by mammographic features, so a larger tissue biopsy is recommended either by way of vacuum assisted biopsy or an open surgical excisional biopsy. The mammographic appearance of a radial scar or sclerosing adenosis (mass density with spiculated margins) will usually lead to an assessment that the results of a core-needle biopsy specimen showing benign disease are discordant with the radiographic findings.

Periductal Mastitis. Painful and tender masses behind the nipple-areola complex are aspirated with a 21-gauge needle attached to a 10-mL syringe. Any fluid obtained is submitted for culture using a transport medium appropriate for the detection of anaerobic organisms. In the absence of pus, women are started on a combination of metronidazole and dicloxacillin while awaiting the results of culture. Antibiotics are then continued based on sensitivity tests. Many cases respond satisfactorily to antibiotics alone, but when considerable purulent material is present, repeated ultrasound guided aspiration is performed and ultimately in a proportion of cases surgical treatment is required. Unlike puerperal abscesses, a subareolar abscess is usually unilocular and often is associated with a single duct system. Ultrasound will accurately delineate its extent. In those cases which come to surgery, the surgeon may either undertake simple drainage with a view toward formal surgery, should the problem recur, or proceed with definitive surgery. In a woman of childbearing age, simple drainage is preferred, but if there is an anaerobic infection, recurrent infection frequently develops. Recurrent abscess with fistula is a difficult problem. Treatment of periductal fistula was initially recommended to be opening up of the fistulous track and allowing it to granulate.⁴⁰ This approach may still be used especially if the fistula is recurrent after previous attempts at fistulectomy. However, nowadays the preferred initial surgical treatment is by fistulectomy and primary closure with antibiotic coverage.⁴¹ Excision of all the major ducts is an alternative option depending on the circumstances (Table 17-5). When a localized periareolar abscess

recurs at the previous site and a fistula is present, the preferred operation is fistulectomy, which has minimal complications and a high degree of success. However, when subareolar sepsis is diffuse rather than localized to one segment or when more than one fistula is present, total duct excision is the most expeditious approach. The first circumstance is seen in young women with squamous metaplasia of a single duct, whereas the latter circumstance is seen in older women with multiple ectatic ducts. Age is not always a reliable guide, however, and fistula excision is the preferred initial procedure for localized sepsis irrespective of age. Antibiotic therapy is useful for recurrent infection after fistula excision, and a 2- to 4-week course is recommended before total duct excision.

Nipple Inversion. More women request correction of congenital nipple inversion than request correction for the nipple inversion that occurs secondary to duct ectasia. Although the results are usually satisfactory, women seeking correction for cosmetic reasons should always be made aware of the surgical complications of altered nipple sensation, nipple necrosis, and postoperative fibrosis with nipple retraction. Because nipple inversion is a result of shortening of the subareolar ducts, a complete division of these ducts is necessary for permanent correction of the disorder.

RISK FACTORS FOR BREAST CANCER

Hormonal and Nonhormonal Risk Factors

Increased exposure to estrogen is associated with an increased risk for developing breast cancer, whereas reducing exposure is thought to be protective.⁴²⁻⁴⁸ Correspondingly, factors that increase the number of menstrual cycles, such as early menarche, nulliparity, and late menopause, are associated with increased risk. Moderate levels of exercise and a longer lactation period, factors that decrease the total number of menstrual cycles, are protective. The terminal differentiation of breast epithelium associated with a full-term pregnancy is also protective, so older age at first live birth is associated with an increased risk of breast cancer. Finally, there is an association between obesity and increased breast cancer risk. Because the major source of estrogen in postmenopausal women is the conversion of androstenedione to estrone by adipose tissue, obesity is associated with a long-term increase in estrogen exposure.

Nonhormonal risk factors include radiation exposure. Young women who receive mantle radiation therapy for Hodgkin's lymphoma have a breast cancer risk that is 75 times greater than that of age-matched control subjects. Survivors of the atomic bomb blasts in Japan during World War II have a very high incidence of breast cancer, likely because of somatic mutations induced by the radiation exposure. In both circumstances, radiation exposure during adolescence, a period of active breast development, magnifies the deleterious effect. Studies also suggest that the risk of breast cancer increases as the amount of alcohol a woman consumes increases.⁴⁹ Alcohol consumption is known to increase serum levels of estradiol. Finally, evidence suggests that long-term consumption of foods with a high fat content contributes to an increased risk of breast cancer by increasing serum estrogen levels.

Risk Assessment Models

The average lifetime risk of breast cancer for newborn U.S. females is 12%.^{50,51} The longer a woman lives without cancer,

Table 17-5

Treatment of recurrent subareolar sepsis

SUITABLE FOR FISTULECTOMY	SUITABLE FOR TOTAL DUCT EXCISION
Small abscess localized to one segment	Large abscess affecting >50% of the areolar circumference
Recurrence involving the same segment	Recurrence involving a different segment
Mild or no nipple inversion	Marked nipple inversion
Patient unconcerned about nipple inversion	Patient requests correction of nipple inversion
Younger patient	Older patient
No discharge from other ducts	Purulent discharge from other ducts
No prior fistulectomy	Recurrence after fistulectomy

Source: Modified with permission from Hughes LE: The duct ectasia/periductal mastitis complex, in Hughes LE, et al (eds): *Benign Disorders and Diseases of the Breast: Concepts and Clinical Management*. London: WB Saunders, 2000, p 162. Copyright © Elsevier.

the lower her risk of developing breast cancer. Thus, a woman aged 50 years has an 11% lifetime risk of developing breast cancer, and a woman aged 70 years has a 7% lifetime risk of developing breast cancer. Because risk factors for breast cancer interact, evaluating the risk conferred by combinations of risk factors is difficult. There are several risk assessment models available to predict the risk of breast cancer. From the Breast Cancer Detection Demonstration Project, a mammography screening program conducted in the 1970s, Gail et al developed the model most frequently used in the United States, which incorporates age, age at menarche, age at first live birth, the number of breast biopsy specimens, any history of atypical hyperplasia, and number of first-degree relatives with breast cancer.⁵² It predicts the cumulative risk of breast cancer according to decade of life. To calculate breast cancer risk using the Gail model, a woman's risk factors are translated into an overall risk score by multiplying her relative risks from several categories (Table 17-6). This risk score is then compared

5► to an adjusted population risk of breast cancer to determine a woman's individual or absolute risk. The output is a five-year risk and a lifetime risk of developing breast cancer. A software program incorporating the Gail model is available from the National Cancer Institute at <http://bcra.nci.nih.gov/brc>. This model was recently modified to more accurately assess risk in African American women.^{52,53} The Gail model is the most widely used model in the United States. Gail and colleagues have also described a revised model that includes body weight and mammographic density but excludes age at menarche.⁵⁴

Claus et al, using data from the Cancer and Steroid Hormone Study, a case-control study of breast cancer, developed the other frequently used risk assessment model, which is based on assumptions about the prevalence of high-penetrance breast cancer susceptibility genes.⁵⁵ Compared with the Gail model, the Claus model incorporates more information about family history but excludes other risk factors. The Claus model provides individual estimates of breast cancer risk according to decade of life based on presence of first- and second-degree relatives with breast cancer and their age at diagnosis. Risk factors that are less consistently associated with breast cancer (diet, use of oral contraceptives, lactation) or are rare in the general population (radiation exposure) are not included in either the Gail or Claus risk assessment model. Other models have been proposed that account for mammographic breast density in assessing breast cancer risk.^{54,56}

Neither the Gail model nor the Claus model accounts for the risk associated with mutations in the breast cancer susceptibility genes *BRCA1* and *BRCA2* (described in detail below). The BRCAPRO model is a Mendelian model that calculates the probability that an individual is a carrier of a mutation in one of the breast cancer susceptibility genes based on their family history of breast and ovarian cancer.⁵⁷ The probability that an individual will develop breast or ovarian cancer is derived from this mutation probability based on age-specific incidence curves for both mutation carriers and noncarriers.⁵⁸ Use of the BRCAPRO model in the clinic is challenging since it requires input of all family history information regarding breast and ovarian cancer. The Tyrer-Cuzick model attempts to utilize both family history information and individual risk information. It uses the family history to calculate the probability that an individual carries a mutation in one of the breast cancer susceptibility genes and then the risk is adjusted based on personal risk factors, including age at menarche, parity, age at first live birth, age at menopause,

Table 17-6

Relative risk estimates for the Gail model

VARIABLE	RELATIVE RISK
Age at menarche (years)	
≥14	1.00
12–13	1.10
<12	1.21
Number of biopsy specimens/history of benign breast disease, age <50 y	
0	1.00
1	1.70
≥2	2.88
Number of biopsy specimens/history of benign breast disease, age ≥50 y	
0	1.02
1	1.27
≥2	1.62
Age at first live birth (years)	
<20 y	
Number of first-degree relatives with history of breast cancer	
0	1.00
1	2.61
≥2	6.80
20–24 y	
Number of first-degree relatives with history of breast cancer	
0	1.24
1	2.68
≥2	5.78
25–29 y	
Number of first-degree relatives with history of breast cancer	
0	1.55
1	2.76
≥2	4.91
≥30 y	
Number of first-degree relatives with history of breast cancer	
0	1.93
1	2.83
≥2	4.17

Source: Modified from Armstrong K, et al: Primary care: Assessing the risk of breast cancer. *N Engl J Med*. 342:564, 2000.

history of atypical hyperplasia or LCIS, height and body mass index.⁵⁹ Once a risk model has been utilized to assess breast cancer risk, this must be communicated to the individual and put into context with competing risk and medical comorbidities. This information can then be used to discuss options that are available to the individual for managing risk.

Risk Management

Several important medical decisions may be affected by a woman's underlying risk of developing breast cancer.⁶⁰⁻⁶⁸ These decisions include when to use postmenopausal hormone replacement therapy, at what age to begin mammography screening or incorporate magnetic resonance imaging (MRI) screening, when

to use tamoxifen to prevent breast cancer, and when to perform prophylactic mastectomy to prevent breast cancer. Postmenopausal hormone replacement therapy was widely prescribed in the 1980s and 1990s because of its effectiveness in controlling the symptoms of estrogen deficiency; namely, vasomotor symptoms such as hot flashes, night sweats and their associated sleep deprivation, osteoporosis, and cognitive changes. Furthermore, these hormone supplements were thought to reduce coronary artery disease as well. Use of combined estrogen and progesterone became standard for women who had not undergone hysterectomy, because unopposed estrogen increases the risk of uterine cancer. Concerns of prolonging a woman's lifetime exposure to estrogen, coupled with conflicting data regarding the impact of these hormones on cardiovascular health, motivated the implementation of large-scale phase III clinical trials to definitively evaluate the risks vs. benefits of postmenopausal hormone replacement therapy. The Women's Health Initiative was therefore designed by the National Institutes of Health as a series of clinical trials to study the effects of diet, nutritional supplements, and hormones on the risk of cancer, cardiovascular disease, and bone health in postmenopausal women. Findings from primary studies of postmenopausal hormone replacement therapy were released in 2002, demonstrating conclusively that breast cancer risk is threefold to fourfold higher after >4 years of use and there is no significant reduction in coronary artery or cerebrovascular risks. The Collaborative Group on Hormonal Factors in Breast Cancer combined and re-analyzed data from a number of studies totaling 52,705 women with breast cancer and 108,411 women without breast cancer. They found an increased risk of breast cancer with ever use of estrogen replacement therapy. They also reported increased risk among current users but not past users and risk increased with increasing duration of use of hormone replacement therapy.⁶⁹ Cheblowski et al also reported from the WHI study that estrogen + progesterone increased the incidence of breast cancer.⁷⁰ This was confirmed by the Million Women study which also showed that the increased risk was substantially greater for the combined estrogen + progesterone replacement therapy than other types of hormone replacement therapy.⁷¹

Breast Cancer Screening. Routine use of screening mammography in women ≥ 50 years of age has been reported to reduce mortality from breast cancer by 25%.⁷² This reduction

6► comes at an acceptable economic cost. More recently, there has been debate over the potential harms associated with breast screening.⁷³ As a result the United Kingdom recently established an independent expert panel to review the published literature and estimate the benefits and harms associated with screening women >50 years in its national screening program.⁷⁴ The expert panel estimated that an invitation to breast screening delivers about a 20% reduction in breast cancer mortality while at the same time the panel estimated that in women invited to screening, about 11% of the cancers diagnosed in their lifetime constitute over-diagnosis. Despite the overdiagnosis, the panel concluded that breast screening confers significant benefit and should continue. The use of screening mammography in women <50 years of age is more controversial for several reasons: (a) breast density is greater and screening mammography is less likely to detect early breast cancer (i.e., reduced sensitivity); (b) screening mammography results in more false-positive test findings (i.e., reduced specificity), which results in unnecessary biopsy specimens; and (c) younger women are less likely to have breast cancer (i.e., lower incidence), so fewer young

women will benefit from screening.^{75,76} In the United States, on a population basis, however, the benefits of screening mammography in women between the ages of 40 and 49 years is still felt to outweigh the risks; although targeting mammography to women at higher risk of breast cancer improves the balance of risks and benefits and is the approach some health care systems have taken. In one study of women aged 40 to 49 years, an abnormal mammography finding was three times more likely to be cancer in a woman with a family history of breast cancer than in a woman without such a history. Furthermore, as noted previously in the section *Risk Assessment Models*, mounting data regarding mammographic breast density demonstrate an independent correlation with breast cancer risk. Incorporation of breast density measurements into breast cancer risk assessment models appears to be a promising strategy for increasing the accuracy of these tools. Unfortunately, widespread application of these modified models is hampered by inconsistencies in the reporting of mammographic density. Ultrasonography can also be used for breast cancer screening in women with dense breasts but there is no data available that the additional cancers detected with this modality reduce mortality from breast cancer.

Current recommendations by the United States Preventive Services Task Force are that women undergo biennial mammographic screening between the ages of 50 and 74 years.⁷⁷ The American Cancer Society (ACS) continues to recommend annual mammography for women beginning at age 40 years to continue as long as she is in good health. In addition, a clinical breast examination by a health professional is recommended annually. The use of MRI for breast cancer screening is recommended by the ACS for women with a 20% to 25% or greater lifetime risk using risk assessment tools based mainly on family history, BRCA mutation carriers, those individuals who have a family member with a BRCA mutation who have not been tested themselves, individuals who received radiation to the chest between the ages of 10 to 30 years, and those individuals with a history of Li-Fraumeni syndrome, Cowden syndrome, or Bannayan-Riley-Ruvalcaba syndrome or those who have a first-degree relative with one of these syndromes. MRI is an extremely sensitive screening tool that is not limited by the density of the breast tissue as mammography is, however, its specificity is moderate leading to more false-positive events and the increased need for biopsy.

Chemoprevention. Tamoxifen, a selective estrogen receptor modulator, was the first drug shown to reduce the incidence of breast cancer in healthy women. There have been 4 prospective studies published evaluating tamoxifen vs. placebo for reducing the incidence of invasive breast cancer for women at increased risk. The largest trial was the Breast Cancer Prevention Trial (NSABP P-01) which randomly assigned >13,000 women with a 5-year Gail relative risk of breast cancer of 1.66% or higher or LCIS to receive tamoxifen or placebo. After a mean follow-up period of 4 years, the incidence of breast cancer was reduced by 49% in the group receiving tamoxifen.⁶⁰ The decrease was evident only in ER-positive breast cancers with no significant change in ER-negative tumors. The Royal Marsden Hospital Tamoxifen Chemoprevention Trial⁷⁸, the Italian Tamoxifen Prevention Trial⁷⁹, and the International Breast Cancer Intervention Study I (IBIS-I) trial all⁸⁰ showed a reduction in ER-positive breast cancers with the use of tamoxifen compared with placebo. There was no effect on mortality; however, the trials were not powered to assess either breast cancer mortality or all-cause mortality events. The adverse events were similar in all

4 randomized trials including an increased risk of endometrial cancer, thromboembolic events, cataract formation, and vasomotor disturbances in individuals receiving tamoxifen.

Tamoxifen therapy currently is recommended only for women who have a Gail relative risk of 1.66% or higher, who are aged 35 to 59, women over the age of 60 or women with a diagnosis of LCIS or atypical ductal or lobular hyperplasia. In addition, deep vein thrombosis occurs 1.6 times as often, pulmonary emboli 3.0 times as often, and endometrial cancer 2.5 times as often in women taking tamoxifen. The increased risk for endometrial cancer is restricted to early stage cancers in postmenopausal women. Cataract surgery is required almost twice as often among women taking tamoxifen. Gail et al subsequently developed a model that accounts for underlying risk of breast cancer as well as comorbidities to determine the net risk-benefit ratio of tamoxifen use for chemoprevention.⁸¹

The NSABP completed a second chemoprevention trial, designed to compare tamoxifen and raloxifene for breast cancer risk reduction in high-risk postmenopausal women. Raloxifene, another selective estrogen receptor modulator, was selected for the experimental arm in this follow-up prevention trial because its use in managing postmenopausal osteoporosis suggested that it might be even more effective at breast cancer risk reduction, but without the adverse effects of tamoxifen on the uterus. The P-2 trial, the Study of Tamoxifen and Raloxifene (known as the *STAR trial*), randomly assigned 19,747 postmenopausal women at high-risk for breast cancer to receive either tamoxifen or raloxifene. The initial report of the P-2 trial showed the two agents were nearly identical in their ability to reduce breast cancer risk, but raloxifene was associated with a more favorable adverse event profile.⁸² An updated analysis revealed that raloxifene maintained 76% of the efficacy of tamoxifen in prevention of invasive breast cancer with a more favorable side effect profile. The risk of developing endometrial cancer was significantly higher with tamoxifen use at longer follow-up.⁸³ Although tamoxifen has been shown to reduce the incidence of LCIS and DCIS, raloxifene did not have an effect on the frequency of these diagnoses.

Aromatase inhibitors (AIs) have been shown to be more effective than tamoxifen in reducing the incidence of contralateral breast cancers in postmenopausal women receiving AIs for adjuvant treatment of invasive breast cancer. The MAP.3 trial was the first study to evaluate an AI as a chemopreventive agent in postmenopausal women at high risk for breast cancer. The trial randomized 4,560 women to exemestane 25 mg daily vs. placebo for five years. After a median follow-up of 35 months, exemestane was shown to reduce invasive breast cancer incidence by 65%. Side effect profiles demonstrated more grade 2 or higher arthritis and hot flashes in patients taking exemestane.⁸⁴ The IBIS II trial has recruited 6,000 patients randomized to the non-steroidal aromatase inhibitor, anastrozole, vs. placebo with a further randomization to bisphosphonate or not based on bone density.⁸⁵ The trial also had an initial sub-study which looked at the effect of the aromatase inhibitor on cognitive function and reported no adverse effects.⁸⁶ The American Society of Clinical Oncology recently updated recommendations for chemoprevention in women at increased risk of breast cancer as did the U.S. Preventive Services Task Force. Both groups recommend offering tamoxifen to women at increased risk for breast cancer or raloxifene to postmenopausal women who are noted to be at increased risk.^{87,88} The discussion with an individual patient should include risk assessment and potential risks and benefits with each agent.

Risk-reducing Surgery. A retrospective study of women at high risk for breast cancer found that prophylactic mastectomy reduced their risk by >90%.⁶² However, the effects of prophylactic mastectomy on the long-term quality of life are poorly quantified. A study involving women who were carriers of a breast cancer susceptibility gene (BRCA) mutation found that the benefit of prophylactic mastectomy differed substantially according to the breast cancer risk conferred by the mutations. For women with an estimated lifetime risk of 40%, prophylactic mastectomy added almost 3 years of life, whereas for women with an estimated lifetime risk of 85%, prophylactic mastectomy added >5 years of life.⁶⁶ Domchek et al evaluated a cohort of BRCA1/2 mutation carriers who were followed prospectively and reported on outcomes with risk-reducing surgery.⁸⁹ They found that risk-reducing mastectomy was highly effective at preventing breast cancer in both BRCA1 and 2 mutation carriers. Risk-reducing salpingo-oophorectomy was highly effective at reducing the incidence of ovarian cancer and breast cancer in BRCA mutation carriers and was associated with a reduction in breast cancer-specific mortality, ovarian cancer-specific mortality, and all-cause mortality. While studies of bilateral prophylactic or risk-reducing mastectomy have reported dramatic reductions in breast cancer incidence among those without known BRCA mutations, there is little data to support a survival benefit. Another consideration is that while most patients are satisfied with their decision to pursue risk-reducing surgery, some are dissatisfied with the cosmetic outcomes mostly due to reconstructive issues.

BRCA Mutations

BRCA1. Up to 5% of breast cancers are caused by inheritance of germline mutations such as *BRCA1* and *BRCA2*, which are inherited in an autosomal dominant fashion with varying degrees of penetrance (Table 17-7).⁹⁰⁻⁹⁶ *BRCA1* is located on chromosome arm 17q, spans a genomic region of approximately 100 kilobases (kb) of DNA, and contains 22 coding exons for 1863 amino acids. Both *BRCA1* and *BRCA2* function as tumor-suppressor genes, and for each gene, loss of both alleles is required for the initiation of cancer. Data accumulated since the isolation of the *BRCA1* gene suggest a role in transcription,

Table 17-7

Incidence of sporadic, familial, and hereditary breast cancer

Sporadic breast cancer	65%–75%
Familial breast cancer	20%–30%
Hereditary breast cancer	5%–10%
<i>BRCA1</i> ^a	45%
<i>BRCA2</i>	35%
p53^a (Li-Fraumeni syndrome)	1%
STK11/LKB1^a (Peutz-Jeghers syndrome)	<1%
PTEN^a (Cowden disease)	<1%
MSH2/MLH1^a (Muir-Torre syndrome)	<1%
ATM^a (Ataxia-telangiectasia)	<1%
Unknown	20%

^aAffected gene.

Source: Adapted from Martin.⁹²

cell-cycle control, and DNA damage repair pathways. More than 500 sequence variations in *BRCA1* have been identified. It now is known that germline mutations in *BRCA1* represent a predisposing genetic factor in as many as 45% of hereditary breast cancers and in at least 80% of hereditary ovarian cancers. Female mutation carriers have been reported to have up to a 85% lifetime risk (for some families) for developing breast cancer and up to a 40% lifetime risk for developing ovarian cancer. The initial families reported had high penetrance and subsequently the average lifetime risk has been reported to lie between 60%–70%. Breast cancer susceptibility in these families appears as an autosomal dominant trait with high penetrance. Approximately 50% of children of carriers inherit the trait. In general, *BRCA1*-associated breast cancers are invasive ductal carcinomas, are poorly differentiated, are in the majority hormone receptor negative and have a triple receptor negative (immunohistochemical profile: ER-negative, PR-negative and *HER-2*-negative) or basal phenotype (based on gene expression profiling). *BRCA1*-associated breast cancers have a number of distinguishing clinical features, such as an early age of onset compared with sporadic cases; a higher prevalence of bilateral breast cancer; and the presence of associated cancers in some affected individuals, specifically ovarian cancer and possibly colon and prostate cancers.

Several founder mutations have been identified in *BRCA1*. The two most common mutations are 185delAG and 5382insC, which account for 10% of all the mutations seen in *BRCA1*. These two mutations occur at a 10-fold higher frequency in the Ashkenazi Jewish population than in non-Jewish caucasians. The carrier frequency of the 185delAG mutation in the Ashkenazi Jewish population is 1% and, along with the 5382insC mutation, accounts for almost all *BRCA1* mutations in this population. Analysis of germline mutations in Jewish and non-Jewish women with early-onset breast cancer indicates that 20% of Jewish women who develop breast cancer before age 40 years carry the 185delAG mutation. There are founder *BRCA1* mutations in other populations including, among others, Dutch, Polish, Finnish, and Russian populations.⁹⁷⁻¹⁰¹

BRCA2. *BRCA2* is located on chromosome arm 13q and spans a genomic region of approximately 70 kb of DNA. The 11.2-kb coding region contains 26 coding exons.⁹⁰⁻⁹⁶ It encodes a protein of 3418 amino acids. The *BRCA2* gene bears no homology to any previously described gene, and the protein contains no previously defined functional domains. The biologic function of *BRCA2* is not well defined, but like *BRCA1*, it is postulated to play a role in DNA damage response pathways. *BRCA2* messenger RNA also is expressed at high levels in the late G₁ and S phases of the cell cycle. The kinetics of *BRCA2* protein regulation in the cell cycle is similar to that of *BRCA1* protein, which suggests that these genes are coregulated. The mutational spectrum of *BRCA2* is not as well established as that of *BRCA1*. To date, >250 mutations have been found. The breast cancer risk for *BRCA2* mutation carriers is close to 85%, and the lifetime ovarian cancer risk, while lower than for *BRCA1*, is still estimated to be close to 20%. Breast cancer susceptibility in *BRCA2* families is an autosomal dominant trait and has a high penetrance. Approximately 50% of children of carriers inherit the trait. Unlike male carriers of *BRCA1* mutations, men with germline mutations in *BRCA2* have an estimated breast cancer risk of 6%, which represents a 100-fold increase over the risk in the general male population. *BRCA2*-associated breast cancers are invasive ductal carcinomas, which are more likely to

be well differentiated and to express hormone receptors than are *BRCA1*-associated breast cancers. *BRCA2*-associated breast cancer has a number of distinguishing clinical features, such as an early age of onset compared with sporadic cases, a higher prevalence of bilateral breast cancer, and the presence of associated cancers in some affected individuals, specifically ovarian, colon, prostate, pancreatic, gallbladder, bile duct, and stomach cancers, as well as melanoma. A number of founder mutations have been identified in *BRCA2*. The 6174delT mutation is found in Ashkenazi Jews with a prevalence of 1.2% and accounts for 60% of ovarian cancer and 30% of early-onset breast cancer patients among Ashkenazi women.¹⁰² Another *BRCA2* founder mutation, 999del5, is observed in Icelandic and Finnish populations while more recently 3036delACAA has been observed in a number of Spanish families.¹⁰³⁻¹⁰⁵

Identification of BRCA Mutation Carriers. Identifying hereditary risk for breast cancer is a four-step process that includes: (a) obtaining a complete, multigenerational family history, (b) assessing the appropriateness of genetic testing for a particular patient, (c) counseling the patient, and (d) interpreting the results of testing.¹⁰⁶ Genetic testing should not be offered in isolation, but only in conjunction with patient education and counseling, including referral to a genetic counselor. Initial determinations include whether the individual is an appropriate candidate for genetic testing and whether genetic testing will be informative for personal and clinical decision making. A thorough and accurate family history is essential to this process, and the maternal and paternal sides of the family are both assessed, because 50% of the women with a *BRCA* mutation have inherited the mutation from their fathers. To help clinicians advise women about genetic testing, statistically based models that determine the probability that an individual carries a *BRCA* mutation have been developed. A method for calculating carrier probability which has been demonstrated to have acceptable performance (i.e., both in terms of calibration and discrimination) such as the Manchester scoring system and BODICEA should be used to offer referral to a specialist genetic clinic. A hereditary risk of breast cancer is considered if a family includes Ashkenazi Jewish heritage; a first-degree relative with breast cancer before age 50; a history of ovarian cancer at any age in the patient or first- or second-degree relative with ovarian cancer; breast and ovarian cancer in the same individual; two or more first- or second-degree relatives with breast cancer at any age; patient or relative with bilateral breast cancer; and male breast cancer in a relative at any age.¹⁰⁷ The threshold for genetic testing is lower in individuals who are members of ethnic groups in whom the mutation prevalence is increased.

BRCA Mutation Testing. Appropriate counseling for the individual being tested for a *BRCA* mutation is strongly recommended, and documentation of informed consent is required.^{106,108} The test that is clinically available for analyzing *BRCA* mutations is gene sequence analysis. In a family with a history suggestive of hereditary breast cancer and no previously tested member, the most informative strategy is first to test an affected family member. This person undergoes complete sequence analysis of both the *BRCA1* and *BRCA2* genes. If a mutation is identified, relatives are usually tested only for that specific mutation. An individual of Ashkenazi Jewish ancestry is tested initially for the three specific mutations that account for hereditary breast and ovarian cancer in that population.

If results of that test are negative, it may then be appropriate to fully analyze the *BRCA1* and *BRCA2* genes.

A positive test result is one that discloses the presence of a *BRCA* mutation that interferes with translation or function of the *BRCA* protein. A woman who carries a deleterious mutation has a breast cancer risk of up to 85% (in some families) as well as a greatly increased risk of ovarian cancer. A negative test result is interpreted according to the individual's personal and family history, especially whether a mutation has been previously identified in the family, in which case the woman is generally tested only for that specific mutation. If the mutation is not present, the woman's risk of breast or ovarian cancer may be no greater than that of the general population. In addition, no *BRCA* mutation can be passed on to the woman's children. In the absence of a previously identified mutation, a negative test result in an affected individual generally indicates that a *BRCA* mutation is not responsible for the familial cancer. However, the possibility remains of an unusual abnormality in one of these genes that cannot yet be identified through clinical testing. It also is possible that the familial cancer is indeed caused by an identifiable *BRCA* mutation but that the individual tested had sporadic cancer, a situation known as *phenocopy*. This is especially possible if the individual tested developed breast cancer close to the age of onset of the general population (age 60 years or older) rather than before age 50 years, as is characteristic of *BRCA* mutation carriers. Overall, the false-negative rate for *BRCA* mutation testing is <5%. Some test results, especially when a single base-pair change (missense mutation) is identified, may be difficult to interpret. This is because single base-pair changes do not always result in a nonfunctional protein. Thus, missense mutations not located within critical functional domains, or those that cause only minimal changes in protein structure, may not be disease associated and are usually reported as indeterminate results. In communicating indeterminate results to women, care must be taken to relay the uncertain cancer risk associated with this type of mutation and to emphasize that ongoing research might clarify its meaning. In addition, testing other family members with breast cancer to determine if a genetic variant tracks with their breast cancer may provide clarification as to its significance. Indeterminate genetic variance currently accounts for 12% of the test results.

Concern has been expressed that the identification of hereditary risk for breast cancer may interfere with access to affordable health insurance. This concern refers to discrimination directed against an individual or family based solely on an apparent or perceived genetic variation from the normal human genotype. The Health Insurance Portability and Accountability Act of 1996 (HIPAA) made it illegal in the United States for group health plans to consider genetic information as a preexisting condition or to use it to deny or limit coverage. Most states also have passed laws that prevent genetic discrimination in the provision of health insurance. In addition, individuals applying for health insurance are not required to report whether relatives have undergone genetic testing for cancer risk, only whether those relatives have actually been diagnosed with cancer. Currently there is little documented evidence of genetic discrimination resulting from findings of available genetic tests.

Cancer Prevention for *BRCA* Mutation Carriers. Risk management strategies for *BRCA1* and *BRCA2* mutation carriers include the following:

1. Risk-reducing mastectomy and reconstruction
2. Risk-reducing salpingo-oophorectomy

3. Intensive surveillance for breast and ovarian cancer
4. Chemoprevention

Although removal of breast tissue reduces the likelihood that *BRCA1* and *BRCA2* mutation carriers will develop breast cancer, mastectomy does not remove all breast tissue and women continue to be at risk because a germline mutation is present in any remaining breast tissue. For postmenopausal *BRCA1* and *BRCA2* mutation carriers who have not had a mastectomy, it may be advisable to avoid hormone replacement therapy, because no data exist regarding the effect of the therapy on the penetrance of breast cancer susceptibility genes. Because breast cancers in *BRCA* mutation carriers have the same mammographic appearance as breast cancers in noncarriers, a screening mammogram is likely to be effective in *BRCA* mutation carriers, provided it is performed and interpreted by an experienced radiologist with a high level of suspicion. Present screening recommendations for *BRCA* mutation carriers who do not undergo risk-reducing mastectomy include clinical breast examination every 6 months and mammography every 12 months beginning at age 25 years, because the risk of breast cancer in *BRCA* mutation carriers increases after age 30 years. Recent attention has been focused on the use MRI for breast cancer screening in high-risk individuals and known *BRCA* mutation carriers. MRI appears to be more sensitive at detecting breast cancer in younger women with dense breasts.¹⁰⁹ However, as noted previously, MRI does lead to the detection of benign breast lesions that cannot easily be distinguished from malignancy, and these false-positive events can result in more interventions, including biopsy specimens. The current recommendations from the American Cancer Society are for annual MRI in women with a 20% to 25% or greater lifetime risk of developing breast cancer, including women with a strong family history of breast or ovarian cancer and women who were treated for Hodgkin's disease in their teens or early twenties.¹¹⁰ Despite a 49% reduction in the overall incidence of breast cancer and a 69% reduction in the incidence of estrogen receptor positive tumors in high-risk women taking tamoxifen reported in the NSABP P1 trial, there is insufficient evidence to recommend the use of tamoxifen uniformly for *BRCA1* mutation carriers.⁶⁰ Cancers arising in *BRCA1* mutation carriers are usually high grade and are most often hormone receptor negative. Approximately 66% of *BRCA1*-associated DCIS lesions are estrogen receptor negative, which suggests early acquisition of the hormone-independent phenotype. In the NSABP P1 trial there was a 62% reduction in the incidence of breast cancer in *BRCA2* carriers, similar to the overall reduction seen in the P1 trial. In contrast, there was no reduction seen in breast cancer incidence in *BRCA1* carriers who started tamoxifen in P1 age 35 years or older.¹¹¹ Tamoxifen appears to be more effective at preventing estrogen receptor-positive breast cancers.

The risk of ovarian cancer in *BRCA1* and *BRCA2* mutation carriers ranges from 20% to 40%, which is 10 times higher than that in the general population. Risk-reducing salpingo-oophorectomy is a reasonable prevention option in mutation carriers. In women with a documented *BRCA1* or *BRCA2* mutation, consideration for bilateral risk-reducing salpingo-oophorectomy should be between the ages of 35 and 40 years at the completion of childbearing. Removing the ovaries reduces the risk of ovarian cancer and breast cancer when performed in premenopausal *BRCA* mutation carriers. Hormone replacement therapy is discussed with the patient at the time of oophorectomy. The Cancer Genetics Studies Consortium recommends yearly transvaginal

ultrasound timed to avoid ovulation and annual measurement of serum cancer antigen 125 levels beginning at age 25 years as the best screening modalities for ovarian carcinoma in *BRCA* mutation carriers who have opted to defer prophylactic surgery.

Other hereditary syndromes associated with an increased risk of breast cancer include Cowden disease (*PTEN* mutations, in which cancers of the thyroid, GI tract, and benign skin and subcutaneous nodules are also seen), Li-Fraumeni syndrome (p53 mutations, also associated with sarcomas, lymphomas, and adrenocortical tumors), and syndromes of breast and melanoma.

EPIDEMIOLOGY AND NATURAL HISTORY OF BREAST CANCER

Epidemiology

Breast cancer is the most common site-specific cancer in women and is the leading cause of death from cancer for women aged 20 to 59 years. It accounts for 29% of all newly diagnosed cancers in females and is responsible for 14% of the cancer-related deaths in women. It is predicted that approximately 234,580 breast cancers will be diagnosed in the United States in 2013 and that 40,030 individuals will die from breast cancer.¹¹² Breast cancer was the leading cause of cancer-related mortality in women until 1987, when it was surpassed by lung cancer. In the 1970s, the probability that a woman in the United States would develop breast cancer at some point in her lifetime was estimated at 1 in 13; in 1980 it was 1 in 11; and in 2004 it was 1 in 8. Cancer registries in Connecticut and upper New York State document that the age-adjusted incidence of new breast cancer cases had steadily increased since the mid-1940s. The incidence in the United States, based on data from nine Surveillance, Epidemiology, and End Results (SEER) registries, has been decreasing by 23% per year since 2000. The increase had been approximately 1% per year from 1973 to 1980, and there was an additional increase in incidence of 4% between 1980 and 1987, which was characterized by frequent detection of small primary cancers. The increase in breast cancer incidence occurred primarily in women ≥ 55 years and paralleled a marked increase in the percentage of older women who had mammograms taken. At the same time, incidence rates for regional metastatic disease dropped and breast cancer mortality declined. From 1960 to 1963, 5-year overall survival rates for breast cancer were 63% and 46% in white and African American women, respectively, whereas the rates for 1981 to 1983 were 78% and 64%, respectively. For 2002 to 2008 rates were 92% and 78%, respectively.

There is a 10-fold variation in breast cancer incidence among different countries worldwide. Cyprus and Malta have the highest age-adjusted mortality for breast cancer (29.6 per 100,000 population), whereas Haiti has the lowest (2.0 deaths per 100,000 population). The United States has an age-adjusted mortality for breast cancer of 19.0 cases per 100,000 population. Women living in less-industrialized nations tend to have a lower incidence of breast cancer than women living in industrialized countries, although Japan is an exception. In the United States, Mormons, Seventh Day Adventists, American Indians, Alaska natives, Hispanic/Latina Americans, and Japanese and Filipino women living in Hawaii have a below-average incidence of breast cancer, whereas nuns (due to nulliparity) and Ashkenazi Jewish women have an above-average incidence.

The incidence rates of breast cancer increased in most countries through the 1990s. Since the estimates for 1990, there

was an overall increase in incidence rates of approximately 0.5% annually. It was predicted that there would be approximately 1.4 million new cases in 2010. The cancer registries in China have noted annual increases in incidence of up to 3% to 4%, and in eastern Asia, increases are similar.

Recent data from the SEER program reveal declines in breast cancer incidence over the past decade, and this is widely attributed to decreased use of hormone replacement therapy as a consequence of the Women's Health Initiative reports.¹¹³

Breast cancer burden has well-defined variations by geography, regional lifestyle, and racial or ethnic background.¹¹⁴ In general, both breast cancer incidence and mortality are relatively lower among the female populations of Asia and Africa, relatively underdeveloped nations, and nations that have not adopted the Westernized reproductive and dietary patterns. In contrast, European and North American women and women from heavily industrialized or westernized countries have a substantially higher breast cancer burden. These international patterns are mirrored in breast cancer incidence and mortality rates observed for the racially, ethnically, and culturally diverse population of the United States.¹¹⁵

Although often related, the factors that influence breast cancer incidence may differ from those that affect mortality. Incidence rates are lower among populations that are heavily weighted with women who begin childbearing at young ages and who have multiple full-term pregnancies followed by prolonged lactation. These are features that characterize many underdeveloped nations and also many eastern nations. Breast cancer mortality rates should be lower in populations that have a lower incidence, but the mortality burden will simultaneously be adversely affected by the absence of effective mammographic screening programs for early detection and diminished access to multidisciplinary cancer treatment programs. These features are likely to account for much of the disproportionate mortality risks that are seen in underdeveloped nations. Similar factors probably account for differences in breast cancer burden observed among the various racial and ethnic groups within the United States. Interestingly, breast cancer incidence and mortality rates rise among second- and third-generation Asian Americans as they adopt Western lifestyles.

Disparities in breast cancer survival among subsets of the American population are generating increased publicity because they are closely linked to disparities in socioeconomic status. Poverty rates and proportions of the population that lack health care insurance are two to three times higher among minority racial and ethnic groups such as African Americans and Hispanic/Latino Americans. These socioeconomic disadvantages create barriers to effective breast cancer screening and result in delayed breast cancer diagnosis, advanced stage distribution, inadequacies in comprehensive treatment, and ultimately increased mortality rates. Furthermore, the rapid growth in the Hispanic population is accompanied by increasing problems in health education because of linguistic barriers between physicians and recently immigrated, non-English-speaking patients. Recent studies also are documenting inequities in the treatments delivered to minority breast cancer patients, such as increased rates of failure to provide systemic therapy, use of sentinel lymph node dissection, and breast reconstruction. Some of the treatment delivery disparities are related to inadequately controlled comorbidities (such as hypertension and diabetes), which are more prevalent in minority populations. However, some studies that adjust for these factors report persistent and unexplained

unevenness in treatment recommendations. It is clear that breast cancer disparities associated with racial or ethnic background have a multifactorial cause, and improvements in outcome will require correction of many public health problems at both the patient and provider levels.

Advances in the ability to characterize breast cancer subtypes and the genetics of the disease are now provoking speculation regarding possible hereditary influences on breast cancer risk that are related to racial or ethnic ancestry.¹¹⁶ These questions become particularly compelling when one looks at disparities in breast cancer burden between African Americans and Caucasians. Lifetime risk of breast cancer is lower for African Americans, yet a paradoxically increased breast cancer mortality risk also is seen. African Americans also have a younger age distribution for breast cancer; among women <45 years of age, breast cancer incidence is highest among African Americans compared to other subsets of the American population. Lastly and most provocatively, African American women of all ages have notably higher incidence rates for estrogen receptor-negative tumors. These same patterns of disease are seen in contemporary female populations of western, sub-Saharan Africa, who are likely to share ancestry with African American women as a consequence of the Colonial-era slave trade. Interestingly, male breast cancer also is seen with increased frequency among both African Americans and Africans.

Natural History

Bloom and colleagues described the natural history of breast cancer based on the records of 250 women with untreated breast cancers who were cared for on charity wards in the Middlesex Hospital, London, between 1805 and 1933. The median survival of this population was 2.7 years after initial diagnosis (Fig. 17-13).¹¹⁷ The 5- and 10-year survival rates

for these women were 18.0% and 3.6%, respectively. Only 0.8% survived for 15 years or longer. Autopsy data confirmed that 95% of these women died of breast cancer, whereas the remaining 5% died of other causes. Almost 75% of the women developed ulceration of the breast during the course of the disease. The longest surviving patient died in the nineteenth year after diagnosis.

Primary Breast Cancer. More than 80% of breast cancers show productive fibrosis that involves the epithelial and stromal tissues. With growth of the cancer and invasion of the surrounding breast tissues, the accompanying desmoplastic response entraps and shortens Cooper's suspensory ligaments to produce a characteristic skin retraction. Localized edema (peaud'orange) develops when drainage of lymph fluid from the skin is disrupted. With continued growth, cancer cells invade the skin, and eventually ulceration occurs. As new areas of skin are invaded, small satellite nodules appear near the primary ulceration. The size of the primary breast cancer correlates with disease-free and overall survival, but there is a close association between cancer size and axillary lymph node involvement (Fig. 17-14). In general, up to 20% of breast cancer recurrences are local-regional, >60% are distant, and 20% are both local-regional and distant.

Axillary Lymph Node Metastases. As the size of the primary breast cancer increases, some cancer cells are shed into cellular spaces and transported via the lymphatic network of the breast to the regional lymph nodes, especially the axillary lymph nodes. Lymph nodes that contain metastatic cancer are at first ill-defined and soft but become firm or hard with continued growth of the metastatic cancer. Eventually the lymph nodes adhere to each other and form a conglomerate mass. Cancer cells may grow through the lymph node capsule and fix to contiguous structures in the axilla, including the chest wall. Typically, axillary lymph nodes are involved sequentially from the low (level I) to the central (level II) to the apical (level III) lymph node groups. Approximately 95% of the women who die of breast cancer have distant metastases, and traditionally the most important prognostic correlate of disease-free and overall survival was axillary lymph node status (see Fig. 17-14A). Women with node-negative disease had less than a 30% risk of recurrence, compared with as much as a 75% risk for women with node-positive disease.

Distant Metastases. At approximately the twentieth cell doubling, breast cancers acquire their own blood supply (neovascularization). Thereafter, cancer cells may be shed directly into the systemic venous blood to seed the pulmonary circulation via the axillary and intercostal veins or the vertebral column via Batson's plexus of veins, which courses the length of the vertebral column. These cells are scavenged by natural killer lymphocytes and macrophages. Successful implantation of metastatic foci from breast cancer predictably occurs after the primary cancer exceeds 0.5 cm in diameter, which corresponds to the twenty-seventh cell doubling. For 10 years after initial treatment, distant metastases are the most common cause of death in breast cancer patients. For this reason, conclusive results cannot be derived from breast cancer trials until at least 5 to 10 years have elapsed. Although 60% of the women who develop distant metastases will do so within 60 months of treatment, metastases may become evident as late as 20 to 30 years after treatment of the primary cancer.¹¹⁸ Patients with estrogen receptor negative breast cancers are proportionately more likely to develop

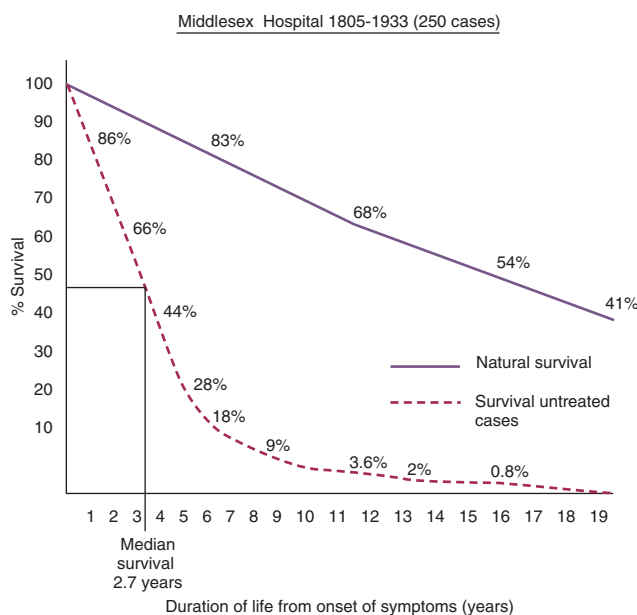


Figure 17-13. Survival of women with untreated breast cancer compared with natural survival. (Reproduced with permission from Bloom HJG, Richardson WW, Harries EJ. *Natural history of untreated breast cancer [1803–1933]: Comparison of untreated and treated cases according to histological grade of malignancy.* Br Med J. With permission from BMJ Publishing Group, Ltd.)

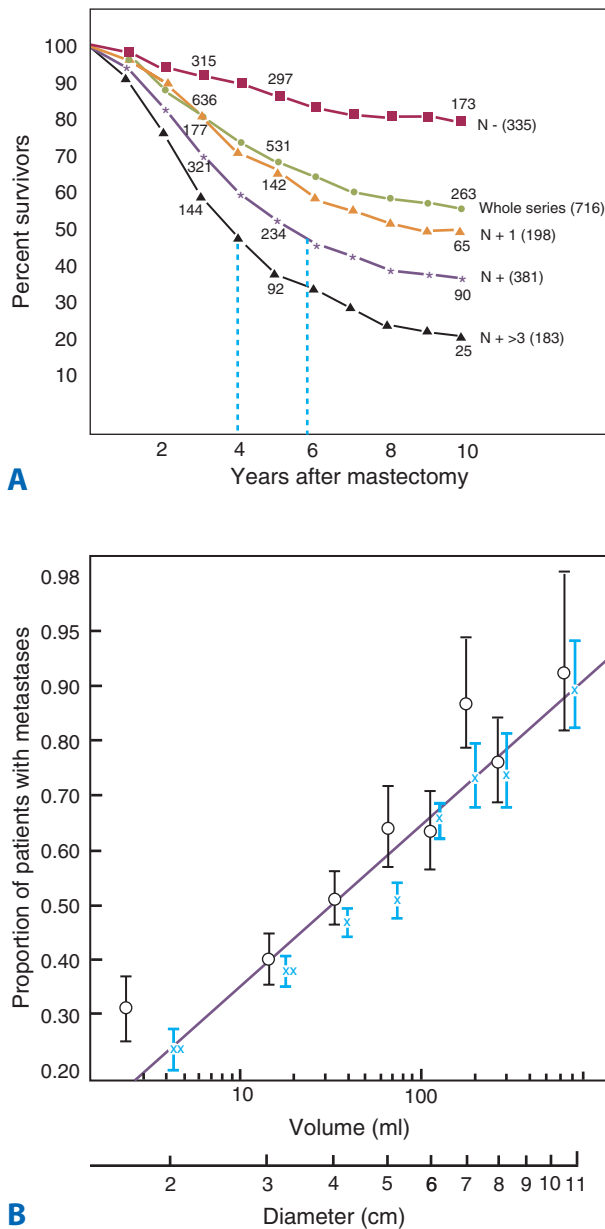


Figure 17-14. **A.** Overall survival for women with breast cancer according to axillary lymph node status. The time periods are years after radical mastectomy. (Reproduced with permission from Valagussa P, et al: Patterns of relapse and survival following radical mastectomy. Analysis of 716 consecutive patients. *Cancer*. 1978;11:1170. Copyright © American Cancer Society. This material is reproduced with permission of Wiley-Liss, Inc., a subsidiary of John Wiley & Sons, Inc.) **B.** Risk of metastases according to breast cancer volume and diameter. (Reproduced with permission from Koscielny S et al. Breast cancer: Relationship between the size of the primary tumour and the probability of metastatic dissemination. *Br J Cancer*. 1984;49:709.)

recurrence in the first 3 to 5 years, whereas those with estrogen receptor positive tumors have a risk of developing recurrence which drops off more slowly beyond 5 years than is seen with ER negative tumors.¹¹⁹ Recently a report showed that tumor size and nodal status remain powerful predictors of late recurrences compared to more recently developed tools such as the

immunohistochemical score (IHC4) and two gene expression profile tests (Recurrence Score and PAM50).¹²⁰ Common sites of involvement, in order of frequency, are bone, lung, pleura, soft tissues, and liver. Brain metastases are less frequent overall although with the advent of adjuvant systemic therapies it has been reported that CNS disease may be seen earlier.^{121,122} There are also reports of factors which are associated with the risk of developing brain metastases.¹²³ For example, they are more likely to be seen in patients with triple receptor negative breast cancer (ER-negative, PR-negative and HER2-negative) or patients with HER2-positive breast cancer who have received chemotherapy and HER2-directed therapies.

HISTOPATHOLOGY OF BREAST CANCER

Carcinoma In Situ

Cancer cells are in situ or invasive depending on whether or not they invade through the basement membrane.^{124,125} Broders' original description of in situ breast cancer stressed the absence of invasion of cells into the surrounding stroma and their confinement within natural ductal and alveolar boundaries.¹²⁴ Because areas of invasion may be minute, the accurate diagnosis of in situ cancer necessitates the analysis of multiple microscopic sections to exclude invasion. In 1941, Foote and Stewart published a landmark description of LCIS, which distinguished it from DCIS.¹²⁵ In the late 1960s, Gallagher and Martin published their study of whole-breast sections and described a stepwise progression from benign breast tissue to in situ cancer and subsequently to invasive cancer. Before the widespread use of mammography, diagnosis of breast cancer was by physical examination. At that time, in situ cancers constituted <6% of all breast cancers, and LCIS was more frequently diagnosed than DCIS by a ratio of >2:1. However, when screening mammography became popular, a 14-fold increase in the incidence of in situ cancer (45%) was demonstrated, and DCIS was more frequently diagnosed than LCIS by a ratio of >2:1. Table 17-8 lists the clinical and pathologic characteristics of DCIS and LCIS. *Multicentricity* refers to the occurrence of a second breast cancer outside the breast quadrant of the primary cancer (or at least 4 cm away), whereas *multifocality* refers to the occurrence of a second cancer within the same breast quadrant as the primary cancer (or within 4 cm of it). Multicentricity occurs in 60% to 90% of women with LCIS, whereas the rate of multicentricity for DCIS is reported to be 40% to 80%. LCIS occurs bilaterally in 50% to 70% of cases, whereas DCIS occurs bilaterally in 10% to 20% of cases.

Lobular Carcinoma In Situ. LCIS originates from the terminal duct lobular units and develops only in the female breast. It is characterized by distention and distortion of the terminal duct lobular units by cells which are large but maintain a normal nuclear: cytoplasmic ratio. Cytoplasmic mucoid globules are a distinctive cellular feature. LCIS may be observed in breast tissues that contain microcalcifications, but the calcifications associated with LCIS typically occur in adjacent tissues. This neighborhood calcification is a feature that is unique to LCIS and contributes to its diagnosis. The frequency of LCIS in the general population cannot be reliably determined because it usually presents as an incidental finding. The average age at diagnosis is 45 years, which is approximately 15 to 25 years younger than the age at diagnosis for invasive breast cancer. LCIS has a distinct racial predilection, occurring 12 times more frequently

Table 17-8

Salient characteristics of in situ ductal (DCIS) and lobular (LCIS) carcinoma of the breast

	LCIS	DCIS
Age (years)	44–47	54–58
Incidence ^a	2%–5%	5%–10%
Clinical signs	None	Mass, pain, nipple discharge
Mammographic signs	None	Microcalcifications
Premenopausal	2/3	1/3
Incidence of synchronous invasive carcinoma	5%	2%–46%
Multicentricity	60%–90%	40%–80%
Bilaterality	50%–70%	10%–20%
Axillary metastasis	1%	1%–2%
Subsequent carcinomas:		
Incidence	25%–35%	25%–70%
Laterality	Bilateral	Ipsilateral
Interval to diagnosis	15–20 y	5–10 y
Histologic type	Ductal	Ductal

^aIn biopsy specimens of mammographically detected breast lesions. Source: Reproduced with permission from Frykberg ER, et al: Current concepts on the biology and management of in situ (Tis, stage 0) breast carcinoma, in Bland KI, et al (eds): *The Breast: Comprehensive Management of Benign and Malignant Diseases*. Philadelphia: WB Saunders;1998:1020. Copyright Elsevier.

in white women than in African American women. Invasive breast cancer develops in 25% to 35% of women with LCIS. Invasive cancer may develop in either breast, regardless of which breast harbored the initial focus of LCIS, and is detected synchronously with LCIS in 5% of cases. In women with a history of LCIS, up to 65% of subsequent invasive cancers are ductal, not lobular, in origin. For these reasons, LCIS is regarded as a marker of increased risk for invasive breast cancer rather than as an anatomic precursor. Individuals should be counseled regarding their risk of developing breast cancer and appropriate

risk reduction strategies, including observation with screening, chemoprevention, and risk-reducing bilateral mastectomy.

Ductal Carcinoma In Situ. Although DCIS is predominantly seen in the female breast, it accounts for 5% of male breast cancers. Published series suggest a detection frequency of 7% in all biopsy tissue specimens. The term *intraductal carcinoma* is frequently applied to DCIS, which carries a high risk for progression to an invasive cancer. Histologically, DCIS is characterized by a proliferation of the epithelium that lines the minor ducts, resulting in papillary growths within the duct lumina. Early in their development, the cancer cells do not show pleomorphism, mitoses, or atypia, which leads to difficulty in distinguishing early DCIS from benign hyperplasia. The papillary growths (papillary growth pattern) eventually coalesce and fill the duct lumina so that only scattered, rounded spaces remain between the clumps of atypical cancer cells, which show hyperchromasia and loss of polarity (cribriform growth pattern). Eventually pleomorphic cancer cells with frequent mitotic figures obliterate the lumina and distend the ducts (solid growth pattern). With continued growth, these cells outstrip their blood supply and become necrotic (comedo growth pattern). Calcium deposition occurs in the areas of necrosis and is a common feature seen on mammography. DCIS is now frequently classified based on nuclear grade and the presence of necrosis (Table 17-9). Based on multiple consensus meetings, grading of DCIS has been recommended. Although there is no universal agreement on classification, most systems endorse the use of cytologic grade and presence or absence of necrosis.¹²⁶

The risk for invasive breast cancer is increased nearly fivefold in women with DCIS.¹²⁷ The invasive cancers are observed in the ipsilateral breast, usually in the same quadrant as the DCIS that was originally detected, which suggests that DCIS is an anatomic precursor of invasive ductal carcinoma (Fig. 17-15A and B).

Invasive Breast Carcinoma

Invasive breast cancers have been described as lobular or ductal in origin.¹²⁸⁻¹³¹ Early classifications used the term *lobular* to describe invasive cancers that were associated with LCIS, whereas all other invasive cancers were referred to as *ductal*. Current histologic classifications recognize special types of breast cancers (10% of total cases), which are defined by specific histologic features. To qualify as a special-type cancer, at least 90% of the cancer must contain the defining histologic features. About 80% of invasive breast cancers are described as

Table 17-9

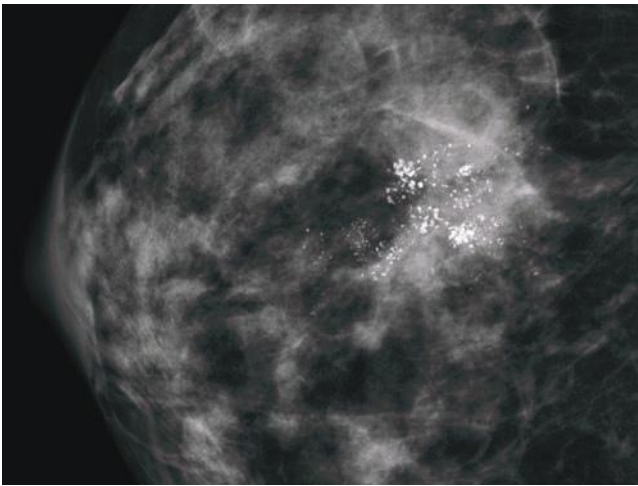
Classification of breast ductal carcinoma in situ (DCIS)

HISTOLOGIC SUBTYPE	DETERMINING CHARACTERISTICS		DCIS GRADE
	NUCLEAR GRADE	NECROSIS	
Comedo	High	Extensive	High
Intermediate ^a	Intermediate	Focal or absent	Intermediate
Noncomedo ^b	Low	Absent	Low

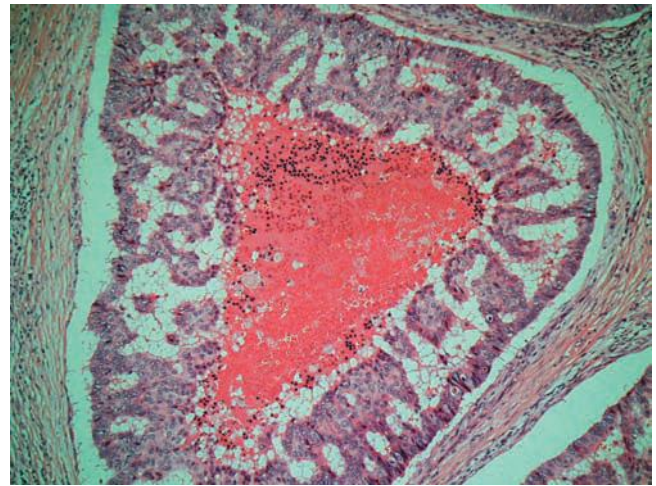
^aOften a mixture of noncomedo patterns.

^bSolid, cribriform, papillary, or focal micropapillary.

Source: Adapted with permission from Connolly JL, et al: Ductal carcinoma in situ of the breast: Histologic subtyping and clinical significance. *PPO Updates* 10:1, 1996.



A



B

Figure 17-15. Ductal carcinoma in situ (DCIS). **A.** Craniocaudal mammographic view shows a poorly defined mass containing microcalcifications. (Photo used with permission of Dr. Anne Turnbull, Consultant Radiologist/Director of Breast Screening, Royal Derby Hospital.) **B.** Histopathologic preparation of the surgical specimen confirms DCIS with necrosis (100x) (Photo used with permission of Dr. Sindhu Menon, Consultant Histopathologist & Dr. Rahul Deb, Consultant Histopathologist and Lead Breast Pathologist, Royal Derby Hospital, Derby, UK.)

invasive ductal carcinoma of no special type (NST). These cancers generally have a worse prognosis than special-type cancers. Foote and Stewart originally proposed the following classification for invasive breast cancer¹²⁵:

1. Paget's disease of the nipple
2. Invasive ductal carcinoma—Adenocarcinoma with productive fibrosis (scirrhous, simplex, NST), 80%
3. Medullary carcinoma, 4%
4. Mucinous (colloid) carcinoma, 2%
5. Papillary carcinoma, 2%
6. Tubular carcinoma, 2%
7. Invasive lobular carcinoma, 10%
8. Rare cancers (adenoid cystic, squamous cell, apocrine)

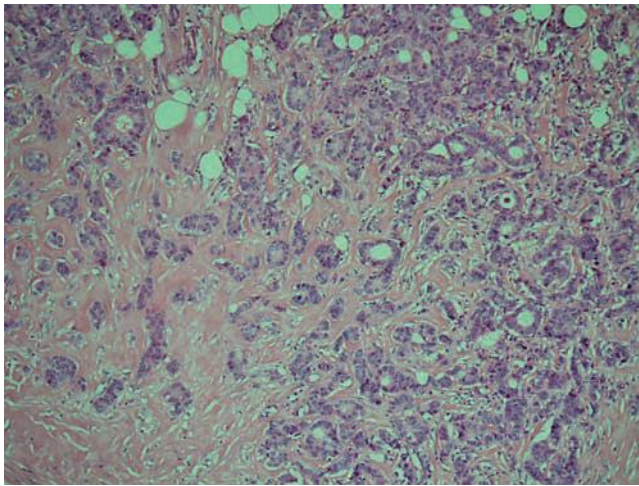
Paget's disease of the nipple was described in 1874. It frequently presents as a chronic, eczematous eruption of the nipple, which may be subtle but may progress to an ulcerated, weeping lesion. Paget's disease usually is associated with extensive DCIS and may be associated with an invasive cancer. A palpable mass may or may not be present. A nipple biopsy specimen will show a population of cells that are identical to the underlying DCIS cells (pagetoid features or pagetoid change). Pathognomonic of this cancer is the presence of large, pale, vacuolated cells (Paget cells) in the rete pegs of the epithelium. Paget's disease may be confused with superficial spreading melanoma. Differentiation from pagetoid intraepithelial melanoma is based on the presence of S-100 antigen immunostaining in melanoma and carcinoembryonic antigen immunostaining in Paget's disease. Surgical therapy for Paget's disease may involve lumpectomy or mastectomy, depending on the extent of involvement of the nipple-areolar complex and the presence of DCIS or invasive cancer in the underlying breast parenchyma.

Invasive ductal carcinoma of the breast with productive fibrosis (scirrhous, simplex, NST) accounts for 80% of breast cancers and presents with macroscopic or microscopic axillary lymph node metastases in up to 25% of screen-detected cases and up to 60% of symptomatic cases. This cancer occurs most frequently in perimenopausal or postmenopausal women in the

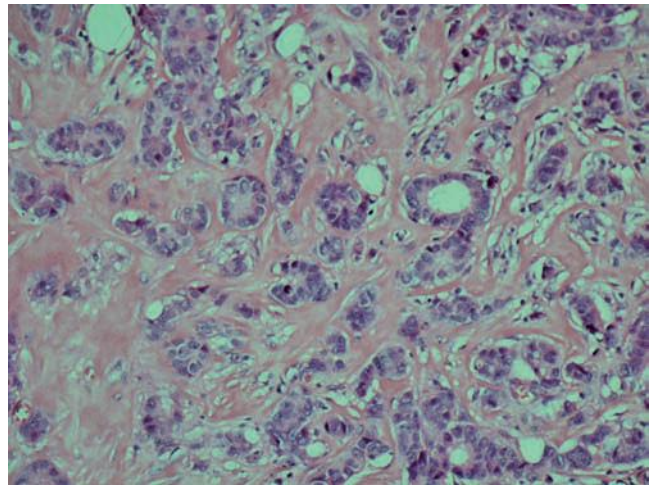
fifth to sixth decades of life as a solitary, firm mass. It has poorly defined margins and its cut surfaces show a central stellate configuration with chalky white or yellow streaks extending into surrounding breast tissues. The cancer cells often are arranged in small clusters, and there is a broad spectrum of histologic types with variable cellular and nuclear grades (Fig. 17-16A and B). In a large patient series from the SEER database, 75% of ductal cancers showed estrogen receptor expression.¹³²

Medullary carcinoma is a special-type breast cancer; it accounts for 4% of all invasive breast cancers and is a frequent phenotype of *BRCA1* hereditary breast cancer. Grossly, the cancer is soft and hemorrhagic. A rapid increase in size may occur secondary to necrosis and hemorrhage. On physical examination, it is bulky and often positioned deep within the breast. Bilaterality is reported in 20% of cases. Medullary carcinoma is characterized microscopically by: (a) a dense lymphoreticular infiltrate composed predominantly of lymphocytes and plasma cells; (b) large pleomorphic nuclei that are poorly differentiated and show active mitosis; and (c) a sheet-like growth pattern with minimal or absent ductal or alveolar differentiation. Approximately 50% of these cancers are associated with DCIS, which characteristically is present at the periphery of the cancer, and <10% demonstrate hormone receptors. In rare circumstances, mesenchymal metaplasia or anaplasia is noted. Because of the intense lymphocyte response associated with the cancer, benign or hyperplastic enlargement of the lymph nodes of the axilla may contribute to erroneous clinical staging. Women with this cancer have a better 5-year survival rate than those with NST or invasive lobular carcinoma.

Mucinous carcinoma (colloid carcinoma), another special-type breast cancer, accounts for 2% of all invasive breast cancers and typically presents in the elderly population as a bulky tumor. This cancer is defined by extracellular pools of mucin, which surround aggregates of low-grade cancer cells. The cut surface of this cancer is glistening and gelatinous in quality. Fibrosis is variable, and when abundant it imparts a firm consistency to the cancer. Over 90% of mucinous carcinomas display hormone receptors.¹³² Lymph node metastases occur in 33%



A



B

Figure 17-16. Invasive ductal carcinoma with productive fibrosis (scirrhous, simplex, no special type) **A**, 100x and **B**, 200x. (Used with permission of Dr. Sindhu Menon, Consultant Histopathologist & Dr. Rahul Deb, Consultant Histopathologist and Lead Breast Pathologist, Royal Derby Hospital, Derby, UK).

of cases, and 5- and 10-year survival rates are 73% and 59%, respectively. Because of the mucinous component, cancer cells may not be evident in all microscopic sections, and analysis of multiple sections is essential to confirm the diagnosis of a mucinous carcinoma.

Papillary carcinoma is a special-type cancer of the breast that accounts for 2% of all invasive breast cancers. It generally presents in the seventh decade of life and occurs in a disproportionate number of nonwhite women. Typically, papillary carcinomas are small and rarely attain a size of 3 cm in diameter. These cancers are defined by papillae with fibrovascular stalks and multilayered epithelium. In a large series from the SEER database 87% of papillary cancers have been reported to express estrogen receptor.¹³² McDivitt and colleagues noted that these tumors showed a low frequency of axillary lymph node metastases and had 5- and 10-year survival rates similar to those for mucinous and tubular carcinoma.¹³³

Tubular carcinoma is another special-type breast cancer and accounts for 2% of all invasive breast cancers. It is reported in as many as 20% of women whose cancers are diagnosed by mammographic screening and usually is diagnosed in the perimenopausal or early menopausal periods. Under low-power magnification, a haphazard array of small, randomly arranged tubular elements is seen. In a large SEER database 94% of tubular cancers were reported to express estrogen receptor.¹³² Approximately 10% of women with tubular carcinoma or with invasive cribriform carcinoma, a special-type cancer closely related to tubular carcinoma, will develop axillary lymph node metastases. However, the presence of metastatic disease in one or two axillary lymph nodes does not adversely affect survival. Distant metastases are rare in tubular carcinoma and invasive cribriform carcinoma. Long-term survival approaches 100%.

Invasive lobular carcinoma accounts for 10% of breast cancers. The histopathologic features of this cancer include small cells with rounded nuclei, inconspicuous nucleoli, and scant cytoplasm (Fig. 17-17). Special stains may confirm the presence of intracytoplasmic mucin, which may displace the nucleus (signet-ring cell carcinoma). At presentation, invasive

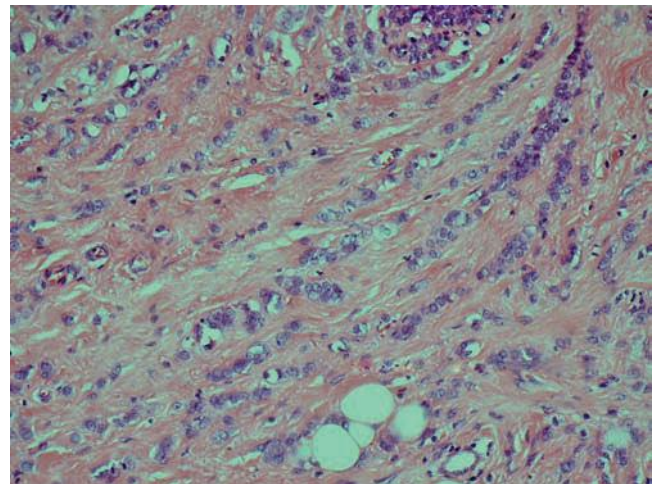


Figure 17-17. Lobular carcinoma (100x). Uniform, relatively small lobular carcinoma cells are seen arranged in a single-file orientation ("Indian file"). (Used with permission of Dr. Sindhu Menon, Consultant Histopathologist & Dr. Rahul Deb, Consultant Histopathologist and Lead Breast Pathologist, Royal Derby Hospital, Derby, UK.)

lobular carcinoma varies from clinically inapparent carcinomas to those that replace the entire breast with a poorly defined mass. It is frequently multifocal, multicentric, and bilateral. Because of its insidious growth pattern and subtle mammographic features, invasive lobular carcinoma may be difficult to detect. Over 90% of lobular cancers express estrogen receptor.¹³²

DIAGNOSIS OF BREAST CANCER

In ~30% of cases, the woman discovers a lump in her breast. Other less frequent presenting signs and symptoms of breast cancer include: (a) breast enlargement or asymmetry; (b) nipple changes, retraction, or discharge; (c) ulceration or erythema of the

skin of the breast; (d) an axillary mass; and (e) musculoskeletal discomfort. However, up to 50% of women presenting with breast complaints have no physical signs of breast pathology. Breast pain usually is associated with benign disease.

Misdiagnosed breast cancer accounts for the greatest number of malpractice claims for errors in diagnosis and for the largest number of paid claims. Litigation often involves younger women, whose physical examination and mammogram may be misleading. If a young woman (≤ 45 years) presents with a palpable breast mass and equivocal mammographic findings, ultrasound examination and biopsy are used to avoid a delay in diagnosis.

Examination

Inspection. The surgeon inspects the woman's breast with her arms by her side (Fig. 17-18A), with her arms straight up in the air (Fig. 17-18B), and with her hands on her hips (with and without pectoral muscle contraction).^{134,135} Symmetry, size, and shape of the breast are recorded, as well as any evidence of edema (peaud'orange), nipple or skin retraction, or erythema. With the arms extended forward and in a sitting position, the woman leans forward to accentuate any skin retraction.

Palpation. As part of the physical examination, the breast is carefully palpated. With the patient in the supine position (see Fig. 17-18C) the surgeon gently palpates the breasts, making certain to examine all quadrants of the breast from the sternum laterally to the latissimus dorsi muscle and from the clavicle inferiorly to the upper rectus sheath. The surgeon performs the examination with the palmar aspects of the fingers, avoiding a grasping or pinching motion. The breast may be cupped or molded in the surgeon's hands to check for retraction. A systematic search for lymphadenopathy then is performed. Figure 17-18D shows the position of the patient for examination of the axilla. By supporting the upper arm and elbow, the surgeon stabilizes the shoulder girdle. Using gentle palpation, the surgeon assesses all three levels of possible axillary lymphadenopathy. Careful palpation

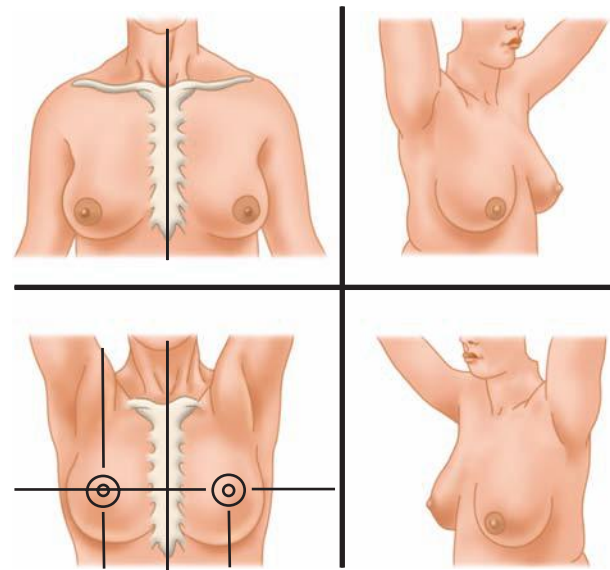


Figure 17-19. A breast examination record. (Reproduced with permission from Cliggett Publishing Co.)

of supraclavicular and parasternal sites also is performed. A diagram of the chest and contiguous lymph node sites is useful for recording location, size, consistency, shape, mobility, fixation, and other characteristics of any palpable breast mass or lymphadenopathy (Fig. 17-19).

Imaging Techniques

Mammography. Mammography has been used in North America since the 1960s, and the techniques used continue to be modified and improved to enhance image quality.¹³⁶⁻¹³⁹ Conventional mammography delivers a radiation dose of 0.1 cGy per study. By comparison, chest radiography delivers 25% of this dose. However, there is no increased breast cancer risk associated with the radiation dose delivered with screening mammography. Screening mammography is used to detect unexpected breast cancer in asymptomatic women. In this regard, it supplements history taking and physical examination. With screening mammography, two views of the breast are obtained, the craniocaudal (CC) view (Fig. 17-20A and B) and the mediolateral oblique (MLO) view (Fig. 17-20 C and D). The MLO view images the greatest volume of breast tissue, including the upper outer quadrant and the axillary tail of Spence. Compared with the MLO view, the CC view provides better visualization of the medial aspect of the breast and permits greater breast compression. Diagnostic mammography is used to evaluate women with abnormal findings such as a breast mass or nipple discharge. In addition to the MLO and CC views, a diagnostic examination may use views that better define the nature of any abnormalities, such as the 90-degree lateral and spot compression views. The 90-degree lateral view is used along with the CC view to triangulate the exact location of an abnormality. Spot compression may be done in any projection by using a small compression device, which is placed directly over a mammographic abnormality that is obscured by overlying tissues (Fig. 17-21C). The compression device minimizes motion artifact, improves definition, separates overlying tissues, and decreases the radiation dose needed to penetrate the breast. Magnification techniques ($\times 1.5$) often are combined with spot compression to better resolve

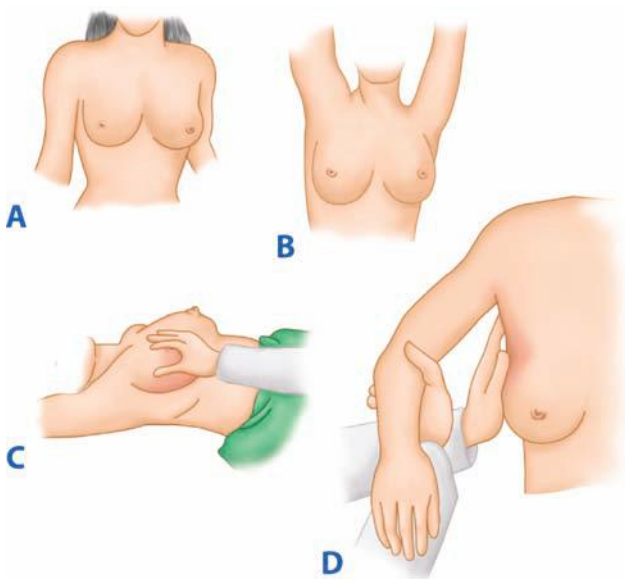
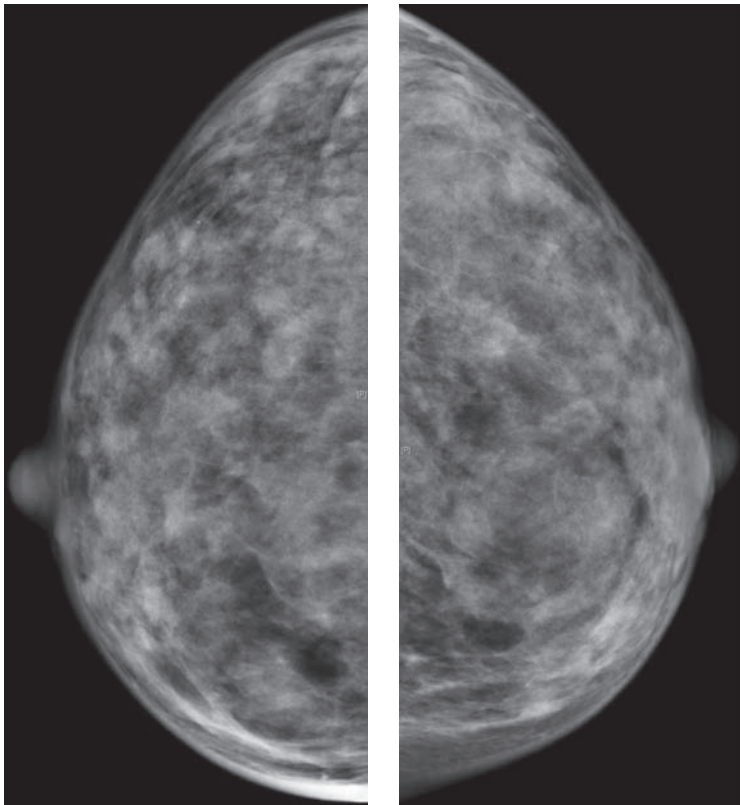
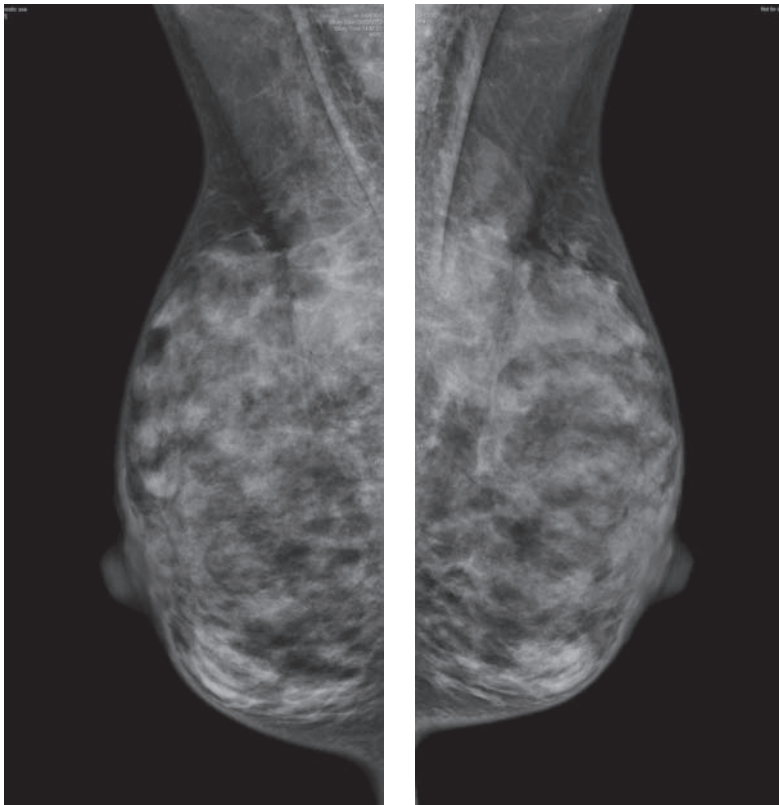


Figure 17-18. Examination of the breast. **A.** Inspection of the breast with arms at sides. **B.** Inspection of the breast with arms raised. **C.** Palpation of the breast with the patient supine. **D.** Palpation of the axilla.



A

B



C

D

Figure 17-20. A-D. Mammogram of a premenopausal breast with a dense fibroglandular pattern. E-H. Mammogram of a postmenopausal breast with a sparse fibroglandular pattern. (Photos used with permission of Dr. Anne Turnbull, Consultant Radiologist/Director of Breast Screening, Royal Derby Hospital, Derby, UK.)

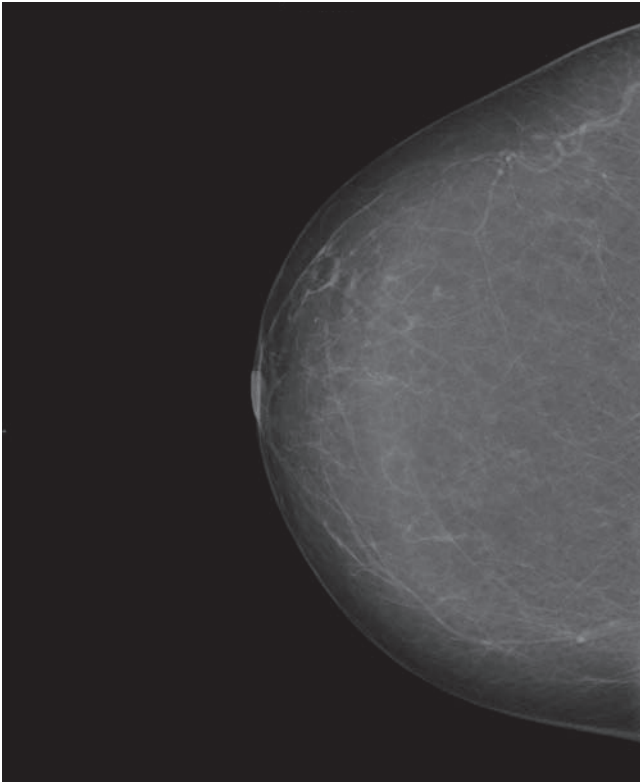
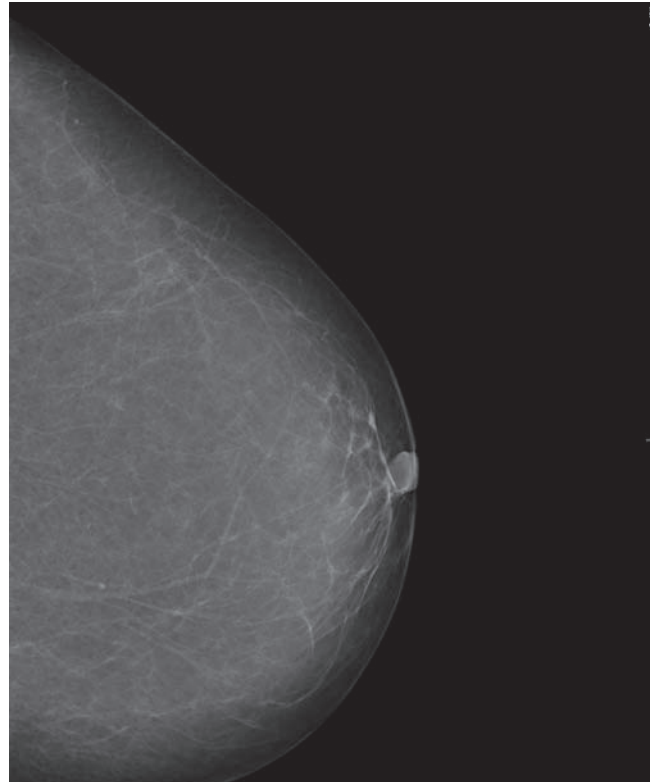
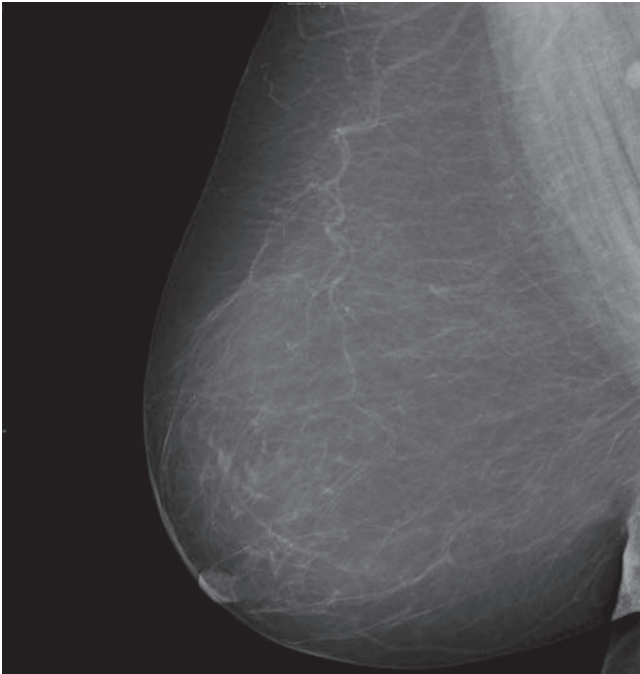
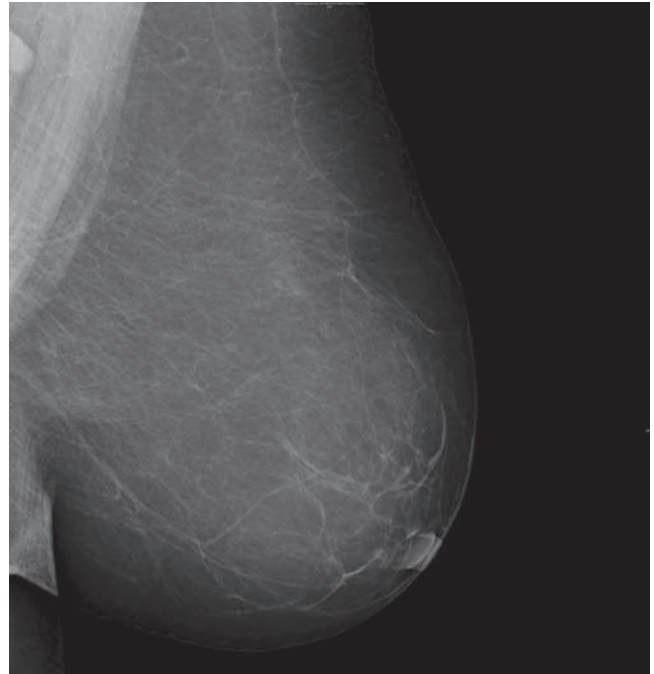**E****F****G****H**

Figure 17-20. (Continued)

calcifications and the margins of masses. Mammography also is used to guide interventional procedures, including needle localization and needle biopsy.

Specific mammographic features that suggest a diagnosis of breast cancer include a solid mass with or without stellate features, asymmetric thickening of breast tissues, and clustered

microcalcifications. The presence of fine, stippled calcium in and around a suspicious lesion is suggestive of breast cancer and occurs in as many as 50% of nonpalpable cancers. These microcalcifications are an especially important sign of cancer in younger women, in whom it may be the only mammographic abnormality. The clinical impetus for screening mammography

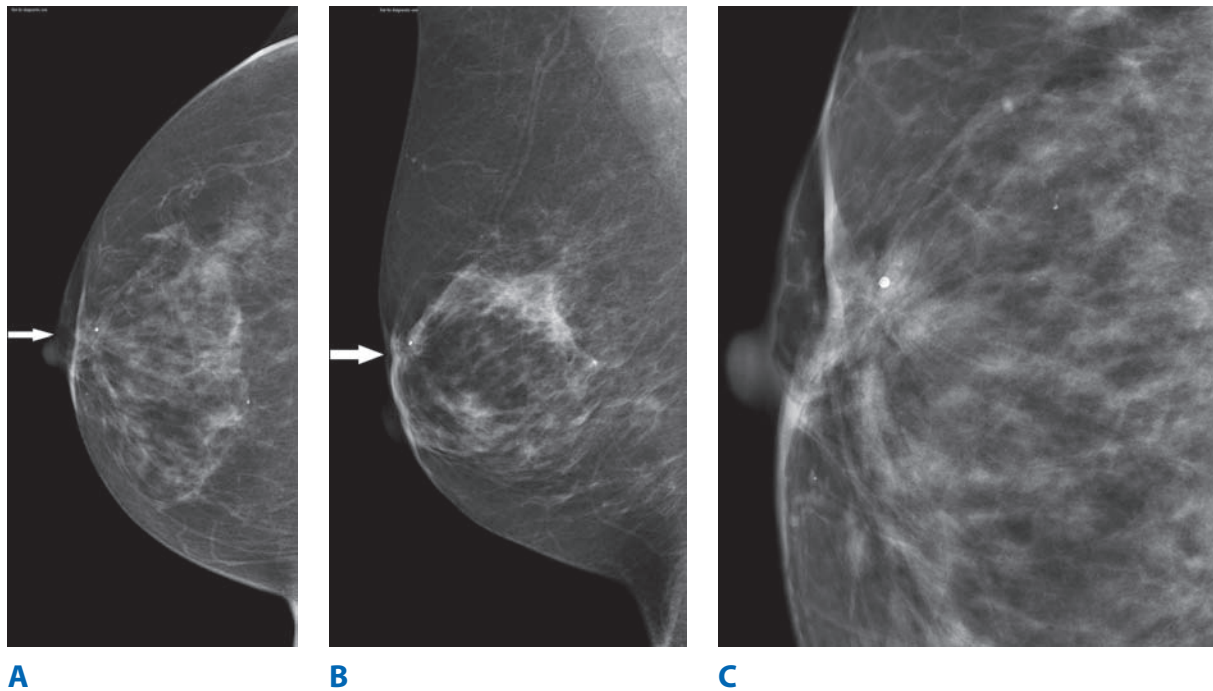


Figure 17-21. Mammogram revealing a small, spiculated mass in the right breast **A**. A small, spiculated mass is seen in the right breast with skin tethering (CC view). **B**. Mass seen on oblique view of the right breast. **C**. Spot compression mammography view of the cancer seen in **A** and **B**. The spiculated margins of the cancer are accentuated by compression. (Photos used with permission of Dr. Anne Turnbull, Consultant Radiologist/Director of Breast Screening, Royal Derby Hospital, Derby, UK).

came from the Health Insurance Plan study and the Breast Cancer Detection Demonstration Project, which demonstrated a 33% reduction in mortality for women after⁷² screening mammography. Mammography was more accurate than clinical examination for the detection of early breast cancers, providing a true-positive rate of 90%. Only 20% of women with nonpalpable cancers had axillary lymph node metastases, compared with 50% of women with palpable cancers.¹⁴⁰ Current guidelines of the National Comprehensive Cancer Network suggest that normal-risk women ≥ 20 years of age should have a breast examination at least every 3 years. Starting at age 40 years, breast examinations should be performed yearly and a yearly mammogram should be taken. The benefits from screening mammography in women ≥ 50 years of age has been noted above to be between 20% and 25% reduction in breast cancer mortality.^{72,74} With the increased discussion about the potential harms associated with breast screening the United Kingdom recently established an independent expert panel to review the published literature and estimate the benefits and harms associated with its national screening program for women >50 years. The expert panel estimated that in women invited to screening, about 11% of the cancers diagnosed in their lifetime constitute over-diagnosis. Despite the over-diagnosis the panel concluded that breast screening programs confer significant benefit and should continue. The use of screening mammography in women <50 years of age is more controversial again for reasons noted above: (a) reduced sensitivity; (b) reduced specificity; and (c) lower incidence of breast cancer. For the combination of these three reasons targeting mammography screening to women <50 years at higher risk of breast cancer improves the balance of risks and benefits and is the approach some health care systems have taken. There are now a number of risk assessment

models—as described earlier in that section—which can be used to estimate a younger woman’s risk of developing breast cancer to help assess the risks and benefits of regular screening.

Screen film mammography has replaced xeromammography because it requires a lower dose of radiation and provides similar image quality. Digital mammography was developed to allow the observer to manipulate the degree of contrast in the image. This is especially useful in women with dense breasts and women <50 years of age. Recently, investigators directly compared digital vs. screen film mammography in a prospective (DMIST) trial enrolling over 42,000 women.¹⁴¹ They found that digital and screen film mammography had similar accuracy; however, digital mammography was more accurate in women <50 years of age, women with mammographically dense breasts, and premenopausal or perimenopausal women. The use of digital breast tomosynthesis with 3D images has been introduced as an alternative to standard 2D mammography imaging that is limited by superimposition of breast parenchyma and breast density. The STORM trial reported that in 7,292 women screened, 3D mammography had a higher cancer detection rate and fewer false-positive recalls than the standard 2D imaging.¹⁴² Randomized controlled trials are planned to further study tomosynthesis and its role in breast cancer screening.

Ductography. The primary indication for ductography is nipple discharge, particularly when the fluid contains blood. Radiopaque contrast media is injected into one or more of the major ducts and mammography is performed. A duct is gently enlarged with a dilator and then a small, blunt cannula is inserted under sterile conditions into the nipple ampulla. With the patient in a supine position, 0.1 to 0.2 mL of dilute contrast media is injected and CC and MLO mammographic views

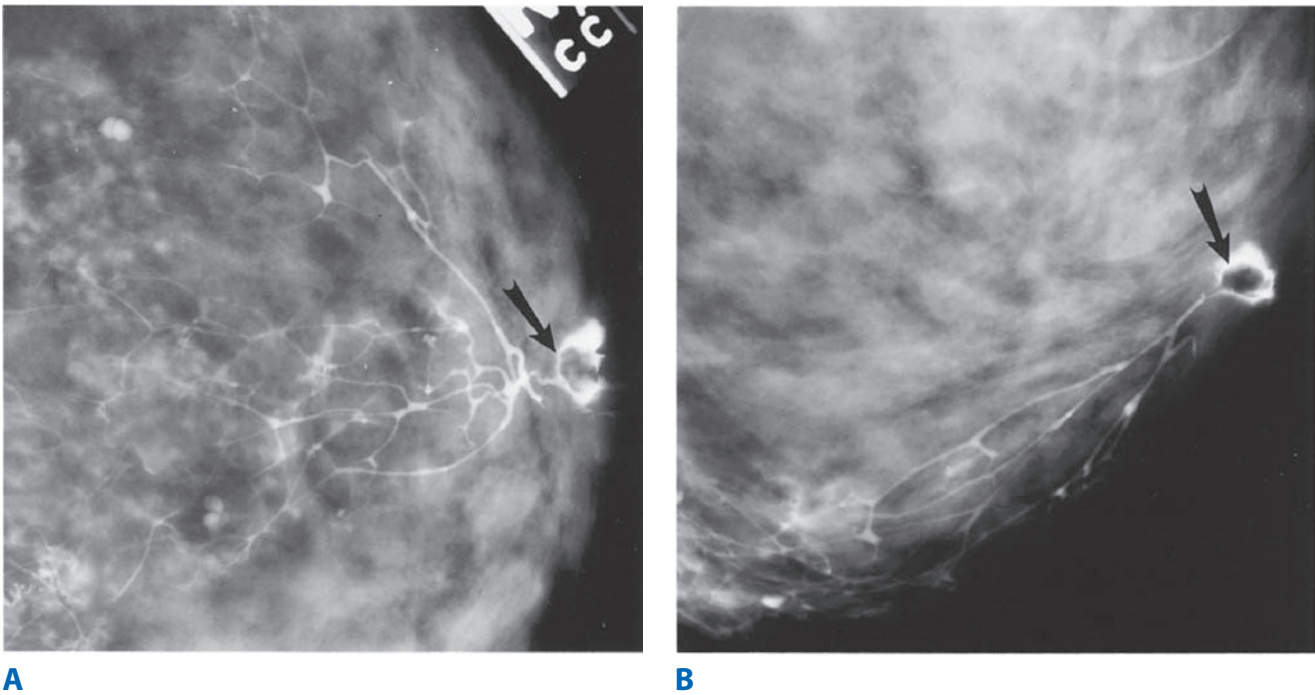


Figure 17-22. Ductogram. Craniocaudal (A) and mediolateral oblique (B) mammographic views demonstrate a mass (arrows) posterior to the nipple and outlined by contrast, which also fills the proximal ductal structures. (Photos used with permission of B. Steinbach.)

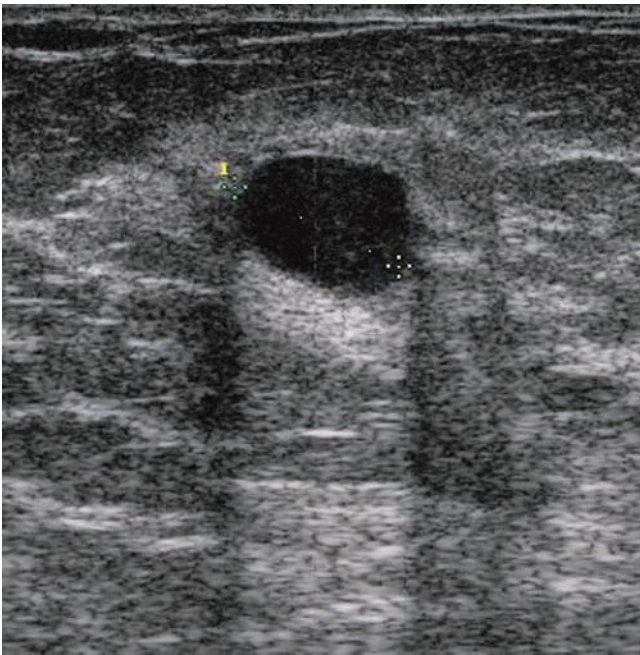
are obtained without compression. Intraductal papillomas are seen as small filling defects surrounded by contrast media (Fig. 17-22). Cancers may appear as irregular masses or as multiple intraluminal filling defects.

Ultrasonography. Second only to mammography in frequency of use for breast imaging, ultrasonography is an important method of resolving equivocal mammographic findings, defining cystic masses, and demonstrating the echogenic qualities of specific solid abnormalities. On ultrasound examination, breast cysts are well circumscribed, with smooth margins and an echo-free center (Fig. 17-23). Benign breast masses usually show smooth contours, round or oval shapes, weak internal echoes, and well-defined anterior and posterior margins (Fig 17-24). Breast cancer characteristically has irregular walls (Fig. 17-25) but may have smooth margins with acoustic enhancement. Ultrasonography is used to guide fine-needle aspiration biopsy, core-needle biopsy, and needle localization of breast lesions. Its findings are highly reproducible and it has a high patient acceptance rate, but it does not reliably detect lesions that are ≤ 1 cm in diameter. Ultrasonography can also be utilized to image the regional lymph nodes in patients with breast cancer (Fig. 17-26). The sensitivity of examination for the status of axillary nodes ranges from 35% to 82% and specificity ranges from 73% to 97%. The features of a lymph node involved with cancer include cortical thickening, change in shape of the node to more circular appearance, size larger than 10 mm, absence of a fatty hilum and hypoechoic internal echoes.¹⁴³

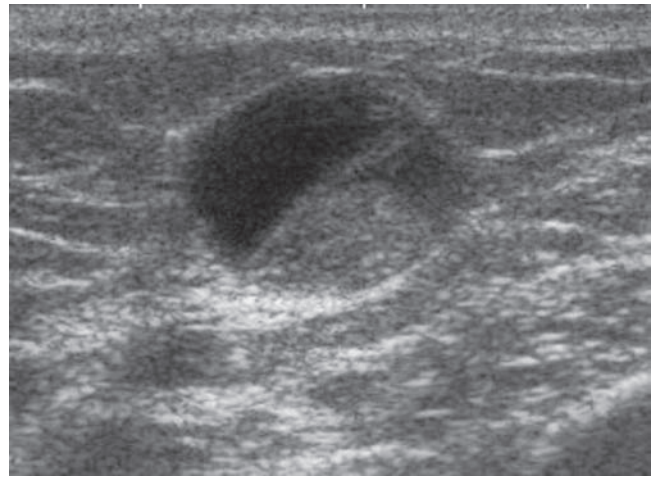
Magnetic Resonance Imaging. In the process of evaluating magnetic resonance imaging (MRI) as a means of characterizing mammographic abnormalities, additional breast lesions have been detected. However, in the circumstance of negative findings on both mammography and physical examination, the probability of a breast cancer being diagnosed by MRI is extremely low. There is current interest in the use of MRI to screen the

breasts of high-risk women and of women with a newly diagnosed breast cancer. In the first case, women who have a strong family history of breast cancer or who carry known genetic mutations require screening at an early age, because mammographic evaluation is limited due to the increased breast density in younger women. In the second case, an MRI study of the contralateral breast in women with a known breast cancer has shown a contralateral breast cancer in 5.7% of these women (Fig. 17-27). MRI can also detect additional tumors in the index breast (multifocal or multicentric disease) that may be missed on routine breast imaging and this may alter surgical decision making (Fig. 17-28). In fact, MRI has been advocated by some for routine use in surgical treatment planning based on the fact that additional disease can be identified with this advanced imaging modality and the extent of disease may be more accurately assessed. A randomized trial performed in the United Kingdom (COMICE trial) which enrolled 1,623 women did not show a decrease in rates of reoperation in those women randomized to undergo MRI in addition to mammography and ultrasonography (19%) compared to those undergoing standard breast imaging without MRI (19%).¹⁴⁴ Houssami and colleagues performed a meta-analysis including 2 randomized trials and 7 comparative cohort studies to examine the effect of preoperative MRI compared to standard preoperative evaluation on surgical outcomes.¹⁴⁵ They reported that the use of MRI was associated with increased mastectomy rates. This is problematic since there is no evidence that the additional disease detected by MRI is of clinical or biologic significance, particularly in light of the low local-regional failure rates currently reported in patients undergoing breast conserving surgery who receive whole breast irradiation and systemic therapies.

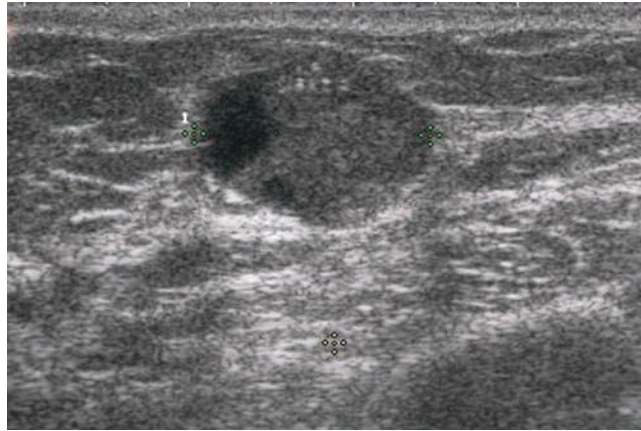
The use of dedicated breast coils is mandatory in the MRI imaging of the breast. A BIRADS lexicon is assigned to each examination and an abnormality noted on MRI that is not seen



A

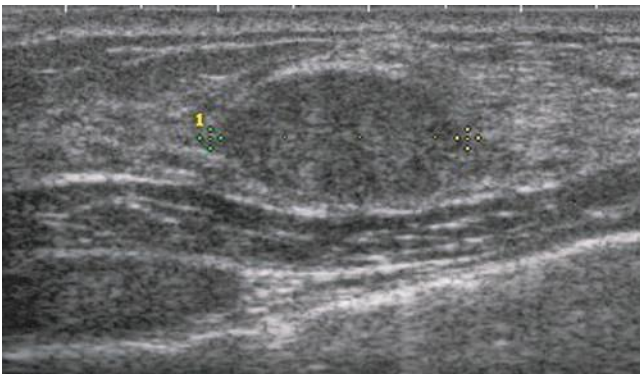


B

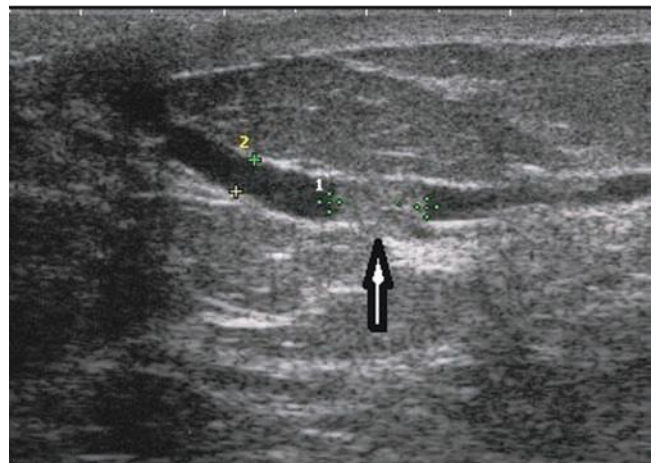


C

Figure 17-23. Breast cyst. **A.** Simple cyst. Ultrasound image of the mass shows it to be anechoic with a well-defined back wall, characteristic of a cyst. **B.** Complex solid and cystic mass. **(C)** Complex solid and cystic mass characteristic of intracystic papillary tumor. (Photos used with permission of Dr. Anne Turnbull, Consultant Radiologist/Director of Breast Screening, Royal Derby Hospital, Derby, UK).

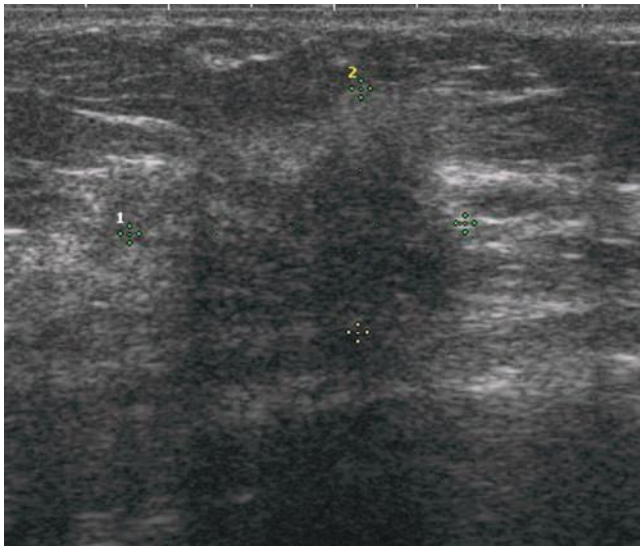


A

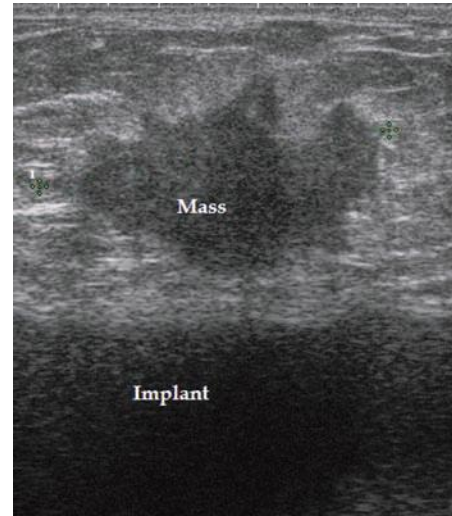


B

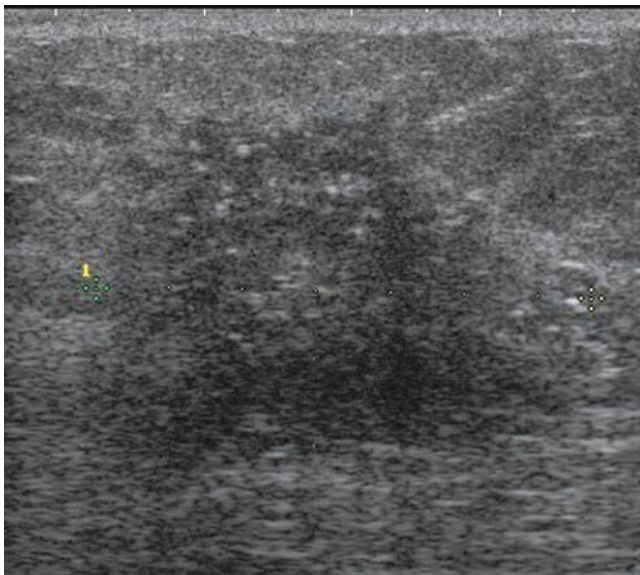
Figure 17-24. Ultrasonography images of benign breast tumors. **A.** Fibroadenoma. **B.** Intraductal papilloma. (Photos used with permission of Dr. Anne Turnbull, Consultant Radiologist/Director of Breast Screening, Royal Derby Hospital, Derby, UK.)



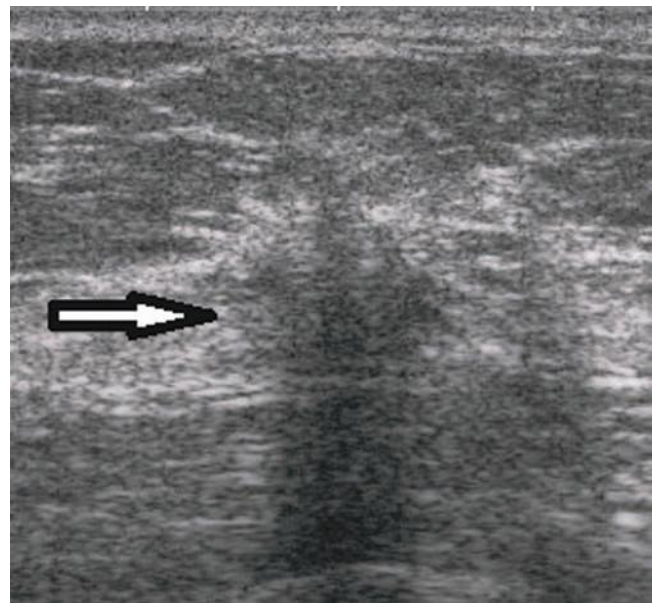
A



B



C



D

Figure 17-25. Ultrasonography images of malignant breast lesions. **A.** 25 mm irregular mass. **B.** Ultrasound 30 mm mass anterior to an implant. **C.** Ultrasound breast cancer with calcification. **D.** Ultrasound 9 mm spiculated mass with attenuation. (Photos used with permission of Dr. Anne Turnbull, Consultant Radiologist/Director of Breast Screening, Royal Derby Hospital, Derby, UK).

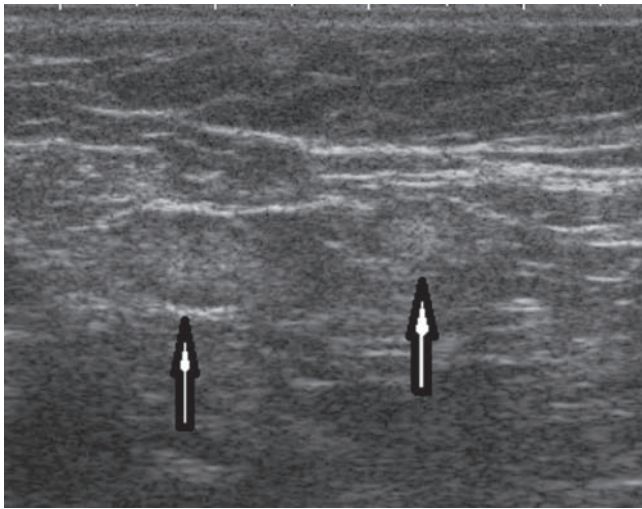
on mammography requires a focused ultrasound examination for further assessment. If the abnormality is not seen on corresponding mammogram or ultrasound then MRI guided biopsy is necessary. Some clinical scenarios where MRI may be useful include the evaluation of a patient who presents with nodal metastasis from breast cancer without an identifiable primary tumor; to assess response to therapy in the setting of neoadjuvant systemic treatment; to select patients for partial breast irradiation techniques; and evaluation of the treated breast for tumor recurrence.

Breast Biopsy

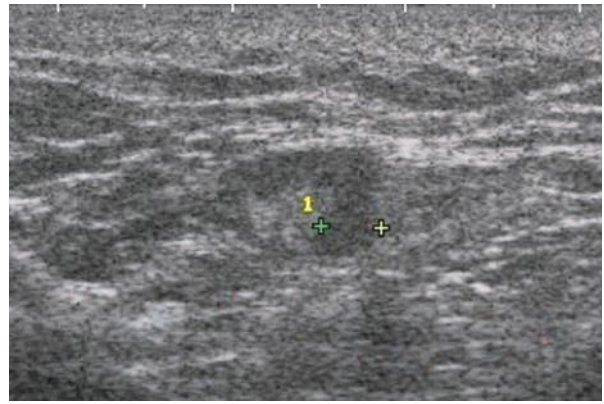
Nonpalpable Lesions. Image-guided breast biopsy specimens are frequently required to diagnose nonpalpable lesions.¹⁴⁶ Ultrasound localization techniques are used when a mass is present, whereas stereotactic techniques are used when no mass is present (microcalcifications or architectural distortion only). The combination of diagnostic mammography, ultrasound or stereotactic

localization, and fine-needle aspiration (FNA) biopsy achieves almost 100% accuracy in the preoperative diagnosis of breast cancer. However, although FNA biopsy permits cytologic evaluation, core-needle permits the analysis of breast tissue architecture and allows the pathologist to determine whether invasive cancer is present. This permits the surgeon and patient to discuss the specific management of a breast cancer before therapy begins. Core-needle biopsy is preferred over open biopsy for nonpalpable breast lesions because a single surgical procedure can be planned based on the results of the core biopsy. The advantages of core-needle biopsy include a low complication rate, minimal scarring, and a lower cost compared with excisional breast biopsy.

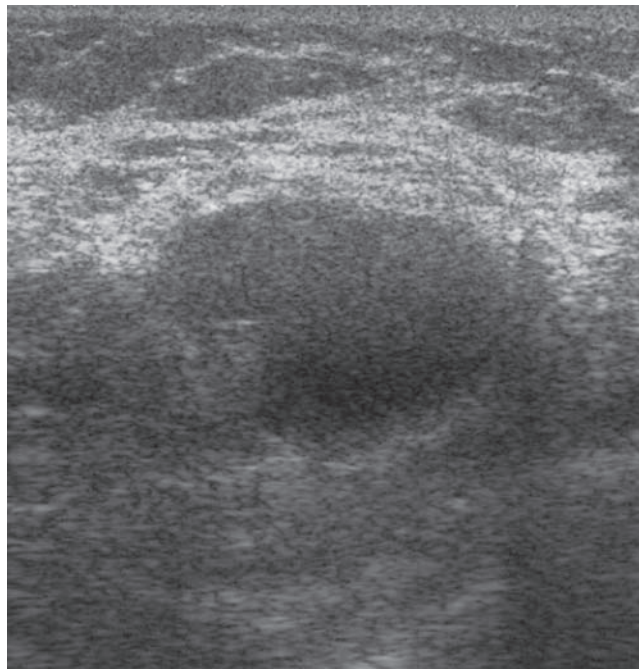
Palpable Lesions. FNA or core biopsy of a palpable breast mass can usually be performed in an outpatient setting.¹⁴⁷ A 1.5-in, 22-gauge needle attached to a 10-mL syringe or a 14 gauge core biopsy needle is used. For FNA, use of a syringe holder



A



B



C

Figure 17-26. Ultrasonography images of lymph nodes. **A.** Normal axillary lymph node. **B.** Indeterminate axillary lymph node. **C.** Malignant appearing axillary lymph node. (Photos used with permission of Dr. Anne Turnbull, Consultant Radiologist/Director of Breast Screening, Royal Derby Hospital, Derby, UK.)

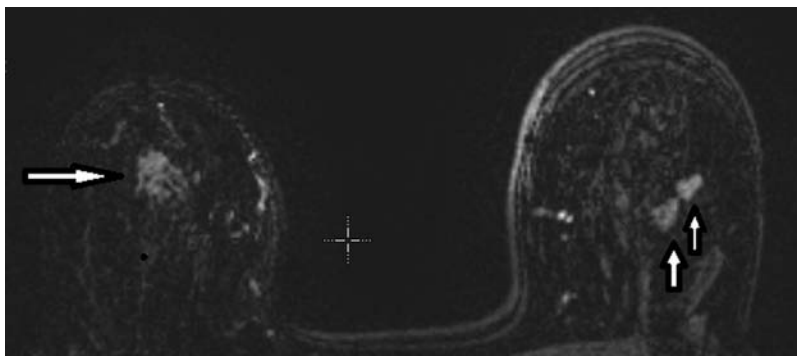


Figure 17-27. MRI examination revealing contralateral breast cancer in a patient diagnosed with unilateral breast cancer on mammography. (Photo used with permission of Dr. Anne Turnbull, Consultant Radiologist/Director of Breast Screening, Royal Derby Hospital, Derby, UK.)




Figure 17-28. MRI imaging of the breast revealing multifocal tumors not detected with standard breast imaging. (Photo used with permission of Dr. Anne Turnbull, Consultant Radiologist/Director of Breast Screening, Royal Derby Hospital, Derby, UK.)

enables the surgeon performing the FNA biopsy to control the syringe and needle with one hand while positioning the breast mass with the opposite hand. After the needle is placed in the mass, suction is applied while the needle is moved back and forth within the mass. Once cellular material is seen at the hub of the needle, the suction is released and the needle is withdrawn. The cellular material is then expressed onto microscope slides. Both air-dried and 95% ethanol-fixed microscopic sections are prepared for analysis. When a breast mass is clinically and mammographically suspicious, the sensitivity and specificity of FNA biopsy approaches 100%. Core-needle biopsy of palpable breast masses is performed using a 14-gauge needle, such as the Tru-Cut needle. Automated devices also are available. Vacuum assisted core biopsy devices (with 8–10 gauge needles) are commonly utilized with image guidance where between 4 and 12 samples can be acquired at different positions within a mass, area of architectural distortion or microcalcifications. If the target lesion was microcalcifications, the specimen should be radiographed to confirm appropriate sampling. A radiopaque marker should be placed at the site of the biopsy to mark the area for future intervention. In some cases the entire lesion is removed with the biopsy technique and clip placement allows for accurate targeting of the site for surgical resection. Tissue specimens are placed in formalin and then processed to paraffin blocks. Although the false-negative rate for core-needle biopsy specimens is very low, a tissue specimen that does not show breast cancer cannot conclusively rule out that diagnosis because a sampling error may have occurred. The clinical, radiographic, and pathologic findings should be in concordance. If the biopsy findings do not concur with the clinical and radiographic findings, the multi-disciplinary team (including clinician, radiologist, and pathologist) should review the findings and decide whether or not to recommend an image-guided or open biopsy to be certain that the target lesion has been adequately sampled for diagnosis.

BREAST CANCER STAGING AND BIOMARKERS

Breast Cancer Staging

The clinical stage of breast cancer is determined primarily through physical examination of the skin, breast tissue, and regional lymph nodes (axillary, supraclavicular, and internal mammary).¹⁴⁸ However, clinical determination of axillary lymph node metastases has an accuracy of only 33%. Ultrasound (US) is more sensitive than physical examination alone in determining axillary lymph node involvement during

preliminary staging of breast carcinoma. Fine-needle aspiration (FNA) or core biopsy of sonographically indeterminate or suspicious lymph nodes can provide a more definitive diagnosis than US alone.^{143,149} Pathologic stage combines the findings from pathologic examination of the resected primary breast cancer and axillary or other regional lymph nodes. Fisher and colleagues found that accurate predictions regarding the occurrence of distant metastases were possible after resection and pathologic analysis of 10 or more level I and II axillary lymph nodes.¹⁵⁰ A frequently used staging system is the TNM (tumor, nodes, and metastasis) system. The American Joint Committee on Cancer (AJCC) has modified the TNM system for breast cancer (Tables 17-10 and 17-11).¹⁵¹ Koscielny and colleagues demonstrated that tumor size correlates with the presence of axillary lymph node metastases (see Fig. 17-14B). Others have shown an association between tumor size, axillary lymph node metastases, and disease-free survival. One of the most important predictors of 10- and 20-year survival rates in breast cancer is the number of axillary lymph nodes involved with metastatic disease. Routine biopsy of internal mammary lymph nodes is not generally performed; however, it has been reported that in the context of a ‘triple node’ biopsy approach either the internal mammary node or a low axillary node when positive alone carried the same prognostic weight. When both nodes were positive the prognosis declined to the level associated with apical node positivity. A double node biopsy of the low axillary node and either the apical or the internal mammary node gave the same maximum prognostic information as a triple node biopsy.¹⁵² With the advent of sentinel lymph node dissection and the use of preoperative lymphoscintigraphy for localization of the sentinel nodes, surgeons have again begun to biopsy the internal mammary nodes but in a more targeted manner. The 7th edition of the AJCC staging system does allow for staging based on findings from the internal mammary sentinel nodes.¹⁵¹ Drainage to the internal mammary nodes is more frequent with central and medial quadrant cancers. Clinical or pathologic evidence of metastatic spread to supraclavicular lymph nodes is no longer considered stage IV disease, but routine scalene or supraclavicular lymph node biopsy is not indicated.

Biomarkers

Breast cancer biomarkers are of several types. Risk factor biomarkers are those associated with increased cancer risk.¹⁵³⁻¹⁵⁷ These include familial clustering and inherited germline abnormalities, proliferative breast disease with atypia, and mammographic densities. Exposure biomarkers are a subset of

Table 17-10

TNM staging system for breast cancer

Primary tumor (T)

The T classification of the primary tumor is the same regardless of whether it is based on clinical or pathologic criteria, or both. Size should be measured to the nearest millimeter. If the tumor size is slightly less than or greater than a cutoff for a given T classification, it is recommended that the size be rounded to the millimeter reading that is closest to the cutoff. For example, a reported size of 1.1 mm is reported as 1 mm, or a size of 2.01 cm is reported as 2.0 cm. Designation should be made with the subscript “c” or “p” modifier to indicate whether the T classification was determined by clinical (physical examination or radiologic) or pathologic measurements, respectively. In general, pathologic determination should take precedence over clinical determination of T size.

TX	Primary tumor cannot be assessed
T0	No evidence of primary tumor
Tis	Carcinoma in situ
Tis (DCIS)	Ductal carcinoma in situ
Tis (LCIS)	Lobular carcinoma in situ
Tis (Paget's)	Paget's disease of the nipple NOT associated with invasive carcinoma and/or carcinoma in situ (DCIS and/or LCIS) in the underlying breast parenchyma. Carcinomas in the breast parenchyma associated with Paget's disease are categorized based on the size and characteristics of the parenchymal disease, although the presence of Paget's disease should still be noted
T1	Tumor ≤20 mm in greatest dimension
T1mi	Tumor ≤1 mm in greatest dimension
T1a	Tumor >1 mm but ≤5 mm in greatest dimension
T1b	Tumor >5 mm but ≤10 mm in greatest dimension
T1c	Tumor >10 mm but ≤20 mm in greatest dimension
T2	Tumor >20 mm but ≤5 cm in greatest dimension
T3	Tumor >50 mm in greatest dimension
T4	Tumor of any size with direct extension to the chest wall and/or to the skin (ulceration or skin nodules)*
T4a	Extension to chest wall, not including only pectoralis muscle adherence/invasion
T4b	Ulceration and/or ipsilateral satellite nodules and/or edema (including peau d'orange) of the skin, which do not meet the criteria for inflammatory carcinoma
T4c	Both T4a and T4b
T4d	Inflammatory carcinoma**

*Note: Invasion of the dermis alone does not qualify as T4

**Note: Inflammatory carcinoma is restricted to cases with typical skin changes involving a third or more of the skin of the breast. While the histologic presence of invasive carcinoma invading dermal lymphatics is supportive of the diagnosis, it is not required, nor is dermal lymphatic invasion without typical clinical findings sufficient for a diagnosis of inflammatory breast cancer.

Regional lymph nodes—Clinical (N)

NX	Regional lymph nodes cannot be assessed (e.g., previously removed)
N0	No regional lymph node metastases
N1	Metastases to movable ipsilateral level I, II axillary lymph node(s)
N2	Metastases in ipsilateral level I, II axillary lymph nodes that are clinically fixed or matted; or in clinically detected* ipsilateral internal mammary nodes in the absence of clinically evident axillary lymph node metastases
N2a	Metastases in ipsilateral level I, II axillary lymph nodes fixed to one another (matted) or to other structures
N2b	Metastases only in clinically detected* ipsilateral internal mammary nodes and in the absence of clinically evident level I, II axillary lymph node metastases
N3	Metastasis in ipsilateral infraclavicular (level III axillary) lymph node(s) with or without level I, II axillary lymph node involvement; or in clinically detected* ipsilateral internal mammary lymph node(s) with clinically evident level I, II axillary lymph node metastases; or metastases in ipsilateral supraclavicular lymph node(s) with or without axillary or internal mammary lymph node involvement
N3a	Metastasis in ipsilateral infraclavicular lymph node(s)
N3b	Metastasis in ipsilateral internal mammary lymph nodes(s) and axillary lymph node(s)
N3c	Metastasis in ipsilateral supraclavicular lymph node(s)

*Notes: “Clinically detected” is defined as detected by imaging studies (excluding lymphoscintigraphy) or by clinical examination and having characteristics highly suspicious for malignancy or a presumed pathologic macrometastasis based on fine needle aspiration biopsy with cytologic examination. Confirmation of clinically detected metastatic disease by fine needle aspiration without excision biopsy is designated with an (f) suffix, e.g., cN3a(f). Excisional biopsy of a lymph node or biopsy of a sentinel node, in the absence of assignment of a pT, is classified as a clinical N, e.g., cN1. Information regarding the confirmation of the nodal status will be designated in site-specific factors as clinical, fine needle aspiration, core biopsy, or sentinel lymph node biopsy. Pathologic classification (pN) is used for excision or sentinel lymph node biopsy only in conjunction with a pathologic T assignment.

Table 17-10

TNM staging system for breast cancer (continued)

Regional lymph nodes—Pathologic (pN)

pNX pN0 ^b	Regional lymph nodes cannot be assessed (e.g., previously removed, or not removed for pathologic study) No regional lymph node metastasis identified histologically Note: Isolated tumor cell clusters (ITC) are defined as small clusters of cells not greater than 0.2 mm, or single tumor cells, or a cluster of fewer than 200 cells in a single histologic cross-section. ITCs may be detected by routine histology or by immunohistochemical (IHC) methods. Nodes containing only ITCs are excluded from the total positive node count for purposes of N classification but should be included in the total number of nodes evaluated.
pN0(i-)	No regional lymph node metastasis histologically, negative IHC
pN0(i+)	Malignant cells in regional lymph node(s) no greater than 0.2 mm (detected by H&E or IHC including ITC)
pN0(mol-)	No regional lymph node metastasis histologically, negative molecular findings [reverse-transcriptase polymerase chain reaction (RT-PCR)]
pN0(mol+)	Positive molecular findings (RT-PCR)**, but no regional lymph node metastases detected by histology or IHC
pN1	Micrometastases; or metastases in 1-3 axillary lymph nodes; and/or in internal mammary nodes with metastases detected by sentinel lymph node biopsy but not clinically detected***
pN1mi	Micrometastases (greater than 0.2 mm and/or more than 200 cells, but none greater than 2.0 mm)
pN1a	Metastases in 1-3 axillary lymph nodes, at least one metastasis greater than 2.0 mm
pN1b	Metastases in internal mammary nodes with micrometastases or macrometastases detected by sentinel lymph node biopsy but not clinically detected***
pN1c	Metastases in 1-3 axillary lymph nodes and in internal mammary lymph nodes with micrometastases or macrometastases detected by sentinel lymph node biopsy but not clinically detected
pN2	Metastases in 4-9 axillary lymph nodes; or in clinically apparent*** internal mammary lymph nodes in the absence of axillary lymph node metastases
pN2a	Metastases in 4-9 axillary lymph nodes (at least one tumor deposit greater than 2.0 mm)
pN2b	Metastases in clinically detected*** internal mammary lymph nodes in the absence of axillary lymph node metastases
pN3	Metastases in 10 or more axillary lymph nodes; or in infraclavicular (level III axillary) lymph nodes; or in clinically detected **** ipsilateral internal mammary lymph nodes in the presence of one or more positive level I, II axillary lymph nodes; or in more than three axillary lymph nodes and in internal mammary lymph nodes with micrometastases or macrometastases detected by sentinel lymph node biopsy but not clinically detected***; or in ipsilateral supraclavicular lymph nodes
pN3a	Metastases in 10 or more axillary lymph nodes (at least one tumor deposit greater than 2.0 mm); or metastases to the infraclavicular (level III axillary lymph) nodes
pN3b	Metastases in clinically detected**** ipsilateral internal mammary lymph nodes in the presence of one or more positive axillary lymph nodes; or in more than three axillary lymph nodes and in internal mammary lymph nodes with micrometastases or macrometastases detected by sentinel lymph node biopsy but not clinically detected***
pN3c	Metastasis in ipsilateral supraclavicular lymph nodes

* Classification is based on axillary lymph node dissection with or without sentinel lymph node biopsy. Classification based solely on sentinel lymph node biopsy without subsequent axillary lymph node dissection is designated (sn) for “sentinel node,” e.g., pN0(sn).
 ** RT-PCR: reverse transcriptase/polymerase chain reaction.
 *** “Not clinically detected” is defined as not detected by imaging studies (excluding lymphoscintigraphy) or not detected by clinical examination.
 **** “Clinically detected” is defined as detected by imaging studies (excluding lymphoscintigraphy) or by clinical examination and having characteristics highly suspicious for malignancy or a presumed pathologic macrometastasis based on fine needle aspiration biopsy with cytologic examination.

Distant metastasis (M)

M0	No clinical or radiographic evidence of distant metastases
cM0(i+)	No clinical or radiographic evidence of distant metastases, but deposits of molecularly or microscopically detected tumor cells in circulating blood, bone marrow, or other nonregional nodal tissue that are no larger than 0.2 mm in a patient without symptoms or signs of metastases
M1	Distant detectable metastases as determined by classic clinical and radiographic means and/or histologically proven larger than 0.2 mm

Source: Reprinted with permission from American Joint Committee on Cancer: *AJCC Cancer Staging Manual*, 7th ed. New York: Springer; 2010:358-361. Used with permission of the American Joint Committee on Cancer (AJCC), Chicago, Illinois. The original source of the material is the *AJCC Cancer Staging Manual*, Seventh Edition (2010) published by Springer Science and Business Media LLC, www.springerlink.com.

Table 17-11

TNM stage groupings

STAGE 0	TIS	NO	M0
Stage IA	T1 ^a	N0	M0
Stage IB	T0	N1mi	M0
	T1 ^a	N1mi	M0
Stage IIA	T0	N1 ^b	M0
	T1 ^a	N1 ^b	M0
	T2	N0	M0
Stage IIB	T2	N1	M0
	T3	N0	M0
Stage IIIA	T0	N2	M0
	T1 ^a	N2	M0
	T2	N2	M0
	T3	N1	M0
	T3	N2	M0
Stage IIIB	T4	N0	M0
	T4	N1	M0
	T4	N2	M0
Stage IIIC	Any T	N3	M0
Stage IV	Any T	Any N	M1

^aT1 includes T1mi

^bT0 and T1 tumors with nodal micrometastases only are excluded from Stage IIA and are classified Stage IB

—M0 includes M0(i+).

—The designation pM0 is not valid; any M0 should be clinical.

—If a patient presents with M1 prior to neoadjuvant systemic therapy, the stage is considered Stage IV and remains Stage IV regardless of response to neoadjuvant therapy.

—Stage designation may be changed if postsurgical imaging studies reveal the presence of distant metastases, provided that the studies are carried out within 4 months of diagnosis in the absence of disease progression and provided that the patient has not received neoadjuvant therapy.

—Postneoadjuvant therapy is designated with “yc” or “yp” prefix.

Of note, no stage group is assigned if there is a complete pathologic response (CR) to neoadjuvant therapy, e.g., ypT0ypN0cM0.

Source: Reprinted with permission from American Joint Committee on Cancer: *AJCC Cancer Staging Manual*, 7th ed. New York: Springer; 2010:360-361. Used with permission of the American Joint Committee on Cancer (AJCC), Chicago, Illinois. The original source of the material is the *AJCC Cancer Staging Manual*, Seventh Edition (2010) published by Springer Science and Business Media LLC, www.springerlink.com.

risk factors that include measures of carcinogen exposure such as DNA adducts. Surrogate endpoint biomarkers are biologic alterations in tissue that occur between cancer initiation and development. These biomarkers are used as endpoints in short-term chemoprevention trials and include histologic changes, indices of proliferation, and genetic alterations leading to cancer. Prognostic biomarkers provide information regarding cancer outcome irrespective of therapy, whereas predictive biomarkers provide information regarding response to therapy.¹⁵⁸ Candidate prognostic and predictive biomarkers and biologic targets for breast cancer include (a) the steroid hormone receptor pathway; (b) growth factors and growth factor receptors such as

human epidermal growth factor receptor 2 (HER-2)/*neu*, epidermal growth factor receptor (EGFR), transforming growth factor, platelet-derived growth factor, and the insulin-like growth factor family; (c) indices of proliferation such as proliferating cell nuclear antigen (PCNA) and Ki-67; (d) indices of angiogenesis such as vascular endothelial growth factor (VEGF) and the angiogenesis index; (e) the mammalian target of rapamycin (mTOR) signaling pathway; (f) tumor-suppressor genes such as p53; (g) the cell cycle, cyclins, and cyclin-dependent kinases; (h) the proteasome; (i) the COX-2 enzyme; (j) the peroxisome proliferator-activated receptors (PPARs); and (k) indices of apoptosis and apoptosis modulators such as bcl-2 and the bax:bcl-2 ratio.

Steroid Hormone Receptor Pathway. Hormones play an important role in the development and progression of breast cancer. Estrogens, estrogen metabolites, and other steroid hormones such as progesterone all have been shown to have an effect. Breast cancer risk is related to estrogen exposure over time. In postmenopausal women, hormone replacement therapy consisting of estrogen plus progesterone increases the risk of breast cancer by 26% compared to placebo.⁷⁰ Patients with hormone receptor-positive tumors survive two to three times longer after a diagnosis of metastatic disease than do patients with hormone receptor-negative tumors. Patients with tumors negative for both estrogen receptors and progesterone receptors are not considered candidates for hormonal therapy. Tumors positive for estrogen or progesterone receptors have a higher response rate to endocrine therapy than tumors that do not express estrogen or progesterone receptors. Tumors positive for both receptors have a response rate of >50%, tumors negative for both receptors have a response rate of <10%, and tumors positive for one receptor but not the other have an intermediate response rate of 33%. The determination of estrogen and progesterone receptor status used to require biochemical evaluation of fresh tumor tissue. Today, however, estrogen and progesterone receptor status can be measured in archived tissue using immunohistochemical techniques. Hormone receptor status also can be measured in specimens obtained with fine-needle aspiration biopsy or core-needle biopsy, and this can help guide treatment planning. Testing for estrogen and progesterone receptors should be performed on all primary invasive breast cancer specimens. The tumor hormone receptor status should be ascertained for both premenopausal and postmenopausal patients to identify patients who are most likely to benefit from endocrine therapy.

Growth Factor Receptors and Growth Factors. Overexpression of EGFR in breast cancer correlates with estrogen receptor-negative status and with p53 overexpression.¹⁵⁹⁻¹⁶¹ Similarly, increased immunohistochemical membrane staining for the *HER-2/neu* growth factor receptor in breast cancer is associated with mutated p53, Ki-67 overexpression, and estrogen receptor-negative status. *HER-2/neu* is a member of the EGFR family of growth factor receptors in which ligand binding results in receptor homodimerization and tyrosine phosphorylation by tyrosine kinase domains within the receptor. Tyrosine phosphorylation is followed by signal transduction, which results in changes in cell behavior. An important property of this family of receptors is that ligand binding to one receptor type also may result in heterodimerization between two different receptor types that are coexpressed; this leads to transphosphorylation and transactivation of both receptors in the complex (transmodulation). In this context, the lack of a specific ligand for the *HER-2/neu*

receptor suggests that *HER-2/neu* may function solely as a coreceptor, modulating signaling by other EGFR family members. *HER-2/neu* is both an important prognostic factor and a predictive factor in breast cancer.¹⁶² When overexpressed in breast cancer, *HER-2/neu* promotes enhanced growth and proliferation, and increases invasive and metastatic capabilities. Clinical studies have shown that patients with *HER-2/neu*-overexpressing breast cancer have poorly differentiated tumors with high proliferation rates, positive lymph nodes, decreased hormone receptor expression, and an increased risk of recurrence and death due to breast cancer.¹⁶²⁻¹⁶⁶ Routine testing of the primary tumor specimen for *HER-2/neu* expression should be performed on all invasive breast cancers. This can be done with immunohistochemical analysis to evaluate for overexpression of the cell-surface receptor at the protein level or by using fluorescence in situ hybridization to evaluate for gene amplification. Patients whose tumors overexpress *HER-2/neu* are candidates for anti-*HER-2/neu* therapy. Trastuzumab (Herceptin) is a recombinant humanized monoclonal antibody directed against *HER-2/neu*. Randomized clinical trials have demonstrated that single-agent trastuzumab therapy is an active and well-tolerated option for first-line treatment of women with *HER-2/neu*-overexpressing metastatic breast cancer. More recently, adjuvant trials demonstrated that trastuzumab also was highly effective in the treatment of women with early-stage breast cancer when used in combination with chemotherapy. Patients who received trastuzumab in combination with chemotherapy had between a 40%–50% reduction in the risk of breast cancer recurrence and approximately a third reduction in breast cancer mortality compared with those who received chemotherapy alone.¹⁶⁷⁻¹⁷⁰

Indices of Proliferation. PCNA is a nuclear protein associated with a DNA polymerase whose expression increases in phase G₁ of the cell cycle, reaches its maximum at the G₁/S interface, and then decreases through G₂.¹⁷¹⁻¹⁷⁴ Immunohistochemical staining for PCNA outlines the proliferating compartments in breast tissue. Good correlation is noted between PCNA expression and (a) cell-cycle distributions seen on flow cytometry based on DNA content, and (b) uptake of bromodeoxyuridine and the proliferation-associated Ki-67 antigen. Individual proliferation markers are associated with slightly different phases of the cell cycle and are not equivalent. PCNA and Ki-67 expression are positively correlated with p53 overexpression, high S-phase fraction, aneuploidy, high mitotic index, and high histologic grade in human breast cancer specimens, and are negatively correlated with estrogen receptor content. Ki67 was included with three other widely measured breast cancer markers (ER, PR, and HER2) into a panel of four immunohistochemical makers (IHC4) which together provided similar prognostic information to that in the Genomic Health 21 Gene Recurrence Score.¹⁷⁵ While there has been significant interest in using Ki67 as a biomarker, and while the IHC4 panel would be much less costly than the 21 Gene Recurrence Score there remain issues regarding reproducibility across laboratories.

Indices of Angiogenesis. Angiogenesis is necessary for the growth and invasiveness of breast cancer and promotes cancer progression through several different mechanisms, including delivery of oxygen and nutrients and the secretion of growth-promoting cytokines by endothelial cells.^{176,177} VEGF induces its effect by binding to transmembrane tyrosine kinase receptors. Overexpression of VEGF in invasive breast cancer is correlated with increased microvessel density and recurrence

in node-negative breast cancer. An angiogenesis index has been developed in which microvessel density (CD31 expression) is combined with expression of thrombospondin (a negative modulator of angiogenesis) and p53 expression. Both VEGF expression and the angiogenesis index may have prognostic and predictive significance in breast cancer. Antiangiogenesis breast cancer therapy is now being studied in human trials. Bevacizumab (a monoclonal antibody to VEGF) was approved by the U.S. Food and Drug Administration (FDA) for use in metastatic breast cancer in combination with paclitaxel chemotherapy. This approval was based on results from a phase III trial by the Eastern Cooperative Oncology Group. The group's E2100 trial showed that when bevacizumab was added to paclitaxel chemotherapy, median progression-free survival increased to 11.3 months from the 5.8 months seen in patients who received paclitaxel alone.¹⁷⁸ The results were not reproduced in other trials and the indication for the drug was revoked by the FDA in 2011.

Indices of Apoptosis. Alterations in programmed cell death (apoptosis), which may be triggered by p53-dependent or p53-independent factors, may be important prognostic and predictive biomarkers in breast cancer.¹⁷⁹⁻¹⁸¹ Bcl-2 family proteins appear to regulate a step in the evolutionarily conserved pathway for apoptosis, with some members functioning as inhibitors of apoptosis and others as promoters of apoptosis. *Bcl-2* is the only oncogene that acts by inhibiting apoptosis rather than by directly increasing cellular proliferation. The death-signal protein bax is induced by genotoxic stress and growth factor deprivation in the presence of wild-type (normal) p53 and/or AP-1/ fos. The bax:bcl-2 ratio and the resulting formation of either bax-bax homodimers, which stimulate apoptosis, or bax-bcl-2 heterodimers, which inhibit apoptosis, represent an intracellular regulatory mechanism with prognostic and predictive implications. In breast cancer, overexpression of bcl-2 and a decrease in the bax:bcl-2 ratio correlate with high histologic grade, the presence of axillary lymph node metastases, and reduced disease-free and overall survival rates. Similarly, decreased bax expression correlates with axillary lymph node metastases, a poor response to chemotherapy, and decreased overall survival.

The remaining biomarkers and biologic targets listed earlier are still in preclinical and clinical trials evaluating their importance in breast cancer for both prognostic and predictive purposes.

Coexpression of Biomarkers. Selection of optimal therapy for breast cancer requires both an accurate assessment of prognosis and an accurate prediction of response to therapy. The breast cancer markers that are most important in determining therapy are estrogen receptor, progesterone receptor, and *HER-2/neu*. Clinicians evaluate clinical and pathologic staging and the expression of estrogen receptor, progesterone receptor, and *HER-2/neu* in the primary tumor to assess prognosis and assign therapy. Adjuvant! Online (<http://www.adjuvantonline.com>) is one of a number of programs available to clinicians that incorporates clinical and pathologic factors for an individual patient and calculates risk of recurrence and death due to breast cancer and then provides an assessment of the reduction in risk of recurrence that would be expected with the use of combination chemotherapy, endocrine therapy, or both of these. Adjuvant! Online was developed using information from the SEER database, the EBCTCG overview analyses, and results from other individual published trials.¹⁸² The website is updated and modified as new information becomes available. Clinicopathologic factors are used to separate breast cancer patients into broad

Table 17-12

Traditional prognostic and predictive factors for invasive breast cancer

TUMOR FACTORS	HOST FACTORS
Nodal status	Age
Tumor size	Menopausal status
Histologic/nuclear grade	Family history
Lymphatic/vascular invasion	Previous breast cancer
Pathologic stage	Immunosuppression
Hormone receptor status	Nutrition
DNA content (ploidy, S-phase fraction)	Prior chemotherapy
Extent of intraductal component	Prior radiation therapy
HER-2/ <i>neu</i> expression	

Source: Modified with permission from Beenken SW, et al: Breast cancer genetics, in Ellis N (ed): *Inherited Cancer Syndromes*. New York: Springer-Verlag;2003:112. With kind permission of Springer Science + Business Media.

prognostic groups, and treatment decisions are made on this basis (Table 17-12). Other indices and programs which are validated and used include the Nottingham Prognostic Index, and PREDICT.¹⁸³⁻¹⁸⁵ When an approach, which combines prognostic factors is used, up to 70% of early breast cancer patients receive adjuvant chemotherapy that is either unnecessary or ineffective. As described earlier, a wide variety of biomarkers have been shown to individually predict prognosis and response to therapy, but they do not improve the accuracy of either the assessment of prognosis or the prediction of response to therapy.

As knowledge regarding cellular, biochemical, and molecular biomarkers for breast cancer increases, prognostic indices are being developed that combine the predictive power of several individual biomarkers with the relevant clinicopathologic factors.

Most recently, technologic advances have led to the ability to measure the expression of multiple genes in a tumor sample simultaneously. This gene expression profiling can provide information about tumor behavior that can be used in determining prognosis and therapy.¹⁸⁶ These high-throughput analyses require bioinformatics support that can categorize and analyze the immense amount of data that are generated. This allows for a detailed stratification of breast cancer patients for assessment of prognosis and for prediction of response to therapy. The *Oncotype DX* is a 21-gene assay that has been validated in newly diagnosed patients with node-negative, estrogen receptor-positive breast cancer.¹⁸⁷ A recurrence score is generated, and those patients with high recurrence scores are found to benefit the most from chemotherapy, whereas those with low recurrence scores benefit most from endocrine therapy and may not require chemotherapy. The 21-gene recurrence score assay has been validated to quantify the risk of recurrence in patients with ER-positive, node-negative breast cancer and also predicts the potential for chemotherapy benefit. Recent data have demonstrated that knowledge of the recurrence score alters treatment recommendations by oncologists and patients likewise change their decision to undergo treatment based on results of the recurrence score.¹⁸⁸ A recently completed clinical trial, the Trial Assessing Individualized Options for Treatment for breast cancer (TAILORx), randomly assigned patients with an

intermediate recurrence score to endocrine therapy alone or to chemotherapy followed by endocrine therapy. When these trial results mature we will learn whether this intermediate risk group of patients with hormone receptor positive disease benefit from the addition of chemotherapy. The MammaPrint test was approved by the FDA for use in patients with newly diagnosed, node-negative breast cancer. The MammaPrint test is based on a 70-gene profile, and although fresh tissue was initially required to perform the assay, it has recently been adapted for use in paraffin-embedded tissue samples. The MINDACT (MicroarrayIn-Node negative and 1-3 positive lymph node Disease may Avoid ChemoTherapy) trial is a phase III randomized trial comparing MammaPrint to Adjuvant! Online for selecting node negative and node-positive (1-3 nodes) breast cancer patients for adjuvant chemotherapy. This trial has completed enrollment with 6,700 patients and will provide important information regarding the use of molecular over standard clinic-pathologic predictors in clinical practice.

OVERVIEW OF BREAST CANCER THERAPY

Before diagnostic biopsy, the surgeon must consider the possibility that a suspicious mass or mammographic finding may be a breast cancer. Once a diagnosis of breast cancer is made, the type of therapy offered to a breast cancer patient is determined by the stage of the disease, the biologic subtype and the general health status of the individual. Laboratory tests and imaging studies are performed based on the initial stage as presented in Table 17-13. Before therapy is initiated, the patient and the surgeon must share a clear perspective on the planned

Table 17-13

Diagnostic studies for breast cancer patients

	CANCER STAGE				
	0	I	II	III	IV
History & physical	X	X	X	X	X
Complete blood count, platelet count			X	X	X
Liver function tests and alkaline phosphatase level			X	X	X
Chest radiograph			X	X	X
Bilateral diagnostic mammograms, ultrasound as indicated	X	X	X	X	X
Hormone receptor status	X	X	X	X	X
HER-2/ <i>neu</i> expression		X	X	X	X
Bone scan				X	X
Abdominal (without or without pelvis) computed tomographic scan or ultrasound or magnetic resonance imaging				X	X

Abdominal imaging and bone scanning are indicated for evaluation of symptoms or abnormal laboratory test results at any presenting stage. Source: Adapted from Carlson RW, et al: Breast cancer, in *NCCN Practice Guidelines in Oncology*. Fort Washington, PA: National Comprehensive Cancer Network, 2006.

course of treatment. Before initiating local therapy, the surgeon should determine the clinical stage, histologic characteristics, and appropriate biomarker levels.

8► In Situ Breast Cancer (Stage 0)

Both LCIS and DCIS may be difficult to distinguish from atypical hyperplasia or from cancers with early invasion.^{60,189-194} Expert pathologic review is required in all cases. Bilateral mammography is performed to determine the extent of the in situ cancer and to exclude a second cancer. Because LCIS is considered a marker for increased risk rather than an inevitable precursor of invasive disease, the current treatment options for LCIS include observation, chemoprevention, and bilateral total mastectomy. The goal of treatment is to prevent or detect at an early stage the invasive cancer that subsequently develops in 25% to 35% of these women. There is no benefit to excising LCIS, because the disease diffusely involves both breasts in many cases and the risk of developing invasive cancer is equal for both breasts. The use of tamoxifen as a risk reduction strategy should be considered in women with a diagnosis of LCIS.

Women with DCIS and evidence of extensive disease (>4 cm of disease or disease in more than one quadrant) usually require mastectomy (Fig. 17-29). For women with limited disease, lumpectomy and radiation therapy are generally recommended. For nonpalpable DCIS, needle localization or other image-guided techniques are used to guide the surgical resection. Specimen mammography is performed to ensure that all visible evidence of cancer is excised. Adjuvant tamoxifen therapy is considered for DCIS patients with ER-positive disease.

The gold standard against which breast conservation therapy for DCIS is evaluated is mastectomy. Women treated with mastectomy have local recurrence and mortality rates of <2%. There is no randomized trial comparing mastectomy vs. breast conserving surgery and none of the randomised trials of breast conserving surgery with or without radiotherapy for DCIS were powered to show a difference in mortality. Women treated with lumpectomy and adjuvant radiation therapy have a local recurrence rate that is increased compared to mastectomy. About 45% of these recurrences will be invasive cancer when radiation therapy is not used. The B-17 trial was conducted by the NSABP to assess the need for radiation in patients treated with breast conserving surgery for DCIS.¹⁹⁵ Patients were randomly assigned to lumpectomy with radiation or lumpectomy alone and after a mean follow-up time of 90 months, rates of both ipsilateral noninvasive and invasive recurrences were significantly lower in patients who received radiation. However in the B-17 trial the margins were not prospectively assessed and it is estimated that up to half the patients may have had tumor at the margin of resection. The benefit of the addition of radiation over breast-conserving surgery alone for DCIS has also been demonstrated in several other randomized trials where margins were prospectively assessed including the European Organization for Research and Treatment of Cancer (EORTC) protocol 10853; the United Kingdom, Australia, New Zealand DCIS Trial; and the Swedish Trial.^{189,196-198}

Despite the data from randomized trials showing a benefit in all patient subgroups with the addition of radiation in DCIS there has been an interest in trying to define a subset where radiation could be avoided in order to minimize the cost and inconvenience

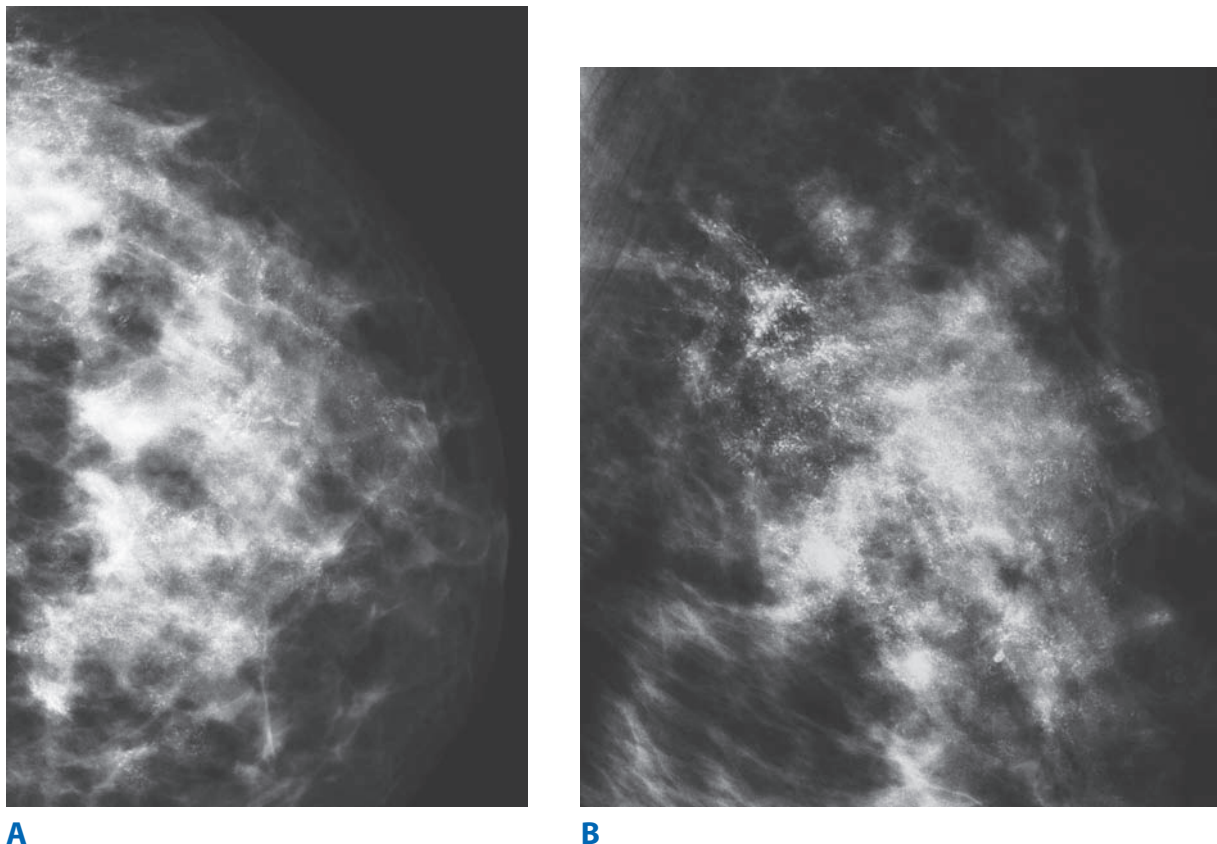


Figure 17-29. Extensive DCIS seen on mammography. **A.** Extensive calcifications are seen throughout the breast on this CC view. **B.** Magnification view of calcifications. Due to the extent of the disease the patient is not a good candidate for breast conserving surgery. (Photos used with permission of Dr. Anne Turnbull, Consultant Radiologist/Director of Breast Screening, Royal Derby Hospital, Derby, UK.)

associated with radiation. In addition, there have been several studies published where patients were treated with excision alone and never developed invasive breast cancer even at 25 years of follow-up. Silverstein and colleagues have been proponents of avoiding radiation therapy in selected patients with DCIS who have widely negative margins after surgery.¹⁹³ They reported that when greater than 10 mm margins were achieved, there was no additional benefit from radiation therapy. When margins were between 1- to 10-mm there was a relative risk of local recurrence of 1.49, compared to 2.54 for those with margins less than 1 mm. These data suggested that appropriately selected patients with DCIS might not require postoperative radiation therapy.

The Eastern Cooperative Oncology Group (ECOG) initiated a prospective registry trial (ECOG 5194) to identify those patients who could safely undergo breast conserving surgery without radiation.¹⁹⁹ Eligible patients were those with low or intermediate grade DCIS measuring 2.5 cm or less who had negative margins of at least 3 mm and those with high grade DCIS who had tumors measuring 1 cm or less with a negative margin of at least 3 mm. At a median follow-up of 6.2 years, patients with low or intermediate grade DCIS had an in-breast recurrence rate of 6.1% while those with high grade DCIS had a recurrence rate of 15.3%. Approximately 4% of patients developed a contralateral breast cancer during follow-up in both the low/intermediate and high grade groups. This study identified an acceptable recurrence rate for those patients with low or intermediate grade DCIS treated with excision alone with a margin of at least 3 mm. In contrast, patients with high grade DCIS had an unacceptably high local recurrence rate.

The Radiation Therapy Oncology Group (RTOG) initiated the 9804 trial for patients with “good risk” DCIS and randomized them to lumpectomy vs. lumpectomy with whole breast irradiation. Eligible patients were those with unicentric, low or intermediate grade DCIS measuring 2.5 cm or less with a margin of 3 mm or greater. The trial was closed early due to slow accrual, however the results for 585 patients were recently reported with a median follow-up of 6.46 years.²⁰⁰ The local recurrence rate at 5 years was 0.4% for patients randomized to receive radiation and 3.2% for those who did not receive radiation. This study has only been reported in abstract form and continued follow-up for enrolled patients is planned.

Solin et al utilized samples from the ECOG 5194 trial to develop a quantitative multigene RT-PCR assay for predicting recurrence risk in patients with DCIS treated with surgery alone.²⁰¹ They were able to define low, intermediate and high risk groups using a DCIS Score. The DCIS Score was able to quantify the risk of recurrence in the breast for both DCIS and invasive events. This tool will need to be evaluated in additional studies but appears to be a promising tool for clinical use. When selecting therapy for patients with DCIS, one must consider clinical and pathologic factors, including tumor size, grade, mammographic appearance, and patient preference. There is no single correct surgical treatment and many patients will require extensive counseling in order to make a decision regarding surgical therapy. The role of axillary staging in patients with DCIS is limited. One consideration is for patients undergoing mastectomy. Since most lesions are currently diagnosed with needle core biopsy, there is about a 20% incidence of invasive breast cancer on final pathologic assessment of the primary tumor.

Since it is not feasible to perform sentinel node dissection after mastectomy, most surgeons will recommend the use of sentinel node dissection at the time of mastectomy for DCIS.

Results from the NSABP B-24 trial reported a significant reduction in local recurrence after 5 years of tamoxifen in women with ER-positive DCIS. Based on this some guidelines have advocated that all patients (women with ER-positive DCIS without contraindications to tamoxifen therapy) should be offered tamoxifen following surgery and radiation therapy for a duration of 5 years. The B-24 trial revealed a significant reduction in recurrence with adjuvant tamoxifen therapy for patients with DCIS, however the results were not initially assessed based on ER status.²⁰² There were 1,804 women with DCIS randomized to lumpectomy and radiation with or without tamoxifen. The rate of breast cancer events was significantly lower in those who received tamoxifen at a median follow-up of 74 months (8.2% vs. 13.4%, $P = 0.0009$). Subsequently, Allred and colleagues evaluated 41% of patients with DCIS in the NSABP B-24 trial to determine the effect of tamoxifen based on ER status measured in the primary tumor.²⁰³ They found that 76% of women had DCIS that was ER-positive and these women had a greater reduction in ipsilateral breast tumor recurrence with tamoxifen than did patients with ER-negative DCIS (11% vs. 5.2%, $P < 0.001$). However it should be noted that 15% of patients in B-24 had tumor at the resection margins for whom tamoxifen could be viewed as treating what by current standard would be viewed as inadequate local excision of the primary tumor. Five years of tamoxifen is not uniformly prescribed across the world as adjuvant therapy following breast conserving surgery and radiation therapy for DCIS.

Early Invasive Breast Cancer (Stage I, IIA, or IIB)

There have been six prospective randomized trials comparing breast conserving surgery to mastectomy in early stage breast cancer and all have shown equivalent survival rates regardless of the surgical treatment type. One caveat however is that the majority of studies had a restriction of tumor size; most were either 2 cm or 2.5 cm while the NSABP B-06 trial was 4 cm and the NCI trial was up to 5 cm. NSABP B-06, which is the largest of all the breast conservation trials, compared total mastectomy to lumpectomy with or without radiation therapy in the treatment of women with stage I and II breast cancer.^{11,204-210} After 5- and 8-year follow-up periods, the disease-free (DFS), distant disease-free, and overall survival (OS) rates for lumpectomy with or without radiation therapy were similar to those observed after total mastectomy. However, the incidence of ipsilateral breast cancer recurrence was higher in the group not receiving radiation therapy. These findings supported the use of lumpectomy and radiation therapy in the treatment of stage I and II breast cancer and this has since become the preferred method of treatment for women with early stage breast cancer who have unifocal disease and who are not known BRCA mutation carriers. Reanalysis of the B-06 study results was undertaken after 20 years of follow-up and confirmed that there was no difference in disease-free survival rates after total mastectomy or after lumpectomy with or without adjuvant radiation therapy. The in-breast recurrence rate was substantially higher in the lumpectomy alone group (39.2%) compared with the lumpectomy plus adjuvant radiation therapy group (14.3%) confirming the importance of radiation therapy in the management of patients with invasive disease. However it should be noted that there were several criteria in the B-06 study. There was a specific lymphadenopathy exclusion criteria. Secondly, all patients randomized to breast conserving surgery had a frozen section and if the margins were involved they were converted to mastectomy

but were included in the analysis as having had a breast conserving operation (on the basis of intention to treat). Finally, in the breast conserving group recurrences in the treated breast were considered as a ‘non event’.

Data from all of the randomized trials where breast conservation was performed with or without radiation therapy have been examined by the EBCTCG.¹² At 15 years of follow-up, the absolute reduction in mortality with the use of radiation therapy after lumpectomy was 5.1% in node-negative patients and 7.1% in node-positive patients. These data support the concept that the addition of radiation not only improves local control but also has an impact on survival. Similar to DCIS, clinicians have sought to identify subgroups of patients who may not benefit from the addition of radiation therapy, particularly older patients who may have a shorter life expectancy due to medical comorbidities. Two randomized trials have shown that in selected patients with small, low-grade tumors, lumpectomy alone without radiation therapy may be appropriate.^{211,212} The Cancer and Leukemia Group B (CALGB) C9343 trial enrolled women over the age of 70 with T1N0 breast cancer and randomized them to lumpectomy with or without radiation therapy. All patients received adjuvant tamoxifen. Although there were fewer local recurrences with radiation (1% vs. 4%, $P < 0.001$), there were no differences in DFS and OS. A trial similar to CALGB C9343 was conducted in Canada where they enrolled women 50 years and older and randomized them to lumpectomy with or without radiation. Mean age was 68 years, and 80% of women had ER-positive tumors. Again, local recurrence rates were lower in women who received radiation (0.6% vs. 7.7%, $P < 0.001$), however, at a median follow-up of 5.6 years, there were no differences in DFS or OS. These studies suggest that radiation can be avoided in early-stage breast cancer patients over the age of 70 when they are diagnosed with T1, N0, ER-positive breast cancer.

Accelerated partial breast irradiation (APBI) is also an option for carefully selected patients with DCIS and early-stage breast cancer. Since the majority of recurrences after breast conservation occur in or adjacent to the tumor bed there has been interest in limiting the radiation to the area of the primary tumor bed with a margin of normal tissue. APBI is delivered in an abbreviated fashion (twice daily for 5 days) and at a lower total dose compared with the standard course of 5 to 6 weeks of radiation (50 Gray with or without a boost) in the case of whole breast irradiation. Proponents have suggested that this shortened course of treatment may increase the feasibility of breast conservation for some women and may improve radiation therapy compliance. The RTOG 04-13/NSABP B-39 trial is a randomized comparison of whole breast irradiation to APBI in women with early stage breast cancer. The trial recently completed accrual and it will likely be several years before data are mature to report outcomes between the two radiation treatment strategies. TARGIT is another study which randomized 3,451 patients in 33 centers over 10 countries to intraoperative breast irradiation (IORT) or external beam radiotherapy (EBRT). The preliminary results were reported in 2012—with a median follow-up of 2.4 years use of IORT had a recurrence rate of 3.3% vs. 1.3% with EBRT, a 2% increased recurrence risk.²¹³

The American Society for Radiation Oncology (ASTRO) developed guidelines for the use of APBI outside of clinical trials based on data reported from published studies.²¹⁴ The ASTRO guidelines describe patients “suitable” for APBI to

include women 60 years of age or older with a unifocal, T1, ER-positive tumor with no lymphovascular invasion, and margins of at least 2 mm. They describe a group where there is uncertainty about the appropriateness of APBI (“cautionary” group) to include patients with invasive lobular histology, a tumor size of 2.1 cm to 3 cm, ER-negative disease, focal lymphovascular invasion, or margins less than 2 mm. Finally, a group felt to be “unsuitable” for APBI includes those with T3 or T4 disease, ER-negative disease, multifocality, multicentricity, extensive LVI, or positive margins.

Currently, mastectomy with axillary staging and breast conserving surgery with axillary staging and radiation therapy are considered equivalent treatments for patients with stage I and II breast cancer. Breast conservation is considered for all patients because of the important cosmetic advantages and equivalent survival outcomes, however, this approach is not advised in women who are known BRCA mutation carriers due to the high lifetime risk for development of additional breast cancers. Relative contraindications to breast conservation therapy include (a) prior radiation therapy to the breast or chest wall, (b) persistently positive surgical margins after reexcision, (c) disease, and (d) scleroderma or lupus erythematosus.

For most patients with early-stage disease, reconstruction can be performed immediately at the time of mastectomy. Immediate reconstruction allows for skin-sparing, thus optimizing cosmetic outcomes. Skin-sparing mastectomy with immediate reconstruction has been popularized over the past decade as reports of low local-regional failure rates have been reported and reconstructive techniques have advanced. There is a growing interest in the use of nipple-areolar sparing mastectomy although few reports on the long-term safety of this approach are available at this time. Patients who are planned for postmastectomy radiation therapy are not ideal candidates for nipple-sparing mastectomy because of the effects of radiation on the preserved nipple. In addition to providing optimal cosmesis from preservation of the skin and/or the nipple-areolar complex, immediate reconstruction allows patients to wake up with a breast mound which provides some psychological benefit for the patient. Immediate reconstruction is also more economical as both the extirpative and reconstructive surgery are combined in one operation.

Immediate reconstruction can be performed using implants or autologous tissue; tissue flaps commonly used include the transverse rectus abdominis myocutaneous flap, deep inferior epigastric perforator flap, and latissimus dorsi flap (with or without an implant). If postmastectomy radiation therapy is needed, a tissue expander can be placed at the time of mastectomy to save the shape of the breast and reduce the amount of skin replacement needed at the time of definitive reconstruction. The expander can be deflated at the initiation of radiation therapy to allow for irradiation of the chest wall and regional nodal basins. Removal of the tissue expander and definitive reconstruction, usually with autologous tissue, can proceed 6 months to 1 year after completion of radiation therapy.

Axillary lymph node status has traditionally been an important determinant in staging and prognosis for women with early stage breast cancer. Historically, axillary lymph node dissection (ALND) was utilized for axillary staging and regional control by removing involved lymph nodes. Randomized trials evaluating immediate ALND over ALND performed in a delayed fashion once clinically palpable axillary disease became evident have not shown any detriment in survival.^{9,215} With increased mammographic screening and detection of

smaller, node-negative breast cancers, it became clear that routine use of ALND for axillary staging was not necessary in up to 75% percent of women with operable breast cancer presenting with a negative axilla at the time of screening. Lymphatic mapping and sentinel lymph node (SLN) dissection were initially developed for assessment of patients with clinically node-negative melanoma. Given the changing landscape of newly diagnosed breast cancer patients with a clinically node-negative axilla, surgeons quickly began to explore the utility of SLN dissection as a replacement for ALND in axillary staging.

In the early 1990s, David Krag at the University of Vermont began performing SLN dissection with injection of a radioisotope in the primary tumor site and localizing the SLN node with a handheld gamma probe.²¹⁶ He was able to identify a SLN in 18 of 22 patients examined and the SLN was positive in all 7 patients with positive lymph nodes. Giuliano and colleagues initiated a pilot study in 1991 to examine the use of SLN dissection using blue dye in patients with clinically negative nodes. They reported successful identification of a SLN in 114 (65.5%) of 174 patients and in 109 (95.6%), the SLN accurately predicted the status of the axillary nodes.^{217,218} These studies along with initial work by Doug Reintgen and Charles Cox at the Moffitt Cancer Center and Umberto Veronesi and his colleagues at the European Institute of Oncology in Milan led the way toward validation of the technique in large single institution and multicenter studies.

Following validation of the technique of SLN dissection for staging of the axilla by multiple centers, randomized trials were initiated in order to determine if SLN dissection could replace ALND in the contemporary management of breast cancer patients. The ALMANAC trial randomized 1,031 patients with primary operable breast cancer to SLN dissection vs. standard axillary surgery. The incidence of lymphedema and sensory loss for the SLN group was significantly lower than with the standard axillary treatment. At 12 months, drain usage, length of hospital stay, and time to resumption of normal day-to-day activities after surgery were also statistically significantly lower in the SLN group.²¹⁹

The NSABP B-32 trial compared clinically node negative patients undergoing SLN dissection followed by ALND with patients undergoing SLN dissection with ALND only if a SLN was positive for metastatic disease.²²⁰ A total of 5,611 patients were randomized with a SLN identification rate of 97%, and a false-negative rate of 9.7%. A total of 26% of these clinically node-negative patients had a positive SLN. Over 60% of patients with positive SLNs had no additional positive lymph nodes within the ALND specimen. The B-32 trial and other randomized trials demonstrated no difference in DFS, OS, and local-regional recurrence rates between patients with negative SLNs who had SLN dissection alone compared with those who underwent ALND.^{221,222} Most important, patients who had SLN dissection alone were found to have decreased morbidity (arm swelling and range of motion) and improved quality of life vs. patients who underwent ALND.^{222,223}

The American College of Surgeons Oncology Group (ACOSOG) initiated the Z0010 and Z0011 trials in order to evaluate the incidence and prognostic significance of occult metastases identified in the bone marrow and SLNs (Z0010) of early-stage clinically node-negative patients and to evaluate the utility of ALND in patients with clinical T1-2, N0 breast cancer with 1 or 2 positive SLNs for patients treated with breast conserving surgery and whole breast irradiation (WBI).^{224,225}

The Z0010 study enrolled 5,539 patients with clinical T1-2 breast cancer planned for breast conserving surgery and WBI.²²⁴ There were 24% of patients who proved to have positive SLNs based on standard pathologic assessment and of the negative SLNs subjected to immunohistochemical staining for cytokeratin, 10.5% proved to have occult metastasis. Of the patients who had bone marrow aspiration, 3.0% had immunohistochemically detected tumor cells in the bone marrow. Although the presence of disease in the bone marrow identified a population at high risk for recurrence, neither immunohistochemical detection of disease in the SLNs or the bone marrow was statistically significant on multivariable analysis with clinicopathologic and treatment factors included. The investigators concluded that routine use of immunohistochemistry to detect occult disease in SLNs is not warranted.

The Z0011 trial was a companion study to Z0010 and was designed to study the role of completion ALND on survival in women with positive SLNs. Patients were not eligible if they received neoadjuvant chemotherapy or neoadjuvant hormonal therapy or if their treatment plan included mastectomy, lumpectomy without radiation, or lumpectomy with APBI. WBI was to be administered using standard tangential fields without specific treatment of the axilla or additional fields targeting other nodal basins. Patients with 1 or 2 positive SLNs were randomized to completion ALND or no further surgery. Adjuvant systemic therapy recommendations were left to the treating clinicians. After median follow-up of 6.3 years, there was no difference between patients randomized to ALND and those randomized to no further surgery (SLN only) in terms of OS (91.9% and 92.5%, respectively; $P=0.25$) or DFS (82.2% and 83.8%, respectively; $P=0.14$).

The morbidity of SLN dissection alone vs. SLN dissection with completion ALND has been reported by the ACOSOG investigators.^{226,227} Immediate effects of SLN dissection in the Z0010 trial included wound infection in 1%, axillary seroma in 7.1%, and axillary hematoma in 1.4%.²²⁶ At 6 months following surgery, axillary paresthesias were noted in 8.6% of patients, decreased range of motion in the upper extremity was reported in 3.8%, and 6.9% of patients had a change in the arm circumference of >2 cm on the ipsilateral side, which was reported as lymphedema. Younger patients were more likely to report paresthesias, whereas increasing age and body mass index were more predictive of lymphedema. When adverse surgical effects were examined in the Z0011 trial, patients undergoing SLN dissection with ALND had more wound infections, seromas, and paresthesias than those women undergoing SLN dissection alone. Lymphedema at one year after surgery was reported by 13% in the SLN plus ALND group but only 2% in the SLN dissection alone group. Arm circumference measurements were greater at one year in patients undergoing SLN dissection plus ALND, but the difference between study groups was not statistically significant.²²⁷ This supports the results published from the ALMANAC trial.

Prior to the publication of ACOSOG Z0011, completion ALND was standard of care for patients with positive SLNs. Since the reporting of ACOSOG Z0011, the National Comprehensive Cancer Network (NCCN) guidelines now state that there was no OS difference for patients with 1 or 2 positive SLNs treated with breast conserving surgery who underwent completion ALND vs. those who had no further axillary surgery. In addition, the American Society of Breast Surgeons issued a consensus statement supporting omission of ALND for patients who meet Z0011 criteria.²²⁸ The results of ACOSOG Z0011

have revolutionized management of the axilla and changed practice such that selected patients with axillary metastasis can now avoid ALND if they have clinical and pathologic features similar to those patients enrolled on Z0011. However, there have been some concerns raised about the Z0011 study which include the fact that the study only recruited about half of the intended patients and that there was no standardization of whether or not patients received irradiation to the low axilla when the radiation oncologist irradiated the breast. These issues have thus far limited the uptake of the results of Z0011 by some centers.

The International Breast Cancer Study Group (IBCSG) 23-01 trial was similar in design to Z0011 but enrolled only patients with micrometastases in the SLNs. Patients with SLN micrometastases were randomized to ALND vs. no further surgery. Unlike Z0011, the 23-01 trial did not exclude patients treated with mastectomy. Approximately 9% of patients randomized to each study arm underwent mastectomy. The investigators published the primary and secondary endpoints of the trial showing no differences in OS or local-regional recurrence between the study arms.²²⁹ However, as with the Z0011 trial, some concerns have been raised regarding the 23-01 study. For example, in the statistics on the primary endpoint, local recurrence included contralateral breast cancer and other tumor types as events. No hypothesis was presented as to why the difference in axillary surgery should impact on either of these events. Including these events therefore reduced the power of the study to show a statistical difference between treatment arms. There is also concern that the study appears underpowered to show a meaningful difference in overall survival.

Most pathology laboratories perform a more detailed analysis of the SLN than is routinely done for axillary nodes recovered from a level I and II dissection. This can include examining thin sections of the node with step sectioning at multiple levels through the paraffin blocks or performing immunohistochemical staining of the SLN for cytokeratin or a combination of these techniques. The results of ACOSOG Z0010 and NSABP B-32 showed no clinically meaningful difference in survival based on detection of occult metastases in the SLNs using immunohistochemical staining and do not support the routine use in SLN processing. The type of intraoperative assessment of SLNs also varies for different clinicians and pathology laboratories. Some centers prefer to use touch preparation cytologic analysis of the SLNs, whereas others use frozen-section analysis, and the sensitivity and specificity of these assays vary considerably. The GeneSearch Breast Lymph Node Assay is a real-time reverse-transcriptase polymerase chain reaction assay that detects breast tumor cell metastasis in lymph nodes through the identification of the gene expression markers *mamaglobin* and *cytokeratin 19*. These markers are present in higher levels in breast tissue and not in nodal tissue (cell type-specific messenger RNA). The GeneSearch assay generates expression data for genes of interest, which are then evaluated against predetermined criteria to provide a qualitative (positive/negative) result. The assay is designed to detect foci that correspond to metastases which are seen with examination by standard hematoxylin and eosin staining and measure >0.2 mm. The GeneSearch assay results have been compared with permanent-section histologic analysis and frozen-section analysis of sentinel nodes in a prospective trial, and the assay was recently approved by the FDA for the intraoperative assessment of sentinel nodes.²³⁰ When a positive node is identified intraoperatively by touch preparation, frozen-section analysis, or GeneSearch assay, the surgeon can proceed with

immediate ALND. With the findings of ACOSOG Z0011 that there is not a survival benefit to the use of ALND in selected patients, many surgeons have abandoned the intraoperative evaluation of SLNs. There are a number of nomograms and predictive models designed to determine which patients with a positive SLN are at risk for harboring additional positive non-SLNs in the axilla. These tools can be helpful in determining the likelihood of additional disease in the axilla and may be used clinically to counsel patients.²³¹

In patients who present with axillary lymphadenopathy that is confirmed to be metastatic disease on FNA or core biopsy, SLN dissection is not necessary and patients can proceed directly to ALND or be considered for preoperative systemic therapy (see section on Neoadjuvant [Preoperative] Chemotherapy under Non-Surgical Breast Cancer Therapies). Initially there was controversy about the suitability of SLN dissection in women with larger primary tumors (T3) and those treated with neoadjuvant chemotherapy. The American Society of Clinical Oncology has included SLN dissection in its guidelines as appropriate for axillary staging in these patients.²³² If a SLN cannot be identified, then ALND is generally performed for appropriate staging. However, this is not universally accepted and there are as yet no randomized studies which have assessed how a patient with a locally advanced cancer at presentation should be treated if their SLN dissection reveals no metastases or micrometastases after neoadjuvant therapy.

Adjuvant chemotherapy for patients with early-stage invasive breast cancer is considered for patients with node-positive cancers, patients with cancers that are >1 cm, and patients with node-negative cancers of >0.5 cm when adverse prognostic features are present. Adverse prognostic factors include blood vessel or lymph vessel invasion, high nuclear grade, high histologic grade, *HER-2/neu* overexpression or amplification, and negative hormone receptor status. Adjuvant endocrine therapy is considered for women with hormone receptor-positive cancers, and use of an aromatase inhibitor is recommended if the patient is postmenopausal. There remains some debate as to whether patients should have 5 years of an aromatase inhibitor or two years of tamoxifen followed by 3 years of an aromatase inhibitor (the so called, 'switch' regime); the majority of clinicians appear to favor 5 years of an aromatase inhibitor, especially with increasing risk of recurrence. *HER-2/neu* status is determined for all patients with newly diagnosed invasive breast cancer and when positive, should be used to guide systemic therapy recommendations. Trastuzumab is the only *HER-2/neu*-targeted agent that is currently approved for use in the adjuvant setting. The FDA approved trastuzumab in November 2006 for use as part of a treatment regimen containing doxorubicin, cyclophosphamide, and paclitaxel for treatment of *HER-2/neu*-positive, node-positive breast cancer.^{167,168} Subsequently, the BCIRG 006 study reported that giving trastuzumab concurrently with docetaxel and carboplatin appeared as effective as giving trastuzumab following an anthracycline containing regimen.^{169,170}

Advanced Local-Regional Breast Cancer (Stage IIIA or IIIB)

Women with stage IIIA and IIIB breast cancer have advanced local-regional breast cancer but have no clinically detected distant metastases (Fig. 17-30).²³³ In an effort to provide optimal local-regional disease-free survival as well as distant disease-free survival for these women, surgery is integrated with radiation therapy and chemotherapy (Fig. 17-31). However, it should

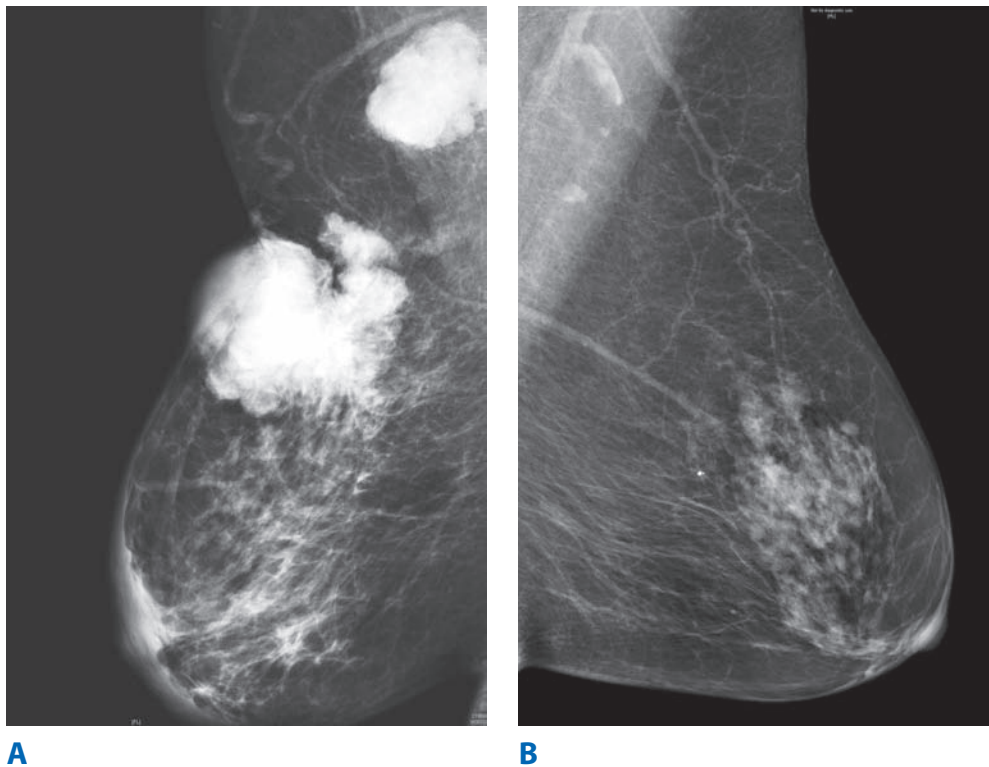


Figure 17-30. Locally advanced breast cancer. **A.** Mammography of the right breast reveals a large tumor with enlarged axillary lymph nodes. **B.** Imaging of the left breast is normal. (Photos used with permission of Dr. Anne Turnbull, Consultant Radiologist/Director of Breast Screening, Royal Derby Hospital, Derby, UK.)

be noted that most of these patients will already have distant metastasis which is often highlighted by radiological evidence when bone scans, PET &/or CT scans are performed. Even when they are negative, elevated serum tumor markers may be another indicator that distant spread has already occurred. The paradigm therefore which is appropriate for small screen detected cancers where cure can be expected in >90% of patients, often by local treatment alone is not the same clinical scenario as with locally advanced disease. Indeed, a previous

randomized study of neoadjuvant therapy followed by modified radical mastectomy, post-operative radiotherapy and endocrine therapy vs. primary endocrine therapy followed by sequential therapy on progression of disease showed no difference in either overall survival or uncontrolled local disease at death.²³⁴

Preoperative (also known as neoadjuvant) chemotherapy should be considered in the initial management of patients with locally advanced stage III breast cancer, especially those with estrogen receptor negative tumors. For selected clinically indolent,

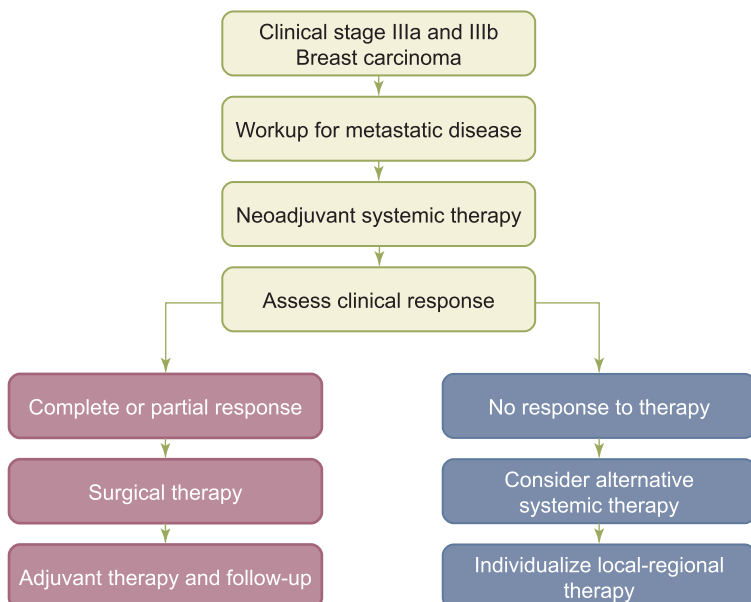


Figure 17-31. Treatment pathways for stage IIIA and stage IIIB breast cancer.

estrogen receptor positive, locally advanced tumors, primary endocrine therapy may be considered, especially if the patient has other co-morbid conditions. A series of 195 patients with ER-positive locally advanced breast cancer treated by endocrine therapy—median age 69 years, median tumor size 6 cm, median follow-up 61 months—reported a five year overall survival of 76%, a breast cancer specific survival of 86%, and a metastasis free survival of 77%. The median time to an alternative treatment was 48 months.²³⁵ Given that this was a 20-year series, the number of such patients is small but should be considered when the clinician is discussing treatment options. Surgical therapy for women with stage III disease is usually a modified radical mastectomy, followed by adjuvant radiation therapy. Chemotherapy is used to maximize distant disease-free survival, whereas radiation therapy is used to maximize local-regional control and disease-free survival. In selected patients with stage IIIA cancer, preoperative chemotherapy can reduce the size of the primary cancer and permit breast-conserving surgery. Investigators from the MD Anderson Cancer Center reported that low local-regional failure rates could be achieved in selected patients with stage III disease treated with preoperative chemotherapy followed by breast-conserving surgery and radiation.²³⁶ The 5-year actuarial ipsilateral breast tumor recurrence-free survival rates in this study were 95%. They noted that the ipsilateral breast tumor recurrence rates increased when patients had clinical N2 or N3 disease, >2 cm of residual disease in the breast at surgery, a pattern of multifocal residual disease in the breast at surgery, and lymphovascular space invasion in the primary tumor. This study demonstrates that breast-conserving surgery can be used for appropriately selected patients with locally advanced breast cancer who achieve a good response with preoperative chemotherapy. However, the Oxford overview of all randomized studies of neoadjuvant therapy (vs. adjuvant therapy) reported a hazard ratio of 1.5 (i.e., 50% increase) in local recurrence rates. A meta-analysis reported a hazard ratio of 1.3.²³⁷ These findings are important in view of the previous findings that the avoidance of recurrence in a conserved breast avoids about one breast cancer death over the next 15 years for every four such recurrences avoided.¹² Furthermore, the German Breast Cancer Group recently reported their local recurrence rate in 5,535 patients in seven studies. With a median of 46 months (range 1–127) follow-up the local recurrence rates ranged from 7.6% to 19.5% for T1-T4 tumors and from 6.4%–17.9% for N0-N3 tumors treated with neoadjuvant therapy.²³⁸ Therefore, this is an important issue which needs to be addressed in future locally advanced and neoadjuvant studies. For patients with stage IIIA disease who experience minimal response to chemotherapy and for patients with stage IIIB breast cancer, preoperative chemotherapy can decrease the local-regional cancer burden enough to permit subsequent modified radical mastectomy to establish local-regional control. In both stage IIIA and IIIB disease, surgery is followed by adjuvant radiation therapy. However there is a small percentage of patients who experience progression of disease during neoadjuvant therapy and therefore the surgeon should review patients with the oncologist at regular points during the neoadjuvant regimen.

Internal Mammary Lymph Nodes

Metastatic disease to internal mammary lymph nodes may be occult, may be evident on chest radiograph or CT scan, or may present as a painless parasternal mass with or without skin involvement. There is no consensus regarding the need for

internal mammary lymph node radiation therapy in women who are at increased risk for occult involvement (cancers involving the medial aspect of the breast, axillary lymph node involvement) but who show no signs of internal mammary lymph node involvement. Systemic chemotherapy and radiation therapy are indicated in the treatment of grossly involved internal mammary lymph nodes.

Distant Metastases (Stage IV)

Treatment for stage IV breast cancer is not curative but may prolong survival and enhance a woman's quality of life.²³⁹ Endocrine therapies that are associated with minimal toxicity are preferred to cytotoxic chemotherapy in estrogen receptor positive disease. Appropriate candidates for initial endocrine therapy include women with hormone receptor-positive cancers who do not have immediately life threatening disease (or 'visceral crisis'). This includes not only women with bone or soft tissue metastases but also women with limited visceral metastases. Symptoms per se (e.g., breathlessness) are not in themselves an indication for chemotherapy. For example, breathlessness due to a pleural effusion can be treated with percutaneous drainage and if the breathlessness is relieved the patient should be commenced on endocrine therapy whereas if the breathlessness is due to lymphangitic spread then chemotherapy would be the treatment of choice. The same approach should be taken to other symptoms such as pain. Systemic chemotherapy is indicated for women with hormone receptor-negative cancers, 'visceral crisis', and hormone-refractory metastases. Women with stage IV breast cancer may develop anatomically localized problems that will benefit from individualized surgical or radiation treatment, such as brain metastases, pleural effusion, pericardial effusion, biliary obstruction, ureteral obstruction, impending or existing pathologic fracture of a long bone, spinal cord compression, and painful bone or soft tissue metastases. Bisphosphonates, which may be given in addition to chemotherapy or endocrine therapy, should be considered in women with bone metastases. Whether to perform surgical resection of the local-regional disease in women with stage IV breast cancer has been debated after several reports have suggested that women who undergo resection of the primary tumor have improved survival over those who do not. Khan and associates used the National Cancer Data Base to identify patterns of treatment in women with metastatic breast cancer and found that those who had surgical resection with negative margins had a better prognosis than those women who did not have surgical therapy.²⁴⁰ Gnerlich et al reported similar findings using the SEER database, and there have been several reports subsequent to this study from single institutions that have confirmed these findings.²⁴¹ Some have suggested that the finding of improved survival is due to selection bias and that local therapy should be reserved for palliation of symptoms. A randomized trial is currently underway through ECOG to address this question. In the meantime, surgical management of patients with stage IV disease should be addressed by obtaining multidisciplinary input and by considering the treatment goals of each individual patient and the patient's treating physicians.

Local-Regional Recurrence

Women with local-regional recurrence of breast cancer may be separated into two groups: those who have had mastectomy and those who have had lumpectomy. Women treated previously with mastectomy undergo surgical resection of the local-regional recurrence and appropriate reconstruction.

Chemotherapy and antiestrogen therapy are considered, and adjuvant radiation therapy is given if the chest wall has not previously received radiation therapy or if the radiation oncologist feels that given the time from previous treatment there is scope for further radiation therapy, particularly if this is palliative. Women treated previously with a breast conservation procedure undergo a mastectomy and appropriate reconstruction. Chemotherapy and antiestrogen therapy are considered.

Breast Cancer Prognosis

Survival rates for women diagnosed with breast cancer in the United States can be obtained from the SEER Program of the National Cancer Institute. Data have been collected since 1973 and is updated at regular intervals. The overall 5-year relative survival for breast cancer patients from the time period of 2003–2009 from 18 SEER geographic areas was 89.2%. The 5-year relative survival by race was reported to be 90.4% for white women and 78.7% for black women. The 5-year survival rate for patients with localized disease (61% of patients) is 98.6%; for patients with regional disease (32% of patients), 84.4%; and for patients with distant metastatic disease (5% of patients), 24.3%. Breast cancer survival has significantly increased over the past two decades due to improvements in screening and local and systemic therapies. Data from the American College of Surgeons National Cancer Data Base can also be accessed and reports survival based on stage of disease at presentation using the AJCC staging system.

SURGICAL TECHNIQUES IN BREAST CANCER THERAPY

Excisional Biopsy with Needle Localization

Excisional biopsy implies complete removal of a breast lesion with a margin of normal-appearing breast tissue. In the past, surgeons would obtain prior consent from the patient allowing mastectomy if the initial biopsy results confirmed cancer. Today it is

important to consider the options for local therapy (lumpectomy vs. mastectomy with or without reconstruction) and the need for nodal assessment with SLN dissection. Needle core biopsy is the preferred diagnostic method and excisional biopsy should be reserved for those cases where the needle biopsy results are discordant with the imaging findings or clinical examination (Fig. 17-32). In general circumareolar incisions can be used to access lesions which are subareolar or within a short distance of the nipple-areolar complex. Elsewhere in the breast, incisions should be placed which are in the lines of tension in the skin that are generally concentric with the nipple-areola complex. In the lower half of the breast, the use of radial incisions typically provides the best outcome. When the tumor is quite distant from the central breast, the biopsy incision can be excised separately from the primary mastectomy incision, should a mastectomy be required. Radial incisions in the upper half of the breast are not recommended because of possible scar contracture resulting in displacement of the ipsilateral nipple-areola complex. Similarly, curvilinear incisions in the lower half of the breast may displace the nipple-areolar complex downward.

After excision of a suspicious breast lesion, the specimen should be x-rayed to confirm the lesion has been excised with appropriate margins. The biopsy tissue specimen is orientated for the pathologist using sutures, clips, or dyes. Additional margins (superior, inferior, medial, lateral, superficial, and deep) may be taken from the surgical bed if the specimen x-ray shows the lesion is close to one or more margins. Some surgeons also take additional shavings from the margins as one approach to confirm complete excision of the suspicious lesion. Electrocautery or absorbable ligatures are used to achieve wound hemostasis. Cosmesis may be facilitated by approximation of the surgical defect using 3-0 absorbable sutures. A running subcuticular closure of the skin using 4-0 or 5-0 absorbable monofilament sutures is performed. Wound drainage is usually not required.

Excisional biopsy with needle localization requires a preoperative visit to the mammography suite for placement of a

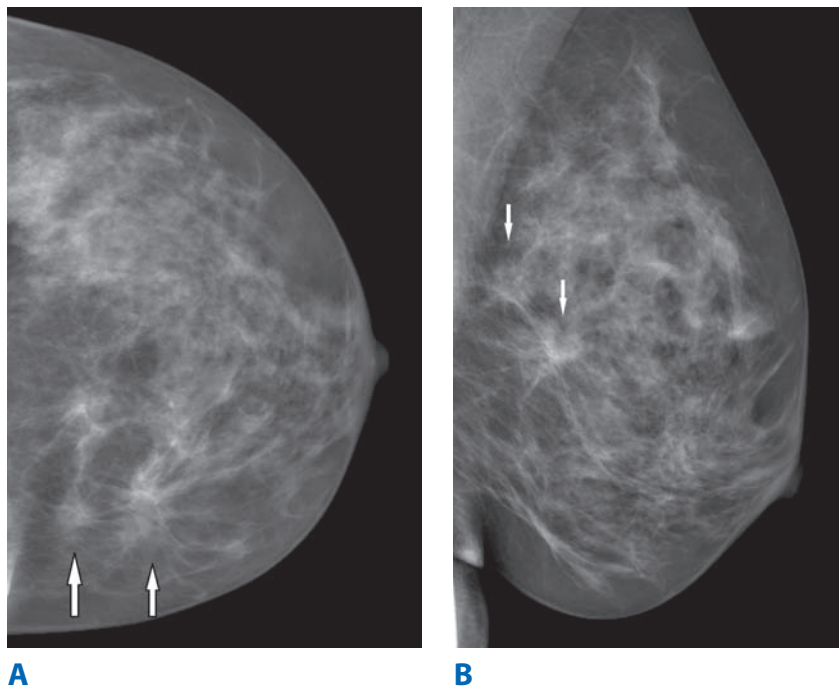


Figure 17-32. Lesion to be targeted to excisional biopsy. **A.** Cranio-caudal view of the left breast demonstrating 2 lesions (arrows) to be targeted for needle localization and excision. **B.** Oblique view demonstrating target lesions. (Photos used with permission of Dr. Anne Turnbull, Consultant Radiologist/Director of Breast Screening, Royal Derby Hospital, Derby, UK.)

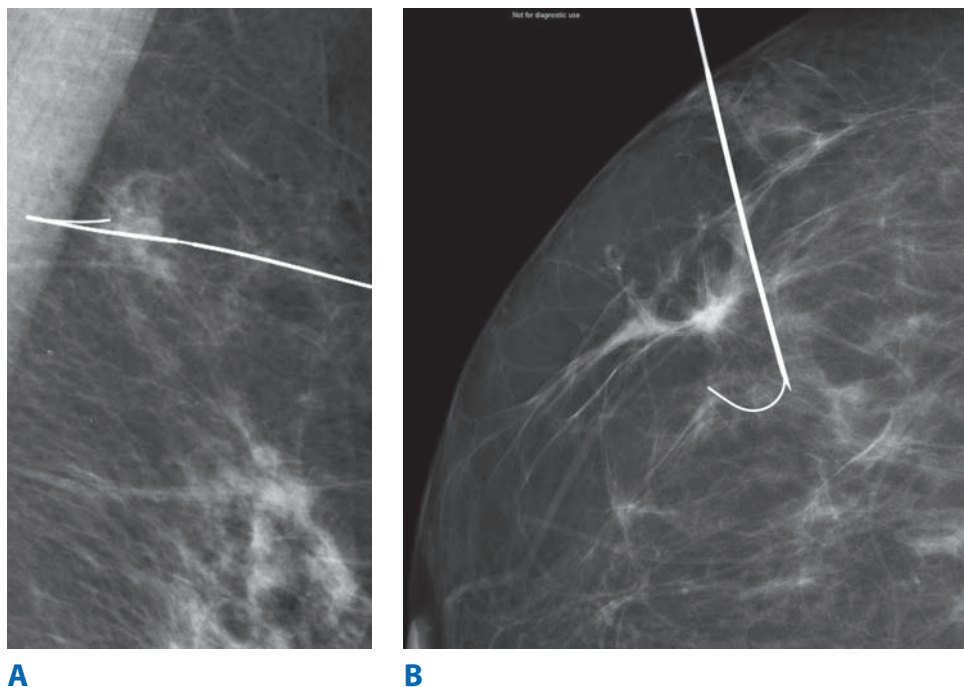


Figure 17-33. Wire localization procedure. Mammographic images of hookwire in place targeting lesions for excision in the left breast (A) and the right breast (B). (Photos used with permission of Dr. Anne Turnbull, Consultant Radiologist/Director of Breast Screening, Royal Derby Hospital, Derby, UK.)

localization wire or a radiolabeled seed that can be detected intraoperatively with a handheld probe. The lesion can also be targeted by sonography in the imaging suite or in the operating room. The lesion to be excised is accurately localized by mammography, and the tip of a thin wire hook is positioned close to the lesion (Fig. 17-33). Using the wire hook as a guide, the surgeon subsequently excises the suspicious breast lesion while removing a margin of normal-appearing breast tissue. Before the patient leaves the operating room, specimen radiography is performed to confirm complete excision of the suspicious lesion (Fig. 17-34).

Sentinel Lymph Node Dissection

Sentinel lymph node (SLN) dissection is primarily used to assess the regional lymph nodes in women with early breast cancers who are clinically node negative by physical examination and imaging studies.²⁴²⁻²⁵⁰ This method also is accurate in women with larger tumors (T3 N0), but nearly 75% of these women will prove to have axillary lymph node metastases on histologic examination and wherever possible it is better to identify them preoperatively as this will allow a definitive procedure for known axillary disease. SLN dissection has also been reported to be accurate for staging of the axilla after chemotherapy in women with clinically node-negative disease at initial presentation.^{251,252} Tan et al in a review and meta-analysis of 449 cases of SLN biopsy in clinically lymph node negative disease reported a sensitivity of 93% giving a false negative rate of 7% with a negative predictive value of 94% and an overall accuracy of 95%.²⁵³ Clinical situations where SLN dissection is not recommended include patients with inflammatory breast cancers, those with palpable axillary lymphadenopathy and biopsy proven metastasis, DCIS without mastectomy, or prior axillary surgery. Although limited data are available, SLN

dissection appears to be safe in pregnancy when performed with radioisotope alone.

Evidence from large prospective studies suggests that the combination of intraoperative gamma probe detection of radioactive colloid and intraoperative visualization of blue dye (isosulfan blue dye or methylene blue) is more accurate for identification of SLNs than the use of either agent alone. Some surgeons use preoperative lymphoscintigraphy, although it is not required for identification of the SLNs. On the day before surgery, or the day of surgery, the radioactive colloid is injected either in the breast parenchyma around the primary tumor or prior biopsy site, into the subareolar region, or subdermally in proximity to the primary tumor site. With a 25-gauge needle, 0.5 mCi of 0.2- μ m technetium 99m-labeled sulfur colloid is injected for same-day surgery or a higher dose of 2.5 mCi of technetium-labeled sulfur colloid is administered when the isotope is to be injected on the day before surgery. Subdermal injections are given in proximity to the cancer site or in the subareolar location. Later, in the operating room, 3 to 5 mL of blue dye is injected either in the breast parenchyma or in the subareolar location. It is not recommended that the blue dye be used in a subdermal injection because this can result in tattooing of the skin (isosulfan blue dye) or skin necrosis (methylene blue). For nonpalpable cancers, the injection of the technetium-labeled sulfur colloid solution can be guided by ultrasound or by mammographic guidance. It is helpful for the radiologist to mark the skin overlying the breast cancer at the time of needle localization using an indelible marker. In women who have undergone previous excisional biopsy, the injections are made in the breast parenchyma around the biopsy cavity but not into the cavity itself. Women are told preoperatively that the isosulfan blue dye injection will cause a change in the color of their urine and that there is a very small risk of allergic reaction to

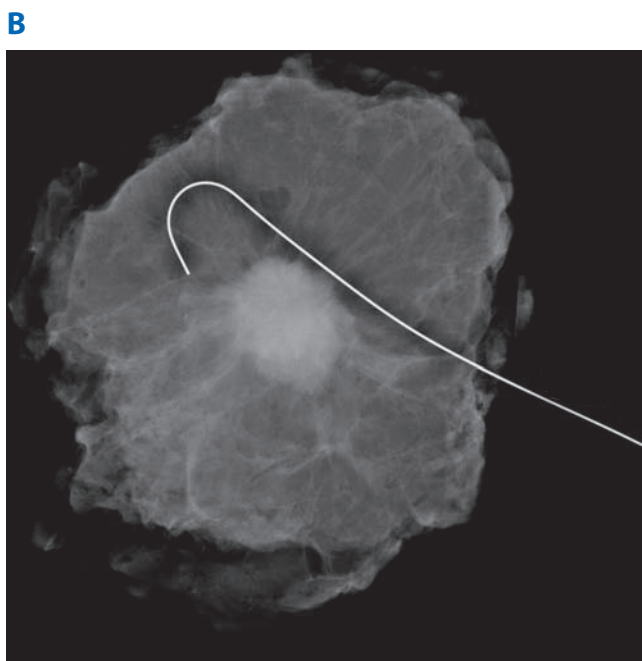
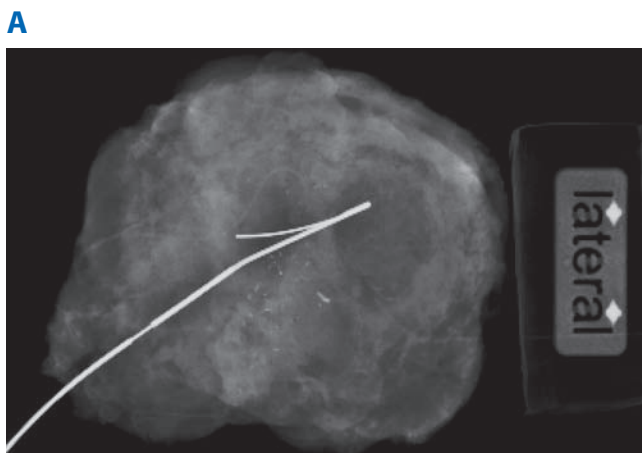
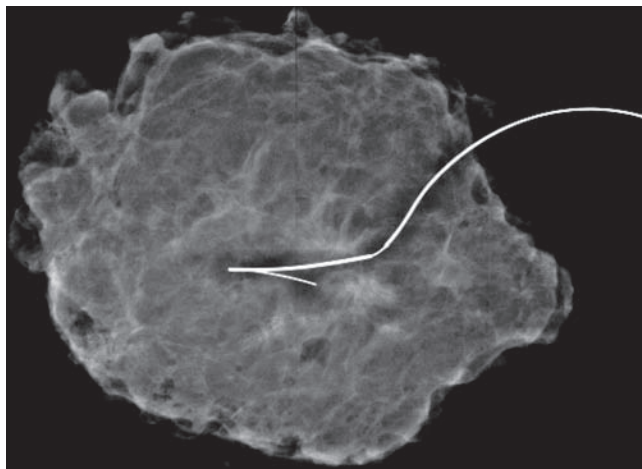


Figure 17-34. Specimen mammography. Specimen mammograms demonstrating excision of targeted (A) density, (B) calcifications, and (C) spiculated mass seen on preoperative imaging. (Photos used with permission of Dr. Anne Turnbull, Consultant Radiologist/Director of Breast Screening, Royal Derby Hospital, Derby, UK.)

the dye (1 in 10,000). Anaphylactic reactions have been documented and some groups administer a regimen of antihistamine, steroids, and a histamine H-2 receptor antagonist preoperatively as a prophylactic regimen to prevent allergic reactions. The use of radioactive colloid is safe, and radiation exposure is very low. Sentinel node dissection can be performed in pregnancy with the radioactive colloid without the use of blue dye.

A hand-held gamma counter is used to transcutaneously identify the location of the SLN. This can help to guide placement of the incision. A 3- to 4-cm incision is made in line with that used for an axillary dissection, which is a curved transverse incision in the lower axilla just below the hairline. After dissecting through the subcutaneous tissue, the surgeon dissects through the axillary fascia, being mindful to identify blue lymphatic channels. Following these channels can lead directly to the SLN and limit the amount of dissection through the axillary tissues. The gamma probe is used to facilitate the dissection and to pinpoint the location of the SLN. As the dissection continues, the signal from the probe increases in intensity as the SLN is approached. The SLN also is identified by visualization of blue dye in the afferent lymph vessel and in the lymph node itself. Before the SLN is removed, a 10-second in vivo radioactivity count is obtained. After removal of the SLN, a 10-second ex vivo radioactive count is obtained, and the node is then sent to the pathology laboratory for either permanent- or frozen-section analysis. The lowest false-negative rates for SLN dissection have been obtained when all blue lymph nodes and all lymph nodes with counts >10% of the 10-second ex vivo count of the SLN are harvested ("10% rule"). Based on this, the gamma counter is used before closing the axillary wound to measure residual radioactivity in the surgical bed. A search is made for additional SLNs if the counts remain high. This procedure is repeated until residual radioactivity in the surgical bed is less than 10% of the 10-second ex vivo count of the most radioactive SLN and all blue nodes have been removed. Studies have demonstrated that 98% of all positive SLNs will be recovered with the removal of four SLNs, therefore it is not necessary to remove greater than four SLNs for accurate staging of the axilla.

Results from the NSABP B-32 trial showed that the false-negative rate for SLN dissection is influenced by tumor location, type of diagnostic biopsy, and number of SLNs removed at surgery.²²⁰ The authors reported that tumors located in the lateral breast were more likely to have a false-negative SLN. This may be explained by difficulty in discriminating the hot spot in the axilla when the radioisotope has been injected at the primary tumor site in the lateral breast. Those patients who had undergone an excisional biopsy before the SLN procedure were significantly more likely to have a false-negative SLN. This report further confirms that surgeons should use needle biopsy for diagnosis whenever possible and reserve excisional biopsy for the rare situations in which needle biopsy findings are non-diagnostic or discordant. Finally, removal of a larger number of SLNs at surgery appears to reduce the false-negative rate. In B-32, the false-negative rate was reduced from 17.7% to 10% when two SLNs were recovered and to 6.9% when three SLNs were removed. Yi and associates reported that the number of SLNs that need to be removed for accurate staging is influenced by individual patient and primary tumor factors.²⁵⁴

In the B-32 trial, SLNs were identified outside the level I and II axillary nodes in 1.4% of cases. This was significantly influenced by the site of radioisotope injection. When a subareolar or periareolar injection site was used, there were no instances

of SLNs identified outside the level I or II axilla, compared with a rate of 20% when a peritumoral injection was used. This supports the overall concept that the SLN is the first site of drainage from the lymphatic vessels of the primary tumor. Although many patients will have similar drainage patterns from injections given at the primary tumor site and at the subareolar plexus, some patients will have extra-axillary drainage, either alone or in combination with axillary node drainage, and this is best assessed with a peritumoral injection of the radioisotope. Kong et al reported that internal mammary node drainage on preoperative lymphoscintigraphy was associated with worse distant disease-free survival in early-stage breast cancer patients.²⁵⁵

Breast Conservation

Breast conservation involves resection of the primary breast cancer with a margin of normal-appearing breast tissue, adjuvant radiation therapy, and assessment of regional lymph node status.^{256,257} Resection of the primary breast cancer is alternatively called *segmental mastectomy*, *lumpectomy*, *partial mastectomy*, *wide local excision*, and *tylectomy*. For many women with stage I or II breast cancer, breast-conserving therapy (BCT) is preferable to total mastectomy because BCT produces survival rates equivalent to those after total mastectomy while preserving the breast.²⁵⁸ Six prospective randomized trials have shown that overall and disease-free survival rates are similar with BCT and mastectomy, however three of the studies showed higher local-regional failure rates in patients undergoing BCT. In two of these studies, there were no clear criteria for histologically negative margins.^{12,256-258} Data from the EBCTCG meta-analysis revealed that the addition of radiation reduces recurrence by half and improves survival at year 15 by about a sixth.²⁵⁹ When all of this information is taken together, BCT is considered to be oncologically equivalent to mastectomy.

In addition to being equivalent to mastectomy in terms of oncologic safety, BCT appears to offer advantages over mastectomy with regard to quality of life and aesthetic outcomes. BCT allows for preservation of breast shape and skin as well as preservation of sensation, and provides an overall psychologic advantage associated with breast preservation.

Breast conservation surgery is currently the standard treatment for women with stage 0, I, or II invasive breast cancer. Women with DCIS require only resection of the primary cancer and adjuvant radiation therapy without assessment of regional lymph nodes. When a lumpectomy is performed, a curvilinear incision lying concentric to the nipple-areola complex is made in the skin overlying the breast cancer when the tumor is in the upper aspect of the breast. Radial incisions are preferred when the tumor is in the lower aspect of the breast. Skin excision is not necessary unless there is direct involvement of the overlying skin by the primary tumor. The breast cancer is removed with an envelope of normal-appearing breast tissue that is adequate to achieve a cancer-free margin. Significant controversy exists on the appropriate margin width for BCT.²⁶⁰ Specimen x-ray should routinely be performed to confirm the lesion has been excised and that there appears to be an appropriate margin. Specimen orientation is performed by the surgeon. Additional margins from the surgical bed are taken as needed to provide a histologically negative margin. Requests for determination of ER, PR, and HER-2 status are conveyed to the pathologist.

It is the surgeon's responsibility to ensure complete removal of cancer in the breast. Ensuring surgical margins that

are free of breast cancer will minimize the chances of local recurrence and will enhance cure rates. Local recurrence of breast cancer after conservation surgery is determined primarily by the adequacy of surgical margins. Cancer size and the extent of skin excision are not significant factors in this regard. It is the practice of many North American and European surgeons to undertake re-excision when residual cancer within 2 mm of a surgical margin is determined by histopathologic examination. If clear margins are not obtainable with re-excision, mastectomy is required. SLN is performed before removal of the primary breast tumor. When indicated, intraoperative assessment of the sentinel node can proceed while the segmental mastectomy is being performed.

The use of oncoplastic surgery can be entertained at the time of segmental mastectomy or at a later time to improve the overall aesthetic outcome. The use of oncoplastic techniques range from a simple re-shaping of breast tissue to local tissue rearrangement to the use of pedicled flaps or breast reduction techniques. The overall goal is to achieve the best possible aesthetic result. In determining which patients are candidates for oncoplastic breast surgery, several factors should be considered, including the extent of the resection of breast tissue necessary to achieve negative margins, the location of the primary tumor within the breast, and the size of the patient's breast and body habitus. Oncoplastic techniques are of prime consideration when: (a) a significant area of breast skin will need to be resected with the specimen to achieve negative margins; (b) a large volume of breast parenchyma will be resected resulting in a significant defect; (c) the tumor is located between the nipple and the inframammary fold, an area often associated with unfavorable cosmetic outcomes; or (d) excision of the tumor and closure of the breast may result in malpositioning of the nipple.

Mastectomy and Axillary Dissection

A skin-sparing mastectomy removes all breast tissue, the nipple-areola complex, and scars from any prior biopsy procedures.^{261,262} There is a recurrence rate of less than 6% to 8%, comparable to the long-term recurrence rates reported with standard mastectomy, when skin-sparing mastectomy is used for patients with T1s to T3 cancers. A total (simple) mastectomy without skin sparing removes all breast tissue, the nipple-areola complex, and skin. An extended simple mastectomy removes all breast tissue, the nipple-areola complex, skin, and the level I axillary lymph nodes. A modified radical ('Patey') mastectomy removes all breast tissue, the nipple-areola complex, skin, and the levels I, II and III axillary lymph nodes: the pectoralis minor which was divided and removed by Patey may be simply divided, giving improved access to level III nodes, and then left in-situ or occasionally the axillary clearance can be performed without dividing pectoralis minor. The Halsted radical mastectomy removes all breast tissue and skin, the nipple-areola complex, the pectoralis major and pectoralis minor muscles, and the level I, II, and III axillary lymph nodes. The use of systemic chemotherapy and hormonal therapy as well as adjuvant radiation therapy for breast cancer have nearly eliminated the need for the radical mastectomy.

Nipple-areolar sparing mastectomy has been popularized over the last decade especially for risk-reducing mastectomy in high risk women. For those patients with a cancer diagnosis, many consider the following factors for eligibility: tumor located more than 2–3 cm from the border of the areola, smaller breast size, minimal ptosis, no prior breast surgeries with

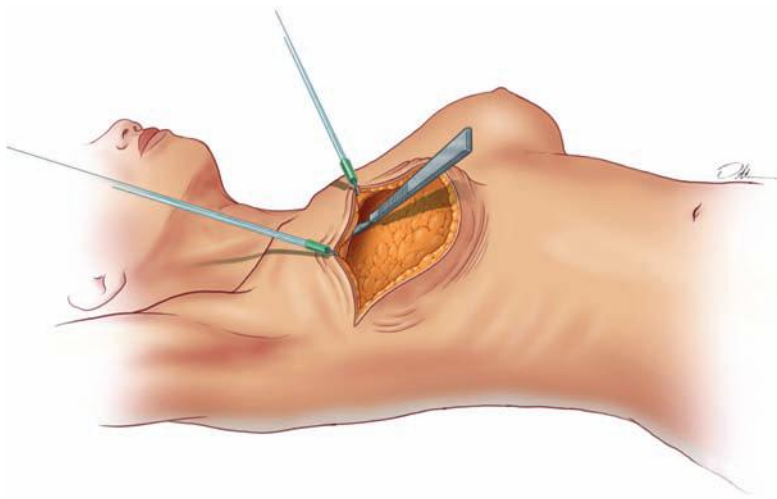


Figure 17-35. Modified radical mastectomy: elevation of skin flaps. Skin flaps are 7 to 8 mm in thickness, inclusive of the skin and telasubcutanea. (Visual Art: © 2012. The University of Texas MD Anderson Cancer Center.)

periareolar incisions, body mass index less than 40 kg/m², no active tobacco use, no prior breast irradiation, and no evidence of collagen vascular disease.

For a variety of biologic, economic, and psychosocial reasons, some women desire mastectomy rather than breast conservation. Women who are less concerned about cosmesis may view mastectomy as the most expeditious and desirable therapeutic option because it avoids the cost and inconvenience of radiation therapy. Some women whose primary breast cancers cannot be excised with a reasonable cosmetic result or those who have extensive microcalcifications are best treated with mastectomy. Similarly women with large cancers that occupy the subareolar and central portions of the breast and women with multicentric primary cancers also undergo mastectomy.

Modified Radical Mastectomy

A modified radical mastectomy preserves the pectoralis major muscle with removal of level I, II, and III (apical) axillary lymph nodes.²⁶¹ The operation was first described by David Patey, a surgeon at St Bartholomew's Hospital London, who reported a series of cases where he had removed the pectoralis minor muscle allowing complete dissection of the level III axillary lymph nodes while preserving the pectoralis major and the lateral

pectoral nerve. A modified radical mastectomy permits preservation of the medial (anterior thoracic) pectoral nerve, which courses in the lateral neurovascular bundle of the axilla and usually penetrates the pectoralis minor to supply the lateral border of the pectoralis major. Anatomic boundaries of the modified radical mastectomy are the anterior margin of the latissimus dorsi muscle laterally, the midline of the sternum medially, the subclavius muscle superiorly, and the caudal extension of the breast 2 to 3 cm inferior to the inframammary fold inferiorly. Skin-flap thickness varies with body habitus but ideally is 7 to 8 mm inclusive of skin and telasubcutanea (Fig. 17-35). Once the skin flaps are fully developed, the fascia of the pectoralis major muscle and the overlying breast tissue are elevated off the underlying musculature, which allows for the complete removal of the breast (Fig. 17-36).

Subsequently, an axillary lymph node dissection is performed. The most lateral extent of the axillary vein is identified and the areolar tissue of the lateral axillary space is elevated as the vein is cleared on its anterior and inferior surfaces. The areolar tissues at the junction of the axillary vein and the anterior edge of the latissimus dorsi muscle, which include the lateral and subscapular lymph node groups (level I), are cleared. Care is taken to preserve the thoracodorsal neurovascular bundle.

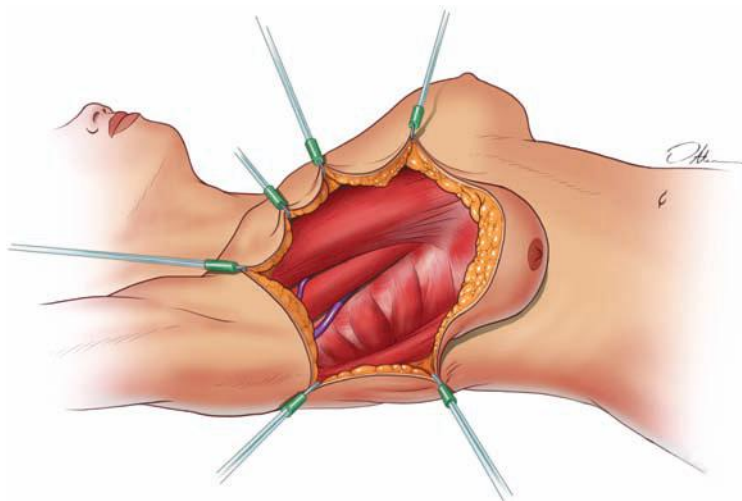


Figure 17-36. Modified radical mastectomy after resection of breast tissue. The pectoralis major muscle is cleared of its fascia as the overlying breast is elevated. The latissimus dorsi muscle is the lateral boundary of the dissection. (Visual Art: © 2012. The University of Texas MD Anderson Cancer Center.)

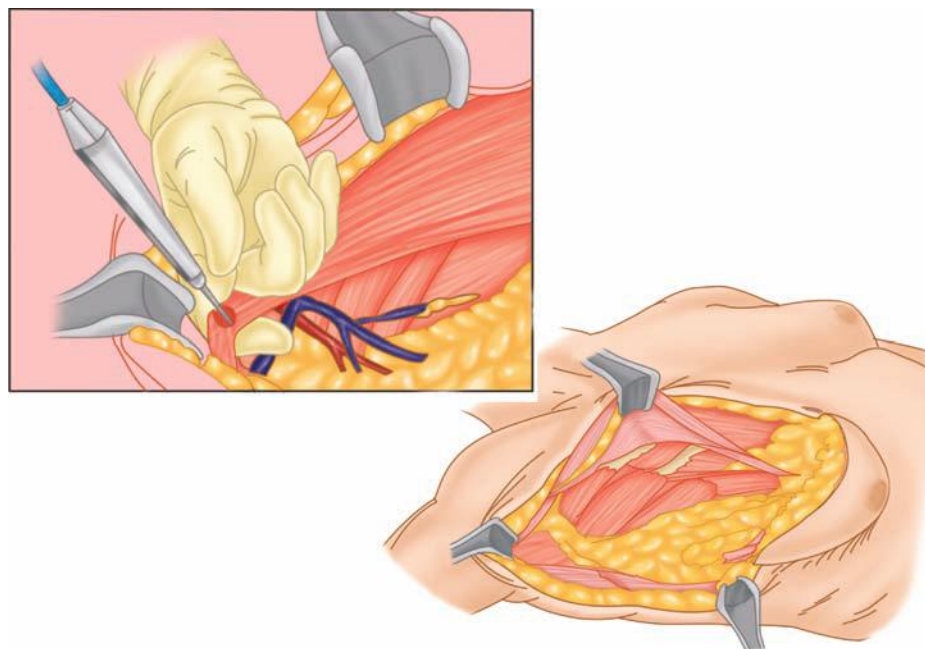


Figure 17-37. Modified radical mastectomy (Patey): axillary lymph node dissection. The dissection proceeds from lateral to medial, with complete visualization of the anterior and inferior aspects of the axillary vein. Loose areolar tissue at the junction of the axillary vein and the anterior margin of the latissimus dorsi muscle is swept inferomedially inclusive of the lateral (axillary) lymph node group (level I). Care is taken to preserve the thoracodorsal artery, vein, and nerve in the deep axillary space. The lateral lymph node group is resected in continuity with the subscapular lymph node group (level I) and the external mammary lymph node group (level I). Dissection anterior to the axillary vein allows removal of the central lymph node group (level II) and the apical (subclavicular) lymph node group (level III). The superomedial limit of this dissection is the clavipectoral fascia (Halsted's ligament). *Inset* depicts division of the insertion of the pectoralis minor muscle at the coracoid process. The surgeon's finger shields the underlying brachial plexus. (Reproduced with permission from Bland KI, et al. *Modified radical mastectomy and total (simple) mastectomy*. In: Bland KI, Copeland EMI, eds. *The Breast: Comprehensive Management of Benign and Malignant Diseases*. Philadelphia: Saunders, 2009. Copyright Elsevier.)

The dissection then continues medially with clearance of the central axillary lymph node group (level II). The long thoracic nerve of Bell is identified and preserved as it travels in the investing fascia of the serratus anterior muscle. Every effort is made to preserve this nerve, because permanent disability with a winged scapula and shoulder weakness will follow denervation of the serratus anterior muscle. Patey divided the pectoralis minor and removed it to allow access right up to the apex of the axilla. The pectoralis minor muscle is usually divided at the tendinous portion near its insertion onto the coracoid process (Fig. 17-37 *inset*), which allows dissection of the axillary vein medially to the costoclavicular (Halsted's) ligament. Finally, the breast and axillary contents are removed from the surgical bed and are sent for pathologic assessment. In Patey's modified radical mastectomy he removed the pectoralis minor muscle. Many surgeons now divide only the tendon of the pectoralis minor muscle at its insertion onto the coracoid process while leaving the rest of the muscle intact, which still provides good access to the apex of the axilla.

Seromas beneath the skin flaps or in the axilla represent the most frequent complication of mastectomy and axillary lymph node dissection, reportedly occurring in as many as 30% of cases. The use of closed-system suction drainage reduces the incidence of this complication. Catheters are retained in the wound until drainage diminishes to <30 mL per day. Wound infections occur infrequently after a mastectomy and the majority are a result of skin-flap necrosis. Cultures of specimens taken from the infected wound for aerobic and anaerobic organisms, débridement, and antibiotic therapy are effective management.

Moderate or severe hemorrhage in the postoperative period is rare and is best managed with early wound exploration for control of hemorrhage and re-establishment of closed-system suction drainage. The incidence of functionally significant lymphedema after a modified radical mastectomy is approximately 20% but can be as high as 50% to 60% when postoperative radiation is employed. Extensive axillary lymph node dissection, the delivery of radiation therapy, the presence of pathologic lymph nodes, and obesity are predisposing factors. Patients should be referred to physical therapy at the earliest signs of lymphedema to prevent progression to the later stages. The use of individually fitted compressive sleeves and complex decongestive therapy may be necessary.

Reconstruction of the Breast and Chest Wall

The goals of reconstructive surgery after a mastectomy for breast cancer are wound closure and breast reconstruction, which is either immediate or delayed.²⁶³ In most cases, wound closure after mastectomy is accomplished with simple approximation of the wound edges. However, if a more radical removal of skin and subcutaneous tissue is necessary, a pedicled myocutaneous flap from the latissimus dorsi muscle is generally the best approach for wound coverage. A skin graft provides functional coverage that will tolerate adjuvant radiation therapy; however, this is not preferred, because poor graft adherence may delay delivery of radiation therapy. Breast reconstruction after risk-reducing mastectomy or after mastectomy for early-stage breast cancer may be performed at the same time as the mastectomy. This allows for a skin-sparing mastectomy to be performed,

which offers the best overall cosmetic outcomes. Reconstruction can proceed with an expander/implant reconstruction or with autologous tissue such as a pedicled myocutaneous flap or a free flap using microvascular techniques. In patients with locally advanced breast cancer, reconstruction is often delayed until after completion of adjuvant radiation therapy to ensure that local-regional control of disease is obtained. The expected use of postmastectomy radiotherapy should also be considered as a reason for delayed reconstruction as radiotherapy to a reconstructed breast has been reported to result in inferior cosmetic outcomes. Consideration can be made for placement of a tissue expander to allow for skin-sparing but this should be discussed with the radiation oncologist and other members of the treatment team. If chest wall coverage is needed to replace a large skin or soft tissue defect, many different types of myocutaneous flaps are employed, but the latissimus dorsi and the rectus abdominis myocutaneous flaps are most frequently used. The latissimus dorsi myocutaneous flap consists of a skin paddle based on the underlying latissimus dorsi muscle, which is supplied by the thoracodorsal artery with contributions from the posterior intercostal arteries. A transverse rectus abdominis myocutaneous (TRAM) flap consists of a skin paddle based on the underlying rectus abdominis muscle, which is supplied by vessels from the deep inferior epigastric artery. The free TRAM flap uses microvascular anastomoses to establish blood supply to the flap. When the bony chest wall is involved with cancer, resection of a portion of the bony chest wall is indicated. If only one or two ribs are resected and soft tissue coverage is provided, reconstruction of the bony defect is usually not necessary, because scar tissue will stabilize the chest wall. If more than two ribs are sacrificed, it is advisable to stabilize the chest wall with prosthetic material, which is then covered with soft tissue by using a latissimus dorsi or TRAM flap.

NONSURGICAL BREAST CANCER THERAPIES

Radiation Therapy

Radiation therapy is used for all stages of breast cancer depending on whether the patient is undergoing BCT or mastectomy.²⁶⁴⁻²⁷⁰ Adjuvant radiation for patients with DCIS and early-stage breast cancer are described above. Those women treated with mastectomy who have cancer at the surgical margins are at sufficiently high risk for local recurrence to warrant the use of adjuvant radiation therapy to the chest wall postoperatively. Women with metastatic disease involving four or more axillary lymph nodes and premenopausal women with metastatic disease involving one to three lymph nodes also are at increased risk for recurrence and are candidates for the use of chest wall and supraclavicular lymph node radiation therapy. In advanced local-regional breast cancer (stage IIIA or IIIB), women are at high risk for recurrent disease after surgical therapy, and adjuvant radiation therapy is used to reduce the risk of recurrence. Current recommendations for stages IIIA and IIIB breast cancer are: (a) adjuvant radiation therapy to the breast and supraclavicular lymph nodes after neoadjuvant chemotherapy and segmental mastectomy with or without axillary lymph node dissection, (b) adjuvant radiation therapy to the chest wall and supraclavicular lymph nodes after neoadjuvant chemotherapy and mastectomy with or without axillary lymph node dissection, and (c) adjuvant radiation therapy to the chest wall and supraclavicular lymph nodes after segmental mastectomy or

mastectomy with axillary lymph node dissection and adjuvant chemotherapy.

The use of partial breast irradiation (APBI) for patients treated with breast-conserving surgery is also described above. APBI can be delivered via brachytherapy, external beam radiation therapy using three-dimensional conformal radiation, or intensity-modulated radiation therapy. Although initial results are promising in highly selected low-risk populations, APBI should be used in the clinical setting only as part of a prospective trial.

Chemotherapy Adjuvant

Chemotherapy. The Early Breast Cancer Trialists' Collaborative Group overview analysis of adjuvant chemotherapy demonstrated reductions in the odds of recurrence and of death in women ≤ 70 years of age with stage I, IIA, or IIB breast cancer.^{118,271-275} For those ≥ 70 years of age, the lack of definitive clinical trial data regarding adjuvant chemotherapy prevented definitive recommendations. Adjuvant chemotherapy is of minimal benefit to women with negative nodes and cancers ≤ 0.5 cm in size and is not recommended. Women with negative nodes and cancers 0.6 to 1.0 cm are divided into those with a low risk of recurrence and those with unfavorable prognostic features that portend a higher risk of recurrence and a need for adjuvant chemotherapy. Adverse prognostic factors include blood vessel or lymph vessel invasion, high nuclear grade, high histologic grade, *HER-2/neu* overexpression, and negative hormone receptor status. Adjuvant chemotherapy is recommended by the NCCN guidelines for women with these unfavorable prognostic features. Table 17-14 lists the frequently used chemotherapy regimens for breast cancer.

For women with hormone receptor-negative cancers that are >1 cm in size, adjuvant chemotherapy is appropriate. However, women with node-negative hormone receptor-positive cancers and T1 tumors are candidates for antiestrogen therapy with or without chemotherapy. Assessment of overall risk using known prognostic factors or additional testing such as the 21-gene recurrence score assay can help to guide decision making regarding chemotherapy in patients with node-negative ER-positive breast cancer. For special-type cancers (tubular, mucinous, medullary, etc), which are usually strongly estrogen receptor positive, adjuvant antiestrogen therapy should be advised for cancers >1 cm. For women with node-positive tumors or with a special-type cancer that is >3 cm, the use of chemotherapy is appropriate: those with hormone receptor-positive tumors should receive antiestrogen therapy.

For stage IIIA breast cancer preoperative chemotherapy with an anthracycline-containing or taxane-containing regimen followed by either a modified radical mastectomy or segmental mastectomy with axillary dissection followed by adjuvant radiation therapy should be considered, especially for estrogen receptor negative disease. While the same regimen may be considered for estrogen receptor positive disease it is known that these tumors respond less well to chemotherapy with $<10\%$ pCR rate overall and $<3\%$ pCR rate for lobular cancers. Other options such as neoadjuvant endocrine therapy followed by local-regional treatment or in a minority of cases primary endocrine therapy may be considered depending on other tumor characteristics and the patient's co-morbid conditions and preference.

Neoadjuvant (Preoperative) Chemotherapy. In the early 1970s, the National Cancer Institute in Milan, Italy, initiated

Table 17-14

Adjuvant chemotherapy regimens for breast cancer

HER-2/ <i>neu</i> NEGATIVE (NON-TRASTUZUMAB-CONTAINING REGIMENS)	HER-2/ <i>neu</i> POSITIVE (TRASTUZUMAB-CONTAINING REGIMENS)
FAC/CAF	AC → T + concurrent trastuzumab (T = paclitaxel)
FEC/CEF	Docetaxel + trastuzumab → FEC
AC or EC	TCH (docetaxel, carboplatin, trastuzumab)
TAC (T = docetaxel)	Chemotherapy followed by trastuzumab sequentially
A → CMF	AC → docetaxel + trastuzumab
E → CMF	
CMF	
AC × 4	
A → T → C (T = paclitaxel)	
FEC → T (T = docetaxel)	
TC (T = docetaxel)	

A = Adriamycin (doxorubicin); C = cyclophosphamide; E = epirubicin; F = 5-fluorouracil; M = methotrexate; T = Taxane (docetaxel or paclitaxel); → = followed by.

Source: Adapted from Carlson RW, et al: Breast cancer, in *NCCN Practice Guidelines in Oncology*. Fort Washington, PA: National Comprehensive Cancer Network, 2006.

two prospective randomized multimodality clinical trials for women with T3 or T4 breast cancer.²⁷⁶ The best results were achieved when surgery was interposed between chemotherapy courses, with 82% local-regional control and 25% having a 5-year disease-free survival. The NSABP B-18 trial evaluated the role of neoadjuvant chemotherapy in women with operable stage II and III breast cancer.¹⁸⁸ Women entered into this study were randomly assigned to receive either surgery followed by chemotherapy or neoadjuvant chemotherapy followed by surgery. There was no difference in the 5-year disease-free survival rates for the two groups, but after neoadjuvant chemotherapy there was an increase in the number of lumpectomies performed and a decreased incidence of node positivity. It was suggested that neoadjuvant chemotherapy be considered for the initial management of breast cancers judged too large for initial lumpectomy.

Several prospective clinical trials have evaluated the neoadjuvant approach and two meta-analyses have been performed each showing that neoadjuvant vs. adjuvant chemotherapy are equivalent in terms of OS.^{237,277} These analyses also evaluated local-regional recurrence (LRR) and found that there was an increase in LRR rates for patients receiving neoadjuvant chemotherapy when radiation therapy was used alone without surgery after completion of chemotherapy. Mittendorf and colleagues evaluated a contemporary series of almost 3000 patients treated with breast conserving surgery and radiation therapy who received either neoadjuvant or adjuvant chemotherapy for breast

cancer.²⁷⁸ They found that the risk of LRR was driven by biologic factors and disease stage and was not impacted by the timing of chemotherapy delivery. These data highlight the importance of the multidisciplinary management of patients with breast cancer in achieving the best outcomes.

10▶ The use of neoadjuvant chemotherapy offers the opportunity to observe the response of the intact primary tumor and any regional nodal metastases to a specific chemotherapy regimen.²⁷⁹ For patients whose tumors remain stable in size or even progress with the initial neoadjuvant chemotherapy regimen, a new regimen may be considered that uses another class of agents, although there is no randomized data confirming this will improve outcome.

After treatment with neoadjuvant chemotherapy, patients are assessed for clinical and pathologic response to the regimen. Patients whose tumors achieve a pathologic complete response to neoadjuvant chemotherapy have been shown to have statistically improved survival outcomes to those of patients whose tumors demonstrate only a partial response, remain stable, or progress on treatment. Patients who experience progression of disease during neoadjuvant chemotherapy have the poorest survival.^{280,281} This means that while patients who achieve a pCR will have a better outlook based on their response to neoadjuvant chemotherapy. Equally other patients will have a poorer outlook compared to when they started neoadjuvant therapy based on the non-response to treatment. The FDA is now proposing to use the neoadjuvant platform and pathologic response rates as a mechanism of accelerated approval for new agents although the short term endpoints (i.e., pCR) have not yet been shown to correlate with long-term outcomes (i.e., disease free survival and overall survival).

Current NCCN recommendations for treatment of operable advanced local-regional breast cancer are neoadjuvant chemotherapy with an anthracycline-containing or taxane-containing regimen or both, followed by mastectomy or lumpectomy with axillary lymph node dissection if necessary, followed by adjuvant radiation therapy. For patients with HER-2-positive breast cancer, trastuzumab can be combined with chemotherapy in the preoperative setting to increase pathologic complete response rates. For inoperable stage IIIA and for stage IIIB breast cancer, neoadjuvant chemotherapy is used to decrease the local-regional cancer burden. This may then permit subsequent modified radical or radical mastectomy, which is followed by adjuvant radiation therapy.

Nodal Evaluation in Patients Receiving Neoadjuvant Chemotherapy

The management of the axilla after neoadjuvant chemotherapy has not been specifically addressed in randomized trials. Standard practice has been to perform an axillary lymph node dissection after chemotherapy or to perform a sentinel lymph node dissection before chemotherapy for nodal staging before chemotherapy is initiated. A number of small single-institution studies, one multicenter study, and a recent meta-analysis have explored the use of SLN dissection at the completion of chemotherapy. The published results from these studies have demonstrated the feasibility of SLN dissection in breast cancer patients after neoadjuvant chemotherapy. Review of 14 studies with 818 patients showed a false negative rate of 11% with an overall accuracy of 94%.^{251,252,282} Although the issue has not been specifically addressed in the published trials, the presence of suspected or documented axillary metastases at initial presentation generally is considered a contraindication to SLN

dissection after neoadjuvant chemotherapy, and these patients usually undergo axillary lymph node dissection after completion of chemotherapy.

Neoadjuvant Endocrine Therapy. There is little randomized data on neoadjuvant endocrine therapy and virtually none which reports local recurrence rates. Neoadjuvant endocrine therapy has not been based on randomized controlled trials. It has most commonly been used in elderly women who were deemed poor candidates for surgery or cytotoxic chemotherapy. As clinicians have gained experience with neoadjuvant treatment strategies, it is now clear from examination of predictors of complete pathologic response that ER-positive tumors do not shrink in response to chemotherapy as readily as ER-negative tumors.²⁸³ Indeed the pCR rate in estrogen receptor negative tumors is approximately three times that of estrogen receptor positive tumors. Fisher et al examined the results of the NSABP B-14 and B-20 trials and found that, as age increased, women obtained less benefit from chemotherapy. They recommended that factors¹⁹⁴ including tumor estrogen receptor concentration, nuclear grade, histologic grade, tumor type, and markers of proliferation should be considered in these patients before choosing between the use of chemotherapy and hormonal therapy. If in fact the tumor is estrogen receptor rich, these patients may benefit more from endocrine therapy in the neoadjuvant setting than they might if they received standard chemotherapy. Neoadjuvant endocrine therapy has been shown to shrink tumors, enabling breast-conserving surgery in women with hormone receptor-positive disease who otherwise would have to be treated with mastectomy although long-term recurrence rates have not been reported.²⁸⁴

With the use of neoadjuvant chemotherapy or endocrine therapy, observation of the response of the intact tumor and/or nodal metastases to a specific regimen could ultimately help to define which patients will benefit from specific therapies in the adjuvant setting. In adjuvant trials the primary endpoint is typically survival, whereas in neoadjuvant trials the endpoints have more often been clinical or pathologic response rates. However, with the reported increase in local recurrence and the link between local recurrence and survival by the Early Breast Cancer Trialists' Collaborative Group, surgeons need to become more focused on local recurrence as a primary endpoint of neoadjuvant therapies. There are a number of clinical trials underway comparing neoadjuvant chemotherapy and endocrine therapy regimens with pretreatment and posttreatment biopsy samples obtained from the primary tumors in all of the participants. These samples are being subjected to intensive genomic and proteomic analyses that may help to define a more personalized or individualized approach to breast cancer treatment in the future.

Antiestrogen Therapy

Tamoxifen. Within the cytosol of breast cancer cells are specific proteins (receptors) that bind and transfer steroid moieties into the cell nucleus to exert specific hormonal effects.^{274,285-289} The most widely studied hormone receptors are the estrogen receptor and progesterone receptor. Hormone receptors are detectable in >90% of well-differentiated ductal and lobular invasive cancers. Although the receptor status may remain the same between the primary cancer and metastatic disease in the same patient in the vast majority of cases, there are instances where the status is changed in the metastatic focus and therefore

biopsy of newly diagnosed metastatic disease should be considered for assessment of hormone receptor and HER-2 status.

After binding to estrogen receptors in the cytosol, tamoxifen blocks the uptake of estrogen by breast tissue. Clinical responses to antiestrogen are evident in >60% of women with hormone receptor-positive breast cancers but in <10% of women with hormone receptor-negative breast cancers. A meta-analysis by the Early Breast Cancer Trialists' Collaborative Group showed that adjuvant therapy with tamoxifen for 5 years reduced breast cancer mortality by about a third through the first 15 years of follow-up.²⁹⁰ This mortality benefit continues to be statistically significant in the second and third 5-year periods (i.e., years 5–9 and 10–15) when the patients are no longer receiving endocrine treatment—the so called 'carry-over effect'. The analysis also showed a 39% reduction in the risk of cancer in the contralateral breast. The antiestrogens do have defined toxicity, including bone pain, hot flashes, nausea, vomiting, and fluid retention. Thrombotic events occur in <3% of treated women. Cataract surgery is more frequently performed in patients receiving tamoxifen. A long-term risk of tamoxifen use is endometrial cancer. Tamoxifen therapy usually is discontinued after 5 years although recent data from randomized trials suggest a survival benefit for 10 years of tamoxifen therapy over 5 years. However, somewhat surprisingly the benefit is not seen in the second five years (i.e., years 5–9) while the patients are on treatment but only from years 10–15. In high risk patients who have received 5 years of adjuvant tamoxifen extended adjuvant therapy with at least 3 years of an aromatase inhibitor has been shown to provide a significant benefit in terms of disease outcome.²⁹¹

Tamoxifen therapy is also considered for women with DCIS that is found to be estrogen receptor positive on immunohistochemical studies. The goals of such therapy are to decrease the risk of an ipsilateral recurrence after breast conservation therapy for DCIS and to decrease the risk of a primary invasive breast cancer or a contralateral breast cancer event. This approach has not been universally accepted.

Aromatase inhibitors. In postmenopausal women, aromatase inhibitors are now considered first-line therapy in the adjuvant setting or as a secondary agent after 1 to 2 years of adjuvant tamoxifen therapy. The nonsteroidal third generation aromatase inhibitors, anastrozole and letrozole, have both been shown to result in significantly fewer local and distant recurrences.^{292,293} While neither trial on its own has shown a significant survival advantage, an overview of all the studies of adjuvant aromatase inhibitors has reported a survival advantage to the use of aromatase inhibitors. The HR is about 0.80 for 5 years of an aromatase inhibitor vs. 5 years of tamoxifen and this is irrespective of absolute risk. This has led some to suggest a switch policy—2 years of tamoxifen followed by 3 years of an aromatase inhibitor—for low risk patients where the absolute benefits may be small and the cost of an aromatase inhibitor may be significant for some individuals. As aromatase inhibitors come off patent, the cost issue should decrease and even for small benefits the additional cost of an aromatase inhibitor should become cost-effective. Whether 10 years of an aromatase inhibitor will be better than 5 years is currently the subject of a randomised trial by the NSABP (B-42). For patients who have completed 5 years of adjuvant endocrine therapy and are 6–20 years from presentation, the question of whether reintroducing endocrine therapy

might decrease long term recurrence rates is being addressed by the later study which randomizes patients to 5 years of letrozole or placebo.

The aromatase inhibitors are less likely than tamoxifen to cause endometrial cancer but do lead to changes in bone mineral density that may result in osteoporosis and an increased rate of fractures in postmenopausal women. The risk of osteoporosis can be averted by treatment with bisphosphonates. Joint pains are a side effect which affects a significant number of patients.

Node-negative and node-positive breast cancer patients whose tumors express hormone receptors should be considered for endocrine therapy in the adjuvant setting. Women with hormone receptor-positive cancers achieve significant reduction in risk of recurrence and mortality due to breast cancer through the use of endocrine therapies. For women with stage IV breast cancer, a third generation non-steroidal aromatase inhibitor is the preferred initial therapy. For postmenopausal women with prior aromatase inhibitor exposure, recommended second-line endocrine therapies include the pure anti-estrogen fulvestrant (at the 500-mg dose) or tamoxifen followed by progestins, high-dose estrogen, and androgens. For postmenopausal patients who received tamoxifen as prior endocrine therapy, subsequent endocrine therapies would be an aromatase inhibitor or fulvestrant (500 mg) followed by progestins, high dose estrogens, and androgens. In premenopausal patients with stage IV breast cancer either tamoxifen or oophorectomy (medical, surgical, or radioablative) could be used alone with the other then being added in on progression. An overview of four randomized trials suggested combining oophorectomy and tamoxifen would be the initial treatment options. If a tumor progresses while a premenopausal patient is on ovarian ablation plus tamoxifen then the tamoxifen can be stopped and an aromatase inhibitor added to the ovarian ablation. Subsequent therapies if the patient's tumor is still deemed to be potentially hormone responsive can include ovarian ablation plus fulvestrant, ovarian ablation plus exemestane, and then progestins followed by high dose estrogens. Women whose tumors respond to an endocrine therapy with either shrinkage of their breast cancer (objective response) or long-term stabilization of disease (stable disease) are together considered to represent 'clinical benefit' and should receive additional endocrine therapy at the time of progression since their chances of a further response remain high.²⁹⁴⁻²⁹⁶ Patients whose tumors progress de-novo on an endocrine agent have a low rate of clinical benefit (<20%) to subsequent endocrine therapy; the choice of endocrine or chemotherapy should be considered based on the disease site and extent as well as the patient's general condition and treatment preference.²⁹⁴

Ablative Endocrine Therapy

In the past, oophorectomy, adrenalectomy, and/or hypophysectomy were the primary endocrine modalities used to treat metastatic breast cancer, but today they are rarely used. Oophorectomy was used in premenopausal breast cancer patients. In contrast, pharmacologic doses of exogenous estrogens were given to postmenopausal women with similar recurrences. For both groups, the response rates were nearly 30%. Adrenalectomy and hypophysectomy were effective in individuals who had previously responded to either oophorectomy or exogenous estrogen therapy, and the response to these additional procedures was nearly 30%. Aminoglutethimide blocks enzymatic conversion of cholesterol to γ -5-pregnenolone and inhibits the

conversion of androstenedione to estrogen in peripheral tissues. Dose-dependent and transient side effects include ataxia, dizziness, and lethargy. After treatment with this agent (medical adrenalectomy), adrenal suppression necessitates glucocorticoid therapy. Neither permanent adrenal insufficiency nor acute crises have been observed. Because the adrenal glands are the major site for production of endogenous estrogens after menopause, treatment with aminoglutethimide has been compared prospectively with surgical adrenalectomy and hypophysectomy in postmenopausal women and is equally efficacious.

Anti-HER-2/*neu* Therapy

The determination of tumor HER-2/*neu* expression or gene amplification for all newly diagnosed patients with breast cancer is now recommended.²⁹⁷⁻³⁰⁰ It is used to assist in the selection of adjuvant chemotherapy in both node-negative and node-positive patients. Patients with HER-2-positive disease appear to have better outcomes with anthracycline-based adjuvant chemotherapy regimens. Patients with HER-2-positive tumors benefit if trastuzumab is added to paclitaxel chemotherapy. Cardiotoxicity may develop if trastuzumab is delivered concurrently with anthracycline-based chemotherapy.

Trastuzumab was initially approved for the treatment of HER-2/*neu*-positive breast cancer in patients with metastatic disease. Once efficacy was demonstrated for patients with metastatic disease, the NSABP and the North Central Cancer Treatment Group conducted phase III trials evaluating the impact of adjuvant trastuzumab therapy in patients with early-stage breast cancer. After approval from the FDA, these groups amended their adjuvant trastuzumab trials (B-31 and N9831, respectively), to provide for a joint efficacy analysis. The first joint interim efficacy analysis demonstrated an improvement in 3-year disease-free survival from 75% in the control arm to 87% in the trastuzumab arm (hazard ratio = 0.48, $P < .0001$). There was an accompanying 33% reduction in mortality in the patients who received trastuzumab (hazard ratio = 0.67, $P = 0.015$). The magnitude of reduction in hazard for disease-free survival events crossed prespecified early reporting boundaries, so the data-monitoring committees for both groups recommended that randomized accrual to the trials be ended, and the results were subsequently published.¹⁶⁷

Buzdar and colleagues reported the results of a randomized neoadjuvant trial of trastuzumab in combination with sequential paclitaxel followed by FEC-75 (5-fluorouracil, epirubicin, cyclophosphamide) vs. the same chemotherapy regimen without trastuzumab in 42 women with early-stage operable breast cancer. The pathologic complete response rates in this trial increased from 25 to 66.7% when chemotherapy was given concurrently with trastuzumab. None of the patients receiving the concurrent trastuzumab and FEC regimen developed symptoms of congestive heart failure. However, given the small sample size in this report, the 95% confidence interval for developing heart failure was 0% to 14.8%.³⁰¹ A subsequent report which included additional patients treated with concurrent chemotherapy and trastuzumab further confirmed the high pathologic complete response rates and continued to show that cardiac function was preserved.³⁰² This regimen was tested in a phase III multicenter trial (ACOSOG Z1041) which recently completed accrual.

Several new agents have been approved for the treatment of women with metastatic HER-2-positive breast cancers. Lapatinib is a dual tyrosine kinase inhibitor that targets both HER-2

and EGFR. It was approved for use with capecitabine in patients with *HER-2*-positive metastatic disease. Ado-trastuzumab (previously known as TDM1) was approved for patients who have previously received trastuzumab and a taxane either separately or in combination. Ado-trastuzumab binds to the *HER-2* receptor and releases a cytotoxic agent into the cell that leads to apoptosis. The FDA has also approved pertuzumab, which also targets the *HER-2* receptor, in combination with trastuzumab and docetaxel for treatment of metastatic *HER-2*-positive breast cancer. There is significant interest in dual targeting of *HER-2* and multiple trials are ongoing in the metastatic and neoadjuvant settings.

SPECIAL CLINICAL SITUATIONS

Nipple Discharge

Unilateral Nipple Discharge Nipple discharge is a finding that can be seen in a number of clinical situations. It may be suggestive of cancer if it is spontaneous, unilateral, localized to a single duct, present in women ≥ 40 years of age, bloody, or associated with a mass. A trigger point on the breast may be present so that pressure around the nipple-areolar complex induces discharge from a single duct. In this circumstance, mammography and ultrasound are indicated for further evaluation. A ductogram also can be useful and is performed by cannulating a single discharging duct with a small nylon catheter or needle and injecting 1.0 mL of water-soluble contrast solution. Nipple discharge associated with a cancer may be clear, bloody, or serous. Testing for the presence of hemoglobin is helpful, but hemoglobin may also be detected when nipple discharge is secondary to an intraductal papilloma or duct ectasia. Definitive diagnosis depends on excisional biopsy of the offending duct and any associated mass lesion. A 3.0 lacrimal duct probe can be used to identify the duct that requires excision. Another approach is to inject methylene blue dye within the duct after ductography. The nipple must be sealed with collodion or a similar material so that the blue dye does not discharge through the nipple but remains within the distended duct facilitating its localization. Needle localization biopsy is performed when there is an associated mass that lies >2.0 to 3.0 cm from the nipple.

Bilateral Nipple Discharge Nipple discharge is suggestive of a benign condition if it is bilateral and multiductal in origin, occurs in women ≤ 39 years of age, or is milky or blue-green. Prolactin-secreting pituitary adenomas are responsible for bilateral nipple discharge in $<2\%$ of cases. If serum prolactin levels are repeatedly elevated, plain radiographs of the sellaturcica are indicated and thin section CT scan is required. Optical nerve compression, visual field loss, and infertility are associated with large pituitary adenomas.

Axillary Lymph Node Metastases in the Setting of an Unknown Primary Cancer

A woman who presents with an axillary lymph node metastasis that is consistent with a breast cancer metastasis has a 90% probability of harboring an occult breast cancer.³⁰³ However, axillary lymphadenopathy is the initial presenting sign in only 1% of breast cancer patients. Fine-needle aspiration biopsy or core-needle biopsy can be used to establish the diagnosis when an enlarged axillary lymph node is identified. When metastatic

cancer is found, immunohistochemical analysis may classify the cancer as epithelial, melanocytic, or lymphoid in origin. The presence of hormone receptors (estrogen or progesterone receptors) suggests metastasis from a breast cancer but is not diagnostic. The search for a primary cancer includes careful examination of the thyroid, breast, and pelvis, including the rectum. The breast should be examined with diagnostic mammography, ultrasonography, and MRI to evaluate for an occult primary lesion. Further radiologic and laboratory studies should include chest radiography and liver function studies. Additional imaging of the chest, abdomen, and skeleton may be indicated if the extent of nodal involvement is consistent with stage III breast cancer. Suspicious findings on mammography, ultrasonography, or MRI necessitate breast biopsy. When a breast cancer is found, treatment consists of an axillary lymph node dissection with a mastectomy or preservation of the breast followed by whole-breast radiation therapy. Chemotherapy and endocrine therapy should be considered.

Breast Cancer During Pregnancy

Breast cancer occurs in 1 of every 3000 pregnant women, and axillary lymph node metastases are present in up to 75% of these women.³⁰⁴ The average age of the pregnant woman with breast cancer is 34 years. Fewer than 25% of the breast nodules developing during pregnancy and lactation will be cancerous. Ultrasonography and needle biopsy specimens are used in the diagnosis of these nodules. Mammography is rarely indicated because of its decreased sensitivity during pregnancy and lactation; however, the fetus can be shielded if mammography is needed. Approximately 30% of the benign conditions encountered will be unique to pregnancy and lactation (galactoceles, lobular hyperplasia, lactating adenoma, and mastitis or abscess). Once a breast cancer is diagnosed, complete blood count, chest radiography (with shielding of the abdomen), and liver function studies are performed.

Because of the potential deleterious effects of radiation therapy on the fetus, radiation cannot be considered until the fetus is delivered. A modified radical mastectomy can be performed during the first and second trimesters of pregnancy, even though there is an increased risk of spontaneous abortion after first-trimester anesthesia. During the third trimester, lumpectomy with axillary node dissection can be considered if adjuvant radiation therapy is deferred until after delivery. Lactation is suppressed. Chemotherapy administered during the first trimester carries a risk of spontaneous abortion and a 12% risk of birth defects. There is no evidence of teratogenicity resulting from administration of chemotherapeutic agents in the second and third trimesters. For this reason, many clinicians now consider the optimal strategy to be delivery of chemotherapy in the second and third trimesters as a neoadjuvant approach, which allows local therapy decisions to be made after the delivery of the baby. Pregnant women with breast cancer often present at a later stage of disease because breast tissue changes that occur in the hormone-rich environment of pregnancy obscure early cancers. However, pregnant women with breast cancer have a prognosis, stage by stage, that is similar to that of nonpregnant women with breast cancer.

Male Breast Cancer

Fewer than 1% of all breast cancers occur in men.^{305,306} The incidence appears to be highest among North Americans and the British, in whom breast cancer constitutes as much as 1.5% of

all male cancers. Jewish and African American males have the highest incidence. Male breast cancer is preceded by gynecomastia in 20% of men. It is associated with radiation exposure, estrogen therapy, testicular feminizing syndromes, and Klinefelter's syndrome (XXY). Breast cancer is rarely seen in young males and has a peak incidence in the sixth decade of life. A firm, nontender mass in the male breast requires investigation. Skin or chest wall fixation is particularly worrisome.

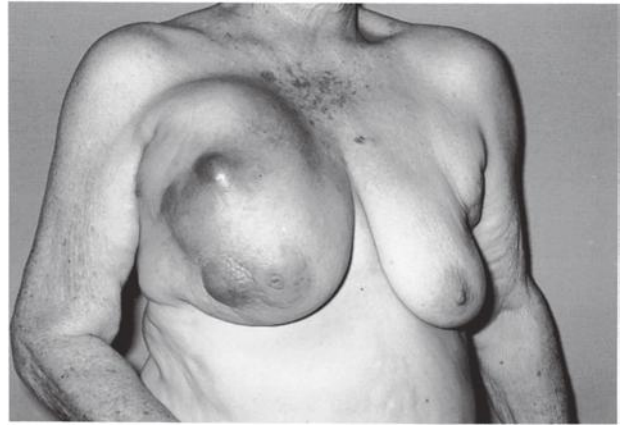
DCIS makes up <15% of male breast cancer, whereas infiltrating ductal carcinoma makes up >85%. Special-type cancers, including infiltrating lobular carcinoma, have occasionally been reported. Male breast cancer is staged in the same way as female breast cancer, and stage by stage, men with breast cancer have the same survival rate as women. Overall, men do worse because of the more advanced stage of their cancer (stage II, III or IV) at the time of diagnosis. The treatment of male breast cancer is surgical, with the most common procedure being a modified radical mastectomy. SLN dissection has been shown to be feasible and accurate for nodal assessment in men presenting with a clinically node-negative axilla. Adjuvant radiation therapy is appropriate in cases in which there is a high risk for local-regional recurrence. Approximately 80% of male breast cancers are hormone receptor positive, and adjuvant tamoxifen is considered. Systemic chemotherapy is considered for men with hormone receptor-negative cancers and for men with large primary tumors, multiple positive nodes, and locally advanced disease.

Phyllodes Tumors

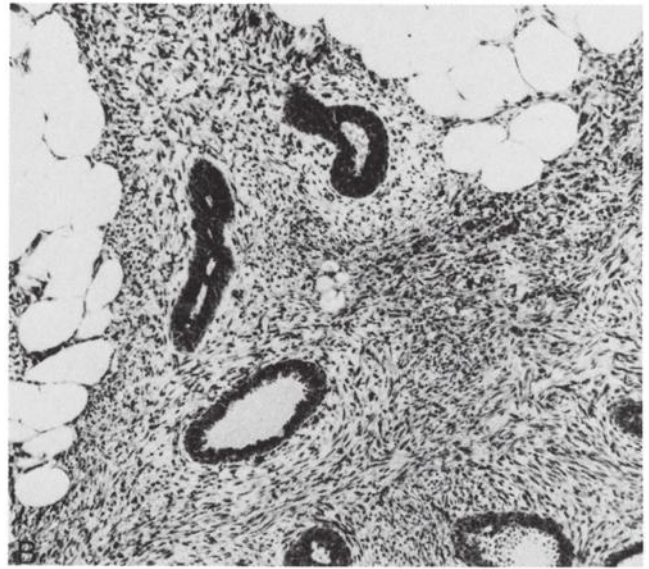
The nomenclature, presentation, and diagnosis of phyllodes tumors (including cystosarcoma phyllodes) have posed many problems for surgeons.³⁰⁷ These tumors are classified as benign, borderline, or malignant. Borderline tumors have a greater potential for local recurrence.

Mammographic evidence of calcifications and morphologic evidence of necrosis do not distinguish between benign, borderline, and malignant phyllodes tumors. Consequently, it is difficult to differentiate benign phyllodes tumors from the malignant variant and from fibroadenomas. Phyllodes tumors are usually sharply demarcated from the surrounding breast tissue, which is compressed and distorted. Connective tissue composes the bulk of these tumors, which have mixed gelatinous, solid, and cystic areas. Cystic areas represent sites of infarction and necrosis. These gross alterations give the gross cut tumor surface its classical leaf-like (phyllodes) appearance. The stroma of a phyllodes tumor generally has greater cellular activity than that of a fibroadenoma. After microdissection to harvest clusters of stromal cells from fibroadenomas and from phyllodes tumors, molecular biology techniques have shown the stromal cells of fibroadenomas to be either polyclonal or monoclonal (derived from a single progenitor cell), whereas those of phyllodes tumors are always monoclonal.

Most malignant phyllodes tumors (Fig. 17-38) contain liposarcomatous or rhabdomyosarcomatous elements rather than fibrosarcomatous elements. Evaluation of the number of mitoses and the presence or absence of invasive foci at the tumor margins may help to identify a malignant tumor. Small phyllodes tumors are excised with a margin of normal-appearing breast tissue. When the diagnosis of a phyllodes tumor with suspicious malignant elements is made, reexcision of the biopsy specimen site to ensure complete excision of the tumor with a 1-cm margin of normal-appearing breast tissue is indicated.



A



B

Figure 17-38. A. Malignant phyllodes tumor (cystosarcoma-phyllodes). B. Histologic features of a malignant phyllodes tumor (hematoxylin and eosin stain, $\times 100$).

Large phyllodes tumors may require mastectomy. Axillary dissection is not recommended because axillary lymph node metastases rarely occur.

Inflammatory Breast Carcinoma

Inflammatory breast carcinoma (stage IIIB) accounts for <3% of breast cancers. This cancer is characterized by the skin changes of brawny induration, erythema with a raised edge, and edema (peaud'orange).³⁰⁸ Permeation of the dermal lymph vessels by cancer cells is seen in skin biopsy specimens. There may be an associated breast mass (Fig. 17-39). The clinical differentiation of inflammatory breast cancer may be extremely difficult, especially when a locally advanced scirrhous carcinoma invades dermal lymph vessels in the skin to produce peaud'orange and lymphangitis (Table 17-15). Inflammatory breast cancer also may be mistaken for a bacterial infection of the breast. More than 75% of women who have inflammatory breast cancer present with palpable axillary lymphadenopathy, and distant metastases also are frequently present. A positron emission

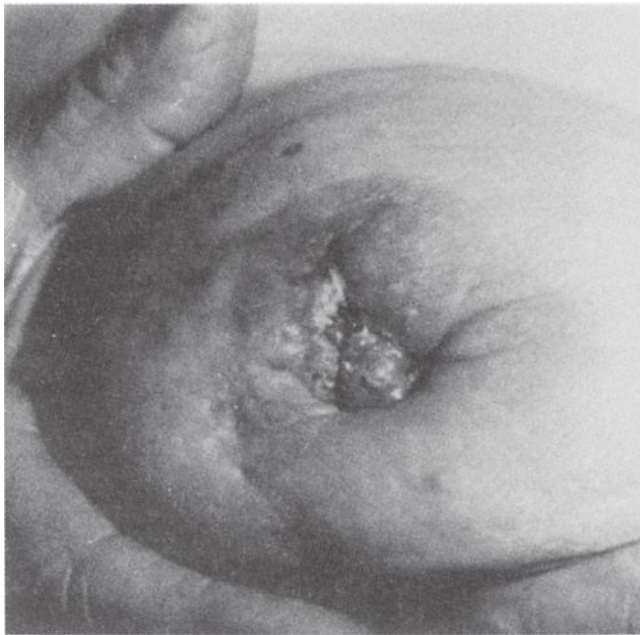


Figure 17-39. Inflammatory breast carcinoma. Stage IIIB cancer of the breast with erythema, skin edema (peau d'orange), nipple retraction, and satellite skin nodules.

tomography (PET)-computed tomography (CT) scan should be considered at the time of diagnosis to rule out concurrent metastatic disease. A report of the SEER program described distant metastases at diagnosis in 25% of white women with inflammatory breast carcinoma.

Table 17-15

Inflammatory vs. noninflammatory breast cancer

INFLAMMATORY	NONINFLAMMATORY
Dermal lymph vessel invasion is present with or without inflammatory changes.	Inflammatory changes are present without dermal lymph vessel invasion.
Cancer is not sharply delineated.	Cancer is better delineated.
Erythema and edema frequently involve >33% of the skin over the breast.	Erythema is usually confined to the lesion, and edema is less extensive.
Lymph node involvement is present in >75% of cases.	Lymph nodes are involved in approximately 50% of the cases.
Distant metastases are present in 25% of cases.	Distant metastases are less common at presentation.
Distant metastases are more common at initial presentation.	

Source: Modified with permission from Chittoor SR, et al: Locally advanced breast cancer: Role of medical oncology, in Bland KI, et al (eds): *The Breast: Comprehensive Management of Benign and Malignant Diseases*. Philadelphia: WB Saunders;1998;1281. Copyright Elsevier.

Surgery alone and surgery with adjuvant radiation therapy have produced disappointing results in women with inflammatory breast cancer. However, neoadjuvant chemotherapy with an anthracycline-containing regimen may affect dramatic regressions in up to 75% of cases. Tumor should be assessed for *HER-2* and hormone receptors with treatment dictated based on receptor status. Modified radical mastectomy is performed after demonstrated response to systemic therapy to remove residual cancer from the chest wall and axilla. Adjuvant chemotherapy may be indicated depending on final pathologic assessment of the breast and regional nodes. Finally, the chest wall and the supraclavicular, internal mammary, and axillary lymph node basins receive adjuvant radiation therapy. This multimodal approach results in 5-year survival rates that approach 30%. Patients with inflammatory breast cancer should be encouraged to participate in clinical trials.

Rare Breast Cancers

Squamous Cell (Epidermoid) Carcinoma. Squamous cell (epidermoid) carcinoma is a rare cancer that arises from metaplasia within the duct system and generally is devoid of distinctive clinical or radiographic characteristics.³⁰⁹ Regional metastases occur in 25% of patients, whereas distant metastases are rare.

Adenoid Cystic Carcinoma. Adenoid cystic carcinoma is very rare, accounting for <0.1% of all breast cancers. It is typically indistinguishable from adenoid cystic carcinoma arising in salivary tissues. These cancers are generally 1 to 3 cm in diameter at presentation and are well circumscribed. Axillary lymph node metastases are rare, but deaths from pulmonary metastases have been reported.

Apocrine Carcinomas. Apocrine carcinomas are well-differentiated cancers that have rounded vesicular nuclei and prominent nucleoli. There is a very low mitotic rate and little variation in cellular features. However, apocrine carcinomas may display an aggressive growth pattern.

Sarcomas. Sarcomas of the breast are histologically similar to soft tissue sarcomas at other anatomic sites. This diverse group includes fibrosarcoma, malignant fibrous histiocytoma, liposarcoma, leiomyosarcoma, malignant schwannoma, rhabdomyosarcoma, osteogenic sarcoma, and chondrosarcoma. The clinical presentation is typically that of a large, painless breast mass with rapid growth. Diagnosis is by core-needle biopsy or by open incisional biopsy. Sarcomas are graded based on cellularity, degree of differentiation, nuclear atypia, and mitotic activity. Primary treatment is wide local excision, which may necessitate mastectomy. Axillary dissection is not indicated unless there is biopsy proven lymph node involvement. Angiosarcomas are classified as de novo, as postradiation, or as arising in association with postmastectomy lymphedema. In 1948, Stewart and Treves described lymphangiosarcoma of the upper extremity in women with ipsilateral lymphedema after radical mastectomy.³¹⁰ *Angiosarcoma* is now the preferred name. The average interval between modified radical or radical mastectomy and the development of an angiosarcoma is 7 to 10 years. Sixty percent of women developing this cancer have a history of adjuvant radiation therapy. Forequarter amputation may be necessary to palliate the ulcerative complications and advanced lymphedema.

Lymphomas. Primary lymphomas of the breast are rare, and there are two distinct clinicopathologic variants. One type occurs in women ≤39 years of age, is frequently bilateral, and

has the histologic features of Burkitt's lymphoma. The second type is seen in women ≥ 40 years of age and is usually of the B-cell type. Breast involvement by Hodgkin's lymphoma has been reported. An occult breast lymphoma may be diagnosed after detection of palpable axillary lymphadenopathy. Treatment depends on the stage of disease. Lumpectomy or mastectomy may be required. Axillary dissection for staging and for clearance of palpable disease is appropriate. Recurrent or progressive local-regional disease is best managed by chemotherapy and radiation therapy. The prognosis is favorable, with 5- and 10-year survival rates of 74% and 51%, respectively.

REFERENCES

Entries highlighted in bright blue are key references.

- Breasted JH. The Edwin Smith Surgical Papyrus, University of Chicago Press, 1930;405.
- Celsus AC. De Medicina (ed Loeb Classical Library Ed). Cambridge, Harvard University Press, 1935;131.
- Beenken SW. History of the therapy of breast cancer. In: Copeland BA, ed. The Breast: Comprehensive Management of Benign and Malignant Disorder. Philadelphia: Saunders; 2004;5.
- Le Dran F. Mémoire avec une précis de plusieurs observations sur le. *Mem Acad Roy Chir Paris*. 1757;3:1.
- Moore C. On the influence of inadequate operations on the theory of cancer. *R Med Chir Soc*. 1867;1:244.
- Halsted WS I. The results of operations for the cure of cancer of the breast performed at the Johns Hopkins Hospital from June, 1889, to January, 1894. *Ann Surg*. 1894;20:497-555.
- Haagensen CD, Stout AP. Carcinoma of the Breast. II-Criteria of Operability. *Ann Surg*. 1943;118:1032-1051.
- Patey DH, Dyson WH. The prognosis of carcinoma of the breast in relation to the type of operation performed. *Br J Cancer*. 1948;2:7-13.
- Fisher B, Jeong JH, Anderson S, et al. **Twenty-five-year follow-up of a randomized trial comparing radical mastectomy, total mastectomy, and total mastectomy followed by irradiation.** *N Engl J Med*. 2002;347:567-75.
- Keynes G. Conservative Treatment of Cancer of the Breast. *Br Med J*. 1937;2(3):643-666.
- Fisher B, Anderson S, Bryant J, et al. **Twenty-year follow-up of a randomized trial comparing total mastectomy, lumpectomy, and lumpectomy plus irradiation for the treatment of invasive breast cancer.** *N Engl J Med*. 2002;347:1233-1241.
- Clarke M, Collins R, Darby S, et al. **Effects of radiotherapy and of differences in the extent of surgery for early breast cancer on local recurrence and 15-year survival: an overview of the randomised trials.** *Lancet*. 2005;366:2087-2106.
- Peto R, Davies C, Godwin J, et al. **Comparisons between different polychemotherapy regimens for early breast cancer: meta-analyses of long-term outcome among 100,000 women in 123 randomised trials.** *Lancet*. 2012;379:432-444.
- Davies C, Godwin J, Gray R, et al. Relevance of breast cancer hormone receptors and other factors to the efficacy of adjuvant tamoxifen: patient-level meta-analysis of randomised trials. *Lancet*. 2011;378:771-784.
- Sorlie T, Perou CM, Tibshirani R, et al. Gene expression patterns of breast carcinomas distinguish tumor subclasses with clinical implications. *Proc Natl Acad Sci U S A*. 2001;98:10869-10874.
- Bland KI, Romrell LJ. Congenital and acquired disturbances of breast development and growth. In: Bland KI, Copeland EMI, eds. The Breast: Comprehensive Management of Benign and Malignant Diseases. Philadelphia: WB Saunders; 1998:214.
- Lonnerdal B. Nutritional and physiologic significance of human milk proteins. *Am J Clin Nutr*. 2003;77:1537S-1543S.
- Rosenbloom AL. Breast physiology: normal and abnormal development and function. In: Bland KI, Copeland EMI eds. The Breast: Comprehensive Management of Benign and Malignant Diseases. Philadelphia: WB Saunders; 1998:38.
- Van de Perre P. Transfer of antibody via mother's milk. *Vaccine*. 2003;21(24):3374-3376.
- Bland KI, Graves TA. Gynecomastia. In: Bland KI, Copeland EMI, eds. The Breast: Comprehensive Management of Benign and Malignant Diseases. Philadelphia: WB Saunders; 1998:153.
- Dixon JM. Outpatient treatment of non-lactational breast abscesses. *Br J Surg*. 1992;79:56-57.
- Furlong AJ, al-Nakib L, Knox WF, et al. Periductal inflammation and cigarette smoke. *J Am Coll Surg*. 1994;179:417-420.
- Zuska JJ, Crile G, Jr., Ayres WW. Fistulas of lactiferous ducts. *Am J Surg*. 1951;81:312-317.
- Dixon JM. Infection in surgical practice. In: Taylor EW, ed. Breast Surgery. Oxford, Oxford Medical Publications: 1992;187.
- Dixon JM. Preiductal mastitis and duct ectasia: an update. *The Breast*. 1998;7:128-130.
- Dixon JM, Kohlhardt SR, Dillon P. Total duct excision. *The Breast*. 1998;7:216-219.
- Frykberg ER, Bland KI. Current concepts on the biology and management of in situ (Tis, stage 0) breast carcinoma. In: Bland KI, Copeland EMI, eds. The Breast: Comprehensive Management of Benign and Malignant Diseases. Philadelphia: WB Saunders; 1998:1020.
- Camiel MR. Mondor's disease in the breast. *Am J Obstet Gynecol*. 1985;152:879-881.
- Mondor H. Tronculite sous-cutanée subaiguë de la paroi thoracique antero-latérale. *Mem Acad Chir Paris*. 1939;65:1271.
- Hughes LE, Mansel RE, Webster DJ. Aberrations of normal development and involution (ANDI): a new perspective on pathogenesis and nomenclature of benign breast disorders. *Lancet*. 1987;2:1316-1319.
- Archer F, Omar M. The fine structure of fibro adenoma of the human breast. *J Pathol*. 1969;99:113-117.
- Page DL, Anderson TJ. Diagnostic Histopathology of the Breast. Edinburgh: Churchill Livingstone;1987.
- Page DL, Simpson JF. Benign, high-risk, and premalignant lesions of the breast. In: Bland KI, Copeland EMI, eds. The Breast: Comprehensive Management of Benign and Malignant Diseases. Philadelphia: WB Saunders; 1998:191.
- Haagensen CD. Diseases of the Breast 3rd ed. Philadelphia: WB Saunders;1986.
- Haagensen CD, Lane N, Lattes R, et al. Lobular neoplasia (so-called lobular carcinoma in situ) of the breast. *Cancer*. 1978;42:737-769.
- Gadd MA, Souba WW. Evaluation and treatment of benign breast disorders. In: Bland KI, Copeland EMI, eds. The Breast: Comprehensive Management of Benign and Malignant Diseases. Philadelphia: WB Saunders; 1998:233.
- Marchant DJ. Benign breast disease. *Obstet Gynecol Clin North Am*. 2002;29:1-20.
- Nurko J, Mabry CD, Whitworth P, et al. Interim results from the FibroAdenoma Cryoablation Treatment Registry. *Am J Surg*. 2005;190:647-651; discussion 651-652.
- Dixon JM. Conservative management of fibroadenoma of the breast. *Br J Surg*. 1996;83:1798-1799.
- Atkins HJ. Mammillary fistula. *Br Med J*. 1955;2:1473-1474.
- Dixon JM, Thompson AM. Effective surgical treatment for mammary duct fistula. *Br J Surg*. 1991;78:1185-1186.
- Bernstein L, Henderson BE, Hanisch R, et al. Physical exercise and reduced risk of breast cancer in young women. *J Natl Cancer Inst*. 1994;86:1403-1408.

43. Blackburn GL, Copeland T, Khaodhilar L, et al. Diet and breast cancer. *J Womens Health (Larchmt)*. 2003;12:183-192.
44. Goss PE, Sierra S. Current perspectives on radiation-induced breast cancer. *J Clin Oncol*. 1998;16:338-347.
45. Hulka BS. Epidemiologic analysis of breast and gynecologic cancers. *Prog Clin Biol Res*. 1997;396:17-29.
46. Pujol P, Galtier-Dereure F, Bringer J: Obesity and breast cancer risk. *Hum Reprod*. 1997;12(1):116-125.
47. Singletary SE. Rating the risk factors for breast cancer. *Ann Surg*. 2003;237:474-482.
48. Wynder EL, Cohen LA, Muscat JE, et al. Breast cancer: weighing the evidence for a promoting role of dietary fat. *J Natl Cancer Inst*. 1997;89:766-775.
49. Baan R, Straif K, Grosse Y, et al. Carcinogenicity of alcoholic beverages. *Lancet Oncol*. 2007;8:292-293.
50. Howlander N, Noone AM, Krapcho M, et al. SEER Cancer Statistics Review, 1975-2010, National Cancer Institute, based on November 2012 SEER data submission. Bethesda;2013.
51. Domchek SM, Eisen A, Calzone K, et al: Application of breast cancer risk prediction models in clinical practice. *J Clin Oncol*. 2003;21:593-601.
52. Gail MH, Brinton LA, Byar DP, et al. **Projecting individualized probabilities of developing breast cancer for white females who are being examined annually.** *J Natl Cancer Inst*. 1989;81:1879-1886.
53. Edwards BK, Brown ML, Wingo PA, et al. Annual report to the nation on the status of cancer, 1975-2002, featuring population-based trends in cancer treatment. *J Natl Cancer Inst*. 2005;97:1407-1427.
54. Chen J, Pee D, Ayyagari R, et al. Projecting absolute invasive breast cancer risk in white women with a model that includes mammographic density. *J Natl Cancer Inst*. 2006;98:1215-1226.
55. Claus EB, Risch N, Thompson WD. The calculation of breast cancer risk for women with a first degree family history of ovarian cancer. *Breast Cancer Res Treat*. 1993;28:115-120.
56. Kerlikowske K, Ichikawa L, Miglioretti DL, et al. Longitudinal measurement of clinical mammographic breast density to improve estimation of breast cancer risk. *J Natl Cancer Inst*. 2007;99:386-395.
57. Berry DA, Parmigiani G, Sanchez J, et al. Probability of carrying a mutation of breast-ovarian cancer gene BRCA1 based on family history. *J Natl Cancer Inst*. 1997;89:227-238.
58. Parmigiani G, Berry D, Aguilar O. Determining carrier probabilities for breast cancer-susceptibility genes BRCA1 and BRCA2. *Am J Hum Genet*. 1998;62:145-158.
59. Tyrer J, Duffy SW, Cuzick J. A breast cancer prediction model incorporating familial and personal risk factors. *Stat Med*. 2004;23:1111-1130.
60. Fisher B, Costantino JP, Wickerham DL, et al. **Tamoxifen for prevention of breast cancer: report of the National Surgical Adjuvant Breast and Bowel Project P-1 Study.** *J Natl Cancer Inst*. 1998;90:1371-1388.
61. Grodstein F, Stampfer MJ, Colditz GA, et al. Postmenopausal hormone therapy and mortality. *N Engl J Med*. 1997;336:1769-1775.
62. Hartmann LC, Schaid DJ, Woods JE, et al. Efficacy of bilateral prophylactic mastectomy in women with a family history of breast cancer. *N Engl J Med*. 1999;340:77-84.
63. Kerlikowske K, Grady D, Rubin SM, et al. Efficacy of screening mammography. A meta-analysis. *JAMA*. 1995;273:149-154.
64. Rowe TC, Chen GL, Hsiang YH, et al. DNA damage by antitumor acridines mediated by mammalian DNA topoisomerase II. *Cancer Res*. 1986;46:2021-2026.
65. Sakorafas GH. The management of women at high risk for the development of breast cancer: risk estimation and preventative strategies. *Cancer Treat Rev*. 2003;29:79-89.
66. Schrag D, Kuntz KM, Garber JE, et al. Decision analysis—effects of prophylactic mastectomy and oophorectomy on life expectancy among women with BRCA1 or BRCA2 mutations. *N Engl J Med*. 1997;336:1465-1471.
67. Vogel VG. Management of the high-risk patient. *Surg Clin North Am*. 2003;83:733-751.
68. Wu K, Brown P. Is low-dose tamoxifen useful for the treatment and prevention of breast cancer? *J Natl Cancer Inst*. 2003;95:766-767.
69. Breast cancer and hormone replacement therapy: collaborative reanalysis of data from 51 epidemiological studies of 52,705 women with breast cancer and 108,411 women without breast cancer. Collaborative Group on Hormonal Factors in Breast Cancer. *Lancet*. 1997;350:1047-1059.
70. Chlebowski RT, Hendrix SL, Langer RD, et al. Influence of estrogen plus progestin on breast cancer and mammography in healthy postmenopausal women: the Women's Health Initiative Randomized Trial. *JAMA*. 2003;289:3243-3253.
71. Beral V. Breast cancer and hormone-replacement therapy in the Million Women Study. *Lancet*. 2003;362:419-427.
72. Glasziou P, Houssami N. The evidence base for breast cancer screening. *Prev Med*. 2011;53:100-102.
73. Olsen O, Gotzsche PC. Cochrane review on screening for breast cancer with mammography. *Lancet*. 2001;358:1340-1342.
74. The benefits and harms of breast cancer screening: an independent review. *Lancet*. 2012;380:1778-1786.
75. Nystrom L, Andersson I, Bjurstam N, et al. Long-term effects of mammography screening: updated overview of the Swedish randomised trials. *Lancet*. 2002;359:909-919.
76. Moss S, Thomas I, Evans A, et al. Randomised controlled trial of mammographic screening in women from age 40: results of screening in the first 10 years. *Br J Cancer*. 2005;92:949-954.
77. **Screening for breast cancer. U.S. Preventive Services Task Force recommendation statement.** *Ann Intern Med*. 2009;151:716-726, W-236.
78. Powles TJ, Ashley S, Tidy A, et al. Twenty-year follow-up of the Royal Marsden randomized, double-blinded tamoxifen breast cancer prevention trial. *J Natl Cancer Inst*. 2007;99:283-290.
79. Veronesi U, Maisonneuve P, Sacchini V, et al. Tamoxifen for breast cancer among hysterectomised women. *Lancet*. 2002;359:1122-1124.
80. Cuzick J, Forbes JF, Sestak I, et al. Long-term results of tamoxifen prophylaxis for breast cancer—96-month follow-up of the randomized IBIS-I trial. *J Natl Cancer Inst*. 2007;99:272-282.
81. Gail MH, Costantino JP, Bryant J, et al. Weighing the risks and benefits of tamoxifen treatment for preventing breast cancer. *J Natl Cancer Inst*. 1999;91:1829-1846.
82. Vogel VG, Costantino JP, Wickerham DL, et al. Effects of tamoxifen vs. raloxifene on the risk of developing invasive breast cancer and other disease outcomes: the NSABP Study of Tamoxifen and Raloxifene (STAR) P-2 trial. *JAMA*. 2006;295:2727-241.
83. Vogel VG, Costantino JP, Wickerham DL, et al. Update of the National Surgical Adjuvant Breast and Bowel Project Study of Tamoxifen and Raloxifene (STAR) P-2 Trial: Preventing breast cancer. *Cancer Prev Res (Phila)*. 2010;3:696-706.
84. Goss PE, Ingle JN, Ales-Martinez JE, et al. Exemestane for breast-cancer prevention in postmenopausal women. *N Engl J Med*. 2011;364:2381-2391.
85. Cuzick J. IBIS II: a breast cancer prevention trial in postmenopausal women using the aromatase inhibitor anastrozole. *Expert Rev Anticancer Ther*. 2008;8:1377-1385.
86. Jenkins VA, Ambroisine LM, Atkins L, et al. Effects of anastrozole on cognitive performance in postmenopausal women: a randomised, double-blind chemoprevention trial (IBIS II). *Lancet Oncol*. 2008;9:953-961.

87. Nelson HD, Smith ME, Griffin JC, et al. Use of medications to reduce risk for primary breast cancer: a systematic review for the U.S. Preventive Services Task Force. *Ann Intern Med.* 2013;158:604-614.
88. Visvanathan K, Hurley P, Bantug E, et al. Use of pharmacologic interventions for breast cancer risk reduction: american society of clinical oncology clinical practice guideline. *J Clin Oncol* 2013;31:2942-2962.
89. Domchek SM, Friebel TM, Singer CF, et al. Association of risk-reducing surgery in BRCA1 or BRCA2 mutation carriers with cancer risk and mortality. *JAMA.* 2010;304:967-975.
90. Ford D, Easton DF, Stratton M, et al. Genetic heterogeneity and penetrance analysis of the BRCA1 and BRCA2 genes in breast cancer families. The Breast Cancer Linkage Consortium. *Am J Hum Genet.* 1998;62:676-689.
91. Gowen LC, Avrutskaya AV, Latour AM, et al. BRCA1 required for transcription-coupled repair of oxidative DNA damage. *Science.* 1998; 281:1009-1012.
92. Martin AM, Weber BL. Genetic and hormonal risk factors in breast cancer. *J Natl Cancer Inst.* 2000;92:1126-1135.
93. Oddoux C, Struwing JP, Clayton CM, et al. The carrier frequency of the BRCA2 6174delT mutation among Ashkenazi Jewish individuals is approximately 1%. *Nat Genet.* 1996;14:188-190.
94. Roa BB, Boyd AA, Volcik K, et al. Ashkenazi Jewish population frequencies for common mutations in BRCA1 and BRCA2. *Nat Genet.* 1996;14:185-187.
95. Rosen EM, Fan S, Pestell RG, et al. BRCA1 gene in breast cancer. *J Cell Physiol.* 2003;196:19-41.
96. Wooster R, Weber BL. Breast and ovarian cancer. *N Engl J Med.* 2003;348:2339-2347.
97. Petrij-Bosch A, Peelen T, van Vliet M, et al.: BRCA1 genomic deletions are major founder mutations in Dutch breast cancer patients. *Nat Genet.* 1997;17:341-345.
98. Gorski B, Byrski T, Huzarski T, et al. Founder mutations in the BRCA1 gene in Polish families with breast-ovarian cancer. *Am J Hum Genet.* 2000;66:1963-1968.
99. Sarantaus L, Huusko P, Eerola H, et al. Multiple founder effects and geographical clustering of BRCA1 and BRCA2 families in Finland. *Eur J Hum Genet.* 2000; 8:757-763.
100. Gayther SA, Harrington P, Russell P, et al. Frequently occurring germ-line mutations of the BRCA1 gene in ovarian cancer families from Russia. *Am J Hum Genet.* 1997;60:1239-1242.
101. Szabo CI, King MC. Population genetics of BRCA1 and BRCA2. *Am J Hum Genet.* 1997; 60:1013-1020.
102. Abeliovich D, Kaduri L, Lerer I, et al. The founder mutations 185delAG and 5382insC in BRCA1 and 6174delT in BRCA2 appear in 60% of ovarian cancer and 30% of early-onset breast cancer patients among Ashkenazi women. *Am J Hum Genet.* 1997;60:505-514.
103. Johannesdottir G, Gudmundsson J, Bergthorsson JT, et al. High prevalence of the 999del5 mutation in Icelandic breast and ovarian cancer patients. *Cancer Res.* 1996;56:3663-3665.
104. Hakansson S, Johannsson O, Johannsson U, et al. Moderate frequency of BRCA1 and BRCA2 germ-line mutations in Scandinavian familial breast cancer. *Am J Hum Genet.* 1997;60:1068-1078.
105. Infante M, Duran M, Acedo A, et al. The highly prevalent BRCA2 mutation c.2808_2811del (3036delACAA) is located in a mutational hotspot and has multiple origins. *Carcinogenesis.* 2013.34:2505-2511.
106. Warner E, Foulkes W, Goodwin P, et al. Prevalence and penetrance of BRCA1 and BRCA2 gene mutations in unselected Ashkenazi Jewish women with breast cancer. *J Natl Cancer Inst.* 1999; 91:1241-1247.
107. Khatcheressian JL, Hurley P, Bantug E, et al. Breast cancer follow-up and management after primary treatment: American Society of Clinical Oncology clinical practice guideline update. *J Clin Oncol.* 2013;31:961-965.
108. Schneider KA. Genetic counseling for BRCA1/BRCA2 testing. *Genet Test.* 1997 1:91-98.
109. Kriege M, Brekelmans CT, Boetes C, et al. Efficacy of MRI and mammography for breast-cancer screening in women with a familial or genetic predisposition. *N Engl J Med.* 2004;351:427-437.
110. Saslow D, Boetes C, Burke W, et al. American Cancer Society guidelines for breast screening with MRI as an adjunct to mammography. *CA Cancer J Clin.* 2007; 57:75-89.
111. King MC, Wieand S, Hale K, et al. Tamoxifen and breast cancer incidence among women with inherited mutations in BRCA1 and BRCA2: National Surgical Adjuvant Breast and Bowel Project (NSABP-P1) Breast Cancer Prevention Trial. *JAMA.* 2001;286:2251-2256.
112. Siegel R, Naishadham D, Jemal A. Cancer statistics, 2013. *CA Cancer J Clin.* 2013; 63:11-30.
113. Clarke CA, Glaser SL, Uratsu CS, et al. Recent declines in hormone therapy utilization and breast cancer incidence: clinical and population-based evidence. *J Clin Oncol.* 2006;24:e49-e50.
114. Ferlay J, al. E. Globocan 2002: Cancer Incidence, Mortality and Prevalence Worldwide. Lyon, France:IARC Press; 2004.
115. Ries LA. SEER Cancer Statistics Review, 1975-2002, National Cancer Institute. Bethesda.
116. Fregene A, Newman LA. Breast cancer in sub-Saharan Africa: how does it relate to breast cancer in African-American women? *Cancer.* 2005;103:1540-1550.
117. Bloom HJ, Richardson WW, Harries EJ. Natural history of untreated breast cancer (1805-1933). Comparison of untreated and treated cases according to histological grade of malignancy. *Br Med J.* 1962;2:213-221.
118. Tamoxifen for early breast cancer. an overview of the randomised trials. Early Breast Cancer Trialists' Collaborative Group. *Lancet.* 1998;351:1451-1467.
119. Saphner T, Tormey DC, Gray R. Annual hazard rates of recurrence for breast cancer after primary therapy. *J Clin Oncol.* 1996;14:2738-2746.
120. Sestak I, Dowsett M, Zabaglo L, et al. Factors predicting late recurrence for estrogen receptor-positive breast cancer. *J Natl Cancer Inst.* 2013;105:1504-1511.
121. Gonzalez-Angulo AM, Cristofanilli M, Strom EA, et al. Central nervous system metastases in patients with high-risk breast carcinoma after multimodality treatment. *Cancer.* 2004; 101:1760-1766.
122. Carey LA, Ewend MG, Metzger R, et al. Central nervous system metastases in women after multimodality therapy for high risk breast cancer. *Breast Cancer Res Treat.* 2004; 88:273-80.
123. Evans AJ, James JJ, Cornford EJ, et al. Brain metastases from breast cancer: identification of a high-risk group. *Clin Oncol (R Coll Radiol).* 2004;16:345-349.
124. Broders AC. Carcinoma in situ contrasted with benign penetrating epithelium. *JAMA* 1932;99:1670.
125. Foote FW, Stewart FW. Lobular carcinoma in situ: A rare form of mammary cancer. *Am J Pathol.* 1941;17:491-496.
126. Consensus conference on the classification of ductal carcinoma in situ. *Hum Pathol.* 1997; 28:1221-1225.
127. Recht A, Rutgers EJ, Fentiman IS, et al. The fourth EORTC DCIS Consensus meeting (Chateau Marquette, Heemskerk, The Netherlands, 23-24 January 1998)—conference report. *Eur J Cancer.* 1998; 34:1664-1669.
128. Devitt JE, Barr JR. The clinical recognition of cystic carcinoma of the breast. *Surg Gynecol Obstet.* 1984;159:130-132.
129. Gallager HS, Martin JE. The study of mammary carcinoma by mammography and whole organ sectioning. Early observations. *Cancer.* 1969;23:855-873.

130. Seth A, Kitching R, Landberg G, et al. Gene expression profiling of ductal carcinomas in situ and invasive breast tumors. *Anticancer Res.* 2003; 23:2043-2051.
131. Simpson JF, Wilkinson EJ. Malignant neoplasia of the breast: Infiltrating carcinomas. In: Bland KI, Copeland EMI, eds. *The Breast: Comprehensive Management of Benign and Malignant Diseases.* Philadelphia:WB Saunders; 1998:285.
132. Dunnwald LK, Rossing MA, Li CI. Hormone receptor status, tumor characteristics, and prognosis: a prospective cohort of breast cancer patients. *Breast Cancer Res.* 2007 9:R6.
133. McDivitt RW, Boyce W, Gersell D. Tubular carcinoma of the breast. Clinical and pathological observations concerning 135 cases. *Am J Surg Pathol.* 1982;6:401-411.
134. Jatoi I. Screening clinical breast examination. *Surg Clin North Am.* 2003;83:789-801.
135. Rosato FE, Rosato EL. Examination techniques: Roles of the physician and patient evaluating breast diseases. In: Bland KI, Copeland EMI, eds. *The Breast: Comprehensive Management of Benign and Malignant Diseases.* Philadelphia:WB Saunders;1998:615.
136. Bassett LW. Breast imaging. In: Bland KI, Copeland EMI, eds. Philadelphia: WB Saunders; 1998:648.
137. Fletcher SW, Elmore JG. Clinical practice. Mammographic screening for breast cancer. *N Engl J Med.* 2003;348:1672-1680.
138. Miller AB. Screening and detection. In: Bland KI, Copeland EMI, eds. *The Breast: Comprehensive Management of Benign and Malignant Diseases.* Philadelphia: WB Saunders; 1998:625.
139. Schnall MD. Breast MR imaging. *Radiol Clin North Am.* 2003;41:43-50.
140. Seidman H, Gelb SK, Silverberg E, et al. Survival experience in the Breast Cancer Detection Demonstration Project. *CA Cancer J Clin.* 1987;37:258-290.
141. Pisano ED, Gatsonis C, Hendrick E, et al. Diagnostic performance of digital versus film mammography for breast-cancer screening. *N Engl J Med.* 2005;353:1773-1783.
142. Ciatto S, Houssami N, Bernardi D, et al. Integration of 3D digital mammography with tomosynthesis for population breast-cancer screening (STORM): a prospective comparison study. *Lancet Oncol.* 2013; 14:70134-70137.
143. Krishnamurthy S, Sneige N, Bedi DG, et al. Role of ultrasound-guided fine-needle aspiration of indeterminate and suspicious axillary lymph nodes in the initial staging of breast carcinoma. *Cancer.* 2002;95:982-988.
144. Turnbull L, Brown S, Harvey I, et al. **Comparative effectiveness of MRI in breast cancer (COMICE) trial: a randomised controlled trial.** *Lancet.* 2010;375:563-571.
145. Houssami N, Turner R, Morrow M. Preoperative magnetic resonance imaging in breast cancer: meta-analysis of surgical outcomes. *Ann Surg.* 2013; 257:249-255.
146. Robinson DS, Sundaram M. Stereotactic imaging and breast biopsy. In: Bland KI, Copeland EMI, eds. *The Breast: Comprehensive Management of Benign and Malignant Diseases.* Philadelphia: WB Saunders; 1998:698.
147. Wilkinson EJ, Masood S. Cytologic needle samplings of the breast: Techniques and end results. In: Bland KI, Copeland EMI, eds. *The Breast: Comprehensive Management of Benign and Malignant Diseases.* Philadelphia: WB Saunders; 1998:705.
148. Greene FL, Page DL, Fleming ID, eds. *Breast. AJCC Cancer Staging Manual 6th ed.* New York: Springer-Verlag; 2002.
149. Britton PD, Goud A, Godward S, et al. Use of ultrasound-guided axillary node core biopsy in staging of early breast cancer. *Eur Radiol.* 2009;19:561-569.
150. Fisher B, Slack NH. Number of lymph nodes examined and the prognosis of breast carcinoma. *Surg Gynecol Obstet.* 1970.131:79-88.
151. **AJCC Cancer Staging Manual 7th ed.** Springer:2010.
152. Du Toit RS, Locker AP, Ellis IO, et al. Evaluation of the prognostic value of triple node biopsy in early breast cancer. *Br J Surg.* 77:163-167.
153. Dillon DA. Molecular markers in the diagnosis and staging of breast cancer. *Semin Radiat Oncol.* 2002;12:305-318.
154. Esteva FJ, Sahin AA, Cristofanilli M, et al. Molecular prognostic factors for breast cancer metastasis and survival. *Semin Radiat Oncol.* 2002;12:319-328.
155. Haffty BG. Molecular and genetic markers in the local-regional management of breast cancer. *Semin Radiat Oncol.* 2002;12:329-340.
156. Morabito A, Magnani E, Gion M, et al. Prognostic and predictive indicators in operable breast cancer. *Clin Breast Cancer.* 2003; 3:381-390.
157. Rogers CE, Loveday RL, Drew PJ, et al. Molecular prognostic indicators in breast cancer. *Eur J Surg Oncol.* 2002;28:467-478.
158. Rampaul R, Ellis IO, Robertson JFR. Prognostic indices in breast cancer. In: Autier BP, Adebamowo C, Anderson BO, et al, eds. *World Breast Cancer Report, iPRI:2012:323-332.*
159. Athanassiadou PP, Veneti SZ, Kyrkou KA, et al. Presence of epidermal growth factor receptor in breast smears of cyst fluids: relationship to electrolyte ratios and pH concentration. *Cancer Detect Prev.* 1992;16:113-118.
160. Tsutsumi Y, Naber SP, DeLellis RA, et al. Neu oncogene protein and epidermal growth factor receptor are independently expressed in benign and malignant breast tissues. *Hum Pathol* 1990;21:750-758.
161. van de Vijver MJ, Peterse JL, Mooi WJ, et al. Neu-protein overexpression in breast cancer. Association with comedo-type ductal carcinoma in situ and limited prognostic value in stage II breast cancer. *N Engl J Med.* 1988;319:1239-1245.
162. Slamon DJ, Clark GM, Wong SG, et al. Human breast cancer: correlation of relapse and survival with amplification of the HER-2/neu oncogene. *Science.* 1987;235:177-182.
163. Gusterson BA, Gelber RD, Goldhirsch A, et al. Prognostic importance of c-erbB-2 expression in breast cancer. International (Ludwig) Breast Cancer Study Group. *J Clin Oncol.* 1992; 10:1049-1056.
164. McCann AH, Dervan PA, O'Regan M, et al. Prognostic significance of c-erbB-2 and estrogen receptor status in human breast cancer. *Cancer Res.*1991; 51:3296-3303.
165. Slamon DJ, Godolphin W, Jones LA, et al. Studies of the HER-2/neu proto-oncogene in human breast and ovarian cancer. *Science.* 1989;244:707-712.
166. Wright C, Angus B, Nicholson S, et al. Expression of c-erbB-2 oncoprotein: a prognostic indicator in human breast cancer. *Cancer Res.* 1989;49:2087-2090.
167. **Romond EH, Perez EA, Bryant J, et al. Trastuzumab plus adjuvant chemotherapy for operable HER2-positive breast cancer.** *N Engl J Med.* 2005;353:1673-1684.
168. Smith I, Procter M, Gelber RD, et al. 2-year follow-up of trastuzumab after adjuvant chemotherapy in HER2-positive breast cancer: a randomised controlled trial. *Lancet.* 2007;369:29-36.
169. Slamon D, Eiermann W, Robert N, et al. Adjuvant trastuzumab in HER2-positive breast cancer. *N Engl J Med.* 2011;365:1273-1283.
170. Dahabreh IJ, Linardou H, Siannis F, et al. Trastuzumab in the adjuvant treatment of early-stage breast cancer: a systematic review and meta-analysis of randomized controlled trials. *Oncologist.* 2008;13:620-630.
171. Monaghan P, Perusinghe NP, Nicholson RI, et al. Growth factor stimulation of proliferating cell nuclear antigen (PCNA) in human breast epithelium in organ culture. *Cell Biol Int Rep.* 1991;15:561-570.
172. Siitonen SM, Isola JJ, Rantala IS, et al. Intratumor variation in cell proliferation in breast carcinoma as determined by

- antiproliferating cell nuclear antigen monoclonal antibody and automated image analysis. *Am J Clin Pathol.* 1993;99:226-231.
173. Tuccari G, Rizzo A, Muscara M, et al. PCNA/cyclin expression in breast carcinomas: its relationships with Ki-67, ER, PgR immunostainings and clinico-pathologic aspects. *Pathologica.* 1993; 85:47-55.
 174. van Dierendonck JH, Wijsman JH, Keijzer R, et al. Cell-cycle-related staining patterns of anti-proliferating cell nuclear antigen monoclonal antibodies. Comparison with BrdUrd labeling and Ki-67 staining. *Am J Pathol.* 1991;138:1165-1172.
 175. Cuzick J, Dowsett M, Pineda S, et al. Prognostic value of a combined estrogen receptor, progesterone receptor, Ki-67, and human epidermal growth factor receptor 2 immunohistochemical score and comparison with the Genomic Health recurrence score in early breast cancer. *J Clin Oncol.* 2011;29:4273-4278.
 176. Brown LF, Berse B, Jackman RW, et al. Expression of vascular permeability factor (vascular endothelial growth factor) and its receptors in breast cancer. *Hum Pathol.* 26:86-91, 1995
 177. Gasparini G, Toi M, Gion M, et al. Prognostic significance of vascular endothelial growth factor protein in node-negative breast carcinoma. *J Natl Cancer Inst.* 1997;89:139-147.
 178. Miller K, Wang M, Gralow J, et al. Paclitaxel plus bevacizumab versus paclitaxel alone for metastatic breast cancer. *N Engl J Med.* 2007;357:2666-2676.
 179. Allan DJ, Howell A, Roberts SA, et al. Reduction in apoptosis relative to mitosis in histologically normal epithelium accompanies fibrocystic change and carcinoma of the premenopausal human breast. *J Pathol.* 1992;167:25-32.
 180. Bargou RC, Daniel PT, Mapara MY, et al. Expression of the bcl-2 gene family in normal and malignant breast tissue: low bax-alpha expression in tumor cells correlates with resistance towards apoptosis. *Int J Cancer.* 1995; 60:854-859.
 181. Binder C, Marx D, Binder L, et al. Expression of Bax in relation to Bcl-2 and other predictive parameters in breast cancer. *Ann Oncol.* 1996;7:129-133.
 182. Ravdin PM, Siminoff LA, Davis GJ, et al. Computer program to assist in making decisions about adjuvant therapy for women with early breast cancer. *J Clin Oncol.* 2001;19:980-991.
 183. Blamey RW, Ellis IO, Pinder SE, et al. Survival of invasive breast cancer according to the Nottingham Prognostic Index in cases diagnosed in 1990-1999. *Eur J Cancer.* 2007;43:1548-1555.
 184. Blamey RW, Pinder SE, Ball GR, et al. Reading the prognosis of the individual with breast cancer. *Eur J Cancer.* 2007;43:1545-1547.
 185. Wishart GC, Azzato EM, Greenberg DC, et al. PREDICT: a new UK prognostic model that predicts survival following surgery for invasive breast cancer. *Breast Cancer Res.* 2010;12:R1.
 186. Perou CM, Jeffrey SS, van de Rijn M, et al. Distinctive gene expression patterns in human mammary epithelial cells and breast cancers. *Proc Natl Acad Sci U S A.* 1999;96:9212-9217.
 187. Paik S, Shak S, Tang G, et al. A multigene assay to predict recurrence of tamoxifen-treated, node-negative breast cancer. *N Engl J Med.* 2004;351:2817-2826.
 188. Lo SS, Mumby PB, Norton J, et al. Prospective multicenter study of the impact of the 21-gene recurrence score assay on medical oncologist and patient adjuvant breast cancer treatment selection. *J Clin Oncol.* 28:1671-1676.
 189. Julien JP, Bijker N, Fentiman IS, et al. Radiotherapy in breast-conserving treatment for ductal carcinoma in situ: first results of the EORTC randomised phase III trial 10853. EORTC Breast Cancer Cooperative Group and EORTC Radiotherapy Group. *Lancet.* 2000;355:528-533.
 190. Lagios MD, Margolin FR, Westdahl PR, et al. Mammographically detected duct carcinoma in situ. Frequency of local recurrence following tylectomy and prognostic effect of nuclear grade on local recurrence. *Cancer.* 1989;63:618-624.
 191. Rosai J. Borderline epithelial lesions of the breast. *Am J Surg Pathol.* 1991;15:209-221.
 192. Schnitt SJ, Connolly JL, Tavassoli FA, et al. Interobserver reproducibility in the diagnosis of ductal proliferative breast lesions using standardized criteria. *Am J Surg Pathol.* 1992;16:1133-1143.
 193. Silverstein MJ, Lagios MD, Groshen S, et al. The influence of margin width on local control of ductal carcinoma in situ of the breast. *N Engl J Med.* 1999;340:1455-1461.
 194. Tan-Chiu E. The effect of tamoxifen on benign breast disease: Findings from the National Surgical Adjuvant Breast and Bowel Project (NSABP) breast cancer prevention trial (BCPT). *Breast Cancer Res Treat.* 2001; 69:Abstract 7.
 195. Fisher B, Dignam J, Wolmark N, et al. Lumpectomy and radiation therapy for the treatment of intraductal breast cancer: findings from National Surgical Adjuvant Breast and Bowel Project B-17. *J Clin Oncol.* 1998;16:441-452.
 196. Bijker N, Meijnen P, Peterse JL, et al. Breast-conserving treatment with or without radiotherapy in ductal carcinoma-in-situ: ten-year results of European Organisation for Research and Treatment of Cancer randomized phase III trial 10853—a study by the EORTC Breast Cancer Cooperative Group and EORTC Radiotherapy Group. *J Clin Oncol.* 2006;24:3381-3387.
 197. Houghton J, George WD, Cuzick J, et al. Radiotherapy and tamoxifen in women with completely excised ductal carcinoma in situ of the breast in the UK, Australia, and New Zealand: randomised controlled trial. *Lancet.* 2003; 362:95-102.
 198. Emdin SO, Granstrand B, Ringberg A, et al. SweDCIS: Radiotherapy after sector resection for ductal carcinoma in situ of the breast. Results of a randomised trial in a population offered mammography screening. *Acta Oncol.* 2006;45:536-543.
 199. Hughes LL, Wang M, Page DL, et al. Local excision alone without irradiation for ductal carcinoma in situ of the breast: a trial of the Eastern Cooperative Oncology Group. *J Clin Oncol.* 2009;27:5319-5324.
 200. McCormick B. RTOG 9804: A prospective randomized trial for “good risk” ductal carcinoma in situ (DCIS), comparing radiation (RT) to observation (OBS). *J Clin Oncol* 30, 2012.
 201. Solin LJ, Gray R, Baehner FL, et al. A multigene expression assay to predict local recurrence risk for ductal carcinoma in situ of the breast. *J Natl Cancer Inst.* 2013;105:701-710.
 202. Fisher B, Dignam J, Wolmark N, et al. Tamoxifen in treatment of intraductal breast cancer: National Surgical Adjuvant Breast and Bowel Project B-24 randomised controlled trial. *Lancet.* 1999;353:1993-2000.
 203. Allred DC, Anderson SJ, Paik S, et al. Adjuvant tamoxifen reduces subsequent breast cancer in women with estrogen receptor-positive ductal carcinoma in situ: a study based on NSABP protocol B-24. *J Clin Oncol.* 2012;30:1268-1273.
 204. Effects of radiotherapy and surgery in early breast cancer. An overview of the randomized trials. Early Breast Cancer Trialists' Collaborative Group. *N Engl J Med.* 1995;333:1444-1455.
 205. Arriagada R, Le MG, Rochard F, et al. Conservative treatment versus mastectomy in early breast cancer: patterns of failure with 15 years of follow-up data. Institut Gustave-Roussy Breast Cancer Group. *J Clin Oncol.* 1996;14:1558-1564.
 206. Cooke T, Reeves J, Lanigan A, et al. HER2 as a prognostic and predictive marker for breast cancer. *Ann Oncol.* 2001;12 Suppl 1:S23-S28.
 207. Fisher B, Anderson S, Redmond CK, et al. Reanalysis and results after 12 years of follow-up in a randomized clinical trial comparing total mastectomy with lumpectomy with or without irradiation in the treatment of breast cancer. *N Engl J Med.* 1995;333:1456-1461.

208. Gump FE, Jicha DL, Ozello L. Ductal carcinoma in situ (DCIS): a revised concept. *Surgery*. 102:790-795.
209. Paik S, Bryant J, Tan-Chiu E, et al. HER2 and choice of adjuvant chemotherapy for invasive breast cancer: National Surgical Adjuvant Breast and Bowel Project Protocol B-15. *J Natl Cancer Inst*. 2000;92:1991-1998.
210. Veronesi U, Cascinelli N, Mariani L, et al. Twenty-year follow-up of a randomized study comparing breast-conserving surgery with radical mastectomy for early breast cancer. *N Engl J Med*. 2002;347:1227-1232.
211. Fyles AW, McCreedy DR, Manchul LA, et al. Tamoxifen with or without breast irradiation in women 50 years of age or older with early breast cancer. *N Engl J Med*. 2004;351:963-970.
212. Hughes KS, Schnaper LA, Berry D, et al. Lumpectomy plus tamoxifen with or without irradiation in women 70 years of age or older with early breast cancer. *N Engl J Med*. 2004;351:971-977.
213. Vaidya JS, Wenz F, Bulsara M, et al. Targeted intraoperative radiotherapy for early breast cancer: TARGIT-A trial—updated analysis of local recurrence and first analysis of survival. *Cancer Res*. 2012;72.
214. Smith BD, Arthur DW, Buchholz TA, et al. Accelerated partial breast irradiation consensus statement from the American Society for Radiation Oncology (ASTRO). *J Am Coll Surg*. 2009;209:269-277.
215. Fisher B, Redmond C, Fisher ER, et al. Ten-year results of a randomized clinical trial comparing radical mastectomy and total mastectomy with or without radiation. *N Engl J Med*. 1985;12:674-681.
216. Krag D, Weaver DL, Alex JC, et al. Surgical resection and radiolocalization of the sentinel lymph node in breast cancer using a gamma probe. *Surg Oncol*. 1993;2:335-339.
217. Giuliano AE, Dale PS, Turner RR, et al. Improved axillary staging of breast cancer with sentinel lymphadenectomy. *Ann Surg*. 1995;222:394-399; discussion 399-401.
218. Giuliano AE, Kirgan DM, Guenther JM, et al. Lymphatic mapping and sentinel lymphadenectomy for breast cancer. *Ann Surg*. 1994;220:391-398; discussion 398-401.
219. Mansel RE, Fallowfield L, Kissin M, et al. Randomized multicenter trial of sentinel node biopsy versus standard axillary treatment in operable breast cancer: the ALMANAC Trial. *J Natl Cancer Inst*. 2006;98:599-609.
220. Krag DN, Anderson SJ, Julian TB, et al. Technical outcomes of sentinel-lymph-node resection and conventional axillary-lymph-node dissection in patients with clinically node-negative breast cancer: results from the NSABP B-32 randomised phase III trial. *Lancet Oncol*. 2007;8:881-888.
221. Veronesi U, Paganelli G, Viale G, et al. **A randomized comparison of sentinel-node biopsy with routine axillary dissection in breast cancer.** *N Engl J Med*. 2003;349:546-553.
222. Veronesi U, Viale G, Paganelli G, et al. Sentinel lymph node biopsy in breast cancer: ten-year results of a randomized controlled study. *Ann Surg*. 2010;251:595-600.
223. Ashikaga T, Krag DN, Land SR, et al. Morbidity results from the NSABP B-32 trial comparing sentinel lymph node dissection versus axillary dissection. *J Surg Oncol*. 2010;102:111-118.
224. Giuliano AE, Hawes D, Ballman KV, et al. **Association of Occult Metastases in Sentinel Lymph Nodes and Bone Marrow With Survival Among Women With Early-Stage Invasive Breast Cancer.** *JAMA*. 2011;306:385-393.
225. Giuliano AE, Hunt KK, Ballman KV, et al. **Axillary dissection vs no axillary dissection in women with invasive breast cancer and sentinel node metastasis: a randomized clinical trial.** *JAMA*. 2011;305:569-575.
226. Wilke LG, McCall LM, Posther KE, et al. Surgical complications associated with sentinel lymph node biopsy: results from a prospective international cooperative group trial. *Ann Surg Oncol*. 2006;13:491-500.
227. Lucci A, McCall LM, Beitsch PD, et al. Surgical complications associated with sentinel lymph node dissection (SLND) plus axillary lymph node dissection compared with SLND alone in the American College of Surgeons Oncology Group Trial Z0011. *J Clin Oncol*. 2007;25:3657-3663.
228. The American Society of Breast Surgeons position statement on management of the axilla in patients with invasive breast cancer. Available at http://www.breastsurgeons.org/statements/PDF_Statements/Axillary_Management.pdf. Accessed 26 February, 2014.
229. Galimberti V, Cole BF, Zurrada S, et al. Axillary dissection versus no axillary dissection in patients with sentinel-node micrometastases (IBCSG 23-01): a phase 3 randomised controlled trial. *Lancet Oncol*. 2013;14:297-305.
230. Julian TB, Blumencranz P, Deck K, et al. Novel intraoperative molecular test for sentinel lymph node metastases in patients with early-stage breast cancer. *J Clin Oncol*. 2008;26:3338-3345.
231. Van Zee KJ, Manasseh DM, Bevilacqua JL, et al. A nomogram for predicting the likelihood of additional nodal metastases in breast cancer patients with a positive sentinel node biopsy. *Ann Surg Oncol*. 2003;10:1140-1151.
232. Lyman GH, Giuliano AE, Somerfield MR, et al. American Society of Clinical Oncology guideline recommendations for sentinel lymph node biopsy in early-stage breast cancer. *J Clin Oncol*. 2005;23:7703-7720.
233. Hortobagyi GN, Singletary SE, et al. Treatment of locally advanced and inflammatory breast cancer. In: Harris JR, et al. eds. *Diseases of the Breast*. Philadelphia: Lippincott Williams & Wilkins; 2000:645.
234. Willsher PC, Robertson JF, Chan SY, et al. Locally advanced breast cancer: early results of a randomised trial of multimodal therapy versus initial hormone therapy. *Eur J Cancer*. 33:45-49.
235. Mathew J, Agrawal A, Asgeirsson KS, et al. Primary endocrine therapy in locally advanced breast cancers—the Nottingham experience. *Breast Cancer Res Treat*. 2009;113:403-407.
236. Chen AM, Meric-Bernstam F, Hunt KK, et al. Breast conservation after neoadjuvant chemotherapy: the MD Anderson cancer center experience. *J Clin Oncol*. 2004;22:2303-2312.
237. Mieog JS, Van Der Hage JA, Van de Velde CJ. Neoadjuvant chemotherapy for operable breast cancer. *Br J Surg*. 2007;94:1189-1200.
238. Von Minckwitz G, Kaufmann M, Kummel S, et al. PD07-05: Local Recurrence Risk in 6377 Patients with Early Breast Cancer Receiving Neoadjuvant Anthracycline-Taxane +/- Trastuzumab Containing Chemotherapy, ty-Fourth Annual CTRC-AACR San Antonio Breast Cancer Symposium. San Antonio. 2011; Suppl 3.
239. Favret AM, Carlson RW, Goffinet DR, et al. Locally advanced breast cancer: is surgery necessary? *Breast J*. 2001;7:131-137.
240. Khan SA, Stewart AK, Morrow M. Does aggressive local therapy improve survival in metastatic breast cancer? *Surgery*. 2002;132:620-626; discussion 626-627.
241. Gnerlich J, Jeffe DB, Deshpande AD, et al. Surgical removal of the primary tumor increases overall survival in patients with metastatic breast cancer: analysis of the 1988-2003 SEER data. *Ann Surg Oncol*. 2007;14:2187-2194.
242. Bass SS, Lyman GH, McCann CR, et al. Lymphatic Mapping and Sentinel Lymph Node Biopsy. *Breast J*. 1999; 5:288-295.
243. Cox CE, Nguyen K, Gray RJ, et al. Importance of lymphatic mapping in ductal carcinoma in situ (DCIS): why map DCIS? *Am Surg*. 2001;67:513-519; discussion 519-521.
244. Dupont E, Cox C, Shivers S, et al. Learning curves and breast cancer lymphatic mapping: institutional volume index. *J Surg Res*. 2001;97:92-96.
245. Krag D, Weaver D, Ashikaga T, et al. The sentinel node in breast cancer—a multicenter validation study. *N Engl J Med*. 1988;339:941-946.

246. McMasters KM, Giuliano AE, Ross MI, et al. Sentinel-lymph node biopsy for breast cancer—not yet the standard of care. *N Engl J Med.* 1998;339:990-995.
247. O’Hea BJ, Hill AD, El-Shirbiny AM, et al. Sentinel lymph node biopsy in breast cancer: initial experience at Memorial Sloan-Kettering Cancer Center. *J Am Coll Surg.* 1998;186:423-427.
248. Souba WW, Bland KI. Indications and techniques for biopsy. In: Bland KI, Copeland EMI, eds. *The Breast: Comprehensive Management of Benign and Malignant Diseases.* Philadelphia: WB Saunders; 1998:802.
249. Veronesi U, Paganelli G, Galimberti V, et al. Sentinel-node biopsy to avoid axillary dissection in breast cancer with clinically negative lymph-nodes. *Lancet.* 1997;349:1864-1867.
250. Wilke LG, Giuliano A: Sentinel lymph node biopsy in patients with early-stage breast cancer: status of the National Clinical Trials. *Surg Clin North Am.* 2003;83:901-910.
251. Xing Y, Foy M, Cox DD, et al. Meta-analysis of sentinel lymph node biopsy after preoperative chemotherapy in patients with breast cancer. *Br J Surg.* 2006;93:539-546.
252. Hunt KK, Yi M, Mittendorf EA, et al. Sentinel lymph node surgery after neoadjuvant chemotherapy is accurate and reduces the need for axillary dissection in breast cancer patients. *Ann Surg.* 2009;250:558-566.
253. Tan VK, Goh BK, Fook-Chong S, et al. The feasibility and accuracy of sentinel lymph node biopsy in clinically node-negative patients after neoadjuvant chemotherapy for breast cancer—a systematic review and meta-analysis. *J Surg Oncol.* 2011;104:97-103.
254. Yi M, Meric-Bernstam F, Ross MI, et al. How many sentinel lymph nodes are enough during sentinel lymph node dissection for breast cancer? *Cancer.* 2008; 113:30-37.
255. Kong AL, Tereffe W, Hunt KK, et al. Impact of Internal Mammary Lymph Node Drainage Identified by Preoperative Lymphoscintigraphy on Outcomes in Patients With Stage I to III Breast Cancer. *Cancer.* 2012;118:6287-6296.
256. Fisher B. Lumpectomy (segmental mastectomy and axillary dissection). In: Bland KI, Copeland EMI, eds. *The Breast: Comprehensive Management of Benign and Malignant Diseases.* Philadelphia: WB Saunders; 1998:917.
257. Newman LA, Washington TA. New trends in breast conservation therapy. *Surg Clin North Am.* 2003;83:841-883.
258. NIH consensus conference. Treatment of early-stage breast cancer. *JAMA.* 1991;265:391-395.
259. Group EBCTC. Effect of radiotherapy after breast-conserving surgery on 10-year recurrence and 15-year breast cancer death: meta-analysis of individual patient data for 10 801 women in 17 randomised trials. *Lancet.* 2011;378:1707-1716.
260. Houssami N, Macaskill P, Marinovich ML, et al. Meta-analysis of the impact of surgical margins on local recurrence in women with early-stage invasive breast cancer treated with breast-conserving therapy. *Eur J Cancer.* 2010;46:3219-3232.
261. Bland KI, Chang HR. Modified radical mastectomy and total (simple) mastectomy. In: Bland KI, Copeland EMI, eds. *The Breast: Comprehensive Management of Benign and Malignant Diseases.* Philadelphia: WB Saunders; 1998:881.
262. Simmons RM, Adamovich TL. Skin-sparing mastectomy. *Surg Clin North Am.* 2003;83:885-899.
263. McCraw JB, Papp C. Breast reconstruction following mastectomy. In: Bland KI, Copeland EMI, eds. *The Breast: Comprehensive Management of Benign and Malignant Diseases.* Philadelphia: WB Saunders; 1998:96.
264. Fortin A, Dagnault A, Larochelle M, et al. Impact of locoregional radiotherapy in node-positive patients treated by breast-conservative treatment. *Int J Radiat Oncol Biol Phys.* 2003;56:1013-1022.
265. Hellman S. Stopping metastases at their source. *N Engl J Med.* 1997;337:996-997.
266. Overgaard M, Hansen PS, Overgaard J, et al. Postoperative radiotherapy in high-risk premenopausal women with breast cancer who receive adjuvant chemotherapy. Danish Breast Cancer Cooperative Group 82b Trial. *N Engl J Med.* 1997; 337:949-955.
267. Overgaard M, Jensen MB, Overgaard J, et al. Postoperative radiotherapy in high-risk postmenopausal breast-cancer patients given adjuvant tamoxifen: Danish Breast Cancer Cooperative Group DBCG 82c randomised trial. *Lancet.* 1999;353:1641-1648.
268. Ragaz J, Jackson SM, Le N, et al. Adjuvant radiotherapy and chemotherapy in node-positive premenopausal women with breast cancer. *N Engl J Med.* 1997;337:956-962.
269. Recht A, Edge SB. Evidence-based indications for postmastectomy irradiation. *Surg Clin North Am.* 2003;83:995-1013.
270. Recht A, Edge SB, Solin LJ, et al. Postmastectomy radiotherapy: clinical practice guidelines of the American Society of Clinical Oncology. *J Clin Oncol.* 2001;19:1539-1569.
271. Polychemotherapy for early breast cancer: an overview of the randomised trials. Early Breast Cancer Trialists’ Collaborative Group. *Lancet.* 352:930-942.
272. Fisher B, Brown AM, Dimitrov NV, et al. Two months of doxorubicin-cyclophosphamide with and without interval reinduction therapy compared with 6 months of cyclophosphamide, methotrexate, and fluorouracil in positive-node breast cancer patients with tamoxifen-nonresponsive tumors: results from the National Surgical Adjuvant Breast and Bowel Project B-15. *J Clin Oncol.* 1990; 8:1483-1496.
273. Kelleher M, Miles D. 21. The adjuvant treatment of breast cancer. *Int J Clin Pract.* 2003;57:195-199.
274. Loprinzi CL, Thome SD. Understanding the utility of adjuvant systemic therapy for primary breast cancer. *J Clin Oncol.* 2001;19:972-979.
275. Wood WC, Budman DR, Korzun AH, et al. Dose and dose intensity of adjuvant chemotherapy for stage II, node-positive breast carcinoma. *N Engl J Med.* 1994;330:1253-1259.
276. Bonadonna G, Bignami P, Buzzoni R, et al. New adjuvant trials for resectable breast cancer at the Istituto Nazionale Tumori of Milan. Recent Results. *Cancer Res.* 1984;91:210-213.
277. Mauri D, Pavlidis N, Ioannidis JP. Neoadjuvant versus adjuvant systemic treatment in breast cancer: a meta-analysis. *J Natl Cancer Inst.* 2005; 97:188-194.
278. Mittendorf EA, Buchholz TA, Tucker SL, et al. Impact of chemotherapy sequencing on local-regional failure risk in breast cancer patients undergoing breast-conserving therapy. *Ann Surg.* 257:173-179.
279. Buchholz TA, Hunt KK, Whitman GJ, et al. Neoadjuvant chemotherapy for breast carcinoma: multidisciplinary considerations of benefits and risks. *Cancer.* 2003;98:1150-1160.
280. Kuerer HM, Newman LA, Smith TL, et al. Clinical course of breast cancer patients with complete pathologic primary tumor and axillary lymph node response to doxorubicin-based neoadjuvant chemotherapy. *J Clin Oncol.* 1999;17:460-469.
281. Caudle AS, Gonzalez-Angulo AM, Hunt KK, et al. Predictors of tumor progression during neoadjuvant chemotherapy in breast cancer. *J Clin Oncol.* 2010;28:1821-828.
282. Mamounas EP, Brown A, Anderson S, et al. Sentinel node biopsy after neoadjuvant chemotherapy in breast cancer: results from National Surgical Adjuvant Breast and Bowel Project Protocol B-27. *J Clin Oncol.* 2005;23:2694-2702.
283. Guarneri V, Broglio K, Kau SW, et al. Prognostic value of pathologic complete response after primary chemotherapy in relation to hormone receptor status and other factors. *J Clin Oncol.* 24:1037-1044.
284. Ellis MJ, Suman VJ, Hoog J, et al. Randomized Phase II Neoadjuvant Comparison Between Letrozole, Anastrozole, and Exemestane for Postmenopausal Women With Estrogen Receptor-Rich Stage 2 to 3 Breast Cancer: Clinical and

- Biomarker Outcomes and Predictive Value of the Baseline PAM50-Based Intrinsic Subtype-ACOSOG Z1031. *J Clin Oncol*. 2011;29:2342-2349.
285. Baum M, Buzdar A: The current status of aromatase inhibitors in the management of breast cancer. *Surg Clin North Am*. 83:973-994.
286. Bonnetterre J, Thurlimann B, Robertson JF, et al. Anastrozole versus tamoxifen as first-line therapy for advanced breast cancer in 668 postmenopausal women: results of the Tamoxifen or Arimidex Randomized Group Efficacy and Tolerability study. *J Clin Oncol*. 2000;18:3748-3757.
287. Buzdar A, Douma J, Davidson N, et al. Phase III, multicenter, double-blind, randomized study of letrozole, an aromatase inhibitor, for advanced breast cancer versus megestrol acetate. *J Clin Oncol*. 2001;19:3357-3366.
288. Buzdar AU, Jonat W, Howell A, et al. Anastrozole versus megestrol acetate in the treatment of postmenopausal women with advanced breast carcinoma: results of a survival update based on a combined analysis of data from two mature phase III trials. Arimidex Study Group. *Cancer*. 1998;83:1142-1152.
289. Campos SM, Winer EP. Hormonal therapy in postmenopausal women with breast cancer. *Oncology*. 2003;64:289-299.
290. Group EBCTC. Relevance of breast cancer hormone receptors and other factors to the efficacy of adjuvant tamoxifen: patient-level meta-analysis of randomised trials. *Lancet*. 2011; 6736:60993-60998.
291. Goss PE, Ingle JN, Martino S, et al. Randomized trial of letrozole following tamoxifen as extended adjuvant therapy in receptor-positive breast cancer: updated findings from NCIC CTG MA.17. *J Natl Cancer Inst*. 2005;97:1262-1271.
292. Cuzick J, Sestak I, Baum M, et al. Effect of anastrozole and tamoxifen as adjuvant treatment for early-stage breast cancer: 10-year analysis of the ATAC trial. *Lancet Oncol*. 2010;11:1135-1141.
293. Coates AS, Keshaviah A, Thurlimann B, et al. Five years of letrozole compared with tamoxifen as initial adjuvant therapy for postmenopausal women with endocrine-responsive early breast cancer: update of study BIG 1-98. *J Clin Oncol*. 2007;25:486-492.
294. Robertson JF, Williams MR, Todd J, et al. Factors predicting the response of patients with advanced breast cancer to endocrine (Megace) therapy. *Eur J Cancer Clin Oncol*. 1989;25:469-475.
295. Cheung KL, Willsher PC, Pinder SE, et al. Predictors of response to second-line endocrine therapy for breast cancer. *Breast Cancer Res Treat*. 1997; 45:219-224.
296. Robertson JF, Willsher PC, Cheung KL, et al. The clinical relevance of static disease (no change) category for 6 months on endocrine therapy in patients with breast cancer. *Eur J Cancer*. 1997;33:1774-1779.
297. Early Breast Cancer Trialists' Collaborative Group (EBCTCG). Effects of chemotherapy and hormonal therapy for early breast cancer on recurrence and 15-year survival: an overview of the randomised trials. *Lancet*. 2005;365:1687-1717.
298. Paik S, Bryant J, Tan-Chiu E, et al. Real-world performance of HER2 testing—National Surgical Adjuvant Breast and Bowel Project experience. *J Natl Cancer Inst*. 2002;94:852-854.
299. Press MF, Slamon DJ, Flom KJ, et al. Evaluation of HER-2/neu gene amplification and overexpression: comparison of frequently used assay methods in a molecularly characterized cohort of breast cancer specimens. *J Clin Oncol*. 2002;20:3095-3105.
300. Volpi A, De Paola F, Nanni O, et al. Prognostic significance of biologic markers in node-negative breast cancer patients: a prospective study. *Breast Cancer Res Treat*. 63:181-192.
301. Buzdar AU, Ibrahim NK, Francis D, et al. Significantly higher pathologic complete remission rate after neoadjuvant therapy with trastuzumab, paclitaxel, and epirubicin chemotherapy: results of a randomized trial in human epidermal growth factor receptor 2-positive operable breast cancer. *J Clin Oncol*. 2005; 23:3676-3685.
302. Buzdar AU, Valero V, Ibrahim NK, et al. Neoadjuvant therapy with paclitaxel followed by 5-fluorouracil, epirubicin, and cyclophosphamide chemotherapy and concurrent trastuzumab in human epidermal growth factor receptor 2-positive operable breast cancer: an update of the initial randomized study population and data of additional patients treated with the same regimen. *Clin Cancer Res*. 2007;13:228-233.
303. Tench DW. The unknown primary presenting with axillary lymphadenopathy. In: Bland KI, Copeland EMI, eds. *The Breast: Comprehensive Management of Benign and Malignant Diseases*. Philadelphia: WB Saunders;1998:1447.
304. Robinson DS, Sundaram M, et al. Carcinoma of the breast in pregnancy and lactation. In: Bland KI, Copeland EMI, eds. *The Breast: Comprehensive Management of Benign and Malignant Diseases*. Philadelphia: WB Saunders;1998:1433.
305. Giordano SH, Buzdar AU, Hortobagyi GN: Breast cancer in men. *Ann Intern Med*. 2002;137:678-687.
306. Wilhelm MC. Cancer of the male breast. In: Bland KI, Copeland EMI, eds. *The Breast: Comprehensive Management of Benign and Malignant Diseases*. Philadelphia: WB Saunders; 1998:1416.
307. Khan SA, Badve S. Phyllodes tumors of the breast. *Curr Treat Options Oncol*. 2001;2:139-147.
308. Chittoor SR, Swain SM. Locally advanced breast cancer: Role of medical oncology. In: Bland KI, Copeland EMI, eds. *The Breast: Comprehensive Management of Benign and Malignant Diseases*. Philadelphia: WB Saunders;1998:1403.
309. Mies C. Mammary sarcoma and lymphoma. In: Bland KI, Copeland EMI, eds. *The Breast: Comprehensive Management of Benign and Malignant Diseases*. Philadelphia: WB Saunders;1998:307.
310. Stewart FW, Treves N. Lymphangiosarcoma in postmastectomy lymphedema; a report of six cases in elephantiasis chirurgica. *Cancer*. 1948;1:64-81.

18 chapter

Disorders of the Head and Neck

Richard O. Wein, Rakesh K. Chandra,
C. René Leemans, and Randal S. Weber

A Complex Region	565	Etiology and Epidemiology / 578	Reconstruction in Head and Neck Surgery	600
Benign Conditions of the Head and Neck	565	Anatomy and Histopathology / 579	Skin Grafts / 600	
Ear Infections / 565		Carcinogenesis / 580	Local Flaps / 600	
Sinus Inflammatory Disease / 567		Second Primary Tumors in the Head and Neck / 580	Regional Flaps / 600	
Pharyngeal and Adenotonsillar Disease / 570		Staging / 580	Free-Tissue Transfer / 601	
Benign Conditions of the Larynx / 572		Upper Aerodigestive Tract / 580	Tracheostomy	602
Vascular Lesions / 574		Nose and Paranasal Sinuses / 592	Long-Term Management and Rehabilitation	602
Trauma of the Head and Neck	575	Nasopharynx / 593	Palliative Care / 602	
Tumors of the Head and Neck	578	Ear and Temporal Bone / 594	Follow-Up Care / 602	
		Neck / 595		
		Salivary Gland Tumors / 599		

A COMPLEX REGION

The head and neck constitute a complex anatomic region where different pathologies may affect an individual's ability to see, smell, hear, speak, obtain nutrition and hydration, or breathe. The use of a multidisciplinary approach to many of the disorders in this region is essential in an attempt to achieve the best functional results with care. This chapter reviews many of the common diagnoses encountered in the field of otolaryngology—head and neck surgery—and aims to provide an overview that clinicians can use as a foundation for understanding of this region. As is the case with every field of surgery, care for patients with disorders of the head and neck is constantly changing as issues of quality of life and the economics of medicine continue to evolve.

BENIGN CONDITIONS OF THE HEAD AND NECK

Ear Infections

Infections may involve the external, middle, and/or internal ear. In each of these scenarios, the infection may follow an acute or chronic course and may be associated with both otologic and intracranial complications. *Otitis externa* typically refers to infection of the skin of the external auditory canal.¹ Acute otitis externa is commonly known as *swimmer's ear*, because moisture that persists within the canal after swimming often initiates the process and leads to skin maceration and itching. Typically, the patient subsequently traumatizes the canal skin by scratching (i.e., with a cotton swab or fingernail), thus eroding the normally protective skin/cerumen barrier. Because the environment within the external ear canal is already dark, warm, and humid, it then becomes susceptible to rapid microbial proliferation and tissue cellulitis. The most common organism responsible is *Pseudomonas aeruginosa*, although other bacteria and fungi may also be implicated. Symptoms and signs of otitis

externa include itching during the initial phases and pain with swelling of the canal soft tissues as the infection progresses. Infected, desquamated debris accumulates within the canal. In the chronic inflammatory stage of the infection, the pain subsides, but profound itching occurs for prolonged periods with gradual thickening of the external canal skin. Standard treatment requires removal of debris under otomicroscopy and application of appropriate topical antimicrobials, such as neomycin/polymyxin or quinolone-containing eardrops, which often include topical steroid such as hydrocortisone or dexamethasone to nonspecifically decrease pain and swelling. Nonantibiotic antimicrobial preparations, such as 2% acetic acid, may also have a role, particularly for mixed bacterial/fungal infections. For this reason, the patient should also be instructed to keep the ear dry. Systemic antibiotics are reserved for those with severe infections, diabetics, and immunosuppressed patients.

Diabetic, elderly, and immunodeficient patients are susceptible to a condition called *malignant otitis externa*, a fulminant necrotizing infection of the otologic soft tissues combined with osteomyelitis of the temporal bone. In addition to the previously mentioned findings, cranial neuropathies may be observed. The classic physical finding is granulation tissue along the floor of the external auditory canal (EAC). Symptoms include persistent otalgia for longer than 1 month and purulent otorrhea for several weeks. These patients require aggressive medical therapy; including IV antibiotics covering *Pseudomonas*.² Other gram-negative bacteria and fungi are occasionally implicated, necessitating culture-directed therapy in those cases. Patients who do not respond to medical management require surgical debridement. This condition may progress to involvement of the adjacent skull base and soft tissues, meningitis, brain abscess, and death.

In its acute phase, otitis media typically implies a bacterial infection of the middle ear. This diagnosis accounts for 25% of

Key Points

- 1▶ Patients with obstructive sleep apnea require evaluation to determine the specific anatomic site(s) of involvement. Long-term cardiovascular problems are a significant concern in these patients.
- 2▶ Repair of traumatic soft tissue injuries requires precise re-alignment of anatomic landmarks such as the grey line and vermilion border.
- 3▶ The key principle in the surgical repair of facial fractures is immobilization, which may require plates, screws, wires, and/or intermaxillary fixation.
- 4▶ Concurrent abuse of tobacco and alcohol are synergistic in increasing the risk of developing head and neck cancer
- 5▶ Monomodality therapy (surgery or radiation) is used for early stage (I/II) head and neck cancer, whereas combination surgery and chemoradiation is utilized with advanced stage (III/IV) malignancies.
- 6▶ Infectious conditions of the head and neck may present with life-threatening sequelae such as loss of airway or intracranial extension.
- 7▶ Disorders of the head and neck can cause significant cosmetic and functional impairment. The practitioner must be empathetic to the effect of these morbidities on quality of life.
- 8▶ Hoarseness, odynophagia, referred otalgia, nonhealing oral ulceration and/or cervical lymphadenopathy present for >2 weeks duration require consideration for subspecialty consultation for evaluation.

pediatric antibiotic prescriptions and is the most common bacterial infection of childhood. Most cases occur before 2 years of age and are secondary to immaturity of the Eustachian tube. Contributing factors include upper respiratory viral infection and day-care attendance, as well as craniofacial conditions affecting Eustachian tube function, such as cleft palate. It is also possible that social factors such as day-care attendance and the inappropriate prescribing of antibiotics have led to antibiotic resistance.

Classification of the infection as acute is based upon the duration of the process being less than 3 weeks. In this phase, otalgia and fever are the most common symptoms and physical exam reveals a bulging, opaque tympanic membrane (Fig. 18-1). The most common organisms responsible are *Streptococcus pneumoniae*, *Haemophilus influenzae*, and *Moraxella catarrhalis*. If the process lasts 3 to 8 weeks, it is deemed subacute. Chronic otitis media, lasting more than 8 weeks, usually results from an unresolved acute otitis media. About 20% of patients demonstrate a persistent middle ear effusion 8 weeks after resolution of the acute phase. Rather than a purely infectious process, however, it represents chronic inflammation and hypersecretion by the middle ear mucosa associated with Eustachian tube dysfunction, viruses, allergy, ciliary

dysfunction, and other factors. The bacteriology is variable, but often includes those found in acute otitis media and may be polymicrobial. The exact role of bacteria in the pathophysiology is controversial. The patient experiences otalgia, ear fullness, and conductive hearing loss. Physical examination reveals a retracted tympanic membrane that may exhibit an opaque character or an air-fluid level. Bubbles may be seen behind the retracted membrane.

Treatment for uncomplicated otitis media is oral antibiotic therapy. However, penicillin resistance of the commonly implicated organisms is rising such that almost 100% of *Moraxella*, 50% to 70% of *Haemophilus*, and up to 40% of pneumococcal strains are resistant.³ Beta-lactamase-resistant combinations, cephalosporins, and macrolides are often required, although amoxicillin and sulfas are still considered first-line drugs. Chronic otitis media is frequently treated with myringotomy and tube placement (Fig. 18-2). This is indicated for frequent acute episodes, chronic effusions persisting beyond 3 months, and those associated with significant conductive hearing loss. The purpose of this procedure is to remove the effusion and provide a route for middle ear ventilation. Tympanic membrane perforation during acute otitis media frequently results in resolution of severe pain and provides for drainage of purulent

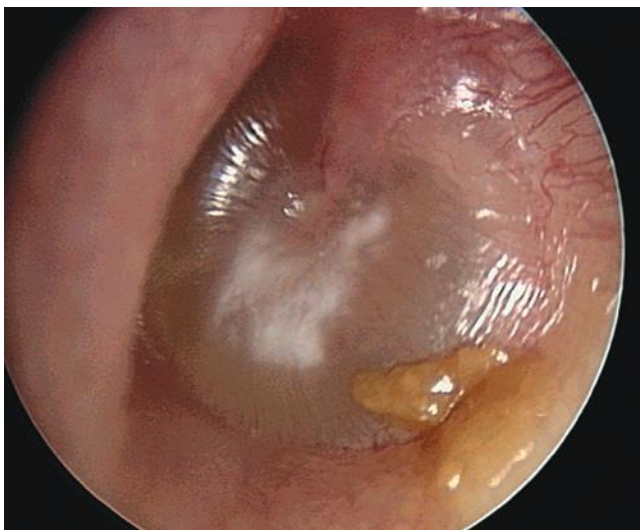

Figure 18-1. Acute otitis media.

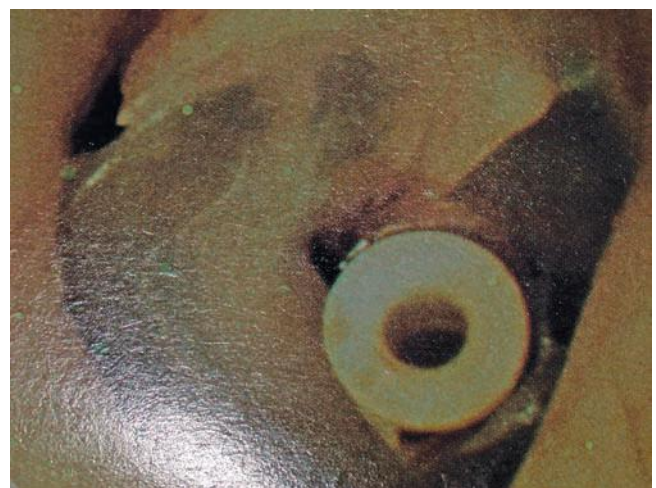


Figure 18-2. Myringotomy and tube.

fluid and middle ear ventilation. These perforations will heal spontaneously after the infection has resolved in the majority of cases. Chronic otitis media, however, may be associated with nonhealing tympanic membrane perforations. Patients may have persistent otorrhea, which is treated with topical drops. Preparations containing aminoglycoside are avoided, because this class of drugs is toxic to the inner ear. Solutions containing alcohol or acetic acid may be irritative or caustic to the middle ear, and are also avoided in the setting of a perforation.

Nonhealing perforation requires surgical closure (tympanoplasty) after medical treatment of any residual acute infection. Chronic inflammation may also be associated with erosion of the ossicular chain, which can be reconstructed with various prostheses or autologous ossicular replacement techniques. Cholesteatoma is an epidermoid cyst of the middle ear and/or mastoid, which causes bone destruction secondary to its expansile nature and through enzymatic destruction. Cholesteatoma develops as a consequence of Eustachian tube dysfunction and chronic otitis media secondary to retraction of squamous elements of the tympanic membrane into the middle ear space. Squamous epithelium may also migrate into the middle ear via a perforation. Chronic mastoiditis that fails medical management or is associated with cholesteatoma is treated by mastoidectomy.

Complications of otitis media may be grouped into two categories: intratemporal (otologic) and intracranial.⁴ Fortunately, complications are rare in the antibiotic era, but mounting antibiotic resistance necessitates an increased awareness of these conditions. Intratemporal complications include acute coalescent mastoiditis, petrositis, facial nerve paralysis, and labyrinthitis. In acute coalescing mastoiditis, destruction of the bony lamellae by an acute purulent process results in severe pain, fever, and swelling behind the ear. The mastoid air cells coalesce into one common space filled with pus. Mastoid infection may also spread to the petrous apex, causing retro-orbital pain and sixth-nerve palsy. These diagnoses are confirmed by computed tomographic (CT) scan.

Facial nerve paralysis may also occur secondary to an acute inflammatory process in the middle ear or mastoid.⁵ Intratemporal complications are managed by myringotomy tube placement in addition to appropriate IV antibiotics. In acute coalescent mastoiditis, and petrositis, mastoidectomy is also performed as necessary to drain purulent foci. Labyrinthitis refers to inflammation of the inner ear. Most cases are idiopathic or are secondary to viral infections of the endolymphatic space. The patient experiences vertigo with sensorineural hearing loss and symptoms may smolder over several weeks. Labyrinthitis associated with middle ear infection may be serous or suppurative. In the former case, bacterial products and/or inflammatory mediators transudate into the inner ear via the round window membrane, establishing an inflammatory process therein. Total recovery is eventually possible after the middle ear is adequately treated. Suppurative labyrinthitis, however, is a much more toxic condition in which the acute purulent bacterial infection extends into the inner ear and causes marked destruction of the sensory hair cells and neurons of the eighth-nerve ganglion. This condition may hallmark impending meningitis and must be treated rapidly. The goal of management of inner ear infection, which occurs secondary to middle ear infection, is to “sterilize” the middle ear space with antibiotics and the placement of a myringotomy tube.

Meningitis is the most common intracranial complication. Otologic meningitis in children is most commonly associated with a *H. influenzae* type B infection. Other intracranial

complications include epidural abscess, subdural abscess, brain abscess, otitic hydrocephalus (pseudotumor), and sigmoid sinus thrombophlebitis. In these cases, the otogenic source must be urgently treated with antibiotics and myringotomy tube placement. Mastoidectomy and neurosurgical consultation may be necessary.

Bell’s palsy, or idiopathic facial paralysis, may be considered within the spectrum of otologic disease given the facial nerve’s course through the temporal bone. This entity is the most common etiology of facial nerve paralysis and is clinically distinct from that occurring as a complication of otitis media in that the otologic exam is normal. Historically, Bell’s palsy was synonymous with “idiopathic” facial paralysis. It is now accepted, however, that the majority of these cases represent a viral neuropathy caused by herpes simplex. Treatment includes oral steroids plus antiviral therapy (i.e., valacyclovir). Complete recovery is the norm, but does not occur universally, and selected cases may benefit from surgical decompression of the nerve within its bony canal. Electrophysiologic testing has been used to identify those patients in whom surgery might be indicated.⁶ The procedure involves decompression of the nerve via exposure in the mastoid and middle cranial fossa. Varicella zoster virus may also cause facial nerve paralysis when the virus reactivates from dormancy in the nerve. This condition, known as *Ramsay Hunt syndrome*, is characterized by severe otalgia followed by the eruption of vesicles of the external ear. Treatment is similar to Bell’s palsy, but full recovery is only seen in approximately two-thirds of cases.

Traumatic facial nerve injuries may occur secondary to accidental trauma or surgical injury. Iatrogenic facial nerve trauma most often occurs during mastoidectomy.⁷ When the facial nerve is injured during an operative procedure, it is explored. Injury to >50% of the neural diameter of the facial nerve is addressed either with primary re-anastomosis or reconstructed with the use of a nerve graft. Complete recovery of nerve function is uncommon in these cases.

Sinus Inflammatory Disease

Sinusitis is a clinical diagnosis based on patient signs and symptoms.⁸ The Task Force on Rhinosinusitis (sponsored by the American Academy of Otolaryngology–Head and Neck Surgery) has established criteria to define “a history consistent with sinusitis.” To establish the diagnosis a patient must exhibit at least two major factors or one major and two minor factors. The classification of sinusitis as acute vs. subacute or chronic is primarily based on the time course over which those criteria have been met. If signs and symptoms are present for at least 7 to 10 days, but for less than 4 weeks, the process is designated acute sinusitis. Subacute sinusitis is present for 4 to 12 weeks and chronic sinusitis is diagnosed when the patient has had signs and symptoms for at least 12 weeks. In addition, the diagnosis of chronic sinusitis requires some objective demonstration of mucosal inflammatory disease. This may be accomplished by endoscopic or radiologic examination (i.e., CT scan).

Acute sinusitis typically follows a viral upper respiratory infection whereby sinonasal mucosal inflammation results in closure of the sinus ostium. This results in stasis of secretions, tissue hypoxia, and ciliary dysfunction. These conditions promote bacterial proliferation and acute inflammation. The mainstay of treatment is the use of antibiotics that are empirically directed toward the three most common organisms *S. pneumoniae*, *H. influenzae*, and *M. catarrhalis*. As with otitis media, antibiotic

resistance is a mounting concern. Nosocomial acute sinusitis frequently involves *Pseudomonas* or *S. aureus*, both of which may also exhibit significant antibiotic resistance. Other treatments include topical and systemic decongestants, nasal saline spray, topical nasal steroids, and oral steroids in selected cases. In the acute setting, surgery is reserved for complications or pending complications, which may include extension to the eye (orbital cellulitis or abscess) or the intracranial space (meningitis, intracranial abscess). It should also be noted that, strictly speaking, a viral upper respiratory infection (common cold) is a form of acute sinusitis. The working definition outlined previously, however, attempts to exclude these cases by requiring that symptoms be present for at least 7 to 10 days, by which time the common cold should be in a resolution phase. Use of this working definition strives to avoid unnecessary antibiotic prescriptions and further promotion of resistance.

Chronic sinusitis represents a heterogeneous group of patients with multifactorial etiologies contributing to ostial obstruction, ciliary dysfunction, and inflammation. Components of genetic predisposition, allergy, anatomic obstruction, bacteria, fungi, and environmental factors play various roles, depending on the individual patient.⁸ Diagnosis is suspected with clinical signs and symptoms persisting for at least 12 weeks. Chronic sinusitis may also be associated with the presence of nasal polyps, particularly when there is heavy eosinophilic inflammation. Mucosal inflammation in nonpolypoid chronic sinusitis is predominantly mediated by neutrophils, or is mixed in nature.

Nasal endoscopy is a critical element of the diagnosis of chronic sinusitis. Anatomic abnormalities, such as septal deviation, nasal polyps, and purulence may be observed (Fig. 18-3 and 18-4). The finding of purulence or polypoid change by nasal endoscopy is supportive of the diagnosis of chronic sinusitis, if symptoms persist for at least 12 weeks. In this setting, purulence may represent an acute exacerbation of chronic sinusitis. Pus found on endoscopic exam may be cultured, and subsequent antibiotic therapy can be directed accordingly. Further, the spectrum of bacteria found in chronic sinusitis is highly variable and includes higher prevalence of polymicrobial infections and antibiotic-resistant organisms. Overall, *S. aureus*, coagulase-negative staphylococci, gram-negative bacilli, and streptococci are isolated, in addition to the typical pathogens of acute

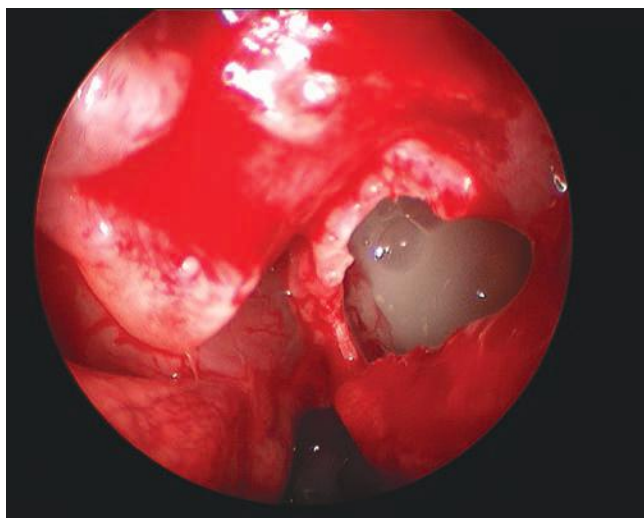


Figure 18-3. Endoscopic view of purulence within a surgically opened maxillary sinus cavity.

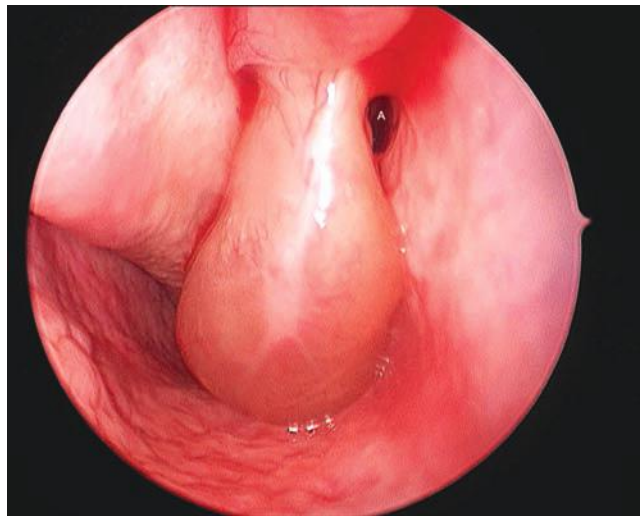


Figure 18-4. Endoscopic image of a nasal polyp.

sinusitis. Thus, the increased prevalence of community acquired methicillin resistant *S. aureus* is a mounting concern.⁹

The diagnosis of chronic sinusitis can be confirmed by CT scan, which demonstrates mucosal thickening and/or sinus opacification. It should be underscored, however, that CT scan is not the positive gold standard because many asymptomatic patients will demonstrate findings on a sinus CT scan, and many patients with presumed sinusitis will have negative findings. CT scan has excellent negative predictive value when performed in the setting of active symptoms. Thus, if a patient complains of sinusitis-like symptoms but has no specific physical (endoscopic) findings, and the scan is negative, other diagnoses (e.g., allergies, migraines, tension headaches) should be sought. This has led to the utility of point-of-care CT (POC-CT) scan that can be performed in the physician's office. POC-CT utilizes cone beam technology¹⁰, which acquires the equivalent of >100 axial slices in approximately 1 minute at an effective resolution of 0.3 mm or less. The equipment occupies a room of 8' × 10' and can thus be accommodated in almost any office setting (Fig. 18-5). Perhaps most important, the radiation dosing for

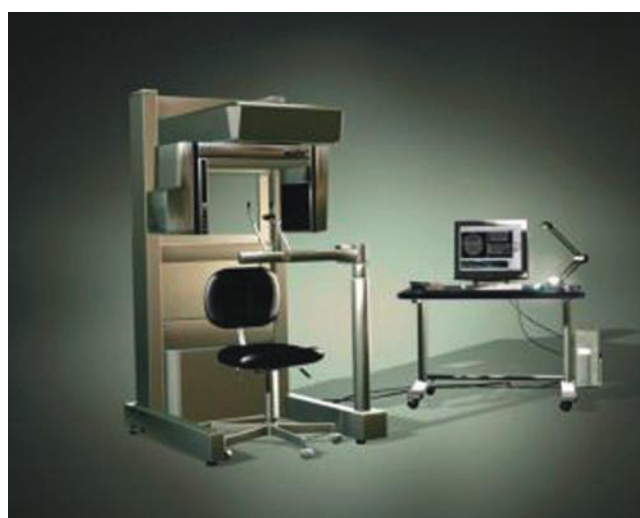

Figure 18-5. POC-CT system. All components can be fit within an 8' × 10' room in an outpatient office setting.

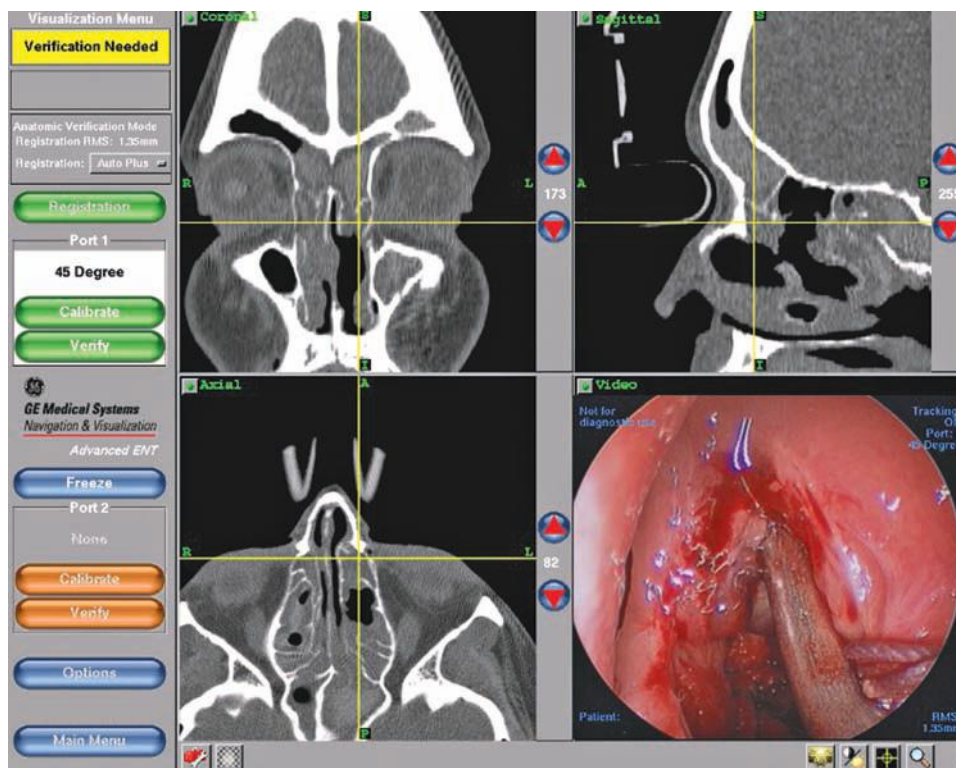


Figure 18-6. Triplanar imaging revealing proximity to critical structures such as the orbital wall and skull base. This can be used for diagnosis of sinus opacification as well as stereotactic intraoperative navigation, where endoscope view (lower right) can be radiologically correlated with location in the 3 cardinal planes. This case reflects classic allergic fungal sinusitis where the opacified sinuses are filled with heterogeneous whitish material on CT images. Polyps in the ethmoid cavity are seen on the endoscope image.

even the most sophisticated protocol is 0.17 mSv, which is <10% the dose of a conventional head CT and equivalent to approximately 20 days of background radiation. One theoretical shortcoming of this technology is that it does not permit soft tissue imaging. This is seldom a concern in sinonasal evaluation, as this is typically undertaken in bone windows. The acquired data are immediately formatted into triplanar (axial, sagittal, coronal) reconstructions and is also compatible with devices used for intraoperative stereotactic navigation, which can be used to confirm relationships between the disease process, medial orbital wall, and skull base during surgery (Fig. 18-6 and 18-7). Variations of this and other technologies have also been adapted for intraoperative use to ensure completeness of resection and to update anatomic relationships for further intraoperative stereotaxis. Notably, imaging of the temporal bone for evaluation of middle ear structures can be performed via POC-CT as well.

Medical management of chronic sinusitis includes a prolonged course of oral antibiotics for 3 to 6 weeks, nasal and/or oral steroids, and nasal irrigations with saline or antibiotic solutions.⁸ Underlying allergic disease may be managed with antihistamines and possible allergy immunotherapy. Although the role of these treatments in resolving chronic sinusitis remains questionable, they may be considered in patients with comorbid allergic rhinitis or as part of empirical management before consideration of surgery. The use of oral steroids may also be selected empirically, particularly in patients with comorbid chronic airway inflammatory diseases such as nasal polyps, allergic rhinitis, or asthma. The decision to use oral steroids must be individualized with consideration of the risks and side effects of these medications. As yet, there is no consensus

regarding what constitutes a “maximum” course of medical therapy that should be attempted before consideration of surgery for chronic sinusitis. It should be noted that unless there is suspicion of neoplasm or pending complication of sinusitis, the decision to proceed with surgery is highly individualized. This is because surgery for uncomplicated chronic sinusitis is elective, and patients who “fail” medical management will exhibit significant variability in symptoms, physical signs, and CT findings. More aggressive medical and surgical management may be necessary in patients with comorbid chronic inflammatory disease of the airways such as allergic rhinitis, nasal polyposis, and asthma. Surgery is typically performed endoscopically where the goals are to remove polyps, enlarge the natural sinus ostia (see Fig. 18-3), and to remove chronically infected bone to promote both ventilation and drainage of the sinus cavities. Inspissated mucin or pus is drained and cultured. Eventual resolution of the chronic inflammatory process can be attained with a combination of meticulous surgery and directed medical therapy, although the patient must understand that surgery may not alter the underlying immunologic pathophysiology. In cases where resection of inflammatory tissue and polyps are not required, recent trends have also included use of angioplasty-type balloons to dilate sinus ostia. The exact role for this technology is unclear, but appears to have promise in outpatient office management of patients with focal or limited obstructive pathology.

The role of fungi in sinusitis is an area of active investigation. Fungal sinusitis may take on both noninvasive and invasive forms. The noninvasive forms include intracavitary fungal ball and allergic fungal sinusitis, both of which occur in immunocompetent patients. A fungal ball is typically seen in individuals with chronic (or recurrent acute) symptoms that are often

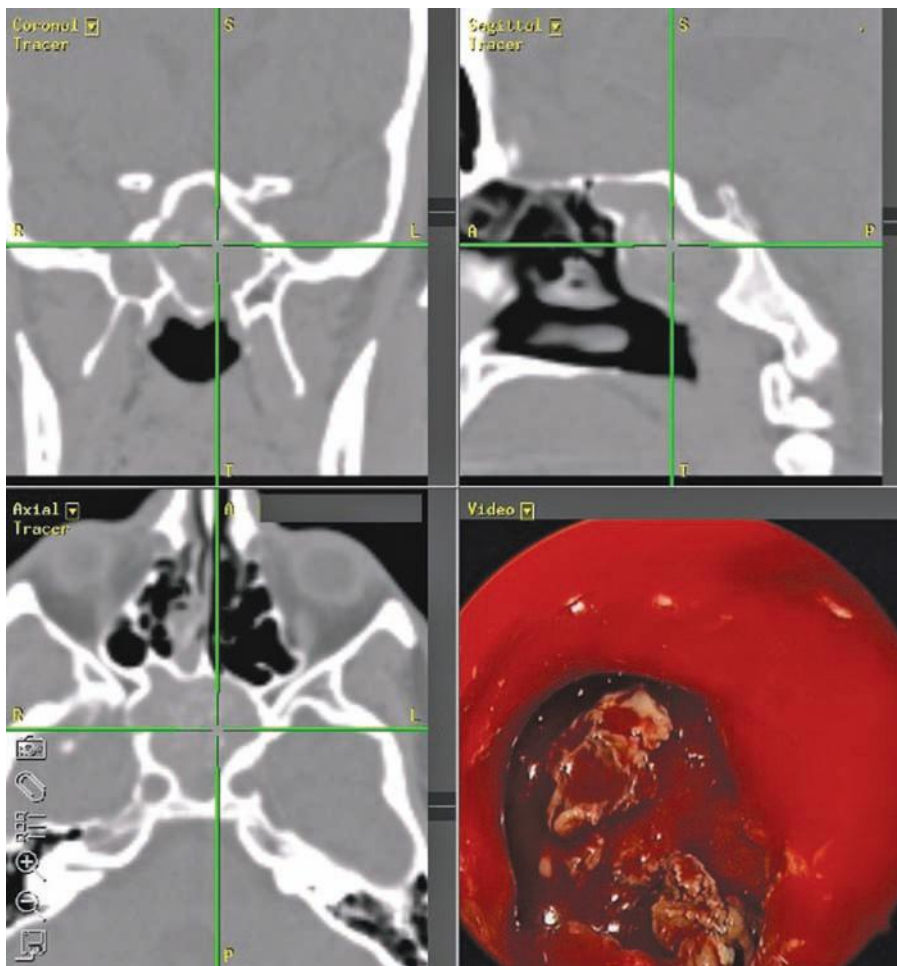


Figure 18-7. Sphenoid sinus fungal ball. The sinus has been opened revealing cheesy material during this intraoperative endoscopic view (lower right). The crosshairs stereotactically confirm location within the sphenoid sinus radiologically in the cardinal planes.

subtle and limited to a single sinus. Patients may complain about the perception of a foul odor and occasionally report expelling crusty debris upon nose blowing. Fungus balls represent a significant proportion of isolated sphenoid sinus pathology (Fig. 18-7). The most common scenario, however, is surgery to remove the debris and re-establish sinus ventilation, which is almost always curative.

Classic allergic fungal sinusitis is thought to involve direct stimulation of eosinophils by a subset of helper T cells (T_H2) primed by fungal antigens. Patients often present with chronic sinusitis that has been especially refractory to medical management. CT scan has characteristic features, and endoscopic evaluation reveals florid polyposis and inspissated mucin containing fungal debris and products of eosinophil breakdown. The implicated organisms are usually those of the Dematiaceae family, but *Aspergillus* species are also seen.¹¹ Treatment includes systemic steroids, surgery, and nasal irrigations. Oral antifungal therapy is sometimes indicated as well.

Immunocompetent patients may occasionally develop an indolent form of invasive fungal sinusitis, but more commonly, invasive fungal sinusitis affects immunocompromised patients, diabetics, or the elderly.¹¹ Fungal invasion of the microvasculature causes ischemic necrosis and black eschar of the sino-nasal mucosa. *Aspergillus* and fungi of the Mucoraceae family are often implicated with the latter more common in diabetic patients. Treatment requires aggressive surgical debridement and IV antifungals, but the prognosis is dismal.¹²

Pharyngeal and Adenotonsillar Disease

The pharyngeal mucosa contains significant concentrations of lymphoid tissue, predisposing this area to reactive inflammatory changes. Lymphoid tissue of various pharyngeal subsites forms the so-called *Waldeyer's ring*, consisting of the palatine tonsils (“the tonsils”), lingual tonsil (lymphoid tissue accumulation within the tongue base), and adenoid. The mucosa of the posterior and lateral pharyngeal walls is also rich with lymphoid cells. Infection, immune-mediated inflammatory disease, or local stressors, such as radiation or acid reflux, may initiate lymphoid reactivity and associated symptoms. Chronic or recurrent adenotonsillitis and adenotonsillar hypertrophy are the most common disorders affecting these structures.

In the vast majority of cases, infectious pharyngitis is viral rather than bacterial in origin. Most cases resolve without complication from supportive care and possibly antibiotics. Patients with tonsillitis typically present with sore throat, dysphagia, and fever. The mucosa is inflamed. Tonsillar exudates and cervical adenitis may be seen, especially when the etiology is bacterial. If adenoiditis is present, symptoms may be similar to those of sinusitis. Objective evaluation of the adenoid requires endoscopy and/or radiographic imaging (lateral neck soft-tissue X-ray). Tonsillitis and adenoiditis may follow acute, recurrent acute, and chronic temporal patterns.

It should be noted, however, that clinical diagnosis often is inaccurate for determining whether the process is bacterially induced. When the patient also has hoarseness, rhinorrhea,

cough, and no evidence of exudates or adenitis, an upper respiratory viral infection can be presumed. When a bacterial cause is suspected antibiotics should be initiated to cover the usual organisms: group A beta-hemolytic streptococci (*Streptococcus pyogenes*), *S. pneumoniae*, and group C and G streptococci.¹³ *H. influenzae* and anaerobes also have been implicated. It is particularly important to identify group A beta-hemolytic streptococci in pediatric patients to initiate timely antibiotic therapy, given the risk of rheumatic fever, which may occur in up to 3% of cases if antibiotics are not used. Historically, if bacterial pharyngitis was suspected in a child, oropharyngeal swab with culture was performed to identify group A beta-hemolytic streptococci. Currently, rapid antigen assays are available with sensitivity and specificity of approximately 85% and 90%, respectively. Some experts advocate culture only when these are negative. Unnecessary antibiotic therapy for patients who are unlikely to have a bacterial etiology should be avoided, given the already mounting antibiotic resistance problem. When suspicion for a bacterial process is high, or with positive culture/antigen assay results, treatment may include penicillin, cephalosporin, or macrolide antibiotics in penicillin-allergic patients.

Complications of *S. pyogenes* pharyngitis may be systemic, including rheumatic fever, poststreptococcal glomerulonephritis, and scarlet fever. The incidence of glomerulonephritis is not influenced by antibiotic therapy. Scarlet fever results from production of erythrogenic toxins by streptococci. This causes a punctate rash, first appearing on the trunk and then spreading distally, sparing the palms and soles. The so-called *strawberry tongue* also is seen. Locoregional complications include peritonsillar abscess and, rarely, deep-neck space abscess. Peritonsillar abscess is typically drained with transoral technique under local anesthesia, as is the authors' practice, but some suggest that needle aspiration without incision is sufficient.¹³ Deep neck space abscess, which more commonly is odontogenic in origin, usually requires operative incision and drainage via a transcervical approach.

Candida albicans is the most common fungal organism to cause pharyngitis. This organism is a normal component of the oral flora, but under conditions of immunosuppression, broad-spectrum antibacterial therapy, poor oral hygiene, or vitamin deficiency, it may become pathogenic. Whitish-cheesy or creamy mucosal patches are observed with underlying erythema. Diagnosis is easily established by Gram's stain of this material, revealing budding yeast and pseudohyphae. Oral (-azole) and topical (nystatin) antifungals are usually effective, and immunosuppressed patients may require prophylactic therapy.

Atypical cases of pharyngitis may be caused by *Corynebacterium diphtheriae*, *Bordetella pertussis* (whooping cough), *Neisseria gonorrhoeae*, and secondary syphilis. Diphtheria and pertussis are fortunately rare in developed countries as a result of pediatric vaccination. Atypical viral causes include herpes simplex virus, Epstein-Barr virus (EBV), cytomegalovirus, and HIV are associated with pharyngitis. Systemic EBV infection represents clinical mononucleosis, although syphilis, cytomegalovirus, and HIV are known to cause mononucleosis-like syndromes. These conditions, particularly EBV, may exhibit an exudative pharyngotonsillitis that may be confused with a bacterial etiology. Progression of the clinical picture reveals lymphadenopathy, splenomegaly, and hepatitis. Diagnosis is established based on the detection of heterophile antibodies or atypical lymphocytes in the peripheral blood.

Occasionally, pharyngeal biopsy specimen or cervical lymph node biopsy specimen is required to establish the diagnosis.

Noninfectious causes of pharyngitis must also be considered. These include mucositis from chemoradiation therapy, which may be associated with fungal superinfection. Pharyngitis may also be seen in immune-mediated conditions such as erythema multiforme, bullous pemphigoid, and pemphigus vulgaris. In addition, reflux is being increasingly identified as a cause of both laryngitis and pharyngitis, particularly when the symptoms are chronic. A 24-hour pH probe is the gold standard diagnostic test, and treatment is usually successful with lifestyle modification, although proton pump inhibitors are often prescribed.¹⁴

Obstructive adenotonsillar hypertrophy may present with nasal obstruction, rhinorrhea, voice changes, dysphagia, and sleep-disordered breathing or OSA depending on the particular foci of lymphoid tissue involved.

Tonsillectomy and adenoidectomy are indicated for chronic or recurrent acute infection and for obstructive hypertrophy.¹⁵ The American Academy of Otolaryngology–Head and Neck Surgery Clinical Indicators Compendium suggests tonsillectomy after three or more infections per year despite adequate medical therapy. Tonsillectomy has also been advocated in children who miss 2 or more weeks of school annually secondary to recurrent tonsil infection. Multiple techniques have been described, including electrocautery, sharp dissection, laser, and radiofrequency ablation. There is no consensus as to the best method. In cases of chronic or recurrent infection, surgery is considered only after failure of medical therapy. Patients with recurrent peritonsillar abscess should undergo tonsillectomy when the acute inflammatory changes have resolved. Selected cases, however, require tonsillectomy in the acute setting for the management of severe inflammation, systemic toxicity, or impending airway compromise. Adenoidectomy, in conjunction with myringotomy and tube placement, may be beneficial for children with chronic or recurrent otitis media.¹⁶ This is because the adenoid appears to function as a bacterial reservoir that seeds the middle ear via the Eustachian tube. Adenoidectomy is also the first line of surgical management for children with chronic sinusitis. In addition to acting as a bacterial reservoir, an obstructive adenoid impairs mucociliary clearance from the sinonasal tract into the pharynx.

The primary complications of tonsillectomy include perioperative bleeding, airway obstruction, death, and readmission for dehydration secondary to postoperative dysphagia.¹⁷ Complications of adenoidectomy also include hemorrhage, as well as nasopharyngeal stenosis. In both procedures, there is risk of velopharyngeal insufficiency. In the latter condition, nasal regurgitation of liquids and hypernasal speech are experienced. Patients with significant airway obstruction secondary to adenotonsillar hypertrophy are also at risk for postobstructive pulmonary edema syndrome, once the obstruction is relieved by adenotonsillectomy. Overall, bleeding is the most prevalent risk and may require a return trip to the operating room for control. With the exception of bleeding, which is observed in 3% to 5% of patients, most of these complications are rare or self-limiting. It deserves special notation that adenotonsillectomy in a child with Down syndrome requires attention to the cervical spine. Patients with this syndrome may exhibit atlantoaxial instability, resulting in cervical spine injury if the neck is extended for the procedure. Baseline radiographs, with appropriate orthopedic or neurosurgical consultation, are indicated preoperatively.

Sleep disorders represent a continuum from simple snoring to upper airway resistance syndrome to obstructive sleep apnea (OSA).¹⁸ Upper airway resistance syndrome and OSA are associated with snoring, excessive daytime somnolence, fatigue, and frequent sleep arousals. In OSA, polysomnogram demonstrates at least 10 episodes of apnea or hypopnea per hour of sleep. The average number of apneas and hypopneas per hour can be used to calculate a respiratory disturbance index, which, along with oxygen saturation, can be used to grade the severity of OSA. These episodes occur as a result of collapse of the pharyngeal soft tissues during sleep. In adults, it should be noted that in addition to tonsil size, factors such as tongue size and body mass index (especially $>35 \text{ kg/m}^2$) are significant predictors of OSA. Other anatomic findings associated with OSA include obese neck, retrognathia, low hyoid bone, and enlarged soft palate. Surgery should be considered after failure of more conservative measures, such as weight loss, elimination of alcohol use, use of oral appliances to open the airway during sleep, and continuous positive airway pressure (CPAP). Recent trends have also included the use of oral appliances to prevent base of tongue retro-prolapsed and subsequent narrowing of the pharyngeal airway during sleep. Oral appliances are useful to avert simple snoring and mild OSA, but their role in more advanced cases is unclear. It is well accepted that CPAP is much more efficacious than an oral appliance, while the latter is associated with improved patient compliance. Those failing conservative therapies may elect a surgical procedure should be tailored to the particular patient's pattern of obstruction. In children, surgical management typically involves tonsillectomy and/or adenoidectomy, because the disorder is usually caused, at least in part, by hypertrophy or collapse of these structures. In any individual patient, the anatomy must be carefully evaluated to determine whether the site of airway collapse is in the retropalatal region, retrolingual area, or both. In adults, uvulopalatoplasty is frequently performed to alleviate soft-palate collapse and is the most common operation performed for sleep-disordered breathing. The goal of this procedure is to remove redundant tissue from the uvula and soft palate, along with obstructive tonsillar tissue. This can be accomplished with cold steel, laser, and/or cautery. Adults with significant nasal obstruction may benefit from adenoidectomy, septoplasty, reduction in size of the inferior turbinates, and possibly external nasal surgery. Patients with a significant component of retrolingual obstruction may be candidates for tongue base reduction, tongue base advancement, or hyoid suspension. Additionally, a variety of maxillomandibular advancement procedures also have been described to enlarge the anterior-posterior dimension of the retrolingual airway. Patients with moderate to severe sleep apnea frequently manifest involvement of the tongue base. However, management of this subgroup may be difficult, as procedures addressing the retrolingual airway can involve difficult recovery, significant morbidity, and limited success. These patients often continue to require continuous positive airway pressure despite performance of multilevel surgical procedures. Patients with severe OSA (respiratory disturbance index >40 , lowest nocturnal oxygen saturation $<70\%$) and unfavorable anatomy or comorbid cardiopulmonary disease may require tracheotomy,¹⁹ which is the only surgical "cure" for OSA. Tracheotomy should be offered in patients with evidence of right heart failure (cor pulmonale), which is a potential sequela of severe OSA or undertreated cases of moderate OSA.

On the opposite end of the spectrum, many patients present with snoring but fail to exhibit OSA according to polysomnographic criteria. These "social snorers" may pursue elective procedures that stiffen the uvula and soft palate. This may be accomplished by the application of radiofrequency energy or cautery to induce submucosal scar, or by palatal implants. Elective uvulopharyngoplasty may also be a consideration in this population.

Benign Conditions of the Larynx

Disorders of voice may affect a wide array of patients with respect to age, gender, and socioeconomic status. The principal symptom of these disorders, at least when a mass lesion is present, is hoarseness. Other vocal manifestations include hypophonia or aphonia, breathiness, and pitch breaks. Benign laryngeal disorders may also be associated with airway obstruction, dysphagia, and reflux.²⁰ Smoking may also be a risk factor for benign disease, but this element of the history should raise the index of suspicion for malignancy.

Recurrent respiratory papillomatosis (RRP) reflects involvement of human papillomavirus (HPV) within the mucosal epithelium of the upper aerodigestive tract. The larynx is the most frequently involved site, and subtypes 6 and 11 are the most often implicated. The disorder typically presents in early childhood, secondary to viral acquisition during vaginal delivery. Many cases resolve after puberty, but the disorder may progress into adulthood. Adult-onset RRP typically occurs in the third or fourth decade of life, is usually less severe, and is more likely to involve extralaryngeal sites of the upper aerodigestive tract. With laryngeal involvement, RRP is most likely to present with hoarseness, although airway compromise may be observed. The diagnosis can be established with office endoscopy. Currently, there is no "cure" for RRP. Treatment involves operative microlaryngoscopy with excision or laser ablation, and the natural history is eventual recurrence. Therefore, surgery has an ongoing role for palliation of the disease. Multiple procedures are typically required over the patient's lifetime. Several medical therapies, including intralésional cidofovir injection and oral indole-3-carbinol, are being investigated to determine their abilities to retard recurrence. Additionally, the advent of HPV vaccines has suggested a role for this therapy in prevention of RRP.²¹

Laryngeal granulomas typically occur in the posterior larynx on the arytenoid mucosa (Fig. 18-8). These lesions are

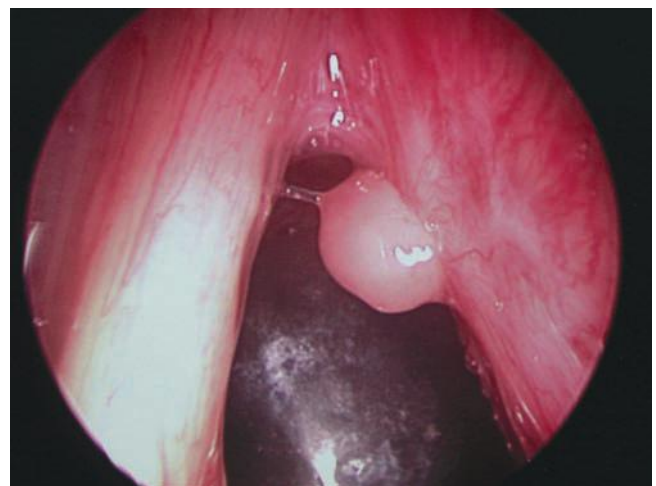


Figure 18-8. Laryngeal granuloma.

typically secondary to multiple factors,²² including reflux, voice abuse, chronic throat clearing, endotracheal intubation, and vocal fold paralysis. Effective management requires identification of the underlying cause(s). Patients report pain (often with swallowing) more commonly than vocal changes. In addition to fiber-optic laryngoscopy, work-up may include voice analysis, laryngeal electromyography (EMG), and pH probe testing.²³ Treatment is individualized, depending on the contributing factors identified. First-line modalities that may be used include voice rest, voice retraining therapy, and anti-reflux therapy. The management of vocal cord paresis/paralysis is discussed later in this section. It is notable that the majority of cases demonstrate a component of reflux and when maximal medical therapy has failed, fundoplication may be indicated. The role of surgical excision is somewhat controversial, because it does not address the underlying etiology and is frequently associated with recurrence. Nonetheless, excision is indicated when carcinoma is suspected or when the patient has airway obstruction. Surgery may also be indicated in selected cases when a granuloma has matured into a fibroepithelial polyp, or when the patient (e.g., a performing artist) requires prompt removal for voice restoration. Surgical excision is optimally performed under jet ventilation so as to avoid endotracheal intubation. During surgery, it is important to preserve the arytenoid perichondrium to promote epithelialization postoperatively.

Edema in the superficial lamina propria of the vocal cord is known as *polypoid corditis*, *polypoid laryngitis*, *polypoid degeneration of the vocal cord*, or *Reinke's edema*. The superficial lamina propria just underlies the vibratory epithelial surface. Edema is thought to arise from injury to the capillaries that exist in this layer, with subsequent extravasation of fluid. Patients report progressive development of a rough, low-pitched voice. Females more commonly present for medical attention because the lowered vocal frequency is more evident, given the higher fundamental frequency of the female voice. The etiology is also multifactorial and may involve smoking, laryngopharyngeal reflux, hypothyroidism, and vocal hyperfunction. Most of these patients are heavy smokers and findings are typically bilateral.²⁴

Focal, unilateral hemorrhagic vocal cord polyps are more common in men. These occur secondary to capillary rupture within the mucosa by shearing forces during voice abuse. Use of anticoagulant or antiplatelet drugs may be a risk factor. As with laryngeal granulomas, treatment of polypoid corditis and vocal cord polyps requires addressing the underlying factors. Conservative management includes absolute discontinuance of smoking, reflux management, and voice therapy. Notably, topical and systemic steroids are ineffective for these conditions. For polypoid corditis, elective surgery may be performed under microlaryngoscopy to evacuate the gelatinous matrix within the superficial lamina propria and trim excess mucosa. Focal polyps may be excised superficially under microlaryngoscopy. Surgery, particularly for polypoid corditis, will be less effective in patients who continue to smoke, although it should be noted that because of their heavy smoking history, surgery might be necessary to rule out occult malignancy. Surgery for polypoid corditis and hemorrhagic polyps may be accomplished either with cold steel or by using the carbon dioxide (CO₂) laser. Postoperative voice therapy is usually indicated.

Vocal cord cysts may occur under the laryngeal mucosa, particularly in regions containing mucous-secreting glands, such

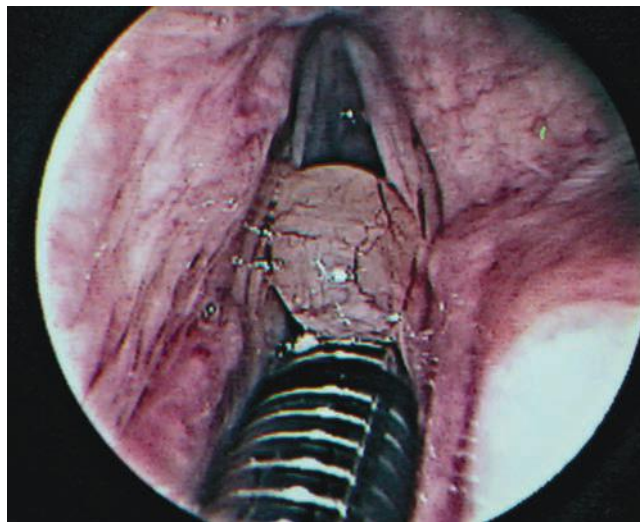


Figure 18-9. Large cyst of vocal cord.

as the supraglottic larynx. Occasionally, they derive from minor salivary glands, and congenital cysts may persist as remnants of the branchial arch. Cysts may present in a variety of ways depending on the size and site of origin (Fig. 18-9). Cysts of the vocal cord may be difficult to distinguish from vocal polyps, and video stroboscopic laryngoscopy may be necessary to help establish the diagnosis. Cysts observed in children can be quite large, thus compromising the airway. Lesions of the true vocal cord usually present with hoarseness. Treatment again depends on the size and site of the cyst. Large cysts of the supraglottic larynx are treated by marsupialization with cold steel or a CO₂ laser. Those of the vocal cord itself require careful microsurgical technique for complete removal of the cyst while preserving the overlying mucosa.

Leukoplakia of the vocal fold represents a white patch (which cannot be wiped off) on the mucosal surface, usually on the superior surface of the true vocal cord. Rather than a diagnosis per se, the term *leukoplakia* describes a finding on laryngoscopic examination. The significance of this finding is that it may represent squamous hyperplasia, dysplasia, and/or carcinoma. Lesions exhibiting hyperplasia have a 1% to 3% risk of progression to malignancy. In contrast, that risk is 10% to 30% for those demonstrating dysplasia. Furthermore, leukoplakia may be observed in association with inflammatory and reactive pathologies, including polyps, nodules, cysts, granulomas, and papillomas. The wide, differential diagnosis for leukoplakia necessitates sound clinical judgment when selecting lesions that require operative direct laryngoscopy with biopsy specimen for histopathologic analysis. Features of ulceration and erythroplasia are particularly suggestive of possible malignancy. A history of smoking and alcohol abuse should also prompt a malignancy work-up. In the absence of suspected malignancy, conservative measures are used for 1 month. These include reduction of caffeine and alcohol, which are dehydrating and promote laryngopharyngeal reflux, proper hydration, and elimination of vocal abuse behaviors. Antireflux therapy, including proton pump inhibitors, may be prescribed. Investigational therapies, including retinoids, also have been attempted. Any lesions that progress, persist, or recur should be considered for excisional biopsy specimen.

Unilateral vocal cord paralysis is typically iatrogenic in origin,²⁵ following surgery to the thyroid, parathyroid, carotid, or cardiothoracic structures. Vocal cord paralysis may also be secondary to malignant processes in the lungs, thoracic cavity, skull base, or neck. In the pediatric population up to one fourth of cases may be neurologic in origin, with Arnold-Chiari malformation being the most common. Overall, the left vocal cord is more commonly involved secondary to the longer course of the recurrent laryngeal nerve (RLN) on that side, which extends into the thoracic cavity. When anterior approaches to the cervical spine are performed, however, the right RLN is at an increased risk, because it courses more laterally to the tracheoesophageal complex. Neurotoxic medications, trauma, intubation injury, and atypical infections are less common causes of vocal cord paralysis. The cause remains idiopathic in up to 20% of adults and 35% of children. These cases should prompt an imaging work-up to examine the course of the vagal/RLN in question: from the skull base to the aortic arch on the left, and from skull base to the subclavian on the right.

“Idiopathic” left true vocal cord paralysis may be a presenting sign of malignancy involving the lung, thyroid, or esophagus. Adults typically present with hoarseness and the voice may be breathy if the contralateral vocal cord has not compensated to close the glottic valve. If the proximal vagus nerve or the superior laryngeal nerve is involved, the patient may demonstrate aspiration secondary to diminished supraglottic sensation. Stridor, weak cry, and respiratory distress are seen in children, but adults typically do not exhibit signs of airway compromise unless paralysis is bilateral. Flexible fiber-optic laryngoscopy usually confirms the diagnosis, but laryngeal EMG may be necessary to distinguish vocal cord paralysis from mechanical fixation secondary to scar tissue or cricoarytenoid joint fixation. The position of the paralyzed fold depends on the residual innervation, pattern of reinnervation, and the degrees of atrophy and fibrosis of the laryngeal musculature. In bilateral vocal cord paralysis, the cords are often paralyzed in a paramedian position, creating airway compromise that necessitates tracheotomy. Once an airway is secure, vocal cord lateralization or arytenoidectomy may be performed electively to provide an adequate airway. Treatment of unilateral vocal cord paralysis includes speech therapy, which promotes glottic closure to optimize the voice and prevent aspiration. Some patients do well with this modality alone.

Surgical treatment to augment or medialize the paralyzed vocal fold is performed to provide a surface against which the contralateral normal fold may make contact. Injection laryngoplasty may be performed under office or operative laryngoscopy with a variety of autologous (fat, collagen) or alloplastic (hydroxyapatite, hyaluronic acid, micronized cadaveric human collagen) compounds. Teflon injection is of historical significance only secondary to the incidence of severe foreign body inflammatory reactions. Injection of the vocal fold increases its bulk to optimize closure with the contralateral normal fold. This technique also is useful for vocal cord atrophy, which may occur with aging. Laryngeal framework surgery involves the implantation of cartilage, hydroxyapatite, Gore-Tex, or silicone under the musculomembranous fold via an external approach through a window in the thyroid cartilage (Fig. 18-10).²⁶ This may be combined with procedures to adduct the vocal process of the arytenoids. Laryngeal reinnervation (with the ansa cervicalis to the RLN transfer) and pacing have also been attempted with various success.

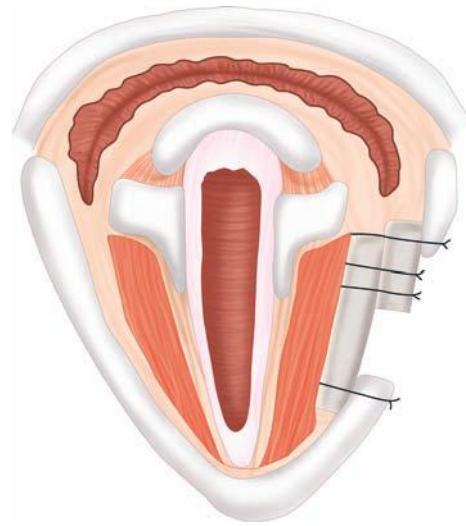


Figure 18-10. Cross-section of the larynx demonstrating the principle of medialization laryngoplasty. An implant is used to push the paralyzed vocal cord toward the midline.

Vascular Lesions

Vascular lesions can be broadly classified into two groups: hemangiomas and vascular malformations.²⁷ Hemangiomas are the most common vascular lesions present in infancy and childhood. These lesions are present at birth in up to 30% of cases, but usually become apparent in the first few weeks of life. The lesions proliferate in size over the first year before beginning involution, which subsequently occurs over the next 2 to 12 years. While 40% of cases will resolve completely, the remainder will require intervention. Once the proliferative phase has ended, the lesion should be observed every 3 months for involution, and surgery should be considered for those that have not significantly involuted by 3 to 4 years of age. Surgical treatment of proliferating hemangiomas is reserved for lesions associated with severe functional or cosmetic problems, such as those involving the nasal tip or periorbital region. Treatment is performed with either the flashlamp-pumped pulsed-dye laser (FPDL), the potassium titanyl phosphate (KTP) laser, or the neodymium yttrium-aluminum garnet (Nd:YAG) laser, repeated every 4 to 6 weeks until the lesion disappears. Systemic steroids may be used to halt rapidly proliferating lesions until the child reaches 12 to 18 months, after which growth should stabilize or involution begin. Subcutaneous interferon- α -2a may also be used for this purpose. This treatment, however, is associated with neurologic side effects and should be used with caution.^{27,28} There have also been recent trends of using propranolol to inhibit hemangioma growth, and this practice is gaining popularity in complicated cases.

Vascular malformations, in contrast, are almost always present at birth and slowly enlarge without proliferation.²⁹ These may arise from capillaries, venules, veins, arteriovenous channels, and/or lymphatics. Capillary malformations usually involve the midline neck or forehead, and may fade with age. Venular malformations are also known as *port-wine stains*. These lesions often follow facial dermatomes and usually thicken with age. Venous malformations are composed of ectatic veins within the lips, tongue, or buccal area. These may present as purple masses or subcutaneous/submucosal nodules. Arteriovenous malformations are rare malformations of arteriovenous channels that failed to regress during development.

Lymphatic malformations or lymphangiomas of the head and neck usually involve the cervical area, in which case they are more commonly macrocystic and well demarcated. Those arising above the hyoid bone tend to be microcystic and have an infiltrative quality. Lymphangiomas may become secondarily infected and may rapidly enlarge, causing airway compromise. These lesions may also be associated with feeding difficulties and failure to thrive.

Capillary hemangiomas and superficial port-wine stains are effectively treated by FPD. The KTP or Nd:YAG laser is used for deeper port-wine stains. Venous malformations may be treated with laser, sclerotherapy, and/or surgical excision, depending on the depth, size, and location. Superficial lesions are treated with the Nd:YAG laser, which has deeper penetration than either the FPD or KTP laser. Deeper venous malformations may benefit from Nd:YAG therapy of the superficial component followed by meticulous surgical excision of the deeper component. Sclerotherapy should be undertaken with extreme caution in the head and neck, because the valveless quality of the veins in this region introduces significant risk of cavernous sinus thrombosis. Arteriovenous malformations require formal surgical resection with negative margins. Preoperative angiographic embolization is frequently used to facilitate surgery. Microvascular reconstruction may be necessary, depending on the extent of the resection required. Surgical excision is also required for lymphatic malformations, although superficial lesions are sometimes treatable with the CO₂ laser. This often is difficult for microcystic cases given the infiltrative nature. Sclerotherapy with OK-432 is effective in macrocystic lymphangiomas, and multiple other sclerosing agents, including bleomycin, have been explored.³⁰

TRAUMA OF THE HEAD AND NECK

Management of head and neck soft-tissue trauma follows general surgical principles, with several salient features. In the acute setting, patients should be managed with head-of-bed elevation to decrease tissue edema. Most lacerations without significant tissue loss can be closed primarily, which is preferred where possible. Head and neck soft tissues have the benefit of a robust blood supply. Thus, nearly devitalized soft tissues often survive, such that any tissue debridement should be very conservative. Closure of trapdoor lacerations requires conservative undermining of surrounding tissue and good approximation of subdermal levels prior to epidermal closure. A pressure dressing is also applied. These measures are employed to avoid a pincushion deformity (Fig. 18-11). Typically, when repairing facial lacerations, subdermal layers are approximated with an absorbable 3-0 or 4-0 suture such as Vicryl or polydioxanone, and the skin is closed using 5-0 or 6-0 monofilament nylon or Prolene. Sutures are removed after 4 to 5 days, but may be removed earlier in thin-skinned areas. Systemic antibiotics are reserved for through-and-through mucosal lacerations, contaminated wounds, bite injuries, and when delayed closure is performed (>72 hours). The chosen antibiotic should cover *S. aureus*. After skin injuries, the patient is instructed to avoid sunlight, because this can cause pigmentary abnormalities in the abrasion or scar line, which matures over a 6- to 12-month period.

Wound closure must be understood in the context of the cosmetic and functional anatomic landmarks of the head and neck. Management of injuries to the eyelid requires identification of the orbicularis oculi, which is closed in a separate layer. The gray line (conjunctival margin; Fig. 18-12) must

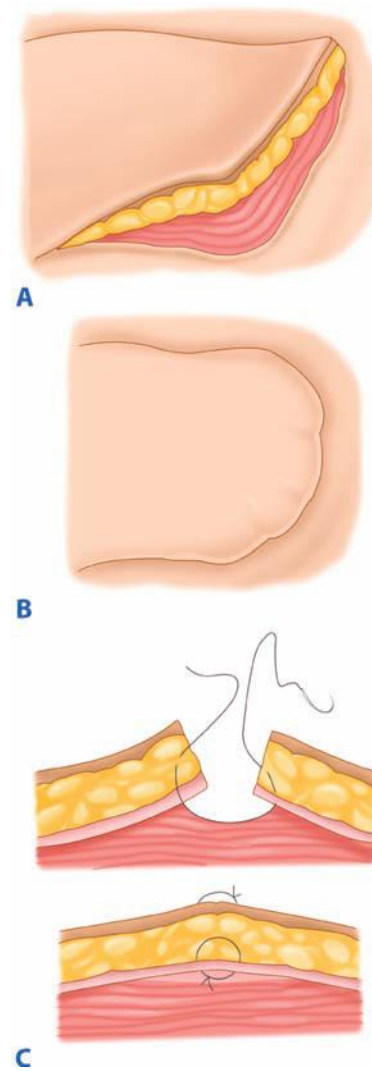


Figure 18-11. Trap door laceration (A) healed with a “pin cushion” deformity (B) soft-tissue layers must be meticulously approximated (C) to avoid this complication.

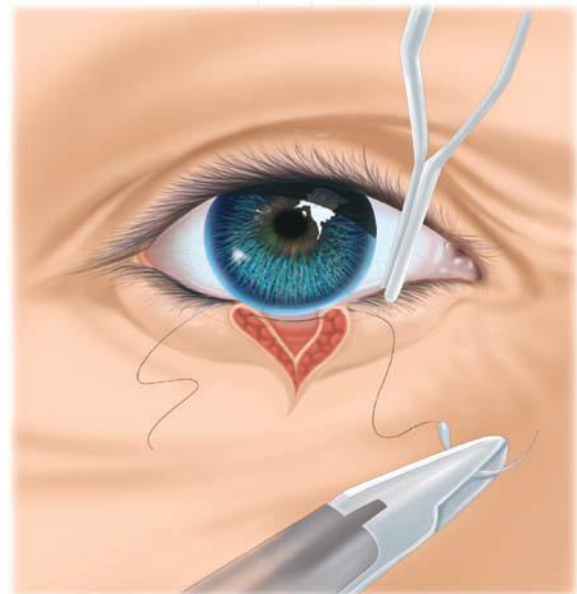

Figure 18-12. Alignment of the gray line is the key step in the repair of eyelid lacerations.

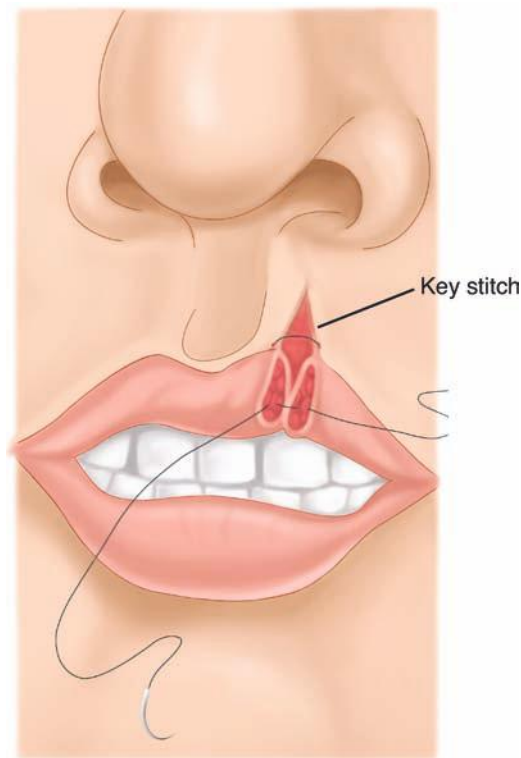


Figure 18-13. Approximation of the vermilion border is the key step in the repair of lip lacerations.

be carefully approximated to avoid lid notching or height mismatch. Management of lip injuries follows the same principle.

2▶ The orbicularis oris must be closed, and the vermilion border carefully approximated (Fig. 18-13). Injuries involving one-fourth the width of the eyelid or one third the width of the lip may be closed primarily; otherwise, flap or grafting procedures may be required. With laceration of the auricle, key structures such as the helical rim and antihelix must be carefully aligned. These injuries must be repaired so that the cartilage is covered. The principles of auricular repair are predicated on the fact that the cartilage has no intrinsic blood supply and is thus susceptible to ischemic necrosis following trauma. The suture should be passed through the perichondrium, while placement through the cartilage itself should be avoided.

Auricular hematomas should be drained promptly, with placement of a bolster as a pressure dressing. A pressure dressing is frequently advocated after closure of an ear laceration. It also deserves note that the surgeon must avoid the temptation to perform aggressive debridement after injuries to the eyelid or auricle. Given the rich vascular supply to the face and neck, many soft-tissue components that appear devitalized will indeed survive.

Most traumatic facial nerve injuries are secondary to temporal bone trauma, which is discussed later in this section. Soft-tissue injuries occurring in the midface may involve distal facial nerve branches. Those injured anterior to a vertical line dropped from the lateral cantus do not require repair secondary to collateral innervation in the anterior midface. Posterior to this line, the nerve should be repaired, primarily if possible, using 8-0 to 10-0 monofilament suture to approximate the epineurium under microscopic visualization. If neural segments are missing, cable

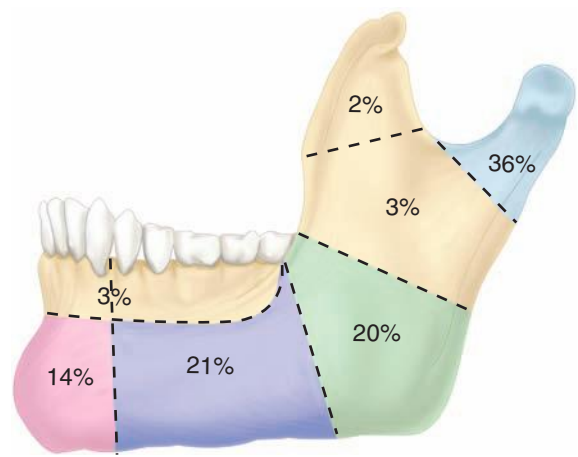


Figure 18-14. Sites of common mandible fractures.

grafting is performed using either the greater auricular (provides 7 to 8 cm) or sural nerve (up to 30 cm) as a donor. Injuries to the buccal branch should alert the examiner to a possible parotid duct injury. This structure lies along an imaginary line drawn from the tragus to the midline upper lip, running along with the buccal branch of the facial nerve. The duct should be repaired over a 22-gauge stent or marsupialized into the oral cavity.

Facial bone fractures most commonly involve the mandible. Fractures most often involve the angle, body, or condyle, and in most cases, two or more sites are almost always involved (Fig. 18-14). Fractures are described as either favorable or unfavorable, depending on whether or not the masticatory musculature tends to pull the fracture into reduction or distraction. Vertically favorable fractures are brought into reduction by the masseter, while horizontally favorable fractures are brought into reduction by the pterygoid musculature. The fracture is usually evaluated by radiographic exam using a Panorex, but specialized plain film views, and occasionally CT scan, are necessary in selected cases. Classical management of mandible fractures dictated closed reduction and a 4- to 6-week period of intermaxillary fixation (IMF) with arch bars applied via circumdental wiring. Comminuted, displaced, or unfavorable fractures underwent open reduction and wire fixation in addition to IMF. Currently, arch bars and IMF are performed to establish occlusion. The fracture is then exposed and reduced, using transoral approaches where possible.

Transcervical approaches are required to address fractures of the ramus or posterior body, with careful attention given to preserving the marginal mandibular branch of the facial nerve. Rigid fixation is then accomplished by the application of plates

3▶ and screws. Selected fractures, such as those of the body, benefit from dynamic compression plating, which applies pressure toward the fracture line. With rigid fixation, IMF is required to establish occlusion, and may not be necessary for a full 6 postoperative weeks. This is preferable because IMF is associated with gingival and dental disease, as well as with significant weight loss and malnutrition, during the fixation period. New techniques have included the 4-point fixation technique, where the maxilla and mandible are held in occlusion by wires attached to intraoral cortical bone screws, with two screws above and below the occlusal line anteriorly. In edentulous patients, determining the baseline occlusion is of less

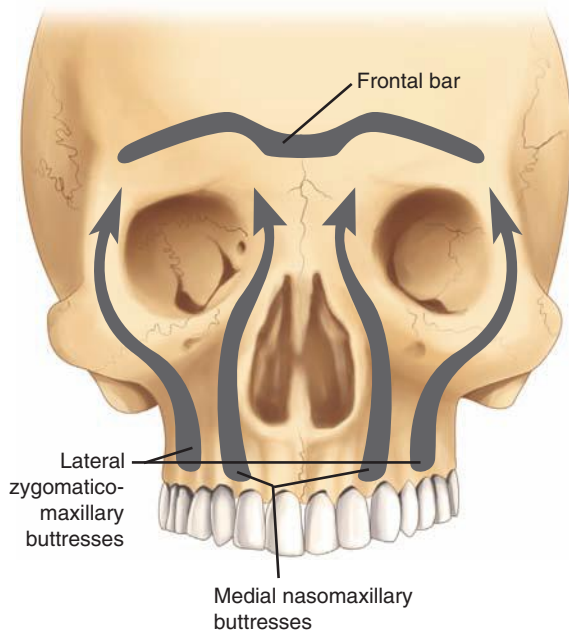


Figure 18-15. Major buttresses of the midface.

significance because dentures may be refashioned once healing is complete. If IMF is required to aid in immobilization of the fracture in an edentulous patient, interosseous wiring and/or the fabrication of custom-made splints is required.

Midface fractures are classically described in three patterns: Le Fort I, II, and III. A full understanding of midface structure is first necessary (Fig. 18-15). Three vertical buttresses support the midface: the nasofrontal-maxillary, the frontozygomaticomaxillary, and pterygomaxillary.³¹ The five horizontal buttresses include the frontal bone, nasal bones, upper alveolus, zygomatic arches, and the infraorbital region. Classical signs of midface fractures in general include subconjunctival hemorrhage; malocclusion; midface numbness or hypesthesia (maxillary division of the trigeminal nerve); facial ecchymoses/hematoma; ocular signs/symptoms; and mobility of the maxillary complex.

Le Fort I fractures occur transversely across the alveolus, above the level of the teeth apices. In a pure Le Fort I fracture, the palatal vault is mobile while the nasal pyramid and orbital rims are stable. The Le Fort II fracture extends through the nasofrontal buttress, medial wall of the orbit, across the infraorbital rim, and through the zygomaticomaxillary articulation. The nasal dorsum, palate, and medial part of the infraorbital rim are mobile. The Le Fort III fracture is also known as *craniofacial disjunction*. The frontozygomaticomaxillary, frontomaxillary, and frontonasal suture lines are disrupted. The entire face is mobile from the cranium. It is convenient to conceptualize complex midface fractures according to these patterns (Fig. 18-16); however, in reality, fractures reflect a combination of these three types. Also, the fracture pattern may vary between the left and right sides of the midface. Lateral blows to the cheek may be associated with isolated zygoma fractures. The zygoma is typically displaced inferiorly and medially with disruption of the suture lines between the temporal, frontal, and maxillary bones and the zygoma. Disruption of the latter articulation may be associated with depression into the maxillary sinus and blood in the sinus cavity. Fractures of the midface and/or zygoma may be

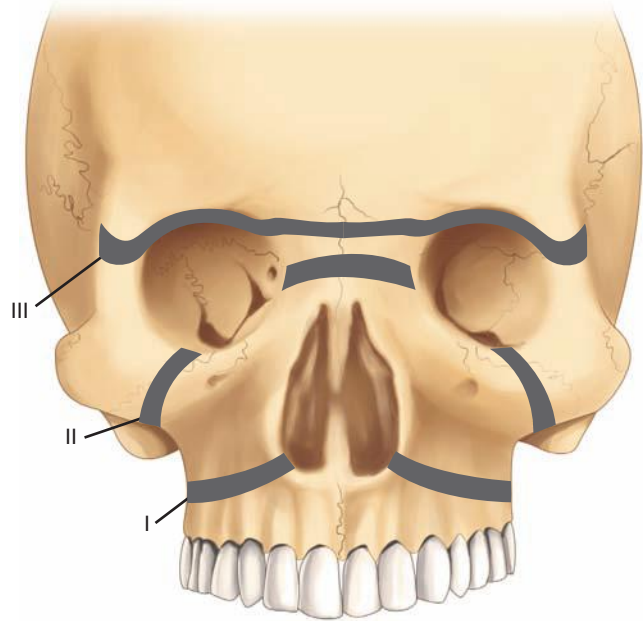


Figure 18-16. Classic Le Fort fracture patterns.

associated with an orbital blowout, whereas the orbital floor is disrupted and orbital soft tissues subsequently herniate into the maxillary sinus (Fig. 18-17). The mechanism of orbital blowout may involve propagation of adjacent fracture lines or may be the result of a sudden increase in intraorbital pressure during the injury. This may be associated with enophthalmos or entrapment of the inferior oblique muscle. The latter results in diplopia upon upward gaze. Entrapment is confirmed by forced duction testing, where, under topical or general anesthesia, the muscular attachment of the inferior oblique is grasped with forceps and manipulated to determine passive ocular mobility. Fractures of the midface, zygoma, and orbital floor are best evaluated using CT scan, and repair requires a combination of transoral and external approaches to achieve at least two points of fixation for each fractured segment.³² Significant areas of bone loss can be reconstructed with commercially available hydroxyapatite

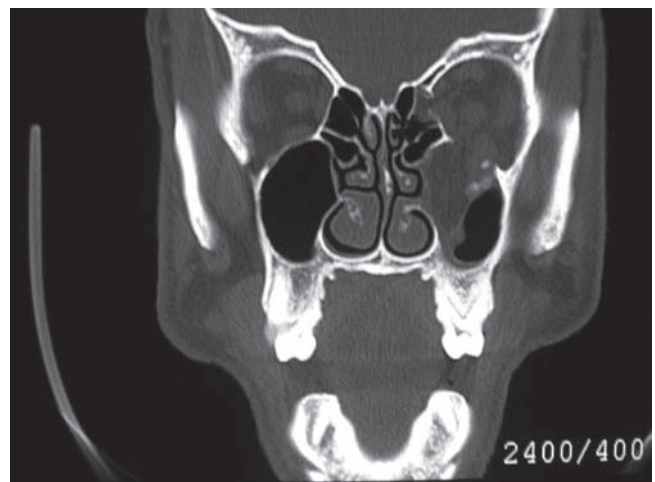


Figure 18-17. Coronal computed tomography demonstrating an orbital blowout fracture with herniation of orbital contents into the maxillary sinus.

bone cements, an osteoconductive calcium-phosphate matrix. Blowout fractures demonstrating significant entrapment or enophthalmos are treated by orbital exploration and reinforcement of the floor with mesh or bone grafting.

Temporal bone fractures occur in approximately one fifth of skull fractures. As with fractures of the mandible and mid-face, blunt trauma (from motor vehicle accident or assault) usually is implicated. Unfortunately, the incidence of temporal bone fracture from gunshot wounds to the head is rising. Fractures are divided into two patterns (Fig. 18-18), longitudinal and transverse, based on the clinical picture and CT imaging. In practice, most fractures are oblique. By classical descriptions, longitudinal fractures constitute 80% and are associated with lateral skull trauma. Signs and symptoms include conductive hearing loss, ossicular injury, bloody otorrhea, and labyrinthine concussion. The facial nerve is injured in approximately 20% of cases. In contrast, the transverse pattern constitute only 20% of temporal bone fractures and occurs secondary to fronto-occipital trauma. The facial nerve is injured in 50% of cases. These injuries frequently involve the otic capsule to cause sensorineural hearing loss and loss of vestibular function. Hemotympanum may be observed. A cerebrospinal fluid (CSF) leak must be suspected in temporal bone trauma. This resolves with conservative measures in most cases. The most significant consideration in the management of temporal bone injuries is the status of the facial nerve. Delayed or partial paralysis will almost always resolve with conservative management. However, immediate paralysis that does not recover within 1 week should be considered

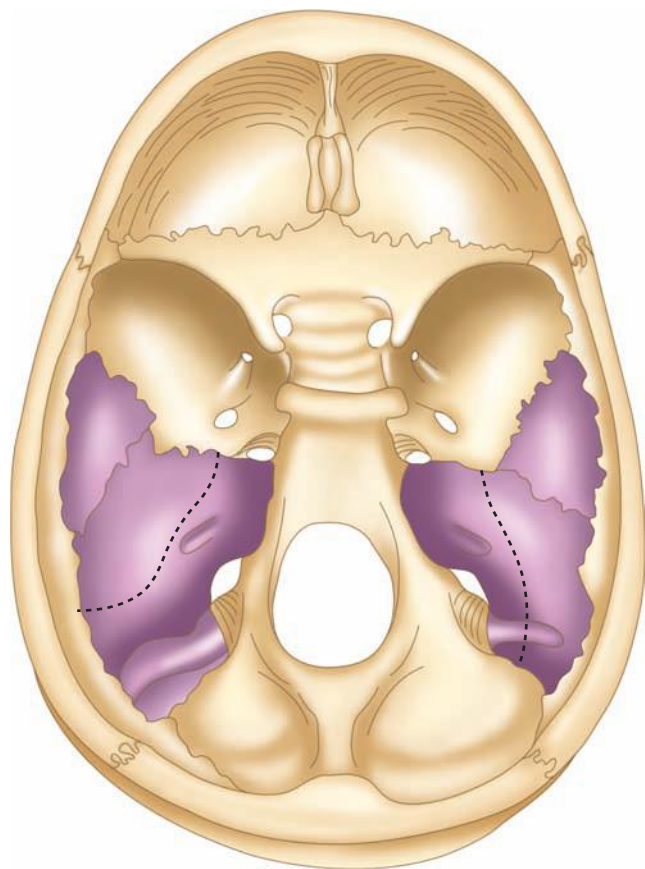


Figure 18-18. View of cranial surface of skull base. Longitudinal (*left*) and transverse (*right*) temporal bone fractures.

for nerve decompression. Electroneurography and EMG have been used to help determine which patients with delayed-onset complete paralysis will benefit from surgical decompression. The finding of >90% degeneration more than 72 hours after the onset of complete paralysis is considered an indication for surgery.³³ Multiple approaches have been described for facial nerve decompression, some of which require the sacrifice of hearing. These patients may have severe intracranial or vascular injuries such that the decision to operate must also be made in the context of the patient's overall medical stability. It is of paramount importance to protect the eye in patients with facial nerve paralysis of any etiology, because absence of an intact blink reflex will predispose to corneal drying and abrasion. This requires the placement of artificial tears throughout the day with lubricant ointment, eye taping, and/or a humidity chamber at night.^{34,35}

TUMORS OF THE HEAD AND NECK

When a discussion of neoplasms of the head and neck is initiated, the conversation frequently focuses on squamous cell carcinoma. This is because the majority of malignancies of this region are represented by this pathology. The diagnosis and treatment of lesions spanning from the lips and oral cavity to the larynx and hypopharynx requires a similar methodic approach.

The selection of treatment protocols varies for each site within the upper aerodigestive tract. The importance of multidisciplinary management cannot be underestimated. Presentation of cases before a tumor board allowing review of a patient's history, physical examination findings, imaging, and prior pathology specimens allows for confirmation of the patient's status. Additionally, it should encourage discussion from multiple points of view concerning the most appropriate treatment options available. Participation in the discussion with representatives of radiation oncology, medical oncology, surgical oncology, oral maxillofacial surgery/dental medicine, along with radiologists and pathologists specializing in upper aerodigestive tract disorders benefits not only the patient but also represents an excellent teaching opportunity for all disciplines.

The development of organ preservation protocol and the evolution of free tissue reconstructive techniques are some of the most significant advances made within the field during the last two decades. The future of the treatment of head and neck cancer lies within the field of molecular biology. As more is understood about the genetics of cancer, tailoring treatment options to a particular tumor mutation has the capacity to maximize survival while achieving the highest quality of life.

Etiology and Epidemiology

It should come as no surprise that abuse of tobacco and alcohol are the most common preventable risk factors associated with the development of head and neck cancers. This relationship is **4▶** synergistic rather than additive. Smoking confers a 1.9-fold increased risk to males and a threefold increased risk to females for developing a head and neck carcinoma, compared to nonsmokers. The risk increases as the number of years smoking and number of cigarettes smoked per day increases. Alcohol alone confers a 1.7-fold increased risk to males drinking one to two drinks per day, compared to nondrinkers. This increased risk rises to > threefold for heavy drinkers. Individuals who both smoke (two packs per day) and drink (four units of alcohol

per day) had a 35-fold increased risk for the development of a carcinoma compared to controls.³⁶ Users of smokeless tobacco have a four times increased risk of oral cavity carcinoma compared to nonusers.

Tobacco is the leading preventable cause of death in the United States and is responsible for one of every five deaths.³⁷ Approximately one fourth of U.S. adults habitually use tobacco products, with recent trends demonstrating an increase in the use of tobacco products by women. The evidence supporting the need for head and neck cancer patients to pursue smoking cessation after treatment is compelling. In a study by Moore, 40% of patients who continued to smoke after definitive treatment for an oral cavity malignancy went on to recur or develop a second head and neck malignancy.³⁸ For patients who stopped smoking after treatment, only 6% went on to develop a recurrence. Induction of specific p53 mutations within upper aerodigestive tract tumors has been noted in patients with histories of tobacco and alcohol use.^{39,40}

When smokers who develop head and neck squamous cell carcinomas are compared to nonsmokers, differences between the two populations emerge. Koch and associates⁴¹ noted that nonsmokers were represented by a disproportionate number of women and were more frequently at the extremes of age (<30 or >85 years of age). Tumors from nonsmokers presented more frequently in the oral cavity, specifically within the oral tongue, buccal mucosa, and alveolar ridge. Smokers presented more frequently with tumors of the larynx, hypopharynx, and floor of mouth. Former smokers, defined as those individuals who had quit >10 years prior, demonstrated a profile more consistent with nonsmokers.

In India and Southeast Asia, the product of the areca catechu tree, known as a betel nut, is chewed in a habitual manner and acts as a mild stimulant similar to that of coffee. The nut is chewed in combination with lime and cured tobacco as a mixture known as a quid. The long-term use of the betel nut quid can be destructive to oral mucosa and dentition and is highly carcinogenic.⁴² Another habit associated with oral malignancy is that of reverse smoking, where the lighted portion of the tobacco product is within the mouth during inhalation. The risk of hard palate carcinoma is 47 times greater in reverse smokers compared to nonsmokers.

HPV is an epitheliotropic virus that has been detected to various degrees within samples of oral cavity squamous cell carcinoma. Infection alone is not considered sufficient for malignant conversion; however, results of multiple studies suggest a role of HPV in a subset of head and neck squamous cell carcinoma. Multiple reports reflect that up to 40% to 60% of current diagnoses of tonsillar carcinoma demonstrate evidence of HPV types 16 or 18.

Environmental ultraviolet light exposure has been associated with the development of lip cancer. The projection of the lower lip, as it relates to this solar exposure, has been used to explain why the majority of squamous cell carcinomas arise along the vermilion border of the lower lip. In addition, pipe smoking also has been associated with the development of lip carcinoma. Factors such as mechanical irritation, thermal injury, and chemical exposure have been described as an explanation for this finding.

Other entities associated with oral malignancy include Plummer-Vinson syndrome (achlorhydria, iron-deficiency anemia, mucosal atrophy of mouth, pharynx, and esophagus), chronic infection with syphilis, and immunocompromised status (30-fold increase with renal transplant).

Although evidence linking HIV infection to squamous cell carcinoma of the head and neck is lacking, several AIDS-defining malignancies, including Kaposi's sarcoma, and non-Hodgkin's lymphoma may require the care of an otolaryngologist.

Anatomy and Histopathology

The upper aerodigestive tract is divided into several distinct sites that include the oral cavity, pharynx, larynx, and nasal cavity/paranasal sinuses. Within these sites are individual subsites with specific anatomic relationships that affect diagnosis, tumor spread, and selection of treatment options. The spread of a tumor from one site to another is determined by the course of the nerves, blood vessels, lymphatic pathways, and fascial planes. The fascial planes serve as barriers to the direct invasion of tumor and facilitate the pattern of spread to regional lymph nodes.

The oral cavity extends from the vermilion border of the lip to the hard-palate/soft-palate junction superiorly, to circumvallate papillae inferiorly, and to the anterior tonsillar pillars laterally (Fig. 18-19). It is divided into seven subsites: lips, alveolar ridges, oral tongue, retromolar trigone, floor of mouth, buccal mucosa, and hard palate. Advanced oral cavity lesions may present with mandibular and/or maxillary involvement requiring special consideration at the time of resection and reconstruction. Regional metastatic spread of lesions of the oral cavity is to the lymphatics of the submandibular and the upper jugular region (e.g., levels I, II, and III).

The pharynx is divided into three regions: nasopharynx, oropharynx, and hypopharynx. The nasopharynx extends from the posterior nasal septum and choana to the skull base and includes the fossa of Rosenmüller and torus tubarius of the Eustachian tubes laterally. The inferior margin of the nasopharynx is the superior surface of the soft palate. The adenoids, typically involuted in adults, are located with the posterior aspect of this site. Given the midline location of the nasopharynx, bilateral regional metastatic spread is common in these lesions. Lymphadenopathy of the posterior triangle (level V) of the neck should provoke consideration for a nasopharyngeal primary.

The major sites within the oropharynx are the tonsillar region, base of tongue, soft palate, and posterolateral pharyngeal walls. Regional lymphatic drainage for oropharyngeal lesions

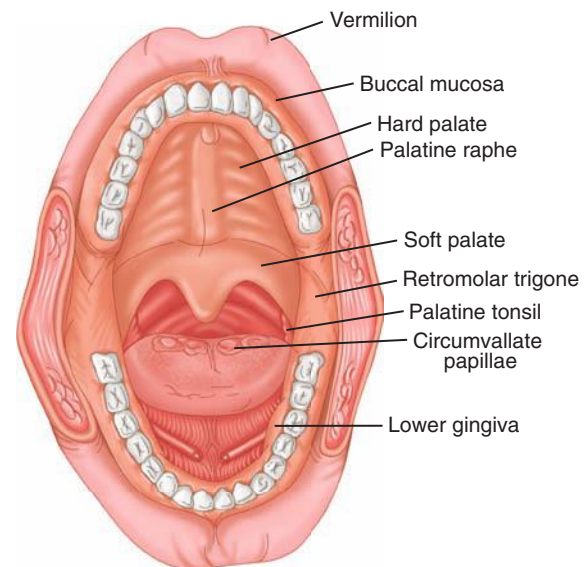


Figure 18-19. Oral cavity landmarks.

frequently occurs to the upper and lower cervical lymphatics (e.g., levels II, III, IV). Retropharyngeal metastatic lymphatic spread may occur with oropharyngeal lesions.

The hypopharynx extends from the vallecula to the lower border of the cricoid posterior and lateral to the larynx. The subsites of this region include the pyriform fossa, the postcricoid space, and posterior pharyngeal wall. Regional lymphatic spread is frequently bilateral and to the mid- and lower cervical lymph nodes (e.g., levels III, IV).

The larynx is divided into three regions: the supraglottis, glottis, and subglottis. The supraglottic larynx includes the epiglottis, false vocal cords, medial surface of the aryepiglottic folds, and the roof of the laryngeal ventricles. The glottis includes the true vocal cords, anterior and posterior commissure, and the floor of the laryngeal ventricle. The subglottis extends from below the true vocal cords to the cephalic border of the cricoid within the airway. The supraglottis has a rich lymphatic network, which accounts for the high rate of bilateral spread of metastatic disease that is not typically seen with the glottis. Glottic and subglottic lesions, in addition to potential spread to the cervical chain lymph nodes, may also spread to the paralaryngeal and paratracheal lymphatics and require attention to prevent lower central neck recurrence.

Carcinogenesis

Development of a tumor represents the loss of cellular signaling mechanisms involved in the regulation of growth. Following malignant transformation, the processes of replication (mitosis), programmed cell death (apoptosis), and the interaction of a cell with its surrounding environment are altered. Advances in molecular biology have allowed for the identification of many of the mutations associated with this transformation.

Overexpression of mutant p53 is associated with carcinogenesis at multiple sites within the body. Point mutations in p53 have been reported in up to 45% of head and neck carcinomas. Koch et al noted that p53 mutation is a key event in the malignant transformation of >50% of head and neck squamous cell carcinomas in smokers.⁴¹

Carcinogenesis has long been explained as a two-hit process, involving DNA damage and the progression of mutated cells through the cell cycle. These two events also are known as *initiation* and *promotion*. It has been proposed that approximately 6 to 10 independent genetic mutations are required for the development of a malignancy. Overexpression of mitogenic receptors, loss of tumor-suppressor proteins, expression of oncogene-derived proteins that inhibit apoptosis, and overexpression of proteins that drive the cell cycle can allow for unregulated cell growth.

Genetic mutations may occur as a result of environmental exposure (e.g., radiation or carcinogen exposure), viral infection, or spontaneous mutation (deletions, translocations, frame shifts). Common genetic alterations, such as loss of heterozygosity at 3p, 4q, and 11q13, and the overall number of chromosomal microsatellite losses are found more frequently in the tumors of smokers than in the tumors of nonsmokers.⁴¹

Second Primary Tumors in the Head and Neck

Patients diagnosed with a head and neck cancer are predisposed to the development of a second tumor within the aerodigestive tract. The overall rate of second primary tumors is approximately 14%. A second primary tumor detected within 6 months

of the diagnosis of the initial primary lesion is defined as a synchronous neoplasm. The prevalence of synchronous tumors is approximately 3% to 4%. The detection of a second primary lesion more than 6 months after the initial diagnosis is referred to as metachronous tumor. About 80% of second primaries are metachronous and at least half of these lesions develop within 2 years of the diagnosis of the original primary. The incidence and site of the second primary tumor vary and depend on the site and the inciting factors associated with the initial primary tumor. The importance of advocating smoking cessation and addressing alcoholism in these patients cannot be overemphasized.

Patients with a primary malignancy of the oral cavity or pharynx are most likely to develop a second lesion within the cervical esophagus, whereas patients with a carcinoma of the larynx are at risk for developing a neoplasm in the lung. As such, the presentation of a new-onset dysphagia, unexplained weight loss, or chronic cough/hemoptysis must be assessed thoroughly in patients with a history of prior treatment for a head and neck cancer.

A staging examination is recommended at the initial evaluation of all patients with primary cancers of the upper aerodigestive tract. This may involve a direct laryngoscopy, rigid/flexible esophagoscopy, and rigid/flexible bronchoscopy also known as "*panendoscopy*." Some surgeons argue against the use of bronchoscopy because of the low yield of the examination in asymptomatic patients with a normal chest X-ray. Additionally, barium swallow has been used instead of esophagoscopy as a preoperative evaluation.

Staging

Staging for upper aerodigestive tract malignancies is defined by the American Joint Committee on Cancer and follows the TNM (primary tumor, regional nodal metastases, distant metastasis) staging format⁴³. The T staging criteria for each site varies depending upon the relevant anatomy (e.g., vocal cord immobility is seen with T3 lesions). Table 18-1 demonstrates TNM staging for oral cavity lesions. The N classification system is uniform for all head and neck sites except for the nasopharynx.

Upper Aerodigestive Tract

Lip. The lips represent a transition from external skin to internal mucous membrane that occurs at the vermilion border. The underlying musculature of the orbicularis oris creates a circumferential ring that allows the mouth to have a sphincter-like function. Cancer of the lip is most commonly seen in white men from the ages of 50 to 70 years, but can be seen in younger patients, particularly those with fair complexions. Risk factors include prolonged exposure to sunlight, fair complexion, immunosuppression, and tobacco use.

The majority of lip malignancies are diagnosed on the lower lip (88%–98%), followed by the upper lip (2%–7%) and oral commissure (1%). The histology of lip cancers is predominantly squamous cell carcinoma; however, other tumors, such as keratoacanthoma, verrucous carcinoma, basal cell carcinoma, malignant melanoma, minor salivary gland malignancies, and tumors of mesenchymal origin (e.g., malignant fibrous histiocytoma, leiomyosarcoma, and rhabdomyosarcoma), may also present in this location. Basal cell carcinoma presents more frequently on the upper lip than lower.

Clinical findings in lip cancer include an ulcerated lesion on the vermilion or cutaneous surface. Careful palpation is important in determining the actual size and extent of these lesions.

Table 18-1

TNM staging for oral cavity carcinoma

Primary Tumor			
TX	Unable to assess primary tumor		
T0	No evidence of primary tumor		
Tis	Carcinoma in situ		
T1	Tumor is < 2 cm in greatest dimension		
T2	Tumor > 2 cm and < 4 cm in greatest dimension		
T3	Tumor > 4 cm in greatest dimension		
T4 (lip)	Primary tumor invading cortical bone, inferior alveolar nerve, floor of mouth, or skin of face (e.g., nose or chin)		
T4a (oral)	Tumor invades adjacent structures (e.g., cortical bone, into deep tongue musculature, maxillary sinus) or skin of face		
T4b (oral)	Tumor invades masticator space, pterygoid plates, or skull base and/or encases the internal carotid artery		
Regional lymphadenopathy			
NX	Unable to assess regional lymph nodes		
N0	No evidence of regional metastasis		
N1	Metastasis in a single ipsilateral lymph node, 3 cm or less in greatest dimension		
N2a	Metastasis in single ipsilateral lymph node, >3 cm and < 6 cm		
N2b	Metastasis in multiple ipsilateral lymph nodes, all nodes < 6 cm		
N2c	Metastasis in bilateral or contralateral lymph nodes, all nodes < 6 cm		
N3	Metastasis in a lymph node > 6 cm in greatest dimension		
Distant metastases			
MX	Unable to assess for distant metastases		
M0	No distant metastases		
M1	Distant metastases		
TMN Staging			
Stage 0	Tis	N0	M0
Stage I	T1	N0	M0
Stage II	T2	N0	M0
Stage III	T3	N0	M0
	T1-3	N1	M0
Stage IVa	T4a	N0	M0
	T4a	N1	M0
	T1-4a	N2	M0
Stage IVb	Any T	N3	M0
	T4b	Any N	M0
Stage IVc	Any T	Any N	M1

Source: Used with permission of the American Joint Committee on Cancer (AJCC), Chicago, Illinois. The original source of the material is the AJCC Cancer Staging Manual, Seventh Edition (2010) published by Springer Science and Business Media LLC, www.springerlink.com.

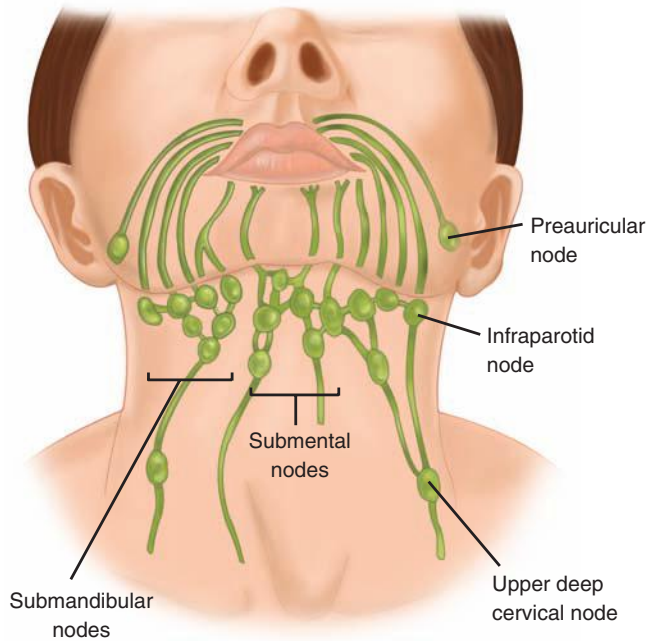


Figure 18-20. Lymphatics of the lip.

The presence of paresthesia in the area adjacent to the lesion may indicate mental nerve involvement.

Characteristics of lip primaries that negatively affect prognosis include perineural invasion, involvement of the underlying maxilla/mandible, presentation on the upper lip or commissure, regional lymphatic metastasis, and age younger than 40 years at onset. Lip cancer results in fewer than 200 patient deaths annually and is stage dependent. Early diagnosis coupled with adequate treatment results in a high likelihood of disease control.

The selection of treatment for any given lip cancer is determined by the overall health of the patient, size of the primary lesion, and the presence of regional metastases. Small primary lesions may be treated with surgery or radiation with equal success and acceptable cosmetic results. However, surgical excision with histologic confirmation of tumor-free margins is the preferred treatment modality. Lymph node metastasis occurs in fewer than 10% of patients with lip cancer (Fig. 18-20). The primary echelon of nodes at risk is in the submandibular and submental regions. In the presence of clinically evident neck metastasis, neck dissection is indicated. The overall 5-year cure rate of lip cancer approximates 90% and drops to 50% in the presence of neck metastases. Postoperative radiation is administered to the primary site and neck for patients with close or positive margins, lymph node metastases, when tumor thickness is >4mm or in the setting of perineural invasion.⁴⁴

The reconstruction of lip defects after tumor excision requires innovative techniques to provide oral competence, maintenance of dynamic function, and acceptable cosmesis. The typical lip length is 6 to 7 cm. This simple fact is important because the reconstructive algorithms available to the head and neck surgeon are based on the proportion of lip resected. Realignment of the vermilion border during the reconstruction and preservation of the oral commissure (when possible) are important principles in attempting to attain an acceptable cosmetic result. Resection with primary closure is possible with a defect of up to one third of the lip (Fig. 18-21). When the

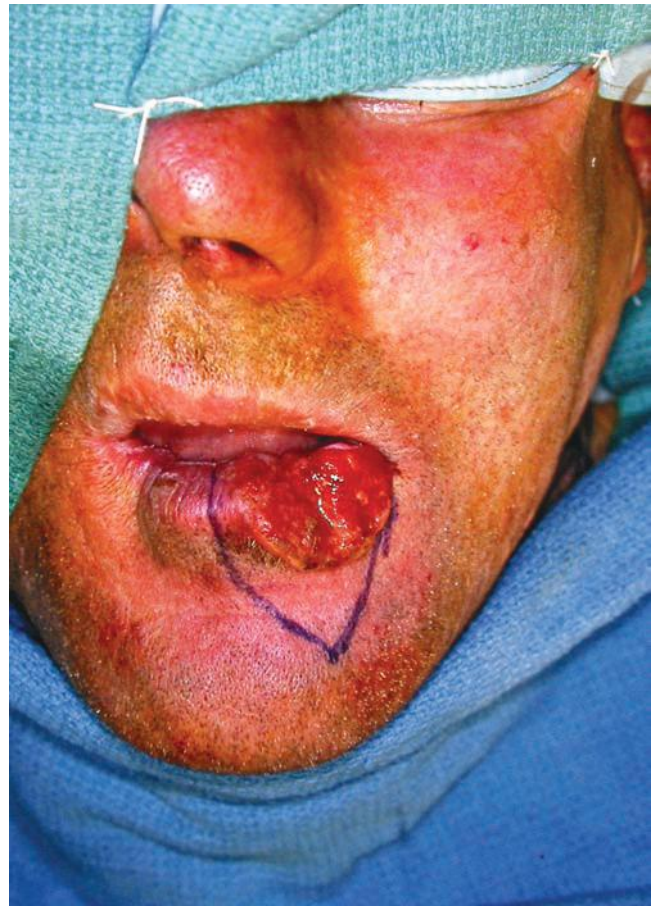

Figure 18-21. Wedge resection of lower lip squamous cell carcinoma.

resection includes one third to one half of the lip, rectangular excisions can be closed using Burrow's triangles in combination with advancement flaps and releasing incisions in the mental crease.⁴⁵ Rotational transposition of tissue from the upper lip can repair other medium-size defects. For larger defects of up to 75%, the Karapandzic flap uses a sensate, neuromuscular flap that includes the remaining orbicularis oris muscle, conserving its blood supply from branches of the labial artery (Fig. 18-22). The lip-switch (Abbe-Estlander) flap or a stair-step advancement technique can be used to repair defects of either the upper or lower lip. Microstomia is a potential complication with these types of lip reconstruction. For very large defects, Webster or Bernard types of repair using lateral nasolabial flaps with buccal advancement have also been described.⁴⁶

Oral Cavity. As previously mentioned in *Anatomy and Histopathology*, the oral cavity is composed of several sites with different anatomic relationships. The majority of tumors in the oral cavity are squamous cell carcinomas (>90%). Each site is briefly reviewed with emphasis placed on anatomy, diagnosis, and treatment options.

Oral Tongue. The oral tongue is a muscular structure with overlying nonkeratinizing squamous epithelium. The posterior limit of the oral tongue is the circumvallate papillae, whereas its ventral portion is contiguous with the anterior floor of mouth. The tongue is composed of four intrinsic and four extrinsic muscles separated at the midline by the median fibrous septum.

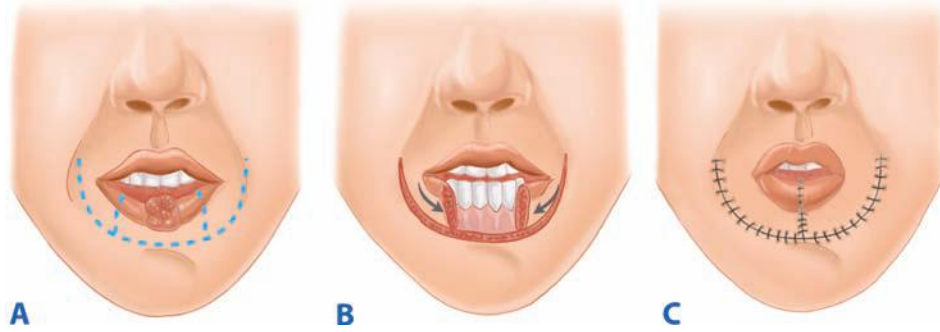


Figure 18-22. A-C. Karapandzic labiaplasty for lower lip carcinoma.

Tumors of the tongue begin in the stratified epithelium of the surface and eventually invade into the deeper muscular structures. The tumors may present as ulcerations or as exophytic masses (Fig. 18-23).⁴⁷ The regional lymphatics of the oral cavity are to the submandibular space and the upper cervical lymph nodes (Fig. 18-24). The lingual nerve and the hypoglossal nerve may be directly invaded by locally extensive tumors (Fig. 18-25). Involvement can result in ipsilateral paresthesias and deviation of the tongue on protrusion with fasciculations and eventual atrophy. Tumors on the tongue may occur on any surface, but are most commonly seen on the lateral and ventral surfaces.⁴⁸ Primary tumors of the mesenchymal components of the tongue include leiomyomas, leiomyosarcomas, rhabdomyosarcomas, and neurofibromas.

Surgical treatment of small (T1–T2) primary tumors is wide local excision with either primary closure or healing by secondary intention. The CO₂ laser may be used for excision

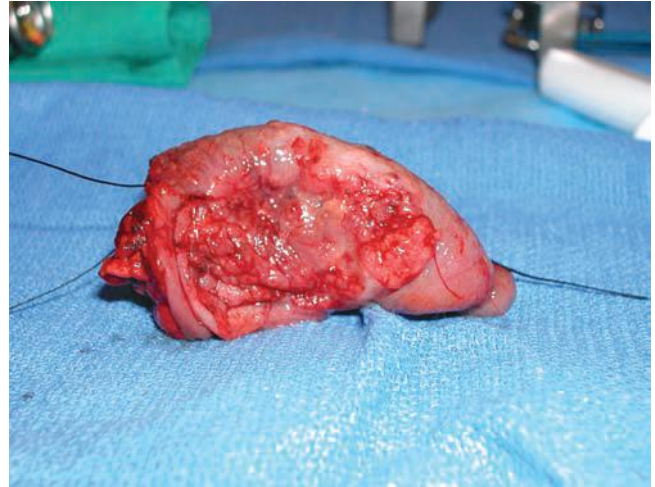


Figure 18-23. Oral tongue squamous cell carcinoma.

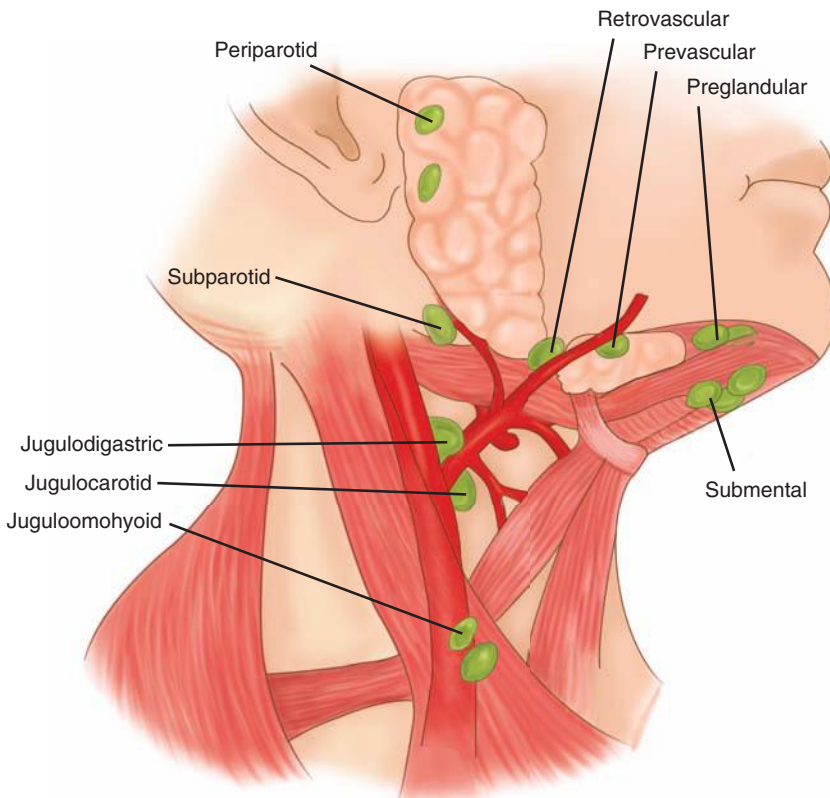
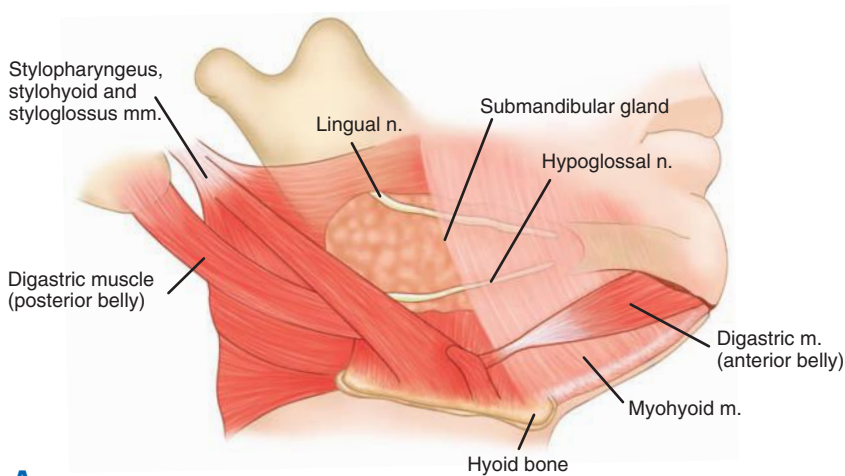
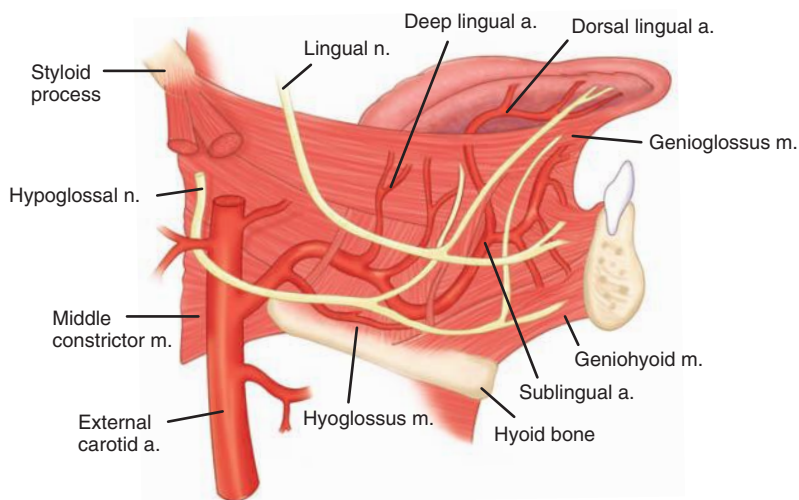


Figure 18-24. Primary lymphatics for regional spread of oral cavity malignancies.



A



B

Figure 18-25. A and B. Anatomy of the floor of mouth and submandibular space. a. = artery; m. = muscle; n. = nerve.

of early tongue cancers or for ablation of premalignant lesions. A partial glossectomy, which removes a significant portion of the lateral oral tongue, still permits reasonably effective postoperative function. Resection of larger tumors of the tongue that invade deeply can result in significant functional impairment. If lingual contact with the palate, lip, and teeth is decreased, it will result in impaired articulation. The use of soft, pliable fasciocutaneous free flaps can provide intraoral bulk and preservation of tongue mobility. Prosthetic augmentation can allow for contact between the remaining tongue tissue and the palate, improving a patient's ability to speak and swallow. Treatment of the regional lymphatics is typically performed with the same modality used to address the primary site. When the primary site is addressed surgically, modified radical neck dissection (MRND) or selective neck dissection (SND) is performed. Depth of invasion of the primary tumor can direct the need for elective lymph node dissection with early stage lesions.⁴⁹

Floor of Mouth. The floor of mouth is a mucosal covered semilunar area that extends from the anterior tonsillar pillar posteriorly to the frenulum anteriorly, and from the inner surface of the mandible to the ventral surface of the oral tongue. The ostia of the submaxillary and sublingual glands are contained in the anterior floor of mouth. The muscular floor of mouth is composed of the sling-like genioglossus, mylohyoid,

and hyoglossus muscles, which serve as a barrier to spread of disease. Invasion into these muscles can result in decreased tongue mobility and poor articulation. Another pathway for spread of tumor is along the salivary ducts, which can result in direct extension into the sublingual space.

Anterior or lateral extension to the mandibular periosteum is of primary importance in the preoperative assessment for these lesions. Imaging studies of the mandible, including CT scan, magnetic resonance imaging (MRI), and Panorex radiography, are helpful for ascertaining bone invasion. A careful clinical evaluation, which includes bimanual palpation to assess adherence or fixation to adjacent bone, is also essential (Fig. 18-26). The absence of fixation of the lesion to the inner mandibular cortex indicates that a mandible-sparing procedure is feasible.⁵⁰ Deep invasion into the intrinsic musculature of the tongue causes fixation and mandates a partial glossectomy in conjunction with resection of the floor of mouth. Lesions in the anterior floor of mouth may invade the sublingual gland or submandibular duct and require resection of either of these structures in continuity with the primary lesion. Direct extension of tumors into or through the sublingual space and into the submaxillary space may necessitate the need for removal of the primary tumor with the neck dissection specimen in continuity.

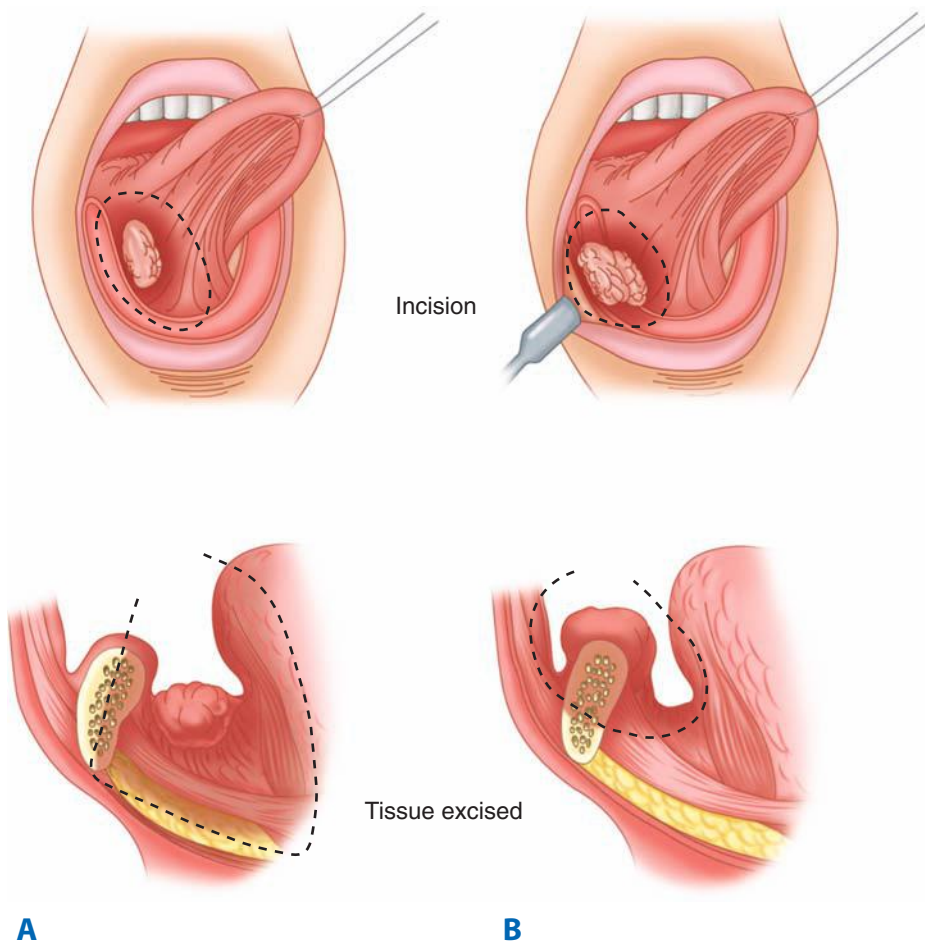


Figure 18-26. A and B. Differences in the transoral resection of a floor of mouth and alveolar ridge lesion.

The resection of large tumors of the floor of mouth may require a lip-splitting incision (Fig. 18-27) and immediate reconstruction. The goals are to obtain watertight closure to avoid a salivary fistula and to avoid tongue tethering to maximize mobility. For small mucosal lesions, wide local excision can be followed by placement of a split-thickness skin graft over the

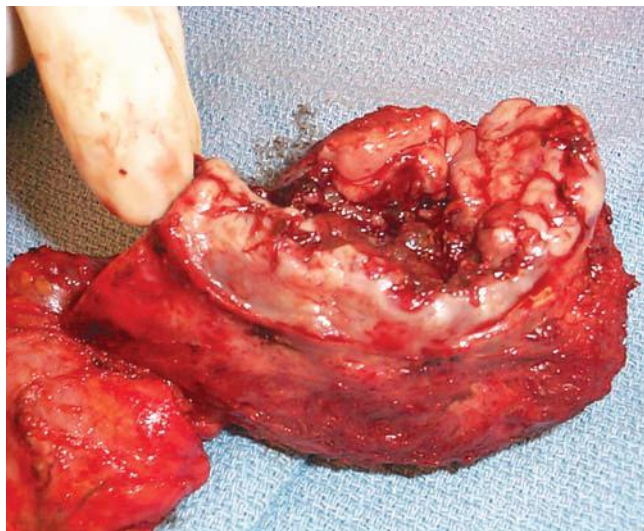


Figure 18-27. Composite resection specimen of a T4 floor of mouth squamous cell carcinoma.

muscular bed. Larger defects that require marginal or segmental mandibulectomy require complex reconstruction with a fasciocutaneous or a vascularized osseous free flap.

Alveolus/Gingiva. The alveolar mucosa overlies the bone of the mandible and maxilla. It extends from the gingivobuccal sulcus to the mucosa of the floor of mouth and hard palate. The posterior limits are the pterygopalatine arch and the ascending portion of the ramus of the mandible. Because of the tight attachment of the alveolar mucosa to the mandibular and maxillary periosteum, treatment of lesions of the alveolar mucosa frequently requires resection of the underlying bone.

Marginal resection of the mandible can be performed for tumors of the alveolar surface that present with minimal bone invasion. Although access for such a procedure can be performed by using an anterior mandibulotomy (Fig. 18-28), use of transoral and pull-through procedures is preferred if a coronal or sagittal marginal mandibulotomy is performed. For more extensive tumors that invade into the medullary cavity, segmental mandibulectomy is necessary. Preoperative radiographic evaluation of the mandible plays an important role in determining the type of bone resection required. For radiographic evaluation of the mandible, Panorex views demonstrate gross cortical invasion. MRI is the best modality for demonstrating invasion of the medullary cavity of the mandible. Sectional CT scanning with bone settings is the optimum modality for imaging subtle cortical invasion. Gross bony invasion involvement at the mandibular symphysis negatively impacts locoregional control.⁵¹

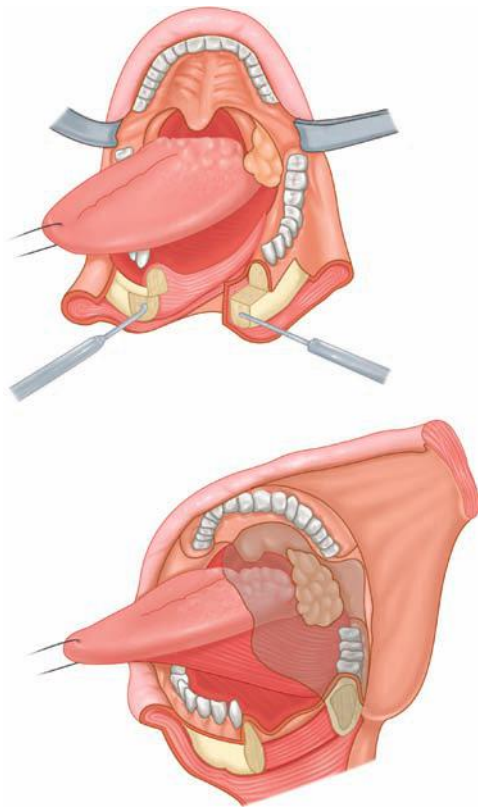


Figure 18-28. Anterior mandibulotomy with mandibular swing to approach a posterior lesion.

Retromolar Trigone. The retromolar trigone is represented by tissue posterior to the posterior inferior alveolar ridge and ascends over the inner surface of the ramus of the mandible. Similar to alveolar lesions, early involvement of the mandible is common because of the lack of intervening soft tissue in the region. The clinical presentation of trismus represents involvement of the muscles of mastication and may indicate spread to the skull base. Tumors of the region may extend posteriorly into the oropharyngeal anatomy or laterally to invade the mandible. As a result, resection of retromolar trigone tumors usually requires a marginal or segmental mandibulectomy with a soft-tissue and/or osseous reconstruction to maximize a patient's postoperative ability for speech and swallowing. Ipsilateral neck dissection is performed because of the risk of metastasis to the regional lymphatics. Huang and associates demonstrated a 5-year, disease-free survival rate for T1 lesions of 76%, which declined to 54% for T4 disease. Patients with N0 disease had a 5-year survival rate of 69%.⁵²

Buccal Mucosa. The buccal mucosa includes all of the mucosal lining from the inner surface of the lips to the line of attachment of mucosa of the alveolar ridges and pterygomandibular raphe. The etiologies of malignancies in the buccal area include lichen planus, chronic dental trauma, and the habitual use of tobacco and alcohol. Tumors in this area have a propensity to spread locally and to metastasize to regional lymphatics. Local intraoral spread may necessitate resection of the alveolar ridge of the mandible or maxilla. Lymphatic drainage is to the facial and the submandibular nodes (level I). Small lesions can be excised surgically, but more advanced tumors require combined surgery and postoperative radiation.⁵³ Deep invasion into the

cheek may require through-and-through resection. Reconstruction aimed at providing both an internal and external lining may be accomplished with a folded fasciocutaneous free flap or a combination of pedicled and free tissue techniques.

Palate. The hard palate is defined as the semilunar area between the upper alveolar ridge and the mucous membrane covering the palatine process of the maxillary palatine bones. It extends from the inner surface of the superior alveolar ridge to the posterior edge of the palatine bone. Most squamous cell carcinomas of the hard palate are caused by habitual tobacco and alcohol use. Chronic irritation from ill-fitting dentures also may play a causal role. Inflammatory lesions arising on the palate may mimic malignancy and can be differentiated by biopsy specimen. Necrotizing sialometaplasia appears on the palate as a butterflyshaped ulcer that clinically appears similar to a neoplasm. Treatment is symptomatic and biopsy specimen confirms its benign nature. Torus palatini are bony outgrowths of the midline palate and do not specifically require surgical treatment unless symptomatic.

Squamous cell carcinoma and minor salivary gland tumors are the most common malignancies of the palate.⁵⁴ The latter include adenoid cystic carcinoma, mucoepidermoid carcinoma, adenocarcinoma, and polymorphous low-grade adenocarcinoma. Mucosal melanoma may occur on the palate and presents as a nonulcerated, pigmented plaque. Kaposi's sarcoma of the palate is the most common intraoral site for this tumor. Tumors may present as either an ulcerative, exophytic, or submucosal mass. Minor salivary gland tumors tend to arise at the junction of the hard and soft palate. Direct infiltration of bone leads to extension into the floor of the nasal cavity and/or maxillary sinus. Squamous cell carcinoma of the hard palate is treated surgically. Adjuvant radiation is indicated for advanced staged tumors. Because the periosteum of the palate can act as a barrier to spread of tumor, mucosal excision may be adequate for very superficial lesions. Involvement of the periosteum requires removal of a portion of the bony palate. Partial palatotomy of infrastructure maxillectomy may be required for larger lesions involving the palate or maxillary antrum. Malignancies may extend along the greater palatine nerve making biopsy specimen important for identifying neurotropic spread. Through-and-through defects of the palate require a dental prosthesis for rehabilitation of swallowing and speech.

Oropharynx. The oropharynx extends from the soft palate to the superior surface of the hyoid bone (or floor of the vallecula) and includes the base of tongue, the inferior surface of the soft palate and uvula, the anterior and posterior tonsillar pillars, the glossotonsillar sulci, tonsils, and the lateral and posterior pharyngeal walls. Laterally, the borders of this region are the pharyngeal constrictors and the medial aspect of the mandible. Direct extension of tumors from the oropharynx into these lateral tissues may involve spread into the parapharyngeal space. The ascending ramus of the mandible can be involved when tumors invade the medial pterygoid muscle.

As was true of the oral cavity, the histology of the majority of tumors in this region is squamous cell carcinoma. Although less common, minor salivary gland tumors may present as submucosal masses in the tongue base and soft palate. Additionally, the tonsils and tongue base may be the presenting site for a lymphoma noted clinically as asymmetrical enlargement.

Oropharyngeal cancer may present as an ulcerative lesion or an exophytic mass. Tumor fetor from necrosis is common.

A muffled or “hot potato” voice is seen with large tongue base tumors. Dysphagia and weight loss are common symptoms. Referred otalgia, mediated by the tympanic branches of cranial nerve (CN) IX and CN X, is a common complaint. Trismus may indicate advanced disease and usually results from involvement of the pterygoid musculature. The incidence of regional metastases from cancers of the oropharynx is high. Consequently, ipsilateral or bilateral nontender cervical lymphadenopathy is a common presenting sign.

The incidence of oropharyngeal squamous cell carcinoma has increased significantly over the last three decades. The etiology for this rise has been attributed to the HPV-16 related development of malignancy. HPV infection can induce the production of two viral oncoproteins, E6 and E7, which inactivate tumor suppressors p53 and Rb leading to tumor promotion. In a prospective clinical trial of patients enrolled in the Eastern Cooperative Group (ECOG) trial 2399, Fakhr et al reported on the survival benefit seen in oropharyngeal cancer patients that were HPV-positive. Patients were treated with sequential chemoradiation for advanced stage disease. HPV positivity was found in 57% of all oropharyngeal cancers in the study. HPV-positive cancers demonstrated a higher response rate to induction chemotherapy (82% vs. 55%) and improved 2-year survival (95% vs. 62%). Compared to patients with HPV-negative tumors, HPV-positive cancers presented in younger male patients and were associated with a history of higher lifetime number of sexual partners and oral sex.⁵⁵ HPV-associated oropharyngeal carcinoma is considered to represent a distinct clinicopathologic entity different from the traditional squamous cell carcinoma of the head and neck associated with the long-term use of tobacco and alcohol (Table 18-2). Surprisingly, the rate of distant metastasis is similar in HPV-positive and HPV-negative patients indicating survival benefits are likely from improved locoregional control with treatment. Clinical trials are currently being performed to assess if therapy can be deintensified in the HPV patient population while obtaining the same locoregional and overall survival seen with standard treatment options.

Imaging studies are important for adequate staging and should assess for extension to the larynx, parapharyngeal space, pterygoid musculature, mandible, and nasopharynx. Lymph node metastasis from oropharyngeal cancer most commonly occurs in the subdiaphragmatic area of level II. Metastases also are

found in levels III, IV, and V, in addition to the retropharyngeal and parapharyngeal lymph nodes. Approximately 50% of patients have metastases at the time of presentation and bilateral metastases are common from tumors arising in the tongue base and soft palate.

The treatment goals for patients with oropharyngeal cancer include maximizing survival and preserving function. Management of squamous cell cancers of this region includes surgery alone, primary radiation alone, surgery with postoperative radiation, and combined chemotherapy with radiation therapy.⁵⁶ Tumors of the oropharynx tend to be radiosensitive.⁵⁷ Patients with early stage lesions may be candidates for monomodality radiation alone. Adequate treatment of the neck is important with oropharyngeal squamous cancer because of the high risk of regional metastasis. Concomitant chemoradiation is commonly utilized in patients with advanced stage (III, IV) oropharyngeal carcinoma.⁵⁸ This approach has been effectively demonstrated to preserve function and is associated with survivorship comparable to surgery with postoperative radiation.

In an effort to resect tumors of the oropharynx in a minimally invasive fashion, that might otherwise require a lip-splitting mandibulotomy approach with dissection through the floor of mouth, the transoral robotic surgical approach utilizing the da Vinci Surgical System has been utilized with favorable results. Dean et al reported on the use of robot-assisted primary and salvage surgery for 36 patients with T1 and T2 tumors of the oropharynx compared to traditional open salvage resection. Patients that underwent robot-assisted surgery had shorter lengths of stay and were less likely to be gastrostomy tube or tracheostomy dependent at 6 months.⁵⁹ Of patients undergoing primary transoral robotic surgery to tonsillar carcinoma, 93% still required some form of postoperative adjuvant therapy.⁶⁰ Advocates of the technique believe that initial surgical management of the oropharynx, a site typically treated with primary radiation or chemoradiation therapy, allows for a better long-term functional result with the potential for decreasing the intensity of adjuvant therapy to radiation alone as opposed to postoperative chemoradiation. Clinical trials and experience with the technique and continue evolve with the focus of use directed at early-stage oropharyngeal carcinomas.

Extensive oropharyngeal cancers may require surgical resection and postoperative radiotherapy. Lesions that involve the mandible require composite resections, such as the classic jaw-neck resection or “commando” procedure. Surgical management of the tongue base may require total glossectomy for extensive lesions crossing the anatomic midline. The potential need for synchronous performance of total laryngectomy at the time of tongue base resection should be explained to the patient. Preservation of the larynx after total glossectomy is associated with a significant risk of postoperative dysphagia and aspiration.⁶¹

Swallowing rehabilitation in patients with oropharyngeal carcinoma is an important aspect of posttreatment care. For soft palate defects, palatal obturators may assist in providing a seal between the nasopharynx and the posterior pharyngeal wall. Nasal regurgitation of air and liquids can be decreased with use. Close cooperation between the head and neck surgeon and the maxillofacial prosthodontist is essential to provide patients with the optimum prosthetic rehabilitation. Preoperative planning can result in the creation of a defect that better tolerates obturation. For patients with postglossectomy defects, palatal augmentation prostheses can provide bulk extending inferiorly from

Table 18-2

Head and neck squamous cell carcinoma patterns of presentation

VARIABLE	HPV-POSITIVE	HPV-NEGATIVE
Typical age	40 – 60 years	over 60 years of age
Primary site	tongue base, tonsil	entire UADT
Prognosis with ASD	favorable	poor
Risk factors	oral sex, number of partners	habitual tobacco and alcohol use
Incidence	increasing	stable, decreasing

(UADT – upper aerodigestive tract, ASD -advanced stage disease)

the palate. The prosthesis decreases the volume of the oral cavity and allows the remaining tongue or soft tissue to articulate with the palate. It also facilitates posterior projection of the food bolus during the oral and pharyngeal phases of swallowing.

Hypopharynx and Cervical Esophagus. The hypopharynx extends from the vallecula to the lower border of the cricoid cartilage and includes the pyriform sinuses, the lateral and posterior pharyngeal walls, and the postcricoid region (Fig. 18-29). Squamous cancers of the hypopharynx frequently present at an advanced stage. Clinical findings are similar to those of lower oropharyngeal lesions and include a neck mass, muffled or hoarse voice, referred otalgia, dysphagia, and weight loss. A common symptom is dysphagia, starting with solids and progressing to liquids, leaving patients malnourished at the time of presentation. Invasion of the larynx by direct extension can result in vocal cord paralysis and may lead to airway compromise.

Routine office examination should include flexible fiberoptic laryngoscopy to properly assess the extent of tumor. During examination, the patient should be instructed to perform a Valsalva maneuver, which will result in passive opening of the pyriform sinuses and postcricoid regions, providing improved visualization. Decreased laryngeal mobility or fixation may indicate invasion of the prevertebral fascia and unresectability. Barium swallow can provide information regarding postcricoid and upper esophageal extension, potential multifocality within the esophagus, and document the presence of aspiration. CT and/or MRI imaging should be obtained through the neck

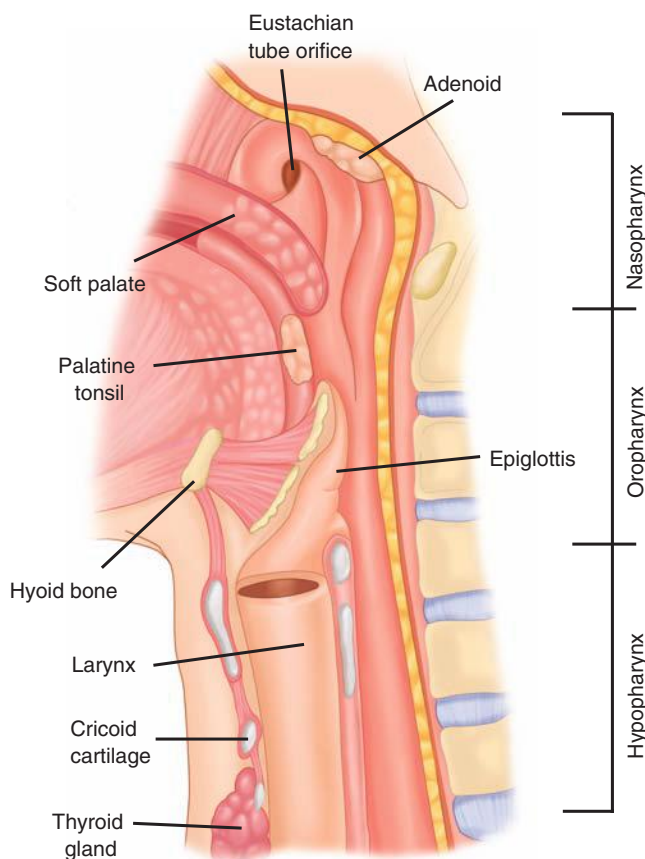


Figure 18-29. Relationship of nasopharynx, oropharynx, and hypopharynx.

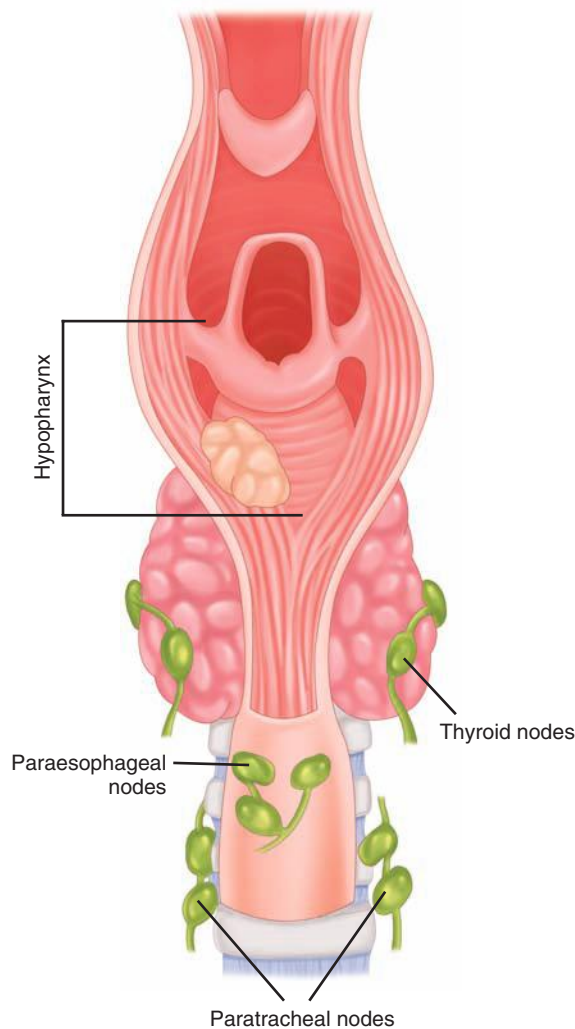


Figure 18-30. View of the hypopharynx demonstrating the potential pathways of spread of tumor and pertinent anatomy.

and upper chest to assess for invasion of the laryngeal framework and to identify for regional metastases, with special attention given to the paratracheal and upper mediastinal lymph nodes (Fig. 18-30). Bilateral metastatic adenopathy in the paratracheal chain is common and the majority of patients present with nodal disease at the time of diagnosis.

Tumors of the hypopharynx and cervical esophagus are associated with poorer survival rates than are other sites in the head and neck because of advanced stage and lymph node metastasis at presentation. Surgery with postoperative radiation therapy improves locoregional control compared to single-modality therapy in the treatment of advanced stage tumors.⁶² Definitive radiation therapy may be effective for limited T1 tumors, whereas concomitant chemoradiation is generally used for T2 and T3 tumors.⁶³ Surgical salvage after radiation failure has a success rate of less than 50% and can be associated with significant wound-healing complications.

Larynx-preserving surgical procedures for tumors of the hypopharynx are possible for only a limited number of lesions. Tumors of the medial pyriform wall or pharyngo-epiglottic fold may be resected with partial laryngopharyngectomy. In this circumstance, the tumor must not involve the apex of the pyriform sinus, vocal cord mobility must be unimpaired, and the patient

must have adequate pulmonary reserve. Given the increased risk for postoperative aspiration associated with various forms of partial laryngectomy, a history significant for pulmonary disease is a contraindication for performing the procedures. Because the majority of patients with tumors of the hypopharynx present with large lesions with significant submucosal spread, total laryngectomy often is required to achieve negative resection margins. Resection of the primary tumor and surrounding pharyngeal tissue is performed en bloc. Bilateral neck dissection is frequently indicated given the elevated risk of nodal metastases found with these lesions.

When laryngopharyngectomy is performed for hypopharyngeal tumors the surgical defect is repaired by primary closure when possible. Generally, 4 cm or more of pharyngeal mucosa is necessary for primary closure to provide an adequate lumen for swallowing and to minimize the risk of stricture formation. Larger surgical defects require closure with the aid of pedicled myocutaneous flaps or microvascular reconstruction with radial forearm or jejunal free flap. When total laryngopharyngoesophagectomy is necessary, gastric pull-up is performed.

Cervical esophageal cancer may be managed surgically or by concomitant chemoradiation. Preservation of the larynx is possible if the cricopharyngeus muscle demonstrates limited involvement. Unfortunately, this is not often the case and many patients with cervical esophageal cancer require laryngectomy. Total esophagectomy is performed because of the tendency for multiple primary tumors and skip lesions seen with esophageal cancers.

Despite aggressive treatment strategies, the 5-year survival rate for cervical esophageal cancer is less than 20%. Given the presence of paratracheal lymphatic spread, surgical treatment for tumors of this area must include paratracheal lymph node dissection, in addition to treatment of the lateral cervical lymphatics.

Larynx. Laryngeal carcinoma is a diagnosis typically entertained in individuals with prominent smoking histories and the complaint of a change in vocal quality (Fig. 18-31). The borders of the larynx span from the epiglottis superiorly to the cricoid

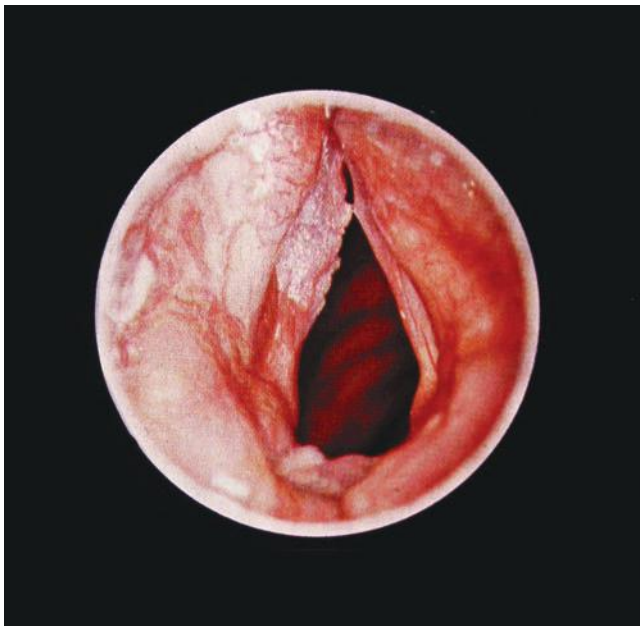


Figure 18-31. Endoscopic view of a laryngeal squamous carcinoma.

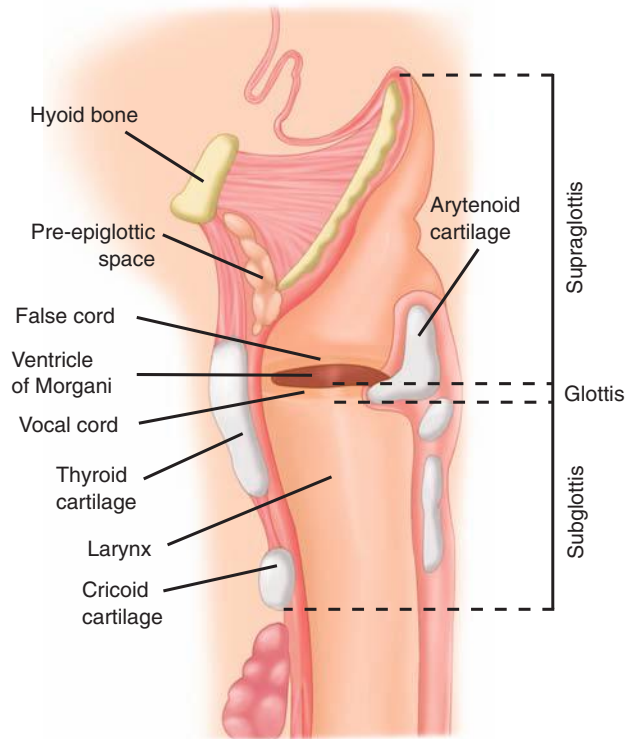


Figure 18-32. Sagittal view of the larynx with the divisions of the supraglottis, glottis, and subglottis demonstrated.

cartilage inferiorly. The lateral limits of the larynx are the aryepiglottic folds. The larynx is composed of three regions: the supraglottis, the glottis, and the subglottic (Fig. 18-32).

The supraglottic includes the epiglottis, aryepiglottic folds, arytenoids, and ventricular bands (false vocal folds). The inferior boundary of the supraglottic is a horizontal plane passing through the lateral margin of the ventricle. The glottis is composed of the true vocal cords (superior and inferior surfaces) and includes the anterior and posterior commissures. The subglottic extends from the inferior surface of the glottis to the lower margin of the cricoid cartilage. The soft-tissue compartments of the larynx are separated by fibroelastic membranes, which can act as barriers to the spread of cancer. These membranes thicken medially to form the false vocal fold and the vocal ligament (the true vocal cord).

The supraglottic larynx contains pseudostratified, ciliated respiratory epithelium that covers the false vocal cords. The epiglottis and the vocal cords are lined by stratified, nonkeratinizing squamous epithelium. The subglottic mucosa is pseudostratified, ciliated respiratory epithelium. Minor salivary glands are also found in the supraglottic and subglottic. Tumor types that arise in the larynx are primarily squamous cell carcinoma but also include tumors of neuroendocrine origin, squamous papillomas, granular cell tumors, and tumors of salivary origin. Several histologic variants of squamous cell carcinoma exist and include verrucous, basaloid squamous cell, adenosquamous, and spindle cell carcinoma. Tumors of the laryngeal framework include synovial sarcoma, chondroma, and chondrosarcoma.

The normal functions of the larynx are airway patency, protection of the tracheobronchial tree during swallowing, and phonation. Patients with tumors of the supraglottic larynx may present with symptoms of chronic sore throat, dysphonia

(“hot potato” voice), dysphagia, or a neck mass secondary to regional metastasis. Supraglottic tumors may cause vocal cord fixation by inferior extension in the paraglottic space or direct invasion of the cricoarytenoid joint. Anterior extension of tumors arising on the laryngeal surface of the epiglottis into the preepiglottic space produces a muffled quality to the voice. Referred otalgia or odynophagia is encountered with advanced supraglottic cancers. Bulky tumors of the supraglottic may result in airway compromise. In contrast to most supraglottic lesions, hoarseness is an early symptom in patients with tumors of the glottis.⁶⁴ Airway obstruction from a glottic tumor is usually a late symptom and is the result of tumor bulk or impaired vocal cord mobility. Decreased vocal cord mobility may be caused by direct muscle invasion or involvement of the RLN. Fixation of the vocal cord indicates invasion into the vocalis muscle, paraglottic space, or cricoarytenoid joint. Superficial tumors that are bulky may appear to cause cord fixation through mass effect. Subglottic cancers are relatively uncommon and typically present with vocal cord paralysis (usually unilateral) and/or airway compromise.

The staging classification for squamous cell cancers of the larynx includes assessment of vocal cord mobility as well as local tumor extension. Accurate clinical staging of laryngeal tumors requires flexible fiber-optic endoscopy in the office and direct microlaryngoscopy under general anesthesia. Direct laryngoscopy, used to assess the extent of local spread, may be combined with esophagoscopy or bronchoscopy to adequately stage the primary tumor and to exclude the presence of a synchronous lesion. Key areas to note for tumor extension in supraglottic tumors are the vallecula, base of tongue, ventricle, arytenoid, and anterior commissure. For glottic cancers, it is important to determine extension to the false cords, anterior commissure, arytenoid, and subglottic.

Radiographic imaging by CT and/or MRI provides important staging information and is crucial for identifying cartilage erosion or invasion and extension into the preepiglottic or paraglottic spaces. High quality, thin-section images through the larynx should be obtained in patients with laryngeal tumors and used with clinical assessment to arrive at a final disease pretreatment staging. Lymph node metastasis may be defined more readily with the use of imaging studies.

Lymphatic drainage of the larynx is distinct for each subsite. Two major groups of laryngeal lymphatic pathways exist: those that drain areas superior to the ventricle, and those that drain areas inferior to it. Supraglottic drainage routes pierce the thyrohyoid membrane with the superior laryngeal artery, vein, and nerve, and drain mainly to the subdigastric and superior jugular nodes.⁶⁴ Those from the glottic and subglottic areas exit via the cricothyroid ligament and end in the prelaryngeal node (the delphian node), the paratracheal lymph nodes, and the deep cervical nodes along the inferior thyroid artery. Limited glottic cancers typically do not spread to regional lymphatics (1%–4%). However, there is a high incidence of lymphatic spread from supraglottic (30%–50%) and subglottic cancers (40%).

When considering treatment for laryngeal tumors, it is useful to categorize them as a continuum from early tumors (those with a small area of involvement resulting in minimal functional impairment) to advanced tumors (those with significant airway compromise and local extension). For example, severe dysplasia and carcinoma in situ often can be treated successfully with CO₂ laser resection or conservative surgical approaches. In contrast, more advanced tumors may require partial laryngectomy (Fig. 18-33) or even total laryngectomy (Fig. 18-34).⁶⁵ Further complicating the

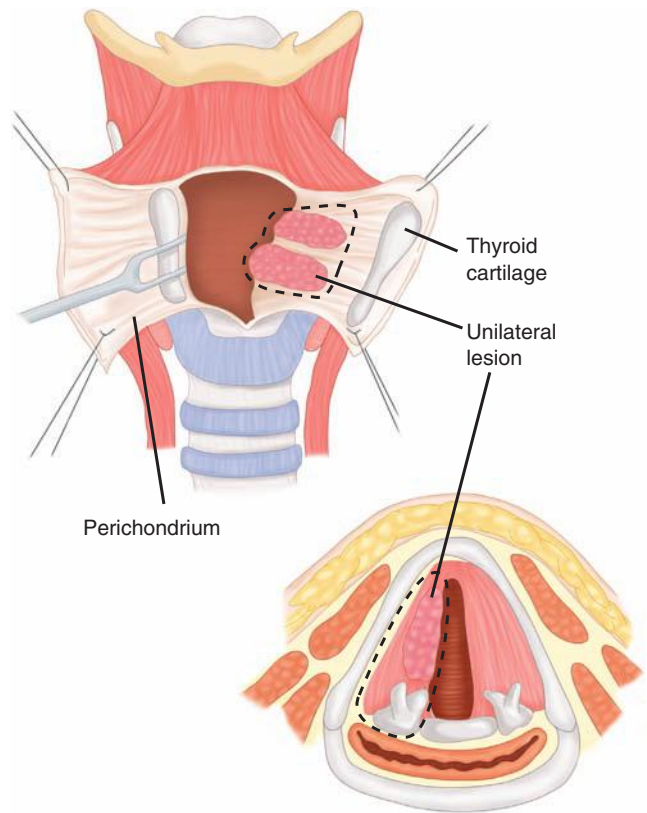


Figure 18-33. Example of the resection of a vertical partial laryngectomy for an early stage glottic carcinoma.

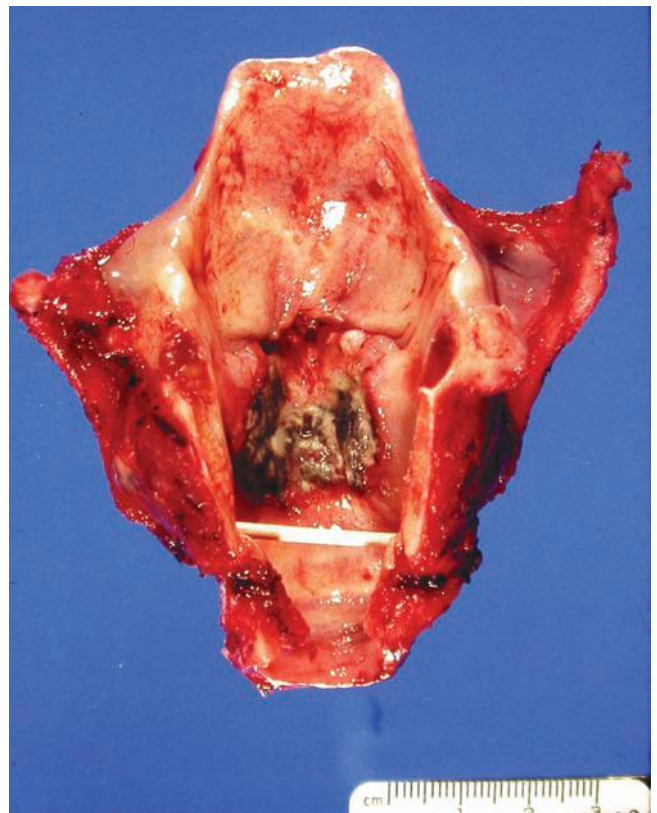


Figure 18-34. Total laryngectomy specimen featuring a locally invasive advanced stage glottic squamous carcinoma.

treatment paradigm is the role of radiotherapy, with or without chemotherapy, with the goal of laryngeal preservation.⁶⁶

Prognostic factors for patients with cancer of the larynx are tumor size, nodal metastasis, perineural invasion, and extracapsular spread of disease in cervical lymph nodes. Patient comorbidities are important to consider when arriving at a treatment plan for patients with laryngeal cancer.

For severe dysplasia or carcinoma in situ of the vocal cord, complete removal of the involved mucosa with microlaryngoscopy is an effective treatment. Patients with limited involvement of the arytenoid or anterior commissure are the best candidates for a good posttreatment vocal quality result with this approach. Multiple procedures may be necessary to control the disease and to prevent progression to an invasive cancer. Close follow-up examinations and smoking cessation are mandatory adjuncts of therapy. For early stage cancers of the glottis and the supraglottis, radiation therapy is equally as effective as surgery in controlling disease.

Critical factors in determining the appropriate treatment modality are comorbid conditions (chronic obstructive pulmonary disease, cardiovascular, and renal disease) and tumor extension. Voice preservation and maintenance of quality of life are key issues and significantly impact therapeutic decisions. The use of radiation therapy for early stage disease of the glottis and supraglottis provides excellent disease control with reasonable, if not excellent, preservation of vocal quality. Partial laryngectomy for small glottic cancers provides excellent tumor control, but vocal quality can vary. For supraglottic cancers without arytenoid or vocal cord extension, standard supraglottic laryngectomy results in excellent disease control with good voice function. For advanced tumors with extension beyond the endolarynx or with cartilage destruction, total laryngectomy followed by postoperative radiation is considered the standard of care.⁶⁷ In this setting, reconstruction by means of a pectoralis major flap (Fig. 18-35) or free flap reconstruction is required for lesions with pharyngeal extension.

Subglottic cancers, constituting only 1% of laryngeal tumors, are typically treated with total laryngectomy. Of note, 40% of patients with these tumors present with regional adenopathy and special attention must be directed to the treatment of paratracheal lymph nodes.⁶⁸

Laryngeal Preservation Techniques. Superficial cancers confined to the true vocal cord can be treated with a variety of surgical options. These include endoscopic vocal cord stripping, microflap dissection, partial cordectomy, and CO₂ laser

resection. Although using a CO₂ laser can provide excellent hemostasis and minimize damage to the adjacent uninvolved tissue, scarring associated with its use is considered more significant than with conventional “cold” techniques. Microflap dissection, using a subepithelial infusion of a saline-epinephrine solution into Reinke’s space, allows for assessment of depth of invasion and the ability to resect the lesion as a single unit. Use of an operative microscope aids the precision of such dissections. Open laryngofissure and cordectomy may be reserved for more invasive tumors.

For larger tumors of the glottis with impaired vocal cord mobility, a variety of partial resections exist that permit preservation of reasonable vocal quality. For lesions involving the anterior commissure with limited subglottic extension, an anterofrontal partial laryngectomy is indicated. For lateralized T2 or T3 glottic tumors without cartilage destruction, a vertical partial laryngectomy is feasible. In this circumstance, reconstruction is accomplished by means of a false vocal cord imbrication to simulate a true vocal cord on the side of the resection.

For T3 glottic lesions not involving the preepiglottic space or cricoarytenoid joint, a supracricoid laryngectomy with cricohyoidopexy or cricohyoidoepiglottopexy (CHEP) are options.⁶⁵ The supracricoid laryngectomy technique uses the remaining arytenoids as the phonatory structures, which come into apposition with epiglottic remnant in the CHEP, or with the tongue base in the cricohyoidopexy. Oncologic advantages of this procedure include the complete removal of the paraglottic spaces and thyroid cartilage. The supracricoid laryngectomy with CHEP is associated with excellent disease control and a high rate of tracheostomy decannulation. Favorable deglutition rates and a breathy vocal quality are seen postoperatively with this procedure. For lesions with involvement of the cricoarytenoid joint and/or extension to the level of the cricoid, total laryngectomy is required.

The risk for aspiration is high following certain partial laryngectomies. Patient selection is vital to successful application of these techniques. Presurgical pulmonary assessment may be necessary. One simple measurement of functional reserve is to have the patient climb two flights of stairs. Those able to do so without stopping are more likely to be candidates for conservation surgical procedures.

The approach to the treatment for patients with advanced tumors of the larynx and hypopharynx has evolved over time. Chemoradiation has demonstrated the ability for comparable locoregional disease control and overall survival similar to

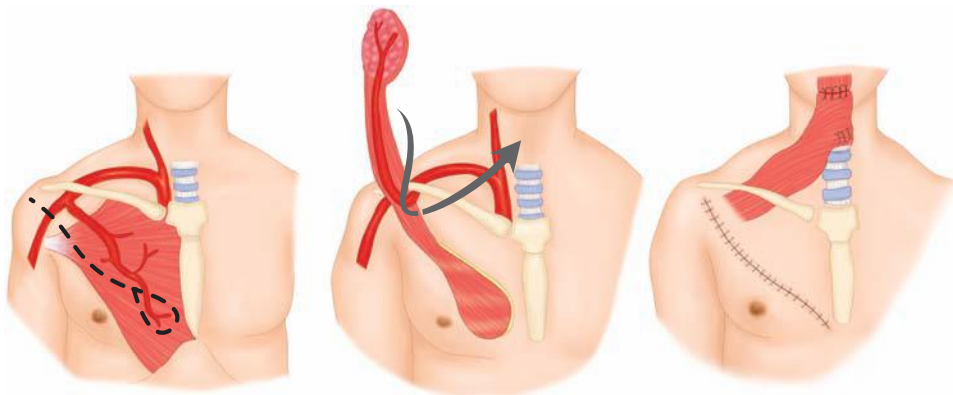


Figure 18-35. Pectoralis flap reconstruction of a laryngectomy patient requires soft-tissue augmentation for pharynx closure.

open surgical approaches. The Radiation Therapy Oncology Group 91-11 trial demonstrated a higher laryngeal preservation rate among patients receiving concomitant chemotherapy and radiotherapy than in those patients receiving radiation alone or sequential chemotherapy followed by radiation therapy.⁶⁹ A randomized laryngeal preservation trial of neoadjuvant induction chemotherapy followed by radiation therapy has yielded survival rates similar to those of laryngectomy, with the benefit of preservation of the larynx in 65% of patients.⁶⁶ Surgical salvage is available in cases of treatment failure or recurrent disease.

Speech and Swallowing Rehabilitation. Involvement of a speech and swallowing therapist is critical in the preoperative counseling and postoperative rehabilitation of patients with laryngeal cancer. Speech rehabilitation options after total laryngectomy include esophageal speech, tracheoesophageal puncture, and use of an electrolarynx. Esophageal speech is produced by actively swallowing and releasing air from the esophagus which results in vibrations of the esophageal walls and pharynx. The sounds produced can be articulated into words. The ability to create esophageal speech depends on the motivation of patients and their ability to control the upper esophageal sphincter, allowing injection and expulsion of air in a controlled fashion. Unfortunately, less than 20% of postlaryngectomy patients develop fluent esophageal speech.

A tracheoesophageal puncture is a fistula created between the trachea and esophagus that permits placement of a one-way valve that allows air from the trachea to enter the upper esophagus. The valve prevents retrograde passage of food or saliva into the trachea. Patients that undergo placement of a tracheoesophageal puncture have a success rate of >80% in achieving functional speech.

For patients unable to develop esophageal speech, the electrolarynx creates vibratory sound waves when held against the neck or cheek. The vibrations create sound waves that the patient articulates into words. A disadvantage of the electrolarynx is the mechanical quality of the sound produced. This device is most useful in the postoperative period before training for esophageal speech.

Postoperative swallowing rehabilitation is another important task performed by the speech and swallowing team. Patient instruction in various swallowing techniques and evaluation for the appropriate diet consistency allow a patient to initiate oral intake of nutrition while minimizing the risk of aspirating. Flexible fiberoptic laryngoscopy can be performed transnasally and provides valuable information to assist in the assessment of dysphagia. The oral intake of various consistencies of liquids and solids can be observed with endoscopic assessment of laryngeal penetration. A similar assessment may be performed with a modified barium swallow allowing the analysis of the various phases of swallowing.

Unknown Primary Tumors. When patients present with cervical nodal metastases without clinical or radiologic evidence of an upper aerodigestive tract primary tumor, they are referred to as having an unknown primary. Given the difficulty in performing a detailed examination in the clinical setting of the base of tongue, the tonsillar fossa, and the nasopharynx, examination under anesthesia with directed tissue biopsy specimens has been advocated. Ipsilateral tonsillectomy, direct laryngoscopy with base of tongue and pyriform biopsy specimens, examination of the nasopharynx, and bimanual examination can allow for identification of a primary site in a portion of

patients previously considered to have an unknown primary. In those individuals in whom a primary site cannot be ascertained, empiric treatment of the mucosal sources of the upper aerodigestive tract at risk (from nasopharynx to hypopharynx) and the cervical lymphatics with concomitant chemoradiation is advocated. For patients with advanced neck disease (N2a or greater) or with persistent lymphadenopathy after radiation, a postradiation neck dissection may be necessary. For patients in whom the primary lesion is identified, a more limited radiation treatment field may be used.

Nose and Paranasal Sinuses

The nose and paranasal sinuses are the sites of a great deal of infectious and inflammatory pathology. The diagnosis of tumors within this region is frequently made after a patient has been unsuccessfully treated for recurrent sinusitis and undergoes diagnostic imaging. Symptoms associated with sinonasal tumors are subtle and insidious. They include chronic nasal obstruction, facial pain, headache, epistaxis, and facial numbness. As such, tumors of the paranasal sinuses frequently present at an advanced stage. Orbital invasion can result in proptosis, diplopia, epiphora, and vision loss. Paresthesia within the distribution of CN V2 is suggestive of pterygopalatine fossa or skull base invasion and is generally a poor prognostic factor. Maxillary sinus tumors can present with loose dentition indicating erosion of the alveolar and/or palatal bones. Tumors found to arise posterior to Ohngren's line are associated with a worse prognosis than are more anteriorly based lesions (Fig. 18-36).⁷⁰

A variety of benign tumors arise in the nasal cavity and paranasal sinuses and include inverted papillomas, hemangiomas, hemangiopericytomas, angiofibromas, minor salivary tumors, and benign fibrous histiocytomas. Fibro-osseous and osseous lesions, such as fibrous dysplasias, ossifying fibromas, osteomas, and myxomas, can also arise in this region. Additionally, herniation of intracranial contents into the nasal cavity can

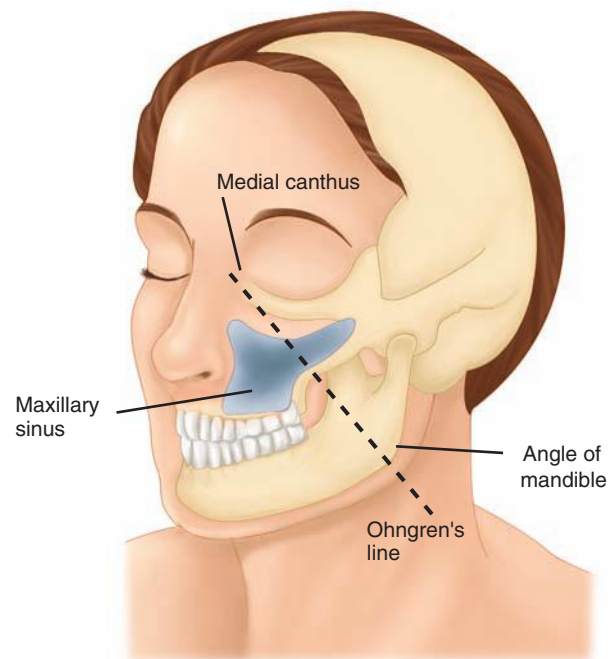


Figure 18-36. Example of the Ohngren's line and the relationship to the maxilla.

occur with the erosion of the anterior skull base with the resultant presentation of a sinonasal mass on clinical examination.

Malignant tumors of the sinuses are predominantly squamous cell carcinomas. Sinonasal undifferentiated carcinoma,⁷¹ adenocarcinoma, mucosal melanoma, lymphoma, olfactory neuroblastoma, rhabdomyosarcoma, and angiosarcoma are some of the other malignancies that have been described. Metastases from the kidney, breast, lung, and thyroid may also present as an intranasal mass. Regional metastasis is uncommon with tumors of the paranasal sinuses (14%–16%) and occurs in the parapharyngeal, retropharyngeal, and subdiaphragmatic nodes of the jugular chain.

The diagnosis of an intranasal mass is made with the assistance of a headlight and nasal speculum or nasal endoscopy. The site of origin, involved bony structures, and the presence of vascularity should be assessed. For paranasal sinus tumors, MRI and CT scanning often are complementary studies in determining orbital and intracranial extension.⁷² Benign processes frequently present as slow-growing expansile tumors with limited erosion of surrounding bone, compared to the lytic destruction typically associated with malignancies. Skull base foramen should be closely examined for enlargement that may be suggestive of perineural invasion. Examination for cavernous sinus extension, cribriform plate erosion, and dural enhancement is necessary to assess for resectability and the type of surgical approach that is possible. A meningocele or encephalocele will present as a unilateral pulsatile mass. Biopsy of a unilateral nasal mass should be deferred until imaging studies are obtained. An untimely biopsy specimen can result in a CSF leak. If hypervascularity is suspected, biopsy should be performed under controlled conditions in the operating room.

The standard treatment for malignant tumors of the paranasal sinuses is surgical resection with postoperative radiation therapy. Tumors arising along the medial wall of the maxillary sinus may be treated by means of a medial maxillectomy. The treatment of advanced tumors of the paranasal sinuses frequently involves a multispecialty approach. Members of this team include the head and neck surgeon, neurosurgeon, prosthodontist, ophthalmologist, and reconstructive surgeon. Each team member is necessary to facilitate the goal of safe and complete tumor removal. For vascular tumors, preoperative embolization performed within 24 hours of the planned surgical resection may reduce intraoperative hemorrhage.

Prognosis is dependent on tumor location and extension to the surrounding anatomy. Infrastructure maxillectomy, which includes removal of the hard palate and the lower maxillary sinus, is necessary for inferiorly based tumors of the maxillary sinus. For tumors in the upper portion of the maxillary sinus, complete maxillectomy (including removal of the orbital floor) is performed. If there is invasion of the orbital fat, exenteration of the orbital contents is required. Removal of the bony floor of the orbit and preservation of the globe are possible where there is absence of invasion through the orbital periosteum. However, reconstruction of the orbital floor to recreate a stable support for the orbital contents is essential. Removal of anterior cheek skin is indicated when there is tumor extension into the overlying subcutaneous fat and dermis.

For tumors involving the ethmoid sinuses, the integrity of the cribriform plate is assessed with preoperative imaging. Complete sphenoidectomy or medial maxillectomy may suffice if the tumor is localized to the lateral nasal wall. Endoscopic resection with the assistance of image-guidance technology is

gaining increasing acceptance for low-grade resectable lesions such as inverted papilloma.

If erosion of the cribriform has occurred, an anterior craniofacial resection is the standard operative approach. The head and neck surgeon and neurosurgeon work in concert to perform this procedure. The neurosurgeon performs a frontal craniotomy for exposure of the anterior cranial fossa floor, whereas the head and neck surgeon proceeds through a transfacial or endoscopic approach to resect the inferior bony attachments. Paranasal sinus malignancies that are deemed unresectable are those with bilateral optic nerve involvement, massive brain invasion, or carotid encasement.⁷³ Postoperative rehabilitation after orbital exenteration is accomplished by soft-tissue reconstruction and placement of a maxillofacial prosthesis. Combined treatment with surgery and postoperative radiotherapy for squamous cell carcinoma of the sinuses results in survival superior to either radiation or surgery alone. Chemotherapy has a limited application and may be used for specific indications. Rhabdomyosarcoma is primarily treated with chemotherapy followed by radiation therapy. Surgery is reserved for persistent disease after chemoradiation. Sinonasal undifferentiated carcinoma is highly aggressive and typically is not adequately controlled with standard therapy. Chemotherapy in this setting may help to reduce the tumor bulk and allow for orbital preservation.

Nasopharynx

The nasopharynx extends in a plane superior to the hard palate from the choana, to the posterior nasal cavity, to the posterior pharyngeal wall. It includes the fossa of Rosenmüller, the Eustachian tube orifices (torus tubarius), and the site of the adenoid pad. Tumors arising in the nasopharynx are usually of squamous cell origin and range from lymphoepithelioma to well-differentiated carcinoma. However, the differential diagnosis for nasopharyngeal tumors is broad and also includes lymphoma, chordoma, chondroma, nasopharyngeal cyst (Tornwaldt's cyst), angiofibroma, minor salivary gland tumor, paraganglioma, rhabdomyosarcoma, extramedullary plasmacytoma, and sarcoma.

Risk factors for nasopharyngeal carcinoma include area of habitation, ethnicity, and tobacco use. There is an increased incidence of nasopharyngeal cancer in southern China, Africa, Alaska, and in Greenland Eskimos. A strong correlation exists between nasopharyngeal cancer and the presence of EBV infection, such that EBV titers may be used as a means to follow a patient's response to treatment.

Symptoms associated with nasopharyngeal tumors include nasal obstruction, posterior (level V) neck mass, epistaxis, headache, serous otitis media with hearing loss, and otalgia. Cranial nerve involvement is indicative of skull base extension and advanced disease. Lymphatic spread occurs to the posterior cervical, upper jugular, and retropharyngeal nodes. Bilateral regional metastatic spread is common. Distant metastasis is present in 5% of patients at presentation.

Examination of the nasopharynx is facilitated by the use of the flexible or rigid fiber-optic endoscope. Evaluation with imaging studies is important for staging and treatment planning. CT with contrast is used for determining bone destruction, while MRI is used to assess for intracranial and soft-tissue extension. Erosion or enlargement of neural foramina (on CT imaging) or enhancement of cranial nerves (on MRI) is indicative of perineural spread of disease and portends a worse prognosis. The status of the cavernous sinus and optic chiasm should also be assessed.

The standard treatment for nasopharyngeal carcinoma is chemoradiation. Combination therapy produces superior survival rates for nasopharyngeal carcinoma in comparison to radiation alone.⁷⁴ Intracavitary radiation boost with implants to the tumor may be included as an adjunct to external beam radiotherapy to improve local control of advanced tumors. Surgical treatment for nasopharyngeal carcinoma is rarely feasible, but may be considered in selected cases as salvage therapy for patients with localized recurrences.

For minor salivary gland and low-grade tumors of the nasopharynx, resection can be performed via a variety of approaches. Lateral rhinotomy or midface degloving approaches can provide good access for removal of tumors in the posterior nasal cavity extending into the nasopharynx. Endoscopic removal is also possible in selected cases. A variety of surgical approaches also exist for more posteriorly located tumors extending to the sphenoid and clivus. Transpalatal approaches used in combination with transmaxillary and transcervical routes can provide good surgical access in addition to providing adequate control of the carotid artery. The emergence of endoscopic techniques has provided a significant advancement in the surgical management of lesions in these two sites.

Ear and Temporal Bone

Tumors of the ear and temporal bone are uncommon and account for less than 1% of all head and neck malignancies. Primary sites include the external ear (pinna), EAC, middle ear, mastoid, or petrous portion of the temporal bone. The most common histology is squamous cell carcinoma. Minor salivary gland tumors, including adenoid cystic carcinoma and adenocarcinoma, may also present in this region. The pinna, because of its exposure to ultraviolet light, is a common site for basal cell and squamous cell carcinoma to arise. Direct extension of tumors from the parotid gland and periauricular skin may occur in this region. Metastases from distant sites occur primarily to the petrous bone and arise in the breast, kidney, lung, and prostate. In the pediatric population, tumors of the temporal bone are most commonly soft-tissue sarcomas. For advanced stage tumors with extensive temporal bone extension, the complex anatomy of the temporal bone makes removal of tumors with functional preservation challenging.

The diagnosis of tumors of the ear and temporal bone is frequently delayed because the initial presentation of these patients is mistaken for benign infectious disease. When patients fail to improve with conservative care and symptoms evolve to potentially include facial nerve paralysis or worsening hearing loss, the need for imaging and biopsy become obvious. Granulation tissue in the EAC or middle ear should be biopsied in patients with atypical presentations or histories consistent with chronic otologic disease.⁷⁵ The complexity of the temporal bone anatomy makes the use of imaging studies of paramount importance in the staging and treatment of tumors in this region.

Small skin cancers on the helix of the ear can be readily treated with simple excision and primary closure. Mohs' microsurgery with frozen section margin control also can be used for cancer of the external ear. In lesions that are recurrent or invade the underlying perichondrium and cartilage, rapid spread through tissue planes can occur. Tumors may extend from the cartilaginous external canal to the bony canal and invade the parotid, temporomandibular joint, and skull base. For extensive, pinna-based lesions, procedures such as auriculectomy may be required. Postoperative radiation therapy may be required for

advanced skin cancer with positive margins, perineural spread, or multiple involved lymph nodes.

Tumors involving the EAC and middle ear may present with persistent otorrhea, otalgia, EAC or periauricular mass, hearing loss, and facial nerve weakness or paralysis. The patient resembles the presentation of an external otitis unresponsive to standard medical therapy. Sleeve resections are reserved for small superficial tumors involving the cartilaginous external canal. Tumors involving the petrous apex or intracranial structures may present with headache and palsies of CN V and VI. The optimal treatment for tumors of the middle ear and bony external canal is en bloc resection followed by radiation therapy. Management of the regional lymphatics is determined by the site and stage of the tumor at presentation. Temporal bone resections are classified as lateral or subtotal (Fig. 18-37). The lateral temporal bone resection removes the bony and cartilaginous canal, tympanic membrane, and ossicles. The subtotal temporal bone resection includes the removal of the ear canal, middle ear, inner ear, and facial nerve. It is indicated for malignant tumors extending into the middle ear.

Postoperative radiation therapy in the treatment of malignancies of the temporal bone usually is indicated and improves local control over surgery alone. Five-year survival rates are approximately 50% for patients with tumors confined to the external canal and decrease with medial tumor extension. Prognosis is poor when tumor involves the petrous apex.⁷⁶

The purpose of reconstruction after temporal bone resection is to provide vascularized tissue and bulk to the site of resection. Prevention of CSF leak by watertight dural closure and prevention of meningitis are important goals of repair. Additionally, the reconstruction enables protection of vascular structures and the surrounding bone to prepare the patient for postoperative radiation therapy. Commonly used reconstruction methods are regional pedicle myocutaneous flaps (e.g.,

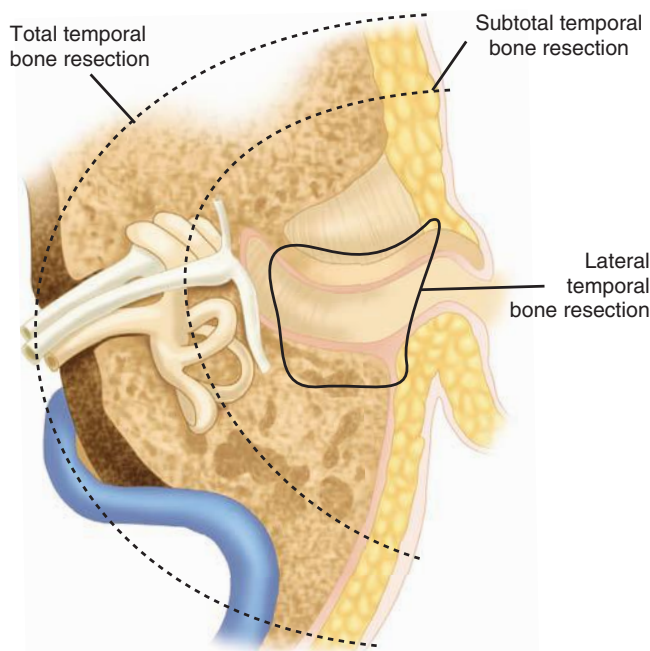


Figure 18-37. Examples of resection specimens for lateral temporal bone resection, subtotal temporal bone resection, and total temporal bone resection.

pectoralis major) and free flaps (e.g., rectus abdominis, radial forearm, or latissimus dorsi). The loss of the pinna produces significant external deformity; however, a prosthetic ear may produce acceptable rehabilitation. When the facial nerve is sacrificed, rehabilitation is necessary and includes the use of interposition nerve grafts, hypoglossal to facial nerve anastomosis, and static or dynamic sling techniques. In patients with poor eye closure, taping of the eyelids and the liberal use of eye lubrication can prevent exposure keratitis. Additionally, tarsorrhaphy, lid-shortening procedures, and the use of gold weight implants can provide upper eyelid closure and protect the cornea.

Neck

The diagnostic evaluation of a neck mass requires a planned approach that does not compromise the effectiveness of future treatment options. A neck mass in a 50-year-old smoker/drinker with a synchronous oral ulcer is different from cystic neck mass in an 18-year-old that enlarges with an upper respiratory infection. As with all diagnoses, a complete history with full head and neck exam, including flexible laryngoscopy, are critical to complete evaluation. The differential diagnosis of a neck mass is dependent on its location and the patient's age. In children, most neck masses are inflammatory or congenital. However, in the adult population, a neck mass >2 cm in diameter has a >80% probability of being malignant. Once the physician has developed a differential diagnosis, interventions to confirm or dispute diagnoses are initiated. Fine-needle aspiration (FNA), with or without the assistance of ultrasound or CT guidance, can provide valuable information for early treatment planning. The use of imaging (CT and/or MRI) is dictated by the patient's clinical presentation. Imaging enables the physician to evaluate the anatomic relationships of the mass to the surrounding anatomy of the neck and sharpen the differential. A cystic lesion may represent benign pathology such as a branchial cleft cyst; however, it may also represent a regional metastasis of a tonsil/base of tongue squamous cell carcinoma or a papillary thyroid carcinoma. In this circumstance, evaluation of these potential primary sites can alter the planned operative intervention.

If a variety of diagnoses are still being entertained after FNA and imaging, an open biopsy may be necessary. For patients with the potential diagnosis of lymphoma, a biopsy sacrificing normal anatomical structures is not necessary. Ensuring appropriate processing of biopsied materials, sent in saline or in formalin, and sparing undue trauma to tissues can decrease the need for re-biopsy. Appropriate placement of the incision for an open biopsy should be considered if the need for neck dissection or composite resection is later required.

Patterns of Lymph Node Metastasis. The regional lymphatic drainage of the neck is divided into seven levels. These levels allow for a standardized format for radiologists, surgeons, pathologists, and radiation oncologists to communicate concerning specific sites within the neck (Fig. 18-38). The levels are defined as the following:

- Level I—the submental and submandibular nodes
 - Level Ia—the submental nodes; medial to the anterior belly of the digastric muscle bilaterally, symphysis of mandible superiorly, and hyoid inferiorly
 - Level Ib—the submandibular nodes and gland; posterior to the anterior belly of digastric, anterior to the posterior belly of digastric, and inferior to the body of the mandible
- Level II—upper jugular chain nodes

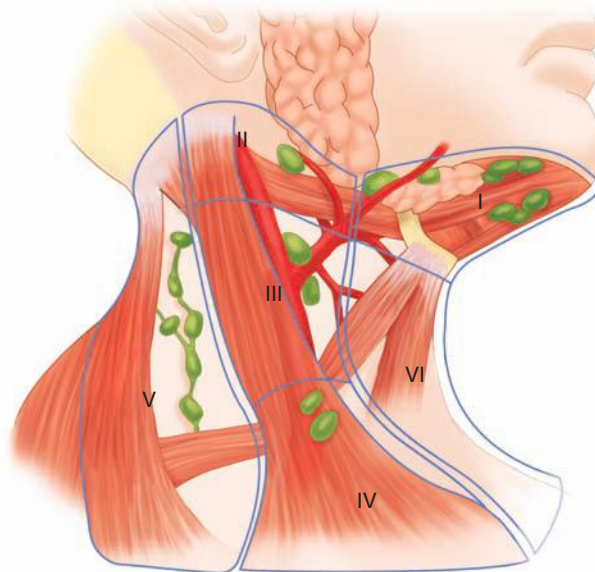


Figure 18-38. Levels of the neck denoting lymph node bearing regions.

Level IIa—jugulodigastric nodes; deep to sternocleidomastoid (SCM) muscle, anterior to the posterior border of the muscle, posterior to the posterior aspect of the posterior belly of digastric, superior to the level of the hyoid, inferior to spinal accessory nerve (CN XI)

Level IIb—submuscular recess; superior to spinal accessory nerve to the level of the skull base

Level III—middle jugular chain nodes; inferior to the hyoid, superior to the level of the cricoid, deep to SCM muscle from posterior border of the muscle to the strap muscles medially

Level IV—lower jugular chain nodes; inferior to the level of the cricoid, superior to the clavicle, deep to SCM muscle from posterior border of the muscle to the strap muscles medially

Level V—posterior triangle nodes

Level Va—lateral to the posterior aspect of the SCM muscle, inferior and medial to splenius capitis and trapezius, superior to the spinal accessory nerve

Level Vb—lateral to the posterior aspect of SCM muscle, medial to trapezius, inferior to the spinal accessory nerve, superior to the clavicle

Level VI—anterior compartment nodes; inferior to the hyoid, superior to suprasternal notch, medial to the lateral extent of the strap muscles bilaterally

Level VII—paratracheal nodes; inferior to the suprasternal notch in the upper mediastinum

Patterns of spread from primary tumor sites in the head and neck to cervical lymphatics are well described.⁷⁷ The location and incidence of metastasis vary according to the primary site. Primary tumors within the oral cavity and lip metastasize to the nodes in levels I, II, and III. Skip metastases may occur with oral tongue cancers such that involvement of nodes in level III or IV may occur without involvement of higher echelon nodes (levels I & II). Tumors arising in the oropharynx, hypopharynx, and larynx most commonly spread to the lymph nodes of the lateral neck in levels II, III, and IV. Isolated level V lymphadenopathy

is uncommon with oral cavity, pharyngeal, and laryngeal primaries. Malignancies of the nasopharynx and thyroid commonly spread to level V nodes in addition to the jugular chain nodes. Retropharyngeal lymph nodes are sites for metastasis from tumors of the nasopharynx, soft palate, and lateral and posterior walls of the oropharynx and hypopharynx. Tumors of the hypopharynx, cervical esophagus, and thyroid frequently involve the paratracheal nodal compartment, and may extend to the lymphatics in the upper mediastinum (level VII). The delphian node, a pretracheal lymph node, may become involved by advanced tumors of the glottis with subglottic spread.

The philosophy for the treatment of the cervical lymphatics in head and neck cancer has evolved significantly since the mid-1970s. The presence of cervical metastasis decreases the 5-year survival rate in patients with upper aerodigestive malignancies by approximately 50%. As such, adequate treatment of the N_0 and N_+ neck in these patients has always been viewed as a priority in an effort to increase disease-free survival rates. Traditionally, the gold standard for control of cervical metastasis has been the radical neck dissection (RND) first described by Crile. The classic RND removes levels I to V of the cervical lymphatics in addition to the SCM, internal jugular vein, and the spinal accessory nerve (CN XI). Any modification of the RND that preserves nonlymphatic structures (i.e., CN XI, SCM muscle, or internal jugular vein) is defined as a *modified radical neck dissection* (MRND). A neck dissection that preserves lymphatic compartments normally removed as part of a classic RND is termed a *selective neck dissection* (SND). Bocca and colleagues demonstrated that the MRND, or “functional neck dissection,” was equally effective in controlling regional metastasis as the RND, in addition to noting that the functional results in patients were superior.⁷⁸ With outcome data supporting the use of SND and MRND, these procedures have become the preferred alternative for the treatment of cervical metastases when indicated.^{79,80}

SND options have become increasingly popular given the benefits of improved shoulder function and cosmetic impact on neck contour compared to MRND. The principle behind preservation of certain nodal groups is that specific primary sites preferentially drain their lymphatics in a predictable pattern. Types of SND include the supraomohyoid neck dissection, the lateral neck dissection, and the posterolateral neck dissection.⁸¹ The supraomohyoid dissection, typically used with oral cavity malignancies, removes lymph nodes in levels I to III (Fig. 18-39). The lateral neck dissection, frequently used for laryngeal malignancies, removes those nodes in levels II through IV (Fig. 18-40). The posterolateral neck dissection, used with thyroid cancer, removes the lymphatics in levels II to V (Fig. 18-41). In the clinically negative neck (N_0), if the risk for occult metastasis is >20%, elective treatment of the nodes at risk is generally advocated. This may be in the form of elective neck irradiation or elective neck dissection. An additional role of SND is as a staging tool to determine the need for postoperative radiation therapy. Regional control after selective dissection has been shown to be as effective for controlling regional disease as the MRND in the N_0 patient. Awareness of the potential for “skip metastases,” in particular with lateral oral tongue lesions, may require extension of a standard SND to include additional levels for selected lesions.⁸² The treatment option selected for the primary site cancer is a significant factor in determining which therapeutic modality will be selected for the treatment of the regional lymphatics.

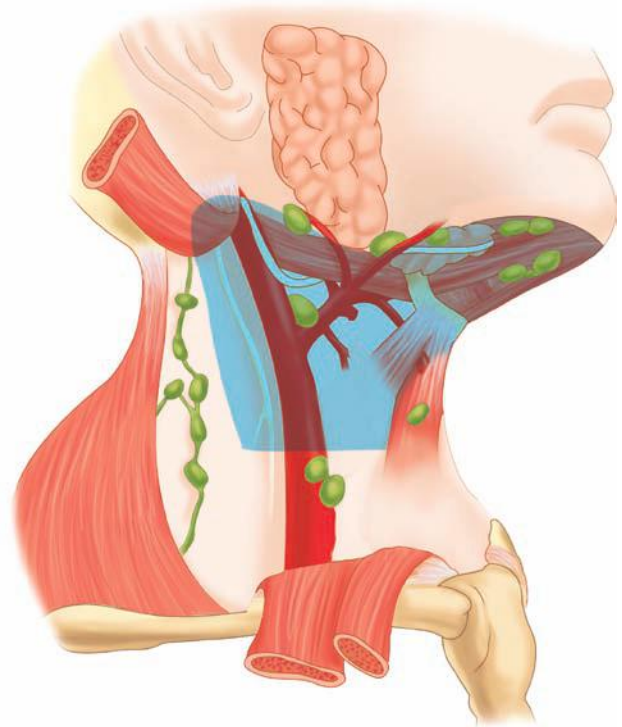


Figure 18-39. Shaded region indicates the region included in a supraomohyoid neck dissection.

For clinically N_+ necks, frequently the surgical treatment of choice is the MRND or RND. SND options have been advocated by some authors for treatment of limited N1 disease, however, they do not have a role in the treatment of advanced N stage disease. When extracapsular spread, perineural invasion,

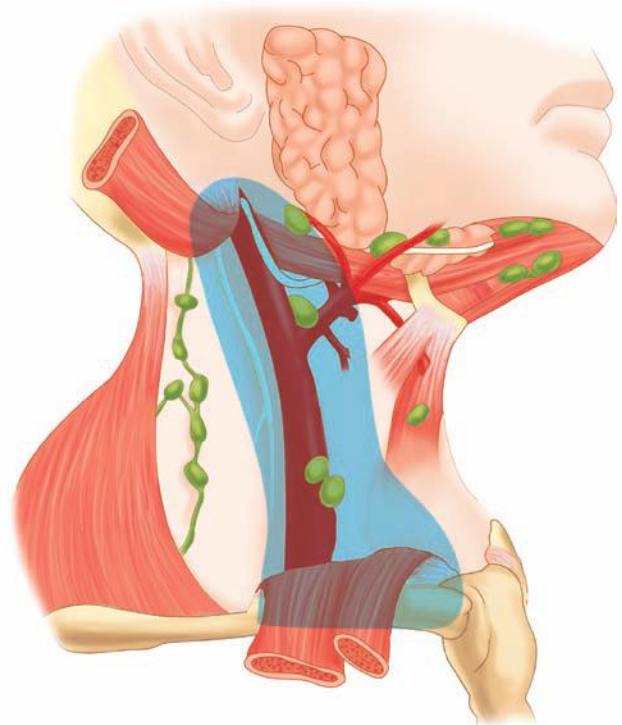


Figure 18-40. Shaded region indicates the region included in a lateral neck dissection.

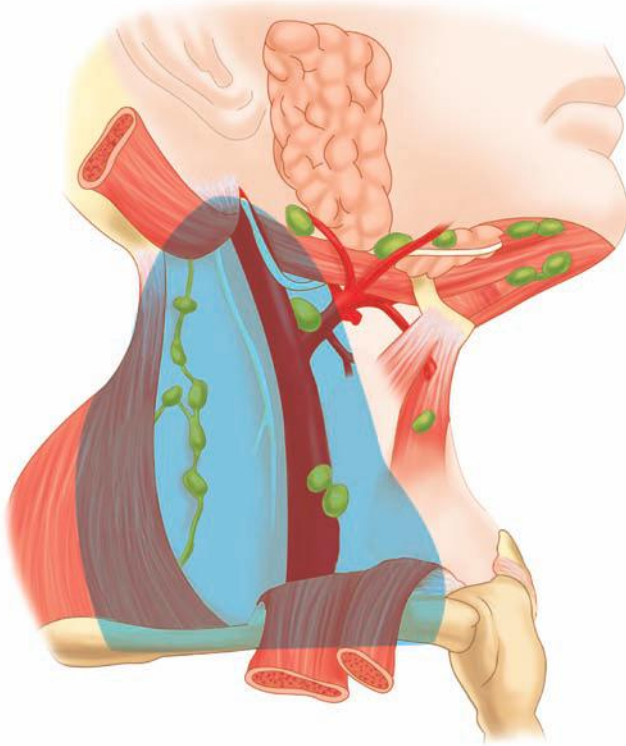


Figure 18-41. Shaded region indicates the region included in a posterolateral neck dissection.

vascular invasion, and the presence of multiple involved lymph nodes are noted, surgical management of the neck alone is not adequate.⁸³ Adjuvant radiation therapy, and possibly chemoradiation, is indicated in these cases.

A planned postradiation neck dissection for patients undergoing radiation as a primary therapy is another indication for the use of neck dissection. In patients with existing advanced N stage disease (N2a or greater) or in patients with a partial response in the neck to therapy, neck dissection is performed 6 to 8 weeks after completion of radiation.

Regional metastases that encase the carotid artery or that demonstrate fixation of nodes to surrounding structures (e.g., prevertebral muscles) decrease 5-year survival rates significantly, to the range of 15% to 22%. The associated morbidity is high with procedures involving carotid resection (e.g., cerebrovascular accident and death) and must be weighed carefully when deciding if surgery is to be pursued. Surgically debulking metastatic disease does not improve survival and is not advocated. Recurrent neck metastasis after comprehensive neck dissection or radiation is associated with very poor survival.

Parapharyngeal Space Masses. The parapharyngeal space is a potential space, shaped like an inverted pyramid spanning the skull base to the hyoid. The boundaries of the space are separated by the styloid process and its associated fascial attachments into the “prestyloid” and “poststyloid” compartments.⁸⁴ The contents of the prestyloid space are the parotid, fat, and lymph nodes. The poststyloid compartment is composed of CN’s IX to XII, the carotid space contents, cervical sympathetic chain, fat, and lymph nodes. Tumors in this space can produce displacement of the lateral pharyngeal wall medially into the oropharynx (Fig. 18-42), dysphagia, cranial nerve dysfunction, Horner’s syndrome, or vascular compression.

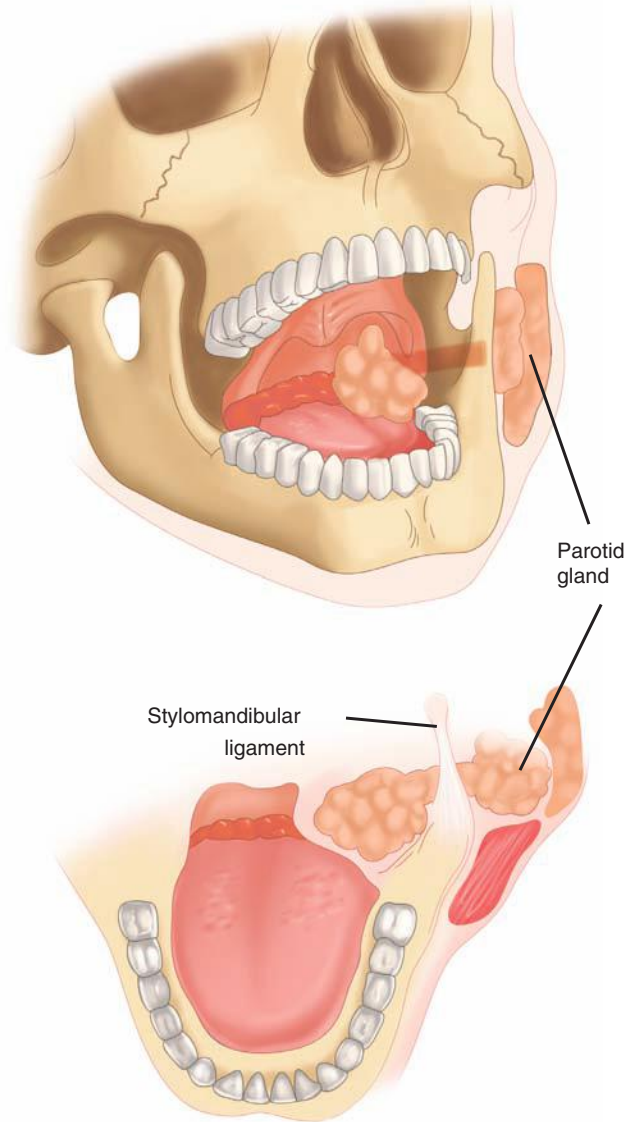


Figure 18-42. Parapharyngeal mass—prestyloid with prominent oropharyngeal presentation typical of a dumbbell tumor.

Of the masses found in the parapharyngeal space, 40% to 50% of the tumors are of salivary gland origin. Tumors of neurogenic origin such as paragangliomas (glomus vagale, carotid body tumor), schwannomas, and neurofibromas are responsible for 20% to 25% of parapharyngeal masses. Lymph node metastases and primary lymphoma represent 15% of lesions. With this in mind, when reviewing preoperative imaging, one can assume that tumors arising anterior to the styloid process are most likely of salivary gland origin, whereas those of the poststyloid compartment are vascular or neurogenic. This is helpful in that angiography is not as necessary for prestyloid lesions as it may be for vascular poststyloid tumors. If a paraganglioma is suspected, a 24-hour urinary catecholamine collection should be obtained to allow for optimal premedication for patients with functional tumors. Embolization may be considered for vascular tumors before surgery in an attempt to decrease intraoperative blood loss.

Surgical access to these tumors may require a transmandibular and/or lateral cervical approach. It is inadvisable to approach parapharyngeal space tumors transorally without

having the necessary exposure and control of the associated vasculature that is afforded by these approaches. Some tumors of the parapharyngeal space (e.g., dumbbell tumors of deep parotid origin) are amenable to removal by a combined transparotid and transcervical approach while allowing for dissection and displacement of the facial nerve to assist removal of tumor.

Benign Neck Masses. A number of benign masses of the neck occur that require surgical management. Many of these masses are seen in the pediatric population. The differential diagnosis includes thyroglossal duct cyst, branchial cleft cyst, lymphangioma (cystic hygroma), hemangioma, and dermoid cyst.

Thyroglossal duct cysts represent the vestigial remainder of the tract of the descending thyroid gland from the foramen cecum, at the tongue base, into the lower anterior neck during fetal development. They present as a midline or paramedian cystic mass adjacent to the hyoid bone. After an upper respiratory infection, the cyst may enlarge or become infected. Surgical management of a thyroglossal duct cyst requires removal of the cyst, the tract, and the central portion of the hyoid bone (Sistrunk procedure), as well as a portion of the tongue base up to the foramen cecum. Before excision of a thyroglossal duct cyst, an imaging study such as ultrasound is performed to identify if normal thyroid tissue exists in the lower neck, and lab assay is performed to assess if the patient is euthyroid.

Congenital branchial cleft remnants are derived from the branchial cleft apparatus that persists after fetal development. There are several types, numbered according to their corresponding embryologic branchial cleft. First branchial cleft cysts and sinuses are associated intimately with the EAC and the parotid gland. Second and third branchial cleft cysts are found along the anterior border of the SCM muscle and can produce drainage via a sinus tract to the neck skin (Fig. 18-43). Secondary infections can occur, producing enlargement, cellulitis, and neck abscess that requires operative drainage. The removal of

branchial cleft cysts and fistula requires removal of the fistula tract to the point of origin to decrease the risk of recurrence. The second branchial cleft remnant tract courses between the internal and external carotid arteries and proceeds into the tonsillar fossa. The third branchial cleft remnant courses posterior to the common carotid artery, ending in the pyriform sinus region. Cystic metastasis from squamous cell carcinoma of the tonsil or tongue base to a cervical lymph node can be confused for a branchial cleft cyst in an otherwise asymptomatic patient. Dermoid cysts tend to present as midline masses and represent trapped epithelium originating from the embryonic closure of the midline.

Lymphatic malformations such as lymphangiomas and cystic hygromas can be difficult management problems. They typically present as mobile, fluid-filled masses. Because of their predisposition to track extensively into the surrounding soft tissues, complete removal of these lesions can be challenging. Recurrence and re-growth occur with incomplete removal. Cosmetic deformity and/or nerve injury can result when extensive surgical dissection is performed for large lesions. In newborns and infants, there is higher associated morbidity when cystic hygromas and lymphangiomas become massive, require tracheostomy, and involve the deep neck and mediastinum.

Deep Neck Fascial Planes. The fascial planes of the neck provide boundaries that are clinically applicable because they determine the pathway of spread of an infection. The deep cervical fascia is composed of three layers. These are the investing (superficial deep), pretracheal, and the prevertebral fascias. The superficial layer of the deep cervical fascia forms a cone around the neck and spans from skull base and mandible to the clavicle and manubrium. This layer surrounds the SCM muscle and covers the anterior and posterior triangles of the neck. The pretracheal fascia is found within the anterior compartment, deep to the strap muscles and surrounds the thyroid gland, trachea, and esophagus. This fascia blends laterally to the carotid sheath.

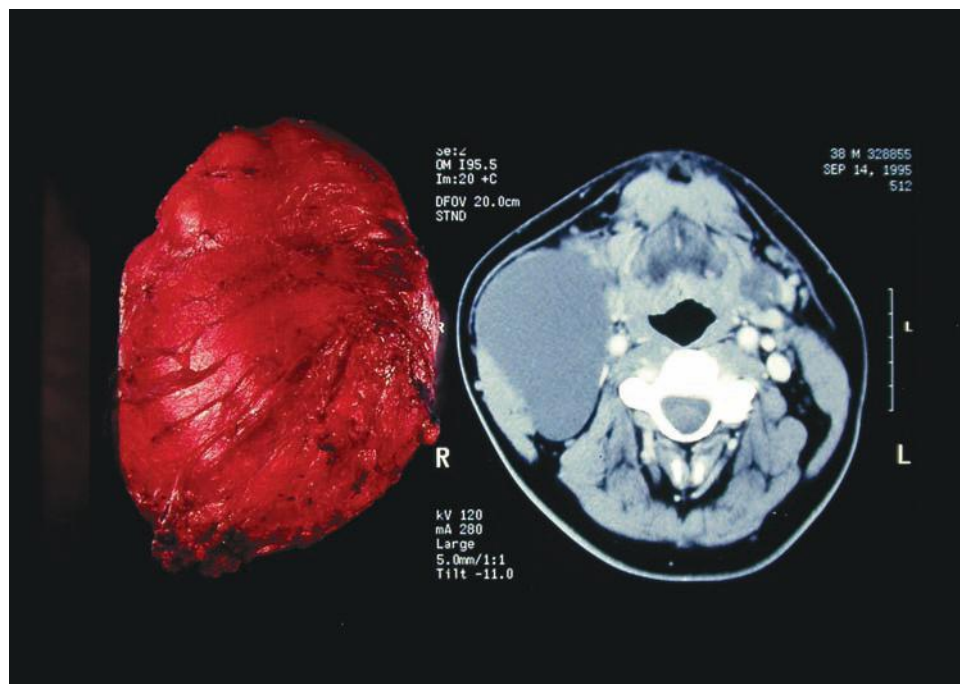


Figure 18-43. CT scan demonstrating a branchial cleft cyst with operative specimen.

Infections in this region may track along the trachea or esophagus into the mediastinum. The prevertebral fascia extends from the skull base to the thoracic vertebra and covers the prevertebral musculature and cervical spine. If an infection were to communicate anteriorly through the prevertebral fascia, it would enter the retropharyngeal space. Infectious extension into this space is complicated by the fact that this region, located posterior to the buccopharyngeal fascia, extends from the skull base to the mediastinum.

Salivary Gland Tumors

Tumors of the salivary gland are relatively uncommon and represent less than 2% of all head and neck neoplasms. The major salivary glands are the parotid, submandibular, and sublingual glands. Minor salivary glands are found throughout the submucosa of the upper aerodigestive tract with the highest density found within the palate. About 85% of salivary gland neoplasms arise within the parotid gland (Fig. 18-44). The majority of these neoplasms are benign, with the most common histology being pleomorphic adenoma (benign mixed tumor). In contrast, approximately 50% of tumors arising in the submandibular and sublingual glands are malignant. Tumors arising from minor salivary gland tissue carry an even higher risk for malignancy (75%).

Salivary gland tumors are usually slow growing and well circumscribed. Patients with a mass and findings of rapid growth, pain, paresthesias, and facial nerve weakness are at increased risk of harboring a malignancy. The facial nerve, which separates the superficial and deep lobes of the parotid, may be directly involved by tumors in 10% to 15% of patients. Additional findings ominous for malignancy include skin invasion and fixation to the mastoid tip. Trismus suggests invasion of the masseter or pterygoid muscles.⁸⁵

Submandibular and sublingual gland tumors present as a neck mass or floor of mouth swelling, respectively. Malignant tumors of the sublingual or submandibular gland may invade the lingual or hypoglossal nerves, causing paresthesias or paralysis.⁸⁶ Bimanual examination is important for determining the size of the

tumor and possible fixation to the mandible or involvement of the tongue.

Minor salivary gland tumors present as painless submucosal masses and are most frequently seen at the junction of the hard and soft palate. Minor salivary gland tumors arising in the prestyloid parapharyngeal space may produce medial displacement of the lateral oropharyngeal wall and tonsil.

The incidence of metastatic spread to cervical lymphatics is variable and depends on the histology, primary site, and stage of the tumor. Parotid gland malignancies can metastasize to the intra- and periglandular nodes. The next echelon of lymphatics for the parotid is the upper jugular nodal chain. Although the risk of lymphatic metastasis is low for most salivary gland malignancies, lesions that are considered high grade or that demonstrate perineural invasion have a higher propensity for regional spread. Tumors arising in patients of advanced age also tend to have more aggressive behavior. Initial nodal drainage for the submandibular gland is the level Ia and Ib lymph nodes and submental nodes followed by the upper and midjugular nodes. Extracapsular extension of tumor and lymph node metastases are adverse prognostic factors for submandibular gland tumors.

Diagnostic imaging is standard for the evaluation of salivary gland tumors. MRI is the most sensitive study to determine soft-tissue extension and involvement of adjacent structures. Unfortunately, imaging studies lack the specificity for differentiating benign and malignant neoplasms. Diagnosis of salivary gland tumors is frequently aided by the use of FNA. In the hands of an experienced cytologist familiar with salivary gland pathology, FNA can provide an accurate preoperative diagnosis in 70% to 80% of cases. This can help the operative surgeon with treatment planning and patient counseling, but should be viewed in the context that a more extensive procedure may be ultimately required. The final histopathologic diagnosis is confirmed by surgical excision.

Benign and malignant tumors of the salivary glands are divided into epithelial, nonepithelial, and metastatic neoplasms. Benign epithelial tumors include pleomorphic adenoma (80%), monomorphic adenoma, Warthin's tumor, oncocytoma, or sebaceous neoplasm. Nonepithelial benign lesions include hemangioma, neural sheath tumor, and lipoma. Treatment of benign neoplasms is surgical excision of the affected gland or, in the case of the parotid, excision of the superficial lobe with facial nerve dissection and preservation. The minimal surgical procedure for neoplasms of the parotid is superficial parotidectomy with preservation of the facial nerve. Enucleation of the tumor mass is not recommended because of the risk of incomplete excision and tumor spillage. Tumor spillage of a pleomorphic adenoma during removal can lead to problematic recurrences.

Malignant epithelial tumors range in aggressiveness from low to high grade. Their behavior depends on tumor histology, degree of invasiveness, and the presence of regional metastasis. The most common malignant epithelial neoplasm of the salivary glands is mucoepidermoid carcinoma. The low-grade mucoepidermoid carcinoma is composed of largely mucin-secreting cells, whereas in high-grade tumors, the epidermoid cells predominate. High-grade mucoepidermoid carcinomas resemble nonkeratinizing squamous cell carcinoma in their histologic features and clinical behavior. Adenoid cystic carcinoma, which has a propensity for neural invasion, is the second most common malignancy in adults. Skip lesions along nerves are common

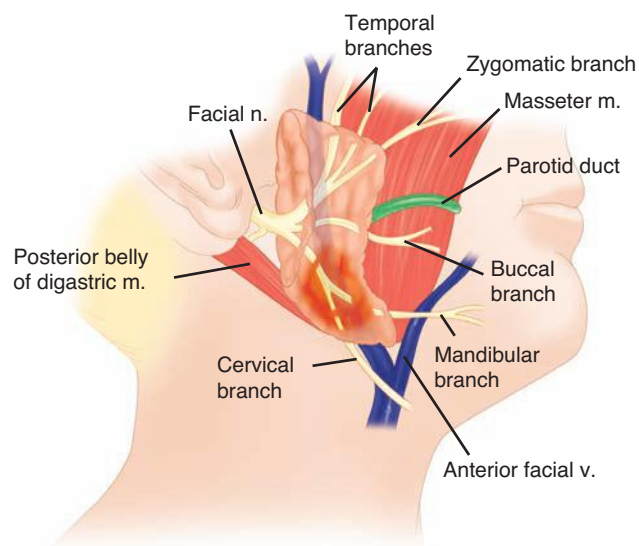


Figure 18-44. Example of a tumor in the parotid with the pattern of the facial nerve and associated anatomy. m. = muscle; n. = nerve; v. = vein.

and can lead to treatment failures because of the difficulty in treating the full extent of invasion. Adenoid cystic carcinomas have a high incidence of distant metastasis, but display indolent growth. It is not uncommon for patients to experience lengthy survival despite the presence of disseminated disease. The most common malignancies in the pediatric population are mucoepidermoid carcinoma and acinic cell carcinoma. For minor salivary glands, the most common malignancies are adenoid cystic carcinoma, mucoepidermoid carcinoma, and low-grade polymorphous adenocarcinoma. Carcinoma ex pleomorphic adenoma is an aggressive malignancy that arises from a preexisting benign mixed tumor.

The primary treatment of salivary malignancies is surgical excision. In this setting, basic surgical principles include the en bloc removal of the involved gland with preservation of all nerves unless directly invaded by tumor. For parotid tumors that arise in the lateral lobe, superficial parotidectomy with preservation of CN VII is indicated. If the tumor extends into the deep lobe of the parotid, a total parotidectomy with nerve preservation is performed. Although malignant tumors may about the facial nerve, if a plane of dissection can be developed without leaving gross tumor, it is preferable to preserve the nerve. If the nerve is encased by tumor (or is noted to be nonfunctional preoperatively) and preservation would result leaving gross residual disease, nerve sacrifice should be considered.

The removal of submandibular malignancies includes en bloc resection of the gland and submental and submandibular lymph nodes. Radical resection is indicated with tumors that invade the mandible, tongue, or floor of mouth. Therapeutic removal of the regional lymphatics is indicated for clinical adenopathy or when the risk of occult regional metastasis exceeds 20%. High-grade mucoepidermoid carcinomas, for example, have a high risk of regional disease and require elective treatment of the regional lymphatics. When gross nerve invasion is found (lingual or hypoglossal), sacrifice of the nerve is indicated with retrograde frozen section biopsy specimens to determine the extent of involvement. If the nerve is invaded at the level of the skull base foramina, a surgical clip may be left in place to mark the area for inclusion in postoperative radiation fields. The presence of skip metastases in the nerve with adenoid cystic carcinoma makes recurrence common with this pathology.

Postoperative radiation treatment plays an important role in the treatment of salivary malignancies. The presence of extraglandular disease, perineural invasion, direct invasion of regional structures, regional metastasis, and high-grade histology are all indications for radiation treatment.

RECONSTRUCTION IN HEAD AND NECK SURGERY

Defects of soft tissue and bony anatomy of the head and neck can occur after oncologic resection. Tumor surgery frequently necessitates removal of structures related to speech and swallowing. Loss of sensation and motor function can produce dysphagia through impairment of food bolus formation, manipulation, and propulsion. Removal of laryngeal, tongue base, and hypopharyngeal tumors can lead to impairment in airway protective reflexes and predispose to aspiration. Cosmetic deformities that result from surgery can also significantly impact the quality of life of a patient. Current surgical management of head and neck tumors requires restoration of form and function through application of contemporary reconstruction techniques.

Basic principles of reconstruction include attempting to replace resected tissue components (bone, skin, soft tissue) with tissue with similar qualities. However, restoring a patient's functional capacity does not always require strict observation of this rule. The head and neck reconstructive surgeon must consider a patient's preoperative comorbidities and anatomy when constructing a care plan.

A stepladder analogy has been used to describe the escalation in complexity of reconstructive options in the repair of head and neck defects. It is important to remember that the most complex procedure is not always the most appropriate. Progression for closure by secondary intention, primary closure, skin grafts, local flaps, regional flaps, and free-tissue transfer flaps (free flaps) run the gamut of options available. The most appropriate reconstructive technique used is based on the medical condition of the patient, the location and size of the defect to be repaired, and the functional impairment associated with the defect.

Small defects of the skin of the medial canthus, scalp, and nose may be allowed to heal by secondary intention with excellent cosmetic and functional results. When considering primary closure, the excision should be placed in the lines of relaxed skin tension and should attempt to not distort surrounding anatomy such as the hairline, eyelids, or lips.

Skin Grafts

Split and full-thickness skin grafts are used in the head and neck for a variety of defects. Following oral cavity resections, split-thickness grafts can provide adequate reconstruction of the mucosal surface if an adequate vascular tissue bed is available to support the blood supply needed for graft survival. These grafts start to incorporate into the recipient site in approximately 5 days and do not provide replacement of absent soft-tissue bulk; however, they are a simple low morbidity technique for covering mucosal defects that allow for monitoring for local recurrence. Full-thickness grafts are used on the face when local rotational flaps are not available. These grafts have less contracture over time than split-thickness grafts. Grafts can be harvested from the postauricular or supraclavicular areas to maximize the match of skin characteristics. Dermal grafts have been used to provide coverage for exposed vessels in the neck, reconstruct mucosal defects, and assist in providing soft-tissue bulk.

Local Flaps

Local flaps encompass a large number of mainly random-pattern flaps used to reconstruct defects in adjacent areas. It is beyond the scope of this chapter to enumerate all of these flaps, but they should be designed according to the relaxed skin tension lines of the face and neck skin. These lines are tension lines inherent in the facial regions and caused in part by the insertions of muscles of facial animation. Incisions paralleling the relaxed skin tension lines that respect the aesthetic subunits of the face heal with the least amount of tension and camouflage into a more appealing cosmetic result. Poorly designed incisions or flaps result in widened scars and distortion of important aesthetic units.

Regional Flaps

Regional flaps are those that are available as pedicled transfer of soft tissue from areas adjacent to the defect. These flaps have an axial blood supply that traverses the flap longitudinally from proximal to distal between the fascia and subcutaneous tissue. Single-stage reconstruction is possible, and harvest may occur simultaneously with the resection of primary disease resulting in a decrease in overall operative time.

The deltopectoral fasciocutaneous flap is a medially based flap from the anterior chest wall reliant on the perforators of the internal mammary artery. Its pliability permits folding, making it capable for use with reconstruction of pharyngoesophageal defects. A disadvantage is that use of the flap requires a second stage detaching the proximal chest component and completion of inseting approximately 3 to 4 weeks after the original procedure.

Several myocutaneous flaps exist for head and neck reconstruction. The vascular pedicle of these flaps permits a wide arc of rotation, making them ideal for a variety of different reconstructive needs. The trapezius muscle provides a number of soft-tissue flaps that can be rotated to reconstruct a number of defects in the head and neck. The superior trapezius flap is based on paraspinous perforators and is ideal for lateral neck defects. The lateral island trapezius flap, based on the transverse cervical and dorsal scapular vessels, allows for harvest of a soft-tissue paddle below the inferior border of the scapula. This flap is ideal for reconstruction of scalp and lateral skull base defects.

The pectoralis myocutaneous flap is based on the pectoral branch of the thoracoacromial artery (medial) and the lateral thoracic artery (lateral). The latter vessel may be sacrificed to increase the arc of rotation. This workhorse flap includes the pectoralis major muscle, either alone or with overlying anterior chest skin. The pectoralis myocutaneous flap has enjoyed tremendous popularity because of its ease of harvest, the ability to tailor its thickness to the defect, and limited donor site morbidity. It can be used for reconstruction of the oropharynx, oral cavity, and the hypopharynx and in some cases can be tubed to replace cervical esophageal defects. Bulk associated with this flap may make certain applications less practical, and this problem is exacerbated in obese patients. The arc of rotation limits the superior extent of this flap to the zygomatic arch externally and the superior pole of the tonsil internally.

The latissimus dorsi flap provides a large source of soft tissue and has a wide arc of rotation. The flap is based on the thoracodorsal vasculature. This flap can be used as a regional rotational flap or as a free flap. Lateral decubitus positioning is typically required for harvesting this flap, making it less attractive for simultaneous cancer ablation and reconstruction.

Free-Tissue Transfer

Free-tissue transfer with microvascular anastomosis affords the reconstructive surgeon unparalleled ability to replace tissue loss with tissues of similar characteristics. There are a number of donor sites available for various types of flaps, including osteomyocutaneous, myocutaneous, fasciocutaneous, fascial, and myo-osseous flaps. The flaps most popular in head and neck reconstructive armamentarium are those with ease of harvest from a standpoint of patient positioning and those that allow for a two-teamed approach for simultaneous flap harvesting and oncologic resection.⁸⁷

The radial forearm fasciocutaneous flap (Fig. 18-45) is a hardy flap with constant vascular anatomy and a long vascular pedicle, allowing for ease of inseting and choice in anastomotic vascular recipient sites. It is pliable and can be reinnervated as a sensate flap, making it ideal for repair of oral cavity and oropharyngeal defects. It can be tubed to repair hypopharyngeal and upper esophageal defects.^{88,89}

The anterolateral thigh flap, based on the descending branch of the lateral circumflex femoral artery, has the capacity for a large pliable skin paddle with muscle that is capable of being tubed and is used to reconstruct similar defects as that of the radial forearm flap while providing more tissue bulk.

The fibular osteocutaneous or osteomyocutaneous flap allows for one-stage reconstruction of resected mandible. In the adult, up to 20 cm of bone can be harvested with a cuff of soleus and flexor hallucis longus muscle for additional soft-tissue bulk. The donor site defect is well tolerated as long as approximately 7 cm of bone are retained proximally and distally for knee and ankle stability.⁹⁰

Iliac crest osteocutaneous flaps are also used for the reconstruction of mandible defects. The natural shape of this donor site bone is similar to the mandibular angle. The thick stock of bone provided by the iliac crest allows for better vertical reconstruction of the mandible while spanning a segmental defect. However, for lengthy mandibular defects (>10 cm), the fibular flap usually is chosen. Additionally, for shorter mandible defects, other free flaps, including osseous components such as scapular and radial forearm flaps, can be used. The scapular flap can provide approximately 12 cm of scapula bone and is based on

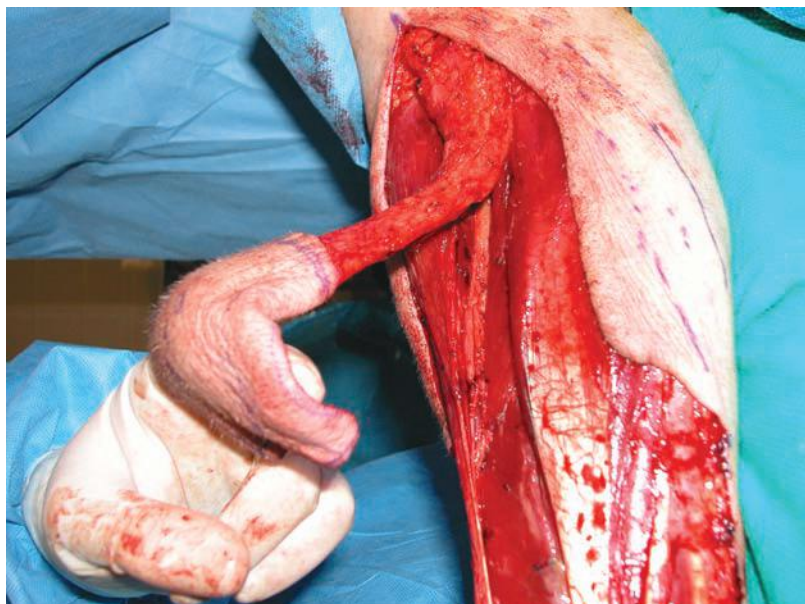


Figure 18-45. Radial forearm free flap before harvest from the arm.

the circumflex scapular artery. This flap can be combined with parascapular and scapular skin islands and portions of latissimus dorsi and serratus anterior muscle. The radial forearm osteocutaneous flap can provide a limited quantity of bone with the soft-tissue component of the flap but is associated with an increased risk of donor site fracture.

Large soft-tissue defects can result from trauma, excision of skull base tumors, and tumors involving large segments of skin. Furthermore, after extensive skull base resections in the anterior and lateral skull base, the need for separation of the oropharyngeal and sinonasal tracts from the dura requires soft-tissue interposition between the dura and the contaminated upper aerodigestive tract. The rectus abdominis flap, based on the deep inferior epigastric vessels, provides a large amount of soft tissue and is ideal for closure of wounds of the lateral skull base and dura.

For reconstruction of defects of the hypopharynx and cervical esophagus, both free flaps and regional pedicled flaps are available. The free transfer of a jejunal segment can be performed based on branches of the superior mesenteric artery. Other free flaps used in this area include fasciocutaneous flaps, such as tubed radial forearm flap. The gastric pull-up is a regional flap that is also in use for reconstruction of cervical esophageal defects. The stomach is mobilized and pedicled on the right gastric and gastroepiploic vessels into the defect via tunneling through the thoracic cavity.

TRACHEOSTOMY

Tracheostomy is indicated in the management of patients who require prolonged intubation, access for frequent pulmonary suctioning, and in those patients with neurologic deficits that impair protective airway reflexes. Its use in head and neck surgery is often for the temporary management of the airway in the perioperative period. After surgical resection of oral cavity and oropharyngeal cancers, edema of the upper aerodigestive tract occurs necessitating perioperative tracheostomy to prevent loss of the airway.

The avoidance of prolonged orotracheal and nasotracheal intubation decreases the risk of laryngeal and subglottic injury and potential stenosis, facilitates oral and pulmonary suctioning, and decreases patient discomfort. When the tracheostomy is no longer needed, the tube is removed and closure of the opening usually occurs spontaneously over a 2-week period. Complications of tracheostomy include pneumothorax, RLN injury, tracheal stenosis, wound infection with large-vessel erosion, and failure to close after decannulation. The use of cricothyroidotomy as an alternative to tracheostomy for patients who require prolonged intubation is associated with a higher incidence of vocal cord dysfunction and subglottic stenosis. When cricothyroidotomy is used in the setting of establishing an emergency airway, conversion to a standard tracheostomy should be considered if decannulation is not anticipated within 5 to 7 days.

Placement of a tracheostomy does not obligate a patient to loss of speech. When a large cuffed tracheostomy tube is in place, expecting a patient to be capable of normal speech is impractical. However, after a patient is downsized to an uncuffed tracheostomy tube, intermittent finger occlusion or Passy-Muir valve placement will allow a patient to communicate while still using the tracheostomy to bypass the upper airway. When a patient no longer has the original indication for the tracheostomy and can tolerate capping of the tracheal tube for >24 hours, decannulation is considered safe.

LONG-TERM MANAGEMENT AND REHABILITATION

Palliative Care

For patients with unresectable disease or distant metastases, palliative care options exist. Palliative treatment is aimed at improving a patient's symptoms and may include radiation, chemotherapy, or consultation with a pain specialist. The head and neck surgeon has the options of tracheostomy and gastrostomy tube placement for patients progressing with worsening airway compromise and dysphagia, respectively. Hospice is also an option for patients with a limited short-term outlook; hospice allows a patient to retain dignity at the time of greatest adversity.

Follow-Up Care

Patients diagnosed and treated for a head and neck tumor require follow-up care aimed at monitoring for recurrence and the side effects of therapy. For patients undergoing successful treatment for malignancies of the upper aerodigestive tract, the American Head and Neck Society advocates for follow-up assessment every 1 to 3 months for the first year after treatment, expanding to every 2 to 6 months for years 2 to 4, with an annual follow-up at 5 years posttreatment and thereafter.⁹¹

In addition to a formal head and neck examination, patients should be questioned about any emerging symptoms related to their primary tumor. New-onset pain, otalgia, and dysphagia are some of the problems that may indicate the need to

8 ▶ evaluate further for recurrence. Worsening dysphagia may also be a presenting symptom for a patient developing a pharyngeal stricture. Such a patient may require dilatation and/or placement of a gastrostomy tube for nutrition. Additionally, a number of patients who undergo head and neck radiation will develop hypothyroidism years after treatment. Patients with shoulder dysfunction after surgery should be considered for physical therapy consultation to minimize the long-term effects of their surgical care. Patients with chronic pain-related issues can benefit from consultation with a pain specialist to construct a treatment regimen to provide adequate control of long-term discomfort. Long-term follow-up with a dentist experienced in caring for patients with a history of therapeutic radiation therapy is vital if prevention of osteoradionecrosis is to be achieved.

REFERENCES

Entries highlighted in bright blue are key references.

1. Kaushik V, Malik T, Saeed SR. Interventions for acute otitis externa. *Cochrane Database Syst Rev*. 2010 Jan 20;(1):CD004740.
2. Carfrae MJ, Kesser BW. Malignant otitis externa. *Otolaryngol Clin North Am*. 2008; 41(3):537-549.
3. Sutton D, Derkay CS, Darrow DH, et al: Resistant bacteria in the middle ear fluid at the time of tympanostomy tube surgery. *Ann Otol Rhinol Laryngol* 2000;109:24.
4. Cunningham M, Guardiani E, Kim HJ, et al. Otitis media. *Future Microbiol*. 2012 7(6):733-753.
5. Antonelli PJ, Garside JA, Mancuso AA, et al: Computed tomography and the diagnosis of coalescent mastoiditis. *Otolaryngol Head Neck Surg* 1999;120:350.
6. Gantz BJ, Rubinstein JT, Gidley P, et al: Surgical management of Bell's palsy. *Laryngoscope* 1999;109:1177-1188.
7. Danner CJ. Facial nerve paralysis. *Otolaryngol Clin North Am*. 2008; 41(3):619-632.
8. Rosenfeld RM, Andes D, Bhattacharyya N, et al. **Clinical practice guideline: adult sinusitis.** *Otolaryngol Head Neck Surg* 2007;137(3 Suppl):S1-31.

9. McCoul ED, Jourdy DN, Schaberg MR, et al. Methicillin-resistant *Staphylococcus aureus* sinusitis in nonhospitalized patients: A systematic review of prevalence and treatment outcomes. *Laryngoscope*. 2012;122(10):2125-2131.
10. Miracle AC, Mukherji SK. Conebeam CT of the head and neck, part 2: clinical applications. *AJNR Am J Neuroradiol* 2009;30:1285-1292.
11. Ryan MW. Allergic fungal rhinosinusitis. *Otolaryngol Clin North Am*. 2011 44(3):697-710.
12. deShazo RD, O'Brien M, Chapin K, et al: A new classification and diagnostic criteria for invasive fungal sinusitis. *Arch Otolaryngol Head Neck Surg*. 1997;123:1181-1188.
13. Bisno AL, Gerber MA, Gwaltney JM, et al: Diagnosis and management of group A streptococcal pharyngitis: a practice guideline. Infectious Diseases Society of America. *Clin Infect Dis*. 1997;25:574-583.
14. Thompson LDR, Wenig BM, Kornblut BM: Pharyngitis. In Bailey BJ, Calhoun KH, Derkay CS, et al, eds. *Head and Neck Surgery—Otolaryngology*, 3rd ed. Philadelphia: Lippincott Williams and Wilkins; 2001:543.
15. Paradise J, Bluestone C, Bachman R, et al. Efficacy of tonsillectomy for recurrent throat infections in severely affected children. Results of parallel randomized and nonrandomized clinical trials. *N Engl J Med* 1984;310:674-683.
16. Gates G, Cooper J, Avery C, et al: Chronic secretory otitis media: effects of surgical management. *Ann Otol Rhinol Laryngol Suppl*. 1989;98:2-32.
17. Statham MM, Myer CM III. Complications of adenotonsillectomy. *Curr Opin Otolaryngol Head Neck Surg*. 2010; 18(6):539-543.
18. Friedman M, Tanyeri H, La Rossa M, et al: Clinical predictors of obstructive sleep apnea. *Laryngoscope* 1999;109:1901-1907.
19. Vasu TS, Grewal R, Doghranji K. Obstructive sleep apnea syndrome and perioperative complications: a systematic review of the literature. *J Clin Sleep Med*. 2012;8(2):199-207.
20. Zeitel SM, Casiano RR, Gardner GM, et al: **Management of common voice problems: committee report.** *Otolaryngol Head Neck Surg*. 2002;126:333.
21. Rosen CA, Woodson GE, Thompson JW, et al: Preliminary results of the use of indole 3-carbinol for recurrent respiratory papillomatosis. *Otolaryngol Head Neck Surg*. 1998;118:810-815.
22. Gray S, Hammond E, Hanson DF: Benign pathologic responses of the larynx. *Ann Otol Rhinol Laryngol*. 1995;104:13-18.
23. Koufman JA: **The otolaryngologic manifestations of gastroesophageal reflux disease (GERD); a clinical investigation of 225 patients using ambulatory 24-hour pH monitoring and an experimental investigation of the role of acid and pepsin in the development of laryngeal injury.** *Laryngoscope*. 1991; 53(1):1-78.
24. Kamargiannis N, Gouveris H, Katsinelos P, et al. Chronic pharyngitis is associated with severe acidic laryngopharyngeal reflux in patients with Reinke's edema. *Ann Otol Rhinol Laryngol*. 2011;120(11):722-726.
25. Tsikoudas A, Paleri V, El-Badaway MR, et al. Recommendations on follow-up strategies for idiopathic vocal fold paralysis: evidence-based review. *J Laryngol Otol*. 2012;126(6):570-573.
26. Modi VK. Vocal fold injection medialization laryngoplasty. *Adv Otorhinolaryngol*. 2012;73:90-94.
27. Hochman M, Vural E, Suen J, et al: Contemporary management of vascular lesions of the head and neck. *Curr Opin Otolaryngol Head Neck Surg*. 1999;7:161.
28. Scherer K, Waner M. Nd:Yag lasers (1064nm) in the treatment of venous malformations of the face and neck:challenges and benefits. *Lasers Med Sci*. 2007;22(2):119-26.
29. Richter GT, Suen JY. **Pediatric extracranial arteriovenous malformations.** *Curr Opin Otolaryngol Head Neck Surg*. 2011;19(6):455-461.
30. Giguere CM, Bauman NM, Smith RJH: New treatment options for lymphangioma in infants and children. *Ann Otol Rhinol Laryngol*. 2002;111:1066-1075.
31. Manson PN, Clark N, Robertson B, et al. Subunit principles in midface fractures: the importance of sagittal buttresses, soft-tissue reductions, and sequencing treatment of segmental fractures. *Plast Reconstr Surg*. 1999;103(4):1287-1306.
32. Sharabi SE, Koshy JC, Thornton JF, et al. Facial fractures. *Plast Reconstr Surg*. 2011;127(2):25e-34e.
33. Coker NJ: Facial electroneurography: analysis of techniques and correlation with degenerating motor neurons. *Laryngoscope*. 1992;102:747-759.
34. Brodie HA, Thompson TC. Management of complications from 820 temporal bone fractures. *Am J Otol*. 1997;18:188-197.
35. Darrouzet V, Duclos J, Liguoro D: Management of facial paralysis resulting from temporal bone fractures: our experience in 115 cases. *Otolaryngol Head Neck Surg*. 2001;125: 77-84.
36. Blot WJ, McLaughlin JK, Winn DM, et al: Smoking and drinking in relation to oral and pharyngeal cancer. *Cancer Res*. 1988;48:3282-3287.
37. Rigotti NA: Treatment of tobacco use and dependence. *N Engl J Med*. 2002;346:506.
38. Moore C: Cigarette smoking and cancer of the mouth, pharynx and larynx. *JAMA*. 1971;218:553-558.
39. Brennan JA, Boyle JO, Koch WM, et al: **Association between cigarette smoking and mutation of the p53 gene in squamous cell carcinoma of the head and neck.** *N Engl J Med*. 1995;332:712-717.
40. Boyle JO, Koch W, Hrubin PA, et al: The incidence of p53 mutations increase with progression of head and neck cancer. *Cancer Res*. 1993;53:4477-4480.
41. Koch WM, Lango M, Sewell D, et al: Head and neck cancer in non-smokers: a distinct clinical and molecular entity. *Laryngoscope*. 1999;109:1544-1551.
42. Chen YJ, Chang JT, Liao CT, et al. Head and neck cancer in the betel quid chewing area: recent advances in molecular carcinogenesis. *Cancer Sci*. 2008;99(8):1507-1514.
43. Joint Committee on Cancer: *American Joint Committee on Cancer Staging Manual*, 7th ed. Chicago: American; 2009.
44. Najim M, Cross S, GebSKI V, et al. Early-stage squamous cell carcinoma of the lip: The Australian experience and the benefits of radiotherapy in improving outcome in high-risk patients after resection. *Head Neck*. 2012 Sep 10. doi: 10.1002/hed.23148. [Epub ahead of print]
45. Calhoun K: Reconstruction of small- and medium-sized defects of the lower lip. *Am J Otolaryngol*. 1992;13:16-22.
46. Baumann D, Robb G. Lip reconstruction. *Semin Plast Surg*. 2008;22(4):269-280.
47. Hessel AC, Moreno MA, Hanna EY, et al. **Compliance with quality assurance measures in patients treated for early oral tongue cancer.** *Cancer*. 2010;116(14):3408-3416.
48. Huang SF, Kang CJ, Lin CY, et al. Neck treatment of patients with early stage oral tongue cancer: comparison between observation, supraomohyoid dissection, and extended dissection. *Cancer*. 2008;112(5):1066-1075.
49. Ganly I, Patel S, Shah J. Early stage squamous cell cancer of the oral tongue—clinicopathologic features affecting outcome. *Cancer*. 2012;118(1):101-111.
50. Rodgers LW Jr., Stringer SP, Mendenhall WM, et al: Management of squamous cell carcinoma of the floor of mouth. *Head Neck*. 1993;15:16-19.
51. Overholt SM, Eicher SA, Wolf P, et al: Prognostic factors affecting outcome in lower gingival carcinoma. *Laryngoscope*. 1996;106:1335-1339.
52. Huang CJ, Chao KSC, Tsai J, et al: Cancer of retromolar trigone: long-term radiation therapy outcome. *Head Neck*. 2001;23:758-763.
53. Lubek JE, Dyalram D, Perera EH, Liu X, Ord RA: A retrospective analysis of squamous carcinoma of the buccal mucosa: an aggressive subsite within the oral cavity. *J Oral Maxillofac Surg*. 2013;71(6):1126-1131.

54. Beckhardt RN, Weber RS, Zane R, et al: Minor salivary gland tumors of the palate: clinical and pathologic correlates of outcome. *Laryngoscope*. 1995;11:1155-1160.
55. Fakhy C, Westra WH, Cmelak A, et al. Improved survival of patients with human papillomavirus-positive head and neck squamous cell carcinoma in a prospective clinical trial. *J Natl Cancer Inst*. 2008;100:261-269.
56. Lee, HJ, Zelefsky MJ, Kraus DH, et al: Long-term regional control after radiation therapy and neck dissection for base of tongue carcinoma. *Int J Rad Oncology Biol Phys*. 1997;38:995-1000.
57. Peters LJ, Weber RS, Morrison WH, et al: Neck surgery in patients with primary oropharyngeal cancer treated by radiotherapy. *Head Neck*. 1996;18:552-559.
58. Ang KK, Peters LJ, Weber RS, et al: Concomitant boost radiotherapy schedules in the treatment of carcinoma of the oropharynx and nasopharynx. *Int J Radiat Oncol Biol Phys*. 1990;19:1339-1345.
59. Dean NR, Rosenthal EL, Carroll WR, et al. Robot-assisted surgery for primary and recurrent oropharyngeal carcinoma. *Arch Otolaryngol Head Neck Surg*. 2010;136(4):380-384.
60. Weinstein GS, O'Malley BW, Snyder W, et al. Transoral robotic surgery: radical tonsillectomy. *Arch Otolaryngol Head Neck Surg*. 2007;133(12):1220-1226.
61. Weber RS, Ohlms L, Bowman J, et al: Functional results after total or near total glossectomy with laryngeal preservation. *Arch Otolaryngol Head Neck Surg*. 1991;117:512-515.
62. Frank J, Garb J, Kay S, et al: Postoperative radiotherapy improves survival in squamous cell carcinoma of the hypopharynx. *Am J Surg*. 1994;168:476-480.
63. Lefebvre JL, Chevalier D, Luboinski B, et al: Larynx preservation in piriform sinus cancer: preliminary results of a European organization for research and treatment of cancer phase III trial. *J Natl Cancer Inst*. 1996;88:890-899.
64. Hartig G, Truelson J, Weinstein GS. Supraglottic cancer. *Head Neck*. 2000;22:426-434.
65. Laccourreye H, Laccourreye O, Weinstein GS, et al: Supracricoid laryngectomy with cricothyroidopiglottopexy: a partial laryngeal procedure for selected glottic carcinoma. *Ann Otol Rhinol Laryngol*. 1990;99:421-426.
66. Wolf GT, Hong WK, Fischer SG, et al: Induction chemotherapy plus radiation compared with surgery plus radiation in patients with advanced laryngeal cancer. *N Engl J Med*. 1991;324:1685-1690.
67. Medina JE, Khafif A: Early oral feeding following total laryngectomy. *Laryngoscope*. 2001;111:368-372.
68. Weber RS, Marvel J, Smith P, et al: Paratracheal lymph node dissection for carcinoma of the larynx, hypopharynx, and cervical esophagus. *Otolaryngol Head Neck Surg*. 1993;108:11-17.
69. Weber RS, Berket BA, Forastiere A, et al: Outcome of salvage total laryngectomy following organ preservation therapy: the Radiation Therapy Oncology Group trial 91-11. *Arch Otolaryngol Head Neck Surg*. 2003;129:44-49.
70. Lund VJ, Chisholm EJ, Takes RP, et al. Evidence for treatment strategies in sinonasal adenocarcinoma. *Head Neck*. 2012;34(8):1168-1178.
71. Reiersen DA, Pahilan ME, Devaiah AK. Meta-analysis of treatment outcomes for sinonasal undifferentiated carcinoma. *Otolaryngol Head Neck Surg*. 2012;147(1):7-14.
72. Eggesbø HB. Imaging of sinonasal tumours. *Cancer Imaging*. 2012;12:136-152.
73. Robbins KT, Ferlito A, Silver CE, et al. Contemporary management of sinonasal cancer. *Head Neck*. 2011;33(9):1352-1365.
74. Al-Sarraf M, LeBlanc M, Giri PG, et al: Chemoradiotherapy vs. radiotherapy in patients with advanced nasopharyngeal cancer: Phase III randomized intergroup 0099. *J Clin Oncol*. 1998;16:1310-1317.
75. Kuhel W, Hume CR, Selesnick SH: Cancer of the external auditory canal and temporal bone. *Otolaryngol Clin North Am*. 1996;29:827-852.
76. Morris LG, Mehra S, Shah JP, et al. Predictors of survival and recurrence after temporal bone resection for cancer. *Head Neck*. 2012; 34(9):1231-1239.
77. Wang Y, Ow TJ, Myers JN. Pathways for cervical metastasis in malignant neoplasms of the head and neck region. *Clin Anat*. 2012;25(1):54-71.
78. Bocca E, Pignataro O, Oldino C: Functional neck dissection: an evaluation and review of 843 cases. *Laryngoscope*. 1984;94:942-945.
79. Medina JE, Byers RM: Supraomohyoid neck dissection: rationale, indications and surgical technique. *Head Neck*. 1989;11:111-122.
80. Eicher SA, Weber RS: Surgical management of cervical lymph node metastases. *Curr Opin Oncol*. 1996;8:215-220.
81. Robbins KT, Atkinson JLD, Byers RM, et al: The use and misuse of neck dissection for head and neck cancer. *J Am Coll Surg*. 2001;193:91-102.
82. Byers RM, Weber RS, Andrews T, et al: Frequency and therapeutic implications of "skip metastases" in the neck from squamous carcinoma of the oral tongue. *Head Neck*. 1997;19:14-19.
83. Strojan P, Ferlito A, Langendijk JA, et al. Indications for radiotherapy after neck dissection. *Head Neck*. 2012; 34(1):113-119.
84. Eisele DE, Netterville J, Hoffman H, et al: Parapharyngeal space masses. *Head Neck*. 1999;21:154-159.
85. Gidley PW, Thompson CR, Roberts DB, et al. The results of temporal bone surgery for advanced or recurrent tumors of the parotid gland. *Laryngoscope*. 2011;121(8):1702-1707.
86. Weber RS, Byers RM, Petit B, et al: Submandibular gland tumors: Adverse histologic factors and therapeutic implications. *Arch Otolaryngol Head Neck Surg*. 1990;116:1055-1060.
87. Blackwell KE, Buchbinder D, Biller HF: Reconstruction of massive defects in the head and neck: the role of simultaneous distant and regional flaps. *Head Neck*. 1997;19:620-628.
88. Agrawal A, Husein OF, Schuller DE. Esophageal reconstruction with larynx preservation using forearm-free flap. *Laryngoscope*. 2008;118(10):1750-1752.
89. Fujiwara T, Shih HS, Chen CC, et al. Interdigitation of the distal anastomosis between tubed fasciocutaneous flap and cervical esophagus for stricture prevention. *Laryngoscope*. 2011;121(2):289-293.
90. Urken ML, Buchbinder D, Costantino PD, et al: Oromandibular reconstruction using microvascular composite flaps: report of 210 cases. *Arch Otolaryngol Head Neck Surg*. 1998;124:46-56.
91. The American Society for Head and Neck Surgery and the Society of Head and Neck Surgeons: *Clinical Practice Guidelines for the Diagnosis and Management of Cancer of the Head and Neck*. 1996. Also see <http://www.headandneckcancer.org/clinicalresources/docs/oralcavity.php>.

19

chapter

Chest Wall, Lung, Mediastinum, and Pleura

Katie S. Nason, Michael A. Maddaus, and James D. Luketich

Trachea	605	Options for Thoracic Surgical Approaches / 645	Diagnostic Nonsurgical Biopsies of the Mediastinum / 672	
Anatomy / 605		Postoperative Care / 647	Surgical Biopsies and Resection of Mediastinal Masses / 673	
Tracheal Injury / 605		Postoperative Complications / 649	Mediastinal Neoplasms / 674	
Tracheal Fistulas / 608		Spontaneous Pneumothorax / 649	Mediastinal Cysts / 679	
Tracheal Neoplasms / 609		Pulmonary Infections / 650	Mediastinitis / 679	
Lung	611	Massive Hemoptysis / 661	Pleura and Pleural Space	680
Anatomy / 611		End-Stage Lung Disease / 663	Anatomy / 680	
Normal Lung Histology / 612		Chest Wall	Pleural Effusion / 680	
Preinvasive Lesions / 613		Chest Wall Mass / 664	Access and Drainage of Pleural Fluid Collections / 680	
Invasive or Malignant Lesions / 614		Benign Chest Wall Neoplasms / 666	Malignant Pleural Effusion / 682	
Lung Cancer Epidemiology / 617		Primary Malignant Chest Wall Tumors / 666	Empyema / 682	
Screening for Lung Cancer in High-Risk Populations / 619		Other Tumors of the Chest Wall / 669	Chylothorax / 685	
Solitary Pulmonary Nodule / 621		Chest Wall Reconstruction / 669	Tumors of the Pleura / 687	
Metastatic Lesions to the Lung / 622		Mediastinum	Acknowledgement	690
Primary Lung Cancer-Associated Signs and Symptoms / 623		Anatomy and Pathologic Entities / 670		
Lung Cancer Management / 627		History and Physical Examination / 671		
Lung Cancer Treatment / 637		Imaging and Serum Markers / 671		

TRACHEA

Anatomy

The trachea is composed of cartilaginous and membranous portions, beginning with the cricoid cartilage, the first complete cartilaginous ring of the airway. The cricoid cartilage consists of an anterior arch and a posterior broad-based plate. Articulating with the posterior cricoid plate are the arytenoid cartilages. The vocal cords originate from the arytenoid cartilages and then attach to the thyroid cartilage. The subglottic space, the narrowest part of the trachea with an internal diameter of approximately 2 cm, begins at the inferior surface of the vocal cords and extends to the first tracheal ring. The remainder of the distal trachea is 10.0 to 13.0 cm long, consists of 18 to 22 rings, and has an internal diameter of 2.3 cm (Fig. 19-1).¹ Bronchoscopically, the tracheal rings are visible as C-shaped hyaline cartilaginous structures that provide rigidity to the anterior and lateral tracheal walls. The open ends of the C-rings are connected by the trachealis smooth muscle and encased in a dense band of connective tissue called perichondrium. The first tracheal ring is attached directly to the cricoid cartilage; there are approximately two rings for every 1 cm of tracheal length.

The tracheal blood supply, which includes the inferior thyroid, subclavian, supreme intercostal, internal thoracic,

innominate, and superior and middle bronchial arteries, enters the airway near the junction of the membranous and cartilaginous portions (Fig. 19-2). Each arterial branch supplies a segment of 1.0 to 2.0 cm, thereby limiting circumferential mobilization to that same distance. The vessels are interconnected along the lateral surface of the trachea by an important longitudinal vascular anastomosis that feeds transverse segmental vessels to the soft tissues between the cartilages.

Tracheal Injury

Tracheal injury can result from a variety of causes, including inhalation of smoke or toxic fumes, aspiration of liquids or solid objects, endotracheal intubation, blunt and penetrating trauma, and iatrogenic injury during operative procedures. Early diagnosis is critical to avoid subsequent complications, including respiratory infection and tracheal stenosis. Management of smoke or toxic fume inhalation and liquid aspiration is commonly supportive; use of antibiotics, respiratory support, and airway clearance with flexible bronchoscopy is dictated by the patient's condition. In rare circumstances, extracorporeal membrane oxygenation is required if there is associated injury to the more distal airways and lung parenchyma.

Despite ubiquitous use of high-volume–low-pressure cuffs, overinflation of the endotracheal cuff is the most common

Key Points

- 1▶ Historically, non-small cell cancer (NSCLC) subtypes were considered to be a uniform group based on limited understanding of the distinct clinical behaviors of the subtypes as well as the fact that there were few treatment options available. With increasing understanding of the molecular biology underlying these tumor subtypes, however, the approach to diagnosis and management and the terminology used in describing these tumors are evolving rapidly. In particular, the evaluation and management of adenocarcinoma of the lung has shifted dramatically and firm establishment of NSCLC cell type prior to chemotherapy for advanced stage lung cancer is essential.
- 2▶ A multidisciplinary approach to evaluation of NSCLC, with standardized criteria and terminology for diagnosis in cytologic and small biopsy specimens, and routine molecular testing for known mutations, such as *EGFR* mutations and *EML4-ALK* fusion oncogenes is now recommended for the evaluation and management of lung nodules due to major advances in targeted therapy. Adequate tissue acquisition at the time of diagnostic workup is critical and facilitates patient care while minimizing the number of procedures to which the patient is subjected.
- 3▶ The terms *bronchioloalveolar carcinoma* and *mixed subtype adenocarcinoma* have been eliminated from the classification of lung adenocarcinoma as a result of increased understanding of important clinical, radiologic, pathologic, and genetic differences between mucinous and nonmucinous adenocarcinomas. The new classification system delineated a stepwise pathologic progression, from AAH to invasive adenocarcinoma based on the predominant histologic growth patterns.
- 4▶ Lung cancer continues to be a highly lethal and extremely common cancer, with 5-year survival of 16%. Lung cancer incidence is second only to the incidence of prostate cancer in men and breast cancer in women. Squamous cell carcinoma and adenocarcinoma of the lung are the most common subtypes and are rarely found in the absence of a smoking history. Nonsmokers who live with smokers have a 24% increased risk of lung cancer compared to nonsmokers who do not live with smokers.
- 5▶ Navigational bronchoscopy is a valuable new tool that can be used to obtain tissue diagnosis for intraparenchymal lesions or small, peripherally located lesions that have historically been difficult to biopsy with transbronchial or transthoracic approaches. It is also a useful tool for tattooing the lung lesion for subsequent operative resection and for placement of fiducial markers for stereotactic body radiation. This technique should become part of the surgeon's armamentarium for the diagnosis and treatment of lung cancer.
- 6▶ Impaired exchange of carbon monoxide is associated with a significant increase in the risk of postoperative pulmonary complications, independent of the patient's smoking history. In patients undergoing pulmonary resection, the risk of any pulmonary complication increases by 42% for every 10% decline in the percent carbon monoxide diffusion capacity (%DLCO), and this measure may be a useful parameter in risk stratification of patients for surgery.
- 7▶ Maximum oxygen consumption ($\dot{V}O_2$ max) values provide important additional information in those patients with severely impaired DLCO and forced expiratory volume in 1 second. Values of <10 mL/kg per minute generally prohibit any major pulmonary resection, because the mortality in patients with these levels is 26% compared with only 8.3% in patients whose is ≥ 10 mL/kg per minute; values of >15 mL/kg per minute generally indicate the patient's ability to tolerate pneumonectomy.
- 8▶ The assessment of patient risk before thoracic resection is based on clinical judgment and data.
- 9▶ Tumor ablative strategies are viable alternatives to surgical resection for early stage lung cancer in inoperable patients. While premature, ablative techniques may ultimately be shown to have efficacy equivalent to lobectomy for the primary treatment of very small peripheral early-stage lung cancers and become primary therapy, even in operable patients. Multidisciplinary collaboration between thoracic surgery, interventional radiology/pulmonology, and radiation oncology is required to ensure that development of these ablative techniques occurs through properly designed and well-controlled prospective studies and will ensure that patients receive the best available therapy, regardless of whether it is surgical resection or ablative therapy.
- 10▶ Increasing evidence suggests a significant role for gastroesophageal reflux disease in the pathogenesis of chronic lung diseases such as bronchiectasis and idiopathic pulmonary fibrosis, and it may also contribute to bronchiolitis obliterans syndrome in lung transplant patients.
- 11▶ Treatment of pulmonary aspergilloma is individualized. Asymptomatic patients can be observed without any additional therapy. Similarly, mild hemoptysis, which is not life-threatening, can be managed with medical therapy, including antifungals and cough suppressant. Amphotericin B is the drug of choice, although voriconazole has recently been used for treatment of aspergilloma, with fewer side effects and equivalent efficacy. Massive hemoptysis had traditionally been an indication for urgent or emergent operative intervention. However, with the advancement of endovascular techniques, bronchial artery embolization in select centers with experience in these techniques has been effective.
- 12▶ In patients with malignant pleural effusion, poor expansion of the lung (because of entrapment by tumor or adhesions) generally predicts a poor result with pleurodesis and is the primary indication for placement of indwelling pleural catheters. These catheters have dramatically changed the management of end-stage cancer treatment because they substantially shorten the amount of time patients spend in the hospital during their final weeks of life.

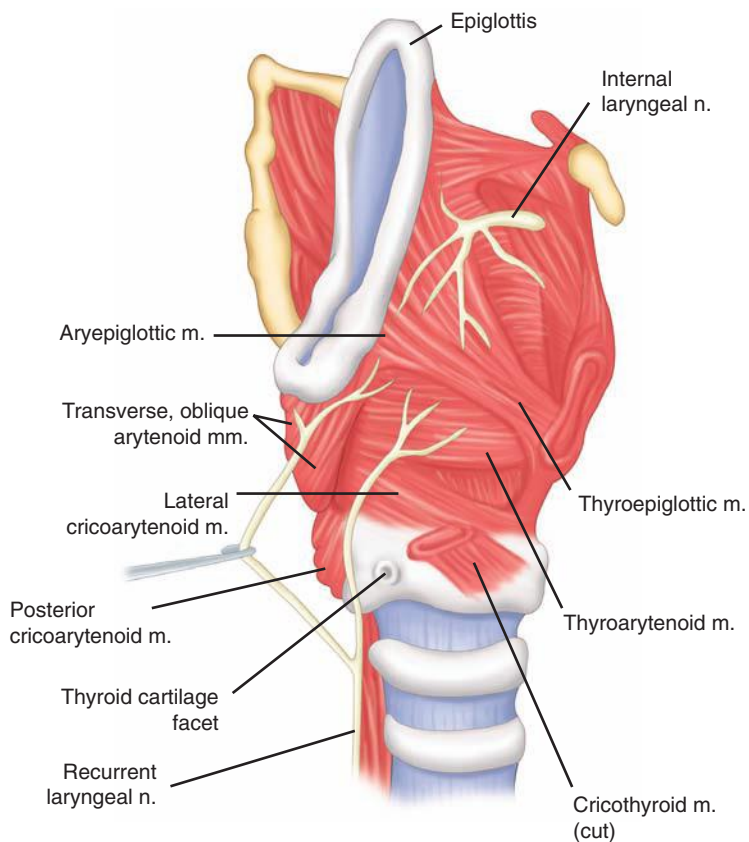


Figure 19-1. Anatomy of the larynx and upper trachea. m. = muscle; n. = nerve.

cause of injury secondary to endotracheal intubation. High cuff pressures can cause ischemia of the contiguous airway wall in as short as 4 hours. Prolonged overinflation can lead to scarring and stenosis; full-thickness injury can result in fistulae between the innominate artery anteriorly and the esophagus posteriorly. Avoidance requires careful cuff management to keep pressures

as low as possible; in circumstances of prolonged ventilatory support and high airway pressure, cuff pressure monitoring (to maintain pressures <20 mmHg) is advisable.

Historically, clinically significant tracheal stenosis after tracheostomy occurred in 3% to 12% of cases, with severe stenosis in 1% to 2%.² With the use of low-pressure cuffs, the estimated incidence has decreased to 4.9 cases per million patients per year.³ Intubation-related risk factors include: prolonged intubation; high tracheostomy through the first tracheal ring or cricothyroid membrane; transverse rather than vertical incision on the trachea; oversized tracheostomy tube; prior tracheostomy or intubation; and traumatic intubation. Stenosis is also more common in older patients, in females, after radiation, or after excessive corticosteroid therapy, and in the setting of concomitant diseases such as autoimmune disorders, severe reflux disease, or obstructive sleep apnea and the setting of severe respiratory failure. However, even a properly placed tracheostomy can lead to tracheal stenosis because of scarring and local injury. Mild ulceration and stenosis are frequently seen after tracheostomy removal. Use of the smallest tracheostomy tube possible, rapid downsizing, and a vertical tracheal incision minimize the risk for posttracheostomy stenosis.

Stridor and dyspnea on exertion are the primary symptoms of tracheal stenosis. In the setting of postintubation injury, a significant portion of the cartilaginous structural support to the airway is destroyed by regional ischemic necrosis; during healing, a web-like fibrous growth develops and narrows the airway (Fig. 19-3). In contrast, stenosis caused by tracheostomy is most commonly due to an excess of granulation tissue formation around the tracheal stoma site. Time to onset of symptoms after extubation or tracheostomy decannulation usually ranges from 2 to 12 weeks, but symptoms can appear immediately or as long

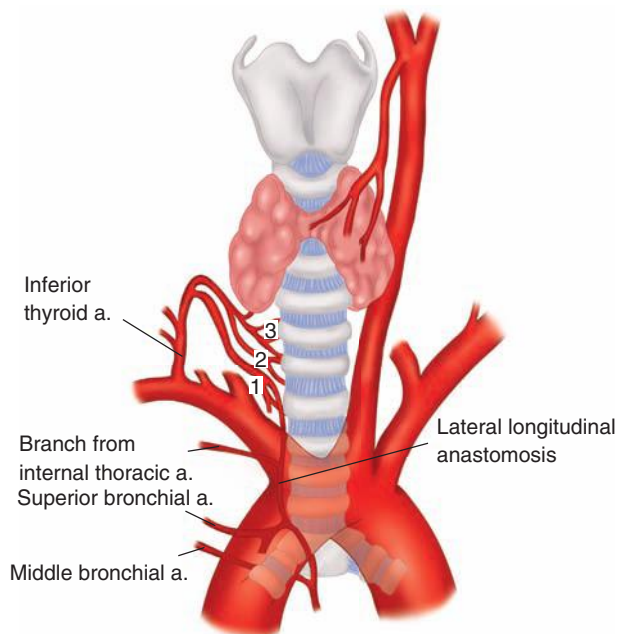


Figure 19-2. Arterial blood supply to the larynx and upper trachea. a. = artery.

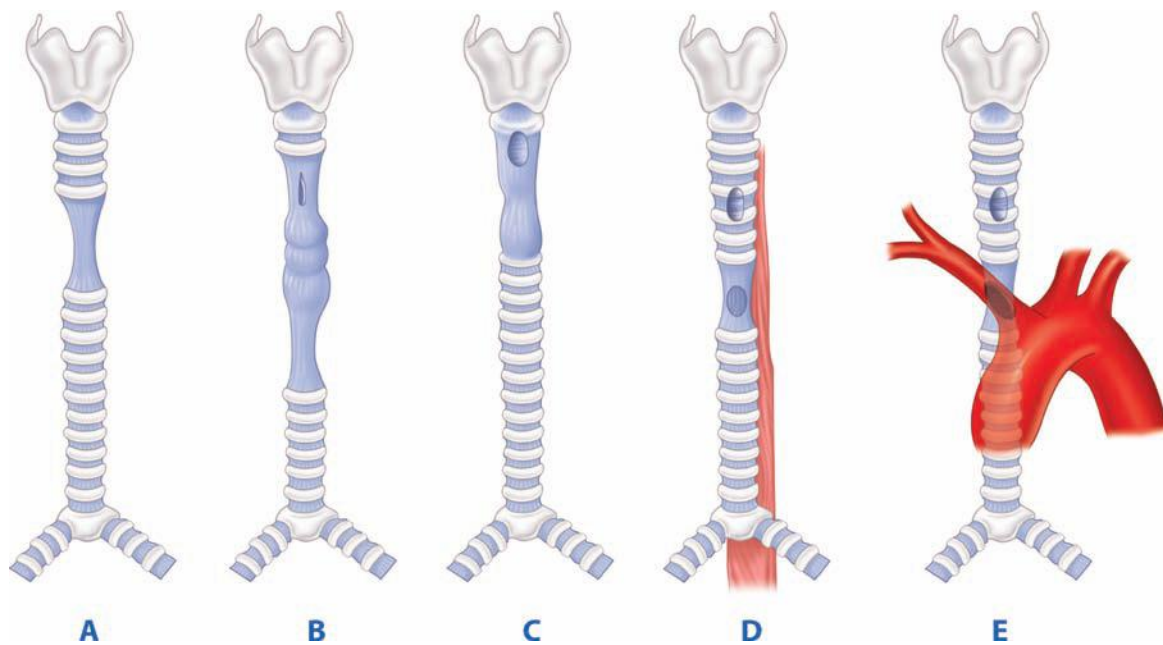


Figure 19-3. Diagram of the principal postintubation lesions. **A.** A circumferential lesion at the cuff site after the use of an endotracheal tube. **B.** Potential lesions after the use of tracheostomy tubes. Anterolateral stenosis can be seen at the stomal level. Circumferential stenosis can be seen at the cuff level (lower than with an endotracheal tube). The segment in between is often inflamed and malacotic. **C.** Damage to the subglottic larynx. **D.** Tracheoesophageal fistula occurring at the level of the tracheostomy cuff; circumferential damage is usual at this level. **E.** Tracheoinnominate artery fistula. (Adapted with permission from Grillo H. *Surgical treatment of postintubation tracheal injuries.* J Thorac Cardiovasc Surg. 1979;78:860. Copyright Elsevier)

as 1 to 2 years later. Frequently, patients are misdiagnosed as having asthma or bronchitis, and treatment for such illnesses can persist for some time before the correct diagnosis is discovered. Generally, symptom intensity is related to the degree of stenosis and to the patient's underlying pulmonary disease.

Acute Management. A comprehensive bronchoscopic evaluation is critical in the initial phase of evaluation. Stenosis length, location, distance between the vocal cords and proximal stenosis, and distance from the distal aspect to the major carina must be documented. In patients with severe stenosis and respiratory compromise, rigid bronchoscopy can be used to dilate the stenosis; this provides immediate relief of the airway obstruction and facilitates thorough evaluation of the stenosis. Rarely, if ever, is tracheostomy necessary.

Most intubation injuries are located in the upper third of the trachea and can be accessed for resection through a collar incision. Resection typically involves 2 to 4 cm of trachea for benign stenosis. It is critical to fully resect all inflamed and scarred tissue. However, a primary anastomosis can still be performed without undue tension, even if up to one half of the trachea requires resection.² Ideally, the patient is extubated in the operating room or shortly thereafter. For patients in whom tracheal resection is not possible, such as patients with significant comorbidities or with an excessively long stenosis, endotracheal stenting, typically silicone T-tubes, can provide palliation. Wire mesh stents should not be used, given their known propensity to erode through the wall of the airway. Balloon dilation, laser ablation, and tracheoplasty have also been described, although the efficacy is marginal.

Tracheal replacement is evolving as an option for management of tracheal stenosis as bioengineering techniques for decellularizing donor trachea have been developed. This removes all

antigens against which the recipient immune system might react and enables use of the donor trachea scaffolding without risk of rejection. Following decellularization, the donor tracheal scaffolding is seeded with recipient chondrocytes, to restore tracheal rigidity, and with recipient epithelial cells, to recreate the inner epithelial lining. Several case reports of successful allogeneic tracheal transplantation have been published, but the technique continues to be limited to a few highly specialized centers. This is due, in part, to the scarcity of donor trachea and the need for tissue bioengineering expertise. Current efforts are focused on creation of biosynthetic scaffolding that can be used instead of donor trachea. This would substantially increase the availability of the tracheal replacement material and enable widespread use of the technique.

Tracheal Fistulas

Tracheoinnominate Artery Fistula. Tracheoinnominate artery fistula has two main causes: low placement of a tracheostomy and hyperinflation of the tracheal cuff. Tracheostomy placement should be through the second to fourth tracheal rings without reference to the location of the sternal notch. When placed below the fourth tracheal ring, the inner curve of the tracheostomy cannula will be positioned to exert pressure on the posterior aspect of the innominate artery, leading to arterial erosion. Similarly, the tracheal cuff, when hyperinflated, will cause ischemic injury to the anterior airway and subsequent erosion into the artery. Most cuff-induced fistulas will develop within 2 weeks after placement of the tracheostomy.

Clinically, tracheoinnominate artery fistulas present with bleeding. A premonitory hemorrhage often occurs and, although it is usually not massive, must not be ignored or simply attributed to general airway irritation or wound bleeding. With significant

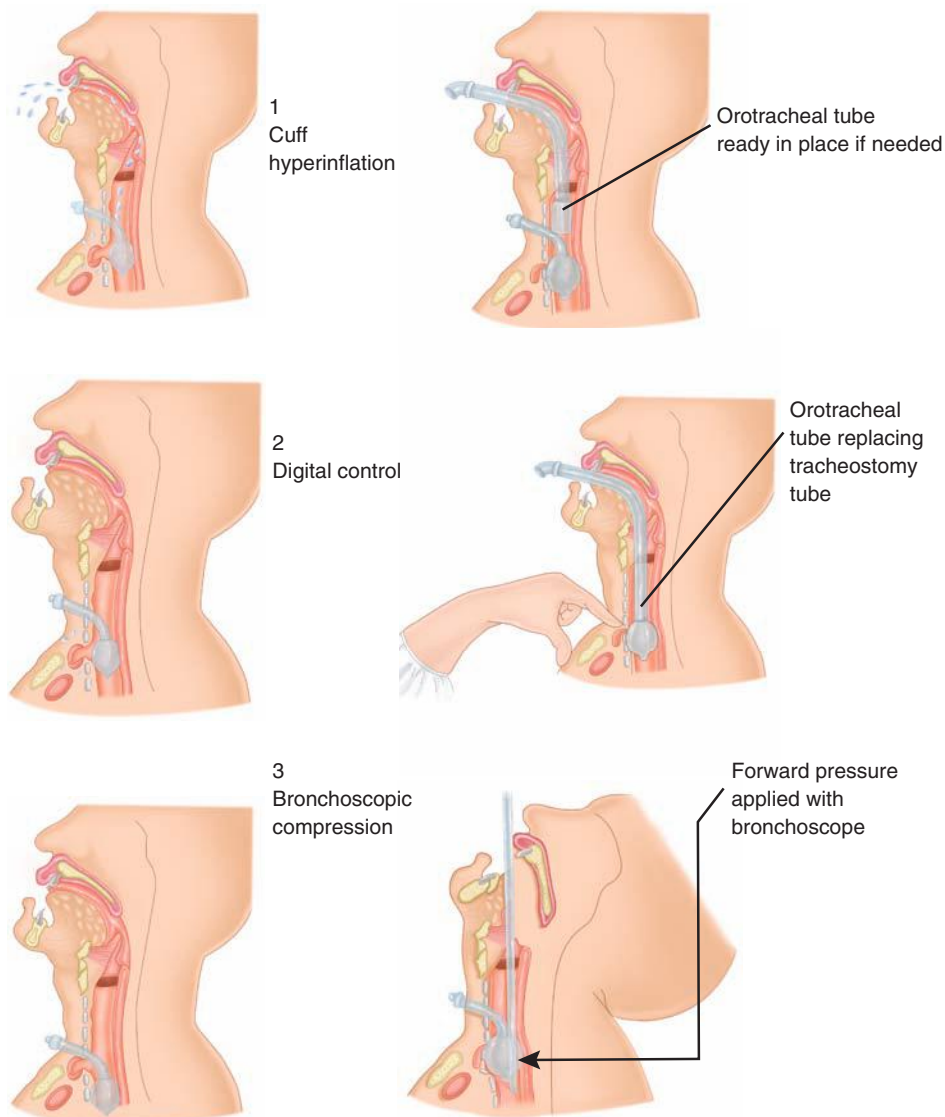


Figure 19-4. Steps in the emergency management of a tracheoinnominate artery fistula.

bleeding, the tracheostomy cuff can be hyperinflated to temporarily occlude the arterial injury. If such an effort is unsuccessful, the tracheostomy incision should be immediately opened widely and a finger inserted to compress the artery against the manubrium (Fig. 19-4). The patient can then be orally intubated, and the airway suctioned free of blood. Emergent surgical resection of the involved segment of artery is performed, usually without reconstruction.

Tracheoesophageal Fistula. Tracheoesophageal fistulas (TEFs) occur primarily in patients receiving prolonged mechanical ventilatory support concomitant with an indwelling nasogastric tube.⁴ Cuff compression of the membranous trachea against the nasogastric tube leads to airway and esophageal injury and fistula development. Clinically, airway suctioning reveals saliva, gastric contents, or tube feedings. Gastric insufflation, secondary to positive pressure ventilation, can occur. Bronchoscopy is diagnostic; with the bronchoscope inserted, the endotracheal tube is withdrawn and the fistula at the cuff site is exposed. Alternatively, esophagoscopy demonstrates the cuff of the endotracheal tube in the esophagus.

Treatment, first and foremost, requires removing tubes from the esophagus and weaning the patient from the ventilator.

The cuff of the endotracheal tube should be placed below the fistula, avoiding overinflation. To minimize aspiration, a gastrostomy tube should be placed for gastric decompression (to prevent reflux) and a jejunostomy tube for feeding. If aspiration persists, esophageal diversion with cervical esophagostomy can be performed. Once weaned from the ventilator, tracheal resection and primary anastomosis, repair of the esophageal defect, and interposition of a muscle flap between the trachea and esophagus can be performed (Fig. 19-5).⁵

Tracheal Neoplasms

Although extremely rare, the most common primary tracheal neoplasms are squamous cell carcinomas (related to smoking) and adenoid cystic carcinomas. Clinically, tracheal tumors present with cough, dyspnea, hemoptysis, stridor, or symptoms of invasion of contiguous structures (such as the recurrent laryngeal nerve or the esophagus). The most common radiologic finding of tracheal malignancy is tracheal stenosis, but is found in only 50% of cases. With tumors other than squamous cell carcinomas, symptoms may persist for months because of slow tumor growth rates. Stage of presentation is advanced, with approximately 50% of patients presenting with stage IV disease.

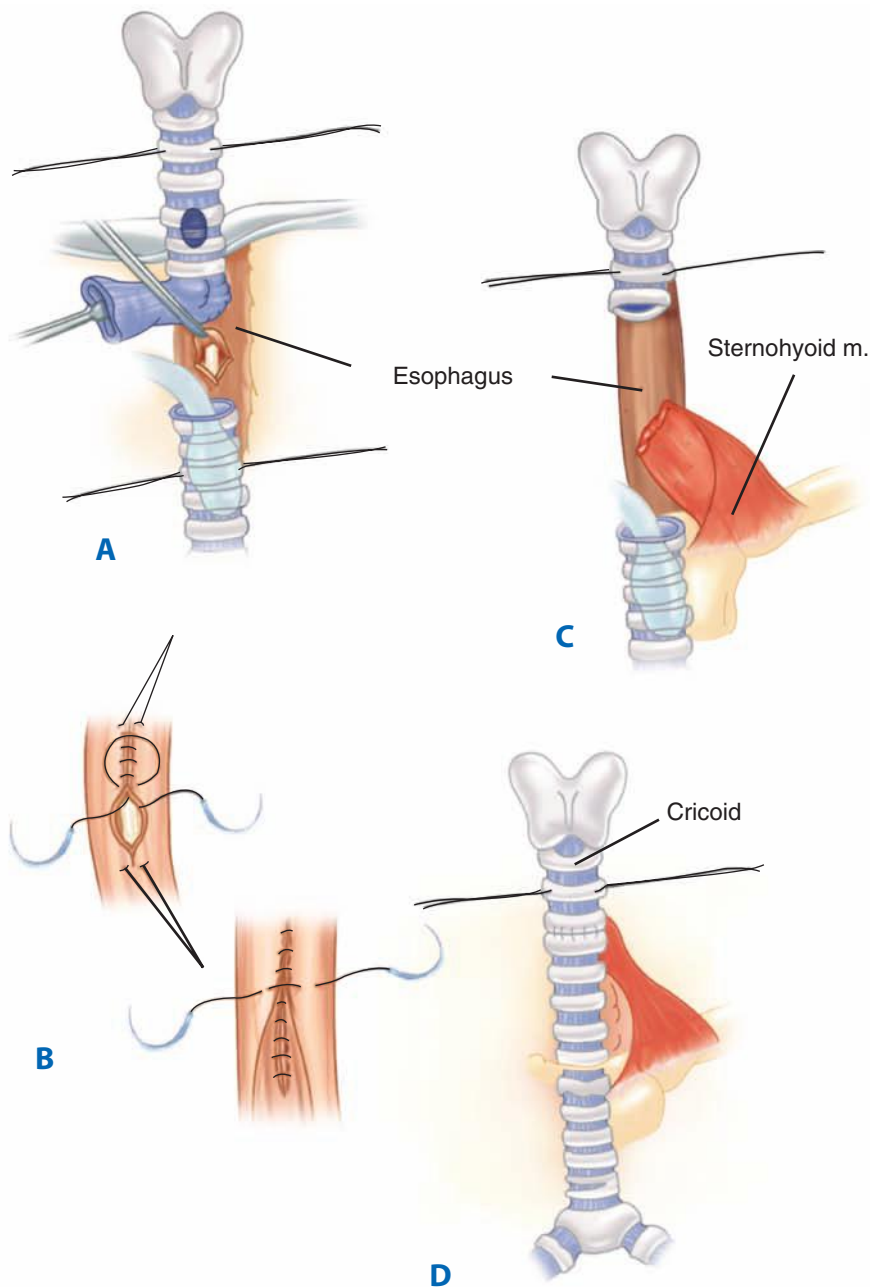


Figure 19-5. Single-stage operation for closure of a tracheoesophageal fistula and tracheal resection. **A.** The fistula is divided and the trachea is transected below the level of damage. **B.** The fistula is closed on the tracheal side in a single layer and the esophageal side in a double layer. The damaged trachea segment is resected. **C.** View of completed tracheal anastomosis. m. = muscle.

Five-year survival for all tracheal neoplasms is 40% but falls to 15% for those with stage IV disease.⁶

Squamous cell carcinomas often present with regional lymph node metastases and are frequently unresectable at presentation. Their biologic behavior is similar to that of squamous cell carcinoma of the lung. Adenoid cystic carcinomas, a type of salivary gland tumor, are generally slow-growing, spread submucosally, and tend to infiltrate along nerve sheaths and within the tracheal wall. Although indolent in nature, adenoid cystic carcinomas are malignant and can spread to regional lymph nodes, lung, and bone. Squamous cell carcinoma and adenoid cystic carcinomas represent approximately 65% of all tracheal neoplasms. The remaining 35% is comprised of small cell carcinomas, mucoepidermoid carcinomas, adenocarcinomas, lymphomas, and others.⁷

Therapy. Evaluation and treatment of patients with tracheal tumors should include neck and chest computed tomography

(CT) and rigid bronchoscopy. Rigid bronchoscopy permits general assessment of the airway and tumor; it also allows debridement or laser ablation of the tumor to provide relief of dyspnea. If the tumor is judged to be completely resectable, primary resection and anastomosis is the treatment of choice for these tumors (Fig. 19-6). Up to 50% of the length of the trachea can be resected with primary anastomosis. In most tracheal resections, anterolateral tracheal mobilization and suturing of the chin to the sternum for 7 days are done routinely. Use of laryngeal and hilar release is determined at the time of surgery, based on the surgeon's judgment of the degree of tension present. For longer resections, specialized maneuvers are necessary such as laryngeal release and right hilar release to minimize tension on the anastomosis.

Postoperative mortality, which occurs in up to 10% of patients, is associated with the length of tracheal resection, use of laryngeal release, the type of resection, and the histologic

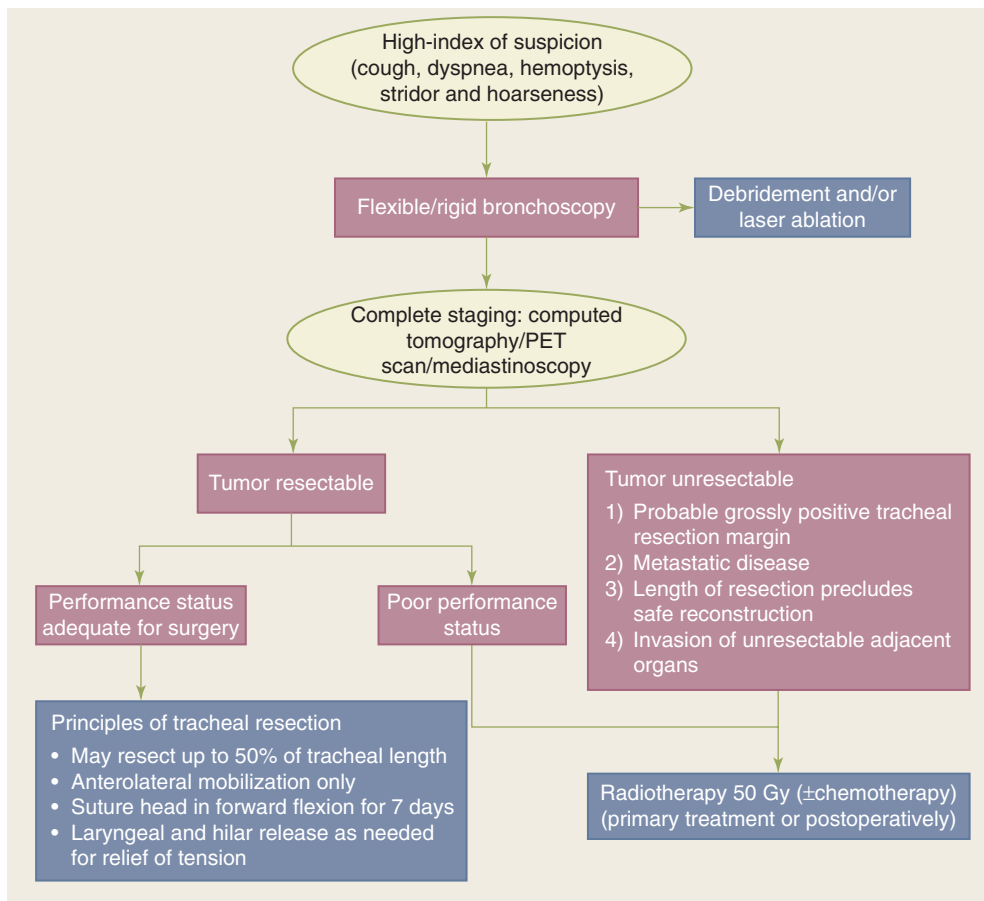


Figure 19-6. Algorithm for evaluation and treatment of tracheal neoplasm. PET = positron emission tomography.

type of the cancer. Factors associated with improved long-term survival include complete resection and use of radiation as adjuvant therapy in the setting of incomplete resection.⁸ Due to their radiosensitivity, radiotherapy is frequently given postoperatively after resection of both adenoid cystic carcinomas and squamous cell carcinomas.⁹ A dose of 50 Gy or greater is usual. Nodal positivity does not seem to be associated with worse survival. Survival at 5 and 10 years is much better for adenoid cystic (73% and 57%, respectively) than for tracheal cancers (47% and 36%, respectively; $P < .05$). For patients with unresectable tumors, radiation may be given as the primary therapy to improve local control, but is rarely curative. For recurrent airway compromise, stenting or laser therapies should be considered part of the treatment algorithm.

LUNG

Anatomy

Segmental Anatomy. The segmental bronchial and vascular anatomy of the lungs allows subsegmental and segmental resections, if the clinical situation requires it or if lung tissue can be preserved¹⁰ (Fig. 19-7). Note the continuity of the pulmonary parenchyma between adjacent segments of each lobe.

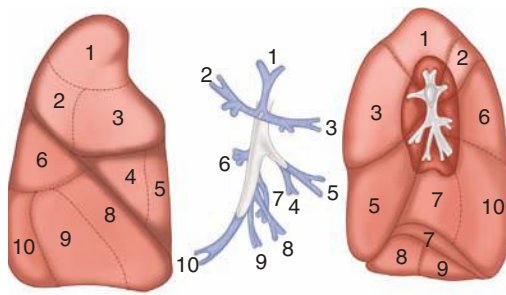
Lymphatic Drainage. Lymph nodes that drain the lungs are divided into two groups according to the tumor-node-metastasis (TNM) staging system for lung cancer: the pulmonary lymph nodes (N1) and the mediastinal nodes (N2) (Fig. 19-8).

The N1 lymph nodes constitute the following: (a) intrapulmonary or segmental nodes that lie at points of division

of segmental bronchi or in the bifurcations of the pulmonary artery; (b) lobar nodes that lie along the upper, middle, and lower lobe bronchi; (c) interlobar nodes located in the angles formed by the main bronchi bifurcating into the lobar bronchi; and (d) hilar nodes along the main bronchi. The interlobar lymph nodes lie in the depths of the interlobar fissure on each side and constitute a lymphatic sump for each lung, referred to as the *lymphatic sump of Borrie*; all of the pulmonary lobes of the corresponding lung drain into this group of nodes (Fig. 19-9). On the right, the nodes of the lymphatic sump lie around the bronchus intermedius (bounded above by the right upper lobe bronchus and below by the middle lobe and superior segmental bronchi). On the left, the lymphatic sump is confined to the interlobar fissure, with the lymph nodes in the angle between the lingular and lower lobe bronchi and in apposition to the pulmonary artery branches.

The N2 lymph nodes consist of four main groups. (a) The anterior mediastinal nodes are located in association with the upper surface of the pericardium, the phrenic nerves, the ligamentum arteriosum, and the left innominate vein. (b) The posterior mediastinal group includes paraesophageal lymph nodes within the inferior pulmonary ligament and, more superiorly, between the esophagus and trachea near the arch of the azygos vein. (c) The tracheobronchial lymph nodes are made up of three subgroups that are located near the bifurcation of the trachea. These include the subcarinal nodes, which lie in the obtuse angle between the trachea and each main stem bronchus, and the nodes that lay anterior to the lower end of the trachea. (d) Paratracheal lymph nodes are located in proximity to the

Right lung and bronchi



Segments

- | | |
|--------------|---------------------|
| 1. Apical | 6. Superior |
| 2. Posterior | 7. Medial Basal * |
| 3. Anterior | 8. Anterior Basal |
| 4. Lateral | 9. Lateral Basal |
| 5. Medial | 10. Posterior Basal |

* Medial basal (7) not present in left lung

Left lung and bronchi

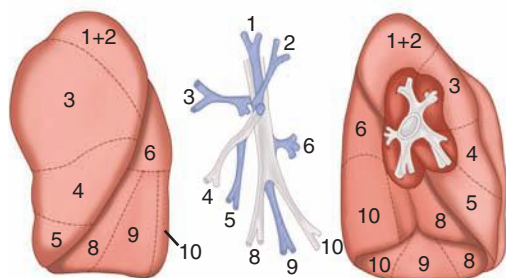


Figure 19-7. Segmental anatomy of the lungs and bronchi.

trachea in the superior mediastinum. Those on the right side form a chain with the tracheobronchial nodes inferiorly and with some of the deep cervical nodes above (scalene lymph nodes).

Lymphatic drainage to the mediastinal lymph nodes from the right lung is ipsilateral, except for occasional bilateral drainage to the superior mediastinum. In contrast, in the left lung, particularly the left lower lobe, lymphatic drainage occurs with equal frequency to ipsilateral and contralateral superior mediastinal nodes.

Normal Lung Histology

The lung can be conveniently viewed as two linked components: the tracheobronchial tree (or conducting airways component) and the alveolar spaces (or gas exchange component). The tracheobronchial tree consists of approximately 23 airway divisions to the level of the alveoli. It includes the main bronchi, lobar bronchi, segmental bronchi (to designated bronchopulmonary segments), and terminal bronchioles (i.e., the smallest airways still lined by bronchial epithelium and without alveoli). The tracheobronchial tree is normally lined by pseudostratified ciliated columnar cells and mucous (or goblet) cells, which both derive from basal cells (Fig. 19-10). Ciliated cells predominate. Goblet cells, which release mucus, can significantly increase in number in acute bronchial injury, such as exposure to cigarette smoke. The normal bronchial epithelium also contains bronchial submucosal glands, which are mixed salivary-type glands containing mucous cells, serous cells, and neuroendocrine cells called Kulchitsky cells, which are also found within the surface epithelium. The bronchial submucosal glands can give rise to salivary gland-type tumors, including mucoepidermoid carcinomas and adenoid cystic carcinomas.

Two cell types, called type I and type II pneumocytes, make up the alveolar epithelium. Type I pneumocytes comprise 40% of the total number of alveolar epithelial cells, but cover 95% of the surface area of the alveolar wall. These cells are not

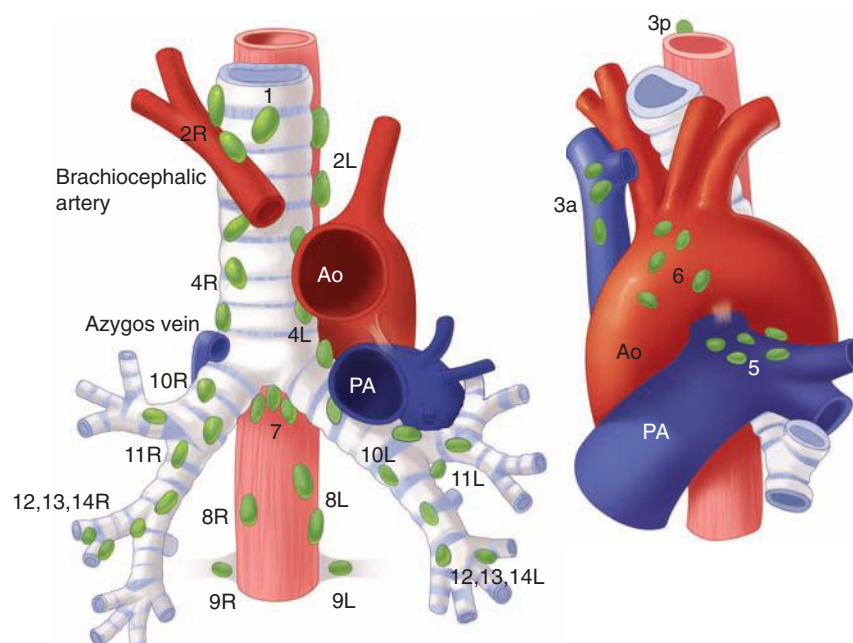


Figure 19-8. The location of regional lymph node stations for lung cancer. (Reproduced with permission from Mountain CF, Dresler CM. Regional lymph node classification for lung cancer staging. *Chest*. 1997;111:1718.)

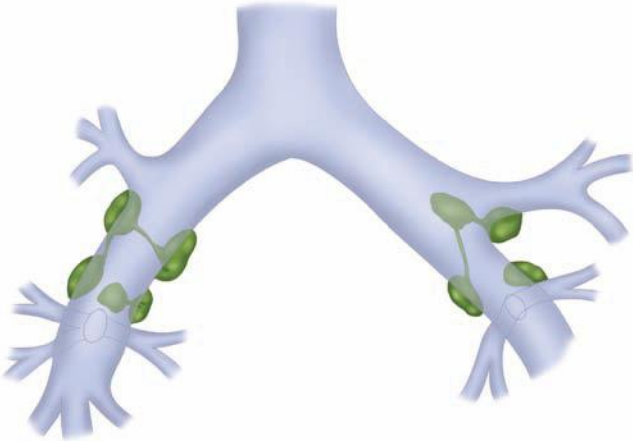


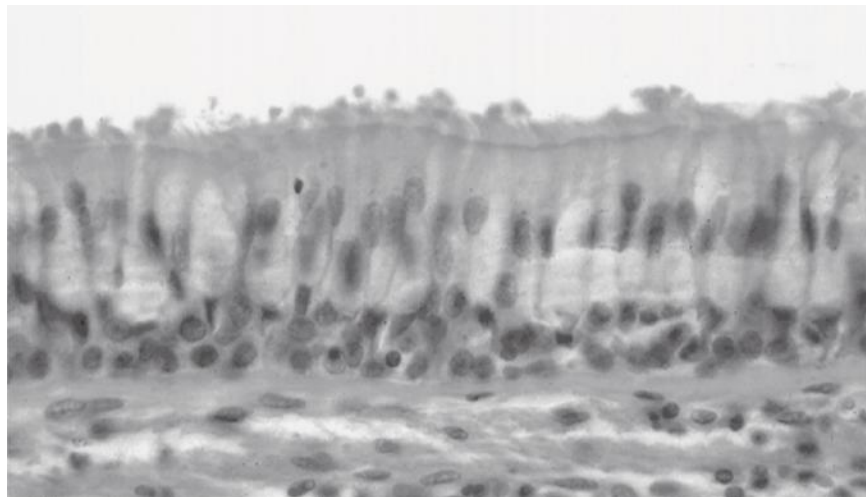
Figure 19-9. The lymphatic sump of Borrie includes the groups of lymph nodes that receive lymphatic drainage from all pulmonary lobes of the corresponding lung.

capable of regeneration because they have no mitotic potential. Type II pneumocytes cover only 3% of the alveolar surface, but comprise 60% of the alveolar epithelial cells. In addition, clusters of neuroendocrine cells are seen in the alveolar spaces.

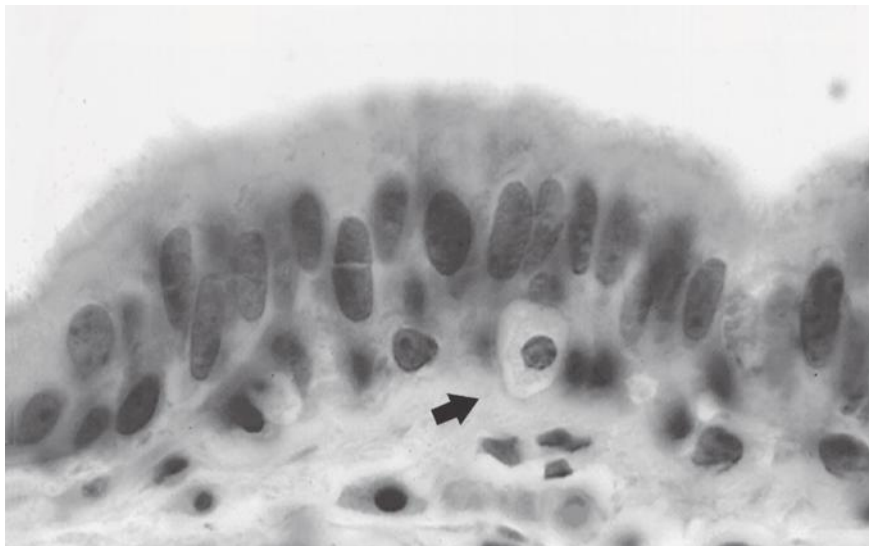
Preinvasive Lesions

The term “precancerous” does not mean that an inevitable progression to invasive carcinoma will occur, but such lesions, particularly those with high-grade dysplasia,^{11,12} do constitute a clear marker for potential development of invasive cancer. Three precancerous lesions of the respiratory tract are currently recognized.

1. **Squamous dysplasia and carcinoma in situ.** Cigarette smoke can induce a transformation of the tracheobronchial pseudostratified epithelium to metaplastic squamous mucosa, with subsequent evolution to dysplasia as cellular abnormalities accumulate. Dysplastic changes include



A



B

Figure 19-10. Normal lung histology. **A.** Pseudostratified ciliated columnar cells and mucous cells normally line the tracheobronchial tree. **B.** A Kulchitsky cell is depicted (arrow).

altered cellular polarity and increased cell size, number of cell layers, nuclear-to-cytoplasmic ratio, and number of mitoses. Gradations are considered mild, moderate, or severe. Carcinoma in situ represents carcinoma still confined by the basement membrane.

2. **Atypical adenomatous hyperplasia (AAH).** AAH is a lesion smaller than 5.0 mm, comprising epithelial cells lining the alveoli that are similar to type II pneumocytes. Histologically, AAH is similar to adenocarcinoma in situ; it represents the beginning stage of a stepwise evolution to adenocarcinoma in situ and then to adenocarcinoma. With the availability of thin-section CT, it is possible to detect preinvasive adenocarcinoma lesions as early as AAH. These lesions can be multiple, are typically small (5 mm or less), and have a ground-glass appearance.
3. **Diffuse idiopathic pulmonary neuroendocrine cell hyperplasia.** This rare lesion represents a diffuse proliferation of neuroendocrine cells, but without invasion of the basement membrane. It can exist as a diffuse increase in the number of single neuroendocrine cells, or as small lesions less than 5.0 mm in diameter. Lesions over 5.0 mm in size or that breach the basement membrane are carcinoid tumors.

Invasive or Malignant Lesions

The pathologic diagnosis of lung cancer is currently based on light microscopic criteria and is broadly divided into two main groups: *non-small cell lung carcinoma* and neuroendocrine tumors.¹³ Immunohistochemical staining and electron microscopy are used as adjuncts in diagnosis, particularly in the assessment of potential neuroendocrine tumors.

Non-Small Cell Lung Carcinoma. The term *non-small cell lung carcinoma (NSCLC)* includes many tumor cell types,

including large cell, squamous cell, and adenocarcinoma. Historically, these subtypes were considered to be a uniform group based on limited understanding of the distinct clinical behaviors of the subtypes as well as the fact that there were few treatment options available. With increasing understanding of the molecular biology underlying these tumor subtypes, however, the approach to diagnosis and management and the terminology used in describing these tumors are evolving rapidly.

Adenocarcinoma. The incidence of adenocarcinoma has increased over the last several decades, and it is now the most common lung cancer, accounting for 30% of lung cancers in male smokers and 40% of lung cancers in female smokers. Adenocarcinoma is the histologic subtype for 80% and 60% of lung cancers in nonsmoking females and males, respectively. It occurs more frequently in females than in males. It is the most frequent histologic subtype in women, patients who are under 45 years of age, and Asian populations.¹⁴

Histologic Subtyping of Adenocarcinoma. Increasing understanding of lung adenocarcinoma, such as important clinical, radiologic, pathologic, and genetic differences between mucinous and nonmucinous adenocarcinomas, prompted multiple changes in the classification system in 2011.¹⁵ Based on consensus, the international working group proposed a multidisciplinary approach, with standardized criteria and terminology for diagnosis in cytologic and small biopsy specimens, and routine molecular testing for known mutations, such as *EGFR* and *KRAS* mutations (Table 19-1). The new classification system delineated a stepwise pathologic progression, from AAH to invasive adenocarcinoma based on the predominant histologic growth patterns; the terms *bronchioloalveolar carcinoma* and *mixed subtype adenocarcinoma* were eliminated in favor of more biologically driven classification (Table 19-2).

Table 19-1

Difference between invasive mucinous adenocarcinoma and nonmucinous adenocarcinoma in situ/minimally invasive adenocarcinoma/lepidic predominant adenocarcinoma

	INVASIVE MUCINOUS ADENOCARCINOMA (FORMERLY MUCINOUS BAC)	NONMUCINOUS AIS/MIA/LPA (FORMERLY NONMUCINOUS BAC)
Female	49/84 (58%) ^{52,120-123}	101/140 (72%) ^{52,120-123}
Smoker	39/87 (45%) ^{52,120-122,124}	75/164 (46%) ^{52,120-122,124}
Radiographic appearance	Majority consolidation; air bronchogram ¹²⁵ Frequent multifocal and multilobar presentation ^{56,125-128}	Majority ground-glass attenuation ^{23,56,58,103,129-134}
Cell type	Mucin-filled, columnar, and/or goblet ^{50-52,125,135}	Type II pneumocyte and/or Clara cell ^{50-52,125,135}
Phenotype		
CK7	Mostly positive (~88%) ^{a54,55,136-139}	Positive (~98%) ^{a54,55,136-139}
CK20	Positive (~54%) ^{a54,55,136-139}	Negative (~5%) ^{a54,55,136-139}
TTF-1	Mostly negative (~17%) ^{1 a54,55,120,137-139}	Positive (~67%) ^{a54,55,120,137-139}
Genotype		
<i>KRAS</i> mutation	Frequent (~76%) ^{a55,94,121,127,140-144}	Some (~13%) ^{a55,121,127,140-144}
<i>EGFR</i> mutation	Almost none (~3%) ^{a55,121,127,140-142}	Frequent (~45%) ^{a55,121,127,140-142}

Source: Reproduced with permission from Travis W, Brambilla E, Noguchi M, et al. International Association for the Study of Lung Cancer/American Thoracic Society/European Respiratory Society: International multidisciplinary classification of lung adenocarcinoma. *J Thorac Oncol.* 2011;6:244.

^aNumbers represent the percentage of cases that are reported to be positive.

BAC, bronchioloalveolar carcinoma; AIS, adenocarcinoma in situ; MIA, minimally invasive adenocarcinoma; LP A, lepidic predominant adenocarcinoma; EGFR, epidermal growth factor receptor; TTF, thyroid transcription factor.

Table 19-2

New classification system for lung adenocarcinoma

Preinvasive lesions
Atypical adenomatous hyperplasia
Adenocarcinoma in situ (≤ 3 cm formerly BAC)
Nonmucinous
Mucinous
Mixed mucinous/nonmucinous
Minimally invasive adenocarcinoma (≤ 3 cm lepidic predominant tumor with ≤ 5 mm invasion)
Nonmucinous
Mucinous
Mixed mucinous/nonmucinous
Invasive adenocarcinoma
Lepidic predominant (formerly nonmucinous BAC pattern, with >5 mm invasion)
Acinar predominant
Papillary predominant
Micropapillary predominant
Solid predominant with mucin production
Variants of invasive adenocarcinoma
Invasive mucinous adenocarcinoma (formerly mucinous BAC)
Colloid
Fetal (low and high grade)
Enteric

Source: Reproduced with permission from Travis W, Brambilla E, Noguchi M, et al. International Association for the Study of Lung Cancer/American Thoracic Society/European Respiratory Society: International multidisciplinary classification of lung adenocarcinoma. *J Thorac Oncol.* 2011;6:244.

BAC = bronchioloalveolar carcinoma; IASLC = International Association for the Study of Lung Cancer; ATS = American Thoracic Society; ERS = European Respiratory Society.

- Adenocarcinoma in situ (AIS).** AISs are small (≤ 3 cm) solitary adenocarcinomas that have pure lepidic growth; lepidic growth is characterized by tumor growth within the alveolar spaces. These lesions are not invasive into the stroma, vascular system, or pleura and do not have papillary or micropapillary patterns or intra-alveolar tumor cells. They are very rarely mucinous, consisting of type II pneumocytes or Clara cells. These patients are expected to have 100% disease-specific survival with complete surgical resection. On CT scan, AIS can appear as a pure ground-glass neoplasm, but occasionally will present as part of a solid or part-solid nodule. Mucinous AIS is more likely to appear solid or to have the appearance of consolidation. As with AAH, the lesions can be single or multiple; the ground-glass changes in AIS, however, tend to have a higher attenuation compared to AAH.
 - Minimally invasive adenocarcinoma (MIA).** In the same size solitary lesion, if less than 5 mm of invasion are noted within a predominantly lepidic growth pattern, the lesion is termed *minimally invasive adenocarcinoma (MIA)* to indicate a patient group with near 100% survival when the lesion is completely resected. This differentiates patients with AIS, but recognizes the fact that the presence of invasion becomes prognostically significant when the size of the invasive component reaches 5 mm or greater in size.¹⁶ If multiple areas of microscopic invasion are found within
- the lepidic growth, the size of the largest invasive area, measured in the largest dimension, is used; this area must be ≤ 5 mm to be considered MIA. As with AIS, MIA is very rarely mucinous. The invasive component histologically is acinar, papillary, micropapillary, and/or solid and shows tumor cells infiltrating into the surrounding myofibroblastic stroma. On CT scan, the appearance of MIA is often a part-solid nodule (≤ 5 mm) with a predominant ground-glass component, but can be highly variable.
- Lepidic predominant adenocarcinoma (LPA).** If lymphovascular invasion, pleural invasion, tumor necrosis, or more than 5 mm of invasion are noted in a lesion that has lepidic growth as its predominant component, MIA is excluded and the lesion is called *lepidic predominant adenocarcinoma (LPA)*, and the size of the invasive component is recorded for the T stage.
 - Invasive adenocarcinoma.** The new classification system now recommends classifying invasive adenocarcinoma by the most predominant subtype after histologic evaluation of the resection specimen. To determine the predominant subtype, histologic sections are evaluated and the patterns are determined, in 5% increments, throughout the specimen. This semiquantitative method encourages the viewer to identify and quantify all patterns present, rather than focusing on a single pattern. In the pathology report, the tumor is classified by the predominant pattern, with percentages of the subtypes also reported (Fig. 19-11). Subtypes include:
 - Lepidic predominant
 - Acinar predominant
 - Papillary predominant
 - Micropapillary predominant
 - Solid predominant
 Adenocarcinoma is often peripherally located and frequently discovered incidentally on routine chest radiographs, unlike squamous cell cancers. When symptoms occur, they are due to pleural or chest wall invasion (pleuritic or chest wall pain) or pleural seeding with malignant pleural effusion. Invasive adenocarcinoma is usually solid by CT scan, but can also be part-solid and even a ground-glass nodule. Occasionally, a lobar ground-glass opacification may be present, which is often associated with significant respiratory compromise and can be mistaken for lobar pneumonia. Bubble-like or cystic lucencies on CT scan in small (≤ 2 cm) adenocarcinomas or extensive associated ground-glass components correlate with slow growth and well-differentiated tumors and a more favorable prognosis. Intratumoral air bronchograms are usually indicative of well-differentiated tumor, whereas spiculations that are coarse and thick (≥ 2 mm) portend vascular invasion and nodal metastasis and are associated with decreased survival following complete surgical resection. Pleural retraction is also a poor prognostic indicator.
 - Additional histologic variants include colloid adenocarcinoma (formerly mucinous cystadenocarcinoma), fetal adenocarcinoma, and enteric adenocarcinoma. Clear cell and signet ring cell types are no longer considered to be distinct subtypes as they are found in association with most of the five dominant histologic patterns (lepidic, acinar, papillary, micropapillary, and solid). However, they are still notable, as they can signal clinically relevant molecular changes, such as the presence of the *EML4-ALK* fusion gene in solid tumors with signet ring features.

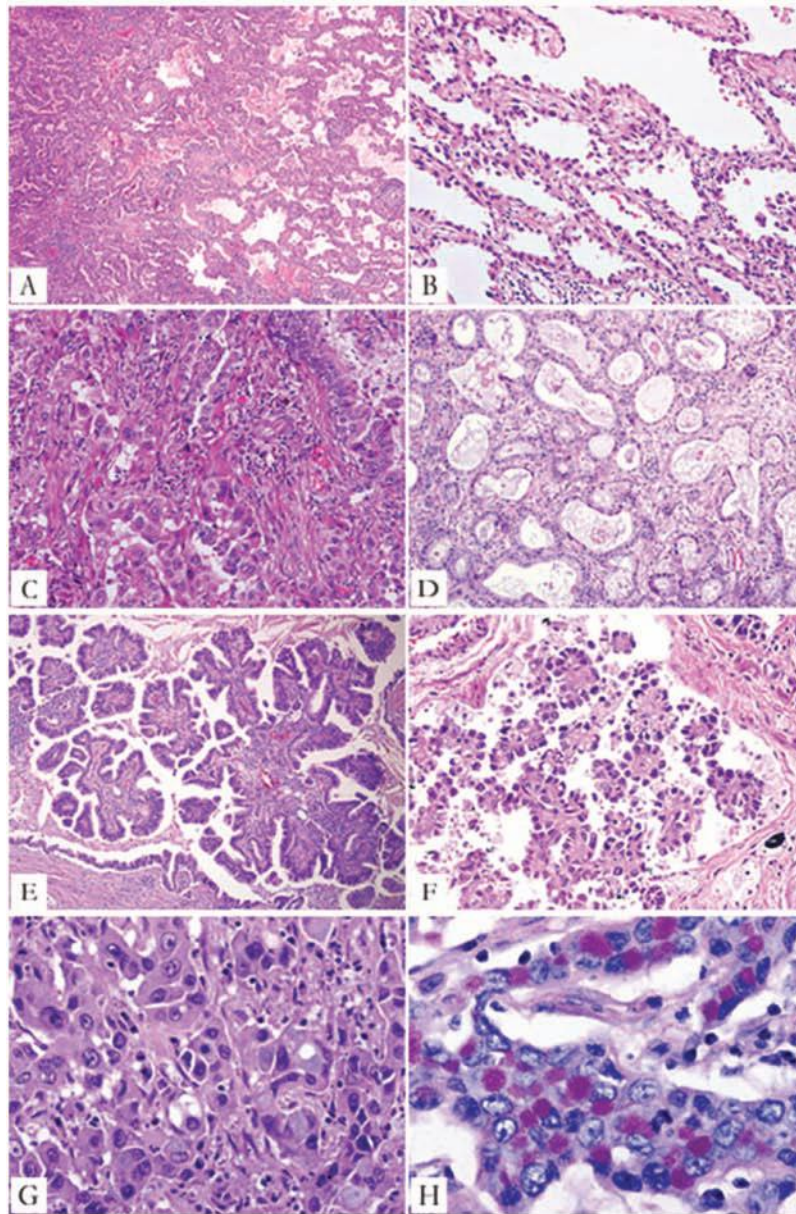


Figure 19-11. Major histologic patterns of invasive adenocarcinoma. **A.** Lepidic predominant pattern with mostly lepidic growth (*right*) and a smaller area of invasive acinar adenocarcinoma (*left*). **B.** Lepidic pattern consists of a proliferation type II pneumocytes and Clara cells along the surface alveolar walls. **C.** Area of invasive acinar adenocarcinoma (same tumor as in **A** and **B**). **D.** Acinar adenocarcinoma consists of round to oval-shaped malignant glands invading a fibrous stroma. **E.** Papillary adenocarcinoma consists of malignant cuboidal to columnar tumor cells growing on the surface of fibrovascular cores. **F.** Micropapillary adenocarcinoma consists of small papillary clusters of glandular cells growing within this airspace, most of which do not show fibrovascular cores. **G.** Solid adenocarcinoma with mucin consisting of sheets of tumor cells with abundant cytoplasm and mostly vesicular nuclei with several conspicuous nucleoli. No acinar, papillary, or lepidic patterns are seen, but multiple cells have intracytoplasmic basophilic globules that suggest intracytoplasmic mucin. **H.** Solid adenocarcinoma with mucin. Numerous intracytoplasmic droplets of mucin are highlighted with this diastase-periodic acid Schiff stain. (*Reproduced with permission from Travis W, Brambilla E, Noguchi M, et al. International Association for the Study of Lung Cancer/American Thoracic Society/European Respiratory Society: International multidisciplinary classification of lung adenocarcinoma. J Thorac Oncol. 2011;6:244.*)

Squamous Cell Carcinoma. Representing 30% to 40% of lung cancers, squamous cell carcinoma is the most frequent cancer in men and highly correlated with cigarette smoking. They arise primarily in the main, lobar, or first segmental bronchi, which are collectively referred to as the central airways. Symptoms of airway irritation or obstruction are common, and include cough, hemoptysis, wheezing (due to high-grade airway obstruction), dyspnea (due to bronchial

obstruction with or without postobstructive atelectasis), and pneumonia (caused by airway obstruction with secretion retention and atelectasis).

Occasionally a more peripherally based squamous cell carcinoma will develop in a tuberculosis scar or in the wall of a bronchiectatic cavity. Histologically, cells develop a pattern of clusters with intracellular bridges and keratin pearls. Central necrosis is frequent and may lead to the radiographic findings

of a cavity (possibly with an air-fluid level). Such cavities may become infected, with resultant abscess formation.

Large Cell Carcinoma. Large cell carcinoma accounts for 10% to 20% of lung cancers and may be located centrally or peripherally. These tumors have cell diameters of 30 to 50 μm , which are often admixed with various other malignant cell types. Large cell carcinoma can be confused with a large cell variant of neuroendocrine carcinoma, but can be differentiated by special immunohistochemical stains.

Salivary Gland-Type Neoplasms. Salivary-type submucosal bronchial glands throughout the tracheobronchial tree can give rise to tumors that are histologically identical to those seen in the salivary glands. The two most common are adenoid cystic carcinoma and mucoepidermoid carcinoma. Both tumors occur centrally due to their site of origin. Adenoid cystic carcinoma is a slow-growing tumor that is locally and systemically invasive, growing submucosally and infiltrating along perineural sheaths. Mucoepidermoid carcinoma consists of squamous and mucous cells and is graded as low or high grade, depending on the mitotic rate and degree of necrosis.

Neuroendocrine Neoplasms. Neuroendocrine lung tumors are classified into neuroendocrine hyperplasia and three separate grades of neuroendocrine carcinoma (NEC). Immunohistochemical staining for neuroendocrine markers (including chromogranins, synaptophysin, CD57, and neuron-specific enolase) is essential to accurately diagnose most tumors.¹⁷

Grade I NEC (classic or typical carcinoid) is a low-grade NEC; 80% arise in the epithelium of the central airways. It occurs primarily in younger patients. Because of the central location, it classically presents with hemoptysis, with or without airway obstruction and pneumonia. Histologically, tumor cells are arranged in cords and clusters with a rich vascular stroma. This vascularity can lead to life-threatening hemorrhage with even simple bronchoscopic biopsy maneuvers. Regional lymph node metastases are seen in 15% of patients, but rarely spread systemically or cause death.

Grade II NECs (atypical carcinoid) have a much higher malignant potential and, unlike grade I NEC, are etiologically linked to cigarette smoking and are more likely to be peripherally located. Histologic findings may include areas of necrosis, nuclear pleomorphism, and higher mitotic rates. Lymph node metastases are found in 30% to 50% of patients. At diagnosis, 25% of patients already have remote metastases.

Grade III NEC large cell-type tumors occur primarily in heavy smokers and in the mid to peripheral lung fields. They are often large with central necrosis and a high mitotic rate. Their neuroendocrine nature is revealed by positive immunohistochemical staining for at least one neuroendocrine marker.

Grade IV NEC (small cell lung carcinoma [SCLC]) is the most malignant NEC and accounts for 25% of all lung cancers; these NECs often have early, widespread metastases. These cancers also arise primarily in the central airways. As with squamous cell cancers, symptoms include cough, hemoptysis, wheezing (due to high-grade airway obstruction), dyspnea (due to bronchial obstruction with or without postobstructive atelectasis), and pneumonia (caused by airway obstruction with secretion retention and atelectasis). Evaluation includes expert pathology review and comprehensive evaluation for metastatic disease. Three groups of grade IV NEC are recognized: pure small cell carcinoma (sometimes referred to as oat cell carcinoma),

small cell carcinoma with a large cell component, and combined (mixed) tumors.

Grade IV NECs consist of smaller cells (diameter 10 to 20 μm) with little cytoplasm and very dark nuclei; they can be difficult to distinguish from lymphoproliferative lesions and atypical carcinoid tumors. Histologically, a high mitotic rate with easily visualized multiple mitoses and areas of extensive necrosis are characteristic. Importantly, very small bronchoscopic biopsies can distinguish NSCLC from SCLC, but crush artifact may make NSCLC appear similar to SCLC. If uncertainty exists, special immunohistochemical stains or rebiopsy (or both) will be necessary. These tumors are the leading producer of paraneoplastic syndromes.

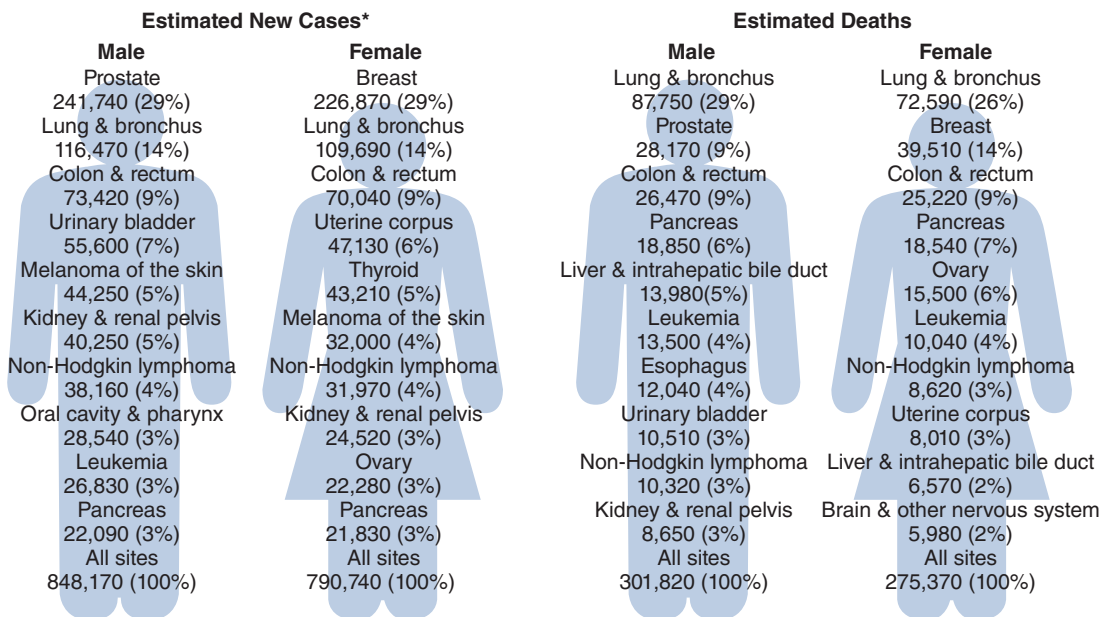
Lung Cancer Epidemiology

Lung cancer is the leading cancer killer and second most frequently diagnosed cancer in the United States, accounting for nearly 28% of all cancer deaths—more than cancers of the breast, prostate, ovary, and colon and rectum combined (Fig. 19-12). In 2008, it was estimated that 1 in 13 men and 1 in 16 women would develop lung cancer in their lifetime. The overall 5-year survival for all patients with lung cancer is 16%, making lung cancer the most lethal of the leading four cancers (Fig. 19-13A, B). It is encouraging, however, that the average annual death rate declined by 2.8% per year for men and 1.1% per year for women from 2005 to 2009.¹⁸ Unfortunately, most patients are still diagnosed at an advanced stage of disease, so therapy is rarely curative.

Prognostic markers for lung cancer survival include female sex (5-year survival of 18.3% for women vs. 13.8% for men), younger age (5-year survival of 22.8% for those <45 years vs. 13.7% for those >65 years), and white race (5-year survival of 16.1% for whites vs. 12.2% for blacks). When access to advanced medical care is unrestricted, as for the military population, the racial difference in survival disappears, suggesting that, at least in part, differences in survival may be explained by less access to advanced medical care and later diagnosis.¹⁹

Risk Factors for Lung Cancer. Cigarette smoking was implicated as a causal factor in approximately 75% of all lung cancers worldwide in 2007. According to the U.S. Surgeon General's report in 2004, 90% of lung cancers in men and nearly 80% in women can be attributed to cigarette smoking or secondhand cigarette smoke exposure. Two lung cancer types—squamous cell and small cell carcinoma—are extraordinarily rare in the absence of cigarette smoking. The risk of developing lung cancer escalates with the number of cigarettes smoked, the number of years of smoking, and the use of unfiltered cigarettes. Conversely, the risk of lung cancer declines with smoking cessation, but never drops to that of never smokers, regardless of the length of abstinence (Table 19-3).²⁰ Radon exposure accounts for the vast majority of the remaining cancers. Approximately 25% of all lung cancers worldwide and 53% of cancers in women are not related to smoking, and most of them (62%) are adenocarcinomas. Table 19-4 summarizes the existing data regarding the etiology of lung cancer in nonsmokers.²¹

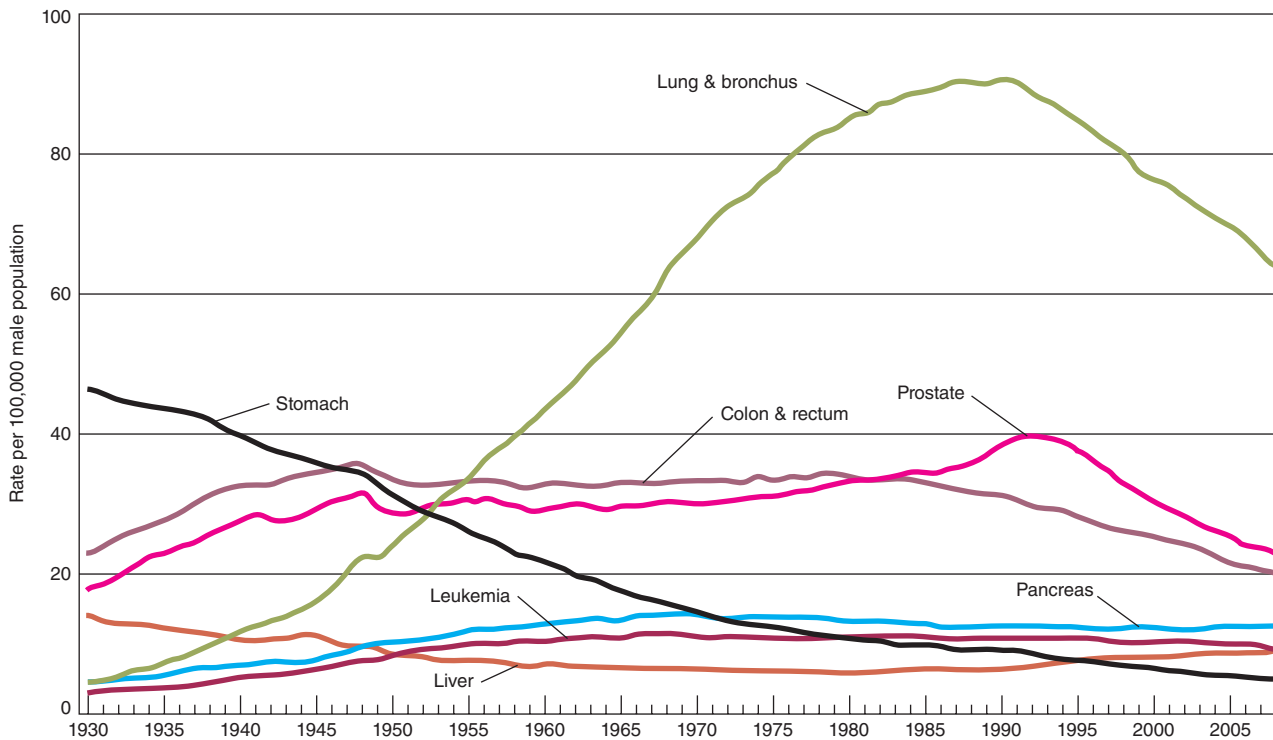
Nearly 3500 deaths from lung cancer each year are attributable to secondhand (environmental) smoke exposure, which confers an excess risk for lung cancer of 24% when a nonsmoker lives with a smoker.²² Risk is conferred by exposure to any burning tobacco, including cigars. The amount of secondhand exposure from one large cigar is equivalent to the exposure from 21 cigarettes. As with active smoking, risk of developing lung



* Excludes basal and squamous cell skin cancers and in situ carcinoma except urinary bladder.

Figure 19-12. Leading new cancer cases and deaths: 2012 estimates. *Excludes basal and squamous cell skin cancers and in situ carcinomas except urinary bladder. (Modified with permission from John Wiley and Sons: Siegel R, Naishadham D, Jemal A. Cancer statistics, 2013. CA Cancer J Clin. 2012;62:10. © 2012 American Cancer Society, Inc.)

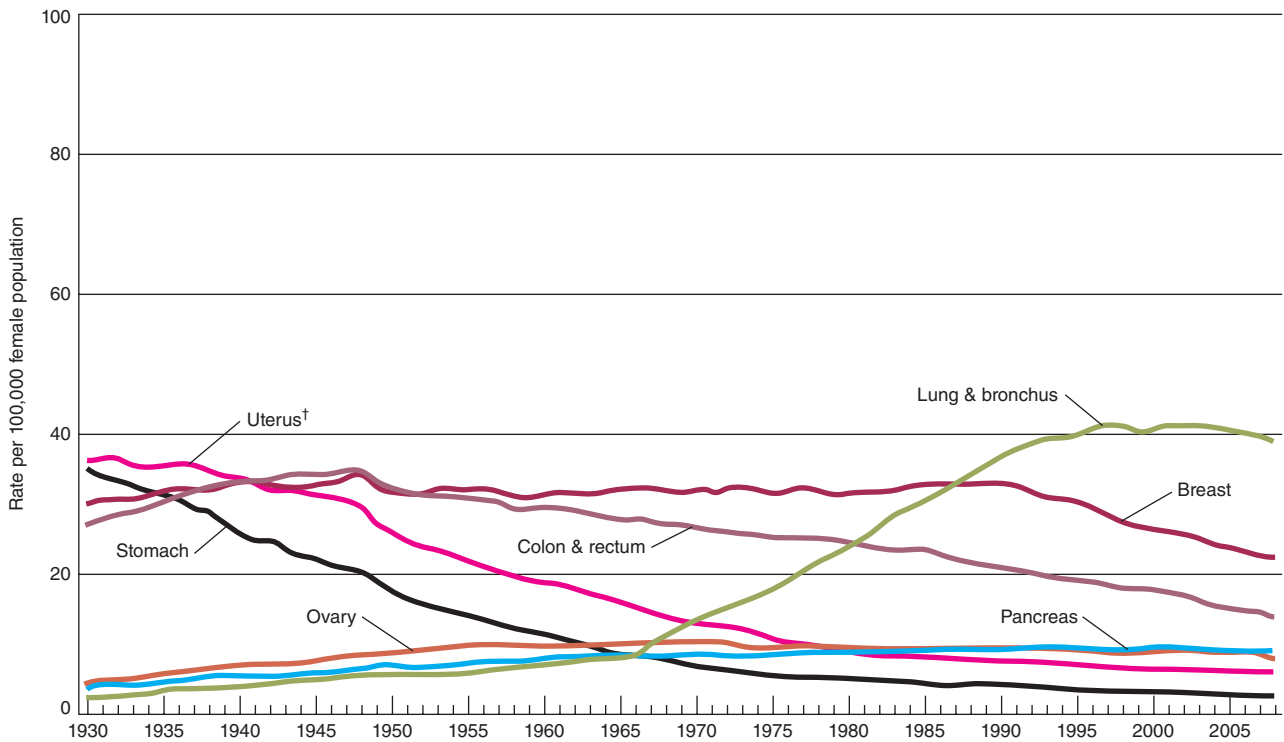
Age-adjusted Cancer Death Rates,* Males by Site, US, 1930–2008



*Per 100,000, age adjusted to the 2000 US standard population.

Note: Due to changes in ICD coding, numerator information has changed over time. Rates for cancer of the liver, lung and bronchus, and colon and rectum are affected by these coding changes.

Figure 19-13. Age-adjusted cancer death rates. **A.** Males by site, United States, 1930 to 2008. **B.** Females by site, United States, 1930 to 2008. *Per 100,000, age adjusted to the 2000 U.S. standard population. (Modified with permission from John Wiley and Sons: Siegel R, Naishadham D, Jemal A. Cancer statistics, 2013. CA Cancer J Clin. 2012;62:10. © 2012 American Cancer Society, Inc.)



*Per 100,000, age adjusted to the 2000 US standard population. †Uterus cancer death rates are for uterine cervix and uterine corpus combined. **Note:** Due to changes in ICD coding, numerator information has changed over time. Rates for cancer of the lung and bronchus, colon and rectum, and ovary are affected by these coding changes.

Figure 19-13. (Continued)

4▶ cancer increases with longer duration and higher level of exposure to environmental tobacco.

Over 7000 chemicals have been identified in tobacco smoke, and more than 70 of the compounds are known to be carcinogens. The main chemical carcinogens are polycyclic aromatic hydrocarbons, which are actively or passively inhaled in the tobacco smoke and absorbed; these compounds are activated by specific enzymes and become mutagenic, bind to macromolecules such as deoxyribonucleic acid (DNA), and induce genetic mutations. In treating any patient with a previous smoking

history, it is important to remember that there has been field cancerization of the entire aerodigestive tract. The patient’s risk is increased for cancers of the oral cavity, pharynx, larynx, tracheobronchial tree and lung, and esophagus. In examining such patients, a detailed history and physical examination of these organ systems must be performed.

Other causes of lung cancer include exposure to a number of industrial compounds, including asbestos, arsenic, and chromium compounds. In fact, the combination of asbestos and cigarette smoke exposure has a multiplicative effect on risk. Pre-existing lung disease confers an increased risk of lung cancer—up to 13%—for individuals who have never smoked. Patients with chronic obstructive pulmonary disease are at higher risk for lung cancer than would be predicted based on smoking risk alone. Patients with secondary scar formation related to a history of tuberculosis also have a higher risk of primary lung carcinoma. This increase is thought to be related to poor clearance of inhaled carcinogens and/or to the effects of chronic inflammation.

Screening for Lung Cancer in High-Risk Populations

In 2002, the National Lung Screening Trial (NLST) was launched to determine whether screening with CT in high-risk populations would reduce mortality from lung cancer. The study randomized 53,353 eligible patients age 55 to 74 years to either three annual low-dose helical CT scans (LDCT; aka spiral CT) or posteroanterior view chest radiograph. Patients were eligible

Table 19-3

Relative risk of lung cancer in smokers

SMOKING CATEGORY	RELATIVE RISK
Never smoked	1.0
Currently smoke	15.8–16.3
Formerly smoked	
Years of abstinence	
1–9	5.9–19.5
10–19	2.0–6.1
>20	1.9–3.7

Source: Adapted from Samet,²⁰ p 673.

Table 19-4

Summary of selected studies of risk factors for lung cancer in individuals who never smoked

RISK FACTOR	RISK ESTIMATE (95% CI)	COMMENTS	REFERENCE
Environmental tobacco smoke	1.19 (90% CI: 1.04–1.35)	Meta-analysis of 11 U.S. studies of spousal exposure (females only)	225
	1.21 (1.13–1.30)	Meta-analysis of 44 case-control studies worldwide of spousal exposure	226
	1.22 (1.13–1.33)	Meta-analysis of 25 studies worldwide of workplace exposure	226
	1.24 (1.18–1.29)	Meta-analysis of 22 studies worldwide of workplace exposure	227
Residential radon	8.4% (3.0%–15.8%) per 100 Bq m ³ increase in measured radon	Meta-analysis of 13 European studies	228
	11% (0%–28%) per 100 Bq m ³	Meta-analysis of 7 North American studies	229
Cooking oil vapors	2.12 (1.81–2.47)	Meta-analysis of 7 studies from China and Taiwan (females who never smoked)	230
Indoor coal and wood burning	2.66 (1.39–5.07)	Meta-analysis of 7 studies from China and Taiwan (both sexes)	230
	1.22 (1.04–1.44)	Large case-control study (2861 cases and 3118 controls) from Eastern and Central Europe (both sexes)	231
	2.5 (1.5–3.6)	Large case-control study (1205 cases and 1541 controls) from Canada (significant for women only)	232
Genetic factors: family history, CYP1A1 Ile462Val polymorphism, XRCC1 variants	1.51 (1.11–2.06)	Meta-analysis of 28 case-control, 17 cohort, and 7 twin studies	233
	2.99 (1.51–5.91)	Meta-analysis of 14 case-control studies of Caucasian never smokers	234
	2.04 (1.17–3.54)	Meta-analysis of 21 case-control studies of Caucasian and Asian never smokers (significant for Caucasians only)	235
	No association	Meta-analysis of 13 case-control studies	236
	No association overall; reduced risk 0.65 (0.46–0.83) with Arg194Trp polymorphism and 0.56 (0.36–0.86) with Arg280His for heavy smokers	Large case-control study from Europe (2188 cases and 2198 controls)	237
	Increased risk for never smokers 1.3 (1.0–1.8) and decreased risk for heavy smokers 0.5 (0.3–1.0) with Arg299Gln	Large case-control study from the United States (1091 cases and 1240 controls)	238
Viral factors: HPV 16 and 18	10.12 (3.88–26.4) for never smoking women >60 y	Case-control study (141 cases, 60 controls) from Taiwan of never smoking women	239

Bq = becquerels; CI = confidence interval; CYP1A1 = cytochrome P450 enzyme 1A1; HPV = human papilloma virus.

Source: Reprinted by permission from Macmillan Publishers Ltd. Sun S, Schiller JH, Gazdar AF. Lung cancer in never smokers—a different disease. *Nat Rev Cancer*. 2007;7:778 Copyright © 2007.

for the trial if they had a greater than 30 pack-year history of cigarette smoking; had smoked within the past 15 years if a former smoker; had no prior history of lung cancer; had no history of other life-threatening cancers in the prior 5 years; did not have symptoms suggestive of an undiagnosed lung cancer (such as hemoptysis or weight loss); and had not had a chest CT scan in the prior 18 months. Accrual to the study was excellent, and the primary endpoint of a 20% relative reduction in mortality was achieved in 2010. An absolute risk reduction of lung cancer death of four per 1000 individuals screened by LDCT was realized. Interestingly, all-cause mortality was also reduced by nearly 7% in the LDCT group, further emphasizing the impact

of lung cancer on the mortality of smokers and former smokers.²³ An estimated 320 individuals need to be screened to save one life from lung cancer. Additional considerations require further evaluation before widespread LDCT screening will become reality. First, there was a 7% false-positive rate in this trial. False-positive scans lead to patient anxiety, invasive testing, and potentially morbid procedures to further evaluate the finding. The impact of these issues on patient quality of life and cost-effectiveness has yet to be elucidated. It is also critical that regulatory guidelines for patient eligibility, frequency of screening, interpretation of the scans, processes for further evaluation and management of positive findings, and dose of radiation are

well established and well accepted to ensure the generalizability of the results for patients who will be screened in the general medical community rather than in the specialized centers that performed the trial.

Solitary Pulmonary Nodule

A solitary pulmonary nodule is typically described as a single, well-circumscribed, spherical lesion that is 3 cm or less in diameter and completely surrounded by normal aerated lung parenchyma.²⁴ Lung atelectasis, hilar enlargement, and pleural effusion are absent. The majority are detected incidentally on chest radiographs (CXR) or CT scans obtained for some other purpose. About 150,000 solitary nodules are found incidentally each year. The clinical significance of such a lesion depends on whether or not it represents a malignancy.

The differential diagnosis of a solitary pulmonary nodule should include a broad variety of congenital, neoplastic, inflammatory, vascular, and traumatic disorders. The probability of cancer in a solitary pulmonary nodule increases if the patient has a history of smoking (50% or higher for smokers compared to 20%–40% in never smokers). It is also more likely to be

malignant if it is symptomatic or the patient is older, male, or has had occupational exposures.

Solitary pulmonary nodules were defined by findings on CXR, but with the increased sensitivity of low-dose screening CT, up to 50% of solitary lesions are found to be associated with multiple (one to six) other, usually subcentimeter, nodules. In the Early Lung Cancer Action project, almost 7% of healthy volunteers were found to have between one and three nodules and 25% had up to six nodules. CT scanning is necessary to characterize nodule number, location, size, margin morphology, calcification pattern, and growth rate.²⁵ Spiral (helical) CT allows continuous scanning as the patient is moved through a scanning gantry, allowing the entire thorax to be imaged during a single breath hold (Fig. 19-14). Compared to conventional CT, this provides a superior image quality, because motion artifacts are eliminated, and improves detection of pulmonary nodules and central airway abnormalities.²⁶ The shorter acquisition time of spiral CT also allows for consistent contrast filling of the great vessels, resulting in markedly improved visualization of pathologic states and anatomic variation contiguous to vascular structures. In addition, three-dimensional spiral CT images can

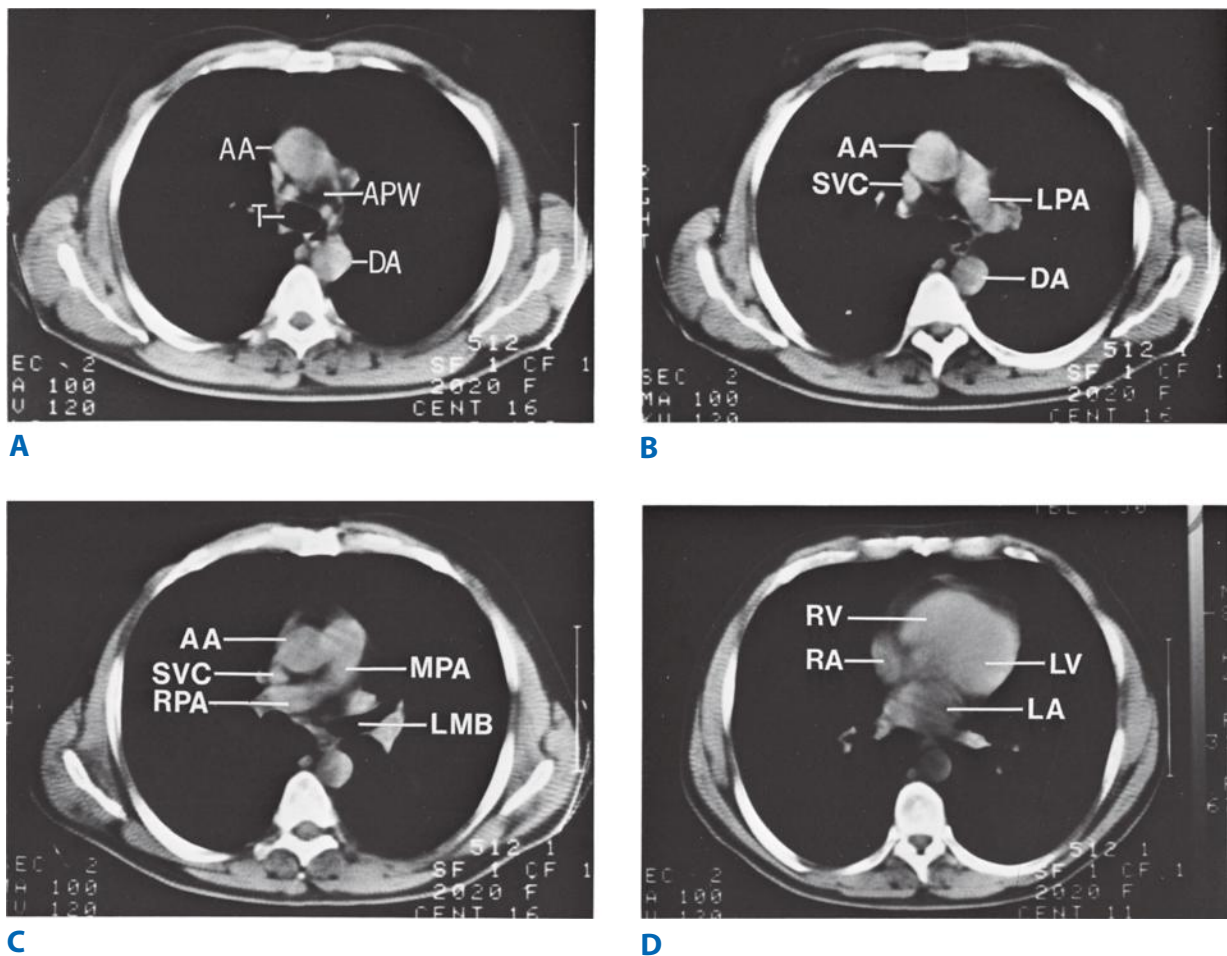


Figure 19-14. Spiral computed tomography scan showing normal transverse chest anatomy at four levels. **A.** At the level of the tracheal bifurcation, the aortopulmonary window can be seen. **B.** The origin of the left pulmonary artery can be seen at a level 1 cm inferior to **A.** **C.** The origin and course of the right pulmonary artery can be seen at this next most cephalad level. The left upper lobe bronchus can be seen at its origin from the left main bronchus. **D.** Cardiac chambers and pulmonary veins are seen in the lower thorax. AA = ascending aorta; APW = aortopulmonary window; DA = descending aorta; LA = left ventricle; LMB = left main bronchus; LPA = left pulmonary artery; MPA = main pulmonary artery; RA = right atrium; RPA = right pulmonary artery; RV = right ventricle; SVC = superior vena cava; T = trachea.

be reconstructed for enhanced visualization of spatial anatomic relationships.²⁷ Thin sections (1–2 mm collimation) at 1-cm intervals should be used to evaluate pulmonary parenchyma and peripheral bronchi. If the goal is to find any pulmonary metastases, thin sections at intervals of 5 to 7 mm collimation are recommended. For assessing the trachea and central bronchi, collimation of 3 to 5 mm is recommended. Providing accurate clinical history and data is of paramount importance to obtaining appropriate imaging.

CT findings characteristic of benign lesions include small size, calcification within the nodule, and stability over time. Four patterns of benign calcification are common: diffuse, solid, central, and laminated or “popcorn.” Granulomatous infections such as tuberculosis can demonstrate the first three patterns, whereas the popcorn pattern is most common in hamartomas. In areas of endemic granulomatous disease, differentiating benign versus malignant can be challenging. Infectious granulomas arising from a variety of organisms account for 70% to 80% of this type of benign solitary nodules; hamartomas are the next most common single cause, accounting for about 10%.

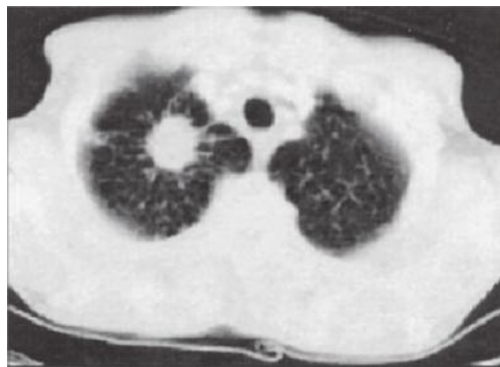
CT findings characteristic of malignancy include growth over time; increasing density on CT scan (40%–50% of partial solid lesions are malignant compared to only 15% of sub-centimeter solid or nonsolid nodules); size >3 cm; irregular, lobulated, or spiculated edges; and the finding of the corona radiata sign (consisting of fine linear strands extending 4–5 mm outward and appearing spiculated on radiographs) (Fig. 19-15). Calcification that is stippled, amorphous, or eccentric is usually associated with cancer.

Growth over time is an important characteristic for differentiating benign and malignant lesions. Lung cancers have volume-doubling times from 20 to 400 days; lesions with shorter doubling times are likely due to infection, and longer doubling times suggest benign tumors, but can represent slower-growing lung cancer. Positron emission tomography (PET) scanning can differentiate benign from malignant nodules²⁸; most lung tumors have increased signatures of glucose uptake, as compared with healthy tissues and, thus, glucose metabolism can be measured using radio-labeled ¹⁸F-fluorodeoxyglucose (FDG). Meta-analysis estimates 97% sensitivity and 78% specificity for predicting malignancy in a nodule. False-negative results can occur (especially in patients who have AIS, MIA, or LPA, carcinoids, and tumors <1 cm in diameter), as well as false-positive results (because of confusion with other infectious or inflammatory processes).

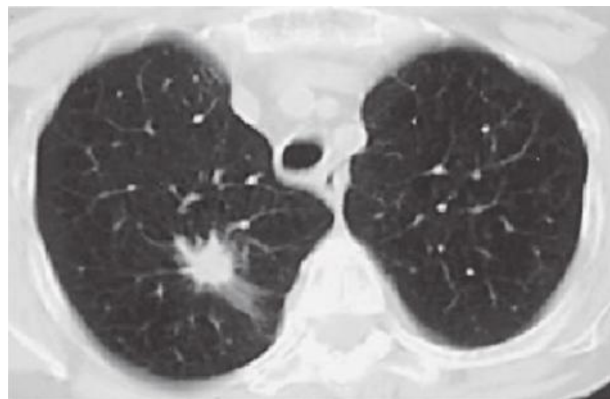Metastatic Lesions to the Lung

The cause of a new pulmonary nodule(s) in a patient with a previous malignancy can be difficult to discern.²⁹ Features suggestive of metastatic disease are multiplicity; smooth, round borders on CT scan; and temporal proximity to the original primary lesion. One must always entertain the possibility that a single new lesion is a primary lung cancer. The probability of a new primary cancer vs. metastasis in patients presenting with solitary lesions depends on the type of initial neoplasm. The highest likelihood of a new primary lung cancer is in patients with a history of uterine (74%), bladder (89%), lung (92%), and head and neck (94%) carcinomas.

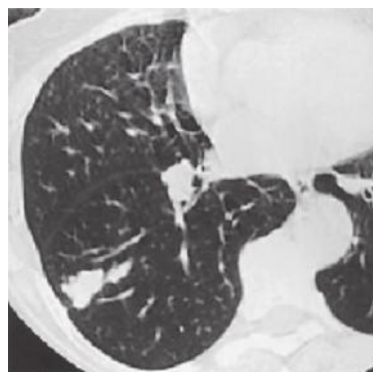Surgical resection of pulmonary metastases has a role in properly selected patients.³⁰ The best data regarding outcomes of resection of pulmonary metastases come from the International Registry of Lung Metastases (IRLM). The registry



A



B



C

Figure 19-15. Computed tomography scan images of solitary pulmonary nodules. **A.** The corona radiata sign demonstrated by a solitary nodule. Multiple fine striations extend perpendicularly from the surface of the nodule like the spokes of a wheel. **B.** A biopsy-proven adenocarcinoma demonstrating spiculation. **C.** A lesion with a scalloped border, an indeterminate finding suggesting an intermediate probability for malignancy.

was established in 1991 by 18 thoracic surgery departments in Europe, the United States, and Canada, and included data on 5206 patients. About 88% of patients underwent complete resection. Survival analysis at 5, 10, and 15 years (grouping all primary tumor types) was performed (Table 19-5). Multivariate analysis showed a better prognosis for patients with germ cell tumors, osteosarcomas, a disease-free interval over 36 months, and a single metastasis.³¹ Depicted in Fig. 19-16, survival after metastasectomy in a variety of cancers is optimal when metastatic

Table 19-5

Actuarial survival data from the International Registry of Lung Metastases

SURVIVAL	COMPLETE RESECTION (%)	INCOMPLETE RESECTION (%)
5 years	36	13
10 years	26	7
15 years	22	—

disease is resectable, solitary, and identified 36 or more months after initial treatment. When any or all of these optimal characteristics are absent, survival progressively declines.

The general principles of patient selection for metastasectomy are listed in Table 19-6. The technical aim of pulmonary metastasectomy is complete resection of all macroscopic tumors. In addition, any involved adjacent structures should be resected en bloc (i.e., chest wall, diaphragm, and pericardium). Multiple lesions and/or hilar lesions may require lobectomy. Pneumonectomy is rarely justified or employed.

Pulmonary metastasectomy can be approached through a thoracotomy or via video-assisted thoracic surgery (VATS) techniques. McCormack and colleagues reported their experience at Memorial Sloan-Kettering in a prospective study of 18 patients who presented with no more than two pulmonary metastatic lesions and underwent VATS resection.³² A thoracotomy was performed during the same operation; if palpation identified any additional lesions, they were resected. The study concluded that the probability that a metastatic lesion will be missed by VATS excision is 56%. Patients in the Memorial study were evaluated before the advent of spiral CT scanning, however, and it remains controversial whether metastasis resection should be performed via VATS. Proponents of VATS argue that the resolution of spiral CT scanning is so superior that prior studies using standard CT scanners are no longer relevant. Indeed, a recent study suggested that only 18% of malignant nodules would be missed using a VATS approach in the current era while another study from the United Kingdom found equivalent outcomes with regard to missed lesions and pulmonary progression comparing open and VATS approaches. To date, no prospective study using spiral CT scan has been performed to resolve this clinical dilemma.

Primary Lung Cancer-Associated Signs and Symptoms

Lung cancer displays one of the most diverse presentation patterns of all human maladies (Table 19-7). The wide range of symptoms and signs is related to (a) histologic features, which often help determine the anatomic site of origin in the lung; (b) the specific tumor location in the lung and its relationship to surrounding structures; (c) biologic features and the production of a variety of paraneoplastic syndromes; and (d) the presence or absence of metastatic disease. Symptoms related to the local intrathoracic effect of the primary tumor can be conveniently divided into two groups: pulmonary and nonpulmonary thoracic.

Pulmonary Symptoms. Pulmonary symptoms result from the direct effect of the tumor on the bronchus or lung tissue. Symptoms (in order of frequency) include cough (secondary to irritation

or compression of a bronchus), dyspnea (usually due to central airway obstruction or compression, with or without atelectasis), wheezing (with narrowing of a central airway of >50%), hemoptysis (typically, blood streaking of mucus that is rarely massive; indicates a central airway location), pneumonia (usually due to airway obstruction by the tumor), and lung abscess (due to necrosis and cavitation, with subsequent infection).

Nonpulmonary Thoracic Symptoms. Nonpulmonary thoracic symptoms result from invasion of the primary tumor directly into a contiguous structure (e.g., chest wall, diaphragm, pericardium, phrenic nerve, recurrent laryngeal nerve, superior vena cava, and esophagus), or from mechanical compression of a structure (e.g., esophagus or superior vena cava) by enlarged tumor-bearing lymph nodes.

Peripherally located tumors (often adenocarcinomas) extending through the visceral pleura lead to irritation or growth into the parietal pleura and potentially to continued growth into the chest wall structures. Three types of symptoms, depending on the extent of chest wall involvement, are possible: (a) **pleuritic pain**, from noninvasive contact of the parietal pleura with inflammatory irritation or direct parietal pleural invasion; (b) **localized chest wall pain**, from deeper invasion and involvement of the rib and/or intercostal muscles; and (c) **radicular pain**, from involvement of the intercostal nerve(s). Radicular pain may be mistaken for renal colic in the case of tumors invading the inferoposterior chest wall.

Other specific nonpulmonary thoracic symptoms include:

1. **Pancoast's syndrome.** Tumors originating in the superior sulcus (posterior apex) elicit: apical chest wall and/or shoulder pain (from involvement of the first rib and chest wall); Horner's syndrome (unilateral enophthalmos, ptosis, miosis, and facial anhidrosis from invasion of the stellate sympathetic ganglion); and radicular arm pain (from invasion of T1, and occasionally C8, brachial plexus nerve roots).
2. **Phrenic nerve palsy.** The phrenic nerve traverses the hemithorax along the mediastinum, parallel and posterior to the superior vena cava and anterior to the pulmonary hilum. Tumors at the medial lung surface or anterior hilum can directly invade the nerve; symptoms include shoulder pain (referred), hiccups, and dyspnea with exertion because of diaphragm paralysis. Radiographically, unilateral diaphragm elevation on CXR is present; the diagnosis is confirmed by fluoroscopic examination of the diaphragm with breathing and sniffing (the "sniff" test).
3. **Recurrent laryngeal nerve palsy.** Recurrent laryngeal nerve (RLN) involvement most commonly occurs on the left side, given the hilar location of the left RLN as it passes under the aortic arch. Paralysis results from: (a) invasion of the vagus nerve above the aortic arch by a medially based left upper lobe tumor; or (b) direct invasion of the RLN by hilar tumor and/or hilar or aortopulmonary lymph node metastases. Symptoms include voice change, often referred to as hoarseness, but more typically a loss of tone associated with a breathy quality, and coughing, particularly when drinking liquids.
4. **Superior vena cava (SVC) syndrome.** As a result of bulky enlargement of involved mediastinal lymph nodes compressing or a medially based right upper lobe tumor invading the SVC, SVC syndrome symptoms include variable degrees of swelling of the head, neck, and arms; headache;

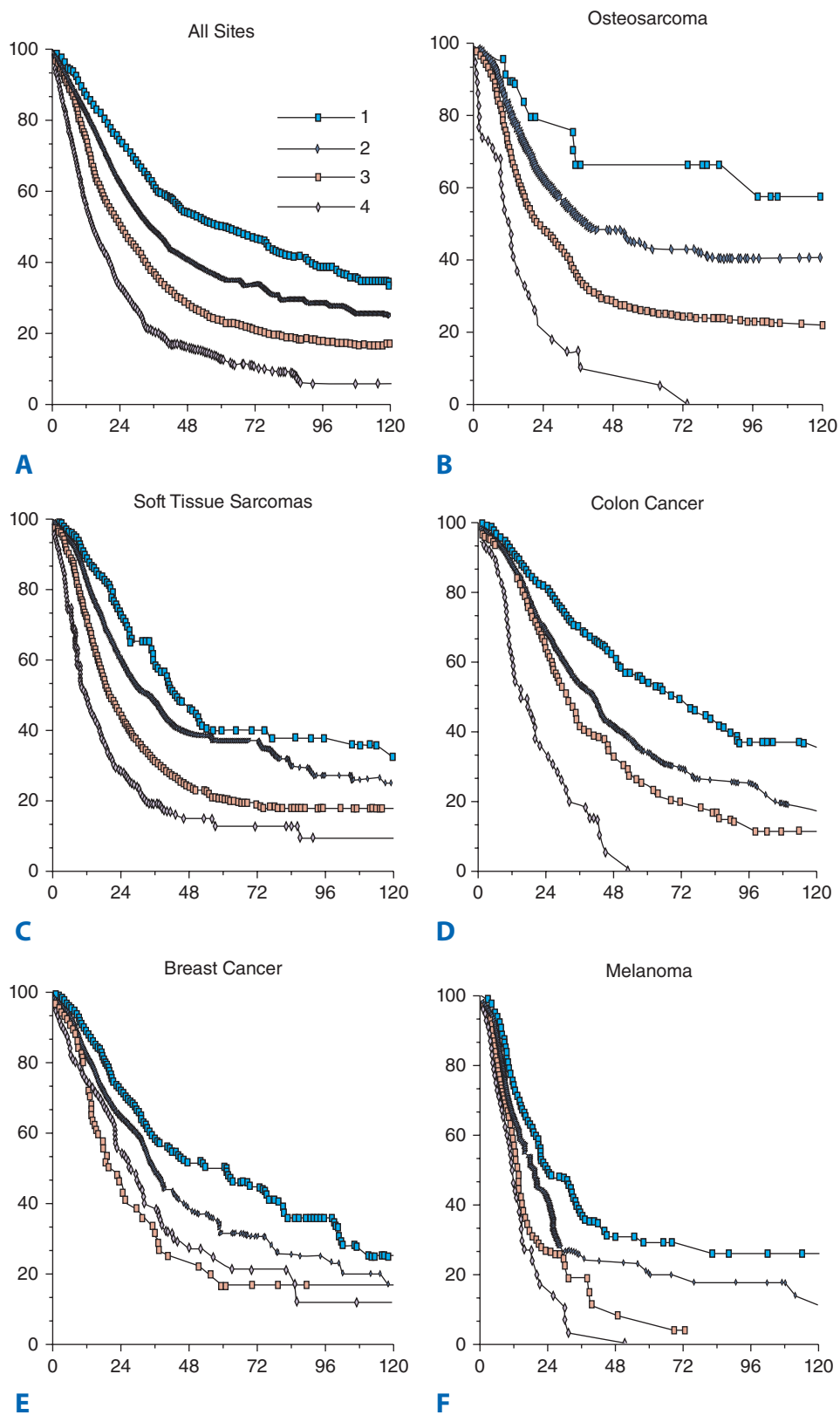


Figure 19-16. The actuarial survival after metastasectomy is depicted for patients with various tumor types further categorized into four groups according to resectability, solitary or multiple, the interval between primary resection and metastasectomy, and a combination of factors known in our work and in others, as follows: (1) resectable, solitary, and disease-free interval (DFI) greater than or equal to 36 months; (2) resectable, solitary, or DFI 36+ months; (3) resectable, multiple metastases, and DFI < 36 months; and (4) unresectable. (Reprinted with permission from Pastorino, U. (2010). *The Development of an International Registry*. *J Thorac Oncol*. 5(6): S196-S197)

Table 19-6

General principles governing appropriate selection of patients for pulmonary metastasectomy

1. Primary tumor must already be controlled.
2. Patient must be able to tolerate general anesthesia, potential single-lung ventilation, and the planned pulmonary resection.
3. Metastases must be completely resectable based on computed tomographic imaging.
4. There is no evidence of extrapulmonary tumor burden.
5. Alternative superior therapy must not be available.

and conjunctival edema. It is seen most commonly with NEC grade IV (small cell) lung cancer.

5. **Pericardial tamponade.** Pericardial effusions (benign or malignant), associated with increasing levels of dyspnea and/or arrhythmias, and pericardial tamponade occur with direct pericardial invasion. Diagnosis requires a high index of suspicion in the setting of a medially based tumor with symptoms of dyspnea and is confirmed by CT scan or echocardiography.
6. **Back pain.** Results from direct invasion of a vertebral body and is often localized and severe. If the neural foramina are involved, radicular pain may also be present.
7. **Other local symptoms.** Dysphagia is usually secondary to external esophageal compression by enlarged lymph

Table 19-7

Clinical presentation of lung cancer

CATEGORY	SYMPTOM	CAUSE
Pulmonary symptoms	Cough	Bronchus irritation or compression
	Dyspnea	Airway obstruction or compression
	Wheezing	>50% airway obstruction
	Hemoptysis	Tumor erosion or irritation
Nonpulmonary thoracic symptoms	Pneumonia	Airway obstruction
	Pleuritic pain	Parietal pleural irritation or invasion
	Local chest wall pain	Rib and/or muscle involvement
	Radicular chest pain	Intercostal nerve involvement
	Pancoast's syndrome	Stellate ganglion, chest wall, brachial plexus involvement
	Hoarseness	Recurrent laryngeal nerve involvement
	Swelling of head and arms	Bulky involved mediastinal lymph nodes
		Medially based right upper lobe tumor

nodes involved with metastatic disease, usually with lower lobe tumors. Finally, dyspnea, pleural effusion, or referred shoulder pain can result from invasion of the diaphragm by a tumor at the base of a lower lobe.

Associated Paraneoplastic Syndromes All lung cancer histologies are capable of producing a variety of paraneoplastic syndromes, most often from systemic release of tumor-derived biologically active materials (Table 19-8). Paraneoplastic

Table 19-8

Paraneoplastic syndromes in patients with lung cancer

Endocrine

Hypercalcemia (ectopic parathyroid hormone)
 Cushing's syndrome
 Syndrome of inappropriate secretion of antidiuretic hormone
 Carcinoid syndrome
 Gynecomastia
 Hypercalcitoninemia
 Elevated growth hormone level
 Elevated levels of prolactin, follicle-stimulating hormone, luteinizing hormone
 Hypoglycemia
 Hyperthyroidism

Neurologic

Encephalopathy
 Subacute cerebellar degeneration
 Progressive multifocal leukoencephalopathy
 Peripheral neuropathy
 Polymyositis
 Autonomic neuropathy
 Eaton-Lambert syndrome
 Optic neuritis

Skeletal

Clubbing
 Pulmonary hypertrophic osteoarthropathy

Hematologic

Anemia
 Leukemoid reactions
 Thrombocytosis
 Thrombocytopenia
 Eosinophilia
 Pure red cell aplasia
 Leukoerythroblastosis
 Disseminated intravascular coagulation

Cutaneous

Hyperkeratosis
 Dermatomyositis
 Acanthosis nigricans
 Hyperpigmentation
 Erythema gyratum repens
 Hypertrichosis lanuginosa acqvista

Other

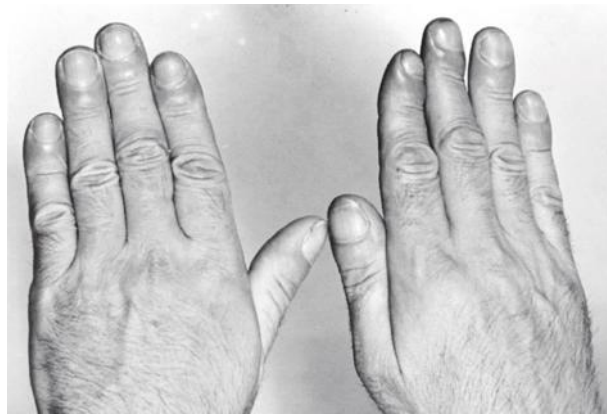Nephrotic syndrome
 Hypouricemia
 Secretion of vasoactive intestinal peptide with diarrhea
 Hyperamylasemia
 Anorexia or cachexia

syndromes may produce symptoms even before any local symptoms are produced by the primary tumor, thereby aiding in early diagnosis. Their presence does not influence resectability or treatment options. Symptoms often abate with successful treatment; paraneoplastic symptom recurrence may herald tumor recurrence. The majority of such syndromes are associated with grade IV NEC (small cell carcinoma), including many endocrinopathies.

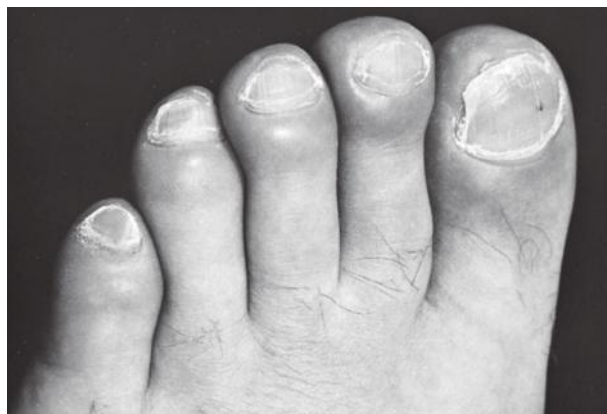1. **Hypertrophic pulmonary osteoarthropathy (HPO).** Often severely debilitating, symptoms of HPO may antedate the diagnosis of cancer by months. Clinically, ankle, feet, forearm, and hand tenderness and swelling are characteristic, resulting from periostitis of the fibula, tibia, radius, metacarpals, and metatarsals. Clubbing of the digits may occur in up to 30% of patients with grade IV NEC (Fig. 19-17). Plain radiographs show periosteal inflammation and elevation, while bone scans demonstrate intense but symmetric uptake in the long bones. Aspirin or nonsteroidal anti-inflammatory agents provide temporary relief; treatment requires successful surgical or medical tumor eradication.
2. **Hypercalcemia.** Up to 10% of patients with lung cancer will have hypercalcemia, most often due to metastatic disease. Ectopic parathyroid hormone secretion by the tumor, most often squamous cell carcinoma, is causative in up to 15%, however, and should be suspected if metastatic bone

disease is not present. Symptoms of hypercalcemia include lethargy, depressed level of consciousness, nausea, vomiting, and dehydration. Most patients have resectable tumors, and, following complete resection, the calcium level will normalize. Unfortunately, tumor recurrence is extremely common and may manifest as recurrent hypercalcemia.

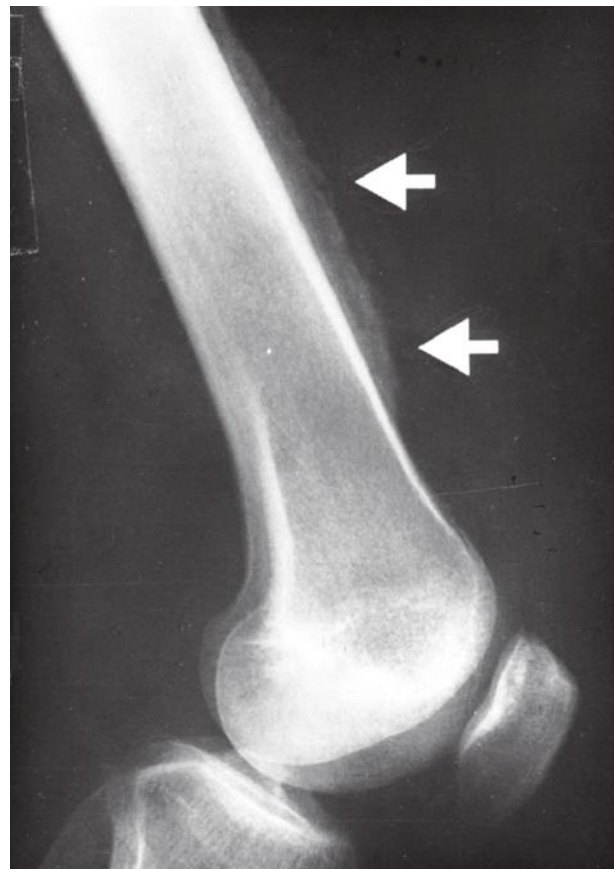3. **Hyponatremia.** Characterized by confusion, lethargy, and possible seizures, hyponatremia can result from the inappropriate secretion of antidiuretic hormone from the tumor into the systemic circulation (syndrome of inappropriate secretion of antidiuretic hormone [SIADH]) in 10% to 45% of patients with grade IV NEC (small cell). It is diagnosed by the presence of hyponatremia, low serum osmolality, and high urinary sodium and osmolality. Another cause of hyponatremia can be the ectopic secretion of atrial natriuretic peptide (ANP).
4. **Cushing's syndrome.** Autonomous tumor production of an adrenocorticotropic hormone (ACTH)-like molecule leads to rapid serum elevation of ACTH and subsequent severe hypokalemia, metabolic alkalosis, and hyperglycemia. Symptoms are primarily related to the metabolic changes while the physical signs of Cushing's syndrome (e.g., truncal obesity, buffalo hump, striae) are unusual due to the rapidity of ACTH elevation. Diagnosis is made by demonstrating hypokalemia (<3.0 mmol/L); nonsuppressible elevated plasma cortisol levels that lack the normal diurnal variation; elevated blood ACTH levels; or elevated



A



B



C

Figure 19-17. Hypertrophic pulmonary osteoarthropathy associated with small cell carcinoma. **A.** Painful clubbing of the fingers. **B.** Painful clubbing of the toes (close-up). **C.** The arrows point to new bone formation on the femur.

urinary 17-hydroxycorticosteroids, all of which are not suppressible by administration of exogenous dexamethasone. Immunoreactive ACTH is present in nearly all extracts of SCLC, and a high percentage of patients with SCLC have elevated ACTH levels by radioimmunoassay, yet fewer than 5% have symptoms of Cushing's syndrome.

5. **Peripheral and central neuropathies.** Unlike other paraneoplastic syndromes, which are usually due to ectopic secretion of an active substance, these syndromes are felt to be immune mediated. Cancer cells are thought to secrete antigens normally expressed only by the nervous system, generating antibodies leading either to interference with neurologic function or to immune neurologic destruction. Up to 16% of lung cancer patients have neuromuscular disability, and, of these, half have grade IV NEC (small cell) and 25% have squamous cell carcinomas. In patients with neurologic or muscular symptoms, central nervous system (CNS) metastases must be ruled out with CT or magnetic resonance imaging (MRI) of the head. Other metastatic disease leading to disability must also be excluded.
6. **Lambert-Eaton syndrome.** This myasthenia-like syndrome is caused by tumor secretion of immunoglobulin G (IgG) antibodies targeting voltage-gated calcium channels, which causes a neuromuscular conduction defect by decreasing the amount of acetylcholine released from presynaptic sites at the motor end plate. Symptoms, including gait abnormalities from proximal muscle weakness and impaired coordination, may actually precede radiographic evidence of the tumor. Therapy is directed at the primary tumor with resection, radiation, and/or chemotherapy. Many patients have dramatic improvement after successful therapy. For patients with refractory symptoms, treatment consists of guanidine hydrochloride, immunosuppressive agents such as prednisone and azathioprine, and occasionally plasma exchange. Unlike with myasthenia gravis patients, neostigmine is usually ineffective.

Symptoms Associated with Metastatic Lung Cancer. Lung cancer metastasizes most commonly to the CNS, vertebral bodies, bone, liver, adrenal glands, lungs, skin, and soft tissues. CNS metastases are present at diagnosis in 10% of patients; another 10% to 15% will develop CNS metastases following diagnosis. Focal symptoms, including headache, nausea, vomiting, seizures, hemiplegia, and dysarthria, are common. Lung cancer is the most common cause of spinal cord compression, either by primary tumor invasion of an intervertebral foramen or direct extension of vertebral metastases. Bony metastases are identified in 25% of all patients with lung cancer. They are primarily lytic and produce pain locally; thus any new and localized skeletal symptoms must be evaluated radiographically. Liver metastases are most often an incidental finding on CT scan. Adrenal metastases are also typically asymptomatic and are usually discovered by routine CT scan. They may lead to adrenal hypofunction. Skin and soft tissue metastases occur in 8% of patients dying of lung cancer and generally present as painless subcutaneous or intramuscular masses. Occasionally, the tumor erodes through the overlying skin, with necrosis and creation of a chronic wound; excision may then be necessary for both mental and physical palliation.

Nonspecific Cancer-Related Symptoms. Lung cancer often produces a variety of nonspecific symptoms such as anorexia, weight loss, fatigue, and malaise. The cause of these symptoms

is often unclear, but should raise concern about possible metastatic disease.

Lung Cancer Management

Role of Histologic Diagnosis and Molecular Testing. Establishing a clear histologic diagnosis early in the evaluation and management of lung cancer is critical to effective treatment. Molecular signatures are also key determinants of treatment algorithms for adenocarcinoma and will likely become important for squamous cell carcinoma as well. Currently, differentiation between adenocarcinoma and squamous cell carcinoma in cytologic specimens or small biopsy specimens is imperative in patients with advanced stage disease, as treatment with pemetrexed or bevacizumab-based chemotherapy is associated with improved progression-free survival in patients with adenocarcinoma but not squamous cell cancer. Furthermore, life-threatening hemorrhage has occurred in patients with squamous cell carcinoma who were treated with bevacizumab. Finally, *EGFR* mutation predicts response to *EGFR* tumor kinase inhibitors and is now recommended as first-line therapy in advanced adenocarcinoma. Because adequate tissue is required for histologic assessment and molecular testing, each institution should have a clear, multidisciplinary approach to patient evaluation, tissue acquisition, tissue handling/processing, and tissue analysis (Fig. 19-18). In many cases, tumor morphology differentiates adenocarcinoma from the other histologic subtypes. If no clear morphology can be identified, then additional testing for one immunohistochemistry marker for adenocarcinoma and one for squamous cell carcinoma will usually enable differentiation. Immunohistochemistry for neuroendocrine markers is reserved for lesions exhibiting neuroendocrine morphology. Additional molecular testing should be performed on all adenocarcinoma specimens for known predictive and prognostic tumor markers (e.g. *EGFR*, *KRAS*, and *EML4-ALK* fusion gene). Ideally, use of tissue sections and cell block material is limited to the minimum necessary at each decision point. This emphasizes the importance of a multidisciplinary approach; surgeons and radiologists must work in direct cooperation with the cytopathologist to ensure that tissue samples are adequate for morphologic diagnosis as well as providing sufficient cellular material to enable molecular testing. With adoption of endobronchial and endoscopic ultrasound, electromagnetic navigational bronchoscopy, VATS, and even transthoracic image-guided fine-needle and core-needle biopsy, surgeons are increasingly involved in the acquisition of diagnostic tissue for primary, metastatic, and recurrent intrathoracic disease, and a thorough understanding of key issues is necessary to ensure optimal treatment and patient outcomes.

Patient Evaluation. Evaluation prior to treatment encompasses three areas: diagnosis and assessment of the primary tumor, assessment for metastatic disease, and determination of functional status (the patient's ability to tolerate the prescribed treatment regimen). A discrete approach to each area allows the surgeon to systematically evaluate the patient, perform accurate clinical staging, and enable assessment of the patient's functional suitability for therapy, including pulmonary resection (Table 19-9).

Assessment of the Primary Tumor. Assessment of the primary tumor begins with the history and directed questions regarding the presence or absence of pulmonary, nonpulmonary, thoracic, and paraneoplastic symptoms. Because patients often present to

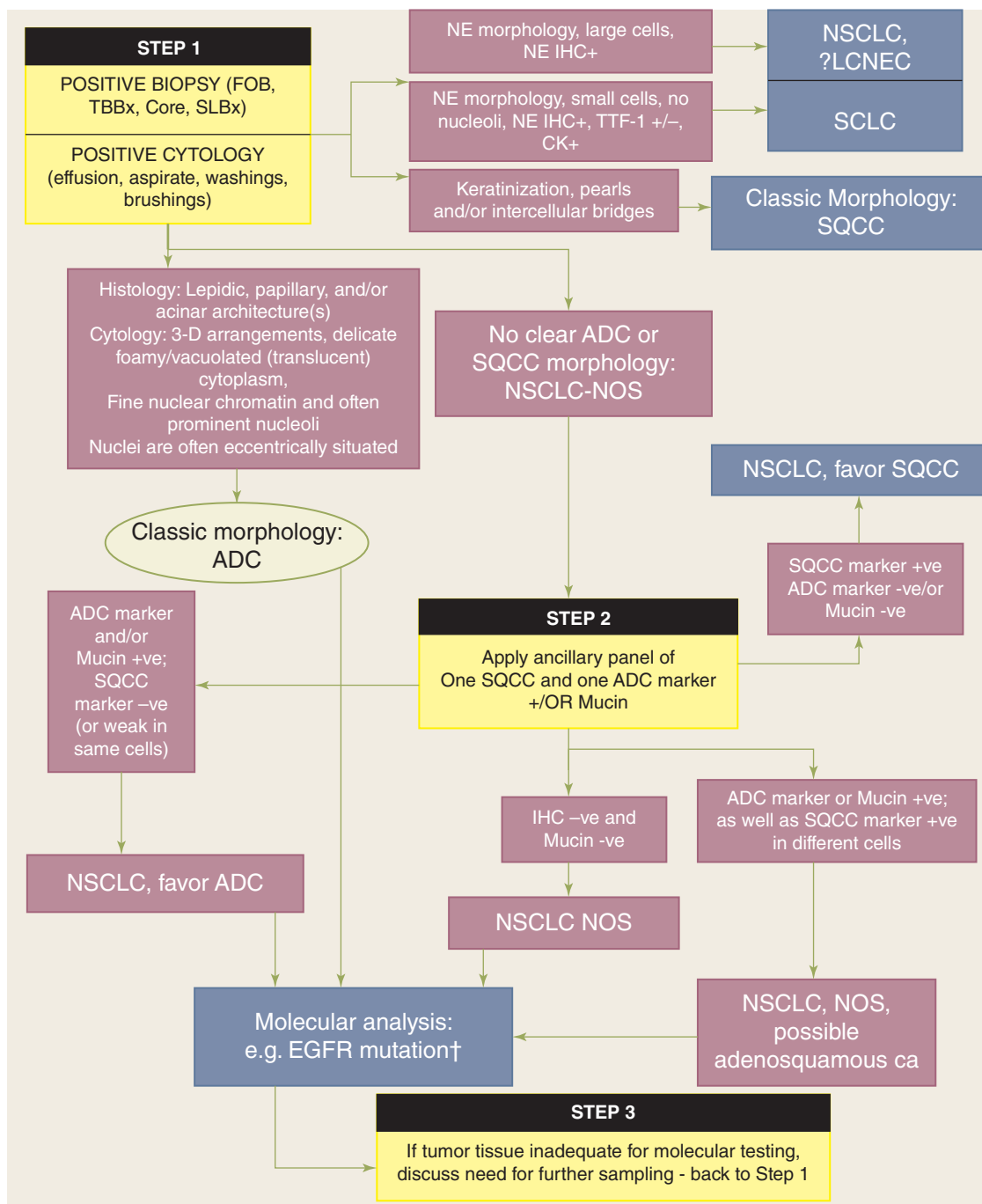


Figure 19-18. Algorithm for adenocarcinoma diagnosis in small biopsies and/or cytology. Step 1: When positive biopsies (fiberoptic bronchoscopy [FOB], transbronchial [TBBx], core, or surgical lung biopsy [SLBx]) or cytology (effusion, aspirate, washings, and brushings) show clear adenocarcinoma (ADC) or squamous cell carcinoma (SQCC) morphology, the diagnosis can be firmly established. If there is neuroendocrine (NE) morphology, the tumor may be classified as small cell carcinoma (SCLC) or non-small cell lung carcinoma (NSCLC), probably large cell neuroendocrine carcinoma (LCNEC) according to standard criteria (+ = positive, - = negative, and ± = positive or negative). If there is no clear ADC or SQCC morphology, the tumor is regarded as NSCLC—not otherwise specified (NOS). Step 2: NSCLC-NOS can be further classified based on (a) immunohistochemical stains, (b) mucin (DPAS or mucicarmin) stains, or (c) molecular data. If the stains all favor ADC-positive ADC marker(s) (i.e., TTF-1 and/or mucin positive) with negative SQCC markers, then the tumor is classified as NSCLC, favor ADC. If SQCC markers (i.e., p63 and/or CK5/6) are positive with negative ADC markers, the tumor is classified as NSCLC, favor SQCC. If the ADC and SQCC markers are both strongly positive in different populations of tumor cells, the tumor is classified as NSCLC-NOS, with a comment it may represent adenosquamous carcinoma. If all markers are negative, the tumor is classified as NSCLC-NOS. †EGFR mutation testing should be performed in (1) classic ADC, (2) NSCLC, favor ADC, (3) NSCLC-NOS, and (4) NSCLC-NOS, possible adenosquamous carcinoma. In NSCLC-NOS, if EGFR mutation is positive, the tumor is more likely to be ADC than SQCC. Step 3: If clinical management requires a more specific diagnosis than NSCLC-NOS, additional biopsies may be indicated. CD = cluster designation; CK = cytokeratin; DPAS = diastase-periodic acid Schiff; DPAS +ve = periodic-acid Schiff with diastase; EGFR = epidermal growth factor receptor; IHC = immunohistochemistry; NB = of note; TTF-1 = thyroid transcription factor-1; -ve = negative; +ve = positive. (Reproduced with permission from Travis W, Brambilla E, Noguchi M, et al. *International Association for the Study of Lung Cancer/American Thoracic Society/European Respiratory Society: International multidisciplinary classification of lung adenocarcinoma.* *J Thorac Oncol.* 2011;6:244.

Table 19-9

Evaluation of patients with lung cancer

	PRIMARY TUMOR	METASTATIC DISEASE	FUNCTIONAL ASSESSMENT
History	Pulmonary	Weight loss	Ability to walk up two flights of stairs
	Nonpulmonary thoracic	Malaise	Ability to walk on a flat surface indefinitely
	Paraneoplastic	New bone pain	
Physical examination		Neurologic signs or symptoms	
		Skin lesions	
	Voice	Supraclavicular node palpation	Accessory muscle usage
		Skin examination	Air flow by auscultation
Radiographic examination		Neurologic examination	Force of cough
	Chest CT	Chest CT, PET	Chest CT: tumor anatomy, atelectasis
	Tissue analysis	Bronchoscopy	Quantitative perfusion scan
Tissue analysis	Transthoracic needle aspiration and biopsy	Bone scan, head MRI, abdominal CT	
		Bronchoscopic lymph node FNA	
		Endoscopic ultrasound	
		Mediastinoscopy	
Other		Biopsy of suspected metastasis	
	Thoracoscopy	—	Pulmonary function tests (FEV ₁ , DLCO, O ₂ consumption)

CT = computed tomography; DLCO = carbon monoxide diffusion capacity; FEV₁ = forced expiratory volume in 1 second; FNA = fine-needle aspiration; MRI = magnetic resonance imaging; O₂ = oxygen; PET = positron emission tomography.

the surgeon with a CXR or CT scan demonstrating the lesion, the location of the tumor can help direct the clinician in performing the history and physical examination.

If the patient does not already have a chest CT scan, this should be performed expeditiously as the next stage in evaluating a new patient. A routine chest CT scan should include intravenous contrast material to enable assessment of the primary tumor, delineation of mediastinal lymph nodes relative to normal mediastinal structures, and the tumor's relationship to surrounding and contiguous structures. Recommendations for treatment and options for obtaining tissue diagnosis require a thorough understanding and assessment of CT findings.

Concern for contiguous invasion of adjacent structures often is raised in response to a combination of symptom history, location of the primary tumor, and CT imaging. It is common to see the primary tumor abutting the chest wall without clear radiographic evidence of rib destruction. In this circumstance, a history of pain in the area is an accurate guide to the likelihood of parietal pleural, rib, or intercostal nerve involvement. Similar observations apply to tumors abutting the recurrent laryngeal nerve, phrenic nerve, diaphragm, vertebral bodies, and chest apex. Thoracotomy should not be denied because of presumptive evidence of invasion of the chest wall, vertebral body, or mediastinal structures; proof of invasion may require thoracoscopy or even thoracotomy.

MRI of pulmonary lesions and mediastinal nodes, overall, offers no real improvement over CT scanning. It is an excellent modality, however, for defining a tumor's relationship to a major vessel, given its excellent imaging of vascular structures. This is

especially true if the use of iodine contrast material is contraindicated. Thus, use of MRI in lung cancer patients is reserved for those with contrast allergies or with suspected mediastinal, vascular, or vertebral body invasion.

Options for Tissue Acquisition. The surgeon must have an evidence-based algorithm for approaching the diagnosis and treatment of a pulmonary nodule and masses (Fig. 19-19).²⁴ Depending on nodule size, proximity to the bronchial tree, and the prevalence of cancer in the population being sampled, bronchoscopy has 20% to 80% sensitivity for detecting neoplastic processes within a pulmonary lesion. Diagnostic tissue from bronchoscopy can be obtained by one of four methods:

1. Brushings and washings for cytology
2. Direct forceps biopsy of a visualized lesion
3. Endobronchial ultrasound-guided fine-needle aspiration (FNA) of an externally compressing lesion without visualized endobronchial tumor
4. Transbronchial biopsy with fluoroscopy to guide forceps to the lesion or electromagnetic navigational bronchoscopy

Electromagnetic navigation bronchoscopy is a recent addition to the surgeon's armamentarium for transbronchial biopsy of peripheral lung lesions. Using electromagnetic markers that create a three-dimensional image and align the recorded CT images to the patient's true anatomy, a catheter is advanced transbronchially and brushings, FNA, cup biopsy, and washings can be performed. Diagnostic yield using electromagnetic navigation bronchoscopy as an adjunct to standard bronchoscopy is reported as high as 80%. The

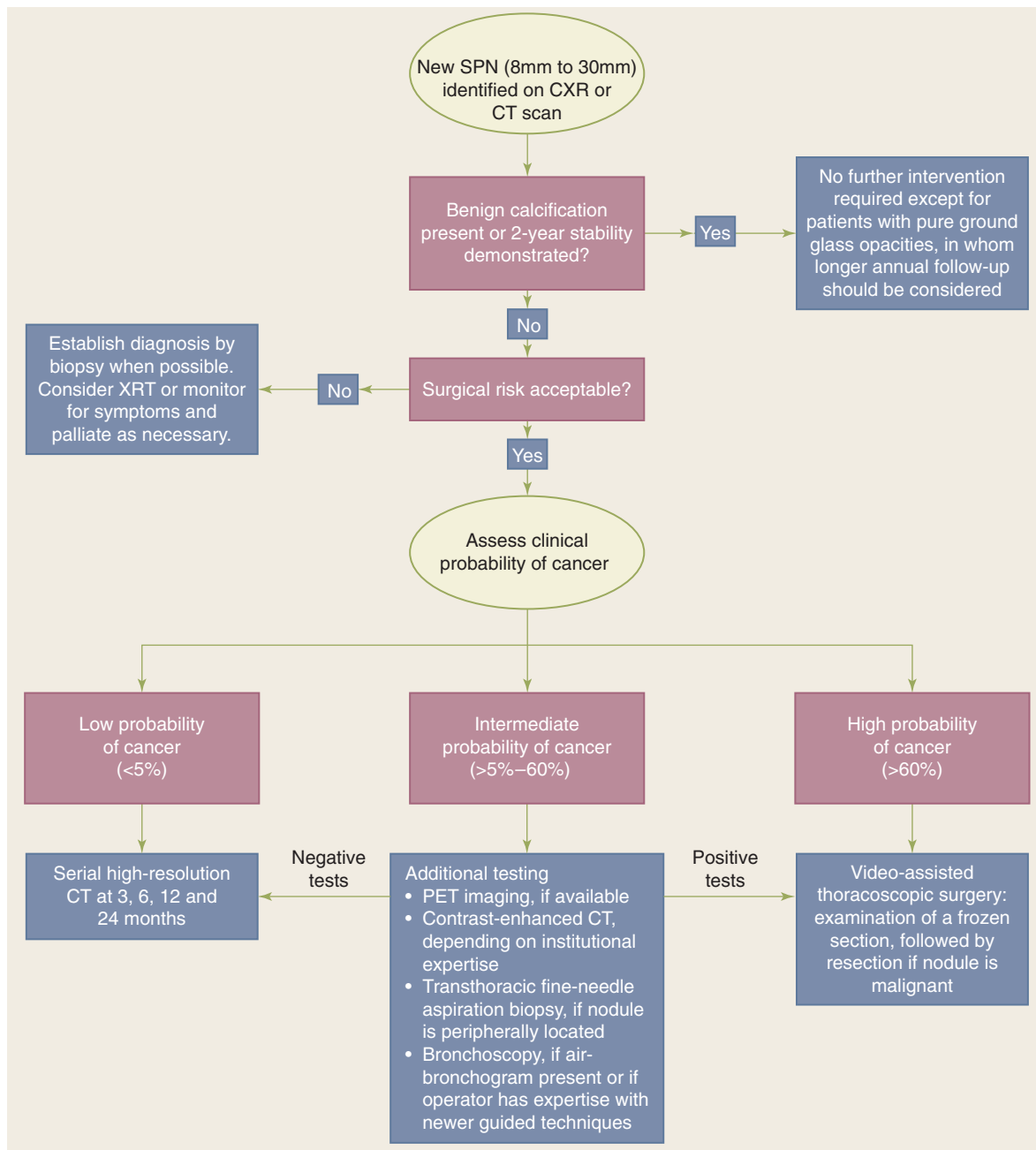


Figure 19-19. Recommended management algorithm for patients with solitary pulmonary nodules (SPNs) measuring 8 mm to 30 mm in diameter. CT = computed tomography; CXR = chest radiograph; PET = positron emission tomography; XRT = radiotherapy. (Reproduced with permission from the American College of Chest Physicians from Gould MK, et al. *Evaluation of patients with pulmonary nodules: when is it lung cancer?*: ACCP Evidence-based Clinical Practice Guidelines. (2nd edition) Chest. 2007;132:108S.)

approach can also be used for placement of fiducial markers for subsequent stereotactic body radiation therapy and for tattooing the perilesional region to guide subsequent video-assisted thoracoscopic resection. Pneumothorax rates with this approach are approximately 1% in larger series and up to 3.5% in reports of early experience.

For peripheral lesions (roughly the outer half of the lung), transbronchial biopsy is performed first, followed by brushings and washings. This improves diagnostic yield by disrupting the lesion with the biopsy forceps and mobilizing additional cells. For central lesions, direct forceps biopsy by bronchoscopic visualization is often possible. For central lesions with external airway compression but no visible endobronchial lesions, endobronchial ultrasound (EBUS) is highly accurate and safe for

transbronchial biopsies of both the primary tumor (when it abuts the central airways) as well as the mediastinal lymph nodes.³³

Image-guided transthoracic FNA (ultrasound or CT FNA) biopsy can accurately diagnose appropriately selected peripheral pulmonary lesions in up to 95% of patients. Three biopsy results are possible after image-guided biopsy procedures: malignant, a specific benign process, or indeterminate. Because false-negative rates range from 3% to 29%, further diagnostic efforts are warranted in the absence of a specific benign diagnosis (such as granulomatous inflammation or hamartoma) because malignancy is not ruled out.³⁴ The primary complication is pneumothorax in as many as 30% of cases. Intrapulmonary bleeding occurs, but rarely causes clinically significant hemoptysis or respiratory compromise.

Some groups advocate use of video-assisted thoracoscopic biopsy as the first option for diagnosis, citing superior diagnostic accuracy and low surgical risk. With VATS, the nodule can be excised with a wedge or segmental resection, if less than 3 cm, or a core-needle biopsy can be performed under direct vision for larger lesions. VATS can also provide valuable staging information, including sampling/dissection of mediastinal lymph nodes and assessing whether the primary tumor has invaded a contiguous structure (such as the chest wall or mediastinum). Lesions most suitable for VATS are those that are located in the outer one third of the lung. The surgeon should avoid direct manipulation of the nodule or violation of the visceral pleura overlying the nodule. In addition, the excised nodule must be extracted from the chest within a bag to prevent seeding of the chest wall. If the patient's pulmonary reserve is adequate, the surgeon can proceed to lobectomy (either VATS or open) after frozen section diagnosis.

A thoracotomy is occasionally necessary to diagnose and stage a primary tumor. Although this occurs rarely, two circumstances may require such an approach: (a) a deep-seated lesion that yielded an indeterminate needle biopsy result or that could not be biopsied for technical reasons; or (b) inability to determine invasion of a mediastinal structure by any method short of palpation. In the circumstance of a deep-seated lesion without a diagnosis, tissue can be obtained via thoracotomy using FNA, core-needle biopsy, or excisional biopsy. Intraoperative frozen-section analysis is required; if the open biopsy frozen-section result is indeterminate, a lobectomy may be necessary in extremely rare situations. If a pneumonectomy is required to remove the lesion, a tissue diagnosis of cancer *must* be made before proceeding.

Assessment for Metastatic Disease. Distant metastases are found in approximately 40% of patients with newly diagnosed lung cancer. The presence of lymph node or systemic metastases may imply inoperability. As with the primary tumor, assessment for the presence of metastatic disease should begin with the history and physical examination, focusing on the presence or absence of new bone pain, neurologic symptoms, and new skin lesions. In addition, constitutional symptoms (e.g., anorexia, malaise, and unintentional weight loss of >5% of body weight) suggest either a large tumor burden or the presence of metastases. Physical examination should focus on the patient's overall appearance, noting any evidence of weight loss such as redundant skin or muscle wasting, and a complete examination of the head and neck, including evaluation of cervical and supraclavicular lymph nodes and the oropharynx. This is particularly true for patients with a significant tobacco history. The skin should be thoroughly examined. Routine laboratory studies include serum levels of hepatic enzymes (e.g., serum glutamic oxaloacetic transaminase and alkaline phosphatase), as well as those of serum calcium (to detect bone metastases or the ectopic parathyroid syndrome). Elevation of either hepatic enzymes or serum calcium levels typically occurs with extensive metastases.

Mediastinal Lymph Nodes. Chest CT scanning permits assessment of possible metastatic spread to the mediastinal lymph nodes. It continues to be the most effective noninvasive method available to assess the mediastinal and hilar nodes for enlargement. However, a positive CT result (i.e., nodal diameter >1.0 cm) predicts actual metastatic involvement in only about 70% of lung cancer patients. Thus even with enlarged mediastinal lymph nodes on a CT scan, up to 30% of such nodes are enlarged

from noncancerous reactive causes such as inflammation due to atelectasis or pneumonia secondary to the tumor. Therefore, no patient should be denied an attempt at curative resection just because of a positive CT result for mediastinal lymph node enlargement. Any CT finding of metastatic nodal involvement must be confirmed histologically. The negative predictive value of normal-appearing lymph nodes by CT (lymph nodes <1.0 cm) is better than the positive predictive value of a suspicious-appearing lymph node, particularly with small squamous cell tumors. With normal-size lymph nodes and a T1 tumor, the false-negative rate is less than 10%, leading many surgeons to omit mediastinoscopy. However, the false-negative rate increases to nearly 30% with centrally located and T3 tumors. It has also been demonstrated that T1 adenocarcinomas or large cell carcinomas have a higher rate of early micrometastasis. Therefore, all such patients should undergo mediastinoscopy.

Mediastinal lymph node staging by PET scanning appears to have greater accuracy than CT scanning. PET staging of mediastinal lymph nodes has been evaluated in two meta-analyses. The overall sensitivity for mediastinal lymph node metastasis was 79% (95% confidence interval 76%–82%), with a specificity of 91% (95% CI 89%–93%) and an accuracy of 92% (95% CI 90%–94%).³⁵

In comparing PET with CT scans in patients who also underwent lymph node biopsies, PET had a sensitivity of 88% and a specificity of 91%, whereas CT scanning had a sensitivity of 63% and a specificity of 76%. Combining CT and PET scanning may lead to even greater accuracy.³⁶ In one study of CT, PET, and mediastinoscopy in 68 patients with potentially operable NSCLC, CT correctly identified the nodal stage in 40 patients (59%). It understaged the tumor in 12 patients and overstaged it in 16 patients. PET correctly identified the nodal stage in 59 patients (87%). It understaged the tumor in five patients and overstaged it in four. For detecting N2 and N3 disease, the combination of PET and CT scanning yielded a sensitivity, specificity, and accuracy of 93%, 95%, and 94%, respectively. CT scan alone yielded 75%, 63%, and 68%, respectively. Studies examining combined PET-CT consistently show improved accuracy compared to PET or CT alone; accuracy for PET-CT nodal positivity confirmed by mediastinoscopy is approximately 75%, with a negative predictive value of approximately 90%. Right upper lobe lesions were more likely to have occult N2 disease than other lobes of the lung.^{37–40} PET-positive mediastinal lymph nodes require histologic verification of node positivity, either by EBUS-guided FNA/core-needle biopsy or mediastinoscopy, to minimize the risk of undertreatment. Assuming node positivity without histologic confirmation relegates the patient to, at a minimum, induction chemotherapy. If there is a suggestion of N3 disease, the patient would be incorrectly staged as having IIIB disease and would not be considered a candidate for potentially curative surgical resection.

It is important for surgeons who are managing patients with lung cancer to have a clear algorithm for invasive mediastinal staging. In general, invasive staging is underused, placing many patients at risk for over- or understaging and, thus, inappropriate treatment. An absolute indication for obtaining a tissue diagnosis is mediastinal lymph node enlargement greater than 1.0 cm by CT scan. There are several options for invasive mediastinal staging:

1. Less invasive than mediastinoscopy, EBUS enables image-guided transtracheal and transbronchial FNA cytologic

samples from hilar masses and lymph nodes from level 4R and 4L, level 7, level 10, and level 11. A core-needle biopsy device recently became available for the EBUS and will improve the diagnostic yield when sampling mediastinal lymphadenopathy. Rapid onsite pathologic evaluation with expert cytopathologist evaluation greatly increases the diagnostic accuracy of the procedure; importantly, the intraoperative evaluation will confirm whether the target lesion is being sampled and greatly facilitates acquisition of satisfactory samples for determining the morphologic diagnosis as well as sufficient material for cell block for immunohistochemistry and molecular testing. Like mediastinoscopy, EBUS does not allow assessment of level 3, 5, or 6 nodal stations.

2. Endoscopic ultrasound (EUS) can accurately visualize mediastinal paratracheal lymph nodes (stations 4R, 7, and 4L) and other lymph node stations (stations 8 and 9) and is able to visualize primary lung lesions contiguous with or near the esophagus (see Fig. 19-8). Using FNA or core-needle biopsy, samples of lymph nodes or primary lesions can be obtained. Diagnostic yield is improved with intraoperative cytologic evaluation, which can be performed with the cytopathologist in the operating room. Limitations of EUS include the inability to visualize the anterior (pretracheal) mediastinum; thus, EUS does not replace mediastinoscopy for complete mediastinal nodal staging. However, it may not be necessary to perform mediastinoscopy if findings on EUS are positive for N2 nodal disease, particularly if more than one station is found to harbor metastases.
3. Cervical mediastinoscopy provides tissue sampling of all paratracheal and subcarinal lymph nodes and permits visual determination of the presence of extracapsular extension of nodal metastasis (Fig. 19-20). With complex hilar or right paratracheal primary tumors, it allows direct biopsies and assessment of invasion into the mediastinum. When the size of mediastinal lymph nodes is normal, mediastinoscopy

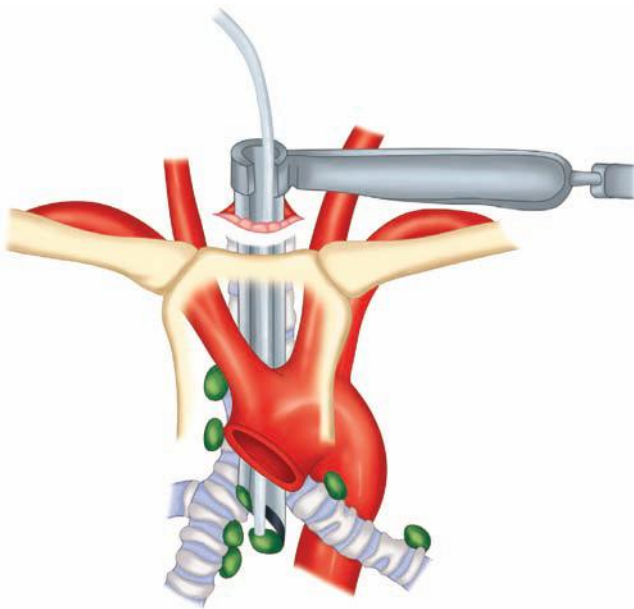


Figure 19-20. Cervical mediastinoscopy. Paratracheal and subcarinal lymph node tissues (within the pretracheal space) can be sampled using a mediastinoscope introduced through a suprasternal skin incision.

is generally recommended for centrally located tumors, for T2 and T3 primary tumors, and occasionally for T1 adenocarcinomas or large cell carcinomas (due to their higher rate of metastatic spread). Some surgeons perform mediastinoscopy in all lung cancer patients because of the poor survival associated with surgical resection of N2 disease.

It is important to note that EBUS or EUS can be used for initial diagnosis in enlarged lymph nodes, but the predictive value of a negative EBUS in a patient with radiographically suspicious mediastinal disease is not sufficient to accurately guide treatment. At the authors' institutions, it is standard to begin mediastinal lymph node staging with EBUS-guided FNA of clinically suspicious mediastinal lymphadenopathy. If the FNA is negative by intraoperative rapid onsite cytologic evaluation, cervical video mediastinoscopy is performed in the same operative setting to ensure accurate staging of the mediastinal nodes. However, if the FNA is positive, mediastinoscopy is not performed and the patient is referred to medical oncology for induction chemotherapy; avoiding a pretreatment mediastinoscopy in this manner facilitates the safe performance of a postinduction mediastinoscopy for restaging of the mediastinum in patients who respond favorably to induction therapy.

4. Left video-assisted thoracoscopic lymph node sampling may be needed for patients with left upper lobe tumors who have localized regional spread to station 5 and 6 lymph nodes, without mediastinal paratracheal involvement (see Fig. 19-8). If there is a low index of suspicion for nodal metastasis, the patient can be scheduled for VATS biopsy and lobectomy under the same anesthesia; the procedure begins by sampling the level 5 and 6 nodes for frozen section, and if the nodes are negative, the anatomic lung resection is performed. If the index of suspicion is high, the VATS biopsy is performed as a separate procedure. Cervical mediastinoscopy should precede VATS biopsy, even if patients have normal paratracheal lymph nodes. Additional diagnostic evaluation of the lymph nodes in station 5 and 6 may be unnecessary if the mediastinal lymph nodes are proven to be benign with biopsy during cervical mediastinoscopy and the preoperative CT scan suggests complete respectability of the tumor. There are, however, several indications for prethoracotomy biopsy of station 5 and 6 lymph nodes, which are listed in Table 19-10. It is particularly important to prove that mediastinal lymph nodes are pathologically involved and not just radiographically suspicious for nodal metastasis prior to deciding that the patient is *not* a candidate for resection.

Pleural Effusion. The presence of pleural effusion on radiographic imaging should not be assumed to be malignant.

Table 19-10

Indications for prethoracotomy biopsy of station 5 and 6 lymph nodes

1. Enrollment criteria for induction therapy protocol require pathologic confirmation of N2 disease.
2. Computed tomographic scan shows evidence of bulky nodal metastases or extracapsular spread that could prevent complete resection.
3. Tissue diagnosis of a hilar mass or of lymph nodes causing recurrent laryngeal nerve paralysis is needed.

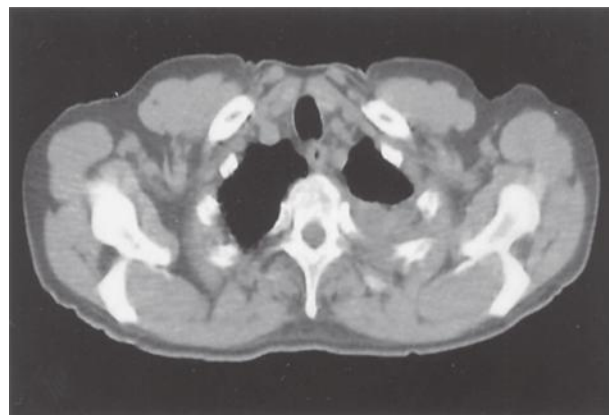
Pleural effusion may be secondary to atelectasis or consolidation, seen with central tumors, reactive, or secondary to cardiac dysfunction. Pleural effusion associated with a peripherally based tumor, particularly one that abuts the visceral or parietal pleural surface, does have a higher probability of being malignant, which would alter the pathologic stage of the disease to stage IV by the American Joint Committee on Cancer (AJCC) 7th edition TNM staging criteria. If this is the only site concerning for metastatic disease, pathologic confirmation is mandatory. Cytology reveals malignant cells in 50% of malignant effusions. Thoracoscopy, performed as part of a separate staging procedure, often with mediastinoscopy or immediately before a planned thoracotomy, may be needed to rule out pleural metastases in select patients.

Distant Metastases. Currently, chest CT and PET are routine in the evaluation of patients with lung cancer. Integrated PET-CT scanners have become standard and have substantially improved accuracy of detection and localization of lymph node and distant metastases, as compared with independently performed PET and CT scans (Fig. 19-21). This technology overcomes the imprecise information on the exact location of focal abnormalities seen on PET and has become the standard imaging modality for lung cancer. Compared to routine chest or abdominal CT and bone scans, PET scanning detects 10% to 15% more distant metastases, but should be confirmed with MRI and/or biopsies if the patient otherwise has early-stage disease. Brain MRI should be performed when the suspicion or risk of brain metastases is increased, such as in patients with clinical stage III disease. In the absence of neurologic symptoms or signs, the probability of a negative head CT scan is 95%. Liver abnormalities that are not clearly simple cysts or hemangiomas and adrenal enlargement, nodules, or masses are further evaluated by MRI scanning and, occasionally, by needle biopsy. Adrenal adenomas have a high lipid content (secondary to steroid production), but metastases and most primary adrenal malignancies contain little if any lipid; thus MRI is usually able to distinguish the two.

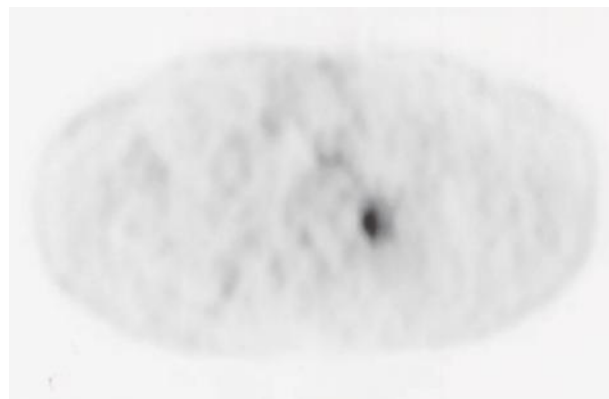
Tumor, Node, and Metastasis: Lung Cancer Staging. The staging of any tumor is an attempt to estimate the extent of disease and determine the patient's prognosis; in a given patient, tumors are typically classified into a clinical stage and a pathologic stage. Clinical staging information includes the history and physical examination, radiographic test results, and diagnostic biopsy information. Therapeutic plans are generated based on clinical stage. After surgical resection of the tumor and lymph nodes, a postoperative pathologic stage (pTNM) is determined, providing further prognostic information.

The staging of solid epithelial tumors is based on the TNM staging system. The primary tumor "T" status provides information about tumor size and relationship to surrounding structures; the "N" status provides information about regional lymph nodes; and the "M" status provides information about the presence or absence of metastatic disease. The designation of lymph nodes as N1, N2, or N3 requires familiarity with the lymph node mapping system⁴¹ (see Fig. 19-8). Based on clearly delineated anatomic boundaries, accurate and reproducible localization of thoracic lymph nodes is possible, which facilitates detailed nodal staging for individual patients and standardization of nodal assessment between surgeons.

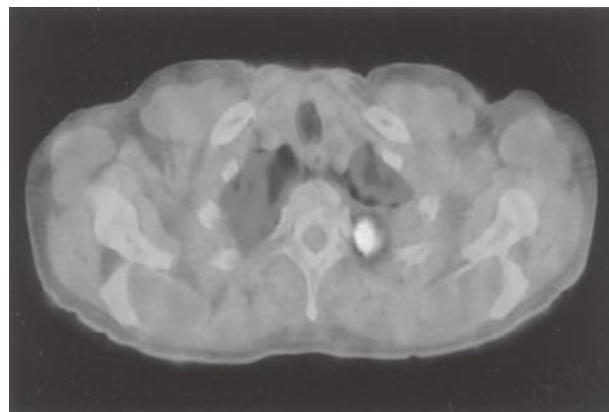
Pathologic staging criteria are based on the predicted survival relative to each combination of tumor, node, and metasta-



A



B



C

Figure 19-21. Imaging of non-small cell lung cancer by integrated positron emission tomography (PET)-computed tomography (CT) scan. **A.** CT of the chest showing a tumor in the left upper lobe. **B.** PET scan of the chest at the identical cross-sectional level. **C.** Coregistered PET-CT scan clearly showing tumor invasion (confirmed intraoperatively). (Reprinted with permission from Lardinois D, Weder W, Hany TF, et al. Staging of non-small-cell lung cancer with integrated positron-emission tomography and computed tomography. *N Engl J Med.* 2003;348:2504. Copyright © 2003 Massachusetts Medical Society.)

sis status. In 2010, the AJCC 7th edition incorporated multiple changes into the staging system for NSCLC based on analysis of survival predictors from more than 100,000 patients worldwide. Table 19-11 shows the clinical and pathologic criteria for each

Table 19-11

American Joint Committee on Cancer Seventh Edition Staging of Non-Small Cell Lung Cancer

CLINICAL Extent of disease before any treatment	STAGE CATEGORY DEFINITIONS		PATHOLOGIC Extent of disease through completion of definitive surgery
<input type="checkbox"/> Any clinical-staging completed after neoadjuvant therapy but before subsequent surgery	TUMOR SIZE: ———	LATERALITY: <input type="checkbox"/> LEFT <input type="checkbox"/> RIGHT <input type="checkbox"/> BILATERAL	<input type="checkbox"/> Any pathologic-staging completed after neoadjuvant therapy AND subsequent surgery
<input type="checkbox"/> TX <input type="checkbox"/> TO <input type="checkbox"/> Tis <input type="checkbox"/> T1 <input type="checkbox"/> T1a <input type="checkbox"/> T1b <input type="checkbox"/> T2 <input type="checkbox"/> T2a <input type="checkbox"/> T2b <input type="checkbox"/> T3 <input type="checkbox"/> T4	<p style="text-align: center;">PRIMARY TUMOR (T)</p> Primary tumor cannot be assessed No evidence of primary tumor Tis Carcinoma <i>in situ</i> Tumor ≤3 cm in greatest dimension, surrounded by lung or visceral pleura, without bronchoscopic evidence of invasion more proximal than the lobar bronchus (i.e., not in the main bronchus)* Tumor ≤2 cm in greatest dimension Tumor > 2 cm but ≤3 cm in greatest dimension Tumor > 3 cm but ≤7 cm or tumor with any of the following features (T2 tumors with these features are classified T2a if ≤5 cm) Involves main bronchus, ≥2 cm distal to the carina Invades visceral pleura (PL1 or PL2) Associated with atelectasis or obstructive pneumonitis that extends to the hilar region but does not involve the entire lung Tumor > 3 cm but ≤5 cm in greatest dimension Tumor > 5 cm but ≤7 cm in greatest dimension Tumor > 7 cm or one that directly invades any of the following: parietal pleural (PL3) chest wall (including superior sulcus tumors), diaphragm, phrenic nerve, mediastinal pleura, parietal pericardium; or tumor in the main bronchus (< 2 cm distal to the carina* but without involvement of the carina; or associated atelectasis or obstructive pneumonitis of the entire lung or separate tumor nodule(s) in the same lobe Tumor of any size that invades any of the following: mediastinum, heart, great vessels, trachea, recurrent laryngeal nerve, esophagus, vertebral body, carina, separate tumor nodule(s) in a different ipsilateral lobe * The uncommon superficial spreading tumor of any size with its invasive component limited to the bronchial wall, which may extend proximally to the main bronchus, is also classified as T1a.		<input type="checkbox"/> TX <input type="checkbox"/> TO <input type="checkbox"/> Tis <input type="checkbox"/> T1 <input type="checkbox"/> T1a <input type="checkbox"/> T1b <input type="checkbox"/> T2 <input type="checkbox"/> T2a <input type="checkbox"/> T2b <input type="checkbox"/> T3 <input type="checkbox"/> T4
<input type="checkbox"/> NX <input type="checkbox"/> NO <input type="checkbox"/> N1 <input type="checkbox"/> N2 <input type="checkbox"/> N3	<p style="text-align: center;">REGIONAL LYMPH NODES (N)</p> Regional lymph nodes cannot be assessed No regional lymph node metastasis Metastasis in ipsilateral peribronchial and/or ipsilateral hilar lymph nodes and intrapulmonary nodes, including involvement by direct extension Metastasis in ipsilateral mediastinal and/or subcarinal lymph node(s) Metastasis in contralateral mediastinal, contralateral hilar, ipsilateral or contralateral scalene, or supraclavicular lymph node(s)		<input type="checkbox"/> NX <input type="checkbox"/> NO <input type="checkbox"/> N1 <input type="checkbox"/> N2 <input type="checkbox"/> N3
<input type="checkbox"/> MO <input type="checkbox"/> M1 <input type="checkbox"/> M1a <input type="checkbox"/> M1b	<p style="text-align: center;">DISTANT METASTASIS (M)</p> No distant metastasis (no pathologic MO; use clinical M to complete stage group) Distant metastasis Separate tumor nodule(s) in a contralateral lobe; tumor with pleural nodules or malignant pleural (or pericardial) effusion** Distant metastasis **Most pleural (and pericardial) effusions with lung cancer are due to tumor. In a few patients, however, multiple cytopathologic examinations of pleural (pericardial) fluid are negative for tumor, and the fluid is nonbloody and is not an exudate. Where these elements and clinical judgement dictate that the effusion is not related to the tumor, the effusion should be excluded as a staging element and the patient should be classified as MO.		<input type="checkbox"/> M1 <input type="checkbox"/> M1a <input type="checkbox"/> M1b

Table 19-11

American Joint Committee on Cancer Seventh Edition Staging of Non–Small Cell Lung Cancer (continued)

ANATOMIC STAGE · PROGNOSTIC GROUPS							
CLINICAL				PATHOLOGIC			
GROUP	T	N	M	GROUP	T	N	M
<input type="checkbox"/> Occult	TX	N0	M0	<input type="checkbox"/> Occult	TX	N0	M0
<input type="checkbox"/> 0	Tis	N0	M0	<input type="checkbox"/> 0	Tis	N0	M0
<input type="checkbox"/> IA	T1a	N0	M0	<input type="checkbox"/> IA	T1a	N0	M0
	T1b	N0	M0		T1b	N0	M0
<input type="checkbox"/> IB	T2a	N0	M0	<input type="checkbox"/> IB	T2a	N0	M0
<input type="checkbox"/> IIA	T2b	N0	M0	<input type="checkbox"/> IIA	T2b	N0	M0
	T1a	N1	M0		T1a	N1	M0
	T1b	N1	M0		T1b	N1	M0
<input type="checkbox"/> IIB	T2a	N1	M0	<input type="checkbox"/> IIB	T2a	N1	M0
	T2b	N1	M0		T2b	N1	M0
<input type="checkbox"/> IIB	T3	N0	M0	<input type="checkbox"/> IIB	T3	N0	M0
	T3	N1	M0		T3	N1	M0
<input type="checkbox"/> IIIA	T1a	N2	M0	<input type="checkbox"/> IIIA	T1a	N2	M0
	T1b	N2	M0		T1b	N2	M0
	T2a	N2	M0		T2a	N2	M0
	T2b	N2	M0		T2b	N2	M0
	T3	N1	M0		T3	N1	M0
	T3	N2	M0		T3	N2	M0
<input type="checkbox"/> IIIB	T4	N0	M0	<input type="checkbox"/> IIIB	T4	N0	M0
	T4	N1	M0		T4	N1	M0
	T1a	N3	M0		T1a	N3	M0
	T1b	N3	M0		T1b	N3	M0
	T2a	N3	M0		T2a	N3	M0
	T2b	N3	M0		T2b	N3	M0
<input type="checkbox"/> IIB	T3	N3	M0	<input type="checkbox"/> IIB	T3	N3	M0
	T4	N2	M0		T4	N2	M0
	T4	N3	M0		T4	N3	M0
	T4	N3	M0		T4	N3	M0
<input type="checkbox"/> IV	Any T	Any N	M1a	<input type="checkbox"/> IV	Any T	Any N	M1a
	Any T	Any N	M1b		Any T	Any N	M1b
<input type="checkbox"/> Stage unknown				<input type="checkbox"/> Stage unknown			

PROGNOSTIC FACTORS (SITE-SPECIFIC FACTORS)**REQUIRED FOR STAGING:** None**CLINICALLY SIGNIFICANT:**

Pleural/Elastic Layer Invasion (based on H&E and elastic stains) _____

Separate Tumor Nodules _____

General Notes:

For identification of special cases of TNM or pTNM classifications, the “m” suffix and “y,” “r,” and “a” prefixes are used. Although they do not affect the stage grouping, they indicate cases needing separate analysis.

Source: Used with permission of the American Joint Committee on Cancer (AJCC), Chicago, Illinois. The original source of the material is the AJCC Cancer Staging Manual, Seventh Edition (2010) published by Springer Science and Business Media LLC, www.springerlink.com.

of the TNM descriptors currently used in staging NSCLC and the overall stage classifications. In addition to the TNM stage, it is recommended that histologic grade, presence or absence of pleural/elastic layer invasion, separate tumor nodules, lympho-vascular invasion, and residual tumor after treatment also be recorded into cancer registries to facilitate evaluation of these potential predictors in future analysis of staging criteria.

Staging for small cell lung cancer (SCLC) is typically based on the extent of disease. SCLC presenting with bulky locoregional disease confined to the ipsilateral hemithorax, with no evidence for distant metastatic disease, is termed “limited” SCLC. Limited disease must be treatable within a tolerable field of radiation. Using AJCC descriptors, this includes any T stage, any N stage, without metastatic disease (M0). The

only exception is when multiple lung nodules are widely spread throughout the ipsilateral lung in the same hemithorax; in these patients, the size of the involved area would preclude a “safe” radiation field. In contrast, in “disseminated” disease, tumor is beyond the ipsilateral hemithorax or widely spread within the ipsilateral lung and to distant sites. Metastases to the pleura and pericardium, with resultant effusions, are considered disseminated disease. Metastases to brain, bone, bone marrow, and the pleural and pericardial spaces are common.

Assessment of Functional Status. Patients with potentially resectable tumors require careful assessment of their functional status and ability to tolerate either lobectomy or pneumonectomy. The surgeon should first estimate the likelihood

of pneumonectomy, lobectomy, or possibly sleeve resection, based on the CT images. A sequential process of evaluation then unfolds.

A patient's history is the most important tool for gauging risk. Specific questions regarding performance status should be routinely asked. If the patient can walk on a flat surface indefinitely, without oxygen and without having to stop and rest secondary to dyspnea, he will be very likely to tolerate lobectomy. If the patient can walk up two flights of stairs (up two standard levels), without having to stop and rest secondary to dyspnea, she will likely tolerate pneumonectomy. Finally, nearly all patients, except those with carbon dioxide (CO₂) retention on arterial blood gas analysis, will be able to tolerate periods of single-lung ventilation and wedge resection.

Current smoking status and sputum production are also pertinent. Current smokers and patients with a greater than 60 pack-year history of smoking have a significantly increased risk of postoperative pulmonary complications; heavy smokers are 2.5 times more likely to develop pulmonary complications and three times more likely to develop pneumonia compared to patients with a ≤60 pack-year history (odds ratio [OR] 2.54; 95% CI 1.28–5.04; *P* = .0008). Impaired exchange of CO₂ is also predictive of increased risk, independent of the smoking history. For every 10% decline in percent carbon monoxide diffusion capacity (%DLCO), the risk of any pulmonary complication increased by 42% (OR 1.42; 95% CI 1.16–1.75; *P* = .008).⁴² Risk reduction requires smoking cessation at least 8 weeks preoperatively, a requirement that is often not feasible in a cancer patient. Nevertheless, abstinence for at least 2 weeks before surgery should be encouraged. Smoking cessation on the day of surgery leads to increased sputum production and potential secretion retention postoperatively, and some authors have reported increased rates of pulmonary complications in this group.⁴³ Patients with chronic daily sputum production will have more problems postoperatively with retention and atelectasis; they are also at higher risk for pneumonia. Sputum culture, antibiotic administration, and bronchodilators may be warranted preoperatively.

6► Pulmonary function studies are routinely performed when any resection greater than a wedge resection will be performed. Of all the measurements available, the two most valuable are forced expiratory volume in 1 second (FEV₁) and carbon monoxide diffusion capacity (DLCO). General guidelines for the use of FEV₁ in assessing the patient's ability to tolerate pulmonary resection are as follows: greater than 2.0 L can tolerate pneumonectomy, and greater than 1.5 L can tolerate lobectomy. It must be emphasized that these are guidelines only. It is also important to note that the raw value is often imprecise because normal values are reported as "percent predicted" based on corrections made for age, height, and gender. For example, a raw FEV₁ value of 1.3 L in a 62-year-old, 75-inch male has a percent predicted value of 30% (because the normal expected value is 4.31 L); in a 62-year-old, 62-inch female, the predicted value is 59% (normal expected value 2.21 L). The male patient is at high risk for lobectomy, while the female could potentially tolerate pneumonectomy.

To calculate the predicted postoperative value for FEV₁ or DLCO, the percent predicted value of FEV₁ or DLCO is multiplied by the fraction of remaining lung after the proposed surgery. For example, with a planned right upper lobectomy, a total of three segments will be removed. Therefore, three of a total 20 segments will leave the patient with $(20 - 3/20) \times 100 = 85\%$

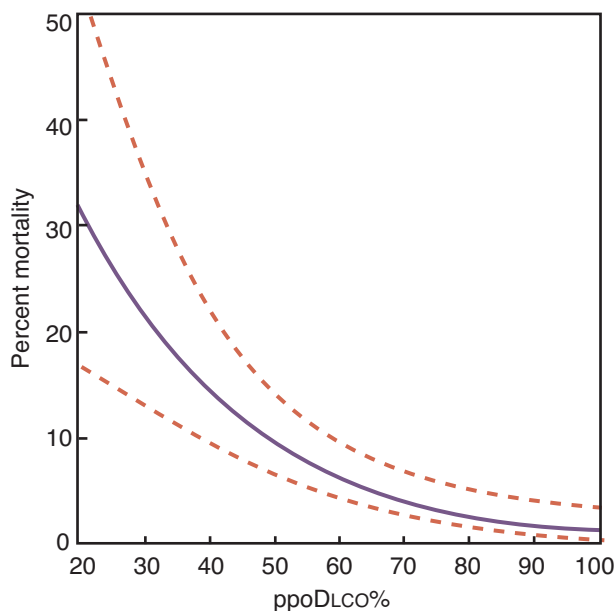


Figure 19-22. Operative mortality after major pulmonary resection for non-small cell lung cancer (334 patients) as a function of percent predicted postoperative carbon monoxide diffusion capacity (ppoDLCO%). Solid line indicates logistic regression model; dashed lines indicate 95% confidence limits. (Adapted with permission from Wang J, Olak K, Ferguson M. Diffusing capacity predicts operative mortality but not long-term survival after resection for lung cancer. *J Thorac Cardiovasc Surg.* 1999;117:582. Copyright Elsevier.)

of their original lung capacity. In the two patients mentioned earlier, the man will have a predicted postoperative FEV₁ of $30\% \times 0.85 = 25\%$, whereas the woman will have a predicted postoperative FEV₁ of 50%. Percent predicted value of less than 50% for either FEV₁ or DLCO correlates with risk for postoperative complications, particularly pulmonary complications; the risk of complications increases in a stepwise fashion for each 10% decline. Figure 19-22 shows the relationship between predicted postoperative DLCO and estimated operative mortality.

Quantitative perfusion scanning is used in select circumstances to help estimate the functional contribution of a lobe or whole lung. Such perfusion scanning is most useful when the impact of a tumor on pulmonary physiology is difficult to discern. With complete collapse of a lobe or whole lung, the impact is apparent, and perfusion scanning is usually unnecessary. Figure 19-23 shows a tumor with significant right main stem airway obstruction with associated atelectasis and volume loss of the right lung. At presentation, the patient was dyspneic with ambulation, and the FEV₁ was 1.38 L. Six months prior, this patient could walk up two flights of stairs without dyspnea. The surgeon can anticipate that the patient will tolerate pneumonectomy because the lung is already not functioning due to main stem airway obstruction, and may, in fact, be contributing to a shunt. However, with centrally located tumors associated with partial obstruction of a lobar or main bronchus or of the pulmonary artery, perfusion scanning may be valuable in predicting the postoperative result of resection. For example, if the quantitative perfusion to the right lung is measured to be 21% (normal is 55%) and the patient's percent predicted FEV₁ is 60%, the predicted postoperative FEV₁ after a right pneumonectomy would be $60\% \times 0.79 = 47\%$, indicating the ability to tolerate pneumonectomy. If the perfusion value is 55%, the predicted

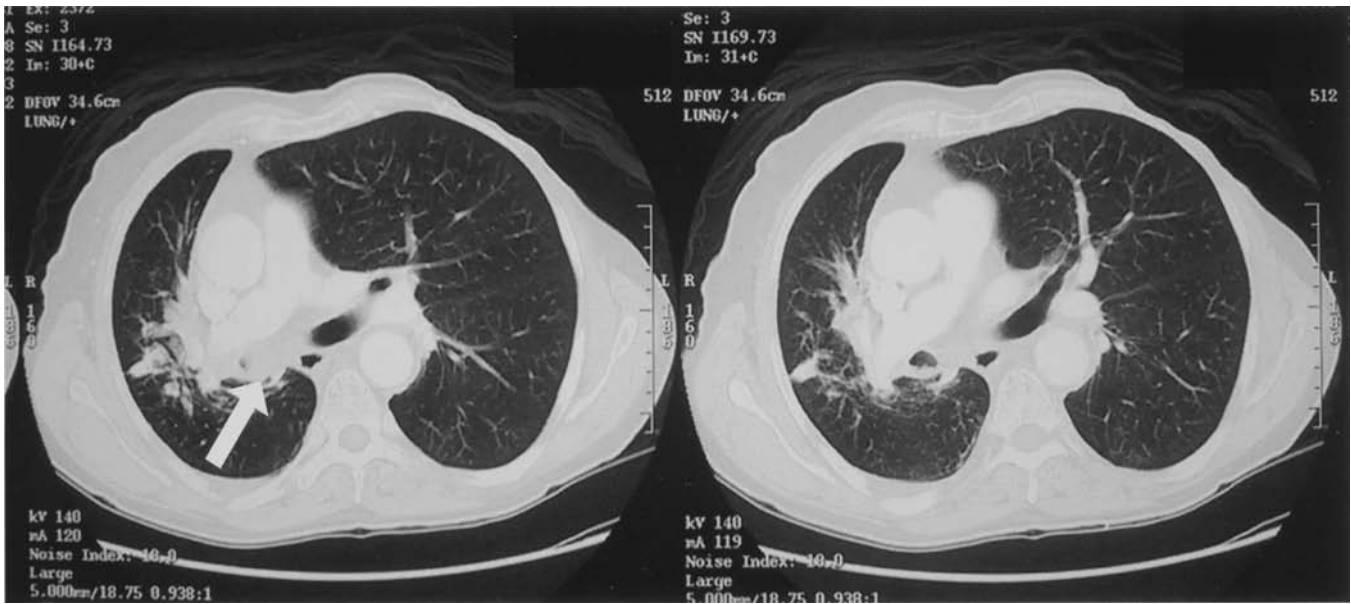


Figure 19-23. Chest computed tomography scan of an obstructing right main stem lung tumor. *Arrow* indicates location of right main bronchus. The right lung volume is much less than the left lung volume.

postoperative value would be 27%, and pneumonectomy would pose a significantly higher risk.

It is not uncommon to encounter patients with significant reductions in their percent predicted FEV₁ and DLCO whose history shows a functional status that is inconsistent with the pulmonary function tests. In these circumstances, exercise testing that yields maximal oxygen consumption ($\dot{V}O_2$ max) has emerged as a valuable decision-making technique to help patients with abnormal FEV₁ and DLCO (Table 19-12). Values of less than 10 mL/kg/min are associated with a 26% mortality **7▶** after major pulmonary resection compared to only 8.3% with $\dot{V}O_2$ max \geq 10 mL/kg/min. Values greater than 15 mL/kg/min generally indicate the patient's ability to tolerate pneumonectomy.

The risk assessment of a patient is an amalgam of clinical judgment and data. The risk assessment described earlier must **8▶** be integrated with the experienced clinician's sense of the patient and with the patient's attitude toward the disease and toward life. Figure 19-24 provides a useful algorithm for determining suitability for lung resection.⁴⁴

Lung Cancer Treatment

Grade IV NEC (Small Cell) Lung Carcinoma. In rare circumstances where SCLC presents as an isolated lung lesion, lobectomy followed by chemotherapy is warranted after surgical mediastinal staging has confirmed the absence of N2 disease. Often, ultrasound-guided FNA provides a definitive positive diagnosis and more invasive approaches are not needed. However, less than 5% are stage I, and there is no benefit from surgical resection for more advanced-stage disease; treatment is chemotherapy with or without radiation therapy depending on the extent of disease and the patient performance status.

Early-Stage Non-Small Cell Lung Cancer. Early-stage disease includes T1 and T2 tumors (with or without N1 nodal involvement) and T3 tumors (without N1 nodal involvement). This group represents a small but increasing proportion of the total number of patients diagnosed with lung cancer each year (approximately 20% of 101,844 patients from 1989 to 2003).⁴⁵ Surgical resection

is the current standard, ideally accomplished by video-assisted lobectomy or pneumonectomy, depending on the tumor location.

Despite the term "early-stage," the overall 5-year survival rate for stage I is 65% and only 41% for stage II. Median survival

Table 19-12

Relation between maximum oxygen consumption ($\dot{V}O_2$ max) as determined by preoperative exercise testing and perioperative mortality

STUDY	DEATHS/TOTAL
$\dot{V}O_2$ max 10–15 mL/kg per minute	
Smith et al ¹⁹⁶	1/6 (33%)
Bechard and Wetstein ¹⁹⁷	0/15 (0%)
Olsen et al ¹⁹⁸	1/14 (7.1%)
Walsh et al ¹⁹⁹	1/5 (20%)
Bolliger et al ²⁰⁰	2/17 (11.7%)
Markos et al ²⁰¹	1/11 (9.1%)
Wang et al ²⁰²	0/12 (0%)
Win et al ²⁰³	2/16 (12.5%)
Total	8/96 (8.3%)
$\dot{V}O_2$ max <10 mL/kg per minute	
Bechard and Wetstein ¹⁹⁷	2/7 (29%)
Olsen et al ¹⁹⁸	3/11 (27%)
Holden et al ²⁰⁴	2/4 (50%)
Markos et al ²⁰¹	0/5 (0%)
Total	7/27 (26%)

Source: Reproduced with permission from the American College of Chest Physicians from Colice GL, et al: Physiologic evaluation of the patient with lung cancer being considered for resectional surgery: ACCP Evidence-based Clinical Practice Guidelines. (2nd edition) *Chest*. 2007;132:161S.

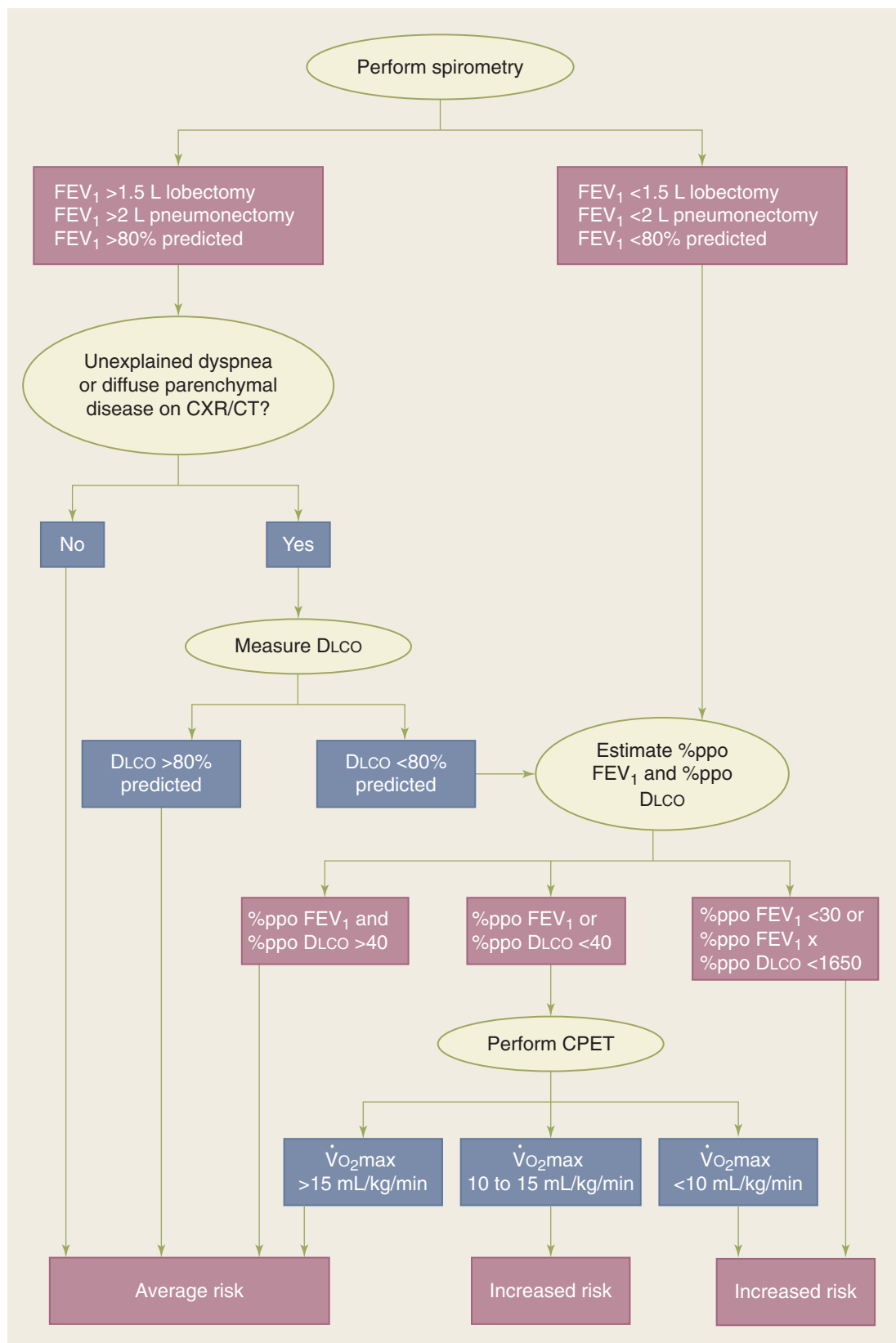


Figure 19-24. Algorithm for preoperative evaluation of pulmonary function and reserve prior to resectional lung surgery. CPET = cardiopulmonary exercise test; CT = computed tomographic scan; CXR = chest radiograph; DLCO = carbon monoxide diffusion capacity; FEV₁ = forced expiratory volume in 1 second; %ppo = percent predicted postoperative lung function; $\dot{V}O_2$ max = maximum oxygen consumption. (Reproduced with permission from the American College of Chest Physicians from Colice GL, et al: *Physiologic evaluation of the patient with lung cancer being considered for resectional surgery: ACCP Evidence-based Clinical Practice Guidelines*. (2nd edition) Chest. 2007;132:161S.)

for untreated patients with stage IA NSCLC is 14 months, and 5-year survival rate is 22%.⁴⁶ After surgical resection of post-operative pathologic stage IA disease, 5-year survival is better than with no treatment, but still only 67%.⁴¹ Survival declines with higher stages. Advanced age at diagnosis, male sex, low socioeconomic status, nonsurgical treatment, and poor histologic grade are associated with increased mortality risk on multivariate analysis.⁴⁵

Depending on tumor size and location, lobectomy, sleeve lobectomy, and occasionally pneumonectomy, with mediastinal lymph node dissection or sampling, are appropriate for patients with clinical early-stage disease. Sleeve resection is performed for tumors located at airway bifurcations when an adequate bronchial margin cannot be obtained by standard lobectomy. Pneumonectomy is rarely performed; primary indications for pneumonectomy in early-stage disease include large central tumors involving the distal main stem bronchus and inability to completely resect involved N1 lymph nodes. The latter circumstance occurs with bulky adenopathy or with extracapsular nodal spread.

Management of Early-Stage Lung Cancer in the High-Risk Patient. Lobectomy may not be an option for some patients with early-stage disease, due to poor cardiopulmonary function or other comorbid illnesses. The ultimate decision that a patient is not operable, both with regard to the ability of the patient to tolerate surgery and the likelihood of successful resection, should be accepted only after evaluation by an expert surgeon. Surgeons with limited expertise, when faced with a complicated patient, should refer the patient to a high-volume center for further evaluation if they are unable to offer the patient surgical resection in their own center.

Rationale for Limited Resection in Early-Stage Lung Cancer. Limited resection, defined as segmentectomy or wedge resection, is a viable option for achieving local control in high-risk patients. Historically, limited resection with wedge or segmentectomy has been considered a compromise operation due to unacceptably high rates of local recurrence and concerns for worse survival.^{47,48} Subsequent meta-analysis of the literature shows that the difference in death rate is likely negligible⁴⁹ (Table 19-13). The high rates of local recurrence demonstrated by Ginsberg and others, however, remain a significant concern and continue to restrict the use of limited resection for early-stage lung cancer to the high-risk patient.

With the recent publication of a 20% reduction in lung cancer mortality with screening CT scans in high-risk populations, the topic of limited resection is again the subject of intensive review. Studies investigating anatomic segmentectomy (or extended wedge resection) with hilar and mediastinal lymph node dissection suggest that close attention to the ratio of surgical margin to tumor diameter and a careful assessment of the lymph nodes substantially reduce local recurrence.⁵⁰⁻⁵² Recurrence rates were 6.2%, comparable to rates associated with lobectomy, when the margin-to-tumor diameter ratio exceeded 1, compared to 25% if the margin-to-tumor diameter ratio was less than 1.⁵⁰ In most centers, this requires use of a thoracotomy, although increasing experience with VATS in high-volume centers shows that limited resection is safe and feasible, with perioperative adverse outcomes that are comparable to lobectomy.⁵²⁻⁵⁵

Rationale for Tumor Ablation in the Management of Primary Lung Cancer. Limited resection, by definition, requires that the patient has sufficient cardiopulmonary reserve to undergo

a general anesthesia and loss of at least one pulmonary segment. For the high-risk or nonoperable patient, as determined by experience pulmonary surgeons, tumor ablation techniques have been developed for treatment of early-stage lung cancers.

Current limitations of this approach include the absence of nodal staging, lack of tissue for molecular profiling, chemoresistance, or sensitivity testing, concerns about definitions of locoregional recurrence, and a lack of uniformity across centers. Surgeons typically define locoregional recurrence as tumor growth within the operative field, including resectable lymph nodes, whereas local recurrence after ablation is most commonly defined as tumor growth within the field of treatment. Despite the fact that in-transit or lymph node metastases are present in up to 27% of clinically stage I NSCLCs at resection, any tumor growth outside the field of ablative treatment is not considered treatment failure.⁵⁶

Despite these limitations, tumor ablative strategies are increasingly proposed as viable alternatives to surgical resection, even in potentially operable patients.⁵⁷⁻⁶² While premature, ablative techniques may ultimately be shown to have efficacy equivalent to lobectomy for the primary treatment of very small peripheral early-stage lung cancers. Multidisciplinary collaboration between thoracic surgery, interventional radiology/pulmonology, and radiation oncology is required to ensure that

9► development of these ablative techniques occurs through properly designed and well-controlled prospective studies and will ensure that patients receive the best available therapy, regardless of whether it is surgical resection or ablative therapy.

The two most commonly applied ablation techniques are radiofrequency ablation and stereotactic body radiotherapy.

1. **Radiofrequency ablation.** Radiofrequency ablation is performed using either monopolar or bipolar delivery of electrical current to electrodes placed within the tumor tissue. In lung tumors, the electrodes are typically inserted into the tumor mass under CT guidance. An electrical current is delivered; the current is converted by means of friction into heat, which quickly leads to immediate and irreparable tissue destruction in the tissue surrounding the electrode. The efficacy of radiofrequency ablation for controlling the primary tumor and improving survival in poor operative candidates (either due to significant comorbid diseases precluding general anesthesia or poor pulmonary function excluding lung resection) is safe and feasible for peripheral lung nodules. In tumors <3.5 cm, the rate of radiographic resolution of tumor is up to 80% and cancer-specific survival at 2 years was approximately 90%, indicating excellent local control of the primary site.^{57-59,63} It has become the preferred modality for small peripheral tumors over standard external-beam radiation in centers where the technique is available.

Radiofrequency ablation is an excellent modality for the patient at risk for adverse outcomes with pulmonary resection or for patients who refuse surgery, and surgeons should have an algorithm for determining which patients are optimal for this modality.⁶⁴⁻⁶⁹ (see Fig. 19-24). Target lesions larger than 5 cm, tumor abutting the hilum, associated malignant pleural or pericardial effusion, greater than three lesions in one lung, and the presence of pulmonary hypertension are all contraindications to radiofrequency ablation.⁶⁴ Proximity to a large vessel is a contraindication not only due to the risk of massive bleeding, but also

Table 19-13

Summary of studies comparing limited resection and lobectomy

STUDY	STUDY DESIGN	STAGE	NO. OF LIMITED RESECTIONS	NO. OF LOBECTOMIES	REASONS FOR LIMITED RESECTION	SURVIVAL DIFFERENCE
Hoffman and Ransdell (1980) ⁷⁰	RS	IA	33 (W)	40 ^a	Poor cardiopulmonary function and smaller lesions	NS
Read et al (1990) ⁷¹	RS	IA	113 (107 S + 6 W)	131	ND	NS (CSS)
Date et al (1994) ⁷²	MPS	IA	16 (6 S + 10 W)	16	Poor pulmonary function	Lobectomy better
Warren and Faber (1994) ⁴⁸	RS	IA + IB	66 (S)	103	Poor cardiopulmonary function and smaller lesions	Lobectomy better
Harpole et al (1995) ⁷³	RS	IA + IB	75 (W)	193	Poor cardiopulmonary function and smaller lesions	NS (CSS)
LCSG (1996) ^{47, 74}	RCT	IA	122 (82 S + 40 W)	125	Randomization	NS
Kodama et al (1997) ⁷⁵	RS	IA	46 ^b (W)	77	Intentional resection for small lesions	NS
Landreneau et al (1997) ⁷⁶	RS	IA	102 (W)	117	Poor cardiopulmonary function	NS
Pastorino et al (1997) ⁷⁷	RS	IA + IB	53 (S + W)	367	ND	NS
Kwiatkowski et al (1998) ⁷⁸	RS	IA + IB	58 (S + W)	186 ^c	ND	Lobectomy better
Okada et al (2001) ⁷⁹	RS	IA ≤2 cm	70 (S)	139	Intentional resection for small lesions ≤2 cm	NS
Koike et al (2003) ⁸⁰	RS	IA ≤2 cm	74 (60 S + 14 W)	159	Intentional resection for small lesions ≤2 cm	NS
Campione et al (2004) ⁸¹	RS	IA	21 (S)	100	Poor cardiopulmonary function	NS
Keenan et al (2004) ⁸²	RS	IA + IB	54 (S)	147	Poor pulmonary function	NS

^aTumors peripherally located.

^bOnly intentional resection.

^cIncluding 13 pneumonectomies.

CSS = cancer-specific survival; LCSG = Lung Cancer Study Group; MPS = matched-pair study; ND = not described; NS = not significant; RCT = randomized controlled trial; RS = retrospective study; S = segmentectomy; W = wedge resection.

Source: Reprinted by permission from Macmillan Publishers Ltd on behalf of Cancer Research UK: Nakamura H, Kawasaki N, Taguchi M, et al. Survival following lobectomy vs limited resection for stage I lung cancer: a meta-analysis. *Br J Cancer*. 2005;92:1033. Copyright © 2005.

because large blood vessels act as a heat sink and lethal cellular temperatures are less likely to be achieved. For these patients, stereotactic body radiotherapy may provide local tumor control with less risk of major complications. Combination therapy with either external-beam radiation or stereotactic body radiotherapy is also under investigation.

2. **Stereotactic body radiotherapy.** Stereotactic body radiotherapy applies highly focused, high-intensity, three-dimensional conformal radiation to the target lesion over a few sessions. Tumor motion quantification and image guidance technologies have significantly improved the delivery of radiation with high levels of precision to the target lesion. This accuracy is important because the lung is extremely sensitive to radiation injury and the majority of patients with early-stage lung cancer who are currently

considered candidates for ablative therapy have marginal lung function; excessive injury to normal surrounding lung tissue is not desirable. Importantly, these techniques allow the safe delivery of up to 66 Gy of radiation to the target tumors without exceeding the maximum-tolerated dose.^{62,83} A phase II North American multicenter study recently demonstrated the safety and efficacy of this approach in 59 nonoperable patients.⁶² Patients with biopsy-proven, node-negative peripheral NSCLCs less than 5 cm in diameter (T1 or T2) were treated with stereotactic body radiotherapy after they were deemed inoperable, based on coexisting medical conditions, by a thoracic surgeon and/or pulmonologist. Primary tumor control was excellent; at 3 years, 97.6% were deemed to have primary tumor control by the authors and 90.6% had local control. However, it is important

to note that primary tumor failure was defined specifically as at least a 20% increase in the longest diameter of the gross tumor volume by CT scan *and* evidence of tumor viability either by biopsy confirming carcinoma or by demonstration of FDG avidity on PET scan. For viability to be confirmed with PET scan, the uptake was required to be of similar intensity to the pretreatment staging PET scan. Failure beyond a 1.5- to 2-cm margin around the primary tumor volume was considered local failure. Failure in regional node basins was seen in two patients. When compared to locoregional control rates of approximately 6.5% with limited resection, the 3-year locoregional recurrence was higher at 12.8%.

Patient selection for stereotactic body radiotherapy, as with limited resection and radiofrequency ablation, is important. Because the radiation field is so precise, patients with severe emphysema and chronic obstructive pulmonary disease can be safely treated without significant concern for worsening lung function. However, patients with central tumors near the mediastinum and hilum have increased incidence of significant hypoxia, hemoptysis, atelectasis, pneumonitis, and reduced pulmonary function.⁸³ In the multicenter trial detailed earlier, treated tumors were required to be greater than 2 cm from the proximal bronchial tree in all directions (which they defined as the distal 2 cm of the trachea, carina, and named major lobar bronchi up to their first bifurcation).⁶²

Rationale for Chemotherapy in the Management of Early-Stage NSCLC. The role of chemotherapy in early-stage (stage I and II) NSCLC is evolving, with several prospective phase II studies having shown a potential benefit.^{84,85} Initial concerns that induction chemotherapy may result in increased perioperative morbidity or mortality appear to be unwarranted, as the incidence of perioperative morbidity and mortality is not different between the two groups, except in patients undergoing right-sided pneumonectomy after induction chemotherapy.⁸⁶ As shown in Table 19-14, an absolute survival benefit of 4% to 7% can be realized using induction for all stages of lung cancer, and in situations where use of adjuvant chemotherapy is anticipated, induction chemotherapy is an acceptable alternative.

Table 19-14

Five-year stage-specific survival after induction chemotherapy followed by surgery

STAGE	5-YEAR SURVIVAL (%)	ABSOLUTE BENEFIT (%)	NEW 5-YEAR SURVIVAL (%)
IA	75	4	79
IB	55	6	61
IIA	50	7	57
IIB	40	7	47
IIIA	15–35	6–7	21–42
IIIB	5–10	3–5	8–15

Source: Reproduced with permission from Burdett SS, Stewart LA, Rydzewska L. Chemotherapy and surgery versus surgery alone in non-small cell lung cancer. *Cochrane Database Syst Rev.* 2007;CD006157. John Wiley & Sons, Ltd. Copyright Cochrane Collaboration.

National Comprehensive Cancer Network guidelines currently recommend observation for T1a (≤ 2 cm) and T1b (>2 – ≤ 3 cm), node-negative, completely resected NSCLCs (T1abN0M0). For patients with larger tumors (T2a tumor >3 cm but ≤ 5 cm; T2b tumor >5 cm but ≤ 7 cm) that are node-negative, it is recommended that chemotherapy be considered in high-risk patients, ideally in the setting of a clinical trial. High-risk tumor characteristics include poorly differentiated tumors, moderately to poorly differentiated lung neuroendocrine tumors, vascular invasion, resection limited to wedge resection only, tumors >4 cm in size, visceral pleural involvement, and when lymph node sampling at the time of resection was incomplete (Nx).

Evaluation and Management of Locally Advanced NSCLC. Five-year relative survival in patients with locoregional disease is 25%, but there is significant heterogeneity within the group. Stage III disease includes patients with small tumors that have metastasized to the mediastinal lymph nodes as well as large tumors invading unresectable structures or the major carina with no nodal metastasis at all. Patients with clinically evident N2 disease (i.e., bulky adenopathy present on CT scan or mediastinoscopy, with lymph nodes often replaced by tumor) have a 5-year survival rate of 5% to 10% with surgery alone. In contrast, patients with microscopic N2 disease discovered incidentally in one lymph node station after surgical resection have a 5-year survival rate that may be as high as 30%. As a result, many surgeons and oncologists differentiate between microscopic and bulky N2 lymphadenopathy and the number of involved N2 nodal stations in determining whether to proceed with resection following induction therapy. It is generally accepted that surgical resection is appropriate for patients with a single-station metastasis with a single lymph node smaller than 3 cm, although randomized trials specifically investigating resection following induction therapy for patients with single-station microscopic disease have not yet been performed.

Histologic confirmation of N2 nodal metastases is imperative; false-positive findings on PET scan are unacceptably high, and reliance on this modality will lead to significant undertreatment of patients with earlier stage cancers. This is particularly true in regions with high incidence of granulomatous diseases. When N2 nodes are found, incidentally, to harbor metastasis at the time of planned anatomic lung resection, the decision to proceed with resection varies depending on surgeon preference; it is acceptable to either proceed with anatomic resection and mediastinal lymph node sampling/dissection or to stop the procedure, refer the patient for induction therapy, and re-evaluate for resection after induction therapy is completed. When histologically confirmed metastases are found during preoperative staging evaluation, patients should be referred for induction chemotherapy; patients in whom the mediastinal nodes are sterilized by induction therapy have a better prognosis, and surgical resection is generally warranted as part of a multimodal approach. As with preinduction evaluation, histologic confirmation of persistent N2 disease after induction therapy is imperative; patients should not be denied surgical resection following induction chemotherapy based on radiographic evidence for N2 disease because the survival for resected NSCLC is significantly better than with definitive chemotherapy.

Surgery in T4 and Stage IV Disease. Surgery is occasionally appropriate for highly selected patients with tumors invading the SVC, carinal or vertebral body involvement, or satellite nodules in the same lobe (T3, N0-1, M0) or in T4, N0-1 tumors

with limited invasion into the mediastinum, heart, great vessels, trachea, recurrent laryngeal nerve, esophagus, vertebral body, or carina through direct extension. Surgery generally does *not* have a role in the care of patients with any tumor with N3 disease or T4 tumors with N2 disease. Survival rates remain extremely low for these patients. Similarly, the treatment of patients with stage IV disease is chemotherapy. However, on occasion, patients with a single site of metastasis are encountered, particularly with adenocarcinomas presenting with a solitary brain metastasis. In this highly select group, 5-year survival rates of 10% to 15% can be achieved with surgical excision of the brain metastasis and the primary tumor, assuming it is early stage.

Surgery for Management of Pancoast's Tumor. Carcinoma arising in the extreme apex of the chest with associated arm and shoulder pain, atrophy of the muscles of the hand, and Horner's syndrome presents a unique challenge to the surgeon. Any tumor of the superior sulcus, including tumors without evidence for involvement of the neurovascular bundle, is now commonly known as Pancoast's tumors, after Henry Pancoast who described the syndrome in 1932. The designation is reserved for tumors involving the parietal pleura or deeper structures overlying the first rib. Chest wall involvement at or below the second rib is not a Pancoast's tumor.⁷⁴ Treatment is multidisciplinary; due to the location of the tumor and involvement of the neurovascular bundle that supplies the ipsilateral extremity, preserving postoperative function of the extremity is critical. For

this reason, resection should only be performed in patients who are proven negative for mediastinal lymph node involvement. Survival with N2 positive nodes is poor, and the morbidity and mortality associated with surgical resection are high. If bulky lymphadenopathy is present, EBUS- or EUS-guided FNA/core-needle biopsy may prove nodal involvement. However, a negative FNA is not sufficient for proving the absence of mediastinal involvement and should be followed by mediastinoscopy to ensure accurate and complete evaluation of the mediastinum.

Because Pancoast's tumors have high rates of local recurrence and incomplete resection, induction chemoradiotherapy followed by surgery is recommended. This treatment regimen was well tolerated in a study performed by the Southwest Oncology Group, with 95% of patients completing induction treatment. Complete resection was achieved in 76%. Five-year survival was 44% overall and 54% when complete resection was achieved. Disease progression with this regimen was predominantly at distant sites, with the brain being the most common.⁷⁵ The current treatment algorithm for Pancoast's tumors is presented in Fig. 19-25.

Surgical excision is performed via thoracotomy with en bloc resection of the chest wall and vascular structures and anatomic lobectomy. A portion of the lower trunk of the brachial plexus and the stellate ganglion are also typically resected. With chest wall involvement, en bloc chest wall resection, along with lobectomy, is performed, with or without chest wall reconstruction.

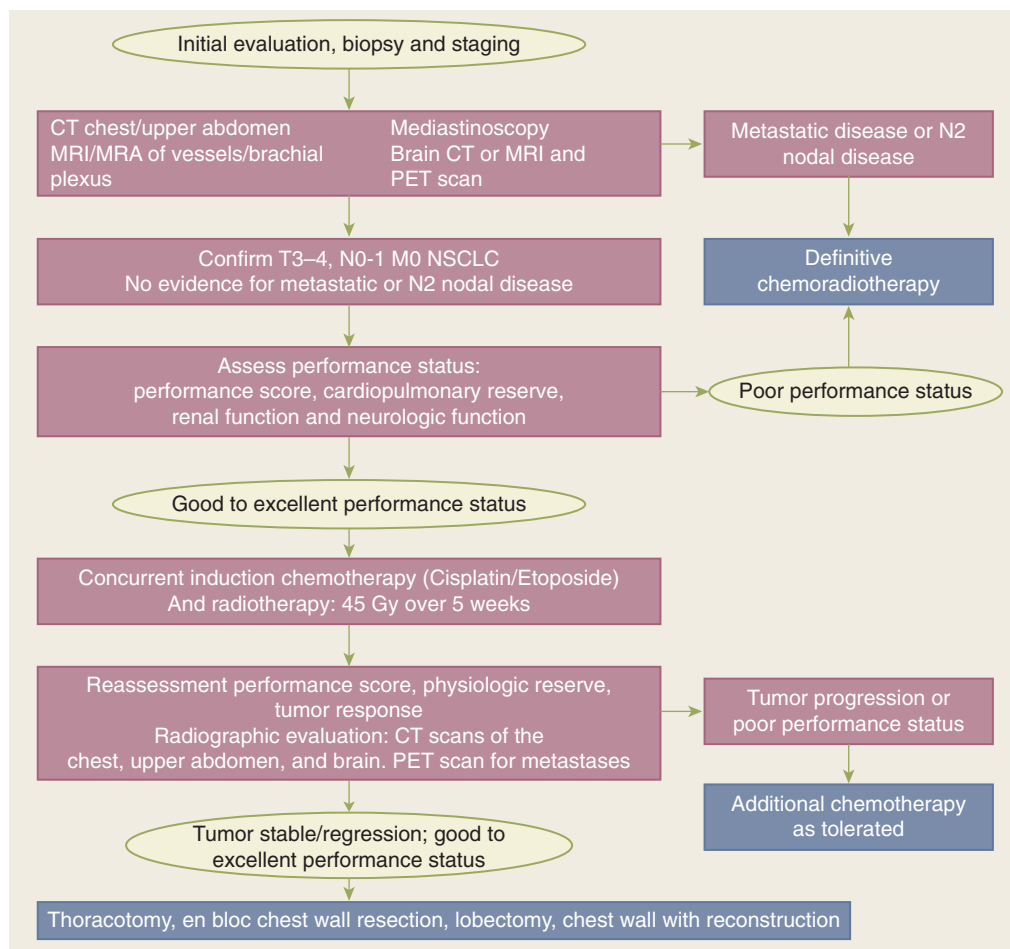


Figure 19-25. Treatment algorithm for Pancoast's tumors. CT = computed tomography; MRA = magnetic resonance angiography; MRI = magnetic resonance imaging; NSCLC = non-small cell lung cancer; PET = positron emission tomography.

For small rib resections or those posterior to the scapula, chest wall reconstruction is usually unnecessary. Larger defects (two rib segments or more) are usually reconstructed with Gore-Tex to provide chest wall contour and stability. En bloc resection is also used for other locally advanced tumors (T3) with direct invasion of the adjacent chest wall, diaphragm, or pericardium. If a large portion of the pericardium is removed, reconstruction with thin Gore-Tex membrane will be required to prevent cardiac herniation and venous obstruction.

Preoperative (Induction) Chemotherapy for NSCLC. The use of chemotherapy before anatomic surgical resection has a number of potential advantages:

1. The tumor's blood supply is still intact, allowing better chemotherapy delivery and avoiding tumor cell hypoxia (in any residual microscopic tumor remaining postoperatively), which would increase radioresistance.
2. The primary tumor may be downstaged, enhancing resectability.
3. Patients are better able to tolerate chemotherapy before surgery and are more likely to complete the prescribed regimen than after surgery.
4. It functions as an *in vivo* test of the primary tumor's sensitivity to chemotherapy.
5. Response to chemotherapy can be monitored and used to guide decisions about additional therapy.
6. Systemic micrometastases are treated.
7. It identifies patients with progressive disease/non-responders and spares them a pulmonary resection.

Potential disadvantages include:

1. There is a possible increase in the perioperative complication rate in patients requiring right pneumonectomy after induction chemotherapy.
2. While the patient is receiving chemotherapy, potentially curative resection is delayed; if the patient does not respond, this delay could result in tumor spread.

In stage IIIA N2 disease, the response rates to induction chemotherapy are high, in the range of 70%. The treatment is generally safe, as it does not cause a significant increase in perioperative morbidity. Two randomized trials have now compared surgery alone for patients with N2 disease to preoperative chemotherapy followed by surgery. Both trials were stopped before complete accrual because of a significant increase in survival for the chemotherapy arm. The initially observed survival differences have been maintained for up to 3 years and beyond (5-year data not shown). Given these results, induction chemotherapy with cisplatin-based regimens (two to three cycles) has become standard for patients with N2 disease. Table 19-15 summarizes the findings of a systematic review and meta-analysis reporting response rates, progression-free survival, and overall survival after induction chemotherapy followed by surgical resection.

Postoperative (Adjuvant) Chemotherapy for NSCLC. Postoperative adjuvant chemotherapy was previously thought to confer no benefit based on multiple prospective randomized trials, in part because patients who had undergone thoracotomy and lung resection had difficulty tolerating the adjuvant regimens. More recently, however, newer, more effective agents have shown promise and adjuvant therapy is better tolerated after minimally invasive lung resection (i.e., VATS or robotic anatomic resection).

Targeted therapies, which have been shown to be beneficial in advanced-stage lung cancer, are of particular interest.

Any patient with nodal metastasis (N1 or N2) or with T3 tumors (defined as tumors >7 cm; invading chest wall, diaphragm, phrenic nerve, mediastinal pleura, parietal pericardium, or main bronchus tumor <2 cm distal to the carina; causing atelectasis or obstructive pneumonitis; or with separate nodules in the same lobe of the lung) should receive adjuvant chemotherapy if they are able to tolerate the regimens. In the situation where the margins of resection are positive, re-resection is recommended. If not possible, concurrent chemoradiation is recommended for macroscopic residual tumor and sequential chemoradiation for microscopic residual tumor.

Definitive Nonsurgical Treatment for NSCLC. Recent advances in targeted therapies have changed the management of advanced NSCLC from a generalized, platinum-based approach to one in which molecular analysis and targeted, personalized therapies are now standard of care. It is now mandatory that the pathologist clearly differentiate between squamous cell carcinoma and adenocarcinoma because the therapeutic options are different and use of bevacizumab, while beneficial in patients with adenocarcinoma, has been found to cause excessive pulmonary hemorrhage in patients with squamous histology. For the surgeon, this requirement translates into a much more aggressive approach to tissue diagnosis. At our institution, the cytopathologist provides onsite rapid assessment of the fine-needle aspirate to determine whether tumor cells are present and confirm that sufficient tumor cells are present to enable molecular testing. This has increased the number of passes performed during an EBUS-guided FNA or during CT-guided aspiration of a pulmonary or intrathoracic lesion; typically, an additional two passes are made for cell block material after confirming the presence of tumor cells in the target area. When insufficient cells are obtained for molecular testing, despite having a diagnosis, additional sampling is warranted; this is mandatory in patients with adenocarcinoma and likely to become necessary for other non-small cell histologic types as advances in targeted therapies become available for clinical use. Acquiring adequate tissue for diagnosis may require mediastinoscopy or VATS; close communication between the oncologist, surgeon, pathologist, and patient is needed to ensure that the benefits to the patient clearly outweigh the risks and that results obtained through more aggressive diagnostic measures are needed to direct subsequent care.

Once a treatment plan has been devised, two strategies for delivery are available. "Sequential" chemoradiation involves full-dose systemic chemotherapy (i.e., cisplatin combined with a second agent) followed by standard radiotherapy (approximately 60 Gy). The combination of chemotherapy followed by radiation has improved 5-year survival from 6% with radiotherapy alone to 17%.⁸⁹ An alternative approach, referred to as "concurrent chemoradiation," administers chemotherapy and radiation at the same time. Certain chemotherapeutic agents sensitize tumor cells to radiation and, thus, enhance the radiation effect. The advantages of this approach are improved primary tumor and locoregional lymph node control and elimination of the delay in administering radiotherapy that occurs with sequential treatment. A disadvantage, however, is the necessary reduction in chemotherapy dosage in order to diminish overlapping toxicities; this can potentially lead to undertreatment of systemic micrometastases. Randomized trials have shown a

Table 19-15

Selected randomized trials of neoadjuvant chemotherapy for stage III non–small cell lung cancer

TRIAL (REFERENCE)	NO. OF PATIENTS (STAGE III)	CHEMOTHERAPY	RESPONSE RATE (%)	PCR (%)	COMPLETE RESECTION	PFS	OS	5-YEAR SURVIVAL
Rosell et al ⁸⁵	60 (60)	Mitomycin Ifosfamide Cisplatin	60	4	85%	12 vs. 5 mo (DFS; $P = .006$)	22 vs. 10 mo ($P = .005$)	16% vs. 0%
Roth et al ⁹⁰	60 (60)	Cyclophosphamide Etoposide Cisplatin	35	NR	39% vs. 31%	Not reached vs. 9 mo ($P = .006$)	64 vs. 11 mo ($P = .008$)	56% vs. 15% ^a
Pass et al ⁹¹	27 (27)	Etoposide Cisplatin	62	8	85% vs. 86%	12.7 vs. 5.8 mo ($P = .083$)	28.7 vs. 15.6 mo ($P = .095$)	NR
Nagai et al ⁹²	62 (62)	Cisplatin Vindesine	28	0	65% vs. 77%	NR	17 vs. 16 mo ($P = .5274$)	10% vs. 22%
Gilligan et al ⁹³	519 (80)	Platinum based ^b	49	4	82% vs. 80%	NR	54 vs. 55 mo ($P = .86$)	44% vs. 45%
Depierre et al ⁹⁴	355 (167)	Mitomycin Ifosfamide Cisplatin	64	11	92% vs. 86%	26.7 vs. 12.9 mo ($P = .033$)	37 vs. 26 mo ($P = .15$)	43.9% vs. 35.3% ^c
Pisters et al ⁹⁵	354 (113) ^d	Carboplatin Paclitaxel	41	NR	94% vs. 89%	33 vs. 21 mo ($P = .07$)	75 vs. 46 mo ($P = .19$)	50% vs. 43%
Sorensen et al ⁹⁶	90 (NR)	Paclitaxel Carboplatin	46	0	79% vs. 70%	NR	34.4 vs. 22.5 mo (NS)	36% vs. 24% (NS)
Mattson et al ⁹⁷	274 (274)	Docetaxel	28	NR	77% vs. 76% ^e	9 vs. 7.6 mo (NS)	14.8 vs. 12.6 mo (NS)	NR

^a3-year survival.^bOptions included MVP (mitomycin C, vindesine, and platinum), MIC (mitomycin, ifosfamide, and cisplatin), NP (cisplatin and vinorelbine), PacCarbo (paclitaxel and carboplatin), GemCis (gemcitabine and cisplatin), and DocCarbo (docetaxel and carboplatin).^c4-year survival.^d113 patients (32%) were reported to have stage IIB or IIIA disease.^e22 patients in the chemotherapy arm and 29 patients in the control arm had resectable disease.

DFS = disease-free survival; NR = not recorded; NS = not significant; OS = overall survival; pCR = pathologic complete response; PFS = progression-free survival.

Source: Reproduced with permission from JNCCN—*Journal of the National Comprehensive Cancer Network*.

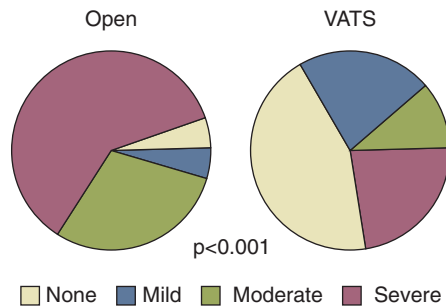


Figure 19-26. Pie chart comparison of pain control at 3 weeks after lobectomy by standard thoracotomy or video-assisted thoracic surgery (VATS). The pie charts show that patients undergoing VATS have significantly less pain ($P < .01$) as measured by the most potent analgesic still required: severe—schedule II narcotic; moderate—schedule III or lower narcotic; mild—nonsteroidal anti-inflammatory drug (NSAID) or acetaminophen. (Reproduced with permission from Demmy TL, Nwogu C. Is video-assisted thoracic surgery lobectomy better? Quality of life considerations. *Ann Thorac Surg*. 2008;85:S719. Copyright Elsevier.)

modest 5-year survival benefit as compared with chemotherapy. In a systematic review of 47 trials and six meta-analyses, an absolute survival benefit of 4% at 2 years was seen when concurrent platinum-based chemoradiation was given compared to sequential radiation.⁹⁸

Definitive radiotherapy is predominantly used for palliation of symptoms in patients with poor performance status; cure rates with radiation as a single modality in patients with N2 or N3 disease is less than 7%. Recent improvement has been seen with three-dimensional conformal radiotherapy

and altered fractionation. Such poor results for patients with stage III lung cancer reflect the limitations of locoregional treatment in a disease where death results from systemic metastatic spread.

Options for Thoracic Surgical Approaches

Thoracic surgical approaches have changed over recent years with advancements in minimally invasive surgery. A surgeon trained in advanced minimally invasive techniques can now perform pleural-based, pulmonary and mediastinal procedures through multiple thoracoscopic ports without the need for a substantial, rib-spreading incision. Subjective measures of quality of life after VATS, such as pain (Fig. 19-26) and perceived functional recovery, consistently and reproducibly favor VATS over thoracotomy. Objective measures such as functional status as measured by 6-minute walk, return to work, and ability to tolerate chemotherapy also favor VATS over thoracotomy. Finally, recovery of respiratory function occurs earlier in VATS patients. These findings are pronounced in patients with chronic obstructive pulmonary disease and in the elderly—populations whose quality of life can be dramatically impacted by changes in their respiratory symptoms and function, thoracic pain, and physical performance. Table 19-16 provides a summary of populations that may benefit from VATS approaches.

Video-Assisted Thoracoscopic Surgery. VATS has become the recommended approach to diagnosis and treatment of pleural effusions, recurrent pneumothoraces, lung biopsies, lobectomy or segmental resection, resection of bronchogenic and mediastinal cysts, and intrathoracic esophageal mobilization for esophagectomy.⁹⁹ It is also utilized for pneumonectomy in some centers of excellence with very high volumes of VATS lung resection. VATS is performed via two to four incisions measuring 0.5 to 1.2 cm in length to allow insertion of the thoracoscope

Table 19-16

Special circumstances under which lobectomy by video-assisted thoracic surgery may be preferable

CONDITION	EXAMPLES
Pulmonary compromise	Poor FEV ₁ /DLCO, heavy smoking, sleep apnea, recent pneumonia
Cardiac dysfunction	Congestive heart failure, severe coronary artery disease, recent myocardial infarction, valvular disease
Extrathoracic malignancy	Solitary brain metastasis from lung cancer, deep pulmonary metastases requiring lobectomy
Poor physical performance	Performance status equivalent to a Zubrod score of 2 or 3, morbid obesity
Rheumatologic/orthopedic condition	Spinal disease, severe rheumatoid arthritis, severe kyphosis, lupus erythematosus, osteomyelitis
Advanced age	Age >70 years
Vascular problems	Aneurysm, severe peripheral vascular disease
Recent or impending major operation	Urgent abdominal operation, joint replacement requiring use of crutches, need for contralateral thoracotomy
Psychological/neurologic conditions	Substance abuse, poor command following, pain syndromes
Immunosuppression/ impaired wound healing	Recent transplantation, diabetes

DLCO = carbon monoxide diffusion capacity; FEV₁ = forced expiratory volume in 1 second.

Source: Reproduced with permission from Demmy TL, Nwogu C. Is video-assisted thoracic surgery lobectomy better? Quality of life considerations. *Ann Thorac Surg*. 2008;85:S719. Copyright © Elsevier. Copyright Elsevier.

and instruments. An access incision, typically in the fourth or fifth intercostal space in the anterior axillary line, is used for dissection of the hilum during lung resection. The incision location varies according to the procedure. With respect to VATS lobectomy, port placement varies according to the lobe being resected and is highly variable among surgeons.¹⁰⁰ The basic principle is to position the ports high enough on the thoracic cage to have

access to the hilar structures. Endoscopic staplers are used to divide the major vascular structures and bronchus (Fig. 19-27).

Open approaches to Thoracic Surgery. When video-assisted thoracoscopic approach is not possible, an open approach, most frequently the posterolateral thoracotomy, is used to gain access to the intrathoracic space.^{101,102} The posterolateral thoracotomy

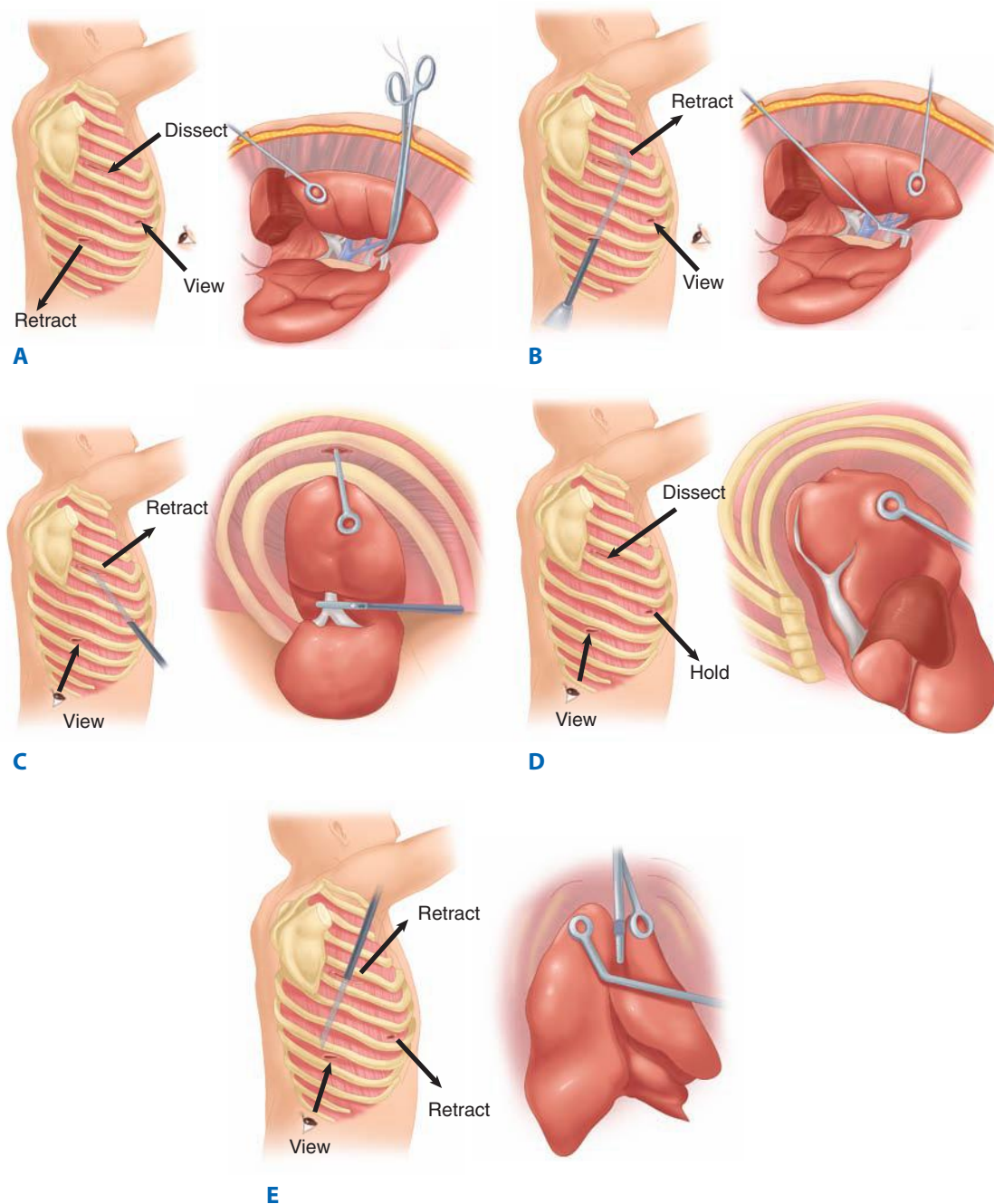


Figure 19-27. Selected video-assisted thoracic surgery lobectomy maneuvers. All the maneuvers are shown with the patient positioned in the left lateral decubitus position. The same maneuvers can be performed in mirror image for left-sided work. **A.** Medial viewing and inferior holding of lung to allow dissection through the access incision. Example shows dissection of the apical hilum. **B.** Medial viewing and access holding of lung to allow stapling of hilar structures from below. Example shows division of the apical pulmonary artery trunk to the right upper lobe (upper lobe branch of vein divided and reflected away). **C.** Standard viewing and use of working port to dissect and divide structures while lung is retracted through access incision. Example shows use of stapler to divide pulmonary artery to right lower lobe. **D.** Standard viewing and use of working port to retract lung and access incision to dissect structures. This method is commonly used to dissect the pulmonary artery in the major fissure. Example shows inferior pulmonary vein after the pulmonary ligament was divided using this maneuver. **E.** Standard viewing and use of access incision to deliver stapler to divide fissures. Example shows division of the posterior fissure between the right lower lobe and the upper lobe. (Reproduced with permission from Demmy et al.¹⁰⁰ Copyright Elsevier.)

incision can be used for most pulmonary resections, esophageal operations, and operations in the posterior mediastinum and vertebral column (Fig. 19-28). The anterolateral thoracotomy has traditionally been used in trauma victims. This approach allows quick entry into the chest with the patient supine. In the face of hemodynamic instability, the lateral decubitus position significantly compromises control over the patient's cardiopulmonary system and resuscitation efforts, whereas the supine position allows the anesthesiologist full access to the patient. A bilateral anterior thoracotomy incision with a transverse sternotomy ("clamshell" thoracotomy) is a standard operative approach to the heart and mediastinum in certain elective circumstances. It is the preferred incision for double-lung transplantation in many

centers. A partial median sternotomy can also be added to an anterior thoracotomy ("trap-door" or "hemiclamshell" thoracotomy) for access to mediastinal structures. A hypesthetic nipple is a frequent complication of this approach. The median sternotomy incision allows exposure of anterior mediastinal structures and is principally used for cardiac operations. Although the surgeon has access to both pleural cavities, incision into the pleural cavity can be avoided if entry is unnecessary (Fig. 19-29).

Postoperative Care

Chest Tube Management. At the conclusion of most thoracic operations, the pleural cavity is drained with a chest tube(s). If the visceral pleura has not been violated and there is no concern

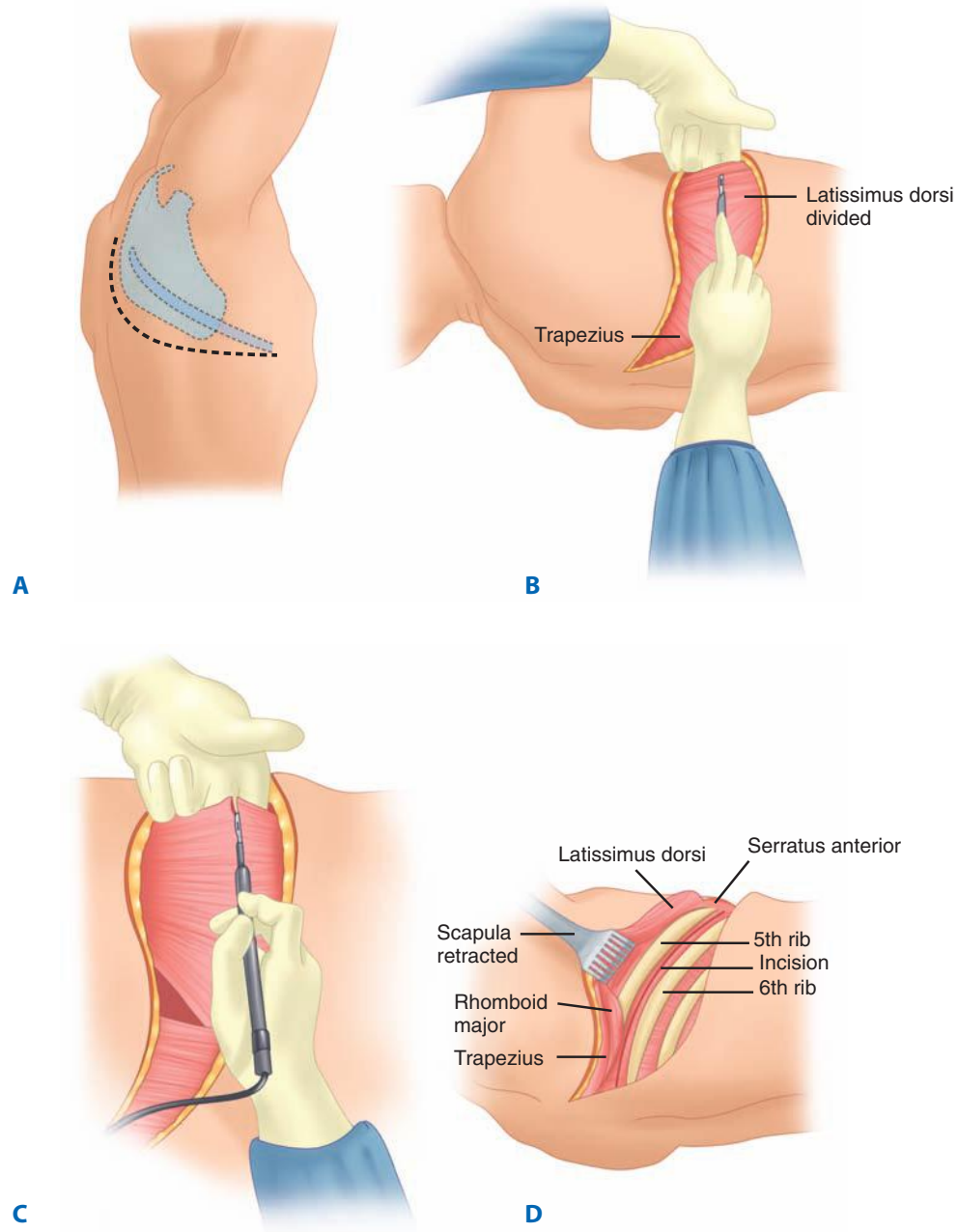


Figure 19-28. The posterolateral thoracotomy incision. **A.** Skin incision from the anterior axillary line to the lower extent of the scapula tip. **B** and **C.** Division of the latissimus dorsi and shoulder girdle musculature. **D.** The pleural cavity is entered after dividing the intercostal muscles along the lower margin of the interspace, taking care not to injure the neurovascular bundle lying below each rib.

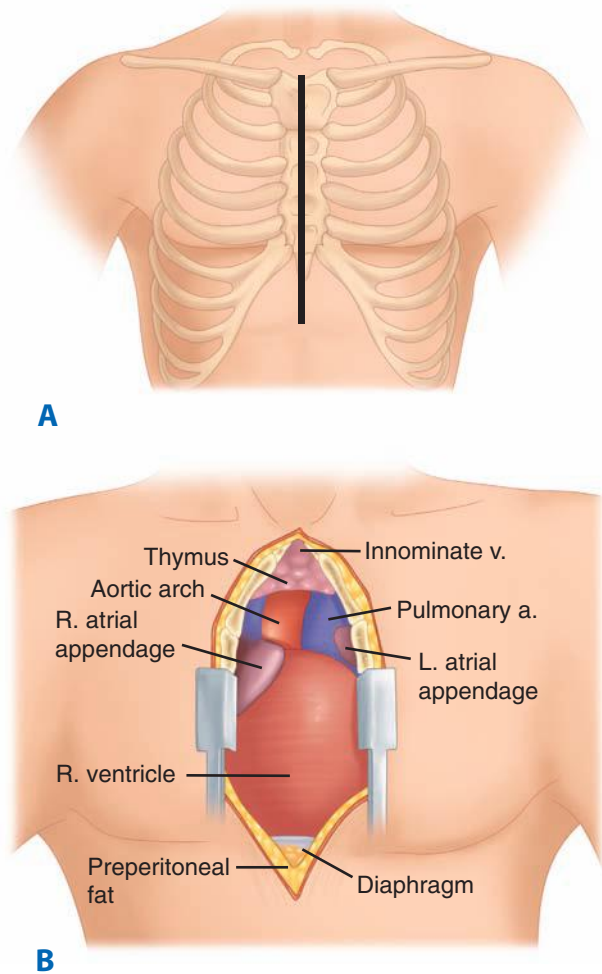


Figure 19-29. The median sternotomy incision. **A.** Skin incision from the suprasternal notch to the xiphoid process. **B.** Exposure of the pleural space. a. = artery; v. = vein.

for pneumo- or hemothorax (e.g., after VATS sympathectomy), a chest tube is unnecessary. After chest tube placement, the lung is re-expanded with positive-pressure ventilation. There are two reasons for the use of pleural tubes in this setting: first, the tube allows evacuation of air if an air leak is present; second, blood and pleural fluid can be drained, thereby preventing accumulation within the pleural space that would compromise the patient's respiratory status. The tube is removed when the air leak is resolved and when the volume of drainage decreases below an acceptable level over 24 hours.

Historically, many surgeons have somewhat arbitrarily required less than 150 mL of drainage volume over 24 hours prior to removing a chest tube to minimize risk of reaccumulation. The pleural lymphatics, however, can absorb up to 0.40 mL/kg per hour in a healthy individual, which may be as much as 500 mL over a 24-hour period. In fact, studies have shown that pleural tubes can be removed after VATS lobectomy or thoracotomy with 24-hour drainage volumes as high as 400 mL, without subsequent development of pleural effusions.¹⁰³ It is our current practice to remove chest tubes with 24-hour outputs of 400 mL or less after lobectomy or lesser pulmonary resections. In settings where normal pleural fluid dynamics have been altered, such as malignant pleural effusion, pleural space

infections or inflammation, and pleurodesis, strict adherence to a volume requirement before tube removal is appropriate (typically 100–150 mL over 24 hours).

For operations involving lung resection or parenchymal injury, suction levels of -20 cm H_2O are routinely used to eradicate residual air spaces and to control postoperative parenchymal air leaks for the first 12 to 24 hours. The following day, however, the decision to continue suction or place the patient to water seal (off suction) must be made. Applying suction to an air leak has been shown to prolong the duration of the air leak and extend the time frame during which tube thoracostomy is needed.¹⁰⁴ The main guidelines for the continued use of suction if an air leak is present depend on the expansion of the remaining lung as determined by CXR. If the lung is well-expanded, the chest tube can remain to water seal drainage. If an undrained pneumothorax is present on CXR, the chest tube and its attached tubing should be examined to ensure that the chest tube is patent and the attached tubing is not kinked or mechanically obstructed, such as occurs when the patient is lying on the tube. If the tube is a small caliber tube (aka pigtail catheter), it should be flushed with sterile saline through a three-way stopcock that has been cleaned with alcohol because these tubes tend to become clogged with fibrin. These catheters are also prone to kinking at the insertion site into the skin. Once the surgeon has confirmed that the chest tube is patent, the patient is asked to voluntarily cough or perform the Valsalva maneuver. This maneuver increases the intrathoracic pressure and will push air that is contained within the hemithorax out of the chest tube. During the voluntary cough, the fluid level in the water seal chamber should move up and down with the cough and with deep respiration, reflecting the pleural pressure changes occurring with these maneuvers. A stationary fluid level implies either a mechanical blockage (e.g., due to external tube compression or to a clot/debris within the tube) or pleurodesis of the pleural space. If bubbles pass through the water seal chamber, an air leak is presumed. If the leak is significant enough to induce atelectasis or collapse of the lung during use of water seal, suction should be used to achieve lung re-expansion.

Pain Control. Good pain control after intrathoracic procedures is critical; it permits the patient to actively clear and manage secretions and promotes ambulation and a feeling of well-being. The most common techniques of pain management are epidural, paravertebral, and intravenous. Epidural catheters are commonly used, although we prefer to use paravertebral catheters in our center. To maximize efficacy, epidural catheters should be inserted at about the T6 level, roughly at the level of the scapular tip. Lower placement risks inadequate pain control, and higher placement may provoke hand and arm numbness. Typically, combinations of fentanyl at 0.3 μ g/mL with either bupivacaine (0.125%) or ropivacaine (0.1%) are used. Ropivacaine has less cardiotoxicity than bupivacaine; thus, the potential for refractory complete heart block, in the case of inadvertent intravenous injection, is significantly less with ropivacaine. Paravertebral blocks can be placed using the same epidural catheter kit 2.5 cm lateral to the spinous process at T4 to T6. Combinations of narcotic and topical analgesia are then infused as with the epidural catheter.

When properly placed, a well-managed epidural can provide outstanding pain control without significant systemic sedation.¹⁰⁵ Thoracic epidurals do not commonly cause urinary retention, although a low thoracic epidural may block the sensory fibers to the bladder. Motor function, however, remains

intact. In some patients who are having difficulty voiding, it may be possible to avoid Foley catheterization by simply reminding the patient to void on a regular basis. In male patients with voiding difficulty prior to surgery, urinary catheterization may be required. In addition, the use of local anesthetics may cause sympathetic outflow blockade, leading to vasodilation and hypotension often requiring intravenous vasoconstrictors (an α -agonist such as phenylephrine) and/or fluid administration. In such circumstances, fluid administration for hypotension may be undesirable in pulmonary surgery patients, particularly after pneumonectomy. Paravertebral catheters provide equivalent pain control with less effect on hemodynamics.¹⁰⁶

Alternatively, intravenous narcotics via patient-controlled analgesia can be used, often in conjunction with ketorolac and intravenous Tylenol. Dosing must be titrated to balance the degree of pain relief with the degree of sedation. Oversedated patients are as ominous as patients without adequate pain control, because of the significant risk of secretion retention, atelectasis/pneumonia, and pulmonary aspiration. These concerns are particularly relevant in elderly patients who should be carefully assessed for aspiration risk when ordered for dietary advancement. Proper pain control with intravenous narcotics requires a carefully regulated balance between pain relief and sedation; maximizing the benefits of pain control while minimizing these very real and potentially life-threatening complications.

Whether on epidural, paravertebral, or intravenous pain control, the patient is typically transitioned to oral pain medication on the third or fourth postoperative day. During both the parenteral and oral phase of pain management, a standardized regimen of stool softeners and laxatives is advisable in order to prevent severe constipation.

Respiratory Care. The best respiratory care is achieved when the patient is able to deliver an effective cough to clear secretions and results from the commitment and proper training of all involved healthcare providers. The process begins preoperatively, with clear instructions on using pillows (or other support techniques) over the wound and then applying pressure. Postoperatively, proper pain control (as outlined earlier) is essential, without oversedation. Daily morning rounds should include a careful assessment of the patient's pulmonary status, reminders to the patient and family about the importance of coughing and deep breathing, including use of adjunctive respiratory equipment if ordered, and mobilization of the patient. Early transition to a chair and to ambulation is the best respiratory therapy and should be strongly encouraged. When available, physical and/or cardiopulmonary rehabilitation services are vital additional members of the care team.

In patients whose pulmonary function is significantly impaired preoperatively, generating an effective cough postoperatively may be nearly impossible. In this setting, routine nasotracheal suctioning can be employed, but is uncomfortable for the patient. A better alternative is placement of a percutaneous transtracheal suction catheter at the time of surgery. This catheter is well-tolerated by most patients and allows regular and convenient suctioning.

Postoperative Complications

Postoperative complications after pulmonary resection range from minor to life-threatening. Strict attention to volume status, early and aggressive pulmonary toilet, and good pain control can reduce the risk of most complications, but does not completely eliminate them, even in centers of excellence.

The most devastating complication after pulmonary resection is postpneumonectomy pulmonary edema, which occurs in 1% to 5% of patients undergoing pneumonectomy and more often after right compared to left pneumonectomy. Clinically, symptoms of respiratory distress manifest hours to days after surgery. Radiographically, diffuse interstitial infiltration or frank alveolar edema is seen. The pathophysiologic causes are related to factors that increase permeability and filtration pressure and decrease lymphatic drainage from the affected lung. Judicious use of intravenous fluids perioperatively, including use of vasopressors rather than fluid boluses for hypotension intraoperatively and postoperatively, is critical to minimizing the risk of this syndrome. Treatment consists of ventilatory support, fluid restriction, and diuretics. Extracorporeal membrane oxygenation may be life-saving in centers where this option is available. The syndrome reportedly has a nearly 100% mortality rate despite aggressive therapy.

Other postoperative complications include air leak and bronchopleural fistula. Although these are two very different problems, distinguishing between them may be difficult. Postoperative air leaks are common after pulmonary resection, particularly in patients with emphysematous lung, because the fibrosis and destroyed blood supply impairs healing of surface injuries. Prolonged air leaks (i.e., those lasting >5 days) may be treated by diminishing or discontinuing suction (if used), by continuing chest drainage, or by instilling a pleurodesis agent, usually doxycycline or talcum powder, which will cause pleurodesis of the lung within the chest cavity and minimize the possible collapse of the lung due to persistent air leak. This is useful only in patients in whom full lung expansion is achieved, either with suction or on water seal, as patients with a persistent pneumothorax on CXR will not have adequate lung-to-parietal pleural apposition to achieve adequate pleurodesis.

If the leak is moderate to large, a high index of suspicion for bronchopleural fistula from the resected bronchial stump should be maintained, particularly if the patient is immunocompromised or had induction chemotherapy and/or radiation therapy. If a bronchopleural fistula is suspected, flexible bronchoscopy is performed to evaluate the bronchial stump. Management options include continued prolonged chest tube drainage, reoperation, and reclosure (with stump reinforcement with an intercostal muscle flap or a pedicled serratus muscle flap). If the fistula is very small (<4 mm), bronchoscopic fibrin glue application has been used successfully to seal the hole in some patients. Patients often have concomitant empyema, and open drainage may be necessary.

Spontaneous Pneumothorax

Spontaneous pneumothorax is secondary to intrinsic abnormalities of the lung and can be classified as primary and secondary. Primary spontaneous pneumothorax is defined as a spontaneous pneumothorax without underlying lung disease. The most common cause is rupture of an apical subpleural bleb. The cause of these blebs is unknown, but they occur more frequently in smokers and males, and they tend to predominate in young postadolescent males with a tall thin body habitus. Treatment is generally chest tube insertion with water seal. If a leak is present and persists for greater than 3 days, thorascopic management (i.e., bleb resection with pleurodesis by talc or pleural abrasion) is performed. Recurrences or complete lung collapse with the first episode are generally indications for thorascopic intervention.¹⁰⁷ Additional indications for intervention on the first

episode include occupational hazards such as air travel, deep-sea diving, or travel to remote locations. CT findings of multiple small bullae or a large bleb are associated with an increased risk of recurrent pneumothorax.¹⁰⁸ Many surgeons are now using screening CT scan to recommend VATS bleb resection with pleurodesis for first-episode spontaneous pneumothorax.

Secondary spontaneous pneumothorax occurs in the setting of underlying lung disease, such as emphysema (rupture of a bleb or bulla), cystic fibrosis, acquired immunodeficiency syndrome (AIDS), metastatic cancer (especially sarcoma), asthma, lung abscess, and occasionally primary lung cancer. Catamenial pneumothorax, a rare but interesting cause of spontaneous pneumothorax in women in their second and third decades, occurs within 72 hours of the onset of menses and is possibility related to endometriosis. Management of pneumothorax in these circumstances is similar to that of primary spontaneous pneumothorax in that drainage and lung re-expansion are required. Additional therapy, however, is often tied to therapy of the specific disease process and may involve lung resection, thoracoscopic pleurectomy, or talc pleurodesis.

Pulmonary Infections

Lung Abscess. A *lung abscess* is a localized area of pulmonary parenchymal necrosis caused by an infectious organism; tissue destruction results in a solitary or dominant cavity measuring at least 2 cm in diameter. Less often, there may be multiple, smaller cavities (<2 cm). In that case, the infection is typically referred to as a necrotizing pneumonia. An abscess that is present for more than 6 weeks is considered chronic.

Based on the etiology (Table 19-17), lung abscesses are further classified as primary or secondary. A primary lung abscess occurs, for example, in immunocompromised patients, as a result of highly virulent organisms inciting a necrotizing pulmonary infection, or in patients who have a predisposition to aspirate oropharyngeal or gastrointestinal secretions. A secondary lung abscess occurs in patients with an underlying condition such as a partial bronchial obstruction, a lung infarct, or adjacent suppurative infections (subphrenic or hepatic abscesses).¹⁰⁹

Pathogenesis. Lung abscesses result when necrotizing microorganisms infect the lower respiratory tract via inhalation of aerosolized particles, aspiration of oropharyngeal secretions, or hematogenous spread from distant sites. Direct extension from a contiguous site is less frequent. Most primary lung abscesses are suppurative bacterial infections secondary to aspiration. Risk factors for pulmonary aspiration include advanced age, conditions of impaired consciousness, suppressed cough reflex, dysfunctional esophageal motility, laryngopharyngeal reflux disease, and centrally acting neurologic diseases (e.g., stroke). At the time of aspiration, the composition of the oropharyngeal flora determines the etiologic organisms. With increasing use of proton pump inhibitors to suppress acid secretion in the stomach, the oropharyngeal flora has shifted and the risk of developing bacterial lung infections after an aspiration event has increased.¹¹⁰ Secondary lung abscesses occur most often distal to an obstructing bronchial carcinoma. Infected cysts or bullae are not considered true abscesses.

Microbiology. Normal oropharyngeal secretions contain many more *Streptococcus* species and more anaerobes (approximately 1×10^8 organisms/mL) than aerobes (approximately 1×10^7 organisms/mL). Pneumonia that follows from aspiration, with or without abscess development, is typically polymicrobial.

Table 19-17

Causes of lung abscess

- I. Primary
 - A. Necrotizing pneumonia
 1. *Staphylococcus aureus*, *Klebsiella*, *Pseudomonas*, *Mycobacterium*
 2. *Bacteroides*, *Fusobacterium*, *Actinomyces*
 3. *Entamoeba*, *Echinococcus*
 - B. Aspiration pneumonia
 1. Anesthesia
 2. Stroke
 3. Drugs or alcohol
 - C. Esophageal disease
 1. Achalasia, Zenker's diverticulum, gastroesophageal reflux
 - D. Immunodeficiency
 1. Cancer (and chemotherapy)
 2. Diabetes
 3. Organ transplantation
 4. Steroid therapy
 5. Malnutrition
- II. Secondary
 - A. Bronchial obstruction
 1. Neoplasm
 2. Foreign body
 - B. Systemic sepsis
 1. Septic pulmonary emboli
 2. Seeding of pulmonary infarct
 - C. Complication of pulmonary trauma
 1. Infection of hematoma or contusion
 2. Contaminated foreign body or penetrating injury
 - D. Direct extension from extraparenchymal infection
 1. Pleural empyema
 2. Mediastinal, hepatic, subphrenic abscess

Source: Adapted with permission from Rusch VW, et al. Chest wall, pleura, and mediastinum. In: Schwartz SI, et al, eds. *Principles of Surgery*. 7th ed. New York: McGraw-Hill; 1999:735.

An average of two to four isolates present in large numbers have been cultured from lung abscesses sampled percutaneously. Overall, at least 50% of these infections are caused by purely anaerobic bacteria, 25% are caused by mixed aerobes and anaerobes, and 25% or fewer are caused by aerobes only. In nosocomial pneumonia, 60% to 70% of the organisms are gram-negative bacteria, including *Klebsiella pneumoniae*, *Haemophilus influenzae*, *Proteus* species, *Pseudomonas aeruginosa*, *Escherichia coli*, *Enterobacter cloacae*, and *Eikenella corrodens*. Immunosuppressed patients may develop abscesses because of the usual pathogens as well as less virulent and opportunistic organisms such as *Salmonella* species, *Legionella* species, *Pneumocystis carinii*, atypical mycobacteria, and fungi.

Clinical Features and Diagnosis. The typical presentation may include productive cough, fever (>38.9°C), chills, leukocytosis (>15,000 cells/mm³), weight loss, fatigue, malaise, pleuritic chest pain, and dyspnea. Lung abscesses may also present in a more indolent fashion, with weeks to months of cough, malaise, weight loss, low-grade fever, night sweats, leukocytosis, and anemia. After aspiration pneumonia, 1 to 2 weeks typically elapse before cavitation occurs; 40% to 75% of such patients produce putrid, foul-smelling sputum. Severe complications

such as massive hemoptysis, endobronchial spread to other portions of the lungs, rupture into the pleural space and development of pyopneumothorax, or septic shock and respiratory failure are rare in the modern antibiotic era. The mortality rate is about 5% to 10%, except in the presence of immunosuppression, where rates range from 9% to 28%.

The CXR is the primary tool for diagnosing a lung abscess (Fig. 19-30). Its distinguishing characteristic is a density or mass with a relatively thin-walled cavity. An air-fluid level observed within the abscess indicates communication with the tracheobronchial tree. CT scan of the chest clarifies the diagnosis when CXR is equivocal and identifies endobronchial obstruction and/or an associated mass and other pathologic anomalies. A cavitating lung carcinoma is frequently mistaken for a lung abscess. Differential diagnosis also includes loculated or interlobar empyema, infected lung cysts or bullae, tuberculosis, bronchiectasis, fungal infections, and noninfectious inflammatory conditions (e.g., Wegener's granulomatosis).

Ideally, the specific etiologic organism is identified before antibiotic administration. Bronchoscopy, which is essential to rule out endobronchial obstruction due to tumor or foreign body, is ideal for obtaining uncontaminated cultures using bronchoalveolar lavage. Culture samples can also be obtained by percutaneous, transthoracic FNA under ultrasound or CT guidance. Routine sputum cultures are often of limited usefulness because of contamination with upper respiratory tract flora.

Actinomycosis and nocardiosis, although rare, are particularly virulent infections associated with lung abscess, and diagnosis can be difficult.¹¹¹ Both frequently masquerade as other clinical syndromes; thus, it is important for the surgeon to keep these bacteria in mind when considering the differential diagnosis for cavitary lung lesions. *Actinomyces*, a normal oropharyngeal bacterium, causes extensive pulmonary damage as the result of aspiration. Actinomycosis lung infection typically begins as acute pneumonitis after an aspiration. The symptoms mimic pulmonary tuberculosis, including chronic cough, night sweats, weight loss, and hemoptysis. Ongoing infection leads to chronic inflammation and fibrosis; cavitation occurs due to destruction of the pulmonary tissues. Without treatment, the infection continues to destroy surrounding structures, which can result in fistula formation into the adjacent structures, including the adjacent lung, interlobar fissures, pleural space, chest wall, and mediastinum. *Actinomyces israelii* is the most common cause of disease among the *Actinomyces* species. Nocardiosis is also a rare opportunistic infection that usually occurs in an immunocompromised host (human immunodeficiency virus [HIV] or cancer patients) and causes both local and systemic suppurative infections. The most common site is pulmonary, caused by *Nocardia asteroides* in 90% of cases; one series, however, reported a high prevalence of the particularly virulent species, *Nocardia farcinica*. Similar to actinomycosis, infection is slowly progressive, with weight loss, fatigue, cough, and hemoptysis. An acute pulmonary infection is common, with necrotizing pneumonia and cavitation or slowly enlarging pulmonary nodule(s). In some cases, empyema also develops.

Management of Lung Abscess. Systemic antibiotics directed against the causative organism represent the mainstay of therapy. The duration of antimicrobial therapy varies from 3 to 12 weeks for necrotizing pneumonia and lung abscess. It is likely best to treat until the cavity is resolved or until serial radiographs show significant improvement. Parenteral therapy is generally used until the patient is afebrile and able to demonstrate consistent

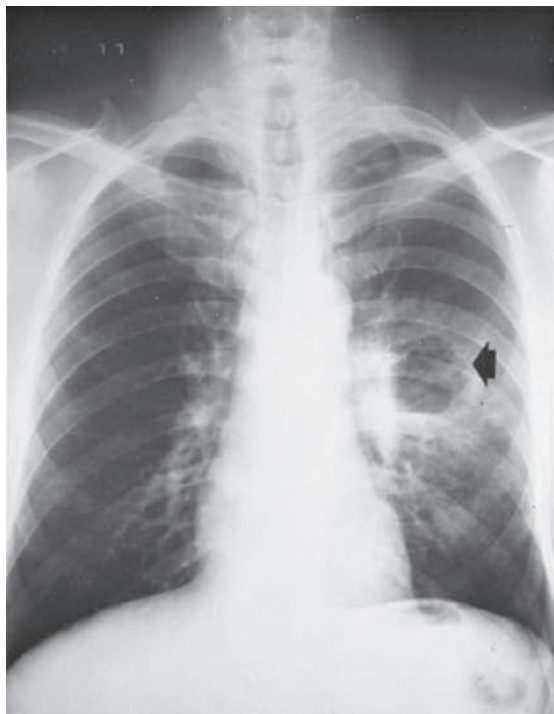
enteral intake. Oral therapy can then be used to complete the course of therapy. For community-acquired infections secondary to aspiration, likely pathogens are oropharyngeal streptococci and anaerobes. Penicillin G, ampicillin, and amoxicillin are the main therapeutic agents, but a β -lactamase inhibitor or metronidazole should be added to cover the increasing prevalence of gram-negative anaerobes that produce β -lactamase. Clindamycin is also a primary therapeutic agent. For hospital-acquired infections, *Staphylococcus aureus* and aerobic gram-negative bacilli are common organisms of the oropharyngeal flora. Piperacillin or ticarcillin with a β -lactamase inhibitor (or equivalent alternatives) provide better coverage of likely pathogens.

Surgical drainage of lung abscesses is uncommon since drainage usually occurs spontaneously via the tracheobronchial tree. Indications for intervention are listed in Table 19-18. Drainage and resection may be required for actinomycosis and nocardiosis; diagnosis is often delayed because the bacteria are difficult to culture; invasion of the infection into surrounding structures is, therefore, common. Once identified, long-term antibiotics (months to years) are typically required along with drainage, debridement, and resection as needed. While penicillin derivatives are effective against most *Actinomyces* species, the infections are typically polymicrobial, and broad-spectrum parenteral antibiotics may be required. *Nocardia* species, in contrast, are highly variable; specific identification of the infecting species with antibiotic sensitivities is needed to direct appropriate therapy. Evaluation for malignant spread, particularly to the brain, is also required in the management of nocardiosis, as systemic dissemination occurs early and frequently.

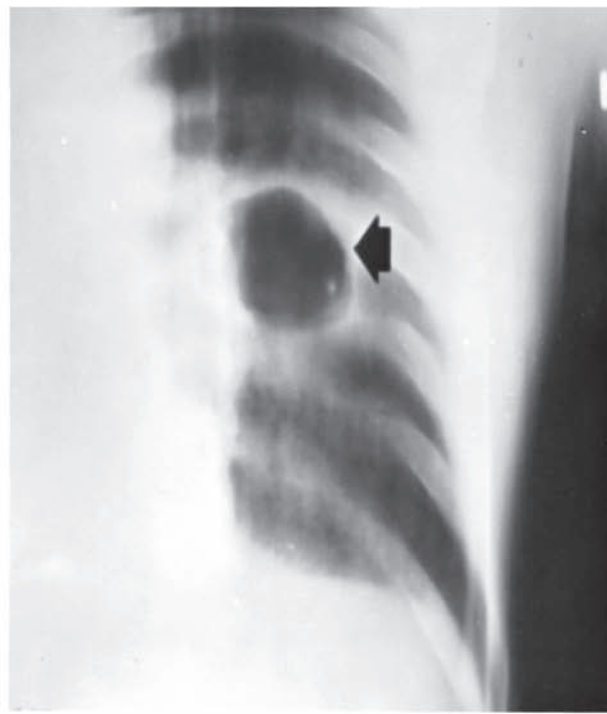
External drainage may be accomplished with tube thoracostomy, percutaneous drainage, or surgical cavernostomy. The choice between tube thoracostomy versus radiographically guided catheter placement depends on the treating physician's preference and the availability of interventional radiology. Surgical resection is required in fewer than 10% of lung abscess patients. Lobectomy is the preferred intervention for bleeding from a lung abscess or pyopneumothorax. An important intraoperative consideration is to protect the contralateral lung with a double-lumen tube, bronchial blocker, or contralateral main stem intubation. Surgical treatment has a 90% success rate, with an associated mortality of 1% to 13%.

Bronchiectasis. Bronchiectasis is defined as a pathologic and permanent dilation of bronchi with bronchial wall thickening. This condition may be localized to certain bronchial segments, or it may be diffuse throughout the bronchial tree, typically affecting the medium-sized airways. Overall, this is a rare clinical entity in the United States with a prevalence of less than 1 in 10,000, although the incidence has increased in recent years and noncystic fibrosis-related bronchiectasis is now thought to affect 27.5 out of every 10,000 persons over age 75.

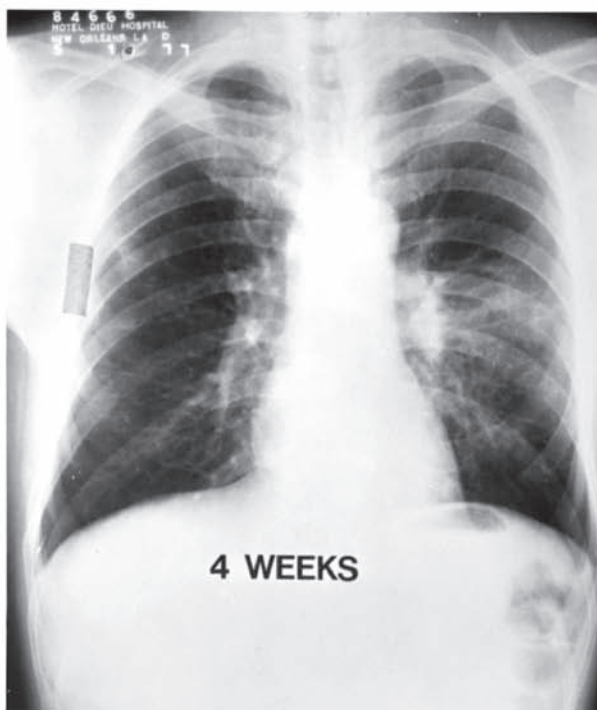Pathogenesis. Development of bronchiectasis can be attributed to either congenital or acquired causes. The principal congenital diseases that lead to bronchiectasis include cystic fibrosis, primary ciliary dyskinesia, and immunoglobulin deficiencies (e.g., selective IgA deficiency). Congenital causes tend to produce a diffuse pattern of bronchial involvement. Acquired causes are categorized broadly as infectious and inflammatory. Bronchial obstruction from cancer, inhaled objects, extrinsic airway compression, or inspissated sputum promotes localized infection and subsequent medium airway destruction. Diffuse pneumonic processes from pathogens including necrotizing bacterial



A



B



C

Figure 19-30. Lung abscess resulting from emesis and aspiration after an alcoholic binge. **A.** Chest x-ray showing an abscess cavity in the left upper lobe. **B.** A coronal tomogram highlights the thin wall of the abscess. **C.** Healing of the abscess cavity after 4 weeks of antibiotic therapy and postural drainage.

Table 19-18

Indications for surgical drainage procedures for lung abscesses

1. Failure of medical therapy
2. Abscess under tension
3. Abscess increasing in size during appropriate treatment
4. Contralateral lung contamination
5. Abscess >4–6 cm in diameter
6. Necrotizing infection with multiple abscesses, hemoptysis, abscess rupture, or pyopneumothorax
7. Inability to exclude a cavitating carcinoma

pneumonia, pertussis and measles pneumonia, severe influenza, or varicella pneumonia can lead to widespread bronchiectasis. Chronic granulomatous disease, immunodeficiency disorders, and hypersensitivity disorders can also lead to diffuse bronchiectasis.

Noninfectious causes of bronchiectasis include inhalation of toxic gases such as ammonia, which results in severe and destructive airway inflammatory responses. Allergic bronchopulmonary aspergillosis, Sjögren's syndrome, and α_1 -antitrypsin deficiency are some additional examples of presumed immunologic disorders that may be accompanied by bronchiectasis.

In addition, recent studies have suggested an association between chronic gastroesophageal reflux disease, acid suppression, and nontuberculous mycobacterial infection with bronchiectasis.^{112,113} This interaction is thought to be related to chronic aspiration of colonized gastric secretions in the setting of acid suppression; while not proven to be causative, these findings suggest a role for gastroesophageal reflux disease in the pathogenesis of bronchiectasis.

The process shared by all causes of bronchiectasis is impairment of airway defenses or deficits in immunologic mechanisms, which permit bacterial colonization and chronic infection. Common organisms include *Haemophilus* species (55%), *Pseudomonas* species (26%), and *Streptococcus pneumoniae* (12%).¹¹⁴ Both the bacterial organisms and the inflammatory cells recruited to thwart the bacteria elaborate proteolytic and oxidative molecules, which progressively destroy the muscular and elastic components of the airway walls; those components are then replaced by fibrous tissue. Thus chronic airway inflammation is the essential pathologic feature of bronchiectasis. The dilated airways are usually filled with thick purulent material; more distal airways are often occluded by secretions or obliterated by fibrous tissue. Bronchial wall vascularity increases, bronchial arteries become hypertrophied, and abnormal anastomoses form between the bronchial and pulmonary arterial circulation.

There are three principal types of bronchiectasis, based on pathologic morphology: cylindrical—uniformly dilated bronchi; varicose—an irregular or beaded pattern of dilated bronchi; and saccular (cystic)—peripheral balloon-type bronchial dilation. The saccular type is the most common after bronchial obstruction or infection (Fig. 19-31).

Clinical Manifestations and Diagnosis. Typical symptoms are a daily persistent cough and purulent sputum production; the quantity of daily sputum production (10 mL to >150 mL) correlates with disease extent and severity. Other patients

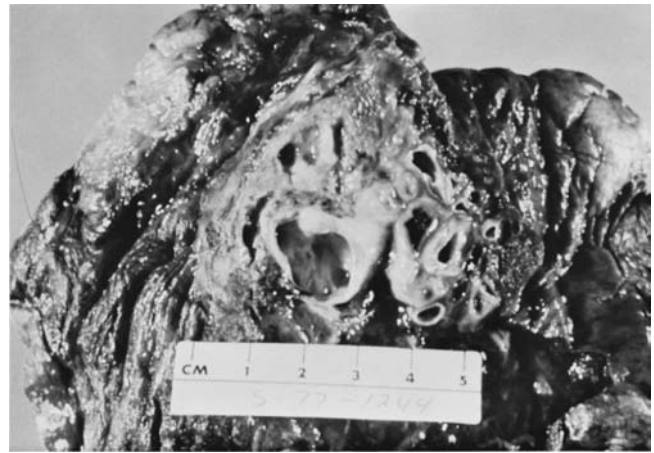

Figure 19-31. Multiple cystic-type bronchiectatic cavities can be seen on a cut section of right lower lobe lung.

may appear asymptomatic or have a dry nonproductive cough (“dry bronchiectasis”). These patients are prone to have involvement of the upper lobes. The clinical course is characterized by progressive symptoms and respiratory impairment. Increasing resting and exertional dyspnea are the result of progressive airway obstruction. Acute exacerbations may be triggered by viral or bacterial pathogens. Bleeding attributable to chronically inflamed, friable airway mucosa causes increasingly more frequent hemoptysis with disease progression. Massive bleeding may result from erosion of the hypertrophied bronchial arteries.

Both mild and severe forms of bronchiectasis are readily demonstrated with chest CT scanning because it provides a highly detailed, cross-sectional view of bronchial architecture. CXRs, although less sensitive, may reveal characteristic signs of bronchiectasis such as lung hyperinflation, bronchiectatic cysts, and dilated, thick-walled bronchi forming track-like patterns radiating from the lung hila. Sputum culture may identify characteristic pathogens. Sputum acid-fast bacillus smears and cultures should be performed to evaluate for the presence of nontuberculous mycobacteria, which is common in this setting. Spirometry provides an assessment of the severity of airway obstruction and can be followed to track the course of disease.

Management of Bronchiectasis. Standard therapy includes optimizing airway clearance, use of bronchodilators to reverse any airflow limitation, and correction of reversible underlying causes whenever possible.¹¹⁵ Chest physiotherapy based on vibration, percussion, and postural drainage is widely accepted, although randomized trials demonstrating efficacy are lacking. Acute exacerbations should be treated with a 2- to 3-week course of broad-spectrum intravenous antibiotics tailored to culture and sensitivity profiles, followed by an oral regimen; this will result in a longer-lasting remission.

Macrolide antibiotics have been shown to decrease sputum production, inhibit cytokine release, and inhibit neutrophil adhesion and formation of reactive oxygen species. They also inhibit migration of *Pseudomonas*, disrupt biofilm, and prevent release of virulence factors.¹¹⁶ While macrolide therapy does appear to be efficacious, it is important to remember that macrolides have significant activity against nontuberculous mycobacteria, and widespread prophylactic use for patients with bronchiectasis may lead to multidrug-resistant nontuberculous mycobacterial species. It has also been suggested that inhaled antibiotics, such

as tobramycin and colistin, improve rates of bacterial clearance and slow the decline in pulmonary function associated with bronchiectasis, but large, randomized trials showing overall clinical benefit have not yet been published.^{117,118}

In addition to antibiotics, daily nebulized hypertonic saline appears to be effective. A recent randomized crossover study comparing lung function and quality of life has shown that 7% normal saline, compared to isotonic saline, results in a statistically significant 15% increase in FEV₁ and an 11% increase in forced vital capacity (compared to 1.8% and 0.7%, respectively, with isotonic saline). Antibiotic use and emergency room utilization were significantly decreased; from this, hypertonic saline appears to be a reasonable adjunct to maintaining quality of life and decreasing exacerbations by reducing sputum volume, improving mucociliary clearance, and slowing the decline in lung function.¹¹⁹ Studies supporting mucolytics such as DNase and N-acetylcysteine for non-cystic fibrosis bronchiectasis have shown either no change or a worsening of pulmonary status and require further study in the non-cystic fibrosis population.

Surgical resection of a localized bronchiectatic segment or lobe, preserving as much functional lung as possible, may benefit patients with refractory symptoms while on maximal medical therapy. Multifocal disease must be excluded before any attempt at surgery; any uncorrectable predisposing factor (e.g., ciliary dyskinesia) must also be excluded. Patients with end-stage lung disease from bronchiectasis may be potential candidates for a bilateral lung transplant. Surgical resection is also indicated in patients with significant hemoptysis, although bronchial artery embolization is the preferred first option. Antireflux surgery may also prove beneficial in patients with chronic aspiration, but further studies are required. It is particularly important to recognize that antireflux surgery in patients with severe underlying pulmonary dysfunction has higher risk for perioperative adverse outcomes than in the general population. It should be undertaken only by very experienced surgeons with direct involvement of the pulmonary medicine physicians to minimize postoperative pulmonary compromise.

Mycobacterial Infections

Epidemiology. Tuberculosis is a widespread problem that affects nearly one third of the world's population. Between 8.3 and 9 million new cases of tuberculosis and 12 million prevalent cases (range 10–13 million) were estimated worldwide in 2011 according to the World Health Organization. Only 10,521 new cases were reported to the World Health Organization in the United States in 2011. HIV infection is the strongest risk factor for developing active tuberculosis. The elderly, minorities, and recent immigrants are the most common populations to have clinical manifestations of infection, yet no age group, sex, or race is exempt from infection. In most large urban centers, reported cases of tuberculosis are more numerous among the homeless, prisoners, and drug-addicted populations. Immunocompromised patients additionally contribute to an increased incidence of tuberculosis infection, often developing unusual systemic as well as pulmonary manifestations.¹²⁰ As compared with past decades, presently surgical intervention is required more frequently in patients with multidrug-resistant tuberculosis organisms (MDRTB) who do not respond to medical treatment and in selected patients with nontuberculous mycobacterial infections (NTM).

Microbiology. Mycobacterial species are obligate aerobes. They are primarily intracellular parasites with slow rates of growth. Their defining characteristic is the property of acid-fastness,

which is the ability to withstand decolorization by an acid-alcohol mixture after being stained. *Mycobacterium tuberculosis* is the highly virulent bacillus of this species that produces invasive infection among humans, principally pulmonary tuberculosis.¹²¹ Infections with *M. tuberculosis* are primary when they are the first infection in a previously unsensitized host and secondary or postprimary when reactivation of a previous infection occurs.

Because of improper application of antimycobacterial drugs and multifactorial interactions, MDRTB organisms, defined by their resistance to at least two of the first-line antimycobacterial drugs (isoniazid and rifampin), have emerged. It is estimated that 1.4% of new tuberculosis cases and 7.6% of retreatment cases in the United States in 2011 are from MDRTB organisms. In addition, there is another rare variant termed *extensively drug-resistant tuberculosis*, which is resistant to isoniazid and rifampin, all fluoroquinolones, and at least one of the injectable second-line drugs (e.g., capreomycin, amikacin, kanamycin). It is estimated that 9% of all MDRTB cases are extensively drug resistant.

The more important NTM organisms include *Mycobacterium kansasii*, *M. avium* and *M. intracellulare* complex (MAC), and *M. fortuitum*. The highest incidence of *M. kansasii* infection is in midwestern U.S. cities among middle-aged males from good socioeconomic surroundings. MAC organisms are important infections in elderly and immunocompromised patient groups. *M. fortuitum* infections are common complications of underlying severe debilitating disease. None of these organisms are as contagious as *M. tuberculosis*.

Pathogenesis and Pathology. The main route of transmission is via airborne inhalation of viable mycobacteria. Three stages of primary infection have been described. In the first stage, alveolar macrophages become infected through ingesting the bacilli. In the second stage, from days 7 to 21, the patient typically remains asymptomatic while the bacteria multiply within the infected macrophages. The third stage is characterized by the onset of cell-mediated immunity (CD4⁺ helper T cells) and delayed-type hypersensitivity. Activated macrophages acquire an increased capacity for bacterial killing. Macrophage death increases, resulting in the formation of a granuloma, the characteristic lesion found on pathologic examination.

Tuberculous granulomas are composed of blood-derived macrophages, degenerating macrophages or epithelioid cells, and multinucleated giant cells (fused macrophages with nuclei around the periphery; also known as Langerhans cells). The low oxygen content of this environment inhibits macrophage function and bacillary growth, with subsequent central caseation as macrophage death occurs. A Ghon complex is a single, small lung lesion that is often the only remaining trace of a primary infection. The primary infection is usually located in the peripheral portion of the middle zone of the lungs.

Reactivation tuberculosis may occur after hydrolytic enzymes liquefy the caseum. Typically, the apical and posterior segments of the upper lobes and the superior segments of the lower lobes are involved. Edema, hemorrhage, and mononuclear cell infiltration are also present. The tuberculous cavity may become secondarily infected with other bacteria, fungi, or yeasts, all of which may contribute to enhanced tissue destruction.

The pathologic changes caused by NTM organisms are similar to those produced by *M. tuberculosis*. *M. intracellulare* complex infections commonly occur, not only in immunocompromised patients, but also in patients with previously damaged lungs. Caseous necrosis is uncommon and is characterized by

clusters of tissue macrophages filled with mycobacteria. It has a poor granulomatous response and confinement of immune cell infiltration to the interstitium and alveolar walls. Cavitory disease is infrequent, although nodules may be noted.

Clinical Presentation and Diagnosis. The clinical course of infection and the presentation of symptoms are influenced by many factors, including the site of primary infection, the stage of disease, and the degree of cell-mediated immunity. About 80% to 90% of tuberculosis patients present with clinical disease in the lungs. In 85% to 90% of these patients, involution and healing occur, leading to a dormant phase that may last a lifetime. The only evidence of tuberculosis infection may be a positive skin reaction to tuberculin challenge or a Ghon complex observed on CXR. Within the first 2 years of primary infection, reactivation may occur in up to 10% to 15% of infected patients. In 80%, reactivation occurs in the lungs; other reactivation sites include the lymph nodes, pleura, and the musculoskeletal system.

After primary infection, pulmonary tuberculosis is frequently asymptomatic. Systemic symptoms of low-grade fever, malaise, and weight loss are subtle and may go unnoticed. A productive cough may develop, usually after tubercle cavitation. Many radiographic patterns can be identified at this stage, including local exudative lesions, local fibrotic lesions, cavitation, bronchial wall involvement, acute tuberculous pneumonia, bronchiectasis, bronchostenosis, and tuberculous granulomas. Hemoptysis often develops from complications of disease such as bronchiectasis or erosion into vascular malformations associated with cavitation. Extrapulmonary involvement is due to hematogenous or lymphatic spread from pulmonary lesions. Virtually any organ can become infected, giving rise to the protean manifestations of tuberculosis. The pleura, chest wall, and mediastinal organs may all be involved. More than one third of immunocompromised patients have disseminated disease, with hepatomegaly, diarrhea, splenomegaly, and abdominal pain.

The definitive diagnosis of tuberculosis requires identification of the mycobacterium in a patient's bodily fluids or involved tissues. Skin testing using purified protein derivative is important for epidemiologic purposes and can help exclude infection in uncomplicated cases. For pulmonary tuberculosis, sputum examination is inexpensive and has a high diagnostic yield. Bronchoscopy with alveolar lavage may also be a useful diagnostic adjunct and has high diagnostic accuracy. Chest CT scan can delineate the extent of parenchymal disease.

Management. Medical therapy is the primary treatment of pulmonary tuberculosis and is often initiated before a mycobacterial pathogen is definitively identified. Combinations of two or more drugs are routinely used in order to minimize resistance, which inevitably develops with only single-agent therapy. A current treatment algorithm is outlined in Fig. 19-32. Generally, therapy lasts about 18 months. The overall response rate is satisfactory in 70% to 80% of patients with *M. kansasii* infection. Surgical intervention is rarely required in the 20% to 30% of patients who are not responsive to medical therapy. In contrast, pulmonary *M. intracellulare* complex infections respond poorly, even to combinations of four or more drugs, and most of the patients will eventually require surgical intervention. Overall, sputum conversion is achieved in only 50% to 80% of NTM infections, and relapses occur in up to 20% of patients.

In the United States, surgical intervention is most often required in order to treat patients with MDRTB organisms

whose lungs have been destroyed and who have persistent thick-walled cavitation.¹²² The indications for surgery related to mycobacterial pulmonary infections are presented in Table 19-19. The governing principle of mycobacterial surgery is to remove all gross disease while preserving any uninvolved lung tissue. Scattered nodular disease may be left intact, given its low mycobacterial burden. Antimycobacterial medications should be given preoperatively (for about 3 months) and continued postoperatively for 12 to 24 months. Overall, more than 90% of patients who were deemed good surgical candidates are cured when appropriate medical and surgical therapy is used.

Pulmonary Fungal Infections. The incidence of fungal infections has increased significantly, with many new opportunistic fungi emerging. This increase is attributed to the growing population of immunocompromised patients (e.g., organ transplant recipients, cancer patients undergoing chemotherapy, HIV patients, and young and elderly patients) who are more likely to become infected with fungi.¹²³ Clinically significant examples include species of *Aspergillus*, *Cryptococcus*, *Candida*, and *Mucor*. Other at-risk patient populations include those who are malnourished, severely debilitated, or diabetic or who have hematologic disorders. Patients receiving high-dose, intensive antibiotic therapies are also susceptible. There are, however, some fungi that are primary or true pathogens, able to cause infections in otherwise healthy patients. Some endemic examples in the United States include species of *Histoplasma*, *Coccidioides*, and *Blastomyces*.¹²⁴

Direct identification of the organism in body exudates or tissues, preferably as growth in culture, provides definitive diagnosis. Serologic testing to identify mycotic-specific antibodies may also be useful. Several new classes of antifungal agents have proven effective against many life-threatening fungi and are less toxic than older agents. In addition, thoracic surgery may be a useful therapeutic adjunct for patients with pulmonary mycoses.

Aspergillosis. The genus *Aspergillus* comprises over 150 species and is the most common cause of mortality due to invasive mycoses in the United States. It is typically acute in onset and life-threatening and occurs in the setting of neutropenia, chronic steroid therapy, or cytotoxic chemotherapy. It can also occur in the general intensive care unit population of critically ill patients, including patients with underlying chronic obstructive pulmonary disease (COPD), postoperative patients, patients with cirrhosis or alcoholism, and postinfluenza patients, without any of these factors present. The species most commonly responsible for clinical disease include *A. fumigatus*, *A. flavus*, *A. niger*, and *A. terreus*. *Aspergillus* is a saprophytic, filamentous fungus with septate hyphae. Spores (2.5–3 µm in diameter) are released and easily inhaled by susceptible patients; because the spores are microns in size, they are able to reach the distal bronchi and alveoli.

Aspergillosis can manifest as one of three clinical syndromes: *Aspergillus* hypersensitivity lung disease, aspergilloma, or invasive pulmonary aspergillosis. Overlap occurs between these syndromes, depending on the patient's immune status.¹²⁵ *Aspergillus* hypersensitivity manifests as a productive cough, fever, wheezing, pulmonary infiltrates, eosinophilia, and elevation of IgE antibodies to *Aspergillus*, whereas aspergilloma (fungal ball) is a matted sphere of hyphae, fibrin, and inflammatory cells that tends to colonize pre-existing intrapulmonary cavities. Grossly, aspergilloma appears as a round or oval, friable,

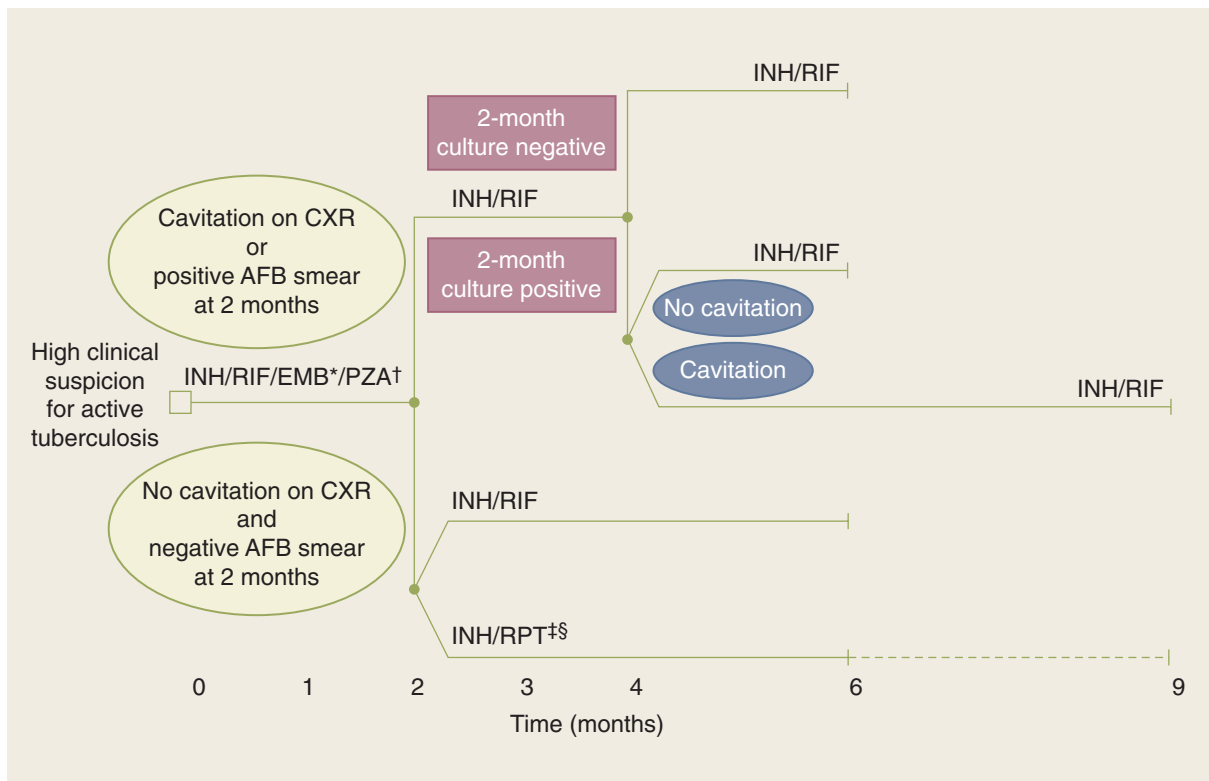


Figure 19-32. Treatment algorithm for tuberculosis. Patients in whom tuberculosis is proven or strongly suspected should have treatment initiated with isoniazid (INH), rifampin (RIF), pyrazinamide (PZA), and ethambutol (EMB) for the initial 2 months. A repeat smear and culture should be performed when 2 months of treatment has been completed. If cavities were seen on the initial chest radiograph (CXR) or the acid-fast bacillus (AFB) smear results are positive at completion of 2 months of treatment, the continuation phase of treatment should consist of INH and RIF daily or twice daily for 4 months to complete a total of 6 months of treatment. If cavitation was present on the initial CXR and the culture results at the time of completion of 2 months of therapy are positive, the continuation phase should be lengthened to 7 months (total of 9 months of treatment). If the patient has HIV infection and the CD4⁺ cell count is <100/μL, the continuation phase should consist of daily or three times weekly INH and RIF. In HIV-uninfected patients with no cavitation on CXR and negative results on AFB smears at completion of 2 months of treatment, the continuation phase may consist of either once weekly INH and rifapentine (RPT) or daily or twice weekly INH and RIF to complete a total of 6 months of treatment (bottom). For patients receiving INH and RPT whose 2-month culture results are positive, treatment should be extended by an additional 3 months (total of 9 months). *EMB may be discontinued when results of drug susceptibility testing indicate no drug resistance. †PZA may be discontinued after it has been taken for 2 months (56 doses). ‡RPT should not be used in HIV-infected patients with tuberculosis or in patients with extrapulmonary tuberculosis. §Therapy should be extended to 9 months if results of 2-month culture are positive. (Reproduced with permission of the American Thoracic Society. Copyright © American Thoracic Society. Blumberg HM, et al. American Thoracic Society/Centers for Disease Control and Prevention/Infectious Diseases Society of America: Treatment of tuberculosis. Am J Respir Crit Care Med. 2003;167:603.)

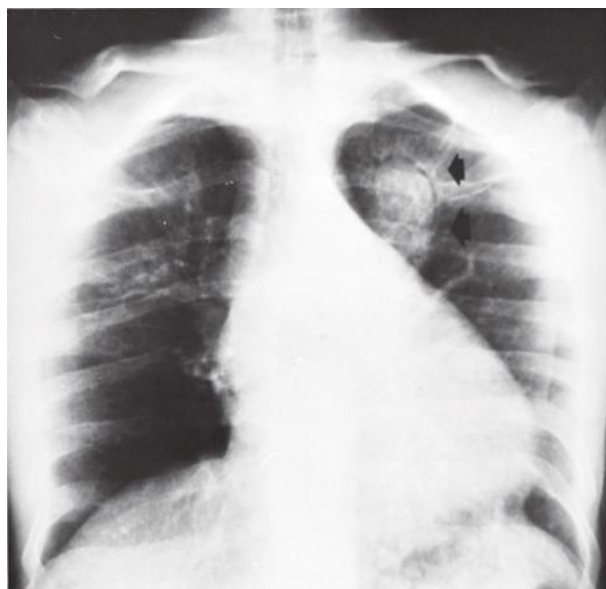Table 19-19

Indications for surgery to treat mycobacterial pulmonary infections

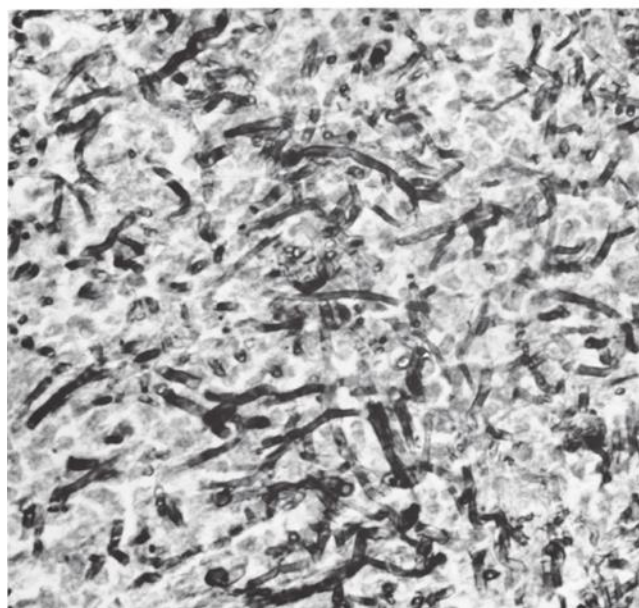
1. Complications resulting from previous thoracic surgery to treat tuberculosis
2. Failure of optimized medical therapy (e.g., progressive disease, lung gangrene, or intracavitary aspergillosis superinfection)
3. Need for tissue acquisition for definitive diagnosis
4. Complications of pulmonary scarring (e.g., massive hemoptysis, cavernomas, bronchiectasis, or bronchostenosis)
5. Extrapulmonary thoracic involvement
6. Pleural tuberculosis
7. Nontuberculous mycobacterial infection

gray (or red, brown, or even yellow), necrotic-looking mass (Fig. 19-33). This form is the most common presentation of non-invasive pulmonary aspergillosis. The most common symptoms are hemoptysis, chronic and productive cough, clubbing, malaise, or weight loss. CXR can suggest the diagnosis by the finding of a crescentic radiolucency above a rounded radiopaque lesion (Monad sign).

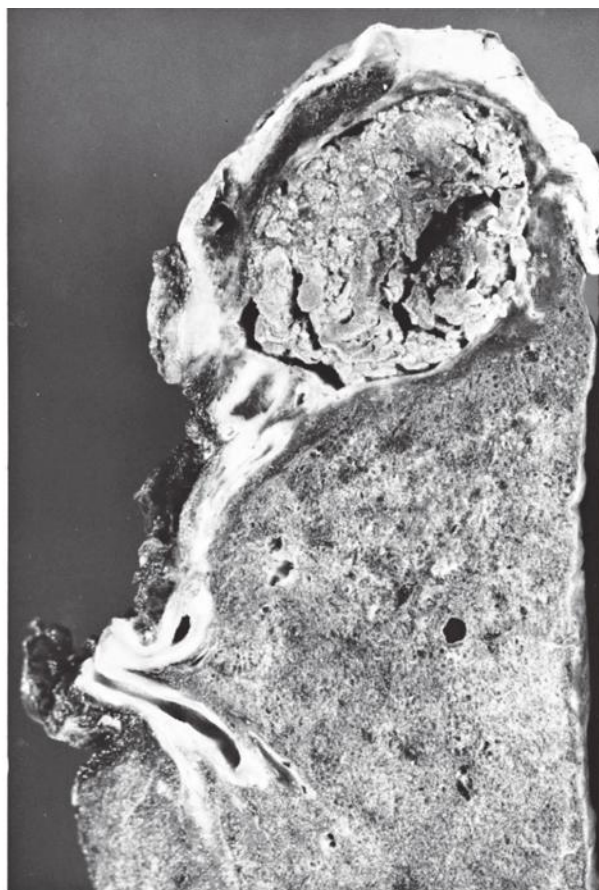
The natural history varies greatly between patients and, therefore, treatment is individualized. Factors associated with poor prognosis include severe underlying pulmonary disease, growth in the number or size of the aspergilloma(s) during observation, immunosuppression or HIV infection, history of lung transplantation, chronic pulmonary sarcoidosis, and increasing *Aspergillus*-specific IgG titers. Asymptomatic patients can be observed without any additional therapy. Antifungals have limited utility due to the poor blood supply to the aspergilloma. Amphotericin B is the drug of



A



C



B

Figure 19-33. Pulmonary aspergilloma. **A.** The chest x-ray shows a solid mass within a cavity surrounded by a rim of air between the mass and cavity wall (Monad sign, *arrows*). **B.** A cut section shows the “fungus ball” occupying an old, fibrotic cavity. **C.** Histologic stain reveals characteristic *Aspergillus* hyphae invading the wall of the cavity.

choice, although voriconazole has recently been used for treatment of aspergillosis, with fewer side effects and equivalent efficacy. Hemoptysis is a harbinger of erosion of the disease into adjacent bronchial arteries and typically requires intervention. In the setting of very mild hemoptysis (e.g., blood-streaked sputum), cough suppression is warranted while further therapeutic evaluation is performed.

Bronchial artery embolization is the first-line therapy for massive hemoptysis and may be definitive therapy.¹²⁶ This is particularly important to consider for patients with severely impaired pulmonary function who may not have sufficient reserve to tolerate even a very small pulmonary resection. Operative intervention may be required for recurrent hemoptysis,

particularly after bronchial artery embolization, chronic cough with systemic symptoms, progressive infiltrate around the mycetoma, and a pulmonary mass of unknown cause.¹²⁷

When operative intervention is indicated, the surgeon must remain cognizant of the goals of the procedure. As this disease typically occurs in patients with significantly impaired pulmonary function, attempts should be made to excise all diseased tissue with as limited a resection as possible. Once resection is completed, the postresection space in the hemithorax should be obliterated with a pleural tent, pneumoperitoneum, decortication of the remaining lung, intrathoracic rotation of a muscle or omental flap, or thoracoplasty. Long-term follow-up is necessary, given that the recurrence rate after surgery is about 7%.

Invasive pulmonary aspergillosis typically affects immunocompromised patients who have dysfunctional cellular immunity, namely defective polymorphonuclear leukocytes. Invasion of pulmonary parenchyma and blood vessels by a necrotizing bronchopneumonia may be complicated by thrombosis, hemorrhage, and then dissemination. Patients present with fever that is nonresponsive to antibiotic therapy in the setting of neutropenia. They may also have pleuritic chest pain, cough, dyspnea, or hemoptysis. Characteristic signs on CT scan include the halo sign and cavitary lesions. Treatment with voriconazole must be prompt and aggressive, including reversal of neutropenia, if there is to be any chance for recovery. Mortality ranges from 93% to 100% in bone marrow transplant recipients, to approximately 38% in kidney transplant recipients, although this improves to approximately 60% at 12 weeks with voriconazole therapy. Several other advances in diagnosis and treatment, including CT scans in high-risk populations and development of additional triazoles and echinocandins, have improved the early identification and response to therapy in this patient population. Additional treatment considerations include the use of hematopoietic growth factors to minimize the neutropenic period, which contributes to uncontrolled disease. Surgical removal of the infectious nidus is advocated by some groups because medical treatment has such poor outcomes. Treatment continues until microbiologic clearance is achieved and clinical signs and radiographic imaging indicate resolution of disease. In addition, the patient should no longer be immunosuppressed. If continuation of immunosuppressive medications is required, antifungal therapy should also continue to prevent recurrence of invasive disease.

Cryptococcosis. Cryptococcosis is a subacute or chronic infection caused by *Cryptococcus neoformans*, a round, budding yeast (5–20 µm in diameter) that is sometimes surrounded by a characteristic wide gelatinous capsule. Cryptococci are typically present in soil and dust contaminated by pigeon droppings. When inhaled, such droppings can cause a nonfatal disease primarily affecting the pulmonary and central nervous systems. At present, cryptococcosis is the fourth most common opportunistic infection in patients with HIV infection, affecting 6% to 10% of that population. Four basic pathologic patterns are seen in the lungs of infected patients: granulomas; granulomatous pneumonia; diffuse alveolar or interstitial involvement; and proliferation of fungi in alveoli and lung vasculature. Symptoms are nonspecific, as are the radiographic findings. *Cryptococcus* may be isolated from sputum, bronchial washings, percutaneous needle aspiration of the lung, or cerebrospinal fluid. If disease is suspected, serum cryptococcal antigen titers should be obtained; if positive or if the patient has persistent fever, evidence of progression, physiologic compromise, or dissemination, treatment should be promptly initiated. Multiple antifungal agents are effective against *C. neoformans*, including amphotericin B and the azoles. The choice of antifungal and duration of treatment depend on the severity of disease. Duration of therapy is longer in patients who are immunocompromised.

Candidiasis. *Candida* organisms are oval, budding cells (with or without mycelial elements) that colonize the oropharynx of many healthy individuals. The fungi of this genus are common hospital and laboratory contaminants. Usually, *Candida albicans* causes disease in the oral or bronchial mucosa, among other anatomic sites. Other potentially pathogenic *Candida* species include *C. tropicalis*, *C. glabrata*, and *C. krusei*. Historically,

C. albicans was the most common pathogen to cause invasive candidal infection. However, more recent reports suggest that other *Candida* species, particularly *C. glabrata* and *C. krusei*, are becoming more prevalent and now account for between 40% and 50% of all cases. These species are relatively resistant to fluconazole, and the shift is likely related to the widespread use of this antifungal agent.¹²⁸

The incidence of *Candida* infections has increased and is no longer confined to immunocompromised patients. Increasing incidence of infection has been identified in patients with any of the following risk factors: critical illness of long duration; use of long-term antibiotics, particularly multiple; indwelling urinary or vascular catheter; gastrointestinal perforation; or burn wounds.¹²⁹ With respect to the thorax, such patients commonly have candidal pneumonia, pulmonary abscess, esophagitis, and mediastinitis. Pulmonary candidal infections typically result in an acute or chronic granulomatous reaction. Because *Candida* can invade blood vessel walls and a variety of tissues, systemic or disseminated infections can occur, but are less common.

Treatment for candidal infection includes both fungicidal and fungistatic agents. The fungicidal medications include polyenes (amphotericin B deoxycholate [AmB-D] and various lipid-associated amphotericin B preparations) and the echinocandins (caspofungin, micafungin, and anidulafungin). Fungistatic drugs include the triazoles (fluconazole, itraconazole, voriconazole, and posaconazole).¹²⁸ The availability of multiple effective therapies allows for specific tailoring of treatment, including combination regimens, based on the patient's ability to tolerate associated toxicities, the microbiologic information for the specific candidal species, and the route of administration. While demonstrated efficacy is similar, the triazoles and echinocandins appear to have fewer side effects and are better tolerated than the other classes of antifungal drugs.

In addition to prompt institution of antifungal therapy, it is advisable to remove all central venous catheters. For fungemia, an eye examination should be performed. Treatment should continue for at least 2 weeks after the last positive blood culture. For patients with *Candida* mediastinitis (which has a mortality rate of >50%), surgical intervention to debride all infected tissues is required, in addition to prolonged administration of antifungal drugs.

Mucormycosis. The *Mucor* species, rare members of the class Zygomycetes, are responsible for rapidly fatal disease in immunocompromised patients. Other disease-causing species of the class Zygomycetes include *Absidia*, *Rhizopus*, and *Mortierella*.¹³⁰ Characteristic of these fungi are nonseptate, branching hyphae that are difficult to culture. Infection occurs via inhalation of spores. Immunocompromised patients, including patients with neutropenia, acidosis, diabetes, and hematologic malignancy all predispose to clinical susceptibility. In the lungs, disease consists of blood vessel invasion, thrombosis, and infarction of infected organs. Tissue destruction is significant, along with cavitation and abscess formation. Initial treatment is to correct underlying risk factors and administer antifungal therapies, although the optimal duration and optimal total dose are unknown. Lipid formulations of amphotericin B are recommended at this time. Surgical resection of any localized disease should be performed after initial medical treatment attempts fail.

Primary Fungal Pathogens

Histoplasma capsulatum. *Histoplasma capsulatum* is a dimorphic fungus existing in mycelial form in soil contaminated by

fowl or bat excreta and in yeast form in human hosts. The most common of all fungal pulmonary infections, histoplasmosis primarily affects the respiratory system after spores are inhaled. It is endemic in the Midwest and Mississippi River Valley of the United States, where about 500,000 new cases arise each year. In immunocompromised patients, the infection becomes systemic and more virulent; because cell-mediated immunity is impaired, uninhibited fungal proliferation occurs within pulmonary macrophages and then spreads. Acute forms of the disease present as primary or disseminated pulmonary histoplasmosis; chronic forms present as pulmonary granulomas (histoplasmoses), chronic cavitary histoplasmosis, mediastinal granulomas, fibrosing mediastinitis, or bronchiolithiasis. Histoplasmosis is definitively diagnosed by fungal smear, culture, direct biopsy of infected tissues, or serologic testing.

The clinical presentation depends on the inoculum size and on host factors. Symptoms of acute pulmonary histoplasmosis are fever, chills, headache, chest pain, musculoskeletal pain, and nonproductive cough. CXRs may be normal or may show mediastinal lymphadenopathy and patchy parenchymal infiltrates. Most patients improve in a few weeks; mild to moderate disease can be treated with itraconazole. Amphotericin B is the treatment of choice if moderate symptoms persist for 2 to 4 weeks or if the illness is extensive, including dyspnea and hypoxia, and if patients are immunosuppressed.¹³¹

As the pulmonary infiltrates from acute histoplasmosis heal, consolidation into an asymptomatic solitary nodule or histoplasma may occur and is usually seen incidentally on radiographs as a coin-shaped lesion. Central and concentric calcification may occur; if so, no further treatment is required. Noncalcification of the lesion requires further diagnostic workup including chest CT scan, needle biopsy, or surgical excision to rule out a malignancy. Figure 19-34 demonstrates the differences in pathologic findings between infections in normal and immunocompromised hosts.¹³²

When lymph nodes and pulmonary granulomas calcify over time, pressure atrophy on the bronchial wall may result in erosion and migration of the granulomatous mass into the bronchus, causing bronchiolithiasis. Typical symptoms include cough, hemoptysis, and dyspnea. Life-threatening complications include massive hemoptysis or bronchoesophageal fistula. In addition to radiography, bronchoscopy should be performed to aid in diagnosis. Definitive treatment requires surgical excision of the bronchial mass and repair of the airway and contiguous structures. Endobronchial debridement is not advised as this can result in massive, fatal bleeding.

Fibrosing mediastinitis is an uncommon manifestation of histoplasmosis but can be fatal due to progressive distortion and compression of the major vessels and central airways. Diagnosis can be difficult and symptoms may be present for extended periods, even years, before the diagnosis is made. The differential diagnosis for the disease process includes granulomatous mediastinitis related to recent infection, malignancy, and chronic pulmonary thromboembolism. A trial of itraconazole is worthwhile, although it is not proven to be effective. In cases where radiographic or physiologic improvement is achieved after a trial of 12 weeks of therapy, continuation of therapy is considered for a full 12 months. In the majority of patients, however, antifungal therapy has not been proven effective. There is no role for corticosteroids at this time or for antifibrotics. Occasionally, intravascular stents have been helpful for severe vascular compromise. Balloon dilatation and endobronchial

silicone stents may be needed for airway compromise, although this should be directed by a surgeon with expertise in mediastinal and airway disease management.

Chronic pulmonary histoplasmosis occurs in about 10% of patients who become symptomatic after infection. Most such patients have pre-existing lung pathology, particularly emphysema, which becomes colonized. Subsequent pneumonitis and necrosis, cavity enlargement, new cavity formation, and pulmonary dissemination occur. Nonspecific symptoms, such as cough, sputum production, fever, weight loss, weakness, and hemoptysis are common. Chest radiography may reveal intrapulmonary cavitation and scarring. Occasionally, partial resolution of the inflammatory changes may be observed. Itraconazole provides effective therapy, but must be given for 12 to 24 months. It is superior to ketoconazole and fluconazole; these should only be used if itraconazole is not tolerated. Voriconazole and posaconazole have been found to be useful for salvage therapy. Serum itraconazole levels should be monitored to ensure that the drug is being absorbed. Occasionally, lipid-associated amphotericin B is necessary for more severe infections. Surgical excision should be considered in patients with adequate pulmonary reserve and localized, thick-walled cavities that have been unresponsive to antifungal therapy.

Disseminated histoplasmosis occurs most frequently in patients who are severely immunocompromised, such as post-transplantation patients, patients with HIV, and patients using immunosuppressive medications. Presentation ranges from nonspecific signs of fever, weight loss, and malaise, to shock, respiratory distress, and multiorgan failure. Diagnosis can be made with a combination of *Histoplasma* urine antigen, serologic assay, and fungal culture and should be suspected in patients with the above symptoms in any endemic area, particularly if the patient is immunosuppressed.¹³³ Any of the antifungal therapies can be used in treatment of disseminated histoplasmosis. Use of amphotericin B has decreased the mortality rate to less than 25% in this type of serious infection.

Coccidioides immitis. *Coccidioides immitis* is an endemic fungus found in soil and dust of the southwestern United States. Agricultural workers, military personnel, and other occupations with extensive exposure to soil, especially in areas of endemic growth, are at highest risk, as are immunocompromised individuals.¹³⁴ Spores (arthroconidia) are inhaled, swell into spherules, and subdivide into endospores, and subsequent infection develops. Diagnosis can be achieved through serum analysis for anticoccidioidal antibody, spherule identification in tissue, or by isolating the fungus in cultures from sputum, other body fluid, or tissue.

Inhalation of the fungus causes pulmonary involvement in 95% of patients with symptomatic disease. Three main categories of pulmonary involvement, based on the associated signs and symptoms, are possible: primary; complicated; and residual pulmonary coccidioidomycosis. Primary pulmonary coccidioidomycosis occurs in about 40% of people who inhale spores. The other 60% will remain asymptomatic and develop life-long immunity. The constellation of symptoms of "valley fever," including fever, chills, headache, erythema multiforme, erythema nodosum, polyarthralgias, nonproductive cough, and chest pain, and a CXR showing hilar and paratracheal adenopathy are highly suggestive of pulmonary coccidioidomycosis. In many patients, initial diagnosis is community-acquired pneumonia, and it is only when the patient fails to respond to appropriate antibiotic therapy that pulmonary coccidioidomycosis

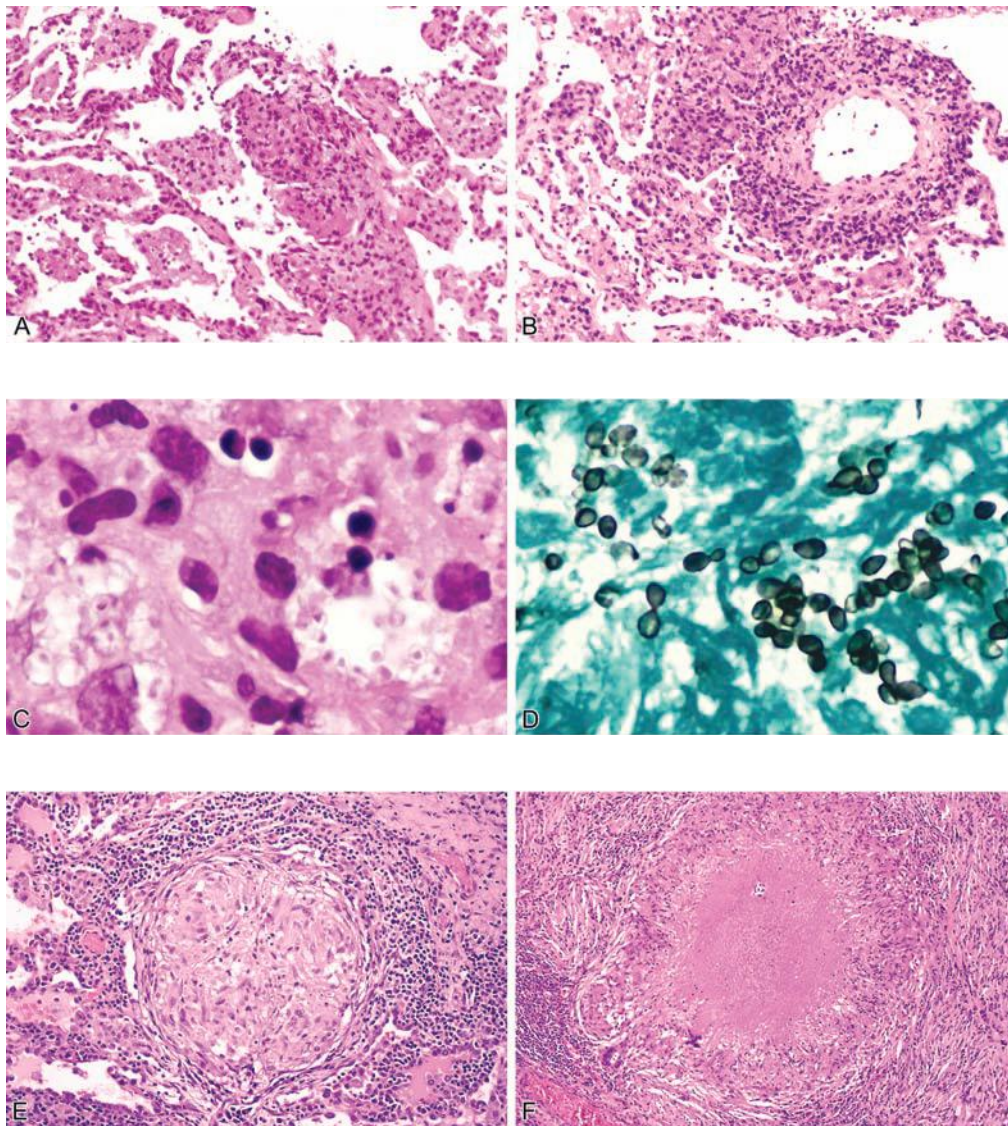


Figure 19-34. Pathologic findings of infection in normal and immunocompromised hosts. Histopathologic preparations are shown contrasting acute diffuse pulmonary involvement in a lung segment of a normal host with a probable primary infection (A through D) with pulmonary granulomas from an immunocompromised patient who had an opportunistic reinfection with *Histoplasma capsulatum* (E, F). **A.** Diffuse interstitial pneumonitis in an adult (normal host) with recent heavy environmental exposure and subsequent development of progressive pulmonary disease. There is an inflammatory cell infiltrate primarily involving the interalveolar interstitial spaces but present within many alveolar spaces as well. The exudate consists mostly of mononuclear phagocytes, lymphocytes, and occasional plasma cells. Many of the alveolar walls are markedly thickened (hematoxylin and eosin stain [H&E], $\times 50$). **B.** Another area from the same lung as in A showing focal vasculitis with an infiltrate of lymphocytes and macrophages (H&E, $\times 25$). **C.** Relatively large alveolar macrophages packed with single and budding yeasts 2 to 4 μm in diameter (same lung as in A and B). The basophilic cytoplasm of these yeasts is retracted from their thin outer cell walls, leaving halo-like clear areas that can be confused with capsules (H&E, $\times 500$). **D.** Intracellular and extracellular yeasts, 2 to 4 μm in diameter, some of which are single, budding, or in short chains (Gomori methenamine silver stain, $\times 500$). **E.** Nonnecrotizing (sometimes called epithelioid cell or noncaseating) granuloma from a patient who had recently received chemotherapy for a germ cell tumor (different patient than in A through D). This lesion consists of a focal collection of macrophages (sometimes referred to as histiocytes or epithelioid cells) plus lymphocytes and occasional plasma cells. A few multinucleated macrophages are present. A thin layer of fibroblasts circumscribes the lesion. Yeasts of *H. capsulatum*, probably present within macrophages of this lesion at an earlier stage, were not identified in this granuloma or in any of several other nonnecrotizing granulomas within the specimen. Lesions of this type often undergo necrosis to become necrotizing granulomas (H&E, $\times 50$). **F.** Necrotizing (sometimes referred to as caseating) granuloma from the same lung as in E. This lesion has a necrotic center surrounded by macrophages, encapsulating fibroblasts, fibrous connective tissue in the periphery, and scattered lymphocytes. A prominent giant cell is present in the lower left of the granuloma (at approximately 8 o'clock). Microorganisms are usually present only in relatively small numbers in these types of lesions. They are most frequently detected within the most central necrotic material in these granulomas (H&E, $\times 25$). (Reproduced with permission from Hage et al.¹³²)

is considered. The disease is self-limited in the majority of patients, and treatment is not required in these cases.

Therapy should be considered for (a) patients with impaired cellular immunity; (b) comorbid illnesses that are adversely impacted by the infection, including chronic pulmonary dysfunction, renal failure, and congestive heart failure; and (c) when symptoms and radiographic findings persist for more than 6 to 8 weeks, at which time the disease is considered to be persistent coccidioid pneumonia and occurs in approximately 1% of patients. Progression to caseous nodules, cavities, and calcified, fibrotic, or ossified lesions indicates complicated or residual stages of coccidioidomycosis.

There are several relative indications for surgery in pulmonary coccidioidomycosis. A rapidly expanding (>4 cm) cavity that is close to the visceral pleura is a high risk for rupture into the pleural space and subsequent empyema. Other indications for operative intervention include life-threatening hemoptysis; hemoptysis that is persistent despite medical therapy; symptomatic fungus ball; bronchopleural fistula; cavitory lesions with persistent positive sputum; and pulmonary nodules that degenerate over time. Finally, any nodule with signs that are concerning for malignancy should undergo further evaluation, including biopsy or resection, to determine the underlying etiology.

Diagnosis of coccidioidomycosis is confirmed by histopathologic, mycologic, and serologic evaluation. Extrapulmonary disease may develop in approximately 0.5% of infected patients, with involvement of meninges, bones, joints, skin, or soft tissues. Immunocompromised patients are especially susceptible to disseminated coccidioidomycosis, which carries a mortality rate over 40%. Treatment options for this disease vary depending on the severity of the disease as well as the stage. Amphotericin B deoxycholate or the triazoles continue to be the primary antifungal medications. If meningeal involvement is identified, fluconazole or itraconazole therapy is required for the remainder of the patient's life. Intrathecal amphotericin B can also be administered in some cases.

Blastomyces dermatitidis. *Blastomyces dermatitidis* is a round, single-budding yeast with a characteristic thick, refractile cell wall. It resides in the soil as a nonmotile spore called conidia. Exposure occurs when contaminated soil is disturbed and the conidia are aerosolized. The spore is inhaled and transforms into a yeast phase at body temperature.¹³⁵ Infection is typically self-limited. A small minority of patients will develop chronic pulmonary infection or disseminated disease, including cutaneous, osteoarticular, and genitourinary involvement. *B. dermatitidis* has a worldwide distribution; in the United States, it is endemic in the central states.¹³⁶ With chronic infection, the organism induces a granulomatous and pyogenic reaction with microabscesses and giant cells; caseation, cavitation, and fibrosis may also occur. Symptoms are nonspecific and consistent with chronic pneumonia in 60% to 90% of patients. They include cough, mucoid sputum production, chest pain, fever, malaise, weight loss, and, uncommonly, hemoptysis. In acute disease, radiographs are either completely negative or have nonspecific findings; in chronic disease, fibronodular lesions (with or without cavitation) similar to tuberculosis are noted. Pulmonary parenchymal abnormalities in the upper lobe(s) may be noted. Mass lesions similar to carcinoma are frequent, and lung biopsy is frequently used. Over 50% of patients with chronic blastomycosis also have extrapulmonary manifestations, but less than 10% of patients present with severe clinical manifestation.¹³⁵

Once a patient manifests symptoms of chronic blastomycosis, antifungal treatment is required to achieve resolution. Mortality approaches 60% if untreated.¹³⁵ While controversial, a short course of triazole therapy (oral itraconazole 200 mg daily) for 6 months is the treatment of choice for most patients with mild to moderate forms of the disease. Because itraconazole has poor CNS penetration, the most common site of recurrence after apparently successful therapy is in the CNS. In the absence of therapy, close follow-up is warranted for evidence of progression to chronic or extrapulmonary disease. Amphotericin B is warranted for patients with severe or life-threatening disease, CNS involvement, disseminated disease, or extensive lung involvement and in immunocompromised patients. After adequate drug therapy, surgical resection of known cavitory lesions should be considered because viable organisms are known to persist in such lesions.

Massive Hemoptysis

Massive hemoptysis is generally defined as expectoration of over 600 mL of blood within a 24-hour period. It is a medical emergency associated with a mortality rate of 30% to 50%. Most clinicians would agree that losing over a liter of blood via the airway within 1 day is significant, yet use of an absolute volume criterion presents difficulties. First, it is difficult for the patient or caregivers to quantify the volume of blood being lost. Second, and most relevant, the rate of bleeding necessary to incite respiratory compromise is highly dependent on the individual's prior respiratory status. For example, the loss of 100 mL of blood over 24 hours in a 40-year-old male with normal pulmonary function would be of little immediate consequence, because his normal cough would ensure his ability to clear the blood and secretions. In contrast, the same amount of bleeding in a 69-year-old male with severe COPD, chronic bronchitis, and an FEV₁ of 1.1 L may be life-threatening.

Anatomy. The lungs have two sources of blood supply: the pulmonary and bronchial arterial systems. The pulmonary system is a high-compliance, low-pressure system, and the walls of the pulmonary arteries are very thin and delicate. The bronchial arteries, part of the systemic circulation, have systemic pressures and thick walls; most branches originate from the proximal thoracic aorta. Most cases of massive hemoptysis involve bleeding from the bronchial artery circulation or from the pulmonary circulation pathologically exposed to the high pressures of the bronchial circulation. In many cases of hemoptysis, particularly those due to inflammatory disorders, the bronchial arterial tree becomes hyperplastic and tortuous. The systemic pressures within these arteries, combined with a disease process within the airway and erosion, lead to bleeding.

Causes. Significant hemoptysis occurs as a result of pulmonary, extrapulmonary, and iatrogenic causes. Table 19-20 summarizes the most common causes of hemoptysis. Most are secondary to inflammatory processes. Aneurysms of the pulmonary artery (referred to as Rasmussen's aneurysm) can develop within pulmonary cavities and can result in massive bleeding. Hemoptysis due to lung cancer is usually mild, resulting in blood-streaked sputum. Massive hemoptysis in patients with lung cancer is typically caused by malignant invasion of pulmonary artery vessels by large central tumors. Although rare, it is often a terminal event.

Management. Life-threatening hemoptysis is best managed by a multidisciplinary team of intensive care physicians,

Table 19-20

Pulmonary and extrapulmonary causes of massive hemoptysis

PULMONARY	EXTRAPULMONARY	IATROGENIC
Pulmonary parenchymal disease Bronchitis Bronchiectasis Tuberculosis Lung abscess Pneumonia Cavitory fungal infection (e.g., aspergilloma) Lung parasitic infection (ascariasis, schistosomiasis, paragonimiasis) Pulmonary neoplasm Pulmonary infarction or embolism Trauma Arteriovenous malformation Pulmonary vasculitis Pulmonary endometriosis Wegener's granulomatosis Cystic fibrosis Pulmonary hemosiderosis	Congestive heart failure Coagulopathy Mitral stenosis Medications	Intrapulmonary catheter

interventional radiologists, and thoracic surgeons. Treatment priorities begin with respiratory stabilization; intubation with isolation of the bleeding lung may be required to prevent asphyxiation. This can be done with main-stem intubation into the nonbleeding lung, endobronchial blockers into the bleeding lung, or double-lumen endotracheal intubation, depending on the urgency of the situation and the expertise of the providers. Once adequate ventilation has been achieved, the bleeding site should be localized; bronchoscopy can often provide direct visualization of blood coming from a specific area of the tracheobronchial anatomy. Control of the hemorrhage is then achieved endobronchially with laser or bronchial occlusion, endovascularly with bronchial and/or pulmonary artery embolization, or surgically with resection of the involved area.¹³⁷ The order of priorities in management is detailed in Table 19-21.

The clinically pragmatic definition of massive hemoptysis is a degree of bleeding that threatens respiratory stability. Therefore, clinical judgment of respiratory compromise is the first step in evaluating a patient.^{138,139} Two scenarios are possible: (1) bleeding is significant and persistent, but its rate allows a rapid, sequential diagnostic and therapeutic approach, or (2) bleeding is so rapid that emergency airway control and therapy are necessary.

Table 19-21

Treatment priorities in the management of massive hemoptysis

1. Achieve respiratory stabilization and prevent asphyxiation.
2. Localize the bleeding site.
3. Control the hemorrhage.
4. Determine the cause.
5. Definitively prevent recurrence.

Scenario 1: Significant, Persistent, but Nonmassive Bleeding.

Although bleeding is brisk in scenario 1, the patient may be able to maintain clearance of the blood and secretions with his or her own respiratory reflexes. Immediate measures are admission to an intensive care unit; strict bed rest; Trendelenburg positioning with the affected side down (if known); administration of humidified oxygen; cough suppression; monitoring of oxygen saturation and arterial blood gases; and insertion of large-bore intravenous catheters. Strict bed rest with sedation may lead to slowing or cessation of bleeding, and the judicious use of intravenous narcotics or other relaxants to mildly sedate the patient and diminish some of the reflexive airway activity is often necessary. Also recommended are administration of aerosolized adrenaline, intravenous antibiotic therapy if needed, and correction of abnormal blood coagulation study results. Finally, unless contraindicated, intravenous vasopressin (20 U over 15 minutes, followed by an infusion of 0.2 U/min) can be given.

A CXR is the first test and often proves to be the most revealing. Localized lesions may be seen, but the effects of blood soiling of other areas of the lungs may predominate, obscuring the area of pathology. Chest CT scan provides more detail and is nearly always performed if the patient is stable. Pathologic areas may be obscured by blood soiling.

Flexible bronchoscopy is the next step in evaluating the patient's condition. Some clinicians argue that rigid bronchoscopy should always be performed. However, if the patient is clinically stable and the ongoing bleeding is not imminently threatening, flexible bronchoscopy is appropriate. It allows diagnosis of airway abnormalities and will usually permit localization of the bleeding site to either a lobe or even a segment. The person performing the bronchoscopy must be prepared with excellent suction and must be able to perform saline lavage with a dilute solution of epinephrine.

Most cases of massive hemoptysis arise from the bronchial arterial tree; therefore, the next therapeutic option frequently is selective bronchial arteriography and embolization. Bronchoscopy

prior to arteriogram is extremely useful to direct the angiographer. However, if bronchoscopy fails to localize the bleeding site, then bilateral bronchial arteriograms can be performed. More recently, use of multidetector CT angiography in patients with hemoptysis that is not immediately life-threatening has been shown to facilitate endovascular intervention; reformatting of the images in multiple projections allows clear delineation of the pulmonary vascular anatomy.¹²⁶ With this approach, abnormal bronchial and nonbronchial arteries can be visualized and subsequently targeted for therapeutic arterial embolization.¹⁴⁰ Once the targeted arterial system has been embolized, immediate control and cessation of the hemoptysis is achieved in more than 80% of patients. If bleeding persists after bronchial artery embolization, a pulmonary artery source should be suspected and a pulmonary angiogram performed at the same setting.

Recurrence is seen in 30% to 60% of cases and is very common in the setting of invasive fungal infections such as aspergilloma. Recurrence after bronchial artery embolization is less common in the setting of malignancy and active tuberculosis but does occur and can ultimately result in patient death.¹⁴¹ Repeat embolization can be effective and is warranted for initial management of recurrent hemoptysis, but early surgical intervention should be considered, particularly in the setting of aspergilloma or other cavitary lesions.¹²⁶

If respiratory compromise is impending, orotracheal intubation should be performed. After intubation, flexible bronchoscopy should be performed to clear blood and secretions and to attempt localization of the bleeding site. Depending on the possible causes of the bleeding, bronchial artery embolization or (if appropriate) surgery can be considered.

Scenario 2: Significant, Persistent, and Massive Bleeding. Life-threatening bleeding requires emergency airway control and preparation for potential surgery. Such patients are best cared for in an operating room equipped with rigid bronchoscopy. Immediate orotracheal intubation may be necessary to gain control of ventilation and suctioning. However, rapid transport to the operating room with rigid bronchoscopy should be facilitated. Rigid bronchoscopy allows adequate suctioning of bleeding with visualization of the bleeding site; the nonbleeding side can be cannulated with the rigid scope and the patient ventilated. After stabilization, ice-saline lavage of the bleeding site can then be performed (up to 1 L in 50-mL aliquots); bleeding stops in up to 90% of patients.¹⁴²

Alternatively, blockade of the main stem bronchus of the affected side can be accomplished with a double-lumen endotracheal tube, with a bronchial blocker, or by intubation of the nonaffected side by an uncut standard endotracheal tube. Placement of a double-lumen endotracheal tube is challenging in these circumstances, given the bleeding and secretions. Proper placement and suctioning may be difficult, and attempts could compromise the patient's ventilation. The best option is to place a bronchial blocker in the affected bronchus with inflation. Endovascular embolization can be performed to stop the bleeding after control has been achieved with the bronchial blocker. The blocker is left in place for 24 hours; after 24 hours, the area is re-examined bronchoscopically.

Surgical Intervention. In most patients, bleeding can be stopped, recovery can occur, and plans to definitively treat the underlying cause can be made. In scenario 1 (significant, persistent, but nonmassive bleeding), the patient may undergo further evaluation as an inpatient or outpatient. A chest CT scan and

Table 19-22

General indications for urgent operative intervention for massive hemoptysis

1. Presence of a fungus ball
2. Presence of a lung abscess
3. Presence of significant cavitary disease
4. Failure to control the bleeding

pulmonary function studies should be obtained preoperatively. In scenario 2 (patients with significant, persistent, and massive bleeding), surgery, if appropriate, will usually be performed during the same hospitalization as the rigid bronchoscopy or main stem bronchus blockade. In a small number of patients (<10%), immediate surgery will be necessary due to the extent of bleeding. The bleeding site in these patients is localized using rigid bronchoscopy with immediate thoracotomy or sternotomy to follow.

Surgical treatment is individualized according to the source of bleeding and the patient's medical condition, prognosis, and pulmonary reserve. General indications for urgent surgery are presented in Table 19-22. In patients with significant cavitary disease or with fungus balls, the walls of the cavities are eroded and necrotic; rebleeding will likely ensue. In addition, bleeding from cavitary lesions may be due to pulmonary artery erosion, which requires surgery for control.

End-Stage Lung Disease

Lung Volume Reduction Surgery. The ideal patient for lung volume reduction surgery (LVRS) has heterogeneous emphysema with apical predominance, meaning the worst emphysematous changes are in the apex (seen on chest CT scan) of the lungs. The physiologic lack of function of these areas is demonstrated by quantitative perfusion scan, which shows minimal or no perfusion. By surgically excising these nonfunctional areas, the volume of the lung is reduced, theoretically restoring respiratory mechanics. Diaphragm position and function are improved, and there may be an improvement in the dynamic small airway collapse in the remaining lung.

Operative mortality in the initial experience was 16.9%, with a 1-year mortality of 23%. In response, the National Emphysema Treatment Trial (NETT) performed a randomized trial of 1218 patients in a noncrossover design to medical vs. surgical management after a 10-week pretreatment pulmonary rehabilitation program. Subgroup analysis demonstrated that in patients with the anatomic changes delineated by Cooper and colleagues, LVRS significantly improved exercise capacity, lung function, quality of life, and dyspnea compared to medical therapy. After 2 years, functional improvements began to decline toward baseline. Similar parameters in medically treated patients steadily decline below baseline. LVRS was associated with increased short-term morbidity and mortality and did not confer a survival benefit over medical therapy.¹⁴³

Lung Transplantation. The most common indications for lung transplant are COPD and idiopathic pulmonary fibrosis (IPF). Most patients with IPF and older patients with COPD are offered a single-lung transplant. Younger COPD patients and patients with α_1 -antitrypsin deficiency and severe hyperinflation of the native lungs are offered a bilateral-lung transplant.

Most patients with primary pulmonary hypertension and almost all patients with cystic fibrosis are treated with a bilateral-lung transplant. A heart-lung transplant is reserved for patients with irreversible ventricular failure or uncorrectable congenital cardiac disease.

Patients with COPD are considered for placement on the transplant waiting list when their FEV₁ has fallen to below 25% of its predicted value. Patients with significant pulmonary hypertension should be listed earlier. IPF patients should be referred when their forced vital capacity has fallen to less than 60% or their DLCO has fallen to less than 50% of their predicted values.

In the past, patients with primary pulmonary hypertension and New York Heart Association (NYHA) class III or IV symptoms were listed for a lung transplant. However, treatment of such patients with intravenous prostacyclin and other pulmonary vasodilators has now markedly altered that strategy. Virtually all patients with primary pulmonary hypertension are now treated with intravenous epoprostenol. Several of these patients have experienced a marked improvement in their symptoms associated with a decrease in their pulmonary arterial pressures and an increase in exercise capacity. Listing of these patients is deferred until they develop NYHA class III or IV symptoms or until their mean pulmonary artery pressure rises above 75 mmHg.

Medium-term and bronchiolitis obliterans syndrome (BOS)-free survival rates of patients who underwent a lung transplant during a recent 5-year period at the University of Minnesota are shown in Figs. 19-35 and 19-36. The mortality of patients while waiting for transplants is about 10%. In an effort to expand the number of lung donors, many transplant groups have liberalized their criteria for donor selection. Still, the partial pressure of arterial oxygen (PaO₂) should be greater than 300 mmHg on a fraction of inspired oxygen (FIO₂) of 100%. In special circumstances, lungs may be used from donors with a smoking history; from donors older than 50 years of age; and from donors with positive Gram stains or infiltrates on CXR.^{144,145} The use of two living donors, each donating a single lower lobe, is another strategy for increasing the donor pool. Recipient outcomes are similar to those with cadaver donors in carefully selected patients.

Most of the early mortality after lung transplant is related to primary graft failure resulting from a severe ischemia-reperfusion

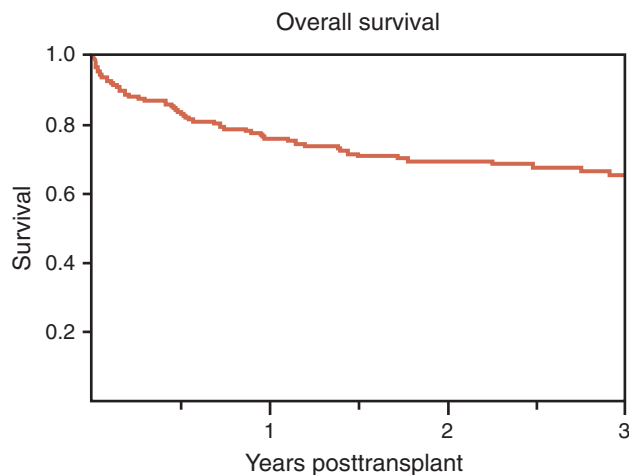


Figure 19-35. The overall survival rate after lung transplantation at the University of Minnesota.

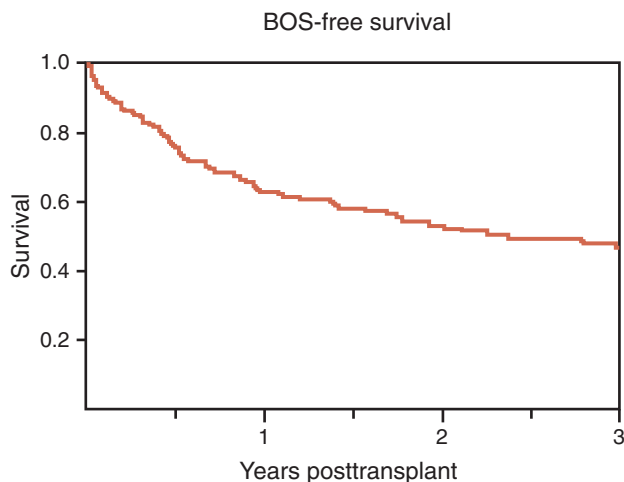


Figure 19-36. The survival rate after lung transplantation in the absence of bronchiolitis obliterans syndrome (BOS) at the University of Minnesota.

injury to the lung(s) (Fig. 19-37). Reperfusion injury is characterized radiographically by interstitial and alveolar edema and clinically by hypoxia and ventilation-perfusion mismatch. Donor neutrophils and recipient lymphocytes probably play an important role in the pathogenesis of reperfusion injury. The most important impediment to longer-term survival after a lung transplant is the development of BOS, a manifestation of chronic rejection. Episodes of acute rejection are the major risk factors for developing BOS. Other injuries to the lung (including early reperfusion injury and chronic gastroesophageal reflux disease) may also adversely affect long-term outcomes of patients.^{146,147}

CHEST WALL

Chest Wall Mass

Clinical Approach. Surgeons confronted with a patient with a chest wall mass must be cognizant that their approach to diagnosis

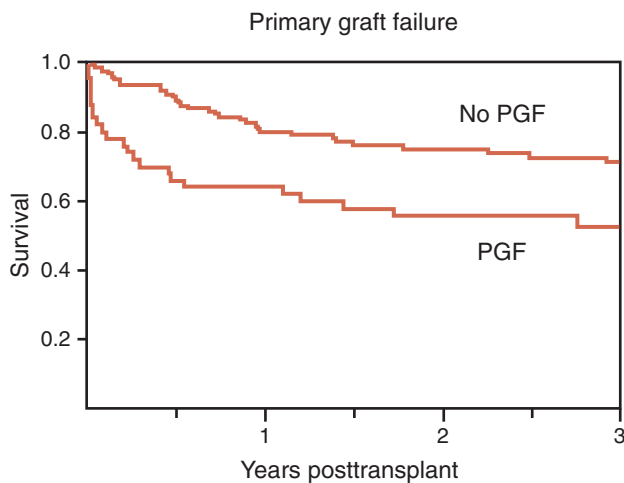


Figure 19-37. The survival rate after lung transplantation at the University of Minnesota as a function of primary graft failure (PGF).

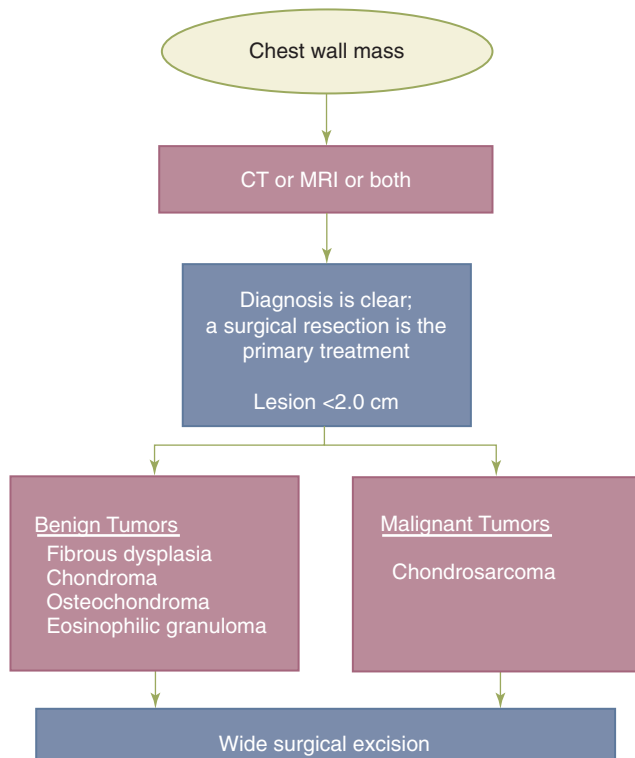


Figure 19-38. Systematic approach for evaluating a chest wall mass when the clinical scenario is uncomplicated and initial imaging studies suggest a clear diagnosis. CT = computed tomography; MRI = magnetic resonance imaging.

and treatment has significant impact on the patient's chances for long-term survival. All chest wall tumors should be considered malignant until proven otherwise. It is critically important that the surgeon(s) be mindful of this tenet and well-versed in the diagnostic and treatment principles for chest wall malignancies. These tenets must be applied from the initial biopsy, as the placement of the incision can impact significantly on the successful complete resection and reconstruction of the chest wall. Complete resection is imperative if there is any hope for cure and/or long-term survival. A general approach is outlined in Figs. 19-38 and 19-39.

Patients with chest wall tumors, regardless of etiology, typically complain of a slowly enlarging palpable mass (50%–70%), chest wall pain (25%–50%), or both. Interestingly, growing masses are often not noticed by the patient until they suffer a trauma to the area. Pain from a chest wall mass is typically localized to the area of the tumor; it occurs more often and more intensely with malignant tumors, but it can also be present in up to one third of patients with benign tumors. With Ewing's sarcoma, fever and malaise may also be present. Benign chest wall tumors tend to occur in younger patients (average age 26 years), whereas malignant tumors tend to be found in older patients (average age 40 years). Overall, between 50% and 80% of chest wall tumors are malignant.

Evaluation and Management. Laboratory evaluations are useful in assessing chest wall masses for the following:

1. **Plasmacytoma:** Serum protein electrophoresis demonstrates a single monoclonal spike, which is measuring the overproduction of one immunoglobulin from the malignant plasma cell clone.

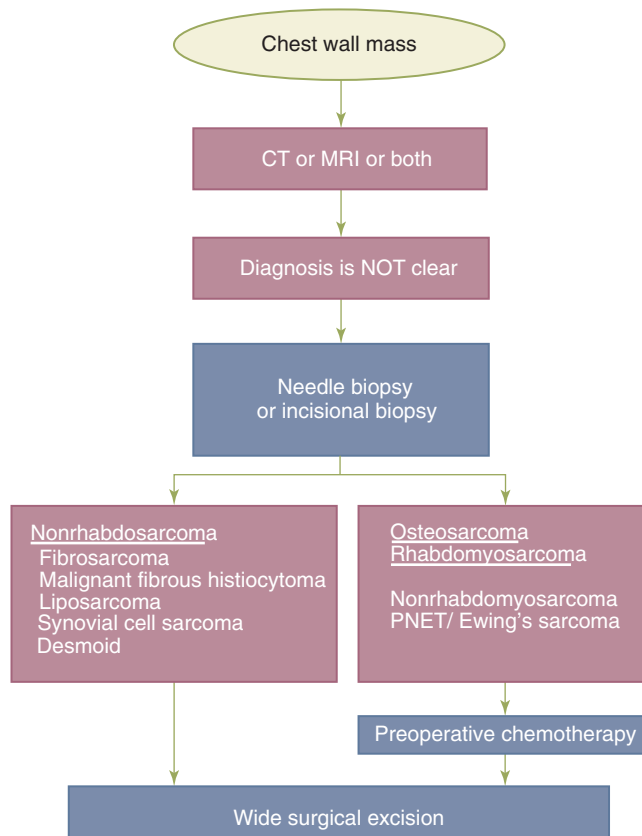


Figure 19-39. Systematic approach for evaluating a chest wall mass for which the diagnosis is not unequivocal. A tissue diagnosis is critical for effective management of chest wall masses. CT = computed tomography; MRI = magnetic resonance imaging; PNET = primitive neuroectodermal tumor.

2. **Osteosarcoma:** Alkaline phosphatase levels may be elevated.
3. **Ewing's sarcoma:** Erythrocyte sedimentation rates may be elevated.

Radiography. CXR may reveal rib destruction, calcification within the lesion, and if old films are available, a clue to growth rate. CT scanning, however, is necessary to determine the relationship of the chest wall mass to contiguous structures (e.g., mediastinum, lung, soft tissues, and other skeletal elements), evaluate for pulmonary metastases, and assess for extraosseous bone formation and bone destruction, both typically seen with osteosarcoma.

Because MRI provides multiple planes of imaging (coronal, sagittal, and oblique), better definition of the relationship between tumor and muscle, and tumor and contiguous or nearby neurovascular structures or the spine, it is an important radiographic adjunct for preoperative planning. Compared to CT scan alone, MRI may further delineate tissue abnormalities, potentially enhancing the ability to distinguish benign from malignant sarcoma.

Biopsy. The first step in the management of all chest wall tumors is to obtain a tissue diagnosis. Inappropriate or misguided attempts at tissue diagnosis through casual open biopsy techniques have the potential (if the lesion is a sarcoma) to seed surrounding tissues and contiguous body cavities (e.g., the pleural space) with tumor cells, potentially compromising local tumor control and patient survival. Tissue diagnosis is accomplished using one of three methods: needle biopsy (typically

CT-guided FNA or a core biopsy), incisional biopsy, or excisional biopsy in limited and specific situations.

1. **Needle biopsy:** Pathologists experienced with sarcomas can accurately diagnose approximately 90% of patients using FNA cytology. A needle biopsy (FNA or core) has the advantage of avoiding wound and body cavity contamination (a potential complication with an incisional biopsy).
2. **Incisional biopsy:** If a needle biopsy is nondiagnostic, an incisional biopsy may be performed, with caveats. First, the skin incision must be placed directly over the mass and oriented to allow subsequent scar excision; skin flaps and drains should be avoided. However, if the surgeon believes a hematoma is likely to develop, a drain is useful for limiting soft tissue contamination by tumor cells. At the time of definitive surgical resection, the en bloc resection includes the biopsy scar and the drain tract along with the tumor.
3. **Excisional biopsy:** Any lesion less than 2.0 cm can be excised as long as the resulting wound is small enough to close primarily. Otherwise, excisional biopsy is performed only when the initial diagnosis (based on radiographic evaluation) indicates that the lesion is benign or when the lesion has the classic appearance of a chondrosarcoma (in which case, definitive surgical resection can be undertaken).

Benign Chest Wall Neoplasms

1. **Chondroma.** Chondromas, seen primarily in children and young adults, are one of the more common benign tumors of the chest wall. They usually occur at the costochondral junction anteriorly and may be confused with costochondritis, except that a painless mass is present. Radiographically, the lesion is lobulated and radiodense; it may have diffuse or focal calcifications; and it may displace the bony cortex without penetration. Chondromas may grow to huge sizes if left untreated. Treatment is surgical resection with a 2-cm margin. Large chondromas may harbor well-differentiated chondrosarcoma and should be managed with a 4-cm margin to prevent local recurrence.¹⁴⁸
2. **Fibrous dysplasia.** As with chondromas, fibrous dysplasia most frequently occurs in young adults and may be associated with trauma. Pain is an infrequent complaint, and the lesion is typically located in the posterolateral aspect of the rib cage. Radiographically, an expansile mass is present, with cortical thinning and no calcification. Local excision with a 2-cm margin is curative.
3. **Osteochondroma.** Osteochondromas, often found incidentally as a solitary lesion on radiograph, are the most common benign bone tumor. Osteochondromas occur in the first two decades of life, and they arise at or near the growth plate of bones. Osteochondromas in the thorax arise from the rib cortex. They are one of several components to the autosomal dominant syndrome, hereditary multiple exostoses. When part of this syndrome, osteochondromas have a high rate of degeneration into chondrosarcomas. Any patient with hereditary multiple exostoses syndrome who develops new pain at the site of an osteochondroma or who notes gradual growth in the mass over time should be carefully evaluated for osteosarcoma. Local excision of a benign osteochondroma is sufficient. If malignancy is determined, wide excision is performed with a 4-cm margin.
4. **Eosinophilic granuloma.** Eosinophilic granulomas are benign osteolytic lesions. Eosinophilic granulomas of the

ribs can occur as solitary lesions or as part of a more generalized disease process of the lymphoreticular system termed Langerhans cell histiocytosis (LCH). In LCH, the involved tissue is infiltrated with large numbers of histiocytes (similar to Langerhans cells seen in skin and other epithelia), which are often organized as granulomas. The cause is unknown. Of all LCH bone lesions, 79% are solitary eosinophilic granulomas, 7% involve multiple eosinophilic granulomas, and 14% belong to other forms of more systemic LCH. Isolated single eosinophilic granulomas can occur in the ribs or skull, pelvis, mandible, humerus, and other sites. They are diagnosed primarily in children between the ages of 5 and 15 years. Because of the associated pain and tenderness, they may be confused with Ewing's sarcoma or with an inflammatory process such as osteomyelitis. Healing may occur spontaneously, but the typical treatment is limited surgical resection with a 2-cm margin.

5. **Desmoid tumors.** Soft tissue neoplasms arising from fascial or musculoaponeurotic structures, desmoid tumors consist of proliferations of benign-appearing fibroblastic cells, abundant collagen, and few mitoses. Desmoid tumors possess alterations in the adenomatous polyposis coli (APC)/ β -catenin pathway. Cyclin D1 dysregulation is thought to play a significant role in their pathogenesis.¹⁴⁹ Associations with other diseases and conditions are well documented, especially those with similar alterations in the APC pathway, such as familial adenomatous polyposis (Gardner's syndrome). Other conditions with increased risk of desmoid tumor formation include increased estrogen states (pregnancy) and trauma. Surgical incisions (abdominal and thorax) have been the site of desmoid development, either in or near the scar.

Clinically, patients are usually in the third to fourth decade of life and have pain, a chest wall mass, or both. The tumor is usually fixed to the chest wall, but not to the overlying skin. There are no typical radiographic findings, but MRI may delineate muscle or soft tissue infiltration. Desmoid tumors do not metastasize, but they have a significant propensity to recur locally, with reported rates ranging from 5% to 50%, sometimes despite complete initial resection with histologically negative margins.¹⁵⁰ Such locally aggressive behavior is secondary to microscopic tumor infiltration of muscle and surrounding soft tissues and prompts some to consider them a low-grade form of fibrosarcoma.

Because the lesions have low cellularity and poor yield with FNA, an open incisional biopsy for lesions over 3 to 4 cm is often necessary, following the caveats listed earlier (see biopsy section). Surgery consists of wide local excision with a 2- to 4-cm margin and intraoperative frozen section assessment of resection margins. Typically, chest wall resection, including the involved rib(s) and one rib above and below the tumor with a 4- to 5-cm margin of rib, is required. A margin of less than 1 cm results in much higher local recurrence rates. If a major neurovascular structure would have to be sacrificed, leading to high morbidity, then a margin of less than 1 cm would have to suffice. Survival after wide local excision with negative margins is 90% at 10 years.¹⁵¹

Primary Malignant Chest Wall Tumors

Malignant tumors of the chest wall are either metastatic lesions from another primary tumor or sarcoma. Soft tissue sarcomas of

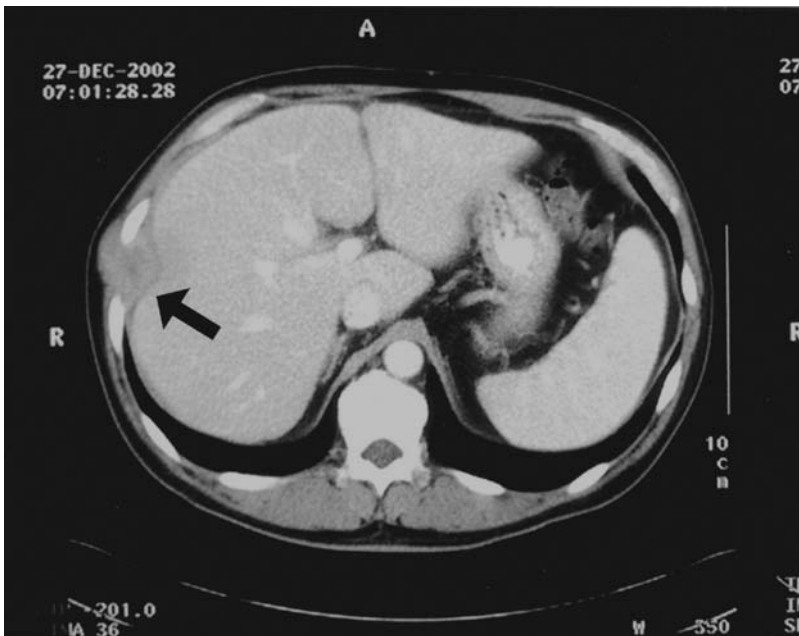


Figure 19-40. Chest computed tomography scan showing a right chest wall tumor (*arrow*). Tissue diagnosis revealed that this mass was a leiomyosarcoma.

the chest wall include fibrosarcomas, liposarcomas, malignant fibrous histiocytomas (MFHs), rhabdomyosarcomas, angiosarcomas, and other extremely rare lesions (Fig. 19-40). Despite the prevalence of localized disease, soft tissue sarcomas of the chest wall have significantly worse survival than similar tumors located on the extremities or the head and neck region. The factors impacting on risk of death from soft tissue sarcomas of the chest wall are presented in Table 19-23. All sarcomas have a propensity to spread to the lungs.

While many varieties of sarcoma exist, the primary features affecting prognosis are histologic grade and responsiveness to chemotherapy (Table 19-24). Preoperative (neoadjuvant) chemotherapy offers the ability to: (a) assess tumor chemosensitivity by the degree of tumor size reduction and microscopic necrosis; (b) determine tumor sensitivity to specific chemotherapeutic agents; and (c) improve resectability by reducing tumor size. Patients whose tumors are responsive to preoperative chemotherapy have a much better prognosis than those with a poor response. Information about tumor response to chemotherapy, the patient's physiologic state and capacity to receive treatment, and metastatic disease status is used to determine optimal therapy. The initial treatment is either: (a) preoperative chemotherapy (for patients with osteosarcoma, rhabdomyosarcoma, primitive neuroectodermal tumor, or Ewing's sarcoma) followed by surgery and postoperative chemotherapy; (b) primary surgical resection and reconstruction (for patients with nonmetastatic MFH, fibrosarcoma, liposarcoma, or synovial sarcoma); or (c) preoperative chemotherapy followed by surgical resection if indicated in patients presenting with metastatic soft tissue sarcomas. Contiguous involvement of underlying lung or other soft tissues or the presence of pulmonary metastases does not preclude successful surgery. In fact, patients receiving surgical intervention have significantly better overall survival. Median survival with surgical resection is 25 months compared to 8 months without resection. Additional prognostic variables that are important for long-term survival include tumor size, grade, stage, and negative re-resection margin.¹⁵² With the exception of rhabdomyosarcomas, the primary treatment of these lesions is wide surgical resection with 4-cm margins and reconstruction.¹⁵³

The following is an overview of several chest wall sarcomas.

1. **Chondrosarcoma.** Chondrosarcomas are the most common primary chest wall malignancy. As with chondromas, they usually arise anteriorly from the costochondral arches. CT scan shows a radiolucent lesion often with stippled calcifications pathognomonic for chondrosarcomas (Fig. 19-41). The involved bony structures are also destroyed. Most chondrosarcomas are slow-growing, low-grade tumors; these often painful masses can reach massive proportions.¹⁴⁸ For this reason, any lesion in the anterior chest wall likely to be a low-grade chondrosarcoma should be treated with wide (4-cm) resection after metastatic disease to the lungs or bones is ruled out. Chondrosarcomas are not sensitive to radiation or chemotherapy. Prognosis is determined by tumor grade and extent of resection. With a low-grade tumor and wide resection, patient survival at 5 to 10 years can be as high as 60% to 80%.
2. **Osteosarcoma.** While osteosarcomas are the most common bone malignancy, they represent only 10% to 15% of all malignant chest wall tumors.^{154,155} They primarily occur in young adults as rapidly enlarging, painful masses; however, osteosarcomas can occur in older patients as well, sometimes in association with previous radiation, Paget's disease, or chemotherapy. Radiographically, the typical appearance consists of spicules of new periosteal bone formation producing a sunburst appearance. Osteosarcomas have a propensity to spread to the lungs, and up to one third of patients present with metastatic disease. Osteosarcomas are potentially sensitive to chemotherapy. Currently, preoperative chemotherapy is common. After chemotherapy, complete resection is performed with wide (4-cm) margins, followed by reconstruction. In patients presenting with lung metastases that are potentially amenable to surgical resection, induction chemotherapy may be given, followed by surgical resection of the primary tumor and of the pulmonary metastases. Following surgical treatment of known disease, additional maintenance chemotherapy is usually recommended.

Table 19-23

Cox proportional hazards model for risk of death from soft tissue sarcoma

	N	HAZARD RATIO	95% CI	P VALUE
Gender				
Male	3937	Reference group	Reference group	Reference group
Female	4113	0.897	0.843–0.955	.001
Age				
50 years	1837	Reference group	Reference group	Reference group
51–70 years	3099	1.131	1.026–1.247	.013
>70 years	3114	1.538	1.395–1.697	<.001
Race				
Caucasian	7152	Reference group	Reference group	Reference group
Non-Caucasian	898	1.212	1.093–1.344	<.001
Histologic type				
Fibrosarcoma	489	Reference group	Reference group	Reference group
MFH	2529	1.281	1.097–1.495	.002
Liposarcoma	1534	0.894	0.759–1.054	.182
LMS/GIST	3498	1.204	1.033–1.403	.018
Location				
Head and neck	576	Reference group	Reference group	Reference group
Trunk	4054	1.255	1.096–1.438	.001
Extremity	2474	1.003	0.875–1.151	.960
Retroperitoneum	946	1.276	1.093–1.489	.002
Stage				
Localized	5006	Reference group	Reference group	Reference group
Regional	1724	1.575	1.458–1.702	<.001
Distant	1320	2.897	2.660–3.155	<.001
Surgical treatment				
Yes	6754	Reference group	Reference group	Reference group
No	1296	1.562	1.443–1.691	<.001
Radiation therapy				
Yes	2175	Reference group	Reference group	Reference group
No	5875	1.151	1.070–1.239	<.001
Chemotherapy				
Yes	1062	Reference group	Reference group	Reference group
No	6988	0.909	0.829–0.996	.041

CI = confidence interval; GIST = gastrointestinal stromal tumor; LMS = leiomyosarcoma; MFH = malignant fibrous histiocytoma.

Source: Reproduced with permission from Gutierrez et al.¹⁵² Copyright Elsevier.

Table 19-24

Classification of sarcomas by therapeutic response

TUMOR TYPE	CHEMOTHERAPY SENSITIVITY
Osteosarcoma	+
Rhabdomyosarcoma	+
Primitive neuroectodermal tumor	+
Ewing's sarcoma	+
Malignant fibrous histiocytoma	±
Fibrosarcoma	±
Liposarcoma	±
Synovial sarcoma	±

3. **Malignant fibrous histiocytoma.** Originally thought to derive from histiocytes because of the microscopic appearance of cultured tumor cells, these tumors likely originate from the fibroblast. MFHs are generally the most common soft tissue sarcoma of late adult life, although they are rare on the chest wall. The typical age at presentation is between age 50 and 70 years. Presentation is pain, with or without a palpable mass. Radiographically, a mass is usually evident, with destruction of surrounding tissue and bone. Treatment is wide resection with a margin of 4 cm or more and reconstruction. Over two thirds of patients suffer from distant metastasis or local recurrence.
4. **Liposarcoma.** Liposarcomas make up 15% of chest wall sarcomas. Most liposarcomas are low-grade tumors that have a propensity to recur locally, given their infiltrative nature. They typically present as a painless mass. Treatment is wide resection and reconstruction. Intraoperative

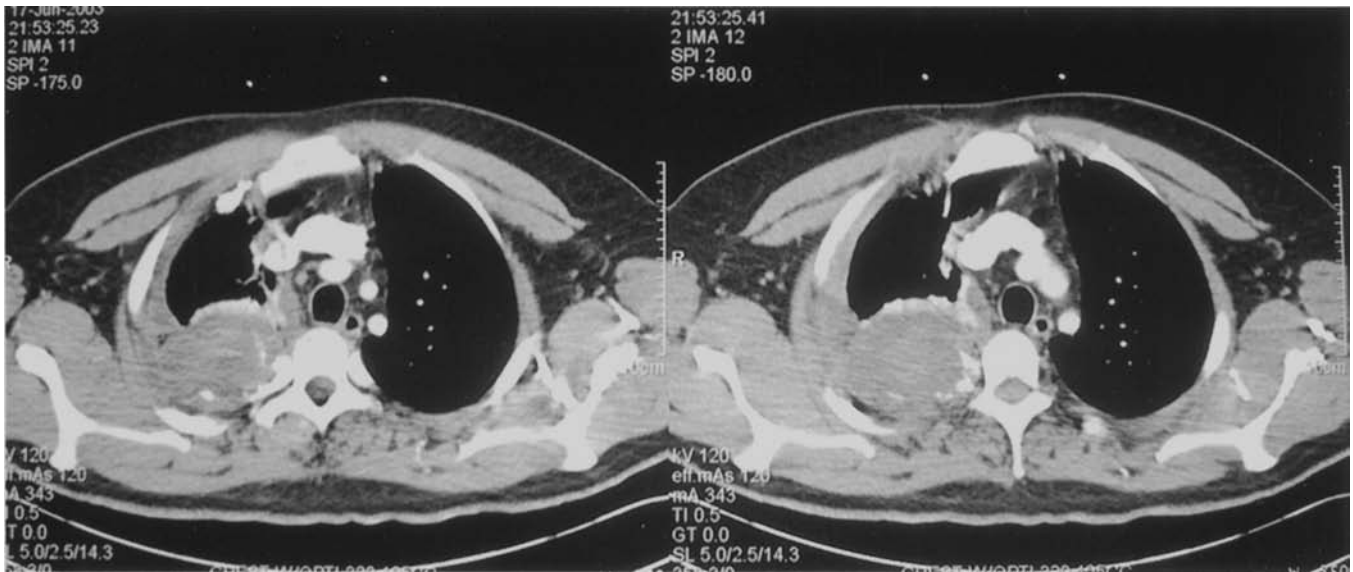


Figure 19-41. Chest computed tomography scan showing a right posterior lung tumor. In the appropriate clinical setting, stippled calcifications (white streaks in right lung mass) are highly indicative of chondrosarcomas.

margins should be evaluated (as with all sarcomas) and resection continued, if feasible, until margins are negative. Local recurrence can be treated with re-excision, with occasional use of radiotherapy.

5. **Fibrosarcoma.** Often presenting as a large, painful mass, these lesions are visible on plain radiograph or CT, with surrounding tissue destruction. Treatment is wide local excision with intraoperative frozen-section analysis of margins, followed by reconstruction. Local and systemic recurrence is frequent. Patient survival at 5 years is about 50% to 60%.
6. **Rhabdomyosarcoma.** Rhabdomyosarcomas are rare tumors of the chest wall. Microscopically, they are a spindle cell tumor. The diagnosis often depends on immunohistochemical staining for muscle markers. Rhabdomyosarcomas are sensitive to chemotherapy. Treatment consists of preoperative chemotherapy with subsequent surgical resection.

Other Tumors of the Chest Wall

1. **Primitive neuroectodermal tumors (PNETs) and Ewing's sarcoma.** PNETs (neuroblastomas, ganglioneuroblastomas, and ganglioneuromas) derive from primordial neural crest cells that migrate from the mantle layer of the developing spinal cord. Histologically, PNETs and Ewing's sarcomas are small, round cell tumors; both possess a translocation between the long arms of chromosomes 11 and 22 within their genetic makeup. They also share a consistent pattern of proto-oncogene expression and have been found to express the product of the *MIC2* gene. Ewing's sarcoma occurs in adolescents and young adults who present with progressive chest wall pain, but without the presence of a mass. Systemic symptoms of malaise and fever are often present. Laboratory studies reveal an elevated erythrocyte sedimentation rate and mild white blood cell elevation. Radiographically, the characteristic onion peel appearance is produced by multiple layers of periosteum in the bone formation. Evidence of bony destruction is also common. The diagnosis can be made by a percutaneous needle biopsy or an incisional biopsy.

These tumors have a strong propensity to metastasize to the lungs and skeleton; patient survival rates are thus only 50% or less at 3 years. Increasing tumor size is associated with decreasing survival. Treatment has improved significantly and now consists of multiagent chemotherapy, radiation therapy, and surgery. Patients are typically treated preoperatively with chemotherapy and re-evaluated with radiologic imaging. When residual disease is identified, surgical resection and reconstruction are performed followed by maintenance chemotherapy.

2. **Plasmacytoma.** Solitary plasmacytomas of the chest wall are very rare, with approximately 25 to 30 cases per year in the United States.¹⁵⁴ The typical presentation is pain without a palpable mass. Plain radiographs show an osteolytic lesion in the region of the pain. As with other chest wall tumors, a needle biopsy under CT guidance is performed for diagnosis. Histologically, the lesion is identical to multiple myeloma, with sheets of plasma cells. It occurs at an average age of 55 years. Evaluation for systemic myeloma is performed with bone marrow aspiration, testing of calcium levels, and measurement of urinary Bence Jones proteins. If the results of these studies are negative, then a solitary plasmacytoma is diagnosed. Surgery is usually limited to a biopsy only, which may be excisional.¹⁵⁵ Treatment consists of radiation with doses of 4000 to 5000 cGy. Up to 75% of patients develop systemic multiple myeloma with 10-year survival of approximately 20%.

Chest Wall Reconstruction

The primary determinant of long-term freedom from recurrence and overall survival is margin status; therefore, adequate margins of normal tissue must be included in the en bloc resection. En bloc resection should include involved ribs, sternum, superior sulcus, or spine if necessary; invasion of these structures should not be considered a contraindication to surgery in an otherwise fit patient. The resection should include at least one normal adjacent rib above and below the tumor, with all intervening intercostal muscles and pleura. In addition, an en bloc resection of overlying chest wall muscles is often necessary, such as of the

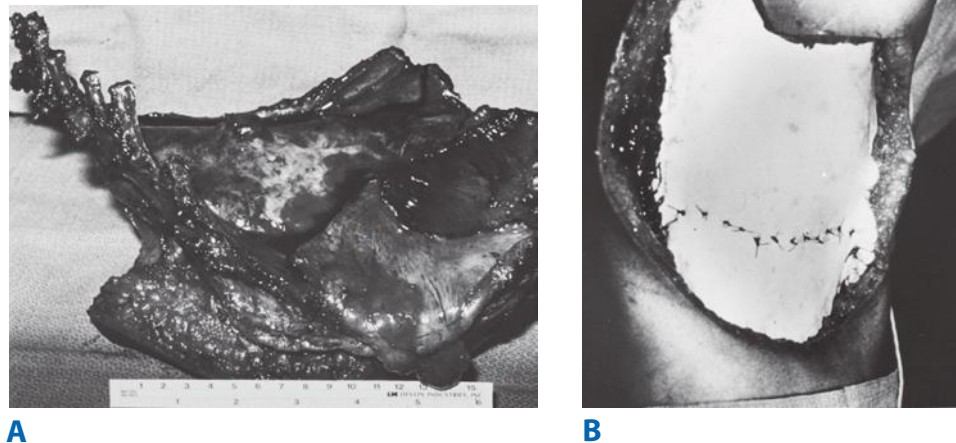


Figure 19-42. Principles of reconstruction after resection of a chest wall tumor (osteogenic sarcoma) are shown. **A.** En bloc resection of the involved chest wall, including normal ribs above and below the tumor as well as pulmonary parenchyma, must be performed. The resected specimen is shown. **B.** A prosthesis has been sewn in place. In the lower third of the prosthesis, the line of diaphragm reattachment is seen. The skin defect was closed with a myocutaneous flap from the ipsilateral rectus muscle.

pectoralis minor or major, serratus anterior, or latissimus dorsi. When the periphery of the lung is involved with the neoplasm, it is appropriate to resect the adjacent part of the pulmonary lobe in continuity (Fig. 19-42). Involvement of the sternum by a malignant tumor requires total resection of the sternum with the adjacent cartilage. Techniques for postoperative respiratory support are now good enough that resection should not be compromised because of any concern about the patient's ability to be adequately ventilated in the early postoperative period.

The extent of resection depends on the tumor's location and on any involvement of contiguous structures. Laterally based lesions often require simple wide excision, with resection of any contiguously involved lung, pleura, muscle, or skin. Anteriorly based lesions contiguous with the sternum require partial sternectomy. Primary malignant tumors of the sternum may require complete sternectomy. Posterior lesions involving the rib heads over their articulations with the vertebral bodies may, depending on the extent of rib involvement, require partial en bloc vertebrectomy.

Optimal management of larger tumors includes careful preoperative planning and execution of the surgery by the thoracic surgeon and an experienced plastic surgeon, in order to ensure optimal physiologic and cosmetic results. With this, reconstruction at the same operation can be accomplished.¹⁵⁶ Reconstruction of a large defect in the chest wall requires the use of some type of material to prevent lung herniation and to provide stability for the chest wall (see Fig. 19-42). Mild degrees of paradoxical motion are often well tolerated if the area of instability is relatively small. Historically, a wide variety of materials have been used to re-establish chest wall stability, including rib autografts, steel struts, acrylic plates, and numerous synthetic meshes. The current preference is either a 2-mm polytetrafluoroethylene (Gore-Tex) patch or a double-layer polypropylene (Marlex) mesh sandwiched with methylmethacrylate. There are several properties that make Gore-Tex an excellent material for

use in chest wall reconstruction: (a) it is impervious to fluid, which prevents pleural fluid from entering the chest wall and minimizes the formation of seromas, which can compromise the myocutaneous flap viability and provide a nidus for infection; and (b) it provides excellent rigidity and stability when secured taut to the surrounding bony structure and, as a result, provides a firm platform for myocutaneous flap reconstruction. Except for smaller lesions, tissue coverage requires the use of myocutaneous flaps (latissimus dorsi, serratus anterior, rectus abdominis, or pectoralis major muscles).^{157,158}

MEDIASTINUM

Anatomy and Pathologic Entities

The mediastinum can be divided into compartments for classification of anatomic components and disease processes, which, despite substantial overlap, facilitates understanding of general concepts of surgical interest. Several classification schemes exist, but for the purposes of this chapter, the three-compartment model is used (Fig. 19-43). The anterior compartment lies between the sternum and the anterior surface of the heart and great vessels. The visceral or middle compartment is located between the great vessels and the trachea. As the name implies, the posterior compartment lies posterior and includes the paravertebral sulci, bilaterally, and the paraesophageal area.

The normal content of the anterior compartment includes the thymus gland or its remnant, the internal mammary artery and vein, lymph nodes, and fat. The thymus gland is large during childhood, occupying the entire anterior mediastinum (Fig. 19-44) but decreases in both thickness and length after adolescence and takes on a more fatty content, with only residual islands of thymic cellular components (Fig. 19-45). The middle mediastinal compartment contains the pericardium and its contents, the ascending and transverse aorta, the superior and

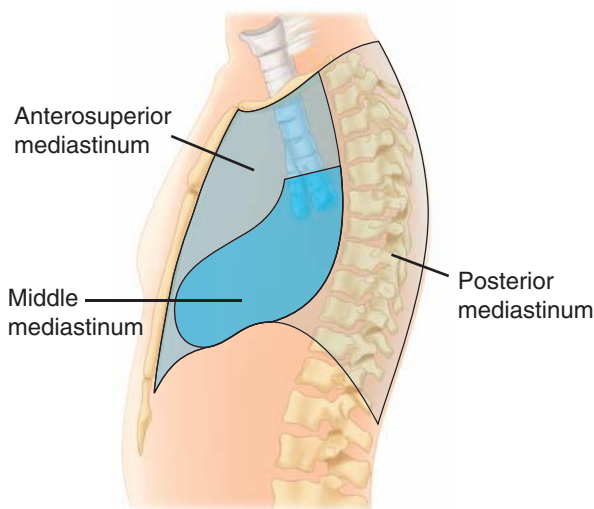


Figure 19-43. Anatomic division of the mediastinum.

inferior vena cavae, the brachiocephalic artery and vein, the phrenic and upper vagus nerves, the trachea and main bronchi and corresponding lymph nodes, and the central portions of the pulmonary arteries and veins. The posterior compartment contains the descending aorta, esophagus, thoracic duct, azygos and hemiazygos veins, and lymph nodes. Numerous pathologic variants may be present in the various compartments, with much overlap. Table 19-25 includes the most common pathologic entities listed by compartment.^{159,160}

History and Physical Examination

Mediastinal pathology varies significantly by patient age. In children, neurogenic tumors of the posterior mediastinum are most common, followed by lymphoma, which is usually located in the anterior or middle compartment. Thymoma in childhood is rare (Table 19-26). In adults, the most common tumors include neurogenic tumors of the posterior compartment, benign cysts occurring in any compartment, and thymomas of the anterior mediastinum (Table 19-27). In both age groups, about 25%

of mediastinal tumors are malignant. Pediatric tumors will be discussed in Chapter 39.

Up to two thirds of mediastinal tumors in adults are discovered as asymptomatic abnormalities on radiologic studies ordered for other problems, particularly now that screening CT examinations are more prevalent. When symptomatic, these tumors are significantly more likely to be malignant. Characteristics such as size, location, rate of growth, and associated inflammation are important factors that correlate with symptoms. Large, bulky tumors, expanding cysts, and teratomas can cause compression of mediastinal structures, in particular the trachea, and lead to cough, dyspnea on exertion, or stridor. Chest pain or dyspnea may be reported secondary to associated pleural effusions, cardiac tamponade, or phrenic nerve involvement. Occasionally, a mediastinal mass near the aortopulmonary window may be identified in a workup for hoarseness because of left recurrent laryngeal nerve involvement. The patient in Fig. 19-46 presented with hoarseness due to nodal compression of the left recurrent laryngeal nerve from a primary lung cancer with metastases to the level 5 and 6 lymph nodes in the region of the aortopulmonary window.

The history and physical examination in conjunction with the imaging findings may suggest a specific diagnosis (Table 19-28). In one recent series, systemic symptoms were present in 50% of patients with a mediastinal mass and a lymphoproliferative disorder, as compared with only 29% of patients with other masses (such as thymic or neurogenic). Laboratory signs of inflammation were also noted; the erythrocyte sedimentation rate and C-reactive protein levels were elevated and leukocytosis was present in 86% of patients with a lymphoproliferative disorder, as compared with only 58% of patients with other types of mediastinal masses.

Imaging and Serum Markers

Chest CT or MRI is required to fully delineate the anatomy.¹⁶¹ A contrast-enhanced CT scan enables clear delineation of the soft tissue structures from the vasculature and is preferred over noncontrast studies. If there is concern for invasion of vascular structures or spinal involvement, MRI is more accurate than CT scan and provides important information regarding respectability.

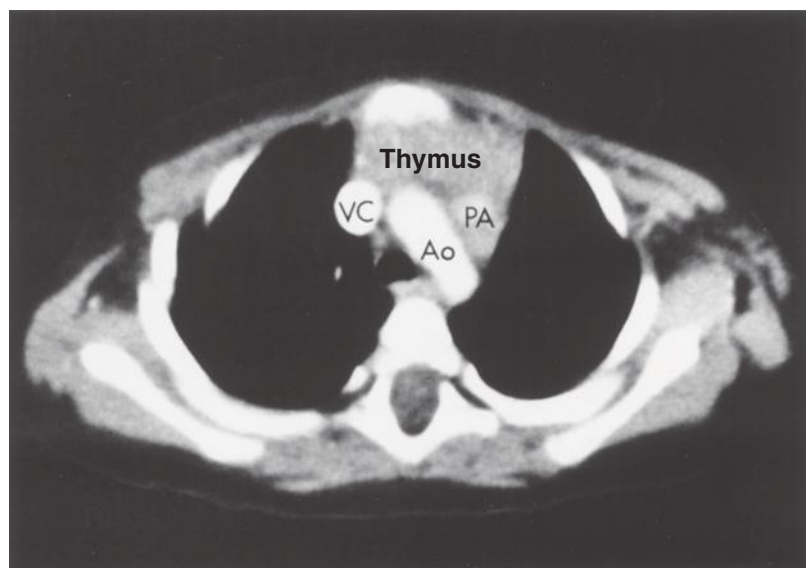


Figure 19-44. Normal appearance of the thymus gland in childhood. Ao = aorta; PA = pulmonary artery; VC = vena cava.

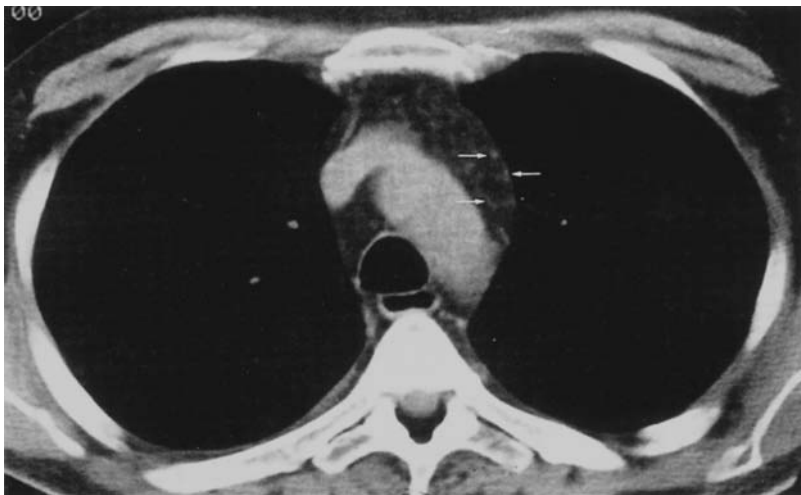


Figure 19-45. Computed tomography scan showing the normal appearance of an involuted thymus gland in an adult. Note the near-total fatty appearance of the gland with only tiny islands of soft tissue scattered within it (*small arrows*).

If an endocrine origin is suspected, several other imaging modalities are available (Table 19-29). Single-photon emission CT (SPECT) technology may be used to improve image contrast and give information on three-dimensional localization, largely replacing conventional two-dimensional nuclear imaging studies. If a thyroid origin is suspected, a thyroid scan using ^{131}I or ^{123}I can identify most intrathoracic goiters and identify the extent of functioning thyroid tissue. If indicated, the thyroid scan should precede other scans requiring iodine-containing contrast agents, because they would subsequently interfere with iodine tracer uptake by thyroid tissue. If a pheochromocytoma or neuroblastoma is suspected, the octreotide scan or ^{123}I -metaiodobenzylguanidine (MIBG) scans are helpful in diagnosis and localization. The sestamibi scan may be useful for diagnosing and localizing a mediastinal parathyroid gland. PET is useful for distinguishing malignant from benign tumors and may help detect distant metastases in some patients. However, the role of routine PET imaging for staging surgically resectable lesions of the mediastinum has not been established.

The use of serum markers to evaluate a mediastinal mass can be invaluable in some patients. For example, nonseminomatous

and seminomatous germ cell tumors can frequently be diagnosed and often distinguished from one another by the levels of α -fetoprotein (AFP) and human chorionic gonadotropin (hCG). In over 90% of nonseminomatous germ cell tumors, either the AFP or the hCG level will be elevated. Results are close to 100% specific if the level of either AFP or hCG is greater than 500 ng/mL. Some centers institute chemotherapy based on this result alone, without biopsy confirmation of the diagnosis. In contrast, the AFP level in patients with mediastinal seminoma is always normal; only 10% will have elevated hCG, which is usually less than 100 ng/mL. Other serum markers, such as intact parathyroid hormone level for ectopic parathyroid adenomas, may be useful for diagnosing and also for intraoperatively confirming complete resection. After successful resection of a parathyroid adenoma, this hormone level should rapidly normalize.

Diagnostic Nonsurgical Biopsies of the Mediastinum

The treatment of up to 60% of patients with anterior mediastinal masses is ultimately nonsurgical, so it is essential to

Table 19-25

Usual location of the common primary tumors and cysts of the mediastinum

ANTERIOR COMPARTMENT	VISCERAL COMPARTMENT	PARAVERTEBRAL SULCI
Thymoma	Enterogenous cyst	Neurilemoma-schwannoma
Germ cell tumor	Lymphoma	Neurofibroma
Lymphoma	Pleuropericardial cyst	Malignant schwannoma
Lymphangioma	Mediastinal granuloma	Ganglioneuroma
Hemangioma	Lymphoid hamartoma	Ganglioneuroblastoma
Lipoma	Mesothelial cyst	Neuroblastoma
Fibroma	Neuroenteric cyst	Paraganglioma
Fibrosarcoma	Paraganglioma	Pheochromocytoma
Thymic cyst	Pheochromocytoma	Fibrosarcoma
Parathyroid adenoma	Thoracic duct cyst	Lymphoma

Source: Reproduced with permission from Shields TW. The mediastinum and its compartments. In: Shields TW, ed. *Mediastinal Surgery*. Philadelphia: Lea & Febiger; 1991:5.

Table 19-26

Mediastinal tumors in children

TUMOR TYPE	PERCENTAGE OF TOTAL	LOCATION
Neurogenic tumors	40	Posterior
Lymphomas	18	Anterior/middle
Cysts	18	All
Germ cell tumors	11	Anterior
Mesenchymal tumors	9	All
Thymomas	Rare	Anterior

Source: Reproduced with permission from Silverman NA, Sabiston DC Jr. Mediastinal masses. *Surg Clin North Am.* 1980;60:760. Copyright Elsevier.

understand all options for obtaining adequate tissue for a definitive diagnosis using the least invasive approach. CT-guided needle biopsy, and EUS-guided FNA, and even core-needle biopsy (either CT-guided EBUS-guided, or EUS-guided) have proven most useful for cytologic and tissue diagnosis of mediastinal masses and lymphadenopathy. When FNA and core-needle biopsy were combined, the accuracy was 98%, compared to 79% for each modality independently. In addition, core-needle biopsy changed the diagnosis in nine cases that had been missed by FNA due to inadequate specimens. Finally, core-needle biopsy was better at diagnosis for benign diseases compared to FNA. Accessible nodal stations include subcarinal (level 7), aortopulmonary (level 5), paraesophageal (level 8), and inferior pulmonary ligament (level 9) as well as paratracheal (level 4).¹⁶² Technical expertise in these modalities should be pursued by thoracic and general surgeons.

Historically, needle biopsies of anterior mediastinal masses were reportedly sensitive and specific for most carcinomatous tumors, but there were questions regarding accuracy for diagnosing lymphomas.¹⁶³ However, advances in cytopathology as well as needle biopsy technology have substantially improved diagnostic accuracy such that most centers are reporting yields

Table 19-27

Mediastinal tumors in adults

TUMOR TYPE	PERCENTAGE OF TOTAL	LOCATION
Neurogenic tumors	21	Posterior
Cysts	20	All
Thymomas	19	Anterior
Lymphomas	13	Anterior/middle
Germ cell tumors	11	Anterior
Mesenchymal tumors	7	All
Endocrine tumors	6	Anterior/middle

Source: Data from Shields TW. Primary lesions of the mediastinum and their investigation and treatment. In: Shields TW, ed. *General Thoracic Surgery*, 4th ed. Baltimore: Lippincott Williams & Wilkins; 1994:1731.

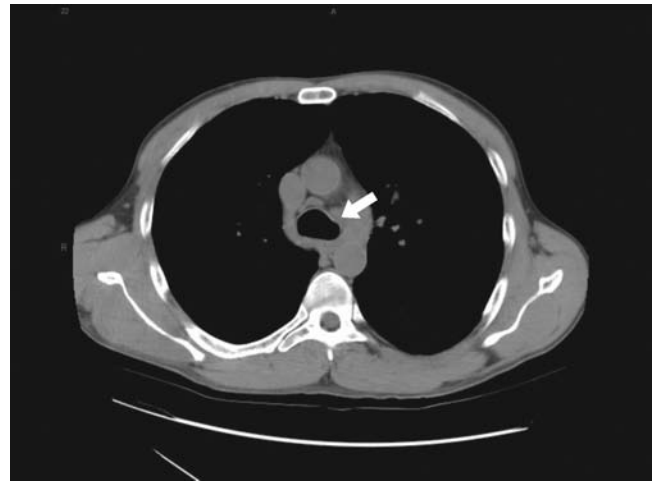


Figure 19-46. Computed tomography scan of a patient who presented with hoarseness due to compression of the left recurrent laryngeal nerve caused by mediastinal lymph node metastases to the aortopulmonary window area (*arrow*) from a primary lung cancer.

ranging from 75% to 80% for the diagnosis of lymphoma as well. To achieve maximal diagnostic yield for mediastinal masses suggestive of a lymphoma, it is necessary to obtain multiple fine-needle aspirates, preferably with immediate onsite rapid cytologic analysis to confirm sampling of the target tissue and adequate cellularity. This also facilitates processing of the sample to ensure that proper studies for lymphoma, including flow cytometry, are obtained. If the needle biopsy is inconclusive, surgical biopsy can be performed.^{164,165} If the lesion is accessible by CT-guided or EUS-guided core-needle biopsy, intraoperative frozen section or immediate cytologic smear of a core biopsy can also be performed. Recently, core-needle biopsy with EBUS became possible with release of a EBUS-core needle device. This addition to the surgeon's armamentarium will greatly facilitate tissue sampling for evaluation of mediastinal masses. The authors perform their own endobronchial, endoscopic, and CT-guided transbronchial and transthoracic biopsies and, in our experience, lack of cellularity in the aspirate is readily apparent. In general, plans to proceed with surgical biopsy are made in combination with the image-guided aspiration and, as such, are performed in the same setting. This enables the authors to avoid a more invasive surgical procedure when FNA or core-needle biopsy is sufficient without contributing to delays in diagnosis by having multiple attempts from multiple providers (such as interventional radiology and pulmonology) before involvement of the surgeon in the diagnostic workup.

Surgical Biopsies and Resection of Mediastinal Masses

For tumors of the mediastinum that are not amenable to an endoscopic or CT-guided needle biopsy or that do not yield sufficient tissue for diagnosis, a surgical biopsy is indicated. The definitive approach to a surgical biopsy of the anterior mediastinum is through a median sternotomy. At the time of sternotomy, if the lesion is easily resectable, it should be completely removed. Given the invasiveness of the procedure and the inability in some patients to obtain a definitive diagnosis by frozen section, less invasive procedures are preferable if the lesion is large or if the CT scan or history suggests that surgery is not the best definitive treatment. Masses in the paratracheal region are easily biopsied by mediastinoscopy. For tumors of the anterior or

Table 19-28

Signs and symptoms suggestive of various diagnoses in the setting of a mediastinal mass

DIAGNOSIS	HISTORY AND PHYSICAL FINDINGS	COMPARTMENT LOCATION OF MASS
Lymphoma	Night sweats, weight loss, fatigue, extrathoracic adenopathy, elevated erythrocyte sedimentation rate or C-reactive protein level, leukocytosis	Any compartment
Thymoma with myasthenia gravis	Fluctuating weakness, early fatigue, ptosis, diplopia	Anterior
Mediastinal granuloma	Dyspnea, wheezing, hemoptysis	Visceral (middle)
Germ cell tumor	Male gender, young age, testicular mass, elevated levels of human chorionic gonadotropin and/or α -fetoprotein	Anterior

posterior mediastinum, a left or right VATS approach often allows safe and adequate surgical biopsies. In some patients, an anterior mediastinotomy (i.e., Chamberlain procedure) may be ideal for an anterior tumor or a tumor with significant parasternal extension. Before a surgical biopsy is pursued, a discussion should be held with the pathologist regarding routine histologic assessment, special stains and markers, and requirements for lymphoma workup.

Surgical resection using minimally invasive approaches, including video-assisted and robotic thoracoscopic surgery and transcervical, are now routine for the vast majority of middle and posterior tumors and for moderate sized (<5 to 6 cm) anterior mediastinal tumors.¹⁶⁶⁻¹⁶⁹ Outcomes comparing VATS to open thymectomy in patients with myasthenia gravis without thymoma were prospectively evaluated by Chang and colleagues in 2005, and no differences were seen in terms of response to therapy and recurrence of symptoms. Pain scores were significantly better in the VATS approach.¹⁷⁰ These reports and others support application of VATS for the majority of anterior mediastinal masses.

Other minimally invasive approaches are under study. For example, good results have been reported using a cervical incision with a sternal retractor for thymus removal. The upward lift allows the surgeon reasonable access to the anterior mediastinum and has proven adequate in some centers for definitive resection of the thymus gland for myasthenia gravis.¹⁷¹

For larger anterior mediastinal masses or in centers where expertise in thoracoscopy is not available, median sternotomy and thoracotomy remain excellent options for resection of anterior mediastinal masses. Occasionally, a lateral thoracotomy with sternal extension (hemi-clamshell) provides excellent exposure for extensive mediastinal tumors that have a lateral component. Most surgeons would agree that if a larger anterior mediastinal tumor is seen or malignancy is suspected, a median sternotomy with a more radical resection should be performed.

Mediastinal Neoplasms

Thymic Hyperplasia. Diffuse thymic hyperplasia was first described in children after successful chemotherapy for lymphoma. It has now been described in adults and is referred to as

Table 19-29

Nuclear imaging relevant to the mediastinum

RADIOPHARMACEUTICAL, RADIONUCLIDE, OR RADIOCHEMICAL	LABEL	DISEASE OF INTEREST
Iodine	¹³¹ I, ¹²³ I	Retrosternal goiter, thyroid cancer
Monoclonal antibodies	¹¹¹ In, ^{99m} Tc	NSCLC, colon and breast cancer, prostate cancer metastases
Octreotide	¹¹¹ In	Amine precursor uptake decarboxylation tumors: carcinoid, gastrinoma, insulinoma, small cell lung cancer, pheochromocytoma, glucagonoma, medullary thyroid carcinoma, paraganglioma
Gallium	⁶⁷ Ga	Lymphoma, NSCLC, melanoma
Sestamibi	^{99m} Tc	Medullary thyroid carcinoma, nonfunctional papillary or follicular thyroid carcinoma, Hürthle cell thyroid carcinoma, parathyroid adenoma or carcinoma
Thallium	²⁰¹ Tl	See sestamibi
MIBG	¹³¹ I, ¹²³ I	Pheochromocytoma, neuroblastoma; see also octreotide
Fluorodeoxyglucose	¹⁸ F	General oncologic imaging, breast and colon cancer, melanoma

MIBG = metaiodobenzylguanidine; NSCLC = non-small cell lung cancer.

Source: Reproduced with permission from McGinnis KM, et al. Markers of the mediastinum. In: Pearson FG, et al, eds. *Thoracic Surgery*. 2nd ed. New York: Churchill Livingstone; 2002:1675. Copyright Elsevier.

“rebound thymic hyperplasia.”¹⁷² It is most frequently reported after chemotherapy for lymphoma or germ cell tumors. Initially, atrophy of the thymic gland is seen with subsequent thymic gland enlargement, which can be dramatic. The usual time course for thymic hyperplasia is about 9 months after cessation of chemotherapy (range 2 weeks–12 months). Benign hyperplasia must be clearly distinguished from recurrent lymphoma or germ cell tumors, which may be difficult since thymic hyperplasia is dramatic in some patients; careful follow-up with serial CT scans is the minimum requirement. The role of PET scanning is unclear. Thymic hyperplasia is a known cause of false-positive PET scans; in many patients, CT scan will show a triangular soft tissue density in the retrosternal space that has a characteristic bilobed anatomic appearance consistent with thymus gland.¹⁷³ In addition, a low standardized uptake value of tracer on PET scan suggests a benign tumor.¹⁷⁴ Biopsies may be required if the clinical index of suspicion is high.

Thymoma. The most frequently encountered neoplasm of the anterior mediastinum in adults (seen most frequently between 40 and 60 years of age), thymoma is rare in children. Between 10% and 50% of patients with thymoma will have symptoms suggestive of myasthenia gravis or have circulating antibodies to acetylcholine receptor, but less than 10% of patients with myasthenia gravis have a thymoma. Most patients with thymoma are asymptomatic. Thymectomy leads to improvement or resolution of symptoms of myasthenia gravis in only about 25% of patients with thymomas. In contrast, in patients with myasthenia gravis and no thymoma, thymectomy results are superior: up to 50% of patients have a complete remission and 90% improve. In 5% of patients with thymomas, other paraneoplastic syndromes, including red cell aplasia, hypogammaglobulinemia, systemic lupus erythematosus, Cushing’s syndrome, or SIADH, may be present. Large thymic tumors may present with symptoms related to a mass effect, which may include cough, chest pain, dyspnea, or SVC syndrome.

The diagnosis may be suspected based on CT scan and history, but imaging alone is not diagnostic. In most centers, the diagnosis is made after surgical resection because of the relative difficulty of obtaining a needle biopsy and the likelihood that removal will ultimately be recommended. Biopsy should be avoided in cases where imaging is highly suggestive of thymoma. In most patients, the distinction between lymphomas and thymomas can be made on CT scan, since most lymphomas have marked lymphadenopathy and thymomas most frequently appear as a solitary encapsulated mass. PET scan may have a role in differentiating thymic cancer from thymoma, as thymic cancer tends to be very FDG avid.¹⁷⁴ In addition, PET scan may facilitate identification of low-risk and minimally invasive thymoma; a standardized uptake value (SUV) <5 was associated with Masaoka stage I or II thymoma, whereas invasive thymoma and mediastinal lymphoma were more likely when the SUV was >5.¹⁷⁵ In cases where the diagnosis is unclear, transmediastinal, not transpleural, CT-guided FNA biopsy has a diagnostic sensitivity of 87% and a specificity of 95% in specialized centers.

The most commonly accepted staging system for thymoma is that of Masaoka.¹⁷⁶ It is based on the presence or absence of gross or microscopic invasion of the capsule and of surrounding structures, as well as on the presence or absence of metastases (Table 19-30). Histologically, thymomas are characterized by a mixture of epithelial cells and mature lymphocytes. Grossly, many thymomas remain well encapsulated. Even those with capsular invasion often lack histologic features of malignancy;

Table 19-30

Masaoka staging system for thymoma

Stage I	Encapsulated tumor with no gross or microscopic evidence of capsular invasion
Stage II	Gross capsular invasion or invasion into the mediastinal fat or pleura or microscopic capsular invasion
Stage III	Gross invasion into the pericardium, great vessels, or lung
Stage IVA	Pleural or pericardial dissemination
Stage IVB	Lymphogenous or hematogenous metastasis

they appear cytologically benign and identical to early-stage tumors. This lack of classic cellular features of malignancy is why most pathologists use the term “thymoma” or “invasive thymoma” rather than “malignant thymoma.” Thymic tumors with malignant cytologic features are classified separately and referred to as “thymic carcinoma.”

The definitive treatment for thymoma is complete surgical removal; local recurrence rates and survival vary according to stage (Fig. 19-47). In centers with significant experience with VATS procedures, thymoma is not a contraindication to VATS approach, provided the principles of resection are adhered to, such as a complete resection without disrupting the capsule.¹⁷⁷ Otherwise, resection is generally accomplished by median sternotomy with extension to hemi-clamshell in more advanced cases. Even advanced tumors with local invasion of resectable structures such as the pericardium, SVC, or innominate vessels should be considered for resection with reconstruction.

A multidisciplinary approach to nonresectable and more advanced lesions (stage ≥II) is mandatory to optimize patient care. The goal for surgical resection should be complete excision of the mass with total thymectomy. All contiguous and noncontiguous disease is removed at the same setting; this may include resection of the pericardium or pleura, adjacent adherent lung, phrenic nerve, major vascular structures, and pleural metastasis. Bilateral phrenic nerve resection should be avoided, however, due to the major respiratory morbidity associated with bilateral paralyzed hemidiaphragms.

The role of adjuvant or neoadjuvant therapies for advanced-stage tumors remains unclear. Traditionally, stage II

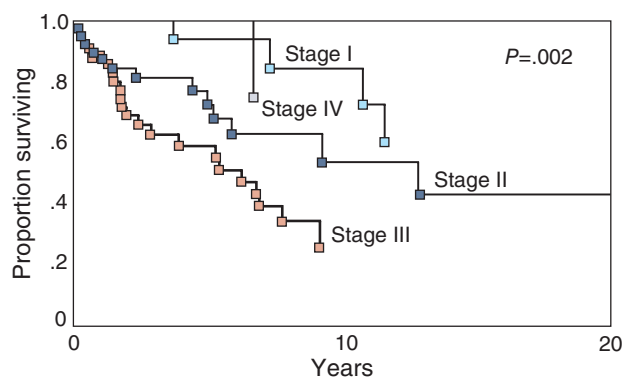


Figure 19-47. Stage-specific survival for thymomas.

thymomas have been treated by complete surgical resection followed by mediastinal radiation, but randomized trials have not been done. A recent retrospective review of a single-institution series of stage II thymoma patients showed no difference in survival or local recurrence after complete surgical resection alone, as compared with surgical resection with radiotherapy. Advanced thymomas have been shown to respond to platinum-based chemotherapy and to corticosteroids.¹⁷⁸ One summary of chemotherapy trials showed an overall response rate of about 70%. Cisplatin/doxorubicin-based regimens appear to yield the best results. The combination radiotherapy and chemotherapy for local progression appears to prolong survival in some small series.¹⁷⁹ Radiation therapy in surgically resected stage III thymoma is likely beneficial in extending disease-specific survival; a recent analysis of the Surveillance, Epidemiology, and End Results (SEER) database identified 476 patients with stage III thymoma treated with primary surgery. Postoperative radiation was given to 322 patients with a significant improvement in survival (127 months compared to 105 months, $P = .038$) despite the fact that these patients were more likely to have had debulking rather than curative resection. In multivariate analysis, disease-specific survival was better in the adjuvant radiation group.¹⁸⁰ Therefore, it is imperative that all patients with thymomas undergo a thorough evaluation for potential resection. Current guidelines recommend radiation for patients with unresectable thymoma who have failed induction chemotherapy or for patients with incompletely resected invasive thymoma or thymic cancer. Planning the radiation ports requires input from the surgeon; it is important for the surgeon to carefully document areas of adherence between the thymoma and adjacent structures during the operation, with clips or other radiopaque markers placed to guide radiation therapy postoperatively. Extracapsular extension and positive surgical margins should be noted by the pathologist and correlated anatomically so that

the surgeon and radiation oncologist can ensure appropriate radiation treatment.

Thymic Carcinoma. Thymic carcinomas are unequivocally malignant at the microscopic level. Suster and Rosai classified thymic carcinomas into low-grade and high-grade tumors.¹⁸¹ Low-grade tumors are well differentiated with squamous cell, mucoepidermoid, or basaloid features. High-grade thymic carcinomas include those with lymphoepithelial, small cell neuroendocrine, sarcomatoid, clear cell, and undifferentiated or anaplastic features. Care must be taken to differentiate thymic carcinoma from lung cancer metastatic to the thymus gland as the histologic features can be similar between the two. Compared with thymomas, they are a more heterogeneous group of malignancies with a propensity for early local invasion and widespread metastases. Malignant pleural and pericardial effusions occur frequently.

Five-year survival rates are between 30% and 50%. Complete resection is occasionally curative and leads to improved survival, but most thymic carcinomas will recur and are refractory to chemotherapy.¹⁷⁸ Management, therefore, depends on the completeness of the resection. Postoperative care includes radiation therapy, guided by residual gross disease or microscopically positive margins from the resection specimen. Chemotherapy may also be given, with carboplatin/paclitaxel recommended based on the best response rates with the least toxicity in clinical trials. The prognosis of patients with thymic cancer remains poor.

Thymolipoma. Thymolipomas are rare benign tumors that may grow to a very large size prior to diagnosis. On CT scan, their appearance can be dramatic, with a characteristic fat density dotted by islands of soft tissue density representing islands of thymic tissue (Fig. 19-48). Thymolipomas are generally well-encapsulated, soft, and pliable masses that do not invade

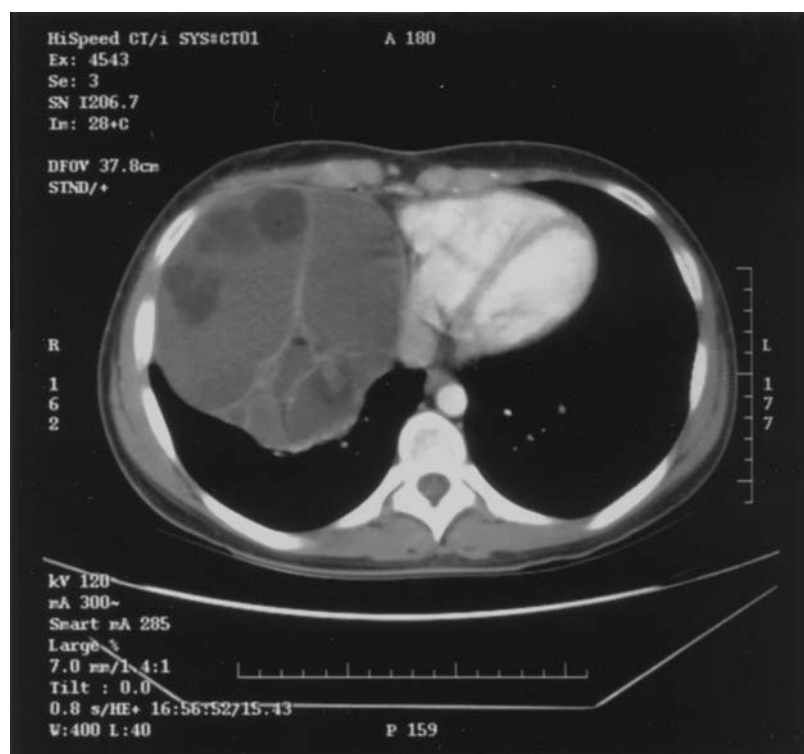

Figure 19-48. Massive thymolipoma that was asymptomatic in an 18-year-old female.

Table 19-31

Classification of neurogenic tumors of the mediastinum

TUMOR ORIGIN	BENIGN	MALIGNANT
Nerve sheath	Neurilemoma, neurofibroma, melanotic schwannoma, granular cell tumor	Neurofibrosarcoma
Ganglion cell	Ganglioneuroma	Ganglioneuroblastoma, neuroblastoma
Paraganglionic cell	Chemodectoma, pheochromocytoma	Malignant chemodectoma, malignant pheochromocytoma

Source: Reproduced with permission from Bousamra.¹⁸² Copyright Elsevier.

surrounding structures. Resection is recommended for large masses.

Neurogenic Tumors. Most neurogenic tumors of the mediastinum arise from the cells of the nerve sheath, from ganglion cells, or from the paraganglionic system (Table 19-31). The incidence, cell types, and risk of malignancy strongly correlate with patient age. Tumors of nerve sheath origin predominate in adults. Most present as asymptomatic incidental findings, and most are benign. In children and young adults, tumors of the autonomic ganglia predominate, with up to two thirds being malignant.¹⁸²

Nerve Sheath Tumors. Nerve sheath tumors account for 20% of all mediastinal tumors. More than 95% of nerve sheath tumors are benign neurilemmomas or neurofibromas. Malignant neurosarcomas are much less common.

Neurilemoma. Neurilemmomas, also called schwannomas, arise from Schwann cells in intercostal nerves. They are firm, well-encapsulated, and generally benign. Two characteristic histologic components are referred to as Antoni type A and Antoni type B regions. Antoni type A regions contain compact spindle cells with twisted nuclei and nuclear palisading. Antoni type B regions contain loose and myxoid connective tissue with haphazard cellular arrangement. These characteristics distinguish neurilemoma from malignant, fibrosarcomatous tumors, which lack encapsulation and have no Antoni features. If routine CT scan suggests extension of a neurilemoma into the intervertebral foramen, MRI is used to evaluate the extent of this “dumbbell” configuration (Fig. 19-49). Such a configuration may lead to cord compression and paralysis and requires a more complex surgical approach. Resection is recommended; VATS has been established as safe and effective for simple and, in experienced centers, even the more complex operations.¹⁸³ It is reasonable to follow small, asymptomatic paravertebral tumors in older patients or in patients at high risk for surgery. In children, ganglioneuroblastomas or neuroblastomas are more common; therefore, all neurogenic tumors should be completely resected.

Neurofibroma. Neurofibromas consist of both nerve sheath and nerve cells and account for up to 25% of nerve sheath tumors. Up to 40% of patients with mediastinal fibromas have generalized neurofibromatosis (von Recklinghausen’s disease). About 70% of neurofibromas are benign, but malignant degeneration to neurofibrosarcoma occurs in 25% to 30% of patients.¹⁸⁴ The risk of malignant degeneration increases with advancing age,

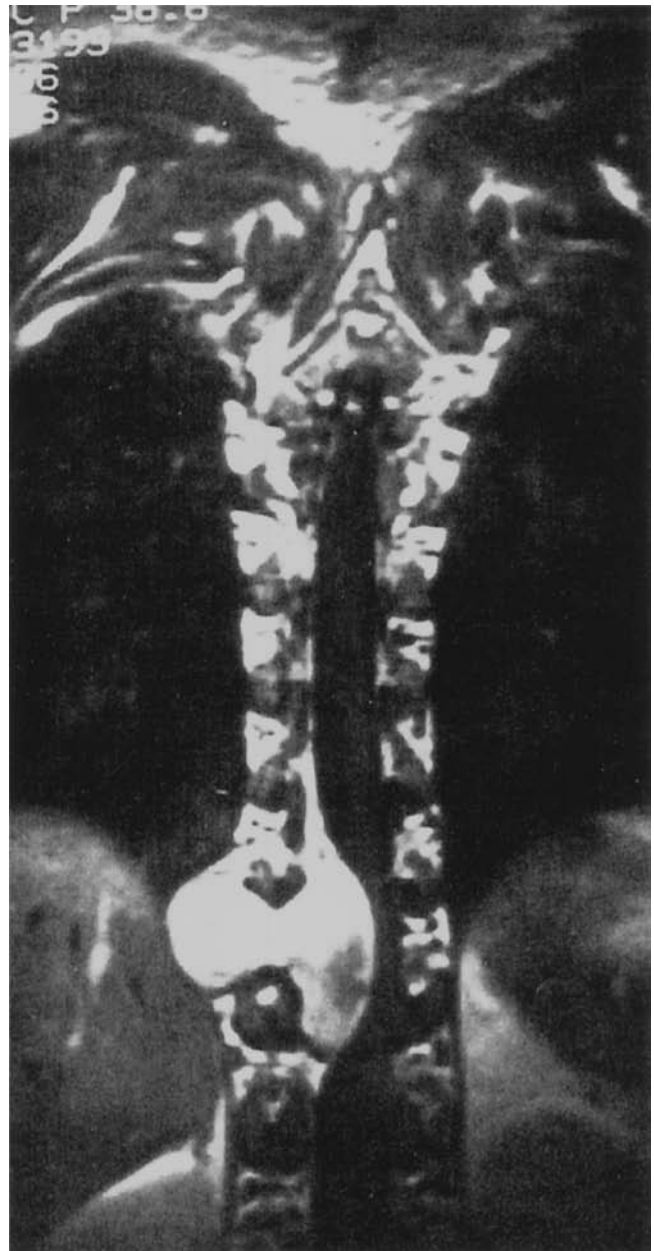


Figure 19-49. Magnetic resonance image of a neurogenic tumor with extension into the spinal canal via the foramen, giving a typical dumbbell appearance.

von Recklinghausen's disease, and exposure to previous radiation. Neurofibrosarcomas carry a poor prognosis because of rapid growth and aggressive local invasion along nerve bundles. Complete surgical resection is the mainstay of treatment. Adjuvant radiotherapy or chemotherapy does not confer a significant benefit, but may be added if complete resection is not possible.¹⁸⁵ The 5-year survival rate is 53%, but drops to 16% in patients with neurofibromatosis or with large tumors (>5 cm).

Ganglion Cell Tumors. Ganglion cell tumors (ganglioneuromas, ganglioneuroblastomas, and neuroblastomas) arise from the sympathetic chain or from the adrenal medulla.

Ganglioneuroma. Well-differentiated, benign tumors characterized histologically by well-differentiated ganglion cells with a background of Schwann cells, these are most often found incidentally in asymptomatic young adults. Diarrhea related to secretion of a vasoactive intestinal peptide has been described in some patients. These tumors have a propensity for intraspinal canal extension, although they remain well-encapsulated; complete resection is curative, with a low risk of local recurrence.

Ganglioneuroblastoma. Ganglioneuroblastomas contain a mixture of benign ganglion cells and malignant neuroblasts. The distribution of these cells within the tumor is predictive of the clinical course. The nodular pattern has a high incidence of metastatic disease, whereas the diffuse pattern rarely metastasizes. Gross examination typically reveals encapsulated tumor; histologically, there are focal calcifications around regions of neuroblasts. Ganglioneuroblastomas arise most frequently in infants and children <3 years old. The majority are resectable, with 80% 5-year survival.

Neuroblastoma. Highly malignant, neuroblastomas are the most common extracranial solid malignancy of childhood. The primary site is intrathoracic malignancy in 14%; extension into the spinal canal and osseous invasion is commonly present. These thoracic tumors are not as recalcitrant to chemotherapy and surgical resection as other chest malignancies; they are more likely to be resectable, with less invasion of surrounding organs. More than half occur in children under 2 years old; 90% arise within the first decade of life, and thus, these malignancies are discussed in more detail in Chapter 39.

Paraganglionic Tumors. Paraganglionic tumors arising in the thoracic cavity include chemodectomas and pheochromocytomas. Only 10% of all pheochromocytomas are located in an extra-adrenal site. Intrathoracic pheochromocytomas are one of the rarest tumors. Approximately 10% of thoracic pheochromocytomas are malignant, a rate similar to that of adrenal tumors. The most common thoracic location is within the costovertebral sulcus, but paraganglionic tumors also arise within the visceral compartment of the mediastinum. These catecholamine-producing lesions can lead to life-threatening hemodynamic problems, so complete removal is important. Diagnosis is generally confirmed by measuring elevated levels of urinary catecholamines and their metabolites. Localization is by CT scan, aided by MIBG scintigraphy. Preoperative care includes α - and β -adrenergic blockade to prevent intraoperative malignant hypertension and arrhythmias. These tumors tend to be highly vascular and should be approached with care. Chemodectomas are rare tumors that may be located around the aortic arch, vagus nerves, or aorticosympathetics. They rarely secrete catecholamines and are malignant in up to 30% of patients.

Lymphoma. Overall, lymphomas are the most common malignancy of the mediastinum. In about 50% of patients who have

both Hodgkin's and non-Hodgkin's lymphoma, the mediastinum may be the primary site. The anterior compartment is most commonly involved, with occasional involvement of the middle compartment and hilar nodes. The posterior compartment is rarely involved. Chemotherapy and/or radiation results in a cure rate of up to 90% for patients with early-stage Hodgkin's disease and up to 60% with more advanced stages.

Mediastinal Germ Cell Tumors. Germ cell tumors are uncommon neoplasms, with only about 7000 diagnosed each year. However, they are the most common malignancy in young men 15 to 35 years of age. Most germ cell tumors are gonadal in origin; primary mediastinal germ cell tumors comprise less than 5% of all germ cell tumors and less than 1% of all mediastinal tumors (usually occurring in the anterior compartment). If a malignant mediastinal germ cell tumor is found, it is important to exclude a gonadal primary tumor. Primary mediastinal germ cell tumors (including teratomas, seminomas, and non-seminomatous malignant germ cell tumors) are a heterogeneous group of benign and malignant neoplasms thought to originate from primitive pluripotent germ cells "misplaced" in the mediastinum during embryonic development. Previously, most mediastinal germ cell tumors were thought to be metastatic. However, two lines of evidence suggest that many mediastinal germ cell tumors are primary, developing from pluripotent primordial germ cells in the mediastinum: (a) several autopsy series showed that patients with extragonadal sites of germ cell tumors, presumed previously to have originated from the gonads, had no evidence of an occult primary tumor or of any residual scar of the gonads, even after an exhaustive search; and (b) patients treated by surgery or radiation for their mediastinal germ cell tumors had long-term survival with no late testicular recurrences.¹⁸⁶

About one third of all primary mediastinal germ cell tumors are seminomatous. Two thirds are nonseminomatous tumors or teratomas. Treatment and prognosis vary considerably within these two groups. Mature teratomas are benign and can generally be diagnosed by the characteristic CT findings of multilocular cystic tumors, encapsulated with combinations of fluid, soft tissue, calcium, and/or fat attenuation in the anterior compartment. FNA biopsy alone may be diagnostic for seminomas, usually with normal serum markers, including hCG and AFP. In 10% of seminomas, hCG levels may be slightly elevated. FNA findings, along with high hCG and AFP levels, can accurately diagnose nonseminomatous tumors. If the diagnosis remains uncertain after assessment of FNA findings and serum marker levels, then core-needle biopsies or surgical biopsies may be required. Thoracoscopy is the most frequent diagnostic surgical approach.

Seminoma. Most patients with seminomas have advanced disease at the time of diagnosis and present with symptoms of local compression, including SVC syndrome, dyspnea, or chest discomfort. With advanced disease, the preferred treatment is combination cisplatin-based chemotherapy regimens with bleomycin and either etoposide or vinblastine. Complete responses have been reported in over 75% of patients treated with these regimens. Surgical resection may be curative for small asymptomatic seminomas that are found incidentally with screening CT scans. Surgical resection of residual masses after chemotherapy may be indicated.

Nonseminomatous germ cell tumors. Nonseminomatous germ cell tumors include embryonal cell carcinomas, choriocarcinomas,

endodermal sinus tumors, and mixed types. They are often bulky, irregular tumors of the anterior mediastinum with areas of low attenuation on CT scan because of necrosis, hemorrhage, or cyst formation. Frequently, adjacent structures have been involved, with metastases to regional lymph nodes, pleura, and lungs. Lactate dehydrogenase (LDH), AFP, and hCG levels are frequently elevated. Chemotherapy is the preferred treatment and includes combination therapy with cisplatin, bleomycin, and etoposide, followed by surgical resection of residual disease. With this regimen, survival is 67% at 2 years and 60% at 5 years. Surgical resection of residual masses is indicated, as it may guide further therapy. Up to 20% of residual masses contain additional tumors; in another 40%, mature teratomas; and the remaining 40%, fibrotic tissue. It is important to note that oxygen toxicity can occur in patients who have been exposed to bleomycin; high levels of oxygen supplementation in the perioperative setting should be avoided in these patients as respiratory failure and death can ensue.¹⁸⁷ Factors independently predictive of survival after induction chemotherapy followed by resection are elevated serum tumor markers after resection, postchemotherapy pathologic findings (complete necrosis vs. teratoma), and persistent germ cell or non-germ cell cancer in the pathologic specimen.¹⁸⁷

Teratoma. Teratomas are the most common type of mediastinal germ cell tumors, accounting for 60% to 70% of mediastinal germ cell tumors. They contain two or three embryonic layers that may include teeth, skin, and hair (ectodermal), cartilage and bone (mesodermal), or bronchial, intestinal, or pancreatic tissue (endodermal). Therapy for mature, benign teratomas is surgical resection, which confers an excellent prognosis.

Rarely, teratomas may contain a focus of carcinoma; these malignant teratomas (or teratocarcinomas) are locally aggressive. Often diagnosed at an unresectable stage, they respond poorly to chemotherapy and in a limited manner to radiotherapy; prognosis is uniformly poor.

Mediastinal Cysts

Benign cysts account for up to 25% of mediastinal masses and are the most frequently occurring mass in the middle mediastinal compartment. A CT scan showing characteristic features of near water density in a typical location is virtually 100% diagnostic.¹⁸⁸

Pericardial cyst. Usually asymptomatic and detected incidentally in the right costophrenic angle, pericardial cysts typically contain a clear fluid and are lined with a single layer of mesothelial cells. For most simple, asymptomatic pericardial cysts, observation alone is recommended. Surgical resection or aspiration may be indicated for complex cysts or large symptomatic cysts.

Bronchogenic cyst. Developmental anomalies that occur during embryogenesis and occur as an abnormal budding of the foregut or tracheobronchial tree, bronchogenic cysts arise most often in the mediastinum just posterior to the carina or main stem bronchus. Approximately 15% occur within the pulmonary parenchyma. Thin-walled and lined with respiratory epithelium, they contain a protein-rich mucoid material and varying amounts of seromucous glands, smooth muscle, and cartilage. They may communicate with the tracheobronchial tree. In adults, over half of all bronchogenic cysts are found incidentally during workup for an unrelated problem or during screening. The natural history of an incidentally diagnosed, asymptomatic bronchogenic

cyst is unknown, but it is clear that many such cysts do not lead to clinical problems. In one study of young military personnel, 78% of all bronchogenic cysts found on routine CXRs were asymptomatic. However, in other reports with more comprehensive follow-up, up to 67% of adults with incidentally found bronchogenic cysts eventually became symptomatic. Symptoms include chest pain, cough, dyspnea, and fever. If large (>6 cm) or symptomatic, resection is generally recommended since serious complications may occur if the cyst becomes larger or infected. Complications include airway obstruction, infection, rupture, and rarely, malignant transformation.^{189,190}

Traditionally, complete removal of the cyst wall has been via posterolateral thoracotomy.¹⁹¹ Resection of infected cysts may be quite difficult because of dense adhesions; elective removal is often recommended before infection has a chance to occur. Thoracoscopic exploration and resection are possible for small cysts with minimal adhesions. With increasing experience using video-assisted or robotic-assisted thoracoscopy, a greater proportion of these lesions are amenable to minimally invasive resection.

Enteric cyst. Most clinicians agree that in contrast to bronchogenic cysts, esophageal cysts should be removed, regardless of the presence or absence of symptoms. Esophageal cysts have a propensity for serious complications secondary to enlargement, leading to hemorrhage, infection, or perforation. Thus, surgical resection is the treatment of choice in both adults and children. As with bronchogenic cysts, experienced surgeons are approaching enteric cyst resections using minimally invasive techniques with great success.

Thymic cyst. Generally asymptomatic, thymic cysts are often discovered incidentally. Simple cysts are of no consequence; however, the occasional cystic neoplasm must be ruled out. Cystic components occasionally are seen in patients with thymoma and Hodgkin's disease.

Ectopic endocrine glands. Up to 5% of all mediastinal masses are of thyroid origin; most are simple extensions of thyroid masses. Usually nontoxic, over 95% can be completely resected through a cervical approach. True ectopic thyroid tissue of the mediastinum is rare. About 10% to 20% of abnormal parathyroid glands are found in the mediastinum; most can be removed during exploration from a cervical incision. In cases of true mediastinal parathyroid glands, thoracoscopic or open resection may be indicated. Location can generally be pinpointed by a combination of CT scan and Sestamibi scans.

Mediastinitis

Acute Mediastinitis. Acute mediastinitis is a fulminant infectious process that spreads rapidly along the continuous fascial planes connecting the cervical and mediastinal compartments. Infections originate most commonly from esophageal perforations, sternal infections, and oropharyngeal or neck infections, but a number of less common etiologic factors can lead to this deadly process (Table 19-32). Clinical signs and symptoms include fever, chest pain, dysphagia, respiratory distress, and cervical and upper thoracic subcutaneous crepitus. In severe cases, the clinical course can rapidly deteriorate to florid sepsis, hemodynamic instability, and death. Thus, a high index of suspicion is required in the context of any infection with access to the mediastinal compartments.

A chest CT scan illuminates the extent of spread and guides selection of the best approach to surgical drainage. Acute

Table 19-32

Etiologic factors in acute mediastinitis**Esophageal perforation**

Iatrogenic

- Balloon dilatation (for achalasia)
- Bougienage (for peptic stricture)
- Esophagoscopy
- Sclerotherapy (for variceal bleeding)

Spontaneous

- Postemetic (Boerhaave's syndrome)

Straining during:

- Elimination
- Weight lifting

Seizure

- Pregnancy
- Childbirth

Ingestion of foreign bodies

Trauma

- Blunt
- Penetrating

Postsurgical

- Infection
- Anastomotic leak
- Erosion by cancer

Deep sternotomy wound infection**Oropharynx and neck infections****Ludwig's angina****Quinsy****Retropharyngeal abscess****Cellulitis and suppurative lymphadenitis of the neck****Infections of the lung and pleura****Subphrenic abscess****Rib or vertebral osteomyelitis****Hematogenous or metastatic abscess**

Source: Reproduced with permission from Razzuk MA, et al. Infections of the mediastinum. In: Pearson FG, et al, eds. *Thoracic Surgery*. 2nd ed. New York: Churchill Livingstone; 2002:1604. Copyright Elsevier.

mediastinitis is a true surgical emergency; treatment must be instituted immediately and aimed at correcting the primary problem, such as the esophageal perforation or oropharyngeal abscess, and debridement and drainage of the spreading infectious process within the mediastinum, neck, pleura, and other tissue planes. Antibiotics, fluid resuscitation, and other supportive measures are also important. Debridement may need to be repeated and other planes and cavities explored depending on the patient's clinical status. Blood cell counts and serial CT scans may also be required. Persistent sepsis or collections on CT scan may require further radical surgical debridement.

Chronic Mediastinitis. Sclerosing or fibrosing mediastinitis results from chronic mediastinal inflammation that originates in the lymph nodes, most frequently from granulomatous infections such as histoplasmosis or tuberculosis. Chronic, low-grade inflammation leads to fibrosis and scarring, which can, in some patients, result in entrapment and compression of the low-pressure veins (including the SVC and innominate and azygos veins), the esophagus, and pulmonary arteries. There is no definitive treatment. Surgery is indicated only for diagnosis or in specific patients to relieve airway or esophageal obstruction or to

achieve vascular reconstruction. Reports of palliative success with less invasive procedures (such as dilation and stenting of airways, the esophagus, or the SVC) are promising. In one series of 22 patients, ketoconazole was effective in controlling progression. In another series of 71 patients, 30% died during long-term follow-up. Chronic mediastinitis is similar to retroperitoneal fibrosis, sclerosing cholangitis, and Riedel's thyroiditis.

PLEURA AND PLEURAL SPACE**Anatomy**

Each hemithorax has a mesothelial lining that invaginates at the hilum of each lung and continues on to cover each lung. The portion lining the bony rib cage, mediastinum, and diaphragm is called the parietal pleura, whereas the portion encasing the lung is known as the visceral pleura. Between these two surfaces is the potential pleural space, which is normally occupied by a thin layer of lubricating pleural fluid. A network of somatic, sympathetic, and parasympathetic fibers innervates the parietal pleura. Irritation of the parietal surface by inflammation, tumor invasion, trauma, and other processes can lead to a sensation of chest wall pain. The visceral pleura have no somatic innervation.^{192,193}

Pleural Effusion

Pleural effusion refers to any significant collection of fluid within the pleural space. Normally, between 5 and 10 L of fluid enters the pleural space each day by filtration through microvessels supplying the parietal pleura (located mainly in the less dependent regions of the cavity). The net balance of pressures in these capillaries leads to fluid flow from the parietal pleural surface into the pleural space, and the net balance of forces in the pulmonary circulation leads to absorption through the visceral pleura. Normally, 15 to 20 mL of pleural fluid is present at any given time. Any disturbance in these forces can lead to imbalance and accumulation of pleural fluid. Common pathologic conditions in North America that lead to pleural effusion include congestive heart failure, bacterial pneumonia, malignancy, and pulmonary emboli (Table 19-33).¹⁹⁴

Access and Drainage of Pleural Fluid Collections

Most patients with pleural effusions of unknown cause should undergo thoracentesis with only two exceptions: effusions in the setting of congestive heart failure or renal failure or small effusions associated with an improving pneumonia. If the clinical history suggests congestive heart failure as a cause, particularly in the setting of bilateral effusions, a trial of diuresis may be indicated (rather than thoracentesis). Up to 75% of effusions due to congestive heart failure resolve within 48 hours with diuresis alone. Similarly, thoracentesis can be avoided in patients with small effusions associated with resolving pneumonia. These patients typically present with cough, fever, leukocytosis, and unilateral infiltrate, and the effusion is usually a result of a reactive, parapneumonic process. If the effusion is small and the patient responds to antibiotics, a diagnostic thoracentesis may be unnecessary. If the effusion is large and compromising respiratory efforts, or if the patient has a persistent white blood cell count despite improving signs of pneumonia, an empyema of the pleural space must be considered. In these patients, early and aggressive drainage with chest tubes is required, possibly with surgical intervention.

Once the decision is made to access a pleural effusion, the next step is to determine if a sample of the fluid or complete

Table 19-33

Leading causes of pleural effusion in the United States, based on data from patients undergoing thoracentesis

CAUSE	ANNUAL INCIDENCE	TRANSUDATE	EXUDATE
Congestive heart failure	500,000	Yes	No
Pneumonia	300,000	No	Yes
Cancer	200,000	No	Yes
Pulmonary embolus	150,000	Sometimes	Sometimes
Viral disease	100,000	No	Yes
Coronary artery bypass surgery	60,000	No	Yes
Cirrhosis with ascites	50,000	Yes	No

Source: Reproduced with permission from Light RW. Pleural effusion. *N Engl J Med* 2002;346:1971. Copyright © Massachusetts Medical Society. All rights reserved. Adapted from Light RW. Approach to the patient. In: Light RW, ed. *Pleural Diseases*. 5th ed. Philadelphia: Lippincott Williams & Wilkins; 2007:111.

drainage of the pleural space is desired. This step is influenced by the clinical history, the type and amount of fluid present, the nature of the collection (such as free-flowing or loculated), the cause, and the likelihood of recurrence. For small, free-flowing effusions, an outpatient diagnostic and/or therapeutic thoracentesis with a relatively small-bore needle or catheter (14- to 16-gauge) can be performed (Fig. 19-50). The appearance of the fluid is informative: clear straw-colored fluid is often transudative; turbid or bloody fluid is often exudative.

The site of entry for drainage of a pleural effusion or pneumothorax may be based on the CXR alone if the effusion is

demonstrated to be free-flowing. For free-flowing effusions, a low approach at the eighth or ninth intercostal space in the posterior midclavicular line facilitates complete drainage. If the effusion is loculated, CT- or ultrasound-guided drainage may be indicated. If the goal is complete drainage of nonbloody and nonviscous fluid, a small-bore pigtail catheter is inserted and connected to a closed drainage system with applied suction (typically -20 cm H_2O). If the fluid is bloody or turbid, a larger-diameter drainage tube (such as a 28F chest tube) may be required. In general, the smallest-bore drainage catheter that will effectively drain the pleural space should be chosen.

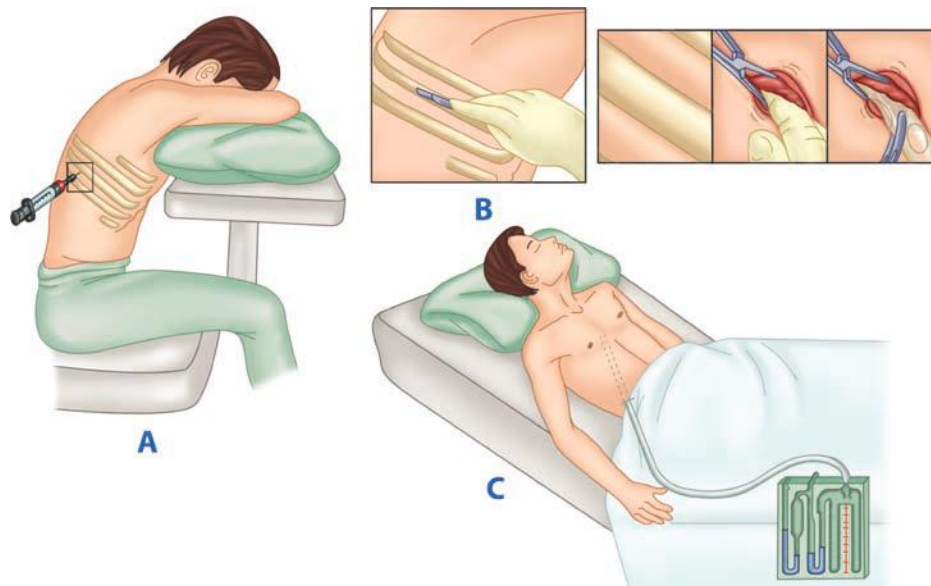


Figure 19-50. Techniques for aspiration and drainage of a pleural effusion. **A.** Needle aspiration. With careful appraisal of the x-ray findings, the best interspace is selected, and fluid is aspirated with a needle and syringe. Large volumes of fluid can be removed with a little patience and a large-bore needle. **B.** Chest tube insertion. After careful skin preparation, draping, and administration of local anesthesia, a short skin incision is made over the correct interspace. The incision is deepened into the intercostal muscles, and the pleura is penetrated (usually with a clamp). When any doubt exists about the status of the pleural space at the site of puncture, the wound is enlarged bluntly to admit a finger, which can be swept around the immediately adjacent pleural space to assess the situation and break down any adhesions. The tube is inserted, with the tip directed toward the optimal position suggested by the chest x-rays. In general, a high anterior tube is best for air (pneumothorax), and a low posterior tube is best for fluid. A 28F to 32F tube is adequate for most situations. A 36F tube is preferred for hemothorax or for a viscous empyema. Many surgeons prefer a very small tube (16F–20F) for drainage of simple pneumothorax. **C.** The tube is connected to a water-seal drainage system. Suction is added, if necessary, to expand the lung; it usually will be required in a patient with a substantial air leak (bronchopleural fistula).

Smaller-diameter catheters significantly decrease the pain associated with the placement of chest tubes but are more prone to clogging and twisting.^{195,196} For clinical situations requiring biopsy or for potential interventions such as adhesiolysis or pleurodesis, minimally invasive surgery may be indicated, using a VATS approach.

Complications of Pleural Drainage. The most common complications of invasive pleural procedures are inadvertent injury to adjacent organs, including lung, with air leakage and pneumothorax; subdiaphragmatic entry and damage to the liver, spleen, or other intra-abdominal viscera; intercostal vessel injury with subsequent bleeding or larger vessel injury; and even cardiac puncture. Sometimes bleeding may be the result of an underlying coagulopathy or anticoagulant therapy. Other technical complications include loss of a catheter, guidewire, or fragment in the pleural space and infections. Occasionally, rapid drainage of a large effusion can be followed by shortness of breath, clinical instability, and a phenomenon referred to as postexpansion pulmonary edema. For this reason, it is recommended to drain only up to 1500 mL initially. Most complications can be avoided by consulting with a clinician experienced in pleural drainage techniques.

Pleural Fluid Analysis. Pleural fluid collections are generally classified as transudates and exudates (Table 19-34). Transudates are protein-poor ultrafiltrates of plasma that result from alterations in the systemic hydrostatic pressures or colloid osmotic pressures (for example, with congestive heart failure or cirrhosis). On gross visual inspection, a transudative effusion is generally clear or straw-colored. Exudates are protein-rich pleural fluid collections that generally result from inflammation or pleural invasion by tumor. Grossly, they are often turbid, bloody, or purulent. Absent trauma, grossly bloody effusions are frequently malignant, but may also occur in the setting of a pulmonary embolism or pneumonia.

Transudates and exudates can be differentiated using Light's criteria. An effusion is exudative if the pleural fluid-to-serum ratio of protein is greater than 0.5 and the LDH ratio is greater than 0.6 or the absolute pleural LDH level is greater than two thirds of the normal upper limit for serum. If criteria suggest a transudate, a careful evaluation for congestive heart failure, cirrhosis, or conditions associated with transudates is undertaken. If criteria suggest an exudate, further diagnostic studies may be helpful. If total and differential cell counts reveal a predominance of neutrophils (>50% of cells), the effusion is likely associated with an acute inflammatory process (such as a parapneumonic effusion or empyema, pulmonary embolus, or pancreatitis). A predominance of mononuclear cells suggests a more chronic inflammatory process (such as cancer or tuberculosis). Gram stains and cultures should be obtained if possible, with inoculation into culture bottles at the bedside. Pleural fluid glucose levels are frequently decreased (<60 mg/dL) with complex parapneumonic effusions or malignant effusions.

A pleural effusion occurring in association with pleuritic chest pain, hemoptysis, or dyspnea out of proportion to the size of the effusion should raise concern for pulmonary embolism. These effusions may be transudative, but if an associated infarct near the pleural surface occurs, an exudate may be seen. If a pulmonary embolism is suspected in a postoperative patient, most clinicians would obtain a spiral CT scan. Alternatively, duplex ultrasonography of the lower extremities may yield a diagnosis of deep vein thrombosis, thereby indicating anticoagulant therapy

and precluding the need for a specific diagnosis of pulmonary embolism. In some patients, a blood test for levels of D-dimer may be helpful; if a sensitive D-dimer blood test is negative, pulmonary embolism may be ruled out.

Malignant Pleural Effusion

Malignant pleural effusions may occur in association with a number of different malignancies, most commonly lung cancer, breast cancer, and lymphomas, depending on the patient's age and gender (Tables 19-35 and 19-36).¹⁹⁷ Cytologic testing should be done on exudative effusions to rule out an associated malignancy; accuracy is 70% when associated with adenocarcinomas, but is less sensitive for mesotheliomas (<10%), squamous cell carcinomas (20%), or lymphomas (25%–50%). If the diagnosis remains uncertain after drainage and fluid analysis, thoracoscopy and direct biopsies are indicated.^{198,199} Malignant effusions are exudative and often tinged with blood. An effusion in the setting of a malignancy means a more advanced stage; mean survival ranges from 3 to 11 months, depending on the primary tumor location. Occasionally, effusions associated with a bronchogenic NSCLC are benign, and surgical resection may still be indicated.

Effusion size and degree of associated dyspnea influence management. Symptomatic, moderate to large effusions should be drained by tunneled indwelling pleural catheter, tube thoracostomy (chest tube or pigtail catheter) with subsequent instillation of doxycycline as a sclerosing agent, or VATS with talc instillation. Management is based on patient preference, degree of known or anticipated lung re-expansion, and patient tolerance for operative intervention. Lung entrapment by tumor or adhesions limits re-expansion and generally predicts a poor result with pleurodesis; it is the primary indication for placement of indwelling pleural catheters. Patient preference is also considered, as is their life expectancy. Tunneled indwelling pleural catheters have dramatically changed the management of end-stage cancer treatment because they substantially shorten the amount of time patients spend in the hospital during their final weeks of life.²⁰⁰ If the lung is expected to fully expand and the patient has a longer life expectancy (e.g., malignant effusions in the setting of breast cancer), drainage with sclerosis is the preferred option. The choice of sclerosant includes mechanical, talc, bleomycin, or doxycycline. Success rates range from 60% to 90% and are highest with talc. Typically, talc is administered as an aerosolized powder during video-assisted thoracoscopy, whereas doxycycline is infused at the bedside through a previously placed pigtail catheter or larger bore chest tube. Figure 19-51 presents a decision algorithm for the management of malignant pleural effusion.

Empyema

Thoracic empyema is defined by a purulent pleural effusion. Patients of all ages can develop empyema, but the frequency is increased in older or debilitated patients. Common associated conditions include a pneumonic process in patients with pulmonary disorders and neoplasms, cardiac problems, diabetes mellitus, drug and alcohol abuse, neurologic impairments, postthoracotomy problems, and immunologic impairments. The mortality of empyema frequently depends on the degree of associated comorbid diseases, ranging from as low as 1% to over 40% in immunocompromised patients.

Pathophysiology. The most common causes of empyema are parapneumonic, but postsurgical or posttraumatic empyema

Table 19-34

Differential diagnosis of pleural effusions

- | | |
|---|--|
| <ul style="list-style-type: none"> I. Transudative pleural effusions <ul style="list-style-type: none"> A. Congestive heart failure B. Cirrhosis C. Nephrotic syndrome D. Superior vena caval obstruction E. Fontan procedure F. Urinothorax G. Peritoneal dialysis H. Glomerulonephritis I. Myxedema J. Cerebrospinal fluid leaks to pleura K. Hypoalbuminemia L. Pulmonary emboli M. Sarcoidosis II. Exudative pleural effusions <ul style="list-style-type: none"> A. Neoplastic diseases <ul style="list-style-type: none"> 1. Metastatic disease 2. Mesothelioma 3. Body cavity lymphoma 4. Pyothorax-associated lymphoma B. Infectious diseases <ul style="list-style-type: none"> 1. Tuberculosis 2. Other bacterial infections 3. Fungal infections 4. Parasitic infections 5. Viral infections C. Pulmonary embolization D. Gastrointestinal disease <ul style="list-style-type: none"> 1. Pancreatic disease 2. Subphrenic abscess 3. Intrahepatic abscess 4. Intrasplenic abscess 5. Esophageal perforation 6. After abdominal surgery 7. Diaphragmatic hernia 8. Endoscopic variceal sclerosis 9. After liver transplantation E. Heart diseases <ul style="list-style-type: none"> 1. After coronary artery bypass graft surgery 2. Post-cardiac injury (Dressler's) syndrome 3. Pericardial disease F. Obstetric and gynecologic diseases <ul style="list-style-type: none"> 1. Ovarian hyperstimulation syndrome 2. Fetal pleural effusion | <ul style="list-style-type: none"> 3. Postpartum pleural effusion 4. Meigs' syndrome 5. Endometriosis G. Collagen vascular diseases <ul style="list-style-type: none"> 1. Rheumatoid pleuritis 2. Systemic lupus erythematosus 3. Drug-induced lupus 4. Immunoblastic lymphadenopathy 5. Sjögren's syndrome 6. Familial Mediterranean fever 7. Churg-Strauss syndrome 8. Wegener's granulomatosis H. Drug-induced pleural disease <ul style="list-style-type: none"> 1. Nitrofurantoin 2. Dantrolene 3. Methysergide 4. Ergot alkaloids 5. Amiodarone 6. Interleukin-2 7. Procarbazine 8. Methotrexate 9. Clozapine I. Miscellaneous diseases and conditions <ul style="list-style-type: none"> 1. Asbestos exposure 2. After lung transplantation 3. After bone marrow transplantation 4. Yellow nail syndrome 5. Sarcoidosis 6. Uremia 7. Trapped lung 8. Therapeutic radiation exposure 9. Drowning 10. Amyloidosis 11. Milk of calcium pleural effusion 12. Electrical burns 13. Extramedullary hematopoiesis 14. Rupture of mediastinal cyst 15. Acute respiratory distress syndrome 16. Whipple's disease 17. Iatrogenic pleural effusions J. Hemothorax K. Chylothorax |
|---|--|

Source: Reproduced with permission from Light RW. *Approach to the patient*. In: Light RW, ed. *Pleural Diseases*. 5th ed. Philadelphia: Lippincott Williams & Wilkins; 2007:110.

is also common (Table 19-37). The spectrum of organisms involved in pneumonic processes that progress to empyema is changing. Pneumococci and staphylococci continue to be the most frequent causative organisms, but gram-negative aerobic bacteria and anaerobes are becoming more prevalent. Cases involving mycobacteria or fungi are rare. Multiple organisms may be found in up to 50% of patients. Cultures may be sterile, however, if antibiotics were initiated before the culture or if the culture process was not efficient. The choice of antibiotics,

therefore, is guided by the clinical scenario and not just the organisms found on culture. Broad-spectrum coverage may be required even when cultures do not grow out an organism or if a single organism is grown when the clinical picture is more consistent with a multiorganism process. Common gram-negative organisms include *Escherichia coli*, *Klebsiella*, *Pseudomonas*, and Enterobacteriaceae. Anaerobic organisms may be fastidious and difficult to document by culture and are associated with periodontal diseases, aspiration syndromes, alcoholism, general

Table 19-35

Primary organ site or neoplasm type in male patients with malignant pleural effusions

PRIMARY SITE OR TUMOR TYPE	NO. OF MALE PATIENTS	PERCENTAGE OF MALE PATIENTS
Lung	140	49.1
Lymphoma/leukemia	60	21.1
Gastrointestinal tract	20	7.0
Genitourinary tract	17	6.0
Melanoma	4	1.4
Miscellaneous less common tumors	10	3.5
Primary site unknown	31	10.9
Total	285	100.0

Source: Reproduced with permission from Johnston WW. The malignant pleural effusion: a review of cytopathologic diagnoses of 584 specimens from 472 consecutive patients. *Cancer*. 1985;56:905.

anesthesia, drug abuse, or other functional associations with gastroesophageal reflux.

Organisms gain entry into the pleural cavity through contiguous spread from pneumonia, lung abscess, liver abscess, or another, adjacent infectious processes. Organisms may also enter the pleural cavity by direct contamination from thoracentesis, thoracic surgical procedures, esophageal injuries, or trauma. As organisms enter the pleural space, an influx of polymorphonuclear cells and fluid occurs, with subsequent release of inflammatory mediators and toxic oxygen radicals. These mechanisms lead to variable degrees of endothelial injury and capillary instability. This process overwhelms the normal pleural lymphatic drainage. This early effusion is watery and

Table 19-36

Primary organ site or neoplasm type in female patients with malignant pleural effusions

PRIMARY SITE OR TUMOR TYPE	NO. OF FEMALE PATIENTS	PERCENTAGE OF FEMALE PATIENTS
Breast	70	37.4
Female genital tract	38	20.3
Lung	28	15.0
Lymphoma	14	8.0
Gastrointestinal tract	8	4.3
Melanoma	6	3.2
Urinary tract	2	1.1
Miscellaneous less common tumors	3	1.6
Primary site unknown	17	9.1
Total	187	100.0

Source: Reproduced with permission from Johnston WW. The malignant pleural effusion: a review of cytopathologic diagnoses of 584 specimens from 472 consecutive patients. *Cancer*. 1985;56:905.

free-flowing in the pleural cavity. Thoracentesis at this stage yields fluid with a pH typically above 7.3, a glucose level greater than 60 mg/dL, and a low LDH level (<500 U/L). At this stage, the decision to use antibiotics alone or perform a repeat thoracentesis, chest tube drainage, thoracoscopy, or open thoracotomy depends on the amount of pleural fluid, its consistency, the clinical status of the patient, the degree of expansion of the lung after drainage, and the presence of loculated fluid in the pleural space (vs. free-flowing purulent fluid). Early in the parapneumonic process, when the purulent fluid is relatively

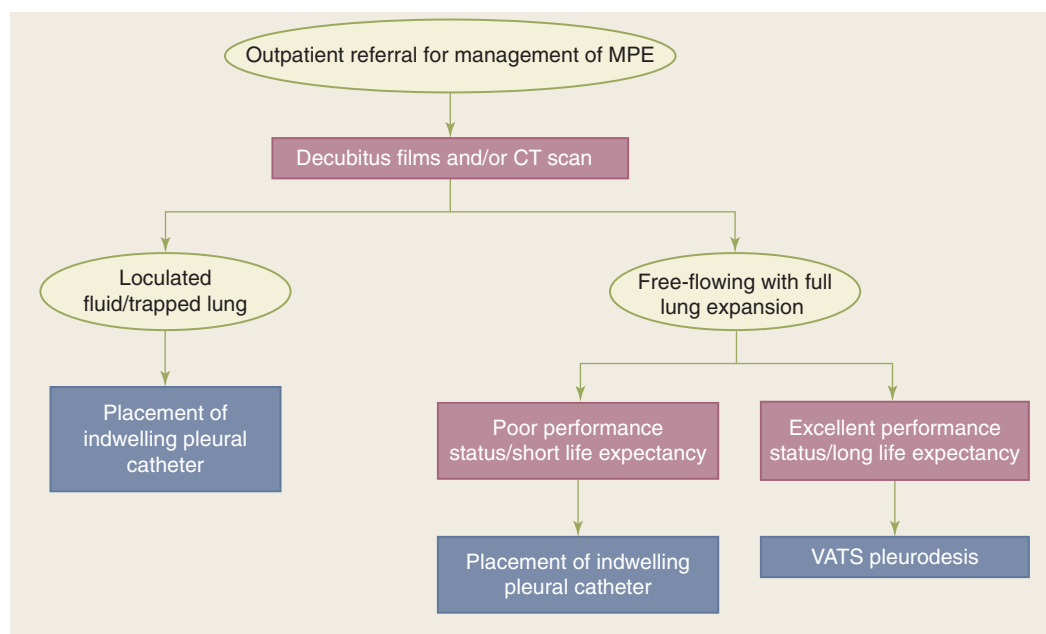


Figure 19-51. Treatment decision algorithm for the management of malignant pleural effusion (MPE). CT = computed tomography; VATS = video-assisted thoracic surgery.

Table 19-37

Pathogenesis of empyema

Contamination from a source contiguous to the pleural space (50%–60%)

- Lung
- Mediastinum
- Deep cervical area
- Chest wall and spine
- Subphrenic area

Direct inoculation of the pleural space (30%–40%)

- Minor thoracic interventions
- Postoperative infections
- Penetrating chest injuries

Hematogenous infection of the pleural space from a distant site (<1%)

Source: Reproduced with permission from Paris F, et al. Empyema and bronchopleural fistula. In: Pearson FG, et al, eds. *Thoracic Surgery*. 2nd ed. New York: Churchill Livingstone; 2002:1177. Copyright Elsevier.

thin, complete drainage with simple large-bore thoracentesis is possible. If complete lung expansion is obtained and the pneumonic process is responding to antibiotics, no further drainage may be necessary. Pleural fluid with a pH lower than 7.2 and with a glucose level of less than 40 mg/dL means that a more aggressive approach to drainage should be pursued.

The pleural fluid may become thick and loculated over the course of hours to days and may be associated with fibrinous adhesions (the fibrinopurulent stage). At this stage, chest tube insertion with closed-system drainage or drainage with thoracoscopy may be necessary to remove the fluid and adhesions and facilitate complete lung expansion.²⁰¹ Further progression of the inflammatory process leads to the formation of a pleural peel, which may be flimsy and easy to remove early on. However, as the process progresses, a thick pleural rind may develop, leaving a trapped lung; complete lung decortication by either thoracoscopy or thoracotomy would then be necessary.

The use of intrapleural fibrinolytic therapy for management of empyema has been investigated in several large prospective trials. Intrapleural infusion of tissue plasminogen activator (t-PA) alone did not improve outcomes, whereas combined intrapleural t-PA and DNase was associated with a reduction in hospital stay of nearly 7 days, 77% fewer referrals for surgical intervention at 3 months, and more than double the reduction in the infected pleural fluid collection by CXR imaging.²⁰² In this trial, the medications were given twice daily by intrapleural injection; the dose was 5 mg for the DNase and 10 mg for t-PA. The chest drain was clamped for 1 hour after injection and released. This study suggests that the combination of fibrinolysis (t-PA) and cleavage of uncoiled DNA by DNase reduces fluid viscosity and facilitates pleural clearance.

Management. If there is a residual space, persistent pleural infection is likely to occur. A persistent pleural space may be secondary to contracted, but intact, underlying lung; or it may be secondary to surgical lung resection. If the space is small and well-drained by a chest tube, a conservative approach may be possible. This requires leaving the chest tubes in place and attached to closed-system drainage until symphysis of the visceral and parietal surfaces takes place. At this point, the chest tubes can be removed from suction; if the residual pleural space remains stable, the tubes can be cut and advanced out of the

chest over the course of several weeks. If the patient is stable, tube removal can frequently be done in the outpatient setting, guided by the degree of drainage and the size of the residual space visualized on serial CT scans. Larger spaces may require open thoracotomy and decortication in an attempt to re-expand the lung to fill this residual space. If re-expansion has failed or appears too high risk, then open drainage, rib resection, and prolonged packing may be required, with delayed closure with muscle flaps or thoracoplasty.²⁰³ Most chronic pleural space problems can be avoided by early specialized thoracic surgical consultation and complete drainage of empyema, allowing space obliteration by the reinflated lung.

Chylothorax

Chylothorax develops most commonly after surgical trauma to the thoracic duct or a major branch, but may be also associated with a number of other conditions (Table 19-38).²⁰⁴ It is generally unilateral; for example, it may occur after dissection of the distal esophagus where the duct lies in close proximity to the esophagus as it enters the right chest from its origin in the abdomen at the cisterna chyli (Fig. 19-52). If the mediastinal pleura are disrupted on both sides, bilateral chylothoraces may occur. Left-sided chylothoraces may develop after a left-sided neck dissection, especially in the region of the confluence of the subclavian and internal jugular veins. Chylothorax may also follow nonsurgical trauma, including penetrating or blunt injuries to the chest or neck area, central line placements, and other surgical misadventures. It may be seen in association with a variety of benign and malignant diseases that generally involve the lymphatic system of the mediastinum or neck. Given the significant variability of the course of the thoracic duct within the chest, some injuries are inevitable.

Pathophysiology. Most commonly, the thoracic duct originates in the abdomen from the cisterna chyli, which is located in the midline, near the level of the second lumbar vertebra. From this origin, the thoracic duct ascends into the chest through the aortic hiatus at the level of T10 to T12, and courses just to the right of the aorta (see Fig. 19-52). As the thoracic duct courses cephalad above the diaphragm, it most commonly remains in the right chest, lying just behind the esophagus, between the aorta and azygos vein. The duct continues superiorly, lying just to the right of the vertebral column. Then, at the fifth or sixth thoracic vertebra, it crosses behind the aorta and the aortic arch into the left posterior mediastinum and travels superiorly, staying near the esophagus and mediastinal pleura as it exits the thoracic inlet. As it exits the thoracic inlet, it passes to the left, just behind the carotid sheath and anterior to the inferior thyroid and vertebral bodies. Just medial to the anterior scalene muscle, it courses inferiorly and drains into the union of the internal jugular and subclavian veins. Given the extreme variability in the main duct and its branches, accumulation of chyle in the chest or flow from penetrating wounds may be seen after a variety of traumatic and medical conditions.²⁰⁵

The main function of the duct is to transport fat absorbed from the digestive system along with variable amounts of protein and lymphatic material (Table 19-39). Given the high volume of chyle that flows through the thoracic duct, significant injuries can cause leaks in excess of 2 L per day; if left untreated, protein, lymphocyte, and volume depletion can lead to serious metabolic effects and death. Thoracentesis is usually grossly suggestive, revealing milky, nonpurulent pleural fluid. However, if the patient is taking nothing by mouth, the pleural

Table 19-38

Etiology of chylothorax

Congenital

- Atresia of thoracic duct
- Thoracic duct-pleural space fistula
- Birth trauma

Traumatic and/or iatrogenic

- Blunt injury
- Penetrating injury
- Surgery
 - Cervical
 - Excision of lymph nodes
 - Radical neck dissection
 - Thoracic
 - Correction of patent ductus arteriosus
 - Correction of coarctation of the aorta
 - Vascular procedure involving the origin of the left subclavian artery
 - Esophagectomy
 - Sympathectomy
 - Resection of thoracic aneurysm
 - Resection of mediastinal tumors
 - Left pneumonectomy
 - Abdominal
 - Sympathectomy
 - Radical lymph node dissection
- Diagnostic procedures
 - Translumbar arteriography
 - Subclavian vein catheterization
 - Left-sided heart catheterization

Neoplasms**Infections**

- Tuberculous lymphadenitis
- Nonspecific mediastinitis
- Ascending lymphangitis
- Filariasis

Miscellaneous

- Venous thrombosis
 - Left subclavian-jugular vein
 - Superior vena cava
- Pulmonary lymphangiomatosis

Source: Reproduced with permission from Cohen RG, et al. The pleura. In: Sabiston DC, et al, eds. *Surgery of the Chest*. 6th ed. Philadelphia: Elsevier; 1995. Copyright Elsevier.

fluid may not be grossly abnormal. Laboratory analysis of the pleural fluid shows a high lymphocyte count and high triglyceride levels. If the triglyceride level is greater than 110 mg/100 mL, a chylothorax is almost certainly present (a 99% accuracy rate). If the triglyceride level is less than 50 mg/mL, there is only a 5% chance of chylothorax. In many clinical situations, the accumulation of chyle may be slow, because of minimal digestive fat flowing through the gastrointestinal tract after major trauma or surgery, so the diagnosis may be more difficult to establish.

Management. The treatment plan for any chylothorax depends on its cause, the amount of drainage, and the patient's clinical status (Fig. 19-53). In general, most patients are treated with a short period of chest tube drainage, nothing by mouth (NPO) orders, total parenteral nutrition (TPN), and observation.

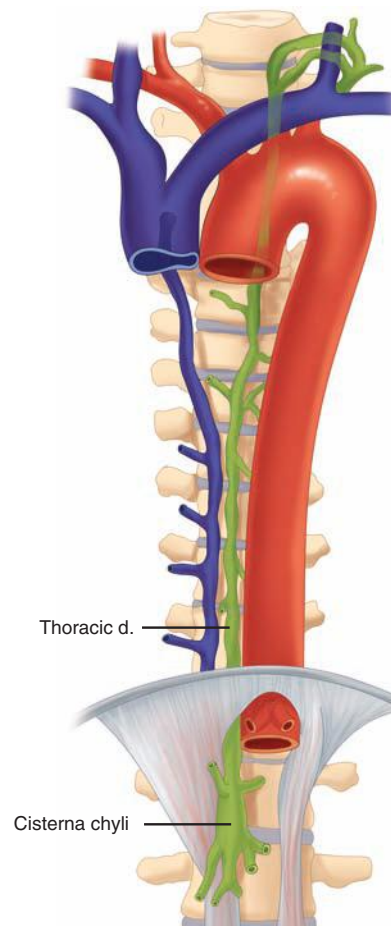


Figure 19-52. Normal thoracic duct anatomy. The esophagus comes into close proximity with the thoracic duct as it enters the chest from its origin in the abdomen at the cisterna chyli.

Table 19-39

Composition of chyle

COMPONENT	AMOUNT (PER 100 ML)
Total fat	0.4–5 g
Total cholesterol	65–220 mg
Total protein	2.21–5.9 g
Albumin	1.1–4.1 g
Globulin	1.1–3.1 g
Fibrinogen	16–24 g
Sugars	48–200 g
Electrolytes	Similar to levels in plasma
Cellular elements	
Lymphocytes	400–6800/mm ³
Erythrocytes	50–600/mm ³
Antithrombin globulin	>25% of plasma concentration
Prothrombin	>25% of plasma concentration
Fibrinogen	>25% of plasma concentration

Source: Reproduced with permission from Miller.²⁰⁴ Copyright Elsevier.

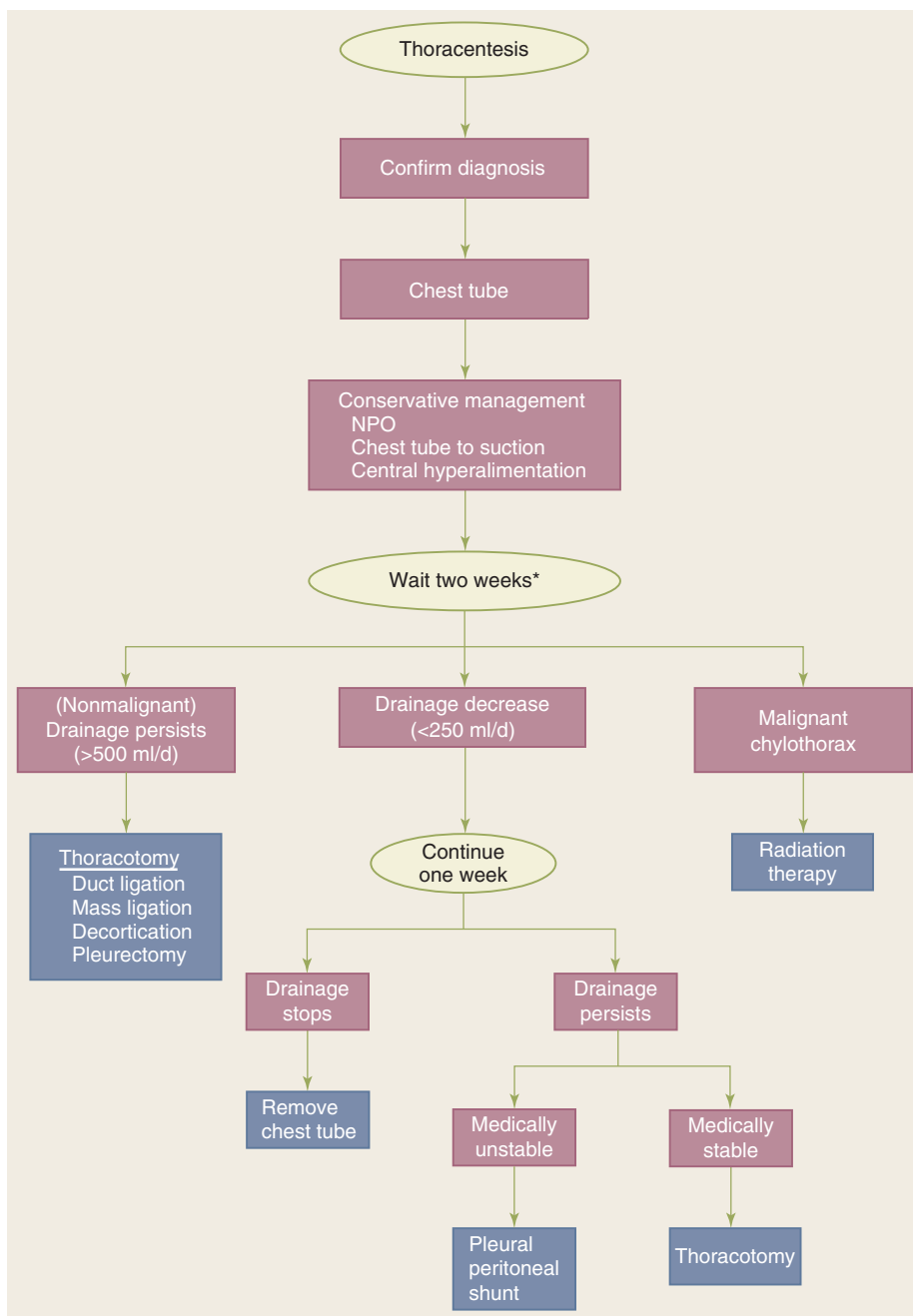


Figure 19-53. Algorithm for the management of chylothorax. *If high output persists (>500 mL/d), early surgical ligation of the thoracic duct may be considered. NPO = nothing by mouth.

Chest cavity drainage must be adequate to allow complete lung re-expansion. Somatostatin has been advocated by some authors, with variable results. If significant chyle drainage (>500 mL per day in an adult, >100 mL in an infant) continues despite TPN and good lung expansion, early surgical duct ligation or embolization is recommended. Ligation can be approached best by right thoracotomy, and in some experienced centers, by right VATS. Chylothoraces due to malignant conditions often respond to radiation and/or chemotherapy and less commonly require surgical ligation. Significant nutritional and immunologic depletion results from untreated chylothorax; associated mortality is in excess of 50%. With early recognition and aggressive medical management as well as early surgical ligation or embolization for persistent leaks, the mortality rate of chylothorax is now less than 10%.

Tumors of the Pleura

Malignant mesothelioma is the most common type of tumor of the pleura, with approximately 3000 cases per year in the

United States. Other, less common tumors include benign and malignant fibrous tumors of the pleura, lipomas, and cysts.

Malignant Mesothelioma. The only known risk factor for mesothelioma is exposure to asbestos, identified in over 50% of cases. Exposure is typically work-related in industries using asbestos in the manufacturing process, such as shipbuilding. The risk extends to family members who are exposed to the dust of the clothing or to the work environment. Asbestos exposure and smoking synergistically increase the risk for lung cancer, but smoking does not increase risk for malignant mesotheliomas. Male predominance is 2:1, and it occurs most commonly after the age of 40.

Risk of developing mesothelioma after asbestos exposure differs depending on the physical characteristics of the asbestos and similar fibers (either serpentine or amphibole). The serpentine fibers are large and curly and are generally not able to travel beyond larger airways. However, the narrow, straight

amphibole fibers, in particular the crocidolite fibers, may navigate distally into the pulmonary parenchyma and are most clearly associated with mesotheliomas. The latency period between asbestos exposure and the development of mesothelioma is at least 20 years. The tumor generally is multicentric, with multiple pleural-based nodules coalescing to form sheets of tumor. This process initially involves the parietal pleura, generally with early spread to the visceral surfaces and with a variable degree of invasion of surrounding structures. Autopsy studies have shown that most patients have distant metastases, but the natural history of the disease in untreated patients culminates in death due to local extension. Other risk factors include radiation exposure.

Clinical Presentation. Most patients present with dyspnea and chest pain. Over 90% have a pleural effusion, but thoracentesis is diagnostic in less than 10% of patients. Frequently, a thoracoscopy or open pleural biopsy with special stains is required to differentiate mesotheliomas from adenocarcinomas (Table 19-40). Epithelial subtypes are associated with a more favorable prognosis, and long-term survival may be seen in rare patients with no treatment. Sarcomatous and mixed tumors share a more aggressive course.

Management. The treatment of malignant mesotheliomas remains controversial. Prognosis depends on the stage of the disease (Table 19-41),²⁰⁶ but most patients present with advanced local or distant disease beyond curative potential. Treatment options include supportive care only, surgical resection, and multimodality approaches (using a combination of surgery, chemotherapy, and radiation therapy).²⁰⁷ Palliative approaches, such as pleurectomy or talc pleurodesis, may lead to local control and a modest improvement in short-term survival. Several reports of trials of extrapleural pneumonectomy and adjuvant chemotherapy and radiation have shown reasonable improvements in survival for patients with early-stage tumors (as compared with historical controls). In one series of 183 patients, a subset of 31 patients had favorable prognostic features (i.e., epithelial cell type), negative resection margins, and negative extrapleural node status. This favorable subset had a 5-year survival rate of 46%, as compared with 15% for the entire group.²⁰⁸ In another series, 88 patients with mesotheliomas were studied prospectively. Adjuvant radiation therapy was given to 54 patients after extrapleural pneumonectomy; the median survival

was 17 months. However, in patients with stage I and II disease, the median survival was significantly better at 33.0 months.²⁰⁹

Intrapleural therapy has been explored to improve the locoregional control of malignant mesotheliomas. In a phase II trial, 37 patients underwent pleurectomy with decortication, followed by intrapleural and systemic therapy with cisplatin and mitomycin C. Their median survival was 17 months, with a locoregional recurrence rate of 80%.²¹⁰ According to another study, the addition of hyperthermic intrapleural perfusion seems to be pharmacokinetically advantageous; of seven patients, three underwent pleurectomy with decortication and received hyperthermic cisplatin. Systemic drug concentrations were greater after pleurectomy with decortication than after pleuropneumectomy. The local tissue:perfusate ratio of platinum concentrations tended to be higher after hyperthermic perfusion rather than normothermic perfusion.²¹¹

Another promising alternative to enhance the local efficacy of chemotherapy against malignant mesotheliomas is L-NDDP (cis-bis-neodecanoato-trans-R,R-1,2-diaminocyclohexane platinum). A phase II trial of L-NDDP enrolled 33 patients to receive a thoracoscopic biopsy and a thoracoscopic posttreatment pleural biopsy after each cycle. Of those 33 patients, 14 (42%) had a complete pathologic response, with three treatment-related deaths due to infection. Buried residual tumor was found at pleural decortications in another two patients who had pathologic response.²¹² These findings are encouraging, but the optimal regimen for intrapleural treatment for mesothelioma remains to be fully defined.

The authors' current approach to malignant mesothelioma is based on tumor stage and patient performance status. Extrapleural pneumonectomy is recommended, especially for epithelial mesotheliomas, early-stage mesotheliomas, and good pulmonary function. For more advanced disease, decortication with intrapleural chemotherapy is administered, using an institutional protocol, for patients who are fit for surgery. Whenever possible, patients are referred for clinical trials of multimodality therapy. For more advanced disease, or if patients have less-than-optimal pulmonary function or performance status, talc pleurodesis or supportive therapy is recommended.

Fibrous Tumors of the Pleura. Fibrous tumors of the pleura are unrelated to asbestos exposure or malignant mesotheliomas. They generally occur as a single pedunculated mass arising from the visceral pleura but can occasionally arise from the parietal pleura. They can grow to be quite large, with most ranging from 5 to 10 cm and 100 to 400 g in size by the time they are discovered. Architecturally, the most common microscopic feature is the "patternless pattern." This is characterized by randomly situated areas of hypercellularity, containing spindle cells with bland, vesicular, ovoid nuclei and scarce cytoplasm, and hypocellularity, with fibrous connective tissue, hemorrhage, myxoid, or necrosis. They can also have an hemangiopericytoma-like appearance. The neoplastic cells are immunoreactive for CD34 and CD99 but negative for cytokeratins and desmin. Immunoreactivity for Bcl-2 is variably positive.²¹³

They are frequently discovered incidentally on routine CXRs, without an associated pleural effusion. They occur with equal frequency in males and females and are most common in the sixth to seventh decade of life. Fibrous tumors of the pleura may be benign or malignant.²¹⁴ Symptoms such as cough, chest pain, and dyspnea occur in 30% to 40% of patients but are found in 75% of patients with malignant tumors. Malignant tumors

Table 19-40

Differentiation of mesothelioma from adenocarcinoma

	MESOTHELIOMA	ADENOCARCINOMA
Immunohistochemical results		
Carcinoembryonic antigen	Negative	Positive
Vimentin	Positive	Negative
Low molecular weight cytokeratins	Positive	Negative
Electron microscopic features	Long, sinuous villi	Short, straight villi with fuzzy glycocalyx

Table 19-41

International Mesothelioma Interest Group staging system for diffuse malignant pleural mesothelioma

<i>T Tumor</i>			
T1	T1a	Tumor limited to the ipsilateral parietal ± mediastinal ± diaphragmatic pleura No involvement of the visceral pleura	
	T1b	Tumor involving the ipsilateral parietal ± mediastinal ± diaphragmatic pleura Tumor also involving the visceral pleura	
T2	Tumor involving each of the ipsilateral pleural surfaces (parietal, mediastinal, diaphragmatic, and visceral pleurae) with at least one of the following features: Involvement of diaphragmatic muscle Extension of tumor from visceral pleura into the underlying pulmonary parenchyma		
T3	Describes locally advanced but potentially resectable tumor Tumor involving all of the ipsilateral pleural surfaces (parietal, mediastinal, diaphragmatic, and visceral pleurae) with at least one of the following features: Involvement of the endothoracic fascia Extension into the mediastinal fat Solitary, completely resectable focus of tumor extending into the soft tissues of the chest wall Nontransmural involvement of the pericardium		
T4	Describes locally advanced technically unresectable tumor Tumor involving all of the ipsilateral pleural surfaces (parietal, mediastinal, diaphragmatic, and visceral pleurae) with at least one of the following features: Diffuse extension or multifocal masses of tumor in the chest wall, with or without associated rib destruction Direct transdiaphragmatic extension of tumor to the peritoneum Direct extension of tumor to the contralateral pleura Direct extension of tumor to mediastinal organs Direct extension of tumor into the spine Tumor extending through to the internal surface of the pericardium with or without a pericardial effusion; or tumor involving the myocardium		
<i>N Lymph Nodes</i>			
NX	Regional lymph nodes cannot be assessed		
N0	No regional lymph node metastasis		
N1	Metastases in the ipsilateral bronchopulmonary or hilar lymph nodes		
N2	Metastases in the subcarinal or the ipsilateral mediastinal lymph nodes including the ipsilateral internal mammary nodes		
N3	Metastases in the contralateral mediastinal, contralateral internal mammary, or ipsilateral or contralateral supraclavicular lymph nodes		
<i>M Metastases</i>			
MX	Presence of distant metastases cannot be assessed		
M0	No distant metastases		
M1	Distant metastases present		
<i>Staging</i>			
Stage I			
IA	T1a	N0	M0
IB	T1b	N0	M0
Stage II			
	T2	N0	M0
Stage III			
	Any T3	Any N1	M0
		Any N2	
Stage IV			
	Any T4	Any N3	Any M1

Source: Reproduced with permission from International Mesothelioma Interest Group. A proposed new international TNM staging system for malignant pleural mesothelioma. *Chest*. 1995;108:1122.

are differentiated from benign tumors based on high cellularity, more than 4 mitotic figures per 10 high-power fields, nuclear pleomorphism, tumor necrosis, and hemorrhage. They are more likely to arise from the parietal pleura of the chest wall, diaphragm, or mediastinum, or in the fissures or invaginating into the lung parenchyma. Hypoglycemia, associated pleural effusion, and hypertrophic pulmonary osteoarthropathy (clubbed digits, long bone ossifying periostitis, and arthritis) are associated with these lesions in approximately 25% of patients. Less common are fever and hemoptysis.

Symptoms resolve with surgical resection. Given the well-circumscribed and often pedunculated nature of fibrous tumors of the pleura, all benign lesions and approximately 50% of malignant lesions are cured by complete surgical resection.²¹⁴ Incompletely resected malignant tumors may recur locally or metastasize, and more than 50% of patients with malignant tumors will die from the disease; frequently, they are fatal within 2 to 5 years.

ACKNOWLEDGEMENT

The authors wish to thank Shannon Wyzomierski for her invaluable help in compiling and editing this chapter. The authors also express appreciation to their spouses, Chris, Lee, and Chris.

REFERENCES

Entries highlighted in bright blue are key references.

1. Cusimano RJ, Pearson FG. Anatomy, physiology, and embryology of the upper airway. In: Pearson FG, Cooper JD, Deslauriers J, et al, eds. *Thoracic Surgery*. 2nd ed. New York: Churchill Livingstone; 2002:215.
2. Grillo HC. Surgical treatment of postintubation tracheal injuries. *J Thorac Cardiovasc Surg*. 1979;78(6):860-875.
3. Nouraei SA, Ma E, Patel A, et al. Estimating the population incidence of adult post-intubation laryngotracheal stenosis. *Clin Otolaryngol*. 2007;32(5):411-412.
4. Couraud L, Ballester MJ, Delaisement C. Acquired tracheoesophageal fistula and its management. *Semin Thorac Cardiovasc Surg*. 1996;8:392.
5. Mathisen DJ, Grillo HC, Wain JC, et al. Management of acquired nonmalignant tracheoesophageal fistula. *Ann Thorac Surg*. 1991;52:759.
6. Bhattacharyya N. Contemporary staging and prognosis for primary tracheal malignancies: a population-based analysis. *Otolaryngol Head Neck Surg*. 2004;131:639-642.
7. Gaissert HA, Grillo HC, Shadmehr MB, et al. Uncommon primary tracheal tumors. *Ann Thorac Surg*. 2006;82:268.
8. Regnard JF, Fourquier P, Lévassieur P. Results and prognostic factors in resections of primary tracheal tumors: a multicenter retrospective study. The French Society of Cardiovascular Surgery. *J Thorac Cardiovasc Surg*. 1996;111:808; discussion 813.
9. Chow DC, Komaki R, Libshitz HI, et al. Treatment of primary neoplasms of the trachea. The role of radiation therapy. *Cancer*. 1993;71:2946.
10. Rice TW. Anatomy of the lung. In: Pearson FG, Cooper JD, Deslauriers J, et al, eds. *Thoracic Surgery*. 2nd ed. New York: Churchill Livingstone; 2002:427.
11. Jeremy George P, Banerjee AK, Rea CA, et al. Surveillance for the detection of early lung cancer in patients with bronchial dysplasia. *Thorax*. 2007;62:43.
12. Wang GF, Lai MD, Yang RR, et al. Histological types and significance of bronchial epithelial dysplasia. *Mod Pathol*. 2006;19:429.

13. Gould VE, Warren WH. Epithelial tumors of the lung. *Chest Surg Clin N Am*. 2000;10:709-728.
14. Fu JB, Kau TY. Lung cancer in women: analysis of the national Surveillance, Epidemiology, and End Results database. *Chest*. 2005;127:768-777.
15. Travis WD, Brambilla E, Riely G. International Association for the Study of Lung Cancer/American Thoracic Society/European Respiratory Society international multidisciplinary classification of lung adenocarcinoma. *J Thorac Oncol*. 2011; 6:244-285.
16. Schmidt L, Myers J. Bronchioloalveolar carcinoma and the significance of invasion: predicting biologic behavior. *Arch Pathol Lab Med*. 2010;134:1450-1454.
17. Cerilli LA, Ritter JH, Mills SE, et al. Neuroendocrine neoplasms of the lung. *Am J Clin Pathol*. 2001;116(Suppl):S65.
18. Jemal A, Simard EP, Dorell C, et al. Annual report to the nation on the status of cancer, 1975-2009, featuring the burden and trends in human papillomavirus (HPV)-Associated Cancers and HPV vaccination coverage levels. *J Natl Cancer Inst*. 2013;105:175-201.
19. Mulligan CR, Meram AD, Proctor CD, et al. Unlimited access to care: effect on racial disparity and prognostic factors in lung cancer. *Cancer Epidemiol Biomarkers Prev*. 2006;15:25.
20. Samet JM. Health benefits of smoking cessation. *Clin Chest Med*. 1991;12:669.
21. Sun S, Schiller JH, Gazdar AF. Lung cancer in never smokers—a different disease. *Nat Rev Cancer*. 2007;7:778.
22. Hackshaw AK, Law MR, Wald NJ. The accumulated evidence on lung cancer and environmental tobacco smoke. *BMJ*. 1997;315:980.
23. Aberle DR, Adams AM, Berg CD, et al. Reduced lung-cancer mortality with low-dose computed tomographic screening. *N Engl J Med*. 2011;365:395-409.
24. Gould MK, Fletcher J, Iannettoni MD, et al. Evaluation of patients with pulmonary nodules: when is it lung cancer? ACCP evidence-based clinical practice guidelines. 2nd ed. *Chest*. 2007;132(3 Suppl):108S.
25. Marten K, Grabbe E. The challenge of the solitary pulmonary nodule: diagnostic assessment with multislice spiral CT. *Clin Imaging*. 2003;27:156.
26. Remy-Jardin M, Remy J, Giraud F, et al. Pulmonary nodules: detection with thick-section spiral CT versus conventional CT. *Radiology*. 1993;187:513.
27. Naidich DP. Helical computed tomography of the thorax: clinical applications. *Radiol Clin North Am*. 1994;32:759.
28. Stroobants S, Verschakelen J, Vansteenkiste J. Value of FDG-PET in the management of non-small cell lung cancer. *Eur J Radiol*. 2003;45:49.
29. Cahan WG, Shah JP, Castro EB. Benign solitary lung lesions in patients with cancer. *Ann Surg*. 1978;187:241.
30. Davidson RS, Nwogu CE, Brentjens MJ, et al. The surgical management of pulmonary metastasis: current concepts. *Surg Oncol*. 2001;10:35.
31. Pastorino U, Buyse M, Friedel G, et al. Long-term results of lung metastasectomy: prognostic analyses based on 5206 cases. *J Thorac Cardiovasc Surg*. 1997;113:37.
32. McCormack PM, Bains MS, Begg CB, et al. Role of video-assisted thoracic surgery in the treatment of pulmonary metastases: results of a prospective trial. *Ann Thorac Surg*. 1996;62:213; discussion 216.
33. Rivera MP, Mehta AC. Initial diagnosis of lung cancer: ACCP evidence-based clinical practice guidelines. 2nd ed. *Chest*. 2007;132(3 Suppl):131S.
34. Ost D, Fein AM, Feinsilver SH. Clinical practice. The solitary pulmonary nodule. *N Engl J Med*. 2003;348:2535.
35. Toloza EM, Harpole L, McCrory DC. Noninvasive staging of non-small cell lung cancer: a review of the current evidence. *Chest*. 2003;123(1 Suppl):137S.

36. Goldberg M, Unger M. Lung cancer. Diagnostic tools. *Chest Surg Clin N Am*. 2000;10:763.
37. Vaz AP, Fernandes G, Souto Moura C, et al. Integrated PET/CT in non small cell lung cancer staging: clinical and pathological agreement. *Rev Port Pneumol*. 2012;18:109-114.
38. Iskender I, Kapicibasi HO. Comparison of integrated positron emission tomography/computed tomography and mediastinoscopy in mediastinal staging of non-small cell lung cancer: analysis of 212 patients. *Acta Chir Belg*. 2012;112:219-225.
39. Li X, Zhang H, Xing L, et al. Mediastinal lymph nodes staging by 18F-FDG PET/CT for early stage non-small cell lung cancer: a multicenter study. *Radiother Oncol*. 2012;102:246-250.
40. Lv YL, Yuan DM. Diagnostic performance of integrated positron emission tomography/computed tomography for mediastinal lymph node staging in non-small cell lung cancer: a bivariate systematic review and meta-analysis. *J Thorac Oncol*. 2011;6(8):1350-1358.
41. Mountain CF, Dresler CM. Regional lymph node classification for lung cancer staging. *Chest*. 1997;111:1718.
42. Barrera R, Shi W, Amar D, et al. Smoking and timing of cessation: impact on pulmonary complications after thoracotomy. *Chest*. 2005;127:1977.
43. Nakagawa M, Tanaka H, Tsukuma H, et al. Relationship between the duration of the preoperative smoke-free period and the incidence of postoperative pulmonary complications after pulmonary surgery. *Chest*. 2001;120:705.
44. Colice GL, Shafazand S, Griffin JP, et al. **Physiologic evaluation of the patient with lung cancer being considered for resectional surgery: ACCP evidenced-based clinical practice guidelines. 2nd ed. *Chest*. 2007;132(3 Suppl):161S.**
45. Ou SH, Zell JA, Ziogas A, et al. Prognostic factors for survival of stage I nonsmall cell lung cancer patients: A population-based analysis of 19,702 stage I patients in the California Cancer Registry from 1989 to 2003. *Cancer*. 2007;110:1532.
46. Raz DJ, Zell JA, Ou SH, et al. Natural history of stage I non-small cell lung cancer: implications for early detection. *Chest*. 2007;132:193.
47. Ginsberg RJ, Rubinstein LV. Randomized trial of lobectomy versus limited resection for T1 N0 non-small cell lung cancer. Lung Cancer Study Group. *Ann Thorac Surg*. 1995;60:615.
48. Warren WH, Faber LP. Segmentectomy versus lobectomy in patients with stage I pulmonary carcinoma. Five-year survival and patterns of intrathoracic recurrence. *J Thorac Cardiovasc Surg*. 1994;107:1087; discussion 1093.
49. Nakamura H, Kawasaki N, Taguchi M, et al. Survival following lobectomy vs. limited resection for stage I lung cancer: a meta-analysis. *Br J Cancer*. 2005;92:1033-1037.
50. Schuchert MJ, Pettiford BL, Keeley S, et al. Anatomic segmentectomy in the treatment of stage I non-small cell lung cancer. *Ann Thorac Surg*. 2007;84(3), 926-932; discussion 932-923.
51. Siel W, Stremmel C, Kirschbaum A, et al. Frequency of local recurrence following segmentectomy of stage IA non-small cell lung cancer is influenced by segment localisation and width of resection margins—implications for patient selection for segmentectomy. *Eur J Cardiothorac Surg*. 2007;31(3):522-527; discussion 527-528.
52. Shapiro M, Weiser TS, Wisnivesky JP, Chin C, Arustamyan M, Swanson SJ. Thoracoscopic segmentectomy compares favorably with thoracoscopic lobectomy for patients with small stage I lung cancer. *J Thorac Cardiovasc Surg*. 2009;137(6):1388-1393.
53. Oizumi H, Kanauchi N, Kato H, et al. Total thoracoscopic pulmonary segmentectomy. *Eur J Cardiothorac Surg*. 2009;36(2):374-377; discussion 377.
54. Schuchert MJ, Pettiford BL, Pennathur A, et al. Anatomic segmentectomy for stage I non-small cell lung cancer: comparison of video-assisted thoracic surgery versus open approach. *J Thorac Cardiovasc Surg*. 2009;138(6):1318-1325 e1311.
55. Watanabe A, Ohori S, Nakashima S, et al. Feasibility of video-assisted thoracoscopic surgery segmentectomy for selected peripheral lung carcinomas. *Eur J Cardiothorac Surg*. 2009;35(5):775-780; discussion 780.
56. Fuwa N, Mitsudomi T, Daimon T, et al. Factors involved in lymph node metastasis in clinical stage I non-small cell lung cancer—from studies of 604 surgical cases. *Lung Cancer*. 2007;57(3):311-316.
57. Fernando HC, De Hoyos A, Landreneau, et al. Radiofrequency ablation for the treatment of non-small cell lung cancer in marginal surgical candidates. *J Thorac Cardiovasc Surg*. 2005;129(3):639-644.
58. Pennathur A, Luketich JD, Abbas G, et al. Radiofrequency ablation for the treatment of stage I non-small cell lung cancer in high-risk patients. *J Thorac Cardiovasc Surg*. 2007;134(4):857-864.
59. Lencioni R, Crocetti L, Cioni R, et al. Response to radiofrequency ablation of pulmonary tumours: a prospective, intention-to-treat, multicentre clinical trial (the RAPTURE study). *Lancet Oncol*. 2008;9(7):621-628.
60. Fakiris AJ, McGarry RC, Yiannoutsos CT, et al. Stereotactic body radiation therapy for early-stage non-small-cell lung carcinoma: four-year results of a prospective phase II study. *Int J Radiat Oncol Biol Phys*. 2009;75(3):677-682.
61. Potters L, Kavanagh B, Galvin JM, et al. American Society for Therapeutic Radiology and Oncology (ASTRO) and American College of Radiology (ACR) practice guideline for the performance of stereotactic body radiation therapy. *Int J Radiat Oncol Biol Phys*. 2010;76(2):326-332.
62. Timmerman R, Paulus R, Galvin J, et al. Stereotactic body radiation therapy for inoperable early stage lung cancer. *JAMA*. 2010;303(11):1070-1076.
63. Simon CJ, Dupuy DE, DiPetrillo TA, et al. Pulmonary radiofrequency ablation: long-term safety and efficacy in 153 patients. *Radiology*. 2007;243(1):268-275.
64. Abbas G, Pennathur A, Landreneau RJ, Luketich JD. Radiofrequency and microwave ablation of lung tumors. *J Surg Oncol*. 2009;100(8):645-650.
65. Lanuti M, Sharma A, Digumarthy SR, et al. Radiofrequency ablation for treatment of medically inoperable stage I non-small cell lung cancer. *J Thorac Cardiovasc Surg*. 2009;137(1):160-166.
66. Pua BB, Solomon SB. Radiofrequency ablation of primary and metastatic lung cancers. *Semin Ultrasound CT MR*. 2009;30(2):113-124.
67. Casal RF, Tam AL, Eapen GA. Radiofrequency ablation of lung tumors. *Clin Chest Med*. 2010;31(1):151-163.
68. Crocetti L, Lencioni R. Radiofrequency ablation of pulmonary tumors. *Eur J Radiol*. 2010;75(1):23-27.
69. Fernando HC, Schuchert M, Landreneau R, Daly BT. Approaching the high-risk patient: sublobar resection, stereotactic body radiation therapy, or radiofrequency ablation. *Ann Thorac Surg*. 2010;89(6):S2123-2127.
70. Hoffmann TH, Ransdell HT: Comparison of lobectomy and wedge resection for carcinoma of the lung. *J Thorac Cardiovasc Surg* 79:211, 1980.
71. Read RC, Yoder G, Schaeffer RC: Survival after conservative resection for T1 N0 M0 non-small cell lung cancer. *Ann Thorac Surg* 49:391, 1990.
72. Date H, Andou A, Shimizu N: The value of limited resection for “clinical” stage I peripheral non-small cell lung cancer in poor-risk patients: comparison of limited resection and lobectomy by a computer-assisted matched study. *Tumori* 80:422, 1994.
73. Harpole DH, Jr., Herndon JE, 2nd, Young WG, Jr., et al: Stage I nonsmall cell lung cancer. A multivariate analysis of treatment methods and patterns of recurrence. *Cancer* 76:787, 1995.
74. Lederle FA: Lobectomy versus limited resection in T1 N0 lung cancer. *Ann Thorac Surg* 62:1249, 1996.

75. Kodama K, Doi O, Higashiyama M, et al: Intentional limited resection for selected patients with T1 N0 M0 non-small-cell lung cancer: A single-institution study. *J Thorac Cardiovasc Surg* 114:347, 1997.
76. Landreneau RJ, Sugarbaker DJ, Mack MJ, et al: Wedge resection versus lobectomy for stage I (T1 N0 M0) non-small-cell lung cancer. *J Thorac Cardiovasc Surg* 113:691, 1997.
77. Pastorino U, Andreola S, Tagliabue E, et al: Immunocytochemical markers in stage I lung cancer: relevance to prognosis. *J Clin Oncol* 15:2858, 1997.
78. Kwiatkowski DJ, Harpole DH, Jr., Godleski J, et al: Molecular pathologic substaging in 244 stage I non-small-cell lung cancer patients: Clinical implications. *J Clin Oncol* 16:2468, 1998.
79. Okada M, Yoshikawa K, Hatta T, et al: Is segmentectomy with lymphnode assessment an alternative to lobectomy for non-small cell lung cancer of 2 cm or smaller? *Ann Thorac Surg* 71:956, 2001.
80. Koike T, Yamato Y, Yoshiya K, et al: Intentional limited pulmonary resection for peripheral T1 N0 M0 small-sized lung cancer. *J Thorac Cardiovasc Surg* 125:924, 2003.
81. Campione A, Ligabue T, Luzzi L, et al: Comparison between segmentectomy and larger resection of stage IA non-small cell lung carcinoma. *J Cardiovasc Surg (Torino)* 45:67, 2004.
82. Keenan RJ, Landreneau RJ, Maley RH, Jr., et al: Segmental resection spares pulmonary function in patients with stage I lung cancer. *Ann Thorac Surg* 78:228, 2004.
83. Timmerman R, McGarry R, Yiannoutsos C, et al: Excessive toxicity when treating central tumors in a phase II study of stereotactic body radiation therapy for medically inoperable early-stage lung cancer. *J Clin Oncol*. 2006;24(30):4833-4839.
84. Pisters KM, Ginsberg RJ, Giroux DJ, et al: Induction chemotherapy before surgery for early-stage lung cancer: a novel approach. Bimodality Lung Oncology Team. *J Thorac Cardiovasc Surg*. 2000;119:429.
85. Rosell R, Gomez-Codina J, Camps C, et al: A randomized trial comparing preoperative chemotherapy plus surgery with surgery alone in patients with non-small-cell lung cancer. *N Engl J Med*. 1994;330:153.
86. Bouchet L, Bauvin E, Marcheix B, et al: Impact of induction treatment on postoperative complications in the treatment of non-small cell lung cancer. *J Thorac Oncol*. 2007;2:626.
87. Rusch VW. Management of Pancoast tumours. *Lancet Oncol*. 2006;7:997.
88. Rusch VW, Giroux DJ, Kraut MJ, et al: Induction chemoradiation and surgical resection for superior sulcus non-small-cell lung carcinomas: long-term results of Southwest Oncology Group Trial 9416 (Intergroup Trial 0160). *J Clin Oncol*. 2007; 25:313.
89. Dillman RO, Herndon J, Seagren SL, et al: Improved survival in stage III non-small-cell lung cancer: seven-year follow-up of Cancer and Leukemia Group B (CALGB) 8433 trial. *J Natl Cancer Inst*. 1996;88:1210.
90. Roth JA, Atkinson EN, Fossella F, et al: Long-term follow-up of patients enrolled in a randomized trial comparing perioperative chemotherapy and surgery with surgery alone in resectable stage IIIA non-small-cell lung cancer. *Lung Cancer* 21:1, 1998.
91. Pass HI, Pogrebnik HW, Steinberg SM, et al: Randomized trial of neoadjuvant therapy for lung cancer: interim analysis. *Ann Thorac Surg* 53:992, 1992.
92. Nagai K, Tsuchiya R, Mori T, et al: A randomized trial comparing induction chemotherapy followed by surgery with surgery alone for patients with stage IIIA N2 non-small cell lung cancer (JCOG 9209). *J Thorac Cardiovasc Surg* 125:254, 2003.
93. Gilligan D, Nicolson M, Smith I, et al: Preoperative chemotherapy in patients with resectable non-small cell lung cancer: results of the MRC LU22/NVALT 2/EORTC 08012 multicentre randomised trial and update of systematic review. *Lancet* 369:1929, 2007.
94. Depierre A, Milleron B, Moro-Sibilot D, et al: Preoperative chemotherapy followed by surgery compared with primary surgery in resectable stage I (except T1N0), II, and IIIa non-small-cell lung cancer. *J Clin Oncol* 20:247, 2002.
95. Pisters K, Vallieres E, Bunn PA, Jr., et al: S9900: Surgery alone or surgery plus induction (ind) paclitaxel/carboplatin (PC) chemotherapy in early stage non-small cell lung cancer (NSCLC): Follow-up on a phase III trial. *J Clin Oncol* 25:7520, 2007.
96. Sorensen JB, Riska H, Ravn J, et al: Scandinavian phase III trial of neoadjuvant chemotherapy in NSCLC stages IB-IIIa/T3. *ASCO Meeting Abstracts* 23:7146, 2005.
97. Mattson KV, Abratt RP, ten Velde G, et al: Docetaxel as neoadjuvant therapy for radically treatable stage III non-small-cell lung cancer: A multinational randomised phase III study. *Ann Oncol* 14:116, 2003.
98. Okawara G, Mackay JA, Evans W, et al: Management of unresected stage III non-small cell lung cancer: a systematic review. *J Thorac Oncol*. 2006;1:377-393.
99. Swanson SJ, Herndon JE II, D'Amico TA, et al: Video-assisted thoracic surgery lobectomy: report of CALGB 39802—a prospective, multi-institution feasibility study. *J Clin Oncol*. 2007;25:4993.
100. Demmy TL, James TA, Swanson SJ, et al: Troubleshooting video-assisted thoracic surgery lobectomy. *Ann Thorac Surg*. 2005;79:1744; discussion 1753.
101. Fry WA. Thoracic incisions. *Chest Surg Clin N Am*. 1995; 5:177-188.
102. Dewey TM, Mack MJ. Lung cancer. Surgical approaches and incisions. *Chest Surg Clin N Am*. 2000;10:803-820.
103. Cerfolio RJ, Bryant AS. Results of a prospective algorithm to remove chest tubes after pulmonary resection with high output. *J Thorac Cardiovasc Surg*. 2008;135:269.
104. Cerfolio RJ, Bass C, Katholi CR. Prospective randomized trial compares suction versus water seal for air leaks. *Ann Thorac Surg*. 2001;71:1613.
105. Bauer C, Hentz JG, Ducrocq X, et al: Lung function after lobectomy: a randomized, double-blinded trial comparing thoracic epidural ropivacaine/sufentanil and intravenous morphine for patient-controlled analgesia. *Anesth Analg*. 2007;105:238.
106. Casati A, Alessandrini P, Nuzzi M, et al: A prospective, randomized, blinded comparison between continuous thoracic paravertebral and epidural infusion of 0.2% ropivacaine after lung resection surgery. *Eur J Anaesthesiol*. 2006;23:999.
107. Inderbitzi RG, Leiser A, Furrer M, et al: Three years' experience in video-assisted thoracic surgery (VATS) for spontaneous pneumothorax. *J Thorac Cardiovasc Surg*. 1994;107:1410.
108. Warner BW, Bailey WW, Shipley RT. Value of computed tomography of the lung in the management of primary spontaneous pneumothorax. *Am J Surg*. 1991;162:39.
109. Mansharamani N, Balachandran D, Delaney D, et al: Lung abscess in adults: clinical comparison of immunocompromised to non-immunocompromised patients. *Respir Med*. 2002; 96:178.
110. Laheij RJ, Sturkenboom MC, Hassing RJ, et al: Risk of community-acquired pneumonia and use of gastric acid-suppressive drugs. *JAMA* 2004;292:1955.
111. Conant EF, Wechsler RJ. Actinomycosis and nocardiosis of the lung. *J Thorac Imaging*. 1992;7:75.
112. Thomson RM, Armstrong JG, Looke DF. Gastroesophageal reflux disease, acid suppression, and *Mycobacterium avium* complex pulmonary disease. *Chest*. 2007;131:1166.
113. Koh WJ, Lee JH, Kwon YS, et al: Prevalence of gastroesophageal reflux disease in patients with nontuberculous mycobacterial lung disease. *Chest*. 2007;131:1825.
114. Angrill J, Agusti C, de Celis R, et al: Bacterial colonisation in patients with bronchiectasis: microbiological pattern and risk factors. *Thorax*. 2002;57:15.
115. Barker AF. Bronchiectasis. *N Engl J Med*. 2002;346:1383.
116. Ilowite J, Spiegler P, Chawla S. Bronchiectasis: new findings in the pathogenesis and treatment of this disease. *Curr Opin Infect Dis*. 2008;21:163.

117. Bilton D, Henig N, Morrissey B, et al. Addition of inhaled tobramycin to ciprofloxacin for acute exacerbations of *Pseudomonas aeruginosa* infection in adult bronchiectasis. *Chest*. 2006;130:1503.
118. Steinfurt DP, Steinfurt C. Effect of long-term nebulized colistin on lung function and quality of life in patients with chronic bronchial sepsis. *Intern Med J*. 2007;37:495.
119. Kellett F, Robert NM. Nebulised 7% hypertonic saline improves lung function and quality of life in bronchiectasis. *Respir Med*. 2011;105:1831-1835.
120. Frieden TR, Sterling TR, Munsiff SS, et al. Tuberculosis. *Lancet*. 2003;362:887.
121. Haque AK. The pathology and pathophysiology of mycobacterial infections. *J Thorac Imaging*. 1990;5:8-16.
122. Iseman MD. Treatment of multidrug-resistant tuberculosis. *N Engl J Med*. 1993;329:784.
123. Kubak BM. Fungal infection in lung transplantation. *Transpl Infect Dis*. 2002;4(Suppl 3):24.
124. Wheat LJ, Goldman M, Sarosi G. State-of-the-art review of pulmonary fungal infections. *Semin Respir Infect*. 2002; 17:158.
125. Marr KA, Patterson T, Denning D. Aspergillosis. Pathogenesis, clinical manifestations, and therapy. *Infect Dis Clin North Am*. 2002;16:875.
126. Chun JY, Belli AM. Immediate and long-term outcomes of bronchial and non-bronchial systemic artery embolisation for the management of haemoptysis. *Eur Radiol*. 2010;20:558-565.
127. Corr P. Management of severe haemoptysis from pulmonary aspergilloma using endovascular embolization. *Cardiovasc Intervent Radiol*. 2006;9:807.
128. Playford EG, Sorrell TC. Optimizing therapy for *Candida* infections. *Semin Respir Crit Care Med*. 2007;28:678.
129. Ostrosky-Zeichner L, Rex JH, Bennett J, et al. Deeply invasive candidiasis. *Infect Dis Clin North Am*. 2002;16:821.
130. Gonzalez CE, Rinaldi MG, Sugar AM. Zygomycosis. *Infect Dis Clin North Am*. 2002;16:895.
131. Wheat LJ, Kauffman CA. Histoplasmosis. *Infect Dis Clin North Am*. 2003;17:1.
132. Hage CA, Wheat LJ, Loyd J, et al. Pulmonary histoplasmosis. *Semin Respir Crit Care Med*. 2008;29:151.
133. Assi MA, Sandid MS, Baddour LM, et al. Systemic histoplasmosis: a 15-year retrospective institutional review of 111 patients. *Medicine (Baltimore)*. 2007;86:162.
134. Spinello IM, Munoz A, Johnson RH. Pulmonary coccidioidomycosis. *Semin Respir Crit Care Med*. 2008;29:166.
135. Pappas PG. Blastomycosis. *Semin Respir Crit Care Med*. 2004;25:113.
136. Bradsher RW, Chapman SW, Pappas PG. Blastomycosis. *Infect Dis Clin North Am*. 2003;17:21.
137. Corder R. Hemoptysis. *Emerg Med Clin North Am*. 2003; 21:421.
138. Conlan AA. Massive hemoptysis—diagnostic and therapeutic implications. *Surg Annu* 1985;17:337.
139. Cahill BC, Ingbar DH. Massive hemoptysis. Assessment and management. *Clin Chest Med* 1994;15:147.
140. Noe GD, Jaffe SM, Molan MP. CT and CT angiography in massive haemoptysis with emphasis on pre-embolization assessment. *Clin Radiol*. 2011;66:869-875.
141. Poyanli A, Acunas B, Rozanes I, et al. Endovascular therapy in the management of moderate and massive haemoptysis. *Br J Radiol*. 2007;80:331-336.
142. Conlan AA, Hurwitz SS. Management of massive haemoptysis with the rigid bronchoscope and cold saline lavage. *Thorax*. 1980;35:901.
143. Russi EW, Bloch KE, Weder W. Lung volume reduction surgery: what can we learn from the National Emphysema Treatment Trial? *Eur Respir J*. 2003;22:571.
144. Bhorade SM, Vigneswaran W, McCabe MA, et al. Liberalization of donor criteria may expand the donor pool without adverse consequence in lung transplantation. *J Heart Lung Transplant*. 2000;19:1199.
145. Pierre AF, Sekine Y, Hutcheon MA, et al. Marginal donor lungs: a reassessment. *J Thorac Cardiovasc Surg*. 2002; 123:421; discussion 427.
146. Palmer SM, Miralles AP, Howell DN, et al. Gastroesophageal reflux as a reversible cause of allograft dysfunction after lung transplantation. *Chest*. 2000;118:1214.
147. Dahlberg PS, Prekker ME, Hertz M, et al. Recent trends in lung transplantation: the University of Minnesota experience. *Clin Transpl*. 2002;243.
148. Somers J, Faber LP. Chondroma and chondrosarcoma. *Semin Thorac Cardiovasc Surg*. 1999;11:270.
149. Andino L, Cagle PT, Murer B, et al. Pleuropulmonary desmoid tumors: immunohistochemical comparison with solitary fibrous tumors and assessment of beta-catenin and cyclin D1 expression. *Arch Pathol Lab Med*. 2006;130:1503.
150. Baliski CR, Temple WJ, Arthur K, et al. Desmoid tumors: a novel approach for local control. *J Surg Oncol*. 2002;80:96.
151. Abbas AE, Deschamps C, Cassivi SD, et al: Chest-wall desmoid tumors: results of surgical intervention. *Ann Thorac Surg*. 2004;78:1219; discussion 1219.
152. Gutierrez JC, Perez EA, Franceschi D, et al. Outcomes for soft-tissue sarcoma in 8249 cases from a large state cancer registry. *J Surg Res*. 2007;141:105.
153. Walsh GL, Davis BM, Swisher SG, et al. A single-institutional, multidisciplinary approach to primary sarcomas involving the chest wall requiring full-thickness resections. *J Thorac Cardiovasc Surg*. 2001;121:48.
154. Liptay MJ, Fry WA. Malignant bone tumors of the chest wall. *Semin Thorac Cardiovasc Surg*. 1999;11:278.
155. Shah AA, D'Amico TA. Primary chest wall tumors. *J Am Coll Surg*. 2010;210:360-366.
156. Incarbone M, Pastorino U. Surgical treatment of chest wall tumors. *World J Surg*. 2001;25:218.
157. Deschamps C, Tirnaksiz BM, Darbandi R, et al. Early and long-term results of prosthetic chest wall reconstruction. *J Thorac Cardiovasc Surg*. 1999;117:588; discussion 591.
158. Graeber GM. Chest wall resection and reconstruction. *Semin Thorac Cardiovasc Surg*. 1999;11:251.
159. Kirschner PA. Anatomy and surgical access of the mediastinum. In: Pearson FG, ed. *Thoracic Surgery*. 2nd ed. New York: Churchill Livingstone; 2002:1563.
160. Strollo DC, Rosado-de-Christenson ML, Jett JR. Primary mediastinal tumors. Part II: tumors of the middle and posterior mediastinum. *Chest*. 1997;112:1344.
161. Takahashi K, Al-Janabi NJ. Computed tomography and magnetic resonance imaging of mediastinal tumors. *J Magn Reson Imaging*. 2010;32:1325-1339.
162. Storch I, Shah M, Thurer R, et al. Endoscopic ultrasound-guided fine-needle aspiration and Tru-Cut biopsy in thoracic lesions: when tissue is the issue. *Surg Endosc J*. 2008;22:86.
163. Herman SJ, Holub RV, Weisbrod GL, et al. Anterior mediastinal masses: utility of transthoracic needle biopsy. *Radiology*. 1991;180:167.
164. Assaad MW, Pantanowitz L. Diagnostic accuracy of image-guided percutaneous fine needle aspiration biopsy of the mediastinum. *Diagn Cytopathol*. 2007;35:705-709.
165. Pedote P, Gaudio F, Moschetta M, et al. CT-guided needle biopsy performed with modified coaxial technique in the diagnosis of malignant lymphomas. *Radiol Med*. 2010;115: 1292-1303.
166. Demmy TL, Krasna MJ. Multicenter VATS experience with mediastinal tumors. *Ann Thorac Surg*. 1998;66:187-192.
167. Bodner J, Wykypiel H, Greiner A, et al. Early experience with robot-assisted surgery for mediastinal masses. *Ann Thorac Surg*. 2004;78:259-265.
168. Yim AP. Video-assisted thoracoscopic resection of anterior mediastinal masses. *Int Surg*. 1996;81:350.
169. Weksler B, Tavares J. Robot-assisted thymectomy is superior to transsternal thymectomy. *Surg Endosc*. 2012;26:261-266.

170. Chang PC, Chou SH, Kao EL, et al. Bilateral video-assisted thoracoscopic thymectomy vs. extended transsternal thymectomy in myasthenia gravis: a prospective study. *Eur Surg Res.* 2005;37:199-203.
171. Meyers BF, Cooper JD. Transcervical thymectomy for myasthenia gravis. *Chest Surg Clin N Am.* 2001;11:363.
172. Small EJ, Venook AP, Damon LE. Gallium-avid thymic hyperplasia in an adult after chemotherapy for Hodgkin disease. *Cancer.* 1993;72:905.
173. Smith CS, Schoder H. Thymic extension in the superior mediastinum in patients with thymic hyperplasia: potential cause of false-positive findings on 18F-FDG PET/CT. *AJR Am J Roentgenol.* 2007;188:1716-1721.
174. Quint LE. PET: other thoracic malignancies. *Cancer Imaging.* 2006;6:S82.
175. Luzzi L, Campione A, Gorla A, et al. Role of fluorine-fluorodeoxyglucose positron emission tomography/computed tomography in preoperative assessment of anterior mediastinal masses. *Eur J Cardiothorac Surg.* 2009;36:475-479.
176. Masaoka A, Monden Y, Nakahara K, et al. Follow-up study of thymomas with special reference to their clinical stages. *Cancer.* 1981;48:2485.
177. Pennathur A, Qureshi I, et al. Comparison of surgical techniques for early-stage thymoma: feasibility of minimally invasive thymectomy and comparison with open resection. *J Thorac Cardiovasc Surg.* 2011;141:694-701.
178. Chahinian AP. Chemotherapy of thymomas and thymic carcinomas. *Chest Surg Clin N Am.* 2001;11:447.
179. Blumberg D, Port JL, Weksler B, et al. Thymoma: a multivariate analysis of factors predicting survival. *Ann Thorac Surg.* 1995;60:908; discussion 914.
180. Weksler B, Shende M. The role of adjuvant radiation therapy for resected stage III thymoma: a population-based study. *Ann Thorac Surg.* 2012;93:1822-1828; discussion 1828-1829.
181. Suster S, Rosai J. Thymic carcinoma. A clinicopathologic study of 60 cases. *Cancer.* 1991;67:1025.
182. Bousamra M. Neurogenic tumors of the mediastinum. In: Pearson FG, ed. *Thoracic Surgery.* 2nd ed. New York: Churchill Livingstone; 2002:1732.
183. Venissac N, Leo F, Hofman P, et al. Mediastinal neurogenic tumors and video-assisted thoracoscopy: always the right choice? *Surg Laparosc Endosc Percutan Tech.* 2004; 14:20.
184. Coleman BG, Arger PH, Dalinka MK, et al. CT of sarcomatous degeneration in neurofibromatosis. *AJR Am J Roentgenol.* 1983;140:383.
185. Ducatman BS, Scheithauer BW, Piepgras DG, et al. Malignant peripheral nerve sheath tumors. A clinicopathologic study of 120 cases. *Cancer.* 1986;57:2006.
186. Nichols CR, Saxman S, Williams SD, et al. Primary mediastinal nonseminomatous germ cell tumors. A modern single institution experience. *Cancer.* 1990;65:1641.
187. Kesler KA, Rieger KM, Hammoud Z, et al. A 25-year single institution experience with surgery for primary mediastinal nonseminomatous germ cell tumors. *Ann Thorac Surg.* 2008;85:371-378.
188. Rice TW. Benign neoplasms and cysts of the mediastinum. *Semin Thorac Cardiovasc Surg.* 1992;4:25.
189. Di Lorenzo M, Collin PP, Vaillancourt R, et al. Bronchogenic cysts. *J Pediatr Surg.* 1989;24:988.
190. Ribet ME, Copin MC, Gosselin B. Bronchogenic cysts of the mediastinum. *J Thorac Cardiovasc Surg.* 1995;109:1003.
191. St-Georges R, Deslauriers J, Duranceau A, et al. Clinical spectrum of bronchogenic cysts of the mediastinum and lung in the adult. *Ann Thorac Surg.* 1991;52:6.
192. Agostoni E. Mechanics of the pleural space. In: Fisherman AP, Macklem PT, Mead J, et al, eds. *Mechanics of Breathing: Handbook of Physiology.* vol 3. Bethesda: American Physiological Society; 1986.
193. Lawrence GH. Considerations of the anatomy and physiology of the pleural space. In: Lawrence GH, ed. *Problems of the Pleural Space.* Philadelphia: WB Saunders; 1983.
194. Rusch VW. Pleural effusion: benign and malignant. In: Pearson FG, ed. *Thoracic Surgery.* 2nd ed. New York: Churchill Livingstone; 2002:1157.
195. Gammie JS, Banks MC, Fuhrman CR, et al. The pigtail catheter for pleural drainage: a less invasive alternative to tube thoracostomy. *JSLs.* 1999;3:57.
196. Luketich JD, Kiss M, Hershey J, et al. Chest tube insertion: a prospective evaluation of pain management. *Clin J Pain.* 1998;14:152.
197. Johnston WW. The malignant pleural effusion. A review of cytopathologic diagnoses of 584 specimens from 472 consecutive patients. *Cancer.* 1985;56:905.
198. Ocana I, Martinez-Vazquez JM, Segura RM, et al. Adenosine deaminase in pleural fluids. Test for diagnosis of tuberculous pleural effusion. *Chest.* 1983;84:51.
199. Lee YC, Rogers JT, Rodriguez RM, et al. Adenosine deaminase levels in nontuberculous lymphocytic pleural effusions. *Chest.* 2001;120:356.
200. Tremblay A, Michaud G. Single-center experience with 250 tunnelled pleural catheter insertions for malignant pleural effusion. *Chest.* 2006;129:362.
201. Light RW. Parapneumonic effusions and empyema. *Clin Chest Med.* 1985;6:55.
202. Rahman NM, Maskell NA, West A, et al. Intrapleural use of tissue plasminogen activator and DNase in pleural infection. *N Engl J Med.* 2011;365:518-526.
203. Miller JI Jr. The history of surgery of empyema, thoracoplasty, Eloesser flap, and muscle flap transposition. *Chest Surg Clin N Am.* 2000;10:45.
204. Miller JI Jr. Diagnosis and management of chylothorax. *Chest Surg Clin N Am.* 1996;6:139.
205. Malthaner RA, Incullet RI. The thoracic duct and chylothorax. In: Pearson FG, ed. *Thoracic Surgery.* 2nd ed. New York: Churchill Livingstone; 2002:1228.
206. Rusch VW. A proposed new international TNM staging system for malignant pleural mesothelioma. From the International Mesothelioma Interest Group. *Chest.* 1995;108:1122.
207. Khalil MY, Mapa M, Shin HJ, et al. Advances in the management of malignant mesothelioma. *Curr Oncol Rep.* 2003; 5:334.
208. Sugarbaker DJ, Flores RM, Jaklitsch MT, et al. Resection margins, extrapleural nodal status, and cell type determine postoperative long-term survival in trimodality therapy of malignant pleural mesothelioma: results in 183 patients. *J Thorac Cardiovasc Surg.* 1999;117:54; discussion 63.
209. Rusch VW, Rosenzweig K, Venkatraman E, et al. A phase II trial of surgical resection and adjuvant high-dose hemithoracic radiation for malignant pleural mesothelioma. *J Thorac Cardiovasc Surg.* 2001;122:788.
210. Rusch V, Saltz L, Venkatraman E, et al. A phase II trial of pleurectomy/decortication followed by intrapleural and systemic chemotherapy for malignant pleural mesothelioma. *J Clin Oncol.* 1994;12:1156.
211. Ratto GB, Civalleri D, Esposito M, et al. Pleural space perfusion with cisplatin in the multimodality treatment of malignant mesothelioma: a feasibility and pharmacokinetic study. *J Thorac Cardiovasc Surg.* 1999;117:759.
212. Lu C, Perez-Soler R, Piperdi B, et al. Phase II study of a liposome-entrapped cisplatin analog (L-NDDP) administered intrapleurally and pathologic response rates in patients with malignant pleural mesothelioma. *J Clin Oncol.* 2005;23:3495.
213. Fletcher CDM, Unni KK, Mertens F. *World Health Organization Classification of Tumours. Pathology and Genetics of Tumours of Soft Tissue and Bone.* Lyon, France: IARC Press; 2002.
214. England DM, Hochholzer L, McCarthy MJ. Localized benign and malignant fibrous tumors of the pleura. A clinicopathologic review of 223 cases. *Am J Surg Pathol.* 1989;13:640.

20 chapter

Congenital Heart Disease

Tara Karamlou, Yasuhiro Kotani, and
Glen A. Van Arsdell

Introduction	695	Tricuspid Atresia / 712	Double-Outlet Right Ventricle with Subaortic or Doubly Committed Ventricular Septal Defect with Pulmonary Stenosis / 723	
Defects Where Repair Is the Only or Best Option	695	Hypoplastic Left Heart Syndrome / 716	Taussig-Bing Syndrome without Pulmonary Stenosis / 723	
Atrial Septal Defect / 695		Defects That May Be Palliated or Repaired	719	Taussig-Bing Syndrome with Pulmonary Stenosis / 723
Aortic Stenosis / 698		Ebstein's Anomaly / 719		Tetralogy of Fallot / 724
Patent Ductus Arteriosus / 702		Transposition of the Great Arteries / 720		Ventricular Septal Defect / 726
Aortic Coarctation / 705		Double-Outlet Right Ventricle / 721		Atrioventricular Canal Defects / 727
Truncus Arteriosus / 706		Double-Outlet Right Ventricle with Noncommitted Ventricular Septal Defect / 722		Interrupted Aortic Arch / 729
Total Anomalous Pulmonary Venous Connection / 707		Double-Outlet Right Ventricle with Subaortic or Doubly Committed Ventricular Septal Defect Without Pulmonary Stenosis / 723		
Cor Triatriatum / 710				
Aortopulmonary Window / 711				
Defects Requiring Palliation	712			

INTRODUCTION

Congenital heart surgery is a dynamic and evolving field. The last 20 years have brought about rapid developments in technology, emphasis on a multidisciplinary approach to treatment, and a more thorough understanding of both the anatomy and pathophysiology of congenital heart disease, leading to the improved care of these challenging patients.

These advancements have created and sustained a paradigm shift in the field of congenital heart surgery. The traditional strategy of initial palliation followed by definitive correction at a later age, which had pervaded the thinking of most surgeons, began to evolve to one emphasizing early repair, even in the tiniest patients. Furthermore, some of the defects that were virtually uniformly fatal (such as hypoplastic left heart syndrome) are now successfully treated with aggressive forms of palliation using cardiopulmonary bypass, resulting in outstanding survival for many of these children.

Because the goal in most cases of congenital heart disease (CHD) is now early repair, as opposed to subdividing lesions into cyanotic or noncyanotic lesions, a more appropriate classification scheme divides particular defects into three categories based on the feasibility of achieving this goal: (a) defects that have no reasonable palliation and for which repair is the only option; (b) defects for which repair is not possible and for which palliation is the only option; and (c) defects that can either be repaired or palliated in infancy. It bears mentioning that all defects in the second category are those in which the appropriate anatomic components either are not present, as in hypoplastic left heart syndrome, or cannot be created from existing structures.

DEFECTS WHERE REPAIR IS THE ONLY OR BEST OPTION

Atrial Septal Defect

An atrial septal defect (ASD) is defined as an opening in the interatrial septum that enables the mixing of blood from the systemic venous and pulmonary venous circulations.

Embryology. The atrial and ventricular septa form between the third and sixth weeks of fetal development. After the paired heart tubes fuse into a single tube folded onto itself, the distal portion of the tube causes an indentation to form in the roof of the common atrium. Near this portion of the roof, the septum primum arises and extends into a crescentic formation toward the atrioventricular (AV) junction. The gap remaining between the septum primum and the developing tissues of the AV junction is called the ostium primum. Before the septum primum fuses completely with the endocardial cushions, a series of fenestrations appear in the septum primum that coalesce into the ostium secundum. During this coalescence, the septum secundum grows downward from the roof of the atrium, parallel to and to the right of the septum primum. The septum primum does not fuse, but creates an oblique pathway, called the foramen ovale, within the interatrial septum. After birth, the increase in left atrial pressure normally closes this pathway, obliterating the interatrial connection.

Anatomy. ASDs can be classified into three different types: (a) sinus venosus defects, comprising approximately 5% to 10% of all ASDs; (b) ostium primum defects, which are more correctly described as partial AV canal defects; and (c)

Key Points

- 1▶ Congenital heart disease comprises a wide morphologic spectrum. In general, lesions can be conceptualized as those that can be completely repaired, those that should be palliated, and those that can be either repaired or palliated depending on particular patient and institutional characteristics.
- 2▶ Percutaneous therapies for congenital heart disease are quickly becoming important adjuncts, and in some cases, alternatives, to standard surgical therapy. Important examples include percutaneous closure of atrial and ventricular septal defects, the hybrid approach to hypoplastic left heart syndrome, radiofrequency perforation of the pulmonary valve, and percutaneous pulmonary valve placement. Further studies are necessary to establish criteria and current benchmarks for the safe integration of these novel approaches into the care of patients with congenital heart surgery.
- 3▶ Patients with critical left ventricular outflow tract obstruction, such as neonatal critical aortic stenosis, represent a challenging population. It is critical that the correct decision (whether to pursue a univentricular or biventricular) be made at the initial operation, as attrition when the incorrect decision is made is high. There are several published criteria (Congenital Heart Surgeons' Society critical stenosis calculator) to help surgeons decide which strategy to pursue.
- 4▶ Optimum strategy for repair of total anomalous pulmonary venous connection (TAPVC) remains a topic of some contention. Sutureless repair, formerly reserved for initial restenosis after conventional repair, has evolved in many centers to be

- the primary treatment of choice for high-risk patients. Defining whether sutureless repair should be considered in all patients with TAPVC will require further study.
- 5▶ A recent prospective, randomized, multi-institutional trial sponsored by the National Institutes of Health, the Systemic Ventricle Reconstruction (SVR) trial, compared the outcomes of neonates with hypoplastic left heart syndrome having either a modified Blalock-Taussig shunt versus a right ventricle-to-pulmonary artery (RV-PA) shunt. The SVR trial demonstrated that transplantation-free survival 12 months after randomization was higher with the RV-PA shunt than with the modified Blalock-Taussig shunt. However, data collected over a mean follow-up period of 32 ± 11 months showed a nonsignificant difference in transplantation-free survival between the two groups.
 - 6▶ Outcomes have improved substantially over time in congenital heart surgery, and most complex lesions can be operated in early infancy. Neurologic protection, however, remains a key issue in the care of neonates undergoing surgery with cardiopulmonary bypass and deep hypothermic circulatory arrest. New monitoring devices and perioperative strategies are currently under investigation. Attention in the field has shifted currently from analyses of perioperative mortality, which for most lesions is under 10%, to longer-term outcomes, including quality of life and neurologic function.

ostium secundum defects, which are the most prevalent subtype, comprising 80% of all ASDs (Fig. 20-1).¹

Pathophysiology. ASDs result in an increase in pulmonary blood flow secondary to left-to-right shunting through the defect. The direction of the intracardiac shunt is predominantly determined by the compliance of the respective ventricles. In utero, the distensibility, or compliance, of the right and left ventricles is equal, but postnatally the left ventricle (LV) becomes less compliant than the right ventricle (RV). This shift occurs because the resistance of the downstream vascular beds changes after birth. The pulmonary vascular resistance falls with the infant's first breath, decreasing RV pressure, whereas the systemic vascular resistance rises dramatically, increasing LV pressure. The increased LV pressure creates a thicker muscle mass, which offers a greater resistance to diastolic filling than does the RV; thus, the majority of flow through the ASD occurs from left to right. The greater volume of blood returning to the right atrium causes volume overload in the RV, but because of its lower muscle mass and low-resistance output, it easily distends to accommodate this load.

The long-term consequences of RV volume overload include hypertrophy with elevated RV end-diastolic pressure and a relative pulmonary stenosis across the pulmonary valve, because it cannot accommodate the increased RV flow. The resistance at the level of the pulmonary valve then contributes a further pressure load on the RV, which accelerates RV hypertrophy. Compliance gradually decreases as the right ventricular pressure approaches systemic pressure, and the

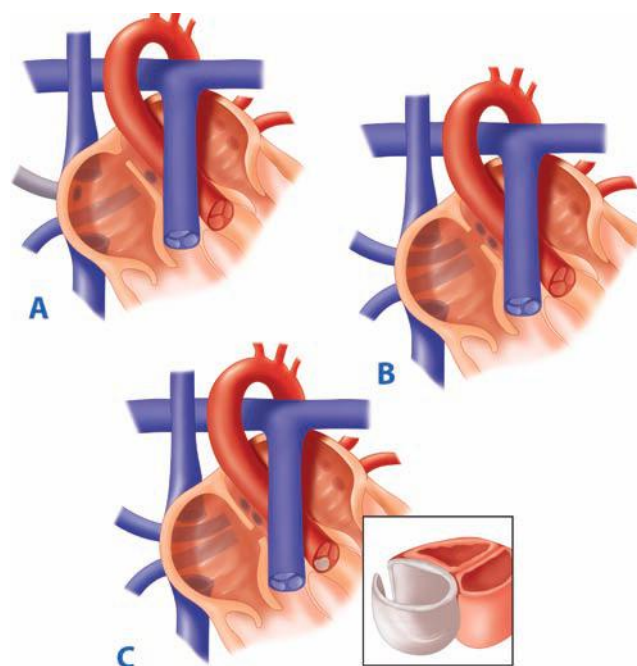


Figure 20-1. The anatomy of atrial septal defects. In the sinus venosus type (A), the right upper and middle pulmonary veins frequently drain to the superior vena cava or right atrium. B. Secundum defects generally occur as isolated lesions. C. Primum defects are part of a more complex lesion and are best considered as incomplete atrioventricular septal defects. (Reproduced with permission from Greenfield LJ, Mulholland MW, Oldham KT, et al, eds. *Surgery: Scientific Principles and Practice*. 3rd ed. Philadelphia: Lippincott Williams & Wilkins; 2001:1444.)

size of the left-to-right shunt decreases. Patients at this stage have a balanced circulation and may deceptively appear less symptomatic.

A minority of patients with ASDs develop progressive pulmonary vascular changes as a result of chronic overcirculation. The increased pulmonary vascular resistance in these patients leads to an equalization of left and right ventricular pressures, and their ratio of pulmonary (Qp) to systemic flow (Qs), Qp:Qs, will approach 1.² This does not mean, however, that there is no intracardiac shunting, only that the ratio between the left-to-right component and the right-to-left component is equal.

The ability of the RV to recover normal function is related to the duration of chronic overload, because those undergoing ASD closure before age 10 years have a better likelihood of achieving normal RV function in the postoperative period.³

The physiology of sinus venosus ASDs is similar to that discussed earlier, except that these are frequently accompanied by anomalous pulmonary venous drainage. This often results in significant hemodynamic derangements that accelerate the clinical course of these infants.

The same increase in symptoms is true for those with ostium primum defects because the associated mitral insufficiency from the “cleft” mitral valve can lead to more atrial volume load and increased atrial level shunting.

Diagnosis. Patients with ASDs may present with few physical findings. Auscultation may reveal prominence of the first heart sound with fixed splitting of the second heart sound. This results from the relatively fixed left-to-right shunt throughout all phases of the cardiac cycle. A diastolic flow murmur indicating increased flow across the tricuspid valve may be discerned, and frequently, an ejection flow murmur can be heard across the pulmonary valve. A right ventricular heave and increased intensity of the pulmonary component of the second heart sound indicates pulmonary hypertension and possible unrepairability.

Chest radiographs in the patient with an ASD may show evidence of increased pulmonary vascularity, with prominent hilar markings and cardiomegaly. The electrocardiogram shows right axis deviation with an incomplete bundle-branch block. When right bundle-branch block is associated with a leftward or superior axis, an AV canal defect should be strongly suspected.

Diagnosis is clarified by two-dimensional echocardiography, and use of color-flow mapping facilitates an understanding of the physiologic derangements created by the defects. Older children and adults with unrepaired ASDs may present with stroke or systemic embolism from paradoxical embolism or atrial arrhythmias from dilation of the right atrium.

Echocardiography also enables the clinician to estimate the amount of intracardiac shunting, can demonstrate the degree of mitral regurgitation in patients with ostium primum defects, and with the addition of microcavitation, can assist in the detection of sinus venosus defects.

The advent of two-dimensional echocardiography with color-flow Doppler has largely obviated the need for cardiac catheterization because the exact nature of the ASD can be precisely defined by echocardiography alone. However, in cases where the patient is older than age 40 years, catheterization can quantify the degree of pulmonary hypertension present, because those with a fixed pulmonary vascular resistance greater than 12 U/mL are considered inoperable.⁴ Cardiac catheterization also can be useful in that it provides data that enable the calculation of Qp and Qs so that the magnitude of the intracardiac shunt can

be determined. The ratio (Qp:Qs) can then be used to determine whether closure is indicated in equivocal cases, because a Qp:Qs greater than 1.5:1 is generally accepted as the threshold for surgical intervention. Finally, in patients older than age 40 years, cardiac catheterization can be important to disclose the presence of coronary artery disease.

In general, ASDs are closed when patients are between 4 and 5 years of age. Children of this size can usually be operated on without the use of blood transfusion and generally have excellent outcomes. Patients who are symptomatic may require repair earlier, even in infancy. Some surgeons, however, advocate routine repair in infants and children, as even smaller defects are associated with the risk of paradoxical embolism. In a recent review by Reddy and colleagues, 116 neonates weighing less than 2500 g who underwent repair of simple and complex cardiac defects with the use of cardiopulmonary bypass were found to have no intracerebral hemorrhages, no long-term neurologic sequelae, and a low operative mortality rate (10%). These results correlated with the length of cardiopulmonary bypass and the complexity of repair.⁵ These investigators also found an 80% actuarial survival at 1 year and, more importantly, that growth following complete repair was equivalent to weight-matched neonates free from cardiac defects.⁵

Treatment. ASDs can be repaired in a facile manner using standard cardiopulmonary bypass (CPB) techniques through a midline sternotomy approach. The details of the repair itself are generally straightforward. An oblique atriotomy is made, the position of the coronary sinus and all systemic and pulmonary veins are determined, and the rim of the defect is completely visualized. Closure of ostium secundum defects is accomplished either by primary repair or by insertion of a patch that is sutured to the rim of the defect. The decision of whether patch closure is necessary can be determined by the size and shape of the defect as well as by the quality of the edges.

The type of repair used for sinus venosus ASDs associated with partial anomalous pulmonary venous connection is dictated by the location of the anomalous pulmonary veins. If the anomalous veins connect to the atria or to the superior vena cava caudal to where the cava is crossed by the right pulmonary artery, the ASD can be repaired by inserting a patch, with redirection of the pulmonary veins behind the patch to the left atrium. Care must be taken with this approach to avoid obstruction of the pulmonary veins or the superior vena cava, although usually the superior vena cava is dilated and provides ample room for patch insertion. If the anomalous vein connects to the superior vena cava cranial to the right pulmonary artery, an alternative technique, the Warden procedure, may be necessary. In this operation, the superior vena cava is transected cranial to the connection of the anomalous vein (usually the right superior pulmonary vein). The caudal end of the transected cava is oversewn. The cranial end of the transected cava is anastomosed to the auricle of the right atrium. Inside the atrium, a patch is used to redirect pulmonary venous blood flow to the left atrium. In contrast to the repair for a defect where the pulmonary veins enter the right atrium or the superior vena cava below the right pulmonary artery, the patch covers the superior vena caval right atrial junction so that blood from the anomalous pulmonary vein that enters the cava is directed to the left atrium. Blood returning from the upper body enters the right atrium via the anastomosis between the superior vena cava and the right atrial appendage.

Results and Complications of Surgical ASD Closure.

Traditional operative strategies, such as pericardial or synthetic patch closure, have been well established, with a low complication rate and a mortality rate of zero among patients without pulmonary hypertension.⁶ The most frequently reported immediate complications include postpericardiotomy syndrome and atrial arrhythmias. Beyond immediate postoperative outcomes, long-term outcomes following surgical closure (up to 20 years) document the low attrition rate and durability of functional status benefit. Importantly, however, atrial arrhythmias are not completely mitigated by closure and can occur in 10% to 40% of patients, especially in older patients (>40 years) or those with pre-existing arrhythmias.⁷ Kutty and colleagues⁸ followed 300 patients from their institution, 152 of whom had surgical closure. Late mortality at 10 years was 3%, and functional health status had declined in only 15 patients during follow-up. Recently, there have been an increasing number of reports regarding the results following surgical closure among elderly patients (>60 years of age), which demonstrate equivalent survival to younger patients, albeit with slightly higher complication rates.⁸⁻¹⁰ Hanninen and colleagues¹¹ studied 68 patients between 68 and 86 years at their institution undergoing either surgical (n = 13) or device (n = 54) closure. Although the 23% incidence of major complications (including pneumothorax, heart failure, and pneumonia) was higher than that recently reported by Mascio et al¹² using the Society of Thoracic Surgeons' Congenital Database (20%) or a single-institution review by Hopkins et al¹³ (12%), there were no operative deaths among the elderly cohort. Moreover, after ASD closure, echocardiographic indices of right ventricular size and function were significantly improved from preoperative values, and functional capacity as measured by standardized survey instruments was also significantly improved.

New and Future Approaches to Traditional Surgical ASD Closure.

Because of the uniformly excellent outcomes with traditional surgery, attention has shifted to improving the cosmetic result and minimizing hospital stay and convalescence. Multiple strategies have been described to achieve these aims, including the right submammary incision with anterior thoracotomy, limited bilateral submammary incision with partial sternal split, and limited midline incision with partial sternal split. Some surgeons use either video-assisted thoracic surgery (VATS) in conjunction with the submammary and transxiphoid approaches to facilitate closure within a constricted operative field or totally endoscopic repair in selected patients.¹⁴⁻¹⁶ Use of robotics has also been reported in a small series of 12 adult patients by Argenziano and colleagues.¹⁵ The morbidity and mortality of all of these approaches are comparable to those of the traditional median sternotomy; however, each has technical drawbacks. Operative precision must be maintained with limited exposure in any minimally invasive technique. Extended CPB and aortic cross-clamp times, coupled with increased cost, may limit the utility of totally endoscopic or robotic-assisted ASD closure except at limited centers. Certain approaches have a specific patient population in whom they are applicable. For example, the anterolateral thoracotomy should not be employed in prepubescent girls because it will interfere with breast development. Most totally endoscopic approaches are not feasible in very young patients due to the size of the thoracoscopic ports. Despite these potential drawbacks, however, in carefully selected patients, minimally invasive techniques have demonstrated

benefits. Luo and associates performed a prospective randomized study comparing ministernotomy (division of the upper sternum for aortic and pulmonary lesions and the lower sternum for septal lesions) to full sternotomy in 100 consecutive patients undergoing repair of septal lesions.¹⁶ The patients in the ministernotomy group had longer procedure times (by 15 to 20 minutes), but had less bleeding and shorter hospital stays. Consistent with these initiatives, conversion of "low-risk" patients undergoing minimally invasive ASD closure to an ambulatory population (discharge from hospital within 24 hours) has recently been described.¹⁷

First performed in 1976, transcatheter closure of ASDs with the use of various occlusion devices is gaining widespread acceptance.¹⁸ Certain types of ASDs, including patent foramen ovale, secundum defects, and some fenestrated secundum defects, are amenable to device closure, as long as particular anatomic criteria (e.g., an adequate superior and inferior rim for device seating and distance from the AV valve) are met. Since the introduction of percutaneous closure, there has been a dramatic rise in device closure prevalence to the point where device closure has supplanted surgical therapy as the dominant treatment modality for secundum ASD.¹⁹ A study from Karamlou et al¹⁹ recently found that ASD and patent foramen ovale closures per capita increased dramatically from 1.08 per 100,000 population in 1988 to 2.59 per 100,000 population in 2005, an increase of 139%. When analyzed by closure type, surgical closure increased by only 24% (from 0.86 per 100,000 population in 1988 to 1.07 per 100,000 in 2005), whereas transcatheter closure increased by 3475% (from 0.04 per 100,000 population in 1988 to 1.43 per 100,000 in 2005). Importantly, this study determined that the paradigm shift favoring transcatheter closure has occurred mainly due to increased prevalence of closure in adults over age 40 years rather than an increase in closure in infants or children.

Despite the simplicity of ASD repair, there are a myriad of options for patients and physicians who care for patients with CHD. The patient population that might benefit from closure (whether device or surgical) is likely to increase, challenging current ideas and treatment algorithms that optimize outcomes.

Aortic Stenosis

Anatomy and Classification. The spectrum of aortic valve abnormality represents the most common form of CHD, with the great majority of patients being asymptomatic until midlife. Obstruction of the left ventricular outflow tract (LVOT) occurs at multiple levels: subvalvular, valvular, and supra- valvular (Fig. 20-2). The critically stenotic aortic valve in the neonate or infant is commonly unicommissural or bicommissural, with thickened, dysmorphic, and myxomatous leaflet tissue and a reduced cross-sectional area at the valve level. Associated left-sided lesions are often present. In a review of 32 cases from the Children's Hospital in Boston, 59% had unicommissural valves and 40% had bicommissural valves.²⁰ Associated lesions were frequent, occurring in 88% of patients, most commonly patent ductus arteriosus, mitral regurgitation, and hypoplastic LV. Endocardial fibroelastosis also is common among infants with critical aortic stenosis (AS). In this condition, the LV is largely nonfunctional, and these patients are not candidates for balloon valvotomy, simple valve replacement, or repair, because the LV

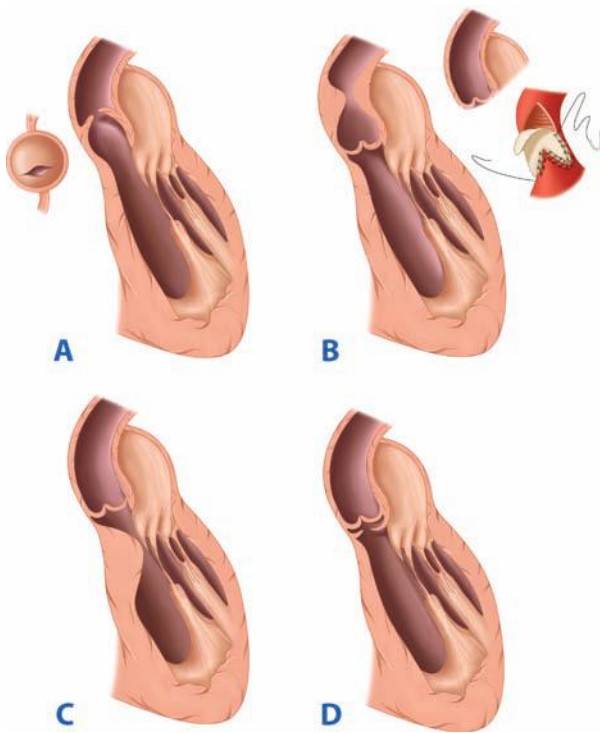


Figure 20-2. The anatomy of the types of congenital aortic stenosis. **A.** Valvar aortic stenosis. **B.** Supralvalvar aortic stenosis and its repair (*insert*). **C.** Tunnel-type subvalvar aortic stenosis. **D.** Membranous subvalvar aortic stenosis. (Reproduced with permission from Greenfield LJ, Mulholland MW, Oldham KT, et al, eds. *Surgery: Scientific Principles and Practice*. 3rd ed. Philadelphia: Lippincott Williams & Wilkins; 2001:1448.)

is incapable of supporting the systemic circulation. Often, the LV is markedly hypertrophic with a reduced cavity size, but on rare occasion, a dilated LV, reminiscent of overt heart failure, is encountered.²⁰

Pathophysiology. The unique intracardiac and extracardiac shunts present in fetal life allow even neonates with critical AS to survive. In utero, left ventricular hypertrophy and ischemia cause left atrial hypertension, which reduces the right-to-left flow across the foramen ovale. In severe cases, a reversal of flow may occur, causing right ventricular volume loading. The RV then provides the entire systemic output via the patent ductus arteriosus (ductal-dependent systemic blood flow). Although cardiac output is maintained, the LV suffers continued damage as the intracavitary pressure precludes adequate coronary perfusion, resulting in LV infarction and subendocardial fibroelastosis. The presentation of the neonate with critical AS is then determined by the morphology of the LV and other left-sided heart structures, the degree of left ventricular dysfunction, and the completeness of the transition from a parallel circulation to an in-series circulation (i.e., on closure of the foramen ovale and the ductus arteriosus). Those infants with mild-to-moderate AS in whom LV function is preserved are asymptomatic at birth. The only abnormalities may be a systolic ejection murmur and electrocardiogram (ECG) evidence of left ventricular hypertrophy. However, those neonates with severe AS and compromised LV function are unable to provide adequate cardiac output at birth and will present in circulatory collapse

once the ductus closes, with dyspnea, tachypnea, irritability, narrowed pulse pressure, oliguria, and profound metabolic acidosis.^{7,21} If ductal patency is maintained, systemic perfusion will be provided by the RV via ductal flow, and cyanosis may be the only finding.

Diagnosis. Neonates and infants with severe valvular AS may have a relatively nonspecific history of irritability and failure to thrive. Angina, if present, is usually manifested by episodic, inconsolable crying that coincides with feeding. As discussed previously, evidence of poor peripheral perfusion, such as extreme pallor, indicates severe LVOT obstruction. Differential cyanosis is an uncommon finding, but is present when enough antegrade flow occurs only to maintain normal upper body perfusion, while a large patent ductus arteriosus produces blue discoloration of the abdomen and legs.

Physical findings include a systolic ejection murmur, although a quiet murmur may paradoxically indicate a more severe condition with reduced cardiac output. A systolic click correlates with a valvular etiology of obstruction. As LV dysfunction progresses, evidence of congestive heart failure occurs.

The chest radiograph is variable but may show dilatation of the aortic root, and the ECG often demonstrates LV hypertrophy. Echocardiography with Doppler flow is extremely useful in establishing the diagnosis, as well as quantifying the transvalvular gradient.²² Furthermore, echocardiography can facilitate evaluation for the several associated defects that can be present in critical neonatal AS, including mitral stenosis, LV hypoplasia, LV endocardial fibroelastosis, subaortic stenosis, VSD, or coarctation. The presence of any or several of these defects has important implications related to treatment options for these patients. Although cardiac catheterization is not routinely performed for diagnostic purposes, it can be invaluable as part of the treatment algorithm if the lesion is amenable to balloon valvotomy.

Treatment. The first decision that must be made in the neonate with critical LVOT obstruction is whether the patient is a candidate for biventricular or univentricular repair. Central to this decision is assessment of the degree of hypoplasia of the LV and other left-sided structures. Alsoufi and colleagues²³ recently described a rational approach to the neonate with critical LVOT obstruction (Fig. 20-3). The infant with severe AS requires urgent intervention. Preoperative stabilization, however, has dramatically altered the clinical algorithm and outcomes for this patient population.^{19,21} The preoperative strategy begins with endotracheal intubation and inotropic support. Prostaglandin infusion is initiated to maintain ductal patency, and confirmatory studies are performed prior to operative intervention.

Therapy is generally indicated in the presence of a transvalvular gradient of 50 mmHg with associated symptoms including syncope, CHF, or angina, or if a gradient of 50 to 75 mmHg exists with concomitant ECG evidence of LV strain or ischemia. In the critically ill neonate, there may be little gradient across the aortic valve because of poor LV function. These patients depend on patency of the ductus arteriosus to provide systemic perfusion from the RV, and all ductal-dependent patients with critical AS require treatment. However, the decision regarding treatment options must be based on a complete understanding of associated defects. For example, in the presence of a hypoplastic LV (left ventricular end-diastolic

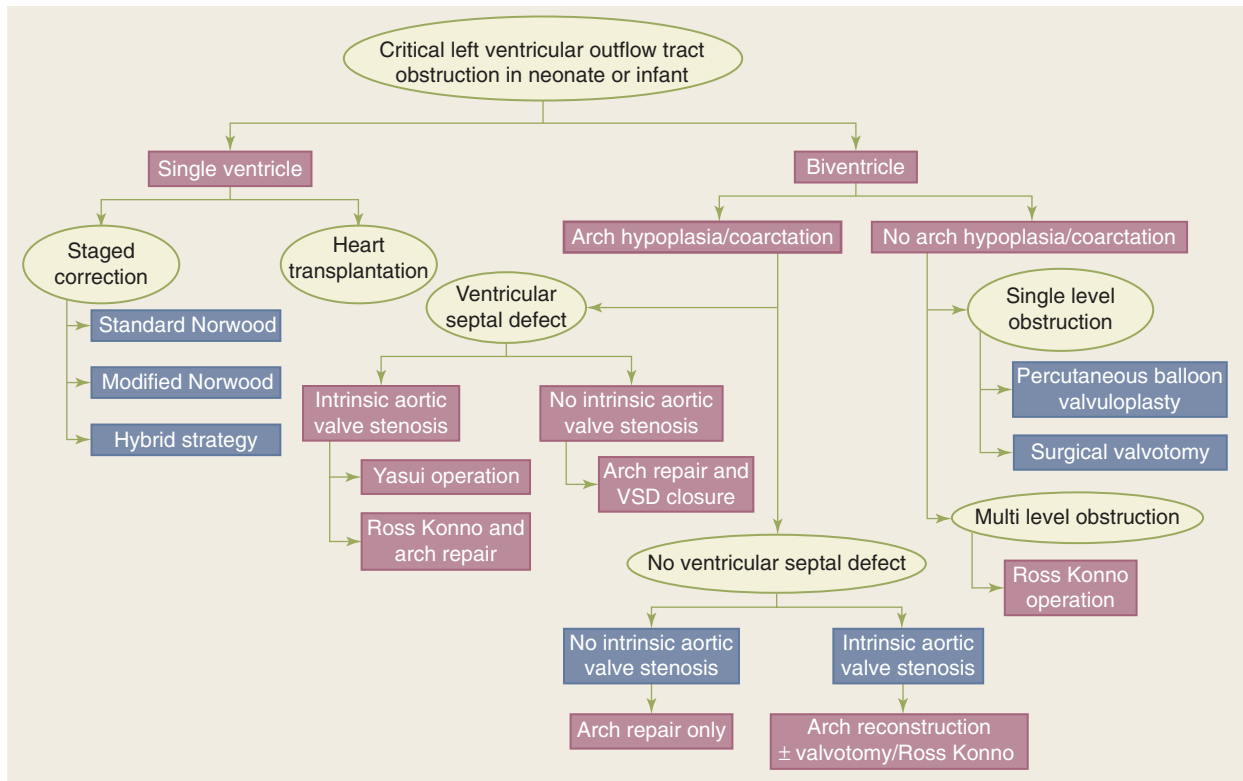


Figure 20-3. Treatment algorithm for neonates and infants with critical left ventricular outflow tract obstruction. Patients can be initially triaged to either a single or a biventricular approach depending on presenting morphologic, demographic, and institutional factors. VSD = ventricular septal defect. (From Alsoufi B, et al. *Management options in neonates and infants with critical left ventricular outflow tract obstruction*. Eur J Cardiothorac Surg. 2007;31:1013. Fig 1. By permission of Oxford University Press.)

volume $<20 \text{ mL/m}^2$) or a markedly abnormal mitral valve, isolated aortic valvotomy should not be performed because studies have demonstrated high mortality in this population following isolated valvotomy.²⁴

Patients who have an LV capable of providing systemic output are candidates for intervention to relieve AS, generally through balloon valvotomy. Very rarely, if catheter-based therapy is not an option, relief of valvular AS in infants and children can be accomplished with surgical valvotomy using standard techniques of CPB and direct exposure to the aortic valve. A transverse incision is made in the ascending aorta above the sinus of Valsalva, extending close to, but not into, the noncoronary sinus. Exposure is attained with placement of a retractor into the right coronary sinus. After inspection of the valve, the chosen commissure is incised to within 1 to 2 mm of the aortic wall (Fig. 20-4).

Balloon valvotomy performed in the catheterization lab is the procedure of choice for reduction of transvalvular gradients in symptomatic infants and children. This procedure is an ideal palliative option because mortality from surgical valvotomy can be high due to the critical nature of these patients' condition. Furthermore, balloon valvotomy provides relief of the valvular gradient and allows future surgical intervention (which is generally required in most patients when a larger prosthesis can be implanted) to be performed on an unscarred chest. An important issue when planning aortic valvotomy, whether percutaneously or via open surgical technique, is the risk of inducing hemodynamically significant aortic regurgitation. Induction of more than moderate aortic regurgitation is poorly tolerated in

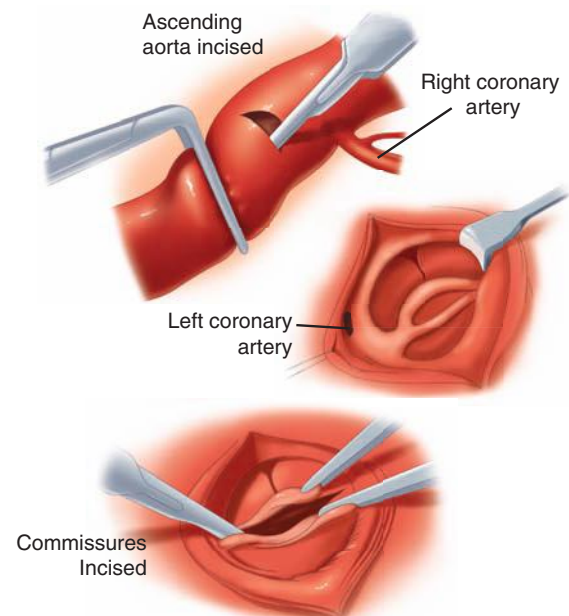


Figure 20-4. Aortic valvotomy with cardiopulmonary bypass. A transverse incision is made in the ascending aorta above the sinuses of Valsalva, extending close to, but not into, the noncoronary sinus. Exposure is accomplished with placement of a retractor into the right coronary sinus. After inspection of the valve, the chosen commissure is incised to within 1 to 2 mm of the aortic wall. (Reproduced with permission from Doty DB. *Cardiac Surgery: A Looseleaf Workbook and Update Service*. Chicago: Year Book; 1986. Copyright Elsevier)

the infant with critical AS and may require an urgent procedure to replace or repair the aortic valve.

In general, catheter-based balloon valvotomy has supplanted open surgical valvotomy. The decision regarding the most appropriate method to use depends on several factors, including the available medical expertise, the patient's overall status and hemodynamics, and the presence of associated cardiac defects requiring repair.²⁵ Although evidence is emerging to the contrary, simple valvotomy, whether performed using percutaneous or open technique, is generally considered a palliative procedure. The goal is to relieve LVOT obstruction without producing clinically significant regurgitation, in order to allow sufficient annular growth for eventual aortic valve replacement. The majority of infants who undergo aortic valvotomy will require further intervention on the aortic valve within 10 years following initial intervention.²⁶

Valvotomy may result in aortic insufficiency that, while not important enough to require intervention in infancy, may alone or in combination with AS result in the need for an aortic valve replacement. Neonates with severely hypoplastic LVs or significant LV endocardial fibroelastosis may not be candidates for two-ventricle repair and are treated the same as infants with

the hypoplastic left heart syndrome (HLHS), which is discussed later (see later section, Hypoplastic Left Heart Syndrome).

Many surgeons previously avoided aortic valve replacement for AS in early childhood because the more commonly used mechanical valves would be outgrown and require replacement later and the obligatory anticoagulation for mechanical valves resulted in a substantial risk for complications. In addition, mechanical valves had an important incidence of bacterial endocarditis or perivalvular leak requiring re-intervention.

The use of allografts and the advent of the Ross procedure have largely obviated these issues and made early definitive correction of critical AS a viable option.^{19,27,28} Donald Ross first described transposition of the pulmonary valve into the aortic position with allograft reconstruction of the pulmonary outflow tract in 1967.²⁷ The result of this operation is a normal trileaflet semilunar valve made of a patient's native tissue with the potential for growth to adult size in the aortic position in place of the damaged aortic valve (Fig. 20-5). The Ross procedure has become a useful option for aortic valve replacement in children, because it has improved durability and can be performed with acceptable morbidity and mortality rates. The placement of a pulmonary conduit, which does not grow and becomes calcified

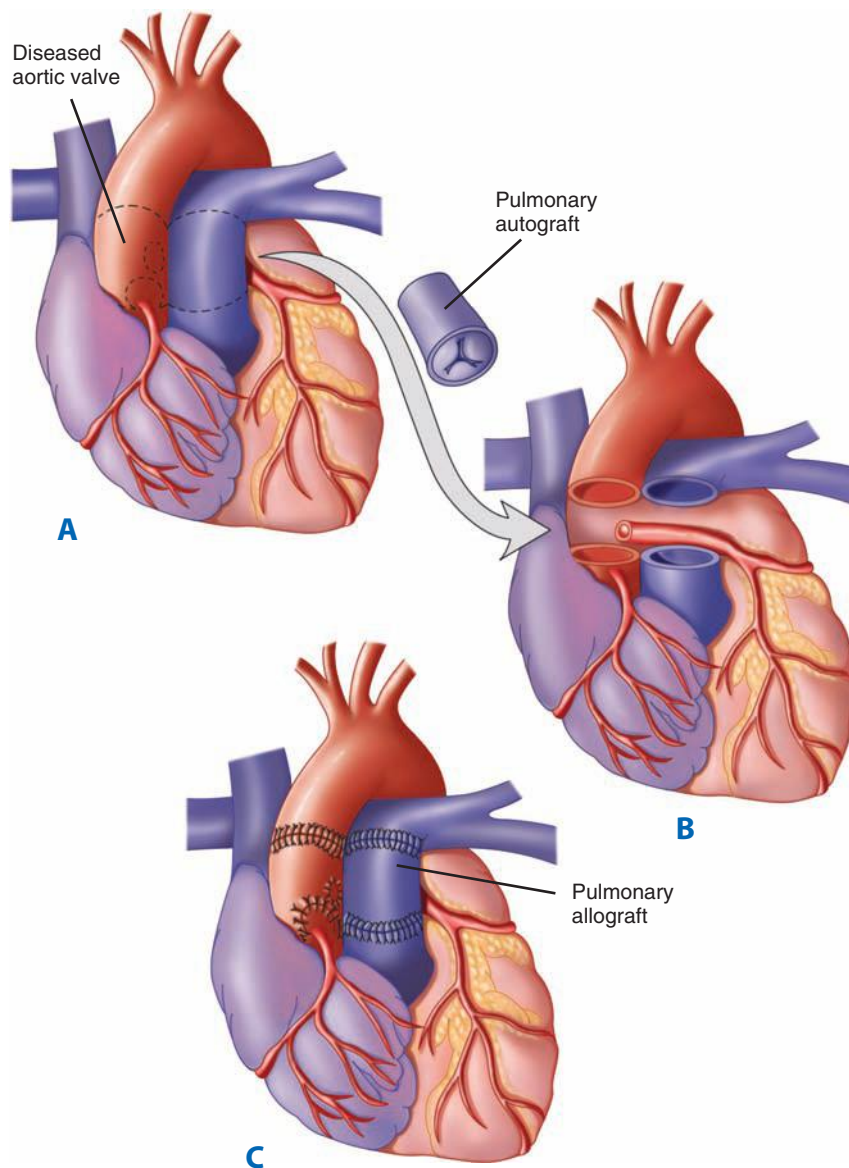


Figure 20-5. A through C. The pulmonary autograft for aortic valve replacement. The aortic valve and adjacent aorta are excised, preserving button of aortic tissue around the coronary ostia. The pulmonary valve and main pulmonary artery are excised and transferred to the aortic position. The coronary buttons are then attached to the neo-aortic root. A pulmonary allograft is inserted to re-establish the right ventricular outflow tract. (From Kouchoukos NT, Davila-Roman VG, Spray TL, et al. Replacement of the aortic root with a pulmonary autograft in children and young adults with aortic-valve disease. *N Engl J Med.* 1994;330:1.)

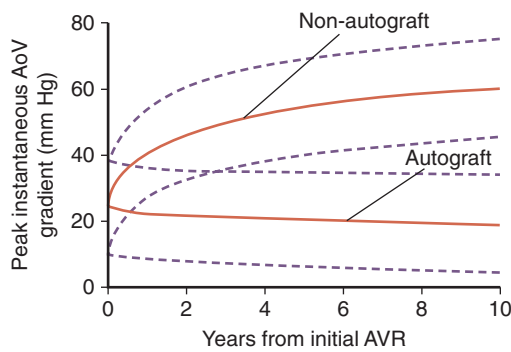


Figure 20-6. Predicted progression of the peak instantaneous prosthetic valve gradient after initial aortic valve replacement (AVR) stratified by prosthesis type (autograft vs. nonautograft) for a hypothetical patient of 3 years undergoing AVR in 1990. Solid lines represent point estimates from a mixed linear regression model (surrounded by their 90% confidence intervals in dashed lines). AoV = aortic valve. (Reproduced with permission from Karamlou T, et al. *Outcomes and associated risk factors for aortic valve replacement in 160 children: A competing risks analysis*. *Circulation*. 2005;112:3462.)

and stenotic over time, does obligate the patient to reoperation to replace the RV-to-pulmonary artery conduit. Karamlou and colleagues²⁹ recently reviewed the outcomes and associated risk factors for aortic valve replacement in 160 children from the Hospital for Sick Children in Toronto. They found that younger age, lower operative weight, concomitant performance of aortic root replacement or reconstruction, and use of prosthesis type other than a pulmonary autograft were significant predictors of death, whereas the use of a bioprosthetic or allograft valve type and earlier year of operation were identified as significant risk factors for repeated aortic valve replacement. Autograft use was associated with a blunted progression of the peak prosthetic valve gradient and a rapid decrease in the left ventricular end-diastolic dimension (Fig. 20-6). In agreement with these findings, Lupinetti and Jones²⁸ compared allograft aortic valve replacement with the Ross procedure and found a more significant transvalvular gradient reduction and regression of left ventricular hypertrophy in those patients who underwent the Ross procedure. In some cases, the pulmonary valve may not be usable because of associated defects or congenital absence. These children are not candidates for the Ross procedure and are now most frequently treated with cryopreserved allografts (cadaveric human aortic valves). At times, there may be a size discrepancy between the right ventricular outflow tract (RVOT) and the LVOT, especially in cases of severe critical AS in infancy. For these cases, the pulmonary autograft is placed in a manner that also provides enlargement of the aortic annulus (Ross/Konno) (Fig. 20-7).

Subvalvular AS occurs beneath the aortic valve and may be classified as discrete or tunnel-like (diffuse). A thin, fibromuscular diaphragm immediately proximal to the aortic valve characterizes discrete subaortic stenosis. This diaphragm typically extends for 180° or more in a crescentic or circular fashion, often attaching to the mitral valve as well as the interventricular septum.²¹ The aortic valve itself is usually normal in this condition, although the turbulence imparted by the subvalvular stenosis may affect leaflet morphology and valve competence.

Diffuse subvalvular AS results in a long, tunnel-like obstruction that may extend to the left ventricular apex. In

some individuals, there may be difficulty in distinguishing between hypertrophic cardiomyopathy and diffuse subaortic stenosis. Operation for subvalvular AS is indicated with a gradient exceeding 30 mmHg, in the presence of aortic valve insufficiency, or when symptoms indicating LVOT obstruction are present.³⁰ Given that repair of isolated discrete subaortic stenosis can be done with low rates of morbidity and mortality, some surgeons advocate repair in all cases of discrete AS to avoid progression of the stenosis and the development of aortic insufficiency, although more recent data demonstrates that subaortic resection should be delayed until the LV gradient exceeds 30 mmHg because most children with an initial LV gradient less than 30 mmHg have quiescent disease.³¹ Diffuse AS is a more complex lesion and often requires aortoventriculoplasty as previously described. Results are generally excellent, with operative mortality less than 5%.³²

Supravalvular AS occurs more rarely and also can be classified into a discrete type, which produces an hourglass deformity of the aorta, and a diffuse form that can involve the entire arch and brachiocephalic arteries. The aortic valve leaflets are usually normal, but in some cases, the leaflets may adhere to the supravalvular stenosis, thereby narrowing the sinuses of Valsalva in diastole and restricting coronary artery perfusion. In addition, accelerated intimal hyperplastic changes in the coronary arteries can be demonstrated in these patients because the proximal position of the coronary arteries subjects them to abnormally high perfusion pressures.

The signs and symptoms of supravalvular AS are similar to other forms of LVOT obstruction. An asymptomatic murmur is the presenting manifestation in approximately half of these patients. Syncope, poor exercise tolerance, and angina may all occur with nearly equal frequency. Supravalvular AS is associated with Williams' syndrome, a constellation of elfin facies, mental retardation, and hypercalcemia.³³ Following routine evaluation, cardiac catheterization should be performed in order to delineate coronary anatomy, as well as to delineate the degree of obstruction. A gradient of 50 mmHg or greater is an indication for operation. However, the clinician must be cognizant of any coexistent lesions, most commonly pulmonic stenosis, which may add complexity to the repair.

The localized form of supravalvular AS is treated by creating an inverted Y-shaped aortotomy across the area of stenosis, straddling the right coronary artery. The obstructing shelf is then excised and a pantaloony-shaped patch is used to close the incision.²¹

The diffuse form of supravalvular stenosis is more variable, and the particular operative approach must be tailored to each specific patient's anatomy. In general, either an aortic endarterectomy with patch augmentation can be performed, or if the narrowing extends past the aorta arch, a prosthetic graft can be placed between the ascending and descending aorta. Operative results for discrete supravalvular AS are generally good, with a hospital mortality of less than 1% and an actuarial survival rate exceeding 90% at 20 years.³⁴ In contrast, however, the diffuse form is more hazardous to repair and carried a mortality of 15% in a recent series.^{34,35}

Patent Ductus Arteriosus

Anatomy. The ductus arteriosus is derived from the sixth aortic arch and normally extends from the main or left pulmonary artery to the upper descending thoracic aorta, distal to the left subclavian artery. In the normal fetal cardiovascular

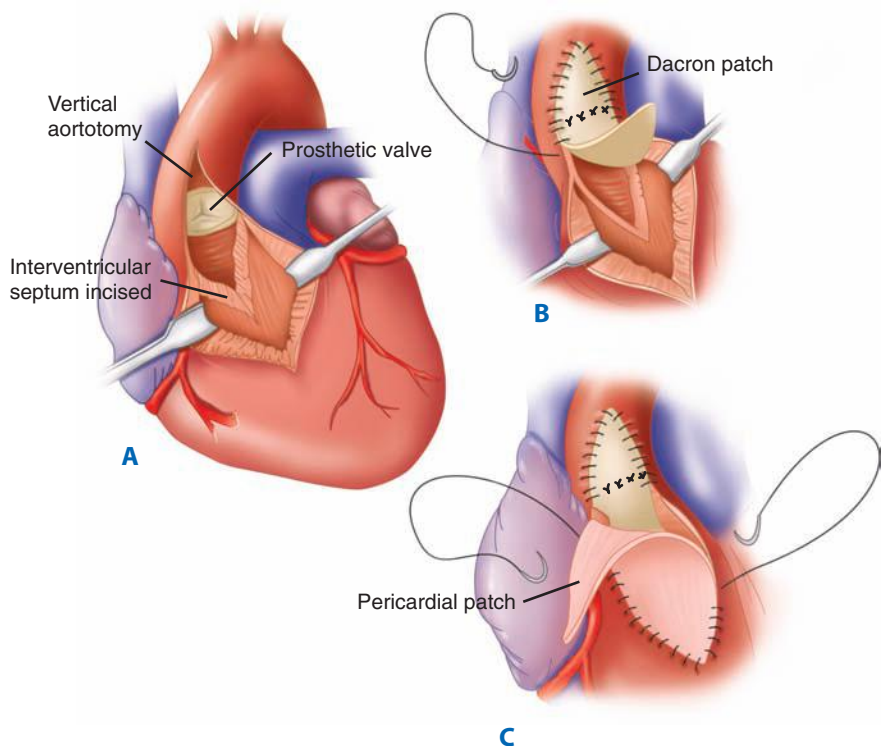


Figure 20-7. The Konno-Rastan aortoventriculoplasty permits significant enlargement of the aortic annulus and subaortic region. **A.** A vertical aortotomy is made to the left of the right coronary artery and extended into the right ventricular outflow tract. After excising the aortic valve, the interventricular septum is incised and an aortic valve prosthesis is secured within the enlarged annulus. **B.** A Dacron patch that is attached to the sewing ring of the prosthesis closes the interventricular septum and the aortotomy. **C.** A separate pericardial patch closes the right ventriculotomy. (Reproduced with permission from Misbach GA, Turley K, Ulyot DJ, et al. Left ventricular outflow enlargement by the Konno procedure. *J Thorac Cardiovasc Surg.* 1982;84:696. Copyright Elsevier.)

system, ductal flow is considerable (approximately 60% of the combined ventricular output) and is directed exclusively from the pulmonary artery to the aorta.³⁶ In infancy, the length of the ductus may vary from 2 to 8 mm, with a diameter of 4 to 12 mm.

Locally produced and circulating prostaglandin E_2 (PGE_2) and prostaglandin I_2 (PGI_2) induce active relaxation of the ductal musculature, maintaining maximal patency during the fetal period.³⁷ At birth, increased pulmonary blood flow metabolizes these prostaglandin products, and absence of the placenta removes an important source of them, resulting in a marked decrease in these ductal-relaxing substances. In addition, release of histamines, catecholamines, bradykinin, and acetylcholine all promote ductal contraction. Despite all of these complex interactions, the rising oxygen tension in the fetal blood is the main stimulus causing smooth muscle contraction and ductal closure within 10 to 15 hours postnatally.³⁸ Anatomic closure by fibrosis produces the ligamentum arteriosum connecting the pulmonary artery to the aorta.

Delayed closure of the ductus is termed prolonged patency, whereas failure of closure causes persistent patency, which may occur as an isolated lesion or in association with more complex congenital heart defects. In many of these infants with more complex congenital heart defects, either pulmonary or systemic perfusion may depend on ductal flow, and these infants may decompensate if exogenous PGE is not administered to maintain ductal patency.

Natural History. The incidence of patent ductus arteriosus (PDA) is approximately 1 in every 2000 births; however, it increases dramatically with increasing prematurity.³⁹ In some series, PDAs have been noted in 75% of infants of 28 to 30 weeks gestation. Persistent patency occurs more commonly in females, with a 2:1 ratio.³⁹

PDA is not a benign entity, although prolonged survival has been reported. The estimated death rate for infants with isolated, untreated PDA is approximately 30%.⁴⁰ The leading cause of death is congestive heart failure, with respiratory infection as a secondary cause. Endocarditis is more likely to occur with a small ductus and is rarely fatal if aggressive antibiotic therapy is initiated early.

Clinical Manifestations and Diagnosis. After birth, in an otherwise normal cardiovascular system, a PDA results in a left-to-right shunt that depends on both the size of the ductal lumen and its total length. As the pulmonary vascular resistance falls 16 to 18 weeks postnatally, the shunt will increase, and its flow will ultimately be determined by the relative resistances of the pulmonary and systemic circulations.

The hemodynamic consequences of an unrestrictive ductal shunt are left ventricular volume overload with increased left atrial and pulmonary artery pressures, and right ventricular strain from the augmented afterload. These changes result in increased sympathetic discharge, tachycardia, tachypnea, and ventricular hypertrophy. The diastolic shunt results in lower aortic diastolic pressure and increases the potential for myocardial ischemia and underperfusion of other systemic organs, while the increased pulmonary flow leads to increased work of breathing and decreased gas exchange. Unrestrictive ductal flow may lead to pulmonary hypertension within the first year of life. These changes will be significantly attenuated if the size of the ductus is only moderate, and completely absent if the ductus is small.

Physical examination of the afflicted infant will reveal evidence of a hyperdynamic circulation with a widened pulse pressure and a hyperactive precordium. Auscultation demonstrates a systolic or continuous murmur, often termed a machinery murmur. Cyanosis is not present in uncomplicated isolated PDA.

The chest radiograph may reveal increased pulmonary vascularity or cardiomegaly, and the ECG may show LV strain, left atrial enlargement, and possibly RV hypertrophy. Echocardiogram with color mapping reliably demonstrates the patency of the ductus as well as estimates the shunt size. Cardiac catheterization is necessary only when pulmonary hypertension is suspected.

Therapy. The presence of a persistent PDA is sufficient indication for closure because of the increased mortality and risk of endocarditis.^{2,4} In older patients with pulmonary hypertension, closure may not improve symptoms and is associated with much higher mortality.

In premature infants, aggressive intervention with indomethacin or ibuprofen to achieve early closure of the PDA is beneficial unless contraindications such as necrotizing enterocolitis or renal insufficiency are present.⁴¹ Term infants, however, are generally unresponsive to pharmacologic therapy with indomethacin, so mechanical closure must be undertaken once the diagnosis is established. This can be accomplished either surgically or with catheter-based therapy.^{12,42,43} Currently, transluminal placement of various occlusive devices, such as the Rashkind double-umbrella device or embolization with Gianturco coils, is in widespread use.⁴² However, there are a number of complications inherent with the use of percutaneous devices, such as thromboembolism, endocarditis, incomplete occlusion, vascular injury, and hemorrhage secondary to perforation.⁴³ In addition, these techniques may not be applicable in very young infants, because the peripheral vessels do not provide adequate access for the delivery devices.

Surgical closure can be achieved via either open or video-assisted approaches. The open approach employs a posterior lateral thoracotomy in the fourth or fifth intercostal

space on the side of the aorta (generally the left). The lung is then retracted anteriorly. In the neonate, the PDA is singly ligated with a surgical clip or permanent suture. In older patients, the PDA is triply ligated. Care must be taken to avoid the recurrent laryngeal nerve, which courses around the PDA. The PDA can also be ligated via a median sternotomy; however, this approach is generally reserved for patients who have additional cardiac or great vessel lesions requiring repair. Occasionally, a short, broad ductus, in which the dimension of its width approaches that of its length, will be encountered. In this case, division between vascular clamps with oversewing of both ends is advisable (Fig. 20-8). In extreme cases, the use of CPB to decompress the large ductus during ligation is an option.

Video-assisted thoracoscopic occlusion, using metal clips, also has been described, although it offers few advantages over the standard surgical approach.¹² Preterm newborns and children may do well with the thoracoscopic technique, while older patients (older than age 5 years) and those with smaller ducts (<3 mm) do well with coil occlusion. In fact, Moore and colleagues recently concluded from their series that coil occlusion is the procedure of choice for ducts smaller than 4 mm.⁴⁴ Complete closure rates using catheter-based techniques have steadily improved. Comparative studies of cost and outcome between open surgery and transcatheter duct closure, however, have shown no overwhelming choice between the two modalities. Burke prospectively reviewed coil occlusion and VATS at Miami Children's Hospital and found both options to be effective and less morbid than traditional thoracotomy.¹²

Outcomes. In premature infants, the surgical mortality is very low, although the overall hospital death rate is significant as a

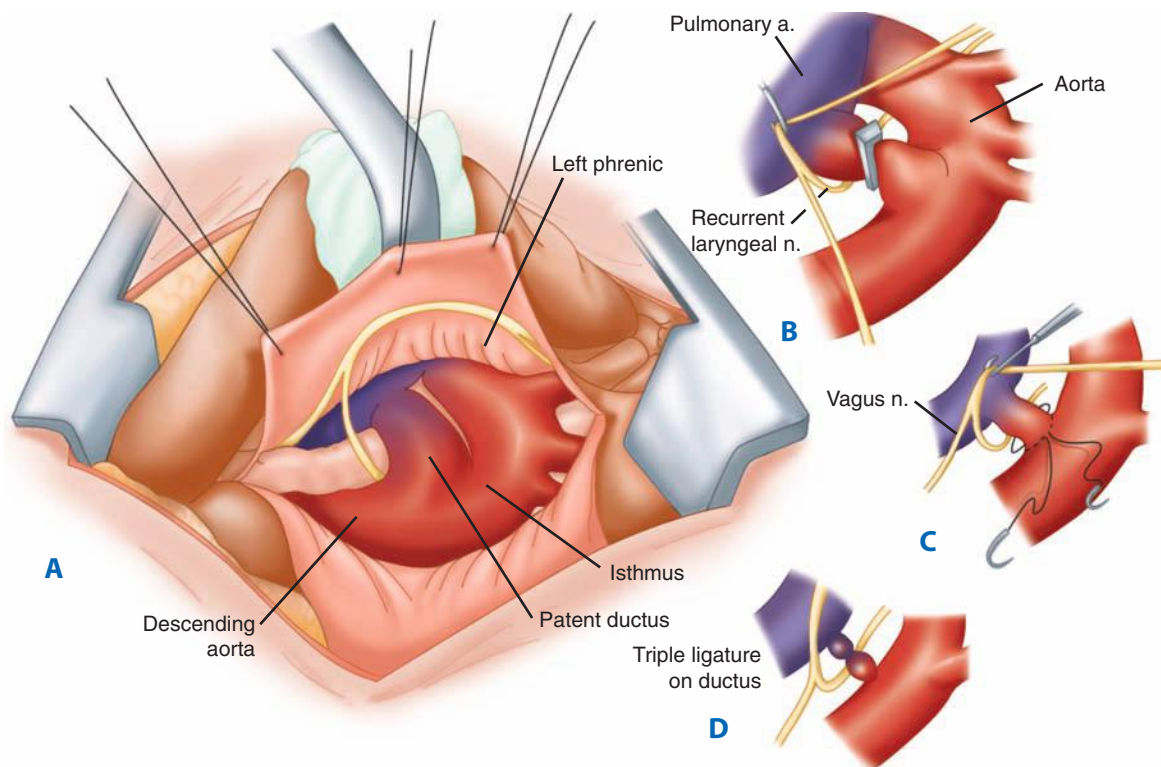


Figure 20-8. A. Surgeon's perspective of infant patent ductus arteriosus exposed via a left thoracotomy. B. The pleura over the aortic isthmus is incised and mobilized. C and D. Technique of triple ligation. a. = artery; n. = nerve. (From Castaneda AR, Jonas RA, Mayer JE, et al. *Cardiac Surgery of the Neonate and Infant*. Philadelphia: W.B. Saunders; 1994:208, with permission. Copyright Elsevier.)

consequence of other complications of prematurity. In older infants and children, mortality is less than 1%. Bleeding, chylothorax, vocal cord paralysis, and the need for reoperation occur infrequently. With the advent of muscle-sparing thoracotomy, the risk of subsequent arm dysfunction or breast abnormalities is virtually eliminated.⁴⁵

Aortic Coarctation

Anatomy. Coarctation of the aorta (COA) is defined as a luminal narrowing in the aorta that causes an obstruction to blood flow. This narrowing is most commonly located distal to the left subclavian artery. The embryologic origin of COA is a subject of some controversy. One theory holds that the obstructing shelf, which is largely composed of tissue found within the ductus, forms as the ductus involutes.⁴⁶ The other theory holds that a diminished aortic isthmus develops secondary to decreased aortic flow in infants with enhanced ductal circulation.

Extensive collateral circulation develops, predominantly involving the intercostals and mammary arteries as a direct result of aortic flow obstruction. This translates into the well-known finding of “rib-notching” on chest radiograph, as well as a prominent pulsation underneath the ribs.

Other associated anomalies, such as ventricular septal defect, PDA, and ASD, may be seen with COA, but the most common is that of a bicuspid aortic valve, which can be demonstrated in 25% to 42% of cases.⁴⁷

Pathophysiology. Infants with COA develop symptoms consistent with left ventricular outflow obstruction, including pulmonary overcirculation and, later, biventricular failure. In addition, proximal systemic hypertension develops as a result of mechanical obstruction to ventricular ejection, as well as hypoperfusion-induced activation of the renin-angiotensin-aldosterone system. Interestingly, hypertension is often persistent after surgical correction despite complete amelioration of the mechanical obstruction and pressure gradient.⁴⁸ It has been shown that early surgical correction may prevent the development of long-term hypertension, which undoubtedly contributes to many of the adverse sequelae of COA, including the development of circle of Willis aneurysms, aortic dissection and rupture, and an increased incidence of coronary arteriopathy with resulting myocardial infarction.⁴⁹

Diagnosis. COA is likely to become symptomatic either in the newborn period if other anomalies are present or in the late adolescent period with the onset of left ventricular failure.

Physical examination will demonstrate a hyperdynamic precordium with a harsh murmur localized to the left chest and back. Femoral pulses will be dramatically decreased when compared to upper extremity pulses, and differential cyanosis may be apparent until ductal closure.

Echocardiography will reliably demonstrate the narrowed aortic segment, as well as define the pressure gradient across the stenotic segment. In addition, detailed information regarding other associated anomalies can be gleaned. Aortography is reserved for those cases in which the echocardiographic findings are equivocal.

Therapy. The routine management of hemodynamically significant COA in all age groups has traditionally been surgical. Transcatheter repairs are used with increasing frequency in older patients and those with re-coarctation

following surgical repair. Balloon dilatation of native coarctation in neonates has been recently utilized with poor results. The most common surgical techniques in current use are resection with end-to-end anastomosis or extended end-to-end anastomosis, taking care to remove all residual ductal tissue.^{50,51} Extended end-to-end anastomosis may also allow the surgeon to treat transverse arch hypoplasia, which is commonly encountered in infants with aortic coarctation.^{52,53} The subclavian flap aortoplasty is another repair, although it is used less frequently in the modern era because of the risk of late aneurysm formation and possible underdevelopment of the left upper extremity or ischemia.⁵¹ In this method, the left subclavian artery is transected and brought down over the coarcted segment as a vascularized patch. The main benefit of these techniques is that they do not involve the use of prosthetic materials, and evidence suggests that extended end-to-end anastomosis may promote arch growth, especially in infants with the smallest initial aortic arch diameters.⁵²

Despite the benefits, however, extended end-to-end anastomosis may not be feasible when there is a long segment of coarctation or in the presence of previous surgery, because sufficient mobilization of the aorta above and below the lesion may not be possible. In this instance, prosthetic materials, such as a patch aortoplasty, in which a prosthetic patch is used to enlarge the coarcted segment, or an interposition tube graft must be employed.

The most common complications after COA repair are late restenosis and aneurysm formation at the repair site.⁵⁴⁻⁵⁶ Aneurysm formation is particularly common after patch aortoplasty when using Dacron material. In a large series of 891 patients, aneurysms occurred in 5.4% of the total, with 89% occurring in the group who received Dacron-patch aortoplasty and only 8% occurring in those who received resection with primary end-to-end anastomosis.⁵⁴ A further complication, although uncommon, is lower-body paralysis resulting from ischemic spinal cord injury during the repair. This dreaded outcome complicates 0.5% of all surgical repairs, but its incidence can be lessened with the use of some form of distal perfusion, preferably left heart bypass with the use of femoral arterial or distal thoracic aorta for arterial inflow and the femoral vein or left atrium for venous return.⁵⁰ These techniques are generally reserved for older patients with complex coarctations that may need prolonged aortic cross clamp times for repair, often in the setting of large collateral vessels and/or previous surgery.

Hypertension is also well recognized following repair of COA. Bouchart and colleagues reported that in a cohort of 35 hypertensive adults (mean age, 28 years) undergoing repair, despite a satisfactory anatomic outcome, only 23 patients were normotensive at a mean follow-up period of 165 months.⁵⁵ Likewise, Bhat and associates reported that in a series of 84 patients (mean age at repair, 29 years), 31% remained hypertensive at a mean follow-up of 5 years following surgery.⁵⁶

Although operative repair is still the gold standard, treatment of COA by catheter-based intervention has become more widespread. Both balloon dilatation and primary stent implantation have been used successfully. The most extensive study of the results of balloon angioplasty reported on 970 procedures: 422 native and 548 recurrent COAs. Mean gradient reduction was 74% ± 24% for native and 70% ± 31% for recurrent COA.⁵⁷ This demonstrated that catheter-based therapy could produce equally effective results both in

recurrent and in primary COA, a finding with far-reaching implications in the new paradigm of multidisciplinary treatment algorithms for CHD. In the Valvuloplasty and Angioplasty of Congenital Anomalies (VACA) report, higher preangioplasty gradient, earlier procedure date, older patient age, and the presence of recurrent COA were independent risk factors for suboptimal procedural outcome.⁵⁷

The gradient after balloon dilatation in most series is generally acceptable. However, there is a significant minority of patients (0%–26%) for whom the procedural outcome is suboptimal, with a postprocedure gradient of 20 mmHg or greater. These patients may be ideal candidates for primary stent placement. Restenosis is much less common in children, presumably reflecting the influence of vessel wall scarring and growth in the pediatric age group.

Deaths from the procedure also are infrequent (<1% of cases), and the main major complication is aneurysm formation, which occurs in 7% of patients.⁵⁰ With stent implantation, many authors have demonstrated improved resolution of stenosis compared with balloon dilatation alone, yet the long-term complications on vessel wall compliance remain largely unknown because only mid-term data are widely available.

In summary, children younger than age 6 months with native COA should be treated with surgical repair, while those requiring intervention at later ages may be ideal candidates for balloon dilatation or primary stent implantation.⁵⁰ Additionally, catheter-based therapy should be employed for those cases of restenosis following either surgical or primary endovascular management.

Truncus Arteriosus

Anatomy. Truncus arteriosus is a rare anomaly, comprising between 1% and 4% of all cases of CHD.⁵⁸ It is characterized by a single great artery that arises from the heart, overrides the ventricular septum, and supplies the pulmonary, systemic, and coronary circulations.

The two major classification systems are those of Collett and Edwards, described in 1949, and Van Praagh and Van Praagh, described in 1965 (Fig. 20-9).^{59,60} The Collett and Edwards classification focuses mainly on the origin of the pulmonary arteries from the common arterial trunk, whereas the Van Praagh system is based on the presence or absence of a VSD, the degree of formation of the aorticopulmonary septum, and the status of the aortic arch.

During embryonic life, the truncus arteriosus normally begins to separate and spiral into a distinguishable anterior pulmonary artery and posterior aorta. Persistent truncus, therefore, represents an arrest in embryologic development at this stage.⁶¹ Other implicated events include twisting of the dividing truncus because of ventricular looping, subinfundibular atresia, and abnormal location of the semilunar valve anlagen.⁶²

The neural crest may also play a crucial role in the normal formation of the great vessels, as experimental studies in chick embryos have shown that ablation of the neural crest results in persistent truncus arteriosus.⁶³ The neural crest also develops into the pharyngeal pouches that give rise to the thymus and parathyroids, which likely explains the prevalent association of truncus arteriosus and DiGeorge's syndrome.⁶⁴

The annulus of the truncal valve usually straddles the ventricular septum in a "balanced" fashion; however, it is not unusual for it to be positioned predominantly over the RV, which increases the potential for LVOT obstruction following surgical repair. In the great majority of cases, the leaflets are thickened and deformed, which leads to valvular insufficiency. There are usually three leaflets (60%), but occasionally a bicuspid (50%) or even a quadricuspid valve (25%) is present.⁶⁵

In truncus arteriosus, the pulmonary trunk bifurcates, with the left and right pulmonary arteries forming posteriorly and to the left in most cases. The caliber of the pulmonary arterial branches is usually normal, with stenosis or diffuse hypoplasia occurring in rare instances.

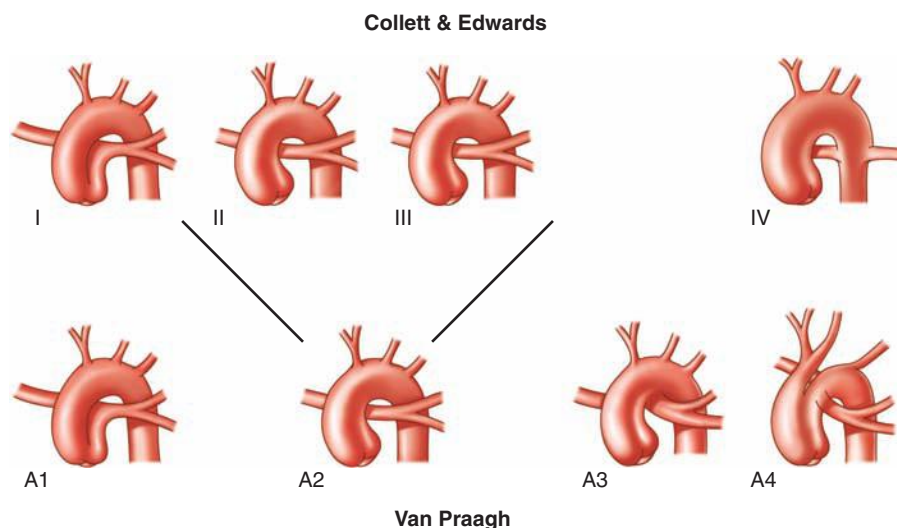


Figure 20-9. There are similarities between the Collett and Edwards and the Van Praagh classifications of truncus arteriosus. Type I is the same as A1. Types II and III are grouped as a single type A2 because they are not significantly distinct embryologically or therapeutically. Type A3 denotes unilateral pulmonary artery with collateral supply to the contralateral lung (hemitruncus). Type A4 is truncus associated with interrupted aortic arch (13% of all cases of truncus arteriosus). (Reproduced with permission from Fyler DC. *Truncus arteriosus*. In: Fyler DC, ed. *Nadas' Pediatric Cardiology*. Philadelphia: Hanley & Belfus; 1992:676. Copyright Elsevier. As adapted with permission from Hernanz-Schulman M, Fellows KE. *Persistent truncus arteriosus: pathologic, diagnostic and therapeutic considerations*. *Semin Roentgenol*. 1985;20:121. Copyright Elsevier.)

The coronary arteries may be normal; however, anomalies are not unusual and occur in 50% of cases.^{65,66} Many of these are relatively minor, although two variations are of particular importance, because they have implications in the conduct of operative repair. The first is that the left coronary ostium may arise high in the sinus of Valsalva or even from the truncal tissue at the margin of the pulmonary artery tissue. This coronary artery can be injured during repair when the pulmonary arteries are removed from the trunk or when the resulting truncal defect is closed. The second is that the right coronary artery can give rise to an important accessory anterior descending artery, which often passes across the RV in the exact location where the right ventriculotomy is commonly performed during repair.^{65,66}

Physiology and Diagnosis. The main pathophysiologic consequences of truncus arteriosus are (a) the obligatory mixing of systemic and pulmonary venous blood at the level of the ventricular septal defect (VSD) and truncal valve, which leads to arterial saturations near 85%, and (b) the presence of a nonrestrictive left-to-right shunt, which occurs during both systole and diastole, the volume of which is determined by the relative resistances of the pulmonary and systemic circulations.⁶⁵ Additionally, truncal valve stenosis or regurgitation, the presence of important LVOT obstruction, and stenosis of pulmonary artery branches can further contribute to both pressure- and volume-loading of the ventricles. The presence of these lesions often results in severe heart failure and cardiovascular instability early in life. Pulmonary vascular resistance may develop as early as 6 months of age, leading to poor results with late surgical correction.

Patients with truncus arteriosus usually present in the neonatal period, with signs and symptoms of congestive heart failure and mild to moderate cyanosis. A pansystolic murmur may be noted at the left sternal border, and occasionally a diastolic murmur may be heard in the presence of truncal regurgitation.

Chest radiography will be consistent with pulmonary overcirculation, and a right aortic arch can be appreciated 35% of the time. The ECG is usually nonspecific, demonstrating normal sinus rhythm with biventricular hypertrophy.

Echocardiography with Doppler color-flow or pulsed Doppler is diagnostic and usually provides sufficient information to determine the type of truncus arteriosus, the origin of the coronary arteries and their proximity to the pulmonary trunk, the character of the truncal valves, and the extent of truncal insufficiency.⁶⁵ Cardiac catheterization can be helpful in cases where pulmonary hypertension is suspected or to further delineate coronary artery anomalies prior to repair.

The presence of truncus is an indication for surgery. Repair should be undertaken in the neonatal period or as soon as the diagnosis is established. Eisenmenger's physiology, which is found primarily in older children, is the only absolute contraindication to correction.

Repair. Truncus arteriosus was first managed with pulmonary artery banding as described by Armer and colleagues in 1961.⁶⁷ However, this technique led to only marginal improvements in 1-year survival rates because ventricular failure inevitably occurred. In 1967, however, complete repair was accomplished by McGoon and his associates based on the experimental work of Rastelli, who introduced the idea that an extracardiac valved conduit could be used to restore ventricular-to-pulmonary artery

continuity.⁶⁸ Over the next 20 years, improved survival rates led to uniform adoption of complete repair even in the youngest and smallest infants.^{58,65,69}

Surgical correction entails the use of CPB. Repair is completed by separation of the pulmonary arteries from the aorta, closure of the aortic defect (occasionally with a patch) to minimize coronary flow complications, placement of a valved cryopreserved allograft or jugular venous valved conduit (Contegra) to reconstruct the RVOT, and VSD closure. Important branch pulmonary arterial stenosis should be repaired at the time of complete repair and can usually be accomplished with longitudinal allograft patch arterioplasty. Severe truncal valve insufficiency occasionally requires truncal valve replacement, which can be accomplished with a cryopreserved allograft.⁷⁰

Results. The results of complete repair of truncus have steadily improved. Ebert reported a 91% survival rate in his series of 77 patients who were younger than 6 months of age; later reports by others confirmed these findings and demonstrated that excellent results could be achieved in even smaller infants with complex-associated defects.^{11,69}

Newer extracardiac conduits also have been developed and used with success, which has widened the repertoire of the modern congenital heart surgeon and improved outcomes.⁷¹ Severe truncal regurgitation, interrupted aortic arch, coexistent coronary anomalies, chromosomal or genetic anomalies, and age younger than 100 days are risk factors associated with perioperative death and poor outcome.

Total Anomalous Pulmonary Venous Connection

Total anomalous pulmonary venous connection (TAPVC) occurs in 1% to 2% of all cardiac malformations and is characterized by abnormal drainage of the pulmonary veins into the right heart, whether through connections into the right atrium or into its tributaries.⁷² Accordingly, the only mechanism by which oxygenated blood can return to the left heart is through an ASD, which is almost uniformly present with TAPVC.

Unique to this lesion is the absence of a definitive form of palliation. Thus, TAPVC with concomitant obstruction represents one of the only true surgical emergencies across the entire spectrum of congenital heart surgery.

Anatomy and Embryology. The lungs develop from an outpouching of the foregut, and their venous plexus arises as part of the splanchnic venous system. TAPVC arises when the pulmonary vein evagination from the posterior surface of the left atrium fails to fuse with the pulmonary venous plexus surrounding the lung buds. In place of the usual connection to the left atrium, at least one connection of the pulmonary plexus to the splanchnic plexus persists. Accordingly, the pulmonary veins drain to the heart through a systemic vein (Fig. 20-10).

Darling and colleagues classified TAPVC according to the site or level of connection of the pulmonary veins to the systemic venous system⁷³: type I (45%), anomalous connection at the supracardiac level; type II (25%), anomalous connection at the cardiac level; type III (25%), anomalous connection at the infracardiac level; and type IV (5%), anomalous connection at multiple levels.⁷⁴ Within each category, further subdivisions can be implemented, depending on whether pulmonary venous obstruction exists. Obstruction to pulmonary venous drainage

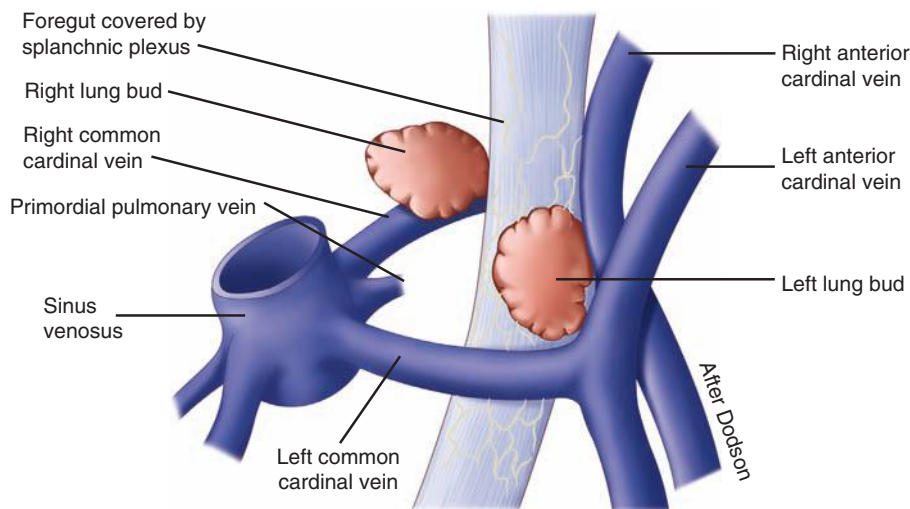


Figure 20-10. Total anomalous pulmonary venous connection results when the primordial pulmonary vein fails to unite with the plexus of veins that surround the lung buds and is derived from the splanchnic venous plexus, including the cardinal veins and umbilicovitelline veins. (From Castaneda AR, Jonas RA, Mayer JE, et al. *Cardiac Surgery of the Neonate and Infant*. Philadelphia: W.B. Saunders; 1994:158, with permission. Copyright Elsevier.)

is a powerful predictor of adverse natural outcome and occurs most frequently with the infracardiac type, especially when the pattern of infracardiac connection prevents the ductus venosus from bypassing the liver.⁷⁵

Pathophysiology and Diagnosis. Because both pulmonary and systemic venous blood returns to the right atrium in all forms of TAPVC, a right-to-left intracardiac shunt must be present in order for the afflicted infant to survive. This invariably occurs via a nonrestrictive patent foramen ovale. Because of this obligatory mixing, cyanosis is usually present, and its degree depends on the ratio of pulmonary to systemic blood flow. Decreased pulmonary blood flow is a consequence of pulmonary venous obstruction, the presence of which is unlikely if the right ventricular pressure is less than 85% of systemic pressure.⁷⁶

The child with TAPVC may present with severe cyanosis and respiratory distress, necessitating urgent surgical intervention if a severe degree of pulmonary venous obstruction is present. However, in cases where there is no obstructive component, the clinical picture is usually one of pulmonary overcirculation, hepatomegaly, tachycardia, and tachypnea with feeding. In a child with serious obstruction, arterial blood gas analysis reveals severe hypoxemia (partial pressure of oxygen [PO₂] <20 mmHg), with metabolic acidosis.⁷⁷

Chest radiography will show normal heart size with generalized pulmonary edema. Two-dimensional echocardiography is very useful in establishing the diagnosis and also can assess ventricular septal position, which may be leftward secondary to small left ventricular volumes, as well as estimate the right ventricular pressure based on the height of the tricuspid regurgitant jet. Echocardiography can usually identify the pulmonary venous connections (types I to IV), and it is rarely necessary to perform other diagnostic tests.

Cardiac catheterization is not recommended in these patients because the osmotic load from the intravenous contrast can exacerbate the degree of pulmonary edema.⁷⁸ When cardiac catheterization is performed, equalization of oxygen saturations in all four heart chambers is a hallmark finding in this disease since the mixed blood returned to the right atrium gets distributed throughout the heart.

Therapy. Operative correction of TAPVC requires anastomosis of the common pulmonary venous channel to the left atrium, obliteration of the anomalous venous connection, and closure of the ASD.^{77,79}

All types of TAPVC are approached through a median sternotomy, and many surgeons use deep hypothermic circulatory arrest in order to achieve an accurate and widely patent anastomosis. The technique for supracardiac TAPVC includes early division of the vertical vein, retraction of the aorta and the superior vena cava laterally to expose the posterior aspect of the left atrium and the pulmonary venous confluence, and a side-to-side anastomosis between a long, horizontal biatrial incision and a longitudinal incision within the pulmonary venous confluence. The ASD can then be closed with an autologous pericardial or synthetic patch.

In patients with TAPVC to the coronary sinus without obstruction, a simple unroofing of the coronary sinus can be performed through a single right atriotomy with concomitant closure of the ASD. If pulmonary venous obstruction is present, the repair should include generous resection of roof of the coronary sinus.⁷⁷

Repair of infracardiac TAPVC entails ligation of the vertical vein at the diaphragm, followed by construction of a proximal, patulous longitudinal venotomy. This repair is usually performed by “rolling” the heart toward the left, thus exposing the left atrium where it usually overlies the descending vertical vein (Fig. 20-11).

As originally described by Lacour-Gayet and colleagues at the Marie-Lannelongue Hospital, Paris, and Coles and colleagues at The Hospital for Sick Children, Toronto, the sutureless technique was developed for patients with anastomotic stenosis occurring after TAPVC repair.^{78,79} After determining that favorable outcomes were possible using this technique, it is currently used in selected patients upon initial presentation of TAPVC.⁷⁹ Incisions are made in the venous confluence. Based on the surgeon’s discretion, the incisions are extended into both upper and lower pulmonary veins separately if judged to be important for an unobstructed pathway. An atriopericardial anastomosis is created using the pericardium adjacent to where the pulmonary veins enter the pericardium (Fig. 20-12). This anastomosis avoids direct contact with the incision site in the wall of the pulmonary veins and allows the free egress of blood from the lungs to the left atrium.



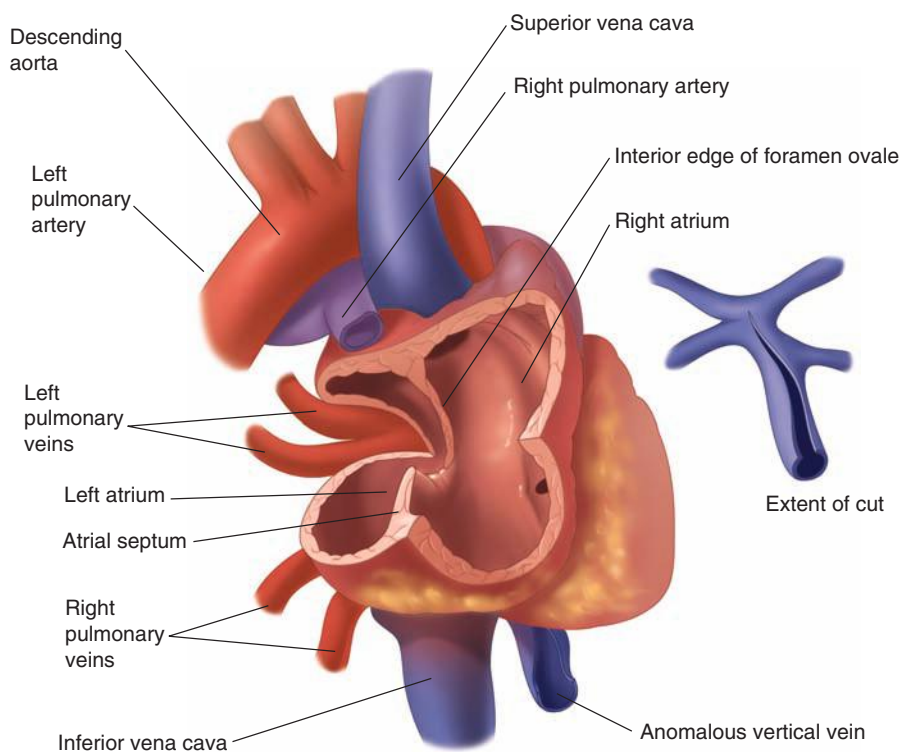


Figure 20-11. Operative exposure obtained with infradiaphragmatic total anomalous pulmonary venous connection, using an approach from the right. (From Castaneda AR, Jonas RA, Mayer JE, et al. *Cardiac Surgery of the Neonate and Infant*. Philadelphia: W.B. Saunders; 1994:161, with permission. Copyright Elsevier.)

The perioperative care of these infants is crucial because episodes of pulmonary hypertension can occur within the first 48 hours, which contribute significantly to mortality following repair.⁶ Muscle relaxants and narcotics should be administered during this period to maintain a constant state of anesthesia. Arterial partial pressure of carbon dioxide (PCO_2) should be maintained at 30 mmHg with use of a volume ventilator, and the fraction of inspired oxygen (FiO_2) should be increased to keep the pulmonary arterial pressure at less than two thirds of the systemic pressure.

Results. Results of TAPVC in infancy have markedly improved in recent years, with an operative mortality of 5% or

less in some series.⁷⁷⁻⁸⁰ This improvement is probably multifactorial, mainly as a consequence of early noninvasive diagnosis and aggressive perioperative management. The routine use of echocardiography; improvements in myocardial protection with specific attention to the RV; creation of a large, tension-free anastomosis with maximal use of the venous confluence and atrial tissue; use of a sutureless technique in selected cases; and prevention of pulmonary hypertensive events have likely played a major role in reducing operative mortality. The importance of risk factors for early mortality, such as venous obstruction at presentation, urgency of operative repair, and infradiaphragmatic anatomic type, have been debated.^{79,81}

Bando and colleagues⁸² made the controversial statement that both preoperative pulmonary venous obstruction and anatomic type had been neutralized as potential risk factors beyond calendar year 1991. Hyde et al⁸⁰ similarly reported that connection type was not related to outcome. However, a recent large single-institution report of 377 children with TAPVC by the author from the Hospital for Sick Children in Toronto⁸³ found that, although outcomes had improved over time, patient anatomic factors were still important determinants of both survival and the need for subsequent reoperation. Risk factors for postrepair death were earlier operation year, younger age at repair, cardiac connection type, and postoperative pulmonary venous obstruction. Risk-adjusted estimated 1-year survival for a patient repaired at birth with unfavorable morphology in 2006 was 37% (95% confidence interval [CI], 8%–80%) compared with 96% (95% CI, 91%–99%) for a patient with favorable morphology repaired at age 1 year. Freedom from reoperation was $82\% \pm 6\%$ at 11 years after repair, with increased risk associated with mixed connection and postoperative pulmonary venous obstruction (Fig. 20-13). A recent study from the Hospital for Sick Children, Toronto, showed a lower incidence of reoperation in the sutureless technique compared to conventional pulmonary

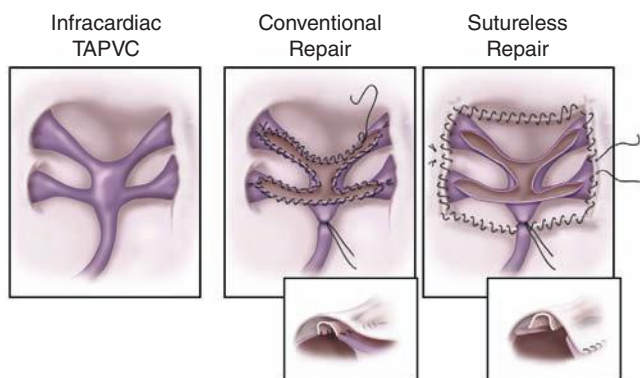


Figure 20-12. Differences between conventional repair of total anomalous pulmonary venous connection (TAPVC) and sutureless repair of TAPVC. In the sutureless techniques, there are no sutures placed in the fragile veins themselves. Rather, the pericardial flaps are used to create a “well” for the pulmonary venous return (*bottom inset*). Early and late extrinsic stenosis are thought to be reduced using this latter technique.

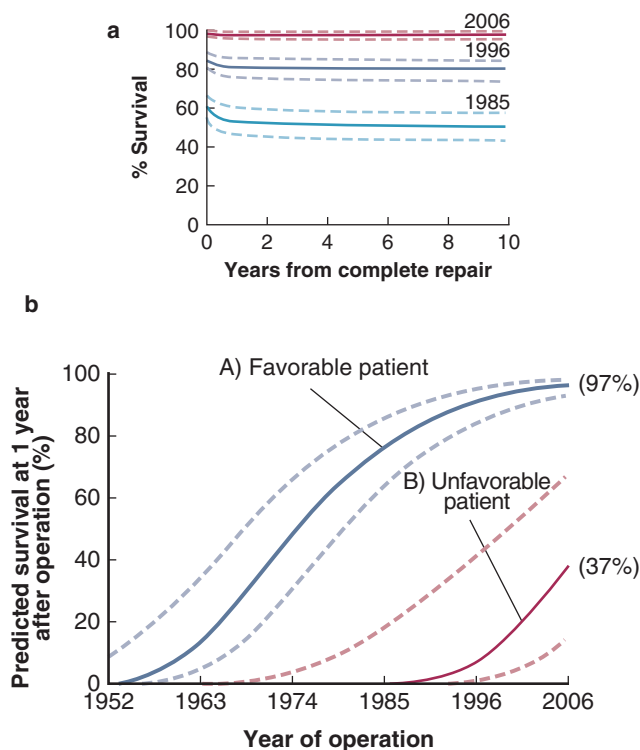


Figure 20-13. **a.** Risk-adjusted survival from repair improved significantly with increasing year of operation, indicating a strong era effect. Solid lines are continuous point estimates enclosed by dashed 95% confidence limits showing three different solutions to the multivariable equation for death after repair. All other predictors have been set to mean values to illustrate the favorable influence of later operation year on survival after repair. **b.** Risk-adjusted nomograms show 1-year survival after repair expressed as a function of increasing year of operation for two different patients. The top line (A) shows the multivariable solution for a patient with favorable anatomic characteristics (noncardiac connection without pulmonary venous obstruction) undergoing repair at 1 year of age; the bottom line (B) shows the solution for a patient with unfavorable characteristics (cardiac connection with pulmonary venous obstruction) undergoing operation at birth. The nomograms show that the more recent era has improved survival in all patients, especially within the last few decades. However, unfavorable anatomic characteristics have not been neutralized as important determinants of postrepair survival despite improvements in perioperative care. Numbers in parentheses represent parametric estimates of median survival at 1 year after repair in 2005. (Reproduced with permission from Karamlou T, et al. Factors associated with mortality and reoperation in 377 children with total anomalous pulmonary venous connection. *Circulation*. 2007;115:1591.)

venous confluence–left atrial anastomosis.⁸⁴ However, there was no statistically significant difference suggesting similar results between the strategies.⁹ Although the sutureless technique appears to have favorable outcomes at primary repair for TAPVC, long-term follow-up is necessary to evaluate the occurrence of arrhythmias, such as complete heart block and atrial tachycardia, since an incision on the atrial septum and atrial wall is more invasive compared to the conventional technique.

The most significant postoperative complication of TAPVC repair is pulmonary venous obstruction, which occurs 9% to 11% of the time, regardless of the surgical

technique employed. Mortality varies between 30% and 45%, and alternative catheter interventions do not offer definitive solutions.⁷⁸ Recurrent pulmonary venous obstruction can be localized at the site of the pulmonary venous anastomosis (extrinsic), which can usually be cured with patch enlargement or balloon dilatation, or it may be secondary to endocardial thickening of the pulmonary venous ostia frequently resulting in diffuse pulmonary venous sclerosis (intrinsic), which carries a 66% mortality rate because few good solutions exist.⁷⁵ More commonly, postrepair left ventricular dysfunction can occur as the noncompliant LV suddenly is required to handle an increased volume load from redirected pulmonary venous return. This can manifest as an increase in pulmonary artery pressure but is distinguishable from primary pulmonary hypertension (another possible postoperative complication following repair of TAPVC) from the elevated left atrial pressure and LV dysfunction along with echocardiographic evidence of poor LV contractility. In pulmonary hypertension, the left atrial pressure may be low, the LV may appear “underfilled” (by echocardiography), and the RV may appear dilated. In either case, postoperative support for a few days with extracorporeal membrane oxygenation may be lifesaving, and TAPVC should be repaired in centers that have this capacity.

Some investigators have speculated that preoperative pulmonary venous obstruction is associated with increased medial thickness within the pulmonary vasculature, which may predispose these infants to intrinsic pulmonary venous stenosis despite adequate pulmonary venous decompression.⁸⁰ The majority of studies demonstrating that preoperative pulmonary venous obstruction is a predictor of subsequent need for reoperation to correct recurrent pulmonary venous obstruction lend credence to this notion.

Cor Triatriatum

Anatomy. Cor triatriatum is a rare CHD characterized by the presence of a fibromuscular diaphragm that partitions the left atrium into two chambers: a superior chamber that receives drainage from the pulmonary veins, and an inferior chamber that communicates with the mitral valve and the LV (Fig. 20-14). An ASD frequently exists between the superior chamber and the right atrium, or, more rarely, between the right atrium and the inferior chamber.

Pathophysiology and Diagnosis. Cor triatriatum results in obstruction of pulmonary venous return to the left atrium. The degree of obstruction is variable and depends on the size of fenestrations present in the left atrial membrane, the size of the ASD, and the existence of other associated anomalies. If the communication between the superior and inferior chambers is less than 3 mm, patients usually are symptomatic during the first year of life. The afflicted infant will present with the stigmata of low cardiac output and pulmonary venous hypertension, as well as congestive heart failure and poor feeding.

Physical examination may demonstrate a loud pulmonary S₂ sound and a right ventricular heave, as well as jugular venous distention and hepatomegaly. Chest radiography will show cardiomegaly and pulmonary vascular prominence, and the ECG will suggest right ventricular hypertrophy. Two-dimensional echocardiography provides a definitive diagnosis in most cases,

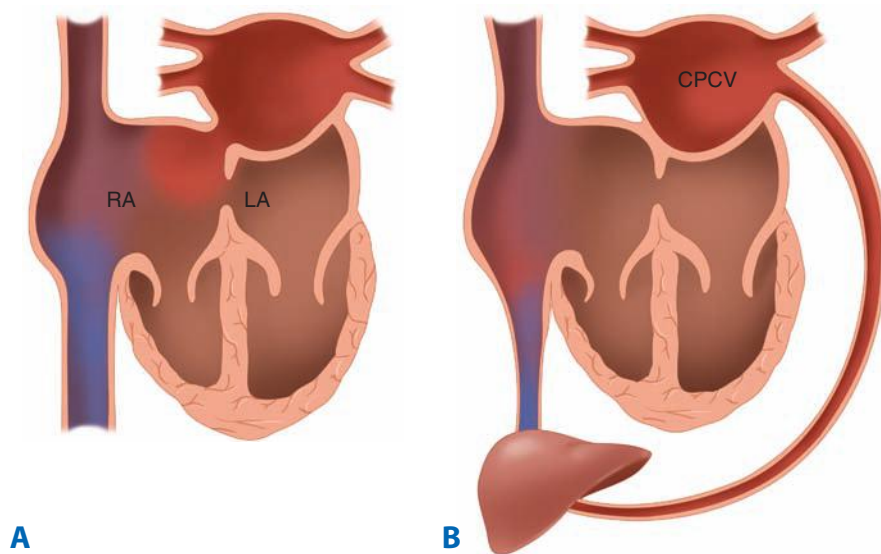


Figure 20-14. Variants of cor triatriatum with imperforate membrane between common pulmonary venous chamber (CPVC) and left atrium (LA). **A.** Common chamber draining to right atrium directly. **B.** Common chamber draining into systemic venous circulation via anomalous vein. RA = right atrium. (Adapted with permission from Krabill KA, Lucas RV Jr. *Abnormal pulmonary venous connections*. In: Emmanouilides GC, ed. *Moss and Adams' Heart Disease in Infants, Children, and Adolescents*. 5th ed. Baltimore: Lippincott Williams & Wilkins, 1995.)

with catheterization necessary only when echocardiographic evaluation is equivocal.

Therapy. Operative treatment for cor triatriatum is fairly simple. CPB and cardioplegic arrest are used. A right atriotomy usually allows access to the left atrial membrane through the existing ASD, because it is dilated secondary to communication with the pulmonary venous chamber. The membrane is then excised, taking care not to injure the mitral valve or the interatrial septum, and the ASD is closed with a patch. Alternatively, if the right atrium is small, the membrane can be exposed through an incision directly into the superior left atrial chamber, just anterior to the right pulmonary veins.^{7,82} Surgical results are uniformly excellent for this defect, with survival approaching 100%.

The utility of catheter-based intervention for this diagnosis remains controversial, although there have been two recent reports of successful balloon dilatation.^{83,85}

Aortopulmonary Window

Embryology and Anatomy. Aortopulmonary window (APW) is a rare congenital lesion, occurring in about 0.2% of patients, characterized by incomplete development of the septum that normally divides the truncus into the aorta and the pulmonary artery.⁸⁶

In the vast majority of cases, APW occurs as a single defect of minimal length, which begins a few millimeters above the semilunar valves on the left lateral wall of the aorta (Fig. 20-15). Coronary artery anomalies, such as aberrant origin of the right or left coronary artery from the main pulmonary artery, are occasionally present.

Pathophysiology and Diagnosis. The dominant pathophysiology of APW is that of a large left-to-right shunt with increased pulmonary flow and the early development of congestive heart failure. Like other lesions with left-to-right flow, the magnitude of the shunt is determined by both the size of the defect and the pulmonary vascular resistance.

Infants with APW present with frequent respiratory tract infections, tachypnea with feeding, and failure to thrive.

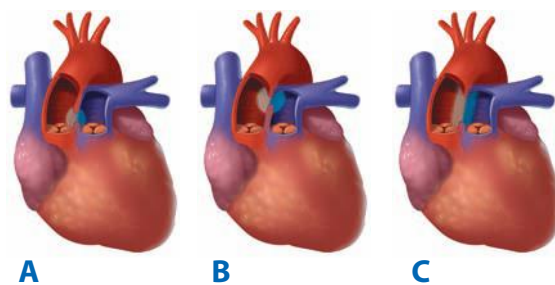


Figure 20-15. A through C. Classification of aortopulmonary window. (Reproduced with permission from Mori K, Ando M, Takao A. *Distal type of aortopulmonary window: report of 4 cases*. *Br Heart J*. 1978;40:681. With permission from the BMJ Publishing Group.)

Cyanosis is usually absent because these infants deteriorate prior to the onset of significant pulmonary hypertension. The rapid decline with this defect occurs because shunt flow continues during both phases of the cardiac cycle, which limits systemic perfusion and increases ventricular work.⁸⁶

The diagnosis of APW begins with the physical examination, which may demonstrate a systolic flow murmur, a hyperdynamic precordium, and bounding peripheral pulses. The chest radiograph will show pulmonary overcirculation and cardiomegaly, and the ECG will usually demonstrate either left ventricular hypertrophy or biventricular hypertrophy. Echocardiography can detect the defect and also provide information about associated anomalies. Retrograde aortography will confirm the diagnosis but is rarely necessary.

Therapy. All infants with APW require surgical correction once the diagnosis is made. Repair is undertaken through a median sternotomy and the use of CPB. The pulmonary arteries are occluded once the distal aorta is cannulated, and a transaortic repair using a prosthetic patch for pulmonary artery closure is then carried out. The coronary ostia must be carefully visualized and included on the aortic side of the patch. Alternatively, a two-patch technique can be used, which may eliminate recurrent fistulas from suture line

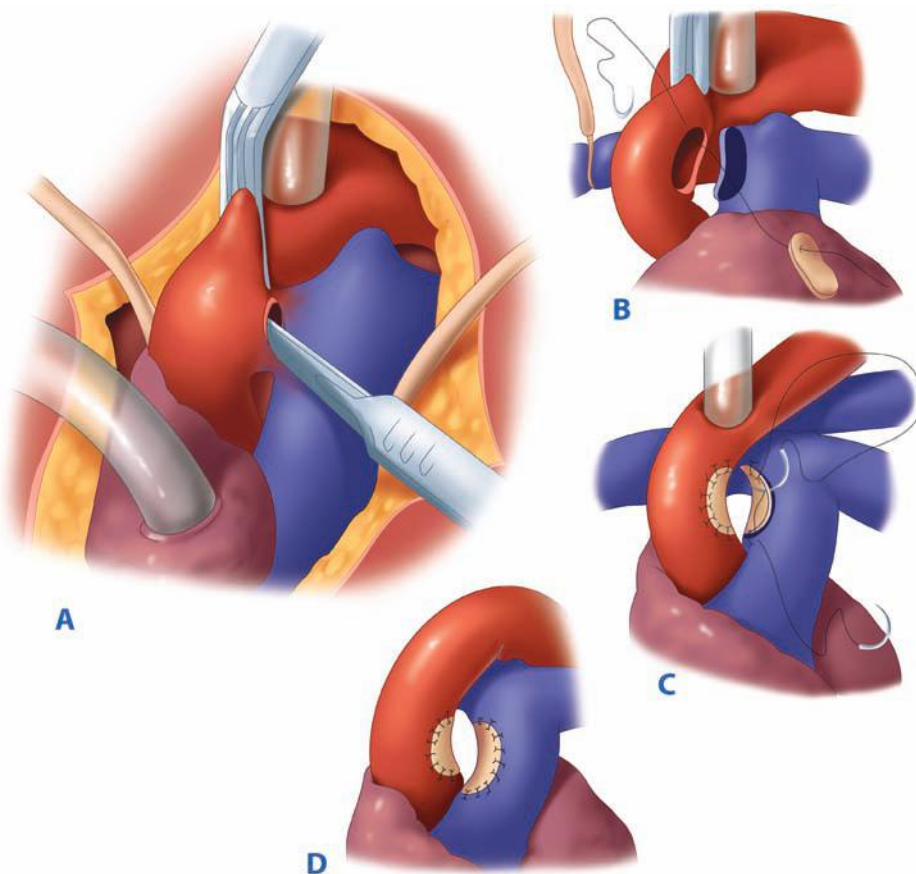


Figure 20-16. Two-patch repair of aortopulmonary window. **A.** The aorta and right atrium are cannulated through a median sternotomy, and once the patient is on cardiopulmonary bypass, the right and left pulmonary arteries are occluded with snares. The ductus arteriosus (when present) can be ligated. The aorta is cross-clamped and the heart arrested with cardioplegia. The aortopulmonary window is then divided, with the left coronary ostia being carefully protected. **B.** A piece of previously prepared pulmonary homograft material is used to patch the aortic defect. In older children, polytetrafluoroethylene material can be safely used. **C.** Once the aortic portion of the defect has been safely repaired, the aortic cross-clamp may be removed to restore perfusion to the heart. During rewarming, the pulmonary portion of the defect is repaired using a similar piece of homograft or polytetrafluoroethylene. **D.** At the completion of repair, the patient is easily weaned from cardiopulmonary bypass, and the cannulas are removed. This type of repair restores normal anatomy, with a reduced likelihood of long-term fistula formation. (From Gaynor et al,⁸⁸ with permission.)

leaks that occasionally occur with the single-patch method (Fig. 20-16).⁸⁶

Results. Results are generally excellent, with an operative mortality in most large series of less than 5%.⁸⁶⁻⁸⁸

DEFECTS REQUIRING PALLIATION

Tricuspid Atresia

Tricuspid atresia occurs in 2% to 3% of patients with CHD and is characterized by atresia of the tricuspid valve. This results in discontinuity between the right atrium and RV. The RV is generally hypoplastic, and left-heart filling is dependent on an ASD. Tricuspid atresia is the most common form of the single-ventricle complex, indicating that there is functionally only one ventricular chamber.

Anatomy. As mentioned, tricuspid atresia results in a lack of communication between the right atrium and the RV, and in the majority of patients, there is no identifiable valve tissue or remnant.⁸⁹ The right atrium is generally enlarged and muscular, with a fibrofatty floor. An unrestrictive ASD is usually present. The LV is often enlarged as it receives both systemic and pulmonary blood flow, but the left AV valve is usually normal.

The RV, however, is usually severely hypoplastic, and there is sometimes a VSD in its trabeculated or infundibular portion. In many cases, the interventricular communication is a site of obstruction to pulmonary blood flow, but obstruction may also occur at the level of the outlet valve or in the subvalvular infundibulum.⁹⁰ In most cases, pulmonary blood

flow is dependent on the presence of a PDA, and there may be no flow into the pulmonary circulation except for this PDA.

Tricuspid atresia is classified according to the relationship of the great vessels and by the degree of obstruction to pulmonary blood flow (Fig. 20-17). Because of the rarity of tricuspid atresia with transposed great arteries, we will restrict our discussion to tricuspid atresia with normally related great vessels.

Pathophysiology. The main pathophysiology in tricuspid atresia is that of a univentricular heart of left ventricular morphology. That is, the LV must receive systemic blood via the interatrial communication and then distribute it to both the pulmonary circulation and the systemic circulation. Unless there is a VSD (as is found in some cases), pulmonary flow is dependent on the presence of a PDA. As the ductus begins to close shortly after birth, infants become intensely cyanotic. Re-establishing ductal patency (with PGE₁) restores pulmonary blood flow and stabilizes patients for surgical intervention. Pulmonary hypertension is unusual in tricuspid atresia. However, occasional patients have a large VSD between the LV and the infundibular portion of the RV (just below the pulmonary valve). If there is no obstruction at the level of this VSD or at the valve, these infants may actually present with heart failure from excessive pulmonary blood flow. Regardless of whether these infants are “ductal-dependent” for pulmonary blood flow or have pulmonary blood flow provided across a VSD, they will be cyanotic since the obligatory right-to-left shunt at the atrial level will provide complete mixing of systemic and pulmonary venous

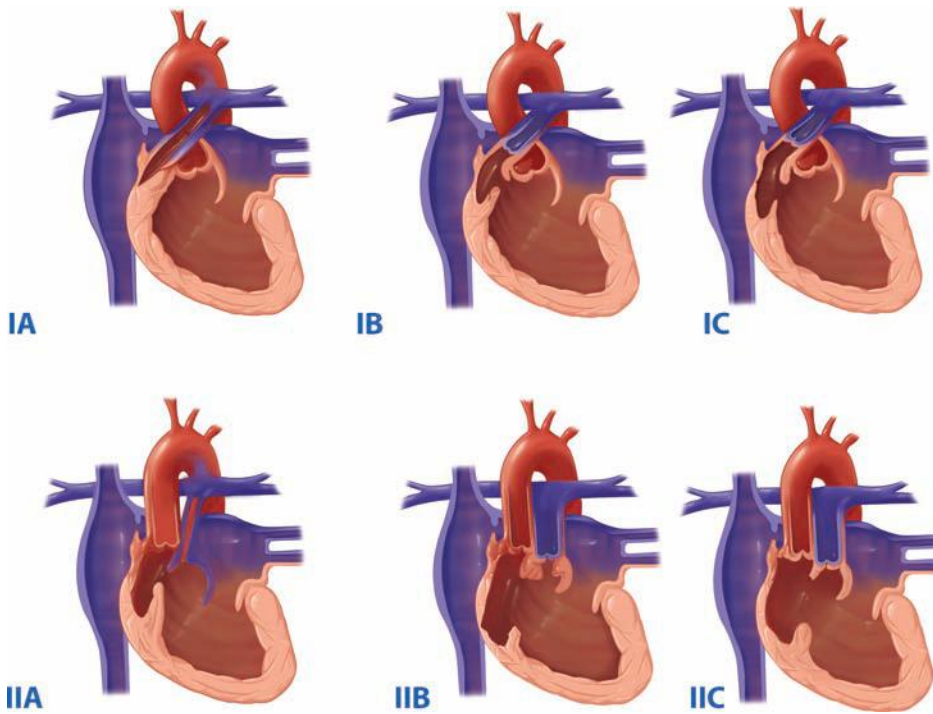


Figure 20-17. Classification of tricuspid atresia. Type I, normally related great arteries with: **IA**, pulmonary atresia with virtual absence of right ventricle; **IB**, pulmonary stenosis with small ventricular septal defect; **IC**, normal pulmonary valve, large ventricular septal defect. Type II, transposed great arteries with: **IIA**, pulmonary atresia; **IIB**, pulmonary or subpulmonary stenosis; **IIC**, normal or enlarged pulmonary valve and artery without subpulmonary stenosis. (Reproduced with permission from *Tricuspid atresia*. In: Mavroudis C, Backer CL, eds. *Pediatric Cardiac Surgery*. 2nd ed. St. Louis: Mosby; 1994:381.)

return so that the LV ejects a hypoxemic mixture into the aorta.

Diagnosis. The signs and symptoms of tricuspid atresia are dependent on the underlying anatomic variant, but most infants are cyanotic and hypoxic as a result of decreased pulmonary blood flow and the complete mixing at the atrial level. When pulmonary blood flow is provided through a VSD, there may be a prominent systolic murmur. Tricuspid atresia with pulmonary blood flow from a PDA may present with the soft, continuous murmur of a PDA in conjunction with cyanosis.

In the minority of patients with tricuspid atresia, symptoms of congestive heart failure will predominate. This is often related to excessive flow across a VSD. The natural history of the muscular VSDs in these infants is that they will close and the congestive heart failure will dissipate and transform into cyanosis with reduced pulmonary blood flow. Chest radiography will show decreased pulmonary vascularity. The ECG is strongly suggestive, because uncharacteristic left axis deviation will be present, due to underdevelopment of the RV. Two-dimensional echocardiography readily confirms the diagnosis and the anatomic subtype.

Treatment. The treatment for tricuspid atresia in the earlier era of palliation was aimed at correcting the defect in the pulmonary circulation. That is, patients with too much pulmonary flow received a pulmonary band, and those with insufficient flow received a systemic-to-pulmonary artery shunt. Systemic-to-pulmonary artery shunts, or Blalock-Taussig (B-T) shunts, were first applied to patients with tricuspid atresia in the 1940s and 1950s.⁹¹ Likewise pulmonary artery banding was applied to patients with tricuspid atresia and congestive failure in 1957. However, despite the initial relief of either cyanosis or congestive heart failure, long-term mortality was high, as the single ventricle was left unprotected from either volume or pressure overload.⁹²

Recognizing the inadequacies of the initial repairs, Glenn described the first successful cavopulmonary anastomosis, an end-to-side right pulmonary artery-to-superior vena cava shunt in 1958, and later modified this to allow flow to both pulmonary arteries.⁹³ This end-to-side right pulmonary artery-to-superior vena cava anastomosis was known as the bidirectional Glenn, and is the first stage to final Fontan repair in widespread use today (Fig. 20-18). The Fontan repair was a major advancement in the treatment of CHD, as it essentially bypassed the right heart and allowed separation of the pulmonary and systemic circulations. It was first performed by Fontan in 1971, and consisted of a classic Glenn anastomosis, ASD closure, and direct connection of the right atrium to the proximal end of the left pulmonary artery using an aortic homograft.⁹⁴ The main pulmonary artery was ligated, and a homograft valve was inserted into the orifice of the inferior vena cava.

Multiple modifications of this initial repair were performed over the next 20 years. One of the most important was the description by deLeval and colleagues of the creation of an interatrial lateral tunnel that allowed the inferior vena caval blood to be channeled exclusively to the superior vena cava.⁹⁵ A total cavopulmonary connection could then be accomplished by dividing the superior vena cava and suturing the superior portion to the upper side of the right pulmonary artery and the inferior end to the augmented undersurface of the right pulmonary artery. Pulmonary flow then occurs passively, in a laminar fashion, driven by the central venous pressure. This repair became known as the modified Fontan operation.

Another important modification, the fenestrated Fontan repair, was introduced in 1988.⁹⁶ In this procedure, a residual 20% to 30% right-to-left shunt is either created or left unrepaired at the time of cavopulmonary connection to help sustain systemic output in the face of transient elevations in the pulmonary vascular resistance postoperatively (Fig. 20-19).⁹⁶

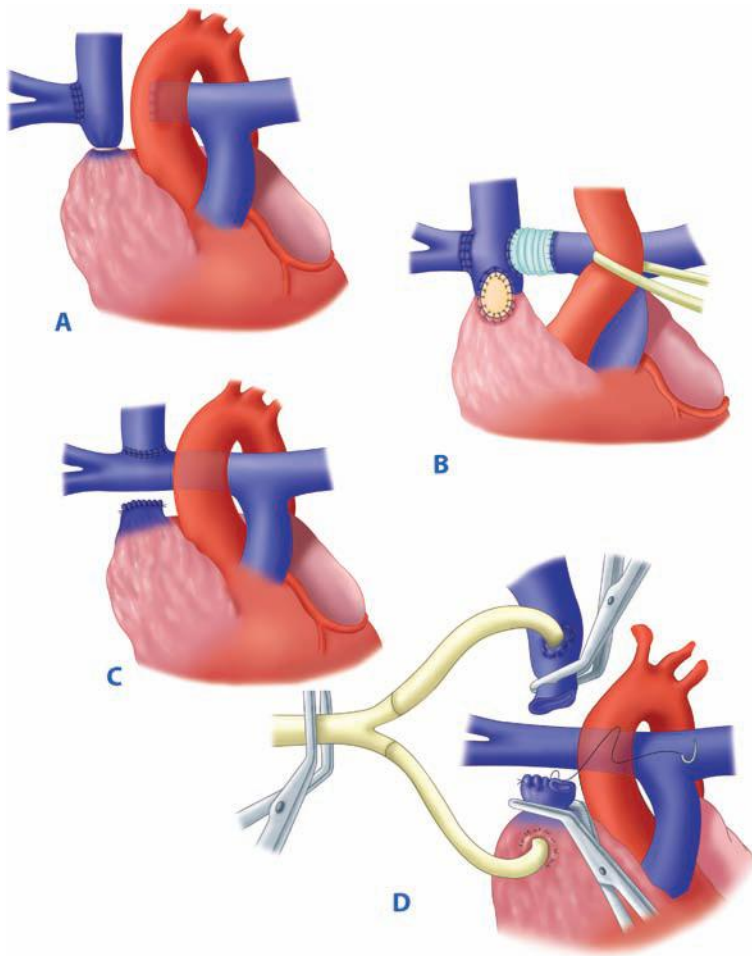


Figure 20-18. Superior vena cava–pulmonary artery shunts. **A.** Classic Glenn shunt. End-to-side right pulmonary artery (RPA)-to-superior vena cava (SVC) anastomosis with ligation of SVC–right atrial junction. **B.** Method of takedown of classic Glenn shunt and creation of total cavopulmonary anastomosis during Fontan operation. **C.** Bidirectional Glenn shunt (bidirectional SVC–pulmonary artery shunt), end-to-side SVC-to-RPA anastomosis. **D.** Method of construction of bidirectional Glenn shunt, one cannula in the high SVC or innominate vein and another cannula in the right atrium connected to a Y-connector. (Reproduced with permission from *Tricuspid atresia*. In: Mavroudis C, Backer CL, eds. *Pediatric Cardiac Surgery*. 2nd ed. St. Louis: Mosby; 1994:383.)

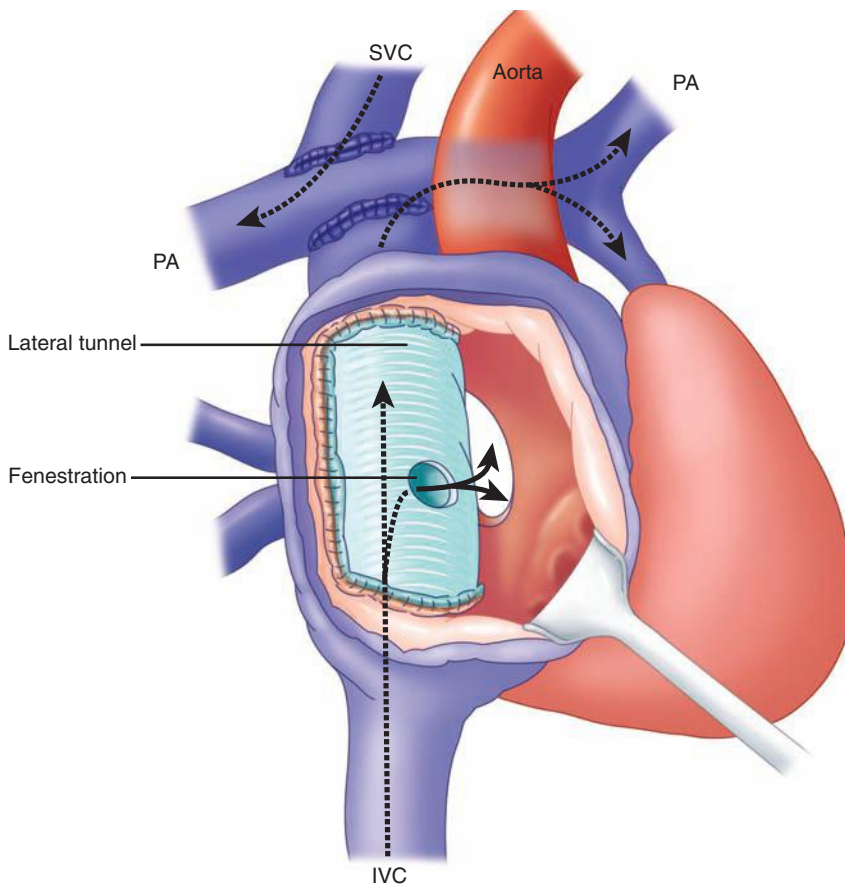


Figure 20-19. The fenestrated Fontan procedure. Using a polytetrafluoroethylene patch, a tunnel is created in the lateral wall of the right atrium to direct inferior vena cava (IVC) flow to the superior vena cava (SVC) that is anastomosed to the pulmonary artery (PA). A 4- to 5-mm fenestration in the baffle diminishes systemic venous pressure and improves cardiac output at the expense of a small decrease in systemic arterial oxygen saturation. (Reproduced with permission from Kopf GS, Kleinman CS, Hijazi ZM, et al. *Fenestrated Fontan operation with delayed transcatheter closure of atrial septal defect: improved results in high-risk patients*. *J Thorac Cardiovasc Surg*. 1992;103:1039. Copyright Elsevier.)

The last notable variation on the original Fontan repair uses an extracardiac prosthetic tube graft, usually 20 mm in diameter, as the conduit directing inferior vena cava blood to the pulmonary arteries.⁹⁵ This technique has the advantages of decreasing atrial geometric alterations by avoiding intra-atrial suture lines and improving flow dynamics in the systemic venous pathway by maximizing laminar flow. Several investigators have shown a decrease in supraventricular arrhythmias, as well as an improvement in ventricular function, which may be secondary to decreased atrial tension and alleviation of chronic elevations in coronary sinus pressure.^{95,96} The extracardiac Fontan operation can be completed without the use of CPB in selected cases, which may further improve outcomes.⁹⁷

One potential disadvantage of the extracardiac Fontan is that it delays performance of the Fontan in order to allow placement of a conduit of sufficient size. Despite these innovative approaches, the current strategy for operative management still relies on the idea of palliation. Patients are approached in a staged manner, to maximize their physiologic state so that they will survive to undergo a Fontan operation. The therapeutic strategy must begin in the neonatal period and should be directed toward reducing the patient's subsequent risk factors for a Fontan procedure. Accordingly, small systemic pulmonary shunts, which are usually performed through a median sternotomy, should be constructed for palliation of ductus-dependent univentricular physiology. This can easily be replaced with a bidirectional Glenn shunt or hemi-Fontan operation at 6 months of life. In non-ductus-dependent univentricular physiology, the infant can be managed medically until primary construction of a bidirectional cavopulmonary anastomosis becomes feasible. This is possible in the majority of cases because the physiologically elevated pulmonary vascular resistance prevents pulmonary overcirculation during the neonatal period.

Occasionally, if a previous B-T shunt was performed, arterioplasty of the right pulmonary artery may be required to ensure adequate size and unobstructed bilateral flow.² The bidirectional Glenn shunt or hemi-Fontan operation effectively avoids recirculation of both systemic and pulmonary venous return, thus preventing volume overload of the single ventricle and its attendant sequelae.⁹⁵ Pulmonary artery banding is necessary in 10% to 15% of patients with markedly increased pulmonary blood flow and florid congestive heart failure.

The Fontan is usually performed when the child is between 2 and 4 years of age, and it is generally successful if the infant was staged properly, with a protected single ventricle, and there is adequate pulmonary artery growth. The pulmonary vascular resistance should be below 4 Wood units, and the ejection fraction should be more than 45% to ensure success.⁹⁸ In patients with high pulmonary artery pressure, fenestration of the atrial baffle may be helpful because their pulmonary vascular resistance may preclude adequate cardiac output postoperatively.^{92,96}

Results. Recent reports of the Fontan procedure for tricuspid atresia have been encouraging, with an overall survival of 86% and an operative mortality of 2%.⁸ The main complications following repair are atrial arrhythmias, particularly atrial flutter; conduit obstruction requiring reoperation; protein-losing enteropathy; and decreased exercise tolerance.

A recent prospective multi-institutional study from the Congenital Heart Surgeons Society reported the outcomes of 150 neonates with tricuspid atresia and normally related great vessels.⁹⁹ Five-year survival was 86%, and by the age of 2 years, 89% had undergone cavopulmonary anastomosis, and 75% of those surviving cavopulmonary anastomosis underwent Fontan operation within 3 years. Competing risks methodology was used in this study to determine the rates of transition to

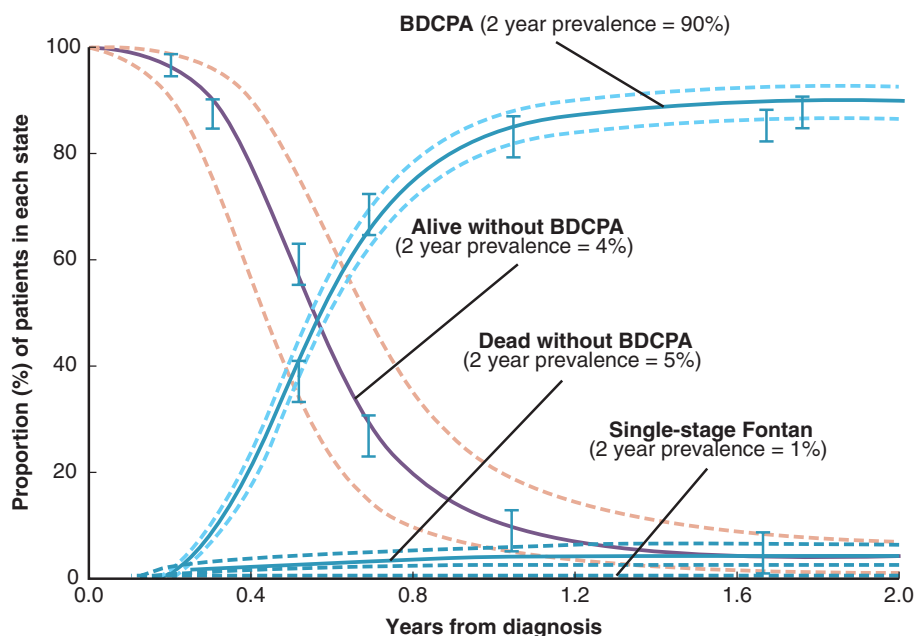


Figure 20-20. Competing risks depiction of events after diagnosis in 150 patients with tricuspid atresia. All patients began alive and thereafter migrated to one of four mutually exclusive end states (death, bidirectional cavopulmonary anastomosis [BDCPA], single-stage Fontan completion, or remaining alive without BDCPA) at time-dependent rates defined by the underlying hazard functions. At any point in time, the sum of proportions of children in each state is 100%. For example, estimated prevalences after 2 years from diagnosis are as follows: 89% BDCPA, 6% dead without BDCPA, 4% alive without BDCPA, and 1% single-stage Fontan completion. Solid lines represent parametric point estimates; dashed lines enclose 70% confidence intervals; circles with error bars represent nonparametric estimates; numbers in parentheses indicate the estimated proportion of patients in each state at 2 years from diagnosis. (From Karamlou et al,⁹⁹ Fig. 1, with permission. Copyright Elsevier.)

end-states and their associated determinants (Fig. 20-20). Risk factors for death without cavopulmonary anastomosis in this study included the presence of mitral regurgitation and palliation with systemic-to-pulmonary artery shunts not originating from the innominate artery. Factors associated with decreased transition rate to cavopulmonary anastomosis included patient variables (younger age at admission to a participating institution and noncardiac anomalies) and procedural variables (larger systemic-to-pulmonary arterial shunt diameter and previous palliation).⁹⁹

Hypoplastic Left Heart Syndrome

HLHS comprises a wide spectrum of cardiac malformations, including hypoplasia or atresia of the aortic and mitral valves and hypoplasia of the LV and ascending aorta.¹⁰⁰ HLHS has a reported prevalence of 0.2 per 1000 live births and occurs twice as often in boys as in girls. Left untreated, HLHS is invariably fatal and is responsible for 25% of early cardiac deaths in neonates.¹⁰¹ However, the recent evolution of palliative surgical procedures has dramatically improved the outlook for patients with HLHS, and an improved understanding of anatomic and physiologic alterations has spurred advances in parallel arenas such as intrauterine diagnosis and fetal intervention, echocardiographic imaging, and neonatal critical care.

Anatomy. As implied by its name, HLHS involves varying degrees of underdevelopment of left-sided structures, including the LV and the aortic and mitral valves. Thus, HLHS can be classified into four anatomic subtypes based on the valvular morphology: (a) aortic and mitral stenosis; (b) aortic and mitral atresia; (c) aortic atresia and mitral stenosis; and (d) AS and mitral atresia. Aortic atresia tends to be associated with more severe degrees of hypoplasia of the ascending aorta than does AS.

Even in cases without frank aortic atresia, however, the aortic arch is generally hypoplastic and, in severe cases, may even be interrupted. There is an associated coarctation shelf in 80% of patients with HLHS, and the ductus itself is usually quite large, as is the main pulmonary artery.⁷ The segmental pulmonary arteries, however, are small, secondary to reduced intrauterine pulmonary blood flow, which is itself a consequence of the left-sided outflow obstruction. The left atrial cavity is generally smaller than normal and is accentuated because of the leftward displacement of the septum primum. There is almost always an interatrial communication via the foramen ovale, which can be large, but more commonly restricts right-to-left flow. In rare cases, there is no atrial-level communication, which can be lethal for these infants because there is no way for pulmonary venous return to cross over to the RV.

Associated defects can occur with HLHS, and many of them have importance with respect to operative repair. For example, if a VSD is present, the LV can retain its normal size during development even in the presence of mitral atresia. This is because a right-to-left shunt through the defect impels growth of the LV.¹⁰² This introduces the feasibility of biventricular repair for this subset of patients.

Although HLHS undoubtedly results from a complex interplay of developmental errors in the early stages of cardiogenesis, many investigators have hypothesized that the altered blood flow is responsible for the structural underdevelopment that characterizes HLHS. In other words, if the stimulus for normal development of the ascending aorta from the primordial aortic sac is high-pressure systemic blood flow from the LV

through the aortic valve, then an atretic or stenotic aortic valve, which impedes flow and leads to only low-pressure diastolic retrograde flow via the ductus, will change the developmental signals and result in hypoplasia of the downstream structures. Normal growth and development of the LV and mitral valve can be secondarily affected, resulting in hypoplasia or atresia of these structures.¹⁰⁰

Pathophysiology and Diagnosis. In HLHS, pulmonary venous blood enters the left atrium, but atrial systole cannot propel blood across the stenotic or atretic mitral valve into the LV. Thus, the blood is shunted across the foramen ovale into the right atrium, where it contributes to volume loading of the RV. The end result is pulmonary venous hypertension from outflow obstruction at the level of the left atrium, as well as pulmonary overcirculation and right ventricular failure. As the pulmonary vascular resistance falls postnatally, the condition is exacerbated because right ventricular output is preferentially directed away from the systemic circulation, resulting in profound underperfusion of the coronary arteries and the vital organs. Closure of the ductus is incompatible with life in these neonates.

Neonates with severe HLHS receive all pulmonary, systemic, and coronary blood flow from the RV. Generally, a child with HLHS will present with respiratory distress within the first day of life, and mild cyanosis may be noted. These infants must be rapidly triaged to a tertiary center, and echocardiography should be performed to confirm the diagnosis. Prostaglandin E₁ must be administered to maintain ductal patency, and the ventilatory settings must be adjusted to avoid excessive oxygenation and increase carbon dioxide tension. These maneuvers will maintain pulmonary vascular resistance and promote improved systemic perfusion.^{2,7,100} Cardiac catheterization should generally be avoided because it is not usually helpful and might result in injury to the ductus and compromised renal function secondary to the osmotic dye load.

Treatment. In 1983, Norwood and colleagues described a two-stage palliative surgical procedure for relief of HLHS¹⁰³ that was later modified to the currently used three-stage method of palliation.¹⁰⁴ Stage 1 palliation, also known as the modified Norwood procedure, bypasses the LV by creating a single outflow vessel, the neo-aorta, which arises from the RV.

The current technique of arch reconstruction involves completion of a connection between the pulmonary root, the native ascending aorta, and a piece of pulmonary homograft used to augment the diminutive native aorta. There are several modifications of this anastomosis, most notably the Damus-Kaye-Stansel (DKS) anastomosis, which involves dividing both the aorta and the pulmonary artery at the sinotubular junction. The proximal aorta is anastomosed to the proximal pulmonary artery, creating a “double-barreled” outlet from the heart. This outlet is anastomosed to the distal aorta, which can be augmented with homograft material if there is an associated coarctation. At the completion of arch reconstruction, a 3.5- or 4-mm shunt is placed from the innominate artery to the right pulmonary artery. The interatrial septum is then widely excised, thereby creating a large interatrial communication and preventing pulmonary venous hypertension (Fig. 20-21).

The DKS connection, as described earlier, might avoid postoperative distortion of the tripartite connection in the neo-aorta, and thus decrease the risk of coronary insufficiency.¹⁰⁵ It can be used when the aorta is 4 mm or larger. Unfortunately, in

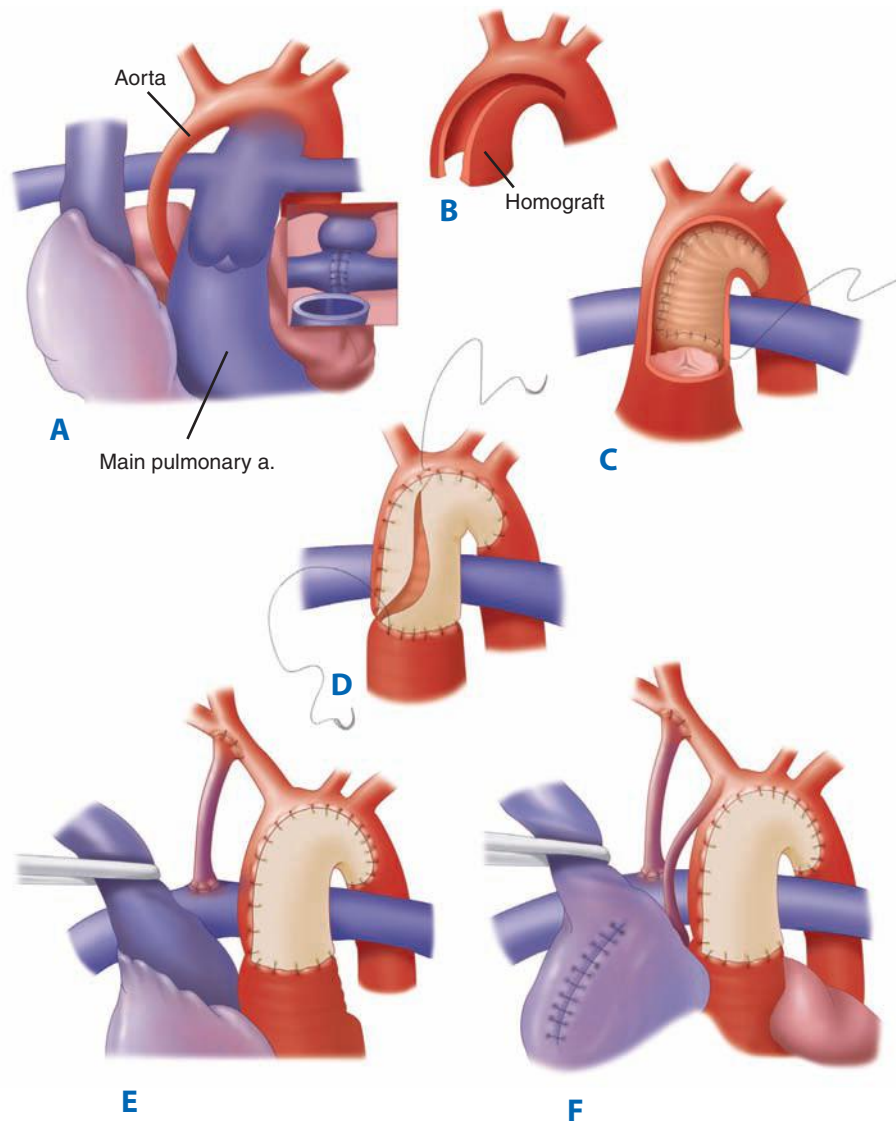


Figure 20-21. Current techniques for first-stage palliation of the hypoplastic left-heart syndrome. **A.** Incisions used for the procedure, incorporating a cuff of arterial wall allograft. The distal divided main pulmonary artery may be closed by direct suture or with a patch. **B.** Dimensions of the cuff of the arterial wall allograft. **C.** The arterial wall allograft is used to supplement the anastomosis between the proximal divided main pulmonary artery and the ascending aorta, aortic arch, and proximal descending aorta. **D** and **E.** The procedure is completed by atrial septectomy and a 3- to 5-mm modified right Blalock shunt. **F.** When the ascending aorta is particularly small, an alternative procedure involves placement of a complete tube of arterial allograft. The tiny ascending aorta may be left in situ, as indicated, or implanted into the side of the neo-aorta. a. = artery. (From Castaneda AR, Jonas RA, Mayer JE, et al. *Cardiac Surgery of the Neonate and Infant*. Philadelphia: W.B. Saunders; 1994:371, with permission. Copyright Elsevier.)

many infants with HLHS, especially if there is aortic atresia, the aorta is diminutive and often less than 2 mm in diameter.

The postoperative management of infants following stage 1 palliation is complex because favorable outcomes depend on establishing a delicate balance between pulmonary and systemic perfusion. Recent literature suggests that these infants require adequate postoperative cardiac output in order to supply both the pulmonary and the systemic circulations and that the use of oximetric catheters to monitor mixed venous oxygen saturation (SvO_2) aids clinicians in both the selection of inotropic agents and in ventilatory management.¹⁰⁶ Recent introduction of a modification that includes arch reconstruction and placement of the shunt between the RV and the pulmonary artery (Sano shunt) diminishes the diastolic flow created by the classical B-T shunt and may augment coronary perfusion, resulting in improved postoperative cardiac function. A recent prospective, randomized,

multi-institutional trial sponsored by the National Institutes of Health, the Systemic Ventricle Reconstruction (SVR) trial, compared the outcomes of neonates having either a modified B-T shunt vs. a Sano shunt.¹⁰⁷ The SVR trial demonstrated that transplantation-free survival 12 months after randomization was higher with the Sano shunt than with the modified B-T shunt (74% vs. 64%, $P = .01$). However, the Sano shunt group had more unintended interventions ($P = .003$) and complications ($P = .002$). Right ventricular size and function at the age of 14 months and the rate of nonfatal serious adverse events at the age of 12 months were similar in the two groups. Data collected over a mean (\pm standard deviation) follow-up period of 32 ± 11 months showed a nonsignificant difference in transplantation-free survival between the two groups ($P = .06$).¹⁰⁷

Although surgical palliation with the Norwood procedure is still the mainstay of therapy for infants with HLHS,

a combined surgical and percutaneous option (hybrid procedure), which consists of bilateral pulmonary artery banding and placement of a ductal stent, has emerged as a promising alternative that obviates the need for CPB in the fragile neonatal period.^{108,109} The hybrid procedure is performed in a “hybrid suite,” incorporating both advanced fluoroscopic imaging facilities combined with complete operating room capabilities. A 3- or 3.5-mm PTFE tube graft is cut to a width of 3 to 4 mm and used as the bands on the branch pulmonary arteries, placed just distal to the main pulmonary artery. The ductal stent is then positioned in order to cover all ductal tissue and is deployed through a purse-string suture in the main pulmonary artery. A reverse systemic-to-pulmonary shunt is considered in patients with aortic atresia and preductal coarctation to improve coronary perfusion; however, a recent study demonstrated no difference in survival between those with and without the shunt.¹¹⁰ The hybrid procedure can also be used as a bridge to heart transplantation in those infants with severe AV valve regurgitation or otherwise unsuitable single-ventricle anatomy.

Following stage 1 palliation, the second surgical procedure is the creation of a bidirectional cavopulmonary shunt or hemi-Fontan, generally at 3 to 6 months of life when the pulmonary vascular resistance has decreased to normal levels. This is the first step in separating the pulmonary and systemic circulations, and it decreases the volume load on the single ventricle. The existing innominate artery-to-pulmonary shunt (or RV-to-pulmonary shunt) is eliminated during the same operation (Fig. 20-22).

The third stage of surgical palliation, known as the modified Fontan procedure, completes the separation of the systemic

and pulmonary circulations and is performed between 18 months and 3 years of age, or when the patient experiences increased cyanosis (i.e., has outgrown the capacity to perfuse the systemic circulation with adequately oxygenated blood). This has traditionally required a lateral tunnel within the right atrium to direct blood from the inferior vena cava to the pulmonary artery, allowing further relief of the volume load on the RV and providing increased pulmonary blood flow to alleviate cyanosis. More recently, many favor using an extracardiac conduit (e.g., 20-mm tube graft) to connect the inferior vena cava to the pulmonary artery.

Not all patients with HLHS require this three-stage palliative repair. Some infants afflicted with a milder form of HLHS, recently described as hypoplastic left heart complex (HLHC), have aortic or mitral hypoplasia without intrinsic valve stenosis and antegrade flow in the ascending aorta. In this group, a two-ventricle repair can be achieved with reasonable outcome. Tchervenkov recently published the results with 12 patients with HLHC who underwent biventricular repair at a mean age of 7 days.¹⁰⁶ The operative technique consisted of a pulmonary homograft patch aortoplasty of the aortic arch and ascending aorta and closure of the interatrial and interventricular communications. The left heart was capable of sustaining systemic perfusion in 92% of patients, and early mortality was 15.4%. Four patients required reoperations to relieve LVOT obstruction, most commonly between 12 and 39 months following repair.

Although the Norwood procedure is the most widely performed initial operation for HLHS, transplantation can be used as a first-line therapy and may be preferred when anatomic or physiologic considerations exist that preclude a

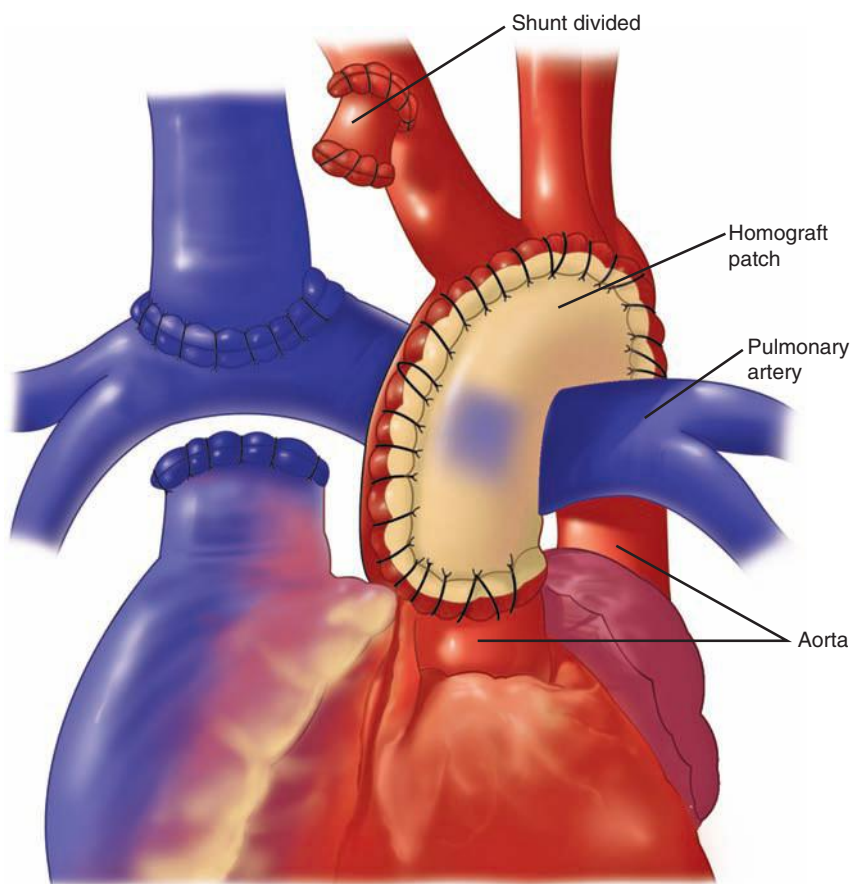


Figure 20-22. Technique of a bidirectional Glenn shunt. The divided right superior vena cava has been anastomosed at the previous site of the distal anastomosis of the modified right Blalock shunt. The cardiac end of the divided superior vena cava may also be anastomosed to the right pulmonary artery, with the internal orifice being closed with a Gore-Tex patch. (From Castaneda AR, Jonas RA, Mayer JE, et al. *Cardiac Surgery of the Neonate and Infant*. Philadelphia: W.B. Saunders; 1994:376, with permission. Copyright Elsevier.)

favorable outcome with palliative repair. Significant tricuspid regurgitation, intractable pulmonary artery hypertension, or progressive right ventricular failure are cases where cardiac replacement may be advantageous. Widespread adaptation of transplantation as first-line treatment for HLHS has been limited by improved Norwood survival rates as the operation and pre- and postoperative management of the patient have evolved and by limited organ availability. Organ availability should be considered prior to electing transplantation, as 24% of infants died awaiting transplantation in the largest series to date.^{111,112}

Results. Outcomes for HLHS are still significantly worse than those for other complex cardiac defects. However, with improvements in perioperative care and modifications in surgical technique, the survival following the Norwood procedure now exceeds 80% in experienced centers.^{100,105,107,109} The outcome for low-birth-weight infants has improved, but low weight still remains a major predictor of adverse survival, especially when accompanied by additional cardiac defects, such as systemic outflow obstruction or extracardiac anomalies.

DEFECTS THAT MAY BE PALLIATED OR REPAIRED

Ebstein's Anomaly

Anatomy. This is a rare defect, occurring in less than 1% of CHD patients. The predominant maldevelopment in this lesion is the inferior displacement of the tricuspid valve into the RV, although Bove¹¹³ and others have emphasized the fact that Ebstein's anomaly is primarily a defect in right ventricular morphology rather than an isolated defect in the tricuspid valve. The anterior leaflet is usually attached in its normal position to the annulus, but the septal and posterior leaflets are displaced toward the ventricle. This effectively divides the RV into two parts: the inlet portion (atrialized RV) and the outlet portion (true or trabeculated RV). The atrialized RV is usually thin and dilated. Similarly, the tricuspid annulus and the right atrium are extremely dilated, and the tricuspid valve is usually regurgitant with a "sail-like" leaflet. There is commonly an ASD present, which results in a right-to-left shunt at the atrial level. Occasionally, there is true anatomic pulmonary atresia or milder forms of RVOT obstruction.

A Wolff-Parkinson-White syndrome type of accessory pathway with associated pre-excitation is present in 15% of patients.¹¹³

Pathophysiology. Right ventricular dysfunction occurs in patients with Ebstein's anomaly because of two basic mechanisms: the inflow obstruction at the level of the atrialized ventricle, which produces ineffective RV filling and contractile dysfunction. Inflow obstruction and tricuspid regurgitation, which is exacerbated by progressive annular dilatation, both produce ineffective RV filling. Contractile dysfunction of the RV is a result of a decrease in the number of myocardial fibers, as well as the discordant contraction of the large atrialized portion.

The lack of forward flow at the right ventricular level may lead to physiologic or functional pulmonary atresia, and the infant is dependent on ductal patency for survival. All systemic venous return must be directed through an ASD to

the left atrium, where it can be shunted through the ductus for gas exchange. However, the left ventricular function is usually compromised in infants with severe Ebstein's anomaly as well, because the enormous RV and the to-and-fro flow within the atrialized RV prevent adequate intracardiac mixing. Left ventricular function may also be severely compromised in Ebstein's anomaly because the large RV causes left ventricular compression.

Diagnosis. There is a spectrum of clinical presentation in infants with Ebstein's anomaly that mirrors the anatomic spectrum of this anomaly. Some infants with less severe forms may present with a mild degree of cyanosis, whereas the onset of clinical symptoms in patients surviving childhood is gradual, with the average age of diagnosis in the mid-teens.

However, the infant with severe atrialization and pulmonary stenosis will be both cyanotic and acidotic at birth. The chest radiograph may demonstrate the classic appearance, which consists of a globular "wall-to-wall" heart, similar to that seen with pericardial effusion. The ECG may show right bundle-branch block and right axis deviation. Wolff-Parkinson-White (WPW) syndrome, as mentioned earlier, is a common finding in these patients. Echocardiography will confirm the diagnosis and provide critical information including tricuspid valvular function, size of the atrialized portion of the RV, degree of pulmonary stenosis, and the atrial size.^{6,113}

The Great Ormond Street Score (GOSE),¹¹⁴ which consists of the area of the right atrium plus the area of the atrialized portion of the RV divided by the diastolic area of the remaining cardiac chambers, has been proposed as a useful prognostic tool to stratify neonates with Ebstein's anomaly. A score of greater than 1 translates into uniformly fatal outcome. Electrophysiology study with radiofrequency ablation is indicated in patients with evidence of WPW syndrome or in children with a history of supraventricular tachycardia, undefined wide-complex tachycardia, or syncope.

Treatment. Surgery is indicated for symptomatic infants and for older children and adults with arrhythmias, progressive cyanosis, or New York Heart Association class III or IV. However, the operative repair may be different, depending on the patient's age, because older children usually are candidates for a biventricular or one-and-a-half ventricle repair, whereas moderate survival has been reported for neonates, using a procedure that converts the anatomy to a single-ventricle physiology, as described by Starnes and coworkers.¹¹⁵

The surgical approach in widespread use today for patients surviving infancy was described by Danielson and colleagues in 1992.^{6,113,116} This procedure entails excision of redundant right atrial tissue and patch closure of any associated ASD, plication of the atrialized portion of the ventricle with obliteration of the aneurysmal cavity, posterior tricuspid annuloplasty to narrow the tricuspid annulus, reconstruction of the tricuspid valve if the anterior leaflet is satisfactory, or replacement of the tricuspid valve if necessary.¹¹⁶ If the tricuspid valve is not amenable to reconstruction, valve replacement should be considered. Care must be taken when performing the posterior annuloplasty, or during the conduct of tricuspid valve replacement, to avoid the conduction system, because complete heart block can complicate this procedure. In addition, patients who demonstrated preoperative evidence of pre-excitation should undergo electrophysiologic mapping and ablation.

Neonatal Ebstein's anomaly is a separate entity. Results with surgical correction have been poor, and many neonates are not candidates for operative repair as previously described. Surgical options for the symptomatic neonate include palliative procedures, the one-and-a-half ventricle repair, or conversion to single-ventricle physiology.^{1,7,117} Arguably, the most favorable outcomes in symptomatic neonatal Ebstein's anomaly or repair in slightly older infants have been achieved using the right ventricular exclusion premise. This technique, known as the "Starnes" procedure,¹¹⁵ uses a fenestrated patch to close the tricuspid valve orifice coupled with systemic-to-pulmonary artery shunt. The patch must be fenestrated to allow decompression of the RV in instances of anatomic pulmonary atresia. Although Knott-Craig and colleagues¹¹⁷ have described tricuspid valve repair for the full spectrum of neonates and infants with excellent short- and mid-term results, these results have not been reproduced in other institutions.¹¹⁸ The one-and-a-half ventricle repair was first described by Billingsly and coworkers as an attempt to achieve a more physiologic "pulsatile" pulmonary circulation in patients with a hypoplastic or dysplastic RV.¹¹⁹ This is accomplished by diverting the superior vena caval blood directly into the pulmonary arterial system by a bidirectional cavopulmonary shunt while recruiting the RV to propel the inferior vena caval blood directly to the pulmonary arteries via the RVOT. Thus the hemodynamics of the one-and-a-half ventricle repair are characterized by separate systemic and pulmonary circulations in series. The systemic circulation is fully supported by a systemic ventricle, and the pulmonary circulation is supported by both the bidirectional Glenn shunt and the hypoplastic (pulmonary) ventricle. Proponents of this approach report a decreased right atrial pressure and a decrease in inferior vena cava hypertension, which is theorized to be responsible for many of the dreaded complications of the Fontan circulation, including protein-losing encephalopathy, hepatic congestion, atrial arrhythmias, and systemic ventricular failure. In addition, the maintenance of pulsatile pulmonary blood flow, as opposed to continuous laminar flow as in the Fontan circulation, may be advantageous to the pulmonary microcirculation, although it has not been proven in any studies thus far.^{119,120} Certain criteria, most notably an adequate tricuspid valve Z score, as well as the absence of severe pulmonary hypertension or concomitant defects requiring intricate intracardiac repair, should be satisfied prior to electing the one-and-a-half ventricle approach.¹²¹ Patients who do not fulfill these criteria may be approached with a two-ventricle repair and atrial fenestration or a Fontan repair.

In the infant with severe Ebstein's anomaly, initial stabilization with prostaglandin to maintain ductal patency, mechanical ventilation, and correction of cyanosis is mandatory. Metabolic acidosis, if present from compromised systemic perfusion, must be aggressively treated with afterload reduction. Many of these infants will improve over 1 to 2 weeks as pulmonary vascular resistance falls and they are able to improve antegrade flow into the pulmonary circulation through their abnormal RV and tricuspid valve. When stabilization and medical palliation fail, surgical management remains an option, although its success depends on numerous anatomic factors (e.g., adequacy of the tricuspid valve, RV and pulmonary outflow tract), and surgery for symptomatic neonates with Ebstein's anomaly carries a high risk. Recently, Knott-Craig and associates reported three cases where two-ventricle repair was undertaken by subtotal closure of the ASD, extensive resection of the right atrium, and vertical plication of the atrialized chamber.¹¹⁷ Five-year follow-up

revealed all patients to be asymptomatic and in sinus rhythm without medications.

Results. In the neonatal period, the most common postoperative problem, whether after a simple palliative procedure such as a B-T shunt or following a more extensive procedure such as attempted exclusion of the RV, has been low cardiac output. Supraventricular tachycardia also has been problematic postoperatively. Complete heart blockage necessitating pacemaker implantation should be uncommon if the techniques described to avoid suturing between the coronary sinus and the tricuspid annulus are used.

There are few published reports of outcomes, due to the rarity of this defect. However, based on the natural history of this condition, which is remarkably benign for the majority of older patients, the outlook should be excellent for patients who have survived ASD closure, plication, and tricuspid annuloplasty.^{7,112,116,117}

Transposition of the Great Arteries

Anatomy. Complete transposition is characterized by connection of the atria to their appropriate ventricles with inappropriate ventriculoarterial connections. Thus, the aorta arises anteriorly from the RV, while the pulmonary artery arises posteriorly from the LV. Van Praagh and coworkers introduced the term D-transposition of the great arteries (D-TGA) to describe this defect, whereas L-TGA describes a form of corrected transposition where there is concomitant AV discordance.^{122,123}

D-TGA requires an obligatory intracardiac mixing of blood, which usually occurs at both the atrial and the ventricular levels or via a patent ductus. Significant coronary anomalies occur frequently in patients with D-TGA.⁷ The most common pattern, occurring in 68% of cases, is characterized by the left main coronary artery arising from the leftward coronary sinus, giving rise to the left anterior descending and circumflex arteries. The most common variant is for the circumflex coronary artery to arise as a branch from the right coronary artery instead of from the left coronary artery.

Pathophysiology. D-TGA results in parallel pulmonary and systemic circulations, with patient survival dependent on intracardiac mixing of blood. After birth, both ventricles are relatively noncompliant, and thus, infants initially have higher pulmonary flow due to the decreased downstream resistance. This causes left atrial enlargement and a left-to-right shunt via the patent foramen ovale.

Postnatally, the LV does not hypertrophy because it is not subjected to systemic afterload. The lack of normal extrauterine left ventricular maturation has important implications for the timing of surgical repair because the LV must be converted to the systemic ventricle and be able to function against systemic vascular resistance. If complete repair is done within the first few weeks of life, the LV usually adapts easily to systemic resistance since it is conditioned to high intrauterine pulmonary vascular resistance. After a few weeks of life, the LV that is conditioned to the decrease in pulmonary resistance that occurs when the lungs inflate after birth may have difficulty adapting to systemic vascular resistance without preoperative preparation or postoperative support. Novel techniques of LV "preparation" using a pulmonary arterial band have been used in cases where complete repair has been delayed.

Clinical Manifestations and Diagnosis. Infants with D-TGA and an intact ventricular septum are usually cyanotic

at birth, with an arterial Po_2 between 25 and 40 mmHg. If ductal patency is not maintained, deterioration will be rapid with ensuing metabolic acidosis and death. Conversely, those infants with a coexisting VSD may be only mildly hypoxemic and may come to medical attention after 2 to 3 weeks, when the falling pulmonary vascular resistance leads to symptoms of congestive heart failure.

The ECG will reveal right ventricular hypertrophy, and the chest radiograph will reveal the classic egg-shaped configuration. Definitive diagnosis is made by echocardiography, which reliably demonstrates ventriculoarterial discordance and any associated lesions. Cardiac catheterization is rarely necessary, except in infants requiring surgery after the neonatal period to assess the suitability of the LV to support the systemic circulation. Limited catheterization, however, is useful for performance of atrial septostomy in neonates with inadequate intracardiac mixing.

Surgical Repair. Blalock and Hanlon introduced the first operative intervention for D-TGA with the creation of an atrial septectomy to enhance intracardiac mixing.¹²⁴ This initial procedure was feasible in the pre-CPB era, but carried a high mortality rate. Later, Rashkind and Causo developed a catheter-based balloon septostomy, which largely obviated the need for open septectomy.⁴²

These early palliative maneuvers, however, met with limited success, and it was not until the late 1950s, when Senning and Mustard developed the first “atrial repair,” that outcomes improved. The Senning operation consisted of rerouting venous flow at the atrial level by incising and realigning the atrial septum over the pulmonary veins and using the right atrial free wall to create a pulmonary venous baffle (Fig. 20-23).¹²⁵

Although the Mustard repair was similar, it made use of either autologous pericardium or synthetic material to create the interatrial baffle.¹²⁶ These atrial switch procedures resulted in a physiologic correction, but not an anatomic one, as the systemic circulation is still based on the RV. Still, survival rose to 95% in most centers by using an early balloon septostomy followed by an atrial switch procedure at 3 to 8 months of age.^{125,126}

Despite the improved early survival rates, long-term problems, such as superior vena cava or pulmonary venous obstruction, baffle leak, arrhythmias, tricuspid valve regurgitation, and right ventricular failure, prompted the development of the arterial switch procedure by Jatene in 1975.¹²⁷ The arterial switch procedure involves the division of the aorta and the pulmonary artery, posterior translocation of the aorta (LeCompte maneuver), mobilization of the coronary arteries, placement of a pantaloons-shaped pericardial patch, and proper alignment of the coronary arteries on the neo-aorta (Fig. 20-24).

The most important consideration is the timing of surgical repair, because arterial switch should be performed within 2 weeks after birth, before the LV loses its ability to pump against systemic afterload.^{2,4,7} In patients presenting later than 2 weeks, the LV can be retrained with preliminary pulmonary artery banding and aortopulmonary shunt followed by definitive repair. Alternatively, the unprepared LV can be supported following arterial switch with a mechanical assist device for a few days while it recovers ability to manage systemic pressures. Echocardiography can be used to assess left ventricular performance and guide operative planning in these circumstances.

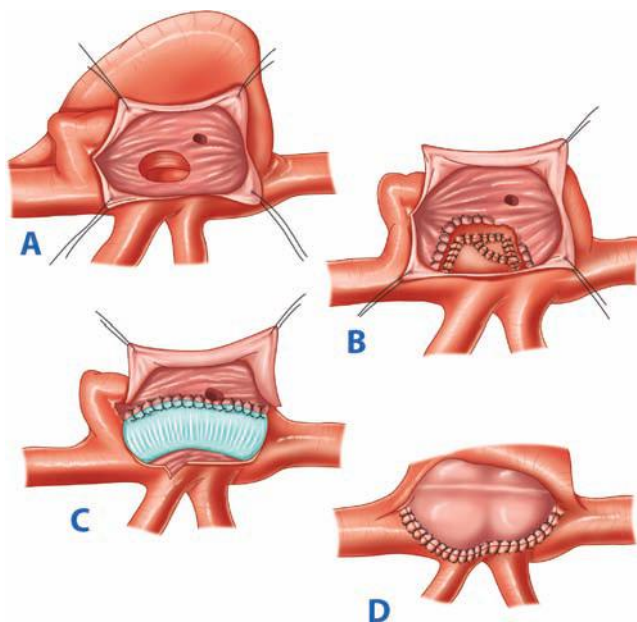


Figure 20-23. The Senning operation. **A.** The atrial septum is cut near the tricuspid valve, creating a flap attached posteriorly between the caval veins. **B.** The flap of atrial septum is sutured to the anterior lip of the orifices of the left pulmonary veins, effectively separating the pulmonary and systemic venous channels. **C.** The posterior edge of the right atrial incision is sutured to the remnant of the atrial septum, diverting the systemic venous channel to the mitral valve. **D.** The anterior edge of the right atrial incision (lengthened by short incisions at each corner) is sutured around the cava above and below to the lateral edge of the LA incision, completing the pulmonary channel and diversion of pulmonary venous blood to the tricuspid valve area. (Reproduced with permission from *D-Transposition of the great arteries*. In: Mavroudis C, Backer CL, eds. *Pediatric Cardiac Surgery*. 2nd ed. St. Louis: Mosby; 1994:345.)

The subset of patients who present with D-TGA complicated by LVOT obstruction and VSD may not be suitable for an arterial switch operation. The Rastelli operation, first performed in 1968, uses placement of an intracardiac baffle to direct left ventricular blood to the aorta and an extracardiac valved conduit to establish continuity between the RV and the pulmonary artery, which has led to successful outcomes in these complex patients.¹²⁸

Results. For patients with D-TGA, intact ventricular septum, and VSD, the arterial switch operation provides excellent long-term results with a mortality rate of less than 5%. Operative risk is increased when unfavorable coronary anatomic configurations are present or when augmentation of the aortic arch is required. The most common complication is supravalvular pulmonary stenosis, occurring 10% of the time, which may require reoperation.^{4,7,129}

Results of the Rastelli operation have improved substantially, with an early mortality rate of 5% in a 2001 review.¹³⁰ Late mortality rate results were less favorable because conduit failure requiring reoperation, pacemaker insertion, or relief of LVOT obstruction was frequent.

Double-Outlet Right Ventricle

Anatomy. Double-outlet RV (DORV) accounts for 5% of CHD and exists when both the aorta and pulmonary artery arise wholly, or in large part, from the RV. DORV encompasses a spectrum of malformations, because the incomplete shift of the

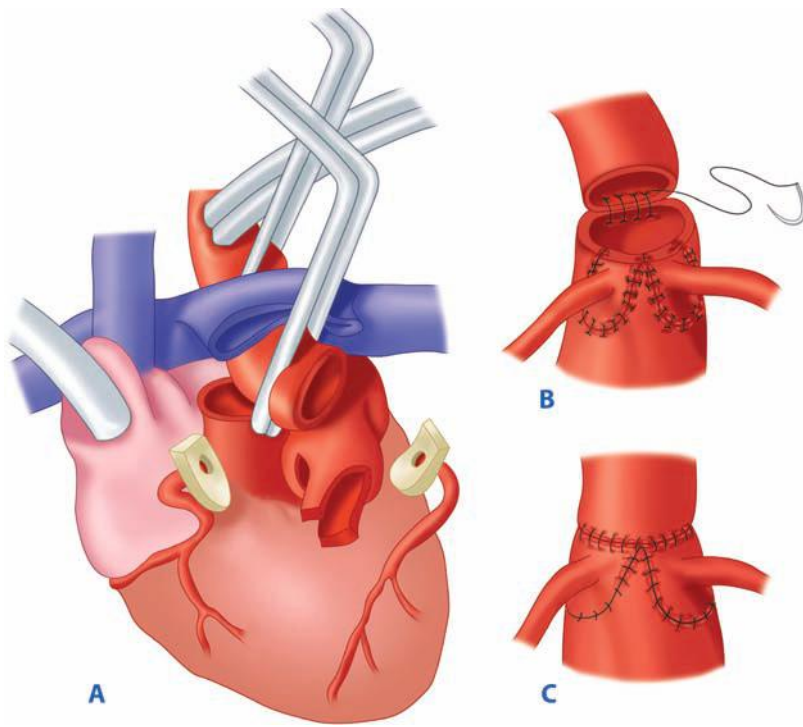


Figure 20-24. A. The maneuver of Lecompte (positioning the pulmonary artery anterior to the aorta) is shown with aortic cross-clamp repositioning to retract the pulmonary artery during the neo-aortic reconstruction. **A** and **B**. After the coronary patches are rotated for an optimal lie, they are sutured to the linearly incised sinuses of Valsalva at the old pulmonary artery (neo-aorta) (**C**). (Reproduced with permission from Backer CL, Idriss FS, Mavroudis C. *Surgical techniques and intraoperative judgments to facilitate the arterial switch operation in transposition with intact ventricular septum*. In: Mavroudis C, Backer CL, eds. *Arterial Switch. Cardiac Surgery: State of the Art Review*. Vol. 5, no. 1. Philadelphia: Hanley & Belfus; 1991:108. Copyright Elsevier.)

aorta toward the LV is often associated with other abnormalities of cardiac development, such as ventricular looping and infundibular-truncal spiraling.¹³¹ The vast majority of hearts exhibiting DORV have a concomitant VSD, which varies in its size and spatial association with the great vessels. The VSD is usually nonrestrictive and represents the only outflow for the LV; its location relative to the great vessels dictates the dominant physiology of DORV, which can be analogous to that of a large isolated VSD, tetralogy of Fallot, or D-TGA. Lev et al, in 1972,¹³² suggested considering DORV as a spectrum of hearts that “pass imperceptibly from tetralogy with VSD with overriding aorta into double-outlet right ventricle with subaortic VSD.” Thus, Lev and colleagues described a classification scheme for DORV based on the “commitment” of the VSD to either or both great arteries.^{7,132} The VSD can be subaortic, doubly committed, noncommitted, or subpulmonic.

The subaortic type is the most common (50%) and occurs when the VSD is located directly beneath the aortic annulus. Doubly committed VSD (10%) is present when the VSD lies beneath both the aorta and the pulmonary artery, which are usually side-by-side in this lesion. The noncommitted VSD (10%–20%) exists when the VSD is remote from the great vessels. The subset of DORV hearts with the VSD located beneath the pulmonary valve also are classified as the Taussig-Bing syndrome.¹³³ This occurs in 30% of cases of DORV with VSD, and it occurs when the aorta rotates more anteriorly, with the pulmonary artery rotated more posteriorly (Fig. 20-25).

Clinical Manifestations and Diagnosis. Patients with DORV typically present with one of the following three scenarios: (a) those with doubly committed or subaortic VSD present with congestive heart failure and a high propensity for pulmonary hypertension, much like infants with a large single VSD; (b) those with a subaortic VSD and pulmonary stenosis present with cyanosis and hypoxia, much like infants with tetralogy of Fallot; and (c) those with subpulmonic VSD present

with cyanosis, much like those with D-TGA, because streaming directs desaturated systemic venous blood to the aorta and oxygenated blood to the pulmonary artery.¹³¹ Thus, the three critical factors influencing the clinical presentation and subsequent management of infants with DORV are the size and location of the VSD, the presence or absence of important RVOT obstruction, and the presence of other anomalies (especially associated hypoplasia of left-sided structures sometimes seen with subpulmonary VSD).

Echocardiography is the mainstay of diagnosis and can also provide valuable information regarding the feasibility of biventricular repair. Specific anatomic questions that should be resolved to assist in surgical planning in addition to those mentioned earlier include the coronary anatomy (presence of a conal branch or left anterior descending from the right coronary coursing across the conus), the presence of additional muscular VSDs remote from either great vessel, and the distance between the tricuspid and pulmonary valve. Cardiac catheterization is rarely necessary in neonates or infants, except to determine the degree of pulmonary hypertension and to determine the effects of previous palliative procedures on the pulmonary arterial anatomy.

Therapy. The goals of corrective surgery are to relieve pulmonary stenosis, to provide separate and unobstructed outflow pathways from each ventricle to the correct great vessel, and to achieve separation of the systemic and pulmonary circulations.

Double-Outlet Right Ventricle with Noncommitted Ventricular Septal Defect

The repair of hearts with DORV and noncommitted VSD can be accomplished by constructing an intraventricular tunnel connecting the VSD to the aorta, closing the pulmonary artery, and placing a valved extracardiac conduit from the RV to the pulmonary artery. In patients without pulmonary stenosis who

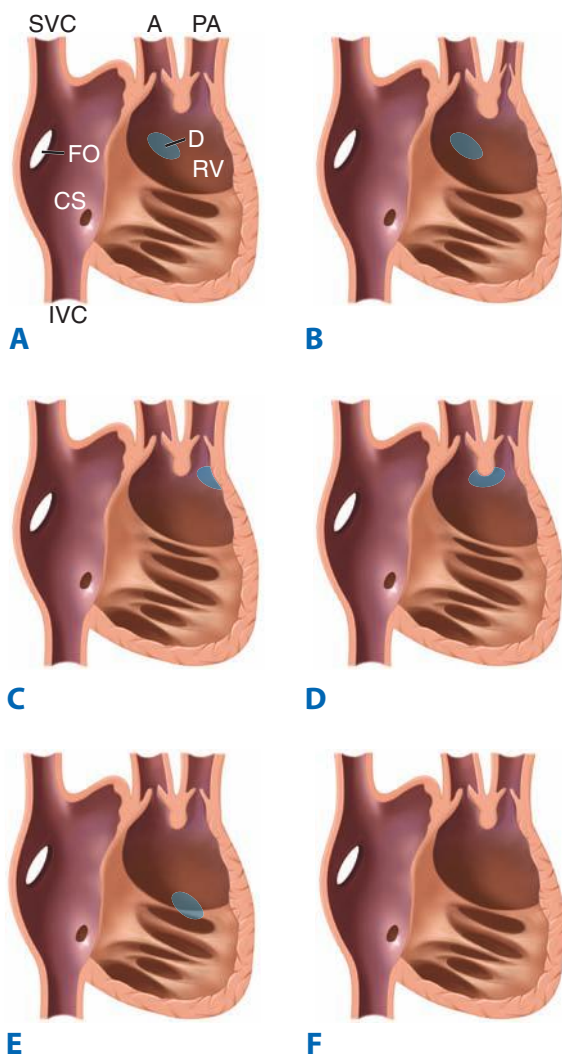


Figure 20-25. The relationship of the ventricular septal defect (VSD) to the great arteries in double-outlet right ventricle (DORV). **A.** Subaortic VSD without pulmonary stenosis. **B.** Subaortic VSD with pulmonary stenosis. **C.** Subpulmonary VSD (Taussig-Bing malformation). **D.** Doubly committed VSD. **E.** Noncommitted (remote) VSD. **F.** Intact interventricular septum. A = aorta; CS = coronary sinus; D = ventricular septal defect; FO = foramen ovale; IVC = inferior vena cava; PA = pulmonary artery; RV = right ventricle; SVC = superior vena cava. (Adapted with permission from Zamora R, Moller JH, Edwards JE. Double-outlet right ventricle. *Chest*. 1975;68:672.)

have intractable congestive failure, a pulmonary artery band can be placed in the first 6 months to control pulmonary artery overcirculation and prevent the development of pulmonary hypertension.

Infants with pulmonary stenosis can be managed with a systemic-to-pulmonary shunt followed by biventricular repair as described by Belli and colleagues in 1999, or with a modified Fontan.¹³⁴ There is no consensus on the timing of repair, but recent literature suggests that repair within the first 6 months is associated with better outcome. However, in cases where an extracardiac valved conduit is necessary, it is better to delay definitive repair until the child is 2 to 3 years of age, because this allows placement of a larger conduit and possibly reduces the number of future obligatory conduit replacements.^{7,131}

Double-Outlet Right Ventricle with Subaortic or Doubly Committed Ventricular Septal Defect Without Pulmonary Stenosis

This group of patients can be treated by creating an intracardiac baffle that directs blood from the LV into the aorta. Enlargement of the VSD may be necessary to allow ample room for the baffle; this should be done anterosuperiorly to avoid injury to the conduction system that normally lies inferoposteriorly along the border of the VSD. In addition, other important considerations in constructing the LV outflow tunnel include the prominence of the conal septum, the attachments of the tricuspid valve to the conal septum, and the distance between the tricuspid and pulmonary valves. In some instances, unfavorable anatomy may preclude placement of an adequate intracardiac baffle, necessitating single ventricle repair.

Double-Outlet Right Ventricle with Subaortic or Doubly Committed Ventricular Septal Defect with Pulmonary Stenosis

Repair of this defect is similar to the above except that concomitant RVOT reconstruction must be performed in addition to the intracardiac tunnel. The RVOT augmentation can be accomplished with the placement of a transannular patch or with placement of an extracardiac valved conduit when an anomalous left anterior descending artery precludes use of a patch.

Taussig-Bing Syndrome without Pulmonary Stenosis

These infants are best treated with a balloon septostomy during the neonatal period to improve mixing, followed by VSD closure baffling LV egress to the pulmonary artery and an arterial switch operation. The Kawashima procedure,¹³⁵ in which an intraventricular tunnel is used to baffle LV egress directly to the aorta, may alternatively be used when the aorta is more posterior or when there is associated pulmonary stenosis.

Taussig-Bing Syndrome with Pulmonary Stenosis

This defect may be treated with a variety of techniques, depending on the specific anatomic details and the expertise of the treatment team. A Rastelli-type repair, which involves construction of an intraventricular tunnel through the existing VSD that connects the LV to both great vessels, followed by division of the pulmonary artery at its origin and insertion of a valved conduit from the RV to the distal pulmonary artery, can be performed.¹³⁶ Alternatively, a Yasui procedure, which involves baffling the VSD to the pulmonary artery and creation of a DKS anastomosis between the pulmonary artery and the aorta with patch augmentation, can be accomplished concomitant with placement of a RV-pulmonary artery conduit.¹³⁷

Results. The results of DORV repairs are generally favorable, especially for the tetralogy-type DORV with subaortic VSD.^{138,139} However, more complex types of DORV, including noncommitted VSD and Taussig-Bing type, still carry important morbidity and mortality.^{134,138,139} Furthermore, repeated interventions for RVOT reconstruction or staged operations for patients triaged to single-ventricle pathways pose late hazards for patients surviving initial repair. A recent single-institution series evaluated 393 patients with DORV.¹³⁸ The authors found that the need for reintervention approached 37% at 15 years following repair. Arterial switch operation, as opposed

to Rastelli-type repair, was associated with an increased risk of early postrepair mortality, but mitigated against the risk of late death. Patients with hypoplastic left-sided structures and a nonsubaortic VSD may fare better with a single-ventricle repair.

Tetralogy of Fallot

Anatomy. The original description of tetralogy of Fallot (TOF) by Etienne Louis Fallot,¹⁴⁰ as the name implies, included four abnormalities: a large perimembranous VSD adjacent to the tricuspid valve; an overriding aorta; a variable degree of RVOT obstruction, which might include hypoplasia and dysplasia of the pulmonary valve as well as obstruction at the subvalvar and pulmonary artery level; and right ventricular hypertrophy. More recently, the Van Praagh et al¹⁴¹ pointed out that TOF could be more correctly termed monology of Fallot, since the four components are explained by the malposition of the infundibular septum. When the infundibular septum is displaced anteriorly and leftward, the RVOT is narrowed and its anterior displacement results in failure of fusion of the ventricular septum between the arms of the trabeculo-septo-marginalis (Fig. 20-26).

The morphology of TOF is markedly heterogeneous and includes an absent pulmonary valve, concomitant AV septal defects, and pulmonary atresia with major aortopulmonary collaterals. The present discussion will focus only on the so-called classic presentation of TOF without coexisting intracardiac defects.

Anomalous coronary artery patterns, related to either origin or distribution, have been described in TOF.¹⁴² However, the most surgically important coronary anomaly occurs when the left anterior descending artery arises as a branch of the right coronary artery. This occurs in approximately 3% of cases of TOF and may preclude placement of a transannular patch, as the left anterior descending coronary artery crosses the RVOT at varying distances from the pulmonary valve annulus.¹⁴³

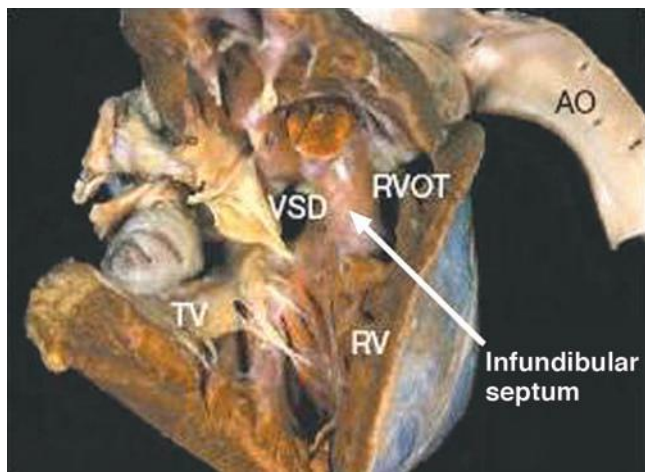


Figure 20-26. Pathologic specimen of the heart in a patient with tetralogy of Fallot. The four anatomic components comprising tetralogy of Fallot can be conceptualized as a monology of Fallot, because they can be explained by malposition of the interventricular septum. AO = aorta; RV = right ventricle; RVOT = right ventricular outflow tract; TV = tricuspid valve; VSD = ventricular septal defect. (From Van Praagh et al,¹⁴¹ with permission. © Elsevier Ltd.)

Pathophysiology and Clinical Presentation. The initial presentation of a child afflicted with TOF depends on the degree of RVOT obstruction. Children with cyanosis at birth usually have severe pulmonary annular hypoplasia with concomitant hypoplasia of the peripheral pulmonary arteries. Most children, however, present with mild cyanosis at birth, which then progresses as the right ventricular hypertrophy further compromises the RVOT. Cyanosis usually becomes significant within the first 6 to 12 months of life, and the child may develop characteristic “tet” spells, which are periods of extreme hypoxemia. These spells are characterized by decreased pulmonary blood flow and an increase in systemic blood flow. They can be triggered by any stimulus that decreases systemic vascular resistance, such as fever, agitation, or vigorous physical activity. Cyanotic spells increase in severity and frequency as the child grows, and older patients with uncorrected TOF may often squat, which increases peripheral vascular resistance and relieves the cyanosis.

Evaluation in the older patient with TOF may demonstrate clubbing, polycythemia, hemoptysis, or brain abscesses. Chest radiography will demonstrate a boot-shaped heart, and ECG will show the normal pattern of right ventricular hypertrophy. Echocardiography confirms the diagnosis because it demonstrates the position and nature of the VSD, defines the character of the RVOT obstruction, and often visualizes the branch pulmonary arteries and the proximal coronary arteries. Cardiac catheterization is rarely necessary and is actually risky in TOF since it can create spasm of the RVOT muscle and result in a hypercyanotic episode (tet spell). Occasionally, aortography is necessary to delineate the coronary artery anatomy.

Treatment. John Deanfield¹⁴⁴ stated “...long follow-up inevitably means surgery in an earlier era: More recent surgery, at a younger age, with better preoperative, operative, and postoperative care, will improve long-term results. Data from the former (earlier) era will be overly pessimistic.” This statement is particularly pertinent as surgical correction of TOF has evolved from a staged approach of antecedent palliation in infancy followed by intracardiac repair to primary repair during the first few months of life without prior palliative surgery.

However, systemic-to-pulmonary shunts, generally a B-T shunt, may still be preferred with an unstable neonate younger than 3 months of age, when an extracardiac conduit is required because of an anomalous left anterior descending coronary artery, or when pulmonary atresia, significant branch pulmonary artery hypoplasia, or severe noncardiac anomalies coexist with TOF.

Traditionally, TOF was repaired through a right ventriculotomy, providing excellent exposure for closure of the VSD and relief of the RVOT obstruction, but concerns that the resultant scar would significantly impair right ventricular function or lead to lethal arrhythmias led to the development of a transatrial approach. Transatrial repair, except in cases when the presence of diffuse RVOT hypoplasia requires insertion of a transannular patch, is now being increasingly advocated by many, although its superiority has not been conclusively demonstrated.¹⁴⁵

The operative technique involves the use of CPB. All existing systemic-to-pulmonary arterial shunts, as well as the ductus arteriosus, are ligated. A right atriotomy is then made, and the anatomy of the VSD and the RVOT are assessed by

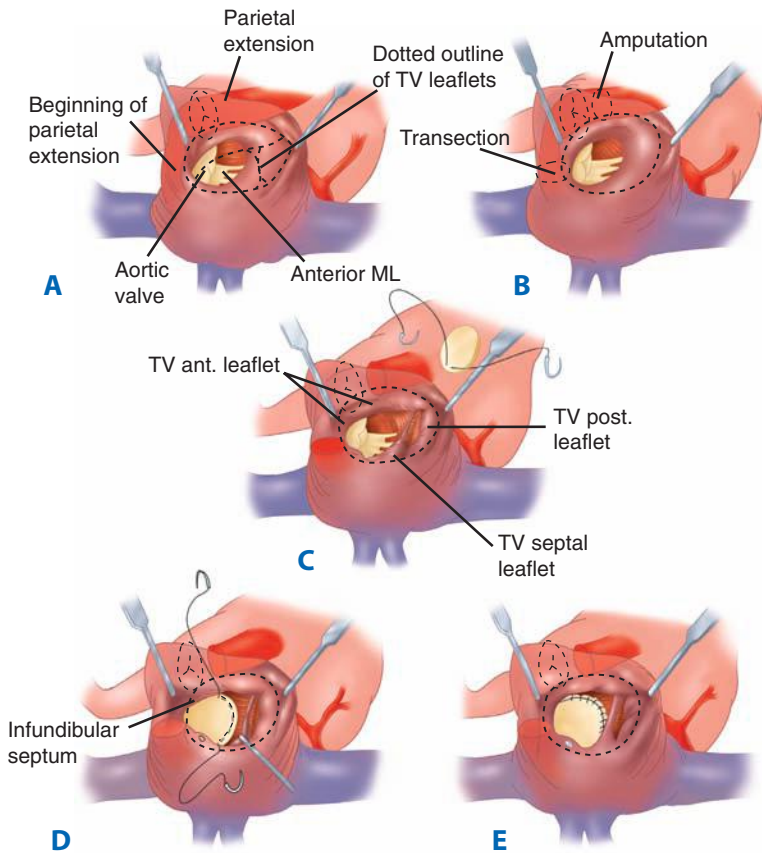


Figure 20-27. The anatomy from the perspective of the right atrial (RA) approach, shown as if the right atrial free wall and tricuspid valve were translucent. The free edge of the tricuspid leaflets is shown by dashed lines. **A.** The difference from the right ventricular (RV) perspective is in the apparent position of the parietal extension. From the RA perspective, the surgeon looks *beneath* this, as the parietal extension arches *over* the right ventricular outflow tract. **B.** The same perspective without the outline of the tricuspid valve leaflets. The parietal extension is transected at its origin from the infundibular septum, dissected up toward the free wall, and amputated at the free wall. **C.** A pledgetted mattress suture is placed from the RA side through the base of the commissural tissue between septal and tricuspid leaflets and through the patch. **D.** The suturing is continued onto the parietal extension and infundibular septum, visualizing and staying close to the aortic valve leaflets to avoid leaving a hole between muscular bands. When working from the RA, it is particularly important to stay close to the aortic valve leaflets in the direction of the septum to avoid narrowing the RV outflow tract. **E.** The repair of the ventricular septal defect is completed. Note that the suture line is away from the bundle of His and its branches, except where it crosses the right bundle branch anteroinferiorly. ant. = anterior; ML = mitral leaflet; post. = posterior; TV = tricuspid valve. (Reproduced with permission from Kouchoukos NT, Blackstone EH, et al: *Kirklin/Barratt-Boyes Cardiac Surgery*. 4th ed. Philadelphia: Elsevier, 2013, p 1384. Copyright Elsevier.)

retracting the tricuspid valve (Fig. 20-27). The outflow tract obstruction is relieved by resecting the offending portion of the infundibular septum as well as any muscle trabeculations. If necessary, a pulmonary valvotomy or, alternatively, a longitudinal incision in the main pulmonary artery can be performed to improve exposure. The diameter of the pulmonary valve annulus is assessed by inserting Hegar dilators across the outflow tract; if the pulmonary artery/aorta diameter is less than 0.5, or the estimated RV/LV pressure is greater than 0.7, a transannular patch is inserted.²¹ Patch closure of the VSD is then accomplished, taking care when placing sutures along the posteroinferior portion to avoid the conduction system.

Results. Operative mortality for primary repair of TOF in infancy is less than 5% in most series.^{4,7,145} Previously reported risk factors such as transannular patch insertion or younger age at time of repair have been eliminated secondary to improved intraoperative and postoperative care. According to the Society of Thoracic Surgeons Congenital Heart Surgery Database, discharge mortality from 3059 operations from 2002 to 2007 was 7.5% for initial palliation, 1.3% for primary repair, and 0.9% for staged repair, indicating receiving outcomes for patients getting primary repair compared to staged repair.¹⁴⁶ Nevertheless, for neonatal repair, discharge mortality increased to 6.2% with palliation and 7.8% with primary repair. This may be partly explained by a higher chance of postoperative complications in neonates.

A major complication of repaired TOF is the development of pulmonary insufficiency, which subjects the RV to the adverse effects of acute and chronic volume overload. This

is especially problematic if residual lesions such as a VSD or peripheral pulmonary stenosis exist. Pulmonary valve regurgitation after repair of TOF is relatively well tolerated in the short term, partly because the hypertrophied RV usually adapts to the altered hemodynamic load.^{147,148} The detrimental effects of chronic pulmonary valve regurgitation are, however, numerous, and include progressive right ventricular dilatation and failure, tricuspid valve regurgitation, exercise intolerance, arrhythmia, and sudden death. Mechano-electrical interaction, by which a dilated RV provides the substrate for electrical instability, might underlie the propensity toward ventricular arrhythmia.¹⁴⁹ In support of this contention, Gatzoulis and colleagues^{147,149} found that the risk of symptomatic arrhythmia was high in patients with marked right ventricular enlargement and QRS prolongation on resting ECG of more than 180 ms. Karamlou et al have shown that similar structural and hemodynamic abnormalities, including a larger right atrial volume and right ventricular chamber size, are also related to atrial arrhythmias in patients following TOF repair.¹⁵⁰ We found that prolongation of the QRS duration beyond a threshold of 160 ms increased the risk of atrial arrhythmias.¹⁵⁰ Together, these data show that a similar mechanism could be responsible for both atrial and ventricular arrhythmias after repair in TOF patients.

When significant deterioration of ventricular function occurs, insertion of a pulmonary valve may be required, although this is rarely necessary in infants. Unfortunately, there are no universal criteria establishing the timing of pulmonary valve replacement, although dilation of the RV, prolongation of the QRS duration beyond 180 ms, important atrial arrhythmias, and impaired ventricular function are widely used.

Arrhythmias are potentially the most serious late complication following TOF repair. In a multicenter cohort of 793 patients studied by Gatzoulis et al,¹⁴⁹ a steady increase was documented in the prevalence of ventricular and atrial tachyarrhythmia and sudden cardiac death in the first 5 to 10 years after intracardiac repair. Clinical events were reported in 12% of patients at 35 years after repair. Prevalence of atrial arrhythmias from other studies, however, ranges from 1% to 11%,^{147,149} which is a reflection of the strong time dependence of arrhythmia onset.

Underlying causes of arrhythmia following repair are complex and multifactorial, resulting in poorly defined optimum screening and treatment algorithms. Older repair age has been associated with an increased frequency of both atrial and ventricular arrhythmias. Impaired ventricular function secondary to a protracted period of cyanosis before repair might contribute to the propensity for arrhythmia in older patients.

Ventricular Septal Defect

Anatomy. VSD refers to a hole between the LV and RV. These defects are common, comprising 20% to 30% of all cases of CHD, and may occur as an isolated lesion or as part of a more complex malformation.¹⁵¹ VSDs vary in size from 3 to 4 mm to more than

3 cm and are classified into four types based on their location in the ventricular septum: perimembranous, AV canal, outlet or supracristal, and muscular (Fig. 20-28).

Perimembranous VSDs are the most common type requiring surgical intervention, comprising approximately 80% of cases.¹⁵¹ These defects involve the membranous septum and include the malalignment defects seen in tetralogy of Fallot. In rare instances, the anterior and septal leaflets of the tricuspid valve adhere to the edges of the perimembranous defect, forming a channel between the LV and the right atrium. These defects result in a large left-to-right shunt due to the large pressure differential between the two chambers.

AV canal defects, also known as inlet defects, occur when part or all of the septum of the AV canal is absent. The VSD lies beneath the tricuspid valve and is limited upstream by the tricuspid annulus, without intervening muscle.

The supracristal or outlet VSD results from a defect within the conal septum. Characteristically, these defects are limited upstream by the pulmonary valve and are otherwise surrounded by the muscle of the infundibular septum.

Muscular VSDs are the most common type and may lie in four locations: anterior, midventricular, posterior, or apical. These are surrounded by muscle and can occur anywhere

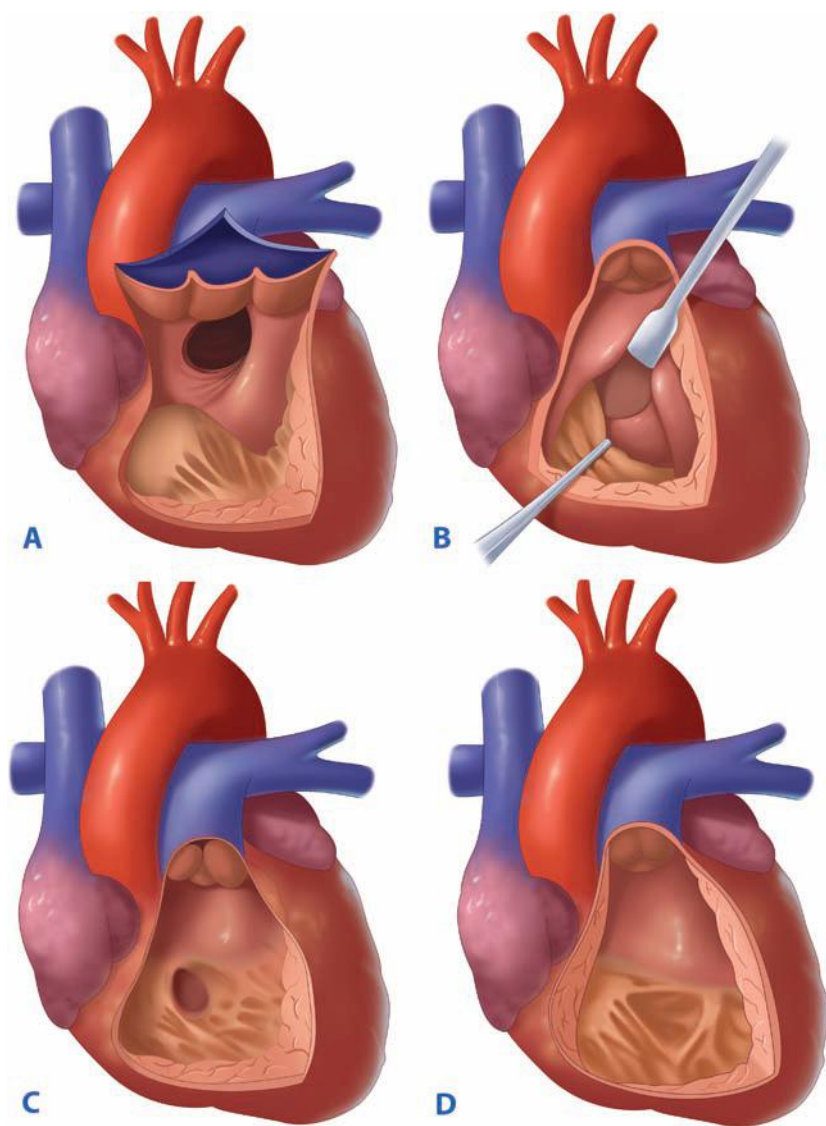


Figure 20-28. Classic anatomic types of ventricular septal defect (VSD). **A.** Type I (conal, infundibular, supracristal, subarterial) VSD. **B.** Type II or perimembranous VSD. **C.** Type III VSD (atrioventricular canal type or inlet septum type). **D.** Type IV VSD (single or multiple). (Reproduced with permission from *Ventricular septal defect*. In: Mavroudis C, Backer CL, eds. *Pediatric Cardiac Surgery*. 2nd ed. St. Louis: Mosby; 1994:70.)

along the trabecular portion of the septum. The rare “Swiss-cheese” type of muscular VSD consists of multiple communications between the RV and LV, complicating operative repair.

Pathophysiology and Clinical Presentation. The size of the VSD determines the initial pathophysiology of the disease. Large VSDs are classified as nonrestrictive and are at least equal in diameter to the aortic annulus. These defects allow free flow of blood from the LV to the RV, elevating right ventricular pressures to the same level as systemic pressure. Consequently, the pulmonary-to-systemic flow ratio ($Q_p:Q_s$) is inversely dependent on the ratio of pulmonary vascular resistance to systemic vascular resistance. Nonrestrictive VSDs produce a large increase in pulmonary blood flow, and the afflicted infant will present with symptoms of congestive heart failure. However, if untreated, these defects will cause pulmonary hypertension with a corresponding increase in pulmonary vascular resistance. This will lead to a reversal of flow (a right-to-left shunt), which is known as Eisenmenger’s syndrome.

Small restrictive VSDs offer significant resistance to the passage of blood across the defect, and therefore right ventricular pressure is either normal or only minimally elevated and $Q_p:Q_s$ rarely exceeds 1.5.^{4,7} These defects are generally asymptomatic because there are few physiologic consequences. However, there is a long-term risk of endocarditis, because endocardial damage from the jet of blood through the defect may serve as a possible nidus for colonization.

Diagnosis. The child with a large VSD will present with severe congestive heart failure and frequent respiratory tract infections. Children with Eisenmenger’s syndrome may be deceptively asymptomatic until frank cyanosis develops.

The chest radiograph will show cardiomegaly and pulmonary overcirculation, and the ECG will show signs of left ventricular or biventricular hypertrophy. Echocardiography provides definitive diagnosis and can estimate the degree of shunting as well as pulmonary arterial pressures. Cardiac catheterization has largely been supplanted by echocardiography, except in older children where measurement of pulmonary resistance is necessary prior to recommending closure of the defect.

Treatment. VSDs may close or narrow spontaneously, and the probability of closure is inversely related to the age at which the defect is observed. Thus, infants at 1 month of age have an 80% incidence of spontaneous closure, whereas a child at 12 months of age has only a 25% chance of closure.¹⁵² This has an important impact on operative decision making, because a small or moderate-size VSD may be observed for a period of time in the absence of symptoms. Large defects and those in severely symptomatic neonates should be repaired during infancy to relieve symptoms and because irreversible changes in pulmonary vascular resistance may develop during the first year of life.

Repair of isolated VSDs requires the use of CPB with moderate hypothermia and cardioplegic arrest. The right atrial approach is preferable for most defects, except apical muscular defects, which often require a right ventriculotomy for adequate exposure. Supracristal defects may alternatively be exposed via a transverse or longitudinal incision in the RV immediately beneath the pulmonary valve. Regardless of the type

of defect present, a right atrial approach can be used initially to inspect the anatomy, as this may be abandoned should it offer inadequate exposure for repair. After careful inspection of the heart for any associated malformations, a patch repair is employed, taking care to avoid the conduction system (Fig. 20-29). Routine use of intraoperative transesophageal echocardiography should be used to assess for any residual defects.

Successful percutaneous device closure of VSDs using the Amplatzer muscular VSD was recently described.¹⁵³ The device has demonstrated a 100% closure rate in a small series of patients with isolated or residual VSDs, or as a collaborative treatment strategy for the VSD component in more complex congenital lesions. Proponents of device closure argue that its use can decrease the complexity of surgical repair, avoid reoperation for a small residual lesion, or avoid the need for a ventriculotomy.

Multiple or “Swiss-cheese” VSDs represent a special case, and many cannot be repaired during infancy. In patients in whom definitive VSD closure cannot be accomplished, temporary placement of a pulmonary artery band can be employed to control pulmonary flow. This allows time for spontaneous closure of many of the smaller defects, thus simplifying surgical repair.

Some centers, however, have advocated early definitive repair of the Swiss-cheese septum, by using oversize patches, fibrin glue, and combined intraoperative device closure, as well as techniques to complete the repair transatrially.¹⁵⁴ At the University of California, San Francisco, 69% of patients with multiple VSDs underwent single-stage correction, and the repaired group had improved outcome compared with the palliated group.¹⁵⁴

Results. Even in very small infants, closure of VSDs can be safely performed with hospital mortality near 0%.^{4,7,155} The main risk factor remains the presence of other associated lesions, especially when present in symptomatic neonates with large VSDs.

Atrioventricular Canal Defects

Anatomy. AV canal defects result from failure of fusion of the endocardial cushions in the central portion of the heart, causing a lesion that involves the atrial and the ventricular septum, as well as the anterior mitral and septal tricuspid valve leaflets. Defects involving primarily the atrial septum are known as partial AV canal defects and frequently occur in conjunction with a cleft anterior mitral leaflet. Complete AV canal defects have a combined deficiency of the atrial and ventricular septum associated with a common AV orifice rather than separate tricuspid and mitral valves. The common AV valve generally has five leaflets, three lateral (free wall) and two bridging (septal) leaflets. The defect in the ventricular septum can lie either between the two bridging leaflets or beneath them. The relationship between the septal defect and the anterior bridging leaflet forms the basis of the Rastelli classification for complete AV canal defects (Fig. 20-30).¹⁵⁶

Pathophysiology and Diagnosis. Partial AV canal defects, in the absence of AV valvular regurgitation, frequently resemble isolated ASDs. Left-to-right shunting predominates as long as pulmonary vascular resistance remains low. However, 40% of patients with partial AV canal defects have moderate-to-severe valve incompetence, and progressive heart failure

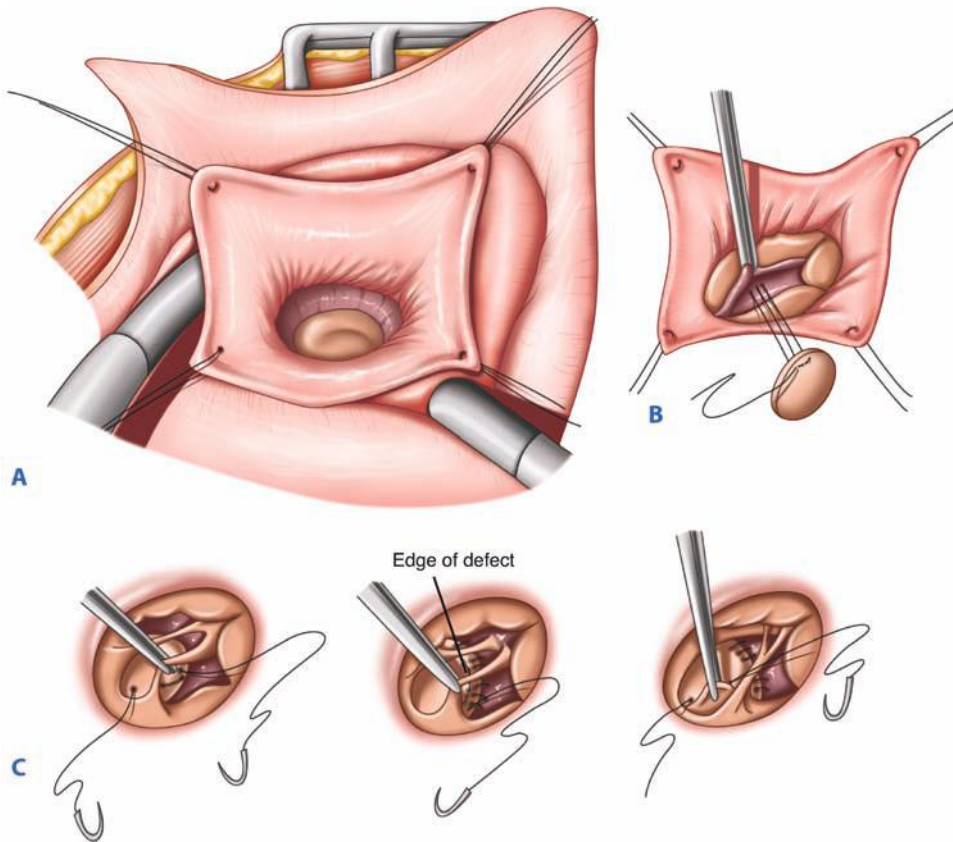


Figure 20-29. **A.** Right atrial incision and exposure of perimembranous ventricular septal defect (VSD) in the region of the tricuspid antero-septal commissure. Stay sutures have been placed to slightly evert the atrial wall. Note that initially, the superior edge of this typical perimembranous defect is not visible. The atrioventricular node is in the muscular portion of the atrioventricular septum, just on the atrial side of the commissure between the tricuspid septal and anterior leaflets. The bundle of His thus penetrates at the posterior angle of the VSD, where it is vulnerable to injury. **B** and **C.** The repair of the perimembranous VSD is completed with use of a slightly oversized Dacron patch, taking care to place stitches 3 to 5 mm away from the edge of the defect itself to avoid injury to the conduction system. (Reproduced with permission from Walters HL, Pacifico AD, Kirklin JK: *Ventricular septal defects*. In: Sabiston DC, Lyerly HK, eds. *Textbook of Surgery: The Biologic Basis of Modern Surgical Practice*. Philadelphia: W.B. Saunders; 1997:2014. Copyright Elsevier.)

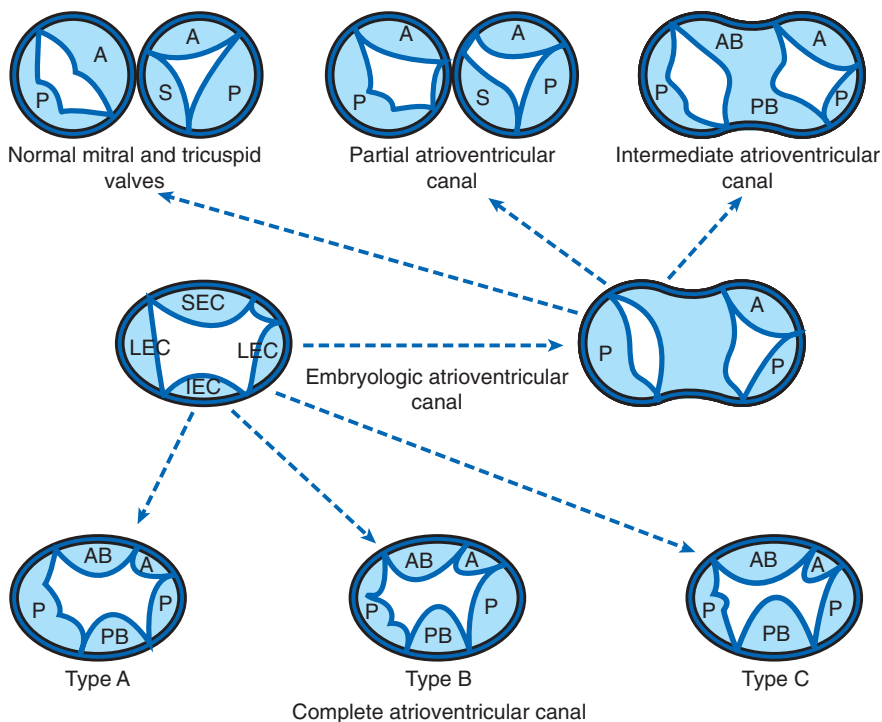


Figure 20-30. Formation of mitral and tricuspid leaflets and probable embryogenesis of partial, intermediate, and complete forms of atrioventricular canal defects. A = anterior; AB = anterior bridging leaflet; IEC = inferior endocardial cushion; LEC = lateral endocardial cushion; P = posterior; PB = posterior bridging leaflet; S = septal; SEC = superior endocardial cushion. (Reproduced from Feldt RH, Porter CJ, Edwards WD, et al. *Defects of the atrial septum and the atrioventricular canal*. In: Adams FH, Emmanouilides GC, eds. *Moss' Heart Disease in Infants, Children, and Adolescents*. 4th ed. Baltimore: Lippincott Williams & Wilkins; 1989. © Mayo Clinic ID #: CP1214116B-2. Used with permission of Mayo Foundation for Medical Education and Research.)

occurs early in this patient population.¹⁵⁷ Complete AV canal defects produce more severe pathophysiologic changes, because the large intracardiac communication and significant AV valve regurgitation contribute to ventricular volume loading and pulmonary hypertension. Children with complete AV canal defects develop signs of congestive heart failure within the first few months of life.

Physical examination may reveal a right ventricular heave and a systolic murmur. Children may also present with endocarditis or paradoxical emboli as a result of the intracardiac communication. Chest radiography will be consistent with congestive heart failure, and the ECG demonstrates right ventricular hypertrophy with a prolonged PR interval.

Two-dimensional echocardiography with color-flow mapping is confirmatory, but cardiac catheterization can be employed to define the status of the pulmonary vasculature, with a pulmonary vascular resistance greater than 12 Wood units indicating inoperability.¹⁵⁷

Treatment. The management of patients with AV canal defects can be especially challenging. Timing of operation is individualized. Patients with partial defects can be electively repaired between 2 and 5 years of age, whereas complete AV canal defects should be repaired within the first year of life to prevent irreversible changes in the pulmonary circulation. Complete repair in infancy should be accomplished, with palliative procedures such as pulmonary artery banding reserved for only those infants with other complex lesions or who are too ill to tolerate CPB.

The operative technique requires the use of either continuous hypothermic CPB or, for small infants, deep hypothermic circulatory arrest. The heart is initially approached through an oblique right atriotomy, and the anatomy is carefully observed. In the case of a partial AV canal, the cleft in the mitral valve is repaired with interrupted sutures and the ASD is closed with a pericardial patch.¹⁴⁸ Complete AV canal defects are repaired by patch closure of the VSD, separating the common AV valve into tricuspid and mitral components and suspending the neovalves from the top of the VSD patch and closing the ASD.

Results. Partial AV canal defects have an excellent outcome, with a mortality rate of 0% to 2% in most series.¹⁵⁶ Complete AV canal defects are associated with a poorer prognosis, with an operative mortality of 3% to 13%.

The most frequently encountered postoperative problems are complete heart block (1%–2%), right bundle-branch block (22%), arrhythmias (11%), RVOT obstruction (11%), and severe mitral regurgitation (13%–24%).¹⁵⁶ The increasing use of intraoperative transesophageal echocardiography may positively influence outcomes, as the adequacy of repair can be assessed and treated without need for subsequent reoperation.^{156–158}

Interrupted Aortic Arch

Anatomy. Interrupted aortic arch (IAA) is a rare defect, comprising approximately 1% of all cases of CHD.^{7,148} It is defined as an absence of luminal continuity between the ascending and descending aorta and does not occur as an isolated defect in most cases, because a VSD or PDA is usually present. IAA is classified based on the location of the interruption (Fig. 20-31).

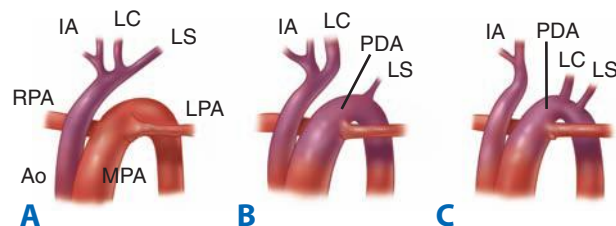


Figure 20-31. Anatomic types of interrupted aortic arch. **A.** Interruption distal to the left subclavian artery. **B.** Interruption between the left subclavian and left carotid arteries. **C.** Interruption between the left carotid and innominate arteries. Ao = aorta; IA = innominate artery; LPA, MPA, RPA = left, main, and right pulmonary arteries; LC = left carotid artery; LS = left subclavian artery; PDA = patent ductus arteriosus. (Reproduced with permission from Jonas RA. *Interrupted aortic arch*. In: Mavroudis C, Backer CL, eds. *Pediatric Cardiac Surgery*. 2nd ed. St. Louis: Mosby; 1994:184.)

Clinical Manifestations and Diagnosis. Infants with IAA have ductal-dependent systemic blood flow and will develop profound metabolic acidosis and hemodynamic collapse upon ductal closure. In the rare instance of failed ductal closure, the diagnosis may be missed during infancy, and the child will present with symptoms of congestive heart failure from a persistent left-to-right shunt.

Once definitive diagnosis is made in infants, usually with echocardiography, preparations are made for operative intervention, and prostaglandin E₁ is infused to maintain ductal patency and correct acidosis. The infant's hemodynamic status should be optimized with mechanical ventilation and inotropic support. An effort should be made to increase pulmonary vascular resistance by decreasing the fractional inspired oxygen and avoiding hyperventilation, because this will preferentially direct blood into the systemic circulation.

Treatment. Initial strategies for the management of IAA involved palliation through a left thoracotomy by using one of the arch vessels as a conduit to restore aortic continuity. Pulmonary artery banding can be simultaneously performed to limit left-to-right shunting, because it is not feasible to repair the VSD or other intracardiac communications with this approach.

However, complete surgical repair in infants with IAA is now preferable. The operative technique involves use of a median sternotomy and CPB with short periods of circulatory arrest. Aortic arch reconstruction can be accomplished with either direct anastomosis or patch aortoplasty followed by closure of the VSD.¹⁴⁸

In certain cases, the defect will involve hypoplasia of the left heart, precluding attempts at definitive repair. These infants should be managed with a Norwood procedure followed by a Fontan repair.

Results. Outcomes in infants with IAA have improved substantially over the last decades as a result of improved perioperative care. Operative mortality is now less than 10% in most series.¹⁵⁷ Some authors advocate the use of patch augmentation of the aorta to ensure adequate relief of LVOT obstruction and to diminish anastomotic tension, thus reducing the subsequent risk of restenosis and tracheobronchial compression.^{7,157,159}

Entries highlighted in bright blue are key references.

1. Kouchoukos NT, Blackstone EH, Doty DB, et al. Atrial septal defect and partial anomalous pulmonary venous connection. In: Kouchoukos NT, Blackstone EH, Doty DB, et al, eds. *Kirklin/Barrat-Boyes Cardiac Surgery*. 3rd ed. Philadelphia: Churchill Livingstone; 2003:716.
2. Kirklin JW, Pacifico AD, Kirklin JK. The surgical treatment of atrioventricular canal defects. In: Arciniegas E, ed. *Pediatric Cardiac Surgery*. Chicago: Yearbook Medical; 1985:2398.
3. Peterson GE, Brickner ME, Reimold SC. Transesophageal echocardiography: clinical indications and applications. *Circulation*. 2003;107:2398.
4. Kouchoukos NT, Blackstone EH, Doty DB, et al. Atrial septal defect and partial anomalous pulmonary venous connection. In: Kouchoukos NT, Blackstone EH, Doty DB, et al, eds. *Kirklin/Barrat-Boyes Cardiac Surgery*. 3rd ed. Philadelphia: Churchill Livingstone; 2003:740.
5. Reddy VM. Cardiac surgery for premature and low birth weight neonates. *Semin Thorac Cardiovasc Surg Pediatr Card Surg Annu*. 2001;4:271.
6. Thompson JD, Abuwari EH, Watterson KG, et al. Surgical and transcatheter (Amplatzer) closure of atrial septal defect: a prospective comparison of results and cost. *Heart*. 2002;87:466-469.
7. Du ZD, Hijazi ZM, Kleinman CS, et al. Comparison between transcatheter and surgical closure of secundum atrial septal defect in children and adults: results of a multicenter nonrandomized trial. *J Am Coll Cardiol*. 2002;39:1836-1844.
8. Kutty S, Hazeem AA, Brown K, et al. Long-term (5-to 20-year) outcomes after transcatheter or surgical treatment of hemodynamically significant isolated secundum atrial septal defect. *Am J Cardiol*. 2012;109:1348-1352.
9. Highes ML, Maskell G, Goh TH, Wilkinson JL. Prospective comparison of costs and short term health outcomes of surgical versus device closure of atrial septal defect in children. *Heart*. 2002;88:67-70.
10. **Murphy JG, Gersh BJ, McGoon MD, et al. Long-term outcome after surgical repair of isolated atrial septal defect. *N Engl J Med*. 1990;323:1645-1650.**
11. Hanninen M, Kmet A, Taylor DA, et al. Atrial septal defect closure in the elderly is associated with excellent quality of life, functional improvement, and ventricular remodeling. *Can J Cardiol*. 2011;27:698-704.
12. Mascio CE, Pasquali SK, Jacobs JP, et al. Outcomes in adult congenital heart surgery: Analysis of the Society of Thoracic Surgeons (STS) Database. *J Thorac Cardiovasc Surg*. 2011;142:1090-1097.
13. Hopkins RA, Bert AA, Buchholz B, et al. Surgical patch closure of atrial septal defects. *Ann Thorac Surg*. 2004;77:2144-2150.
14. Liu G, Qiao Y, Zou C, et al. Totally thoracoscopic surgical treatment for atrial septal defect: mid-term follow-up results in 45 consecutive patients. *Heart Lung Circ*. 2012;S1443-S9506.
15. Argenziano M, Oz M, Kohmoto T, et al. Totally endoscopic atrial septal defect repair with robotic assistance. *Circulation*. 2003;108(suppl II):II-191-II-194.
16. Luo W, Chang C, Chen S. Ministernotomy vs. full sternotomy in congenital heart defects: a prospective randomized study. *Ann Thorac Surg*. 2001;71:473.
17. Srivastava AR, Banerjee A, Tempe DK, et al. A comprehensive approach to fast tracking in cardiac surgery: ambulatory low-risk open-heart surgery. *Eur J Cardiothorac Surg*. 2008;33:955-960.
18. King TD, Mills NL. Secundum atrial septal defects: non-operative closure during cardiac catheterization. *JAMA*. 1976;235:2506.
19. **Karamlou T, Diggs BS, McCrindle BW, Ungerleider RM, Welke KF. The rush to atrial septal defect closure: is the introduction of percutaneous closure driving utilization? *Ann Thorac Surg*. 2008;86:1584-1590.**
20. Zeevi B, Keane JF, Castaneda AR, et al. Neonatal critical valvular aortic stenosis. A comparison of surgical and balloon dilatation therapy. *Circulation*. 1989;80:831.
21. Lupinetti FM, Bove EL. Left ventricular outflow tract obstruction. In: Mavroudis C, Backer CL, eds. *Pediatric Cardiac Surgery*. 2nd ed. St. Louis: Mosby; 1994:435.
22. Gupta ML, Lantin-Hermoso MR, Rao PS. What's new in pediatric cardiology. *Indian J Pediatr*. 2003;70(1):41.
23. **Alsoufi B, Karamlou T, McCrindle BW, Caldarone CA. Management options in neonates and infants with critical left ventricular outflow tract obstruction. *Eur J Cardiothorac Surg*. 2007;31:1013.**
24. Hammon JW Jr., Lupinetti FM, Maples MD, et al: Predictors of operative mortality in critical aortic stenosis presenting in infancy. *Ann Thorac Surg*. 1988;45:537.
25. Mosca RS, Iannetoni MD, Schwartz SM, et al. Critical aortic stenosis in the neonate: a comparison of balloon valvuloplasty and transventricular dilatation. *J Thorac Cardiovasc Surg*. 1995;109:147.
26. Moore P, Egito E, Mowrey H, et al. Midterm results of balloon dilatation of congenital aortic stenosis: predictors of success. *J Am Coll Cardiol*. 1996;27:1257.
27. Ross DN. Replacement of aortic and mitral valves with a pulmonary autograft. *Lancet*. 1967;57:956.
28. Jones TK, Lupinetti FM. Comparison of Ross procedures and aortic valve allografts in children. *Ann Thorac Surg*. 1998;66:S170.
29. **Karamlou T, Jang K, Williams WG, et al. Outcomes and associated risk factors for aortic valve replacement in 160 children: a competing risks analysis. *Circulation*. 2005;29:3462-3469.**
30. Marasini M, Zannini L, Ussia GP, et al. Discrete subaortic stenosis: incidence, morphology, and surgical impact of associated subaortic anomalies. *Ann Thorac Surg*. 2003;75:1763.
31. Karamlou T, Gurofsky R, Bojcevski A, et al. Prevalence and associated risk factors for intervention in 313 children with subaortic stenosis. *Ann Thorac Surg*. 2007;84:900-906.
32. Somerville J, Stone S, Ross D. Fate of patients with fixed subaortic stenosis after surgical removal. *Br Heart J*. 1980;43:629.
33. Williams JCP, Barratt-Boyes BG, Lowe JB. Supravalvular aortic stenosis. *Circulation*. 1961;24:1311.
34. van Son JM, Danielson GK, Puga FJ, et al. Supravalvular aortic stenosis: long-term results of surgical treatment. *J Thorac Cardiovasc Surg*. 1994;107:103.
35. Sharma BK, Fujiwara H, Hallman GL, et al. Supravalvular aortic stenosis: a 29-year review of surgical experience. *Ann Thorac Surg*. 1991;51:1031.
36. McElhinney DB, Petrossian E, Tworetzky W, et al. Issues and outcomes in the management of supravalvular aortic stenosis. *Ann Thorac Surg*. 2000;69:562.
37. Clyman RI, Mauray F, Roman C, et al. Circulating PGE₂ concentration and patent ductus arteriosus in fetal and neonatal lambs. *J Pediatr*. 1982;97:455.
38. McMurphy DM, Heymann MA, Rudolph AM, et al. Developmental change in constriction of the ductus arteriosus: response to oxygen and vasoactive substances in the isolated ductus arteriosus of the fetal lamb. *Pediatr Res*. 1972;6:231.
39. Mitchell SC, Korones SB, Berendes HW. Congenital heart disease in 56,109 births. Incidence and natural history. *Circulation*. 1971;43:323.
40. Campbell M. Natural history of persistent ductus arteriosus. *Br Heart J*. 1968;30:4.

41. Itabashi K, Ohno T, Nishida H. Indomethacin responsiveness of patent ductus arteriosus and renal abnormalities in preterm infants treated with indomethacin. *J Pediatr*. 2003;143:203.
42. Rashkind WJ, Cuaso CC. Transcatheter closure of patent ductus arteriosus. *Pediatr Cardiol*. 1979;1:3.
43. Moore JW, Schneider DJ, Dimeglio D. The duct-occluder device: design, clinical results, and future directions. *J Interv Cardiol*. 2001;14:231.
44. Moore P, Egito E, Mowrey H, et al. Midterm results of balloon dilation of congenital aortic stenosis: predictors of success. *J Am Coll Cardiol*. 1996;27:1257.
45. Mavroudis C, Backer CL, Gevitz M. Forty-six years of patent ductus arteriosus division at Children's Memorial Hospital of Chicago. Standards for comparison. *Ann Thorac Surg*. 1994;220:402.
46. Elzenga NJ, Gittenberger-de Groot AC, Oppenheimer-Dekker A. Coarctation and other obstructive arch anomalies: their relationship to the ductus arteriosus. *Int J Cardiol*. 1986;13:289.
47. Locher JP, Kron IL. Coarctation of the aorta. In: Mavroudis C, Backer CL, eds. *Pediatric Cardiac Surgery*. St. Louis: Mosby; 1994:167.
48. Presbitero P, Demaie D, Villani M, et al. Long-term results (15–30 years) of surgical repair of coarctation. *Br Heart J*. 1987;57:462.
49. Cohen M, Fuster V, Steele PM, et al. Coarctation of the aorta: long-term follow-up and prediction of outcome after surgical correction. *Circulation*. 1989;80:840.
50. Hornung TS, Benson LN, McLaughlin PR. Interventions for aortic coarctation. *Cardiol Rev*. 2002;10:139.
51. Waldhausen JA, Nahrwold DL. Repair of coarctation of the aorta with a subclavian flap. *J Thorac Cardiovasc Surg*. 1966;51:532.
52. Karamlou T, Bernasconi A, Jaeggi E, et al. Factors associated with arch reintervention and growth of the aortic arch after coarctation repair in neonates weighing less than 2.5 kg. *J Thorac Cardiovasc Surg*. 2009;137:1163-1167.
53. van Heum LW, Wong CM, Speigelhalter DJ, et al. Surgical treatment of aortic coarctation in infants younger than 3 months: 1985-1990. Success of extended end-to-end arch aortoplasty. *J Thorac Cardiovasc Surg*. 1994;107:74-85.
54. Knyshov GV, Sitar LL, Glagola MD, et al. Aortic aneurysms at the site of the repair of coarctation of the aorta: a review of 48 patients. *Ann Thorac Surg*. 1996;61:935.
55. Bouchart F, Dubar A, Tabley A, et al. Coarctation of the aorta in adults: surgical results and long-term follow-up. *Ann Thorac Surg*. 2000;70:1483.
56. Bhat MA, Neelakhandran KS, Unnikrishnan M, et al. Fate of hypertension after repair of coarctation of the aorta in adults. *Br J Surg*. 2001;88:536.
57. McCrindle BW, Jones TK, Morrow WR, et al. Acute results of balloon angioplasty of native coarctation versus recurrent aortic obstruction are equivalent. Valvuloplasty and Angioplasty of Congenital Anomalies (VACA) Registry Investigators. *J Am Coll Cardiol*. 1996;28:1810.
58. Hopkins RA, Wallace RB. Truncus arteriosus. In: Sabiston DC, Lysterly HK, eds. *Textbook of Surgery: The Biological Basis of Modern Surgical Practice*. 15th ed. Philadelphia: W.B. Saunders; 1997:2052.
59. Collett RW, Edwards JE. Persistent truncus arteriosus: a classification according to anatomic subtypes. *Surg Clin North Am*. 1949;29:1245.
60. Van Praagh R, Van Praagh S. The anatomy of common aorticopulmonary trunk (truncus arteriosus communis) and its embryologic implications: a study of 57 necropsy cases. *Am J Cardiol*. 1965;16:406.
61. De la Cruz MV, Pio da Rocha J. An ontogenic theory for the explanation of congenital malformations involving the truncus and conus. *Am Heart J*. 1976;51:782.
62. Manner J. Cardiac looping in the chick embryo: a morphologic review with special reference to terminological and biomechanical aspects of the looping process. *Anat Rec*. 2000;259:242.
63. Hutson MR, Kirby ML. Neural crest and cardiovascular development: a 20-year perspective. *Birth Defects Res Part C Embryo Today*. 2003;69:2.
64. Kouchoukos NT, Blackstone EH, Doty DB, et al. Truncus arteriosus. In: Kouchoukos NT, Blackstone EH, Doty DB, et al, eds. *Kirklin/Barrat-Boyes Cardiac Surgery*. 3rd ed. Philadelphia: Churchill Livingstone; 2003:1201.
65. Mavroudis C, Backer CL. Truncus arteriosus. In: Mavroudis C, Backer CL, eds. *Pediatric Cardiac Surgery*. 2nd ed. St. Louis: Mosby; 1994:237.
66. Chiu IS, Wu SJ, Chen MR, et al. Anatomic relationship of the coronary orifice and truncal valve in truncus arteriosus and their surgical implication. *J Thorac Cardiovasc Surg*. 2002;123:350.
67. Armer RM, De Oliveira PF, Lurie PR. True truncus arteriosus. Review of 17 cases and report of surgery in 7 patients. *Circulation*. 1961;24:878.
68. McGoon DC, Rastelli GC, Ongley PA. An operation for the correction of truncus arteriosus. *JAMA*. 1968;205:69.
69. Ebert PA. Truncus arteriosus. In: Glenn WWL, Baue AE, Geha AS, eds. *Thoracic and Cardiovascular Surgery*. 4th ed. Norwalk: Appleton-Century-Crofts; 1983:731.
70. Forbess JM, Shah AS, St Louis JD, et al. Cryopreserved homografts in the pulmonary position: determinants of durability. *Ann Thorac Surg*. 2001;71:54.
71. Aupeple B, Serraf A, Belli E, et al. Intermediate follow-up of a composite stentless porcine valved conduit of bovine pericardium in the pulmonary circulation. *Ann Thorac Surg*. 2002;74:127.
72. Kouchoukos NT, Blackstone EH, Doty DB, et al. Total anomalous pulmonary venous connection. In: Kouchoukos NT, Blackstone EH, Doty DB, et al, eds. *Kirklin/Barrat-Boyes Cardiac Surgery*. 3rd ed. Philadelphia: Churchill Livingstone; 2003:758.
73. Darling RC, Rothney WB, Craij JM. Total pulmonary venous drainage into the right side of the heart. *Lab Invest*. 1957;6:44.
74. Delisle G, Ando M, Calder AL, et al. Total anomalous pulmonary venous connection: report of 93 autopsied cases with emphasis on diagnostic and surgical considerations. *Am Heart J*. 1976;91:99.
75. Michielon G, Di Donato RM, Pasquini L, et al. Total anomalous pulmonary venous connection: long-term appraisal with evolving technical solutions. *Eur J Cardiothorac Surg*. 2002;22:184.
76. Jonas RA, Smolinsky A, Mayer JE, et al. Obstructed pulmonary venous drainage with total anomalous pulmonary venous connection to the coronary sinus. *Am J Cardiol*. 1987;59:431.
77. Austin EH. Disorders of pulmonary venous return. In: Sabiston DC, Lysterly HK, eds. *Textbook of Surgery: The Biological Basis of Modern Surgical Practice*. 15th ed. Philadelphia: W.B. Saunders; 1997:2001.
78. Lacour-Gayet F, Rey C, Planche C. [Pulmonary vein stenosis. Description of a sutureless surgical procedure using the pericardium in situ.] *Arch Mal Coeur Vaiss*. 1996;89(5): 633-636.
79. Najm HK, Caldarone CA, Smallhorn J, Coles JG. A sutureless technique for the relief of pulmonary vein stenosis with the use of in situ pericardium. *J Thorac Cardiovasc Surg*. 1998;115(2):468-470.
80. Hyde JAJ, Stumper O, Barth MJ, et al. Total anomalous pulmonary venous connection: outcome of surgical correction and management of recurrent venous obstruction. *Eur J Cardiothorac Surg*. 1999;15:735.

81. Korbmacher B, Buttgen S, Schulte HD, et al. Long-term results after repair of total anomalous pulmonary venous connection. *Thorac Cardiovasc Surg*. 2001;49:101.
82. Bando K, Turrentine MW, Ensing GJ, et al. Surgical management of total anomalous pulmonary venous connection. Thirty-year trends. *Circulation*. 1996;95(9 Suppl):II12-II26.
83. Karamlou T, Gurofsky R, Al Sukhni E, et al. Factors associated with mortality and reoperation in 377 children with total anomalous pulmonary venous connection. *Circulation*. 2007;115:1591-1598.
84. Salomone G, Tiraboschi R, Bianchi T, et al. Cor triatriatum: clinical presentation and operative results. *J Thorac Cardiovasc Surg*. 1991;101:1088.
85. Huang TC, Lee CL, Lin CC, et al. Use of an Inoue balloon dilatation method for treatment of cor triatriatum stenosis in a child. *Catheter Cardiovasc Interv*. 2002;57:252.
86. Cooley DA, McNamara DG, Latson JR. Aorticopulmonary septal defect: diagnosis and surgical treatment. *Surgery*. 1957;42:101.
87. Ohtake S, Mault JR, Lilly MK, et al. Effect of a systemic-pulmonary artery shunt on myocardial function and perfusion in a piglet model. *Surg Forum*. 1991;42:200.
88. Gaynor JW, Ungerleider RM. Aortopulmonary window. In: Mavroudis C, Backer CL, eds. *Pediatric Cardiac Surgery*. 2nd ed. St. Louis: Mosby; 1994:250.
89. Scalia D, Russo P, Anderson RH, et al. The surgical anatomy of hearts with no direct communication between the right atrium and the ventricular mass—so-called tricuspid atresia. *J Thorac Cardiovasc Surg*. 1984;87:743.
90. Cheung HC, Lincoln C, Anderson RH, et al. Options for surgical repair in hearts with univentricular atrioventricular connection and subaortic stenosis. *J Thorac Cardiovasc Surg*. 1990;100:672.
91. Trusler GA, Williams WG. Long-term results of shunt procedures for tricuspid atresia. *Ann Thorac Surg*. 1980;29:312.
92. Dick M, Gyler DC, Nadas AS. Tricuspid atresia: clinical course in 101 patients. *Am J Cardiol*. 1975;36:327.
93. Glenn WWL, Patino JF. Circulatory by-pass of the right heart. Preliminary observations on the direct delivery of vena caval blood into the pulmonary arterial circulation. Azygous vein-pulmonary artery shunt. *Yale J Biol Med*. 1954;27:147.
94. Fontan F, Baudet E. Surgical repair of tricuspid atresia. *Thorax*. 1971;26:240.
95. deLeval MR, Kilner P, Gerwillig M, et al. Total cavopulmonary connection: a logical alternative to atriopulmonary connection for complex Fontan operations. *J Thorac Cardiovasc Surg*. 1988;96:682.
96. Laks H, Haas GS, Pearl JM, et al. The use of an adjustable interatrial communication in patients undergoing the Fontan and definitive heart procedures [abstract]. *Circulation*. 1988;78:357.
97. Haas GS, Hess H, Black M, et al. Extracardiac conduit Fontan procedure: early and intermediate results. *Eur J Cardiothorac Surg*. 2000;17:648.
98. Tokunaga S, Kado H, Imoto Y, et al. Total cavopulmonary connection with an extracardiac conduit: experience with 100 patients. *Ann Thorac Surg*. 2002;73:76.
99. Karamlou T, Ashburn DA, Caldarone CA, Blackstone EH. Matching procedure to morphology improves outcome in neonates with tricuspid atresia. *J Thorac Cardiovasc Surg*. 2005;130:1503-1510.
100. Bardo DME, Frankel DG, Applegate KE, et al. Hypoplastic left heart syndrome. *Radiographics*. 2001;21:706.
101. Norwood WI. Hypoplastic left heart syndrome. *Ann Thorac Surg*. 1991;52:688.
102. Bronshtein M, Zimmer EZ. Early sonographic diagnosis of fetal small left heart ventricle with a normal proximal outlet tract: a medical dilemma. *Prenat Diagn*. 1997;17:249.
103. Norwood WI, Lang P, Hansen DD. Physiologic repair of aortic atresia-hypoplastic left heart syndrome. *N Engl J Med*. 1983;308:23.
104. Norwood WI. Hypoplastic left heart syndrome. *Ann Thorac Surg*. 1991;52:688.
105. Tweddell JS, Hoffman GM, Ghanayem NS, et al. Ventilatory control of pulmonary vascular resistance is not necessary to achieve a balanced circulation in the postoperative Norwood patient. *Circulation*. 1999;100(18 Suppl):I-671.
106. Tchervenkov CI. Two-ventricle repair for hypoplastic left heart syndrome. *Semin Thorac Cardiovasc Surg Pediatr Card Surg Annu*. 2001;4:89.
107. Ohye RG, Sleeper Ia, Mahony L, et al. Comparison of shunt types in the Norwood procedure for single ventricle lesions. *N Engl J Med* 2010;362:1980-92.
108. Akintuerk H, Michel-Behnke I, Valeske K, et al. Stenting of the arterial duct and banding of the pulmonary arteries: basis for combined Norwood Stage I and II repair in hypoplastic left heart. *Circulation*. 2002;105:1099-1103.
109. Caldarone CA, Benson L, Holtby H, Li J, Redington AN, VanArsdell GS. Initial experience with hybrid palliation for neonates with single ventricle physiology. *Ann Thorac Surg*. 2007;84:1294-1300.
110. Baba K, Honjo O, Chaturvedi R, et al. "Reverse Blalock-Taussig shunt": application in single ventricle hybrid palliation. *J Thorac Cardiovasc Surg*. 2013;146(2):352-357.
111. Bailey LL, Gundry SR, Razzouk AJ, et al. Bless the babies: 115 late survivors of heart transplantation during the first year of life. The Loma Linda University Pediatric Heart Transplant Group. *J Thorac Cardiovasc Surg*. 1993;105:805.
112. Gaynor JW, Mahle WT, Cohen MI, et al. Risk factors for mortality after the Norwood procedure. *Eur J Cardiothorac Surg*. 2002;22:88.
113. Bove EL. Ebstein's anomaly in the neonate. *Am Assoc Thorac Surg*. 2008 (abstr).
114. Celermajer DS, Cullen S, Sullivan ID, et al. Outcome in neonates with Ebstein's anomaly. *J Am Coll Cardiol*. 1992;19:1041-1046.
115. Starnes VA, Pitlick PT, Bernstein D, et al. Ebstein's anomaly appearing in the neonate. *J Thorac Cardiovasc Surg*. 1991;101:1082.
116. Danielson GK, Driscoll DJ, Mair DD, et al. Operative treatment of Ebstein's anomaly. *J Thorac Cardiovasc Surg*. 1992;104:1195.
117. Knott-Craig CJ, Overholt ED, Ward KE, et al. Neonatal repair of Ebstein's anomaly: indications, surgical technique, and medium-term follow-up. *Ann Thorac Surg*. 2000;69:1505.
118. Yetman AT, Freedom RM, McCrindle BW. Outcome in cyanotic neonates with Ebstein's anomaly. *Am J Cardiol*. 1998;81:749.
119. Billingsly AM, Laks H, Boyce SW, et al. Definitive repair in patients with pulmonary atresia and intact ventricular septum. *J Thorac Cardiovasc Surg*. 1989;97:746.
120. Stellin G, Vida VL, Milanese O, et al. Surgical treatment of complex cardiac anomalies: the "one and one half ventricle repair." *Eur J Cardiothorac Surg*. 2002;22:435.
121. Chowdhury UK, Airan B, Sharma R, et al. One and a half ventricle repair with pulsatile Glenn: results and guidelines for patient selection. *Ann Thorac Surg*. 2001;71:2000.
122. Van Praagh R, Van Praagh S, Vlad P. Anatomic subtypes of congenital dextrocardia: diagnostic and embryologic implications. *Am J Cardiol*. 1964;13:510.
123. Van Praagh R, Van Praagh S. Isolated ventricular inversion: a consideration of the morphogenesis, definition, and diagnosis of nontransposed and transposed great arteries. *Am J Cardiol*. 1966;17:395.

124. Blalock A, Hanlon CR. The surgical treatment of complete transposition of the aorta and the pulmonary artery. *Surg Gynecol Obstet.* 1950;90:1.
125. Senning A. Surgical correction of transposition of the great vessel. *Surgery.* 1959;45:966.
126. Mustard WT, Chute AL, Keith JD. A surgical approach to transposition of the great vessels with extracorporeal circuit. *Surgery.* 1954;36:39.
127. Jatene AD, Fontes VF, Paulista PP, et al. Successful anatomic correction of transposition of the great vessels: a preliminary report. *Arq Bras Cardiol.* 1975;28:461.
128. Rastelli GC. A new approach to the "anatomic" repair of transposition of the great arteries. *Mayo Clin Proc.* 1969;44:1.
129. Culbert EL, Ashburn DA, Cullen-Dean G, et al. Quality of life after repair of transposition of the great arteries. *Circulation.* 2003;108:857.
130. Dearani JA, Danielson GK, Puga FJ, et al. Late results of the Rastelli operation for transposition of the great arteries. *Semin Thorac Cardiovasc Surg Pediatr Card Surg Annu.* 2001;4:3.
131. Freedom RM, Yoo SJ. Double-outlet right ventricle: pathology and angiocardiology. *Semin Thorac Cardiovasc Surg Pediatr Card Surg Annu.* 2000;3:3.
132. Lev M, Bharati S, Meng CCL, et al. A concept of double outlet right ventricle. *J Thorac Cardiovasc Surg.* 1972;64:271.
133. Taussig HB, Bing RJ. Complete transposition of the aorta and a levoposition of the pulmonary artery. *Am Heart J.* 1949;37:551.
134. Belli E, Serraf A, Lacour-Gayet F, et al. Double-outlet right ventricle with non-committed ventricular septal defect. *Eur J Cardiothorac Surg.* 1999;15:747.
135. Kawashima Y, Matsuda H, Yagihara T, et al. Intraventricular repair for Taussig-Bing anomaly. *J Thorac Cardiovasc Surg.* 1993;105:591-596.
136. Rastelli GC, McGoon DC, Wallace RB. Anatomic correction of transposition of the great arteries with ventricular septal defect and subpulmonic stenosis. *J Thorac Cardiovasc Surg.* 1969;58:545.
137. Yasui H, Kado H, Nakano E, et al. Primary repair of interrupted aortic arch with severe stenosis in neonates. *J Thorac Cardiovasc Surg.* 1987;93:539-545.
138. Bradley TJ, Karamlou T, Kulik A, et al. Determinants of repair type, reintervention, and mortality in 393 children with double-outlet right ventricle. *J Thorac Cardiovasc Surg.* 2007;134:967-973.
139. Brown JW, Ruzmetov M, Okada Y, et al. Surgical results in patients with double outlet right ventricle: a 20-year experience. *Ann Thorac Surg.* 2001;72:1630.
140. Fallot A. Contribution a l'anatomie pathologique de la maladie bleue (cyanose cardiaque) [French]. *Marseille Med.* 1888;25:77-403.
141. Van Praagh R, Van Praagh S, Nebesar RA, et al. Tetralogy of Fallot: underdevelopment of the pulmonary infundibulum and its sequelae. *Am J Cardiol.* 1970;26:25-53.
142. Need LR, Powell AJ, del Nido P, et al: Coronary echocardiography in tetralogy of Fallot: diagnostic accuracy, resource utilization, and surgical implications over 13 years. *J Am Coll Cardiol.* 2000;36:1371.
143. Mahle WT, McBride MG, Paridon SM. Exercise performance in tetralogy of Fallot: the impact of primary complete repair in infancy. *Pediatr Cardiol.* 2002;23:224.
144. Deanfield JE. Adult congenital heart disease with special reference to the data on long-term follow-up of patients surviving to adulthood with or without surgical correction. *Eur Heart J.* 1992;13(Suppl H):111-116.
145. Alexiou C, Chen Q, Galogavrou M, et al. Repair of tetralogy of Fallot in infancy with a transventricular or a transatrial approach. *Eur J Cardiothorac Surg.* 2002;22:174.
146. Al Habib HF, Jacobs JP, Mavroudis C, et al. Contemporary patterns of management of tetralogy of Fallot: data from the Society of Thoracic Surgeons database. *Ann Thorac Surg.* 2010;90(3):813-819; discussion 819-820.
147. Karamlou T, McCrindle BW, Williams WG. Surgery insight: late complications following repair of tetralogy of Fallot and related surgical strategies for management. *Nature Cardiovasc Med.* 2006;3:611-622.
148. Kouchoukos NT, Blackstone EH, Doty DB, et al: Ventricular septal defect. In: Kouchoukos NT, Blackstone EH, Doty DB, et al, eds. *Kirklin/Barrat-Boyes Cardiac Surgery.* 3rd ed. Philadelphia: Churchill Livingstone; 2003:851.
149. Gatzoulis MA, Till JA, Somerville J, et al. Mechano-electrical interaction in tetralogy of Fallot. QRS prolongation relates to right ventricular size and predicts malignant ventricular arrhythmias and sudden death. *Circulation.* 1995;92:231-237.
150. Karamlou T, Silber I, Lao R, et al. Outcomes after late reoperation in patients with repaired tetralogy of Fallot: the impact of arrhythmia and arrhythmia surgery. *Ann Thorac Surg.* 2006;81:1786-1793.
151. Turner SW, Hornung T, Hunter S. Closure of ventricular septal defects: a study of factors influencing spontaneous and surgical closure. *Cardiol Young.* 2002;12:357.
152. Waight DJ, Bacha EA, Khahana M, et al. Catheter therapy of Swiss cheese ventricular septal defects using the Amplatzer muscular VSD occluder. *Catheter Cardiovasc Interv.* 2002;55:360.
153. Seddio F, Reddy VM, McElhinney DB, et al. Multiple ventricular septal defects: how and when should they be repaired? *J Thorac Cardiovasc Surg.* 1999;117:134.
154. Tsang VT, Hsia TY, Yates RW, et al. Surgical repair of supposedly multiple defects within the apical part of the muscular ventricular septum. *Ann Thorac Surg.* 2002;73:58.
155. Rastelli G, Kirklin JW, Titus JL. Anatomic observations on complete form of persistent common atrioventricular canal with special reference to atrioventricular valves. *Mayo Clin Proc.* 1966;41:296.
156. Ungerleider RM. Atrial septal defects, ostium primum defects, and atrioventricular canals. In: Sabiston DC, Lyerly HK, eds. *Textbook of Surgery: The Biologic Basis of Modern Surgical Practice.* Philadelphia: W.B. Saunders; 1997:1993.
157. Kouchoukos NT, Blackstone EH, Doty DB, et al. Coarctation of the aorta and interrupted aortic arch. In: Kouchoukos NT, Blackstone EH, Doty DB, et al, eds. *Kirklin/Barrat-Boyes Cardiac Surgery.* 3rd ed. Philadelphia: Churchill Livingstone; 2003:1353.
158. Ungerleider RM, Kisslo JA, Greeley WJ, et al. Intraoperative prebypass and postbypass epicardial color flow imaging in the repair of atrioventricular septal defects. *J Thorac Cardiovasc Surg.* 1989;98:1146.
159. Roussin R, Belli E, Lacour-Gayet F, et al. Aortic arch reconstruction with pulmonary autograft patch aortoplasty. *J Thorac Cardiovasc Surg.* 2002;123:443.

This page intentionally left blank

21 chapter

Acquired Heart Disease

Shoichi Okada, Jason O. Robertson,
Lindsey L. Saint, and Ralph J. Damiano, Jr.

Cardiac Assessment	735	Summary / 743	Etiology and Pathophysiology / 765
Clinical Evaluation / 735		Operative Techniques and Results / 743	CABG for Ischemic Cardiomyopathy / 765
History / 735		New Developments / 747	Secondary Mitral Regurgitation / 765
Physical Examination / 737		Valvular Heart Disease	Left Ventricular Aneurysmorrhaphy and Surgical Ventricular Restoration / 766
Cardiac Risk Assessment in General Surgery Patients / 737		747	Mechanical Circulatory Support / 768
Diagnostic Studies / 738		General Principles / 747	Right Ventricular Assist Devices and Biventricular Assist Devices / 770
Extracorporeal Perfusion	740	Surgical Options / 747	Total Artificial Heart / 770
History / 740		Mitral Valve Disease	Surgery for Arrhythmias
Technique / 740		751	Atrial Fibrillation / 771
Adverse Effects / 741		Mitral Stenosis / 751	Surgery for Pericardial Disease
Myocardial Protection / 741		Mitral Regurgitation / 753	772
Coronary Artery Disease	741	Mitral Valve Operative Techniques and Results / 755	Acute Pericarditis / 772
History / 741		Aortic Valve Disease	Relapsing Pericarditis / 773
Etiology and Pathogenesis / 741		756	Chronic Constrictive Pericarditis / 773
Risk Factors and Prevention / 741		Aortic Stenosis / 756	Cardiac Neoplasms
Clinical Manifestations / 742		Aortic Insufficiency / 758	774
Preoperative Evaluation / 742		Aortic Valve Operative Techniques and Results / 761	Overview and General Clinical Features / 774
Coronary Artery Bypass Grafting	742	Tricuspid Valve Disease	Myxoma / 775
Indications / 742		762	Other Benign Cardiac Tumors / 776
Percutaneous Coronary Intervention vs. Coronary Artery Bypass Grafting / 742		Tricuspid Stenosis and Insufficiency / 762	Malignant Cardiac Tumors / 776
		Multivalve Disease / 764	Metastatic Cardiac Tumors / 776
		Surgical Therapy for the Failing Heart	
		764	
		Epidemiology of Heart Failure / 764	

CARDIAC ASSESSMENT

Clinical Evaluation

As with any other field in medicine, history, and physical examination form the foundation for the evaluation of a patient with acquired heart disease requiring surgical intervention. Obtaining a complete history will help identify comorbid conditions and assist in delineating the operative risks and prognosis after surgery. Physical examination not only reveals factors that may increase the complexity of surgery, such as previous surgery or peripheral or cerebral vascular disease. These may influence the operative approach but also help guide the choice and sequencing of diagnostic studies. A complete assessment of the patient allows the surgeon to make educated decisions regarding the optimal treatment strategy for the patient.

History

Symptoms suggestive of heart disease include: chest discomfort, fatigue, edema, dyspnea, palpitations, and syncope. Adequate definition of these symptoms calls for a detailed history-taking

paying particular attention to onset, intensity, radiation, duration, and exacerbating/alleviating factors. The demands on the heart are determined by its loading conditions and metabolic state of the body, and symptoms are commonly accentuated with physical exertion or postural changes.

Angina pectoris is the hallmark of coronary artery disease (CAD), but may occur with other cardiac pathologies which results in ischemia from a mismatch between the supply of oxygen by the coronary circulation and the metabolic demand of the myocardium. Typically, angina is described as tightness, heaviness, or dull pain, most frequently substernal in location, lasting for a few minutes. This discomfort may radiate to the left arm, neck, mandible, or epigastrium. It is most often provoked by activities that increase metabolic demand on the heart such as exercise, eating, and states of intense emotion, and is typically alleviated by rest or use of nitroglycerin. It is important to note that a significant number of patients with myocardial ischemia, particularly diabetics, females, and the elderly, may have “silent” angina or angina equivalents (dyspnea, diaphoresis, nausea, or fatigue). The overlap of these features with those

Key Points

- ▶ Although advances have been made in percutaneous coronary intervention techniques for coronary artery disease, survival is superior with coronary artery bypass grafting in patients with left main disease, multivessel disease, and in diabetic patients.
- ▶ Coronary artery bypass grafting has become increasingly safe, and improves late mortality in patients with left main or proximal left anterior descending disease, multivessel disease, and in patients with diabetes.
- ▶ Despite the theoretical advantages, the superiority of off-pump coronary artery bypass to conventional coronary artery bypass grafting has not been clearly established and other factors likely dominate the overall outcome for either technique.
- ▶ Although mechanical valves offer enhanced durability over tissue valve prosthesis, they require permanent systemic anticoagulation therapy to mitigate the risk of valve thrombosis and thromboembolic sequelae, and thus are associated with an increased risk of hemorrhagic complications.
- ▶ Mitral valve repair is recommended over mitral valve replacement in the majority of patients with severe chronic mitral regurgitation. The decision to proceed with mitral valve repair is based on the skill and experience of the surgeon in performing repair, and on the location and type of mitral valve disease encountered at the time of operation.
- ▶ Although open aortic valve replacement has traditionally been the only effective treatment in patients with severe calcific aortic stenosis, transcatheter aortic valve replacement is a developing technology that has proven beneficial for the treatment of aortic stenosis in seriously ill patients that had previously been deemed high risk or inoperable.
- ▶ Mechanical circulatory support with newer generation continuous flow left ventricular assist devices has proven to be durable and effective both in bridging patients to transplant and as a means of “destination therapy” for patients who are not transplant candidates. Recent results for destination therapy have approached those of cardiac transplantation.
- ▶ Performing a biatrial Cox-Maze lesion set results in freedom from atrial fibrillation in approximately 90% of patients and is superior to both catheter-ablation and more limited lesion sets for patients with persistent atrial fibrillation or enlarged left atria. Surgical ablation of atrial fibrillation is recommended for patients referred with concomitant valvular disease and those who have previously failed or are poor candidates for catheter-based approaches.
- ▶ The preferred treatment for pericarditis depends on the underlying cause, although the disease typically follows a self-limited course and is best managed medically. Surgical pericardiectomy may have a role in treating relapsing pericarditis and, more commonly, chronic constrictive pericarditis.
- ▶ Myxomas are the most common cardiac tumors, and, while benign, they should be promptly excised after diagnosis due to the risk of embolization, obstructive complications, and arrhythmias.

of noncardiac etiologies such as costochondritis, biliary colic, gastroesophageal reflux disease, diffuse esophageal spasm, and peptic ulcer disease, to name a few, can lead to misdiagnosis.

Heart failure can occur in the left and/or right heart and respective symptoms arise from congestion of blood flow owing to the inadequacies of the cardiac pump function. Left heart failure manifests as dyspnea, usually with exertion. Orthopnea suggests worsened pulmonary congestion with increased venous return and these patients are not able to lie flat. Ascites, peripheral edema, and hepatomegaly reflect congestion in the systemic venous circulation and are prominent features of right heart failure. Peripheral edema can occur in right heart failure secondary to systemic venous congestion, or in left heart failure due to salt and fluid retention due to impaired renal perfusion. Patients with chronic suboptimal perfusion and oxygenation can also have digital clubbing and cyanosis.

It is difficult to implicate cardiac disease based solely on the presence of fatigue as it is a very nonspecific symptom. However, most cardiac pathologies do result in fatigue or exercise intolerance of some degree. It is important to differentiate fatigue from exertional dyspnea which some patients may describe as “fatigue.”

Dyspnea is another common symptom seen in many heart diseases. Although generally a late symptom in patients with valvular heart disease or cardiomyopathy, it may be a relatively early complaint in some patients, particularly those with

mitral stenosis. As stated previously, dyspnea is also an anginal equivalent and may signal a myocardial ischemic episode. Many primary pulmonary disorders feature dyspnea as their cardinal symptom and should be evaluated simultaneously as the physiology of the heart and lungs are intimately related, and can have dramatic influences on each other.

Patients typically describe palpitations as a “skipped beat” or “racing heart”. Depending on the clinical context, such as occasional premature atrial or ventricular beats in otherwise healthy individuals, these may be benign. Clinically significant arrhythmias, however, require thorough investigation. Atrial fibrillation is the most common arrhythmia and can occur alone or with concomitant cardiac pathologies. It results in an irregular, and at times, rapid heartbeat. Concurrent symptoms such as angina or lightheadedness/syncope are particularly worrisome for life threatening arrhythmias such as ventricular tachycardia or ventricular fibrillation, particularly in those with preexisting heart failure or ischemic heart disease.

Syncope associated with heart disease results from abrupt reduction of cerebral perfusion. Many of the potential etiologies are serious, including sinus node dysfunction, atrioventricular-conduction abnormalities, malignant arrhythmias, aortic stenosis, and hypertrophic obstructive cardiomyopathy. Any episode of syncope warrants a thorough evaluation and search for the root cause.¹

Table 21-1

New York Heart Association (NYHA) functional classification

CLASS	DESCRIPTION
I	Physical activity not limited by symptoms: fatigue, palpitations, or dyspnea.
II	Comfortable at rest. Slight limitation of physical activity. Fatigue, palpitations, or dyspnea with ordinary physical activity.
III	Comfortable at rest. Marked limitation of physical activity. Fatigue, palpitations, or dyspnea with less than ordinary physical activity.
IV	Inability to carry out any physical activity. Symptoms may be present at rest and increase with activity.

In addition to a thorough inquiry regarding the above symptoms, it is important to obtain details about the patients' medical/surgical history, family history, social habits (with regards to alcohol and tobacco use), current medications, and a focused review of systems, including an assessment of the patients' functional status and frailty. Specific attention should be directed to the patients' comorbidities which not only sheds light on the patients' general health, but also helps delineate the risks if the patient were to undergo surgery. A strong family history of coronary artery disease, myocardial infarction, hypertension, or diabetes is of particular importance as they increase the individuals' risks.

Functional Disability and Angina. With regard to heart failure, functional capacity is strongly correlated with mortality. The New York Heart Association (NYHA) functional classification is the most widely used classification system in categorizing patients based on their functional status (Table 21-1). The NYHA classification has become a basis by which to assess patient characteristics in many studies to compare patient populations. Although less commonly used, the Canadian Cardiovascular Society (CCS) angina classification is also used to incorporate anginal symptoms into the functional assessment for prognostic value (Table 21-2).

Physical Examination

The physical examination is an invaluable tool in directing further diagnostic studies and management of a patient with suspected heart disease. The astute clinician will detect subtle signs that may further characterize the underlying pathologic process.

The general appearance of a patient is important in the clinical assessment. A pale, diaphoretic, and obviously uncomfortable patient is more likely to be in a clinically critical condition than one who is conversing comfortably with an unremarkable demeanor. In addition to basic vital signs, particular attention should be directed to the patients' mental status and skin (color, temperature, diaphoresis) as these may be reflective of the general adequacy of perfusion. Overall frailty and dementia have also been shown to be predictors of operative and late mortality.²

Palpation of the precordium may demonstrate deviations in the point of maximal impulse indicative of ventricular

Table 21-2

Canadian Cardiovascular Society (CCS) anginal classification

CLASS	DESCRIPTION
I	Ordinary physical activity (walking, climbing stairs) does not cause angina. Angina occurs with strenuous, rapid, or prolonged exertion during work or recreation.
II	Slight limitation of ordinary activity. Angina occurs with climbing stairs rapidly, walking uphill in the wind, under emotional stress, in the cold, or after meals. Walking more than 2 blocks or climbing one flight of stairs causes angina.
III	Marked limitation of ordinary physical activity (climbing a flight of stairs or walking 1 to 2 blocks at a normal pace).
IV	Inability to carry out any physical activity without discomfort. Angina may be present at rest.

hypertrophy or parasternal heaves seen in right ventricular overload. Auscultation should be performed in a quiet environment as critical murmurs, rubs, or gallops may be subtle. Murmurs are characterized by their location, timing, quality, and radiation. They are typically secondary to valvular or other structural pathology and new findings require further investigation. A rub due to pericardial friction is specific and virtually pathognomonic for pericarditis. A third heart sound (S_3) is generated by the rapid filling of a stiff ventricle and can be normal in young patients, but when present in older adults, is indicative of diastolic dysfunction and is pathologic. Increased contribution of the atrial pump function to ventricular filling may manifest as a fourth heart sound (S_4) and is also suggestive of ventricular dysfunction.

Palpation of peripheral pulses is important not only to assess the adequacy of perfusion, but the burden of coronary artery disease often correlates with the degree of peripheral arterial disease. Discovery of carotid stenosis by auscultation for carotid bruits has significant implications for operative planning.

Heart disease will frequently have extracardiac manifestations and examination of the other organ systems should not be neglected. Auscultation of the lung fields may reveal rales in patients with pulmonary edema. The work of breathing may also be assessed simply by observing the patient. Jugular venous distention and hepatosplenomegaly are seen in right heart failure.

Cardiac Risk Assessment in General Surgery Patients

Approximately one half of the mortality in patients undergoing noncardiac surgery is due to complications which are cardiovascular in origin.³ The American College of Cardiology and American Heart Association have formed a joint task force to publish a consensus statement on guidelines and recommendations which was revised in 2007.⁴ The aim of these guidelines is to incorporate surgery-specific risks and patient characteristics to stratify patients in order to guide perioperative decision-making.

Surgical procedures have been categorized based on cardiovascular risk into low and moderate risk, and vascular procedures.

Vascular procedures (aortic, peripheral vascular, and other major vascular surgery), likely due to both the nature of the procedures themselves as well as the associated cardiovascular pathology in many of these patients, carries the highest reported cardiac risk at more than 5%. Low risk procedures, including endoscopic procedures, superficial operations, cataract surgery, breast surgery, and ambulatory surgeries have a risk generally less than 1%. Intermediate risk procedures are: intraperitoneal and intrathoracic surgery, head and neck surgery, orthopedic procedures, and prostate surgery.

Patient characteristics can be classified by the status of the patients' cardiac disease, comorbid conditions, and functional capacity. Patients are considered to be at major perioperative clinical risk if they have one or more of the following active cardiac conditions: unstable coronary syndrome, decompensated heart failure, significant arrhythmias, or severe valvular heart disease. In these patients, intensive evaluation and treatment prior to surgery (unless emergent) is warranted, even if the noncardiac surgery needs to be delayed or cancelled.

If the patient does not have any of the previously mentioned conditions, and is scheduled for a low risk surgery or if they have functional capacity greater than or equal to 4 metabolic equivalents (or METs), the official recommendation is to proceed with the planned operation. The previous guidelines contained intermediate and low cardiovascular risk profiles, but this has been replaced by cardiovascular risk factors in the update. These risk factors are: history of ischemic heart disease, history of prior or compensated heart failure, history of cerebrovascular disease, diabetes mellitus, and renal insufficiency. Based on the number of present risk factors and the surgery-specific risk, the guideline recommends pathways for further evaluation and risk management (Table 21-3).

Diagnostic Studies

Electrocardiogram and Chest X-ray. Electrocardiograms (ECGs) and chest X-rays are simple, noninvasive, and inexpensive diagnostic studies that are invaluable in the preoperative assessment of patients with cardiac pathology. ECGs can be useful in detecting old myocardial infarction, dilation or

hypertrophy of cardiac chambers, arrhythmias, and conduction abnormalities. A stress ECG requires a patient to exercise to a target heart rate, and is used to help diagnose ischemic pathologies which may not be evident at rest.

A plain film of the chest can detect pulmonary pathology, sequelae of heart failure (e.g., pulmonary edema, cardiac enlargement, pleural effusions) as well as hardware from previous procedures such as, prosthetic valves, sternal wires, pacemakers, and defibrillators.

Echocardiography. Echocardiography utilizes reflected sound waves to image the heart, and is used widely due to its noninvasive nature and low cost. It is the primary diagnostic tool used to evaluate structural diseases of the heart, including: valvular pathology, septal defects, cardiomyopathies, and cardiac masses. Echocardiography is indispensable in assessing surgical prosthetics such as valves, leads, or mechanical circulatory support devices. These examinations can be performed with M-mode imaging (motion along a single line) as well as 2-D and 3-D imaging depending on the graphical information required.

Doppler technology has become a standard addition to assess changes in flow patterns across both stenotic and regurgitant valves. Velocity measurements can be obtained to estimate pressure gradients across structures using the continuity equation. A common example would be the estimation of pulmonary arterial systolic pressure calculated from the regurgitant tricuspid jet profile during right ventricular systole.

Transthoracic echocardiography (TTE) requires no sedation and is generally performed with the patient in a slight left lateral decubitus position. Standardized views are obtained with the ultrasound probe placed in the apical, parasternal, subcostal, and suprasternal positions. The apical four-chamber view is a useful window for visualizing all four cardiac chambers simultaneously as well as the tricuspid and mitral valves. Other windows can be obtained to assess specific structures such as the individual valve anatomy or myocardial wall segments. Dobutamine-stress echocardiography is a study similar in idea to the stress ECG which utilizes a pharmacologic agent to assess the patient for ischemia or stress-induced valvular abnormalities.

A slightly invasive variant of this technology is transesophageal echocardiography (TEE) which takes advantage of the anatomic proximity of the heart to the esophagus. The exam is performed using a special endoscope with an ultrasound probe mounted on its end which is introduced orally into the esophagus under sedation. Posterior structures such as the mitral valve and left atrium are particularly well visualized. TEEs are frequently used intraoperatively during cardiothoracic surgery to assess global cardiac function, integrity of valve repairs and replacements, intracavitary thrombus and/or air, and aortic atherosclerosis or dissections which can have significant influences on operative strategy.

There are some new additions to the echocardiographic armamentarium which capitalize on the strengths of ultrasound imaging. Three dimensional TEE is playing an increasing role in the preoperative and intraoperative evaluation of patients with valvular heart disease and is particularly useful in the valuation of mitral regurgitation. Tissue Doppler imaging is based on principles akin to conventional Doppler echocardiography, but attention is directed to the myocardium itself as opposed to the motion of blood to quantify abnormalities in wall motion. Strain imaging with speckle-tracking echocardiography measures the actual deformation of the myocardium by following

Table 21-3

Algorithm set forth by ACC/AHA guidelines for preoperative cardiovascular evaluation before noncardiac surgery for patients who are scheduled for nonemergent, non-low risk surgery, no active cardiac disease, and less than 3 METs

NUMBER OF RISK FACTORS*	RECOMMENDATION
0	Proceed with planned surgery.
1–2	Control HR and proceed with planned surgery or pursue further testing if it will change management.
3–5	Pursue further testing if it will advance management.

*Risk factors are: history of ischemic heart disease, history of prior or compensated heart failure, history of cerebrovascular disease, diabetes mellitus, and renal insufficiency.

inhomogeneities inherent to the myocardium, and is a useful measure of myocardial function.

Radionuclide Studies. Although ECGs are useful, inexpensive, and safe, baseline abnormalities in the ECG may limit its diagnostic capacity. In particular, ventricular rhythms, bundle-branch blocks, left ventricular hypertrophy, drug effects, and baseline ST-segment depressions can make stress ECGs uninterpretable. In this setting, myocardial perfusion imaging (MPI) using radionuclides can be utilized to assess myocardial ischemia.

Thallium 201 (^{201}Tl) was the initial radionuclide used for MPI, but due to its long half-life and relatively low photopeak, it has largely been replaced by Technetium-99m (sestamibi and tetrofosmin) which has more favorable characteristics. In the past, planar imaging with three separate two-dimensional views of the heart were obtained. Currently, it is more common to have the images acquired by single-photon emission computed tomography (SPECT) technology which detects emitted photons from 180- to 360-degrees around the patients. The signals are then processed to reconstruct multiple slices which together provide a three-dimensional view. The amount of uptake at both rest and stressed states are compared to assess ischemia and viability of the myocardium. The distribution of radionuclides depend on perfusion and therefore areas which show uptake at rest, but not during stress are concerning for ischemia.

Territories that do not show uptake at rest or during stress are likely to be nonviable scar. The sensitivity and specificity of exercise SPECT are 90% and 70%, respectively.⁵

The image acquisition may also be gated to a simultaneously obtained ECG to assess global ventricular function. The endocardial and epicardial borders (as delineated by radionuclide uptake) are detected throughout the cardiac cycle and the ejection fraction, along with end-systolic and end-diastolic volumes, can be calculated. This study is also useful in revealing hypokinetic segments of the myocardium.

One of the most significant weaknesses of SPECT imaging is that it shows regional ischemia well, but does not adequately detect global or “balanced” ischemia which can occur with diffuse CAD. Positron emission tomography (PET) scans have been used due to its ability to obtain absolute quantitative data on both myocardial perfusion and metabolism. Tracers used in PET scans can be divided into those that assess perfusion (Oxygen-15, Nitrogen-13, and Rubidium-82) and those that assess metabolism (Carbon-11 and Fluorine-18). The specificity of PET in detecting CAD is better than SPECT at 86% due to its superior spatial resolution.⁶

Magnetic Resonance Imaging. Magnetic resonance imaging (MRI) has a wide variety of uses in cardiac imaging depending on the pulse sequence and signal weighting. Cine-loop of the heart throughout the cardiac cycles can yield information on global chamber function and valvular pathologies. The differential response of normal and ischemic myocardium to certain pulse sequences allows imaging of myocardial perfusion using MRI. Use of contrast agents such as gadolinium can enhance scar tissue and are very useful in viability assessment. Myocardial strain imaging can also be performed using newer technologies taking advantage of radio-frequency tagging of the myocardium which deforms with the tissue and can be followed throughout the cardiac cycle.

Cardiac Catheterization. Cardiac catheterization involves access to the cardiac chambers and great vessels with a peripherally inserted catheter under fluoroscopic guidance. It is a

versatile tool used for diagnostic purposes of: cardiac chamber pressures, valvular abnormalities, wall motion assessment, and coronary artery anatomy. While some of these roles are being replaced by less invasive techniques mentioned previously, cardiac catheterization studies continue to be widely performed and is the gold standard for the assessment of coronary artery disease.

A left-heart catheterization is performed by percutaneous access of the femoral, or less commonly, the radial artery. Under fluoroscopic guidance, the catheter is threaded into the aorta where a contrast aortogram may be performed. Coronary angiography requires manipulation of this catheter into the coronary ostia where contrast is directly injected. With advancement of the catheter retrograde past the aortic valve, left ventricular pressures can be obtained. This pressure is used to calculate pressure gradients across the aortic valve which becomes particularly important in the evaluation of aortic stenosis. Again, contrast injection will result in a ventriculogram used to estimate ejection fraction and visualize hypokinetic segments of the walls. Inappropriate retrograde leakage of contrast may indicate insufficiency of the aortic and/or mitral valves.

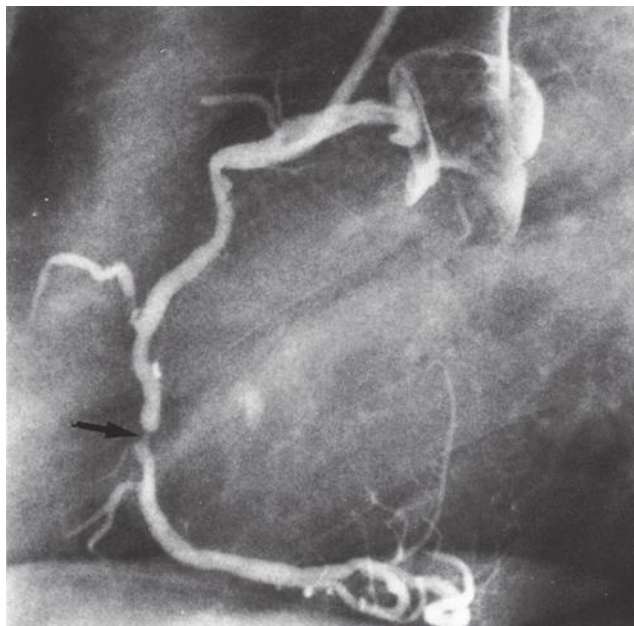
Right heart catheterization is performed through a peripheral vein and the catheter is threaded into the right atrium. Right-sided pressures and structures are assessed in a similar fashion as in the left heart. Extension of the catheter into the pulmonary artery allows measurement of the pulmonary artery pressures as well as the pulmonary capillary wedge pressure (reflecting left ventricular end diastolic pressure) with an occlusive balloon.

In addition to these measurements, cardiac output can be measured using thermodilution or by the Fick method using oxygen saturations of blood sampled from the various locations during the procedure.

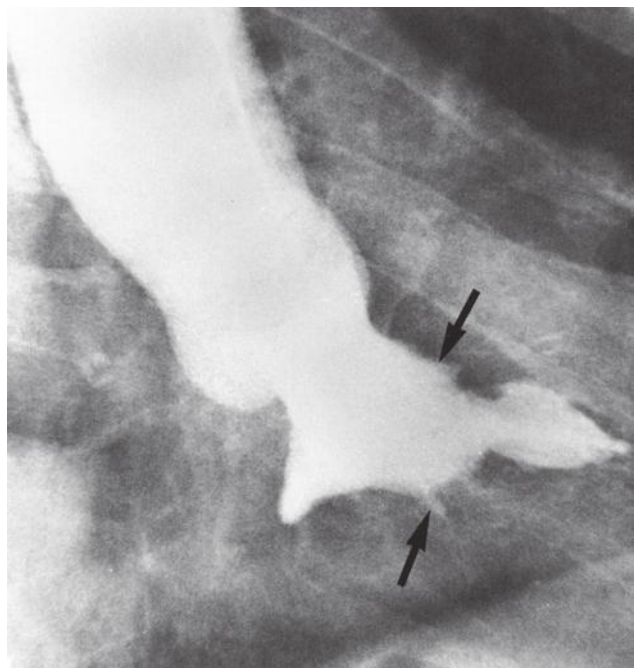
Coronary angiography provides information on hemodynamically significant stenoses in the coronary circulation as well as an anatomical roadmap for surgeons to planning revascularization. (Fig. 21-1A & B) A stenosis is considered to be significant if it narrows the lumen of the artery by 70% (or 50% in the case of left main coronary artery). There is some variability in the coronary arterial anatomy with the posterior descending artery being supplied by the right coronary artery in approximately 80% of patients (right dominant), or the left coronary artery in approximately 15% of patients (left dominant). The remaining patients have a codominant circulation where the posterior descending artery is supplied by both the right and left coronaries.

An advantage of catheterization is that it offers an opportunity for interventional therapy of coronary artery disease, arrhythmias, valvular abnormalities, and other structural defects of the heart. Cardiac catheterization is generally safe, but being an invasive procedure, it is associated with complications. Overall mortality is 0.11%, and total rate of major complications, including: MI, stroke, arrhythmia, vascular injury, contrast reaction, hemodynamic instability, and cardiac perforation is usually <2%.⁷

Cardiac Computed Tomography. Multislice computed tomography (CT) imaging can be used to assess the coronary vasculature. The coronary calcium score is an index developed to quantify the degree of coronary atherosclerotic burden by measuring Hounsfield units in a noncontrast cardiac CT. Although this technique is quite sensitive for angiographic stenoses >50%, it remains fairly nonspecific as calcification often precedes significant luminal narrowing.⁸ CT coronary angiography using intravenous contrast is also utilized clinically to assess coronary pathology and is particularly useful in the emergency room to perform a “triple rule-out” for acute coronary events,



A



B

Figure 21-1. Cardiac catheterization angiography. **A.** Stenosis of right coronary artery indicated by the arrow. **B.** Still image of a normal left ventriculogram.

pulmonary embolism, and aortic dissection in patients who present with undifferentiated chest pain. LV ejection fraction may be measured by this technique, and together with the degree of coronary stenoses, incremental prognostic value has been demonstrated in addition to routine clinical predictors.⁹

EXTRACORPOREAL PERFUSION

History

Prior to the development of extracorporeal perfusion, heart surgery was rarely performed and was limited to brief periods of

asystole and hypothermia. The need for a bloodless operating field, while maintaining perfusion of heart and other organs, was evident.

John Gibbon's motivation to develop a means for extracorporeal perfusion came from a desire to safely open the pulmonary artery in a patient who suffered from a pulmonary embolus following cholecystectomy. After numerous experimental iterations, Gibbon's cardiopulmonary bypass machine was first used clinically in 1953 to repair a large atrial septal defect in an 18-year-old female.¹⁰

Although Gibbon is credited for its invention, the development of modern cardiopulmonary bypass (CPB) is a culmination of the work of many investigators throughout the world. The early bubble oxygenators have evolved into the modern membrane oxygenators. The search for an ideal biocompatible material which minimizes the inflammatory cascade initiated by the contact of blood with the circuit components continues to this day.

Technique

The basic CPB circuit consists of the venous cannulae, a venous reservoir, pump, oxygenator, filter, and the arterial cannula.

Anticoagulation is required during CPB, and 300 to 400 units/kg of heparin is given to increase the activated clotting time (ACT) to greater than 450 seconds. Once adequate anticoagulation is achieved, arterial cannulation is performed through a purse-string suture, or through a side graft which is sewn on to the native artery. The distal ascending aorta is the most common site of cannulation, but there may be concern for atheroembolization when the aorta is atherosclerotic. Other sites of cannulation include the femoral artery, axillary artery, or the distal aortic arch. Venous cannulation is performed through purse-string sutures placed on the right atrium either for a single cannula or for two separate cannulae extending into the superior and inferior vena cava, respectively. Alternatively, the venous cannula may be inserted from the femoral vein and advanced into the right atrium.

Effective communication between the surgeon, the anesthesiologist, and the perfusionist is mandatory for effective cardiopulmonary bypass. Once the appropriate cannulations and connections are complete, CPB is commenced. Venous return is initiated followed by arterial flow while monitoring systemic blood pressures. At normothermia, the flow required is approximately 2.4 L/min/m², but with hypothermia, oxygen consumption is reduced by 50% for every 10°C drop in temperature, and a flow of only 1L/min/m² is required at 18°C. Once the heart is decompressed and hemodynamics are acceptable, ventilation is stopped. The oxygenator is adjusted to maintain a PaO₂ of 150 mm Hg and normocarbia. Blood can also be filtered and returned through vents that are placed in the heart or through the cardiotomy suction used to aspirate blood from the surgical field.

When the cardiac procedure is complete, the patient is rewarmed, the lungs ventilated, and the heart defibrillated if needed. The venous return to the CPB machine is gradually reduced allowing the heart to fill. The pump is also slowed while hemodynamics and global cardiac function are assessed with a TEE probe. Inotropic and vasopressor support may be used to augment cardiac function and treat hypotension. Once CPB has been stopped and stable hemodynamics achieved, the cannulae are removed. The heparin anticoagulation is reversed with protamine and hemostasis is achieved.¹¹

Adverse Effects

Cardiopulmonary bypass has a number of deleterious effects as various intertwining processes result in derangements in hemostasis, systemic inflammatory response, and end-organ function.

Anticoagulation prior to the commencement of CPB is required as contact of blood with the artificial surfaces of the circuit can initiate a thrombogenic cascade. Generation of thrombin plays a major role in both thrombotic and bleeding phenomena during CPB. The endothelium which normally regulates the fine balance between procoagulant and anticoagulant pathways is perturbed. Fibrinogen is consumed rapidly as thrombin converts fibrinogen to fibrin while fibrinolytic mechanisms (initiated by the activated endothelium) degrade the fibrin macromolecules. Platelets are activated by the converging hemostatic pathways and are consumed.

The response of the humoral and cellular immune systems partly overlap with the hemostatic pathways. The classic and alternative complement pathways are activated by CPB generating powerful chemotactic molecules and anaphylatoxins. Monocytes, platelets, and neutrophils are activated releasing acute inflammatory mediators and cytokines which persist even after conclusion of CPB.¹² These inflammatory cells also produce reactive oxidants which may have cytotoxic effects.

The large quantity of unfractionated heparin used during cardiac surgery predisposes patients to developing heparin induced thrombocytopenia (HIT) with an incidence of 1% to 2%. Platelet factor-4 (PF4) is produced by platelets and avidly binds to heparin to form a heparin-PF4 complex which can be antigenic in some patients binding IgG. The IgG-heparin-PF4 complex can bind to platelets which causes release of more PF4, perpetuating the process. The earliest sign is a sudden drop of more than 50% of the platelet count, and HIT can be confirmed with an ELISA or serotonin release assay. Of the patients with HIT, 20% to 50% of patients develop thromboses in arterial or venous beds, designated as heparin induced thrombocytopenia and thrombosis (HITT), which can be life-threatening.¹³

The etiology of end-organ dysfunction resulting from extracorporeal circulation can mostly be categorized into one of three mechanisms. Although cardiac output and blood pressure are monitored carefully during CPB, they are surrogates for regional perfusion and cannot detect end-organ hypoperfusion directly. This can be a problem particularly with the cerebral, renal, and mesenteric circulations. With manipulation of diseased vessels and dysregulation of the native coagulation system, macroscopic and microscopic emboli are a concern despite various strategies to minimize this problem. Activated cells and circulating cytotoxic products of the immune response may cause microvascular injury and edema of other organs manifesting as neurocognitive deficits, respiratory failure, and renal injury.¹⁴

Myocardial Protection

During CPB, pharmacologic agents in cardioplegic solutions may be delivered into the coronary circulation to arrest the heart allowing for a still operating target and improved myocardial protection. The most common cardioplegia consists of potassium-rich solutions that can be mixed with autologous blood and are delivered into the coronary circulation. Antegrade cardioplegia is delivered into the root of a cross-clamped aorta or directly into the individual coronary ostial via specialized catheters. A retrograde cardioplegia catheter is a balloon-cuffed

catheter that is placed through the right atrium into the coronary sinus and is used to perfuse the coronary circulation in the opposite direction through the venous circulation. This has the advantage of more uniform distribution in patients with diffuse coronary artery disease and is not dependent on a competent aortic valve for delivery.

There are controversies regarding the method (antegrade retrograde vs. both), type (crystalloid vs. blood), temperature (cold vs. warm vs. tepid), and interval (continuous vs. intermittent) of cardioplegia delivery. The optimal combination is beyond the scope of this text. However, most surgeons in the United States favor cold blood potassium cardioplegia.

CORONARY ARTERY DISEASE

History

The Vineberg operation, one of the initial attempts at surgical revascularization of the myocardium, was first performed in 1950s. This procedure involved implantation of the internal thoracic artery directly into the myocardium itself. While some patients were relieved of their anginal symptoms, this resulted in very little increase in coronary flow and was supplanted by methods to restore flow directly. Coronary endarterectomy was introduced by Longmire during this time period, but was met with high rates of restenosis and occlusion. The use of vein patches to repair the arteriotomy sites was described by Senning in 1961. The first saphenous vein coronary artery bypass grafting (CABG) was performed by Sabiston in 1962, but was popularized by Favalaro in 1967. In 1968, the internal thoracic artery was introduced as a bypass conduit by Green who used it to bypass the left anterior descending coronary artery.¹⁵

Etiology and Pathogenesis

Atherosclerotic stenoses are the primary mechanism of coronary artery disease (CAD). The pathophysiologic process is initiated with vascular endothelial injury and is potentiated by inflammatory mechanisms, circulating lipids, toxins, and other vasoactive agents in the blood. Macrophages and platelets are attracted to this area of endothelial dysfunction inciting a local inflammatory response. During this process, macrophages infiltrate into the intimal layers and accumulate cholesterol-containing low-density lipoproteins. The growth factors secreted promote proliferation of smooth muscle cells within the intima and media of the arteries. Together with the accumulation of the lipid-laden macrophages, the smooth muscle hyperplasia results in an atheroma and subsequently stenosis of the vessel. These atheromas have a fibrous cap which may rupture, exposing the underlying cells and extracellular matrix which are very prothrombotic. Acute plaque rupture and thrombus formation is thought to be the main pathophysiologic mechanism responsible for acute coronary syndromes.¹⁶⁻¹⁸

Risk Factors and Prevention

Prior to the establishment of modern management strategies, the annual mortality rated from ischemic heart disease was quoted to be around 4% by the Framingham study. Since then, risk factor modification along with use of medications, such as aspirin and β -blockers, has dramatically improved survival.

The major risk factors of atherosclerosis include: age, cigarette smoking, hypertension, dyslipidemias, sedentary lifestyles, obesity, and diabetes. Likely due to increased public awareness and aggressive medical management, these risk factors (with the

exception of glucose intolerance and obesity) have recently been on the decline.

Current guidelines outlined in the AHA/ACC consensus statement summarizes secondary prevention recommendations. Class I recommendations are: smoking cessation and avoidance of environmental tobacco exposure, blood pressure control to under 140/90 mm Hg (under 130/80 mm Hg in those with diabetes or chronic kidney disease), LDL cholesterol levels less than 100 mg/dL, aspirin therapy in all patients without contraindications, BMI target of less than 25 kg/m², diabetes management with target HbA1c <7%, and encouragement of daily aerobic exercise routines. Beta-blockers are to be considered in patients with LV dysfunction and following MI or ACS. Renin-angiotensin-aldosterone system blockade in patients with hypertension, LV dysfunction, diabetes, or chronic kidney disease should also be considered.¹⁹

Clinical Manifestations

Patients with CAD may have a spectrum of presentations, including angina pectoris, myocardial infarction, ischemic heart failure, arrhythmias, and sudden death.

Angina pectoris is the pain or discomfort caused by myocardial ischemia and is typically substernal and may radiate to the left upper extremity, left neck, or epigastrium. The variety of presentations can make myocardial ischemia difficult to diagnose. Characteristics of chest pain that make myocardial ischemia less likely include: pleuritic chest pain, pain reproducible by movement or palpation, or brief episodes lasting only seconds. Typical angina is relieved by rest and/or use of sublingual nitroglycerin. Differential diagnoses to be considered include, but are not limited to: musculoskeletal pain, pulmonary disorders, esophageal spasm, pericarditis, aortic dissection, gastroesophageal reflux, neuropathic pain, and anxiety.

Myocardial infarction is a serious consequence of CAD occurring when ischemia results in myocardial necrosis. This may be silent and need not be preceded by angina. Necrosis may result in disruption of the myocardial integrity leading to devastating conditions such as intracardiac shunts from ventricular septal defects, acute valvular regurgitation from rupture of necrotic papillary muscles, and cardiac aneurysms which have the catastrophic potential to rupture.

The ischemic insults from CAD may lead to congestive heart failure. The initial myocardial damage sets off a cascade of responses, both local and systemic. Over time, these changes can cause deleterious myocardial loading and abnormal neurohumoral responses that result in pathologic remodeling of the heart. Heart failure should be suspected in patients who present dyspnea, orthopnea, fatigue, and edema.

Arrhythmias may also be a sequela of CAD. Ischemic etiologies should be investigated in patients who present with new arrhythmias. CAD may result in arrhythmias following an acute MI or as the result of ultrastructural and electrophysiologic remodeling secondary to chronic ischemic heart disease. Ischemia of the electrical conduction system may be seen as the new onset complete or partial atrioventricular conduction blocks.

Preoperative Evaluation

A focused history and physical examination is essential with particular attention directed to the signs, symptoms, and clinical manifestations mentioned previously. The patient's functional status is of importance not only because it is a component of preoperative risk assessment, but also because quality of life

improvement and symptomatic relief are both goals of surgical therapy.

Coronary angiography is the primary diagnostic tool. The coronary anatomy and degrees of stenoses are delineated allowing for planning of surgical revascularization.

Noninvasive diagnostic studies, in combination with provocative maneuvers (exercise or pharmacologic agents) offer information regarding the functional significance of ischemic disease. A stress ECG is frequently used as a screening tool with a high sensitivity. The positive predict value is 90% in patients with ST-segment depression >1mm. This test however, requires patients to achieve a certain elevation in their heart rate, and is therefore not suitable for those that cannot achieve this goal. Furthermore, baseline ECG abnormalities may render it impossible to detect typical ischemic changes with stress.

Echocardiography and nuclear imaging may be performed under pharmacologic stress (with dobutamine or dipyridamole) to assess reversible ischemia and myocardial viability. Technetium-99m or thallium-201 perfusion scans have an average sensitivity and specificity of 90% and 75%, respectively. Stress echocardiography has a similar sensitivity and specificity of approximately 85%.²⁰ These studies also have the ability to assess global ventricular function in terms of LV ejection fraction which can be used to determine operative risk.

CORONARY ARTERY BYPASS GRAFTING

Indications

A joint committee established by the American College of Cardiology and the American Heart Association have published guidelines for surgical revascularization (CABG) in CAD. The indications, categorized by presentation and angiographic disease burden as well as by treatment intention (survival improvement and symptom relief), are summarized later (Tables 21-4,5,6).²¹

Percutaneous Coronary Intervention vs. Coronary Artery Bypass Grafting

In recent years, there have been multiple prospective randomized, controlled trials as well as retrospective studies looking at the comparative effectiveness of percutaneous coronary interventions (PCI) and CABG. Some of the representative studies are summarized here.

The New York State Study (2005). A retrospective review of 59,314 patients in two of New York's registry with multivessel (2 or more) coronary disease was performed. Of these, 37,212 patients received a CABG and the others underwent a PCI. After adjusting by means of proportional-hazards methods, CABG was associated with higher adjusted rates of long-term survival than PCI.²²

Stent or Surgery Trial (2008). An international multicenter randomized controlled trial of 988 patients ($n = 488$ PCI, $n = 500$ CABG) with multivessel CAD was performed to compare revascularization strategies. At 2-year median follow-up, the PCI group had significantly higher rates of repeat revascularizations and mortality compared to the CABG group (incidence of nonfatal Q-wave myocardial infarctions were similar in both groups). The median follow-up was extended to 6-years, and a survival advantage persisted in the CABG group over the PCI group.²³

Table 21-4

Data from ACC/AHA guidelines for CABG in CAD to improve survival

ANATOMY	CLASS OF RECOMMENDATION	LEVEL OF EVIDENCE
• LM	I	B
• 3-vessel +/- proximal LAD	I	B
• 2-vessel + proximal LAD	I	B
• 2-vessel – proximal LAD	IIa – with extensive ischemia IIb – without extensive ischemia	B C
• Multivessel disease with DM	IIa (CABG preferred over PCI)	B
• Proximal LAD only	IIa – with LITA for long-term benefit	B
• 1-vessel – proximal LAD	III – Harm	B
• LV dysfunction	IIa – LVEF 35%–50% IIb – LVEF <35% without LM disease	B B
• Survivor of ischemia-mediated VT	I	B

DM = Diabetes mellitus; LITA = Left internal thoracic/mammary artery; LM = Left main coronary artery; LV = left ventricle; VT = ventricular tachycardia. Class of recommendation: I – Benefit far outweighs risks and procedure should be performed; IIa – Benefit outweighs risks and procedure is considered to be reasonable; IIb – Potential benefits may exceed risks and procedure may be considered; III – Procedure not helpful and may cause harm. Level of evidence: A – Strong; multiple supporting randomized controlled trials or meta-analyses, B – Limited; data based on a single randomized trial or non-randomized trials, C – Very limited; based on expert consensus, case studies or standards of care.

Synergy between Percutaneous Coronary Intervention with Taxus and Cardiac Surgery (SYNTAX Trial, 2009). Revascularization strategies, CABG vs. PCI, were compared in a 1:1 randomized prospective trial of 1800 patients with high risk coronary artery disease (left-main or triple-vessel disease). Rates of requirement for repeat revascularization and major adverse cardiac or cerebrovascular events at 12-months were lower in the CABG patients (5.9% and 12.4%, respectively) compared to PCI patients (13.5% and 17.8%, respectively). No difference in mortality was seen between the groups at 12-months.²⁴

The ACCF and STS Database Collaboration on the Comparative Effectiveness of Revascularization Strategies (ASCERT Study, 2012). This study, performed by collaboration of the American College of Cardiology Foundation and the Society of Thoracic Surgeons, reviewed their respective national databases of patients over the age of 65 who had multivessel coronary disease (excluding those with left main disease). CABG was performed on 86,244 patients and 103,549

underwent PCI. There was no difference in adjusted mortality at 1 year, but there was a significantly lower mortality with CABG than PCI at 4 years.²⁵

Summary

PCI technology has improved over time and rates of periprocedural adverse events have decreased significantly. Management strategies must be tailored to the individual patient's clinical status and context, but CABG maintains improved long-term outcome and remains the standard of care for left-main and multivessel coronary artery disease.

Operative Techniques and Results

Bypass Conduit Selection. The most important criterion in conduit selection is graft patency. The conduit with the highest patency rate (98% at 5 years and 85%–90% at 10 years) is the internal thoracic artery which is most commonly left attached proximally to the subclavian artery (although occasionally used as a free graft) and anastomosed distally to the

Table 21-5

Data from ACC/AHA guidelines for CABG in CAD to improve symptoms

ANATOMY ASSOCIATED SYMPTOMS	CLASS OF RECOMMENDATION	LEVEL OF EVIDENCE
• Unacceptable angina with presence of ≥ 1 stenoses amenable to revascularization despite medical treatment	I	A
• Complex 3-vessel CAD +/- proximal LAD involvement	IIa (CABG preferred over PCI)	B
• Unacceptable angina with presence of ≥ 1 stenoses amenable to revascularization but medical treatment is not possible	IIa	C
• Previous CABG with ≥ 1 stenoses associated with ischemia and angina despite medical treatment	IIb	C

Table 21-6

Data from ACC/AHA guidelines for CABG in CAD in specific clinical contexts

CLINICAL SETTING	CLASS OF RECOMMENDATION	LEVEL OF EVIDENCE
EMERGENT CABG FOLLOWING ACUTE MI		
• Failure or inability to perform PCI, anatomy suitable for CABG, persistent ischemia/hemodynamic instability refractory to nonsurgical therapy	I	B
• Patients undergoing surgical repair of postinfarction complication (e.g., VSD, papillary or free wall rupture)	I	B
• Cardiogenic shock with anatomy suitable for CABG	I	B
• Life-threatening ventricular arrhythmia, ischemic in origin, with 3-vessel disease or >50% LM stenosis	I	C
• Multivessel disease, recurrent angina or MI within 48 hrs of STEMI (instead of a more delayed strategy)	IIa	B
• Age >75 with ST-elevation or new left bundle branch block who are suitable for revascularization, regardless of time between MI and cardiogenic shock.	IIa	B
• Persistent angina with only small area of viable myocardium	III – Harm	C
SURVIVAL FROM SUDDEN CARDIAC DEATH OR SUSTAINED VT		
• If thought to be due to significant CAD (amenable to revascularization).	I	B
• If only scar present, and no evidence of ischemia	III- Harm	C
PATIENTS UNDERGOING CONCOMITANT NON-CORONARY CARDIAC SURGERY		
• In presence of significant CAD (>50% LM stenosis or >70% stenosis of another major coronary artery).	I	C
• LITA graft to significantly narrowed LAD or CABG of moderately diseased (>50% stenosis) coronary artery.	IIa	C
EMERGENT CABG AFTER FAILED PCI		
• Ongoing ischemia, threatened occlusion with substantial myocardium at risk, or hemodynamic compromise (without coagulopathy or previous sternotomy).	I	B
• Retrieval of foreign bodies (from PCI) or hemodynamic compromise with coagulopathy and without previous sternotomy.	IIa	C
• Absence of ischemia or threatened occlusion	III – Harm	C

LM = Left Main; VT = ventricular tachycardia.

target coronary artery.^{26,27} The use of both internal thoracic arteries has been shown to increase event-free survival in a number of studies.^{28,29}

The greater saphenous vein can be harvested using an open or endoscopic technique. In the open technique, the initial incision is made along the course of the vein on the medial aspect of the lower extremity. The vein is harvested with meticulous attention directed towards minimizing manipulation of the vein itself. The incision may be continuous or bridged in an attempt to decrease the size of the incision, but multiple bridged incisions may have the potential risk of increased conduit manipulation during harvest. Endoscopic harvest is performed by making a small incision just above and medial to the knee where the endoscope is inserted. Side branches are cauterized under endoscopic visualization using bipolar electrocautery until dissection is carried proximally until the required length of vein is mobilized. A proximal counterincision is then made to extract the venous conduit which is prepared in the standard fashion.

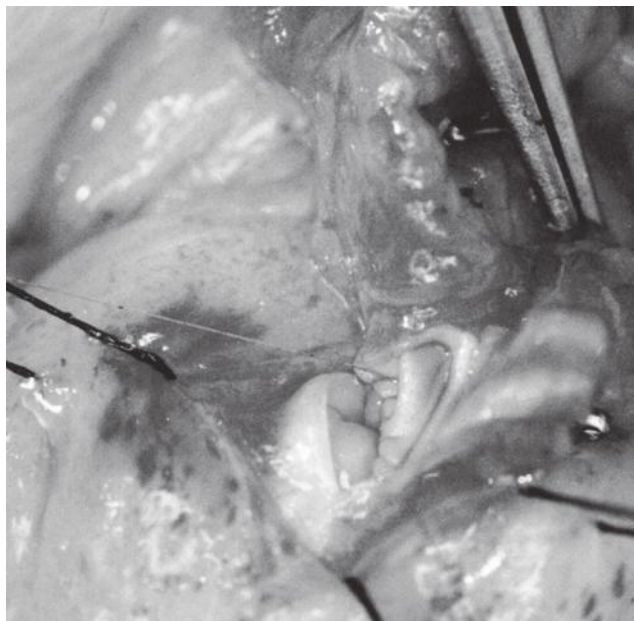
The radial artery is another frequently used conduit. After confirmation of ulnar collateral flow to the hand by the clinical Allen's test or a duplex ultrasound study, an incision is made from a point just proximal to the radial styloid process ending just medial and distal to the biceps tendon on the nondominant

hand. With lateral retraction of the brachioradialis muscle, the radial artery is dissected sharply with care to avoid injury to the cutaneous nerves in this area and minimize manipulation of the artery itself. This artery can also be harvested using an endoscopic technique.

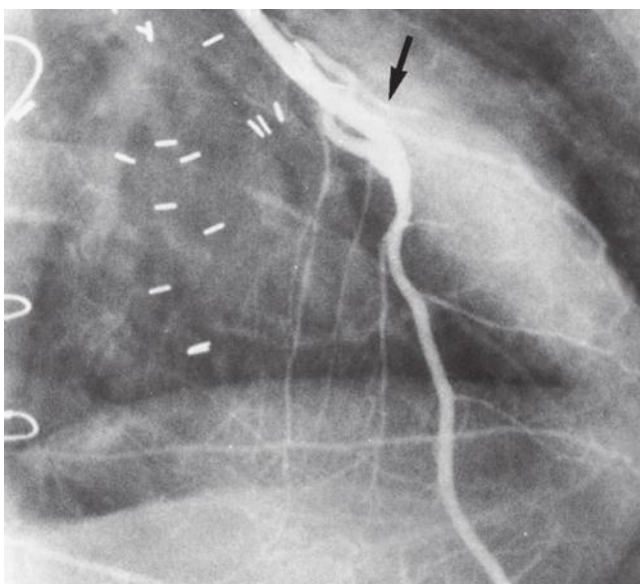
Many studies have looked at the patency rates of the radial artery graft in comparison to the saphenous vein graft. Although some studies have resulted in equivocal data, general consensus favors the use of radial arterial grafts over vein grafts with 5 year patency rates of 98% and 86%, respectively.^{30,31}

From a historical perspective, the anterior circulation (left main or left anterior descending artery) is generally bypassed using the internal thoracic artery and the lateral (circumflex artery) or inferior (right coronary artery) territories are bypassed using a saphenous vein or radial artery graft. These conduits may be combined to form a composite T- or Y-graft, or sewn to multiple targets as sequential grafts. Since patency is best with arterial grafts, recent data has suggested that the best long term results are achieved with multiple or all-arterial revascularization, particularly in patients >70 years of age.^{32,33} Other conduits such as the gastroepiploic arteries, lesser saphenous veins, and cephalic veins have been described, but are not widely used and will not be discussed here.

Conventional Coronary Artery Bypass Grafting. Traditionally, CABGs are performed with the patient lying supine through a median sternotomy. After the patient is heparinized, cardiopulmonary bypass is initiated. The aorta is cross-clamped and cardioplegia is delivered. Once adequate myocardial protection has been achieved, coronary arteriotomies are made and distal anastomoses are performed using Prolene suture. (Fig. 21-2A & B) The proximal anastomoses are then performed directly onto the ascending aorta or onto preexisting grafts. It



A



B

Figure 21-2. Coronary artery bypass grafting. **A.** Intraoperative photograph of the distal anastomoses performed between the left internal thoracic artery and left anterior descending coronary artery with a continuous 8-0 suture. **B.** Fifteen-year follow-up coronary angiogram of a left internal thoracic artery to left anterior descending coronary artery bypass demonstrating a widely patent free of any significant atherosclerotic stenosis. Anastomotic site is shown by the arrow.

is important to note that significant coronary stenoses can cause differential distribution of cardioplegia and myocardial protection. It is therefore recommended to use retrograde cardioplegia or to revascularize the area with the most concern for ischemia first, and give cardioplegia down the completed graft. The left internal thoracic artery to left anterior descending (LAD) graft is frequently performed last to avoid kinking or disruption of this important bypass. Once all grafts are in place, the patient is weaned from bypass. During this time, the heart is monitored closely by direct visual inspection, and transesophageal echocardiography to detect abnormalities which may signify inadequate revascularization or technical problems with the bypasses. Upon confirmation of hemostasis, chest tubes are placed, the sternum is approximated with sternal wires, and the incisions are closed.

Conventional CABG Results Several early randomized trials have shown improved survival in patients who receive a CABG as opposed to medical therapy.³⁴⁻³⁶ A propensity-matched study identified that CABG greatly benefited patients with LV dysfunction and left main stenosis >50% compared to medical management.³⁷ The Bypass Angioplasty Revascularization Investigation (BARI) trial demonstrated impressively superior results with CABG compared to PCI in terms of 5-year cardiac mortality (5.8% vs. 20.6%) in patients with diabetes in addition to CAD.³⁸ In a study examining the benefits of CABG over medical management for specific CAD distributions, survival was better in patients with proximal LAD stenoses, regardless of the number of diseased vessels.³⁹ In general, these studies show survival rates of over 90% at 5 years and approximately 75% at 10 years following CABG.

The mortality and morbidity of the procedure itself has changed over time. Data from the Society of Thoracic Surgeons (STS) database accounts for 1,497,254 patients who underwent a solitary CABG from 2000 to 2009. The mortality rate of CABGs have improved significantly from 2.4% in 2000 to 1.9% in 2009 despite the relatively constant predicted mortality rate of around 2.3%. In parallel with this, postoperative complication rates have decreased as: stroke (1.6%–1.2%), bleeding requiring reoperation (2.4%–2.2%), and deep sternal wound infection (0.59%–0.37%).⁴⁰

There are marked improvements in the functional status of patients receiving CABG. Patients' 6-minute walk test distances were significantly increased 2 years postoperatively compared to their preoperative assessment.⁴¹ After 10 years, 54% of patients were free of chest pain and 31% were free of dyspnea.⁴²

Off-pump Coronary Artery Bypass. To avoid the adverse consequences of cardiopulmonary bypass, off-pump coronary artery bypass (OPCAB) was developed and has been adopted in some centers over the past two decades.

With OPCAB the heart is left beating. Performing anastomoses on the beating heart requires the use of myocardial stabilization devices which help portions of the epicardial surface to remain relatively immobile while the anastomoses are being performed. (Fig. 21-3) Carbon dioxide blower-misters are also used to clear blood from the operative site and improve visualization.

Apical suction devices are used to aid in exposure, particularly of the lateral and inferior vessels. Many creative maneuvers have been developed, including patient repositioning, opening the right pleural space to allow for cardiac displacement, and creation of a pericardial cradle to minimize compromise of cardiac function while exposing the various surfaces of the heart.

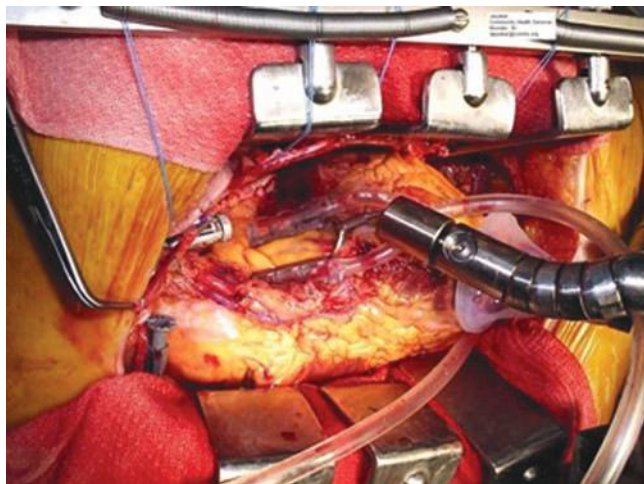


Figure 21-3. Epicardial stabilizing device used during off-pump coronary anastomosis. (Reproduced with permission from Estech.)

Temporary proximal occlusion of the coronary artery being grafted is necessary to provide a bloodless target. This occlusion causes temporary ischemia, and if not tolerated, coronary shunts can be employed.

OPCAB Results The superiority of OPCAB over on-pump CABG remains a controversy despite the large body of literature on this topic. A pooled analysis of two randomized trials, the Beating Heart Against Cardioplegic Arrest Studies (BHACAS 1 & 2), is one of several studies that have touted lower short term mortality rates with the off-pump compared to the on-pump technique.⁴³⁻⁴⁵ Other studies, however, have demonstrated equivocal or contrary results.^{46,47} Furthermore, the recent prospective and much larger ROOBY (Randomized On/Off Bypass) trial showed increased rates of adverse cardiac events with OPCAB compared to conventional CABG.⁴⁸ Despite the initial enthusiasm for the theoretical advantages of avoiding cardiopulmonary bypass, consistent benefits in clinical outcome have not been observed. There does seem to be a more or less uniform trend towards decreased perioperative blood product transfusions with OPCAB compared to on-pump CABG. In terms of other measures of early outcome, postoperative renal failure, stroke, and acute MI, the superiority of OPCAB has been unclear.^{47,49,50}

There have been questions whether the technical challenge of sewing on a beating heart leads to increased rates of graft occlusion following an OPCAB. The higher cardiac morbidity in the ROOBY trial was associated with decreased 1-year angiographic patency rates.⁴⁸ However, studies with contrasting findings exist, quoting equivalent rates of graft patency for OPCAB usage.^{51,52} The broad variety in results may be suggestive that other factors (e.g., surgeon skill, technical difficulty, patient factors) may be dominating the outcome rather than the use or avoidance of cardiopulmonary bypass.⁵³ After almost two decades, OPCAB has not been widely adopted and remains less than 2% of all CABG procedures in the United States.

Minimally Invasive Direct Coronary Artery Bypass. As an extension of the off-pump coronary revascularization technique, minimally invasive direct coronary artery bypass (MIDCAB) has been described. MIDCAB is performed using a left anterior mini-thoracotomy through which mobilization of the left internal thoracic and direct in situ anastomosis to the left

anterior descending artery (or its diagonal branches) is performed. This technique is primarily applicable to single-vessel disease, although reports of multivessel revascularizations do exist.

MIDCAB Results A review of 411 patients undergoing MIDCAB quotes an operative mortality >1%. In this study, all patients received revascularization of the LAD only, regardless of the number of diseased vessels. The 3-year mortality in patients with single-vessel disease following a MIDCAB was 3.1%, which was, not surprisingly, lower than those with multivessel disease (8.7%).⁵⁴

There is an inherent selection bias in retrospective reviews comparing MIDCAB to OPCAB or conventional CABG as MIDCAB patients tend to have less extensive disease. Because of this, there have been multiple randomized controlled trials looking at the efficacy of MIDCAB compared to PCI. A meta-analysis of 5 randomized prospective trials comparing PCI to MIDCAB revascularization of isolated proximal left anterior descending artery demonstrated comparable results in terms of mortality, MI, and repeat revascularization requirement. It is worth noting however, that only one of these trials used drug-eluting stents (DES) in the PCI arm.⁵⁵ Hong et al showed similar efficacy with MIDCAB and DES PCI, and when this study was excluded from the meta-analysis, superiority of MIDCAB to PCI in regards to mortality, MI, and repeat revascularizations was seen.⁵⁶ Although no further prospective trials have been performed to compare DES PCI and MIDCAB in this patient cohort, a retrospective review of 186 patients has demonstrated significantly higher rates of angina recurrence and major adverse cardiac events in the DES PCI group.⁵⁷

Total Endoscopic Coronary Artery Bypass. With the advent of robotic surgical technology allowing stereoscopic visualization and increased instrument dexterity, total endoscopic coronary artery bypass (TECAB) has become possible. In July of 2004, the da Vinci robotic surgical system received FDA approval for use in coronary anastomoses. Extracorporeal circulation with peripheral cannulation has been used in earlier reports, but the development of mechanical stabilizers has provided the ability to perform the internal thoracic artery harvest and coronary anastomosis off-pump with use of the robotic arms only. Several studies have looked at the feasibility of TECAB, and have shown acceptable results, but this procedure has not been adopted by most surgeons due to its steep learning curve, longer operative times, and lack of demonstrable clinical benefit.⁵⁸⁻⁶⁰

Hybrid Coronary Revascularization. With the continually increasing collaboration between cardiothoracic surgeons and interventional cardiologists, hybrid coronary revascularization (HCR) combining a minimally invasive surgical technique (MIDCAB or TECAB) with PCI has become a reality. This capitalizes on a major advantage of both treatments, utilizing the durable left internal thoracic artery to left anterior descending coronary artery bypass while treating other stenoses with PCI obviating the need for a large surgical incision or cardiopulmonary bypass. HCR is not without its downsides as there are some concerns with this approach since aggressive anti-platelet therapy is required with PCI and may increase the hemorrhagic complications of surgical revascularization. A small study comparing HCR to OPCAB showed comparable graft patency and decreased hospital stay with HCR without an increase in complication rates.⁶¹ There are, however, some studies that have reported increased rates of requirement for re-intervention

in patients undergoing HCR, and this aspect requires further study.^{62,63} These procedures have not gained widespread acceptance and their clinical value remains a matter of debate.

Transmyocardial Laser Revascularization. Despite the advancement of technology and revascularization strategies, patients with end-stage coronary artery disease may not be amenable to complete revascularization. Transmyocardial laser revascularization (TMR) relies on a CO₂ or holmium:yttrium-aluminum-garnet (Ho:YAG) laser to create multiple transmural channels (1mm in diameter) through the myocardium. The initial concept was that these channels would serve as conduits for direct perfusion from the ventricle, but evidence suggests that the resultant angiogenesis is primarily responsible for the improved perfusion. A meta-analysis of seven randomized controlled trials comparing TMR to medical therapy for chronic angina have shown higher rates of angina improvement in the TMR but was not able to show a difference in mortality between the two groups.⁶⁴

TMR is also being used as an adjunct to CABG in the treatment of extensive CAD that is not amenable to surgical revascularization alone. In a study looking at the benefits of TMR in addition to CABG, Allen et al concluded that TMR decreases angina burden when added to CABG in patients who cannot be revascularized by CABG alone.⁶⁵ The current STS guidelines support the consideration of TMR in patients with ischemic myocardial territories that cannot be revascularized by PCI or CABG.⁶⁶ Because of equivocal late results at most centers, this therapeutic strategy has not gained widespread acceptance.

New Developments

Regenerative Medicine and Tissue Engineering. Provocative investigations are being performed on the level of signaling molecules, gene therapy, stem cells, and tissue engineering to regenerate or replace damaged tissue in patients with ischemic heart disease. Growth factors, such as FGF and VEGF, are receiving focused attention due their ability to induce ingrowth of new vessels. Although concerns regarding systemic administration of these pleiotropic signaling molecules exist, early placebo-controlled clinical trials have shown some promising results with administration of these agents.^{67,68} Adenoviral transfection of diseased tissue with transgenes for these same growth factors has also been attempted with variable results.

Research in tissue engineering has been directed at creation of vascular conduits that are resistant to atherosclerosis. Stem cells have also been infused directly into the site of injury or in the generation of new tissue around a biodegradable scaffold. Despite their potential, these technologies are still in their infancy and significant progress will be needed before more widespread clinical adoption.

VALVULAR HEART DISEASE

General Principles

The number of patients referred for the surgical management of valvular heart disease has increased substantially in recent years, with the percentage of isolated valve procedures performed in the United States increasing from 14% of all cardiac operations in 1996, to 22% in 2006.⁶⁹ In 2012, valve procedures represented over 50% of the cases performed at our institution. Although congenital and inherited etiologies represent important

clinical entities, age-associated and acquired conditions still represent the primary causes of valvular heart disease, and are the focus of this section.

The most common screening method for valvular heart disease is cardiac auscultation, with murmurs classified based primarily on their timing in the cardiac cycle, but also on their configuration, location and radiation, pitch, intensity and duration (Table 21-7).⁷⁰ Although some systolic murmurs are related to normal physiologic increases in blood flow, some may indicate cardiac disease, such as valvular aortic stenosis (AS), that are important to diagnose, even when asymptomatic. Diastolic and continuous murmurs, on the other hand, are frequently pathologic in nature. Dynamic cardiac auscultation provides further evidence as to the significance and origin of many murmurs (Table 21-8).⁷⁰

Although auscultation may provide initial evidence to the existence of valvular disease, associated signs and symptoms may help narrow the diagnosis. Abnormalities in the splitting of the heart sounds and additional heart sounds should be noted, as should the presence of pulmonary rales. Peripheral pulses should be checked for abnormal intensity or timing, and the presence of a jugular venous wave should be documented. Additionally, symptoms of syncope, angina pectoris, heart failure, and peripheral thromboembolism are important and may help guide diagnosis and management.

Several imaging examinations are also available to aid in the diagnosis and classification of various valvular disorders. Electrocardiograms (EKGs) are widely available, and may provide information regarding ventricular hypertrophy, atrial enlargement, arrhythmias, conduction abnormalities, prior myocardial infarction, and evidence of active ischemia that would prompt further workup. Posteroanterior and lateral chest X-rays are also easy to obtain, and may yield information regarding cardiac chamber size, pulmonary blood flow, pulmonary and systemic venous pressure, and cardiac calcifications. The gold standard for the evaluation of valvular heart disease is transthoracic echocardiography (TTE).

Although helpful in the noninvasive evaluation of valve morphology and function, chamber size, wall thickness, ventricular function, pulmonary and hepatic vein flow, and pulmonary artery pressures, TTE may be unnecessary for some patients with asymptomatic cardiac murmurs. Current recommendations for evaluation via TTE are listed in Table 21-9.⁷⁰ Specialized examinations based on the specific findings of TTE examinations are discussed as appropriate in the following sections.

Regardless of the etiology, valvular heart disease can produce a myriad of hemodynamic derangements. Left untreated, valvular stenosis and insufficiency can produce significant pressure and volume overload on the affected cardiac chamber, respectively, with mixed disease consequently causing mixed pathology. Although the heart can initially compensate for alterations in cardiac physiology, cardiac function eventually deteriorates, leading to heart failure, decreasing patient functional status, ventricular dysfunction, and eventually death. In order to optimize long-term survival, surgery is recommended in various forms of valvular heart disease, and in an increasing number of elderly and high-risk patients.

Surgical Options

Although valve repair is increasingly indicated, especially in patients with aortic, mitral or tricuspid insufficiency, valve replacement may be necessary in certain patient populations.

Table 21-7

Classification of cardiac murmurs.

MURMUR	CONDITION	MECHANISM/ETIOLOGY
SYSTOLIC MURMURS		
Holosystolic (pansystolic)	VSD	Flow between chambers that have widely different pressures throughout systole
Mid-systolic (systolic ejection)	High flow rate, MS, MR, TS, TI	Often crescendo-decrescendo in configuration; occur as blood is ejected into the left and right ventricular outflow tracts
Early systolic	Early TI, acute MR	Less common
Mid to late systolic	MR, MVP	Soft to moderate high-pitched murmurs at the LV apex; often due to apical tethering and malcoaptation of MV leaflets; an associated click indicates prolapse of the MV leaflets
DIASTOLIC MURMURS		
Early high-pitched	AI, PR	Generally decrescendo in configuration; occur when the associated ventricular pressure drops sufficiently below that of the outflow tract
Mid-diastolic	MS, TS, PDA*, VSD*, ASD*	Due to a relative disproportion between valve orifice size and diastolic blood flow volume; seen in normal MV and TV with increased diastolic blood flow associated with these conditions*
Presystolic	MS, TS	Occur during the period of ventricular filling that follows atrial contraction (i.e., only occur in sinus rhythm)
CONTINUOUS MURMURS		
Systolic and diastolic	PDA	Uncommon, due to shunts that persist through the end of systole and the some or all of diastole

AI = aortic insufficiency; ASD = atrial septal defect; MR = mitral regurgitation; MS = mitral stenosis. MVP = mitral valve prolapse; PDA = patent ductus arteriosus; PR = pulmonary regurgitation; TI = tricuspid insufficiency; TS = tricuspid stenosis; VSD = ventricular septal defect.

Table 21-8

Hemodynamic alterations in cardiac murmur intensity.

INTERVENTION	EFFECT
Respiration	Right-sided murmurs increase with inspiration. Left-sided murmurs increase with expiration.
Valsalva maneuver	Most murmurs decrease in length and intensity. The murmur of HCM becomes louder, and the murmur of MVP becomes louder and longer.
Exercise	Benign flow murmurs and murmurs caused by stenotic valves become louder with isotonic and isometric exercise. The murmurs of MR, VSD, and AI also increase with isometric exercise.
Positional changes	Most murmurs decrease with standing; the murmur of HCM becomes louder, and the murmur of MVP becomes louder and longer. Brisk squatting and passive leg raising increases most murmurs; the murmurs of HCM and MVP diminish.
Postventricular premature beat or atrial fibrillation	Benign flow murmurs and stenosis at the semilunar valves increase in intensity following a ventricular premature beat or a long cycle length in atrial fibrillation. Systolic murmurs of atrioventricular valve regurgitation do not change.
Pharmacologic interventions	The initial hypotensive phase following inhalation of amyl nitrate decreases the murmurs of MR, VSD, and AI, and increases the murmur of AS. The later tachycardic phase following inhalation of amyl nitrate increases right-sided murmurs and the murmur of MS. The response in MVP is biphasic (softer then louder than control).
Transient arterial occlusion	Transient external compression of the upper extremity increases the murmurs of MR, VSD, and AI.

AI = aortic insufficiency; AS = aortic stenosis; HCM = hypertrophic cardiomyopathy; MR = mitral regurgitation; MS = mitral stenosis; MVP = mitral valve prolapse; VSD = ventricular septal defect.

Table 21-9

Data from ACC/AHA guidelines for echocardiographic examination in patients with cardiac murmurs.

CLINICAL SETTING	CLASS OF RECOMMENDATION	LEVEL OF EVIDENCE
• Echocardiography is recommended for asymptomatic patients with diastolic murmurs, continuous murmurs, holosystolic murmurs, late systolic murmurs, murmurs associated with ejection clicks, or murmurs that radiate to the neck or back.	I	C
• Echocardiography is recommended for patients with heart murmurs and symptoms or signs of heart failure, myocardial ischemia or infarction, syncope, thromboembolism, infective endocarditis, or other clinical evidence of structural heart disease.	I	C
• Echocardiography is recommended for asymptomatic patients who have grade 3 or louder midpeaking systolic murmurs.	I	C
• Echocardiography can be useful for the evaluation of asymptomatic patients with murmurs associated with other abnormal cardiac physical findings or murmurs associated with an abnormal electrocardiogram or chest x-ray.	IIa	C
• Echocardiography can be useful for patients whose symptoms and/or signs are likely noncardiac in origin but in whom a cardiac basis cannot be excluded by standard evaluation.	IIa	C
• Echocardiography is not recommended for patients who have a grade 2 or softer midsystolic murmur identified as innocent or functional by an experienced observer.	III – Harm	C

In some cases valve replacement can be accomplished with either mechanical or biological prostheses, and the choice of valve depends on many patient-specific factors such as age, health status, and desire for future pregnancy. Preexisting indications or contraindications to anticoagulation therapy also influence the choice of mechanical vs. tissue valve prosthesis.

Current options for mechanical valve replacement include 4▶ tilting disc valves and bileaflet valves. Although mechanical valves are highly durable, they require permanent anticoagulation therapy to mitigate the otherwise high risk of valve thrombosis and thromboembolic sequelae.⁷¹ Due to the concordant risk of hemorrhagic complications, patient characteristics such as debility, lifestyle, and contraindications to systemic anticoagulation therapy may preclude mechanical valve replacement. Moreover, young women who are planning future pregnancies cannot take warfarin due to its teratogenic potential. Conversely, patients with other indications for systemic anticoagulation, such as other risk factors for thromboembolism (i.e., atrial fibrillation), or the existence of a mechanical prosthetic valve already in place in another position, may benefit from mechanical valve replacement. Additionally, patients with renal failure, on hemodialysis, or with hypercalcemia experience accelerated degeneration of bioprosthetic valves, and are thus, recommended to receive mechanical prostheses.⁷² In general, mechanical valve replacement is preferred in patients with expected long life spans who are acceptable candidates for anticoagulation therapy, in order to minimize reoperation and bleeding risks.

The potential to avoid the hazards of serious bleeding complications spurred the development of valve prostheses using biological materials, which obviate the need for systemic anticoagulation therapy. As tissue valves are naturally less thrombogenic, the attendant yearly risks of both thromboembolic and anticoagulation-related complications are considerably less than with mechanical valves.⁷³ Consequently, tissue valve replacement is generally recommended for patients averse to systemic anticoagulation therapy, with potential concerns

regarding compliance or follow-up while taking anticoagulant medications, and in the case of reoperation for a thrombosed mechanical valve. However, biological valves are more prone to degeneration, especially when implanted in the mitral position, in younger patients, and in patients in renal failure, on hemodialysis, or with hypercalcemia.⁷³ Improved manufacturing methods have made currently available tissue valves more durable than previous versions, and valve replacement with a biological prosthesis is generally preferred in patients without other indications for anticoagulation therapy, who are >60 years of age for the aortic position, and >70 years of age for the mitral position.

Mechanical Valves. The first bileaflet valve was introduced in 1977. Bileaflet valves are comprised of two semicircular leaflets which open and close, creating one central and two peripheral orifices (Fig. 21-4). Bileaflet mechanical valves have demonstrated excellent flow characteristics, low risks of late valve-related complications, including valve failure, and are currently the most commonly implanted type of mechanical valve prosthesis in the world.⁷²

Although mechanical valves necessitate systemic anticoagulation, careful monitoring of the International Normalized Ratio (INR) reduces the risk of thromboembolic events and hemorrhagic complications, and improves overall survival.⁷⁴ Patients undergoing mechanical aortic valve replacement generally have a target INR of 2 to 3 times normal. Patients undergoing mechanical mitral valve replacement frequently have increased left atrial size, concomitant atrial fibrillation, and are at higher risk for thromboembolism than those undergoing mechanical aortic valve replacement, and are thus recommended to have a target INR 2.5 to 3.5 times normal. When managed appropriately, the yearly thromboembolic and bleeding risks in these patients are 1% to 2%, and 0.5% to 2%, respectively.

Tissue Valves. A xenograft valve is one implanted from another species, such as porcine xenograft valves, or manufactured from tissue such as bovine pericardium. A variety of




Figure 21-4. St. Jude bileaflet mechanical valve. (Photo reproduced with permission of St. Jude Medical, Inc., St. Paul, MN. All rights reserved.)

xenograft tissue valves exist, and are primarily differentiated by the presence or absence of a mounting stent. Stented valves are the most commonly implanted, and the most popular valve in the United States is a stented bovine pericardial valve.

The more traditional stented valves are attached to a sewing ring, which decreases the technical complexity of valve replacement compared with stentless valves (Fig. 21-5). The chief disadvantage of stented tissue valves is a smaller effective orifice area, which increases the transvalvular gradient. This effect is most pronounced in patients with small prosthetic

valve areas, specifically $<0.85\text{cm}^2$ valve area per square meter body surface area, and may affect symptomatic improvement and the hemodynamic response to exercise following surgery.⁷⁵

Stentless porcine xenograft valves were developed in order to minimize the limitations in flow characteristics seen in patients with small prosthetic valve areas, and have demonstrated an increase in effective valve area of approximately 10% over stented xenografts of equivalent size.⁷² They can result in improved hemodynamics, both at rest and with exercise.⁷⁶ The absence of a stent and sewing ring both increases the technical complexity of valve replacement, and takes advantage of the biologic mobility of the aortic valve apparatus. Though results with stentless valves seem promising, long-term durability remains to be shown, and they have not been widely adopted due to the technical complexity associated with implantation.

Homografts. Homograft valves from human cadavers, also known as *allografts*, have been used for aortic valve replacement since the technique was originally described over 50 years ago.⁷⁷ Since that time, homografts have typically been used for aortic and pulmonary valve replacements, and have been successfully harvested from brain dead organ donors and the explanted hearts of heart transplant patients. Following harvest, these valves are sterilized using an antibiotic solution, and subsequently stored in fixative or cryopreserved.

Like other types of tissue valves, the risk of thromboembolic complications with homograft valves is low, and systemic anticoagulation therapy is not required. Additionally, the structure of homograft valves is naturally low-profile, allowing for larger effective valve orifices and lower postoperative transvalvular gradients compared with stented xenograft valves. Additionally, they have been shown to have some advantages in patients with endocarditis.⁷⁸

The major shortcoming of homograft valves is their uncertain long-term durability in the face of significant tissue degeneration. Within one year of implantation, these valves undergo substantial loss of cellular components and subsequent



Figure 21-5. Edwards' Magna Ease stented porcine bioprosthesis. (Image reproduced with permission of Edwards Lifesciences, LLC, Irvine, CA.)

structural compromise, which may ultimately lead to valve failure.⁷⁹ Although enhanced preservation techniques significantly improve cellular viability, which approach the 15-year viability of xenograft valves, the availability of these techniques has limited the use of homograft tissue valves.

Autografts. In 1967, Donald Ross described a procedure in which the diseased aortic valve is replaced using the patient's native pulmonary valve as an autograft, which is in turn replaced with a homograft in the pulmonic position.⁸⁰ The procedure results in minimal transvalvular gradients, and favorable left ventricular mechanics, both at rest and during exercise. Known as the *Ross procedure*, this operation is particularly beneficial in children, as the pulmonary trunk grows with the child and long-term anticoagulation is not required.⁸¹

The late results of the Ross procedure are discussed later in this chapter. In addition to potential concerns with durability, performance of the Ross procedure has also been limited by its technical complexity, and the increased surgical risk associated with double valve replacement.

Valve Repair. Valve repair offers several advantages over valve replacement, due in large part to the preservation of the patient's native valve and subvalvular apparatus. In the case of mitral valve (MV) surgery, preservation of the mitral apparatus has been shown to lead to better postoperative left ventricular function and survival.^{82,83} Additionally, as there is no implanted prosthesis, the patient avoids the risks of chronic anticoagulation, infection, thromboembolic complications, and prosthetic valve failure after surgery.

In the case of MV repair, freedom from reoperation and valve-related complications has been excellent in certain patient populations, even at 20-year follow-up.⁸⁴ It has also been demonstrated that patients undergoing MV surgery with moderate functional tricuspid regurgitation (TR) do not experience increased perioperative complication rates when a concomitant tricuspid valve (TV) repair is performed.⁸⁵ Midterm results in this group are encouraging, with greater than 98% freedom from reoperation reported by some groups at 5 years, suggesting further indications for valve repair.

Despite its advantages for the patient, valve repair is generally more technically demanding than valve replacement, and may occasionally fail. Both the suitability of the patient for valve repair and the skill and expertise of the surgeon performing the operation are important when considering valve repair in the individual patient.

MITRAL VALVE DISEASE

Mitral Stenosis

Etiology. Acquired mitral stenosis (MS) is most often caused by rheumatic fever, with approximately 60% of patients with pure MS presenting with a positive clinical history of rheumatic heart disease.⁷⁰ Rarely, other conditions can cause obstruction to filling of the left ventricle (LV), mimicking MS. Acquired causes of MV obstruction include left atrial myxoma, ball valve thrombus, mucopolysaccharidosis, previous chest radiation, and severe annular calcification.

Pathology. Although rheumatic heart disease is associated with a transmural pancarditis, pathological fibrosis of the valves results primarily from the endocarditic process. The damage caused by endocardial inflammation and fibrosis is progressive, causing commissural fusion, subvalvular shortening of the

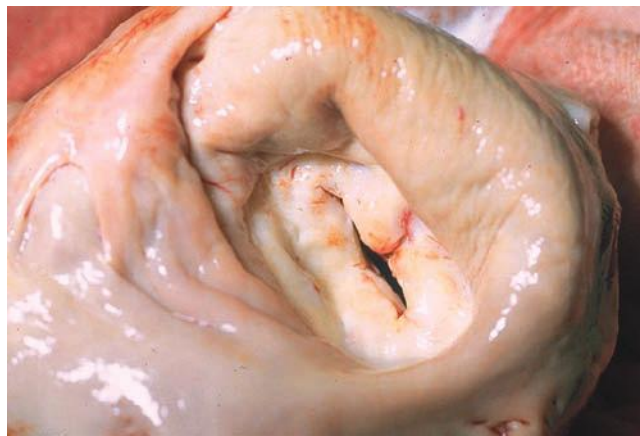

Figure 21-6. Mitral stenosis. The thickened, fused leaflets of the diseased mitral valve are viewed through a left atriotomy. (Image courtesy of the Centers for Disease Control and Prevention, Edwin P. Ewing, Jr.)

chordae tendineae, and calcification of the valve and subvalvular apparatus.⁸⁶ The resulting stenotic MV has a funnel-shaped apparatus, with a significantly narrowed orifice obliterated by interchordal and commissural fusion (Fig. 21-6). The degree of mitral stenosis should be determined preoperatively, as these pathological features may help determine the timing and type of intervention to perform.⁷⁰

Pathophysiology. As the normal MV area of 4.0 to 5.0 cm² is reduced by the rheumatic process, blood can flow from the left atrium to the left ventricle only if it is propelled by an ever-increasing pressure gradient. The diastolic transmitral gradient, which is a function of the square of the transvalvular flow rate and the diastolic filling period, is a fundamental expression of the severity of MS. When the valve area is reduced to <2.5 cm², patients may begin to experience symptoms when the transmitral gradient is exacerbated by conditions that either increase transmitral flow or decrease diastolic filling time, such as exercise, emotional stress, infection, pregnancy, or atrial fibrillation with a rapid ventricular response.⁸⁷ Symptoms may begin to occur at rest with the onset of moderate stenosis, defined as a cross-sectional area of 1.0 to 1.5 cm², and any physical exertion is typically limited by the time the MV area is <0.8 to 1.0 cm² (Table 21-10).⁷⁰

The progression of symptoms is due to the evolution of pathophysiological processes, beginning with an elevation in left atrial pressure. The increased left atrial pressure is subsequently transmitted to the pulmonary venous system, causing pulmonary edema as the hydrostatic pressure in the vessels exceeds the plasma oncotic pressure. Decreased pulmonary venous compliance exacerbates the pulmonary venous hypertension, though a concomitant decrease in microvascular permeability may preclude pulmonary edema in the chronic setting.⁸⁸ Patients may also develop pulmonary arterial hypertension, owing to vasoconstriction, intimal hyperplasia, and medial hypertrophy of the pulmonary arterioles in response to the increased pulmonary venous pressure. The secondary obstruction to flow caused by reactive pulmonary arterial hypertension may serve to protect against pulmonary edema, but also exacerbates the intractable decrease in cardiac output that develops as stenosis worsens.⁸⁹

Throughout the process, the left atrium becomes dilated and hypertrophied due to increased work in filling the ventricle

Table 21-10

Data from ACC/AHA guidelines for the classification of the severity of mitral valve disease in adults

MITRAL STENOSIS			
INDICATOR	MILD	MODERATE	SEVERE
Mean gradient (mm Hg)*	<5	5–10	>10
Pulmonary artery systolic pressure (mm Hg)	<30	30–50	>50
Valve area (cm ²)	>1.5	1.0–1.5	<1.0
MITRAL REGURGITATION			
QUALITATIVE	MILD	MODERATE	SEVERE
Angiographic grade	1+	2+	3+
Color Doppler jet area	Small, central jet (<4 cm ² or <20% left atrial area)	More than mild criteria, but no severe criteria present	Vena contracta width >0.7 cm with large central jet (area >40% of left atrial area) or with a wall-impinging jet of any size, swirling in left atrium
Doppler vena contracta width (cm)	<0.3	0.3–0.69	≥0.7
QUANTITATIVE (CATH OR ECHO)			
Regurgitant volume (ml per beat)	<30	30–59	≥60
Regurgitant fraction (%)	<30	30–49	≥50
Regurgitant orifice area (cm ²)	0.2	0.2–0.39	≥0.4
ADDITIONAL ESSENTIAL CRITERIA			
Left atrial size			Enlarged
Left ventricular size			Enlarged

*Valve gradients are flow dependent and when used as estimates of severity of valve stenosis should be assessed with knowledge of cardiac output or forward flow across the valve.

against a fixed obstruction. Atrial fibrillation may develop, exacerbating the patient's symptoms and increasing the risk of atrial thrombus and subsequent embolization. Left ventricular structure and function are typically preserved, however, owing to the protective effect of the stenotic valve.

Clinical Manifestations. The sudden opening of the thickened, nonpliable valve with left atrial contraction produces an opening snap, followed by a diastolic rumble caused by rapid entry of blood into the left ventricle. When diastole is complete, the MV subsequently closes very rapidly, causing an increased first heart sound. The murmur, classically known as the *auscultatory triad*, is best heard at the apex. Associated mitral and tricuspid insufficiencies are heard as a pansystolic murmur radiating to the axilla, and a systolic murmur at the xiphoid process, respectively.

The first clinical signs of MS are those associated with pulmonary venous congestion, namely exertional dyspnea, decreased exercise capacity, orthopnea, and paroxysmal nocturnal dyspnea. Hemoptysis, and pulmonary edema may develop as the venous hypertension worsens. Advanced MS can also cause pulmonary arterial hypertension and subsequent right heart failure, manifested as jugular venous distention, hepatomegaly, ascites, and lower extremity edema.¹

As mentioned previously, atrial fibrillation may develop as left atrial pathology worsens, causing atrial stasis and subsequent thromboembolism. Patients with MS may initially present with signs of arterial embolization, even rarely with angina from coronary occlusion.¹

Diagnostic Studies. All patients with a clinical history and physical exam suggestive of MS should undergo EKG and chest X-ray. Abnormalities in the EKG may include atrial fibrillation, left atrial enlargement, or right-axis deviation. Chest X-ray findings may include enlargement of the left atrium and pulmonary artery, creating a double contour behind the right atrial shadow, and obliterating the normal concavity between the aorta and left ventricle. Findings consistent with pulmonary congestion may also be present.¹

The diagnostic tool of choice is TTE, which not only confirms the diagnosis of MS, but also rules out other causes of stenosis and other concomitant myocardial or valvular heart disease.⁹⁰ Two-dimensional TTE can be used to calculate the MV orifice area and to determine the morphology of the MV apparatus, including leaflet mobility and flexibility, leaflet thickness and calcification, subvalvular fusion, and the appearance of the commissures. Doppler TTE can also be used in combination with various equations to estimate the hemodynamic severity of MS in terms of the mean transmitral gradient, the MV area, and the pulmonary artery systolic pressure.

In most cases further examinations are not necessary. A preoperative TEE is usually unnecessary, unless there is a need to rule out left atrial appendage thrombus, the patient is being considered for percutaneous mitral balloon valvotomy, or the preoperative TTE is insufficient for diagnosis. Exercise TTE is indicated when resting TTE parameters are discordant with symptom severity.⁹¹ Routine cardiac angiography should be performed prior to valve surgery in patients with evidence of

ischemia, decreased LV systolic function, a history of coronary artery disease or coronary risk factors, including postmenopausal status and age ≥ 35 in men and premenopausal women.⁷⁰

Indications for Operation. Depending on the severity and the morphology of the diseased MV (Table 21-10), balloon valvuloplasty, surgical commissurotomy or repair, or MV replacement may be indicated for the treatment of MS (Table 21-11).⁷⁰

Mitral Regurgitation

Etiology. The most important cause of MR in the United States is myxomatous degenerative disease of the MV, which occurs in approximately 2.4% of the population.¹ Other important causes of MR include rheumatic heart disease, infective endocarditis, ischemic heart disease, and dilated cardiomyopathy. Less frequently, MR can be caused by collagen vascular diseases, trauma, previous chest radiation, the hypereosinophilic syndrome, carcinoid disease, and exposure to certain drugs.⁷⁰

Pathology. The MV apparatus consists of the mitral leaflets, chordae tendineae, papillary muscles, and mitral annulus, and abnormalities in any one of these components has the potential to cause MR.⁹² The system for classifying MR proposed by Carpentier focuses on the functional anatomic and physiologic characteristics of the MV pathology, and proposes three basic types of diseased valves based on the motion of the free edge of the leaflet relative to the plane of the mitral annulus.⁹³

In Type I MR, valvular insufficiency occurs secondary to annular dilatation or leaflet perforation, and normal leaflet motion is maintained. Type II MR is seen in patients with mitral valve prolapse, and is due to prolapse of often thickened excessive leaflet tissue that gives the valve a “billowing” appearance, frequently in addition to ruptured or elongated chordae tendineae causing increased leaflet motion. Type III insufficiency, as seen in patients with rheumatic and ischemic heart disease, occurs from restricted leaflet motion, either during systole and diastole (Type IIIA) or during systole alone (Type IIIB).

Pathophysiology. The basic pathophysiologic abnormality of MR is the retrograde flow of a portion of the LV stroke volume into the left atrium during systole due to an incompetent MV or dilated MV annulus.

Acute severe MR can result from ruptured chordae tendineae, a ruptured papillary muscle, or infective endocarditis, and causes a sudden volume overload on both the left atrium and ventricle.⁷⁰ Although an acute increase in preload provides a modest increase in overall stroke volume, the left atrium and ventricle are unable to fully accommodate the regurgitant volume or maintain forward stroke volume in the acute setting due to a lack of remodeling.

Chronic MR generally has a more indolent course, with increasing volume overload of the left atrium and ventricle as the effective valve orifice size becomes larger. The resulting increase in left atrial and ventricular volume initially allows for an increase in the total stroke volume by Starling’s law and accommodation of the regurgitant volume, thus maintaining forward cardiac output and alleviating pulmonary congestion during the compensatory phase of chronic MR.⁹⁴ However, as the left atrium becomes more dilated, the development of AF becomes more likely, disrupting atrioventricular synchrony and predisposing to thrombus formation. Additionally, chronic volume overload may lead to LV contractile dysfunction, resulting in impaired ejection and end-systolic volume increases. LV dilatation and filling pressure may also worsen throughout the

progression of MR, reducing cardiac output and causing congestion of the pulmonary vasculature. These changes herald LV decompensation and heart failure, and often indicate significant irreversible injury to the ventricular myocardium.

Clinical Manifestations. In cases of acute severe MR, patients are often very symptomatic and present with pulmonary congestion and reduced forward stroke volume. In very severe cases, patients may present with cardiogenic shock.¹ Because the LV has not remodeled in the acute setting, a hyperdynamic apical impulse may not be present in the precordium. The typical systolic murmur of MR may be holosystolic or absent, with a third heart sound and/or diastolic flow murmur being the only auscultatory findings.

In cases of chronic MR, patients may remain asymptomatic for long periods of time due to the compensatory mechanisms of the remodeled LV. However, once the LV begins to fail, patients become increasingly symptomatic from exertional dyspnea, decreased exercise capacity, orthopnea, and eventually pulmonary hypertension and right heart failure.¹ Physical examination may demonstrate displacement of the LV apical impulse due to cardiac enlargement from chronic volume overload, and a third heart sound or early diastolic flow rumble. The characteristic auscultatory findings also include an apical systolic murmur which is variably transmitted to the axilla or the left sternal border, depending on the location of the pathology. As mentioned previously, patients may present with AF due to dilatation of the left atrium. Findings consistent with pulmonary hypertension frequently indicate late-stage disease.

Diagnostic Studies. In the setting of acute heart failure, TTE should be performed and may demonstrate the anatomical location and severity of the MV pathology. However, TTE may underestimate lesion severity due to inadequate views of the color flow jet. In this case, severe MR should be suspected if hyperdynamic systolic function of the LV is visualized, and TEE may be used to confirm the diagnosis and direct repair strategies.⁹⁵ In the hemodynamically stable patient, coronary angiography should be performed preoperatively in the majority of patients so that myocardial revascularization may be performed in combination with MV surgery if necessary.⁷⁰

In cases of chronic MR, EKG and chest X-ray are performed to assess rhythm status and the degree of pulmonary vascular congestion.⁷⁰ An initial two-dimensional and Doppler TTE should be performed for a baseline estimation of LV and left atrial size, LV systolic function, pulmonary artery pressure, MV morphology, and MR severity.⁹⁶ A central color flow jet in the setting of a structurally normal MV on TTE suggests functional MR, which may be due to LV dilatation or tethering of the posterior leaflet in patients with coronary artery disease. In the setting of organic MR, which is suggested by the presence of an eccentric color flow jet and morphological abnormalities in the MV apparatus on TTE, the presence of calcium in the annulus or leaflets, the redundancy of the leaflets, and the anatomy of the MV pathology should be assessed. Follow-up TTE is indicated on an annual or semiannual basis in patients with asymptomatic moderate to severe MR in order to assess changes from baseline parameters and direct the timing of surgery. Any abrupt change in signs or symptoms in a patient with chronic MR is also an indication for TTE examination.⁷⁰

Additional preoperative studies are variably indicated in certain patient populations. Preoperative TEE is indicated in patients with poor diagnostic windows on TTE in order to

Table 21-11

Data from ACC/AHA guidelines for MV surgery in specific clinical contexts

CLINICAL SETTING	CLASS OF RECOMMENDATION	LEVEL OF EVIDENCE
Balloon Valvotomy for Mitral Stenosis		
• Symptomatic patients (NYHA II, III, IV) with moderate or severe MS and favorable valve morphology, without left atrial thrombus or moderate to severe MR	I	A
• Asymptomatic patients with moderate or severe MS, favorable valve morphology, and pulmonary hypertension (PASP >50 mm Hg at rest, >60 mm Hg with exercise), without left atrial thrombus or moderate to severe MR	I	C
• Symptomatic patients (NYHA III, IV) with moderate or severe MS and favorable valve morphology, who are high risk or not candidates for surgery	IIa	C
• Asymptomatic patients with moderate or severe MS, favorable valve morphology, and new onset atrial fibrillation, without left atrial thrombus or moderate to severe MR	IIb	C
• Symptomatic patients (NYHA II, III, IV) with MV area >1.5 cm ² if there is evidence of hemodynamically significant MS (PASP >60 mm Hg, PAWP ≥25 mm Hg, mean MV gradient >15 mm Hg during exercise)	IIb	C
• Symptomatic patients (NYHA III, IV) with moderate or severe MS and favorable valve morphology, as an alternative to surgery	IIb	C
• Patients with mild MS	III – Harm	C
• Patients with moderate to severe MR or left atrial thrombus	III – Harm	C
Surgery for Mitral Stenosis*		
• Symptomatic patients (NYHA III, IV) with moderate or severe MS when: Balloon valvotomy is unavailable Balloon valvotomy is contraindicated due to thrombus or MR Valve morphology is not favorable for balloon valvotomy	I	B
• Symptomatic patients with moderate to severe MS who also have moderate to severe MR	I	C
• Mildly symptomatic patients (NYHA I, II) with severe MS and severe pulmonary hypertension (PASP >60 mm Hg)	IIa	C
• Asymptomatic patients with moderate or severe MS and recurrent embolic events while receiving adequate anticoagulation, when the likelihood of successful MVr is high	IIb	C
• MVr in the setting of mild MS	III – Harm	C
• Closed commissurotomy in the setting of MVr; open commissurotomy should be performed	III – Harm	C
Surgery for Mitral Regurgitation*		
• Symptomatic patients with acute severe MR	I	B
• Symptomatic patients (NYHA II, III, IV) with chronic severe MR without LV dysfunction (LVEF <0.30) and/or end-systolic dimension >55 mm	I	B
• Asymptomatic patients with chronic severe MR and mild to moderate LV dysfunction (LVEF 0.30–0.60) and/or end-systolic dimension ≥40 mm	I	B
• Asymptomatic patients with chronic severe MR and preserved LV function (LVEF >0.60, end-systolic dimension <40 mm), when the likelihood of successful MVr is >90%	IIa	B
• Asymptomatic patients with chronic severe MR, preserved LV function, and 1) New onset atrial fibrillation, 2) Pulmonary hypertension (PASP >50 mm Hg at rest, >60 mm Hg with exercise)	IIa	C
• Symptomatic patients (NYHA III, IV) with chronic severe MR due to a primary abnormality of the mitral apparatus and severe LV dysfunction (LVEF <0.30, end-systolic dimension >55 mm), when the likelihood of successful MVr is high	IIa	C
• Symptomatic patients (NYHA III, IV) with chronic severe MR secondary to severe LV dysfunction (LVEF <0.30) who remain symptomatic despite optimal medical management for heart failure, including biventricular pacing	IIb	C
• Asymptomatic patients with MR and preserved LV function (LVEF >0.60, end-systolic dimension <40 mm), when the likelihood of successful repair is low	III – Harm	C
• Isolated MV surgery in the setting of mild or moderate MR	III – Harm	C

LV = left ventricular; LVEF = left ventricular ejection fraction; MR = mitral regurgitation; MS = mitral stenosis; MV = mitral valve; MVr = mitral valve repair; MVR = mitral valve replacement; NYHA = New York Heart Association; PASP = pulmonary artery systolic pressure; PAWP = pulmonary artery wedge pressure; * = mitral valve repair should be performed when possible in this population.

determine the severity and anatomic basis of MR, and to evaluate LV systolic function.⁷⁰ Preoperative TEE is also indicated in cases when discrepancy exists between a patient's functional status and the severity of MR on TTE, and is helpful for preoperative planning when assessing the feasibility of repair in the individual patient. Exercise stress-echocardiography may also be useful to detect LV systolic dysfunction in well-compensated patients, who may not demonstrate a rise in the end-systolic dimension of the heart or a drop in ejection fraction on routine TTE.⁹⁷ Coronary angiography should be performed prior to valve surgery in patients with evidence of ischemia, decreased LV systolic function, a history of coronary artery disease or coronary risk factors, including postmenopausal status and age ≥ 35 in men and premenopausal women.⁷⁰

Indications for Operation. Based on the morphology and severity of MR (Table 21-10), MV repair, MV replacement with preservation of part or all of the mitral apparatus, or MV replacement with removal of the mitral apparatus may be variably performed for the treatment of MR. As the intraoperative findings may dictate MV replacement whenever a MV repair is planned, current recommendations are for MV surgery in general (Table 21-11).⁷⁰

Mitral Valve Operative Techniques and Results

Mitral valve surgery is performed on the arrested heart with the assistance of cardiopulmonary bypass. Traditionally, a median sternotomy incision is used; however, the left atrium can also be approached via minimally-invasive incisions, such as a mini-thoracotomy or a partial sternotomy. The MV is commonly exposed through a left atrial incision placed posterior and parallel to the intra-atrial groove, or through a right atriotomy with transseptal incision.

Commissurotomy. Upon opening the left atrium, the MV is visualized and the left atrium is examined for thrombus. A nerve hook or right-angle clamp is subsequently introduced beneath the commissures and used to evaluate the MV apparatus for leaflet mobility, commissural fusion, and subvalvular chordal abnormalities. The commissure is then carefully incised in a slightly anterior direction 2 to 3mm at a time, making sure with each extension of the incision that the chordae tendineae remain attached to the commissural leaflets. The commissurotomy is generally stopped 1 to 2mm from the annulus where the leaflet tissue thins, indicating the transition to normal commissural tissue. The papillary muscles are subsequently examined and incised as necessary in order to maximize the mobility of the leaflets.

After the commissurotomy is complete, and the associated chordae tendineae and papillary muscles are mobilized, leaflet mobility is assessed. The anterior leaflet is grasped with forceps and brought through its complete range of motion. If subvalvular restriction or leaflet rigidity is identified, further division or excision of fused chordae and debridement of calcium may be necessary. Occasionally, the leaflets can be debrided carefully to increase mobility. Valve replacement may be more appropriate if extensive secondary mobilization is required. At the end of the procedure, competence of the valve is assessed with injection of cold saline into the ventricle.

Open surgical commissurotomy has an operative risk of $<1\%$, and has been shown to have good long term results, with freedom from reoperation as high as 88.5%, 80.3%, and 78.7% at 10, 20, and 30 years, respectively.⁹⁸ The incidence of postoperative thromboembolic complications is generally $<1\%$

per patient-year, and the lack of required systemic anticoagulation precludes the development of hemorrhagic complications long-term.⁹⁹

Mitral Valve Replacement. After exposing the valve, an incision is made in the anterior mitral leaflet at approximately the 12 o'clock position, and leaflet tissue is excised as needed. The papillary muscles are reattached to the annulus and, if possible, the posterior leaflet along with its associated subvalvular structures are preserved. The annulus is subsequently sized, and an appropriate mitral prosthesis is implanted using pledgeted horizontal mattress sutures. The annular sutures may be placed from the atrial to the ventricular side, seating the valve intra-annularly, or from the ventricular to the atrial side, seating the valve in a supra-annular position. When placing the mattress sutures, care must be taken to stay within the annular tissue, as excessively deep bites may cause injury to critical structures such as the circumflex coronary artery posterolaterally, the atrioventricular node anteromedially, or the aortic valve anterolaterally. The sutures are subsequently placed through the sewing ring, and the valve prosthesis is lowered onto the annulus, where it is secured (Fig. 21-7).

The factors associated with increased operative risk for MV replacement include age, left ventricular function, emergent procedure status, NYHA functional status, previous cardiac surgery, associated coronary artery disease, and concomitant disease in another valve. However, for most patients, MV replacement is associated with an operative mortality between 2% to 6%, and 65% to 70% five-year survival.^{100,101} Although preservation of the mitral apparatus during MV replacement is important for subsequent left ventricular function, there appears to be no difference between complete and partial preservation with respect to 30-day and 5-year mortality.¹⁰⁰ Mechanical valves are associated with increased durability compared to bioprosthetic valves, and have demonstrated a freedom from reoperation of 98% vs. 79% at 15 years, respectively.¹⁰² Despite these findings, the choice of prosthetic valve depends on many factors, and should be decided on a patient-by-patient basis.

Mitral Valve Repair. There are many techniques available for MV repair that are variably used depending on the

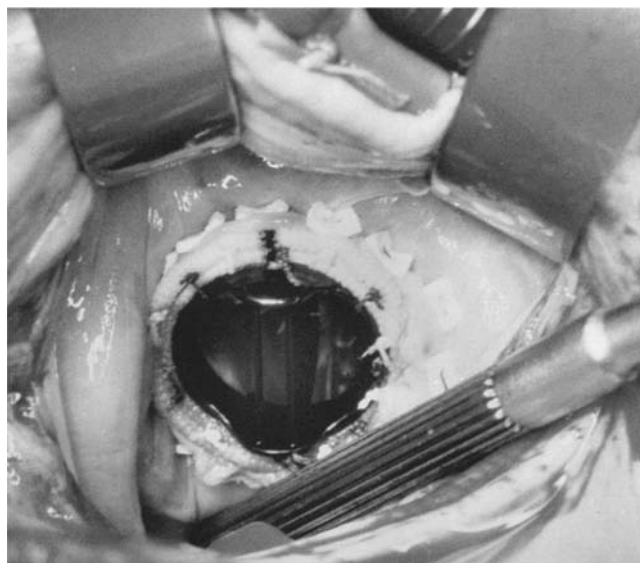


Figure 21-7. Mitral valve replacement. A St. Jude bileaflet mechanical valve is viewed through a left atriotomy.

intraoperative assessment of valvular pathology. On opening the atrium, the endocardium is examined for a *jet lesion*, a roughened area caused by a regurgitant jet striking the wall, in order to better localize the area of valvular insufficiency. The commissures are examined for evidence of prolapse, fusion, and malformation. The subvalvular apparatus and individual leaflets are subsequently examined, and areas of prolapse, restriction, fibrosis, and calcification are identified. Leaflet perforations are generally repaired primarily, or with a pericardial patch. The degree of annular dilation is also noted. The basic components of MV repair based on this assessment may include resection of the posterior leaflet, chordal shortening, chordal transposition, artificial chordal replacement, triangular resection of the anterior leaflet, and annuloplasty. Recent trends have been toward leaflet preservation.

One of the mainstays of MV repair is triangular resection of the posterior leaflet. Excision of the diseased leaflet tissue extends down towards but generally not to the mitral annulus. After repair has been completed, valvular competency is evaluated by injecting saline into the ventricle with a bulb syringe and assessing leaflet mobility and apposition. If focal insufficiency is identified in other areas, additional procedures are performed.

The anterior leaflet may be repaired via chordal shortening, chordal transposition, artificial chordal replacement, and triangular resection of the anterior leaflet. Chordal shortening has generally been abandoned in favor of chordal replacement. During chordal transposition, a resected portion of the posterior leaflet with attached chordae is transposed onto the prolapsed portion of the anterior leaflet to provide structural support, and followed with posterior leaflet repair as described above. The procedure of artificial chordal replacement uses polytetrafluoroethylene sutures to attach the papillary muscle to the free edge of the prolapsing anterior leaflet. Triangular resection with primary repair of the anterior leaflet removes the prolapsing segment of the anterior MV leaflet, while preserving adjacent chordal tissue, and may be especially helpful in patients with a ruptured chord or large amount of redundant anterior leaflet tissue.

Annular dilation is generally corrected using a MV annuloplasty device, such as a ring or partial band, and is known to improve the durability of MV repair (Fig. 21-8).¹⁰³ Several devices are available, and include rigid or semirigid rings that geometrically remodel the annulus, flexible rings or bands that restrict annular dilation while maintaining the physiologic sphincter motion of the annulus, and semirigid bands that provide a combination of annular remodeling and support of physiologic motion.

Another technique known as the “*double-orifice*” or “*edge-to-edge*” repair was introduced in 1995, and involves tacking the free edge of the anterior leaflet to the opposing free edge of the posterior leaflet.¹⁰⁴ This procedure effectively gives the valve a double-orifice “*bow tie*” configuration, and has been used as both a primary repair technique and an adjunct to other repair techniques, usually in cases of anterior leaflet pathology, or Barlow’s disease. While some groups report excellent late results, its use remains controversial.

Due to the variety in operations and etiologies of MV disease, there is heterogeneity in outcomes following MV repair. In general, the operative risk for patients undergoing MV repair is generally <1%, and late results across a broad range of patients have demonstrated benefits in survival and valve-related complications, such as thromboembolic events, infective endocarditis, and anticoagulation-related hemorrhage, compared to

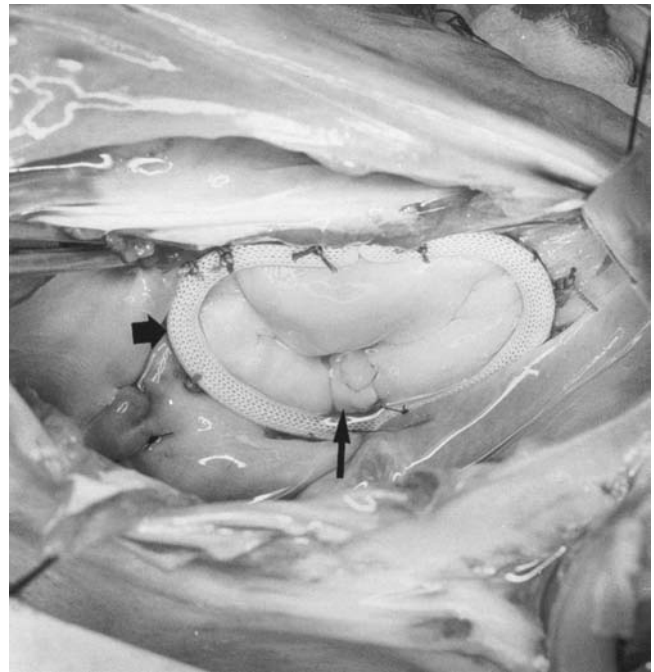


Figure 21-8. Mitral valve repair. The narrow arrow indicates the posterior leaflet repair, and the wide arrow indicates the ring annuloplasty as viewed through a left atriotomy.

MV replacement.^{69,84} Patients with MR due to degenerative disease have especially encouraging outcomes, demonstrating rates of survival and freedom from reoperation of >50% and >94% at 20 years, respectively.⁸⁴ Historically, isolated anterior leaflet prolapse increased the risk of reoperation five-fold in this population. However, increasing experience and the expanded use of chordal replacement has greatly improved these results in recent series.¹⁰⁵ Independent predictors of mortality have included higher NYHA class, lower left ventricular ejection fraction, and age. Older patients have demonstrated slightly worse outcomes overall, with an operative mortality of approximately 4%, and a 10-year survival of 54% in patients ≥ 65 years of age. However, the superiority of repair over replacement persists even for patients >80 years of age.¹⁰¹

Patients with rheumatic disease have also demonstrated slightly worse outcomes, with one study showing significantly better freedom from operation at 10 years in patients with non-rheumatic MV disease (88% vs. 73%, $p < .005$).¹⁰⁶ Despite these differences in outcomes, MV repair remains the procedure of choice for the majority of patients with amenable MV disease.

AORTIC VALVE DISEASE

Aortic Stenosis

Etiology. The most common cause of adult aortic stenosis (AS) is calcification of a normal trileaflet or congenital bicuspid aortic valve, particularly in patients >70 years of age. Another important cause of AS is rheumatic heart disease, which is particularly common in developing countries (Fig. 21-9).

Pathology. Calcific aortic valve disease, also known as *senile* or *degenerative disease*, is an age-related disorder characterized by lipid accumulation, proliferative and inflammatory changes, upregulation of angiotensin-converting enzyme activity, oxidative stress, and infiltration of macrophages and

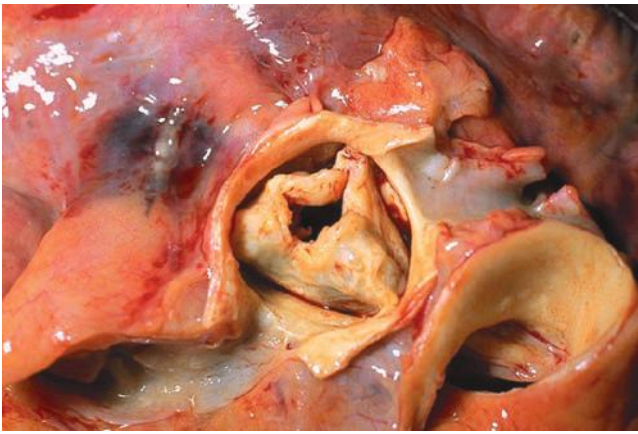


Figure 21-9. Aortic stenosis. The aorta has been removed to demonstrate the thickened, fused aortic valve leaflets associated with rheumatic heart disease. (Image courtesy of the Centers for Disease Control and Prevention, Edwin P. Ewing, Jr.)

T lymphocytes.¹⁰⁷ This process, which closely resembles atherosclerotic vascular calcification, initially results in bone formation within the base of the cusps, reducing leaflet motion. Calcification progresses to involve the leaflets, and eventually results in obstructive disease, with a reduced effective valve area without signs of leaflet fusion.

Pathophysiology. In general, once moderate AS is present, the average rate of progression includes an increase in jet velocity of 0.3 m/s/year, an increase in mean pressure gradient of 7 mm Hg/year, and a decrease in valve area of 0.1 cm²/year (Table 21-12).⁷⁰

In most adult patients with AS, obstruction develops gradually and includes a long latent period free from symptoms. During this time, the left ventricle typically hypertrophies in response to systolic pressure overload, and normal intracavitary volume is maintained.¹⁰⁸ Afterload, which is defined as left ventricular systolic wall stress, and thus ejection fraction remain normal early in this process, as the increase in myocardial thickness is usually enough to counter increased intracavitary systolic pressures. Patients without a typical hypertrophic response to systolic pressure overload, or with a depressed contractile state of the myocardium, do not follow the common clinical course, but experience an early decrease in ejection fraction due to excessively increased afterload, without a compensatory response.¹⁰⁹

Concentric left ventricular hypertrophy without chamber dilatation eventually leads to increased end-diastolic pressures and early diastolic dysfunction. Forceful atrial contraction in the face of elevated end-diastolic pressures becomes an important component of ventricular filling, even as mean left atrial and pulmonary venous pressures remain in the normal range. Disorders such as atrial fibrillation that disrupt atrial contraction typically lead to clinical deterioration. Although systolic function is generally preserved long into the natural history of the disease, left ventricular decompensation eventually occurs in the setting of longstanding increased afterload and is an indication for surgery even in the absence of other symptoms.

Although concentric hypertrophy is a compensatory mechanism to maintain ejection fraction in the face of high intracavitary pressures, the hypertrophied heart becomes increasingly vulnerable to ischemic injury. Coronary blood flow may become inadequate, despite the absence of epicardial coronary artery disease.¹¹⁰ Coronary vasodilation is mitigated

Table 21-12

Data from ACC/AHA guidelines for the classification of the severity of aortic valve disease in adults

AORTIC STENOSIS			
INDICATOR	MILD	MODERATE	SEVERE
Jet velocity (m per s)	<30	3.0–4.0	>40
Mean gradient (mm Hg)*	<25	25–40	>4.0
Valve area (cm ²)	>1.5	1.0–1.5	<1.0
Valve area index (cm ² per m ²)			<0.6
AORTIC REGURGITATION			
QUALITATIVE	MILD	MODERATE	SEVERE
Angiographic grade	1+	2+	3–4+
Color Doppler jet width	Central jet, width <25% of left ventricular outflow tract	Greater than mild, but no signs of severe regurgitation	Central jet, width >65% of left ventricular outflow tract
Doppler vena contracta width (cm)	<0.3	0.3–0.6	>0.6
QUANTITATIVE (CATH OR ECHO)			
Regurgitant volume (ml per beat)	<30	30–59	≥60
Regurgitant fraction (%)	<30	30–49	≥50
Regurgitant orifice area (cm ²)	<0.1	0.1–0.29	≥0.3
ADDITIONAL ESSENTIAL CRITERIA			
Left ventricular size			Enlarged

*Valve gradients are flow dependent and when used as estimates of severity of valve stenosis should be assessed with knowledge of cardiac output or forward flow across the valve.

by the hypertrophied myocardium, and the hemodynamic stress of exercise or tachyarrhythmias can lead to subendocardial ischemia and further systolic or diastolic dysfunction. When ischemic injuries occur, patients with ventricular hypertrophy experience larger infarcts and higher mortality rates than those without hypertrophy.¹¹¹ In some patients, ventricular hypertrophy occurs in excess of what is needed to compensate for increased intracavitary pressures, creating a high-output state that is also associated with increased perioperative morbidity and mortality.¹¹²

Clinical Manifestations. The characteristic auscultatory findings of AS include a harsh, crescendo-decrescendo systolic murmur at the right second intercostal space, often with radiation to the carotid arteries.¹ As the disease progresses, aortic valve closure may follow pulmonic valve closure, causing paradoxical splitting of the second heart sound. Other physical findings associated with AS include an apical impulse commonly described as a “prolonged heave,” and the presence of a narrow and sustained peripheral pulse, known as *pulsus parvus et tardus*.

The classic symptoms of AS are exertional dyspnea, angina, and syncope.¹ Although many patients are diagnosed prior to the onset of symptoms, the most common clinical presentation in patients with a known diagnosis of AS followed prospectively is worsening exertional dyspnea due to a limited capacity to increase cardiac output with exercise, and a progressive rise in end-diastolic pressures leading to pulmonary congestion. Angina occurs in over half of patients with AS, and is due to the increased oxygen demand of the hypertrophied myocardium in the setting of reduced oxygen supply secondary to coronary compression. Although some patients may have concomitant ischemic disease, angina occurs *without* significant epicardial coronary artery disease in half of all patients with AS. Syncope is most common during exertion, as systemic vasodilation in the setting of a fixed cardiac output causes decreased cerebral perfusion. However, at times, it may occur at rest secondary to paroxysmal atrial fibrillation and subsequent loss of atrial booster pump function. Late findings of AS include atrial fibrillation, pulmonary hypertension, systemic venous hypertension, and rarely sudden death.

Diagnostic Studies. Evidence of left ventricular hypertrophy is found in approximately 85% of patients with AS on routine EKG, though the correlation between the absolute electrocardiographic voltages in precordial leads and the severity of AS is poor.¹ EKG also may demonstrate signs of left atrial enlargement, and various forms and degrees of atrioventricular or intraventricular block due to calcific infiltration of the conduction system. Routine chest X-ray usually demonstrates a normal heart size, with rounding of the left ventricular border and apex. Cardiac enlargement on chest X-ray is a sign of left ventricular failure and cardiomegaly, and is a late finding.

Transthoracic echocardiography is indicated in all patients with a systolic murmur graded $\geq 2/6$, a single second heart sound, or symptoms characteristic of AS.⁷⁰ Initial TTE examinations are often diagnostic, and provide an assessment of left ventricular size and function, the degree of left ventricular hypertrophy, the degree of valvular calcification, and the presence of other associated valvular disease. Doppler evaluation should be performed to define the maximum jet velocity, which is the most useful measure for following disease severity and predicting clinical outcome.¹ Additionally, color flow Doppler assesses the severity of the stenotic lesion by allowing calculations of the

mean transvalvular pressure gradient, and effective valve orifice area (Table 21-12).⁷⁰ Follow-up TTE is variably indicated depending on the severity of AS in order to assess changes from baseline parameters and direct the timing of surgery: yearly for severe AS; every 1 to 2 years for moderate AS; and every 3 to 5 years for mild AS. Any abrupt change in signs or symptoms in a patient with AS is an indication for TTE examination.

Additional preoperative studies may be necessary in some patients. Rarely, when TTE images are suboptimal, TEE or fluoroscopy may be indicated to assess the degree of valve calcification and effective valve orifice area. As in other patients with valvular heart disease, coronary angiography should be performed prior to aortic valve surgery in most patients.⁷⁰ Since the symptoms of AS oftentimes mimic those of ischemic disease, cardiac catheterization and coronary angiography may be necessary at the initial evaluation in patients with AS. Stress-echocardiography may also be useful in the asymptomatic patient with AS in order to elicit exercise-induced symptoms, or abnormal blood pressure responses during exertion. It is also useful in the evaluation of low-gradient AS in patients with depressed LV function.⁷⁰ However, exercise stress-echocardiography is contraindicated in patients with ischemic heart disease.⁷⁰ In patients with evidence of aortic root disease by TTE, chest computed tomography is useful in evaluating aortic dilatation at several anatomic levels, and is necessary for clinical decision making and surgical planning.¹

Indications for Operation. Based on the severity of AS and the overall physical condition of the patient (Table 21-12), AVR may be recommended for the treatment of AS (Table 21-13).⁷⁰ In patients with severe calcific AS, AVR is the only effective treatment, though controversy exists as to the timing of intervention in asymptomatic patients. Balloon valvotomy creates a modest hemodynamic effect and temporary symptom improvement in patients with calcific AS. However, the procedure has not been shown to affect long-term outcomes, and is often used in high-risk patients in which the contribution of the AS to the patients' symptoms is a matter of debate.¹¹³

Aortic Insufficiency

Etiology. The most common cause of isolated aortic insufficiency (AI) in patients undergoing AVR is aortic root disease, and represents over 50% of such patients in some studies.¹ Other common causes of AI include congenital abnormalities of the aortic valve such as bicuspid aortic valve, calcific degeneration, rheumatic disease, infective endocarditis, systemic hypertension, myxomatous degeneration, dissection of the ascending aorta, and Marfan syndrome. Less common causes of AI include traumatic injuries to the aortic valve, ankylosing spondylitis, syphilitic aortitis, rheumatoid arthritis, osteogenesis imperfecta, giant cell aortitis, Ehlers-Danlos syndrome, Reiter's syndrome, discrete subaortic stenosis, and ventricular septal defects with prolapse of an aortic cusp.⁷⁰ Although most of these lesions produce chronic aortic insufficiency, rarely acute severe aortic regurgitation can result, often with devastating consequences.

Pathology. Regardless of its cause, AI produces volume overload with dilation and hypertrophy of the left ventricle, and subsequent dilation of the MV annulus. Depending on the severity of AI, the left atrium may undergo dilation and hypertrophy as well. Frequently, the regurgitant jet causes endocardial lesions at the site of impact on the left ventricular wall.

Table 21-13

Data from ACC/AHA guidelines for AV surgery in specific clinical contexts.

CLINICAL SETTING	CLASS OF RECOMMENDATION	LEVEL OF EVIDENCE
Balloon Valvotomy for Aortic Stenosis		
• Bridge to surgery in hemodynamically unstable patients with AS at high risk for AVR	IIb	C
• Palliation in adult patients with AS, who are not candidates for AVR	IIb	C
• Alternative to AVR in adult patients with AS	III – Harm	B
Surgery for Aortic Stenosis		
• Symptomatic patients with severe AS	I	B
• Severe AS in the setting of 1) Concomitant CABG 2) Concomitant valvular or aortic surgery 3) LV systolic dysfunction (LVEF <0.50)	I	C
• Moderate AS in the setting of 1) Concomitant CABG 2) Concomitant valvular or aortic surgery	IIa	B
• Asymptomatic patients with severe AS and • Abnormal response to exercise • High likelihood of rapid progression • High likelihood of delay if surgery is withheld until time of symptom onset • Expected operative mortality ≤1.0%	IIb	C
• Mild AS in patients undergoing CABG, when there is high likelihood of rapid progression	IIb	C
• AVR for prevention of sudden death in asymptomatic patients with AS without any of the findings above	III – Harm	B
Surgery for Aortic Insufficiency		
• Symptomatic patients with severe AI	I	B
• Asymptomatic patients with chronic severe AI in the setting of 1) Concomitant CABG 2) Concomitant valvular or aortic surgery 3) LV systolic dysfunction (LVEF ≤0.50)	I	C C B
• Asymptomatic patients with severe AI, normal LV systolic function (LVEF >0.50), but severe LV dilatation (end-diastolic dimension >75 mm, end-systolic dimension >55 mm)	IIa	B
• Moderate AI in the setting of 1) Concomitant CABG 2) Concomitant surgery on the ascending aorta	IIb	C
• Asymptomatic patients with severe AI, normal LV systolic function at rest (LVEF >0.50), and LV dilatation (end-diastolic dimension ≥70 mm, end-systolic dimension ≥50 mm) in the setting of 1) Progressive LV dilatation 2) Declining exercise tolerance 3) Abnormal hemodynamic responses to exercise	IIb	C
• Asymptomatic patients with mild, moderate, or severe AI and normal LV systolic function (LVEF >0.50), when the degree of LV dilatation is not moderate or severe (end-diastolic dimension <70 mm, end-systolic dimension <50 mm)	III – Harm	B

AS = aortic stenosis; AVR = aortic valve replacement; CABG = coronary artery bypass grafting; LV = left ventricular; LVEF = left ventricular ejection fraction; NYHA = New York Heart Association.

Diseases causing AI can be classified as primary disorders of the aortic valve leaflets, and/or disorders involving the wall of the aortic root. Diseases causing dilation of the ascending aorta are a more common indication for AVR due to isolated AI, and include disorders such as age-related (degenerative) aortic dilation, cystic medial necrosis of the aorta as is seen in

Marfan syndrome, aortic dilation secondary to bicuspid valves, and aortic dissection, to name a few.¹¹⁴ In these disorders, the aortic annulus becomes dilated, causing separation of the valve leaflets and subsequent AI. The diseased aortic wall may dissect secondarily and further escalate regurgitation across the valve, and secondary thickening and shortening of the valve

cusps may occur due to undue tension placed on the valvular apparatus by the dilated aortic root. As the disease progresses, the valves become too small to close the aortic orifice, causing further aortic insufficiency and exacerbating dilation of the ascending aorta.

There are also many primary valvular diseases that cause AI, generally in association with AS. One such disorder is age-related calcific AS, which causes some degree of AI in up to 75% of patients.¹ Infective endocarditis may involve the aortic valve apparatus and cause AI through direct destruction of the valve leaflets, perforation of a leaflet, or formation of vegetations that interfere with proper coaptation of the valve cusps. Rheumatic disease causes fibrous infiltration of the valve cusps and subsequent retraction of the valve leaflets, inhibiting apposition of the cusps during diastole and producing a central regurgitant jet. Patients with large ventricular septal defects or membranous subaortic stenosis may develop progressive AI, owing to a Venturi effect that results in prolapse of the aortic valve leaflets.

Pathophysiology. The basic pathophysiologic abnormality of AI is the retrograde flow of a portion of the LV stroke volume into the left ventricle during diastole, producing left ventricular volume overload.

Acute severe AI results most commonly from infective endocarditis, acute aortic dissection, or trauma, and causes a sudden volume overload on the left ventricle.³¹ Although an acute increase in preload provides a small increase in overall stroke volume due to the Starling mechanism, the left ventricle is unable to accommodate the large regurgitant volume and maintain forward stroke volume in the acute setting due to a lack of remodeling. Left ventricular end-diastolic and left atrial pressures increase dramatically, as the left ventricle is unable to develop compensatory chamber dilation. Although tachycardia develops as a compensatory mechanism to maintain forward flow, this attempt is often inadequate, and patients frequently present in heart failure and even cardiogenic shock. Moreover, subendocardial myocardial ischemia frequently develops as a result of decreased coronary diastolic perfusion pressures and increased left ventricular end-diastolic pressure, as well as increased myocardial oxygen demand due to acute dilation. In the setting of a chronic ventricular hypertrophy and preexisting diastolic dysfunction, the pressure-volume relationship is even more extreme, exacerbating the hemodynamic derangements seen in acute AI.

Chronic AI generally has a more indolent course, with volume overload of the left ventricle causing compensatory increases in left ventricular end-diastolic volume and chamber compliance, and a combination of eccentric and concentric hypertrophy.¹¹⁵ Compensatory remodeling of the left ventricle allows for accommodation of the regurgitant volume without a significant increase in filling pressures, and maintains the preload reserve of the chamber. Eccentric left ventricular hypertrophy develops, permitting normal contractile performance across the enlarged chamber circumference and subsequent ejection of a larger total stroke volume in order to maintain forward flow, despite the regurgitant fraction.^{115,116} However, the enlarged chamber size results in an increase in systolic myocardial wall stress, and causes further ventricular hypertrophy. As the disease progresses, recruitment of preload reserve and compensatory hypertrophy maintains ejection fraction within the normal range despite elevated afterload, causing many patients to remain asymptomatic throughout the compensatory phase.^{115,117}

Eventually, left ventricular compensatory mechanisms fail and systolic dysfunction ensues. As the disease progresses, preload reserve may become exhausted, the hypertrophic response may become inadequate, and/or impaired myocardial contractility may develop so that ejection fraction begins to decline.¹¹⁸ Although left ventricular systolic dysfunction related to excessive afterload is reversible early in the course, irreversible damage occurs once chamber enlargement predominates as the primary cause of diminished myocardial contractility.

Clinical Manifestations. In cases of acute severe AI, patients are symptomatic and invariably present with compensatory tachycardia, often associated with acute pulmonary congestion and cardiogenic shock.¹ Because the left ventricular and aortic pressures often equalize before the end of diastole, the diastolic murmur of AI may be short and/or soft. The reduced systolic pressure may attenuate the increase in peripheral pulse pressure seen in chronic AI, and early closing of the mitral valve due to elevated left ventricular end-diastolic pressures may diminish the intensity of the first heart sound in the acute setting.

In patients with chronic AI, symptoms of heart failure and myocardial ischemia develop after the compensatory phase.¹ Patients gradually begin to complain of exertional dyspnea, fatigue, orthopnea, and paroxysmal nocturnal dyspnea, often after significant myocardial dysfunction has developed. Angina is a common complaint late in the course, especially during sleep when heart rate slows and arterial diastolic pressure falls. Patients may also experience exertional angina secondary to diminished coronary perfusion in the setting of myocardial hypertrophy. Occasionally, the compensatory tachycardia that develops with chronic AI will cause palpitations, and the increased pulse pressure will cause a sensation of pounding in the patient's head. Peripherally, the widened pulse pressure causes a forceful, bounding, and quickly collapsing pulse known as Corrigan's or water-hammer pulses. Premature ventricular contractions have been reported to cause particularly troubling symptoms, owing to the heave of the volume-loaded left ventricle during the postextrasystolic beat. The classic auscultatory finding associated with AI is a high-pitched decrescendo diastolic murmur heard best in the left third intercostal space; an associated S₃ gallop is often indicative of late disease. The Austin Flint murmur has also been described, and is heard as a middiastolic rumble at the apex that simulates mitral stenosis, and occurs in severe AI when the regurgitant jet impedes mitral opening.

Diagnostic Studies. In the acute setting, TTE should be performed to confirm the presence and severity of aortic regurgitation, the degree of pulmonary hypertension, and the cause of valvular dysfunction.⁷⁰ When aortic dissection is suspected as the cause of acute AI, TEE should be performed for diagnosis, though chest computed tomography may be substituted if more readily available.^{119,120} Cardiac catheterization, aortography, and coronary angiography are rarely indicated, and often delay necessary urgent surgical intervention.

In cases of chronic AI, the EKG frequently demonstrates signs consistent with left axis deviation and, late in the course, intraventricular conduction defects associated with left ventricular dysfunction. On chest X-ray, the left ventricle enlarges predominantly in an inferior and leftward direction, causing marked increase in the long axis diameter of the heart, frequently with little or no change in the transverse diameter. The chest X-ray should be examined for aneurysmal dilation of the aorta.¹ An initial

TTE should be performed to confirm the diagnosis and severity of AI, assess the cause of AI (including valve morphology, and aortic root size and morphology), and assess the degree of left ventricular hypertrophy, volume, and systolic function.⁷⁰ Follow-up TTE is indicated on an annual or semiannual basis in patients with asymptomatic moderate to severe AI in order to assess changes from baseline parameters and direct the timing of surgery. Any abrupt change in signs or symptoms in a patient with chronic AI is also an indication for TTE examination.

Additional preoperative studies are variably indicated in certain patient populations.⁷⁰ In patients with poor windows on TTE, TEE, or magnetic resonance imaging is indicated for initial and serial assessment of AI severity, and left ventricular volume and function at rest. In symptomatic patients with chronic AI, it is reasonable to proceed directly to TEE or cardiac catheterization if TTE examinations are inadequate. Exercise stress testing may be helpful for an assessment of functional capacity and symptomatic responses in patients with a history of equivocal symptoms. Coronary angiography should be performed prior to valve surgery in most patients.⁷⁰

Indications for Operation. Based on the morphology and severity of valve dysfunction (Table 21-12), AV repair or replacement may be performed for the treatment of AI (Table 21-13).⁷⁰ Although the indications for AV repair and AV replacement do not differ, it is recommended that AV repair be performed only in those surgical centers that have developed the appropriate technical expertise, gained experience in patient selection, and demonstrated outcomes equivalent to those of valve replacement.

Aortic Valve Operative Techniques and Results

Aortic valve surgery has traditionally been performed through a median sternotomy incision with the assistance of cardiopulmonary bypass and moderate systemic hypothermia. However, minimally invasive incisions for aortic valve surgery have been introduced, including mini-sternotomy and mini-thoracotomy approaches. After the aorta is cross-clamped, cold blood cardioplegia is delivered antegrade through the aortic root, and/or retrograde through the coronary sinus. A left ventricular vent may be inserted through the right superior pulmonary vein to help maintain a bloodless field during the procedure, and to aid in de-airing at the conclusion of the operation.

Aortic Valve Replacement. During aortic valve replacement, an aortotomy is performed, extending medially from approximately 1 to 2 cm above the right coronary artery and inferiorly into the noncoronary sinus, and the valve is completely excised. The annulus is thoroughly debrided of calcium deposits. After the calcium has been removed, the ventricle is copiously irrigated with saline. At this point, the annulus is sized and an appropriate prosthesis is selected. Pledged horizontal mattress sutures are then placed into the aortic valve annulus and subsequently through the sewing ring of the prosthetic valve, taking care to avoid damage to the coronary ostia, the conduction system, and the MV apparatus. The annular sutures may be placed from below the annulus, seating the valve supra-annularly, or from above the annulus for intra-annular placement (Fig. 21-10).

The major components to increased operative risk associated with surgical AVR include age, body surface area, diabetes, renal failure, hypertension, chronic lung disease, peripheral vascular disease, neurologic events, infectious endocarditis, previous cardiac surgery, myocardial infarction, cardiogenic shock, NYHA functional status, and pulmonary hypertension. For

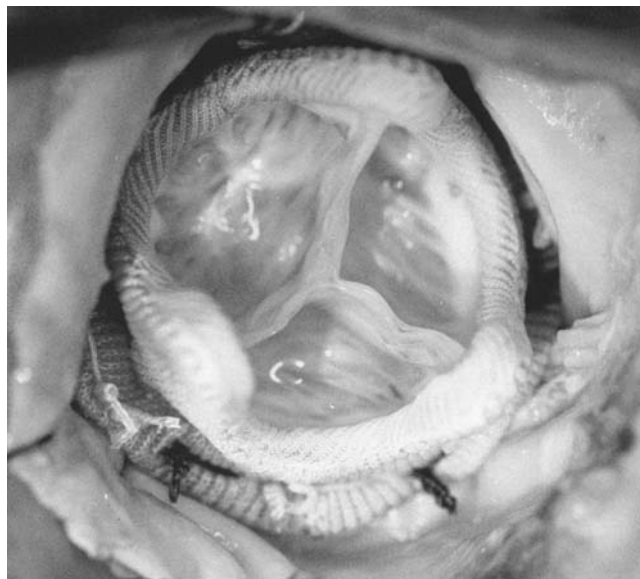

Figure 21-10. Aortic valve replacement. The stented porcine bioprosthesis as viewed through an aortotomy.

most patients, the risk associated with AVR is 1% to 5%, and 5-year survival has been reported to be >80%, even in patients >70 years of age.^{69,121} The choice of valve is dependent on many patient-related factors, and is accompanied by the attendant postoperative risks of decreased durability, and thromboembolic vs. hemorrhagic complications for biological and mechanical valves, respectively.

Aortic Valve Repair. Although aortic valve replacement is performed more commonly, AV repair may be recommended at surgical centers with extensive experience, technical expertise, and outcomes equivalent to valve replacement.⁷⁰

For patients with aortoannular ectasia, AI is due to annular dilatation and distortion of the sinotubular junction. For these patients, competence of the aortic valve can be achieved by functionally repairing the annulus in a method analogous to homograft implantation. The aneurysmal portion of the aortic root is excised, and the aortic valve is reimplanted inside a tubular Dacron graft, with concomitant reimplantation of the coronary arteries. Alternatively, the aneurysmal tissue and supra-annular tissue can be excised in their entirety, with subsequent implantation of the Dacron graft onto the superior aspect of the annulus and reimplantation of the coronary arteries.

Valve-sparing root replacement for root and annular stabilization in patients with AI due to aortoannular ectasia has led to a more durable outcome than is seen with subcommissural annuloplasty or leaflet-related procedures alone. One study demonstrated equivalent overall survival between patients undergoing subcommissural annuloplasty or aortic valve repair without annuloplasty, and patients undergoing valve-sparing root replacement at 6 years.¹²² However, patients that underwent valve-sparing root replacement had higher freedoms from reoperation and aortic insufficiency >2+ (100% vs. 90%, $P=0.03$; and 100% vs. 77%, $P=0.002$, respectively) at midterm follow-up.

For patients with AI associated with redundant leaflet tissue, aortic valve repair may be accomplished with free margin plication or resuspension of the valve cusps, with or without triangular resection of the redundant segment. Excision of the

diseased portion of the involved valve cusp improves symmetry of the valve leaflets, and annular plication of one or both commissures helps to ensure adequate coaptation. Generally, the free margins of the excised leaflets are reapproximated primarily, but in the absence of adequate cusp tissue, a triangular autologous or bovine pericardial patch may be used for cusp restoration.

AV cusp repair with a free margin plication or resuspension technique has demonstrated encouraging results, both in patients with tricuspid and bicuspid aortic valves. Freedom from AV reoperation in patients with a tricuspid AV has been reported to be 89% to 92% at 10 years, with a freedom from recurrent AI >2+ of 80% to 86% at the same time point. In patients with bicuspid aortic valves, who generally represent a younger cohort of patients, 10-year survival has been reported at 94% following AV repair, with a freedom from AV reoperation of 81% at the same time point.¹²³

Ross Procedure. As mentioned previously, the Ross procedure involves replacing the diseased AV with the patient's native pulmonary valve as an autograft, which is in turn replaced with a homograft in the pulmonic position.⁸⁰ The autograft may be implanted in the aortic position directly with resuspension of the valve commissures, or in association with a root replacement, which requires reimplantation of the coronary ostia.

The cylinder root replacement technique is most reproducible, and involves transecting the native aorta approximately 5mm above the sinotubular ridge, with subsequent excision of the aortic valve leaflets and supra-annular tissue. The main pulmonary artery is transected at the bifurcation and the right ventricular outflow tract is incised, allowing the pulmonary valve and artery to be removed en bloc from the outflow tract. The annulus of the pulmonary autograft is sewn to the native aortic annulus with continuous or interrupted sutures, and the coronary ostia are reimplanted into the pulmonary artery graft. The pulmonary valve and right ventricular outflow tract are subsequently reconstructed using homograft tissue.

The primary benefit of the Ross procedure compared to traditional AV surgery is a low risk of thromboembolism without the need for systemic anticoagulation. Although patients undergoing the Ross procedure are generally younger, perioperative mortality has been reported to be as low as 2.5% in this group, with an overall survival of 90% at 18-year follow-up.¹²⁴ However, the long-term durability of the procedure is somewhat questionable. Although Ross reported a freedom from autograft replacement of 75% at 20 years, other groups have reported freedom from autograft reoperation and allograft reintervention of 51% and 82%, respectively, at 18-year follow-up.^{124,125} Progressive aortic insufficiency has been described as a cause of late failure in these patients, as well as calcification of the pulmonary homograft and pulmonary stenosis.

Transcatheter Aortic Valve Replacement. Transcatheter aortic valve replacement (TAVR) is relatively new technology that has proven beneficial for the treatment of AS in seriously ill patients who are not candidates for conventional surgery. The procedure remains the focus of ongoing clinical trials, and thus there are no published indications for operation endorsed by the American College of Cardiology or the American Heart Association. However, the Edwards SAPIEN heart-valve system that has been used thus far in the TAVR experience has been recently approved by the Food and Drug Administration for labeled-indications associated with published early results.

The Edwards SAPIEN heart-valve system consists of a trileaflet bovine pericardial valve with a balloon-expandable stainless steel support frame, and can be inserted by either the transfemoral, transaortic, or transapical route. The transfemoral route involves performing a standard balloon aortic valvuloplasty, followed by transfemoral insertion of either a 22- or 24-French sheath, depending on the size of the valve selected for implantation. The balloon catheter and overlying collapsed bioprosthetic heart valve is then advanced across the native aortic valve under fluoroscopy, and deployed during rapid right ventricular pacing. If the patient's peripheral vascular system is not amenable to femoral arterial cannulation, the transapical or transaortic route is chosen. In the transapical approach, a small intercostal incision is performed over the left ventricular apex, and a dedicated delivery catheter is inserted through the left ventricular apex and across the native aortic valve as described above. The transaortic approach is usually done through a ministernotomy. Other approaches that have been described include transaxillary, transsubclavian, and transcarotid. The particular role of each approach in a specific patient still remains to be defined, and continues to change as the technology improves.

A large multicenter clinical trial has been performed on patients that were judged to be too high risk or inoperable for traditional AVR, based on assumed risks of $\geq 10\%$ to 15% and $\geq 50\%$ 30-day mortality, respectively. In patients that had previously been deemed inoperable, TAVR markedly reduced the rate of death from any cause (49.7% vs. 30.7%, $P = <0.001$), the rate of death from cardiovascular causes (41.9% vs. 19.6%, $p = <.001$), and the rate of repeat hospitalization (44.1% vs. 22.3%, $p = <.001$) at one year compared with standard medical therapy.¹²⁶ Although the rates of neurological events (10.6% vs. 4.5%, $P = 0.04$), major vascular complications (16.8% vs. 2.2%, $P = <.001$), and major bleeding events (22.3% vs. 11.2%, $P = 0.007$) were higher in the TAVR group, these patients also experienced a significant reduction in symptoms and increased functional capacity compared with patients receiving standard medical therapy. In patients at high risk for traditional AVR, the rate of death from any cause, and from cardiovascular causes, was found to be noninferior in the TAVR group, compared with the surgical group.¹²⁷ The rate of major bleeding events was higher in the surgical group (19.5% vs. 9.3%, $P = <0.001$) at 30 days, and patients in the TAVR group had a significantly shorter length of stay in the intensive care unit (3 vs. 5 days, $P = <0.001$), and a shorter index hospitalization (8 vs. 12 days, $P = <.001$). Although more patients in the TAVR group experienced a reduction in symptoms to NYHA class II or lower ($P = <0.001$), they also experienced more neurological events (8.3% vs. 4.3%, $P = 0.04$), and major vascular complications (11.3% vs. 3.5%, $P = <.001$) at one year.

Although it is clear that TAVR represents a distinct set of periprocedural risks, it has demonstrated benefits in morbidity and mortality, especially in patients deemed inoperable for surgical AVR. Ongoing trials are examining the potential role of TAVR in patients with AS at moderate risk for traditional AVR.

TRICUSPID VALVE DISEASE

Tricuspid Stenosis and Insufficiency

Etiology. Acquired tricuspid valve (TV) disease can be classified as either organic or functional, and affects approximately 0.8% of the general population.¹²⁸ Tricuspid stenosis is almost

always a result of organic disease, namely rheumatic heart disease and endocarditis. In the case of rheumatic disease, tricuspid stenosis with or without associated insufficiency is invariably associated with mitral valve disease. Other less common causes of obstruction to right atrial emptying include congenital tricuspid atresia, right atrial tumors, and endomyocardial fibrosis.

Tricuspid insufficiency, on the other hand, is most often a functional disease caused by secondary dilation of the tricuspid annulus due to pulmonary hypertension and/or right heart failure. This is most commonly caused by MV disease. Conditions such as right ventricular infarction and pulmonic stenosis can also lead to increased right ventricular pressures and functional tricuspid insufficiency (TI). The less common causes of organic TI, with or without associated stenosis, include carcinoid syndrome, radiation therapy, trauma such as repeated endomyocardial biopsy specimens, and Marfan syndrome.

Pathology. The changes associated with tricuspid stenosis (TS) closely resemble those associated with MS, including fusion of the commissures.¹²⁸ In the case of rheumatic disease, mixed TS and TI may result from fusion and shortening of the chordae tendineae, and fusion of the commissures, causing retraction of the valve leaflets. The right atrium is frequently dilated and thickened in chronic TS, and chronic obstruction to right ventricular filling often produces signs of systemic venous congestion such as hepatomegaly and splenomegaly.¹

In most cases of TI, dilation and deformation of the tricuspid annulus is the most prominent feature; the valve leaflets oftentimes appear stretched, but are otherwise pliable and normal in appearance.¹ When TI is caused by carcinoid syndrome, white fibrous carcinoid plaques are found on the ventricular surfaces of the TV, causing the cusps to adhere to the underlying right ventricular wall and stenting the valve open.¹

Pathophysiology. The basic pathophysiologic abnormality of both TS and severe TI is elevated right atrial pressures, producing signs of systemic congestion and right heart failure. Severe TS is marked by a valve area $<1.0 \text{ cm}^2$, and severe TI is defined as a vena contracta width of $>0.7 \text{ cm}$ in combination with systolic flow reversal in the hepatic veins.⁷⁰ However, in patients with TS, a diastolic pressure gradient of only 5 mm Hg, or a TV orifice $<1.5 \text{ cm}^2$, is frequently enough to cause jugular venous distention, organomegaly, and peripheral edema. In severe cases, cardiac output is compromised, especially during exercise when the fixed obstruction prevents an increase in forward flow. Patients with severe insufficiency and pulmonary hypertension experience similar hemodynamic derangements.

Clinical Manifestations. Patients with TS and severe TI develop symptoms of right heart failure associated with chronically elevated right atrial pressures.¹ The classic clinical signs and symptoms of TS and severe TI are jugular venous distention, hepatomegaly, splenomegaly, ascites, and lower extremity edema. Uncomfortable fluttering in the neck has been reported in patients with TV disease, and sensations of throbbing in the eyeballs and pulsatile varicose veins have been reported to occur, especially in patients with severe TI.

The low cardiac output occasionally associated with TS and severe TI can cause fatigue, weakness, and exercise intolerance in these patients. In the absence of pulmonary hypertension, dyspnea is not a prominent feature of tricuspid disease. The auscultatory findings associated with TS include a presystolic and middiastolic murmur characterized by a tricuspid opening snap that increases on inspiration. The lower left parasternal murmur

of TI may be holosystolic or less than holosystolic, depending on the degree of regurgitation, may be associated with a middiastolic murmur in severe cases, and may increase on inspiration.

Diagnostic Studies. In patients with TV disease, chest X-ray frequently demonstrates enlargement of the right atrium and ventricle. Patients with TS demonstrate an exaggerated *a* wave and a diminished rate of *y* descent in the jugular venous pulse, while patients with TR have abnormal systolic *c* and *v* waves.¹ TTE examination should be performed in patients with TV disease in order to characterize the structure and motion of the TV, the size of the tricuspid annulus, and other cardiac abnormalities that may affect TV function.⁷⁰ In patients with a pulmonary artery systolic pressure $>55 \text{ mm Hg}$, TI commonly occurs in the setting of structurally normal valves; however, structural derangement of the TV apparatus is frequently present if TI is documented with a pulmonary artery systolic pressure $<40 \text{ mm Hg}$. Doppler TTE allows estimations of the severity of TI, the right ventricular systolic pressure, and the TV diastolic gradient.

Indications for Operation. As an isolated lesion, mild or moderate TV disease does not require surgical correction. However, patients with severe TV disease should be considered for surgical intervention, especially in the setting of right ventricular enlargement and impaired systolic function, as this improves life expectancy and the development of sequelae such as heart failure and atrial fibrillation.¹²⁸ Depending on the patient's clinical status and the cause of TV dysfunction, TV repair and TV replacement be variably recommended for the treatment of TV dysfunction (Table 21-14).⁷⁰ In patients with TI, the valve can usually be repaired with modern techniques.

Operative Techniques and Results. The TV can be approached through a median sternotomy, a right thoracotomy, or minimally invasive port-based techniques. Surgery is performed with the assistance of cardiopulmonary bypass and, though TV surgery is usually performed on the beating heart, a brief period of cardioplegic arrest is rarely needed to allow for complete inspection of the interatrial septum, and close any defects that may be present.

TV repair may include a suture or ring annuloplasty as well as valvuloplasty, and multiple methods have been described.¹²⁸ Historically, bicuspidization of the TV was accomplished by a figure-of-eight suture plication of the annulus of the posterior leaflet; however, this technique has been essentially replaced by suture or ring annuloplasty. Suture annuloplasty is generally performed by placing 0 polypropylene pledgeted sutures along the base of the anterior and posterior leaflets, partially encircling the annulus. Ring annuloplasty can be accomplished by suturing the TV annulus to a variety of rigid or semirigid annuloplasty rings, which generally have an opening at the level of the anteroposterior commissure to avoid passing the anchoring sutures too close to the conduction system. Most surgeons favor ring over suture annuloplasty. In severe annular dilatation, augmentation of the anterior leaflet with autologous pericardium has been used with some success. Tricuspid valvuloplasty is infrequently performed and may include commissurotomy, triangular leaflet resection, primary perforation repair, and traditional leaflet repair techniques such as chordal transfer, shortening, and replacement, papillary muscle plication, tricuspid leaflet augmentation, and the edge-to-edge repair technique used in MV prolapse.

For patients with functional TV disease, TV repair is generally preferred to replacement due to favorable results without the associated risks of thrombosis and anticoagulation. In the

Table 21-14

Data from ACC/AHA guidelines for TV surgery in specific clinical contexts.

CLINICAL SETTING	CLASS OF RECOMMENDATION	LEVEL OF EVIDENCE
Surgery for Tricuspid Valve Disease		
• TVr for severe TI in patients with MV disease requiring MV surgery	I	B
• TVR or annuloplasty for severe symptomatic primary TI	IIa	C
• TVR for severe TI secondary to diseased/abnormal TV leaflets not amenable to annuloplasty or TVr	IIa	C
• Annuloplasty for less than severe TI in patients undergoing MV surgery in the setting of 1) Pulmonary hypertension 2) Tricuspid annular dilatation	IIb	C
• TVR or annuloplasty is not indicated in asymptomatic patients with TI, a normal MV, and a PASP <60 mm Hg	III – Harm	C
• TVR or annuloplasty is not indicated in patients with mild primary TI	III – Harm	C

MV = mitral valve; PASP = pulmonary artery systolic pressure; TI = tricuspid insufficiency; TV = tricuspid valve; TVr = tricuspid valve repair; TVR = tricuspid valve replacement.

setting of concomitant mitral valve surgery, TV repair has not been associated with additional perioperative complications, and 5-year freedom from reoperation has been impressive at 98%.⁸⁵ However, a subgroup of patients report late failure following TV repair, and this may be worse following suture annuloplasty compared with ring annuloplasty.

Prosthetic valve replacement may be necessary due to extensive leaflet destruction or marked annular dilatation not amenable to repair. In some cases, the valve prosthesis may be anchored directly to the leaflet tissue instead of the valve annulus, reducing the risk of injury to the conduction system.¹²⁸ If this technique is used, it should be confirmed that the residual tissue does not interfere with the movement of the prosthetic leaflets after implantation. Pledged sutures should be used, and may be placed on the ventricular or atrial side of the annulus.

Outcomes data following TV replacement are difficult to interpret, as most reports are in patients with previous TV surgery and/or signs of severe right heart failure. Operative mortality has been over 20% in some studies.¹²⁸ One study of 87 patients undergoing TV replacement between 1994 and 2007 showed an in-hospital mortality of only 1.4%. The choice of prosthetic valve is also somewhat controversial. Though bioprosthetic valves are more durable in the tricuspid than mitral or aortic positions, valve degeneration is an important cause of bioprosthetic valve dysfunction at reoperation. The increased risk of valve thrombosis seen with mechanical valves, however, underlines the need for rigorous systemic anticoagulation. Even with these precautions, mechanical tricuspid valves are associated with an increased risk of hemorrhagic and thrombotic complications. The choice of valve is usually decided on a case-by-case basis and late outcomes have been similar with biological and mechanical valves in this position. In general, TV replacement may be a reasonable choice in select patients, though more data are needed regarding long-term outcomes in the modern era.

Multivalve Disease

Pathology involving multiple valves is relatively common, and may result from diseases such as rheumatic fever, calcific

disease, Marfan syndrome, and other connective tissue disorders.¹ However, multivalve disease may also be caused by secondary valvular dysfunction due to a distal valvular lesion, as in the case of myxomatous degeneration of the mitral valve, resulting in pulmonary hypertension, dilation of the tricuspid annulus, and functional TI. If the primary pathology is corrected early in the disease course, these secondary functional changes may resolve without further intervention.

In patients with multivalve disease, the clinical manifestations may be dependent on the severity of each individual valve lesion, but this is not always the case.¹ In patients with concomitant mitral and tricuspid dysfunction, the prominent symptoms of dyspnea, paroxysmal nocturnal dyspnea, and orthopnea commonly associated with MV dysfunction are frequently diminished by associated TV dysfunction. Symptoms of multivalve disease are most commonly masked when valvular abnormalities are of approximately equal severity, highlighting the importance of careful examination of each valve both preoperatively and in the operating room.

Surgery for multivalve disease is associated with a higher perioperative mortality than single-valve procedures, and this risk is exacerbated by factors such as pulmonary artery hypertension, age, triple-valve procedures, concomitant coronary artery bypass grafting, previous heart surgery, and diabetes.¹²⁹ Failing to recognize significant concomitant valvular dysfunction at the time of surgery is also associated with higher perioperative mortality. For this reason, patients suspected of having multivalve involvement should undergo full preoperative Doppler TTE or TEE evaluation, and heart catheterization.⁷⁰ In selected patients, procedures correcting multivalve disease demonstrate significant clinical improvement in symptoms and quality of life, as well as acceptable mortality and survival rates.¹²⁹

SURGICAL THERAPY FOR THE FAILING HEART

Epidemiology of Heart Failure

Heart failure affects approximately 5 million patients in the United States, with >550,000 new cases diagnosed annually.¹³⁰

The disorder is the primary reason for 12 to 15 million office visits and >1 million hospitalizations each year. Overall 1-year mortality is estimated to be around 25%, but this can increase to as high as 75% for patients with more advanced heart failure (NYHA class IV).¹³¹ While heart transplantation remains the gold standard for the treatment of end stage disease, an increasing number of patients deteriorate while on the waiting list and up to 30% die before transplantation.¹³² The total direct and indirect costs associated with the treatment of heart failure are estimated to be \$32 billion, and this is projected to increase to \$70 billion by 2030.¹³³ Advances in the surgical management of heart failure over the last decade have pushed surgery for CHF into the mainstream. As a result, there is an increasing number of patients with late- or end-stage disease who are being considered for surgical therapies.

Etiology and Pathophysiology

Heart failure can be classified as acute vs. chronic, genetic vs. acquired, left-sided vs. right-sided and systolic vs. diastolic dysfunction. The underlying causes and treatments for each of these vary considerably. In the Framingham Heart Study, coronary artery disease accounted for 67% of heart failure cases, valvular heart disease accounted for 10%, and 20% of cases were attributable to primary myocardial diseases, of which dilated cardiomyopathy predominated.¹³⁴ In all cases, heart failure is a progressive disorder that through complex mechanisms of ventricular remodeling, altered hemodynamics, neurohumoral activation, cytokine overexpression, and vascular and endothelial dysfunction either disrupts the ability of the myocardium to generate force or results in a loss of functioning cardiac myocytes, thereby preventing normal myocardial contraction.

CABG for Ischemic Cardiomyopathy

Surgical coronary revascularization is among the most commonly performed procedures for CHF. CABG is beneficial as it protects from further myocardial infarction and/or malignant ventricular arrhythmias. It is most successful when treating hibernating as opposed to infarcted myocardium.

While the majority of evidence supporting CABG for patients with ischemic cardiomyopathy comes from nonrandomized, retrospective studies, the prospective, randomized, multicenter international Surgical Treatment of Ischemic Heart Failure (STICH) trial compared CABG with medical therapy to medical therapy alone. Entry criteria included an EF \leq 35% with CAD and anatomy suitable for CABG. No significant difference was seen in overall mortality by study completion, but patients who underwent CABG did have fewer deaths or hospitalizations from cardiovascular causes (58% vs. 68%, $P < 0.001$).^{135,136} This difference is despite the facts that only 50% of patients had myocardial viability testing, that 17% of patients in the medical therapy group underwent CABG and that 9% of patients randomized to CABG did not have surgery.

Myocardial viability testing has been shown by multiple studies to be pivotal in identifying patients that will have improved outcomes following CABG for ischemic cardiomyopathy.^{137,138} A meta-analysis performed by Allman et al demonstrated an 80% reduction in mortality in patients who underwent revascularization with viable myocardium compared to patients who received medical therapy alone (3.2% vs. 16%, $p < 0.0001$). Most important, in this analysis CABG had no benefit over medical therapy for patients without viable myocardium. A more

recent study by Gerber et al prospectively compared CABG and medical therapy to medical therapy alone in 114 patients with CAD and low EF (24 ± 8) who underwent viability testing using delayed-enhancement cardiac MRI.¹³⁹ That study demonstrated worse 3-year survival in medically treated patients with dysfunctional but viable myocardium than in medically treated patients with nonviable myocardium (48% vs. 77%, $P = 0.02$). This corresponded with a 4.56 hazard of death of viable myocardium when medical treatment was selected over full revascularization. In contrast, survival after CABG was not significantly different whether myocardium was viable or not (88% vs. 71%, $P = \text{NS}$). These studies underscore both the importance of viable myocardium as well as the adverse consequences of not offering a patient with viability surgical intervention.

Patients with ischemic cardiomyopathy are a heterogeneous group, and, as with any surgery, appropriate patient selection is central to success. In one retrospective study of 96 patients with ischemic cardiomyopathy (EF \leq 25%), age, and poor distal vessel quality were predictors of poor outcomes.¹⁴⁰ Mortality in patients with poor vessel quality was 100%, compared with 90% when vessel quality was fair and 10% when it was good. Therefore, poor vessel quality should be considered a contraindication to surgical revascularization even in the presence of angina.

LV size and LV dyssynchrony are also risk factors for adverse short and intermediate term outcomes. A LV end diastolic dimension of >100 mL/m² is associated with a significantly reduced 5-year survival following CABG (85% vs. 53%, $p < 0.05$), as well as worse 5-year freedom from recurrent CHF (85% vs. 31%).¹⁴¹ Moreover, LV dyssynchrony has been shown to have a significant impact on mortality in patients undergoing moderate to high risk revascularization and may compound risk in patients with nonviable myocardium.¹⁴² In patients with severe preoperative LV dyssynchrony the 30-day mortality was 27% vs. 3% in patients without significant dyssynchrony ($p < 0.001$). Similar differences were seen with the presence of postoperative LV dyssynchrony, and outcomes were worse when patients also had fewer segments of viable myocardium.

Secondary Mitral Regurgitation

Secondary mitral regurgitation describes MR that results from damage to the left ventricle as a result of either ischemia or dilated cardiomyopathy rather than from a problem with the valve itself.¹⁴³ Ischemic MR (IMR) typically results from systolic restriction of the mitral leaflets due to tethering of the subvalvular apparatus. This occurs mainly from regional wall motion abnormalities in areas of the LV adjacent to papillary muscle attachments. Alterations in the size and shape of the mitral annulus and posterior displacement of the posteromedial papillary muscle, which occurs primarily after an inferoposterior MI, may also contribute. Additionally, functional MR (FMR) is caused by LV dilatation and increased sphericity, which displace the papillary muscles apically and radially, creating lateral forces on the valve that lead to increased retraction of the mitral leaflets by the chordae tendineae. LV dyssynchrony may also contribute to FMR through poor coordination of the contraction of the septum and lateral walls, producing MR that may vary in intensity during the cardiac cycle. Functional MR is usually referred to as a Carpentier class I/IIIb lesion due to the presence of both annular dilatation (Carpentier type I) and systolic restriction of the mitral leaflets due to LV dysfunction (Carpentier type IIIb). Ultimately, increased regurgitation leads

to increased preload, LV wall tension, and LV work load, all of which contribute to progressive dysfunction of the LV and worsening heart failure.

Several observational and population based studies have demonstrated a significant impact of secondary MR on long-term survival. Following MI, the 5-year survival rate dropped significantly from 61% in patients who did not have MR to 47% and 29% in patients with mild and moderate to severe MR, respectively.¹⁴⁴ Similarly, in a series of 2,057 patients with symptomatic heart failure and a LVEF <40%, the 5-year survival rate for patients without MR was 54%, and it decreased to 40% in patients with moderate to severe secondary MR.¹⁴⁵ In a cox proportional hazards analysis, increasing severity of MR was an independent predictor of decreased survival (HR = 1.23, [1.13–1.34], $p = 0.0001$), and this observation held for patients with both ischemic and nonischemic disease etiologies. Moreover, medical therapy and PCI have not reduced the impact of IMR on late mortality.¹⁴⁶

Although specific recommendations to intervene for secondary MR are controversial and have not been rigorously defined, guidelines are available (Table 21-15).^{70,147} Some surgeons initially advocated performing only revascularization in cases of moderate ischemic MR with the idea that revascularizing viable myocardium would lead to improvements in LV function and effect reverse remodeling, ultimately contributing to a decrease in MR. While several studies have shown that MR often persists following revascularization alone, the addition of a mitral valve annuloplasty in those studies did not improve long-term functional status or survival in patients with ischemic MR.¹⁴⁸⁻¹⁵⁰ Nevertheless, other studies have shown that the persistence of MR after CABG is associated with a decreased survival rate and that CABG alone only has modest effects on reducing MR at 1 month follow-up.¹⁴³ As a result, a growing number of centers have elected to repair moderate MR in this patient population. Indications for surgery in ischemic MR patients in the absence of revascularization options are even less well-defined.

For patients with functional MR, the goal of mitral valve surgery is to avoid or postpone transplantation in eligible patients, but it should generally not be performed in patients

with end-stage heart failure who present with low EF and limited myocardial viability. Those patients are often best suited by transplantation and/or ventricular assist device implantation.

Mitral valve repair is the procedure of choice when surgery is indicated for secondary MR. Currently, recommendations are to use a semirigid or rigid annuloplasty ring to downsize the mitral annulus.¹⁴³ There have also been various techniques proposed to correct the papillary muscle displacement, but most reports are single center, retrospective and small. Mitral valve replacement with preservation of the subvalvular apparatus is indicated when repair is not feasible due to severe tethering of the leaflets or massive LV dilation.

Outcomes from surgery vary between centers and amongst patients in this heterogeneous group. Operative mortality ranges between 0% to 9% in most modern series.¹⁴³ Generally speaking, mortality and recurrence rates are higher and long term prognosis is worse compared to outcomes for primary MR. Recurrent MR is as high as 15% to 30% in some series and 5-year mortality is between 44% to 48%.^{143,151,152} Some reductions in left atrial dimension and LV reverse remodeling may be achieved.¹⁵³

Left Ventricular Aneurysmorrhaphy and Surgical Ventricular Restoration

Pathophysiology of Ventricular Aneurysms. A transmural infarction of approximately 5% to 10% of the myocardium may result in formation of an LV aneurysm as necrotic myocardium is replaced by fibrous tissue. This usually occurs 4 to 8 weeks following the infarct. In the last decade, prompt revascularization of the culprit artery by either surgical or interventional techniques generally results in sparing of the subepicardial muscle while the subendocardial muscle remains necrotic.¹⁵⁴ Therefore, it is not uncommon for the LV wall to show both living myocardium during thallium testing and an akinetic zone on echocardiogram or angiogram. It has been demonstrated that once more than 20% of the myocardium is necrosed there is irreversible progression to ventricular dilation and failure.¹⁵⁵ The classic aneurysm is a 4 to 6 mm thick scar, which bulges outward in paradoxical motion as the LV contracts during systole. More than 80% develop in the anteroseptal and apical portions of the

Table 21-15

Data guidelines for surgical intervention for secondary mitral regurgitation.

CLINICAL SETTING	CLASS OF RECOMMENDATION	LEVEL OF EVIDENCE
Chronic Ischemic MR (ESC Guidelines)		
• Severe MR, LVEF >30%, undergoing CABG	I	C
• Moderate MR, undergoing CABG, if mitral repair is feasible	IIa	C
• Severe MR, symptomatic patients, LVEF <30%, candidate for revascularization	IIa	C
• Severe MR, LVEF >30%, no option for revascularization, refractory to optimal medical therapy, low comorbidity	IIb	C
Chronic Functional MR (ESC and ACC/AHA Guidelines)		
• Chronic severe MR due to LV dysfunction, EF <30%, persistent NYHA class III-IV, symptoms despite optimal medical therapy	IIb	C

MR = mitral regurgitation, ESC = European Society of Cardiology, CABG = coronary artery bypass grafting, LVEF = left ventricular ejection fraction, LV = left ventricle, ACC = American College of Cardiology, AHA = American Heart Association, NYHA = New York Heart Association.

left ventricle as a result of left anterior descending artery occlusion. The rest are inferior in location and the result of circumflex or right coronary occlusion.

This patient population typically suffers from associated ventricular arrhythmias for several reasons. First, electrical dyssynchrony results from postinfarction remodeling, and triggers for ventricular arrhythmias typically occur in the scar border zone in patients with ischemic cardiomyopathy.^{156,157} Second, increased ventricular volume causes high wall stress and stretch, and stretch has been shown to be arrhythmogenic.¹⁵⁸ Third, LV aneurysms represent an independent risk factor for SCD after MI.¹⁵⁹ Surgical ventricular restoration (SVR) addresses each of these issues by removing the anatomic substrate during resection of the postinfarct scar and/or aneurysm, accomplishing volume reduction and mechanical resynchronization and relieving ischemia through complete revascularization and reduction in myocardial wall tension and oxygen demand.

Clinical Presentation and Diagnosis. Symptoms of LV aneurysms include angina, CHF, ventricular arrhythmias and rarely embolic phenomenon. Rupture is extremely uncommon. Patients generally present for coronary artery bypass or during evaluation of CHF or arrhythmias. While transthoracic echocardiography gives pertinent information regarding LV function, size, mitral valve function and the presence of thrombus, it is generally accepted that cardiac MRI is the best diagnostic modality to accurately identify areas of scar and viable tissue and to best define ventricular geometry.¹⁵⁵

Surgical Treatment and Results. In 1985, Vincent Dor described a surgical technique called the endoventricular circular patch plasty that was intended to improve geometric reconstruction compared with the standard linear repair in LV aneurysm surgery. SVR is a somewhat broader term that arose from surgical repair of ventricular aneurysms and has now come to be applied to a group of surgical procedures designed to correct the effects of postinfarction ventricular remodeling. It is also sometimes referred to as surgical ventricular remodeling or reconstruction, surgical anterior ventricular endocardial reconstruction (SAVER), or the Dor procedure. SVR is specifically intended to reduce the size and sphericity of the LV by excluding akinetic and dyskinetic areas, most often by using a circular patch inserted inside the ventricle on contractile myocardium (Fig. 21-11A & B).

Candidates for SVR are typically patients who have had a remote anterior or anteroseptal myocardial infarction, significant ventricular enlargement with a significant area of akinetic or dyskinetic myocardium, a discrete aneurysm, a clinical picture consistent with heart failure (LVEF <40%), retained function of the basilar and lateral portions of the heart and good right ventricular function. These patients should also be candidates for repair of any other concomitant cardiac disease. Dor currently emphasizes the importance of complete revascularization and repair of any mitral pathology at the time of operative SVR. In patients with spontaneous (13%) or inducible (25%) ventricular tachycardia (VT), it is additionally necessary to perform nonguided endocardial resection and cryoablation encircling the resected area.¹⁵⁵

Results with this approach have been good in treating both heart failure and its sequelae, such as VT. In Dor's series of 1150 patients, the operative mortality was dependent on the EF and ranged from 1% for patients with EF >40% to 13% for patients with EF <30%, and the 5-year survival approached 85%.¹⁵⁵ Overall, more than 80% of survivors are either stabilized or improved, and quality of life has been shown to improve significantly by 6 months after the Dor procedure.¹⁶⁰ This is likely due in part to the fact that the Dor procedure restores LV geometry, resulting in a mean ejection fraction increase between 10% to 15%, with significant alleviation of symptoms.^{155,161-163} These data are reinforced by the international RESTORE group, which examined SVR in a registry of 1198 postinfarction patients between 1998 and 2003.¹⁶⁴ They found that 5-year overall freedom from hospital readmission for CHF was 78%. Moreover, 67% of patients had preoperative NYHA class III or IV symptoms, whereas 85% of patients were NYHA functional class I or II postoperatively.

With respect to VT, Dor et al. reported on 106 patients with ischemic ventricular arrhythmias that underwent reconstruction for postinfarction LV aneurysm and visually-directed endocardectomy plus or minus cryoablation and coronary revascularization¹⁶⁵. At a mean follow-up of 21.3 months, only 10.8% of patients had inducible VT and no spontaneous VT was documented. Results from similar series have also been excellent,^{148,163,166} but the efficacy of left ventricular restoration alone has been controversial.^{167,168} Inferior results seen in some series have been attributed to failure to perform endocardial resection and/or cryoablation at the border of the transitional zone, as well

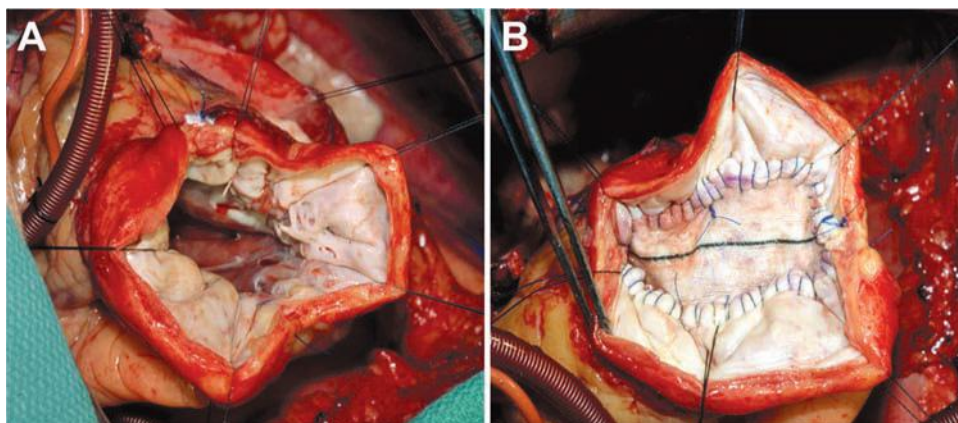


Figure 21-11. Surgical ventricular restoration of a ventricular aneurysm using the Dor Procedure. **A.** The size and sphericity of the left ventricle are reduced by excluding akinetic and dyskinetic areas. **B.** Most often this is completed using a circular patch inserted inside the ventricle on contractile myocardium.

as differences in stimulation protocols and possible inadequate volume reduction of the ventricle.

Recently, a large, randomized, multicenter study, the STICH trial, has reported the conclusion that adding SVR to reduce ventricular volume to CABG does not improve symptoms or exercise tolerance and fails to lower death rate or cardiac rehospitalization compared to CABG alone¹³⁵. While this trial has some shortcomings, it has resulted in a marked decrease in referrals for this procedure. The main problem is that the LV volume was reduced by only 19% in the STICH trial, reflecting an inadequate repair as determined by the Surgery Therapy Committee, whose “acceptable STICH procedure” guideline required a 30% reduction at the 4-month postoperative cardiac MRI.¹⁶⁹ Previous studies have reported an average reduction of end-systolic volume index (ESVI) of 40% with a range between 30% and 58%, suggesting that the STICH SVR procedure may have involved an inadequately small LV plication or limited intracavitary reconstruction.¹⁶⁹ Moreover, this trial enrolled 13% of patients who had never had an MI and changed criteria such that enrollment required documented LV anterior wall dysfunction rather than demonstration of scar. This could have captured patients with hibernating myocardium that would recover following CABG alone. Dor subsequently published the results of 117 patients who would have been eligible for the STICH trial and demonstrated durable improvement in left ventricular function.¹⁷⁰ However, this was a single-center, retrospective experience. Caution should be exercised so as not to broadly extrapolate the results of the STICH trial and inappropriately deny appropriate patients effective treatment.

Mechanical Circulatory Support

Intra-aortic Balloon Pump. The intra-aortic balloon pump (IABP) is the most commonly used device for mechanical circulatory support, and it may be easily deployed in the catheterization laboratory, in the operating room or at the bedside. The device is inserted percutaneously through the femoral artery into the thoracic aorta. It is synchronized so that the balloon is inflated during diastole and deflated during systole, resulting in augmentation of diastolic perfusion of the coronary arteries and decreased afterload. Typically, this improves cardiac index and decreases both preload and myocardial oxygen consumption.

The indication for use of an IABP is most often cardiogenic shock during or after cardiac catheterization or cardiac surgery. It also is indicated for preoperative stabilization of high-risk patients with either severe coronary artery disease, LV dysfunction, or refractory, unstable angina. Kang et al have reported that risk-adjusted mortality was significantly lower for selected high-risk patients undergoing open heart surgery when a preoperative IABP was used.¹⁷¹

Generally, an IABP is used for a few days and weaned as the patient’s condition improves. Morbidity associated with device use is typically minimal; however, in one series of 911 patients undergoing CABG who received an IABP, there was a 12% incidence of minor or major vascular complications, including an approximately 3% incidence of limb ischemia requiring thromboembolectomy. This is the most serious complication of IABP placement. To prevent this problem, frequent lower extremity neurovascular checks are necessary while an IABP is in place¹⁷².

Ventricular Assist Device Indications and Cannulation. Patients in need of ventricular assist devices (VADs) may have preexisting chronic heart failure, refractory ventricular arrhythmias, or acute heart failure following an MI,

cardiopulmonary arrest, viral illness, pregnancy, or cardiomyopathy. Device therapy is intended to preserve end-organ perfusion and function and may be categorized as short- or long-term support for the left heart, the right heart, or both. In general, VADs may be used for support while the heart recovers (bridge to recovery, BTR), while the patient waits for a heart transplant (bridge to transplant, BTT) or as a final option to treat a chronic heart failure patient who is not a transplant candidate (destination therapy, DT). The Interagency Registry for Mechanically Assisted Circulatory Support (INTERMACS) database, a joint effort by the NHLBI, FDA, CMS, academia, and industry to prospectively track patient outcomes, reported that between January 2009 and June 2010 indications for device implantation were BTR (1%), BTT (41%), bridge to decision (43%), DT (14%), and rescue therapy (0.5%).¹⁷³ However, the percentage of patients receiving a VAD as destination therapy is increasing as results and devices improve. In 2011, 38% of patients had a primary device strategy of DT, whereas only 23% were considered BTT.

Left ventricular assist devices (LVADs) provide support for the failing heart by unloading blood from the left ventricle and pumping it into the aorta. Cannulas may be inserted into the LV apex or the left atrium for inflow into the pump, and return is through an arterial cannula or graft sewn to either the ascending or descending aorta. For right sided devices, inflow drainage is most often from a cannula in the right atrium, and blood is returned through a graft sewn to the pulmonary artery or right ventricular outflow tract.

Left Ventricular Assist Devices. The first generation LVADs were pulsatile devices. They provided adequate support for the heart but were limited by their large size and durability.¹⁷⁴ More recently, continuous-flow LVADs based on rotary pump technology have been introduced. These devices are smaller, quieter, and durable enough for long term support. The two most commonly used devices today are the HeartMate II (Thoratec, Pleasanton, CA) and the HeartWare HVAD (HeartWare, Inc., Framingham, MA) (Fig. 21-12A & B, 21-13A & B). These devices differ in that the HeartMate II is implanted subdiaphragmatically, whereas the smaller HeartWare HVAD is implanted within the pericardium. Frequently used short-term support devices include the Abiomed BVS 5000 (Abiomed, Inc., Danvers, MA) and the CentriMag (Thoratec), which are both extracorporeal pumps, as well as the Impella (Abiomed), which may be inserted percutaneously. These devices are commonly used in either post-MI or postcardiotomy heart failure. They have the benefit of faster and easier insertion, making them ideal rescue devices and allowing time for patient transfer to a tertiary referral center, device weaning, transplantation, or transition to a permanent VAD as DT or BTT.

Bridge to Recovery. The ideal clinical situation would be for all LVADs to be temporary with the goal of myocardial recovery. However, as noted above, this is rare with only 1% of devices in the most recent INTERMACS data placed with intent for bridge to recovery.¹⁷⁵ The LVAD Working Group Recovery Study, a prospective multicenter trial investigating myocardial recovery in BTT patients, has shown significant improvements in left ventricular ejection fraction and significant reductions in left ventricular end-diastolic diameter following support with continuous flow pumps, but myocardial recovery resulting in device explantation was still only seen in six patients (9%).¹⁷⁶ Current data suggest that significant reverse remodeling is more likely to occur in the young and those with myocarditis.¹⁷⁷

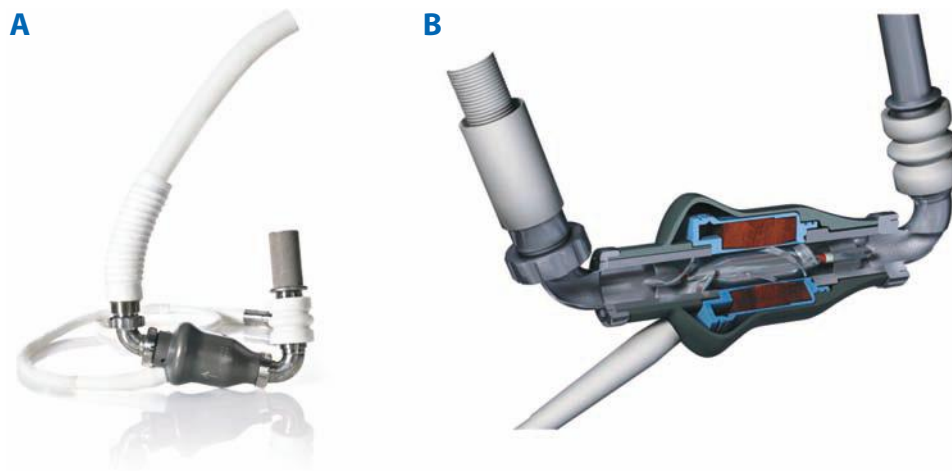


Figure 21-12. The HeartMate II LVAD viewed from the (A) outside and (B) inside. The device is an axial flow, rotary pump that produces no pulsatile action. The pump contains a magnet, and the rotor assembly functions by the electromotive force generated by the motor. The result is that blood is propelled from the inflow cannula to systemic circulation at flows up to 10 L/min. (Images reprinted with the permission of Thoratec Corporation.)

Nevertheless, some encouraging results have been reported using a combination of treatment modalities. In a few small studies of patients with LVADs inserted for nonischemic cardiomyopathy, deliberate and aggressive medical therapy, including the β_2 -agonist clenbuterol resulted in successful LVAD explantation in 69% to 73% of patients,^{178,179} but these results have been difficult to replicate. Moreover, early results from clinical trials using stem cell therapy to treat patients with ischemic cardiomyopathy suggest that stem cells may be another adjuvant treatment with potential to aid in myocardial recovery.^{180,181}

Bridge to Transplant. LVADs are used as a bridge to transplant in patients who are candidates for heart transplantation but are not predicted to survive the waiting list period due to sequelae of cardiac failure, including end-organ dysfunction, rising pulmonary artery pressures, escalating inotrope

requirements, malignant ventricular arrhythmias, and risk for sudden death. Due to the scarcity of donor organs, the improved survival seen with LVAD usage has resulted in more patients remaining alive while on the transplantation waiting list. It is currently estimated that 35% of patients who go on to receive a heart transplant have had a previous LVAD implantation, although at more aggressive tertiary care facilities this number may be as high as 75% to 90%.¹³¹

The HeartMate II pump was evaluated as a BTT in an observational, prospective multicenter trial of 133 patients with persistent NYHA class IV heart failure despite optimal medical management who were status 1A or 1B on the transplant list.¹⁸² At 6 months, 100 patients (75%) had undergone transplantation, had cardiac recovery, or continued on mechanical support while remaining eligible for transplantation. There were significant improvements in both quality of life and functional status with

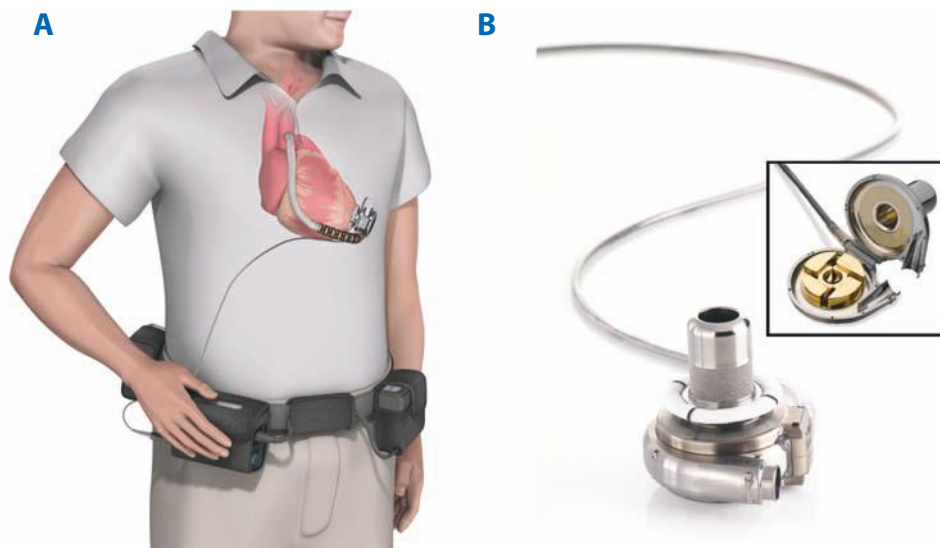

Figure 21-13. The HeartWare HVAD system. **A.** Both the device controller and batteries are held in a wearable carrying case and connected to the ventricular assist device through the driveline. **B.** The main component is a centrifugal blood pump, called the HVAD, which is implanted within the pericardium. The only moving part in the device, the impeller, is suspended within the pump using magnets and thrust bearings. Similar to the HeartMate II, it can deliver a flow rate of up to 10 L/min. (Images reproduced with permission from HeartWare.)

device therapy. At 3 months, 81% of patients were in class I or II heart failure. Moreover, complications, including bleeding requiring reoperation, stroke, drive-line infection, and need for right ventricular assist device support, were significantly less frequent than with the previous generation HeartMate XVE.¹⁸³ These data led to FDA approval of the HeartMate II as a BTT LVAD in 2008, and clinical use of the device increased dramatically. More recently, a multicenter, prospective trial compared the HeartWare HVAD to contemporaneously inserted devices for use as a BTT.¹⁸⁴ This trial demonstrated noninferiority of the HeartWare HVAD, but in contrast to the 2007 trial, approximately 90% of patients in both groups were transplanted, explanted for recovery, or remained alive and eligible for transplant with LVAD support at 6 months. Most important, data suggest that patients bridged to transplant with an LVAD in the current era experience similar short- and long-term post-transplant survival and complications and do not have a higher incidence of allosensitization compared to standard cardiac transplant patients.^{185,186}

Destination Therapy. The Randomized Evaluation of Mechanical Assistance for Treatment of Congestive Heart Failure (REMATCH) trial was conducted to compare the efficacy of LVAD insertion against optimal medical management in patients with NYHA class IV heart failure. While the pulsatile devices used in this trial had high failure rates, poor durability, and high associated mortality, there was still a clear survival benefit in patients treated with LVADs. This led to the FDA approval of the first LVADs for destination therapy in 2002.¹⁷⁴

Subsequent trials have proven the increased efficacy of second generation devices for DT. In one such landmark trial, patients with advanced heart failure who were ineligible for transplantation were randomized in a 2:1 ratio to either a HeartMate II or HeartMate XVE.¹⁸⁷ While both groups showed significant improvements in functional capacity and quality of life, actuarial survival at 2 years was superior for HeartMate II patients (58% vs. 24%, $P=0.008$) and adverse event rates were significantly lower. These data established the benefit of continuous flow LVADs over optimal medical management for end-stage heart failure, and led to FDA approval of the HeartMate II for DT in 2010. In certain populations, 2-year survival with the HeartMate II is now 80%.¹⁷⁵ Several smaller third generation devices are in various stages of development or clinical trials. Some of these devices eliminate the drive line by using alternative energy sources, thereby removing a significant nidus for device infections. Long-term outcomes with these devices are expected to continue to improve, approaching that of cardiac transplantation and providing a viable solution to organ shortage for many patients.¹⁷⁵

Current eligibility criteria for mechanical support as destination therapy include: (a) medically refractory NYHA class III or IV heart failure for at least 60 days, (b) peak oxygen consumption <12 ml/kg/min or failure to wean from continuous IV inotropes, (c) left ventricular ejection fraction $<25\%$, and (d) presence of a contraindication for heart transplantation (i.e., age >65 years, irreversible pulmonary hypertension, chronic renal failure, insulin-dependent diabetes with end organ damage, or other clinically significant comorbidities).¹³¹ Once a patient has an LVAD inserted as DT, close and intensive follow-up by a multidisciplinary heart failure team is required in order to optimize medical therapy, reduce device-related morbidity and improve survival.

It is also important to keep in mind that while some contraindications to transplantation are irreversible, others can

be modified. As such, approximately 10% of patients implanted with an initial strategy of destination therapy become BTT patients,¹³¹ and in some patients, the LVAD itself facilitates this transition. For example, an improvement in mean pulmonary vascular resistance was reported following implantation of the HeartMate II in patients with end-stage heart failure (2.1 vs. 3.6 Woods units, $P<0.001$).¹⁸⁸ These data are also relevant to the 43% of patients that receive LVADs as a bridge to decision.

Right Ventricular Assist Devices and Biventricular Assist Devices

Most patients who present with advanced heart failure and a failing left ventricle also have some degree of right-ventricular dysfunction, but the majority of these patients do well with only an LVAD. However, implantation of an LVAD may cause acute worsening of tricuspid regurgitation and exacerbations of right-heart failure through leftward deviation of the intraventricular septum and as a result of the significant volume-loading and transfusion requirement that is often necessary to achieve adequate flows postoperatively. Overall, approximately 20% of HeartMate II BTT patients had persistent right ventricular failure (RVF) requiring either a subsequent RVAD (6%) or intravenous inotropic support for >14 days (14%), and these patients had significantly worsened 6 month survival compared to those without RVF (71% vs. 89%, $P<0.001$).¹⁸⁹ Typically, mechanical right-ventricular support is temporary with intent to wean the device, and isolated right-ventricular assist devices are unusual.

Biventricular support is most commonly indicated for acute cardiogenic shock after an MI or postcardiotomy heart failure. Biventricular support is temporary, although some patients may be successfully bridged to transplant or permanent left-sided assist devices. There is currently no destination therapy device for biventricular failure.

Total Artificial Heart

The total artificial heart (TAH, SynCardia Systems, Tucson, AZ) is currently indicated as a bridge to transplant for patients in biventricular failure, particularly for those who are critically ill and too large for extracorporeal BiVAD support. Unlike ventricular assist devices, the TAH replaces the entire heart. The ventricles of the TAH are implanted orthotopically to the atrial cuffs on the ventricular side of the AV groove, and the outflow conduits are attached to the great vessels. This approach has the benefit of obviating the hemodynamic influence of pulmonary hypertension, right heart failure, myocardial or valvular problems, cardiac arrhythmias, and inotropic agents.¹⁹⁰ While this device has failed to reach its potential as a replacement for cardiac transplantation, the TAH has achieved favorable results as a BTT with a $>70\%$ survival in selected centers.¹⁹¹⁻¹⁹³ However, at most centers results with the TAH have been suboptimal, and it is not frequently used.

SURGERY FOR ARRHYTHMIAS

The success of catheter-based ablation and implantable cardioverter defibrillators (ICDs) has significantly diminished referrals for the surgical treatment of arrhythmias such as ventricular tachycardia, Wolff-Parkinson-White syndrome, atrial flutter, and atrioventricular nodal reentry. On the other hand, the introduction of surgical ablation modalities such as radiofrequency and cryothermal energy, has simplified the surgical treatment of atrial fibrillation (AF) and has led to a dramatic increase in the number of surgical procedures performed annually for AF.¹⁹⁴

Atrial Fibrillation

Epidemiology of Atrial Fibrillation. Atrial fibrillation remains the most common arrhythmia in the world with an overall incidence of 0.4% to 1% that increases to 8% in those older than 80 years old.¹⁹⁵ The most serious complication of AF is thromboembolism with resultant stroke,¹⁹⁶ but serious morbidity and mortality may also result from hemodynamic compromise due to loss of atrial contraction, exacerbations of congestive heart failure from atrioventricular asynchrony and tachycardia-induced cardiomyopathy.

Medical Management. Most patients are treated medically, but the shortcomings of pharmacological management have left an important role for interventional therapies. Antiarrhythmic medications have been limited by modest efficacies and significant proarrhythmic and systemic toxicities.¹⁹⁷ Conversely, rate control strategies leave the patient in AF, do not address the impaired hemodynamics or symptoms associated with this arrhythmia, and may render subsequent attempts at rhythm control therapies less effective for younger patients that may suffer irreversible cardiac remodeling due to the prolonged period of time in AF.

Restoration of normal sinus rhythm has several potential benefits over other strategies¹⁹⁸⁻²⁰⁰. These include improvements in atrial systolic function, which improves cardiac output and often improves symptoms in patients with congestive heart failure; a lower risk of stroke; possible discontinuation of anticoagulation; and the benefit of potentially reversing atrial structural and/or electrical remodeling.

Indications for Surgical Management. Recent consensus guidelines published by the Heart Rhythm Society state that surgical ablation for atrial fibrillation is indicated for: (a) all symptomatic AF patients undergoing other cardiac surgery; (b) selected asymptomatic AF patients undergoing cardiac surgery in which the ablation can be performed with minimal additional risk; and (c) symptomatic patients with lone AF who have failed medical therapy and prefer a surgical approach, have failed one or more attempts at catheter ablation, or are poor candidates for catheter ablation.¹⁹⁵ At our institution, relative indications for surgical ablation in patients with permanent AF that were not included in the consensus statement are: (a) a contraindication to long term anticoagulation for patients at high

risk for stroke (CHADS2 score ≥ 2) and (b) a history of stroke while on therapeutic anticoagulation.

The Cox-Maze IV Procedure. The first successful operation for atrial fibrillation, the Cox-Maze procedure, was introduced clinically in 1987 by James Cox. The procedure involved the completion of a maze-like pattern of surgical incisions across both the right and left atrial that were designed to interrupt the multiple macroreentrant circuits that were thought to be responsible for AF, while still allowing propagation of the sinus impulse, restoring atrioventricular synchrony, and preserving atrial transport function. While effective at eliminating AF and reducing the risk of thromboembolism, it was not widely performed due to the fact that it was technically difficult and significantly prolonged time on cardiopulmonary bypass. In 2002, the Cox-Maze IV, was introduced. The Cox-Maze IV uses a combination of bipolar radiofrequency (RF) ablation and cryoablation to effectively replace the majority of incisions that comprise the Cox-Maze III while significantly shortening cross-clamp time and reducing operative complexity.

The Cox-Maze IV is performed on cardiopulmonary bypass through either a median sternotomy, often in combination with other cardiac surgery, or a right minithoracotomy.²⁰¹ In most cases, the right atrial lesion set is performed on the beating heart, whereas the left atrial lesions are performed during cardioplegic arrest (Fig. 21-14).

Results from the Cox-Maze IV procedure have been excellent. A recent, prospective analysis of 100 consecutive lone

Cox-Maze IV patients demonstrated postoperative freedom from AF of 93%, 90%, and 90% at 6, 12, and 24 months, respectively, and freedom from AF off antiarrhythmic drugs was 82%, 82%, and 84% at the same intervals.²⁰¹ Outcomes are comparable when patients undergo concomitant cardiac surgery,²⁰² and a propensity analysis has shown that results are similar between the traditional “cut-and-sew” maze and the Cox-Maze IV.²⁰³ This procedure is often successful in patients who are poor candidates for catheter-based ablation, such as those with large left atria and patients with long-standing persistent AF.

The combination of surgical excision of the LAA and restoration of normal sinus rhythm after the Cox-Maze procedure significantly reduces stroke risk. It is our practice to stop warfarin at 3 months postoperatively in patients who are in

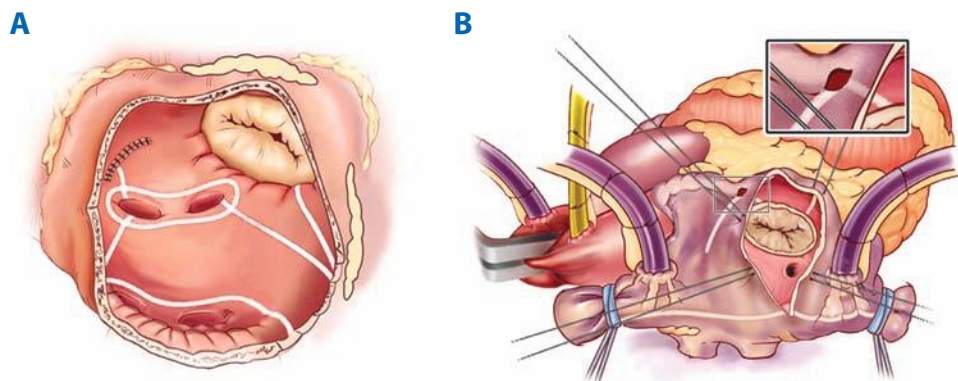


Figure 21-14. The Cox-Maze IV Lesion Set. **A.** The left atrial lesion set is comprised of right and left pulmonary vein isolation, connecting lesions between the left and right superior and inferior pulmonary veins, a lesion from the left atrial appendage excision site to the pulmonary vein and a lesion to the mitral valve annulus. **B.** The right atrial lesion set consists of lines of ablation along the superior and inferior vena cavae, the free wall of the right atrium and down to the tricuspid valve annulus. (From Weimar T, Bailey MS, Watanabe Y, et al. The Cox-Maze IV procedure for lone atrial fibrillation: a single center experience in 100 consecutive patients. *J Interv Card Electrophysiol.* 2011;31:47-54. With kind permission from Springer Science & Business Media.)

normal sinus rhythm and without another indication for anticoagulation, regardless of CHADS2 score. With this approach, the stroke rate following the Cox-Maze procedure off anticoagulation has been remarkably low (annual risk = 0.2%).²⁰⁴ In contrast, in one report the annual rate of intracranial hemorrhage in anticoagulated patients with AF was 0.9% per year, and the overall rate of major bleeding complications was 2.3% per year.²⁰⁵

Left Atrial Lesion Sets. Some surgeons perform more limited ablation procedures, such as isolated pulmonary vein isolation or lesion sets that are limited to the left side of the heart. This is done in order to further reduce the complexity of the procedure and takes advantage of the fact that in most patients AF originates from the pulmonary veins and posterior left atrium. Although, there is seldom justification for limited lesion sets in experienced hands.

While there is a high degree of variability in both the techniques and energy sources that have been attempted for left-sided atrial lesion sets, these procedures have all incorporated some subset of the left atrial lesion set of the Cox-Maze procedure. Pulmonary vein isolation is ubiquitously performed, and the LAA is often excised. Results differ greatly between series, but a meta-analysis of the published literature by Ad and colleagues revealed that a biatrial lesion set resulted in a significantly higher late freedom from AF compared with a left atrial lesion set alone (87% vs. 73%, $P = 0.05$).²⁰⁶ These results are not surprising, as our intraoperative mapping experience with such patients showed a distinct region of stable dominant frequency in the left atrium only 30% of the time.²⁰⁷ The dominant frequency was located in the right atrium 12% of the time and moved during the recording period in almost half of all patients. It must also be kept in mind that recurrent right atrial flutter is a known complication of performing only the left atrial lesions. When it does occur, atrial flutter can be treated with catheter-based ablation; however, recurrent left atrial flutter can be very difficult to ablate.

Pulmonary Vein Isolation. Pulmonary vein isolation (PVI) is an attractive therapeutic option due to the fact that it can be performed off of cardiopulmonary bypass (CPB) through small or thoracoscopic incisions. The results of PVI have been variable and highly dependent on patient selection since outcomes are consistently worse in patients with longstanding persistent AF. In a study from Edgerton et al, only 56% of patients were free from AF at 6 months (35% off antiarrhythmic drugs), and with concomitant procedures, the success rate of PVI has been even lower.²⁰⁸ Several devices are available to close the LAA at the time of PVI. These include staplers and epicardial clips that can be placed without the need for CPB.

While surgical PVI has had poorer results than a Cox-Maze procedure, it has had superior results to catheter-based PVI. The Atrial Fibrillation Catheter Ablation Versus Surgical Ablation Treatment (FAST) Trial, which was a two center, randomized clinical trial, compared catheter-based ablation to thoracoscopic PVI in patients with antiarrhythmic drug-refractory AF and either left atrial dilatation and hypertension or failed prior catheter-ablation.²⁰⁹ This study demonstrated that the 12-month freedom from AF and antiarrhythmic drugs was 37% for the catheter ablation group and 66% for the PVI group ($P = 0.0022$).

SURGERY FOR PERICARDIAL DISEASE

Acute Pericarditis

Pericarditis is characterized by infiltration of the cellular and fibrous pericardium by inflammatory cells. The exact incidence

and prevalence of pericarditis is unknown, but it is estimated that pericarditis is found in approximately 1% of autopsies and accounts for up to 5% of presentations of nonischemic chest pain.^{210,211} The etiologies of acute pericarditis are diverse and may result from primary pericardial disorders or occur secondary to a systemic illness.²¹² In developed countries, 80% to 90% of cases are now considered idiopathic or related to a viral pathogen, but nonviral infection, autoimmune diseases, myocardial infarction, radiation, malignancy, endocrinopathy, myocarditis, aortic dissection, uremia, trauma, pharmacological side effects, and previous cardiothoracic surgery must be included in the differential diagnosis. The relative incidences of peri-infarction pericarditis, which was once common, and post-cardiac injury syndrome have been dramatically reduced with the advent of thrombolytics and coronary angioplasty.²¹²

Clinical Presentation and Diagnosis. Diagnosis of acute pericarditis typically requires the identification of at least two of four cardinal features (Table 21-16). The presentation may be confused with several more common cardiopulmonary conditions, particularly myocardial infarction, making a careful history and physical critical. Patients with pericarditis classically complain of sudden onset, retrosternal pain that may be pleuritic in nature. The pain may also be positional, with alleviation of pain when the patient is upright and leaning forward. Pain from pericarditis is typically sharp or stabbing, as opposed to the dull pain or pressure that is common with angina, and it typically does not crescendo. While both conditions cause pain that often radiates to the neck, arms, and shoulders, pericarditis pain may uniquely radiate to the trapezius ridge due to innervation from the phrenic nerve.^{213,214}

The presence of a pericardial friction rub is pathognomonic for pericarditis, but it tends to vary in intensity over time and may be absent in 15% to 65% of patients.^{213,215} As such, the sensitivity of this physical finding is dependent on the frequency and quality of auscultation. A pericardial friction rub is best heard at the left lower sternal border and is typically described as a high-pitched scratchy or squeaky sound with a triphasic cadence corresponding to the movement of the heart during atrial systole, ventricular systole, and early ventricular diastole. However, it may be monophasic or biphasic in up to 50% of patients.

Electrocardiogram (EKG) changes typically progress through four stages representing global subepicardial myocarditis and subsequent recovery. Pericarditis patients may have concave ST deflections with diffuse changes, spanning the leads of multiple coronary artery distributions, but ST segment abnormalities are absent in 20% to 40% of patients.^{216,217} Acute pericarditis should not result in the development of infarct patterns, such as Q-waves or loss of R-waves, and T-wave inversions from pericarditis tend to result later in the disease process after the ST segment has returned to baseline.

Table 21-16

Features of acute pericarditis.

- Pleuritic and positional, retrosternal chest pain
- Pericardial friction rub
- EKG changes: diffuse ST elevation and PR depression
- Pericardial effusion

EKG = Electrocardiogram.

Echocardiography is routinely performed in the evaluation of acute pericarditis. Its role is primarily to assess for a pericardial effusion. Although, in a patient who can be demonstrated to have previously had normal cardiac function, it may be used to exclude segmental wall motion abnormalities that may suggest ischemia.

The remaining work-up should attempt to determine the underlying cause of the pericarditis and should be directed by the history and physical. Most inflammatory markers and laboratory tests are nonspecific, but C-reactive protein (CRP) may be useful in predicting recurrence risks and in guiding the duration of anti-inflammatory medications.²¹⁸ Rarely, other imaging modalities, such as CT scanning, pericardial biopsies, or pericardiocentesis may aid in diagnosis.

Treatment. The preferred treatment depends on the underlying cause of the pericarditis. The disease usually follows a self-limited and benign course and can be successfully treated with a short course of nonsteroidal anti-inflammatory agents (NSAIDs). Some patients may require judicious use of steroids or IV antibiotics. In cases of purulent pyogenic pericarditis, surgical exploration and drainage are occasionally necessary. Rarely, accumulation of fluid in the pericardium may lead to tamponade, requiring prompt evacuation of the pericardial space. While pericardiocentesis will typically suffice, surgical drainage may be required for thick, viscous, or clotted fluid or in patients with significant scarring from previous surgeries. More commonly, surgical intervention is required to manage recurrent disease.

Relapsing Pericarditis

As many as one-third of patients with acute pericarditis will develop at least one episode of relapse.²¹² While many of these patients can be treated medically during their initial relapse and do not experience further episodes, a subset of patients experience chronic relapsing pericarditis that can significantly impact their quality of life. Recurrence may develop either from the original etiology or from an autoimmune process that occurs as a consequence of damage from the initial episode. Relapsing pericarditis normally responds to a longer course of NSAIDs \pm colchicine. While steroids may induce rapid symptomatic response, their use should be limited to patients who have multiple relapses and are unresponsive to first-line agents, as several studies have suggested that steroid administration may favor relapse.²¹⁹

Pericardiectomy may be considered a last resort treatment in patients with relapsing pericarditis who are severely symptomatic despite optimal medical management, are unable to tolerate steroids or have recurrence with tamponade. Evidence for this approach is lacking, as few studies have described pericardiectomy in this population.²²⁰⁻²²² The largest study and the only one to compare surgical treatment with medical management for patients with persistent relapsing pericarditis was a report of 184 patients from the Mayo Clinic.²²¹ About 58 patients were identified as having undergone a pericardiectomy after failed medical treatment, whereas the remainder were treated with medical management only. Compared to medical treatment only, pericardiectomy resulted in significantly fewer relapses (8.6% vs. 28.6%, $P = 0.009$) at long term follow-up, as well as a nonsignificant trend towards less medication and corticosteroid usage. Of note, 80% of patients in the pericardiectomy group who had relapses reported significant improvements in their symptoms and had fewer relapses than before

pericardiectomy. No perioperative deaths were observed, and only 2 patients (3%) had major complications. Hence, at experienced centers pericardiectomy may be a safe and viable option in select patients with relapsing pericarditis.

Chronic Constrictive Pericarditis

Etiology, Pathology, and Pathophysiology. Constrictive pericarditis can occur after any pericardial disease process but remains a rare outcome of recurrent pericarditis. It results when chronic pericardial scarring and fibrosis cause adhesion of the visceral and parietal layers and resultant obliteration of the pericardial space. While the pericardium is often grossly thickened with either focal or diffuse calcification in chronic disease, constriction may occur with normal pericardial thickness in approximately 20% of cases.^{212,223} In developed nations, idiopathic causes and cardiac surgery (accounting for almost 40% of cases in some series) are the predominant underlying etiologies, followed by mediastinal radiation, pyogenic infections (i.e., *Staphylococcus*), and other miscellaneous causes. Tuberculosis is an additional common cause in immunosuppressed patients and in developing or underdeveloped countries.

Clinically, pericardial constriction limits diastolic filling of the ventricles and mimics right heart failure since the right-sided chambers are more affected by a rise in filling pressures. Subsequent increases in central venous pressure result in the progressive development of hepatomegaly, ascites, peripheral edema, abdominal pain, dyspnea on exertion, anorexia, and nausea (in part due to hepatic and bowel congestion). In many patients, these symptoms develop insidiously over a course of years. Since many of these symptoms are similar to those seen in patients with restrictive cardiomyopathy, the distinction between the two entities is difficult, but it remains critical because the treatment is completely different for restriction. The primary difference is that restrictive cardiomyopathy is defined by a nondilated ventricle with a rigid myocardium that causes a significant decrease in myocardial compliance, which is not seen in constrictive pericarditis.

Clinical and Diagnostic Findings. Classic physical exam findings include jugular venous distention with Kussmaul's sign, diminished cardiac apical impulses, peripheral edema, ascites, pulsatile liver, a pericardial knock, and, in advanced disease, signs of liver dysfunction, such as jaundice or cachexia. The "pericardial knock" is an early diastolic sound that reflects a sudden impediment to ventricular filling, similar to an S3 but of higher pitch.

Several findings are characteristic on noninvasive and invasive testing. CVP is often elevated 15 to 20 mm Hg or higher. EKG commonly demonstrates nonspecific low voltage QRS complexes and isolated repolarization abnormalities. Chest X-ray may demonstrate calcification of the pericardium, which is highly suggestive of constrictive pericarditis in patients with heart failure, but this is present in only 25% of cases.²¹⁹ Cardiac CT or MRI (cMRI) typically demonstrate increased pericardial thickness (>4 mm) and calcification, dilation of the inferior vena cava, deformed ventricular contours, and flattening or leftward shift of the ventricular septum. Pericardial adhesions may also be seen on tagged cine MRI studies.

As discussed, it is most important to distinguish pericardial constriction from restrictive cardiomyopathy, which is best done with either echocardiography or right heart catheterization. Findings favoring constriction on echocardiography include respiratory variation of ventricular septal motion and

mitral inflow velocity, preserved or increased mitral annulus early diastolic filling velocity, and increased hepatic vein flow reversal with expiration.^{212,219} Cardiac catheterization will show increased atrial pressures, equalization of end-diastolic pressure and early ventricular diastolic filling with a subsequent plateau, called the “square-root sign.” Additional findings upon catheterization that would favor constriction include respiratory variation in ventricular filling and increased ventricular interdependence, manifest as a discordant change in the total area of the LV and RV systolic pressure curve with respiration.

Surgical Treatment. Transient constrictive pericarditis may occur weeks to months after an initial injury and follows a self-limiting course of weeks to a few months. These patients are best treated with medical therapy alone. They often lack calcification of their pericardium, and the degree of late gadolinium enhancement of the pericardium on cardiac MRI has shown promise in predicting which patients may have resolution of the process.²²⁴ Still, there is no ideal way to distinguish these patients from those who will develop chronic constrictive pericarditis, which is permanent. Therefore, if a newly diagnosed patient is hemodynamically stable, it is recommended that conservative management is attempted for two to three months prior to performing a pericardiectomy.²²³ Surgical therapy should not be delayed indefinitely, however, as results are improved when the operation is performed earlier in the course of the disease. Additional factors that predict adverse long-term outcomes include older age and prior ionizing radiation, as well as cardiopulmonary and renal dysfunction.²¹⁹ Surgery should therefore be approached cautiously in patients with very advanced, “end-stage” constrictive pericarditis, patients with mixed constrictive-restrictive disease (often from radiation), and those with significant myocardial or renal dysfunction, as those patients are at increased risk from surgery and may not experience improvement of symptoms.

In order to minimize recurrence following pericardiectomy, complete pericardial resection is desirable. This is typically performed through either a median sternotomy or left anterolateral thoracotomy while on cardiopulmonary bypass. Radical pericardiectomy involves wide resection of the constricting pericardium from the anterior surface of the heart between the phrenic nerves and the diaphragmatic surface. Decortication of the right atrium and vena cavae is not universally performed, but doing so improves the risk of persistent disease or relapse.^{225,226}

The extent of myocardial involvement may also affect long-term outcomes, and, thus, the depth of decortication is an important consideration.²²⁵ Even when an adequate pericardiectomy is performed, epicardial sclerosis can cause persistent hemodynamic instability or a delayed response to surgery. Sclerotic epicardium is often thin and nearly transparent, but in cases of severe chronic constrictive pericarditis it can be difficult to remove it without injury to the heart.

Surgical Results. While most patients experience significant improvement in their symptoms following pericardiectomy, symptomatic relief may take several months. Since there is a significant perioperative morbidity and mortality, pericardiectomy is best performed by experienced surgeons at high-volume centers. Between 1970 and 1985, the operative mortality was reported to be 12%, but a lower mortality of approximately 4% to 8% was noted between 1977 and 2006 at several experienced centers.^{223,226-230}

Long-term survival is in part determined by etiology of the disease. In a report from the Cleveland Clinic, seven-year survival rates following pericardiectomy for idiopathic, postsurgical, and radiation-induced constrictive pericarditis were 88%, 66%, and 27%, respectively.²²⁷ Results are worst for radiation-induced disease because ionizing radiation is often associated with myocardial injury as well as pericardial disease.

Despite the risks, many patients experience significant benefits from surgical treatment. In one large series, 83% of patients were reported to be free of symptoms at last follow-up.²³⁰ This is in agreement with other studies that have shown a significant improvement in NYHA functional status from class III/IV preoperatively to class I/II following pericardiectomy in >95% of patients.^{226,228-230}

CARDIAC NEOPLASMS

Overview and General Clinical Features

Cardiac neoplasms are rare, with an incidence ranging from 0.001% to 0.3% in autopsy studies and a 0.15% incidence in major echocardiographic series.^{231,232} Benign cardiac tumors are most common and account for 75% of primary neoplasms. Approximately 50% of benign cardiac tumors are myxomas, with the remainder being papillary fibroelastomas, lipomas, rhabdomyomas, fibromas, hemangiomas, teratomas, lymphangiomas, and others, in order of decreasing frequency. Most malignant primary cardiac tumors are sarcomas (angiosarcoma, rhabdomyosarcoma, fibrosarcoma, leiomyosarcoma, and liposarcoma), with a small incidence of malignant lymphomas. Metastatic cardiac tumors, while still infrequent, have been reported to occur 100-fold more often than primary lesions.

Clinical Presentation. The clinical presentation of cardiac neoplasms varies greatly depending on the location of the tumor, as well as its size, rate of growth, invasiveness, and friability. While as many as 10% of patients are asymptomatic, most manifest some combination of symptoms from the classic triad resulting from blood flow obstruction, tumor embolization, and constitutional symptoms.^{233,234} Systemic manifestations of disease include fever, myalgias, chills, night sweats, weight loss, and fatigue and occur in up to one-third of patients.

Obstruction of cardiac blood flow accounts for the majority of presenting symptoms.²³⁴ When the tumor is located in the left atrium, symptoms tend to mimic mitral valve disease with dyspnea and pulmonary edema; although more severe presentations with syncopal episodes, hypotension, and sudden cardiac death have been reported from temporary valve orifice occlusion. When the tumor is located in the right atrium, symptoms may mimic right heart failure and include hepatomegaly, ascites, and peripheral edema. Outflow tract obstruction is rare but may be caused by large ventricular tumors.²³⁵

Tumor lysis and embolization may also lead to neurologic presentations such as stroke, retinal artery occlusion, or cerebral aneurysms, particularly in the case of pedunculated tumors and those with frond-like projections.²³⁶ Embolic tumor cells are able to lodge and penetrate distant vessel walls via subintimal growth, which leads to weakening of the arterial wall and subsequent aneurysm formation. This has been documented as late as five years out from successful primary myxoma resection.²³⁷ Alternatively, embolic implants may metastasize and create space occupying lesions. While rare, myxomatous tumor emboli have also been identified in the coronary arteries, common iliac and femoral arteries, kidney, spleen, pancreas, and liver.²³⁶

Certain clinical features may be helpful in distinguishing benign from malignant primary cardiac tumors.²³⁴ Malignant tumors, primarily sarcomas, do not demonstrate a gender preference and tend to present after the fourth decade of life. They are often multifocal within the right atrium, and intramyocardial invasion can lead to refractory congestive heart failure, arrhythmias, hemopericardium, and ischemia. Conversely, benign tumors, primarily myxomas, are typically unifocal in the left atrium, have a 3:1 female preference, and occur in younger patients. Arrhythmias and pericardial effusions are very rare in this population.

Diagnosis and Characterization of Cardiac Masses. Trans-thoracic echocardiography is the mainstay imaging technique for the detection of cardiac tumors.²³⁴ However, echocardiography is limited by dependence on an acoustic window, suboptimal visualization of extracardiac extension, and poor soft-tissue visualization. Transesophageal echocardiography is generally only beneficial for small localized tumors due to its limited field of view. Cardiac MRI is therefore the current standard for delineating the anatomical extent of the tumor and assessing the paracardiac space and great vessels. Advantages of cMRI over CT scans include better soft-tissue evaluation without the need for iodinated contrast and no exposure to ionizing radiation.

It is important in the initial workup to distinguish a cardiac tumor from an intracardiac thrombus, which may be common in the atria of patients with AF and can mimic echocardiographic features of atrial myxomas. This determination is critical, as an atrial thrombus may be expected to resolve with anticoagulation, whereas a tumor requires surgical intervention. Moreover, anticoagulation can potentially increase the risk of peripheral embolization in patients with cardiac tumors. Delayed enhancement cMRI is the best modality to separate these two entities. cMRI may show vascularization, areas of necrosis, hemorrhage, or calcification in cardiac tumors that are not present in thrombi.

Myxoma

Pathology and Genetics. Cardiac myxomas are the most common cardiac tumor and are characterized by several distinguishing features. About 75% of the time, they arise from the interatrial septum near the fossa ovalis in the left atrium.²³⁸ Most others will develop in the right atrium, but, less commonly, they can arise from valvular surfaces and the walls of other cardiac chambers. Macroscopically, these tumors are pedunculated with a gelatinous consistency, and the surface may be smooth (65%), villous, or friable.²³³ Size varies greatly

with these tumors and ranges from 1 to 15 cm in diameter. Internally, myxomas are heterogeneous and often contain hemorrhage, cysts, necrosis, or calcification. Histologically, these tumors contain cells that arise from a multipotent mesenchyme and are contained within a mucopolysaccharide stroma.²³⁹

While the majority of myxomas occur spontaneously with the highest incidence in women aged 40 to 60 years old, approximately 7% of cases are familial as part of Carney complex.²³³ Carney complex is an autosomal dominant disorder characterized by two or more of the following conditions: atrial and extracardiac myxomas, schwannomas, cutaneous lentiginosis, spotty pigmentation, myxoid fibroadenomas of the breast, endocrine overactivity (pituitary adenomas or primary adrenal hyperplasia with Cushing's syndrome), and testicular tumors. Compared to sporadic myxomas, those that occur as part of Carney complex are more commonly found in the right atrium (37% vs. 18%) or one of the ventricles (25% vs. 0%), more often multicentric (33% vs. 6%) and more likely to recur (20% vs. 3%).²³⁸ They also present earlier at an average age of 24 years old (range 4–48 years).

Pathophysiology. Larger tumors are more likely to be associated with cardiovascular symptoms from obstruction, and embolic symptoms tend to occur from organized thrombi present on friable or villous tumors (Fig. 21-15). The relative frequencies of symptoms was illustrated by a series of 112 patients who reported cardiovascular symptoms (67%), most commonly resembling mitral valve obstruction; systemic embolization (29%); neurologic deficits (20%); and constitutional symptoms (34%).²³³ Similar incidences of symptoms have been reported in other large studies.

Treatment. Cardiac myxomas should be promptly excised after diagnosis due to the significant risk of embolization and cardiovascular complications, including sudden death. Resection may be performed through either a median sternotomy or a minimally invasive right thoracotomy while on cardiopulmonary bypass. Care is taken not to manipulate the tumor before cross clamping of the aorta in order to avoid embolization. Left atrial tumors may be approached through a standard left atriotomy.²⁴⁰ Exposure of large tumors attached to the interatrial septum may be facilitated by an additional parallel incision in the right atrium, but this is rarely necessary. An ideal resection encompasses both the tumor and a portion of the cardiac wall or interatrial septum to which it is attached. In order to prevent recurrence, a full thickness excision of the attachment site is

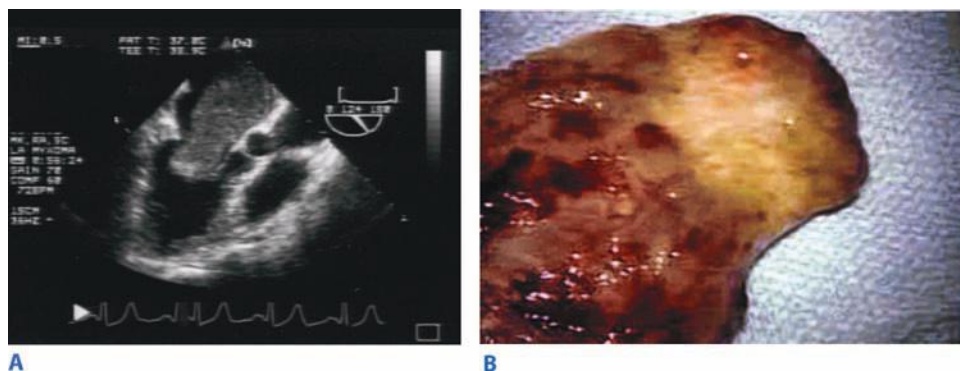


Figure 21-15. Massive left atrial myxoma. **A.** Intraoperative echocardiogram of a large left atrial mass, diagnosed preoperatively as a left atrial myxoma. The mass can be seen prolapsing through the mitral valve orifice causing intermittent symptoms of mitral stenosis. **B.** The resected specimen. The neck of the mass that was obstructing the mitral orifice is clearly delineated.

preferred, but partial thickness excisions and cryoablation of the base have been performed with good late results.²⁴⁰ The defect created in the atrial septum can either be repaired primarily or with a small patch. Finally, patients with valvular involvement may require additional valvular reconstruction or replacement, and rare cases of cardiac autotransplantation (with atrial reconstruction) or transplantation have been reported as strategies for complex cases of recurrent atrial myxoma.^{241,242}

Short- and long-term results following excision are excellent for benign cardiac myxomas. Operative mortality is low, and the probability of disease-free survival at 20 years has been reported to be as high as 92% for benign, sporadic myxomas.^{233,240} Risk of recurrence is significantly higher for familial cases.

Other Benign Cardiac Tumors

There are several benign cardiac tumors apart from myxomas that are infrequent but have distinct pathophysiologic features.²³⁴ Papillary fibroelastomas are the second most common primary cardiac tumor, representing approximately 8% of all cases. These tumors typically occur in more elderly patients; are small (<1 cm in diameter) sessile, pedunculated masses that arise from the mitral or aortic valves; and frequently result in embolization. Fibroelastomas can almost always be resected with preservation of the native valve leaflets, and cryoablation of the valve leaflet after resection can help prevent recurrence. Lipomas are encapsulated tumors that usually arise from the epicardium and remain asymptomatic in most patients. Hemangiomas, which may arise from any cardiac structure, including the pericardium, account for 2% of benign cardiac tumors, and atrioventricular node tumors, which often lead to sudden cardiac death from heart block and ventricular fibrillation, are exceedingly rare.

In children, rhabdomyomas are the most common primary cardiac tumor, whereas fibromas are the most commonly resected cardiac tumor. Rhabdomyomas are myocardial hamartomas that are often multicentric in the ventricles. About 50% of cases are associated with tuberous sclerosis, and while resection is occasionally necessary, most disappear spontaneously. Fibromas are congenital lesions that one-third of the time are found in children younger than one-year old. These tumors, conversely, are ordinarily solitary lesions found in the inner interventricular septum, and they may present with heart failure, cyanosis, arrhythmias, syncopal episodes, chest pain, or sudden cardiac death.

Malignant Cardiac Tumors

Primary cardiac malignancies are very rare, but when they occur they tend to have a right-sided predominance and frequently demonstrate extracardiac extension and involvement.^{234,243} Malignant cardiac tumors include angiosarcoma, osteosarcoma, leiomyosarcoma, rhabdomyosarcoma, liposarcoma, and primary cardiac lymphomas. Angiosarcomas are aggressive, rapidly invading adjacent structures, and 47% to 89% of patients present with lung, liver, or brain metastases by the time of diagnosis. Leiomyosarcomas are sessile masses with a mucous appearance that are typically found in the posterior wall of the left atrium. Rhabdomyosarcomas are bulky (>10 cm in diameter) tumors that usually occur in children and do not have a predilection for any particular chamber. They frequently invade nearby cardiac structures and are multicentric in 60% of cases. Finally, while not as frequent as secondary cardiac lymphomas, primary

cardiac lymphomas are increasing in frequency due to lymphoproliferative disorders caused by Epstein-Barr virus in immunosuppressed patients. The absence of necrotic foci in lymphomas can be used to differentiate these tumors from cardiac sarcomas.

Metastatic Cardiac Tumors

Cardiac metastases have been found in approximately 10% of autopsies performed for malignant disease.²³⁴ Secondary cardiac tumors, unlike primary tumors, are therefore relatively common. They may arise from direct extension of mediastinal tumors, hematological spread, intracavitary extension from the inferior vena cava or lymphatic extension, although the latter is the most common mechanism.

While they can occur with most any primary tumor, they are generally observed late in the course of disease. Malignant melanomas have a high potential for cardiac involvement, but other soft tissue tumors such as lung cancer, breast cancer, sarcomas, renal carcinoma, esophageal cancer, hepatocellular carcinoma, and thyroid cancer may all progress to cardiac involvement. Cardiac metastases may also develop from leukemia and lymphoma in 25% to 40% of cases.²⁴⁴

Metastatic cardiac tumors are typically found in random locations, excluding the valvular tissue where lymphatics are absent, and they may be multifocal or diffusely extend along the epicardial surface. Signs of malignant cardiac involvement in cancer patients include pericardial effusion or tamponade, tachyarrhythmias, and heart failure symptoms. Workup is similar to other cardiac tumors. Treatment is generally with combined chemotherapy and radiation and is rarely effective.

REFERENCES

Entries highlighted in bright blue are key references.

1. Braunwald E, Bonow RO. Braunwald's heart disease: a textbook of cardiovascular medicine. 9th ed. Philadelphia: Saunders; 2012.
2. Lee DH, Buth KJ, Martin BJ, Yip AM, Hirsch GM. Frail patients are at increased risk for mortality and prolonged institutional care after cardiac surgery. *Circulation*. 2010;121:973-978.
3. Williams FM, Bergin JD. Cardiac screening before noncardiac surgery. *Surg Clin North Am*. 2009;89:747-762, vii.
4. Fleisher LA, Beckman JA, Brown KA, et al. ACC/AHA 2007 guidelines on perioperative cardiovascular evaluation and care for noncardiac surgery: a report of the American College of Cardiology/American Heart Association Task Force on Practice Guidelines (Writing Committee to Revise the 2002 Guidelines on Perioperative Cardiovascular Evaluation for Noncardiac Surgery) developed in collaboration with the American Society of Echocardiography, American Society of Nuclear Cardiology, Heart Rhythm Society, Society of Cardiovascular Anesthesiologists, Society for Cardiovascular Angiography and Interventions, Society for Vascular Medicine and Biology, and Society for Vascular Surgery. *J Am Coll Cardiol*. 2007;50:e159-e241.
5. Badheka AO, Hendel RC. Radionuclide cardiac stress testing. *Curr Opin Cardiol*. 2011;26:370-378.
6. Bax JJ, Boogers MM, Schuijff JD. Nuclear imaging in heart failure. *Cardiol Clin*. 2009;27:265-276, Table of Contents.
7. Scanlon PJ, Faxon DP, Audet AM, et al. ACC/AHA guidelines for coronary angiography. A report of the American College of Cardiology/American Heart Association Task Force on practice guidelines (Committee on Coronary Angiography). Developed in collaboration with the Society for

- Cardiac Angiography and Interventions. *J Am Coll Cardiol*. 1999;33:1756-1824.
8. Berman DS, Hachamovitch R, Shaw LJ, et al. Roles of nuclear cardiology, cardiac computed tomography, and cardiac magnetic resonance: assessment of patients with suspected coronary artery disease. *J Nucl Med*. 2006;47:74-82.
 9. Chow BJ, Small G, Yam Y, et al. Incremental prognostic value of cardiac computed tomography in coronary artery disease using CONFIRM: COroNary computed tomography angiography evaluation for clinical outcomes: an International Multicenter registry. *Circ Cardiovasc Imaging*. 2011;4:463-472.
 10. Edmunds LH Jr. The evolution of cardiopulmonary bypass: lessons to be learned. *Perfusion*. 2002;17:243-251.
 11. Cohn LH. Cardiac surgery in the adult. 4th ed. New York: McGraw-Hill Professional; 2012.
 12. Asimakopoulos G. Systemic inflammation and cardiac surgery: an update. *Perfusion*. 2001;16:353-360.
 13. Arepally GM, Ortel TL. Heparin-induced thrombocytopenia. *Annu Rev Med*. 2010;61:77-90.
 14. Murphy GJ, Angelini GD. Side effects of cardiopulmonary bypass: what is the reality? *J Card Surg*. 2004;19:481-488.
 15. Greason KL, Schaff HV. Myocardial revascularization by coronary arterial bypass graft: past, present, and future. *Curr Probl Cardiol*. 2011;36:325-368.
 16. Crea F, Liuzzo G. Pathogenesis of acute coronary syndromes. *J Am Coll Cardiol*. 2013;61(1):1-11.
 17. Fuster V, Badimon L, Badimon JJ, Chesebro JH. The pathogenesis of coronary artery disease and the acute coronary syndromes (1). *N Engl J Med*. 1992;326:242-250.
 18. Libby P, Ridker PM, Hansson GK. Progress and challenges in translating the biology of atherosclerosis. *Nature*. 2011;473:317-325.
 19. Smith SC Jr., Allen J, Blair SN, et al. AHA/ACC guidelines for secondary prevention for patients with coronary and other atherosclerotic vascular disease: 2006 update: endorsed by the National Heart, Lung, and Blood Institute. *Circulation*. 2006;113:2363-2373.
 20. Gibbons RJ, Chatterjee K, Daley J, et al. ACC/AHA/ACP-ASIM guidelines for the management of patients with chronic stable angina: a report of the American College of Cardiology/American Heart Association Task Force on Practice Guidelines (Committee on Management of Patients With Chronic Stable Angina). *J Am Coll Cardiol*. 1999;33:2092-2197.
 21. Hillis LD, Smith PK, Anderson JL, et al. 2011 ACCF/AHA Guideline for Coronary Artery Bypass Graft Surgery: a report of the American College of Cardiology Foundation/American Heart Association Task Force on Practice Guidelines. *Circulation*. 2011;124:e652-e735.
 22. Hannan EL, Racz MJ, Walford G, et al. Long-term outcomes of coronary-artery bypass grafting versus stent implantation. *N Engl J Med*. 2005;352:2174-2183.
 23. Booth J, Clayton T, Pepper J, et al. Randomized, controlled trial of coronary artery bypass surgery versus percutaneous coronary intervention in patients with multivessel coronary artery disease: six-year follow-up from the Stent or Surgery Trial (SoS). *Circulation*. 2008;118:381-388.
 24. Serruys PW, Morice MC, Kappetein AP, et al. Percutaneous coronary intervention versus coronary-artery bypass grafting for severe coronary artery disease. *N Engl J Med*. 2009;360:961-972.
 25. Weintraub WS, Grau-Sepulveda MV, Weiss JM, et al. Comparative effectiveness of revascularization strategies. *N Engl J Med*. 2012;366:1467-1476.
 26. Tatoulis J, Buxton BF, Fuller JA. Patencies of 2127 arterial to coronary conduits over 15 years. *Ann Thorac Surg*. 2004;77:93-101.
 27. Goldman S, Zadina K, Moritz T, et al. Long-term patency of saphenous vein and left internal mammary artery grafts after coronary artery bypass surgery: results from a Department of Veterans Affairs Cooperative Study. *J Am Coll Cardiol*. 2004;44:2149-2156.
 28. Dorman MJ, Kurlansky PA, Traad EA, Galbut DL, Zucker M, Ebra G. Bilateral internal mammary artery grafting enhances survival in diabetic patients: a 30-year follow-up of propensity score-matched cohorts. *Circulation*. 2012;126:2935-2942.
 29. Kelly R, Buth KJ, Legare JF. Bilateral internal thoracic artery grafting is superior to other forms of multiple arterial grafting in providing survival benefit after coronary bypass surgery. *J Thorac Cardiovasc Surg*. 2012;144:1408-1415.
 30. Athanasiou T, Saso S, Rao C, et al. Radial artery versus saphenous vein conduits for coronary artery bypass surgery: forty years of competition—which conduit offers better patency? A systematic review and meta-analysis. *Eur J Cardiothorac Surg*. 2011;40:208-220.
 31. Collins P, Webb CM, Chong CF, Moat NE. Radial artery versus saphenous vein patency randomized trial: five-year angiographic follow-up. *Circulation*. 2008;117:2859-2864.
 32. Zacharias A, Schwann TA, Riordan CJ, Durham SJ, Shah AS, Habib RH. Late results of conventional versus all-arterial revascularization based on internal thoracic and radial artery grafting. *Ann Thorac Surg*. 2009;87:19-26 e2.
 33. Zacharias A, Habib RH, Schwann TA, Riordan CJ, Durham SJ, Shah A. Improved survival with radial artery versus vein conduits in coronary bypass surgery with left internal thoracic artery to left anterior descending artery grafting. *Circulation*. 2004;109:1489-1496.
 34. Caracciolo EA, Davis KB, Sopko G, et al. Comparison of surgical and medical group survival in patients with left main equivalent coronary artery disease. Long-term CASS experience. *Circulation*. 1995;91:2335-2344.
 35. Grover FL, Hammermeister KE, Burchfiel C. Initial report of the Veterans Administration Preoperative Risk Assessment Study for Cardiac Surgery. *Ann Thorac Surg*. 1990;50:12-26; discussion 7-8.
 36. Yusuf S, Zucker D, Peduzzi P, et al. Effect of coronary artery bypass graft surgery on survival: overview of 10-year results from randomised trials by the Coronary Artery Bypass Graft Surgery Trialists Collaboration. *Lancet*. 1994;344:563-570.
 37. De Lorenzo A, Tura B, Bassan F, Pittella F, Rocha AS. Outcomes of patients with left main coronary artery disease undergoing medical or surgical treatment: a propensity-matched analysis. *Coron Artery Dis*. 2011;22:585-589.
 38. Influence of diabetes on 5-year mortality and morbidity in a randomized trial comparing CABG and PTCA in patients with multivessel disease: the Bypass Angioplasty Revascularization Investigation (BARI). *Circulation*. 1997;96:1761-1769.
 39. Jones RH, Kesler K, Phillips HR III, et al. Long-term survival benefits of coronary artery bypass grafting and percutaneous transluminal angioplasty in patients with coronary artery disease. *J Thorac Cardiovasc Surg*. 1996;111:1013-1025.
 40. ElBardissi AW, Aranki SF, Sheng S, O'Brien SM, Greenberg CC, Gammie JS. Trends in isolated coronary artery bypass grafting: an analysis of the Society of Thoracic Surgeons adult cardiac surgery database. *J Thorac Cardiovasc Surg*. 2012;143:273-281.
 41. Nery RM, Martini MR, Vidor Cda R, et al. Changes in functional capacity of patients two years after coronary artery bypass grafting surgery. *Rev Bras Cir Cardiovasc*. 2010;25:224-228.
 42. Herlitz J, Brandrup-Wognsen G, Caidahl K, et al. Symptoms of chest pain and dyspnea and factors associated with chest pain and dyspnea 10 years after coronary artery bypass grafting. *Am Heart J*. 2008;156:580-587.
 43. Angelini GD, Taylor FC, Reeves BC, Ascione R. Early and midterm outcome after off-pump and on-pump surgery in

- Beating Heart Against Cardioplegic Arrest Studies (BHACAS 1 and 2): a pooled analysis of two randomised controlled trials. *Lancet*. 2002;359:1194-1199.
44. Lemma MG, Coscioni E, Tritto FP, et al. On-pump versus off-pump coronary artery bypass surgery in high-risk patients: operative results of a prospective randomized trial (on-off study). *J Thorac Cardiovasc Surg*. 2012;143:625-631.
 45. Mack MJ, Brown P, Houser F, et al. On-pump versus off-pump coronary artery bypass surgery in a matched sample of women: a comparison of outcomes. *Circulation*. 2004;110:III-II6.
 46. Hu S, Zheng Z, Yuan X, et al. Increasing long-term major vascular events and resource consumption in patients receiving off-pump coronary artery bypass: a single-center prospective observational study. *Circulation*. 2010;121:1800-1808.
 47. Lamy A, Devereaux PJ, Prabhakaran D, et al. Off-pump or on-pump coronary-artery bypass grafting at 30 days. *N Engl J Med*. 2012;366:1489-1497.
 48. Hattler B, Messenger JC, Shroyer AL, et al. **Off-Pump coronary artery bypass surgery is associated with worse arterial and saphenous vein graft patency and less effective revascularization: Results from the Veterans Affairs Randomized On/Off Bypass (ROOBY) trial.** *Circulation* 2012;125:2827-2835.
 49. Hannan EL, Wu C, Smith CR, et al. Off-pump versus on-pump coronary artery bypass graft surgery: differences in short-term outcomes and in long-term mortality and need for subsequent revascularization. *Circulation*. 2007;116:1145-1152.
 50. Hueb W, Lopes NH, Pereira AC, et al. Five-year follow-up of a randomized comparison between off-pump and on-pump stable multivessel coronary artery bypass grafting. The MASS III Trial. *Circulation*. 2010;122:S48-S52.
 51. Widimsky P, Straka Z, Stros P, et al. One-year coronary bypass graft patency: a randomized comparison between off-pump and on-pump surgery angiographic results of the PRAGUE-4 trial. *Circulation*. 2004;110:3418-3423.
 52. Puskas JD, Williams WH, O'Donnell R, et al. Off-pump and on-pump coronary artery bypass grafting are associated with similar graft patency, myocardial ischemia, and freedom from reintervention: long-term follow-up of a randomized trial. *Ann Thorac Surg*. 2011;91:1836-1842; discussion 1842-1843.
 53. Sellke FW, DiMaio JM, Caplan LR, et al. Comparing on-pump and off-pump coronary artery bypass grafting: numerous studies but few conclusions: a scientific statement from the American Heart Association council on cardiovascular surgery and anesthesia in collaboration with the interdisciplinary working group on quality of care and outcomes research. *Circulation*. 2005;111:2858-2864.
 54. Lichtenberg A, Klima U, Paeschke H, et al. Impact of multivessel coronary artery disease on outcome after isolated minimally invasive bypass grafting of the left anterior descending artery. *Ann Thorac Surg*. 2004;78:487-491.
 55. Hong SJ, Lim DS, Seo HS, et al. Percutaneous coronary intervention with drug-eluting stent implantation vs. minimally invasive direct coronary artery bypass (MIDCAB) in patients with left anterior descending coronary artery stenosis. *Catheter Cardiovasc Interv*. 2005;64:75-81.
 56. Jaffery Z, Kowalski M, Weaver WD, Khanal S. A meta-analysis of randomized control trials comparing minimally invasive direct coronary bypass grafting versus percutaneous coronary intervention for stenosis of the proximal left anterior descending artery. *Eur J Cardiothorac Surg*. 2007;31:691-697.
 57. Ben-Gal Y, Mohr R, Braunstein R, et al. Revascularization of left anterior descending artery with drug-eluting stents: comparison with minimally invasive direct coronary artery bypass surgery. *Ann Thorac Surg*. 2006;82:2067-2071.
 58. Acharya MN, Ashrafian H, Athanasiou T, Casula R. Is totally endoscopic coronary artery bypass safe, feasible and effective? *Interact Cardiovasc Thorac Surg*. 2012;15:1040-1046.
 59. Bonatti J, Schachner T, Bonaros N, et al. Effectiveness and safety of total endoscopic left internal mammary artery bypass graft to the left anterior descending artery. *Am J Cardiol*. 2009;104:1684-1688.
 60. Srivastava S, Gadasalli S, Agusala M, et al. Beating heart totally endoscopic coronary artery bypass. *Ann Thorac Surg*. 2010;89:1873-1879; discussion 1879-1880.
 61. Reicher B, Poston RS, Mehra MR, et al. Simultaneous "hybrid" percutaneous coronary intervention and minimally invasive surgical bypass grafting: feasibility, safety, and clinical outcomes. *Am Heart J*. 2008;155:661-667.
 62. Holzhey DM, Jacobs S, Mochalski M, et al. Minimally invasive hybrid coronary artery revascularization. *Ann Thorac Surg*. 2008;86:1856-1860.
 63. Katz MR, Van Praet F, de Canniere D, et al. Integrated coronary revascularization: percutaneous coronary intervention plus robotic totally endoscopic coronary artery bypass. *Circulation*. 2006;114:I473-I476.
 64. Briones E, Lacalle JR, Marin I. Transmyocardial laser revascularization versus medical therapy for refractory angina. *Cochrane Database Syst Rev*. 2009:CD003712.
 65. Allen KB, Dowling RD, Schuch DR, et al. Adjunctive transmyocardial revascularization: five-year follow-up of a prospective, randomized trial. *Ann Thorac Surg*. 2004;78:458-465; discussion-65.
 66. Bridges CR, Horvath KA, Nugent WC, et al. The Society of Thoracic Surgeons practice guideline series: transmyocardial laser revascularization. *Ann Thorac Surg*. 2004;77:1494-1502.
 67. Henry TD, Annex BH, McKendall GR, et al. The VIVA trial: Vascular endothelial growth factor in Ischemia for Vascular Angiogenesis. *Circulation*. 2003;107:1359-1365.
 68. Simons M, Annex BH, Laham RJ, et al. Pharmacological treatment of coronary artery disease with recombinant fibroblast growth factor-2: double-blind, randomized, controlled clinical trial. *Circulation*. 2002;105:788-793.
 69. O'Brien SM, Shahian DM, Filardo G, et al. **The Society of Thoracic Surgeons 2008 cardiac surgery risk models: part 2—isolated valve surgery.** *Ann Thorac Surg*. 2009;88:S23-S42.
 70. Bonow RO, Carabello BA, Chatterjee K, et al. **2008 focused update incorporated into the ACC/AHA 2006 guidelines for the management of patients with valvular heart disease: a report of the American College of Cardiology/American Heart Association Task Force on Practice Guidelines (Writing Committee to revise the 1998 guidelines for the management of patients with valvular heart disease). Endorsed by the Society of Cardiovascular Anesthesiologists, Society for Cardiovascular Angiography and Interventions, and Society of Thoracic Surgeons.** *J Am Coll Cardiol*. 2008;52:e1-e142.
 71. Rosendaal FR. The Scylla and Charybdis of oral anticoagulant treatment. *N Engl J Med*. 1996;335:587-589.
 72. Bloomfield P. Choice of heart valve prosthesis. *Heart*. 2002;87:583-589.
 73. Hammermeister K, Sethi GK, Henderson WG, Grover FL, Oprian C, Rahimtoola SH. Outcomes 15 years after valve replacement with a mechanical versus a bioprosthetic valve: final report of the Veterans Affairs randomized trial. *J Am Coll Cardiol*. 2000;36:1152-1158.
 74. Butchart EG, Payne N, Li HH, Buchan K, Mandana K, Grunkemeier GL. Better anticoagulation control improves survival after valve replacement. *J Thorac Cardiovasc Surg*. 2002;123:715-723.
 75. Pibarot P, Dumesnil JG, Jobin J, Cartier P, Honos G, Durand LG. Hemodynamic and physical performance during maximal exercise in patients with an aortic bioprosthetic valve: comparison of stentless versus stented bioprostheses. *J Am Coll Cardiol*. 1999;34:1609-1617.

76. Fries R, Wendler O, Schieffer H, Schafers HJ. Comparative rest and exercise hemodynamics of 23-mm stentless versus 23-mm stented aortic bioprostheses. *Ann Thorac Surg.* 2000;69:817-822.
77. Ross DN. Homograft replacement of the aortic valve. *Lancet.* 1962;2:487.
78. Anguera I, Miro JM, San Roman JA, et al. Periannular complications in infective endocarditis involving prosthetic aortic valves. *Am J Cardiol.* 2006;98:1261-1268.
79. Vogt F, Kowert A, Beiras-Fernandez A, et al. Pulmonary homografts for aortic valve replacement: long-term comparison with aortic grafts. *Heart Surg Forum.* 2011;14:E237-E241.
80. Ross DN. Replacement of aortic and mitral valves with a pulmonary autograft. *Lancet.* 1967;2:956-958.
81. Gerosa G, McKay R, Davies J, Ross DN. Comparison of the aortic homograft and the pulmonary autograft for aortic valve or root replacement in children. *J Thorac Cardiovasc Surg.* 1991;102:51-60; discussion-61.
82. David TE, Uden DE, Strauss HD. The importance of the mitral apparatus in left ventricular function after correction of mitral regurgitation. *Circulation.* 1983;68:II76-II82.
83. Enriquez-Sarano M, Schaff HV, Orszulak TA, Tajik AJ, Bailey KR, Frye RL. Valve repair improves the outcome of surgery for mitral regurgitation. A multivariate analysis. *Circulation.* 1995;91:1022-1028.
84. David TE, Armstrong S, McCrindle BW, Manlhiot C. Late outcomes of mitral valve repair for mitral regurgitation due to degenerative disease. *Circulation.* 2013;127:1485-1492.
85. Pfannmueller B, Verevkin A, Borger MA, et al. Role of tricuspid valve repair for moderate tricuspid regurgitation during minimally invasive mitral valve surgery. *Thorac Cardiovasc Surg.* 2013;61(5):386-391.
86. Roberts WC, Perloff JK. Mitral valvular disease. A clinicopathologic survey of the conditions causing the mitral valve to function abnormally. *Ann Intern Med.* 1972;77:939-975.
87. Hugenholtz PG, Ryan TJ, Stein SW, Abelmann WH. The spectrum of pure mitral stenosis. Hemodynamic studies in relation to clinical disability. *Am J Cardiol.* 1962;10:773-784.
88. Snopek G, Pogorzelska H, Rywik TM, Browarek A, Janas J, Korewicki J. Usefulness of endothelin-1 concentration in capillary blood in patients with mitral stenosis as a predictor of regression of pulmonary hypertension after mitral valve replacement or valvuloplasty. *Am J Cardiol.* 2002;90:188-189.
89. Gorlin R. The mechanism of the signs and symptoms of mitral valve disease. *Br Heart J.* 1954;16:375-380.
90. Martin RP, Rakowski H, Kleiman JH, Beaver W, London E, Popp RL. Reliability and reproducibility of two dimensional echocardiograph measurement of the stenotic mitral valve orifice area. *Am J Cardiol.* 1979;43:560-568.
91. Cheriex EC, Pieters FA, Janssen JH, de Swart H, Palmans-Meulemans A. Value of exercise Doppler-echocardiography in patients with mitral stenosis. *Int J Cardiol.* 1994;45:219-226.
92. Enriquez-Sarano M, Akins CW, Vahanian A. Mitral regurgitation. *Lancet.* 2009;373:1382-1394.
93. Carpentier A. Cardiac valve surgery—the “French correction.” *J Thorac Cardiovasc Surg.* 1983;86:323-337.
94. Zile MR, Gaasch WH, Carroll JD, Levine HJ. Chronic mitral regurgitation: predictive value of preoperative echocardiographic indexes of left ventricular function and wall stress. *J Am Coll Cardiol.* 1984;3:235-242.
95. Castello R, Fagan L Jr., Lenzen P, Pearson AC, Labovitz AJ. Comparison of transthoracic and transesophageal echocardiography for assessment of left-sided valvular regurgitation. *Am J Cardiol.* 1991;68:1677-1680.
96. Enriquez-Sarano M, Avierinos JF, Messika-Zeitoun D, et al. Quantitative determinants of the outcome of asymptomatic mitral regurgitation. *N Engl J Med.* 2005;352:875-883.
97. Picano E, Pibarot P, Lancellotti P, Monin JL, Bonow RO. The emerging role of exercise testing and stress echocardiography in valvular heart disease. *J Am Coll Cardiol.* 2009;54:2251-2260.
98. Reichart DT, Sodian R, Zenker R, Klinner W, Schmitz C, Reichart B. Long-term (≤ 50 years) results of patients after mitral valve commissurotomy—a single-center experience. *J Thorac Cardiovasc Surg.* 2012;143:S96-S98.
99. Choudhary SK, Dhadeshwar J, Govil A, Airan B, Kumar AS. Open mitral commissurotomy in the current era: indications, technique, and results. *Ann Thorac Surg.* 2003;75:41-46.
100. Mohty D, Orszulak TA, Schaff HV, Avierinos JF, Tajik JA, Enriquez-Sarano M. Very long-term survival and durability of mitral valve repair for mitral valve prolapse. *Circulation.* 2001;104:11-17.
101. Vassileva CM, Mishkel G, McNeely C, et al. Long-term survival of patients undergoing mitral valve repair and replacement: a longitudinal analysis of Medicare fee-for-service beneficiaries. *Circulation.* 2013;127(18):1870-1876.
102. Khan SS, Trento A, DeRobertis M, et al. Twenty-year comparison of tissue and mechanical valve replacement. *J Thorac Cardiovasc Surg.* 2001;122:257-269.
103. Gillinov AM, Cosgrove DM. Mitral valve repair for degenerative disease. *J Heart Valve Dis.* 2002;11 Suppl 1:S15-S20.
104. Fucci C, Sandrelli L, Pardini A, Torracca L, Ferrari M, Alfieri O. Improved results with mitral valve repair using new surgical techniques. *Eur J Cardiothorac Surg.* 1995;9:621-626 discuss 626-627.
105. Castillo JG, Anyanwu AC, El-Eshmawi A, Adams DH. All anterior and bileaflet mitral valve prolapses are repairable in the modern era of reconstructive surgery. *Eur J Cardiothorac Surg.* 2013.
106. Braunberger E, Deloche A, Berrebi A, et al. Very long-term results (more than 20 years) of valve repair with carpentier’s techniques in nonrheumatic mitral valve insufficiency. *Circulation.* 2001;104:18-111.
107. O’Brien KD. Pathogenesis of calcific aortic valve disease: a disease process comes of age (and a good deal more). *Arterioscler Thromb Vasc Biol.* 2006;26:1721-1728.
108. Murakami T, Hess OM, Gage JE, Grimm J, Krayenbuehl HP. Diastolic filling dynamics in patients with aortic stenosis. *Circulation.* 1986;73:1162-1174.
109. Gunther S, Grossman W. Determinants of ventricular function in pressure-overload hypertrophy in man. *Circulation.* 1979;59:679-688.
110. Marcus ML, Doty DB, Hiratzka LF, Wright CB, Eastham CL. Decreased coronary reserve: a mechanism for angina pectoris in patients with aortic stenosis and normal coronary arteries. *N Engl J Med.* 1982;307:1362-1366.
111. Gaasch WH, Zile MR, Hoshino PK, Weinberg EO, Rhodes DR, Apstein CS. Tolerance of the hypertrophic heart to ischemia. Studies in compensated and failing dog hearts with pressure overload hypertrophy. *Circulation.* 1990;81:1644-1653.
112. Orsinelli DA, Aurigemma GP, Battista S, Krendel S, Gaasch WH. Left ventricular hypertrophy and mortality after aortic valve replacement for aortic stenosis. A high risk subgroup identified by preoperative relative wall thickness. *J Am Coll Cardiol.* 1993;22:1679-1683.
113. Khawaja MZ, Sohal M, Valli H, et al. Standalone balloon aortic valvuloplasty: indications and outcomes from the UK in the transcatheter valve era. *Catheter Cardiovasc Interv.* 2013;81:366-373.
114. Roberts WC, Ko JM, Moore TR, Jones WH III. Causes of pure aortic regurgitation in patients having isolated aortic valve replacement at a single US tertiary hospital (1993 to 2005). *Circulation.* 2006;114:422-429.
115. Grossman W, Jones D, McLaurin LP. Wall stress and patterns of hypertrophy in the human left ventricle. *J Clin Invest.* 1975;56:56-64.

116. Ross J Jr., McCullagh WH. Nature of enhanced performance of the dilated left ventricle in the dog during chronic volume overloading. *Circ Res*. 1972;30:549-556.
117. Wisenbaugh T, Spann JF, Carabello BA. Differences in myocardial performance and load between patients with similar amounts of chronic aortic versus chronic mitral regurgitation. *J Am Coll Cardiol*. 1984;3:916-923.
118. Ross J Jr. Afterload mismatch in aortic and mitral valve disease: implications for surgical therapy. *J Am Coll Cardiol*. 1985;5:811-826.
119. Nienaber CA, von Kodolitsch Y, Nicolas V, et al. The diagnosis of thoracic aortic dissection by noninvasive imaging procedures. *N Engl J Med*. 1993;328:1-9.
120. Smith MD, Cassidy JM, Souther S, et al. Transesophageal echocardiography in the diagnosis of traumatic rupture of the aorta. *N Engl J Med*. 1995;332:356-362.
121. Sasaki Y, Hirai H, Hosono M, et al. Adding coronary artery bypass grafting to aortic valve replacement increases operative mortality for elderly (70 years and older) patients with aortic stenosis. *Gen Thorac Cardiovasc Surg*. 2013.
122. de Kerchove L, Boodhwani M, Glineur D, et al. Valve sparing-root replacement http://www.ncbi.nlm.nih.gov/pubmed/?term=Glineur%20D%5BAuthor%5D&cauthor=true&cauthor_uid=21955470with the reimplantation technique to increase the durability of bicuspid aortic valve repair. *J Thorac Cardiovasc Surg*. 2011;142:1430-1438.
123. El Khoury G, de Kerchove L. Principles of aortic valve repair. *J Thorac Cardiovasc Surg*. 2013;145:S26.
124. Mokhles MM, Rizopoulos D, Andrinopoulou ER, et al. Autograft and pulmonary allograft performance in the second post-operative decade after the Ross procedure: insights from the Rotterdam Prospective Cohort Study. *Eur Heart J*. 2012;33:2213-2224.
125. Chambers JC, Somerville J, Stone S, Ross DN. Pulmonary autograft procedure for aortic valve disease: long-term results of the pioneer series. *Circulation*. 1997;96:2206-2214.
126. Leon MB, Smith CR, Mack M, et al. Transcatheter aortic-valve implantation for aortic stenosis in patients who cannot undergo surgery. *N Engl J Med*. 2010;363:1597-1607.
127. Smith CR, Leon MB, Mack MJ, et al. Transcatheter versus surgical aortic-valve replacement in high-risk patients. *N Engl J Med*. 2011;364:2187-2198.
128. Shinn SH, Schaff HV. Evidence-based surgical management of acquired tricuspid valve disease. *Nat Rev Cardiol*. 2013;10:190-203.
129. Galloway AC, Grossi EA, Baumann FG, et al. Multiple valve operation for advanced valvular heart disease: results and risk factors in 513 patients. *J Am Coll Cardiol*. 1992;19:725-732.
130. Hunt SA, Abraham WT, Chin MH, et al. 2009 focused update incorporated into the ACC/AHA 2005 Guidelines for the Diagnosis and Management of Heart Failure in Adults: a report of the American College of Cardiology Foundation/American Heart Association Task Force on Practice Guidelines: developed in collaboration with the International Society for Heart and Lung Transplantation. *Circulation*. 2009;119:e391-e479.
131. Kilic A, Ailawadi G. Left ventricular assist devices in heart failure. *Expert Rev Cardiovasc Ther*. 2012;10:649-656.
132. Harper AM, Rosendale JD. The UNOS OPTN Waiting List and Donor Registry: 1988-1996. *Clin Transpl*. 1996:69-90.
133. Go AS, Mozaffarian D, Roger VL, et al. Heart disease and stroke statistics—2013 update: a report from the American Heart Association. 2012;e6-e245.
134. Levy D, Kenchaiah S, Larson MG, et al. Long-term trends in the incidence of and survival with heart failure. *N Engl J Med*. 2002;347:1397-1402.
135. Jones RH, Velazquez EJ, Michler RE, et al. Coronary bypass surgery with or without surgical ventricular reconstruction. *N Engl J Med*. 2009;360:1705-1717.
136. McGee EC Jr., McCarthy PM. Do patients with heart failure benefit from coronary artery bypass grafting? *Curr Opin Cardiol*. 2012;27:629-633.
137. Allman KC, Shaw LJ, Hachamovitch R, Udelson JE. Myocardial viability testing and impact of revascularization on prognosis in patients with coronary artery disease and left ventricular dysfunction: a meta-analysis. *J Am Coll Cardiol*. 2002;39:1151-1158.
138. Chareonthaitawee P, Gersh BJ, Araoz PA, Gibbons RJ. Revascularization in severe left ventricular dysfunction: the role of viability testing. *J Am Coll Cardiol*. 2005;46:567-574.
139. Gerber BL, Rousseau MF, Ahn SA, et al. Prognostic value of myocardial viability by delayed-enhanced magnetic resonance in patients with coronary artery disease and low ejection fraction: impact of revascularization therapy. *J Am Coll Cardiol*. 2012;59:825-835.
140. Langenburg SE, Buchanan SA, Blackbourne LH, et al. Predicting survival after coronary revascularization for ischemic cardiomyopathy. *Ann Thorac Surg*. 1995;60:1193-1196; discussion 1196-1197.
141. Yamaguchi A, Ino T, Adachi H, et al. Left ventricular volume predicts postoperative course in patients with ischemic cardiomyopathy. *Ann Thorac Surg*. 1998;65:434-438.
142. Penicka M, Bartunek J, Lang O, et al. Severe left ventricular dyssynchrony is associated with poor prognosis in patients with moderate systolic heart failure undergoing coronary artery bypass grafting. *J Am Coll Cardiol*. 2007;50:1315-1323.
143. Ciarka A, Van de Veire N. Secondary mitral regurgitation: pathophysiology, diagnosis, and treatment. *Heart*. 2011;97:1012-1023.
144. Grigioni F, Enriquez-Sarano M, Zehr KJ, Bailey KR, Tajik AJ. Ischemic mitral regurgitation: long-term outcome and prognostic implications with quantitative Doppler assessment. *Circulation*. 2001;103:1759-1764.
145. Trichon BH, Felker GM, Shaw LK, Cabell CH, O'Connor CM. Relation of frequency and severity of mitral regurgitation to survival among patients with left ventricular systolic dysfunction and heart failure. *Am J Cardiol*. 2003;91:538-543.
146. Ellis SG, Whitlow PL, Raymond RE, Schneider JP. Impact of mitral regurgitation on long-term survival after percutaneous coronary intervention. *Am J Cardiol*. 2002;89:315-318.
147. Vahanian A, Baumgartner H, Bax J, et al. Guidelines on the management of valvular heart disease: The Task Force on the Management of Valvular Heart Disease of the European Society of Cardiology. *Eur Heart J*. 2007;28:230-268.
148. DiDonato M, Sabatier M, Dor V, Buckberg G. Ventricular arrhythmias after LV remodelling: surgical ventricular restoration or ICD? *Heart Fail Rev*. 2004;9:299-306; discussion 347-351.
149. Mihaljevic T, Lam BK, Rajeswaran J, et al. Impact of mitral valve annuloplasty combined with revascularization in patients with functional ischemic mitral regurgitation. *J Am Coll Cardiol*. 2007;49:2191-2201.
150. Wu AH, Aaronson KD, Bolling SF, Pagani FD, Welch K, Koelling TM. Impact of mitral valve annuloplasty on mortality risk in patients with mitral regurgitation and left ventricular systolic dysfunction. *J Am Coll Cardiol*. 2005;45:381-387.
151. Acker MA, Bolling S, Shemin R, et al. Mitral valve surgery in heart failure: insights from the Acorn Clinical Trial. *J Thorac Cardiovasc Surg*. 2006;132:568-577;77 e1-e4.
152. McGee EC, Gillinov AM, Blackstone EH, et al. Recurrent mitral regurgitation after annuloplasty for functional ischemic mitral regurgitation. *J Thorac Cardiovasc Surg*. 2004;128:916-924.
153. Bax JJ, Braun J, Somer ST, et al. Restrictive annuloplasty and coronary revascularization in ischemic mitral regurgitation results in reverse left ventricular remodeling. *Circulation*. 2004;110:II103-II108.

154. Bogaert J, Maes A, Van de Werf F, et al. Functional recovery of subepicardial myocardial tissue in transmural myocardial infarction after successful reperfusion: an important contribution to the improvement of regional and global left ventricular function. *Circulation*. 1999;99:36-43.
155. Dor V, Sabatier M, Montiglio F, Civaia F, DiDonato M. Endoventricular patch reconstruction of ischemic failing ventricle. A single center with 20 years experience. Advantages of magnetic resonance imaging assessment. *Heart Fail Rev*. 2004;9:269-286.
156. Fenoglio JJ Jr, Pham TD, Harken AH, Horowitz LN, Josephson ME, Wit AL. Recurrent sustained ventricular tachycardia: structure and ultrastructure of subendocardial regions in which tachycardia originates. *Circulation*. 1983;68:518-533.
157. Scherlag BJ, el-Sherif N, Hope R, Lazzara R. Characterization and localization of ventricular arrhythmias resulting from myocardial ischemia and infarction. *Circ Res*. 1974;35:372-383.
158. Koilpillai C, Quinones MA, Greenberg B, et al. Relation of ventricular size and function to heart failure status and ventricular dysrhythmia in patients with severe left ventricular dysfunction. *Am J Cardiol*. 1996;77:606-611.
159. Hassapoyannes CA, Stuck LM, Hornung CA, Berbin MC, Flowers NC. Effect of left ventricular aneurysm on risk of sudden and nonsudden cardiac death. *Am J Cardiol*. 1991;67:454-459.
160. Sartipy U, Albage A, Lindblom D. Improved health-related quality of life and functional status after surgical ventricular restoration. *Ann Thorac Surg*. 2007;83:1381-1387.
161. Isomura T. Surgical left ventricular reconstruction. *Gen Thorac Cardiovasc Surg*. 2011;59:315-325.
162. Maxey TS, Reece TB, Ellman PI, et al. Coronary artery bypass with ventricular restoration is superior to coronary artery bypass alone in patients with ischemic cardiomyopathy. *J Thorac Cardiovasc Surg*. 2004;127:428-434.
163. Mickleborough LL, Merchant N, Ivanov J, Rao V, Carson S. Left ventricular reconstruction: Early and late results. *J Thorac Cardiovasc Surg*. 2004;128:27-37.
164. Athanasuleas CL, Buckberg GD, Stanley AW, et al. Surgical ventricular restoration: the RESTORE Group experience. *Heart Fail Rev*. 2004;9:287-297.
165. Dor V, Sabatier M, Montiglio F, Rossi P, Toso A, Di Donato M. Results of nonguided subtotal endocardectomy associated with left ventricular reconstruction in patients with ischemic ventricular arrhythmias. *J Thorac Cardiovasc Surg*. 1994;107:1301-1307; discussion 1307-1308.
166. Sartipy U, Albage A, Straat E, Insulander P, Lindblom D. Surgery for ventricular tachycardia in patients undergoing left ventricular reconstruction by the Dor procedure. *Ann Thorac Surg*. 2006;81:65-71.
167. Matthias Bechtel JF, Tolg R, Graf B, et al. High incidence of sudden death late after anterior LV-aneurysm repair. *Eur J Cardiothorac Surg*. 2004;25:807-811.
168. O'Neill JO, Starling RC, Khaykin Y, et al. Residual high incidence of ventricular arrhythmias after left ventricular reconstructive surgery. *J Thorac Cardiovasc Surg*. 2005;130:1250-1256.
169. Buckberg GD, Athanasuleas CL. The STICH trial: misguided conclusions. *J Thorac Cardiovasc Surg*. 2009;138:1060-1064e2.
170. Dor V, Civaia F, Alexandrescu C, Sabatier M, Montiglio F. Favorable effects of left ventricular reconstruction in patients excluded from the Surgical Treatments for Ischemic Heart Failure (STICH) trial. *J Thorac Cardiovasc Surg*. 2011;141:905-916, 16 e1-e4.
171. Kang N, Edwards M, Larbalestier R. Preoperative intraaortic balloon pumps in high-risk patients undergoing open heart surgery. *Ann Thorac Surg*. 2001;72:54-57.
172. Meharwal ZS, Trehan N. Vascular complications of intra-aortic balloon insertion in patients undergoing coronary revascularization: analysis of 911 cases. *Eur J Cardiothorac Surg*. 2002;21:741-747.
173. Kirklin JK, Naftel DC, Kormos RL, et al. Third INTERMACS Annual Report: the evolution of destination therapy in the United States. *J Heart Lung Transplant*. 2011;30:115-123.
174. Rose EA, Gelijns AC, Moskowitz AJ, et al. Long-term use of a left ventricular assist device for end-stage heart failure. *N Engl J Med*. 2001;345:1435-1443.
175. Kirklin JK, Naftel DC, Pagani FD, et al. Long-term mechanical circulatory support (destination therapy): on track to compete with heart transplantation? *J Thorac Cardiovasc Surg*. 2012;144:584-603; discussion 597-598.
176. Maybaum S, Mancini D, Xydias S, et al. Cardiac improvement during mechanical circulatory support: a prospective multicenter study of the LVAD Working Group. *Circulation*. 2007;115:2497-2505.
177. Lamarche Y, Kearns M, Josan K, et al. Successful weaning and explantation of the Heartmate II left ventricular assist device. *Can J Cardiol*. 2011;27:358-362.
178. Birks EJ, George RS, Hedger M, et al. Reversal of severe heart failure with a continuous-flow left ventricular assist device and pharmacological therapy: a prospective study. *Circulation*. 2011;123:381-390.
179. Birks EJ, Tansley PD, Hardy J, et al. Left ventricular assist device and drug therapy for the reversal of heart failure. *N Engl J Med*. 2006;355:1873-1884.
180. Chugh AR, Beache GM, Loughran JH, et al. Administration of cardiac stem cells in patients with ischemic cardiomyopathy: the SCPIO trial: surgical aspects and interim analysis of myocardial function and viability by magnetic resonance. *Circulation*. 2012;126:S54-S64.
181. Hare JM, Fishman JE, Gerstenblith G, et al. Comparison of allogeneic vs. autologous bone marrow-derived mesenchymal stem cells delivered by transendocardial injection in patients with ischemic cardiomyopathy: the POSEIDON randomized trial. *JAMA*. 2012;308:2369-2379.
182. Miller LW, Pagani FD, Russell SD, et al. Use of a continuous-flow device in patients awaiting heart transplantation. *N Engl J Med*. 2007;357:885-896.
183. Frazier OH, Rose EA, Oz MC, et al. Multicenter clinical evaluation of the HeartMate vented electric left ventricular assist system in patients awaiting heart transplantation. *J Thorac Cardiovasc Surg*. 2001;122:1186-1195.
184. Aaronson KD, Slaughter MS, Miller LW, et al. Use of an intrapericardial, continuous-flow, centrifugal pump in patients awaiting heart transplantation. *Circulation*. 2012;125:3191-3200.
185. John R, Pagani FD, Naka Y, et al. Post-cardiac transplant survival after support with a continuous-flow left ventricular assist device: impact of duration of left ventricular assist device support and other variables. *J Thorac Cardiovasc Surg*. 2010;140:174-181.
186. Pal JD, Piacentino V, Cuevas AD, et al. Impact of left ventricular assist device bridging on posttransplant outcomes. *Ann Thorac Surg*. 2009;88:1457-1461; discussion 1461.
187. Slaughter MS, Rogers JG, Milano CA, et al. Advanced heart failure treated with continuous-flow left ventricular assist device. *N Engl J Med*. 2009;361:2241-2251.
188. John R, Liao K, Kamdar F, Eckman P, Boyle A, Colvin-Adams M. Effects on pre- and posttransplant pulmonary hemodynamics in patients with continuous-flow left ventricular assist devices. *J Thorac Cardiovasc Surg*. 2010;140:447-452.
189. Kormos RL, Teuteberg JJ, Pagani FD, et al. Right ventricular failure in patients with the HeartMate II continuous-flow left

- ventricular assist device: incidence, risk factors, and effect on outcomes. *J Thorac Cardiovasc Surg.* 2010;139:1316-1324.
190. Neragi-Miandoab S. A ventricular assist device as a bridge to recovery, decision making, or transplantation in patients with advanced cardiac failure. *Surg Today.* 2012;42:917-926.
 191. Copeland JG, Smith RG, Arabia FA, et al. Cardiac replacement with a total artificial heart as a bridge to transplantation. *N Engl J Med.* 2004;351:859-867.
 192. El-Hamamsy I, Jacques F, Perrault LP, et al. Results following implantation of mechanical circulatory support systems: the Montreal Heart Institute experience. *The Can J Cardiol.* 2009;25:107-110.
 193. Meyer A, Slaughter M. The total artificial heart. *Panminerva Med.* 2011;53:141-154.
 194. Gammie JS, Haddad M, Milford-Beland S, et al. Atrial fibrillation correction surgery: lessons from the Society of Thoracic Surgeons National Cardiac Database. *Ann Thorac Surg.* 2008;85:909-914.
 195. Calkins H, Kuck KH, Cappato R, et al. 2012 HRS/EHRA/ECAS expert consensus statement on catheter and surgical ablation of atrial fibrillation: recommendations for patient selection, procedural techniques, patient management and follow-up, definitions, endpoints, and research trial design. *Heart Rhythm* 2012;(4):632-696 e21.
 196. Hart RG, Halperin JL. Atrial fibrillation and thromboembolism: a decade of progress in stroke prevention. *Ann Intern Med.* 1999;131:688-695.
 197. Zimetbaum P. Antiarrhythmic drug therapy for atrial fibrillation. *Circulation.* 2012;125:381-389.
 198. Corley SD, Epstein AE, DiMarco JP, et al. Relationships between sinus rhythm, treatment, and survival in the Atrial Fibrillation Follow-Up Investigation of Rhythm Management (AFFIRM) Study. *Circulation.* 2004;109:1509-1513.
 199. Cox JL, Ad N, Palazzo T. Impact of the maze procedure on the stroke rate in patients with atrial fibrillation. *J Thorac Cardiovasc Surg.* 1999;118:833-840.
 200. Feinberg MS, Waggoner AD, Kater KM, Cox JL, Lindsay BD, Perez JE. Restoration of atrial function after the maze procedure for patients with atrial fibrillation. Assessment by Doppler echocardiography. *Circulation.* 1994;90:II285-II292.
 201. Weimar T, Bailey MS, Watanabe Y, et al. **The Cox-maze IV procedure for lone atrial fibrillation: a single center experience in 100 consecutive patients.** *J Interv Card Electrophysiol.* 2011;31:47-54.
 202. Damiano RJ Jr., Schwartz FH, Bailey MS, et al. The Cox maze IV procedure: predictors of late recurrence. *J Thorac Cardiovasc Surg.* 2011;141:113-121.
 203. Lall SC, Melby SJ, Voeller RK, et al. The effect of ablation technology on surgical outcomes after the Cox-maze procedure: a propensity analysis. *J Thorac Cardiovasc Surg.* 2007;133:389-396.
 204. Pet M, Robertson JO, Bailey M, et al. The impact of CHADS(2) score on late stroke after the Cox maze procedure. *J Thorac Cardiovasc Surg.* 2013;146(1):85-9.
 205. Bleeding during antithrombotic therapy in patients with atrial fibrillation. The Stroke Prevention in Atrial Fibrillation Investigators. *Arch Intern Med.* 1996;156:409-416.
 206. Barnett SD, Ad N. Surgical ablation as treatment for the elimination of atrial fibrillation: a meta-analysis. *J Thorac Cardiovasc Surg.* 2006;131:1029-1035.
 207. Schuessler RB, Kay MW, Melby SJ, Branham BH, Boineau JP, Damiano RJ Jr. Spatial and temporal stability of the dominant frequency of activation in human atrial fibrillation. *J Electrocardiol.* 2006;39:S7-S12.
 208. Edgerton JR, Edgerton ZJ, Weaver T, et al. Minimally invasive pulmonary vein isolation and partial autonomic denervation for surgical treatment of atrial fibrillation. *Ann Thorac Surg.* 2008;86:35-38; discussion 39.
 209. Boersma LV, Castella M, van Boven W, et al. Atrial fibrillation catheter ablation versus surgical ablation treatment (FAST): a 2-center randomized clinical trial. *Circulation.* 2012;125:23-30.
 210. Imazio M, Trincherio R. Clinical management of acute pericardial disease: a review of results and outcomes. *Ital Heart J.* 2004;5:803-817.
 211. Launbjerg J, Fruergaard P, Hesse B, Jorgensen F, Elsborg L, Petri A. Long-term risk of death, cardiac events, and recurrent chest pain in patients with acute chest pain of different origin. *Cardiology.* 1996;87:60-66.
 212. Dudzinski DM, Mak GS, Hung JW. Pericardial diseases. *Curr Probl Cardiol.* 2012;37:75-118.
 213. Lange RA, Hillis LD. Clinical practice. Acute pericarditis. *N Engl J Med.* 2004;351:2195-2202.
 214. Spodick DH. Acute pericarditis: current concepts and practice. *JAMA.* 2003;289:1150-1153.
 215. Imazio M, Demichelis B, Parrini I, et al. Day-hospital treatment of acute pericarditis: a management program for outpatient therapy. *J Am Coll Cardiol.* 2004;43:1042-1046.
 216. Bruce MA, Spodick DH. Atypical electrocardiogram in acute pericarditis: characteristics and prevalence. *J Electrocardiol.* 1980;13:61-66.
 217. Salisbury AC, Olalla-Gomez C, Rihal CS, et al. Frequency and predictors of urgent coronary angiography in patients with acute pericarditis. *Mayo Clin Proc.* 2009;84:11-15.
 218. Imazio M, Brucato A, Maestroni S, et al. Prevalence of C-reactive protein elevation and time course of normalization in acute pericarditis: implications for the diagnosis, therapy, and prognosis of pericarditis. *Circulation.* 2011;123:1092-1097.
 219. Khandaker MH, Espinosa RE, Nishimura RA, et al. Pericardial disease: diagnosis and management. *Mayo Clinic Proc.* 2010;85:572-593.
 220. Fowler NO. Recurrent pericarditis. *Cardiol Clin.* 1990;8:621-626.
 221. Khandaker MH, Schaff HV, Greason KL, et al. Pericardiectomy vs. Medical Management in Patients With Relapsing Pericarditis. *Mayo Clinic Proc.* 2012;87:1062-1070.
 222. Tuna IC, Danielson GK. Surgical management of pericardial diseases. *Cardiol Clin.* 1990;8:683-696.
 223. **Azam S, Hoit BD. Treatment of pericardial disease.** *Cardiovasc Ther.* 2011;29:308-314.
 224. Feng D, Glockner J, Kim K, et al. Cardiac magnetic resonance imaging pericardial late gadolinium enhancement and elevated inflammatory markers can predict the reversibility of constrictive pericarditis after anti-inflammatory medical therapy: a pilot study. *Circulation.* 2011;124:1830-1837.
 225. Ariyoshi T, Hashizume K, Taniguchi S, et al. Surgical experience with chronic constrictive pericarditis. *Gen Thorac Cardiovasc Surg.* 2012;60:796-802.
 226. Chowdhury UK, Subramaniam GK, Kumar AS, et al. Pericardiectomy for constrictive pericarditis: a clinical, echocardiographic, and hemodynamic evaluation of two surgical techniques. *Ann Thorac Surg.* 2006;81:522-529.
 227. Bertog SC, Thambidorai SK, Parakh K, et al. Constrictive pericarditis: etiology and cause-specific survival after pericardiectomy. *J Am Coll Cardiol.* 2004;43:1445-1452.
 228. DeValeria PA, Baumgartner WA, Casale AS, et al. Current indications, risks, and outcome after pericardiectomy. *Ann Thorac Surg.* 1991;52:219-224.
 229. Ghavidel AA, Gholampour M, Kyavar M, Mirmesdagh Y, Tabatabaie MB. Constrictive pericarditis treated by surgery. *Tex Heart Inst J.* 2012;39:199-205.
 230. Ling LH, Oh JK, Schaff HV, et al. Constrictive pericarditis in the modern era: evolving clinical spectrum and impact on outcome after pericardiectomy. *Circulation.* 1999;100:1380-1386.
 231. Abushaban L, Denham B, Duff D. 10 year review of cardiac tumours in childhood. *Br Heart J.* 1993;70:166-169.

232. Reynen K. Frequency of primary tumors of the heart. *Am J Cardiol.* 1996;77:107.
233. Pinede L, Duhaut P, Loire R. Clinical presentation of left atrial cardiac myxoma. A series of 112 consecutive cases. *Medicine.* 2001;80:159-172.
234. **Castillo JG, Silvey G. Characterization and management of cardiac tumors. *Semin Cardiothorac Vasc Anesth.* 2010;14:6-20.**
235. Kusano KF, Ohe T. Cardiac tumors that cause arrhythmias. *Card Electrophysiol Rev.* 2002;6:174-177.
236. Lee VH, Connolly HM, Brown RD Jr. Central nervous system manifestations of cardiac myxoma. *Arch Neurol.* 2007;64:1115-1120.
237. Jean WC, Walski-Easton SM, Nussbaum ES. Multiple intracranial aneurysms as delayed complications of an atrial myxoma: case report. *Neurosurgery.* 2001;49:200-202; discussion 202-203.
238. Jain D, Maleszewski JJ, Halushka MK. Benign cardiac tumors and tumorlike conditions. *Ann Diagn Pathol.* 2010;14:215-230.
239. Pucci A, Gagliardotto P, Zanini C, Pansini S, di Summa M, Mollo F. Histopathologic and clinical characterization of cardiac myxoma: review of 53 cases from a single institution. *Am Heart J.* 2000;140:134-138.
240. Bakaeen FG, Reardon MJ, Coselli JS, et al. Surgical outcome in 85 patients with primary cardiac tumors. *Am J Surg.* 2003;186:641-647; discussion 647.
241. Gammie JS, Abrishamchian AR, Griffith BP. Cardiac auto-transplantation and radical bi-atrial resection for recurrent atrial myxoma. *Ann Thorac Surg.* 2007;83:1545-1547.
242. Goldstein DJ, Oz MC, Michler RE. Radical excisional therapy and total cardiac transplantation for recurrent atrial myxoma. *Ann Thorac Surg.* 1995;60:1105-1107.
243. Putnam JB Jr., Sweeney MS, Colon R, Lanza LA, Frazier OH, Cooley DA. Primary cardiac sarcomas. *Ann Thorac Surg.* 1991;51:906-910.
244. Neragi-Miandoab S, Kim J, Vlahakes GJ. Malignant tumours of the heart: a review of tumour type, diagnosis and therapy. *Clin Oncol (R Coll Radiol).* 2007;19:748-756.

This page intentionally left blank

22 chapter

Thoracic Aneurysms and Aortic Dissection

Scott A. LeMaire, Raja R. Gopaldas, and Joseph S. Coselli

Anatomy of the Aorta	785	Pathology and Classification / 806	Repair of Distal Aortic Aneurysms / 819	
Thoracic Aortic Aneurysms	785	Causes and Clinical History / 809	Treatment of Acute Descending Aortic Dissection / 820	
Causes and Pathogenesis / 786		Clinical Manifestations / 809		
Clinical History / 789		Diagnostic Evaluation / 810	Conclusions	820
Clinical Manifestations / 789		Treatment / 812	Acknowledgments	820
Diagnostic Evaluation / 789		Outcomes		
Treatment / 791		Repair of Proximal Aortic Aneurysms / 817		
Aortic Dissection	806	Treatment of Acute Ascending Aortic Dissection / 819		

ANATOMY OF THE AORTA

The aorta consists of two major segments—the proximal aorta and the distal aorta—whose anatomic characteristics affect both the clinical manifestations of disease in these segments and the selection of treatment strategies for such disease (Fig. 22-1). The proximal aortic segment includes the ascending aorta and the transverse aortic arch. The ascending aorta begins at the aortic valve and ends at the origin of the innominate artery. The first portion of the ascending aorta is the aortic root, which includes the aortic valve annulus and the three sinuses of Valsalva; the coronary arteries originate from two of these sinuses. The aortic root joins the tubular portion of the ascending aorta at the sinotubular ridge. The transverse aortic arch is the area from which the brachiocephalic branches arise. The distal aortic segment includes the descending thoracic aorta and the abdominal aorta. The descending thoracic aorta begins distal to the origin of the left subclavian artery and extends to the diaphragmatic hiatus, where it joins the abdominal aorta. The descending thoracic aorta gives rise to multiple bronchial and esophageal branches, as well as to the segmental intercostal arteries, which provide circulation to the spinal cord.

The volume of blood that flows through the thoracic aorta at high pressure is far greater than that found in any other vascular structure. For this reason, any condition that disrupts the integrity of the thoracic aorta, such as aortic dissection, aneurysm rupture, or traumatic injury, can have catastrophic consequences.

Historically, open surgical repair of such conditions has been an intimidating undertaking associated with significant morbidity and mortality. Strategies for protecting the brain and spinal cord during such repairs have become critical in preventing devastating complications. In recent years, endovascular therapy for thoracic aortic disease in selected patients has become accepted practice, producing fewer adverse outcomes than traditional approaches do.

THORACIC AORTIC ANEURYSMS

Aortic aneurysm is defined as a permanent, localized dilatation of the aorta to a diameter that is at least 50% greater than is normal at that anatomic level.¹ The annual incidence of thoracic aortic aneurysms is estimated to be 5.9 per 100,000 persons.² The clinical manifestations, methods of treatment, and treatment results in patients with aortic aneurysms vary according to the cause and the aortic segment involved. Causes of thoracic aortic aneurysms include degenerative disease of the aortic wall, aortic dissection, aortitis, infection, and trauma. Aneurysms can be localized to a single aortic segment, or they can involve multiple segments. Thoracoabdominal aortic aneurysms, for example, involve both the descending thoracic aorta and the abdominal aorta. In the most extreme cases, the entire aorta is aneurysmal; this condition is often called *mega-aorta*.

Aortic aneurysms can be either “true” or “false.” True aneurysms can take two forms: fusiform and saccular. Fusiform aneurysms are more common and can be described as symmetrical dilatations of the aorta. Saccular aneurysms are localized outpouchings of the aorta. False aneurysms, also called *pseudoaneurysms*, are leaks in the aortic wall that are contained by the outer layer of the aorta and/or the periaortic tissue; they are caused by disruption of the aortic wall and lead blood to collect in pouches of fibrotic tissue.

Aneurysms of the thoracic aorta consistently increase in size and eventually progress to cause serious complications. These include rupture, which is usually a fatal event. Therefore, aggressive treatment is indicated in all but the poorest surgical candidates. Small, asymptomatic thoracic aortic aneurysms can be followed, especially in high-surgical-risk patients, and can be treated surgically later if symptoms or complications develop, or if progressive enlargement occurs. Meticulous control of hypertension is the primary medical treatment for patients with small, asymptomatic aneurysms.

Key Points

- 1▶ Assessing urgency of repair is essential to developing the appropriate management plan. Although emergent repair carries greater operative risk than does elective repair, any inappropriate delay of repair risks death.
- 2▶ The clinical progression of an aortic aneurysm is continued expansion and eventual rupture. Hence, regular noninvasive imaging studies, as part of a lifelong surveillance plan, are necessary to ensure long-term patient health. Even small asymptomatic aneurysms should be routinely imaged to assess overall growth and yearly rate of expansion.
- 3▶ Endovascular repair devices are approved for the treatment of descending thoracic aortic aneurysms, and some of the newer devices are also approved for the treatment of aortic trauma and penetrating aortic ulcer.
- 4▶ Practice guidelines were recently published that have helped to standardize the decision-making process and select an appropriate surgical intervention, as well as to standardize the use of imaging studies for patients with thoracic aortic disease.
- 5▶ Ascending aortic aneurysms that are symptomatic or >5.5 cm should be repaired. This threshold is lowered for patients with connective tissue disorders.
- 6▶ Surgical repair involves the development of a patient-tailored plan based on careful preoperative medical evaluation. When appropriate, optimizing a patient's health status—to mitigate existing comorbidities—is important before surgical intervention.
- 7▶ The development and use of surgical adjuncts like antegrade selective cerebral perfusion and cerebrospinal fluid drainage have significantly reduced the morbidity rates traditionally associated with complex aortic repair.
- 8▶ Proximal aortic dissection is a life-threatening condition, and immediate operative repair is generally indicated, although definitive aortic repair may be delayed until after severe malperfusion has been treated.

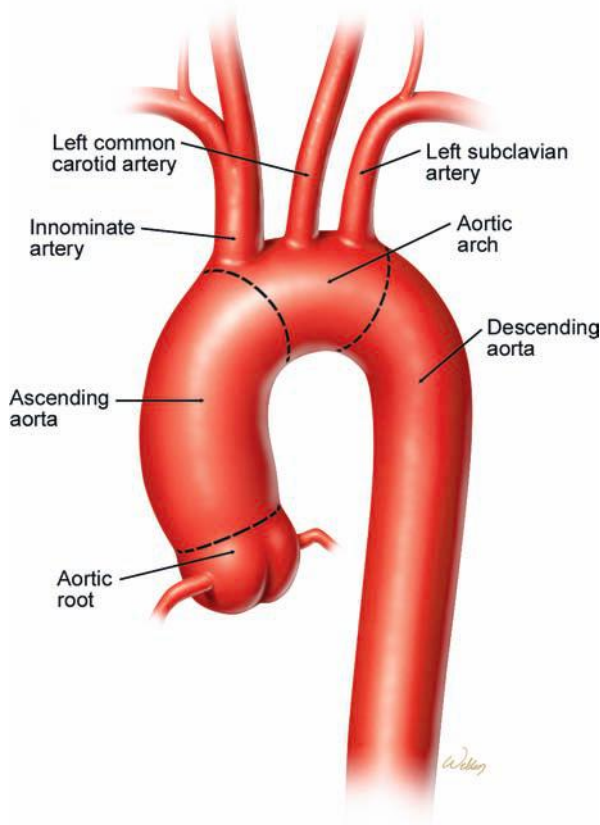


Figure 22-1. Illustration of normal thoracic aortic anatomy. The brachiocephalic vessels arise from the transverse aortic arch and are used as anatomic landmarks to define the aortic regions. The ascending aorta is proximal to the innominate artery, whereas the descending aorta is distal to the left subclavian artery.

Elective resection with graft replacement is indicated in asymptomatic patients with an aortic diameter of at least twice normal in the involved segment (5–6 cm in most thoracic segments). Elective repair is contraindicated by extreme operative risk due to severe coexisting cardiac or pulmonary disease and by other conditions that limit life expectancy, such as malig-

nancy. An emergency operation is performed for any patient in whom a ruptured aneurysm is suspected.

Patients with thoracic aortic aneurysm often have coexisting aneurysms of other aortic segments. A common cause of death after repair of a thoracic aortic aneurysm is rupture of a different aortic aneurysm. Therefore, staged repair of multiple aortic segments often is necessary. As with any major operation, careful preoperative evaluation for coexisting disease and subsequent medical optimization are important for successful surgical treatment.

An alternative to traditional open repair of a descending thoracic aortic aneurysm is endovascular stent grafting. Certain anatomic criteria need to be satisfied for this treatment option to be considered, including the presence of at least a 2-cm landing zone of healthy aortic tissue proximally and distally to the aneurysm to be excluded. Although data on long-term outcomes are still lacking, endovascular repair of a descending thoracic aortic aneurysm has become an accepted practice that produces excellent midterm results.

Causes and Pathogenesis

General Considerations. The normal aorta derives its elasticity and tensile strength from the medial layer, which contains approximately 45 to 55 lamellae of elastin, collagen, smooth muscle cells, and ground substance. Elastin content is highest within the ascending aorta, as would be expected because of its compliant nature, and decreases distally into the descending and abdominal aorta. Maintenance of the aortic matrix involves complex interactions among smooth muscle cells, macrophages, proteases, and protease inhibitors. Any alteration in this delicate balance can lead to aortic disease.

Thoracic aortic aneurysms have a variety of causes (Table 22-1). Although these disparate pathologic processes differ in biochemical and histologic terms, they share the final common pathway of progressive aortic expansion and eventual rupture.

Hemodynamic factors clearly contribute to the process of aortic dilatation. The vicious cycle of increasing diameter and increasing wall tension, as characterized by Laplace's law

Table 22-1

Causes of thoracic aortic aneurysms

Nonspecific medial degeneration
Aortic dissection
Genetic disorders
Marfan syndrome
Loeys-Dietz syndrome
Ehlers-Danlos syndrome
Familial aortic aneurysms
Aneurysms-Osteoarthritis syndrome
Congenital bicuspid aortic valve
Bovine aortic arch
Poststenotic dilatation
Infection
Aortitis
Takayasu arteritis
Giant cell arteritis
Rheumatoid aortitis
Trauma

(tension = pressure \times radius), is well established. Turbulent blood flow is also recognized as a factor. Poststenotic aortic dilatation, for example, occurs in some patients with aortic valve stenosis or coarctation of the descending thoracic aorta. Hemodynamic derangements, however, are only one piece of a complex puzzle.

Atherosclerosis is commonly cited as a cause of thoracic aortic aneurysms. However, although atherosclerotic disease often is found in conjunction with aortic aneurysms, the notion that atherosclerosis is a distinct cause of aneurysm formation has been challenged. In most thoracic aortic aneurysms, atherosclerosis appears to be a coexisting process, rather than the underlying cause.

Research into the pathogenesis of abdominal aortic aneurysms has focused on the molecular mechanisms of aortic wall degeneration and dilatation. For example, imbalances between proteolytic enzymes (e.g., matrix metalloproteinases) and their inhibitors contribute to abdominal aortic aneurysm formation. Building on these advances, current investigations are attempting to determine whether similar inflammatory and proteolytic mechanisms are involved in thoracic aortic disease, in hope of identifying potential molecular targets for pharmacologic therapy.

Nonspecific Medial Degeneration. Nonspecific medial degeneration is the most common cause of thoracic aortic disease. Histologic findings of mild medial degeneration, including fragmentation of elastic fibers and loss of smooth muscle cells, are expected in the aging aorta. However, an advanced, accelerated form of medial degeneration leads to progressive weakening of the aortic wall, aneurysm formation, and eventual dissection, rupture, or both. The underlying causes of medial degenerative disease remain unknown.

Aortic Dissection. An aortic dissection usually begins as a tear in the inner aortic wall, which initiates a progressive separation of the medial layers and creates two channels within the aorta. This event profoundly weakens the outer wall. As the most common catastrophe involving the aorta, dissection represents a major, distinct cause of thoracic aortic aneurysms and is discussed in detail in the second half of this chapter.

Genetic Disorders.

Marfan Syndrome Marfan syndrome is an autosomal dominant genetic disorder characterized by a specific connective tissue

defect that leads to aneurysm formation. The phenotype of patients with Marfan syndrome typically includes a tall stature, high palate, joint hypermobility, eye lens disorders, mitral valve prolapse, and aortic aneurysms. The aortic wall is weakened by fragmentation of elastic fibers and deposition of extensive amounts of mucopolysaccharides (a process previously called *cystic medial degeneration* or *cystic medial necrosis*). Patients with Marfan syndrome have a mutation in the fibrillin gene located on the long arm of chromosome 15. The traditionally held view is that abnormal fibrillin in the extracellular matrix decreases connective tissue strength in the aortic wall and produces abnormal elasticity, which predisposes the aorta to dilatation from wall tension caused by left ventricular ejection impulses.³ More recent evidence, however, shows that the abnormal fibrillin causes degeneration of the aortic wall matrix by increasing the activity of transforming growth factor beta (TGF- β).⁴ Between 75% and 85% of patients with Marfan syndrome have dilatation of the ascending aorta and annuloaortic ectasia (dilatation of the aortic sinuses and annulus).⁵ Such aortic abnormalities are the most common cause of death among patients with Marfan syndrome.⁶ Marfan syndrome also is frequently associated with aortic dissection.

Loeys-Dietz Syndrome Loeys-Dietz syndrome is phenotypically distinct from Marfan syndrome. It is characterized as an aneurysmal syndrome with widespread systemic involvement. Loeys-Dietz syndrome is an aggressive, autosomal dominant condition that is distinguished by the triad of arterial tortuosity and aneurysms, hypertelorism (widely spaced eyes), and bifid uvula or cleft palate. It is caused by heterozygous mutations in the genes encoding TGF- β receptors.^{7,8} Patients with Loeys-Dietz syndrome—including young children—are at increased risk of aortic rupture and aortic dissection; diameter-based thresholds of repair tend to be lower for patients with this syndrome than for patients with other connective tissue disorders.

Ehlers-Danlos Syndrome Ehlers-Danlos syndrome includes a spectrum of inherited connective tissue disorders of collagen synthesis. The subtypes represent differing defective steps of collagen production. Vascular type Ehlers-Danlos syndrome is characterized by an autosomal dominant defect in type III collagen synthesis, which can have life-threatening cardiovascular manifestations. Spontaneous arterial rupture, usually involving the mesenteric vessels, is the most common cause of death in these patients. Thoracic aortic aneurysms and dissections are less commonly associated with Ehlers-Danlos syndrome, but when they do occur, they pose a particularly challenging surgical problem because of the reduced integrity of the aortic tissue.⁹ An Ehlers-Danlos variant of periventricular heterotopia associated with joint and skin hyperextensibility and aortic dilation has been described as being caused by mutations in the gene encoding filamin A (*FLNA*), an actin-binding protein that links the smooth muscle cell contractile unit to the cell surface.¹⁰

Familial Aortic Aneurysms Families without the heritable connective tissue disorders described earlier also can be affected by genetic conditions that cause thoracic aortic aneurysms. In fact, it is estimated that at least 20% of patients with thoracic aortic aneurysms and dissections have a genetic predisposition to them. The involved mutations are characterized by autosomal dominant inheritance with decreased penetrance and variable expression. Thus far, mutations involving the genes for TGF- β receptors (*TGF β 1* and *TGF β 2*), TGF- β 2, β -myosin (*MYH11* and *MYLK*), and α -smooth muscle cell actin (*ACTA2*)

have been identified as causes of familial thoracic aortic aneurysms and dissection.¹¹⁻¹³ *ACTA2* mutations are present in approximately 14% of families with familial thoracic aortic aneurysms and dissections.

Aneurysms-Osteoarthritis Syndrome Aneurysms-osteoarthritis syndrome is a recently identified autosomal dominant disorder. Patients with this syndrome suffer from aortic and arterial aneurysms, arterial tortuosity, aortic dissection, mild craniofacial abnormalities, and early onset osteoarthritis. Aneurysms-osteoarthritis syndrome is caused by mutations in the gene encoding SMAD3, a transcription factor for TGF- β . Affected patients have a high incidence of aortic dissection, which often occurs in a mildly dilated aorta (4–4.5 cm) and causes sudden death.¹⁴

Congenital Bicuspid Aortic Valve Bicuspid aortic valve is the most common congenital malformation of the heart or great vessels, affecting up to 2% of Americans.¹⁵ Compared to patients with a normal, trileaflet aortic valve, patients with bicuspid aortic valve have an increased incidence of ascending aortic aneurysm formation and, often, a faster rate of aortic enlargement.¹⁶ The location of the fused leaflet, or raphe, may be predictive of aortic dilation and other abnormalities.¹⁷ About 50% to 70% of adults with bicuspid aortic valve, but without significant valve dysfunction, have echocardiographically detectable aortic dilatation.^{18,19} This dilatation usually is limited to the ascending aorta and root.²⁰ Dilatation occasionally is found in the arch and only rarely in the descending or abdominal aorta. In addition, aortic dissection occurs 10 times more often in patients with bicuspid valves than in the general population.²¹ Recent findings suggest that aneurysms associated with bicuspid aortic valve have a fundamentally different pathobiologic cause than aneurysms that occur in patients with trileaflet valves.²²

Although the exact mechanism responsible for aneurysm formation in patients with bicuspid aortic valve remains unclear, evidence suggests that these patients have a congenital connective tissue abnormality that predisposes the aorta to medial degeneration.²²⁻²⁸ For example, fibrillin 1 content is significantly lower and matrix metalloproteinase activity is significantly higher in the aortic media in patients with bicuspid aortic valve than in persons with a normal, tricuspid aortic valve.²²⁻²⁴ Further, the process of medial degeneration in patients with bicuspid aortic valve may be exacerbated by the presence of chronic turbulent flow through the deformed valve.

Bovine aortic arch Bovine aortic arch—a common origin of the innominate and left common carotid arteries—has been considered a normal anatomic variant. Recent studies from Yale University have identified a higher prevalence of bovine aortic arch in patients with thoracic aortic disease; an association was found between this anomaly and a generalized increase in aortic aneurysmal disease (without any predisposition to a particular aortic region). However, bovine aortic arch was not associated distinctly with bicuspid aortic valve or aortic dissection, but with a higher mean aortic growth rate: 0.29 cm/year in patients with bovine aortic arch, compared with 0.09 cm/year in controls. Therefore, bovine aortic arch may be better characterized as a precursor of aortic aneurysm than as a simple normal anatomic variant.²⁹ Further studies are needed to delineate the underlying mechanism for this association.

Infection. Primary infection of the aortic wall resulting in aneurysm formation is rare. Although these lesions are termed *mycotic aneurysms*, the responsible pathogens usually are bacteria rather than fungi. Bacterial invasion of the aortic wall may

result from bacterial endocarditis, endothelial trauma caused by an aortic jet lesion, or extension from an infected laminar clot within a preexisting aneurysm. The most common causative organisms are *Staphylococcus aureus*, *Staphylococcus epidermidis*, *Salmonella*, and *Streptococcus*.^{30,31} Unlike most other causes of thoracic aortic aneurysms, which generally produce fusiform aneurysms, infection often produces saccular aneurysms located in areas of aortic tissue destroyed by the infectious process.

Although syphilis was once the most common cause of ascending aortic aneurysms, the advent of effective antibiotic therapy has made syphilitic aneurysms a rarity in developed nations. In other parts of the world, however, syphilitic aneurysms remain a major cause of morbidity and mortality. The spirochete *Treponema pallidum* causes an obliterative endarteritis of the vasa vasorum that results in medial ischemia and loss of the elastic and muscular elements of the aortic wall. The ascending aorta and arch are the most commonly involved areas. The emergence of HIV infection in the 1980s was associated with a substantial increase in the incidence of syphilis in both HIV-positive and HIV-negative patients. Because syphilitic aortitis often presents 10 to 30 years after the primary infection, the incidence of associated aneurysms may increase in the near future.

Aortitis. In patients with preexisting degenerative thoracic aortic aneurysms, localized transmural inflammation and subsequent fibrosis can develop. The dense aortic infiltrate responsible for the fibrosis consists of lymphocytes, plasma cells, and giant cells. The cause of the intense inflammatory reaction is unknown. Although the severe inflammation is a superimposed problem rather than a primary cause, its onset within an aneurysm can further weaken the aortic wall and precipitate expansion.

Systemic autoimmune disorders also cause thoracic aortitis. Aortic Takayasu arteritis generally produces obstructive lesions related to severe intimal thickening, but associated medial necrosis can lead to aneurysm formation. In patients with giant cell arteritis (temporal arteritis), granulomatous inflammation may develop that involves the entire thickness of the aortic wall, causing intimal thickening and medial destruction. Rheumatoid aortitis is an uncommon systemic disease that is associated with rheumatoid arthritis and ankylosing spondylitis. The resulting medial inflammation and fibrosis can affect the aortic root, causing annular dilatation, aortic valve regurgitation, and ascending aortic aneurysm formation.

Pseudoaneurysms. Pseudoaneurysms of the thoracic aorta usually represent chronic leaks that are contained by surrounding tissue and fibrosis. By definition, the wall of a pseudoaneurysm is not formed by intact aortic tissue; rather, the wall develops from organized thrombus and associated fibrosis. Pseudoaneurysms can arise from primary defects in the aortic wall (e.g., after trauma or contained aneurysm rupture) or from anastomotic or cannulation site leaks that occur after cardiovascular surgery. Anastomotic pseudoaneurysms can be caused by technical problems or by deterioration of the native aortic tissue, graft material, or suture. Commonly, they occur in patients with Marfan syndrome.³² Tissue deterioration usually is related to either progressive degenerative disease or infection. Improvements in sutures, graft materials, and surgical techniques have decreased the incidence of thoracic aortic pseudoaneurysms. Should thoracic aortic pseudoaneurysms occur, they typically require expeditious surgical or other intervention because they are associated with a high incidence of morbidity and rupture.

Clinical History

Treatment decisions in cases of thoracic aortic aneurysm are guided by our current understanding of the clinical history of these aneurysms, which classically is characterized as progressive aortic dilatation and eventual dissection, rupture, or both.

1▶ An analysis by Elefteriades of data from 1600 patients with thoracic aortic disease has helped quantify these well-recognized risks.³³ Average expansion rates were 0.07 cm/y in ascending aortic aneurysms and 0.19 cm/y in descending thoracic aortic aneurysms. As expected, aortic diameter was a strong predictor of rupture, dissection, and mortality. For thoracic aortic aneurysms >6 cm in diameter, annual rates of catastrophic complications were 3.6% for rupture, 3.7% for dissection, and 10.8% for death. Critical diameters, at which the incidence of expected complications significantly increased, were 6.0 cm for aneurysms of the ascending aorta and 7.0 cm for aneurysms of the descending thoracic aorta; the corresponding risks of rupture after reaching these diameters were 31% and 43%, respectively.³⁴

Certain types of aneurysms have an increased propensity for expansion and rupture. For example, aneurysms in patients with Marfan or Loays-Dietz syndrome dilate at an accelerated rate and rupture or dissect at smaller diameters than non-connective tissue disorder-related aneurysms. Before the era of surgical treatment for aortic aneurysms, this aggressive form of aortic disease resulted in an average life expectancy of 32 years for Marfan patients; aortic root complications caused the majority of deaths.³⁵ Sacular aneurysms, which commonly are associated with aortic infection and typically affect only a discrete small section of the aorta, tend to grow more rapidly than fusiform aneurysms, which are associated with more widespread degenerative changes and generally affect a larger section of the aorta.

One common clinical scenario deserves special attention. A moderately dilated ascending aorta (i.e., 4–5 cm) often is encountered during aortic valve replacement or coronary artery bypass operations. The clinical history of these ectatic ascending aortas has been defined by several studies. Michel and colleagues³⁶ studied patients whose ascending aortic diameters were >4 cm at the time of aortic valve replacement; 25% of these patients required reoperation for ascending aortic replacement. Prenger and colleagues³⁷ reported that aortic dissection occurred in 27% of patients who had aortic diameters of >5 cm at the time of aortic valve replacement. Recently, attention has been directed toward whether or not a mildly dilated aortic root should be replaced in patients with bicuspid aortic valve who are undergoing isolated valve replacement, and at what threshold to intervene. Although this is a controversial issue, many surgeons believe that the tendency toward late aortic dilatation in these patients warrants aggressive treatment.^{38,39} Current practice guidelines indicate that such early replacement should be considered in these patients when the ascending aorta is 4.0 to 4.5 cm.⁴⁰

Clinical Manifestations

In many patients with thoracic aortic aneurysms, the aneurysm is discovered incidentally when imaging studies are performed for unrelated reasons. Therefore, patients often are asymptomatic at the time of diagnosis. However, thoracic aortic aneurysms that initially go undetected eventually create symptoms and signs that correspond with the segment of aorta that is involved. These aneurysms have a wide variety of manifestations, including compression or erosion of adjacent structures, aortic valve regurgitation, distal embolism, and rupture.

Local Compression and Erosion. Initially, aneurysmal expansion and impingement on adjacent structures causes mild, chronic pain. The most common symptom in patients with ascending aortic aneurysms is anterior chest discomfort; the pain is frequently precordial in location but may radiate to the neck and jaw, mimicking angina. Aneurysms of the ascending aorta and transverse aortic arch can cause symptoms related to compression of the superior vena cava, the pulmonary artery, the airway, or the sternum. Rarely, these aneurysms erode into the superior vena cava or right atrium, causing acute high-output failure. Expansion of the distal aortic arch can stretch the recurrent laryngeal nerve, which results in left vocal cord paralysis and hoarseness. Descending thoracic and thoracoabdominal aneurysms frequently cause back pain localized between the scapulae. When the aneurysm is largest in the region of the aortic hiatus, it may cause middle back and epigastric pain. Thoracic or lumbar vertebral body erosion typically causes severe, chronic back pain; extreme cases can present with spinal instability and neurologic deficits from spinal cord compression. Although mycotic aneurysms have a peculiar propensity to destroy vertebral bodies, spinal erosion also occurs with degenerative aneurysms. Descending thoracic aortic aneurysms may cause various degrees of airway obstruction, manifesting as cough, wheezing, stridor, or pneumonitis. Pulmonary or airway erosion presents as hemoptysis. Compression and erosion of the esophagus cause dysphagia and hematemesis, respectively. Thoracoabdominal aortic aneurysms can cause duodenal obstruction or, if they erode through the bowel wall, gastrointestinal bleeding. Jaundice due to compression of the liver or porta hepatis is uncommon. Erosion into the inferior vena cava or iliac vein presents with an abdominal bruit, widened pulse pressure, edema, and heart failure.

Aortic Valve Regurgitation. Ascending aortic aneurysms can cause displacement of the aortic valve commissures and annular dilatation. The resulting deformation of the aortic valve leads to progressively worsening aortic valve regurgitation. In response to the volume overload, the heart remodels and becomes increasingly dilated. Patients with this condition may present with progressive heart failure, a widened pulse pressure, and a diastolic murmur.

Distal Embolization. Thoracic aortic aneurysms—particularly those involving the descending and thoracoabdominal aorta—are commonly lined with friable, atheromatous plaque and mural thrombus. This debris may embolize distally, causing occlusion and thrombosis of the visceral, renal, or lower-extremity branches.

Rupture. Patients with ruptured thoracic aortic aneurysms often experience sudden, severe pain in the anterior chest (ascending aorta), upper back or left chest (descending thoracic aorta), or left flank or abdomen (thoracoabdominal aorta). When ascending aortic aneurysms rupture, they usually bleed into the pericardial space, producing acute cardiac tamponade and death. Descending thoracic aortic aneurysms rupture into the pleural cavity, producing a combination of severe hemorrhagic shock and respiratory compromise. External rupture is extremely rare; sacular syphilitic aneurysms have been observed to rupture externally after eroding through the sternum.

Diagnostic Evaluation

Diagnosis and characterization of thoracic aneurysms require imaging studies, which also provide critical information that

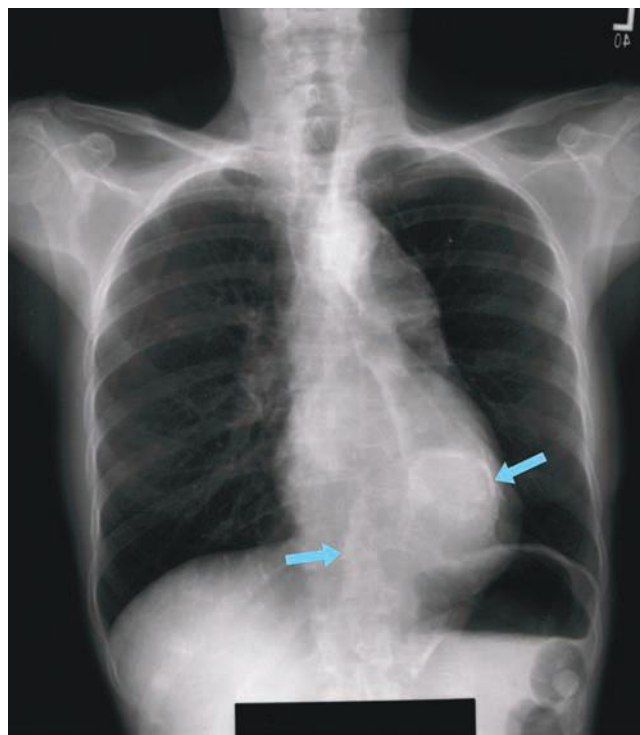
guides the selection of treatment options. Although the best choice of imaging technique for the thoracic and thoracoabdominal aorta is somewhat institution-specific, varying with the availability of imaging equipment and expertise, efforts have been made to standardize key elements of image acquisition and reporting. Recent practice guidelines⁴⁰ recommend that aortic imaging reports plainly state the location of aortic abnormalities (including calcification and the extent to which abnormalities extend into branch vessels), the maximum external aortic diameters (rather than internal, lumen-based diameters), internal filling defects, and any evidence of rupture. Whenever possible, all results should be compared to those of prior imaging studies.

Plain Radiography. Plain radiographs of the chest, abdomen, or spine often provide enough information to support the initial diagnosis of thoracic aortic aneurysm. Ascending aortic aneurysms produce a convex shadow to the right of the cardiac silhouette. The anterior projection of an ascending aneurysm results in the loss of the retrosternal space in the lateral view. An aneurysm may be indistinguishable from elongation and tortuosity.⁴¹ Above all, chest radiographs (CXR) may appear normal in patients with thoracic aortic disease and, thus, cannot exclude the diagnosis of aortic aneurysm. Aortic root aneurysms, for example, often are hidden within the cardiac silhouette. Plain CXRs may reveal convexity in the right superior mediastinum, loss of the retrosternal space, or widening of the descending thoracic aortic shadow, which may be highlighted by a rim of calcification outlining the dilated aneurysmal aortic wall. Aortic calcification also may be seen in the upper abdomen on a standard radiograph made in the anteroposterior or lateral projection (Fig. 22-2). Once a thoracic aortic aneurysm is detected on plain radiographs, additional studies are required to define the extent of aortic involvement.

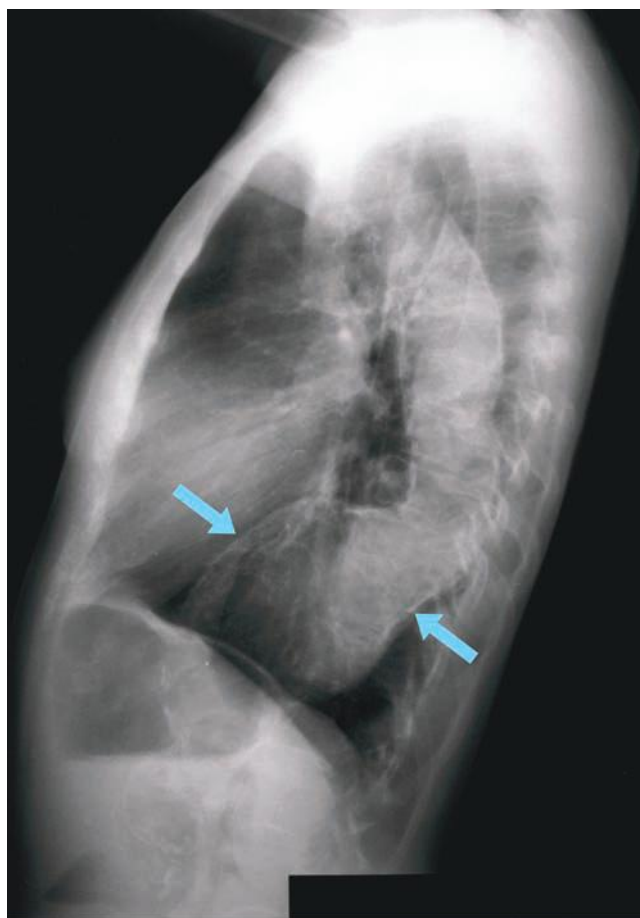
Echocardiography and Abdominal Ultrasonography.

Ascending aortic aneurysms are commonly discovered during echocardiography in patients presenting with symptoms or signs of aortic valve regurgitation. Both transthoracic and transesophageal echocardiography provide excellent visualization of the ascending aorta, including the aortic root.⁴² Transesophageal echocardiography also allows visualization of the descending thoracic aorta but is not ideal for evaluating the transverse aortic arch (which is obscured by air in the tracheobronchial tree) or the upper abdominal aorta. Effective echocardiography requires considerable technical skill, both in obtaining adequate images and in interpreting them. This imaging modality has the added benefit of assessing cardiac function and revealing any other abnormalities that may be present. During ultrasound evaluation of a suspected infrarenal abdominal aortic aneurysm, if a definitive neck cannot be identified at the level of the renal arteries, the possibility of thoracoabdominal aortic involvement should be suspected and investigated by using other imaging modalities. Caution should be exercised while interpreting aneurysm dimensions from ultrasound imaging because intraluminal measurements are often reported, whereas external measurements are usually used in other imaging modalities.

Computed Tomography. Computed tomographic (CT) scanning is widely available, provides visualization of the entire thoracic and abdominal aorta, and permits multiplanar and 3-dimensional aortic reconstructions. Consequently, CT is the most common—and arguably the most useful—imaging modality for evaluating thoracic aortic aneurysms.⁴³ In addition to establishing the diagnosis, CT provides information about



A



B

Figure 22-2. Chest radiographs showing a calcified rim (*arrows*) in the aortic wall of a thoracoabdominal aortic aneurysm. **A.** Anteroposterior view. **B.** Lateral view.

an aneurysm's location, extent, anatomic anomalies, and relationship to major branch vessels. CT is particularly useful in determining the absolute diameter of the aorta, especially in the presence of a laminated clot, and also detects aortic calcification. Contrast-enhanced CT provides information about the aortic lumen and can detect mural thrombus, aortic dissection, inflammatory periaortic fibrosis, and mediastinal or retroperitoneal hematoma due to contained aortic rupture. To increase consistency and ensure uniform reporting, current practice

2▶ guidelines suggest that measurements be taken perpendicular to blood flow and at standard anatomic locations⁴⁰ (Fig. 22-3); this should reduce the likelihood of erroneous measurements, especially during serial imaging surveillance.

The major disadvantage of contrast-enhanced CT scanning is the possibility of contrast-induced acute renal failure in patients who are at risk (e.g., patients with preexisting renal

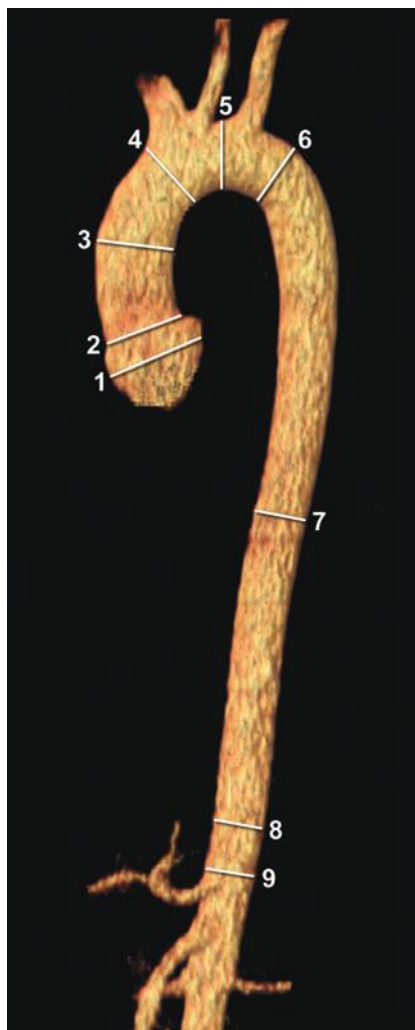


Figure 22-3. Current practice guidelines⁴⁰ seek to standardize the reporting of aortic diameters by indicating key locations of measurement. These include (1) the sinuses of Valsalva, (2) the sinotubular junction, (3) the mid-ascending aorta, (4) the proximal aortic arch at the origins of the innominate artery, (5) the mid-aortic arch, which is between the left common carotid and left subclavian arteries, (6) the proximal descending thoracic aorta, which begins at the isthmus (approximately 2 cm distal to the origins of the left subclavian artery), (7) the mid-descending thoracic artery, (8) the aorta at the diaphragm, and (9) the abdominal aorta at the origins of the celiac axis. (Used with permission of Baylor College of Medicine.)

disease or diabetes).⁴⁴ If possible, surgery is performed ≥ 1 day after contrast administration to allow time to observe renal function and to permit diuresis of the contrast agent. If renal insufficiency occurs or is worsened, elective surgery is postponed until renal function returns to normal or stabilizes.

Magnetic Resonance Angiography. Magnetic resonance angiography (MRA) is becoming widely available and can facilitate visualization of the entire aorta. This modality produces aortic images comparable to those produced by contrast-enhanced CT but does not necessitate exposure to ionizing radiation. In addition, MRA offers excellent visualization of branch vessel details, and it is useful in detecting branch vessel stenosis.⁴⁵ However, MRA is limited by high expense and a susceptibility to artifacts created by ferromagnetic materials, and gadolinium—the contrast agent for MRA—may be linked to nephrogenic systemic fibrosis and acute renal failure in patients with advanced renal insufficiency.⁴⁶ Furthermore, the MRA environment is not appropriate for many critically ill patients, and unlike CT imaging, MRA imaging is suboptimal in patients with extensive aortic calcification.

Invasive Aortography and Cardiac Catheterization. Although catheter-based contrast aortography was previously considered the gold standard for evaluating thoracic aortic disease, cross-sectional imaging (i.e., CT and MRA) has largely replaced this modality. Technologic improvements have enabled CT and MRA to provide excellent aortic imaging while causing less morbidity than catheter-based studies do, so CT and MRA are now the primary modes for evaluating thoracic aortic disease. Today, the use of invasive aortography in patients with thoracic aortic disease is generally limited to those undergoing endovascular therapies or when other types of studies are contraindicated or have not provided satisfactory results.

Unlike standard aortography, cardiac catheterization continues to play an important role in diagnosis and preoperative planning, especially in patients with ascending aortic involvement. Proximal aortography can reveal not only the status of the coronary arteries and left ventricular function but also the degree of aortic valve regurgitation, the extent of aortic root involvement, coronary ostial displacement, and the relationship of the aneurysm to the arch vessels.

The value of the information one can obtain from catheter-based diagnostic studies should be weighed against the established limitations and potential complications of such studies. A key limitation of aortography is that it images only the lumen and may therefore underrepresent the size of large aneurysms that contain laminated thrombus. Manipulation of intraluminal catheters can result in embolization of laminated thrombus or atheromatous debris. Proximal aortography carries a 0.6% to 1.2% risk of stroke. Other risks include allergic reaction to contrast agent, iatrogenic aortic dissection, and bleeding at the arterial access site. In addition, the volumes of contrast agent required to adequately fill large aneurysms can cause significant renal toxicity. To minimize the risk of contrast nephropathy, patients receive periprocedural intravenous (IV) fluids for hydration, mannitol for diuresis, and acetylcysteine.^{47,48} As with contrast-enhanced CT, surgery is performed ≥ 1 day after angiography whenever possible to ensure that renal function has stabilized or returned to baseline.

Treatment

Selecting the Appropriate Treatment. Once a thoracic aortic aneurysm is detected, management begins with patient

education, particularly if the patient is asymptomatic, because aortic disease may progress rapidly and unexpectedly in some patients. A detailed medical history is collected, a physical examination is performed, and a systematic review of medical records is carried out to clearly assess the presence or absence of pertinent symptoms and signs, despite any initial denial of symptoms by the patient. Signs of genetic diseases such as Marfan syndrome or Loeys-Dietz syndrome are thoroughly reviewed. If clinical criteria are met for such a genetic condition, confirmatory laboratory tests are conducted. Patients with such genetic diseases are best treated in a dedicated aortic clinic where they can be appropriately followed up. Surveillance imaging and aggressive blood pressure control are the mainstays of initial management for asymptomatic patients. When patients become symptomatic or their aneurysms grow to meet certain size criteria, the patients become surgical candidates.

Although long-term data are still lacking, endovascular therapy has become an accepted treatment for thoracic aortic aneurysms.⁴⁹ Its role in treating proximal aortic disease and thoracoabdominal aortic aneurysms remains experimental. Nonetheless, endoluminal stenting is approved by the U.S. Food and Drug Administration for the treatment of isolated descending thoracic aortic aneurysms, and some newer devices are approved for the treatment of blunt aortic injury and penetrating aortic ulcer. In practice, however, the off-label application of aortic stent grafts is widespread and accounts for well over half their use.⁵⁰ Endovascular approaches may be helpful in emergent aneurysm repair, such as for patients with aortic rupture.⁵¹ Recently, endovascular therapy has evolved to include hybrid repairs, which combine open “debranching” techniques (to reroute branching vessels) with endovascular aortic repair. Despite these advances, for the repair of aneurysms with proximal aortic involvement and of thoracoabdominal aortic aneurysms, open procedures remain the gold standard and preferred approach.

Determination of the Extent and Severity of Disease. Cross-sectional imaging with reconstruction is critical when one is evaluating a thoracic aneurysm, determining treatment strategy, and planning necessary procedures. Note that, commonly, patients with a thoracic aortic aneurysm also have a remote aneurysm.² In such cases, the more threatening lesion usually is addressed first. In many patients, staged operative procedures are necessary for complete repair of extensive aneurysms involving the ascending aorta, transverse arch, and descending thoracic or thoracoabdominal aorta.⁵² When the descending segment is not disproportionately large (compared with the proximal aorta) and is not causing symptoms, the proximal aortic repair is carried out first. An important benefit of this approach is that it allows treatment of valvular and coronary artery occlusive disease at the first operation.

Proximal aneurysms (proximal to the left subclavian artery) usually are addressed via a sternotomy approach. Aneurysms involving the descending thoracic aorta are evaluated in terms of criteria (described later) for potential endovascular repair; those unsuitable for an endovascular approach are repaired with open techniques through a left thoracotomy. A CT scan can reveal detailed information about aortic calcification and luminal thrombus. These details are important in preventing embolization during surgical manipulation.

Indications for Operation Thoracic aortic aneurysms are repaired to prevent fatal rupture. Therefore, on the basis of the

natural history studies and other data, practice guidelines for thoracic aortic disease⁴⁰ recommend elective operation in asymptomatic patients when the diameter of an ascending aortic aneurysm is >5.5 cm, when the diameter of a descending thoracic aortic aneurysm is >6.0 cm, or when the rate of dilatation is >0.5 cm/y. In patients with connective tissue disorders such as Marfan and Loeys-Dietz syndromes, the threshold for operation is based on a smaller aortic diameter (4.0–5.0 cm for the ascending aorta and 5.5 to 6.0 cm for the descending thoracic aorta). For women with connective tissue disorders who are considering pregnancy, prophylactic aortic root replacement is considered because the risk of aortic dissection or rupture increases at an aortic diameter of 4.0 cm or greater. For low-risk patients with chronic aortic dissection, descending thoracic repair is recommended at an aortic diameter of 5.5 cm or greater.

For patients undergoing aortic valve replacement or repair, smaller ascending aortic aneurysms (>4.5 cm) are considered for concomitant repair.

The acuity of presentation is a major factor in decisions about the timing of surgical intervention. Many patients are asymptomatic at the time of presentation, so there is time for thorough preoperative evaluation and improvement of their current health status, such as through smoking cessation and other optimization programs. In contrast, patients who present with symptoms may need urgent operation. Symptomatic patients are at increased risk of rupture and warrant expeditious evaluation. The onset of new pain in patients with known aneurysms is especially concerning, because it may herald significant expansion, leakage, or impending rupture. Emergent intervention is reserved for patients who present with aneurysm rupture or superimposed acute dissection.⁵³

Open Repair vs. Endovascular Repair As noted earlier, endovascular repair of thoracic aortic aneurysms has become an accepted treatment option in selected patients, particularly patients with isolated degenerative descending thoracic aortic aneurysms; in fact, practice guidelines recommend that endovascular repair be strongly considered for patients with descending thoracic aneurysm at an aortic diameter of 5.5 cm (which is slightly below the 6.0-cm threshold for open repair).⁴⁰ For endovascular repairs to produce optimal outcomes, several anatomic criteria must be met. For one, the proximal and distal neck diameters should fall within a range that will allow proper sealing. Also, the proximal and distal landing zones should ideally be at least 20 mm long so that an appropriate seal can be made. Note that the limiting structures proximally and distally are the brachiocephalic vessels and celiac axis, respectively. Another anatomic limitation for this therapy relates to vascular access: The femoral and iliac arteries have to be wide enough to accommodate the large sheaths necessary to deploy the stent grafts, although newer devices use a smaller sheath (or are “sheathless” self-deployed stent grafts) to accommodate smaller arteries. Tortuosity of the iliac vessels and abdominal aorta can make these procedures technically challenging. Occasionally, a “side graft” anastomosed to the iliac artery through a retroperitoneal incision is used because of poor distal access. When any of these anatomic criteria are not met, an open approach is preferable to an endovascular approach.

Of note, attempts have been made to extend the use of endovascular therapy to aortic arch aneurysms and thoracoabdominal aortic aneurysms. Although reports of purely endovascular repair of the aortic arch remain limited, Greenberg and colleagues⁵⁴ have reported their experience with a large series of

purely endovascular thoracoabdominal aortic repairs. Additionally, there have been numerous reports of small series of off-label, experimental hybrid procedures that involve debranching the aortic arch or the visceral vessels of the abdominal aorta, followed by endovascular exclusion of the aneurysm. The majority of hybrid approaches involve repairing the aortic arch. In its simplest form, hybrid arch repair involves an open bypass from the left subclavian to the left common carotid artery, which is followed by deliberate coverage of the origins of the left subclavian artery by the stent graft. In its most complex form, hybrid arch repair involves rerouting all of the brachiocephalic vessels, followed by proximal placement of the stent graft in the ascending aorta and extending repair distally into the aortic arch and descending thoracic aorta.

The patients who theoretically may benefit more from an endovascular approach than from traditional open techniques are those who are of advanced age or have significant comorbidities. For example, the open repair of a descending thoracic aortic aneurysm can result in significant pulmonary morbidity. Therefore, patients with borderline pulmonary reserve may better tolerate an endovascular procedure than standard open repair. In contrast, patients with significant intraluminal atheroma may be better served by an open approach because of the risk of embolization and stroke posed by catheter manipulation. Similarly, patients with connective tissue disorders generally are not considered candidates for elective endovascular repair. Endovascular repair in patients with connective tissue disorders has produced poor results, which are mainly due to progressive dilatation, stent graft migration, and endoleak.⁵⁵

Preoperative Assessment and Preparation. Given the impact of comorbid conditions on perioperative complications, a careful preoperative assessment of physiologic reserve is critical in assessing operative risk. Therefore, most patients undergo a thorough evaluation—with emphasis on cardiac, pulmonary, and renal function—before undergoing elective surgery.^{56,57}

Cardiac Evaluation Coronary artery disease is common in patients with thoracic aortic aneurysm and is responsible for a substantial proportion of early and late postoperative deaths in such patients. Similarly, valvular disease and myocardial dysfunction have important implications when one is planning anesthetic management and surgical approaches for aortic repair. Transthoracic echocardiography is a satisfactory noninvasive method for evaluating both valvular and biventricular function. Dipyridamole-thallium myocardial scanning identifies regions of myocardium that have reversible ischemia, and this test is more practical than exercise testing in older patients with concomitant lower-extremity peripheral vascular disease. Cardiac catheterization and coronary arteriography are performed in patients who have evidence of coronary disease—as indicated by either the patient's history or the results of noninvasive studies—or who have a left ventricular ejection fraction of $\leq 30\%$. If significant valvular or coronary artery disease is identified before a proximal aortic operation, the disease can be addressed directly during the procedure. Patients who have asymptomatic distal aortic aneurysms and severe coronary occlusive disease undergo percutaneous transluminal angioplasty or surgical revascularization before the aneurysmal aortic segment is replaced.

Pulmonary Evaluation Pulmonary function screening with arterial blood gas measurement and spirometry is routinely performed before thoracic aortic operations. Patients with a forced

expiratory volume in 1 second of >1.0 L and a partial pressure of carbon dioxide of <45 mmHg are considered surgical candidates. In suitable patients, borderline pulmonary function can be improved by implementing a regimen that includes smoking cessation, weight loss, exercise, and treatment of bronchitis for a period of 1 to 3 months before surgery. Although surgery is not withheld from patients with symptomatic aortic aneurysms and poor pulmonary function, adjustments in operative technique should be made to maximize these patients' chances of recovery. In such patients, preserving the left recurrent laryngeal nerve, the phrenic nerves, and diaphragmatic function is particularly important.

Renal Evaluation Renal function is assessed preoperatively by measuring serum electrolyte, blood urea nitrogen, and creatinine levels. Information about kidney size and perfusion can be obtained from the imaging studies used to evaluate the aorta.

Obtaining accurate information about baseline renal function has important therapeutic and prognostic implications. For example, perfusion strategies and perioperative medications are adjusted according to renal function. Patients with severely impaired renal function frequently require at least temporary hemodialysis after surgery. These patients also have a mortality rate that is significantly higher than normal. Patients with thoracoabdominal aortic aneurysms and poor renal function secondary to severe proximal renal occlusive disease undergo renal artery endarterectomy, stenting, or bypass grafting during the aortic repair.

Operative Repair.

Proximal Thoracic Aortic Aneurysms

Open Repair Traditional open operations to repair proximal aortic aneurysms—which involve the ascending aorta, transverse aortic arch, or both—are performed through a midsternal incision and require cardiopulmonary bypass. The best choice of aortic replacement technique depends on the extent of the aneurysm and the condition of the aortic valve. The spectrum of operations (Fig. 22-4) ranges from simple graft replacement of the tubular portion of the ascending aorta (Fig. 22-4A) to graft replacement of the entire proximal aorta, including the aortic root, and reattachment of the coronary arteries and brachiocephalic branches. The options for treating aortic valve disease, repairing aortic aneurysms, and maintaining perfusion during repair procedures each deserve detailed consideration (Table 22-2).

Aortic Valve Disease and Root Aneurysms Many patients undergoing proximal aortic operations have aortic valve disease that requires concomitant surgical correction. When such disease is present and the sinus segment is normal, separate repair or replacement of the aortic valve and graft replacement of the tubular segment of the ascending aorta are carried out. In such cases, mild to moderate valve regurgitation with annular dilatation can be addressed by plicating the annulus with mattress sutures placed below each commissure, thereby preserving the native valve. In patients with more severe valvular regurgitation or with valvular stenosis, the valve is replaced with a stented biologic or mechanical prosthesis. Mechanical prostheses necessitate following a lifelong anticoagulation regimen. Separate replacement of the aortic valve and ascending aorta is not performed in patients with Marfan syndrome, because progressive dilatation of the remaining sinus segment eventually leads to complications that necessitate reoperation. Therefore, patients with Marfan syndrome or those with annuloaortic ectasia require some form of aortic root replacement.⁵⁸

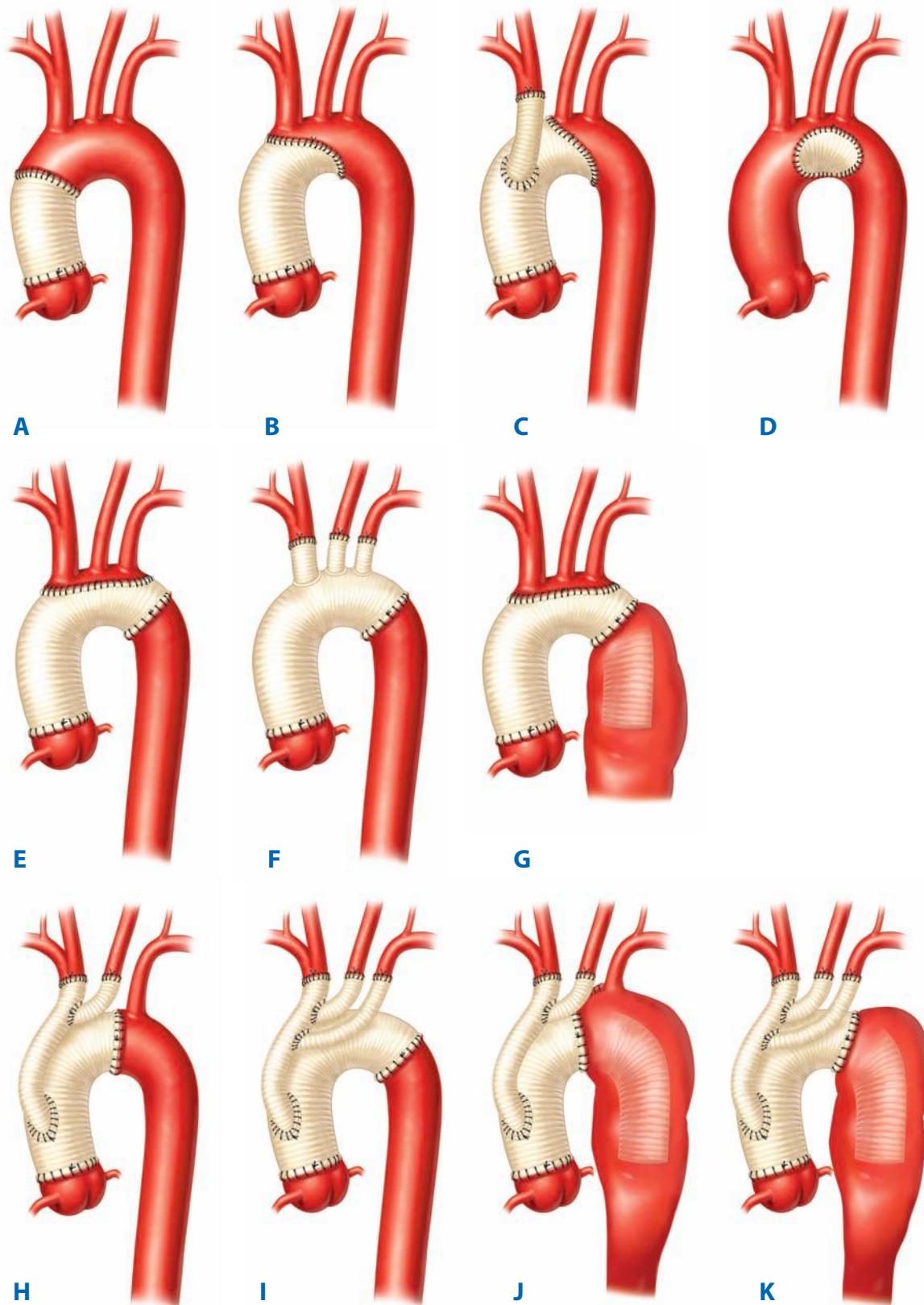


Figure 22-4. Illustrations of proximal aortic repairs in which the native aortic root is left intact. **A.** Graft replacement of the tubular portion of the ascending aorta with the aortic arch left intact. **B.** Hemiarch beveled graft replacement, in which the ascending aorta and a portion of the lesser curvature of the aortic arch are replaced. **C.** A modified hemiarch with additional graft replacement of the innominate artery. **D.** Patch repair of the aortic arch. **E.** Traditional total arch replacement using an island approach to reattach the brachiocephalic vessels. **F.** The branched graft approach, which replaces the brachiocephalic vessels by following their original anatomic location. **G.** The elephant trunk approach with a concomitant island brachiocephalic artery reattachment. Contemporary Y-graft arch repairs include **H.** the single Y-graft approach, **I.** the double Y-graft approach, **J.** the elephant trunk approach with a single Y-graft, and **K.** the elephant trunk approach with a double Y-graft. (Used with permission of Baylor College of Medicine.)

Table 22-2

Options for open surgical repair of proximal aortic aneurysms

Options for treating aortic valve disease

- Aortic valve annuloplasty (annular plication)
- Aortic valve replacement with mechanical or biologic prosthesis
- Aortic root replacement
 - Composite valve graft
 - Aortic homograft
 - Stentless porcine root
 - Pulmonary autograft (Ross procedure)
 - Valve-sparing techniques

Options for graft repair of the aortic aneurysm

- Patch aortoplasty
- Ascending replacement only
- Beveled hemiarch replacement
- Total arch replacement with reattachment of brachiocephalic branches
- Total arch replacement with bypass grafts to the brachiocephalic branches (Y-graft approaches)
- Elephant trunk technique with island reattachment
- Elephant trunk technique with Y-graft approach

Perfusion options

- Standard cardiopulmonary bypass
- Profound hypothermic circulatory arrest without adjuncts
- Hypothermic circulatory arrest with adjuncts
 - Retrograde cerebral perfusion
 - Antegrade cerebral perfusion
 - Balloon perfusion catheters
 - Right axillary artery cannulation
 - Innominate artery cannulation
 - Combined antegrade and retrograde cerebral perfusion

In many cases, the aortic root is replaced with a mechanical or biologic graft that has both a valve and an aortic conduit. Currently, three graft options are commercially available: composite valve grafts, which consist of a bileaflet mechanical valve attached to a polyester tube graft; aortic root homografts, which are harvested from cadavers and cryopreserved; and stentless porcine aortic root grafts.^{59,60} Another option for surgeons is to construct a bioprosthetic composite valve graft during the operation by suturing a stented tissue valve to a polyester graft tube.

Although select patients may be offered the Ross procedure, in which the patient's pulmonary artery root is excised and placed in the aortic position and then the right ventricular outflow tract is reconstructed by using a cryopreserved pulmonary homograft, this option is rarely used. This is largely because it is a technically demanding procedure, and there are concerns about the potential for autograft dilatation in patients with connective tissue disorders.⁶¹

An additional option is valve-sparing aortic root replacement, which has evolved substantially during the past decade.⁶² The valve-sparing technique that is currently favored is called *aortic root reimplantation* and involves excising the aortic sinuses, attaching a prosthetic graft to the patient's annulus (Fig. 22-5), and resuspending the native aortic valve inside

the graft. The superior hemodynamics of the native valve and the avoidance of anticoagulation are major advantages of the valve-sparing approach. Long-term results in carefully selected patients have been excellent.⁶³ Although the durability of this procedure in patients with either Marfan syndrome or bicuspid aortic valve has been questioned, reports suggest that long-term durability is possible for patients with Marfan syndrome who undergo the procedure at experienced centers.^{64,65} Further, acceptable midterm outcomes have been reported for patients with bicuspid aortic valve.⁶⁶ Patients who have structural leaflet deterioration or excessive annular dilatation are typically deemed unsuitable for valve-sparing repair.

Regardless of the type of conduit used, aortic root replacement requires reattaching the coronary arteries to openings in the graft. In the original procedure described by Bentall and De Bono,⁶⁷ this was accomplished by suturing the intact aortic wall surrounding each coronary artery to the openings in the graft. The aortic wall was then wrapped around the graft to establish hemostasis. However, this technique frequently produced leaks at the coronary reattachment sites that eventually led to pseudoaneurysm formation. The Cabrol modification, in which a separate, small tube graft is sutured to the coronary ostia and the main aortic graft, achieves tension-free coronary anastomoses and reduces the risk of pseudoaneurysm formation.⁶⁸ Kouchoukos's button modification of the Bentall procedure is currently the most widely used technique.⁶⁹ The aneurysmal aorta is excised, and buttons of aortic wall are left surrounding both coronary arteries, which are then mobilized and sutured to the aortic graft (Fig. 22-6). The coronary suture lines may be reinforced with polytetrafluoroethylene felt or pericardium to enhance hemostasis. When the coronary arteries cannot be mobilized adequately because of extremely large aneurysms or scarring from previous surgery, the Cabrol technique or a related modification can be used. Another option, originally described by Zubieta and Kay,⁷⁰ is the construction of bypass grafts by using interposition saphenous vein or synthetic grafts.

Aortic Arch Aneurysms Several options are also available for handling aneurysms that extend into the transverse aortic arch (Fig. 22-4). The surgical approach depends on the extent of involvement and the need for cardiac and cerebral protection. Sacular aneurysms that arise from the lesser curvature of the distal transverse arch and that encompass <50% of the aortic circumference can be treated by patch graft aortoplasty. For fusiform aneurysms, when the distal portion of the arch is a reasonable size, a single, beveled replacement of the lower curvature (hemiarch) is performed. More extensive arch aneurysms require total replacement involving a distal anastomosis to the proximal descending thoracic aorta and separate reattachment of the brachiocephalic branches. The brachiocephalic vessels are reattached to one or more openings made in the graft, or if these vessels are aneurysmal, they are replaced with separate, smaller grafts. Recently, Y-graft approaches to aortic arch repair have been introduced⁷¹ that essentially debranch the brachiocephalic vessels and move them forward. This permits the distal anastomosis to be brought forward and aids in hemostasis. When the aneurysm involves the entire arch and extends into the descending thoracic aorta, it is approached by using Borst's elephant trunk technique of staged total arch replacement.⁷² The distal anastomosis may be constructed by using a collared graft to accommodate any discrepancy in aortic diameter⁷³ and is performed such that a portion of the graft is

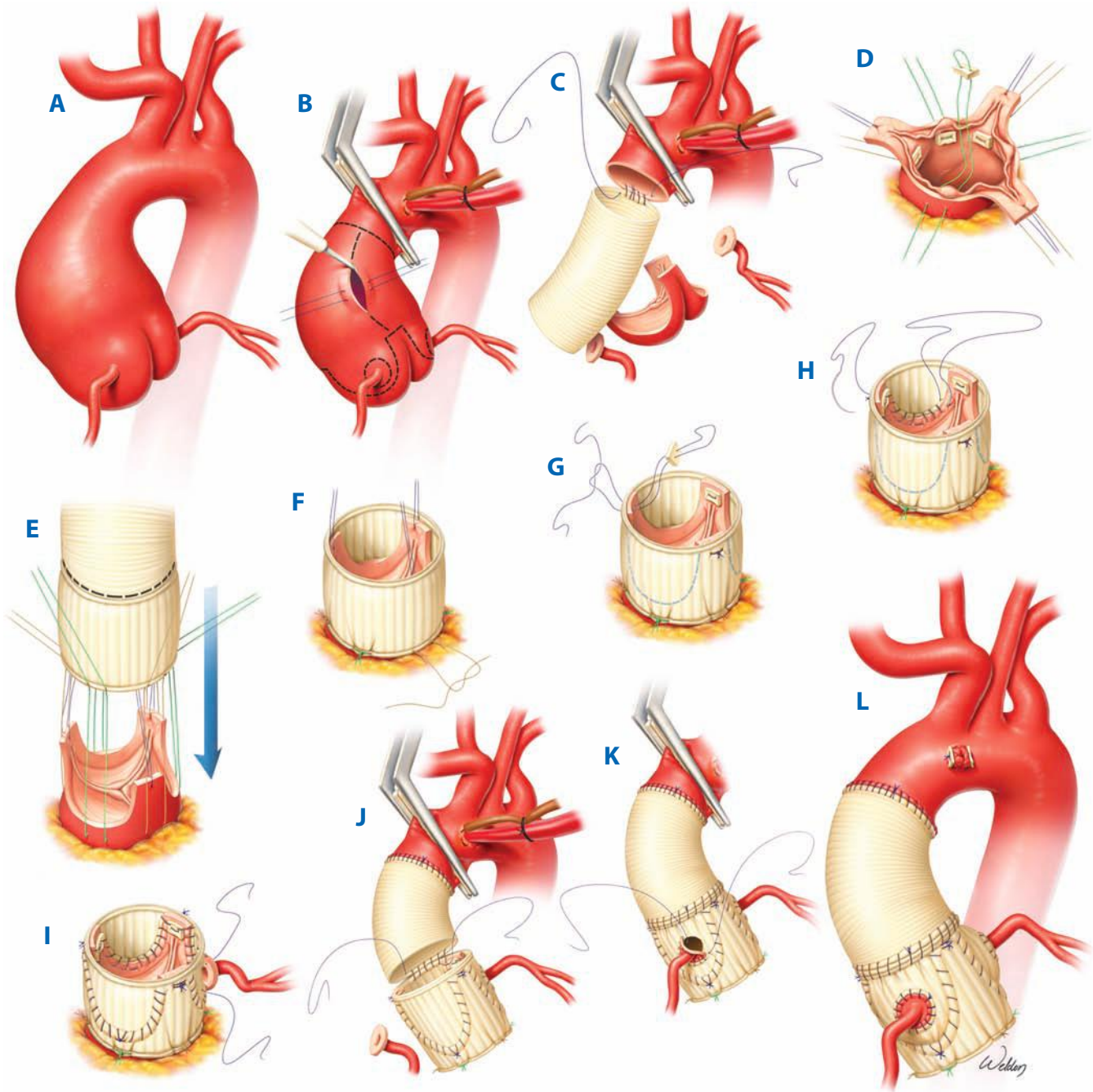


Figure 22-5. Illustration of our current valve-sparing procedure for replacing the aortic root and ascending aorta for treatment of **A.** aortic root aneurysm. **B.** The ascending aorta is opened after cardiopulmonary bypass and cardioplegic arrest are established and the distal ascending aorta is clamped. The diseased aortic tissue (including the sinuses of Valsalva) is excised. Buttons of surrounding tissue are used to mobilize the origins of the coronary arteries. **C.** A synthetic graft is sewn to the distal ascending aorta with continuous suture. **D.** After the distal anastomosis is completed, six sutures reinforced with Teflon pledgets are placed in the plane immediately below the aortic valve annulus. **E.** The subannular sutures are placed through the base of a synthetic aortic root graft, which is then is parachuted down around the valve. **F.** After the root graft is cut to an appropriate length, the valve commissures and leaflets are positioned within the graft. The annular sutures are then tied. **G.** Each of the three commissures is then secured near the top of the graft. **H.** The supra-annular aortic tissue is sewn to the graft in continuous fashion. **I.** The button surrounding the origin of the left main coronary artery is sewn to an opening cut in the root graft. **J.** The two aortic grafts are sewn together with continuous suture. **K.** The button surrounding the origin of the right coronary artery is sewn to an opening cut in the root graft. **L.** The completed valve-sparing aortic root replacement and graft repair of the ascending aorta is shown. (Used with permission of Baylor College of Medicine.)

left suspended within the proximal descending thoracic aorta (Fig. 22-7). During a subsequent operation, this “trunk” is used to facilitate repair of the descending thoracic aorta through a thoracotomy incision. This technique permits access to the distal portion of the graft during the second operation without the

need for dissection around the distal transverse aortic arch; this reduces the risk of injuring the left recurrent laryngeal nerve, esophagus, and pulmonary artery if an open approach is used at the second stage. As described in the section on hybrid repair of arch aneurysms (see later), the elephant trunk can be completed

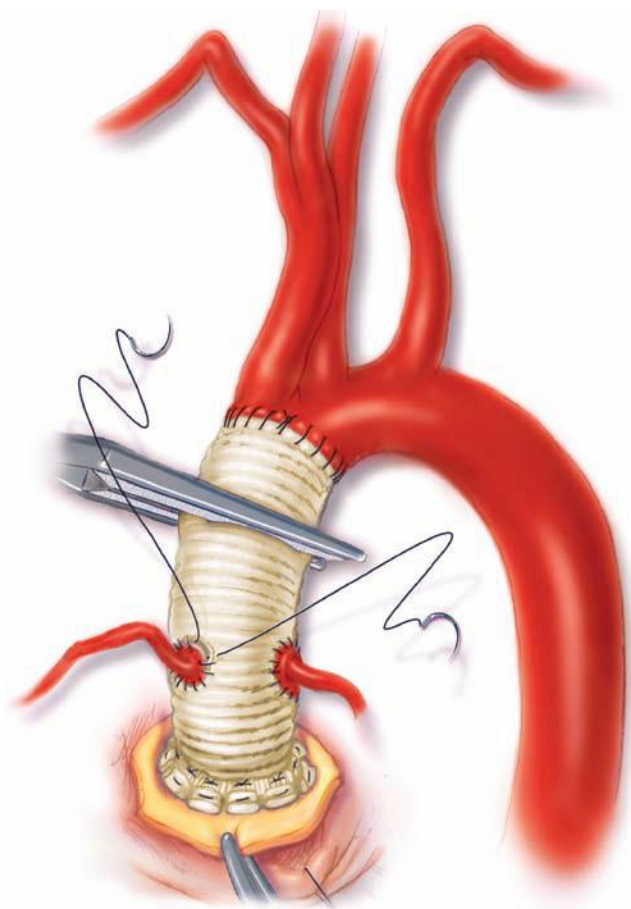


Figure 22-6. Illustration of a modified Bentall procedure for replacing the aortic root and ascending aorta. The aortic valve and entire ascending aorta, including the sinuses of Valsalva, have been replaced by a mechanical composite valve graft. The coronary arteries with buttons of surrounding aortic tissue have been mobilized and are being reattached to openings in the aortic graft.

by using a hybrid endovascular approach (Fig. 22-8) in certain settings.

Cardiopulmonary Bypass Perfusion Strategies Like the operations themselves, perfusion strategies used during proximal aortic surgery depend on the extent of the repair. Aneurysms that are isolated to the ascending segment can be replaced by using standard cardiopulmonary bypass and distal ascending aortic clamping. This provides constant perfusion of the brain and other vital organs during the repair. Aneurysms involving the transverse aortic arch, however, cannot be clamped during the repair, which necessitates the temporary withdrawal of cardiopulmonary bypass support; this is called *circulatory arrest*. To protect the brain and other vital organs during the circulatory arrest period, hypothermia must be initiated before pump flow is stopped. However, hypothermia is not without risk, and coagulopathy is associated with deep levels of hypothermia (below 20°C), which have been traditionally used in open arch repair. Recently, more moderate levels of hypothermia (often between 22°C and 24°C) have been introduced that appear to decrease risks associated with deep hypothermia while still providing sufficient brain protection. Nonetheless, although brief periods of circulatory arrest generally are well tolerated, even this recently modified technique continues to have substantial limitations; as the duration of circulatory arrest

increases, the well-recognized risks of brain injury and death increase dramatically. Additionally, some authors have raised the concern that reducing the degree of hypothermia narrows the safety margin that deep hypothermia provides, because it increases the risk of ischemic complications involving the spinal cord, kidneys, and other organs that now receive less hypothermic protection.⁷⁴

Because of the inherent complexity of aortic arch repairs and their general tendency to require longer periods of hypothermic circulatory arrest, two cerebral perfusion strategies—retrograde cerebral perfusion (RCP) and antegrade cerebral perfusion (ACP)—were developed to supplement this process by delivering cold, oxygenated blood to the brain and further reduce the risks associated with repair. Retrograde cerebral perfusion involves directing blood from the cardiopulmonary bypass circuit into the brain through the superior vena cava.⁷⁵ However, RCP is thought to be less beneficial than ACP,⁷⁶ and although it may be helpful in the retrograde flushing of air and debris from the arch, most centers have stopped using RCP.

In contrast, ACP delivers blood directly into the brachiocephalic arteries to maintain cerebral flow. Although its use was cumbersome in the past, contemporary ACP techniques (Fig. 22-9) have been simplified and commonly involve cannulating either the right axillary artery or the innominate artery and subsequent connection to the cardiopulmonary bypass circuit.^{77,78} Often, a small section of graft is used as a conduit to ease cannulation, but there remains a small procedure-related risk of brachial plexus or vascular injury. Upon initiation, cold blood is delivered into the brain via the right common carotid artery. Note that, with this technique, blood flow to the left side of the brain requires an intact circle of Willis.

Methods to help determine the adequacy of unilateral ACP to deliver cerebral cross-circulation include preoperative imaging and intraoperative monitoring. Our preferred method of intraoperative monitoring is brain near-infrared spectroscopy (NIRS), which measures cerebral oxygenation. If NIRS monitoring indicates inadequate perfusion, an additional perfusion catheter can be inserted into the left common carotid artery to provide blood flow to the left side of the brain. Because of the use of more moderate levels of hypothermia, some groups supplement ACP with additional perfusion strategies that provide flow to the descending aorta during arch repair.^{79,80}

Endovascular Repair Experience with purely endovascular treatment of proximal aortic disease remains limited and only investigational. The unique anatomy of the aortic arch and the need for uninterrupted cerebral perfusion pose difficult challenges. There are reports of the use of “homemade” grafts to exclude arch aneurysms; however, these grafts are highly experimental at this time. For example, in 1999, Inoue and colleagues⁸¹ reported placing a triple-branched stent graft in a patient with an aneurysm of the aortic arch. The three brachiocephalic branches were positioned by placing percutaneous wires in the right brachial, left carotid, and left brachial arteries. The patient underwent two subsequent procedures: surgical repair of a right brachial pseudoaneurysm and placement of a distal stent graft extension to control a major perigraft leak. Since then, efforts to employ endovascular techniques in the treatment of the proximal aorta have been essentially limited to the use of approved devices for off-label indications, such as the exclusion of pseudoaneurysms in the ascending aorta.

Hybrid Repair Unlike purely endovascular approaches, hybrid repairs of the aortic arch have entered the mainstream clinical

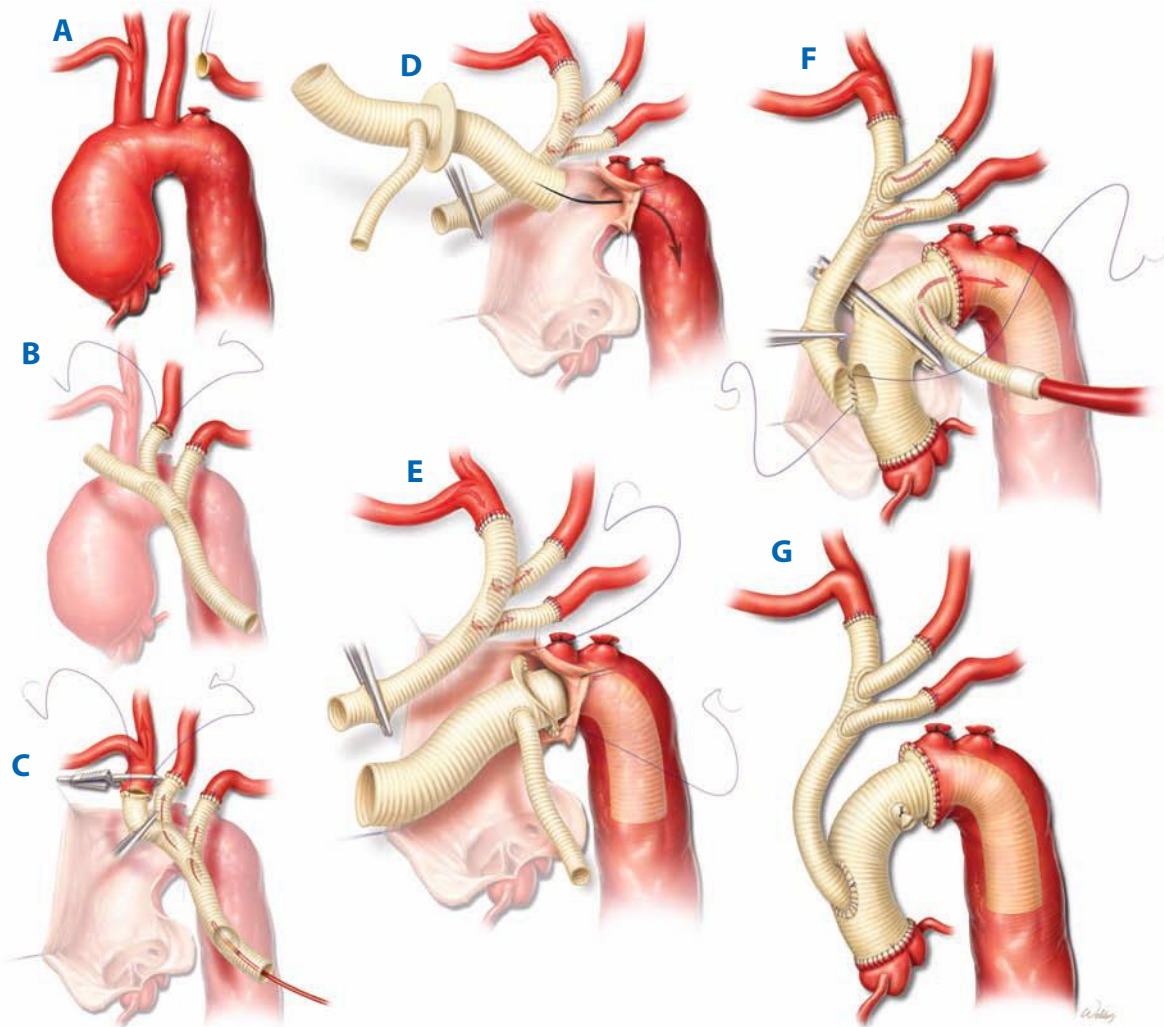


Figure 22-7. Illustration of a contemporary Y-graft approach to total arch replacement for aortic arch aneurysm. **A.** The proximal portions of the brachiocephalic arteries are exposed. **B.** The first two branches of the graft are sewn end-to-end to the transected left subclavian and left common carotid arteries. The proximal ends of the transected brachiocephalic arteries are ligated. **C.** A balloon-tipped perfusion cannula is placed inside the double Y-graft and used to deliver antegrade cerebral perfusion. After systemic circulatory arrest is initiated, the innominate artery is clamped, transected, and sewn to the distal end of the main graft. **D.** The proximal aspect of the Y-graft is clamped. This directs flow from the axillary artery to all three brachiocephalic arteries. The arch is then replaced with a collared elephant trunk graft. **E.** The distal anastomosis between the elephant trunk graft and the aorta is created between the innominate and left common carotid arteries. The collared graft accommodates any discrepancy in aortic diameter. **F.** The aortic graft is clamped, and a second limb from the arterial inflow tubing of the cardiopulmonary bypass circuit is used to deliver systemic perfusion through a side-branch of the arch graft while the proximal portion of the ascending aorta is replaced. Once the proximal aortic anastomosis is completed, the main trunk of the double Y-graft is cut to an appropriate length, and the beveled end is then sewn to an oval opening created in the right anterolateral aspect of the ascending aortic graft, which completes the repair **G.** (Adapted from LeMaire et al,⁷³ Fig. 2. Used with permission. Copyright The Society of Thoracic Surgeons.)

arena, although they remain controversial. Hybrid arch repairs involve some form of “debranching” of the brachiocephalic vessels (which are not unlike Y-graft approaches), followed by endovascular exclusion of some or all of the aortic arch (Fig. 22-10). Although this technique has many variants, they often involve sewing a branched graft to the proximal ascending aorta with the use of a partial aortic clamp. The branches of the graft are then sewn to the arch vessels. Once the arch is “debranched,” the arch aneurysm can be excluded with an endograft. Commonly, a zone 0 approach (Fig. 22-11) is undertaken, in which the proximal end of the endograft lies between the ascending aorta and the origins of the innominate artery. Other hybrid approaches aim to extend repair

into the distal arch and descending thoracic aorta (see later). The arguments for using a hybrid approach to treat aortic arch aneurysms include the elimination of cardiopulmonary bypass, circulatory arrest, and cardiac ischemia, although in practice, these adjuncts are frequently used during hybrid proximal aortic repairs.⁸²

It is not yet clear whether hybrid repairs are as durable as traditional ones because little mid- or long-term data have been published, and no large-scale studies have compared hybrid and traditional repairs. Procedure-related risks include the risk of embolization and stroke due to wire and device manipulation within the aortic arch (this risk appears to be greatest in zone 0 repairs⁸³), retrograde acute aortic dissection,⁸⁴ type I endoleak,⁸⁵

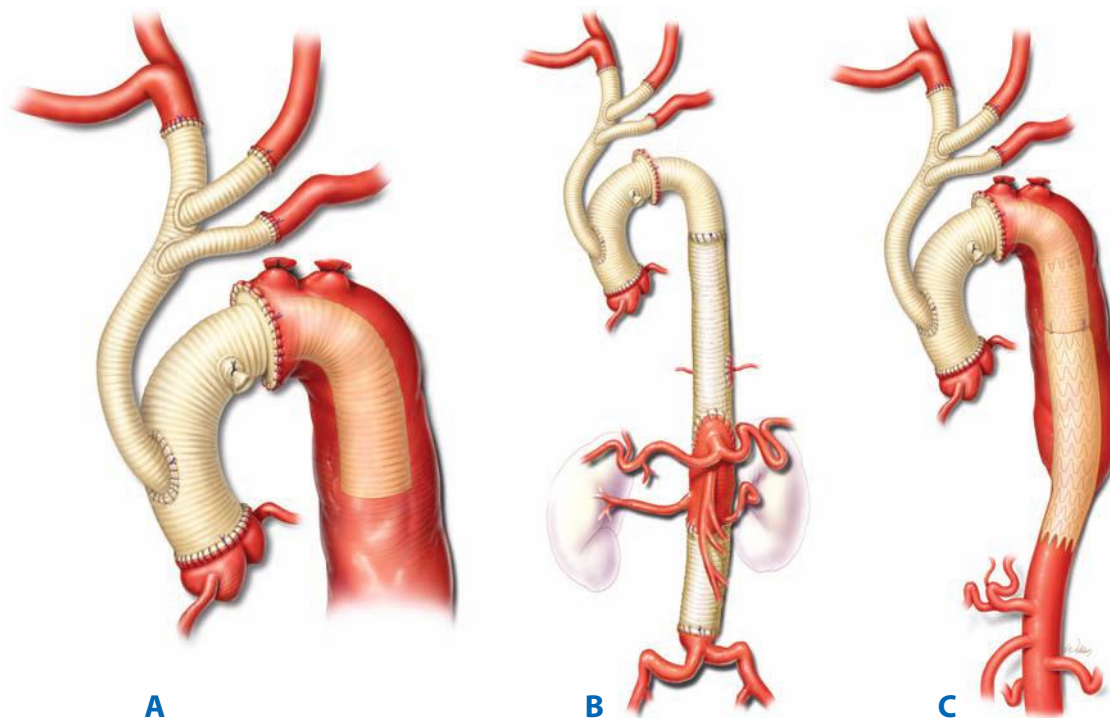


Figure 22-8. Illustration of Borst's elephant trunk technique using a contemporary Y-graft approach. **A.** Stage 1: The proximal repair includes replacing the ascending aorta and entire arch, with Y-graft reattachment of the brachiocephalic vessels. The distal anastomosis is facilitated by using a collared elephant trunk graft to accommodate the larger diameter of the distal aorta. A section of the graft is left suspended within the proximal descending thoracic aorta. **B.** Stage 2: The distal repair uses the floating "trunk" for the proximal anastomosis. **C.** An alternate "hybrid" approach may be used in patients with less extensive distal aortic disease. Endovascular stent grafts are placed within the elephant trunk to complete the repair. (Used with permission of Baylor College of Medicine.)

and paraplegia.²⁴ Some centers have begun to replace a small section of the ascending aorta such that the endograft does not land in native aortic tissue, because this may reduce the risk of iatrogenic dissection.⁸⁴ In a recent expert consensus document, the recommendation was to limit direct stenting of the aortic arch to patients who fall into the high surgical risk category.

These are patients with significant comorbidities such as chronic pulmonary disease.⁸⁶

Distal Thoracic Aortic Aneurysms

Open Repair In patients with descending thoracic or thoracoabdominal aortic aneurysms, several aspects of treatment—including

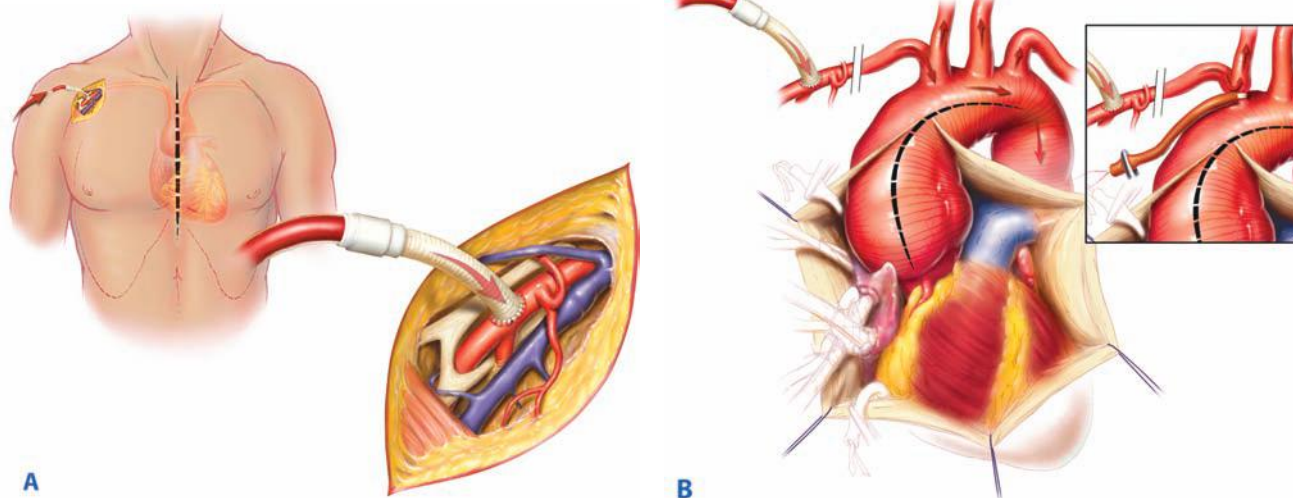


Figure 22-9. Illustration of a contemporary technique for delivering antegrade cerebral perfusion during aortic arch repair. **A.** A graft sewn to the right axillary artery is used to return oxygenated blood from the cardiopulmonary bypass circuit. **B.** After adequate hypothermia is established, the innominate artery is occluded with a tourniquet (*inset*) so that flow is diverted to the right common carotid artery, which maintains cerebral circulation. (Images adapted from Gravlee GP, Davis RF, Stammers AH, et al, eds. *Cardiopulmonary Bypass: Principles and Practice*, 3rd ed. Philadelphia: Lippincott Williams & Wilkins; 2008, Chap. 32, Fig. 1A,B. Copyright Wolters Kluwer Health.)

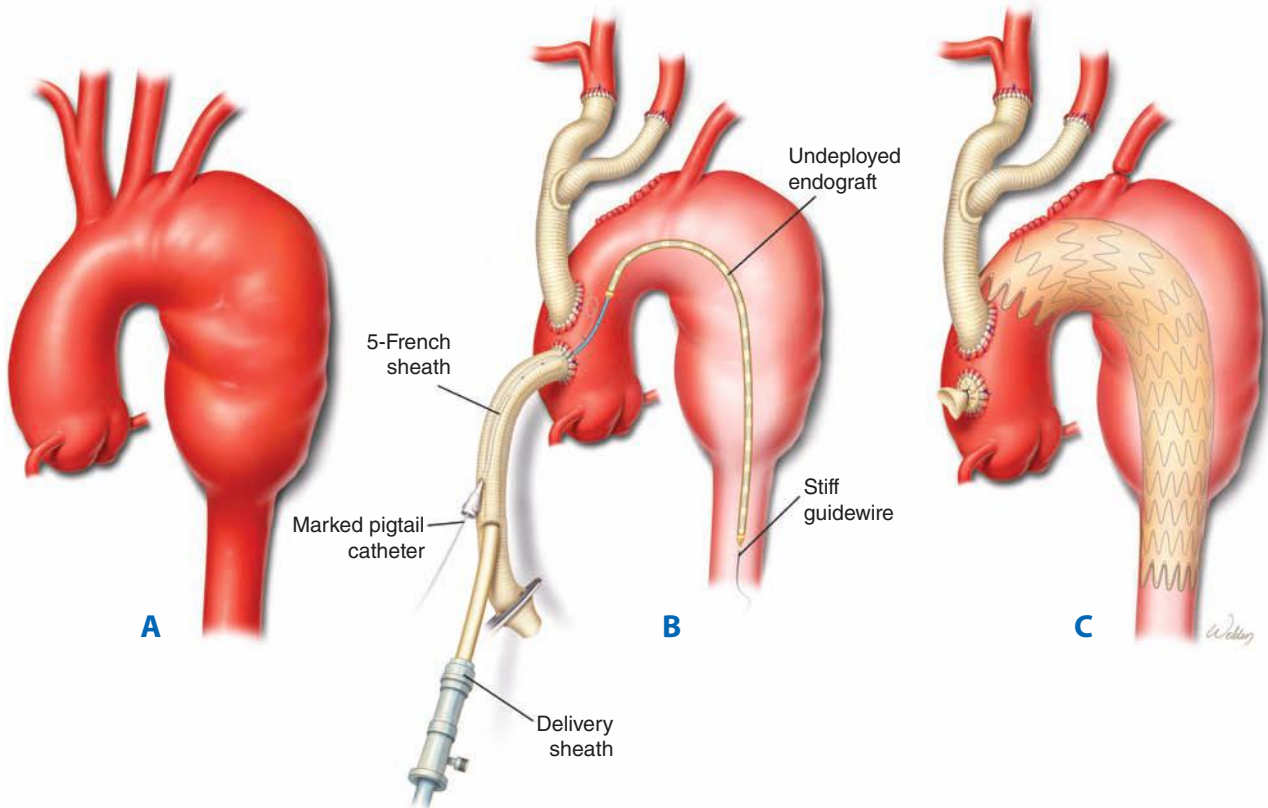


Figure 22-10. Illustration of a hybrid arch repair. **A.** A distal arch aneurysm, which extends into the proximal aspect of the descending thoracic aorta, is shown. **B.** The brachiocephalic vessels are debranched onto a double Y-graft, and a separate graft is used as a conduit for antegrade endovascular deployment of the stent-graft. **C.** The completed repair. The proximal landing zone of the endograft is within zone 0. (Used with permission from Baylor College of Medicine.)

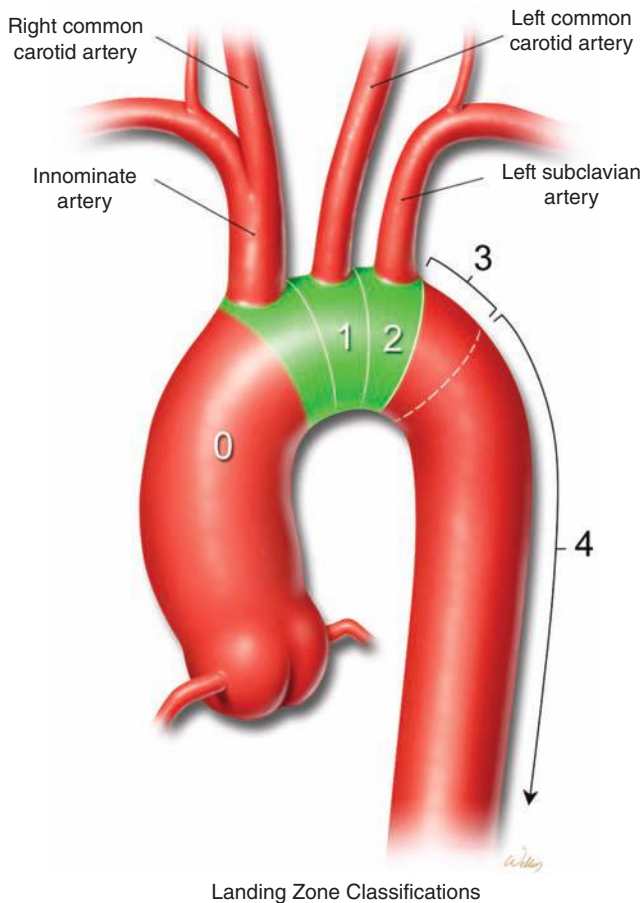


Figure 22-11. Illustration of the Criado landing zones, which are used to describe aortic anatomy during thoracic endovascular repair. The arch is the short segment that includes the origins of the three brachiocephalic arteries—the innominate artery, the left common carotid artery, and the left subclavian artery. Zone 0 includes the ascending aorta and the origin of the innominate artery. Zone 1 includes the origin of the left common carotid artery. Zone 2 includes the left subclavian artery origin. Zone 3 is a short section of the aorta that comprises the 2 cm immediately distal to the origin of the left subclavian artery, and Zone 4 begins where Zone 3 ends. (Used with permission from Baylor College of Medicine.)

preoperative risk assessment, anesthetic management, choice of incision, and use of protective adjuncts—are dictated by the overall extent of aortic involvement. By definition, descending thoracic aortic aneurysms involve the portion of the aorta between the left subclavian artery and the diaphragm. Thoracoabdominal aneurysms can involve the entire thoracoabdominal aorta, from the origin of the left subclavian artery to the aortic bifurcation. Surgical repair of thoracoabdominal aortic aneurysms is categorized by the extent of aortic replacement according to the Crawford classification scheme (Fig. 22-12). Extent I thoracoabdominal aortic aneurysm repairs involve most of the descending thoracic aorta, usually beginning near the left subclavian artery, and extend down into the suprarenal abdominal aorta. Extent II repairs also begin near the left subclavian artery but extend distally into the infrarenal abdominal aorta, and they often reach the aortic bifurcation. Extent III repairs extend from the lower descending thoracic aorta (below the sixth rib) and into the abdomen. Extent IV repairs begin at the diaphragmatic hiatus and often involve the entire abdominal aorta.

Descending thoracic aortic aneurysms are repaired through a left thoracotomy. In patients with thoracoabdominal aortic aneurysms, the thoracotomy is extended across the costal margin and into the abdomen. Use of a double-lumen endobronchial tube allows selective ventilation of the right lung and deflation of the left lung. Transperitoneal exposure of the thoracoabdominal aorta is achieved by performing medial visceral rotation and circumferential division of the diaphragm. During a period of aortic clamping, the diseased segment is replaced with a polyester tube graft. Important branch arteries—including intercostal arteries and the celiac, superior mesenteric, and renal arteries—are reattached to openings made in the side of the graft. Visceral and renal artery occlusive disease is commonly encountered during aneurysm repair; options for correcting branch vessel stenosis include endarterectomy, direct arterial stenting, and bypass grafting.

Clamping the descending thoracic aorta causes ischemia of the spinal cord and abdominal viscera. Clinically significant manifestations of hepatic, pancreatic, and bowel ischemia are relatively uncommon. However, both acute renal failure and spinal cord injury resulting in paraplegia or paraparesis remain major causes of morbidity and mortality after these

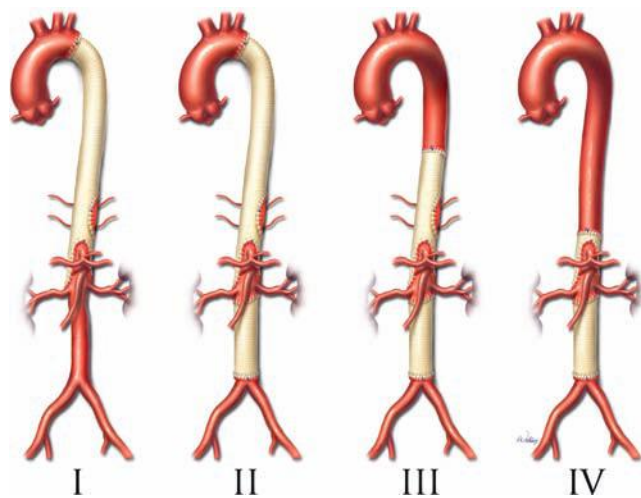


Figure 22-12. Illustration of the Crawford classification of thoracoabdominal aortic aneurysm repair based on the extent of aortic replacement. (Reproduced with permission from Coselli et al,²³² Fig. 1. Copyright The Society of Thoracic Surgeons.)

Table 22-3

Current strategy for spinal cord and visceral protection during repair of distal thoracic aortic aneurysms

All extents

- Permissive mild hypothermia (32°C–34°C, nasopharyngeal)
- Moderate heparinization (1 mg/kg)
- Aggressive reattachment of segmental arteries, especially between T8 and L1
- Sequential aortic clamping when possible
- Perfusion of renal arteries with 4°C crystalloid solution when possible

Crawford extent I and II thoracoabdominal repairs

- Cerebrospinal fluid drainage
- Left heart bypass during proximal anastomosis
- Selective perfusion of celiac axis and superior mesenteric artery during intercostal and visceral anastomoses

operations. Therefore, several aspects of the operation are devoted to minimizing spinal and renal ischemia (Table 22-3). Our multimodal approach to spinal cord protection includes expeditious repair to minimize aortic clamping time, moderate systemic heparinization (1.0 mg/kg) to prevent small-vessel thrombosis, mild permissive hypothermia (32°C–34°C [89.6°–93.2°F] nasopharyngeal temperature), and reattachment of segmental intercostal and lumbar arteries. As the aorta is replaced from proximal to distal, the aortic clamp is moved sequentially to lower positions along the graft to restore perfusion to newly reattached branch vessels. During extensive thoracoabdominal aortic repairs (i.e., Crawford extent I and II repairs), cerebrospinal fluid drainage is used. The benefits of this adjunct, which improves spinal perfusion by reducing cerebrospinal fluid pressure, have been confirmed in a prospective, randomized trial performed by our group.⁸⁷ Motor evoked potentials are used by some groups to monitor the spinal cord throughout the operation.^{88,89} Left heart bypass, which provides perfusion of the distal aorta and its branches during the clamping period, is also used during extensive thoracoabdominal aortic repairs.⁹⁰⁻⁹² Because left heart bypass unloads the heart, it is also useful in patients with poor cardiac reserve. Balloon perfusion cannulas connected to the left heart bypass circuit can be used to deliver blood directly to the celiac axis and superior mesenteric artery during their reattachment. The potential benefits of reducing hepatic and bowel ischemia include reduced risks of postoperative coagulopathy and bacterial translocation, respectively. Whenever possible, renal protection is achieved by perfusing the kidneys with cold (4°C [39.2°F]) crystalloid. In a randomized clinical trial, reduced kidney temperature was found to be associated with renal protection, and the use of cold crystalloid independently predicted preserved renal function.⁹³

Hypothermic circulatory arrest can also be used during descending thoracic or thoracoabdominal aortic repairs.⁹⁴ At our center, the primary indication for this approach is the inability to clamp the aorta because of rupture, extremely large aneurysm size, or extension of the aneurysm into the distal transverse aortic arch, or because a prior endovascular repair hinders clamping.⁵⁵

As discussed previously, complete repair of extensive aneurysms involving the ascending aorta, transverse arch, and

descending thoracic aorta generally requires staged operations. In such procedures, when the descending or thoracoabdominal component is symptomatic (e.g., causes back pain or has ruptured) or is disproportionately large (compared with the ascending aorta), the distal segment is treated during the initial operation, and repair of the ascending aorta and transverse aortic arch is performed as a second procedure. A reversed elephant trunk repair, in which a portion of the proximal end of the aortic graft is inverted down into the lumen, can be performed during the first

operation; this technique facilitates the second-stage repair of the ascending aorta and transverse aortic arch (Fig. 22-13).⁹⁵

Although spinal cord ischemia and renal failure receive the most attention, several other complications warrant consideration. The most common complication of extensive repairs is pulmonary dysfunction. With aneurysms adjacent to the left subclavian artery, the vagus and left recurrent laryngeal nerves are often adherent to the aortic wall and thus are susceptible to injury. Vocal cord paralysis should be

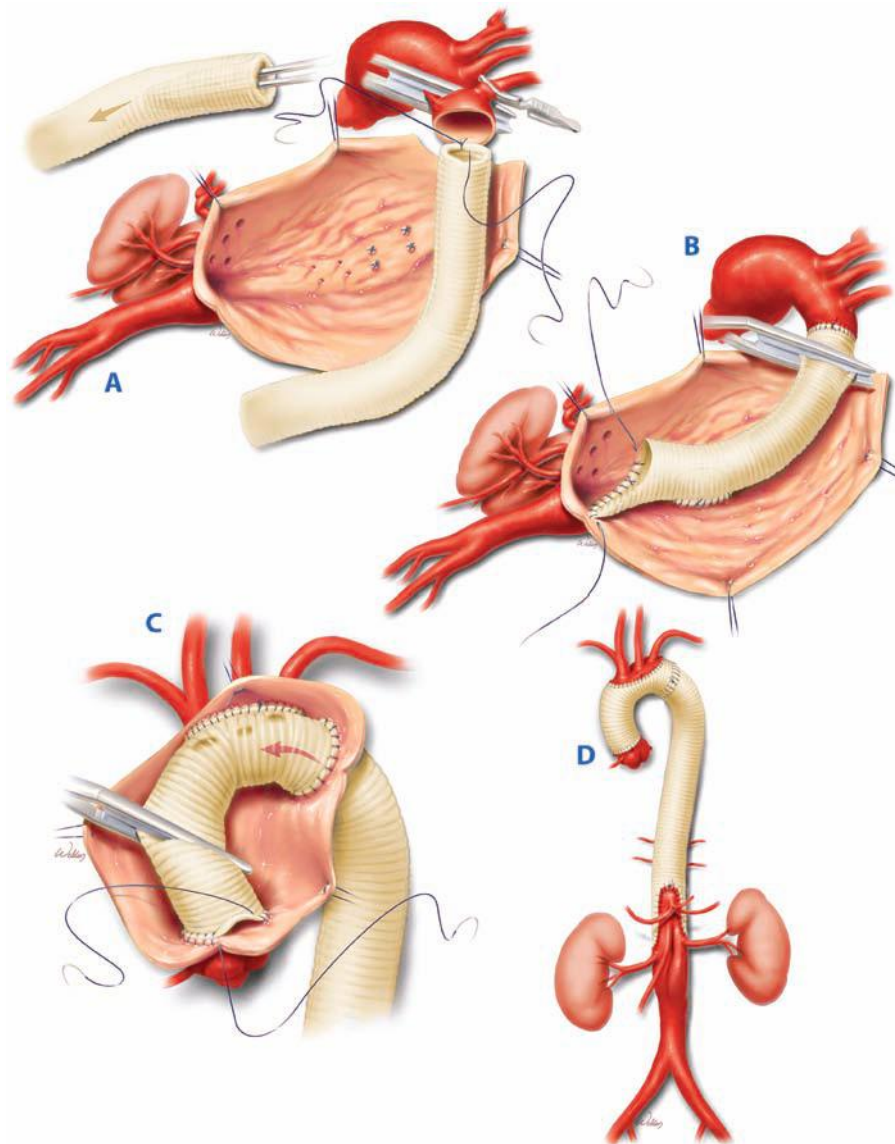


Figure 22-13. Illustration of the reversed elephant trunk technique using a traditional “island” approach to total aortic arch replacement. **A.** Stage 1: The distal aorta is repaired through a left thoracoabdominal approach. The aneurysm is opened after the aorta is clamped between the left common carotid artery and the left subclavian artery, which is also clamped. Before the proximal anastomosis is performed, the end of the graft is partly invaginated to leave a “trunk” for the subsequent repair. Proximal intercostal arteries are oversewn. **B.** After the proximal suture line is completed, the clamps are repositioned to restore blood flow to the left subclavian artery. The repair is completed by reattaching patent intercostal arteries to an opening in the side of the graft and creating a beveled distal anastomosis at the level of the visceral branches. **C.** Stage 2: The proximal aorta is repaired through a median sternotomy. The aortic arch is opened under hypothermic circulatory arrest. The “trunk” is pulled out and used to replace the aortic arch and ascending aorta. This eliminates the need for a new distal anastomosis and simplifies the procedure. Circulatory arrest and operative time, along with their attendant risks, are reduced. **D.** The completed two-stage repair of the entire thoracic aorta. (Reproduced with permission from Coselli JS, LeMaire SA, Carter SA, et al: *The reversed elephant trunk technique used for treatment of complex aneurysms of the entire thoracic aorta*. *Ann Thorac Surg* 2005; 80:2166, Figs. 2, 3, 7, and 8. Copyright The Society of Thoracic Surgeons.)

suspected in patients who have postoperative hoarseness, and the presence of nerve damage should be confirmed by endoscopic examination. Vocal cord paralysis can be treated effectively by direct cord medialization (type 1 thyroplasty). Injury to the esophagus during the proximal anastomosis can have catastrophic consequences. Carefully separating the proximal descending thoracic aorta from the underlying esophagus before performing the proximal anastomosis minimizes the risk of a secondary aorto-esophageal fistula. In patients who have previously undergone coronary artery bypass with a left internal thoracic artery graft, clamping proximal to the left subclavian artery can precipitate severe myocardial ischemia and cardiac arrest. When the need to clamp at this location is anticipated in these patients, a left common carotid to subclavian bypass is performed to prevent cardiac complications (Fig. 22-14).⁹⁶

Endovascular Repair

Descending Thoracic Aortic Aneurysms Stent graft repair of descending thoracic aortic aneurysms has become an accepted treatment option for selected patients.⁸⁶ Although aortic repair with a self-fixing endoprosthesis was reported by Volodos⁹⁷ in the mid-1980s, it was the report by Parodi and associates⁹⁸ of using endovascular stent grafting to repair abdominal aortic aneurysms that helped popularize this approach. Only 3 years after this seminal report was published, Dake and colleagues⁹⁹

reported performing endovascular descending thoracic aortic repair with “homemade” stent grafts in 13 patients.

Although endografting was initially approved to treat degenerative descending thoracic aortic aneurysms, recently some newer devices have been approved for use in blunt aortic injury, as well as for penetrating aortic ulcers (see *Penetrating Aortic Ulcer* discussed later). However, in practice, off-label use of stent-grafts is exceedingly common, and they are frequently used in patients with aortic dissection or ruptured aneurysm. Although the use of stent-grafts in cases of aortic infection is not ideal, patients with fistula or mycotic aneurysm may be treated endovascularly as a bridge to open repair. Reporting standards to uniformly describe the endovascular repair process have been recently introduced,¹⁰⁰ as have guidelines for the use of endovascular repair in thoracic aortic disease.⁴⁰

In elderly patients with severe comorbidity and patients who have undergone previous complex thoracic aortic procedures, endovascular repair is a particularly attractive alternative to standard surgical procedures. The patients tend to have a lower incidence of intraoperative complications, a shorter length of stay, and a higher likelihood of being discharged to home than those who undergo open repair.⁴⁹ As mentioned previously, appropriate patient selection depends on specific measurements taken from preoperative CT angiograms.

To protect patients against spinal cord ischemia during these endovascular repairs, many surgeons use cerebrospinal

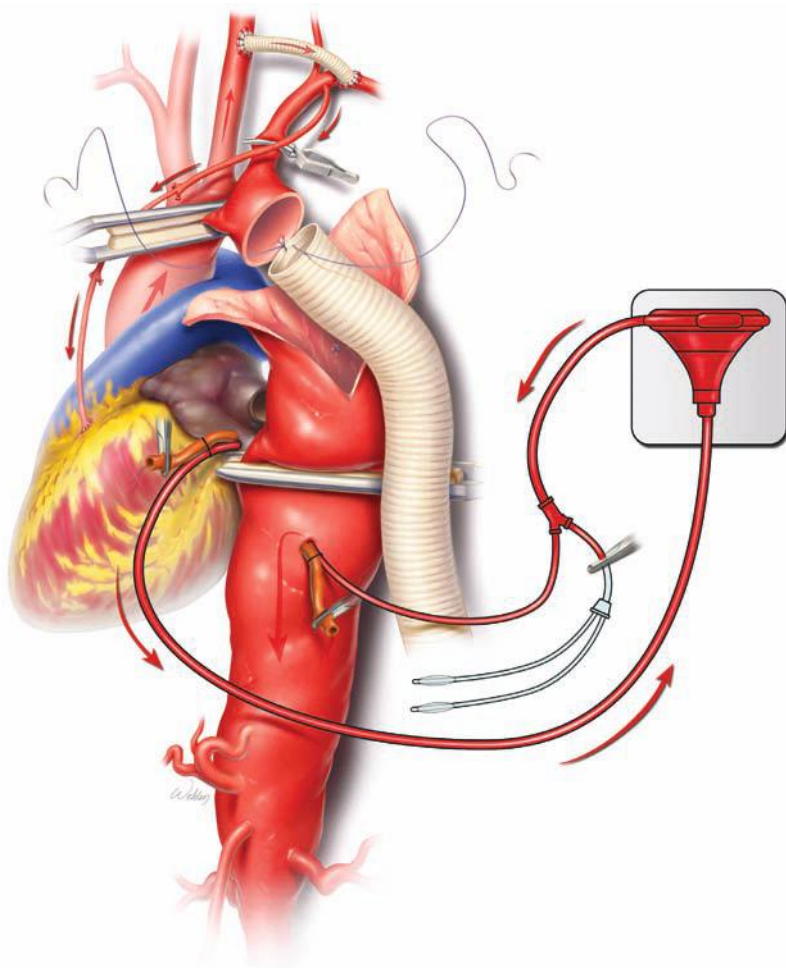


Figure 22-14. Illustration of a thoracoabdominal aortic aneurysm repair in a patient with a patent left internal thoracic artery-to-left anterior descending coronary artery graft. The proximal anastomosis is being performed while the aorta is clamped between the left common carotid and subclavian arteries. Myocardial perfusion is maintained through the carotid-subclavian bypass graft. (Reproduced with permission from Jones et al,⁹⁶ Fig. 2. Copyright The Society of Thoracic Surgeons.)

fluid drainage. The first step in the repair procedure is to obtain appropriate vascular access for the insertion of the thoracic stent graft. If the femoral artery will not accommodate the necessary sheath, then an iliac artery is exposed. A graft can be sewn to the iliac artery in an end-to-side fashion to facilitate the deployment of the endograft. After 5000 to 10,000 units of heparin are administered, a guidewire and the delivery sheath are typically inserted into the access artery under fluoroscopic guidance; recently, sheathless stent-grafts have been introduced, which are less bulky. The endograft is then advanced into the aorta and suitably positioned. Note that the best view of the distal arch and descending thoracic aorta is usually in the left anterior oblique position at an angle of approximately 40 to 50 degrees. The device is then deployed, and the proximal and distal ends are expanded by using a balloon catheter ("ballooned"), which optimizes the seal between the device and the aortic wall at this landing zone. An aortogram is then taken to rule out any endoleak, and protamine is administered.

Although it is not uncommon to cover the left subclavian artery with the endograft to lengthen the proximal landing zone,¹⁰¹ findings suggest that the risk of spinal cord complications is heightened when the subclavian artery is covered and not revascularized, presumably because of a loss of collateral circulation to the spinal cord.¹⁰² To prevent this complication, a carotid-to-subclavian bypass can be easily constructed to maintain vertebral artery blood flow and minimize neurologic injury (Fig. 22-15).^{103,104} In addition, new generations of stent grafts are being designed with side branches that can be placed within the left subclavian artery. This feature is particularly attractive if the proximal neck is short or if the patient has a patent left internal thoracic artery-to-left anterior descending coronary artery bypass. Because a significant number of patients have coexisting coronary artery disease, care must be taken to avoid left subclavian artery occlusion in patients with previous coronary surgery unless a carotid-to-subclavian bypass has been performed.

Elephant Trunk Completion In select patients, elephant trunk completion repairs may be done endovascularly (Fig. 22-8C), rather than by an open approach through a thoracotomy.¹⁰⁵ Recall that an elephant trunk is used when an aortic aneurysm extends from the distal arch to the descending thoracic aorta. An endograft can be deployed at the time of elephant trunk construction or during a separate, subsequent procedure.^{84,106} When the stent is deployed in a retrograde manner in such a second-stage procedure, the procedure is facilitated by placing radiopaque markers at the end of the elephant trunk during the first-stage procedure. This allows the distal end of the trunk to be identified via fluoroscopy. A guidewire can then be manipulated into the trunk and advanced into the ascending aorta to stabilize it during stent deployment. Note that advancing a wire in retrograde fashion from the femoral artery into the elephant trunk can be challenging. Occasionally, the wire must be advanced in an antegrade fashion from a brachial artery. Variations of this approach include the frozen elephant trunk, but this technique is most commonly used in patients with extensive aortic dissection (see *Acute Dissection* discussed later).

Thoracoabdominal Aortic Aneurysms Although endovascular thoracoabdominal aortic aneurysm repair remains experimental, it has been shown to be feasible in a few specialized centers. Endovascular thoracoabdominal aortic aneurysm repairs are quite complex, because at least one of the visceral arteries is incorporated into the repair. The number of visceral branches

that need to be addressed varies with the extent of aortic coverage.¹⁰⁷ The types of stent grafts used include fenestrated grafts, reinforced fenestrated grafts, branched or cuffed grafts, modular combinations of grafts, and multilayer stents.¹⁰⁸ Graft fenestrations and branch vessels are typically aligned by using inflatable angioplasty balloons. Procedure time is not insignificant, nor is the amount of contrast medium required to obtain the highly detailed images needed to plan these procedures. In addition, some of the stent grafts used in endovascular thoracoabdominal aortic aneurysm repair are custom-made in advance and thus may take several weeks to obtain; therefore, their use is limited to cases of elective repair.⁸⁴ In efforts to hasten repair and utilize off-the-shelf devices, parallel graft approaches, which use a combination of large- and small-diameter stents, have been reported.¹⁰⁹ And, although some centers now propose distal coverage of the celiac axis¹¹⁰ for extent I thoracoabdominal aortic aneurysm repairs, this potentially risky approach is not widely used.

It should be noted that, like open thoracoabdominal aortic aneurysm repair, endovascular repair carries risks of paraplegia, renal failure, stroke, and death, despite the apparent benefits of its being a less invasive procedure. Notably, reports from centers experienced in endovascular thoracoabdominal aortic repair primarily describe limited extent IV repairs.⁵⁴ For the near future, endovascular thoracoabdominal aortic aneurysm repair should be considered investigational.

Hybrid Repair As discussed previously, hybrid aortic repairs are extremely heterogeneous. For extensive distal aortic repairs, approaches such as the hybrid elephant trunk (described previously) are not feasible because the aneurysm extends beyond the visceral arteries. However, extensive hybrid thoracoabdominal aortic aneurysm repair^{111,112} may be a life-saving option in patients at high surgical risk, such as those who have limited physiologic reserve, are of advanced age, or have significant comorbidities. Hybrid procedures use open surgical techniques to reroute blood supply to the visceral arteries so that their aortic origins can be covered by stent grafts without causing visceral ischemia (see Fig. 22-16). Endovascular methods are then used (either as part of the same procedure or at a later stage) to repair the aortic aneurysm, often with simple tube stent grafts; such devices are more readily available than the customized, modular stent grafts deployed in strictly endovascular repairs. Overall, results for hybrid thoracoabdominal aortic aneurysm repair have been somewhat disappointing.¹¹³ However, a few centers report acceptable outcomes in high-risk patients, particularly when a staged hybrid approach is used.¹¹⁴

Postoperative Considerations

Open Procedures Aortic anastomoses are often extremely fragile during the early postoperative period. Even brief episodes of postoperative hypertension can disrupt suture lines and precipitate severe bleeding or pseudoaneurysm formation. Therefore, during the initial 24 to 48 hours, meticulous blood pressure control is maintained to protect the integrity of the anastomoses. Generally, we liberally use IV vasoactive agents to keep the mean arterial blood pressure between 80 and 90 mmHg. In patients with extremely friable aortic tissue, such as those with Marfan syndrome, we lower the target range to between 70 and 80 mmHg. It is a delicate balancing act, because one must be mindful of spinal cord perfusion and avoid periods of relative hypotension while maintaining these low pressures.

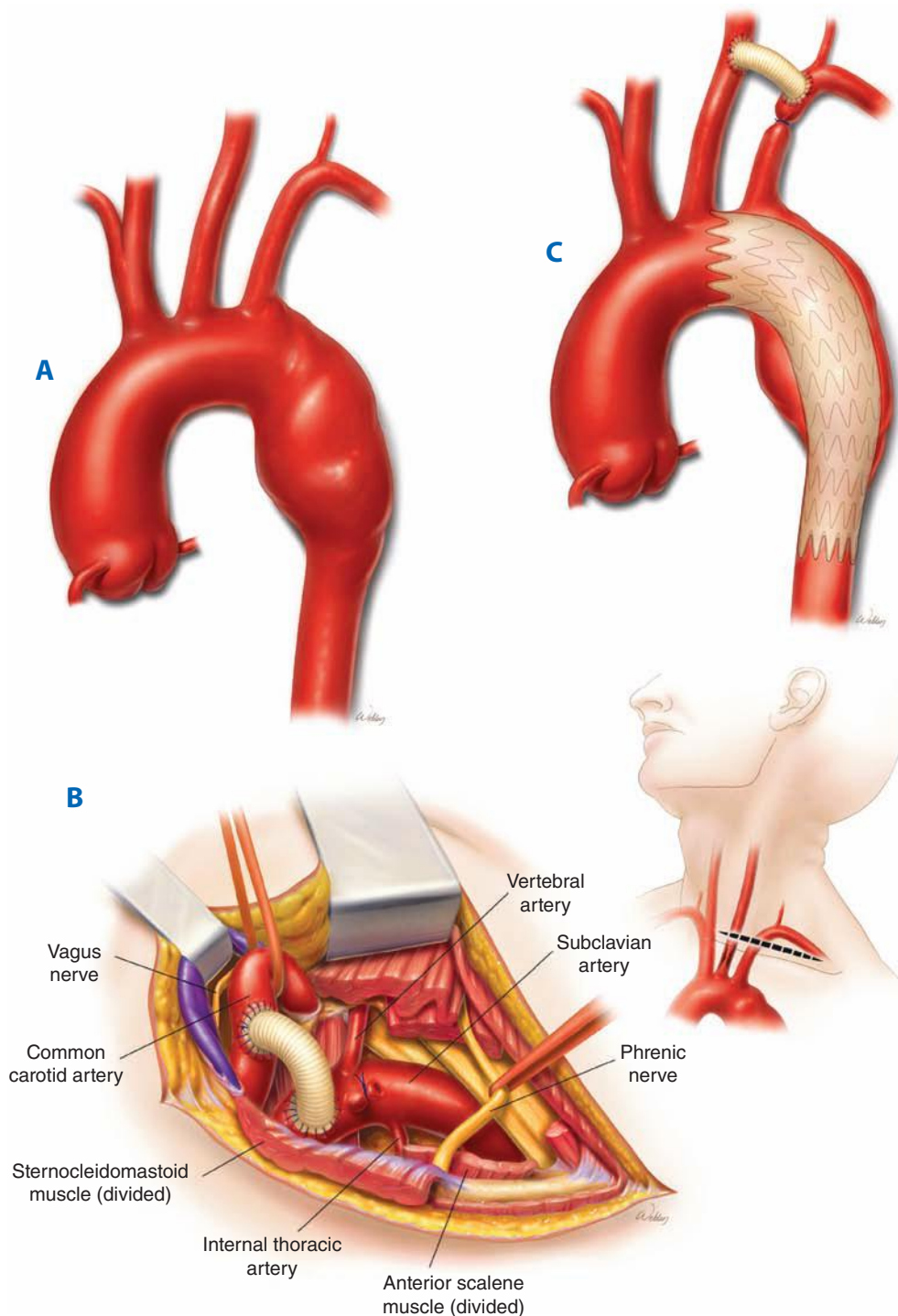


Figure 22-15. Illustration of a hybrid repair of the proximal descending thoracic aorta. **A.** The preoperative representation of the aneurysm shows that establishing a 2-cm proximal landing zone for a stent graft will require covering the origin of the left subclavian artery. **B.** Through a supraclavicular approach, a bypass from the left common carotid artery to the left subclavian artery is performed to reroute circulation and create a landing zone for the stent graft. After the bypass is completed, the left subclavian artery is ligated proximal to the graft. **C.** In the completed zone 2 hybrid repair, the aneurysm has been excluded successfully by a stent graft that covers the origin of the left subclavian artery, and blood flow to the left vertebral artery and arm is preserved by the bypass graft. (Reproduced with permission from Bozinovski et al,¹⁰³ Figs. 9, 10, and 11. Copyright The Society of Thoracic Surgeons.)

Endovascular Procedures As experience with descending thoracic aortic stent grafts continues to accumulate, so too do reports of both early and late complications.^{55,115,116} Many of these complications are directly related to manipulation of the delivery system within the iliac arteries and aorta.¹¹⁷ Patients

with small, calcified, tortuous iliofemoral arteries are at particularly high risk for life-threatening iliac artery rupture. Although aortic rupture appears to be rare during thoracic stent graft procedures, acute iatrogenic retrograde dissection into the aortic arch and ascending aorta is a relatively common and life-threatening

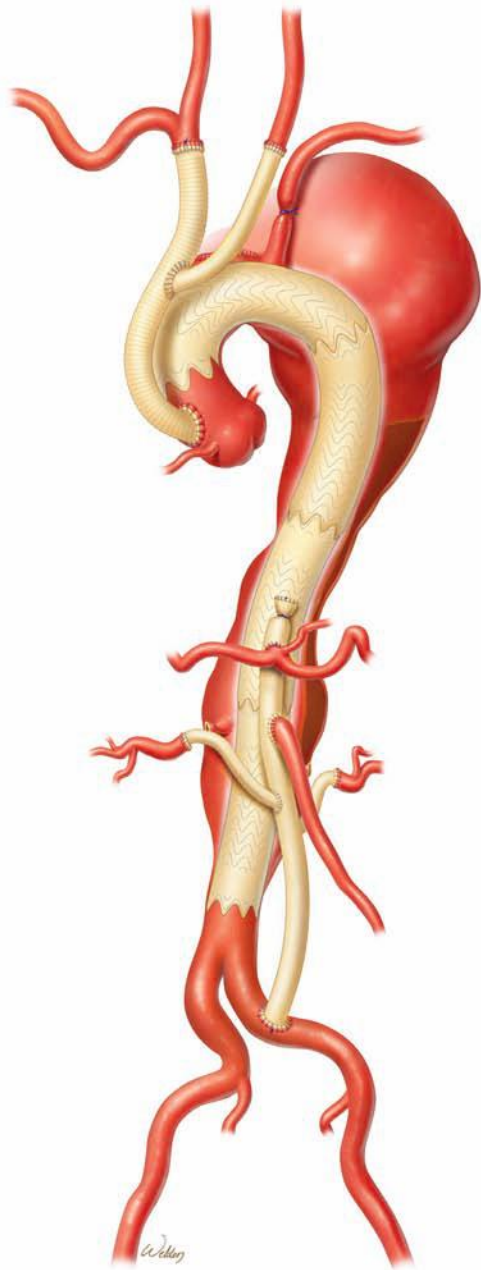


Figure 22-16. Illustration of a hybrid approach—which combines open and endovascular techniques—for repair of an extensive aortic aneurysm. Debranching the arch and thoracoabdominal segments allows the use of a series of endovascular stent grafts to exclude the entire aneurysm.

complication that requires emergency repair of the ascending aorta and aortic arch via sternotomy and cardiopulmonary bypass. There are many reports of this complication, and it appears most common in off-label applications⁵⁵ such as hybrid arch approaches⁸⁴ and the treatment of descending thoracic aortic dissection.¹¹⁸ Retrograde proximal dissection converts a localized descending thoracic aortic aneurysm into an acute problem involving the entire thoracic aorta. Of note, retrograde aortic dissection may also occur several months after initial repair.¹¹⁹

Another significant complication of descending thoracic aortic stent grafting is endoleak. An endoleak occurs when there is a persistent flow of blood (visible on radiologic imaging) into the aneurysm sac, and it may occur during the initial proce-

Table 22-4

Classification of and common treatment strategies for endoleak

Type I

- Incomplete seal between stent graft and aorta at the proximal landing site (Type Ia), the distal landing site (Type Ib), or branch module, fenestration, or plug (Type Ic)
- Early reintervention to improve seal or conversion to open surgery

Type II

- Retrograde perfusion of sac from excluded collateral arteries
- Surveillance; as-needed occlusion with percutaneous or other interventions

Type III

- Incomplete seal between overlapping stent graft or module (Type IIIa), or tear in graft fabric (Type IIIb)
- Early reintervention to cover gap or tear or conversion to open surgery

Type IV

- Perfusion of sac due to porosity of material
- Surveillance; as-needed reintervention to reline stent graft

Type V

- Expansion of sac with no identifiable source
- Surveillance; as-needed reintervention to reline stent graft

sure or develop over time. Although endoleaks are a relatively common complication,¹²⁰ they are not benign, because they lead to continual pressurization of the sac, which can cause expansion or even rupture. These complications are categorized (Table 22-4) according to the site of the leak.¹⁰⁰ Although all endoleaks may progress such that they can be considered life-threatening, type I and type III endoleaks generally necessitate early and aggressive intervention. Recently published reporting guidelines aid standardized reporting.¹⁰⁰

Other complications include stent graft misdeployment, device migration, endograft kinking, and stent-graft infection, including fistula. Although not all complications related to stent grafts are fatal, endovascular repairs should be performed by expert teams qualified to address the variety of problems that may arise; some patients may need to have these devices removed and replaced with polyester grafts.^{55,115,116} Complications of endovascular repair are relatively common, so regularly scheduled radiologic imaging surveillance is of the utmost importance.

AORTIC DISSECTION

Pathology and Classification

Aortic dissection, the most common catastrophic event involving the aorta, is a progressive separation of the aortic wall layers that usually occurs after a tear forms in the intima and inner media. As the separation of the layers of the media propagates, at least two channels form (Fig. 22-17): the original lumen, which remains lined by the intima and which is called the *true lumen*, and the newly formed channel within the layers of the media, which is called the *false lumen*. The dissecting membrane separates the true and false lumens. Additional tears in the dissecting membrane that allow communication between

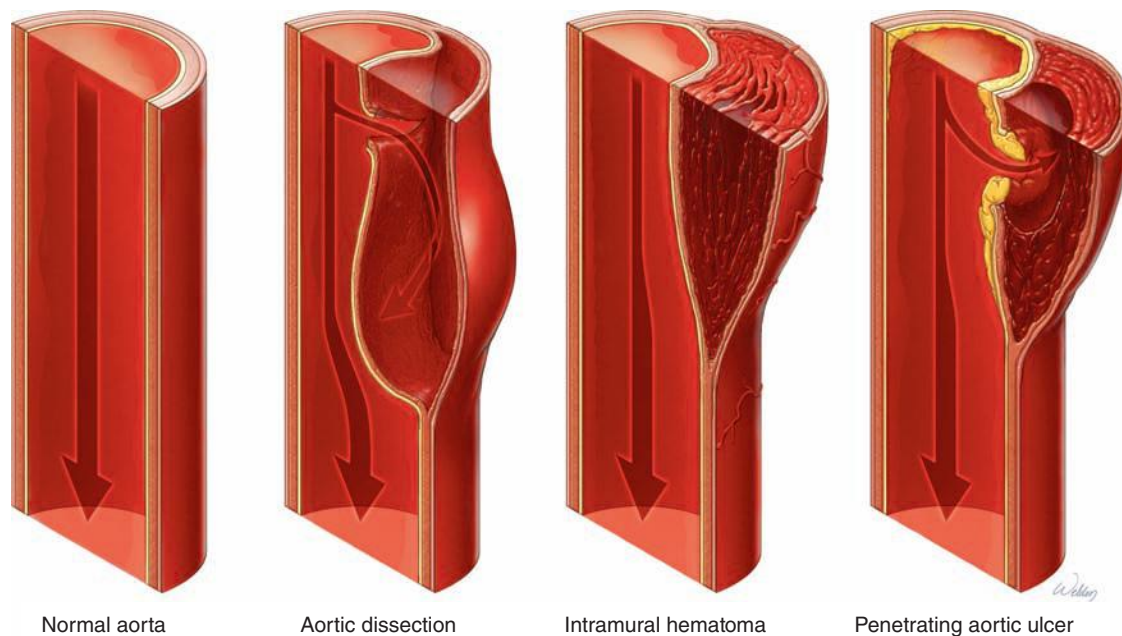


Figure 22-17. Illustration of longitudinal sections of the aortic wall and lumen. Blood flows freely downstream in normal aortic tissue. In classic aortic dissection, blood entering the media through a tear creates a false channel in the wall. Intramural hematomas arise when hemorrhage from the vasa vasorum causes blood to collect within the media; the intima is intact. Penetrating aortic ulcers are deep atherosclerotic lesions that burrow into the aortic wall and allow blood to enter the media. In each of these conditions, the outer aortic wall is severely weakened and prone to rupture.

the two channels are called *reentry sites*. Although the separation of layers primarily progresses distally along the length of the aorta, it can also proceed in a proximal direction; this process often is referred to as *proximal extension* or *retrograde dissection*.

The extensive disruption of the aortic wall has severe anatomic consequences (Fig. 22-18). First, the outer wall of the false lumen is extremely thin, inflamed, and fragile, which makes it prone to expansion or rupture in the face of ongoing hemodynamic stress. Second, the expanding false lumen can compress the true lumen and cause *malperfusion syndrome* by interfering with blood flow in the aorta or any of its branch vessels, including the coronary, carotid, intercostal, visceral, renal, and iliac arteries. Finally, when the separation of layers occurs within the aortic root, the aortic valve commissures can become unhinged, which results in acute valvular regurgitation. The clinical consequences of each of these sequelae are addressed in detail in the section on clinical manifestations.

Dissection vs. Aneurysm. The relationship between dissection and aneurysmal disease requires clarification. Dissection and aneurysm are separate entities, although they often coexist and are mutual risk factors. In most cases, dissection occurs in patients without aneurysms. The subsequent progressive dilatation of the weakened outer aortic wall results in an aneurysm. On the other hand, in patients with degenerative aneurysms, the ongoing deterioration of the aortic wall can lead to a superimposed dissection. The overused term *dissecting aneurysm* should be reserved for this specific situation.

Classification. For management purposes, aortic dissections are classified according to their location and chronicity. Improvements in imaging have increasingly revealed variants of aortic dissection that probably represent different forms along the spectrum of this condition.

Location To guide treatment, dissections are categorized according to their anatomic location and extent. The two traditional classification schemes that remain in common use are the DeBakey and the Stanford classification systems (Fig. 22-19).^{121,122} In their current forms, both of these schemes describe the segments of aorta that are involved in the dissection, rather than the site of the initial intimal tear. The main drawback of the Stanford classification system is that it does not distinguish between patients with isolated ascending aortic dissection and patients with dissection involving the entire aorta. Both types of patients would be classified as having type A dissections, despite the fact that their treatment, follow-up, and prognosis are substantially different.

Additional classification schemas include that by Borst and associates,¹²³ in which the ascending and descending aorta are considered independently; the recent modification of the DeBakey classification by Tsagakis et al,¹²⁴ which extends type II dissection into the aortic arch; and the Penn modification of the Stanford classification,^{125,126} which expands the classification to include the presence of tissue and global malperfusion. These modifications may help to better streamline the primary surgical intervention; patients with isolated proximal aortic dissection usually undergo emergent operation, as do patients with both proximal and distal aortic dissection. Patients with isolated distal aortic dissection are typically treated medically, unless complications requiring surgery develop. Additionally, these changes are reflective of a shift in some aortic centers from the more traditional approach that is primarily focused on emergent surgical repair of the ascending aorta toward one that, in select patients, additionally treats distal dissection entry points with off-label endovascular therapy.¹²⁷

Chronicity Aortic dissection also is categorized according to the time elapsed since the initial tear. Dissection is considered

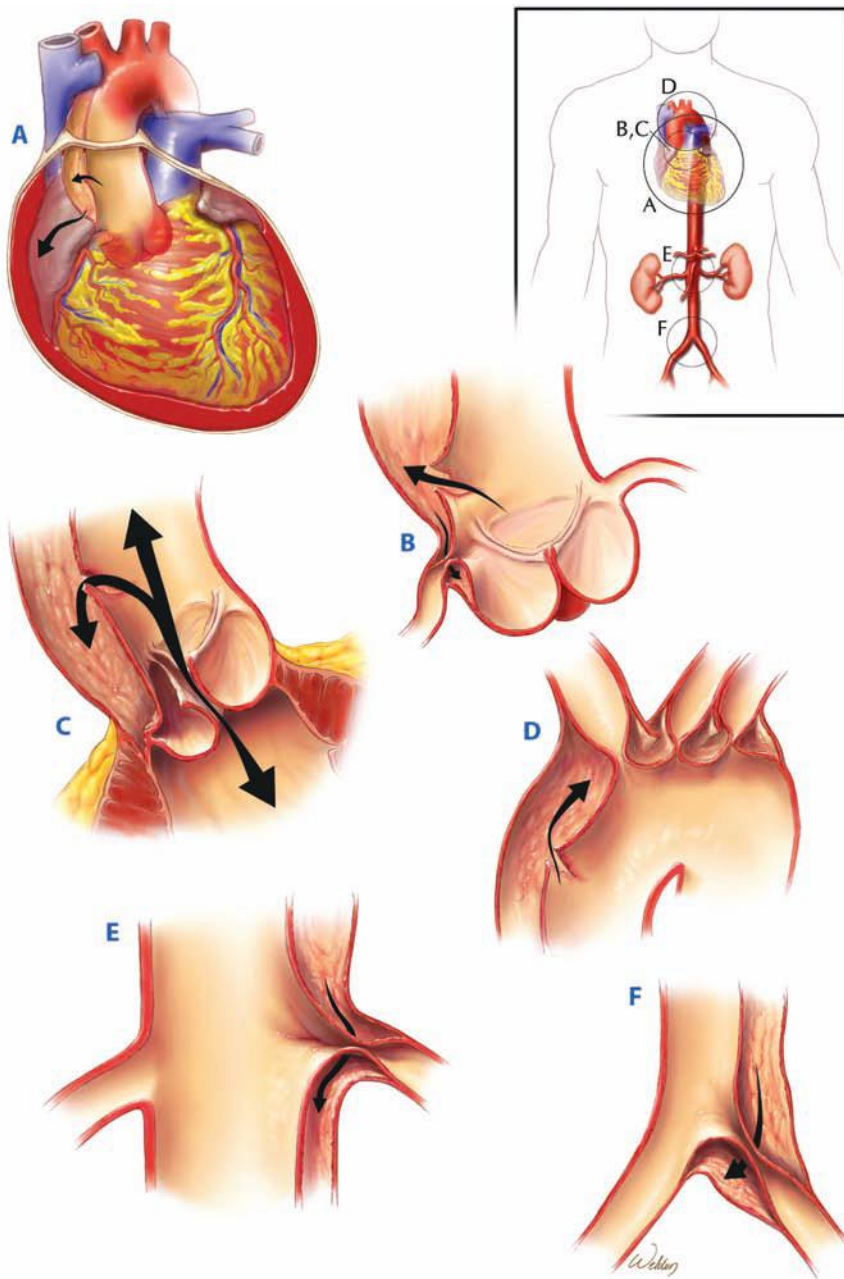


Figure 22-18. Illustration of the potential anatomic consequences of aortic dissection, with a mapped diagram of affected regions (*inset*). **A.** Ascending aortic rupture and cardiac tamponade. **B.** Disruption of coronary blood flow. **C.** Injury to the aortic valve causing regurgitation. **D, E, and F.** Compromised blood flow to branch vessels, causing ischemic complications. (Images adapted from Creager MA, Dzau VS, Loscalzo J, eds. *Vascular Medicine*. Philadelphia: WB Saunders; 2006. Copyright © Saunders/Elsevier, 2006. Fig. 35-1.)

acute within the first 14 days after the initial tear; after 14 days, the dissection is considered chronic. Although arbitrary, the distinction between acute and chronic dissections has important implications, not only for decision-making about perioperative management strategies and operative techniques, but also for evaluating surgical results. Figure 22-20 provides an algorithm for the management of acute aortic dissection. In light of the importance of acuity, Borst and associates¹²³ have proposed a third phase—termed *subacute*—to describe the transition between the acute and chronic phases. The subacute period encompasses days 15 through 60 after the initial tear. Although this is past the traditional 14-day acute phase, patients with subacute dissection continue to have extremely fragile aortic tissue, which may complicate operative treatment and increase the risks associated with surgery.

Variants As noted earlier, advancements in noninvasive imaging of the aorta have revealed variants of aortic dissection (see Fig. 22-17). The recently introduced term *acute aortic*

syndrome encompasses classic aortic dissection and its variants. Other aortic syndromes, which were once thought to be rare, include *intramural hematoma (IMH)* and *penetrating aortic ulcer (PAU)*. Although the issue is somewhat controversial, the current consensus is that, in most cases, these variants of dissection should be treated identically to classic dissection.

An IMH is a collection of blood within the aortic wall, without an intimal tear, that is believed to be due to rupture of the vasa vasorum within the media. The accumulation of blood can result in a secondary intimal tear that ultimately leads to a dissection.¹²⁸ Because IMH and aortic dissection represent a continuum, it is possible that IMH is seen less frequently than aortic dissection because IMH rapidly progresses to true dissection. The prevalence of IMH among patients with acute aortic syndromes is approximately 6%, and 16% progress to full dissection.¹²⁹ An IMH can be classified according to its location (i.e., ascending or descending) and should be treated analogously to classic dissection.¹³⁰

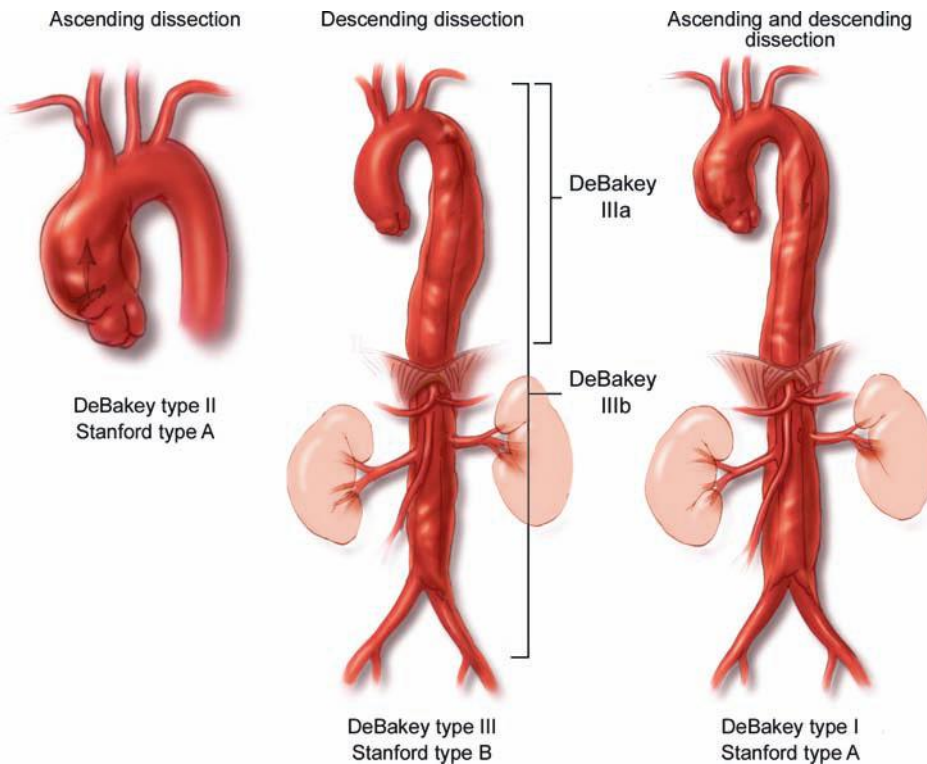


Figure 22-19. Illustration of the classification schemes for aortic dissection based on which portions of the aorta are involved. Dissection can be confined to the ascending aorta (*left*) or descending aorta (*middle*), or it can involve the entire aorta (*right*). (Reproduced with permission from Creager MA, Dzau VS, Loscalzo J, eds. *Vascular Medicine*. Philadelphia: WB Saunders; 2006. Copyright © Saunders/Elsevier, 2006, Fig. 35-2).

A PAU is essentially a disrupted atherosclerotic plaque that projects into the aortic wall and is associated with surrounding hematoma. Eventually, the ulcer can penetrate the aortic wall, which leads to dissection or rupture. The rate of disease progression is higher than that of IMH alone.¹³¹

Causes and Clinical History

Aortic dissection is a lethal condition with a reported incidence of 3.5 per 100,000 in the United States.¹³² Without appropriate modern medical or surgical treatment, most patients (approximately 90%) die within 3 months of dissection, mostly from rupture.^{133,134}

Although several risk factors for aortic dissection have been identified, the specific causes remain unknown. Ultimately, any condition that weakens the aortic wall increases the risk of aortic dissection. Common general cardiovascular risk factors, such as smoking, hypertension, atherosclerosis, and hypercholesterolemia, are associated with aortic dissection. Patients with connective tissue disorders, aortitis, bicuspid aortic valve, or preexisting medial degenerative disease are at risk for dissection, especially if they already have a thoracic aortic aneurysm.²¹ Aortic injury during cardiac catheterization, surgery, or endovascular aortic repair is a common cause of iatrogenic dissection. Other conditions that are associated with aortic dissection include cocaine and amphetamine abuse,¹³⁵ as well as severe emotional stress or extreme physical exertion such as during weightlifting.¹³⁶ Advances in the understanding of the molecular mechanisms behind abdominal aortic aneurysms have prompted similar investigations of thoracic aortic dissection.¹³⁷⁻¹³⁹

Clinical Manifestations

The onset of dissection often is associated with severe chest or back pain, classically described as “tearing,” that migrates

distally as the dissection progresses along the length of the aorta. The location of the pain often indicates which aortic segments are involved. Pain in the anterior chest suggests involvement of the ascending aorta, whereas pain in the back and abdomen generally indicates involvement of the descending and thoracoabdominal aorta. Additional clinical sequelae of acute aortic dissection vary substantially and are best considered in terms of the dissection’s potential anatomic manifestations at each level of the aorta (see Fig. 22-18 and Table 22-5). Thus, potential complications of dissection of the aorta (and involved secondary arteries) may include cardiac ischemia (coronary artery) or tamponade, stroke (brachiocephalic arteries), paraplegia or paraparesis (intercostal arteries), mesenteric ischemia (superior mesenteric artery), kidney failure (renal arteries), and limb ischemia or loss of motor function (brachial or femoral arteries).

Ascending aortic dissection can directly injure the aortic valve, causing regurgitation. The severity of the regurgitation varies with the degree of commissural disruption, which ranges from partial separation of only one commissure, producing mild valvular regurgitation, to full separation of all three commissures and complete prolapse of the valve into the left ventricle, producing severe acute heart failure. Patients with acute aortic valve regurgitation may report worsening dyspnea.

Ascending dissections also can extend into the coronary arteries or shear the coronary ostia off of the true lumen, causing acute coronary occlusion; when this occurs, it most often involves the right coronary artery. The sudden disruption of coronary blood flow can cause a myocardial infarction. This presentation of acute myocardial ischemia can mask the presence of aortic dissection, which results in delayed diagnosis and treatment.¹⁴⁰

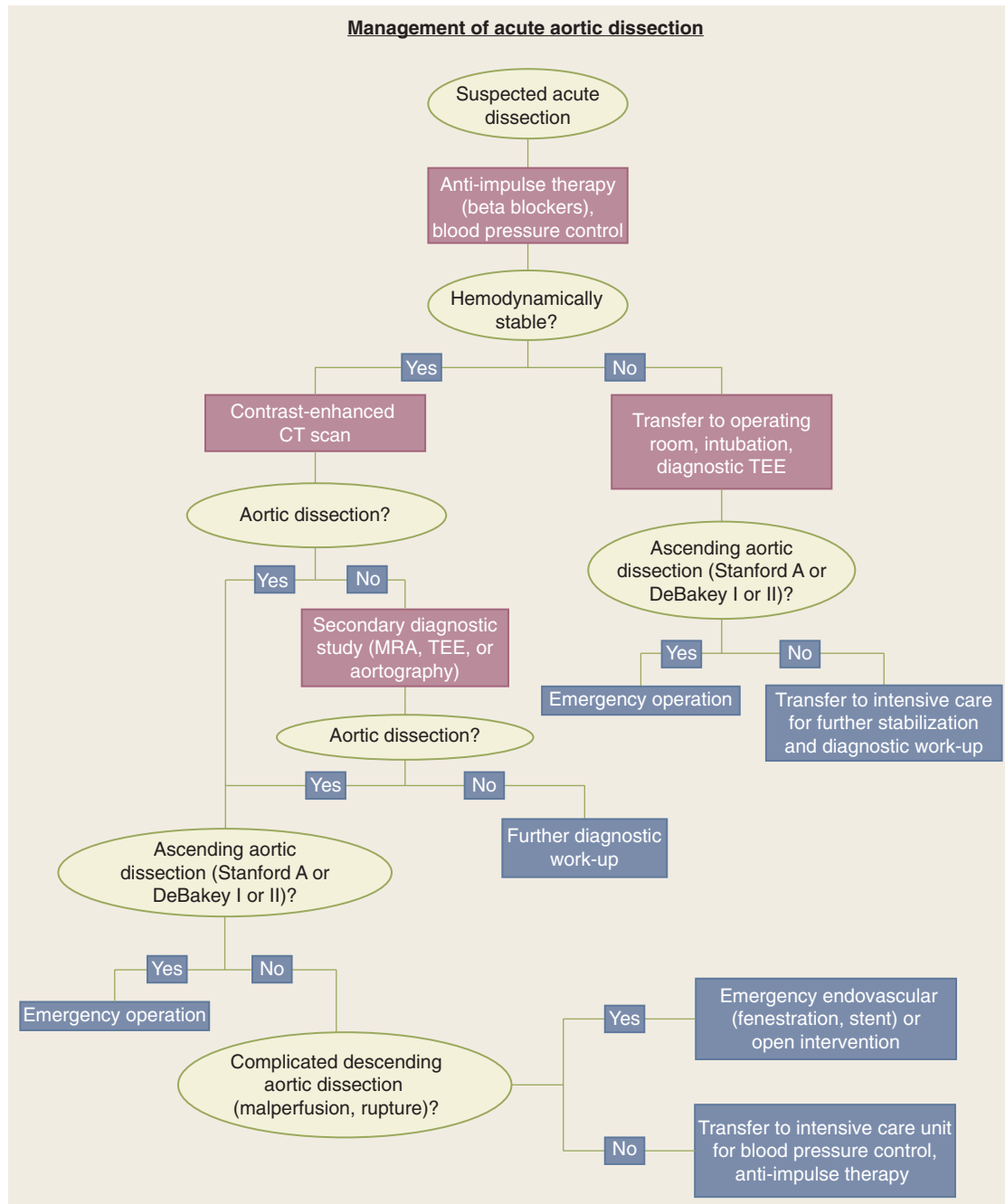


Figure 22-20. Algorithm used to facilitate decisions regarding treatment of acute aortic dissection. CT = computed tomography; MRA = magnetic resonance angiography; TEE = transesophageal echocardiography.

The thin and inflamed outer wall of a dissected ascending aorta often produces a serosanguineous pericardial effusion that can accumulate and cause tamponade. Suggestive signs include jugular venous distention, muffled heart tones, pulsus paradoxus, and low-voltage electrocardiogram (ECG) tracings. Free rupture into the pericardial space produces rapid tamponade and is generally fatal.

As the dissection progresses, any branch vessel from the aorta can become involved, which results in compromised blood flow and ischemic complications (i.e., malperfusion). Therefore, depending on which arteries are involved, the dissection can produce acute stroke, paraplegia, hepatic failure, bowel infarction, renal failure, or a threatened ischemic limb.

Diagnostic Evaluation

Because of the variations in severity and the wide variety of potential clinical manifestations, the diagnosis of acute aortic dissection can be challenging.¹⁴¹⁻¹⁴³ Only 3 out of every 100,000 patients who present to an emergency department with acute chest, back, or abdominal pain are eventually diagnosed with aortic dissection. Not surprisingly, diagnostic delays are common; delays beyond 24 hours after hospitalization occur in up to 39% of cases. Unfortunately, delays in diagnosis lead to delays in treatment, which can have disastrous consequences. The European Society of Cardiology Task Force on Aortic Dissection stated, “The main challenge in managing acute aortic dissection is to suspect and thus diagnose the disease as early

Table 22-5

Anatomic complications of aortic dissection and their associated symptoms and signs

ANATOMIC MANIFESTATION	SYMPTOMS AND SIGNS
Aortic valve insufficiency	Dyspnea Murmur Pulmonary rales Shock
Coronary malperfusion	Chest pain with characteristics of angina Nausea/vomiting Shock Ischemic changes on electrocardiogram Elevated cardiac enzymes
Pericardial tamponade	Dyspnea Jugular venous distension Pulsus paradoxus Muffled cardiac tones Shock Low-voltage electrocardiogram
Subclavian or iliofemoral artery malperfusion	Cold, painful extremity Extremity sensory and motor deficits Peripheral pulse deficit
Carotid artery malperfusion	Syncope Focal neurologic deficit (transient or persistent) Carotid pulse deficit Coma
Spinal malperfusion	Paraplegia Incontinence
Mesenteric malperfusion	Nausea/vomiting Abdominal pain
Renal malperfusion	Oliguria or anuria Hematuria

as possible.”¹⁴¹ A recent study by the International Registry of Acute Aortic Dissection examined the reasons for delayed diagnosis and found that diagnosis lagged in women, as well as in patients with atypical symptoms, such as fever or mild pain (rather than severe pain).¹⁴⁰ A high index of suspicion is critical, particularly in younger, atypical patients, who may have connective tissue disorders or other, less common risk factors.

Most patients with acute aortic dissection (80%–90%) experience severe pain in the chest, back, or abdomen.^{141–143} The pain usually occurs suddenly, has a sharp or tearing quality, and often migrates distally as the dissection progresses along the aorta. For classification purposes (acute vs. subacute vs. chronic), the onset of pain is generally considered to represent the beginning of the dissection process. Most of the other common symptoms either are nonspecific or are caused by the secondary manifestations of dissection.

A discrepancy between the extremities in pulse, blood pressure, or both is the classic physical finding in patients with aortic dissection. It often occurs because of changes in flow in

the true and false lumens, and it does not necessarily indicate extension into an extremity branch vessel. Involvement of the aortic arch often creates differences between the right and left arms, whereas descending aortic dissection often causes differences between the upper and lower extremities. Like symptoms, most of the physical signs after dissection are related to the secondary manifestations and therefore vary considerably (Table 22-5). For example, signs of stroke or a threatened ischemic limb may dominate the physical findings in patients with carotid or iliac malperfusion, respectively.

Unfortunately, laboratory studies are of little help in diagnosing acute aortic dissection. There has been continued interest in using D-dimer level to aid in making this diagnosis.¹⁴⁴ Several reports indicate that D-dimer is an extremely sensitive indicator of acute aortic dissection; elevated levels are found in approximately 97% of affected patients.¹⁴⁵ Tests that are commonly used to detect acute coronary events—including ECG and tests for serum markers of myocardial injury—deserve special consideration and need to be interpreted carefully. Normal ECGs and serum marker levels in patients with acute chest pain should raise suspicion about the possibility of aortic dissection. It is important to remember that ECG changes and elevated serum marker levels associated with myocardial infarction do not exclude the diagnosis of aortic dissection, because dissection can cause coronary malperfusion. Of note, abnormal ECGs have recently been shown to delay the diagnosis of aortic dissection, and the possibility of aortic dissection should not be prematurely ruled out.^{140,146} Similarly, although CXRs may show a widened mediastinum or abnormal aortic contour, up to 16% of patients with dissection have a normal-appearing CXR.¹⁴² The value of the CXR for detecting aortic dissection is limited, with a sensitivity of 67% and a specificity of 86%.¹⁴⁷

Once the diagnosis of dissection is considered, the thoracic aorta should be imaged with CT, MRA, or echocardiography. The accuracy of these noninvasive imaging tests has all but eliminated the need for diagnostic aortography in most patients with suspected aortic dissection. Currently, the diagnosis of aortic dissection is usually established with contrast-enhanced CT, which has a sensitivity of 98% and a specificity of 87%, and, acquires images swiftly.¹⁴⁸ The classic diagnostic feature is a double-lumen aorta (Fig. 22-21). In addition, CT scans provide essential information about the segments of the aorta involved; the acuity of the dissection; aortic dilatation, including the presence of preexisting degenerative aneurysms; and the development of threatening sequelae, including pericardial effusion, early aortic rupture, and branch vessel compromise. Although MRA also provides excellent imaging (with both a sensitivity and specificity of 98%), the MR suite is not well suited for critically ill patients. In patients who cannot undergo contrast-enhanced CT or MRA, transthoracic echocardiography can be used to establish the diagnosis.

Transesophageal echocardiography (TEE) is excellent for detecting dissection, aneurysm, and IMH in the ascending aorta. In appropriate hands, TEE has a demonstrated sensitivity and specificity as high as 98% and 95%, respectively.¹⁴⁹ Furthermore, TEE offers important information about ventricular function and aortic valve competency. Finally, TEE is the diagnostic modality of choice for hemodynamically unstable patients in whom the diagnosis of ascending dissection is suspected; ideally, these patients should be taken to the operating room, where the TEE can be performed and, if the TEE is confirmatory, surgery can be started immediately.

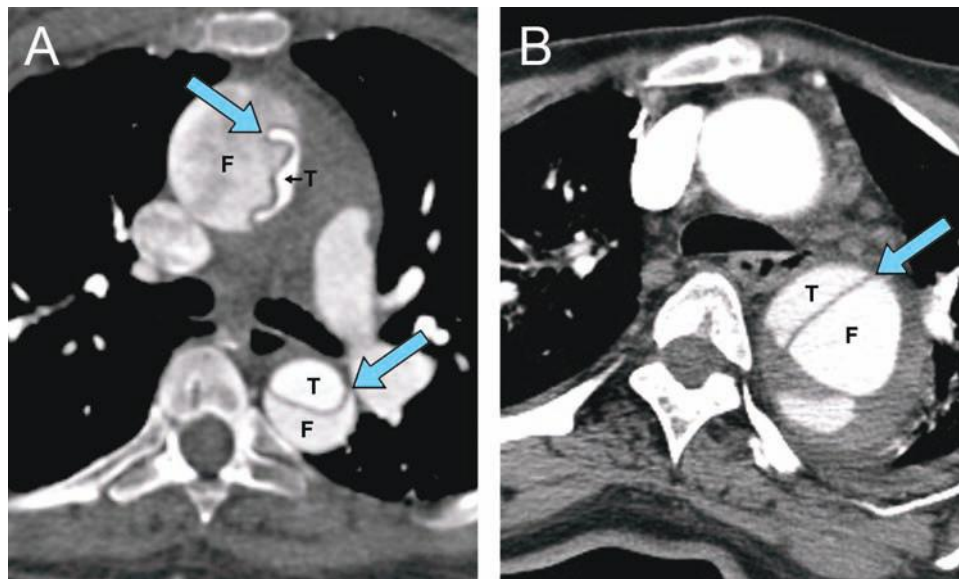


Figure 22-21. Computed tomographic scans showing that the aorta has been separated into two channels—the true (T) and false (F) lumens—in two patients with different phases of aortic dissection. **A.** An acute DeBakey type I aortic dissection. The dissecting membrane appears wavy (arrows) in the early phase of dissection. Here, the true lumen of the proximal aorta can be seen to be extensively compressed. This may lead to malperfusion of the heart. **B.** A chronic DeBakey type III aortic dissection. In the chronic phase, the membrane appears straighter and less mobile (arrow) because it has stabilized over time. (Used with permission of Baylor College of Medicine.)

In selected patients with ascending aortic dissection (i.e., those who have evidence of preexisting coronary artery disease), coronary angiography can be considered before surgery. Specific relative indications in these patients include a history of angina or myocardial infarction, a recent myocardial perfusion study with abnormal results, previous coronary artery bypass or angioplasty, and acute ischemic changes on ECG. Contraindications include hemodynamic instability, aortic rupture, and pericardial effusion.¹⁵⁰ In our practice, patients with acute aortic dissections rarely undergo coronary angiography. However, all patients presenting for elective repair of chronic ascending dissections have diagnostic coronary angiograms taken.

Of note, when malperfusion of the renal, visceral, or lower extremity arteries develops, the patient is usually treated in an angiography suite or hybrid operating room.¹²⁷ Although the dissection usually is diagnosed on CT scan, these patients also undergo aortography, during which the mechanism of the malperfusion is ascertained and, if possible, corrected. Hence, catheter-based aortography may be obsolete as a diagnostic test for dissection, but it remains beneficial for patients with malperfusion.

Treatment

Initial Assessment and Management. Regardless of the location of the dissection, the initial treatment is the same for all patients with suspected or confirmed acute aortic dissection (see Fig. 22-20). Furthermore, because of the potential for rupture before the diagnosis is confirmed, aggressive pharmacologic management is started once there is clinical suspicion of dissection, and this treatment is continued during the diagnostic evaluation. The goals of pharmacologic treatment are to stabilize the dissection and prevent rupture.

Patients are monitored closely in an intensive care unit. Indwelling radial arterial catheters are used to monitor blood pressure and optimize titration of antihypertensive agents. In

cases of limb malperfusion, blood pressures in the affected limb can underrepresent the central aortic pressure; therefore, blood pressure is measured in the arm with the better pulse. Central venous catheters ensure reliable IV access for delivering vasoactive medications. Pulmonary artery catheters are reserved for patients with severe cardiopulmonary dysfunction.

In addition to confirming the diagnosis of dissection and defining its acuity and extent, the initial evaluation focuses on determining whether any of several life-threatening complications are present. Particular attention is paid to changes in neurologic status, peripheral pulses, and urine output. Serial laboratory studies—including arterial blood gas concentrations, complete blood cell count, prothrombin and partial thromboplastin times, and serum levels of electrolytes, creatinine, blood urea nitrogen, and liver enzymes—are useful for detecting organ ischemia and optimizing management.

The initial management strategy, commonly described as *anti-impulse therapy* or *blood pressure control*, focuses on reducing aortic wall stress, the force of left ventricular ejection, chronotropy, and the rate of change in blood pressure (dP/dT). Reductions in dP/dT are achieved by lowering both cardiac contractility and blood pressure. The drugs initially used to accomplish these goals include IV beta-adrenergic blockers, direct vasodilators, calcium channel blockers, and angiotensin-converting enzyme inhibitors. These agents are used to achieve a heart rate between 60 and 80 bpm, a systolic blood pressure between 100 and 110 mmHg, and a mean arterial blood pressure between 60 and 75 mmHg. These hemodynamic targets are maintained as long as urine output remains adequate and neurologic function is not impaired. Achieving adequate pain control with IV opiates, such as morphine and fentanyl, is important for maintaining acceptable blood pressure control.

Beta antagonists are administered to all patients with acute aortic dissections unless there are strong contraindications, such as severe heart failure, bradyarrhythmia, high-grade atrioventricular

conduction block, or bronchospastic disease. Esmolol can be useful in patients with bronchospastic disease because it is a cardioselective, ultrafast-acting agent with a short half-life. Labetalol, which causes both nonselective beta blockade and postsynaptic α_1 -blockade, reduces systemic vascular resistance without impairing cardiac output. Doses of beta antagonists are titrated to achieve a heart rate of 60 to 80 bpm. In patients who cannot receive beta antagonists, calcium channel blockers such as diltiazem are an effective alternative. Nitroprusside, a direct vasodilator, can be administered once beta blockade is adequate. When used alone, however, nitroprusside can cause reflex increases in heart rate and contractility, elevated dP/dT, and progression of aortic dissection. Enalapril and other angiotensin-converting enzyme inhibitors are useful in patients with renal malperfusion. These drugs inhibit renin release, which may improve renal blood flow.

Treatment of Ascending Aortic Dissection

Acute Dissection Because of the risk of aortic rupture, acute ascending aortic dissection is usually considered an absolute indication for emergency surgical repair. However, specific patient groups may benefit from nonoperative management or delayed operation.¹⁵¹ Delayed repair should be considered

8► for patients who (a) present with severe acute stroke or mesenteric ischemia, (b) are elderly and have substantial comorbidity, (c) are in stable condition and may benefit from transfer to specialized centers, or (d) have undergone a cardiac operation in the remote past. Regarding the last group, it is important that the previous operation not be too recent; dissections that occur during the first 3 weeks after cardiac surgery pose a high risk of rupture and tamponade, and such dissections warrant early operation.¹⁵²

In the absence of the circumstances listed earlier, most patients with acute ascending aortic dissection undergo emergent graft replacement of the ascending aorta. Operative repair is similar to that for aneurysm of the transverse aortic arch (described previously) because hypothermic circulatory arrest is commonly used regardless of the extent of repair. Immediately before the operation begins, intraoperative TEE is commonly performed to further assess baseline myocardial and valvular function and, if necessary, to confirm the diagnosis. The operation is performed via a median sternotomy with cardiopulmonary bypass and hypothermic circulatory arrest (Fig. 22-22). In preparation for circulatory arrest, cannulas are placed in the right axillary artery (to provide arterial inflow) and in the right atrium (to provide venous drainage).⁷⁷ After an appropriate level of cooling has been achieved (usually between 22°C and 24°C), cardiopulmonary bypass is stopped, and the ascending aorta is opened. The innominate artery is then occluded with a clamp or snare, and flow from the axillary artery cannula is used to provide ACP. A separate perfusion catheter can be placed in the left common carotid artery to ensure perfusion of the left side of the brain. This strategy of performing the distal anastomosis during a brief period of circulatory arrest, often termed *open distal anastomosis*, obviates the need to place a clamp across the fragile aorta, avoiding further aortic damage. Also, it allows the surgeon to carefully inspect the aortic arch for intimal tears. Traditionally, the entire arch is replaced only if a primary intimal tear is located in the arch or if the arch is aneurysmal; most commonly, repair is limited to replacement of the entire ascending aorta or to a beveled “hemiarch” repair.¹⁵³ Conservative repair has

been shown to increase the likelihood of early survival.¹⁵⁴ The distal aortic cuff is prepared by tacking the inner and outer walls together and using surgical adhesive to obliterate the false lumen and strengthen the tissue. A polyester tube graft is sutured to the distal aortic cuff. The anastomosis between the graft and the aorta is fashioned so that blood flow will be directed into the true lumen; this often alleviates any distal malperfusion problems that were present preoperatively. After the distal anastomosis is reinforced with additional adhesive, the graft is de-aired and clamped, full cardiopulmonary bypass is resumed, rewarming is initiated, and the proximal portion of the repair is started. In the absence of annuloaortic ectasia or connective tissue disorders—which generally necessitate aortic root replacement—aortic valve regurgitation can be corrected by resuspending the commissures onto the outer aortic wall.¹⁵⁵ The proximal aortic cuff is prepared with tacking sutures and surgical adhesive before the proximal aortic anastomosis is performed.

In the majority of patients who undergo surgical repair of acute ascending dissection, the dissection persists distal to the site of the operative repair; the residually dissected aorta, which generally includes at least a portion of the transverse aortic arch as well as a large portion of the distal aorta, is susceptible to dilatation over time. Extensive dilatation of the arch or distal aorta develops in 25% to 40% of survivors^{156,157} and often necessitates further aortic repair. Additionally, long-term survival after acute proximal aortic dissection is generally poor, and rupture of the dilated distal aorta is a common cause of late death in these patients.^{154,156-158}

The challenges that survivors of acute proximal aortic dissection commonly face over time have led to the development of alternate acute dissection strategies such as total arch replacement¹⁵⁹ and hybrid arch strategies to extend proximal aortic repair into the distal aorta. The goal of hybrid arch approaches in acute dissection is to thrombose the residual false lumen by compressing it with the radial force that is exerted by a stent-graft placed in the true lumen, thereby facilitating remodeling and preventing late aneurysm formation.¹⁶⁰ However, in such repairs, the compressed false lumen may continue to be perfused in a retrograde fashion.

In Europe, Japan, and elsewhere, one-piece hybrid prostheses are now available that incorporate a polyester graft for the proximal repair and a stent-graft component for the descending aorta. These devices are deployed in an antegrade fashion after the arch has been resected; this procedure is termed a “frozen elephant trunk” repair.¹⁶¹ In the United States, such devices are unavailable, so this repair is commonly done by concomitantly deploying a commercially available stent-graft in an antegrade fashion after fully or partly¹⁶² replacing the ascending aorta and aortic arch. In some variations of this off-label approach, the stent-graft is directly sutured to the distal aspect of the proximal open repair, whereas in others, there may be a gap of native tissue between the open and endovascular repair. Although this technique appears to be extensively used outside the United States, and with early and midterm success,^{160,163-165} only a few U.S. reports describe its use.^{162,166,167} Emerging reports describe an enhanced risk of spinal cord ischemia, a risk that is not usually associated with open arch repair. This is probably due to the extensive coverage of the intercostal vessels by the stent-graft. Uncertainties in the frozen elephant trunk procedure need to be addressed before it becomes a standard recommendation for this subset of patients.¹⁶⁸

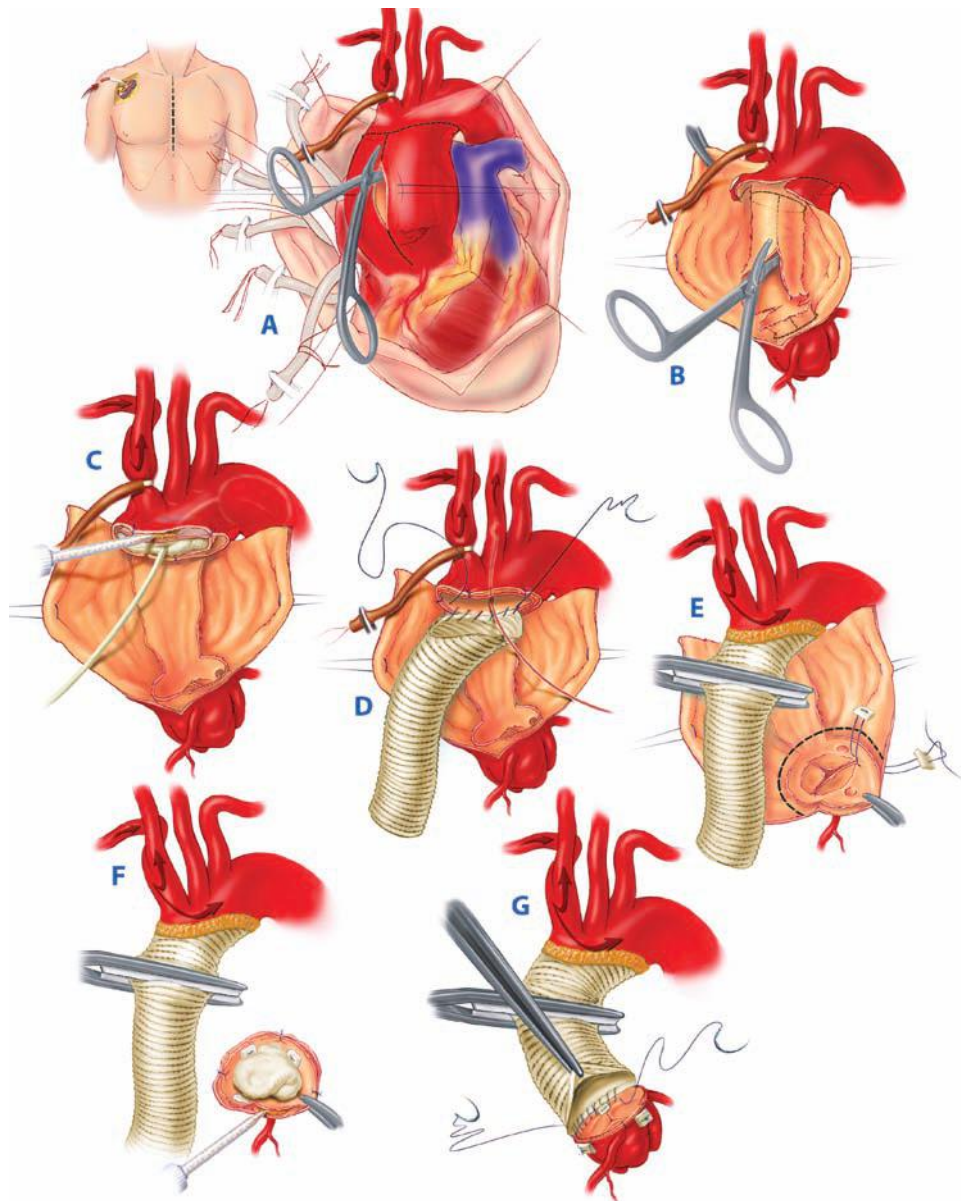


Figure 22-22. Illustration of proximal aortic repair for acute ascending aortic dissection. **A.** This repair requires a median sternotomy and cardiopulmonary bypass. The ascending aorta is opened during hypothermic circulatory arrest, while antegrade cerebral perfusion is delivered via an axillary artery graft (see Fig. 22-8). **B.** The dissecting membrane is removed to expose the true lumen. **C.** Surgical adhesive is used to obliterate the false lumen and strengthen the aorta for the distal anastomosis. A 30-mL balloon catheter is placed in the true lumen to compress the distal false lumen; this helps keep the adhesive (which strengthens the repair) within the proximal false lumen and prevents distal embolization of the adhesive through re-entry sites. A moist gauze sponge is placed in the true lumen to prevent the adhesive from running into the brachiocephalic vessels. **D.** An open distal anastomosis prevents clamp injury of the arch tissue and allows inspection of the arch lumen. A balloon perfusion catheter in the left common carotid artery ensures antegrade perfusion of the left cerebral circulation. If the origin of the dissection (i.e., intimal tear or disruption) does not extensively involve the greater curvature of the aortic arch, and if there is no evidence of a preexisting arch aneurysm, a beveled, hemi-arch repair is carried out, preserving most of the greater curvature of the arch. The aorta is transected, beginning at the greater curvature immediately proximal to the origin of the innominate artery and extending distally toward the lesser curvature to the level of the left subclavian artery. Consequently, most of the transverse aortic arch, except for the dorsal segment containing the brachiocephalic arteries, is removed. An appropriately sized, sealed (with collagen or gelatin) Dacron tube graft is selected, and the beveled distal anastomosis is made with continuous 3-0 or 4-0 monofilament suture. **E.** After the anastomosis is covered with additional adhesive and cardiopulmonary bypass is resumed, the aortic valve is assessed. Disrupted commissures are resuspended with pledgeted mattress sutures to restore valvular competence. **F.** The aorta is generally transected at the sinotubular junction, and adhesive is used to obliterate the false lumen within the proximal aortic stump. A moist gauze sponge is placed within the true lumen to prevent the adhesive from injuring the aortic valve leaflets or entering the coronary artery ostia. **G.** After the adhesive has set, the proximal anastomosis is carried out at the sinotubular junction, incorporating the distal margin of the commissures. (Reproduced with permission from Creager MA, Dzau VS, Loscalzo J, eds. *Vascular Medicine*. Philadelphia: WB Saunders; 2006. Copyright © Saunders/Elsevier, 2006, Fig. 35-3A–G.)

Chronic Dissection Occasionally, patients with ascending aortic dissection present for repair in the chronic phase. In most respects, the operation is similar to that for acute dissection repair. One notable difference is that the tissue is stronger in chronic dissection than in acute dissection, which makes suturing safer. In addition, the false lumen is not obliterated at the distal anastomosis; instead, the dissecting membrane is fenestrated into the arch to ensure perfusion of both lumens and to prevent postoperative malperfusion complications. Unlike operations for acute dissection, operations for chronic dissection are often aggressive repairs that extend into the arch and root, because the tissues are much less fragile.

Treatment of Descending Aortic Dissection

Nonoperative Management Nonoperative, pharmacologic management of acute descending aortic dissection results in lower morbidity and mortality rates than traditional surgical treatment does.¹⁴² The most common causes of death during nonoperative treatment are aortic rupture and end-organ malperfusion. Therefore, patients are continually reassessed for new complications. At least two serial CT scans—usually obtained on day 2 or 3 and on day 8 or 9 of treatment—are compared with the initial scan to rule out significant aortic expansion.

Once the patient's condition has been stabilized, pharmacologic management is gradually shifted from IV to oral medications. Oral therapy, which usually includes a beta antagonist, is initiated when systolic pressure is consistently between 100 and 110 mmHg and the neurologic, renal, and cardiovascular systems are stable. Many patients can be discharged after their blood pressure is well controlled with oral agents and after serial CT scans confirm the absence of aortic expansion.

Long-term pharmacologic therapy is important for patients with chronic aortic dissection. Beta blockers remain the drugs of choice.¹⁶⁹ In a 20-year follow-up study, DeBaakey and colleagues¹⁷⁰ found that inadequate blood pressure control was associated with late aneurysm formation. Aneurysms developed in only 17% of patients with “good” blood pressure control, compared with 45% of patients with “poor” control.

Aggressive imaging follow-up is recommended for all patients with chronic aortic dissection.¹⁷¹ Both contrast-enhanced CT and MRA scans provide excellent aortic imaging and facilitate serial comparisons to detect progressive aortic expansion. The first surveillance scan is obtained approximately 6 weeks after the onset of dissection. Subsequent scans are obtained at least every 3 months for the first year, every 6 months for the second year, and annually thereafter. Scans are obtained more frequently in high-risk patients, such as those with Marfan syndrome, and in those in whom significant aortic expansion is detected. For patients who have undergone graft repair of descending aortic dissection, annual CT or MRA scans are also obtained to detect false aneurysm formation or dilatation of unrepaired segments of aorta. Early detection of worrisome changes allows timely, elective intervention before rupture or other complications develop; rupture of the distal aorta is relatively common in patients with chronic aortic dissection and often results in death.¹⁵⁸

Indications for Surgery In the acute phase, surgery has been traditionally reserved for patients who experience complications.¹⁷² In general terms, such intervention is intended to prevent or repair ruptures and relieve life-threatening ischemic manifestations.

During the acute phase of a dissection, the specific indications for operative intervention include aortic rupture, increasing

periaortic or pleural fluid volume, rapidly expanding aortic diameter, uncontrolled hypertension, and persistent pain despite adequate medical therapy. Aortic rupture may be contained by nearby tissues (such as a localized periaortic hematoma detected on imaging studies) or it may be free and uncontained (presenting as a hemothorax, hemoperitoneum, or massive retroperitoneal hematoma accompanied by shock). Acute dissection superimposed on a preexisting aneurysm is considered a life-threatening condition and is therefore another indication for operation. Finally, patients who have a history of noncompliance with medical therapy may ultimately benefit more from surgical treatment if they are otherwise reasonable operative candidates.

Acute malperfusion syndromes also warrant intervention. In the recent past, visceral and renal malperfusion were considered indications for operation. Percutaneous interventions, however, have largely replaced open surgery for treatment of these complications. When the endovascular approach is unavailable or unsuccessful, surgical options can be used.

In the chronic phase, the indications for operative intervention for aortic dissections are similar to those for degenerative thoracic aortic aneurysms, although a slightly lower threshold of repair is now recommended. Guidelines for thoracic aortic disease⁴⁰ recommend elective operation in otherwise healthy patients when the affected segment has reached a diameter of 5.5 cm, especially in patients with connective tissue disorders. Rapid aortic enlargement (>1 cm per year) and other factors that increase the likelihood of aortic rupture may also be considered.

Endovascular Treatment

Malperfusion Syndrome Endovascular therapy is routinely used in patients with descending aortic dissection complicated by visceral malperfusion.¹⁷³ Abdominal malperfusion syndrome often is fatal; prompt identification of visceral ischemia and expedited treatment to restore hepatic, gastrointestinal, and renal perfusion are imperative for a positive outcome. As described in a later section, several open surgical techniques can be used to re-establish blood flow to compromised organs. However, in acute cases, open surgery is associated with poor outcomes. Therefore, endovascular intervention is the preferred initial approach in such cases. In one endovascular technique known as *endovascular fenestration*, a balloon is used to create a tear in the dissection flap, which allows blood to flow in both the true and false lumens. This technique can be used when a visceral branch is being supplied by an underperfused true or false lumen. Placement of a stent graft in the true lumen of the aorta can resolve a “dynamic” malperfusion. Occasionally, a small stent must be placed directly in the lumen of a visceral or renal artery because the dissection has propagated into the branch, resulting in “static” malperfusion at the origin.

Iliofemoral malperfusion causing limb-threatening leg ischemia also can be treated via an endovascular approach. However, direct surgical revascularization—usually by placing a femoral-to-femoral arterial bypass graft—is a better option whenever the endovascular procedure cannot be performed expeditiously.

Acute Dissection Although surgery has been traditionally recommended for patients with complicated acute descending aortic dissection, many centers have shifted toward using endovascular stent grafts as the preferred approach in these cases,¹⁷⁴ even though this is an off-label application of stent grafts. Evidence suggests that emergent endovascular repair in patients with true

lumen collapse and complications such rupture or dynamic malperfusion may be lifesaving in these difficult-to-treat patients. However, these patients remain at risk of further complication or future reintervention. Although endovascular repair in patients with connective tissue disorder is generally not recommended, this technique may be used as a bridge to later definitive repair in such life-threatening circumstances.

Less convincing is the evidence in support of using endovascular stent grafts to treat uncomplicated acute descending dissection. The goal of this treatment strategy is to use the stent graft to cover the intimal tear, seal the entry site of the dissection, and eventually cause thrombosis of the false lumen to aid in aortic remodeling and reduce late aortic expansion. However, whether this approach is more effective than conventional nonoperative management remains controversial. Moreover, inadvertent retrograde perfusion or pressurization of the endovascularly repaired aortic section is still a risk; therefore, at this time, the use of endografts in patients with uncomplicated, classic dissection remains investigational.^{175,176} Such procedures take place in a hybrid operating room, where access to the true lumen is gained through the femoral arteries. An aortogram is taken, and the intimal tear is identified. Note that the diameter of the true lumen is measured on both the aortogram and a preoperative contrast-enhanced CT scan. A stent graft approximately 10% wider in diameter than the true lumen is selected for these cases. Unlike stents deployed to treat most descending thoracic aortic aneurysms, stents deployed to treat descending aortic dissections must *not* be ballooned, because ballooning can cause a new intimal tear, retrograde dissection into the ascending aorta, or even aortic rupture.

Chronic Dissection Endovascular treatment of chronic descending aortic dissection is also controversial and remains under investigation.^{174,177} These dissections are particularly challenging because the relative rigidity of the dissecting membrane and the presence of multiple re-entry sites make it difficult to exclude the false lumen. Furthermore, interfering with false lumen perfusion may cause ischemic complications, such as bowel infarction or renal failure. Until the safety and effectiveness of endovascular repair for this condition have been demonstrated, patients with chronic descending aortic dissection should be treated with conventional nonoperative management until indications for open surgical repair develop.

Penetrating Aortic Ulcer Unlike patients with classic descending aortic dissection, those with PAUs appear to be very well suited for endovascular intervention. Covering the focal ulceration with a stent graft has been shown to be an effective treatment.¹⁷⁸ In a recent study by Patel and colleagues,¹⁷⁹ endovascular repair of PAU was associated with better early outcomes than open repair. However, when PAU was associated with adjacent hematoma within the aortic wall, rates of subsequent reintervention were increased.

Open Repair

Acute Dissection In patients with acute aortic dissection, surgical repair of the descending thoracic or thoracoabdominal aorta is traditionally associated with high morbidity and mortality.¹⁴² Therefore, the primary goals of surgery are to prevent fatal rupture and to restore branch vessel perfusion.¹⁷² A limited graft repair of the life-threatening aortic lesion achieves these goals while minimizing risks. Because the most common site of rupture in descending aortic dissection is in the proximal third of the descending thoracic aorta, the upper half of the descending thoracic aorta is usually repaired. The

distal half also may be replaced if it exceeds 4 cm in diameter. Graft replacement of the entire thoracoabdominal aorta is not attempted in such cases unless a large coexisting aneurysm mandates this radical approach. Similarly, the repair is not extended into the aortic arch unless the arch is aneurysmal, even if the primary tear is located there. Patients with chronic dissection who require emergency repair because of acute pain or rupture also undergo limited graft replacement of the symptomatic segment.

Because repairing acute dissections entails an increased risk of paraplegia, adjuncts that provide spinal cord protection, such as cerebrospinal fluid drainage and left heart bypass, are used liberally during such repairs,¹⁸⁰ even if the repair is confined to the upper descending thoracic aorta. Proximal control usually is obtained between the left common carotid and left subclavian arteries; any mediastinal hematoma near the proximal descending thoracic aorta is avoided until proximal control is established. After the aorta is opened, the dissecting membrane is excised from the section undergoing graft replacement. The proximal and distal anastomoses use all layers of the aortic wall, thereby excluding the false lumen in the suture lines and directing all blood flow into the true lumen. Although the relative lack of mural thrombus ensures the presence of multiple patent intercostal arteries, extreme tissue fragility may preclude their reattachment.

Malperfusion Syndrome Lower-extremity ischemia is commonly addressed with surgical extra-anatomic revascularization techniques, such as femoral-to-femoral bypass grafting. In patients with abdominal organ ischemia, flow to the compromised bed must be re-established swiftly. When an endovascular approach is unavailable or unsuccessful, open surgery is necessary. Although they are considered second-line therapies, multiple techniques are available, including graft replacement of the aorta (with flow redirected into the true lumen), open aortic fenestration, and visceral or renal artery bypass.

Chronic Dissection A more aggressive replacement usually is performed during elective aortic repairs in patients with chronic dissection. In many regards, the operative approach used in these patients is identical to that used for descending thoracic and thoracoabdominal aortic aneurysms, as described in the first half of this chapter (Fig. 22-23). One key difference is the need to excise as much dissecting membrane as possible to clearly identify the true and false lumens and to locate all important branch vessels. When the dissection extends into the visceral or renal arteries, the membrane can be fenestrated, or the false lumen can be obliterated with sutures or intraluminal stents. Asymmetric expansion of the false lumen can create wide separation of the renal arteries. This problem is addressed by reattaching the mobilized left renal artery to a separate opening in the graft or by performing a left renal artery bypass with a side graft. Wedges of dissecting membrane also are excised from the aorta adjacent to the proximal and distal anastomoses, which allows blood to flow through both true and false lumens. When placing the proximal clamp is not technically feasible, hypothermic circulatory arrest can be used to facilitate the proximal portion of the repair.

OUTCOMES

Improvements in anesthesia, surgical techniques, and perioperative care have led to substantial improvements in outcome after thoracic aortic aneurysm repair. When performed in specialized centers, these operations are associated with excellent survival

rates and acceptable morbidity rates. The interpretation of outcomes data is complicated by site-specific variables, such as the number of years reported and whether data are taken from single-practice centers or from pooled, multicenter, or national registries, and by patient-specific variables, such as type of enrollment, urgency and extent of repair, concomitant procedures performed, and the presence of preexisting risk factors such as advanced age, previous cardiovascular repair, disease of any system or organ, or connective tissue disorder.

Repair of Proximal Aortic Aneurysms

Risks associated with the open repair of the proximal aorta vary by extent of repair and are greatest for repairs involving total arch replacement. All varieties of aortic root replacement have shown acceptable early mortality rates and few complications. Two groups with 20 and 27 years' experience with composite valve graft replacement reported early mortality rates of 5.6% and 1.9%, respectively; the more recent repairs had better outcomes.^{181,182} Early mortality rates for stentless porcine

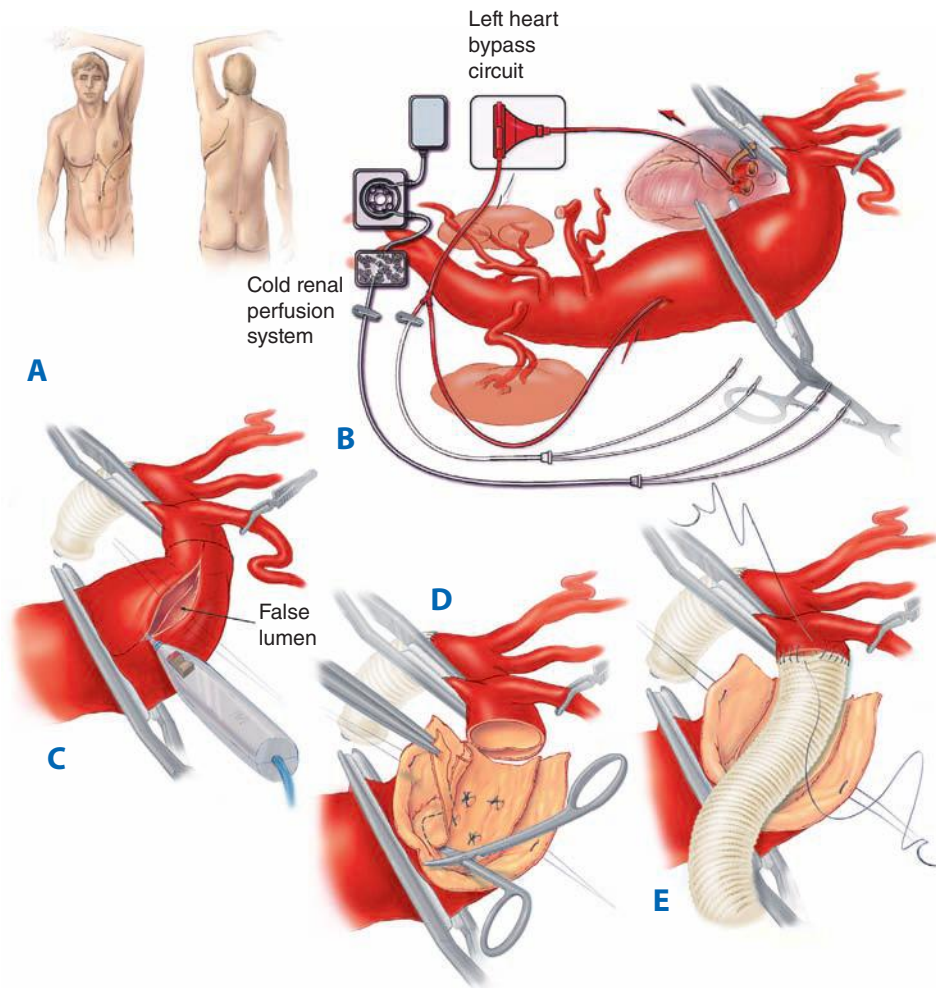


Figure 22-23. Illustration of distal aortic repair of a chronic dissection. **A.** Thoracoabdominal incision. **B.** Extent II thoracoabdominal aortic aneurysm resulting from chronic aortic dissection. The patient has previously undergone composite valve graft replacement of the aortic root and ascending aorta. After left heart bypass is initiated, the proximal portion of the aneurysm is isolated by placing clamps on the left subclavian artery, between the left common carotid and left subclavian arteries, and across the middle descending thoracic aorta. **C.** The isolated segment of aorta is opened by using electrocautery. **D.** The dissecting membrane is excised, and bleeding intercostal arteries are oversewn. The aorta is prepared for proximal anastomosis by transecting it distal to the proximal clamp and separating this portion from the esophagus (not shown). **E.** The proximal anastomosis between the aorta and an appropriately sized Dacron graft is completed with continuous polypropylene suture. **F.** After left heart bypass has been stopped and the distal aortic cannula has been removed, the proximal clamp is repositioned onto the graft, the other two clamps are removed, and the remainder of the aneurysm is opened. **G.** The rest of the dissecting membrane is excised, and the openings to the celiac, superior mesenteric, and renal arteries are identified. **H.** Selective visceral perfusion with oxygenated blood from the bypass circuit is delivered through balloon perfusion catheters placed in the celiac and superior mesenteric arterial ostia. Cold crystalloid is delivered to the renal arteries. The critical intercostal arteries are reattached to an opening cut in the graft. **I.** To minimize spinal cord ischemia, the proximal clamp is repositioned distal to the intercostal reattachment site. A second oval opening is fashioned in the graft adjacent to the visceral vessels. Selective perfusion of the visceral arteries continues during their reattachment to the graft. A separate anastomosis is often required to reattach the left renal artery. **J.** After the balloon perfusion catheters are removed and the visceral anastomosis is completed, the clamp is again moved distally, restoring blood flow to the celiac, renal, and superior mesenteric arteries. The final anastomosis is created between the graft and the distal aorta. (Reproduced with permission from Creager MA, Dzau VS, Loscalzo J, eds. *Vascular Medicine*. Philadelphia: WB Saunders; 2006. Copyright © Saunders/Elsevier, 2006, Fig. 35-8A–J.)

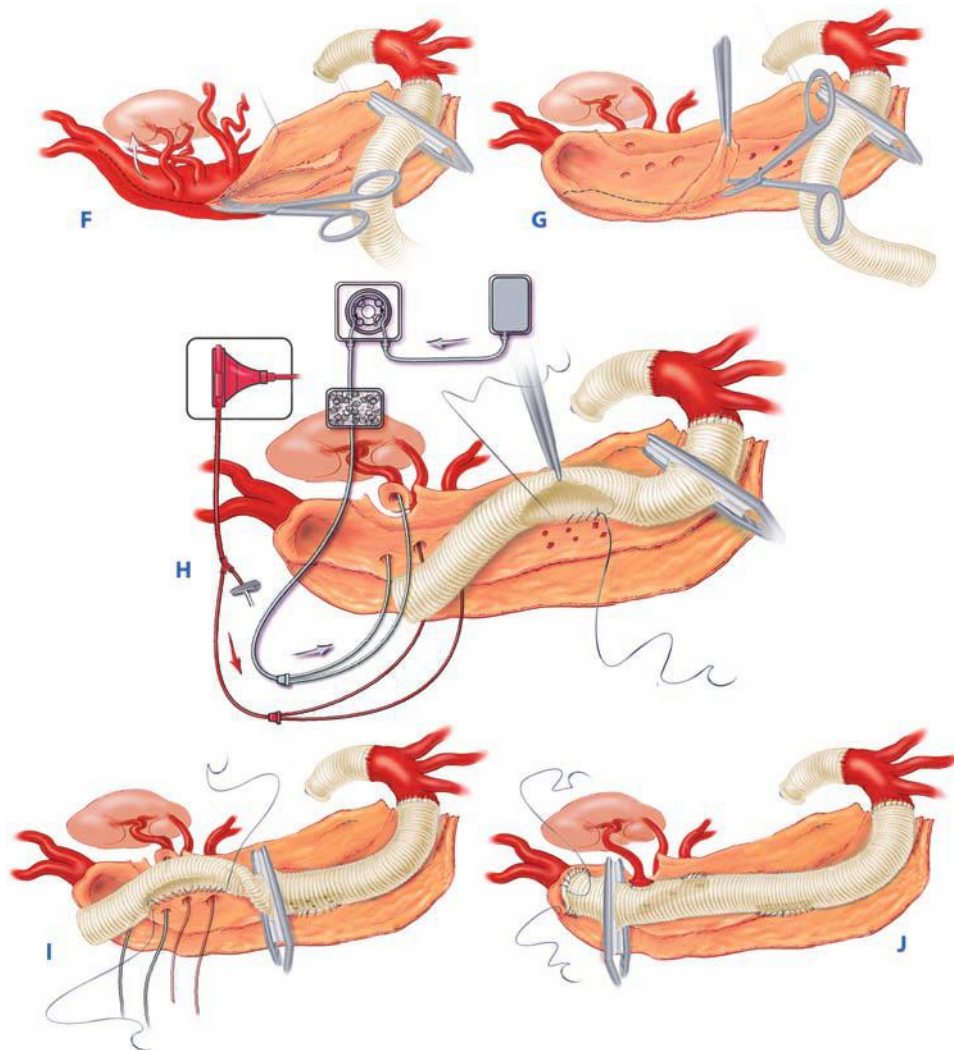


Figure 22-23. (Continued)

tissue root replacements are also low, ranging from 3.6% to 6.0%.¹⁸³⁻¹⁸⁷ Early mortality rates for contemporary valve-sparing approaches to aortic root replacement are quite low (1%–2%) in experienced centers.^{66,188,189} Late survival rates after valve-sparing root procedures range from 97% to 99% at 5 years^{66,188,189} and approach 94% at 10 years.⁶⁶

Repairs incorporating the ascending aorta and aortic arch have acceptable outcomes; risk increases with patient-specific factors such as severe atherosclerosis¹⁹⁰ or as larger sections of the aortic arch are incorporated into the repair.^{191,192} A revised surgical strategy—such as the use of hypothermic circulatory arrest—is often needed to avoid clamping atherosclerotic sections in the “porcelain” aorta. In Zingone and colleagues’ series¹⁹⁰ of 64 patients who underwent replacement of atherosclerotic ascending aorta, hypothermic circulatory arrest was used in 61 patients (95%). Even though these patients had substantial comorbidity and 83% underwent concomitant cardiac repairs, acceptable rates of early mortality (11%) and stroke (6%) were obtained. Other studies indicate that the enhanced risk of neurocognitive disturbances in ascending repairs using circulatory arrest are not offset by lower rates of early mortality.^{193,194} Regarding extended proximal repair, reported early mortality rates after traditional stage 1 elephant trunk repairs

(primarily using island reattachment strategies) range from 2.3% to 13.9%.¹⁹⁵⁻¹⁹⁹

Contemporary mortality rates for extensive proximal aortic repair have improved as new strategies and modified adjuncts have been adopted. For example, by adopting contemporary approaches, we have reduced early mortality for stage 1 elephant trunk repairs from 12% to 2% in our patients.^{73,196} Similarly, in a report by Kazui and colleagues²⁰⁰ covering 20 years of experience and 472 consecutive patients who underwent aortic arch repair with selective ACP, operative mortality was 16.0% for early repairs and 4.1% for more recent repairs. Other contemporary reports of the use of techniques such as moderate hypothermia and Y-graft approaches²⁰¹⁻²⁰⁴ indicate similarly improved outcomes; early mortality ranges from 1% to 7%, stroke rates range from 1% to 6%, and no cases of paraplegia are reported. Although paraplegia has traditionally been an unusual and infrequent complication of aortic arch repair, it has been reported as a complication of “long” elephant trunk approaches²⁰⁵ and frozen elephant trunk approaches.²⁰⁶

Because of the heterogeneity of hybrid arch approaches and the tendency to use these approaches in high-risk patients, results of hybrid arch repair are difficult to interpret. A meta-analysis conducted by Koullias and Wheatley⁸² of data from

15 studies with 463 patients found an average 30-day mortality rate of 8.3%; stroke, 4.4%; paraplegia, 3.9%; and endoleak, 9.2%. Of note, relatively few repairs (30%) were performed “off-pump,” and the majority of repairs used cardiopulmonary bypass or hypothermic circulatory arrest. Additionally, several reports of small series (ranging from 33 to 66 patients) have documented a substantial risk of acute retrograde aortic dissection during hybrid arch repairs; rates range from 3.0% to 7.5%, and these patients face significant mortality risk (ranging from 33% to 100%) should this occur.^{85,207-209}

Treatment of Acute Ascending Aortic Dissection

The International Registry of Acute Aortic Dissection (IRAD) provides the most comprehensive data on contemporary outcomes in patients with acute aortic dissection. This registry was established in 1996 and has accumulated data from >3000 patients treated for acute aortic dissection at 30 centers in 11 countries. A recent IRAD analysis of data from 776 patients who underwent surgical repair of acute ascending aortic dissection revealed an in-hospital mortality rate of 23.8%.²¹⁰ The investigators identified several preoperative predictors of early mortality, including age >70 years, previous cardiac surgery, hypotension or shock at presentation, abrupt onset of symptoms, migrating pain, cardiac tamponade, preoperative renal failure, pulse deficit, and evidence of myocardial ischemia or infarction on ECG.^{210,211} The German Registry for Acute Aortic Dissection (GERAADA) has collected data on more than 2500 patients from 52 centers since 2006. In a report of 1436 patients with acute proximal dissection that was surgically repaired using hypothermic circulatory arrest with or without unilateral and bilateral ACP, the early mortality rates ranged from 13.9% to 19.4%; the 628 patients with unilateral ACP had the lowest rate of early death.²¹²

Repair of Distal Aortic Aneurysms

Endovascular Repair of Descending Thoracic Aortic Aneurysms. In the earliest series of endovascular repairs of descending thoracic aortic aneurysms, mortality and morbidity were difficult to assess. Most of the reported series were small and included a large proportion of high-risk patients with substantial comorbidity. For example, in the Stanford experience with “first-generation” stent grafts in 103 patients with descending thoracic aortic aneurysms, the operative mortality rate was 9%, the stroke rate was 7%, the paraplegia/paraparesis rate was 3%, and actuarial survival was only $73 \pm 5\%$ at 2 years. However, 62 patients (60%) were not considered candidates for thoracotomy and open surgical repair; as expected, this group experienced the majority of the morbidity and mortality.²¹³ In a follow-up series, the Stanford group reported survival rates of 74% at 1 year and 31% at 5 years after stent grafting in patients who were deemed not to be surgical candidates; in contrast, survival rates were 93% at 1 year and 78% at 5 years ($P < 0.001$) after stent grafting in patients who were deemed reasonable candidates for conventional open repair.²¹⁴ This study also found a 30% incidence of late aortic complications, which stresses the necessity for appropriate follow-up.

Evidence from pivotal, nonrandomized trials that compared patients who underwent endograft exclusion with historical or concurrent patients who underwent open repair²¹⁵⁻²¹⁷ shows that the stent graft groups had significantly less morbidity and early mortality than the open repair groups, although in two of the trials, a nonsignificant between-group difference

was observed in the rate of stroke.^{215,217} Available 5-year comparative data show that the two groups differed significantly in their aneurysm-related mortality rates (2.8% for endovascular patients and 11.7% for open repair patients) but not in their rates of all-cause mortality (which were 32% and 31%, respectively).²¹⁸ Additional pivotal trial 5-year outcomes²¹⁹ indicate the growing disparity between aneurysm-related (96.1%) and all-cause survival (58.5%) in patients with endovascular repair, leading some to comment on the possible futility of repair in many patients.¹⁷⁴

Although the feasibility of endovascular treatment of chronic descending thoracic aortic dissection has been shown in small series,^{148,220} the efficacy of such repairs has not been established. The eagerly anticipated initial outcomes of the INSTEAD trial (INvestigation of STEnt grafts in patients with type B Aortic Dissection), which involves 136 patients with uncomplicated chronic descending aortic dissection, show no survival benefit of stent grafting over standard medical antihypertensive therapy in the first 2 years after randomization.²²¹ However, it appears that the extended study may find a survival advantage at 5 years.¹⁷⁴ Likewise, the ADSORB (A Prospective Randomized Trial in Acute Uncomplicated Type B Dissections) trial²²² is currently underway, and once complete, it may help elucidate whether endovascular repair in patients with uncomplicated descending dissection provides an advantage over standard medical antihypertensive therapy as pertains to its study endpoints—thrombosis of the false lumen, aortic enlargement, and aortic rupture. Thus, at present, the use of stent grafts to treat chronic descending aortic dissection should be considered experimental.

Open Repair of Descending Thoracic and Thoracoabdominal Aortic Aneurysms. Contemporary results of open repairs of descending thoracic aortic aneurysms, including those performed in select patients with chronic dissection, indicate that early mortality rates range from 4.1% to 8.0%, renal failure rates range from 4.2% to 7.5%, and paraplegia rates range from 2.3% to 5.7%; stroke rates are generally lower, ranging from 1.8% to 2.1%.²²³⁻²²⁵ In our series, although the risk of paraplegia increased with the extent of repair, the risk of mortality was greatest for those undergoing repair of the proximal two thirds of the descending aorta.²²³ As expected, stroke rates after distal aortic repairs were highest when the clamp site was near the left subclavian artery.

Several studies have compared endovascular and surgical approaches to descending thoracic aortic repair. Some studies found no significant differences in rates of early death, stroke, and paraplegia,^{217,226,227} whereas others found that surgical patients had higher rates of early mortality (27%)²²⁸ and paraplegia (14%).²¹⁵ However, a recent study of Medicare patients showed that the early survival advantage associated with stent grafts is soon lost in the majority of patients.²²⁹

Contemporary series of open thoracoabdominal aortic repairs show acceptable survival. Reported outcome rates range from 5% to 12% for early mortality, 3.8% to 9.5% for paraplegia, 1.7% to 5.2% for stroke, and 6% to 12% for renal complications.²³⁰⁻²³⁴ Many of these series summarize 10 to 20 years of surgical experience,²³¹⁻²³⁴ although some present a shorter but more contemporary experience.²³⁰ Even for complex thoracoabdominal aortic repairs, such as stage 2 elephant trunk repairs, several centers report acceptable early mortality rates ranging from 0% to 10%.¹⁹⁵⁻¹⁹⁹ Worse outcomes are also documented, as in a statewide, nonfederal analysis of data from 1010 patients whose early mortality rate was 25%. Of note, 40% of these patients

were treated at centers averaging only one thoracoabdominal aortic aneurysm repair per year.²³⁵ Cowan and colleagues,²³⁶ who examined the influence of familiarity with the procedure on rates of mortality and morbidity after thoracoabdominal aortic aneurysm repair, reported that patients treated at low-volume centers fared less well. Replacing the entire thoracoabdominal aorta (i.e., performing an extent II repair) carries the highest risk of death, bleeding, renal failure, and paraplegia.^{92,231,232} Early survival has been estimated at 79% at 2 years,²³⁷ and midterm survival has been estimated at 63% at 5 years.²³⁴

Treatment of Acute Descending Aortic Dissection

Nonoperative Management. The in-hospital mortality rate is nearly 10% for patients with acute descending aortic dissection who receive nonoperative treatment¹⁴²; however, when IRAD stratified patients according to clinical presentation, the mortality rate for patients with uncomplicated dissection was less than 4%, whereas the mortality rate for patients with complicated dissection was more than 20%.^{142,238} The primary causes of death during nonoperative management are rupture, malperfusion, and cardiac failure. Risk factors associated with treatment failure—defined as death or need for surgery—include an enlarged aorta, persistent hypertension despite maximal treatment, oliguria, and peripheral ischemia. Among patients who receive nonoperative treatment for descending aortic dissection and who survive the acute period, approximately 90% remain alive 1 year later, and approximately 76% are alive 3 years later.²³⁹

Endovascular Treatment. For malperfusion of the visceral or renal arteries, an endovascular approach is ideal. The Stanford group reported a 93% technical success rate for endovascular reperfusion of an ischemic bed.²⁴⁰ Their experience with the use of first-generation stents to treat acute complicated descending dissections was also encouraging: Complete thrombosis of the false lumen occurred in 79% of patients. The early mortality rate was 16%, comparable to that associated with open techniques.²⁴¹ A meta-analysis of observational studies of endovascular stenting, which included 248 patients with acute descending aortic dissection, found a 30-day mortality rate of 9.8%.²⁴² Compared with early mortality rates obtained from IRAD data,¹⁴² this rate is substantially lower than the rate associated with open surgical treatment but is similar to the rate achieved with nonoperative management. However, patients with complicated acute descending dissection remain susceptible to late events; at 1 year, survival is approximately 70%, and reintervention is needed in about 10% of survivors.²⁴³

Open Repair. We recently reported our contemporary experience with 32 patients with acute complicated descending aortic dissection, including 7 patients (22%) with aortic rupture. Complexities included dangerously large aneurysms in the majority of patients (69%), which implied either rapid expansion or an aneurysm superimposed on the dissection. Malperfusion was present in one patient; this patient had an open fenestration procedure. A substantial number of patients (n = 7, 22%) had connective tissue disorders. The operative mortality rate was 6% overall.²⁴⁴ There were 3 cases of permanent spinal cord complications (10%), 1 stroke (3%), and 2 cases of permanent renal failure (6%). In recent multicenter studies by IRAD, investigators found a 29% in-hospital mortality rate among 70 patients with acute dissection who underwent open surgical replacement of the descending thoracic aorta²³⁸ and a 22% in-hospital mor-

tality rate among 18 patients who underwent open fenestration procedures. Another study found that, of patients who survived surgical treatment of acute descending aortic dissection, approximately 96% were alive at 1 year and approximately 83% were alive at 3 years after the procedure,²³⁹ which is substantially better than 1-year survival after endovascular repair in acute complicated distal dissection.^{239,243}

CONCLUSIONS

Aortic aneurysm may present as localized or extensive disease. The availability and development of adjuncts and endovascular techniques have supported the constant evolution of surgical strategies to tackle these complex problems. Repair strategies range from isolated, totally endovascular aortic repair for descending thoracic aneurysms to extensive total aortic and staged replacements with a combination of both open and endovascular techniques. Regardless of the difficulty of accurately assessing the risks associated with aortic repair, surgical repair of the thoracoabdominal aorta clearly remains the most challenging aortic repair in terms of mortality and morbidity. Accordingly, replacing the entire thoracoabdominal aorta (i.e., performing an extent II repair) carries the highest risk of death, renal failure, and paraplegia.^{89,221,226}

ACKNOWLEDGMENTS

The authors wish to thank Susan Y. Green, MPH, and Stephen N. Palmer, PhD, ELS, for editorial assistance; Scott A. Weldon, MA, CMI, and Carol P. Larson, CMI, for creating the illustrations; and Kapil Sharma, MD, for his substantial contributions to the chapter published in the 9th edition of the textbook, on which this updated chapter was based.

REFERENCES

Entries highlighted in bright blue are key references.

1. Johnston KW, Rutherford RB, Tilson MD, et al. Suggested standards for reporting on arterial aneurysms. Subcommittee on Reporting Standards for Arterial Aneurysms, Ad Hoc Committee on Reporting Standards, Society for Vascular Surgery and North American Chapter, International Society for Cardiovascular Surgery. *J Vasc Surg.* 1991;13(3):452-458.
2. Bickerstaff LK, Pairolo PC, Hollier LH, et al. Thoracic aortic aneurysms: a population-based study. *Surgery.* 1982; 92(6):1103-1108.
3. Segura AM, Luna RE, Horiba K, et al. Immunohistochemistry of matrix metalloproteinases and their inhibitors in thoracic aortic aneurysms and aortic valves of patients with Marfan's syndrome. *Circulation.* 1998;98(19 Suppl):II331-II337.
4. Neptune ER, Frischmeyer PA, Arking DE, et al. Dysregulation of TGF- β activation contributes to pathogenesis in Marfan syndrome. *Nat Genet.* 2003;33(3):407-411.
5. Marsalese DL, Moodie DS, Vacante M, et al. Marfan's syndrome: natural history and long-term follow-up of cardiovascular involvement. *J Am Coll Cardiol.* 1989;14(2):422-428.
6. Adams JN, Trent RJ. Aortic complications of Marfan's syndrome. *Lancet.* 1998;352(9142):1722-1723.
7. LeMaire SA, Pannu H, Tran-Fadulu V, et al. Severe aortic and arterial aneurysms associated with a TGFBR2 mutation. *Nat Clin Pract Cardiovasc Med.* 2007;4(3):167-171.
8. Loeys BL, Schwarze U, Holm T, et al. Aneurysm syndromes caused by mutations in the TGF- β receptor. *N Engl J Med.* 2006;355(8):788-798.

9. Oderich GS, Panneton JM, Bower TC, et al. The spectrum, management and clinical outcome of Ehlers-Danlos syndrome type IV: a 30-year experience. *J Vasc Surg.* 2005;42(1):98-106.
10. Sheen VL, Jansen A, Chen MH, et al. Filamin A mutations cause periventricular heterotopia with Ehlers-Danlos syndrome. *Neurology.* 2005;64(2):254-262.
11. Boileau C, Guo DC, Hanna N, et al. TGFB2 mutations cause familial thoracic aortic aneurysms and dissections associated with mild systemic features of Marfan syndrome. *Nat Genet.* 2012;44(8):916-921.
12. Guo DC, Pannu H, Tran-Fadulu V, et al. Mutations in smooth muscle alpha-actin (ACTA2) lead to thoracic aortic aneurysms and dissections. *Nat Genet.* 2007;39(12):1488-1493.
13. Pannu H, Tran-Fadulu V, Papke CL, et al. MYH11 mutations result in a distinct vascular pathology driven by insulin-like growth factor 1 and angiotensin II. *Hum Mol Genet.* 2007;16(20):2453-2462.
14. van de Laar IM, Oldenburg RA, Pals G, et al. Mutations in SMAD3 cause a syndromic form of aortic aneurysms and dissections with early-onset osteoarthritis. *Nat Genet.* 2011;43(2):121-126.
15. Hoffman JI, Kaplan S. The incidence of congenital heart disease. *J Am Coll Cardiol.* 2002;39(12):1890-1900.
16. Keane MG, Wiegers SE, Plappert T, et al. Bicuspid aortic valves are associated with aortic dilatation out of proportion to coexistent valvular lesions. *Circulation.* 2000;102(19 Suppl 3):III35-III39.
17. Jassal DS, Bhagirath KM, Tam JW, et al. Association of bicuspid aortic valve morphology and aortic root dimensions: a sub-study of the aortic stenosis progression observation measuring effects of rosuvastatin (ASTRONOMER) study. *Echocardiography.* 2010;27(2):174-179.
18. Cecconi M, Manfrin M, Moraca A, et al. Aortic dimensions in patients with bicuspid aortic valve without significant valve dysfunction. *Am J Cardiol.* 2005;95(2):292-294.
19. Nistri S, Sorbo MD, Marin M, et al. Aortic root dilatation in young men with normally functioning bicuspid aortic valves. *Heart.* 1999;82(1):19-22.
20. Sabet HY, Edwards WD, Tazelaar HD, Daly RC. Congenitally bicuspid aortic valves: a surgical pathology study of 542 cases (1991 through 1996) and a literature review of 2,715 additional cases. *Mayo Clin Proc.* 1999;74(1):14-26.
21. Larson EW, Edwards WD. Risk factors for aortic dissection: a necropsy study of 161 cases. *Am J Cardiol.* 1984;53(6):849-855.
22. LeMaire SA, Wang X, Wilks JA, et al. Matrix metalloproteinases in ascending aortic aneurysms: bicuspid versus trileaflet aortic valves. *J Surg Res.* 2005;123(1):40-48.
23. Fedak PW, de Sa MP, Verma S, et al. Vascular matrix remodeling in patients with bicuspid aortic valve malformations: implications for aortic dilatation. *J Thorac Cardiovasc Surg.* 2003;126(3):797-806.
24. Koullias GJ, Korkolis DP, Ravichandran P, et al. Tissue microarray detection of matrix metalloproteinases, in diseased tricuspid and bicuspid aortic valves with or without pathology of the ascending aorta. *Eur J Cardiothorac Surg.* 2004;26(6):1098-1103.
25. Martin LJ, Ramachandran V, Cripe LH, et al. Evidence in favor of linkage to human chromosomal regions 18q, 5q, and 13q for bicuspid aortic valve and associated cardiovascular malformations. *Hum Genet.* 2007;121(2):275-284.
26. McKellar SH, Tester DJ, Yagubyan M, et al. Novel *NOTCH1* mutations in patients with bicuspid aortic valve disease and thoracic aortic aneurysms. *J Thorac Cardiovasc Surg.* 2007;134(2):290-296.
27. Wessels MW, Berger RM, Frohn-Mulder IM, et al. Autosomal dominant inheritance of left ventricular outflow tract obstruction. *Am J Med Genet.* 2005;134A(2):171-179.
28. Yasuda H, Nakatani S, Stugaard M, et al. Failure to prevent progressive dilation of ascending aorta by aortic valve replacement in patients with bicuspid aortic valve: comparison with tricuspid aortic valve. *Circulation.* 2003;108 Suppl 1:II291-II294.
29. Hornick M, Moomiaie R, Mojibian H, et al. 'Bovine' aortic arch—a marker for thoracic aortic disease. *Cardiology.* 2012;123(2):116-124.
30. Brown SL, Busuttill RW, Baker JD, et al. Bacteriologic and surgical determinants of survival in patients with mycotic aneurysms. *J Vasc Surg.* 1984;1(4):541-547.
31. Johnson JR, Ledgerwood AM, Lucas CE. Mycotic aneurysm: new concepts in therapy. *Arch Surg.* 1983;118(5):577-582.
32. Schwill S, LeMaire SA, Green SY, Bakaeen FG, Coselli JS. Endovascular repair of thoracic aortic pseudoaneurysms and patch aneurysms. *J Vasc Surg.* 2010;52(4):1034-1037.
33. Elefteriades JA. Natural history of thoracic aortic aneurysms: indications for surgery, and surgical versus nonsurgical risks. *Ann Thorac Surg.* 2002;74(5):S1877-1880.
34. Davies RR, Goldstein LJ, Coady MA, et al. Yearly rupture or dissection rates for thoracic aortic aneurysms: simple prediction based on size. *Ann Thorac Surg.* 2002;73(1):17-27.
35. Murdoch JL, Walker BA, Halpern BL, Kuzma JW, McKusick VA. Life expectancy and causes of death in the Marfan syndrome. *N Engl J Med.* 1972;286(15):804-808.
36. Michel PL, Acar J, Chomette G, Iung B. Degenerative aortic regurgitation. *Eur Heart J.* 1991;12(8):875-882.
37. Prenger K, Pieters F, Cheriex E. Aortic dissection after aortic valve replacement: incidence and consequences for strategy. *J Card Surg.* 1994;9(5):495-498.
38. Bonow RO. Bicuspid aortic valves and dilated aortas: a critical review of the ACC/AHA practice guidelines recommendations. *Am J Cardiol.* 2008;102(1):111-114.
39. Girdauskas E, Disha K, Raisin HH, et al. Risk of late aortic events after an isolated aortic valve replacement for bicuspid aortic valve stenosis with concomitant ascending aortic dilation. *Eur J Cardiothorac Surg.* 2012;42(5):832-837; discussion 837-838.
40. Hiratzka LF, Bakris GL, Beckman JA, et al. 2010 ACCF/AHA/AATS/ACR/ASA/SCA/SCAI/SIR/STS/SVM guidelines for the diagnosis and management of patients with thoracic aortic disease: a report of the American College of Cardiology Foundation/American Heart Association Task Force on Practice Guidelines, American Association for Thoracic Surgery, American College of Radiology, American Stroke Association, Society of Cardiovascular Anesthesiologists, Society for Cardiovascular Angiography and Interventions, Society of Interventional Radiology, Society of Thoracic Surgeons, and Society for Vascular Medicine. *Circulation.* 2010;121(13):e266-e369.
41. Isselbacher EM. Thoracic and abdominal aortic aneurysms. *Circulation.* 2005;111(6):816-828.
42. Wiet SP, Pearce WH, McCarthy WJ, et al. Utility of transesophageal echocardiography in the diagnosis of disease of the thoracic aorta. *J Vasc Surg.* 1994;20(4):613-620.
43. Fillinger MF. Imaging of the thoracic and thoracoabdominal aorta. *Semin Vasc Surg.* 2000;13(4):247-263.
44. Weisbord SD, Palevsky PM. Radiopaque-contrast-induced acute renal failure. *J Intensive Care Med.* 2005;20(2):63-75.
45. Danias P, Eldeman R, Manning W. Magnetic resonance angiography of the great vessels and the coronary arteries. In: Pohost GM, ed. *Imaging in Cardiovascular Disease.* Philadelphia: Lippincott Williams & Wilkins; 2000:449.
46. Ergun I, Keven K, Uruc I, et al. The safety of gadolinium in patients with stage 3 and 4 renal failure. *Nephrol Dial Transplant.* 2006;21(3):697-700.
47. Merten GJ, Burgess WP, Gray LV, et al. Prevention of contrast-induced nephropathy with sodium bicarbonate: a randomized controlled trial. *JAMA.* 2004;291(19):2328-2334.

48. Tepel M, van der Giet M, Schwarzfeld C, et al. Prevention of radiographic-contrast-agent-induced reductions in renal function by acetylcysteine. *N Engl J Med*. 2000;343(3):180-184.
49. Gopaldas RR, Huh J, Dao TK, et al. Superior nationwide outcomes of endovascular versus open repair for isolated descending thoracic aortic aneurysm in 11,669 patients. *J Thorac Cardiovasc Surg*. 2010;140(5):1001-1010.
50. Walker KL, Shuster JJ, Martin TD, et al. Practice patterns for thoracic aneurysms in the stent graft era: health care system implications. *Ann Thorac Surg*. 2010;90(6):1833-1839.
51. Gopaldas RR, Dao TK, LeMaire SA, Huh J, Coselli JS. Endovascular versus open repair of ruptured descending thoracic aortic aneurysms: a nationwide risk-adjusted study of 923 patients. *J Thorac Cardiovasc Surg*. 2011;142(5):1010-1018.
52. Coselli JS, LeMaire SA, Buket S. Marfan syndrome: the variability and outcome of operative management. *J Vasc Surg*. 1995;21(3):432-443.
53. LeMaire SA, Rice DC, Schmittling ZC, Coselli JS. Emergency surgery for thoracoabdominal aortic aneurysms with acute presentation. *J Vasc Surg*. 2002;35(6):1171-1178.
54. Greenberg R, Eagleton M, Mastracci T. Branched endografts for thoracoabdominal aneurysms. *J Thorac Cardiovasc Surg*. 2010;140(6 Suppl):S171-S178.
55. LeMaire SA, Green SY, Kim JH, et al. Thoracic or thoracoabdominal approaches to endovascular device removal and open aortic repair. *Ann Thorac Surg*. 2012;93(3):726-732; discussion 733.
56. LeMaire SA, Miller CC III, Conklin LD, Schmittling ZC, Coselli JS. Estimating group mortality and paraplegia rates after thoracoabdominal aortic aneurysm repair. *Ann Thorac Surg*. 2003;75(2):508-513.
57. LeMaire SA, Miller CC III, Conklin LD, et al. A new predictive model for adverse outcomes after elective thoracoabdominal aortic aneurysm repair. *Ann Thorac Surg*. 2001;71(4):1233-1238.
58. **Gott VL, Cameron DE, Alejo DE, et al. Aortic root replacement in 271 Marfan patients: a 24-year experience. *Ann Thorac Surg*. 2002;73(2):438-443.**
59. Carrel TP, Berdat P, Englberger L, et al. Aortic root replacement with a new stentless aortic valve xenograft conduit: preliminary hemodynamic and clinical results. *J Heart Valve Dis*. 2003;12(6):752-757.
60. Deleuze PH, Fromes Y, Khoury W, et al. Eight-year results of Freestyle stentless bioprosthesis in the aortic position: a single-center study of 500 patients. *J Heart Valve Dis*. 2006;15(2):247-252.
61. Oury JH. Clinical aspects of the Ross procedure: indications and contraindications. *Semin Thorac Cardiovasc Surg*. 1996;8(4):328-335.
62. Fazel SS, David TE. Aortic valve-sparing operations for aortic root and ascending aortic aneurysms. *Curr Opin Cardiol*. 2007;22(6):497-503.
63. **David TE, Ivanov J, Armstrong S, Feindel CM, Webb GD. Aortic valve-sparing operations in patients with aneurysms of the aortic root or ascending aorta. *Ann Thorac Surg*. 2002;74(5):S1758-S1761.**
64. David TE, Armstrong S, Maganti M, Colman J, Bradley TJ. Long-term results of aortic valve-sparing operations in patients with Marfan syndrome. *J Thorac Cardiovasc Surg*. 2009;138(4):859-864; discussion 863-864.
65. Kallenbach K, Baraki H, Khaladj N, et al. Aortic valve-sparing operation in Marfan syndrome: what do we know after a decade? *Ann Thorac Surg*. 2007;83(2):S764-768.
66. Kvitting JP, Kari FA, Fischbein MP, et al. David valve-sparing aortic root replacement: equivalent mid-term outcome for different valve types with or without connective tissue disorder. *J Thorac Cardiovasc Surg*. 2013;145(1):117-126, 127.e1-127.e5; discussion 126-127.
67. Bentall H, De Bono A. A technique for complete replacement of the ascending aorta. *Thorax*. 1968;23(4):338-339.
68. Cabrol C, Pavie A, Gandjbakhch I, et al. Complete replacement of the ascending aorta with reimplantation of the coronary arteries: new surgical approach. *J Thorac Cardiovasc Surg*. 1981;81(2):309-315.
69. Kouchoukos NT, Wareing TH, Murphy SF, Perrillo JB. Sixteen-year experience with aortic root replacement: results of 172 operations. *Ann Surg*. 1991;214(3):308-318.
70. Zubiato P, Kay JH. Surgical treatment of aneurysm of the ascending aorta with aortic insufficiency and marked displacement of the coronary ostia. *J Thorac Cardiovasc Surg*. 1976;71(3):415-421.
71. **Spielvogel D, Etz CD, Silovitz D, Lansman SL, Griep RB. Aortic arch replacement with a trifurcated graft. *Ann Thorac Surg*. 2007;83(2):S791-S795.**
72. Borst HG, Frank G, Schaps D. Treatment of extensive aortic aneurysms by a new multiple-stage approach. *J Thorac Cardiovasc Surg*. 1988;95(1):11-13.
73. LeMaire SA, Price MD, Parenti JL, et al. Early outcomes after aortic arch replacement by using the Y-graft technique. *Ann Thorac Surg*. 2011;91(3):700-707; discussion 707-708.
74. Svensson LG. Antegrade perfusion during suspended animation? *J Thorac Cardiovasc Surg*. 2002;124(6):1068-1070.
75. Ueda Y, Miki S, Kusuhara K, et al. Surgical treatment of aneurysm or dissection involving the ascending aorta and aortic arch, utilizing circulatory arrest and retrograde cerebral perfusion. *J Cardiovasc Surg (Torino)*. 1990;31(5):553-558.
76. Sundt TM III, Orszulak TA, Cook DJ, Schaff HV. Improving results of open arch replacement. *Ann Thorac Surg*. 2008;86(3):787-796; discussion 796.
77. Wong DR, Coselli JS, Palmero L, et al. Axillary artery cannulation in surgery for acute or subacute ascending aortic dissections. *Ann Thorac Surg*. 2010;90(3):731-737.
78. Preventza O, Bakaeen FG, Stephens EH, et al. Innominate artery cannulation: An alternative to femoral or axillary cannulation for arterial inflow in proximal aortic surgery. *J Thorac Cardiovasc Surg*. 2013;145(3 Suppl):S191-S196.
79. Della Corte A, Scardone M, Romano G, et al. Aortic arch surgery: Thoracoabdominal perfusion during antegrade cerebral perfusion may reduce postoperative morbidity. *Ann Thorac Surg*. 2006;81(4):1358-1364.
80. Panos A, Myers PO, Kalangos A. Novel technique for aortic arch surgery under mild hypothermia. *Ann Thorac Surg*. 2008;85(1):347-348.
81. Inoue K, Hosokawa H, Iwase T, et al. Aortic arch reconstruction by transluminally placed endovascular branched stent graft. *Circulation*. 1999;100(19 Suppl):II316-321.
82. Koullias GJ, Wheatley GH III. State-of-the-art of hybrid procedures for the aortic arch: a meta-analysis. *Ann Thorac Surg*. 2010;90(2):689-697.
83. Melissano G, Tshomba Y, Bertoglio L, Rinaldi E, Chiesa R. Analysis of stroke after TEVAR involving the aortic arch. *Eur J Vasc Endovasc Surg*. 2012;43(3):269-275.
84. Andersen ND, Williams JB, Hanna JM, et al. Results with an algorithmic approach to hybrid repair of the aortic arch. *J Vasc Surg*. 2013;57(3):655-667.
85. Lotfi S, Clough RE, Ali T, et al. Hybrid repair of complex thoracic aortic arch pathology: long-term outcomes of extra-anatomic bypass grafting of the supra-aortic trunk. *Cardiovasc Intervent Radiol*. 2013;36(1):46-55.
86. Svensson LG, Kouchoukos NT, Miller DC, et al. Expert consensus document on the treatment of descending thoracic aortic disease using endovascular stent-grafts. *Ann Thorac Surg*. 2008;85(1 Suppl):S1-S41.
87. **Coselli JS, LeMaire SA, Köksoy C, Schmittling ZC, Curling PE. Cerebrospinal fluid drainage reduces paraplegia after thoracoabdominal aortic aneurysm repair: results of a randomized clinical trial. *J Vasc Surg*. 2002;35(4):631-639.**

88. Jacobs MJ, Mess W, Mochtar B, et al. The value of motor evoked potentials in reducing paraplegia during thoracoabdominal aneurysm repair. *J Vasc Surg.* 2006;43(2):239-246.
89. van Dongen EP, Schepens MA, Morshuis WJ, et al. Thoracic and thoracoabdominal aortic aneurysm repair: use of evoked potential monitoring in 118 patients. *J Vasc Surg.* 2001;34(6):1035-1040.
90. Coselli JS. The use of left heart bypass in the repair of thoracoabdominal aortic aneurysms: current techniques and results. *Semin Thorac Cardiovasc Surg.* 2003;15(4):326-332.
91. Coselli JS, LeMaire SA. Left heart bypass reduces paraplegia rates after thoracoabdominal aortic aneurysm repair. *Ann Thorac Surg.* 1999;67(6):1931-1934.
92. Safi HJ, Miller CC, III, Huynh TT, et al. Distal aortic perfusion and cerebrospinal fluid drainage for thoracoabdominal and descending thoracic aortic repair: ten years of organ protection. *Ann Surg.* 2003;238(3):372-380.
93. **Köksoy C, LeMaire SA, Curling PE, et al. Renal perfusion during thoracoabdominal aortic operations: cold crystalloid is superior to normothermic blood. *Ann Thorac Surg.* 2002;73(3):730-738.**
94. Kouchoukos NT, Masetti P, Rokkas CK, Murphy SF. Hypothermic cardiopulmonary bypass and circulatory arrest for operations on the descending thoracic and thoracoabdominal aorta. *Ann Thorac Surg.* 2002;74(5):S1885-S1887.
95. Coselli JS, Oberwalder P. Successful repair of mega aorta using reversed elephant trunk procedure. *J Vasc Surg.* 1998;27(1):183-188.
96. Jones MM, Akay M, Murariu D, LeMaire SA, Coselli JS. Safe aortic arch clamping in patients with patent internal thoracic artery grafts. *Ann Thorac Surg.* 2010;89(4):e31-e32.
97. Volodos NL, Shekhanin VE, Karpovich IP, Troian VI, Gur'ev Iu A. [A self-fixing synthetic blood vessel endoprosthesis]. *Vestn Khir Im I I Grek.* 1986;137(11):123-125.
98. Parodi JC, Palmaz JC, Barone HD. Transfemoral intraluminal graft implantation for abdominal aortic aneurysms. *Ann Vasc Surg.* 1991;5(6):491-499.
99. Dake MD, Miller DC, Semba CP, et al. Transluminal placement of endovascular stent-grafts for the treatment of descending thoracic aortic aneurysms. *N Engl J Med.* 1994;331(26):1729-1734.
100. **Fillinger MF, Greenberg RK, McKinsey JF, Chaikof EL, Society for Vascular Surgery Ad Hoc Committee on TEVAR Reporting Standards. Reporting standards for thoracic endovascular aortic repair (TEVAR). *J Vasc Surg.* 2010;52(4):1022-1033, 11033e.1-1033e.5.**
101. Riesenman PJ, Farber MA, Mendes RR, et al. Coverage of the left subclavian artery during thoracic endovascular aortic repair. *J Vasc Surg.* 2007;45(1):90-94.
102. Buth J, Harris PL, Hobo R, et al. Neurologic complications associated with endovascular repair of thoracic aortic pathology: incidence and risk factors. A study from the European Collaborators on Stent/Graft Techniques for Aortic Aneurysm Repair (EUROSTAR) registry. *J Vasc Surg.* 2007;46(6):1103-1110.
103. Bozinovski J, LeMaire SA, Weldon SA, Coselli JS. Hybrid repairs of the distal aortic arch and proximal descending thoracic aorta. *Op Tech Thorac Cardiovasc Surg.* 2007;12(3):167-177.
104. Woo EY, Bavaria JE, Pochettino A, et al. Techniques for preserving vertebral artery perfusion during thoracic aortic stent grafting requiring aortic arch landing. *Vasc Endovascular Surg.* 2006;40(5):367-373.
105. Fann JI, Dake MD, Semba CP, et al. Endovascular stent-grafting after arch aneurysm repair using the "elephant trunk". *Ann Thorac Surg.* 1995;60(4):1102-1105.
106. Lin PH, Dardik A, Coselli JS. A simple technique to facilitate antegrade thoracic endograft deployment using a hybrid elephant trunk procedure under hypothermic circulatory arrest. *J Endovasc Ther.* 2007;14(5):669-671.
107. Greenberg RK, West K, Pfaff K, et al. Beyond the aortic bifurcation: branched endovascular grafts for thoracoabdominal and aortoiliac aneurysms. *J Vasc Surg.* 2006;43(5):879-886.
108. Greenberg RK, Qureshi M. Fenestrated and branched devices in the pipeline. *J Vasc Surg.* 2010;52(4 Suppl):15S-21S.
109. Moulakakis KG, Mylonas SN, Avgerinos E, et al. The chimney graft technique for preserving visceral vessels during endovascular treatment of aortic pathologies. *J Vasc Surg.* 2012;55(5):1497-1503.
110. Mehta M, Darling RC III, Taggert JB, et al. Outcomes of planned celiac artery coverage during TEVAR. *J Vasc Surg.* 2010;52(5):1153-1158.
111. Black SA, Wolfe JH, Clark M, et al. Complex thoracoabdominal aortic aneurysms: endovascular exclusion with visceral revascularization. *J Vasc Surg.* 2006;43(6):1081-1089.
112. Zhou W, Reardon M, Peden EK, Lin PH, Lumsden AB. Hybrid approach to complex thoracic aortic aneurysms in high-risk patients: surgical challenges and clinical outcomes. *J Vasc Surg.* 2006;44(4):688-693.
113. Patel R, Conrad MF, Paruchuri V, et al. Thoracoabdominal aneurysm repair: hybrid versus open repair. *J Vasc Surg.* 2009;50(1):15-22.
114. Hughes GC, Barfield ME, Shah AA, et al. Staged total abdominal debranching and thoracic endovascular aortic repair for thoracoabdominal aneurysm. *J Vasc Surg.* 2012;56(3):621-629.
115. Geisbusch P, Hoffmann S, Kotelis D, et al. Reinterventions during midterm follow-up after endovascular treatment of thoracic aortic disease. *J Vasc Surg.* 2011;53(6):1528-1533.
116. Dumfarth J, Michel M, Schmidli J, et al. Mechanisms of failure and outcome of secondary surgical interventions after thoracic endovascular aortic repair (TEVAR). *Ann Thorac Surg.* 2011;91(4):1141-1146.
117. Modine T, Lions C, Destrieux-Garnier L, et al. Iatrogenic iliac artery rupture and type A dissection after endovascular repair of type B aortic dissection. *Ann Thorac Surg.* 2004;77(1):317-319.
118. Dong Z, Fu W, Wang Y, et al. Stent graft-induced new entry after endovascular repair for Stanford type B aortic dissection. *J Vasc Surg.* 2010;52(6):1450-1457.
119. Tshomba Y, Bertoglio L, Marone EM, et al. Retrograde type A dissection after endovascular repair of a "zone 0" nondissecting aortic arch aneurysm. *Ann Vasc Surg.* 2010;24(7):952.e1-952.e7
120. Desai ND, Pochettino A, Szeto WY, et al. Thoracic endovascular aortic repair: evolution of therapy, patterns of use, and results in a 10-year experience. *J Thorac Cardiovasc Surg.* 2011;142(3):587-594.
121. Daily PO, Trueblood HW, Stinson EB, Wuerflein RD, Shumway NE. Management of acute aortic dissections. *Ann Thorac Surg.* 1970;10(3):237-247.
122. DeBakey ME, Henly WS, Cooley DA, et al. Surgical management of dissecting aneurysms of the aorta. *J Thorac Cardiovasc Surg.* 1965;49:130-149.
123. Borst HG, Heinemann MK, Stone CD. *Surgical Treatment of Aortic Dissection.* New York: Churchill Livingstone; 1996.
124. Tsagakis K, Tossios P, Kamler M, et al. The DeBakey classification exactly reflects late outcome and re-intervention probability in acute aortic dissection with a slightly modified type II definition. *Eur J Cardiothorac Surg.* 2011;40(5):1078-1084.
125. Augoustides JG, Geirsson A, Szeto WY, et al. Observational study of mortality risk stratification by ischemic presentation in patients with acute type A aortic dissection: the Penn classification. *Nat Clin Pract Cardiovasc Med.* 2009;6(2):140-146.
126. Augoustides JG, Szeto WY, Woo EY, et al. The complications of uncomplicated acute type-B dissection: the introduction of the Penn classification. *J Cardiothorac Vasc Anesth.* 2012;26(6):1139-1144.
127. Tsagakis K, Konorza T, Dohle DS, et al. Hybrid operating room concept for combined diagnostics, intervention and surgery in acute type A dissection. *Eur J Cardiothorac Surg.* 2013;43(2):397-404.

128. Nienaber CA, Sievers HH. Intramural hematoma in acute aortic syndrome: more than one variant of dissection? *Circulation*. 2002;106(3):284-285.
129. Evangelista A, Mukherjee D, Mehta RH, et al. Acute intramural hematoma of the aorta: a mystery in evolution. *Circulation*. 2005;111(8):1063-1070.
130. Maraj R, Rerkpattanapipat P, Jacobs LE, Makornwattana P, Kotler MN. Meta-analysis of 143 reported cases of aortic intramural hematoma. *Am J Cardiol*. 2000;86(6):664-668.
131. Ganaha F, Miller DC, Sugimoto K, et al. Prognosis of aortic intramural hematoma with and without penetrating atherosclerotic ulcer: a clinical and radiological analysis. *Circulation*. 2002;106(3):342-348.
132. Clouse WD, Hallett JW Jr., Schaff HV, et al. Acute aortic dissection: population-based incidence compared with degenerative aortic aneurysm rupture. *Mayo Clin Proc*. 2004;79(2):176-180.
133. Anagnostopoulos CE, Prabhakar MJ, Kittle CF. Aortic dissections and dissecting aneurysms. *Am J Cardiol*. 1972;30(3):263-273.
134. Hirst AE Jr., Johns VJ Jr., Kime SW Jr. Dissecting aneurysm of the aorta: a review of 505 cases. *Medicine (Baltimore)*. 1958;37(3):217-279.
135. Daniel JC, Huynh TT, Zhou W, et al. Acute aortic dissection associated with use of cocaine. *J Vasc Surg*. 2007;46(3):427-433.
136. Hatzaras IS, Bible JE, Koullias GJ, et al. Role of exertion or emotion as inciting events for acute aortic dissection. *Am J Cardiol*. 2007;100(9):1470-1472.
137. Wang X, LeMaire SA, Chen L, et al. Decreased expression of fibulin-5 correlates with reduced elastin in thoracic aortic dissection. *Surgery*. 2005;138(2):352-359.
138. Wang X, LeMaire SA, Chen L, et al. Increased collagen deposition and elevated expression of connective tissue growth factor in human thoracic aortic dissection. *Circulation*. 2006;114(1 Suppl):I200-205.
139. Shen YH, Zhang L, Ren P, et al. AKT2 confers protection against aortic aneurysms and dissections. *Circ Res*. 2013;112(4):618-632.
140. Harris KM, Strauss CE, Eagle KA, et al. Correlates of delayed recognition and treatment of acute type A aortic dissection: the International Registry of Acute Aortic Dissection (IRAD). *Circulation*. 2011;124(18):1911-1918.
141. Erbel R, Alfonso F, Boileau C, et al. Diagnosis and management of aortic dissection. *Eur Heart J*. 2001;22(18):1642-1681.
142. Hagan PG, Nienaber CA, Isselbacher EM, et al. The International Registry of Acute Aortic Dissection (IRAD): new insights into an old disease. *JAMA*. 2000;283(7):897-903.
143. Klompas M. Does this patient have an acute thoracic aortic dissection? *JAMA*. 2002;287(17):2262-2272.
144. Shimony A, Filion KB, Mottillo S, Dourian T, Eisenberg MJ. Meta-analysis of usefulness of D-dimer to diagnose acute aortic dissection. *Am J Cardiol*. 2011;107(8):1227-1234.
145. Sodeck G, Domanovits H, Schillinger M, et al. D-dimer in ruling out acute aortic dissection: a systematic review and prospective cohort study. *Eur Heart J*. 2007;28(24):3067-3075.
146. Rapezzi C, Longhi S, Graziosi M, et al. Risk factors for diagnostic delay in acute aortic dissection. *Am J Cardiol*. 2008;102(10):1399-1406.
147. von Kodolitsch Y, Nienaber CA, Dieckmann C, et al. Chest radiography for the diagnosis of acute aortic syndrome. *Am J Med*. 2004;116(2):73-77.
148. Nienaber CA, von Kodolitsch Y, Nicolas V, et al. The diagnosis of thoracic aortic dissection by noninvasive imaging procedures. *N Engl J Med*. 1993;328(1):1-9.
149. Keren A, Kim CB, Hu BS, et al. Accuracy of biplane and multiphase transesophageal echocardiography in diagnosis of typical acute aortic dissection and intramural hematoma. *J Am Coll Cardiol*. 1996;28(3):627-636.
150. Miller JS, LeMaire SA, Coselli JS. Evaluating aortic dissection: when is coronary angiography indicated? *Heart*. 2000;83(6):615-616.
151. Scholl FG, Coady MA, Davies R, et al. Interval or permanent nonoperative management of acute type A aortic dissection. *Arch Surg*. 1999;134(4):402-405.
152. Gillinov AM, Lytle BW, Kaplon RJ, et al. Dissection of the ascending aorta after previous cardiac surgery: differences in presentation and management. *J Thorac Cardiovasc Surg*. 1999;117(2):252-260.
153. Kirsch M, Soustelle C, Houel R, Hillion ML, Loisanche D. Risk factor analysis for proximal and distal reoperations after surgery for acute type A aortic dissection. *J Thorac Cardiovasc Surg*. 2002;123(2):318-325.
154. Crawford ES, Kirklin JW, Naftel DC, et al. Surgery for acute dissection of ascending aorta. Should the arch be included? *J Thorac Cardiovasc Surg*. 1992;104(1):46-59.
155. Westaby S, Saito S, Katsumata T. Acute type A dissection: conservative methods provide consistently low mortality. *Ann Thorac Surg*. 2002;73(3):707-713.
156. Geirsson A, Bavaria JE, Swarr D, et al. Fate of the residual distal and proximal aorta after acute type A dissection repair using a contemporary surgical reconstruction algorithm. *Ann Thorac Surg*. 2007;84(6):1955-1964.
157. Malvindi PG, van Putte BP, Sonker U, et al. Reoperation after acute type A aortic dissection repair: a series of 104 patients. *Ann Thorac Surg*. 2013;95(3):922-927.
158. Glower DD, Speier RH, White WD, et al. Management and long-term outcome of aortic dissection. *Ann Surg*. 1991;214(1):31-41.
159. Kazui T, Washiyama N, Muhammad BA, et al. Extended total arch replacement for acute type A aortic dissection: experience with seventy patients. *J Thorac Cardiovasc Surg*. 2000;119(3):558-565.
160. Hoffman A, Damberg AL, Schalte G, et al. Thoracic stent graft sizing for frozen elephant trunk repair in acute type A dissection. *J Thorac Cardiovasc Surg*. 2013;145(4):964-969.
161. Karck M, Chavan A, Khaladj N, et al. The frozen elephant trunk technique for the treatment of extensive thoracic aortic aneurysms: operative results and follow-up. *Eur J Cardiothorac Surg*. 2005;28(2):286-290; discussion 290.
162. Roselli EE, Rafael A, Soltesz EG, Canale L, Lytle BW. Simplified frozen elephant trunk repair for acute DeBakey type I dissection. *J Thorac Cardiovasc Surg*. 2013;145(3 Suppl):S197-S201.
163. Gorlitzer M, Weiss G, Meinhart J, et al. Fate of the false lumen after combined surgical and endovascular repair treating Stanford type A aortic dissections. *Ann Thorac Surg*. 2010;89(3):794-799.
164. Di Bartolomeo R, Di Marco L, Armario A, et al. Treatment of complex disease of the thoracic aorta: the frozen elephant trunk technique with the E-vita open prosthesis. *Eur J Cardiothorac Surg*. 2009;35(4):671-675; discussion 675-676.
165. Uchida N, Katayama A, Tamura K, et al. Long-term results of the frozen elephant trunk technique for extended aortic arch disease. *Eur J Cardiothorac Surg*. 2010;37(6):1338-1345.
166. Lima B, Roselli EE, Soltesz EG, et al. Modified and "reverse" frozen elephant trunk repairs for extensive disease and complications after stent grafting. *Ann Thorac Surg*. 2012;93(1):103-109; discussion 109.
167. Roselli EE, Soltesz EG, Mastracci T, Svensson LG, Lytle BW. Antegrade delivery of stent grafts to treat complex thoracic aortic disease. *Ann Thorac Surg*. 2010;90(2):539-546.
168. Kouchoukos NT. Frozen elephant trunk technique for extensive chronic thoracic aortic dissection: is it the final answer? *Ann Thorac Surg*. 2011;92(5):1557-1558.

169. Genoni M, Paul M, Jenni R, et al. Chronic beta-blocker therapy improves outcome and reduces treatment costs in chronic type B aortic dissection. *Eur J Cardiothorac Surg.* 2001;19(5):606-610.
170. DeBakey ME, McCollum CH, Crawford ES, et al. Dissection and dissecting aneurysms of the aorta: twenty-year follow-up of five hundred twenty-seven patients treated surgically. *Surgery.* 1982;92(6):1118-1134.
171. Fann JI, Smith JA, Miller DC, et al. Surgical management of aortic dissection during a 30-year period. *Circulation.* 1995;92(9 Suppl):II113-II121.
172. Elefteriades JA, Hartleroad J, Gusberg RJ, et al. Long-term experience with descending aortic dissection: the complication-specific approach. *Ann Thorac Surg.* 1992;53(1):11-20.
173. Barnes DM, Williams DM, Dasika NL, et al. A single-center experience treating renal malperfusion after aortic dissection with central aortic fenestration and renal artery stenting. *J Vasc Surg.* 2008;47(5):903-910.
174. Miller DC. Through the looking glass: The first 20 years of thoracic aortic stent-grafting. *J Thorac Cardiovasc Surg.* 2013;145(3 Suppl):S142-S148.
175. Hughes GC, Andersen ND, McCann RL. Management of acute type B aortic dissection. *J Thorac Cardiovasc Surg.* 2013;145(3 Suppl):S202-S207.
176. Kusagawa H, Shimono T, Ishida M, et al. Changes in false lumen after transluminal stent-graft placement in aortic dissections: six years' experience. *Circulation.* 2005;111(22):2951-2957.
177. Nienaber CA, Rousseau H, Eggebrecht H, et al. Randomized comparison of strategies for type B aortic dissection: the INVESTIGATION of STEnt Grafts in Aortic Dissection (INSTEAD) trial. *Circulation.* 2009;120(25):2519-2528.
178. Demers P, Miller DC, Mitchell RS, et al. Stent-graft repair of penetrating atherosclerotic ulcers in the descending thoracic aorta: mid-term results. *Ann Thorac Surg.* 2004;77(1):81-86.
179. Patel HJ, Sood V, Williams DM, et al. Late outcomes with repair of penetrating thoracic aortic ulcers: the merits of an endovascular approach. *Ann Thorac Surg.* 2012;94(2):516-522; discussion 522-523.
180. Coselli JS, LeMaire SA, de Figueiredo LP, Kirby RP. Paraplegia after thoracoabdominal aortic aneurysm repair: is dissection a risk factor? *Ann Thorac Surg.* 1997;63(1):28-35.
181. Aomi S, Nakajima M, Nonoyama M, et al. Aortic root replacement using composite valve graft in patients with aortic valve disease and aneurysm of the ascending aorta: twenty years' experience of late results. *Artif Organs.* 2002;26(5):467-473.
182. Kindo M, Billaud P, Gerelli S, et al. Twenty-seven-year experience with composite valve graft replacement of the aortic root. *J Heart Valve Dis.* 2007;16(4):370-377.
183. David TE, Mohr FW, Bavaria JE, et al. Initial experience with the Toronto Root bioprosthesis. *J Heart Valve Dis.* 2004;13(2):248-251.
184. Gleason TG, David TE, Coselli JS, Hammon JW Jr., Bavaria JE. St. Jude Medical Toronto biologic aortic root prosthesis: early FDA phase II IDE study results. *Ann Thorac Surg.* 2004;78(3):786-793.
185. Kincaid EH, Cordell AR, Hammon JW, Adair SM, Kon ND. Coronary insufficiency after stentless aortic root replacement: risk factors and solutions. *Ann Thorac Surg.* 2007;83(3):964-968.
186. Kon ND, Cordell AR, Adair SM, Dobbins JE, Kitzman DW. Aortic root replacement with the freestyle stentless porcine aortic root bioprosthesis. *Ann Thorac Surg.* 1999;67(6):1609-1615.
187. Melina G, De Robertis F, Gaer JA, et al. Mid-term pattern of survival, hemodynamic performance and rate of complications after Medtronic Freestyle versus homograft full aortic root replacement: results from a prospective randomized trial. *J Heart Valve Dis.* 2004;13(6):972-975.
188. Badiu CC, Eichinger W, Bleiziffer S, et al. Should root replacement with aortic valve-sparing be offered to patients with bicuspid valves or severe aortic regurgitation? *Eur J Cardiothorac Surg.* 2010;38(5):515-522.
189. David TE, Maganti M, Armstrong S. Aortic root aneurysm: principles of repair and long-term follow-up. *J Thorac Cardiovasc Surg.* 2010;140(6 Suppl):S14-S19; discussion S45-S51.
190. Zingone B, Gatti G, Spina A, et al. Current role and outcomes of ascending aortic replacement for severe nonaneurysmal aortic atherosclerosis. *Ann Thorac Surg.* 2010;89(2):429-434.
191. Achneck HE, Rizzo JA, Tranquilli M, Elefteriades JA. Safety of thoracic aortic surgery in the present era. *Ann Thorac Surg.* 2007;84(4):1180-1185.
192. Estrera AL, Miller CC III, Madisetty J, et al. Ascending and transverse aortic arch repair: the impact of glomerular filtration rate on mortality. *Ann Surg.* 2008;247(3):524-529.
193. Fleck TM, Czerny M, Hutschala D, et al. The incidence of transient neurologic dysfunction after ascending aortic replacement with circulatory arrest. *Ann Thorac Surg.* 2003;76(4):1198-1202.
194. Immer FF, Barmettler H, Berdat PA, et al. Effects of deep hypothermic circulatory arrest on outcome after resection of ascending aortic aneurysm. *Ann Thorac Surg.* 2002;74(2):422-425.
195. Heinemann MK, Buehner B, Jurmann MJ, Borst HG. Use of the "elephant trunk technique" in aortic surgery. *Ann Thorac Surg.* 1995;60(1):2-6.
196. LeMaire SA, Carter SA, Coselli JS. The elephant trunk technique for staged repair of complex aneurysms of the entire thoracic aorta. *Ann Thorac Surg.* 2006;81(5):1561-1569.
197. Safi HJ, Miller CC III, Estrera AL, et al. Staged repair of extensive aortic aneurysms: long-term experience with the elephant trunk technique. *Ann Surg.* 2004;240(4):677-684.
198. Sundt TM, Moon MR, DeOliviera N, et al. Contemporary results of total aortic arch replacement. *J Card Surg.* 2004;19(3):235-239.
199. Svensson LG, Kim KH, Blackstone EH, et al. Elephant trunk procedure: newer indications and uses. *Ann Thorac Surg.* 2004;78(1):109-116.
200. Kazui T, Yamashita K, Washiyama N, et al. Aortic arch replacement using selective cerebral perfusion. *Ann Thorac Surg.* 2007;83(2):S796-S798; discussion S824-S831.
201. Bischoff MS, Brenner RM, Scheumann J, et al. Long-term outcome after aortic arch replacement with a trifurcated graft. *J Thorac Cardiovasc Surg.* 2010;140(6 Suppl):S71-76; discussion S86-S91.
202. Iba Y, Minatoya K, Matsuda H, et al. Contemporary open aortic arch repair with selective cerebral perfusion in the era of endovascular aortic repair. *J Thorac Cardiovasc Surg.* 2013;145(3 Suppl):S72-S77.
203. Thomas M, Li Z, Cook DJ, Greason KL, Sundt TM. Contemporary results of open aortic arch surgery. *J Thorac Cardiovasc Surg.* 2012;144(4):838-844.
204. Urbanski PP, Lenos A, Bougioukakis P, et al. Mild-to-moderate hypothermia in aortic arch surgery using circulatory arrest: a change of paradigm? *Eur J Cardiothorac Surg.* 2012;41(1):185-191.
205. Kondoh H, Taniguchi K, Funatsu T, et al. Total arch replacement with long elephant trunk anastomosed at the base of the innominate artery: a single-centre longitudinal experience. *Eur J Cardiothorac Surg.* 2012;42(5):840-848; discussion 848.
206. Flores J, Kunihara T, Shiiya N, et al. Extensive deployment of the stented elephant trunk is associated with an increased risk of spinal cord injury. *J Thorac Cardiovasc Surg.* 2006;131(2):336-342.
207. Antoniou GA, Mireskandari M, Bicknell CD, et al. Hybrid repair of the aortic arch in patients with extensive aortic disease. *Eur J Vasc Endovasc Surg.* 2010;40(6):715-721.

208. Geisbusch P, Kotelis D, Muller-Eschner M, Hyhlik-Durr A, Bockler D. Complications after aortic arch hybrid repair. *J Vasc Surg.* 2011;53(4):935-941.
209. Czerny M, Weigang E, Sodeck G, et al. Targeting landing zone 0 by total arch rerouting and TEVAR: midterm results of a transcontinental registry. *Ann Thorac Surg.* 2012;94(1):84-89.
210. Trimarchi S, Eagle KA, Nienaber CA, et al. Role of age in acute type A aortic dissection outcome: report from the International Registry of Acute Aortic Dissection (IRAD). *J Thorac Cardiovasc Surg.* 2010;140(4):784-789.
211. Rampoldi V, Trimarchi S, Eagle KA, et al. Simple risk models to predict surgical mortality in acute type A aortic dissection: the International Registry of Acute Aortic Dissection score. *Ann Thorac Surg.* 2007;83(1):55-61.
212. Kruger T, Weigang E, Hoffmann I, et al. Cerebral protection during surgery for acute aortic dissection type A: results of the German Registry for Acute Aortic Dissection Type A (GERAADA). *Circulation.* 2011;124(4):434-443.
213. Dake MD, Miller DC, Mitchell RS, et al. The "first generation" of endovascular stent-grafts for patients with aneurysms of the descending thoracic aorta. *J Thorac Cardiovasc Surg.* 1998;116(5):689-703.
214. Demers P, Miller DC, Mitchell RS, et al. Midterm results of endovascular repair of descending thoracic aortic aneurysms with first-generation stent grafts. *J Thorac Cardiovasc Surg.* 2004;127(3):664-673.
215. Bavaria JE, Appoo JJ, Makaroun MS, et al. Endovascular stent grafting versus open surgical repair of descending thoracic aortic aneurysms in low-risk patients: a multicenter comparative trial. *J Thorac Cardiovasc Surg.* 2007;133(2):369-377.
216. Fairman RM, Criado F, Farber M, et al. Pivotal results of the Medtronic Vascular Talent Thoracic Stent Graft System: the VALOR trial. *J Vasc Surg.* 2008;48(3):546-554.
217. Matsumura JS, Cambria RP, Dake MD, et al. International controlled clinical trial of thoracic endovascular aneurysm repair with the Zenith TX2 endovascular graft: 1-year results. *J Vasc Surg.* 2008;47(2):247-257.
218. Makaroun MS, Dillavou ED, Wheatley GH, Cambria RP. Five-year results of endovascular treatment with the Gore TAG device compared with open repair of thoracic aortic aneurysms. *J Vasc Surg.* 2008;47(5):912-918.
219. Foley PJ, Criado FJ, Farber MA, et al. Results with the Talent thoracic stent graft in the VALOR trial. *J Vasc Surg.* 2012;56(5):1214-1221. doi:10.1007/s10014-012-0121-1.
220. Czerny M, Zimpfer D, Rodler S, et al. Endovascular stent-graft placement of aneurysms involving the descending aorta originating from chronic type B dissections. *Ann Thorac Surg.* 2007;83(5):1635-1639.
221. Nienaber CA. Results from the INSTEAD trial. Paper presented at: Sixth Annual International Symposium on Advances in Understanding Aortic Diseases; Sept 30-Oct 1, 2005; Berlin, Germany.
222. Brunkwall J, Lammer J, Verhoeven E, Taylor P. ADSORB: a study on the efficacy of endovascular grafting in uncomplicated acute dissection of the descending aorta. *Eur J Vasc Endovasc Surg.* 2012;44(1):31-36.
223. Coselli JS, LeMaire SA, Conklin LD, Adams GJ. Left heart bypass during descending thoracic aortic aneurysm repair does not reduce the incidence of paraplegia. *Ann Thorac Surg.* 2004;77(4):1298-1303.
224. Chiesa R, Tshomba Y, Civilini E, et al. Open repair of descending thoracic aneurysms. *HSR Proc Intensive Care Cardiovasc Anesth.* 2010;2(3):177-190.
225. Estrera AL, Miller CC, III, Chen EP, et al. Descending thoracic aortic aneurysm repair: 12-year experience using distal aortic perfusion and cerebrospinal fluid drainage. *Ann Thorac Surg.* 2005;80(4):1290-1296.
226. Dick F, Hinder D, Immer FF, et al. Outcome and quality of life after surgical and endovascular treatment of descending aortic lesions. *Ann Thorac Surg.* 2008;85(5):1605-1612.
227. Stone DH, Brewster DC, Kwolek CJ, et al. Stent-graft versus open-surgical repair of the thoracic aorta: mid-term results. *J Vasc Surg.* 2006;44(6):1188-1197.
228. Brandt M, Hussel K, Walluscheck KP, et al. Stent-graft repair versus open surgery for the descending aorta: a case-control study. *J Endovasc Ther.* 2004;11(5):535-538.
229. Goodney PP, Travis L, Lucas FL, et al. Survival after open versus endovascular thoracic aortic aneurysm repair in an observational study of the Medicare population. *Circulation.* 2011;124(24):2661-2669.
230. LeMaire SA, Price MD, Green SY, Zarda S, Coselli JS. Results of open thoracoabdominal aortic aneurysm repair. *Ann Cardiothorac Surg.* 2012;1(3):286-292.
231. Chiesa R, Melissano G, Civilini E, et al. Ten years experience of thoracic and thoracoabdominal aortic aneurysm surgical repair: lessons learned. *Ann Vasc Surg.* 2004;18(5):514-520.
232. Coselli JS, Bozinovski J, LeMaire SA. Open surgical repair of 2286 thoracoabdominal aortic aneurysms. *Ann Thorac Surg.* 2007;83(2):S862-S864.
233. Conrad MF, Crawford RS, Davison JK, Cambria RP. Thoracoabdominal aneurysm repair: a 20-year perspective. *Ann Thorac Surg.* 2007;83(2):S856-S861.
234. Schepens MA, Kelder JC, Morshuis WJ, et al. Long-term follow-up after thoracoabdominal aortic aneurysm repair. *Ann Thorac Surg.* 2007;83(2):S851-S855.
235. Rigberg DA, McGory ML, Zingmond DS, et al. Thirty-day mortality statistics underestimate the risk of repair of thoracoabdominal aortic aneurysms: a statewide experience. *J Vasc Surg.* 2006;43(2):217-222.
236. Cowan JA Jr., Dimick JB, Henke PK, et al. Surgical treatment of intact thoracoabdominal aortic aneurysms in the United States: hospital and surgeon volume-related outcomes. *J Vasc Surg.* 2003;37(6):1169-1174.
237. Wong DR, Parenti JL, Green SY, et al. Open repair of thoracoabdominal aortic aneurysm in the modern surgical era: contemporary outcomes in 509 patients. *J Am Coll Surg.* 2011;212(4):569-579; discussion 579-581.
238. Trimarchi S, Tolenaar JL, Tsai TT, et al. Influence of clinical presentation on the outcome of acute B aortic dissection: evidences from IRAD. *J Cardiovasc Surg (Torino).* 2012;53(2):161-168.
239. Tsai TT, Fattori R, Trimarchi S, et al. Long-term survival in patients presenting with type B acute aortic dissection: insights from the International Registry of Acute Aortic Dissection. *Circulation.* 2006;114(21):2226-2231.
240. Slonim SM, Miller DC, Mitchell RS, et al. Percutaneous balloon fenestration and stenting for life-threatening ischemic complications in patients with acute aortic dissection. *J Thorac Cardiovasc Surg.* 1999;117(6):1118-1126.
241. Dake MD, Kato N, Mitchell RS, et al. Endovascular stent-graft placement for the treatment of acute aortic dissection. *N Engl J Med.* 1999;340(20):1546-1552.
242. Eggebrecht H, Nienaber CA, Neuhauser M, et al. Endovascular stent-graft placement in aortic dissection: a meta-analysis. *Eur Heart J.* 2006;27(4):489-498.
243. White RA, Miller DC, Criado FJ, et al. Report on the results of thoracic endovascular aortic repair for acute, complicated, type B aortic dissection at 30 days and 1 year from a multidisciplinary subcommittee of the Society for Vascular Surgery Outcomes Committee. *J Vasc Surg.* 2011;53(4):1082-1090.
244. Coselli JS, LeMaire SA. Acute type B dissections: open surgical options. In: Eskandari MK, Pearce WH, Yao JST, eds. *Current Vascular Surgery 2012*. Shelton: People's Medical Publishing House-USA; 2013:351-362.

23 chapter

Arterial Disease

Peter H. Lin, Mun Jye Poi, Jesus Matos,
Panagiotis Kougiyas, Carlos Bechara, and
Changyi Chen

- General Approach to the Vascular Patient** 828
- The Vascular History / 828
 - The Vascular Physical Examination / 829
 - Noninvasive Diagnostic Evaluation of the Vascular Patient / 829
 - Radiologic Evaluation of the Vascular Patient / 830
 - Preoperative Cardiac Evaluation / 833
- Basic Principles of Endovascular Therapy** 834
- Needles and Access / 834
 - Guidewires / 835
 - Hemostatic Sheaths / 835
 - Catheters / 835
 - Angioplasty Balloons / 835
 - Stents / 836
 - Stent Grafts / 836
- Carotid Artery Disease** 837
- Epidemiology and Etiology of Carotid Occlusive Disease / 837
 - Clinical Manifestations of Cerebral Ischemia / 838
 - Diagnostic Evaluation / 839
 - Treatment of Carotid Occlusive Disease / 841
 - Carotid Endarterectomy versus Angioplasty and Stenting / 842
 - Surgical Techniques of Carotid Endarterectomy / 843
 - Techniques of Carotid Angioplasty and Stenting / 845
 - Nonatherosclerotic Disease of the Carotid Artery / 847
- Abdominal Aortic Aneurysm** 850
- Causes and Risk Factors / 850
 - Natural History of Aortic Aneurysm / 850
 - Clinical Manifestations / 851
 - Relevant Anatomy / 851
 - Diagnostic Evaluation / 852
 - Surgical Repair of Abdominal Aortic Aneurysm / 852
 - Endovascular Repair of Abdominal Aortic Aneurysm / 853
 - Results from Clinical Studies Comparing Endovascular versus Open Repair / 857
 - Classification and Management of Endoleak / 858
- Mesenteric Artery Disease** 859
- Anatomy and Pathophysiology / 860
 - Types of Mesenteric Artery Occlusive Disease / 860
 - Clinical Manifestations / 861
 - Diagnostic Evaluation / 861
 - Surgical Repair / 863
 - Endovascular Treatment / 864
 - Clinical Results of Interventions for Mesenteric Ischemia / 865
- Renal Artery Disease** 866
- Etiology / 866
 - Clinical Manifestations / 867
 - Diagnostic Evaluation / 867
 - Treatment Indications / 869
 - Surgical Reconstruction / 869
 - Clinical Results of Surgical Repair / 870
 - Endovascular Treatment / 870
 - Clinical Results of Endovascular Interventions / 871
- Aortoiliac Occlusive Disease** 872
- Diagnostic Evaluation / 872
 - Differential Diagnosis / 872
 - Collateral Arterial Network / 873
 - Disease Classification / 873
 - General Treatment Considerations / 875
 - Surgical Reconstruction of Aortoiliac Occlusive Disease / 876
 - Complications of Surgical Aortoiliac Reconstruction / 878
 - Endovascular Treatment for Aortic Disease / 879
 - Endovascular Treatment for Iliac Artery Disease / 879
 - Complications of Endovascular Aortoiliac Interventions / 880
 - Clinical Results Comparing Surgical and Endovascular Treatment of Aortoiliac Disease / 880
- Lower Extremity Arterial Occlusive Disease** 881
- Epidemiology / 882
 - Diagnostic Evaluation / 882
 - Differential Diagnosis / 882
 - Lower Extremity Occlusive Disease Classification / 883
 - Etiology of Acute Limb Ischemia / 885
- Clinical Manifestations of Acute Limb Ischemia / 886
 - Treatment Considerations for Acute Limb Ischemia / 887
 - Endovascular Treatment / 887
 - Surgical Treatment / 887
 - Complications Related to Treatment for Acute Limb Ischemia / 888
 - Clinical Manifestations of Chronic Limb Ischemia / 889
 - Treatment Considerations for Chronic Limb Ischemia / 890
 - Endovascular Treatment / 891
 - Complications of Endovascular Interventions / 896
 - Surgical Treatment for Chronic Limb Ischemia due to Femoropopliteal Disease / 897
 - Complications of Surgical Reconstruction / 898
 - Choice of Conduit for Infrainguinal Bypass Grafting / 898
 - Clinical Results of Surgical and Endovascular Interventions for Femoropopliteal Occlusive Disease / 899
- Nonatherosclerotic Disorders of Blood Vessels** 900
- Giant Cell Arteritis (Temporal Arteritis) / 901
 - Takayasu's Arteritis / 901
 - Ehlers-Danlos Syndrome / 901
 - Marfan's Syndrome / 902
 - Pseudoxanthoma Elasticum / 902
 - Kawasaki's Disease / 902
 - Inflammatory Arteritis and Vasculitis / 902
 - Behçet's Disease / 903
 - Polyarteritis Nodosa / 903
 - Radiation-Induced Arteritis / 903
 - Raynaud's Syndrome / 904
 - Fibromuscular Dysplasia / 904
 - Nonatherosclerotic Disease Affecting the Popliteal Artery Disease / 905
 - Buerger's Disease (Thromboangiitis Obliterans) / 906

Key Points

- 1▶ Carotid intervention as a preventive strategy should be performed in patients with 50% or greater symptomatic internal carotid artery stenosis and those with 80% or greater asymptomatic internal carotid artery stenosis. Carotid intervention for asymptomatic stenosis between 60% and 79% remains controversial and is a function of an operator's stroke rate. The choice of intervention—carotid endarterectomy versus carotid stenting—remains controversial; currently, carotid endarterectomy appears to be associated with lower stroke rate, whereas carotid stenting is more suitable under certain anatomic or physiologic conditions.
- 2▶ Abdominal aortic aneurysms should be repaired when the risk of rupture, determined mainly by aneurysm size, exceeds the risk of death due to perioperative complications or concurrent illness. Endovascular repair is associated with less perioperative morbidity and mortality compared to open reconstruction and is preferred for high-risk patients who meet specific anatomic criteria.
- 3▶ Symptomatic mesenteric ischemia should be treated to improve quality of life and prevent bowel infarction. Operative treatment—bypass—is superior to endovascular intervention, although changes in wire and stent technology have improved the results of mesenteric stenting in recent series.
- 4▶ Aortoiliac occlusive disease can be treated with either endovascular means or open reconstruction, depending on patient risk stratification, occlusion characteristics, and symptomatology.
- 5▶ Claudication is a marker of extensive atherosclerosis and is mainly managed with risk factor modification and pharmacotherapy. Only 5% of patients with claudication will need intervention because of disabling extremity pain. The 5-year mortality of a patient with claudication approaches 30%. Patients with rest pain or tissue loss need expeditious evaluation and vascular reconstruction to ameliorate the severe extremity pain and prevent limb loss.

GENERAL APPROACH TO THE VASCULAR PATIENT

Since the vascular system involves every organ system in our body, the symptoms of vascular disease are as varied as those encountered in any medical specialty. Lack of adequate blood supply to target organs typically presents with pain; for example, calf pain with lower extremity claudication, postprandial abdominal pain from mesenteric ischemia, and arm pain with axillo-subclavian arterial occlusion. In contrast, stroke and transient ischemic attack (TIA) are the presenting symptoms from middle cerebral embolization as a consequence of a stenosed internal carotid artery. The pain syndrome of arterial disease is usually divided clinically into acute and chronic types, with all shades of severity between the two extremes. Sudden onset of pain can indicate complete occlusion of a critical vessel, leading to more severe pain and critical ischemia in the target organ, resulting in lower limb gangrene or intestinal infarction. Chronic pain results from a slower, more progressive atherosclerotic occlusion, which can be totally or partially compensated by developing collateral vessels. Acute on chronic is another pain pattern in which a patient most likely has an underlying arterial stenosis that suddenly occludes; for example, the patient with a history of calf claudication who now presents with sudden, severe acute limb-threatening ischemia. The clinician should always try to understand and relate the clinical manifestations to the underlying pathologic process.

The Vascular History

Appropriate history should be focused based on the presenting symptoms related to the vascular system (Table 23-1). Of particular importance in the previous medical history is noting prior vascular interventions (endovascular or open surgical), and all vascular patients should have inquiry made about their prior cardiac history and current cardiac symptoms. Approximately 30% of vascular patients will be diabetic. A history of prior and current smoking status should be noted.

Table 23-1

Pertinent elements in vascular history

- History of stroke or transient ischemic attack
- History of coronary artery disease, including previous myocardial infarction and angina
- History of peripheral arterial disease
- History of diabetes
- History of hypertension
- History of tobacco use
- History of hyperlipidemia

The patient with carotid disease in most cases is completely asymptomatic, having been referred based on the finding of a cervical bruit or duplex finding of stenosis. Symptoms of carotid territory TIAs include transient monocular blindness (amaurosis), contralateral weakness or numbness, and dysphasia. Symptoms persisting longer than 24 hours constitute a stroke. In contrast, the patient with chronic mesenteric ischemia is likely to present with postprandial abdominal pain and weight loss. The patient fears eating because of the pain, avoids food, and loses weight. It is very unlikely that a patient with abdominal pain who has not lost weight has chronic mesenteric ischemia.

The patient with lower extremity pain on ambulation has intermittent claudication that occurs in certain muscle groups; for example, calf pain upon exercise usually reflects superficial femoral artery disease, while pain in the buttocks reflects iliac disease. In most cases, the pain manifests in one muscle group below the level of the affected artery, occurs only with exercise, and is relieved with rest only to recur at the same location, hence the term “window gazer’s disease.” Rest pain (a manifestation of severe underlying occlusive disease) is constant and occurs in the foot (not the muscle groups), typically at the metatarsophalangeal junction, and is relieved by dependency. Often the

patient is prompted to sleep with their foot hanging off one side of the bed to increase the hydrostatic pressure.

The Vascular Physical Examination

Specific vascular examination should include abdominal aortic palpation, carotid artery examination, and pulse examination of the lower extremity (femoral, popliteal, posterior tibial, and dorsalis pedis arteries). The abdomen should be palpated for an abdominal aortic aneurysm, detected as an expansile pulse above the level of the umbilicus. It should also be examined for the presence of bruits. Because the aorta typically divides at the level of the umbilicus, an aortic aneurysm is most frequently palpable in the epigastrium. In thin individuals, a normal aortic pulsation is palpable, while in obese patients, even large aortic aneurysms may not be detectable. Suspicion of a clinically enlarged aorta should lead to the performance of an ultrasound scan for a more accurate definition of aortic diameter.

The carotids should be auscultated for the presence of bruits, although there is a higher correlation with coronary artery disease than underlying carotid stenosis. A bruit at the angle of the mandible is a significant finding, leading to follow-up duplex scanning. The differential diagnosis is a transmitted murmur from a sclerotic or stenotic aortic valve. The carotid is palpable deep to the sternocleidomastoid muscle in the neck. Palpation, however, should be gentle and rarely yields clinically useful information.

Upper extremity examination is necessary when an arteriovenous graft is to be inserted in patients who have symptoms of arm pain with exercise. Thoracic outlet syndrome (TOS) can result in occlusion or aneurysm formation of the subclavian artery. Distal embolization is a manifestation of TOS; consequently, the fingers should be examined for signs of ischemia and ulceration. The axillary artery enters the limb below the middle of the clavicle, where it can be palpated in thin patients. It is usually easily palpable in the axilla and medial upper arm. The brachial artery is most easily located at the antecubital fossa immediately medial to the biceps tendon. The radial artery is palpable at the wrist anterior to the radius.

For lower extremity vascular examination, the femoral pulse is usually palpable midway between the anterior superior iliac spine and the pubic tubercle. The popliteal artery is palpated in the popliteal fossa with the knee flexed to 45° and the foot supported on the examination table to relax the calf muscles. Palpation of the popliteal artery is a bimanual technique. Both thumbs are placed on the tibial tuberosity anteriorly and the fingers are placed into the popliteal fossa between the two heads of the gastrocnemius muscle. The popliteal artery is palpated by compressing it against the posterior aspect of the tibia just below the knee. The posterior tibial pulse is detected by palpation 2 cm posterior to the medial malleolus. The dorsalis pedis is detected 1 cm lateral to the hallucis longus extensor tendon, which dorsiflexes the great toe and is clearly visible on the dorsum of the foot. Pulses can be graded using either the traditional four-point scale or the basic two-point scale system (Table 23-2). The foot should also be carefully examined for pallor on elevation and rubor on dependency, as these findings are indicative of chronic ischemia. Note should also be made of nail changes and loss of hair. Ulceration and other findings specific to disease states are described in relevant sections later in this chapter.

After reconstructive vascular surgery, the graft may be available for examination, depending on its type and course.

Table 23-2

Grading scales for peripheral pulses

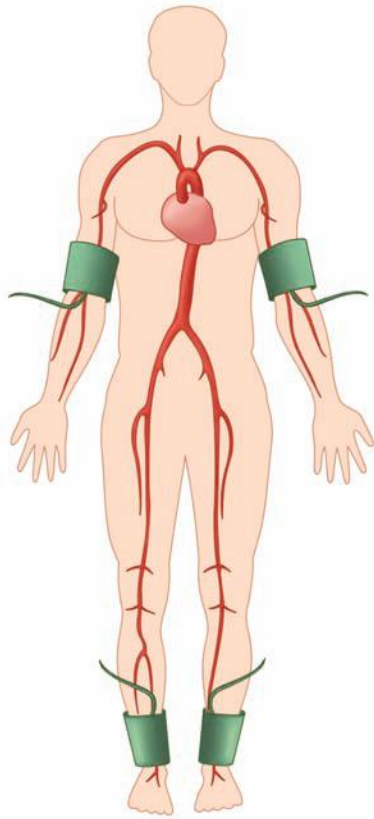
TRADITIONAL SCALE		BASIC SCALE	
4+	Normal	2+	Normal
3+	Slightly reduced	1+	Diminished
2+	Markedly reduced	0	Absent
1+	Barely palpable		

The in situ lower extremity graft runs in the subcutaneous fat and can be palpated along most of its length. A change in pulse quality, aneurysmal enlargement, or a new bruit should be carefully noted. Axillofemoral grafts, femoral-to-femoral grafts, and arteriovenous access grafts can usually be easily palpated as well.

Noninvasive Diagnostic Evaluation of the Vascular Patient

Ankle-Brachial Index. There is increasing interest in the use of the ankle-brachial index (ABI) to evaluate patients at risk for cardiovascular events. An ABI less than 0.9 correlates with increased risk of myocardial infarction and indicates significant, although perhaps asymptomatic, underlying peripheral vascular disease. The ABI is determined in the following ways. Blood pressure is measured in both upper extremities using the highest systolic blood pressure as the denominator for the ABI. The ankle pressure is determined by placing a blood pressure cuff above the ankle and measuring the return to flow of the posterior tibial and dorsalis pedis arteries using a pencil Doppler probe over each artery. The ratio of the systolic pressure in each vessel divided by the highest arm systolic pressure can be used to express the ABI in both the posterior tibial and dorsalis pedis arteries (Fig. 23-1). Normal is more than 1. Patients with claudication typically have an ABI in the 0.5 to 0.7 range, and those with rest pain are in the 0.3 to 0.5 range. Those with gangrene have an ABI of less than 0.3. These ranges can vary depending on the degree of compressibility of the vessel. The test is less reliable in patients with heavily calcified vessels. Due to non-compressibility, some patients, such as diabetics and those with end-stage renal disease, may have $ABI \geq 1.40$ and require additional noninvasive diagnostic testing to evaluate for peripheral artery disease. Alternative tests include toe-brachial pressures, pulse volume recordings, transcutaneous oxygen measurements, or vascular imaging (duplex ultrasound).

Segmental Limb Pressures. By placing serial blood pressure cuffs down the lower extremity and then measuring the pressure with a Doppler probe as flow returns to the artery below the cuff, it is possible to determine segmental pressures down the leg. This data can then be used to infer the level of the occlusion. The systolic pressure at each level is expressed as a ratio, with the highest systolic pressure in the upper extremities as the denominator. Normal segmental pressures commonly show high thigh pressures 20 mmHg or greater in comparison to the brachial artery pressures. The low thigh pressure should be equivalent to brachial pressures. Subsequent pressures should fall by no more than 10 mmHg at each level. A pressure gradient of 20 mmHg between two subsequent levels is usually indicative of occlusive disease at that level. The most frequently used

**Right ABI = ratio of**

 Higher of the right ankle systolic pressures (posterior tibial or dorsalis pedis)

 Higher arm systolic pressure (left or right arm)
Left ABI = ratio of

 Higher of the left ankle systolic pressures (posterior tibial or dorsalis pedis)

 Higher arm systolic pressure (left or right arm)

Figure 23-1. Calculating the ankle-brachial index (ABI).

index is the ratio of the ankle pressure to the brachial pressure, the ABI. Normally, the ABI is greater than 1.0, and a value of less than 0.9 indicates some degree of arterial obstruction and has been shown to be correlated with an increased risk of coronary heart disease.¹ Limitations of relying on segmental limb pressures include: (a) missing isolated moderate stenoses (usually iliac) that produce little or no pressure gradient at rest; (b) falsely elevated pressures in patients with diabetes and end-stage renal disease; and (c) the inability to differentiate between stenosis and occlusion.² Patients with diabetes and end-stage renal disease have calcified vessels that are difficult to compress, thus rendering this method inaccurate, due to recording of falsely elevated pressure readings. Noncompressible arteries yield ankle systolic pressures ≥ 250 mmHg and ABIs >1.40 . In this situation, absolute toe and ankle pressures can be measured to gauge critical limb ischemia. Ankle pressures less than 50 mmHg or toe pressures less than 30 mmHg are indicative of critical limb ischemia. The toe pressure is normally 30 mmHg less than the ankle pressure, and a toe-brachial index (TBI) <0.70 is abnormal. False-positive results with the TBI are unusual. The main limitation of this technique is that it may be impossible to measure pressures in the first and second toes due to pre-existing ulceration.

Pulse Volume Recording. In patients with noncompressible vessels, segmental plethysmography can be used to determine underlying arterial occlusive disease. Cuffs placed at different levels on the leg detect changes in blood volume and produce a pulse volume recording (PVR) when connected to a plethysmograph (Fig. 23-2). To obtain accurate PVR waveforms, the cuff is inflated to 60 to 65 mmHg, so as to detect volume changes without causing arterial occlusion. Pulse volume tracings are suggestive of proximal disease if the upstroke of the pulse is not brisk, the peak of the wave tracing is rounded, and there is disappearance of the dicrotic notch.

Although isolated segmental limb pressures and PVR measurements are 85% accurate when compared with angiography in detecting and localizing significant atherosclerotic lesions, when used in combination, accuracy approaches 95%.³ For this reason, it is suggested that these two diagnostic modalities be used in combination when evaluating peripheral artery disease.

Radiologic Evaluation of the Vascular Patient

Ultrasound. Ultrasound examinations are relatively time consuming, require experienced technicians, and may not visualize all arterial segments. Doppler waveform analysis can suggest atherosclerotic occlusive disease if the waveforms in the insonated arteries are biphasic, monophasic, or asymmetrical. B-mode ultrasonography provides black and white, real-time images. B-mode ultrasonography does not evaluate blood flow; thus, it cannot differentiate between fresh thrombus and flowing blood, which have the same echogenicity. Calcification in atherosclerotic plaques will cause acoustic shadowing. B-mode ultrasound probes cannot be sterilized. Use of the B-mode probe intraoperatively requires a sterile covering and gel to maintain an acoustic interface. Experience is needed to obtain and interpret images accurately. Duplex ultrasonography entails performance of B-mode imaging, spectral Doppler scanning, and color-flow duplex scanning. The caveat to performance of duplex ultrasonography is meticulous technique by a certified vascular ultrasound technician, so that the appropriate 60° Doppler angle is maintained during insonation with the ultrasound probe. Alteration of this angle can markedly alter waveform appearance and subsequent interpretation of velocity measurements. Direct imaging of intra-abdominal vessels with duplex ultrasound is less reliable because of the difficulty in visualizing the vessels through overlying bowel. These disadvantages currently limit the applicability of duplex scanning in the evaluation of aortoiliac and infrapopliteal disease. In a recent study, duplex ultrasonography had lower sensitivity in the calculation of infrapopliteal vessel stenosis in comparison to conventional digital subtraction or computed tomography angiography.⁴ Few surgeons rely solely on duplex ultrasonography for preoperative planning in lower extremity revascularizations; but with experience, lower extremity arteries can be insonated to determine anatomy, and the functional significance of lesions can be determined by calculation of degree of stenosis from velocity ratios. Duplex scanning is unable to evaluate recently implanted polytetrafluoroethylene (PTFE) and polyester (Dacron) grafts because they contain air, which prevents ultrasound penetration.

Computed Tomography Angiography. Computed tomography angiography (CTA) is a noninvasive, contrast-dependent method for imaging the arterial system. It depends on intravenous infusion of iodine-based contrast agents. The patient is advanced through a rotating gantry, which images serial transverse

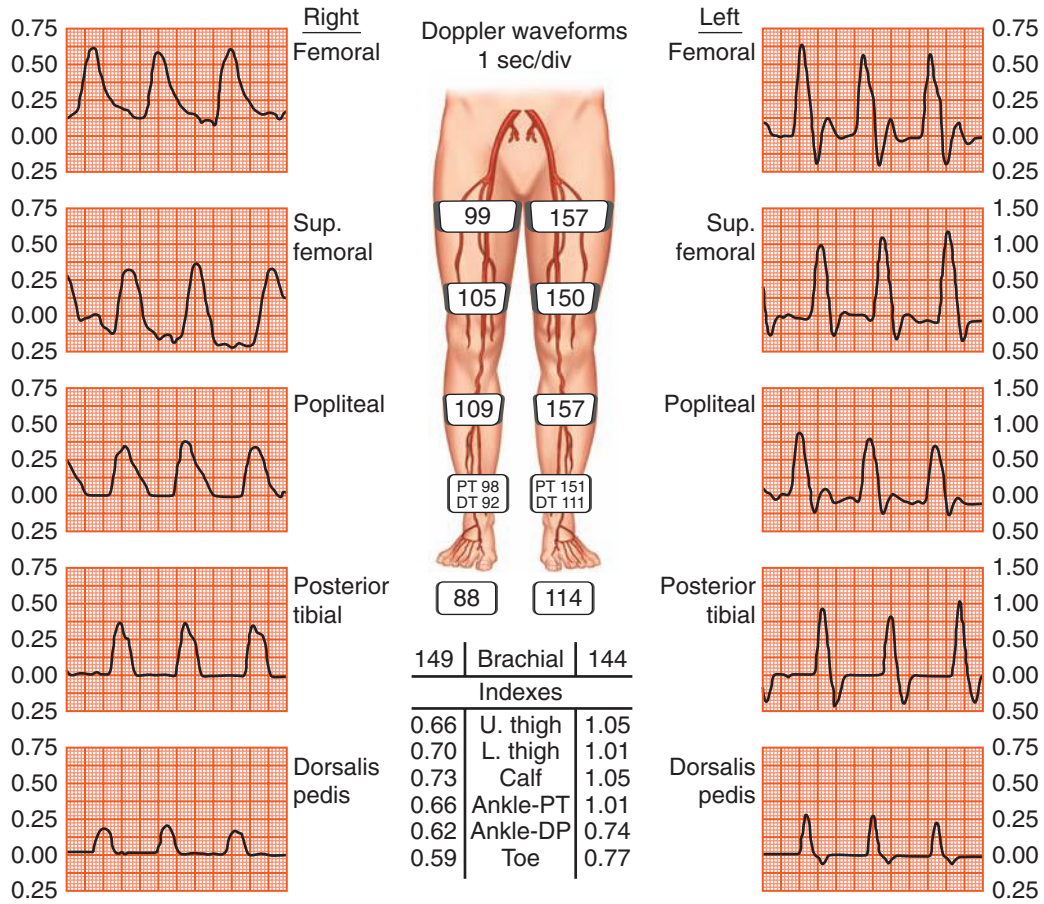


Figure 23-2. Typical report of peripheral vascular study with arterial segmental pressure measurement plus Doppler evaluation of the lower extremity.

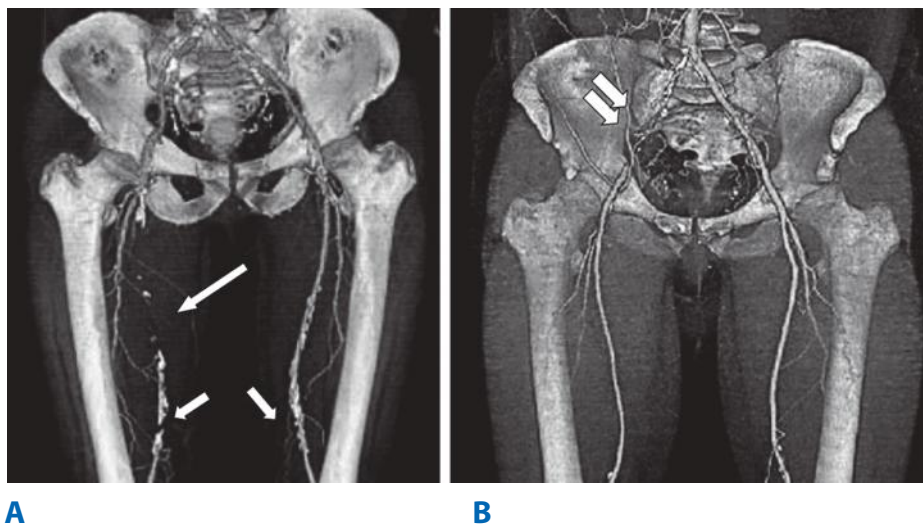


Figure 23-3. A multidetector computed tomography angiography with three-dimensional reconstruction of the iliofemoral arterial circulation in two patients with lower leg claudication. **A.** A 50-year-old male with an occluded right superficial femoral artery (*single long arrow*) with reconstituted superficial femoral artery at the level of mid-thigh. Arterial calcifications (*single short arrows*) are present in the bilateral distal superficial femoral arteries. **B.** A 53-year-old male with occluded right common iliac artery (*double arrows*).

slices. The contrast-filled vessels can be extracted from the slices and rendered in three-dimensional format (Fig. 23-3). The extracted images can also be rotated and viewed from several different directions during postacquisition image processing. This technology has been advanced as a consequence of aortic endografting. CTA provides images for postprocessing that can be used to display the aneurysm in a format that demonstrates thrombus, calcium, lumen, and the outer wall, and allows “fitting” of a proposed endograft into the aneurysm (Fig. 23-4). CTA is increasingly being used to image the carotid bifurcation, and as computing power increases, the speed of image acquisition and resolution will continue to increase. The major limitations of multidetector CTA are use of contrast and presence of artifacts caused by calcification and stents. CTA can overestimate the degree of in-stent stenosis, while heavy calcification can limit the diagnostic accuracy of the method by causing a “blooming artifact.”⁵ The artifacts can be overcome with alteration in image acquisition technique. There are no randomized trials to document the superiority of multidetector CTA over traditional angiography, but there is emerging evidence to support the claim that multidetector CTA has sensitivity, specificity, and accuracy that rival invasive angiography.⁵

Magnetic Resonance Angiography. Magnetic resonance angiography (MRA) has the advantage of not requiring iodinated contrast agents to provide vessel opacification (Fig. 23-5). Gadolinium is used as a contrast agent for MRA studies, and because it is generally not nephrotoxic, it can be used in patients with elevated creatinine. MRA is contraindicated in patients with pacemakers, defibrillators, spinal cord stimulators, intracerebral shunts, cochlear implants, and cranial clips. Patients with claustrophobia may require sedation to be able to complete the test. The presence of metallic stents causes artifacts and signal drop-out; however, these can be dealt with using alternations in image acquisition and processing. Nitinol stents produce minimal artifact.⁶ Compared to other modalities, MRA is relatively slow and expensive. However, due to its noninvasive nature and decreased nephrotoxicity, MRA is being used more frequently for imaging vasculature in various anatomic distributions.

Diagnostic Angiography. Diagnostic angiography is considered the gold standard in vascular imaging. In many centers, its use is rapidly decreasing due to the development of noninvasive imaging modalities such as duplex arterial mapping, CTA, and MRA. Nevertheless, contrast angiography still remains in

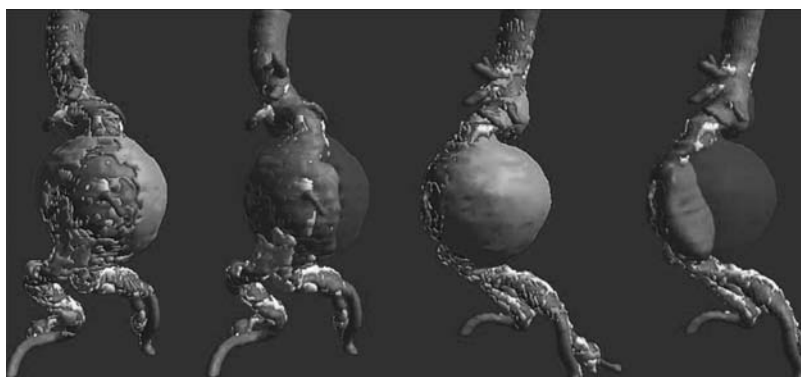


Figure 23-4. Three-dimensional computed tomography angiogram of an abdominal aortic aneurysm that displays various aneurysm components including thrombus, aortic calcification, blood circulation, and aneurysm wall.

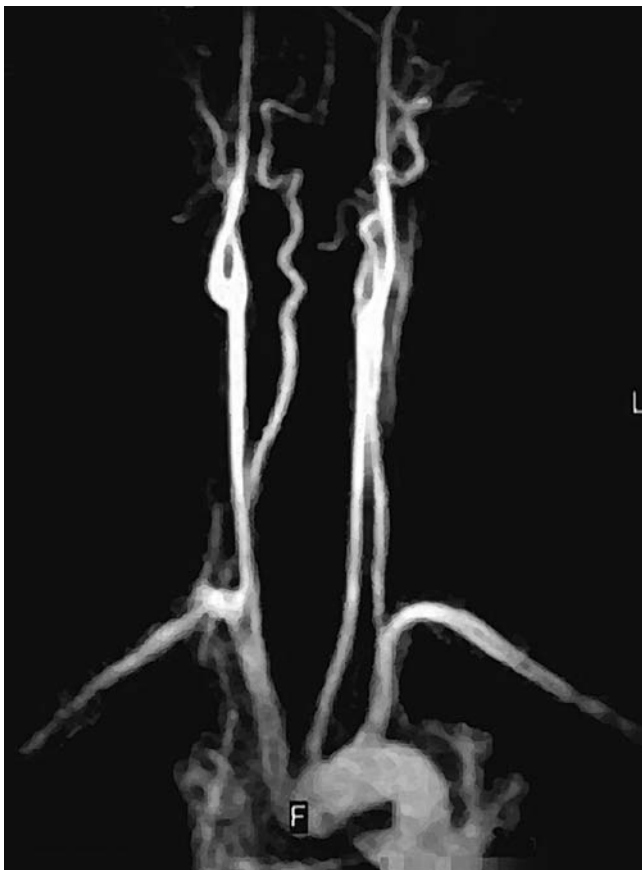


Figure 23-5. Magnetic resonance angiogram of aortic arch and carotid arteries. This study can provide a three-dimensional analysis of vascular structure such as aortic arch branches and carotid and vertebral arteries.

widespread use. The essential aspects of angiography are vascular access and catheter placement in the vascular bed that requires examination. The imaging system and the contrast agent are used to opacify the target vessel. Although in the past this function has largely been delegated to the interventional radiology service, an increasing number of surgeons are performing this procedure and following the diagnostic imaging with immediate surgical or endovascular intervention. There are several considerations when relying on angiography for imaging.

Approximately 70% of atherosclerotic plaques occur in an eccentric location within the blood vessel; therefore, images can be misleading when trying to evaluate stenoses because angiography is limited to a uniplanar “lumenogram.” With increased use of intravascular stent deployment, it has also been noted that assessment of stent apposition and stent position in relation to surrounding branches may be inaccurate. Furthermore, angiography exposes the patient to the risks of both ionizing radiation and intravascular contrast. Nevertheless, contrast angiography remains the most common invasive method of vascular investigation for both diagnostic and therapeutic intervention. The angiogram usually provides the final information needed to decide whether or not to proceed with operation or endovascular interventions.

Digital subtraction angiography (DSA) offers some advantages over conventional cut-film angiography such as excellent visualization despite use of lower volumes of contrast media. In

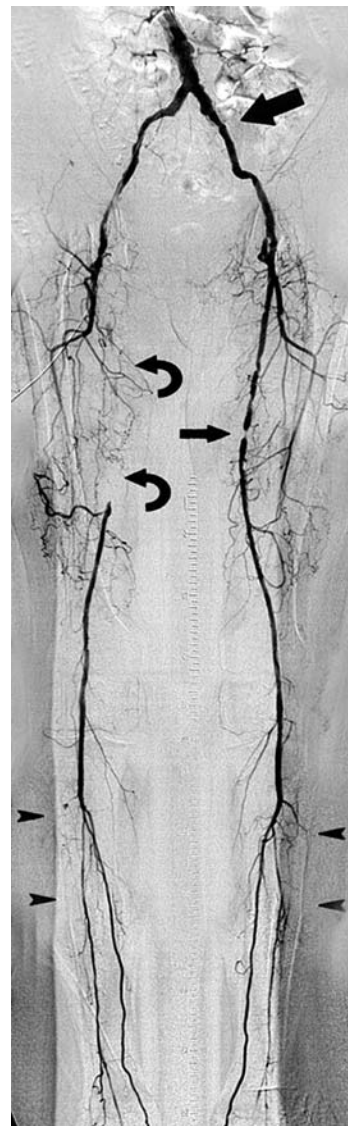


Figure 23-6. Digital subtraction angiography (DSA) provides excellent visualization of intravascular circulation with intra-arterial contrast administration. As depicted in this DSA study, multilevel lesions are demonstrated, which include a focal left iliac artery stenosis (*large arrow*), right superficial femoral occlusion (*curved arrows*), left superficial femoral stenosis (*small arrow*), and multiple tibial artery stenoses (*arrowheads*).

particular, when multilevel occlusive lesions limit the amount of contrast reaching distal vessels, supplemental use of digital subtraction angiographic techniques may enhance visualization and definition of anatomy. Intra-arterial DSA uses a portable, axially rotatable imaging device that can obtain views from different angles. DSA also allows for real-time video replay (Fig. 23-6). An entire extremity can be filmed with DSA using repeated injections of small amounts of contrast agent to obtain sequential angiographic images, the so-called pulse-chase technique.

Preoperative Cardiac Evaluation

The most important and most controversial aspect of preoperative evaluation in patients with atherosclerotic disease requiring surgical intervention is the detection and subsequent management of associated coronary artery disease.⁷ Several studies

have documented the existence of significant coronary artery disease in 40% to 50% or more of patients requiring peripheral vascular reconstructive procedures, 10% to 20% of whom may be relatively asymptomatic largely because of their inability to exercise.⁸ Myocardial infarction is responsible for the majority of both early and late postoperative deaths. Most available screening methods lack sensitivity and specificity to predict postoperative cardiac complications. There have been conflicting reports regarding the utility of preoperative dipyridamole-thallium nuclear imaging or dobutamine-echocardiography to stratify vascular patients in terms of perioperative cardiac morbidity and mortality. In nearly half of patients, thallium imaging proves to be unnecessary because cardiac risk can be predicted by clinical information alone.⁷ Even with coronary angiography, it is difficult to relate anatomic findings to functional significance and, hence, surgical risk. There are no data confirming that percutaneous coronary interventions or surgical revascularization prior to vascular surgical procedures impact mortality or incidence of myocardial infarctions. In fact, coronary angiography is associated with its own inherent risks, and patients undergoing coronary artery bypass grafting or coronary percutaneous transluminal angioplasty (PTA) before needed aortoiliac reconstructions are subjected to the risks and complications of both procedures.

The Coronary Artery Revascularization Prophylaxis (CARP) trial showed that coronary revascularization in patients with peripheral vascular disease and significant coronary artery disease, who are considered high risk for perioperative complications, did not reduce overall mortality or perioperative myocardial infarction.⁹ Additionally, patients who underwent prophylactic coronary revascularization had significant delays prior to undergoing their vascular procedure and increased limb morbidity compared to patients who did not. Studies do support improvement in cardiovascular and overall prognosis with medical optimization of patients. Therefore, use of perioperative β -blockade, as well as use of antiplatelet medication, statins, and angiotensin-converting enzyme inhibitors, is encouraged in vascular patients.^{10,11}

BASIC PRINCIPLES OF ENDOVASCULAR THERAPY

Cardiovascular disease remains a major cause of mortality in the developed world since the beginning of the twenty-first century. Although surgical revascularization has played a predominant role in the management of patients with vascular disease, the modern treatment paradigms have evolved significantly with increased emphasis of catheter-based percutaneous interventions over the past two decades. The increasing role of this minimally invasive vascular intervention is fueled by various factors, including rapid advances in imaging technology, reduced morbidity and mortality in endovascular interventions, and faster convalescence following percutaneous therapy when compared to traditional operations. There is little doubt that with continued device development and refined image-guided technology, endovascular intervention will provide improved clinical outcomes and play an even greater role in the treatment of vascular disease.

The technique of percutaneous access for both the diagnostic and therapeutic management of vascular disease has resulted in tremendous changes in the practice of several subspecialties, including interventional radiology, invasive cardiology, and vascular surgery. The development of catheter and endoscopic

instrumentation allows the vascular surgeon to operate via an intra- or extraluminal route. Endovascular techniques are now able to treat the full spectrum of vascular pathology, including stenoses and occlusions resulting from several etiologies, aneurysmal pathology, and traumatic lesions. Many of these procedures have only recently been developed and, as such, have not been investigated in a manner that would enable an accurate comparison with the more traditional methods of open surgical intervention. Long-term follow-up for these procedures is frequently lacking; however, because of the potential to treat patients with decreased mortality and morbidity, endovascular skills and techniques are being adopted into mainstream vascular surgery.

Needles and Access

Needles are used to achieve percutaneous vascular access. The size of the needle will be dictated by the diameter of the guidewire used. Most often, an 18-gauge needle is used, as it will accept a 0.035-inch guidewire. A 21-gauge micropuncture needle will accept a 0.018-inch guidewire. The most popular access needle is the Seldinger needle, which can be used for single- and double-wall puncture techniques.

Femoral arterial puncture is the most common site for access. The common femoral artery (CFA) is punctured over the medial third of the femoral head, which is landmarked using fluoroscopy. The single-wall puncture technique requires a sharp, beveled needle tip and no central stylet. The anterior wall of the vessel is punctured with the bevel of the needle pointing up, and pulsatile back-bleeding indicates an intraluminal position. This method is most useful for graft punctures, patients with abnormal clotting profiles, or if thrombolytic therapy is anticipated. Once the needle assumes an intraluminal position, verified by pulsatile back-bleeding, the guidewire may be advanced. This is always passed gently and under fluoroscopic guidance to avoid subintimal dissection or plaque disruption. Double-wall puncture techniques are performed with a blunt needle that has a removable inner cannula. The introducer needle punctures both walls of the artery and is withdrawn until bleeding is obtained to confirm intraluminal position prior to advancing a guidewire. There can be troublesome bleeding from the posterior arterial wall puncture; therefore, single puncture techniques are preferred.

Retrograde femoral access is the most common arterial access technique (Fig. 23-7). The advantages of this technique include the size and fixed position of the CFA, as well as the relative ease of compression against the femoral head at the end of the procedure. Care should be taken to avoid puncturing the external iliac artery above the inguinal ligament because this can result in retroperitoneal hemorrhage secondary to ineffective compression of the puncture site. Likewise, puncturing too low, at or below the CFA bifurcation, can result in thrombosis or pseudoaneurysm formation of the superficial femoral artery (SFA) or profunda femoris artery (PFA). Antegrade femoral access is more difficult than retrograde femoral access, and there is a greater tendency to puncture the SFA, but it is invaluable when the aortic bifurcation cannot be traversed or when devices are not long enough to reach a lesion from a contralateral femoral access approach. Occasionally, when the distal aorta or bilateral iliac arteries are inaccessible because of the extent of atherosclerotic lesions, scarring, or presence of bypass conduits, the brachial artery must be used to obtain access for diagnostic and therapeutic interventions. The left brachial artery is punctured because this avoids the origin of the carotid artery

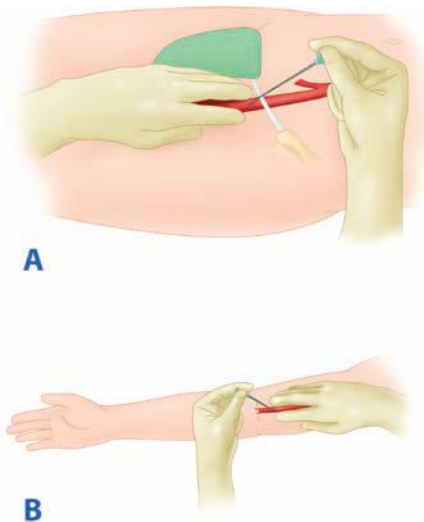


Figure 23-7. **A.** Antegrade femoral artery access. The needle is inserted just below the inguinal ligament in the common femoral artery whereby the guidewire is inserted in the ipsilateral superficial femoral artery. **B.** Brachial artery approach. The needle is inserted in a retrograde fashion in the brachial artery just above the antecubital fossa, whereby the guidewire is next inserted in the brachial artery.

and thus decreases the risk of catheter-related emboli to the brain. The artery is accessed with a micropuncture needle just proximal to the antecubital crease. The use of brachial access is associated with a higher risk of thrombosis and nerve injuries than femoral access.

Guidewires

Guidewires are used to introduce, position, and exchange catheters. A guidewire generally has a flexible and stiff end. In general, only the flexible end of the guidewire is placed in the vessel. All guidewires are composed of a stiff inner core and an outer tightly coiled spring that allows a catheter to track over the guidewire. There are five essential characteristics of guidewires: size, length, stiffness, coating, and tip configuration.

Guidewires come in different maximum transverse diameters, ranging from 0.011 to 0.038 inches. For most aortoiliac procedures, a 0.035-inch wire is most commonly used, whereas the smaller diameter 0.018-inch guidewires are reserved for selective small vessel angiography such as infrageniculate or carotid lesions. In addition to diameter size, guidewires come in varying lengths, usually ranging from 180 to 260 cm in length. Increasing the length of the wire always makes it more difficult to handle and increases the risk of contamination. While performing a procedure, it is important to maintain the guidewire across the lesion until the completion arteriogram has been satisfactorily completed.

The stiffness of the guidewire is also an important characteristic. Stiff wires allow for passage of large aortic stent graft devices without kinking. They are also useful when trying to perform sheath or catheter exchanges around a tortuous artery. An example of a stiff guidewire is the Amplatz wire. Hydrophilic coated guidewires, such as the Glidewire, have become invaluable tools for assisting in difficult catheterizations. The coating is primed by bathing the guidewire in saline solution. The slippery nature of this guidewire along with its torque capability significantly facilitate in difficult catheterizations.

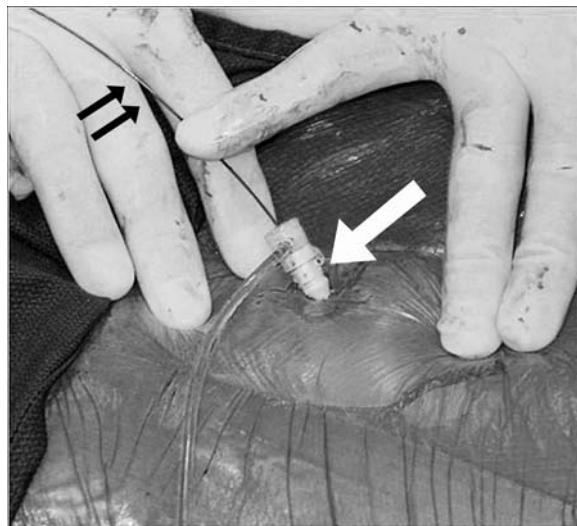


Figure 23-8. All percutaneous endovascular procedures are performed through an introducer sheath (*large arrow*), which provides an access conduit from skin to intravascular compartment. The sheath also acts to protect the vessel from injury as guidewires (*small arrows*) and catheters are introduced.

Guidewires also come in various tip configurations. Angled tip wires like the angled Glidewire can be steered to manipulate a catheter across a tight stenosis or to select a specific branch of a vessel. The Rosen wire has a soft curled end, which makes it ideal for renal artery stenting. The soft curl of this wire prevents it from perforating small renal branch vessels.

Hemostatic Sheaths

The hemostatic sheath is a device through which endovascular procedures are performed. The sheath acts to protect the vessel from injury as wires and catheters are introduced (Fig. 23-8). A one-way valve prevents bleeding through the sheath, and a side-port allows contrast or heparin flushes to be administered during the procedure. Sheaths are sized by their inner diameter. The most commonly used sheaths for percutaneous access have a 5- to 9-French inner diameter, but with open surgical exposure of the CFA, sheaths as large as 26 French can be introduced. Sheaths also vary in length, and long sheaths are available so that interventions remote from the site of arterial access can be performed.

Catheters

A wide variety of catheters exist that differ primarily in the configuration of the tip. The multiple shapes permit access to vessels of varying dimensions and angulations. Catheters are used to perform angiography and protect the passage of balloons and stents, and can be used to direct the guidewire through tight stenoses or tortuous vessels.

Angioplasty Balloons

Angioplasty balloons differ primarily in their length and diameter, as well as the length of the catheter shaft. As balloon technology has advanced, lower profiles have been manufactured (i.e., the size that the balloon assumes upon deflation). Balloons are used to perform angioplasty on vascular stenoses, to deploy stents, and to assist with additional expansion after insertion of self-expanding stents (Fig. 23-9). Besides length and diameter,

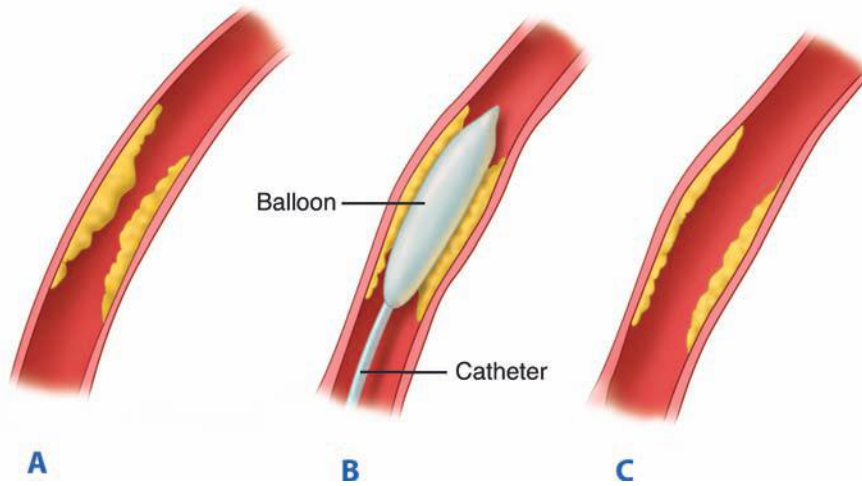


Figure 23-9. A. An artery with luminal narrowing caused by plaque. B. A balloon angioplasty catheter is positioned within the diseased artery, which is inflated to enlarge the intravascular channel. C. The plaque is compressed with widened flow lumen as the result of balloon angioplasty.

operators need to be familiar with several other balloon characteristics. Noncompliant and low-compliance balloons tend to be inflated to their preset diameter and offer greater dilating force at the site of stenosis. Low-compliance balloons are the mainstay for peripheral intervention. Lower profile balloons are less likely to get caught during passage through stents and are easier to pull out of sheaths. Under fluoroscopic guidance, balloon inflation is performed until the waist of the atherosclerotic lesion disappears and the balloon is at the full profile. The duration of balloon inflation and pressures used for the angioplasty depend on the indication for the intervention and the location and characteristics of the lesion being treated. Frequently, several inflations are required to achieve a full profile of the balloon. Occasionally, a lower profile balloon is needed to predilate the tight stenosis so that the selected balloon catheter can cross the lesion. After inflation, most balloons do not regain their preinflation diameter and assume a larger profile. Trackability, pushability, and crossability of the balloon should all be considered when choosing a particular balloon. Lastly, shoulder length is an important characteristic to consider when selecting a balloon because of the potential to cause injury during performance of PTA in adjacent arterial segments. There is always risk of causing dissection or rupture during PTA; thus a completion angiogram is performed while the wire is still in place. Leaving the wire in place provides access for repeating the procedure, placing a stent or stent graft if warranted.

Stents

Vascular stents are commonly used after an inadequate angioplasty with dissection or elastic recoil of an arterial stenosis. They serve to buttress collapsible vessels and help prevent atherosclerotic restenosis. Appropriate indications for primary stenting of a lesion without an initial trial of angioplasty alone are evolving in manners that are dependent on the extent and site of the lesion. Stents are manufactured from a variety of metals including stainless steel, tantalum, cobalt-based alloy, and nitinol. Vascular stents are classified into two basic categories: balloon-expandable stents and self-expanding stents.

Self-expanding stents (Fig. 23-10) are deployed by retracting a restraining sheath and usually consist of Elgiloy (a cobalt, chromium, nickel alloy) or nitinol (a shape memory alloy composed of nickel and titanium), the latter of which will contract and assume a heat-treated shape above a transition temperature that depends on the composition of the alloy.

Self-expanding stents will expand to a final diameter that is determined by stent geometry, hoop strength, and vessel size. The self-expanding stent is mounted on a central shaft and is placed inside an outer sheath. It relies on a mechanical spring-like action to achieve expansion. With deployment of these stents, there is some degree of foreshortening that has to be taken into account when choosing the area of deployment. In this way, self-expanding stents are more difficult to place with absolute precision. There are several advantages related to self-expanding stents. Self-expanding stents generally come in longer lengths than balloon-expandable stents and are therefore used to treat long and tortuous lesions. Their ability to continually expand after delivery allows them to accommodate adjacent vessels of different size. This makes these stents ideal for placement in the internal carotid artery. These stents are always oversized by 1 to 2 mm relative to the largest diameter of normal vessel adjacent to the lesion in order to prevent immediate migration.

Balloon-expandable stents are usually composed of stainless steel, mounted on an angioplasty balloon, and deployed by balloon inflation (Fig. 23-11). They can be manually placed on a chosen balloon catheter or obtained premounted on a balloon catheter. The capacity of a balloon-expandable stent to shorten in length during deployment depends on both stent geometry and the final diameter to which the balloon is expanded. These stents are more rigid and are associated with a shorter time to complete endothelialization. They are often of limited flexibility and have a higher degree of crush resistance when compared to self-expanding stents. This makes them ideal for short-segment lesions, especially those that involve the ostia such as proximal common iliac or renal artery stenosis.

The most exciting area of development in stents is the evolution of drug-eluting stents (DES). These stents are usually composed of nitinol and have various anti-inflammatory drugs bonded to them. Over time, the stents release the drug into the surrounding arterial wall and help prevent restenosis. Numerous randomized controlled trials have proven their benefit in coronary arteries.¹² Clinical studies have similarly proved early efficacy of DES in the treatment of peripheral arterial disease.^{13,14}

Stent Grafts

The combination of a metal stent covered with fabric gave birth to the first stent grafts. Covered stents have been designed

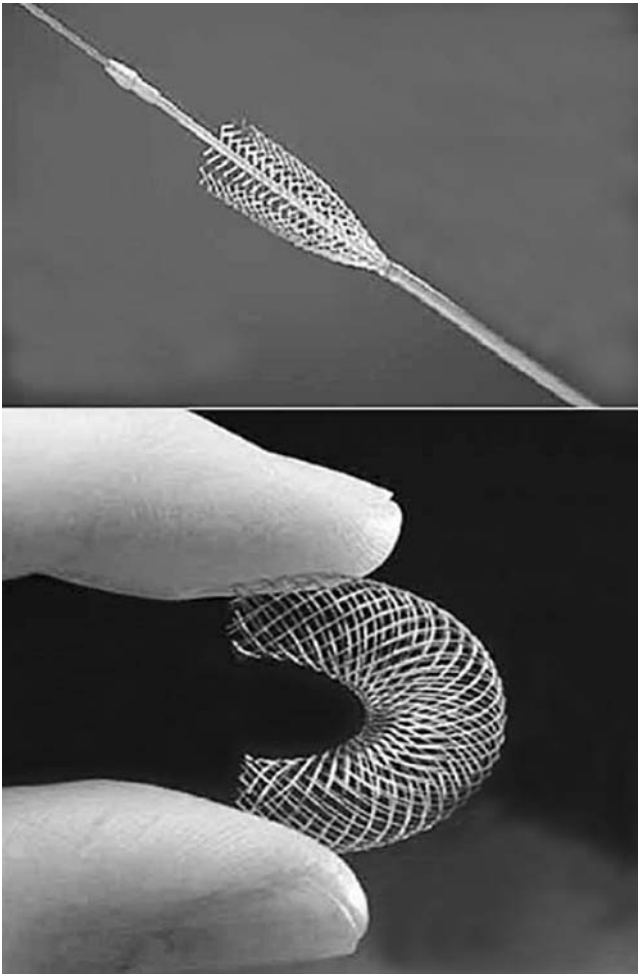


Figure 23-10. Self-expanding stents are made of tempered stainless steel or nitinol, an alloy of nickel and titanium, and are restrained when folded inside a delivery catheter. After being released from the restraining catheter, the self-expanding stents will expand to a final diameter that is determined by stent geometry, hoop strength, and vessel size.




Figure 23-11. In a balloon-expandable stent, the stent is pre-mounted on a balloon catheter. The balloon stretches the stent members beyond their elastic limit. The stent is deployed by full balloon expansion. This type of stent has a higher degree of crush resistance when compared to self-expanding stents, which is ideal for short-segment calcified ostial lesions.

with either a surrounding PTFE or polyester fabric and have been used predominantly for treatment of traumatic vascular lesions, including arterial disruption and arteriovenous fistulas (Fig. 23-12). However, these devices may well find a growing role in treatment of iliac or femoral arterial occlusive disease as well as popliteal aneurysms.

Endovascular aneurysm repair using the concept of stent grafts was initiated by Parodi in 1991.¹⁵ Since that time, a large number of endografts have been inserted under the auspice of clinical trials initially and now as Food and Drug Administration (FDA)–approved devices. Current available FDA-approved devices include the following: (a) AneuRx device (Medtronic/AVE, Santa Rosa, CA); (b) Gore Excluder device (WL Gore & Associates, Flagstaff, AZ); (c) Endologix Powerlink device (Endologix Inc., Irvine, CA); (d) Zenith device (Cook Inc., Bloomington, IN); (e) Talent device (Medtronic/AVE, Santa Rosa, CA); and (f) Endurant device (Medtronic/AVE, Santa Rosa, CA) for the treatment of abdominal aortic aneurysms. All of these devices require that patients have an infrarenal aneurysm with at least a 15-mm proximal aortic neck below the renal arteries and not greater than 60° of angulation. For those patients with associated common iliac artery aneurysmal disease, endovascular treatment can be achieved by initial coil embolization of the ipsilateral hypogastric artery with extension of the endovascular device into the external iliac artery. Newer generation endografts, including devices such as AFX Endovascular AAA System (Endologix Inc., Irvine, CA), Aorfix Flexible Stent (Lombard Medical Inc., Framingham, MA), and Ovation Prime Stent (TriVascular Inc., Santa Rosa, CA), are designed to overcome previous challenges of difficult anatomy by incorporating more flexible stents and lower profile delivery systems. Clinical trials are under way with devices that will expand indications to aneurysms involving the visceral segment of the abdominal aorta. The FDA has similarly approved several thoracic endograft devices for the treatment of descending thoracic aortic aneurysm. Early studies have demonstrated short-term efficacy of thoracic aortic devices in the treatment of traumatic aortic transections and aortic dissections.¹⁶⁻¹⁸ More experience with these devices exists in both Europe and Asia, and trials are under way in the United States with several devices.

CAROTID ARTERY DISEASE

Atherosclerotic occlusive plaque is by far the most common pathology seen in the carotid artery bifurcation. Thirty percent to 60% of all ischemic strokes are related to atherosclerotic carotid bifurcation occlusive disease. In the following section, we first focus our discussion on the clinical presentation, diagnosis, and management, including medical therapy, surgical carotid endarterectomy, and stenting, of atherosclerotic carotid occlusive disease. In the second part of the section, we provide a review on other less common nonatherosclerotic diseases involving the extracranial carotid artery, including kink and coil, fibromuscular dysplasia, arterial dissection, aneurysm, radiation arteritis, Takayasu's arteritis, and carotid body tumor.

Epidemiology and Etiology of Carotid Occlusive Disease

Approximately 700,000 Americans suffer a new or recurrent stroke each year.¹⁹ Eighty-five percent of all strokes are ischemic, and 15% are hemorrhagic. Hemorrhagic strokes are caused by head trauma or spontaneous disruption of intracerebral blood

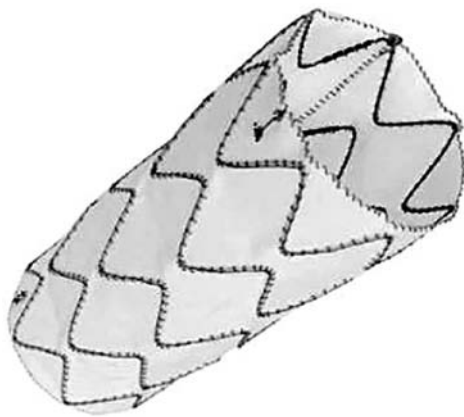


Figure 23-12. A stent graft is a metal stent covered with fabric that is commonly used for aneurysm exclusion.

vessels. Ischemic strokes are due to hypoperfusion from arterial occlusion or, less commonly, to decreased flow resulting from proximal arterial stenosis and poor collateral network. Common causes of ischemic strokes are cardiogenic emboli in 35%, carotid artery disease in 30%, lacunar in 10%, miscellaneous in 10%, and idiopathic in 15%.¹⁹ The term *cerebrovascular accident* is often used interchangeably to refer to an ischemic stroke. A transient ischemic attack (TIA) is defined as a temporary focal cerebral or retinal hypoperfusion state that resolves spontaneously within 24 hours after its onset. However, the majority of TIAs resolve within minutes, and longer lasting neurologic deficits more likely represent a stroke. Recently, the term *brain attack* has been coined to refer to an acute stroke or TIA, denoting the condition as a medical emergency requiring immediate attention, similar to a heart attack.

Stroke due to carotid bifurcation occlusive disease is usually caused by atheroemboli (Fig. 23-13). The carotid bifurcation is an area of low flow velocity and low shear stress. As the blood circulates through the carotid bifurcation, there is separation of flow into the low-resistance internal carotid artery and the high-resistance external carotid artery. Characteristically, atherosclerotic plaque forms in the outer wall opposite to the flow divider (Fig. 23-14). Atherosclerotic plaque formation is complex, beginning with intimal injury, platelet deposition, smooth muscle cell proliferation, and fibroplasia, and leading to subsequent luminal narrowing. With increasing degree of stenosis in the internal carotid artery, flow becomes more turbulent, and the risk of atheroembolization escalates. The severity of stenosis is commonly divided into three categories according to the luminal diameter reduction: mild (<50%), moderate (50%–69%), and severe (70%–99%). Severe carotid stenosis is a strong predictor for stroke.²⁰ In turn, a prior history of neurologic symptoms (TIA or stroke) is an important determinant for recurrent ipsilateral stroke. The risk factors for the development of carotid artery bifurcation disease are similar to those causing atherosclerotic occlusive disease in other vascular beds. Increasing age, male gender, hypertension, tobacco smoking, diabetes mellitus, homocysteinemia, and hyperlipidemia are well-known predisposing factors for the development of atherosclerotic occlusive disease.

Clinical Manifestations of Cerebral Ischemia

TIA is a focal loss of neurologic function, lasting for less than 24 hours. Crescendo TIAs refer to a syndrome comprising

repeated TIAs within a short period of time that is characterized by complete neurologic recovery in between. At a minimum, the term should probably be reserved for those with either daily events or multiple resolving attacks within 24 hours. Hemodynamic TIAs represent focal cerebral events that are aggravated by exercise or hemodynamic stress and typically occur after short bursts of physical activity, postprandially, or after getting out of a hot bath. It is implied that these are due to severe

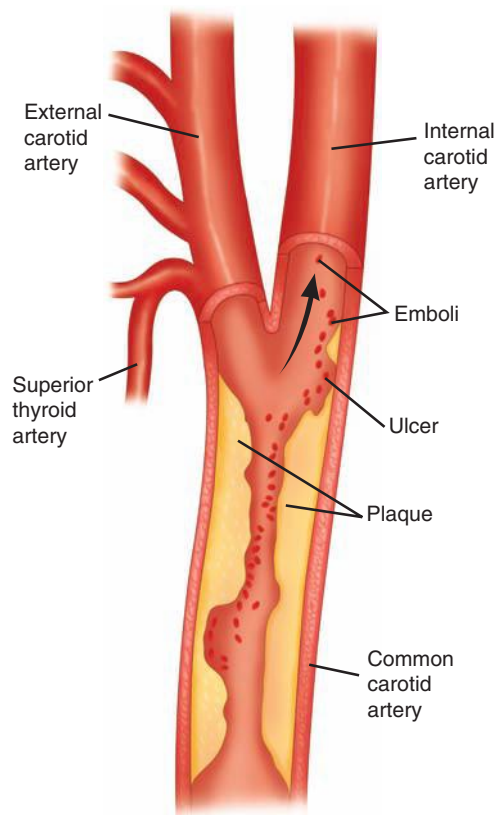


Figure 23-13. Stroke due to carotid bifurcation occlusive disease is usually caused by atheroemboli arising from the internal carotid artery, which provides the majority of blood flow to the cerebral hemisphere. With increasing degree of stenosis in the carotid artery, flow becomes more turbulent, and the risk of atheroembolization escalates.

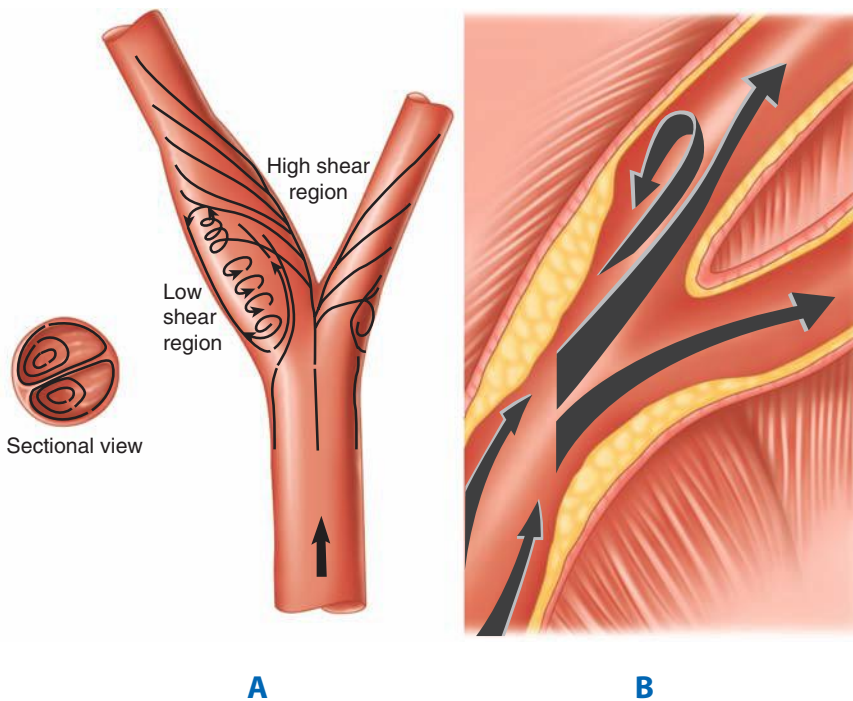


Figure 23-14. A. The carotid bifurcation is an area of low flow velocity and low shear stress. As the blood circulates through the carotid bifurcation, there is separation of flow into the low-resistance internal carotid artery and the high-resistance external carotid artery. B. The carotid atherosclerotic plaque typically forms in the outer wall opposite to the flow divider due in part to the effect of the low shear stress region, which also creates a transient reversal of flow during the cardiac cycle.

extracranial disease and poor intracranial collateral recruitment. *Reversible ischemic neurologic deficits* refer to ischemic focal neurologic symptoms lasting longer than 24 hours but resolving within 3 weeks. When a neurologic deficit lasts longer than 3 weeks, it is considered a *completed stroke*. *Stroke in evolution* refers to progressive worsening of the neurologic deficit, either linearly over a 24-hour period or interspersed with transient periods of stabilization and/or partial clinical improvement.

Patients who suffer cerebrovascular accidents typically present with three categories of symptoms including ocular symptoms, sensory/motor deficit, and/or higher cortical dysfunction. The common ocular symptoms associated with extracranial carotid artery occlusive disease include amaurosis fugax and presence of Hollenhorst plaques. Amaurosis fugax, commonly referred to as transient monocular blindness, is a temporary loss of vision in one eye that patients typically describe as a window shutter coming down or grey shedding of the vision. This partial blindness usually lasts for a few minutes and then resolves. Most of these phenomena (>90%) are due to embolic occlusion of the main artery or the upper or lower divisions. Monocular blindness progressing over a 20-minute period suggests a migrainous etiology. Occasionally, the patient will recall no visual symptoms while the optician notes a yellowish plaque within the retinal vessels, which is also known as Hollenhorst plaque. These plaques are frequently derived from cholesterol embolization from the carotid bifurcation and warrant further investigation. Additionally, several ocular symptoms may be caused by microembolization from extracranial carotid diseases including monocular visual loss due to retinal artery or optic nerve ischemia, the ocular ischemia syndrome, and visual field deficits secondary to cortical infarction and ischemia of the optic tracts. Typical motor and/or sensory symptoms associated with cerebrovascular accidents are lateralized or focal neurologic deficits. Ischemic events tend to have an abrupt onset, with the severity of the insult being apparent from the onset and not usually associated with seizures or paresthesia. In

contrast, they represent loss or diminution of neurologic function. Furthermore, motor or sensory deficits can be unilateral or bilateral, with the upper and lower limbs being variably affected depending on the site of the cerebral lesion. The combination of a motor and sensory deficit in the same body territory is suggestive of a cortical thromboembolic event as opposed to lacunar lesions secondary to small vessel disease of the penetrating arterioles. However, a small proportion of the latter may present with a sensorimotor stroke secondary to small vessel occlusion within the posterior limb of the internal capsule. Pure sensory and pure motor strokes and those strokes where the weakness affects one limb only or does not involve the face are more typically seen with lacunar as opposed to cortical infarction. A number of higher cortical functions, including speech and language disturbances, can be affected by thromboembolic phenomena from the carotid artery, with the most important clinical example for the dominant hemisphere being dysphasia or aphasia and visuospatial neglect being an example of nondominant hemisphere injury.

Diagnostic Evaluation

Duplex ultrasonography is the most widely used screening tool to evaluate for atherosclerotic plaque and stenosis of the extracranial carotid artery. It is also commonly used to monitor patients serially for progression of disease or after intervention (carotid endarterectomy or angioplasty). Duplex ultrasound of the carotid artery combines B-mode gray scale imaging and Doppler waveform analysis. Characterization of the carotid plaque on gray scale imaging provides useful information about its composition. However, there are currently no universal recommendations that can be made based solely on the sonographic appearance of the plaque. On the other hand, criteria have been developed and well refined for grading the degree of carotid stenosis based primarily on Doppler-derived velocity waveforms.

The external carotid artery has a high-resistance flow pattern with a sharp systolic peak and a small amount of flow in

diastole. In contrast, a normal internal carotid artery will have a low-resistance flow pattern with a broad systolic peak and a large amount of flow during diastole. The flow pattern in the common carotid artery resembles that in the internal carotid artery, as 80% of the flow is directed to the internal carotid artery, with waveforms that have broad systolic peaks and moderate amount of flow during diastole. Conventionally, velocity measurements are recorded in the common, external, carotid bulb, and the proximal, mid, and distal portions of the internal carotid artery. Characteristically, the peak systolic velocity is increased at the site of the vessel stenosis. The end-diastolic velocity is increased with greater degree of stenosis. In addition, stenosis of the internal carotid artery can lead to color shifts with color mosaics indicating a poststenotic turbulence. Dampening of the Doppler velocity waveforms is typically seen in areas distal to severe carotid stenosis where blood flow is reduced. It is well known that occlusion of the ipsilateral internal carotid artery can lead to a “falsely” elevated velocity on the contralateral side due to an increase in compensatory blood flow. In the presence of a high-grade stenosis or occlusion of the internal carotid artery, the ipsilateral common carotid artery displays high flow resistance waveforms, similar to those seen in the external carotid artery. If there is a significant stenosis in the proximal common carotid artery, its waveforms may be dampened with low velocities.

The Doppler grading systems of carotid stenosis were initially established by comparison to angiographic findings of disease. Studies have shown variability in the measurements of the duplex properties by different laboratories, as well as heterogeneity in the patient population, study design, and techniques. One of the most commonly used classifications was established at the University of Washington School of Medicine in Seattle. Diameter reduction of 50% to 79% is defined by peak systolic velocity greater than 125 cm/s with extensive spectral broadening. For stenosis in the range of 80% to 99%, the peak systolic velocity is greater than 125 cm/s, and peak diastolic velocity is greater than 140 cm/s. The ratio of internal carotid to common carotid artery peak systolic velocity has also been part of various ultrasound diagnostic classifications. A ratio greater than 4 is a great predictor of angiographic stenosis of 70% to 99%. A multispecialty consensus panel has developed a set of criteria for grading carotid stenosis by duplex examination (Table 23-3).²¹

MRA is increasingly being used to evaluate for atherosclerotic carotid occlusive disease and intracranial circulation. MRA is noninvasive and does not require iodinated contrast agents. MRA uses phase contrast or time-of-flight, with either two-dimensional or three-dimensional data sets for greater accuracy. Three-dimensional contrast-enhanced MRA allows data to be obtained in coronal and sagittal planes with improved image qualities due to shorter study time. In addition, the new MRA techniques allow for better reformation of images in various planes to allow better grading of stenosis. There have been numerous studies comparing the sensitivity and specificity of MRA imaging for carotid disease to duplex and selective contrast angiography.²² Magnetic resonance imaging (MRI) of the brain is essential in the assessment of acute stroke patients. MRI with diffusion-weighted imaging can differentiate areas of acute ischemia, areas still at risk for ischemia (penumbra), and chronic cerebral ischemic changes. However, computed tomography (CT) imaging remains the most expeditious test in the evaluation of acute stroke patients to rule out intracerebral hemorrhage. Recently, multidetector CTA has gained increasing popularity in the evaluation of carotid disease.²³ This imaging modality can provide volume rendering, which allows rotation of the object with accurate anatomic structures from all angles (Fig. 23-15). The advantages of CTA over MRA include faster data acquisition time and better spatial resolution. However, grading of carotid stenosis by CTA requires further validation at the time of this writing before it can be widely applied.

Historically, DSA has been the gold standard test to evaluate the extra- and intracranial circulation (Fig. 23-16). This is an invasive procedure, typically performed via a transfemoral puncture, and involves selective imaging of the carotid and vertebral arteries using iodinated contrast. The risk of stroke during cerebral angiography is generally reported at approximately 1% and is typically due to atheroembolization related to wire and catheter manipulation in the arch aorta or proximal branch vessels. Over the last few decades, however, the incidence of neurologic complications following angiography has been reduced, due to the use of improved guidewires and catheters, better resolution digital imaging, and increased experience. Local access complications of angiography are infrequent and include development of hematoma, pseudoaneurysm, distal embolization, and acute vessel thrombosis. Currently, selective angiography is particularly used for patients with suspected intracranial

Table 23-3

Carotid duplex ultrasound criteria for grading internal carotid artery stenosis

DEGREE OF STENOSIS (%)	ICA PSV (CM/S)	ICA/CCA PSV RATIO	ICA EDV (CM/S)	PLAQUE ESTIMATE (%) ^a
Normal	<125	<2.0	<40	None
<50	<125	<2.0	<40	<50
50–69	125–230	2.0–4.0	40–100	≥50
≥70 to less than near occlusion	>230	>4.0	>100	≥50
Near occlusion	High, low, or not detected	Variable	Variable	Visible
Total occlusion	Not detected	Not applicable	Not detected	Visible, no lumen

^aPlaque estimate (diameter reduction) with gray scale and color Doppler ultrasound.

CCA = common carotid artery; EDV = end-diastolic velocity; ICA = internal carotid artery; PSV = peak systolic velocity.

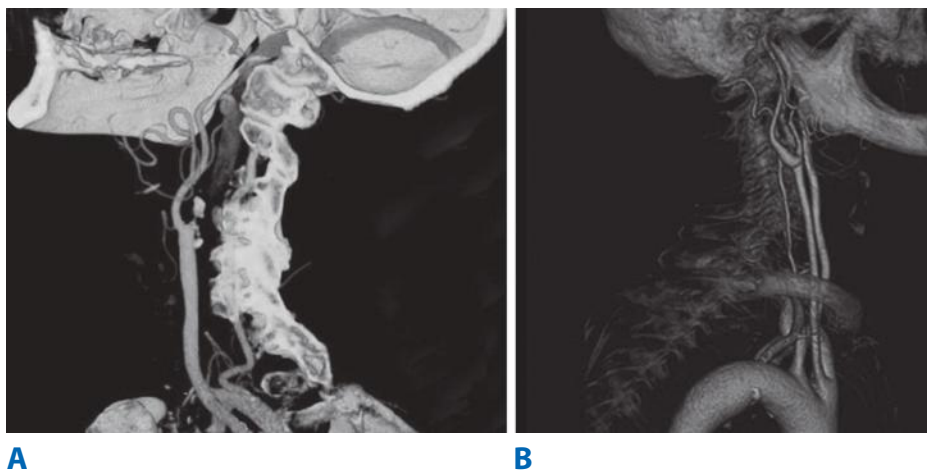


Figure 23-15. A. Carotid computed tomography angiography is a valuable imaging modality that can provide a three-dimensional image reconstruction with high image resolution. A carotid artery occlusion is noted in the internal carotid artery B. The entire segment of extracranial carotid artery is visualized from the thoracic compartment to the base of skull.

disease and for patients in whom percutaneous revascularization is considered. The techniques of carotid angioplasty and stenting for carotid bifurcation occlusive disease are described in detail later in this chapter. We generally use CTA or MRA to get information about the aortic arch anatomy and presence of concomitant intracranial disease and collateral pathway in planning our strategy for carotid stenting or endarterectomy.

Treatment of Carotid Occlusive Disease

Conventionally, patients with carotid bifurcation occlusive disease are divided into two broad categories: patients without prior history of ipsilateral stroke or TIA (asymptomatic) and those with prior or current ipsilateral neurologic symptoms

(symptomatic). It is estimated that 15% of all strokes are preceded by a TIA. The 90-day risk of a stroke in a patient presenting with a TIA is 3% to 17%.¹⁹ According to the Cardiovascular Health Study, a longitudinal population-based study of coronary artery disease and stroke in men and women, the prevalence of TIA in men was 2.7% for ages of 65 and 69 and 3.6% for ages 75 to 79; the prevalence in women was 1.4% and 4.1%, respectively.²⁴ There have been several studies reporting on the effectiveness of stroke prevention with medical treatment and carotid endarterectomy for symptomatic patients with moderate to severe carotid stenosis. Early and chronic aspirin therapy has been shown to reduce stroke recurrence rate in several large clinical trials.²⁵

Symptomatic Carotid Stenosis. Currently, most stroke neurologists prescribe both aspirin and clopidogrel for secondary stroke prevention in patients who have experienced a TIA or stroke.¹⁹ In patients with symptomatic carotid stenosis, the degree of stenosis appears to be the most important predictor in determining risk for an ipsilateral stroke. The risk of a recurrent ipsilateral stroke in patients with severe carotid stenosis approaches 40%. Two large multicenter randomized clinical trials, the European Carotid Surgery Trial (ECST) and the North American Symptomatic Carotid Endarterectomy Trial (NASCET), have both shown a significant risk reduction in stroke for patients with symptomatic high-grade stenosis (70%–99%) undergoing carotid endarterectomy when compared to medical therapy alone.^{26,27} There has been much discussion regarding the different methodology used in the measurement of carotid stenosis and calculation of the life-table data between the two studies, yet they both studies had similar results.²⁸ Findings of these two landmark trials have also been reanalyzed in many subsequent publications. The main conclusions of the trials remain validated and widely acknowledged. Briefly, the NASCET study showed that for high-grade carotid stenosis, the cumulative risk of ipsilateral stroke was 26% in the medically treated group and 9% in the surgically treated group at 2 years. For patients with moderate carotid artery stenosis (50%–69%), the benefit of carotid endarterectomy is less but still favorable when compared to medical treatment alone; the 5-year fatal or nonfatal ipsilateral stroke rate was 16% in the surgically treated group versus 22% in the medically treated group.²⁹ The risk of stroke was similar for the remaining group of symptomatic patients with less than 50% carotid stenosis, whether they had

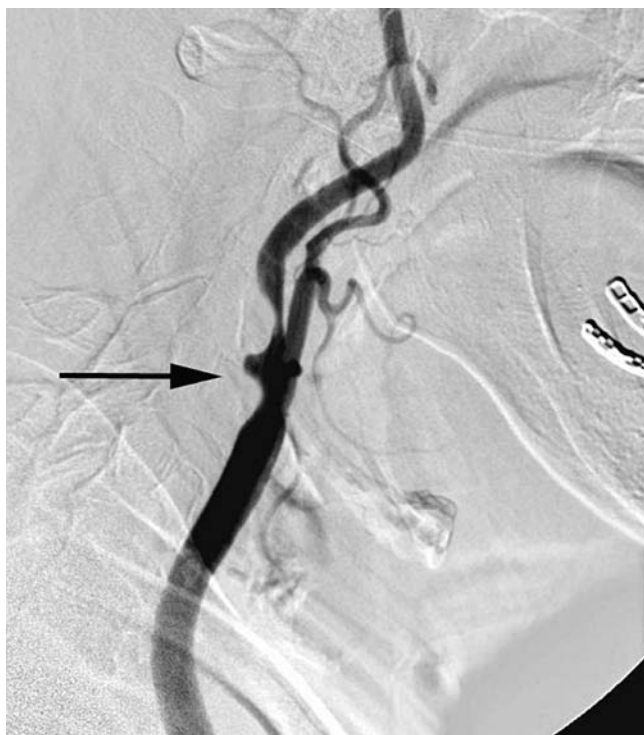

Figure 23-16. A carotid angiogram reveals an ulcerated carotid plaque (arrow) in the proximal internal carotid artery, which also resulted in a high-grade internal carotid artery stenosis.

endarterectomy or medical treatment alone. The ECST reported similar stroke risk reduction for patients with severe symptomatic carotid stenosis and no benefit in patients with mild stenosis, when carotid endarterectomy was performed versus medical therapy.²⁷

The optimal timing of carotid intervention after acute stroke, however, remains debatable. Earlier studies showed an increased rate of postoperative stroke exacerbation and conversion of a bland to hemorrhagic infarction when carotid endarterectomy was carried out within 5 to 6 weeks after acute stroke. The dismal outcome reported in the early experience was likely related to poor patient selection. The rate of stroke recurrence is not insignificant during the interval period and may be reduced with early intervention for symptomatic carotid stenosis. Contemporary series have demonstrated acceptable low rates of perioperative complications in patients undergoing carotid endarterectomy within 4 weeks after acute stroke.²⁹ In a recent retrospective series, carotid artery stenting when performed early (<2 weeks) after the acute stroke was associated with higher mortality than when delayed (>2 weeks).³⁰

Asymptomatic Carotid Stenosis. Whereas there is universal agreement that carotid revascularization (endarterectomy or stenting) is effective in secondary stroke prevention for patients with symptomatic moderate and severe carotid stenosis, the management of asymptomatic patients remains an important controversy to be resolved. Generally, the detection of carotid stenosis in asymptomatic patients is related to the presence of a cervical bruit or based on screening duplex ultrasound findings. In one of the earlier observational studies, the authors showed that the annual occurrence rate of neurologic symptoms was 4% in a cohort of 167 patients with asymptomatic cervical bruits followed prospectively by serial carotid duplex scan.³¹ The mean annual rate of carotid stenosis progression to a greater than 50% stenosis was 8%. The presence of or progression to a greater than 80% stenosis correlated highly with either the development of a total occlusion of the internal carotid artery or new symptoms. The major risk factors associated with disease progression were cigarette smoking, diabetes mellitus, and age. This study supported the contention that it is prudent to follow a conservative course in the management of asymptomatic patients presenting with a cervical bruit.

One of the first randomized clinical trials on the treatment of asymptomatic carotid artery stenosis was the Asymptomatic

Carotid Atherosclerosis Study (ACAS), which evaluated the benefits of medical management with antiplatelet therapy versus carotid endarterectomy.³² Over a 5-year period, the risk of ipsilateral stroke in individuals with a carotid artery stenosis greater than 60% was 5.1% in the surgical arm. On the other hand, the risk of ipsilateral stroke in patients treated with medical management was 11%. Carotid endarterectomy produced a relative risk reduction of 53% over medical management alone. The results of a larger randomized trial from Europe, the Asymptomatic Carotid Surgery Trial (ACST), recently confirmed similar beneficial stroke risk reduction for patients with asymptomatic, greater than 70% carotid stenosis undergoing endarterectomy versus medical therapy.³³ An important point derived from this latter trial was that even with improved medical therapy, including the addition of statin drugs and clopidogrel, medical therapy was still inferior to endarterectomy in the primary stroke prevention for patients with high-grade carotid artery stenosis. It is generally agreed that asymptomatic patients with severe carotid stenosis (80%–99%) are at significantly increased risk for stroke and stand to benefit from either surgical or endovascular revascularization. However, revascularization for asymptomatic patients with a less severe degree of stenosis (60%–79%) remains controversial.

Carotid Endarterectomy versus Angioplasty and Stenting

Currently, the argument is no longer whether medical therapy alone is inferior to surgical endarterectomy in stroke prevention for severe carotid stenosis. Rather, the debate now revolves around whether carotid angioplasty and stenting produce the same benefits demonstrated by carotid endarterectomy. Since carotid artery stenting was approved by the FDA for clinical application in 2004, this percutaneous procedure has become a treatment alternative in patients who are deemed “high risk” for endarterectomy (Table 23-4). In contrast to many endovascular peripheral arterial interventions, percutaneous carotid stenting represents a much more challenging procedure, because it requires complex catheter-based skills using the 0.014-inch guidewire system and distal protection device. Moreover, current carotid stent devices predominantly use the monorail guidewire system, which requires more technical agility compared with the over-the-wire catheter system that is routinely used in peripheral interventions. This percutaneous intervention often

Table 23-4

Conditions qualifying patients as high surgical risk for carotid endarterectomy

ANATOMIC FACTORS	PHYSIOLOGIC FACTORS
<ul style="list-style-type: none"> • High carotid bifurcation (above C2 vertebral body) 	<ul style="list-style-type: none"> • Age ≥80 years • Left ventricular ejection fraction ≤30%
<ul style="list-style-type: none"> • Low common carotid artery (below clavicle) • Contralateral carotid occlusion • Restenosis of ipsilateral prior carotid endarterectomy • Previous neck irradiation 	<ul style="list-style-type: none"> • New York Heart Association class III/IV congestive heart failure • Unstable angina: Canadian Cardiovascular Society class III/IV angina pectoris • Recent myocardial infarction
<ul style="list-style-type: none"> • Prior radical neck dissection • Contralateral laryngeal nerve palsy • Presence of tracheostomy 	<ul style="list-style-type: none"> • Clinically significant cardiac disease (congestive heart failure, abnormal stress test, or need for coronary revascularization) • Severe chronic obstructive pulmonary disease • End-stage renal disease on dialysis

requires balloon angioplasty and stent placement through a long carotid guiding sheath via a groin approach. Poor technical skills can result in devastating treatment complications such as stroke, which can occur in part due to plaque embolization during the balloon angioplasty and stenting of the carotid artery. Because of these various procedural components that require high technical proficiency, many early clinical investigations of carotid artery stenting, which included physicians with little or no carotid stenting experience, resulted in alarmingly poor clinical outcomes. A recent Cochrane review noted that, before 2006, a total of 1269 patients had been studied in five randomized controlled trials comparing percutaneous carotid intervention and surgical carotid reconstruction.³⁴ Taken together, these trials revealed that carotid artery stenting had a greater procedural risk of stroke and death when compared to carotid endarterectomy (odds ratio, 1.33; 95% confidence interval, 0.86 to 2.04). Additionally, a greater incidence of carotid restenosis was noted in the stenting group than the endarterectomy cohorts.

However, the constant improvement of endovascular devices, procedural techniques, and adjunctive pharmacologic therapy will likely improve the treatment success of percutaneous carotid intervention. Critical appraisals of several prospective randomized trials comparing the efficacy of carotid stenting versus endarterectomy are available for review.³⁵ Two recently published randomized controlled trial, the Carotid Revascularization Endarterectomy Versus Stent Trial (CREST) and the International Carotid Stenting Study (ICSS) have reported somewhat differing results.³⁶ CREST compared the efficacy of carotid endarterectomy and carotid stenting in both symptomatic and asymptomatic patients.³⁷ Primary end points included 30-day periprocedural composite death, stroke, myocardial infarction, or any ipsilateral stroke up to 4 years. CREST investigators reported no difference between stenting (5.2%) and endarterectomy (4.5%) in terms of primary end point. When each variable was independently analyzed, there was a higher rate of stroke in the stenting group at 30 days (4.1% vs. 2.3%) and a higher rate of myocardial infarction in the endarterectomy group (2.3% vs. 1.1%). The ICSS was a multicenter, international, randomized controlled trial comparing carotid stenting versus endarterectomy in patients with symptomatic carotid stenosis.³⁸ The risk of stroke, death, and myocardial infarction in the stenting group (8.5%) was significantly higher than in the surgical arm (5.2%). The finding that carotid endarterectomy is safer than carotid stenting is also supported by the results of an MRI substudy, which showed significantly more new lesions by diffusion-weighted imaging in the carotid stenting than the carotid endarterectomy patients.

All available randomized studies have provided some answers and raised some questions. Some ongoing clinical trials will undoubtedly provide more insights on the efficacy of carotid stenting in the near future. Currently, the Society for Vascular Surgeons recommends carotid endarterectomy as first-line treatment for most symptomatic patients with stenosis of 50% to 99% and asymptomatic patients with stenosis of 60% to 99%.³⁹ The perioperative risk of stroke and death in asymptomatic patients must be below 3% to ensure benefit for the patient. Carotid artery stenting should be reserved for symptomatic patients with stenosis of 50% to 99% at high risk for carotid endarterectomy for anatomic or medical reasons. Carotid artery stenting is not recommended for asymptomatic patients at this time. Asymptomatic patients at high risk for intervention or with a life expectancy of less than 3 years should be considered for medical management as the first-line therapy.

Surgical Techniques of Carotid Endarterectomy

Although carotid endarterectomy is one of the earliest vascular operations ever described and its techniques have been perfected in the last two decades, surgeons continue to debate many aspects of this procedure. For instance, there is no universal agreement with regard to the best anesthetic of choice, the best intraoperative cerebral monitoring, whether to “routinely” shunt, open versus eversion endarterectomy, and patch versus primary closure. Various anesthetic options are available for patient undergoing carotid endarterectomy including general, local, and regional anesthesia. Typically the anesthesia of choice depends on the preference of the surgeon, anesthesiologist, and patient. However, depending on the anesthetic given, the surgeon must decide whether intraoperative cerebral monitoring is necessary or intra-arterial carotid shunting will be used. In general, if the patient is awake, then his or her abilities to respond to commands during carotid clamp period determine the adequacy of collateral flow to the ipsilateral hemisphere. On the other hand, intraoperative electroencephalogram (EEG) or transcranial power Doppler (TCD) has been used to monitor for adequacy of cerebral perfusion during the clamp period for patients undergoing surgery under general anesthesia. Focal ipsilateral decreases in amplitudes and slowing of EEG waves are indicative of cerebral ischemia. Similarly, a decrease to less than 50% of baseline velocity in the ipsilateral middle cerebral artery is a sign of cerebral ischemia. For patients with poor collateral flow exhibiting signs of cerebral ischemia, intra-arterial carotid shunting with removal of the clamp will restore cerebral flow for the remaining part of the surgery. Stump pressures have been used to determine the need for intra-arterial carotid shunting. Some surgeons prefer to shunt all patients on a routine basis and do not use intraoperative cerebral monitoring.

The patient’s neck is slightly hyperextended and turned to the contralateral side, with a roll placed between the shoulder blades. An oblique incision is made along the anterior border of the sternocleidomastoid muscle centered on top of the carotid bifurcation (Fig. 23-17). The platysma is divided completely. Typically tributaries of the anterior jugular vein are ligated and

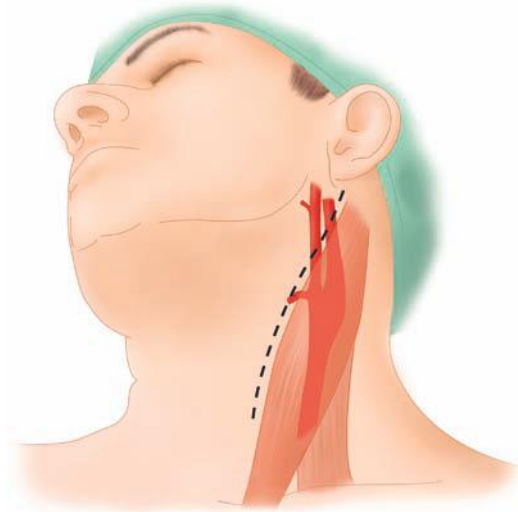


Figure 23-17. To perform carotid endarterectomy, the patient’s neck is slightly hyperextended and turned to the contralateral side. An oblique incision is made along the anterior border of the sternocleidomastoid muscle centered on top of the carotid bifurcation.

divided. The dissection is carried medial to the sternocleidomastoid. The superior belly of the omohyoid muscle is usually encountered just anterior to the common carotid artery. This muscle can be divided. The carotid fascia is incised, and the common carotid artery is exposed. The common carotid artery is mobilized cephalad toward the bifurcation. The dissection of the carotid bifurcation can cause reactive bradycardia related to stimulation of the carotid body. This reflex can be blunted with injection of lidocaine 1% into the carotid body or reversed with administration of intravenous atropine. A useful landmark in the dissection of the carotid bifurcation is the common facial vein. This vein can be ligated and divided. Frequently the 12th cranial nerve (hypoglossal nerve) traverses the carotid bifurcation just behind the common facial vein. The external carotid artery is mobilized just enough to get a clamp across. Often, a branch of the external carotid artery crossing to the sternocleidomastoid can be divided to allow further cephalad mobilization of the internal carotid artery. For high bifurcation, division of the posterior belly of the digastric muscle is helpful in establishing distal exposure of the internal carotid artery.

Intravenous heparin sulfate (1 mg/kg) is routinely administered just prior to carotid clamping. The internal carotid artery is clamped first using a soft noncrushing vascular clamp to prevent distal embolization. The external and common carotid arteries are clamped subsequently. A longitudinal arteriotomy is made in the distal common carotid artery and extended into the bulb and past the occlusive plaque into the normal part of the internal carotid artery. Endarterectomy is carried out to remove the occlusive plaque (Fig. 23-18). If necessary, a temporary shunt can be inserted from the common carotid artery to the internal carotid artery to maintain continuous antegrade cerebral blood flow (Fig. 23-19). Typically, a plane is teased

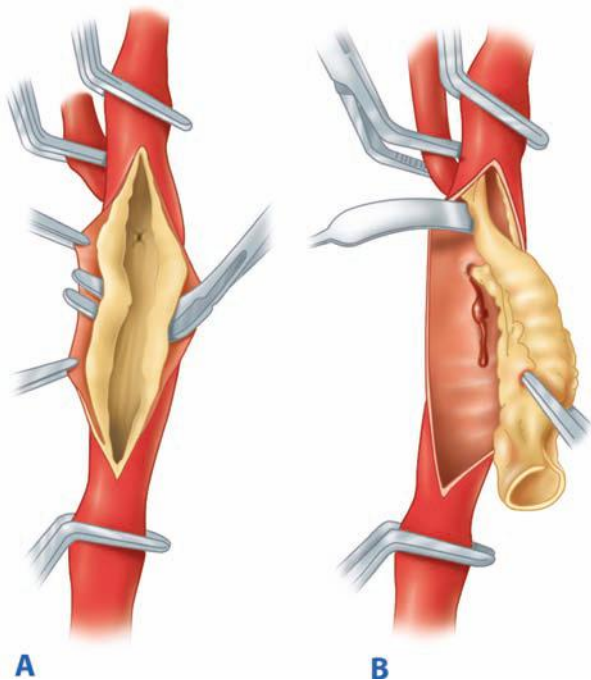


Figure 23-18. **A.** During carotid endarterectomy, vascular clamps are applied in the common carotid, external carotid, and internal carotid arteries. Carotid plaque is elevated from the carotid lumen. **B.** Carotid plaque is removed, and the arteriotomy is closed either primarily or with a patch angioplasty.



Figure 23-19. A temporary carotid shunt is inserted from the common carotid artery (*long arrow*) to the internal carotid artery (*short arrow*) during carotid endarterectomy to provide continuous antegrade cerebral blood flow.

out from the vessel wall, and the entire plaque is elevated and removed. The distal transition line in the internal carotid artery where the plaque had been removed must be examined carefully and should be smooth. Tacking sutures are placed when an intimal flap remains in this transition to ensure no obstruction to flow (Fig. 23-20). The occlusive plaque is usually removed from the origin of the external carotid artery using the eversion technique. The endarterectomized surface is then irrigated and any debris removed. A patch (autogenous saphenous vein, synthetic such as polyester, PTFE, or biologic material) is sewn to close the arteriotomy (Fig. 23-21). Whether patch closure is necessary in all patients and which patch is the best remain controversial. However, most surgeons agree that patch closure is indicated particularly for the small vessel (<7 mm). The eversion technique has also been advocated for removing the plaque from the internal carotid artery. In the eversion technique, the internal carotid artery is transected at the bulb, the edges of the divided vessel are everted, and the occluding plaque is “peeled”

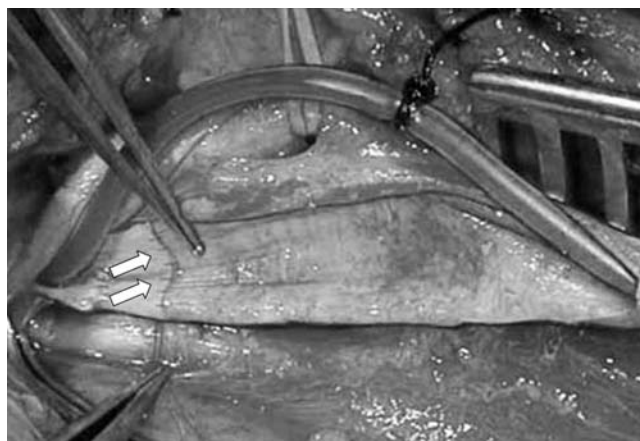


Figure 23-20. The distal transition line (*left side of the picture*) in the internal carotid artery where the plaque had been removed must be examined carefully and should be smooth. Tacking sutures (*arrows*) are placed when an intimal flap remains in this transition to ensure no obstruction to flow.




Figure 23-21. A. An autologous or synthetic patch can be used to close the carotid arteriotomy incision, which maintains the luminal patency. B. A completion closure of carotid endarterectomy incision using a synthetic patch.

off the vessel wall. The purported advantages of the eversion technique are no need for patch closure and a clear visualization of the distal transition area. Reported series have not shown a clear superiority of one technique over the others.⁴⁰ Surgeons will likely continue to use the technique of their choice. Just prior to completion of the anastomosis to close the arteriotomy, we thoroughly flush the vessels of any potential debris. When the arteriotomy is closed, flow is restored to the external carotid artery first and to the internal carotid artery second. Intravenous protamine sulfate can be given to reverse the effect of heparin anticoagulation following carotid endarterectomy. The wound is closed in layers. After surgery, the patient's neurologic condition is asserted in the operating room prior to transfer to the recovery area.

Complications of Carotid Endarterectomy. Most patients tolerate carotid endarterectomy very well and typically are discharged home within 24 hours after surgery. Complications after endarterectomy are infrequent but can be potentially life-threatening or disabling. Acute ipsilateral stroke is a dreaded complication following carotid endarterectomy. Cerebral ischemia can be due to either intraoperative or postoperative events. Embolizations from the occlusive plaque or prolonged cerebral ischemia are potential causes of intraoperative stroke. The most common cause of postoperative stroke is due to embolization. Less frequently, acute carotid artery occlusion can cause acute postoperative stroke. This is usually due to carotid artery thrombosis related to closure of the arteriotomy, an occluding intimal flap, or distal carotid dissection. When patients experience acute symptoms of neurologic ischemia after endarterectomy, immediate intervention may be indicated. Carotid duplex scan can be done expeditiously to assess patency of the extracranial internal carotid artery. Re-exploration is mandated for acute carotid artery occlusion. Cerebral angiography can be useful if intracranial revascularization is considered.

Local complications related to surgery include excessive bleeding and cranial nerve palsies. Postoperative hematoma in the neck after carotid endarterectomy can lead to devastating airway compromise. Any expanding hematoma should be evacuated and active bleeding stopped. Securing an airway is critical and can be extremely difficult in patients with large postoperative neck hematoma. The reported incidence of postoperative cranial nerve palsies after carotid endarterectomy varies from 1% to 30%.⁴¹ Well-recognized injuries involve the marginal mandibular, vagus, hypoglossal, superior laryngeal, and recurrent laryngeal nerves. Often these are traction injuries but can also be due to severance of the respective nerves.

Techniques of Carotid Angioplasty and Stenting

Percutaneous carotid artery stenting has become an accepted alternative treatment in the management of patients with carotid bifurcation disease (Fig. 23-22). The perceived advantages of percutaneous carotid revascularization are related to the minimal invasiveness of the procedure compared to surgery. There are anatomic conditions based on angiographic evaluation in which carotid artery stenting should be avoided due to increased procedure-related risks (Table 23-5). In preparation for carotid stenting, the patient should be given oral clopidogrel 3 days prior to the intervention if the patient was not already taking the drug. The procedure is done in either the operating room with angiographic capabilities or in a dedicated angiography room. The patient is placed in the supine position. The patient's blood pressure and cardiac rhythm are closely monitored.

To gain access to the carotid artery, a retrograde transfemoral approach is most commonly used as the access site for carotid intervention. Using the Seldinger technique, we insert a diagnostic 5- or 6-French sheath in the CFA. A diagnostic arch aortogram is obtained. The carotid artery to be treated is then selected using a 5-French diagnostic catheter, and contrast is injected to show the carotid anatomy. It is important to assess the contralateral carotid artery, vertebrobasilar, and intracranial circulation if these are not known based on the preoperative noninvasive studies. Once the decision is made to proceed with carotid artery stenting, with the tip of the diagnostic catheter still in the common carotid artery, a 0.035-inch, 260-cm long stiff guidewire is placed in the ipsilateral external carotid artery. Anticoagulation with intravenous bivalirudin bolus (0.75 mg/kg) followed by an infusion rate of 2.5 mg/kg/h for the remainder of the procedure is routinely administered. Next the diagnostic catheter is withdrawn and a 90-cm, 6-French guiding sheath is advanced into the common carotid artery over the stiff glide wire. It is critical not to advance the sheath beyond the occlusive plaque in the carotid bulb. The stiff wire is then removed, and preparation is made to deploy the distal embolic protection device (EPD). Several distal EPDs are available (Table 23-6). The EPD device is carefully deployed beyond the target lesion. With regard to the carotid stents, there are several stents that have received approval from the FDA and are commercially available for carotid revascularization (Table 23-7). All current carotid stents use the rapid-exchange monorail 0.014-inch platform. The size selection is typically based on the size of common carotid artery. Predilatation using a 4-mm balloon may be necessary to allow passage of the stent delivery catheter. Once

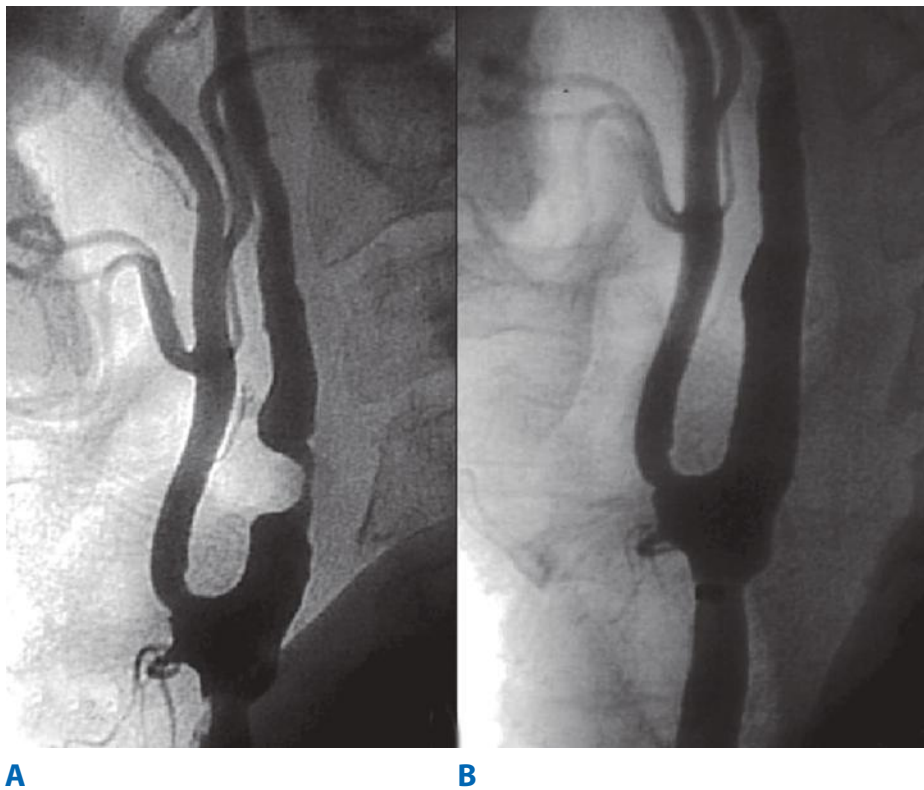

Figure 23-22. **A.** Carotid angiogram demonstrating a high-grade stenosis of the left internal carotid artery. **B.** Completion angiogram demonstrating a satisfactory result following a carotid stent placement.

the stent is deployed across the occlusive plaque, postdilatation is usually performed using a ≤ 5.5 -mm balloon. It is noteworthy that balloon dilation of the carotid bulb may lead to immediate bradycardia due to stimulation of the glossopharyngeal nerve. The EPD is then retrieved and the procedure is completed with removal of the sheath from the femoral artery. The puncture site is closed using available closure device or with manual compression. Throughout the procedure, the patient's neurologic function is closely monitored. The bivalirudin infusion is stopped and the patient is kept on clopidogrel (75 mg daily) for at least 1 month and aspirin indefinitely.

Complications of Carotid Stenting. Although there have been no randomized trials comparing carotid stenting with and without EPD, the availability of EPDs appears to have reduced the risk of distal embolization and stroke. The results of the various clinical trials and registries of carotid stenting have been reported and compared. It is well known that distal embolization as detected by TCD is much more frequent with carotid stenting even with EPD, when compared with carotid endarterectomy.

Table 23-5

Unfavorable carotid angiographic appearance in which carotid stenting should be avoided

- Extensive carotid calcification
- Polypoid or globular carotid lesions
- Severe tortuosity of the common carotid artery
- Long-segment stenoses (>2 cm in length)
- Carotid artery occlusion
- Severe intraluminal thrombus (angiographic defects)
- Extensive middle cerebral artery atherosclerosis

However, the clinical significance of the distal embolization detected by TCD is not clear because most are asymptomatic. Acute carotid stent thrombosis is rare. The incidence of in-stent carotid restenosis is not well known but is estimated at 10% to 30%. Duplex surveillance shows elevated peak systolic velocities within the stent after carotid stenting not infrequently. However, velocity criteria are being formulated to determine the severity of in-stent restenosis after carotid stenting by ultrasound duplex.⁴² It appears that systolic velocities exceeding 300 to 400 cm/s would represent >70% to 80% restenosis. Bradycardia and hypotension occur in up to 20% of patients undergoing carotid stenting.⁴³ Systemic administration of atropine is usually effective in reversing the bradycardia. Other technical complications

Table 23-6

Commonly used embolic protection devices (EPDs)

MECHANISM	NAME OF EPD	PORE SIZE (μM)
Distal balloon occlusion	PercuSurge Guard Wire, Export catheter (Medtronic)	NA
Distal filter	Angioguard (Cordis)	100
	AccUNET (Abbott)	150
	Embosshield (Abbott)	140
	FilterWire (Boston Scientific)	110
	SpiderRx (EV3)	<100
Flow reversal ^a	Parodi Neuro Protection (Gore)	NA

^aClinical trial (EMPIRE) in United States. NA = not applicable.

Table 23-7

Currently approved carotid stents in the United States

NAME OF STENT	MANUFACTURER	CELL DESIGN	TAPERED STENT	DELIVERY SYSTEM SIZE (FRENCH)
Acculink	Abbott	Open	Yes	6
Exact	Abbott	Closed	Yes	6
NexStent	Boston Scientific	Closed	Self-tapering	5
Protégé RX	EV3	Open	Yes	6
Precise RX	Cordis	Open	No	6
Exponent	Medtronic	Open	No	6

of carotid stenting are infrequent and include carotid artery dissection and access site complications, such as groin hematoma, femoral artery pseudoaneurysm, distal embolization, and acute femoral artery thrombosis.

Nonatherosclerotic Disease of the Carotid Artery

Carotid Coil and Kink. A carotid coil consists of an excessive elongation of the internal carotid artery producing tortuosity of the vessel (Fig. 23-23). Embryologically, the carotid artery is

derived from the third aortic arch and dorsal aortic root and is uncoiled as the heart and great vessels descend into the mediastinum. In children, carotid coils appear to be congenital in origin. In contrast, elongation and kinking of the carotid artery in adults are associated with the loss of elasticity and an abrupt angulation of the vessel. Kinking is more common in women than men. Cerebral ischemic symptoms caused by kinks of the carotid artery are similar to those from atherosclerotic carotid lesions but are more likely due to cerebral hypoperfusion than embolic episodes. Classically, sudden head rotation, flexion, or extension can accentuate the kink and provoke ischemic symptoms. Most carotid kinks and coils are found incidentally on carotid duplex scan. However, interpretation of the Doppler frequency shifts and spectral analysis in tortuous carotid arteries can be difficult because of the uncertain angle of insonation. Cerebral angiography, with multiple views taken in neck flexion, extension, and rotation, is useful in the determination of the clinical significance of kinks and coils.

Fibromuscular Dysplasia. Fibromuscular dysplasia (FMD) usually involves medium-sized arteries that are long and have few branches (Fig. 23-24). Women in the fourth or fifth decade of life are more commonly affected than men. Hormonal effects on the vessel wall are thought to play a role in the pathogenesis of FMD. FMD of the carotid artery is commonly bilateral, and in about 20% of patients, the vertebral artery is also involved.⁴⁴ An intracranial saccular aneurysm of the carotid siphon or middle cerebral artery can be identified in up to 50% of the patients with FMD. Four histologic types of FMD have been described in the literature. The most common type is medial fibroplasia, which may present as a focal stenosis or multiple lesions with intervening aneurysmal outpouchings. The disease involves the media with the smooth muscle being replaced by fibrous connective tissue. Commonly, mural dilations and microaneurysms can be seen with this type of FMD. Medial hyperplasia is a rare type of FMD, with the media demonstrating excessive amounts of smooth muscle. Intimal fibroplasia accounts for 5% of all cases and occurs equally in both sexes. The media and adventitia remain normal, and there is accumulation of subendothelial mesenchymal cells with a loose matrix of connective tissue causing a focal stenosis in adults. Finally, premedial dysplasia represents a type of FMD with elastic tissue accumulating between the media and adventitia. FMD can also involve the renal and external iliac arteries. It is estimated that approximately 40% of patients with FMD present with a TIA due to embolization of platelet aggregates.⁴⁴ DSA demonstrates the

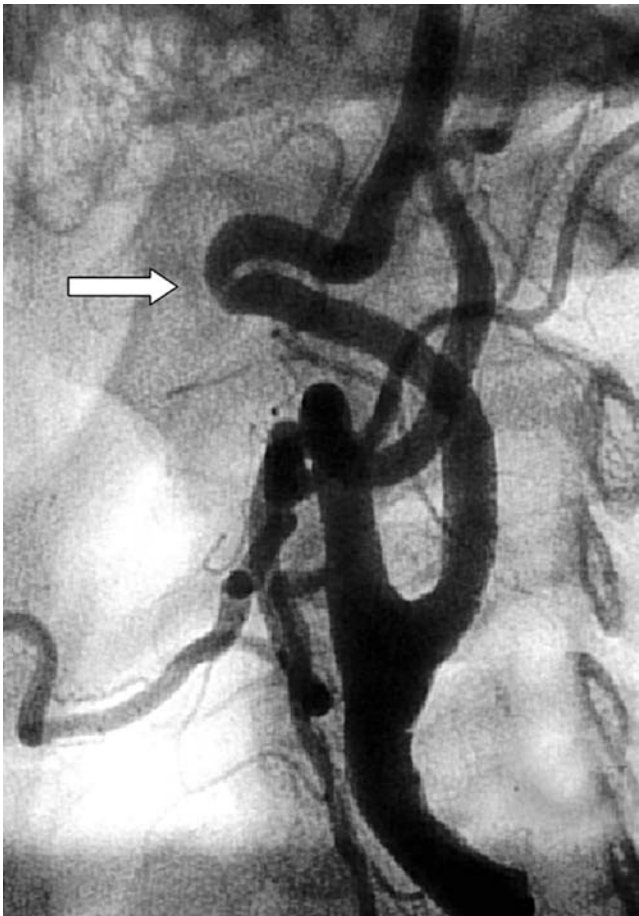


Figure 23-23. Excessive elongation of the carotid artery can result in carotid kinking (arrow), which can compromise cerebral blood flow and lead to cerebral ischemia.

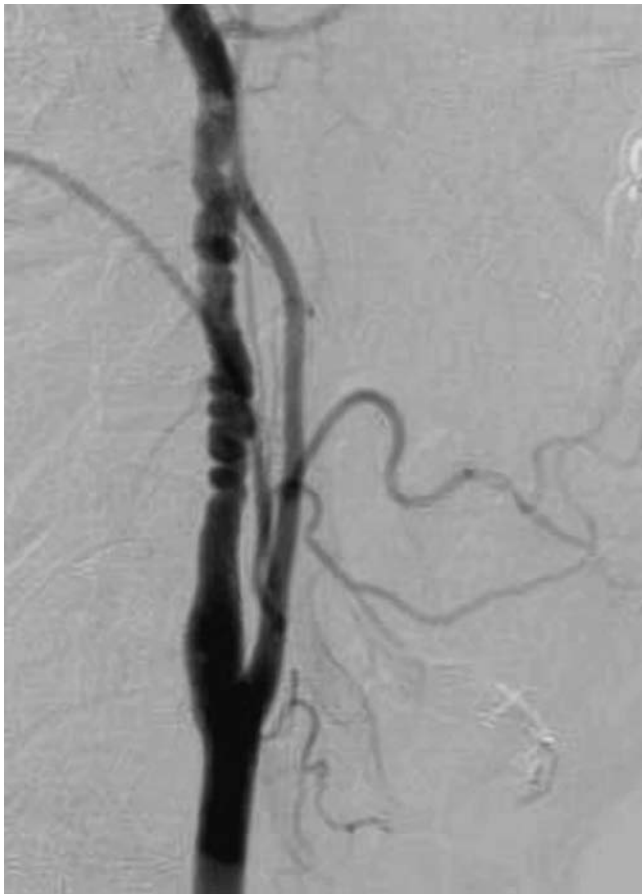


Figure 23-24. A carotid fibromuscular dysplasia with typical characteristics of multiple stenoses with intervening aneurysmal outpouching dilatations. The disease involves the media, with the smooth muscle being replaced by fibrous connective tissue.

characteristic “string of beads” pattern, which represents alternating segments of stenosis and dilatation. The string of beads can also be shown noninvasively by CTA or MRA. FMD should be suspected when an increased velocity is detected across a stenotic segment without associated atherosclerotic changes on carotid duplex ultrasound. Antiplatelet medication is the generally accepted therapy for asymptomatic lesions. Endovascular treatment is recommended for patients with documented lateralizing symptoms. Surgical correction is rarely indicated.

Carotid Artery Dissection. Dissection of the carotid artery accounts for approximately 20% of strokes in patients younger than 45 years of age. The etiology and pathogenesis of spontaneous carotid artery dissection remain incompletely understood. Arterial dissection involves hemorrhage within the media, which can extend into the subadventitial and subintimal layers. When the dissection extends into the subadventitial space, there is an increased risk of aneurysm formation. Subintimal dissections can lead to intramural clot or thrombosis. Traumatic dissection is typically a result of hyperextension of the neck during blunt trauma, neck manipulation, strangulation, or penetrating injuries to the neck. Even in supposedly spontaneous cases, a history of preceding unrecognized minor neck trauma is not uncommon. Connective disorders, such as Ehlers-Danlos syndrome, Marfan’s syndrome, α_1 -antitrypsin deficiency, or FMD, may predispose to carotid artery dissection. Iatrogenic dissections can also occur due to catheter manipulation or balloon angioplasty.

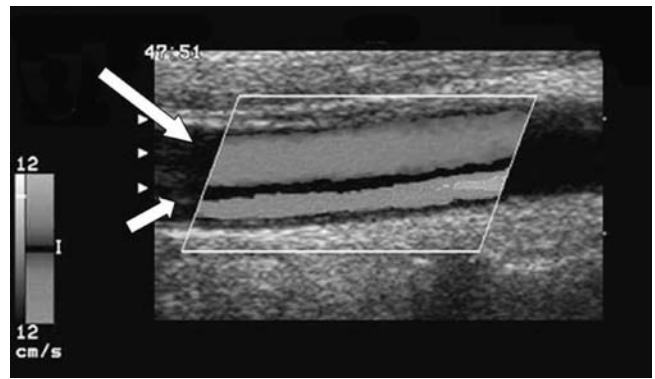


Figure 23-25. Carotid ultrasound reveals a patient with a carotid artery dissection in which carotid flow is separated in the true flow lumen (long arrow) from the false lumen (short arrow).

Typical clinical features of carotid artery dissection include unilateral neck pain, headache, and ipsilateral Horner’s syndrome in up to 50% of patients, followed by manifestations of the cerebral or ocular ischemia and cranial nerve palsies. Neurologic deficits can result either because of hemodynamic failure (caused by luminal stenosis) or by an artery-to-artery thromboembolism. The ischemia may cause TIAs or infarctions, or both. Catheter angiography has been the method of choice to diagnose arterial dissections, but with the advent of duplex ultrasonography, MRI/MRA, and CTA, most dissections can now be diagnosed using noninvasive imaging modalities (Fig. 23-25). The dissection typically starts in the internal carotid artery distal to the bulb. Uncommonly, the dissection can start in the common carotid artery or is an extension of a more proximal aortic dissection. Medical therapy has been the accepted primary treatment of symptomatic of carotid artery dissection. Anticoagulation (heparin and warfarin) and antiplatelet therapy have been commonly used, although there have not been any randomized studies to evaluate their effectiveness. The prognosis depends on the severity of neurologic deficit but is generally good in extracranial dissections. The recurrence rate is low. Therapeutic interventions have been reserved for recurrent TIAs or strokes or failure of medical treatment. Endovascular options include intra-arterial stenting, coiling of associated pseudoaneurysms, or, more recently, deployment of covered stents.

Carotid Artery Aneurysms. Carotid artery aneurysms are rare, encountered in less than 1% of all carotid operations (Fig. 23-26). The true carotid artery aneurysm is generally due to atherosclerosis or medial degeneration. The carotid bulb is involved in most carotid aneurysms, and bilaterality is present in 12% of the patients. Patients typically present with a pulsatile neck mass. The available data suggest that, untreated, these aneurysms lead to neurologic symptoms from embolization. Thrombosis and rupture of the carotid aneurysm are rare. Pseudoaneurysms of the carotid artery can result from injury or infection. Mycotic aneurysms often involved syphilis in the past, but are now more commonly associated with peritonsillar abscesses caused by *Staphylococcus aureus* infection. FMD and spontaneous dissection of the carotid artery can lead to the formation of true aneurysms or pseudoaneurysms. Whereas conventional surgery has been the primary mode of treatment in the past, carotid aneurysms are currently being treated more commonly using endovascular approaches.⁴⁵

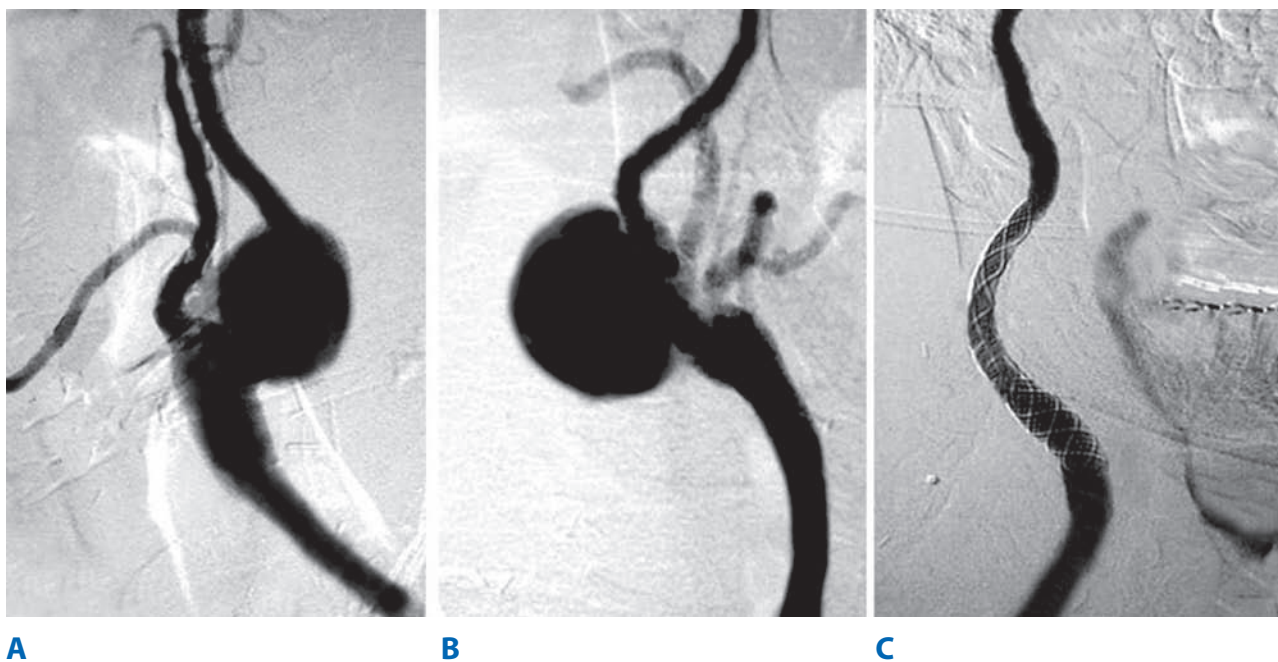


Figure 23-26. **A.** An anteroposterior angiogram of the neck revealing a carotid artery aneurysm. **B.** A lateral projection of the carotid artery aneurysm. **C.** Following endovascular placement, the carotid artery aneurysm is successfully excluded.

Carotid Body Tumor. The carotid body originates from the third branchial arch and from neuro-ectodermal derived neural crest lineage. The normal carotid body is located in the adventitia or periadventitial tissue at the bifurcation of the common carotid artery (Fig. 23-27). The gland is innervated by the glossopharyngeal nerve. Its blood supply is derived predominantly from the external carotid artery but can also come from the vertebral artery. Carotid body tumor is a rare lesion of the neuroendocrine system. Other glands of neural crest origin are seen in the neck, parapharyngeal spaces, mediastinum, retroperitoneum,

and adrenal medulla. Tumors involving these structures have been referred to as paraganglioma, glomus tumor, or chemodectoma. Approximately 5% to 7% of carotid body tumors are malignant. Although chronic hypoxemia has been invoked as a stimulus for hyperplasia of carotid body, approximately 35% of carotid body tumors are hereditary. The risk of malignancy is greatest in young patients with familial tumors.

Symptoms related to the endocrine products of the carotid body tumor are rare. Patients usually present between the fifth and seventh decades of life with an asymptomatic lateral neck

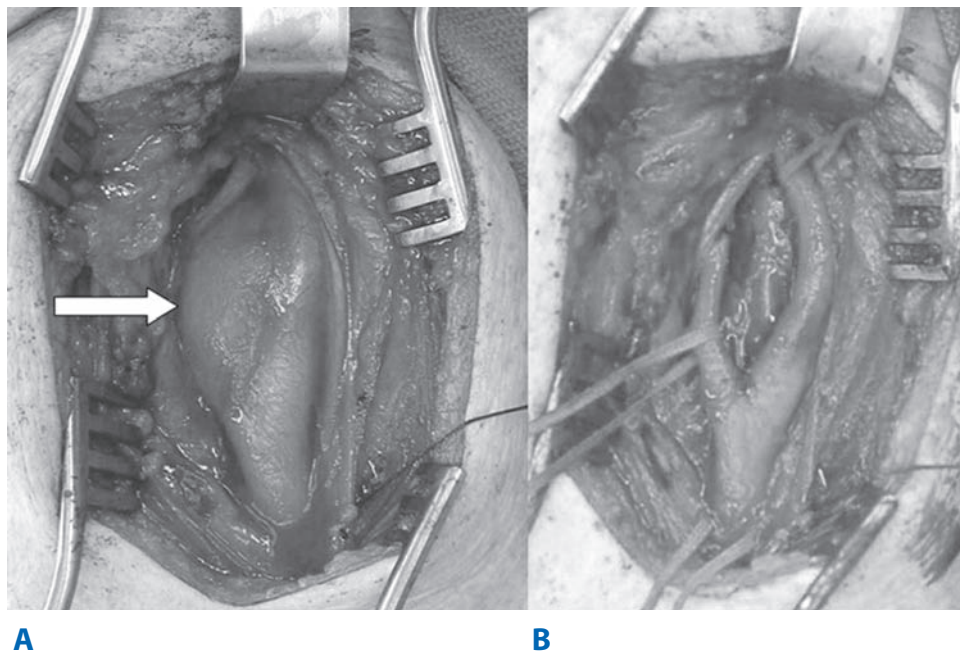


Figure 23-27. **A.** A carotid body tumor (*arrow*) located adjacent to the carotid bulb. **B.** Following periadventitial dissection, the carotid body tumor is removed.

mass. The diagnosis of carotid body tumor requires confirmation on imaging studies. Carotid duplex scan can localize the tumor to the carotid bifurcation, but CT or MRI is usually required to further delineate the relationship of the tumor to the adjacent structures. Classically, a carotid body tumor will widen the carotid bifurcation. The Shamblin classification describes the tumor extent: I, tumor is less than 5 cm and relatively free of vessel involvement; II, tumor is intimately involved but does not encase the vessel wall; and III, tumor is intramural and encases the carotid vessels and adjacent nerves.⁴⁶ With good-resolution CT and MRI, arteriography is usually not required. However, arteriography can provide an assessment of the vessel invasion and intracranial circulation and allows for preoperative embolization of the feeder vessels, which has been reported to reduce intraoperative blood loss. Surgical resection is the recommended treatment for suspected carotid body tumor.

Carotid Trauma. Blunt or penetrating trauma to the neck can cause injury to the carotid artery. Notwithstanding the massive bleeding from carotid artery transection, injury to the carotid artery can result in carotid dissection, thrombosis, or pseudoaneurysm formation. Carotid duplex ultrasound can be useful to locate the site of injury in the cervical segment of the carotid artery. Spiral CTA has become the modality of choice to detect extracranial carotid artery injury. Confirmation of carotid injury by contrast cerebral angiography remains the gold standard diagnostic test. Injuries to the cervical segment of the common and internal carotid arteries can be repaired surgically. Acute carotid artery thrombosis is usually treated medically with anticoagulation if the patient is asymptomatic. Revascularization should be considered for patients presenting with ongoing cerebral ischemia related to carotid artery thrombosis. Traumatic carotid artery dissection can cause cerebral ischemia due to thromboembolization, decreased flow, or thrombosis. Commonly, the dissection involves the distal portion of the cervical and petrous segment of the internal carotid artery. Medical management with antiplatelet or anticoagulation therapy is usually adequate for uncomplicated traumatic carotid dissection. In patients with pseudoaneurysms of the carotid artery that are located in a segment that is out of surgical reach, the use of selective coil embolization of the pseudoaneurysm or exclusion of the pseudoaneurysm by a covered stent graft has been reported. Bare metal stent has been used with success in the treatment of traumatic carotid artery dissection.

ABDOMINAL AORTIC ANEURYSM

Despite more than 50,000 patients undergoing elective repair of abdominal aortic aneurysm (AAA) each year in the United States, approximately 15,000 patients die annually as a result of ruptured aneurysm, making it the 10th leading cause of death in men in this country.⁴⁷ The incidence appears to be increasing, and this is due in part to improvements in diagnostic imaging and, more importantly, a growing elderly population. With early diagnosis and timely intervention, aneurysm rupture-related death is largely preventable. Conventional treatment of an AAA involves replacing the aneurysmal segment of the aorta with a prosthetic graft, with the operation performed through a large abdominal incision. Techniques for this open abdominal surgery have been refined, adapted, and extensively studied by vascular surgeons over the past four decades. Despite a well-documented low perioperative mortality rate of 2% to 3% in large academic institutions, the thought of undergoing an open abdominal aortic

operation often provokes a sense of anxiety in many patients due in part to the postoperative pain associated with the large abdominal incision as well as the long recovery time needed before the patient can return to normal physical activity.

The most common location of aortic aneurysms is the infrarenal aorta. Endovascular stent graft placement represents a revolutionary and minimally invasive treatment for infrarenal AAAs that only requires 1 to 2 days of hospitalization, and the patient can return to normal physical activity within 1 week. The concept of using an endoluminal device in the management of vascular disease was first proposed by Dotter and colleagues, who successfully treated a patient with iliac occlusion using transluminal angioplasty in 1964.⁴⁸ Nearly two decades later, Parodi and colleagues reported the first successful endovascular repair of AAA using a stent graft device.¹⁵ Since then, a variety of stent graft technologies have been developed to treat AAA. The rapid innovation of this new treatment modality has undoubtedly captured the attention of patients with aortic aneurysms as well as physicians who practice endovascular therapy. Physicians in general should be knowledgeable regarding available treatment options of AAA in order to provide adequate evaluation and education to patients and their families. The purpose of this section is to outline the treatment options for AAAs, including conventional repair and endovascular approach. Advantages and potential complications of these treatments will also be addressed.

Causes and Risk Factors

The pathogenesis of aneurysmal disease of the aorta is complex and multifactorial. A degenerative process in the aortic wall is the most common cause of AAA development.⁴⁹ Matrix metalloproteinases (MMP), proteolytic enzymes, are found abundantly in the wall of AAA. Atherosclerotic disease, age, male sex, smoking history, family history, hypertension, coronary artery disease, and chronic obstructive pulmonary disease are associated with the development of AAA.^{50,51} Diabetes and black race have negative association with AAA.⁵⁰ Other less common causes include inflammation, infection, and connective tissue disease. Inflammatory AAA accounts for 5% to 10% of all AAAs.⁵² In contrast to atherosclerotic AAA, the inflammatory variant is characterized pathologically by marked thickening of the aneurysm wall, fibrosis of the adjacent retroperitoneum, and rigid adherence of the adjacent structures to the anterior aneurysm wall.⁵³ Male sex and smoking are even stronger risk factors in inflammatory AAA.⁵⁴ Smoking cessation is the first step of medical therapy, followed by surgical repair. Infectious or mycotic AAA is rare but is associated with high mortality.⁵⁵ Patients with connective tissue disorders such as Marfan's syndrome and Ehlers-Danlos syndrome tend to have more extensive and larger aneurysms at a younger age.⁵⁶

Natural History of Aortic Aneurysm

The natural history of an AAA is to expand and rupture. AAA exhibits a "staccato" pattern of growth, where periods of relative quiescence may alternate with expansion. Therefore, although an individual pattern of growth cannot be predicted, average aggregate growth is approximately 3 to 4 mm/year. There is some evidence to suggest that larger aneurysms may expand faster than smaller aneurysms, but there is significant overlap between the ranges of growth rates at each strata of size.

Rupture risk appears to be directly related to aneurysm size as predicted by Laplace's Law. Although more sophisticated

Table 23-8

Annualized risk of rupture of abdominal aortic aneurysm (AAA) based on size

DESCRIPTION	DIAMETER OF AORTA (CM)	ESTIMATED ANNUAL RISK OF RUPTURE (%)	ESTIMATED 5-YEAR RISK OF RUPTURE (%) ^a
Normal aorta	2–3	0	0 (unless AAA develops)
Small AAA	4–5	1	5–10
Moderate AAA	5–6	2–5	30–40
Large AAA	6–7	3–10	>50
Very large AAA	>7	>10	Approaching 100

^aThe estimated 5-year risk is more than five times the estimated annual risk because over that 5 years, the AAA, if left untreated, will continue to grow in size.

methods of assessing rupture risk based on finite element analysis of wall stress are under active investigation, maximum transverse diameter remains the standard method of risk assessment for aneurysm rupture. In the past, AAA rupture risk has been overestimated. More recently, two landmark studies have served to better define the natural history of AAA.^{57,58} Based on best available evidence, the annualized risk of rupture is given in

▶ Table 23-8. The rupture risk is quite low below 5.5 cm and begins to rise exponentially thereafter. This size can serve as an appropriate threshold for recommending elective repair provided one's surgical mortality is below 5%. For each size strata, however, women appear to be at higher risk for rupture than men, and a lower threshold of 4.5 to 5.0 cm may be reasonable in good-risk patients. Although data are less compelling, a pattern of rapid expansion of >0.5 cm within 6 months can be considered a relative indication for elective repair. Aneurysms that fall below these indications may safely be followed with CT or ultrasound at 6-month intervals, with long-term outcomes equivalent to earlier surgical repair. Interestingly, in the Aneurysm Detection and Management (ADAM) study, 80% of all AAAs that were followed in this manner eventually came to repair within 5 years.⁵⁸

Unless symptomatic or ruptured, AAA repair is a prophylactic repair. The rationale for recommending repair is predicated on the assumption that the risk of aneurysm rupture exceeds the combined risk of death from all other causes such as cardiopulmonary disease and cancer. On the other hand, our limitation in predicting timing and cause of death is underscored by the observation that over 25% of patients who were deemed unfit for surgical repair because of their comorbidities died from rupture of their aneurysms within 5 years.

Clinical Manifestations

Most AAAs are asymptomatic and are usually found incidentally during workup for chronic back pain or kidney stones. Physical examination is neither sensitive nor specific except in thin patients. Large aneurysms may be missed in the obese, while normal aortic pulsations may be mistaken for an aneurysm in thin individuals. Rarely patients present with back pain and/or abdominal pain with a tender pulsatile mass. Patients with these symptoms must be treated as a rupture until proven otherwise. If the patient is hemodynamically stable and the aneurysm is intact on a CT scan, the patient is admitted for blood pressure control with intravenous antihypertensive agents and undergoes repair usually within 12 to 24 hours or at least during the same hospitalization. In contrast, patients who are hemodynamically

unstable with a history of acute back pain and/or syncope and a known unrepaired AAA or a pulsatile abdominal mass should be immediately taken to the operating room with a presumed diagnosis of a ruptured AAA.

Overall mortality of AAA rupture is 71% to 77%, which includes all out-of-hospital and in-hospital deaths, as compared with 2% to 6% for elective open surgical repair.⁵⁹ Nearly half of all patients with ruptured AAA will die before reaching the hospital. For the remainder, surgical mortality is 45% to 50% and has not substantially changed in the last 30 years.

Relevant Anatomy

An AAA is defined as a pathologic focal dilation of the aorta that is greater than 30 mm or 1.5 times the adjacent diameter of the normal aorta (Fig. 23-28). Male aortas tend to be larger

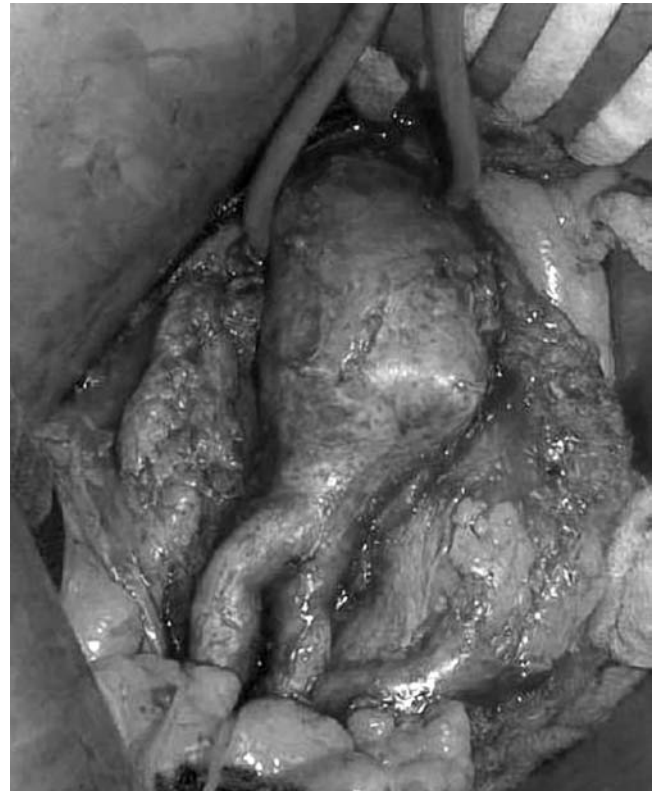


Figure 23-28. An operative view of an infrarenal aortic aneurysm.

than female aortas, and there is generalized growth of the aortic diameter with each decade of life. Ninety percent of AAAs are infrarenal in location and have a fusiform morphology. There is a higher predilection for juxtarenal and suprarenal AAAs in women compared with men. Concomitant common iliac and/or hypogastric artery aneurysms can be found in 20% to 25% of patients. Although the etiology of most aortic aneurysms is atherosclerotic, clinically significant peripheral occlusive disease is unusual and present in less than 10% of all cases.

Although extravascular anatomy is important for open surgical repair of AAA, intravascular anatomy and aortoiliac morphology are important for endovascular repair. Pertinent anatomic dimensions include the diameter of the proximal non-dilated infrarenal aortic neck, which can range from 18 to 30 mm; common iliac artery, which can range from 8 to 16 mm; and external iliac arteries, which can range from 6 to 10 mm. Morphologically, the aortic neck can manifest complex angulation above and below the renal arteries due to combination of elongation and anterolateral displacement by the posterior bulge of the aneurysmal aorta. Furthermore, the shape of the proximal neck is rarely tubular, but often is conical, reverse conical, or barrel-shaped. Distally, the iliac arteries can have severe tortuosity with multiple compound turns. Although significant from hemodynamic standpoint, severe iliac calcifications combined with extreme tortuosity can pose a formidable challenge during endovascular repair.

Diagnostic Evaluation

Preoperative evaluation should include routine history and physical exam with particular attention to (a) any symptoms referable to the aneurysm, which may impact the timing of repair; (b) history of pelvic surgery or radiation, in the event retroperitoneal exposure is required or interruption of hypogastric circulation is planned; (c) claudication suggestive of significant iliac occlusive disease; (d) lower extremity bypass or other femoral reconstructive procedures; and (e) chronic renal insufficiency or contrast allergy.

Cross-sectional imaging is required for definitive evaluation of AAA. Although ultrasound is safe, widely available, relatively accurate, and inexpensive and thus the screening modality of choice, CT scan remains the gold standard for determination of anatomic eligibility for endovascular repair. Size of AAA may differ up to 1 cm between CT and ultrasound, and during longitudinal follow-up, comparisons should be made between identical modalities. With modern multirow detector scanners, a timed-bolus intravenous contrast-enhanced, 2.5- to 3.0-mm slice spiral CT of the chest, abdomen, and pelvis can be performed in less than 30 seconds with a single breath hold. Extremely high-resolution images are obtained with submillimeter spatial resolution (Fig. 23-29). Proper window level and width (brightness and contrast) are important for discrimination among aortic wall, calcific plaque, thrombus, and lumen. The only major drawback to CT is the risk of contrast nephropathy in diabetics and in patients with renal insufficiency.

The spiral technique further affords the ability for three-dimensional reconstruction. Three-dimensional reconstructions can yield important morphologic information that is critical to endovascular therapy. Using third-party software, these images can be viewed and manipulated on one's desktop computer, and so-called "center-line" (transverse slices perpendicular to the central flow lumen of the aorta) diameter and length measurements obtained. Conventional angiography has a minimal role

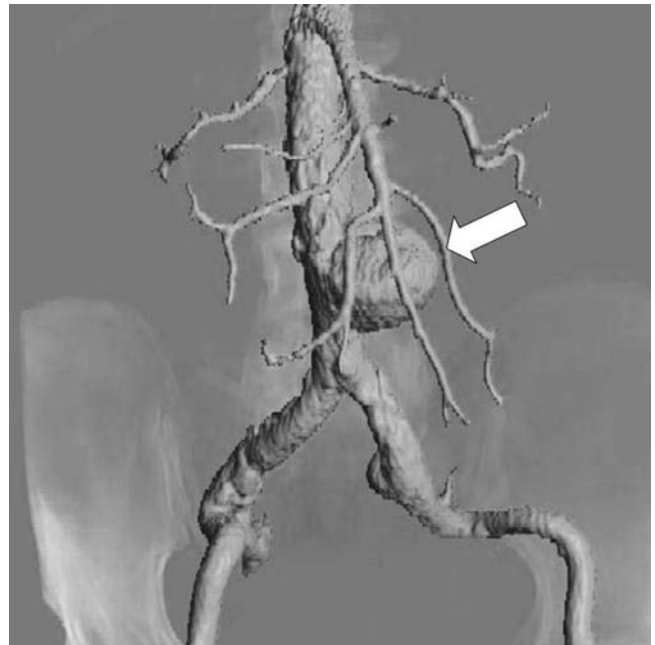


Figure 23-29. High resolution of image displaying an aortic aneurysm (arrow) can be achieved with multidetector computed tomography angiography.

in the current management of AAA. Angiography is invasive with an increased risk of complications. Indications for angiography are isolated to concomitant iliac occlusive disease (present in <10% of patients with AAA) and unusual renovascular anatomy.

Surgical Repair of Abdominal Aortic Aneurysm

General anesthesia is necessary when performing a conventional open AAA repair. While a retroperitoneal incision is a well-accepted surgical approach, a midline transabdominal incision remains the more common approach for open aortic aneurysm operation. Since the abdominal incision can lead to significant pain and discomfort, an epidural catheter can be placed prior to the operation for postoperative analgesic infusion to provide pain control. Once the abdominal cavity is opened, the small intestines and transverse colon are retracted to expose the retroperitoneum overlying the AAA. The retroperitoneum is next divided, followed by isolation of both proximal and distal segments of the AAA. Intravenous heparin (100 IU/kg) is given followed by clamping of the proximal and distal segments of the aneurysm. The aneurysm sac is open next, and a prosthetic graft is used to reconstruct the aorta. If the aneurysm only involves the abdominal aorta, a tube graft can be used to replace the aorta (Fig. 23-30). If the aneurysm extends distally to the iliac arteries, a prosthetic bifurcated graft is used for either an aorto-bi-iliac or aorto-bi-femoral bypass reconstruction (Fig. 23-31). The overlying aneurysm sac and the retroperitoneum are closed to cover the prosthetic bypass graft to minimize potential bowel contact to the graft. Small and large intestines are returned to the abdominal cavity followed by the closure of the abdominal fascia and skin.

Advantages and Risks of Open Abdominal Aortic Aneurysm Repair. The main advantage of a conventional open repair is that the AAA is permanently eliminated because it is entirely replaced by a prosthetic aortic graft. The risk of aneurysm

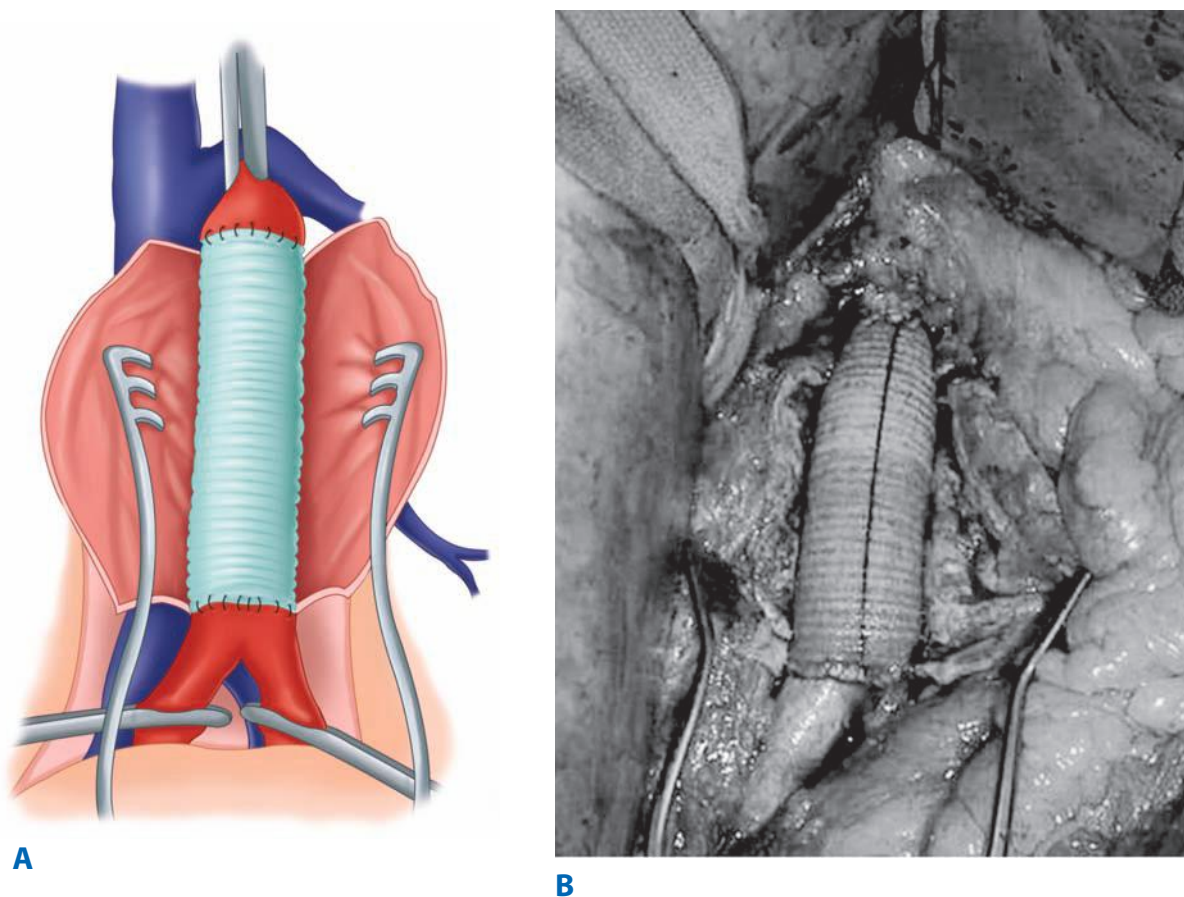


Figure 23-30. A. Schematic depiction of an aortic tube graft used to repair an aortic aneurysm. B. Intraoperative image of an aortic tube graft reconstruction.

recurrence or delayed rupture no longer exists. As a result, long-term imaging surveillance is not needed with these patients. In contrast, the long-term efficacy of endovascular repair remains unclear. Consequently, long-term imaging surveillance is critical to ensure that the aortic aneurysm remains properly sealed by the stent graft. Other potential advantages of open repair include direct assessment of the circulatory integrity of the colon. If signs of colonic ischemia become evident after aortic bypass grafting, a concomitant mesenteric artery bypass can be performed to revascularize the colonic circulation. In addition, open repair permits the surgeons to explore for other abdominal pathologies, such as gastrointestinal tumors, liver mass, or cholelithiasis.

As for the risks associated with open repair, cardiac complications, in the form of either myocardial infarction or arrhythmias, remain the most common morbidity, with an incidence between 2% and 6%.⁶⁰ Another significant complication is renal failure or transient renal insufficiency as a result of perioperative hypotension, atheromatous embolization, inadvertent injury to the ureter, preoperative contrast-induced nephropathy, or suprarenal aortic clamping. Although the incidence of renal failure is less than 2% in elective aneurysm repair, it can occur in more than 20% of patients after repair of a ruptured AAA.⁶⁰

Ischemic colitis is a devastating potential complication after open repair. The likelihood of such a complication is highest in those who had a prior colon resection and undergo repair of a ruptured AAA, due to the loss of collateral blood supply to the rectosigmoid colon. It is estimated that 5% of patients who undergo elective aneurysm repair will develop

partial-thickness ischemic colitis but without significant clinical sequelae.⁶¹ However, if the partial-thickness ischemia progresses to full-thickness gangrene and peritonitis, mortality can be as high as 90%.⁶¹

The incidence of prosthetic graft infection ranges between 1% and 4% after open repair.⁶¹ It is more common in those who undergo repair of a ruptured AAA. If the prosthetic graft is not fully covered by the aneurysm sac or retroperitoneum, intestinal adhesion with subsequent bowel erosion may occur, resulting in an aortoenteric fistula. The predominant sign of such a complication is massive hematemesis, and it typically occurs years after the operation. Despite these potential complications, however, the majority of patients who undergo successful elective open repair have an uneventful recovery.

Endovascular Repair of Abdominal Aortic Aneurysm

Over a decade has passed since the first report of human implantation of a homemade stent graft for endovascular repair of an AAA by Parodi in 1991.³ Several prospective clinical trials across different devices and analysis of large Medicare administrative databases and meta-analyses of published literature have consistently demonstrated significantly decreased operative time, blood loss, hospital length of stay, and overall perioperative morbidity and mortality of endovascular repair compared with open surgical repair. For patients who are at increased risk for surgery because of age or comorbidity, endovascular repair is a superior minimally invasive alternative.

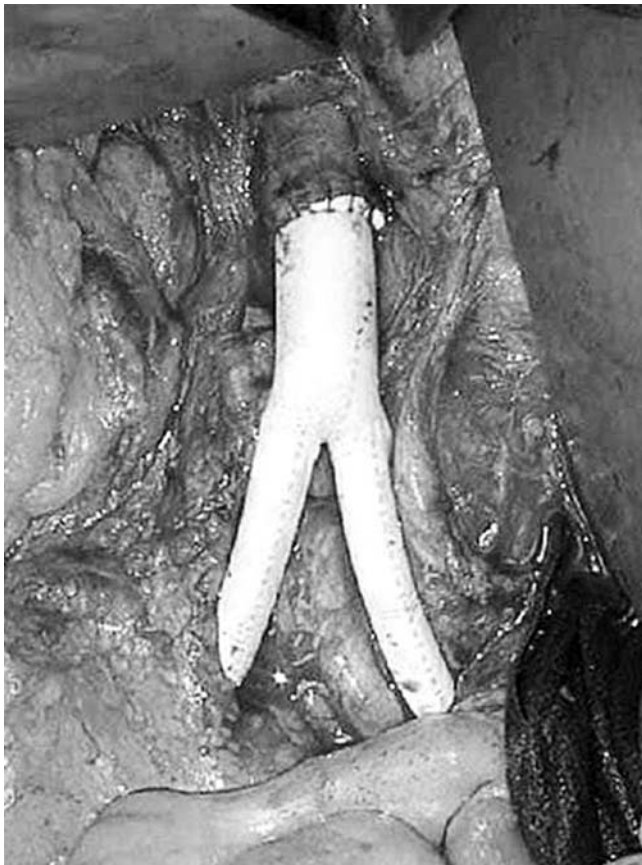

Figure 23-31. Intraoperative view of a bifurcated graft used to repair an aortic aneurysm.

The principle of endovascular repair of AAA involves the implantation of an aortic stent graft that is fixed proximally and distally to nonaneurysmal aortoiliac segment and thereby endoluminally excluding the aneurysm from the aortic circulation (Fig. 23-32). Unlike open surgical repair, the aneurysm sac is not

resected, which is subjected for potential aneurysm expansion or even rupture. Importantly, aortic branches, such as lumbar arteries or the inferior mesenteric artery (IMA), are occluded, which can lead to persistent aneurysm pressurization and aneurysm expansion. Currently, the following nine devices are available for elective repair of intact infrarenal AAA: AneuRx device (Medtronic/AVE, Santa Rosa, CA), Gore Excluder device (WL Gore & Associates, Flagstaff, AZ), Endologix Powerlink device (Endologix Inc., Irvine, CA), Zenith device (Cook Inc., Bloomington, IN), Talent device (Medtronic/AVE, Santa Rosa, CA), Endurant device (Medtronic/AVE, Santa Rosa, CA), AFX Endovascular AAA System (Endologix Inc., Irvine, CA), Aorfix Flexible Stent (Lombard Medical Inc., Framingham, MA), and Ovation Prime Stent (TriVascular Inc., Santa Rosa, CA). Despite some differences in physical appearance, mechanical properties, and materials, they will be discussed collectively for this chapter. Most of these devices are modular devices consisting of a primary device or main body and one or two iliac limbs that insert into the main body to complete the repair. Depending on the choice of iliac limbs that can be matched to the main body, which can impact the customizability for a particular anatomy.

A severe limitation of the endovascular repair devices is the need for adequate proximal neck to achieve a durable sealing zone. Several techniques have been proposed to overcome this limitation. These include fenestrated or branched endografts and the “chimney,” “snorkel,” and “periscope” techniques. The fenestrated stent grafts rely on precise alignment between the fenestration and the corresponding visceral artery.⁶² Multiple clinical trials using customized fenestrated stent graft for the treatment of short-necked and juxtarenal aortic aneurysm repair have shown promising short- and mid-term results.^{63,64} However, restricted access to these investigational devices and the delays due to device customization limit the current use of these devices to a few centers. Alternatively, some centers have reported good results with intraoperative surgeon-modified endograft to create fenestrations for the treatment of complex aortic aneurysms in high-risk patients.⁶⁵ Further development

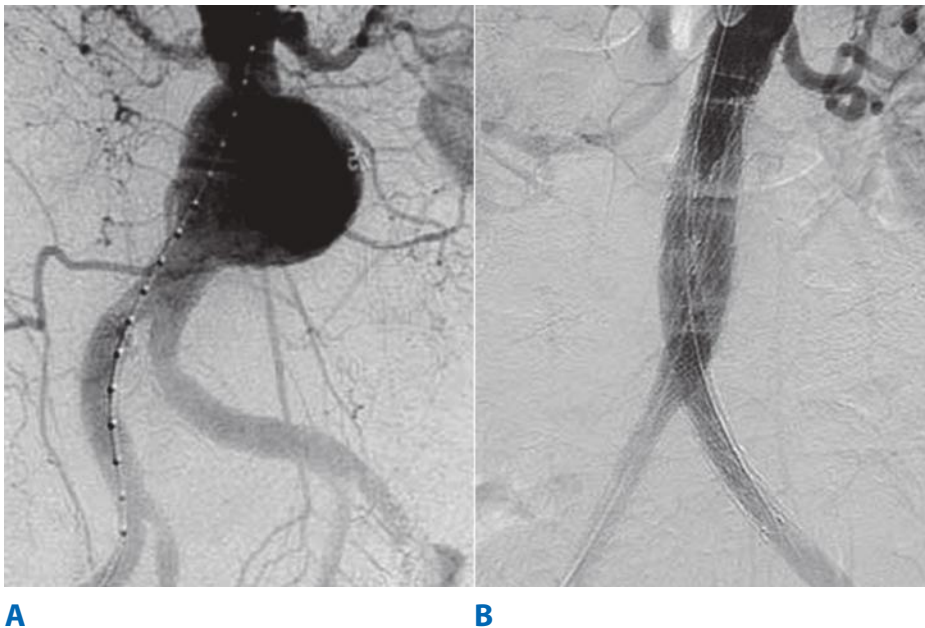


Figure 23-32. **A.** An aortogram demonstrating a large infrarenal abdominal aortic aneurysm. **B.** Following endovascular stent graft implantation, the aortic aneurysm is successfully excluded.

of the fenestrated techniques also opens the way for endovascular treatment of suprarenal and thoracoabdominal aneurysm.⁶⁶ Recently, an “off-the-shelf” Zenith Fenestrated AAA endovascular graft has been approved by the FDA. This device has fenestrations or scallops in the graft material to allow the proximal edge of the stent graft to be placed above the renal arteries while still permitting blood flow to vessels accommodated by the fenestrations or scallops. The “chimney” technique involves placing renal or mesenteric stents parallel to the aortic stent graft to preserve blood flow in the visceral aortic branches.⁶⁷ This technique has been suggested as a rescue procedure for visceral arteries that have been covered by the stent graft during endovascular repair.⁶⁸ The review of literature showed that open surgery remains a safe and effective treatment option for good-risk patients with juxtarenal aortic aneurysm.⁶⁹ Fenestrated endovascular repair is associated with low mortality and compares favorably with open surgery in terms of morbidity, especially renal function impairment and cardiac complications.⁶⁹ The “chimney” technique demonstrated feasibility, but because of the limited number of reports and the lack of long-term data, it should be considered only in acute poor surgical risk patients and in case of unintentional visceral artery coverage or elective poor surgical cases for fenestrated endovascular repair.⁶⁹

Patient Selection for Endovascular Aortic Aneurysm Repair. Anatomic eligibility for endovascular repair is mainly based on three areas: the proximal aortic neck, common iliac arteries, and external iliac and common femoral arteries, which relate to the proximal and distal landing zones or fixation sites and the access vessels, respectively. The requirements for the proximal aortic neck are a diameter of 18 to 28 mm and a minimum length of 15 mm (Table 23-9). Usually, multiple measurements of the diameter are taken along the length of the neck to assess its shape. All diameter measurements are mid-wall to mid-wall of the vessel. Secondary considerations include mural calcifications (<50% circumference), luminal thrombus (<50% circumference), and angulation (<45°). Presence of a significant amount of any one of these secondary features in combination with a relatively short proximal neck may compromise successful short- and long-term fixation of the stent graft and exclusion of the aneurysm. The usual distal landing zone is the common iliac artery. The external iliac artery may serve as an alternate site when the ipsilateral common iliac artery is aneurysmal or

ectatic. The treatable diameters of common iliac arteries range from 8 to 20 mm, and there should be at least 20 mm of patent artery of uniform diameter to allow adequate fixation. Finally, at least one of two common femoral and external iliac arteries must be at least 7 mm in diameter in order to safely introduce the main delivery sheath. Slightly smaller iliac diameters may be tolerated depending on the specific device and in the absence of severe tortuosity and calcific disease. Difficult access is one of the main causes of increased procedural time and intraoperative complications. Using these criteria, approximately 60% of all AAAs are anatomic candidates for endovascular repair.

The next step in the preoperative planning is device selection. Typically, the proximal diameter of the main device is oversized by 10% to 20% of the nominal diameter of the aortic neck. Distally, the iliac limbs are oversized by 1 to 4 mm depending on the individual device’s instructions for use. The biggest challenge to proper device selection remains determining the optimal length from the renal arteries to the hypogastric arteries. Despite availability of sophisticated three-dimensional reconstructions, the exact path that a device will take from the proximal aortic neck to the distal iliac arteries is difficult to predict. It is dependent on a host of factors related to the mechanical properties of the stent graft and the morphology of the aortoiliac flow lumen. “Plumb-line” measurements of axial CT images can be quite inaccurate, typically grossly underestimating the length, whereas center-line measurements usually overestimate the length. Angiographic measurements using a marker catheter are invasive, require contrast and radiation exposure, and are also inaccurate because they fail to account for the stiffness of the stent graft. The consequences of not choosing the correct length of the device include inadvertent coverage of the hypogastric artery if too long and the need for additional devices if too short.

Advantages and Risks of Endovascular Repair. The obvious advantage of an endovascular AAA repair is its minimally invasive nature. Typically, patients who undergo this procedure stay in the hospital for only 1 to 3 days, in contrast to the 5- to 10-day stay required after conventional open surgical repair. In our institution, patients who have had an endovascular repair are routinely transferred to a general vascular ward from the post-anesthesia recovery unit, avoiding admission to a more costly intensive care unit.

Because an abdominal incision is not necessary in endovascular repair, the procedure is particularly beneficial in patients with severe pulmonary disease, such as chronic obstructive pulmonary disease or emphysema. Patients can sustain adequate breathing in the postoperative period, avoiding respiratory complications or prolonged mechanical ventilation. Because the abdominal cavity has not been entered, the risk of gastrointestinal complications, such as ileus, ventral hernia, or bowel obstruction due to intestinal adhesion, is also greatly reduced. Moreover, regional or epidural anesthesia can be used, avoiding the risks associated with general anesthesia in patients with severe cardiopulmonary dysfunction.

Despite its many advantages, endovascular repair does have potential complications. Since the stent graft device is attached endoluminally within the abdominal aorta, an endoleak due to incomplete stent graft exclusion of the aneurysm can occur. With this type of leak, blood flow persists outside the lumen of the endoluminal graft but within an aneurysm sac. A meta-analysis of 1118 patients who underwent successful endovascular repair found an endoleak incidence of 24%.⁷⁰ Although

Table 23-9

Ideal characteristics of an aneurysm for endovascular abdominal aortic aneurysm repair

Neck length (mm)	>15
Neck diameter (mm)	>18, <32
Aortic Neck angle (degrees)	<60
Neck mural calcification (% circumference)	<50
Neck luminal thrombus (% circumference)	<50
Common iliac artery diameter (mm)	Between 8 and 20
Common iliac artery length (mm)	>20
External iliac artery diameter (mm)	>7

a small endoleak usually poses little clinical significance because it will typically become thrombosed spontaneously, a large or persistent endoleak may lead to continuous aneurysm perfusion and ultimately to aneurysm rupture. The rupture rate following an endovascular AAA repair has been reported to be less than 0.8%.⁷¹

Stent graft iliac limb dysfunction resulting in thrombosis has been reported following endovascular repair.^{18,70} One possible cause is aneurysm remodeling, resulting in a shortening in the aortic length, which can cause the stent graft to kink. Alternatively, progression of an underlying iliac atherosclerotic lesion may cause compression of the iliac limb and ultimately result in graft-limb occlusion. Treatment options include thrombolysis or graft thrombectomy to determine the underlying cause and possibly additional stent graft placement. Renal artery occlusion may occur due to improper stent graft positioning or migration.^{18,60,70} Graft limb separation or dislocation has also been reported.^{18,60,70}

In patients with AAA and concurrent iliac artery aneurysms who undergo preoperative coil embolization of the internal iliac artery, 20% to 45% experience symptoms of pelvic ischemia.⁷² These symptoms may include buttock claudication, impotence, gluteal skin sloughing, and colonic ischemia. Other complications pertaining to endovascular repair relate to the access site and include groin hematoma and wound infection. Occasionally, the stent graft device can malfunction by either failing to deploy or dislodging during the deployment procedure.^{18,71} If the device cannot be salvaged or rescued endoluminally, open surgical repair of the aneurysm may be necessary.

Technical Considerations of Endovascular Aortic Aneurysm Repair. Although endovascular AAA repair may be performed in any venue with appropriate digital fluoroscopic imaging capability, due to the need for absolute sterility and aseptic technique, it is most safely performed in a surgical suite. The patient is prepped and draped just as in open AAA repair. Patients with renal insufficiency should be started on perioperative oral *N*-acetylcysteine (Mucomyst) and sodium bicarbonate infusion to reduce the risk of contrast nephropathy. A variety of anesthetic options may be used. Regional anesthesia may be appropriate for patients with pulmonary disease. There are reports of success with local anesthetics alone, as the incisions are typically smaller than a typical open inguinal hernia repair.⁷³

Bilateral transverse oblique incisions are made just below the inguinal ligament to expose approximately 2 to 3 cm of CFA and obtain proximal control. Special attention is paid to avoid the groin crease to decrease the risk of wound complications. Some have advocated a completely percutaneous access using the “pre-close” technique with the Perclose suture-mediated vascular closure device (Abbott Perclose, Redwood City, CA). Review of reported series on this technique suggest a technical success rate of 95% for medium-size sheaths ranging from 12 to 16 French, and 75% success for 18- to 24-French sizes.

Transfemoral access is obtained using standard Seldinger technique. Initial soft-tipped starter guidewires are exchanged for stiff guidewires that are advanced to the thoracic arch. Intravenous heparin at 80 IU/kg are administered, and the activated clotting time is maintained at 200 to 250 seconds. These guidewires provide the necessary support for the subsequent introduction of the large-diameter delivery catheters and devices. In the absence of special anatomic considerations, the primary device is inserted through the right side and the contralateral iliac limb is inserted through the left side. After administration of heparin,

the delivery catheter or the introducer sheath is advanced to the L1-L2 vertebral space, which typically marks the location of the renal arteries. An angiographic catheter is advanced from the contralateral femoral artery to the same level.

A road-mapping aortogram is obtained to localize the renal arteries. The primary device is rotated to the desired orientation and deployed immediate below the lowest renal artery (Fig. 23-33). The angiographic catheter is replaced with a directional catheter and an angled guidewire, and the opening for the contralateral limb on the main device is cannulated. Intrastent passage of the guidewire is confirmed, and the angled guidewire is replaced with a stiff guidewire. The contralateral iliac limb is inserted into the docking opening of the primary device and deployed. A completion angiogram is performed looking for patency of the renal and hypogastric arteries, the device limbs, proximal and distal fixation, and endoleak. Adjunctive interventions including additional devices, balloons, and bare stents are performed as needed. The procedure is concluded with routine repairs of the femoral arteries and closure of the groin incisions. The patients recover in the recovery room for 2 to 4 hours and admitted to the general care floor. Although in the past, patients

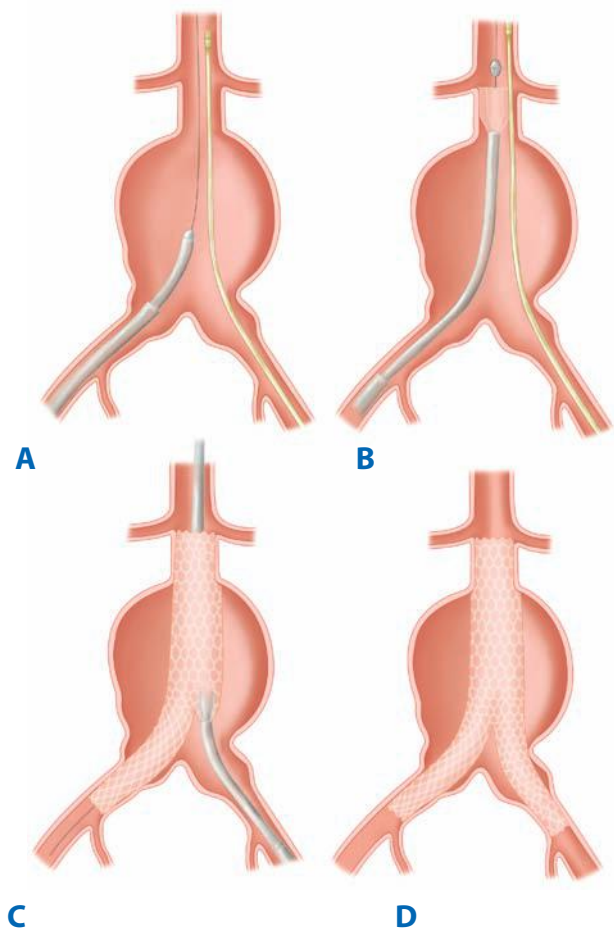


Figure 23-33. **A.** During an endovascular aortic aneurysm repair, the main endograft device is inserted through a femoral artery approach. **B.** The device is deployed in the aorta just below the renal arteries. **C.** A contralateral iliac endograft device is inserted through a contralateral gate opening, which is next deployed. **D.** Completion of deployment of the endograft device should fully exclude an aortic aneurysm while preserving flow of the renal and hypogastric arteries.

were admitted to the intensive care unit, this is rarely needed. Most patients can be started on a regular diet that evening and discharged the next morning.

Surveillance Following Endovascular Aortic Aneurysm Repair. Life-long follow-up is essential to the long-term success after endovascular AAA repair. Indeed, one may go so far as to say that absence of appropriate follow-up is tantamount to not having had a repair at all. A triple-phase (noncontrast, contrast, and delayed) spiral CT scan and a four-view (anteroposterior, lateral, and two obliques) abdominal x-ray should be obtained within the first month. Subsequent imaging can be obtained at 6-month intervals in the first 1 to 2 years and yearly thereafter. After the first 6 months, patients who cannot travel easily may obtain their studies locally and submit them for review. The CT scan is for detection of endoleaks, subtle proximal migrations, and changes in aneurysm size. The abdominal x-ray gives a “birds-eye” view of the overall morphology of the stent graft. Subtle changes in conformation of the iliac limbs relative to each other and/or the spine can provide early signs of impending component separation or loss of fixation. Further, stent fractures and/or suture breaks that can compromise long-term device integrity can sometimes only be detected on a plain film and not on a CT scan.

Results from Clinical Studies Comparing Endovascular versus Open Repair

The primary success rate after endovascular repair of AAA has been reported to be as high as 95%.^{18,59} The less invasive nature of this procedure is appealing to many physicians and patients. In addition, virtually all reports indicate a decreased blood loss, transfusion requirements, and length of intensive care unit and hospital stay for endovascular repair of AAAs compared with the standard surgical approach.^{18,59,74} With the advent of bifurcated grafts and improved delivery systems in the future, the only real limitation will be cost. When evaluating the literature for results from clinical series, it is important to look at a comparison of endoluminal versus open repair and device-specific outcome and cost analysis studies.

Early reports on results with endovascular repair were often flawed due to selection biases. This is because from its inception, endovascular repair has been used mostly in patients who are at higher risk for open repair. At the same time, only patients with favorable anatomy including less tortuosity and the presence of a suitable infrarenal neck were considered for endovascular repair. Randomization is also difficult because most patients who anatomically qualify for endovascular repair would withdraw from the study if randomized to open repair. Consequently, there are very few randomized controlled trials that have compared outcomes in patients with similar risk factors and anatomy who are eligible for both types of repair. Two such European trials have recently published short-term outcome data that are unbiased in design.

The DREAM trial is a multicenter randomized trial that compared open versus endovascular repair among a group of 345 patients at 28 European centers using multiple different devices including Gore, AneuRx, and Zenith.⁷⁵ Patients were included only if they were considered to be candidates for both types of repairs. The operative mortality rate was 4.6% in the operative group versus 1.2% in the endoluminal group at 30 days. When looking at the combined rate of operative mortality and severe complications, there was an incidence of 9.8% in the open repair group versus 4.7% in the endoluminal group.

The difference here was largely due to the higher frequency of pulmonary complications seen in the open group. There was a higher incidence of graft-related complications in the endoluminal group. There was no difference in the nonvascular local complication rate among the two groups. The Endovascular Repair-1 (EVAR-1) trial is also a multicenter randomized trial that compared open to endoluminal repair.⁷⁴ This study was conducted on 1082 patients at 34 centers in the United Kingdom using all available devices. Short-term mortality at 30 days was 4.7% in the open group and 1.7% in the endoluminal group. The in-hospital mortality rate was also increased in the open when compared to the endoluminal group (6.2% vs. 2.1%). As expected, the secondary intervention rate was higher in the endoluminal group (9.8% vs. 5.8%). Complication rates were not reported in the EVAR-1 trial. Criticisms can be applied to both of these trials. Patients had to be eligible for either type of repair in order to be included in the study. Consequently, these findings cannot be generalized to patients who are too sick to undergo open surgery or to patients whose anatomy precludes them from undergoing endovascular repair.

The Open Versus Endovascular Repair (OVER) Veterans Affairs Cooperative Study Group randomly assigned 881 patients with asymptomatic AAAs who were candidates for both procedures to either endovascular repair (n = 444) or open repair (n = 437) and followed them for up to 9 years.⁷⁶ Reduction in perioperative mortality with endovascular repair was sustained at 3 years but not thereafter. There was no difference in primary outcome of all-cause mortality. Endovascular repair and open repair resulted in similar long-term survival. Six aneurysm ruptures were confirmed in the endovascular repair group versus none in the open repair group. Rupture after endovascular repair remains a concern. A significant interaction was observed between age and type of treatment. Endovascular repair led to increased long-term survival among younger patients but not among older patients, for whom a greater benefit from the endovascular approach had been expected.

Device-Specific Outcome. Matsumura and associates compared endoluminal versus open repair using the Excluder device.⁷⁷ In their review, they demonstrated a 30-day mortality rate of 1% along with endoleak rates of 17% and 20% at 1- and 2-year intervals, respectively.⁷⁷ The limb narrowing, limb migration, and trunk migration were all 1% at 2 years. There were no deployment failures or early conversions. There was an annual 7% reintervention rate. Aneurysm growth was demonstrated in 14% of patients at 2 years. The Zenith device by Cook has been studied by Greenberg and associates, who compared standard surgical repair with endoluminal repair in low-risk patients and endoluminal repair in high-risk patients.⁷⁸ They reported a 30-day mortality rate of 3.5%, which was equal to the open group. The endoleak rates were 7.4% and 5.4% at 1- and 2-year intervals, respectively. There was a 5.3% migration of 5 mm at 1 year. Freedom from rupture was 100% in the low-risk group and 98.9% in the high-risk endoluminal group at 2 years. Experience with the AneuRx device has been reported by Zarins.⁷⁹ In this 4-year review, they found a 30-day mortality rate of 2.8%. Endoleak rate at 4 years was 13.9%, aneurysm enlargement was 11.5%, and stent graft migration was 9.5%. Freedom from rupture was noted to be 98.4% at 4 years. Criado and associates have reported on their 1-year experience with the Talent LPS device by Medtronic.⁸⁰ They report a 30-day mortality rate of 0.8%. Endoleak rate was 10%. Three deployment failures were noted, and freedom from rupture was 100%.

Aneurysm growth and migration rates were divided into three different neck size groups. Patients with a wide neck (>26 mm) had a 3% growth and migration rate. Narrow-neck patients (<26 mm) had a 1% growth rate and a 2% migration neck. Interestingly, short-neck patients (<15 mm) had no aneurysm growths and a 2% migration rate.

Cost Analysis. The current climate of cost containment and limited reimbursement for healthcare services mandates a critical analysis of the economic impact of any new medical technology on the market. The in-hospital costs for both endovascular and open repair include graft cost, operating room fees, radiology, pharmacy, ancillary care, intensive care unit charges, and floor charges. Despite the improved morbidity and mortality rates, several early studies have reported no cost benefit with the application of endovascular repair.^{81,82} The limiting factor appears to be the cost of the device. Despite commercialization of endovascular repair, the device costs are still in the range of \$5000 to \$6000 with no signs of abating. A recent report by Angle and associated further corroborates previous studies.⁸³ In their review, despite decreased hospital and intensive care unit stays and utilization of pharmacy and respiratory services, cost of endovascular repair was 1.74 times greater than the standard surgical approach. In addition, these cost analysis studies are centered on in-hospital costs and do not even begin to address secondary costs such as postoperative surveillance that is required with endovascular repair. In the OVER trial, endovascular repair was found to be a cost-effective alternative to open repair in the U.S. Veterans Affairs healthcare system for at least the first 2 years.⁸⁴ The primary outcomes were mean total healthcare cost per life-year and per quality-adjusted life-year. There were no differences found in survival, quality of life, and costs after 2 years between the endovascular and the open group. Although graft costs were higher in the endovascular group, length of stay was shorter, resulting in lower cost of AAA repair hospitalization in the endovascular group. Costs remained lower after 2 years in the endovascular group, but the difference was no longer significant.

Classification and Management of Endoleak

An endoleak is an extravasation of contrast outside the stent graft and within the aneurysm sac (Fig. 23-34). It can be present in up to 20% to 30% of all endovascular AAA repairs in the early postoperative period.⁸⁵ In general, over half of these endoleaks will resolve spontaneously during the first 6 months, resulting in a 10% incidence of chronic endoleaks in all cases

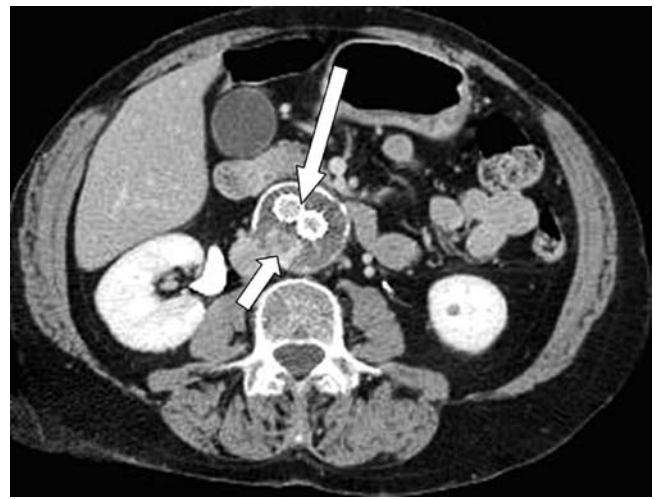


Figure 23-35. A computed tomography scan demonstrating an endoleak (*small arrow*) as evidenced by contrast flow outside the aortic endograft (*long arrow*).

beyond the first year of follow-up. Endoleaks can be detected using conventional angiography, contrast CT (Fig. 23-35), MRA, and color-flow duplex ultrasound. Although there is no recognized gold standard, in practice, angiography is considered the least sensitive but most specific for characterizing the source of the endoleak, whereas the CT scan is the most sensitive but least specific. Widespread availability and reliability that is relatively independent of technique have made the CT scan the de facto standard imaging modality for postoperative surveillance. Conversely, routine use of duplex ultrasound and MRA has been limited by the lack of proper equipment and local expertise. On the other hand, investigational techniques such as time-resolved MRA may provide greater sensitivity and specificity than either angiography or CT in the future.

Four types of endoleaks have been described (Table 23-10). Type I endoleak refers to fixation-related leaks that occur at the proximal or distal attachment sites. These represent less than 5% of all endoleaks and are seen as an early blush of contrast into the aneurysm sac from the proximal or distal ends of the device during completion angiography.^{85,86} Although seen as marker of poor patient selection or inadequate repair, over 80% of these leaks spontaneously seal in the first 6 months. Persistent type I endoleaks, on the other hand, require prompt treatment. Type II

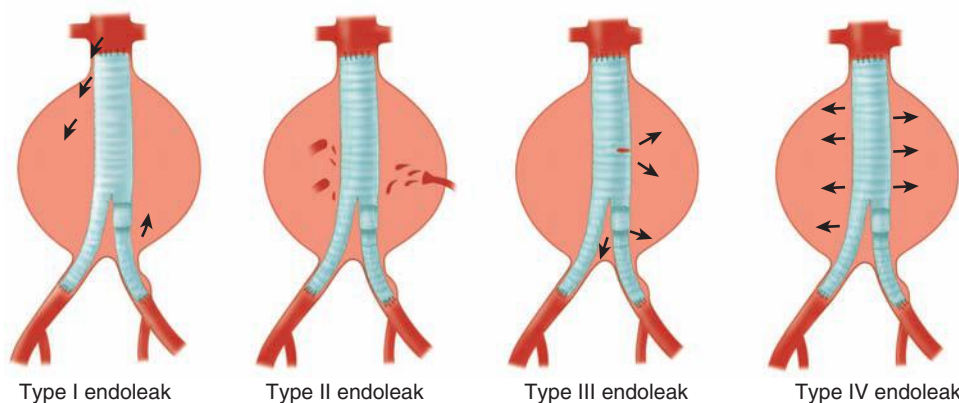


Figure 23-34. The four types of endoleak include the following: type I endoleak = attachment site leak; type II endoleak = side branch leak caused by lumbar or side branches; type III endoleak = endograft junctional leak due to overlapping device components; and type IV endoleak = endograft fabric or porosity leak.

Table 23-10

Endoleak classification

CLASSIFICATION	DESCRIPTION
Type I endoleak	Attachment site leak
Type II endoleak	Side branch leak caused by lumbar or inferior mesenteric arteries
Type III endoleak	Junctional leak (of overlapping endograft components) and graft fabric defect
Type IV endoleak	Endograft fabric porosity leak

endoleak refers to retrograde flow originating from a lumbar, inferior mesenteric, accessory renal, or hypogastric artery. They are the most common type of endoleak, accounting for 20% to 30% of all cases, and about half resolve spontaneously. On angiography, they are seen as a late filling of the aneurysm sac from a branch vessel(s). Type II endoleaks carry a relatively benign natural history and do not merit intervention unless associated with aneurysm growth. Type III endoleaks refer to failure of device integrity or component separation from modular systems. If detected intraoperatively or in the early perioperative period, it is usually from inadequate overlap between two stent grafts, whereas in the late period, the endoleak may be from a fabric tear or junctional separation from conformational changes of the aneurysm. Regardless of the etiology or timing, these should be promptly repaired. Finally, type IV endoleak refers to the diffuse, early blush seen during completion angiography due to graft porosity and/or suture holes of some Dacron-based devices. It does not have any clinical significance and usually cannot be seen after 48 hours and heparin reversal. Endoleaks that are initially considered type IV but persist become type III endoleaks by definition, because this indicates a more significant material defect than simple porosity or a suture hole.

Endotension Following Endovascular Aortic Aneurysm Repair. In approximately 5% of cases after an apparently successful endovascular repair, the aneurysm continues to grow without any demonstrable endoleak.⁸⁷ This phenomenon has been described as endotension. Although it was initially thought that an endoleak was really present but simply not detected, case have been reported where the aneurysm has been surgically opened and the contents were completely devoid of any blood and no extravasation could be found. The mechanism of continued pressurization of the aneurysm sac following successful exclusion from the arterial circulation remains unsolved at this time. One putative mechanism has been linked to a transudative process related to certain expanded PTFE graft materials.⁸⁸ More importantly, however, the natural history of these enlarging aneurysms without endoleaks is unknown, but to date, there has been no evidence to suggest that they carry an increased risk of rupture. Conservatively speaking, until further long-term data become available, if the patient is a suitable surgical risk, elective open conversion should be considered.

Secondary Interventions Following Endovascular Aortic Aneurysm Repair. There is approximately 10% to 15% per year risk of secondary interventions following endovascular AAA repair.^{18,78,89} These procedures are critical in the long-term

success of the primary procedure in prevention of aneurysm rupture and aneurysm-related death. These secondary procedures, in order of frequency, include proximal or distal extender placement for migrations, highly selective or translumbar embolization for type II endoleaks, direct surgical or laparoscopic branch vessel ligations, bridging cuffs for component separations, and late open surgical conversions.

Multiple large series have reported that an annual rupture rate of approximately 1% to 1.5% per year after endovascular repair.^{18,78,89} The EUROSTAR registry reports a rupture rate of 2.3% over 15.4 months in patients with an endoleak, compared with 0.3% in those without.⁹⁰ Various causes of late ruptures have been reported in the literature, although presence of a persistent endoleak with aneurysm enlargement remains a common culprit for this complication. It has been shown that even successfully excluded aneurysms can lead to the development of attachment-site leaks and device failure, caused in part by aneurysm remodeling resulting in stent migration or kinking.⁹¹ Mehta and colleagues reported that 63% of delayed AAA ruptures after endovascular repair were caused by type I endoleaks with endograft migration, 11% by type I without migration, 19% by type II, and the rest of unknown type.⁹²

Treatment of rupture may be open conversion or endovascular stent graft placement. May and associates reported a mortality rate of 43% in those patients who underwent open conversion.⁹³ Emergent endovascular repair should be considered in these patients since it is potentially much faster and less likely to cause physiologic stress than open conversion. Several reports have shown that endovascular repair can be performed successfully in patients previously treated with endoluminal prostheses.^{94,95}

MESENTERIC ARTERY DISEASE

Vascular occlusive disease of the mesenteric vessels is a relatively uncommon but potentially devastating condition that generally presents in patients over 60 years of age, is three times more frequent in women, and has been recognized as an entity since 1936.⁹⁶ The incidence of such a disease is low and represents 2% of the revascularization operations for atheromatous lesions. The most common cause of mesenteric ischemia is atherosclerotic vascular disease. Autopsy studies have demonstrated splanchnic atherosclerosis in 35% to 70% of cases.⁹⁷ Other etiologies exist and include FMD, panarteritis nodosa, arteritis, and celiac artery compression from a median arcuate ligament, but they are unusual and have an incidence of one in nine compared with that of atherosclerosis.

Chronic mesenteric ischemia is related to a lack of blood supply in the splanchnic region and is caused by disease in one or more visceral arteries: the celiac trunk, the superior mesenteric artery, and the IMA. Mesenteric ischemia is thought to occur when two of the three visceral vessels are affected with severe stenosis or occlusion; however, in as many as 9% of cases, only a single vessel is involved (SMA in 5% and celiac trunk in 4% of cases).⁹⁸ This disease process may evolve in a chronic fashion, as in the case of progressive luminal obliteration due to atherosclerosis. On the other hand, mesenteric ischemia can occur suddenly, as in the case of thromboembolism. Despite recent progress in perioperative management and better understanding of pathophysiology, mesenteric ischemia is considered one of the most catastrophic vascular disorders with mortality rates ranging from 50% to 75%. Delays in diagnosis

and treatment are the main contributing factors in its high mortality. It is estimated that mesenteric ischemia accounts for 1 in every 1000 hospital admissions in this country. The prevalence is rising due in part to the increased awareness of this disease, the advanced age of the population, and the significant comorbidity of these elderly patients. Early recognition and prompt treatment before the onset of irreversible intestinal ischemia are essential to improve the outcome.

Anatomy and Pathophysiology

Mesenteric arterial circulation is remarkable for its rich collateral network. Three main mesenteric arteries provide the arterial perfusion to the gastrointestinal system: the celiac artery (CA), the superior mesenteric artery (SMA), and the IMA. In general, the CA provides arterial circulation to the foregut (distal esophagus to duodenum), hepatobiliary system, and spleen; the SMA supplies the midgut (jejunum to mid-colon); and the IMA supplies the hindgut (mid-colon to rectum). The CA and SMA arise from the ventral surface of the infradiaphragmatic suprarenal abdominal aorta, whereas the IMA originates from the left lateral portion of the infrarenal aorta. These anatomic origins in relation to the aorta are important when a mesenteric angiogram is performed to determine the luminal patency. In order to fully visualize the origins of the CA and SMA, it is necessary to perform both an anteroposterior and a lateral projection of the aorta since most arterial occlusive lesions occur in the proximal segments of these mesenteric trunks.

Because of the abundant collateral flow between these mesenteric arteries, progressive diminution of flow in one or even two of the main mesenteric trunks is usually tolerated, provided that uninvolved mesenteric branches can enlarge over time to provide sufficient compensatory collateral flow. In contrast, acute occlusion of a main mesenteric trunk may result in profound ischemia due to lack of sufficient collateral flow. Collateral networks between the CA and the SMA exist primarily through the superior and inferior pancreaticoduodenal arteries. The IMA may provide collateral arterial flow to the SMA through the marginal artery of Drummond, the arc of Riolan, and other unnamed retroperitoneal collateral vessels termed meandering mesenteric arteries (Fig. 23-36). Lastly, collateral visceral vessels may provide important arterial flow to the IMA and the hindgut through the hypogastric arteries and the hemorrhoidal arterial network.

Regulation of mesenteric blood flow is largely modulated by both hormonal and neural stimuli, which characteristically regulate systemic blood flow. In addition, the mesenteric circulation responds to the gastrointestinal contents. Hormonal regulation is mediated by splanchnic vasodilators, such as nitric oxide, glucagon, and vasoactive intestinal peptide. Certain intrinsic vasoconstrictors, such as vasopressin, can diminish the mesenteric blood flow. On the other hand, neural regulation is provided by the extensive visceral autonomic innervation.

Clinical manifestation of mesenteric ischemia is predominantly postprandial abdominal pain, which signifies that the increased oxygen demand of digestion is not met by the gastrointestinal collateral circulation. The postprandial pain frequently occurs in the mid-abdomen, suggesting that the diversion of blood flow from the SMA to supply the stomach impairs perfusion to the small bowel. This leads to transient anaerobic metabolism and acidosis. Persistent or profound mesenteric ischemia will lead to mucosal compromise with release of intracellular contents and by-products of anaerobic metabolism to

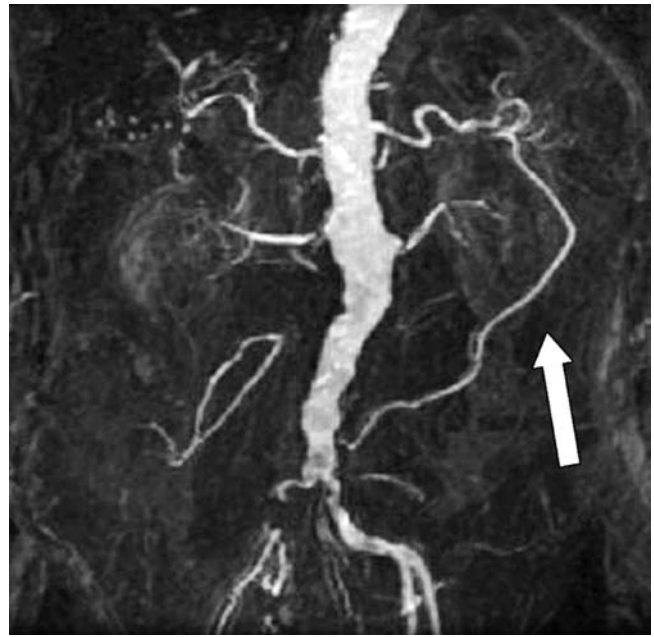

Figure 23-36. An aortogram showing a prominent collateral vessel, which is the arc of Riolan (*arrow*) in a patient with an inferior mesenteric artery (IMA) occlusion. This vessel network provides collateral flow between the superior mesenteric artery and IMA.

the splanchnic and systemic circulation. Injured bowel mucosa allows unimpeded influx of toxic substances from the bowel lumen with systemic consequences. If full-thickness necrosis occurs in the bowel wall, intestinal perforation ensues, which will lead to peritonitis. Concomitant atherosclerotic disease in cardiac or systemic circulation frequently compounds the diagnostic and therapeutic complexity of mesenteric ischemia.

Types of Mesenteric Artery Occlusive Disease

There are three major mechanisms of visceral ischemia involving the mesenteric arteries: (a) acute mesenteric ischemia, which can be either embolic or thrombotic in origin; (b) chronic mesenteric ischemia; and (c) nonocclusive mesenteric ischemia. Despite the variability of these syndromes, a common anatomic pathology is involved in these processes. The superior mesenteric artery (SMA) is the most commonly involved vessel in acute mesenteric ischemia. Acute thrombosis occurs in patients with underlying mesenteric atherosclerosis, which typically involves the origin of the mesenteric arteries while sparing the collateral branches. In acute embolic mesenteric ischemia, the emboli typically originate from a cardiac source and frequently occur in patients with atrial fibrillation or following myocardial infarction (Figs. 23-37 and 23-38). Nonocclusive mesenteric ischemia is characterized by a low flow state in otherwise normal mesenteric arteries and most frequently occurs in critically ill patients on vasopressors. Finally, chronic mesenteric ischemia is a functional consequence of a long-standing atherosclerotic process that typically involves at least two of the three main mesenteric vessels. The gradual development of the occlusive process allows the development of collateral vessels that prevent the manifestations of acute ischemia, but are not sufficient to meet the high postprandial intestinal oxygen requirements, giving rise to the classical symptoms of postprandial abdominal pain and the resultant food fear.

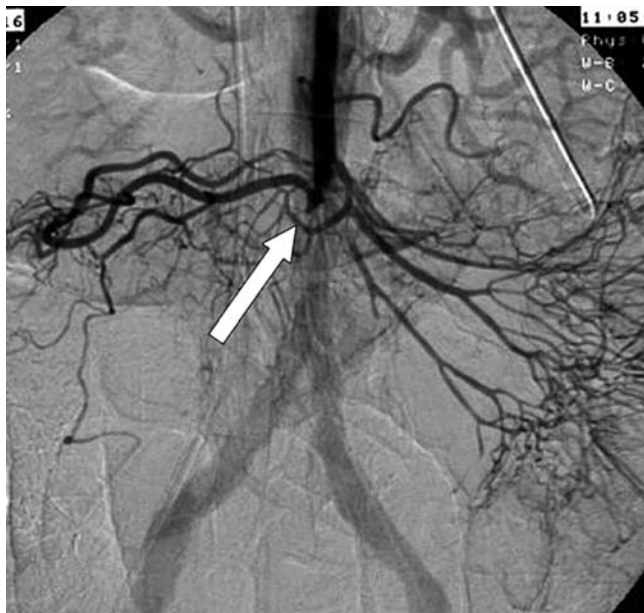


Figure 23-37. An anteroposterior view of a selective superior mesenteric artery angiogram shows an abrupt cutoff of the middle colic artery, which was caused by emboli (*arrow*) due to atrial fibrillation.

Several less common syndromes of visceral ischemia involving the mesenteric arteries can also cause serious debilitation. Chronic mesenteric ischemic symptoms can occur due to extrinsic compression of the celiac artery by the diaphragm, which is termed median arcuate ligament syndrome or celiac artery compression syndrome. Acute visceral ischemia may occur following an aortic operation, due to ligation of the IMA in the absence of adequate collateral vessels. Furthermore, acute visceral ischemia may develop in aortic dissection, which involves the mesenteric arteries, or after coarctation repair. Finally, other unusual causes of ischemia include mesenteric arteritis, radiation arteritis, and cholesterol emboli.

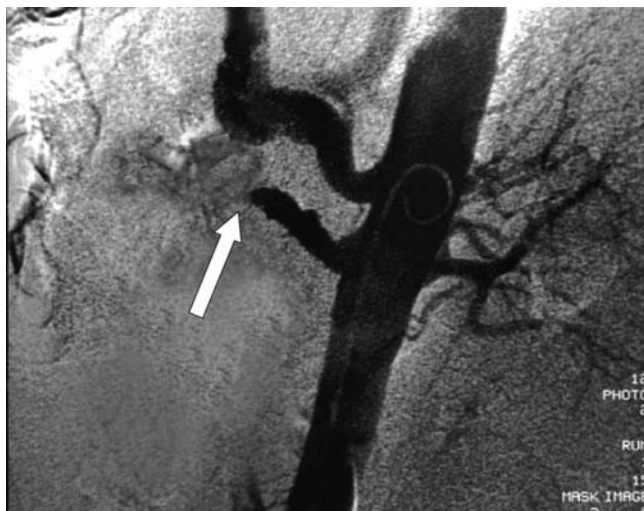

Figure 23-38. A lateral mesenteric angiogram showing an abrupt cutoff of the proximal superior mesenteric artery (SMA), which is consistent with SMA embolism (*arrow*).

Clinical Manifestations

Abdominal pain out of proportion to physical findings is the classic presentation in patients with acute mesenteric ischemia and occurs following an embolic or thrombotic ischemic event of the SMA. Other manifestations include sudden onset of abdominal cramps in patients with underlying cardiac or atherosclerotic disease, often associated with bloody diarrhea, as a result of mucosal sloughing secondary to ischemia. Fever, nausea, vomiting, and abdominal distention are some common but nonspecific manifestations. Diffuse abdominal tenderness, rebound, and rigidity are late signs and usually indicate bowel infarction and necrosis.

Clinical manifestations of chronic mesenteric ischemia are more subtle due to the extensive collateral development. However, when intestinal blood flow is unable to meet the physiologic gastrointestinal demands, mesenteric insufficiency ensues. The classical symptoms include postprandial abdominal pain, food fear, and weight loss. Persistent nausea and occasionally diarrhea may coexist. Diagnosis remains challenging, and most of the patients will undergo an extensive and expensive gastrointestinal tract workup for the above symptoms prior to referral to a vascular service.

The typical patient who develops nonocclusive mesenteric ischemia is an elderly patient who has multiple comorbidities, such as congestive heart failure, acute myocardial infarction with cardiogenic shock, hypovolemic or hemorrhagic shock, sepsis, pancreatitis, and administration of digitalis or vasoconstrictor agents such as epinephrine. Abdominal pain is only present in approximately 70% of these patients. When present, the pain is usually severe but may vary in location, character, and intensity. In the absence of abdominal pain, progressive abdominal distention with acidosis may be an early sign of ischemia and impending bowel infarction.

Abdominal pain due to narrowing of the origin of the CA may occur as a result of extrinsic compression or impingement by the median arcuate ligament (Fig. 23-39). This condition is known as celiac artery compression syndrome or median arcuate ligament syndrome. Angiographically, there is CA compression that augments with deep expiration and poststenotic dilatation. The celiac artery compression syndrome has been implicated in some variants of chronic mesenteric ischemia. Most patients are young females between 20 and 40 years of age. Abdominal symptoms are nonspecific, but the pain is localized in the upper abdomen, which may be precipitated by meals.

Diagnostic Evaluation

The differential diagnosis of acute mesenteric ischemia includes other causes of severe abdominal pain of acute onset, such as perforated viscus, intestinal obstruction, pancreatitis, cholecystitis, and nephrolithiasis. Laboratory evaluation is neither sensitive nor specific in distinguishing these various diagnoses. In the setting of mesenteric ischemia, complete blood count may reveal hemoconcentration and leukocytosis. Metabolic acidosis develops as a result of anaerobic metabolism. Elevated serum amylase may indicate a diagnosis of pancreatitis but is also common in the setting of intestinal infarction. Finally, increased lactate levels, hyperkalemia, and azotemia may occur in the late stages of mesenteric ischemia.

Plain abdominal radiographs may provide helpful information to exclude other causes of abdominal pain such as intestinal obstruction, perforation, or volvulus, which may exhibit symptoms mimicking intestinal ischemia. Pneumoperitoneum,

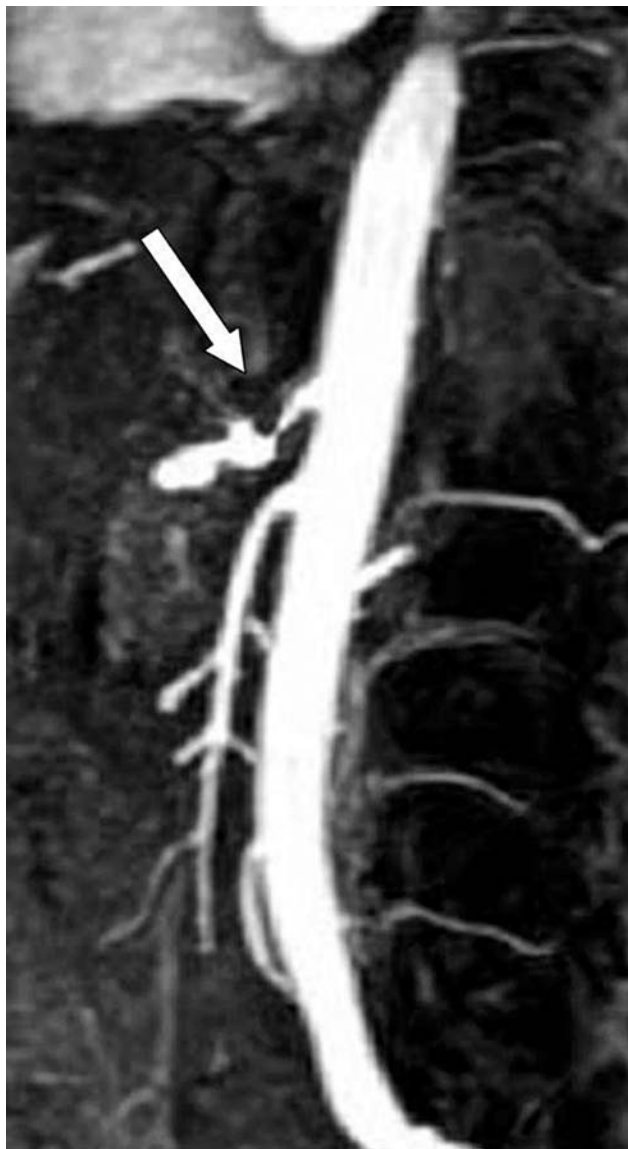

Figure 23-39. A lateral projection of the magnetic resonance angiography of the aorta showing a chronic compression of the celiac artery by the median arcuate ligament (*arrow*).

pneumatosis intestinalis, and gas in the portal vein may indicate infarcted bowel. In contrast, radiographic appearance of an adynamic ileus with a gasless abdomen is the most common finding in patients with acute mesenteric ischemia.

Upper endoscopy, colonoscopy, or barium radiography does not provide any useful information when evaluating acute mesenteric ischemia. Moreover, barium enema is contraindicated if the diagnosis of mesenteric ischemia is being considered. The intraluminal barium can obscure accurate visualization of mesenteric circulation during angiography. In addition, intraperitoneal leakage of barium can occur in the setting of intestinal perforation, which can lead to added therapeutic challenges during mesenteric revascularization.

Diagnosis of chronic mesenteric ischemia can be more challenging. Usually prior to the evaluation by a vascular service, the patients have undergone an extensive workup for the symptoms of chronic abdominal pain, weight loss, and anorexia. Rarely, the vascular surgeon is the first to encounter a patient with the above symptoms. In this situation, it is advisable to

keep in mind that mesenteric ischemia is a rare entity and that a full diagnostic workup that should include CT scan of the abdomen and evaluation by gastroenterologist should be performed. Mesenteric occlusive disease may coexist with malignancy, and symptoms of mesenteric vessel stenosis may be the result of extrinsic compression by a tumor.

Duplex ultrasonography is a valuable noninvasive means of assessing the patency of the mesenteric vessels. Moneta and associates evaluated the use of duplex ultrasound in the diagnosis of mesenteric occlusive disease in a blinded prospective study.^{99,100} A peak systolic velocity in the SMA >275 cm/s demonstrated a sensitivity of 92%, specificity of 96%, and overall accuracy of 96% for detecting $>70\%$ stenosis. The same authors found sensitivity and specificity of 87% and 82%, respectively, with an accuracy of 82% in predicting $>70\%$ celiac trunk stenosis. Duplex has been successfully used for follow-up after open surgical reconstruction or endovascular treatment of the mesenteric vessels to assess recurrence of the disease. Finally, spiral CT with three-dimensional reconstruction (Fig. 23-40) and MRA (Fig. 23-41) have been promising in providing clear radiographic assessment of the mesenteric vessels.

The definitive diagnosis of mesenteric vascular disease is made by biplanar mesenteric arteriography, which should be performed promptly in any patient with suspected mesenteric occlusion. It typically shows occlusion or near-occlusion of the CA and SMA at or near their origins from the aorta. In most

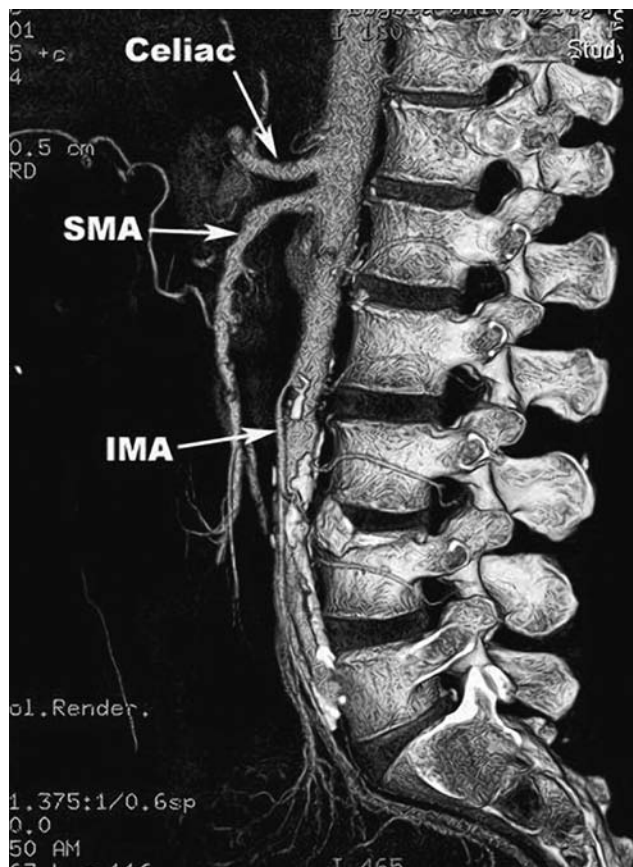


Figure 23-40. Computed tomography angiogram of the abdomen with three-dimensional reconstruction provides a clear view of the celiac artery, superior mesenteric artery (SMA), and inferior mesenteric artery (IMA).

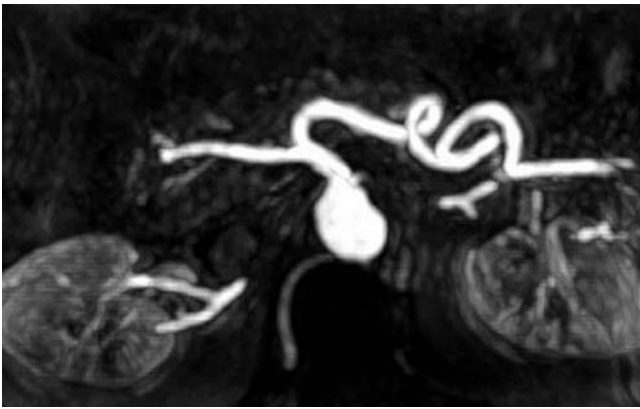


Figure 23-41. A cross-sectional view of a magnetic resonance angiogram provides a clear view of the luminal patency of the superior mesenteric artery.

cases, the IMA has been previously occluded secondary to diffuse infrarenal aortic atherosclerosis. The differentiation of the different types of mesenteric arterial occlusion may be suggested with biplanar mesenteric arteriogram. Mesenteric emboli typically lodge at the orifice of the middle colic artery, which creates a “meniscus sign” with an abrupt cutoff of a normal proximal SMA several centimeters from its origin on the aorta. Mesenteric thrombosis, in contrast, occurs at the most proximal SMA, which tapers off at 1 to 2 cm from its origin. In the case of chronic mesenteric occlusion, the appearance of collateral circulation is typically present. Nonocclusive mesenteric ischemia produces an arteriographic image of segmental mesenteric vasospasm with a relatively normal-appearing main SMA trunk (Fig. 23-42).

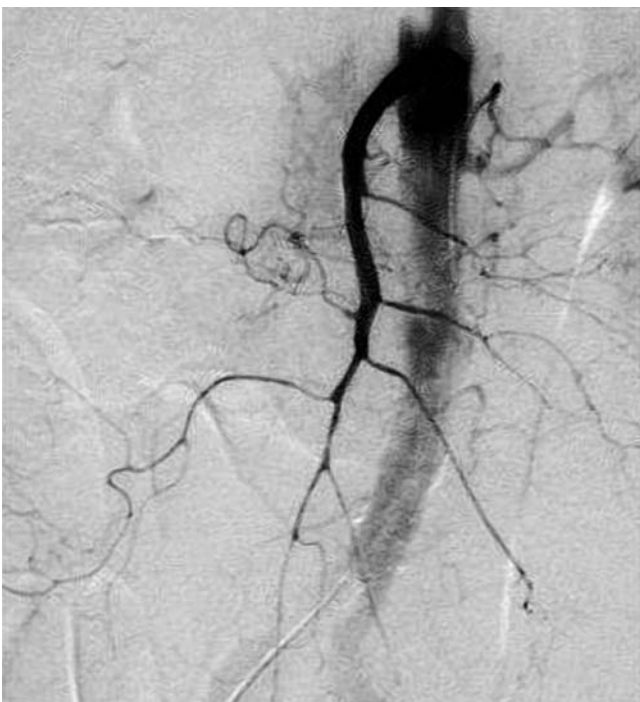

Figure 23-42. Mesenteric arteriogram showing nonocclusive mesenteric ischemia as evidenced by diffuse spasm of intestinal arcades with poor filling of intramural vessels.

Mesenteric arteriography can also play a therapeutic role. Once the diagnosis of nonocclusive mesenteric ischemia is made on the arteriogram, an infusion catheter can be placed at the SMA orifice, and vasodilating agents, such as papaverine, can be administered intra-arterially. The papaverine infusion may be continued postoperatively to treat persistent vasospasm, a common occurrence following mesenteric reperfusion. Transcatheter thrombolytic therapy has little role in the management of thrombotic mesenteric occlusion. Although thrombolytic agents may transiently recannulate the occluded vessels, the underlying occlusive lesions require definitive treatment. Furthermore, thrombolytic therapy typically requires a prolonged period of time to restore perfusion, during which the intestinal viability will be difficult to assess.

A word of caution would be appropriate here regarding patients with typical history of chronic intestinal angina who present with an acute abdomen and classical findings of peritoneal irritation. Arteriography is the gold standard for the diagnosis of mesenteric occlusive disease; however, it can be a time-consuming diagnostic modality. In this group of patients, immediate exploration for assessment of intestinal viability and vascular reconstruction is the best choice.

Surgical Repair

Acute Embolic Mesenteric Ischemia. Initial management of patients with acute mesenteric ischemia includes fluid resuscitation and systemic anticoagulation with heparin to prevent further thrombus propagation. Significant metabolic acidosis not responding to fluid resuscitation should be corrected with sodium bicarbonate. A central venous catheter, peripheral arterial catheter, and Foley catheter should be placed for hemodynamic status monitoring. Appropriate antibiotics are given prior to surgical exploration. The operative management of acute mesenteric ischemia is dictated by the cause of the occlusion. It is helpful to obtain a preoperative mesenteric arteriogram to confirm the diagnosis and to plan appropriate treatment options. However, the diagnosis of mesenteric ischemia frequently cannot be established prior to surgical exploration, and therefore, patients in a moribund condition with acute abdominal symptoms should undergo immediate surgical exploration, avoiding the delay required to perform an arteriogram.

The primary goal of surgical treatment in embolic mesenteric ischemia is to restore arterial perfusion with removal of the embolus from the vessel. The abdomen is explored through a midline incision, which often reveals variable degrees of intestinal ischemia from the mid-jejunum to the ascending or transverse colon. The transverse colon is lifted superiorly, and the small intestine is reflected toward the right upper quadrant. The SMA is approached at the root of the small bowel mesentery, usually as it emerges from beneath the pancreas to cross over the junction of the third and fourth portions of the duodenum. Alternatively, the SMA can be approached by incising the retroperitoneum lateral to the fourth portion of the duodenum, which is rotated medially to expose the SMA. Once the proximal SMA is identified and controlled with vascular clamps, a transverse arteriotomy is made to extract the embolus, using standard balloon embolectomy catheters. In the event the embolus has lodged more distally, exposure of the distal SMA may be obtained in the root of the small bowel mesentery by isolating individual jejunal and ileal branches to allow a more comprehensive thromboembolectomy. Following the restoration of SMA flow, an assessment of intestinal viability must be

made, and nonviable bowel must be resected. Several methods have been described to evaluate the viability of the intestine, which include intraoperative intravenous fluorescein injection and inspection with a Wood's lamp, and Doppler assessment of antimesenteric intestinal arterial pulsations. A second-look procedure should be considered in many patients and is performed 24 to 48 hours following embolectomy. The goal of the procedure is reassessment of the extent of bowel viability, which may not be obvious immediately following the initial embolectomy. If nonviable intestine is evident in the second-look procedure, additional bowel resections should be performed at that time.

Acute Thrombotic Mesenteric Ischemia. Thrombotic mesenteric ischemia usually involves a severely atherosclerotic vessel, typically the proximal CA and SMA. Therefore, these patients require a reconstructive procedure to the SMA to bypass the proximal occlusive lesion and restore adequate mesenteric flow. The saphenous vein is the graft material of choice, and prosthetic materials should be avoided in patients with nonviable bowel, due to the risk of bacterial contamination if resection of necrotic intestine is performed. The bypass graft may originate from either the aorta or iliac artery. Advantages from using the supraceliac infradiaphragmatic aorta as opposed to the infrarenal aorta as the inflow vessel include a smoother graft configuration with less chance of kinking and the absence of atherosclerotic disease in the supraceliac aortic segment. Exposure of the supraceliac aorta is technically more challenging and time consuming than that of the iliac artery, which unless calcified is an appropriate inflow. Patency rates are similar regardless of inflow vessel choice.¹⁰¹

Chronic Mesenteric Ischemia. The therapeutic goal in patients with chronic mesenteric ischemia is to revascularize mesenteric circulation and prevent the development of bowel infarction. Mesenteric occlusive disease can be treated successfully by either transaortic endarterectomy or mesenteric artery bypass. Transaortic endarterectomy is indicated for 3► ostial lesions of patent CA and SMA. A left medial rotation is performed, and the aorta and the mesenteric branches are exposed. A lateral aortotomy is performed encompassing both the CA and SMA orifices. The visceral arteries must be adequately mobilized so that the termination site of endarterectomy can be visualized. Otherwise, an intimal flap may develop, which can lead to early thrombosis or distal embolization.

For occlusive lesions located 1 to 2 cm distal to the mesenteric origin, mesenteric artery bypass should be performed. Multiple mesenteric arteries are typically involved in chronic mesenteric ischemia, and both the CA and SMA should be revascularized whenever possible. In general, bypass grafting may be performed either antegrade from the supraceliac aorta or retrograde from either the infrarenal aorta or iliac artery. Both autogenous saphenous vein grafts and prosthetic grafts have been used with satisfactory and equivalent success. An antegrade bypass also can be performed using a small-caliber bifurcated graft from the supraceliac aorta to both the CA and SMA, which yields an excellent long-term result.¹⁰¹

Celiac Artery Compression Syndrome. The decision to intervene in patients with CA compression syndrome should be based on both an appropriate symptom complex and the finding of celiac artery compression in the absence of other findings to explain the symptoms. The treatment goal is to release the ligamentous structure that compresses the proximal CA

and to correct any persistent stricture by bypass grafting. Some surgeons advocate careful celiac plexus sympathectomy in addition to arcuate ligament decompression to ensure good treatment outcome.¹⁰² The patient should be cautioned that relief of the celiac compression cannot be guaranteed to relieve the symptoms. In a number of reports on endovascular management of chronic mesenteric ischemia, the presence of CA compression syndrome has been identified as a major factor of technical failure and recurrence. Therefore, angioplasty and stenting should not be undertaken if extrinsic compression of the CA by the median arcuate ligament is suspected based on preoperative imaging studies. Open surgical treatment should be performed instead.^{103,104} A recent review of laparoscopic and open median arcuate ligament release cases in the literature by Jimenez and colleagues showed both approaches to be effective in symptom relief (85%), with no difference in late symptom recurrence rate (6.8% in the open group and 5.7% in the laparoscopic group).¹⁰⁵

Endovascular Treatment

Chronic Mesenteric Ischemia. Endovascular treatment of mesenteric artery stenosis or short segment occlusion by balloon dilatation or stent placement represents a less invasive therapeutic alternative to open surgical intervention, particularly in patients whose medical comorbidities place them at a high operative risk category. Endovascular therapy is also suited in patients with recurrent disease or anastomotic stenosis following previous open mesenteric revascularization. Prophylactic mesenteric revascularization is rarely performed in the asymptomatic patient undergoing an aortic procedure for other indications.¹⁰⁶ However, the natural history of untreated chronic mesenteric ischemia may justify revascularization in some minimally symptomatic or asymptomatic patients if the operative risks are acceptable, since the first clinical presentation may be acute intestinal ischemia in as many as 50% of the patients, with a mortality rate that ranges from 15% to 70%.¹⁰⁶ This is particularly true when the SMA is involved. Mesenteric angioplasty and stenting is particularly suitable for this patient subgroup given its low morbidity and mortality. Because of the limited experience with stent use in mesenteric vessels, appropriate indications for primary stent placement have not been clearly defined. Guidelines generally include calcified ostial stenoses, high-grade eccentric stenoses, chronic occlusions, and significant residual stenosis >30% or the presence of dissection after angioplasty. Restenosis after PTA is also an indication for stent placement.¹⁰⁷

Acute Mesenteric Ischemia. Catheter-directed thrombolytic therapy is a potentially useful treatment modality for acute mesenteric ischemia, which can be initiated with intra-arterial delivery of thrombolytic agent into the mesenteric thrombus at the time of diagnostic angiography. Various thrombolytic medications, including urokinase (Abbokinase; Abbott Laboratory, North Chicago, IL) or recombinant tissue plasminogen activator (Activase; Genentech, South San Francisco, CA), have been reported to be successful in a small series of case reports. Catheter-directed thrombolytic therapy has a higher probability of restoring mesenteric blood flow success when performed within 12 hours of symptom onset. Successful resolution of a mesenteric thrombus will facilitate the identification of the underlying mesenteric occlusive disease process. As a result, subsequent operative mesenteric revascularization or mesenteric balloon angioplasty and stenting may be performed

electively to correct the mesenteric stenosis. There are two main drawbacks with regard to thrombolytic therapy in mesenteric ischemia. Percutaneous catheter-directed thrombolysis does not allow the possibility to inspect the potentially ischemic intestine following restoration of the mesenteric flow. Additionally, a prolonged period of time may be necessary in order to achieve successful catheter-directed thrombolysis, due in part to serial angiographic surveillance to document thrombus resolution. An incomplete or unsuccessful thrombolysis may lead to delayed operative revascularization, which may further necessitate bowel resection for irreversible intestinal necrosis. Therefore, catheter-directed thrombolytic therapy for acute mesenteric ischemia should only be considered in selected patients under a closely scrutinized clinical protocol.

Nonocclusive Mesenteric Ischemia. The treatment of non-occlusive mesenteric ischemia is primarily pharmacologic with selective mesenteric arterial catheterization followed by infusion of vasodilatory agents, such as tolazoline or papaverine. Once the diagnosis is made on the mesenteric arteriography (see Fig. 23-42), intra-arterial papaverine is given at a dose of 30 to 60 mg/h. This must be coupled with the cessation of other vasoconstricting agents. Concomitant intravenous heparin should be administered to prevent thrombosis in the cannulated vessels. Treatment strategy thereafter is dependent on the patient's clinical response to the vasodilator therapy. If abdominal symptoms improve, mesenteric arteriography should be repeated to document the resolution of vasospasm. The patient's hemodynamic status must be carefully monitored during papaverine infusion as significant hypotension can develop in the event that the infusion catheter migrates into the aorta, which can lead to systemic circulation of papaverine. Surgical exploration is indicated if the patient develops signs of continued bowel ischemia or infarction as evidenced by rebound tenderness or involuntary guarding. In these circumstances, papaverine infusion should be continued intraoperatively and postoperatively. The operating room should be kept as warm as possible, and warm irrigation fluid and laparotomy pads should be used to prevent further intestinal vasoconstriction during exploration.

Techniques of Endovascular Interventions. To perform endovascular mesenteric revascularization, intraluminal access is performed via a femoral or brachial artery approach. Once an introducer sheath is placed in the femoral artery, an anteroposterior and lateral aortogram just below the level of the diaphragm is obtained with a pigtail catheter to identify the origin of the CA and SMA. Initial catheterization of the mesenteric artery can be performed using a variety of selective angled catheters, which include the RDC, Cobra-2, Simmons I (Boston Scientific/Meditech, Natick, MA), or SOS Omni catheter (Angiodynamics, Queensbury, NY). Once the mesenteric artery is cannulated, systemic heparin (5000 IU) is administered intravenously. A selective mesenteric angiogram is then performed to identify the diseased segment, which is followed by the placement of a 0.035-inch or less traumatic 0.014- to 0.018-inch guidewire to cross the stenotic lesion. Once the guidewire is placed across the stenosis, the catheter is carefully advanced over the guidewire across the lesion. In the event that the mesenteric artery is severely angulated as it arises from the aorta, a second stiffer guidewire (Amplatz or Rosen Guidewire, Boston Scientific) may be exchanged through the catheter to facilitate the placement of a 6-French guiding sheath (Pinnacle, Boston Scientific).

With the image intensifier angled in a lateral position to fully visualize the proximal mesenteric segment, a balloon angioplasty is advanced over the guidewire through the guiding sheath and positioned across the stenosis. The balloon diameter should be chosen based on the vessel size of the adjacent normal mesenteric vessel. Once balloon angioplasty is completed, a postangioplasty angiogram is necessary to document the procedural result. Radiographic evidence of either residual stenosis or mesenteric artery dissection constitutes suboptimal angioplasty results that warrants mesenteric stent placement. Moreover, atherosclerotic involvement of the proximal mesenteric artery or vessel orifice should be treated with balloon-expandable stent placement. These stents can be placed over a low-profile 0.014- or 0.018-inch guidewire system. It is preferable to deliver the balloon-mounted stent through a guiding sheath, which is positioned just proximal to the mesenteric orifice while the balloon-mounted stent is advanced across the stenosis. The stent is next deployed by expanding the angioplasty balloon to its designated inflation pressure. The balloon is then deflated and carefully withdrawn through the guiding sheath.

Completion angiogram is performed by hand injecting a small volume of contrast through the guiding sheath. It is critical to maintain the guidewire access until satisfactory completion angiogram is obtained. If the completion angiogram reveals suboptimal radiographic results, such as residual stenosis or dissection, additional catheter-based intervention can be performed through the same guidewire. These interventions may include repeat balloon angioplasty for residual stenosis or additional stent placement for mesenteric artery dissection. During the procedure, intra-arterial infusion of papaverine or nitroglycerine can be used to decrease vasospasm. Administration of antiplatelet agents is also recommended for at least 6 months or even indefinitely if other risk factors of cardiovascular disease are present.

Complications of Endovascular Treatment. Complications are not common and rarely become life threatening. These include access site thrombosis, hematomas, and infection. Dissection can occur during PTA and is managed with placement of a stent. Balloon-mounted stents are preferred over the self-expanding ones because of the higher radial force and the more precise placement. Distal embolization has also been reported, but it never resulted in acute intestinal ischemia, likely due to the rich network of collaterals already developed.¹⁰⁸

Clinical Results of Interventions for Mesenteric Ischemia

The first successful percutaneous angioplasty of the SMA was reported in 1980.¹⁰⁹ Since 1995, multiple series and scattered case reports have reported results from endovascular management of mesenteric occlusive disease.^{101,108} A literature review by AbuRahma and colleagues in 2003 showed that endovascular intervention had an overall technical success rate of 91%, early and late pain relief rates of 84% and 71%, respectively, and 30-day morbidity and mortality rates of 16.4% and 4.3%, respectively. The average patency was 63% during an average 26-month follow-up.¹⁰⁸

In our review of the literature from published series since 1995, restenosis developed in 22% of patients during 24.5 months of average follow-up.¹⁰¹ The long-term clinical relief without reintervention was 82%. Among the patients who experienced a technical failure, 15 were ultimately diagnosed

with median arcuate ligament syndrome and underwent successful surgical treatment, an observation that emphasizes the need for careful patient selection. Interestingly, the addition of selective stenting after PTA that was started in 1998, while it slightly increases the technical success rate, is not correlated with any substantial overall clinical benefit or improved long-term patency rates.

In contrast to endovascular treatment, open surgical techniques have achieved an immediate clinical success rate that approaches 100%, a surgical mortality rate of 0% to 17%, and an operative morbidity rate that ranges from 19% to 54% in a number of different series.^{101,104,106} AbuRahma and colleagues reported their experience of endovascular interventions of 22 patients with symptomatic mesenteric ischemia due to either SMA or CA stenosis.¹⁰⁸ They noted an excellent initial technical and clinical success rates, which were 96% (23 of 24 patients) and 95% (21 of 22 patients), respectively, with no perioperative mortality or major morbidity. During a mean follow-up of 26 months (range, 1–54 months), the primary late clinical success rate was 61%, and freedom from recurrent stenosis was 30%. The freedom from recurrent stenosis rates at 1, 2, 3, and 4 years were 65%, 47%, 39%, and 13%, respectively. The authors concluded that mesenteric stenting, which provides excellent early results, is associated with a relative high incidence of late restenosis.¹⁰⁸

Several studies have attempted to compare the endovascular with the standard open surgical approach.^{110,111} The results of the open surgery appear to be more durable, but it tends to be associated with higher morbidity and mortality rates and an overall longer hospital stay. In one study that compared the clinical outcome of open revascularization with percutaneous stenting for patients with chronic mesenteric ischemia, 28 patients underwent endovascular treatment and 85 patients underwent open mesenteric bypass grafting.¹¹¹ With both patient cohorts having similar baseline comorbidities and symptom duration, there was no difference in early in-hospital complication or mortality rates. Moreover, both groups had similar 3-year cumulative recurrent stenosis and mortality rates. However, patients treated with mesenteric stenting had a significantly higher incidence of recurrent symptoms. The authors concluded that operative mesenteric revascularization should be offered to patients with low surgical risk.¹¹¹

Based on the above results one could argue that mesenteric angioplasty and stenting demonstrate an inferior technical and clinical success rate. Long-term patency rates appear to also be superior with the open technique. There is a general consensus, however, that the endovascular approach is associated with lower morbidity and mortality rates and is therefore more suitable for high-risk patients. One should also keep in mind that practices representing standard of care for stent placement today were absent in the early era of endovascular experience. These include perioperative heparinization and short-term antiplatelet therapy, use of stents with higher radial force, routine use of postoperative surveillance with arterial duplex and early reintervention to prevent a high-grade stenosis from progressing to occlusion, and placement of drug-eluting stents. One such example is a recent nonrandomized study to compare the outcomes of mesenteric angioplasty using covered stents or bare metal stents in patients undergoing primary or reintervention for chronic mesenteric ischemia. The study showed that covered stents are associated with less restenosis (18% vs. 47%), symptom recurrence (18% vs. 50%), and reintervention (9% vs. 44%)

at 24 months and better primary patency at 3 years (92% vs. 52%) than bare metal stents in the primary intervention group.¹¹² Similar results were found in the reintervention group as well.

RENAL ARTERY DISEASE

Obstructive lesions of the renal artery can produce hypertension, resulting in a condition known as renovascular hypertension, which is the most common form of hypertension amenable to therapeutic intervention, and affects 5% to 10% of all hypertensive patients in the United States.¹¹³ Patients with renovascular hypertension are at an increased risk for irreversible end-organ dysfunction, including permanent kidney damage, if inadequate pharmacologic therapies are used to control the blood pressure. The majority of patients with renal artery obstructive disease have vascular lesions of either atherosclerotic disease or fibrodysplasia involving the renal arteries. The proximal portion of the renal artery represents the most common location for the development of atherosclerotic disease. It is well established that renal artery intervention, either by surgical or endovascular revascularization, provides an effective treatment for controlling renovascular hypertension as well as preserving renal function. The decision for intervention is complex and needs to consider a variety of anatomic, physiologic, and clinical features, unique for the individual patient.

Etiology

Approximately 80% of all renal artery occlusive lesions are caused by atherosclerosis, which typically involves a short segment of the renal artery ostia and represents spillover disease from a severely atheromatous aorta (Fig. 23-43).¹¹⁴ Atherosclerotic lesions are bilateral in two thirds of patients. Individuals with this disease commonly present during the sixth decade of life. Men are affected twice as frequently as women. Atherosclerotic lesions in other territories such as the coronary, mesenteric, cerebrovascular, and peripheral arterial circulation are common. When a unilateral lesion is present, the disease process equally affects the right and left renal arteries.¹¹⁵

The second most common cause of renal artery stenosis is FMD, which accounts for 20% of cases and is most frequently encountered in young, often multiparous women.¹¹⁶ FMD of

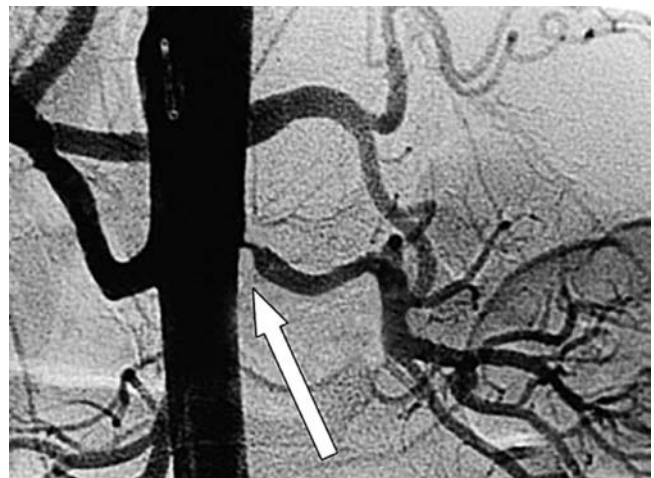

Figure 23-43. Occlusive disease of the renal artery typically involves the renal ostium (*arrow*) as a spillover plaque extension from aortic atherosclerosis.

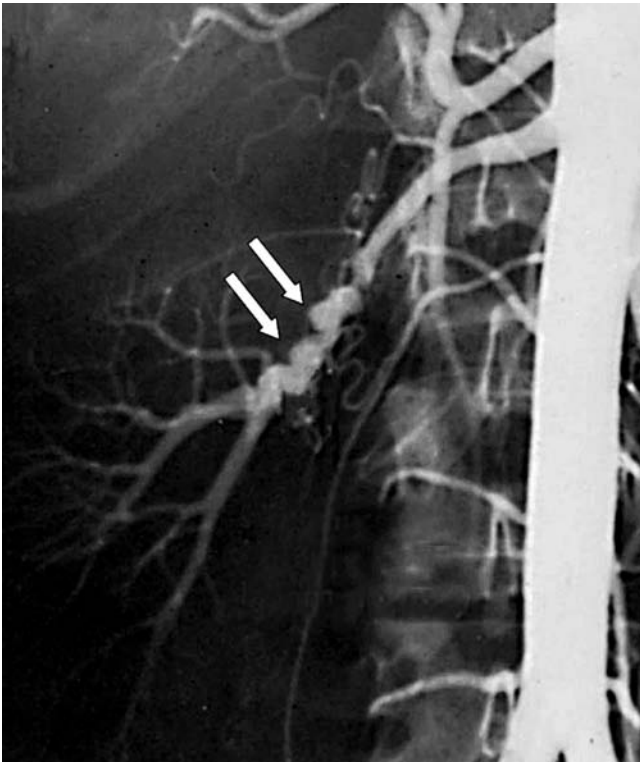

Figure 23-44. Abdominal aortogram reveals a left renal artery fibromuscular dysplasia (*arrows*) with a characteristic “string of beads” appearance.

the renal artery represents a heterogeneous group of lesions that can produce histopathologic changes in the intima, media, or adventitia. The most common variety consists of medial fibroplasia, in which thickened fibromuscular ridges alternate with attenuated media producing the classic angiographic “string of beads” appearance (Figs. 23-44 and 23-45). The cause of medial fibroplasia remains unclear. Most common theories involve a modification of arterial smooth muscle cells in response to

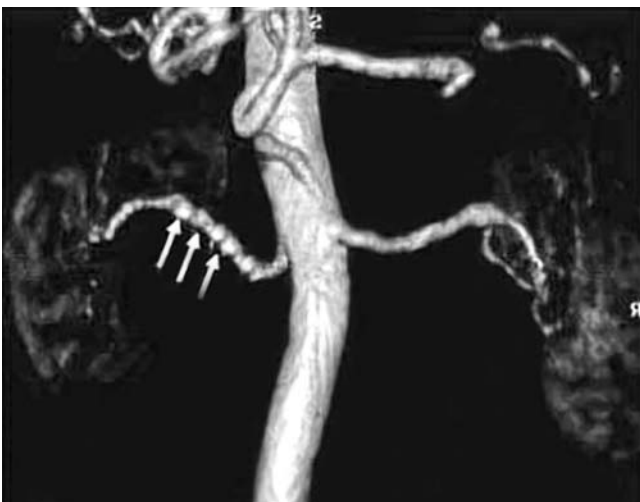

Figure 23-45. Magnetic resonance angiography of the abdominal aorta reveals the presence of a left renal artery fibromuscular dysplasia (*arrows*).

estrogenic stimuli during the reproductive years, unusual traction forces on affected vessels, and mural ischemia from impairment of vasa vasorum blood flow.¹¹⁶ Fibromuscular hyperplasia usually affects the distal two thirds of the main renal artery, and the right renal artery is affected more frequently than the left. Other less common causes of renal artery stenosis include renal artery aneurysm (compressing the adjacent normal renal artery), arteriovenous malformations, neurofibromatosis, renal artery dissections, renal artery trauma, Takayasu’s arteritis, and renal arteriovenous fistula.

Clinical Manifestations

Renovascular hypertension is the most common sequela of renal artery occlusive disease. Its prevalence varies from 2% in patients with diastolic blood pressure greater than 100 mmHg to almost 30% in those with diastolic blood pressure over 125 mmHg.¹¹⁴ Clinical features that may indicate the presence of renovascular hypertension include the following: (a) systolic and diastolic upper abdominal bruits; (b) diastolic hypertension of greater than 115 mmHg; (c) rapid onset of hypertension after the age of 50 years; (d) a sudden worsening of mild to moderate essential hypertension; (e) hypertension that is difficult to control with three or more antihypertensives; (f) development of renal insufficiency after angiotensin-converting enzyme inhibitors; and (g) development of hypertension during childhood.

All patients with significant hypertension, especially elevated diastolic blood pressure, must be considered as suspect for renovascular disease. Young adults with hypertension have a great deal to gain by avoiding lifelong treatment if renovascular hypertension is diagnosed and corrected. Appropriate diagnostic studies and intervention must be timely instituted to detect the possibility of renovascular hypertension in patients with primary hypertension who present for clinical evaluation.

Diagnostic Evaluation

The diagnostic requisites for renovascular hypertension include both hypertension and renal artery stenosis. Impairment of the renal function may coexist, although the occurrence of renal insufficiency prior to the development of hypertension is uncommon. Nearly all diagnostic studies for renovascular hypertension evaluate either the anatomic stenosis or renal parenchymal dysfunction attributed to the stenosis. The following section provides an overview of the strengths and limitations of the most common tests used in the diagnostic evaluation of the patient with suspected renovascular hypertension prior to intervention.

Captopril renal scanning is a functional study that assesses renal perfusion before and after administration of the angiotensin-converting enzyme inhibitor captopril. Captopril inhibits the secretion of angiotensin II. Through this mechanism, it reduces the efferent arteriole vasoconstriction and, as a result, the glomerular filtration rate (GFR). The test consists of a baseline renal scan and a second renal scan after captopril administration. A positive result indicates that captopril administration (a) increases the time to peak activity to more than 11 minutes or (b) the GFR ratio between sides increases to greater than 1.5:1 compared to a normal baseline scan. Significant parenchymal disease limits the reliability of this study.

Renal artery duplex ultrasonography is a noninvasive test of assessing renal artery stenosis both by visualization of the vessel and measurement of the effect of stenosis on blood flow velocity and waveforms. The presence of a severe renal artery stenosis correlates with peak systolic velocities of greater than

Table 23-11

Renal duplex diagnostic criteria

RENAL ARTERY DIAMETER REDUCTION	RENAL ARTERY PSV	RAR
Normal	<180 cm/s	<3.5
<60%	≥180 cm/s	<3.5
≥60%	≥180 cm/s	≥3.5
Occlusion	No signal	No signal

PSV = peak systolic velocity; RAR = renal-to-aortic ratio.

180 cm/s and the ratio of these velocities to those in the aorta of greater than 3.5 (Table 23-11). Renal artery duplex is a technically demanding exam, requiring a substantial amount of operator expertise. In addition, the presence of bowel gas and obesity make the exam difficult to perform and interpret. However, in experienced hands and with appropriate patient selection, it can be a high-yield exam and is typically the initial screening test for patients with suspected renal artery occlusive disease.

Selective catheterization of the renal vein via a femoral vein approach for assessing renin activity is a more invasive test of detecting the physiologic sequelae of renal artery stenosis. If unilateral disease is present, the affected kidney should secrete high levels of renin while the contralateral kidney should have low renin production. A ratio between the two kidneys, or the renal vein renin ratio (RVRR), of greater than 1.5 is indicative of functionally important renovascular hypertension, and it also predicts a favorable response from renovascular revascularization. Since this study assesses the ratio between the two kidneys, it is not useful in patients with bilateral disease because both kidneys may secrete abnormally elevated renin levels.

The renal:systemic renin index (RSRI) is calculated by subtracting systemic renin activity from individual renal vein renin activity and dividing the remainder by systemic renin activity. This value represents the contribution of each kidney to renin production. In the absence of renal artery stenosis, the renal vein renin activity from each kidney is typically 24% or 0.24 higher than the systemic level. As the result, the total of both kidneys' renin activity is usually 48% greater than the systemic activity, a value that represents a steady state of renal renin activity. The RSRI of the affected kidney in patients with renovascular hypertension is greater than 0.24. In the case of unilateral renal artery stenosis with normal contralateral kidney, the increase in ipsilateral renin release is normally balanced by suppression of the contralateral kidney renin production, which results in a drop in its RSRI to less than 0.24. Bilateral renal artery disease may negate the contralateral compensatory response, and the autonomous release of renin from both diseased kidneys may result in the sum of the individual RSRIs to be considerably greater than 0.48. The prognostic value of RSRI remains limited in that approximately 10% of patients with favorable clinical response following renovascular revascularization do not exhibit contralateral renin suppression. As a result, the use of RSRI must be applied with caution in the management of patients with renovascular hypertension.

MRA with intravenous gadolinium contrast enhancement has been increasingly used for renal artery imaging because of its ability to provide high-resolution images (Figs. 23-46 and 23-47)

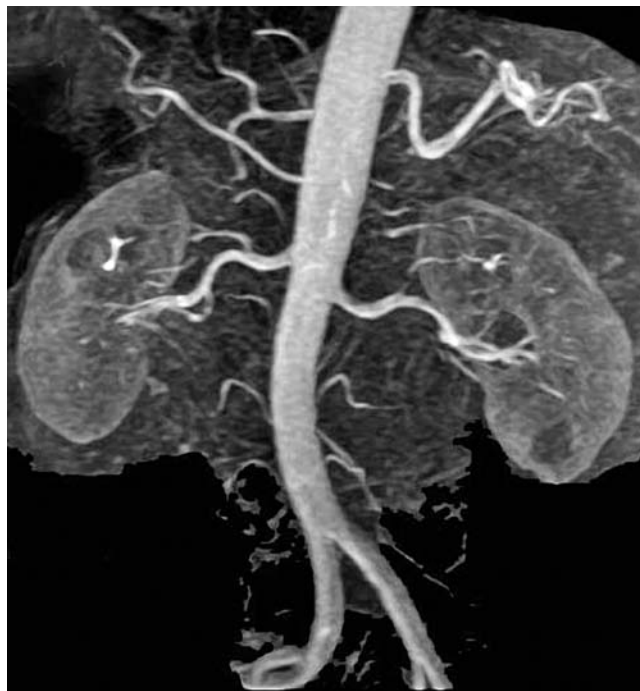

Figure 23-46. Magnetic resonance angiography of the abdominal aorta reveals bilateral normal renal arteries.

while using a minimally nephrotoxic agent. Flow void may be inaccurately interpreted as occlusion or stenosis in MRA. Therefore, unless the quality of the image analysis software is superior, MRA should be interpreted with caution and used in conjunction with other modalities prior to making plans for operative or endovascular treatment.

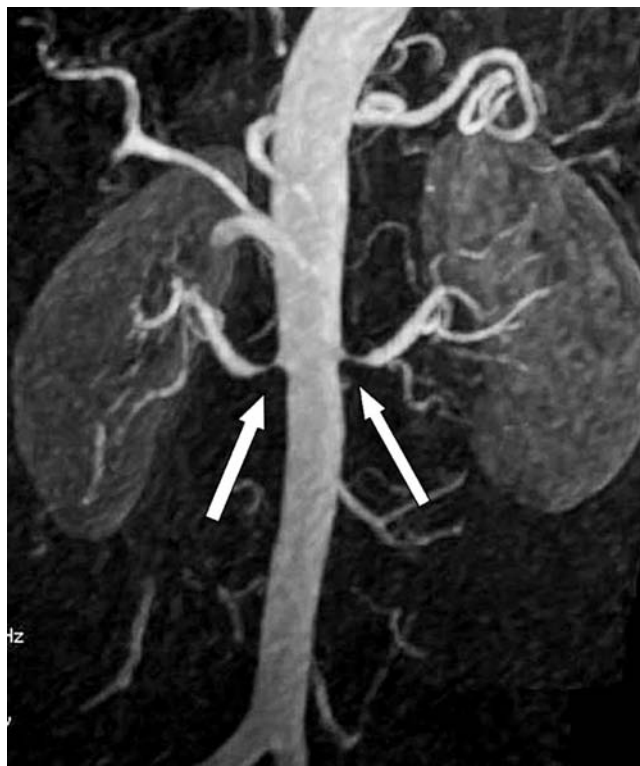


Figure 23-47. Magnetic resonance angiography of the abdominal aorta reveals bilateral ostial renal artery stenosis (arrows).

DSA remains the gold standard to assess renal artery occlusive disease. A flush aortogram is performed first so that any accessory renal arteries can be detected and the origins of all the renal arteries are adequately displayed. The presence of collateral vessels circumventing a renal artery stenosis strongly supports the hemodynamic importance of the stenosis. A pressure gradient of 10 mmHg or greater is necessary for collateral vessel development, which is also associated with activation of the renin-angiotensin cascade.

Treatment Indications

The therapeutic goals in patients with renovascular disease include: (a) improved blood pressure control, in order to prevent end-organ damage on systems such as the cerebral, coronary, pulmonary, and peripheral circulations; and (b) preservation and possibly improvement of the renal function (Table 23-12).

The indications for endovascular treatment for renal artery occlusive disease include 70% or greater stenosis of one or both renal arteries and at least one of the following clinical criteria:

- Inability to adequately control hypertension despite appropriate antihypertensive regimen.
- Chronic renal insufficiency related to bilateral renal artery occlusive disease or stenosis to a solitary functioning kidney.
- Dialysis-dependent renal failure in a patient with renal artery stenosis but without another definite cause of end-stage renal disease.
- Recurrent congestive heart failure or flash pulmonary edema not attributable to active coronary ischemia.

Prior to 1990, the most common treatment modality in patients with renal artery occlusive disease is surgical revascularization, with either renal artery bypass grafting or renal artery endarterectomy. The advancement of endovascular therapy in the past decade has led to various minimally invasive treatment

strategies such as renal artery balloon angioplasty or stenting to control hypertension or to preserve renal function.

Surgical Reconstruction

The typical approach for surgical renal artery revascularization involves a midline xiphoid-to-pubis incision. The posterior peritoneum is incised, and the duodenum is mobilized to the right, starting at the ligament of Treitz. The left renal hilum can be exposed by extending the retroperitoneal dissection to the left along the avascular plane along the inferior border of the pancreas. Mobilization of the left renal vein is essential in these cases and can be achieved by dividing the gonadal, ilio-lumbar, and adrenal veins. The proximal portion of the right renal artery can be exposed through the base of the mesentery by retraction of the left renal vein cephalad and the vena cava to the right. Accessing the most distal portion of the right renal artery requires a Kocher maneuver and duodenal mobilization. Another approach useful for treating bilateral renal artery lesions involves mobilization of the entire small bowel and the right colon, with a dissection that starts at the ligament of Treitz and proceeds toward the cecum and then along the line of Todd in the right paracolic gutter. Simultaneous dissection along the inferior border of the pancreas provides additional visualization of the left renal artery. Finally, division of the diaphragmatic crura that encircle the suprarenal aorta may sometimes be necessary to achieve suprarenal clamping.

Types of Surgical Reconstruction. Aortorenal bypass is the most frequently performed reconstruction of ostial occlusive renal artery disease. After proximal and distal control is obtained, an elliptical segment of the aorta is excised, and the proximal anastomosis is performed in end-to-side fashion. Autologous vein is the preferred conduit. If the vein is not suitable, then prosthetic material can be used. An end-to-end anastomosis is then performed between the conduit of choice and the renal artery using either a 6-0 or 7-0 polypropylene suture. The length of the arteriotomy needs to be at least three times the diameter of the renal artery to prevent anastomotic restenosis. In the event that the surgeon plans to perform a side-to-side anastomosis between the conduit and the renal artery, this is performed first, and the aortic anastomosis follows.

Endarterectomy, either transrenal or transaortic, is an alternative to bypass for short ostial lesions or in patients with multiple renal arteries. The transrenal endarterectomy is performed with a transverse longitudinal incision on the aorta that extends into the diseased renal artery. After plaque removal, the arteriotomy is closed with a prosthetic patch. Transaortic endarterectomy is well suited for patients with multiple renal arteries and short ostial lesions. The aorta is opened longitudinally and aortic sleeve endarterectomy is performed, followed by eversion endarterectomy of the renal arteries. Adequate mobilization of the renal arteries is essential for a safe and complete endarterectomy.

Hepatorenal and splenorenal bypass are alternative options of revascularization for patients who might not tolerate aortic clamping or for those with calcified aorta that precludes adequate control. For hepatorenal bypass, a right subcostal incision is used, and the hepatic artery is exposed with an incision in the lesser omentum. A Kocher maneuver is performed, the right renal vein is identified and mobilized, and the right renal artery is identified and controlled posteriorly to the vein. Greater saphenous vein is the conduit of choice. The anastomosis is performed end-to-side with the common hepatic artery, and end-to-end with the renal artery anterior to the inferior vena cava.

Table 23-12

Indications for renal artery revascularization

Angiography Criteria

- Documented renal artery stenosis (>70% diameter reduction)
- Fibromuscular dysplasia lesion
- Pressure gradient >20 mmHg
- Affected/unaffected kidney renin ratio >1.5 to 1

Clinical Criteria

- Refractory or rapidly progressive hypertension
- Hypertension associated with flash pulmonary edema without coronary artery disease
- Rapidly progressive deterioration in renal function
- Intolerance to antihypertensive medications
- Chronic renal insufficiency related to bilateral renal artery occlusive disease or stenosis to a solitary functioning kidney
- Dialysis-dependent renal failure in a patient with renal artery stenosis but without another definite cause of end-stage renal disease
- Recurrent congestive heart failure or flash pulmonary edema not attributable to active coronary ischemia

The splenorenal bypass is performed via a left subcostal incision. The splenic artery is mobilized from the lesser sac, brought through a retropancreatic plane, and anastomosed end-to-end to the renal artery.

Reimplantation of the renal artery is an attractive option of reconstruction in children or in adults with ostial lesions. A redundant renal artery is a prerequisite for the procedure. After mobilization, the artery is transected and spatulated, eversion endarterectomy is performed if necessary, and an end-to-side anastomosis with the aorta is created.

Clinical Results of Surgical Repair

Results reflect the need for performance of renal artery bypass in high-volume and experienced centers. In a review from a large tertiary center, 92% of the patients with nonatherosclerotic vascular disease had improvement in hypertension, but only 43% were completely cured and taken off antihypertensives.¹¹⁷ Patients younger than age 45 fair better, with a cure rate of 68% and improvement rate of 32%. In patients with atherosclerotic renal artery disease, the cure rate was even smaller (12%), and the overall response to hypertension rate was 85%. The operative mortality rates were 3.1% and 0% in the atherosclerotic and nonatherosclerotic groups, respectively.

Renal function improvement occurs within the first week of the operation in approximately two thirds of patients. A progressive decrease in the GFR is seen after this initial improvement, but the rate of decrease is less compared with patients who did not respond at all to operative intervention. Up to three quarters of patients were permanently removed from dialysis in a large series.¹¹⁸ Favorable response of renal function to revascularization improves overall survival.

Endovascular Treatment

Endovascular treatment of renal artery occlusive disease was first introduced by Grüntzig who successfully dilated a renal artery stenosis using a balloon catheter technique. This technique requires passage of a guidewire under fluoroscopic control typically from a femoral artery approach to across the stenosis in the renal artery. A balloon dilating catheter is passed over the guidewire and positioned within the area of stenosis and inflated to produce a controlled disruption of the arterial wall. Alternatively, a balloon-mounted expandable stent can be used to primarily dilate the renal artery stenosis. Completion angiography is usually performed to assess the immediate results. The technical aspect of an endovascular renal artery revascularization is discussed below.

Techniques of Renal Artery Angioplasty and Stenting.

Access to the renal artery for endovascular intervention is typically performed via a femoral artery approach, although a brachial artery approach can be considered in the event of severe aortoiliac occlusive disease, aortoiliac aneurysm, or severe caudal renal artery angulation. Once an introducer sheath is placed in the femoral artery, an aortogram is performed with a pigtail catheter placed in the suprarenal aorta. Additional oblique views are frequently necessary to more precisely visualize the orifice of the stenosed renal artery and thoroughly assess the presence of accessory renal arteries. Noniodinated contrast agents, such as carbon dioxide and gadolinium, can be used in endovascular renal intervention in patients with renal dysfunction or history of allergic reaction.

After systemic heparinization, catheterization of the renal artery can be performed using a variety of selective angled

catheters, including the RDC, Cobra-2, Simmons I, or SOS Omni catheter. A selective renal angiogram is then performed to confirm position, and the lesion is crossed with either 0.035-inch or a 0.018- to 0.014-inch guidewires. It is important to maintain the distal wire position without movement in the tertiary renal branches during guiding sheath placement to reduce the possibility of parenchymal perforation and spasm. A guiding sheath or a guiding catheter is then advanced at the orifice of the renal artery and provides a secure access for balloon and stent deployment.

Balloon angioplasty is performed with a balloon sized to the diameter of the normal renal artery adjacent to the stenosis. Choosing a balloon with diameter 4 mm is a reasonable first choice. The luminal diameter of the renal artery can be further assessed by comparing it to the fully inflated balloon. Such a comparison may provide a reference guide to determine whether renal artery dilatation with a larger diameter angioplasty balloon is necessary.

Once balloon angioplasty of the renal artery is completed, an angiogram is performed to document the procedural result. Radiographic evidence of either residual stenosis or renal artery dissection constitutes suboptimal angioplasty results, which warrants an immediate renal artery stent placement. Moreover, atherosclerotic involvement of the very proximal renal artery that involves the vessel orifice typically requires stent placement. A balloon-expandable stent is typically used and is positioned in such a way that it protrudes into the aorta by 1 to 2 mm. The size of the stent is determined by the size of the renal artery, taking into account a desirable 10% to 20% oversizing. After the stent deployment, the angiogram is repeated, and upon a satisfactory result, the devices are withdrawn. It is critical to maintain the guidewire access across the renal lesion until satisfactory completion angiogram is obtained. Spasm of the branches of the renal artery will usually respond to nitroglycerin 100 to 200 μ g administered through the guiding sheath directly into the renal artery.

While endovascular therapy of renal artery occlusive disease is considerably less invasive than conventional renal artery bypass operation, complications relating to this treatment modality can occur. In a study in which Guzman and colleagues compared the complications following renal artery angioplasty and surgical revascularization, the authors noted that major complication rates following endovascular and surgical treatment were 17%, and 31 %, respectively.¹¹⁹ In contrast, significantly greater minor complications were associated with the endovascular cohort, with a minor complication rate of 48% compared with 7% in the surgical group.¹¹⁹ In a prospective randomized study that compared the clinical outcome of renal artery balloon angioplasty versus stenting for renal ostial atherosclerotic lesion, comparable complications rates were found in the two groups (39% vs. 43%, respectively). However, the incidence of restenosis at 6 months was significantly higher in the balloon angioplasty cohort than the stenting group (48% vs. 14%, respectively). This study underscores the clinical superiority of renal stenting compared to renal balloon angioplasty alone in patients with ostial stenosis.¹²⁰

Deterioration in renal function, albeit transient, is a common complication following endovascular renal artery intervention. This is most likely the combined result of the use of iodinated contrast and the occurrence of renal parenchymal embolism due to wire and catheter manipulation. In most cases, this is a temporary problem, as supportive care with adequate

fluid hydration is sufficient to reverse the renal dysfunction. However, transient hemodialysis may become necessary in approximately 1% of patients. Other complications include vascular access complications (bleeding, hematoma, femoral nerve injury, arteriovenous fistula, and pseudoaneurysm), target vessel dissection, perinephric hematoma, early postoperative renal artery thrombosis, and extremity atheroembolism from thrombus in the aorta or the iliac arteries.

Clinical Results of Endovascular Interventions

Percutaneous Transluminal Balloon Angioplasty. FMD of the renal artery is the most common treatment indication for percutaneous transluminal balloon angioplasty. Patients with symptomatic FMD such as hypertension or renal insufficiency usually respond well to renal artery balloon angioplasty alone.¹²¹ In contrast, balloon angioplasty generally is not an effective treatment for patients with renal artery stenosis or proximal occlusive disease of the renal artery, due to the high incidence of restenosis with balloon angioplasty alone. In the latter group of patients, primary stent placement is the preferred endovascular treatment. The long-term benefit of renal artery balloon angioplasty in patients with FMD was reported by Surowiec and colleagues.¹²¹ They followed 14 patients who underwent 19 interventions on 18 renal artery segments. The technical success rate of balloon angioplasty for FMD was 95%. Primary patency rates were 81%, 69%, 69%, and 69% at 2, 4, 6, and 8 years, respectively. Assisted primary patency rates were 87%, 87%, 87%, and 87% at 2, 4, 6, and 8 years, respectively. The restenosis rate was 25% at 8 years. Clinical benefit, as defined by either improved or cured hypertension, was found in 79% of patients overall, with two thirds of patients having maintained this benefit at 8 years. The authors concluded that balloon angioplasty is highly effective in symptomatic FMD with excellent durable functional benefits.¹²¹

The utility of balloon angioplasty alone in the treatment of renovascular hypertension appears to be limited. van Jaarsveld and associates performed a prospective study in which patients with renal artery stenosis were randomized to either drug therapy or balloon angioplasty treatment.¹²² A total of 106 patients with 50% diameter stenosis or greater plus hypertension or renal insufficiency were randomized in the study.

At 3 months, there was no difference in the degree to which blood pressure was controlled between the two groups. However, the degree and dose of antihypertensive medications were slightly lowered in the balloon angioplasty group. The above advantage of the angioplasty group completely disappeared at 12 months, making the authors conclude that in the treatment of patients with hypertension and renal artery stenosis, percutaneous transluminal balloon angioplasty alone offers minimal advantage over antihypertensive drug therapy.

Renal Artery Stenting. Endovascular stent placement is the treatment of choice for patients with symptomatic or high-grade renal artery occlusive disease (Fig. 23-48) This is due in part to the high incidence of restenosis with balloon angioplasty alone, particularly in the setting of ostial stenosis. Renal artery stenting is also indicated for renal artery dissection caused by balloon angioplasty or other catheter-based interventions. Numerous studies have clearly demonstrated the clinical efficacy of renal artery stenting when compared to balloon angioplasty alone in patients with high-grade renal artery stenosis.

White and colleagues conducted a study to evaluate the role of renal artery stenting in patients with poorly controlled hypertension and renal artery lesions that did not respond well to balloon angioplasty alone.¹²³ The technical success of the procedure was 99%. The mean blood pressure values were $173 \pm 25/88 \pm 17$ mmHg prior to stent implantation and $146 \pm 20/77 \pm 12$ mmHg 6 months after renal artery stenting ($P < 0.01$). Angiographic follow-up with 67 patients (mean 8.7 ± 5 months) demonstrated that restenosis, as defined by 50% or greater luminal narrowing, occurred in 15 patients (19%). The study concluded that renal artery stenting is a highly effective treatment for renovascular hypertension, with a low angiographic restenosis rate. In another similar study, Blum and colleagues prospectively performed renal artery stenting in 68 patients (74 lesions) with ostial renal artery stenosis and suboptimal balloon angioplasty.¹²⁴ Patients were followed for a mean of 27 months with measurements of blood pressure and serum creatinine, duplex sonography, and intra-arterial angiography. Five-year patency was 84.5% (mean follow-up, 27 months). Restenosis occurred in 8 of 74 arteries (11%), but after reintervention, the secondary 5-year patency rate was 92.4%. Hypertension was cured or improved in 78% of patients. The authors concluded that primary

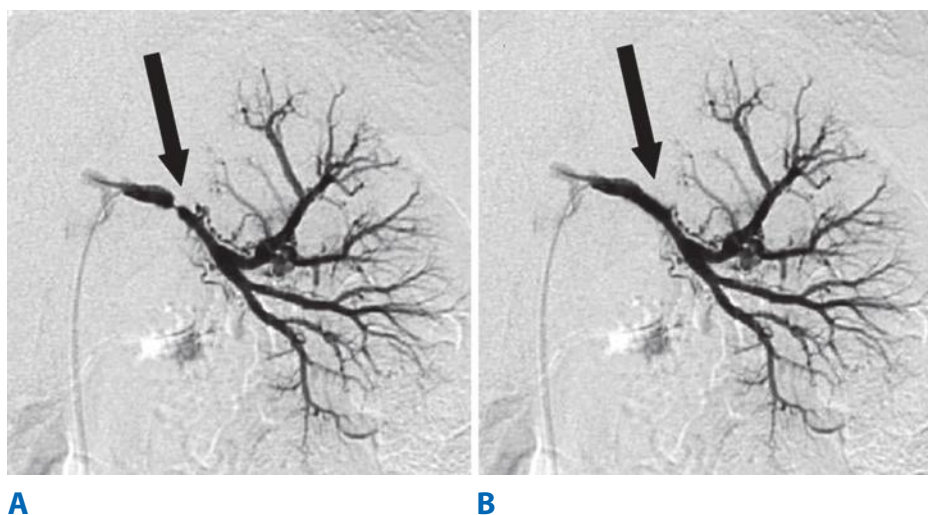


Figure 23-48. Renal artery stenting. **A.** Focal lesion in the renal artery (arrow). **B.** Poststenting angiogram reveals a satisfactory result following a renal artery stenting placement (arrow).

stent placement is an effective treatment for renal artery stenosis involving the ostium.

The clinical utility of renal artery stenting in renal function preservation was analyzed by several studies, which measured serial serum creatinine levels to determine the response of renal function following endovascular intervention.¹²⁵ In a study reported by Harden and colleagues who performed 33 renal artery stenting procedures in 32 patients with renal insufficiency, they noted that renal function improved or stabilized in 22 patients (69%).¹²⁶ In a similar study, Watson and associates evaluated the effect of renal artery stenting on renal function by comparing the slopes of the regression lines derived from the reciprocal of serum creatinine versus time.¹²⁵ A total of 61 renal stenting procedures were performed in 33 patients, and the authors found that after stent placement, the slopes of the reciprocal of the serum creatinine (1/Scr) were positive in 18 patients and less negative in 7 patients. The study concluded that in patients with chronic renal insufficiency due to obstructive renal artery stenosis, renal artery stenting is effective in improving or stabilizing renal function.

The clinical outcome of several large clinical studies of renal artery stenting in the treatment of renovascular hypertension or chronic renal insufficiency is shown in Table 23-13.^{123,124,126-132} These studies uniformly demonstrated an excellent technical success rate with low incidence of restenosis or procedural-related complications. A similar analysis was reported by Leertouwer and colleagues who performed a meta-analysis of 14 studies comparing patients with renal arterial stent placement to those who underwent balloon angioplasty alone for renal arterial stenosis.¹³³ The study found that stent placement proved highly successful, with an initial technical success of 98%. The overall cure rate for hypertension was 20%, whereas hypertension was improved in 49%. Renal function improved in 30% of patients and stabilized in 38% of patients. The restenosis rate at follow-up of 6 to 29 months was 17%. Renal stenting resulted in a higher technical success rate and a lower restenosis rate when compared to balloon angioplasty alone.

AORTOILIAC OCCLUSIVE DISEASE

The distal abdominal aorta and the iliac arteries are common sites affected by atherosclerosis. The symptoms and natural history of the atherosclerotic process affecting the aortoiliac arterial segment are influenced by the disease distribution and extent. Atherosclerotic plaques may cause clinical symptoms by restricting blood flow due to luminal obstruction or by embolizing atherosclerotic debris to the lower extremity circulation. If the aortoiliac plaques reach sufficient mass and impinge on the arterial lumen, obstruction of blood flow to lower extremities occurs. Various risk factors exist that can lead to the development of aortoiliac occlusive disease. Recognition of these factors and understanding of this disease entity will enable physicians to prescribe the appropriate treatment strategy, which may alleviate symptoms and improve quality of life.

Diagnostic Evaluation

On clinical examination patients often have weakened femoral pulses and a reduced ABI. Verification of iliac occlusive disease is usually made by color duplex scanning, which reveals either a peak systolic velocity ratio ≥ 2.5 at the site of stenosis and/or a monophasic waveform. Noninvasive tests such as pulse volume recordings (PVRs) of the lower extremity with estimation of the thigh-brachial pressure index may be suggestive of aortoiliac disease. MRA and multidetector CTA are increasingly being used to determine the extent and type of obstruction. DSA offers the interventionalist the benefit of making a diagnosis and the option of performing an endovascular treatment in a single session. Angiography provides important information regarding distal arterial runoff vessels as well as the patency of the PFA. Presence of pelvic and groin collaterals is important to provide crucial collateral flow in maintaining lower limb viability. It must be emphasized, however, that patients should be subjected to angiography only if their symptoms warrant surgical intervention.

Differential Diagnosis

Degenerative hip or spine disease, lumbar disk herniation, spinal stenosis, diabetic neuropathy, and other neuromuscular

Table 23-13

Clinical outcome of renal artery stent placement in the treatment of renovascular hypertension and renal insufficiency

AUTHOR	YEAR	PATIENT NO.	TECHNICAL SUCCESS (%)	FOLLOW-UP (MONTHS)	RENAL INSUFFICIENCY (%)		RENOVASCULAR HYPERTENSION (%)		COMPLICATION (%)	RESTENOSIS (%)
					STABLE	IMPROVED	CURED	IMPROVED		
Iannone ¹³⁰	1996	63	99	10	45	36	4	35	13	14
Harden ¹²⁶	1997	32	100	6	34	34	N/A	N/A	3	13
Blum ¹²⁴	1997	68	100	27	N/A	N/A	16	62	0	11
White ¹²³	1997	100	99	6	N/A	20	N/A	N/A	2	19
Shannon ¹³²	1998	21	100	9	29	43	N/A	N/A	9	0
Rundback ¹³¹	1998	45	94	17	N/A	N/A	N/A	N/A	9	25
Dorros ¹²⁸	1998	163	100	48	N/A	N/A	3	51	11	N/A
Henry ¹²⁹	1999	210	99	25	N/A	29	19	61	3	9
Bush ¹²⁷	2001	73	89	20	21	38	13	61	12	16

N/A = not applicable.

problems can produce symptoms that may be mistaken for vascular claudication. Such cases can be distinguished from true claudication by the fact that the discomfort from neuromuscular problems is often relieved by sitting or lying down, as opposed to cessation of ambulation. In addition, complaints that are experienced upon standing suggest nonvascular causes. When confusion persists, the use of noninvasive vascular laboratory testing modalities, including treadmill exercise, can help establish the diagnosis.

Collateral Arterial Network

The principal collateral pathways in severe aortoiliac artery occlusive disease or chronic aortic occlusion that may provide blood flow distal to the aortoiliac lesion include: (a) the superior mesenteric artery to the distal IMA via its superior hemorrhoidal branch to the middle and inferior hemorrhoids to the internal iliac artery (39%); (b) the lumbar arteries to the superior gluteal artery to the internal iliac system (37%); (c) the lumbar arteries to the lateral and deep circumflex arteries to the CFA (12%); and (d) Winslow's pathway from the subclavian to the superior epigastric artery to the inferior epigastric artery to the external iliac arteries at the groin (Fig. 23-49). In general, treatment indications for aortoiliac artery occlusive disease include disabling claudication, ischemic rest pain, nonhealing lower extremity tissue wound, and lower extremity microembolization that arises from aortoiliac lesions.

Disease Classification

Based on the atherosclerotic disease pattern, aortoiliac occlusive disease can be classified into three types (Fig. 23-50). Type I aortoiliac disease, which occurs in 5% to 10% of patients, is confined to the distal abdominal aorta and common iliac vessels (Fig. 23-51). Due to the localized nature of this type of aortic

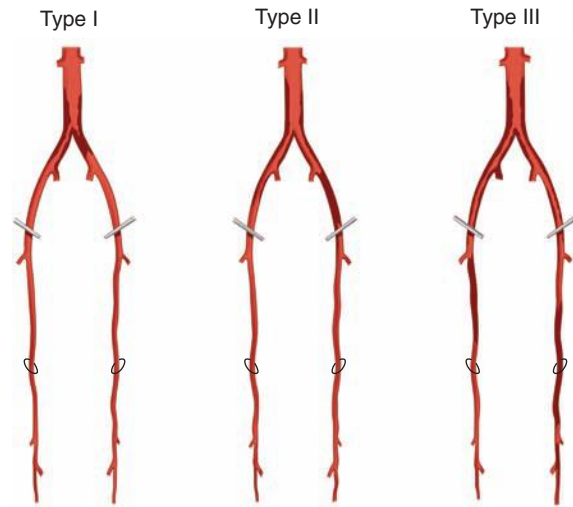


Figure 23-50. Aortoiliac disease can be classified into three types. Type I represents focal disease affecting the distal aorta and proximal common iliac artery. Type II represents diffuse aortoiliac disease above the inguinal ligament. Type III represents multisegment occlusive diseases involving aortoiliac and infrainguinal arterial vessels.

obstruction and formation of collateral blood flow around the occluded segment, limb-threatening symptoms are rare in the absence of more distal disease (Fig. 23-52). This type of aortoiliac occlusive disease occurs in a relatively younger group of patients (in their mid-50s), compared with patients who have more femoropopliteal disease. Patients with a type I disease pattern have a lower incidence of hypertension and diabetes, but a

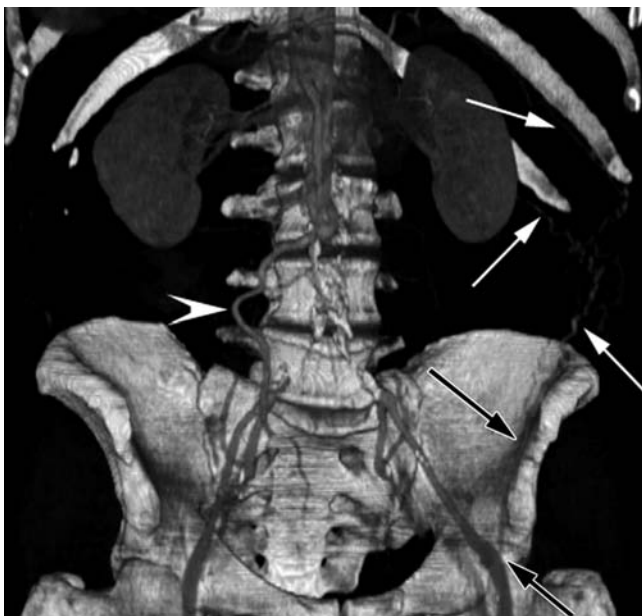

Figure 23-49. Pertinent collateral pathways are developed in the event of chronic severe aortoiliac occlusive disease. As illustrated in this multidetector computed tomography angiography, these collaterals include epigastric arteries (*large white arrows*), an enlarged inferior mesenteric artery (*arrowhead*), and enlarged lumbar arteries (*black arrows*).

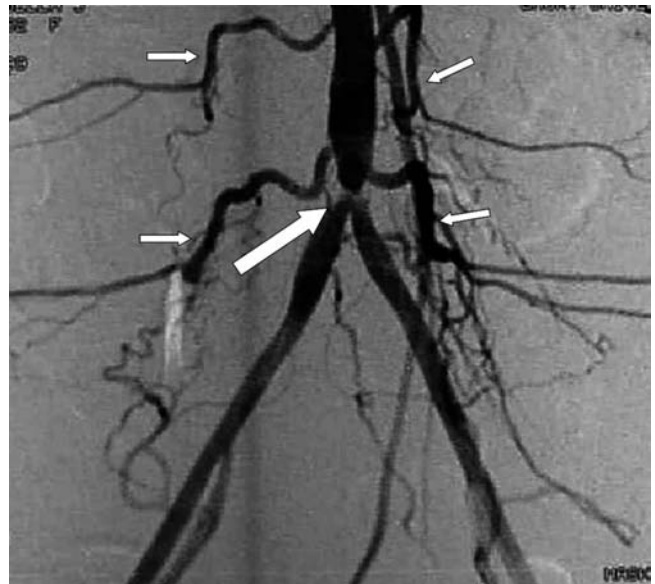


Figure 23-51. Type I aortoiliac disease is confined to the distal abdominal aorta (*long arrow*) or proximal common iliac arteries. Due to the localized nature of this type of aortic obstruction and formation of collateral blood flow around the occluded segment (*short arrows*), limb-threatening symptoms are rare in the absence of more distal disease.

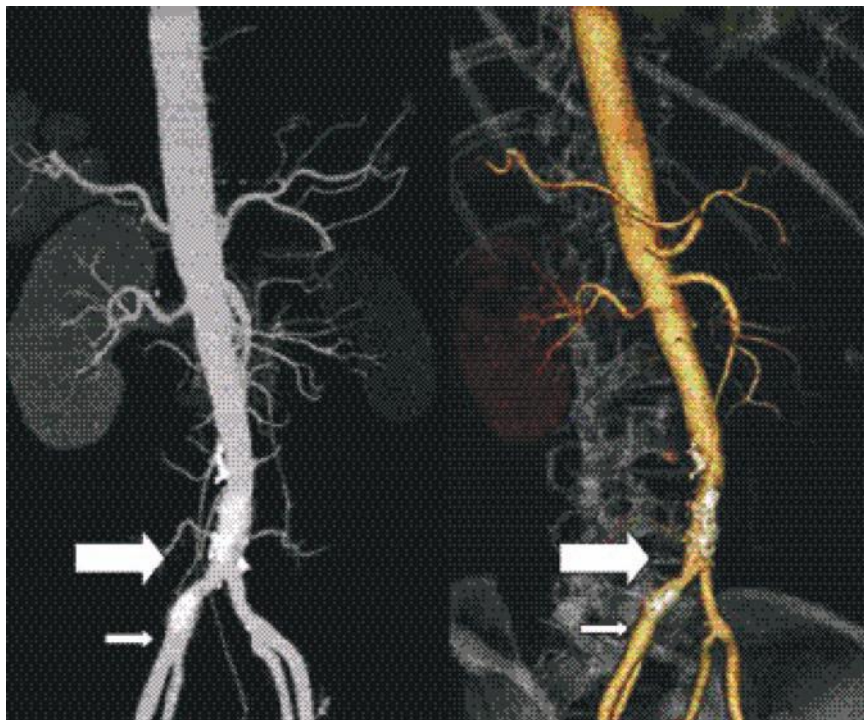


Figure 23-52. **A.** Multidetector computed tomography angiography of the aortoiliac artery circulation in a 63-year-old male with buttock claudication. **B.** Three-dimensional image reconstruction shows intra-arterial calcification of the aorta (*large arrow*) and right common iliac artery (*small arrow*). This is consistent with type I aortoiliac occlusive disease.

significant frequency of abnormal blood lipid levels, particularly type IV hyperlipoproteinemia. Symptoms typically consist of bilateral thigh or buttock claudication and fatigue. Men report diminished penile tumescence and may have complete loss of erectile function. These symptoms in the absence of femoral pulses constitute Leriche's syndrome. Rest pain is unusual with isolated aortoiliac disease unless distal disease coexists. Occasionally patients report a prolonged history of thigh and buttock claudication that recently becomes more severe. It is likely that this group has underlying aortoiliac disease that has progressed to acute occlusion of the terminal aorta. Others may present with "trash foot," which represents microembolization into the distal vascular bed (Fig. 23-53). Type II aortoiliac disease represents a more diffuse atherosclerotic progression that involves pre-

dominately the abdominal aorta with disease extension into the common iliac artery. This disease pattern affects approximately 25% patients with aortoiliac occlusive disease. Type III aortoiliac occlusive disease, which affects approximately 65% of patients with aortoiliac occlusive disease, is widespread disease that is seen above and below the inguinal ligament (Fig. 23-54). Patients with "multilevel" disease are older, more commonly male (with a male-to-female ratio of 6:1), and much more likely to have diabetes, hypertension, and associated atherosclerotic disease involving cerebral, coronary, and visceral arteries. Progression of the occlusive process is more likely in these patients than in those with localized aortoiliac disease. For these reasons, most patients with a type III pattern tend to present with symptoms of advanced ischemia and require revascularization for

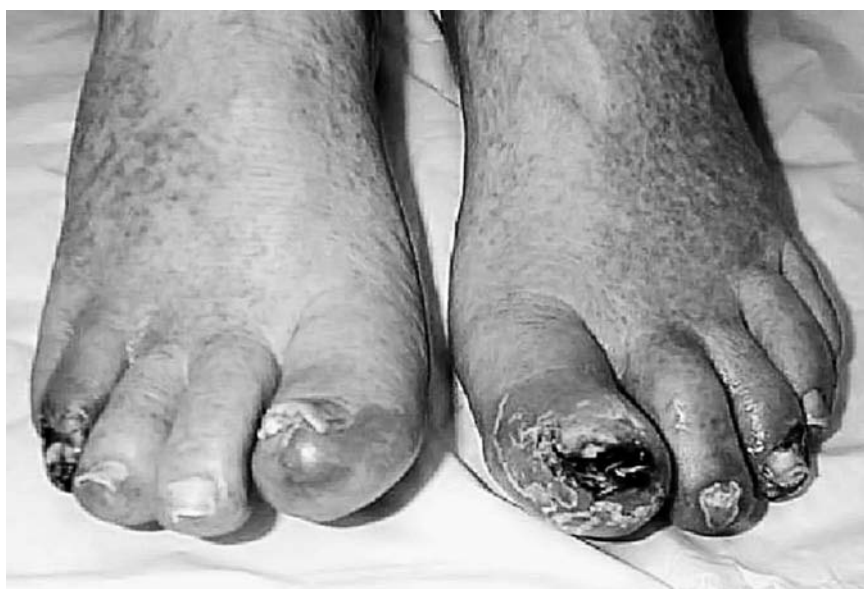

Figure 23-53. Atherosclerotic disease involving the aortoiliac segment can result in microembolization of the lower leg circulation, resulting in trash foot or digital gangrene of toes.

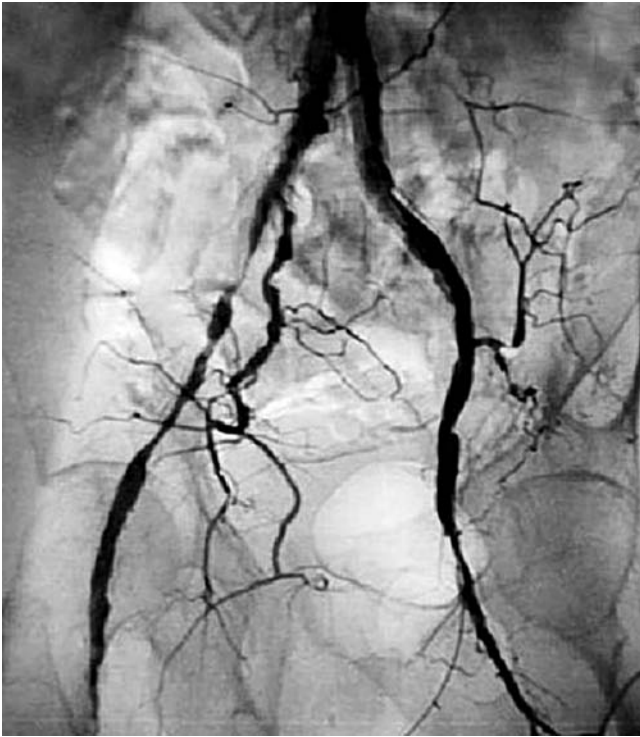

Figure 23-54. Type III aortoiliac occlusive disease is a multilevel disease pattern that affects the aortoiliac segment as well as infrarenal femoropopliteal vessels. Most patients with this disease pattern tend to present with symptoms of advanced ischemia and require revascularization for limb salvage rather than for claudication.

limb salvage rather than for claudication. These patients have a decreased 10-year life expectancy when compared to patients with localized aortoiliac disease.

The most commonly used classification system of iliac lesions has been set forth by the TransAtlantic Inter-Society Consensus (TASC) group with recommended treatment options. This lesion classification categorizes the extent of atherosclerosis and has suggested a therapeutic approach based on this classification (Table 23-14 and Fig. 23-55).² According to this consensus document, endovascular therapy is the treatment of choice for type A lesions, and surgery is the treatment of choice for type D lesions. Endovascular treatment is the preferred treatment for type B lesions, and surgery is the preferred treatment for good-risk patients with type C lesions. In comparison to the 2000 TASC document, the commission has not only made allowances for treatment of more extensive lesions, but also takes into account the continuing evolution of endovascular technology and the skills of individual interventionalists when stating that the patient's comorbidities, fully informed patient preference, and the local operator's long-term success rates must be considered when making treatment decisions for type B and type C lesions.^{2,134}

General Treatment Considerations

There is no effective medical therapy for the management of aortoiliac disease, but control of risk factors may help slow progression of atherosclerosis. Patients should have hypertension, hyperlipidemia, and diabetes mellitus controlled. They should be advised to stop smoking. Most patients are empirically placed on antiplatelet therapy. A graduated exercise program

Table 23-14

TASC classification of aortoiliac occlusive lesions

Type A lesions

- Unilateral or bilateral stenoses of CIA
- Unilateral or bilateral single short (≤ 3 cm) stenosis of EIA

Type B lesions

- Short (≤ 3 cm) stenosis of infrarenal aorta
- Unilateral CIA occlusion
- Single or multiple stenosis totaling 3–10 cm involving the EIA not extending into the CFA
- Unilateral EIA occlusion not involving the origins of internal iliac artery or CFA

Type C lesions

- Bilateral CIA occlusions
- Bilateral EIA stenoses 3–10 cm long not extending into the CFA
- Unilateral EIA stenosis extending into the CFA
- Unilateral EIA occlusion that involves the origins of internal iliac artery and/or CFA
- Heavily calcified unilateral EIA occlusion with or without involvement of origins of internal iliac artery and/or CFA

Type D lesions

- Infrarenal aortoiliac occlusion
- Diffuse disease involving the aorta and both iliac arteries requiring treatment
- Diffuse multiple stenoses involving the unilateral CIA, EIA, and CFA
- Unilateral occlusions of both CIA and EIA
- Bilateral occlusions of EIA
- Iliac stenoses in patients with AAA requiring treatment and not amenable to endograft placement or other lesions requiring open aortic or iliac surgery

AAA = abdominal aortic aneurysm; CFA = common femoral artery; CIA = common iliac artery; EIA = external iliac artery.

may improve walking efficiency, endothelial function, and metabolic adaptations in skeletal muscle, but, there is usually minimal improvement in patients with aortoiliac disease who are treated with these measures. Failure to respond to exercise and/or drug therapy should prompt consideration for limb




Figure 23-55. Schematic depiction of the TransAtlantic Inter-Society Consensus classification of aortoiliac occlusive lesions.

revascularization. Patients with buttock claudication and reduced or absent femoral pulses who fail to respond to exercise and drug therapy should be considered for revascularization because they are less likely than patients with more distal lesions to improve without concomitant surgical or endovascular intervention.

Surgical Reconstruction of Aortoiliac Occlusive Disease

Aortobifemoral Bypass. Surgical options for treatment of aortoiliac occlusive diseases consist of various configurations of aortobifemoral bypass grafting, various types of extra-anatomic bypass grafts, and aortoiliac endarterectomy. The procedure performed is determined by several factors, including anatomic distribution of the disease, clinical condition of the patient, and personal preference of the surgeon.

In most cases, aortobifemoral bypass is performed because patients usually have disease in both iliac systems. Although one side may be more severely affected than the other, progression does occur, and bilateral bypass does not complicate the procedure or add to the physiologic stress of the operation. Aortobifemoral bypass reliably relieves symptoms, has excellent long-term patency (approximately 70%–80% at 10 years), and can be completed with a tolerable perioperative mortality (2%–3%).¹³⁵

Technical Considerations for Aortobifemoral Bypass. Both femoral arteries are initially exposed to ensure that they are adequate for the distal anastomoses. The abdomen is then opened in the midline, the small intestine is retracted to the right, and the posterior peritoneum overlying the aorta is incised. A retroperitoneal approach may be selected as an alternative in certain situations. This approach involves making a left flank incision and displacing the peritoneum and its contents to the right. Such an approach is contraindicated if the right renal artery is acutely occluded, since visualization from the left flank is very poor. Tunneling of a graft to the right femoral artery is also more difficult from a retroperitoneal approach, but can be achieved. The retroperitoneal approach has been reputed to be better tolerated than midline laparotomy for patients with multiple previous abdominal operations and with severe pulmonary disease. Further proposed advantages of the retroperitoneal approach include less gastrointestinal disturbance, decreased third space fluid losses, and ease with which the pararenal aorta can be accessed. There are randomized reports, however, that support and refute the superiority of this approach. A collagen-impregnated, knitted Dacron graft is used to perform the proximal aortic anastomosis, which can then be made in either an end-to-end or end-to-side fashion using 3-0 polypropylene suture. The proximal anastomosis should be made as close as possible to the renal arteries to decrease the incidence of restenosis from progression of the atherosclerotic occlusive process in the future.

An end-to-end proximal aortic anastomosis is necessary in patients with an aortic aneurysm or complete aortic occlusion extending up to the renal arteries (Fig. 23-56). Although in theory the end-to-end configuration allows for less turbulence and less chance of competitive flow with still patent host iliac vessels, there have not been consistent results to substantiate differences in patency between end-to-end and end-to-side grafts. Relative indications for an end-to-side proximal aortic anastomosis include the presence of large aberrant renal arteries, an unusually large IMA with poor back-bleeding suggesting

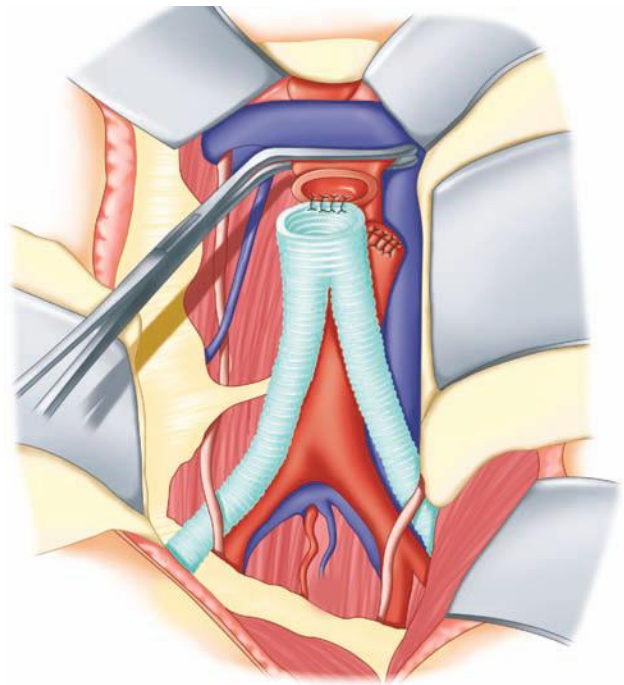


Figure 23-56. In an end-to-end proximal aortic anastomosis, the aorta is divided in half. The proximal end of the aorta is anastomosed to the end of a prosthetic graft, while the distal divided aortic stump is oversewn.

inadequate collateralization, and/or occlusive disease involving bilateral external iliac arteries. Under such circumstances, end-to-end bypass from the proximal aorta to the femoral level devascularizes the pelvic region because there is no antegrade or retrograde flow in the occluded external iliac arteries to supply the hypogastric arteries. As a result of the pelvic devascularization, there is an increased incidence of impotence, postoperative colon ischemia, buttock ischemia, and paraplegia secondary to spinal cord ischemia despite the presence of excellent femoral and distal pulses.

An end-to-side proximal aortic anastomosis can be associated with certain disadvantages, which include the potential for distal embolization when applying a partially occlusive aortic clamp (Fig. 23-57). Furthermore, the distal aorta often proceeds to total occlusion after an end-to-side anastomosis. There may also be a higher incidence of aortoenteric fistula following construction of end-to-side proximal anastomoses because the anterior projection makes subsequent tissue coverage and reperitonealization of the graft more difficult. The limbs of the

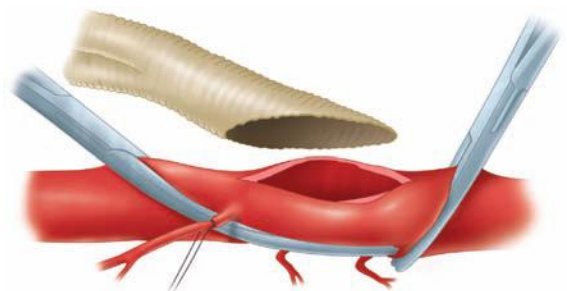


Figure 23-57. In an end-to-side aortic anastomosis, the end of a prosthetic graft is connected to the side of an aortic incision.

graft are tunneled through the retroperitoneum to the groin, where an end-to-side anastomosis is fashioned between the graft and the bifurcation of the CFA using 5-0 polypropylene suture. Endarterectomy or patch angioplasty of the profunda femoris may be required concurrently. Once the anastomoses have been fashioned and the graft thoroughly flushed, the clamps are removed and the surgeon carefully controls the degree of aortic occlusion until full flow is re-established. During this period, the patient must be carefully monitored for hypotension. Declamping hypotension is a complication of sudden restoration of aortic flow, particularly following prolonged occlusion. Once flow has been re-established, the peritoneum is carefully reapproximated over the prosthesis to prevent fistulization into the intestine.

Despite the presence of multilevel disease in most patients, a properly performed aortobifemoral operation can provide arterial inflow and alleviate claudication symptoms in 70% to 80% of patients; however, 10% to 15% of patients will require simultaneous outflow reconstruction to address distal ischemia and facilitate limb salvage. The advantage of concomitant distal revascularization is avoidance of reoperation in a scarred groin. As a rule, if the profunda femoris can accept a 4-mm probe and if a No. 3 Fogarty embolectomy catheter can be passed distally for 20 cm or more, the PFA will be sufficient for outflow, and concomitant distal revascularization is not necessary.

Aortic Endarterectomy. Aortoiliac endarterectomy is rarely performed because it is associated with greater blood loss and greater sexual dysfunction and is more difficult to perform. Long-term patency is comparable with aortobifemoral grafting, and thus it remains a reasonable option in cases in which the risk of infection of a graft is excessive, because it involves no prosthetic tissue. Aortoiliac endarterectomy was useful when disease was localized to either the aorta or common iliac arteries; however, at present, aortoiliac PTA, stents, and other catheter-based therapies have become first-line treatment in this scenario. Endarterectomy should not be performed if the aorta is aneurysmal because of continued aneurysmal degeneration of the endarterectomized segment. If there is total occlusion of the aorta to the level of the renal arteries, aortic transection several centimeters below the renal arteries with thrombectomy of the aortic cuff followed by graft insertion is easier and more expeditious when compared to endarterectomy. Involvement of the external iliac artery makes aortic endarterectomy more difficult to complete because of decreased vessel diameter, increased length, and exposure issues. The ability to establish an appropriate endarterectomy plane is compromised due to the muscular and inherently adherent nature of the media in this location. There is a higher incidence of early thrombosis and late failure with extended aortoiliofemoral endarterectomy when compared to bypass grafting as a result of recurrent stenosis.

Axillofemoral Bypass. An axillofemoral bypass is an extra-anatomic reconstruction that derives arterial inflow from the axillary artery to the femoral artery. This is a treatment option for patients with medical comorbidities that prohibit an abdominal vascular reconstruction. It may be performed under local anesthesia and is used for limb salvage. Extra-anatomic bypasses have lower patency when compared to aortobifemoral and, therefore, are seldom recommended for claudication. Before performing this operation, the surgeon should check pulses and blood pressure in both arms to ensure that there is no obvious disease affecting flow through the axillary system. Angiography of the axillosubclavian vasculature is not necessary,

but can be helpful if performed at the time of aortography. The axillary artery is exposed below the clavicle, and a 6- to 8-mm externally reinforced PTFE graft is tunneled subcutaneously down the lateral chest wall and lateral abdomen to the groin. It is anastomosed ipsilaterally at the CFA bifurcation into the SFA and PFA. A femorofemoral crossover graft using a 6- to 8-mm externally reinforced PTFE graft is then used to revascularize the opposite extremity if necessary. Reported patency rates over 5 years vary from 30% to 80%.¹³⁶ Paradoxically, although it is a less complex procedure than aortofemoral grafting, the mortality rate is higher (10%), reflecting the compromised medical status of these patients.¹³⁶

Iliofemoral Bypass. One option for patients with unilateral occlusion of the distal common iliac or external iliac arteries is iliofemoral grafting (Fig. 23-58). Long-term patency is comparable to aortounifemoral bypass, and because the procedure can be performed using a retroperitoneal approach without clamping the aorta, the perioperative mortality is less.¹³⁶

Femorofemoral Bypass. A femorofemoral bypass is another option for patients with unilateral stenosis or occlusion of the common or external iliac artery who have rest pain, tissue loss, or intractable claudication. The primary (assisted) patency at 5 years is reported to be 60% to 70%, and although this is inferior when compared to aortofemoral bypass, there are physiologic benefits, especially for patients with multiple comorbidities because it is not necessary to cross-clamp the aorta.¹³⁷ There are no studies supporting the superiority of unsupported or externally supported PTFE over Dacron for choice of conduit. The fear of the recipient extremity stealing blood from the extremity ipsilateral to the donor limb is not realized unless the donor iliac artery and donor outflow arteries are diseased.¹³⁷ Depending on the skills of the interventionalist or surgeon, many iliac lesions classified as TASC B, C, or D can now be addressed using an endovascular approach, thus obviating the need to perform a femorofemoral bypass. Additionally, femorofemoral bypass can be used as an adjuvant procedure after iliac inflow has been optimized with endovascular methods.

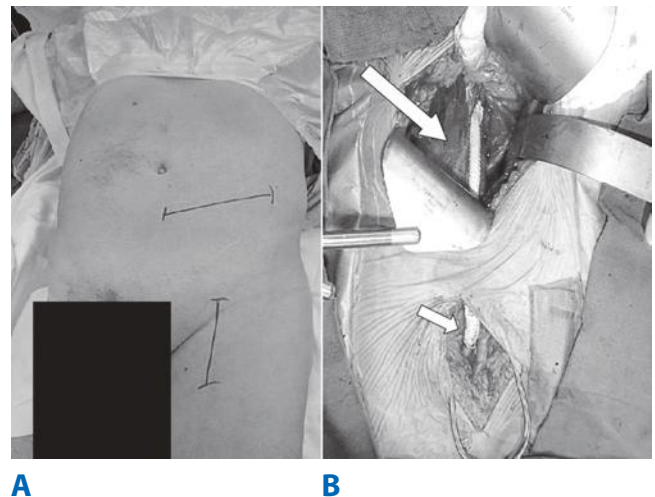


Figure 23-58. A. Skin markings showing the incisions of an iliofemoral bypass. B. A prosthetic bypass graft is used for an iliofemoral artery bypass in which the proximal anastomosis is connected to the common iliac artery (*long arrow*) while the distal anastomosis is connected to the common femoral artery (*short arrow*).

Obturator Bypass. An obturator bypass is used to reconstruct arterial anatomy in patients with groin sepsis resulting from prior prosthetic grafting, intra-arterial drug abuse, groin neoplasm, or damage from prior groin irradiation. This bypass can originate from the common iliac artery, external iliac artery, or uninvolvement of an aortobifemoral bypass. A conduit of Dacron, PTFE, or autologous vein is tunneled through the anteromedial portion of the obturator membrane to the distal SFA or popliteal artery. The obturator membrane must be divided sharply so as to avoid injury to adjacent structures, and care must be taken to identify the obturator artery and nerve that pass posterolaterally. After the bypass is completed and the wounds isolated, the infected area is entered, the involved arteries are débrided to healthy tissue, and vascularized muscle flaps are mobilized to cover the ligated ends.¹³⁸ There have been varied results in terms of patency and limb salvage for obturator bypass. Some authors have reported 57% 5-year patency and 77% 5-year limb salvage rates, whereas others have shown a high rate of reinfection and low patency requiring reintervention.^{138,139}

Thoracofemoral Bypass. The indications for thoracofemoral bypass are (a) multiple prior surgeries with a failed infrarenal aortic reconstruction and (b) infected aortic prosthesis. This procedure is more physiologically demanding than other extra-anatomic reconstructions because the patient must not only tolerate clamping the descending thoracic aorta but also performance of a left thoracotomy. The graft is tunneled to the left CFA from the left thorax posterior to the left kidney in the anterior axillary line using a small incision in the periphery of the diaphragm and an incision in the left inguinal ligament to gain access to the extraperitoneal space from below. The right limb is tunneled in the space of Retzius in an attempt to decrease kinking that is more likely to occur with subcutaneous, suprapubic tunneling. Thoracofemoral bypass has long-term patency comparable to aortofemoral bypass.

Complications of Surgical Aortoiliac Reconstruction

With current surgical techniques and conduits, early postoperative hemorrhage is unusual and occurs in 1% to 2%. It is usually the result of technical oversight or coagulation abnormality.¹⁴⁰ Acute limb ischemia occurring after aortoiliac surgery may be the result of acute thrombosis or distal thromboembolism. The surgeon can prevent thromboembolic events by (a) avoiding excessive manipulation of the aorta, (b) ensuring adequate systemic heparinization, (c) judicious placement of vascular clamps, and (d) thorough flushing prior to restoring blood flow. Acute thrombosis of an aortofemoral graft limb in the early perioperative period occurs in 1% to 3% of patients.¹⁴⁰ Thrombectomy of the graft limb is performed through a transverse opening in the hood of the graft at the femoral anastomosis. With this approach it is possible to inspect the interior of the anastomosis and pass embolectomy catheters distally to clear the superficial femoral and profunda arteries. Various complications may be encountered following aortoiliac or aortobifemoral reconstruction (Table 23-15).

Intestinal ischemia following aortic reconstruction occurs in approximately 2% of cases; however, with colonoscopy mucosal ischemia, which is a milder form, is seen more frequently. The surgeon can identify patients who require concomitant revascularization of the IMA, hypogastric arteries, or mesenteric arteries by examining the preoperative arteriogram for the presence of associated occlusive lesions in the celiac

Table 23-15

Perioperative complications of aortobifemoral bypass grafting

Medical Complications

- Perioperative myocardial infarction
- Respiratory failure
- Ischemia-induced renal failure
- Bleeding from intravenous heparinization
- Stroke

Procedure-Related Complications

Early

- Declamping shock
- Graft thrombosis
- Retroperitoneal bleeding
- Groin hematoma
- Bowel ischemia/infarction
- Peripheral embolization
- Erectile dysfunction
- Lymphatic leak
- Chylous ascites
- Paraplegia

Late

- Graft infection
- Anastomotic pseudoaneurysm
- Aortoenteric fistula
- Aortourinary fistula
- Graft thrombosis

axis, the superior mesenteric arteries, or both. Likewise, patients with a patent and enlarged IMA or a history of prior colonic resections will benefit from IMA reimplantation.

In a comprehensive review of 747 patients who had aortoiliac operations for occlusive disease, secondary operations for late complications such as reocclusion, pseudoaneurysms, and infection were necessary in 21% over a 22-year period.¹⁴¹ The most frequent late complication is graft thrombosis. Limb occlusion occurs in 5% to 10% of patients within 5 years of the index operation and in 15% to 30% of patients ≥ 10 years after the index operation.^{140,141} Anastomotic pseudoaneurysms occur in 1% and 5% of femoral anastomoses in patients with aortofemoral grafts.¹⁴² Predisposing factors to pseudoaneurysm formation include progression of degenerative changes within the host artery, excessive tension at the anastomosis, and infection.¹⁴² Due to the associated risks of thrombosis, distal embolization, infection, and rupture, anastomotic aneurysms should be repaired expeditiously.

Infection following aortoiliac reconstruction is a devastating complication that occurs in 1% of cases. Femoral anastomoses of aortofemoral reconstructions and axillofemoral bypasses are prone to infection.^{141,142} Use of prophylactic antibiotics and meticulous surgical technique are vital in preventing contamination of the graft at the time of implantation. If infection appears localized to a single groin, graft preservation and local measures such as antibiotic irrigation, aggressive debridement, and soft tissue coverage with rotational muscle flaps may prove successful. Most patients with infected aortoiliacofemoral reconstructions usually require graft excision and revascularization via remote uncontaminated routes or the use of in situ replacement to clear the infective process and maintain limb viability. Aortoenteric

fistula and associated gastrointestinal hemorrhage are devastating complications, with a 50% incidence of death or limb loss. The incidence of aortoenteric fistula formation appears to be higher after an end-to-side proximal anastomosis, because it is more difficult to cover the prosthesis with viable tissue and avoid contact with the gastrointestinal tract with this configuration.^{141,142} Treatment of aortoenteric fistula requires resection of all prosthetic material, closure of the infrarenal abdominal aorta, repair of the gastrointestinal tract, and revascularization by means of an extra-anatomic graft.

Endovascular Treatment for Aortic Disease

Although aortofemoral bypass surgery has excellent long-term patency and can be performed with low mortality rates, there are patients who are unable to withstand the physiologic stress of longer open procedures performed under general anesthesia, which require aortic cross-clamping and which are associated with greater blood loss. These patients are more suited to endovascular interventions despite the decreased durability and requirement for more frequent reinterventions.

Focal Aortic Stenosis. The endovascular technique used to treat infrarenal aortic stenoses is similar to that used for iliac artery disease. Bilateral CFA access is established followed by insertion of a 10-French sheath. The lesion is crossed using a hydrophilic wire and a supporting selective catheter and then changed for a stiffer guidewire. A self-expanding nitinol stent or a balloon-expandable stent mounted on a larger-caliber angioplasty balloon is implanted followed by adequate postdilatation. At the physician's discretion, "kissing" stents, simultaneous bilateral proximal iliac stents, are deployed if the lesion is in the distal aorta in the proximity of the aortic bifurcation. The role of covered stents such as cuffs made for endoluminal AAA repair has not been rigorously studied. The aortic diameter should be sized with a calibrated catheter during the angiography or by preintervention CT scanning to avoid undersizing. Balloon size will range from 12 to 18 mm in most cases. A single stent is generally sufficient in most cases. Large Palmaz-type stents mounted on XXL balloons (Meditech, Westwood, MA) have been successfully used and may be inflated up to 25 mm in diameter if needed. Newer self-expanding stents have also been used. Concentric aortic stenosis may encroach upon the IMA, and coverage of this vessel may be unavoidable. Care should be taken to use low inflation pressures (5 mmHg) to minimize the risk of aortic rupture. Patient complaints of back or abdominal pain during balloon inflation should be taken seriously as they may suggest impending rupture. In case of a calcified small-caliber, hypoplastic aorta (≤ 12 mm, typically in female patients), it is recommended to use smaller diameter stents. To achieve clinical improvement, these patients can be recanalized to an aortic diameter of 8 or 9 mm. Distal embolization is one of the potential complications of endovascular treatment for aortic stenoses. Full heparinization, meticulous technique during wire and catheter manipulations, and primary stenting reduce the risk of this complication. Since calcified aortic stenoses are prone to rupture during dilation, it is recommended to be cognizant of the extent of the calcification with preoperative CT scans. In case of aortic rupture, as long as wire access has been maintained, an occlusion balloon can be inflated proximal to the disrupted segment to achieve hemostasis, and the rupture can be covered with a stent graft or repaired with open surgery.

Occlusive Lesions of the Aortic Bifurcation. Occlusive lesions are treated with the kissing balloon technique to avoid

dislodging aortic plaque. Two angioplasty balloons of equal size are positioned across the ostia of the common iliac arteries, using a retrograde approach, and inflated. Simultaneous balloon dilatation at the origins of both common iliac arteries is advocated, even in the presence of unilateral lesion, to protect the contralateral common iliac artery from dissection or plaque embolization. Calcified lesions that typically occur at the aortic bifurcation are not amenable to balloon dilatation and frequently require that a distal aortic reconstruction be performed using "kissing stents." Fears that the proximal ends of the stents that extend into the distal aorta will become a nidus for thrombus formation or cause hemolysis have not been realized. The results are difficult to interpret because these bifurcation lesions are usually included in studies with iliac artery lesions. Patency rates for aortic bifurcation PTA range from 76% to 92% at 3 years.¹⁴³ The largest series reported to date includes 79 patients with aortic bifurcation lesions. The cumulative clinical success rate at a mean of 4 years was 93%.¹⁴⁴ In more recent years, stents have been used to reconstruct the aortic bifurcation.¹⁴⁵ The kissing stent technique is well-suited for orificial lesions. Technical success with kissing stents at the aortic bifurcation has been reported to be 95% to 100%.¹⁴⁵ In the largest series reported, the primary patency at 3 years was 79%.¹⁴⁶

Endovascular Treatment for Iliac Artery Disease

Percutaneous Transluminal Angioplasty. PTA is most useful in the treatment of isolated iliac stenoses of less than 4 cm in length. When used for stenoses rather than occlusion, a 2-year patency of 86% can be achieved.¹⁴⁷ The complication rate is approximately 2%, consisting of distal embolization, medial dissection, and acute thrombosis.

Technical Considerations for Iliac Interventions. Crossing a high-grade stenosis or occlusion can be challenging in the iliac arteries. It is vital to image the lesion well because multiple views and use of the image intensifier will frequently uncover the anatomic reason for the difficulty. Frequently, the difficulty is the result of vessel tortuosity that cannot be appreciated on the original view. Use of an angled hydrophilic guidewire and an angled catheter can provide steering and add extra support for the wire trying to cross the lesion. Patience, persistence, and periodic reimaging will facilitate the crossing of a lesion in the great majority of cases. Guidewire traversal must be achieved for performance of endovascular iliac intervention. Over 90% of iliac occlusions can be passed with simple guidewire techniques. The preferred approach for recanalizing a common iliac artery occlusion is retrograde passage of devices from an ipsilateral CFA puncture because, in this manner, distance to the lesion is short and access is straighter. A stenosis is normally crossed using a combination of a soft-tip 0.035-inch guidewire (i.e., Bentson-type wire) or hydrophilic wire and a 5-French straight or selective catheter. One of the hazards of retrograde recanalization is that the guidewire stays in a sub-intimal location and cannot be redirected into the true lumen at the aortic bifurcation. There are several approaches that can be used to achieve re-entry of total chronic occlusions. Specialized catheters allow passage of a needle and guidewire across the intima distal to the occlusion. Intravascular ultrasound can be used for true lumen re-entry under fluoroscopic guidance. Another method of achieving true lumen re-entry involves performing the recanalization from an antegrade contralateral

CFA approach. A 4-French Berenstein catheter (Cordis Corp., Miami Lakes, FL) is used to probe the occlusion. The lesion can be crossed in most instances (5%–20% failure rate) with a hydrophilic guidewire or occasionally with its stiffer back end. As soon as the guidewire has crossed the obstruction and lies within the ipsilateral external iliac artery lumen, it is snared and partially pulled out of the ipsilateral CFA. A short catheter is then inserted in a retrograde fashion over the wire end into the abdominal aorta proximal to the lesion. The hydrophilic guidewire is then exchanged for a stiffer Amplatz (Boston Scientific, Natick, MA) guidewire to facilitate iliac stenting.

Obtaining arterial access when there are absent femoral pulsations is aided by the use of ultrasound guidance and “road-map” imaging software, which is available on modern angiographic equipment. When the lesion is successfully crossed, balloons of an appropriate size and length are selected for the angioplasty. Most common iliac arteries will accommodate 8- to 10-mm diameter balloons, whereas most external iliac arteries will accommodate 6- to 8-mm diameter balloons. Inflation is performed with caution, especially if there is heavy calcification, and should be guided by patient discomfort, pressure gauge readings, and changes in balloon outline.

If guidewire traversal is straightforward, consideration should be given to the presence of an acute thrombosis that may benefit from catheter-directed thrombolysis. If guidewire traversal is challenging, it is unlikely that catheter-directed thrombolysis will be beneficial. Investigators have found that routine thrombolysis and balloon dilation of occluded arteries prior to stent placement are associated with an increased incidence of distal embolic events.¹⁴⁸ Stents should be placed after inadequate angioplasty. Stents are warranted when there is a greater than 30% residual stenosis, when there is a flow-limiting dissection, or when there is a pressure gradient of ≥ 5 mmHg across the treated segment.¹⁴⁹ Placement of stents can precipitate distal embolization in up to 10%, especially if lesions are friable and vulnerable to manipulation. Routine primary stent placement is not recommended because it has not been found to be superior to selective stenting in terms of outcomes or cost.¹⁵⁰

Primary Stenting versus Selective Stenting in Iliac Arteries. Primary stenting rather than selective stenting should be considered for longer iliac lesions and for all TASC C and D lesions. The primary patency rates at 1, 2, and 3 years were 96%, 90%, and 72%, respectively, for longer lesions (>5 cm) that were primarily stented versus 46%, 46%, and 28%, respectively, with selective stenting.¹⁵⁰ Primary stenting is generally advocated for chronic iliac artery occlusions, recurrent stenosis after previous iliac PTA, and complex stenoses with eccentric, calcified, ulcerated plaques or plaques with spontaneous dissection. All of these lesions are prone to distal embolization during manipulation of wires and angioplasty balloons. Distal embolization with isolated PTA is not common for uncomplicated lesions, but can occur in up to 24% of cases, when treating ulcerated plaques, aortoiliac bifurcation lesions, or iliac occlusions.¹⁵⁰ It is believed that direct stent placement without predilation significantly reduces the risk of distal embolization by trapping potentially embologenic material between the arterial wall and the stent mesh. While PTA has demonstrated excellent results in focal stenoses of the abdominal aorta and iliacs, primary stenting in these locations is safe, improves patency rates, reduces the degree of restenosis when compared with PTA alone, and decreases the risk of distal embolization. Additional

potential advantages of direct stenting include shorter procedural time and less radiation exposure. The Dutch Iliac Stent Trial has provided evidence that refutes the superiority of primary stenting over angioplasty alone.¹⁵¹ Most interventionalists continue to perform angioplasty first and stent selectively for inadequate results. The approach to aortoiliac stenting is intuitive. Individual judgment and experience are important in the decision-making process, and there are lesions with unstable morphology such as long occlusions, ulceration, and dissection that warrant primary stenting.

Stent Graft Placement for Aortoiliac Interventions. Stent grafts have been used to treat complex iliac lesions in an attempt to exclude these sources of embolization. A recent report suggested that the use of stent grafts was beneficial for TASC C and D lesions.¹⁵² Bosiers and colleagues published a series of 91 limbs with diseased iliacs that they treated with 107 stent grafts. They reported successful deployment in all patients without distal embolization or vessel rupture and a primary patency rate of 91.1% at 1 year.¹⁵³ The authors commented about their concerns of causing embolization during placement of the stent grafts and recommended that once an occlusion was traversed with the guidewire, to gently predilate with a 5-mm balloon, followed by smooth stent graft insertion into the newly created channel. The role of stent grafts in aortoiliac occlusive disease has not been fully elucidated yet.

Complications of Endovascular Aortoiliac Interventions

Iliac artery angioplasty is associated with a 2% to 4% major complication rate and 4% to 15% minor complication rate. Many of these minor complications are related to the arterial puncture site. The most frequent complications relate to access site cannulation. Hemorrhage can range from the more common access site hematoma to the rarer retroperitoneal and intraperitoneal hemorrhage. Distal embolization occurs in 2% to 10% of iliac PTA and stenting procedures.¹⁴⁰ Percutaneous catheter aspiration should be the initial treatment for calf vessel embolization, but, for larger emboli, such as those that lodge in the profunda femoris or common femoral arteries, surgical embolectomy may be required because the embolic material contains atherosclerotic plaque, which is not amenable to transcatheter aspiration or catheter-directed thrombolysis. The incidence of pseudoaneurysm formation at the puncture site is 0.5%. The treatment of choice for pseudoaneurysms >2 cm in diameter is percutaneous thrombin injection under ultrasound guidance. Arterial rupture may complicate the procedure in 0.3% of cases. Tamponade of the ruptured artery with an occlusion balloon should be performed, and a covered stent should be placed. In case of failure, surgical treatment is required.

Clinical Results Comparing Surgical and Endovascular Treatment of Aortoiliac Disease

The mortality risk of aortobifemoral bypass in patients with isolated, localized aortoiliac disease is relatively low, whereas for patients with concomitant atherosclerosis in coronary, carotid, and visceral vessels, mortality and morbidity are higher. For this reason, the cumulative long-term survival rate for patients receiving aortoiliac reconstruction remains 10 to 15 years less than anticipated for a normal age- and sex-matched population. Twenty-five percent to 30% of patients with concomitant atherosclerosis in other vascular distributions are dead within 5 years, and 50% to 60% will have died by 10 years.¹⁴²

Compared with conventional aortobifemoral bypass, common iliac angioplasty was shown to have a 10% to 20% lower overall patency rate. It should be noted that these results were reported in early trials that used older generations of endovascular equipment. With continued progress and newer angioplasty balloons and stenting practices, more comparable outcomes are being reported. Review of the literature confirms that there is an 85% to 90% graft patency rate at 5 years and a 70% to 75% graft patency rate at 10 years after aortobifemoral reconstruction.¹⁵⁴ Due in part to factors including continued refinements in anesthetic management, intraoperative monitoring, and postoperative intensive care, low perioperative mortality rates for aortobifemoral bypass can be achieved commonly in today's clinical practice. The most recent systematic review and meta-analysis of 5358 patients who underwent direct open bypass or endovascular treatment for aortoiliac occlusive disease demonstrated superior durability for open bypass, although with longer length of stay and increased risk for complications and mortality, when compared to the endovascular approach.¹⁵⁵ In this study, poor preoperative runoff was greater in the open bypass group (50.0% vs. 24.6%). Mean length of hospital stay was 13 days for open bypass versus 4 days for endovascular treatment procedures. The open bypass group experienced more complications (18.0% vs. 13.4%) and greater 30-day mortality (2.6% vs. 0.7%). At 1, 3, and 5 years, pooled primary patency rates were greater in the open bypass group (94.8% vs. 86.0%, 86.0% vs. 80.0%, and 82.7% vs. 71.4%, respectively); the same was true for secondary patency (95.7% vs. 90.0%, 91.5 vs. 86.5%, and 91.0% vs. 82.5%, respectively).

Despite its lower long-term success, common iliac angioplasty is a useful procedure in patients with focal disease and mild symptoms in whom a major surgical revascularization is not justified. Angioplasty of the iliac vessels can be a useful adjunct to distal surgical bypass as well, increasing the success of distal revascularization and eliminating the risks associated with aortoiliac bypass. Thus, with long-term patency less than, but comparable to, open surgical bypass, and with more favorable morbidity rates, iliac angioplasty has become a well-accepted modality of treatment for iliac occlusive disease. Ideal iliac angioplasty lesions are nonocclusive and short. Patency after intervention is better when lesions occur in larger diameter vessels, when stenoses rather than occlusions are treated, when runoff vessels are patent, and when the indication for intervention is lifestyle-limiting claudication rather than critical limb ischemia.

Becker and colleagues estimated a 5-year patency rate of 72% in an analysis of 2697 cases of iliac angioplasty and noted a better patency (79%) in claudicants.¹⁵⁶ Less favorable results are obtained with long stenoses, external iliac stenoses, and tandem lesions. The reported technical and initial clinical success of balloon angioplasty in iliac artery stenoses exceeds 90% in most series, and the 5-year patency rates range from 54% to 92%.¹⁵⁷ The reported technical and initial clinical success of balloon angioplasty in iliac artery occlusions ranges from 78% to 98%, and the 3-year patency rates range from 48% to 85%.¹⁵⁷

Factors reported to affect the patency of aortoiliac endovascular interventions adversely include quality of runoff vessels, severity of ischemia, and length of diseased segments treated. Likewise as vessel diameter and flow rates change, so do success rates after angioplasty. It was reported in the literature that location of the lesion at the external iliac artery adversely affects both primary and assisted-primary patency. Following angioplasty

of the common iliac artery, patency rates were 81% and 52% at 1 and 6 years, respectively; whereas, after external iliac artery angioplasty, they were 74% and 48% at 1 and 4 years, respectively.¹⁵⁸ Although some literature supports location of the lesion in the external iliac artery as a factor that adversely affects both primary and assisted-primary patency, this has not been a universal finding.¹⁵⁸ Female patients are also reported to have lower patency rates than males following iliac PTA, with or without stent placement in the external iliac artery.¹⁵⁹

Stenting of the iliac arteries provides a durable and curative treatment, with a 3-year patency rate of 41% to 92% for stenosis and a 3-year patency rate of 64% to 85% and 4-year patency rate of 54% to 78% for occlusions.¹⁵⁷ A meta-analysis of 2116 patients by Bosch and Hunink showed that aortoiliac stenting resulted in a 39% improvement in long-term patency compared to balloon angioplasty, despite the fact that complication rates and 30-day mortality rates did not differ significantly.¹⁶⁰ Park and colleagues presented long-term follow-up results in a cohort of patients with all four TASC types of iliac lesions. The authors presented primary patency rates of 87%, 83%, 61%, and 49% at 3, 5, 7, and 10 years, respectively, after the index intervention.¹⁶¹ Leville and colleagues achieved primary and secondary patency rates of 76% and 90%, respectively, after 3 years, in a cohort of patients who received stents for iliac occlusions.¹⁶² The authors postulated that endovascular treatment for iliac occlusive disease should be extended to type C and D lesions, because they observed no detectable differences between the four TASC classifications in terms of primary and secondary patency rates.¹⁶² They concluded that presence of TASC C and D lesions should not preclude endovascular treatment and believe that endovascular attempts should be exhausted before open surgical repair of iliac occlusions is attempted because of the decreased perioperative morbidity and good midterm durability.

Not all results have been in favor of stenting, and at present, universal primary stenting cannot be recommended. Although stents are often used to improve the outcome of PTA, there is no general consensus that stenting should be mandatory in all iliac lesions. Complex, ulcerated iliac lesions with high embologenic potential or recanalized chronic iliac occlusions may be an exception. In the Dutch Iliac Stent Trial, primary stenting did not prove to be superior to iliac angioplasty and selective stenting. The researchers in this prospective randomized multicenter study concluded that balloon angioplasty with selective stenting had comparable 2-year patency rates with primary stenting (77% and 78%, respectively). It must be noted, however, that it was necessary to stent 43% of the patients in the PTA treatment group due to unsatisfactory angioplasty results.¹⁵¹ The 5-year outcomes between the two groups were also similar, with 82% and 80% of the treated iliac segments remaining free of the need for new revascularization procedures after a mean follow-up of 5.6 ± 1.3 years.¹⁵¹

LOWER EXTREMITY ARTERIAL OCCLUSIVE DISEASE

The symptoms of lower extremity occlusive disease are classified into two large categories: acute limb ischemia (ALI) and chronic limb ischemia (CLI). Ninety percent of acute ischemia cases are either thrombotic or embolic. Frequently, sudden onset of limb-threatening ischemia may be the result of acute exacerbation of the pre-existing atherosclerotic disease. Chronic ischemia is largely due to atherosclerotic changes of the lower

extremity that manifest from asymptomatic to limb-threatening gangrene. As the population ages, the prevalence of chronic occlusive disease of the lower extremity is increasing, and it significantly influences lifestyle, morbidity, and mortality. In addition, multiple comorbid conditions increase risks of surgical procedures. Endovascular interventions become an important alternative in treating lower extremity occlusive disease. However, despite rapidly evolving endovascular technology, lower extremity endovascular intervention continues to be one of the most controversial areas of endovascular therapy.

Epidemiology

In a detailed review of the literature, McDaniel and Cronewett concluded that claudication occurred in 1.8% of patients under 60 years of age, 3.7% of patients between 60 and 70 years of age, and 5.2% of patients over 70 years of age.¹⁶³ Leng and his colleagues scanned 784 subjects using ultrasound in a random sample of men and women age 56 to 77 years. Of the subjects who were scanned, 64% demonstrated atherosclerotic plaque.¹⁶⁴ However, a large number of patients had occlusive disease without significant symptoms. In a study by Schroll and Munck, only 19% of patients with peripheral vascular disease were symptomatic.¹⁶⁵ Using ABIs, Stoffers and colleagues scanned 3171 individuals between the ages of 45 and 75 and identified that 6.9% of patients had ABIs <0.95, only 22% of whom had symptoms.¹⁶⁶ In addition, they demonstrated that concomitant cardiovascular and cerebrovascular diseases were three to four times higher among the group with asymptomatic peripheral vascular diseases than those without peripheral vascular disease. Furthermore, they confirmed that 68% of all peripheral arterial obstructive diseases were unknown to the primary care physician, and this group mainly represented less advanced cases of atherosclerosis. However, among patients with an ABI ratio <0.75, 42% were unknown to the primary physicians.

Diagnostic Evaluation

The diagnosis of lower extremity occlusive disease is often made based on a focused history and physical examination and confirmed by the imaging studies. A well-performed physical examination often reveals the site of lesions by detecting changes in pulses, temperature, and appearances. The bedside ABIs using blood pressure cuff also aid in diagnosis. Various clinical signs and symptoms are useful to differentiate conditions of viable, threatened, and irreversible limb ischemia caused by arterial insufficiency (Table 23-16).

Noninvasive studies are important in documenting the severity of occlusive disease objectively. Ultrasound Dopplers

measuring ABIs and segmental pressures are widely used in North America and Europe. Normal ABI is greater than 1.0. In patients with claudication, ABIs decrease to 0.5 to 0.9 and to even lower levels in patients with rest pain or tissue loss.¹⁶⁷ Segmental pressures are helpful in identifying the level of involvement. Decrease in segmental pressure between two segments indicates significant disease. Ultrasound duplex scans are used to identify the site of lesion by revealing flow disturbance and velocity changes. A meta-analysis of 71 studies by Koelemay and associates confirmed that duplex scanning is accurate for assessing arterial occlusive disease in patients suffering from claudication or critical ischemia with an accumulative sensitivity of 80% and specificity of over 95%.¹⁶⁸ Adding an ultrasound contrast agent further increases the sensitivity and specificity of ultrasound technology.¹⁶⁹ Other noninvasive imaging technologies, such as MRA and CTA, are rapidly evolving and gaining popularity in the diagnosis of lower extremity occlusive disease (Figs. 23-59 and 23-60).

Contrast angiography remains the gold standard imaging study. Using contrast angiography, interventionists can locate and size the anatomic significant lesions and measure the pressure gradient across the lesion, as well as plan for potential intervention. Angiography is, however, semi-invasive and should be confined to patients for whom surgical or percutaneous intervention is contemplated. Patients with borderline renal function may need to have alternate contrast agents, such as gadolinium or carbon dioxide, to avoid contrast-induced nephrotoxicity.

Differential Diagnosis

Arterial insufficiency frequently leads to muscle ischemic pain involving the lower extremity muscles, particularly during exercise. Intermittent claudication is pain affecting the calf and, less commonly, the thigh and buttock that is induced by exercise and relieved by rest. Symptom severity varies from mild to severe. Intermittent claudication occurs as a result of muscle ischemia during exercise caused by obstruction to arterial flow. Regarding the differential diagnosis of intermittent claudication, there are a variety of neurologic, musculoskeletal, and venous conditions that may produce symptoms of calf pain (Table 23-17). Additionally, various nonatherosclerotic conditions can also cause symptoms consistent with intermittent lower extremity claudication (Table 23-18). Nocturnal calf muscle spasms or night cramps are not indicative of arterial disease. They are common but are difficult to diagnose with certainty. Foot ulceration is not always the result of arterial insufficiency. Ischemic ulcers occur on the toes or lateral side of the foot and are painful. By comparison, venous ulcers, which are also common, occur above the

Table 23-16

Signs and symptoms of acute limb ischemia

DESCRIPTION	CATEGORY		
	VIABLE	THREATENED	IRREVERSIBLE
Clinical description	Not immediately threatened	Salvageable if promptly treated	Major tissue loss, amputation unavoidable
Capillary return	Intact	Intact, slow	Absent (marbling)
Muscle weakness	None	Mild, partial	Profound, paralysis (rigor)
Sensory loss	None	Mild, incomplete	Profound anesthetic
Arteriovenous Doppler finding	Audible	Inaudible or audible	Inaudible

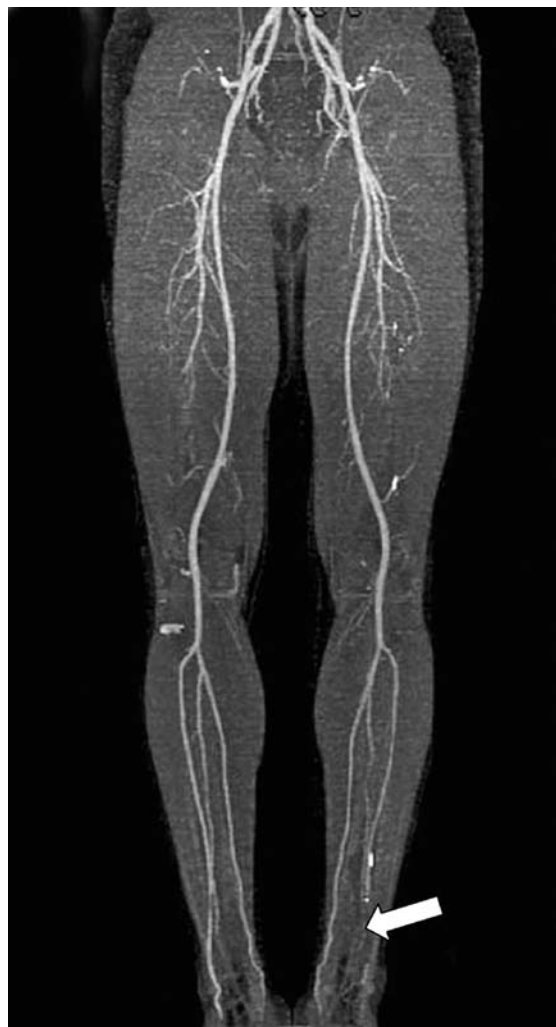

Figure 23-59. High-resolution computed tomography angiography of a patient with normal right lower extremity arterial circulation. Distal occlusive disease is noted in the left tibial arteries (arrow).

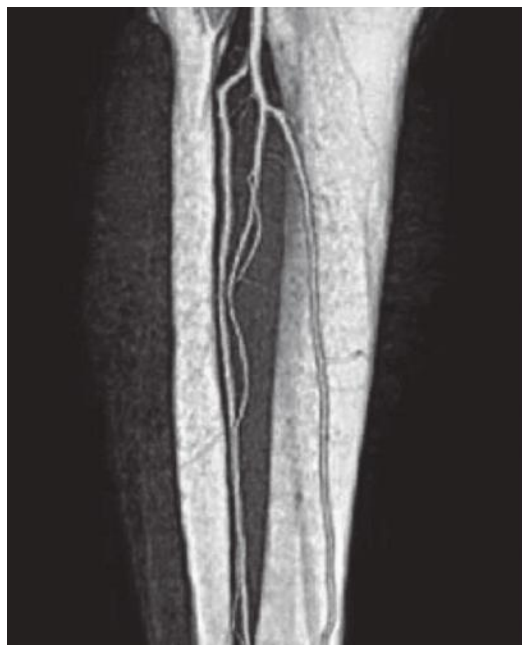
medial malleolus, usually in an area with the skin changes of lipodermatosclerosis, and cause mild discomfort. Neuropathic ulcers are usually found on weight-bearing surfaces, have thick calluses, and are pain free. Ulcers may be the result of more than one etiology. Rest pain must be distinguished from peripheral neuropathy, which is prevalent in diabetic patients. Patients with diabetic neuropathy tend to have decreased vibration and position sense and decreased reflexes. Spinal stenosis causes pain that is exacerbated with standing and back extension.

Lower Extremity Occlusive Disease Classification

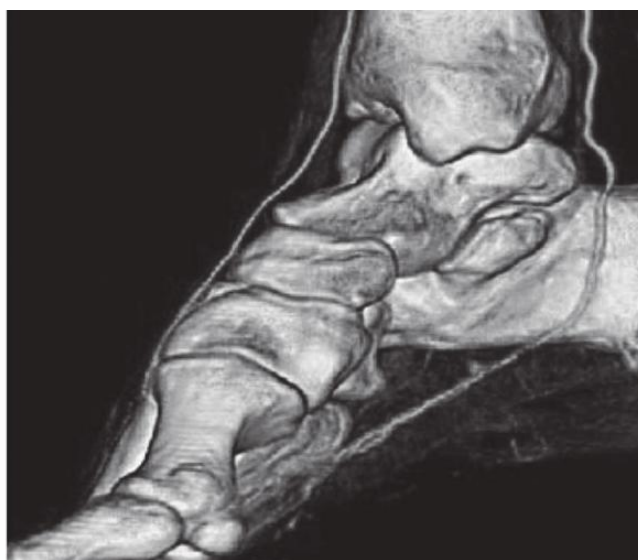Lower extremity occlusive disease may range from exhibiting no symptoms to limb-threatening gangrene. There are two major classifications developed based on the clinical presentations.

The Fontaine classification uses four stages: Fontaine I is the stage when patients are asymptomatic; Fontaine II is when they have mild (IIa) or severe (IIb) claudication; Fontaine III is when they have ischemic rest pain; and Fontaine IV is when patients suffer tissue loss, such as ulceration or gangrene (Table 23-19).¹⁷⁰

The Rutherford classification has four grades (0–III) and seven categories (0–6). Asymptomatic patients are classified



A



B

Figure 23-60. Multidetector computed tomography angiography of a patient with an (A) infrapopliteal arterial circulation and (B) pedal arterial circulation. The high spatial resolution and image quality of these images shows three patent infrapopliteal runoff vessels and patent pedal vessels at the foot level.

into category 0; claudicants are stratified into grade I and divided into three categories based on the severity of the symptoms; patients with rest pain belong to grade II and category 4; and patients with tissue loss are classified into grade III and categories 5 and 6 based on the significance of the tissue loss.² These clinical classifications help to establish uniform standards in evaluating and reporting the results of diagnostic measurements and therapeutic interventions (Table 23-19).

The most clinically useful classification of lower extremity atherosclerotic disease should be based on the morphologic character of the lesions. The TASC taskforce published a guideline separating lower extremity arterial diseases into

Table 23-17

Differential diagnosis of intermittent claudication

CONDITION	LOCATION OF PAIN OR DISCOMFORT	CHARACTERISTIC DISCOMFORT	ONSET RELATIVE TO EXERCISE	EFFECT OF REST	EFFECT OF BODY POSITION	OTHER CHARACTERISTICS
Intermittent claudication (calf)	Calf muscles	Cramping pain	After same degree of exercise	Quickly relieved	None	Reproducible
Chronic compartment syndrome	Calf muscles	Tight, bursting pain	After much exercise (e.g., jogging)	Subsides very slowly	Relief speeded by elevation	Typically heavy-muscled athletes
Venous claudication	Entire leg, but usually worse in thigh and groin	Tight, bursting pain	After walking	Subsides slowly	Relief speeded by elevation	History of iliofemoral deep venous thrombosis, signs of venous congestion, edema
Nerve root compression (e.g., herniated disk)	Radiates down leg, usually posteriorly	Sharp lancinating pain	Soon, if not immediately after onset	Not quickly relieved (also often present at rest)	Relief may be aided by adjusting back position	History of back problems
Symptomatic Baker's cyst	Behind knee, down calf	Swelling, soreness, tenderness	With exercise	Present at rest	None	Not intermittent
Intermittent claudication (hip, thigh, buttock)	Hip, thigh, buttocks	Aching discomfort, weakness	After same degree of exercise	Quickly relieved	None	Reproducible
Hip arthritis	Hip, thigh, buttocks	Aching discomfort	After variable degree of exercise	Not quickly relieved (and may be present at rest)	More comfortable sitting, weight taken off legs	Variable, may relate to activity level, weather changes
Spinal cord compression	Hip, thigh, buttocks (follows dermatome)	Weakness more than pain	After walking or standing for same length of time	Relieved by stopping only if position changed	Relief by lumbar spine flexion (sitting or stooping forward) pressure	Frequent history of back problems, provoked by increased intra-abdominal pressure
Intermittent claudication (foot)	Foot, arch	Severe deep pain and numbness	After same degree of exercise	Quickly relieved	None	Reproducible
Arthritic, inflammatory process	Foot, arch	Aching pain	After variable degree of exercise	Not quickly relieved (and may be present at rest)	May be relieved by not bearing weight	Variable, may relate to activity level

Table 23-18

Nonatherosclerotic causes of intermittent claudication

- Aortic coarctation
- Arterial fibrodysplasia
- Iliac syndrome of the cyclist
- Peripheral emboli
- Persistent sciatic artery
- Popliteal aneurysm
- Popliteal cyst
- Popliteal entrapment
- Primary vascular tumors
- Pseudoxanthoma elasticum
- Remote trauma or radiation injury
- Takayasu's disease
- Thromboangiitis obliterans

femoropopliteal and infrapopliteal lesions (Table 23-20). This guideline is particularly useful in determining intervention strategies based on the disease classifications. Based on the guideline, femoropopliteal lesions are divided into four types: A, B, C, and D. Type A lesions are single focal lesions less than 3 cm in length and do not involve the origins of the SFA or the distal popliteal artery. Type B lesions are single lesions 3 to 5 cm in length not involving the distal popliteal artery or multiple or heavily calcified lesions less than 3 cm in length. Type C lesions are multiple stenoses or occlusions greater than 15 cm in length or recurrent stenoses or occlusions that need treatment after two endovascular interventions. Type D lesions are those with complete occlusion of CFA, SFA, or popliteal artery.²

In a similar fashion, infrapopliteal arterial diseases are classified into four types based on TASC guideline (Fig. 23-61). Type A lesions are single lesions less than 1 cm in length not involving the trifurcation. Type B lesions are multiple lesions less than 1 cm in length or single lesions shorter than 1 cm involving the trifurcation. Type C lesions are lesions that extensively involve trifurcation or 1- to 4-cm stenotic or 1- to 2-cm occlusive lesions. Type D lesions are occlusions longer than 2 cm or diffuse lesions.²

Etiology of Acute Limb Ischemia

ALI is defined as sudden loss of limb perfusion, and the term is applicable up to 2 weeks after an initiating event. While the instances of acute leg ischemia caused by emboli have decreased due to more effective treatment of rheumatic fever and atrial fibrillation, the incidence of thrombotic acute leg ischemia has increased. Even with the extensive use of newer endovascular techniques including thrombolysis, most published series report a 10% to 30% 30-day amputation rate.² The short-term mortality of patients presenting with acute ischemia is 15% to 20%. The most common etiologies of ALI include embolism, native vessel thrombosis, reconstruction thrombosis, trauma, and complications of peripheral aneurysm. Most cases of lower extremity ALI are the result of thrombosis of a prosthetic conduit. This stems from increased use of prosthetic conduits to address CLI.

Presenting symptoms in ALI are pain and loss of sensory or motor function. The abruptness and time of onset of the pain, its location and intensity, and change in severity over time should all be taken into consideration. The duration and intensity of the pain and presence of motor or sensory changes are very important in clinical decision making and urgency of revascularization. Thrombolysis may be less effective for thrombosis of ≥ 2 weeks in duration compared with acute thrombosis.¹⁷¹

Arterial Embolism. The heart is the most common source of distal emboli, which accounts for more than 90% of peripheral arterial embolic events. Atrial fibrillation is the most common source. Sudden cardioversion results in the dilated noncontractile atrial appendage regaining contractile activity, which can dislodge the contained thrombus. Other cardiac sources include mural thrombus overlying a myocardial infarction or thrombus forming within a dilated left ventricular aneurysm. Mural thrombi can also develop within a ventricle dilated by cardiomyopathy. Emboli that arise from a ventricular aneurysm or from a dilated cardiomyopathy can be very large and can lodge at the aortic bifurcation (saddle embolus), thus rendering both legs ischemic. Diseased valves are another source of distal embolization. Historically, this occurred as a result of rheumatic heart disease. Currently, subacute endocarditis and acute bacterial endocarditis are the more common causes. Infected emboli can seed the recipient vessel wall, creating mycotic aneurysms.

Table 23-19

Classification of peripheral arterial disease based on the Fontaine and Rutherford classifications

FONTAINE CLASSIFICATION		RUTHERFORD CLASSIFICATION		
STAGE	CLINICAL	GRADE	CATEGORY	CLINICAL
I	Asymptomatic	0	0	Asymptomatic
IIa	Mild claudication	I	1	Mild claudication
IIb	Moderate to severe claudication	I	2	Moderate claudication
		I	3	Severe claudication
III	Ischemic rest pain	II	4	Ischemic rest pain
IV	Ulceration or gangrene	III	5	Minor tissue loss
		III	6	Major tissue loss

Table 23-20

TransAtlantic Inter-Society Consensus classification of femoral popliteal occlusive lesions

Type A lesions

- Single stenosis ≤ 10 cm in length
- Single occlusion ≤ 5 cm in length

Type B lesions

- Multiple lesions (stenoses or occlusions), each ≤ 5 cm
- Single stenosis or occlusion ≤ 15 cm not involving the infrageniculate popliteal artery
- Single or multiple lesions in the absence of continuous tibial vessels to improve inflow for a distal bypass
- Heavily calcified occlusion ≤ 5 cm in length
- Single popliteal stenosis

Type C lesions

- Multiple stenoses or occlusions totaling >15 cm with or without heavy calcification
- Recurrent stenoses or occlusions that need treatment after two endovascular interventions

Type D lesions

- Chronic total occlusions of CFA or SFA (>20 cm, involving the popliteal artery)
- Chronic total occlusion of popliteal artery and proximal trifurcation vessels

CFA = common femoral artery; SFA = superficial femoral artery.

An electrocardiogram (ECG) will diagnose atrial fibrillation. A transthoracic or transesophageal echocardiogram should be performed looking for a cardiac source. It is important to seek other sources of the embolus using CT scanning of the descending thoracic and abdominal aorta. More unusual sources include mural thrombus from an aortic aneurysm, and occasionally, idiopathic arterial-to-arterial thrombus occurs,

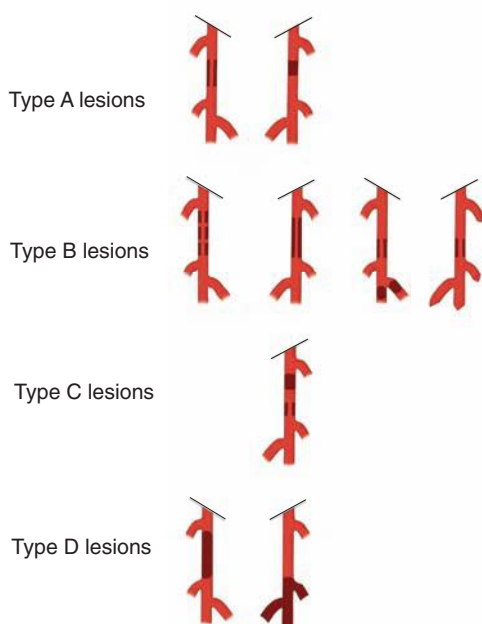


Figure 23-61. Schematic depiction of TransAtlantic Inter-Society Consensus classification of femoral popliteal occlusive lesions.

usually from thrombus that has formed in an atherosclerotic aortic arch or descending thoracic aorta. The presence of mobile plaque on transesophageal echocardiography is suggestive of this source.

Paradoxical embolus occurs when a patient has a patent foramen ovale and an embolus from a deep venous thrombosis crosses through the atrial defect into the left side of the heart and passes into the peripheral circulation. This is diagnosed using a bubble echocardiography, in which air bubbles introduced into the venous circulation can be seen traversing the septal defect.

Arterial Thrombosis. Thrombosis can occur in native arteries and in arterial reconstructions. Patients with thrombosed arterial segments often have an underlying atherosclerotic lesion at the site of thrombosis or aneurysmal degeneration with mural thrombosis. It is important to obtain a history, determine risk factors for atherosclerosis and hypercoagulable status, and examine the contralateral extremity for circulatory problems. Patients with thrombosis of prior arterial reconstructions have limb incisions from previous surgery, and graft occlusion can be confirmed with duplex imaging.

Clinical Manifestations of Acute Limb Ischemia

Acute lower extremity ischemia manifests with the “five Ps”: *pain*, *pallor*, *paresthesias*, *paralysis*, and *pulselessness*, to which some add a sixth “P”—*poikilothermia* or “*perishing cold*.” Pain is the usual symptom that causes a patient to present to the emergency room. The most common location for an embolus to lodge in the leg is at the common femoral bifurcation. Typically a patient will complain of foot and calf pain. Pulses are absent, and there may be diminution of sensation. Inability to move the affected muscle group is a sign of very severe ischemia and necessitates urgent revascularization. During evaluation of the affected extremity, it is important to compare findings with the contralateral limb. Clinical evaluation is extremely important in determining the etiology and location of the obstruction. One of the most important pieces of information to obtain is whether the patient has had prior vascular procedures or if there is a history of lower extremity claudication. Either of these features suggests pre-existing vascular disease, renders revascularization more complicated, and usually mandates angiography to permit surgical planning. On the contrary, in a patient with no history suggestive of prior vascular disease, the etiology is most likely embolic, and simple thrombectomy is more likely to be successful.

Absent bilateral femoral pulses in a patient with bilateral lower extremity ischemia is most likely due to saddle embolus to the aortic bifurcation. A palpable femoral pulse and absent popliteal and distal pulses may either be due to distal common femoral embolus (the pulse being palpable above the level of occlusion) or embolus to the superficial femoral or popliteal arteries. Typically, emboli lodge at arterial bifurcations where they are trapped due to sudden reductions in arterial diameter. A popliteal trifurcation embolus will present with calf ischemia and absent pedal pulses, possibly with a popliteal pulse present. The finding of palpable contralateral pulses and the absence of ipsilateral pulses in the acutely ischemic leg are suggestive of an embolus, irrespective of presence of Doppler signals. Arteriography is not mandatory in patients without antecedent history suggestive of vascular disease; nevertheless, all patients should be positioned on the operating room table in such a way that fluoroscopic access to the entire inflow and outflow tract is possible if necessary.

The main question to be answered by the history and physical examination is the severity of the ALI, which is the major consideration in early management decisions. Patients with ALI should be evaluated in a fashion that considers the severity and duration of ischemia at the time of presentation. Ideally, all patients with acute ischemia should be investigated with imaging, especially if there is an antecedent vascular reconstruction; however, the clinical condition and access to resources must guide further investigations.² Unnecessary delays can result in amputation. Arteriography, if it can be performed in a timely fashion, is an excellent modality for localizing obstructions and deciding which type of intervention (endovascular, embolectomy, or bypass) patients will benefit more from. One of the goals of treatment for ALI is to prevent thrombus propagation; therefore, expedient anticoagulation with heparin is indicated as soon as the diagnosis is suspected.

Treatment Considerations for Acute Limb Ischemia

In the absence of any significant contraindication, the patient with an ischemic lower extremity should be immediately anticoagulated. This will prevent propagation of the clot into unaffected vascular beds. Intravenous fluid should be started and a Foley catheter inserted to monitor urine output. Baseline labs should be obtained and creatinine levels noted. A hypercoagulable workup should be performed prior to initiation of heparin if there is sufficient suspicion. According to results from randomized trials, there is no clear superiority for thrombolysis over surgery in terms of 30-day limb salvage or mortality. Access to each treatment option is a major issue in the decision-making process, as time is often critical. National registry data from the United States reveal that surgery is used three- to five-fold more frequently than thrombolysis. Three randomized studies have investigated the role of catheter-directed thrombolytic therapy in the treatment of ALI.¹⁷²

Endovascular Treatment

The potential to reduce mortality and morbidity while achieving limb salvage is the impetus that makes thrombolysis preferable to open surgery as first-line treatment in patients with ALI (class I and IIa). Advantages of thrombolytic therapy over balloon embolectomy include the reduced endothelial trauma and potential for more gradual and complete clot lysis in branch vessels usually too small to access by embolectomy balloons. It is hoped that the more gradual clot dissolution with thrombolysis may decrease the incidence of reperfusion injury that is encountered after open surgical procedures where rapid return of blood flow may precipitate compartment syndrome. Skeletal muscle tissue appears to be most vulnerable to ischemia. Pathophysiologic studies reveal that irreversible damage to muscle tissue starts after 3 hours of ischemia and is nearly complete at 6 hours. Progressive microvascular damage appears to follow rather than precede skeletal muscle tissue damage. The more severe the cellular damage, the greater are the microvascular changes. When the musculature and microvasculature are severely damaged, amputation rather than attempts at revascularization may be the most prudent course to prevent wash-out of toxic by-product from the ischemic limb into the systemic circulation. The mortality rate associated with reperfusion syndrome is high, because of the development of concomitant adult respiratory distress syndrome, shock, disseminated intravascular coagulation, and renal failure.

Table 23-21

Contraindications to thrombolytic therapy

Absolute contraindications

Established cerebrovascular events (including transient ischemic attack) within last 2 months
Active bleeding diathesis
Recent (<10 days) gastrointestinal bleeding
Neurosurgery (intracranial or spinal) within last 3 months
Intracranial trauma within last 3 months
Intracranial malignancy or metastasis

Relative major contraindications

Cardiopulmonary resuscitation within last 10 days
Major nonvascular surgery or trauma within last 10 days
Uncontrolled hypertension (>180 mmHg systolic or >110 mmHg diastolic)
Puncture of noncompressible vessel
Intracranial tumor
Recent eye surgery

Minor contraindications

Hepatic failure, particularly with coagulopathy
Bacterial endocarditis
Pregnancy
Diabetic hemorrhagic retinopathy

Patients with small-vessel occlusion are poor candidates for surgery because they lack distal target vessels to use for bypass. These patients should be offered a trial of thrombolysis, unless they have contraindications to thrombolysis or their ischemia is so severe that the time needed to achieve adequate lysis is considered too long. The major contraindications of thrombolysis are recent stroke, intracranial primary malignancy, brain metastases, or intracranial surgical intervention. Relative contraindications for performance of thrombolysis include renal insufficiency, allergy to contrast material, cardiac thrombus, diabetic retinopathy, coagulopathy, and recent arterial puncture or surgery (Table 23-21).

Advances in clot removal techniques with percutaneous mechanical thrombectomy and thromboaspiration may extend the applicability of this intervention to patients with more advanced degrees of ALI (class IIb) and contraindications to thrombolysis. Several thrombectomy devices have received FDA approval for acute lower extremity arterial thrombosis. The utility of these thrombectomy devices is that they can be used as standalone therapy when there are contraindications for thrombolytic therapy. Additionally, these thrombectomy devices can be used in conjunction with thrombolytic agents, for pharmacomechanical thrombectomy, to enhance clot lysis and to limit the doses and time required for thrombolysis.^{173,174}

Surgical Treatment

Embolectomy. When a decision is made to proceed with open surgical intervention, the abdomen, contralateral groin, and entire lower extremity are prepped in the field. The groin is opened through a vertical incision, exposing the CFA and its bifurcation. Frequently, the location of the embolus at the femoral bifurcation is readily apparent by the presence of a palpable proximal femoral pulse, which disappears distally. The artery is clamped and opened transversely over the bifurcation.

Thrombus is extracted by passing a Fogarty balloon embolectomy catheter. Good back-bleeding and antegrade bleeding suggest that the entire clot has been removed. Embolic material often forms a cast of the vessel and is sent for culture and histologic examination. Completion angiography is advisable to ascertain the adequacy of clot removal. The artery is then closed and the patient fully anticoagulated.

When an embolus lodges in the popliteal artery, in most cases it can be extracted via a femoral incision using the techniques previously described. A femoral approach is preferred because the larger diameter of the femoral artery results in decreased likelihood of arterial compromise when the arteriotomy is closed. The disadvantage with using the femoral approach for embolectomy is the greater difficulty involved in directing the embolectomy catheter into each of the infrapopliteal arteries. Use of fluoroscopic imaging and an over-the-wire thrombectomy catheter can overcome this problem. Alternatively, use of a separate incision to expose the popliteal bifurcation may be necessary to achieve a complete thrombectomy.

A more complex situation arises when a patient has antecedent peripheral vascular disease and *in situ* thrombosis develops on top of pre-existing atheroma because, frequently, embolectomy catheters will not pass through these occlusions. Similarly, when a bypass graft fails, it is usually due to progression of atheroma proximal or distal to the graft anastomoses or to intrinsic stenoses that develop within a vein graft. In these scenarios, expeditious angiography is useful to determine the extent of the occlusion, to search for inflow and distal outflow vessels, and to decide whether thrombolysis or surgery will be the better intervention. Although the surgeon's preference tends to dictate the approach selected, the decision is based on the presence or absence of good target vessels and availability of a suitable bypass conduit. If there are good distal vessels and the saphenous vein is suitable, surgical bypass is recommended, because it is fast, durable, and reliable. In the absence of a good distal target and saphenous vein, or in a patient at high risk for surgery, lysis is recommended.

Bypass Graft Thrombectomy. Bypass thrombectomy is more likely to succeed with prosthetic bypasses. Bypass graft revision or replacement is more appropriate for acute vein graft failures because they are less likely to respond to thrombolysis and require some type of revision, such as valve lysis, interposition, or extension. Thrombectomy of autogenous grafts is prone to failure unless an anatomic cause for failure such as a retained valve or unligated side branch is found and corrected. The performance of a fasciotomy to circumvent reperfusion injury/compartment syndrome is an important consideration.

Complications Related to Treatment for Acute Limb Ischemia

Adverse events related to catheter-directed thrombolysis are primarily related to bleeding complications. The overall risk of hemorrhagic stroke from a thrombolysis procedure has been reported to be 1% to 2.3%, with 50% of hemorrhagic complications occurring during the thrombolytic procedure.¹⁷⁵ Hematoma at the vascular puncture site has been reported in 12% to 17% of cases. Gastrointestinal bleeding is reported in 5% to 10% of cases. Hematuria following thrombolysis is uncommon and should prompt a search for urinary tumors. Hemorrhage requiring transfusion can occur in approximately 25% of patients undergoing thrombolysis.^{167,172} Lytic agents are absolutely contraindicated in patients with intracranial surgery,

intracranial hemorrhage within the last 3 months, or any active bleeding. Most bleeding complications occur at the arterial puncture sites, but concealed retroperitoneal bleeding is possible. The most feared complication that patients can sustain is intracerebral hemorrhage. Older patients may be more susceptible to this complication, and thus many interventionalists are extremely reticent to use thrombolysis in patients older than 80 years of age.

Patients who are treated for acute ischemia are susceptible to two major complications following revascularization: reperfusion and compartment syndromes. Other procedure-related complications include arterial rethrombosis, recurrent embolization, and arterial injuries secondary to the balloon catheter manipulations.

Reperfusion of the ischemic limb is variable in its physiologic effects and directly relates to the severity and extent of the ischemia. Patients with a saddle embolus of the aortic bifurcation and severely ischemic limbs may develop the full-blown "reperfusion syndrome," whereas patients with minimal muscle ischemia who are reperfused in a timely fashion essentially develop no effects. Many patients with ALI have severe underlying cardiac disease and are unable to tolerate even short ischemic periods. Complications occurring after revascularization of the lower extremity and causes of recurrent thrombosis are listed in Table 23-22.

Compartment syndrome occurs after prolonged ischemia is followed by reperfusion. The capillaries leak fluid into the interstitial space in the muscles, which are enclosed within a nondistensible fascial envelope. When the pressure inside the compartment exceeds the capillary perfusion pressure, nutrient flow ceases and progressive ischemia occurs, even in the presence of peripheral pulses. Consequently, every patient who has sustained an ischemic event and is reperfused is monitored for compartment syndrome, which is characterized by excessive pain in the compartment, pain on passive stretching of the compartment, and sensory loss due to nerve compression of the nerves coursing through the compartment (Table 23-23 and Fig. 23-62). The most commonly affected compartment is the anterior compartment in the leg. Numbness in the web space between the first and second toes is diagnostic due to compression of the deep peroneal nerve. Compartment pressure is measured by inserting an arterial line into the compartment and recording the pressure. Although controversial, pressures greater than 20 mmHg are an indication for fasciotomy. Compartment pressures are relieved in the leg by medial and lateral incisions. Through

Table 23-22

Complications of arterial revascularization

Compartment syndrome
Ischemic neuropathy
Muscle necrosis
Recurrent thrombosis
Lower leg swelling
Reperfusion syndrome
Hypotension
Hyperkalemia
Myoglobinuria
Renal failure

Table 23-23

Fascial compartments of the lower leg

	ANTERIOR COMPARTMENT	LATERAL COMPARTMENT	SUPERFICIAL POSTERIOR COMPARTMENT	DEEP POSTERIOR COMPARTMENT
Muscles	Tibialis anterior Extensor digitorum longus Peroneus tertius Extensor hallucis longus Extensor digitorum brevis Extensor hallucis brevis	Peroneus longus Peroneus brevis	Gastrocnemius Plantaris Soleus	Tibialis posterior Flexor digitorum longus Flexor hallucis longus
Artery	Anterior tibial artery	Anterior and posterior tibial branches of the popliteal artery		Posterior tibial artery Peroneal artery
Nerve	Deep peroneal nerve	Superficial peroneal nerve		Tibial nerve

the medial incision, long openings are then made in the fascia of the superficial and deep posterior compartments. Through the lateral incision, the anterior and peroneal compartments are opened. Both skin and fascial incisions should be of adequate length to ensure full compartment decompression. Laboratory evidence of rhabdomyolysis is seen in 20% of cases. The myoglobin from damaged muscle precipitates in kidney tubules and causes acute tubular necrosis. Alkalinization of urine increases the solubility of myoglobin, thus preventing it from crystallizing in the tubules. In addition to alkalinization, therapy consists of forced saline diuresis and removal of the source of dead muscle that is releasing the myoglobin.

Clinical Manifestations of Chronic Limb Ischemia

The term CLI is reserved for patients with objectively proven arterial occlusive disease and symptoms lasting for more than 2 weeks. Symptoms include rest pain and tissue loss, such as

ulceration or gangrene (Table 23-24). The diagnosis should be corroborated with noninvasive diagnostic tests, such as the ABI, toe pressures, and transcutaneous oxygen measurements. Ischemic rest pain most commonly occurs below an ankle pressure of 50 mmHg or a toe pressure less than 30 mmHg.² Ulcers are not always of an ischemic etiology (Table 23-25). In many instances, there are other etiologic factors (traumatic, venous, or neuropathic) that are contributory, but it is underlying peripheral arterial disease that may be responsible for delayed or absent healing (Fig. 23-63). Healing of ulcers requires an inflammatory response and greater perfusion than is required to support intact skin and underlying tissues. As a result, the ankle and toe pressure levels needed for healing are higher than the pressures seen with ischemic rest pain. For patients with ulcers or gangrene, the presence of CLI is suggested by an ankle pressure less than 70 mmHg or a toe systolic pressure less than 50 mmHg.² It is important to understand that there is no definite consensus regarding the vascular hemodynamic parameters required to make the diagnosis of CLI.

One of the most common sites for occlusive disease is in the distal SFA as it passes deep through the adductor canal. It may be that the entrapment by the adductor hiatus prevents the compensatory dilation that occurs in atherosclerotic vessels. Stenoses, which develop here, progress to occlusion of the distal third of the SFA (Fig. 23-64). When distal SFA occlusion develops slowly, it may be totally asymptomatic because of development of collaterals from the proximal SFA, or the PFA can bypass the occlusion and reconstitute the popliteal artery. Symptom development is a function of the extent of occlusion, adequacy of collaterals, and the activity level of the patients.

Presenting symptoms of femoropopliteal occlusive disease are broadly classified into two types: limb-threatening and non-limb-threatening ischemia. Claudication is non-limb-threatening, while rest pain, ulceration, and gangrene are limb-threatening and warrant urgent intervention. Occlusive disease of the femoral artery may be isolated or occur in conjunction with multilevel disease that involves both the aortoiliac segment and the tibial vessels. Symptoms in patients with multilevel disease are more severe than in those with single-level disease. Pain from isolated SFA and popliteal occlusion typically manifests as calf claudication. Cramping pain develops in the calf on ambulation, occurs at a reproducible distance, and is relieved by rest. Activities such as climbing stairs or going uphill also exacerbate the pain. Many patients report worsening symptoms during cold

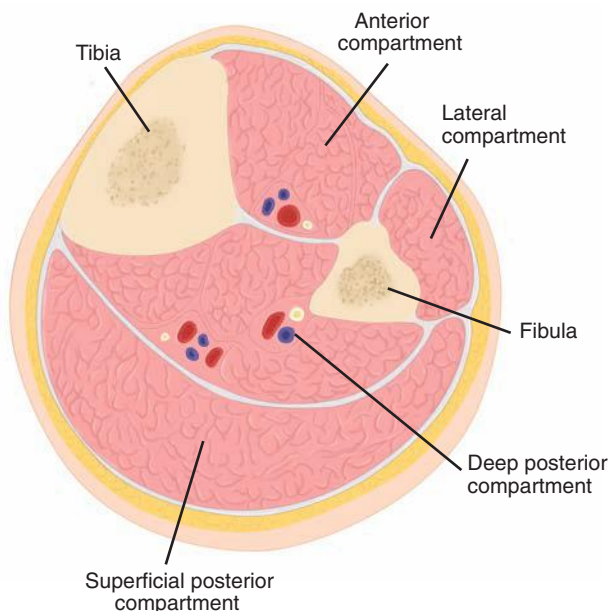


Figure 23-62. Schematic illustration of fascial compartments of the lower extremity.

Table 23-24

Clinical categories of chronic limb ischemia

GRADE	CATEGORY	CLINICAL DESCRIPTION	OBJECTIVE CRITERIA
0	0	Asymptomatic—no hemodynamically significant occlusive disease	Normal treadmill or reactive hyperemia test
	1	Mild claudication	Able to complete treadmill exercise ^a ; AP after exercise >50 mmHg but at least 20 mmHg lower than resting value
I	2	Moderate claudication	Between categories 1 and 3
	3	Severe claudication	Cannot complete standard treadmill exercise ^a and AP after exercise <50 mmHg
II ^b	4	Ischemic rest pain	Resting AP <40 mmHg, flat or barely pulsatile ankle or metatarsal PVR; TP <30 mmHg
III ^b	5	Minor tissue loss—nonhealing ulcer, focal gangrene with diffuse pedal ischemia	Resting AP <60 mmHg, ankle or metatarsal PVR flat or barely pulsatile; TP <40 mmHg
	6	Major tissue loss—extending above TM level, functional foot no longer salvageable	Same as category 5

^aFive minutes at 2 miles per hour on a 12% incline of treadmill exercise.

^bGrades II and III, categories 4, 5, and 6, are encompassed by the term chronic *critical* ischemia.

AP = ankle pressure; PVR = pulse volume recording; TM = transmetatarsal; TP = toe pressure.

weather. It is important to evaluate whether the symptoms are progressive or static. In greater than 70% of patients, the disease is stable, particularly with risk factor modification.

Progression of the underlying atherosclerotic process is more likely to occur in patients with diabetes, those who continue to smoke, and those who fail to modify their atherosclerotic risk factors. In comparison, rest pain is constant, and usually occurs in the forefoot across the metatarsophalangeal joint. It is worse at night and requires placing the foot in a

dependent position to improve symptoms. Patients may report that they either sleep in a chair or hang the foot off the side of the bed. The pain is severe and relentless, even with narcotics. Ischemic ulceration most commonly involves the toes. Any toe can be affected. Occasionally ulcers develop on the dorsum of the foot. Ulceration can occur in atypical positions in an ischemic foot from trauma such as friction from poorly fitting shoes. Injury to a foot with borderline ischemia can convert an otherwise stable situation into one that is limb-threatening. The initial development of gangrene commonly involves the digits. As with all vascular patients, it is important to evaluate their risk factors, intercurrent cardiac diseases, and any prior vascular interventions.

Table 23-25

Symptoms and signs of neuropathic ulcer versus ischemic ulcer

NEUROPATHIC ULCER	ISCHEMIC ULCER
Painless	Painful
Normal pulses	Absent pulses
Regular margins, typically punched-out appearance	Irregular margin
Often located on plantar surface of foot	Commonly located on toes, glabrous margins
Presence of calluses	Calluses absent or infrequent
Loss of sensation, reflexes, and vibration	Variable sensory findings
Increased in blood flow (arteriovenous shunting)	Decreased in blood flow
Dilated veins	Collapsed veins
Dry, warm foot	Cold foot
Bony deformities	No bony deformities
Red or hyperemic in appearance	Pale and cyanotic in appearance

Treatment Considerations for Chronic Limb Ischemia

Patients with vascular diseases frequently have complicated medical comorbidities. Careful patient evaluation and selection should be performed for any peripheral arterial vascular procedure. The fundamental principle is to assess not only the surgical risk from the peripheral arterial system but also the global nature of the atherosclerotic process. Full cardiac evaluations are often necessary due to the high incidence of concomitant atherosclerotic coronary artery disease, resulting in a high risk for ischemic events. Hertzner and associates reviewed coronary angiographies on 1000 patients undergoing elective vascular procedure and identified 25% of concomitant correctable coronary artery disease including 21% in patients undergoing elective peripheral vascular intervention.⁸ Conte and associates analyzed their 20-year experience in 1642 open lower extremity reconstructive surgeries and concluded that patients requiring lower extremity reconstruction presented an increasingly complex medical and surgical challenge compared with the previous decade in a tertiary practice setting.¹⁷⁶ With aging of the population, a growing number of vascular patients have prohibitive medical comorbidities and are deemed high-risk for open surgical repair. Endovascular intervention provides an attractive alternative.

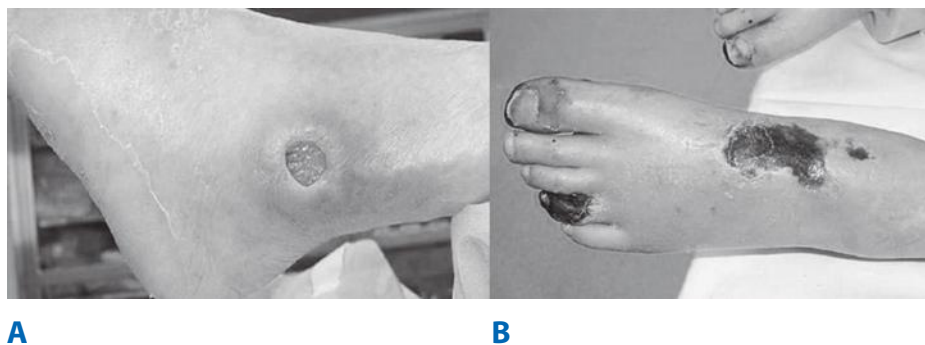


Figure 23-63. **A.** A neuropathic ulcer is characterized by a punched-out appearance with loss of sensation in the surrounding skin. The foot may be warm to touch, and pulses may be present in the distal pedal arteries. **B.** An ischemic ulcer is characterized by a gangrenous skin change in the foot or toes. The foot is usually cold to touch with absent pedal pulses. The foot is painful to touch with decreased distal capillary refills.

As for open surgical repair, the clinical indications for endovascular intervention of lower extremity peripheral arterial diseases include lifestyle-limiting claudication, ischemic rest pain, and tissue loss or gangrene. Importantly, endovascular procedures should be performed by a competent vascular interventionist who understands the vascular disease process and is familiar with a variety of endovascular techniques. In addition, certain lesions may not be amenable to endovascular treatment or may be associated with poor outcomes, such as long segment occlusion, heavily calcified lesion, orifice lesion, or lesions that cannot be traversed by a guide-wire. Proper selection of patients and techniques is critical in achieving good long-term outcome.

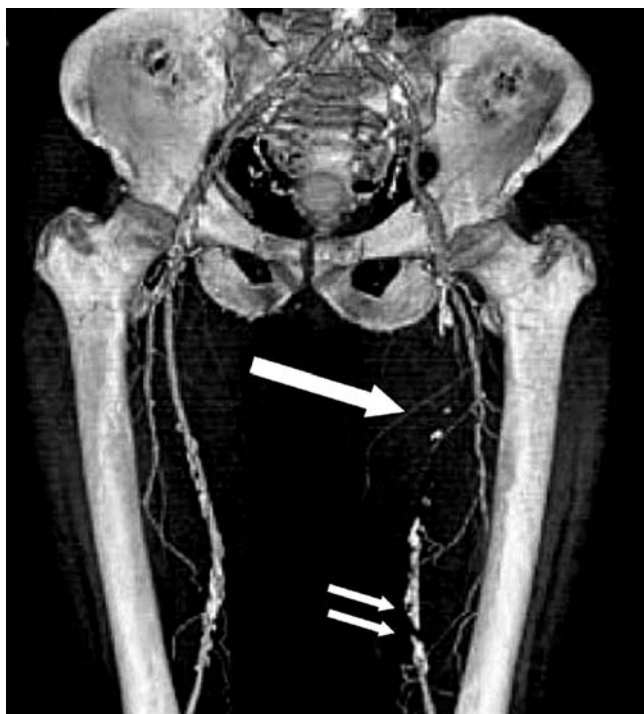

Figure 23-64. Computed tomography angiogram of a patient with an occluded left superficial femoral artery (*single long arrow*) with reconstituted superficial femoral artery at the level of mid-thigh. Diffuse arterial calcifications (*double small arrows*) are noted in the mid and distal left superficial femoral arteries.

Endovascular intervention for lower extremity occlusive disease is continuously evolving. Success and patency rates of endovascular intervention are closely related to the anatomic and morphologic characteristics of the treated lesions. The TASC work group made recommendations on the intervention strategies of lower extremity arterial diseases based on the morphologic characteristics. Based on TASC guidelines, endovascular treatment is recommended for type A lesions, open surgery is recommended for type D lesions, and no recommendations were made for types B and C lesions. However, with rapid advancement in endovascular technologies, there are increased numbers of lesions amenable to endovascular interventions.

There is less literature support for infrapopliteal endovascular intervention due to higher complication and lower success rates. The treatment is restricted for patients with limb-threatening ischemia who lack surgical alternatives. However, with further advancement of endovascular technology and the development of new devices, endovascular intervention is becoming an integral part of treatment (Table 23-26). By itself or combined with open technique, percutaneous intervention plays an important role in therapeutic options for lower extremity occlusive disease. As described by TASC guidelines, four criteria should be measured to evaluate the clinical success of the treatment: improvement in walking distance, symptomatic improvement, quality of life, and overall graft patency. These criteria should all be carefully weighed and evaluated for each individual prior to endovascular therapy.

Endovascular Treatment

Technical Considerations. A sterile field is required in either an operating room or an angiography suite with image capability. The most common and safest access site is CFA via either a retrograde or an antegrade approach. For diagnostic angiography, arterial access should be contralateral to the symptomatic sides. For therapeutic procedures, location of the lesion and the anatomic structures of the arterial tree determine the puncture site. To avoid puncturing the iliac artery or SFA, the femoral head is located under the fluoroscopy and used as the guide for the level of needle entry. In addition, there are several useful techniques to help access a pulseless CFA including ultrasound-guided puncture, using a micro-puncture kit, and targeting calcification in a calcified vessel. The antegrade approach may be challenging, particularly in obese patients. Meticulous technique is crucial in preventing

Table 23-26

Summary of endovascular treatment strategies using device-based infrapopliteal intervention

INTERVENTION	ADVANTAGES	DISADVANTAGES
Angioplasty	<ul style="list-style-type: none"> • Easy to use • Broad range of applications 	<ul style="list-style-type: none"> • Failure in long lesions, calcified lesions, and disease at multiple levels
Balloon-expandable stent	<ul style="list-style-type: none"> • Overcomes arterial recoil from angioplasty • Useful in treatment of flow-limiting dissection 	<ul style="list-style-type: none"> • Crushability can lead to restenosis • Poor distal runoff can result in stent thrombosis • Limited data
Self-expanding stent	<ul style="list-style-type: none"> • Vessel conformability and wall apposition prevent kinking and crushing of stent 	<ul style="list-style-type: none"> • Limited sizes • Limited data; multicenter trials under way
Bioabsorbable stent	<ul style="list-style-type: none"> • Overcomes arterial recoil from angioplasty • Absorbed long term to prevent risk of stent thrombosis 	<ul style="list-style-type: none"> • Limited data; multicenter trials under way
Cryoplasty	<ul style="list-style-type: none"> • Reduces the risk of flow-limiting dissection, therefore reducing the need for stent implantation 	<ul style="list-style-type: none"> • Short-term results of a multicenter trial are promising; however, long-term data are limited
Cutting balloon	<ul style="list-style-type: none"> • Useful in anastomotic segments of bypass grafts and in-stent restenosis where “watermelon seeding” can prevent adequate expansion of plaque 	<ul style="list-style-type: none"> • Limited data
Mechanical atherectomy	<ul style="list-style-type: none"> • Allows for debulking of plaque without the need for stent implantation in most cases • Allows for removal of plaque for histologic analysis 	<ul style="list-style-type: none"> • Limited use in areas of heavy calcification • No large, randomized, prospective trial comparing this technique to angioplasty and stenting
Laser	<ul style="list-style-type: none"> • Useful in acute thrombotic and chronic total occlusions 	<ul style="list-style-type: none"> • Minimal data in infrapopliteal arteries • Need adjunctive treatment with angioplasty, stenting, or atherectomy

complications, and a bony landmark can be used as guidance to ensure CFA puncture.

Traversing the lesion with a wire is the most critical part of the procedure. Typically, 0.035-inch guidewires are used for femoropopliteal lesions, and 0.014- or 0.018-inch guidewires are used for infrapopliteal access. Hydrophilic-coated wires, such as Glidewires, are useful in navigating through tight stenosis or occlusion. An angled-tip wire with a torque device may be helpful in crossing an eccentric lesion, and a shaped selective catheter is frequently used in helping manipulating the wire across the lesion. The soft and floppy end of the wire is carefully advanced crossing the lesion under fluoroscopy, and gentle force is applied while manipulating the wire. Once the lesion is traversed, one needs to pay particular attention on the tip of the wire to ensure a secure wire access and avoid vessel wall perforation or dissection.

Once the access to the diseased vessel is secured and the wire has successfully traversed the lesion, several treatment modalities can be used either alone or in conjunction with others, including angioplasty, stent or stent graft placement, and atherectomy. The available angioplasty techniques are balloon angioplasty, cryoplasty, subintimal angioplasty, and cutting balloon; the most commonly used atherectomy techniques include percutaneous atherectomy catheter and laser atherectomy device.

Systemic anticoagulation should be maintained routinely during lower extremity arterial interventions to minimize the risk of pericatheter thrombosis. Unfractionated heparin is the most commonly used agent, administered using a weight-based formula. We typically use 80 to 100 mg/kg initial bolus for therapeutic procedure to achieve an activated clotting time above 250 seconds upon catheter insertion and administer a

subsequent 1000 units for each additional hour of the procedure. Newer agents, such as low molecular weight heparin, platelet IIb/IIIa inhibitors, direct thrombin inhibitors, or recombinant hirudin, have been available and can be used either alone or in conjunction with heparin particularly in patients sensitive to unfractionated heparin. After the procedure, all patients are placed on antiplatelet therapy, such as aspirin. Additional antiplatelet agents, such as clopidogrel (Plavix), are given to selected patients with stent placement for at least 6 weeks after lower extremity interventions unless otherwise contraindicated.

Percutaneous Transluminal Balloon Angioplasty. After the lesion is crossed with a wire, an appropriated balloon angioplasty catheter is selected and tracked along the wire to traverse the lesion. The length of the selected catheter should be slightly longer than the lesion, and the diameter should be equal to the adjacent normal vessel. The balloon tends to be approximately 10% to 20% oversized. The radiopaque markers of the balloon catheter are placed so that they will straddle the lesion. Then, the balloon is inflated with saline and contrast mixture to allow visualization of the insufflation process under the fluoroscopy (Fig. 23-65). The patient may experience mild pain, which is not uncommon. However, severe pain can be indicative of vessel rupture, dissection, or other complications. An angiography is crucial in confirming the intraluminal location of the catheter and absence of contrast extravasation. The inflation is continued until the waist of the atherosclerotic lesion is disappeared and the balloon is at the full profile. Frequently, several inflations are required to achieve a full profile of the balloon (Fig. 23-66). Occasionally, a lower profile balloon is needed to predilate the tight stenosis so that the selected balloon catheter can cross the lesion.

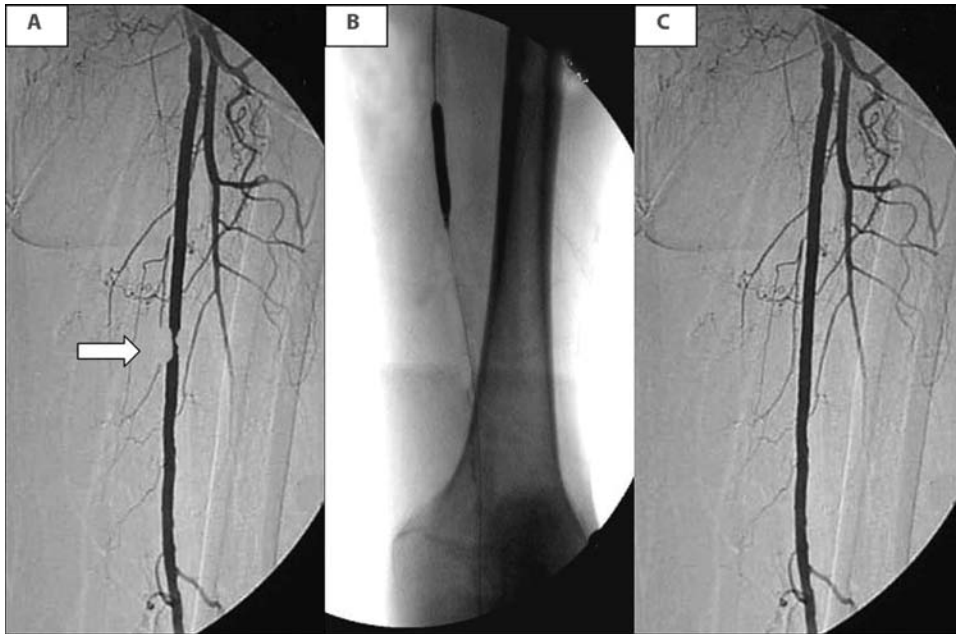


Figure 23-65. A. Angiogram demonstrating a focal stenosis in the superficial femoral artery (*arrow*). B. This lesion was treated with a balloon angioplasty catheter that inflated a dilating balloon and expanded the flow lumen. C. Completion angiogram demonstrating satisfactory radiographic result.

Besides length and diameter, the operators need to be familiar with several balloon characters. Noncompliant and low-compliant balloons tend to be inflated to their preset diameter and offer greater dilating force at the site of stenosis. Low-compliant balloons are the mainstay for peripheral intervention. A balloon with a low profile is used to minimize complications at the entry site and for crossing the tight lesions. Upon inflation, most balloons do not rewrap to their preinflation diameter and assume larger profiles. Furthermore, trackability, pushability, and

crossability of the balloon should be considered when choosing a particular type of balloon. Lastly, shoulder length is an important characteristic when performing PTA to avoid injury to the adjacent arterial segments. After PTA, a completion angiogram is performed while the wire is still in place. Leaving the wire in place provides access for repeating the procedure if the result is unsatisfactory.

PTA is an established and effective therapy for select patients with lower extremity occlusive diseases. Studies have

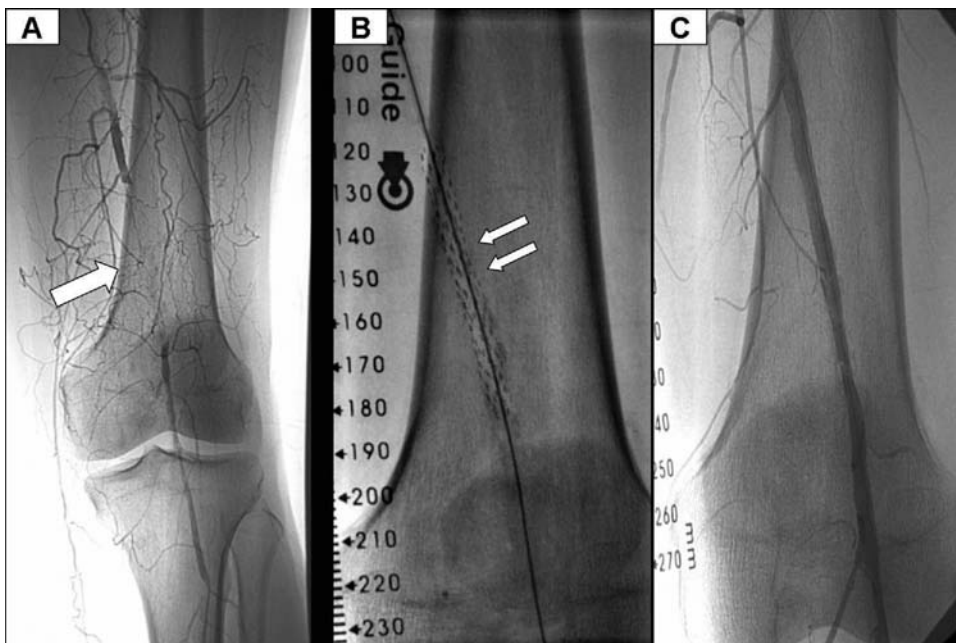


Figure 23-66. A. Angiogram demonstrating a segmental occlusion in the distal superficial femoral artery (*single arrow*). B. This lesion was treated with cryoplasty, which lowered the balloon catheter temperature to a temporary freezing state during the balloon angioplasty procedure (*double arrows*). C. Completion angiogram demonstrated satisfactory result with no evidence of vessel dissection.

shown that PTA of femoropopliteal segment achieved over 90% technical success rate and 38% to 58% 5-year primary patency rates.¹⁷⁷⁻¹⁷⁹ However, efficacy of PTA is highly dependent on anatomic selection and patient condition.¹³⁴ PTA of lesions longer than 7 to 10 cm offers limited patency, whereas PTA of shorter lesions, such as those less than 3 cm, has fairly good results. Lofberg and associates performed 127 femoropopliteal PTA procedures and reported a primary 5-year success rate of 12% in limbs with occlusion longer than 5 cm versus 32% in limbs with occlusion less than 5 cm in length.¹⁸⁰ Occlusive lesions have much worse initial technical success rates than stenotic lesions. Concentric lesions respond better to PTA than eccentric lesions, and heavy calcifications have a negative impact on success rates. A meta-analysis by Hunink and associates showed that adjusted 5-year primary patencies after angioplasty of femoropopliteal lesions varied from 12% to 68%, with the best results being for patients with claudication and stenotic lesions.¹⁷⁹ Distal runoff is another powerful predictor of long-term success. Johnston analyzed 254 consecutive patients who underwent femoral and popliteal PTA and reported a 5-year patency rate of 53% for stenotic lesions and 36% for occlusive lesions in patients with good runoff versus a 5-year patency rate of 31% for stenotic lesions and 16% for occlusive lesions in patients with poor runoff.¹⁷⁸ Literature reviews showed that 5-year patency rates varied from 27% to 67% based on runoff status.¹⁷⁹

Due to limited success with infrapopliteal PTA, the indication for infrapopliteal PTA is stringent and reserved for limb salvage. Current patency rates from infrapopliteal PTA can be improved further by proper patient selection, ensuring straight-line flow to the foot in at least one tibial vessel, and close patient surveillance for early reintervention. Possible future advances, including the use of drug-eluting stents, cutting balloons, and atherectomy devices, are being investigated to improve clinical outcomes following endovascular interventions on the tibial arteries. Varty and associates reported a 1-year limb salvage rate of 77% in patients with critical ischemia who underwent infrapopliteal PTA.¹⁸¹ In patients with favorable anatomies, the 2-year limb salvage rate after infrapopliteal PTA is expected to exceed 80%.

Subintimal Angioplasty. The technique of subintimal angioplasty was first described in 1987 when successful establishment of flow was made by accidental creation of a subintimal channel during treatment of a long popliteal artery occlusion. Subintimal angioplasty is recommended for chronic occlusion, long segment of lesion, and heavily calcified lesions. In addition, this technique is applicable for vessels with diffuse disease and for vessels that had previously failed an intraluminal approach, when it is difficult to negotiate the wire across the entire diseased segment without dissection.

The principle of this technique is to bypass the occlusion by deliberately creating a subintimal dissection plan commencing proximal to the lesion and continuing in the subintimal space before break back into the true lumen distal to the lesion. The occluded lumen is recanalized through the subintimal plan. Subintimal angioplasty can be performed through either an ipsilateral antegrade or contralateral retrograde approach using the CFA approach. If selecting contralateral CFA puncture, a long guiding sheath is placed across the aortic bifurcation to provide access for the femoropopliteal and infrapopliteal vessels. The subintimal dissection is initiated at the origin of an occlusion by directing the tip of an angled guide wire, usually an angled

hydrophilic wire, such as a Glidewire. A supporting catheter is used to guide the tip of the guidewire away from the important collaterals. When the wire is advanced, a loop is naturally formed at the tip of the guidewire. Once the subintimal plan is entered, the wire tends to move freely in dissection space. Subintimal location of the wire and the catheter can be confirmed by injecting a small amount of diluted contrast. At this point, the wire and the catheter are then advanced along the subintimal plan until the occlusion segment is passed. A loss of resistance is often encountered as the guidewire re-enters the true lumen distal to the occlusion. Recanalization is confirmed by advancing the catheter over the guidewire beyond the point of re-entry and obtaining an angiogram. This is followed by a balloon angioplasty. To confirm the patency following balloon dilatation, a completion angiogram is performed prior to withdrawing the catheter and wire. If flow is impaired, repeat balloon dilatation may be necessary. Frequently, a stent is required to maintain a patent lumen and treat residual stenosis if more than 30% luminal reduction is confirmed on completion angiogram.

Multiple studies have demonstrated the efficacy of subintimal angioplasty. Bolia and colleagues reported their extensive experiences on subintimal angioplasty for treating long-segment occlusions of infrainguinal vessels.^{182,183} They achieved a technical success rate of over 80% for both femoropopliteal and tibial arteries. One-year patency rates varied from 53% for infrapopliteal vessels to 71% for femoropopliteal segments. Limb salvage rates reached over 80% at 12 months. They also reported that the factors influencing patency are smoking, number of runoff vessels, and occlusion length. Studies by other groups showed similar results.^{184,185} Treiman and colleagues treated 25 patients with 6- to 18-cm femoropopliteal occlusion and achieved a technical success rate of 92% and a 13-month primary patency rate of 92%,¹⁸⁵ whereas Lipsitz and associates reported a technical success rate of 87% in 39 treated patients and a 12-month cumulative patency rate of 74%.¹⁸⁴ In addition, Ingle and associates reported a technical success rate of 87% in 67 patients with femoropopliteal lesions and a 36-month limb salvage rate of 94%.¹⁸⁶ As demonstrated herein, although technical success rates are similar in most series, the patency rates vary widely in different studies. Patient selection, anatomic character, and lesion locations may account for the wide range of outcomes.

Stent Placement. Although suggested by Dotter during the late 1960s, the use of an endoluminal stent was not pursued until the limitations of PTA were widely recognized. There are several situations where stent placement is appealing. The primary indication is the potential salvage of an unacceptable angioplasty result. Stent placement is typically used when residual stenosis after PTA is 30% or greater. An endoluminal stent is also used for dissection, perforation, and other PTA complications. Primary stent placement has become a viable alternative for treating ulcerative lesions that may potentially be the source for embolization. Primary stent is also used to treat occlusive lesions that have a tendency for reocclusion and distal embolization after PTA. In addition, an endoluminal stent is potentially beneficial for early restenosis after PTA. Drug-eluting stents are currently under investigation in the United States and may be promising in decreasing restenosis rates.

Although technical success rates are high, published series on femoropopliteal artery stents show that patency rates are comparable to PTA alone, with primary patency rates varying from 18% to 72% at 3 years.^{134,187} Gray and associates stented 58 limbs after suboptimal PTA for long SFA lesions and

demonstrated a 1-year primary patency rate of 22%.¹⁸⁸ However, Mewissen treated 137 limbs using self-expanding SMART nitinol stents in patients with TASC A, B, and C femoropopliteal lesions and reported a 1-year primary patency of 76% and a 24-month primary patency rate of 60%.¹⁸⁹ Appropriate patient selection and the anatomic characteristics of the lesions are crucial in the success of treatment outcomes. Additionally, stent characteristics may contribute to the patency rate.

Several clinical studies have demonstrated the significant improvements of the new generation of nitinol stents for the SFA lesions: the German Multicenter Experience, the Mewissen trial, the BLASTER Trial, and the SIROCCO trial.¹⁹⁰ The German Multicenter Experience was a retrospective review of 111 SFA stenting procedures and predicted that the 6-month patency rate for SMART stents was 82% versus 37% for the Wallstent. The BLASTER (Bilateral Lower Arterial Stenting Employing Reopro) Trial evaluated the feasibility of using nitinol stents with and without intravenous abciximab for the treatment of femoral artery disease, and the preliminary results showed a 1-year clinical patency rate of 83%.¹⁹¹

Furthermore, the drug-eluting stent, which proved effective in decreasing restenosis in coronary intervention, may offer another promising alternative in lower extremity diseases. The drug released over a period of time interferes with smooth muscle cell proliferation, the main cellular element and source of extracellular matrix-producing restenosis. The first drug-eluting stent clinical trial used Cordis Cypher SMART stents coated with sirolimus (SIROCCO trial).¹⁹² The SIROCCO results showed binary in-lesion restenosis rates of 0% in the sirolimus-eluting group versus 23.5% in the noneluting group at 6-month follow-up angiography. The PaRADISE (Preventing Amputations Using Drug-Eluting Stents) Trial investigated the efficacy and safety of using balloon-expandable drug-eluting stents to prevent amputations in patients with below-the-knee critical limb ischemia.¹³ One hundred six patients (118 limbs) were treated with drug-eluting stents in this prospective, non-randomized trial. There were 228 drug-eluting stents implanted (83% Cypher [Cordis, Johnson & Johnson, Warren, NJ], 17% Taxus [Boston Scientific, Maple Grove, MN]). The average length treated was 60 mm. The 3-year cumulative incidence of amputation was 6%, the survival rate was 71%, and the amputation-free survival rate was 68%. Only 12% of patients who died had a preceding major amputation. Rutherford category, age, creatinine level, and dialysis were predictors of death but not amputation. Target limb revascularization occurred in 15% of patients.

Stent Graft. The concept of endobypass using stent graft in treating atherosclerotic SFA disease has been entertained. A stent graft is placed percutaneously across a long segment or multiple segments of lesions and is used to create a femoropopliteal bypass. Theoretically, endobypass has the potential of being as successful as surgical bypass graft by relining the vessel wall in its anatomic position without the negative impact of anastomosis. Stent grafts can be divided into two categories: unsupported and fully supported. The unsupported grafts consist of segments of bypass graft, such as PTFE, with an expandable stent at one or both ends. The unsupported grafts are flexible with a low profile, but prone to external compression. The supported stent grafts consist of a metallic skeleton covered with graft fabric. The presence of a dense metal skeleton promotes an extensive inflammatory response and increases the risk of thrombosis. There is no FDA-approved stent graft for peripheral

intervention. However, Viabahn (WL Gore & Associates, Flagstaff, AZ) is the most commonly used device in the United States and is composed of an ultra-thin PTFE graft externally supported by self-expanding nitinol meshwork. The Viabahn device has a specific delivery mechanism by pulling back the attached string, which results in proximal-to-distal delivery of the endoprosthesis.

Although it is an intriguing concept, data on endobypass results are limited, and the graft thrombosis rate is high. Additionally, covering major collateral vessels can potentially jeopardize the viability of the limb if stent graft occlusion occurs. Bauermeister treated 35 patients with Hemobahn and reported a 28.6% occlusion rate at an average 7-month follow-up.¹⁹³ Kedora and colleagues recently conducted a prospective, randomized study comparing covered PTFE/nitinol self-expanding stent grafts with prosthetic above-the-knee femoropopliteal bypass. Fifty limbs were randomized into each group. Primary patency at 1 year was approximately 74% for both cohorts, with a mean follow-up of 18 months. The covered nitinol/PTFE stent graft in the SFA had a 1-year patency comparable to surgical bypass, with a significantly shorter hospital stay (0.9 vs. 3.1 days).¹⁹⁴ A recent randomized prospective study comparing the treatment of SFA occlusive disease percutaneously with an expanded PTFE (ePTFE)/nitinol self-expanding stent graft (stent graft) versus surgical femoral to above-knee popliteal artery bypass with synthetic graft material showed no difference between the two groups with respect to primary or secondary patency rates at 48 months.¹⁹⁵ Mean total lesion length of the treated arterial segment in the stent graft group was 25.6 cm. The stent graft group demonstrated a primary patency of 72%, 63%, 63%, and 59% with a secondary patency of 83%, 74%, 74%, and 74% at 12, 24, 36, and 48 months, respectively. The surgical femoral-popliteal group demonstrated a primary patency of 76%, 63%, 63%, and 58% with a secondary patency of 86%, 76%, 76%, and 71% at 12, 24, 36, and 48 months, respectively. The authors concluded that ePTFE/nitinol self-expanding stent graft placement can be offered as an alternative to treatment of the SFA segment for revascularization when prosthetic bypass is being considered or when autologous conduit is unavailable.

Atherectomy. The basic principle of atherectomy is to remove the atheroma from obstructed arterial vessels. The currently available atherectomy devices can be generally categorized into directional, nondirectional, orbital, and rotational types based on their mechanism. A few examples of FDA-approved atherectomy devices are Simpson AtheroCath (DVI, Redwood City, CA), Transluminal Extraction Catheter (Interventional Technologies, San Diego, CA), Thoratec recanalization arterial catheter (Thoratec, Pleasanton, CA), Auth Rotablator (Heart Technologies, Redmond, WA), SilverHawk system (FoxHollow Technologies, Redwood City, CA), Jetstream atherectomy system (Bayer, Indianola, PA), Diamondback 360° orbital atherectomy device (Cardiovascular Systems, Inc., St. Paul, MN), and Rotablator system (Boston Scientific Corporation, Natick, MA). These devices either cut and remove or pulverize the atheroma plaques.

The Simpson AtheroCath has a directional cutting element that is exposed to one third of the circumference of the arterial wall. The atheroma protruding into the window is excised and pushed into the collection chamber. The Transluminal Extraction Catheter has an over-the-wire nondirectional cutter mounted on the distal end of a torque tube. The excised atheroma is simultaneously removed by aspiration through the

torque tube. The Thoratec recanalization arterial catheter is a nondirectional, noncoaxial, atheroablative device. The rotating cam tip pulverizes the atheromatous lesion into minute particles. The Auth Rotablator is a nondirectional, coaxial, atheroablative device with a metal burr embedded with fine diamond chips. SilverHawk device is a monorail catheter designed to overcome the drawbacks of a directional atherectomy catheter. The working end consists of a hinged housing unit containing a carbide cutting blade. The blade is activated from the motor drive unit, and the catheter is then advanced through the length of the lesion. Once each pass is completed, the cutter then packs the tissue into the distal end of the nosecone to maximize collection capacity. The SilverHawk can then either be removed or torqued to treat a different quadrant in the same lesion or other lesions. Jetstream atherectomy system is a rotating, aspirating catheter with tip sizes of 1.6 and 1.8 mm for tibial arteries, and an expandable catheter with a tip size ranging from 2.1 to 3.4 mm for active removal of atherosclerotic debris and thrombus. The Diamondback 360° orbital atherectomy device uses a drive shaft with an eccentrically mounted, diamond-coated crown to create an orbital spin. As the speed of the crown increases from centrifugal force, it sands wider spaces, thereby providing variability in its working range. It can create a lumen that is >1.75 times the crossing profile depending on the size of the grit and the eccentricity of the offset. The greater the speed of the crown, the larger is the arc of debulking and, ultimately, the resultant lumen size. A constant flow of saline solution is delivered by a roller pump that lubricates the device and helps to flush the debris. The Rotablator system high-speed rotational device uses calcium ablation to achieve larger lumens. It has been used for more than 20 years to treat challenging, calcified coronary artery disease. The diamond-coated burr is designed to preferentially engage calcium and modify lesion compliance.

Despite the promising early technical and clinical success, the mid- and long-term results have been disappointing due to high incidence of restenosis. A multicenter clinical registry of plaque atherectomy in patients with femoropopliteal occlusive disease showed potential clinical efficacy of this technology, as the 6- and 12-month rates of survival free of target lesion revascularization were 90% and 80%, respectively.¹⁹⁶ Importantly, nearly three quarters (73%) of patients treated with plaque excision modality did not require adjunctive endovascular therapy as infrainguinal stenting was necessary in only 6.3% of lesions. Results from the TALON registry support the role of plaque excision in selected patients with lower extremity arterial disease.¹⁹⁶

Recent technologic advances have made it possible to increase the spectrum of treatable peripheral arterial lesions with high acute procedure success rates. Recently presented data from multiple registries have shown some promising results in terms of short-term primary patency rates and freedom from unplanned major amputation.^{197,198} Randomized clinical trials are expected and can hopefully provide conclusions on the effectiveness of these procedures.

Laser Atherectomy. Since laser atherectomy was reported in the 1960s, a variety of innovative approaches have been developed trying to overcome the limitation of laser angioplasty. Recent developments in Excimer laser technology have led to increased optimism regarding the ability to safely deliver laser energy. Excimer laser atherectomy approved by the FDA for peripheral artery intervention employs precision laser energy control (shallow tissue penetration) and safer wavelengths (ultraviolet as opposed to the infrared spectra in older laser

technology), which decrease perforation and thermal injury to the treated vessels.

A laser atherectomy catheter, with diameters varying from 0.9 to 2.5 mm, is tracked over the guidewire to the desired target. Once activated, the Excimer laser uses ultraviolet energy to ablate the lesion and create a nonthrombogenic arterial lumen. This lumen is further dilated by an angioplasty balloon. Because the Excimer laser can potentially reduce the rate of distal embolization by evaporating the lesion, it may be used as an adjunct tool for ostial lesions and lesions that can be traversed by a wire but not an angioplasty balloon catheter.

Several studies regarding the use of Excimer laser atherectomy combined with balloon angioplasty on lower extremity occlusive disease have shown promising clinical outcomes.^{199,200} The Peripheral Excimer Laser Angioplasty (PELA) trial involved 318 patients with chronic SFA occlusion and achieved a technical success rate of 83.2%, a 1-year primary patency rate of 33.6%, and an assisted-primary patency rate of 65%.²⁰⁰ Steinkamp and his colleagues treated 127 patients with long-segment popliteal artery occlusion using laser atherectomy followed by balloon angioplasty and reported a 3-year primary patency rate of 22%.²⁰¹ A multicenter clinical trial, the Laser Angioplasty for Critical Limb Ischemia (LACI) trial, supports the efficacy of this treatment modality in selected patients, with 6-month primary patency and clinical improvement rates of 33% and 89%, respectively.¹⁹⁹ The technology and devices continue to evolve. With the Turbo-Booster and Turbo-Tandem technologies (Spectranetics Corporation, Colorado Springs, CO), the efficacy of plaque reduction was reported to be significantly improved in the CliRpath Excimer Laser System to Enlarge Lumen Openings (CELLO) study.²⁰² The CELLO study was a single-arm, prospective registry trial conducted at 17 investigational sites in the United States to evaluate the safety and efficacy of a modified laser catheter designed for the endovascular treatment of peripheral artery disease affecting the SFA and proximal popliteal artery. Laser ablation reduced percent diameter stenosis from 77% to 21% after adjunctive therapy with balloon angioplasty or balloon angioplasty with stenting; 12.3% patients did not receive postlaser adjunctive therapy. Patency rates were 59% and 54% at 6 and 12 months, respectively. Target lesion revascularization was not required in 76.9% of CELLO participants within the 1-year follow-up.

Complications of Endovascular Interventions

Angioplasty-Related Complications. Complications related to PTA vary widely and include dissection, rupture, embolization, pseudoaneurysms, restenosis, hematoma, and acute occlusion secondary to thrombosis, vasospasm, or intimal injury. Clark and associates analyzed the data from 205 patients in the SCVIR Transluminal Angioplasty and Revascularization (STAR) registry and reported a complication rate of 7.3% for patients undergoing femoropopliteal angioplasty.²⁰³ Minor complications accounted for 75% of the cases, including distal emboli (41.7%), puncture site hematomas (41.7%), contained vessel rupture (8.3%), and vagal reactions (8.3%). In another study, Axisa and colleagues reported an overall rate of significant complications for patients undergoing PTA of the lower extremities of 4.2%, including retroperitoneal bleeding (0.2%), false aneurysm (0.2%), ALI (1.5%), and vessel perforation (1.7%).²⁰⁴

Complications limiting the application of subintimal angioplasty are parallel to those of PTA. A study investigating the use of subintimal angioplasty in 65 patients with

SFA occlusion found that complications developed in 15% of patients.²⁰⁵ These complications included significant stenosis (44%), SFA rupture (6%), distal embolization (3%), retroperitoneal hemorrhage (1.5%), and pseudoaneurysm (1.5%). Additional complications reported included perforation, thrombosis, dissection, and extensions beyond the planned re-entry site.²⁰⁶ Importantly, damage to significant collateral vessels may occur in 1% to 1.5% of patient who undergo subintimal angioplasty. If a successful channel is not achieved in this situation, the patient may have a compromised distal circulation that necessitates distal bypass. Cryoplasty is a modified form of angioplasty, and long-term results on lower extremity intervention are not yet available. Fava and associates treated 15 patients with femoropopliteal disease and had a 13% complication rate involving guidewire dissection and PTA-induced dissection of a tandem lesion remote to the cryoplasty zone.²⁰⁷

Endoluminal Stent- and Stent Graft-Related Complications. In addition to the aforementioned complications with angioplasty, endoluminal stent is associated with the risk of stent fracture and deformity. The adductor canal has nonlaminar flow dynamics, especially with walking. The forces exerted on the SFA include torsion, compression, extension, and flexion. These forces exert significant stress on the SFA and stents. In addition, the lower extremity is subject to external trauma, which further increases the risk of stent deformity and fracture (Fig. 23-67). The SIROCCO study showed that stent fracture, although not associated with clinical symptoms, occurs in 18.2% of the procedures involving both drug-eluting stents and control stents.¹⁹²

Stent grafts may present additional complication of covering important collaterals, which results in compromised distal circulation. A prospective study evaluating Hemobahn stent grafts in the treatment of femoropopliteal arterial occlusions demonstrated a 23% immediate complication rate including distal embolization (7.7%), groin hematoma (13.5%), and arteriovenous fistula (1.9%).²⁰⁸

Atherectomy-Related Complications. Overall complication rates associated with atherectomy range from 15.4% to 42.8%, including spasm, thrombosis, dissection, perforation, distal emboli, no reflow, and hematoma.^{209,210} Jahnke and associates conducted a prospective study evaluating high-speed rotational atherectomy in 15 patients with infrapopliteal occlusive disease. They yielded a 94% technical success rate, but success was complicated by vessel rupture (5%), distal embolization (5%), and arterial spasm (5%).²⁰⁸ Although Excimer laser atherectomy reduces embolic events by evaporating the lesion, embolization still remain a problematic complication. Studies show that distal embolic events occur in 3% to 4% of procedures, and perforation occurs in 2.2% to 4.3% of cases.^{200,201} Other complications compromising laser atherectomy therapy include acute reocclusion, vasospasm, direct vessel injury, and dissection.

Surgical Treatment for Chronic Limb Ischemia due to Femoropopliteal Disease

Endarterectomy. Endarterectomy has a limited, albeit important role in lower extremity occlusive disease. It is most frequently used when there is disease in the CFA or involving the PFA. In this procedure, the surgeon opens the diseased segment longitudinally and develops a cleavage plane within the media that is developed proximally and distally. This permits the inner layer containing the atheroma to be excised. Great care must be

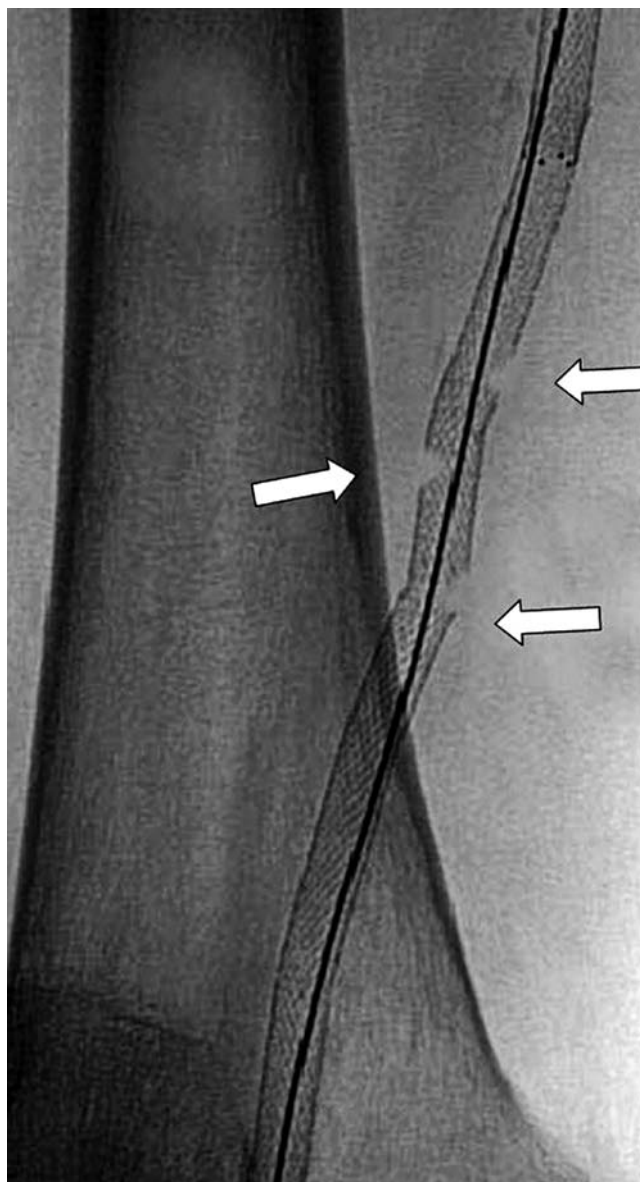


Figure 23-67. Due to various geometric forces, including torsion, compression, extension, and flexion, exerted on the superficial femoral artery (SFA), stent fracture (arrows) is a known complication following SFA stent placement.

taken at the distal end of the endarterectomy to either ensure a smooth transition or tack down the distal endpoint to prevent the flow from elevating a potentially occlusive atheromatous flap. Currently, there is essentially no role for long open endarterectomy in the treatment of SFA stenoses or occlusions. The high incidence of restenosis is what limits utility of endarterectomy in this location. Short-segment stenoses are more appropriately treated with balloon angioplasty. Endarterectomy using a catheter-based approach (e.g., Moll endarterectomy device) supplemented with stent grafting or stenting across the endpoint of the endarterectomy is currently being re-evaluated; however, no long-term data are available.

Bypass Grafting. Bypass grafting remains the primary intervention for lower extremity occlusive disease. The type of bypass and the type of conduit are important variables to consider. Patients with occlusive disease limited to the SFA, who have at least 4 cm

(ideally 10 cm) of normal popliteal artery reconstituted above the knee joint, and with at least one continuous vessel to the foot can be treated with an above-knee femoropopliteal bypass graft. Despite the fact that in this above-knee location, the differential patencies between prosthetic (PTFE) and vein graft are comparable, undoubtedly, it remains ideal to use a saphenous vein as the bypass conduit if possible. Saving the vein for future coronary artery bypass or distal leg bypass grafting has been shown to be a flawed argument. One must also consider that the consequences to the vascular outflow after a thrombosed prosthetic are worse than after a thrombosed vein graft.

When the disease extends to involve the popliteal artery or the tibial vessels, the surgeon must select an appropriate outflow vessel to perform a bypass. Suitable outflow vessels are defined as uninterrupted flow channels beyond the anastomosis into the foot. Listed in order of descending preference, they are as follows: above-knee popliteal artery, below-knee popliteal artery, posterior tibial artery, anterior tibial artery, and peroneal artery. In patients with diabetes, it is frequently the peroneal artery that is spared. Although it has no direct flow into the foot, collateralization to the posterior tibial and anterior tibial arteries makes it an appropriate outflow vessel. There is no objective evidence to preferentially select tibial over peroneal arteries if they are vessels of equal caliber and quality. The dorsalis pedis, which is the continuation of the anterior tibial in the foot, is frequently spared from atherosclerotic disease and can be used as a target for distal bypasses. Patency is affected by the length of the bypass (longer bypasses have reduced patency), quality of the recipient artery, extent of runoff to the foot, and quality of the conduit (saphenous vein/graft). Five-year assisted patency rate for infrapopliteal venous bypasses is 60%. Venous conduits have also been shown to be suitable for bypasses to plantar arteries. In this location, venous conduits have a 3-year limb salvage rate of 84% and a 3-year secondary patency rate of 74%.² A meta-analysis suggests unsatisfactory results when PTFE-coated grafts are used to bypass to infrapopliteal arteries. In this location, prosthetic grafts have a 5-year primary patency rate of 30.5%.²¹¹ Additionally, due to distal embolization and compromise of outflow vessels, prosthetic graft occlusion may have more severe consequences than vein graft occlusion.²¹¹

Two techniques are used for distal bypass grafting: reversed saphenous vein grafting and in situ saphenous vein grafting. There is no difference in outcomes (patency or limb salvage) between these techniques.² In the former, the vein is excised in its entirety from the leg using open or endoscopic vein harvest, reversed to render the valves nonfunctional, and tunneled from the CFA inflow to the distal target vessels. End-to-side anastomoses are then created.

Several adjunctive techniques have been used to try and improve the patency of bypass grafts to tibial arteries. Creation of an arteriovenous fistula at the distal anastomosis is one option, but it has not been shown to improve patency.²¹² Another method involves creating varying configurations of vein cuffs or patches at the distal anastomosis in an attempt to streamline the flow and to reduce the likelihood of neointimal hyperplasia. Results with this approach are more promising, especially when done to improve patency of a below-the-knee prosthetic; however, there are no definitive comparative trials that support the superiority of one configuration over another.

Amputation. Primary amputation is defined as an amputation that is performed without a prior attempt at surgical or endovascular revascularization. It is rarely necessary in patients who, as

a result of neglect, present with class III ALI. Primary amputation may play a role in patients with critical limb ischemia who are deemed nonambulatory because of knee contractures, debilitating strokes, or dementia.

Complications of Surgical Reconstruction

Vein Graft Stenoses. Fifteen percent of vein grafts will develop intrinsic stenoses within the first 18 months following implantation. Consequently, patients with vein grafts were entered into duplex surveillance protocols (scans every 3 months) to detect elevated (>300 cm/s) or abnormally low (<45 cm/s) graft velocities early. Stenoses greater than 50%, especially if associated with changes in ABI, should be repaired to prevent graft thrombosis. Repair usually entails patch angioplasty or short-segment venous interposition, but PTA/stenting is an option for short, focal lesions. Grafts with stenoses that are identified and repaired prior to thrombosis have assisted-primary patency identical to primary patency, whereas a thrombosed autogenous bypass has limited longevity resulting from ischemic injury to the vein wall. Secondary patency is markedly inferior to primary assisted patency. The recommendation for routine duplex ultrasound surveillance of autogenous infrainguinal bypasses was recently brought into question by a randomized controlled trial that demonstrated no cost benefit or quality-of-life improvement in patients with femoropopliteal venous bypasses after 18 months.²¹³ Many surgeons continue with programs of vein graft surveillance, as has been suggested in older trials, awaiting further confirmation of the findings from the more recent study. When intervening in a failing infrainguinal bypass, the original indication for surgery is an important consideration. Limb salvage rates for occluded grafts are better if the indication for the original bypass was claudication rather than rest pain or tissue loss. An acutely occluded infrainguinal graft (≤ 30 postoperative days) has a 25% limb salvage rate.²¹⁴

Limb Swelling. Limb swelling is common following revascularization and usually returns to baseline within 2 to 3 months. The etiology is multifactorial with lymphatic interruption, interstitial edema, and disruption of venous drainage all contributing. Limb swelling tends to worsen with repeat revascularization (see Table 23-22).

Wound Infection. Since the most common inflow vessel for distal bypass is the CFA, groin infection is common and occurs in 7% of cases.²¹⁵ When an autogenous conduit such as the saphenous vein is used, most infections can be managed with local wound care because the infection involves the subcutaneous tissue or skin rather than infection of the actual vein. When a prosthetic graft has been used, management of graft infection is a major undertaking. Infection of a lower extremity prosthetic bypass graft is associated with a significant amputation rate because of the tendency for graft thrombosis and anastomotic disruption. Prosthetic graft infections cannot be eradicated with antibiotics and mandate graft excision and complex revascularization using a vein if available.

Choice of Conduit for Infrainguinal Bypass Grafting

Autogenous Vein. The autogenous vein is superior to prosthetic conduits for all infrainguinal bypasses, even in the above-knee position. This preference is applicable not only for the initial bypass but also for reoperative cases. For long bypasses, the ipsilateral great saphenous vein, contralateral great

saphenous vein, small saphenous vein, arm vein, and spliced vein are used in decreasing order of preference. If only a short segment of vein is missing, the SFA can be endarterectomized and the proximal anastomosis performed distally to decrease the length of the conduit and to avoid harvesting and splicing additional vein. When the great saphenous vein is not available and a relatively short bypass is necessary, the arm vein or small saphenous vein is effective. The small saphenous vein is of particular utility when a posterior approach is used. If a longer bypass with vein is necessary, the arm vein is preferable because it is less awkward to harvest. Another conduit alternative is to harvest the upper arm basilic, median cubital, and cephalic veins in continuity, while incising valves in the basilic segment and using the cephalic segment in reversed configuration to provide a relatively long, unspliced autogenous conduit.²¹⁶

Cryopreserved Grafts. Cryopreserved grafts are usually cadaveric arteries or veins that have been subjected to rate-controlled freezing with dimethyl sulfoxide (DMSO) and other cryopreservatives. Cryopreserved vein grafts are more expensive than prosthetic grafts and are more prone to failure. The endothelial lining is lost as part of the freezing process, making these grafts prone to early thrombosis. Cryopreserved grafts are also prone to aneurysmal degeneration. Despite the fact that these grafts have not performed as well as prosthetic bypasses and autogenous vein bypasses in clinical practice, they can still play a role when revascularization is required following removal of infected prosthetic bypass grafts, especially when the autogenous vein is unavailable to create a new bypass through clean tissue planes.²¹⁷

Human Umbilical Vein. Human umbilical vein (HUV) is less commonly used than PTFE because it is thicker and more cumbersome to handle and because of concerns about aneurysmal degeneration. HUV allografts are stabilized with glutaraldehyde and do not have viable cells or antigenic reactivity. These grafts have poor handling characteristics and require extra care when suturing because of an outer Dacron mesh wrapping that is used to decrease aneurysmal degeneration. Dardik and colleagues have reported favorable results after using HUV and an adjunctive distal arteriovenous fistula.²¹⁸ One trial comparing HUV with PTFE and saphenous vein showed that HUV was better than PTFE but worse than saphenous vein in terms of 5-year patency in the above-knee location.²¹⁹ In a systematic review, HUV appears to perform better than cryopreserved veins.²²⁰

Prosthetic Conduits and Adjunctive Modifications. If a vein is truly unavailable, PTFE or Dacron is the best option for above-knee bypass. The addition of rings to PTFE did not confer benefit in a single prospective, randomized clinical trial.²²¹ For infrageniculate prosthetic bypasses, use of a vein patch, cuff, or other venous anastomotic modification can improve patency (52% patency at 2 years for PTFE with vein cuff vs. 29% for PTFE with no cuff) and also improve limb salvage (84% vs. 62%).²²²

Although prosthetic grafts are quickly available, easy to handle, and do not require extensive dissection to harvest, their propensity to undergo thrombosis and develop neointimal hyperplasia makes them a less favorable alternative when compared to vein. In a recent review of vein and prosthetic above-knee femoropopliteal bypasses, the 5-year primary patency rates were reported to be 74% and 39%, respectively.²²³ Outcomes were even worse for below-knee prosthetic bypasses. Unfortunately, the use of autologous venous conduits is not possible in

as many as 30% of patients. The great saphenous vein may be unsuitable because of small size and poor quality or unavailable due to prior harvest.

Methods to improve prosthetic graft performance have consisted of altering the geometry at the distal anastomosis to get the benefit obtained with vein cuffs (Distaflo; Bard Peripheral Vascular, Tempe, AZ) and covalently bonding agents onto the luminal surface with anticoagulant, anti-inflammatory, and antiproliferative characteristics (Propaten; Gore, Flagstaff, AZ). One randomized trial that compared precuffed PTFE versus PTFE with a vein cuff enrolled 104 patients at 10 centers. Of 89 patients, 47 were randomized to precuffed PTFE bypasses and 44 were randomized to bypasses with a vein cuff. At 1 and 2 years, primary patency rates were 52% and 49% in the precuffed group and 62% and 44% in the vein cuffed group, respectively. At 1 and 2 years, the limb salvage rates were 72% and 65% in the precuffed group and 75% and 62% in the vein cuffed group, respectively. Although numbers are small and follow-up short, the midterm analysis revealed that Distaflo precuffed grafts and PTFE grafts with vein cuff had similar results. The authors concluded that a precuffed graft was a reasonable alternative for infrageniculate reconstruction in the absence of saphenous vein.²²⁴ Other authors have been less optimistic and question whether there is any benefit derived from geometrically altering prosthetic conduits.²²⁵

Another approach for improving outcomes when using prosthetic for bypass grafts involves bonding anticoagulants to the conduit. The Gore Propaten graft has heparin bonded onto the luminal surface of the PTFE graft using Carmeda BioActive Surface (CBAS) technology, which immobilizes the heparin molecule with a single covalent bond that does not alter its anticoagulant properties.²²⁶ The heparin binding does not alter the microstructure and handling characteristics of the PTFE. A prospective, randomized trial by Devine and colleagues suggested that heparin-bonded Dacron or PTFE was superior to plain PTFE for above-knee popliteal bypasses. The 3-year primary patency rate for the heparin-bonded grafts was 55% compared with 42% for PTFE ($P < 0.044$). Both of these patency rates are inferior to great saphenous vein grafts; however, if the improved results with heparin bonding continue to be substantiated, then heparin-bonded prosthetic grafts will become the preferred conduit for above-knee bypass in the absence of suitable vein.²²⁷ A recent review of available studies with this graft showed an 80% 1-year patency rate for below-knee bypasses.²²⁸ Randomized controlled clinical trials with more patients and longer follow-up are necessary to validate whether the Propaten vascular graft is superior to other prosthetics and whether it is comparable to autogenous vein for below-knee interventions.

Clinical Results of Surgical and Endovascular Interventions for Femoropopliteal Occlusive Disease

Balloon angioplasty of the femoropopliteal vessels has not enjoyed the degree of success seen with iliac angioplasty. Patency in this region is dependent on whether the patient presents with claudication versus limb-threatening ischemia, the status of the distal runoff vessels, and lesion morphology.² Initial technical success for femoropopliteal angioplasty is seen in 80% to 90% of cases, with failure to cross a lesion occurring in 7% of stenoses and 18% of occlusive lesions. Studies have shown that PTA of the femoropopliteal segment achieved a greater than 90% technical success rate and had a 38% to 58% 5-year primary

patency rate.^{177,178} PTA of lesions longer than 7 to 10 cm results in compromised patency, whereas PTA of shorter lesions (<3 cm) gives fairly good results. Lofberg and colleagues performed 127 femoropopliteal PTA procedures and reported a primary patency rate at 5-year follow-up of 12% in limbs with occlusion longer than 5 cm versus 32% in limbs with occlusion less than 5 cm in length.¹⁸⁰ Occlusive lesions have much worse initial technical success rates than stenotic lesions. Concentric lesions respond better to PTA than eccentric lesions, and heavy calcifications have a negative impact on success rates. Distal runoff is another powerful predictor of long-term success.

Johnston analyzed 254 consecutive patients who underwent femoropopliteal PTA and reported a 5-year patency rate of 53% for stenotic lesions and 36% for occlusive lesions in patients with good runoff versus a 5-year patency rate of 31% for stenotic lesions and 16% for occlusive lesions in patients with poor runoff.¹⁷⁸ A meta-analysis by Hunink and colleagues showed that adjusted 5-year primary patencies after angioplasty of femoropopliteal lesions varied from 12% to 68%, with the best results occurring in patients with claudication and stenotic lesions.¹⁷⁹ Although the initial technical success is better for stenoses than occlusions, long-term patency rates for stenoses and short occlusions have been variable, and there have been conflicting results regarding the efficacy of stent use. Early published series that examined efficacy of femoropopliteal artery stents showed patency rates that were comparable to standalone PTA, with primary patency rates varying from 18% to 72% at 3 years.¹⁸⁷ Patient selection and the anatomic character of the lesions may play important roles in the outcomes. Additionally, stent characteristics may contribute to the patency rate. Several recent clinical studies have demonstrated significant improvements in patency when the newer generations of nitinol stents are used to treat SFA lesions.^{189,229}

Mewissen treated 137 lower limbs in 122 patients with CLI, secondary to TASC A (n = 12) or TASC B or C (n = 125) lesions in the SFA. Patients were treated with Cordis SMART self-expanding nitinol stents. Binary restenosis (>50%) was measured by standard duplex velocity criteria at various postintervention intervals. Primary stent patency, defined as absence of binary restenosis in this study, was calculated by life-table methods from the time of intervention. The mean lesion length was 12.2 cm (range, 4–28 cm). The technical success was 98%. Mean follow-up was 302 days. The primary stent patency rates were 92%, 76%, 66%, and 60% at 6, 12, 18, and 24 months, respectively.¹⁸⁹ Ferreira and colleagues treated 59 patients who had 74 femoropopliteal lesions (60% TASC D) with Zilver nitinol self-expanding stents (Cook, Bloomington, IN). Mean recanalization length was 19 cm (range, 3–53 cm). Mean follow-up time was 2.4 years (range, 3 days–4.8 years). Kaplan-Meier estimates for primary patency rates were 90%, 78%, 74%, 69%, and 69% at 1, 2, 3, 4, and 4.8 years, respectively.²³⁰

There is general agreement that for suboptimal PTA of an SFA lesion, stent placement is indicated, but a recent randomized trial by Schillinger and associates suggests that primary stenting results in lower restenosis rates than PTA and selective stenting. Restenosis rates at 2 years were 45.7% versus 69.2% in favor of primary stenting compared with PTA and optional secondary stenting using an intent-to-treat analysis ($P = 0.031$). Consistently, stenting, both primary and selective, was superior to standalone PTA with respect to the occurrence of restenosis (49.2% vs. 74.3%; $P = 0.028$) by a treatment-received analysis.²³¹

Nitinol bare metal stents that are designed specifically for below-knee interventions are showing very encouraging results. Bosiers and colleagues reported their 12-month results using the commercially available non-drug-eluting Xpert (Abbott Vascular, Santa Clara, CA) nitinol stent system in below-knee arterial interventions.²³² They had a 12-month primary patency rate of 76.3% and a limb salvage rate of 95.9%. They followed patients for 12 months and performed angiography with quantitative vessel analysis on the 73% of patients available. Angiography revealed a binary restenosis rate (>50%) of only 20.5%, which is comparable to well-accepted coronary drug-eluting stent study outcomes. The authors attributed this optimal performance to the maintenance of flow dynamics because the stent was specifically designed for use in small vessels.²³² Kickuth and colleagues also have obtained good results using the Xpert stent. After stent placement, the primary cumulative patency rate at 6 months for the study group of 35 patients was 82%. The sustained clinical improvement rate as evidenced by improved ABI was 80%, and freedom from major amputation was 100% at the 6-month follow-up. The rate of major complications was 17%.²³³

Wolf and colleagues published a multicenter, prospective randomized trial comparing PTA with bypass in 263 men who had iliac, femoral, or popliteal artery obstruction.²³⁴ In 56 patients, cumulative 1-year primary patency rate was 43% after PTA and 82% after bypass surgery, demonstrating that for long SFA stenoses or occlusions, surgery is better than PTA. Another recent randomized study (BASIL trial) of 452 patients with CLI demonstrated no difference in amputation-free survival at 6 months between surgery and PTA/stenting. The authors commented that surgery was somewhat more expensive and recommended that endovascular intervention should be used as first-line therapy especially in medically unfit patients. They did conclude that at the 2-year follow-up, healthy patients without medical comorbidities derived greater benefit from surgery because it was associated with decreased need for reintervention and had a decreased hazard ratio in terms of all-cause mortality.²³⁵ The recently published randomized prospective study comparing the treatment of SFA occlusive disease percutaneously with an ePTFE/nitinol self-expanding stent graft versus surgical femoral to above-knee popliteal artery bypass with synthetic graft material showed no difference between the two groups with respect to primary or secondary patency rate at 48 months.¹⁹⁵ This finding suggests that ePTFE/nitinol self-expanding stent graft placement can be offered as an alternative to treatment of the SFA segment for revascularization when prosthetic bypass is being considered or when autologous conduit is unavailable. Using the 2000 TASC definitions and a Markov state transition model decision analysis, Nolan and colleagues showed that PTA/stenting surpasses bypass efficacy for TASC C lesions if PTA/stenting primary patency is >32% at 5 years, patient age is >80 years, and/or greater saphenous vein bypass operative mortality is >6%.^{134,236}

NONATHEROSCLEROTIC DISORDERS OF BLOOD VESSELS

The majority of cases of peripheral vascular disease that are seen by vascular surgeons are attributable to underlying atherosclerosis. Nonatherosclerotic disease states that result in arterial pathology are less commonly encountered, but are nonetheless important, as they are potentially treatable lesions that may

mimic atherosclerotic lesions and result in vascular insufficiency (see Table 23-18). A thorough knowledge of these rare disease states is important for the practicing vascular surgeon in order to both make medical recommendations and provide appropriate surgical treatment.

Giant Cell Arteritis (Temporal Arteritis)

Giant cell arteritis is also known as temporal arteritis, which is a systemic chronic inflammatory vascular disease with many characteristics similar to those of Takayasu's disease. The histologic and pathologic changes and laboratory findings are similar. Patients tend to be white women over the age of 50 years, with a high incidence in Scandinavia and women of Northern European descent. Genetic factors may play a role in disease pathogenesis, with a human leukocyte antigen (HLA) variant having been identified. Differences exist between Takayasu's and giant cell arteritis in terms of presentation, disease location, and therapeutic efficacy. The inflammatory process typically involves the aorta and its extracranial branches, of which the superficial temporal artery is specifically affected.

The clinical syndrome begins with a prodromal phase of constitutional symptoms, including headache, fever, malaise, and myalgias. The patients may be initially diagnosed with coexisting polymyalgia rheumatica; an HLA-related association may exist between the two diseases. As a result of vascular narrowing and end-organ ischemia, complications may occur such as visual alterations, including blindness and mural weakness, resulting in acute aortic dissection that may be devastating. Ischemic optic neuritis resulting in partial or complete blindness occurs in up to 40% of patients and is considered a medical emergency. Cerebral symptoms occur when the disease process extends to the carotid arteries. Jaw claudication and temporal artery tenderness may be experienced. Aortic lesions are usually asymptomatic until later stages and consist of thoracic aneurysms and aortic dissections.

The diagnostic gold standard is a temporal artery biopsy, which will show the classic histologic findings of multinucleated giant cells with a dense perivascular inflammatory infiltrate. Treatment regimens are centered on corticosteroids, and giant cell arteritis tends to rapidly respond. Remission rates are high, and treatment tends to have a beneficial and preventative effect on the development of subsequent vascular complications.

Takayasu's Arteritis

Takayasu's arteritis is a rare but well-recognized chronic inflammatory arteritis affecting large vessels, predominantly the aorta and its main branches (Table 23-27).²³⁷ Chronic vessel inflammation leads to wall thickening, fibrosis, stenosis, and thrombus formation. Symptoms are related to end-organ ischemia. The acute inflammation can destroy the arterial media and lead to aneurysm formation. This rare autoimmune disease occurs predominantly in women between the ages of 10 and 40 years who are of Asian descent. Genetic studies have demonstrated a high frequency of HLA haplotypes in patients from Japan and Mexico, suggesting increased susceptibility to developing the disease in patients with certain alleles. However, these associations have not been seen in North America. Vascular inflammation leads to arterial wall thickening, stenosis, and eventually, fibrosis and thrombus formation. The pathologic changes produce stenosis, dilation, aneurysm formation, and/or occlusion.

The clinical course of Takayasu's arteritis begins with a "prepulseless" phase in which the patient demonstrates

Table 23-27

Angiographic classification of Takayasu's arteritis

TYPE	VESSEL INVOLVEMENT
Type I	Branches from the aortic arch
Type IIa	Ascending aorta, aortic arch and its branches
Type IIb	Ascending aorta, aortic arch and its branches, thoracic descending aorta
Type III	Thoracic descending aorta, abdominal aorta, and/or renal arteries
Type IV	Abdominal aorta and/or renal arteries
Type V	Combined features of types IIb and IV

Involvement of the coronary or pulmonary arteries is designated as C (+) or P (+), respectively.

constitutional symptoms. These include fever, anorexia, weight loss, general malaise, arthralgias, and malnutrition. As the inflammation progresses and stenoses develop, more characteristic features of the disease become evident. During the chronic phase, the disease is inactive or "burned out." It is during this latter stage that patients most frequently present with bruits and vascular insufficiency according to the arterial bed involved. Laboratory data may show elevations in erythrocyte sedimentation rate, C-reactive protein, and white blood cell count, or conversely, anemia may predominate. Characteristic clinical features during the second phase vary according to the involved vascular bed and include hypertension reflecting renal artery stenosis, retinopathy, aortic regurgitation, cerebrovascular symptoms, angina and congestive heart failure, abdominal pain or gastrointestinal bleeding, pulmonary hypertension, or extremity claudication.

The gold standard for diagnosis remains angiography showing narrowing or occlusion of the entire aorta or its primary branches, or focal or segmental changes in large arteries in the upper or lower extremities. Six types of Takayasu's arteritis exist and are graded in terms of severity: type I, affecting the aorta and arch vessels; type IIa, affecting the ascending aorta, aortic arch, and branches; type IIb, affecting the ascending aorta, aortic arch and branches, and thoracic descending aorta; type III, affecting the thoracic descending aorta, abdominal aorta, and/or renal arteries; type IV, affecting the abdominal aorta and/or renal arteries; and type V, with combined features of types IIb and IV.²³⁷

Treatment consists of steroid therapy initially, with cytotoxic agents used in patients who do not achieve remission. Surgical treatment is performed only in advanced stages, and bypass needs to be delayed during active phases of inflammation. There is no role for endarterectomy, and synthetic or autogenous bypass grafts need to be placed onto disease-free segments of vessels. For focal lesions, there have been reports of success with angioplasty.²⁰⁸⁻²¹⁰

Ehlers-Danlos Syndrome

Ehlers-Danlos syndrome is one of the more significant inheritable disorders affecting the connective tissue, along with Marfan's syndrome. This syndrome represents a heterogenous group of connective tissue disorders (types I through IV) that were first described in 1682 by van Meekeren.²³⁸ It is an autosomal

dominant disorder affecting approximately 1 in 5000 persons that is characterized by skin elasticity, joint hypermobility, tissue fragility, multiple ecchymoses, and subcutaneous pseudotumors. Ehlers-Danlos syndrome is a disorder of fibrillar collagen metabolism with identifiable, specific defects that have been found in the collagen biosynthetic pathway that produce clinically distinct forms of this disease. Ten different phenotypes have been described, each with variable modes of inheritance and biochemical defects. Of the four basic types of collagen found in the body, the predominant type in blood vessels is type III. Within the vessel wall, type III collagen contributes to structural integrity and tensile strength and plays a role in platelet aggregation and thrombus formation.

Of the three types of Ehlers-Danlos syndrome that have arterial complications, type IV represents 5% of cases and is the one most likely to be seen by a vascular surgeon. These patients synthesize abnormal type III collagen (mutation *COL3A1*) and represent 5% of all cases.²³⁸ Affected individuals do not show the typical skin and joint manifestations, and thus typically present for diagnosis when a major vascular catastrophe occurs. In a review of 36 patients with this disorder, Cikrit and colleagues reported a 44% mortality rate from major hemorrhage prior to any surgical intervention.²³⁹ In the 20 patients who underwent 29 vascular procedures, there was a 29% mortality rate. Arterial rupture, aneurysm formation, and acute aortic dissection may occur in any major artery, with the most frequent site of rupture being the abdominal cavity. Repair is problematic because the vessel wall is soft and sutures pull through the fragile tissue. Ligation may be the only option in many circumstances.

Marfan's Syndrome

Another heterogeneous heritable disorder of connective tissue, Marfan's syndrome is characterized by abnormal musculoskeletal, ocular, and cardiovascular features first described by Antoine Marfan in 1896.²⁴⁰ The inborn error of metabolism in this syndrome has been localized to the long arm of chromosome 15 (15q21.3). Defects occur in fibrillin, a basic protein in the microfibrillar apparatus that serves as a backbone for elastin, which is one of the main extracellular structural proteins in blood vessels. This is an autosomal dominant gene with high penetrance; however, approximately 15% to 20% of cases are secondary to new spontaneous mutations.²⁴⁰

Classic recognizable features of Marfan's syndrome include tall stature, long limbs (dolichostenomelia), long fingers (arachnodactyly), joint hyperextensibility, chest wall deformities, and scoliosis. Ocular manifestations are flattened corneas, lens subluxation, and myopia. Ninety-five percent of patients have cardiovascular involvement, which may include ascending aortic dilatation, mitral valve prolapse, valvular regurgitation, and aortic dissection. Skin, central nervous system, and pulmonary features may be present as well. Aortic root dilatation will generally occur in all patients. This may not be evident on standard chest radiograph until dilatation has resulted in an ascending aortic aneurysm, aortic valve regurgitation, or dissection. Left untreated, the cardiovascular complications are devastating and reduce the life expectancy to about 40 years for men and slightly higher for women. Death is usually attributable to life-threatening complications of aortic regurgitation, dissection, and rupture after the ascending aorta has dilated to 6 cm or more.

Aggressive medical management with β -adrenergic blocking agents and other blood pressure-lowering regimens is

crucial to treatment. Surgical intervention entails replacement of the aortic root with a composite valve graft (e.g., Bentall procedure).²⁴¹ Prophylactic operative repair is indicated for an aneurysm greater than 5.5 cm, with an acceptable perioperative mortality of less than 5%.

Pseudoxanthoma Elasticum

Pseudoxanthoma elasticum is a rare inherited disorder of connective tissue that is characterized by an unbalanced elastic fiber metabolism and synthesis, resulting in fragmentation and calcification of the fibers. Clinical manifestations occur in the skin, ocular, gastrointestinal, and cardiovascular systems.²⁴² Characteristic skin lesions are seen in the axilla, antecubital and popliteal fossae, and groin. The yellow, xanthoma-like papules occur in redundant folds of skin and are said to resemble plucked chicken skin. The inheritance pattern includes both autosomal dominant and recessive types and has a prevalence of 1 in 160,000 individuals.¹⁸³ The ATP-binding cassette subfamily C member 6 (*ABCC6*) gene has been demonstrated to be responsible, and 43 mutations have been identified, all of which lead to calcification of the internal elastic laminae of medium-sized vessel walls.²⁴²

Cardiovascular features are common and include premature coronary artery disease, cerebrovascular disease, renovascular hypertension, diminished peripheral pulses, and restrictive cardiomyopathy. Symptom onset typically occurs in the second decade of life, with onset at an average age of 13 years. Patients should be counseled to reduce potential contributing factors for atherosclerosis such as tobacco use and high cholesterol levels. Calcium intake should be restricted in adolescents, as a positive correlation has been found between disease severity and calcium intake.²⁴² Surgical management involves standard vascular techniques, with the exception that arterial conduits should not be employed in cardiac bypass.

Kawasaki's Disease

Kawasaki's disease was first described in 1967, as a mucocutaneous lymph node syndrome occurring in young children. In most studies, more than half the patients are younger than 2 years of age, with a higher prevalence in boys.²⁴³ Although originally described in Japan, the disease is found worldwide. An infectious agent may be causative; however, no specific agent has been identified. Immune activation with the contribution of cytokines, elastases, growth factors, and metalloproteinases is believed to be a mechanism for inflammation and aneurysm formation. Coronary artery aneurysms, the hallmark of the disease, histologically demonstrate a panarteritis with fibrinoid necrosis. Coronary arteriography may show occlusions, recanalization, and localized stenosis, in addition to multiple aneurysms. A variety of constitutional symptoms and signs resulting from systemic vasculitis are present in the acute phase of the illness.²⁴³

Medical therapy for Kawasaki's disease clearly decreases the manifestations of coronary artery involvement. Intravenous gamma globulin and aspirin therapy are most successful if begun within the first 10 days of illness. Up to 20% of untreated patients will develop coronary arterial lesions.²⁴³ A long-term, low-dose aspirin therapy regimen is usually recommended.

Inflammatory Arteritis and Vasculitis

Chronic inflammatory arteritis and vasculitis (i.e., inflammatory changes within veins as well as arteries) include a spectrum of disease processes caused by immunologic mechanisms. These terms signify a necrotizing transmural inflammation of the

Table 23-28

Classification of vasculitis based on vessel involvement

Large-Vessel Vasculitis
Takayasu's arteritis
Giant cell arteritis
Behçet's disease
Medium-Vessel Vasculitis
Polyarteritis nodosa
Kawasaki's disease
Buerger's disease
Small-Vessel Vasculitis
Hypersensitivity angiitis

vessel wall associated with antigen-antibody immune complex deposition within the endothelium. These conditions show pronounced cellular infiltration in the adventitia, thickened intimal fibrosis, and organized thrombus.²⁰⁴ These disease processes may clinically mimic atherosclerosis, and most are treated by corticosteroid therapy or chemotherapeutic agents. Even so, it is important to recognize distinguishing characteristics of each disease in order to establish the course of treatment and long-term prognosis. A classification system of systemic vasculitis by vessel size is shown in Table 23-28.

Behçet's Disease

Behçet's disease is a rare syndrome characterized by oral and genital ulcerations and ocular inflammation, affecting males in Japan and the Mediterranean. An HLA linkage has been found, indicating a genetic component to the etiology. Vascular involvement is seen in 7% to 38% of patients and is localized to the abdominal aorta, femoral artery, and pulmonary artery.²¹³ Vascular lesions may also include venous complications such as deep venous thrombosis or superficial thrombophlebitis. Arterial aneurysmal degeneration can occur; however, this is an uncommon, albeit potentially devastating, complication. Multiple true aneurysms and pseudoaneurysms may develop, and rupture of an aortic aneurysm is the major cause of death in patients with Behçet's disease.²⁴⁴

Histologically, degeneration of the vasa vasorum with surrounding perivascular lymphocyte infiltration is seen, along with thickening of the elastic laminae around the tunica media.²¹⁵ Aneurysm formation is believed to be associated with a loss of the nutrient flow and elastic component of the vessels, leading to progressive dilatation. Multiple aneurysms are relatively common, with a reported occurrence of 36% in affected Japanese patients.²⁴⁴ Furthermore, pseudoaneurysm formation after surgical bypass is common at anastomotic suture lines due to the vascular wall fragility and medial destruction. Systemic therapy with corticosteroids and immunosuppressive agents may diminish symptoms related to the inflammatory process; however, they have no effect on the rate of disease progression and arterial degeneration.²⁴⁴

Polyarteritis Nodosa

Polyarteritis nodosa (PAN) is another systemic inflammatory disease process, which is characterized by a necrotizing inflammation of medium-sized or small arteries that spares the smallest blood vessels (i.e., arterioles and capillaries). This disease predominantly affects men over women by a 2:1 ratio. PAN

develops subacutely, with constitutional symptoms that last for weeks to months. Intermittent, low-grade fevers, malaise, weight loss, and myalgias are common presenting symptoms. As medium-sized vessels lie within the deep dermis, cutaneous manifestations occur in the form of livedo reticularis, nodules, ulcerations, and digital ischemia.²¹⁸ Skin biopsies of these lesions may be sufficient for diagnosis. Inflammation may be seen histologically, with pleomorphic cellular infiltrates and segmental transmural necrosis leading to aneurysm formation.

Neuritis from nerve infarction occurs in 60% of patients, and gastrointestinal complications occur in up to 50%.²⁴⁵ Additionally, renal involvement is found in 40% and manifests as microaneurysms within the kidney or segmental infarctions. Cardiac disease is a rare finding except at autopsy, where thickened, diseased coronary arteries may be seen, as well as patchy myocardial necrosis. Patients may succumb to renal failure, intestinal hemorrhage, or perforation. End-organ ischemia from vascular occlusion or aneurysm rupture can be disastrous complications with high mortality rates. The mainstay of treatment is steroid and cytotoxic agent therapy. Up to 50% of patients with active PAN will experience remission with high dosing.²⁴⁵

Radiation-Induced Arteritis

Radiation-induced arteritis results from progressive stenosis due to endothelial damage that leads to cellular proliferation and fibrosis. These are well-described complications of combined irradiation and chemotherapy for the treatment of head and neck malignancy. Arterial lesions are known complications of radiation and are similar to those found in atherosclerotic occlusive disease. A history of therapeutic irradiation to the neck can complicate the management of carotid artery occlusive disease. Radiation-induced damage to blood vessels has been well studied. The small capillaries and sinusoids are most susceptible to radiation effects, as endothelial cells are the most radiosensitive cells. The radiation effects on the medium- and large-sized arteries include myointimal proliferation, with or without lipid deposits, and thrombosis. Characteristically, irregular spindle-shaped cells are seen replacing the normal endothelial cells in the healing phase. Occlusive lesions develop in the irradiated carotid arteries and are either the result of vessel wall fibrosis or, more commonly, due to accelerated atherosclerosis. Neurologic complications related to radiation-induced carotid artery disease are similar to those due to nonirradiated atherosclerotic occlusive disease.

Rupture of the carotid artery has been reported following neck irradiation and is likely related to local wound complication and superimposed infection. The diagnosis of radiation arteritis is based on the clinical history and confirmation of the occlusive lesion by duplex ultrasound, MRA, CTA, or subtraction angiography. Irradiated lesions can be confined to the irradiated segment of the internal carotid artery with the remaining part of the vessel spared of disease. Characteristically, the radiation-induced atherosclerotic lesion does not involve the carotid bulb, unlike the nonradiated atherosclerotic lesions. The indications for intervention in radiation-induced carotid lesions are the same as previously discussed for atherosclerotic carotid occlusive lesions. However, asymptomatic irradiated carotid artery lesions should be considered for intervention because they can be more prone to progression and development of neurologic complications. Endovascular treatment with carotid angioplasty/stenting has become the treatment of choice for radiation-induced lesions, although surgical endarterectomy

and bypass have been shown to be safe. The rate of recurrent stenosis is higher in radiation-induced carotid lesions, whether stented or surgically treated.

Raynaud's Syndrome

First described in 1862 by Maurice Reynaud, the term *Raynaud's syndrome* applies to a heterogeneous symptom array associated with peripheral vasospasm, more commonly occurring in the upper extremities. The characteristically intermittent vasospasm classically follows exposure to various stimuli, including cold temperatures, tobacco, or emotional stress. Formerly, a distinction was made between Raynaud's "disease" and Raynaud's "phenomenon" for describing a benign disease occurring in isolation or a more severe disease secondary to another underlying disorder, respectively. However, many patients develop collagen vascular disorders at some point after the onset of vasospastic symptoms; progression to a connective tissue disorder ranges from 11% to 65% in reported series.^{246,247} Therefore, the term Raynaud's syndrome is now used to encompass both the primary and secondary conditions.

Characteristic color changes occur in response to the arteriolar vasospasm, ranging from intense pallor to cyanosis to redness as the vasospasm occurs. The digital vessels then relax, eventually leading to reactive hyperemia. The majority of patients are young women less than 40 years of age. Up to 70% to 90% of reported patients are women, although many patients with only mild symptoms may never present for treatment. Geographic regions with cooler, damp climates such as the Pacific Northwest and Scandinavian countries have a higher reported prevalence of the syndrome. Certain occupational groups, such as those who use vibrating tools, may be more predisposed to Raynaud's syndrome or digital ischemia. The exact pathophysiologic mechanism behind the development of such severe vasospasm remains elusive, and much attention has focused on increased levels of α_2 -adrenergic receptors and their hypersensitivity in patients with Raynaud's syndrome, as well as abnormalities in the thermoregulatory response, which is governed by the sympathetic nervous system.²⁴⁶

The diagnosis of severe vasospasm may be made using noninvasive measurements in the vascular laboratory. Angiography is usually reserved for those who have digital ulceration and in whom an embolic or obstructive cause is believed to be present and potentially surgically correctable. Different changes in digital blood pressure will occur in patients with Raynaud's syndrome. Normal individuals will show only a slight decrease in digital blood pressure in response to external cold stimuli, whereas those with Raynaud's syndrome will show a similar curve until a critical temperature is reached.²⁴⁶ It is at this point that arterial closure acutely occurs.

There is no cure for Raynaud's syndrome; thus all treatments mainly palliate symptoms and decrease the severity and perhaps frequency of attacks. Conservative measures predominate, including the wearing of gloves, use of electric or chemically activated hand warmers, avoiding occupational exposure to vibratory tools, abstinence from tobacco, and relocating to a warmer, dryer climate. The majority (90%) of patients will respond to avoidance of cold and other stimuli. The remaining 10% of patients with more persistent or severe syndromes can be treated with a variety of vasodilatory drugs, albeit with only a 30% to 60% response rate. Calcium channel-blocking agents such as diltiazem and nifedipine are the drugs of choice. The selective serotonin reuptake inhibitor fluoxetine has been shown

to reduce the frequency and duration of vasospastic episodes.²⁴⁶ Intravenous infusions of prostaglandins have been reserved for nonresponders with severe symptoms.

Surgical therapy is limited to debridement of digital ulcerations and amputation of gangrenous digits, which are rare complications. Upper extremity sympathectomy may provide relief in 60% to 70% of patients; however, the results are short-lived with a gradual recurrence of symptoms in 60% of patients within 10 years.^{246,247}

Fibromuscular Dysplasia

FMD is a vasculopathy of uncertain etiology that is characterized by segmental arterial involvement. Histologically, fibrous tissue proliferation, smooth muscle cell hyperplasia, and elastic fiber destruction alternate with mural thinning.²⁴⁸ The characteristic beaded appearance of FMD is due to areas of medial thinning alternating with areas of stenosis. The most commonly affected are medium-sized arteries, including the internal carotid, renal, vertebral, subclavian, mesenteric, and iliac arteries. The internal carotid artery is the second most common site of involvement after the renal arteries. FMD occurs most frequently in women (90%) and is recognized at approximately 55 years of age. Only 10% of patients with FMD will have complications attributable to the disease.²⁴⁸ Pathologically, FMD is a heterogeneous group of four distinct types of lesions that are subgrouped based on the predominant site of involvement within the vessel wall. Of the four types (medial fibroplasia, intimal fibroplasia, medial hyperplasia, and perimedial dysplasia), medial fibroplasia is the most common pathologic type, affecting the internal carotid artery (ICA) and the renal artery, and occurring in 85% of reported cases.²⁴⁸

The two main clinical syndromes associated with FMD are TIAs from disease in the internal carotid artery and hypertension from renal artery involvement. Symptoms produced by FMD are generally secondary to associated arterial stenosis and are clinically indistinguishable from those caused by atherosclerotic disease. Often, asymptomatic disease is found incidentally on conventional angiographic studies being performed for other reasons. Within the internal carotid artery, FMD lesions tend to be located higher in the extracranial segment than with atherosclerotic lesions and may not be readily demonstrated by duplex scan.

Clinically, symptoms are due to encroachment on the vessel lumen and a reduction in flow. Additionally, thrombi may form in areas of mural dilatation from a stagnation of flow, leading to distal embolization. Surgical treatment has been favored for symptomatic patients with angiographically proven disease. Due to the distal location of FMD lesions in the extracranial carotid artery, resection and repair are not usually feasible. Instead, graduated luminal dilatation under direct vision has been used successfully in patients, with antiplatelet therapy continued postoperatively. PTA has been used effectively in patients with FMD-induced hypertension. Several series have documented a high technical success rate, with recurrence rates of 8% to 23% at more than 1 year.²⁴⁹ However, the therapeutic effect of blood pressure control may continue to be observed despite restenosis. Surgical reconstruction of the renal arteries for FMD has good long-term results and is recommended for recurrent lesions after angioplasty.²⁴⁹ Open balloon angioplasty of the ICA has been described, which allows for precise fluoroscopic guidance, rather than blind dilatation with calibrated metal probes, and back-bleeding after dilatation to eliminate

cerebral embolization.²⁴⁷ Distal neuroprotective devices may allow this procedure to be performed completely percutaneously, by lessening the threat of cerebral emboli.

Nonatherosclerotic Disease Affecting the Popliteal Artery Disease

There are three distinct nonatherosclerotic disease entities that may result in lower extremity claudication that predominantly occur in 40- to 50-year-old men. Adventitial cystic disease, popliteal artery entrapment syndrome, and Buerger's disease should be considered in any young patients presenting with intermittent claudication.

Adventitial Cystic Disease of the Popliteal Artery. The first successful operative repair of popliteal artery occlusion caused by a cyst arising from the adventitia was reported in 1954 by Ejrup and Hierton.²⁵⁰ Adventitial cystic disease is a rare arterial condition occurring at an incidence of 0.1%, usually in the popliteal artery. This disease affects men in a ratio of approximately 5:1 and appears predominantly in the fourth and fifth decades. The incidence is approximately 1 in 1200 cases of claudication or 1 in 1000 peripheral arteriograms.²⁵⁰ The predominance of reported cases is found in Japan and Europe. However, this disease may affect other vascular sites, such as the femoral, external iliac, radial, ulnar, and brachial arteries. Besides claudication as a symptom, this diagnosis should be considered in young patients who have a mass in a nonaxial vessel in proximity to a related joint. These synovial-like, mucin-filled cysts reside in the subadventitial layer of the vessel wall and have a similar macroscopic appearance to ganglion cysts. Despite this similarity and suggestion of a joint origin for these lesions, histochemical markers have failed to link the cystic lining to synovium.

Patients presenting at a young age with bilateral lower extremity claudication and minimal risk factors for atheroma formation should be evaluated for adventitial cystic disease, as well as the other two nonatherosclerotic vascular lesions described here. Because of luminal encroachment and compression, peripheral pulses may be present in the limb when extended, but then can disappear during knee joint flexion. Noninvasive studies may suggest arterial stenosis with elevated velocities. Color-flow duplex scanning followed by T2-weighted MRI now appears to be the best diagnostic choice. Angiography will demonstrate a smooth, well-defined, crescent-shaped filling defect, the classic "scimitar" sign.²⁵⁰ There may be associated calcification in the cyst wall and no other evidence of atherosclerotic occlusive disease.

Various therapeutic methods have been described for the treatment of adventitial cystic disease. The recommended treatments are excision of the cyst with the cystic wall, enucleation, or simple aspiration when the artery is stenotic. Retention of the cystic lining leads to continued secretion of the cystic fluid and recurrent lesions. In 30% of patients who have an occluded artery, resection of the affected artery, followed by an interposition graft using autogenous saphenous vein, is recommended.

Popliteal Artery Entrapment Syndrome. Love and colleagues first coined the term *popliteal artery entrapment* in 1965 to describe a syndrome combining muscular involvement with arterial ischemia occurring behind the knee, with the successful surgical repair having taken place 6 years earlier.²⁵¹ This is a rare disorder with an estimated prevalence of 0.16% that occurs with a male-to-female ratio of 15:1. Five types of

Table 23-29

Classification of popliteal entrapment syndrome

TYPE	DESCRIPTION
I	Popliteal artery is displaced medially around a normal medial head of the gastrocnemius
II	Medial head of gastrocnemius, which arises lateral to popliteal artery
III	Popliteal artery is compressed by an accessory slip of muscle from medial head of gastrocnemius
IV	Entrapment by a deeper popliteus muscle
V	Any of the above plus popliteal vein entrapment
VI	Functional entrapment

anatomic entrapment have been defined, according to the position of the medial head of the gastrocnemius muscle, abnormal muscle slips or tendinous bands, or the course of the popliteal artery itself (Table 23-29). Concomitant popliteal vein impingement occurs in up to 30% of cases. Twenty-five percent of cases are bilateral.

The typical patient presents with swelling and claudication of isolated calf muscle groups following vigorous physical activity. Various differential diagnoses must be considered when encountering patients with symptoms and signs suggestive of popliteal artery entrapment syndrome (Table 23-30). In a large series of 240 patients, the median age for surgical treatment was 28.5 years.²⁵¹ Noninvasive studies with ABIs should be performed with the knee extended and the foot in a neutral, forced plantar, and dorsiflexed position. A drop in pressure of 50% or greater or dampening of the plethysmographic waveforms in plantar or dorsiflexion is a classic finding.

Table 23-30

Differential diagnosis for popliteal entrapment syndrome

Vascular Etiologies

- Atherosclerosis
- Buerger's disease
- Trauma
- Popliteal aneurysm
- Adventitial cystic disease
- Extrinsic compression
- Cardiac embolism
- Deep vein thrombosis
- Venous entrapment

Musculoskeletal Etiologies

- Gastrocnemius or soleus strain
- Periostitis
- Compartment syndrome
- Stress fractures
- Tibialis posterior tendonitis
- Muscular anomalies

General Neurologic Etiologies

- Spinal stenosis

Contraction of the gastrocnemius should compress the entrapped popliteal artery. The sudden onset of signs and symptoms of acute ischemia with absent distal pulses is consistent with popliteal artery occlusion secondary to entrapment. Other conditions resulting from entrapment are thrombus formation with distal emboli or popliteal aneurysmal degeneration. Although CT and MRI have been employed, angiography remains the most widely used test. Angiography performed with the foot in a neutral position may demonstrate classical medial deviation of the popliteal artery or normal anatomic positioning. Coexisting abnormalities may include stenosis, luminal irregularity, delayed flow, aneurysm, or complete occlusion. Diagnostic accuracy is increased with the use of ankle stress view-active plantar flexion and passive dorsiflexion.

The treatment of popliteal artery entrapment consists of surgical decompression of the impinged artery with possible arterial reconstruction. Division of the anomalous musculotendinous insertion site with or without saphenous vein interposition grafting to bypass the damaged arterial segment has been described to be the procedure of choice. The natural history of entrapment is progressive arterial degeneration leading to complete arterial thrombosis. In such instances, thrombolytic therapy is needed with subsequent release of the functional arterial impairment. Lysis will improve distal runoff and may improve limb-salvage and bypass patency rates.

Buerger's Disease (Thromboangiitis Obliterans)

Buerger's disease, also known as thromboangiitis obliterans, is a progressive nonatherosclerotic segmental inflammatory disease that most often affects small- and medium-sized arteries, veins, and nerves of the upper and lower extremities.²⁵² The clinical and pathologic findings of this disease entity were published in 1908 by Leo Buerger in a description of 11 amputated limbs.²⁵² The typical age range for occurrence is 20 to 50 years, and the disorder is more frequently found in males who smoke. The upper extremities may be involved, and a migratory superficial phlebitis may be present in up to 16% of patients, thus indicating a systemic inflammatory response. In young adults presenting to the Mayo Clinic (1953–1981) with lower limb ischemia, Buerger's disease was diagnosed in 24%.²⁵² Conversely, the diagnosis was made in 9% of patients with ischemic finger ulcerations. The cause of thromboangiitis obliterans is unknown; however, use of or exposure to tobacco is essential to both the diagnosis and progression of the disease.

Pathologically, thrombosis occurs in small- to medium-sized arteries and veins with associated dense polymorphonuclear leukocyte aggregation, microabscesses, and multinucleated giant cells. The chronic phase of the disease shows a decrease in the hypercellularity and frequent recanalization of the vessel lumen. End-stage lesions demonstrate organized thrombus and blood vessel fibrosis. Although the disease is common in Asia, North American males do not appear to have any particular predisposition, as the diagnosis is made in less than 1% of patients with severe limb ischemia.

Buerger's disease typically presents in young male smokers, with symptoms beginning prior to age 40. Patients initially present with foot, leg, arm, or hand claudication, which may be mistaken for joint or neuromuscular problems. Progression of the disease leads to calf claudication and eventually ischemic rest pain and ulcerations on the toes, feet, or fingers. A complete history should exclude diabetes, hyperlipidemia, or autoimmune

disease as possible etiologies for the occlusive lesions. Because it is likely that multiple limbs are involved, angiography should be performed of all four limbs. Even if symptoms are not yet present in a limb, angiographic findings may be demonstrated. Characteristic angiographic findings show disease confinement to the distal circulation, usually infrapopliteal and distal to the brachial artery. The occlusions are segmental and show "skip" lesions with extensive collateralization, the so-called "corkscrew collaterals."

The treatment of thromboangiitis obliterans revolves around strict smoking cessation. In patients who are able to abstain, disease remission is impressive and amputation avoidance is increased. In the experience reported from the Oregon Health Sciences Center, no disease progression with associated tissue loss occurred after discontinuation of tobacco. The role of surgical intervention is minimal in Buerger's disease, as there is often no acceptable target vessel for bypass. Furthermore, autogenous vein conduits are limited secondary to coexisting migratory thrombophlebitis. Mills and associates reported their results of 31% limb loss in 26 patients over 15 years, thus authenticating the virulence of Buerger's disease involving the lower extremities.²⁵² In addition, others have described a significant discrepancy in limb loss in patients who continued to smoke versus those who discontinued tobacco use (67% vs. 35%).

REFERENCES

Entries highlighted in bright blue are key references.

1. Hooi JD, Stoffers HE, Kester AD, van RJ, Knottnerus JA. Peripheral arterial occlusive disease: prognostic value of signs, symptoms, and the ankle-brachial pressure index. *Med Decis Making*. 2002;22:99-107.
2. Norgren L, Hiatt WR, Dormandy JA, et al. Inter-society consensus for the management of peripheral arterial disease (TASC II). *Eur J Vasc Endovasc Surg*. 2007;33(Suppl 1):S1-S75.
3. Jones DN, Rutherford RB. Peripheral vascular assessment and its role in predicting wound healing potential. *Clin Podiatr Med Surg*. 1991;8:909-921.
4. Favaretto E, Pili C, Amato A, et al. Analysis of agreement between duplex ultrasound scanning and arteriography in patients with lower limb artery disease. *J Cardiovasc Med (Hagerstown)*. 2007;8:337-341.
5. Jakobs TF, Wintersperger BJ, Becker CR. MDCT imaging of peripheral arterial disease. *Semin Ultrasound CT MR*. 2004;25:145-155.
6. Maintz D, Kugel H, Schellhammer F, Landwehr P. In vitro evaluation of intravascular stent artifacts in three-dimensional MR angiography. *Invest Radiol*. 2001;36:218-224.
7. Eagle KA, Coley CM, Newell JB, et al. Combining clinical and thallium data optimizes preoperative assessment of cardiac risk before major vascular surgery. *Ann Intern Med*. 1989;110:859-866.
8. Hertzner NR, Beven EG, Young JR, et al. Coronary artery disease in peripheral vascular patients. A classification of 1000 coronary angiograms and results of surgical management. *Ann Surg*. 1984;199:223-233.
9. McFalls EO, Ward HB, Moritz TE, et al. Predictors and outcomes of a perioperative myocardial infarction following elective vascular surgery in patients with documented coronary artery disease: results of the CARP trial. *Eur Heart J*. 2008; 29:394-401.
10. Brady AR, Gibbs JS, Greenhalgh RM, Powell JT, Sydes MR. Perioperative beta-blockade (pobble) for patients undergoing infrarenal vascular surgery: Results of a randomized double-blind controlled trial. *J Vasc Surg*. 2005;41:602-609.

11. Daumerie G, Fleisher LA. Perioperative beta-blocker and statin therapy. *Curr Opin Anaesthesiol*. 2008;21:60-65.
12. Austin D, Pell JP, Oldroyd KG. Drug-eluting stents: a review of current evidence on clinical effectiveness and late complications. *Scott Med J*. 2008;53:16-24.
13. Feiring AJ, Krahn M, Nelson L, Wesolowski A, Eastwood D, Szabo A. Preventing leg amputations in critical limb ischemia with below-the-knee drug-eluting stents: the paradise (preventing amputations using drug eluting stents) trial. *J Am Coll Cardiol*. 2010;55:1580-1589.
14. Katsanos K, Spiliopoulos S, Diamantopoulos A, Karnabatis D, Sabharwal T, Siablis D. Systematic review of infrapopliteal drug-eluting stents: a meta-analysis of randomized controlled trials. *Cardiovasc Intervent Radiol*. 2013;36:645-658.
15. Parodi JC, Marin ML, Veith FJ. Transfemoral, endovascular stented graft repair of an abdominal aortic aneurysm. *Arch Surg*. 1995;130:549-552.
16. Criado FJ, Fairman RM, Becker GJ, Talent LPS AAA stent graft: results of a pivotal clinical trial. *J Vasc Surg*. 2003;37:709-715.
17. Tanquilut EM, Ouriel K. Current outcomes in endovascular repair of abdominal aortic aneurysms. *J Cardiovasc Surg*. 2003;44:503-509.
18. Zarins CK, White RA, Moll FL, et al. The aneurx stent graft: four-year results and worldwide experience 2000. *J Vasc Surg*. 2001;33:S135-S145.
19. Donnan GA, Fisher M, Macleod M, Davis SM. Stroke. *Lancet*. 2008;371:1612-1623.
20. Chaer RA, DeRubertis B, Patel S, Lin SC, Kent CK, Faries PL. Current management of extracranial carotid artery disease. *Rev Recent Clin Trials*. 2006;1:293-301.
21. Grant EG, Benson CB, Moneta GL, et al. Carotid artery stenosis: grayscale and Doppler ultrasound diagnosis—Society of Radiologists in Ultrasound Consensus Conference. *Ultrasound Q*. 2003;19:190-198.
22. Wardlaw JM, Chappell FM, Stevenson M, et al. Accurate, practical and cost-effective assessment of carotid stenosis in the uk. *Health Technol Assess*. 2006;10:iii-iv, ix-x, 1-182.
23. Saba L, Mallarini G. Mdcta of carotid plaque degree of stenosis: evaluation of interobserver agreement. *AJR Am J Roentgenol*. 2008;190:W41-W46.
24. Price TR, Psaty B, O'Leary D, Burke G, Gardin J. Assessment of cerebrovascular disease in the cardiovascular health study. *Ann Epidemiol*. 1993;3:504-507.
25. Chen ZM, Sandercock P, Pan HC, et al. Indications for early aspirin use in acute ischemic stroke: a combined analysis of 40,000 randomized patients from the Chinese Acute Stroke Trial and the International Stroke Trial. On behalf of the CAST and IST Collaborative Groups. *Stroke*. 2000;31:1240-1249.
26. Kita MW. Carotid endarterectomy in symptomatic carotid stenosis: NASCET comparative results at 30 months of follow-up. *J Insur Med*. 1992;24:42-46.
27. Warlow CP. Symptomatic patients: the European Carotid Surgery Trial (ECST). *J Mal Vasc*. 1993;18:198-201.
28. Strandness DE, Eikelboom BC. Carotid artery stenosis—where do we go from here? *Eur J Ultrasound*. 1998;7(Suppl 3):S17-S26.
29. Rothwell PM, Eliasziw M, Gutnikov SA, et al. Analysis of pooled data from the randomised controlled trials of endarterectomy for symptomatic carotid stenosis. *Lancet*. 2003;361:107-116.
30. Topkian R, Strasak AM, Sonnberger M, et al. Timing of stenting of symptomatic carotid stenosis is predictive of 30-day outcome. *Eur J Neurol*. 2007;14:672-678.
31. Roederer GO, Langlois YE, Jager KA, et al. The natural history of carotid arterial disease in asymptomatic patients with cervical bruits. *Stroke*. 1984;15:605-613.
32. Fisher M, Martin A, Cosgrove M, Norris JW. The NASCET-ACAS Plaque Project. North American Symptomatic Carotid Endarterectomy Trial. Asymptomatic Carotid Atherosclerosis Study. *Stroke*. 1993;24:I24-I25; discussion I31-I22.
33. Halliday A, Mansfield A, Marro J, et al. Prevention of disabling and fatal strokes by successful carotid endarterectomy in patients without recent neurological symptoms: randomised controlled trial. *Lancet*. 2004;363:1491-1502.
34. Coward LJ, Featherstone RL, Brown MM. Safety and efficacy of endovascular treatment of carotid artery stenosis compared with carotid endarterectomy: a Cochrane systematic review of the randomized evidence. *Stroke*. 2005;36:905-911.
35. Lin PH, Barshes NR, Annambhotla S, Huynh TT. Prospective randomized trials of carotid artery stenting versus carotid endarterectomy: an appraisal of the current literature. *Vasc Endovasc Surg*. 2008;42:5-11.
36. Berkefeld J, Chaturvedi S. The International Carotid Stenting Study and the North American Carotid Revascularization Endarterectomy Versus Stenting Trial: fueling the debate about carotid artery stenting. *Stroke*. 2010;41:2714-2715.
37. Brott TG, Hobson RW 2nd, Howard G, et al. Stenting versus endarterectomy for treatment of carotid-artery stenosis. *N Engl J Med*. 2010;363:11-23.
38. Bonati LH, Jongen LM, Haller S, et al. New ischaemic brain lesions on MRI after stenting or endarterectomy for symptomatic carotid stenosis: a substudy of the International Carotid Stenting Study (ICSS). *Lancet Neurol*. 2010;9:353-362.
39. Ricotta JJ, Aburahma A, Ascher E, et al. Updated society for vascular surgery guidelines for management of extracranial carotid disease. *J Vasc Surg*. 2011;54:e1-31.
40. Crawford RS, Chung TK, Hodgman T, Pedraza JD, Corey M, Cambria RP. Restenosis after eversion vs. patch closure carotid endarterectomy. *J Vasc Surg*. 2007;46:41-48.
41. Organ N, Walker PJ, Jenkins J, Foster W, Jenkins J. 15 year experience of carotid endarterectomy at the Royal Brisbane and Women's Hospital: outcomes and changing trends in management. *Eur J Vasc Endovasc Surg*. 2008;35:273-279.
42. Zhou W, Felkai DD, Evans M, et al. Ultrasound criteria for severe in-stent restenosis following carotid artery stenting. *J Vasc Surg*. 2008;47:74-80.
43. Lin PH, Zhou W, Koungias P, El Sayed HF, Barshes NR, Huynh TT. Factors associated with hypotension and bradycardia after carotid angioplasty and stenting. *J Vasc Surg*. 2007;46:846-853; discussion 853-844.
44. Plouin PF, Perdu J, La Batide-Alanore A, Boutouyrie P, Gimenez-Roqueplo AP, Jeunemaitre X. Fibromuscular dysplasia. *Orphanet J Rare Dis*. 2007;2:28.
45. Zhou W, Lin PH, Bush RL, et al. Carotid artery aneurysm: evolution of management over two decades. *J Vasc Surg*. 2006;43:493-496; discussion 497.
46. Athanasiou A, Liappis CD, Rapidis AD, Fassolis A, Stavrianos SD, Kokkalis G. Carotid body tumor: review of the literature and report of a case with a rare sensorineural symptomatology. *J Oral Maxillofac Surg*. 2007;65:1388-1393.
47. Hoornweg LL, Storm-Versloot MN, Ubbink DT, Koelemay MJ, Legemate DA, Balm R. Meta analysis on mortality of ruptured abdominal aortic aneurysms. *Eur J Vasc Endovasc Surg*. 2008;35:558-570.
48. Dotter CT, Judkins MP, Rosch J. Transluminal angioplasty in arteriosclerotic obstruction of the lower extremities. *Med Times*. 1969;97:95-108.
49. Nordon IM, Hinchliffe RJ, Holt PJ, Loftus IM, Thompson MM. Review of current theories for abdominal aortic aneurysm pathogenesis. *Vascular*. 2009;17:253-263.
50. Lederle FA, Johnson GR, Wilson SE, et al. The aneurysm detection and management study screening program: validation cohort and final results. Aneurysm Detection and

- Management Veterans Affairs Cooperative Study Investigators. *Arch Intern Med.* 2000;160:1425-1430.
51. Kent KC, Zwolak RM, Egorova NN, et al. Analysis of risk factors for abdominal aortic aneurysm in a cohort of more than 3 million individuals. *J Vasc Surg.* 2010;52:539-548.
 52. Hellmann DB, Grand DJ, Freischlag JA. Inflammatory abdominal aortic aneurysm. *JAMA.* 2007;297:395-400.
 53. Walker DI, Bloor K, Williams G, Gillie I. Inflammatory aneurysms of the abdominal aorta. *Br J Surg.* 1972;59:609-614.
 54. Pennell RC, Hollier LH, Lie JT, et al. Inflammatory abdominal aortic aneurysms: a thirty-year review. *J Vasc Surg.* 1985; 2:859-869.
 55. Oderich GS, Panneton JM, Bower TC, et al. Infected aortic aneurysms: aggressive presentation, complicated early outcome, but durable results. *J Vasc Surg.* 2001;34:900-908.
 56. Takayama T, Yamanouchi D. Aneurysmal disease: the abdominal aorta. *Surg Clin North Am.* 2013;93:877-891, viii.
 57. Fleming C, Whitlock EP, Beil TL, Lederle FA. Screening for abdominal aortic aneurysm: a best-evidence systematic review for the U.S. Preventive Services Task Force. *Ann Intern Med.* 2005;142:203-211.
 58. Lederle FA, Johnson GR, Wilson SE, et al. Yield of repeated screening for abdominal aortic aneurysm after a 4-year interval. Aneurysm Detection and Management Veterans Affairs Cooperative Study Investigators. *Arch Intern Med.* 2000;160:1117-1121.
 59. Ouriel K. Endovascular therapies: an update on aortic aneurysm repair and carotid endarterectomy. *J Am Coll Surg.* 2002;195:549-552.
 60. Humphreys WV, Byrne J, James W. Elective abdominal aortic aneurysm operations—the results of a single surgeon series of 243 consecutive operations from a district general hospital. *Ann R Coll Surg Engl.* 2000;82:64-68.
 61. Hausegger KA, Schedlbauer P, Deutschmann HA, Tiesenhäuser K. Complications in endoluminal repair of abdominal aortic aneurysms. *Eur J Radiol.* 2001;39:22-33.
 62. Stanley BM, Semmens JB, Lawrence-Brown MM, Goodman MA, Hartley DE. Fenestration in endovascular grafts for aortic aneurysm repair: new horizons for preserving blood flow in branch vessels. *J Endovasc Ther.* 2001;8:16-24.
 63. Greenberg RK, Sternbergh WC III, Makaroun M, et al. Intermediate results of a united states multicenter trial of fenestrated endograft repair for juxtarenal abdominal aortic aneurysms. *J Vasc Surg.* 2009;50:730-737, e731.
 64. Verhoeven EL, Vourliotakis G, Bos WT, et al. Fenestrated stent grafting for short-necked and juxtarenal abdominal aortic aneurysm: an 8-year single-centre experience. *Eur J Vasc Endovasc Surg.* 2010;39:529-536.
 65. Ricotta JJ II, Tsilimparis N. Surgeon-modified fenestrated-branched stent grafts to treat emergently ruptured and symptomatic complex aortic aneurysms in high-risk patients. *J Vasc Surg.* 2012;56:1535-1542.
 66. Verhoeven EL, Tielliu IF, Ferreira M, Zipfel B, Adam DJ. Thoraco-abdominal aortic aneurysm branched repair. *J Cardiovasc Surg.* 2010;51:149-155.
 67. Donas KP, Torsello G, Austermann M, Schwindt A, Troisi N, Pitoulias GA. Use of abdominal chimney grafts is feasible and safe: short-term results. *J Endovasc Ther.* 2010;17:589-593.
 68. Ohrländer T, Sonesson B, Ivancev K, Resch T, Dias N, Malina M. The chimney graft: a technique for preserving or rescuing aortic branch vessels in stent-graft sealing zones. *J Endovasc Ther.* 2008;15:427-432.
 69. Katsargyris A, Oikonomou K, Klonaris C, Topel I, Verhoeven EL. Comparison of outcomes with open, fenestrated, and chimney graft repair of juxtarenal aneurysms: are we ready for a paradigm shift? *J Endovasc Ther.* 2013;20:159-169.
 70. Magennis R, Joekes E, Martin J, White D, McWilliams RG. Complications following endovascular abdominal aortic aneurysm repair. *Br J Radiol.* 2002;75:700-707.
 71. Zarins CK, White RA, Fogarty TJ. Aneurysm rupture after endovascular repair using the aneurx stent graft. *J Vasc Surg.* 2000;31:960-970.
 72. Lin PH, Bush RL, Chaikof EL, et al. A prospective evaluation of hypogastric artery embolization in endovascular aortoiliac aneurysm repair. *J Vasc Surg.* 2002;36:500-506.
 73. Bush RL, Lin PH, Reddy PP, et al. Epidural analgesia in patients with chronic obstructive pulmonary disease undergoing transperitoneal abdominal aortic aneurysmorrhaphy—a multi-institutional analysis. *Cardiovasc Surg.* 2003;11: 179-184.
 74. Greenhalgh RM, Brown LC, Kwong GP, Powell JT, Thompson SG. Comparison of endovascular aneurysm repair with open repair in patients with abdominal aortic aneurysm (EVAR trial 1), 30-day operative mortality results: randomised controlled trial. *Lancet.* 2004;364: 843-848.
 75. Prinssen M, Verhoeven EL, Buth J, et al. A randomized trial comparing conventional and endovascular repair of abdominal aortic aneurysms. *N Engl J Med.* 2004;351: 1607-1618.
 76. Lederle FA, Freischlag JA, Kyriakides TC, et al. Long-term comparison of endovascular and open repair of abdominal aortic aneurysm. *N Engl J Med.* 2012;367:1988-1997.
 77. Matsumura JS, Brewster DC, Makaroun MS, Naftel DC. A multicenter controlled clinical trial of open versus endovascular treatment of abdominal aortic aneurysm. *J Vasc Surg.* 2003;37:262-271.
 78. Greenberg RK, Chuter TA, Sternbergh WC III, Fearnot NE. Zenith AAA endovascular graft: intermediate-term results of the US multicenter trial. *J Vasc Surg.* 2004;39:1209-1218.
 79. Zarins CK. The U.S. aneurx clinical trial: 6-year clinical update 2002. *J Vasc Surg.* 2003;37:904-908.
 80. Criado FJ, Clark NS, McKendrick C, Longway J, Domer GS. Update on the Talent LPS AAA stent graft: results with “enhanced talent.” *Semin Vasc Surg.* 2003;16:158-165.
 81. Bertges DJ, Zwolak RM, Deaton DH, et al. Current hospital costs and medicare reimbursement for endovascular abdominal aortic aneurysm repair. *J Vasc Surg.* 2003;37:272-279.
 82. Seiwert AJ, Wolfe J, Whalen RC, Pigott JP, Kritpracha B, Beebe HG. Cost comparison of aortic aneurysm endograft exclusion versus open surgical repair. *Am J Surg.* 1999;178: 117-120.
 83. Angle N, Dorafshar AH, Moore WS, et al. Open versus endovascular repair of abdominal aortic aneurysms: what does each really cost? *Ann Vasc Surg.* 2004;18:612-618.
 84. Lederle FA, Stroupe KT, Open Versus Endovascular Repair Veterans Affairs Cooperative Study Group. Cost-effectiveness at two years in the VA Open Versus Endovascular Repair Trial. *Eur J Vasc Endovasc Surg.* 2012;44:543-548.
 85. Baum RA, Stavropoulos SW, Fairman RM, Carpenter JP. Endoleaks after endovascular repair of abdominal aortic aneurysms. *J Vasc Interv Radiol.* 2003;14:1111-1117.
 86. Buth J, Harris PL, Van Marrewijk C, Fransen G. Endoleaks during follow-up after endovascular repair of abdominal aortic aneurysm. Are they all dangerous? *J Cardiovasc Surg.* 2003; 44:559-566.
 87. Dubenec SR, White GH, Pasenau J, Tzilalis V, Choy E, Erdelez L. Endotension. A review of current views on pathophysiology and treatment. *J Cardiovasc Surg.* 2003;44: 553-557.
 88. Lin PH, Bush RL, Katzman JB, et al. Delayed aortic aneurysm enlargement due to endotension after endovascular abdominal aortic aneurysm repair. *J Vasc Surg.* 2003;38:840-842.
 89. Criado FJ, Wilson EP, Fairman RM, Abul-Khoudoud O, Wellons E. Update on the Talent aortic stent-graft: a preliminary report from United States phase I and II trials. *J Vasc Surg.* 2001;33:S146-S149.

90. Harris PL, Vallabhaneni SR, Desgranges P, Becquemini JP, van Marrewijk C, Laheij RJ. Incidence and risk factors of late rupture, conversion, and death after endovascular repair of infrarenal aortic aneurysms: the Eurostar experience. European Collaborators on Stent/Graft Techniques for Aortic Aneurysm Repair. *J Vasc Surg.* 2000;32:739-749.
91. Krohg-Sorensen K, Brekke M, Drolsum A, Kvernebo K. Periprosthetic leak and rupture after endovascular repair of abdominal aortic aneurysm: the significance of device design for long-term results. *J Vasc Surg.* 1999;29:1152-1158.
92. Mehta M, Paty PS, Roddy SP, et al. Treatment options for delayed AAA rupture following endovascular repair. *J Vasc Surg.* 2011;53:14-20.
93. May J, White GH, Yu W, et al. Endoluminal repair of abdominal aortic aneurysms: strengths and weaknesses of various prostheses observed in a 4.5-year experience. *J Endovasc Surg.* 1997;4:147-151.
94. Kougiass P, Lin PH, Dardik A, Lee WA, El Sayed HF, Zhou W. Successful treatment of endotension and aneurysm sac enlargement with endovascular stent graft reinforcement. *J Vasc Surg.* 2007;46:124-127.
95. Teufelsbauer H, Prusa AM, Prager M, et al. Endovascular treatment of a multimorbid patient with late AAA rupture after stent-graft placement: 1-year follow-up. *J Endovasc Ther.* 2002;9:896-900.
96. Yasuhara H. Acute mesenteric ischemia: the challenge of gastroenterology. *Surg Today.* 2005;35:185-195.
97. Zelenock GB, Graham LM, Whitehouse WM Jr, et al. Splanchnic arteriosclerotic disease and intestinal angina. *Arch Surg.* 1980;115:497-501.
98. Karwowski J, Arko F. Surgical management of mesenteric ischemia. *Tech Vasc Interv Radiol.* 2004;7:151-154.
99. Moneta GL, Lee RW, Yeager RA, Taylor LM Jr, Porter JM. Mesenteric duplex scanning: a blinded prospective study. *J Vasc Surg.* 1993;17:79-84; discussion 85-76.
100. Mitchell EL, Moneta GL. Mesenteric duplex scanning. *Perspect Vasc Surg Endovasc Ther.* 2006;18:175-183.
101. Kougiass P, El Sayed HF, Zhou W, Lin PH. Management of chronic mesenteric ischemia. The role of endovascular therapy. *J Endovasc Ther.* 2007;14:395-405.
102. Sultan S, Hynes N, Elsafty N, Tawfik W. Eight years experience in the management of median arcuate ligament syndrome by decompression, celiac ganglion sympathectomy, and selective revascularization. *Vasc Endovasc Surgery.* 2013 Aug 13.
103. Glociczki P, Duncan AA. Treatment of celiac artery compression syndrome: does it really exist? *Perspect Vasc Surg Endovasc Ther.* 2007;19:259-263.
104. Kougiass P, Lau D, El Sayed HF, Zhou W, Huynh TT, Lin PH. Determinants of mortality and treatment outcome following surgical interventions for acute mesenteric ischemia. *J Vasc Surg.* 2007;46:467-474.
105. Jimenez JC, Harlander-Locke M, Dutson EP. Open and laparoscopic treatment of median arcuate ligament syndrome. *J Vasc Surg.* 2012;56:869-873.
106. Park WM, Cherry KJ Jr, Chua HK, et al. Current results of open revascularization for chronic mesenteric ischemia: a standard for comparison. *J Vasc Surg.* 2002;35:853-859.
107. Silva JA, White CJ, Collins TJ, et al. Endovascular therapy for chronic mesenteric ischemia. *J Am Coll Cardiol.* 2006;47:944-950.
108. AbuRahma AF, Stone PA, Bates MC, Welch CA. Angioplasty/stenting of the superior mesenteric artery and celiac trunk: early and late outcomes. *J Endovasc Ther.* 2003;10:1046-1053.
109. Furrer J, Gruntzig A, Kugelmeier J, Goebel N. Treatment of abdominal angina with percutaneous dilatation of an arteria mesenterica superior stenosis. Preliminary communication. *Cardiovasc Intervent Radiol.* 1980;3:43-44.
110. Atkins MD, Kwolek CJ, LaMuraglia GM, Brewster DC, Chung TK, Cambria RP. Surgical revascularization versus endovascular therapy for chronic mesenteric ischemia: a comparative experience. *J Vasc Surg.* 2007;45:1162-1171.
111. Kasirajan K, O'Hara PJ, Gray BH, et al. Chronic mesenteric ischemia: open surgery versus percutaneous angioplasty and stenting. *J Vasc Surg.* 2001;33:63-71.
112. Oderich GS, Erdoes LS, Lesar C, et al. Comparison of covered stents versus bare metal stents for treatment of chronic atherosclerotic mesenteric arterial disease. *J Vasc Surg.* 2013;58:1316.
113. Textor SC. Atherosclerotic renal artery stenosis: overtreated but underrated? *J Am Soc Nephrol.* 2008;19:656-659.
114. Klassen PS, Svetkey LP. Diagnosis and management of renovascular hypertension. *Cardiol Rev.* 2000;8:17-29.
115. Chade AR, Rodriguez-Porcel M, Grande JP, et al. Distinct renal injury in early atherosclerosis and renovascular disease. *Circulation.* 2002;106:1165-1171.
116. Vuong PN, Desoutter P, Mickley V, et al. Fibromuscular dysplasia of the renal artery responsible for renovascular hypertension: a histological presentation based on a series of 102 patients. *Vasa.* 2004;33:13-18.
117. Cherr GS, Hansen KJ, Craven TE, et al. Surgical management of atherosclerotic renovascular disease. *J Vasc Surg.* 2002;35:236-245.
118. Hansen KJ, Cherr GS, Craven TE, et al. Management of ischemic nephropathy: dialysis-free survival after surgical repair. *J Vasc Surg.* 2000;32:472-481; discussion 481-472.
119. Guzman RP, Zierler RE, Isaacson JA, Bergelin RO, Strandness DE Jr. Renal atrophy and arterial stenosis. A prospective study with duplex ultrasound. *Hypertension.* 1994;23:346-350.
120. van de Ven PJ, Kaatee R, Beutler JJ, et al. Arterial stenting and balloon angioplasty in ostial atherosclerotic renovascular disease: a randomised trial. *Lancet.* 1999;353:282-286.
121. Surowiec SM, Sivamurthy N, Rhodes JM, et al. Percutaneous therapy for renal artery fibromuscular dysplasia. *Ann Vasc Surg.* 2003;17:650-655.
122. van Jaarsveld BC, Krijnen P. Prospective studies of diagnosis and intervention: the Dutch experience. *Semin Nephrol.* 2000;20:463-473.
123. White CJ, Ramee SR, Collins TJ, Jenkins JS, Escobar A, Shaw D. Renal artery stent placement: utility in lesions difficult to treat with balloon angioplasty. *J Am Coll Cardiol.* 1997;30:1445-1450.
124. Blum U, Krumme B, Flugel P, et al. Treatment of ostial renal-artery stenoses with vascular endoprostheses after unsuccessful balloon angioplasty. *N Engl J Med.* 1997;336:459-465.
125. Watson PS, Hadjipetrou P, Cox SV, Piemonte TC, Eisenhauer AC. Effect of renal artery stenting on renal function and size in patients with atherosclerotic renovascular disease. *Circulation.* 2000;102:1671-1677.
126. Harden PN, MacLeod MJ, Rodger RS, et al. Effect of renal-artery stenting on progression of renovascular renal failure. *Lancet.* 1997;349:1133-1136.
127. Bush RL, Najibi S, MacDonald MJ, et al. Endovascular revascularization of renal artery stenosis: technical and clinical results. *J Vasc Surg.* 2001;33:1041-1049.
128. Dorros G, Jaff M, Mathiak L, et al. Four-year follow-up of Palmaz-Schatz stent revascularization as treatment for atherosclerotic renal artery stenosis. *Circulation.* 1998;98:642-647.
129. Henry M, Amor M, Henry I, et al. Stents in the treatment of renal artery stenosis: long-term follow-up. *J Endovasc Surg.* 1999;6:42-51.
130. Iannone LA, Underwood PL, Nath A, Tannenbaum MA, Ghali MG, Clevenger LD. Effect of primary balloon expandable renal artery stents on long-term patency, renal function, and blood pressure in hypertensive and renal insufficient

- patients with renal artery stenosis. *Cathet Cardiovasc Diagn.* 1996;37:243-250.
131. Rundback JH, Gray RJ, Rozenblit G, et al. Renal artery stent placement for the management of ischemic nephropathy. *J Vasc Interv Radiol.* 1998;9:413-420.
 132. Shannon HM, Gillespie IN, Moss JG. Salvage of the solitary kidney by insertion of a renal artery stent. *AJR Am J Roentgenol.* 1998;171:217-222.
 133. Leertouwer TC, Gussenhoven EJ, Bosch JL, et al. Stent placement for renal arterial stenosis: where do we stand? A meta-analysis. *Radiology.* 2000;216:78-85.
 134. Dormandy JA, Rutherford RB. Management of peripheral arterial disease (PAD). TASC Working Group. Transatlantic Inter-Society Consensus (TASC). *J Vasc Surg.* 2000;31:S1-S296.
 135. Ameli FM. Aortobifemoral bypass—an enduring operation. *Can J Surg.* 1992;35:237-241.
 136. Martin D, Katz SG. Axillofemoral bypass for aortoiliac occlusive disease. *Am J Surg.* 2000;180:100-103.
 137. Criado E, Burnham SJ, Tinsley EA Jr, Johnson G Jr, Keagy BA. Femorofemoral bypass graft: analysis of patency and factors influencing long-term outcome. *J Vasc Surg.* 1993;18:495-504.
 138. Patel A, Taylor SM, Langan EM III, et al. Obturator bypass: a classic approach for the treatment of contemporary groin infection. *Am Surg.* 2002;68:653-658; discussion 658-659.
 139. Sautner T, Niederle B, Herbst F, et al. The value of obturator canal bypass. A review. *Arch Surg.* 1994;129:718-722.
 140. Brewster DC, Cambria RP, Darling RC, et al. Long-term results of combined iliac balloon angioplasty and distal surgical revascularization. *Ann Surg.* 1989;210:324-330; discussion 331.
 141. van den Akker PJ, van Schilfgaarde R, Brand R, van Bockel JH, Terpstra JL. Long term success of aortoiliac operation for arteriosclerotic obstructive disease. *Surg Gynecol Obstet.* 1992;174:485-496.
 142. Szilagyi DE, Elliott JP Jr, Smith RF, Reddy DJ, McPharlin M. A thirty-year survey of the reconstructive surgical treatment of aortoiliac occlusive disease. *J Vasc Surg.* 1986;3:421-436.
 143. Sagic D, Grujicic S, Peric M, Popovic Z, Radevic B, Bojic M. “Kissing-balloon” technique for abdominal aorta angioplasty. Initial results and long term outcome. *Int Angiol.* 1995;14:364-367.
 144. Insall RL, Loose HW, Chamberlain J. Long-term results of double-balloon percutaneous transluminal angioplasty of the aorta and iliac arteries. *Eur J Vasc Surg.* 1993;7:31-36.
 145. Mendelsohn FO, Santos RM, Crowley JJ, et al. Kissing stents in the aortic bifurcation. *Am Heart J.* 1998;136:600-605.
 146. Haulon S, Mounier-Vehier C, Gaxotte V, et al. Percutaneous reconstruction of the aortoiliac bifurcation with the “kissing stents” technique: long-term follow-up in 106 patients. *J Endovasc Ther.* 2002;9:363-368.
 147. Palmaz JC, Laborde JC, Rivera FJ, Encarnacion CE, Lutz JD, Moss JG. Stenting of the iliac arteries with the Palmaz stent: experience from a multicenter trial. *Cardiovasc Intervent Radiol.* 1992;15:291-297.
 148. Sapoval MR, Long AL, Pagny JY, et al. Outcome of percutaneous intervention in iliac artery stents. *Radiology.* 1996;198:481-486.
 149. Uberoi R, Tsetis D. Standards for the endovascular management of aortic occlusive disease. *Cardiovasc Intervent Radiol.* 2007;30:814-819.
 150. Mousa AY, Beauford RB, Flores L, Faries PL, Patel P, Fogler R. Endovascular treatment of iliac occlusive disease: review and update. *Vascular.* 2007;15:5-11.
 151. Tetteroo E, van der Graaf Y, Bosch JL, et al. Randomised comparison of primary stent placement versus primary angioplasty followed by selective stent placement in patients with iliac-artery occlusive disease. Dutch Iliac Stent Trial Study Group. *Lancet.* 1998;351:1153-1159.
 152. Piffaretti G, Tozzi M, Lomazzi C, et al. Mid-term results of endovascular reconstruction for aorto-iliac obstructive disease. *Int Angiol.* 2007;26:18-25.
 153. Bosiers M, Iyer V, Deloose K, Verbist J, Peeters P. Flemish experience using the Advanta v12 stent-graft for the treatment of iliac artery occlusive disease. *J Cardiovasc Surg.* 2007;48:7-12.
 154. Harris RA, Hardman DT, Fisher C, Lane R, Appleberg M. Aortic reconstructive surgery for limb ischaemia: immediate and long-term follow-up to provide a standard for endovascular procedures. *Cardiovasc Surg.* 1998;6:256-261.
 155. Indes JE, Pfaff MJ, Farrokhvar F, et al. Clinical outcomes of 5358 patients undergoing direct open bypass or endovascular treatment for aortoiliac occlusive disease: a systematic review and meta-analysis. *J Endovasc Ther.* 2013;20:443-455.
 156. Becker GJ, Cikrit DF, Lalka SG, et al. Early experience with the Palmaz stent in human iliac angioplasty. *Indiana Med.* 1989;82:286-292.
 157. Tsetis D, Uberoi R. Quality improvement guidelines for endovascular treatment of iliac artery occlusive disease. *Cardiovasc Intervent Radiol.* 2008;31:238-245.
 158. Powell RJ, Fillinger M, Bettmann M, et al. The durability of endovascular treatment of multisegment iliac occlusive disease. *J Vasc Surg.* 2000;31:1178-1184.
 159. Timaran CH, Stevens SL, Grandas OH, Freeman MB, Goldman MH. Influence of hormone replacement therapy on the outcome of iliac angioplasty and stenting. *J Vasc Surg.* 2001;33:S85-S92.
 160. Bosch JL, Hunink MG. Meta-analysis of the results of percutaneous transluminal angioplasty and stent placement for aortoiliac occlusive disease. *Radiology.* 1997;204:87-96.
 161. Park KB, Do YS, Kim JH, et al. Stent placement for chronic iliac arterial occlusive disease: the results of 10 years experience in a single institution. *Korean J Radiol.* 2005;6:256-266.
 162. Leville CD, Kashyap VS, Clair DG, et al. Endovascular management of iliac artery occlusions: extending treatment to Transatlantic Inter-Society Consensus Class C and D patients. *J Vasc Surg.* 2006;43:32-39.
 163. McDaniel MD, Cronenwett JL. Basic data related to the natural history of intermittent claudication. *Ann Vasc Surg.* 1989;3:273-277.
 164. Leng GC, Papacosta O, Whincup P, et al. Femoral atherosclerosis in an older British population: prevalence and risk factors. *Atherosclerosis.* 2000;152:167-174.
 165. Schroll M, Munck O. Estimation of peripheral arteriosclerotic disease by ankle blood pressure measurements in a population study of 60-year-old men and women. *J Chronic Dis.* 1981;34:261-269.
 166. Stoffers HE, Rinkens PE, Kester AD, Kaiser V, Knottnerus JA. The prevalence of asymptomatic and unrecognized peripheral arterial occlusive disease. *Int J Epidemiol.* 1996;25:282-290.
 167. Ouriel K. Peripheral arterial disease. *Lancet.* 2001;358:1257-1264.
 168. Koelemay MJ, den Hartog D, Prins MH, Kromhout JG, Lege-mate DA, Jacobs MJ. Diagnosis of arterial disease of the lower extremities with duplex ultrasonography. *Br J Surg.* 1996;83:404-409.
 169. Eiberg JP, Hansen MA, Jensen F, Rasmussen JB, Schroeder TV. Ultrasound contrast-agent improves imaging of lower limb occlusive disease. *Eur J Vasc Endovasc Surg.* 2003;25:23-28.
 170. Nehler MR, McDermott MM, Treat-Jacobson D, Chetter I, Regensteiner JG. Functional outcomes and quality of life in peripheral arterial disease: current status. *Vasc Med.* 2003;8:115-126.

171. Ouriel K. The use of glycoprotein IIB/IIIa antagonists in peripheral arterial occlusion. *Tech Vasc Interv Radiol*. 2001; 4:107-110.
172. Ouriel K. Current status of thrombolysis for peripheral arterial occlusive disease. *Ann Vasc Surg*. 2002;16:797-804.
173. Lin PH, Barshes NR, Annambhotla S, Koungias P, Huynh TT. Advances in endovascular interventions for deep vein thrombosis. *Expert Rev Med Devices*. 2008;5:153-166.
174. Lin PH, Zhou W, Dardik A, et al. Catheter-direct thrombolysis versus pharmacomechanical thrombectomy for treatment of symptomatic lower extremity deep venous thrombosis. *Am J Surg*. 2006;192:782-788.
175. Ouriel K. Comparison of surgical and thrombolytic treatment of peripheral arterial disease. *Rev Cardiovasc Med*. 2002; 3(Suppl 2):S7-16.
176. Conte MS, Belkin M, Upchurch GR, Mannick JA, Whittemore AD, Donaldson MC. Impact of increasing comorbidity on infrainguinal reconstruction: a 20-year perspective. *Ann Surg*. 2001;233:445-452.
177. Hunink MG, Donaldson MC, Meyerovitz MF, et al. Risks and benefits of femoropopliteal percutaneous balloon angioplasty. *J Vasc Surg*. 1993;17:183-192.
178. Johnston KW. Femoral and popliteal arteries: reanalysis of results of balloon angioplasty. *Radiology*. 1992;183:767-771.
179. Hunink MG, Wong JB, Donaldson MC, Meyerovitz MF, Harrington DP. Patency results of percutaneous and surgical revascularization for femoropopliteal arterial disease. *Med Decis Making*. 1994;14:71-81.
180. Lofberg AM, Karacagil S, Ljungman C, et al. Percutaneous transluminal angioplasty of the femoropopliteal arteries in limbs with chronic critical lower limb ischemia. *J Vasc Surg*. 2001;34:114-121.
181. Varty K, Bolia A, Naylor AR, Bell PR, London NJ. Infrapopliteal percutaneous transluminal angioplasty: a safe and successful procedure. *Eur J Vasc Endovasc Surg*. 1995;9: 341-345.
182. Bolia A, Sayers RD, Thompson MM, Bell PR. Subintimal and intraluminal recanalisation of occluded crural arteries by percutaneous balloon angioplasty. *Eur J Vasc Surg*. 1994;8: 214-219.
183. London NJ, Srinivasan R, Naylor AR, et al. Subintimal angioplasty of femoropopliteal artery occlusions: the long-term results. *Eur J Vasc Surg*. 1994;8:148-155.
184. Lipsitz EC, Ohki T, Veith FJ, et al. Does subintimal angioplasty have a role in the treatment of severe lower extremity ischemia? *J Vasc Surg*. 2003;37:386-391.
185. Treiman GS, Whiting JH, Treiman RL, McNamara RM, Ashrafi A. Treatment of limb-threatening ischemia with percutaneous intentional extraluminal recanalization: a preliminary evaluation. *J Vasc Surg*. 2003;38:29-35.
186. Ingle H, Nasim A, Bolia A, et al. Subintimal angioplasty of isolated infragenicular vessels in lower limb ischemia: long-term results. *J Endovasc Ther*. 2002;9:411-416.
187. Becquemain JP, Favre JP, Marzelle J, Nemoz C, Corsin C, Leizorovicz A. Systematic versus selective stent placement after superficial femoral artery balloon angioplasty: a multicenter prospective randomized study. *J Vasc Surg*. 2003; 37:487-494.
188. Gray BH, Sullivan TM, Childs MB, Young JR, Olin JW. High incidence of restenosis/reocclusion of stents in the percutaneous treatment of long-segment superficial femoral artery disease after suboptimal angioplasty. *J Vasc Surg*. 1997; 25:74-83.
189. Mewissen MW. Self-expanding nitinol stents in the femoropopliteal segment: technique and mid-term results. *Tech Vasc Interv Radiol*. 2004;7:2-5.
190. Laird JR. Interventional options in SFA. *Endovasc Today*. 2004;9-12.
191. Ansel GM, Silver MJ, Botti CF Jr, et al. Functional and clinical outcomes of nitinol stenting with and without abciximab for complex superficial femoral artery disease: a randomized trial. *Catheter Cardiovasc Interv*. 2006;67:288-297.
192. Duda SH, Poerner TC, Wiesinger B, et al. Drug-eluting stents: potential applications for peripheral arterial occlusive disease. *J Vasc Interv Radiol*. 2003;14:291-301.
193. Bauermeister G. Endovascular stent-grafting in the treatment of superficial femoral artery occlusive disease. *J Endovasc Ther*. 2001;8:315-320.
194. Kedora J, Hohmann S, Garrett W, Munschaur C, Theune B, Gable D. Randomized comparison of percutaneous Viabahn stent grafts vs prosthetic femoral-popliteal bypass in the treatment of superficial femoral arterial occlusive disease. *J Vasc Surg*. 2007;45:10-16; discussion 16.
195. McQuade K, Gable D, Pearl G, Theune B, Black S. Four-year randomized prospective comparison of percutaneous ePTFE/nitinol self-expanding stent graft versus prosthetic femoral-popliteal bypass in the treatment of superficial femoral artery occlusive disease. *J Vasc Surg*. 2010;52:584-590; discussion 590-581, 591, e581-591, e587.
196. Ramaiah V, Gammon R, Kiesz S, et al. Midterm outcomes from the Talon Registry: treating peripherals with silverhawk: outcomes collection. *J Endovasc Ther*. 2006;13:592-602.
197. Shammass NW, Lam R, Mustapha J, et al. Comparison of orbital atherectomy plus balloon angioplasty vs. balloon angioplasty alone in patients with critical limb ischemia: results of the Calcium 360 randomized pilot trial. *J Endovasc Ther*. 2012;19:480-488.
198. Franzone A, Ferrone M, Carotenuto G, et al. The role of atherectomy in the treatment of lower extremity peripheral artery disease. *BMC Surg*. 2012;12(Suppl 1):S13.
199. Laird JR Jr, Reiser C, Biamino G, Zeller T. Excimer laser assisted angioplasty for the treatment of critical limb ischemia. *J Cardiovasc Surg*. 2004;45:239-248.
200. Scheinert D, Laird JR Jr, Schroder M, Steinkamp H, Balzer JO, Biamino G. Excimer laser-assisted recanalization of long, chronic superficial femoral artery occlusions. *J Endovasc Ther*. 2001;8:156-166.
201. Steinkamp HJ, Rademaker J, Wissgott C, et al. Percutaneous transluminal laser angioplasty versus balloon dilation for treatment of popliteal artery occlusions. *J Endovasc Ther*. 2002;9:882-888.
202. Dave RM, Patlola R, Kollmeyer K, et al. Excimer laser recanalization of femoropopliteal lesions and 1-year patency: results of the Cello Registry. *J Endovasc Ther*. 2009;16:665-675.
203. Clark TW, Groffsky JL, Soulen MC. Predictors of long-term patency after femoropopliteal angioplasty: results from the Star Registry. *J Vasc Interv Radiol*. 2001;12:923-933.
204. Axisa B, Fishwick G, Bolia A, et al. Complications following peripheral angioplasty. *Ann R Coll Surg Engl*. 2002;84: 39-42.
205. Yilmaz S, Sindel T, Yegin A, Luleci E. Subintimal angioplasty of long superficial femoral artery occlusions. *J Vasc Interv Radiol*. 2003;14:997-1010.
206. Desgranges P, Boufi M, Lapeyre M, et al. Subintimal angioplasty: feasible and durable. *Eur J Vasc Endovasc Surg*. 2004; 28:138-141.
207. Fava M, Loyola S, Polydorou A, Papapavlou P, Mendiz O, Joye JD. Cryoplasty for femoropopliteal arterial disease: late angiographic results of initial human experience. *J Vasc Interv Radiol*. 2004;15:1239-1243.
208. Jahnke T, Andresen R, Muller-Hulsbeck S, et al. Hemobahn stent-grafts for treatment of femoropopliteal arterial obstructions: midterm results of a prospective trial. *J Vasc Interv Radiol*. 2003;14:41-51.
209. Grubnic S, Heenan SD, Buckenham TM, Belli AM. Evaluation of the pullback atherectomy catheter in the treatment

- of lower limb vascular disease. *Cardiovasc Intervent Radiol*. 1996;19:152-159.
210. Savader SJ, Venbrux AC, Mitchell SE, et al. Percutaneous transluminal atherectomy of the superficial femoral and popliteal arteries: long-term results in 48 patients. *Cardiovasc Intervent Radiol*. 1994;17:312-318.
 211. Albers M, Battistella VM, Romiti M, Rodrigues AA, Pereira CA. Meta-analysis of polytetrafluoroethylene bypass grafts to infrapopliteal arteries. *J Vasc Surg*. 2003;37:1263-1269.
 212. Hamsho A, Nott D, Harris PL. Prospective randomised trial of distal arteriovenous fistula as an adjunct to femoro-infrapopliteal ptfе bypass. *Eur J Vasc Endovasc Surg*. 1999;17:197-201.
 213. Davies AH, Hawdon AJ, Sydes MR, Thompson SG. Is duplex surveillance of value after leg vein bypass grafting? Principal results of the Vein Graft Surveillance Randomised Trial (VGST). *Circulation*. 2005;112:1985-1991.
 214. Baldwin ZK, Pearce BJ, Curi MA, et al. Limb salvage after infrainguinal bypass graft failure. *J Vasc Surg*. 2004;39:951-957.
 215. Stone PA, Flaherty SK, Aburahma AF, et al. Factors affecting perioperative mortality and wound-related complications following major lower extremity amputations. *Ann Vasc Surg*. 2006;20:209-216.
 216. Holzenbein TJ, Pomposelli FB Jr, Miller A, et al. The upper arm basilic-cephalic loop for distal bypass grafting: technical considerations and follow-up. *J Vasc Surg*. 1995;21:586-592.
 217. Dosluoglu HH, Kittredge J, Cherr GS. Use of cryopreserved femoral vein for in situ replacement of infected femorofemoral prosthetic artery bypass. *Vasc Endovasc Surg*. 2008;42:74-78.
 218. Dardik H, Wengerter K, Qin F, et al. Comparative decades of experience with glutaraldehyde-tanned human umbilical cord vein graft for lower limb revascularization: an analysis of 1275 cases. *J Vasc Surg*. 2002;35:64-71.
 219. Johnson WC, Lee KK. A comparative evaluation of polytetrafluoroethylene, umbilical vein, and saphenous vein bypass grafts for femoral-popliteal above-knee revascularization: a prospective randomized Department of Veterans Affairs Cooperative Study. *J Vasc Surg*. 2000;32:268-277.
 220. Fahner PJ, Idu MM, van Gulik TM, Legemate DA. Systematic review of preservation methods and clinical outcome of infrainguinal vascular allografts. *J Vasc Surg*. 2006;44:518-524.
 221. Gupta SK, Veith FJ, Kram HB, Wengerter KR. Prospective, randomized comparison of ringed and nonringed polytetrafluoroethylene femoropopliteal bypass grafts: a preliminary report. *J Vasc Surg*. 1991;13:163-172.
 222. Stonebridge PA, Prescott RJ, Ruckley CV. Randomized trial comparing infrainguinal polytetrafluoroethylene bypass grafting with and without vein interposition cuff at the distal anastomosis. The Joint Vascular Research Group. *J Vasc Surg*. 1997;26:543-550.
 223. Klinkert P, van Dijk PJ, Breslau PJ. Polytetrafluoroethylene femorotibial bypass grafting: 5-year patency and limb salvage. *Ann Vasc Surg*. 2003;17:486-491.
 224. Panneton JM, Hollier LH, Hofer JM. Multicenter randomized prospective trial comparing a pre-cuffed polytetrafluoroethylene graft to a vein cuffed polytetrafluoroethylene graft for infragenicular arterial bypass. *Ann Vasc Surg*. 2004;18:199-206.
 225. Bellosta R, Luzzani L, Carugati C, Melloni C, Sarcina A. Which distal anastomosis should be used in PTFE femorotibial bypass? *J Cardiovasc Surg*. 2005;46:499-503.
 226. Begovac PC, Thomson RC, Fisher JL, Hughson A, Gallhagen A. Improvements in Gore-Tex vascular graft performance by Carmeda bioactive surface heparin immobilization. *Eur J Vasc Endovasc Surg*. 2003;25:432-437.
 227. Devine C, Hons B, McCollum C. Heparin-bonded dacron or polytetrafluoroethylene for femoropopliteal bypass grafting: a multicenter trial. *J Vascular Surg*. 2001;33:533-539.
 228. Walluscheck KP, Bierkandt S, Brandt M, Cremer J. Infrainguinal ePTFE vascular graft with bioactive surface heparin bonding. First clinical results. *J Cardiovasc Surg*. 2005;46:425-430.
 229. Duda SH, Bosiers M, Lammer J, et al. Drug-eluting and bare nitinol stents for the treatment of atherosclerotic lesions in the superficial femoral artery: long-term results from the Sirocco trial. *J Endovasc Ther*. 2006;13:701-710.
 230. Ferreira M, Lanzotti L, Monteiro M, et al. Superficial femoral artery recanalization with self-expanding nitinol stents: long-term follow-up results. *Eur J Vasc Endovasc Surg*. 2007;34:702-708.
 231. Schillinger M, Sabeti S, Dick P, et al. Sustained benefit at 2 years of primary femoropopliteal stenting compared with balloon angioplasty with optional stenting. *Circulation*. 2007;115:2745-2749.
 232. Bosiers M, Deloose K, Verbist J, Peeters P. Nitinol stenting for treatment of "below-the-knee" critical limb ischemia: 1-year angiographic outcome after Xpert stent implantation. *J Cardiovasc Surg*. 2007;48:455-461.
 233. Kickuth R, Keo HH, Triller J, Ludwig K, Do DD. Initial clinical experience with the 4-F self-expanding xpert stent system for infrapopliteal treatment of patients with severe claudication and critical limb ischemia. *J Vasc Interv Radiol*. 2007;18:703-708.
 234. Wolf GL, Wilson SE, Cross AP, Deupree RH, Stason WB. Surgery or balloon angioplasty for peripheral vascular disease: a randomized clinical trial. Principal Investigators and Their Associates of Veterans Administration Cooperative Study Number 199. *J Vasc Interv Radiol*. 1993;4:639-648.
 235. Adam DJ, Beard JD, Cleveland T, et al. Bypass versus angioplasty in severe ischaemia of the leg (basil): multicentre, randomised controlled trial. *Lancet*. 2005;366:1925-1934.
 236. Nolan B, Finlayson S, Tosteson A, Powell R, Cronenwett J. The treatment of disabling intermittent claudication in patients with superficial femoral artery occlusive disease—decision analysis. *J Vasc Surg*. 2007;45:1179-1184.
 237. Maffei S, Di Renzo M, Bova G, Auteri A, Pasqui AL. Takayasu's arteritis: a review of the literature. *Intern Emerg Med*. 2006;1:105-112.
 238. Baxter BT. Heritable diseases of the blood vessels. *Cardiovasc Pathol*. 2005;14:185-188.
 239. Cikrit DF, Glover JR, Dalsing MC, Silver D. The Ehlers-Danlos specter revisited. *Vasc Endovasc Surg*. 2002;36:213-217.
 240. Ho NC, Tran JR, Bektas A. Marfan's syndrome. *Lancet*. 2005;366:1978-1981.
 241. Davies JE, Sundt TM. Surgery insight: the dilated ascending aorta—indications for surgical intervention. *Nat Clin Pract Cardiovasc Med*. 2007;4:330-339.
 242. Chassaing N, Martin L, Calvas P, Le Bert M, Hovnanian A. Pseudoxanthoma elasticum: a clinical, pathophysiological, and genetic update including 11 novel ABCC6 mutations. *J Med Genet*. 2005;42:881-892.
 243. Yeung RS. Pathogenesis and treatment of Kawasaki's disease. *Curr Opin Rheumatol*. 2005;17:617-623.
 244. Krause I, Weinberger A. Behcet's disease. *Curr Opin Rheumatol*. 2008;20:82-87.
 245. Pettigrew HD, Teuber SS, Gershwin ME. Polyarteritis nodosa. *Compr Ther*. 2007;33:144-149.
 246. Herrick AL. Pathogenesis of Raynaud's phenomenon. *Rheumatology (Oxford)*. 2005;44:587-596.
 247. Stoyneva Z, Lyapina M, Tzvetkov D, Vodenicharov E. Current pathophysiological views on vibration-induced Raynaud's phenomenon. *Cardiovasc Res*. 2003;57:615-624.

248. Das CJ, Neyaz Z, Thapa P, Sharma S, Vashist S. Fibromuscular dysplasia of the renal arteries: a radiological review. *Int Urol Nephrol*. 2007;39:233-238.
249. Gray BH. Intervention for renal artery stenosis: endovascular and surgical roles. *J Hypertens Suppl*. 2005;23:S23-S29.
250. Pannone A, Di Cesare F, Bartolucci R, Maritati G, Lucchetti G, Rabitti G. Cystic adventitial disease of the popliteal artery. A case report and review of the literature. *Chir Ital*. 2008;60:153-158.
251. di Marzo L, Cavallaro A. Popliteal vascular entrapment. *World J Surg*. 2005;29(Suppl 1):S43-S45.
252. Paraskevas KI, Liapis CD, Briana DD, Mikhailidis DP. Thromboangiitis obliterans (Buerger's disease): searching for a therapeutic strategy. *Angiology*. 2007;58:75-84.

This page intentionally left blank

24 chapter

Venous and Lymphatic Disease

Jason P. Jundt, Timothy K. Liem,
and Gregory L. Moneta

Venous Anatomy	915	Treatment / 921	Nonoperative Treatment of Chronic Venous Insufficiency / 931
Structure of Veins / 915		Prophylaxis / 925	Surgical/Interventional Treatment of Chronic Venous Insufficiency / 933
Lower Extremity Veins / 915		Other Venous Thrombotic Disorders	Lymphedema
Upper Extremity Veins / 916			934
Evaluation of the Venous System	916	Superficial Vein Thrombophlebitis / 927	Pathophysiology / 934
Clinical Evaluation / 916		Upper Extremity Vein Thrombosis / 928	Clinical Diagnosis / 934
Venous Thromboembolism	918	Mesenteric Vein Thrombosis / 929	Radiologic Diagnosis / 935
Epidemiology / 918		Varicose Veins	Management / 935
Risk Factors / 918		929	Summary
Diagnosis / 919		Chronic Venous Insufficiency	936
		930	
		Evaluation of Venous Insufficiency / 930	

VENOUS ANATOMY

Veins are part of a dynamic and complex system that returns low-nutrient deoxygenated blood to the heart. Venous blood flow is dependent on multiple factors such as gravity, venous valves, the cardiac and respiratory cycles, blood volume, and the calf muscle pump. Alterations in the intricate balance of these factors can result in venous pathology.

Structure of Veins

Veins are thin-walled, highly distensible, and collapsible. Their structure specifically supports the primary functions of veins to transport blood toward the heart and serve as a reservoir to prevent intravascular volume overload.

The venous intima is composed of a nonthrombogenic endothelium with an underlying basement membrane and an elastic lamina. The endothelium produces endothelium-derived relaxing factors such as nitric oxide and prostacyclin, which help maintain a nonthrombogenic surface through inhibition of platelet aggregation and promotion of platelet disaggregation.¹ Circumferential rings of elastic tissue and smooth muscle located in the media of the vein allow for changes in vein caliber with minimal changes in venous pressure. The adventitia is most prominent in large veins and consists of collagen, elastic fibers, and fibroblasts. When a vein is maximally distended, its diameter may be several times greater than that in the supine position.

In the axial veins, unidirectional blood flow is achieved with multiple venous valves. The inferior vena cava (IVC), common iliac veins, portal venous system, and cranial sinuses are valveless. In the axial veins, valves are more numerous distally in the extremities than proximally. Each valve consists of two thin cusps of a fine connective tissue skeleton covered by endothelium. Venous valves close in response to cephalad-to-caudal blood flow at a velocity of at least 30 cm/s.²

Lower Extremity Veins

Lower extremity veins are divided into superficial, deep, and perforating veins. The superficial venous system lies above the uppermost fascial layer of the leg and thigh and consists of the great saphenous vein (GSV) and small saphenous vein (SSV) and their tributaries. The GSV originates from the dorsal pedal venous arch and courses cephalad, anterior to the medial malleolus, entering the common femoral vein approximately 4 cm inferior and lateral to the pubic tubercle. The saphenous nerve accompanies the GSV medially from the ankle to the level of the knee and supplies cutaneous sensation to the medial leg and ankle. The SSV originates laterally from the dorsal pedal venous arch and courses cephalad in the posterior calf. Most often, it penetrates the popliteal fossa, between the medial and lateral heads of the gastrocnemius muscle, to join the popliteal vein. The termination of the SSV may be quite variable, however, with a proximal extension of the SSV (the vein of Giacomini) frequently connecting with the deep femoral vein or GSV. The sural nerve accompanies the SSV laterally along its course and supplies cutaneous sensation to the lateral malleolar region.

The deep veins follow the course of major arteries in the extremities. In the lower leg, paired veins parallel the course of the anterior tibial, posterior tibial, and peroneal arteries, to join behind the knee forming the popliteal vein. Venous bridges connect the paired veins in the lower leg. The popliteal vein continues through the adductor hiatus to become the femoral vein. In the proximal thigh, the femoral vein joins with the deep femoral vein to form the common femoral vein, becoming the external iliac vein at the inguinal ligament.

Multiple perforator veins traverse the deep fascia to connect the superficial and deep venous systems. Potentially clinically important perforator veins are the Cockett and Boyd perforators. The Cockett perforator veins drain the medial

Key Points

- 1▶ Thrombolytic therapy, surgical thrombectomy, and placement of inferior vena cava filters are adjunctive treatments that may be indicated in patients with extensive and complicated venous thromboembolism.
- 2▶ Deep vein thrombosis (DVT) and pulmonary embolism are frequent complications after major abdominal and orthopedic procedures. The risk is further increased in patients with malignancy and a history of venous thromboembolism. Options for DVT prophylaxis include intermittent pneumatic compression, use of graduated compression stockings, and administration of low-dose unfractionated heparin, low molecular weight heparin, fondaparinux, and vitamin K antagonists. However, prophylaxis should be stratified based on the patient's level of risk.
- 3▶ In patients with established DVT, unfractionated heparin, low molecular weight heparin, and fondaparinux are options for *initial* antithrombotic therapy. The duration and type of *long-term* anticoagulation should be stratified based on the provoked

or unprovoked nature of the DVT, the location of the DVT, previous occurrence of DVT, and presence of concomitant malignancy.

- 4▶ Saphenous vein stripping, endovenous laser treatment, and radiofrequency ablation are effective therapies for patients with saphenous vein valvular insufficiency. Concomitant varicose veins may be managed with compression therapy, sclerotherapy (for smaller varices), and phlebectomy.
- 5▶ The mainstay of treatment for chronic venous insufficiency is compression therapy. Sclerotherapy, perforator vein ligation, and venous reconstruction may be indicated in patients in whom conservative management fails.
- 6▶ Lymphedema is categorized as primary (with early or delayed onset) or secondary. The goals of treatment are to minimize edema and prevent infection. Lymphatic massage, sequential pneumatic compression, use of compression garments, and limb elevation are effective forms of therapy.

lower leg and are relatively constant. They connect the posterior arch vein (a tributary to the GSV) and the posterior tibial vein. They may become varicose or incompetent in venous insufficiency states. The Boyd perforator veins connect the GSV to the deep veins approximately 10 cm below the knee and 1 to 2 cm medial to the tibia.

Venous sinuses are thin-walled, large veins located within the substance of the soleus and gastrocnemius muscles. These sinuses are valveless and are linked by valved, small venous channels that prevent reflux. A large amount of blood can be stored in the venous sinuses. With each contraction of the calf muscle bed, blood is pumped out through the venous channels into the main conduit veins to return to the heart.

Upper Extremity Veins

As in the lower extremity, there are deep and superficial veins in the upper extremity. Deep veins of the upper extremity are paired and follow the named arteries in the arm. Superficial veins of the upper extremity are the cephalic and basilic veins and their tributaries. The cephalic vein originates at the lateral wrist and courses over the ventral surface of the forearm. In the upper arm, the cephalic vein terminates in the infraclavicular fossa, piercing the clavipectoral fascia to empty into the axillary vein. The basilic vein runs medially along the forearm and penetrates the deep fascia as it courses past the elbow in the upper arm. It then joins with the deep brachial veins to become the axillary vein. The median cubital vein joins the cephalic and the basilic veins on the ventral surface of the elbow.

The axillary vein becomes the subclavian vein at the lateral border of the first rib. At the medial border of the scalenus anterior muscle, the subclavian vein joins with the internal jugular vein to become the brachiocephalic vein, with the subclavian vein coursing anterior to the scalenus anterior muscle. The left and right brachiocephalic veins join to become the superior vena cava, which empties into the right atrium.

EVALUATION OF THE VENOUS SYSTEM

Clinical Evaluation

Evaluation of the venous system begins with a detailed history and physical examination. Risk factors for acute and chronic venous disease are identified. They include increased age, history of venous thromboembolism (VTE), malignancy, trauma and spinal cord injury, hospitalization and immobilization, obesity, nephrotic syndrome, pregnancy and the recently postpartum state, oral contraceptive use or hormone replacement therapy, varicose veins, and hypercoagulable states, as well as the postoperative state. Venous pathology is often, but not always, associated with visible or palpable signs that can be identified during the physical examination. There is variation among individuals in the prominence of superficial veins when the person is standing (Fig. 24-1). The superficial veins of a

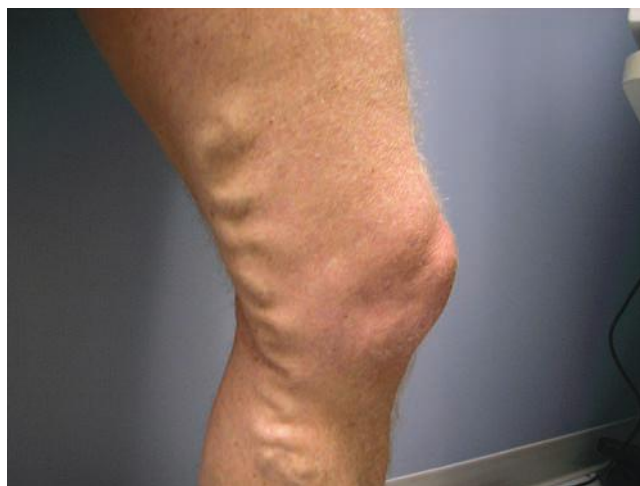

Figure 24-1. Varicose vein demonstrating evidence of chronic venous insufficiency.

Table 24-1

Possible signs of superficial venous abnormalities

Tortuosity
Varicosity
Venous saccule
Distended subdermal venules (corona phlebectatica)
Distended intradermal venules (spider angiomata)
Warmth, erythema, tenderness (superficial thrombophlebitis)

lean athletic person, even when normal, will appear large and easily visualized, but these veins will be far less obvious in the obese individual. Possible signs of superficial venous abnormalities are listed in Table 24-1. The deep veins cannot be directly assessed clinically, and abnormalities within them can only be inferred indirectly from changes found on clinical examination.

Chronic venous insufficiency (CVI) may lead to characteristic changes in the skin and subcutaneous tissues in the affected limb. CVI results from incompetence of venous valves, venous obstruction, or both. Most CVI involves venous reflux, and severe CVI often reflects a combination of reflux and venous obstruction. It is important to remember that although CVI originates with abnormalities of the veins, the target organ of CVI is the skin, and the underlying physiologic and biochemical mechanisms leading to the cutaneous abnormalities associated with CVI are poorly understood. A typical leg affected by CVI will be edematous, with edema increasing over the course of the day. The leg may also be indurated and pigmented with eczema and dermatitis. These changes are associated with excessive proteinaceous capillary exudate and deposition of a pericapillary fibrin cuff that may limit nutritional exchange. In addition, an increase in white blood cell trapping within the skin microcirculation in CVI patients may lead to microvascular congestion and thrombosis. Subsequently, white blood cells may migrate into the interstitium and release necrotizing lysosomal enzymes, potentially leading to tissue destruction and eventual ulceration.

Fibrosis can eventually develop from impaired nutrition, chronic inflammation, and fat necrosis (lipodermatosclerosis). Hemosiderin deposition due to the extravasation of red cells and subsequent lysis in the skin contributes to the characteristic pigmentation of chronic venous disease (Fig. 24-2). Ulceration can develop with longstanding venous hypertension and is associated with alterations in microcirculatory and cutaneous lymphatic anatomy and function. The most common location of venous ulceration is approximately 3 cm proximal to the medial malleolus (Fig. 24-3).

Trendelenburg's test is a clinical test, historically important but now rarely used, that can help determine whether incompetent valves are present and in which of the three venous systems (superficial, deep, or perforator) the valves are abnormal. There are two components to this test. First, with the patient supine, the leg is elevated 45° to empty the veins, and the GSV is occluded with the examiner's hand or with a rubber tourniquet. With the GSV still occluded, the patient stands and the superficial veins are observed for blood filling. The compression on the GSV is released and the superficial veins are observed for filling with blood. A negative result, indicating no clinically relevant venous reflux, is the gradual filling of the veins from arterial inflow. A positive result is the sudden filling of veins with standing while the GSV remains occluded indicating incompetent perforator

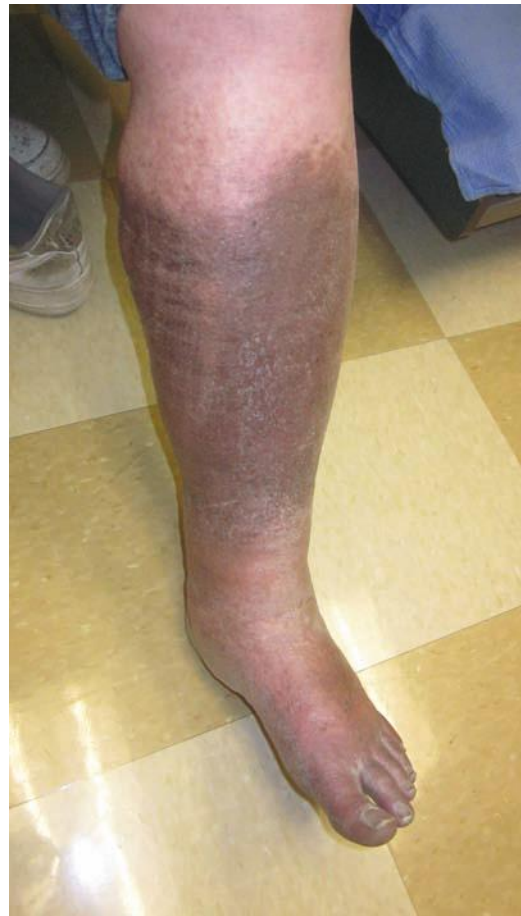

Figure 24-2. Characteristic hyperpigmentation of chronic venous insufficiency.

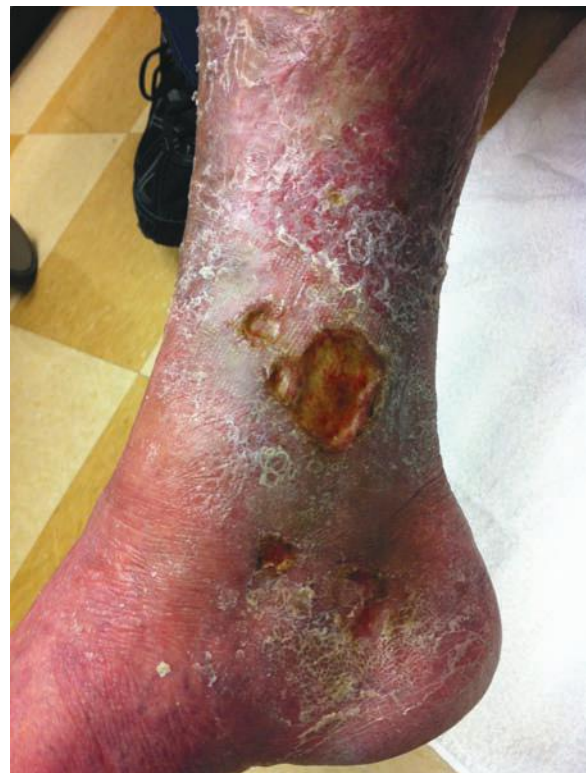

Figure 24-3. Venous ulceration located proximal to the medial malleolus.

and deep veins. The GSV valves are incompetent if the second component of the test yields a positive result. Interpretation of the findings of Trendelenburg's test is subjective, and therefore, it has largely been supplanted by the more objective noninvasive vascular laboratory tests to localize sites of venous reflux.

Noninvasive Evaluation. Before the development of vascular ultrasound, noninvasive techniques to evaluate the venous system were based on plethysmographic techniques. Although a variety of plethysmographic techniques are used in the evaluation of both acute and chronic venous disease, they are all based on the detection of volume changes in the limb in response to blood flow.

Duplex ultrasonography (DUS) augmented by color flow imaging is now the most important noninvasive diagnostic method in the evaluation of the venous system. DUS has become standard for the detection of infrainguinal deep vein thrombosis (DVT), with near 100% sensitivity and specificity in symptomatic patients.³ It is also the preferred method of evaluation for upper extremity venous thrombosis and is useful in the evaluation of CVI by documenting the presence of valvular reflux and venous obstruction. Overlying bowel gas and large body habitus make DUS less applicable to evaluation of intra-abdominal veins. Magnetic resonance venography (MRV) and computed tomography (CT) venography are noninvasive techniques for evaluation of pelvic and intra-abdominal veins.

Invasive Evaluation. Improved accuracy of noninvasive techniques for diagnostic purposes has made the use of invasive procedures more selective. Both venography and intravascular ultrasound (IVUS) are used as adjuncts to percutaneous or open surgical treatment of venous disorders. When planning endovascular or open surgical treatment, venography may be used to identify areas of obstruction in infrainguinal, intra-abdominal, and upper extremity veins as well as reflux in intra-abdominal and infrainguinal veins. IVUS, with access generally via the common femoral vein, is used primarily to assess for occlusive lesions of the iliac veins and appears more sensitive than venography in detecting iliac vein obstruction.

Complications of venography include pain, thrombosis, or hematoma at the puncture site. Pain is lower with nonionic low-osmolality contrast media than with conventional contrast agents (with 18% vs. 44% of patients experiencing discomfort, respectively).⁴ Systemic effects of iodinated contrast media include allergic reaction and risk of renal failure. Postvenography venous thrombosis occurs distal to the venous puncture site in 1% to 9% of patients undergoing venography secondary to intimal damage from the intravenous (IV) contrast agent.⁴ Complications of IVUS are primarily related to the access site.

VENOUS THROMBOEMBOLISM

Epidemiology

Despite increased awareness and use of prophylactic modalities, DVT and pulmonary embolism (PE), or VTE, remain important preventable sources of morbidity and mortality, especially in the surgical patient. The incidence of VTE is approximately 100 per 100,000 people per year in the general population, with 20% of the diagnoses made within 3 months of a surgical procedure. Of the symptomatic patients, one third will present with PE and two thirds with DVT.^{5,6} The estimated number of cases of VTE may well be over 600,000 per year in the United States, making it a major U.S. health problem.⁷ Furthermore, death occurs in 6% of

DVT and 12% of PE cases within 1 month of diagnosis.⁵ Not only does VTE pose a veritable threat to life, but it also places patients at higher risk for recurrence and post-VTE sequelae such as pulmonary hypertension and postthrombotic syndrome, with 4% and up to 30% incidence, respectively.⁸⁻¹⁰

Risk Factors

Three conditions, first described by Rudolf Virchow in 1862, contribute to VTE formation: stasis of blood flow, endothelial damage, and hypercoagulability. Of these risk factors, relative hypercoagulability appears most important in most cases of *spontaneous* VTE, or so-called idiopathic VTE, whereas stasis and endothelial damage likely play a greater role in *secondary* VTE, or so-called provoked VTE, occurring in association with transient risk factors such as immobilization, surgical procedures, and trauma. Identifiable risk factors for VTE generally relate to one of the conditions described by Virchow. Often more than one risk factor is present. Specific risk factors for VTE are listed in Table 24-2.

The more common acquired VTE risk factors include older age (>40 years), hospitalization and immobilization, hormone replacement and oral contraceptive therapy, pregnancy and the recently postpartum state, prior VTE, malignancy, major surgery, obesity, nephrotic syndrome, trauma and spinal cord injury, long-haul travel (>6 hours), varicose veins, antiphospholipid syndrome, myeloproliferative disorders, and polycythemia. Heritable risk factors include male sex, factor V Leiden

Table 24-2

Risk factors for venous thromboembolism

Acquired

- Advanced age
- Hospitalization/immobilization
- Hormone replacement therapy and oral contraceptive use
- Pregnancy and puerperium
- Prior venous thromboembolism
- Malignancy
- Major surgery
- Obesity
- Nephrotic syndrome
- Trauma or spinal cord injury
- Long-haul travel (>6 hours)
- Varicose veins
- Antiphospholipid antibody syndrome
- Myeloproliferative disease
- Polycythemia

Inherited

- Factor V Leiden
- Prothrombin 20210A
- Antithrombin deficiency
- Protein C deficiency
- Protein S deficiency
- Factor XI elevation
- Dysfibrinogenemia

Mixed Etiology

- Homocysteinemia
- Factor VII, VIII, IX, XI elevation
- Hyperfibrinogenemia
- Activated protein C resistance without factor V Leiden

mutation; prothrombin 20210A gene variant; antithrombin, protein C, and protein S deficiencies; and dysfibrinogenemias. In some patients, the cause of the thrombophilia may have both a heritable and an acquired component. These mixed causes include homocysteinemia; factor VII, VIII, IX, and XI elevation; hyperfibrinogenemia; and activated protein C resistance in the absence of factor V Leiden.¹¹ There may be a synergistic effect when particular multiple inherited and acquired risk factors are present in the same patient.

Other patient-specific factors associated with venous thrombosis include the traditional cardiovascular risk factors of obesity, hypertension, and diabetes. VTE is more common in whites and African Americans than Asians and Native Americans.^{12,13} Certain gene variants (single nucleotide polymorphisms) are also associated with a mildly increased risk for VTE, and their presence may interact with other risk factors to increase the overall risk for venous thrombosis.¹⁴

Anatomic factors may also contribute to development of DVT. At the site where the right iliac artery crosses over the left iliac vein, the left iliac vein may become chronically narrowed predisposing to iliofemoral venous thrombosis, so-called May-Thurner syndrome. External compression of major veins by masses of various types can also lead to venous thrombosis.

Many cases of VTE are potentially preventable. Accordingly, in current clinical practice, preoperative VTE risk assessment is becoming increasingly common to identify patients at moderate and high risk. Scoring systems have been developed that take into account the number of VTE risk factors in an individual patient. These risk stratification scores, such as the Rogers score¹⁵ and Caprini score,¹⁶ provide individual patient risk stratification and recommendations for prophylactic anticoagulation. The ninth edition of the American College of Chest Physicians (ACCP) Guidelines for Prevention of VTE in Non-Orthopedic Surgical Patients acknowledges both the Rogers and Caprini scores and provides recommendations for VTE prophylaxis (Table 24-3).

Orthopedic surgical patients are generally excluded from risk assessment scores because of the disproportionately increased risk of VTE in orthopedic surgery compared with the general and abdominopelvic surgery population.

Diagnosis

Clinical Evaluation. Early in the course of DVT development, venous thrombosis is thought to begin in an area of relative stasis, such as a soleal sinus vein or immediately downstream of the cusps of a venous valve in the axial calf veins. Isolated proximal DVT without tibial vein thrombosis is unusual. Early in the course of a DVT, there may be no or few clinical findings such as pain or swelling. Even extensive DVT may sometimes be present without signs or symptoms. History and physical examination are therefore unreliable in the diagnosis of DVT. In addition, symptoms and signs generally associated with DVT, such as extremity pain and/or swelling, are nonspecific. In large studies, DVT has been found by venography or DUS in $\leq 50\%$ of patients in whom it was clinically suspected.^{17,18} Objective studies are therefore required to confirm a diagnosis of VTE or to exclude the presence of VTE.

Clinical symptoms may worsen as DVT propagates and involves the major proximal deep veins. Extensive DVT of the major axial deep venous channels of the lower extremity with relative sparing of collateral veins causes a condition called *phlegmasia cerulea dolens* (Fig. 24-4). This condition is characterized by pain and pitting edema with associated cyanosis. When the thrombosis extends to the collateral veins, massive fluid sequestration and more significant edema ensue, resulting in a condition known as *phlegmasia alba dolens*.¹⁹ The affected extremity in *phlegmasia alba dolens* is extremely painful and edematous and pale secondary to arterial insufficiency from dramatically elevated below lower knee compartment pressures. Both *phlegmasia cerulea dolens* and *phlegmasia alba dolens* can be complicated by venous gangrene and the need for amputation.

Table 24-3

Thromboembolism risk and recommended thromboprophylaxis in surgical patients

LEVEL OF RISK	APPROXIMATE DVT RISK WITHOUT THROMBOPROPHYLAXIS (%)	SUGGESTED THROMBOPROPHYLAXIS OPTIONS
Very low risk General or abdominopelvic surgery	<0.5% (Rogers score <7; Caprini score 0)	No specific thromboprophylaxis Early ambulation
Low risk General or abdominopelvic surgery	~1.5% (Rogers score 7–10; Caprini score 1–2)	Mechanical prophylaxis
Moderate risk General or abdominopelvic surgery	~3.0% (Rogers score >10; Caprini score 3–4)	LMWH (at recommended doses), LDUH, or mechanical prophylaxis
High bleeding risk		Mechanical prophylaxis
High risk General or abdominopelvic surgery	~6% (Caprini score ≥ 5)	LMWH (at recommended doses), fondaparinux and mechanical prophylaxis
High bleeding risk General or abdominopelvic surgery for cancer		Mechanical thromboprophylaxis Extended-duration LMWH (4 weeks)

DVT = deep vein thrombosis; INR = international normalized ratio; LDUH = low-dose unfractionated heparin; LMWH = low molecular weight heparin; VTE = venous thromboembolism.

Source: Summary of recommendations from Gould MK, Garcia DA, Wren SM, et al. Prevention of VTE in nonorthopedic surgical patients: antithrombotic therapy and prevention of thrombosis: American College of Chest Physicians Evidence-Based Clinical Practice Guidelines, 9th ed. *Chest*. 2012;141:227S. Reproduced with permission from the American College of Chest Physicians.

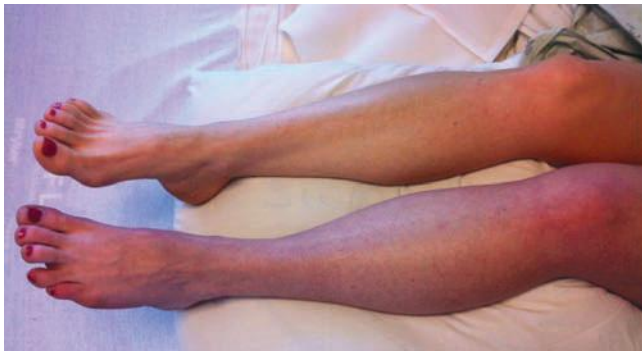


Figure 24-4. Phlegmasia cerulea dolens of the left leg. Note the bluish discoloration.

Vascular Lab and Radiologic Evaluation

Duplex Ultrasound DUS is now the most commonly performed test for the detection of infrainguinal DVT, both above and below the knee, and has a sensitivity and specificity of >95% in symptomatic patients.³ DUS refers to the combination of real-time B-mode ultrasound with pulsed Doppler capability. For VTE detection, color flow imaging is an extremely useful adjunct in the evaluation of possible calf vein DVT and evaluation of intra-abdominal veins. DUS provides the ability to noninvasively visualize venous anatomy, detect occluded and partially occluded venous segments, and demonstrate physiologic flow characteristics using a mobile self-contained device.

In the supine patient, normal lower extremity venous flow is phasic (Fig. 24-5), decreasing with inspiration in response to increased intra-abdominal pressure with the descent of the diaphragm and then increasing with expiration as the diaphragm rises and intra-abdominal pressure decreases. When the patient is upright, the decrease in intra-abdominal pressure with expiration cannot overcome the hydrostatic column of pressure existing between the right atrium and the calf. Muscular contractions of the calf, along with the one-way venous valves, are then required to promote venous return to the heart. Flow also can be increased by leg elevation or compression and decreased by sudden elevation of intra-abdominal pressure (Valsalva maneuver). In a venous DUS examination performed with the patient supine, spontaneous flow, variation of flow with respiration, and response of flow to Valsalva maneuver are all assessed.

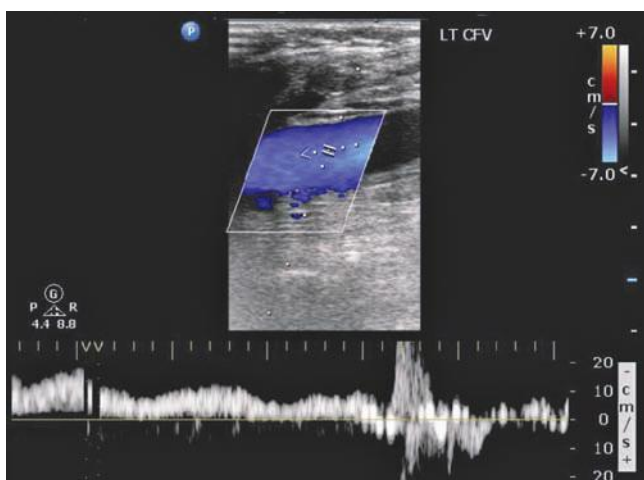


Figure 24-5. Duplex ultrasound scan of a normal femoral vein with phasic flow signals.

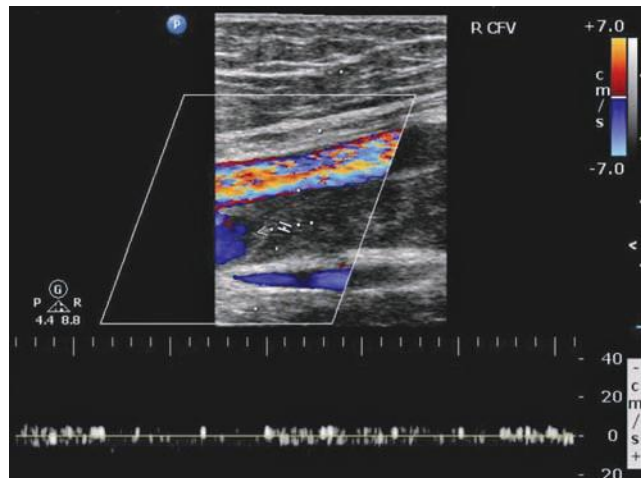


Figure 24-6. Duplex ultrasound of a femoral vein containing thrombus demonstrating no flow within the femoral vein.

From the common femoral through the popliteal vein, the primary method of detecting DVT with ultrasound is demonstration of the lack of compressibility of the vein with probe pressure on B-mode imaging. Normally, in transverse section, the vein walls should coapt with pressure. Lack of coaptation indicates thrombus. Calf vein thrombi are often best detected by abnormalities in color flow imaging.

The examination begins at the ankle and continues proximally to the groin. Each vein is visualized, and the flow signal is assessed with distal and proximal compression. Lower extremity DVT can be diagnosed by any of the following DUS findings: lack of spontaneous flow (Fig. 24-6), inability to compress the vein (Fig. 24-7), absence of color filling of the lumen by color flow DUS, loss of respiratory flow variation, and venous distention. Again, lack of venous compression on B-mode imaging is the primary diagnostic variable. Several studies comparing B-mode ultrasound to venography for the detection of femoropopliteal DVT in patients clinically suspected to have DVT report sensitivities of >91% and specificities of >97%.^{20,21} The ability of DUS to assess isolated calf vein DVT varies greatly, with sensitivities ranging from 50% to 93% and specificities approaching 100%.^{22,23}

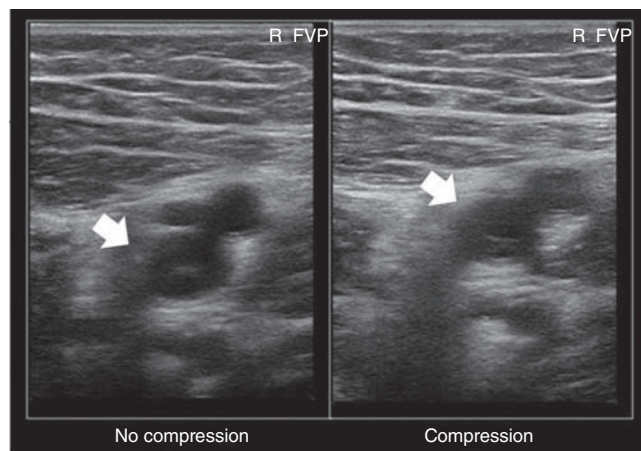


Figure 24-7. B-mode ultrasound of the femoral vein in cross-section. The femoral vein does not collapse with external compression (arrows).

Impedance Plethysmography Impedance plethysmography (IPG) was the primary noninvasive method of diagnosing DVT before the widespread use of DUS but is infrequently used today. Changes in electrical resistance resulting from lower extremity blood volume changes are quantified. IPG is less accurate than DUS for the detection of proximal DVT, with 83% sensitivity in symptomatic patients. It is a poor detector of calf vein DVT.²⁴

Iodine-125 Fibrinogen Uptake Iodine-125 fibrinogen uptake (FUT) is a seldom used technique that involves IV administration of radioactive fibrinogen and monitoring for increased uptake in fibrin clots. An increase of 20% or more in one area of a limb indicates an area of thrombus. FUT can detect DVT in the calf, but high background radiation from the pelvis and the urinary tract limits its ability to detect proximal DVT. It also cannot be used in an extremity that has recently undergone surgery or has active inflammation. In a prospective study, FUT had a sensitivity of 73% and specificity of 71% for identification of DVT in a group of symptomatic and asymptomatic patients.²⁵ Currently, FUT is primarily a research tool of historic interest.

Venography Venography is the gold standard to which other diagnostic modalities are compared. A small catheter is placed in a dorsal foot vein with injection of a radiopaque contrast agent. Radiographs are obtained in at least two projections. A positive study result is failure to fill the deep system with passage of the contrast medium into the superficial system or demonstration of discrete filling defects (Fig. 24-8). A normal

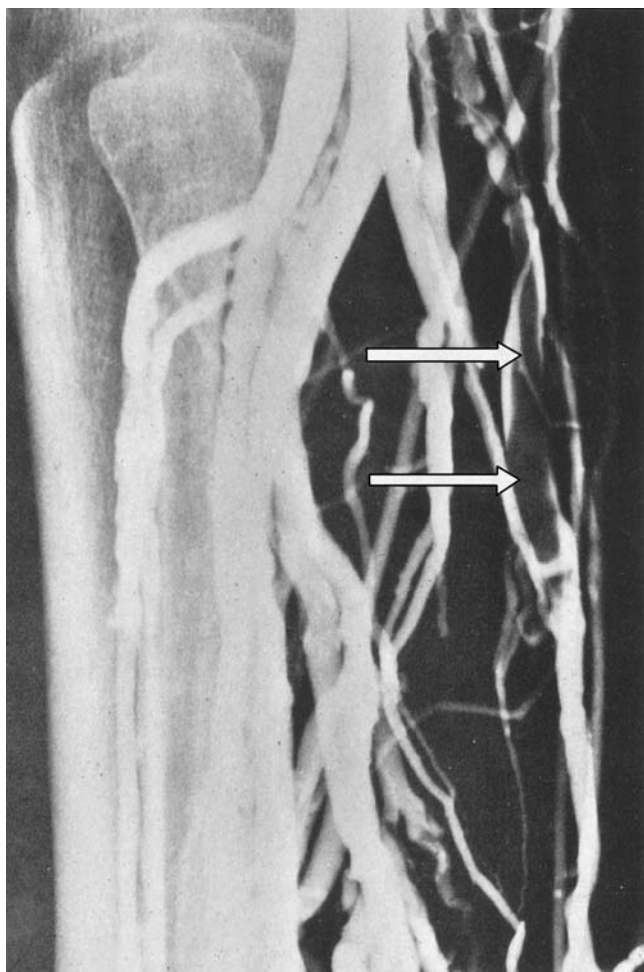


Figure 24-8. Venogram showing a filling defect in the popliteal vein (arrows).

study result virtually excludes the presence of DVT. In a study of 160 patients with a normal venogram followed for 3 months, only two patients (1.3%) subsequently developed DVT and no patients experienced symptoms of PE.²⁶ Venography is not routinely used in clinical practice due to invasiveness and complication risk. It is still, however, frequently used in research studies evaluating DVT prophylaxis.

Treatment

Once the diagnosis of VTE has been made, antithrombotic therapy should be initiated promptly. If clinical suspicion for VTE is high, it may be prudent to start treatment while the diagnosis is objectively confirmed. The goals of VTE treatment are the prevention of mortality and morbidity associated with PE and the prevention of the postthrombotic syndrome (PTS). Treatment regimens may include antithrombotic therapy, temporary or permanent vena cava filter placement, catheter-directed or systemic thrombolytic therapy, and operative thrombectomy.

1▶ permanent vena cava filter placement, catheter-directed or systemic thrombolytic therapy, and operative thrombectomy.

Antithrombotic Therapy. Most often, antithrombotic therapy for VTE is initiated with IV or subcutaneous (SC) unfractionated heparin or SC low molecular weight heparin. Fondaparinux, a synthetic pentasaccharide, is sometimes also used as an alternative to heparin to initiate therapy. An oral vitamin K antagonist, usually sodium warfarin, is begun shortly after initiation of IV or SC therapy. Either SC or IV therapy is continued until effective oral anticoagulation with warfarin is achieved as indicated by an international normalized ratio (INR) ≥ 2 for 24 hours. A minimum of 5 days of heparin or fondaparinux therapy is recommended.²⁷ Recently, the U.S. Food and Drug Administration

2▶ (FDA) has also approved alternative oral anticoagulants for both treatment and prophylaxis for VTE.

Unfractionated heparin (UFH) binds to antithrombin via a specific 18-saccharide sequence. This increases antithrombin activity over 1000-fold. The antithrombin-heparin complex primarily inhibits factor IIa (thrombin) and factor Xa and, to a lesser degree, factors IXa, XIa, and XIIa of the coagulation cascade. In addition, UFH also binds to tissue factor pathway inhibitor, which inhibits the conversion of factor X to Xa, and factor IX to IXa. Finally, UFH catalyzes the inhibition of thrombin by heparin cofactor II via a mechanism independent of antithrombin.

UFH therapy is most commonly administered with an initial IV bolus of 80 units/kg. Weight-based UFH dosages have been shown to be more effective than standard fixed boluses in rapidly achieving therapeutic levels.²⁸ The initial bolus is followed by a continuous IV drip at 18 units/kg per hour. The half-life of IV UFH ranges from 45 to 90 minutes and is dose dependent. The level of antithrombotic therapy should be monitored every 6 hours using the activated partial thromboplastin time (aPTT), with the goal range of 1.5 to 2.5 times control values. This should correspond with plasma heparin anti-Xa activity levels of 0.3 to 0.7 IU/mL.

Initial anticoagulation with UFH may also be administered SC, although this route is less commonly used. Adjusted-dose therapeutic SC UFH is initiated with 17,500 units, followed by 250 units/kg twice daily, and dosing is adjusted to an aPTT goal range similar to that for IV UFH. Fixed-dose unmonitored SC UFH is started with a bolus of 333 units/kg, followed by 250 units/kg twice daily.²⁹

Hemorrhage is the primary complication of UFH therapy. The rate of major hemorrhage (fatal, intracranial, retroperitoneal, or requiring transfusion of >2 units of packed red

blood cells) is approximately 5% in hospitalized patients undergoing UFH therapy (1% in medical patients and 8% in surgical patients).²⁹ For patients with UFH-related bleeding complications, cessation of UFH is required, and anticoagulation may be reversed with protamine sulfate. Protamine sulfate binds to UFH and forms an inactive salt compound. Each milligram of protamine neutralizes 90 to 115 units of heparin, and the dosage should not exceed 50 mg IV over any 10-minute period. Side effects of protamine sulfate include hypotension, pulmonary edema, and anaphylaxis. Patients with prior exposure to protamine-containing insulin (NPH) and patients with allergy to fish may have an increased risk of hypersensitivity, although no direct relationship has been established. Protamine administration should be terminated if any side effects occur.

In addition to hemorrhage, heparin also has unique complications. Heparin-induced thrombocytopenia (HIT) results from heparin-associated antiplatelet antibodies (HAABs) directed against platelet factor 4 complexed with heparin.³⁰ HIT occurs in 1% to 5% of patients being treated with heparin.^{31,32} In patients with repeat heparin exposure (such as vascular surgery patients), the incidence of HAABs may be as high as 21%.³³ HIT occurs most frequently in the second week of therapy and may lead to disastrous venous or arterial thrombotic complications. Therefore, platelet counts should be monitored periodically in patients receiving continuous heparin therapy.

HIT is diagnosed based on previous exposure to heparin, platelet count less than 100,000, and/or platelet count decline of 50% following exposure. All heparin must be stopped and alternative anticoagulation initiated immediately to avoid thrombotic complications, which may approach 50% over the subsequent 30 days in affected individuals.³⁴

Another complication of prolonged high-dose heparin therapy is osteopenia. Heparin-induced osteopenia results from impairment of bone formation and enhancement of bone resorption by heparin.

Low molecular weight heparins (LMWHs) are derived from the depolymerization of porcine UFH. Like UFH, LMWHs bind to antithrombin via a specific pentasaccharide sequence to expose an active site for the neutralization of factor Xa. However, LMWHs have fewer additional saccharide units. This results in less inactivation of thrombin (factor IIa). In comparison to UFH, LMWHs have increased bioavailability (>90% after SC injection), longer half-lives (approximately 4 to 6 hours), and more predictable elimination rates.

Most patients treated with weight-based once- or twice-daily SC LMWH injections do not require laboratory monitoring for anticoagulant effect, a distinct advantage over continuous IV infusions of UFH. Patients who do require monitoring include those with significant renal insufficiency, pediatric patients, obese patients greater than 120 kg, and pregnant patients. Monitoring may be performed using anti-Xa activity assays. The therapeutic anti-Xa goal range depends on the type of LMWH and the frequency of dosing. There are numerous LMWHs available, and the various preparations differ in their anti-Xa and anti-IIa activities. Treatment dosing for one LMWH therefore cannot be extrapolated for use with another. The anticoagulant effect of LMWHs may be partially reversed (approximately 60%) with protamine sulfate.

Numerous well-designed trials comparing SC LMWH with IV and SC UFH for the treatment of DVT have been critically evaluated in several meta-analyses and demonstrate a decrease in thrombotic complications, bleeding, and mortality

with LMWHs.³⁵⁻³⁷ LMWHs also are associated with a decreased rate of HAAb formation and HIT (<2%) compared with UFH (at least in prophylactic doses).²⁹ However, patients with established HIT also should not receive LMWHs because there is cross-reactivity between the drugs.³⁸

A major benefit of LMWHs is that it allows outpatient treatment of VTE.^{39,40} In a randomized study comparing IV UFH and the LMWH nadroparin calcium,³⁹ there was no significant difference in recurrent thromboembolism (8.6% for UFH vs. 6.9% for LMWH) or major bleeding complications (2.0% for UFH vs. 0.5% for LMWH). There was, however, a 67% reduction in mean days in the hospital for the LMWH group.

Fondaparinux currently is a synthetic pentasaccharide that has been approved by the FDA for the initial treatment of DVT and PE. Its five-polysaccharide sequence binds and activates antithrombin, causing specific inhibition of factor Xa. In two large noninferiority trials, fondaparinux was compared with the LMWH enoxaparin for the initial treatment of DVT and with IV UFH for the initial treatment of PE.^{41,42} The rates of recurrent VTE ranged from 3.8% to 5%, with rates of major bleeding of 2% to 2.6%, for all treatment arms. The drug is administered SC once daily with a weight-based dosing protocol: 5 mg, 7.5 mg, or 10 mg for patients weighing <50 kg, 50 to 100 kg, or >100 kg, respectively. The half-life of fondaparinux is approximately 17 hours in patients with normal renal function. There are rare case reports of fondaparinux-induced thrombocytopenia.⁴³

Direct thrombin inhibitors (DTIs) include recombinant hirudin, argatroban, and bivalirudin. These antithrombotic agents bind to thrombin, inhibiting the conversion of fibrinogen to fibrin as well as thrombin-induced platelet activation. These actions are independent of antithrombin. The DTIs should be reserved for (a) patients in whom there is a high clinical suspicion or confirmation of HIT, and (b) patients who have a history of HIT or test positive for heparin-associated antibodies. In patients with established HIT, DTIs should be administered for at least 7 days, or until the platelet count normalizes. Warfarin may then be introduced slowly, overlapping therapy with a DTI for at least 5 days.⁴⁴

Bivalirudin is approved primarily for patients with or without HIT who undergo percutaneous coronary intervention and is rarely used outside of that setting.

Commercially available hirudin is manufactured using recombinant DNA technology. It is indicated for the prophylaxis and treatment of patients with HIT. In patients with normal renal function, recombinant hirudin is administered as an IV bolus dose of 0.4 mg/kg, followed by a continuous IV infusion of 0.15 mg/kg per hour. The half-life ranges from 30 to 60 minutes. The aPTT is monitored, starting approximately 4 hours after initiation of therapy, and dosage is adjusted to maintain an aPTT of 1.5 to 2.5 times the laboratory normal value. The less commonly used ecarin clotting time is an alternative method of monitoring. Recombinant hirudin is eliminated via renal excretion, so dosage adjustments are required in patients with renal insufficiency.

Argatroban is indicated for the prophylaxis and treatment of thrombosis in HIT. It also is approved for patients with, or at risk for, HIT undergoing percutaneous coronary intervention. Antithrombotic prophylaxis and therapy are initiated with a continuous IV infusion of 2 µg/kg per minute, without the need for a bolus. The half-life ranges from 39 to 51 minutes, and the dosage is adjusted to maintain an aPTT of 1.5 to 3 times normal. Large initial boluses and higher rates of continuous infusion

are reserved for patients with coronary artery thrombosis and myocardial infarction. In these patients, therapy is monitored using the activated clotting time. Argatroban is metabolized and excreted by the liver; therefore, dosage adjustments are needed in patients with hepatic impairment. There is no reversal agent for argatroban.

Vitamin K antagonists, which include warfarin and other coumarin derivatives, are the mainstay of long-term antithrombotic therapy in patients with VTE. Warfarin inhibits the γ -carboxylation of vitamin K–dependent procoagulants (factors II, VII, IX, and X) and anticoagulants (proteins C and S), resulting in formation of less functional proteins. Warfarin usually requires several days to achieve full effect because normal circulating coagulation proteins must first undergo their normal degradation. Factors X and II have the longest half-lives, in the range of 36 and 72 hours, respectively. A steady-state concentration of warfarin is usually not reached for 4 to 5 days.

Warfarin therapy is monitored by measuring the INR, calculated using the following equation:

$$\text{INR} = (\text{patient prothrombin time/laboratory normal prothrombin time})^{\text{ISI}}$$

where *ISI* is the international sensitivity index. The ISI describes the strength of the thromboplastin that is added to activate the extrinsic coagulation pathway. The therapeutic target INR range is usually 2.0 to 3.0, but the response to warfarin is variable and depends on liver function, diet, age, and concomitant medications. In patients receiving anticoagulation therapy without concomitant thrombolysis or venous thrombectomy, the vitamin K antagonist may be started on the same day as the initial parenteral anticoagulant, usually at doses ranging from 5 to 10 mg. Smaller initial doses may be needed in older and malnourished patients, in those with liver disease or congestive heart failure, and in those who have recently undergone major surgery.⁴⁵

The recommended duration of warfarin antithrombotic therapy is stratified based on whether the DVT was provoked or unprovoked, whether it was the first or a recurrent episode, where the DVT is located, and whether malignancy or thrombophilia is present. Current ACCP recommendations for duration of warfarin therapy are summarized in Table 24-4.

3► In patients with proximal DVT, several randomized clinical trials have demonstrated that shorter-term antithrombotic therapy (4 to 6 weeks) is associated with a higher rate of VTE recurrence than 3 to 6 months of anticoagulation.⁴⁶⁻⁴⁸ In these trials, most of the patients with transient risk factors had a low rate of recurrent VTE, and most recurrences were in patients with continuing risk factors. The ACCP recommendation, therefore, is that 3 months of anticoagulation are sufficient to prevent recurrent VTE in patients with DVT occurring around the time of a transient risk factor (e.g., hospitalization, orthopedic or major general surgery).

In contrast to patients with thrombosis related to transient risk factors, patients with idiopathic VTE are much more likely to develop recurrence (rates as high as 40% at 10 years). In this latter group of patients, numerous clinical trials have compared 3 to 6 months of anticoagulation therapy with extended-duration warfarin therapy, both at low intensity (INR of 1.5 to 2.0) and at conventional intensity (INR of 2.0 to 3.0).⁴⁹⁻⁵¹ In patients with idiopathic DVT, extended-duration antithrombotic therapy is associated with a relative reduction in the rate of recurrent VTE by 75% to >90%. In addition, conventional-intensity warfarin reduces the risk even further compared with low-intensity

Table 24-4

Summary of American College of Chest Physicians recommendations regarding duration of long-term antithrombotic therapy for deep vein thrombosis (DVT)

CLINICAL SUBGROUP	ANTITHROMBOTIC TREATMENT DURATION
First episode DVT/transient risk/surgery	VKA or LMWH for 3 months
First episode DVT/unprovoked	VKA or LMWH for 3 months Consider for long-term therapy if: <ul style="list-style-type: none"> • Proximal DVT • Minimal bleeding risk • Stable coagulation monitoring
Distal DVT/unprovoked <ul style="list-style-type: none"> • Symptomatic • Asymptomatic and no risk factors for progression 	VKA for 3 months Serial imaging in 2 weeks, if progression VKA for 3 months
Second episode DVT/unprovoked DVT and cancer	VKA for extended therapy LMWH for extended therapy over VKA

LMWH = low molecular weight heparin; VKA = vitamin K antagonist. Source: Summary of recommendations from Kearon C, Akl EA, Comero AJ, et al. Antithrombotic therapy for VTE disease: antithrombotic therapy and prevention of thrombosis: American College of Chest Physicians Evidence-Based Clinical Practice Guidelines, 9th ed. *Chest*. 2012;141:e495S. Reproduced with permission from the American College of Chest Physicians.

warfarin (0.7 events per 100 person-years vs. 1.9 events per 100 person-years) without an increase in bleeding complications.⁵²

In patients with VTE in association with a hypercoagulable condition, the optimal duration of anticoagulation therapy is influenced more by the clinical circumstances at the time of the VTE (idiopathic vs. secondary) than by the actual presence or absence of the more common thrombophilic conditions. In patients with VTE related to malignancy, increasing evidence suggests that longer-term therapy with LMWH (up to 6 months) is associated with a lower VTE recurrence than treatment using conventional vitamin K antagonists.^{53,54} The primary complication of warfarin therapy is hemorrhage, and the risk is related to the magnitude of INR prolongation. Depending on the INR and the presence of bleeding, warfarin anticoagulation may be reversed by (a) omitting or decreasing subsequent dosages, (b) administering oral or parenteral vitamin K, or (c) administering fresh-frozen plasma, prothrombin complex concentrate, or recombinant factor VIIa.⁴⁵

Warfarin therapy rarely may be associated with the development of skin necrosis and limb gangrene. These conditions occur more commonly in women (4:1), and the most commonly affected areas are the breast, buttocks, and thighs. This complication, which usually occurs in the first days of therapy, is occasionally, but not exclusively, associated with protein C or S deficiency and malignancy. Patients who require continued anticoagulation may restart low-dose warfarin (2 mg) while receiving

concomitant therapeutic heparin. The warfarin dosage is then gradually increased over a 1- to 2-week period.⁴⁵

Systemic and Catheter-Directed Thrombolysis. Patients with extensive proximal, iliofemoral DVT may benefit from systemic thrombolysis or catheter-directed thrombolysis (CDT). CDT appears to be more effective (see later in chapter) and potentially reduces acute congestive lower extremity symptoms more rapidly than anticoagulation alone and decreases the development of PTS.

Several thrombolytic agents are available, including streptokinase, urokinase, alteplase (recombinant tissue plasminogen activator), reteplase, and tenecteplase. All share the ability to convert plasminogen to plasmin, which leads to the degradation of fibrin. They differ with regard to their half-lives, their potential for inducing fibrinogenolysis (generalized lytic state), their potential for antigenicity, and their FDA-approved indications for use.

Streptokinase is purified from β -hemolytic *Streptococcus* and is approved for the treatment of acute myocardial infarction, PE, DVT, arterial thromboembolism, and occluded central lines and arteriovenous shunts. It is not specific for fibrin-bound plasminogen, however, and its use is limited by its significant rates of antigenicity. Fevers and shivering occur in 1% to 4% of patients.

Urokinase is derived from human neonatal kidney cells grown in tissue culture. Currently, it is only approved for lysis of massive PE or PE associated with unstable hemodynamics.

Alteplase, reteplase, and tenecteplase all are recombinant variants of tissue plasminogen activator. Alteplase is indicated for the treatment of acute myocardial infarction, acute ischemic stroke, and acute massive PE. However, it often is used for CDT of DVT. Reteplase and tenecteplase are indicated only for the treatment of acute myocardial infarction.

Systemic thrombolysis was evaluated in numerous older prospective and randomized clinical trials, and its efficacy was summarized in a recent Cochrane Review.⁵⁵ In 12 studies involving over 700 patients, systemic thrombolysis was associated with significantly more clot lysis (relative risk [RR] 0.24 to 0.37) and significantly less PTS (RR 0.66). However, venous function was not significantly improved. In addition, more bleeding complications occurred (RR 1.73).

In an effort to minimize bleeding complications and increase efficacy, CDT techniques were developed for the treatment of symptomatic primarily iliofemoral DVT. With catheter-directed therapy, venous access may be achieved through percutaneous catheterization of the ipsilateral popliteal vein, retrograde catheterization through the contralateral femoral vein, or retrograde cannulation from the internal jugular vein. Multi-side-hole infusion catheters, with or without infusion wires, are used to deliver the lytic agent directly into the thrombus. Lytic agents may be administered alone or, now more commonly, in combination with catheter-based methods to physically break up the clot—so-called pharmacomechanical thrombolysis.

The efficacy of CDT for the treatment of symptomatic iliofemoral DVT has been reported in a large multicenter randomized control trial. Two-hundred and nine patients with proximal DVT were assigned to conventional anticoagulant therapy versus conventional anticoagulant therapy plus CDT. In the CDT group, placement of a venous stent was permitted for any identified iliac vein stenotic lesion. At 6 months, iliac vein patency was significantly improved in the thrombolysis

group (65.9% vs. 47.4%). At 2 years, in the CDT group, there was an absolute risk reduction of nearly 15% for development of PTS, translating to a number needed to treat of seven patients to prevent one case of PTS.⁵⁶

Inferior Vena Caval Filters. Since the introduction of the Kimray-Greenfield filter in the United States in 1973, numerous vena caval filters have been developed. Although the designs are variable, they all prevent pulmonary emboli, while allowing continuation of venous blood flow through the IVC. Early filters were placed surgically through the femoral vein. Currently, less invasive techniques allow percutaneous filter placement through a femoral vein, internal jugular vein, or small peripheral vein under fluoroscopic or ultrasound guidance.

Placement of an IVC filter is indicated for patients who have manifestations of lower extremity VTE and absolute contraindications to anticoagulation, those that have a bleeding complication from anticoagulation therapy of acute VTE, or those who develop recurrent DVT or PE despite adequate anticoagulation therapy and for patients with severe pulmonary hypertension.

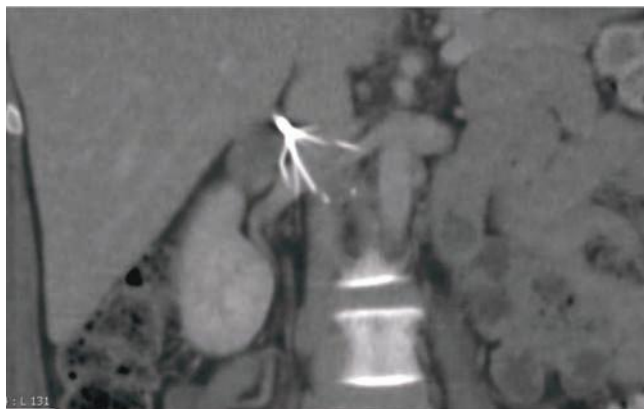When possible, therapy should be continued in patients with vena cava filters. The duration of anticoagulation is determined by the underlying VTE and not by the presence of the IVC filter itself. Practically speaking, however, many patients who require an IVC filter for recurrent VTE are the same ones who would benefit most from indefinite anticoagulation. In patients who are not able to receive anticoagulants due to recent surgery or trauma, the clinician should continually reassess if anticoagulation may be started safely at a later date.

Placement of permanent IVC filters has been evaluated as an adjunct to routine anticoagulation in patients with proximal DVT.⁵⁷ Routine IVC filter placement has not been shown to prolong early or late survival in patients with proximal DVT but did decrease the rate of PE (hazard ratio, 0.22; 95% confidence interval, 0.05–0.90), however; an increased rate of recurrent DVT was seen in patients with IVC filters (hazard ratio, 1.87; 95% confidence interval, 1.10–3.20).

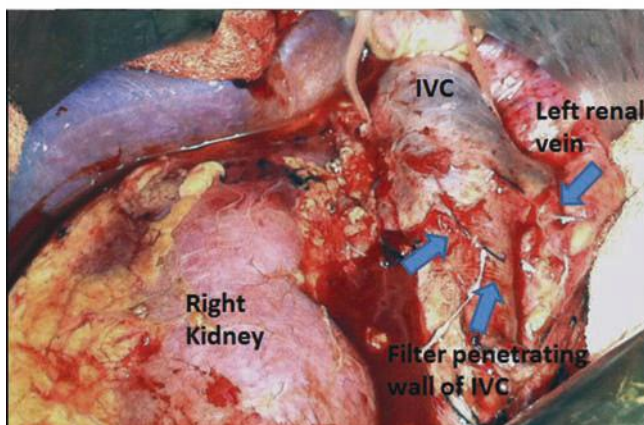
IVC filters are associated with acute and late complications. Acute complications include thrombosis or bleeding at the insertion site and misplacement of the filter. Late complications include thrombosis of the IVC, DVT, breaking, migration, or erosion of the filter through the IVC (Fig. 24-9). The rate of fatal complications is <0.12%.⁵⁸

In some patients, the need for an IVC filter may be self-limited. Such patients can be treated with so-called removable IVC filters. Depending on the device, removable IVC filters are potentially removable by percutaneous endovascular techniques for up to several months after their initial implantation assuming the filter is no longer required and does not have large amounts of trapped thrombi. All temporary IVC filters are approved for permanent implantation, and many so-called temporary filters end up as permanent devices with all the potential complications of permanent IVC filters.

Operative Venous Thrombectomy. In patients with acute iliofemoral DVT, surgical therapy is generally reserved for patients who worsen with anticoagulation therapy and those with phlegmasia cerulea dolens and impending venous gangrene. If the patient has phlegmasia cerulea dolens, a fasciotomy of the calf compartments is first performed. In iliofemoral DVT, a longitudinal venotomy is made in the common femoral vein and a venous balloon embolectomy catheter is passed through



A



B

Figure 24-9. Preoperative computed tomography imaging and intraoperative photo demonstrating erosion of IVC filter through the IVC wall.

the thrombus into the IVC and pulled back several times until no further thrombus can be extracted. The distal thrombus in the leg is removed by manual pressure beginning in the foot. This is accomplished by application of a tight rubber elastic wrap beginning at the foot and extending to the thigh. If the thrombus in the femoral vein is old and cannot be extracted, the vein may be ligated. For a thrombus that extends into the IVC, the IVC is exposed transperitoneally and controlled below the renal veins. The IVC is opened and the thrombus is removed by gentle massage. An intraoperative completion venogram determines if any residual thrombus or stenosis is present. If a residual iliac vein stenosis is present, intraoperative angioplasty and stenting can be performed. In most cases, an arteriovenous fistula is then created by anastomosing the great saphenous vein (GSV) end to side with the superficial femoral artery in an effort to maintain patency of the thrombectomized iliofemoral venous segment. Heparin is administered postoperatively for several days. Warfarin anticoagulation is maintained for at least 6 months after thrombectomy. Complications of iliofemoral thrombectomy include PE in up to 20% of patients⁵⁹ and death in <1% of patients.⁶⁰

One study followed 77 limbs for a mean of 8.5 years after thrombectomy for acute iliofemoral DVT. In limbs with successful thrombectomy, valvular competence in the thrombectomized

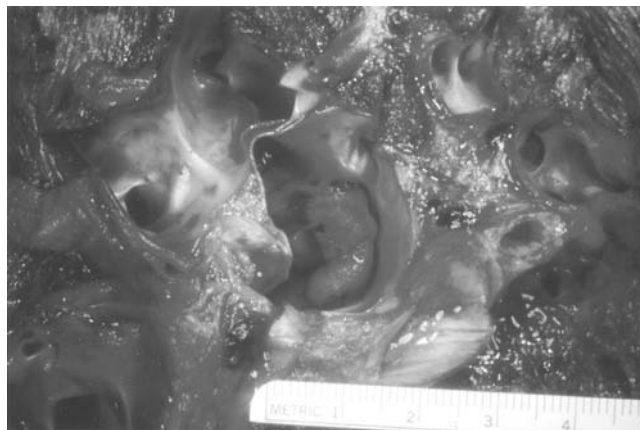


Figure 24-10. Autopsy specimen showing a massive pulmonary embolism.

venous segment was 80% at 5 years and 56% at 10 years. More than 90% of patients had minimal or no symptoms of PTS. There were 12 (16%) early thrombectomy failures. Patients were required to wear compression stockings for at least 1 year after thrombectomy.⁶¹

Survival rates for surgical pulmonary embolectomy have improved over the past 20 years with the addition of cardiopulmonary bypass. Emergency pulmonary embolectomy for acute PE is rarely indicated. Patients with preterminal massive PE (Fig. 24-10) for whom thrombolysis has failed or who have contraindications to thrombolytics may be candidates for this procedure. Open pulmonary artery embolectomy is performed through a posterolateral thoracotomy with direct visualization of the pulmonary arteries. Mortality rates range between 20% and 40%.⁶²⁻⁶⁴

Percutaneous catheter-based techniques for removal of a PE involve mechanical thrombus fragmentation or embolectomy using suction devices. Mechanical clot fragmentation is followed by CDT. Results of catheter-based fragmentation are based on small case series. In a study in which a fragmentation device was used in 10 patients with acute massive PE, fragmentation was successful in 7 patients with a mortality rate of 20%.⁶⁵ Transvenous catheter pulmonary suction embolectomy has also been performed for acute massive PE with a reported 76% successful extraction rate and a 30-day survival of 70%.⁶⁶

Prophylaxis

Patients who undergo major general surgical, gynecologic, urologic, and neurosurgical procedures without thromboprophylaxis have a significant incidence of perioperative DVT. An estimated one third of the 150,000 to 200,000 VTE-related deaths per year in the United States occur following surgery.⁶⁷ The goal of prophylaxis is to reduce the mortality and morbidity associated with VTE. The first manifestation of VTE may be a life-threatening PE (Fig. 24-11), and as indicated earlier, clinical evaluation to detect DVT before PE is unreliable.

Effective methods of VTE prophylaxis involve the use of one or more pharmacologic or mechanical modalities. Currently available pharmacologic agents include low-dose UFH, LMWH, synthetic pentasaccharides, and vitamin K antagonists. Mechanical methods include intermittent pneumatic compression (IPC) and graduated compression stockings.

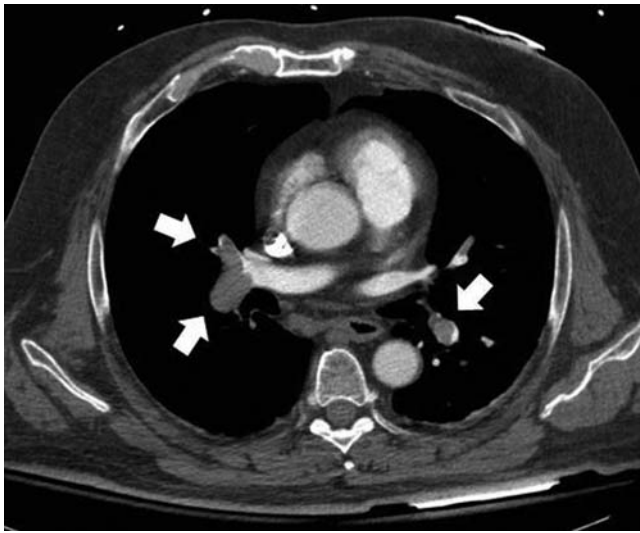


Figure 24-11. Computed tomography angiogram showing multiple pulmonary embolisms (arrows) (Used with permission from Dr. Scott Ambruster.)

There is insufficient evidence to consider aspirin alone as adequate DVT prophylaxis. Methods of prophylaxis vary with regard to efficacy, and the 2012 ACCP Clinical Practice Guidelines stratify their uses according to the patient's level of VTE risk, bleeding risk, and the values and preferences of individual patients (see Table 24-3).

Venous Thromboembolism Prophylaxis in Nonorthopedic Surgery. The risk for VTE associated with a surgical procedure depends on the type of operation, type of anesthesia, duration of surgery, and other risk factors, such as patient age, presence of cancer, prior VTE, obesity, presence of infection, and known thrombophilic disorders. VTE risk can be stratified according to the previously mentioned risk assessment models, the Caprini score and Rogers score. These risk assessment models are included in the prophylaxis guidelines for nonorthopedic surgery (Tables 24-5 and 24-6). A composite score is created using assigned values for each risk factor. The cumulative score for each patient is then used to predict thrombosis risk and provide recommendations regarding VTE prophylaxis.

Patients at very low risk (<0.5%; Rogers score <7; Caprini score 0) who undergo general or abdominopelvic procedures do not require pharmacologic or mechanical prophylaxis; however, early ambulation is required. Patients at low risk (<1.5%; Rogers score 7–10; Caprini score 1–2) should receive mechanical prophylaxis. Patients at moderate risk (3%; Rogers score >10; Caprini score 3–4) should receive LMWH at recommended doses, low-dose UFH, or mechanical prophylaxis. Patients at high risk (6%; Caprini score ≥5) should receive LMWH at recommended doses or low-dose UFH and mechanical prophylaxis. Thromboprophylaxis should continue until discharge, except in select high-risk patients with malignancy in whom extended-duration prophylaxis (up to 4–6 weeks) may be beneficial. Patients with significant risk for bleeding should receive mechanical prophylaxis until this risk subsides.⁶⁷

Overall, low-dose UFH and LMWH reduce the risk for symptomatic and asymptomatic VTE by 60% to 70%. The risks for bleeding differ, depending on the dosage. Lower dosages of LMWH appear to be associated with less bleeding risk than

Table 24-5

Risk assessment model from the Patient Safety in Surgery Study

RISK FACTOR	RISK SCORE POINTS
Operation type other than endocrine	
Respiratory and hernia	9
Thoracoabdominal aneurysm, embolectomy/thrombectomy, venous reconstruction and endovascular repair	7
Aneurysm	4
Mouth, palate	4
Stomach, intestines	4
Integument	3
Hernia	2
ASA, physical status classification	
3, 4, or 5	2
2	1
Female sex	1
Work RVU	
>17	3
10–17	2
Two points for each of these conditions	
Disseminated cancer	2
Chemotherapy for malignancy within 30 days of operation	
Preoperative serum sodium >145 mmol/L	
Transfusion >4 units packed RBCs in 72 hours before operation	
Ventilator dependent	
One point for each of these conditions	
Wound class (clean/contaminated)	1
Preoperative hematocrit ≤38%	
Preoperative bilirubin >1 mg/dL	
Dyspnea	
Albumin ≤3.5 mg/dL	
Emergency	
Zero points for each of these conditions	
ASA physical class of 1	0
Work RVU <10	
Male sex	

ASA = American Society of Anesthesiologists; RBCs = red blood cells; RVU = relative value unit.

Source: Adapted with permission from Rogers SO Jr, Kilaru RK, Hosokawa P, et al. Multivariable predictors of postoperative venous thromboembolic events after general and vascular surgery: results from the patient safety in surgery study. *J Am Coll Surg.* 2007;204:1211. Copyright © American College of Surgeons.

low-dose UFH, but the latter produces less bleeding risk than higher prophylactic dosages of LMWH.⁶⁸ Other advantages of LMWH include once-daily dosing protocols and a lower rate of heparin-associated antibody formation.

Table 24-6

Caprini risk assessment model

1 POINT	2 POINTS	3 POINTS	5 POINTS
Age 41–60	Age 61–74	Age ≥75	Stroke (<1 month)
Minor surgery	Arthroscopic surgery	History of VTE	Elective arthroplasty
BMI >25 kg/m ²	Major open surgery (>45 minutes)	Family history of VTE	Hip, pelvis, or leg fracture
Swollen legs	Laparoscopic surgery (>45 minutes)	Factor V Leiden	Acute spinal cord injury (<1 month)
Varicose veins	Malignancy	Prothrombin 20210A	
Pregnancy or postpartum	Confined to bed (>72 hours)	Lupus anticoagulant	
History of unexplained or recurrent spontaneous abortion	Immobilizing plaster cast	Anticardiolipin antibody	
Oral contraceptives or hormone replacement	Central venous access	Elevated serum homocysteine	
Sepsis (<1 month)		Heparin-induced thrombocytopenia	
Serious lung disease, including pneumonia (<1 month)		Other congenital or acquired thrombophilia	
Abnormal pulmonary function test			
Acute myocardial infarction			
Congestive heart failure			
History of inflammatory bowel disease			
Medical patient at bed rest			

BMI = body mass index; VTE = venous thromboembolism.

Source: Adapted with permission from Bahl V, Hu HM, Henke PK, Wakefield TW, Campbell DA Jr, Caprini JA. A validation study of retrospective venous thromboembolism risk scoring method. *Ann Surg.* 2010;251:344. Copyright Wolters Kluwer Health.

Fondaparinux has been compared with the LMWH dalteparin in patients who undergo high-risk major abdominal surgery. It also has been compared with IPC alone in patients undergoing non-high-risk abdominal surgery.^{69,70} Fondaparinux demonstrated rates of VTE prevention, bleeding complications, and mortality similar to those of LMWH. It was more beneficial than IPC alone in reducing VTE but with a higher rate of bleeding (1.6% vs. 0.2%).

Prophylactic insertion of IVC filters has been suggested for VTE prophylaxis in high-risk trauma patients, bariatric surgical patients, and some patients with malignancy who have contraindications for LMWH therapy.⁷¹ A 5-year study of prophylactic IVC filter placement in 132 trauma patients at high risk of PE (head injury, spinal cord injury, pelvic or long bone fractures) reported a 0% incidence of symptomatic PE in patients with a correctly positioned IVC filter.⁷² In 47 patients with a malpositioned IVC filter (strut malposition or filter tilt), there was a 6.3% incidence of symptomatic PE with three deaths. DVT occurred at the insertion site in 3.1% of the patients. IVC patency was 97.1% at 3 years.

Fatal and nonfatal PE can still occur in patients with vena cava interruption. As noted earlier, long-term complications associated with permanent IVC filters include IVC thrombosis and DVT. Currently, the ACCP recommends IVC filters be

placed only if a proximal DVT is present and anticoagulation therapy is contraindicated. IVC filter insertion is not recommended for primary prophylaxis.⁶⁷

Removable IVC filters may be placed in patients with a temporarily increased risk of PE.⁷³ The best patient groups for retrievable filter placement may include young trauma patients with transient immobility, patients undergoing surgical procedures associated with a high risk of PE, and patients with hypercoagulable states who cannot receive anticoagulation therapy for a short period of time. Careful follow-up is required to assure all potentially removable filters are in fact removed.

OTHER VENOUS THROMBOTIC DISORDERS

Superficial Vein Thrombophlebitis

Superficial vein thrombophlebitis (SVT) most commonly occurs in varicose veins but can occur in normal veins. When SVT recurs at variable sites in normal superficial veins, *thrombophlebitis migrans*, it may signify a hidden visceral malignancy or a systemic disorder such as a blood dyscrasia and/or a collagen vascular disease. SVT also frequently occurs as a complication of indwelling catheters, with or without associated extravasation of injected material. Upper extremity vein

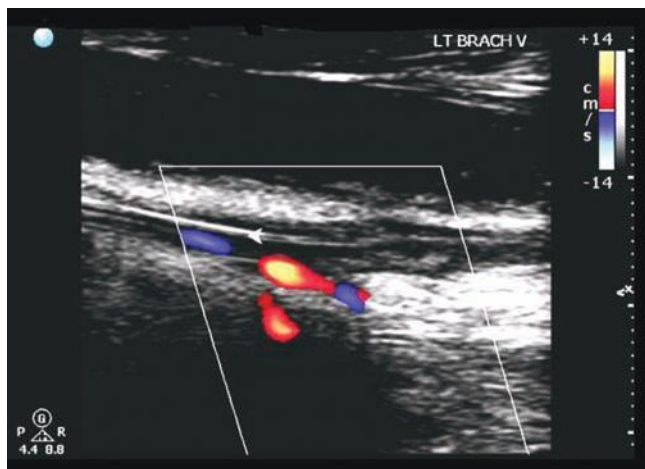


Figure 24-12. Duplex ultrasound of a brachial vein containing thrombus and percutaneously inserted central catheter (PICC).

thrombosis has been reported to occur in 38% of patients with peripherally inserted central catheters; 57% of these developed in the cephalic vein (Fig. 24-12).⁷⁴ Suppurative SVT may occur in veins with indwelling catheters and may be associated with generalized sepsis.

Clinical signs of SVT include redness, warmth, and tenderness along the distribution of the affected veins, often associated with a palpable cord. Patients with suppurative SVT may have fever and leukocytosis. DUS should be performed in patients with signs and symptoms of acute SVT to confirm the diagnosis and to determine if any associated DVT is present. Concomitant lower extremity DVT may be present in 5% to 40% of patients with SVT; most occur in patients with greater saphenous vein SVT within 1 cm of the saphenofemoral junction. A follow-up DUS should be performed in 5 to 7 days in patients with SVT in the proximal GSV but without deep vein involvement. Approximately 10% to 20% of patients with SVT involving the proximal GSV experience progression to deep vein involvement within 1 week.^{75,76}

Treatment of SVT is quite variable. A Cochrane Review reported that LMWHs and nonsteroidal anti-inflammatory drugs both reduce the rate of SVT extension or recurrence. Topical medications appear to improve local symptoms. Surgical treatment, combined with the use of graduated compression stockings, is associated with a lower rate of VTE and SVT progression.⁷⁷ The treatment is individualized and depends on the location of the thrombus and the severity of symptoms. In patients with SVT not within 1 cm of the saphenofemoral junction, treatment consists of compression and administration of an anti-inflammatory medication such as indomethacin. In patients with suppurative SVT, antibiotics and removal of any existing indwelling catheters are mandatory. Excision of the vein may be necessary but is usually reserved for patients with systemic symptoms or when excision of the involved vein is straightforward. If the SVT extends proximally to within 1 cm of the saphenofemoral junction, extension into the common femoral vein is more likely to occur. In these patients, anticoagulation therapy for 6 weeks and GSV ligation appear equally effective in preventing thrombus extension into the deep venous system.^{78,79}

Upper Extremity Vein Thrombosis

Axillary-subclavian venous thrombosis (ASVT) is classified into two forms. Primary ASVT occurs in only a small minority

of all patients with ASVT. In the primary form, no clear cause for the thrombosis is readily identifiable at initial evaluation. Patients with primary ASVT often give a history of performing prolonged, repetitive motion activities, which results in damage to the subclavian vein, usually where it passes between the head of the clavicle and the first rib in association with the subclavius muscle. This condition is also known as *venous thoracic outlet syndrome*, *effort thrombosis*, and *Paget-Schroetter syndrome*. Secondary ASVT is more common and is associated with an easily identified cause such as an indwelling catheter or a hypercoagulable state. Over 30% of patients with tunneled subclavian vein access devices develop ASVT.⁸⁰

A patient with ASVT may be asymptomatic or may present with varying degrees of upper extremity edema, tenderness, and conspicuous superficial venous enlargement. DUS can be performed initially to confirm the diagnosis, but limitations to the exam by the clavicle and collateralization can lead to a false-negative study. Venography is recommended when there is nonconcordance between the duplex study and clinical suspicion. Anticoagulation therapy should be initiated once ASVT is diagnosed to prevent PE and decrease symptoms.

Treatment of patients with primary upper extremity venous thrombosis is controversial because the natural history of the disease may vary from minimal to no symptoms to significant symptoms with vigorous upper extremity activities. In recent years, patients presenting with acute symptomatic primary ASVT are often considered candidates for CDT therapy with the goal of minimizing long-term symptoms of venous congestion. Venography is performed through a catheter placed using an ultrasound-guided percutaneous basilic vein approach to document the extent of the thrombus (Fig. 24-13). A guidewire is traversed through the thrombus, and a catheter is placed within the thrombus. Typically, tissue plasminogen activator is administered through a multi-side-hole infusion catheter. Various catheter-based mechanical techniques may also be employed to speed thrombus removal. Heparin is administered concurrently with the thrombolytic infusion. After completion

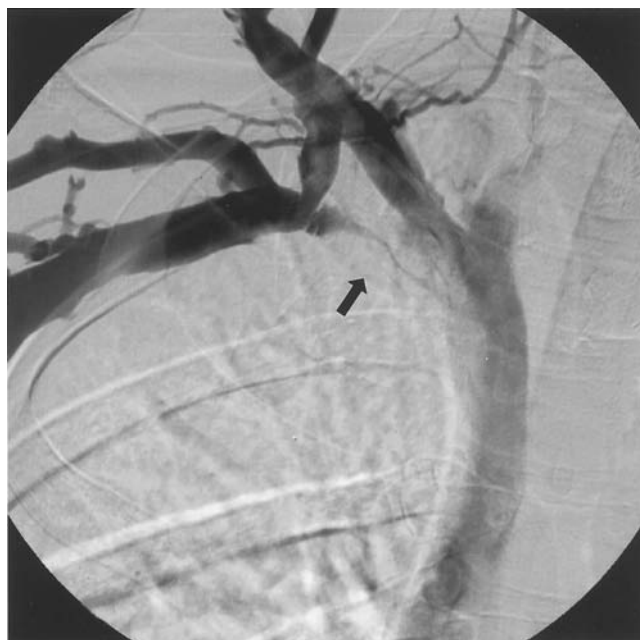

Figure 24-13. Upper extremity venogram showing stenosis of the right subclavian vein (arrow).

of thrombolytic therapy, a follow-up venogram is obtained. Correctable anatomic abnormalities may then be considered for treatment. Adjuvant procedures after thrombolytic therapy may include cervical or first rib resection for thoracic outlet abnormalities, surgical venous reconstruction, and balloon angioplasty of residual venous stenosis.⁸¹

Mesenteric Vein Thrombosis

Five to 15% of cases of acute mesenteric ischemia occur as a result of mesenteric vein thrombosis (MVT). Mortality rates in patients with MVT may approach 50%.⁸² The usual presenting symptom is nonspecific abdominal pain and distention, often accompanied by nausea, vomiting, and diarrhea.⁸³ Peritoneal signs, suggesting intestinal infarction, are present in fewer than half of MVT patients. MVT is more common in patients with a hypercoagulable states, malignancy, and cirrhosis. MVT occurs as a rare complication of laparoscopic surgery.^{83,84}

Most cases of MVT are diagnosed with contrast-enhanced CT scanning or magnetic resonance imaging (MRI) in the course of an evaluation for abdominal pain. The sensitivity and specificity for CT and MRI approach 100% and 98%, respectively.⁸⁵ Ultrasound can also be used and has reported sensitivity and specificity of 93% and 99%, respectively.

Patients with MVT are treated with fluid resuscitation, heparin anticoagulation, and bowel rest. Once the patient's clinical status improves, oral intake can be carefully started. The patient is transitioned to oral anticoagulation over 3 to 4 days and, depending on the etiology of the MVT, continued for 3 to 6 months or indefinitely. Most patients with MVT can be treated nonoperatively, but urgent laparotomy is indicated in patients with peritoneal findings. Broad-spectrum antibiotics are administered perioperatively. Operative findings consist of edema and cyanotic discoloration of the mesentery and bowel wall. In more advanced cases, thrombus involves the distal mesenteric veins. The arterial supply to the involved bowel is usually intact. Nonviable bowel is resected, and primary anastomosis can be performed. If the viability of the remaining bowel is in question, a second-look operation is performed within 24 to 48 hours.

VARICOSE VEINS

Varicose veins are common and are present in at least 10% of the general population.⁸⁶ The findings of varicose veins may include dilated and tortuous veins, telangiectasias, and fine reticular varicosities. Risk factors for varicose veins include obesity, female sex, inactivity, and family history.⁸⁷ Varicose veins can be classified as primary or secondary. Primary varicose veins result from intrinsic abnormalities of the venous wall, whereas secondary varicose veins are associated with deep and/or superficial venous insufficiency.

Patients with varicose veins may complain of unsightly appearance, aching, heaviness, pruritus, and early fatigue of the affected leg. These symptoms worsen with prolonged standing and sitting and are relieved by elevation of the leg above the level of the heart. A mild amount of edema is often present. More severe signs include thrombophlebitis, hyperpigmentation, lipodermatosclerosis, ulceration, and bleeding from attenuated vein clusters.

An important component of treatment for patients with varicose veins is the use of elastic compression stockings. Patients may be prescribed elastic stockings with compression ranging from 20 to 30, 30 to 40, or even 40 to 50 mmHg.

Stockings range in length from knee high to waist high, and they should cover the symptomatic varices. Elastic compression provides sufficient relief of symptoms in many symptomatic patients.

Cosmetic concerns may lead to intervention. Additionally, interventions are warranted in patients whose symptoms worsen or are unrelieved despite compression therapy or who have lipodermatosclerosis or venous ulcer. Randomized trials of symptomatic patients with varicose veins have demonstrated improved quality of life with interventional treatment. Interventional management includes injection sclerotherapy, surgical therapy, or a combination of both techniques. Injection sclerotherapy alone can be successful in varicose veins <3 mm in diameter and in telangiectatic vessels. Sclerotherapy acts by destroying the venous endothelium. Sclerosing agents include hypertonic saline, sodium tetradecyl sulfate, and polidocanol. Concentrations of 11.7% to 23.4% hypertonic saline, 0.125% to 0.250% sodium tetradecyl sulfate, and 0.5% polidocanol are used for telangiectasias. Larger varicose veins require higher concentrations: 23.4% hypertonic saline, 0.50% to 1% sodium tetradecyl sulfate, and 0.75% to 1.0% polidocanol.⁸³ Elastic bandages are wrapped around the leg after injection and worn continuously for 3 to 5 days to produce apposition of the inflamed vein walls and prevent thrombus formation. After the bandages are removed, elastic compression stockings should be worn for a minimum of 2 weeks. Complications from sclerotherapy include allergic reaction, local hyperpigmentation, thrombophlebitis, DVT, and possible skin necrosis.

Patients with symptomatic GSV or SSV reflux may be treated with endovenous ablation techniques or surgical removal of the affected vein. Endovenous laser and radiofrequency ablation (RFA) techniques have gained in popularity in the past several years. Such techniques are generally associated with more rapid postprocedure recovery than traditional open surgical stripping of the GSV.

With either endoluminal technique, the distal thigh or proximal calf GSV is punctured with a 21-gauge needle under ultrasound guidance. A sheath is placed over a guidewire, and the laser fiber or RFA catheter is advanced until it is near to, but not at, the saphenofemoral junction. Tumescence anesthetic is administered around the GSV, and the vein is treated as the catheter is withdrawn. Endovenous laser treatment and RFA result in durable ablation of the GSV, with rates of varicose vein recurrence and clinical severity scores comparable to those seen with open surgery.^{88,89} Risks of endovenous ablation include DVT, ecchymosis, and saphenous nerve injury.

Saphenous vein ligation and stripping is still the more commonly performed procedure worldwide, and it may be the preferred therapy for patients with GSVs of very large diameter (>2 cm). Surgical removal of the GSV usually is performed via small incisions placed medially in the groin and just below the knee. The GSV is removed using a blunt tip catheter or an invagination pin stripper. Complications associated with GSV stripping include ecchymosis, lymphocele formation, DVT, infection, and saphenous nerve injury. GSV stripping is associated with a lower rate of recurrence of varicose veins and a better quality of life than saphenofemoral junction ligation alone.

Larger varicose veins are best treated by surgical excision using the "stab avulsion" technique. Stab avulsions are performed by making 2-mm incisions directly over branch varicosities, and the varicosity is dissected from the surrounding subcutaneous tissue as far proximally and distally as possible

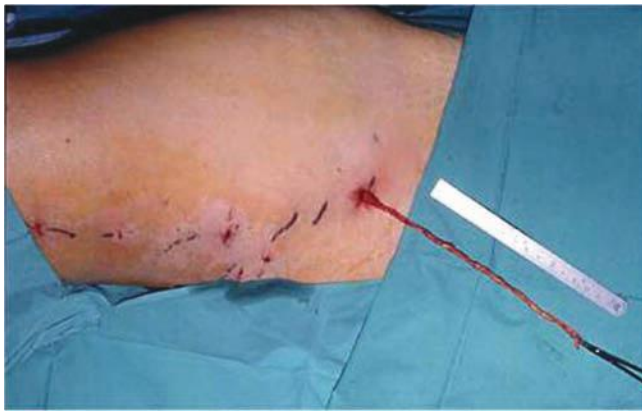

Figure 24-14. Removal of varicose veins via stab avulsions.

through the small incisions (Fig. 24-14). In most cases the vein is simply avulsed with no attempt at ligation. Bleeding is easily controlled with leg elevation, manual compression, and preprocedure tumescent anesthesia.

CHRONIC VENOUS INSUFFICIENCY

Chronic venous insufficiency (CVI) affects an estimated 600,000 people in the United States.⁹⁰ Patients complain of leg fatigue, discomfort, and heaviness. Signs of CVI may include varicose veins, pigmentation, lipodermatosclerosis, and venous ulceration. Importantly, severe CVI is not necessarily associated with varicose veins. Chronic venous ulcers carry significant negative physical, financial, and psychological implications. A quality-of-life study reported that 65% of patients with chronic leg ulcers had severe pain, 81% had decreased mobility, and 100% experienced a negative impact of their disease on their work capacity.⁹¹ The socioeconomic impact of chronic venous leg ulcers is staggering, with an estimated 2 million workdays lost per year.⁹² The annual healthcare cost in the United States to treat CVI is estimated at \$1 billion.⁹³

CVI can be primary or secondary. Primary CVI results from intrinsic abnormalities of the vein wall, whereas secondary CVI, so-called postthrombotic syndrome (PTS), occurs as a result of DVT. The signs and symptoms of CVI can be therefore attributed to venous reflux, venous obstruction, calf muscle pump dysfunction, or a combination of these factors, as well as loss of venous wall elasticity.⁹⁴ In the majority of patients with CVI, the most important factor appears to be venous reflux. Venous reflux results from abnormalities of the venous valve. Primary valvular reflux or incompetence is diagnosed when there is no known underlying cause of valvular dysfunction. Secondary valvular reflux is diagnosed when an identifiable cause is present. The most frequent secondary cause is DVT.

Evaluation of Venous Insufficiency

Early diagnostic studies to evaluate CVI required invasive measurements of ambulatory venous pressure (AVP) and venous recovery time (VRT). To measure AVP and VRT, a needle is inserted into a dorsal foot vein and connected to a pressure transducer. The patient is asked to perform 10 tiptoe exercises. Initially there is often a slight upward deflection of pressure with the onset of exercise followed by a decline in pressure with each subsequent tiptoe maneuver. After approximately 10 tiptoes, the measured pressure stabilizes and reflects a balance of venous inflow and outflow. The pressure at this point

is the AVP, which is measured in millimeters of mercury. The patient is then asked to stop exercising to allow the vein to fill with return of the venous pressure to baseline. The time required for the venous pressure to return from the AVP level to 90% of baseline pressure is referred to as the VRT. Elevations of AVP indicate venous hypertension. The magnitude of AVP reflects the severity of CVI. There is an 80% incidence of venous ulceration in patients with an AVP of >80 mmHg.⁹⁵

Plethysmography. Noninvasive plethysmography has been used to evaluate CVI. Venous photoplethysmography indirectly evaluates venous function through the use of infrared light. A light-emitting diode is placed just above the medial malleolus, and the patient then performs a series of tiptoe maneuvers. Photoplethysmography provides a measurement of VRT. In limbs with CVI, VRT is shortened compared with that in a normal limb. AVP and VRT are only measures of the overall venous function of a lower extremity venous system. They cannot localize the site of reflux or evaluate the function of the calf pump.

Air plethysmography is a theoretically attractive but not widely used method to assess calf pump function, venous reflux, and overall lower extremity venous function.⁹⁶ An air-filled plastic pressure bladder is placed on the calf to detect volume changes in the leg during a standard set of maneuvers. The patient is first supine and then the leg is elevated and the minimum volume of venous blood recorded. The patient is then asked to assume an upright position with the examined leg non-weight bearing. The venous volume of the examined leg is determined when the volume curve flattens. The venous filling index (VFI), a measure of reflux, is calculated by dividing the maximum venous volume by the time required to achieve maximum venous volume. Next, the patient performs a single tiptoe maneuver, and the ejection fraction (EF) is determined. The EF is the volume change between the recorded volume before and after the tiptoe maneuver and is a measure of calf pump function. At this point, the veins of the leg are allowed to refill. The patient then performs 10 tiptoe maneuvers, and the residual volume fraction is calculated by dividing the venous volume in the leg after 10 tiptoe exercises by the venous volume present before the exercises. The residual volume fraction is a reflection of overall venous function. Theoretically, patients with increased VFIs and normal EFs (indicating the presence of reflux with normal calf pump function) would benefit from anti-reflux surgery, whereas patients with normal VFIs and diminished EFs would not.

Venous Duplex Ultrasound. Venous DUS has become the gold standard for evaluation of venous function largely supplanting venographic and plethysmographic techniques. The principle advantage of DUS is that it can be used to evaluate reflux in individual venous segments targeting abnormal areas for treatment. The examination has been validated when performed with the patient in the standing position and the examined leg non-weight bearing. Pneumatic pressure cuffs of appropriate size are placed around the thigh, calf, and foot. The ultrasound transducer is positioned over the venous segment to be examined, just proximal to the pneumatic cuff (Fig. 24-15). The cuff is then inflated to a standard pressure for 3 seconds and then rapidly deflated. Ninety-five percent of normal venous valves close within 0.5 second.⁹⁷ The presence of reflux for >0.5 second is considered abnormal. Typically, the common femoral, femoral, popliteal, and posterior tibial veins, as well as the GSV and SSV, are evaluated in a complete examination.

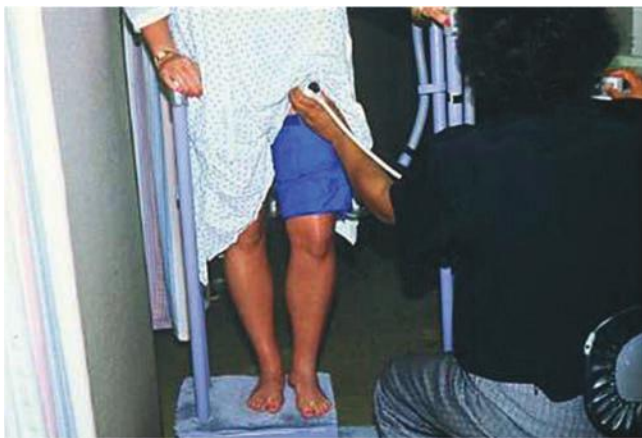

Figure 24-15. Evaluation of a patient with chronic venous insufficiency with duplex ultrasonography.

Nonoperative Treatment of Chronic Venous Insufficiency

Compression Therapy. Compression therapy is the mainstay of CVI management. Compression can be achieved using a variety

of techniques, including elastic compression stockings, **5▶** paste gauze boots (Unna's boots), multilayer elastic wraps or dressings (Fig. 24-16), and pneumatic compression devices. Nonelastic compression bandages generally achieve higher and more prolonged degrees of compression than elastic compression bandages. The exact mechanism by which compression therapy can improve CVI remains uncertain. An improvement in skin and subcutaneous tissue microcirculatory hemodynamics as well as a direct effect on subcutaneous pressure have been hypothesized as the mechanisms of efficacy of compression therapy.⁹⁸ Additionally, compression therapy has demonstrated quantifiable differences in ulcer healing with decreases in matrix metalloproteins and inflammatory cytokines.^{99,100} Clinically, routine use of elastic and nonelastic bandages reduces lower extremity edema in patients with CVI. In addition, supine perimalleolar subcutaneous pressure has been demonstrated to increase with elastic compression.¹⁰¹ With edema reduction, cutaneous metabolism may improve due to enhanced diffusion of oxygen and other nutrients to the cellular elements of skin and subcutaneous tissues. Increases in subcutaneous tissue

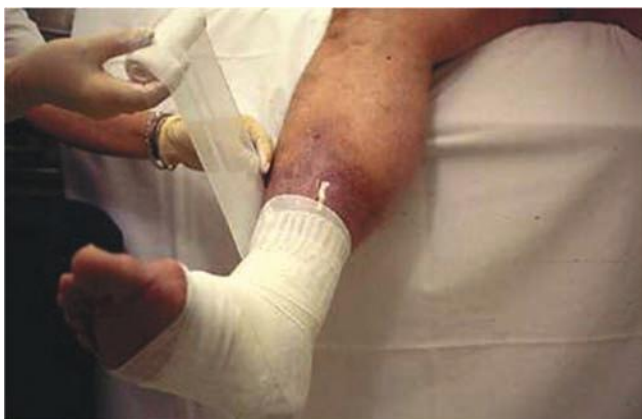

Figure 24-16. Multilayered dressing for treatment of chronic venous insufficiency.

pressure with elastic compression bandages may counteract transcapillary Starling forces, which favor leakage of fluid out of the capillary.

Before the initiation of therapy for CVI, patients must be educated about their chronic disease and the need to comply with their treatment plan to heal ulcers and prevent recurrence. A definitive diagnosis of venous ulceration must be made before treatment is initiated. A detailed history should be obtained from a patient presenting with lower extremity ulcerations, including medications used and associated medical conditions that may promote lower extremity ulceration. Arterial insufficiency is assessed by physical examination or noninvasive studies. In addition, systemic conditions that affect wound healing and leg edema, such as diabetes mellitus, immunosuppression, malnutrition, and congestive heart failure, should be improved as much as possible.

Compression therapy is most commonly achieved with graduated elastic compression stockings. Elastic compression stockings are available in various compositions, strengths, and lengths, and can be customized for a particular patient. The benefits of elastic compression stocking therapy for the treatment of CVI and healing of ulcerations have been well documented.¹⁰²⁻¹⁰⁵ In a retrospective study involving 113 venous ulcer patients,¹⁰³ the use of below-knee, 30- to 40-mmHg elastic compression stockings, after edema and cellulitis were first resolved if present, resulted in 93% healing. Complete ulcer healing occurred in 99 of 102 patients (97%) who were compliant with stocking use vs. 6 of 11 patients (55%) who were noncompliant ($P < .0001$). The mean time to ulcer healing was 5 months. The rate of ulcer recurrence was lower in patients who were compliant with their compression therapy. By life table analysis, ulcer recurrence was 29% at 5 years for compliant patients and 100% at 3 years for noncompliant patients.

In addition to promoting ulcer healing, elastic compression therapy can also improve quality of life in patients with CVI. In one prospective study,¹⁰⁶ 112 patients with CVI documented by DUS were administered a questionnaire to quantify the symptoms of swelling, pain, skin discoloration, cosmesis, activity tolerance, depression, and sleep alterations. Patients were treated with 30- to 40-mmHg elastic compression stockings. There were overall improvements in symptom severity scores at 1 month after initiation of treatment. Further improvements were noted at 16 months after treatment.

Patient compliance with compression therapy is crucial in treating CVI and especially venous leg ulcers. Many patients are initially intolerant of compression in areas of hypersensitivity adjacent to an active ulcer or at sites of previously healed ulcers. They may also have difficulty applying elastic stockings. To improve compliance, patients should be instructed to wear their stockings initially only as long as it is easily tolerated and then gradually to increase the amount of time the stockings are worn. Alternatively, patients can be fitted with lower-strength stockings initially followed by introduction of higher-strength stockings over a period of several weeks. Many commercially available devices, such as silk inner toe liners, adjustable elastic compression with Velcro, stockings with zippered sides (Fig. 24-17), and metal fitting aids (Fig. 24-18), are available to assist patients in applying elastic stockings. However, despite all these available adjuncts, many patients remain noncompliant with elastic compression therapy.

Another method of compression was developed by the German dermatologist Paul Gerson Unna. Unna's boot has

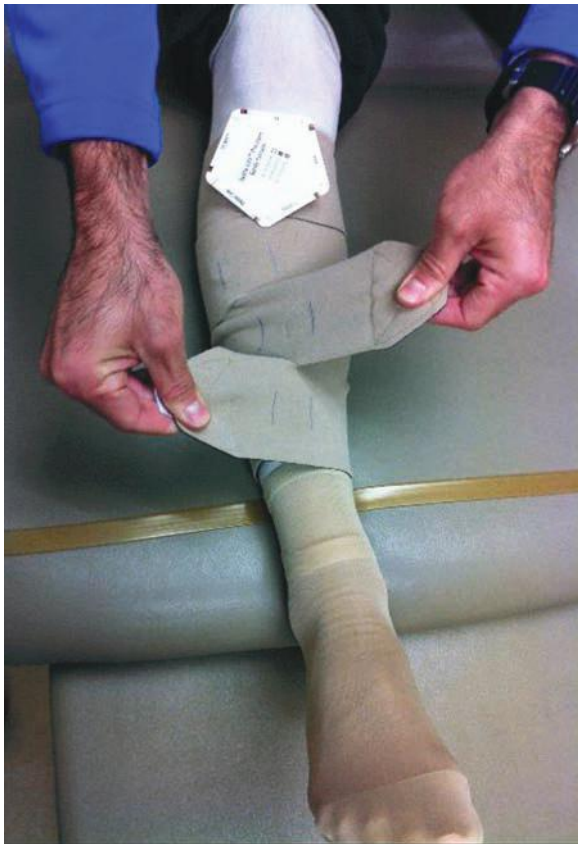


Figure 24-17. Elastic compression device with Velcro to facilitate treatment of chronic venous insufficiency.

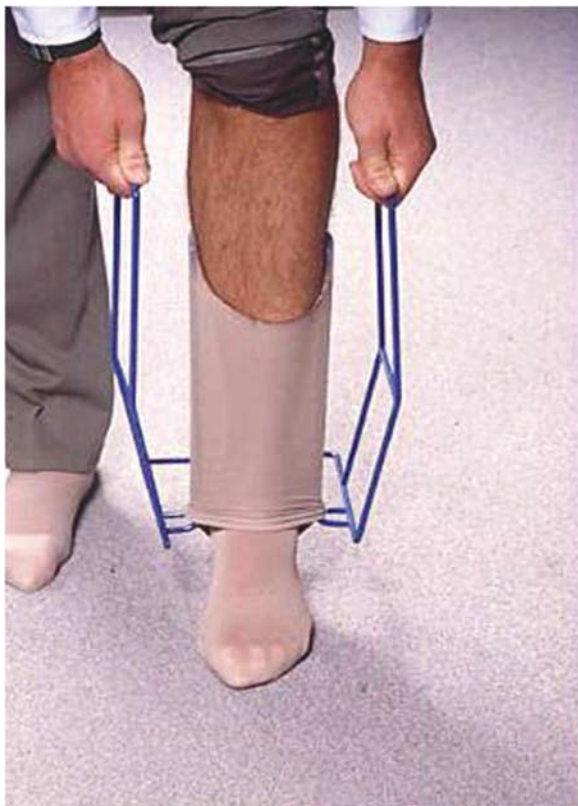

Figure 24-18. Metal fitting aid to assist in placement of elastic compression stockings.

been used for many years to treat venous ulcers and is available in many versions. A typical Unna's boot consists of a three-layer dressing and requires application by trained personnel. A rolled gauze bandage impregnated with calamine, zinc oxide, glycerin, sorbitol, gelatin, and magnesium aluminum silicate is first applied with graded compression from the forefoot to just below the knee. The next layer consists of a 4-in-wide continuous gauze dressing followed by an outer layer of elastic wrap, also applied with graded compression. The bandage becomes stiff after drying, and the rigidity may aid in preventing edema formation. Unna's boot is changed weekly or sooner if the patient experiences significant drainage and soiling of the dressing.

Once applied, Unna's boot requires minimal patient involvement and provides continuous compression and topical therapy. However, Unna's boot has several disadvantages. It is bulky and can be uncomfortable, which may affect patient compliance. In addition, the ulcer cannot be monitored after the boot is applied, the technique is labor intensive, and the degree of compression provided is operator dependent. Occasionally, patients may also develop contact dermatitis to the components of Unna's boot.

The efficacy of Unna's dressing has been studied. A retrospective 15-year survey encompassing 998 patients with one or more venous ulcers treated weekly with Unna's dressing¹⁰⁷ reported that 73% of ulcers healed in patients who returned for more than one treatment. The median time to healing for individual ulcers was 9 weeks. Unna's dressing has been compared to other forms of treatment. A randomized, prospective study¹⁰⁸ comparing Unna's boot to polyurethane foam dressing in 36 patients with venous ulcers demonstrated superior healing over 12 months in patients treated with Unna's boot (94.7% vs. 41.2%).¹⁰⁸ A recent Cochrane Review of 39 randomized controlled trials demonstrated that compression increases ulcer healing rates compared with no compression, multicomponent systems are more effective than single-component systems, and multicomponent systems that include an elastic bandage are more effective than those composed mainly of inelastic constituents.¹⁰⁹

Other forms of compression dressing available to treat CVI include multilayered dressings and legging orthoses. The purported advantages of multilayered dressings include maintenance of compression for a longer period of time, more even distribution of compression, and better absorption of wound exudates. However, the efficacy of multilayered dressings depends on the wrapping technique of healthcare personnel. A commercially available legging orthosis consisting of multiple adjustable loop-and-hook closure compression bands provides compression similar to that of Unna's boot and can be applied daily by the patient.¹¹⁰

Skin Substitutes. Several types of skin substitutes are commercially available or under clinical study in the United States.⁹² Bioengineered skin ranges in composition from acellular skin substitutes to partial living skin substitutes. Their mechanism of action in healing venous ulcers is uncertain; however, they may serve as delivery vehicles for various growth factors and cytokines important in wound healing.

Apligraf is a commercially available bilayered living skin construct that closely approximates human skin for use in the treatment of venous ulcers. It contains a protective stratum corneum and a keratinocyte-containing epidermis overlying a dermis consisting of dermal fibroblasts in a collagen matrix.¹¹¹

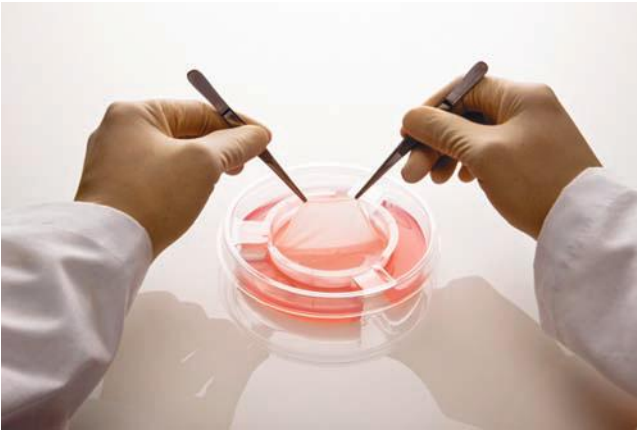


Figure 24-19. Apligraf skin graft material supplied as a disk on an agarose gel nutrient medium.

Apligraf is between 0.5 mm and 1.0 mm thick and is supplied as a disk of living tissue on an agarose gel nutrient medium. It must be used within 5 days of release from the manufacturer¹¹¹ (Fig. 24-19). The disk is easily handled and applied and conforms to irregularly contoured ulcer beds.

A prospective randomized study comparing multilayer compression therapy alone to treatment with Apligraf in addition to multilayered compression therapy has been performed to assess the efficacy of Apligraf in the treatment of venous ulcers.¹⁰⁵ More patients treated with Apligraf had ulcer healing at 6 months (63% vs. 49%, $P = .02$). The median time to complete ulcer closure was significantly shorter in patients treated with Apligraf (61 days vs. 181 days, $P = .003$). The ulcers that showed the greatest benefit with the living skin construct were ones that were large and deep ($>1000 \text{ mm}^2$) or were longstanding (>6 months). No evidence of rejection or sensitization has been reported in response to Apligraf application.

Surgical/Interventional Treatment of Chronic Venous Insufficiency

Perforator Vein Ligation. Incompetence of the perforating veins connecting the superficial and deep venous systems of the lower extremities has been implicated in the development of venous ulcers. The classic open technique described by Linton in 1938 for perforator vein ligation has a high incidence of wound complications and has largely been abandoned.¹¹² A minimally invasive technique termed subfascial endoscopic perforator vein surgery (SEPS) evolved with improvement of endoscopic equipment.

DUS is performed preoperatively in patients undergoing SEPS to document deep venous competence and to identify perforating veins in the posterior compartment. The patient is positioned on the operating table with the affected leg elevated at 45° to 60° . An Esmarch bandage and a thigh tourniquet are used to exsanguinate the limb. The knee is then flexed, and two small incisions are made in the proximal medial leg away from areas of maximal induration at the ankle. Laparoscopic trocars are then positioned, and the subfascial dissection is performed with a combination of blunt and sharp dissection. Carbon dioxide is then used to insufflate the subfascial space. The thigh tourniquet is inflated to prevent air embolism. The perforators are then identified and doubly clipped and divided. After completion of

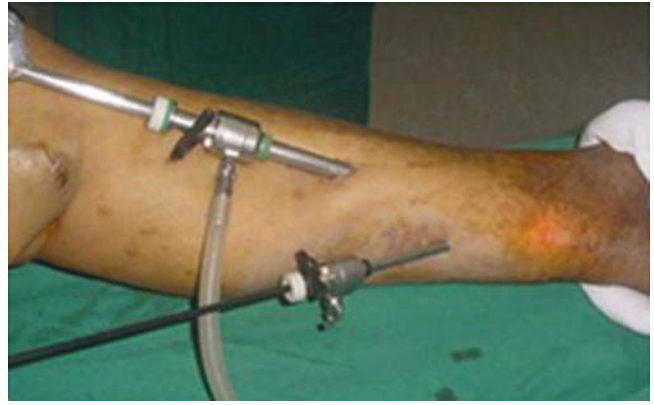

Figure 24-20. Trocar placement for subfascial endoscopic perforator vein surgery. (Used with permission of Dr. Pankaj Patel.)

the procedure, the leg is wrapped in a compression bandage for 5 days postoperatively.

The efficacy of SEPS as a stand-alone procedure in treatment of venous insufficiency is controversial and unproven. In a report from a large North American registry of 146 patients undergoing SEPS¹¹³ (Fig. 24-20), healing was achieved in 88% of ulcers (75 of 85) at 1 year. Adjunctive procedures, primarily superficial vein stripping, were performed in 72% of patients. Ulcer recurrence was predicted to be 16% at 1 year and 28% at 2 years by life table analysis. These results are similar to those achieved in some studies with compression therapy alone. A review of several studies from 2003 to 2011 demonstrated, when taken in aggregate, that 2059 limbs with 896 ulcers underwent SEPS and concomitant saphenous vein ablation (70%) with a 0% to 16% complication rate and achieved ulcer healing in 90% of patients.¹¹⁴ There has been a multicenter, prospective, European trial performed in patients with venous ulcers to evaluate the efficacy of SEPS. Post hoc analysis suggested possible benefit for SEPS in certain categories of patients with venous ulcer. Overall, however, primary analysis of the study's end points indicated no advantage to SEPS in addition to superficial venous surgery and compression in the healing of venous ulcers.¹¹⁵ The technique appears to have fallen out of favor in most institutions.

Superficial Venous Surgery. Currently it is accepted that superficial venous surgery in addition to compression therapy has a role in the treatment of patients with venous ulcer. The ESCHAR trial was a randomized prospective trial performed in the United Kingdom to evaluate the combination of superficial venous surgery and compression vs. compression alone in the treatment of venous ulcer. Superficial venous surgery had no additive effect to compression alone in the healing of a venous ulcer but significantly reduced venous ulcer recurrence at 4 years. Based on the results of this trial, it is reasonable to offer ablation or removal of the GSV in addition to compression therapy in patients with abnormal saphenous veins and signs and/or symptoms of severe CVI.¹¹⁶

Deep Venous Valvular Reconstruction. In the absence of significant deep vein valvular incompetence, saphenous vein stripping and possibly perforator vein ligation can be effective in the treatment of CVI. However, in patients with a combination of superficial and deep vein valvular incompetence, the addition of deep vein valvular reconstruction theoretically may

improve ulcer healing.¹¹⁷ Numerous techniques of deep vein valve correction have been reported. These techniques consist of repair of existing valves, transplant of venous segments from the arm, transposition of an incompetent vein onto an adjacent competent vein, and implantation of cryopreserved vein segments including competent valves.

Successful long-term outcomes of 60% to 80% have been reported for venous valve reconstructions by internal suture repair.^{117,118} However, among patients who initially had ulceration, 40% to 50% still had persistence or recurrence of ulcers in the long term.^{115,116}

Valve transplantation involves replacement of a segment of incompetent femoral vein or popliteal vein with a segment of axillary or brachial vein with competent valves. Early results are similar to those for venous valve reconstruction.^{117,118} However, in the long term, the transplanted venous segments tend to develop incompetence, intimal hyperplasia, and cusp sinus thrombosis with long-term outcomes that are poorer than those for venous valve reconstructions. The outcomes for venous transposition are similar to those for valve transplantation.

Currently, reconstruction techniques for deep venous insufficiency and associated CVI are rarely performed.

Venous Stenting. Currently there is great interest in the role of venous stents in the treatment of CVI. Stenotic lesions of the iliac veins, primarily documented with IVUS, are being reported in a very high percentage of patients with edema, lipodermatosclerosis, or ulceration secondary to venous disease. It appears possible to place percutaneous stents in the iliac veins with near 100% technical success and excellent patency of the stent out to 4 years. Retrospective case series suggest favorable effects on ulcer healing, symptoms of CVI, and quality of life in patients with CVI. The role of venous stenting as a favorable independent procedure in the treatment of patients with CVI remains an area of active investigation.¹¹⁹

LYMPHEDEMA

Pathophysiology

Lymphedema is extremity swelling that results from a reduction in lymphatic transport and accumulation of lymph within the interstitial space. It is caused by anatomic and or physiologic abnormalities such as lymphatic hypoplasia, functional insufficiency, or absence of lymphatic valves.

The original classification system, described by Allen, is based on the cause of the lymphedema. Primary lymphedema is further subdivided into congenital lymphedema, lymphedema praecox, and lymphedema tarda. *Congenital lymphedema* may involve a single lower extremity, multiple limbs, the genitalia, or the face. The edema typically develops before 2 years of age and may be associated with specific hereditary syndromes (Turner syndrome, Milroy syndrome, Klippel-Trénaunay-Weber syndrome). *Lymphedema praecox* is the most common form of primary lymphedema, accounting for 94% of cases. Lymphedema praecox is far more common in women, with the gender ratio favoring women 10:1. The onset is during childhood or the teenage years, and the swelling involves the foot and calf. *Lymphedema tarda* is uncommon, accounting for <10% of cases of primary lymphedema. The onset of edema is after 35 years of age.

Secondary lymphedema is far more common than primary lymphedema. Secondary lymphedema develops as a result of

lymphatic obstruction or disruption. Axillary node dissection leading to lymphedema of the arm is the most common cause of secondary lymphedema in the United States. Other causes of secondary lymphedema include radiation therapy, trauma, infection, and malignancy. Globally, filariasis (an infection caused by *Wuchereria bancrofti*, *Brugia malayi*, and *Brugia timori*) and environmental exposure to minerals in volcanic soil resulting in podoconiosis in barefoot populations are the most common causes of secondary lymphedema.

Clinical Diagnosis

In most patients, the diagnosis of lymphedema can be made based on the history and physical examination alone. Patients commonly complain of heaviness and fatigue in the affected extremity. The limb size increases throughout the day and decreases to some extent over the course of the night when the patient is recumbent. The limb, however, never completely normalizes. In the lower extremity, the swelling classically involves the dorsum of the foot, and the toes have a squared-off appearance. In advanced cases, hyperkeratosis of the skin develops, and fluid weeps from lymph-filled vesicles (Fig. 24-21).

Recurrent cellulitis is a common complication of lymphedema. Repeated infection results in further lymphatic damage, worsening existing disease. The clinical presentation of cellulitis ranges from subtle erythema and worsening of edema to a rapidly progressive soft tissue infection with systemic toxicity.

Many medical conditions can cause edema. If the symptoms are mild, distinguishing lymphedema from other causes of leg swelling can be difficult. Venous insufficiency is often confused with lymphedema. However, patients with advanced venous insufficiency typically have lipodermatosclerosis in the gaiter region, skin ulceration, and/or varicose veins. Bilateral pitting edema is

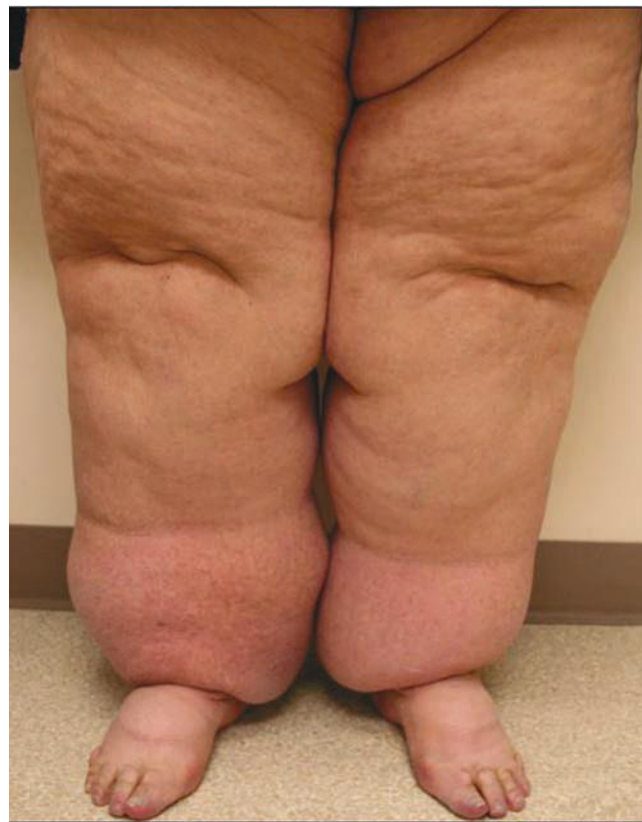

Figure 24-21. Patient with severe longstanding lymphedema.

typically associated with congestive heart failure, renal failure, or a hypoproteinemic state.

Radiologic Diagnosis

Duplex Ultrasound. When a patient is evaluated for edema, it is often difficult to distinguish the early stages of lymphedema from venous insufficiency. DUS of the venous system can determine if there is concomitant venous thrombosis or venous reflux, perhaps contributing to extremity edema. The diagnostic modalities discussed in the following sections have limited use in clinical practice. They are invasive and tedious and rarely change the management of a patient with lymphedema. Most physicians rely on the patient's history and physical examination alone to make the diagnosis of lymphedema.

Lymphoscintigraphy. Lymphoscintigraphy has become the most commonly used diagnostic test to identify lymphatic abnormalities. It has largely replaced lymphangiography. A radiolabeled sulfur colloid (technetium 99m sulfur colloid) is injected into the subdermal, interdigital region of the affected limb. The lymphatic transport is monitored with a whole-body gamma camera, and major lymphatics and nodes can be visualized (Fig. 24-22). In normal individuals, tracer activity may be detected in the inguinal region within 15 to 60 minutes. Within 3 hours, uptake should be present in the pelvic and abdominal lymph nodes. In patients with lymphedema, various patterns may be seen on lymphoscintigraphy. There may be delayed or absent transport to the inguinal nodes. Increased cutaneous

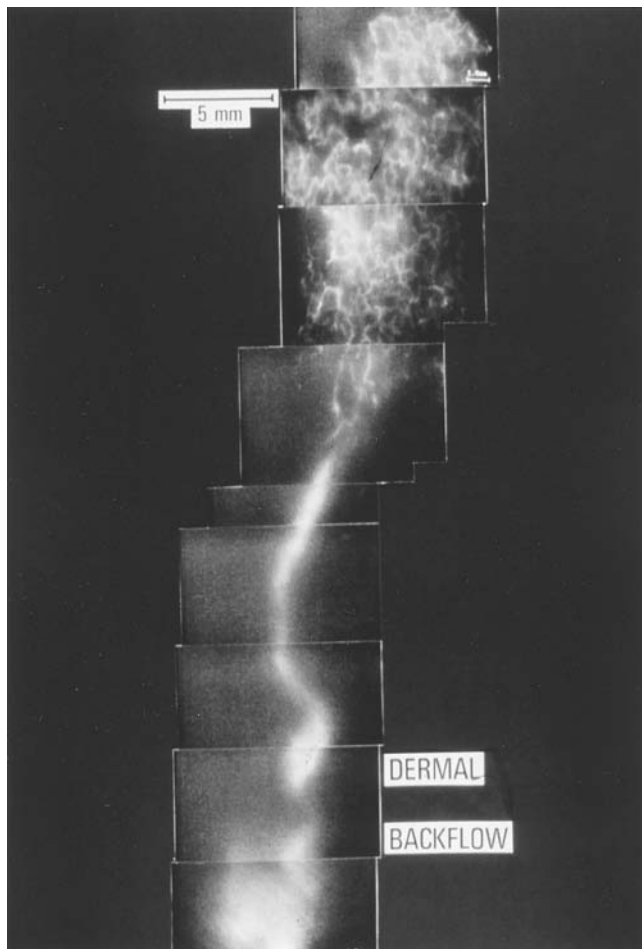


Figure 24-22. Lymphoscintigraphy of the lower extremity.

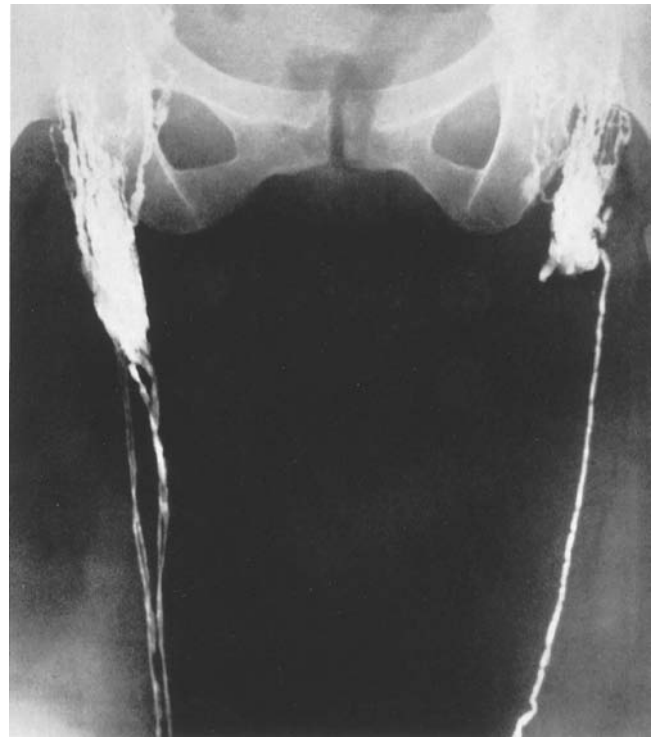


Figure 24-23. Normal lymphangiogram of the pelvis.

collaterals may be seen with obstruction of the primary axial channels. There may be localized regions of reduced uptake in patients with prior node dissection or radiation therapy.

Lymphangiography. Radiologic lymphangiography is performed by first visualizing the lymphatics by injecting colored dye into the hand or foot. The visualized lymphatic segment is exposed through a small incision and cannulated with a 27- to 30-gauge needle. An oil-based dye is then injected slowly into the lymphatics over several hours. The lymphatic channels and nodes are then visualized with traditional radiographs (Figs. 24-23 and 24-24). Lymphangiography is reserved for patients with lymphangiectasia or lymphatic fistulas, and patients who are being considered for microvascular reconstruction.

Management

An important aspect of the management of lymphedema is patient understanding that there is no cure for lymphedema. The primary goals of treatment are to minimize swelling and to prevent recurrent infections. Controlling the chronic limb swelling can improve discomfort, heaviness, and tightness, and potentially reduce the progression of disease.¹²⁰

Compression Garments. Graded compression stockings are widely used in the treatment of lymphedema. The stockings reduce the amount of swelling in the involved extremity by decreasing edema accumulation while the extremity is dependent. When worn daily, compression stockings have been associated with long-term maintenance of reduced limb circumference.¹²¹ They may also protect the tissues against chronically elevated intrinsic pressures, which lead to thickening of the skin and subcutaneous tissue.¹²² Compression stockings also offer a degree of protection against external trauma that may lead to cellulitis.

The amount of compression required for controlling lymphedema ranges from 20 to 60 mmHg and varies

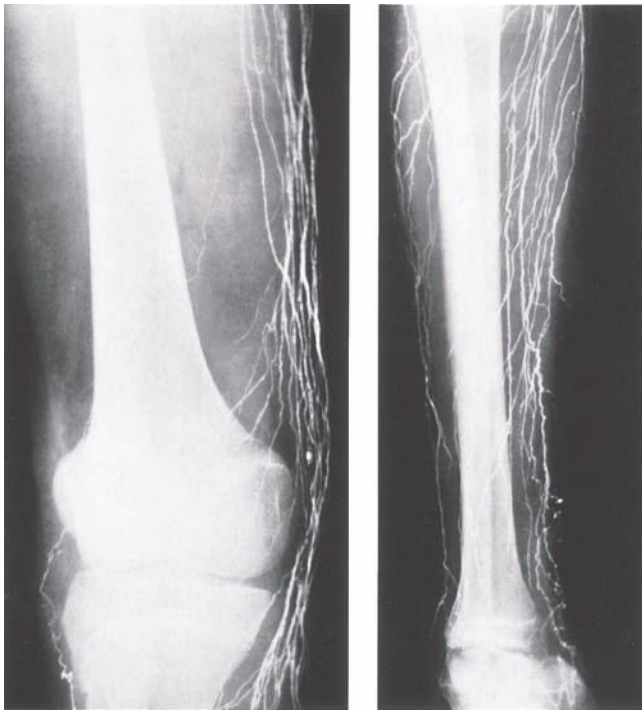

Figure 24-24. Normal lymphangiogram of the thigh and lower leg.

among patients. The stockings can be custom made or prefabricated and are available in above- and below-knee lengths. The stockings should be worn during waking hours. The garments should be replaced approximately every 6 months when they lose elasticity.

Bedrest and Leg Elevation. Elevation is an important aspect of controlling lower extremity swelling and is often the first recommended intervention. However, continuous elevation throughout the day can interfere with quality of life more than lymphedema itself. Elevation is an adjunct to lymphedema therapy but is not the mainstay of treatment.

Intermittent Pneumatic Compression Therapy. The use of IPC with a single-chamber or multichamber pump temporarily reduces edema and provides another adjunct to the use of compression stockings. These devices have been shown to be effective in reducing limb volume; however, use of compression stockings is necessary to maintain the volume reduction when the patient is no longer supine because fluid transport is not associated with the transport of macromolecules (proteins) from the tissue. Typically, IPC is used for 4 to 6 hours per day at home when the patient is supine with pressure ranges between 30 and 60 mmHg demonstrated to be most effective.¹²³

Lymphatic Massage. Manual lymphatic drainage is a form of massage developed by Vodder¹²⁴ that is directed at reducing edema. In combination with the use of compression stockings, manual lymphatic drainage is associated with a long-term reduction in edema and fewer infections per patient per year.¹²⁵

Antibiotic Therapy. Patients with lymphedema are at increased risk of developing cellulitis in the affected extremity due to microscopic breakdown in the skin barrier either secondary to swelling or unrecognized and untreated tinea pedis. Recurrent infection can damage the lymphatics, aggravating the edema and increasing the risk for subsequent infection. Staphylococcus and β -hemolytic

Streptococcus are the most common organisms causing soft tissue infection. Aggressive antibiotic therapy and elevation with compression are recommended at the earliest signs or symptoms of cellulitis. The drug of choice is penicillin or a cephalosporin active against Streptococcus for 5 days. In patients with recurrent lymphedema despite methods to reduced edema, treatment with monthly intramuscular injections of benzathine penicillin 1.2 MU, twice-daily erythromycin 250 mg, or penicillin V 1 g daily has proven effective at suppression.¹²⁶

Surgery. A variety of surgical procedures have been devised for the treatment of lymphedema. Surgical treatment involves either excision of extra tissue¹²⁷ or anastomosis of a lymphatic vessel to another lymphatic or vein.¹²⁸ In excisional procedures, part or all of the edematous tissue is removed. This does not improve lymphatic drainage but debulks redundant tissue. The microsurgical procedures involve the creation of a lymphaticocolymphatic or lymphaticovenous anastomosis, which theoretically improves lymphatic drainage. No long-term follow-up data are available for these interventions, and therefore operative therapy for lymphedema is not well accepted worldwide. Furthermore, operative intervention can further obliterate lymphatic channels, worsening the edema.¹²⁹

SUMMARY

Lymphedema is a chronic condition caused by ineffective lymphatic transport, which results in edema and skin damage. Lymphedema is not curable, but the symptoms and long-term effects can be controlled with a combination of elastic compression stockings, limb elevation, pneumatic compression, and massage. Controlling the edema protects the skin and potentially prevents cellulitis.

REFERENCES

Entries highlighted in bright blue are key references.

1. Moncada S, Radomski MW, Palmer RM. Endothelium-derived relaxing factor. Identification as nitric oxide and role in the control of vascular tone and platelet function. *Biochem Pharmacol.* 1988;37:2495.
2. van Bemmelen PS, Beach K, Bedford G, et al. The mechanism of venous valve closure. Its relationship to the velocity of reverse flow. *Arch Surg.* 1990;125:617.
3. Moneta GL, Strandness DE Jr. Basic data concerning noninvasive vascular testing. *Ann Vasc Surg.* 1989;3:190.
4. Bettman MA, Robbins A, Braun SD, et al. Contrast venography of the leg: diagnostic efficacy, tolerance, and complication rates with ionic and nonionic contrast media. *Radiology.* 1987;165:113.
5. White R. The epidemiology of venous thromboembolism. *Circulation.* 2003;107:I4-8.
6. Spyropoulos AC, Hussein M, Lin J, et al. Rates of symptomatic venous thromboembolism in US surgical patients: a retrospective administrative database. *J Thromb Thrombolysis.* 2009;28:458.
7. Heit JA, Cohen AT, Anderson FA. Estimated annual number of incident and recurrent, non-fatal and fatal venous thromboembolism (VTE) events in the US. *Blood.* 2005;106: 910.
8. Pengo V, Lensing AWA, Prins MH, et al. Incidence of chronic thromboembolic pulmonary hypertension after pulmonary embolism. *N Engl J Med.* 2004;350:2257.
9. Kahn SR, Ginsberg JS. The post-thrombotic syndrome: current knowledge, controversies and directions for future research. *Blood Rev.* 2002;16:155.

10. Mohr DN, Silverstein MD, Heit JA, et al. The venous stasis syndrome after deep venous thrombosis or pulmonary embolism: a population-based study. *Mayo Clin Proc.* 2000;75:1249.
11. Rosendaal FR. Risk factors for venous thrombotic disease. *Thromb Haemost.* 1999;82:610.
12. Ageno W, Becattini C, Brighton T, et al. Cardiovascular risk factors and venous thromboembolism: a meta-analysis. *Circulation.* 2008;117:93.
13. White R, Zhou H, Romano P. Incidence of idiopathic deep venous thrombosis and secondary thromboembolism among ethnic groups in California. *Ann Intern Med.* 1998;128:737.
14. Bezemer ID, Bare LA, Doggen CJM, et al. Gene variants associated with deep vein thrombosis. *JAMA.* 2008;299:106.
15. Rogers SO Jr, Kilaru RK, Hosokawa P, et al. Multivariable predictors of postoperative venous thromboembolic events after general and vascular surgery: results from the patient safety in surgery study. *J Am Coll Surg.* 2007;204:1211.
16. Bahl V, Hu HM, Henke PK, Wakefield TW, Campbell DA Jr, Caprini JA. A validation study of retrospective venous thromboembolism risk scoring method. *Ann Surg.* 2010;251:344.
17. Markel A, Manzo RA, Bergelin RO, et al. Pattern and distribution of thrombi in acute venous thrombosis. *Arch Surg.* 1992;127:305.
18. Nicolaidis AN, Kakkar VV, Field ES, et al. The origin of deep vein thrombosis: a venographic study. *Br J Radiol.* 1971;44:653.
19. Brockman SK, Vasko JS. The pathologic physiology of phlegmasia cerulea dolens. *Surgery.* 1966;59:997.
20. Lensing AW, Prandoni P, Brandjes D, et al. Detection of deep-vein thrombosis by real-time B-mode ultrasonography. *N Engl J Med.* 1989;320:342.
21. O'Leary DH, Kane RA, Chase BM. A prospective study of the efficacy of B-scan sonography in the detection of deep venous thrombosis in the lower extremities. *J Clin Ultrasound.* 1988;16:1.
22. Mussurakis S, Papaioannou S, Voros D, et al. Compression ultrasonography as a reliable imaging monitor in deep venous thrombosis. *Surg Gynecol Obstet.* 1990;171:233.
23. Habscheid W, Hohmann M, Wilhelm T, et al. Real-time ultrasound in the diagnosis of acute deep venous thrombosis of the lower extremity. *Angiology.* 1990;41:599.
24. Comerota AJ, Katz ML, Grossi RJ, et al. The comparative value of noninvasive testing for diagnosis and surveillance of deep vein thrombosis. *J Vasc Surg.* 1988;7:40.
25. Gomes AS, Webber MM, Buffkin D. Contrast venography vs. radionuclide venography: a study of discrepancies and their possible significance. *Radiology.* 1982;142:719.
26. Hull R, Hirsh J, Sackett DL, et al. Clinical validity of a negative venogram in patients with clinically suspected venous thrombosis. *Circulation.* 1981;64:622.
27. **Kearon C, Akl E, Comerota A, et al. Antithrombotic therapy for venous thromboembolic disease: antithrombotic therapy and prevention of thrombosis. American College of Chest Physicians Evidence-Based Clinical Practice Guidelines (9th edition). *Chest.* 2012;141:419S.**
28. Raschke RA, Reilly BM, Guidry JR, et al. The weight-based heparin dosing nomogram compared with a standard care nomogram. A randomized controlled trial. *Ann Intern Med.* 1993;119:874.
29. Hylek EM, Regan S, Henault LE, et al. Challenges to the effective use of unfractionated heparin in the hospitalized management of acute thrombosis. *Arch Intern Med.* 2003;163:621.
30. Amiral J, Bridey F, Dreyfus M, et al. Platelet factor 4 complexed to heparin is the target for antibodies generated in heparin-induced thrombocytopenia. *Thromb Haemost.* 1992;68:95.
31. Warkentin TE, Levine MN, Hirsh J, et al. Heparin-induced thrombocytopenia in patients treated with low-molecular-weight heparin or unfractionated heparin. *N Engl J Med.* 1995;332:1330.
32. Warkentin TE, Kelton JG. Heparin and platelets. *Hematol Oncol Clin North Am.* 1990;4:243.
33. Calatages JG, Liem TK, Spadone D, et al. The role of heparin-associated antiplatelet antibodies in the outcome of arterial reconstruction. *J Vasc Surg.* 1999;29:779.
34. Warkentin TE, Kelton JG. A 14-year study of heparin-induced thrombocytopenia. *Am J Med.* 1996;101:502.
35. Gould MK, Dembitzer AD, Doyle RL, et al. Low-molecular-weight heparins compared with unfractionated heparin for treatment of acute deep venous thrombosis: a meta-analysis of randomized, controlled trials. *Ann Intern Med.* 1999;130:800.
36. Dolovich LR, Ginsberg JS, Douketis JD, et al. A meta-analysis comparing low-molecular-weight heparins with unfractionated heparin in the treatment of venous thromboembolism: examining some unanswered questions regarding location of treatment, product type, and dosing frequency. *Arch Intern Med.* 2000;160:181.
37. Van Dongen CJJ, van der Belt AGM, Prins MH, et al. Fixed dose subcutaneous low molecular weight heparins versus adjusted dose unfractionated heparin for venous thromboembolism. *Cochrane Database Syst Rev.* 2004;4:CD001100.
38. Kikta MJ, Keller MP, Humphrey PW, et al. Can low molecular weight heparins and heparinoids be safely given to patients with heparin-induced thrombocytopenia syndrome? *Surgery.* 1993;114:705.
39. Koopman MM, Prandoni P, Piovella F, et al. Treatment of venous thrombosis with intravenous unfractionated heparin administered in the hospital as compared with subcutaneous low-molecular-weight heparin administered at home. The Tasman Study Group. *N Engl J Med.* 1996;334:682.
40. Levine M, Gent M, Hirsh J, et al. A comparison of low-molecular-weight heparin administered primarily at home with unfractionated heparin administered in the hospital for proximal deep-vein thrombosis. *N Engl J Med.* 1996;334:677.
41. Büller HR, Davidson BL, Decousus H, et al. Fondaparinux or enoxaparin for the initial treatment of symptomatic deep venous thrombosis: a randomized trial. *Ann Intern Med.* 2004;140:867.
42. The Matisse Investigators. Subcutaneous fondaparinux versus intravenous unfractionated heparin in the initial treatment of pulmonary embolism. *N Engl J Med.* 2003;349:1695.
43. Warkentin TE, Maurer BT, Aster RH. Heparin-induced thrombocytopenia associated with fondaparinux. *N Engl J Med.* 2007;356:2653.
44. Kelton JG. The pathophysiology of heparin-induced thrombocytopenia: biological basis for treatment. *Chest.* 2005;127:9.
45. Holbrook A, Schulman S, Witt DM, et al. Evidence based management of anticoagulant therapy. American College of Chest Physicians Evidence-Based Clinical Practice Guidelines, 9th ed. *Chest.* 2012;144:152S.
46. Schulman S, Rhedin A-S, Lindmarker P, et al. A comparison of six weeks with six months of oral anticoagulant therapy after a first episode of venous thromboembolism. *N Engl J Med.* 1995;332:1661.
47. Research Committee of the British Thoracic Society. Optimal duration of anticoagulation for deep vein thrombosis and pulmonary embolism. *Lancet.* 1992;340:873.
48. Levine MN, Hirsh J, Gent M, et al. Optimal duration of oral anticoagulant therapy: a randomized trial comparing four weeks with three months of warfarin in patients with proximal deep vein thrombosis. *Thromb Haemost.* 1995;74:606.
49. Kearon C, Gent M, Hirsh J, et al. A comparison of three months of anticoagulation with extended anticoagulation for a first episode of idiopathic venous thromboembolism. *N Engl J Med.* 1999;340:901.

50. Agnelli G, Prandoni P, Santamaria MG, et al. Three months versus one year of oral anticoagulant therapy for idiopathic deep venous thrombosis. *N Engl J Med.* 2001;345:165.
51. Ridker PM, Goldhaber SZ, Danielson E, et al. Long-term, low-intensity warfarin therapy for the prevention of recurrent venous thromboembolism. *N Engl J Med.* 2003;348:1425.
52. Kearon C, Ginsber JS, Kovacs MJ, et al. Comparison of low-intensity warfarin therapy with conventional-intensity warfarin therapy for long-term prevention of recurrent venous thromboembolism. *N Engl J Med.* 2003;349:631.
53. Lee AYY, Levine MN, Baker RI, et al. Low-molecular-weight heparin versus a coumarin for the prevention of recurrent venous thromboembolism in patients with cancer. *N Engl J Med.* 2003;349:146.
54. Akl EA, Barba M, Rohilla S, et al. Anticoagulation for the long term treatment of venous thromboembolism in patients with cancer. *Cochrane Database Syst Rev.* 2008;2:CD006650.
55. Watson LI, Armon MP. Thrombolysis for treatment of acute deep vein thrombosis. *Cochrane Database Syst Rev.* 2004;4:CD002783.
56. Enden T, Klow NE, Sandvik L, et al. Long-term outcome after additional catheter-directed thrombolysis versus standard treatment for acute iliofemoral deep vein thrombosis (the CaVenT study): a randomized controlled trial. *Lancet.* 2012;379:31.
57. Decousus H, Leizorovicz A, Parent F, et al. A clinical trial of vena caval filters in the prevention of pulmonary embolism in patients with proximal deep-vein thrombosis. Prévention du Risque d'Embolie Pulmonaire par Interruption Cave Study Group. *N Engl J Med.* 1998;338:409.
58. Becker DM, Philbrick JT, Selby JB. Inferior vena cava filters. Indications, safety, effectiveness. *Arch Intern Med.* 1992;152:1985.
59. Plate G, Ohlin P, Eklof B. Pulmonary embolism in acute iliofemoral venous thrombosis. *Br J Surg.* 1985;72:912.
60. Eklof B, Kistner RL, Masuda EM. Surgical treatment of acute iliofemoral deep venous thrombosis. In: Gloviczki P, Yao JST, eds. *Handbook of Venous Disorders.* New York: Arnold; 2001:202.
61. Juhan CM, Alimi YS, Barthelemy PJ, et al. Late results of iliofemoral venous thrombectomy. *J Vasc Surg.* 1997;25:417.
62. Schmid C, Zietlow S, Wagner TO, et al. Fulminant pulmonary embolism: symptoms, diagnostics, operative technique, and results. *Ann Thorac Surg.* 1991;52:1102.
63. Kieny R, Charpentier A, Kieny MT. What is the place of pulmonary embolectomy today? *J Cardiovasc Surg.* 1991;32:549.
64. Gulba DC, Schmid C, Borst HG, et al. Medical compared with surgical treatment for massive pulmonary embolism. *Lancet.* 1994;343:576.
65. Schmitz-Rode T, Janssens U, Schild HH, et al. Fragmentation of massive pulmonary embolism using a pigtail rotation catheter. *Chest.* 1998;114:1427.
66. Greenfield LJ, Proctor MC, Williams DM, et al. Long-term experience with transvenous catheter pulmonary embolectomy. *J Vasc Surg.* 1993;18:450.
67. Gould MK, Garcia DA, Wren SM, et al. Prevention of venous thromboembolism in nonorthopedic surgical patients. American College of Chest Physicians Evidence-Based Clinical Practice Guidelines, 9th ed. *Chest.* 2012; 141:227S.
68. Mismetti P, Laporte S, Darmon JY, et al. Meta-analysis of low molecular weight heparin in the prevention of venous thromboembolism in general surgery. *Br J Surg.* 2001;88:913.
69. Agnelli G, Bergqvist D, Cohen AT, et al. Randomized clinical trial of postoperative fondaparinux versus perioperative dalteparin for prevention of venous thromboembolism in high-risk abdominal surgery. *Br J Surg.* 2005;92:1212.
70. Turpie AG, Bauer KA, Caprini JA, et al. Fondaparinux combined with intermittent pneumatic compression versus intermittent pneumatic compression alone for prevention of venous thromboembolism after abdominal surgery: a randomized, double-blind comparison. *J Thromb Haemost.* 2007;5:1854.
71. Rogers FB, Shackford SR, Ricci MA, et al. Routine prophylactic vena cava filter insertion in severely injured trauma patients decreases the incidence of pulmonary embolism. *J Am Coll Surg.* 1995;180:641.
72. Rogers FB, Strindberg G, Shackford SR, et al. Five-year follow-up of prophylactic vena cava filters in high-risk trauma patients. *Arch Surg.* 1998;133:406.
73. Millward SF, Oliva VL, Bell SD, et al. Gunther tulip retrievable vena cava filter: results from the Registry of the Canadian Interventional Radiology Association. *J Vasc Intervent Radiol.* 2001;12:1053.
74. Allen AW, Megargell JL, Brown DB, et al. Venous thrombosis associated with the placement of peripherally inserted central catheters. *J Vasc Intervent Radiol.* 2000;11:1309.
75. Chengelis DL, Bendick PJ, Glover JL, et al. Progression of superficial venous thrombosis to deep vein thrombosis. *J Vasc Surg.* 1996;24:745.
76. Lutter KS, Kerr TM, Roedersheimer LR, et al. Superficial thrombophlebitis diagnosed by duplex scanning. *Surgery.* 1991;110:42.
77. Di Nisio M, Wichers IM, Middeldorp S. Treatment of superficial thrombophlebitis of the leg. *Cochrane Database Syst Rev.* 2007;2:CD004982.
78. Lohr JM, McDevitt DT, Lutter KS, et al. Operative management of greater saphenous thrombophlebitis involving the saphenofemoral junction. *Am J Surg.* 1992;164:269.
79. Ascer E, Lorensen E, Pollina RM, et al. Preliminary results of a nonoperative approach to saphenofemoral junction thrombophlebitis. *J Vasc Surg.* 1995;22:616.
80. Horne MK III, May DJ, Alexander HR, et al. Venographic surveillance of tunneled venous access devices in adult oncology patients. *Ann Surg Oncol.* 1995;2:174.
81. Landry GL, Liem TK. Endovascular management of Paget-Schroetter syndrome. *Vascular.* 2007;15:290.
82. Rhee RY, Gloviczki P, Jost C, et al. Acute mesenteric venous thrombosis. In: Gloviczki P, Yao JST, eds. *Handbook of Venous Disorders.* New York: Arnold; 2001:244.
83. Morasch MD, Ebaugh JL, Chiou AC, et al. Mesenteric venous thrombosis: a changing clinical entity. *J Vasc Surg.* 2001;34:680.
84. James AW, Rabl C, Westphalen AC, et al. Portomesenteric venous thrombosis after laparoscopic surgery: a systematic literature review. *Arch Surg.* 2009;144:520.
85. Bach AM, Hann LE, Brown KT, et al. Portal vein evaluation with US: comparison to angiography combined with CT arterial portography. *Radiology.* 1996;201:149.
86. Burkitt DP. Varicose veins, deep vein thrombosis, and haemorrhoids: epidemiology and suggested aetiology. *Br Med J.* 1972;2:556.
87. Brand FN, Dannenberg AL, Abbott RD, et al. The epidemiology of varicose veins: the Framingham Study. *Am J Prev Med.* 1988;4:96.
88. Lurie F, Creton D, Eklof B, et al. Prospective randomized study of endovenous radiofrequency obliteration (closure) versus ligation and vein stripping (EVOLVEs): two-year follow-up. *Eur J Vasc Endovasc Surg.* 2005;29:67.
89. Darwood RJ, Theivacumar N, Dellagrammaticas D, et al. Randomized clinical trial comparing endovenous laser ablation with surgery for the treatment of primary great saphenous varicose veins. *Br J Surg.* 2008;95:294.
90. Falanga V. Venous ulceration. *J Dermatol Surg Oncol.* 1993;19:764.

91. Phillips T, Stanton B, Provan A, et al. A study of the impact of leg ulcers on quality of life: financial, social, and psychologic implications. *J Am Acad Dermatol.* 1994;31:49.
92. Skin Substitute Consensus Development Panel. Nonoperative management of venous ulcers: evolving role of skin substitutes. *Vasc Surg.* 1999;33:197.
93. Abenhaim L, Kurz X. The VEINES study (VENous Insufficiency Epidemiologic and Economic Study): an international cohort study on chronic venous disorders of the leg. VEINES Group. *Angiology.* 1997;48:59.
94. Clarke H, Smith SR, Vasdekis SN, et al. Role of venous elasticity in the development of varicose veins. *Br J Surg.* 1989;76:577.
95. Nicolaides AN, Hussein MK, Szendro G, et al. The relation of venous ulceration with ambulatory venous pressure measurements. *J Vasc Surg.* 1993;17:414.
96. Christopoulos DG, Nicolaides AN, Szendro G, et al. Air-plethysmography and the effect of elastic compression on venous hemodynamics of the leg. *J Vasc Surg.* 1987;5:148.
97. van Bemmelen PS, Bedford G, Beach K, et al. Quantitative segmental evaluation of venous valvular reflux with duplex ultrasound scanning. *J Vasc Surg.* 1989;10:425.
98. Nehler MR, Porter JM. The lower extremity venous system. Part II: the pathophysiology of chronic venous insufficiency. *Perspect Vasc Surg.* 1992;5:81.
99. Beidler SK, Douillet CD, Berndt DF, et al. Multiplexed analysis of matrix metalloproteinases in leg ulcer tissue of patients with chronic venous insufficiency before and after compression therapy. *Wound Repair Regen.* 2008;16:642.
100. Beidler SK, Douillet CD, Berndt DF, et al. Inflammatory cytokine levels in chronic venous insufficiency ulcer tissue before and after compression therapy. *J Vasc Surg.* 2009;49:1013.
101. Nehler MR, Moneta GL, Woodard DM, et al. Perimalleolar subcutaneous tissue pressure effects of elastic compression stockings. *J Vasc Surg.* 1993;18:783.
102. Dinn E. Treatment of venous ulceration by injection sclerotherapy and compression hosiery: a 5-year study. *Phlebology.* 1992;7:23.
103. Mayberry JC, Moneta GL, Taylor LM Jr, et al. Fifteen-year results of ambulatory compression therapy for chronic venous ulcers. *Surgery.* 1991;109:575.
104. Falanga V, Margolis D, Alvarez O, et al. Rapid healing of venous ulcers and lack of clinical rejection with an allergenic cultured human skin equivalent. Human Skin Equivalent Investigators Group. *Arch Dermatol.* 1998;134:293.
105. Phillips TJ. New skin for old: developments in biological skin substitutes [editorial; comment]. *Arch Dermatol.* 1998;134:344.
106. Motykie GD, Caprini JA, Arcelus JJ, et al. Evaluation of therapeutic compression stockings in the treatment of chronic venous insufficiency. *Dermatol Surg.* 1999;25:116.
107. Lippmann HI, Fishman LM, Farrar RH, et al. Edema control in the management of disabling chronic venous insufficiency. *Arch Phys Med Rehabil.* 1994;75:436.
108. Rubin JR, Alexander J, Plecha EJ, et al. Unna's boot vs. polyurethane foam dressings for the treatment of venous ulceration. A randomized prospective study. *Arch Surg.* 1990;125:489.
109. O'Meara S, Cullum NA, Nelson EA. Compression for venous leg ulcers. *Cochrane Database Syst Rev.* 2009;1:CD000265.
110. Vernick SH, Shapiro D, Shaw FD. Legging orthosis for venous and lymphatic insufficiency. *Arch Phys Med Rehabil.* 1987;68:459.
111. Sibbald RG. Apligraf living skin equivalent for healing venous and chronic wounds. *J Cutan Med Surg.* 1998;3(Suppl 1):S124.
112. Linton R. The communicating veins of the lower leg and the operative technique for their ligation. *Ann Surg.* 1938;107:582.
113. Gloviczki P, Bergan JJ, Rhodes JM, et al. Mid-term results of endoscopic perforator vein interruption for chronic venous insufficiency: lessons learned from the North American Subfascial Endoscopic Perforator Surgery registry. The North American Study Group. *J Vasc Surg.* 1999;29:489.
114. Vashist MG, Malik V, Singhal N. Role of subfascial endoscopic perforator surgery (SEPS) in management of perforator incompetence in varicose veins: a prospective randomized study. *India J Surg.* DOI 10.1007/s12262-012-0675-5.
115. van Gent WB, Hop WC, van Praag MC, et al. Conservative versus surgical treatment of venous leg ulcers: a prospective randomized, multicenter trial. *J Vasc Surg.* 2006;44:563.
116. Gohel MS, Barwell JR, Taylor M, et al. Long term results of compression therapy alone versus compression plus surgery in chronic venous ulceration (ESCHAR): randomized controlled trial. *BMJ.* 2007;335:83.
117. Sottirai VS. Surgical correction of recurrent venous ulcer. *J Cardiovasc Surg.* 1991;32:104.
118. Raju S, Fredericks R. Valve reconstruction procedures for nonobstructive venous insufficiency: rationale, techniques, and results in 107 procedures with two- to eight-year follow-up. *J Vasc Surg.* 1988;7:301.
119. Raju S, Darcey R, Neglen P. Unexpected major role for venous stenting in deep reflux disease. *J Vasc Surg.* 2010;51:401.
120. Masuda EM, Kistner RL. Long-term results of venous valve reconstruction: a four- to twenty-one-year follow-up. *J Vasc Surg.* 1994;19:391.
121. Rockson SG, Miller LT, Senie R, et al. American Cancer Society Lymphedema Workshop. Workgroup III: diagnosis and management of lymphedema. *Cancer.* 1998;83:2882.
122. Yasuhara H, Shigematsu H, Muto T. A study of the advantages of elastic stockings for leg lymphedema. *Int Angiol.* 1996;15:272.
123. Feldman JL, Stout NL, Wanchai A, et al. Intermittent pneumatic compression therapy: a systematic review. *Lymphology.* 2012;45:13.
124. Vodder E. *Le Drainage Lymphatique, une Nouvelle Méthode Thérapeutique.* Paris: Santé pour tous; 1936.
125. Ko DS, Lerner R, Klose G, et al. Effective treatment of lymphedema of the extremities. *Arch Surg.* 1998;133:452.
126. Stevens DL, Bisno AL, Chambers HF, et al. Practice guidelines for the diagnosis and management of skin and soft tissue infections. *Clin Infect Dis.* 2005;41:1373.
127. Miller TA, Wyatt LE, Rudkin GH. Staged skin and subcutaneous excision for lymphedema: a favorable report of long-term results. *Plast Reconstr Surg.* 1998;102:1486.
128. Baumeister RG, Siuda S. Treatment of lymphedema by microsurgical lymphatic grafting: what is proved? *Plast Reconstr Surg.* 1990;85:64.
129. Bernas MJ, Witte CL, Witte MH. The diagnosis and treatment of peripheral lymphedema: draft revision of the 1995 Consensus Document of the International Society of Lymphology Executive Committee for discussion at the September 3–7, 2001, XVIII International Congress of Lymphology in Genoa, Italy. *Lymphology.* 2001;34:84.

This page intentionally left blank

25 chapter

Esophagus and Diaphragmatic Hernia

Blair A. Jobe, John G. Hunter, and David I. Watson

Surgical Anatomy	941	Treatment / 982	Carcinoma of the Esophagus	1003
Physiology	947	Diaphragmatic Repair / 983	Clinical Manifestations / 1003	
Swallowing Mechanism / 947		The Short Esophagus and PEH / 983	General Approach to Esophageal Cancer / 1004	
Physiologic Reflux / 949		Results / 984	Staging of Esophageal Cancer / 1004	
Assessment of Esophageal Function	950	Schatzki's Ring	Clinical Approach to Carcinoma of the Esophagus and Cardia / 1005	
Tests to Detect Structural Abnormalities / 950			Palliation of Esophageal Cancer / 1008	
Tests to Detect Functional Abnormalities / 953		Scleroderma	Surgical Treatment / 1009	
Video- and Cineradiography / 955		Eosinophilic Esophagitis / 985	Comparative Studies of Esophagectomy Technique / 1011	
Tests to Detect Increased Exposure to Gastric Juice / 961		Symptoms / 986	Alternative Therapies	1012
Tests of Duodenogastric Function / 963		Signs / 986	Sarcoma of the Esophagus	1014
Gastroesophageal Reflux Disease	964	Pathology / 986	Benign Tumors and Cysts	1017
The Human Antireflux Mechanism and the Pathophysiology of Gastroesophageal Reflux Disease / 965		Treatment / 986	Leiomyoma / 1017	
Complications Associated with Gastroesophageal Reflux Disease / 967		Motility Disorders of the Pharynx and Esophagus	Esophageal Cyst / 1018	
Metaplastic (Barrett's Esophagus) and Neoplastic (Adenocarcinoma) Complications / 969			Esophageal Perforation	1018
Respiratory Complications / 969		Clinical Manifestations / 986	Diagnosis / 1018	
Surgical Therapy for Gastroesophageal Reflux Disease / 972		Motility Disorders of the Pharynx and Upper Esophagus – Transit Dysphagia / 987	Management / 1018	
Primary Antireflux Repairs / 974		Motility Disorders of the Esophageal Body and Lower Esophageal Sphincter / 990	Mallory-Weiss Syndrome	1020
Giant Diaphragmatic (Hiatal) Hernias	980	Operations for Esophageal Motor Disorders and Diverticula	Caustic Injury	1020
Incidence and Etiology / 980			Pathology / 1020	
Clinical Manifestations / 981		Long Esophageal Myotomy for Motor Disorders of the Esophageal Body / 995	Clinical Manifestations / 1021	
Diagnosis / 982		Myotomy of the Lower Esophageal Sphincter (Heller Myotomy) / 997	Treatment / 1021	
Pathophysiology / 982		Open Esophageal Myotomy / 1000	Acquired Fistula	1023
		Laparoscopic Cardiomyotomy / 1000	Techniques of Esophageal Reconstruction	1024
		Per Oral Endoscopic Myotomy (POEM) / 1000	Partial Esophageal Resection / 1024	
		Outcome Assessment of the Therapy for Achalasia / 1000	Reconstruction after Total Esophagectomy / 1024	
		Esophageal Resection for End-Stage Motor Disorders of the Esophagus / 1003	Composite Reconstruction / 1025	
			Vagal Sparing Esophagectomy with Colon Interposition / 1025	

SURGICAL ANATOMY

The esophagus is a muscular tube that starts as the continuation of the pharynx and ends as the cardia of the stomach. When the head is in a normal anatomic position, the transition from pharynx to esophagus occurs at the lower border of the sixth cervical vertebra. Topographically this corresponds to the cricoid cartilage anteriorly and the palpable transverse process of the sixth cervical vertebra laterally (Fig. 25-1). The esophagus is firmly attached at its upper end to the cricoid cartilage and at

its lower end to the diaphragm; during swallowing, the proximal points of fixation move cranial the distance of one cervical vertebral body.

The esophagus lies in the midline, with a deviation to the left in the lower portion of the neck and upper portion of the thorax, and returns to the midline in the midportion of the thorax near the bifurcation of the trachea (Fig. 25-2). In the lower portion of the thorax, the esophagus again deviates to the left and anteriorly to pass through the diaphragmatic hiatus.

Key Point

- 1▶ Benign esophageal disease is common and is best evaluated with thorough physiologic testing (high resolution esophageal motility, 24 hour ambulatory pH measurement, and/or esophageal impedance testing) and anatomic testing (esophagoscopy, video esophagography, and/or CT scanning).
- 2▶ GERD is the most common disease of the gastrointestinal tract for which patients seek medical therapy. When GERD symptoms (heartburn, regurgitation, chest pain, and/or supraesophageal symptoms) are troublesome despite adequately dosed PPI, surgical correction may be indicated.
- 3▶ Barrett's esophagus is the transformation of the distal esophageal epithelium from squamous to a specialized columnar epithelium capable of further neoplastic progression. The detection of Barrett's esophagus on endoscopy and biopsy increases the future risk of cancer by >40x compared to individuals without Barrett's esophagus.
- 4▶ Giant hiatal hernia, otherwise known as paraesophageal hernia, should be repaired when symptomatic or associated with iron deficiency anemia. Laparoscopic hiatal hernia repair with fundoplication is the most common approach to repair.
- 5▶ Achalasia is the most common primary esophageal motor disorder. It is characterized by an absence of peristalsis and a hypertensive nonrelaxing lower esophageal sphincter. It is best treated with laparoscopic Heller myotomy and partial fundoplication.
- 6▶ Most esophageal cancer presents with dysphagia, at which time it has invaded the muscularis of the esophagus and is often associated with lymph node metastases. The preferred treatment at this stage is multimodality therapy with chemoradiation therapy followed by open or minimally invasive esophagectomy.

Three normal areas of esophageal narrowing are evident on the barium esophagogram or during esophagoscopy. The uppermost narrowing is located at the entrance into the esophagus and is caused by the cricopharyngeal muscle. Its luminal diameter is 1.5 cm, and it is the narrowest point of the esophagus. The middle narrowing is due to an indentation of the anterior and left lateral esophageal wall caused by the crossing of the left main stem bronchus and aortic arch. The luminal diameter at this point is 1.6 cm. The lowermost narrowing is at the hiatus of the diaphragm and is caused by the gastroesophageal

sphincter mechanism. The luminal diameter at this point varies somewhat, depending on the distention of the esophagus by the passage of food, but has been measured at 1.6 to 1.9 cm. These normal constrictions tend to hold up swallowed foreign objects, and the overlying mucosa is subject to injury by swallowed corrosive liquids due to their slow passage through these areas.

Figure 25-3 shows the average distance in centimeters measured during endoscopic examination between the incisor teeth and the cricopharyngeus, aortic arch, and cardia of the stomach. Manometrically, the length of the esophagus between

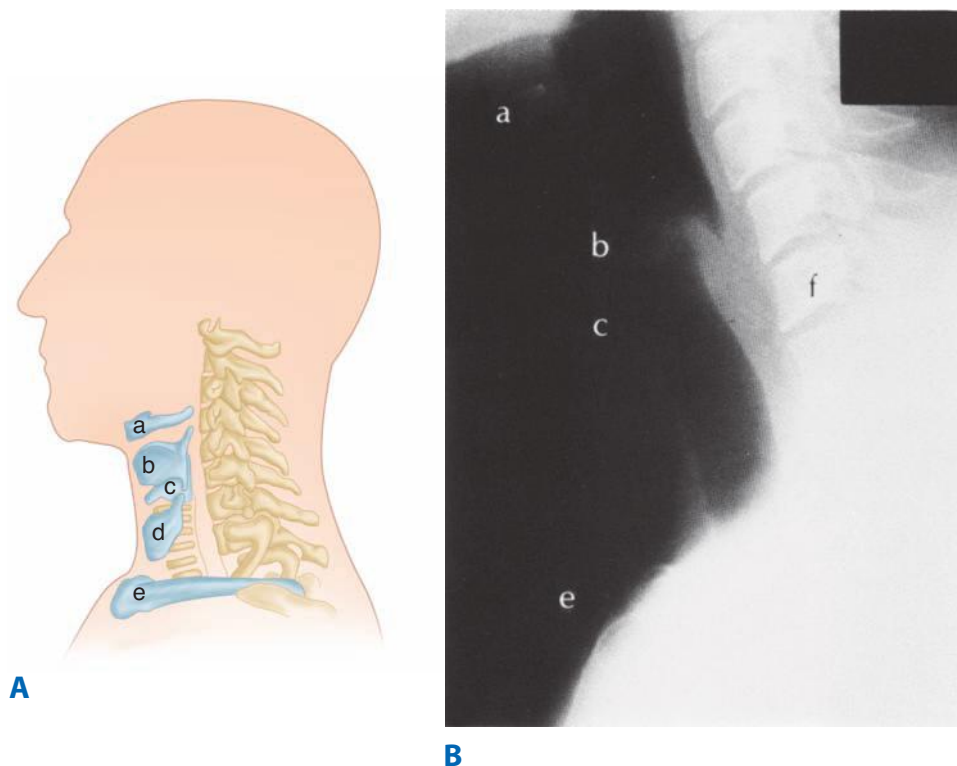
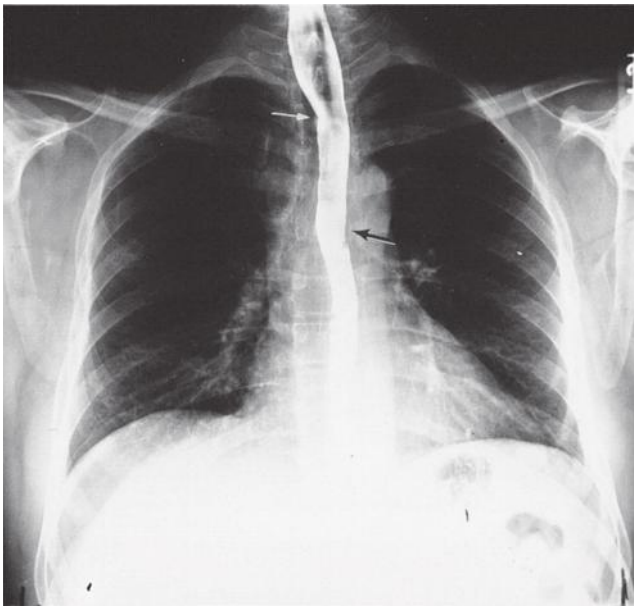
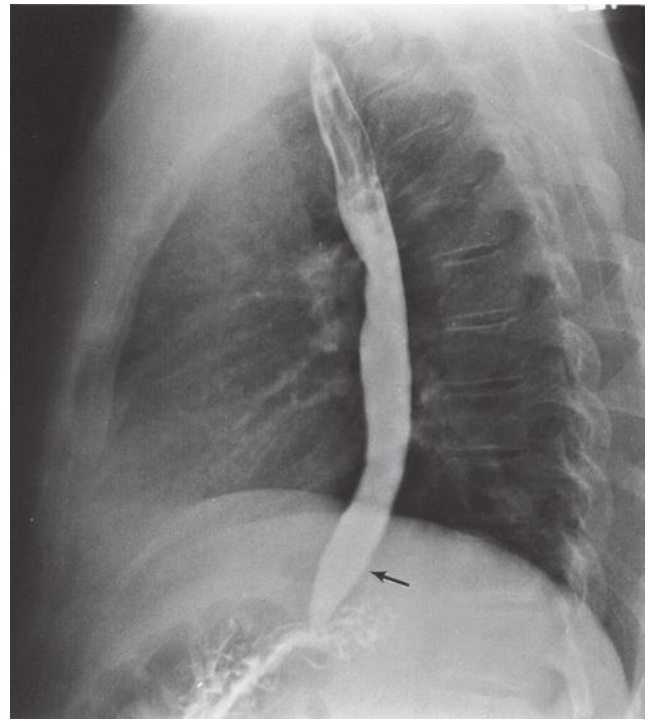


Figure 25-1. A. Topographic relationships of the cervical esophagus: (a) hyoid bone, (b) thyroid cartilage, (c) cricoid cartilage, (d) thyroid gland, (e) sternoclavicular. B. Lateral radio-graphic appearance with landmarks identified as labeled in A. The location of C6 is also included (f). (Reproduced with permission from Rothberg M, DeMeester TR: *Surgical anatomy of the esophagus*, in Shields TW (ed): *General Thoracic Surgery*, 3rd ed. Philadelphia: Lea & Febiger, 1989, p 77.)



A



B

Figure 25-2. Barium esophagogram. **A.** Posterior-anterior view. White arrow shows deviation to left. Black arrow shows return to midline. **B.** Lateral view. Black arrow shows anterior deviation. (Reproduced with permission from Rothberg M, DeMeester TR: *Surgical anatomy of the esophagus*, in Shields TW (ed): *General Thoracic Surgery*, 3rd ed. Philadelphia: Lea & Febiger, 1989, p 77.)

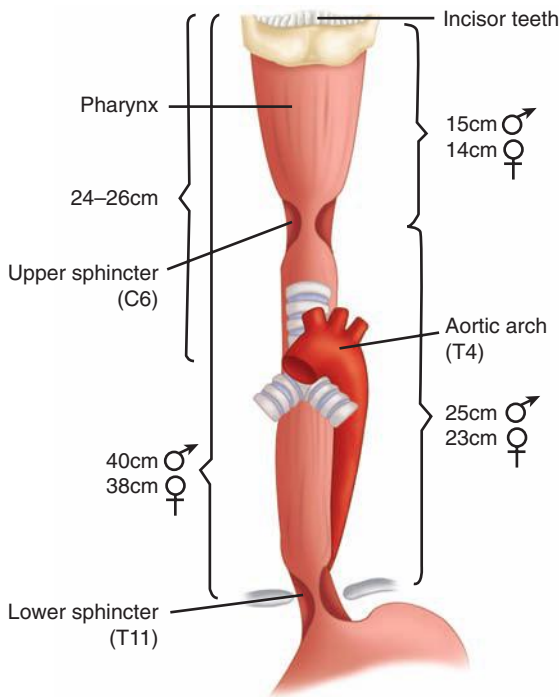
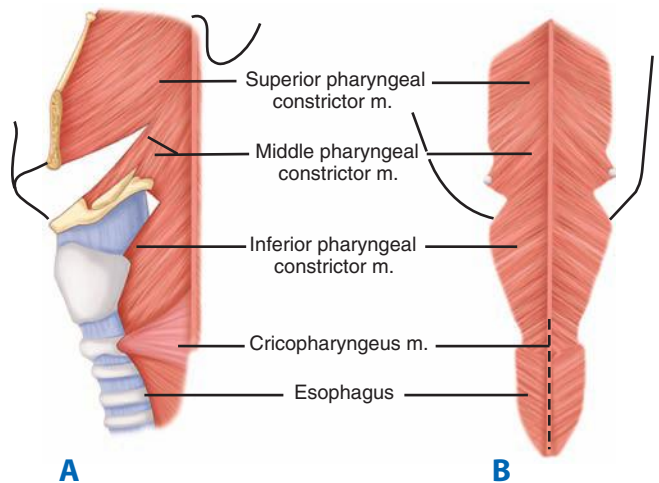


Figure 25-3. Important clinical endoscopic measurements of the esophagus in adults. (Reproduced with permission from Rothberg M, DeMeester TR: *Surgical anatomy of the esophagus*, in Shields TW (ed): *General Thoracic Surgery*, 3rd ed. Philadelphia: Lea & Febiger, 1989, p 78.)

the lower border of the cricopharyngeus and upper border of the lower sphincter varies according to the height of the individual.

The pharyngeal musculature consists of three broad, flat, overlapping fan-shaped constrictors (Fig. 25-4). The opening of the esophagus is collared by the cricopharyngeal muscle, which



A

B

Figure 25-4. External muscles of the pharynx. **A.** Posterolateral view. **B.** Posterior view. Dotted line represents usual site of myotomy. (Reproduced with permission from Rothberg M, DeMeester TR: *Surgical anatomy of the esophagus*, in Shields TW (ed): *General Thoracic Surgery*, 3rd ed. Philadelphia: Lea & Febiger, 1989, p 78.)

arises from both sides of the cricoid cartilage of the larynx and forms a continuous transverse muscle band without an interruption by a median raphe. The fibers of this muscle blend inseparably with those of the inferior pharyngeal constrictor above and the inner circular muscle fibers of the esophagus below. Some investigators believe that the cricopharyngeus is part of the inferior constrictor; that is, that the inferior constrictor has two parts, an upper or retrothyroid portion having diagonal fibers, and a lower or retrocricoid portion having transverse fibers. Keith in 1910 showed that these two parts of the same muscle serve totally different functions. The retrocricoid portion serves as the upper sphincter of the esophagus and relaxes when the retrothyroid portion contracts, to force the swallowed bolus from the pharynx into the esophagus.

The cervical portion of the esophagus is approximately 5 cm long and descends between the trachea and the vertebral column, from the level of the sixth cervical vertebra to the level of the interspace between the first and second thoracic vertebrae posteriorly, or the level of the suprasternal notch anteriorly. The recurrent laryngeal nerves lie in the right and left grooves between the trachea and the esophagus. The left recurrent nerve lies somewhat closer to the esophagus than the right, owing to the slight deviation of the esophagus to the left, and the more lateral course of the right recurrent nerve around the right subclavian artery. Laterally, on the left and right sides of the cervical esophagus are the carotid sheaths and the lobes of the thyroid gland.

The thoracic portion of the esophagus is approximately 20 cm long. It starts at the thoracic inlet. In the upper portion of the thorax, it is in intimate relationship with the posterior wall of the trachea and the prevertebral fascia. Just above the tracheal bifurcation, the esophagus passes to the right of the aorta. This anatomic positioning can cause a notch indentation in its left lateral wall on a barium swallow radiogram. Immediately below this notch, the esophagus crosses both the bifurcation of the trachea and the left main stem bronchus, owing to the slight deviation of the terminal portion of the trachea to the right by the aorta (Fig. 25-5). From there down, the esophagus passes over the posterior surface of the subcarinal lymph nodes (LNs), and

then descends over the pericardium of the left atrium to reach the diaphragmatic hiatus (Fig. 25-6). From the bifurcation of the trachea downward, both the vagal nerves and the esophageal nerve plexus lie on the muscular wall of the esophagus.

Dorsally, the thoracic esophagus follows the curvature of the spine and remains in close contact with the vertebral bodies. From the eighth thoracic vertebra downward, the esophagus moves vertically away from the spine to pass through the hiatus of the diaphragm. The thoracic duct passes through the hiatus of the diaphragm on the anterior surface of the vertebral column behind the aorta and under the right crus. In the thorax, the thoracic duct lies dorsal to the esophagus between the azygos vein on the right and the descending thoracic aorta on the left.

The abdominal portion of the esophagus is approximately 2 cm long and includes a portion of the lower esophageal sphincter (LES). It starts as the esophagus passes through the diaphragmatic hiatus and is surrounded by the phrenoesophageal membrane, a fibroelastic ligament arising from the subdiaphragmatic fascia as a continuation of the transversalis fascia lining the abdomen (Fig. 25-7). The upper leaf of the membrane attaches itself in a circumferential fashion around the esophagus, about 1 to 2 cm above the level of the hiatus. These fibers blend in with the elastic-containing adventitia of the abdominal esophagus and the cardia of the stomach. This portion of the esophagus is subjected to the positive-pressure environment of the abdomen.

The musculature of the esophagus can be divided into an outer longitudinal and an inner circular layer. The upper 2 to 6 cm of the esophagus contains only striated muscle fibers. From then on, smooth muscle fibers gradually become more abundant. Most clinically significant esophageal motility disorders involve only the smooth muscle in the lower two-thirds of the esophagus. When a surgical esophageal myotomy is indicated, the incision needs to extend only this distance.

The longitudinal muscle fibers originate from a cricoesophageal tendon arising from the dorsal upper edge of the anteriorly located cricoid cartilage. The two bundles of muscle diverge and meet in the midline on the posterior wall of the esophagus about 3 cm below the cricoid (see Fig. 25-4).

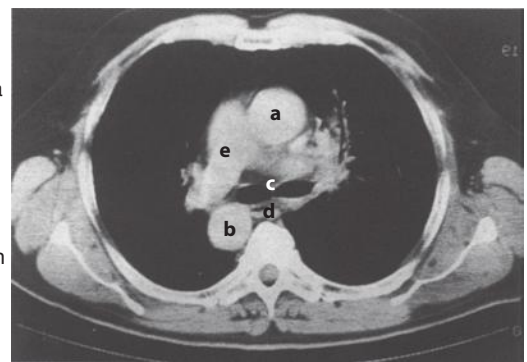
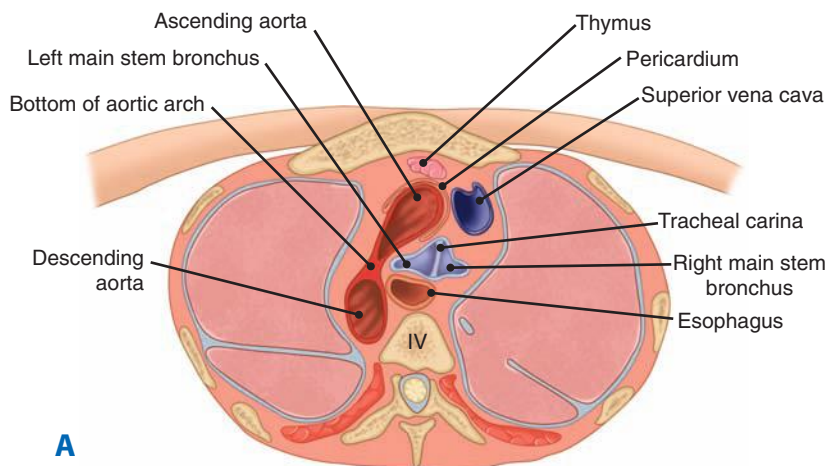


Figure 25-5. **A.** Cross-section of the thorax at the level of the tracheal bifurcation. **B.** Computed tomographic scan at same level viewed from above: (a) ascending aorta, (b) descending aorta, (c) tracheal carina, (d) esophagus, (e) pulmonary artery. (Reproduced with permission from Rothberg M, DeMeester TR: *Surgical anatomy of the esophagus*, in Shields TW (ed): *General Thoracic Surgery*, 3rd ed. Philadelphia: Lea & Febiger, 1989, p 81.)

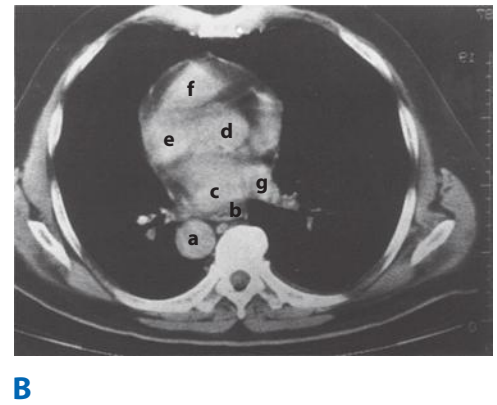
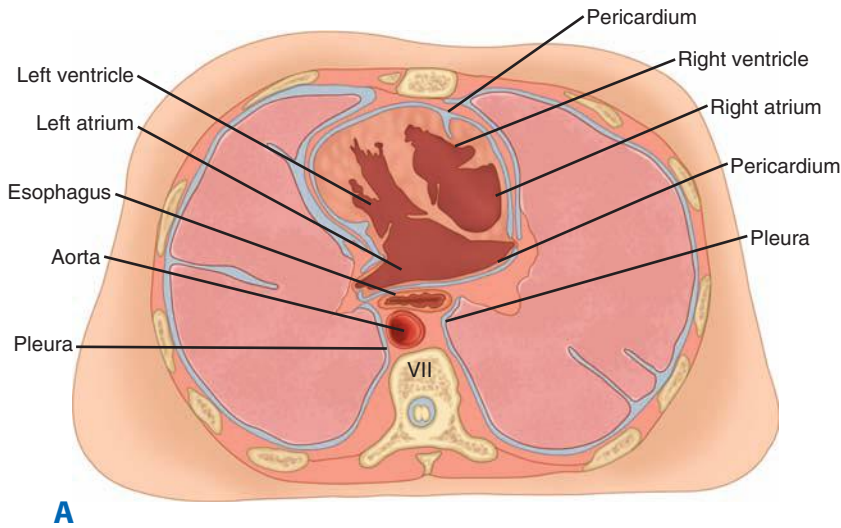


Figure 25-6. **A.** Cross-section of the thorax at the midleft atrial level. **B.** Computed tomographic scan at same level viewed from above: (a) aorta, (b) esophagus, (c) left atrium, (d) right atrium, (e) left ventricle, (f) right ventricle, (g) pulmonary vein. (Reproduced with permission from Rothberg M, DeMeester TR: *Surgical anatomy of the esophagus*, in Shields TW (ed): *General Thoracic Surgery*, 3rd ed. Philadelphia: Lea & Febiger, 1989, p 82.)

From this point on, the entire circumference of the esophagus is covered by a layer of longitudinal muscle fibers. This configuration of the longitudinal muscle fibers around the most proximal part of the esophagus leaves a V-shaped area in the posterior wall covered only with circular muscle fibers. Contraction of the longitudinal muscle fibers shortens the esophagus. The circular muscle layer of the esophagus is thicker than the outer longitudinal layer. In situ, the geometry of the circular muscle is helical and makes the peristalsis of the esophagus assume a worm-like drive, as opposed to segmental and sequential squeezing. As a consequence, severe motor abnormalities of the esophagus assume a corkscrew-like pattern on the barium swallow radiogram.

The cervical portion of the esophagus receives its main blood supply from the inferior thyroid artery. The thoracic portion receives its blood supply from the bronchial arteries, with 75% of individuals having one right-sided and two left-sided branches. Two esophageal branches arise directly from the aorta.

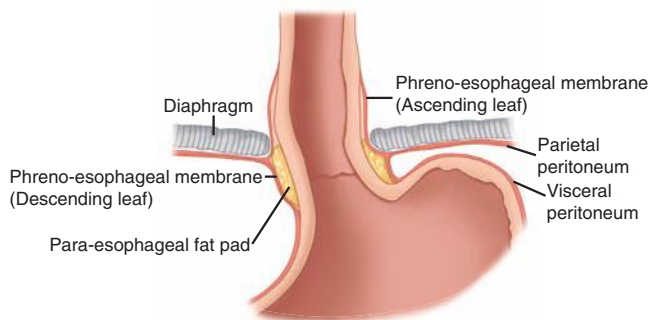


Figure 25-7. Attachments and structure of the phrenoesophageal membrane. Transversalis fascia lies just above the parietal peritoneum. (Reproduced with permission from Rothberg M, DeMeester TR: *Surgical anatomy of the esophagus*, in Shields TW (ed): *General Thoracic Surgery*, 3rd ed. Philadelphia: Lea & Febiger, 1989, p 83.)

The abdominal portion of the esophagus receives its blood supply from the ascending branch of the left gastric artery and from inferior phrenic arteries (Fig. 25-8). On entering the wall of the esophagus, the arteries assume a T-shaped division to form a longitudinal plexus, giving rise to an intramural vascular network in the muscular and submucosal layers. As a consequence, the esophagus can be mobilized from the stomach to the level of the aortic arch without fear of devascularization and ischemic necrosis. Caution should be exercised as to the extent

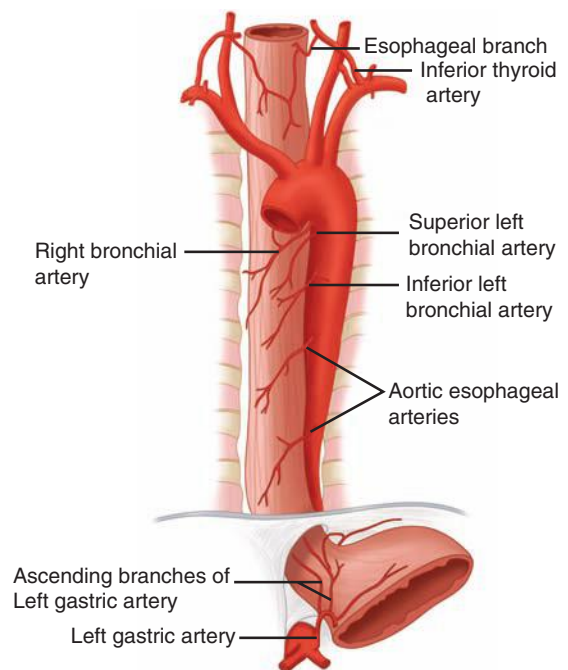


Figure 25-8. Arterial blood supply of the esophagus. (Reproduced with permission from Rothberg M, DeMeester TR: *Surgical anatomy of the esophagus*, in Shields TW (ed): *General Thoracic Surgery*, 3rd ed. Philadelphia: Lea & Febiger, 1989, p 84.)

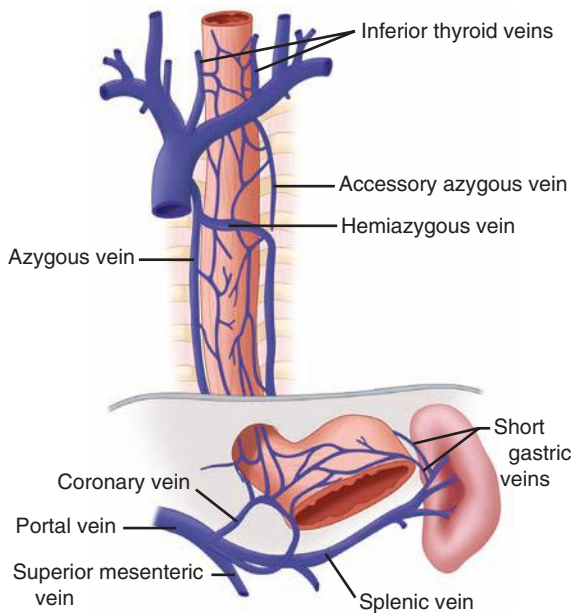


Figure 25-9. Venous drainage of the esophagus. (Reproduced with permission from Rothberg M, DeMeester TR: *Surgical anatomy of the esophagus*, in Shields TW (ed): *General Thoracic Surgery*, 3rd ed. Philadelphia: Lea & Febiger, 1989, p 85.)

of esophageal mobilization in patients who have had a previous thyroidectomy with ligation of the inferior thyroid arteries proximal to the origin of the esophageal branches.

Blood from the capillaries of the esophagus flows into a submucosal venous plexus, and then into a periesophageal venous plexus from which the esophageal veins originate. In the cervical region, the esophageal veins empty into the inferior thyroid vein; in the thoracic region, they empty into the bronchial, azygos, or hemiazygos veins; and in the abdominal region, they empty into the coronary vein (Fig. 25-9). The submucosal venous networks of the esophagus and stomach are in continuity with each other, and, in patients with portal venous obstruction, this communication functions as a collateral pathway for portal blood to enter the superior vena cava via the azygos vein.

The parasympathetic innervation of the pharynx and esophagus is provided mainly by the vagus nerves. The constrictor muscles of the pharynx receive branches from the pharyngeal plexus, which is on the posterior lateral surface of the middle constrictor muscle, and is formed by pharyngeal branches of the vagus nerves with a small contribution from cranial nerves IX and XI (Fig. 25-10). The cricopharyngeal sphincter and the cervical portion of the esophagus receive branches from both recurrent laryngeal nerves, which originate from the vagus nerves—the right recurrent nerve at the lower margin of the subclavian artery and the left at the lower margin of the aortic arch. They are slung dorsally around these vessels and ascend in the groove between the esophagus and trachea, giving branches to each. Damage to these nerves interferes not only with the function of the vocal cords, but also with the function of the cricopharyngeal sphincter and the motility of the cervical esophagus, predisposing the individual to pulmonary aspiration on swallowing.

Afferent visceral sensory pain fibers from the esophagus end without synapse in the first four segments of the thoracic spinal cord, using a combination of sympathetic and vagal

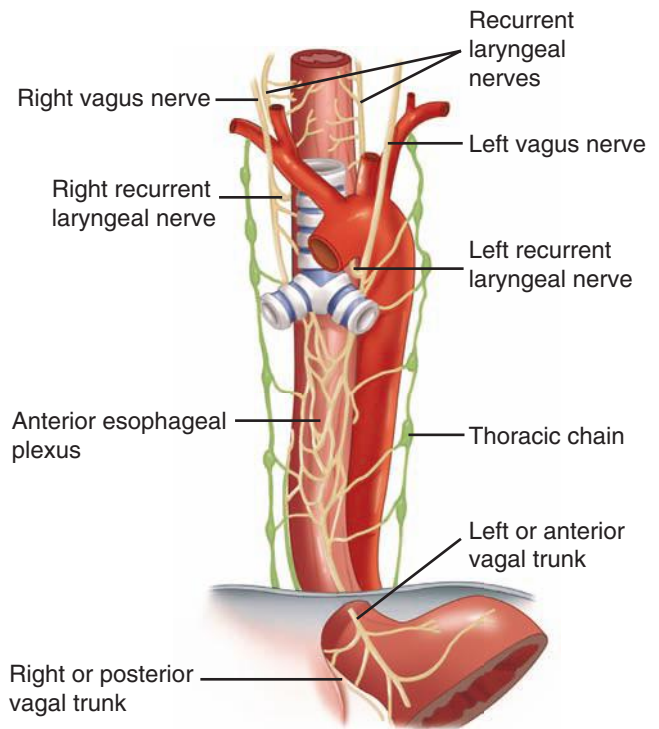


Figure 25-10. Innervation of the esophagus. (Reproduced with permission from Rothberg M, DeMeester TR: *Surgical anatomy of the esophagus*, in Shields TW (ed): *General Thoracic Surgery*, 3rd ed. Philadelphia: Lea & Febiger, 1989, p 85.)

pathways. These pathways are also occupied by afferent visceral sensory fibers from the heart; hence, both organs have similar symptomatology.

The lymphatics located in the submucosa of the esophagus are so dense and interconnected that they constitute a single plexus (Fig. 25-11). There are more lymph vessels than blood

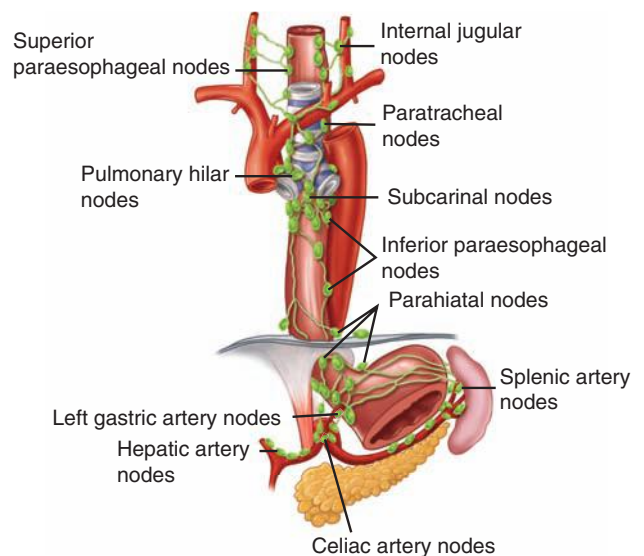


Figure 25-11. Lymphatic drainage of the esophagus. (Reproduced with permission from DeMeester TR, Barlow AP: *Surgery and current management for cancer of the esophagus and cardia: Part I*. *Curr Probl Surg* 25:498, 1988. Copyright Elsevier.)

capillaries in the submucosa. Lymph flow in the submucosal plexus runs in a longitudinal direction, and, on injection of a contrast medium, the longitudinal spread is seen to be about six times that of the transverse spread. In the upper two-thirds of the esophagus, the lymphatic flow is mostly cephalad, and, in the lower third, caudad. In the thoracic portion of the esophagus, the submucosal lymph plexus extends over a long distance in a longitudinal direction before penetrating the muscle layer to enter lymph vessels in the adventitia. As a consequence of this nonsegmental lymph drainage, a primary tumor can extend for a considerable length superiorly or inferiorly in the submucosal plexus. Consequently, free tumor cells can follow the submucosal lymphatic plexus in either direction for a long distance before they pass through the muscularis and on into the regional LNs. The cervical esophagus has more direct segmental lymph drainage into the regional nodes, and, as a result, lesions in this portion of the esophagus have less submucosal extension and a more regionalized lymphatic spread.

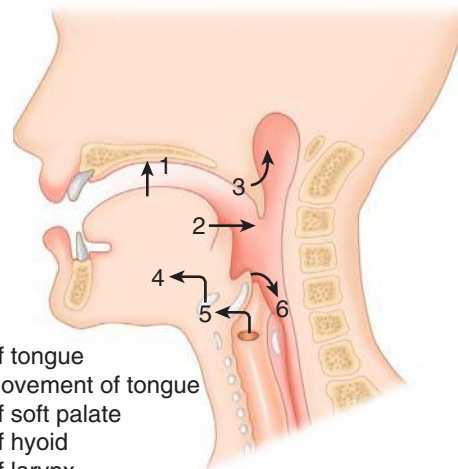
The efferent lymphatics from the cervical esophagus drain into the paratracheal and deep cervical LNs, and those from the upper thoracic esophagus empty mainly into the paratracheal LNs. Efferent lymphatics from the lower thoracic esophagus drain into the subcarinal nodes and nodes in the inferior pulmonary ligaments. The superior gastric nodes receive lymph not only from the abdominal portion of the esophagus, but also from the adjacent lower thoracic segment.

PHYSIOLOGY

Swallowing Mechanism

The act of alimentation requires the passage of food and drink from the mouth into the stomach. One-third of this distance consists of the mouth and hypopharynx, and two-thirds is made up by the esophagus. To comprehend the mechanics of alimentation, it is useful to visualize the gullet as a mechanical model in which the tongue and pharynx function as a piston pump with three valves, and the body of the esophagus and cardia function as a worm-drive pump with a single valve. The three valves in the pharyngeal cylinder are the soft palate, epiglottis, and cricopharyngeus. The valve of the esophageal pump is the LES. Failure of the valves or the pumps leads to abnormalities in swallowing—that is, difficulty in food propulsion from mouth to stomach—or regurgitation of gastric contents into the esophagus or pharynx.

Food is taken into the mouth in a variety of bite sizes, where it is broken up, mixed with saliva, and lubricated. Once initiated, swallowing is entirely a reflex act. When food is ready for swallowing, the tongue, acting like a piston, moves the bolus into the posterior oropharynx and forces it into the hypopharynx (Fig. 25-12). Concomitantly with the posterior movement of the tongue, the soft palate is elevated, thereby closing the passage between the oropharynx and nasopharynx. This partitioning prevents pressure generated in the oropharynx from being dissipated through the nose. When the soft palate is paralyzed, for example, after a cerebrovascular accident, food is commonly regurgitated into the nasopharynx. During swallowing, the hyoid bone moves upward and anteriorly, elevating the larynx and opening the retrolaryngeal space, bringing the epiglottis under the tongue (see Fig. 25-12). The backward tilt of the epiglottis covers the opening of the larynx to prevent aspiration. The entire pharyngeal part of swallowing occurs within 1.5 seconds.



1. Elevation of tongue
2. Posterior movement of tongue
3. Elevation of soft palate
4. Elevation of hyoid
5. Elevation of larynx
6. Tilting of epiglottis

Figure 25-12. Sequence of events during the oropharyngeal phase of swallowing. (Reproduced with permission from DeMeester TR, Stein HJ, Fuchs KH: Physiologic diagnostic studies, in Zuidema GD, Orringer MB (eds): Shackelford's Surgery of the Alimentary Tract, 3rd ed., Vol. I. Philadelphia: W.B. Saunders, 1991, p 95. Copyright Elsevier.)

During swallowing, the pressure in the hypopharynx rises abruptly, to at least 60 mmHg, due to the backward movement of the tongue and contraction of the posterior pharyngeal constrictors. A sizable pressure difference develops between the hypopharyngeal pressure and the less-than-atmospheric midesophageal or intrathoracic pressure (Fig. 25-13). This pressure gradient speeds the movement of food from the hypopharynx

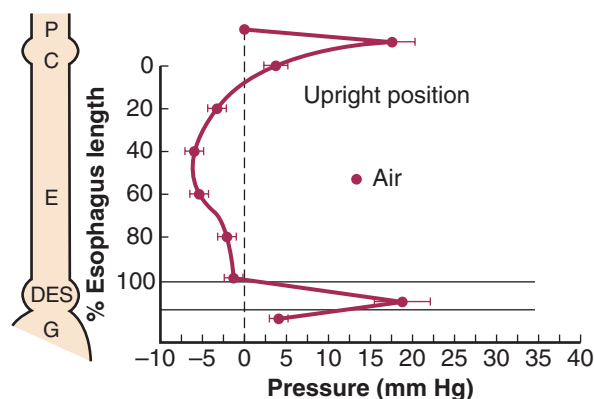


Figure 25-13. Resting pressure profile of the foregut showing the pressure differential between the atmospheric pharyngeal pressure (P) and the less-than-atmospheric midesophageal pressure (E) and greater-than-atmospheric intragastric pressure (G), with the interposed high pressure zones of the cricopharyngeus (C) and distal esophageal sphincter (DES). The necessity for relaxation of the cricopharyngeus and DES pressure to move a bolus into the stomach is apparent. Esophageal work occurs when a bolus is pushed from the midesophageal area (E), with a pressure less than atmospheric, into the stomach, which has a pressure greater than atmospheric (G). (Reproduced with permission from Waters PF, DeMeester TR: Foregut motor disorders and their surgical management. Med Clin North Am 65:1237, 1981. Copyright Elsevier.)

into the esophagus when the cricopharyngeus or upper esophageal sphincter relaxes. The bolus is both propelled by peristaltic contraction of the posterior pharyngeal constrictors and sucked into the thoracic esophagus. Critical to receiving the bolus is the compliance of the cervical esophagus; when compliance is lost due to muscle pathology, dysphagia can result. The upper esophageal sphincter closes within 0.5 second of the initiation of the swallow, with the immediate closing pressure reaching approximately twice the resting level of 30 mmHg. The postrelaxation contraction continues down the esophagus as a peristaltic wave (Fig. 25-14). The high closing pressure and the initiation of the peristaltic wave prevents reflux of the bolus from the esophagus back into the pharynx. After the peristaltic wave has passed farther down the esophagus, the pressure in the upper esophageal sphincter returns to its resting level.

Swallowing can be started at will, or it can be reflexively elicited by the stimulation of areas in the mouth and pharynx, among them the anterior and posterior tonsillar pillars or the posterior lateral walls of the hypopharynx. The afferent sensory nerves of the pharynx are the glossopharyngeal nerves and the superior laryngeal branches of the vagus nerves. Once aroused by stimuli entering via these nerves, the swallowing center in the medulla coordinates the complete act of swallowing by discharging impulses through cranial nerves V, VII, X, XI, and XII, as well as the motor neurons of C1 to C3. Discharges through these nerves occur in a rather specific pattern and last for approximately 0.5 second. Little is known about the organization of the swallowing center, except that it can trigger swallowing after a variety of different inputs, but the response is always a rigidly ordered pattern of outflow. Following a

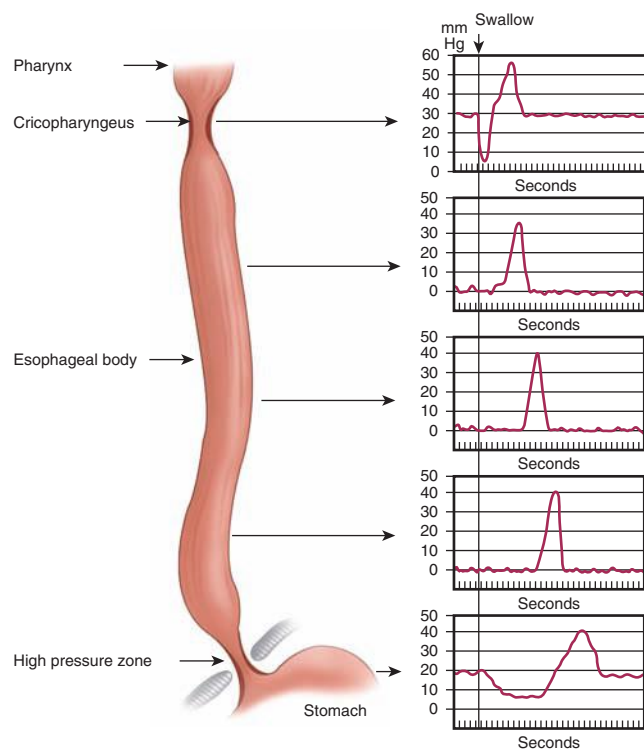


Figure 25-14. Intraluminal esophageal pressures in response to swallowing. (Reproduced with permission from Waters PF, DeMeester TR: *Foregut motor disorders and their surgical management*. Med Clin North Am 65:1238, 1981. Copyright Elsevier.)

cerebrovascular accident, this coordinated outflow may be altered, causing mild to severe abnormalities of swallowing. In more severe injury, swallowing can be grossly disrupted, leading to repetitive aspiration.

The striated muscles of the cricopharyngeus and the upper one-third of the esophagus are activated by efferent motor fibers distributed through the vagus nerve and its recurrent laryngeal branches. The integrity of innervation is required for the cricopharyngeus to relax in coordination with the pharyngeal contraction, and resume its resting tone once a bolus has entered the upper esophagus. Operative damage to the innervation can interfere with laryngeal, cricopharyngeal, and upper esophageal function, and predispose the patient to aspiration.

The pharyngeal activity in swallowing initiates the esophageal phase. The body of the esophagus functions as a worm-drive propulsive pump due to the helical arrangement of its circular muscles, and is responsible for transferring a bolus of food into the stomach. The esophageal phases of swallowing represents esophageal work done during alimentation, in that food is moved into the stomach from a negative-pressure environment of -6 mm Hg intrathoracic pressure, to a positive-pressure environment of 6 mm Hg intra-abdominal pressure, or over a gradient of 12 mm Hg (see Fig. 25-13). Effective and coordinated smooth muscle function in the lower one-third of the esophagus is therefore important in pumping the food across this gradient.

The peristaltic wave generates an occlusive pressure varying from 30 to 120 mmHg (see Fig. 25-14). The wave rises to a peak in 1 second, lasts at the peak for about 0.5 second, and then subsides in about 1.5 seconds. The whole course of the rise and fall of occlusive pressure may occupy one point in the esophagus for 3 to 5 seconds. The peak of a primary peristaltic contraction initiated by a swallow (primary peristalsis) moves down the esophagus at 2 to 4 cm/s and reaches the distal esophagus about 9 seconds after swallowing starts. Consecutive swallows produce similar primary peristaltic waves, but when the act of swallowing is rapidly repeated, the esophagus remains relaxed and the peristaltic wave occurs only after the last movement of the pharynx. Progress of the wave in the esophagus is caused by sequential activation of its muscles, initiated by efferent vagal nerve fibers arising in the swallowing center.

Continuity of the esophageal muscle is not necessary for sequential activation if the nerves are intact. If the muscles, but not the nerves, are cut across, the pressure wave begins distally below the cut as it dies out at the proximal end above the cut. This allows a sleeve resection of the esophagus to be done without destroying its normal function. Afferent impulses from receptors within the esophageal wall are not essential for progress of the coordinated wave. Afferent nerves, however, do go to the swallowing center from the esophagus, because, if the esophagus is distended at any point, a contractile wave begins with a forceful closure of the upper esophageal sphincter and sweeps down the esophagus. This secondary contraction occurs without any movements of the mouth or pharynx. Secondary peristalsis can occur as an independent local reflex to clear the esophagus of ingested material left behind after the passage of the primary wave. Current studies suggest that secondary peristalsis is not as common as once thought.

Despite the powerful occlusive pressure, the propulsive force of the esophagus is relatively feeble. If a subject attempts to swallow a bolus attached by a string to a counterweight, the maximum weight that can be overcome is 5 to 10 g.

Orderly contractions of the muscular wall and anchoring of the esophagus at its inferior end are necessary for efficient aboral propulsion to occur. Loss of the inferior anchor, as occurs with a large hiatal hernia, can lead to inefficient propulsion.

The LES provides a pressure barrier between the esophagus and stomach and acts as the valve on the worm-drive pump of the esophageal body. Although an anatomically distinct LES has been difficult to identify, microdissection studies show that, in humans, the sphincter-like function is related to the architecture of the muscle fibers at the junction of the esophageal tube with the gastric pouch (Fig. 25-15). The sphincter actively remains closed to prevent reflux of gastric contents into the esophagus and opens by a relaxation that coincides with a pharyngeal swallow (see Fig. 25-14). The LES pressure returns to its resting level after the peristaltic wave has passed through the esophagus. Consequently, reflux of gastric juice that may occur through the open valve during a swallow is cleared back into the stomach.

If the pharyngeal swallow does not initiate a peristaltic contraction, then the coincident relaxation of the LES is unguarded and reflux of gastric juice can occur. This may be an explanation for the observation of spontaneous lower esophageal relaxation, thought by some to be a causative factor in gastroesophageal reflux disease (GERD). The power of the worm-drive pump of the esophageal body is insufficient to force open a valve that does not relax. In dogs, a bilateral cervical parasympathetic

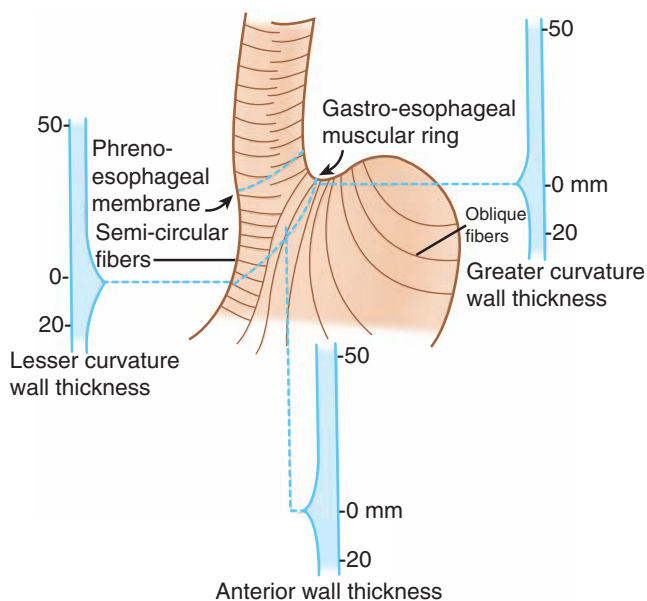


Figure 25-15. Wall thickness and orientation of fibers on microdissection of the cardia. At the junction of the esophageal tube and gastric pouch, there is an oblique muscular ring composed of an increased muscle mass inside the inner muscular layer. On the lesser curve side of the cardia, the muscle fibers of the inner layer are oriented transversely and form semicircular muscle clasps. On the greater curve side of the cardia, these muscle fibers form oblique loops that encircle the distal end of the cardia and gastric fundus. Both the semicircular muscle clasps and the oblique fibers of the fundus contract in a circular manner to close the cardia. (Reproduced with permission from DeMeester TR, Skinner DB: Evaluation of esophageal function and disease, in Glenn WWL (ed): Thoracic and Cardiovascular Surgery, 4th ed. Norwalk, CT: Appleton-Century-Crofts, 1983, p 461.)

blockade abolishes the relaxation of the LES that occurs with pharyngeal swallowing or distention of the esophagus. Consequently, vagal function appears to be important in coordinating the relaxation of the LES with esophageal contraction.

The antireflux mechanism in human beings is composed of three components: a mechanically effective LES, efficient esophageal clearance, and an adequately functioning gastric reservoir. A defect of any one of these three components can lead to increased esophageal exposure to gastric juice and the development of mucosal injury.

Physiologic Reflux

On 24-hour esophageal pH monitoring, healthy individuals have occasional episodes of gastroesophageal reflux. This physiologic reflux is more common when awake and in the upright position than during sleep in the supine position. When reflux of gastric juice occurs, normal subjects rapidly clear the acid gastric juice from the esophagus regardless of their position.

There are several explanations for the observation that physiologic reflux in normal subjects is more common when they are awake and in the upright position than during sleep in the supine position. First, reflux episodes occur in healthy volunteers primarily during transient losses of the gastroesophageal barrier, which may be due to a relaxation of the LES or intra-gastric pressure overcoming sphincter pressure. Gastric juice can also reflux when a swallow-induced relaxation of the LES is not protected by an oncoming peristaltic wave. The average frequency of these “unguarded moments” or of transient losses of the gastroesophageal barrier is far less while asleep and in the supine position than while awake and in the upright position. Consequently, there are fewer opportunities for reflux to occur in the supine position. Second, in the upright position, there is a 12-mmHg pressure gradient between the resting, positive intra-abdominal pressure measured in the stomach and the most negative intrathoracic pressure measured in the esophagus at midthoracic level. This gradient favors the flow of gastric juice up into the thoracic esophagus when upright. The gradient diminishes in the supine position. Third, the LES pressure in normal subjects is significantly higher in the supine position than in the upright position. This is due to the apposition of the hydrostatic pressure of the abdomen to the abdominal portion of the sphincter when supine. In the upright position, the abdominal pressure surrounding the sphincter is negative compared with atmospheric pressure, and, as expected, the abdominal pressure gradually increases the more caudally it is measured. This pressure gradient tends to move the gastric contents toward the cardia and encourages the occurrence of reflux into the esophagus when the individual is upright. In contrast, in the supine position, the gastroesophageal pressure gradient diminishes, and the abdominal hydrostatic pressure under the diaphragm increases, causing an increase in sphincter pressure and a more competent cardia.

The LES has intrinsic myogenic tone, which is modulated by neural and hormonal mechanisms. Alpha-adrenergic neurotransmitters or beta blockers stimulate the LES, and alpha blockers and beta stimulants decrease its pressure. It is not clear to what extent cholinergic nerve activity controls LES pressure. The vagus nerve carries both excitatory and inhibitory fibers to the esophagus and sphincter. The hormones gastrin and motilin have been shown to increase LES pressure; and cholecystikinin, estrogen, glucagon, progesterone, somatostatin, and secretin decrease LES pressure. The peptides bombesin, 1-enkephalin,

and substance P increase LES pressure; and calcitonin gene-related peptide, gastric inhibitory peptide, neuropeptide Y, and vasoactive intestinal polypeptide decrease LES pressure. Some pharmacologic agents such as antacids, cholinergics, agonists, domperidone, metoclopramide, and prostaglandin F₂ are known to increase LES pressure; and anticholinergics, barbiturates, calcium channel blockers, caffeine, diazepam, dopamine, meperidine, prostaglandin E₁ and E₂, and theophylline decrease LES pressure. Peppermint, chocolate, coffee, ethanol, and fat are all associated with decreased LES pressure and may be responsible for esophageal symptoms after a sumptuous meal.

ASSESSMENT OF ESOPHAGEAL FUNCTION

A thorough understanding of the patient's underlying anatomic and functional deficits before making therapeutic decisions is fundamental to the successful treatment of esophageal disease. The diagnostic tests, as presently used, may be divided into four

1► broad groups: (a) tests to detect structural abnormalities of the esophagus; (b) tests to detect functional abnormalities of the esophagus; (c) tests to detect increased esophageal exposure to gastric juice; and (d) tests of duodenogastric function as they relate to esophageal disease.

Tests to Detect Structural Abnormalities

Endoscopic Evaluation. The first diagnostic test in patients with suspected esophageal disease is usually upper gastrointestinal endoscopy. This allows assessment and biopsy of the mucosa of the stomach and the esophagus, as well as the diagnosis and assessment of obstructing lesions in the upper gastrointestinal tract. In any patient complaining of dysphagia, esophagoscopy is indicated, even in the face of a normal radiographic study.

For the initial endoscopic assessment, the flexible fiberoptic esophagoscope is the instrument of choice because of its technical ease, patient acceptance, and the ability to simultaneously assess the stomach and duodenum. Rigid endoscopy is now only rarely required, mainly for the disimpaction of difficult foreign bodies impacted in the esophagus.

When GERD is the suspected diagnosis, particular attention should be paid to detecting the presence of esophagitis and Barrett's columnar-lined esophagus (CLE). When endoscopic esophagitis is seen, severity and the length of esophagitis involved are recorded. Many different grading systems have been proposed. In a commonly used system, Grade I esophagitis is defined as small, circular, nonconfluent erosions (Fig. 25-16). Grade II esophagitis is defined by the presence of linear erosions lined with granulation tissue that bleeds easily when touched. Grade III esophagitis represents a more advanced stage, in which the linear erosions coalesce into circumferential loss of the epithelium and the mucosa may take a "cobblestone" appearance. Grade IV esophagitis is the presence of a stricture. Its severity can be assessed by the ease of passing a 36F endoscope. When a stricture is observed, the severity of the esophagitis above it should be recorded. The absence of esophagitis above a stricture suggests a chemical-induced injury or a neoplasm as a cause. The latter should always be considered and is ruled out only by evaluation of a tissue biopsy of adequate size. It should be remembered that gastroesophageal reflux is not always associated with visible mucosal abnormalities, and patients can experience significant reflux symptoms, despite an apparently normal endoscopy examination.

Barrett's esophagus (BE) is a condition in which the tubular esophagus is lined with columnar epithelium, as opposed to the normal squamous epithelium (Fig. 25-16). Histologically, it appears as intestinal metaplasia (IM). It is suspected at endoscopy when there is difficulty in visualizing the squamocolumnar junction at its normal location, and by the appearance of a redder, more luxuriant mucosa than is normally seen in the lower esophagus. Its presence is confirmed by biopsy. Multiple biopsy specimens should be taken in a cephalad direction to determine the level at which the junction of Barrett's epithelium with normal squamous mucosa occurs. BE is susceptible to ulceration, bleeding, stricture formation, and, most important, malignant degeneration. The earliest sign of the latter is high grade dysplasia or intramucosal adenocarcinoma (Fig. 25-16). These dysplastic changes have a patchy distribution, so a minimum of four biopsy samples spaced 2 cm apart should be taken from the Barrett's-lined portion of the esophagus. Changes seen in one biopsy are significant. Nishimaki has determined that the tumors occur in an area of specialized columnar epithelium near the squamocolumnar junction in 85% of patients, and within 2 cm of the squamocolumnar junction in virtually all patients. Particular attention should be focused on this area in patients suspected of harboring a carcinoma.

Abnormalities of the gastroesophageal flap valve can be visualized by retroflexion of the endoscope. Hill has graded the appearance of the gastroesophageal valve from I to IV according to the degree of unfolding or deterioration of the normal valve architecture (Fig. 25-17). The appearance of the valve correlates with the presence of increased esophageal acid exposure, occurring predominantly in patients with Grade III and IV valves.

A hiatal hernia is endoscopically confirmed by finding a pouch lined with gastric rugal folds lying 2 cm or more above the margins of the diaphragmatic crura, identified by having the patient sniff. A hernia is best demonstrated with the stomach fully insufflated and the gastroesophageal junction observed with a retroflexed endoscope. A prominent sliding hiatal hernia frequently is associated with increased esophageal exposure to gastric juice. When a paraesophageal hernia (PEH) is observed, particular attention is taken to exclude a gastric (Cameron's) ulcer or gastritis within the pouch. The intragastric retroflex or J maneuver is important in evaluating the full circumference of the mucosal lining of the herniated stomach.

When an esophageal diverticulum is seen, it should be carefully explored with the flexible endoscope to exclude ulceration or neoplasia. When a submucosal mass is identified, biopsy specimens are usually not performed. At the time of surgical resection, a submucosal leiomyoma or reduplication cyst can generally be dissected away from the intact mucosa, but if a biopsy sample is taken, the mucosa may become fixed to the underlying abnormality. This complicates the surgical dissection by increasing the risk of mucosal perforation. Endoscopic ultrasound provides a better method for evaluating these lesions.

Radiographic Evaluation. Barium swallow evaluation is undertaken selectively to assess anatomy and motility. The anatomy of large hiatal hernias are more clearly demonstrated by contrast radiology than endoscopy, and the presence of coordinated esophageal peristalsis can be determined by observing several individual swallows of barium traversing the entire length of the organ, with the patient in the horizontal position. Hiatal hernias are best demonstrated with the patient prone because the increased intra-abdominal pressure produced in this

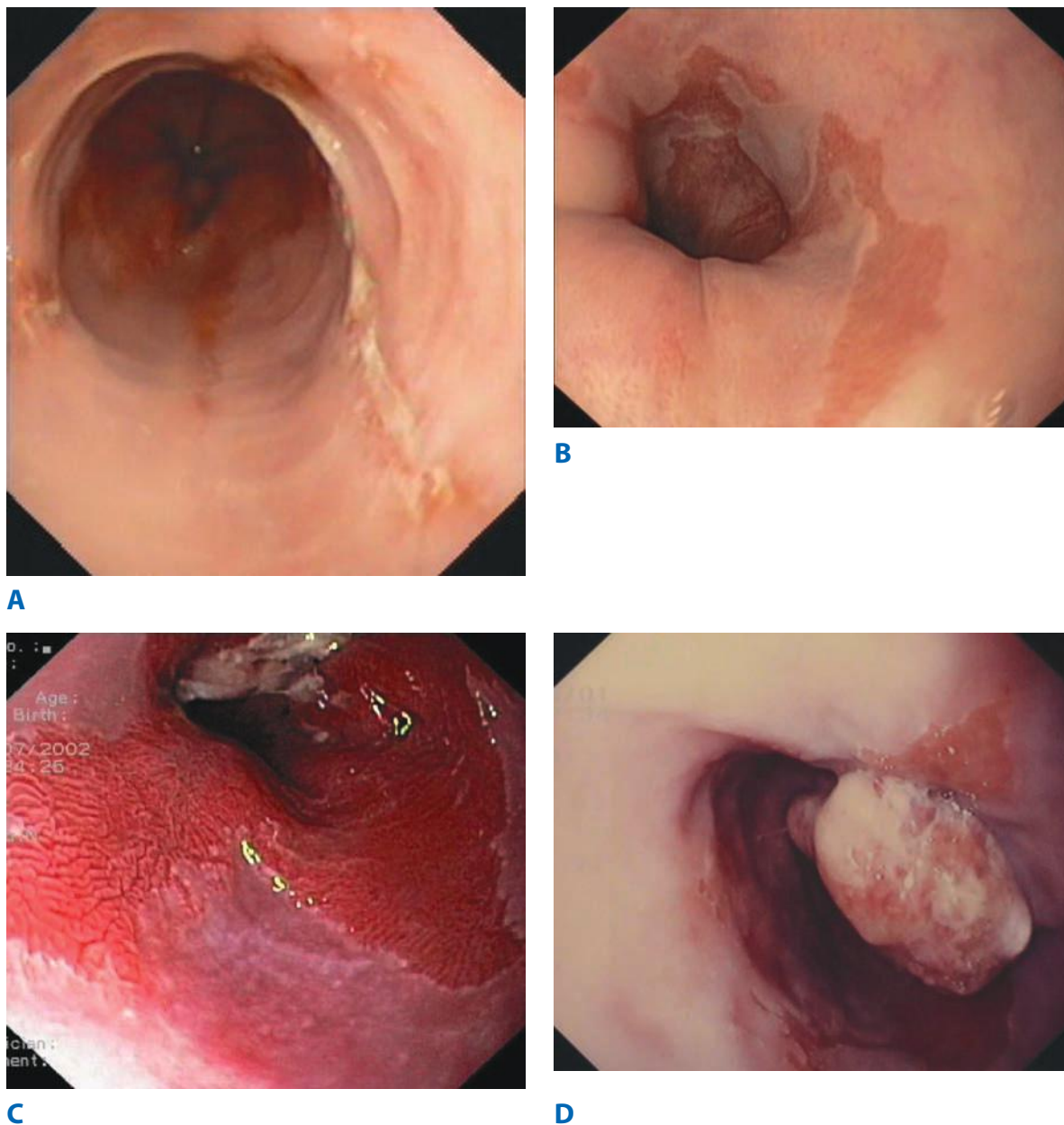


Figure 25-16. Complications of reflux disease as seen on endoscopy. **A.** Linear erosions of grade II esophagitis. **B.** Uncomplicated Barrett's mucosa. **C.** High Grade dysplasia in Barrett's mucosa. **D.** Early adenocarcinoma arising in Barrett's mucosa.

position promotes displacement of the esophagogastric junction above the diaphragm. To detect lower esophageal narrowing, such as rings and strictures, fully distended views of the esophagogastric region are crucial. The density of the barium used to study the esophagus can potentially affect the accuracy of the examination. Esophageal disorders shown clearly by a full-column technique include circumferential carcinomas, peptic strictures, large esophageal ulcers, and hiatal hernias. A small hiatal hernia is usually not associated with significant symptoms or illness, and its presence is an irrelevant finding unless the hiatal hernia is large (Fig. 25-18), or the hernia is of the paraesophageal variety. Lesions extrinsic but adjacent to the esophagus can be reliably detected by the full-column technique if they contact the distended esophageal wall. Conversely, a number of important disorders may go undetected if this is the sole technique used to examine the esophagus. These include small esophageal

neoplasms, mild esophagitis, and esophageal varices. Thus, the full-column technique should be supplemented with mucosal relief or double-contrast films to enhance detection of these smaller or more subtle lesions.

Motion-recording techniques greatly aid in evaluating functional disorders of the pharyngoesophageal and esophageal phases of swallowing. The technique and indications for cine- and videoradiography will be discussed in the section entitled *Video- and Cineradiography*, as they are more useful to evaluate function and seldom used to detect structural abnormalities.

The radiographic assessment of the esophagus is not complete unless the entire stomach and duodenum have been examined. A gastric or duodenal ulcer, partially obstructing gastric neoplasm, or scarred duodenum and pylorus may contribute significantly to symptoms otherwise attributable to an esophageal abnormality.

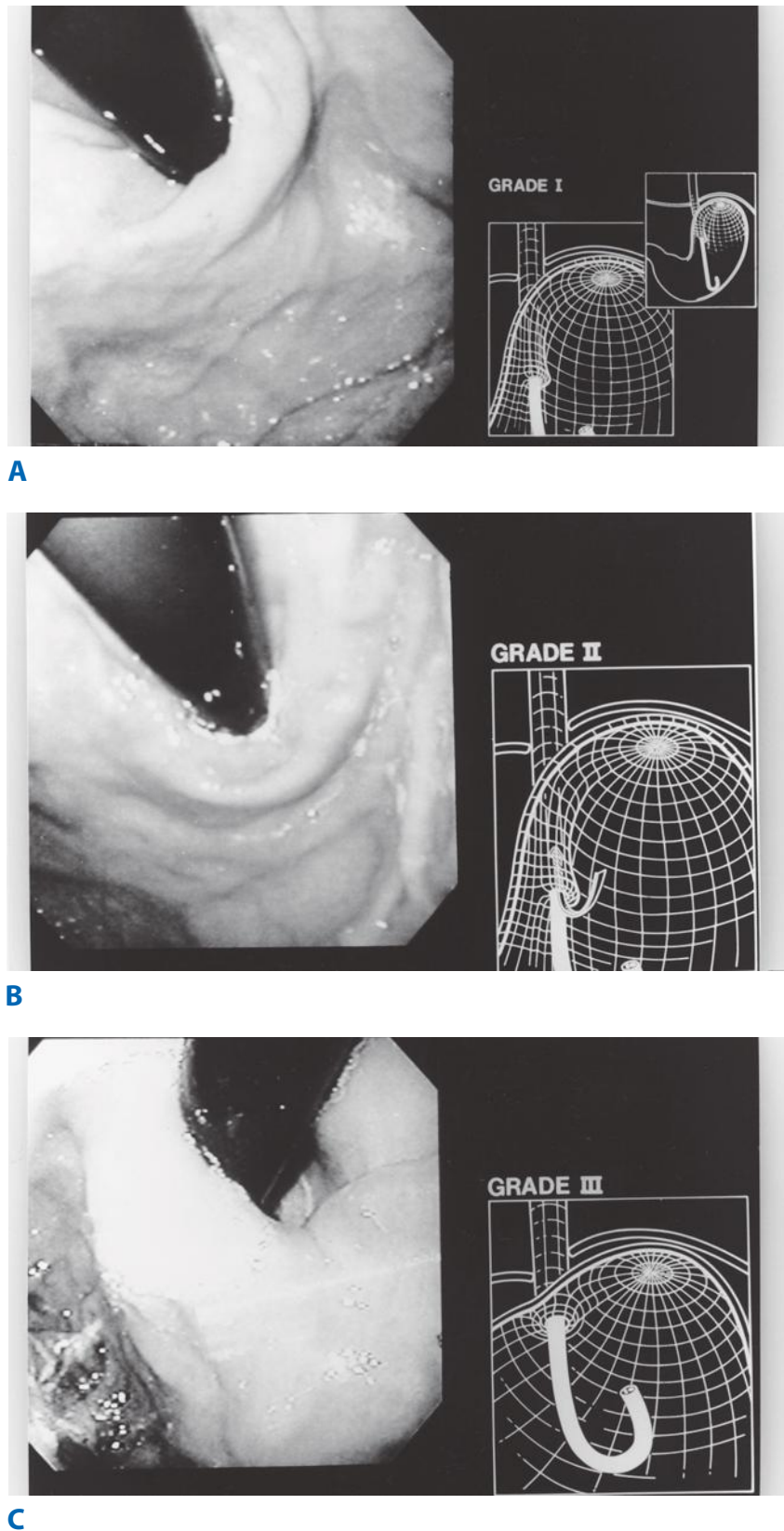
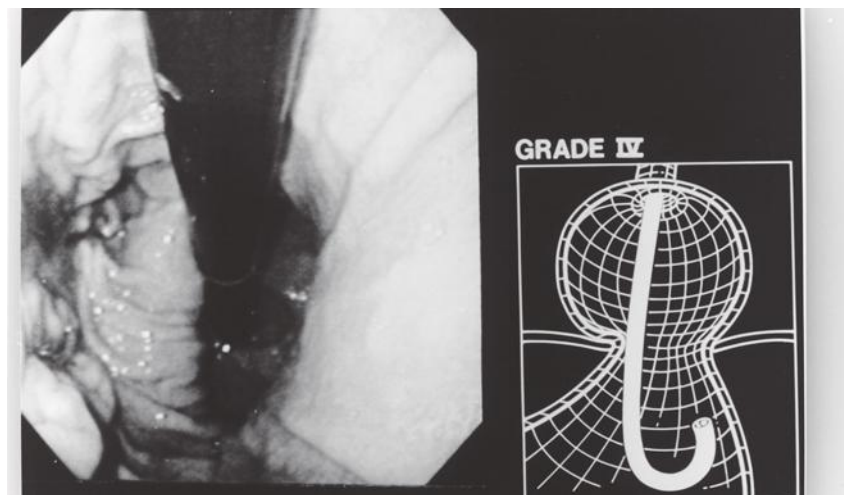


Figure 25-17. **A.** Grade I flap valve appearance. Note the ridge of tissue that is closely approximated to the shaft of the retroflexed endoscope. It extends 3–4 cm along the lesser curve. **B.** Grade II flap valve appearance. The ridge is slightly less well defined than in grade I and it opens rarely with respiration and closes promptly. **C.** Grade III flap valve appearance. The ridge is barely present, and there is often failure to close around the endoscope. It is nearly always accompanied by a hiatal hernia. **D.** Grade IV flap valve appearance. There is no muscular ridge at all. The gastroesophageal valve stays open all the time, and squamous epithelium can often be seen from the retroflexed position. A hiatal hernia is always present. (Reproduced with permission from Hill LD, Kozarek RA, et al.: *The gastroesophageal flap valve. In vitro and in vivo observations.* *Gastrointest Endosc.* 44:541, 1996. Copyright Elsevier.)



D

Figure 25-17. (Continued)

When a patient's complaints include dysphagia and no obstructing lesion is seen on the barium swallow, it is useful to have the patient swallow a barium-impregnated marshmallow, a barium-soaked piece of bread, or a hamburger mixed with barium. This test may bring out a functional disturbance in esophageal transport that can be missed when liquid barium is used.

Tests to Detect Functional Abnormalities

In many patients with symptoms of an esophageal disorder, standard radiographic and endoscopic evaluation fails to demonstrate a structural abnormality. In these situations, esophageal function tests are necessary to identify a functional disorder.

Stationary Manometry. Esophageal manometry is a widely used technique to examine the motor function of the esophagus and its sphincters. Manometry is indicated whenever a motor

abnormality of the esophagus is suspected on the basis of complaints of dysphagia, odynophagia, or noncardiac chest pain, and the barium swallow or endoscopy does not show a clear structural abnormality. Esophageal manometry is particularly necessary to confirm the diagnosis of specific primary esophageal motility disorders (i.e., achalasia, diffuse esophageal spasm [DES], nutcracker esophagus, and hypertensive LES). It also identifies nonspecific esophageal motility abnormalities and motility disorders secondary to systemic disease such as scleroderma, dermatomyositis, polymyositis, or mixed connective tissue disease. In patients with symptomatic GERD, manometry of the esophageal body can identify a mechanically defective LES, and evaluate the adequacy of esophageal peristalsis and contraction amplitude. Manometry has become an essential tool in the preoperative evaluation of patients before antireflux surgery, guiding selection of the appropriate procedure based upon the patient's underlying esophageal function, and excluding patients with achalasia who can be misdiagnosed with gastroesophageal reflux when clinical and endoscopic parameters alone are used for diagnosis.

Esophageal manometry is performed using electronic, pressure-sensitive transducers located within the catheter, or water-perfused catheters with lateral side holes attached to transducers outside the body. The traditional catheter consists of a train of five pressure transducers or five or more water-perfused tubes bound together. The transducers or lateral openings are placed at 5-cm intervals from the tip and oriented radially at 72° from each other around the circumference of the catheter. A special catheter assembly consisting of four lateral openings at the same level, oriented at 90° to each other, is of special use in measuring the three-dimensional vector volume of the LES. Other specially designed catheters can be used to assess the upper sphincter.

As the pressure-sensitive station is brought across the gastroesophageal junction (GEJ), a rise in pressure above the gastric baseline signals the beginning of the LES. The respiratory inversion point is identified when the positive excursions that occur in the abdominal cavity with breathing change to negative deflections in the thorax. The respiratory inversion point serves as a reference point at which the amplitude of LES pressure and the length of the sphincter exposed to abdominal pressure

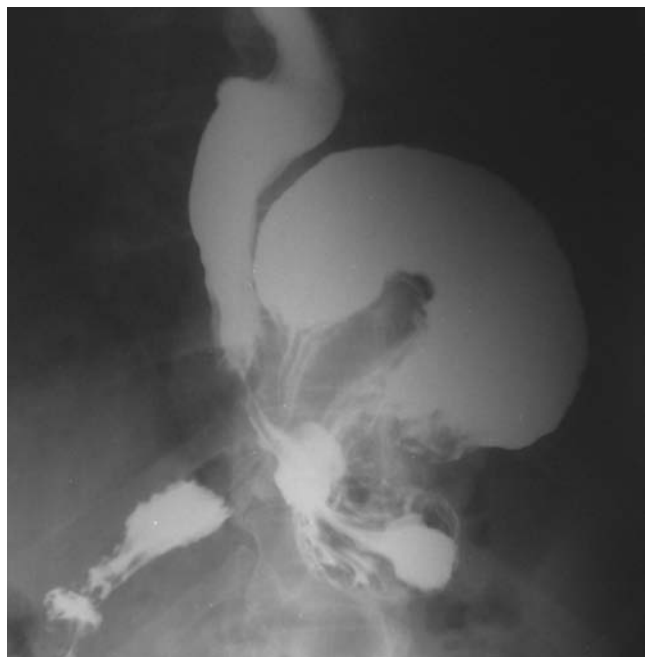
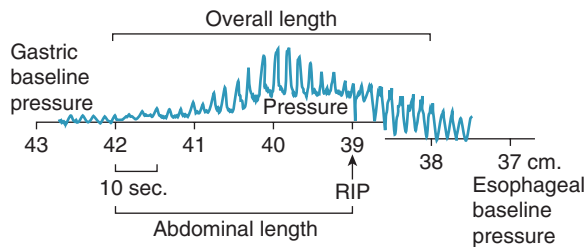


Figure 25-18. Radiogram of an intrathoracic stomach. This is the end stage of a large hiatal hernia, regardless of its initial classification.



RIP = Respiratory inversion point

Figure 25-19. Manometric pressure profile of the lower esophageal sphincter. The distances are measured from the nares. (Reproduced with permission from: Zaninotto G, DeMeester TR, et al.: *The lower esophageal sphincter in health and disease*. Am J Surg. 155:105, 1988. Copyright Elsevier.)

are measured. As the pressure-sensitive station is withdrawn into the body of the esophagus, the upper border of the LES is identified by the drop in pressure to the esophageal baseline. From these measurements, the pressure, abdominal length, and overall length of the sphincter are determined (Fig. 25-19). To account for the asymmetry of the sphincter (Fig. 25-20), the pressure profile is repeated with each of the five radially oriented transducers, and the average values for sphincter pressure above gastric baseline, overall sphincter length, and abdominal length of the sphincter are calculated.

Table 25-1 shows the values for these parameters in 50 normal volunteers without subjective or objective evidence of a foregut disorder. The level at which a deficiency in the mechanics of the LES occurs was defined by comparing the frequency

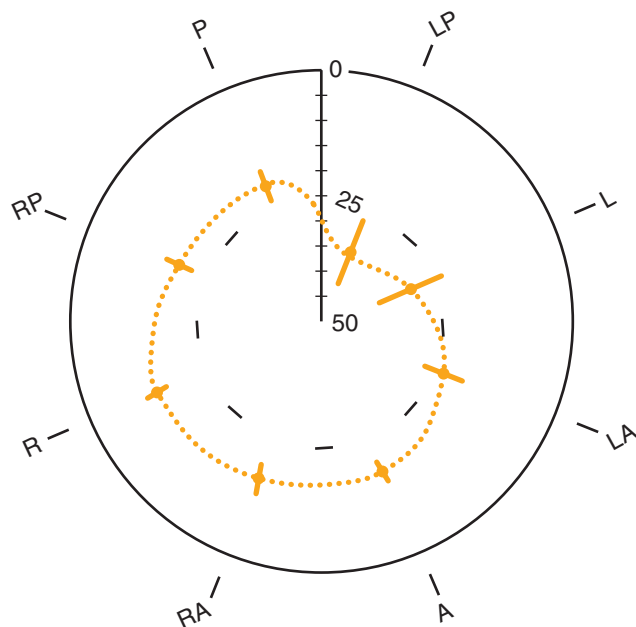


Figure 25-20. Radial configuration of the lower esophageal sphincter. A = anterior; L = left; LA = left anterior; LP = left posterior; P = posterior; R = right; RA = right anterior; RP = right posterior. (Reproduced with permission from Winans CS: *Manometric asymmetry of the lower esophageal high pressure zone*. Dig Dis Sci 22:348, 1977. With kind permission from Springer Science+Business Media.)

Table 25-1

Normal manometric values of the distal esophageal sphincter, n = 50

	MEDIAN	PERCENTILE	
		2.5	97.5
Pressure (mmHg)	13	5.8	27.7
Overall length (cm)	3.6	2.1	5.6
Abdominal length (cm)	2	0.9	4.7
	MEAN	MEAN - 2 SD	MEAN + 2 SD
Pressure (mmHg)	13.8 ± 4.6	4.6	23.0
Overall length (cm)	3.7 ± 0.8	2.1	5.3
Abdominal length (cm)	2.2 ± 0.8	0.6	3.8

SD = standard deviation.

Source: Reproduced with permission from DeMeester TR, et al.: *Gastroesophageal reflux disease*, in Moody FG, Carey LC, et al. (eds): *Surgical Treatment of Digestive Disease*. Chicago: Year Book Medical, 1990, p 89. Copyright Elsevier.

distribution of these values in the 50 healthy volunteers with a population of similarly studied patients with symptoms of GERD. The presence of increased esophageal exposure to gastric juice was documented by 24-hour esophageal pH monitoring. Based on these studies, a mechanically defective sphincter is identified by having one or more of the following characteristics: an average LES pressure of <6 mmHg, an average length exposed to the positive-pressure environment in the abdomen of 1 cm or less, and/or an average overall sphincter length of 2 cm or less. Compared with the normal volunteers, these values are below the 2.5 percentile for sphincter pressure and overall length and for abdominal length.

To assess the relaxation and postrelaxation contraction of the LES, a pressure transducer is positioned within the high-pressure zone, with the distal transducer located in the stomach and the proximal transducer within the esophageal body. Ten wet swallows (5 mL water each) are performed. The normal pressure of the LES should drop to the level of gastric pressure during each wet swallow.

The function of the esophageal body is assessed with the five pressure transducers located in the esophagus. The standard procedure is to locate the most proximal pressure transducer 1 cm below the well-defined cricopharyngeal sphincter, allowing a pressure response throughout the whole esophagus to be obtained on one swallow. Ten wet swallows are recorded. Amplitude, duration, and morphology of contractions following each swallow are calculated at all recorded levels of the esophageal body. The delay between the onset and peak of esophageal contractions at the various levels of the esophagus is used to calculate the speed of wave propagation. The relationship of the esophageal contractions following a swallow is classified as peristaltic or simultaneous. The data are used to identify motor disorders of the esophagus.

The position, length, and pressure of the cricopharyngeal sphincter are assessed with a stationary pull-through technique similar to that used for the LES. The manometric catheter is withdrawn in 0.5-cm intervals from the upper esophagus through the upper esophageal sphincter region into the pharynx. The relaxation of the upper esophageal sphincter is studied by straddling the eight pressure transducers across the sphincter so that some are in the pharynx and some are in the upper esophagus. High-speed graphic recordings (50 mm/s) are necessary to obtain an assessment of the coordination of cricopharyngeal relaxation with hypopharyngeal contraction. It has been difficult to consistently demonstrate a motility abnormality in patients with pharyngoesophageal disorders.

High-Resolution Manometry. Esophageal manometry was introduced into clinical practice in the 1970s and, until recently, has changed little. In 1991, Ray Clouse introduced the concept of improving conventional manometry by increasing the number of recording sites and adding a three-dimensional assessment. This “high-resolution manometry” is a variant of the conventional manometry in which multiple, circumferential recording sites are used, in essence creating a “map” of the esophagus and its sphincters. High-resolution catheters contain 36 miniaturized pressure sensors positioned every centimeter along the length of the catheter. The vast amount of data generated by these sensors is then processed and presented in traditional linear plots or as a visually enhanced spatiotemporal video tracing that is readily interpreted (Fig. 25-21).

Simultaneous acquisition of data for the upper esophageal sphincter, esophageal body, LES, and gastric pressure minimizes the movement artifacts and study time associated with conventional esophageal manometry. Powerful, computer-based, and easy-to-use tools give unprecedented data analysis capability. This technology significantly enhances esophageal diagnostics, bringing it into the realm of “image” based studies. High-resolution manometry may allow the identification of focal motor abnormalities previously overlooked. It has enhanced the ability to predict bolus propagation and increased sensitivity in the measurement of pressure gradients.

Esophageal Impedance. New technology recently introduced into the clinical realm allows measurement of esophageal function and gastroesophageal reflux in a way that has heretofore not been possible. An intraluminal electrical impedance catheter has recently been developed for the measurement of GI function. Impedance is the ratio of voltage to current, and is a measure of the electrical conductivity of a hollow organ and its contents. Intraluminal electrical impedance is inversely proportional to the electrical conductivity of the luminal contents and the cross-sectional area of the lumen. Air has a very low electrical conductivity and, therefore, high impedance. Saliva and food cause an impedance decrease because of their increased conductivity. Luminal dilatation results in a decrease in impedance, whereas luminal contraction yields an impedance increase. Investigators have established the impedance waveform characteristics that define esophageal bolus transport. This allows for the characterization of both esophageal function, via quantification of bolus transport, and gastroesophageal reflux (Fig. 25-22). The probe measures impedance between adjacent electrodes, with measuring segments located at 2, 4, 6, 8, 14, and 16 cm from the distal tip. An extremely low electric current of 0.00025 μ W is transmitted across the electrodes at a frequency of 1 to 2 kHz and is limited to 8 μ A. This is below the stimulation threshold

for nerves and muscles, and is three orders of magnitude below the threshold of cardiac stimulation. A standard pH electrode is located 5 cm from the distal tip, so that the acidic or nonacidic nature of refluxate can be correlated with the number of reflux events.

Esophageal impedance has been validated as an appropriate method for the evaluation of GI function and is becoming increasingly used for the diagnosis of gastroesophageal reflux. It has been compared to cineradiography showing that impedance waves correspond well with actual bolus transport illustrated by radiography. Bolus entry, transit, and exit can be clearly identified by impedance changes in the corresponding measuring segments. Preliminary studies comparing standard esophageal manometry with impedance measurements in healthy volunteers have been performed, and have validated the ability of esophageal impedance to correlate with peristaltic wave progression and bolus length. Clinical investigators are beginning to examine and validate impedance measurement in the evaluation of esophageal and small intestinal pathophysiology.

It is increasingly recognized that 24-hour pH monitoring as the historical gold standard for diagnosing and quantifying gastroesophageal reflux has significant limitations. With 24-hour ambulatory pH testing, reflux is defined as a drop in the pH below 4, which effectively “blinds” the test to reflux occurring at higher pH values. Furthermore, in patients with persistent symptoms on proton pump inhibitor (PPI) therapy, pH monitoring has limited use as it can only detect abnormal acid reflux (pH <4), the occurrence of which has been altered by the antisecretory medication. Given that PPI antisecretory therapy is highly effective in neutralizing gastric acid, the question of whether persistent symptoms are a result of persistent acid reflux, nonacid reflux, or are not reflux related becomes a key issue in surgical decision making. Until recently, this differentiation could not be made. A reliable method for detecting both acid and nonacid reflux has potential to define these populations of patients and thus improve patient selection for antireflux surgery. The recent introduction of multichannel intraluminal impedance technology allows the measurement of both acid and nonacid reflux, with potential to significantly enhance diagnostic accuracy.

Using this technology, Balaji and colleagues showed that most gastroesophageal reflux remains despite acid suppression. Impedance pH may be particularly useful in evaluating patients with persistent symptoms despite PPI treatment, patients with respiratory symptoms, and postoperative patients who are having symptoms that are elusive to diagnosis.

Esophageal Transit Scintigraphy. The esophageal transit of a 10-mL water bolus containing technetium-99m (^{99m}Tc) sulfur colloid can be recorded with a gamma camera. Using this technique, delayed bolus transit has been shown in patients with a variety of esophageal motor disorders, including achalasia, scleroderma, DES, and nutcracker esophagus.

Video- and Cineradiography

High-speed cinematic or video recording of radiographic studies allows re-evaluation by reviewing the studies at various speeds. This technique is more useful than manometry in the evaluation of the pharyngeal phase of swallowing. Observations suggesting oropharyngeal or cricopharyngeal dysfunction include misdirection of barium into the trachea or nasopharynx, prominence of the cricopharyngeal muscle, a Zenker’s diverticulum, a narrow pharyngoesophageal segment, and stasis of the

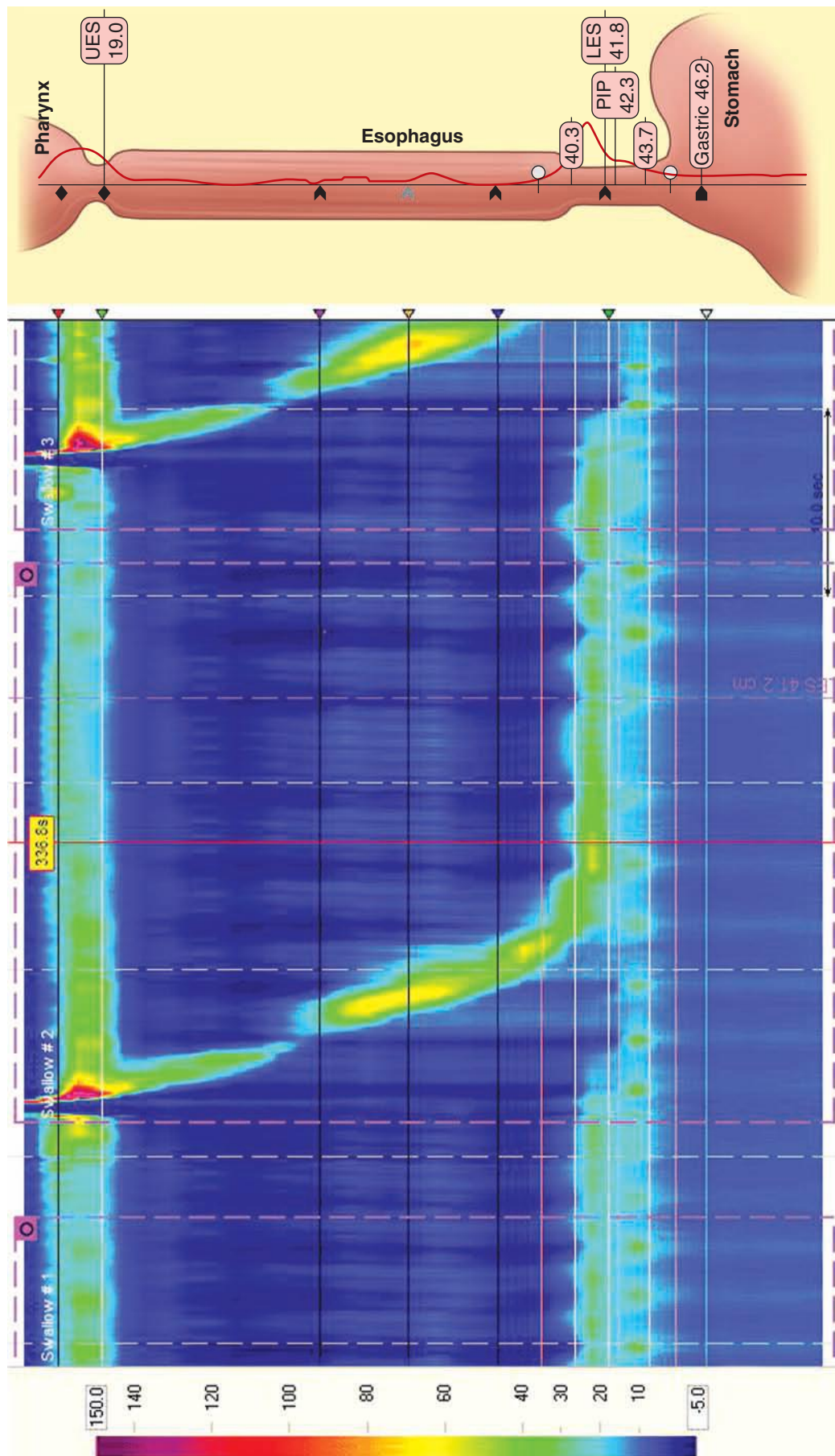


Figure 25-21A. Normal high-resolution manometry motility study. Pressure measurements are recorded with color coding (red = high; blue = low). LES = lower esophageal sphincter; PIP = pressure inversion point; UES = upper esophageal sphincter.

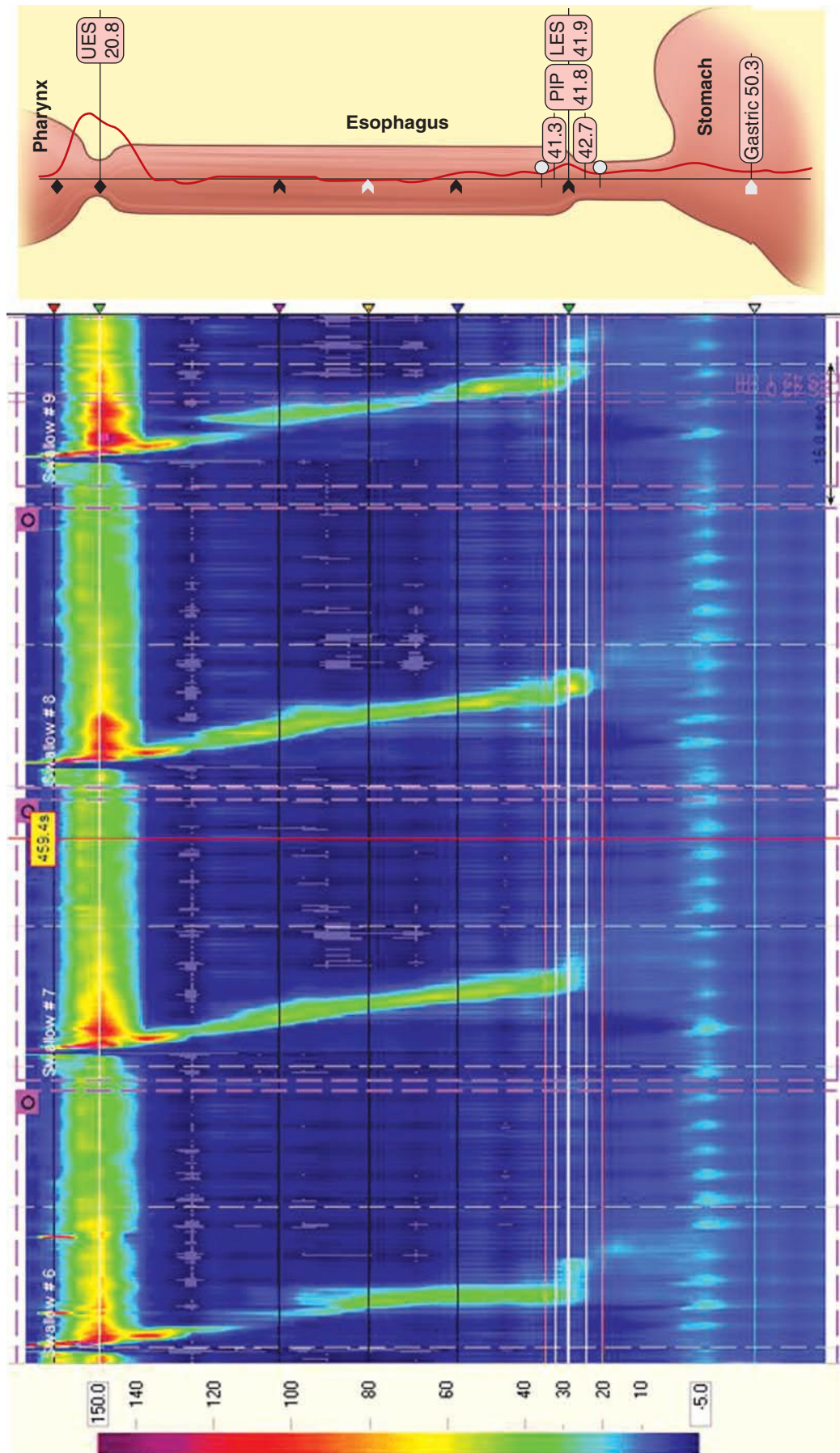


Figure 25-21B. High-resolution manometry motility study in patient with mechanically defective lower esophageal sphincter. Note the absence of lower esophageal sphincter tone. Pressure measurements are recorded with color coding (red = high; blue = low). LES = lower esophageal sphincter; PIP = pressure inversion point; UES = upper esophageal sphincter.

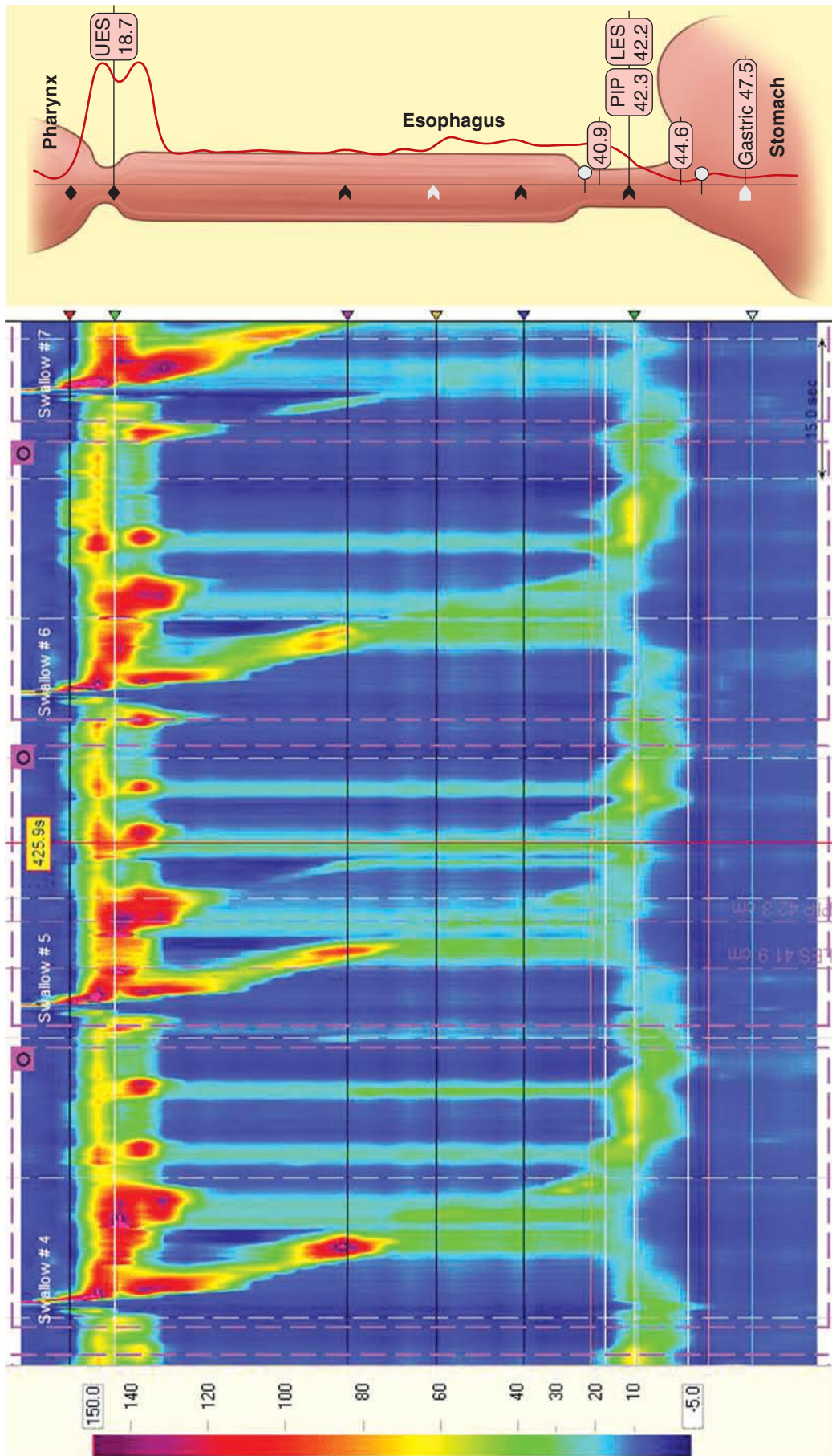


Figure 25-21C. High-resolution manometry motility study in patient with deficient esophageal body peristalsis. Note the very weak peristalsis in the lower two-thirds of the esophagus. Pressure measurements are recorded with color coding (red = high; blue = low). LES = lower esophageal sphincter; PIP = pressure inversion point; UES = upper esophageal sphincter.

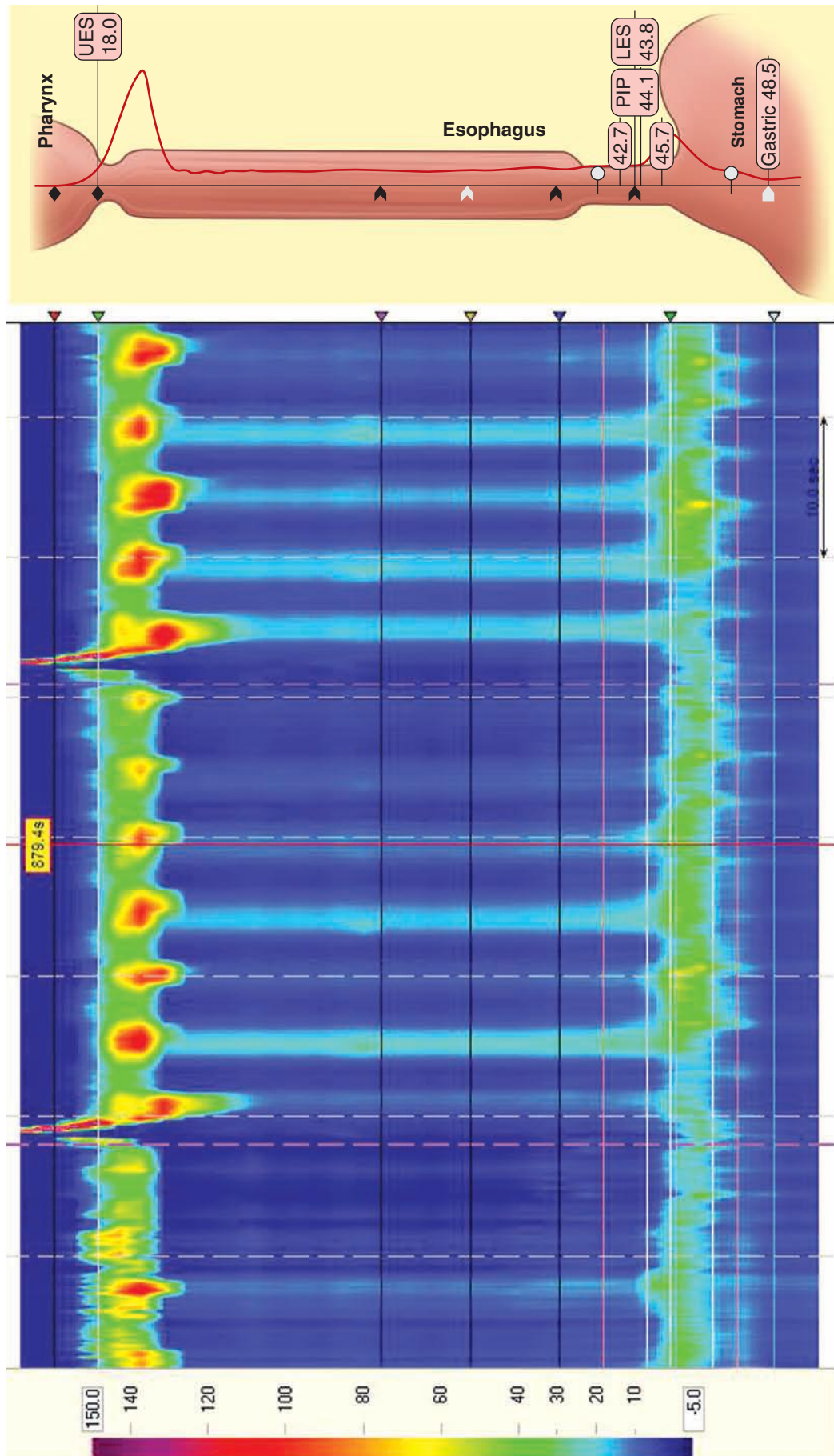


Figure 25-21D. High-resolution manometry motility study in patient with achalasia. Note the complete absence of esophageal body peristalsis, and the lack of relaxation of the lower esophageal sphincter. Pressure measurements are recorded with color coding (red = high; blue = low). LES = lower esophageal sphincter; PIP = pressure inversion point; UES = upper esophageal sphincter.

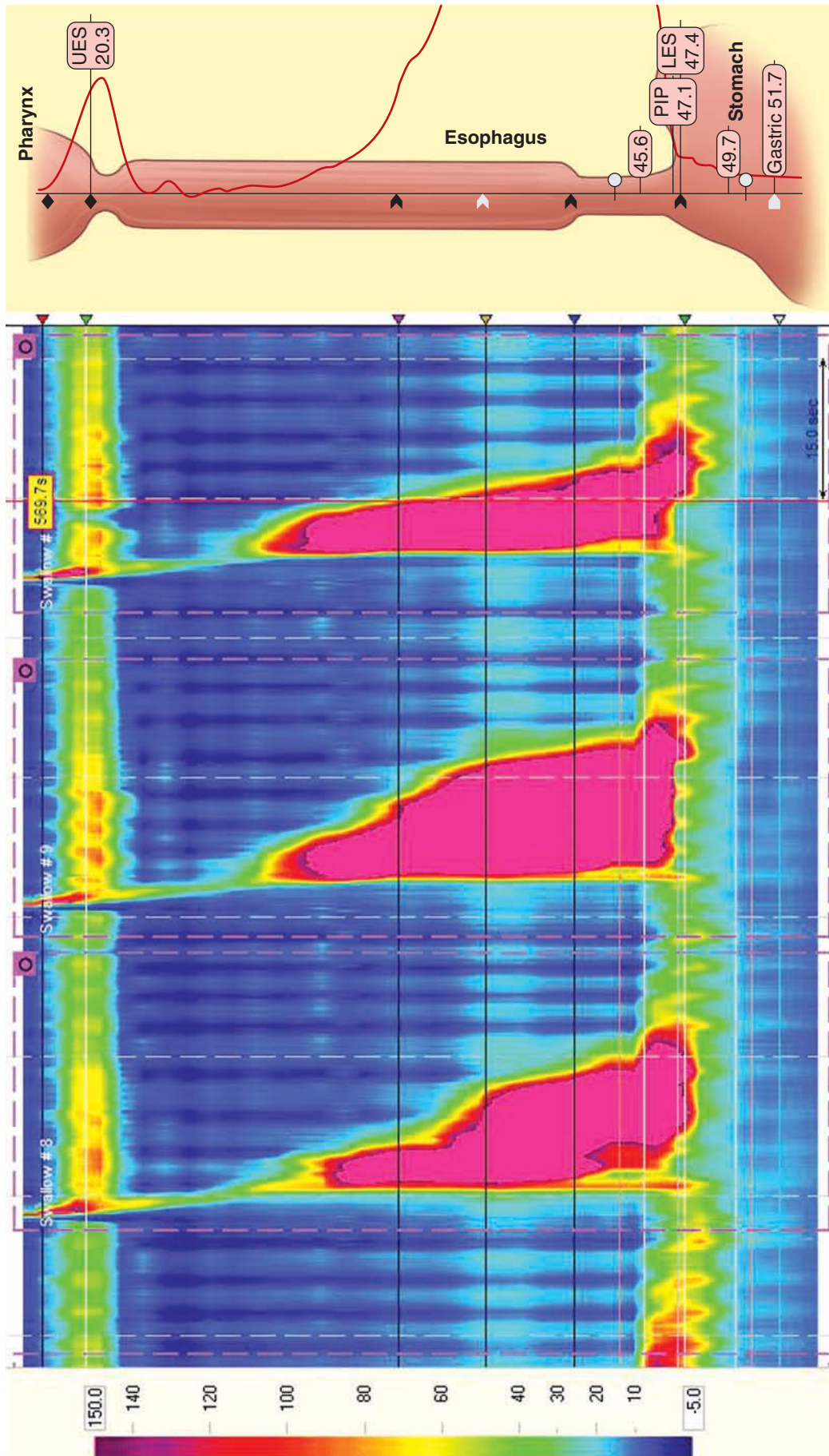


Figure 25-21E. High-resolution manometry motility study in patient with diffuse esophageal spasm. Note the very high amplitude contractions in the esophageal body. Pressure measurements are recorded with color coding (red = high; blue = low). LES = lower esophageal sphincter; PIP = pressure inversion point; UES = upper esophageal sphincter.

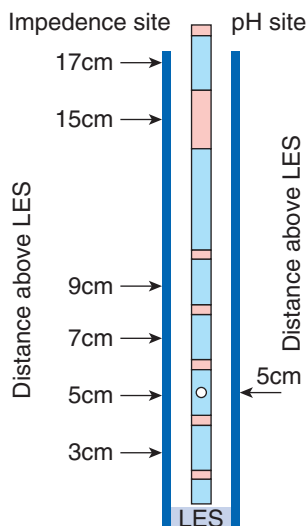


Figure 25-22. Esophageal impedance probe measures electrical resistance between evenly spaced electrodes. LES = lower esophageal sphincter.

contrast medium in the valleculae or hypopharyngeal recesses (Fig. 25-23). These findings are usually not specific, but rather common manifestations of neuromuscular disorders affecting the pharyngoesophageal area. Studies using liquid barium, barium-impregnated solids, or radiopaque pills aid the evaluation of normal and abnormal motility in the esophageal body. Loss of the normal stripping wave or segmentation of the barium column with the patient in the recumbent position correlates with

abnormal motility of the esophageal body. In addition, structural abnormalities such as small diverticula, webs, and minimal extrinsic impressions of the esophagus may be recognized only with motion-recording techniques. The simultaneous computerized capture of videofluoroscopic images and manometric tracings is now available, and is referred to as manofluorography. Manofluorographic studies allow precise correlation of the anatomic events, such as opening of the upper esophageal sphincter, with manometric observations, such as sphincter relaxation. Manofluorography, although not widely available, is presently the best means available to evaluate complex functional abnormalities.

Tests to Detect Increased Exposure to Gastric Juice

24-Hour Ambulatory pH Monitoring. The most direct method of measuring increased esophageal exposure to gastric juice is by an indwelling pH electrode, or, more recently, via a radiotelemetric pH monitoring capsule that can be clipped to the esophageal mucosa. The latter consists of an antimony pH electrode fitted inside a small, capsule-shaped device accompanied by a battery and electronics that allow 48-hour monitoring and transmission of the pH data via transcutaneous radio telemetry to a waist-mounted data logger. The device can be introduced either transorally or transnasally, and clipped to the esophageal mucosa using endoscopic fastening techniques. It passes spontaneously within 1 to 2 weeks. Prolonged monitoring of esophageal pH is performed by placing the pH probe or telemetry capsule 5 cm above the manometrically measured upper border of the distal sphincter for 24 hours. It measures the actual time the esophageal mucosa is exposed to gastric juice, measures the

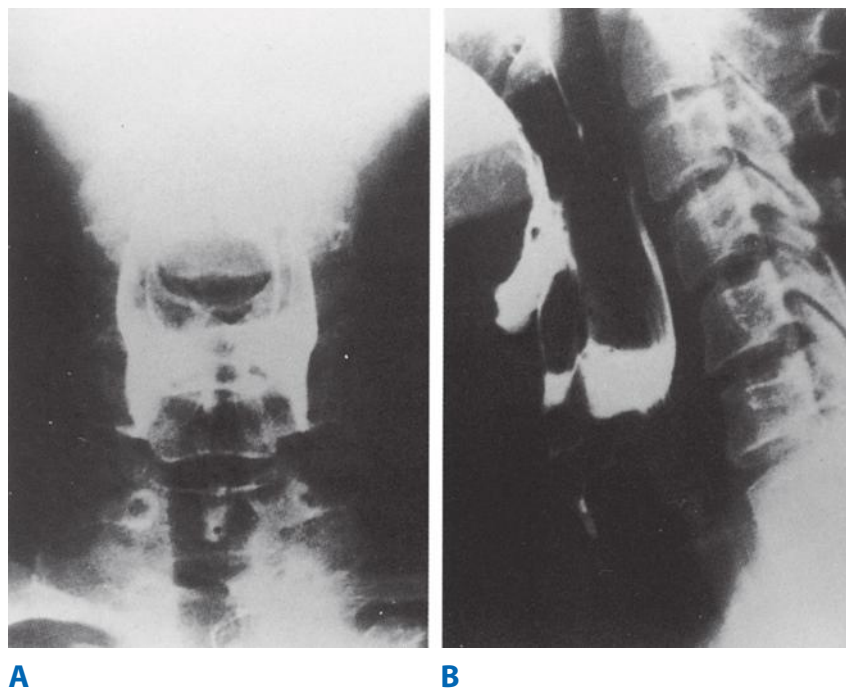


Figure 25-23. Esophagograms from a patient with cricopharyngeal achalasia. **A.** Anteroposterior film showing retention of the contrast medium at the level of the vallecula and piriform recesses, with no barium passing into the esophagus. **B.** Lateral film, taken opposite the C5–C6 vertebrae, showing posterior indentation of the cricopharynx, retention in the hypopharynx, and tracheal aspiration. (Reproduced with permission from Lafontaine E: Pharyngeal dysphagia, in DeMeester TR, Matthews H (eds): *International Trends in General Thoracic Surgery*, Vol. 3. Benign Esophageal Disease. St. Louis: Mosby, 1987, p 345. Copyright Elsevier.)

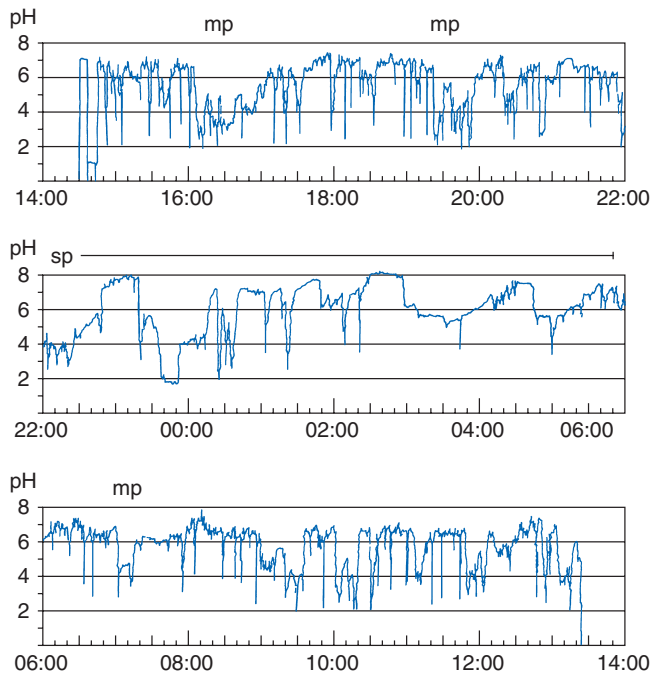


Figure 25-24. Strip chart display of a 24-hour esophageal pH monitoring study in a patient with increased esophageal acid exposure. mp = meal period; sp = supine period. (Reproduced with permission from DeMeester TR, Stein HJ, Fuchs KH: Physiologic diagnostic studies, in Zuidema GD, Orringer MB (eds): Shackelford's Surgery of the Alimentary Tract, 3rd ed, Vol. I. Philadelphia: W.B. Saunders, 1991, p 119. Copyright Elsevier.)

ability of the esophagus to clear refluxed acid, and correlates esophageal acid exposure with the patient's symptoms. A 24- to 48-hour period is necessary so that measurements can be made over one or two complete circadian cycles. This allows measuring the effect of physiologic activity, such as eating or sleeping, on the reflux of gastric juice into the esophagus (Fig. 25-24).

The 24-hour esophageal pH monitoring should not be considered a test for reflux, but rather a measurement of the esophageal exposure to gastric juice. The measurement is expressed by the time the esophageal pH was below a given threshold during the 24-hour period. This single assessment, although concise, does not reflect how the exposure has occurred; that is, did it occur in a few long episodes or several short episodes? Consequently, two other assessments are necessary: the frequency of the reflux episodes and their duration.

The units used to express esophageal exposure to gastric juice are: (a) cumulative time the esophageal pH is below a chosen threshold, expressed as the percentage of the total, upright, and supine monitored time; (b) frequency of reflux episodes below a chosen threshold, expressed as number of episodes per 24 hours; and (c) duration of the episodes, expressed as the number of episodes >5 minutes per 24 hours, and the time in minutes of the longest episode recorded. Table 25-2 shows the normal values for these components of the 24-hour record at the whole-number pH threshold derived from 50 normal asymptomatic subjects. The upper limits of normal were established at the ninety-fifth percentile. Most centers use pH 4 as the threshold.

The components' 24-hour pH record are then combined into one expression of the overall esophageal acid exposure below a pH threshold; the pH score is calculated by using the

Table 25-2

Normal values for esophageal exposure to pH <4 (n = 50)

COMPONENT	MEAN	SD	95%
Total time	1.51	1.36	4.45
Upright time	2.34	2.34	8.42
Supine time	0.63	1.0	3.45
No. of episodes	19.00	12.76	46.90
No. >5 min	0.84	1.18	3.45
Longest episode	6.74	7.85	19.80

SD = standard deviation.

Source: Reproduced with permission from DeMeester TR, et al.: Gastroesophageal reflux disease, in Moody FG, Carey LC, et al. (eds): Surgical Treatment of Digestive Disease. Chicago: Year Book Medical, 1990, p 68. Copyright Elsevier.

standard deviation (SD) of the mean of each of the six components measured in the 50 normal subjects as a weighting factor. By accepting an abstract zero level two SDs below the mean, the data measured in normal subjects could be treated as though they had a normal distribution. Thus, any measured patient value could be referenced to this zero point, and, in turn, be awarded points based on whether it was below or above the normal mean value for that component, according to this formula:

$$\text{Component score} = \frac{\text{Point value} - \text{mean}}{\text{SD} + 1}$$

The upper limits of normal for the composite score for each whole-number pH threshold are shown in Table 25-3.

The detection of increased esophageal exposure to acid gastric juice is more dependable than the detection of increased exposure to alkaline gastric juice. The latter is suggested by an increased alkaline exposure time above pH 7 or 8. Increased

Table 25-3

Normal composite score for various pH thresholds: upper level of normal value

pH THRESHOLD	95TH PERCENTILE
<1	14.2
<2	17.37
<3	14.10
<4	14.72
<5	15.76
<6	12.76
>7	14.90
>8	8.50

Source: Reproduced with permission from DeMeester TR, et al.: Gastroesophageal reflux disease, in Moody FG, Carey LC, et al. (eds): Surgical Treatment of Digestive Disease. Chicago: Year Book Medical, 1990, p 69. Copyright Elsevier.

exposure in this pH range can be caused by abnormal calibration of the pH recorder; dental infection, which increases salivary pH; esophageal obstruction, which results in static pools of saliva with an increase in pH secondary to bacterial overgrowth; or regurgitation of alkaline gastric juice into the esophagus. Using a properly calibrated probe, in the absence of dental infections or esophageal obstruction, the percentage of time the pH is measured above 7 correlates with the concentration of bile acids continuously aspirated over a 24-hour period.

When done in a test population with an equal distribution of normal healthy subjects and patients with the classic reflux symptoms and a defective sphincter, 24-hour esophageal pH monitoring had a sensitivity and specificity of 96%. (Sensitivity is the ability to detect a disease when known to be present; specificity is the ability to exclude the disease when known to be absent.) This gave a predictive value of a positive and negative test of 96%, and an overall accuracy of 96%. Based on these studies and extensive clinical experience, 24-hour esophageal pH monitoring has emerged as the gold standard for the diagnosis of GERD.

Catheter-based, 24-hour, ambulatory, esophageal pH monitoring does have a significant drawback of the physical presence of a transnasal catheter that must be worn for 24 hours. Although most doctors ask patients to go about their normal activities of daily living, many do not comply due to embarrassment about the catheter or from discomfort. The recent development of a wireless capsule, which can be implanted in the esophagus and record pH data for 48 hours, has significantly changed patient satisfaction with the procedure.

The Bravo pH Capsule (Medtronic, Minneapolis, MN) measures pH levels in the esophagus and transmits continuous esophageal pH readings to a receiver worn on the patient's belt or waistband (Fig. 25-27). Symptoms that the patient experience are recorded in a diary and/or by pressing buttons on the receiver unit. Generally, 48 hours of pH data are measured with this probe. A recent study has shown that the addition of a second day of pH monitoring increased the sensitivity of pH measurement by 22%. The capsule eventually detaches and passes through the digestive tract in 5 to 7 days.

Radiographic Detection of Gastroesophageal Reflux. The definition of radiographic gastroesophageal reflux varies depending on whether reflux is spontaneous or induced by various maneuvers. In only about 40% of patients with classic symptoms of GERD is spontaneous reflux (i.e., reflux of barium from the stomach into the esophagus with the patient in the upright position) observed by the radiologist. In most patients who show spontaneous reflux on radiography, the diagnosis of increased esophageal acid exposure is confirmed by 24-hour esophageal pH monitoring. Therefore, the radiographic demonstration of spontaneous regurgitation of barium into the esophagus in the upright position is a reliable indicator that reflux is present. However, failure to see this does not indicate the absence of disease, and for this reason this test is rarely relied on for clinical diagnosis.

Tests of Duodenogastric Function

Esophageal disorders are frequently associated with abnormalities of duodenogastric function. Abnormalities of the gastric reservoir or increased gastric acid secretion can be responsible for increased esophageal exposure to gastric juice. Reflux of alkaline duodenal juice, including bile salts, pancreatic enzymes, and bicarbonate, is thought to have a role in the pathogenesis of

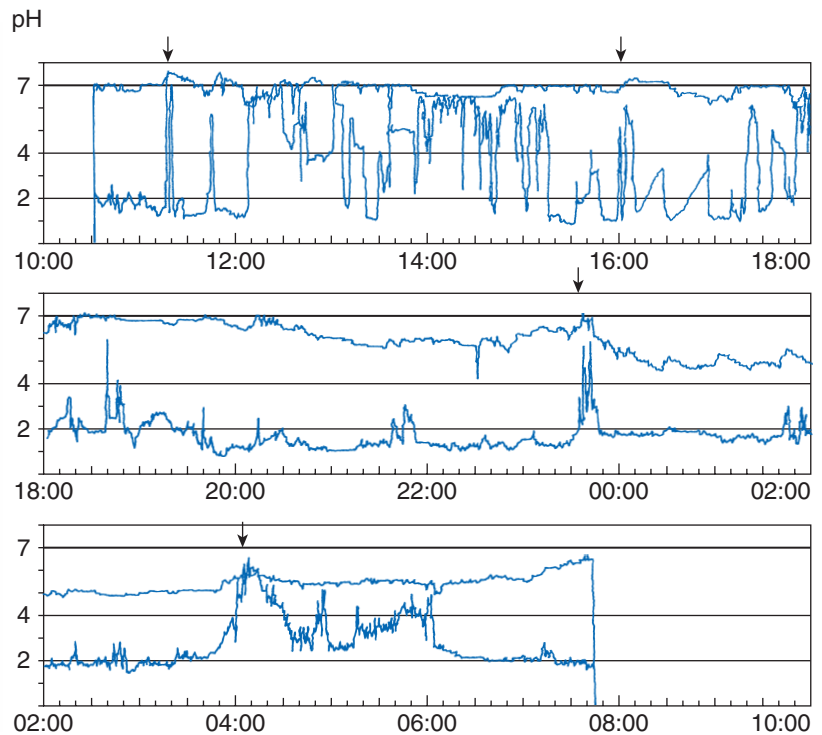
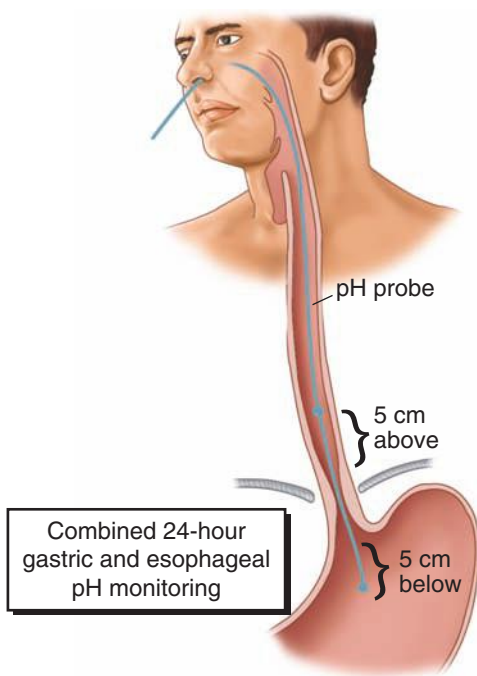
esophagitis and complicated Barrett's esophagus. Furthermore, functional disorders of the esophagus are often not confined to the esophagus alone, but are associated with functional disorders of the rest of the foregut (i.e., stomach and duodenum). Tests of duodenogastric function that are helpful to investigate esophageal symptoms include gastric emptying studies, gastric acid analysis, and cholescintigraphy (for the diagnosis of pathologic duodenogastric reflux). The single test of 24-hour gastric pH monitoring can be used to identify gastric hypersecretion and imply the presence of duodenogastric reflux and delayed gastric emptying.

Gastric Emptying. Gastric emptying studies are performed with radionuclide-labeled meals. Emptying of solids and liquids can be assessed simultaneously when both phases are marked with different tracers. After ingestion of a labeled standard meal, gamma camera images of the stomach are obtained at 5- to 15-minute intervals for 1.5 to 2 hours. After correction for decay, the counts in the gastric area are plotted as the percentage of total counts at the start of the imaging. The resulting emptying curve can be compared with data obtained in normal volunteers. In general, normal subjects will empty 59% of a meal within 90 minutes. Although delayed gastric emptying is often associated with gastroesophageal reflux, in general delayed emptying does not correlate with a poorer clinical outcome after antireflux surgery, and it should not be considered a contraindication to surgical treatment.

24-Hour Gastric pH Monitoring. Monitoring is performed over a complete circadian cycle with a pH electrode placed 5 cm below the manometrically located LES. The patient is fully ambulatory during the test and is encouraged to perform normal daily activity. The gastric pH profile is assessed separately for the meal, postprandial period, and fasting period. The latter is divided into the time spent upright and supine.

The interpretation of continuous gastric pH recordings is more difficult than that of esophageal pH recordings. This is because the gastric pH environment is determined by a complex interplay of acid secretion; mucus secretion; ingested food; swallowed saliva; regurgitated duodenal, pancreatic, and biliary secretions; and the effectiveness of the mixing and evacuation of the chyme. Using 24-hour gastric pH monitoring to evaluate the gastric secretory state is based on studies that have shown that a good correlation exists between increased basal acid output on standard gastric acid analysis, and a left shift on the frequency distribution graph of gastric pH recordings during the supine fasting period. The evaluation of gastric emptying by 24-hour gastric pH monitoring is based on studies demonstrating a good correlation between the emptying of a solid meal and the duration of the postprandial plateau and decline phase of the gastric pH record.

Using 24-hour gastric pH monitoring to evaluate duodenogastric reflux is based on the observation that reflux of alkaline duodenal juice into the stomach can alkalize the gastric pH environment. The measurement is not straightforward because of the effect of meals, and reduction in acid secretion can result in changes in gastric pH that mimic alkaline reflux episodes. To overcome this problem, computerized measurements of the number and height of alkalizing peaks, the baseline pH, the postprandial pH plateau, and the pattern of pH decline from the plateau can be used to identify the probability of duodenogastric reflux. The results are presented as an overall score that indicates the likelihood of pathologic duodenogastric reflux.



A Combined esophageal and gastric pH monitoring showing position of probes in relation to the lower esophageal sphincter. **B** Combined ambulatory esophageal (upper tracing) and gastric (lower tracing) pH monitoring showing duodenogastric reflux (arrows) with propagation of the alkaline juice into the esophagus of a patient with complicated Barrett's esophagus. The gastric tracing (lower) is taken from a probe lying 5 cm below the upper esophageal sphincter. The esophageal tracing (upper) is taken from a probe lying 5 cm above the lower esophageal sphincter. Note that in only a small proportion of time does duodenogastric reflux move the pH of the esophagus above the threshold of 7, causing the iceberg effect. (Reproduced with permission from DeMeester TR, Stein HJ, Fuchs KH: Physiologic diagnostic studies, in Zuidema GD, Orringer MB (eds): Shackelford's Surgery of the Alimentary Tract, 3rd ed., Vol. I. Philadelphia: W.B. Saunders, 1991, p 123. Copyright Elsevier.)

Initial data indicate that this approach has a higher sensitivity and specificity for the diagnosis of pathologic duodenogastric reflux than scintigraphic methods do.

Combined 24-hour esophageal and gastric pH monitoring can identify excessive alkaline duodenogastric and alkaline gastroesophageal reflux in symptomatic patients. The combined tracings can often identify simultaneous gastric and esophageal alkalization, suggesting a duodenal origin for the esophageal alkaline exposure (Fig. 25-25).

GASTROESOPHAGEAL REFLUX DISEASE

GERD was not recognized as a significant clinical problem until the mid-1930s and was not identified as a precipitating cause for esophagitis until after World War II. In the early twenty-first century, it has grown to be a very common problem and now accounts for a majority of esophageal pathology. It is recognized as a chronic disease, and when medical therapy is required, it is often lifelong treatment. Recent efforts at the development of various endoscopic antireflux interventions, although innovative, have not been successful in consistently controlling gastroesophageal reflux. Antireflux surgery is an effective and long-term therapy and is the only treatment that is able to restore the gastroesophageal barrier. Despite the common prevalence of GERD, it can be one of the most challenging diagnostic and therapeutic problems in clinical medicine.

A contributing factor to this is the lack of a universally accepted definition of the disease.

The most simplistic approach is to define the disease by its symptoms. However, symptoms thought to be indicative of GERD, such as heartburn or acid regurgitation, are very common in the general population and many individuals consider them to be normal and do not seek medical attention. Even when excessive, these symptoms are not specific for gastroesophageal reflux. They can be caused by other diseases such as achalasia, DES, esophageal carcinoma, pyloric stenosis, cholelithiasis, gastritis, gastric or duodenal ulcer, and coronary artery disease.

A thorough, structured evaluation of the patient's symptoms is essential before any therapy, particularly any form of esophageal surgery. The presence and severity of both typical symptoms of heartburn, regurgitation, and dysphagia, and atypical symptoms of cough, hoarseness, chest pain, asthma, and aspiration should be discussed with the patient in detail. Many of these atypical symptoms may not be esophageal related and hence will not improve and may even worsen with antireflux surgery.

Heartburn is generally defined as a *substernal burning-type discomfort*, beginning in the epigastrium and radiating upward. It is often aggravated by meals, spicy or fatty foods, chocolate, alcohol, and coffee and can be worse in the supine position. It is commonly, although not universally, relieved by antacid or antisecretory medications. Epidemiologic studies

Table 25-4

American Gastroenterologic Association Gallup poll on nighttime gastroesophageal reflux disease symptoms

- 50 million Americans have nighttime heartburn at least 1/wk
- 80% of heartburn sufferers had nocturnal symptoms—65% both day & night
- 63% report that it affects their ability to sleep and impacts their work the next day
- 72% are on prescription medications
- Nearly half (45%) report that current remedies do not relieve all symptoms

have shown that heartburn occurs monthly in as many as 40% to 50% of the Western population. The occurrence of heartburn at night and its effect on quality of life have recently been highlighted by a Gallup poll conducted by the American Gastroenterologic Society (Table 25-4).

Regurgitation, the effortless return of acid or bitter gastric contents into the chest, pharynx, or mouth, is highly suggestive of foregut pathology. It is often particularly severe at night when supine or when bending over and can be secondary to either an incompetent or obstructed GEJ. With the later, as in achalasia, the regurgitant is often bland, as if food was put into a blender. When questioned, most patients can distinguish the two. It is the regurgitation of gastric contents that may result in associated pulmonary symptoms, including cough, hoarseness, asthma, and recurrent pneumonia. Bronchospasm can be precipitated by esophageal acidification and cough by either acid stimulation or distention of the esophagus.

Dysphagia, or difficulty swallowing, is a relatively nonspecific term but arguably the most specific symptom of foregut disease. It can be a sign of underlying malignancy and should be aggressively investigated until a diagnosis is established. Dysphagia refers to the sensation of difficulty in the passage of food from the mouth to the stomach and can be divided into oropharyngeal and esophageal etiologies. Oropharyngeal dysphagia is characterized by difficulty transferring food out of the mouth into the esophagus, nasal regurgitation, and/or aspiration. Esophageal dysphagia refers to the sensation of food sticking in the lower chest or epigastrium. This may or may not be accompanied by pain (odynophagia) that will be relieved by the passage of the bolus.

Chest pain, although commonly and appropriately attributed to cardiac disease, is frequently secondary to esophageal pathology as well. As early as 1982, DeMeester and associates showed that nearly 50% of patients with severe chest pain, normal cardiac function, and normal coronary arteriograms had positive 24-hour pH studies, implicating gastroesophageal reflux as the underlying etiology. Exercise-induced gastroesophageal reflux is well known to occur, and may result in exertional chest pain similar to angina. It can be quite difficult, if not impossible, to distinguish between the two etiologies, particularly on clinical grounds alone. Nevens and colleagues evaluated the ability of experienced cardiologists to differentiate pain of cardiac vs. esophageal origin. Of 248 patients initially seen by cardiologists, 185 were thought to have typical angina and 63 atypical chest pain. Forty eight (26%) of those thought to have classic angina had normal coronary angiograms and 16 of the 63 with atypical pain had abnormal angiogram. Thus, the cardiologists'

clinical impression was wrong 25% of the time. Finally, Pope and associates investigated the ultimate diagnosis in 10,689 patients presenting to an emergency room with acute chest pain. Approximately 17% were found to have acute ischemia, 6% stable angina, 21% other cardiac causes, and 55% had noncardiac causes. They concluded that the majority of people presenting to the emergency room with chest pain do not have an underlying cardiac etiology for their symptoms. Chest pain precipitated by meals, occurring at night while supine, nonradiating, responsive to antacid medication, or accompanied by other symptoms suggesting esophageal disease such as dysphagia or regurgitation should trigger the thought of possible esophageal origin. Further, the distinction between heartburn and chest pain is also difficult and largely dependent upon the individual patient. One person's heartburn is another's chest pain.

The precise mechanisms accounting for the generation of symptoms secondary to esophageal pathology remain unclear. Considerable insight has been acquired, however. Investigations into the effect of luminal content, esophageal distention and muscular function, neural pathways, and brain localization have provided a basic understanding of the stimuli responsible for symptom generation. It is also clear that the visceroneural pathways of the foregut are complexly intertwined with that of the tracheobronchial tree and heart. This fact accounts for the common overlap of clinical presentations with diverse disease processes in upper GI, cardiac, and pulmonary systems.

The Human Antireflux Mechanism and the Pathophysiology of Gastroesophageal Reflux Disease

There is a high-pressure zone located at the esophagogastric junction in humans. Although this is typically referred to as the lower esophageal "sphincter," there are no distinct anatomical landmarks which define its beginning and end. Architecturally speaking, there is a specialized thickening in this region that is made up of the collar sling musculature and the clasp fibers. The collar sling is located on the greater curvature side of the junction, and the clasp fibers are located on the lesser curvature side. These muscles remain in tonic opposition until the act of swallowing, whereupon receptive relaxation occurs allowing passage of a food bolus into the stomach. In addition, the LES will also open when the gastric fundus is distended with gas and liquid, thus resulting in an unfolding of the valve and enabling venting of gas (a belch). Whether physiologic or pathologic, the common denominator for most episodes of gastroesophageal reflux is the loss of the high-pressure zone and thus, a decrease in the resistance it imparts to the retrograde flow of gastric juice into the esophageal body. The primary cause of GERD is secondary to the permanent attenuation of the collar sling musculature, with a resultant opening of the gastric cardia and loss of the high-pressure zone as measured with esophageal manometry.

The Lower Esophageal Sphincter. As defined by esophageal manometry, there are three characteristics of the LES that work in unison to maintain its barrier function. These characteristics include the resting LES pressure, its overall length, and the intra-abdominal length that is exposed to the positive pressure environment of the abdomen (Table 25-5). The resistance to gastroesophageal reflux is a function of both the resting LES pressure and length over which this pressure is exerted. Thus, as the sphincter becomes shorter, a higher pressure will be required in order to prevent a given amount of reflux (Fig. 25-26).

Table 25-5

Normal manometric values of the distal esophageal sphincter, n = 50

PARAMETER	MEDIAN VALUE	2.5TH PERCENTILE	97.5TH PERCENTILE
Pressure (mmHg)	13	5.8	27.7
Overall length (cm)	3.6	2.1	5.6
Abdominal length (cm)	2	0.9	4.7

Much like the neck of a balloon as it is inflated, as the stomach fills and distends, sphincter length decreases. Therefore, if the overall length of the sphincter is permanently short from repeated distention of the fundus secondary to large volume meals, then with minimal episodes of gastric distention and pressure, there will be insufficient sphincter length for the barrier to remain competent, and reflux will occur.

A third characteristic of the LES that impacts its ability to prevent reflux is its position about the diaphragm. It is important that a portion of the total length of the LES be exposed to the effects of an intra-abdominal pressure. That is, during periods of elevated intra-abdominal pressure, the resistance of the barrier would be overcome if pressure were not applied equally to both the LES and stomach simultaneously. Thus, in the presence of a hiatal hernia, the sphincter resides entirely within the chest cavity and cannot respond to an increase in intra-abdominal pressure because the pinch valve mechanism is lost and gastroesophageal reflux is more liable to occur.

Therefore, a permanently defective sphincter is defined by one or more of the following characteristics: An LES with a mean resting pressure of less than 6 mmHg, an overall sphincter length of <2 cm, and intra-abdominal sphincter length of <1 cm. Compared to normal subjects without GERD these values are below the 2.5 percentile for each parameter. The most common cause of a defective sphincter is an inadequate abdominal length.

Once the sphincter is permanently defective, this condition is irreversible, and although esophageal mucosal injury may

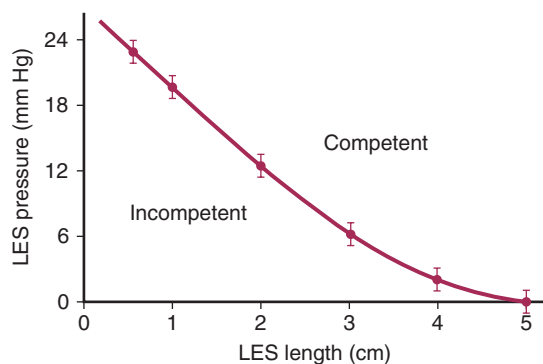


Figure 25-26. As the esophageal sphincter becomes shorter, increased pressure is necessary to maintain competence. LES = lower esophageal sphincter.

be healed with antisecretory medication, reflux will continue to occur. Additionally, the presence of a defective LES may be associated with reduced esophageal body function and thus decrease clearance times of refluxed material. In addition, with the progressive loss of effective esophageal clearance the patient may be predisposed to severe mucosal injury, volume regurgitation, aspiration, and pulmonary failure. Reflux may occur in the face of a normal LES resting pressure. This condition is usually due to a functional problem of gastric emptying or excessive air swallowing. These conditions may lead to gastric distention, increased intra-gastric pressure, a resultant shortening or unfolding of the LES, and subsequent reflux. The mechanism by which gastric distention contributes to LES unfolding provides a mechanical explanation for “transient LES relaxation.” It is thought that with repeated gastric distention secondary to large meal volume or chronic air swallowing, there is repeated unfolding of the LES and subsequent attenuation of the collar sling musculature. It is at this point that the physiologic and normal mechanism of gastric venting is replaced with pathologic and severe postprandial reflux disease. In addition, patients with GERD will increase the frequency of swallowing in an effort to neutralize the refluxed acid with their saliva (pH 7.0). This phenomenon leads to increased air swallowing and further gastric distention thus, compounding the problem. Therefore GERD may have its origins in the stomach secondary to gastric distention due to overeating, and this may be further compounded by the ingestion of fatty meals, which result in delayed gastric emptying.

Relationship Between Hiatal Hernia and Gastroesophageal Reflux Disease. As the collar sling musculature and clasp fibers become attenuated with repeated gastric distention, the esophagogastric junction begins to assume an “upside down funnel” appearance, with progressive opening of the acute angle of His. This in turn may result in attenuation and stretching of the phrenoesophageal ligament, with subsequent enlargement of the hiatal opening and axial herniation. There is a high degree of correlation between reflux threshold and the degree of hiatal herniation (Fig. 25-27).

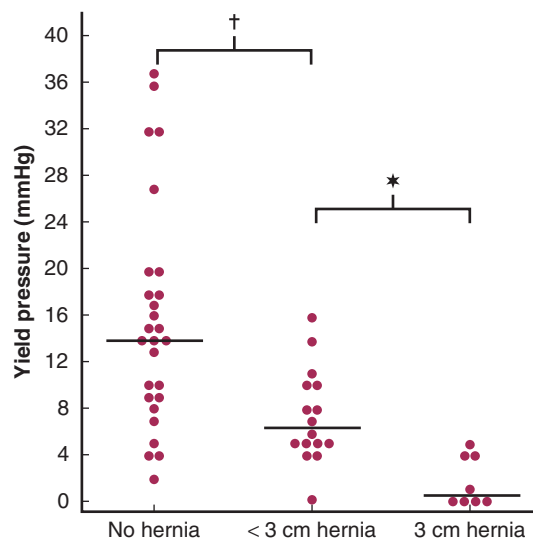


Figure 25-27. Yield pressure of the lower esophageal sphincter decreases as hiatal hernia size increases.

It is believed that the source of postprandial esophageal acid exposure results from a “pocket of acid” at the esophageal gastric junction that is unaffected by the buffering action of the meal. This same process is thought to occur in patients with endoscopy-negative dyspepsia and normal conventional esophageal pH monitoring at a location of 5 cm proximal to the upper boarder of the LES.

Summary. It is believed that GERD has its origins within the stomach. Distention of the fundus occurs because of overeating and delayed gastric emptying secondary to a high-fat diet. The resultant distention causes “unrolling” of the sphincter by the expanding fundus, and this subsequently exposes the squamous epithelium in the region of the distal LES to gastric juice. Repeated exposure results in inflammation and the development of columnar epithelium at the cardia. This is the initial step of the development of carditis and explains why in early disease esophagitis is mild and commonly limited to the very distal aspect of the esophagus. The patient attempts to compensate for this by increased swallowing, allowing the saliva to neutralize the refluxed gastric juice and thus, alleviate the discomfort induced by the reflux event. The increased swallowing results in aerophagia, bloating, and belching. This in turn creates a viscous cycle of increased gastric distention and thus further exposure and repetitive injury to the distal esophagus. The development of carditis explains the complaint of epigastric pain often experienced by patients with early reflux disease. Additionally this process can lead to a fibrotic mucosal ring located at the squamocolumnar junction, which is termed a “Schatzki ring,” and may result in dysphagia. This inflammatory process may extend into muscularis propria and thus result in a progressive loss in the length and pressure of the LES. This explanation for the pathophysiology of GERD is supported by the observation that severe esophagitis is almost always associated with a defective LES.

Complications Associated with Gastroesophageal Reflux Disease

The complications of gastroesophageal reflux disease may result from the direct injurious effects of gastric fluid on the mucosa, larynx, or respiratory epithelium. Complications due to repetitive reflux are esophagitis, stricture, and BE; repetitive aspiration may lead to progressive pulmonary fibrosis. The severity of the complications is directly related to the prevalence of a structurally defective sphincter (Table 25-6). The observation that a structurally defective sphincter occurs in 42% of patients without complications (most of whom have one or two components failed) suggests that disease may be confined to the sphincter due to compensation by a vigorously contracting esophageal body. Eventually, all three components of the sphincter fail, allowing unrestricted reflux of gastric juice into the esophagus and overwhelming its normal clearance mechanisms. This leads to esophageal mucosal injury with progressive deterioration of esophageal contractility, as is commonly seen in patients with strictures and BE. The loss of esophageal clearance increases the potential for regurgitation into the pharynx with aspiration.

The potential injurious components that reflux into the esophagus include gastric secretions such as acid and pepsin, as well as biliary and pancreatic secretions that regurgitate from the duodenum into the stomach. There is a considerable body of experimental evidence to indicate that maximal epithelial injury occurs during exposure to bile salts combined with acid and pepsin. These studies have shown that acid alone does minimal

Table 25-6

Complications of gastroesophageal reflux disease: 150 consecutive cases with proven gastroesophageal reflux disease (24-hour esophageal pH monitoring endoscopy, and motility)

COMPLICATION	NO.	STRUCTURALLY NORMAL SPHINCTER (%)	STRUCTURALLY DEFECTIVE SPHINCTER (%)
None	59	58	42
Erosive esophagitis	47	23	77 ^a
Stricture	19	11	89
Barrett's esophagus	25	0	100
Total	150		

^aGrade more severe with defective cardia.

Source: Reproduced with permission from DeMeester TR, et al.: Gastroesophageal reflux disease, in Moody FG, Carey LC, et al. (eds): Surgical Treatment of Digestive Disease. Chicago: Year Book Medical, 1990, p 81. Copyright Elsevier.

damage to the esophageal mucosa, but the combination of acid and pepsin is highly deleterious. Similarly, the reflux of duodenal juice alone does little damage to the mucosa, although the combination of duodenal juice and gastric acid is particularly noxious.

Experimental animal studies have shown that the reflux of duodenal contents into the esophagus enhances inflammation, increases the prevalence of Barrett's esophagus, and results in the development of esophageal adenocarcinoma. The component of duodenal juice thought to be most damaging is bile acids. For bile acids to injure mucosal cells, it is necessary that they be both soluble and un-ionized, so that the un-ionized, non-polar form may enter mucosal cells. Before the entry of bile into the GI tract, 98% of bile acids are conjugated with either taurine or glycine in a ratio of about 3:1. Conjugation increases the solubility and ionization of bile acids by lowering their pK_a . At the normal duodenal pH of approximately 7, over 90% of bile salts are in solution and completely ionized. At pH ranges from 2 to 7, there is a mixture of the ionized salt and the lipophilic, non-ionized acid. Acidification of bile to below pH 2 results in an irreversible bile acid precipitation. Consequently, under normal physiologic conditions, bile acids precipitate and are of minimal consequence when an acid gastric environment exists. On the other hand, in a more alkaline gastric environment, such as occurs with excessive duodenogastric reflux and after acid suppression therapy or vagotomy and partial or total gastrectomy, bile salts remain in solution, are partially dissociated, and when refluxed into the esophagus can cause severe mucosal injury by crossing the cell membrane and damaging the mitochondria.

Complications of gastroesophageal reflux such as esophagitis, stricture, and Barrett's metaplasia occur in the presence of two predisposing factors: a mechanically defective LES and an increased esophageal exposure to fluid containing duodenal content which includes bile and pancreatic juice. The duodenal origin of esophageal contents in patients with an increased exposure to a pH >7 has previously been confirmed by esophageal

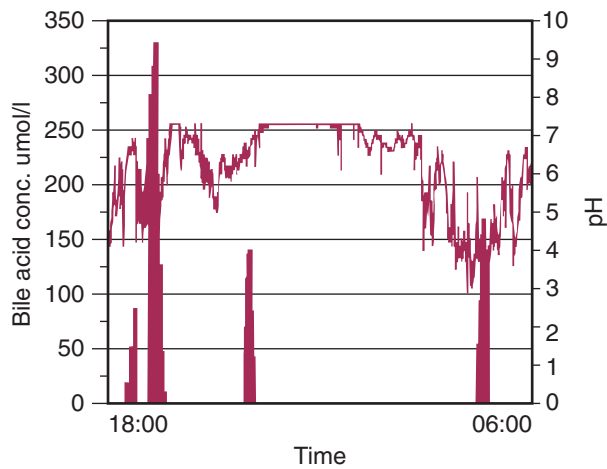
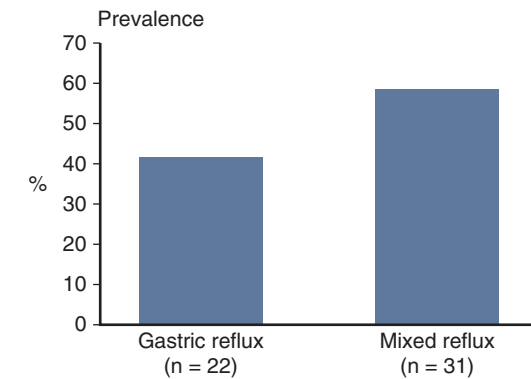


Figure 25-28. Sample bile acid concentration and esophageal pH plotted against time to obtain detailed profiles; in this case showing both significant bile acid (vertical bars) and acid (linear plot) reflux. (Reproduced with permission from Nehra D, Watt P, Pye JK, et al.: Automated oesophageal reflux sampler: A new device used to monitor bile acid reflux in patients with gastroesophageal reflux disease. *J Med Engr Tech* 21:1, 1997.)

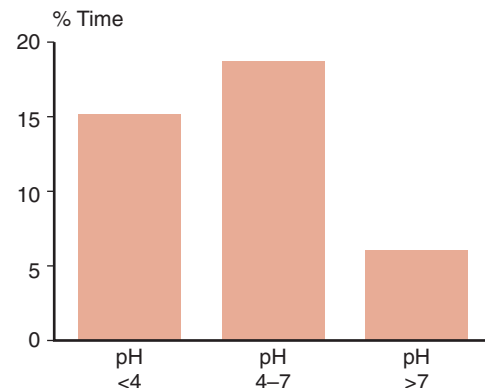
aspiration studies (Fig. 25-28). Studies have clarified and expanded these observations by measuring esophageal bilirubin exposure over a 24-hour period as a marker for the presence of duodenal juice. Direct measurement of esophageal bilirubin exposure as a marker for duodenal juice has shown that 58% of patients with GERD have increased esophageal exposure to duodenal juice, and that this exposure occurs most commonly when the esophageal pH is between 4 and 7 (Fig. 25-29). These earlier studies have been confirmed by other studies which measure volume reflux using impedance technology.

The fact that the combination of refluxed gastric and duodenal juice is more noxious to the esophageal mucosa than gastric juice alone may explain the repeated observation that 25% of patients with reflux esophagitis develop recurrent and/or progressive mucosal damage, often despite medical therapy (Fig. 25-30). A potential reason is that acid suppression therapy is unable to consistently maintain the pH of refluxed gastric and duodenal juice above the range of 6. Lapses into pH ranges from 2 to 6 encourage the formation of undissociated, nonpolarized, soluble bile acids, which are capable of penetrating the cell wall and injuring mucosal cells. To ensure that bile acids remain completely ionized in their polarized form, and thus unable to penetrate the cell, requires that the pH of the refluxed material be maintained above 7, 24 hours a day, 7 days a week, for the patient's lifetime. In practice, this would not only be impractical but likely impossible, unless very high doses of medications were used. The use of lesser doses would allow esophageal mucosal damage to occur while the patient was relatively asymptomatic. Antireflux operative procedures re-establish the barrier between stomach and esophagus, protecting the esophagus from damage in patients with mixed gastroesophageal reflux.

If reflux of gastric juice is allowed to persist and sustained or repetitive esophageal injury occurs, two sequelae can result. First, a luminal stricture can develop from submucosal and



A



B

Figure 25-29. **A.** Prevalence of reflux types in 53 patients with gastroesophageal reflux disease. **B.** Esophageal luminal pH during bilirubin exposure. (Reproduced with permission from Kauer WK, Peters JH, DeMeester TR, et al.: Mixed reflux of gastric juice is more harmful to the esophagus than gastric juice alone: The need for surgical therapy reemphasized. *Ann Surg.* 222:525, 1995.)

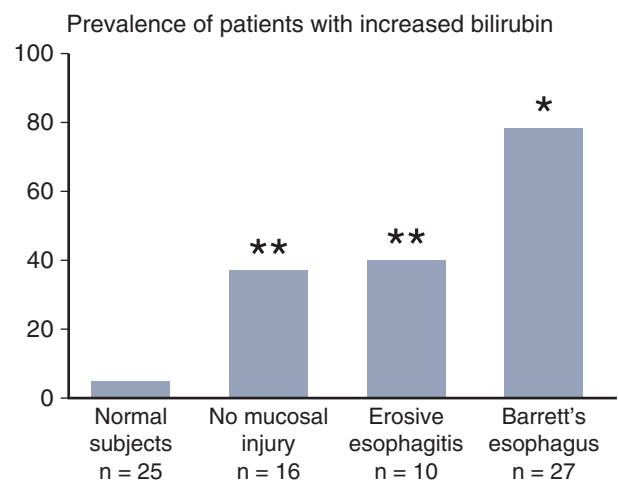


Figure 25-30. Prevalence of abnormal esophageal bilirubin exposure in healthy subjects and in patients with gastroesophageal reflux disease with varied degrees of mucosal injury. (* $P < .03$ vs all other groups, ** $P < .03$ vs. healthy subjects.) (Reproduced with permission from Kauer WK, Peters JH, DeMeester TR, et al.: Mixed reflux of gastric juice is more harmful to the esophagus than gastric juice alone: The need for surgical therapy reemphasized. *Ann Surg.* 222:525, 1995.)

eventually intramural fibrosis. Second, the tubular esophagus may become replaced with columnar epithelium. The columnar epithelium is resistant to acid and is associated with the alleviation of the complaint of heartburn. This columnar epithelium often becomes intestinalized, identified histologically by the presence of goblet cells. This specialized IM is currently required for the diagnosis of BE. Endoscopically, BE can be quiescent or associated with complications of esophagitis, stricture, Barrett's ulceration, and dysplasia. The complications associated with BE may be due to the continuous irritation from refluxed duodenogastric juice. This continued injury is pH dependent and may be modified by medical therapy. The incidence of metaplastic Barrett's epithelium becoming dysplastic and progressing to adenocarcinoma is approximately 0.2% to 0.5% per year.

An esophageal stricture can be associated with severe esophagitis or BE. In the latter situation, it occurs at the site of maximal inflammatory injury (i.e., the columnar-squamous epithelial interface). As the columnar epithelium advances into the area of inflammation, the inflammation extends higher into the proximal esophagus, and the site of the stricture moves progressively up the esophagus. Patients who have a stricture in the absence of Barrett's esophagus should have the presence of gastroesophageal reflux documented before the presence of the stricture is ascribed to reflux esophagitis. In patients with normal acid exposure, the stricture may be due to cancer or a drug-induced chemical injury, the latter resulting from the lodgment of a capsule or tablet in the distal esophagus. In such patients, dilation usually corrects the problem of dysphagia. Heartburn, which may have occurred only because of the chemical injury, need not be treated. It is also possible for drug-induced injuries to occur in patients who have underlying esophagitis and a distal esophageal stricture secondary to gastroesophageal reflux. In this situation, a long, string-like stricture progressively develops as a result of repetitive caustic injury from capsule or tablet lodgment on top of an initial reflux stricture. These strictures are often resistant to dilation. The incidence of this problem has lessened since the introduction of proton pump inhibitor medication.

Metaplastic (Barrett's Esophagus) and Neoplastic (Adenocarcinoma) Complications

The condition whereby the tubular esophagus is lined with columnar epithelium rather than squamous epithelium was first described by Norman Barrett in 1950. He incorrectly believed it to be congenital in origin. It is now realized that it is an acquired abnormality, occurs in 10% to 15% of patients with GERD, and represents the end stage of the natural history of this disease. It is also distinctly different from the congenital condition in which islands of gastric fundic epithelium are found in the upper half of the esophagus.

The definition of BE has evolved considerably over the past decade. Traditionally, BE was identified by the presence of columnar mucosa extending at least 3 cm into the esophagus. It is now recognized that the specialized, intestinal-type epithelium found in the Barrett's mucosa is the only tissue predisposed to malignant degeneration. Consequently, the diagnosis of BE is presently made given any length of endoscopically identifiable columnar mucosa that proves, on biopsy, to show IM. Although long segments of columnar mucosa without IM do occur, they are uncommon and might be congenital in origin.

The hallmark of IM is the presence of intestinal goblet cells. There is a high prevalence of biopsy-demonstrated IM at

the cardia, on the gastric side of the squamocolumnar junction, in the absence of endoscopic evidence of a CLE. Evidence is accumulating that these patches of what appears to be Barrett's in the cardia have a similar malignant potential as in the longer segments, and are precursors for carcinoma of the cardia.

The long-term relief of symptoms remains the primary reason for performing antireflux surgery in patients with BE. Healing of esophageal mucosal injury and the prevention of disease progression are important secondary goals. In this regard, patients with BE are no different than the broader population of patients with gastroesophageal reflux. They should be considered for antireflux surgery when patient data suggest severe disease or predict the need for long-term medical management. Most patients with BE are symptomatic. Although it has been argued that some patients with BE may not have symptoms, careful history taking will reveal the presence of symptoms in most, if not all, patients.

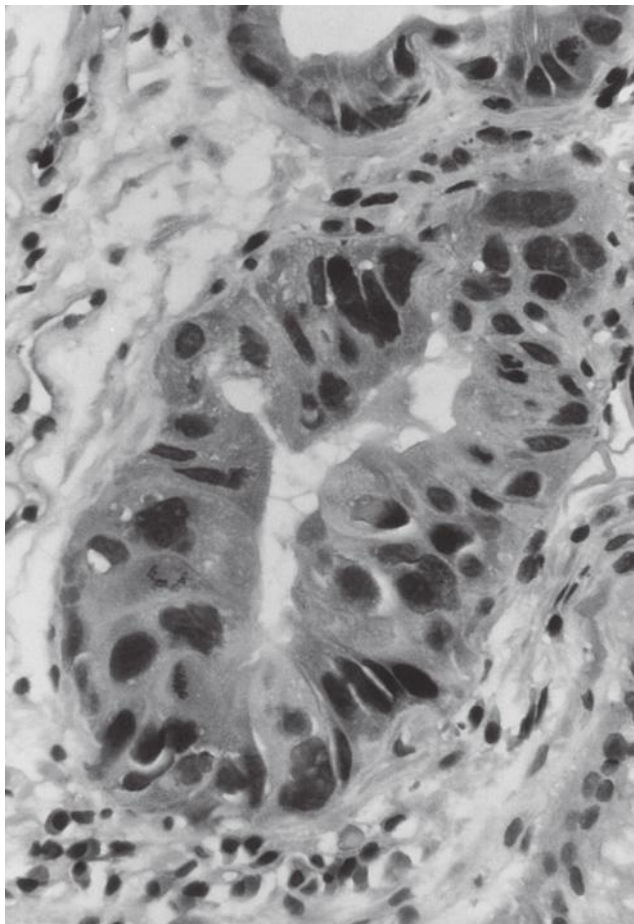
Patients with BE have a spectrum of disease ranging from visually identifiable but short segments, to long segments of classic BE. In general, however, they represent a relatively severe stage of gastroesophageal reflux, usually with markedly increased esophageal acid exposure, deficient LES characteristics, poor esophageal body function, and a high prevalence of duodenogastroesophageal reflux. Gastric hypersecretion occurs in 44% of patients. Most will require long-term PPI therapy for relief of symptoms and control of coexistent esophageal mucosal injury. Given such profound deficits in esophageal physiology, antireflux surgery is an excellent means of long-term control of reflux symptoms for most patients with BE.

The typical complications in BE include ulceration in the columnar-lined segment, stricture formation, and a dysplasia-cancer sequence. Barrett's ulceration is unlike the erosive ulceration of reflux esophagitis in that it more closely resembles peptic ulceration in the stomach or duodenum, and has the same propensity to bleed, penetrate, or perforate. Fortunately this complication occurs very rarely. The strictures found in BE occur at the squamocolumnar junction, and are typically higher than peptic strictures in the absence of BE. Ulceration and stricture in association with BE were commonly reported before 1975, but, with the advent of potent acid suppression medication, they have become less common. In contrast, the complication of adenocarcinoma developing in Barrett's mucosa has become more common. Adenocarcinoma developing in Barrett's mucosa was considered a rare tumor before 1975. Today, it occurs at approximately 0.2% to 0.5% per year of follow-up, which represents a risk 40 times that of the general population. Most, if not all, cases of adenocarcinoma of the esophagus arise in Barrett's epithelium (Fig. 25-31). About one-third of all patients with BE present with malignancy.

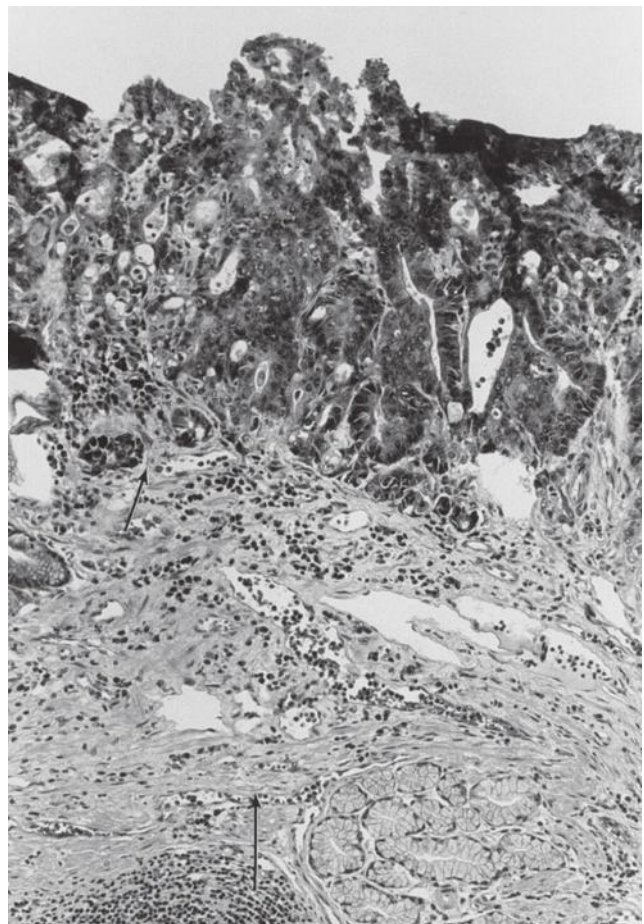The long-term risk of progression to dysplasia and adenocarcinoma, although not the driving force behind the decision to perform antireflux surgery, is a significant concern for both patient and physician. Although to date, there have been no prospective randomized studies documenting that antireflux surgery has an effect on the risk of progression to dysplasia and carcinoma, complete control of reflux of gastric juice into the esophagus is clearly a desirable goal.

Respiratory Complications

A significant proportion of patients with GERD will have associated respiratory symptoms. These patients may have laryngopharyngeal reflux-type symptoms, adult-onset asthma,



A



B

Figure 25-31. Photomicrographs. **A.** Barrett's epithelium with severe dysplasia. ($\times 200$.) Note nuclear irregularity, stratification, and loss of polarity. **B.** Barrett's epithelium with intramucosal carcinoma. ($\times 66$.) Note malignant cells in the mucosa (upper arrow), but not invading the muscularis mucosae (bottom arrow). (Reproduced with permission from DeMeester TR, Stein HJ, Fuchs KH: Physiologic diagnostic studies, in Zuidema GD, Orringer MB (eds): Shackelford's Surgery of the Alimentary Tract, 3rd ed, Vol. I. Philadelphia: W.B. Saunders, 1991, p 113. Copyright Elsevier.)

or even idiopathic pulmonary fibrosis. These symptoms and organ injury may occur in isolation or in conjunction with typical reflux symptoms such as heartburn and regurgitation. Several studies have demonstrated that up to 50% of patients with asthma have either endoscopically evident esophagitis or abnormal distal esophageal acid exposure. These findings support a causal relationship between GERD and aerodigestive symptoms and complications in a proportion of patients.

Etiology of Reflux-Induced Respiratory Symptoms. There are two mechanisms that have been proposed as the cause of reflux-induced respiratory symptoms. The reflux theory suggests that these symptoms are the direct result of laryngopharyngeal exposure and aspiration of gastric contents. The reflex theory suggests that the vagal-mediated afferent fibers result in bronchoconstriction during episodes of distal esophageal acidification. The evidence supporting a mechanism of direct exposure to the aerodigestive system is based in clinical studies that have documented a strong correlation between idiopathic pulmonary fibrosis and hiatal hernia. In addition, the presence of GERD was demonstrated to be highly associated with several pulmonary diseases in a recent Department of Veteran Affairs multivariate analysis. Next, with ambulatory pH testing, acid

exposure within the proximal esophagus is more frequently identified in patients with gastroesophageal reflux and respiratory symptoms than in patients who have gastroesophageal reflux symptoms alone. These findings are supported by scintigraphic studies, which have demonstrated aspiration of ingested radioisotope in patients with both gastroesophageal reflux and pulmonary symptoms. In animal studies, tracheal instillation of acid has been demonstrated to profoundly increase airway resistance. Finally, in patients who have undergone multichannel intraluminal impedance testing with a catheter configured to detect laryngopharyngeal reflux, a correlation between proximal fluid movement and laryngopharyngeal symptoms, such as cough, can be demonstrated.

The reflex mechanism is supported by the bronchoconstriction that occurs with the infusion of acid into the distal esophagus. There is a shared embryologic origin of the tracheoesophageal tract and vagus nerve, and this reflex is thought to be an afferent fiber-mediated reflex that protects the aerodigestive system from the aspiration of refluxate. In patients with respiratory symptoms and documented gastroesophageal reflux without proximal esophageal acid exposure, pulmonary symptoms will often times significantly improve or completely resolve

after undergoing laparoscopic fundoplication. It is likely that both of the proposed mechanisms work simultaneously to cause these symptoms in the face of GERD.

The most difficult clinical challenge in formulating a treatment plan for reflux-associated respiratory symptoms resides in establishing the diagnosis. Although the diagnosis made be straightforward in patients with predominately typical reflux symptoms and secondary respiratory complaints, a substantial number of patients will have respiratory symptoms that dominate the clinical scenario. Typical gastroesophageal reflux symptoms, such as heartburn and regurgitation, may often be completely absent only to be uncovered with objective esophageal physiology testing. Traditionally, the diagnosis of reflux-induced respiratory injury is established using ambulatory dual probe pH monitoring, with one probe positioned within the distal esophagus and the other at a proximal location. Proximal probe positioning has included multiple locations such as the trachea, pharynx, and proximal esophagus. Although ambulatory esophageal pH monitoring allows a direct correlation between esophageal acidification and respiratory symptoms, sensitivity of this testing modality is poor, and the temporal relationship between laryngeal or pulmonary symptoms and reflux events is complex. In addition, as the refluxed gastric fluid travels proximally, it may be neutralized by saliva and therefore go undetected with pH monitoring. Impedance testing may also be used to detect the movement of fluid throughout the entire esophageal column regardless of pH content.

Treatment. Once the diagnosis is established, treatment may be initiated with either PPI therapy or antireflux surgery. A trial of high-dose PPI therapy may help establish the facts that reflux is partly or completely responsible for the respiratory symptoms. It is important to note that the persistence of symptoms in the face of aggressive PPI treatment does not necessarily rule out reflux as a possible cofactor or sole etiology.

Although there is probably some elements of a placebo effect, relief of respiratory symptoms can be anticipated in up to 50% of patients with reflux-induced asthma treated with anti-secretory medications. However, when examined objectively, <15% of patients can be expected to have improvement in their pulmonary function with medical therapy. In properly selected patients, antireflux surgery improves respiratory symptoms in nearly 90% of children and 70% of adults with asthma and reflux disease. Improvements in pulmonary function can be demonstrated in around 30% of patients. Uncontrolled studies of the two forms of therapy (PPI and surgery) and the evidence from the two randomized controlled trials of medical vs. surgical therapy indicate that surgical valve reconstruction is the most effective therapy for reflux-induced asthma. The superiority of the surgery over PPI is most noticeable in the supine position, which corresponds with the nadir of PPI blood levels and resultant acid breakthrough and is the time in the circadian cycle when asthma symptoms are at their worst.

In asthmatic patients with an esophageal motility disorder, performing an antireflux operation will not prevent the regurgitation and possible aspiration of swallowed liquid or food “upstream” to the valve reconstruction. It is critical that esophageal body function be considered prior to surgical intervention in this patient population.

Medical Therapy for Gastroesophageal Reflux Disease. With the widespread availability of over-the-counter antiseecretory medications, most patients with mild or moderate symptoms

will carry self-medication. When initially identified with mild symptoms of uncomplicated GERD, patients can be placed on 12 weeks of simple antacids before diagnostic testing is initiated. This approach may successfully and completely resolve the symptoms. Patients should be counseled to elevate the head of the bed; avoid tight-fitting clothing; eat small, frequent meals; avoid eating the nighttime meal immediately prior to bedtime; and avoid alcohol, coffee, chocolate, and peppermint, which are known to reduce resting LES pressure and may aggravate symptoms.

Used in combination with simple antacids, alginate acid may augment the relief of symptoms by creating a physical barrier to reflux, as well as by acid reduction. Alginate acid reacts with sodium bicarbonate in the presence of saliva to form a highly viscous solution that floats like a raft on the surface of the gastric contents. When reflux occurs, this protective layer is refluxed into the esophagus, and acts as a protective barrier against the noxious gastric contents. Medications to promote gastric emptying, such as metoclopramide or domperidone, are beneficial in early disease, but of little value in more severe disease.

In patients with persistent symptoms, the mainstay of medical therapy is acid suppression. High-dosage regimens of hydrogen potassium PPIs, such as omeprazole (up to 40 mg/d), can reduce gastric acidity by as much as 80% to 90%. This usually heals mild esophagitis. In severe esophagitis, healing may occur in only one-half of the patients. In patients who reflux a combination of gastric and duodenal juice, acid-suppression therapy may give relief of symptoms, while still allowing mixed reflux to occur. This can allow persistent mucosal damage in an asymptomatic patient. Unfortunately, within 6 months of discontinuation of any form of medical therapy for GERD, 80% of patients have a recurrence of symptoms.

Once initiated, most patients with GERD will require life-long treatment with PPIs, both to relieve symptoms and control any coexistent esophagitis or stricture. Although control of symptoms has historically served as the endpoint of therapy, the wisdom of this approach has recently been questioned, particularly in patients with BE. Evidence suggesting that reflux control may prevent the development of adenocarcinoma and lead to regression of dysplastic and nondysplastic Barrett’s segments has led many to consider control of reflux, and not symptom control, a better therapeutic endpoint. However, this hypothesis remains controversial. It should be noted that complete control of reflux using PPIs can be difficult, as has been highlighted by studies of acid breakthrough while on PPI therapy, and of persistent reflux following antireflux surgery. Castell, Triadafilopoulos, and others have shown that 40% to 80% of patients with BE continue to have abnormal esophageal acid exposure despite up to 20 mg twice daily of PPIs. Ablation trials have shown that mean doses of 56 mg of omeprazole were necessary to normalize 24-hour esophageal pH studies. It is likely that antireflux surgery results in more reproducible and reliable elimination of reflux of both acid and duodenal contents, although long-term outcome studies suggest that as many as 25% of postfundoplication patients will have persistent pathologic esophageal acid exposure confirmed by positive 24-hour pH studies.

Suggested Therapeutic Approach. Traditionally a stepwise approach is used for the treatment of GERD. First-line therapy entails antiseecretory medication, usually PPIs, in most patients. Failure of medication, or the immediate return of symptoms after stopping treatment, suggests either that the patient may

have relatively severe disease or a non-GERD cause for his or her symptoms. Endoscopic examination at this stage of the patient's evaluation is recommended and will provide the opportunity to assess the degree of mucosal injury and presence of BE. Treatment options for these patients entails either long term PPI use vs. antireflux surgery. Laparoscopic antireflux surgery in these patients achieves long-term control of symptoms in 85% to 90%. The measurement of esophageal acid exposure via 24-hour pH should be undertaken when patients are considered for surgery. The status of the LES and esophageal body function with esophageal manometry should also be performed at this stage. These studies will serve to establish the diagnosis and assess esophageal body dysfunction.

Surgical Therapy for Gastroesophageal Reflux Disease

Selection of Patients for Surgery. Studies of the natural history of GERD indicate that most patients have a relatively benign form of the disease that is responsive to lifestyle changes and dietary and medical therapy, and do not need surgical treatment. Approximately 25% to 50% of the patients with GERD have persistent or progressive disease, and it is this patient population that is best suited to surgical therapy. In the past, the presence of esophagitis and a structurally defective LES were the primary indications for surgical treatment, and many inter- nists and surgeons were reluctant to recommend operative procedures in their absence. However, one should not be deterred from considering antireflux surgery in a symptomatic patient with or without esophagitis or a defective sphincter, provided the disease process has been objectively documented by 24-hour pH monitoring. This is particularly true in patients who have become dependent upon therapy with PPIs, or require increasing doses to control their symptoms. It is important to note that a good response to medical therapy in this group of patients predicts an excellent outcome following antireflux surgery.

In general, the key indications for antireflux surgery are (a) objectively proven gastroesophageal reflux disease, and (b) typical symptoms of gastroesophageal reflux disease (heartburn and/or regurgitation) despite adequate medical management, or (c) a younger patient unwilling to take lifelong medication. In addition, a structurally defective LES can also predict which patients are more likely to fail with medical therapy. Patients with normal sphincter pressures tend to remain well controlled with medical therapy, whereas patients with a structurally defective LES may not respond as well to medical therapy, and often develop recurrent symptoms within 1 to 2 years of beginning therapy. Such patients should be considered for an antireflux operation, regardless of the presence or absence of endoscopic esophagitis.

Young patients with documented reflux disease with or without a defective LES are also excellent candidates for antireflux surgery. They usually will require long-term medical therapy for control of their symptoms, and some will go on to develop complications of the disease. An analysis of the cost of therapy based on data from the Veterans Administration Cooperative trial indicates that surgery has a cost advantage over medical therapy in patients <49 years of age.

Severe endoscopic esophagitis in a symptomatic patient with a structurally defective LES is also an indication for early surgical therapy. These patients are prone to breakthrough of their symptoms while receiving medical therapy. Symptoms and mucosal injury can be controlled in such patients, but careful

monitoring is required, and increasing dosages of PPIs are necessary. In everyday clinical practice, however, such treatment can be both difficult and impractical, and, in such cases, antireflux surgery can be considered early, especially if PPI therapy is problematic.

The development of a stricture in a patient represents a failure of medical therapy, and is also an indication for a surgical antireflux procedure. In addition, strictures are often associated with a structurally defective sphincter and loss of esophageal contractility. Before proceeding with surgical treatment, malignancy and a drug-related etiology of the stricture should be excluded, and the stricture progressively dilated up to a 50 to 60F bougie. When the stricture is fully dilated, the relief of dysphagia is evaluated and esophageal manometry is performed to determine the adequacy of peristalsis in the distal esophagus. If dysphagia is relieved and the amplitude of esophageal contractions is adequate, an antireflux procedure should be performed; if there is a global loss of esophageal contractility, caution should be exercised in performing an antireflux procedure with a complete fundoplication, and a partial fundoplication should be considered.

Barrett's CLE is commonly associated with a severe structural defect of the LES and often poor contractility of the esophageal body. Patients with BE are at risk of the development of an adenocarcinoma. Whilst surgeons would like to think that an antireflux procedure can reduce the risk of progression to cancer, the evidence supporting this is relatively weak, and for now Barrett's esophagus should be considered to be evidence that the patient has gastroesophageal reflux, and progression to antireflux surgery is indicated for the treatment of reflux symptoms, not cancer progression. If, however, high grade dysplasia or intramucosal carcinoma is found on mucosal biopsy specimens, treatment should then be directed at the BE and the lesion, using either evaluation endoscopic ablation, endoscopic resection or esophageal resection.

The majority of patients requiring treatment for reflux have a relatively mild form of disease and will respond to antise- cretory medications. Patients with more severe forms of disease, particularly those who develop persistent or progressive disease, should be considered for definitive therapy. Laparoscopic fun- duplication will provide a long-term cure in the majority of these patients, with minimal discomfort and an early return to normal activity.

Preoperative Evaluation. Before proceeding with an antire- flux operation, several factors should be evaluated. The clinical symptoms should be consistent with the diagnosis of gastro- esophageal reflux. Patients presenting with the typical symp- toms of heartburn and/or regurgitation which have responded, at least partly, to PPI therapy, will generally do well following surgery, whereas patients with atypical symptoms have a less predictable response. Reflux should also be objectively con- firmed by either the presence of ulcerative esophagitis or an abnormal 24 hour pH study.

The propulsive force of the body of the esophagus should be evaluated by esophageal manometry to determine if it has sufficient power to propel a bolus of food through a newly reconstructed valve. Patients with normal peristaltic contrac- tions can be considered for a 360° Nissen fundoplication or a partial fundoplication, depending on patient and surgeon pref- erences. When peristalsis is absent a partial fundoplication is probably the procedure of choice, but only if achalasia has been ruled out.

Hiatal anatomy should also be assessed. In patients with smaller hiatal hernias endoscopy evaluation usually provides sufficient information. However, when patients present with a very large hiatus hernia or for revision surgery after previous antireflux surgery, contrast radiology provides better anatomical information. The concept of anatomic shortening of the esophagus is controversial, with divergent opinions held about how common this problem is. Believers claim that anatomic shortening of the esophagus compromises the ability of the surgeon to perform an adequate repair without tension, and that this can lead to an increased incidence of breakdown or thoracic displacement of the repair. Some of those that hold this view claim that esophageal shortening is present when a barium swallow X-ray identifies a sliding hiatal hernia that will not reduce in the upright position, or that measures more than 5 cm in length at endoscopy. When identified these surgeons usually undertake add a gastroplasty to the antireflux procedure. Others claim that esophageal shortening is overdiagnosed and rarely seen, and that the morbidity of adding a gastroplasty outweighs any benefits. These surgeons would recommend a standard antireflux procedure in all patients undergoing primary surgery.

Principles of Surgical Therapy. The primary goal of antireflux surgery is to safely create a new antireflux valve at the gastroesophageal junction, while preserving the patient's ability to swallow normally and to belch to relieve gaseous distention. Regardless of the choice of the procedure, this goal can be achieved if attention is paid to some basic principles when reconstructing the antireflux mechanism. First, the operation should create a flap valve which prevents regurgitation of gastric contents into the esophagus. This will result in an increase in the pressure of the distal esophageal sphincter region. Following a Nissen fundoplication the expected increase is to a level twice the resting gastric pressure (i.e., 12 mmHg for a gastric pressure of 6 mmHg). The extent of the pressure rise is often less following a partial fundoplication, although with all types of fundoplication the length of the reconstructed valve should be at least 3 cm. This not only augments sphincter characteristics in patients in whom they are reduced before surgery, but prevents unfolding of a normal sphincter in response to gastric distention (Fig. 25-32). Preoperative and postoperative esophageal manometry measurements have shown that the resting sphincter pressure and the overall sphincter length can be surgically augmented over preoperative values, and that the change in the former is a function of the degree of gastric wrap around the esophagus (Fig. 25-33). However, the aim of any fundoplication

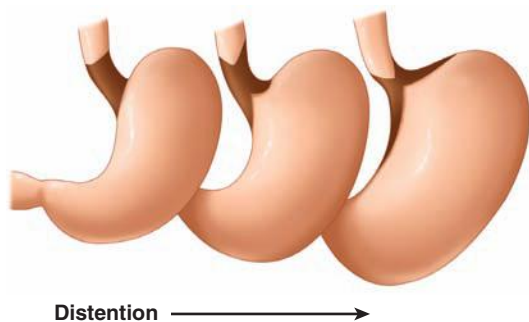


Figure 25-32. A graphic illustration of the shortening of the lower esophageal sphincter that occurs as the sphincter is “taken up” by the cardia as the stomach distends.

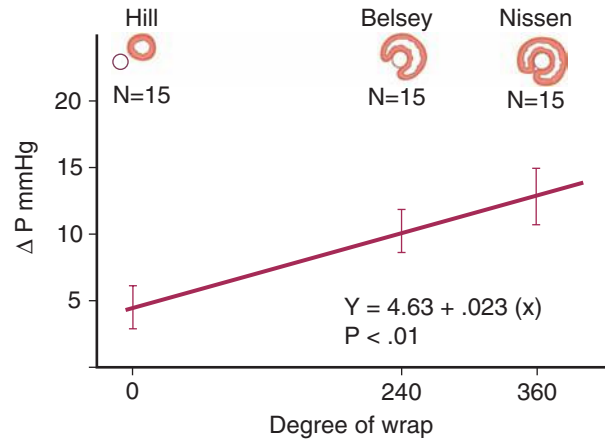


Figure 25-33. The relationship between the augmentation of sphincter pressure over preoperative pressure (ΔP) and the degree of gastric fundic wrap in three different antireflux procedures. (Reproduced with permission from O'Sullivan GC, et al.: *Interaction of lower esophageal pressure and length of sphincter in the abdomen as detriments of gastroesophageal competence.* Am J Surg. 143:43, 1982. Copyright Elsevier.)

is to create a loose wrap, and to maintain the position of the gastric fundus close to the distal intra-abdominal esophagus, in a flap valve arrangement. The efficacy of this relies on the close relationship between the fundus and the esophagus, not the “tightness” of the wrap.

Second, the operation should place an adequate length of the distal esophageal sphincter in the positive-pressure environment of the abdomen by a method that ensures its response to changes in intra-abdominal pressure. The permanent restoration of 2 or more cm of abdominal esophagus ensures the preservation of the relationship between the fundus and the esophagus. All of the popular antireflux procedures increase the length of the sphincter exposed to abdominal pressure by an average of at least 1 cm.

Third, the operation should allow the reconstructed cardia to relax on deglutition. In normal swallowing, a vagally mediated relaxation of the distal esophageal sphincter and the gastric fundus occurs. The relaxation lasts for approximately 10 seconds and is followed by a rapid recovery to the former tonicity. To ensure relaxation of the sphincter, three factors are important: (a) Only the fundus of the stomach should be used to buttress the sphincter, because it is known to relax in concert with the sphincter; (b) the gastric wrap should be properly placed around the sphincter and not incorporate a portion of the stomach or be placed around the stomach itself, because the body of the stomach does not relax with swallowing; and (c) damage to the vagal nerves during dissection of the thoracic esophagus should be avoided because it may result in failure of the sphincter to relax.

Fourth, the fundoplication should not increase the resistance of the relaxed sphincter to a level that exceeds the peristaltic power of the body of the esophagus. The resistance of the relaxed sphincter depends on the degree, length, and diameter of the gastric fundic wrap, and on the variation in intra-abdominal pressure. A 360° gastric wrap should be no longer than 2 cm and constructed over a large (50 to 60F) bougie. This will ensure that the relaxed sphincter will have an adequate diameter with

minimal resistance. A bougie is not necessary when constructing a partial wrap.

Fifth, the operation should ensure that the fundoplication can be placed in the abdomen without undue tension, and maintained there by approximating the crura of the diaphragm above the repair. Leaving the fundoplication in the thorax converts a sliding hernia into a PEH, with all the complications associated with that condition. Maintaining the repair in the abdomen under tension predisposes to an increased incidence of recurrence. How common this problem is encountered is disputed, with some surgeons advocating lengthening the esophagus by gastroplasty and constructing a partial fundoplication, and others claiming that this issue is now rarely encountered.

Procedure Selection. A laparoscopic approach is now used routinely in all patients undergoing primary antireflux surgery. Some surgeons advocate the use of a single antireflux procedure for all patients, whereas others advocate a tailored approach. Advocates of the laparoscopic Nissen fundoplication as the procedure of choice for a primary antireflux repair would generally apply this procedure in all patients with normal or near normal esophageal motility, and reserve a partial fundoplication for use in individuals with poor esophageal body motility. Others, based on the good longer term outcomes now reported following partial fundoplication procedures, advocate the routine application of a partial fundoplication procedure, thereby avoiding any concerns about constructing a fundoplication in individuals with poor esophageal motility.

Experience and randomized studies have shown that both the Nissen fundoplication and various partial fundoplication procedures are all effective and durable antireflux repairs, and generate an excellent outcome in approximately 90% of patients at longer term follow-up.

Primary Antireflux Repairs

Nissen Fundoplication. The most common antireflux procedure is the Nissen fundoplication. In the past this procedure has been performed through an open abdominal or a chest incision, but with the development of laparoscopic approaches primary antireflux surgery is now routinely undertaken using the laparoscope. Rudolph Nissen described this procedure as a 360° fundoplication around the lower esophagus for a distance of 4 to 5 cm, without division of the short gastric blood vessels. Although this provided good control of reflux, it was associated with a number of side effects that have encouraged modifications of the procedure as originally described. These include using only the gastric fundus to envelop the esophagus in a fashion analogous to a Witzel jejunostomy, sizing the fundoplication with a large (50 to 60F) bougie, limiting the length of the fundoplication to 1 to 2 cm, and dividing the short gastric vessels. The essential elements necessary for the performance of a trans-abdominal fundoplication are common to both the laparoscopic and open procedures and include the following:

1. Hiatal dissection and preservation of both vagi along their entire length
2. Circumferential esophageal mobilization
3. Hiatal closure, usually posterior to the esophagus
4. Creation of a short and floppy fundoplication over an esophageal dilator

In addition, many surgeons also routinely divide the short gastric blood vessels, although this step is not universally

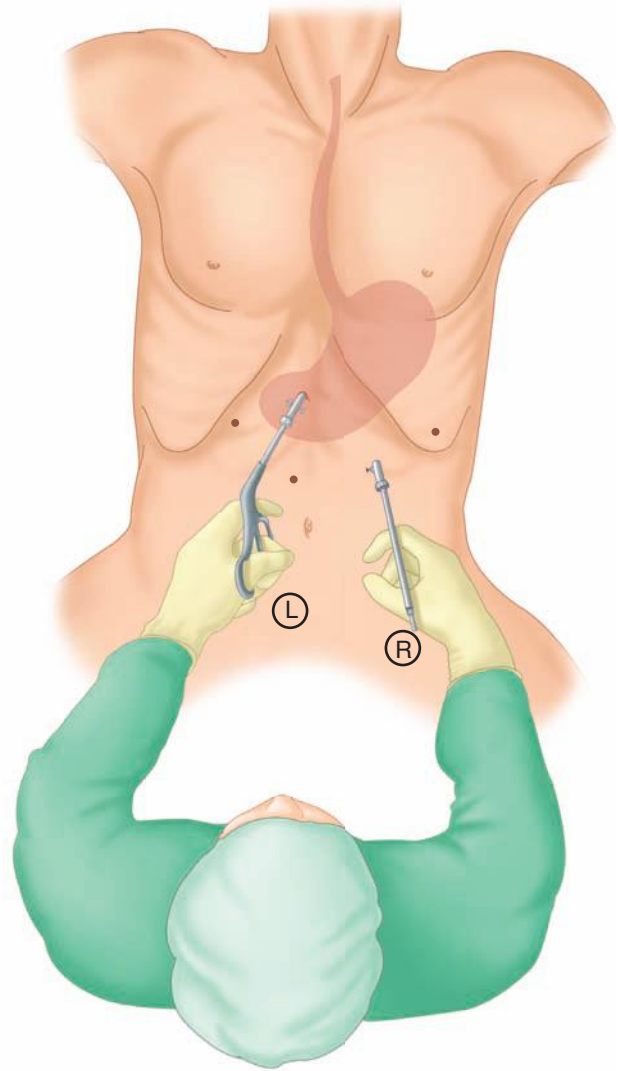


Figure 25-34. Patient positioning and trocar placement for laparoscopic antireflux surgery. The patient is placed with the head elevated approximately 30° in the modified lithotomy position. The surgeon stands between the patient's legs, and the procedure is completed using five abdominal access ports.

applied, and the results of several randomized trials have failed to show that this step yields any benefit.

The laparoscopic approach to fundoplication has now replaced the open abdominal Nissen fundoplication as the procedure of choice. Five ports are usually used (Fig. 25-34), and dissection is begun by incising the gastrohepatic omentum above and below the hepatic branch of the anterior vagus nerve, which is usually preserved. The circumference of the diaphragmatic hiatus is dissected and the esophagus is mobilized by careful dissection of the anterior and posterior soft tissues within the hiatus. The esophagus is held anterior and to the left and the hiatal pillars are approximated with interrupted non-absorbable sutures, starting posteriorly and working anteriorly. A tension-free fundoplication should be constructed. This can usually be achieved either with or without division of the short gastric blood vessels, according to surgeon preference. If the vessels are divided, the upper one third of the greater curvature is mobilized by sequentially dissecting and dividing these vessels, commencing distally and working proximally. Following complete fundal mobilization,

the posterior wall of the fundus is brought behind the esophagus to the right side, and the anterior wall of the fundus is brought anterior to the esophagus. The fundic lips are manipulated to allow the fundus to envelop the esophagus without twisting. A 50 to 60F bougie is passed to properly size the fundoplication, and it is sutured using non-absorbable sutures. Some surgeons use a single U-stitch of 2-0 polypropylene buttressed with felt pledgets (Fig. 25-35), and others use 2-4 interrupted sutures.

Posterior Partial Fundoplication. Partial fundoplications were developed as an alternative to the Nissen procedure in an attempt to minimize the risk of postfundoplication side effects, such as dysphagia, inability to belch, and flatulence. The commonest approach has been a posterior partial or Toupet fundoplication. Some surgeons use this type of procedure for all patients presenting for antireflux surgery, whereas others apply a tailored approach in which a partial fundoplication is

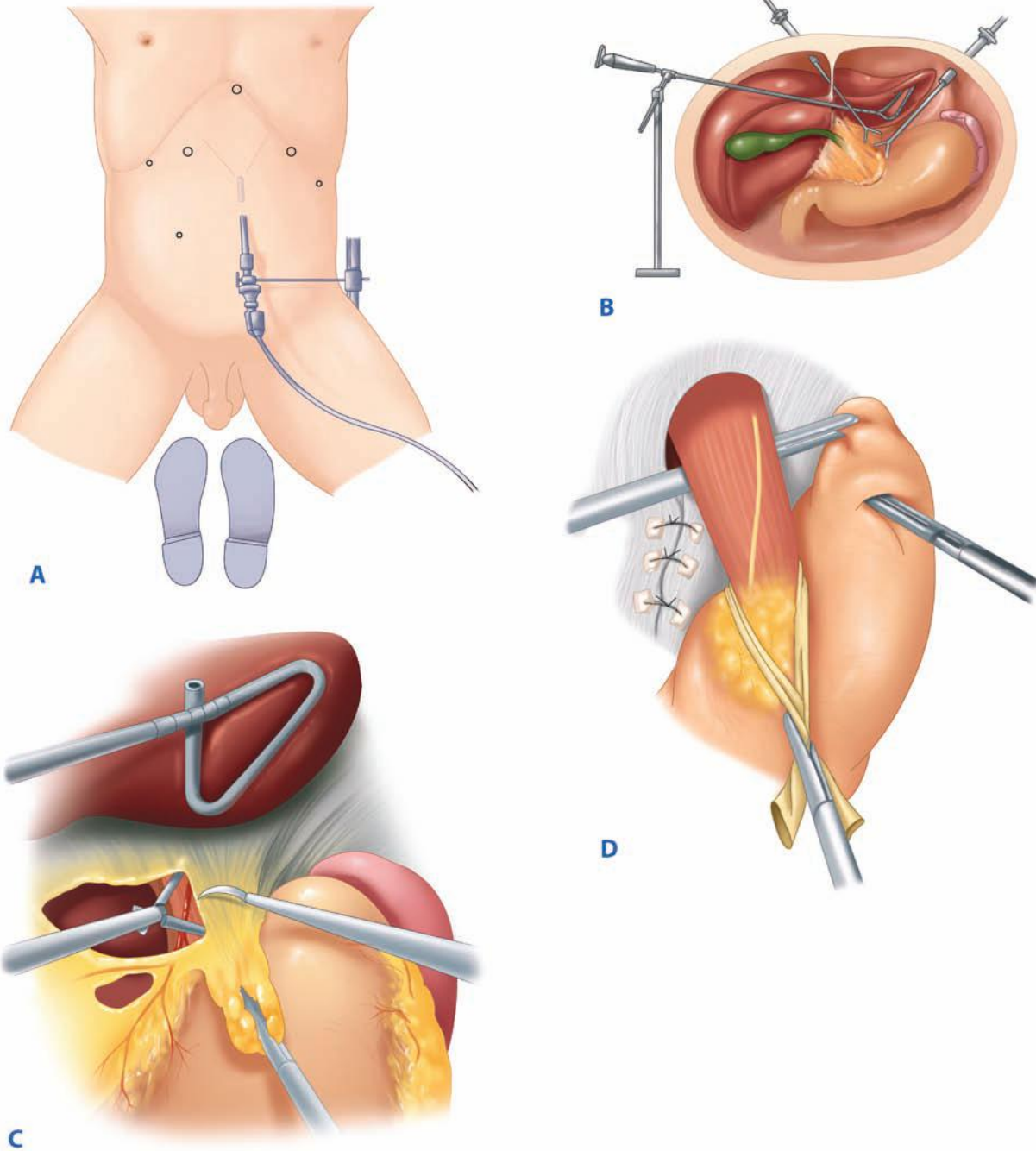


Figure 25-35. A. Laparoscopic Nissen fundoplication is performed with a five-trocar technique. B. The liver retractor is affixed to a mechanical arm to hold it in place throughout the operation. C. After division of the gastrohepatic omentum above the hepatic branch of the vagus (pars flaccida), the surgeon places a blunt atraumatic grasper beneath the phrenoesophageal ligament. D. After completion of the crural closure, an atraumatic grasper is placed right to left behind the gastroesophageal junction. The grasper is withdrawn, pulling the posterior aspect of the gastric fundus behind the esophagus. E. Once the suture positions are chosen, the first stitch (2-0 silk, 20 cm long) is introduced through the 10-mm trocar, and the needle is passed first through the left limb of the fundus, then the esophagus (2.5 cm above the gastroesophageal junction), then through the right limb of the fundus. F. Final position of the fundoplication. (Illustration continued on next page.)

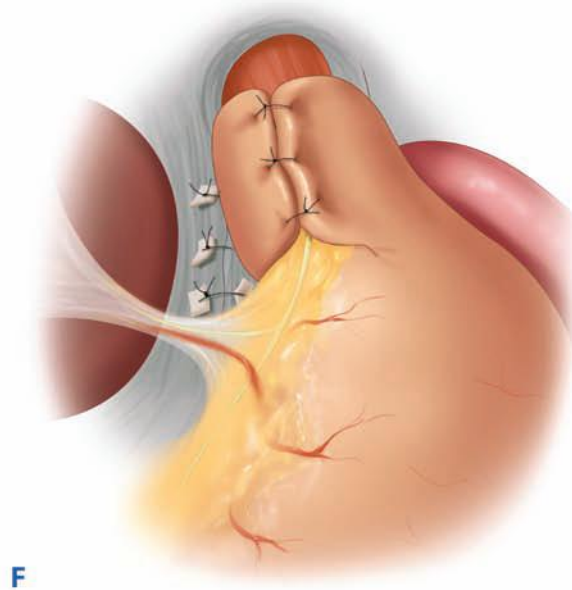
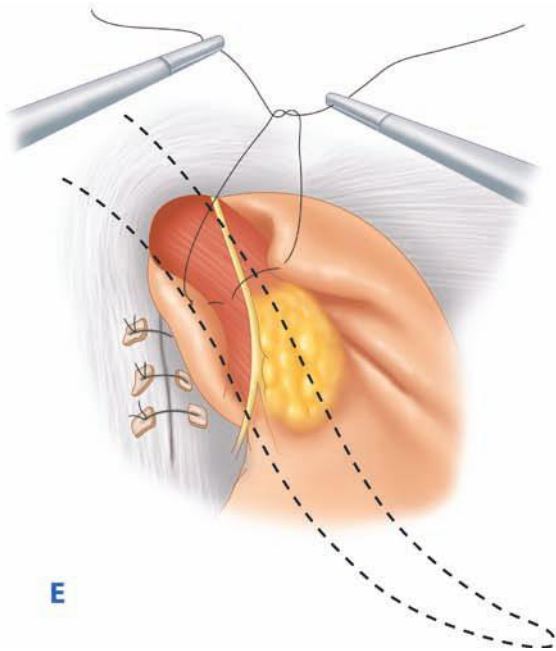


Figure 25-35. (Continued)

constructed in patients with impaired esophageal motility, in which the propulsive force of the esophagus is thought to be insufficient to overcome the outflow obstruction of a complete fundoplication. The Toupet posterior partial fundoplication consists of a 270° gastric fundoplication around the distal 4 cm of esophagus (Fig. 25-36). It is usually stabilized by anchoring the wrap posteriorly to the hiatal rim.

Anterior Partial Fundoplication. An alternative approach to partial fundoplication is to construct an anterior partial fundoplication. Following posterior hiatal repair, the anterior fundus is rolled over the front of the esophagus and sutured to the hiatal

rim and the esophageal wall. Division of the short gastric vessels is never needed when constructing this type of fundoplication. Various degrees of anterior partial fundoplication have been described—90°, 120°, 180°. The anterior 180° partial fundoplication (Fig. 25-37) provides a more robust fundoplication and achieves an excellent longer term outcome in approximately 90% of patients at follow-up of at least 10 years. With this procedure the fundus and esophagus are sutured to the right side of the hiatal rim to create a flap valve at the gastroesophageal junction, and to stabilize a 3-4 cm length of intra-abdominal esophagus.

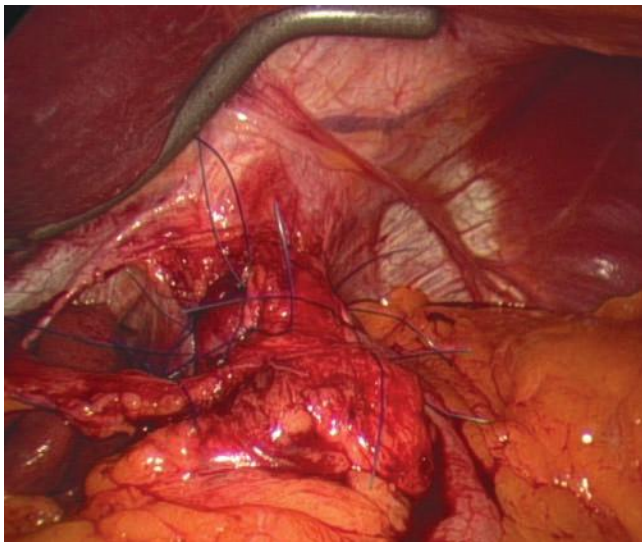


Figure 25-36. Completed laparoscopic posterior partial (Toupet) fundoplication. The fundoplication does not cover the anterior surface of the esophagus, and is stabilized by suturing the fundus to the side of the esophagus, and posteriorly to the right hiatal pillar.

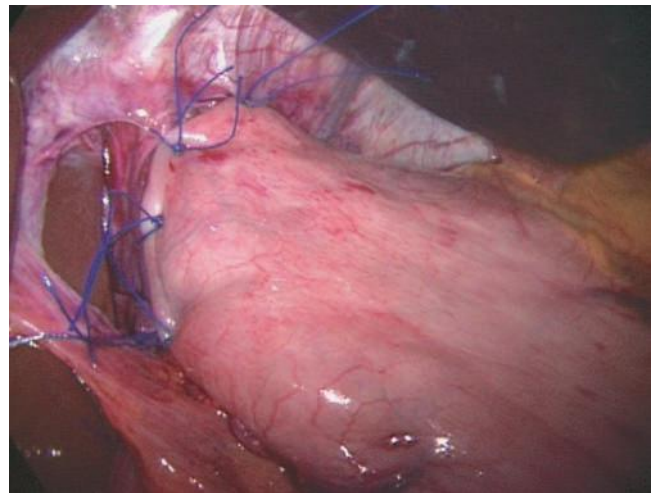


Figure 25-37. Completed laparoscopic anterior 180° partial fundoplication. The fundoplication fully covers the anterior surface of the esophagus, and is stabilized by suturing the fundus to the right side of the esophagus, and to the right hiatal pillar. Unlike the Nissen procedure, the fundus is not pulled behind the esophagus.

Collis Gastroplasty. When a shortened esophagus is encountered, many surgeons choose to add an esophageal lengthening procedure before fundoplication, to reduce the tension on the gastro-esophageal junction, believing this will minimize the risk of failure due to postoperative hiatus hernia. The commonest approach to this is the Collis gastroplasty. This entails using a stapler to divide the cardia and upper stomach, parallel to the lesser curvature of the stomach, thereby creating a gastric tube in continuity with the esophagus, and effectively lengthening the esophagus by several centimeters. Laparoscopic techniques for Collis gastroplasty have been described (Fig. 25-38). Following gastroplasty a fundoplication is constructed, with the highest suture is placed on the native esophagus when constructing a Nissen fundoplication. Not all surgeons choose to undertake a Collis procedure, however, as there is controversy about the

actual incidence of the shortened esophagus and widely divergent views are held about how often this problem is encountered. In addition, some surgeons have questioned the wisdom of creating an amotile tube of gastric wall, which can secrete acid, and then placing a Nissen fundoplication below this.

Outcome after Fundoplication. Studies of long-term outcome following both open and laparoscopic fundoplication document the ability of laparoscopic fundoplication to relieve typical reflux symptoms (heartburn, regurgitation, and dysphagia) in more than 90% of patients at follow-up intervals averaging 2 to 3 years and 80% to 90% of patients 5 years or more following surgery. This includes evidence-based reviews of antireflux surgery, prospective randomized trials comparing antireflux surgery to PPI therapy and open to laparoscopic

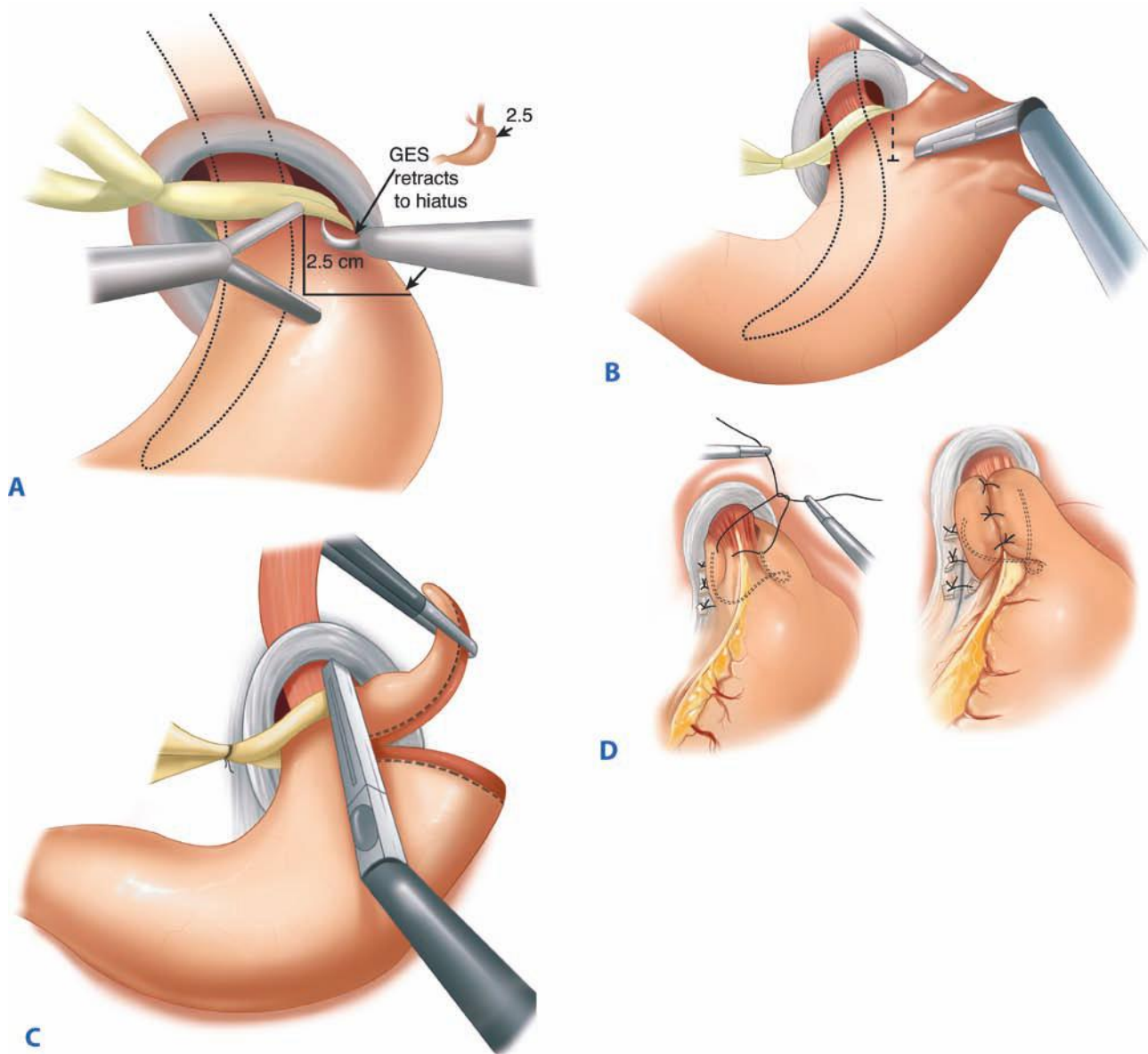


Figure 25-38. **A.** After removal of the fat pad and release of tension on the Penrose drain, the gastroesophageal junction (GES) retracts to the level of the hiatus. The interior end of the staple line is marked $\frac{2}{5}$ cm below the angle of His. **B.** The first horizontal firing of the stapler occurs by maximally articulating the stapler to the left, aiming toward the previously marked spot adjacent to the dilator. **C.** The vertical staple line is created by a single firing of the GIA placed parallel and flush against the 48F dilator. **D.** The highest Nissen fundoplication suture is placed on the native esophagus, and the second suture tucks in the apex of the staple line.

fundoplication and analysis of U.S. national trends in use and outcomes. Postoperative pH studies indicate that more than 90% of patients will normalize their pH tracings. The results of laparoscopic fundoplication compare favorably with those of the “modern” era of open fundoplication. They also indicate the less predictable outcome of atypical reflux symptoms (cough, asthma, laryngitis) after surgery, being relieved in only two-thirds of patients.

The goal of surgical treatment for GERD is to relieve the symptoms of reflux by re-establishing the gastroesophageal barrier. The challenge is to accomplish this without inducing dysphagia or other untoward side effects. Dysphagia, existing before surgery, usually improves following laparoscopic fundoplication. Temporary dysphagia is common after surgery and generally resolves within 3 months, but can take up to 12 months in some individuals, and dysphagia sufficient to require ongoing dietary modification persists in up to 5% of individuals following Nissen fundoplication. Other side effects common to antireflux surgery include the inability to belch and vomit and increased flatulence. Most patients cannot vomit through an intact wrap, though this is rarely clinically relevant. Most patients are unable to belch gas from the stomach in the first 3 to 6 months after fundoplication, but 80%-90% regain the ability to belch normally beyond the first 12 months follow-up. Hyperflatulence is a common and noticeable problem, likely related to increased air swallowing that is present in most patients with reflux disease, aggravated by the inability to belch in some patients.

Randomized Controlled Trials Addressing Surgical Technique

Division of the Short Gastric Blood Vessels Originally, Nissen’s description of a total fundoplication entailed a 360° fundoplication during which the short gastric blood vessels were left intact. However, with reports of troublesome postoperative dysphagia division of these vessels, to achieve full fundal mobilization and thereby ensure a loose fundoplication, was promoted and has entered common practice. The evidence supporting dividing these vessels has been based on the outcomes from uncontrolled case series of patients undergoing Nissen fundoplication either with vs. without division of the short gastric vessels. However, the results from these studies have been conflicting with different proponents reporting good results irrespective of whether these vessels have been divided or not. To address this issue 6 randomized trials which enrolled a total of 438 patients have been reported. None of these trials demonstrated any differences for the postoperative dysphagia or recurrent gastro-esophageal reflux. However, in the 3 largest of the 6 trials an increased incidence of flatulence and bloating symptoms, as well as greater difficulty with belching, was seen in patients in whom the short gastric vessels were divided.

A recent meta-analysis from Engstrom et al, generated by combining the raw data from Australian and Swedish trials, evaluated a larger cohort of 201 patients, with 12 years follow-up in 170, and also confirmed equivalent reflux control, but more abdominal bloating after division of the short gastric vessels. Overall, these trials fail to support the belief that dividing the short gastric vessels improves any outcome following Nissen fundoplication. The trials actually suggest that dividing the vessels increases the complexity of the procedure, and leads to a poorer outcome due to the increase in bloating symptoms.

Nissen vs. Posterior Partial Fundoplication Eleven randomized trials have compared Nissen vs. posterior partial

fundoplication. Some of the trials were relatively small and underpowered, so contribute little to the pool of evidence as they are either small or underpowered, and failed to show significant outcome differences. The larger trials, however, have consistently demonstrated equivalent reflux control, but a reduced incidence of wind related side-effects (flatulence, bloating, and inability to belch) following posterior partial fundoplication procedures, although less dysphagia following a posterior fundoplication was only demonstrated in 2 of the 11 trials. Lundell et al reported the outcomes of Nissen vs. Toupet partial fundoplication in a trial which enrolled 137 patients with reported follow-up to 18 years. Reflux control and dysphagia symptoms were similar, but flatulence was commoner after Nissen fundoplication at some medium-term follow-up time points and revision surgery was more common following Nissen fundoplication, mainly to correct postoperative paraoesophageal herniation. At 18 years follow-up, success rates of more than 80% were reported for both procedures, as well as no significant differences in the incidence of side effects. The data from this trial suggested that the mechanical side effects following Nissen fundoplication progressively improve with very long term follow-up. Strate et al reported 2 year follow-up in a trial that enrolled 200 patients. Approximately 85% of each group was satisfied with the clinical outcome, but dysphagia was significantly more common following Nissen fundoplication (19 vs. 8 patients).

Other trials (Guérin et al–140 patients, Booth et al–127, Khan et al–121, Shaw et al–100) also report similar reflux control within the first few years of follow-up. Only Booth et al. demonstrated less dysphagia following posterior fundoplication. Subgroup analysis in 3 trials (Booth, Shaw, Zornig) did not reveal differences between patients with vs. without poor preoperative oesophageal motility. Overall these trials suggest that some side-effects, mainly wind-related issues, are less common following posterior partial fundoplication. However, the hypothesis that dysphagia is less of a problem following posterior partial fundoplication has only been substantiated in 2 of 11 trials.

Nissen vs. Anterior Fundoplication Six trials have evaluated Nissen vs. anterior partial fundoplication variants. Four have assessed Nissen vs. anterior 180° partial fundoplication (Watson et al–107 patients, Baigrie et al–161, Cao et al–100, Raue et al–64). These trials all demonstrated equivalent reflux control, but less dysphagia and less wind-related side effects after anterior 180° partial fundoplication at up to 5 years follow-up. Only the study from Watson et al has reported follow-up to 10 years, and at late follow-up in their trial there were no significant outcome differences for the 2 procedures, with equivalent control of reflux, and no differences for side effects due to a progressive decline in dysphagia as follow-up extended beyond 5 years.

Two trials compared laparoscopic anterior 90° partial fundoplication vs. Nissen fundoplication (Watson et al–112 patients, Spence et al–79). In both of these trials side-effects were less common following anterior 90° fundoplication, but this was offset by a slightly higher incidence of recurrent reflux at up to 5 years follow-up. Satisfaction with the overall outcome was similar for both fundoplication variants.

Anterior vs. posterior partial fundoplication Two randomized trials have directly compared anterior vs. posterior partial fundoplication. Hagedorn et al randomized 95 patients to undergo either Toupet vs. anterior 120° partial fundoplication, and Khan et al enrolled 103 patients to anterior 180° vs.

posterior partial fundoplication. Both studies demonstrated better reflux control, offset by more side effects following posterior partial fundoplication. The anterior 120° partial fundoplication performed by Hagedorn et al was similar to the anterior 90° variant described above. However, the outcomes following this procedure were much worse in this trial than the outcomes in other studies, with the average exposure time to acid (pH <4%–5.6%) following anterior fundoplication in their study unusually high compared to other studies. Khan et al only reported 6 months follow-up and longer term outcomes are awaited before drawing firm conclusions. The overall results from all 8 trials which included an anterior fundoplication variant suggests that this type of fundoplication achieves satisfactory reflux control, with less dysphagia and other side-effects, yielding a good overall outcome. However, the reduced incidence of troublesome side-effects is traded off against a higher risk of recurrent reflux.

Outcome of Antireflux Surgery in Patients with Barrett's Esophagus. Few studies have focused on the alleviation of symptoms after antireflux surgery in patients with BE (Table 25-7). Those that are available document excellent to good results in 72% to 95% of patients at 5 years following surgery. Several non-randomized studies have compared medical and surgical therapy and report better outcomes after antireflux surgery. Parrilla and colleagues reported the only randomized trial to evaluate this issue. They enrolled 101 patients over 18 years (1982 to 2000), and median follow-up was 6 years. Medical therapy consisted of 20 mg of omeprazole (PPI) twice daily since 1992 in all medically treated patients, and surgical therapy consisted of an open Nissen fundoplication. The symptomatic outcome in the two groups was nearly identical, although esophagitis and/or stricture persisted in 20% of the medically treated patients, compared to only 3% to 7% of patients following antireflux surgery. About 15 % of patients had abnormal acid exposure after surgery. Although pH data were not routinely collected in patients on PPI therapy, in the subgroup of 12 patients that did have 24-hour monitoring on treatment, 3 of 12 (25%) had persistently high esophageal acid exposure, and most (75%) had persistently high bilirubin exposure.

The common belief that Barrett's epithelium cannot be reversed by antireflux surgery is may not be correct. Within the control arm of a randomized trial of ablation vs. surveillance, Bright and associates identified approximately 50% regression in the length of Barrett's esophagus in 20 patients within the control arm of a randomized trial of ablation vs. surveillance.

Current data indicate that patients with BE should remain in an endoscopic surveillance program following

antireflux surgery. Biopsy specimens should be reviewed by a pathologist with expertise in the field. If low-grade dysplasia is confirmed, biopsy specimens should be repeated after 12 weeks of high-dose acid suppression therapy. If high-grade dysplasia or intramucosal cancer is evident on more than one biopsy specimen, then treatment is escalated. Treatment options include endoscopic mucosal resection, endoscopic ablation of the BE, or esophageal resection. Esophageal resection is advisable when an invasive cancer (stage T1b or deeper) is present, or for multifocal long segment BE in younger and fit patients in whom endoscopic treatments are unlikely to be adequate. Endoscopic mucosal resection allows smaller intramucosal tumors to be removed with clear pathology margins, and it can be used as a "big biopsy" to obtain better pathological staging, and even to excise shorter segments of BE in a piecemeal fashion. Ablation, commonly using radiofrequency ablation, has been shown at short term follow-up in a randomized trial to reduce the rate of progression from high grade dysplasia to invasive cancer by approximately 50%. However, following any endoscopic treatment patients need to continue with close endoscopic surveillance as recurrence can occur and the longer term outcome following these treatments remains uncertain. Early detection and treatment have been shown to decrease the mortality rate from esophageal cancer in these patients.

If the dysplasia is reported as lower grade or indeterminant, then inflammatory change that is often confused with dysplasia should be suppressed by a course of acid suppression therapy in high doses for 2 to 3 months, followed by rebiopsy of the Barrett's segment.

Reoperation for Failed Antireflux Repairs. Failure of an antireflux procedure occurs when, after the repair, the patient is unable to swallow normally, experiences upper abdominal discomfort during and after meals, or has recurrence or persistence of reflux symptoms. The assessment of these symptoms and the selection of patients who need further surgery are challenging problems. Functional assessment of patients who have recurrent, persistent, or emergent new symptoms following a primary antireflux repair is critical to identifying the cause of the failure. Analysis of patients requiring reoperation after a previous antireflux procedure shows that placement of the wrap around the stomach is the most frequent cause for failure after open procedures, while herniation of the repair into the chest is the most frequent cause of failure after a laparoscopic procedure. Partial or complete breakdown of the fundoplication and construction of a too-tight a fundoplication or over narrowing the esophageal hiatus occurs with both open and closed procedures.

Table 25-7

Symptomatic outcome of surgical therapy for Barrett's esophagus

AUTHOR	YEAR	NO. OF PATIENTS	% EXCELLENT TO GOOD RESPONSE	MEAN FOLLOW-UP, YEARS
Starnes	1984	8	75	2
Williamson	1990	37	92	3
DeMeester	1990	35	77	3
McDonald	1996	113	82.2	6.5
Ortiz	1996	32	90.6	5

Patients who have recurrence of heartburn and regurgitation without dysphagia and have good esophageal motility are most amenable to reoperation, and can be expected to have an excellent outcome. When dysphagia is the cause of failure, the situation can be more difficult to manage. If the dysphagia occurred immediately following the repair, it is usually due to a technical failure, most commonly a misplaced fundoplication around the upper stomach, or over-narrowing of the esophageal diaphragmatic hiatus and reoperation is usually satisfactory. When dysphagia is associated with poor motility and multiple previous repairs, further revision fundoplication is unlikely to be successful and in otherwise fit patients it is appropriate to seriously consider esophageal resection. With each reoperation the esophagus is damaged further, and the chances of preserving function become less. Also, blood supply is reduced, and ischemic necrosis of the esophagus can occur after several previous mobilizations.

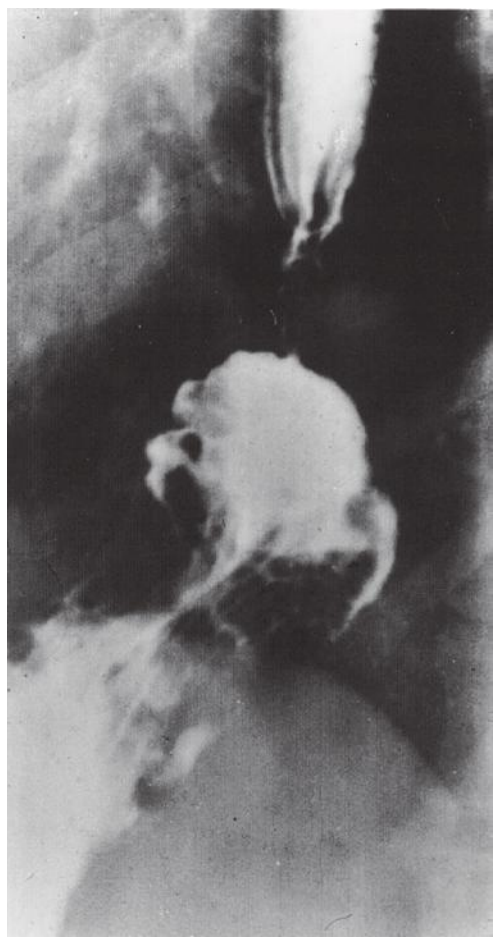GIANT DIAPHRAGMATIC (HIATAL) HERNIAS

With the advent of clinical radiology, it became evident that a diaphragmatic hernia was a relatively common abnormality and was not always accompanied by symptoms. Three types of

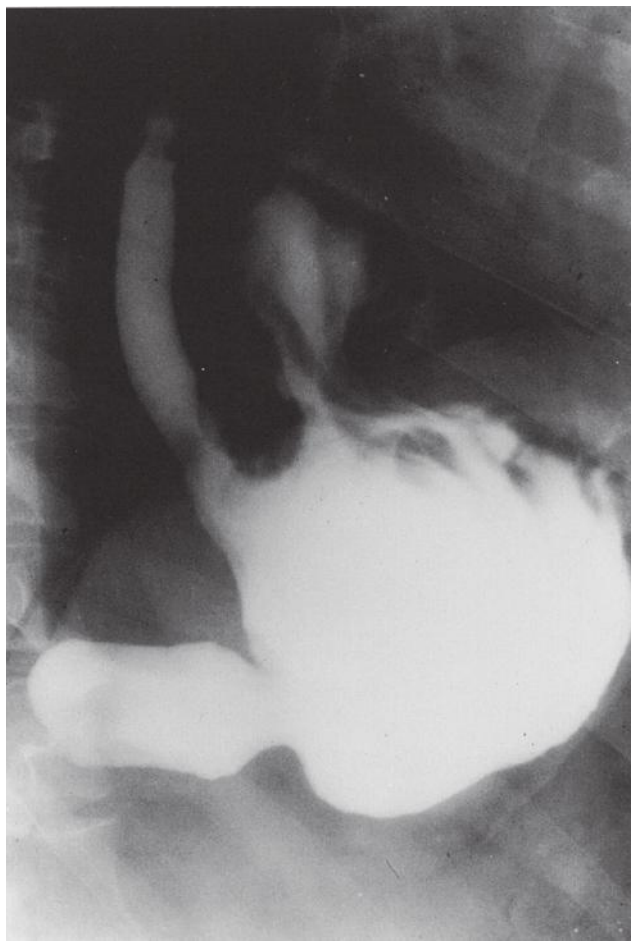
esophageal hiatal hernia were identified: (a) the sliding hernia, type I, characterized by an upward dislocation of the cardia in the posterior mediastinum (Fig. 25-39A); (b) the rolling or PEH, type II, characterized by an upward dislocation of the gastric fundus alongside a normally positioned cardia (Fig. 25-39B); and (c) the combined sliding-rolling or mixed hernia, type III, characterized by an upward dislocation of both the cardia and the gastric fundus (Fig. 25-39C). The end stage of type I and type II hernias occurs when the whole stomach migrates up into the chest by rotating 180° around its longitudinal axis, with the cardia and pylorus as fixed points. In this situation the abnormality is usually referred to as an intrathoracic stomach (Fig. 25-39D). In some taxonomies, a type IV hiatal hernia is declared when an additional organ, usually the colon, herniates as well. Type II-IV hiatal hernias are also referred to as *paraesophageal hernia* (PEH), as a portion of the stomach is situated adjacent to the esophagus, above the gastroesophageal junction.

Incidence and Etiology

The true incidence of a hiatal hernia is difficult to determine because of the absence of symptoms in a large number of patients who are subsequently shown to have a hernia. When radiographic

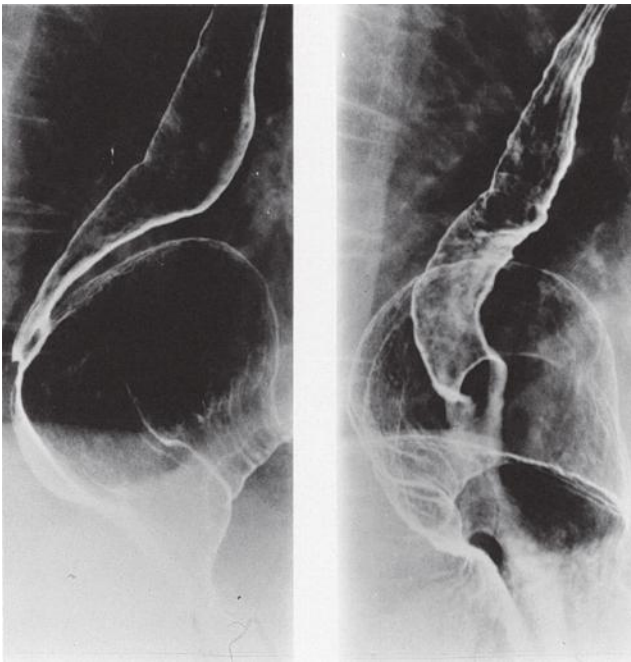


A

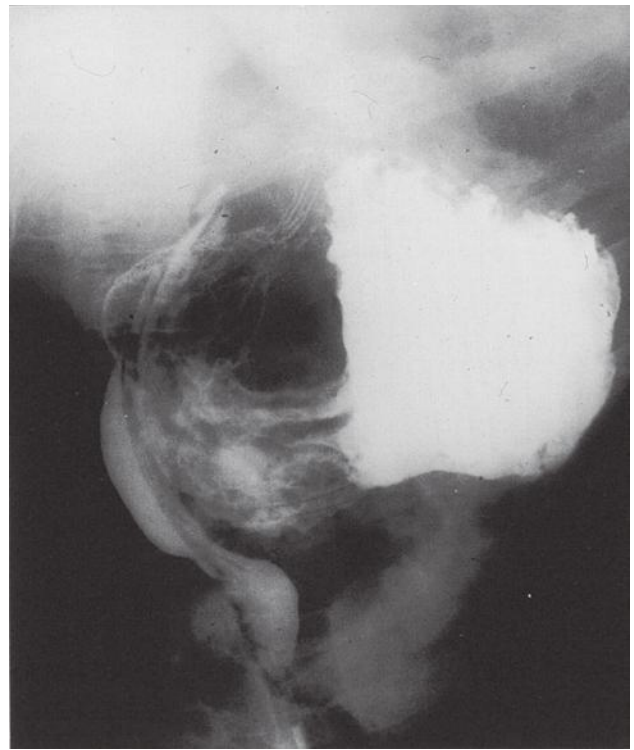

B

Figure 25-39. A. Radiogram of a type I (sliding) hiatal hernia. B. Radiogram of a type II (rolling or paraesophageal) hernia. C. Radiogram of a type III (combined sliding-rolling or mixed) hernia. D. Radiogram of an intrathoracic stomach. This is the end stage of a large hiatal hernia regardless of its initial classification. Note that the stomach has rotated 180° around its longitudinal axis, with the cardia and pylorus as fixed points. (Reproduced with permission from DeMeester TR, Bonavina L: *Paraesophageal hiatal hernia*, in Nyhus LM, Condon RE (eds): *Hernia*, 3rd ed. Philadelphia: Lippincott, 1989, p 684.)



C



D

Figure 25-39. (Continued)

examinations are done in response to GI symptoms, the incidence of a sliding hiatal hernia is seven times higher than that of a PEH. The PEH is also known as the giant hiatal hernia. Over time the pressure gradient between the abdomen and chest enlarges the hiatal hernia. In many cases the type I sliding hernia will evolve into a type III mixed hernia. Type II hernias are quite rare. The age distribution of patients with PEHs is significantly different from that observed in sliding hiatal hernias. The median age of the former is 61 years old; of the latter, 48 years old. PEHs are more likely to occur in women by a ratio of 4:1.

Structural deterioration of the phrenoesophageal membrane over time may explain the higher incidence of hiatal hernias in the older age group. These changes involve thinning of the upper fascial layer of the phrenoesophageal membrane (i.e., the supradiaphragmatic continuation of the endothoracic fascia) and loss of elasticity in the lower fascial layer (i.e., the infra-diaphragmatic continuation of the transversalis fascia). Consequently, the phrenoesophageal membrane yields to stretching in the cranial direction due to the persistent intra-abdominal pressure and the tug of esophageal shortening on swallowing. Interestingly, the stretching and thinning occurs more anteriorly and posteriorly, with fixation of the left crus of the diaphragm to the stomach at the 3 o'clock position, as viewed from the foot. This creates an anterior and posterior hernia sac, the latter of which is often filled with epiphrenic and retroperitoneal fat. These observations point to the conclusion that the development of a hiatal hernia is an age-related phenomenon secondary to repetitive upward stretching of the phrenoesophageal membrane.

Clinical Manifestations

The clinical presentation of a giant hiatal (paraesophageal) hernia differs from that of a sliding hernia. There is usually a

higher prevalence of symptoms of dysphagia and postprandial fullness with PEHs, but the typical symptoms of heartburn and regurgitation present in sliding hiatal hernias can also occur. Both are caused by gastroesophageal reflux secondary to an underlying mechanical deficiency of the cardia. The symptoms of dysphagia and postprandial fullness in patients with a PEH are explained by the compression of the adjacent esophagus by a distended cardia, or twisting of the GEJ by the torsion of the stomach that occurs as it becomes progressively displaced in the chest. The postprandial fullness or retrosternal chest pain is a thought to be a result of distension of the stomach with gas or food in the hiatal hernia. Many patients with sliding hernias and reflux symptoms will lose the reflux symptoms when the hernia evolves into the paraesophageal variety. This can be explained by the re-creation of the cardiophrenic angle when the stomach herniates alongside the GEJ or becomes twisted in the sac. Repair of the hernia without addressing the reflux can create extremely bothersome heartburn. Respiratory complications are frequently associated with a PEH, and consist of dyspnea and recurrent pneumonia from aspiration. New research demonstrates that the cause of dyspnea in the presence of a giant PEH is more likely to be left atrial compression, decreasing cardiac output, than a restrictive pulmonary effect, as has been hypothesized for many years.

Approximately one third of patients with a PEH are found to be anemic, which is due to recurrent bleeding from ulceration of the gastric mucosa in the herniated portion of the stomach, even if ulcerations are not detected at the time of endoscopy. The association of anemia and PEH is best proven by fixing the hernia. Anemia is corrected in >90% of patients with this condition. With time, more and more stomach migrates into the chest and can cause intermittent foregut obstruction due to the

rotation that has occurred. In contrast, many patients with PEH are asymptomatic or complain of minor symptoms. However, the presence of a PEH can be life threatening in that the hernia can lead to sudden catastrophic events, such as excessive bleeding or volvulus with acute gastric obstruction or infarction. With mild dilatation of the stomach, the gastric blood supply can be markedly reduced, causing gastric ischemia, ulceration, perforation, and sepsis. The probability of incarceration/strangulation is not well known, although recent studies suggest that the lifetime risk is less than 5%, making this concern an insufficient concern for routine repair of the asymptomatic PEH.

The symptoms of sliding hiatal hernias are usually due to functional abnormalities associated with gastroesophageal reflux and include heartburn, regurgitation, and dysphagia. These patients have a mechanically defective LES, giving rise to the reflux of gastric juice into the esophagus and the symptoms of heartburn and regurgitation. The symptom of dysphagia occurs from the presence of mucosal edema, Schatzki's ring, stricture, or the inability to organize peristaltic activity in the body of the esophagus as a consequence of the disease.

There is a group of patients with sliding hiatal hernias not associated with reflux disease who have dysphagia without any obvious endoscopic or manometric explanation. Video barium radiograms have shown that the cause of dysphagia in these patients is an obstruction of the swallowed bolus by diaphragmatic impingement on the herniated stomach. Manometrically, this is reflected by a double-humped high-pressure zone at the GEJ. The first pressure rise is due to diaphragmatic impingement on the herniated stomach, and the second to the true distal esophageal sphincter. These patients usually have a mechanically competent sphincter, but the impingement of the diaphragm on the stomach can result in propelling the contents of the supradiaphragmatic portion of the stomach up into the esophagus and pharynx, resulting in complaints of pharyngeal regurgitation and aspiration. Consequently, this abnormality is often confused with typical GERD. Surgical reduction of the hernia results in relief of the dysphagia in 91% of patients.

Diagnosis

A chest X ray with the patient in the upright position can diagnose a hiatal hernia if it shows an air-fluid level behind the cardiac shadow. This is usually caused by a PEH or an intrathoracic stomach. The accuracy of the upper GI barium study in detecting a paraesophageal hiatal hernia is greater than for a sliding hernia because the latter can often spontaneously reduce. The paraesophageal hiatal hernia is a permanent herniation of the stomach into the thoracic cavity, so a barium swallow provides the diagnosis in virtually every case. Attention should be focused on the position of the GEJ, when seen, to differentiate it from a type II hernia (see Fig. 25-39B and C). Fiber-optic esophagoscopy is useful in the diagnosis and classification of a hiatal hernia because the scope can be retroflexed. In this position, a sliding hiatal hernia can be identified by noting a gastric pouch lined with rugal folds extending above the impression caused by the crura of the diaphragm, or measuring at least 2 cm between the crura, identified by having the patient sniff, and the squamocolumnar junction on withdrawal of the scope (Fig. 25-40). A PEH is identified on retroversion of the scope by noting a separate orifice adjacent to the GEJ into which gastric rugal folds ascend. A sliding-rolling or mixed hernia can be identified by noting a gastric pouch lined with rugal folds above the diaphragm, with the GEJ entering about midway up the side of the pouch.

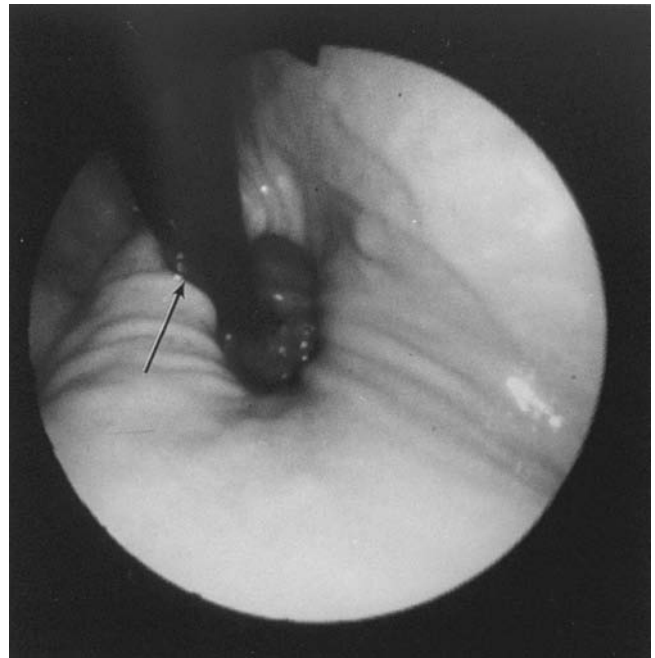


Figure 25-40. Endoscopic view through a retroflexed fiber-optic gastroscope showing the shaft of the scope (arrow) coming down through a sliding hernia. Note the gastric rugal folds extending above the impression caused by the crura of the diaphragm. (Reproduced with permission from DeMeester TR, Bonavina L: *Paraesophageal hiatal hernia*, in Nyhus LM, Condon RE (eds): *Hernia*, 3rd ed. Philadelphia: Lippincott, 1989, p 689.)

Pathophysiology

Physiologic testing with 24-hour esophageal pH monitoring has shown increased esophageal exposure to acid gastric juice in 60% of the patients with a paraesophageal hiatal hernia, compared with the observed 71% incidence in patients with a sliding hiatal hernia. It is now recognized that paraesophageal hiatal hernia can be associated with pathologic gastroesophageal reflux.

Physiologic studies have also shown that the competency of the cardia depends on an interrelationship between distal esophageal sphincter pressure, the length of the sphincter that is exposed to the positive-pressure environment of the abdomen, and the overall length of the sphincter. A deficiency in any one of these manometric characteristics of the sphincter is associated with incompetency of the cardia regardless of whether a hernia is present. Patients with a PEH who have an incompetent cardia have been shown to have a distal esophageal sphincter with normal pressure, but a shortened overall length and displacement outside the positive-pressure environment of the abdomen. One might expect esophageal body function to be diminished with the esophagus "accordioned" up into the chest. Surprisingly, esophageal peristalsis in patients with PEH is normal in 88%.

Treatment

The treatment of paraesophageal hiatal hernia is largely surgical. Controversial aspects include: (a) indications for repair, (b) diaphragmatic repair, (c) role of fundoplication, and (d) existence and treatment of the short esophagus.

Indications and Surgical Approach. The presence of a paraesophageal hiatal hernia has traditionally been considered an indication for surgical repair. This recommendation is largely

based upon two clinical observations. First, retrospective studies have shown a significant incidence of catastrophic, life-threatening complications of bleeding, infarction, and perforation in patients being followed with known paraesophageal herniation. Second, emergency repair carries a high mortality. In the classic report of Skinner and Belsey, six of 21 patients with a PEH, treated medically because of minimal symptoms, died from the complications of strangulation, perforation, exsanguinating hemorrhage, or acute dilatation of the herniated intrathoracic stomach. For the most part, these catastrophes occurred without warning. Others have reported similar findings.

Recent studies suggest that catastrophic complications may be somewhat less common. Allen and colleagues followed 23 patients for a median of 78 months with only four patients progressively worsening. There was a single mortality secondary to aspiration that occurred during a barium swallow examination to investigate progressive symptoms. Although emergency repairs had a median hospital stay of 48 days compared to a stay of 9 days in those having elective repair, there were only three cases of gastric strangulation in 735 patient-years of follow-up.

If surgery is delayed and repair is done on an emergency basis, operative mortality is high, compared to <1% for an elective repair. With this in mind, patients with a PEH are generally counseled to have elective repair of their hernia, particularly if they are symptomatic. Watchful waiting of asymptomatic PEHs may be an acceptable option.

The surgical approach to repair of a paraesophageal hiatal hernia may be either transabdominal (laparoscopic or open) or transthoracic. Each has its advantages and disadvantages.

4▶ A transthoracic approach facilitates complete esophageal mobilization but is rarely used because the access trauma and postoperative pain are significantly greater than a laparoscopic approach.

The transabdominal approach facilitates reduction of the volvulus that is often associated with PEHs. Although some degree of esophageal mobilization can be accomplished transhiatally, complete mobilization to the aortic arch is difficult or impossible without risk of injury to the vagal nerves.

Laparoscopic repair of PEH would appear to have become the standard approach. Laparoscopic repair of a pure type II, or mixed type III PEH is an order of magnitude more difficult than a standard laparoscopic Nissen fundoplication. Most would recommend that these procedures are best avoided until the surgeon has accumulated considerable experience with laparoscopic antireflux surgery. There are several reasons for this. First, the vertical and horizontal volvulus of the stomach often associated with PEHs makes identification of the anatomy, in particular the location of the esophagus, difficult. Second, dissection of a large PEH sac may result in significant bleeding if the surgeon deviates from the correct plane of dissection between the peritoneal sac and the endothoracic fascia. Finally, redundant tissue present at the GEJ following dissection of the sac frustrates the creation of a fundoplication. This tissue, which includes the epiphenic fat pad and hernia sac should be removed at the time of PEH repair. Mindful of these difficulties, and given appropriate experience, patients with PEH may be approached laparoscopically, with expectation of success in the majority.

Diaphragmatic Repair

It has been shown that PEH repair has a relatively high incidence of recurrence (10%–40%) when the crura is closed primarily

with permanent suture. Techniques to reduce hernia recurrence continue to evolve. Most surgeons believe that recurrence may be reduced with the use of synthetic or biologic mesh to reinforce the standard crural closure. Randomized controlled studies have demonstrated a reduction in PEH recurrence rate when mesh was used. Nonabsorbable synthetic mesh must be used carefully and not in a keyhole fashion at the hiatus because of a potential risk of esophagus or gastric erosion and mesh infection. Biologic mesh (acellular porcine dermis, acellular human dermis, porcine small intestinal submucosa) has become more widely used, but these meshes are significantly more expensive than synthetic mesh and the only randomized study supporting biologic mesh usage failed to demonstrate superiority over suture alone, after 5 years of rigorous follow up.

Role of Fundoplication in Giant Hiatal Hernia Repair.

Controversy remains as to whether to perform an antireflux procedure at all, in selected cases only, or in all patients. The case against an antireflux procedure rests on the frequency of significant postoperative complications secondary to the fundoplication, as well as the slightly longer operative time and increased cost that additional surgery entails. Most advocate the routine addition of an antireflux procedure following repair of the hernia defect. There are several reasons for this. Physiologic testing with 24-hour esophageal pH monitoring has shown increased esophageal exposure to acid gastric juice in 60% to 70% of patients with a paraesophageal hiatal hernia, nearly identical to the observed 71% incidence in patients with a sliding hiatal hernia. Furthermore, there is no relation between the symptoms experienced by the patient with a PEH and the competency of the cardia. Finally, dissection of the gastroesophageal esophagus may lead to postoperative reflux despite a negative preoperative pH score.

The Short Esophagus and PEH

Giant PEH can be associated with a short esophagus in up to 5% to 20% of patients as a result of chronic cephalad displacement of the GEJ. The presence of a short esophagus increases the difficulty of laparoscopic PEH repair. Approximately 10% to 20% of surgical failures with PEH repair is due to the lack of recognition of a short esophagus. Preoperative results of barium swallow and esophagogastroduodenoscopy may provide an indication of short esophagus, but no combination of preoperative clinical variables reliably predict the presence of short esophagus, defined as the failure to achieve 2.5 cm of intra-abdominal esophagus with standard mediastinal dissection techniques. Hence, the diagnosis of this entity continues to be made definitively only in the operating room. Collis gastroplasty achieves esophageal lengthening by creation of a neoesophagus using the gastric cardia. The totally laparoscopic approach to the short esophagus has evolved from a method using an end-to-end anastomosis circular stapler to the current approach that uses a linear stapler creating a stapled wedge gastroplasty. Elements of importance in fashioning the fundoplication after Collis gastroplasty include placement of the initial suture of the fundoplication on the esophagus, immediately above the GEJ to ensure that acid-secreting (gastric) mucosa does not reside above the fundoplication. A second element that ensures safety and avoids wrap deformation is to place the gastric portion of the staple line against the neoesophagus, such that the tip of the gastric staple line sits adjacent to the middle suture of the fundoplication on the right side of the esophagus.

Most outcome studies report relief of symptoms following surgical repair of PEHs in more than 90% of patients. The current literature suggests that laparoscopic repair of a paraesophageal hiatal hernia can be successful. Most authors report symptomatic improvement in 80% to 90% of patients, and <10% to 15% prevalence of recurrent symptomatic hernia. However, the problem of recurrent asymptomatic or minimally symptomatic hernia following PEH repair, open or laparoscopic, is becoming increasingly appreciated. Recurrent hiatal hernia is the most common cause of anatomic failure following laparoscopic Nissen fundoplication done for GERD (5%–10%), but this risk is compounded for the giant hernia where radiologic recurrence is detected in 25% to 40% of patients. It appears that optimal results with open or laparoscopic giant hiatal hernia repair should include options for mesh buttressing of hiatal closure and selective esophageal lengthening with one of the many techniques developed for the creation of a Collis gastroplasty. Despite this high incidence of radiologic recurrence, and the surgical pursuit of a remedy, it must be reinforced that asymptomatic recurrent hernia, like primary PEH, do not need to be repaired. The risk of incarceration, strangulation, or obstruction is minimal.

SCHATZKI'S RING

Schatzki's ring is a thin submucosal circumferential ring in the lower esophagus at the squamocolumnar junction, often associated with a hiatal hernia. Its significance and pathogenesis are unclear (Fig. 25-41). The ring was first noted by Templeton, but Schatzki and Gary defined it as a distinct entity in 1953. Its prevalence varies from 0.2% to 14% in the general population, depending on the technique of diagnosis and the criteria used. Stiennon believed the ring to be a pleat of mucosa formed by infolding of redundant esophageal mucosa due to shortening of

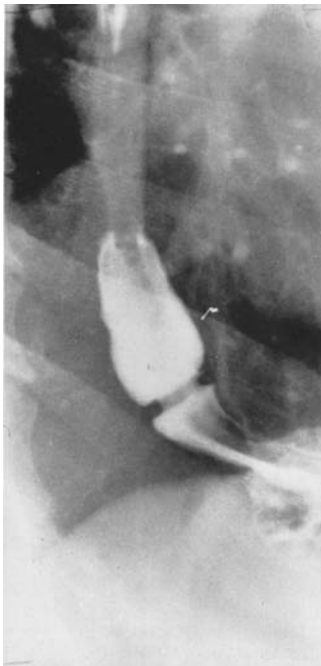


Figure 25-41. Barium esophagogram showing Schatzki's ring (i.e., a thin circumferential ring in the distal esophagus at the squamocolumnar junction). Below the ring is a hiatal hernia.

the esophagus. Others believe the ring to be congenital, and still others suggest it is an early stricture resulting from inflammation of the esophageal mucosa caused by chronic reflux.

Schatzki's ring is a distinct clinical entity having different symptoms, upper GI function studies, and response to treatment compared with patients with a hiatal hernia, but without a ring. Twenty-four-hour esophageal pH monitoring has shown that patients with a Schatzki's ring have a lower incidence of reflux than hiatal hernia controls. They also have better LES function. This, together with the presence of a ring, could represent a protective mechanism to prevent gastroesophageal reflux.

Symptoms associated with Schatzki's ring are brief episodes of dysphagia during hurried ingestion of solid foods. Its treatment has varied from dilation alone to dilation with antireflux measures, antireflux procedure alone, incision, and even excision of the ring. Little is known about the natural progression of Schatzki's rings. Using radiologic techniques, Chen and colleagues showed progressive stenosis of rings in 59% of patients, whereas Schatzki found that the rings decreased in diameter in 29% of patients and remained unchanged in the rest.

Symptoms in patients with a ring are caused more by the presence of the ring than by gastroesophageal reflux. Most patients with a ring but without proven reflux respond to one dilation, while most patients with proven reflux require repeated dilations. In this regard, the majority of Schatzki's ring patients without proven reflux have a history of ingestion of drugs known to be damaging to the esophageal mucosa. Bonavina and associates have suggested drug-induced injury as the cause of stenosis in patients with a ring, but without a history of reflux. Because rings also occur in patients with proven reflux, it is likely that gastroesophageal reflux also plays a part. This is supported by the fact that there is less drug ingestion in the history of these patients. Schatzki's ring is probably an acquired lesion that can lead to stenosis from chemical-induced injury by pill lodgment in the distal esophagus, or from reflux-induced injury to the lower esophageal mucosa.

The best form of treatment of a symptomatic Schatzki's ring in patients who do not have reflux consists of esophageal dilation for relief of the obstructive symptoms. In patients with a ring who have proven reflux and a mechanically defective sphincter, an antireflux procedure is necessary to obtain relief and avoid repeated dilation.

SCLERODERMA

Scleroderma is a systemic disease accompanied by esophageal abnormalities in approximately 80% of patients. In most, the disease follows a prolonged course. Renal involvement occurs in a small percentage of patients and signals a poor prognosis. The onset of the disease is usually in the third or fourth decade of life, occurring twice as frequently in women as in men.

Small vessel inflammation appears to be an initiating event, with subsequent perivascular deposition of normal collagen, which may lead to vascular compromise. In the GI tract, the predominant feature is smooth muscle atrophy. Whether the atrophy in the esophageal musculature is a primary effect or occurs secondary to a neurogenic disorder is unknown. The results of pharmacologic and hormonal manipulation, with agents that act either indirectly via neural mechanisms or directly on the muscle, suggest that scleroderma is a primary neurogenic disorder. Methacholine, which acts directly on smooth muscle receptors, causes a similar increase in LES pressure in normal

controls and in patients with scleroderma. Edrophonium, a cholinesterase inhibitor that enhances the effect of acetylcholine when given to patients with scleroderma, causes an increase in LES pressure that is less marked in these patients than in normal controls, suggesting a neurogenic rather than myogenic etiology. Muscle ischemia due to perivascular compression has been suggested as a possible mechanism for the motility abnormality in scleroderma. Others have observed that in the early stage of the disease, the manometric abnormalities may be reversed by reserpine, an agent that depletes catecholamines from the adrenergic system. This suggests that, in early scleroderma, an adrenergic overactivity may be present that causes a parasympathetic inhibition, supporting a neurogenic mechanism for the disease. In advanced disease manifested by smooth muscle atrophy and collagen deposition, reserpine no longer produces this reversal. Consequently, from a clinical perspective, the patient can be described as having a poor esophageal pump and a poor valve.

The diagnosis of scleroderma can be made manometrically by the observation of normal peristalsis in the proximal striated esophagus, with absent peristalsis in the distal smooth muscle portion (Fig. 25-42). The LES pressure is progressively weakened as the disease advances. Because many of the systemic sequelae of the disease may be nondiagnostic, the motility pattern is frequently used as a specific diagnostic indicator. Gastroesophageal reflux commonly occurs in patients with scleroderma, because they have both hypotensive sphincters and poor esophageal clearance. This combined defect can lead to severe esophagitis and stricture formation. The typical barium swallow shows a dilated, barium-filled esophagus, stomach, and duodenum, or a hiatal hernia with distal esophageal stricture and proximal dilatation (Fig. 25-43).

Traditionally, esophageal symptoms have been treated with PPIs, antacids, elevation of the head of the bed, and

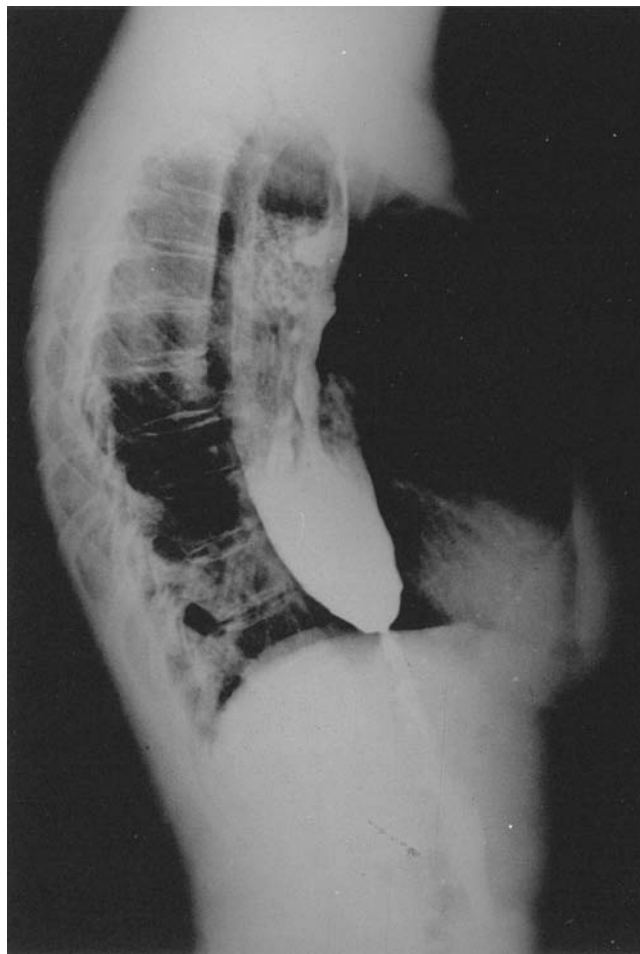


Figure 25-43. Barium esophagogram of a patient with scleroderma and stricture. Note the markedly dilated esophagus and retained food material. (Reproduced with permission from Waters PF, DeMeester TR: *Foregut motor disorders and their surgical management*. Med Clin North Am. 65:1253, 1981. Copyright Elsevier.)

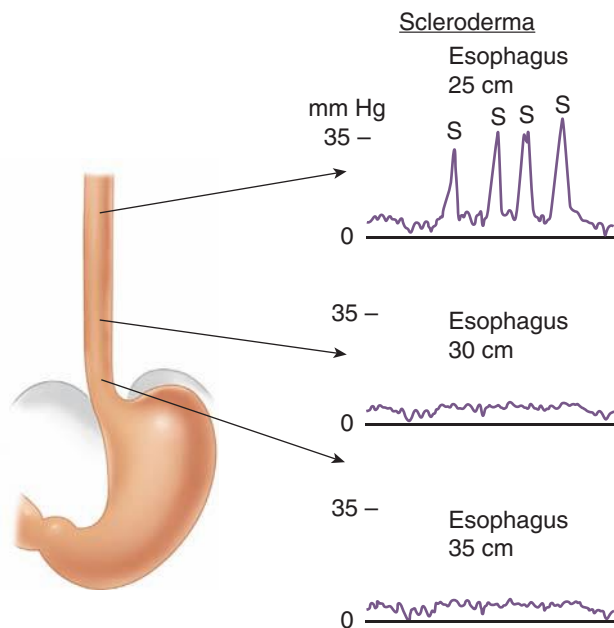


Figure 25-42. Esophageal motility record in a patient with scleroderma showing aperistalsis in the distal two thirds of the esophageal body with peristalsis in the proximal portion. (Reproduced with permission from Waters PF, DeMeester TR: *Foregut motor disorders and their surgical management*. Med Clin North Am. 65:1252, 1981. Copyright Elsevier.)

multiple dilations for strictures, with generally unsatisfactory results. The degree of esophagitis is usually severe and may lead to marked esophageal shortening as well as stricture. Scleroderma patients have frequently had numerous dilations before they are referred to the surgeon. The surgical management is somewhat controversial, but the majority of opinion suggests that a partial fundoplication (anterior or posterior) performed laparoscopically is the procedure of choice. The need for a partial fundoplication is dictated by the likelihood of severe dysphagia if a total fundoplication is performed in the presence of aperistalsis. Esophageal shortening may require a Collis gastroplasty in combination with a partial fundoplication. Surgery reduces esophageal acid exposure, but does not return it to normal because of the poor clearance function of the body of the esophagus. Only 50% of the patients have a good-to-excellent result. If the esophagitis is severe, or there has been a previous failed antireflux procedure and the disease is associated with delayed gastric emptying, a gastric resection with Roux-en-Y gastrojejunostomy has proved the best option.

Eosinophilic Esophagitis

Eosinophilic esophagitis (EE) was first described in 1977, but has become well known only in the last two decades. The condition

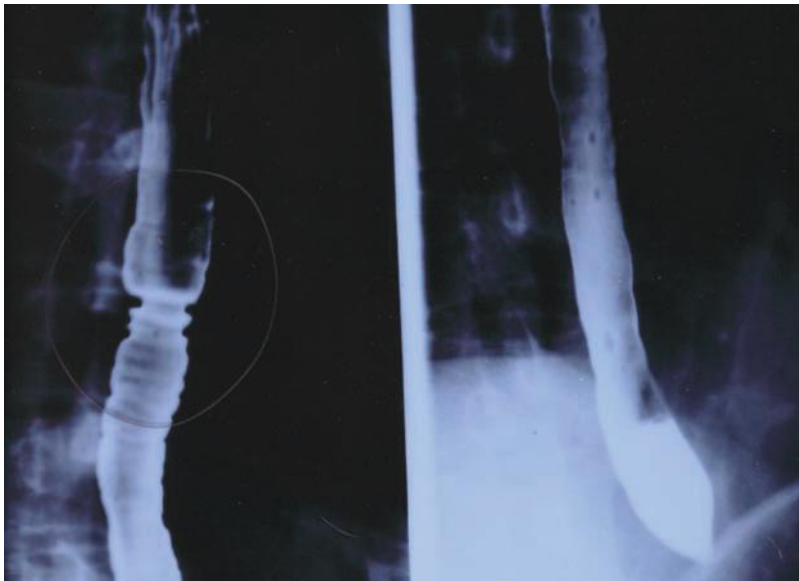


Figure 25-44. The esophagus on the left shows a stacking of rings, demonstrating eosinophilic esophagus. The esophagus on the right is a normal barium swallow.

is characterized by a constellation of symptoms, endoscopic and radiologic findings, and distinctive pathology. The etiology of eosinophilic esophagitis is not entirely known but its similarities, immunologically, to asthma suggest that it is a form of “allergic esophagitis.”

Symptoms

The presentation of eosinophilic esophagitis is chest pain, (often postprandial) and dysphagia. Dysphagia may occur with liquids or solids, but solid food dysphagia is most common. Because dysphagia and chest pain are characteristic of GERD, EE is often confused with GERD; however, EE does not respond to proton pump inhibitors. The evaluation of the patient with EE and dysphagia and chest pain with esophagram and endoscopy usually reveals the diagnosis.

Signs

A barium swallow should be the first test obtained in the patient with dysphagia. EE has a characteristic finding often called the “ringed esophagus” or the “feline esophagus,” as the esophageal rings are felt to look like the stripes on a housecat (Fig. 25-44). The endoscopic appearance of EE is also characteristic, and also appears as a series of rings (Fig. 25-45).

Pathology

Endoscopic biopsy specimens should be taken when eosinophilic esophagus is suspected. To make the diagnosis of EE, the pathologist should see a minimum of 15 eosinophils per high powered field, usually at the base of the epithelium (Fig. 25-46).

Treatment

The treatment of EE is largely symptomatic and includes testing for food allergies, and elimination of identified items from the diet. Second line therapy includes inhaled or ingested corticosteroids, as would be used to treat asthma. If dysphagia is not relieved with steroids, it may be necessary to dilate the esophagus. Because of the length of esophageal involvement, rigid dilators (Maloney or Savary) are often used. Great care must be exercised, as the inflamed EE is quite friable. The mucosal tears easily, and esophageal perforation (full thickness laceration) has been reported with EE dilation.

MOTILITY DISORDERS OF THE PHARYNX AND ESOPHAGUS

Clinical Manifestations

Dysphagia (i.e., difficulty in swallowing) is the primary symptom of esophageal motor disorders. Its perception by the patient is a balance between the severity of the underlying abnormality causing the dysphagia, and the adjustment made by the patient in altering eating habits. Consequently, any complaint of dysphagia must include an assessment of the patient’s dietary history. It must be known whether the patient experiences pain, chokes, or vomits with eating; whether the patient requires liquids with the meal, is the last to finish, or is forced to interrupt or avoid a social meal; and whether he or she has been admitted to the hospital for food impaction. These assessments, plus an evaluation of the patient’s nutritional status, help to determine how severe the dysphagia is and judge the need for surgical

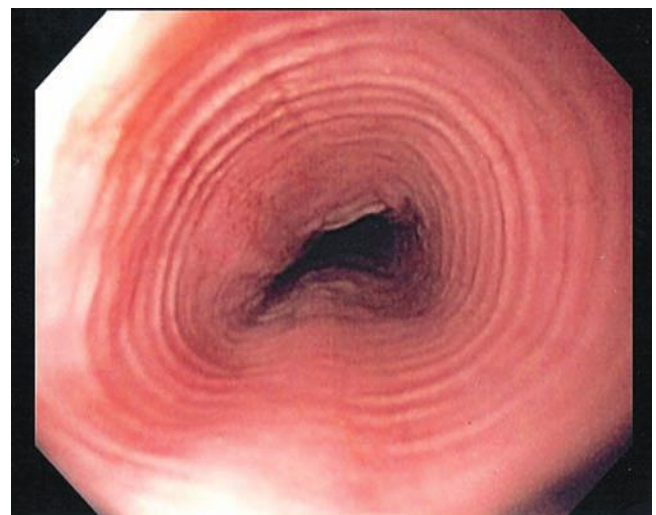

Figure 25-45. The endoscopic appearance of eosinophilic esophagitis is characteristically a series of stacked mucosal rings.

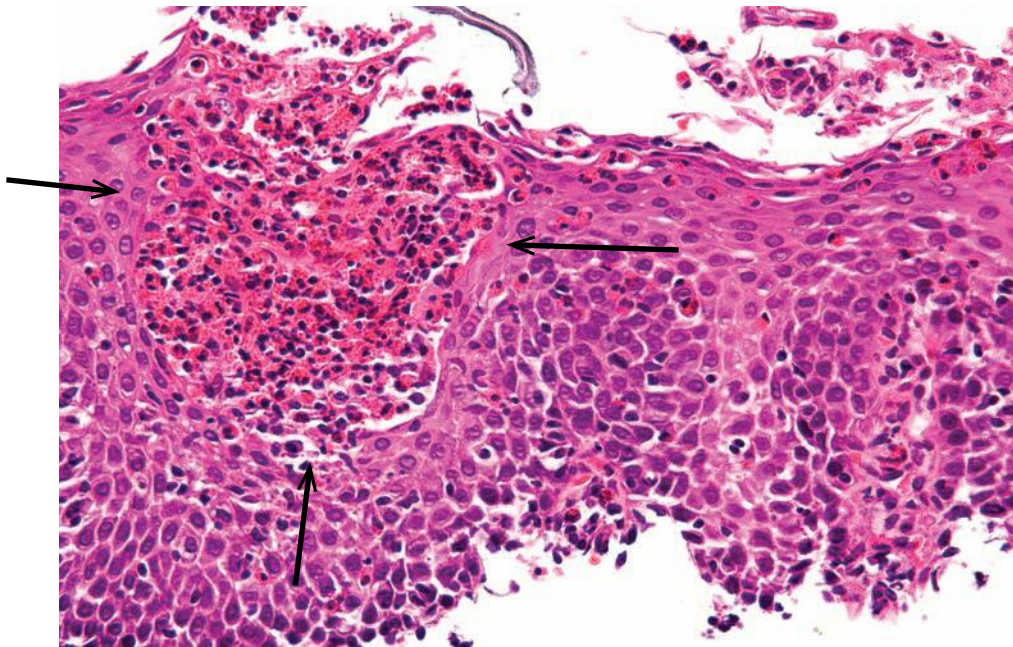


Figure 25-46. A cluster of eosinophils are visualized in the esophageal epithelium in a patient with EE.

intervention, rather than more conservative methods of treating dysphagia.

Motility Disorders of the Pharynx and Upper Esophagus – Transit Dysphagia

Disorders of the pharyngeal phase of swallowing result from a discoordination of the neuromuscular events involved in chewing, initiation of swallowing, and propulsion of the material from the oropharynx into the cervical esophagus. They can be categorized into one or a combination of the following abnormalities: (a) inadequate oropharyngeal bolus transport; (b) inability to pressurize the pharynx; (c) inability to elevate the larynx; (d) discoordination of pharyngeal contraction and cricopharyngeal relaxation; and (e) decreased compliance of the pharyngoesophageal segment secondary to neuromuscular disease. The latter may result in incomplete relaxation of the cricopharyngeus and cervical esophagus during swallowing. Taken together, these disorders are termed transit dysphagia by many

Transit dysphagia is usually congenital or results from acquired disease involving the central and peripheral nervous system. This includes cerebrovascular accidents, brain stem tumors, poliomyelitis, multiple sclerosis, Parkinson's disease, pseudobulbar palsy, peripheral neuropathy, and operative damage to the cranial nerves involved in swallowing. Pure muscular diseases such as radiation-induced myopathy, dermatomyositis, myotonic dystrophy, and myasthenia gravis are less common causes. Rarely, extrinsic compression of the cervical esophagus by thyromegaly, lymphadenopathy, or hyperostosis of the cervical spine can cause transit dysphagia.

Diagnostic Assessment of the Cricopharyngeal Segment.

Transit dysphagia difficult to assess with standard manometric techniques because of the rapidity of the oropharyngeal phase of swallowing, the elevation of the larynx, and the asymmetry of the cricopharyngeus. Video- or cineradiography is currently the most objective test to evaluate oropharyngeal bolus transport, pharyngeal compression, relaxation of the pharyngoesophageal

segment, and the dynamics of airway protection during swallowing. It readily identifies a diverticulum (Fig. 25-47), stasis of the contrast medium in the valleculae, a cricopharyngeal bar, and/or narrowing of the pharyngoesophageal segment. These are anatomic manifestations of neuromuscular disease, and result from the loss of muscle compliance in portions of the pharynx and esophagus composed of skeletal muscle.

Careful analysis of video- or cineradiographic studies combined with manometry using specially designed catheters can identify the cause of a pharyngoesophageal dysfunction in

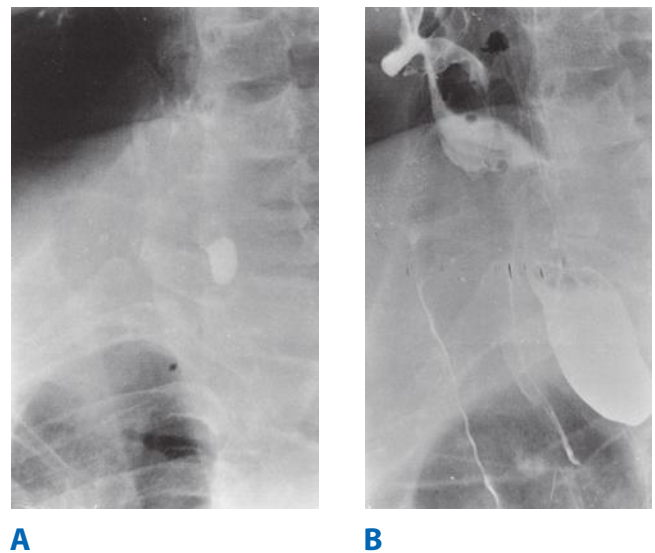


Figure 25-47. **A.** Zenker's diverticulum, initially discovered 15 years ago and left untreated. **B.** Note its marked enlargement and evidence of laryngeal inlet aspiration on recent esophagogram. (Reproduced with permission from Waters PF, DeMeester TR: *Foregut motor disorders and their surgical management*. Med Clin North Am. 65:1257, 1981. Copyright Elsevier.)

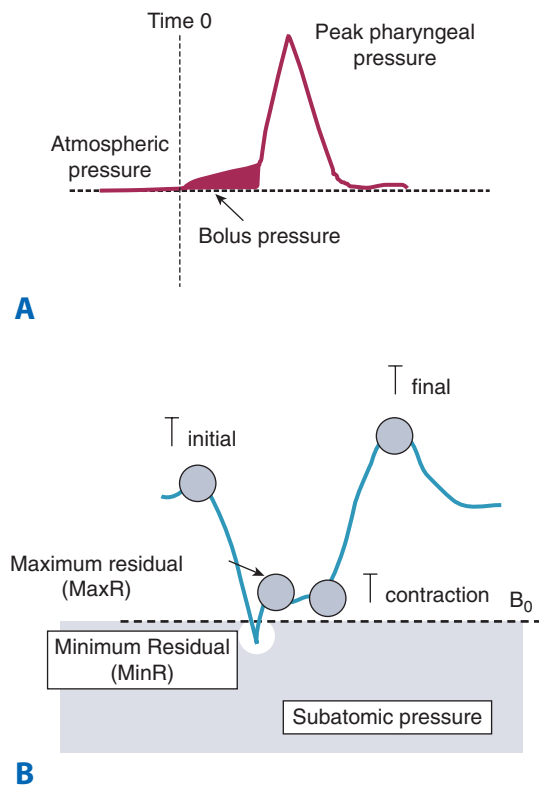


Figure 25-48. A. Schematic drawing of a pharyngeal pressure wave indicating the presence of the bolus pressure. B. Schematic drawing of the manometric recording typically seen during cricopharyngeal sphincter relaxation.

most situations (Fig. 25-48). Motility studies may demonstrate inadequate pharyngeal pressurization, insufficient or lack of cricopharyngeal relaxation, marked discoordination of pharyngeal pressurization, cricopharyngeal relaxation and cervical esophageal contraction, or a hypopharyngeal bolus pressure suggesting decreased compliance of the skeletal portion of the cervical esophagus.

In many patients with cricopharyngeal dysfunction, including those with Zenker's diverticulum, it has been difficult to consistently demonstrate a motility abnormality or discoordination of pharyngoesophageal events. The abnormality most apt to be present is a loss of compliance in the pharyngoesophageal segment manifested by an increased bolus pressure. Cook and colleagues have demonstrated an increased resistance to the

movement of a bolus through what appears on manometry to be a completely relaxed cricopharyngeal sphincter. Using simultaneous manometry and videofluoroscopy, they showed that, in these patients, the cricopharyngeus is only partially relaxed; that is, the sphincter is relaxed enough to allow a drop of its pressure to esophageal baseline on manometry, but insufficiently relaxed to allow unimpaired passage of the bolus into the esophagus. This incomplete relaxation is due to a loss of compliance of the muscle in the pharyngoesophageal segment, and may be associated with a cricopharyngeal bar or Zenker's diverticulum. This decreased compliance of the cricopharyngeal sphincter can be recognized on esophageal manometry by a "shoulder" on the pharyngeal pressure wave, the amplitude of which correlates directly with the degree of outflow obstruction (Fig. 25-49). Increasing the diameter of this noncompliant segment reduces the resistance imposed on the passage of a bolus. Consequently, patients with low pharyngeal pressure (i.e., poor piston function of the pharynx), or patients with increased resistance of the pharyngocervical esophageal segment from loss of skeletal muscle compliance, are improved by a cricopharyngeal myotomy. This enlarges the pharyngoesophageal segment and reduces outflow resistance. Esophageal muscle biopsy specimens from patients with Zenker's diverticulum have shown histologic evidence of the restrictive myopathy in the cricopharyngeous muscle. These findings correlate well with the observation of a decreased compliance of the upper esophagus demonstrated by videoradiography and the findings on detailed manometric studies of the pharynx and cervical esophagus. They suggest that the diverticulum develops as a consequence of the outflow resistance to bolus transport through the noncompliant muscle of the pharyngoesophageal segment.

The requirements for a successful pharyngoesophageal myotomy are: (a) adequate oropharyngeal bolus transport; (b) the presence of an intact swallowing reflex; (c) reasonable coordination of pharyngeal pressurization with cricopharyngeal relaxation; and (d) a cricopharyngeal bar, Zenker's diverticulum, or a narrowed pharyngoesophageal segment on videoesophagogram and/or the presence of excessive pharyngoesophageal shoulder pressure on motility study.

Zenker's Diverticulum. In the past, the most common recognized sign of cricopharyngeal dysfunction was the presence of a Zenker's diverticulum, originally described by Ludlow in 1769. The eponym resulted from Zenker's classic clinicopathologic descriptions of 34 cases published in 1878. Pharyngoesophageal diverticula have been reported to occur in 1 of 1000 routine barium examinations, and classically occur in elderly, white males. Zenker's diverticula tend to enlarge progressively with

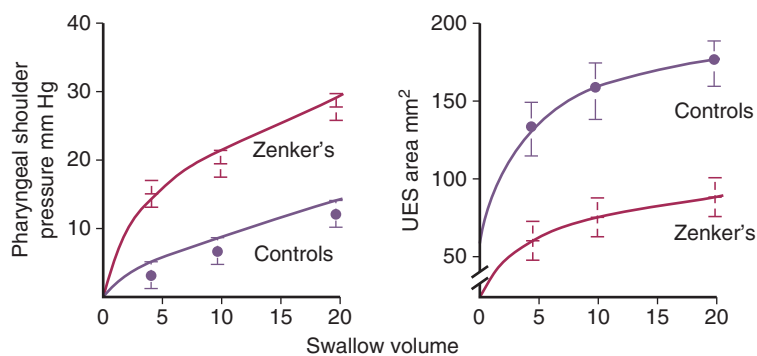


Figure 25-49. Pharyngeal shoulder pressures and diameter of the pharyngoesophageal segment in controls and patients with Zenker's diverticulum. UES = upper esophageal sphincter. (Data from Cook IJ, et al.: Zenker's diverticulum: Evidence for a restrictive cricopharyngeal myopathy. *Gastroenterology*. 96:A98, 1989.)

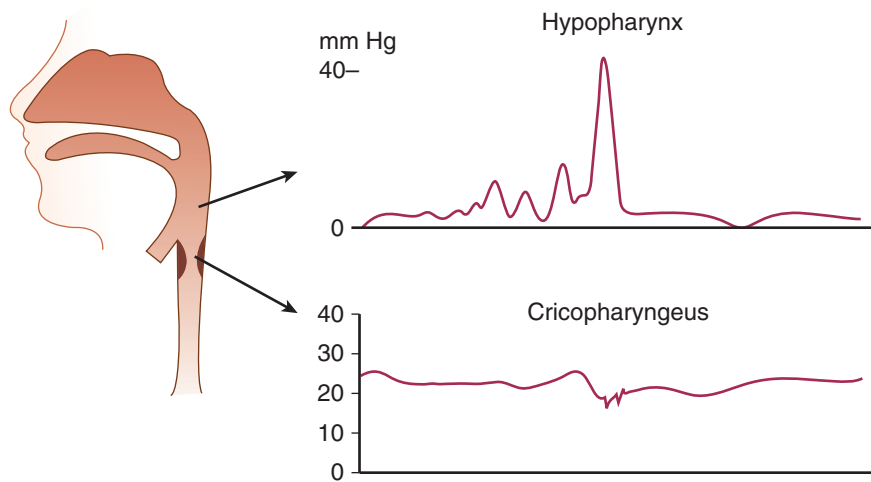


Figure 25-50. Cross-section of the neck at the level of the thyroid isthmus that shows the surgical approach to the hypopharynx and cervical esophagus. (Reproduced with permission from Waters PF, DeMeester TR: *Foregut motor disorders and their surgical management*. Med Clin North Am. 65:1257, 1981. Copyright Elsevier.)

time due to the decreased compliance of the skeletal portion of the cervical esophagus that occurs with aging.

Presenting symptoms include dysphagia associated with the spontaneous regurgitation of undigested, bland material, often interrupting eating, or drinking. On occasion, the dysphagia can be severe enough to cause debilitation and significant weight loss. Chronic aspiration and repetitive respiratory infection are common associated complaints. Once suspected, the diagnosis is established by a barium swallow. Endoscopy is usually difficult in the presence of a cricopharyngeal diverticulum, and potentially dangerous, owing to obstruction of the true esophageal lumen by the diverticulum and the attendant risk of diverticular perforation.

Cricopharyngeal Myotomy. The low morbidity and mortality associated with cricopharyngeal and upper esophageal myotomy have encouraged a liberal approach toward its use for almost any problem in the oropharyngeal phase of swallowing. This attitude has resulted in an overall success rate in the relief of symptoms of only 64%. When patients are selected for surgery using radiographic or motility markers of disease, a much higher proportion will benefit. Two methods of cricopharyngo-esophageal myotomy are in common use, one using traditional surgical approaches, and one using rigid laryngoscopy and a linear cutting stapler.

Open Cricopharyngeal Myotomy, Diverticulopexy, and Diverticulectomy. The myotomy can be performed under local or general anesthesia through an incision along the anterior border of the left sternocleidomastoid muscle. The pharynx and cervical esophagus are exposed by retracting the sternocleidomastoid muscle and carotid sheath laterally, and the thyroid, trachea, and larynx medially (Fig. 25-50). When a pharyngo-esophageal diverticulum is present, localization of the pharyngo-esophageal segment is easy. The diverticulum is carefully freed from the overlying areolar tissue to expose its neck, just below the inferior pharyngeal constrictor and above the cricopharyngeus muscle. It can be difficult to identify the cricopharyngeus muscle in the absence of a diverticulum. A benefit of local anesthesia is that the patient can swallow and demonstrate an area of persistent narrowing at the pharyngo-esophageal junction. Furthermore, before closing the incision, gelatin can be fed to the patient to ascertain whether the symptoms have been relieved, and to inspect the opening of the previously narrowed

pharyngo-esophageal segment. Under general anesthesia, and in the absence of a diverticulum, the placement of a nasogastric tube to the level of the manometrically determined cricopharyngeal sphincter helps in localization of the structures. The myotomy is extended cephalad by dividing 1 to 2 cm of inferior constrictor muscle of the pharynx, and caudad by dividing the cricopharyngeal muscle and the cervical esophagus for a length of 4 to 5 cm. The cervical wound is closed only when all oozing of blood has ceased, because a hematoma after this procedure is common, and is often associated with temporary dysphagia while the hematoma absorbs. Oral alimentation is started the day after surgery. The patient is usually discharged on the first or second postoperative day.

If a diverticulum is present and is large enough to persist after a myotomy, it may be sutured in the inverted position to the prevertebral fascia using a permanent suture (i.e., diverticulopexy) (Fig. 25-51). If the diverticulum is excessively large so that it would be redundant if suspended, or if its walls are thickened, a diverticulectomy should be performed. This is best performed under general anesthesia by placing a Maloney dilator (48F) in the esophagus, after controlling the neck of the diverticulum and after myotomy. A linear stapler is placed across the neck of the diverticulum and the diverticulum is excised distal to the staple line. The security of this staple line and effectiveness of the myotomy may be tested before hospital discharge with a water soluble contrast esophagogram. Postoperative complications include fistula formation, abscess, hematoma, recurrent nerve paralysis, difficulties in phonation, and Horner's syndrome. The incidence of the first two can be reduced by performing a diverticulopexy rather than diverticulectomy.

Endoscopic Cricopharyngotomy. Endoscopic stapled cricopharyngotomy and diverticulotomy recently has been described. This procedure is most effective for larger diverticula (>2 cm), and may be impossible to perform for the small diverticulum. The procedure uses a specialized "diverticuloscope" with two retractable valves passed into the hypopharynx. The lips of the diverticuloscope are positioned so that one lip lies in the esophageal lumen and the other in the diverticular lumen. The valves of the diverticuloscope are retracted appropriately so as to visualize the septum interposed between the diverticulum and the esophagus. An endoscopic linear stapler is introduced into the diverticuloscope and positioned against the common septum with

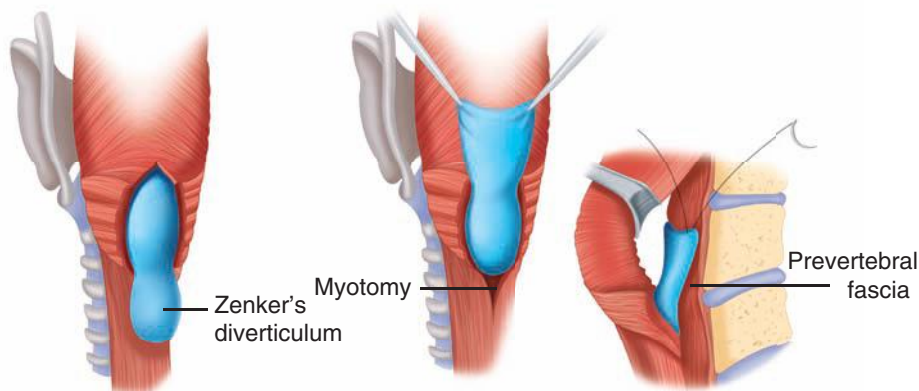


Figure 25-51. Posterior of the anatomy of the pharynx and cervical esophagus showing pharyngoesophageal myotomy and pexing of the diverticulum to the prevertebral fascia.

the anvil in the diverticulum and the cartridge in the esophageal lumen. Firing of the stapler divides the common septum between the posterior esophageal and the diverticular wall over a length of 30 mm, placing three rows of staples on each side. More than one stapler application may be needed, depending on the size of the diverticulum (Fig. 25-52). The patient is allowed to resume liquid feeds immediately, and is usually discharged the day after surgery. Complications are rare and may include perforation at the apex of the diverticulum, and failure to relieve dysphagia resulting from incomplete myotomy. The former complication can usually be treated with antibiotics, but may rarely require neck drainage.

Recurrence of a Zenker's diverticulum may occur with long follow-up, and is more common after diverticulectomy without myotomy, presumably due to persistence of the underlying loss of compliance of the cervical esophagus when a myotomy is not performed. After endoscopic cricopharyngotomy lateral residual "pouches" may be seen on radiographs, but are rarely responsible for residual or recurrent symptoms if the myotomy has been complete.

Postoperative motility studies have shown that the peak pharyngeal pressure generated on swallowing is not affected, the resting cricopharyngeal pressure is reduced but not eliminated, and the cricopharyngeal sphincter length is shortened. Consequently, after myotomy, there is protection against esophagopharyngeal regurgitation.

Motility Disorders of the Esophageal Body and Lower Esophageal Sphincter

Disorders of the esophageal phase of swallowing result from abnormalities in the propulsive pump action of the esophageal

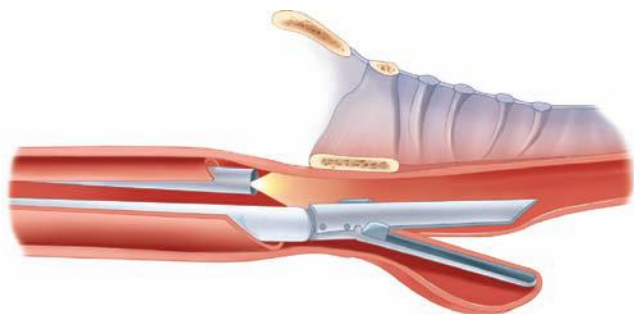


Figure 25-52. The technique for transoral cricopharyngotomy and Zenker's diverticulotomy.

body or the relaxation of the LES. These disorders result from either primary esophageal abnormalities, or from generalized neural, muscular, or collagen vascular disease (Table 25-8). The use of standard and high-resolution esophageal manometry techniques has allowed specific primary esophageal motility disorders to be identified out of a pool of nonspecific motility abnormalities. Primary esophageal motor disorders include achalasia, DES, nutcracker esophagus, and the hypertensive LES. The manometric characteristics of these disorders are shown in Table 25-9.

The boundaries between the primary esophageal motor disorders are vague, and intermediate types exist, some of which may combine more than one type of motility pattern. These findings indicate that esophageal motility disorders should be looked at as a spectrum of abnormalities that reflects various stages of destruction of esophageal motor function.

Achalasia. The best known and best understood primary motility disorder of the esophagus is achalasia, with an incidence of six per 100,000 population per year. Although complete absence of peristalsis in the esophageal body has been proposed as the major abnormality, present evidence indicates achalasia is a primary disorder of the LES. This is based on 24-hour outpatient esophageal motility monitoring, which shows that, even in advanced disease, up to 5% of contractions can be peristaltic. Simultaneous esophageal waves develop as a result of the increased resistance to esophageal emptying caused by the

Table 25-8

Esophageal motility disorders

Primary esophageal motility disorders

Achalasia, "vigorous" achalasia
 Diffuse and segmental esophageal spasm
 Nutcracker esophagus
 Hypertensive lower esophageal sphincter
 Nonspecific esophageal motility disorders

Secondary esophageal motility disorders

Collagen vascular diseases: progressive systemic sclerosis, polymyositis and dermatomyositis, mixed connective tissue disease, systemic lupus erythematosus, etc.
 Chronic idiopathic intestinal pseudoobstruction
 Neuromuscular diseases
 Endocrine and metastatic disorders

Table 25-9

Manometric characteristics of the primary esophageal motility disorders**Achalasia**

Incomplete lower esophageal sphincter (LES) relaxation
($<75\%$ relaxation)

Aperistalsis in the esophageal body

Elevated LES pressure ≤ 26 mmHg

Increased intraesophageal baseline pressures relative to gastric baseline

Diffuse esophageal spasm (DES)

Simultaneous (nonperistaltic contractions) ($>20\%$ of wet swallows)

Repetitive and multip peaked contractions

Spontaneous contractions

Intermittent normal peristalsis

Contractions may be of increased amplitude and duration

Nutcracker esophagus

Mean peristaltic amplitude (10 wet swallows) in distal esophagus ≥ 180 mmHg

Increased mean duration of contractions (>7.0 s)

Normal peristaltic sequence

Hypertensive lower esophageal sphincter

Elevated LES pressure (≥ 26 mmHg)

Normal LES relaxation

Normal peristalsis in the esophageal body

Ineffective esophageal motility disorders

Decreased or absent amplitude of esophageal peristalsis
(<30 mmHg)

Increased number of nontransmitted contractions

Source: Reproduced with permission from DeMeester TR, et al.: Physiologic diagnostic studies, in Zuidema GD, Orringer MB (eds): Shackelford's Surgery of the Alimentary Tract, 3rd ed, Vol. I. Philadelphia: W.B. Saunders, 1991, p 115. Copyright Elsevier.

nonrelaxing LES. This conclusion is supported by experimental studies in which a band placed loosely around the GEJ in experimental models did not change sphincter pressures, but resulted in impaired relaxation of the LES and outflow resistance. This led to a markedly increased frequency of simultaneous waveforms and a decrease in contraction amplitude. The changes were associated with radiographic dilation of the esophagus and were reversible after removal of the band. Observations in patients with pseudoachalasia due to tumor infiltration, a tight stricture in the distal esophagus, or an antireflux procedure that is too tight also provide evidence that dysfunction of the esophageal body can be caused by the increased outflow obstruction of a nonrelaxing LES. The observation that esophageal peristalsis can return in patients with classic achalasia following dilation or myotomy provides further support that achalasia is a primary disease of the LES.

The pathogenesis of achalasia is presumed to be a neurogenic degeneration, which is either idiopathic or due to infection. In experimental animals, the disease has been reproduced by destruction of the nucleus ambiguus and the dorsal motor nucleus of the vagus nerve. In patients with the disease, degenerative changes have been shown in the vagus nerve and in the ganglia in the myenteric plexus of the esophagus itself.

This degeneration results in hypertension of the LES, a failure of the sphincter to relax on swallowing, elevation of intraluminal esophageal pressure, esophageal dilatation, and a subsequent loss of progressive peristalsis in the body of the esophagus. The esophageal dilatation results from the combination of a nonrelaxing sphincter, which causes a functional retention of ingested material in the esophagus, and elevation of intraluminal pressure from repetitive pharyngeal air swallowing (Fig. 25-53). With time, the functional disorder results in anatomic alterations seen on radiographic studies, such as a dilated esophagus with a tapering, "bird's beak"-like narrowing of the distal end (Fig. 25-54). There is usually an air-fluid level in the esophagus from the retained food and saliva, the height of which reflects the degree of resistance imposed by the nonrelaxing sphincter. As the disease progresses, the esophagus becomes massively dilated and tortuous.

A subgroup of patients with otherwise typical features of classic achalasia has simultaneous contractions of their esophageal body that can be of high amplitude. This manometric pattern has been termed vigorous achalasia, and chest pain episodes

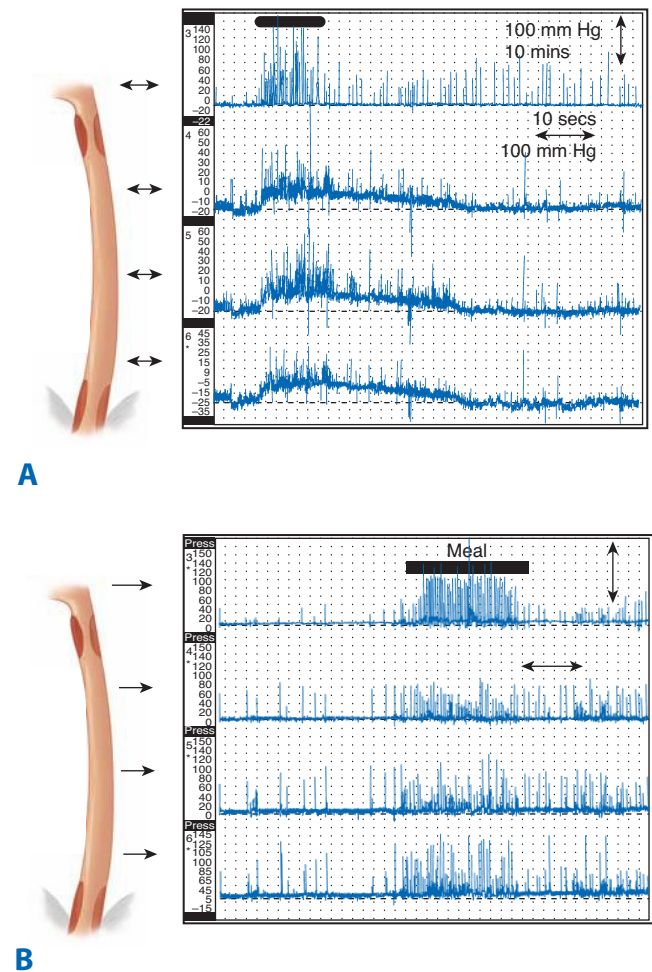


Figure 25-53. Pressurization of esophagus: Ambulatory motility tracing of a patient with achalasia. **A.** Before esophageal myotomy. **B.** After esophageal myotomy. The tracings have been compressed to exaggerate the motility spikes and baseline elevations. Note the rise in esophageal baseline pressure during a meal represented by the rise off the baseline to the left of panel **A**. No such rise occurs postmyotomy (panel **B**).

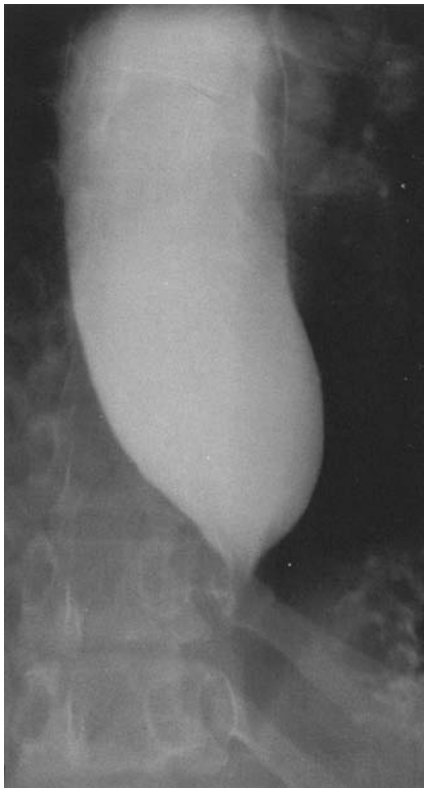

Figure 25-54. Barium esophagogram showing a markedly dilated esophagus and characteristic “bird’s beak” in achalasia. (*Reproduced with permission from Waters PF, DeMeester TR: Foregut motor disorders and their surgical management. Med Clin North Am. 65:1244, 1981. Copyright Elsevier.*)

are a common finding in these patients. Since the development of high resolution esophageal manometry technology, the term *vigorous achalasia* has been replaced with Chicago type 3 achalasia. Differentiation of type 3 achalasia from DES can be difficult. In both diseases, videoradiographic examination may show a corkscrew deformity of the esophagus and diverticulum formation.

Diffuse and Segmental Esophageal Spasm. DES is characterized by substernal chest pain and/or dysphagia. DES differs from classic achalasia in that it is primarily a disease of the esophageal body, produces a lesser degree of dysphagia, causes more chest pain, and has less effect on the patient’s general condition. Nonetheless, it is impossible to differentiate achalasia from DES on the basis of symptoms alone. Esophagogram and esophageal manometry are required to distinguish these two entities. True symptomatic DES is a rare condition, occurring about five times less frequently than achalasia.

The causation and neuromuscular pathophysiology of DES are unclear. The basic motor abnormality is rapid wave progression down the esophagus secondary to an abnormality in the latency gradient. Hypertrophy of the muscular layer of the esophageal wall and degeneration of the esophageal branches of the vagus nerve have been observed in this disease, although these are not constant findings. Manometric abnormalities in DES may be present over the total length of the esophageal body, but usually are confined to the distal two thirds. In segmental esophageal spasm, the manometric abnormalities are confined to a short segment of the esophagus.

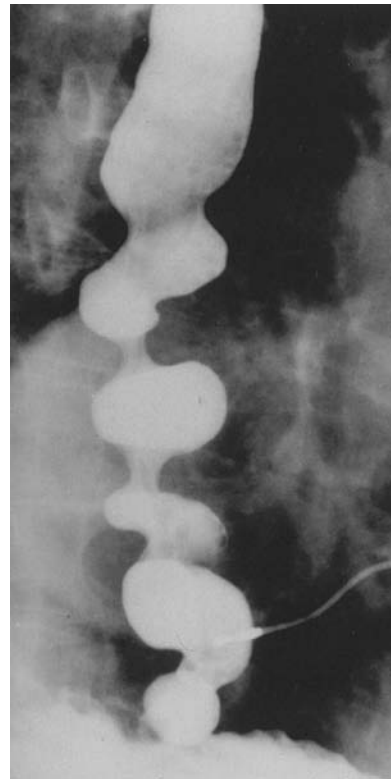


Figure 25-55. Barium esophagogram of patient with diffuse spasm showing the corkscrew deformity.

The classic manometric findings in these patients are characterized by the frequent occurrence of simultaneous waveforms and multi-peaked esophageal contractions, which may be of abnormally high amplitude or long duration. Key to the diagnosis of DES is that there remain some peristaltic waveforms in excess of those seen in achalasia. A criterion of 30% or more peristaltic waveforms out of 10 wet swallows has been used to differentiate DES from vigorous achalasia. However, this figure is arbitrary and often debated.

The LES in patients with DES usually shows a normal resting pressure and relaxation on swallowing. A hypertensive sphincter with poor relaxation may also be present. In patients with advanced disease, the radiographic appearance of tertiary contractions appears helical, and has been termed corkscrew esophagus or pseudodiverticulosis (Fig. 25-55). Patients with segmental or diffuse esophageal spasm can compartmentalize the esophagus and develop an epiphrenic or midesophageal diverticulum between two areas of high pressure occurring simultaneously (Fig. 25-56).

Nutcracker Esophagus. The disorder, termed nutcracker or supersqueezers esophagus, was recognized in the late 1970s. Other terms used to describe this entity are hypertensive peristalsis or high-amplitude peristaltic contractions. It is the most common of the primary esophageal motility disorders. By definition the so-called nutcracker esophagus is a manometric abnormality in patients who are characterized by peristaltic esophageal contractions with peak amplitudes greater than two SDs above the normal values in individual laboratories. Contraction amplitudes in these patients can easily be above 400 mmHg. At the lower end of peak pressure, it is unclear whether nutcracker esophagus causes any symptoms. In fact,

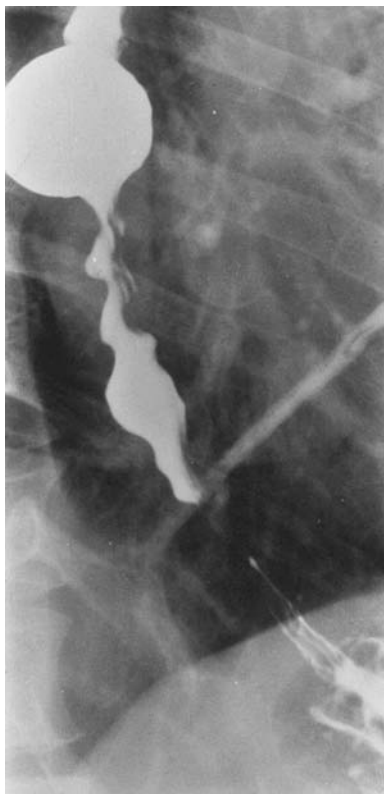

Figure 25-56. Barium esophagogram showing a high epiphrenic diverticulum in a patient with diffuse esophageal spasm. (*Reproduced with permission from DeMeester TR, Stein HJ: Surgery for esophageal motor disorders, in Castell DO (ed): The Esophagus. Boston: Little, Brown, 1992, p 415.*)

chest pain symptoms in nutcracker esophagus patients may be related to GERD rather than intraluminal hypertension. Treatment in these patients should be aimed at the treatment of GERD. At the high end (peak pressures >300 mmHg) chest pain may be the result of the nutcracker physiology, as treatment directed at reducing intraluminal pressure is more effective than when used for those with lower peak pressures.

Hypertensive Lower Esophageal Sphincter. Hypertensive lower esophageal sphincter (LES) in patients with chest pain or dysphagia was first described as a separate entity by Code and associates. This disorder is characterized by an elevated basal pressure of the LES with normal relaxation and normal propulsion in the esophageal body. About one-half of these patients, however, have associated motility disorders of the esophageal body, particularly hypertensive peristalsis and simultaneous waveforms. In the remainder, the disorder exists as an isolated abnormality. Dysphagia in these patients may be caused by a lack of compliance of the sphincter, even in its relaxed state. Myotomy of the LES may be indicated in patients not responding to medical therapy or dilation. When the symptom contribution of the hypertensive sphincter is in doubt, it is possible to inject the LES with botulinum toxin, endoscopically. If symptoms are relieved (temporarily) with this technique, then it is likely that myotomy will provide more permanent benefit.

Secondary Esophageal Motility Disorders. Connective tissue disease, particularly scleroderma and the CREST syndrome, exhibits severe esophageal motility disorders.

Additionally, patients treated as infants for esophageal atresia will often develop secondary motility disorders manifest later in life. Symptoms of these disorders are heartburn and dysphagia. The latter may be a result of a peptic stricture rather than the esophageal dysmotility. An esophageal motility study will usually show severely reduced or absent peristalsis with severely reduced or absent LES pressure. The role of antireflux surgery under these conditions is controversial, but, if performed, should be limited to partial fundoplication, as full (Nissen) fundoplication may result in severe dysphagia.

Nonspecific Esophageal Motor Disorders and Ineffective Esophageal Motility. Many patients complaining of dysphagia or chest pain of noncardiac origin demonstrate a variety of wave patterns and contraction amplitudes on esophageal manometry that are clearly out of the normal range, but do not meet the criteria of a primary esophageal motility disorder. Esophageal motility in these patients frequently shows an increased number of multiphased or repetitive contractions, contractions of prolonged duration, nontransmitted contractions, an interruption of a peristaltic wave at various levels of the esophagus, or contractions of low amplitude. These motility abnormalities have been termed nonspecific esophageal motility disorders. Their significance in the causation of chest pain or dysphagia is still unclear. Surgery plays no role in the treatment of these disorders unless there is an associated diverticulum.

A clear distinction between primary esophageal motility disorders and nonspecific esophageal motility disorders is often not possible. Patients diagnosed as having nonspecific esophageal motility abnormalities on repeated studies will occasionally show abnormalities consistent with nutcracker esophagus. Similarly, progression from a nonspecific esophageal motility disorder to classic DES has been demonstrated. Therefore, the finding of a nonspecific esophageal motility disorder may represent only a manometric marker of an intermittent, more severe esophageal motor abnormality. Combined ambulatory 24-hour esophageal pH and motility monitoring has shown that an increased esophageal exposure to gastric juice is common in patients diagnosed as having a nonspecific esophageal motility disorder. In some situations, the motor abnormalities may be induced by the irritation of refluxed gastric juice; in other situations, it may be a primary event unrelated to the presence of reflux. High-amplitude peristalsis (nutcracker esophagus) and low-amplitude peristalsis (ineffective esophageal motility) are frequently associated with GERD.

Diverticula of the Esophageal Body. Diverticula of the esophagus may be characterized by their location in the esophagus (proximal, mid-, or distal esophagus), or by the nature of concomitant pathology. Diverticula associated with motor disorders are termed pulsion diverticula and those associated with inflammatory conditions are termed traction diverticula. Pulsion diverticula occur most commonly with nonspecific motility disorders, but can occur with all of the primary motility disorders. In the latter situation, the motility disorder is usually diagnosed before the development of the diverticulum. When associated with achalasia, the development of a diverticulum may temporarily alleviate the symptom of dysphagia by becoming a receptacle for ingested food, and substitute the symptom of dysphagia for postprandial pain and regurgitation of undigested food. If a motility abnormality of the esophageal body or LES cannot be identified, a traction or congenital cause for the diverticulum should be considered.

Because development in radiology preceded development in motility monitoring, diverticula of the esophagus were considered historically to be a primary abnormality, the cause, rather than the consequence, of motility disorders. Consequently, earlier texts focused on them as specific entities based upon their location.

Epiphrenic diverticula arise from the terminal third of the thoracic esophagus and are usually found adjacent to the diaphragm. They have been associated with distal esophageal muscular hypertrophy, esophageal motility abnormalities, and increased luminal pressure. They are “pulsion” diverticula, and are associated with diffuse spasm, achalasia, or nonspecific motor abnormalities in the body of the esophagus.

Whether the diverticulum should be surgically resected or suspended depends on its size and proximity to the vertebral body. When diverticula are associated with esophageal motility disorders, esophageal myotomy from the proximal extent of the diverticulum to the stomach should be combined with diverticulectomy. If diverticulectomy alone is performed, one can expect a high incidence of suture line rupture due to the same intraluminal pressure that initially gave rise to the diverticulum. If the diverticulum is suspended to the prevertebral fascia of the thoracic vertebra, a myotomy is begun at the neck of the diverticulum and extended across the LES. If the diverticulum is excised by dividing the neck, the muscle is closed over the excision site and a myotomy is performed on the opposite esophageal wall, starting just above the level of the diverticulum or at the proximal extent of the spastic segment of the esophagus if high resolution motility is used. If complete, the myotomy will cross the LES, reducing distal esophageal peak pressure, and will increase the likelihood that dysphagia will be replaced with GERD symptoms. Increasingly, partial fundoplication (anterior or posterior) is performed after LES myotomy to decrease the frequency of disabling GERD developing after myotomy and diverticulectomy. When a large diverticulum is associated with a hiatal hernia, then hiatal hernia repair is added. All these procedures may be performed with traditional or minimally invasive techniques.

Midesophageal or traction diverticula were first described in the nineteenth century (Fig. 25-57). At that time, they were frequently noted in patients who had mediastinal LN involvement with tuberculosis. It was theorized that adhesions formed between the inflamed mediastinal nodes and the esophagus. By contraction, the adhesions exerted traction on the esophageal wall and led to a localized diverticulum (Fig. 25-58). This theory was based on the findings of early dissections, where adhesions between diverticula and LNs were commonly found. Other conditions associated with mediastinal lymphadenopathy, such as pulmonary fungal infections (e.g., aspergillosis), lymphoma, or sarcoid, may create traction esophageal diverticula after successful treatment. Rarely, when no underlying inflammatory pathology is identified, a motility disorder may be identified.

Most midesophageal diverticula are asymptomatic and incidentally discovered during investigation for nonesophageal complaints. In such patients, the radiologic abnormality may be ignored. Patients with symptoms of dysphagia, regurgitation, chest pain, or aspiration, in whom a diverticulum is discovered, should be thoroughly investigated for an esophageal motor abnormality. Occasionally, a patient will present with a bronchoesophageal fistula manifested by a chronic cough on ingestion of meals. The diverticulum in such patients is most likely to have an inflammatory etiology.

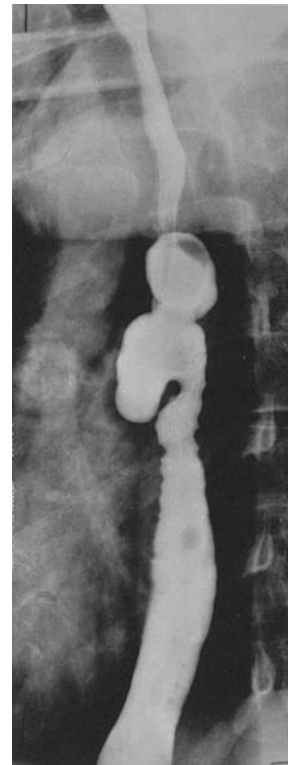

Figure 25-57. Barium esophagogram showing a midesophageal diverticulum. Despite the anatomic distortion, the patient was asymptomatic. (Reproduced with permission from Waters PF, DeMeester TR: *Foregut motor disorders and their surgical management*. Med Clin North Am. 65:1255, 1981. Copyright Elsevier.)

The indication for surgical intervention is dictated by the degree of symptomatic disability. Usually, midesophageal diverticula can be suspended due to their proximity to the spine. If a motor abnormality is documented, a myotomy should be performed as described for an epiphrenic diverticulum.

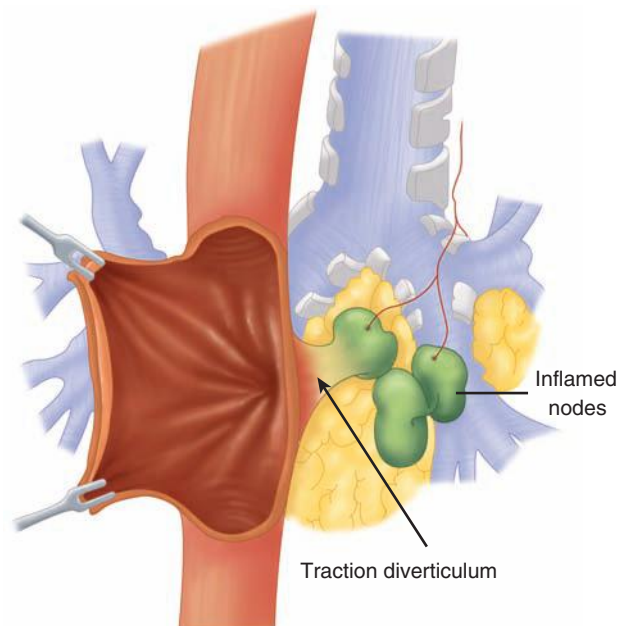


Figure 25-58. Illustration of the pathophysiology of midesophageal diverticulum showing traction on the esophageal wall from adhesions to inflamed subcarinal lymph nodes.

OPERATIONS FOR ESOPHAGEAL MOTOR DISORDERS AND DIVERTICULA

Long Esophageal Myotomy for Motor Disorders of the Esophageal Body

A long esophageal myotomy is indicated for dysphagia caused by any motor disorder characterized by segmental or generalized simultaneous waveforms in a patient whose symptoms are not relieved by medical therapy. Such disorders include diffuse and segmental esophageal spasm, vigorous or Type 3 achalasia, and nonspecific motility disorders associated with a mid- or epiphrenic esophageal diverticulum. However, the decision to operate must be made by a balanced evaluation of the patient's symptoms, diet, lifestyle adjustments, and nutritional status, with the most important factor being the possibility of improving the patient's swallowing disability. The symptom of chest pain alone is not an indication for a surgical procedure.

The identification of patients with symptoms of dysphagia and chest pain who might benefit from a surgical myotomy is difficult. Ambulatory motility studies have shown that when the prevalence of "effective contractions" (i.e., peristaltic waveforms consisting of contractions with an amplitude above 30 mmHg) drops below 50% during meals, the patient is likely to experience dysphagia (Fig. 25-59). This would suggest that relief from the symptom can be expected with an improvement of esophageal contraction amplitude or amelioration of nonperistaltic waveforms. Prokinetic agents may increase esophageal contraction amplitude, but do not alter the prevalence of simultaneous waveforms. Patients in whom the efficacy of esophageal propulsion is severely compromised because of a high prevalence of simultaneous waveforms usually receive little benefit from medical therapy. In these patients, a surgical myotomy of the esophageal body can improve the patients' dysphagia, provided the loss of contraction amplitude in the remaining peristaltic waveforms, caused by the myotomy, has less effect on swallowing function than the presence of the excessive simultaneous contractions. This situation is reached when the prevalence of effective waveforms during meals drops below 30%, (i.e., 70% of esophageal waveforms are ineffective).

In patients selected for surgery, preoperative high resolution manometry is essential to determine the proximal extent of

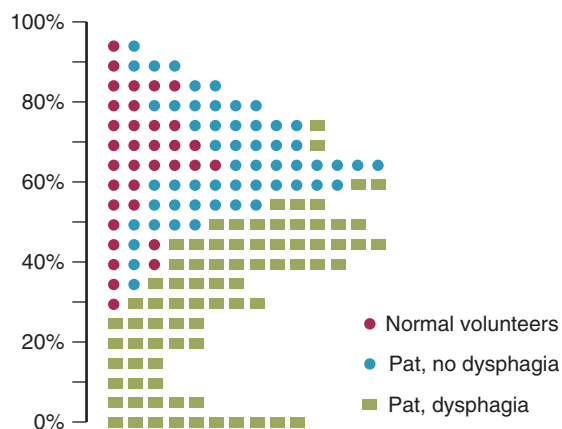


Figure 25-59. Prevalence of effective contractions, (i.e., peristaltic contractions with an amplitude >30 mm Hg) during meal periods in individual normal volunteers, patients (Pat) without dysphagia, and patients with nonobstructive dysphagia.

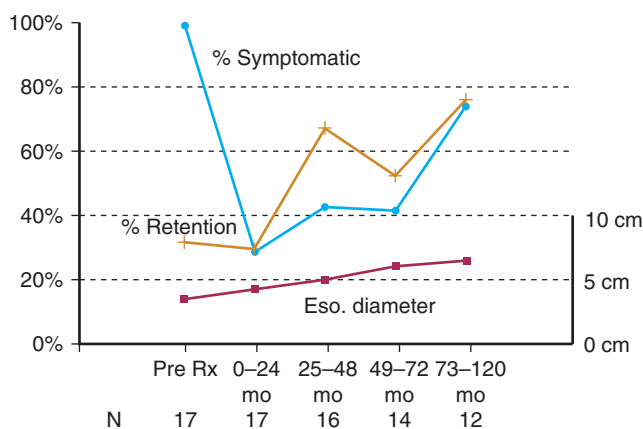


Figure 25-60. Esophageal (Eso.) diameter, dysphagia, and esophageal retention in patients with achalasia treated with myotomy and Nissen fundoplication, 10 years after treatment (Rx). (Based on Topart P, et al.: Long-term effect of total fundoplication on the myotomized esophagus. *Ann Thorac Surg.* 54:1046, 1992.)

the esophageal myotomy. Most surgeons extend the myotomy distally across the LES to reduce outflow resistance. Consequently, some form of antireflux protection is needed to avoid gastroesophageal reflux if there has been extensive dissection of the cardia. In this situation, most authors prefer a partial, rather than a full, fundoplication, in order not to add back-resistance that will further interfere with the ability of the myotomized esophagus to empty (Fig. 25-60). If the symptoms of reflux are present preoperatively, 24-hour pH monitoring is required to confirm its presence.

The procedure may be performed either open or via thoracoscopy. The open technique is performed through a left thoracotomy in the sixth intercostal space (Fig. 25-61). An incision is made in the posterior mediastinal pleura over the esophagus, and the left lateral wall of the esophagus is exposed. The esophagus is not circumferentially dissected unless necessary. A 2-cm incision is made into the abdomen through the parietal peritoneum at the midportion of the left crus. A tongue of gastric fundus is pulled into the chest. This exposes the GEJ and its associated fat pad. The latter is excised to give a clear view of the junction. A myotomy is performed through all muscle layers, extending distally over the stomach 1 to 2 cm below the GEJ, and proximally on the esophagus over the distance of the manometric abnormality. The muscle layer is dissected from the mucosa laterally for a distance of 1 cm. Care is taken to divide all minute muscle bands, particularly in the area of the GEJ. The gastric fundic tongue is sutured to the margins of the myotomy over a distance of 3 to 4 cm and replaced into the abdomen. This maintains separation of the muscle and acts as a partial fundoplication to prevent reflux.

If an epiphrenic diverticulum is present, it is excised by dividing the neck with a stapler sized for the thickness of the diverticulum (2.0- to 4.8-mm staple leg length) followed by a closure of the muscle over the staple line, when possible. The myotomy is then performed on the opposite esophageal wall. If a midesophageal diverticulum is present, the myotomy is made so that it includes the muscle around the neck, and the diverticulum is suspended by attaching it to the paravertebral fascia of the thoracic vertebra above the level of the diverticular neck. Before performing any operation for an esophageal diverticulum,

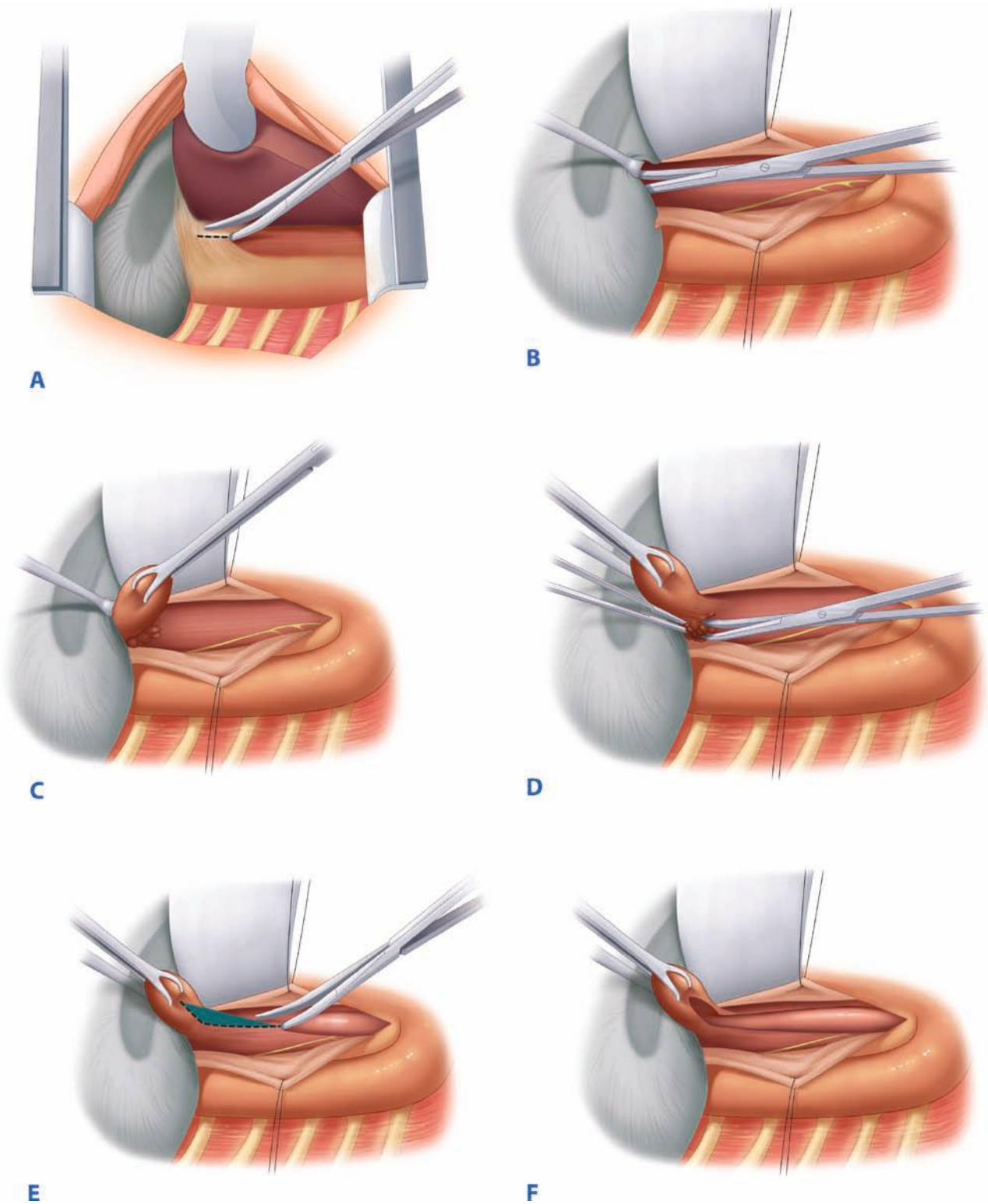


Figure 25-61. Technique of long myotomy: **A.** Exposure of the lower esophagus through the left sixth intercostal space and incision of the mediastinal pleura in preparation for surgical myotomy. **B.** Location of a 2-cm incision made through the phrenoesophageal membrane into the abdomen along the midlateral border of the left crus. **C.** Retraction of tongue of gastric fundus into the chest through the previously made incision. **D.** Removal of the gastroesophageal fat pad to expose the gastroesophageal junction. **E.** A myotomy down to the mucosa is started on the esophageal body. **F.** Completed myotomy extending over the stomach for 1 cm. **G.** Reconstruction of the cardia after a myotomy, illustrating the position of the sutures used to stitch the gastric fundic flap to the margins of the myotomy. **H.** Reconstruction of the cardia after a myotomy, illustrating the intra-abdominal position of the gastric tongue covering the distal 4 cm of the myotomy.

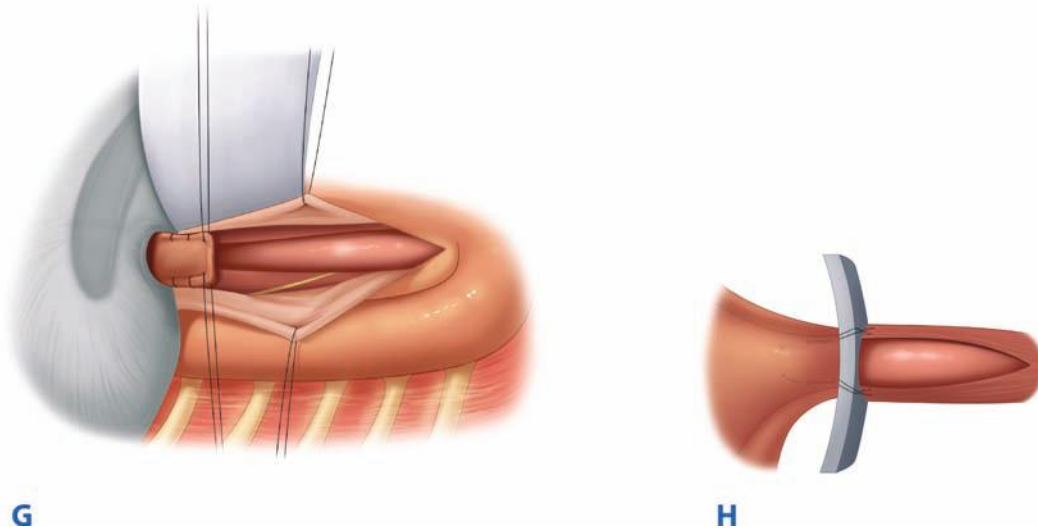


Figure 25-61. (Continued)

it is wise to endoscope the patient to wash all food and other debris from the diverticulum.

The results of myotomy for motor disorders of the esophageal body have improved in parallel with the improved preoperative diagnosis afforded by manometry. Previous published series report between 40% and 92% improvement of symptoms, but interpretation is difficult due to the small number of patients involved and the varying criteria for diagnosis of the primary motor abnormality. When myotomy is accurately done, 93% of the patients have effective palliation of dysphagia after a mean follow-up of 5 years, and 89% would have the procedure again, if it was necessary. Most patients gain or maintain rather than lose weight after the operation. Postoperative motility studies show that the myotomy reduces the amplitude of esophageal contractions to near zero and eliminates simultaneous peristaltic waves. If the benefit of obliterating the simultaneous waves exceeds the adverse effect on bolus propulsion caused by the loss of peristaltic waveforms, the patient's dysphagia is likely to be improved by the procedure. If not, the patient is likely to continue to complain of dysphagia and to have little improvement as a result of the operation.

The thoracoscopic technique may be performed through the left or right chest. There has been little experience gained with doing adequate operations (as described previously with the open exposure) through left thoracoscopy, so most surgeons will combine a right thoracoscopic long myotomy with an abdominal approach for Heller myotomy and partial fundoplication. These two procedures may be done at the same setting, by double positioning the patient, or they may be done at two operations. If this is the case, it is best to do the abdominal component first, as the esophageal outflow obstruction is the source of most of the symptoms. Performing abdominal myotomy (and diverticulectomy, if present) may be all that is required.

A new procedure, peroral endoscopic myotomy (POEM) allows a long myotomy to be performed from the lumen of the esophagus with an endoscope. This procedure is attractive for—at a minimum—those with Type 3 achalasia (vigorous achalasia) where it is necessary to divide esophagogastric circular muscle on both sides of the diaphragm to the extent that might not be possible with laparoscopy or thoracoscopy alone. The POEM

procedure is started by opening the esophageal mucosa several centimeters above the spastic segment with a needle-knife electrosurgery device passed through an endoscope. A long submucosal plane is developed with the endoscope, down to and below the LES. The circular muscle of the LES and the esophagus is divided with endoscopic electrosurgery all the way back until normal (nonspastic) esophagus is reached. The submucosal entry site in the esophagus is then closed with endoscopic clips. While the results of POEM are still accumulating, the procedure is attractive because it is extremely minimally invasive, and can be done as an outpatient.

Epiphrenic diverticula cannot be treated with POEM and are most frequently addressed with laparoscopic access, in combination with a laparoscopic division of the LES (Heller myotomy) (Fig. 25-62). If the diverticulum can be completely mobilized through the hiatus, it may be safely excised from below. The neck of the diverticulum is transected with a GIA stapler after passage of a 48F dilator. Not infrequently, the diverticulum is sufficiently large that access to the neck of the diverticulum across the hiatus is quite difficult. Additionally, the inflammatory reaction to the diverticulum may further make the transhiatal dissection difficult. Under these circumstances, it is safer to perform the diverticulectomy through a right thoracoscopic approach either at the time of the initial procedure or at a later date, depending upon the frailty of the patient. Following diverticulectomy, it is critical that the esophageal staple line be treated with a great deal of care. Closure of the muscle over the staple line is preferable. Additionally, the patient is kept NPO or on clear liquids for 5 to 7 days and a contrast study is obtained before advancing to a full liquid or “mushy food” diet. Solid foods are withheld for 2 weeks to decrease the likelihood of staple line leak. Buttressing or sealing the staple line with fibrin glue is also an attractive option.

Myotomy of the Lower Esophageal Sphincter (Heller Myotomy)

Second only to reflux disease, achalasia is the most common functional disorder of the esophagus to require surgical intervention. The goal of treatment is to relieve the functional outflow obstruction secondary to the loss of relaxation and

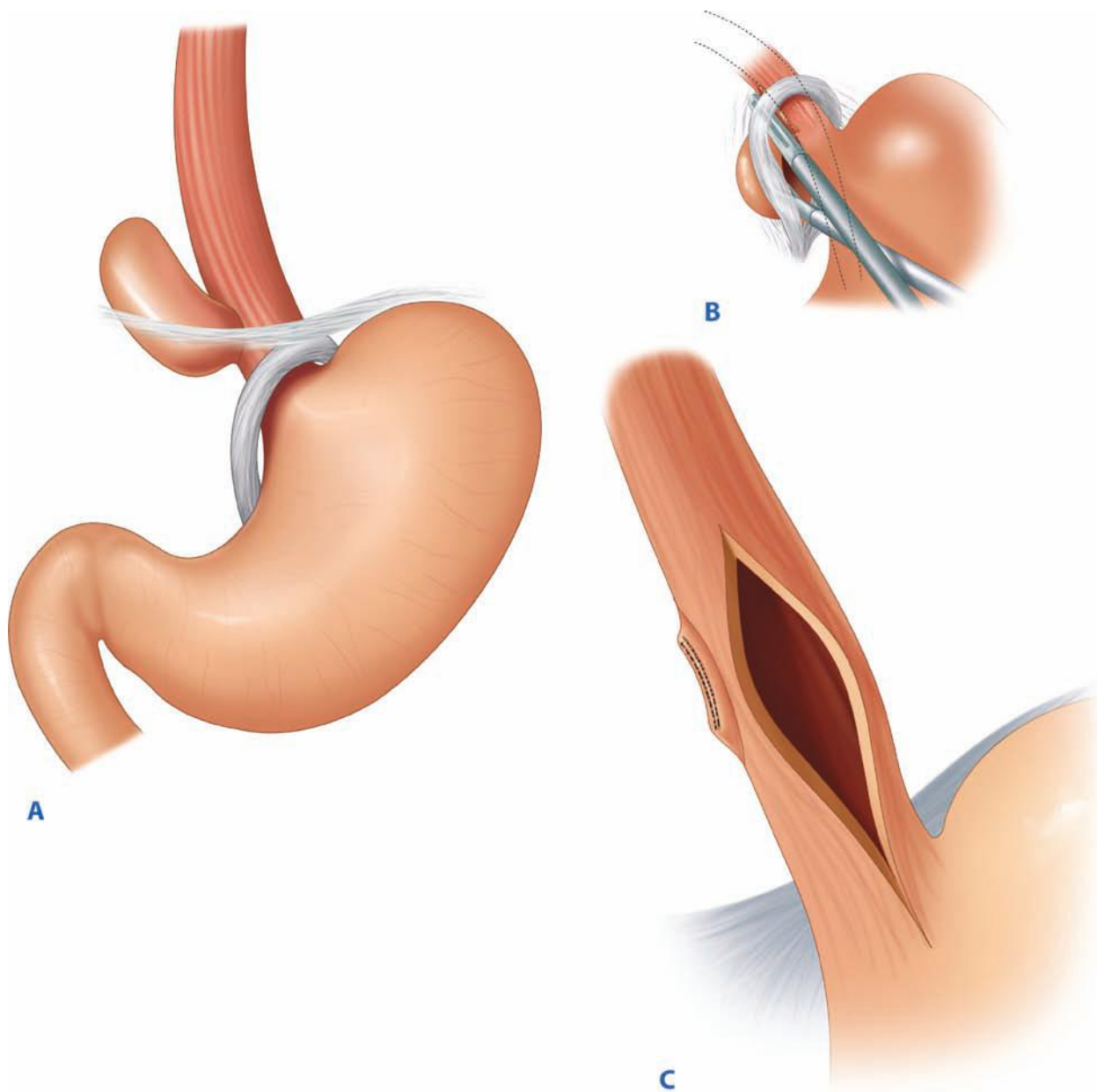


Figure 25-62. A. Epiphrenic diverticula are situated above the lower esophageal sphincter on right side of esophagus. B. Stapler amputates neck of diverticulum. C. Muscle reapproximated over staple line, and Heller myotomy is performed.

compliance of the LES. This requires disrupting the LES muscle. When performed adequately (i.e., reducing sphincter pressure to <10 mmHg), and done early in the course of disease, LES myotomy results in symptomatic improvement with the occasional return of esophageal peristalsis. Reduction in LES resistance can be accomplished intraluminally by hydrostatic balloon dilation, which ruptures the sphincter muscle, by botulinum toxin injection, or by a surgical myotomy that cuts the sphincter. The difference between these three methods appears to be the greater likelihood of reducing sphincter pressure to <10 mmHg by surgical myotomy compared with hydrostatic balloon dilation. However, patients whose sphincter pressure has been reduced by hydrostatic balloon dilation to <10 mmHg have an outcome similar to those after surgical myotomy (Fig. 25-63). Botulinum toxin injection may achieve similar

results, but has a longer duration of action that may be measured in weeks or months, rather than years. Botulinum toxin injection may best be used as a diagnostic tool, when it is not clear whether a hypertensive LES is the primary cause of dysphagia. Responsiveness to botulinum toxin injection may predict a good response to Heller myotomy.

The therapeutic decisions regarding the treatment of patients with achalasia center on four issues. The first issue is the question of whether newly diagnosed patients should be treated with pneumatic dilation or a surgical myotomy. Long-term follow-up studies have shown that pneumatic dilation achieves adequate relief of dysphagia and pharyngeal regurgitation in 50% to 60% of patients (Fig. 25-64). Close follow-up is required, and if dilation fails, myotomy is indicated. For those patients who have a dilated and tortuous esophagus or

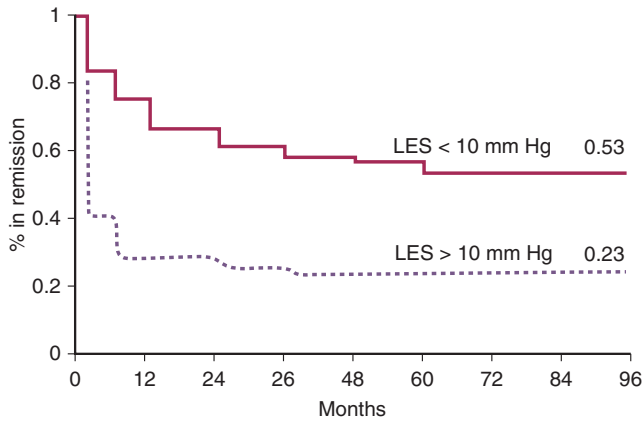


Figure 25-63. Prevalence of clinical remission in 122 patients stratified according to postdilatation lower esophageal sphincter (LES) pressures greater than or <10 mmHg. (Reproduced with permission from Ponce J, Garrigues V, Pertejo V, et al.: Individual prediction of response to pneumatic dilation in patients with achalasia. *Dig Dis Sci* 41:2138, 1996. With kind permission from Springer Science+Business Media.)

an associated hiatal hernia, balloon dilation is dangerous and surgery is the better option. The outcome of the one controlled randomized study (38 patients) comparing the two modes of therapy suggests that surgical myotomy as a primary treatment gives better long-term results. Several randomized trials comparing laparoscopic cardiomyotomy with balloon dilation or botulinum toxin injection have favored the surgical approach as well. Although it has been reported that a myotomy after previous balloon dilation is more difficult, this has not been the

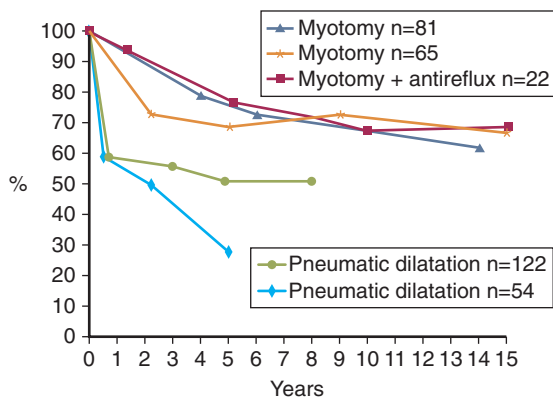


Figure 25-64. Summary of long-term studies reporting the proportion of patients with complete relief or minimal dysphagia (Stage 0–1) stratified according to type of treatment. (Data reproduced from: Ellis FH Jr.: *Oesophagomyotomy for achalasia: A 22-year experience*. *Br J Surg*. 80:882, 1993; Goulbourne IA, Walbaum PR: *Long-term results of Heller's operation for achalasia*. *J Royal Coll Surg*. 30:101, 1985; Malthaner RA, Todd TR, Miller L, et al.: *Long-term results in surgically managed esophageal achalasia*. *Ann Thorac Surg*. 58:1343, 1994; Ponce J, Garrigues V, Pertejo V, et al.: *Individual prediction of response to pneumatic dilation in patients with achalasia*. *Dig Dis Sci*. 41:2135, 1996; Eckardt V, Aignherr C, Bernhard G: *Predictors of outcome in patients with achalasia treated by pneumatic dilation*. *Gastroenterology*. 103:1732, 1992.)

experience of these authors unless the cardia has been ruptured in a sawtooth manner. In this situation, operative intervention, either immediately or after healing has occurred, can be difficult. Similarly, myotomy after botulinum toxin injection has reported to be more difficult, but this is largely a function of the submucosal inflammatory response, which may be a bit unpredictable, and is most intense in the first 6 to 12 weeks after injection. It is important to wait at least 3 months after botulinum toxin injection to perform cardiomyotomy to minimize the risk of encountering dense inflammation.

The second issue is the question of whether a surgical myotomy should be performed through the abdomen or the chest. Myotomy of the LES can be accomplished via either an abdominal or thoracic approach. In the absence of a previous upper abdominal surgery, most surgeons prefer the abdominal approach to LES myotomy as laparoscopy results in less pain and a shorter length of stay than thoracoscopy. In addition, it is a bit easier to ensure a long gastric myotomy when the approach is transabdominal.

The third issue—and one that has been long debated—is the question of whether an antireflux procedure should be added to a surgical myotomy. Excellent results have been reported following meticulously performed myotomy without an antireflux component. Retrospective studies, with long-term follow-up of large cohorts of patients undergoing Heller myotomy demonstrated that, after 10 years, more than 50% of patients had reflux symptoms without a fundoplication. In a recent randomized clinical trial, 7% of patients undergoing Dor fundoplication following LES myotomy had abnormal 24-hour pH probes, and 42% of patients with a myotomy only had abnormal reflux profiles. If an antireflux procedure is used as an adjunct to esophageal myotomy, a complete 360° fundoplication should be avoided. Rather, a 270° Belsey fundoplication, a Toupet posterior 180° fundoplication, or a Dor anterior 180° fundoplication should be used to avoid the long-term esophageal dysfunction secondary to the outflow obstruction afforded by the fundoplication itself.

The fourth issue centers on whether or not a cure of this disease is achievable. Long-term follow-up studies after surgical myotomy have shown that late deterioration in results occurs after this procedure, regardless of whether an antireflux procedure is done, and also after balloon dilation, even when the sphincter pressure is reduced to below 10 mm Hg. It may be that, even though a myotomy or balloon rupture of the LES muscle reduces the outflow obstruction at the cardia, the underlying motor disorder in the body of the esophagus persists and deteriorates further with the passage of time, leading to increased impairment of esophageal emptying. The earlier an effective reduction in outflow resistance can be accomplished, the better the outcome will be, and the more likely some esophageal body function can be restored.

In performing a surgical myotomy of the LES, there are four important principles: (a) complete division of all circular and collar-sling muscle fibers, (b) adequate distal myotomy to reduce outflow resistance, (c) “undermining” of the muscularis to allow wide separation of the esophageal muscle, and (d) prevention of postoperative reflux. In the past, the drawback of a surgical myotomy was the need for an open procedure, which often deterred patients from choosing the best treatment option for achalasia. With the advent of minimally invasive surgical techniques two decades ago, laparoscopic cardiomyotomy (Heller myotomy) has become the treatment of choice for most patients with achalasia.

Open Esophageal Myotomy

Open techniques of distal esophageal myotomy are rarely used outside reoperations. In fact, primary procedures can almost always be successfully completed via laparoscopy. A modified Heller myotomy can be performed through a left thoracotomy incision in the sixth intercostal space along the upper border of the seventh rib. The esophagus and a tongue of gastric fundus are exposed as described for a long myotomy. A myotomy through all muscle layers is performed, extending distally over the stomach to 1 to 2 cm below the junction, and proximally on the esophagus for 4 to 5 cm. The cardia is reconstructed by suturing the tongue of gastric fundus to the margins of the myotomy, to prevent rehealing of the myotomy site, and to provide reflux protection in the area of the divided sphincter. If an extensive dissection of the cardia has been done, a more formal Belsey repair is performed. The tongue of gastric fundus is allowed to retract into the abdomen. Traditionally, nasogastric drainage is maintained for 6 days to prevent distention of the stomach during healing. An oral diet is resumed on the seventh day, after a barium swallow study shows unobstructed passage of the bolus into the stomach without extravasation.

In a randomized, long-term follow-up by Csendes and colleagues of 81 patients treated for achalasia, either by forceful dilation or by surgical myotomy, myotomy was associated with a significant increase in the diameter at the GEJ and a decrease in the diameter at the middle third of the esophagus on follow-up radiographic studies. There was a greater reduction in sphincter pressure and improvement in the amplitude of esophageal contractions after myotomy. After dilation, 13% of patients regained some peristalsis, compared with 28% after surgery. These findings were shown to persist over a 5-year follow-up period, at which time 95% of those treated with surgical myotomy were doing well. Of those who were treated with dilation, only 54% were doing well, while 16% required redilation, and 22% eventually required surgical myotomy to obtain relief.

If simultaneous esophageal contractions are associated with the sphincter abnormality, the so-called vigorous achalasia, then the myotomy should extend over the distance of the abnormal motility as mapped by the preoperative motility study. Failure to do this will result in continuing dysphagia and a dissatisfied patient. The best objective evaluation of improvement in the patient following either balloon dilation or myotomy is a scintigraphic measurement of esophageal emptying time. A good therapeutic response improves esophageal emptying toward normal. However, some degree of dysphagia may persist despite improved esophageal emptying, due to disturbances in esophageal body function. When an antireflux procedure is added to the myotomy, it should be a partial fundoplication. A 360° fundoplication is associated with progressive retention of swallowed food, regurgitation, and aspiration to a degree that exceeds the patient's preoperative symptoms.

Laparoscopic Cardiomyotomy

More commonly known as a laparoscopic Heller myotomy, after Ernst Heller, a German surgeon who described a "double myotomy" in 1913, the laparoscopic approach is similar to the Nissen fundoplication in terms of the trocar placement and exposure and dissection of the esophageal hiatus (Fig. 25-65). The procedure begins by division of the short gastric vessels in preparation for fundoplication. Exposure of the GEJ via removal of the gastroesophageal fat pad follows. The anterior vagus nerve is swept right laterally along with the fat pad. Once completed,

the GEJ and distal 4 to 5 cm of esophagus should be bared of any overlying tissue, and generally follows dissection of the GEJ. A distal esophageal myotomy is performed. It is generally easiest to begin the myotomy 1 to 2 cm above the GEJ, in an area above that of previous botulinum toxin injections or balloon dilation. Either scissors or a hook-type electrocautery can be used to initiate the incision in the longitudinal and circular muscle. Distally, the myotomy is carried across the GEJ and onto the proximal stomach for approximately 2 to 3 cm. After completion, the muscle edges are separated bluntly from the esophageal mucosa for approximately 50% of the esophageal circumference. An antireflux procedure follows completion of the myotomy. Either an anterior hemifundoplication augmenting the angle of His (Dor) or posterior partial fundoplication (Toupet) can be performed. The Dor type fundoplication is slightly easier to perform, and does not require disruption of the normal posterior gastroesophageal attachments (a theoretical advantage in preventing postoperative reflux).

Per Oral Endoscopic Myotomy (POEM)

The POEM procedure was developed in Japan. It is the ultimate minimally invasive myotomy as it requires no incisions through the skin. With the POEM procedure a very effective myotomy is performed entirely from the lumen of the esophagus. The POEM procedure is started by opening the esophageal mucosa 10 cm above the lower esophageal sphincter with a needle-knife electrosurgery device passed through an endoscope. A long submucosal plane is developed with the endoscope, down to and below the LES. The circular muscle of the LES, above and below the gastroesophageal junction is divided with endoscopic electrosurgery. The submucosal entry site in the esophagus is then closed with endoscopic clips. While the results of POEM are still accumulating, the procedure is attractive because it is extremely minimally invasive, and can be done as an outpatient. The major downside of POEM is that an effective antireflux valve cannot be created, exposing the patient to a 40%–50% risk of GERD post procedure.

Outcome Assessment of the Therapy for Achalasia

Critical analysis of the results of therapy for motor disorders of the esophagus requires objective measurement. The use of symptoms alone as an endpoint to evaluate therapy for achalasia may be misleading. The propensity for patients to unconsciously modify their diet to avoid difficulty swallowing is underestimated, making an assessment of results based on symptoms unreliable. Insufficient reduction in outflow resistance may allow progressive esophageal dilation to develop slowly, giving the impression of improvement because the volume of food able to be ingested with comfort increases. A variety of objective measurements may be used to assess success, including LES pressure, esophageal baseline pressure, and scintigraphic assessment of esophageal emptying time. Esophageal baseline pressure is usually negative compared to gastric pressure. Given that the goal of therapy is to eliminate the outflow resistance of a nonrelaxing sphincter, measurement of improvements in esophageal baseline pressure and scintigraphic transit time may be better indicators of success, but are rarely reported.

Eckardt and associates investigated whether the outcome of pneumatic dilation in patients with achalasia could be predicted on the basis of objective measurements. Postdilation LES pressure was the most valuable measurement for predicting

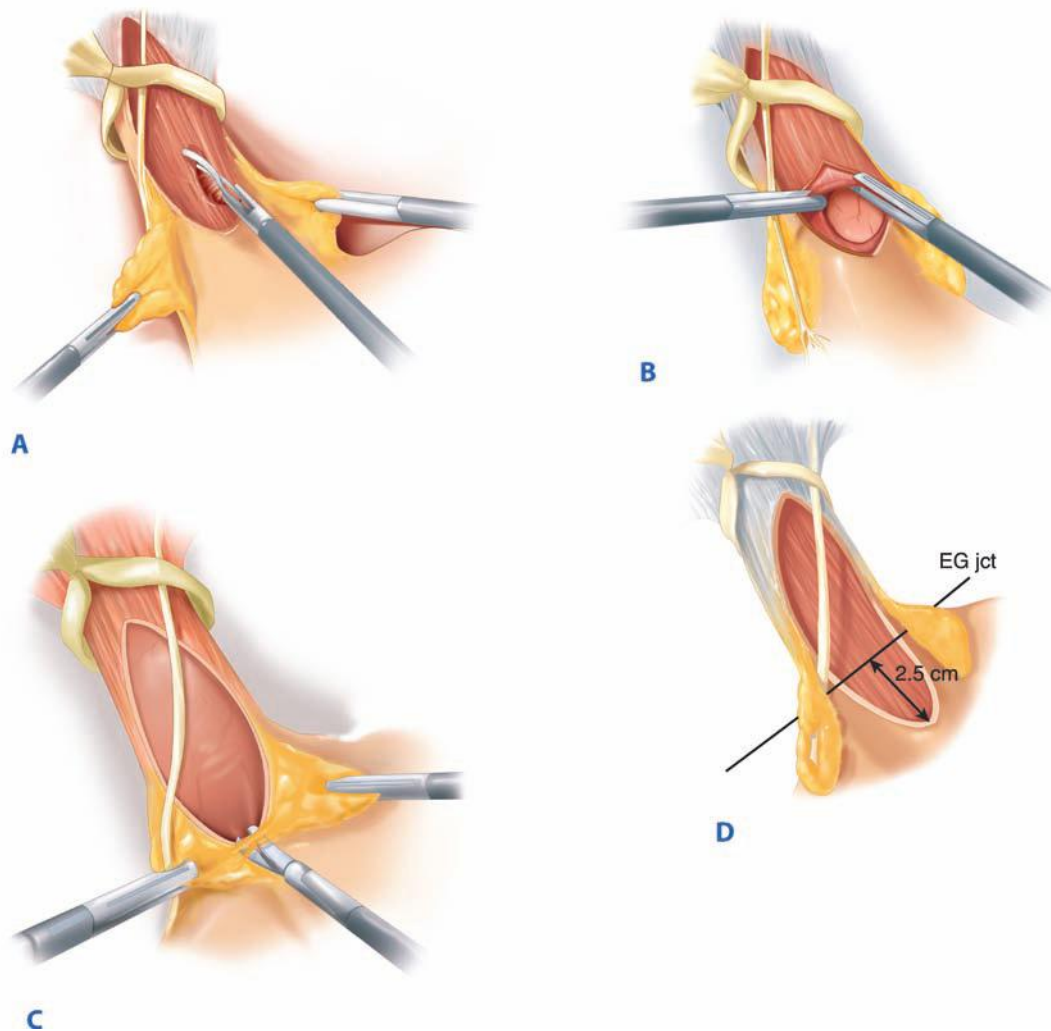


Figure 25-65. **A.** Longitudinal muscle is divided. **B.** Mechanical disruption of lower esophageal sphincter muscle fibers. **C.** Myotomy must be carried across gastroesophageal junction. **D.** Gastric extension should equal 2 to 3 cm. **E.** Anterior (Dor) fundoplication is sutured to the diaphragmatic arch. **F.** Posterior (Toupet) fundoplication is sutured to cut edges of myotomy. EG jct = esophagogastric junction. (Illustration continued on next page.)

long-term clinical response. A postdilatation sphincter pressure <10 mmHg predicted a good response. Approximately 50% of the patients studied had postdilatation sphincter pressures between 10 and 20 mmHg, with a 2-year remission rate of 71%. More important, 16 of 46 patients were left with a postdilatation sphincter pressure of >20 mmHg, and had an unacceptable outcome. Overall, only 30% of patients dilated remained in symptomatic remission at 5 years.

Bonavina and colleagues reported good to excellent results with transabdominal myotomy and Dor fundoplication in 94% of patients after a mean follow-up of 5.4 years. No operative mortality occurred in either of these series, attesting to the safety of the procedure. Malthaner and Pearson reported the long-term clinical results in 35 patients with achalasia, having a minimum follow-up of 10 years (Table 25-10). Twenty-two of these patients underwent primary esophageal myotomy and Belsey hemifundoplication at the Toronto General Hospital. Excellent to good results were noted in 95% of patients at 1 year, declining to 68%, 69%, and 67% at 10, 15, and 20 years, respectively. Two patients underwent early reoperation for an incomplete myotomy, and three underwent an esophagectomy for progressive disease. They concluded that there was a

deterioration of the initially good results after surgical myotomy and hiatal repair for achalasia, which is due to late complications of gastroesophageal reflux.

Ellis reported his lifetime experience with transthoracic short esophageal myotomy without an antireflux procedure. One hundred seventy-nine patients were analyzed at a mean follow-up of 9 years, ranging from 6 months to 20 years. Overall, 89% of patients were improved at the 9-year mark. He also observed that the level of improvement deteriorated with time, with excellent results (patients continuing to be symptom free) decreasing from 54% at 10 years to 32% at 20 years. He concluded that a short transthoracic myotomy without an antireflux procedure provides excellent long-term relief of dysphagia, and, contrary to Malthaner and Pearson's experience, does not result in complications of gastroesophageal reflux. Both studies document nearly identical results 10 to 15 years following the procedure, and both report deterioration over time, probably due to progression of the underlying disease. The addition of an antireflux procedure if the operation is performed transthoracically has no significant effect on the outcome.

The outcome of laparoscopic myotomy and hemifundoplication has been well documented. Two reports of over

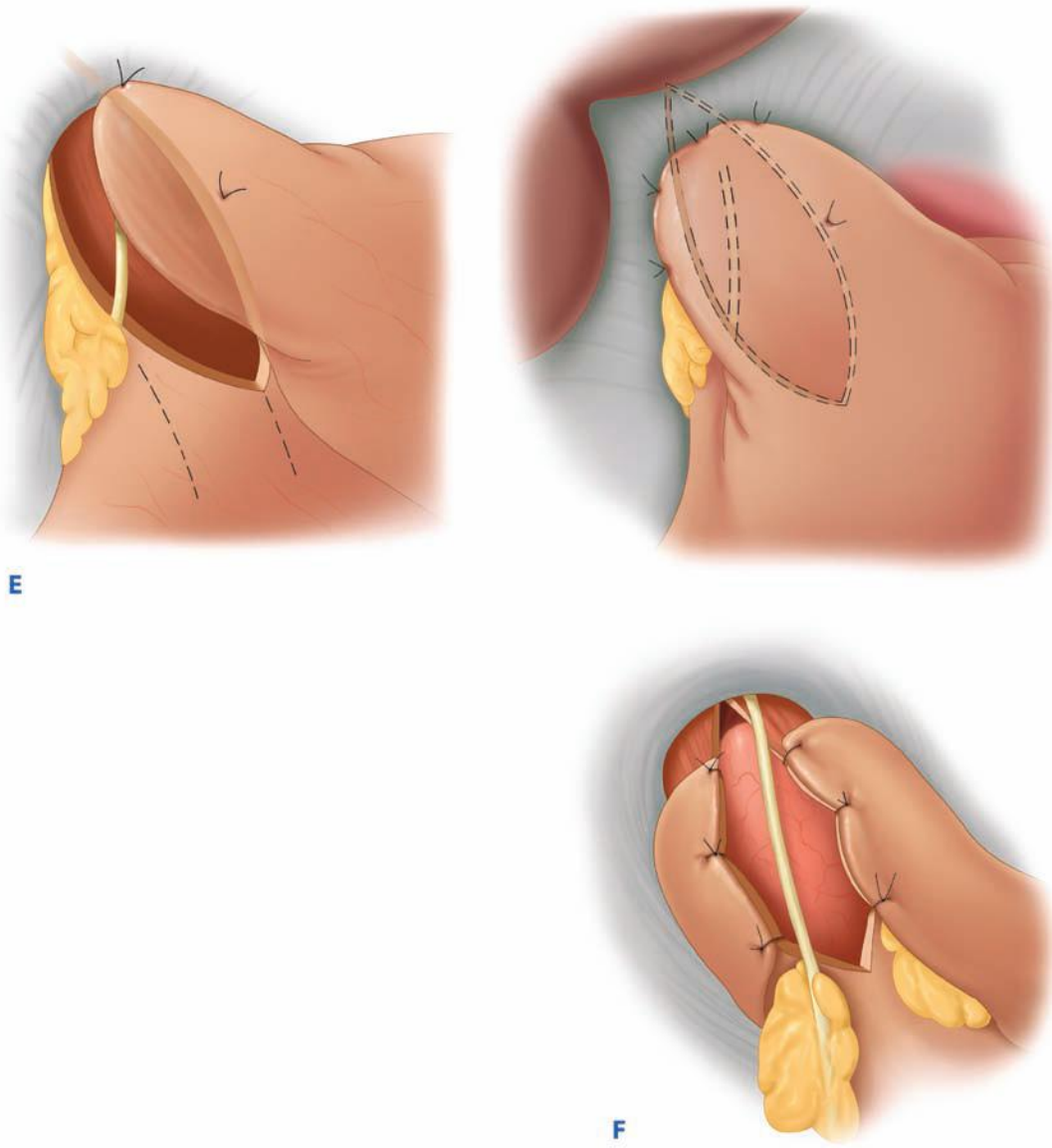


Figure 25-65. (Continued)

Table 25-10

Reasons for failure of esophageal myotomy

REASON	AUTHOR, PROCEDURE (N)		
	ELLIS, MYOTOMY ONLY (N = 81)	GOULBOURNE, MYOTOMY ONLY (N = 65)	MALTHANER, MYOTOMY + ANTIREFLUX (N = 22)
Reflux	4%	5%	18%
Inadequate myotomy	2%	—	9%
Megaesophagus	2%	—	—
Poor emptying	4%	3%	—
Persistent chest pain	1%	—	—

Source: Data from Malthaner RA, et al.: Long-term results in surgically managed esophageal achalasia. *Ann Thorac Surg* 58:1343, 1994; Ellis FH Jr.: Oesophagomyotomy for achalasia: A 22-year experience. *Br J Surg* 80:882, 1993; and Goulbourne IA, et al.: Long-term results of Heller's operation for achalasia. *J R Coll Surg Edinb.* 30:101, 1985.

100 patients have documented relief of dysphagia in 93% of patients. Richter and coworkers reviewed published reports to date, including 254 patients with an average success rate of 93% at 2.5 years. Conversion to an open procedure occurs in 0% to 5% of patients. Complications are uncommon, occurring in <5% of patients. Intraoperative complications consist largely of mucosal perforation, and have been more likely to occur after botulinum toxin injection. The incidence of objective reflux disease as evidenced by abnormal acid exposure is <10%.

A number of randomized clinical trials in the past decade have compared the outcomes of laparoscopic Heller myotomy to pneumatic dilation and to botulinum toxin injection. In each of these trials, laparoscopic Heller myotomy and partial fundoplication was superior to the alternative treatment. Lastly, a randomized clinical trial examining the need for fundoplication following Heller myotomy demonstrated a great deal more reflux in patients without fundoplication, and no better swallowing in the Heller-only group. The best treatment for achalasia is a laparoscopic Heller myotomy and partial fundoplication. The role of POEM in the management of classic (nonspastic) achalasia is yet to be established.

Esophageal Resection for End-Stage Motor Disorders of the Esophagus

Patients with dysphagia and long-standing benign disease, whose esophageal function has been destroyed by the disease process or multiple previous surgical procedures, are best managed by esophagectomy. Fibrosis of the esophagus and cardia can result in weak contractions and failure of the distal esophageal sphincter to relax. The loss of esophageal contractions can result in the stasis of food, esophageal dilatation, regurgitation, and aspiration. The presence of these abnormalities signals end-stage motor disease. In these situations esophageal replacement is usually required to establish normal alimentation. Before proceeding with esophageal resection for patients with end-stage benign disease, the choice of the organ to substitute for the esophagus (i.e., stomach, jejunum, or colon) should be considered. The choice of replacement is affected by a number of factors, as described later in the section on Techniques of Esophageal Reconstruction. If minimally invasive esophagectomy is to be performed, thoroscopic dissection should be combined with abdominal dissection. Attempts at MIS transhiatal esophagectomy for the massively dilated esophagus may result in large volume bleeding from mediastinal vessels that become enlarged with esophageal dilation, and must be directly controlled for hemostasis to be adequate, and the operation to be safe.

CARCINOMA OF THE ESOPHAGUS

Squamous carcinoma accounts for the majority of esophageal carcinomas worldwide. Its incidence is highly variable, ranging from approximately 20 per 100,000 in the United States and Britain, to 160 per 100,000 in certain parts of South Africa and the Honan Province of China, and even 540 per 100,000 in the Guriev district of Kazakhstan. The environmental factors responsible for these localized high-incidence areas have not been conclusively identified, though additives to local foodstuffs (nitroso compounds in pickled vegetables and smoked meats) and mineral deficiencies (zinc and molybdenum) have been suggested. In Western societies, smoking and alcohol consumption are strongly linked with squamous carcinoma.

Other definite associations link squamous carcinoma with long-standing achalasia, lye strictures, tylosis (an autosomal dominant disorder characterized by hyperkeratosis of the palms and soles), and human papillomavirus.

Adenocarcinoma of the esophagus, once an unusual malignancy, is diagnosed with increasing frequency (Fig. 25-66), and now accounts for more than 50% of esophageal cancer in most Western countries. The shift in the epidemiology of esophageal cancer from predominantly squamous carcinoma seen in association with smoking and alcohol, to adenocarcinoma in the setting of BE, is one of the most dramatic changes that have occurred in the history of human neoplasia. Although esophageal carcinoma is a relatively uncommon malignancy, its prevalence is exploding, largely secondary to the well-established association between gastroesophageal reflux, BE, and esophageal adenocarcinoma. Once a nearly uniformly lethal disease, survival has improved slightly because of advances in the understanding of its molecular biology, screening and surveillance practices, improved staging, minimally invasive surgical techniques, and neoadjuvant therapy.

Furthermore, the clinical picture of esophageal adenocarcinoma is changing. It now occurs not only considerably more frequently, but in younger patients, and is often detected at an earlier stage. These facts support rethinking the traditional approach of assuming palliation is appropriate in all patients. The historical focus on palliation of dysphagia in an elderly patient with comorbidities should change when dealing with a young patient with dependent children and a productive life ahead. The potential for cure becomes of paramount importance.

The gross appearance resembles that of squamous cell carcinoma. Microscopically, adenocarcinoma almost always originates in Barrett's mucosa, and resembles gastric cancer. Rarely, it arises in the submucosal glands, and forms intramural growths that resemble the mucoepidermal and adenoid cystic carcinomas of the salivary glands.

The most important etiologic factor in the development of primary adenocarcinoma of the esophagus is a metaplastic columnar-lined or Barrett's esophagus, which occurs in approximately 10% to 15% of patients with GERD. When studied prospectively, the incidence of adenocarcinoma in a patient with BE is one in 100 to 200 patient-years of follow-up (i.e., for every 100 patients with BE followed for 1 year, one will develop adenocarcinoma). Although this risk appears to be small, it is at least 40 to 60 times that expected for a similar population without BE. This risk is similar to the risk for developing lung cancer in a person with a 20-pack-per-year history of smoking. Endoscopic surveillance for patients with BE is recommended for two reasons: (a) at present there is no reliable evidence that medical therapy removes the risk of neoplastic transformation, and (b) malignancy in BE is curable if detected at an early stage.

Clinical Manifestations

Esophageal cancer generally presents with dysphagia, although increasing numbers of relatively asymptomatic patients are now identified on surveillance endoscopy, or present with

6► nonspecific upper GI symptoms and undergo screening endoscopy. Extension of the primary tumor into the tracheobronchial tree can occur primarily with squamous cell carcinoma and can cause stridor, tracheoesophageal fistula and resultant coughing, choking, and aspiration pneumonia. Rarely, severe bleeding from the primary tumor or from erosion into the aorta or pulmonary vessels occurs. Either vocal cord may

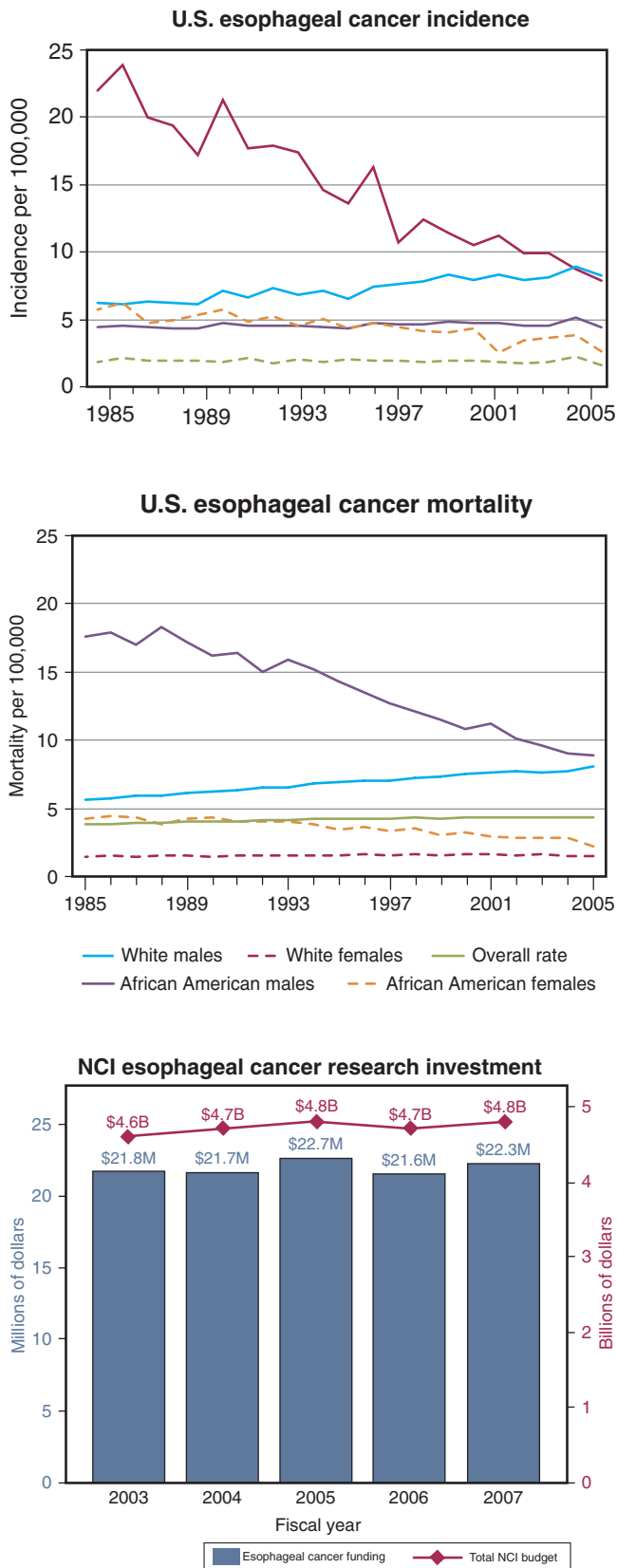


Figure 25-66. Incidence and mortality rate trends for esophageal cancer. NCI = National Cancer Institute. (Reproduced with permission from the National Cancer Institute. Last updated September, 2008.)

be invaded, causing paralysis, but most commonly, paralysis is caused by invasion of the left recurrent laryngeal nerve by the primary tumor or LN metastasis. Systemic organ metastases are usually manifested by jaundice or bone pain. The situation is different in high-incidence areas where screening is practiced. In these communities, the most prominent early symptom is pain on swallowing rough or dry food. In patients that present with back pain at the time of esophageal cancer diagnosis, there is usually distant metastasis or celiac encasement.

Dysphagia usually presents late in the natural history of the disease, because the lack of a serosal layer on the esophagus allows the smooth muscle to dilate with ease. As a result, the dysphagia becomes severe enough for the patient to seek medical advice only when more than 60% of the esophageal circumference is infiltrated with cancer. Consequently, the disease is usually advanced if symptoms herald its presence. Tracheoesophageal fistula may be present in some patients on their first visit to the hospital, and more than 40% will have evidence of distant metastases. With tumors of the cardia, anorexia and weight loss usually precede the onset of dysphagia. The physical signs of esophageal tumors are those associated with the presence of distant metastases.

General Approach to Esophageal Cancer

Therapy of esophageal cancer is dictated by the stage of the cancer at the time of diagnosis. Put simply, one needs to determine if the disease is confined to the esophagus, (T1–T2, N0), locally advanced (T1–3, N1), or disseminated (any T, any N, M1). If cancer is confined to the esophagus, removal of the tumor with adjacent lymph nodes may be curative. Very early tumors confined to the mucosa (T in situ, T1a, intramucosal cancer) may be addressed with endoscopic treatment. When the tumor is locally aggressive, modern therapy dictates a multimodality approach in a surgically fit patient. Multimodality therapy is either chemotherapy followed by surgery or radiation and chemotherapy followed by surgery. When given before surgery, these treatments are referred to as neoadjuvant or induction therapy. For disseminated cancer, treatment is aimed at palliation of symptoms. If the patient has dysphagia, as many do, the most rapid form of palliation is the endoscopic placement of an expandable esophageal stent. For palliation of GEJ cancer, radiation may be the first choice, as stents placed across the GEJ create a great deal of gastroesophageal reflux.

Staging of Esophageal Cancer

Choosing the best therapy for an individual patient requires accurate staging. Staging starts with the history and physical. LN disease remote from the tumor, particularly in the cervical region, may be palpable on neck examination and generally indicates cancer dissemination. This is often referred to as M1a disease, indicating that these patients should not be treated with therapy directed toward locally advanced cancer. Other metastatic LNs are rarely palpable but are equally ominous, especially the umbilical LN in GEJ cancer.

Computed tomographic (CT) scanning of the chest, abdomen, and pelvis provides information on local invasion of the primary cancer, LN involvement, or disseminated disease. The most common sites of esophageal cancer metastases are lung, liver, and peritoneal surfaces, including the omentum and small bowel mesentery. If masses are identified that are not characteristic for cancer or are in a location that precludes resection with the cancer specimen, positron emission tomography

(PET) scanning may be able to tell whether the masses are metabolically active (likely to be cancer) or not. A PET active focus corresponding to a mass on CT scan outside of the field of esophageal resection should be biopsied before resection is performed.

The introduction of endoscopic ultrasound (EUS) has made it possible to identify patients who are potentially curable before surgical therapy. Using an endoscope, the depth of the wall penetration by the tumor and the presence of LN metastases can be determined with 80% accuracy. A curative resection should be encouraged if EUS indicates that the tumor has not invaded adjacent organs (T4b), and/or fewer than six enlarged LNs are imaged. Thoracoscopic and laparoscopic staging of esophageal cancer may add benefit when the nature of enlarged LNs remote from the cancer cannot be determined, or when advanced imaging systems (PET and high-resolution spiral CT) are not available.

Occasionally, diagnostic laparoscopy and jejunostomy tube placement may precede induction chemoradiation in the patient with severe dysphagia and weight loss from a locally advanced cancer. In summary, esophageal cancer is diagnosed with endoscopic biopsy and is staged with CT scanning of the chest and abdomen, EUS, and PET scan for all patients with CT or EUS evidence of advanced disease (T2 or greater, N1-2 or NX). Experience with esophageal resection in patients with early stage disease has identified characteristics of esophageal cancer that are associated with improved survival. A number of studies suggest that only metastasis to LNs and tumor penetration of the esophageal wall have a significant and independent influence on prognosis. Factors known to be important in the survival of patients with advanced disease, such as cell type, degree of cellular differentiation, or location of tumor in the esophagus, have no effect on survival of patients who have undergone resection for early disease. Studies also showed that patients having five or fewer LN metastases have a better outcome. Using these data, Skinner developed the wall penetration, LN, and distant organ metastases system for staging.

The wall penetration, LN, and distant organ metastases system differed somewhat from the previous efforts to develop a satisfactory staging criteria for carcinoma of the esophagus. Most surgeons agreed that the 1983 tumor, nodes, and metastasis system left much to be desired. In the third edition of the manual for Staging of Cancer of the American Joint Committee on Cancer (AJCC) in 1988, an effort was made to provide a finer discrimination between stages than had been contained in the previous edition in 1983. In 2010, further refinements of the staging system of esophageal cancer were approved by the AJCC, recognizing the difference in survival afforded by resection of limited LN disease adjacent to the tumor, compared to multilevel LN disease and positive LNs remote from the primary. Table 25-11 shows the AJCC definitions for the primary tumor, lymph nodes, distant metastasis, and overall staging schema for both squamous cell carcinoma and adenocarcinoma.

Clinical Approach to Carcinoma of the Esophagus and Cardia

The selection of a curative vs. a palliative operation for cancer of the esophagus is based on the location of the tumor, the patient's age and health, the extent of the disease, and preoperative staging. Figure 25-67 shows an algorithm of the clinical decisions important in the selection of curative or palliative therapy.

Tumor Location. The selection of surgical therapy for patients with carcinoma of the esophagus depends not only on the anatomic

stage of the disease and an assessment of the swallowing capacity of the patient, but also on the location of the primary tumor.

It is estimated that 8% of the primary malignant tumors of the esophagus occur in the cervical portion (Fig. 25-68). They are almost always squamous cell cancer, with a rare adenocarcinoma arising from a congenital inlet patch of columnar lining. These tumors, particularly those in the postcricoid area, represent a separate pathologic entity for two reasons: (a) They are more common in females and appear to be a unique entity in this regard; and (b) The efferent lymphatics from the cervical esophagus drain completely differently from those of the thoracic esophagus. The latter drain directly into the paratracheal and deep cervical or internal jugular LNs with minimal flow in a longitudinal direction. Except in advanced disease, it is unusual for intrathoracic LNs to be involved.

Cervical esophageal cancer is frequently unresectable because of early invasion of the larynx, great vessels, or trachea. Radical surgery, including esophagolaryngectomy may occasionally be performed for these lesions, but the ensuing morbidity makes this a less than desirable approach in the face of uncertain cure. Thus, for most patients with cervical esophageal cancer, stereotactic radiation with concomitant chemotherapy is the most desirable treatment.

Tumors that arise within the middle third of the esophagus are squamous carcinomas most commonly and are frequently associated with LN metastasis, which are usually in the thorax but may be in the neck or abdomen, and may skip areas in between. Although it is generally felt that individuals with midthoracic cancer and abdominal LN metastases are incurable with surgery, there are some emerging data that suggest that cervical LN metastases, if isolated, can be resected with benefit. Generally, T1 and T2 cancers without LN metastases are treated with resection only, but there is more and more data to suggest that LN involvement or transmural cancer (T3) warrants treatment with neoadjuvant chemoradiation therapy followed by resection. Although some surgeons prefer a transhiatal esophagectomy for all tumor locations, most surgeons believe that resection of midesophageal cancer should be performed under direct vision with either thoracoscopy (video-assisted thoracic surgery [VATS]) or with thoracotomy.

Tumors of the lower esophagus and cardia are usually adenocarcinomas. Unless preoperative and intraoperative staging clearly demonstrate an incurable lesion, resection in continuity with a LN dissection should be performed. Because of the propensity of GI tumors to spread for long distances submucosally, long lengths of grossly normal GI tract should be resected. The longitudinal lymph flow in the esophagus can result in skip areas, with small foci of tumor above the primary lesion, which underscores the importance of a wide resection of esophageal tumors. Wong has shown that local recurrence at the anastomosis can be prevented by obtaining a 10-cm margin of normal esophagus above the tumor. Anatomic studies have also shown that there is no submucosal lymphatic barrier between the esophagus and the stomach at the cardia, and Wong has shown that 50% of the local recurrences in patients with esophageal cancer who are resected for cure occur in the intrathoracic stomach along the line of the gastric resection. Considering that the length of the esophagus ranges from 17 to 25 cm, and the length of the lesser curvature of the stomach is approximately 12 cm, a curative resection requires a cervical division of the esophagus and a >50% proximal gastrectomy in most patients with carcinoma of the distal esophagus or cardia.

Table 25-11

American Joint Committee on Cancer (AJCC) Staging Schema for Esophageal Cancer

TX	Primary tumor cannot be assessed.
T0	No evidence of primary tumor.
Tis	High-grade dysplasia.
T1	Tumor invades lamina propria, muscularis mucosae, or submucosa.
T1a	Tumor invades lamina propria or muscularis mucosae.
T1b	Tumor invades submucosa.
T2	Tumor invades muscularis propria.
T3	Tumor invades adventitia.
T4	Tumor invades adjacent structures.
T4a	Resectable tumor invading pleura, pericardium, or diaphragm.
T4b	Unresectable tumor invading other adjacent structures, such as aorta, vertebral body, trachea, etc.
NX	Regional lymph nodes cannot be assessed.
N0	No regional lymph node metastasis.
N1	Metastases in 1–2 regional lymph nodes.
N2	Metastases in 3–6 regional lymph nodes.
N3	Metastases in ≥ 7 regional lymph nodes.
M0	No distant metastasis.
M1	Distant metastasis.

SQUAMOUS CELL CARCINOMA^b

STAGE	T	N	M	GRADE	TUMOR LOCATION ^c
0	Tis (HGD)	N0	M0	1, X	Any
IA	T1	N0	M0	1, X	Any
IB	T1	N0	M0	2–3	Any
	T2–3	N0	M0	1, X	Lower, X
IIA	T2–3	N0	M0	1, X	Upper, middle
	T2–3	N0	M0	2–3	Lower, X
IIB	T2–3	N0	M0	2–3	Upper, middle
	T1–2	N1	M0	Any	Any
IIIA	T1–2	N2	M0	Any	Any
	T3	N1	M0	Any	Any
	T4a	N0	M0	Any	Any
IIIB	T3	N2	M0	Any	Any
IIIC	T4a	N1–2	M0	Any	Any
	T4b	Any	M0	Any	Any
	Any	N3	M0	Any	Any
IV	Any	Any	M1	Any	Any

ADENOCARCINOMA

STAGE	T	N	M	GRADE
0	Tis (HGD)	N0	M0	1, X
IA	T1	N0	M0	1–2, X
IB	T1	N0	M0	3
	T2	N0	M0	1–2, X
IIA	T2	N0	M0	3
IIB	T3	N0	M0	Any
	T1–2	N1	M0	Any
IIIA	T1–2	N2	M0	Any
	T3	N1	M0	Any
	T4a	N0	M0	Any
IIIB	T3	N2	M0	Any
IIIC	T4a	N1–2	M0	Any
	T4b	Any	M0	Any
	Any	N3	M0	Any
IV	Any	Any	M1	Any

Source: Used with permission of the American Joint Committee on Cancer (AJCC), Chicago, Illinois. The original source of the material is the AJCC Cancer Staging Manual, Seventh Edition (2010) published by Springer Science and Business Media LLC, www.springerlink.com.

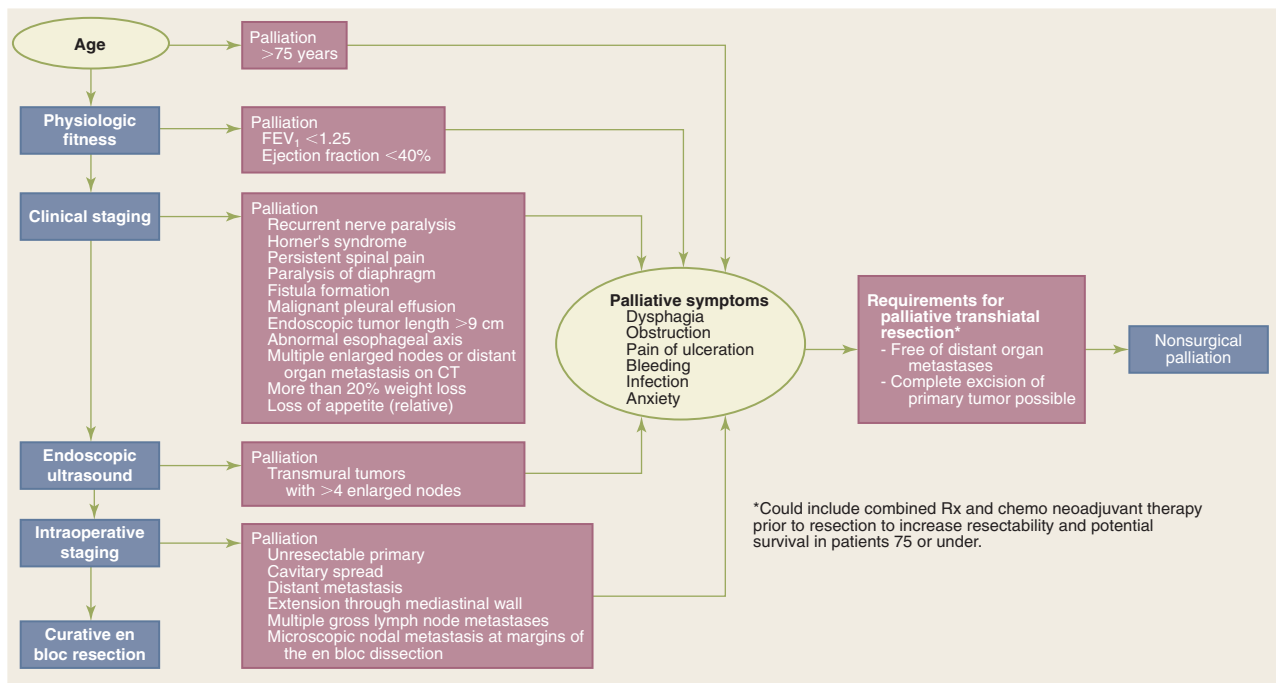


Figure 25-67. Algorithm for the evaluation of esophageal cancer patients to select the proper therapy: curative en bloc resection, palliative transhiatal resection, or nonsurgical palliation. CT = computed tomography; FEV₁ = forced expiratory volume in 1 second. (Reproduced with permission from DeMeester TR: *Esophageal carcinoma: Current controversies*. *Sem Surg Oncol*. 13:217, 1997.)

Age. Resection for cure of carcinoma of the esophagus in a patient older than 80 years is rarely indicated, because of the additional operative risk and the shorter life expectancy. Despite this general guideline, octogenarians with a high performance status and excellent cardio-pulmonary reserve may be considered candidates for esophagectomy and recent case series have

established its success in highly selected patients. It is in this group of patients that the lesser physiologic impact of minimally invasive surgery may reduce the morbidity and mortality associated with open two- or three-field esophagectomy.

Cardiopulmonary Reserve. Patients undergoing esophageal resection should have sufficient cardiopulmonary reserve to tolerate the proposed procedure. The respiratory function is best assessed with the forced expiratory volume in 1 second, which ideally should be 2 L or more. Any patient with a forced expiratory volume in 1 second of <1.25 L is a poor candidate for thoracotomy, because he or she has a 40% risk of dying from respiratory insufficiency within 4 years. In patients with poor pulmonary reserve, the transhiatal esophagectomy should be considered, as the pulmonary morbidity of this operation is less than is seen following thoracotomy. Clinical evaluation and electrocardiogram are not sufficient indicators of cardiac reserve. Echocardiography and dipyridamole thallium imaging provide accurate information on wall motion, ejection fraction, and myocardial blood flow. A defect on thallium imaging may require further evaluation with preoperative coronary angiography. A resting ejection fraction of <40%, particularly if there is no increase with exercise, is an ominous sign. In the absence of invasive testing, observed stair-climbing is an economical (albeit not quantitative) method of assessing cardiopulmonary reserve. Most individuals who can climb three flights of stairs without stopping will do well with two-field open esophagectomy, especially if an epidural catheter is used for postoperative pain relief.

Nutritional Status. The factor most predictive of postoperative complication is the nutritional status of the patient. Profound weight loss, more than 20 lb, associated with hypoalbuminemia (albumin <3.5 g/dL) is associated with a much higher rate of complications and mortality than patients who enter curative

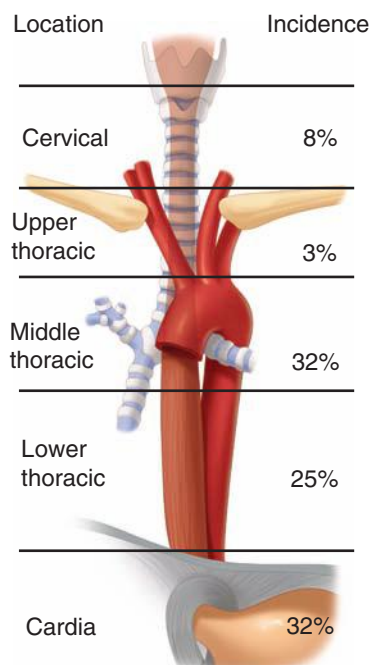


Figure 25-68. Incidence of carcinoma of the esophagus and cardia based on tumor location.

surgery in better nutritional condition. Because malnourished patients generally have locally advanced esophageal cancer, if not metastatic disease, one should consider the placement of a feeding tube before the beginning of induction chemoradiation therapy. Although mild amounts of dysphagia are improved by induction chemoradiation therapy, more pronounced dysphagia and associated malnutrition should be addressed before the initiation of chemoradiation. A laparoscopic jejunostomy tube can be placed prior to induction therapy or at the time of esophagectomy. There are emerging data that 5 days' pretreatment with immune-enhancing nutrition, rich in fish oils, decreases cardiac and other complications, following esophagectomy.

Clinical Staging. Clinical factors that indicate an advanced stage of carcinoma and exclude surgery with curative intent are recurrent nerve paralysis, Horner's syndrome, persistent spinal pain, paralysis of the diaphragm, fistula formation, and malignant pleural effusion. Factors that make surgical cure unlikely include a tumor >8 cm in length, abnormal axis of the esophagus on a barium radiogram, more than four enlarged LNs on CT, a weight loss more than 20%, and loss of appetite. Studies indicate that there are several favorable parameters associated with tumors <4 cm in length, there are fewer with tumors between 4 and 8 cm, and there are no favorable criteria for tumors >8 cm in length. Consequently, the finding of a tumor >8 cm in length should exclude curative resection; the finding of a smaller tumor should encourage an aggressive approach.

Preoperative Staging with Advanced Imaging. For years, clinical staging, contrast radiography, endoscopy, and CT scanning formed the backbone of esophageal cancer staging. More recently, preoperative decision making is guided by endoscopic ultrasonography and PET scanning.

EUS provides the most reliable method of determining depth of cancer invasion. In the absence of enlarged LNs, the degree of wall invasion dictates surgical therapy. If a small focus of esophageal cancer is confined to the mucosa, endoscopic mucosal resection (EMR) is a preferable option. If the tumor invades in to the submucosa, without visible lymph node involvement, most individuals would suggest esophagectomy with LN dissection, as positive nodes can be found in 20% to 25% of those with cancer limited to the mucosa and submucosa. If EUS demonstrates spread through the wall of the esophagus, especially if LNs are enlarged, then induction chemoradiation therapy (neoadjuvant therapy) should be strongly considered. Lastly, when the EUS demonstrates invasion of the trachea, bronchus, aorta, or spine, then surgical resection is rarely indicated. If there is invasion into the pleura (T4a), then surgical resection can be considered in the absence of a malignant effusion. Thus, it can be seen that the therapy of esophageal cancer is largely driven by the findings of an endoscopic ultrasonography. It is difficult to provide modern treatment of esophageal cancer without access to this modality.

PET scanning, usually combined with an axial CT scan (CTPET), usually is performed on patients with locally advanced cancer or questionable lesions on CT scan to determine whether metastases are present. The PET scan uses the injection of radiolabeled deoxyglucose, which is taken up in metabolically active tissues such as cancer. PET-positive areas must be correlated with the CT scan findings to assess the significance of "hot spots." CTPET scanning has been especially useful before the initiation of chemoradiation therapy. An early response to chemoradiotherapy, by PET scan, improves the

prognosis whether or not resection is ultimately performed. Conversely, if a PET-avid tumor shows no change in metabolic activity after 2 weeks of induction chemoradiation therapy, it is unlikely that further chemo- or radiation therapy will be of any benefit. These patients have a worse prognosis, and may be referred for resection or palliation without incurring the morbidity or expense of a full course of chemo- and radiation therapy.

Palliation of Esophageal Cancer

Palliation of esophageal cancer is indicated for individuals with metastatic esophageal cancer or cancer invading adjacent organs (T4b) who are unable to swallow, or individuals with fistulae into the tracheobronchial tree. Aortic esophageal fistulas are extremely rare and nearly 100% lethal. Dysphagia as a result of esophageal cancer can be graded from Grade I, eating normally, to grade VI, unable to swallow saliva (Table 25-12). Grades I–III often can be managed with radiation therapy, usually in combination with chemotherapy. When surgical resection is not anticipated in the future, this is termed definitive chemoradiation therapy and usually is palliative. Radiation dose is increased from 45 Gy to 60 Gy administered over 8 weeks, rather than the 4 weeks given for chemoradiation induction therapy. In 20% of patients, a complete response to chemoradiation therapy will not only palliate the symptoms, but leave the patient with undetectable cancer of the esophagus. Although some of these patients are truly cured, cancer will recur in many either locally or systemically 1 to 5 years following definitive chemoradiation. In a few patients, definitive chemoradiation will be successful in all sites but the esophagus. After a 12-month wait from initial treatment and no other sites of tumor detectable except the esophagus, some of these patients may be candidates for salvage esophagectomy.

For individuals with dysphagia grades IV and higher, additional treatment generally is necessary. The mainstay of therapy is in-dwelling esophageal stents. Covered removable stents may be used to seal fistulae or when stent removal becomes desirable in the future. When large, locally invasive tumors or metastatic esophageal cancer precludes any future hope of resection, uncovered expandable metal stents are the treatment of choice. The major limitations to stenting exist in cancers at the GEJ. A stent placed across the GEJ will result in severe gastroesophageal

Table 25-12

Functional grades of dysphagia

GRADE	DEFINITION	INCIDENCE AT DIAGNOSIS (%)
I	Eating normally	11
II	Requires liquids with meals	21
III	Able to take semisolids but unable to take any solid food	30
IV	Able to take liquids only	40
V	Unable to take liquids, but able to swallow saliva	7
VI	Unable to swallow saliva	12

Source: Modified with permission from Takita H, et al.: Squamous cell carcinoma of the esophagus: A study of 153 cases. *J Surg Oncol* 9:547, 1977.

reflux and heartburn that can be quite disabling. In cancers at this level, radiation therapy alone may be preferable. If feeding access is desirable, a laparoscopic jejunostomy is usually the procedure of choice.

Surgical Treatment

The surgical treatment of esophageal cancer is dependent upon the location of the cancer, the depth of invasion, LN metastases, the fitness of the patient for operation, and the culture and beliefs of the individuals and institutions in which the treatment is performed. In an ideal world, there would be a single, stage-specific method of treating esophageal cancer, because the evidence would be unassailable and noncontroversial. Randomized clinical trials and meta-analyses would prove beyond a shadow of a doubt the value of surgery vs. nonoperative therapy and would dictate the type and extent of surgery that would optimally balance immediate morbidity and mortality with duration and quality of life conferred by the procedure and the perioperative management of the esophagectomy patient. Despite many noble attempts to establish this high level of evidence, many questions relating to the appropriate therapy of esophageal cancer remain controversial. About the only area of complete agreement is that esophagectomy should not be performed if an R0 resection is not possible. In other words, if the surgeon does not believe he or she can remove all LNs invaded by cancer and provide a tumor-free radial margin and esophagus and stomach margins that are tumor free, then a resection should not be performed.

Mucosally Based Cancer. In patients with BE, and especially those with high-grade dysplasia, subcentimeter nodules are frequently discovered. Nodules should be resected in entirety, as they often harbor adenocarcinoma. Five years ago, such resection was performed with a transhiatal esophagectomy, but more recently EMR offers another method for removing intramucosal cancer. In this clinical situation, EMR is typically combined with EUS to rule out more invasive disease. EUS however, is unable to differentiate between cancer that is confined to the mucosa (T1a) and that which invades the submucosa (T1b). Tumors invading the submucosa are not amenable to endoscopic mucosal resection because of the high-frequency (20%–25%) concurrent finding of positive LNs, which cannot be removed without esophagectomy. On the other hand, intramucosal cancers have little risk of spreading to regional LNs. The current approach used involves performing EMR on all nodules identified in a field of Barrett's esophagus and then T staging is performed by histologic analysis. This approach dictates the need for future therapy such as esophagectomy.

For this reason, small intramucosal carcinomas may be removed with EMR in the following manner: The area beneath the nodule is infiltrated with saline through a sclerotherapy needle. A specialized suction cap is mounted on the end of the endoscope and the nodule is drawn up into the cap, following which a snare is applied to resect the tissue. Alternatively, a rubber band can be delivered and the snare can be used to resect above the level of the rubber band. This specimen is then removed and sent to pathology. As long as the tumor is found to be confined to the mucosa and all margins are negative, the resection is complete. A positive margin or involvement of the submucosa warrants esophagectomy. Most importantly, these patients are at high risk for developing small nodular carcinomas elsewhere in their Barrett's segment, and routine surveillance on a 3- to 6-month basis must be continued indefinitely.

Alternatively, one can consider radiofrequency ablation of the remainder of the high-grade dysplasia after careful surveillance biopsy specimens demonstrate no further sign of cancer. This approach to the early esophageal cancer should not be used when there is any suspicion of mediastinal or abdominal lymphadenopathy. Although it is currently rare that EMR provides definitive therapy of small nodular esophageal cancers, this may become more of the norm as greater surveillance reveals earlier cancers, and proficiency of the technique by surgeons and gastroenterologists increases.

Minimally Invasive Transhiatal Esophagectomy. Minimally invasive transhiatal esophagectomy is an increasingly popular procedure; however, the number of these operations performed around the world remains small. Mini-invasive surgery (MIS) transhiatal esophagectomy was first performed by Aureo DePaula in Brazil and has been modified and adopted by many individuals around the world. This operation combines the advantages of transhiatal esophagectomy at minimizing pulmonary complications with the advantages of laparoscopy (less pain, quicker rehabilitation). Several variations of MIS transhiatal esophagectomy have been developed. For the earliest lesions, such as high-grade dysplasia or intramucosal carcinoma, a vagal sparing procedure can be entertained. In such a procedure, the vagal trunks are separated from the esophagus at the level of the diaphragm and the lesser curvature dissection of the stomach allows the vagus and left gastric pedicle to remain intact. Clearly, this dissection, which hugs the stomach and esophagus, provides no LN staging and is thus inadequate for all high-grade dysplasia and intramucosal cancer.

MIS transhiatal esophagectomy is usually performed through five or six small incisions in the upper abdomen and a transverse cervical incision for removing the specimen and performing the cervical esophagogastrostomy. To remove the esophagus from the posterior mediastinum, especially the area behind the pulmonary vessels and the tracheal bifurcation, which cannot be visualized even with a long laparoscope placed in the posterior mediastinum, it is preferred to use a vein stripping "inversion" technique (Fig. 25-69A). The details of this operation are too lengthy to include in this text, but include the laparoscopic creation of a neo-esophagus (gastric conduit) along the greater curvature of the stomach using the right gastroepiploic artery as the primary vascular pedicle. The conduit can be created through a mini-laparotomy or laparoscopically. A Kocher maneuver releases the duodenum, and a pyloroplasty may be performed (optional). Retrograde esophageal stripping is performed by dividing the esophagus below the GEJ and sliding a vein stripper from the neck down into the abdomen followed by an inversion of the esophagus in the posterior mediastinum and removal through the neck (Fig. 25-69B). This technique is reserved for patients with high-grade dysplasia. For small cancers at the GEJ, the esophagus can be stripped in an antegrade fashion by sliding the vein stripper down from the cervical incision and out the tail of the lesser curvature (Fig. 25-69C). The tail of the lesser curvature is pulled out a port site high in the epigastrium while the esophagus is inverted into itself. For GEJ cancers, a wide celiac access LN dissection, splenic artery, hepatic artery, and posterior mediastinal LN dissection can be performed as well or better than through a laparotomy. The gastric conduit is pulled up to the neck with a chest tube and anastomosed to the cervical esophagus in an end-to-side fashion using a surgical stapler or with a handsewn anastomosis. Complications of this technique are primarily limited to leak from the

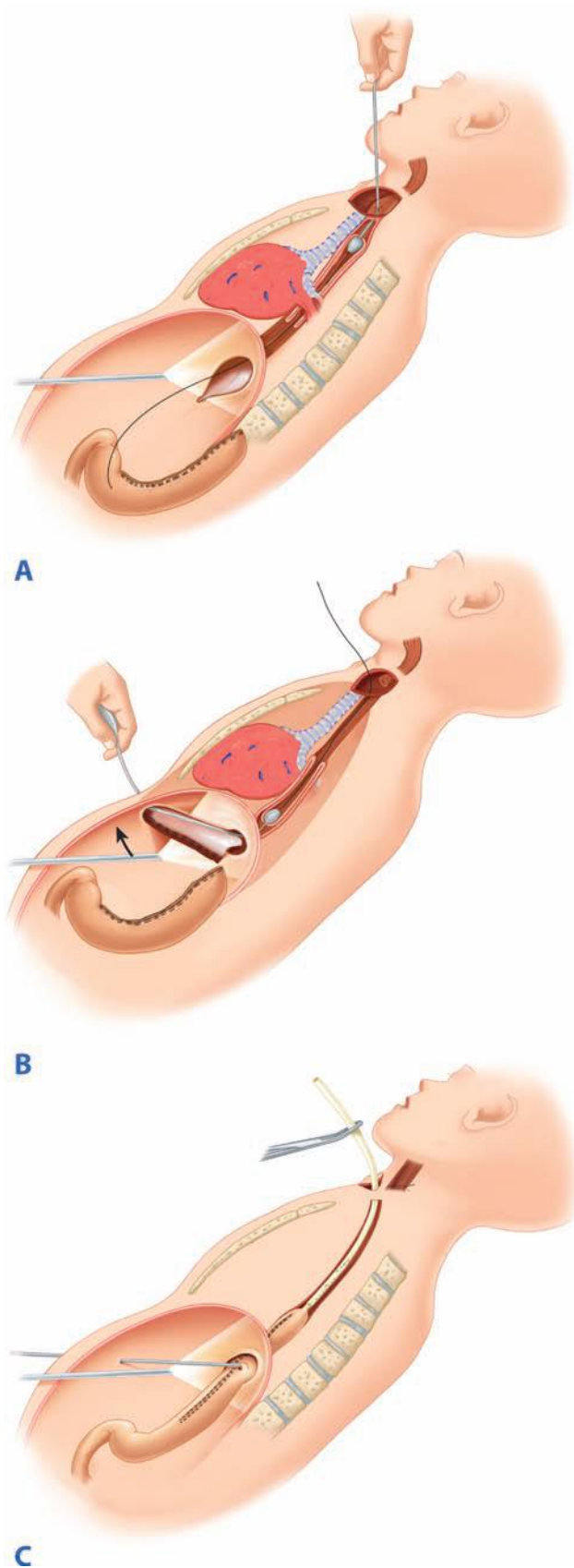


Figure 25-69. A. Laparoscopic retrograde inversion. B. Laparoscopic antegrade inversion. A silk suture holds the tunnel after the esophagus is removed. C. The esophageal conduit is returned to the neck after passing a chest tube down the tunnel and suturing the conduit to the chest tube.

esophagogastric anastomosis, which is self-limited and usually heals within 1 to 3 weeks, spontaneously.

Open Transhiatal Esophagectomy. Transhiatal esophagectomy, also known as blunt esophagectomy or esophagectomy without a thoracotomy, was first performed in 1933 by a British surgeon, but was popularized in the last quarter of the twentieth century by Mark Orringer from the University of Michigan. Although this operation may violate many of the principles of cancer resection, including extended radical LN dissection this operation has performed as well as any of the more radical procedures in randomized trials, and in large database analyses. With transhiatal esophagectomy, the elements of dissection are similar to that described in the section entitled Minimally Invasive Transhiatal Esophagectomy, including the creation of the gastric tube and the posterior mediastinal dissection through the hiatus. Because this dissection is performed with the fingertips rather than under direct vision with surgical instruments, it requires an enlargement of the diaphragmatic hiatus. The lower mediastinal LN basins can be resected as can the upper abdominal LNs, making this an attractive option for GEJ cancers. The mediastinal LNs above the inferior pulmonary vein are not removed with this technique, but rarely result in a point of isolated cancer recurrence.

Of all procedures for esophageal cancer, this operation is the quickest to perform in experienced hands and lies in an intermediate position between minimally invasive esophagectomy and the Ivor Lewis procedure with respect to complications and recovery.

Minimally Invasive Two- and Three-Field Esophagectomy. After a rocky start, minimally invasive esophagectomy using a thoracic dissection through VATS has become reasonably popular. In general, this operation is performed with an anastomosis created in the neck (three-field), but may be performed with the anastomosis stapled in the high thorax (two-field). Both procedures will be described.

With a minimally invasive three-field esophagectomy, the patient is placed in the left lateral decubitus position. Double lumen intubation is required. Videoscopic access to the thorax is obtained in the midaxillary line in the ninth intercostal space and an angled telescope illuminates the chest superiorly. A mini-thoracotomy at about the sixth intercostal space anteriorly allows introduction of conventional surgical instruments, and a high trocar allows retraction of the lung away from the esophagus. In a three-field approach, the esophagus is dissected along its length to include division of the azygos vein and harvesting of the LNs in the upper, middle, and lower posterior mediastinum. Hilar, and posterior mediastinal nodes are all removed and sent with the specimen or individually. The thoracic duct is divided at the level of the diaphragm and removed with the specimen.

Following complete intrathoracic dissection, the patient is placed in the supine position and five laparoscopic ports are placed as with the MIS transhiatal esophagectomy. The abdominal portions of the operation are identical to those described previously in the section entitled Minimally Invasive Transhiatal Esophagectomy, and the gastric conduit is then sewn to the tip of the fully mobilized GEJ and lesser curvature sleeve. A feeding tube is placed and the pyloroplasty may be performed laparoscopically. A transverse cervical incision and dissection between the sternocleidomastoid and the anterior strap muscles allows access to the cervical esophagus. Great care is made to avoid stretching the recurrent laryngeal nerve. The esophagus

and proximal stomach is then pulled up into the neck with the gastric conduit following. Cervical anastomosis is then performed.

The MIS transthoracic two-field esophagectomy is slightly different. In this operation, the abdominal portions of the operation are done first, including placement of the feeding tube, the creation of the conduit, and the sewing of the tip of the conduit to the fully dissected GEJ. The patient is then rolled into the left lateral decubitus position and, through right thoracoscopy, the esophagus is dissected and divided 10 cm above the tumor. Once freed, the specimen is pulled out through the mini-thoracotomy and an end-to-end anastomosis stapler is introduced through the high corner of the gastric conduit and out a stab wound along the greater curvature. The anvil of the stapler is placed in the proximal esophagus and held with a purse-string, the stapler is docked, the anastomosis is created, and a gastrotomy is then closed with another firing of the GIA stapler. The three-field esophagectomy has the advantage of placing the anastomosis in the neck where leakage is unlikely to create a severe systemic consequence. On the other hand, placement of the anastomosis in the high chest minimizes the risks of injury to structures in the neck, particularly the recurrent laryngeal nerve. Although the leak of the intrathoracic anastomosis may be more likely to bear septic consequences, the incidence of leak is diminished. Other complications of this approach relate to pulmonary and cardiac status. In many series, the most common complication is pneumonia, the second is atrial fibrillation, and the third is anastomotic leak.

Ivor Lewis (En Bloc) Esophagectomy. The theory behind radical transthoracic esophagectomy is that greater removal of LNs and periesophageal tissues diminishes the chance of a positive radial margin and LN recurrence. Although there are no randomized data demonstrating this to be superior to other forms of esophagectomy, there are many retrospective data demonstrating improved survival with greater numbers of LNs harvested. A recent study from Sloan-Kettering demonstrates a direct relationship between the number of negative nodes harvested and long-term survival. Although such a survival advantage may be related to the completeness of resection, extended radical resections may also be a surrogate for experienced surgeons working in great institutions. As a time-honored operation, there is no doubt that en bloc esophagectomy is the standard to which less radical techniques must be compared.

Generally, this operation is started in the abdomen with an upper midline laparotomy and extensive LN dissection in and about the celiac access and its branches, extending into the porta hepatis and along the splenic artery to the tail of the pancreas. All LNs are removed en bloc with the lesser curvature of the stomach. Unless the tumor extends into the stomach, reconstruction is performed with a greater curvature gastric tube. For GEJ cancers extending significantly into the gastric cardia or fundus, the proximal stomach is removed and reconstruction is performed with an isoperistaltic section of left colon between the upper esophagus and the remnant stomach, or the colon is connected to a Roux-en-Y limb of jejunum, if total gastrectomy is necessary. In the majority of cases, colon interposition is unnecessary, and a gastric conduit is used.

Following closure of the abdominal incision, the patient is placed in the left lateral decubitus position and an anterolateral thoracotomy is performed through the sixth intercostal space. The azygos vein is divided and the posterior mediastinum is

entirely cleaned out to include the thoracic duct, all periaortic tissues, and all tissue in the upper mediastinum along the course of the current laryngeal nerves and in the peribronchial, hilar, and tracheal LN stations. The proximal stomach is pulled up into the thorax where a conduit is created (if not performed previously) and a handsewn or stapled anastomosis is made between the upper thoracic esophagus and the gastric conduit or transverse colon. Chest tubes are placed, and the patient is taken to the intensive care unit.

Because this is the most radical of dissections, complications are most common, including pneumonia, respiratory failure, atrial fibrillation, chylothorax, anastomotic leak, conduit necrosis, gastrocutaneous fistula, and, if dissection is too near the recurrent laryngeal nerves, hoarseness will occur with an increased risk of aspiration. Tracheobronchial injury resulting in fistulas between the bronchus and conduit may also occur, however rarely. Although this procedure and three-field esophagectomy are fraught with the highest complication rate, the long-term outcome of this procedure provides the greatest survival in many single-center series and retrospective reviews.

Three-Field Open Esophagectomy. *Three-field open esophagectomy* is very similar to a minimally invasive three-field except that all access is through open incisions. This procedure is preferred by certain Japanese surgeons and LN counts achieved through this kind of operation may run from 45 to 60 LNs. Most Western surgeons question the benefit of such radical surgery when it is hard to define a survival advantage. Nonetheless, high intrathoracic cancers probably deserve such an aggressive approach if cure is the goal.

Salvage Esophagectomy. *Salvage esophagectomy* is the nomenclature applied to esophagectomy performed after failure of definitive radiation and chemotherapy. The most frequent scenario is one in which distant disease (bone, lung, brain, or wide LN metastases) renders the patient nonoperable at initial presentation. Then, systemic chemotherapy, usually with radiation of the primary tumor, destroys all foci of metastasis, as demonstrated by CT and CT-PET, but the primary remains present and symptomatic. Following a period of observation, to make sure no new disease will become evident, salvage esophagectomy is performed, usually with an open two-field approach. Surprisingly, the cure rate of salvage esophagectomy is not inconsequential. One in four patients undergoing this operation will be disease free 5 years later, despite the presence of residual cancer in the operative specimen. Because of the dense scarring created by radiation treatment, this procedure is the most technically challenging of all esophagectomy techniques.

Comparative Studies of Esophagectomy Technique

Transthoracic vs. Transhiatal Esophagectomy. There has been a great debate as to whether en bloc esophagectomy will provide a greater long-term benefit and cure rate in esophageal cancer than transhiatal esophagectomy. In a recent 7-year follow-up of a Dutch study addressing GEJ and lower esophageal cancers, there does not appear to be any benefit to the more extensive dissection despite higher morbidity and mortality. In a subgroup analysis of those with one to eight positive LNs, it did appear that the en bloc transthoracic resection may add to longevity. In another large database analysis of the Surveillance, Epidemiology, and End Results database, transthoracic and transhiatal esophagectomy were compared. In this study,

the transhiatal esophagectomy had a greater long-term survival, but, when adjusted by cancer stage, this survival benefit disappeared. The mortality and morbidity after transhiatal esophagectomy appeared to be less. Suffice it to say that this debate over the best procedure for esophagectomy remains an open question.

The role of the minimally invasive surgical procedures for a cancer cure will require further study and longer follow-up. It would appear from preliminary analysis that the transhiatal esophagectomy, like its open cousin, may be performed with less morbidity and mortality than the VATS procedure. Long-term survival analyses will require careful follow-up for at least 5 to 10 years after cancer treatment. A recent European multicenter randomized trial comparing open and minimally invasive approaches revealed a highly significant reduction in pulmonary complications in the patients who underwent the minimally invasive approach. There was no difference in procedure-related mortality between the approaches.

Alternative Therapies

Radiation Therapy. Primary treatment with radiation therapy does not produce results comparable with those obtained with surgery. Currently, the use of radiotherapy is restricted to patients who are not candidates for surgery, and is usually combined with chemotherapy. Radiation alone is used for palliation of dysphagia but the benefit is short lived, lasting only 2 to 3 months. Furthermore, the length and course of treatment are difficult to justify in patients with a limited life expectancy. Radiation is effective in patients who have hemorrhage from the primary tumor.

Adjuvant Chemotherapy. The proposal to use adjuvant chemotherapy in the treatment of esophageal cancer began when it became evident that most patients develop postoperative systemic metastasis without local recurrence. This observation led to the hypothesis that undetected systemic micrometastasis had been present at the time of diagnosis, and, if effective systemic therapy was added to local regional therapy, survival should improve.

Recently, this hypothesis has been supported by the observation of epithelial tumor cells in the bone marrow in 37% of patients with esophageal cancer who were resected for cure. These patients had a greater prevalence of relapse at 9 months after surgery compared to those patients without such cells. Such studies emphasize that hematogenous dissemination of viable malignant cells occurs early in the disease, and that systemic chemotherapy may be helpful if the cells are sensitive to the agent. On the other hand, systemic chemotherapy may be a hindrance, because of its immunosuppressive properties, if the cells are resistant. Unfortunately, current technology is not able to test tumor cell sensitivity to chemotherapeutic drugs. This requires that the choice of drugs be made solely on the basis of their clinical effectiveness against grossly similar tumors.

The decision to use preoperative rather than postoperative chemotherapy was based on the ineffectiveness of chemotherapeutic agents when used after surgery, and animal studies suggesting that agents given before surgery were more effective. The claim that patients who receive chemotherapy before resection are less likely to develop resistance to the drugs is unsupported by hard evidence. The claim that drug delivery is enhanced because blood flow is more robust before patients undergo surgical dissection is similarly flawed, due to the fact

that if enough blood reaches the operative site to heal the wound or anastomosis, then the flow should be sufficient to deliver chemotherapeutic drugs. There are, however, data supporting the claim that preoperative chemotherapy in patients with esophageal carcinoma can, if effective, facilitate surgical resection by reducing the size of the tumor. This is particularly beneficial in the case of squamous cell tumors above the level of the carina. Reducing the size of the tumor may provide a safer margin between the tumor and the trachea, and allow an anastomosis to a tumor-free cervical esophagus just below the cricopharyngeus. Involved margin at this level usually requires a laryngectomy to prevent subsequent local recurrence.

Preoperative Chemotherapy. Eight randomized prospective studies of neoadjuvant chemotherapy vs. surgery alone have demonstrated mixed results. For adenocarcinomas of the distal esophagus and proximal stomach, preoperative neoadjuvant 5-fluorouracil (5-FU) and cisplatin chemotherapy has been shown to provide a survival advantage over surgery alone in a well-powered study from the United Kingdom (MRC trial). This trial is one of the few to include enough patients (800) to detect small differences. The trial had a 10% absolute survival benefit at 2 years for the neoadjuvant chemotherapy group. In a second trial from the United Kingdom (MAGIC trial) of distal esophageal and proximal gastric adenocarcinomas, the use of epirubicin in combination with cisplatin and 5-FU also demonstrated a survival advantage for the induction chemotherapy arm with 4 years median follow-up. As a result of these two trials, standard treatment of locally advanced adenocarcinoma in Europe calls for neoadjuvant chemotherapy with one of these two regimens. Most failures are due to distant metastatic disease, underscoring the need for improved systemic therapy. Postoperative septic and respiratory complications may be more common in patients receiving chemotherapy.

Preoperative Combination Chemo- and Radiotherapy. Preoperative chemoradiotherapy using cisplatin and 5-FU in combination with radiotherapy has been reported by several investigators to be beneficial in both adenocarcinoma and squamous cell carcinoma of the esophagus. There have been 10 randomized prospective studies (Table 25-13). A recent meta-analysis of these trials demonstrates a 13% survival advantage for neoadjuvant chemoradiation therapy, which is more pronounced for patients with adenocarcinoma than for those with squamous carcinoma (Table 25-14). It was also observed that the benefit for chemotherapy alone (7%) was not as dramatic as for chemoradiotherapy used in the neoadjuvant setting. Additionally, other work has demonstrated the importance of obtaining an R0 (tumor-free) resection as the most important variable determining long-term survival. Although there are not direct, randomized comparisons between chemotherapy and chemoradiation therapy, it appears that the addition of radiation may improve local response of the tumor, and may allow a greater opportunity for the surgeon to obtain an R0 resection.

The timing of surgery after chemoradiation induction is generally felt to be optimal between 6 and 8 weeks following the completion of induction therapy. Earlier than this time, active inflammation may make the resection hazardous, and the patients have not had time to recover fully from the chemoradiation. After 8 weeks, edema in the periesophageal tissue starts to turn to scar tissue, making dissection more difficult.

With chemoradiation, the complete response rates for adenocarcinoma range from 17% to 24% (Table 25-15). No tumor

Table 25-13

Randomized trials of neoadjuvant chemoradiotherapy vs. surgery, or neoadjuvant chemotherapy vs. surgery

YEAR ACTIVATED	TREATMENT SCHEDULE (RADIOTHERAPY)	TREATMENT SCHEDULE (CHEMOTHERAPY)	CONCURRENT OR SEQUENTIAL	TUMOR TYPE	SAMPLE SIZE	MEDIAN FOLLOW-UP (MO)
Chemoradiotherapy						
1983	35 Gy, 1.75 Gy/fraction over 4 wk	Two cycles: cisplatin 20 mg/m ² d 1–5; bleomycin 5 mg/m ² d 1–5	Sequential	SCC	78	18 ^a
1986	40 Gy, 2 Gy/fraction over 4 wk	Two cycles: cisplatin 100 mg/m ² d 1; 5-fluorouracil 1000 mg/m ² days 1–4	Concurrent	SCC	69	12 ^a
1988	20 Gy, 2 Gy/fraction over 12 d	Two cycles: cisplatin 100 mg/m ² d 1; 5-fluorouracil 600 mg/m ² d 2–5, 22–25	Sequential	SCC	86	12 ^a
1989	45 Gy, 1.5 Gy/fraction over 3 wk	Two cycles: cisplatin 20 mg/m ² d 1–5; 5-fluorouracil 300 mg/m ² d 1–21; vinblastine 1 mg/m ² d 1–4	Concurrent	SCC and adenocarcinoma	100	98
1989	37 Gy, 3.7 Gy/fraction over 2 wk	Two cycles: cisplatin 80 mg/m ² d 0–2	Sequential	SCC	293	55
1990	40 Gy, 2.7 Gy/fraction over 3 wk	Two cycles: cisplatin 75 mg/m ² d 7; 5-fluorouracil 15 mg/kg d 1–5	Concurrent	Adenocarcinoma	113	24
1990	40 Gy, 2.7 Gy/fraction over 3 wk	Two cycles: cisplatin 75 mg/m ² d 7; 5-fluorouracil 15 mg/kg d 1–5	Concurrent	SCC	61	10
1994	35 Gy, 2.3 Gy/fraction over 3 wk	One cycle: cisplatin 80 mg/m ² d 1; 5-fluorouracil 800 mg/m ² d 2–5	Concurrent	SCC and adenocarcinoma	256	65
2006	50.4 Gy, 1.8 Gy/fraction over 5.6 wk	Two cycles: cisplatin 60 mg/m ² d 1; 5-fluorouracil 1000 mg/m ² d 3–5	Concurrent	SCC and adenocarcinoma	56	60
1999	45.6 Gy, 1.2 Gy/fraction over 28 d	Two cycles: cisplatin 60 mg/m ² d 1; 5-fluorouracil 1000 mg/m ² d 3–5	Concurrent	SCC	101	25
Chemotherapy						
1982	—	Two cycles: cisplatin 120 mg/m ² d 1; vindesine 3 mg/m ² d 1, 8; bleomycin 10 U/m ² d 3–6	—	SCC	39	20
1983	—	Two cycles: cisplatin 20 mg/m ² d 1–5; bleomycin 5 mg/m ² d 1–5	—	SCC	106	18 ^a
1988 ^c	—	Three cycles: cisplatin 20 mg/m ² d 1–5; 5-fluorouracil 1000 mg/m ² d 1–5	—	SCC	46	75
1988	—	Two cycles: cisplatin 100 mg/m ² d 1; bleomycin 10 mg/m ² d 3–8; vinblastine 3 mg/m ² d 1, 8	—	SCC	46	17 ^a
1989	—	Two cycles: cisplatin 100 mg/m ² d 1; 5-fluorouracil 1000 mg/m ² d 1–5	—	SCC	147	17
1990	—	Two cycles: cisplatin 80 mg/m ² d 1; etoposide 200 mg/m ² d 1–5	—	SCC	160	19 ^a
1990	—	Three cycles: cisplatin 100 mg/m ² 1; 5-fluorouracil 1000 mg/m ² days 1–5	—	SCC and adenocarcinoma	467	56
1992	—	Two cycles: cisplatin 100 mg/m ² d 1; 5-fluorouracil 1000 mg/m ² d 1–5	—	SCC	96	24
1992	—	Two cycles: cisplatin 80 mg/m ² d 1; 5-fluorouracil 1000 mg/m ² d 1–4	—	SCC and adenocarcinoma	802	37

^aEstimated as median survival.^bUnpublished thesis.^cYear of activation not reported, but imputed.^dOnly available as an abstract.

SCC = squamous cell carcinoma.

Source: Reproduced with permission from GebSKI V, et al. for the Australasian Gastro-Intestinal Trials Group (eds): Survival benefits from neoadjuvant chemoradiotherapy or chemotherapy in oesophageal carcinoma: A meta-analysis. *Lancet Oncol* 8:226, 2007. Table 1, p 228. Copyright Elsevier.

Table 25-14

Results of the meta-analysis applied to effects of preoperative chemoradiotherapy and chemotherapy on 2-y survival for patients with various levels of risk

RISK GROUP	2-Y SURVIVAL RATE (%)	EXPECTED 2-Y MORTALITY			
		CONTROL (%)	TREATED ^a (%)	ARR (%)	NNT
Chemoradiotherapy					
High	20	80	64.8	15.2	7
Medium	35	65	52.7	12.3	8
Low	50	50	40.5	9.5	10
Chemotherapy					
High	20	80	72.0	12.0	8
Medium	35	65	58.5	6.5	15
Low	50	50	45.0	5.0	20

^aBased on a 19% relative mortality reduction for those receiving concurrent chemoradiotherapy and a 10% relative mortality reduction for those receiving chemotherapy.

ARR = absolute risk reduction; NNT = number needed to treat to prevent one death.

Source: Reproduced with permission from GebSKI V, et al. for the Australasian Gastro-Intestinal Trials Group (eds): Survival benefits from neoadjuvant chemoradiotherapy or chemotherapy in oesophageal carcinoma: A meta-analysis. *Lancet Oncol* 8:226, 2007. Table 2, p 231. Copyright Elsevier.

is detected in the specimen after esophagectomy. Patients demonstrating a complete response to chemoradiation have a better survival rate than those without complete response, but distant failure remains common.

At present, the strongest predictors of outcome of patients with esophageal cancer are the anatomic extent of the tumor at diagnosis and the completeness of tumor removal by surgical resection. After incomplete resection of an esophageal cancer, the 5-year survival rates are 0% to 5%. In contrast, after complete resection, independent of stage of disease, 5-year survival ranges from 15% to 40%, according to selection criteria and stage distribution. The importance of early recognition and adequate surgical resection cannot be overemphasized. Figure 25-70 is a global algorithm for the management of esophageal carcinoma.

SARCOMA OF THE ESOPHAGUS

Sarcomas and carcinosarcomas are rare neoplasms, accounting for approximately 0.1% to 1.5% of all esophageal tumors. They present with the symptom of dysphagia, which does not differ from the dysphagia associated with the more common epithelial carcinoma. Tumors located within the cervical or high thoracic esophagus can cause symptoms of pulmonary aspiration secondary to esophageal obstruction. Large tumors originating at the level of the tracheal bifurcation can produce symptoms of airway obstruction and syncope by direct compression of the tracheobronchial tree and heart (Fig. 25-71). The duration of dysphagia and age of the patients affected with these tumors are similar to those with carcinoma of the esophagus.

Table 25-15

Results of neoadjuvant therapy in adenocarcinoma of the esophagus

INSTITUTION	YEAR	NO. OF PATIENTS	REGIMEN	COMPLETE PATHOLOGIC RESPONSE (%)	SURVIVAL
M. D. Anderson	1990	35	P, E, 5-FU	3	42% at 3 y
SLMC	1992	18	P, 5-FU, RT	17	40% at 3 y
Vanderbilt	1993	39	P, E, 5-FU, RT	19	47% at 4 y
Michigan	1993	21	P, VBL, 5-FU, RT	24	34% at 5 y
MGH	1994	16	P, 5-FU	0	42% at 4 y
MGH	1994	22	E, A, P	5	58% at 2 y

A = doxorubicin; E = etoposide; 5-FU = 5-fluorouracil; MGH = Massachusetts General Hospital; P = cisplatin; RT = radiation therapy; SLMC = St. Louis University Medical Center; VBL = vinblastine.

Source: Reproduced with permission from Wright CD, et al.: Evolution of treatment strategies for adenocarcinoma of the esophagus and gastroesophageal junction. *Ann Thorac Surg* 58:1574, 1994. Copyright Elsevier.

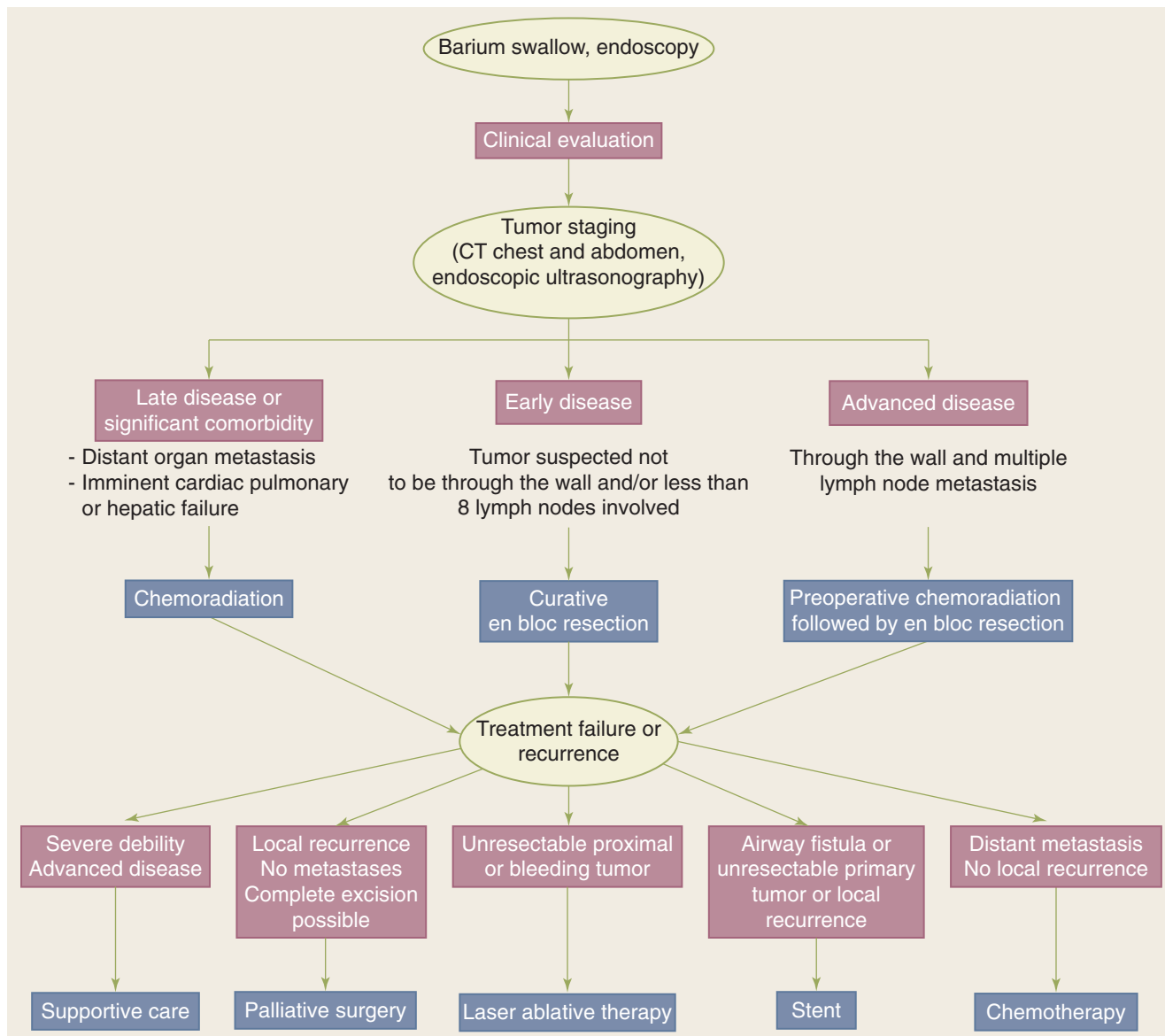


Figure 25-70. Suggested global algorithm for the management of carcinoma of the esophagus. CT = computed tomography.

A barium swallow usually shows a large polypoid intraluminal esophageal mass, causing partial obstruction and dilatation of the esophagus proximal to the tumor (Fig. 25-72). The smooth polypoid nature of the lesion, although not diagnostic, is distinctive enough to suggest the presence of a sarcoma rather than the more common ulcerating, stenosing carcinoma.

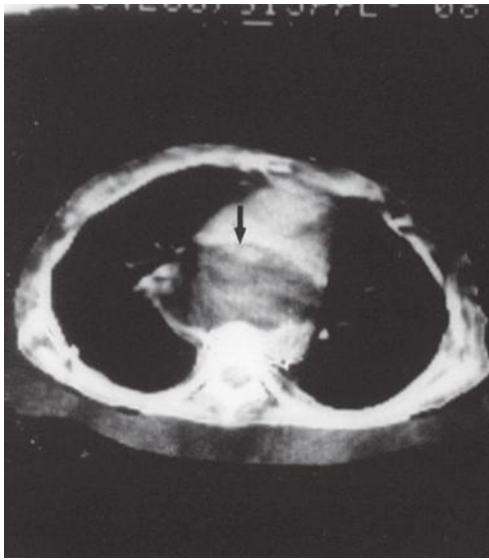
Esophagoscopy commonly shows an intraluminal necrotic mass. When biopsy is attempted, it is important to remove the necrotic tissue until bleeding is seen on the tumor's surface. When this is not done, the biopsy specimen will show only tissue necrosis. Even when viable tumor is obtained on biopsy, it has been these authors' experience that it cannot be definitively identified as carcinoma, sarcoma, or carcinosarcoma on the basis of the histology of the portion biopsied. Biopsy results cannot be totally relied on to identify the presence of sarcoma, and it is often the polypoid nature of the lesion that arouses suspicion that it may be something other than carcinoma.

Polypoid sarcomas of the esophagus, in contrast to infiltrating carcinomas, remain superficial to the muscularis propria

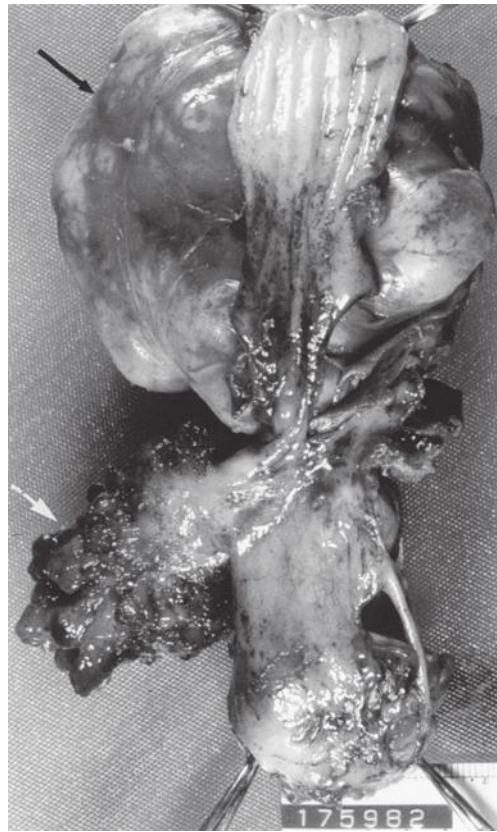
and are less likely to metastasize to regional LNs. In one series of 14 patients, local extension or tumor metastasis would have prevented a potentially curative resection in only five. Thus, the presence of a large polypoid tumor should not deter the surgeon from resecting the lesion.

Sarcomatous lesions of the esophagus can be divided into epidermoid carcinomas with spindle cell features, such as carcinosarcoma, and true sarcomas that arise from mesenchymal tissue, such as leiomyosarcoma, fibrosarcoma, and rhabdomyosarcoma. Based on current histologic criteria for diagnosis, fibrosarcoma and rhabdomyosarcoma of the esophagus are extremely rare lesions.

Surgical resection of polypoid sarcoma of the esophagus is the treatment of choice, because radiation therapy has little success and the tumors remain superficial, with local invasion or distant metastases occurring late in the course of the disease. As with carcinoma, the absence of both wall penetration and LN metastases is necessary for curative treatment, and surgical resection is consequently responsible for the majority of the

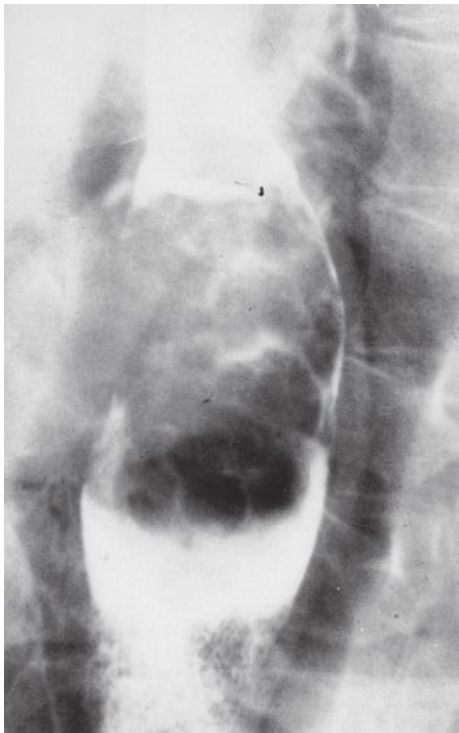

A

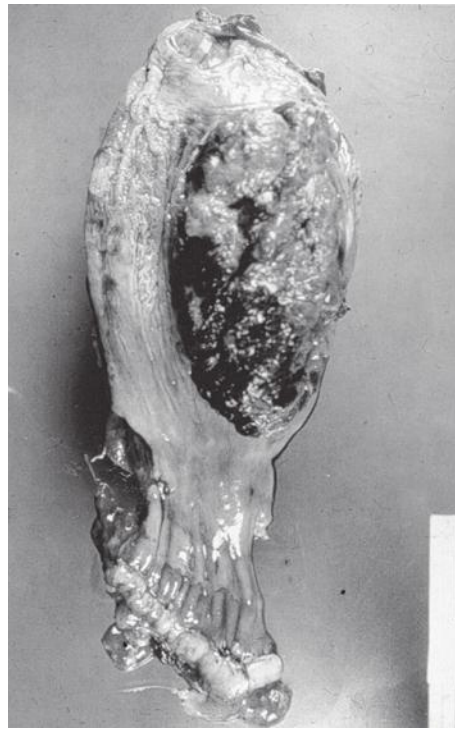

B

Figure 25-71. A. Computed tomographic scan of a leiomyosarcoma (*black arrow*) that caused compression of the heart and symptoms of syncope. B. Surgical specimen of leiomyosarcoma shown in A with a pedunculated luminal lesion (*white arrow*) and a large extraesophageal component (*black arrow*). There was no evidence of lymph node metastasis at the time of operation.



A



B

Figure 25-72. A. Barium swallow showing a large polypoid intraluminal esophageal mass causing partial obstruction and dilation of the proximal esophagus. B. Operative specimen showing 9-cm polypoid leiomyoblastoma.

reported 5-year survivals. Resection also provides an excellent means of palliating the patient's symptoms. The surgical technique for resection and the subsequent restoration of the GI continuity is similar to that described for carcinoma.

In these authors' experience, four of the eight patients with carcinosarcoma survived for 5 years or longer. Even though this number is small, it suggests that resection produces better results in epithelial carcinoma with spindle cell features than in squamous cell carcinoma of the esophagus. Similarly, with leiomyosarcoma of the esophagus, the same scattered reports exist with little information on survival. Of seven patients with leiomyosarcoma, two died from their disease—one in 3 months and the other 4 years and 7 months after resection. The other five patients were reported to have survived more than 5 years.

It is difficult to evaluate the benefits of resection for leiomyoblastoma of the esophagus, due to the small number of reported patients with tumors in this location. Most leiomyoblastomas occur in the stomach, and 38% of these patients succumb to the cancer in 3 years. Fifty-five percent of patients with extragastric leiomyoblastoma also die from the disease, within an average of 3 years. Consequently, leiomyoblastoma should be considered a malignant lesion and apt to behave like a leiomyosarcoma. The presence of nuclear hyperchromatism, increased mitotic figures (more than one per high-power field), tumor size larger than 10 cm, and clinical symptoms of longer than 6 months' duration are associated with a poor prognosis.

BENIGN TUMORS AND CYSTS

Benign tumors and cysts of the esophagus are relatively uncommon. From the perspectives of both the clinician and the pathologist, benign tumors may be divided into those that are within the muscular wall and those that are within the lumen of the esophagus.

Intramural lesions are either solid tumors or cysts, and the vast majority are leiomyomas. They are made up of varying portions of smooth muscle and fibrous tissue. Fibromas, myomas, fibromyomas, and lipomyomas are closely related and occur rarely. Other histologic types of solid intramural tumors have been described, such as lipomas, neurofibromas, hemangiomas, osteochondromas, granular cell myoblastomas, and glomus tumors, but they are medical curiosities.

Intraluminal lesions are polypoid or pedunculated growths that usually originate in the submucosa, develop mainly into the lumen, and are covered with normal stratified squamous epithelium. The majority of these tumors are composed of fibrous tissue of varying degrees of compactness with a rich vascular supply. Some are loose and myxoid (e.g., myxoma and myxofibroma), some are more collagenous (e.g., fibroma), and some contain adipose tissue (e.g., fibrolipoma). These different types of tumor are frequently collectively designated fibrovascular polyps, or simply as polyps. Pedunculated intraluminal tumors should be removed. If the lesion is not too large, endoscopic removal with a snare is feasible.

Leiomyoma

Leiomyomas constitute more than 50% of benign esophageal tumors. The average age at presentation is 38, which is in sharp contrast to that seen with esophageal carcinoma. Leiomyomas are twice as common in males. Because they originate in smooth muscle, 90% are located in the lower two thirds of the esophagus. They are usually solitary, but multiple tumors have been

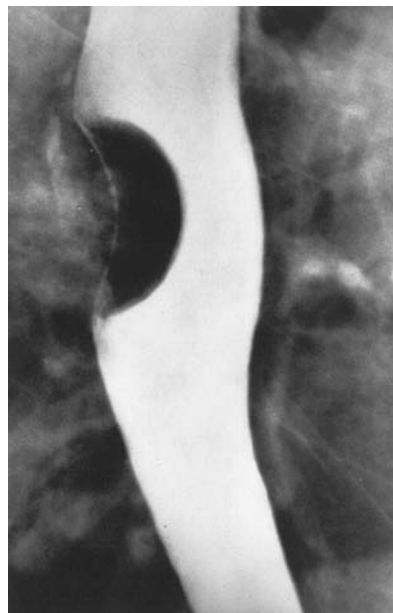


Figure 25-73. Barium esophagogram showing a classical, smooth, contoured, punched-out defect of a leiomyoma.

found on occasion. They vary greatly in size and shape. Actually tumors as small as 1 cm in diameter and as large as 10 lb have been removed.

Typically, leiomyomas are oval. During their growth, they remain intramural, having the bulk of their mass protruding toward the outer wall of the esophagus. The overlying mucosa is freely movable and normal in appearance. Dysphagia and pain are the most common complaints, the two symptoms occurring more frequently together than separately. Bleeding directly related to the tumor is rare, and when hematemesis or melena occurs in a patient with an esophageal leiomyoma, other causes should be investigated.

A barium swallow is the most useful method to demonstrate a leiomyoma of the esophagus (Fig. 25-73). In profile, the tumor appears as a smooth, semilunar, or crescent-shaped filling defect that moves with swallowing, is sharply demarcated, and is covered and surrounded by normal mucosa. Esophagoscopy should be performed to exclude the reported observation of a coexistence with carcinoma. The freely movable mass, which bulges into the lumen, should not be biopsied because of an increased chance of mucosal perforation at the time of surgical enucleation. Endoscopic ultrasound is also a useful adjunct in the workup of leiomyoma and provides detail related to the anatomic extent and relationship to surrounding structures.

Despite their slow growth and limited potential for malignant degeneration, leiomyomas should be removed unless there are specific contraindications. The majority can be removed by simple enucleation. If, during removal, the mucosa is inadvertently entered, the defect can be repaired primarily. After tumor removal, the outer esophageal wall should be reconstructed by closure of the muscle layer. The location of the lesion and the extent of surgery required will dictate the approach. Lesions of the proximal and middle esophagus require a right thoracotomy, whereas distal esophageal lesions require a left thoracotomy. Videothoracoscopic and laparoscopic approaches are now frequently used. The mortality rate associated with enucleation is low, and success in relieving the dysphagia is near 100%.

Large lesions or those involving the GEJ may require esophageal resection.

Esophageal Cyst

Cysts may be congenital or acquired. Congenital cysts are lined wholly or partly by columnar ciliated epithelium of the respiratory type, by glandular epithelium of the gastric type, by squamous epithelium, or by transitional epithelium. In some, epithelial lining cells may be absent. Confusion over the embryologic origin of congenital cysts has led to a variety of names, such as enteric, bronchogenic, duplication, and mediastinal cysts. Acquired retention cysts also occur, probably as a result of obstruction of the excretory ducts of the esophageal glands.

Enteric and bronchogenic cysts are the most common, and arise as a result of developmental abnormalities during the formation and differentiation of the lower respiratory tract, esophagus, and stomach from the foregut. During its embryologic development, the esophagus is lined successively with simple columnar, pseudostratified ciliated columnar, and, finally, stratified squamous epithelium. This sequence probably accounts for the fact that the lining epithelium may be any or a combination of these; the presence of cilia does not necessarily indicate a respiratory origin.

Cysts vary in size from small to very large, and are usually located intramurally in the middle- to lower-third of the esophagus. Their symptoms are similar to those of a leiomyoma. The diagnosis similarly depends on radiographic, endoscopic, and endosonographic findings. Surgical excision by enucleation is the preferred treatment. During removal, a fistulous tract connecting the cysts to the airways should be sought, particularly in patients who have had repetitive bronchopulmonary infections.

ESOPHAGEAL PERFORATION

Perforation of the esophagus constitutes a true emergency. It most commonly occurs following diagnostic or therapeutic procedures. Spontaneous perforation, referred to as Boerhaave's syndrome, accounts for only 15% of cases of esophageal perforation, foreign bodies for 14%, and trauma for 10%. Pain is a striking and consistent symptom and strongly suggests that an esophageal rupture has occurred, particularly if located in the cervical area following instrumentation of the esophagus, or substernally in a patient with a history of resisting vomiting. If subcutaneous emphysema is present, the diagnosis is almost certain.

Spontaneous rupture of the esophagus is associated with a high mortality rate because of the delay in recognition and treatment. Although there usually is a history of resisting vomiting, in a small number of patients, the injury occurs silently, without any antecedent history. When the chest radiogram of a patient with an esophageal perforation shows air or an effusion in the pleural space, the condition is often misdiagnosed as a pneumothorax or pancreatitis. An elevated pleural amylase caused by the extrusion of saliva through the perforation may fix the diagnosis of pancreatitis in the mind of an unwary physician. If the chest radiogram is normal, a mistaken diagnosis of myocardial infarction or dissecting aneurysm is often made.

Spontaneous rupture usually occurs into the left pleural cavity or just above the GEJ. About 50% of patients have concomitant GERD, suggesting that minimal resistance to the transmission of abdominal pressure into the thoracic esophagus is a factor in the pathophysiology of the lesion. During vomiting,

high peaks of intragastric pressure can be recorded, frequently exceeding 200 mmHg, but because extragastric pressure remains almost equal to intragastric pressure, stretching of the gastric wall is minimal. The amount of pressure transmitted to the esophagus varies considerably, depending on the position of the GEJ. When it is in the abdomen and exposed to intra-abdominal pressure, the pressure transmitted to the esophagus is much less than when it is exposed to the negative thoracic pressure. In the latter situation, the pressure in the lower esophagus will frequently equal intragastric pressure if the glottis remains closed. Cadaver studies have shown that when this pressure exceeds 150 mmHg, rupture of the esophagus is apt to occur. When a hiatal hernia is present and the sphincter remains exposed to abdominal pressure, the lesion produced is usually a Mallory-Weiss mucosal tear, and bleeding rather than perforation is the problem. This is due to the stretching of the supra-diaphragmatic portion of the gastric wall. In this situation, the hernia sac represents an extension of the abdominal cavity, and the GEJ remains exposed to abdominal pressure.

Diagnosis

Abnormalities on the chest radiogram can be variable and should not be depended upon to make the diagnosis. This is because the abnormalities are dependent on three factors: (a) the time interval between the perforation and the radiographic examination, (b) the site of perforation, and (c) the integrity of the mediastinal pleura. Mediastinal emphysema, a strong indicator of perforation, takes at least 1 hour to be demonstrated, and is present in only 40% of patients. Mediastinal widening secondary to edema may not occur for several hours. The site of perforation also can influence the radiographic findings. In cervical perforation, cervical emphysema is common and mediastinal emphysema rare; the converse is true for thoracic perforations. Frequently, air will be visible in the erector spinae muscles on a neck radiogram before it can be palpated or seen on a chest radiogram (Fig. 25-74). The integrity of the mediastinal pleura influences the radiographic abnormality in that rupture of the pleura results in a pneumothorax, a finding that is seen in 77% of patients. In two thirds of patients, the perforation is on the left side; in one fifth, it is on the right side; and in one tenth, it is bilateral. If pleural integrity is maintained, mediastinal emphysema (rather than a pneumothorax) appears rapidly. A pleural effusion secondary to inflammation of the mediastinum occurs late. In 9% of patients, the chest radiogram is normal.

The diagnosis is confirmed with a contrast esophagram, which will demonstrate extravasation in 90% of patients. The use of a water-soluble medium such as Gastrografin is preferred. Of concern is that there is a 10% false-negative rate. This may be due to obtaining the radiographic study with the patient in the upright position. When the patient is upright, the passage of water-soluble contrast material can be too rapid to demonstrate a small perforation. The studies should be done with the patient in the right lateral decubitus position (Fig. 25-75). In this, the contrast material fills the entire length of the esophagus, allowing the actual site of perforation and its interconnecting cavities to be visualized in almost all patients.

Management

The key to optimum management is early diagnosis. The most favorable outcome is obtained following primary closure of the perforation within 24 hours, resulting in 80% to 90% survival. Figure 25-76 is an operative photograph taken through a left

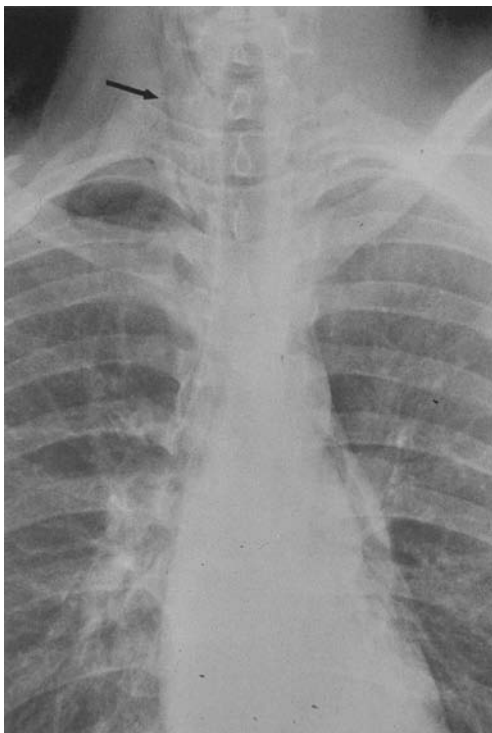


Figure 25-74. Chest radiogram showing air in the deep muscles of the neck following perforation of the esophagus (*arrow*). This is often the earliest sign of perforation and can be present without evidence of air in the mediastinum.

thoracotomy of an esophageal rupture following a pneumatic dilation for achalasia. The most common location for the injury is the left lateral wall of the esophagus, just above the GEJ. To get adequate exposure of the injury, a dissection similar to that described for esophageal myotomy is performed. A flap of stomach is pulled up and the soiled fat pad at the GEJ is

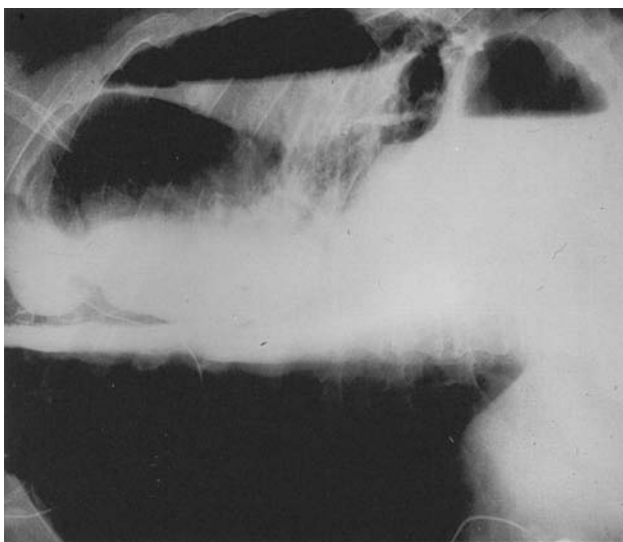


Figure 25-75. Radiographic study of a patient with a perforation of the esophagus using water-soluble contrast material. The patient is placed in the lateral decubitus position with the left side up to allow complete filling of the esophagus and demonstration of the defect.

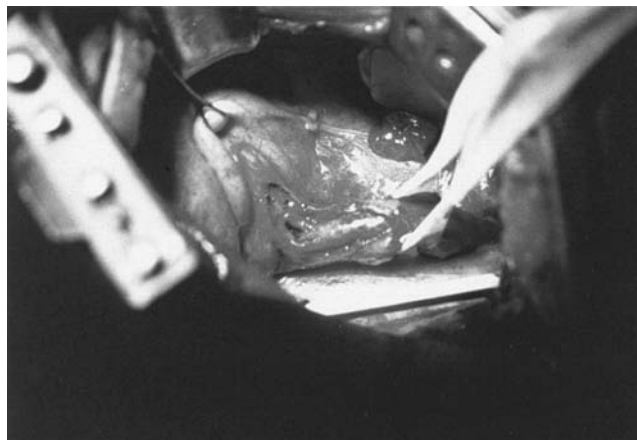


Figure 25-76. Left thoracotomy in a patient with an esophageal rupture at the gastroesophageal junction following forceful dilation of the lower esophagus for achalasia (the surgical clamp is on the stomach, and the Penrose drain encircles the esophagus). The injury consists of a mucosal perforation and extensive splitting of the esophageal muscle from just below the Penrose drain to the stomach.

removed. The edges of the injury are trimmed and closed primarily (Fig. 25-77). The closure is reinforced with the use of a pleural patch or construction of a Nissen fundoplication.

Mortality associated with immediate closure varies between 8% and 20%. After 24 hours, survival decreases to <50%, and is not influenced by the type of operative therapy (i.e., drainage alone or drainage plus closure of the perforation). If the time delay before closing a perforation approaches 24 hours and the tissues are inflamed, division of the cardia and resection of the diseased portion of the esophagus are recommended. The remainder of the esophagus is mobilized, and as much normal esophagus as possible is saved and brought out as an end cervical esophagostomy. In some situations, the retained esophagus may be so long that it loops down into the chest. The contaminated mediastinum is drained and a feeding jejunostomy tube is inserted. The recovery from sepsis is often immediate, dramatic, and reflected by a marked improvement in the patient's condition over a 24-hour period. On recovery from the sepsis, the patient is discharged and returns on a subsequent date for reconstruction with a substernal colon interposition. Failure to apply this aggressive therapy can result in a mortality rate in excess of 50% in patients in whom the diagnosis has been delayed.

Nonoperative management of esophageal perforation has been advocated in select situations. The choice of conservative therapy requires skillful judgment and necessitates careful radiographic examination of the esophagus. This course of management usually follows an injury occurring during dilation of esophageal strictures or pneumatic dilations of achalasia. Conservative management should not be used in patients who have free perforations into the pleural space. Cameron proposed three criteria for the nonoperative management of esophageal perforation: (a) the esophagram must show the perforation to be contained within the mediastinum and drain well back into the esophagus (Fig. 25-78), (b) symptoms should be mild, and (c) there should be minimal evidence of clinical sepsis. If these conditions are met, it is reasonable to treat the patient with

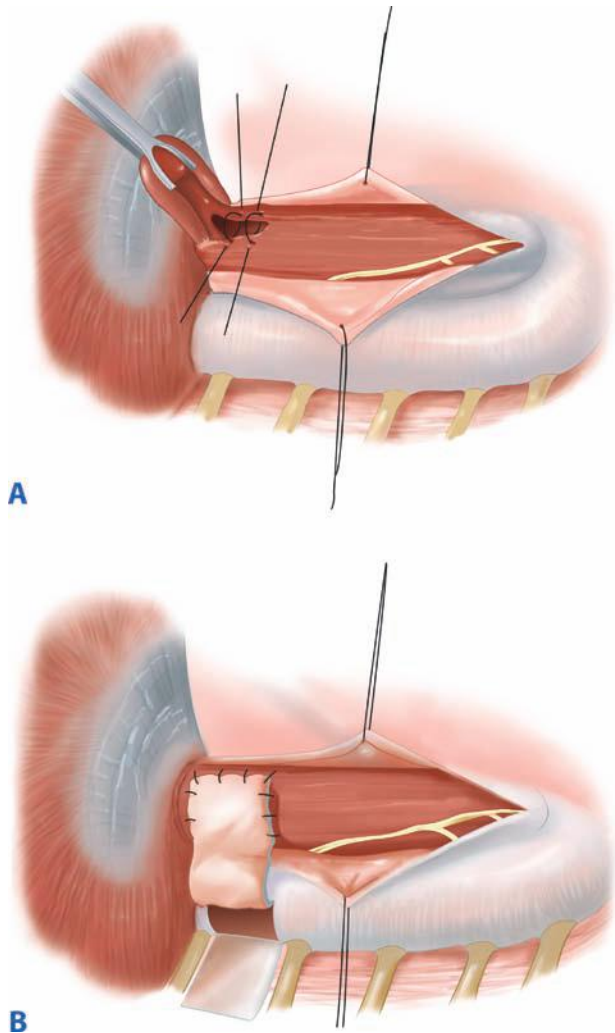


Figure 25-77. The technique of closure of an esophageal perforation through a left thoracotomy. **A.** A tongue of stomach is pulled up through the esophageal hiatus, and the gastroesophageal fat pad is removed; the edges of the mucosal injury are trimmed and closed using interrupted modified Gambee stitches. **B.** Reinforcement of the closure with a parietal pleural patch.

hyperalimentation, antibiotics, and cimetidine to decrease acid secretion and diminish pepsin activity. Oral intake is resumed in 7 to 14 days, dependent on subsequent radiographic examinations.

MALLORY-WEISS SYNDROME

In 1929, Mallory and Weiss described four patients with acute upper GI bleeding who were found at autopsy to have mucosal tears at the GEJ. This syndrome, characterized by acute upper GI bleeding following vomiting, is considered to be the cause of up to 15% of all severe upper GI bleeds. The mechanism is similar to spontaneous esophageal perforation: an acute increase in intra-abdominal pressure against a closed glottis in a patient with a hiatal hernia.

Mallory-Weiss tears are characterized by arterial bleeding, which may be massive. Vomiting is not an obligatory factor, as there may be other causes of an acute increase in intra-abdominal pressure, such as paroxysmal coughing, seizures, and retching. The diagnosis requires a high index of suspicion,

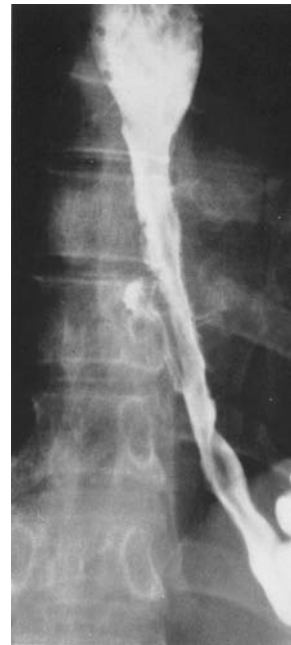

Figure 25-78. Barium esophagogram showing a stricture and a contained perforation following dilation. The injury meets Cameron criteria: It is contained within the mediastinum and drawn back into the esophagus, the patient had mild symptoms, and there was no evidence of clinical sepsis. Nonoperative management was successful.

particularly in the patient who develops upper GI bleeding following prolonged vomiting or retching. Upper endoscopy confirms the suspicion by identifying one or more longitudinal fissures in the mucosa of the herniated stomach as the source of bleeding.

In the majority of patients, the bleeding will stop spontaneously with nonoperative management. In addition to blood replacement, the stomach should be decompressed and antiemetics administered, as a distended stomach and continued vomiting aggravate further bleeding. A Sengstaken-Blakemore tube will not stop the bleeding, as the pressure in the balloon is not sufficient to overcome arterial pressure. Endoscopic injection of epinephrine may be therapeutic if bleeding does not stop spontaneously. Only occasionally will surgery be required to stop blood loss. The procedure consists of laparotomy and high gastrotomy with oversewing of the linear tear. Mortality is uncommon, and recurrence is rare.

CAUSTIC INJURY

Accidental caustic lesions occur mainly in children, and, in general, rather small quantities of caustics are taken. In adults or teenagers, the swallowing of caustic liquids is usually deliberate, during a suicide attempt, and greater quantities are swallowed. Alkalis are more frequently swallowed accidentally than acids, because strong acids cause an immediate burning pain in the mouth.

Pathology

The swallowing of caustic substances causes an acute and a chronic injury. During the acute phase, care focuses on controlling the immediate tissue injury and the potential for perforation. During the chronic phase, the focus is on treatment

of strictures and disturbances in pharyngeal swallowing. In the acute phase, the degree and extent of the lesion are dependent on several factors: the nature of the caustic substance, its concentration, the quantity swallowed, and the time the substance is in contact with the tissues.

Acids and alkalis affect tissue in different ways. Alkalis dissolve tissue, and therefore penetrate more deeply, while acids cause a coagulative necrosis that limits their penetration. Animal experiments have shown that there is a correlation between the depth of the lesion and the concentration of sodium hydroxide solution. When a solution of 3.8% comes into contact with the esophagus for 10 seconds, it causes necrosis of the mucosa and the submucosa, but spares the muscular layer. A concentration of 22.5% penetrates the whole esophageal wall and into the periesophageal tissues. Cleansing products can contain up to 90% sodium hydroxide. The strength of esophageal contractions varies according to the level of the esophagus, being weakest at the striated muscle–smooth muscle interface. Consequently, clearance from this area may be somewhat slower, allowing caustic substances to remain in contact with the mucosa longer. This explains why the esophagus is preferentially and more severely affected at this level than in the lower portions.

The lesions caused by lye injury occur in three phases. First is the acute necrotic phase, lasting 1 to 4 days after injury. During this period, coagulation of intracellular proteins results in cell necrosis, and the living tissue surrounding the area of necrosis develops an intense inflammatory reaction. Second is the ulceration and granulation phase, starting 3 to 5 days after injury. During this period, the superficial necrotic tissue sloughs, leaving an ulcerated, acutely inflamed base, and granulation tissue fills the defect left by the sloughed mucosa. This phase lasts 10 to 12 days, and it is during this period that the esophagus is the weakest. Third is the phase of cicatrization and scarring, which begins the third week following injury. During this period, the previously formed connective tissue begins to contract, resulting in narrowing of the esophagus. Adhesions between granulating areas occur, resulting in pockets and bands. It is during this period that efforts must be made to reduce stricture formation.

Clinical Manifestations

The clinical picture of an esophageal burn is determined by the degree and extent of the lesion. In the initial phase, complaints consist of pain in the mouth and substernal region, hypersalivation, pain on swallowing, and dysphagia. The presence of fever is strongly correlated with the presence of an esophageal lesion. Bleeding can occur, and frequently, the patient vomits. These initial complaints disappear during the quiescent period of ulceration and granulation. During the cicatrization and scarring phase, the complaint of dysphagia reappears and is due to fibrosis and retraction, resulting in narrowing of the esophagus. Of the patients who develop strictures, 60% do so within 1 month, and 80% within 2 months. If dysphagia does not develop within 8 months, it is unlikely that a stricture will occur. Serious systemic reactions such as hypovolemia and acidosis resulting in renal damage can occur in cases in which the burns have been caused by strong acids. Respiratory complications such as laryngospasm, laryngedema, and occasionally pulmonary edema can occur, especially when strong acids are aspirated.

Inspection of the oral cavity and pharynx can indicate that caustic substances were swallowed, but does not reveal that the esophagus has been burned. Conversely, esophageal burns can

Table 25-16

Endoscopic grading of corrosive esophageal and gastric burns

First degree: Mucosal hyperemia and edema
 Second degree: Limited hemorrhage, exudate ulceration, and pseudomembrane formation
 Third degree: Sloughing of mucosa, deep ulcers, massive hemorrhage, complete obstruction of lumen by edema, charring, and perforation

be present without apparent oral injuries. Because of this poor correlation, early esophagoscopy is advocated to establish the presence of an esophageal injury. To lessen the chance of perforation, the scope should not be introduced beyond the proximal esophageal lesion. The degree of injury can be graded according to the criteria listed in Table 25-16. Even if the esophagoscopy is normal, strictures may appear later. Radiographic examination is not a reliable means to identify the presence of early esophageal injury, but is important in later follow-up to identify strictures. The most common locations of caustic injuries are shown in Table 25-17.

Treatment

Treatment of a caustic lesion of the esophagus is directed toward management of both the immediate and late consequences of the injury. The immediate treatment consists of limiting the burn by administering neutralizing agents. To be effective, this must be done within the first hour. Lye or other alkali can be neutralized with half-strength vinegar, lemon juice, or orange juice. Acid can be neutralized with milk, egg white, or antacids. Sodium bicarbonate is not used because it generates carbon dioxide, which might increase the danger of perforation. Emetics are contraindicated, because vomiting renews the contact of the caustic substance with the esophagus and can contribute to perforation if too forceful. Hypovolemia is corrected and broad-spectrum antibiotics are administered to lessen the inflammatory reaction and prevent infectious complications. If necessary, a feeding jejunostomy tube is inserted to provide nutrition. Oral feeding can be started when the dysphagia of the initial phase has regressed.

Table 25-17

Location of caustic injury (n = 62)

Pharynx	10%
Esophagus	70%
Upper	15%
Middle	65%
Lower	2%
Whole	18%
Stomach	20%
Antral	91%
Whole	9%
Both stomach and esophagus	14%

In the past, surgeons waited until the appearance of a stricture before starting treatment. Currently, dilations are started the first day after the injury, with the aim of preserving the esophageal lumen by removing the adhesions that occurred in the injured segments. However, this approach is controversial in that dilations can traumatize the esophagus, causing bleeding, and perforation, and there are data indicating that excessive dilations cause increased fibrosis secondary to the added trauma. The use of steroids to limit fibrosis has been shown to be effective in animals, but their effectiveness in human beings has not been established.

Extensive necrosis of the esophagus frequently leads to perforation, and is best managed by resection. When there is extensive gastric involvement, the esophagus is nearly always necrotic or severely burned, and total gastrectomy and near-total esophagectomy are necessary. The presence of air in the esophageal wall is a sign of muscle necrosis and impending perforation and is a strong indication for esophagectomy.

Management of acute injury is summarized in the algorithm in Fig. 25-79. Some authors have advocated the use of an intraluminal esophageal stent (Fig. 25-80) in patients who are operated on and found to have no evidence of extensive esophagogastric necrosis. In these patients, a biopsy of the posterior

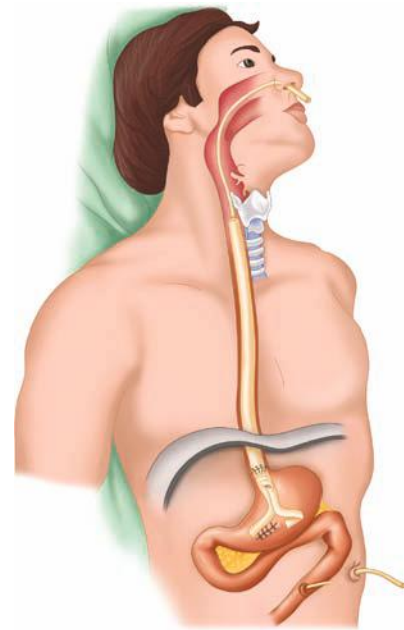


Figure 25-80. The use of an esophageal stent to prevent stricture. The stent is constructed from a chest tube and placed in the esophagus at the time of an exploratory laparotomy. A Penrose drain is placed over the distal end as a flap valve to prevent reflux. The stent is supported at its upper end by attaching it to a suction catheter that is secured to the nares. Continuous suction removes saliva and mucus trapped in the pharynx and upper esophagus.

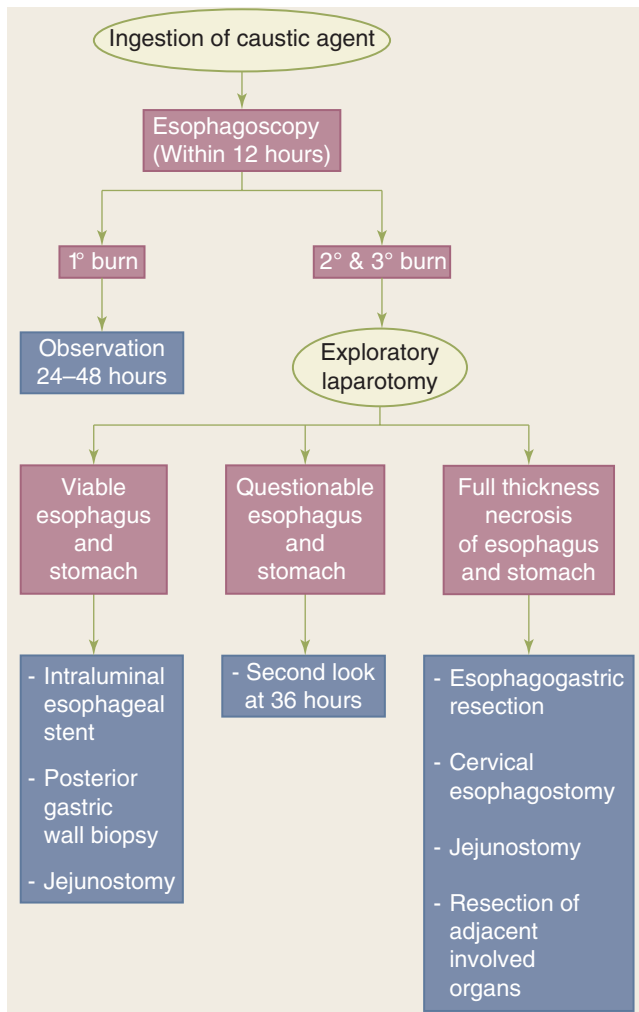


Figure 25-79. Algorithm summarizing the management of acute caustic injury.

gastric wall should be performed to exclude occult injury. If, histologically, there is a question of viability, a second-look operation should be done within 36 hours. If a stent is inserted, it should be kept in position for 21 days, and removed after a satisfactory barium esophagogram. Esophagoscopy should be done, and, if strictures are present, dilations initiated.

Once the acute phase has passed, attention is turned to the prevention and management of strictures. Both antegrade dilation with a Hurst or Maloney bougie and retrograde dilation with a Tucker bougie have been satisfactory. In a series of 1079 patients, early dilations started during the acute phase gave excellent results in 78%, good results in 13%, and poor results in 2%. During the treatment 55 patients died. In contrast, of 333 patients whose strictures were dilated when they became symptomatic, only 21% had excellent results, 46% good, and 6% poor, with three dying during the process. The length of time the surgeon should persist with dilation before consideration of esophageal resection is problematic. An adequate lumen should be re-established within 6 months to 1 year, with progressively longer intervals between dilations. If, during the course of treatment, an adequate lumen cannot be established or maintained (i.e., smaller bougies must be used), operative intervention should be considered. Surgical intervention is indicated when there is (a) complete stenosis in which all attempts from above and below have failed to establish a lumen, (b) marked irregularity and pocketing on barium swallow, (c) the development of a severe periesophageal reaction or mediastinitis with dilatation, (d) a fistula, (e) the inability to dilate or maintain the lumen above a 40F bougie, or (f) a patient who is unwilling or unable to undergo prolonged periods of dilation.

The variety of abnormalities seen requires that creativity be used when considering esophageal reconstruction. Skin tube

esophagoplasties are now used much less frequently than they were in the past, and are mainly of historical interest. Currently, the stomach, jejunum, and colon are the organs used to replace the esophagus, through either the posterior mediastinum or the retrosternal route. A retrosternal route is chosen when there has been a previous esophagectomy or there is extensive fibrosis in the posterior mediastinum. When all factors are considered, the order of preference for an esophageal substitute is (a) colon, (b) stomach, and (c) jejunum. Free jejunal grafts based on the superior thyroid artery have provided excellent results. Whatever method is selected, it must be emphasized that these procedures cannot be taken lightly; minor errors of judgment or technique may lead to serious or even fatal complications.

Critical in the planning of the operation is the selection of cervical esophagus, pyriform sinus, or posterior pharynx as the site for proximal anastomosis. The site of the upper anastomosis depends on the extent of the pharyngeal and cervical esophageal damage encountered. When the cervical esophagus is destroyed and a pyriform sinus remains open the anastomosis can be made to the hypopharynx (Fig. 25-81). When the pyriform sinuses are completely stenosed, a transglottic approach is used to perform an anastomosis to the posterior oropharyngeal wall (Fig. 25-82). This allows excision of supraglottic strictures and elevation and anterior tilting of the larynx. In both of these situations, the patient must relearn to swallow. Recovery is long and difficult and may require several endoscopic dilations, and often reoperations. Sleeve resections of short strictures are not successful because the extent of damage to the wall of the esophagus can be greater than realized, and almost invariably the anastomosis is carried out in a diseased area.

The management of a bypassed damaged esophagus after injury is problematic. If the esophagus is left in place, ulceration from gastroesophageal reflux or the development of carcinoma must be considered. The extensive dissection necessary to

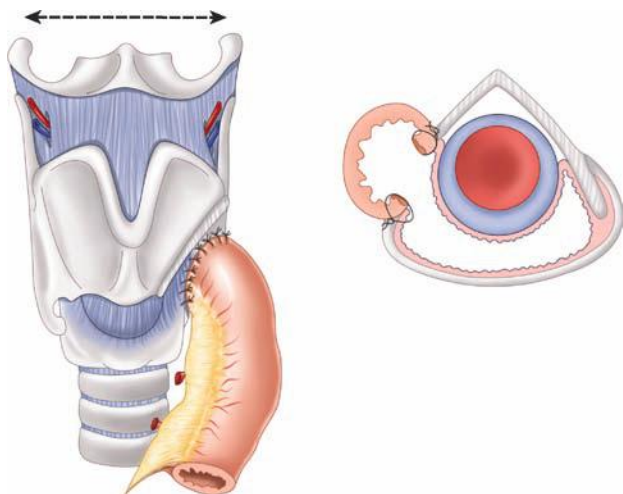


Figure 25-81. Anastomosis of the bowel to a preserved pyriform sinus. To identify the site, a finger is inserted into the free pyriform sinus through a suprahyoid incision (dotted line). This requires removing the lateral inferior portion of the thyroid cartilage as shown in cross-section. (Reproduced with permission from Tran Ba Huy P, Celerier M: *Management of severe caustic stenosis of the hypopharynx and esophagus by ileocolic transposition via suprahyoid or transepiglottic approach. Analysis of 18 cases.* Ann Surg. 207:439, 1988.)

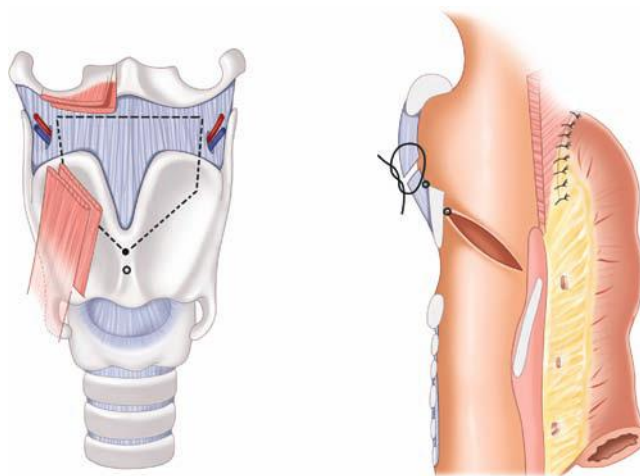


Figure 25-82. Anastomosis of the bowel to the posterior oropharynx. The anastomosis is done through an inverted trapezoid incision above the thyroid cartilage (dotted line). A triangle-shaped piece of the upper half of the cartilage is resected. Closure of the oropharynx is done so that the larynx is pulled up (sagittal section). (Reproduced with permission from Tran Ba Huy P, Celerier M: *Management of severe caustic stenosis of the hypopharynx and esophagus by ileocolic transposition via suprahyoid or transepiglottic approach. Analysis of 18 cases.* Ann Surg. 207:439, 1988.)

remove the esophagus, particularly in the presence of marked periesophagitis, is associated with significant morbidity. Leaving the esophagus in place preserves the function of the vagus nerves, and, in turn, the function of the stomach. On the other hand, leaving a damaged esophagus in place can result in multiple blind sacs and subsequent development of mediastinal abscesses years later. Most experienced surgeons recommend that the esophagus be removed unless the operative risk is unduly high.

ACQUIRED FISTULA

The esophagus lies in close contact with the membranous portion of the trachea and left bronchus, predisposing to the formation of fistula to these structures. Most acquired esophageal fistulas are to the tracheobronchial tree, and secondary to either esophageal or pulmonary malignancy. Traumatic fistulas and those associated with esophageal diverticula account for the remainder. Fistulas associated with traction diverticula are usually due to mediastinal inflammatory disease, and traumatic fistulas usually occur secondary to penetrating wounds, lye ingestion, or iatrogenic injury.

These fistulas are characterized by paroxysmal coughing following the ingestion of liquids, and by recurrent or chronic pulmonary infections. The onset of cough immediately after swallowing suggests aspiration, whereas a brief delay (30–60 seconds) suggests a fistula.

Spontaneous closure is rare, owing to the presence of malignancy or a recurrent infectious process. Surgical treatment of benign fistulas consists of division of the fistulous tract, resection of irreversibly damaged lung tissue, and closure of the esophageal defect. To prevent recurrence, a pleural flap should be interposed. Treatment of malignant fistulas is difficult, particularly in the presence of prior irradiation. Generally, only palliative treatment is indicated. This can best be done by using a

specially designed esophageal endoprosthesis that bridges and occludes the fistula, allowing the patient to eat. A salivary tube is also a good option for proximal esophageal fistulas. This tube has a proximal “lip” that rests on the cricopharyngeal muscle and thereby directs the saliva into the tube and past the fistula. Rarely, esophageal diversion, coupled with placement of a feeding jejunostomy, can be used as a last resort.

TECHNIQUES OF ESOPHAGEAL RECONSTRUCTION

Options for esophageal substitution include gastric advancement, colonic interposition, and either jejunal free transfer or advancement into the chest. Rarely, combinations of these grafts will be the only possible option. The indications for esophageal resection and substitution include malignant and end-stage benign disease. The latter includes reflux- or drug-induced stricture formation that cannot be dilated without damage to the esophagus, a dilated and tortuous esophagus secondary to severe motility disorders, lye-induced strictures, and multiple previous antireflux procedures. The choice of esophageal substitution has significant impact upon the technical difficulty of the procedure, and influences the long-term outcome.

Partial Esophageal Resection

Distal benign lesions, with preserved proximal esophageal function, are best treated with the interposition of a segment of proximal jejunum into the chest and primary anastomosis. A jejunal interposition can reach to the inferior border of the pulmonary hilum with ease, but the architecture of its blood supply rarely allows the use of the jejunum proximal to this point. Because the anastomosis is within the chest, a thoracotomy is necessary.

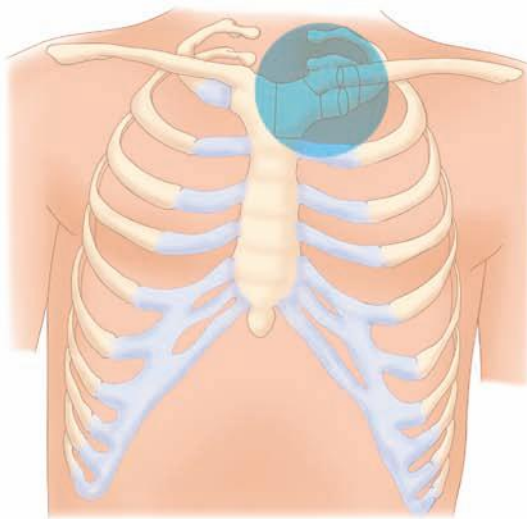
The jejunum is a dynamic graft and contributes to bolus transport, whereas the stomach and colon function more as a conduit. The stomach is a poor choice in this circumstance because of the propensity for the reflux of gastric contents into the proximal remaining esophagus following an intrathoracic

esophagogastrostomy. It is now well recognized that this occurs, and can lead to incapacitating symptoms and esophageal destruction in some patients. Short segments of colon, on the other hand, lack significant motility and have a propensity for the development of esophagitis proximal to the anastomosis.

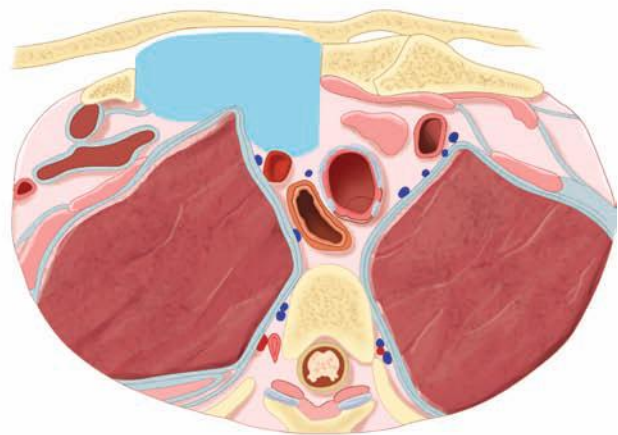
Replacement of the cervical portion of the esophagus, while preserving the distal portion, is occasionally indicated in cervical esophageal or head and neck malignancy, and following the ingestion of lye. Free transfer of a portion of jejunum to the neck has become a viable option and is successful in the majority of cases. Revascularization is achieved via use of the internal mammary artery and the internal mammary or innominate vein. Removal of the sternoclavicular joint aids in performing the vascular and distal esophageal anastomosis (Fig. 25-83).

Reconstruction after Total Esophagectomy

Neither the intrathoracic stomach nor the intrathoracic colon functions as well as the native esophagus after an esophagogastrectomy. The choice between these organs will be influenced by several factors, such as the adequacy of their blood supply and the length of resected esophagus that they are capable of bridging. If the stomach shows evidence of disease, or has been contracted or reduced by previous gastric surgery, the length available for esophageal replacement may not be adequate. The presence of diverticular disease, unrecognized carcinoma, or colitis prohibits the use of the colon. The blood supply of the colon is more affected by vascular disease than the blood supply of the stomach, which may prevent its use. Of the two, the colon provides the longest graft. The stomach can usually reach to the neck if the amount of lesser curvature resected does not interfere with the blood supply to the fundus. Gastric interposition has the advantage that only one anastomosis is required. On the other hand, there is greater potential for aspiration of gastric juice or stricture of the cervical anastomosis from chronic reflux when stomach is used for replacement.



A



B

Figure 25-83. A. The portion of the thoracic inlet to be resected to provide space for a free jejunal graft and access to the internal mammary artery (shaded area). B. Cross-section showing the space available after resection of the sternoclavicular joint and one-half of the manubrium. [Reproduced with permission from Rothberg M, DeMeester TR: *Exposure of the cervical esophagus*, in Shields TW (ed): *General Thoracic Surgery*, 3rd ed. Philadelphia: Lea & Febiger, 1989, p 419.]

Following an esophagogastrectomy, patients may have discomfort during or shortly after eating. The most common symptom is a postprandial pressure sensation or a feeling of being full, which probably results from the loss of the gastric reservoir. This symptom is less common when the colon is used as an esophageal substitute, probably because the distal third of the stomach is retained in the abdomen and the interposed colon provides an additional reservoir function.

King and Hölscher have reported a 40% and 50% incidence of dysphagia after re-establishing GI continuity with the stomach following esophagogastrectomy. This incidence is similar to Orringer's results after using the stomach to replace the esophagus in patients with benign disease. More than one-half of the patients experienced dysphagia postoperatively; two-thirds of this group required postoperative dilation and one-fourth had persistent dysphagia and required home dilation. In contrast, dysphagia is uncommon and the need for dilation is rare following a colonic interposition. Isolauri reported on 248 patients with colonic interpositions and noted a 24% incidence of dysphagia 12 months after the operation. When it occurred, the most common cause was recurrent mediastinal tumor. The high incidence of dysphagia with the use of the stomach is probably related to the esophagogastric anastomosis in the neck and the resulting difficulty of passing a swallowed bolus.

Another consequence of the transposition of the stomach into the chest is the development of postoperative duodenogastric reflux, probably due to pyloric denervation, and adding a pyloroplasty may worsen this problem. Following gastric advancement, the pylorus lies at the level of the esophageal hiatus, and a distinct pressure differential develops between the intrathoracic gastric and intra-abdominal duodenal lumina. Unless the pyloric valve is extremely efficient, the pressure differential will encourage reflux of duodenal contents into the stomach. Duodenogastric reflux is less likely to occur following colonic interposition, because there is sufficient intra-abdominal colon to be compressed by the abdominal pressure, and the pylorus and duodenum remain in their normal intra-abdominal position.

Although there is general acceptance of the concept that an esophagogastric anastomosis in the neck results in less postoperative esophagitis and stricture than one at a lower level, reflux esophagitis following a cervical anastomosis does occur, albeit at a lower rate than when the anastomosis is at a lower level. Most patients undergo cervical esophagogastrostomy for malignancy; thus the long-term sequelae of an esophagogastric anastomosis in the neck are not of concern. However, patients who have had a cervical esophagogastrostomy for benign disease may develop problems associated with the anastomosis in the fourth or fifth postoperative year that are severe enough to require anastomotic revision. This is less likely in patients who have had a colonic interposition for esophageal replacement. Consequently, in patients who have a benign process or a potentially curable carcinoma of the esophagus or cardia, a colonic interposition is used to obviate the late problems associated with a cervical esophagogastrostomy. Colonic interposition for esophageal substitution is a more complex procedure than gastric advancement, with the potential for greater perioperative morbidity, particularly in inexperienced hands.

Composite Reconstruction

Occasionally, a combination of colon, jejunum, and stomach is the only reconstructive option available. This situation may arise when there has been previous gastric or colonic resection,

when dysphagia has recurred after a previous esophageal resection, or following postoperative complications such as ischemia of an esophageal substitute. Although not ideal, combinations of colon, jejunum, and stomach used to restore GI continuity function surprisingly well, and allow alimentary reconstruction in an otherwise impossible situation.

Vagal Sparing Esophagectomy with Colon Interposition

Traditional esophagectomy typically results in bilateral vagotomy and its attendant consequences. It is likely that symptoms such as dumping, diarrhea, early satiety, and weight loss seen in 15% to 20% of patients postesophagectomy are at least in part, if not completely, due to vagal interruption. The technique of vagal sparing esophagectomy with colon interposition has been described in an effort to avoid the morbidities associated with standard esophagectomy.

Through an upper midline abdominal incision, the right and left vagal nerves are identified, circled with a tape, and retracted to the right. A limited, highly selective proximal gastric vagotomy is performed along the cephalad 4 cm of the lesser curvature. The stomach is divided with an Endo-GIA stapler just below the GEJ. The colon is prepared to provide an interposed segment as previously described. A neck incision is made along the anterior border of the left sternocleidomastoid muscle, and the strap muscles are exposed. The omohyoid muscle is divided at its pulley, and the sternohyoid and sternothyroid muscles are divided at their manubrial insertion. The left carotid sheath is retracted laterally and the thyroid and trachea medially. The left inferior thyroid artery is ligated laterally as it passes under the left common carotid artery. The left recurrent laryngeal nerve is identified and protected. The esophagus is dissected circumferentially in an inferior direction, from the left neck to the apex of the right chest, to avoid injury to the right recurrent laryngeal nerve. The esophagus is divided at the level of the thoracic inlet, leaving about 3 to 4 cm of cervical esophagus. The proximal esophagus is retracted anteriorly and to the right with the use of two sutures to keep saliva and oral contents from contaminating the neck wound.

Returning to the abdomen, the proximal staple line of the gastric division is opened and the esophagus is flushed with povidone-iodine solution. A vein stripper is passed up the esophagus into the neck wound. The distal portion of the esophagus in the neck is secured tightly around the stripping cable with "endoloops" and an umbilical tape for a trailer. The tip of the stripper is exchanged for a mushroom head, and the stripper is pulled back into the abdomen, inverting the esophagus as it transverses the posterior mediastinum. This maneuver strips the branches of the esophageal plexus off the longitudinal muscle of the esophagus, preserving the esophageal plexus along with the proximal vagal nerves and the distal vagal nerve trunks. In patients with end-stage achalasia, only the mucosa is secured around the stripping cable, so that it alone is stripped and the dilated muscular wall of the esophagus, with its enriched blood supply, remains. The resulting mediastinal tunnel, or in the case of achalasia the muscular tube, is dilated with a Foley catheter containing 90 mL of fluid in the balloon. The previously prepared interposed portion of the transverse colon is passed behind the stomach and up through the mediastinal tunnel into the neck. An end-to-end anastomosis is performed to the cervical esophagus using a single layer technique. The colon is pulled taut and secured to the left crus with four or

five interrupted sutures. Five centimeters below the crura, an opening is made in the mesentery adjacent to the colon along its mesenteric border, through which an Endo-GIA stapler is passed and the colon is divided. The proximal end, which is the distal end of the interposed colon, is anastomosed high on the posterior fundic wall of the stomach, using a triangular stapling anastomotic technique. This is done by stapling longitudinally the stomach and colon together with a 75-mm Endo-GIA stapler, spreading the base of the incision apart, and closing it with a T-55 stapler. Colonic continuity is re-established by bringing the proximal right colon to the distal staple line in the left colon and performing an end-to-end anastomosis using a double layer technique.

Although conceptually appealing, preservation of vagal nerve integrity or the gastric reservoir function after vagal sparing esophagectomy only recently has been validated. Banki and associates compared patients undergoing vagal sparing esophagectomy to those with conventional esophagectomy and colon or gastric interposition. This study showed that vagal sparing esophagectomy preserved gastric secretion, gastric emptying, meal capacity, and body mass index, compared to esophagogastrectomy with colon interposition or standard esophagectomy with gastric pull-up. Vagal sparing esophagectomy patients functioned, for the most part, similarly to normal subjects, allowing them to eat a normal meal, free of dumping or diarrhea. These results indicate that the vagal sparing esophagectomy procedure does indeed preserve the vagal nerves, and may be considered in the treatment of benign and early malignant lesions requiring esophagectomy.

BIBLIOGRAPHY

Entries highlighted in bright blue are key references.

General References

- Balaji B, Peters JH: Minimally invasive surgery for esophageal motor disorders. *Surg Clin North Am* 82:763, 2002.
- Bremner CG, DeMeester TR, Bremner RM: *Esophageal Motility Testing Made Easy*. St. Louis: Quality Medical Publishing, 2001.
- Castel DW, Richter J (eds): *The Esophagus*. Boston: Little, Brown & Co., 1999.
- DeMeester SR, Peters JH, DeMeester TR: Barrett's esophagus. *Curr Probl Surg* 38:549, 2001.
- DeMeester SR (ed): *Barrett's esophagus*. Problems in General Surgery, Vol. 18, no. 2. Hagerstown, MD: Lippincott Williams & Wilkins, 2001.
- DeMeester TR, Peters JH, Bremner CG, et al.: Biology of gastroesophageal reflux disease; pathophysiology relating to medical and surgical treatment. *Annu Rev Med* 50:469, 1999.
- Hunter JG, Pellagrini CA: Surgery of the esophagus. *Surg Clin North Am* 77:959, 1997.
- McFadyen BV, Arregui ME, Eubanks S, et al.: *Laparoscopic Surgery of the Abdomen*. New York: Springer, 2003.

Surgical Anatomy

- Daffner RH, Halber MD, Postlethwait RW, et al.: CT of the esophagus. II. Carcinoma. *AJR Am J Roentgenol* 133:1051, 1979.
- Gray SW, Rowe JS Jr., Skandalakis JE: Surgical anatomy of the gastroesophageal junction. *Am Surg* 45:575, 1979.
- Liebermann-Meffert D: The pharyngoesophageal segment: Anatomy and innervation. *Dis Esophagus* 8:242, 1995.
- Liebermann-Meffert D, Siewert JR: Arterial anatomy of the esophagus: A review of the literature with brief comments on clinical aspects. *Gullet* 2:3, 1992.
- Liebermann-Meffert DM, Meier R, Siewert JR: **Vascular anatomy of the gastric tube used for esophageal reconstruction.** *Ann Thorac Surg* 54:1110, 1992.

Liebermann-Meffert DM, Walbrun B, Hiebert CA, et al.: Recurrent and superior laryngeal nerves: A new look with implications for the esophageal surgeon. *Ann Thorac Surg* 67:217, 1999.

Physiology

- Barlow AP, DeMeester TR, et al.: The significance of the gastric secretory state in gastroesophageal reflux disease. *Arch Surg* 124:937, 1989.
- DeMeester TR, Lafontaine E, et al.: **The relationship of a hiatal hernia to the function of the body of the esophagus and the gastroesophageal junction.** *J Thorac Cardiovasc Surg* 82:547, 1981.
- Helm JF, Dodds WJ, et al.: **Effect of esophageal emptying and saliva on clearance of acid from the esophagus.** *N Engl J Med* 310:284, 1984.
- Joelsson BE, DeMeester TR, et al.: The role of the esophageal body in the antireflux mechanism. *Surgery* 92:417, 1982.
- Johnson LF, DeMeester TR: Evaluation of elevation of the head of the bed, bethanechol, and antacid foam tablets on gastroesophageal reflux. *Dig Dis Sci* 26:673, 1981.
- Kahrilas PJ, Dodds WJ, Hogan WJ: Effect of peristaltic dysfunction on esophageal volume clearance. *Gastroenterology* 94:73, 1988.
- McCallum RW, Berkowitz DM, Lerner E: Gastric emptying in patients with gastroesophageal reflux. *Gastroenterology* 80:285, 1981.
- Mittal RK, Lange RC, McCallum RW: Identification and mechanism of delayed esophageal acid clearance in subjects with hiatus hernia. *Gastroenterology* 92:130, 1987.
- Rao SSC, Madipalli RS, Mujica VR, et al.: Effects of age and gender on esophageal biomechanical properties and sensation. *Am J Gastroenterol* 98:1688, 2003.
- Tseng D, Rizvi AZ, Fennerty MB, et al.: Forty-eight-hour pH monitoring increases sensitivity in detecting abnormal esophageal acid exposure. *J Gastrointest Surg* 9:1043; discussion 1051, 2005.
- Zaninotto G, DeMeester TR, Schwizer W, et al.: The lower esophageal sphincter in health and disease. *Am J Surg* 155:104, 1988.

Assessment of Esophageal Function

- Adamek RJ, Wegener M, et al.: Long-term esophageal manometry in healthy subjects: Evaluation of normal values and influence of age. *Dig Dis Sci* 39:2069, 1994.
- Barish CF, Castell DO, Richter JE: Graded esophageal balloon distention: A new provocative test for non-cardiac chest pain. *Dig Dis Sci* 31:1292, 1986.
- Battle WS, Nyhus LM, Bombeck CT: Gastroesophageal reflux: Diagnosis and treatment. *Ann Surg* 177:560, 1973.
- Bechi P: Fiberoptic measurement of "alkaline" gastroesophageal reflux: Technical aspects and clinical indications. *Dis Esophagus* 131, 1994.
- Bernstein IM, Baker CA: A clinical test for esophagitis. *Gastroenterology* 34:760, 1958.
- DeMeester TR, Johnson LF, et al.: **Patterns of gastroesophageal reflux in health and disease.** *Ann Surg* 184:459, 1976.
- DeMeester TR, Wang CI, et al.: Technique, indications and clinical use of 24-hour esophageal pH monitoring. *J Thorac Cardiovasc Surg* 79:656, 1980.
- Dodds WJ: Current concepts of esophageal motor function: Clinical implications for radiology. *AJR Am J Roentgenol* 128:549, 1977.
- Fein M, Fuchs KH, Bohrer T, et al.: Fiberoptic technique for 24-hour bile reflux monitoring. Standards and normal values for gastric monitoring. *Dig Dis Sci* 41:216, 1996.
- Fuchs KH, DeMeester TR, Albertucci M: Specificity and sensitivity of objective diagnosis of gastroesophageal reflux disease. *Surgery* 102:575, 1987.

- Iacone C, DeMeester TR, et al.: Barrett's esophagus: Functional assessment, proposed pathogenesis, and surgical therapy. *Arch Surg* 118:543, 1983.
- Johnson LF, DeMeester TR: Development of 24-hour intra-esophageal pH monitoring composite scoring. *J Clin Gastroenterol* 8:52, 1986.
- Johnson LF, DeMeester TR: Twenty-four-hour pH monitoring of the distal esophagus: A quantitative measure of gastroesophageal reflux. *Am J Gastroenterol* 62:325, 1974.
- Kauer WK, Burdiles P, Ireland A, et al.: Does duodenal juice reflux into the esophagus in patients with complicated GERD? Evaluation of a fiberoptic sensor for bilirubin. *Am J Surg* 169:98, 1995.
- Kramer P, Hollander W: Comparison of experimental esophageal pain with clinical pain of angina pectoris and esophageal disease. *Gastroenterology* 29:719, 1955.
- Pandolfino JE, Richter JE, Ours T, et al.: Ambulatory esophageal pH monitoring using a wireless system. *Am J Gastroenterol* 98:740, 2003.
- Reid BJ, Weinstein WM, et al.: Endoscopic biopsy can detect high-grade dysplasia or early adenocarcinoma in Barrett's esophagus without grossly recognizable neoplastic lesions. *Gastroenterology* 94:81, 1988.
- Schwizer W, Hinder RA, DeMeester TR: Does delayed gastric emptying contribute to gastroesophageal reflux disease? *Am J Surg* 157:74, 1989.
- Stein HJ, DeMeester TR, et al.: Three-dimensional imaging of the LES in gastroesophageal reflux disease. *Ann Surg* 214:374, 1991.
- Tutuian R, Vela MF, Balaji NS, et al.: Esophageal function testing with combined multichannel intraluminal impedance and manometry; multicenter study in healthy volunteers. *Clin Gastroenterol Hepatol* 1:174, 2003.
- Wickremesinghe PC, Bayrit PQ, et al.: Quantitative evaluation of bile diversion surgery utilizing 99mTc HIDA scintigraphy. *Gastroenterology* 84:354, 1983.
- Gastroesophageal Reflux Disease**
- Allison PR: Hiatus hernia: A 20 year retrospective survey. *Ann Surg* 178:273, 1973.
- Allison PR: Peptic ulcer of the esophagus. *J Thorac Surg* 15:308, 1946.
- Allison PR: Reflux esophagitis, sliding hiatus hernia and the anatomy of repair. *Surg Gynecol Obstet* 92:419, 1951.
- Barlow AP, DeMeester TR, et al.: The significance of the gastric secretory state in gastroesophageal reflux disease. *Arch Surg* 124:937, 1989.
- Bonavina L, DeMeester TR, et al.: Drug-induced esophageal strictures. *Ann Surg* 206:173, 1987.
- Bremner RM, DeMeester TR, Crookes PF, et al.: The effect of symptoms and non-specific motility abnormalities on surgical therapy for gastroesophageal reflux disease. *J Thorac Cardiovasc Surg* 107:1244, 1994.
- Castell DO: Nocturnal acid breakthrough in perspective: Let's not throw out the baby with the bathwater. *Am J Gastroenterol* 98:517, 2003.
- Chandrasoma P, Barrett N: So close, yet 50 years from the truth. *J Gastrointest Surg* 3:7, 1999.
- Clark GW, Ireland AP, Peters JH, et al.: Short segments of Barrett's esophagus: A prevalent complication of gastroesophageal reflux disease with malignant potential. *J Gastrointest Surg* 1:113, 1997.
- DeMeester SR, Campos GM, DeMeester TR, et al.: The impact of an antireflux procedure on intestinal metaplasia of the cardia. *Ann Surg* 228:547, 1998.
- DeMeester TR, Bonavina L, Albertucci M: Nissen fundoplication for gastroesophageal reflux disease: Evaluation of primary repair in 100 consecutive patients. *Ann Surg* 204:9, 1986.
- DeMeester TR, Bonavina L, et al.: Chronic respiratory symptoms and occult gastroesophageal reflux. *Ann Surg* 211:337, 1990.
- DeMeester SR, DeMeester TR: Columnar mucosa and intestinal metaplasia of the esophagus: Fifty years of controversy. *Ann Surg* 231:303, 2000.
- DeMeester TR, Johansson KE, et al.: Indications, surgical technique, and long-term functional results of colon interposition or bypass. *Ann Surg* 208:460, 1988.
- Desai KM, Klingensmith ME, Winslow ER, et al.: Symptomatic outcomes of laparoscopic antireflux surgery in patients eligible for endoluminal therapies. *Surg Endosc* 16:1669, 2002.
- Donahue PE, Samelson S, et al.: The floppy Nissen fundoplication: Effective long-term control of pathologic reflux. *Arch Surg* 120:663, 1985.
- Farrell TM, Richardson WS, Halkar R, et al.: Nissen fundoplication improves gastric motility in patients with delayed gastric emptying. *Surg Endosc* 15:271, 2001.
- Farrell TM, Richardson WS, Trus TL, et al.: Response of atypical symptoms of gastroesophageal reflux antireflux surgery. *Br J Surg* 88:1649, 2001.
- Farrell TM, Smith CD, Metreveli RE, et al.: Fundoplication provides effective and durable symptom relief in patients with Barrett's esophagus. *Am J Surg* 178:18, 1999.
- Fass R: Epidemiology and pathophysiology of symptomatic gastroesophageal reflux disease. *Am J Gastroenterol* 98:S2, 2003.
- Fiorucci S, Santucci L, et al.: Gastric acidity and gastroesophageal reflux patterns in patients with esophagitis. *Gastroenterology* 103:855, 1992.
- Fletcher J, Wirz A, Young J, et al.: Unbuffered highly acidic gastric juice exists at the gastroesophageal junction after a meal. *Gastroenterology* 121:775, 2001.
- Fuchs KH, DeMeester TR, et al.: Computerized identification of pathologic duodenogastric reflux using 24-hour gastric pH monitoring. *Ann Surg* 213:13, 1991.
- Gerson LB, Shetler K, Triadafilopoulos G: Prevalence of Barrett's esophagus in asymptomatic individuals. *Gastroenterology* 123:461, 2002.
- Gillen P, Keeling P, et al.: Implication of duodenogastric reflux in the pathogenesis of Barrett's oesophagus. *Br J Surg* 75:540, 1988.
- Graham DY: The changing epidemiology of GERD: Geography and *Helicobacter pylori*. *Am J Gastroenterol* 98:1462, 2003.
- Gurski RR, Peters JH, Hagen JA, et al.: Barrett's esophagus can and does regress following antireflux surgery: A study of prevalence and predictive features. *J Am Coll Surg* 196:706, 2003.
- Henderson RD, Henderson RF, Marryatt GV: Surgical management of 100 consecutive esophageal strictures. *J Thorac Cardiovasc Surg* 99:1, 1990.
- Hill LD, Kozarek RA, et al.: The gastroesophageal flap valve. In vitro and in vivo observations. *GastrointestEndosc* 44:541, 1996.
- Hinder RA, Stein HJ, Bremner CG, et al.: Relationship of a satisfactory outcome to normalization of delayed gastric emptying after Nissen fundoplication. *Ann Surg* 210:458, 1989.
- Hirota WK, Loughney TM, Lazas DJ, et al.: Specialized intestinal metaplasia, dysplasia and cancer of the esophagus and esophago-gastric junction: Prevalence and clinical data. *Gastroenterology* 116:277, 1999.
- Hofstetter WA, Peters JH, DeMeester TR, et al.: Long term outcome of antireflux surgery in patients with Barrett's esophagus. *Ann Surg* 234:532, 2001.
- Ireland AP, Clark GWB, et al.: Barrett's esophagus: The significance of p53 in clinical practice. *Ann Surg* 225:17, 1997.
- Isolauro J, Luostarinen M, et al.: Long-term comparison of antireflux surgery versus conservative therapy for reflux esophagitis. *Ann Surg* 225:295, 1997.

- Jamieson JR, Hinder RA, et al.: Analysis of 32 patients with Schatzki's ring. *Am J Surg* 158:563, 1989.
- Johnson WE, Hagen JA, DeMeester TR, et al.: Outcome of respiratory symptoms after antireflux surgery on patients with gastroesophageal reflux disease. *Arch Surg* 131:489, 1996.
- Kahrilas PJ: Diagnosis of symptomatic gastroesophageal reflux disease. *Am J Gastroenterol* 98:S15, 2003.
- Kahrilas PJ: Radiofrequency therapy of the lower esophageal sphincter for treatment of GERD. *Gastrointest Endosc* 57:723; 2003.
- Kaul BK, DeMeester TR, et al.: The cause of dysphagia in uncomplicated sliding hiatal hernia and its relief by hiatal herniorrhaphy: A roentgenographic, manometric, and clinical study. *Ann Surg* 211:406, 1990.
- Khaitan L, Ray WA, Holzman MD, et al.: Health care utilization after medical and surgical therapy for gastroesophageal reflux disease. *Arch Surg* 138:1356, 2003.
- Labenz J, Tillenburg B, et al.: Helicobacter pylori augments the pH-increasing effect of omeprazole in patients with duodenal ulcer. *Gastroenterology* 110:725, 1996.
- Lin KM, Ueda RK, et al.: Etiology and importance of alkaline esophageal reflux. *Am J Surg* 162:553, 1991.
- Little AG, Ferguson MK, Skinner DB: Reoperation for failed anti-reflux operations. *J Thorac Cardiovasc Surg* 91:511, 1986.
- Liu JY, Finlayson SRG, Laycock WS, et al.: Determining the appropriate threshold for referral to surgery for gastroesophageal reflux disease. *Surgery* 133:5, 2003.
- Lundell L, Miettinen P, Myrvold HE, et al.: Long-term management of gastroesophageal reflux disease with omeprazole or open antireflux surgery: Results of a prospective randomized trial. *Eur J Gastroenterol Hepatol* 12:879, 2000.**
- Marshall RE, Anggiansah A, Owen WJ: Bile in the esophagus: Clinical relevance and ambulatory detection. *Br J Surg* 84:21, 1997.
- Morgenthal CB, Shane MD, Stival A, et al.: The durability of laparoscopic Nissen fundoplication: 11-year outcomes. *J Gastrointest Surg* 11:693, 2007.
- Narayani RI, Burton MP, Young GS: Utility of esophageal biopsy in the diagnosis of non-erosive reflux disease. *Dis Esophagus* 16:187, 2003.
- Nissen R: Eine einfache operation zur beeinflussung der refluxo-esophagitis. *Schweiz Med Wochenschr* 86:590, 1956.
- Nissen R: Gastropexy and fundoplication in surgical treatment of hiatus hernia. *Am J Dig Dis* 6:954, 1961.
- Oberg S, Johansson H, Wenner J, et al.: Endoscopic surveillance of columnar lined esophagus: Frequency of intestinal metaplasia detection and impact of antireflux surgery. *Ann Surg* 234:619, 2001.
- Orlando RC: The pathogenesis of gastroesophageal reflux disease: The relationship between epithelial defense, dysmotility, and acid exposure. *Am J Gastroenterol* 92:3S, 1997.
- Orringer MB, Skinner DB, Belsey RHR: Long-term results of the Mark IV operation for hiatal hernia and analyses of recurrences and their treatment. *J Thorac Cardiovasc Surg* 63:25, 1972.
- Parrilla P, Martinez de Haro LF, Ortiz A, et al.: Long term results of a randomized prospective study comparing medical and surgical treatment in Barrett's esophagus. *Ann Surg* 237:291, 2003.
- Patti MG, Debas HT, et al.: Esophageal manometry and 24-hour pH monitoring in the diagnosis of pulmonary aspiration secondary to gastroesophageal reflux. *Am J Surg* 163:401, 1992.
- Pearson FG, Cooper JD, et al.: Gastroplasty and fundoplication for complex reflux problems. *Ann Surg* 206:473, 1987.**
- Pelligrini CA, DeMeester TR, et al.: Gastroesophageal reflux and pulmonary aspiration: Incidence, functional abnormality, and results of surgical therapy. *Surgery* 86:110, 1979.
- Peters JH, Heimbucher J, Incarbone R, et al.: Clinical and physiologic comparison of laparoscopic and open Nissen fundoplication. *J Am Coll Surg* 180:385, 1995.
- Provenzale D, Kemp JA, et al.: A guide for surveillance of patients with Barrett's esophagus. *Am J Gastroenterol* 89:670, 1994.
- Richter JE: Long-term management of gastroesophageal reflux disease and its complications. *Am J Gastroenterol* 92:30S, 1997.
- Romagnuolo J, Meier MA, Sadowski DC: Medical or surgical therapy for erosive reflux esophagitis: Cost utility analysis using a Markov model. *Ann Surg* 236:191, 2002.
- Schwizer W, Hinder RA, DeMeester TR: Does delayed gastric emptying contribute to gastroesophageal reflux disease? *Am J Surg* 157:74, 1989.
- Shaker R, Castell DO, Schoenfeld PS, et al.: Nighttime heartburn is an underappreciated clinical problem that impacts sleep and daytime function: The results of a Gallup survey conducted on behalf of the American Gastroenterologic Association. *Am J Gastroenterol* 98:1487, 2003.
- Siewert JR, Isolauri J, Feussner M: Reoperation following failed fundoplication. *World J Surg* 13:791, 1989.
- Smith CD, McClusky DA, Rajhad MA, et al.: When fundoplication fails: Redo? *Ann Surg* 241:861, 2005.**
- Sontag SJ, O'Connell S, Khandelwal S, et al.: Asthmatics with gastroesophageal reflux: Long term results of a randomized trial of medical and surgical antireflux therapies. *Am J Gastroenterol* 98:987, 2003.**
- Spechler SJ, Department of Veterans Affairs Gastroesophageal Reflux Disease Study Group: Comparison of medical and surgical therapy for complicated gastroesophageal reflux disease in veterans. *N Engl J Med* 326:786, 1992.
- Spechler SJ, Lee E, Ahmen D: Long term outcome of medical and surgical therapies for gastroesophageal reflux disease: Follow-up of a randomized controlled trial. *JAMA* 285:2331, 2001.
- Spivak H, Farrell TM, Trus TL, et al.: Laparoscopic fundoplication for dysphagia and peptic esophageal stricture. *J Gastrointest Surg* 2:555, 1998.
- Stein HJ, Barlow AP, et al.: Complications of gastroesophageal reflux disease: Role of the LES, esophageal acid and acid/alkaline exposure, and duodenogastric reflux. *Ann Surg* 216:35, 1992.**
- Stein HJ, Bremner RM, et al.: Effect of Nissen fundoplication on esophageal motor function. *Arch Surg* 127:788, 1992.
- Terry M, Smith CD, Branum GD, et al.: Outcomes of laparoscopic fundoplication for gastroesophageal reflux disease and paraesophageal hernia: Experience with 1000 consecutive cases. *Surg Endosc* 15:691, 2001.
- Terry ML, Vernon A, Hunter JG: Stapled-wedge Collis gastroplasty for the shortened esophagus. *Am J Surg* 188:195, 2004.
- Trus TL, Laycock WS, Waring JP, et al.: Improvement in quality of life measures after laparoscopic antireflux surgery. *Ann Surg* 229:331, 1999.**
- Tseng D, Rizvi AZ, Fennerty MB, et al.: Forty-eight-hour pH monitoring increases sensitivity in detecting abnormal esophageal acid exposure. *J Gastrointest Surg* 9:1043, 2005.
- Van Den Boom G, Go PM, et al.: Cost effectiveness of medical versus surgical treatment in patients with severe or refractory gastroesophageal reflux disease in the Netherlands. *Scand J Gastroenterol* 31:1, 1996.
- Watson DI, Baigrie RJ, Jamieson GG: A learning curve for laparoscopic fundoplication. Definable, avoidable, or a waste of time? *Ann Surg* 224:198, 1996.
- Wattchow DA, Jamieson GG, et al.: Distribution of peptide-containing nerve fibers in the gastric musculature of patients undergoing surgery for gastroesophageal reflux. *Ann Surg* 290:153, 1992.
- Weston AP, Krmptotich P, et al.: Short segment Barrett's esophagus: Clinical and histological features, associated endoscopic findings, and association with gastric intestinal metaplasia. *Am J Gastroenterol* 91:981, 1996.
- Williamson WA, Ellis FH Jr., et al.: Effect of antireflux operation on Barrett's mucosa. *Ann Thorac Surg* 49:537, 1990.

Wright TA: High-grade dysplasia in Barrett's oesophagus. *Br J Surg* 84:760, 1997.

Zaninotto G, DeMeester TR, et al.: Esophageal function in patients with reflux-induced strictures and its relevance to surgical treatment. *Ann Thorac Surg* 47:362, 1989.

Diaphragmatic Hernias

Bombeck TC, Dillard DH, Nyhus LM: Muscular anatomy of the gastroesophageal junction and role of the phrenoesophageal ligament. *Ann Surg* 164:643, 1966.

Casbella F, Sinanan M, et al.: Systematic use of gastric fundoplication in laparoscopic repair of paraesophageal hernias. *Am J Surg* 171:485, 1996.

Dalgaard JB: Volvulus of the stomach. *Acta Chir Scand* 103:131, 1952.

DeMeester TR, Lafontaine E, et al.: The relationship of a hiatal hernia to the function of the body of the esophagus and the gastroesophageal junction. *J Thorac Cardiovasc Surg* 82:547, 1981.

Eliska O: Phreno-oesophageal membrane and its role in the development of hiatal hernia. *Acta Anat* 86:137, 1973.

Frantzides CT, Madan AK, Carlson MA, et al.: A prospective, randomized trial of laparoscopic polytetrafluoroethylene (PTFE) patch repair vs simple cruroplasty for large hiatal hernia. *Arch Surg* 137:649, 2002.

Fuller CB, Hagen JA, et al.: The role of fundoplication in the treatment of type II paraesophageal hernia. *J Thorac Cardiovasc Surg* 111:655, 1996.

Gangopadhyay N, Perrone JM, Soper NJ, et al.: Outcomes of laparoscopic paraesophageal hernia repair in elderly and high-risk patients. *Surgery*. 140:491; discussion 498, 2006. Epub 2006 Sep 6.

Granderath FA, Schweiger UM, Kamolz T, et al.: Laparoscopic Nissen fundoplication with prosthetic hiatal closure reduces postoperative intrathoracic wrap herniation: Preliminary results of a prospective randomized functional and clinical study. *Arch Surg* 140:40, 2005.

Hashemi M, Peters JH, DeMeester TR, et al.: Laparoscopic repair of large type III hiatal hernia: Objective follow-up reveals high recurrence rate. *J Am Coll Surg* 190:539, 2000.

Kahrilas PJ, Wu S, et al.: Attenuation of esophageal shortening during peristalsis with hiatus hernia. *Gastroenterology* 109:1818, 1995.

Kleitsch WP: Embryology of congenital diaphragmatic hernia. I. Esophageal hiatus hernia. *Arch Surg* 76:868, 1958.

Mattar SG, Bowers SP, Galloway KD, et al.: Long-term outcome of laparoscopic repair of paraesophageal hernia. *Surg Endosc* 16:745, 2002.

Menguy R: Surgical management of large paraesophageal hernia with complete intrathoracic stomach. *World J Surg* 12:415, 1988.

Myers GA, Harms BA, et al.: Management of paraesophageal hernia with a selective approach to antireflux surgery. *Am J Surg* 170:375, 1995.

Oddsdotir M, Franco AL, Laycock WS, et al.: Laparoscopic repair of paraesophageal hernia: New access, old technique. *Surg Endosc* 9:164, 1995.

Oelschlager BK, Pellegrini CA, Hunter J, et al.: Biologic prosthesis reduces recurrence after laparoscopic paraesophageal hernia repair: A multicenter, prospective, randomized trial. *Ann Surg* 244:481, 2006.

Patti MG, Goldberg HI, et al.: Hiatal hernia size affects LES function, esophageal acid exposure, and the degree of mucosal injury. *Am J Surg* 171:182, 1996.

Pierre AF, Luketich JD, Fernando HC, et al.: Results of laparoscopic repair of giant paraesophageal hernias: 200 consecutive patients. *Ann Thorac Surg* 74:1909, 2002.

Skinner DB, Belsey RH: Surgical management of esophageal reflux and hiatus hernia: Long-term results with 1030 patients. *J Thorac Cardiovasc Surg* 53:33, 1967.

Stylopoulos N, Gazelle GS, Ratner DW: Paraesophageal hernias: Operation or observation. *Ann Surg* 236:492, 2002.

Trus TL, Bax T, Richardson WS, et al.: Complications of laparoscopic paraesophageal hernia repair. *J Gastrointest Surg* 1:221; discussion 228, 1997.

Wo JM, Branum GD, Hunter JG, et al.: Clinical features of type III (mixed) paraesophageal hernia. *Am J Gastroenterol* 91:914, 1996.

Miscellaneous Esophageal Lesions

Burdick JS, Venu RP, Hogan WJ: Cutting the defiant lower esophageal ring. *Gastrointest Endosc* 39:616, 1993.

Burt M, Diehl W, et al.: Malignant esophagorespiratory fistula: Management options and survival. *Ann Thorac Surg* 52:1222, 1991.

Chen MYM, Ott DJ, Donati DL: Correlation of lower esophageal mucosal ring and LES pressure. *Dig Dis Sci* 39:766, 1994.

D'Haens G, Rutgeerts P, et al.: The natural history of esophageal Crohn's disease. Three patterns of evolution. *Gastrointest Endosc* 40:296, 1994.

Eckhardt VF, Kanzler G, Willems D: Single dilation of symptomatic Schatzki rings. A prospective evaluation of its effectiveness. *Dig Dis Sci* 37:577, 1992.

Klein HA, Wald A, et al.: Comparative studies of esophageal function in systemic sclerosis. *Gastroenterology* 102:1551, 1992.

Mathisen DJ, Grillo HC, et al.: Management of acquired nonmalignant tracheoesophageal fistula. *Ann Thorac Surg* 52:759, 1991.

Poirier NC, Taillefer R, et al.: Antireflux operations in patients with scleroderma. *Ann Thorac Surg* 58:66, 1994.

Soudah HC, Hasler WL, Owyang C: Effect of octreotide on intestinal motility and bacterial overgrowth in scleroderma. *N Engl J Med* 325:1461, 1991.

Toskes PP: Hope for the treatment of intestinal scleroderma (Letter to the Editor). *N Engl J Med* 325:1508, 1991.

Wilcox CM, Straub RF: Prospective endoscopic characterization of cytomegalovirus esophagitis in AIDS. *Gastrointest Endosc* 40:481, 1994.

Motility Disorders of the Pharynx and Esophagus

Achem SR, Crittenden J, et al.: Long-term clinical and manometric follow-up of patients with nonspecific esophageal motor disorders. *Am J Gastroenterol* 87:825, 1992.

Andreollo NA, Earlam RJ: Heller's myotomy for achalasia: Is an added antireflux procedure necessary? *Br J Surg* 74:765, 1987.

Anselmino M, Perdakis G, et al.: Heller myotomy is superior to dilatation for the treatment of early achalasia. *Arch Surg* 132:233, 1997.

Bianco A, Cagossi M, et al.: Appearance of esophageal peristalsis in treated idiopathic achalasia. *Dig Dis Sci* 90:978, 1986.

Bonavina L, Nosadinia A, et al.: Primary treatment of esophageal achalasia: Long-term results of myotomy and Dor fundoplication. *Arch Surg* 127:222, 1992.

Chen LQ, Chughtau T, Sideris L, et al.: Long term effects of myotomy and partial fundoplication for esophageal achalasia. *Dis Esophagus* 15:171, 2002.

Code CF, Schlegel JF, et al.: Hypertensive gastroesophageal sphincter. *Mayo Clin Proc* 35:391, 1960.

Cook IJ, Blumbergs P, et al.: Structural abnormalities of the cricopharyngeus muscle in patients with pharyngeal (Zenker's) diverticulum. *J Gastroenterol Hepatol* 7:556, 1992.

Cook IJ, Gabb M, et al.: Pharyngeal (Zenker's) diverticulum is a disorder of upper esophageal sphincter opening. *Gastroenterology* 103:1229, 1992.

Csendes A, Braghetto I, et al.: Late results of a prospective randomized study comparing forceful dilatation and oesophagomyotomy in patients with achalasia. *Gut* 30:299, 1989.

- DeMeester TR, Johansson KE, et al.: Indications, surgical technique, and long-term functional results of colon interposition or bypass. *Ann Surg* 208:460, 1988.
- DeMeester TR, Lafontaine E, et al.: The relationship of a hiatal hernia to the function of the body of the esophagus and the gastroesophageal junction. *J Thorac Cardiovasc Surg* 82:547, 1981.
- Eckardt V, Aigherr C, Bernhard G: Predictors of outcome in patients with achalasia treated by pneumatic dilation. *Gastroenterology* 103:1732, 1992.**
- Ekberg O, Wahlgren L: Dysfunction of pharyngeal swallowing: A cineradiographic investigation in 854 dysphagic patients. *Acta Radiol Diagn* 26:389, 1985.
- Ellis FH: Long esophagomyotomy for diffuse esophageal spasm and related disorders: An historical overview. *Dis Esophagus* 11:210, 1998.
- Ellis FH Jr.: Oesophagomyotomy for achalasia: A 22-year experience. *Br J Surg* 80:882, 1993.
- Evander A, Little AG, et al.: Diverticula of the mid and lower esophagus. *World J Surg* 10:820, 1986.
- Ferguson TB, Woodbury JD, Roper CL: Giant muscular hypertrophy of the esophagus. *Ann Thorac Surg* 8:209, 1969.
- Foker JE, Ring WE, Varco RL: Technique of jejunal interposition for esophageal replacement. *J Thorac Cardiovasc Surg* 83:928, 1982.
- Gutschow CA, Hamoir M, Rombaux P, et al.: Management of pharyngoesophageal (Zenker's) diverticulum: Which technique? *Ann Thorac Surg* 74:1677, 2002.
- Hirano I, Tatum RP, Shi G, et al.: Manometric heterogeneity in patients with idiopathic achalasia. *Gastroenterology* 120:789, 2001.
- Jeansonne LO, White BC, Pilger KE, et al.: Ten-year follow-up of laparoscopic Heller myotomy for achalasia shows durability. *Surg Endosc* 21:1498, 2007. Epub 2007 Jul 11.
- Jobe BA, Kim CY, Minjarez RC, et al.: Simplifying minimally invasive transhiatal esophagectomy with the inversion approach: Lessons learned from the first 20 cases.: *Arch Surg* 141:857; discussion 865, 2006.
- Kahrilas PJ, Logemann JA, et al.: Pharyngeal clearance during swallowing: A combined manometric and videofluoroscopic study. *Gastroenterology* 103:128, 1992.
- Kostic S, Kjellin A, Ruth M, et al.: Pneumatic dilation or laparoscopic cardiomyotomy in the management of newly diagnosed idiopathic achalasia. Results of a randomized controlled trial. *World J Surg* 31:470, 2007.
- Lam HG, Dekker W, et al.: Acute noncardiac chest pain in a coronary care unit. *Gastroenterology* 102:453, 1992.
- Mellow MH: Return of esophageal peristalsis in idiopathic achalasia. *Gastroenterology* 70:1148, 1976.
- Meshkinpour H, Haghighat P, et al.: Quality of life among patients treated for achalasia. *Dig Dis Sci* 41:352, 1996.
- Migliore M, Payne H, et al.: Pathophysiologic basis for operation on Zenker's diverticulum. *Ann Thorac Surg* 57:1616, 1994.
- Moser G, Vacariu-Granser GV, et al.: High incidence of esophageal motor disorders in consecutive patients with globus sensation. *Gastroenterology* 101:1512, 1991.
- Moses PL, Ellis LM, Anees MR, et al.: Antineural antibodies in idiopathic achalasia and gastro-oesophageal reflux disease. *Gut* 52:629, 2003.
- Nehra D, Lord RV, DeMeester TR, et al.: Physiologic basis for the treatment of epiphrenic diverticulum. *Ann Surg* 235:346, 2002.
- Oelschlager BK, Chang L, Pellegrini CA: Improved outcome after extended gastric myotomy for achalasia. *Arch Surg* 138:490, 2003.**
- O'Rourke RW, Seltman AK, Chang EY, et al.: A model for gastric banding in the treatment of morbid obesity: The effect of chronic partial gastric outlet obstruction on esophageal physiology. *Ann Surg* 244:723, 2006.
- Patti MG, Fisichella PM, Peretta S, et al.: Impact of minimally invasive surgery on the treatment of esophageal achalasia: A decade of change. *J Am Coll Surg* 196:698, 2003.**
- Pellegrini C, Wetter LA, et al.: Thoracoscopic esophagomyotomy: Initial experience with a new approach for the treatment of achalasia. *Ann Surg* 216:291, 1992.
- Peters JH: An antireflux procedure is critical to the long-term outcome of esophageal myotomy for achalasia. *J Gastrointest Surg* 5:17, 2001.
- Peters JH, Kauer WK, Ireland AP, et al.: Esophageal resection with colon interposition for end-stage achalasia. *Arch Surg* 130:632, 1995.
- Ponce J, Garrigues V, Pertejo V, et al.: Individual prediction of response to pneumatic dilation in patients with achalasia. *Dig Dis Sci* 41:2135, 1996.
- Richards WO, Torquati A, Holzman MD, et al.: Heller myotomy versus Heller myotomy with Dor fundoplication for achalasia: A prospective randomized double-blind clinical trial. *Ann Surg* 240:405; discussion 412, 2004.**
- Shoenut J, Duerksen D: A prospective assessment of gastroesophageal reflux before and after treatment of achalasia patients: Pneumatic dilation versus transthoracic limited myotomy. *Am J Gastroenterol* 92:1109, 1997.
- Spechler S, Castell DO: Classification of oesophageal motility abnormalities. *Gut* 49:145, 2001.
- Streitz JM Jr., Glick ME, Ellis FH Jr.: Selective use of myotomy for treatment of epiphrenic diverticula: Manometric and clinical analysis. *Arch Surg* 127:585, 1992.
- Vaezi MF, Baker ME, Achkar E, et al.: Timed barium oesophogram: Better predictor of long term success after pneumatic dilation in achalasia than symptom assessment. *Gut* 50:765, 2002.
- Verne G, Sallustio JE, et al.: Anti-myenteric neuronal antibodies in patients with achalasia: A prospective study. *Dig Dis Sci* 42:307, 1997.
- Williams RB, Grehan MJ, Andre J, et al.: Biomechanics, diagnosis, and treatment outcome in inflammatory myopathy presenting as oropharyngeal dysphagia. *Gut* 52:471, 2003.
- Zaninotto G, Annese V, Costantini M, et al.: Randomized controlled trial of botulinum toxin versus laparoscopic Heller myotomy for esophageal achalasia. *Ann Surg* 239:364, 2004.**
- Zhao X, Pasricha PJ: Botulinum toxin for spastic GI disorders: A systematic review. *Gastrointest Endosc* 57:219, 2003.

Carcinoma of the Esophagus

- Akiyama H: Surgery for carcinoma of the esophagus. *Curr Probl Surg* 17:53, 1980.
- Akiyama H, Tsurumaru M: Radical lymph node dissection for cancer of the thoracic esophagus. *Ann Surg* 220:364, 1994.**
- Altorki N, Skinner D: Should en-bloc esophagectomy be the standard of care for esophageal carcinoma? *Ann Surg* 234:581, 2001.
- Badwe RA, Sharma V, Bhansali MS, et al.: The quality of swallowing for patients with operable esophageal carcinoma: A randomized trial comparing surgery with radiotherapy. *Cancer* 85:763, 1999.
- Baker JW Jr., Schechter GL: Management of paraesophageal cancer by blunt resection without thoracotomy and reconstruction with stomach. *Ann Surg* 203:491, 1986.
- Biere SS, van Berge Henegouwen MI, Maas KW, et al.: Minimally invasive open oesophagectomy for patient with oesophageal cancer: a multicenter, open-label, randomized controlled trial. *Lancet* 19:1887, 2012.
- Blazebey JM, Williams MH, et al.: Quality of life measurement in patients with oesophageal cancer. *Gut* 37:505, 1995.
- Borrie J: Sarcoma of esophagus: Surgical treatment. *J Thorac Surg* 37:413, 1959.

- Cameron AJ, Ott BJ, Payne WS: The incidence of adenocarcinoma in columnar-lined (Barrett's) esophagus. *N Engl J Med* 313:857, 1985.
- Chang AC, Ji H, Birkmeyer NJ, et al.: Outcomes after transhiatal and transthoracic esophagectomy for cancer. *Ann Thorac Surg* 85:424, 2008.
- Chang EY, Morris CD, Seltman AK, et al.: The effect of antireflux surgery on esophageal carcinogenesis in patients with Barrett's esophagus: A systematic review. *Ann Surg* 246:11, 2007.**
- Clark GWB, Peters JH, Hagen JA, et al.: Nodal metastases and recurrence patterns after en-bloc esophagectomy for adenocarcinoma. *Ann Thorac Surg* 58:646, 1994.
- Clark GW, Smyrk TC, et al.: Is Barrett's metaplasia the source of adenocarcinomas of the cardia? *Arch Surg* 129:609, 1994.
- Collin CF, Spiro RH: Carcinoma of the cervical esophagus: Changing therapeutic trends. *Am J Surg* 148:460, 1984.
- Corley DA, Kerlikowske K, Verma R, et al.: Protective association of aspirin/NSAIDs and esophageal cancer: A systematic review and meta-analysis. *Gastroenterology* 124:47, 2003.
- Cunningham D, Allum WH, Stenning SP, et al.: Perioperative chemotherapy versus surgery alone for resectable gastroesophageal cancer. *N Engl J Med* 6:355:11, 2006.**
- Dallal HJ, Smith GD, Grieve DC, et al.: A randomized trial of thermal ablative therapy versus expandable metal stents in the palliative treatment of patients with esophageal carcinoma. *Gastrointest Endosc* 54:549, 2001.
- DeMeester TR, Skinner DB: Polypoid sarcomas of the esophagus. *Ann Thorac Surg* 20:405, 1975.
- Duhaylongsod FG, Wolfe WG: Barrett's esophagus and adenocarcinoma of the esophagus and gastroesophageal junction. *J Thorac Cardiovasc Surg* 102:36, 1991.
- Ell C, May A, Gossner L, et al.: Endoscopic mucosal resection of early cancer and high grade dysplasia in Barrett's esophagus. *Gastroenterology* 118:670, 2001.
- Ellis FH, Heatley GJ, Krosna MJ, et al.: Esophagogastrectomy for carcinoma of the esophagus and cardia: A comparison of findings and results after standard resection in three consecutive 8 year time intervals, using improved staging criteria. *J Thorac Cardiovasc Surg* 113:836, 1997.
- Frenken M: Best palliation in esophageal cancer; surgery, stenting, radiation, or what? *Dis Esophagus* 14:120, 2001.
- Fujita H, Kakegawa T, et al.: Mortality and morbidity rates, postoperative course, quality of life, and prognosis after extended radical lymphadenectomy for esophageal cancer. *Ann Surg* 222:654, 1995.
- Gebski V, Burmeister B, Smithers BM, et al.: Survival benefits from neoadjuvant chemoradiotherapy or chemotherapy in oesophageal carcinoma: A meta-analysis. *Lancet* 8:226, 2007.**
- Greenstein AJ, Litle VR, Swanson SJ, et al.: Effect of the number of lymph nodes sampled on postoperative survival of lymph node-negative esophageal cancer. *Cancer* 112:1239, 2008.
- Hagen JA, DeMeester TR, Peters JH, et al.: Curative resection for esophageal adenocarcinoma analysis of 100 en bloc esophagectomies. *Ann Surg* 234:520, 2001.**
- Hofstetter W, Swisher SG, Correa AM: Treatment outcomes of resected esophageal cancer. *Ann Surg* 236:376, 2002.
- Hulscher JB, Van Sandick JW, de Boer AG, et al.: Extended transthoracic resection compared with limited transhiatal resection for adenocarcinoma of the esophagus. *N Engl J Med* 347:1662, 2002.**
- Iijima K, Henrey E, Moriya A, et al.: Dietary nitrate generates potentially mutagenic concentrations of nitric oxide at the gastroesophageal junction. *Gastroenterology* 122:1248, 2002.
- Ikedo M, Natsugoe S, Ueno S, et al.: Significant host and tumor related factors for predicting prognosis in patients with esophageal carcinoma. *Ann Surg* 238:197, 2003.
- Jankowski JA, Wight NA, Meltzer SJ, et al.: Molecular evolution of the metaplasia-dysplasia-adenocarcinoma sequence in the esophagus. *Am J Pathol* 154:965, 1999.
- Jobe BA, Kim CY, Minjarez RC, et al.: Simplifying minimally invasive transhiatal esophagectomy with the inversion approach: Lessons learned from the first 20 cases. *Arch Surg* 141:857; discussion 865.
- Johansson J, DeMeester TR, Heger JA, et al.: En bloc is superior to transhiatal esophagectomy for T3 N1 adenocarcinoma of the distal esophagus and GE junction. *Arch Surg* 139:627, 2004.
- Kaklamanos IG, Walker GR, Ferry K, et al.: Neoadjuvant treatment for resectable cancer of the esophagus and the gastroesophageal junction: A meta-analysis of randomized clinical trials. *Ann Surg Oncol* 10:754, 2003.
- Kelsen DP, Winter KA, Gunderson LL, et al.: Long-term results of RTOG trial 8911 (USA Intergroup 113): A random assignment trial comparison of chemotherapy followed by surgery compared with surgery alone for esophageal cancer. *J Clin Oncol* 25:3719, 2007.**
- Krasna MJ, Reed CE, Nedzwiecki D, et al.: CALBG 9380: A prospective trial of the feasibility of thoracoscopy/laparoscopy in staging esophageal cancer. *Ann Thorac Surg* 71:1073, 2001.
- Kirby JD: Quality of life after esophagectomy: The patients' perspective. *Dis Esophagus* 12:168, 1999.
- Lagergren J, Bergstrom R, Lindgren A, et al.: Symptomatic gastroesophageal reflux as a risk factor for esophageal adenocarcinoma. *N Engl J Med* 340:825, 1999.**
- Lavin P, Hajdu SI, Foote FW Jr.: Gastric and extragastric leiomyoblastomas. *Cancer* 29:305, 1972.
- Law SYK, Fok M, Wong J: Pattern of recurrence after oesophageal resection for cancer: Clinical implications. *Br J Surg* 83:107, 1996.
- Law SYK, Fok M, et al.: A comparison of outcomes after resection for squamous cell carcinomas and adenocarcinomas of the esophagus and cardia. *Surg Gynecol Obstet* 175:107, 1992.
- Law S, Kwong DL, Kwok KF, et al.: Improvement in treatment results and long term survival of patients with esophageal cancer: Impact of chemoradiation and change in treatment strategy. *Ann Surg* 238:339, 2003.**
- Lerut T, Coosemans W, et al.: Surgical treatment of Barrett's carcinoma. Correlations between morphologic findings and prognosis. *J Thorac Cardiovasc Surg* 107:1059, 1994.
- Leuketich JD, Alvelo-Rivera M, Buenaventura PO, et al.: Minimally invasive esophagectomy: Outcomes in 222 patients. *Ann Surg* 238:486, 2003.**
- Levine DS, Reid BJ: Endoscopic diagnosis of esophageal neoplasms. *Gastrointest Clin North Am* 2:395, 1992.
- Lewis I: The surgical treatment of carcinoma of the esophagus with special reference to a new operation for the growths of the middle third. *Br J Surg* 34:18, 1946.
- Logan A: The surgical treatment of carcinoma of the esophagus and cardia. *J Thorac Cardiovasc Surg* 46:150, 1963.
- Manner H, May A, Pech O, et al.: Early Barrett's carcinoma with "low-risk" submucosal invasion: Long-term results of endoscopic resection with a curative intent. *Am J Gastroenterol* 103:2589, 2008. Epub 2008 Sep 10.
- McCort JJ: Esophageal carcinosarcoma and pseudosarcoma. *Radiology* 102:519, 1972.
- Medical Research Council Oesophageal Working Party: Surgical resection with or without preoperative chemotherapy in oesophageal cancer: A randomized controlled trial. *Lancet* 359:1727, 2002.
- Naunheim KS, Petruska PJ, et al.: Preoperative chemotherapy and radiotherapy for esophageal carcinoma. *J Thorac Cardiovasc Surg* 103:887, 1992.
- Nicks R: Colonic replacement of the esophagus. *Br J Surg* 54:124, 1967.
- Nigro JJ, Hagen JA, DeMeester TR, et al.: Occult esophageal adenocarcinoma: Extent of disease and implications for effective therapy. *Ann Surg* 230:433, 1999.

- Omloo JM, Lagarde SM, Hulscher JB, et al.: Extended transthoracic resection compared with limited transhiatal resection for adenocarcinoma of the mid/distal esophagus: Five year survival of a randomized clinical trial. *Ann Surg* 246:992, 2007.
- Orringer MB, Marshall B, Iannettoni MD: Transhiatal esophagectomy: Clinical experience and refinements. *Ann Surg* 230:392, 1999.
- Orringer MB, Marshall B, Chang AC, et al.: Two thousand transhiatal esophagectomies: changing trends, lessons learned. *Ann Surg* 246:363; discussion 372, 2007.
- Ott K, Herrmann K, Lordick F, et al.: Early metabolic response evaluation by fluorine-18 fluorodeoxyglucose positron emission tomography allows in vivo testing of chemosensitivity in gastric cancer: long-term results of a prospective study. *Clin Cancer Res* 14:2012, 2008.
- Pacifico RJ, Wang KK, Wongkeesong LM, et al.: Combined endoscopic mucosal resection and photodynamic therapy versus esophagectomy for management of early adenocarcinoma of the esophagus. *Clin Gastroenterol Hepatol* 1:252, 2003.
- Pera M, Cameron AJ, et al.: Increasing incidence of adenocarcinoma of the esophagus and esophagogastric junction. *Gastroenterology* 104:510, 1993.
- Pera M, Trastek VF, et al.: Barrett's esophagus with high-grade dysplasia: An indication for esophagectomy? *Ann Thorac Surg* 54:199, 1992.
- Pera M, Trastek VF, et al.: Influence of pancreatic and biliary reflux on the development of esophageal carcinoma. *Ann Thorac Surg* 55:1386, 1993.
- Peters JH, Clark GWB, et al.: Outcome of adenocarcinoma arising in Barrett's esophagus in endoscopically surveyed and non-surveyed patients. *J Thorac Cardiovasc Surg* 108:813, 1994.
- Peters JH, Hoefft SF, et al.: Selection of patients for curative or palliative resection of esophageal cancer based on preoperative endoscopic ultrasound. *Arch Surg* 129:534, 1994.
- Peters JH: Surgical treatment of esophageal adenocarcinoma: Concepts in evolution. *J Gastrointest Surg* 6:518, 2002.
- Rasanen JV, Sihvo EIT, Knuuti J, et al.: Prospective analysis of accuracy of proton emission tomography, computed tomography and endoscopic ultrasonography in staging of adenocarcinoma of the esophagus and esophagogastric junction. *Ann Surg Oncol* 10:954, 2003.
- Ravitch M: *A Century of Surgery*. Philadelphia: Lippincott, 1981, p 56.
- Reed CE: Comparison of different treatments for unresectable esophageal cancer. *World J Surg* 19:828, 1995.
- Reid BJ, Weinstein WM, et al.: Endoscopic biopsy can detect high-grade dysplasia or early adenocarcinoma in Barrett's esophagus without grossly recognizable neoplastic lesions. *Gastroenterology* 94:81, 1988.
- Ribeiro U Jr., Posner MC, et al.: Risk factors for squamous cell carcinoma of the oesophagus. *Br J Surg* 83:1174, 1996.
- Rice TW, Boyce GA, et al.: Esophageal ultrasound and the preoperative staging of carcinoma of the esophagus. *J Thorac Cardiovasc Surg* 101:536, 1991.
- Rice TW, Rusch VW, Ishwaran H, et al.: Cancer of the esophagus and esophagogastric junction: data driven staging for the seventh edition of the American Joint Committee on Cancer/International Union Against Cancer Cancer Staging Manuals. *Cancer* 115:3763, 2010.
- Robertson CS, Mayberry JF, Nicholson JA: Value of endoscopic surveillance in the detection of neoplastic changes in Barrett's esophagus. *Br J Surg* 75:760, 1988.
- Rösch T, Lorenz R, et al.: Endosonographic diagnosis of submucosal upper gastrointestinal tract tumors. *Scand J Gastroenterol* 27:1, 1992.
- Rosenberg JC, Budev H, et al.: Analysis of adenocarcinoma in Barrett's esophagus utilizing a staging system. *Cancer* 55:1353, 1985.
- Ruol A, Portale G, Castoro C, et al.: Effects of neoadjuvant therapy on perioperative morbidity in elderly patients undergoing esophagectomy for esophageal cancer. *Ann Surg Oncol* 14:3243, 2007.
- Skinner DB, Dowlatshahi KD, DeMeester TR: Potentially curable carcinoma of the esophagus. *Cancer* 50:2571, 1982.
- Skinner DB, Ferguson MK, Little AG: Selection of operation for esophageal cancer based on staging. *Ann Surg* 204:391, 1986.
- Smithers BM, Cullinan M, Thomas JM, et al.: Dis Esophagus 20:471, 2007.
- Sonnenberg A, Fennerty MB: Medical decision analysis of chemoprevention against esophageal adenocarcinoma. *Gastroenterology* 124:1758, 2003.
- Streitz JM Jr., Ellis FH Jr., et al.: Adenocarcinoma in Barrett's esophagus. *Ann Surg* 213:122, 1991.
- Turnbull AD, Rosen P, et al.: Primary malignant tumors of the esophagus other than typical epidermoid carcinoma. *Ann Thorac Surg* 15:463, 1973.
- Urschel JD, Ashiku S, Thurer R, et al.: Salvage or planned esophagectomy after chemoradiation for locally advanced esophageal cancer: A review. *Dis Esophagus* 16:60, 2003.
- Vigneswaran WT, Trastek VK, et al.: Extended esophagectomy in the management of carcinoma of the upper thoracic esophagus. *J Thorac Cardiovasc Surg* 107:901, 1994.
- Walsh TN, Noonan N, et al.: A comparison of multimodal therapy and surgery for esophageal adenocarcinoma. *N Engl J Med* 335:462, 1996.
- Watson WP, Pool L: Cancer of the cervical esophagus. *Surgery* 23:893, 1948.

Benign Tumors and Cysts

- Bardini R, Segalin A, et al.: Videothoroscopic enucleation of esophageal leiomyoma. *Am Thorac Surg* 54:576, 1992.
- Bonavina L, Segalin A, et al.: Surgical therapy of esophageal leiomyoma. *J Am Coll Surg* 181:257, 1995.

Esophageal Perforation

- Brewer LA III, Carter R, et al.: Options in the management of perforations of the esophagus. *Am J Surg* 152:62, 1986.
- Bufkin BL, Miller JJ Jr., Mansour KA: Esophageal perforation. Emphasis on management. *Ann Thorac Surg* 61:1447, 1996.
- Chang C-H, Lin PJ, et al.: One-stage operation for treatment after delayed diagnosis of thoracic esophageal perforation. *Ann Thorac Surg* 53:617, 1992.
- Engum SA, Grosfeld JL, et al.: Improved survival in children with esophageal perforation. *Arch Surg* 131:604, 1996.
- Gouge TH, Depan HJ, Spencer FC: Experience with the Grillo pleural wrap procedure in 18 patients with perforation of the thoracic esophagus. *Ann Surg* 209:612, 1989.
- Jones WG II, Ginsberg RJ: Esophageal perforation: A continuing challenge. *Ann Thorac Surg* 53:534, 1992.
- Pate JW, Walker WA, et al.: Spontaneous rupture of the esophagus: A 30-year experience. *Ann Thorac Surg* 47:689, 1989.
- Reeder LB, DeFilippi VJ, Ferguson MK: Current results of therapy for esophageal perforation. *Am J Surg* 169:615, 1995.
- Salo JA, Isolauro JO, et al.: Management of delayed esophageal perforation with mediastinal sepsis. *Esophagectomy or primary repair? J Thorac Cardiovasc Surg* 106:1088, 1993.
- Sawyer R, Phillips C, Vakil N: Short- and long-term outcome of esophageal perforation. *Gastrointest Endosc* 41:130, 1995.
- Segalin A, Bonavina L, et al.: Endoscopic management of inveterate esophageal perforations and leaks. *Surg Endosc* 10:928, 1996.
- Weiman DS, Walker WA, et al.: Noniatrogenic esophageal trauma. *Ann Thorac Surg* 59:845, 1995.
- Whyte RI, Iannettoni MD, Orringer MB: Intrathoracic esophageal perforation. The merit of primary repair. *J Thorac Cardiovasc Surg* 109:140, 1995.

Caustic Injury

- Anderson KD, Rouse TM, Randolph JG: A controlled trial of corticosteroids in children with corrosive injury of the esophagus. *N Engl J Med* 323:637, 1990.
- Ferguson MK, Migliore M, et al.: Early evaluation and therapy for caustic esophageal injury. *Am J Surg* 157:116, 1989.
- Lahoti D, Broor SL, et al.: Corrosive esophageal strictures. Predictors of response to endoscopic dilation. *Gastrointest Endosc* 41:196, 1995.
- Popovici Z: About reconstruction of the pharynx with colon in extensive corrosive strictures. *Kurume MedJ* 36:41, 1989.
- Sugawa C, Lucas CE: Caustic injury of the upper gastrointestinal tract in adults: A clinical and endoscopic study. *Surgery* 106:802, 1989.
- Wu M-H, Lai W-W: Surgical management of extensive corrosive injuries of the alimentary tract. *Surg Gynecol Obstet* 177:12, 1993.
- Zargar SA, Kochhar R, et al.: The role of fiberoptic endoscopy in the management of corrosive ingestion and modified endoscopic classification of burns. *Gastrointest Endosc* 37:165, 1991.

Techniques of Esophageal Reconstruction

- Akiyama H: Esophageal reconstruction. Entire stomach as esophageal substitute. *Dis Esophagus* 8:7, 1995.
- Banki F, Mason RJ, DeMeester SR, et al.: Vagal sparing esophagectomy: A more physiologic alternative. *Ann Surg* 236:324, 2002.
- Burt M, Scott A, et al.: Erythromycin stimulates gastric emptying after esophagectomy with gastric replacement. A randomized clinical trial. *J Thorac Cardiovasc Surg* 111:649, 1996.
- Cheng W, Heitmiller RF, Jones BJ: Subacute ischemia of the colon esophageal interposition. *Ann Thorac Surg* 57:899, 1994.
- DeMeester TR, Johansson KE, et al.: **Indications, surgical technique, and long-term functional results of colon interposition or bypass.** *Ann Surg* 208:460, 1988.
- DeMeester TR, Kauer WK: Esophageal reconstruction. The colon as an esophageal substitute. *Dis Esophagus* 8:20, 1995.
- Dexter SPL, Martin IG, McMahon MJ: Radical thoracoscopic esophagectomy for cancer. *Surg Endosc* 10:147, 1996.
- Ellis FH Jr., Gibb SP: Esophageal reconstruction for complex benign esophageal disease. *J Thorac Cardiovasc Surg* 99:192, 1990.
- Finley RJ, Lamy A, et al.: Gastrointestinal function following esophagectomy for malignancy. *Am J Surg* 169:471, 1995.
- Fok M, Cheng SW, Wong J: Pyloroplasty versus no drainage in gastric replacement of the esophagus. *Am J Surg* 162:447, 1991.
- Gossot D, Cattani P, Fritsch S: Can the morbidity of esophagectomy be reduced by the thoracoscopic approach? *Surg Endosc* 9:1113, 1995.
- Honkoop P, Siersema PD, et al.: Benign anastomotic strictures after transhiatal esophagectomy and cervical esophagogastronomy. Risk factors and management. *J Thorac Cardiovasc Surg* 111:1141, 1996.
- Liebermann-Meffert DMI, Meier R, Siewert JR: Vascular anatomy of the gastric tube used for esophageal reconstruction.** *Ann Thorac Surg* 54:1110, 1992.
- Maier G, Jehle EC, Becker HD: Functional outcome following oesophagectomy for oesophageal cancer. A prospective manometric study. *Dis Esophagus* 8:64, 1995.
- Naunheim KS, Hanosh J, et al.: Esophagectomy in the septuagenarian. *Ann Thorac Surg* 56:880, 1993.
- Nishihira T, Oe H, et al.: Esophageal reconstruction. Reconstruction of the thoracic esophagus with jejunal pedicled segments for cancer of the thoracic esophagus. *Dis Esophagus* 8:30, 1995.
- Peters JH, Kronson J, Bremner CG, et al.: Arterial anatomic considerations in colon interposition for esophageal replacement. *Arch Surg* 130:858, 1995.
- Stark SP, Romberg MS, et al.: Transhiatal versus transthoracic esophagectomy for adenocarcinoma of the distal esophagus and cardia. *Am J Surg* 172:478, 1996.
- Valverde A, Hay JM, Fingerhut A, et al.: Manual versus mechanical esophagogastric anastomosis after resection for carcinoma. A controlled trial. *French Associations for Surgical Research. Surgery* 120:476, 1996.
- Watson T, DeMeester TR, Kauer WK, et al.: Esophagectomy for end stage benign esophageal disease. *J Thorac Cardiovasc Surg* 115:1241, 1998.
- Wu M-H, Lai W-W: Esophageal reconstruction for esophageal strictures or resection after corrosive injury. *Ann Thorac Surg* 53:798, 1992.

This page intentionally left blank

26 chapter

Stomach

Yuko Kitagawa and Daniel T. Dempsey

Anatomy	1035	Surgical Treatment of Peptic Ulcer Disease / 1061	Isolated Gastric Varices / 1088
Anatomic Relationships and Gross Morphology / 1035		Bleeding Peptic Ulcer / 1064	Hypertrophic Gastropathy (Ménétrier's Disease) / 1088
Arterial and Venous Blood Supply / 1037		Operation for Bleeding Peptic Ulcer / 1065	Watermelon Stomach (Gastric Antral Vascular Ectasia) / 1088
Lymphatic Drainage / 1038		Perforated Peptic Ulcer / 1068	Dieulafoy's Lesion / 1089
Innervation / 1038		Obstructing Peptic Ulcer / 1068	Bezoars/Diverticula / 1089
Histology / 1039		Intractable or Nonhealing Peptic Ulcer / 1069	Foreign Bodies / 1089
Physiology	1041	Zollinger-Ellison Syndrome / 1071	Mallory-Weiss Syndrome / 1090
Acid Secretion / 1041		Gastritis and Stress Ulcer	1073
Pepsinogen Secretion / 1044		Pathogenesis and Prevention / 1073	Gastrostomy
Intrinsic Factor / 1044		Malignant Neoplasms of the Stomach	1074
Gastric Mucosal Barrier / 1044		Adenocarcinoma / 1074	Postgastrectomy Problems
Gastric Hormones / 1045		Gastric Lymphoma / 1084	1090
Gastric Motility and Emptying / 1047		Gastrointestinal Stromal Tumor / 1084	Dumping Syndrome / 1090
Diagnosis of Gastric Disease	1050	Gastric Carcinoid Tumors / 1085	Diarrhea / 1093
Signs and Symptoms / 1050		Benign Gastric Neoplasms	Gastric Stasis / 1093
Diagnostic Tests / 1050		1086	Bile Reflux Gastritis and Esophagitis / 1093
Peptic Ulcer Disease	1053	Leiomyoma / 1086	Roux Syndrome / 1094
Pathophysiology and Etiology / 1053		Lipoma / 1087	Gallstones / 1094
Clinical Manifestations / 1059		Gastric Motility Disorders / 1087	Weight Loss / 1094
Diagnosis / 1059		Massive Upper Gastrointestinal Bleeding / 1087	Anemia / 1094
Complications / 1059			Bone Disease / 1094
Medical Treatment of Peptic Ulcer Disease / 1061			Laparoscopic Gastric Operations
			1095

The stomach is a remarkable organ with important digestive, nutritional, and endocrine functions. The stomach stores and facilitates the digestion and absorption of ingested food, and it helps regulate appetite. Treatable diseases of the stomach are common, and it is accessible and relatively forgiving. Thus, the stomach is a favorite therapeutic target. To provide intelligent diagnosis and treatment, the physician and surgeon must understand gastric anatomy, physiology, and pathophysiology. This includes a sound understanding of the mechanical, secretory, and endocrine processes through which the stomach accomplishes its important functions; and a familiarity with the common benign and malignant gastric disorders of clinical significance. The surgeon must also understand the indications, complications, and outcomes of procedures utilized to treat diseases of the stomach. The purpose of this chapter is to enhance the reader's current understanding and familiarity with these concepts and topics. Some important milestones in the history of gastric surgery¹⁻⁶ are listed in Table 26-1.

ANATOMY

Anatomic Relationships and Gross Morphology

The stomach is readily recognizable as the asymmetrical, pear-shaped, most proximal abdominal organ of the digestive tract (Fig. 26-1).⁷ The part of the stomach attached to the esophagus is called the cardia. Just proximal to the cardia at the gastroesophageal (GE) junction is the anatomically indistinct but physiologically demonstrable lower esophageal sphincter. At the distal end, the readily apparent pyloric sphincter connects the stomach to the proximal duodenum. The stomach is relatively fixed at these points, but the large midportion is quite mobile with the shorter lesser curvature on the right and the longer greater curvature on the left.

The superior-most part of the stomach is the distensible fundus, bounded superiorly by the diaphragm and laterally by the spleen. The angle of His is where the fundus meets the left side of the GE junction. Generally, the inferior extent of the

Key Points

- 1▶ Any patient admitted to a hospital because of peptic ulcer disease should be considered for lifelong acid suppression.
- 2▶ Lifelong acid suppressive medication may be equivalent to surgical vagotomy in preventing recurrent peptic ulcer or ulcer complications.
- 3▶ Roux-en-Y gastrojejunostomy should be avoided unless more than half of the stomach has been removed. Otherwise marginal ulceration and/or gastric stasis (Roux syndrome) may become problematic.
- 4▶ Gastric resection for peptic ulcer should be avoided in the asthenic or high-risk patient, if possible.
- 5▶ Many patients with locally advanced gastric cancer (T2b, T3, T4) are cured by an oncologically sound operation that includes wide margins and adequate lymphadenectomy.
- 6▶ Most patients with primary gastric lymphoma can be treated without gastric resection.
- 7▶ Gastric carcinoids should usually be removed either endoscopically or surgically. The surgeon should treat gastric carcinoid without hypergastrinemia (type III) as if it were malignant.

Table 26-1

Historic milestones in gastric surgery

DATE	EVENT	DATE	EVENT
350 B.C. – 201 A.D.	Existence of gastric ulceration was acknowledged by Diocles of Carystos (350 B.C.), Celsus, and Galen (131–201 A.D.).	1886	Heineke performs pyloroplasty.
1363	Guy de Chauliac describes closure of gastric wound.	1888	Mikulicz performs similar operation.
1586	Marcellus Donatus of Mantua describes gastric ulcer at autopsy.	1892	Jaboulay describes bypassing the intact pylorus with gastroduodenostomy.
1600–1700	Reports of surgeons cutting stomach to remove foreign bodies.	1902	Finney from Baltimore describes pyloroplasty technique.
1688	Muralto describes duodenal ulcer at autopsy.	1891–1913	Different techniques of gastrotomy are described by Witzel (1891), Stamm (1894), and Janeway (1913).
1737	Morgagni describes both gastric and duodenal ulcer at autopsy.	1920–1950	Subtotal gastrectomy grows popular as an operation for peptic ulcer. Von Haberer and Finsterer proponents.
1833	William Beaumont reports data recorded during his care of Alexis St. Martin who developed a gastric fistula from a left upper quadrant musket wound.	1943	Dragstedt and Owen describe transthoracic truncal vagotomy to treat peptic ulcer disease. By the early 1950s, it is well recognized that some patients developed gastric stasis after this procedure, and transabdominal truncal vagotomy and drainage (pyloroplasty or gastrojejunostomy) become a standard ulcer operation.
1869	Maury reportedly performs feeding gastrotomy to palliate esophageal stricture following consultation with Samuel D. Gross.	1952	Farmer and Smithwick describe good results with truncal vagotomy and hemigastrectomy for peptic ulcer.
1875	Sidney Jones in London publishes the first successful gastrotomy for feeding.	1953	Edwards and Herrington (Nashville) describe truncal vagotomy and antrectomy for peptic ulcer.
1879	Paen performed distal gastrectomy and gastroduodenostomy. The patient died 5 d later.	1955	Zollinger and Ellison describe the eponymous syndrome.
1880	Rydygier resected a distal gastric cancer, and the patient died 12 h later.	1957	Griffith and Harkins (Seattle) describe parietal cell vagotomy (highly selective vagotomy) for the elective treatment of peptic ulcer disease.
1880	Billroth resects distal gastric cancer and performs gastroduodenostomy (Billroth I). Patient Therese Heller recovers and survives 4 mo.	1980–2000	Japanese surgeons and other surgical groups from East Asia demonstrate that more aggressive lymphadenectomy may improve survival in patients with gastric cancer.
1881	Anton Wolfler performs loop gastrojejunostomy to palliate an obstructing distal gastric cancer.	1990–current	Evolving role of laparoscopic techniques in the treatment of surgical gastric disease.
1884	Rydygier reports an unsuccessful gastrojejunostomy for benign gastric outlet obstruction.	1995–current	Dramatic increase in bariatric operations.
1885	Billroth performs a successful distal gastrectomy and gastrojejunostomy (Billroth II) for gastric cancer.	2000–current	Development of natural orifice transluminal endoscopic surgery.

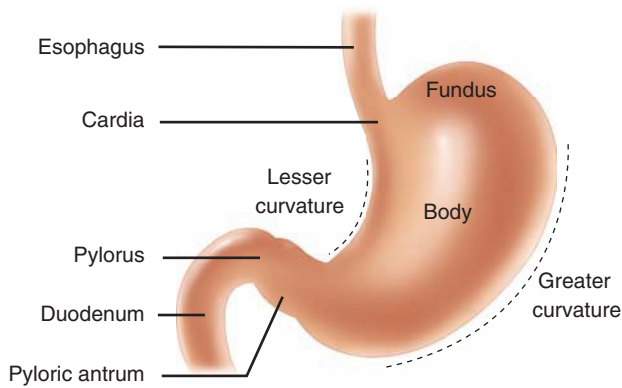


Figure 26-1. Anatomic regions of the stomach. [Reproduced with permission from Mercer DW, Liu TH, Castaneda A: *Anatomy and physiology of the stomach*, in Zuidema GD, Yeo CJ (eds): *Shackelford's Surgery of the Alimentary Tract*, 5th ed., Vol. II. Philadelphia: Saunders, 2002, p 3. Copyright Elsevier.]

fundus is considered to be the horizontal plane of the GE junction, where the body (corpus) of the stomach begins. The body of the stomach contains most of the parietal (oxyntic) cells, some of which are also present in the cardia and fundus. At the angularis, incisura the lesser curvature turns rather abruptly to the right, marking the anatomic beginning of the antrum, which comprises the distal 25% to 30% of the stomach.

The organs that commonly abut the stomach are the liver, colon, spleen, pancreas, and occasionally the kidney (Fig. 26-2). The left lateral segment of the liver usually covers a large part of the anterior stomach. Inferiorly, the stomach is attached to the transverse colon by the gastrocolic omentum. The lesser curvature is tethered to the liver by the hepatogastric ligament, also referred to as the lesser omentum or pars flaccida. Posterior to the stomach is the lesser omental bursa and the pancreas.

Arterial and Venous Blood Supply

The stomach is the most richly vascularized portion of the alimentary tube with ample blood flow and a dense intramural

vascular anastomotic network. The large majority of the gastric blood supply is from the celiac axis via four named arteries (Fig. 26-3). The left and right gastric arteries form an anastomotic arcade along the lesser curvature, and the right and left gastroepiploic arteries form an arcade along the greater gastric curvature. The consistently largest artery to the stomach is the left gastric artery, which usually arises directly from the celiac trunk and divides into an ascending and descending branch along the lesser gastric curvature. Approximately 20% of the time, the left gastric artery supplies an aberrant vessel that travels in the gastrohepatic ligament (lesser omentum) to the left side of the liver. Rarely, this is the only arterial blood supply to this part of the liver, and inadvertent ligation may lead to clinically significant hepatic ischemia in this unusual circumstance. The more common smaller aberrant left hepatic artery may be ligated without significant consequences.

The second largest artery to the stomach is the right gastroepiploic artery, which arises consistently from the gastroduodenal artery behind the first portion of the duodenum. The left gastroepiploic artery arises from the splenic artery, and, together with the right gastroepiploic artery, forms the rich gastroepiploic arcade along the greater curvature. The right gastric artery usually arises from the hepatic artery near the pylorus and hepatoduodenal ligament, and runs proximally along the distal stomach. In the fundus along the proximal greater curvature, the short gastric arteries and veins arise from the splenic circulation. There also may be additional vascular branches to the proximal stomach from the phrenic and splenic circulation.

The veins draining the stomach generally parallel the arteries. The left gastric (coronary vein) and right gastric veins usually drain into the portal vein, though occasionally the coronary vein drains into the splenic vein. The right gastroepiploic vein drains into the superior mesenteric vein near the inferior border of the pancreatic neck, and the left gastroepiploic vein drains into the splenic vein.

The richness of the gastric blood supply and the extensiveness of the anastomotic connections have some important clinical implications, such as: a) At least two of the four named gastric arteries may be occluded or ligated with impunity. This is

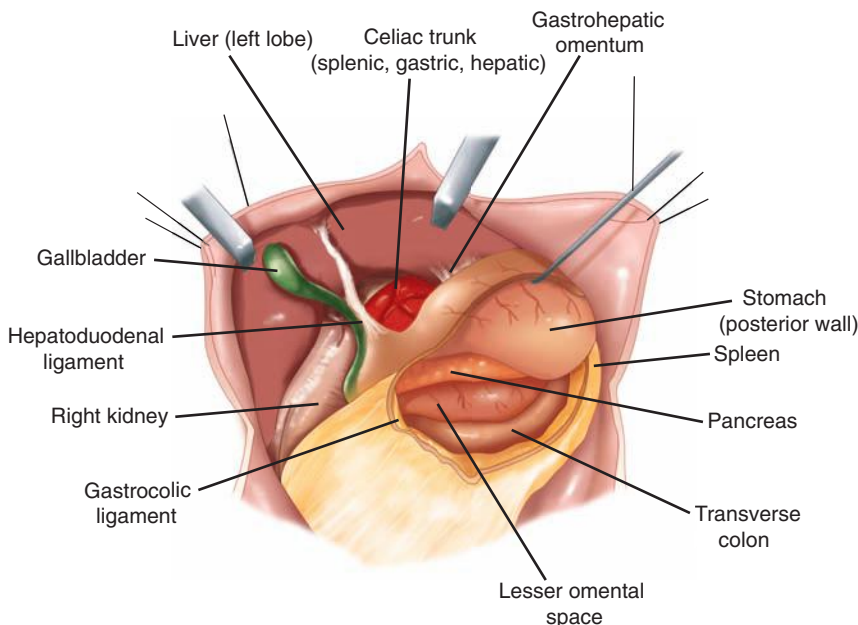


Figure 26-2. Anatomic relationships of the stomach. [Reproduced with permission from Mercer DW, Liu TH, Castaneda A: *Anatomy and physiology of the stomach*, in Zuidema GD, Yeo CJ (eds): *Shackelford's Surgery of the Alimentary Tract*, 5th ed., Vol. II. Philadelphia: Saunders, 2002, p 3. Copyright Elsevier.]

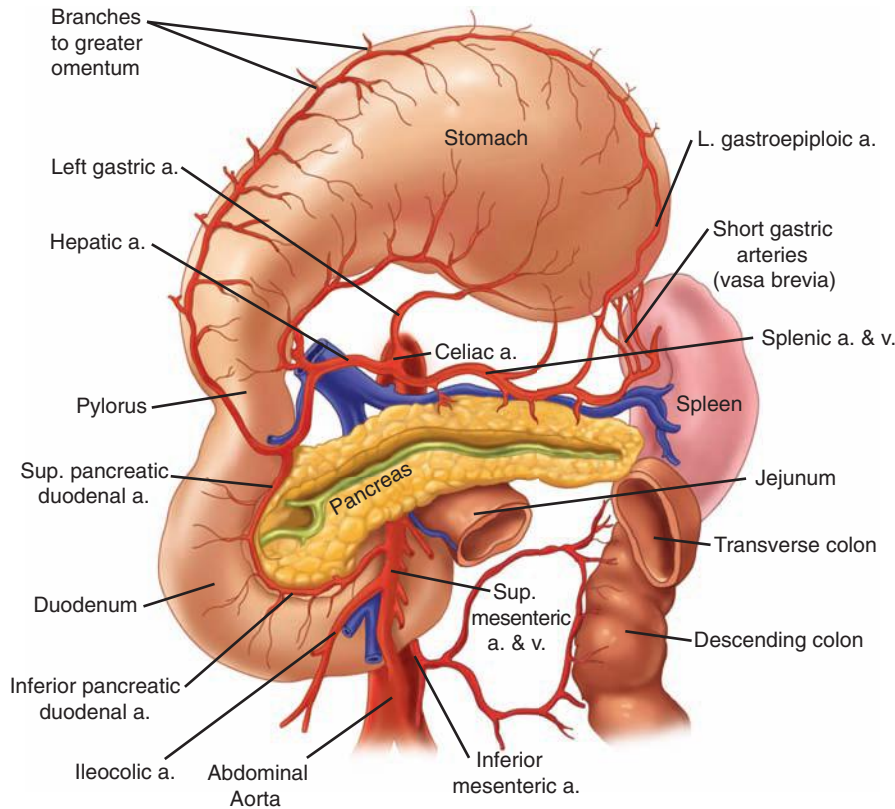


Figure 26-3. Arterial blood supply to the stomach. a. = artery; v. = vein. [Reproduced with permission from Mercer DW, Liu TH, Castaneda A: *Anatomy and physiology of the stomach*, in Zuidema GD, Yeo CJ (eds): *Shackelford's Surgery of the Alimentary Tract*, 5th ed., Vol. II. Philadelphia: Saunders, 2002, p 3. Copyright Elsevier.]

done routinely when the stomach is mobilized and pedicled on the right gastric and right gastroepiploic vessels to reach into the neck as an esophageal replacement (see Chapter 25) or during sleeve gastrectomy for weight loss when the gastroepiploic arcade is interrupted distally and resected (see Chapter 27), b) Following radical subtotal gastrectomy during which the right and left gastric arteries and both gastroepiploic arteries are all ligated, the gastric remnant is adequately supplied by short gastric arteries as long as the splenic artery is patent and intact; c) Angiographic control of gastric bleeding from deep ulcer or tumor often requires embolization of more than one feeding artery; d) Because of the rich venous interconnections in the stomach, a distal splenorenal shunt, which connects the distal end of the divided splenic vein to the side of the left renal vein, can effectively decompress esophagogastric varices in patients with portal hypertension.^{8,9}

Lymphatic Drainage

Generally speaking, the gastric lymphatics parallel the blood vessels (Fig. 26-4).¹⁰ The cardia and medial half of the corpus commonly drain to nodes along the left gastric and celiac axis. The lesser curvature side of the antrum usually drains to the right gastric and pyloric nodes, while the greater curvature half of the distal stomach drains to the nodes along the right gastroepiploic chain. The proximal greater curvature side of the stomach usually drains into nodes along the left gastroepiploic or splenic hilum. The nodes along both the greater and lesser curvature commonly drain into the celiac nodal basin. There is a rich anastomotic network of lymphatics that drain the stomach, often in a somewhat unpredictable fashion. Thus, a tumor arising in the distal stomach may give rise to positive lymph nodes in the splenic hilum. The rich intramural plexus of lymphatics and veins accounts for the fact that there can be microscopic

evidence of malignant cells in the gastric wall at a resection margin that is several centimeters away from palpable malignant tumor. It also helps explain the not infrequent finding of positive lymph nodes which may be many centimeters away from the primary tumor, with closer nodes that remain negative.

Extensive and meticulous lymphadenectomy is considered by many surgeons to be an important part of the operation for gastric cancer. Surgeons and pathologists have numbered the primary and secondary lymph node groups to which the stomach drains (see Fig. 26-4).^{11,12}

Innervation¹³

The vagus nerves provide the extrinsic parasympathetic innervation to the stomach, and acetylcholine is the most important neurotransmitter. From the vagal nucleus in the floor of the fourth cerebral ventricle, the vagus traverses the neck in the carotid sheath and enters the mediastinum, where it gives off the recurrent laryngeal nerve and divides into several branches around the esophagus. These branches come together again above the esophageal hiatus and form the *left (anterior)* and *right (posterior)* vagal trunks (mnemonic LARP). Near the GE junction the anterior vagus sends a branch (or branches) to the liver in the gastrohepatic ligament, and continues along the lesser curvature as the anterior nerve of Latarjet (Fig. 26-5). Similarly, the posterior vagus sends branches to the celiac plexus and continues along the posterior lesser curvature. The nerves of Latarjet send segmental branches to the body of the stomach before they terminate near the angularis incisura as the “crow’s foot,” sending branches to the antropyloric region. There may be additional branches to the distal stomach and pylorus that travel near the right gastric and/or gastroepiploic arteries. In 50% of patients, there are more than two vagal nerves at the esophageal hiatus. The branch that the posterior vagus sends to the posterior fundus

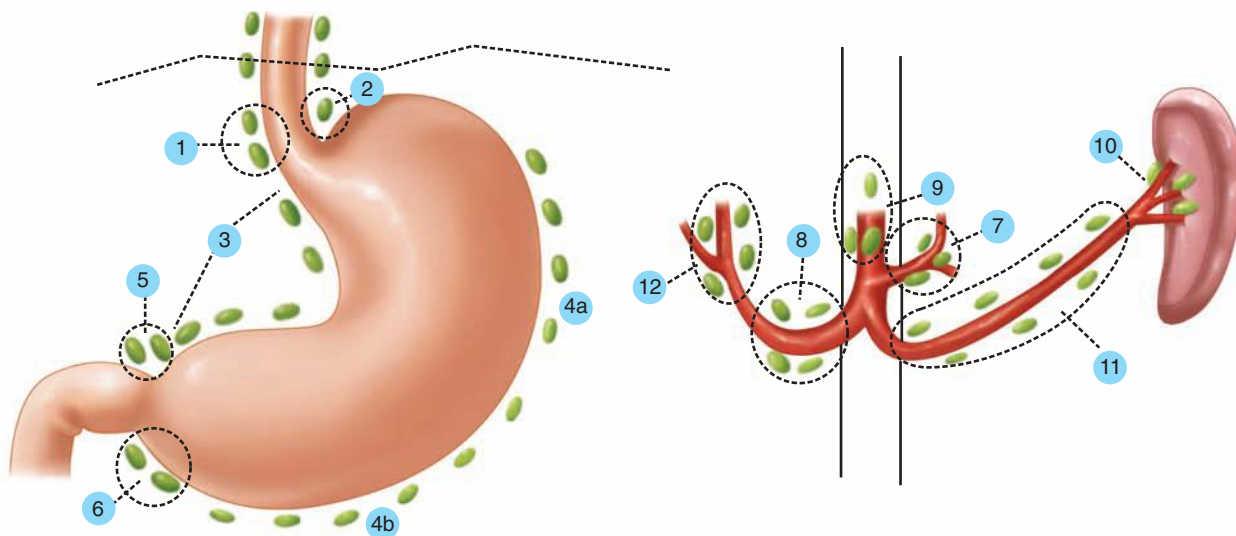


Figure 26-4. Lymph node stations draining the stomach according to the Japanese Research Society for Gastric Cancer. Stations 3 to 6 are commonly removed with D1 gastrectomy. Stations 1, 2, and 7 to 12 are commonly removed with D2 gastrectomy. [Reproduced with permission from Hermanek P, et al (eds): TNM Atlas: Illustrated Guide to the TNM/pTNM Classification of Malignant Tumours, 4th ed. Berlin: Springer-Verlag, 1997, p 82–83. Used with the permission of the International Union Against Cancer (UICC), Geneva, Switzerland.]

is termed the *criminal nerve of Grassi*. This branch typically arises above the esophageal hiatus and is easily missed during truncal or highly selective vagotomy (HSV). Vagal fibers originating in the brain synapse with neurons in Auerbach's myenteric plexus and Meissner's submucosal plexus. In the stomach the vagus nerves affect secretion (including acid), motor function, and mucosal bloodflow and cytoprotection. They also play a role in appetite control and perhaps even mucosal immunity and inflammation. Most of the axons contained in the vagal trunks are afferent (i.e., carrying stimuli from the viscera to the brain).

The extrinsic sympathetic nerve supply to the stomach originates at spinal levels T5 through T10 and travels in the

splanchnic nerves to the celiac ganglion. Postganglionic sympathetic nerves then travel from the celiac ganglion to the stomach along the blood vessels.

Neurons in the myenteric and submucosal plexuses constitute the intrinsic nervous system of the stomach. There may be more intrinsic gastric neurons than extrinsic neurons, but their function is poorly understood.

It is obviously an oversimplification (and incorrect) to think exclusively of the vagus as the cholinergic system and the sympathetic system as the adrenergic system of innervation. Although acetylcholine is an important neurotransmitter mediating vagal function, and epinephrine is important in the sympathetic nerves, both systems (as well as the intrinsic neurons) have various and diverse neurotransmitters, including cholinergic, adrenergic, and peptidergic (e.g., substance P and somatostatin).

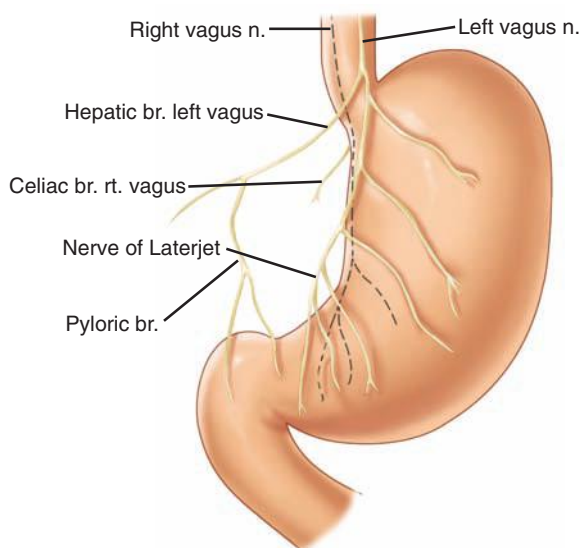


Figure 26-5. Vagal innervation of the stomach. br. = branch; n. = nerve; rt. = right. [Reproduced with permission from Anatomy and physiology of the stomach, in Menguy R: Surgery of Peptic Ulcer. Philadelphia: Saunders, 1976, p 8. Copyright Elsevier.]

Histology

There are four distinct layers of the gastric wall: mucosa, submucosa, muscularis propria, and serosa (Fig. 26-6).⁷ The inner layer of the stomach is the mucosa, which is lined with columnar epithelial cells of various types. Beneath the basement membrane of the epithelial cells is the lamina propria, which contains connective tissue, blood vessels, nerve fibers, and inflammatory cells. Beneath the lamina propria is a thin muscle layer called the *muscularis mucosa*, the deep boundary of the mucosal layer of the gut. The epithelium, lamina propria, and muscularis mucosa constitute the mucosa (Fig. 26-7).¹⁴ The epithelium of the gastric mucosa is columnar glandular. A scanning electron micrograph shows a smooth mucosal carpet punctuated by the openings of the gastric glands. The gastric glands are lined with different types of epithelial cells, depending upon their location in the stomach (Fig. 26-8, Table 26-2).^{15,16} There are also endocrine cells present in the gastric glands. Progenitor cells at the base of the glands differentiate and replenish sloughed cells on a regular basis. Throughout the stomach, the carpet consists primarily of mucus-secreting surface epithelial cells (SECs) that

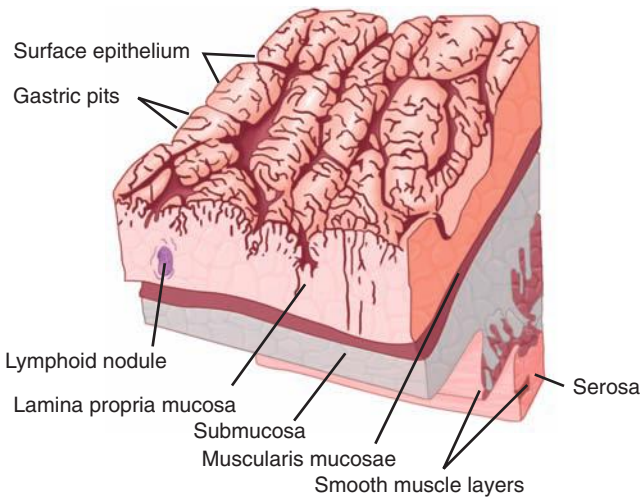


Figure 26-6. Layers of the gastric wall. [Reproduced with permission from *The esophagus and stomach*, in Fawcett DW: Bloom and Fawcett's Textbook of Histology, 11th ed. Philadelphia: Saunders, 1986, p 625. Copyright Elsevier.]

extend down into the gland pits for variable distances. These cells also secrete bicarbonate and play an important role in protecting the stomach from injury due to acid, pepsin, and/or ingested irritants. In fact, all epithelial cells of the stomach (except the endocrine cells) contain carbonic anhydrase and are capable of producing bicarbonate.

In the cardia, the gastric glands are branched and secrete primarily mucus and bicarbonate, but not much acid. In the fundus and body, the glands are more tubular and the pits are deep. Parietal and chief cells are common in these glands (Fig. 26-9). Histamine-secreting enterochromaffin-like (ECL) cells and somatostatin-secreting D cells are also found. Parietal cells secrete acid and intrinsic factor into the gastric lumen, and bicarbonate into the intercellular space. They have a characteristic ultrastructural appearance with secretory canaliculi (deep invaginations of the surface membrane), and cytoplasmic tubulovesicles containing the acid-producing apparatus H^+/K^+ -ATPase (proton pump) (see Fig. 26-9). There are numerous mitochondria; in fact the parietal cell is the most mitochondria rich cell in the body. When the parietal cell is stimulated,

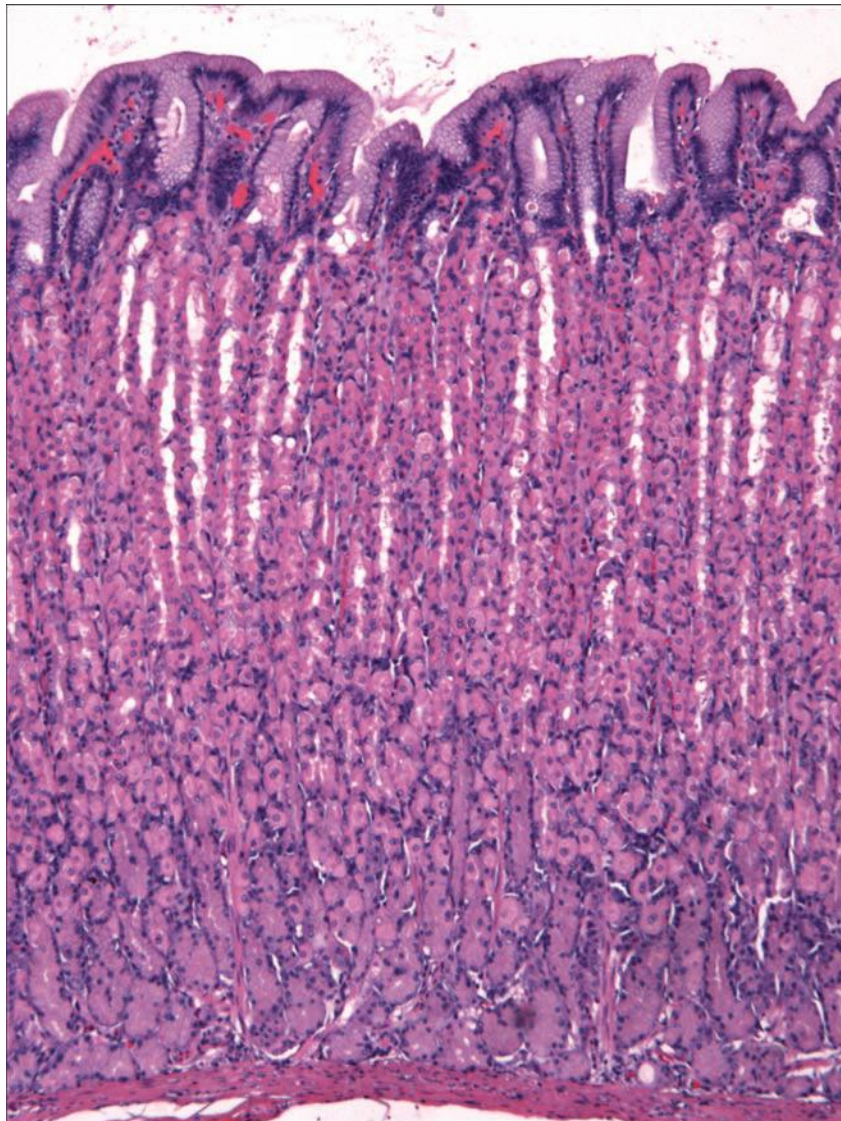


Figure 26-7. Gastric mucosa. (Reproduced with permission from Bloom W, Fawcett DW: A Textbook of Histology, 10th ed. Philadelphia: Saunders, 1975, p 639.)

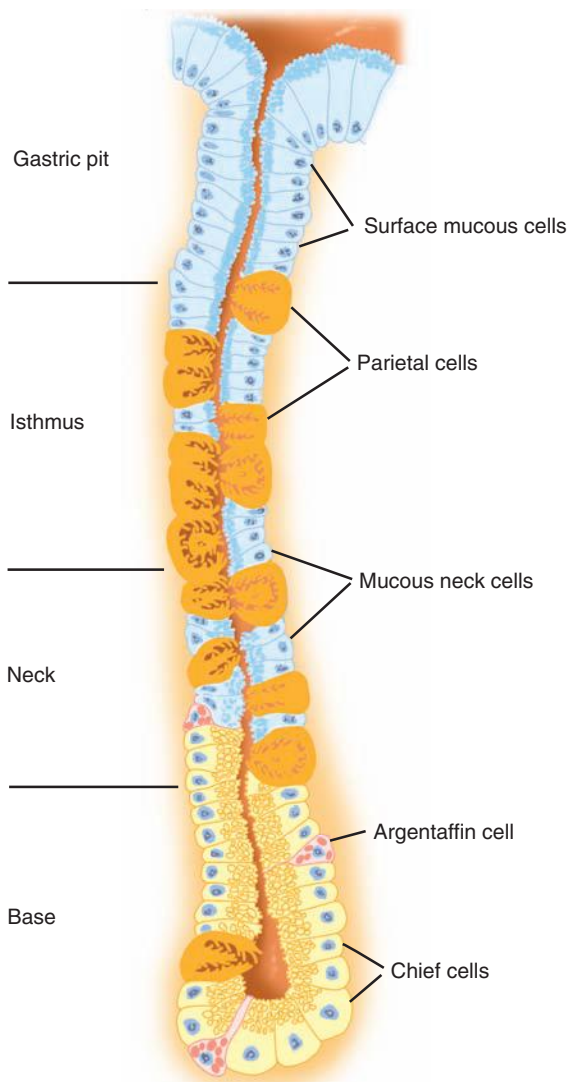


Figure 26-8. Mammalian gastric gland from the body of the stomach. [Reproduced with permission from Ito S, Winchester RJ: *The fine structure of the gastric mucosa in the bat*. *J Cell Biol* 16:541, 1963. Copyright © 1963 The Rockefeller University Press. doi: 10.1083/jcb.16.3.541.]

the cytoplasmic tubulovesicles fuse with the membrane of the secretory canaliculus; when acid production ceases, the process is reversed. Arguably, parietal cells produce the only truly essential substance made by the stomach (i.e., intrinsic factor). Parietal cells tend to occupy the midportion of the gastric glands found in the corpus of the stomach.

Chief cells (also called *zymogenic cells*) secrete pepsinogen I, which is maximally activated at a pH of 2.5. They tend to be clustered toward the base of the gastric glands and have a low columnar shape. Ultrastructurally, chief cells have the characteristics of protein-synthesizing cells: basal granular endoplasmic reticulum, supranuclear Golgi apparatus, and apical zymogen granules (Fig. 26-10). When stimulated, the chief cells produce two immunologically distinct proenzyme forms of pepsinogen: predominantly pepsinogen I and some pepsinogen II, most of which is produced by SECs. These proenzymes are activated in an acidic luminal environment.

In the antrum, the gastric glands are again more branched and shallow, parietal cells are rare, and gastrin-secreting G cells and somatostatin-secreting D cells are present. A variety of

hormone-secreting cells are present in various proportions throughout the gastric mucosa (Fig. 26-11).¹⁷ Histologic analysis suggests that in the normal stomach, 13% of the epithelial cells are oxyntic (parietal) cells, 44% are chief (zymogenic) cells, 40% are mucous cells, and 3% are endocrine cells. In general, the antrum produces gastrin but not acid, and the proximal stomach produces acid but not gastrin. The border between the corpus and antrum migrates proximally with age (especially on the lesser curvature side of the stomach).

Deep to the muscularis mucosa is the submucosa, which is rich in branching blood vessels, lymphatics, collagen, various inflammatory cells, and nerve fibers and ganglion cells of Meissner's autonomic submucosal plexus. The collagen-rich submucosa gives strength to GI anastomoses. The mucosa and submucosa are folded into the grossly visible gastric rugae, which tend to flatten out as the stomach becomes distended.

Below the submucosa is the thick muscularis propria (also referred to as the *muscularis externa*), which consists of an incomplete inner oblique layer, a complete middle circular layer (continuous with the esophageal circular muscle and the circular muscle of the pylorus), and a complete outer longitudinal layer (continuous with the longitudinal layer of the esophagus and duodenum). Within the muscularis propria is the rich network of autonomic ganglia and nerves that make up Auerbach's myenteric plexus. Specialized pacemaker cells, the interstitial cells of Cajal (ICC), also are present.

The outer layer of the stomach is the serosa, also known as the *visceral peritoneum*. This layer provides significant tensile strength to gastric anastomoses. When tumors originating in the mucosa penetrate and breach the serosa, microscopic or gross peritoneal metastases are common, presumably from shedding of tumor cells that would not have occurred if the serosa had not been penetrated. In this way, the serosa may be thought of as an outer envelope of the stomach.

PHYSIOLOGY

The stomach stores food and facilitates digestion through a variety of secretory and motor functions. Important secretory functions include the production of acid, pepsin, intrinsic factor, mucus, and a variety of GI hormones. Important motor functions include food storage (receptive relaxation and accommodation), grinding and mixing, controlled emptying of ingested food, and periodic interprandial “housekeeping.”

Acid Secretion

Hydrochloric acid in the stomach hastens both the physical and (with pepsin) the biochemical breakdown of ingested food. In an acidic environment, pepsin and acid facilitate proteolysis. Gastric acid also inhibits the proliferation of ingested pathogens, which protects against both infectious gastroenteritis and intestinal bacterial overgrowth. Long-term acid suppression with proton pump inhibitors (PPIs) has been associated with an increased risk of community acquired *Clostridium difficile* colitis and other gastroenteritis, presumably because of the absence of this protective germicidal barrier.^{18,19}

Parietal Cell. The parietal cell is stimulated to secrete acid (Fig. 26-12) when one or more of three membrane receptor types is stimulated by acetylcholine (from vagal nerve fibers), gastrin (from D cells), or histamine (from ECL cells).^{7,20,21} The enzyme H^+/K^+ -ATPase is the proton pump. It is stored within the intracellular tubulovesicles and is the final common pathway for gastric

Table 26-2

Epithelial cells of the stomach

CELL TYPE	DISTINCTIVE ULTRASTRUCTURAL FEATURES	MAJOR FUNCTIONS
Surface-foveolar mucous cells	Apical stippled granules up to 1 μm in diameter	Production of neutral glycoprotein and bicarbonate to form a gel on the gastric luminal surface; neutralization of hydrochloric acid ^a
Mucous neck cell	Heterogeneous granules 1–2 μm in diameter dispersed throughout the cytoplasm	Progenitor cell for all other gastric epithelial cells; glycoprotein production; production of pepsinogens I and II
Oxyntic (parietal) cell	Surface membrane invaginations (canaliculi); tubulovesicle structures; numerous mitochondria	Production of hydrochloric acid; production of intrinsic factor; production of bicarbonate
Chief cell	Moderately dense apical granules up to 2 μm in diameter; prominent supranuclear Golgi apparatus; extensive basolateral granular endoplasmic reticulum	Production of pepsinogens I and II, and of lipase
Cardiopyloric mucous cell	Mixture of granules like those in mucous neck and chief cells; extensive basolateral granular endoplasmic reticulum	Production of glycoprotein; production of pepsinogen II
Endocrine cells	See Figure 26-11	

^aBicarbonate is probably produced by other gastric epithelial cells in addition to surface-foveolar mucous cells.

Source: From Antonioli et al,¹⁶ with permission.

acid secretion. When the parietal cell is stimulated, there is a cytoskeletal rearrangement and fusion of the tubulovesicles with the apical membrane of the secretory canaliculus. The heterodimer assembly of the enzyme subunits into the microvilli of the secretory canaliculus results in acid secretion, with extracellular potassium being exchanged for cytosolic hydrogen. Although electro-neutral, this is an energy requiring process because the hydrogen is secreted against a gradient of at least 1 million-fold, which explains why the parietal cell is packed with energy producing mitochondria. During acid production, potassium and

chloride are also secreted into the apical secretory canaliculus through separate channels, providing potassium to exchange for H^+ via the H^+/K^+ -ATPase, and chloride to accompany the secreted hydrogen. At the basolateral membrane, the combined activity of various cotransporters and ion exchangers accomplishes intracellular pH regulation and electrolyte homeostasis.²⁰

The normal human stomach contains approximately 1 billion parietal cells, and total gastric acid production is proportional to parietal cell mass. The potent acid-suppressing PPI drugs irreversibly interfere with the function of the H^+/K^+ -ATPase molecule.

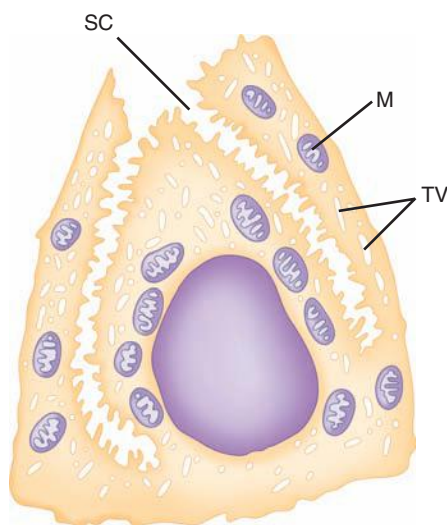


Figure 26-9. Ultrastructural features of the parietal (oxyntic) cell. SC = secretory canaliculus; M = mitochondria; TV = tubulovesicle. [Reproduced with permission from Antonioli DA, Madara JL: *Functional anatomy of the gastrointestinal tract*, in Ming S-C, Goldman H (eds): *Pathology of the Gastrointestinal Tract*, 2nd ed. Baltimore: Williams & Wilkins, 1998, p 13.]

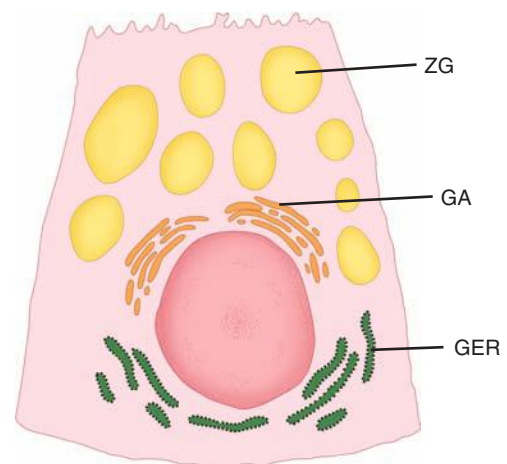


Figure 26-10. Ultrastructural features of the chief (zymogenic) cell. GA = Golgi apparatus; GER = granular endoplasmic reticulum; ZG = zymogen granule. [Reproduced with permission from Antonioli DA, Madara JL: *Functional anatomy of the gastrointestinal tract*, in Ming S-C, Goldman H (eds): *Pathology of the Gastrointestinal Tract*, 2nd ed. Baltimore: Williams & Wilkins, 1998, p 13.]

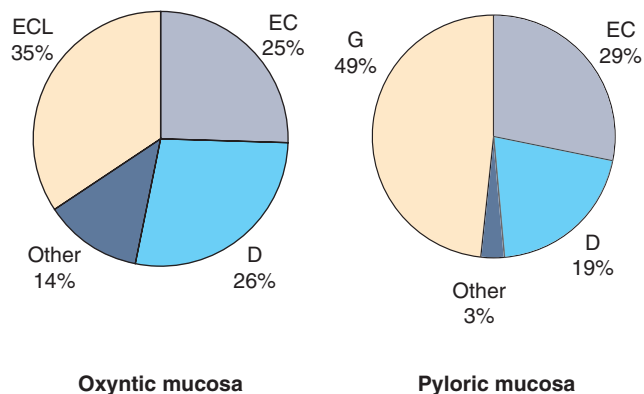


Figure 26-11. Endocrine cells of the stomach—proportion by site. D = d cell (somatostatin); EC = enterochromaffin cell; ECL = enterochromaffin-like cell (histamine); G = g cell (gastrin). [Reproduced with permission from Feldman M: Gastric secretion, in Feldman M, et al (eds): Sleisenger and Fordtran's Gastrointestinal and Liver Disease, 7th ed. Philadelphia: Saunders, 2002, p 715. Copyright Elsevier.]

These agents must be incorporated into the activated enzyme to be effective, and thus work best when taken before or during a meal (when the parietal cell is stimulated). When PPI therapy is stopped, acid secretory capability gradually returns (within days) as new H^+/K^+ -ATPase is synthesized.

Gastrin, acetylcholine, and histamine stimulate the parietal cell to secrete hydrochloric acid (see Fig. 26-12). Gastrin binds to type B cholecystokinin (CCK) receptors, and acetylcholine binds to M_3 muscarinic receptors. Both stimulate phospholipase C via a G-protein-linked mechanism leading to increased production of inositol trisphosphate from membrane bound phospholipids. Inositol trisphosphate stimulates the release of calcium from intracellular stores, which leads to activation of

protein kinases and activation of H^+/K^+ -ATPase. Histamine binds to the histamine 2 (H_2) receptor, which stimulates adenylate cyclase, also via a G-protein-linked mechanism. Activation of adenylate cyclase results in an increase in intracellular cyclic adenosine monophosphate which activates protein kinases, leading to increased levels of phosphoproteins and activation of the proton pump. Somatostatin from mucosal D cells binds to membrane receptors and inhibits the activation of adenylate cyclase through an inhibitory G protein.

Physiologic Acid Secretion. Food ingestion is the physiologic stimulus for acid secretion (Fig. 26-13). The acid secretory response that occurs after a meal is traditionally described in three phases: cephalic, gastric, and intestinal.^{22,23} The cephalic or vagal phase begins with the thought, sight, smell, and/or taste of food. These stimuli activate several cortical and hypothalamic sites (e.g., tractus solitarius, dorsal motor nucleus, and dorsal vagal complex), and signals are transmitted to the stomach by the vagal nerves. Acetylcholine is released, leading to stimulation of ECL cells and parietal cells. Although the acid secreted per unit of time in the cephalic phase is greater than in the other two phases, the cephalic phase is shorter. Thus, the cephalic phase accounts for no more than 30% of total acid secretion in response to a meal. Sham feeding (chewing and spitting) stimulates gastric acid secretion only via the cephalic phase, and results in acid secretion that is about half of that seen in response to IV pentagastrin or histamine.

When food reaches the stomach, the gastric phase of acid secretion begins. This phase lasts until the stomach is empty, and accounts for about 60% of the total acid secretion in response to a meal. The gastric phase of acid secretion has several components. Amino acids and small peptides directly stimulate antral G cells to secrete gastrin, which is carried in the bloodstream to the parietal cells and stimulates acid secretion in an endocrine fashion. In addition, proximal gastric distention

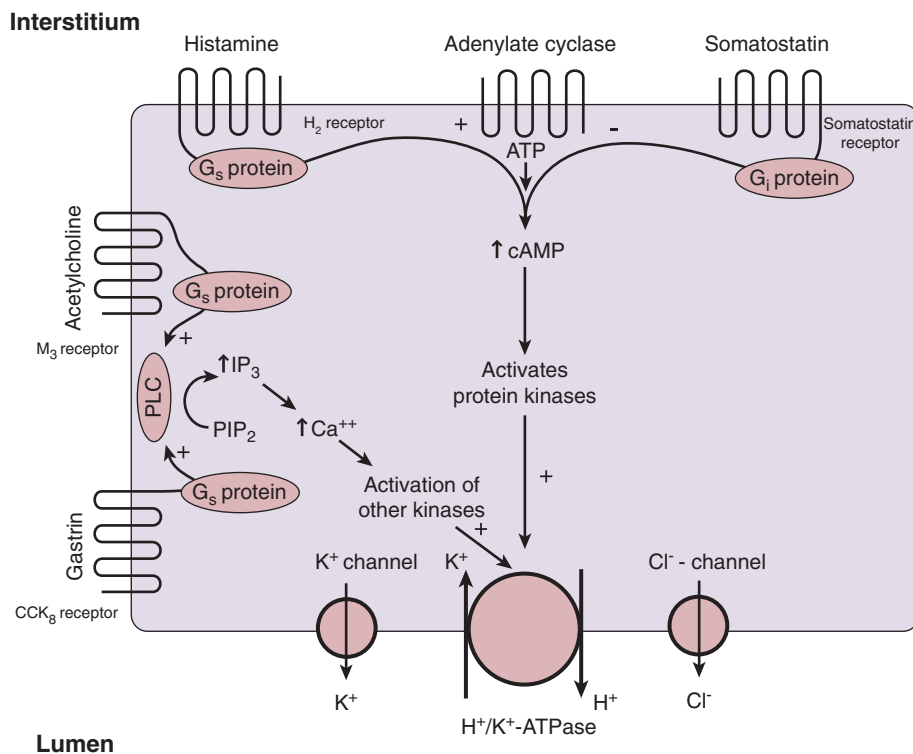


Figure 26-12. Control of acid secretion in the parietal cell. ATP = adenosine triphosphate; cAMP = cyclic adenosine monophosphate; CCK = cholecystokinin; H_2 = histamine 2; IP_3 = inositol trisphosphate; PIP_2 = phosphatidylinositol 4,5-bisphosphate; PLC = phospholipase C. [Reproduced with permission from Mercer DW, Liu TH, Castaneda A: Anatomy and physiology of the stomach, in Zuidema GD, Yeo CJ (eds): Shackelford's Surgery of the Alimentary Tract, 5th ed., Vol. II. Philadelphia: Saunders, 2002, p 3. Copyright Elsevier.]

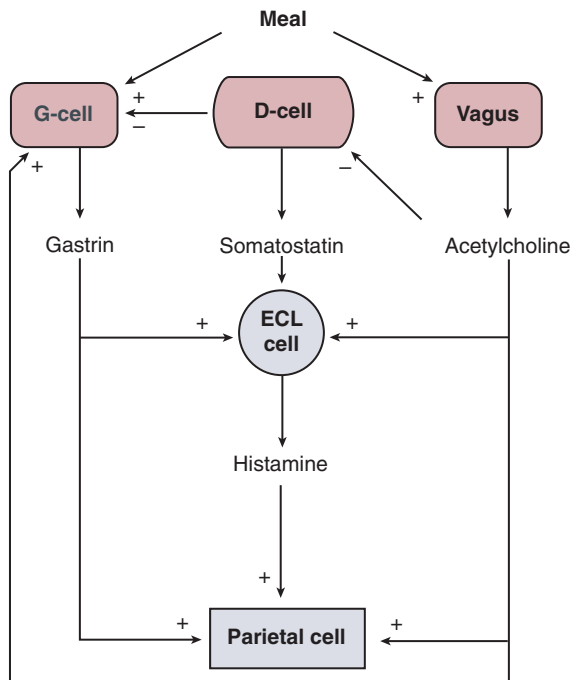


Figure 26-13. Physiologic control of acid secretion. ECL = enterochromaffin-like. [Reproduced with permission from Mercer DW, Liu TH, Castaneda A: *Anatomy and physiology of the stomach*, in Zuidema GD, Yeo CJ (eds): *Shackelford's Surgery of the Alimentary Tract*, 5th ed., Vol. II. Philadelphia: Saunders, 2002, p 3. Copyright Elsevier.]

stimulates acid secretion via a vagovagal reflex arc, which is abolished by truncal or HSV. Antral distention also stimulates antral gastrin secretion. Acetylcholine stimulates gastrin release and gastrin stimulates histamine release from ECL cells.

The intestinal phase of gastric secretion is poorly understood. It is thought to be mediated by a hormone released from the proximal small bowel mucosa in response to luminal chyme. This phase starts when gastric emptying of ingested food begins, and continues as long as nutrients remain in the proximal small intestine. It accounts for about 10% of meal-induced acid secretion.

Interprandial basal acid secretion is 2 to 5 mEq hydrochloric acid per hour, about 10% of maximal acid output (MAO), and it is greater at night. Basal acid secretion probably contributes to the relatively low bacterial counts found in the stomach. Basal acid secretion is reduced 75% to 90% by vagotomy or H_2 receptor blockade.

The pivotal role that ECL cells play in the regulation of gastric acid secretion is emphasized in Fig. 26-13. A large part of the acid stimulatory effects of both acetylcholine and gastrin are mediated by histamine released from mucosal ECL cells. H_2 receptor knockout mice do not secrete acid in response to gastrin.²⁰ This explains why the histamine 2 receptor antagonists (H_2 RAs) are such effective inhibitors of acid secretion, even though histamine is only one of three parietal cell stimulants. The mucosal D cell, which releases somatostatin, is also an important regulator of acid secretion. Somatostatin inhibits histamine release from ECL cells and gastrin release from antral G cells. The function of D cells is inhibited by *Helicobacter pylori* infection, and this leads to an exaggerated acid secretory response (see section *Helicobacter pylori* Infection).

Pepsinogen Secretion

The most potent physiologic stimulus for pepsinogen secretion from chief cells is food ingestion; acetylcholine is the most important mediator. Somatostatin inhibits pepsinogen secretion. Pepsinogen I is produced by chief cells in acid producing glands, whereas pepsinogen II is produced by SECs in both acid producing and gastrin producing (i.e., antral) glands. Pepsinogen is cleaved to the active pepsin enzyme in an acidic environment and is maximally active at pH 2.5, and inactive at pH >5, although pepsinogen II may be activated over a wider pH range than pepsinogen I. Pepsin catalyzes the hydrolysis of proteins and is denatured at alkaline pH.

Intrinsic Factor

Activated parietal cells secrete intrinsic factor in addition to hydrochloric acid. Presumably the stimulants are similar, but acid secretion and intrinsic factor secretion may not be linked. Intrinsic factor binds to luminal vitamin B_{12} , and the complex is absorbed in the terminal ileum via mucosal receptors. Vitamin B_{12} deficiency can be life threatening, and patients with total gastrectomy or pernicious anemia (i.e., patients with no parietal cells) require B_{12} supplementation by a nonenteric route. Some patients develop vitamin B_{12} deficiency following gastric bypass, presumably because there is insufficient intrinsic factor present in the small proximal gastric pouch and oral B_{12} intake may be decreased. Under normal conditions, a significant excess of intrinsic factor is secreted, and acid-suppressive medication does not appear to inhibit intrinsic factor production and release.

Gastric Mucosal Barrier

The stomach's durable resistance to autodigestion by caustic hydrochloric acid and active pepsin is intriguing. Some of the important elements of gastric barrier function and cytoprotection are listed in Table 26-3.^{24,25} When these defenses break down, ulceration occurs. A variety of factors are important in maintaining an intact gastric mucosal layer. The mucus and bicarbonate secreted by SECs form an unstirred mucous gel with a favorable pH gradient. Cell membranes and tight junctions prevent hydrogen

Table 26-3

Important components and mediators of mucosal defenses in the stomach

Components

- Mucous barrier
- Bicarbonate secretion
- Epithelial barrier
 - Hydrophobic phospholipids
 - Tight junctions
 - Restitution
- Microcirculation (reactive hyperemia)
- Afferent sensory neurons

Mediators

- Prostaglandins
- Nitric oxide
- Epidermal growth factor
- Calcitonin gene-related peptide
- Hepatocyte growth factor
- Histamine
- Gastrin-releasing peptide

ions from gaining access to the interstitial space. Hydrogen ions that do break through are buffered by the alkaline tide created by basolateral bicarbonate secretion from stimulated parietal cells. Any sloughed or denuded SECs are rapidly replaced by migration of adjacent cells, a process known as *restitution*. Mucosal blood flow plays a crucial role in maintaining a healthy mucosa, providing nutrients and oxygen for the cellular functions involved in cytoprotection. “Back-diffused” hydrogen is buffered and rapidly removed by the rich blood supply. When “barrier breakers” such as bile or aspirin lead to increased back-diffusion of hydrogen ions from the lumen into the lamina propria and submucosa, there is a protective increase in mucosal blood flow. If this protective response is blocked, gross ulceration can occur. Important mediators of these protective mechanisms include prostaglandins, nitric oxide, intrinsic nerves, and peptides (e.g., calcitonin gene-related peptide, gastrin-releasing peptide [GRP], gastrin, and heat shock proteins). Sucralfate acts locally to enhance mucosal defenses. Protective reflexes involve afferent sensory neurons, and can be blocked by the application of topical anesthetics to the gastric mucosa, or the experimental destruction of the afferent sensory nerves. In addition to these local defenses, there are important protective factors in saliva, duodenal secretions, and pancreatic or biliary secretions.

Gastric Hormones^{13,26}

Gastrin. Gastrin is produced by antral G cells and is the major hormonal stimulant of acid secretion during the gastric phase. A variety of molecular forms exist: big gastrin (34 amino acids; G₃₄), little gastrin (17 amino acids; G₁₇), and mini-gastrin (14 amino acids; G₁₄). The large majority of gastrin released by the human antrum is G₁₇. The biologically active pentapeptide sequence at the C-terminal end of gastrin is identical to that of CCK. Luminal peptides and amino acids are the most potent stimulants of gastrin release, and luminal acid is the most potent inhibitor of gastrin secretion. The latter effect is predominantly mediated in a paracrine fashion by somatostatin released from antral D cells. Gastrin-stimulated acid secretion is significantly blocked by H₂ antagonists, suggesting that the principal mediator of gastrin-stimulated acid production is histamine from mucosal ECL cells (see Fig. 26-13). In fact, chronic hypergastrinemia is associated with hyperplasia of gastric ECL cells and, rarely, gastric carcinoid. Gastrin is trophic to gastric parietal cells and to other GI mucosal cells. Important causes of hypergastrinemia include pernicious anemia, acid-suppressive medication, gastrinoma, retained antrum following distal gastrectomy and Billroth II surgery, and vagotomy.

Somatostatin. Somatostatin is produced by D cells located throughout the gastric mucosa. The predominant form in humans is somatostatin 14, though somatostatin 28 is present as well. The major stimulus for somatostatin release is antral acidification; acetylcholine from vagal nerve fibers inhibits its release. Somatostatin inhibits acid secretion from parietal cells and gastrin release from G cells. It also decreases histamine release from ECL cells. The proximity of the D cells to these target cells suggests that the primary effect of somatostatin is mediated in a paracrine fashion, but an endocrine (i.e., blood-stream) effect also is possible.

Gastrin-Releasing Peptide. GRP is the mammalian equivalent of bombesin, a hormone discovered more than two decades ago in an extract of skin from a frog. In the antrum, GRP stimulates both gastrin and somatostatin release by binding to receptors

on the G and D cells. There are nerve terminals ending near the mucosa in the gastric body and antrum, which are rich in GRP immunoreactivity. When GRP is given peripherally, it stimulates acid secretion, but when it is given centrally into the cerebral ventricles of animals, it inhibits acid secretion, apparently via a pathway involving the sympathetic nervous system. GRP is a mediator of gastroprotective increased mucosal blood flow in response to luminal irritants.

Leptin. Leptin is a protein primarily synthesized in adipocytes. It is also made by chief cells in the stomach, the main source of leptin in the GI tract.²⁶ Leptin works at least in part via vagally mediated pathways to decrease food intake in animals. Not surprisingly, leptin, a satiety signal hormone, and ghrelin, a hunger signal hormone, are both primarily synthesized in the stomach, an organ increasingly recognized as central to the mechanisms of appetite control.^{26,27}

Ghrelin. Ghrelin is a small peptide described in 1999 that is produced primarily in the stomach.²⁸ Ghrelin is a potent secretagogue of pituitary growth hormone (but not adrenocorticotrophic hormone, follicle-stimulating hormone, luteinizing hormone, prolactin, or thyroid-stimulating hormone). Ghrelin appears to be an orexigenic regulator of appetite (i.e., when ghrelin is elevated, appetite is stimulated, and when it is suppressed, appetite is suppressed). Resection of the primary source of this hormone (i.e., the stomach) may partly account for the anorexia and weight loss seen in some patients following gastric resection including sleeve gastrectomy (Fig. 26-14).²⁹ The gastric bypass operation, a very effective treatment for morbid obesity, has been shown by some investigators to be associated with suppression of plasma ghrelin levels (and appetite) in humans (Fig. 26-15A).^{30,31}

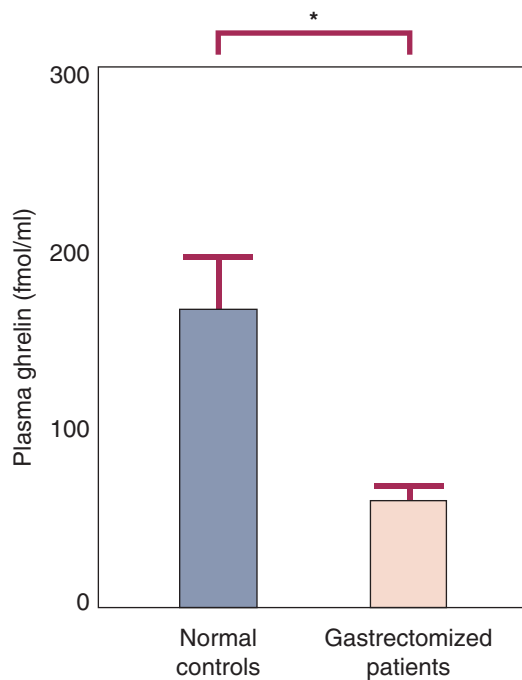


Figure 26-14. Ghrelin levels are decreased after gastrectomy. (Reproduced with permission from Ariyasu H, Takaya K, Tagami T, et al: *Stomach is a major source of circulating ghrelin, and feeding state determines plasma ghrelin-like immunoreactivity levels in humans.* J Clin Endocrinol Metab. 86:4753, 2001.)

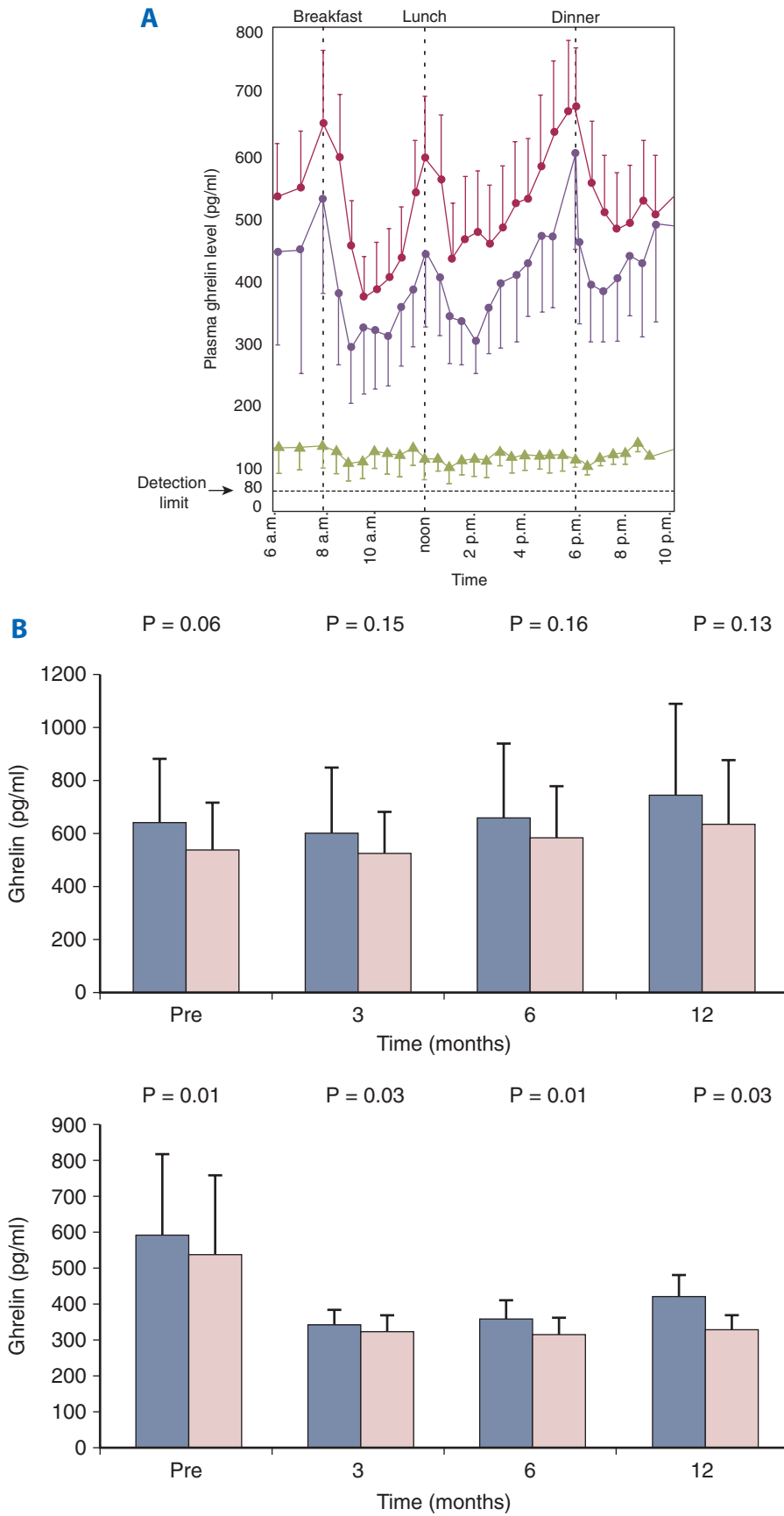


Figure 26-15. A and B. Ghrelin secretion after bariatric surgery. Some investigators have suggested that ghrelin secretion is dramatically decreased after gastric bypass. Other groups have shown statistically insignificant changes in ghrelin levels after gastric bypass, (RYGBP) but significant decreases after sleeve gastrectomy (SG). **A:** green = gastric bypass; blue = obese controls; red = normal weight controls; **B:** blue = fasting; pink = postprandial. **B. Top** = RYGBP; **B bottom** = SG. (Fig. 26-15A reproduced with permission from Cummings DE, et al: Plasma ghrelin levels after diet-induced weight loss or gastric bypass surgery. N Engl J Med 346:1623, 2002. Copyright ©2002 Massachusetts Medical Society. All rights reserved. Fig. 26-15B reproduced with permission from Karamanakos SN, et al: Weight loss, appetite suppression, and changes in fasting and postprandial ghrelin and peptide-YY levels after Roux-en-Y gastric bypass and sleeve gastrectomy: A prospective, double blind study. Ann Surg 247:401, 2008.)

Other groups have failed to show a significant decrease in ghrelin levels following gastric bypass but have found such decreases following sleeve gastrectomy, another effective weight loss operation (Fig. 26-15B).³¹ Possibly subtle differences in operative technique, patient selection, and/or experimental conditions account for the findings that multiple studies have reported disparate results on the effect of bariatric surgery on ghrelin levels in obese patients. Obviously appetite control is complex with redundant and overlapping orexigenic and anorexigenic pathways and signals.^{26,27}

Gastric Motility and Emptying

Gastric motor function has several purposes.^{13,32,33,34} Interprandial motor activity clears the stomach of undigested debris, sloughed cells, and mucus. When feeding begins, the stomach relaxes to accommodate the meal. Regulated motor activity then breaks down the food into small particles and controls the output into the duodenum. The stomach accomplishes these functions by coordinated smooth muscle relaxation and contraction of the various gastric segments (proximal, distal, and pyloric). Smooth muscle myoelectric potentials are translated into muscular activity, which is modulated by extrinsic and intrinsic innervation and hormones. The mechanisms by which gastric distention is translated into a neurohormonal satiety signal have only been partially elucidated.^{26,27}

Intrinsic Gastric Innervation. The extrinsic parasympathetic and sympathetic gastric innervation was discussed previously under Innervation. The intrinsic innervation consists of ganglia and nerves that constitute the enteric nervous system (Fig. 26-16).³⁵ There are a variety of neurotransmitters, which are generally grouped as excitatory (augment muscular activity) and inhibitory (decrease muscular activity). Important excitatory neurotransmitters include acetylcholine, the tachykinins, substance P, and neurokinin A. Important inhibitory neurotransmitters include nitric oxide (NO) and vasoactive intestinal peptide (VIP). Serotonin has been shown to modulate both contraction and relaxation. A variety of other molecules affect motility, including GRP, histamine, neuropeptide Y, norepinephrine, and endogenous opioids.

Specialized cells in the muscularis propria also are important modulators of GI motility. These cells, called *interstitial cells of Cajal*, are distinguishable histologically from neurons and myocytes, and appear to amplify both cholinergic excitatory and nitergic inhibitory input to the smooth muscle of the stomach and intestine.³⁶ They are thought to be the cell of origin for gastrointestinal stromal tumors (GISTs) which are the most common mesenchymal neoplasm in the GI tract.

Segmental Gastric Motility.^{13,36,37} In general, the proximal stomach serves a short-term food storage function and helps regulate basal intragastric tone, and the distal stomach mixes and grinds the food. The pylorus helps the latter process when closed, facilitating retropulsion of the solid food bolus back into the body of the stomach for additional breakdown. The pylorus opens intermittently to allow metered emptying of liquids and small solid particles into the duodenum.

Most of the motor activity of the proximal stomach consists of slow tonic contractions and relaxations, lasting up to 5 minutes. This activity is the main determinant of basal intragastric pressure, an important determinant of liquid emptying. Rapid phasic contractions may be superimposed on the slower tonic motor activity. When food is ingested, intragastric pressure falls as the proximal stomach relaxes. This proximal relaxation is mediated by two important vagovagal reflexes: receptive relaxation and gastric accommodation. Receptive relaxation refers to the reduction in proximal gastric tone associated with the act of swallowing. This occurs before the food reaches the stomach, and can be reproduced by mechanical stimulation of the pharynx or esophagus. Gastric accommodation refers to the proximal gastric relaxation associated with distention of the stomach. Accommodation is mediated through stretch receptors in the gastric wall and does not require esophageal or pharyngeal stimulation. Because both of these reflexes are mediated by afferent and efferent vagal fibers, they are significantly altered by truncal and highly selective vagotomy. Both these operations result in decreased gastric compliance, shifting the volume/pressure curve to the left. That is, interference with normal receptive relaxation and/or accommodation results in decreased gastric compliance, such that for any given amount of

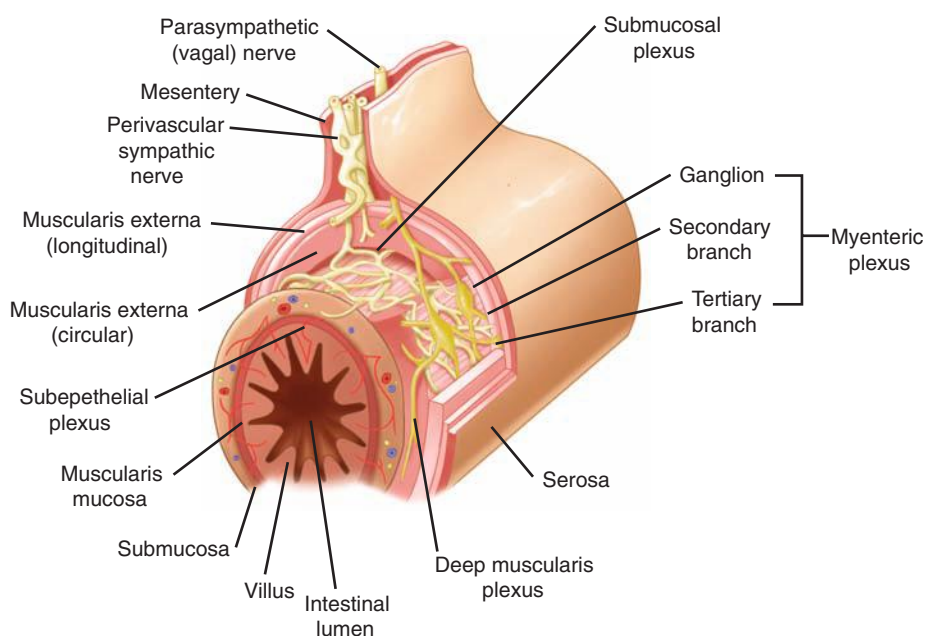


Figure 26-16. Enteric nervous system. [Reproduced with permission from Chial HJ, Camilleri M: *Motility disorders of the stomach and small intestine*, in Friedman SL, McQuaid KR, Grendell JH (eds): *Current Diagnosis and Treatment in Gastroenterology*, 2nd ed. New York: McGraw-Hill, 2003, p 355. Copyright © The McGraw-Hill Companies, Inc.]




Figure 26-17. The relationship between intracellular electrical activity and muscle cell contraction. Note that contractile activity is always associated with electrical activity, but the converse is not so. During mechanical quiescence, there are regular depolarizations that do not reach threshold. In the stimulated state, the threshold for contraction is reached, and motor activity is demonstrable. [Reproduced with permission from Kim CH: *Electrical activity of the stomach: clinical implications*. Mayo Clin Proc. 61:205, 1986.]

food or liquid ingested, the intragastric pressure is greater. This may increase the rate of liquid emptying, perhaps contributing to dumping symptoms after vagotomy.

NO and VIP are the principal mediators of proximal gastric relaxation. But a variety of other agents increase proximal gastric relaxation and compliance, including dopamine, gastrin, CCK, secretin, GRP, and glucagon. Proximal gastric tone also is decreased by duodenal distention, colonic distention, and ileal perfusion with glucose (ileal brake).

The distal stomach breaks up solid food and is the main determinant of gastric emptying of solids. Slow waves of myoelectric depolarization sweep down the distal stomach at a rate of about three per minute. These waves originate from the proximal gastric pacemaker, high on the greater curvature. The pacing cells may be interstitial cells of Cajal, which have been shown to have a similar function in the small intestine and colon. Most of these myoelectric waves are below the threshold for smooth muscle contraction in the quiescent state, and thus are associated with negligible changes in pressure. Neural and/or hormonal input, which increases the plateau phase of the action potential, can trigger muscle contraction, resulting in a peristaltic wave associated with the electrical slow wave, and of the same frequency (three per minute) (Fig. 26-17). It is possible

that implantable gastric pacemakers benefit some patients with gastroparesis by favorably impacting this myoelectric coupling.

During fasting, distal gastric motor activity is controlled by the migrating motor complex (MMC), the “gastrointestinal housekeeper” (Fig. 26-18). The purported function of the MMC is to sweep along any undigested food, debris, sloughed cells, and mucus after the fed phase of digestion is complete. The MMC lasts approximately 100 minutes (longer at night, shorter during daytime) and is divided into four phases. Phase I (about half the length of the entire cycle) is a period of relative motor inactivity. High-amplitude muscular contractions do not occur in phase I of the MMC. Phase II (about 25% of the entire MMC cycle) consists of some irregular, high-amplitude, generally nonpropulsive contractions. Phase III, a period of intense, regular, (about three per minute) propulsive contractions, only lasts about 5 to 10 minutes. Most phase III complexes of the GI MMC begin in the stomach, and the frequency approximates that of the myoelectric gastric slow wave. Phase IV is a transition period.

Neurohormonal control of the MMC is poorly understood, but it appears that different phases are regulated by different mechanisms. For example, vagotomy abolishes phase II of the gastric MMC but has little influence on phase III that persists

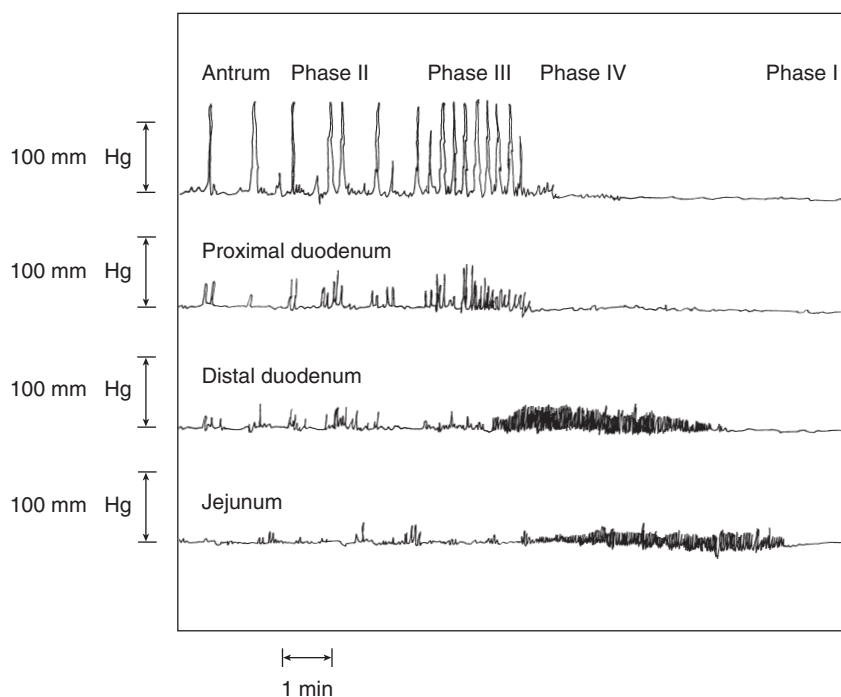


Figure 26-18. Migrating motor complex, the fasting pattern of GI activity. During phase III of the migrating motor complex, effective peristaltic waves progress from the stomach to the distal small intestine. [Reproduced with permission from Rees WDW, et al: *Human interdigestive and postprandial gastrointestinal motor and gastrointestinal hormone patterns*. Dig Dis Sci. 27(4):321, 1982. Copyright 1982, with kind permission of Springer Science + Business Media.]

even in the autotransplanted stomach, totally devoid of extrinsic neural input. This suggests that phase III is regulated by intrinsic nerves and/or hormones. Indeed, the initiation of phase III of the MMC in the distal stomach corresponds temporally to elevation in serum levels of motilin, a hormone produced in the duodenal mucosa. Resection of the duodenum abolishes distal gastric phase III in dogs, and resection of the duodenum in humans (e.g., with pancreaticoduodenectomy, the Whipple procedure) commonly results in early postoperative delayed gastric emptying. There are clearly motilin receptors on antral smooth muscle and nerves. Other modulators of gastric MMC activity include NO, endogenous opioids, intrinsic cholinergic and adrenergic nerves, and duodenal pH.

Feeding abolishes the MMC and leads to the fed motor pattern. The fed motor pattern of gastric activity starts within 10 minutes of food ingestion and persists until all the food has left the stomach. The neurohormonal initiator of this change is unknown, but CCK and the vagus appear to play some role: Sham feeding transiently induces antral motor activity resembling the fed motor pattern, and this is blocked by the CCK receptor antagonist loxiglumide. Gastric motility during the fed pattern resembles phase II of the MMC, with irregular but continuous phasic contractions of the distal stomach. During the fed state, about half of the myoelectric slow waves are associated with strong distal gastric contractions. Some are prograde and some are retrograde, serving to mix and grind the solid components of the meal. The magnitude of gastric contractions and the duration of the pattern are influenced by the consistency and composition of the meal.

The pylorus functions as an effective regulator of gastric emptying and an effective barrier to duodenogastric reflux. Bypass, transection, or resection of the pylorus may lead to uncontrolled gastric emptying of food and the dumping syndrome (see Postgastrectomy Problems). Pyloric dysfunction or disruption may also result in uncontrolled entry of duodenal contents into the stomach. Perfusion of the duodenum with lipids, glucose, amino acids, hypertonic saline, or hydrochloric acid results in closure of the pylorus and decreased transpyloric flow. Ileal perfusion with fat has the same effect. A variety of neurohumoral pathways are involved with these physiologic responses, and there is evidence that different pathways may be involved for different stimuli.

The pylorus is readily apparent grossly as a thick ring of muscle and connective tissue. The density of nerve tissue in the pyloric smooth muscle is several folds higher than in the antrum, with increased numbers of neurons staining positive for substance P, neuropeptide Y, VIP, and galanin. Interstitial cells of Cajal are more closely associated with pyloric myocytes, and the myoelectric slow wave of the pylorus has the same frequency as that seen in the distal stomach. The motor activity of the pylorus is both tonic and phasic. During phase III of the MMC, the pylorus is open as gastric contents are swept into the duodenum. During the fed phase, the pylorus is closed most of the time. It relaxes intermittently, usually in synchronization with lower-amplitude, minor antral contractions. The higher-amplitude, more major antral contractions are usually met with a closed pylorus, facilitating retropulsion and further grinding of food.

Modulation of pyloric motor activity is complex. There is evidence of both inhibitory and excitatory vagal pathways. Some contractile vagal effects are mediated by opioid pathways, because they are blocked by naloxone. Electrical stimulation of

the duodenum causes the pylorus to contract, whereas electrical stimulation of the antrum causes pyloric relaxation. Nitric oxide is an important mediator of pyloric relaxation. Other molecules that may play a physiologic role in controlling pyloric smooth muscle include serotonin, VIP, prostaglandin E₁, and galanin (pyloric relaxation); and histamine, CCK, and secretin (pyloric contraction).

Gastric Emptying.¹³ The control of gastric emptying is complex. In general, liquid emptying is faster than solid emptying. Osmolarity, acidity, caloric content, nutrient composition, and particle size are important modulators of gastric emptying. Stimulation of duodenal osmoreceptors, glucoreceptors, and pH receptors clearly inhibits gastric emptying by a variety of neurohumoral mechanisms. CCK has been consistently shown to inhibit gastric emptying at physiologic doses (Fig. 26-19). Recently, it has been noted that the anorexigenic hormone leptin, secreted by fat and gastric mucosa, inhibits gastric emptying, perhaps through the same pathway as CCK (which also has properties of a satiety hormone). The orexigenic hormone ghrelin has the opposite effect.

Liquid Emptying. The gastric emptying of water or isotonic saline follows first-order kinetics, with a half emptying time around 12 minutes. Thus, if one drinks 200 mL of water, about 100 mL enters the duodenum by 12 minutes, whereas if one drinks 400 mL of water, about 200 mL enters the duodenum by 12 minutes. This emptying pattern of liquids is modified considerably as the caloric density, osmolarity, and nutrient composition of the liquid changes (Fig. 26-20). Up to an osmolarity of about 1 M, liquid emptying occurs at a rate of about 200 kcal per hour. Duodenal osmoreceptors and hormones (e.g., secretin and VIP) are important modulators of liquid gastric emptying. Generally, liquid emptying is delayed in the supine position.

Traditionally, liquid emptying has been attributed to the activity of the proximal stomach, but it is probably more complicated than previously thought. Clearly, receptive relaxation and gastric accommodation play a role in gastric emptying of liquids. Patients with a denervated (e.g., vagotomized),

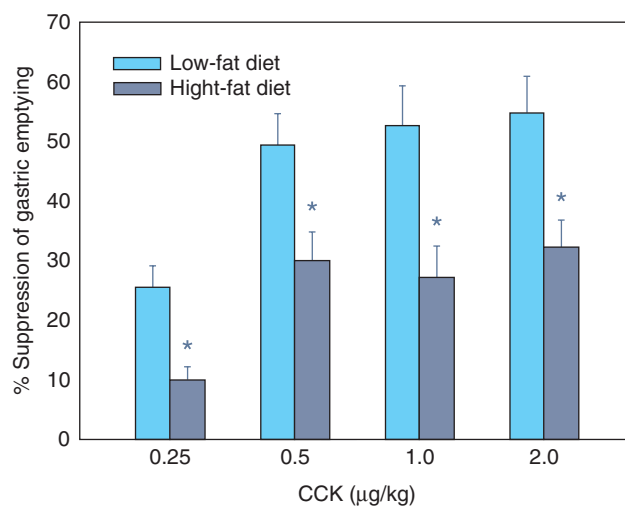


Figure 26-19. Cholecystokinin (CCK) inhibits gastric emptying. [Reproduced with permission from Covasa M, Ritter RC: *Adaptation to high-fat diet reduces inhibition of gastric emptying by CCK and intestinal oleate*. Am J Physiol Regulatory Integrative Comp Physiol 278:R166, 2000.]

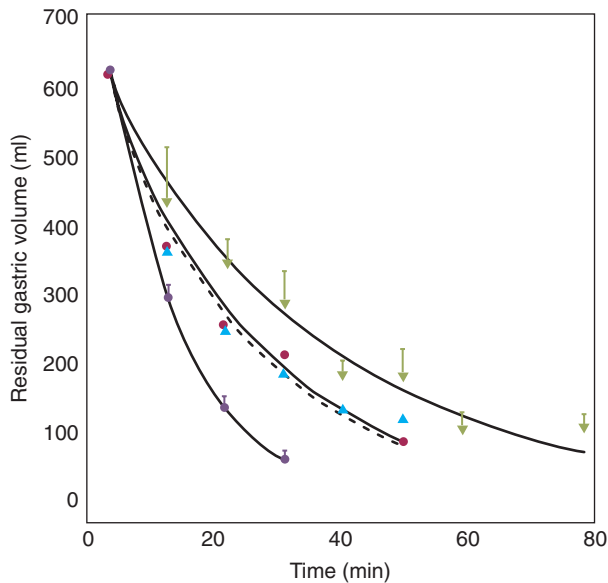


Figure 26-20. Nutrient composition and caloric density affect liquid gastric emptying. Glucose solution (purple circles), the least calorically dense, emptied the fastest. Other more calorically dense solutions, such as milk protein (green triangles) and peptide hydrolysates (red circles and blue triangles), emptied slower. [Reproduced with permission from Calbet JA, MacLean DA: Role of caloric content on gastric emptying in humans. *J Physiol.* 498:533, 1997.]

resected, or plicated (e.g., fundoplication) proximal stomach have decreased gastric compliance and may show accelerated gastric emptying of liquids.

Some observations suggest an active role for the distal stomach in liquid emptying. For instance even if the proximal intragastric pressure is lower than duodenal pressure, normal gastric emptying of liquids can occur. Also, diabetic patients may have normal proximal gastric motor function and profoundly delayed gastric emptying of liquids. Indeed, antral contractile activity does correlate with liquid gastric emptying, and this distal gastric activity appears to vary with the nutrient composition and caloric content of the liquid meal. Depending on the circumstances, distal gastric motor activity can promote or inhibit gastric emptying of liquids. Distal gastrectomy and pyloric stenting both obviously interfere with distal gastric motor activity, and both accelerate the initial rapid phase of liquid gastric emptying.

Solid Emptying. Normally, the half-time of solid gastric emptying is less than 2 hours. Unlike liquids, which display an initial rapid phase followed by a slower linear phase of emptying, solids have an initial lag phase during which little emptying of solids occurs. It is during this phase that much of the grinding and mixing occurs. A linear emptying phase follows, during which the smaller particles are metered out to the duodenum. Solid gastric emptying is a function of meal particle size, caloric content, and composition (especially fat). When liquids and solids are ingested together, the liquids empty first. Solids are stored in the fundus and delivered to the distal stomach at constant rates for grinding. Liquids also are sequestered in the fundus, but they appear to be readily delivered to the distal stomach for early emptying. The larger the solid component of the meal, the slower the liquid emptying. Patients bothered by

Table 26-4

Drugs that accelerate gastric emptying

AGENT	TYPICAL ADULT DOSE	MECHANISM OF ACTION
Metoclopramide	10 mg PO qid	Dopamine antagonist
Erythromycin	250 mg PO qid	Motilin agonist
Domperidone	10 mg PO qid	Dopamine antagonist

dumping syndrome are advised to limit the amount of liquid consumed with the solid meal, taking advantage of this effect. Three prokinetic agents are commonly used to treat delayed gastric emptying. Typical doses and mechanism of action are shown in Table 26-4.

DIAGNOSIS OF GASTRIC DISEASE

Signs and Symptoms

The most common symptoms of gastric disease are pain, weight loss, early satiety, and anorexia. Nausea, vomiting, bloating, and anemia also are frequent complaints. Several of these symptoms (pain, bloating, nausea, and early satiety) are often described by physicians as dyspepsia, synonymous with the common non-medical term *indigestion*. Common causes of dyspepsia include gastroesophageal reflux disease (GERD) and disorders of the stomach, gallbladder, and pancreas. Although none of the above symptoms alone is specific for gastric disease, when elicited in the context of a careful history and physical examination, they point to a differential diagnosis, which can be refined with certain tests.

Diagnostic Tests

Esophagogastroduodenoscopy. Patients with one or more of the alarm symptoms listed in Table 26-5 should undergo expeditious upper endoscopy. Esophagogastroduodenoscopy (EGD) is a safe and accurate outpatient procedure performed under conscious sedation.³⁸ Smaller flexible scopes with excellent optics and a working channel are easily passed transnasally in the unsedated patient. Following an 8-hour fast, the flexible scope is advanced under direct vision into the esophagus, stomach, and duodenum. The fundus and GE junction are inspected by retroflexing the scope. To rule out cancer with a high degree of accuracy, all patients with gastric ulcer diagnosed on upper GI series or found at EGD should have multiple biopsy specimens of the base and rim of the lesion. Brush cytology also should

Table 26-5

Alarm symptoms that indicate the need for upper endoscopy

Weight loss
Recurrent vomiting
Dysphagia
Bleeding
Anemia

be considered. Gastritis should be biopsied both for histologic examination and for a tissue urease test to rule out the presence of *H. pylori*. If *Helicobacter* infection is detected, it should probably be treated because of the etiologic association with peptic ulcers, mucosa-associated lymphoid tissue (MALT), and gastric cancer. The most serious complications of EGD are perforation (which is rare, but can occur anywhere from the cervical esophagus to the duodenum), aspiration, and respiratory depression from excessive sedation. Although EGD is a more sensitive test than double-contrast upper GI series, these modalities should be considered complementary rather than mutually exclusive.

Radiologic Tests. Plain abdominal X-rays may be helpful in the diagnosis of gastric perforation (pneumoperitoneum) or delayed gastric emptying (large air-fluid level).

Double-contrast upper GI series may be better than EGD at elucidating gastric diverticula, fistula, tortuosity, stricture location, and size of hiatal hernia. Although there are radiologic characteristics of ulcers that suggest the presence or absence of malignancy, gastric ulcers always require adequate biopsy.

Computed Tomographic Scanning and Magnetic Resonance Imaging. Usually, significant gastric disease can be diagnosed without these sophisticated imaging studies. However, one or the other should be part of the routine staging work-up for most patients with a malignant gastric tumor. Magnetic resonance imaging (MRI) may prove clinically useful as a quantitative test for gastric emptying, and may even hold some promise for the analysis of myoelectric derangements in patients with gastroparesis. Virtual gastroscopy using multi detector CT scan or MRI is not yet widely used but these techniques may prove useful for screening and staging of gastric disease.³⁹⁻⁴¹ (Fig. 26-21).

Arteriography may be helpful in the occasional poor-risk patient with exsanguinating gastric hemorrhage, or in the patient with occult gastric bleeding.

Endoscopic Ultrasound. Endoscopic ultrasound (EUS) is useful in the evaluation and management of some gastric lesions.⁴²⁻⁴⁴ Local staging of gastric adenocarcinoma with EUS is quite accurate, and this modality can be used to plan therapy. At some centers, patients with transmural and/or node positive adenocarcinoma of the stomach are considered for preoperative (neoadjuvant) chemoradiation therapy. EUS is the best way to clinically stage these patients locoregionally. Suspicious nodes can be sampled with EUS-guided endoscopic needle biopsy. Malignant tumors that are confined to the mucosa on EUS may be amenable to endoscopic mucosal resection (EMR). EUS also can be used to assess tumor response to chemotherapy. Submucosal masses are commonly discovered during routine EGD. Large submucosal masses should be resected because of the risk of malignancy, but observation may be appropriate for some small submucosal masses (e.g., lipoma or small GIST). There are endoscopic characteristics of benign and malignant mesenchymal tumors, and thus, EUS can provide reassurance, but no guarantee, that small lesions under observation are probably benign. Submucosal varices also can be assessed by EUS.

Gastric Secretory Analysis. Analysis of gastric acid output requires gastric intubation, and it is performed infrequently nowadays. This test may be useful in the evaluation of patients with hypergastrinemia, including the Zollinger-Ellison syndrome (ZES), patients with refractory ulcer or GERD, and patients with recurrent ulcer after operation. Historically, gastric

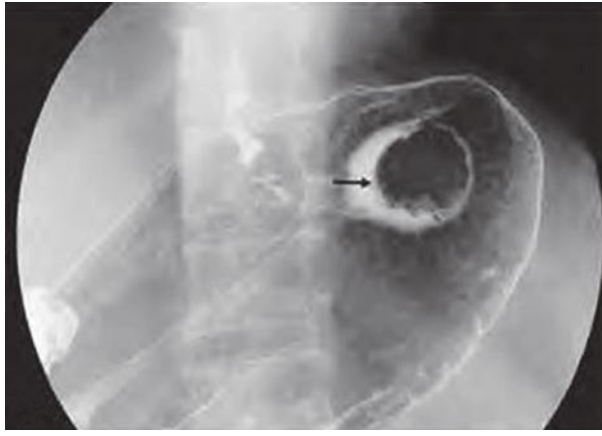analysis was performed most commonly to test for the adequacy of vagotomy in postoperative patients with recurrent or persistent ulcer. Now this can be done by assessing peripheral pancreatic polypeptide levels in response to sham feeding.⁴⁵ A 50% increase in pancreatic polypeptide within 30 minutes of sham feeding suggests vagal integrity.

Normal basal acid output (BAO) is greater than 5 mEq/h. MAO is the average of the two final stimulated 15-minute periods and is usually 10 to 15 mEq/h. Peak acid output is defined as the highest of the four stimulated periods. Patients with a gastrinoma commonly have a high BAO, often above 30 mEq/h, but consistently above 15 mEq/h unless there has been previous vagotomy or gastric resection. In patients with gastrinoma, the ratio of BAO to MAO exceeds 0.6. Normal acid output in the patient prescribed acid-suppressive medication usually means that the patient is noncompliant. To assess acid-secretory capacity in the absence of medication effect, H₂ blockers and PPIs should be withheld before gastric analysis.

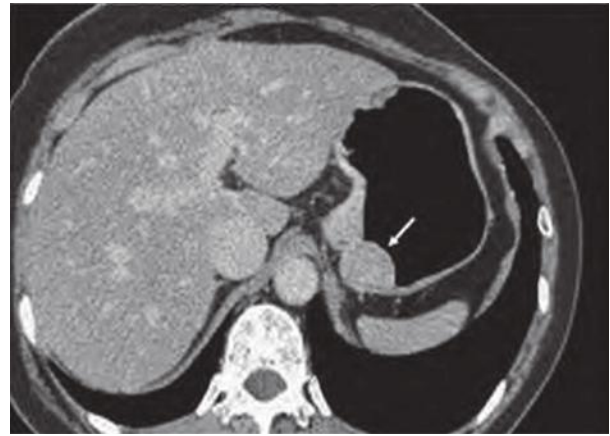
Scintigraphy. The standard scintigraphic evaluation of gastric emptying involves the ingestion of a test meal with one or two isotopes, and scanning the patient under a gamma camera. A curve for liquid and solid emptying is plotted, and the half-time calculated. Normal standards exist for each facility. Duodenogastric reflux can be quantitated by the IV administration of hepatobiliary iminodiacetic acid (HIDA scan), which is concentrated and excreted by the liver into the duodenum. Software allows a semiquantitative assessment of how much of the isotope refluxes into the stomach. Positron emission tomography (PET) scan or CT/PET scan may be useful in staging certain patients with gastric malignancy.

Tests for *Helicobacter pylori*. A variety of tests can help the clinician to determine whether the patient has active *H. pylori* infection.⁴⁶ The predictive value (positive and negative) of any of these tests when used as a screening tool depends on the prevalence of *H. pylori* infection in the screened population. A positive test is quite accurate in predicting *H. pylori* infection, but a negative test is characteristically unreliable. Thus, in the appropriate clinical setting, treatment for *H. pylori* should be initiated on the basis of a positive test, but not necessarily withheld if the test is negative. Because of the association between *H. pylori* infection and gastric lymphoma and carcinoma, many clinicians recommend treating *Helicobacter* infection when the diagnosis is made.

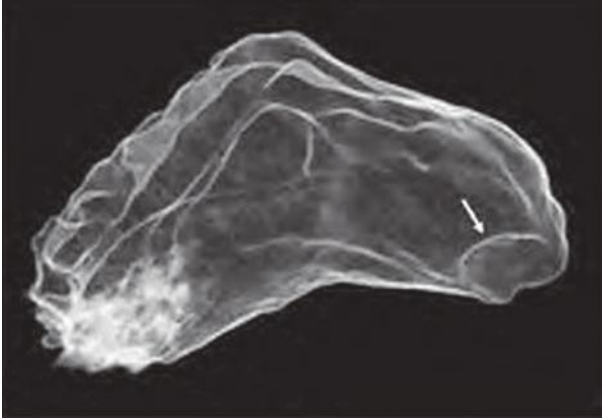A positive serologic test is presumptive evidence of active infection if the patient has never been treated for *H. pylori*. Histologic examination of an antral mucosal biopsy using special stains is the gold standard test. Other sensitive tests include commercially available rapid urease tests, which assay for the presence of urease in mucosal biopsy specimens (strong presumptive evidence of infection). Urease is an omnipresent enzyme in *H. pylori* strains that colonize the gastric mucosa. The labeled carbon-13 urea breath test has become the standard test to confirm eradication of *H. pylori* following appropriate treatment.⁴⁷ In this test, the patient ingests urea labeled with nonradioactive ¹³C. The labeled urea is acted upon by the urease present in the *H. pylori* and converted into ammonia and carbon dioxide. The radiolabeled carbon dioxide is excreted from the lungs and can be detected in the expired air (Fig. 26-22). It also can be detected in a blood sample. The fecal antigen test also is quite sensitive and specific for active *H. pylori* infection and may prove more practical in confirming a cure.



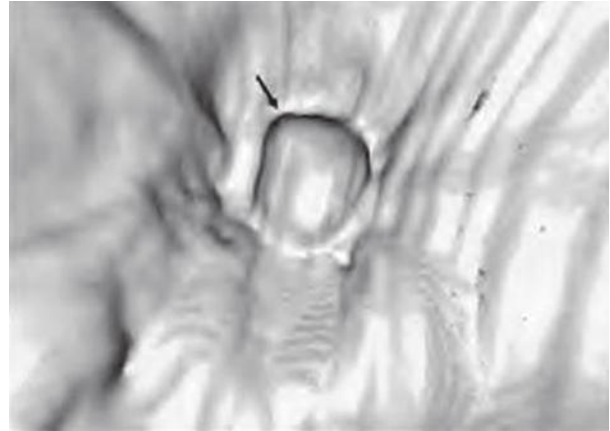
A



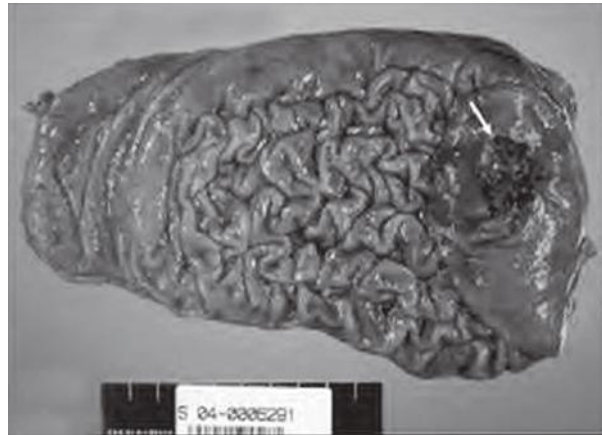B



C



D



E

Figure 26-21. Conventional double-contrast barium study (A) shows a focal protruding mass (*arrow*) on the gastric fundus. Axial computed tomographic scan (B) also shows a protruding polyp (*arrow*). The three dimensional computed tomographic gastrographic images in the transparent (C) and virtual endoscopic (D) modes show an elevated lesion on the gastric fundus (*arrows*). Photograph of the total gastrectomy specimen (E) shows a well-demarcated polypoid mass (*arrow*); this lesion was confirmed as early gastric carcinoma type I on microscopic examination (not shown). (Reproduced with permission from Shin KS, et al: *Three-dimensional MDCT gastrography compared with axial CT for the detection of early gastric cancer*. J Comput Assist Tomogr 31:741, 2007.)

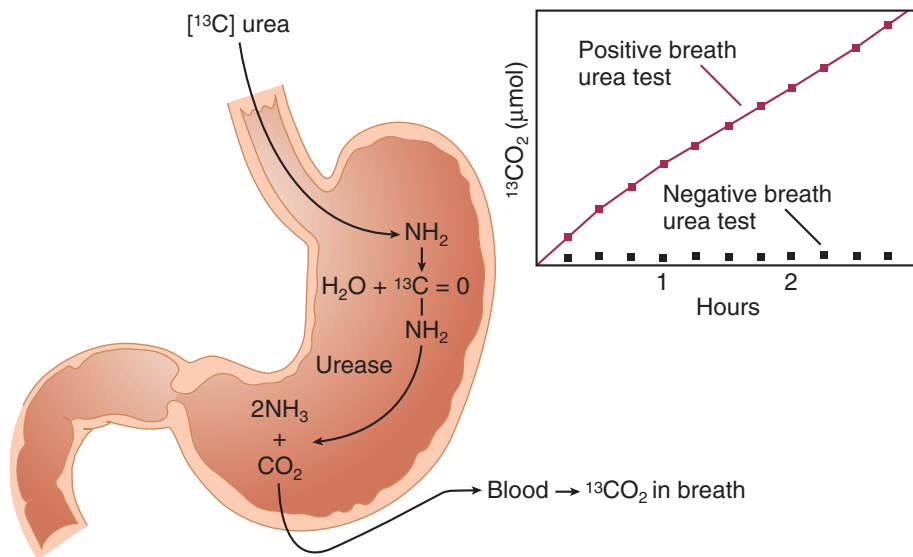


Figure 26-22. Labeled urea breath test to detect *Helicobacter* infection. (Reproduced with permission from Walsh JH, Peterson WL: *The treatment of Helicobacter pylori infection in the management of peptic ulcer disease*. N Engl J Med 333:984, 1995. Copyright ©1995 Massachusetts Medical Society. All rights reserved.)

Antroduodenal Motility Testing and Electrogastrography.

Antroduodenal motility testing and electrogastronomy (EGG) are performed in specialized centers and may be useful in the evaluation of the patient with anomalous epigastric symptoms. EGG consists of the transcutaneous recording of gastric myoelectric activity. Antroduodenal motility testing is done with a tube placed transnasally or transorally into the distal duodenum. There are pressure-recording sensors extending from the stomach to the distal duodenum. The combination of these two tests together with scintigraphy provides a thorough assessment of gastric motility.

PEPTIC ULCER DISEASE

Peptic ulcers are focal defects in the gastric or duodenal mucosa that extend into the submucosa or deeper. They may be acute or chronic and, ultimately, are caused by an imbalance between mucosal defenses and acid/peptic injury (Fig. 26-23).^{48,49} Peptic ulcer remains a common outpatient diagnosis, but the number of physician visits, hospital admissions, and elective operations for PUD has decreased steadily and dramatically over the past three decades. Interestingly, the start of these trends all predated the use of H_2 receptor blockers, or proton pump inhibitors, fiberoptic endoscopy, and highly selective vagotomy. However, the incidence of emergency surgery and the death rate associated with peptic ulcers has not decreased nearly so dramatically.

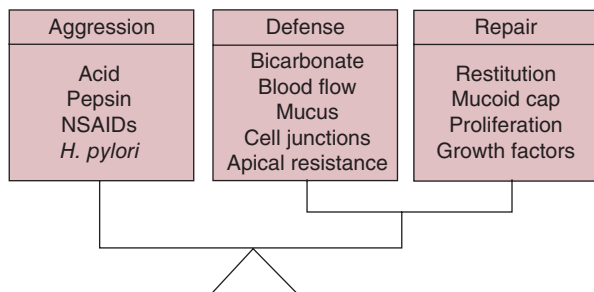


Figure 26-23. Balance of aggressive and defensive factors in the gastric mucosa. (Reproduced with permission from Mertz HR, Walsh JH: *Peptic ulcer pathophysiology*. Med Clin North Am 75:799, 1991. Copyright Elsevier.)

These epidemiologic changes probably represent the net effect of several factors, including (beneficially) decreased prevalence of *H. pylori* infection, better medical therapy, and increased outpatient management; and (detrimentally) the use of NSAIDs and aspirin (with and without ulcer prophylaxis) in an aging population with multiple risk factors.

PUD is one of the most common GI disorders in the United States with a prevalence of about 2%, and a lifetime cumulative prevalence of about 10%, peaking around age 70 years.⁵⁰ The costs of PUD, including lost work time and productivity, are estimated to be above \$8 billion per year in the United States. In 1998, approximately 1.5% of all Medicare hospital costs were spent treating PUD, and the crude mortality rate for peptic ulcer was 1.7 per 100,000 individuals. Using the National Inpatient Sample, it can be estimated that the mortality rate in patients hospitalized in 2006 with duodenal ulcer was 3.7% compared to 2.1% for gastric ulcer.⁵¹ Recent studies have shown an increase in the rates of hospitalization and mortality in elderly patients for the peptic ulcer complications of bleeding and perforation. This may be due in part to the increasingly common use of NSAIDs and aspirin in this elderly cohort, many of whom also have *H. pylori* infection.

Pathophysiology and Etiology

A variety of factors may contribute to the development of PUD. Although it is now recognized that the large majority of duodenal and gastric ulcers are caused by *H. pylori* infection and/or NSAID use^{17,52} (Fig. 26-24), the final common pathway to ulcer formation is acid-peptic injury of the gastroduodenal mucosal barrier. Thus, the adage “no acid, no ulcer” remains true. Acid suppression heals both duodenal and gastric ulcers and prevents recurrence. In general *H. pylori* predisposes to ulceration, both by acid hypersecretion and by compromise of mucosal defense mechanisms. NSAID use causes ulcers predominantly by compromise of mucosal defenses. Duodenal ulcer was traditionally viewed as a disease of increased acid-peptic action on the duodenal mucosa, whereas gastric ulcer was viewed as a disease of weakened mucosal defenses. An increased understanding of peptic ulcer pathophysiology has blurred this overly simplistic distinction. Clearly, weakened mucosal defenses play a role in both duodenal and gastric ulcers and acid hypersecretion may

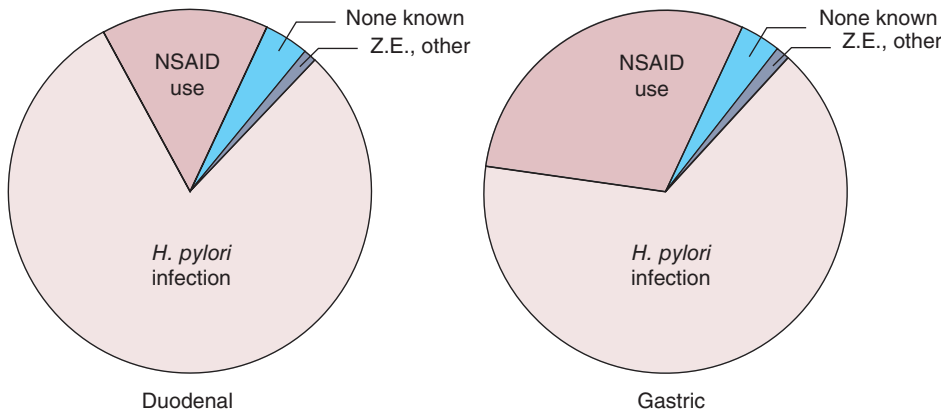


Figure 26-24. “Causes” of peptic ulcer disease. Z.E. = Zollinger-Ellison syndrome. [Reproduced with permission from Spechler SJ: *Peptic ulcer disease and its complications*, in Feldman M (ed): *Sleisinger and Fordtran’s Gastrointestinal and Liver Disease, 7th ed.* Philadelphia: Saunders, 2002, p 747. Copyright Elsevier.]

result in a duodenal or gastric ulcer in the setting of normal mucosal defenses.

Elimination of *H. pylori* infection or NSAID use is important for optimal ulcer healing, and perhaps is even more important in preventing ulcer recurrence and/or complications. A variety of other diseases are known to cause peptic ulcer, including ZES (gastrinoma), antral G-cell hyperfunction and/or hyperplasia, systemic mastocytosis, trauma, burns, and major physiologic stress. Other causative agents include drugs (all NSAIDs, aspirin, and cocaine), smoking, and psychologic stress. In the United States, probably more than 90% of serious peptic ulcer complications can be attributed to *H. pylori* infection, NSAID use, and/or cigarette smoking.

***Helicobacter pylori* Infection.** With specialized flagella and a rich supply of urease, *H. pylori* is uniquely equipped for survival in the hostile environment of the stomach.^{53–55} About 50% of the world’s population is infected with *H. pylori*, a major cause of chronic gastritis. The same sequence of inflammation to metaplasia to dysplasia to carcinoma, that is well known to occur in the esophagus from reflux-induced inflammation (and in the colon from inflammatory bowel disease), is now increasingly well recognized to occur in the stomach with *Helicobacter*-induced gastritis. The influence of prolonged acid suppression with PPIs or H₂RAs on these esophagogastric processes is largely unknown. *Helicobacter* also clearly has an etiologic role in the development of gastric lymphoma.

The organism possesses the enzyme urease, which converts urea into ammonia and bicarbonate, thus creating an environment around the bacteria that buffers the acid secreted by the stomach. The ammonia is damaging to the surface epithelial cells. Mutant strains of *H. pylori* that do not produce urease are unable to colonize the stomach. The organism lives in the mucus layer atop the gastric SECs, and some attach to these cells (Fig. 26-25).^{53,54} Apparently *Helicobacter* strains that lack flagella are unable to navigate through the unstirred mucus layer to get to the apical membrane of the SEC for attachment, and are nonpathogenic. One of the mechanisms by which *Helicobacter* causes gastric injury may be through a disturbance in gastric acid secretion. This is due, in part, to the inhibitory effect that *H. pylori* exerts on antral D cells that secrete somatostatin, a potent inhibitor of antral G-cell gastrin production. *H. pylori* infection is associated with decreased levels of somatostatin, decreased

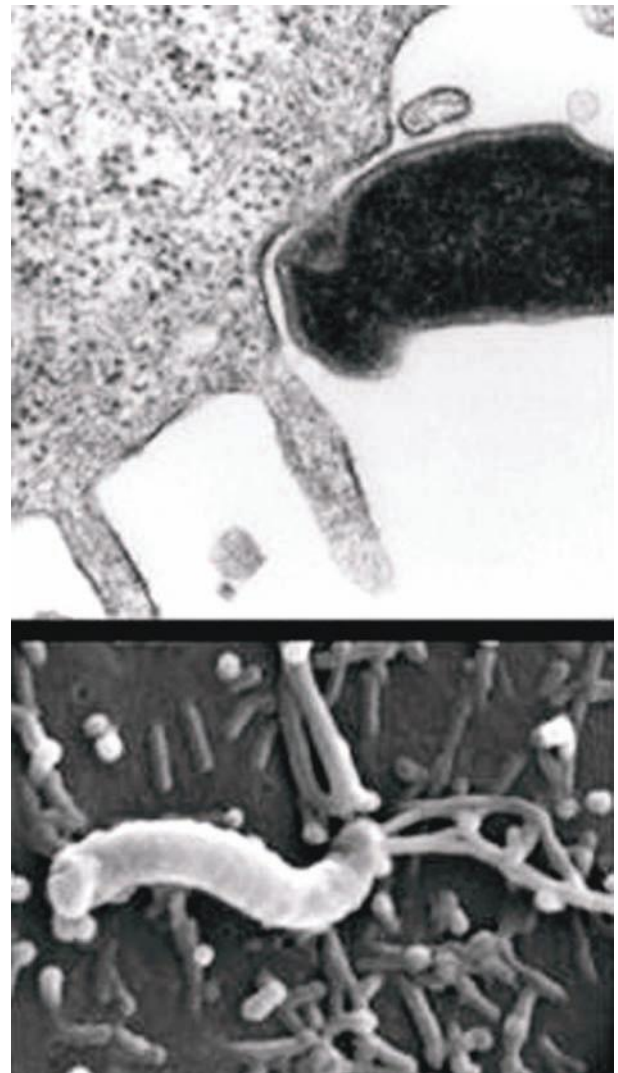


Figure 26-25. *Helicobacter pylori* closely adherent to the cell membrane (top), and spiral-shaped *H. pylori* attached to epithelial surface and surrounding microvilli (bottom). In the image on the bottom, the bacterial flagella can be seen arising from the upper pole of the bacterium. (From Parsonnet J: *Clinician-discoverers—Marshall, Warren, and H. pylori*. *N Engl J Med* 353:2421, 2005. Photomicrographs courtesy of Manuel Amieva, Stanford University.)

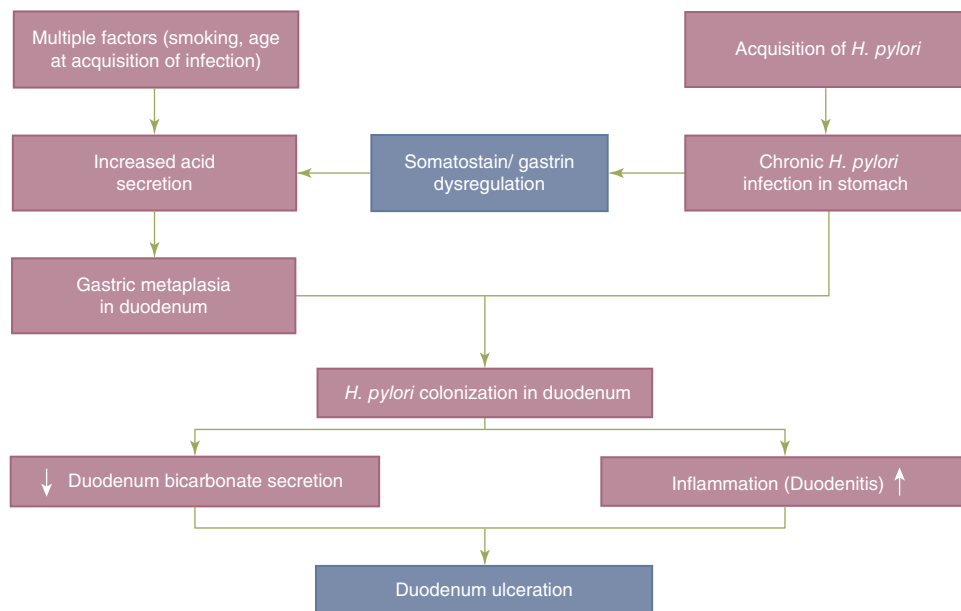


Figure 26-26. Model of *Helicobacter* effects on duodenal ulcer pathogenesis. (Reproduced with permission from Peek RM Jr., Blaser MJ: *Pathophysiology of Helicobacter pylori-induced gastritis and peptic ulcer disease*. *Am J Med* 102:200, 1997. Copyright Elsevier.)

somatostatin messenger RNA production, and fewer somatostatin-producing D cells. These effects are probably mediated by *H. pylori*-induced local alkalinization of the antrum (antral acidification is the most potent antagonist to antral gastrin secretion), and *H. pylori*-mediated increases in other local mediators and cytokines. The result is hypergastrinemia and acid hypersecretion (Fig. 26-26).⁴⁹ This hypergastrinemia presumably leads to the parietal cell hyperplasia seen in many patients with duodenal ulcer. The acid hypersecretion and the antral gastritis are thought to lead to antral epithelial metaplasia in the postpyloric duodenum. This duodenal metaplasia allows *H. pylori* to colonize the duodenal mucosa and, in these patients, the risk of developing a duodenal ulcer increases 50-fold. When *H. pylori* colonizes the duodenum, there is a significant decrease in acid-stimulated duodenal bicarbonate release. When *H. pylori* infection is successfully treated, acid secretory physiology tends to normalize. Other mechanisms whereby *H. pylori* can induce gastroduodenal mucosal injury include the production of toxins (*vacA* and *cagA*), local elaboration of cytokines (particularly interleukin-8) by infected mucosa, recruitment of inflammatory cells and release of inflammatory mediators, recruitment and activation of local immune factors, and increased apoptosis (Fig. 26-27).^{54,55} The net effect is a weakening of mucosal defenses. The mechanism by which the helicobacter organism avoids recognition and destruction by the mucosal immune system is a topic of interest and active research.⁵⁶

The evidence supporting the central role of *H. pylori* in the pathophysiology of PUD is strong. Patients with *H. pylori* infection and antral gastritis are three and one-half times more likely to develop PUD than patients without *H. pylori* infection. Up to 90% of patients with duodenal ulcers, and 70% to 90% of patients with gastric ulcers, have *H. pylori* infection. It is clear from multiple randomized prospective studies that curing *H. pylori* infection dramatically alters the natural history of PUD, decreasing the recurrent ulcer rate from more than 75% in patients treated with a course of acid-suppressive therapy alone (in whom *H. pylori* is not eradicated) to less than 20% in patients treated with a course of antibacterial therapy (Fig. 26-28).⁵⁷

Obviously, other factors are involved in the etiology of PUD because many patients colonized with *H. pylori* do not get

peptic ulcer disease, and many patients with peptic ulcer disease do not have *H. pylori* infection. These observations notwithstanding, it is clear from a variety of well-designed laboratory, clinical, and epidemiologic studies that *H. pylori* is indubitably an important factor in the development and recurrence of PUD. *H. pylori* also plays an etiologic role in gastric cancer and lymphoma.⁵⁴

Acid Secretion and Peptic Ulcer. A variety of abnormalities related to mucosal acid exposure have been described in patients with duodenal ulcer (Fig. 26-29).⁵⁸ Although duodenal ulcer patients as a group have a higher mean BAO and mean MAO compared to normal controls, many duodenal ulcer patients have basal and peak acid outputs in the normal range, and there is no correlation between acid secretion and the severity of the ulcer disease. As a group, duodenal ulcer patients produce more acid than normal controls in response to any known acid secretory stimulus. Although they usually have normal fasting serum gastrin levels, DU patients often produce more gastric acid at any given dose of gastrin than controls. Considering that many duodenal ulcer patients do produce excessive gastric acid, it has been argued that a “normal” fasting gastrin level in these patients is inappropriately high, and that there is an impaired feedback mechanism, especially in light of the apparently increased sensitivity of the parietal cell mass to gastrin. Many of these long-standing observations now seem reasonable in light of recently gained understanding of the perturbations in acid and gastrin secretion associated with *H. pylori* infection. Some patients with duodenal ulcer also have increased rates of gastric emptying that deliver an increased acid load per unit of time to the duodenum. Finally, the buffering capacity of the duodenum in many patients with duodenal ulcer is compromised due to decreased duodenal bicarbonate secretion.

In patients with gastric ulcer, acid secretion is variable. Currently, five types of gastric ulcer are described, although the original Johnson classification contained three types (Fig. 26-30).⁵⁹ The most common, Johnson type I gastric ulcer, is typically located near the angularis incisura on the lesser curvature, close to the border between antral and corpus mucosa. Patients with type I gastric ulcer usually have normal or decreased

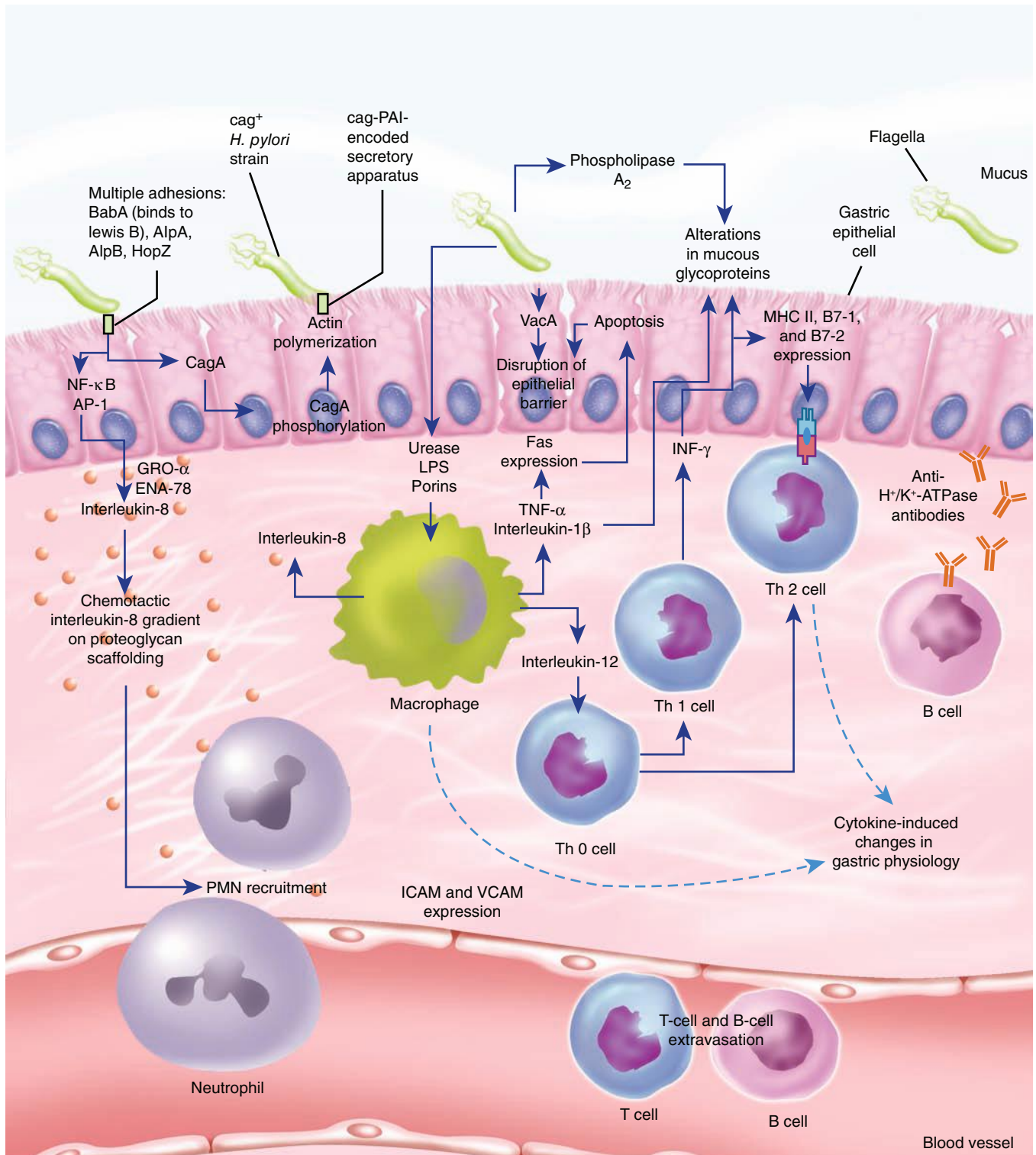


Figure 26-27. Pathogen-host interactions in the pathogenesis of *Helicobacter pylori* infection. ICAM = intercellular adhesion molecule-1; IFN- γ = interferon- γ ; LPS = lipopolysaccharide; NF- κ B = nuclear factor κ B; PAI = pathogenicity island; PMN = polymorphonuclear neutrophil; TNF- α = tumor necrosis factor alpha; VCAM = vascular cell adhesion molecule. (Reproduced with permission from Suerbaum S, Michetti P: *Helicobacter pylori* infection. N Engl J Med 347:1175, 2002. Copyright ©2002 Massachusetts Medical Society. All rights reserved.)

acid secretion. Type II gastric ulcer is associated with active or quiescent duodenal ulcer disease, and type III gastric ulcer is prepyloric ulcer disease. Both type II and type III gastric ulcers are associated with normal or increased gastric acid secretion. Type IV gastric ulcers occur near the GE junction, and acid

secretion is normal or below normal. Type V gastric ulcers are medication induced and may occur anywhere in the stomach. Patients with gastric ulcers may have weak mucosal defenses that permit an abnormal amount of injurious acid back-diffusion into the mucosa. Duodenogastric reflux may play a role in

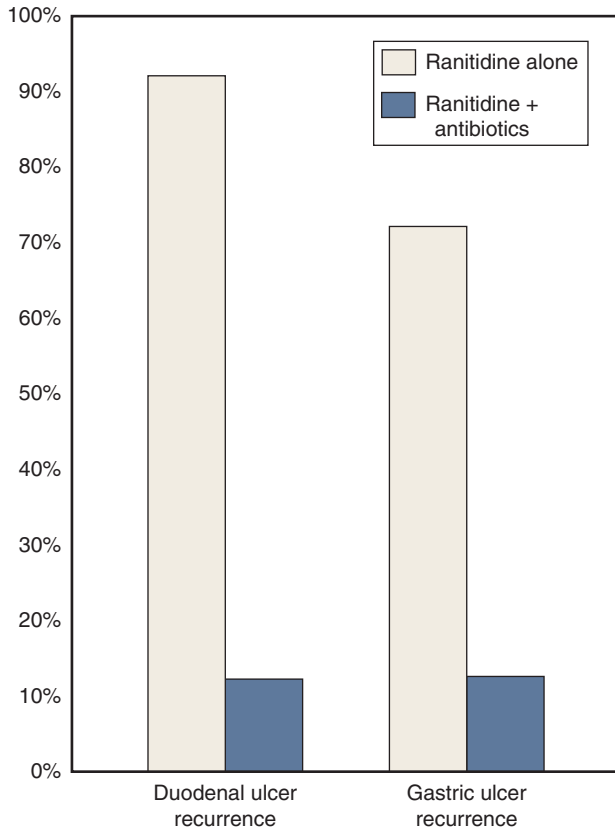


Figure 26-28. *Helicobacter* treatment dramatically decreases the recurrence rate of duodenal and gastric ulcer. (Data from Graham DY, Lew GM, Klein PD, et al: Effect of treatment of *Helicobacter pylori* infection on the long-term recurrence of gastric or duodenal ulcer. A randomized controlled study. *Ann Intern Med* 116:705, 1992.)

weakening the gastric mucosal defenses, and a variety of components in duodenal juice, including bile, lysolecithin, and pancreatic juice, have been shown to cause injury and inflammation in the gastric mucosa. NSAIDs and aspirin have similar effects. Although chronic gastric ulcer usually is associated with surrounding gastritis, it is unproven that the latter leads to the former.

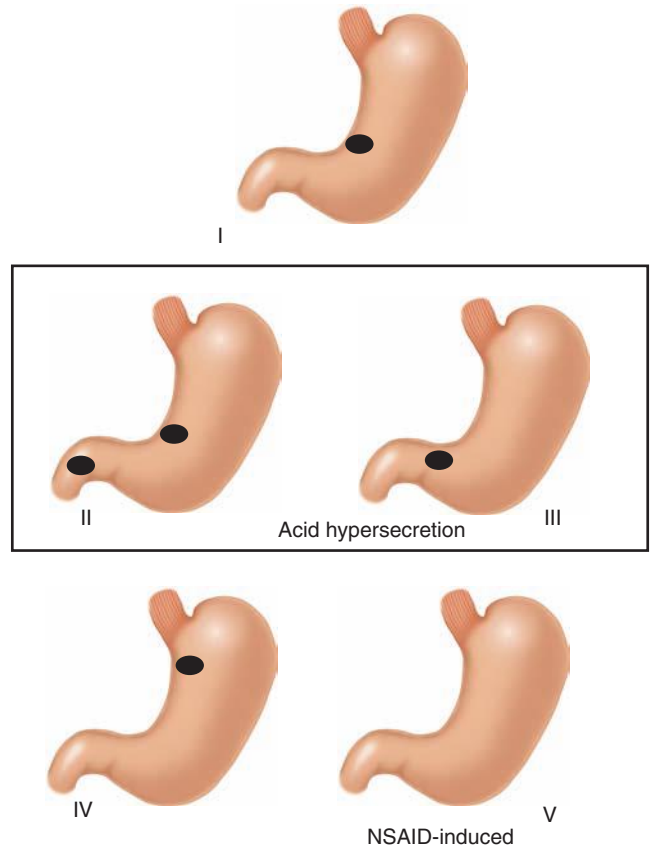


Figure 26-30. Modified Johnson classification for gastric ulcer. I. Lesser curve, incisura. II. Body of stomach, incisura + duodenal ulcer (active or healed). III. Prepyloric. IV. High on lesser curve, near gastroesophageal junction. V. Medication-induced (NSAID/ acetylsalicylic acid), anywhere in stomach. [Reproduced with permission from Fisher WE, Brunicaudi FC: Benign gastric ulcer, in Cameron JL (ed): Current Surgical Therapy, 9th ed. Philadelphia: Mosby Elsevier, 2008, p 81. Copyright Elsevier.]

Nonsteroidal Anti-Inflammatory Drugs in Peptic Ulcer Disease. Chronic use of NSAIDs (including aspirin) increases the risk of peptic ulcer disease about 5-fold and upper GI bleeding about 4-fold.^{60,61} Complications of PUD (specifically hemorrhage and perforation) are much more common in patients

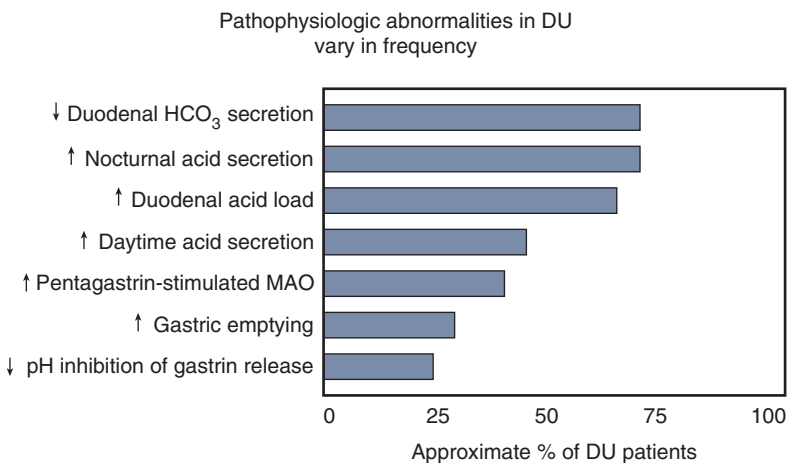


Figure 26-29. Frequency of physiologic abnormalities in patients with duodenal ulcer (DU). HCO₃ = bicarbonate; MAO = maximal acid output. [Reproduced with permission from Del Valle J, Chey WD, Scheiman JM: Acid peptic disorders, in Yamada T, et al (eds): Textbook of Gastroenterology, 4th ed. Philadelphia: Lippincott Williams & Wilkins, 2003, p 1321.]

Table 26-6

Hospitalization rates for GI events with and without NSAID use in selected large populations

ANNUALIZED INCIDENCE ^b						
STUDY ^a	THERAPIES USED		CLINICAL UPPER GI EVENTS ^c		COMPLICATED UPPER GI EVENTS ^d	
	NSAID CONTROL	STUDY DRUGS	CONTROL	STUDY DRUG	CONTROL	STUDY DRUG
MUCOSA	NSAIDs (n = 4439)	Misoprostol 200 µg qid + NSAID (n = 4404)	3.1%	1.6%	1.5%	0.7%
CLASS	Ibuprofen 800 mg tid, diclofenac 75 mg bid (n = 3987)	Celecoxib 400 mg bid (n = 3995)	3.5%	2.1%	1.5%	0.8%
			(No aspirin ^e : 2.9%)	1.4%	1.3%	0.4%
VIGOR	Naproxen 500 mg bid (n = 4047)	Rofecoxib 50 mg qd (n = 4029)	4.5%	2.1%	1.4%	0.6%

^aMUCOSA and VIGOR trials included only rheumatoid arthritis patients; CLASS trial included osteoarthritis (73%) and rheumatoid arthritis (27%).

^bIncidence for MUCOSA trial represents doubling of results provided at 6 months (although median follow-up was <6 months). Incidences for VIGOR and CLASS trials represent rates per 100 patient-years, although VIGOR median follow-up was 9 months and CLASS data include only the first 6 months of the study.

^cIncludes perforations, obstructions, bleeding, and uncomplicated ulcers discovered on clinically indicated work-up.

^dIncludes perforation, obstruction, bleeding (documented due to ulcer or erosions in MUCOSA and CLASS; major bleeding in VIGOR).

^e21% of patients in CLASS study were taking low-dose aspirin.

Note: All differences between controls and study drugs were significant except clinical upper GI events in overall CLASS study ($P = .09$).

Source: Reproduced with permission from Laine L: Approaches to nonsteroidal anti-inflammatory drug use in the high-risk patient. *Gastroenterology* 120:594, 2001. Copyright Elsevier.

taking NSAIDs. More than half of patients who present with peptic ulcer hemorrhage or perforation report the recent use of NSAIDs, including aspirin. Many of these patients remain asymptomatic until they develop these life-threatening complications.

The overall risk of significant serious adverse GI events in patients taking NSAIDs is more than three times that of controls (Table 26-6). This risk increases to five times in patients more than age 60 years old. In elderly patients taking NSAIDs, the likelihood that they will require an operation related to a GI complication is 10 times that of the control group, and the risk that they will die from a GI cause is about four and one-half times higher. This problem is put into perspective when one realizes that approximately 20 million patients in the United States take NSAIDs on a regular basis; probably more regularly take aspirin. Persons who take NSAIDs also have a higher hospitalization rate for serious GI events than those who do not.

Factors that clearly put patients at increased risk for NSAID-induced GI complications include age >60, prior GI event, high NSAID dose, concurrent steroid intake, and concurrent anticoagulant intake. *ANY patient taking NSAIDs or aspirin who has one or more of these risk factors should receive concomitant acid suppressive medication*⁶² (Table 26-7). High dose H2 blockers have been shown to be less effective than PPIs in preventing GI complications in these high risk patients on antiplatelet therapy, but clearly they are better than no acid suppression.

Smoking, Stress, and Other Factors. Epidemiologic studies suggest that smokers are about twice as likely to develop PUD as nonsmokers. Smoking increases gastric acid secretion and duodenogastric reflux. Smoking decreases both gastroduodenal

prostaglandin production and pancreaticoduodenal bicarbonate production. These observations may be related, and any or all could explain the observed association between smoking and PUD.

Although difficult to measure, both physiologic and psychologic stress undoubtedly play a role in the development of peptic ulcer in some patients. In 1842, Curling described duodenal ulcer and/or duodenitis in burn patients. Decades later, Cushing described the appearance of acute peptic ulceration in patients with head trauma (Cushing's ulcer). Even the ancients recognized the undeniable links between PUD and stress. Patients still present with ulcer complications (bleeding, perforation, and obstruction) that are seemingly exacerbated by stressful life events. The use of crack cocaine has been linked to juxtapyloric peptic ulcers with a propensity to perforate. Alcohol is commonly mentioned as a risk factor for PUD, but confirmatory data are lacking.

Table 26-7

Patients taking NSAIDs or aspirin need concomitant acid suppressing medication if any of the following risk factors is present

- Age over 60
- History of acid/peptic disease
- Concurrent steroid intake
- Concurrent anticoagulant intake
- High-dose NSAID or acetylsalicylic acid

Clinical Manifestations

More than 90% of patients with PUD complain of abdominal pain. The pain is typically nonradiating, burning in quality, and located in the epigastrium. The mechanism of the pain is unclear. Patients with duodenal ulcer often experience pain 2 to 3 hours after a meal and at night. Two thirds of patients with duodenal ulcers will complain of pain that awakens them from sleep. The pain of gastric ulcer more commonly occurs with eating and is less likely to awaken the patient at night. A history of PUD, use of NSAIDs, over-the-counter antacids, or antisecretory drugs is suggestive of the diagnosis. Other signs and symptoms include nausea, bloating, weight loss, stool positive for occult blood, and anemia. Duodenal ulcer is about twice as common in men compared to women, but the incidence of gastric ulcer is similar in men and women. On average, gastric ulcer patients are older than duodenal ulcer patients, and the incidence is increasing in the elderly, perhaps because of increasing NSAID and aspirin.

Diagnosis

In the young patient with dyspepsia and/or epigastric pain, it may be appropriate to initiate empirical PPI therapy for PUD without confirmatory testing. In such cases, it is prudent to discuss with the patient the small possibility of an alternative diagnosis, including malignancy, even if symptoms improve with the initiation of therapy. All patients more than 45 years old with the above symptoms should have an upper endoscopy, and all patients, regardless of age, should have this study if any alarm symptoms (see Table 26-5) are present. A double-contrast upper GI X-ray study may be useful. Once an ulcer has been confirmed endoscopically or radiologically, obvious possible causes (*Helicobacter*, NSAIDs, gastrinoma, cancer) should always be considered. All gastric ulcers should be adequately biopsied, and any sites of gastritis should be biopsied to rule out *H. pylori*, and for histologic evaluation. Additional testing for *H. pylori* may be indicated. It is not unreasonable to test all peptic ulcer patients for *H. pylori* (Table 26-8) 63A baseline serum gastrin level is appropriate to rule out gastrinoma.

Table 26-8

Indications for diagnosis and treatment of *Helicobacter pylori*

Established

- Active peptic ulcer disease (gastric or duodenal ulcer)
- Confirmed history of peptic ulcer disease (not previously treated for *H. pylori*)
- Gastric mucosa-associated lymphoid tissue lymphoma (low grade)
- After endoscopic resection of early gastric cancer
- Uninvestigated dyspepsia (depending on *H. pylori* prevalence)

Controversial

- Nonulcer dyspepsia
- Gastroesophageal reflux disease
- Persons using NSAIDs
- Unexplained iron deficiency anemia
- Populations at higher risk for gastric cancer

Source: Reprinted by permission from Macmillan Publishers, Ltd. Chey WD, Wong BCY. ⁶³ Practice Parameters Committee of the American College of Gastroenterology. *Am J Gastroenterol*. 2007;102:1808. Copyright © 2007.

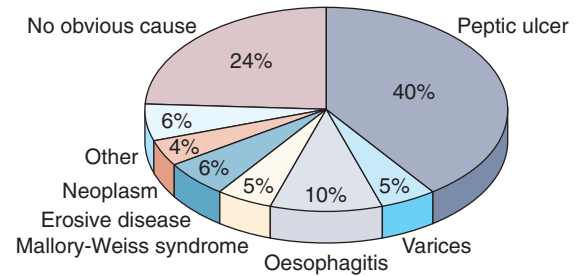


Figure 26-31. Causes of upper GI bleeding. (Reproduced with permission from Dallal HJ, Palmer KR: *Clinical Review: Upper gastrointestinal hemorrhage*. *BMJ* 323:1115, 2001. With permission from the BMJ Publishing Group.)

Complications

The three most common complications of PUD, in decreasing order of frequency, are bleeding, perforation, and obstruction.^{51,52,64} Most peptic ulcer–related deaths in the United States are due to bleeding. Bleeding peptic ulcers are by far the most common cause of upper GI bleeding in patients admitted to hospital (Fig. 26-31).⁶⁵ Patients with a bleeding peptic ulcer typically present with melena and/or hematemesis. Nasogastric aspiration is usually confirmatory of the upper GI bleeding. Abdominal pain is quite uncommon. Shock may be present, necessitating aggressive resuscitation and blood transfusion. Early endoscopy is important to diagnose the cause of the bleeding and to assess the need for hemostatic therapy.

Three-fourths of the patients who come to the hospital with bleeding peptic ulcer will stop bleeding if given acid suppression and nothing by mouth. However, one fourth will continue to bleed or will rebleed after an initial quiescent period, and virtually all the mortalities (and all the operations for bleeding) occur in this group. This group can be fairly well delineated based on clinical factors related to the magnitude of the hemorrhage, comorbidities, age, and endoscopic findings. Shock, hematemesis, transfusion requirement exceeding four units in 24 hours, and certain endoscopic stigmata (active bleeding or visible vessel) define this high-risk group. Two widely used risk stratification tools have proven useful in predicting rebleeding and death: the Blatchford and Rockall scores (Table 26-9).⁶⁶ High-risk patients benefit from endoscopic therapy to stop the bleeding. The most common endoscopic hemostatic modalities used are injection with epinephrine, and electrocautery. In a case with exposed vessel, mechanical hemostasis using a clip is useful to control the bleeding.^{66A} Persistent bleeding or rebleeding after endoscopic therapy is an indication for operation, although repeat endoscopic treatment has been successful in treating rebleeding. Elderly patients and patients with multiple comorbidities do not tolerate repeated episodes of hemodynamically significant hemorrhage, and may benefit from early elective operation after initially successful endoscopic treatment, especially if they have a high-risk ulcer.

Planned surgery under controlled circumstances often yields better outcomes than emergent surgery. Deep bleeding ulcers on the posterior duodenal bulb or lesser gastric curvature are high-risk lesions, because they often erode large arteries not amenable to nonoperative treatment, and early operation should be considered.

Table 26-9

Risk-stratification tools for upper gastrointestinal hemorrhage^a

A. BLATCHFORD SCORE	
AT PRESENTATION	POINTS
Systolic blood pressure	
100–109 mmHg	1
90–99 mmHg	2
<90 mmHg	3
Blood urea nitrogen	
6.5–7.9 mmol/L	2
8.0–9.9 mmol/L	3
10.0–24.9 mmol/L	4
≥25 mmol/L	6
Hemoglobin for men	
12.0–12.9 g/dL	1
10.0–11.9 g/dL	3
<10.0 g/dL	6
Hemoglobin for women	
10.0–11.9 g/dL	1
<10.0 g/dL	6
Other variables at presentation	
Pulse ≥100 beats/min	1
Melena	1
Syncope	2
Hepatic disease	2
Cardiac failure	2

B. ROCKALL SCORE		
VARIABLE	POINTS	
Age	<60 y	0
	60–79 y	1
	≥80 y	2
Shock	Heart rate >100 beats/min	1
	Systolic blood pressure <100 mmHg	2
Coexisting illness	Ischemic heart disease, congestive heart failure, other major illness	2
	Renal failure, hepatic failure, metastatic cancer	3
Endoscopic diagnosis	No lesions observed, Mallory-Weiss syndrome	0
	Peptic ulcer, erosive disease, esophagitis	1
	Cancer of the upper GI tract	2
Endoscopic stigmata of recent hemorrhage	Clean base ulcer, flat pigmented spot	0
	Blood in upper GI tract, active bleeding, visible vessel, clot	2

CLINICAL ROCKALL SCORE (Age, Shock, Coexisting illness)
 COMPLETE ROCKALL SCORE (Clinical Rockall Score + Endoscopic diagnosis + Endoscopic stigmata)

^aPanel A shows the values used in the Blatchford risk-stratification score, which ranges from 0 to 23, with higher scores indicating higher risk. Panel B shows the Rockall score, with point values assigned for each of three clinical variables (age and the presence of shock and coexisting illnesses) and two endoscopic variables (diagnosis and stigmata of recent hemorrhage). The complete Rockall score ranges from 0 to 11, with higher scores indicating higher risk. Patients with a clinical Rockall score (Age + Shock + Coexisting illness) of 0 or a complete Rockall score of 2 or less are considered to be at low risk for rebleeding or death.

Source: Reproduced with permission from Gralnek IM et al: Management of acute bleeding from peptic ulcer. *N Engl J Med.* 359:928, 2008. Copyright ©2008 Massachusetts Medical Society. All rights reserved.

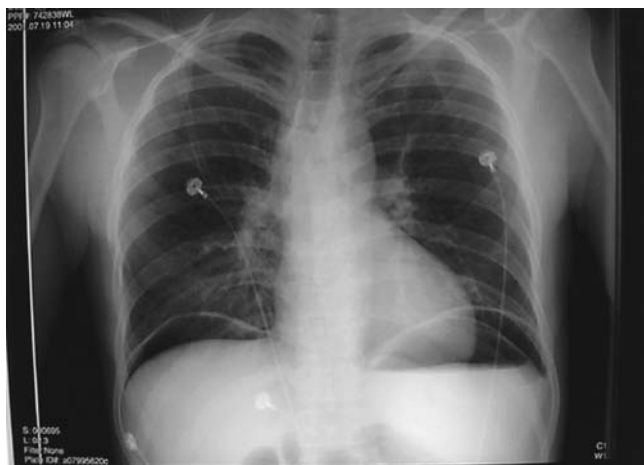

Figure 26-32. Pneumoperitoneum on upright chest X-ray in patient with perforated ulcer.

Perforated peptic ulcer usually presents as an acute abdomen. The patient can often give the exact time of onset of the excruciating abdominal pain. Initially, a chemical peritonitis develops from the gastric and/or duodenal secretions, but within hours a bacterial peritonitis supervenes. The patient is in obvious distress, and the abdominal examination shows peritoneal signs. Usually, marked involuntary guarding and rebound tenderness is evoked by a gentle examination. Upright chest X-ray shows free air in about 80% of patients (Fig. 26-32). Once the diagnosis has been made, the patient is given analgesia and antibiotics, resuscitated with isotonic fluid, and taken to the operating room. Fluid sequestration into the third space of the inflamed peritoneum can be impressive, so preoperative fluid resuscitation is mandatory. Sometimes, the perforation has sealed spontaneously by the time of presentation, and surgery can be avoided if the patient is doing well. Nonoperative management is appropriate only if there is objective evidence that the leak has sealed (i.e., radiologic contrast study), and in the absence of clinical peritonitis.

Gastric outlet obstruction occurs in no more than 5% of patients with PUD. It is usually due to duodenal or prepyloric ulcer disease, and may be acute (from inflammatory swelling and peristaltic dysfunction) or chronic (from cicatrix). Patients typically present with nonbilious vomiting and may have a profound hypokalemic hypochloremic metabolic alkalosis. Pain or discomfort is common. Weight loss may be prominent, depending on the duration of symptoms. A succussion splash may be audible with stethoscope placed in the epigastrium. Initial treatment is nasogastric suction, IV hydration and electrolyte repletion, and acid suppression. The diagnosis is confirmed by endoscopy. Most patients admitted to the hospital nowadays with obstructing ulcer disease require intervention, either balloon dilation or operation. Cancer must be ruled out because most patients who present with the symptoms of gastric outlet obstruction will have a pancreatic, gastric, or duodenal malignancy.

Medical Treatment of Peptic Ulcer Disease

PPIs are the mainstay of medical therapy for PUD, but high dose H_2 RAs and sucralfate are also quite effective. Patients hospitalized for ulcer complications should receive PPI by continuous

IV infusion and, when discharged, should be considered for life-long PPIs unless the definitive cause is eliminated or a definitive operation performed. Peptic ulcer patients should **1▶** stop smoking and avoid alcohol and NSAIDs (including aspirin). Patients who require NSAIDs or aspirin to treat other medical conditions should always take concomitant PPIs or high dose H_2 receptor blockers. If *H. pylori* infection is documented, it should be treated with one of several acceptable regimens (Table 26-10).⁶³ Infectious disease consultation may be helpful in the compliant, symptomatic patient with persistent *H. pylori* infection following treatment, or another regimen could be tried (e.g., quadruple therapy). If initial *H. pylori* testing is negative and ulcer symptoms persist, an empirical trial of anti-*H. pylori* therapy is reasonable since false-negative *H. pylori* tests are common. Generally, acid suppression can be stopped after 3 months if the ulcerogenic stimulus (usually *H. pylori*, NSAIDs, or aspirin) has been removed. However, long-term maintenance PPI therapy should be considered in all patients admitted to hospital with ulcer complications, all high-risk patients on NSAIDs or aspirin (the elderly or debilitated), and all patients with a history of recurrent ulcer or bleeding. Consideration should also be given to maintenance PPI therapy in refractory smokers with a history of peptic ulcer. Sucralfate acts locally on mucosal defects and is well tolerated, and occasionally is useful as a supplement to acid suppression.

Surgical Treatment of Peptic Ulcer Disease

The indications for surgery in PUD are bleeding, perforation, obstruction, and intractability or nonhealing.^{67,68} Gastric cancer must always be considered in patients with gastric ulcer or gastric outlet obstruction.

Today, most patients undergoing operation for PUD have simple oversewing of a bleeding ulcer or simple patch of a perforated ulcer.⁵¹ Simultaneous performance of vagotomy **2▶** either truncal or highly selective is increasingly uncommon,

Table 26-10

Treatment regimens for *Helicobacter pylori*

MEDICATIONS/DOSE/FREQUENCY	DURATION
PPI + clarithromycin 500 mg bid + amoxicillin 1000 mg bid	10–14 d
PPI + clarithromycin 500 bid + metronidazole 500 bid	10–14 d
PPI + amoxicillin 1000 mg bid, then	5 d
PPI + clarithromycin 500 mg bid + tinidazole 500 mg bid	5 d
Salvage regimens for patients who fail one of the above initial regimens:	
Bismuth subsalicylate 525 mg qid + metronidazole 250 mg qid + tetracycline 500 mg qid + PPI	10–14 d
PPI + amoxicillin 1000 mg bid + levofloxacin 500 mg daily	10 d

PPI = proton pump inhibitor.
Source: Data from Chey et al.⁶³

probably due to surgeon unfamiliarity with the procedure and reliance on postoperative PPIs to decrease acid secretion.

Unfortunately, the data from many excellent randomized clinical trials evaluating elective operation for peptic ulcer over the last several decades may be irrelevant to most patients presenting for ulcer surgery today.⁶⁷ The large majority of these excellent studies were done in the pre-PPI, pre-*Helicobacter*, pre-NSAID era, and focused on elective operation for intractable disease, an unusual indication for operation nowadays. Thus, today's surgeon should take great care in applying this literature to inform surgical decision making.

Traditionally, the vast majority of peptic ulcers were treated by a variant of one of the three basic operations: parietal cell vagotomy also called highly selective vagotomy or proximal gastric vagotomy (HSV), vagotomy and drainage (V+D), and vagotomy and distal gastrectomy. Recurrence rates were lowest but morbidity highest with the latter procedure, while the opposite was true for HSV (Table 26-11).⁶⁷⁻⁶⁹

HSV severs the vagal nerve supply to the proximal two thirds of the stomach, where essentially all the parietal cells are located, and preserves the vagal innervation to the antrum and pylorus, and the remaining abdominal viscera (Fig. 26-33). Thus, the operation decreases total gastric acid secretion by about 75%, and GI side effects are rare. Elective HSV has largely been supplanted by long-term PPI treatment, but the operation, which has a learning curve, may still be useful in the patient (elective or emergent) who is noncompliant with, intolerant of, or cannot afford medical treatment. Historically, HSV has not performed particularly well for type II (gastric and duodenal) and III (prepyloric) gastric ulcer, perhaps because of hypergastrinemia caused by gastric outlet obstruction and persistent antral stasis. The Taylor procedure consists of a posterior truncal vagotomy and anterior seromyotomy (but anterior HSV is probably equivalent), and is an attractive and simple alternative to HSV with similar results.

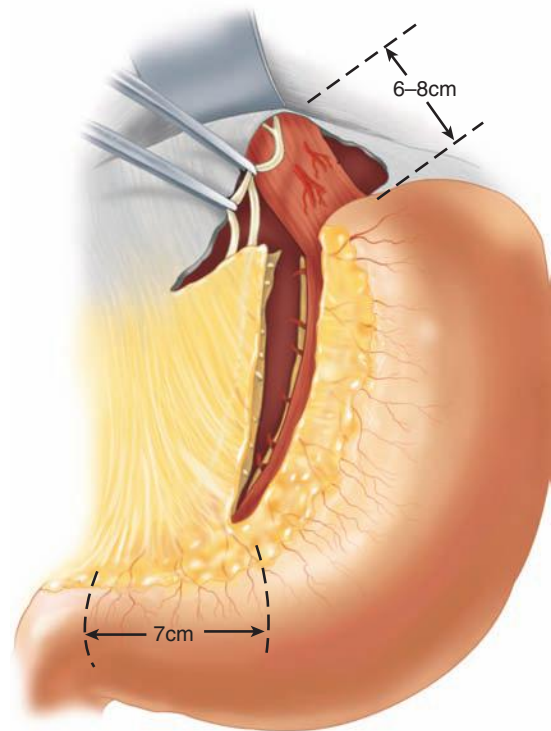


Figure 26-33. Highly selective vagotomy. [Reproduced with permission from Zinner MJ et al (eds): *Maingot's Abdominal Operations, 10th ed., Vol. 1.* Stamford, Connecticut: Appleton & Lange, 1997, p 987. Copyright © The McGraw-Hill Companies, Inc.]

Truncal vagotomy and pyloroplasty, and truncal vagotomy and gastrojejunostomy are the paradigmatic *vagotomy and drainage procedures*. HSV may be substituted for truncal vagotomy. The advantage of V + D is that it can be performed safely and quickly by the experienced surgeon. The main disadvantages are the side effect profile (10% of patients have significant dumping and/or diarrhea). During truncal vagotomy (Fig. 26-34), care must be taken not to perforate the esophagus, a potentially lethal complication. Intraoperative frozen section confirmation of at least two vagal trunks is prudent; additional vagal trunks are common. Unlike HSV, V + D is widely accepted as a successful definitive operation for complicated PUD. It has been described as a useful part of the operative treatment for bleeding duodenal and gastric ulcer, perforated duodenal and gastric ulcer, and obstructing duodenal and gastric (type II and III) ulcer. When applied to gastric ulcer, the ulcer should be excised or biopsied.

Truncal vagotomy denervates the antropyloric mechanism, and therefore, some sort of procedure is necessary to ablate or bypass the pylorus. Gastrojejunostomy is a good choice in patients with gastric outlet obstruction or a severely diseased proximal duodenum. The anastomosis is done between the proximal jejunum and the most dependent portion of the greater gastric curvature, in either an antecolic or retrocolic fashion (Fig. 26-35). Marginal ulceration is a potential complication. Pyloroplasty is useful in patients who require a pyloroduodenotomy to deal with the ulcer complication (e.g., posterior bleeding duodenal ulcer), in those with limited or focal scarring in the pyloric region, or when gastrojejunostomy is technically difficult. The most commonly performed

Table 26-11

Clinical results of surgery for duodenal ulcer

	PARIETAL CELL VAGOTOMY	TRUNCAL VAGOTOMY AND PYLOROPLASTY	TRUNCAL VAGOTOMY AND ANTRECTOMY
Operative mortality rate (%)	0	<1	1
Ulcer recurrence rate (%)	5-15	5-15	<2
Dumping (%)			
Mild	<5	10	10-15
Severe	0	1	1-2
Diarrhea (%)			
Mild	<5	25	20
Severe	0	2	1-2

Source: Modified from Mulholland et al,⁶⁸ with permission. Copyright Elsevier.

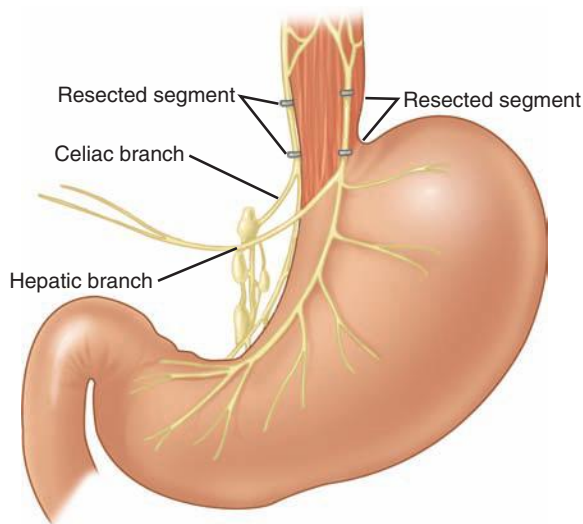
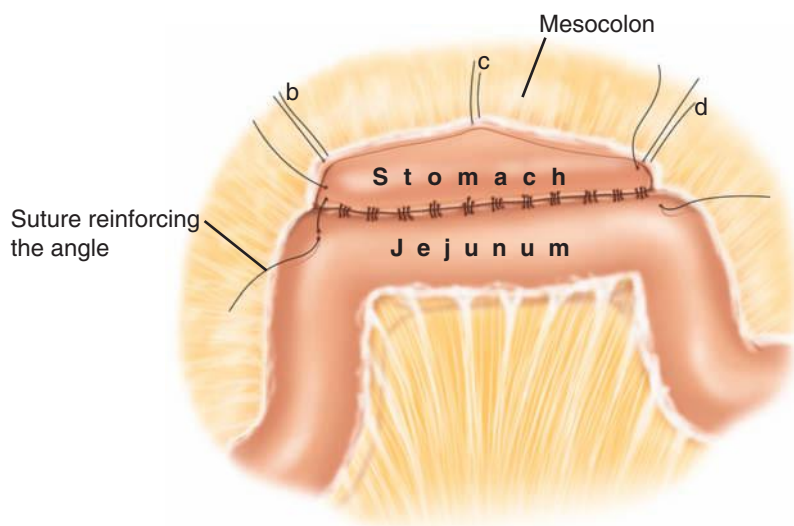


Figure 26-34. Truncal vagotomy. [Reproduced with permission from Zollinger RM Jr., Zollinger RM Sr. (eds): *Zollinger's Atlas of Surgical Operations, 8th ed.* New York: McGraw-Hill, 2003, p 45. Copyright © The McGraw-Hill Companies, Inc.]

pyloroplasty is the Heineke-Mikulicz type (Fig. 26-36). Other occasionally useful techniques include the Finney (Fig. 26-37) and the Jaboulay pyloroplasties (Fig. 26-38). These more extensive pyloroplasty techniques may make subsequent distal gastric resection more difficult and/or hazardous.

Although *vagotomy and antrectomy* (V + A) is associated with a very low ulcer recurrence rate and is applicable to many patients with complicated PUD (e.g., bleeding duodenal and gastric ulcer, obstructing peptic ulcer, nonhealing gastric ulcer, and recurrent ulcer), V + A has a higher operative mortality risk (compared with HSV or V + D), and is irreversible. Following antrectomy, GI continuity may be reestablished with a Billroth I gastroduodenostomy (Fig. 26-39) or a Billroth II loop gastrojejunostomy (Fig. 26-40). Since antrectomy routinely leaves a 60% to 70% gastric remnant, routine reconstruction as a Roux-en-Y gastrojejunostomy should be avoided (Fig. 26-41).



Although the Roux-en-Y operation is an excellent procedure for keeping duodenal contents out of the stomach and esophagus, in the presence of a large gastric remnant, this reconstruction will predispose to marginal ulceration and/or gastric stasis.

V + A should be avoided in hemodynamically unstable patients, and in patients with extensive inflammation and/or scarring of the proximal duodenum, because secure anastomosis (Billroth I) or duodenal closure (Billroth II) may be difficult.

Distal gastrectomy without vagotomy (usually about a 50% gastrectomy to include the ulcer) has traditionally been the procedure of choice for type I gastric ulcer. The addition of vagotomy should be considered for type II and III gastric ulcers (because the pathophysiology is more analogous to duodenal ulcer), or if the patient is believed to be at increased risk for recurrent ulcer, or perhaps even if Billroth II reconstruction is contemplated (to decrease the chance of marginal ulcer). Subtotal gastrectomy (75% distal gastrectomy) without vagotomy is rarely used to treat PUD today, although it was the most popular ulcer operation at the middle of the last century.

Pylorus preserving gastrectomy (PPG) was first reported as a surgical option for gastric ulcer which could minimize both dumping and duodenogastric reflux. Though not widely adopted for this indication, in some centers PPG is considered a good minimally invasive surgical option for early gastric cancer.^{69A,69B}

Choice of Operation for Peptic Ulcer. The choice of operation for the individual patient with PUD depends on a variety of factors, including the type of ulcer (duodenal, gastric, recurrent, or marginal), the indication for operation, and the condition of the patient, among others. Other important considerations are intra-abdominal factors (duodenal scarring/inflammation, adhesions, or difficult exposure), the ulcer diathesis status of the patient, the surgeon's experience and personal preference, whether *H. pylori* infection is present, the need for NSAID therapy, previous treatment, and the likelihood of future compliance with treatment. Table 26-12 shows the surgical options for managing various aspects of PUD. In general, resective procedures have a lower ulcer recurrence rate, but a higher operative morbidity and mortality rate (see Table 26-11) compared to nonresective ulcer operations. Because ulcer recurrence often is related to *H. pylori*

Figure 26-35. Retrocolic gastrojejunostomy. Note mesocolon sutured to stomach (b, c, d). [Reproduced with permission from *Vagotomy and drainage*, in Zuidema GD, Yeo CJ (eds): *Shackelford's Surgery of the Alimentary Tract, 5th ed. Vol. II.* Philadelphia: Saunders, 2002, p 129. Copyright Elsevier.]

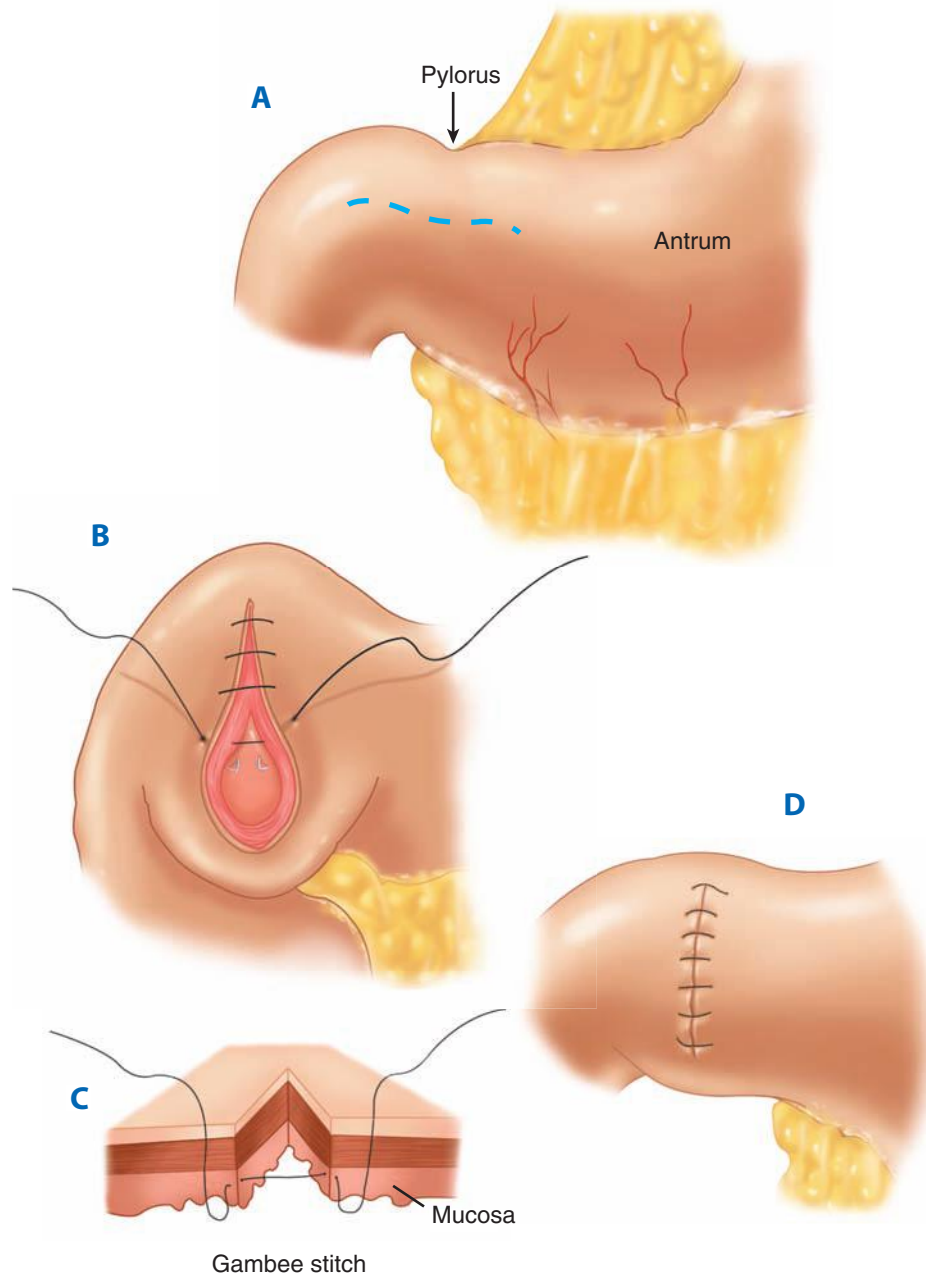


Figure 26-36. A through D. Heineke-Mikulicz pyloroplasty. [Reproduced with permission from Zinner MJ (ed): Atlas of Gastric Surgery. New York: Churchill Livingstone, 1992, p 17. Copyright Elsevier.]

and/or NSAIDs, it is usually managed adequately without reoperation. Thus, gastric resection to minimize recurrence in duodenal ulcer disease is often not justified today; resection for gastric ulcer remains the standard because of the risk of cancer. Clearly, the modern trend in peptic ulcer operation could be described as “less is more.”^{70,71} Vagotomy as a component of emergency ulcer operation is increasingly uncommon.

Bleeding Peptic Ulcer

Bleeding is the most common cause of ulcer-related death, but most patients admitted to hospital with bleeding gastric or duodenal ulcer today will not require an operation. In many hospitals, operation for ulcer perforation is much more common than operation for bleeding ulcer. The success of endoscopic treatment and medical therapy in treating and preventing bleeding PUD

has resulted in the selection of a small subgroup of high-risk patients for today’s surgeon. It is likely that patients currently coming to operation for bleeding PUD are at higher risk for a poor outcome than ever before. The surgical options for treating bleeding PUD include suture ligation of the bleeder; suture ligation and definitive nonresective ulcer operation (HSV or V + D); and gastric resection (usually, including vagotomy and ulcer excision). Gastric ulcer requires biopsy if not resected.

The management of bleeding peptic ulcer is summarized in the algorithm provided in Fig. 26-42. All patients admitted to hospital with bleeding peptic ulcer should be adequately resuscitated and started on continuous IV PPI.⁷² Seventy-five percent of patients will stop bleeding with these measures alone, but 25% will continue to bleed or will rebleed in hospital. It is important to identify this high-risk group early with clinical

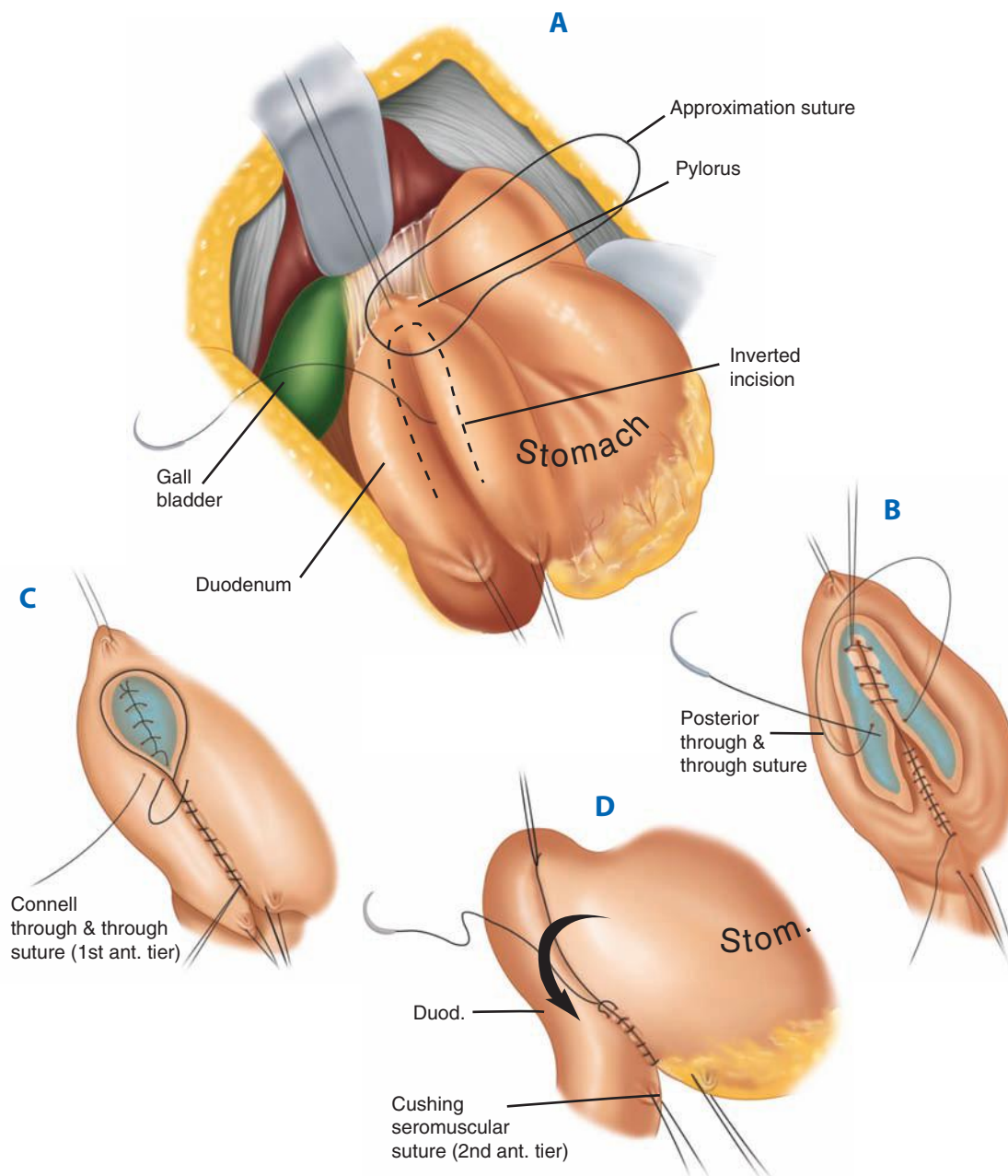


Figure 26-37. A through D. Finney pyloroplasty. ant. = anterior; Duod. = duodenum; Stom. = stomach. [Reproduced with permission from Sawyers JL: *Vagotomy and pyloroplasty*, in Zuidema GD (ed): *Shackelford's Surgery of the Alimentary Tract*, 4th ed. Philadelphia: Saunders, 1996, p 150. Copyright Elsevier.]

and endoscopic parameters because, essentially, all the deaths from bleeding ulcer occur in this group. Surgical consultation is mandatory, and endoscopic hemostatic therapy (cautery, epinephrine injection, clipping) is indicated and usually successful in these high-risk patients.^{73,74} Indications for operation include massive hemorrhage unresponsive to endoscopic control, and transfusion requirement of more than four to six units of blood, despite attempts at endoscopic control. Lack of availability of a therapeutic endoscopist, recurrent hemorrhage after one or more attempts at endoscopic control, lack of availability of blood for transfusion, repeat hospitalization for bleeding ulcer, and concurrent indications for surgery such as perforation or obstruction, are also indications for surgery. Patients with massive bleeding from high-risk lesions (e.g., posterior duodenal ulcer with erosion

of gastroduodenal artery, or lesser curvature gastric ulcer with erosion of left gastric artery or branch) should be considered for early operation. Early operation should also be considered in patients more than 60 years of age, those presenting in shock, those requiring more than four units of blood in 24 hours or eight units of blood in 48 hours, those with rebleeding, and those with ulcers >2 cm in diameter. The mortality rate for surgery for bleeding peptic ulcer is around 20%. Angiography and embolization may be useful in some patients.

Operation for Bleeding Peptic Ulcer (Fig. 26-43)

The two operations most commonly used for bleeding duodenal ulcer are oversewing of the ulcer usually without vagotomy,⁷⁰ or V + A. Oversewing alone results in a higher rebleeding rate

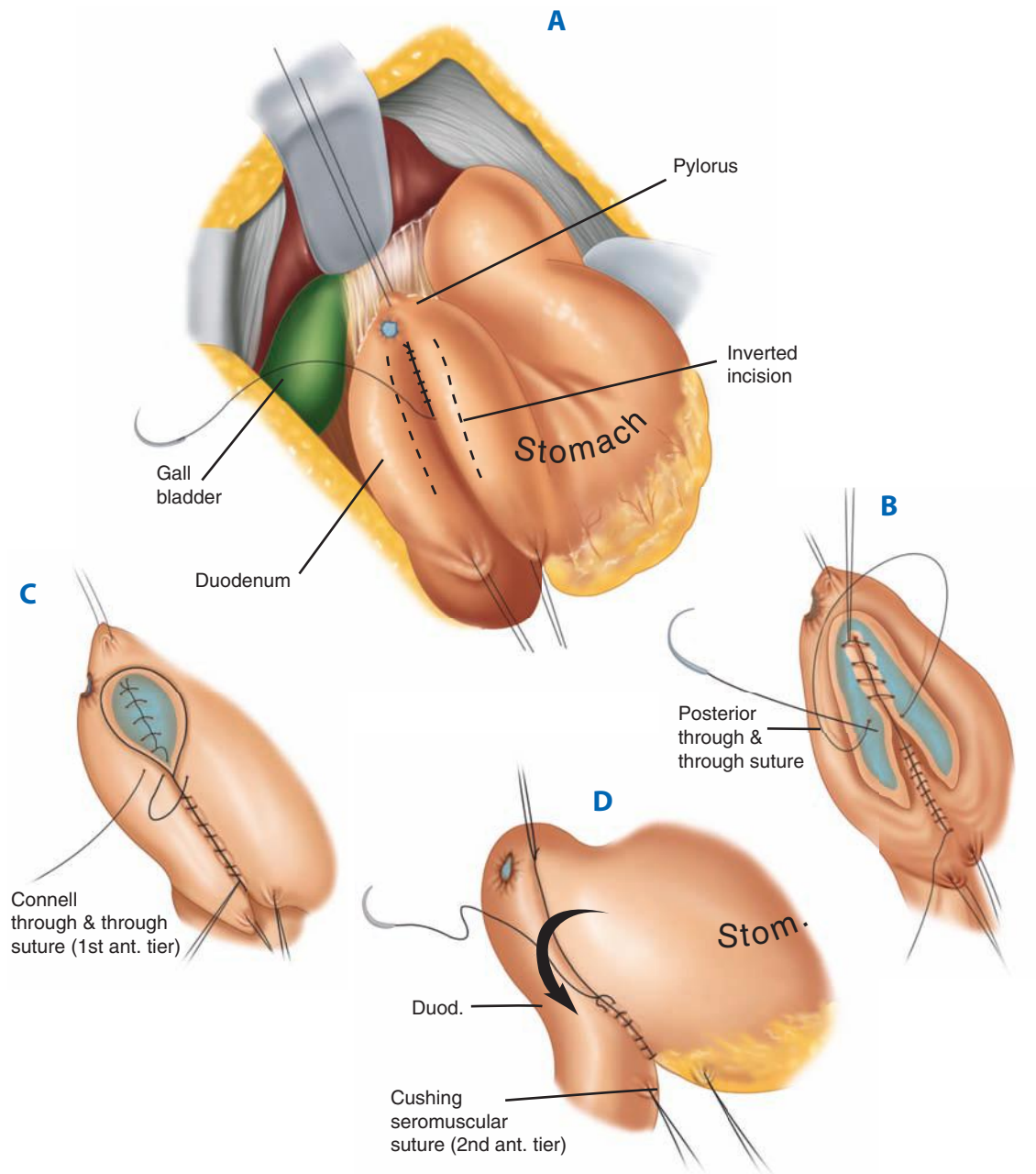


Figure 26-38. A through D. Jaboulay pyloroplasty. ant. = anterior; Duod. = duodenum; Stom. = stomach. [Reproduced with permission from Sawyers JL: *Vagotomy and pyloroplasty*, in Zuidema GD (ed): *Shackelford's Surgery of the Alimentary Tract*, 4th ed. Philadelphia: Saunders, 1996, p 150. Copyright Elsevier.]

but a lower operative mortality rate. When the mortality for reoperation for rebleeding is considered, the overall mortality is probably comparable for the two approaches. Patients who are in shock or medically unstable should not have gastric resection.

An initial pyloromyotomy incision allows access to the bleeding posterior duodenal ulcer, and an expeditious Kocher maneuver allows the surgeon to control the hemorrhage with the left hand if necessary. Heavy suture material on a stout needle is used to place figure-of-eight sutures or a U-stitch to secure the bleeding vessel at the base of the posterior duodenal ulcer. Multiple sutures are usually necessary. Once the surgeon is

unequivocally convinced that hemostasis is secure, a pyloroplasty can be performed. If the patient is stable, vagotomy may be considered if the surgeon is experienced and the vagotomy straightforward. If the patient is not a high operative risk and V + A is selected, smaller duodenal ulcers are resected with the specimen; larger bleeding duodenal ulcers must often be left behind in the duodenal stump. In this situation, suture hemostasis must be attained and a secure duodenal closure accomplished. The anterior wall of the open duodenum can be sutured to either the proximal or distal lip of the posterior ulcer once the bleeding vessel has been sutured. The duodenal closure can be buttressed with omentum and the duodenum should be

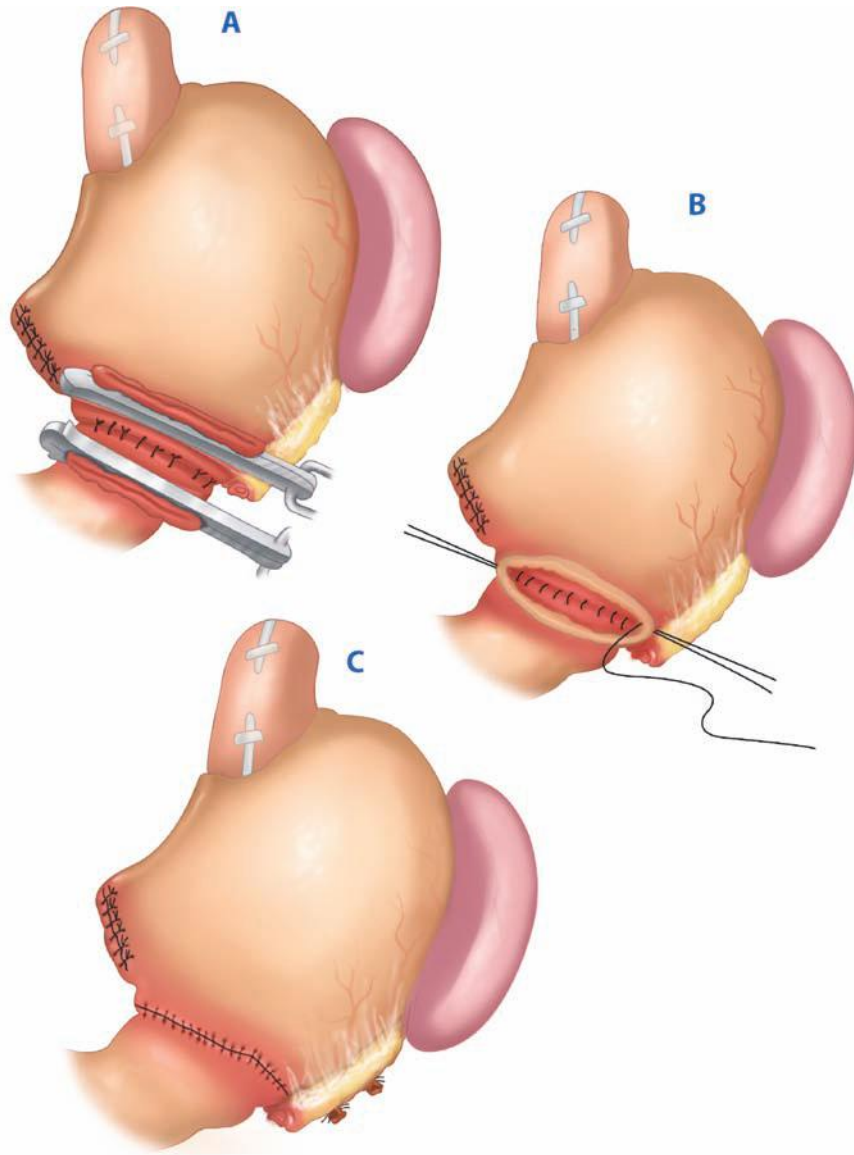


Figure 26-39. A through C. Billroth I gastroduodenostomy. [Reproduced with permission from Zinner MJ (ed): *Atlas of Gastric Surgery*. New York: Churchill Livingstone, 1992, p 35. Copyright Elsevier.]

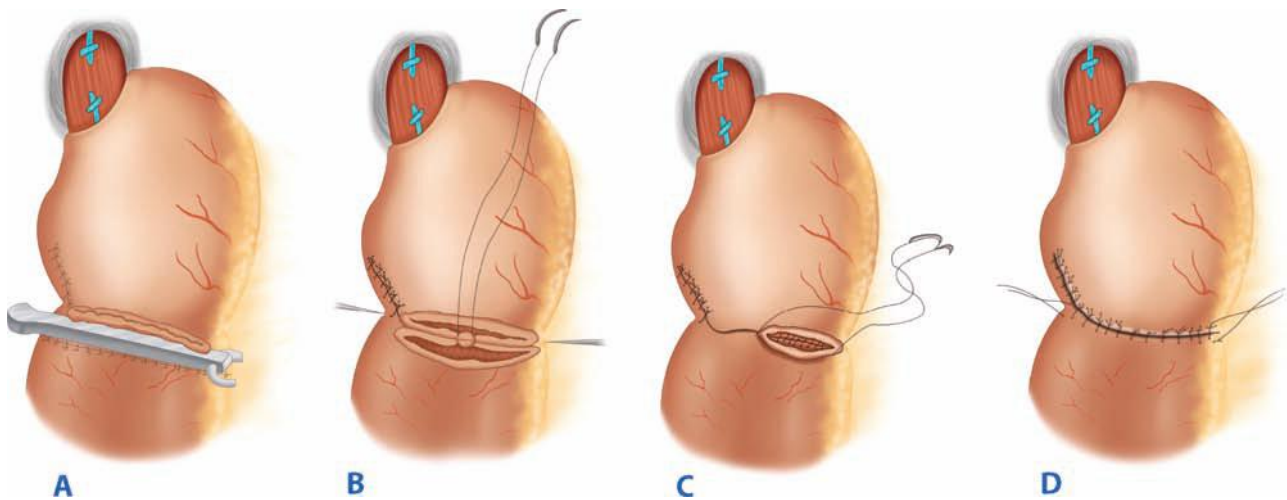


Figure 26-40. A through D. Billroth II antecolic gastrojejunostomy. [Reproduced with permission from Soybel DJ, Zinner MJ: *Stomach and duodenum: Operative procedures*, in Zinner MJ et al (eds): *Maingot's Abdominal Operations, 10th ed., Vol. I*. Stamford, Connecticut: Appleton & Lange, 1997, p 1112. Copyright © The McGraw-Hill Companies, Inc.]

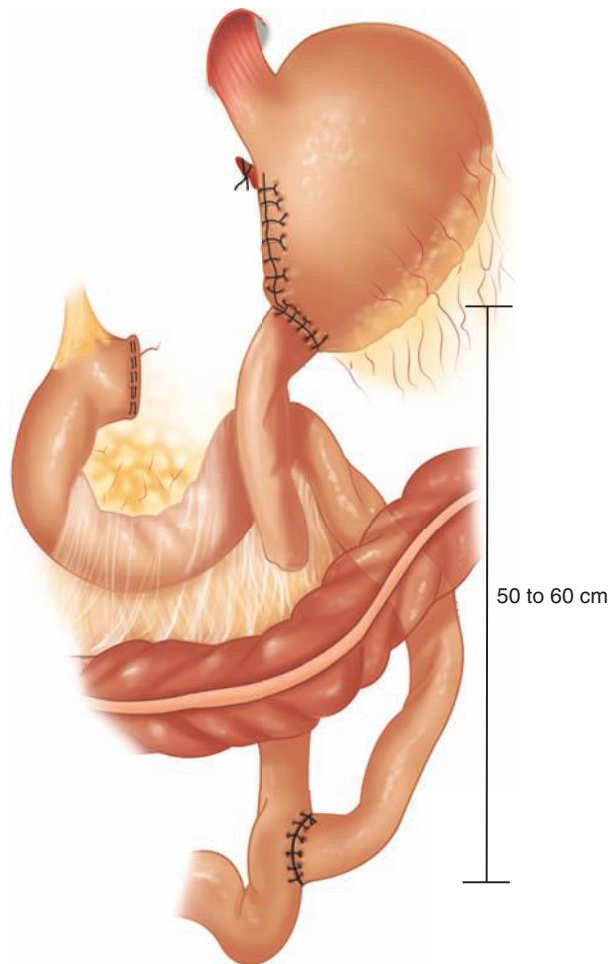


Figure 26-41. Roux-en-Y gastrojejunostomy. [Reproduced with permission from Ritchie WP Jr.: *Benign diseases of the stomach and duodenum*, in Ritchie WP, Steele G, Dean RH (eds): *General Surgery*. Philadelphia: Lippincott, 1995, p 117.]

Table 26-12

Surgical options in the treatment of duodenal and gastric ulcer

INDICATION	DUODENAL	GASTRIC
Bleeding	1. Oversew ^a 2. Oversew, V + D 3. V + A	1. Oversew and biopsy ^a 2. Oversew, biopsy, V + D 3. Distal gastrectomy ^b
Perforation	1. Patch ^a 2. Patch, HSV 3. Patch, V + D	1. Biopsy and patch ^a 2. Wedge excision, V + D 3. Distal gastrectomy ^b
Obstruction	1. HSV + GJ 2. V + A	1. Biopsy; HSV + GJ 2. Distal gastrectomy ^b
Intractability/ nonhealing	1. HSV ^b 2. V + D 3. V + A	1. HSV and wedge excision 2. Distal gastrectomy

^aUnless the patient is in shock or moribund, a definitive procedure should be considered.

^bOperation of choice in low-risk patient.

GJ = gastrojejunostomy; HSV = highly selective vagotomy; V + A = vagotomy and antrectomy; V + D = vagotomy and drainage.

decompressed, either with a lateral duodenostomy or retrograde tube via the proximal jejunum or nasogastric tube secured with tip well into afferent limb. Right upper quadrant closed suction peritoneal drainage is important. Use of a feeding jejunostomy is also considered. A Billroth II anastomosis reestablishes gastrointestinal continuity.

The initial management of bleeding gastric ulcers and the indications for operation are similar to those for bleeding duodenal ulcer. These lesions tend to occur in older and/or medically complicated patients, and this fact may increase the operative risk. However, experience shows that planned surgery in a resuscitated patient results in a better operative survival rate than emergent operation in a patient who has rebled and is in shock. Distal gastric resection to include the bleeding ulcer is the procedure of choice for bleeding gastric ulcer. Second best is V + D with oversewing and biopsy of the ulcer to rule out cancer. Oversewing of the bleeder followed by long-term acid suppression is a reasonable alternative in high-risk or unstable patients.

Perforated Peptic Ulcer (Fig. 26-44)

Perforation is the second most common complication of peptic ulcer but nowadays a more common indication for operation than bleeding. As with bleeding ulcer, NSAID and/or aspirin use have been inextricably linked with perforated PUD, especially in the elderly population.⁶¹ Surgery is almost always indicated for ulcer perforation, although occasionally nonsurgical treatment can be used in the stable patient without peritonitis in whom radiologic studies document a sealed perforation. Patients with acute perforation and GI blood loss (either chronic or acute) should be suspected of having a second ulcer or a GI cancer.

The options for surgical treatment of perforated duodenal ulcer are simple patch closure, patch closure and HSV, or patch closure and V + D. Simple patch closure, currently the most commonly performed operation for perforated peptic ulcer, should be done in patients with hemodynamic instability and/or exudative peritonitis signifying a perforation >24 hours old. In stable patients without longstanding perforation, the addition of HSV may be considered. However, in the United States and Western Europe, there is clearly a trend away from definitive operation for perforated duodenal ulcer, probably because of the ready availability of PPI, and surgeon unfamiliarity with definitive operation in this setting.^{51,70}

In the stable patient without multiple operative risk factors, perforated gastric ulcers are best treated by distal gastric resection. Vagotomy is usually added for type II and III gastric ulcers. Patch closure with biopsy; or local excision and closure; or biopsy, closure, truncal vagotomy, and drainage are alternative operations in the unstable or high-risk patient, or in the patient with a perforation in an inopportune location. All perforated gastric ulcers, even those in the prepyloric position, should be biopsied if they are not removed at surgery.

Obstructing Peptic Ulcer

Acute ulcers associated with obstruction due to edema and/or motor dysfunction may respond to intensive antisecretory therapy and nasogastric suction. But most patients with significant obstruction from chronic ulceration will require some sort of more substantial intervention. Endoscopic balloon dilation can often transiently improve obstructive symptoms, but many of these patients ultimately fail and come to operation.⁷⁵

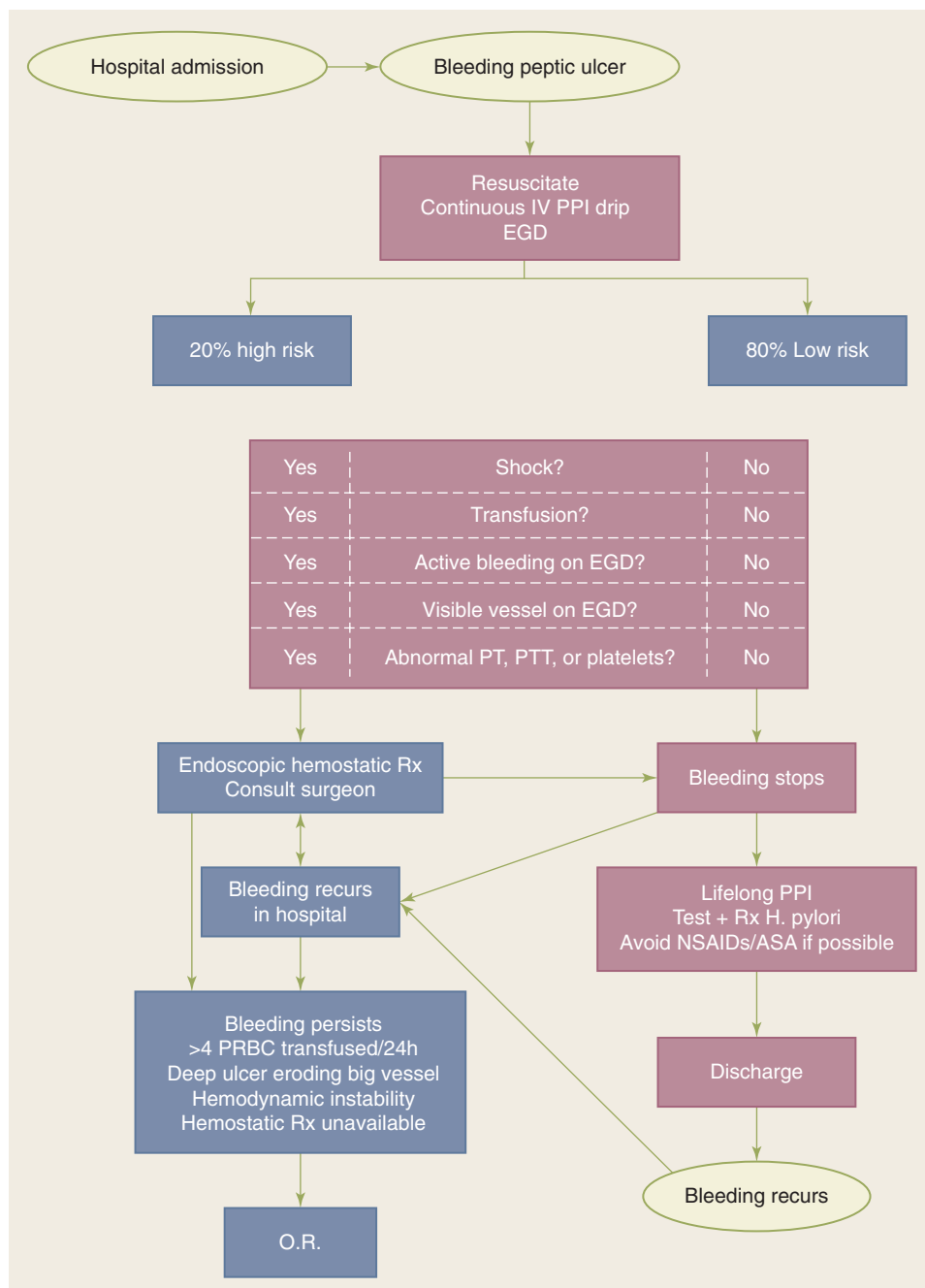


Figure 26-42. Algorithm for the treatment of bleeding peptic ulcer. ASA = acetylsalicylic acid; EGD = esophagogastroduodenoscopy; O.R. = operating room; PPI = proton pump inhibitor; PRBC = unit of packed red blood cells; PT = prothrombin time; PTT = partial thromboplastin time; Rx = treatment.

The standard operation for obstructing PUD is vagotomy and antrectomy. Alternatively vagotomy and gastrojejunostomy should be considered if a difficult duodenal stump is anticipated with resection. HSV and gastrojejunostomy may be comparable to V+A for obstructing ulcer disease,⁷⁶ and sometimes has appeal because it can be done laparoscopically, and because it does not complicate future resection, if needed. However, potentially curable gastric or duodenal cancers can be missed with this approach.

Intractable or Nonhealing Peptic Ulcer

Intractability should be an unusual indication for peptic ulcer operation nowadays. The patient referred for surgical evaluation

because of intractable PUD should raise red flags for the surgeon: Maybe the patient has a missed cancer; maybe the patient is noncompliant (not taking prescribed PPI, still taking NSAIDs, still smoking); maybe the patient has *Helicobacter* despite the presence of a negative test or previous treatment. Because acid secretion can be totally blocked and *H. pylori* eradicated with modern medication, the question remains: “Why does the patient have a persistent ulcer diathesis?” The surgeon should review the differential diagnosis of nonhealing ulcer before any consideration of operative treatment (Table 26-13).

Surgical treatment should be considered in patients with nonhealing or intractable PUD who have multiple recurrences, large ulcers (>2 cm), complications (obstruction, perforation, or

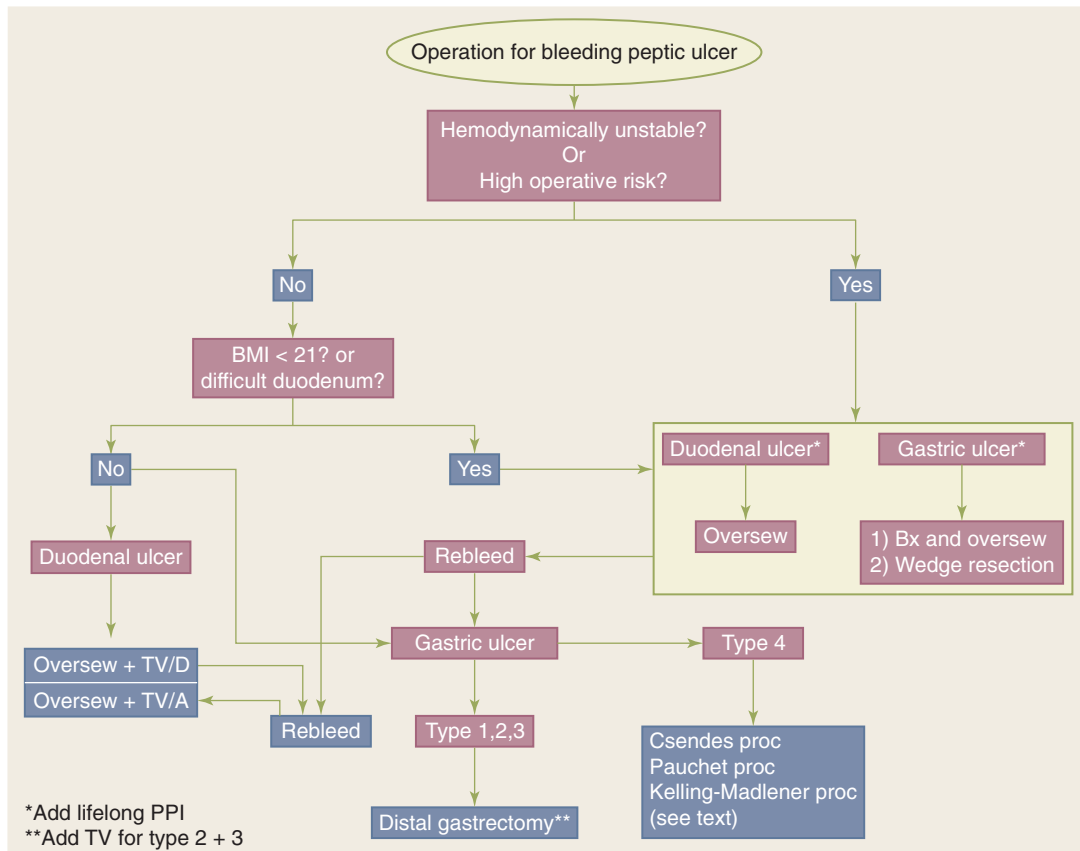


Figure 26-43. Algorithm for operation for bleeding peptic ulcer. BMI = body mass index; Bx = biopsy; PPI = proton pump inhibitor; proc = procedure; TV = truncal vagotomy; TV/A = truncal vagotomy and antrectomy; TV/D = truncal vagotomy and drainage.

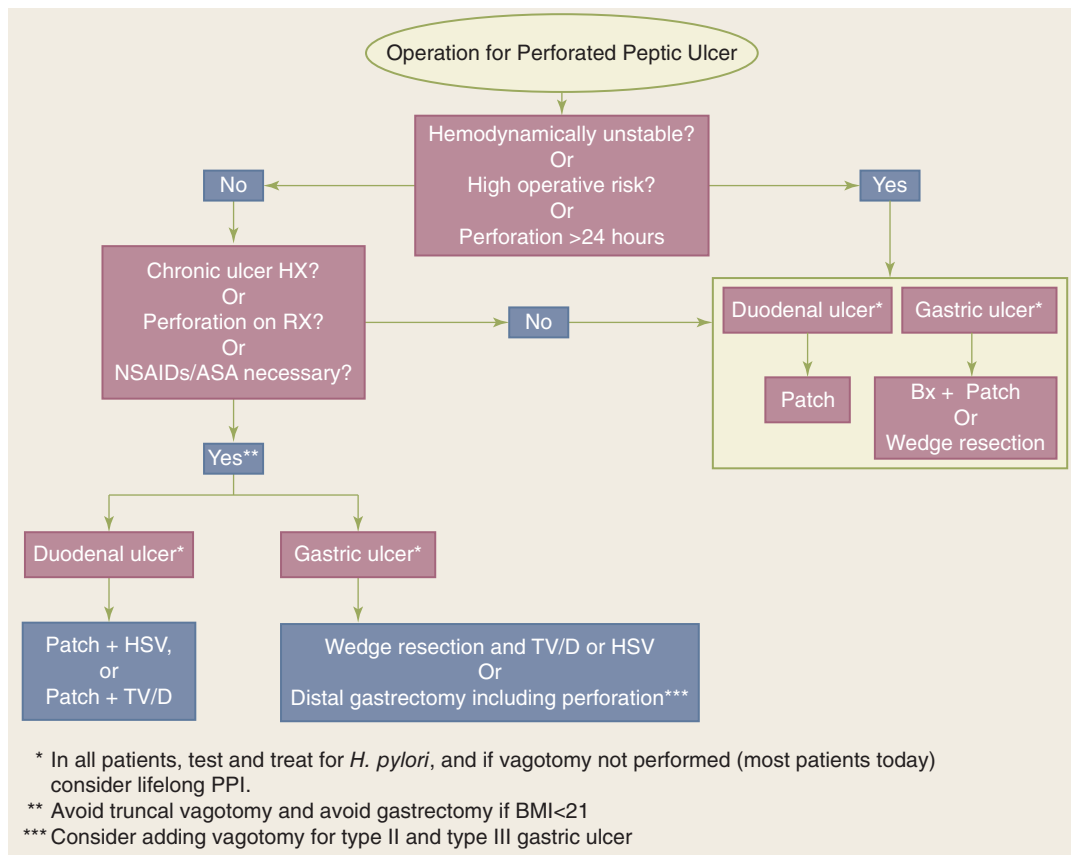


Figure 26-44. Algorithm for operation for perforated peptic ulcer. ASA = acetylsalicylic acid; BMI = body mass index; Bx = biopsy; HSV = highly selective vagotomy; Hx = history; PPI = proton pump inhibitor; Rx = treatment; TV/D = truncal vagotomy and drainage.

Table 26-13

Differential diagnosis of intractability or nonhealing peptic ulcer disease

Cancer
Gastric
Pancreatic
Duodenal
Persistent <i>Helicobacter pylori</i> infection
Tests may be false-negative
Consider empiric treatment
Noncompliant patient
Failure to take prescribed medication
Surreptitious use of NSAIDs
Motility disorder
Zollinger-Ellison syndrome

4► hemorrhage), or suspected malignancy. Definitive operation, particularly gastric resection, should be considered most cautiously in the thin or marginally nourished individual.

It is important that the surgeon not fall into the trap of performing a large, irreversible operation on these patients, based on the unproven theory that if all other methods have failed to heal the ulcer, a large operation is required. Although there is a large quantity of very good data in the surgical literature suggesting that the large majority of patients do well after the larger elective ulcer operations, these data may not be particularly relevant to the modern patient.⁶⁷ Candidates for ulcer operation today are different than those of 30 to 50 years ago. One might argue that current medical care has healed the minor ulcers, and that patients presenting with true intractability or nonhealing will be more difficult to treat and are likely to have chronic problems after a major ulcer operation.

If surgery is necessary, a lesser operation may be preferable. It is prudent to avoid truncal vagotomy and/or distal gastrectomy

as the initial elective operation for intractable peptic ulcer in the thin or asthenic patient. Alternatives for intractable duodenal ulcer include HSV with or without gastrojejunostomy (reversible drainage operation). In patients with nonhealing gastric ulcer, wedge resection with HSV should be considered in thin or frail patients. Otherwise, distal gastrectomy (to include the ulcer) is recommended. It is unnecessary to add a vagotomy in patients with type I or type IV (juxta-esophageal) gastric ulcers because they are usually associated with acid hyposecretion. Type IV gastric ulcers may be difficult to resect as part of a distal gastrectomy, and a variety of surgical techniques have been described to treat these more proximal lesions (Fig. 26-45).

Zollinger-Ellison Syndrome⁷⁷⁻⁷⁹

ZES is caused by the uncontrolled secretion of abnormal amounts of gastrin by a duodenal or pancreatic neuroendocrine tumor (i.e., gastrinoma). Most cases (80%) are sporadic, but 20% are inherited. The inherited or familial form of gastrinoma is associated with multiple endocrine neoplasia type I (MEN I), which consists of parathyroid, pituitary, and pancreatic (or duodenal) tumors. Gastrinoma is the most common pancreatic tumor in patients with MEN I. Patients with MEN I usually have multiple gastrinoma tumors, and surgical cure is less common; sporadic gastrinomas are more often solitary and are more often amenable to surgical cure. Currently, about 50% to 60% of gastrinomas are malignant, with lymph node, liver, or other distant metastases at operation. Five-year survival in patients presenting with metastatic disease is approximately 40%. The larger the primary gastrinoma, the higher the likelihood of metastatic disease. More than 90% of patients with sporadically, completely resected gastrinoma will be cured.

The most common symptoms of ZES are epigastric pain, GERD, and diarrhea. More than 90% of patients with gastrinoma have peptic ulcer. Most ulcers are in the typical location (proximal duodenum), but atypical ulcer location (distal duodenum, jejunum, or multiple ulcers) should prompt an evaluation for gastrinoma. Gastrinoma also should be considered in

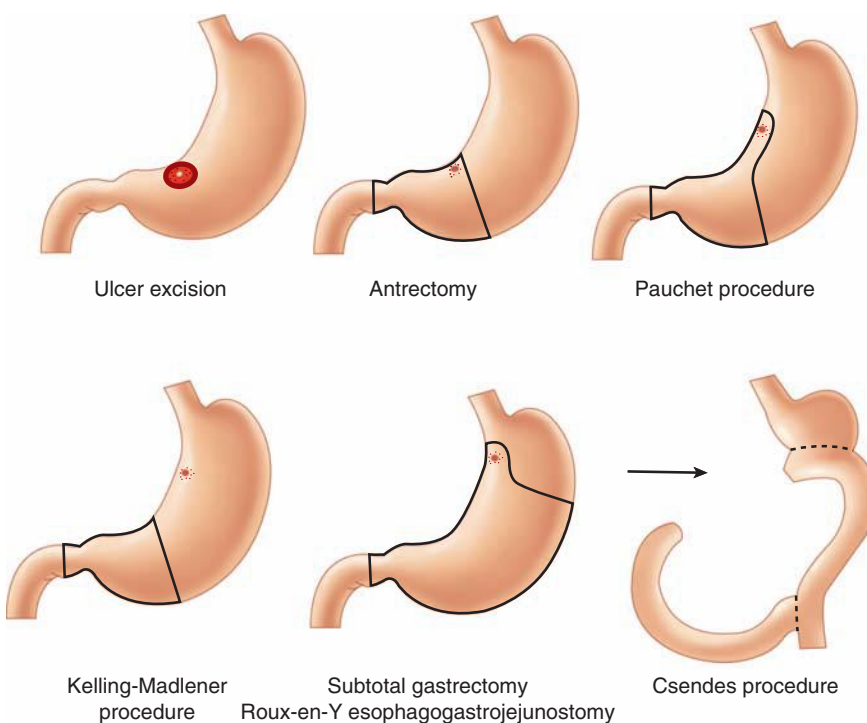


Figure 26-45. Operations for gastric ulcer. [Reproduced with permission from Seymour NE: *Operations for peptic ulcer and their complications*, in Feldman M, Sharschmidt BF, Sleisenger MH (eds): *Gastrointestinal and Liver Disease*, 6th ed. Philadelphia: Saunders, 1998, p 702. Copyright Elsevier.]

the differential diagnosis of recurrent or refractory peptic ulcer, secretory diarrhea, gastric rugal hypertrophy, esophagitis with stricture, bleeding or perforated ulcer, familial ulcer, peptic ulcer with hypercalcemia, and gastric carcinoid. The majority of patients with ZES have been symptomatic for several years before definitive diagnosis and, in general, patients with ZES and MEN1 are diagnosed in their 20s and 30s, while those with sporadic ZES more typically are diagnosed in their 40s and 50s.

ZES is an important part of the differential diagnosis of hypergastrinemia (Fig. 26-46). All patients with gastrinoma have an elevated gastrin level, and hypergastrinemia in the presence of elevated BAO strongly suggests gastrinoma. Patients with gastrinoma usually have a BAO >15 mEq/h or >5 mEq/h if they have had a previous procedure for peptic ulcer. Acid secretory medications should be held for several days before gastrin measurement, because acid suppression may falsely elevate gastrin levels. Causes of hypergastrinemia can be divided into those associated with hyperacidity and those associated with hypoacidity (see Fig. 26-46). The diagnosis of ZES is confirmed by

the secretin stimulation test. An IV bolus of secretin (2 U/kg) is given and gastrin levels are checked before and after injection. An increase in serum gastrin of 200 pg/mL or greater suggests the presence of gastrinoma. Patients with gastrinoma should have serum calcium and parathyroid hormone levels determined to rule out MEN1 and, if present, parathyroidectomy should be considered before resection of gastrinoma.

About 80% of primary tumors are found in the gastrinoma triangle (Fig. 26-47), and many tumors are small (<1 cm), making preoperative localization difficult. Transabdominal ultrasound is quite specific, but not very sensitive. CT will detect most lesions >2 cm in size and MRI is comparable. EUS is more sensitive than these other noninvasive imaging tests, but it still misses many of the smaller lesions, and may confuse normal lymph nodes for gastrinomas. Currently, the preoperative imaging study of choice for gastrinoma is somatostatin receptor scintigraphy (the octreotide scan). When the pretest probability of gastrinoma is high, the sensitivity and specificity of this modality approach 100%. Gastrinoma cells contain type II somatostatin

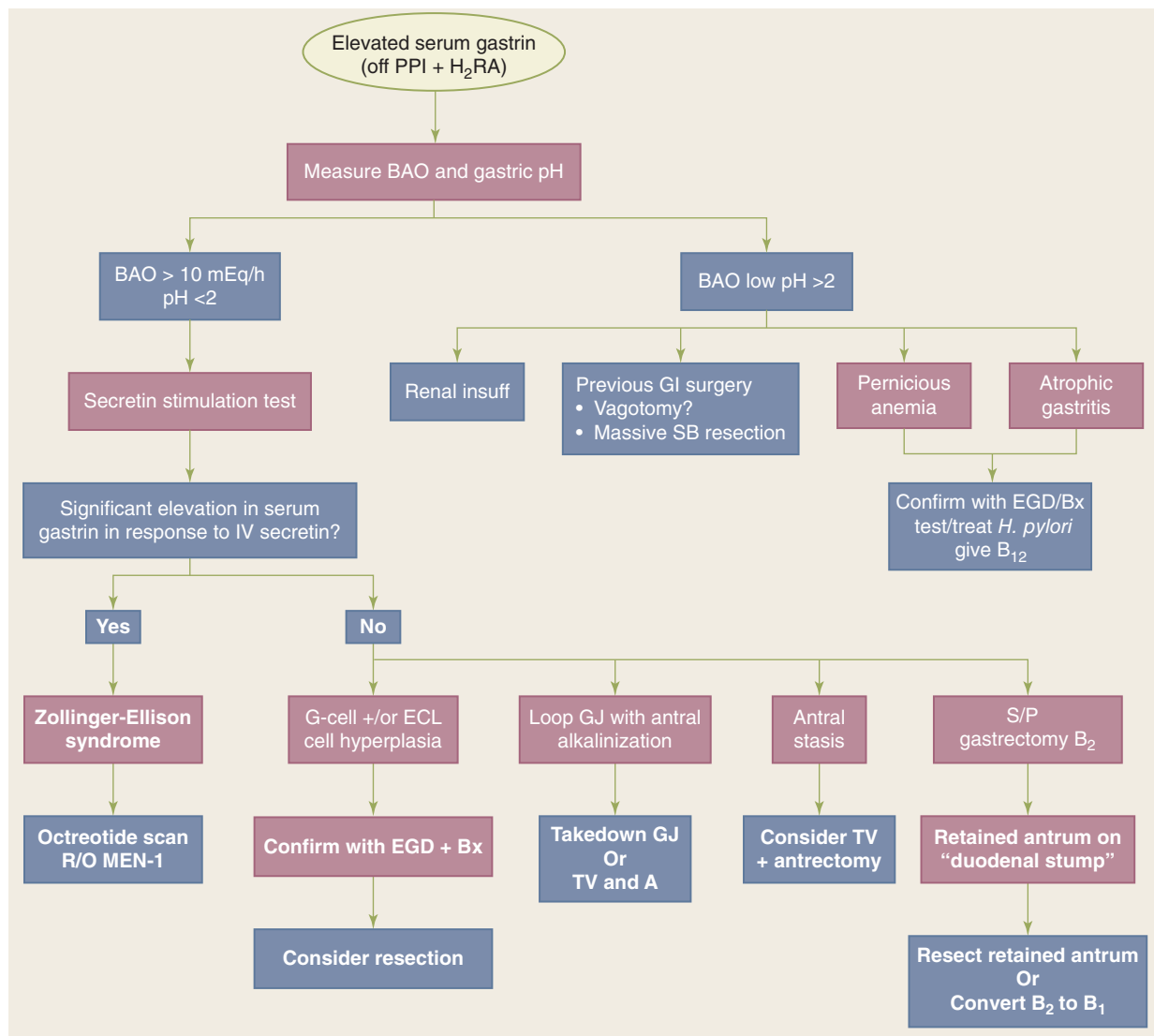


Figure 26-46. Algorithm for diagnosis and management of hypergastrinemia. BAO = basal acid output; B₁ = Billroth 1; B₂ = Billroth 2; Bx = biopsy; ECL = enterochromaffin-like; EGD = esophagogastroduodenoscopy; GJ = gastrojejunostomy; H₂RA = histamine 2 receptor antagonist; insuff = insufficiency; MEN1 = multiple endocrine neoplasia type I; PPI = proton pump inhibitor; R/O = rule out; SB = small bowel; S/P = status post; TV = truncal vagotomy; TV and A = truncal vagotomy and antrectomy.

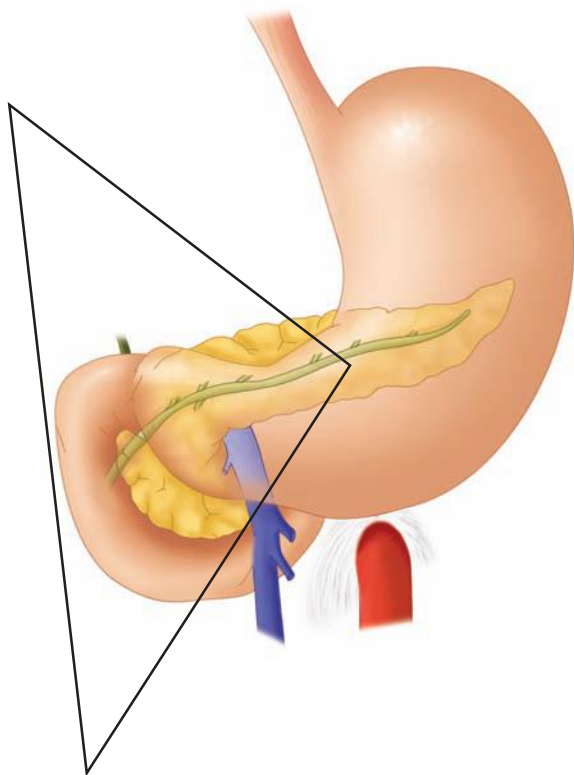


Figure 26-47. Gastrinoma triangle. [Reproduced with permission from Ritchie WP Jr.: *Benign diseases of the stomach and duodenum*, in Ritchie WP, Steele G, Dean RH (eds): *General Surgery*. Philadelphia: Lippincott, 1995, p 128.]

receptors that bind the indium-labeled somatostatin analogue (octreotide) with high affinity, making imaging with a gamma camera possible (Fig. 26-48). Currently, angiographic localization studies are infrequently performed for gastrinoma. Both diagnostic angiography and transhepatic selective venous sampling of the portal system have been supplanted by selective arterial secretin infusion, which helps to localize the tumor as inside or outside the gastrinoma triangle.

In this test, an arterial catheter is selectively placed in a named vessel supplying the pancreas (e.g., gastroduodenal or splenic), and a venous catheter is placed in a hepatic vein. Secretin is injected into the visceral artery and gastrin is sampled in the hepatic vein. A significant elevation in hepatic venous gastrin indicates that the tumor is supplied by the injected artery. This test should be performed if pancreaticoduodenectomy is contemplated. Probably the most important means of locating gastrinomas is intraoperative exploration.

All patients with sporadic (nonfamilial) gastrinoma should be considered for surgical resection and possible cure. The lesions should be located in 90% of patients, and the large majority is cured by extirpation of the gastrinoma(s). A thorough intraoperative exploration of the gastrinoma triangle and pancreas is essential, but other sites (i.e., liver, stomach, small bowel, mesentery, and pelvis) should be evaluated as part of a thorough intra-abdominal evaluation to find the primary tumor, which is usually solitary and often in the duodenal wall. The duodenum and pancreas should be extensively mobilized and intraoperative ultrasound should be used. Intraoperative EGD with transillumination may be considered. If the tumor can not be located, generous longitudinal duodenotomy with

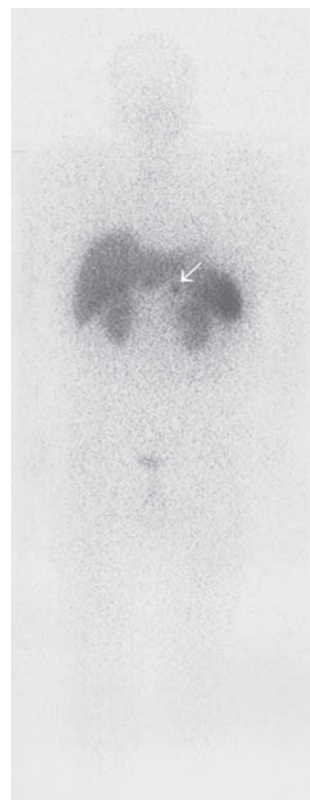

Figure 26-48. Positive octreotide scan in patient with gastrinoma. (Reproduced with permission from Alan Maurer, MD.)

inspection and palpation of the duodenal wall is performed. Lymph nodes from the portal, peripancreatic, and celiac drainage basins should be sampled. Ablation or resection of hepatic metastases should be considered.

The management of gastrinoma in patients with MEN I is controversial because the patients are often not cured by operation, and the tumors tend to be small and multiple. If the tumor can be imaged preoperatively, operation by an experienced gastrinoma surgeon is reasonable.

Acid hypersecretion in patients with gastrinoma can always be managed with high-dose PPIs. Highly selective vagotomy may make management easier in some patients and should be considered in those with surgically untreatable or unresectable gastrinoma. Gastrectomy for ZES is no longer indicated.

GASTRITIS AND STRESS ULCER

Pathogenesis and Prevention

Gastritis is mucosal inflammation. The gross endoscopic diagnosis of gastritis correlates poorly with histologic findings, and is thus relatively useless as a diagnosis without confirmatory biopsy. Additionally, there is poor correlation between symptoms and histologic gastritis. The most common cause of gastritis is *H. pylori*. Other causes of gastritis include alcohol, NSAIDs, Crohn's disease, tuberculosis, and bile reflux (primary or secondary). These agents cause injury by a variety of different mechanisms. In general, the infectious and inflammatory causes result in immune cell infiltration and cytokine production which damage mucosal cells. The chemical agents (alcohol, aspirin, and bile) generally work to disrupt the mucosal barrier, allowing mucosal damage by back diffusion of luminal hydrogen ions.

Stress gastritis is a peculiar entity that has all but disappeared from the clinical (if not endoscopic) lexicon, largely due to better critical care and acid suppression or cytoprotective agents (e.g., sucralfate) in the intensive care unit (ICU). Stress gastritis and stress ulcer are probably due to inadequate gastric mucosal blood flow during periods of intense physiologic stress. Adequate mucosal blood flow is important to maintain the mucosal barrier, and to buffer any back-diffused hydrogen ions. When blood flow is inadequate, these processes fail and mucosal breakdown occurs. Modern intensive care, with emphasis on adequate tissue perfusion and oxygenation, has undoubtedly decreased the severity of gastric mucosal injury seen in the ICU today. Although it is still common to see small mucosal erosions when performing upper endoscopy in the ICU, it is rare for these lesions to coalesce into the larger bleeding erosions that plagued the ICU patient 30 to 50 years ago. The rationale for routine acid suppression in the ICU, supported by excellent data from clinical trials and the laboratory, is that less mucosal injury will be caused in the potentially weakened gastric mucosa if there is less luminal acid.^{80,81} There are some studies suggesting that routine acid suppression leads to overgrowth of gastric bacteria, which increases the incidence and/or severity of aspiration pneumonia in the ICU. Nevertheless, acid suppression, particularly in the severely ill patient, remains an important part of clinical pathways in most ICUs.⁸² In the extraordinarily rare patient requiring operation today for hemorrhagic stress gastritis, the surgical options include V + D with oversewing of the major bleeding lesions, or near total gastrectomy. Angiographic embolization and endoscopic hemostatic treatment should be considered as well.

MALIGNANT NEOPLASMS OF THE STOMACH

The three most common primary malignant gastric neoplasms are adenocarcinoma (95%), lymphoma (4%), and malignant GIST (1%) (Table 26-14). Other rare primary malignancies

Table 26-14

Frequency of gastric tumors

TUMOR TYPE	NO. OF CASES	PERCENT
Malignant tumors	4199	93.0
Carcinoma	3970	87.9
Lymphoma	136	3.0
Leiomyosarcoma	77	1.7
Carcinoid	11	0.3
Others	5	0.1
Benign tumors	315	7.0
Polyp	140	3.1
Leiomyoma	92	2.0
Inflammatory lesions	30	0.7
Heterotopic pancreas	20	0.4
Others	33	0.8

Source: Modified with permission from Ming S-C (ed): Tumors of the Esophagus and Stomach, *AFIP Atlas of Tumor Pathology, Second Series, Fascicle 7*. Washington DC: American Registry of Pathology, 1973, p 82, Table VI.

include carcinoid, angiosarcoma, carcinosarcoma, and squamous cell carcinoma. Occasionally the stomach is the site of hematogenous metastasis from other sites (e.g., melanoma or breast). More commonly, malignant tumors from adjacent organs invade the stomach by direct extension (e.g., colon or pancreas) or by peritoneal seeding (e.g., ovary).

Adenocarcinoma

Epidemiology. Globally, gastric cancer is the fourth most common cancer type and the second leading cause of cancer death. Over the past several decades, there has been a dramatic decrease in the gastric cancer incidence and death rate in most Western industrialized countries (Fig. 26-49). This decrease has been largely in the so-called intestinal form rather than in the diffuse form of gastric cancer. In Asia and Eastern Europe, gastric cancer remains a leading cause of cancer death. In 2012 in the United States, there were approximately 21,320 new cases of stomach cancer (13,020 in men and 8300 in women), and 10,540 deaths from this disease (6190 men and 4350 women.⁸³ The estimated 5-year survival rate is 27%, up from about 15% in 1975.

In general, gastric cancer is a disease of the elderly, and it is twice as common in blacks as in whites. In younger patients, tumors are more often of the diffuse variety and tend to be large, aggressive, and more poorly differentiated, sometimes infiltrating the entire stomach (linitis plastica). Gastric cancer has a higher incidence in groups of lower socioeconomic status.

Etiology. Gastric cancer is more common in patients with pernicious anemia, blood group A, or a family history of gastric cancer. When patients migrate from a high-incidence region to a low-incidence region, the risk of gastric cancer decreases in the subsequent generations born in the new region. This strongly suggests an environmental influence on the development of gastric cancer. Environmental factors appear to be more related etiologically to the intestinal form of gastric cancer than the more aggressive diffuse form. The commonly accepted risk factors for gastric cancer are listed in Table 26-15.

Diet and Drugs Typically, a starchy diet high in pickled, salted, or smoked food is found in many regions of high gastric cancer risk. Dietary nitrates have been impugned as a possible cause of gastric cancer. Gastric bacteria (more common in the achlorhydric stomach of patients with atrophic gastritis, a risk factor for gastric cancer) convert nitrate into nitrite, a proven carcinogen. A diet high in fresh fruits and vegetables and rich in vitamin C and E has been shown to decrease the population's risk of gastric cancer. The reduced consumption of nitrate-rich preserved foods seen with the growth of refrigeration has been suggested as a cause of the dramatic decrease in gastric cancer seen in North America and Western Europe over the last century. Tobacco use probably increases the risk of stomach cancer, and alcohol use probably has no effect. Regular aspirin use may be protective.

Helicobacter pylori^{54,84} The risk of gastric cancer in patients with chronic *H. pylori* infection is increased about threefold. Compared to uninfected patients, patients with a history of gastric ulcer are more likely to develop gastric cancer (incidence ratio 1.8, 95% confidence interval 1.6–2.0), and patients with a history of duodenal ulcer are at decreased risk for gastric cancer (incidence ratio 0.6, 95% confidence interval 0.4–0.7). As diagrammed in Fig. 26-50, this may be due to the fact that some patients develop antral-predominant disease (predisposing to duodenal ulcer and somehow protecting against

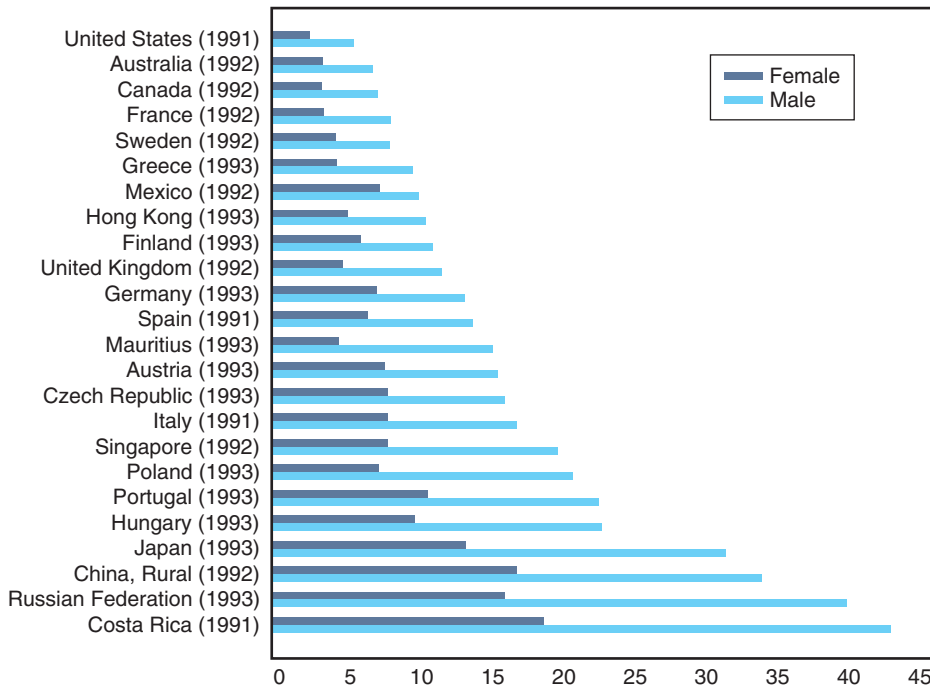


Figure 26-49. Death rates for gastric cancer in different countries. [Reproduced with permission from Ming S-C, Hirota T: *Malignant epithelial tumors of the stomach*, in Ming S-C, Goldman H (eds): *Pathology of the Gastrointestinal Tract*, 2nd ed. Baltimore: Williams & Wilkins, 1998, p 607.]

gastric cancer), while other patients develop corpus-predominant gastritis, resulting in hypochlorhydria and somehow predisposing to gastric ulcer and gastric cancer.⁸⁵ The theoretical sequence for development of gastric adenocarcinoma is diagrammed in Fig. 26-51.^{54,85} Recently, it has been demonstrated that bone marrow-derived stem cells play a key role in the pathogenesis of gastric adenocarcinoma in patients with chronic *H. pylori* infection.⁵⁴ However, it must be recognized that gastric adenocarcinoma is a multifactorial disease. Not all patients with gastric cancer have *H. pylori*, and there are some geographic areas with a high prevalence of chronic *H. pylori* infection and a low prevalence of gastric cancer (the “African enigma”).

Table 26-15

Factors increasing or decreasing the risk of gastric cancer

Increase risk
Family history
Diet (high in nitrates, salt, fat)
Familial polyposis
Gastric adenomas
Hereditary nonpolyposis colorectal cancer
<i>Helicobacter pylori</i> infection
Atrophic gastritis, intestinal metaplasia, dysplasia
Previous gastrectomy or gastrojejunostomy (>10 y ago)
Tobacco use
Ménétrier’s disease
Decrease risk
Aspirin
Diet (high fresh fruit and vegetable intake)
Vitamin C

Finally, *H. pylori*-infected patients seem to be at decreased risk for the development of adenocarcinoma of the distal esophagus and cardia region.⁸⁶ Perhaps the corporeal gastritis decreases acid secretion, creating a less damaging refluxate and thus reducing the risk for Barrett’s esophagus, the precursor lesion for these tumors.

Epstein-Barr Virus About 10% of gastric adenocarcinomas carry the EBV virus. Recently it has been suggested that EBV infection is a rather late step in gastric carcinogenesis, since EBV transcripts are present in cancer cells but not in the metaplastic cells of precursor epithelium.⁸⁷

Genetic Factors A variety of genetic abnormalities have been described in gastric cancer (Table 26-16). Most gastric cancers are aneuploid. The most common genetic abnormalities in sporadic gastric cancer affect the *p53* and *COX-2* genes. Over two thirds of gastric cancers have deletion or suppression of the important tumor-suppressor gene *p53*. Additionally, approximately the same proportion have overexpression of *COX-2*. In the colon, tumors with upregulation of this gene have suppressed apoptosis, more angiogenesis, and higher metastatic potential. Gastric tumors that overexpress *COX-2* are more aggressive tumors. Recently, a germline mutation in the *CDH1* gene encoding E-cadherin was shown to be associated with hereditary diffuse gastric cancer. Prophylactic total gastrectomy should be considered in patients with these mutations.⁸⁸

Recently the role of microRNA abnormalities in gastric cancer have received attention. These are small short sequence molecules (18 to 25 nucleotides) which inhibit the translation or promote the degradation of messenger RNA with complementary sequences. MicroRNAs are important regulators of gene expression, and abnormalities in microRNA have been identified in gastric cancer which effect the cell cycle, apoptosis, and cellular invasiveness and/or metastatic potential.⁸⁹ It is likely

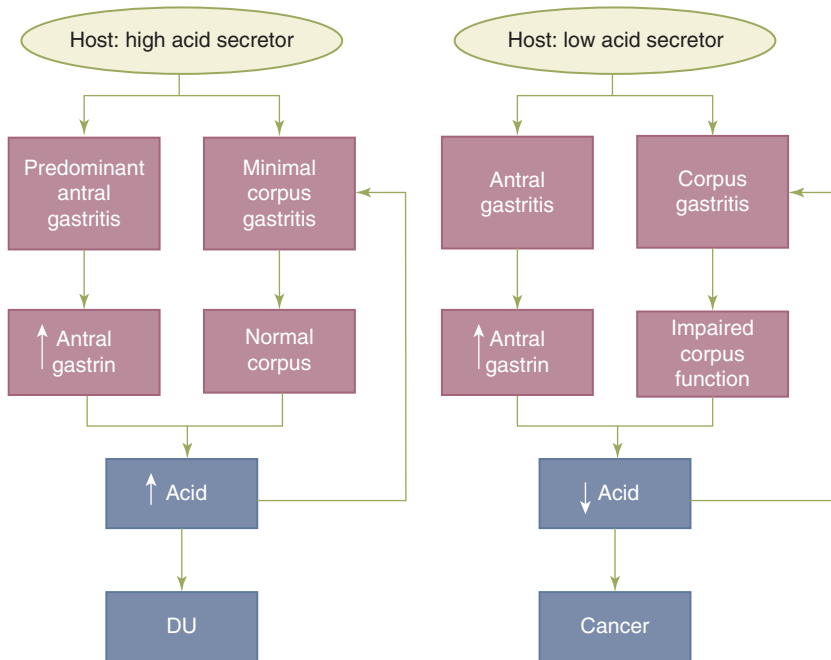


Figure 26-50. *Helicobacter* and gastritis, and the pathogenesis of duodenal ulcer (DU) or gastric cancer. [Reproduced with permission from Leung WK, Ng EKW, Sung JY: *Tumors of the stomach*, in Yamada T, et al (eds): *Textbook of Gastroenterology*, 4th ed. Philadelphia: Lippincott, Williams & Wilkins, 2003, p 1416.]

microRNA will have increasing diagnostic, therapeutic, and prognostic significance in gastric cancer as well as other tumors.

Premalignant Conditions of the Stomach Figure 26-52 shows the prevalence of some premalignant conditions associated with the development of early gastric cancer in a series of 1900 cases from Tokyo. By far the most common precancerous lesion is atrophic gastritis. There is a growing appreciation of the important influence of the chronic inflammatory milieu on the genome of mucosal cells. Chronic inflammation leads to both genetic and epigenetic changes in mucosal cells which in the stomach leads to the development of gastritis associated cancer.⁹⁰

Polyps Benign gastric polyps are classified as neoplastic (adenoma and fundic gland polyps) or nonneoplastic (hyperplastic

polyp, inflammatory polyp, hamartomatous polyp).^{90A} In general, inflammatory and hamartomatous polyps have little or no malignant potential. Fundic gland polyps, commonly seen in patients on long term proton pump inhibitor therapy, are not premalignant but in patients with familial adenomatous polyposis, dysplasia in these lesions is not uncommon. Hyperplastic polyps usually occur in the setting of chronic inflammation. Large hyperplastic polyps (>2cm) may harbor dysplasia or carcinoma in situ, and gastric cancer may develop remote from the hyperplastic polyp in an area of associated chronic inflammation. Gastric adenomas are premalignant, similar to colon adenomas. Patients with familial adenomatous polyposis (FAP) have a high prevalence of gastric adenomatous polyps (about 50%), and are

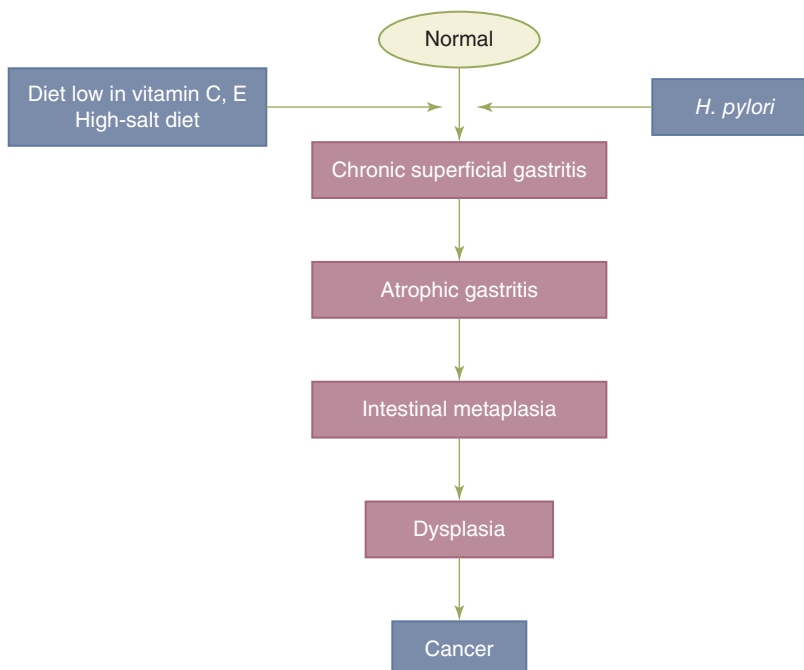


Figure 26-51. Gastric carcinogenesis. [Reproduced with permission from Leung WK, Ng EKW, Sung JY: *Tumors of the stomach*, in Yamada T, et al (eds): *Textbook of Gastroenterology*, 4th ed. Philadelphia: Lippincott, Williams & Wilkins, 2003, p 1416.]

Table 26-16

Genetic abnormalities in gastric cancer

ABNORMALITIES	GENE	APPROXIMATE FREQUENCY %
Deletion/suppression	<i>p53</i>	60–70
	<i>FHIT</i>	60
	<i>APC</i>	50
	<i>DCC</i>	50
	<i>E-cadherin</i>	<5
Amplification/overexpression	<i>COX-2</i>	70
	<i>HGF/SF</i>	60
	<i>VEGF</i>	50
	<i>c-met</i>	45
	<i>AIB-1</i>	40
	β -catenin	25
	<i>k-sam</i>	20
	<i>ras</i>	10–15
<i>c-erb B-2</i>	5–7	
Microsatellite instability		25–40
DNA aneuploidy		60–75

Source: Reproduced with permission from Koh TJ, Wang TC: Tumors of the stomach, in Feldman M et al (eds): *Sleisenger & Fordtran's Gastrointestinal and Liver Diseases*, 7th ed. Philadelphia: Saunders, 2002. Copyright Elsevier.

1900 Cases			
Precancerous lesion		Number of cases	%
Hyperplastic polyp		10	0.53
Adenoma		47	2.47
Chronic ulcer		13	0.68
Atrophic gastritis		1802	94.84
Verrucous gastritis		26	1.37
Stomach remnant		2	0.11
Aberrant pancreas		0	0
		Total 1900	100

N.C.C.H., Tokyo April 1988

Figure 26-52. Precancerous lesions of the stomach. [Reproduced with permission from Ming S-C, Hirota T: *Malignant epithelial tumors of the stomach*, in Ming S-C, Goldman H (eds): *Pathology of the Gastrointestinal Tract*, 2nd ed. Baltimore: Williams & Wilkins, 1998, p 607.]

10 times more likely to develop adenocarcinoma of the stomach than the general population.⁹¹ Screening EGD is indicated in these families. Patients with hereditary nonpolyposis colorectal cancer may also be at risk for gastric cancer.⁹²

Gastric polyps greater than 1cm should be removed to confirm the diagnosis and to eliminate any risk of malignant degeneration. Patients with gastric adenomatous polyps and FAP should have periodic upper endoscopy, which may also be considered in selected patients with hyperplastic polyps and chronic gastric inflammation.

Atrophic Gastritis Chronic atrophic gastritis (Fig. 26-53) is by far the most common precursor for gastric cancer, particularly the intestinal subtype (see Fig. 26-52). The prevalence of atrophic gastritis is higher in older age groups, but it is also common in younger people in areas with a high incidence of gastric cancer. In many patients, it is likely that *H. pylori* is involved in the pathogenesis of atrophic gastritis. Correa described three distinct patterns of chronic atrophic gastritis: autoimmune (involves the acid-secreting proximal stomach), hypersecretory (involving the distal stomach), and environmental (involving multiple random areas at the junction of the oxyntic and antral mucosa).⁸⁴

Intestinal Metaplasia Gastric carcinoma often occurs in an area of intestinal metaplasia. Furthermore, an individual's risk of gastric cancer is proportional to the extent of intestinal metaplasia of the gastric mucosa. These observations strongly suggest that intestinal metaplasia is a precursor lesion to gastric cancer. There are different pathologic subtypes of intestinal metaplasia in the stomach, based upon the histologic and biochemical characteristics of the changed mucosal glands. In the complete type of intestinal metaplasia, the glands are completely lined with goblet cells and intestinal absorptive cells (Fig. 26-54). These cells are indistinguishable histologically and biochemically from their small bowel counterparts, and are not seen in the normal stomach. There is evidence that eradication of *H. pylori* infection leads to significant regression of intestinal metaplasia and improvement in atrophic gastritis. Therefore, treatment of *H. pylori* infection is a reasonable recommendation for patients with these pathologic diagnoses and *H. pylori* infection.

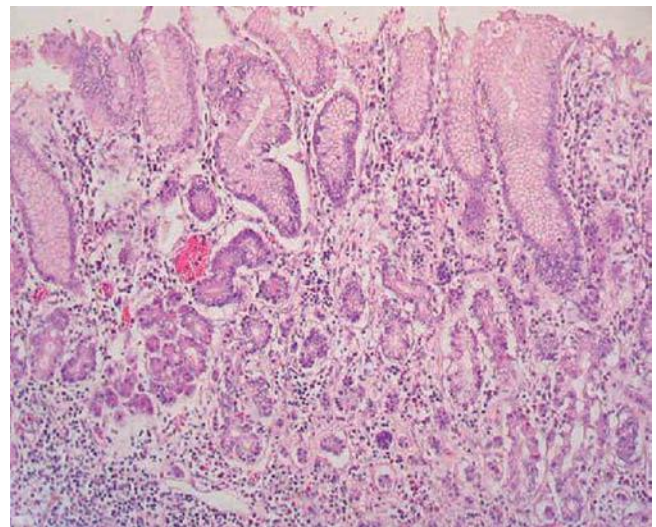


Figure 26-53. Chronic atrophic gastritis. (Reproduced with permission from <http://www.epathologies.com>.)

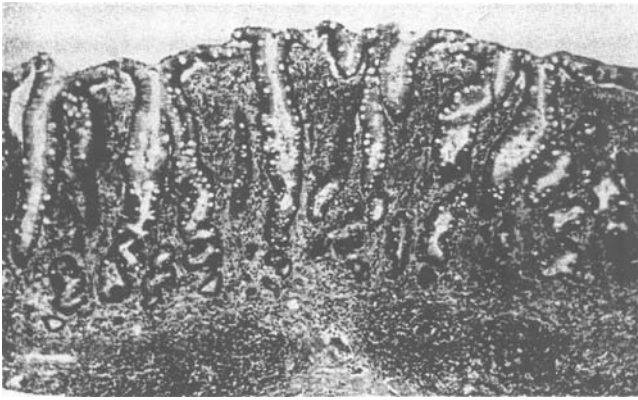


Figure 26-54. Complete intestinal metaplasia of the stomach. Note intestinal type crypts lined with goblet cells and intestinal absorptive cells. [Reproduced with permission from Ming S-C, Hirota T: *Malignant epithelial tumors of the stomach*, in Ming S-C, Goldman H (eds): *Pathology of the Gastrointestinal Tract*, 2nd ed. Baltimore: Williams & Wilkins, 1998, p 607.]

Benign Gastric Ulcer Although once considered a premalignant condition, it is likely that the older literature was confounded by mistakenly labeling inadequately biopsied ulcers and healing ulcers as “benign,” when, in fact, they were malignant to begin with. It is now generally recognized that all gastric ulcers are cancer until proven otherwise with adequate biopsy and follow-up. Even today, carcinomas are occasionally found when adequately biopsied “benign” ulcers are resected for nonhealing. It is more than likely that the factors previously discussed are more significant etiologically in the development of gastric cancer than the history of a benign gastric ulcer.

Gastric Remnant Cancer It has long been recognized that stomach cancer can develop in the gastric remnant, usually years following distal gastrectomy for PUD. The risk is controversial, but the phenomenon is real. Most tumors develop >10 years following the initial operation, and they usually arise in an area of chronic gastritis, metaplasia, and dysplasia. This is often near the stoma, but many of these tumors are quite large at presentation, and are equally divided between intestinal and diffuse subtypes. Most cases have been reported following Billroth II gastroenterostomy, but there also have been cases following Billroth I gastroduodenostomy. Whether simple loop gastrojejunostomy increases a patient’s risk of gastric cancer, and whether a Roux-en-Y anastomosis following gastric resection lowers their risk of gastric cancer is unknown. Stage for stage, the prognosis for gastric stump cancer is similar to proximal gastric cancer.⁹³

Other Premalignant States A mutated E-cadherin gene is associated with hereditary diffuse gastric cancer. Prophylactic total gastrectomy should be considered.⁸⁸ Obviously, a myriad of genetic and environmental factors will affect members of the same family, and up to 10% of gastric cancer cases appear to be familial without a clear-cut genetic diagnosis. First-degree relatives of patients with gastric cancer have a two- to threefold increased risk of developing the disease. Patients with hereditary nonpolyposis colorectal cancer have a 10% risk of developing gastric cancer, predominantly the intestinal subtype. The mucous cell hyperplasia of Ménétrier’s disease is generally considered to carry a 5% to 10% risk of adenocarcinoma. Periodic surveillance EGD is prudent in all the above conditions. The glandular hyperplasia associated with gastrinoma is not premalignant, but ECL hyperplasia and/or carcinoid tumors can occur.

Pathology

Dysplasia It is generally accepted that gastric dysplasia is the universal precursor to gastric adenocarcinoma. Patients with severe dysplasia should be considered for gastric resection if the abnormality is widespread or multifocal, or EMR if the severe dysplasia is localized. Patients with mild dysplasia should be followed with endoscopic biopsy surveillance, and *Helicobacter* eradication.

Early Gastric Cancer Early gastric cancer is defined as adenocarcinoma limited to the mucosa and submucosa of the stomach, regardless of lymph node status. The entity is common in the Orient, where gastric cancer is a common cause of cancer death, and where aggressive surveillance programs have therefore been established. Approximately 10% of patients with early gastric cancer will have lymph node metastases. There are several types and subtypes of early gastric cancer (Table 26-17 and Fig. 26-55). Approximately 70% of early gastric cancers are well differentiated, and 30% are poorly differentiated. The over-

all cure rate with adequate gastric resection and lymphadenectomy is 95%. In some Japanese centers, 50% of the gastric cancers treated are early gastric cancer. In the United States, less than 20% of resected gastric adenocarcinomas are early gastric cancer. Small intramucosal lesions can be treated with EMR.⁹⁴

Gross Morphology and Histologic Subtypes There are four gross forms of gastric cancer: polypoid, fungating, ulcerative, and scirrhous. In the first two, the bulk of the tumor mass is intraluminal. Polypoid tumors are not ulcerated; fungating tumors are elevated intraluminally, but also ulcerated. In the latter two gross subtypes, the bulk of the tumor mass is in the wall of the stomach. Ulcerative tumors are self-descriptive; scirrhous tumors infiltrate the entire thickness of the stomach and cover a very large surface area. Scirrhous tumors (linitis plastica) have a particularly poor prognosis, and commonly involve the entire stomach. Although these latter lesions may be technically resectable with total gastrectomy, it is common for both the esophageal and duodenal margins of resection to show microscopic evidence of tumor infiltration, and death from recurrent disease within 6 months is common. Palliative chemotherapy may prolong median survival^{94A}.

Table 26-17

Macroscopic types of superficial gastric cancer

Type 0-I (protruding)*	Polypoid tumors
Type 0-II (superficial)	Tumors with or without minimal elevation or depression relative to the surrounding mucosa.
Type 0-IIa	Slightly elevated tumors. (superficial elevated)
Type 0-IIb	Tumors without elevation or depression. (superficial flat)
Type 0-IIc	Slightly depressed tumors. (superficial depressed)
Type 0-III (excavated)	Tumors with deep depression

*Tumors with less than 3-mm elevation are usually classified as –IIa, with more elevated tumors being classified as 0-I.

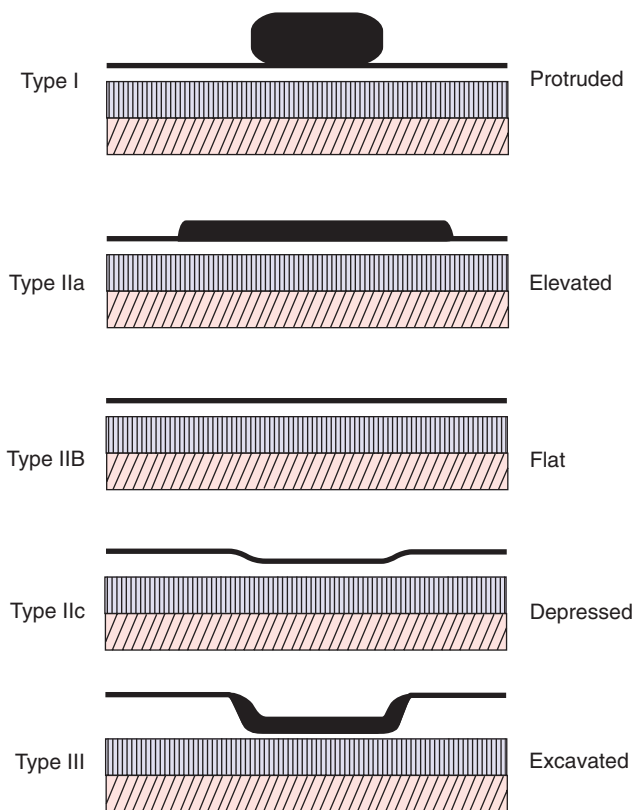


Figure 26-55. Pathologic types of early gastric cancer. [Reproduced with permission from Fenoglio-Preiser CM et al: *Pathologic and phenotypic features of gastric cancer*. Semin Oncol. 23(3):292, 1996. Copyright Elsevier.]

The location of the primary tumor in the stomach is important in planning the operation. Several decades ago, the large majority of gastric cancers were in the distal stomach. Recently, there has been a proximal migration of tumors, so that currently, the distribution is closer to 40% distal, 30% middle, and 30% proximal.

Histology The most important prognostic indicators in gastric cancer are both histologic: lymph node involvement and depth of tumor invasion. Tumor grade (degree of differentiation: well, moderately, or poorly) is also important prognostically.

There are several histologic classifications of gastric cancer. The World Health Organization recognizes several histologic types (Table 26-18). The Japanese classification is similar but more detailed. The commonly used Lauren classification separates gastric cancers into intestinal type (53%), diffuse type (33%), and unclassified (14%). The intestinal type is associated with chronic atrophic gastritis, severe intestinal metaplasia, and dysplasia, and tends to be less aggressive than the diffuse type. The diffuse type of gastric cancer is more likely to be poorly differentiated and is associated with younger patients and proximal tumors. The Ming classification also is useful and easy to remember, with only two types—expanding (67%) and infiltrative (33%).

Recently, the significance of human epidermal growth factor receptor-2 (HER2) was reported in patients with gastric cancer. In breast cancer, overexpression of HER2 has been reported in 15% to 25% and is well recognized as one of the unfavorable prognostic factors. However, the development of molecular targeted agents such as trastuzumab has improved the survival of HER2 positive patients. Likewise, recently in

Table 26-18

World Health Organization histologic typing of gastric cancer

Adenocarcinoma
 Papillary adenocarcinoma
 Tubular adenocarcinoma
 Mucinous adenocarcinoma
 Signet-ring cell carcinoma
 Adenosquamous carcinoma
 Squamous cell carcinoma
 Small cell carcinoma
 Undifferentiated carcinoma
 Others

Source: Reproduced with permission from Ming S-C, Hirota T: Malignant epithelial tumors of the stomach, in Ming S-C, Goldman H (eds): *Pathology of the Gastrointestinal Tract*, 2nd ed. Baltimore: Williams & Wilkins, 1998.

gastric cancer, HER2 overexpression has been reported in 13% to 30% of patients. According to the result of large clinical trial, Immunohistochemistry (IHC) staining of HER2 has become the important examination for recurrent or metastatic gastric cancer to decide the treatment strategy.^{94B}

Pathologic Staging Ultimately, prognosis is related to pathologic stage. The most widespread system for staging of gastric cancer is the tumor-node-metastasis (TNM) staging system based on depth of tumor invasion, extent of lymph node metastases, and presence of distant metastases. This system was developed by the American Joint Committee on Cancer and the International Union Against Cancer, and has undergone several modifications since it was originally conceived (Table 26-19).

Clinical Manifestations. Most patients who are diagnosed with gastric cancer in the United States have advanced stage III or IV disease at the time of diagnosis. The most common symptoms are weight loss and decreased food intake due to anorexia and early satiety. Abdominal pain (usually not severe and often ignored) also is common. Other symptoms include nausea, vomiting, and bloating. Acute GI bleeding is somewhat unusual (5%), but chronic occult blood loss is common and manifests as iron deficiency anemia and heme-positive stool. Dysphagia is common if the tumor involves the cardia of the stomach. Paraneoplastic syndromes such as Trousseau's syndrome (thrombophlebitis), acanthosis nigricans (hyperpigmentation of the axilla and groin), or peripheral neuropathy are rarely present.

Physical examination typically is normal. Other than signs of weight loss, specific physical findings usually indicate incurability. A focused examination in a patient in whom gastric cancer is a likely part of the differential diagnosis should include an examination of the neck, chest, abdomen, rectum, and pelvis. Cervical, supraclavicular (on the left referred to as Virchow's node), and axillary lymph nodes may be enlarged, and today can be sampled in the office with fine-needle aspiration cytology. There may be a metastatic pleural effusion, or aspiration pneumonitis in a patient with vomiting and/or obstruction. An abdominal mass could indicate a large (usually T4 incurable) primary tumor, liver metastases, or carcinomatosis (including Krukenberg's tumor of the ovary). A palpable umbilical nodule (Sister Joseph's nodule) is pathognomonic of advanced disease, or there may be evidence on exam of malignant ascites. Rectal exam may reveal heme-positive stool and hard nodularity

Table 26-19

TNM classification of tumors of the stomach

T: Primary tumor

T0	No evidence of primary tumor
Tis	Carcinoma in situ; intraepithelial tumor without invasion of the lamina propria, high-grade dysplasia
T1	Tumor invades lamina propria, muscularis mucosae, or submucosa
T1a	Tumor invades lamina propria or muscularis mucosae
T1b	Tumor invades submucosa
T2	Tumor invades muscularispropria
T3	Tumor invades subserosa
T4	Tumor perforates serosa or invades adjacent structures
T4a	Tumor perforates serosa
T4b	Tumor invades adjacent structures

N: Regional lymph nodes

N0	No regional lymph-node metastasis
N1	Metastasis in 1 to 2 regional lymph nodes
N2	Metastasis in 3 to 6 regional lymph nodes
N3	Metastasis in 7 or more regional lymph nodes
N3a	Metastasis in 7 to 15 regional lymph nodes
N3b	Metastasis in 16 or more regional lymph nodes

M: Distant metastasis

M0	No distant metastasis
M1	Distant metastasis

STAGE GROUPING

STAGE	T	N	M
Stage 0	Tis	N0	M0
Stage IA	T1	N0	M0
Stage IB	T2	N0	M0
	T1	N1	M0
Stage IIA	T3	N0	M0
	T2	N1	M0
	T1	N2	M0
Stage IIB	T4a	N0	M0
	T3	N1	M0
	T2	N2	M0
	T1	N3	M0
Stage IIIA	T4a	N1	M0
	T3	N2	M0
	T2	N3	M0
Stage IIIC	T4a	N3	M0
	T4b	N2, 3	M0
Stage IV	AnyT	AnyN	M1

Source: Used with permission of the American Joint Commission on Cancer (AJCC), Chicago, Illinois. The original source for this material is the *AJCC Cancer Staging Manual*, Seventh Edition (2010) published by Springer Science and Business Media LLC, www.springer.com.

extraluminally and anteriorly, indicating so-called *drop metastases*, or rectal shelf of Blumer in the pouch of Douglas.

Diagnostic Evaluation. Distinguishing between peptic ulcer and gastric cancer on clinical grounds alone is usually impossible. Patients over the age of 45 years old who have new-onset dyspepsia, as well as all patients with dyspepsia and alarm symptoms (weight loss, recurrent vomiting, dysphagia, evidence of GI bleeding, or anemia) or with a family history of gastric cancer should have prompt upper endoscopy and biopsy if a mucosal lesion is noted. Essentially, all patients in whom gastric cancer is part of the differential diagnosis should have endoscopy and biopsy. If suspicion for cancer is high and the biopsy is negative, the patient should be re-endoscoped and more aggressively biopsied. In some patients with gastric tumors, upper GI series can be helpful in planning treatment. Although a good double-contrast barium upper GI examination is sensitive for gastric tumors (up to 75% sensitive), in most centers, endoscopy has become the gold standard for the diagnosis of gastric malignancy.

In addition, recent advances in endoscopy have contributed to the earlier diagnosis of gastric cancer. Magnifying endoscopy with narrow-band imaging (NBI) has undergone technological improvements and can observe the microvascular architecture of the mucosa and microsurface pattern of the lesion. Magnifying endoscopy with NBI has been reported to be accurate and reliable in the diagnosis of early gastric cancer.^{94C} Furthermore, endocytoscopy, a technique allowing microscopic visualization of the mucosal surface, has been developed and has the potential for pathological diagnosis.^{94D} Another diagnostic innovation is virtual endoscopy which is an imaging examination of the gastrointestinal tract reconstructed by multidetector-row computed tomography. The image of virtual endoscopy is now quite similar to that of upper endoscopy. In the near future, this novel technology may play a role in the screening of the stomach.

Preoperative staging of gastric cancer is best accomplished with abdominal/pelvic CT scanning with IV and oral contrast. MRI is probably comparable. The best way to stage the tumor locally is via EUS, which gives fairly accurate (80%) information about the depth of tumor penetration into the gastric wall, and can usually show enlarged (>5 mm) perigastric and celiac lymph nodes. In some centers, if the tumor is transmural (T3) or involves lymph nodes (enlarged nodes can usually be needled under endoscopic ultrasound guidance), preoperative (neoadjuvant) chemotherapy is given. However, there are limitations to tumor staging with EUS. It largely is operator dependent and may underestimate lymph node involvement because normal-sized nodes (<5 mm) can harbor metastases. EUS is most accurate in distinguishing early gastric cancer (T1) from more advanced tumors.

Positron Emission Tomography Scanning Whole-body PET scanning uses the principle that tumor cells preferentially accumulate positron-emitting 18F-fluorodeoxy glucose. This modality is most useful in the evaluation of distant metastasis in gastric cancer but can also be useful in locoregional staging. PET scan is accurate when combined with spiral CT (PET-CT)⁹⁵ and should be considered before major surgery in patients with particularly high-risk tumors or multiple medical comorbidities.

Staging Laparoscopy and Peritoneal Cytology To some extent, the usefulness of these modalities depends on the individual patient's situation as well as the treatment philosophy of the cancer team. The fundamental question is "will it make a difference to this patient's management?" Patients with gastric cancer who undergo R0 resection (i.e., no gross residual

disease) and are found to have positive peritoneal cytology (no gross carcinomatosis) have a much worse prognosis than the cytology negative group (median survival 14.8 months vs. 98.5 months).⁹⁶ It is controversial how much this information adds prognostically to that of pathologic staging (TNM). Whether this poor prognosis can be improved postresection with aggressive adjuvant treatment (systemic, or local intraperitoneal hyperthermic chemotherapy) is unknown. Unfortunately, it is also unclear how much these patients benefit from gastric resection. Currently peritoneal cytology information is unlikely to change the treatment of patients with gastric cancer, and most patients without detectable distant metastases will have (and should have) gastric resection regardless of the peritoneal cytology results. A quick laparoscopic examination can occasionally reveal small peritoneal implants or liver metastases that were not detected on preoperative imaging studies and, in some patients (e.g., high risk for surgery or impressive carcinomatosis), this will change the operative plan and avoid a major but futile surgical procedure. Laparoscopy may be most useful in patients with proximal tumors or with adenopathy on spiral CT scan.⁹⁷ An extensive laparoscopic staging procedure, although quite accurate, has not been widely adopted.

Treatment. Surgical resection is the only curative treatment for gastric cancer^{98,99} and most patients with clinically resectable locoregional disease should have gastric resection. Obvious exceptions include patients who cannot tolerate an abdominal operation, and patients with overwhelming metastatic disease.

The goal of curative surgical treatment is resection of all tumor (i.e., R0 resection). Thus, all margins (proximal, distal, and radial) should be negative and an adequate lymphadenectomy performed. Generally, the surgeon strives for a grossly negative margin of at least 5 cm. Some gastric tumors, particularly the diffuse variety, are quite infiltrative and tumor cells can extend well beyond the tumor mass; thus, gross margins beyond 5 cm may be desirable. Frozen section confirmation of negative margins is important when performing operation for cure, but it is less important in patients with nodal metastases beyond the N1 nodal basin. It should be strongly emphasized that many patients with positive lymph nodes are cured by adequate surgery. It should also be stressed that often lymph nodes that appear to be grossly involved with tumor turn out to be benign or reactive on pathologic examination. More than 15 resected lymph nodes are required for adequate staging.¹⁰⁰ Therapeutic nihilism should be avoided and, in the low-risk patient, an aggressive attempt to resect all tumor should be made. The primary tumor may be resected en bloc with adjacent involved organs (e.g., distal pancreas, transverse colon, or spleen) during the course of curative gastrectomy. Palliative gastrectomy may be indicated in some patients with obviously incurable disease, but most patients presenting with stage IV gastric cancer can be managed without major operation.^{99,101}

Extent of Gastrectomy The standard operation for gastric cancer is radical subtotal gastrectomy. Unless required for R0 resection, total gastrectomy confers no additional survival benefit and may have adverse nutritional or quality-of-life consequences, and higher peri-operative morbidity and mortality.^{98,99} Subtotal gastric resection typically entails ligation of the left and right gastric and gastroepiploic arteries at the origin, as well as the en bloc removal of the distal 75% of the stomach, including the pylorus and 2 cm of duodenum, the greater and lesser omentum, and all associated lymphatic tissue (Fig. 26-56). Reconstruction

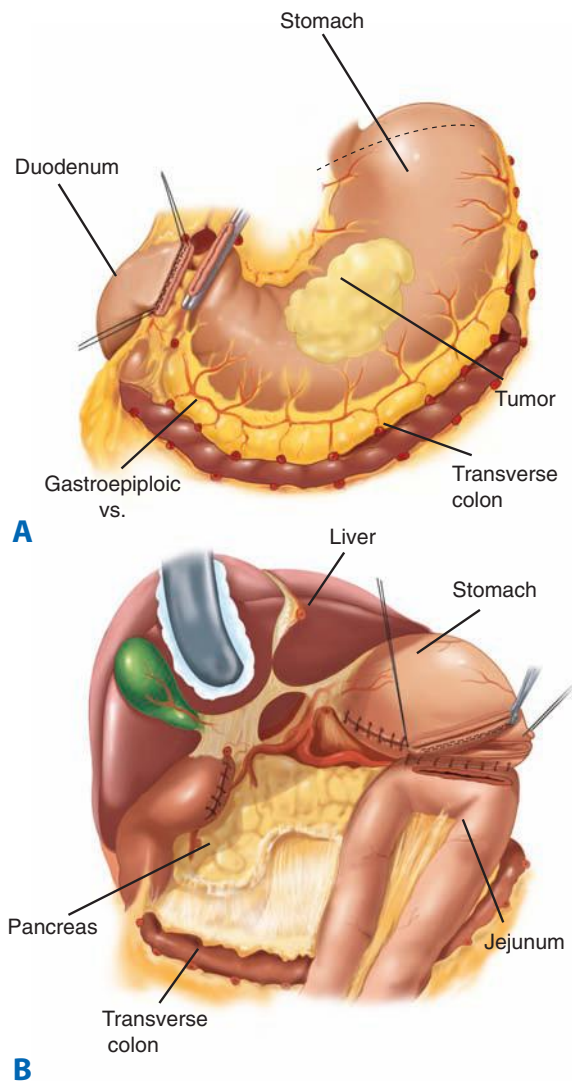


Figure 26-56. A and B. Radical subtotal gastrectomy. vs. = vessels. [Reproduced with permission from Daly JM, Cady B, Low DW (eds): *Atlas of Surgical Oncology*. St. Louis: Mosby-Year Book, 1993, p 231. Copyright Elsevier.]

is usually by Billroth II gastrojejunostomy, but if a small gastric remnant is left, a Roux-en-Y reconstruction is considered. In East Asia especially in Japan, Billroth-I gastroduodenostomy was usually performed after distal gastrectomy. Billroth-I gastroduodenostomy consists of one anastomosis (which is usually straightforward and keeps the duodenum in the food stream). In the United States, traditional surgical teaching eschews gastroduodenostomy following gastric cancer resection because of the possibility of anastomotic recurrence and obstruction. The operative mortality is around 2% to 5%. Radical subtotal gastrectomy is generally deemed to be an adequate cancer operation in most Western countries, provided that tumor-free margins are obtained, >15 lymph nodes are removed, and all gross tumor is resected. In the absence of involvement by direct extension, the spleen and pancreatic tail are not removed.

Total gastrectomy with Roux-en-Y esophagojejunostomy may be required for R0 resection (Fig. 26-57), and may be the best operation for patients with proximal gastric adenocarcinoma. The construction of a jejunal pouch can be beneficial nutritionally, particularly for those patients with a good prognosis.¹⁰²

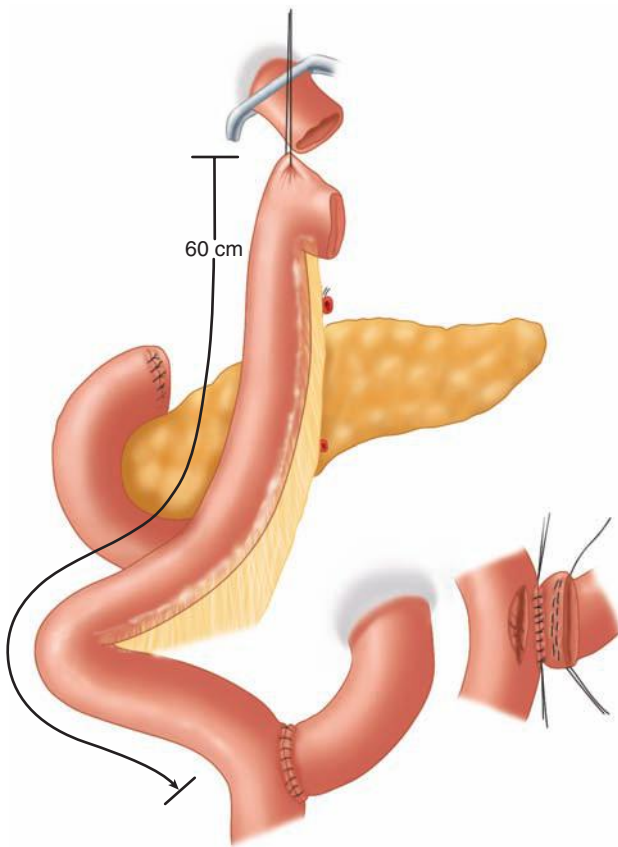


Figure 26-57. Reconstruction after total gastrectomy. Jejunal pouch (not shown here) should be considered. [Reproduced with permission from Zinner MJ (ed): Atlas of Gastric Surgery. New York: Churchill Livingstone, 1992, p 167. Copyright Elsevier.]

Proximal subtotal gastric resection, a technically feasible alternative to total gastrectomy for some proximal gastric tumors, requires an esophagogastrostomy to a vagotomized distal gastric remnant, and the functional outcome is poor. Pyloroplasty in this setting virtually guarantees bile esophagitis, and if the pylorus is left intact, gastric emptying may be problematic. An isoperistaltic jejunal interposition (Henley loop) between the esophagus and antrum could be considered an alternative reconstruction, but, all things considered, total gastrectomy usually results in superior functional, if not oncologic, results for most patients with proximal gastric cancer.

Extent of Lymphadenectomy According to the 3rd edition of Japanese classification of gastric carcinoma, lymph node stations are numbered by anatomical definition. Lymph node stations from 1 to 12, and 14V are classified as regional lymph nodes and metastasis of any other lymph node is classified as distant metastasis (M1) (see Fig. 26-4). According to the type of gastrectomy, the definition of extent of lymphadenectomy is different. D1 lymphadenectomy in distal gastrectomy requires the dissection of the stations 1, 3, 4sb, 4d, 5, 6, 7. Furthermore, additional resection of stations 8a, 9, 11p and 12a is needed for D2 lymphadenectomy. D1 lymphadenectomy in total gastrectomy requires dissection of stations 1 through 7 and in D2, from 8a to 12a too. The operation described above (radical subtotal gastrectomy in the Extent of Gastrectomy section), which is by far the most commonly performed procedure in the United States for gastric cancer, is called a D1 resection because it removes the tumor and the perigastric D1 nodes. The standard operation for gastric cancer in Asia and specialized U.S. centers is

the D2 gastrectomy, which involves a more extensive lymphadenectomy (removal of the D1 and D2 nodes). In addition to the tissue removed in a D1 resection, the standard D2 gastrectomy removes the peritoneal layer over the anterior mesocolon and selectively over the pancreas, along with nodes along the hepatic and splenic arteries, and the crural nodes. Splenectomy and distal pancreatectomy are not routinely performed, because this clearly has been shown to increase the morbidity of the operation. The purported survival advantage of D2 gastrectomy in gastric cancer is shown in Table 26-20, which shows the 5-year survival rates for gastric cancer stratified by pathologic stage for the United States and Japan. Unfortunately, the randomized prospective trials that have been performed have not confirmed this survival advantage, but the morbidity and mortality in the D2 group was higher (Table 26-21).^{103,104,104A} This was mostly attributable to the splenectomy and distal pancreatectomy, which are no longer routinely done as part of the D2 gastrectomy in the United States. However, since D2 lymphadenectomy in total gastrectomy requires the dissection of station 10 which is splenic hilar lymph node as described above, splenectomy is recommended to fulfill the criteria of D2. In Japan, pancreas-preserving splenectomy is generally performed to avoid the severe postoperative complications such as pancreas fistula in patients with advanced upper gastric cancer who underwent total gastrectomy. Some experts have argued that the D2 operation is simply a better staging procedure, and that the apparent improved survival with this more extensive dissection is simply an epiphenomenon of improved pathologic staging. This stage shift suggests that many patients in the U.S. series treated with D1 gastrectomy really had metastatic nodes at the D2 level that went unresected and undetected. Therefore, in the U.S. series, there were patients classified as stage I, who, if they had undergone a D2 gastrectomy, would be classified as stage II; and there were patients classified as stage II, who, if they had undergone a D2 gastrectomy, would be classified as stage III. The stage I survival in the United States would then actually be closer to the (more accurately staged) stage II survival in Japan, because this group includes some patients who really *are* stage II, but the nodes were not found in the D1 resection. All experts would agree that to avoid understaging of gastric cancer, a minimum of 15 nodes should be resected with the gastrectomy specimen. Despite the lack of strong data from RCTs supporting a survival advantage of D₂ gastrectomy for gastric cancer, this

Table 26-20

Gastric cancer 5-year survival and operative mortality in the USA and Japan

	MARUYAMA (JAPAN), 1971–1985	AMERICAN COLLEGE OF SURGEONS, 1982–1987	MEMORIAL SLOAN KETTERING, 1985–1994
No. patients	3176	18,365	675
Stage I	91%	50%	84%
Stage II	72%	29%	61%
Stage III	44%	13%	29%
Stage IV	9%	3%	25%
Operative mortality	1%	7%	3%

Table 26-21

Randomized trials comparing D1 and D2 gastrectomy for gastric cancer

AUTHORS	NUMBER OF PATIENTS	TYPE OF SURGERY	POSTOPERATIVE COMPLICATIONS (%)	POSTOPERATIVE MORTALITY (%)	5-YEAR SURVIVAL (%)
Bonenkamp et al	711	D1	25	4	45
		D2	43	10	47
Cuschieri et al	400	D1	28	6.5	35
		D2	46	13	33

Source: Data from Bonenkamp JJ, Hermans J, Sasako M, et al: Extended lymph node dissection for gastric cancer. *N Engl J Med* 340:908, 1999; and Cuschieri A, Fayers P, Fielding J, et al: Postoperative morbidity and mortality after D1 and D2 resections for gastric cancer: Preliminary results of the MRC randomized controlled surgical trial. The Surgical Cooperative Group. *Lancet*. 347:995, 1996.

has become standard practice in Asia and has been adopted by an increasing number of large Western centers. Reasons for this are safety of operation in experienced hands as well as data from observational studies and subgroup analysis of RCTs suggesting a survival benefit.^{104B}

Chemotherapy and Radiation for Gastric Cancer In general, the actuarial 5-year survival for resected gastric adenocarcinoma stages I, II, and III is about 75%, 50%, and 25%, respectively. Because most surgical patients have stage II disease or greater, it is common to refer gastric cancer patients postoperatively to a medical and/or radiation oncologist. Unfortunately, the existing data suggest that the incremental survival benefit attendant to adjuvant treatment is marginal, particularly in those patients who have had an adequate resection.^{98,99} In one prospective randomized study, adjuvant treatment with chemotherapy (5-fluorouracil and leucovorin) and radiation (4500 cGy) has demonstrated a survival benefit in resected patients with stage II and III adenocarcinoma of the stomach.¹⁰⁵ Unfortunately, only 10% of patients entered in the study actually had D2 gastrectomy, and most (54%) had less than an adequate D1 gastrectomy. Because adequacy of lymphadenectomy has clearly been shown to impact survival, particularly in patients with stage III gastric cancer,^{99,100} it has been suggested that the benefits of adjuvant chemoradiation shown in this study would be vitiated by an adequate operation. Recent clinical trials suggest the potential importance of adjuvant chemotherapy after D2 lymphadenectomy in patients with advanced gastric cancer. These trials compared surgery alone and surgery plus adjuvant chemotherapy including oral fluoropyrimidines for curatively resected advanced gastric cancer. After D2 lymphadenectomy, the benefit of adjuvant chemotherapy has also been established and further improvement in prognosis is expected.^{105A,105B} A recently published study from the Japan Clinical Oncology Group showed a 69% overall 5-year survival rate in patients with clinically curable T2b, T3, and T4 gastric cancer, treated with D2 gastrectomy alone (no chemotherapy).¹⁰⁶ There was no incremental benefit from para-aortic lymph node dissection. There is no indication for the routine use of radiation alone in (D₃) the adjuvant setting, but in certain patients, it can be effective palliation for bleeding or pain. Although the prognosis of metastatic or recurrent gastric cancer is poor, systemic chemotherapy provides a significant survival benefit over the best supportive care.^{106A} Agents that have shown activity against gastric cancer include 5-fluorouracil (5-FU), cisplatin, doxorubicin, methotrexate, taxanes, and camptothecin. Until recently, 5-FU based chemotherapy especially in combination with platinum played a key role in the treatment for the unresectable gastric

cancer as well as several types of cancer, such as colon and lung. In the 1990s, the introduction of novel anticancer agents such as camptothecin, taxanes, third-generation platinum, and new oral fluoropyrimidines, improved the prognosis of unresectable gastric cancer. Recently, although the risk of the toxicities is increased, triple combination chemotherapy is associated with better prognosis than double agent therapy. In the United States, triple chemotherapy consists of 5-FU, cisplatin and docetaxel and is now recognized as a standard first-line regimen. In Europe, triple therapy is more often epirubicin, cisplatin, and 5-FU. Sometimes 5-FU may be replaced by capecitabine which is an oral fluoropyrimidine, and cisplatin can be replaced by oxaliplatin which does not require hydration, respectively. Neoadjuvant treatment of gastric adenocarcinoma is being evaluated, particularly in patients with clinical T3 or N1 disease.

It is likely that targeted molecular agents will have an increasing role in treating gastric cancer. Recently, Trastuzumab, a humanized molecular antibody reactive against the extracellular domain of HER2, increased the effectiveness of cytotoxic chemotherapy in patients with advanced gastric cancer.^{94B} Other large trials are ongoing. Determination of HER2 gene amplification status may have prognostic significance.^{106B}

Endoscopic Resection^{106C} It has been demonstrated initially at numerous East Asian centers that some patients with early gastric cancer can be adequately treated by an endoscopic mucosal resection (EMR). EMR is a minimally invasive procedure that provides curative resection and has dramatically changed the treatment of early gastric cancer. EMR is indicated for patients in whom the probability of lymph node metastasis is low. According to the Japanese treatment guidelines for gastric cancer, EMR is a standard treatment for differentiated mucosal gastric cancer measuring less than 2 cm and without signs of ulceration, which has almost no risk of lymph node metastasis. En bloc resection is required to evaluate the surgical margin for confirmation of curative resection. Furthermore, the development of endoscopic submucosal dissection (ESD) allows en bloc resection of larger tumors. Therefore, the indications for endoscopic treatment of patients with gastric cancer may be broadened. New indications for minimally invasive treatment will require evaluation before implementation. Small tumors (<3 cm) confined to the mucosa have an extremely low chance of lymph node metastasis (3%), which approaches the operative mortality rate for gastrectomy. If the resected specimen demonstrates no ulceration, no penetration of the muscularis mucosae, no lymphatic invasion, and size <3 cm, then the risk of lymph node metastases is less than 1%. Thus, some patients with early gastric cancer might be better treated with the endoscopic technique. Currently, this should be limited

to patients with tumors <2 cm in size that are node negative and confined to the mucosa on EUS, in the absence of other gastric lesions. The addition of laparoscopic lymph node sampling may be considered in selected patients.

Prognosis. The 5-year survival for gastric adenocarcinoma has increased from 15% to 22% in the United States over the past 25 years. Survival is dependent on pathologic stage (TNM stage) and degree of tumor differentiation. Other important prognostic factors are sex, age, primary gastric tumor site, tumor size, and tumor depth.

Palliative gastrectomy may be indicated in some patients with obviously incurable disease, but most patients presenting with stage IV gastric cancer can be managed without major operation.^{99,101}

Screening for Gastric Cancer. In Japan, it clearly has been shown that patients participating in gastric cancer screening programs have a significantly decreased risk of dying from gastric cancer. Thus, screening is effective in a high-risk population. Screening the general population in the United States (a low-risk country) does not make sense, but patients clearly at risk for gastric cancer probably should have periodic endoscopy and biopsy. This includes patients with familial adenomatous polyposis, hereditary nonpolyposis colorectal cancer, gastric adenomas, Ménétrier's disease, intestinal metaplasia or dysplasia, and remote gastrectomy or gastrojejunostomy.

Gastric Lymphoma

Gastric lymphomas generally account for about 4% of gastric malignancies. Over half of patients with non-Hodgkin's lymphoma have involvement of the GI tract. The stomach is the most common site of primary GI lymphoma, and over 95% are non-Hodgkin's type. Most are B-cell type, thought to arise in mucosa associated lymphoid tissue (MALT), although most high-grade gastric lymphomas are without any characteristics of the low-grade MALT neoplasm.¹⁰⁷ About half of gastric lymphomas are histologically low grade, and about half are high grade. Interestingly, the normal stomach is relatively devoid of lymphoid tissue. However, in the setting of chronic gastritis, the stomach acquires MALT, which can undergo malignant degeneration. Again, *H. pylori* is thought to be the culprit. In populations with a high incidence of gastric lymphoma, there is a high incidence of *H. pylori* infection; patients with gastric lymphoma also usually have *H. pylori* infection.^{107A}

Low-grade MALT lymphoma, essentially a monoclonal proliferation of B cells, presumably arises from a background of chronic gastritis associated with *H. pylori*. These relatively innocuous tumors then undergo degeneration to high-grade lymphoma, which is the usual variety seen by the surgeon. Remarkably, when the *H. pylori* is eradicated and the gastritis improves, the low-grade MALT lymphoma often disappears. Thus, low-grade MALT lymphoma is not a surgical lesion. Careful follow-up is necessary particularly in those lesions with a t(11:18) translocation, thought to be a risk factor for a more aggressive MALT lesion. If low-grade lymphoma persists after *H. pylori* eradication, radiation should be considered for disease clinically confined to the stomach (stage I), while chemotherapy with or without radiation is used for more advanced lesions (Fig. 26-58).

Patients with high-grade gastric lymphoma require aggressive oncologic treatment for cure and present with many of the same symptoms as gastric cancer patients. However, systemic symptoms such as fever, weight loss, and night sweats occur in about 50% of patients with gastric lymphoma. The tumors may

bleed and/or obstruct. Lymphadenopathy and/or organomegaly suggest systemic disease. Diagnosis is by endoscopy and biopsy. Much of the tumor may be submucosal, and an assiduous attempt at biopsy is necessary. Primary lymphoma is usually nodular with enlarged gastric folds. A diffusely infiltrative process akin to linitis plastica is more suggestive of secondary gastric involvement by lymphoma. A diligent search for extragastric disease is necessary before the diagnosis of localized primary gastric lymphoma is made. This includes EUS; CT scanning of the chest, abdomen, and pelvis; and bone marrow biopsy. Most patients with high-grade gastric lymphoma are currently treated with chemotherapy

6▶ and radiation, without surgical resection. Treatment-related perforation or bleeding is unusual but recognized. For disease limited to the stomach and regional nodes, radical subtotal D2 gastrectomy may be performed, especially for bulky tumors with bleeding and/or obstruction. Palliative gastrectomy for tumor complications also has a role. Certainly, a multidisciplinary team should be involved with the treatment plan for patients with primary gastric lymphoma.

Gastrointestinal Stromal Tumor

GISTs arise from interstitial cells of Cajal (ICC) and are distinct from leiomyoma and leiomyosarcoma, which arise from smooth muscle.^{108,109} Prognosis in patients with GIST tumors depends mostly on tumor size and mitotic count, and metastasis, when it occurs, is typically by the hematogenous route. Any lesion >1 cm can behave in a malignant fashion and may recur. Thus, all GISTs are best resected along with a margin of normal tissue. Almost all GISTs (and almost no smooth muscle tumors) express c-KIT (CD117) or the related PDGF receptor A, as well as CD34; almost all smooth muscle tumors (and almost no GISTs) express actin and desmin. These markers can often be detected on specimens obtained by fine-needle aspiration¹¹⁰ and are useful in differentiating between GIST and smooth muscle tumor histopathologically. Lesions that are definitively leiomyoma by current histopathologic criteria are adequately treated by enucleation. Lesions that are definitively GIST or leiomyosarcoma are best treated by resection with negative margins. Most equivocal lesions should be resected provided that the patient is a reasonable operative risk.

Two-thirds of all GISTs occur in the stomach. Epithelial cell stromal GIST is the most common cell type arising in the stomach, and cellular spindle type is the next most common. The glomus tumor type is seen only in the stomach.

GISTs are submucosal tumors that are slow growing. Smaller lesions are usually found incidentally, although they occasionally may ulcerate and cause impressive bleeding. Larger lesions generally produce symptoms of weight loss, abdominal pain, fullness, early satiety, and bleeding. An abdominal mass may be palpable. Metastasis is by the hematogenous route, often to liver and/or lung, although positive lymph nodes are occasionally seen in resected specimens.

Diagnosis is by endoscopy and biopsy, although the interpretation of the latter may be problematic. EUS may be helpful, but symptomatic tumors and tumors >1 cm in size should be removed. Metastatic work-up entails CT of the chest, abdomen, and pelvis (chest X-ray may suffice in lieu of CT of the chest). Most gastric GISTs occur in the body of the stomach, but they also can occur in the fundus or antrum. They are almost always solitary. Wedge resection with clear margins is adequate surgical treatment. True invasion of adjacent structures by the primary tumor is evidence of malignancy. If safe, en bloc resection of involved surrounding organs is appropriate to remove all tumor when the primary is large and invasive. Five-year survival

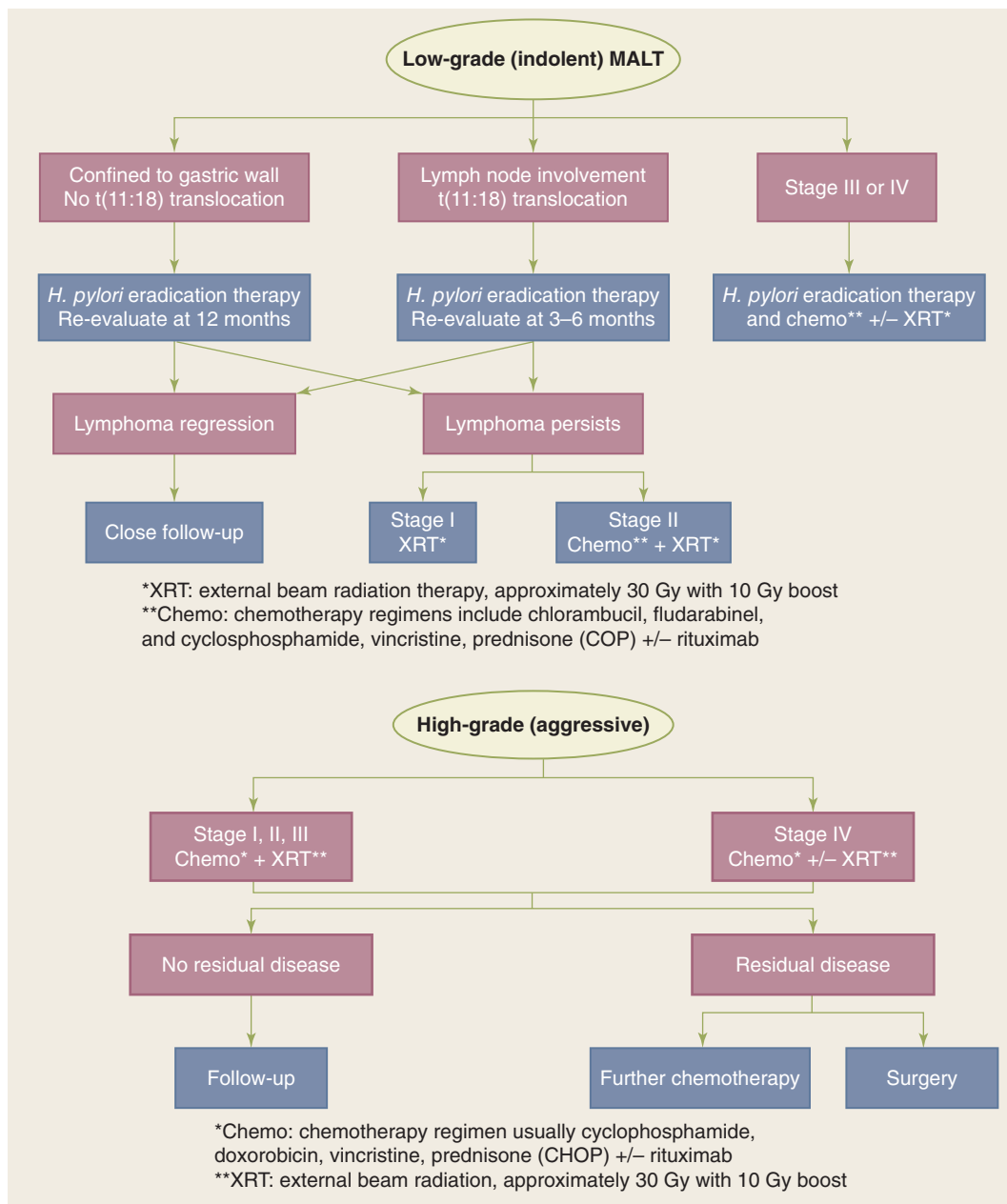


Figure 26-58. Algorithm for the treatment of gastric lymphoma. MALT = mucosa-associated lymphoid tissue. (Reproduced with permission from Yoon SS, Coit DG, Portlock CS, et al: *The diminishing role of surgery in the treatment of gastric lymphoma*. *Ann Surg* 240:28, 2004.)

following resection for GIST is about 50%. Most patients with low-grade lesions are cured (80% 5-year survival), but most patients with high-grade lesions are not (30% 5-year survival).

According to the tumor size and mitotic count,^{110A} the risk of aggressive behavior was classified into four groups. Very low risk was defined as <2 cm and <5/50 HPF (high-power field) and low risk was defined as 2 to 5 cm and <5/50 HPF. Intermediate risk was defined as <5 cm and 6 to 10/50 HPF or 5 to 10 cm and >5/50 HPF. And high risk was defined as >5 cm and >5/50 HPF, >10 cm with any mitotic rate or >10/50 HPF with any size. It was known that the risk of recurrence differs by the primary site of the tumor. Recently, new classification based on tumor location, size, and mitotic rate has been used to evaluate the risk of recurrence and metastasis.^{110B}

GISTs are usually positive for the protooncogene, *c-kit*, a characteristic shared with the ICC. Imatinib (Gleevec), a chemotherapeutic agent that blocks the activity of the tyrosine kinase

product of *c-kit*, yields excellent results in many patients with metastatic or unresectable GIST. Up to 50% of treated patients develop resistance to imatinib by 2 years, and several newer agents show promise for patients with refractory disease. The efficacy of imatinib as adjuvant therapy for high risk patients has been demonstrated in large clinical trials.^{110C,110D} According to the NCCN guidelines for soft tissue sarcoma (version 2, 2012), the administration of imatinib was recommended in high risk groups as an adjuvant therapy.^{110E} An algorithm for the treatment of patients with GIST is shown in Fig. 26-59.

Gastric Carcinoid Tumors¹¹¹⁻¹¹³

Compared to midgut and hindgut locations, carcinoid tumors of the stomach are rather unusual. Gastric carcinoids comprise about 1% of all carcinoid tumors and less than 2% of gastric neoplasms. They arise from gastric enterochromaffin-like (ECL) cells and some have malignant potential. The apparent

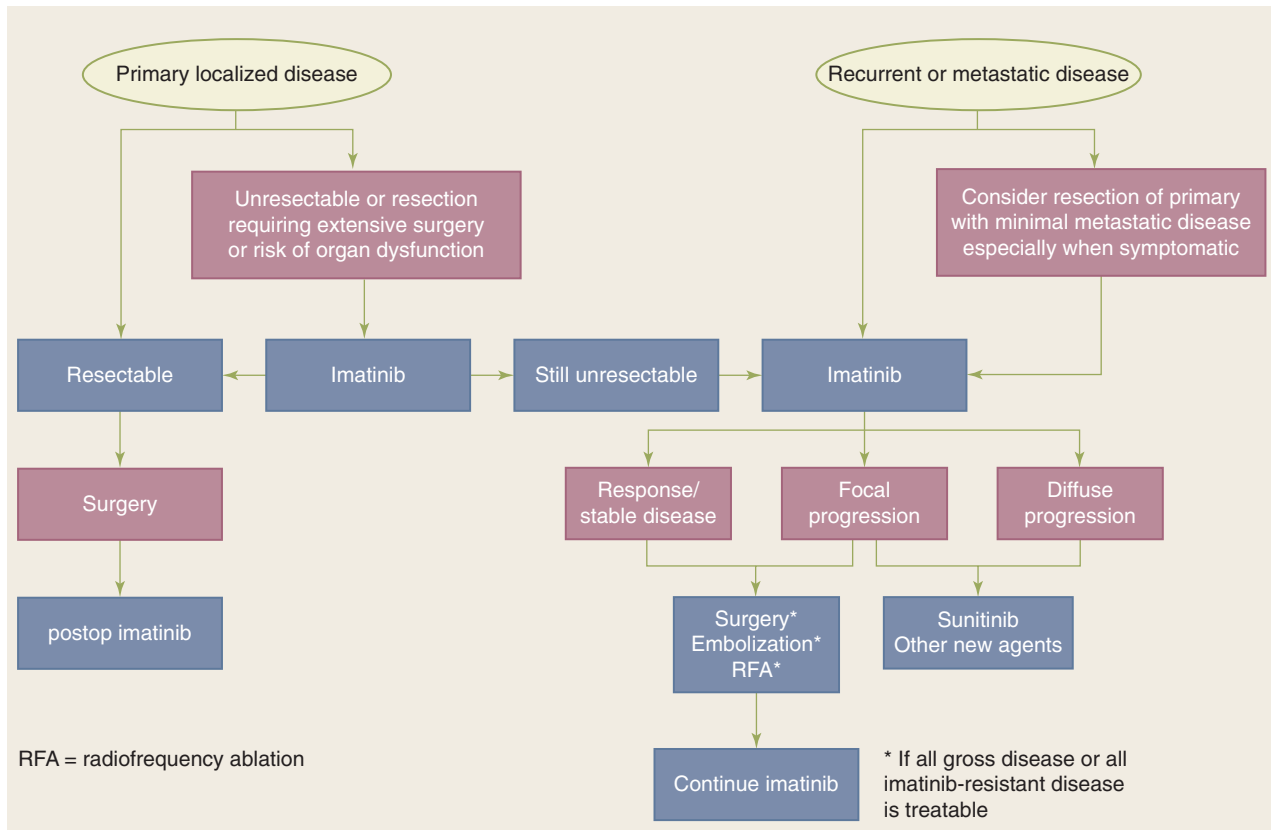


Figure 26-59. Algorithm for the treatment of gastrointestinal stromal tumor. (Reproduced with permission from Gold JS, DeMatteo RP: Combined surgical and molecular therapy: The gastrointestinal stromal tumor model. *Ann Surg* 244:176, 2006.)

incidence of gastric carcinoids is increasing, perhaps related to the more common use of upper endoscopy and/or the increasing use of acid suppressive medication. The latter may cause hypergastrinemia, and gastrin has a recognized trophic effect on gastric ECL cells. Gastric carcinoid is equivalent to neuroendocrine tumor (NET) or well-differentiated neuroendocrine tumor/carcinoma according to WHO classification.

Gastric carcinoids are classified into one of three different types. Type I is the most common type of gastric carcinoid, accounting for about 75% of patients. Type I carcinoids occur in patients with chronic hypergastrinemia secondary to pernicious anemia or chronic atrophic gastritis. These lesions occur more frequently in women, are often multiple and small, and have low malignant potential (<5% metastasize). The role of long-term acid suppression with resultant hypergastrinemia in the pathogenesis of type I gastric carcinoids is unclear.

Type II gastric carcinoids are associated with MEN1 and ZES. These lesions also tend to be small and multiple, but have a somewhat higher malignant potential than type I lesions (10% metastasize). Type II gastric carcinoids are more strongly associated with MEN1; they are quite uncommon in patients with sporadic ZES without MEN1. Gastric acid hypersecretion, hypergastrinemia, and gastric carcinoid imply gastrinoma until proven otherwise.

Type III gastric carcinoids are sporadic tumors. They are most often solitary (usually >2 cm) and occur more commonly in men. They are not associated with hypergastrinemia and biopsy shows a heterogeneous cell population. Most patients have nodal or distant metastases at the time of diagnosis, and some present with symptoms of carcinoid syndrome.

Gastric carcinoids are usually diagnosed with endoscopy and biopsy. Some tumors are submucosal and may be quite small. They are often confused with heterotopic pancreas or small leiomyomas. Biopsy may be difficult because of the submucosal location, and EUS can be helpful in defining the size and depth of the lesion. Plasma chromogranin A levels are elevated in patients with gastric carcinoid. CT scan and octreotide scan are useful for staging.

Gastric carcinoids should be resected. Small lesions confined to the mucosa (typically type I or type II lesions) may be treated endoscopically with EMR if there are only a few lesions (<5) and if margins are histologically negative. Careful follow-up is necessary. Larger lesions should be removed by D1 or D2 gastrectomy. Survival is excellent for node-negative patients (>90% 5-year survival); node-positive patients have a 50% 5-year survival. Gastrinoma should be resected if located in patients with type II carcinoid. The 5-year survival for patients with type I gastric carcinoid is close to 100%; for patients with type III lesions, the 5-year survival is less than 50%. Somatostatin analogue treatment is useful in controlling the symptoms of carcinoid syndrome but apparently does not prolong survival in patients with metastatic gastric carcinoid. Surgical debulking may have a role in selected patients with metastatic disease. Because somatostatin has an antiproliferative effect on gastric ECL cells, there may be a possible primary treatment role for octreotide in poor-risk surgical patients with gastric carcinoid.

BENIGN GASTRIC NEOPLASMS

Leiomyoma

The typical leiomyoma is submucosal and firm. If ulcerated, it has an umbilicated appearance and may bleed. Histologically, these

lesions appear to be of smooth muscle origin. Lesions <2 cm are usually asymptomatic and benign. Larger lesions have greater malignant potential and a greater likelihood to cause symptoms such as bleeding, obstruction, or pain. Asymptomatic lesions <2 cm may be carefully observed or enucleated if fine-needle aspiration and immune markers confirm smooth muscle tumor; larger lesions and symptomatic lesions should be removed by wedge resection (often possible laparoscopically). When lesions thought to be leiomyoma are observed rather than resected, the patient should be made aware of their presence and the small possibility for malignancy.

Lipoma

Lipomas are benign submucosal fatty tumors that are usually asymptomatic, found incidentally on upper GI series or EGD. Endoscopically, they have a characteristic appearance; there also is a characteristic appearance on EUS. Excision is unnecessary unless the patient is symptomatic.

Gastric Motility Disorders

Gastric motility disorders include delayed gastric emptying (gastroparesis), rapid gastric emptying, and motor and sensory abnormalities (e.g., functional dyspepsia). Surgically relevant secondary disorders of gastric motility (e.g., dumping, gastric stasis, and Roux syndrome) are discussed under Postgastrectomy Problems. Gastroparesis is the most surgically relevant primary disorder of gastric motility.^{114,115}

Most patients with primary gastroparesis present with nausea, vomiting, bloating, early satiety, and/or abdominal pain. Eighty percent of these patients are women; some are diabetic. Postprandial vomiting significantly complicates the management of blood glucose in the latter group, predisposing to hypoglycemia following preprandial insulin. In patients with gastroparesis, it is important to rule out mechanical gastric outlet obstruction, and small-bowel obstruction. An upper GI series may suggest slow gastric emptying and relative atony, or it may be normal. EGD may show bezoars or retained food but is frequently normal. Gastric emptying scintigraphy shows delayed solid emptying, and often delayed liquid emptying. Gastroparesis can be a manifestation of a variety of problems (Table 26-22). Medical treatment includes promotility agents, antiemetics, and, perhaps, botulinum injection into the pylorus.

If the diabetic gastroparetic patient is not a candidate for pancreas transplant, both gastrostomy (for decompression) and jejunostomy tubes (for feeding and prevention of hypoglycemia) can be effective. Other surgical options include implantation of a gastric pacemaker, and gastric resection.^{115A} Generally, gastric resection should be done only after other therapeutic options have been exhausted.

Massive Upper Gastrointestinal Bleeding

Although there have been arbitrary definitions of “massive” upper GI bleeding put forth, perhaps the most practical definition in the current era would be acute bleeding proximal to the ligament of Treitz, which requires blood transfusion. In multiple series, the stomach and proximal duodenum is by far the most common source of pathology associated with this diagnosis.^{65,116} The most common causes of acute GI bleeding in emergency room or hospitalized patients are peptic ulcer, gastritis, Mallory-Weiss syndrome, and esophagogastric varices. Less common causes include benign or malignant neoplasm, angiodysplasia, Dieulafoy’s lesion, portal gastropathy, Ménétrier’s disease, and watermelon stomach. Arterioenteric fistula should always be

Table 26-22

Etiology of gastroparesis

Idiopathic
Endocrine or metabolic
Diabetes mellitus
Thyroid disease
Renal insufficiency
After gastric surgery
After resection
After vagotomy
Central nervous system disorders
Brain stem lesions
Parkinson’s disease
Peripheral neuromuscular disorders
Myotonia dystrophica
Duchenne muscular dystrophy
Connective tissue disorders
Scleroderma
Polymyositis/dermatomyositis
Infiltrative disorders
Lymphoma
Amyloidosis
Diffuse gastrointestinal motility disorder
Chronic intestinal pseudo-obstruction
Medication-induced
Electrolyte imbalance
Potassium, calcium, magnesium
Miscellaneous conditions
Infections (especially viral)
Paraneoplastic syndrome
Ischemic conditions
Gastric ulcer

Source: Reprinted by permission from Macmillan Publishers Ltd. Parkman HP et al. Gastrointestinal motility and dysmotility: An update on techniques available for evaluation. *Am J Gastroenterol.* 1995;90:869. Copyright © 1995.

considered in the patient who has an aortic graft or who has undergone repair of a visceral artery aneurysm.

The most important issues in the early hospital management of patients with acute upper GI bleeding are resuscitation and risk stratification. Large-bore IV access and Foley catheterization is accomplished, and nasogastric intubation is considered. Risk stratification is essentially accomplished by answering the following questions:

- What is the magnitude and acuity of the hemorrhage? Hypotension, tachycardia, oliguria, low hematocrit, pallor, altered mentation, and/or hematemesis suggest a large blood loss that has occurred over a short period of time. This is a high-risk situation.
- Does the patient have significant chronic disease, particularly lung, liver, kidney, and/or heart disease, which compromises physiologic reserve? If yes, this is a high-risk situation.
- Is the patient anticoagulated, or immunosuppressed? If yes, this is a high-risk situation.
- On endoscopy, is the patient bleeding from varices, or is there active bleeding, or is there a visible vessel, or is there a deep ulcer overlying a large vessel (e.g., posterior duodenal ulcer overlying the gastroduodenal artery)? Could the patient be bleeding from an Arterio enteric fistula? If yes, this is a high-risk situation.

If judged to be low risk, most patients will stop bleeding with supportive treatment and IV PPI. Selected patients may be discharged from the emergency room and managed on an outpatient basis.

If the patient is judged to be high risk based on one or more of the questions previously listed, then the following should be done immediately:

1. Type and cross-match for transfusion of blood products.
2. Admit to ICU or monitored bed in specialized unit.
3. Consult surgeon.
4. Consult gastroenterologist.
5. Start continuous infusion of PPI.
6. Perform upper endoscopy within 12 hours, after resuscitation and correction of coagulopathy. Endoscopic hemostasis should be considered in most high-risk patients with acute upper GI bleeding.

Although the surgeon should be involved early in the hospital course of all high-risk patients with acute upper GI bleeding, most of these patients will be adequately managed without operation. Mucosal lesions can usually be controlled with endoscopic hemotherapy and medical management. Occasionally, arteriography can be helpful.¹¹⁷ Operation for bleeding ulcer is discussed previously (see Operation for Bleeding Peptic Ulcer and Fig. 26-43).

Isolated Gastric Varices

Isolated gastric varices are those that occur in the absence of esophageal varices and are classified as type I (fundic) or type II (distal to fundus including proximal duodenum).¹¹⁸ The presence of isolated gastric varices is usually associated with portal hypertension or splenic vein thrombosis. Although there is a significant bleeding risk from isolated gastric varices on long-term follow-up, there is no indication for the routine application of prophylactic measures.

Patients with acute upper GI bleeding from isolated gastric varices should be considered high risk. Although data are limited, octreotide and/or vasopressin infusion may decrease bleeding, if tolerated. Balloon tamponade with a Sengstaken-Blakemore tube may provide temporary control of exsanguinating hemorrhage from type isolated gastric varices, but if this is used, endotracheal intubation for airway protection is prudent. Endoscopic treatment with sclerotherapy or varix ligation is less successful than in esophageal varices, but should be considered. Interventional radiology should be consulted and balloon occluded retrograde transvenous obliteration considered. A transjugular intrahepatic portosystemic shunt may be useful if there is nonsegmental portal hypertension. If the patient has splenic vein thrombosis and left-sided (sinistral) or segmental portal hypertension, splenectomy is quite effective in controlling bleeding from isolated gastric varices. The operative mortality is 5%. Liver transplantation should always be considered in the cirrhotic patient.

Hypertrophic Gastropathy (Ménétrier's Disease)

There are two clinical syndromes characterized by epithelial hyperplasia and giant gastric folds: ZES and Ménétrier's disease. The latter is characteristically associated with protein-losing gastropathy and hypochlorhydria. There are large rugal folds in the proximal stomach, and the antrum is usually spared. Mucosal biopsy shows diffuse hyperplasia of the surface

mucus-secreting cells and usually decreased parietal cells (Fig. 26-60). It has recently been suggested that Ménétrier's disease is caused by local overexpression of transforming growth factor alpha in the gastric mucosa, which stimulates the epidermal growth factor receptor, a receptor tyrosine kinase, on gastric SECs. This results in the selective expansion of surface mucous cells in the gastric body and fundus. A few patients with this unusual disease have been successfully treated with the epidermal growth factor receptor blocking monoclonal antibody cetuximab.¹¹⁹

Most patients with Ménétrier's disease are middle-aged men who present with epigastric pain, weight loss, diarrhea, and hypoproteinemia. There may be an increased risk of gastric cancer. Sometimes, the disease regresses spontaneously. Gastric resection may be indicated for bleeding, severe hypoproteinemia, or cancer.

Watermelon Stomach (Gastric Antral Vascular Ectasia)

The parallel red stripes atop the mucosal folds of the distal stomach give this rare entity its sobriquet. Histologically, gastric antral vascular ectasia (GAVE) is characterized by dilated mucosal blood vessels that often contain thrombi, in the lamina propria. Mucosal fibromuscular hyperplasia and hyalinization often are present (Fig. 26-61). The histologic appearance can resemble portal hypertensive gastropathy, but the latter usually affects the proximal stomach, whereas watermelon stomach predominantly affects the distal stomach. Beta blockers and nitrates, useful in the treatment of portal hypertensive gastropathy, are ineffective in patients with gastric antral vascular ectasia. Patients with GAVE are usually elderly women with chronic GI blood loss requiring transfusion. Most have an associated autoimmune connective tissue disorder, and at least 25% have chronic liver disease. Non-surgical treatment options include estrogen and progesterone, and endoscopic treatment with the neodymium yttrium-aluminum garnet (Nd:YAG) laser or argon plasma coagulator.¹²⁰ Antrectomy may be required to control blood loss, and this operation is quite effective but carries increased morbidity in this elderly patient group. Patients with portal hypertension and antral vascular ectasia should be considered for transjugular intrahepatic portosystemic shunt (TIPSS).

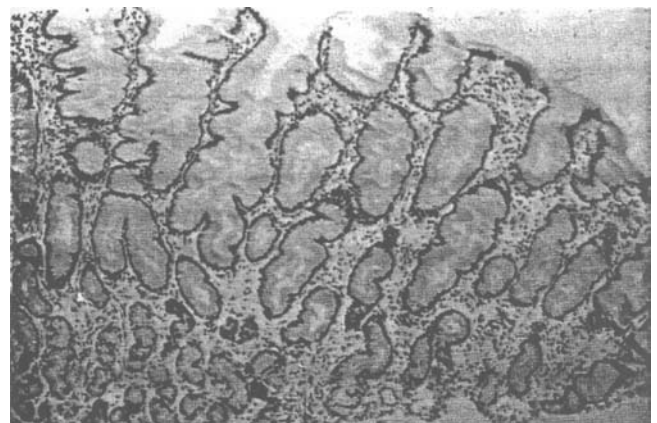


Figure 26-60. Mucosal biopsy in Ménétrier's disease. [Reproduced with permission from Goldman H: *Mucosal hypertrophy and hyperplasia of the stomach*, in Ming S-C, Goldman H (eds): *Pathology of the Gastrointestinal Tract*, 2nd ed. Baltimore: Williams & Wilkins, 1998, p 577.]

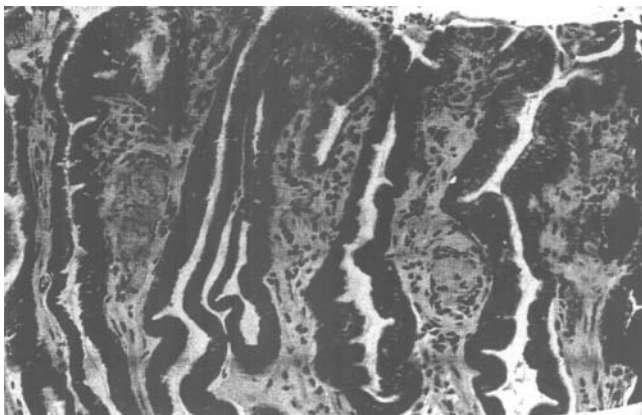


Figure 26-61. Gastric antral vascular ectasia (watermelon stomach). [Reproduced with permission from Goldman H: *Mucosal hypertrophy and hyperplasia of the stomach*, in Ming S-C, Goldman H (eds): *Pathology of the Gastrointestinal Tract*, 2nd ed. Baltimore: Williams & Wilkins, 1998, p 577.]

Dieulafoy's Lesion

Dieulafoy's lesion is a congenital arteriovenous malformation characterized by an unusually large tortuous submucosal artery. If this artery is eroded, impressive pulsatile bleeding may occur. To the endoscopist or surgeon, this appears as a stream of arterial blood emanating from what appears grossly to be a normal gastric mucosa. The lesion typically occurs in middle-aged or elderly men and may be more common in patients with liver disease.¹²¹ Patients typically present with upper GI bleeding, which may be intermittent, and endoscopy can miss the lesion if it is not actively bleeding. Treatment options include endoscopic hemostatic therapy, angiographic embolization, or operation. At surgery, the lesion may be oversewn or resected.

Bezoars/Diverticula

Bezoars are concretions of indigestible matter that accumulate in the stomach. Trichobezoars, composed of hair, occur most commonly in young women who swallow their hair (Fig. 26-62). Phytobezoars are composed of vegetable matter and, in the United States, are usually seen in association with gastroparesis or gastric outlet obstruction. They also are associated with persimmon ingestion. Most commonly, bezoars produce obstructive symptoms, but they may cause ulceration and bleeding. Diagnosis is suggested by upper GI series and confirmed by endoscopy. Treatment options include enzyme therapy (papain, cellulase, or acetylcysteine), endoscopic disruption and removal, or surgical removal.

Gastric diverticula are usually solitary and may be congenital or acquired. Congenital diverticula are true diverticula and contain a full coat of muscularis propria, whereas acquired diverticula (perhaps caused by pulsion) usually have a negligible outer muscle layer. Most gastric diverticula occur in the posterior cardia or fundus (Fig. 26-63) and are usually asymptomatic. However, they can become inflamed and may produce pain or bleeding. Perforation is rare. Asymptomatic diverticula do not require treatment, but symptomatic lesions should be removed. This can often be done laparoscopically.

Foreign Bodies

Ingested foreign bodies are usually asymptomatic. Removal of sharp or large objects should be considered. This can usually be done endoscopically, with an overtube technique.

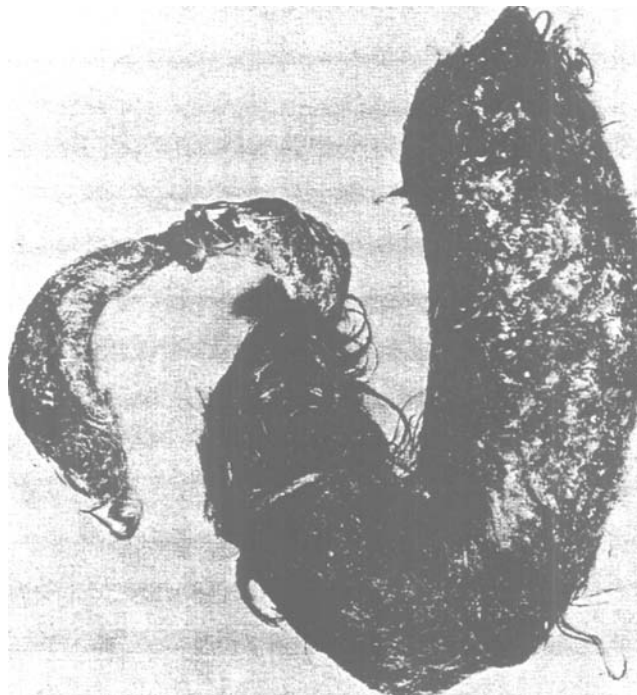


Figure 26-62. Trichobezoar forming cast of stomach and duodenum; removed from 15-year-old girl. [Reproduced with permission from DeBakey M, Ochsner A: *Bezoars and concretions*. *Surgery* 4:934, 1938. Copyright Elsevier.]

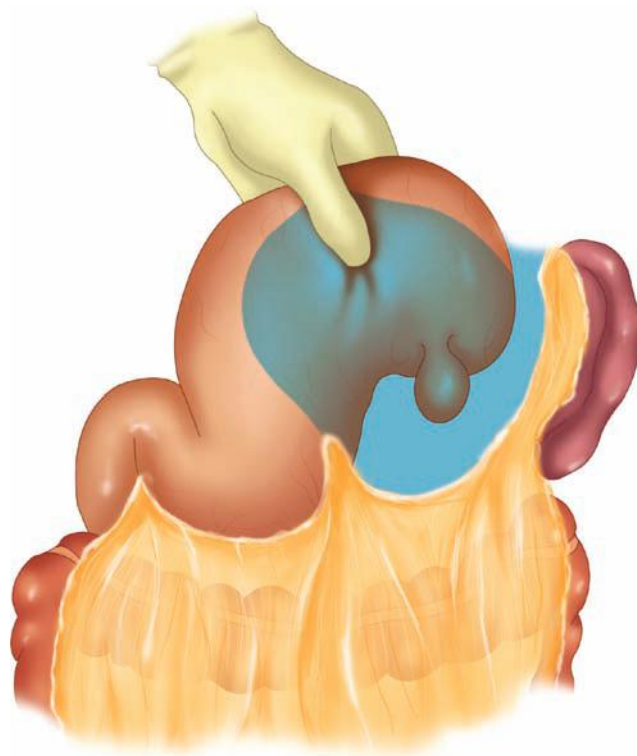


Figure 26-63. Gastric diverticulum. [Reproduced with permission from Ellis H: *Diverticula, volvulus, superior mesenteric artery syndrome, and foreign bodies*, in Schwartz SL, Ellis H, Husser WC (eds): *Maingot's Abdominal Operations*, 9th ed. East Norwalk, Connecticut: Appleton & Lange, 1989, p 577. Copyright © The McGraw-Hill Companies, Inc.]

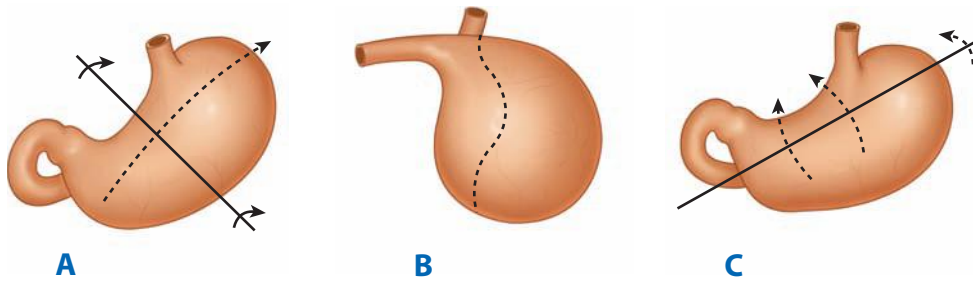


Figure 26-64. A through C. Gastric volvulus. [Reproduced with permission from Buchanan J: *Volvulus of the stomach*. *Br J Surg*. 18:99, 1930. © British Journal of Surgery Society, Ltd. Permission is granted by John Wiley & Sons, Ltd on behalf of BJSS, Ltd.]

Recognized dangers include aspiration of the foreign body during removal, and rupture of drug-containing bags in “body packers.” Both complications can be fatal. Surgical removal is recommended in body packers, and in patients with large jagged objects. Corrosive objects (e.g., watch batteries) should be removed promptly.

Mallory-Weiss Syndrome

The Mallory-Weiss lesion is a longitudinal tear in the mucosa of the GE junction.¹²² It is presumably caused by forceful vomiting and/or retching, and is commonly seen in alcoholics. It presents with upper GI bleeding, often with hematemesis. Endoscopy confirms the diagnosis and may be useful in controlling the bleeding, but 90% of patients stop bleeding spontaneously. Other options to control the bleeding include balloon tamponade, angiographic embolization, or selective infusion of vasopressin, systemic vasopressin, and operation. Surgical treatment consists of oversewing the bleeding lesion through a long gastrostomy.

Volvulus

Gastric volvulus is a twist of the stomach that usually occurs in association with a large hiatal hernia. It also can occur in patients with an unusually mobile stomach without hiatal hernia. Typically, the stomach twists along its long axis (organoaxial volvulus), and the greater curvature flips up (Fig. 26-64C). If the stomach twists around the transverse axis, it is called *mesenteroaxial rotation* (Fig. 26-64A and Fig. 26-64B). Often, volvulus is a chronic condition that can be surprisingly asymptomatic. In these instances, expectant nonoperative management is typically advised, especially in the elderly. The risk of strangulation and infarction has been overestimated in asymptomatic patients. Symptomatic patients should be considered for operation, especially if the symptoms are severe and/or progressive. Patients may present with symptoms of pain and pressure related to the intermittently distending and poorly emptying twisted stomach. Pressure on the lung may produce dyspnea, pressure on the pericardium may produce palpitations, and pressure on the esophagus may produce dysphagia. Symptoms are often relieved with vomiting or passage of a nasogastric tube. Gastric infarction is a surgical emergency, and the patient can be moribund. Gastric necrosis may be extensive or focal. With or without gastropexy, elective operation for gastric volvulus usually involves reduction of the stomach and repair of hiatal hernia. Gastropexy alone may be considered for high-risk patients since it can nearly always be performed laparoscopically and may be surprisingly effective in relieving mechanical symptoms.

GASTROSTOMY

A gastrostomy is performed either for alimentation or for gastric drainage/decompression. Gastrostomy may be done

percutaneously, laparoscopically, or via open technique.^{123,124} Currently, percutaneous endoscopic gastrostomy is the most common method used. The open techniques include the Stamm method (Fig. 26-65), the Witzel method (Fig. 26-66), and the Janeway method (Fig. 26-67). The last method is meant to create a permanent stoma that can be intubated as needed, but does not drain spontaneously. The Janeway gastrostomy is more complicated than the other open techniques, and is rarely necessary. By far the most common surgical technique is the Stamm gastrostomy, which can be performed open or laparoscopically.

Complications of gastrostomy include infection, dislodgment, leakage with peritonitis, and aspiration pneumonia. Although gastrostomy tubes usually do prevent tense gastric dilatation, they may not adequately drain the stomach, especially when the patient is bedridden.

POSTGASTRECTOMY PROBLEMS^{125,126}

Dumping Syndrome

Dumping is a phenomenon caused by the destruction or bypass of the pyloric sphincter.¹²⁷ However, other factors undoubtedly play a role because dumping can occur after operations that

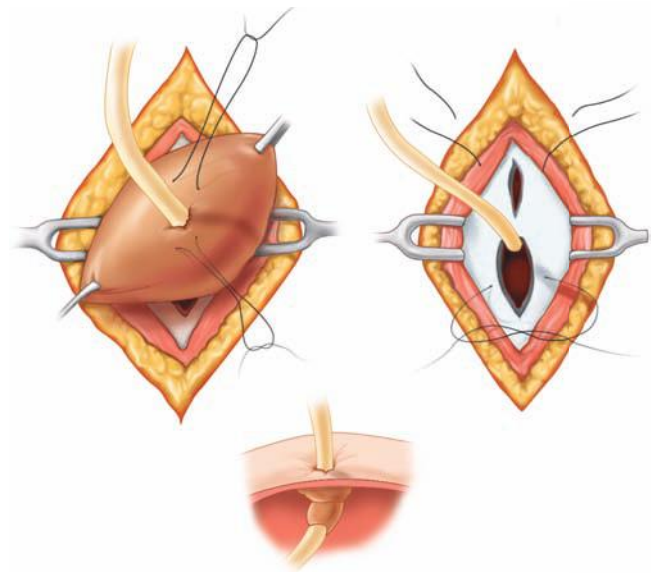


Figure 26-65. Stamm gastrostomy. [Reproduced with permission from Tatum RP, Joehl RJ: *Intubation of the stomach and small intestine*, in Zuidema GD, Yeo CJ (eds): *Shackelford's Surgery of the Alimentary Tract*, 5th ed., Vol. II. Philadelphia: Saunders, 2002, p 46.]

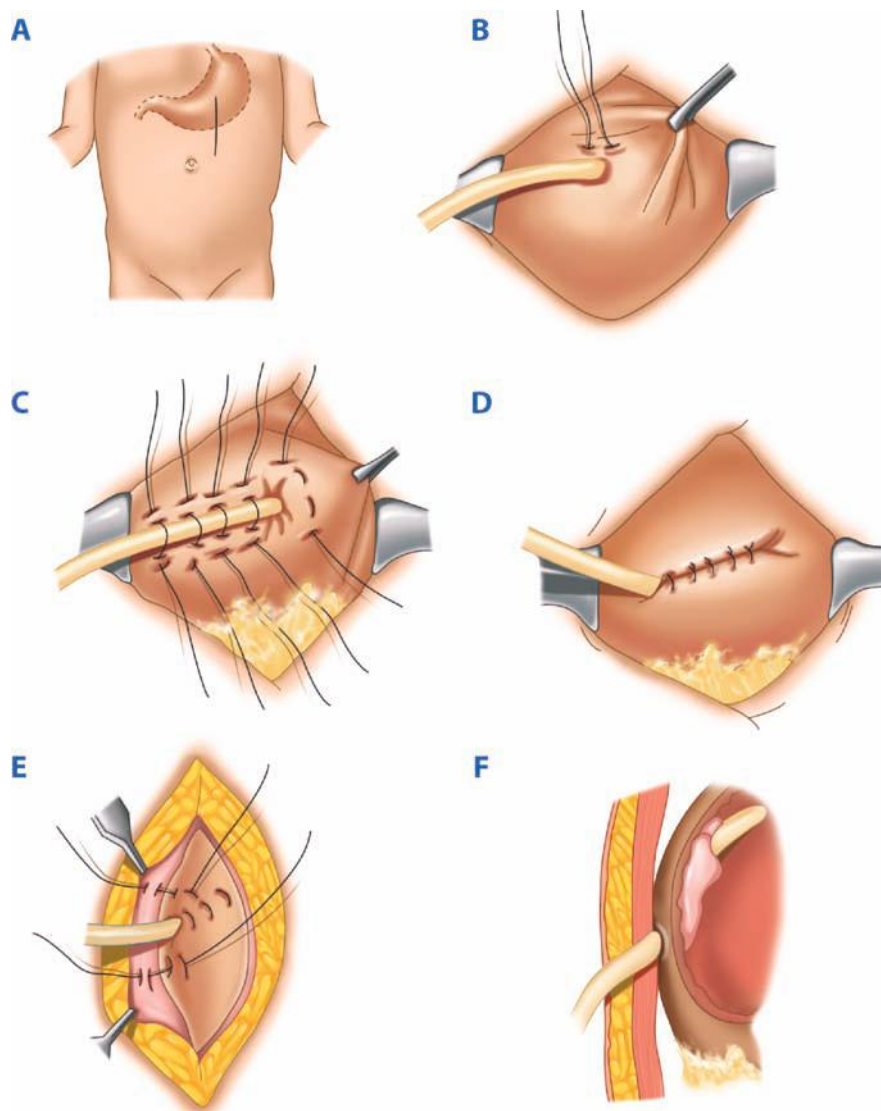


Figure 26-66. A through F. Witzel gastrostomy. [Reproduced with permission from Tatum RP, Joehl RJ: *Intubation of the stomach and small intestine*, in Zuidema GD, Yeo CJ (eds): *Shackelford's Surgery of the Alimentary Tract, 5th ed., Vol. II. Philadelphia: Saunders, 2002, p 46.*]

preserve the pylorus, such as parietal cell vagotomy. The appropriate stimulus can provoke dumping symptoms, even in some patients who have not undergone surgery. Clinically significant dumping occurs in 5% to 10% of patients after pyloroplasty, pyloromyotomy, or distal gastrectomy, and consists of a constellation of postprandial symptoms ranging in severity from annoying to disabling. The symptoms are thought to be the result of the abrupt delivery of a hyperosmolar load into the small bowel due to ablation of the pylorus or decreased gastric compliance. Typically, 15 to 30 minutes after a meal, the patient becomes diaphoretic, weak, light-headed, and tachycardic. These symptoms may be ameliorated by recumbence or saline infusion. Crampy abdominal pain is not uncommon and diarrhea often follows. This is referred to as *early dumping*, and should be distinguished from postprandial (reactive) hypoglycemia, also called *late dumping*, which usually occurs later (2–3 hours following a meal), and is relieved by the administration of sugar. A variety of hormonal aberrations have been observed in early dumping, including increased VIP, CCK, neurotensin, peripheral hormone peptide YY, renin-angiotensin-aldosterone, and

decreased atrial natriuretic peptide. Late dumping is associated with hypoglycemia and hyperinsulinemia.

The medical therapy for the dumping syndrome consists of dietary management and somatostatin analogue (octreotide). Often, symptoms improve if the patient avoids liquids during meals. Hyperosmolar liquids (e.g., milk shakes) may be particularly troublesome. There is some evidence that adding dietary fiber compounds at mealtime may improve the syndrome. If dietary manipulation fails, the patient is started on octreotide, 100 μg subcutaneously twice daily. This can be increased up to 500 μg twice daily if necessary. The long-acting depot octreotide preparation is useful. Octreotide not only ameliorates the abnormal hormonal pattern seen in patients with dumping symptoms, but also promotes restoration of a fasting motility pattern in the small intestine (i.e., restoration of the MMC). The α -glucosidase inhibitor acarbose may be particularly helpful in ameliorating the symptoms of late dumping.

Only a very small percentage of patients with dumping symptoms ultimately require surgery. Most patients improve with time (months and even years), dietary management, and medication.

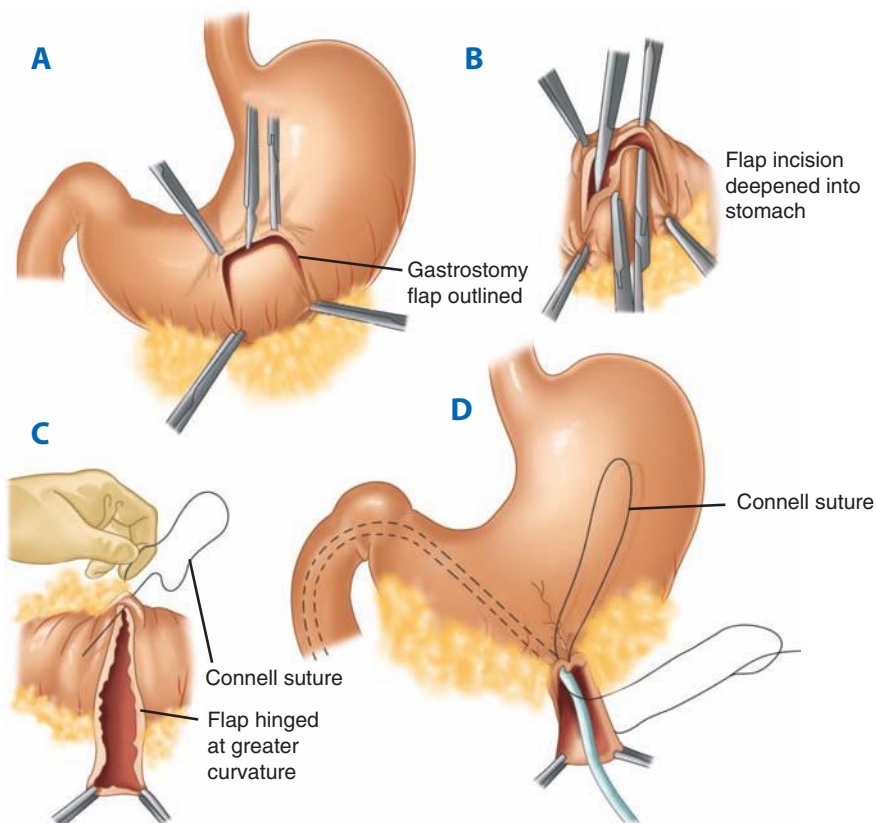


Figure 26-67. A through D. Janeway gastrotomy. [Reproduced with permission from Tatum RP, Joehl RJ: *Intubation of the stomach and small intestine*, in Zuidema GD, Yeo CJ (eds): *Shackelford's Surgery of the Alimentary Tract*, 5th ed., Vol. II. Philadelphia: Saunders, 2002, p 46.]

Therefore, the surgeon should not rush to reoperate on the patient with dumping symptoms. Multidisciplinary nonsurgical management must be optimized first. Before reoperation, a period of in-hospital observation is useful to define the severity of the patient's symptoms, and patient compliance with prescribed dietary and medical therapy.

The results of remedial operation for dumping are variable and unpredictable. There are a variety of surgical approaches, none of which work consistently well. Additionally, there is not a great deal of experience reported in the literature with any of these methods. Long-term follow-up is rare. Patients with disabling refractory dumping after gastrojejunostomy can be considered for simple takedown of this anastomosis provided that the pyloric channel is open endoscopically. The reversed intestinal segment is rarely used today—and rightly so. This operation interposes a 10-cm reversed segment of intestine between the stomach and the proximal small bowel. This slows gastric emptying, but often leads to obstruction, requiring reoperation. Iso-peristaltic interposition (Henley loop) has not been successful in ameliorating severe dumping over the long term. The Roux-en-Y gastrojejunostomy is associated with delayed gastric emptying, probably on the basis of disordered motility in the Roux limb. Taking advantage of this disordered physiology, surgeons have used this operation successfully in the management of the dumping syndrome. Although this is probably the procedure of choice in the small group of patients requiring operation for severe dumping following gastric resection, gastric stasis may result, particularly if a large gastric remnant is left. In the presence of significant gastric acid secretion, marginal ulceration is common after both jejunal interposition and Roux-en-Y procedures; thus concomitant vagotomy and hemigastrectomy should be considered. The theoretical possibility of treating postpyloroplasty

dumping with a Roux-en-Y to the proximal duodenum (the duodenal switch, a potentially reversible operation) has not yet been reported (Fig. 26-68). Because pyloric ablation seems to be the dominant factor in the etiology of dumping, it is not surprising that conversion of Billroth II to Billroth I anastomosis has not been successful in the treatment of dumping.

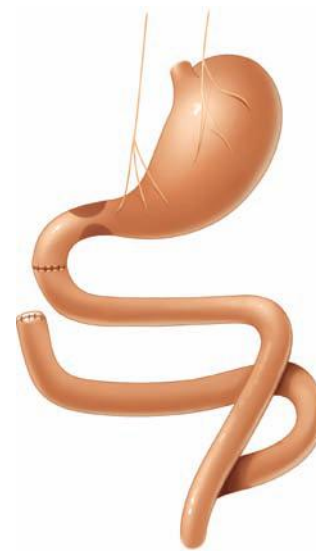

Figure 26-68. Duodenal switch operation. [Reproduced with permission from Hinder RA: *Duodenal switch: A new form of pancreaticobiliary diversion*. *Surg Clin North Am.* 72:487, 1992. Copyright Elsevier.]

Diarrhea

Diarrhea following gastric surgery may be the result of truncal vagotomy, dumping, or malabsorption. Truncal vagotomy is associated with clinically significant diarrhea in 5% to 10% of patients. It occurs soon after surgery and usually is not associated with other symptoms, a fact that helps to distinguish it from dumping. The diarrhea may be a daily occurrence, or there may be significant periods of relatively normal bowel function. The symptoms tend to improve over the months and years after the index operation. The cause of postvagotomy diarrhea is unclear. Possible mechanisms include intestinal dysmotility and accelerated transit, bile acid malabsorption, rapid gastric emptying, and bacterial overgrowth. The latter problem is facilitated by decreased gastric acid secretion and (even small) blind loops. Although bacterial overgrowth can be confirmed with the hydrogen breath test, a simpler test is an empirical trial of oral antibiotics. Some patients with postvagotomy diarrhea respond to cholestyramine, while in others codeine or loperamide may be useful. Octreotide should also be tried. Another theoretical cause of diarrhea following gastric surgery is fat malabsorption due to acid inactivation of pancreatic enzymes or poorly coordinated mixing of food and digestive juices. This can be confirmed with a qualitative test for fecal fat and treated with acid suppression. Postvagotomy diarrhea usually does not respond to treatment with pancreatic enzymes. In the rare patient who is debilitated by postvagotomy diarrhea unresponsive to medical management, operation might be considered but outcomes can be problematic. The operation of choice is probably a 10-cm reversed jejunal interposition placed in continuity 100 cm distal to the ligament of Treitz. Another option is the onlay antiperistaltic distal ileal graft. Both operations can cause obstructive symptoms and/or bacterial overgrowth.^{127B}

Gastric Stasis^{128,129}

Gastric stasis following surgery on the stomach may be due to a problem with gastric motor function or caused by an obstruction. The gastric motility abnormality could have been preexisting and unrecognized by the operating surgeon. Alternatively, it may be secondary to deliberate or unintentional vagotomy, or resection of the dominant gastric pacemaker. An obstruction may be mechanical (e.g., anastomotic stricture, efferent limb kink from adhesions or constricting mesocolon, or a proximal small-bowel obstruction) or functional (e.g., retrograde peristalsis in a Roux limb). Gastric stasis presents with vomiting (often of undigested food), bloating, epigastric pain, and weight loss.

The evaluation of a patient with suspected postoperative gastric stasis includes EGD, upper GI and small bowel series, gastric emptying scan, and gastric motor testing. Endoscopy shows gastritis and retained food or bezoar. The anastomosis and efferent limb should be evaluated for stricture or narrowing. A dilated efferent limb suggests chronic stasis, either from a motor abnormality (e.g., Roux syndrome) or mechanical small bowel obstruction (e.g., chronic adhesion). If the problem is thought to be primarily a disorder of intrinsic motor function, newer techniques such as EGG and GI manometry should be considered, but chronic distal mechanical obstruction may result in disordered motility in the proximal organ confounding interpretation.

Once mechanical obstruction has been ruled out, medical treatment is successful in most cases of motor dysfunction following previous gastric surgery. This consists of dietary modification and promotility agents. Intermittent oral antibiotic

therapy may be helpful in treating bacterial overgrowth, with its attendant symptoms of bloating, flatulence, and diarrhea.

Gastroparesis following V + D may be treated with subtotal gastrectomy but simple loop gastrojejunostomy (GJ) should be tried if previous drainage was pyloroplasty. Billroth II anastomosis with Braun enteroenterostomy may be preferable to Roux-en-Y reconstruction after subtotal gastrectomy for gastric stasis but bile reflux can still occur. Regeneration of gastric stasis is often associated with persistent emptying problems that may subsequently require near-total or total gastrectomy, a nutritionally unattractive option. Delayed gastric emptying following ulcer surgery (V + D or V + A) may represent an anastomotic stricture (often due to recurrent ulcer), or proximal small bowel obstruction. The latter should be dealt with at reoperation. Recurrent ulcer usually responds to medical therapy with PPI and abstinence from NSAIDs, aspirin, and smoking. Endoscopic dilation is occasionally helpful. Gastroparesis following subtotal gastric resection is best treated with near-total (95%) or total gastric resection and Roux-en-Y reconstruction. If total gastrectomy is performed, a jejunal reservoir should be fashioned. Gastric pacing is promising, but it has not achieved widespread clinical usefulness in the treatment of postoperative gastric atony.

Bile Reflux Gastritis and Esophagitis

Most patients who have undergone ablation or resection of the pylorus have bile in the stomach on endoscopic examination, along with some degree of gross or microscopic gastric inflammation. Therefore, attributing postoperative symptoms to bile reflux is problematic because most asymptomatic patients have bile reflux as well. However, it is generally accepted that a small subset of patients have bile reflux gastritis, and present with nausea, bilious vomiting, and epigastric pain, and quantitative evidence of excess enterogastric reflux. Curiously, symptoms often develop months or years after the index operation. The differential diagnosis includes afferent or efferent loop obstruction, gastric stasis, and small-bowel obstruction. Plain abdominal X-rays, upper endoscopy, upper GI series, abdominal CT scan, and gastric emptying scans are helpful in evaluating these possibilities.

Dysfunction of the cardia is one of the causes of bile reflux esophagitis in patients after gastrectomy. Proximal subtotal gastrectomy with esophagoantral anastomosis should be avoided, and if limited resection of the GE junction is performed, the pylorus should be left intact.

Bile reflux may be quantified with gastric analysis or esophageal impedance testing or with scintigraphy (bile reflux scan). Typically, enterogastric reflux is greatest after Billroth II gastrectomy or gastrojejunostomy, and least after vagotomy and pyloroplasty, with Billroth I gastrectomy giving intermediate values. Patients who are well into the abnormal range of bile reflux may be considered for remedial surgery if symptoms are severe. Remedial surgery will eliminate the bile from the vomitus and may improve the patient's pain, but it is quite unusual to render these patients completely asymptomatic, especially if they are narcotic dependent.

Bile reflux gastritis after distal gastric resection may be treated by one of the following options: Roux-en-Y gastrojejunostomy; interposition of a 40-cm isoperistaltic jejunal loop between the gastric remnant and the duodenum (Henley loop); Billroth II gastrojejunostomy with Braun enteroenterostomy; total gastrectomy with Roux esophagojejunostomy. To avoid bile reflux into the stomach or the esophagus the Roux limb should be at least 45 cm long (preferably 60 cm). The Braun

enteroenterostomy should be placed a similar distance from the stomach. Excessively long limbs may be associated with obstruction or malabsorption. All operations can result in marginal ulceration on the jejunal side of the gastrojejunostomy, and thus are combined with a generous distal gastrectomy. If this has already been done at a previous operation, the Roux or Braun operations may be attractively simple. Whether truncal vagotomy is necessary is controversial in the current era of excellent acid-suppressing medications. The benefits of decreased acid secretion following vagotomy may be outweighed by problems with vagotomy-associated dysmotility in the gastric remnant. The Roux operation may be associated with an increased risk of emptying problems compared to the other two options, but controlled data are lacking. Patients with debilitating bile reflux after gastrojejunostomy can be considered for simple takedown of this anastomosis provided that the pyloric channel is open.

Primary bile reflux gastritis (i.e., no previous operation) is rare, and may be treated with the duodenal switch operation, essentially an end-to-end Roux-en-Y to the proximal duodenum (see Fig. 26-68). The Achilles' heel of this operation is, not surprisingly, marginal ulceration. Thus, it should be combined with highly selective vagotomy, and/or long term acid suppressive medication.

Roux Syndrome

A subset of patients who have had distal gastrectomy and Roux-en-Y gastrojejunostomy will have great difficulty with gastric emptying in the absence of mechanical obstruction. These patients present with vomiting, epigastric pain, and weight loss. This clinical scenario has been labeled the *Roux syndrome*. Endoscopy may show retained food or bezoars, dilation of the gastric remnant, and/or dilation of the Roux limb. Anastomotic inflammation and stricture from marginal ulceration is a confounding finding. An upper GI series confirms these findings and may show delayed gastric emptying. This is better quantified by a gastric emptying scan, which always shows delayed solid emptying, and may show delayed liquid emptying as well.

GI motility testing shows abnormal motility in the Roux limb, with propulsive activity toward, rather than away from, the stomach.¹³⁰ Gastric motility also may be abnormal. Presumably, the disordered motility in the Roux limb occurs in all patients with this operation. Why only a subset develops the Roux syndrome is unclear. Perhaps those patients with disordered gastric motility are at most risk. The disorder seems to be more common in patients with a generous gastric remnant. Truncal vagotomy also has been implicated.

Medical treatment consists of promotility agents. Surgical treatment consists of paring down the gastric remnant. Care should be taken to preserve adequate blood supply to the new gastric pouch. If the left gastric artery is intact, a vertically oriented lesser curvature based pouch (similar to gastric bypass) with excision of the fundus can be considered. If gastric motility is severely disordered, 95% gastrectomy or total gastrectomy should be done. The Roux limb should be resected if it is dilated and flaccid, unless doing so puts the patient at risk for short bowel problems.

Gallstones

Gallstone formation following gastric surgery generally is thought to be secondary to vagal denervation of the gallbladder with attendant gallbladder dysmotility and stasis. Although prophylactic cholecystectomy is not justified with most gas-

tric surgery, it should be considered if the gallbladder appears abnormal, especially if subsequent cholecystectomy is likely to be difficult. If preoperative evaluation reveals sludge or gallstones, or if intraoperative evaluation reveals stones, incidental cholecystectomy should be considered if it appears straightforward and the gastric operation has gone well.

Weight Loss

Weight loss is common in patients who have had a vagotomy and/or gastric resection. The degree of weight loss tends to parallel the magnitude of the operation. It may be insignificant in the large person, or devastating in the asthenic female. The surgeon should always consider the possible nutritional consequences before performing a gastric resection for benign disease in a thin patient. The causes of weight loss after gastric surgery generally fall into one of two categories: altered dietary intake or malabsorption. If a stool stain for fecal fat is negative, it is likely that decreased caloric intake is the cause. This is the most common cause of weight loss after gastric surgery, and may be due to small stomach syndrome, postoperative gastroparesis, anorexia due to loss of ghrelin, or self-imposed dietary modification because of dumping and/or diarrhea. Consultation with an experienced dietitian may prove invaluable.

Anemia

Iron absorption takes place primarily in the proximal GI tract, and is facilitated by an acidic environment. Intrinsic factor, essential for the enteric absorption of vitamin B₁₂, is made by the parietal cells of the stomach. Vitamin B₁₂ bioavailability also is facilitated by an acidic environment.

With this as background, it is easy to understand why patients who have had a gastric operation are at risk for anemia. Anemia is the most common metabolic side effect in patients who have had a gastric bypass for morbid obesity. It also occurs in up to one third of patients who have had a vagotomy and/or gastric resection. Iron deficiency is the most common cause, but vitamin B₁₂ or folate deficiency also occurs, even in patients who have not had total gastrectomy. Of course, patients who have had a total gastrectomy will all develop B₁₂ deficiency without parenteral vitamin B₁₂. Gastric bypass patients should be given oral iron supplements, and monitored for iron, B₁₂, and folate deficiency. Patients who have had a vagotomy and/or gastrectomy should be similarly monitored with periodic determination of hematocrit, red blood cell indices, iron and transferrin levels, B₁₂, and folate levels. Marginal nutrient status should be corrected with oral and/or parenteral supplementation.

Bone Disease

Gastric surgery sometimes disturbs calcium and vitamin D metabolism. Calcium absorption occurs primarily in the duodenum, which is bypassed with gastrojejunostomy. Fat malabsorption may occur because of blind loop syndrome and bacterial overgrowth, or because of inefficient mixing of food and digestive enzymes. This can significantly affect the absorption of vitamin D, a fat-soluble vitamin. Both abnormalities of calcium and vitamin D metabolism can contribute to metabolic bone disease in patients following gastric surgery. The problems usually manifest as pain and/or fractures years after the index operation. Musculoskeletal symptoms should prompt a study of bone density. Dietary supplementation of calcium and vitamin D may be useful in preventing these complications. Routine skeletal monitoring of patients at high-risk (e.g., elderly males and females and postmenopausal females) may prove useful

in identifying skeletal deterioration that may be stopped with appropriate treatment.

LAPAROSCOPIC GASTRIC OPERATIONS

The most common laparoscopic gastric operations performed today are for GERD and obesity (see Chapter 27, The Surgical Management of Obesity). However, all of the gastric operations described here can be performed with minimally invasive techniques.¹³¹ Some are technically difficult (e.g., partial or total gastric resection) or are of debatable merit. The operations described in this chapter that lend themselves most readily to minimally invasive techniques are highly selective vagotomy, vagotomy and gastrojejunostomy, and gastrostomy. Laparoscopic wedge resection often is possible for GI stromal tumors, lipomas, or gastric diverticula. Combined endoscopic and laparoscopic techniques occasionally are useful. Robotic gastric operations have been described, but have not yet been widely adopted.¹³² Recently laparoscopic resection has been applied increasingly to patients with gastric cancer¹³³ with promising early results. Advances of laparoscopic instruments particularly energy sources have rendered extended lymph node dissection, including suprapancreatic lymph node dissection feasible. The ratio of D2 lymph node dissection has been increased gradually due to these advances and surgeon's experiences. Laparoscopy surgery has been widely performed in reconstruction in which the intestine is pulled out of the body through a small laparotomy wound.^{133A} Recently, based on the improvement in anastomosis devices, pure laparoscopic surgery has also been used in which a series of procedures (lymphadenectomy, resection, and reconstruction) is completely performed intra-abdominally. Finally, diagnostic laparoscopy may prevent a futile laparotomy in some patients with gastric cancer.

While transgastric appendectomy and transgastric pancreatic necrosectomy appears safe and effective in selected patients in experienced centers,^{134,135} the role of transgastric natural orifice endoscopic surgery has yet to be defined.

REFERENCES

Entries highlighted in bright blue are key references.

1. Beaumont W: *Experiments and Observations on the Gastric Juice and the Physiology of Digestion*. Plattsburgh: PP Allen, 1833.
2. Wangenstein OH, Wangenstein SD. Gastric surgery, in *The Rise of Surgery*. Minneapolis: University of Minnesota Press, 1978.
3. Herrington JL: Historical aspects of gastric surgery, in Scott HW Jr., Sayers JL (eds): *Surgery of the Stomach, Duodenum, and Small Intestine*, 2nd ed. Boston: Blackwell, 1992.
4. Dragstedt LR. Vagotomy for the gastroduodenal ulcer. *Ann Surg*. 1945;122:973-989.
5. Zollinger RM, Ellison EH. Primary peptic ulcerations of the jejunum associated with islet cell tumors of the pancreas. *Ann Surg*. 1955;142:709-728.
6. Flora ED, Wilson TG, Martin IJ, et al. A review of natural orifice transluminal endoscopic surgery (NOTES) for intra-abdominal surgery: experimental models, techniques, and applicability to the clinical setting. *Ann Surg*. 2008;247:583-602.
7. Mercer DW, Liu TH, Castaneda A. Anatomy and physiology of the stomach, in Zuidema GD, Yeo CJ (eds): *Shackelford's Surgery of the Alimentary Tract*, 5th ed, Vol. II. Philadelphia: Saunders, 2002, p 3.
8. Warren WD, Zeppa R, Fomon JJ. Selective trans-splenic decompression of gastroesophageal varices by distal spleno-renal shunt. *Ann Surg*. 1967;166:437-455.
9. Orringer MB, Marshall B, Chang AC, et al. Two thousand transhiatal esophagectomies: changing trends, lessons learned. *Ann Surg*. 2007; 246:363-372.
10. Leung WK, et al: Tumors of the stomach, in Yamada T, et al (eds): *Textbook of Gastroenterology*, 4th ed. Philadelphia: Lippincott, Williams & Wilkins, 2003, p 1416.
11. Japanese Gastric Cancer Association. Japanese classifications of gastric carcinoma: 3rd English edition. *Gastric Cancer*. 2011;14: 101-112.
12. Jansen EPM, Boot H, Verheij M, van de Velde CJ. Optimal locoregional treatment in gastric cancer. *J Clin Oncol*. 2005;23:4509-4517.
13. Johnson LR, (ed). *Physiology of the Gastrointestinal Tract* 5th ed, Elsevier, 2012.
14. Fawcett DW, Jensch R, in. Bloom and Fawcett: *Concise Histology*, 2nd ed Oxford University Press, London.
15. Ashley SW, Evoy D, Daly JM. Stomach, in Schwartz SI (ed): *Principles of Surgery*, 7th ed. New York: McGraw-Hill, 1999, p 1181.
16. Antonioli DA, Madara JL. Functional anatomy of the gastrointestinal tract, in Ming S-C, Goldman H (eds): *Pathology of the Gastrointestinal Tract*, 2nd ed. Baltimore: Williams & Wilkins, 1998, p 13.
17. Feldman M: Gastric secretion, in Feldman M (ed). *Sleisenger and Fordtran's Gastrointestinal and Liver Disease*, 7th ed. Philadelphia: Saunders, 2002, p 715.
18. Loo VG, Bourgault AM, Poirier, L, et al. Host and pathogen factors for Clostridium Difficile infection and colonization. *N Engl J Med*. 2011; 365:1693-1703.
19. Canani RB, Terrin G. Gastric acidity inhibitors and the risk of intestinal infections. *Current Opinion in Gastroenterology* 2010; 26:31-35.
20. Kopic S, Murek M, Geibel JP: Revisiting the parietal cell. *Am J Physiol Cell Physiol*. 2010;298: C1-C10.
21. Wolfe MM, Soll AH. The physiology of gastric acid secretion. *N Engl J Med*. 1988;319:1707-1715.
22. Lloyd KCK, Debas HT. Hormonal and neural regulation of gastric acid secretion, in Johnson LR (ed): *Physiology of the Gastrointestinal Tract*, 3rd ed. New York: Raven, 1993.
23. Del Valle J, Todisco A. Gastric secretion, in Yamada T, et al (eds): *Textbook of Gastroenterology*, 4th ed. Philadelphia: Lippincott, Williams & Wilkins, 2003, p 266.
24. Wallace JL. Prostaglandins, NSAIDs, and gastric mucosal protection: why doesn't the stomach digest itself? *Physiol Rev*. 2008; 88:1547-1565.
25. Choi SR, Lee SA, Kim YJ, et al. Role of heat shock proteins in gastric inflammation and ulcer healing. *J Physiol Pharmacol*. 2009;60: 5-17.
26. Cummings DE, Overduin J. **Gastrointestinal regulation of food intake.** *J Clin Invest*. 2007; 117:13-23.
27. Badman MK, Flier JS. The gut and energy balance: visceral allies in the obesity wars. *Science*. 2005;307:1909-1914.
28. Murray CD, Kamm MA, Bloom SR, et al. Ghrelin for the gastroenterologist: history and potential. *Gastroenterology*. 2003;125:1492-1502.
29. Ariyasu H, Takaya K, Tagami T, et al. Stomach is a major source of circulating ghrelin, and feeding state determines plasma ghrelin-like immuno reactivity levels in humans. *J Clin Endocrinol Metab*. 2001; 86:4753-4758.
30. Cummings DE, Weigle DS, Frayo RS, et al. Plasma ghrelin levels after diet-induced weight loss or gastric bypass surgery. *N Engl J Med*. 2002;346:1623-1630.
31. Karamanakos SN, Vagenas K, Kalfarentzos F, et al. Weight loss, appetite suppression, and changes in fasting and postprandial ghrelin and peptide-YY levels after Roux-en-Y

- gastric bypass and sleeve gastrectomy: a prospective, double blind study. *Ann Surg.* 2008;247:401.
32. Sanjeevi A. Gastric motility. *Curr Opin Gastroenterol.* 2007; 23:625.
 33. Parkman HP, Jones MP. Tests of gastric neuromuscular function. *Gastroenterology.* 2009; 136:1526-1543.
 34. Hasler WL: Physiology of gastric motility and gastric emptying, in Yamada T, et al (eds): *Textbook of Gastroenterology*, 4th ed. Philadelphia: Lippincott, Williams & Wilkins, 2003, p 195.
 35. Chial HJ, Camilleri M: Motility disorders of the stomach and small intestine, in Friedman SL, McQuaid KR, Grendell JH (eds): *Current Diagnosis and Treatment in Gastroenterology*, 2nd ed. New York: McGraw-Hill, 2003, p 355.
 36. Sanders KM, Koh SD, Ro S, Ward SM: Regulation of gastrointestinal motility—insights from smooth muscle biology. *Nature Reviews Gastroenterology and Hepatology.* 2012; 9:633-645.
 37. Deloose E, Janssen P, Depoortere I, Tack J: The migrating motor complex—control mechanisms and its role in health and disease. *Nature Reviews Gastroenterology and Hepatology.* 2012; 9:271-285.
 38. Marks JM, Ponsky JL: Diagnostic and therapeutic endoscopy of the stomach and small bowel, in Yeo CJ, et al (eds): *Shackelford's Surgery of the Alimentary Tract*, 6th ed. Philadelphia: Saunders, 2007.
 39. Furukawa K, Miyahara R, Itoh A, et al. Diagnosis of the invasion depth of gastric cancer using MDCT with virtual gastroscopy: comparison with staging with endoscopic ultrasound. *AJR Am J Roentgenol.* 2011;197:867-875.
 40. Chen CY, Hsu JS, Wu DC, et al. Gastric cancer: preoperative local staging with 3D multidetector row CT—correlation with surgical and histopathologic results. *Radiology.* 2007;242:472-482.
 41. Shin KS, Kim SH, Han JK, et al. Three-dimensional MDCT gastrography compared with axial CT for the detection of early gastric cancer. *J Comput Assist Tomogr.* 2007;31:741-749.
 42. Caddy GR, Chen RY. Current clinical applications of endoscopic ultrasound. *ANZ J Surg* 77:101-111.
 43. Power DG, Schattner MA, Gerdes H, et al. Endoscopic ultrasound can improve the selection for laparoscopy in patients with localized gastric cancer. *J Am Coll Surg* 2009;208:173-178.
 44. Jones DB. Role of endoscopic ultrasound in staging upper gastrointestinal cancers. *ANZ J Surg.* 2007;77:166-172.
 45. Balaji NS, Crookes PF, Banki F, et al. A safe and noninvasive test for vagal integrity revisited. *Arch Surg.* 2002;137: 954-958.
 46. Vaira D, Gatta L, Ricci C, Miglioli M. Review article: diagnosis of *Helicobacter pylori* infection. *Aliment Pharmacol Ther.* 2002;16:105-113.
 47. Walsh JH, Peterson WL. The treatment of *Helicobacter pylori* infection in the management of peptic ulcer disease. *N Engl J Med.* 1995;333:984-991.
 48. Holle GE: Pathophysiology and modern treatment of ulcer disease. *Int J Mol Med.* 2010;25:483-491.
 49. Leong RW: Differences in peptic ulcer between the East and the West. *Gastroenterol Clin North America.* 2009;38:363-379.
 50. Brock J, Sauaia A, Ahnen D, et al: Process of care and outcomes for elderly patients hospitalized with peptic ulcer disease: results from a quality improvement project. *JAMA.* 286:1985-1993.
 51. Yang YR, Richter JE, Dempsey DT. Trends and outcomes of hospitalizations for peptic ulcer disease in the United States 1993-2006. *Annals of Surgery.* 2010; 251:51-58.
 52. Spechler SJ. Peptic ulcer disease and its complications, in Feldman M (ed): *Sleisinger and Fordtran's Gastrointestinal and Liver Disease*, 7th ed. Philadelphia, Saunders, 2002.
 53. Blaser MJ, Atherton JC. *Helicobacter pylori* persistence: biology and disease. *J Clin Invest.* 2004;113:321-333.
 54. Fox JG, Wang TC: Inflammation, atrophy, and gastric cancer. *J Clin Invest.* 2007;117:60.
 55. McColl KE. Clinical practice. *Helicobacter pylori* infection. *N Engl J Med.* 2010;362:1597-1604.
 56. Bedoui S, Kupz A, Wijberg OL, et al. Different bacterial pathogens, different strategies, yet the aim is the same: evasion of intestinal dendritic cell recognition. *J Immunol.* 2010;184:2237-2242.
 57. Graham DY, Lew GM, Klein PD, et al. Effect of treatment of *Helicobacter pylori* infection on the long-term recurrence of gastric or duodenal ulcer: a randomized controlled study. *Ann Intern Med.* 1992;116:705-708.
 58. Del Valle J, Chey WD, Scheiman JM. Acid peptic disorders, in Yamada T, et al (eds): *Textbook of Gastroenterology*, 4th ed. Philadelphia: Lippincott, Williams & Wilkins, 2003, p 1321.
 59. Fisher WE, Brunicaudi FC. Benign gastric ulcer, in Cameron JL (ed): *Current Surgical Therapy*, 9th ed. Philadelphia: Mosby Elsevier, 2008, p 81.
 60. Laine L. Approaches to nonsteroidal anti-inflammatory drug use in the high-risk patient. *Gastroenterology.* 2001;120:594-606.
 61. Lanas A. A review of the gastrointestinal safety data—a gastroenterologist's perspective. *Rheumatology.* 2010;49:ii3-ii10.
 62. Abraham NS, Hlatky MA, Antman EM, et al: ACCF/ACG/AHA Expert consensus document on the concomitant use of proton pump inhibitors and thienopyridines: a focused update of the ACCF/ACG/AHA 2008 consensus document on reducing the gastrointestinal risks of antiplatelet therapy and NSAID use. *Circulation.* 2010;122:2619-2633.
 63. Chey WD, Wong BCY, Practice Parameters Committee of the American College of Gastroenterology. American College of Gastroenterology guideline on the management of *Helicobacter pylori* infection. *Am J Gastroenterol.* 2007;102:1808-1825.
 64. Blatchford O, Murray WR. A risk score to predict need for treatment for upper gastrointestinal hemorrhage. *Lancet.* 2000;356:1318-1321.
 65. Dallal HJ, Palmer KR. ABC of the upper gastrointestinal tract: Upper gastrointestinal haemorrhage. *BMJ.* 2001;323:1115-1117.
 66. Gralnek IM, Barkun AN, Bardou M. Management of acute bleeding from peptic ulcer. *N Engl J Med.* 2008;359:928.
 - 66A. Lo CC, Hsu PI, Lo GH, et al. Comparison of hemostatic efficacy for epinephrine injection alone and injection combined with hemoclip therapy in treating high-risk bleeding ulcers. *Gastrointestinal Endoscopy.* 2006;63:767-773.
 67. Harbison SP, Dempsey DT. Peptic ulcer disease. *Curr Probl Surg.* 2005;42:346.
 68. Mulholland MW, Debas HT. Chronic duodenal and gastric ulcer. *Surg Clin North Am.* 1987;67:489.
 69. Tavakkolizadeh A, Ashley SW. Operations for peptic ulcer, in Yeo CJ, et al (eds): *Shackelford's Surgery of the Alimentary Tract*, 6th ed. Philadelphia: Saunders, 2007, p 791.
 - 69A. Maki T, Shiratoti T, Hatafuku T, et al. Pyrolus-preserving gastrectomy as an improved operation for gastric ulcer. *Surgery.* 1967; 61: 838-842.
 - 69B. Morita S, Katai H, Saka T, et al. Outcome of pyrolus-preserving gastrectomy for early gastric cancer. *Br J Surg.* 2008;95: 1131-1135.
 70. Gilliam AD, Speake WJ, Lobo DN, et al. Current practice of emergency vagotomy and *Helicobacter pylori* eradication for complicated peptic ulcer in the United Kingdom. *Br J Surg.* 2003;90:88-90.
 71. Reuben BC, Neumayer LA. Variations reported in surgical practice for bleeding duodenal ulcers. *Am J Surg.* 2006; 192:e42-e45.
 72. Lau JYW, Sung JYJ, Lee KKC, et al. Effect of intravenous omeprazole on recurrent bleeding after endoscopic treatment of bleeding peptic ulcers. *N Engl J Med.* 2000;343:310-316.

73. Lau JY, Sung JJ, Lam YH, et al. Endoscopic retreatment compared with surgery in patients with recurrent bleeding after initial endoscopic control of bleeding ulcers. *N Engl J Med.* 1999;340:751-756.
74. Kahi CJ, Jensen DM, Sung JJ, et al. Endoscopic therapy versus medical therapy for bleeding peptic ulcer with adherent clot: a meta-analysis. *Gastroenterology.* 2005;129:855-862.
75. Yusuf TE, Brugge WR. Endoscopic therapy of benign pyloric stenosis and gastric outlet obstruction. *Curr Opin Gastroenterol.* 2006;22:570-573.
76. Csendes A, Maluenda F, Braghetto I, et al. Prospective randomized study comparing three surgical techniques for the treatment of gastric outlet obstruction secondary to duodenal ulcer. *Am J Surg.* 1993;166:45-49.
77. Fendrich V, Langer P, Waldmann J, et al. Management of sporadic and multiple endocrine neoplasia type 1 gastrinomas. *Br J Surg.* 2007;94:1331-1341.
78. Dolan JP, Norton JA: Zollinger-Ellison Syndrome, in Yeo CJ, et al (eds). *Shackelford's Surgery of the Alimentary Tract*, 6th ed. Philadelphia: Saunders/Elsevier, 2007, p 862.
79. Orlando LA, Lenard L, Orlando RC: Chronic hypergastrinemia: causes and consequences. *Dig Dis Sci.* 2007;52:2482-2489.
80. Ying L, Harris A, Ying M, et al. Prophylaxis for stress-related gastrointestinal bleeding. Cochrane Upper Gastrointestinal and Pancreatic Diseases Group Cochrane Database of Systematic Reviews. 3, 2008.
81. Alhazzani W, Alenezi F, Jaeschke RZ, et al. Proton pump inhibitors versus histamine 2 receptor antagonists for stress ulcer prophylaxis in critically ill patients: a systematic review and meta-analysis. *Critical Care Medicine.* 2013;41: 693-705.
82. Marik PE, Vasu T, Hirani A, et al: Stress ulcer prophylaxis in the new millennium: A systematic review and meta-analysis. *Crit Care Med.* 2010;38: 2222-2228.
83. Siegel R, Naishadham, D, Jermal A. Cancer statistics 2012. *CaCancer J Clin.* 2012;62: 10-29.
84. Correa P, Houghton J. Carcinogenesis of *Helicobacter pylori*. *Gastroenterology.* 2007;133:659-672.
85. Leung WK, Ng EKW, Sung JY. Tumors of the stomach, in Yamada T, et al (eds): *Textbook of Gastroenterology*, 4th ed. Philadelphia: Lippincott, Williams & Wilkins, 2003.
86. McColl KE, Watabe H, Derakhshan MH. Role of gastric atrophy in mediating negative association between *Helicobacter pylori* infection and reflux oesophagitis, Barrett's oesophagus and oesophageal adenocarcinoma. *Gut.* 2008;57:721.
87. ZurHausen A, van Rees BP, van Beek J, et al. Epstein-Barr virus in gastric carcinomas and gastric stump carcinomas: alate event in gastric carcinogenesis. *J ClinPathol.* 2004;57:487-491.
88. Norton JA, Ham CM, Dam JV, et al. CDH1 truncating mutations in the E-cadherin gene: an indication for total gastrectomy to treat hereditary diffuse gastric cancer. *Ann Surg.* 2007;245:873.
89. Song JH, Meltzer SJ. MicroRNAs in the pathogenesis, diagnosis, and treatment of gastroesophageal cancers. *Gastroenterology.* 2012;143:35-47.
90. Chiba T, Marusawa H, Ushijima T. Inflammation associated cancer development in digestive organs—mechanisms and roles for genetic and epigenetic modulation. *Gastroenterology.* 2012;143:550-563.
- 90A. Park DY, Lauwers GY. Gastric polyps—classification and management. *Arch Pathol Lab Med.* 2008;132:633-640.
91. Shimoyama S, Aoki F, Kawahara M, et al. Early gastric cancer development in a familial adenomatous polyposis patient. *Dig Dis Sci.* 2004;49:260-265.
92. Gylling A, Abdel-Rahman WM, Juhola M, et al. Is gastric cancer part of the tumour spectrum of hereditary non-polyposis colorectal cancer? A molecular genetic study. *Gut.* 2007; 56:926-933.
93. Schaefer N, Sinning C, Standop J, et al. Treatment and prognosis of gastric stump carcinoma in comparison with primary proximal gastric cancer. *Am J Surg.* 2007;194:63-67.
94. Ono H. Early gastric cancer: diagnosis, pathology, treatment techniques, and treatment outcomes. *Eur J Gastroenterol Hepatol.* 2006;18:863-866.
- 94A. Pyrhonen S, Kuitunen T, Nyandoto P, Kouri M. Randomised comparison of fluorouracil, epidoxorubicin, and methotrexate (FEMTX) plus supportive care with supportive care alone in patients with non-resectable gastric cancer. *Br J Cancer.* 1995;71: 587-591.
- 94B. Bang YJ, Van Cutsem E, Feyereislova A, et al. Trastuzumab in combination with chemotherapy versus chemotherapy alone for treatment of HER2-positive advanced gastric or gastroesophageal junction cancer (TOGA): a phase 3 open label randomized controlled trial. *Lancet.* 2010;376:687-697.
- 94C. Li HY, Dai J, Xue HB, et al. Application of magnifying endoscopy with narrow band imaging in diagnosing gastric lesions: a prospective study. *Gastrointestinal Endosc.* 2012; 76:1124-1132.
- 94D. Neumann H, Fuchs FS, Vieth M, et al: Review article—in vivo imaging by endocytoscopy. *Alimentary Pharmacology and Therapeutics.* 2011;33:1183-1193.
95. Chen J, Cheong JH, Yun MJ, et al. Improvement in preoperative staging of gastric adenocarcinoma with positron emission tomography. *Cancer.* 2005;103:2383-2390,2005.
96. Wong J, Coit D. Detection of gastric cancer peritoneal metastases by peritoneal lavage: current limitations and future perspectives. *Surgery.* 2012;152:1-4.
97. Sarela AI, Lefkowitz R, Brennan MF, et al. Selection of patients with gastric adenocarcinoma for laparoscopic staging. *Am J Surg.* 2006;191:134-138.
98. Dicken BJ, Bigam DL, Cass C, et al: Gastric adenocarcinoma: Review and considerations for future directions. *Ann Surg.* 2005;241:27-39.
99. Cho CS, Brennan MF. Gastric adenocarcinoma, in Cameron JL (ed): *Current Surgical Therapy*, 9th ed. Philadelphia: Mosby, 2008.
100. Karpeh MS, Leon L, Klimstra D, Brennan MF. Lymph node staging in gastric cancer: is location more important than number? An analysis of 1038 patients. *Ann Surg.* 2000; 232: 362-371.
101. Saidi RF, ReMine SG, Dudrick PS, et al. Is there a role for palliative gastrectomy in patients with stage IV gastric cancer? *World J Surg.* 2006;30:21-27.
102. Fein M, Fuchs KH, Thalheimer A, et al. Long-term benefits of Roux-en-Y pouch reconstruction after total gastrectomy: A randomized trial. *Ann Surg.* 2008;247:759.
103. Bonenkamp JJ, Hermans J, Sasako M, et al. Extended lymph node dissection for gastric cancer. *N Engl J Med.* 1999; 340:908.
104. Cuschieri A, Fayers P, Fielding J, et al. Postoperative morbidity and mortality after D1 and D2 resections for gastric cancer: preliminary results of the MRC randomised controlled surgical trial. The Surgical Cooperative Group. *Lancet.* 1996;347:995.
- 104A. de Bree E, Charalampakis V, Melissas J, Tsiftsis D. The extent of lymph node dissection for gastric cancer: a critical appraisal. *J Surg Oncol.* 2010;102(6):552-562.
- 104B. Vallbohmer D, Oh DS, Peters JH: The role of lymphadenectomy in surgical treatment of esophageal and gastric cancer. *Current Problems in Surgery.* 2012;49:471-515.
105. Macdonald JS, Smalley SR, Benedetti J, et al. Chemoradiotherapy after surgery compared with surgery alone for adenocarcinoma of the stomach or gastroesophageal junction. *N Engl J Med.* 2001;345:725-730.
- 105A. Sasako M, et al. Five-year outcomes of a randomized phase III trial comparing adjuvant chemotherapy with S-1 versus surgery alone in stage II or III gastric cancer. *J Clin Oncol.* 2011;29: 4387-4393.

- 105B. Bang YJ, Kim YW, Yang HK, et al. Adjuvant capecitabine and oxaliplatin for gastric cancer after D2 gastrectomy (CLASSIC): a phase 3 open-label, randomized controlled trial. *Lancet*. 2012;379: 315-321.
106. Sasako M, Sano T, Yamamoto S, et al. D2 lymphadenectomy alone or with para-aortic nodal dissection for gastric cancer. *N Engl J Med*. 2008;359:453-462.
- 106A. VanCutsem E, Moiseyenko VM, Tjulandin S, et al: Phase III study of docetaxel and cisplatin plus fluorouracil compared with cisplatin and fluorouracil as first-line chemotherapy for advanced gastric cancer: areport of the V325 study group. *J ClinOncol*. 2006;24: 4991-4997.
- 106B. Gomez-Martin C, Garralda E, Echerri MJ; HER2/neu testing for anti-HER2 based therapies in patients with unresectable and/or metastatic gastric cancer. *J Clin Path*. 2012;65: 751-757.
- 106C. Baptista V, Singh A, Wassef W. Early gastric cancer: an update on endoscopic management. *Current Opinion in Gastroenterology*. 2012;28(6):629-635.
107. Yoon SS, Coit DG, Portlock CS, et al. The diminishing role of surgery in the treatment of gastric lymphoma. *Ann Surg*. 2004;240:28-37.
- 107A. Farinha P, Gascoyne RD: Helicobacter pylori and MALT lymphoma. *Gastroenterology*. 2005;128: 1579-1605.
- 108. Gold JS, DeMatteo RP. Combined surgical and molecular therapy: The gastrointestinal stromal tumor model. *Ann Surg*. 2006;244:176-184.**
109. Rubin BP, Heinrich MC, Corless CL. Gastrointestinal stromal tumour. *Lancet*. 2007;369:1731-1741.
110. Stelow EB, Murad FM, Debol SM, et al. A limited immunocytochemical panel for the distinction of subepithelial gastrointestinal mesenchymal neoplasms sampled by endoscopic ultrasound-guided fine-needle aspiration. *Am J ClinPathol*. 2008;129:219-225.
- 110A. Fletcher CD, et al. Diagnosis of gastrointestinal stromal tumors: a consensus approach. *Hum Pathol*. 2002;33: 459-464.
- 110B. Miettinen M, et al: Gastrointestinal stromal tumors: Pathology and prognosis at different sites. *Semin Diagn Pathol*. 2006;23:70-83.
- 110C. DeMatteo RP, Ballman KV, Antonescu CR, et al: Adjuvant imatinib mesylate after resection of localised, primary gastrointestinal stromal tumor: a randomised, double-blind, placebo-controlled trial. *Lancet*. 2009;373:1097-1104.
- 110D. von Mehren M, et al: Soft tissue sarcoma, version 2: featured updates to the NCCN guidelines. *J Natl Compr Canc Netw*. 2012;10(8):951-960.
111. Raut CP, Kulke MH, Glickman JN, et al. Carcinoid tumors. *Curr Probl Surg*. 2006;43:383-450.
112. Modlin IM, Kidd M, Latich I, et al. Current status of gastrointestinal carcinoids. *Gastroenterology*. 2005;128:1717-1751.
113. Mulkeen A, Cha C. Gastric carcinoid. *Curr Opin Oncol*. 2005;17:1-6.
114. Parkman HP, Hasler WL, Fisher RS. American Gastroenterological Association technical review on the diagnosis and treatment of gastroparesis. *Gastroenterology*. 2004;127: 1592-1622.
115. Yin J, Chen JD. Implantable gastric electrical stimulation: Ready for prime time? *Gastroenterology*. 2008;134:665-667.
- 115A. Zehetner J, Ravari F, Ayazi S, et al. Minimally invasive surgical approach for the treatment of gastroparesis. *Surgical Endoscopy*. 2013;27(1):61-66.
116. Cappell MS, Friedel D. Initial management of acute upper gastrointestinal bleeding—from initial evaluation to gastrointestinal endoscopy. *Med Clin North Am*. 2008; 92:491-509.
117. Dempsey DT, Burke DR, Reilly RS, et al. Angiography in poor-risk patients with massive nonvariceal upper gastrointestinal bleeding. *Am J Surg*. 159:282-286.
118. Zaman A. Portal hypertension related bleeding—management of difficult cases. *Clin Liver Dis*. 2006;10:353-370.
119. Coffey RJ, Washington MK, Corless CL, et al. Ménétrier disease and gastrointestinal stromal tumors: hyperproliferative disorders of the stomach. *J Clin Invest*. 2007;117:70.
120. Sebastian S, O'Morain CA, Buckley MJ. Current therapeutic options for gastric antral vascular ectasia. *Aliment Pharmacol-Ther*. 2003; 18:157-165.
121. Akhras J, Patel P, Tobi M. Dieulafoy's lesion-like bleeding: an under-recognized cause of upper gastrointestinal hemorrhage in patients with advanced liver disease. *Dig Dis Sci*. 2007; 52:722-726.
122. Harbison SP, Dempsey DT. Mallory-Weiss syndrome, in Cameron JL (ed): *Current Surgical Therapy*, 9th ed. Philadelphia: Mosby, 2008.
123. Schrag SP, Sharma R, Jaik NP, et al. Complications related to percutaneous endoscopic gastrostomy (PEG) tubes. A comprehensive clinical review. *J Gastrointest Liver Dis*. 2007;16:407-418.
124. McClave SA. Critical care nutrition: getting involved as a gastrointestinal endoscopist. *J ClinGastroenterol*. 2006;40: 870-890.
125. Dempsey DT. Reoperative gastric surgery and postgastrectomy syndromes, in Zuidema GD, Yeo CJ (eds): *Shackelford's Surgery of the Alimentary Tract*, 5th ed., Vol. II. Philadelphia: Saunders, 2002, p 161.
126. Meilahn JE, Dempsey DT. Postgastrectomy problems: Remedial operations and therapy, in Cameron JL (ed): *Current Surgical Therapy*, 8th ed. Philadelphia: Elsevier Mosby, 2004.
127. Ukleja A: Dumping syndrome: pathophysiology and treatment. *NutrClinPract*. 2005; 20:517-525.
- 127A. Cuschieri A: Postvagotomy diarrhea: is there a place for surgical management? *Gut*. 1990; 31:245-246.
128. Forster-Barthell AW, Murr MM, Nitecki S, et al. Near-total completion gastrectomy for severe postvagotomy gastric stasis: analysis of early and long-term results in 62 patients. *J Gastrointest Surg*. 1999;3:15-21.
129. Jones MP, Maganti K. A systematic review of surgical therapy for gastroparesis. *Am J Gastroenterol*. 2003;98:2122-2129.
130. Van der Milje HC, Kleibeuker JH, Limburg AJ, et al. Manometric and scintigraphic studies of the relation between motility disturbances in the Roux limb and the Roux-en-Y syndrome. *Am J Surg*. 1993;166:11-17.
131. Farrell TM, Hunter JG. Laparoscopic surgery of the stomach and duodenum, in Zuidema GD, Yeo CJ (eds): *Shackelford's Surgery of the Alimentary Tract*, 5th ed., Vol. II. Philadelphia: Saunders, 2002, p 202.
132. Anderson C, Ellenhorn J, HellanM, Pigazzi A. Pilot series of robot-assisted laparoscopic assisted subtotal gastrectomy with extended lymphadenectomy for gastric cancer. *Surg Endosc*. 2007;21:1662-1666.
133. Lee J, Kim W. Clinical experience of 528 laparoscopic gastrectomies on gastric cancer in a single institution. *Surgery*. 2013;153(5):611-618.
- 133A. Zeng YK, Yang ZL, Peng JS, et al. Laparoscopy-Assisted versus open distal gastrectomy for early gastric cancer. *Annals of Surgery*. 2012;256: 39-52.
134. Kaehler G, Schoenberg MB, Kienle P, Post S, Magdeburg R. Transgastric appendicectomy. *Br J Surg*. 2013;100(7):911.
135. Bakker OJ, van Santvoort HC, van Brunschot S, et al. Dutch Pancreatitis Study Group. Endoscopic transgastric vs surgical necrosectomy for infected necrotizing pancreatitis: a randomized trial. *JAMA* 2012;307:1053-1061.

27 chapter

The Surgical Management of Obesity

Philip R. Schauer and Bruce Schirmer

Introduction	1099	Patient Selection / 1105	Laparoscopic Sleeve Gastrectomy / 1121	
The Disease of Obesity	1100	Preoperative Preparation / 1105	Special Issues Relating to the Bariatric Patient	1125
Prevalence and Contributing Factors / 1101		Anesthesiology Issues / 1106	Bariatric Procedures in Adolescent and Elderly Patients / 1125	
Concurrent Medical and Social Problems / 1101		Bariatric Surgical Procedures	The Female Patient: Pregnancy and Gynecologic Issues in the Bariatric Surgery Patient / 1126	
Prognosis / 1101		1107	Metabolic Surgery / 1126	
Medical Management	1101	Laparoscopic versus Open Procedures / 1107	Resolution of Other Comorbid Medical Problems / 1128	
Overview of Bariatric Surgery	1102	Postoperative Follow-Up / 1107	Plastic Surgery after Weight Loss / 1129	
Evolution of Bariatric Surgery / 1103		Laparoscopic Adjustable Gastric Banding / 1108	Endoscopic, Electric, and Other Experimental Procedures / 1129	
The Bariatric Revolution / 1103		Laparoscopic Roux-en-Y Gastric Bypass / 1112		
Indications / 1104		Open Roux-en-Y Gastric Bypass / 1118		
Contraindications / 1104		Biliopancreatic Diversion and Duodenal Switch / 1119		
Preoperative Issues	1105			

INTRODUCTION

The surgical treatment of obesity has evolved to focus more specifically on the treatment of medical comorbidities associated with obesity than simply obesity itself. While bariatric surgery remains the overriding name of the field, the importance of treatment of the metabolic aspects of obesity has caused the primary society of surgeons treating these problems to rename the society the American Society for Metabolic and Bariatric Surgery (ASMBS). The nomenclature reflects the new emphasis of treating the metabolic consequences of obesity surgically. For the first time in the history of bariatric surgery, considerable effort is being devoted to scientifically study the physiologic mechanisms that help promote weight loss and, more importantly, resolution of comorbid medical problems associated with obesity.

Other major changes in the field of bariatric surgery in the United States since the last edition of this text include the introduction and rapid adoption worldwide of the laparoscopic sleeve gastrectomy and the simultaneous decreasing popularity of the laparoscopic adjustable gastric banding procedure.

The bariatric surgery community also has focused on improvement of outcomes and treatment for patients. The Centers of Excellence (COE) concept is an obvious example in the United States, but internationally, greater attention to outcomes and optimal results has been uniform. Improved outcomes have been documented in the literature, as have notable prospective randomized trials of medical versus surgical therapy. In the United States, a very recent study has challenged the concept that improved outcomes arise in COEs, citing data that Medicare patients had similar complication rates after surgery before and after the institution of a policy of surgery approval only at COEs.¹

Extension of the indication for metabolic surgery to patients with class 1 obesity (body mass index, 30–35 kg/m²) has been another development during the past few years.² The regulatory and scientific communities have been more willing to acknowledge the efficacy of metabolic surgery for treating comorbid medical problems, such as diabetes, than have the payors. Insurance coverage for appropriately qualified patients remains one of the biggest barriers to the access of appropriate care for patients suffering from morbid obesity.

Acknowledgement of morbid obesity as a disease has recently been adopted by the American Medical Association.³ This comes years after the recognition by the Centers for Medicare and Medicaid Services (CMS) of obesity as a disease,⁴ a reversal of the usual situation in which medical organizations are ahead of payors in recognition of such issues. Despite CMS recognition, regional administrators of CMS still raise unnecessary barriers and make access to care for morbidly obese patients difficult. Long waiting periods, denials for arbitrary issues, and mandatory 6- to 12-month “diet” plans with no requirement for actually losing weight continue to dominate the landscape of the patient seeking metabolic and bariatric surgery. What is also becoming as big an issue for other patients who have had bariatric surgery is denial of subsequent coverage for any emergency complications of the original operation if the patient’s new insurance plan does not cover bariatric surgery. Although the new Affordable Care Act will potentially eliminate the inability to obtain insurance because of pre-existing conditions, there is no guarantee that patients who have had bariatric surgery will be afforded the same rights to payment for emergent and needed surgery should a subsequent complication arise.

Key Points

- 1▶ Surgical therapy is the only effective and proven therapy for patients with severe obesity (body mass index >40 kg/m²). Bariatric operations prolong survival and resolve comorbid medical conditions associated with severe obesity.
- 2▶ During the years 1999 to 2003, called the Bariatric Revolution in the United States, the availability of a laparoscopic approach for bariatric operations caused major changes in the field, including a massive increase in the number of procedures performed as well as an increased public and professional awareness and understanding of the field.
- 3▶ Bariatric operations involve either restriction of caloric intake or malabsorption of nutrients, or both. Long-term follow-up is essential before the merits of an operation can be confirmed.
- 4▶ Patients who develop a bowel obstruction after laparoscopic gastric bypass require surgical and not conservative therapy due to the high incidence of internal hernias and the potential for bowel infarction.
- 5▶ Malabsorptive operations are highly effective in producing durable weight loss but have considerable nutritional side effects. Patients undergoing such procedures require complete follow-up and must take appropriate nutritional supplements.
- 6▶ The Roux-en-Y gastric bypass is the most commonly performed bariatric procedure, whereas the sleeve gastrectomy is the most rapidly increasing procedure worldwide.
- 7▶ All bariatric operations are tools that serve to allow the patient to lose weight, become healthier, and improve their quality of life. These changes are only maintained long-term if the patient permanently adopts the new eating patterns and exercise habits that are taught and expected in the early year(s) after surgery.
- 8▶ Bariatric surgery is also metabolic surgery, treating the varied metabolic consequences of the comorbid diseases arising from severe obesity. Some operations are particularly effective treatments for such metabolic consequences, such as gastric bypass for type 2 diabetes.

The merger of the COE systems of the ASMBS and the American College of Surgeons (ACS) has been a major positive event in recent years as well. Thanks to the leadership of Robin Blackwell, M.D., ASMBS President from 2011 to 2012, supported by the ASMBS Executive Council, the ASMBS took the initiative to merge with the ACS to create a single uniform system acceptable to both groups and clearly more authoritative due to its singular position. The ACS, to its credit, provided large fiscal and human resources to support the merger and adoption of a single COE system. Since the merger, the incorporation of virtually all the centers in the two systems has occurred under one new system. Outcomes, as reported for review by the oversight committee, are better than ever. Our patients have thus been well served.

THE DISEASE OF OBESITY

Obesity is the second leading cause of preventable death in the United States, currently outdone only by smoking. However, obesity as a separate disease entity is still underappreciated and certainly misunderstood. The fact that the American Medical Association waited until the summer of 2013 to acknowledge obesity as a disease entity illustrates this statement.

Obesity is a disease and is likely multifactorial in its origin. We may come to a simpler and direct understanding of its pathogenesis in the future with increased understanding of molecular genetics, but for now, it remains a complex issue. The components of the disease likely include a combination of environmental and genetic factors. The recent rapid rise in the incidence of obesity in less than a generational time suggests that genetic etiologies alone cannot be responsible for the disease. Nevertheless, the numerous factors contributing to the disease increase the difficulty in understanding its causes.

The degrees of obesity are defined by body mass index (BMI = weight [kg]/height [m]²), which correlates body weight with height. Controversy exists as to the most accurate system by

which to classify obesity. BMI has its inaccuracies, especially for the heavily muscled individual who may weigh more but have a low amount of body fat. However, BMI is the clinically easiest system to use, employing the simply measured parameters of height and weight. The World Health Organization classification of obesity is given in Table 27-1. It should be noted that for Asian populations, classifications remain the same as the international classification, but the public health action points for interventions are set at 23, 27.5, 32.5, and 37.5 kg/m².

Table 27-1

World Health Organization classification of obesity by body mass index (BMI) *

CLASSIFICATION	BMI (KG/M ²)	
	PRINCIPAL CUT-OFF POINTS	CUT-OFF POINTS FOR ASIANS*
Normal range	18.5–24.9	18.5–22.9 23.0–24.9
Pre-obese	25.0–29.9	25.0–27.4 27.5–29.9
Obese class I	30.0–34.9	30.0–32.4 32.5–34.9
Obese class II	35.0–39.9	35.0–37.4 37.5–39.9
Obese class III	≥40.0	≥40.0

*For Asian populations, classifications remain the same as the international classification, but that public health action points for interventions are set at 23, 27.5, 32.5 and 37.5 kg/m² 204.

Source: Adapted from the World Health Organization (WHO) 2000²⁰⁵.

Prevalence and Contributing Factors

Severe obesity is reaching epidemic proportions in the United States and dramatically increasing throughout the rest of the world. Since 1960, surveys of the prevalence of obesity have been conducted every decade by the National Center for Health Statistics. Data on obesity statistics have been updated annually since 1985. The latest figures for obesity incidence in the United States are that 35.7% of U.S. adults are obese (class 1 or higher).⁵

Genetic and environmental factors contribute to the development of obesity. While children of parents of normal weight have a 10% chance of becoming obese, the children of two obese parents have an 80% to 90% chance of developing obesity by adulthood. The weight of adopted children correlates strongly with the weight of their birth parents. Furthermore, concordance rates for obesity in monozygotic twins are doubled compared to others.⁶ Diet and culture are important factors as well; these environmental factors contribute significantly to the epidemic of obesity in the United States since the rapid increase in obesity during the past two decades cannot be explained by any genetic etiology.

Other factors appear to contribute significantly to severe obesity. Intermittent or consistent excessive caloric intake occurs. The lack of satiety, on a consistent or intermittent basis, appears to be strongly correlated to such episodes of excessive caloric ingestion. As yet, the physiologic basis for the explanation of such lack of satiety is not understood. Other factors commonly suggested to play a role in the disease of obesity include decreased energy expenditure from reduced metabolic activity, reduction in the thermogenic response to meals, an abnormally high set-point for body weight, or a decrease in the loss of heat energy. Another factor that may influence absorption of ingested food is intraluminal bacterial composition of the intestinal tract. Studies have documented a difference in the composition of the intestinal flora of obese versus normal-weight individuals.⁷

Obese individuals have excessive adipose cells, both in size and number. The number of such cells often is determined early in life; adult-onset obesity is largely a product of increase in adipose cell size. Weight gain results from increase in both adipose cell size and number. Adipose tissue may be deposited in large quantities in the subcutaneous layer of the abdominal wall or the viscera. Males tend to have central visceral fat distribution, whereas females more often have a peripheral or gluteal fat distribution. Central or visceral fat distribution is associated with metabolic diseases such as diabetes, hypertension, and the metabolic syndrome.⁸

Concurrent Medical and Social Problems

The severely obese patient often presents with chronic weight-related problems, detailed below. However, the single most difficult aspect of the disease of severe obesity for those suffering from it is the discrimination they face from the rest of the population with respect to social stigmatization. This prejudice against obesity remains the last unlegislated discrimination in existence. Obese individuals are routinely discriminated against in terms of employment. Public facilities often do not allow them to participate in activities. Examples include the size of airline seats and bathrooms, the availability of appropriate clothing options, and the size of automobile cabins. Severely obese individuals are thought of by much of the public as being

lazy or gluttonous and lacking self-discipline. They often endure not only discrimination and prejudice, but outright ridicule and disrespect. Consequently, the stigma of severe obesity has a major impact on social function and emotional well-being. Thus, psychological disorders such as depression are found in an extraordinarily high incidence in this population versus the general public. Poor self-image is almost universal among obese individuals.

Significant comorbidities, defined as medical problems associated with or caused by obesity, are numerous. The most prevalent and acknowledged of these include degenerative joint disease, low back pain, hypertension, obstructive sleep apnea, gastroesophageal reflux disease (GERD), cholelithiasis, type 2 diabetes, hyperlipidemia, hypercholesterolemia, asthma, hypoventilation syndrome of obesity, fatal cardiac arrhythmias, right-sided heart failure, migraine headaches, pseudotumor cerebri, venous stasis ulcers, deep venous thrombosis, fungal skin rashes, skin abscesses, stress urinary incontinence, infertility, dysmenorrhea, depression, abdominal wall hernias, and an increased incidence of various cancers such as those of the uterus, breast, colon, and prostate.⁹

Prognosis

Obesity has a profound effect on overall health and life expectancy, largely secondary to weight-related comorbidities. It is estimated that a severely obese male at age 21 will live 12 years less and a woman 9 years less than a nonobese individual. The incidence of severe obesity in the population is comparable for females below and above the age of 50 years, whereas for men, it is decreased above age 50. This is due to the fact that the severely obese man often is dead of comorbid medical conditions, especially cardiac arrhythmias and coronary artery disease, by age 50. A study carried out by the Veterans Administration showed a 12-fold increase in mortality among 200 morbidly obese men age 25 to 34 years and a six-fold increase in mortality among those age 35 to 44 years over a 7-year follow-up period.¹⁰ Decreased quality of life also results due to severe obesity. Most patients seeking surgical treatment of severe obesity do so because of the medical issues they face from comorbid conditions or the decreased quality of life they are experiencing as a result of severe obesity. Bariatric surgery

▶ can significantly prolong the lifespan of a severely obese individual, as well as improve the quality of that life.

MEDICAL MANAGEMENT

Medical treatment for severe obesity is aimed at reducing body weight with a combination of decreased caloric intake and accompanying increases in energy expended from moderate exercise. This method of weight loss is the safest possible and may work well for obese individuals who have modest amounts of weight to lose to regain normal body weight or return to being simply overweight instead of obese. However, for the severely obese individual, who usually must lose at least 75 or more pounds to achieve elimination of obesity, this daunting task is extremely difficult. The success rate for the severely obese patient population that tries dieting and exercise as a means of losing enough weight to no longer be obese and maintaining that weight loss is only approximately 3%.

Although the success rate is limited with diet and exercise alone, all severely obese individuals are asked to attempt this route of weight loss prior to undertaking any surgical therapy.

There are two main reasons for this. The first is to allow those who can achieve such weight loss through the safest possible means to do so. The second, and by far the most practical, is to have the severely obese individual begin to appreciate and practice the lifestyle changes that must ultimately become routine for them once weight loss is achieved, by whatever means. Thus the dieting and exercise of conservative weight loss plans are important preparation for the incorporation of such habits into the patient's lifestyle postoperatively after bariatric surgery. The adjustment of the patient's lifestyle to include these measures is the key to long-term success with any bariatric operation. Failure to do so usually results in regain of weight and sacrifice of any health benefits initially gained by the immediate postoperative weight loss.

The treatment of severe obesity should be initiated with simple lifestyle changes, including moderate reduction of caloric intake and beginning an exercise plan. Walking is the most common choice for this patient population, who may be unable to perform extremely vigorous exercise initially. Medical comorbidities must be identified and treated. Usually the patient's primary care physician will have already accomplished this, but we do at times identify bariatric-related comorbidities on initial history and physical examination in our clinic.

The severely obese patient will usually have been given dietary counseling by his or her primary care physician and often placed on a medically supervised diet. Most patients also have attempted commercially sponsored diets and diet plans. Success following these is not uncommon, but sustained weight loss for more than a year after stopping the program is uncommon. While primary care physicians usually do an outstanding job of identifying and treating comorbid medical problems, their offices usually do not have the related support staff in terms of nutritionists and psychologists, who are often very helpful in providing services to the severely obese patient undergoing significant lifestyle changes.

Lifestyle changes of diet, exercise, and behavior modification constitute the first tier of therapy for obesity. Dietary restriction and exercise can each independently create a caloric deficit. A daily energy deficit of 500 kcal/d, resulting in a weekly deficit of 3500 kcal, results in the loss of 1 lb of fat weekly. It has been shown that low-calorie diets (800–1500 kcal/d) are as effective as very-low-calorie diets at 1 year, but result in a lower rate of nutritional deficiencies.¹¹ Such diets may produce an average of 8% body weight loss over a 6-month period. Longer follow-up shows recidivism. Physical activity of a moderate daily nature can produce a 2% to 3% body weight loss.¹²

A behavioral modification program, which provides desirable rewards for meeting short-term dietary or exercise requirements, was shown in combination with diet and exercise to produce as much as a 10% weight loss at 6 months in one study. This weight loss was only sustained in 60% of patients at 40 weeks,¹³ and at 1 year, the average sustained weight loss was decreased to 8.6%.¹⁴

Dietary, exercise, or behavior modification therapy is appropriate treatment for patients who are overweight (BMI <30 kg/m²) and highly recommended for patients with a BMI between 30 and 35 kg/m². Most of the studies looking at dietary therapy do not include a patient population that is largely obese (BMI >30 kg/m²). Dietary therapy can be effective in producing improvements in comorbid conditions such as diabetes mellitus, with weight loss of 2.3% to 3.7% influencing the disease.¹⁵

Thus, lifestyle changes can be effective in improving the health of the nonobese, but less so for the obese population.

Pharmacologic therapy is also an option for patients attempting to lose weight. Unfortunately, the number of effective pharmacologic agents is small compared to the number of products sold with allegations that they will promote or support weight loss. Pharmacotherapy is normally used only after lifestyle changes and dietary therapies have failed. It is used either as primary therapy alone or in conjunction with simultaneous diet and exercise therapy.

Orlistat inhibits gastric and pancreatic lipase enzymes that promote lipid absorption in the intestine.¹⁶ It produces a weight loss of between 6% and 10% of body weight after 1 year, but cessation of the drug usually results in prompt regain of lost weight.¹⁶ Pharmacotherapy is recommended as an adjunctive or supplementary therapy to lifestyle changes including diet and exercise or behavioral therapy by the National Institutes of Health (NIH) consensus guidelines for treatment of obesity.¹⁷ Two new medications have been approved by the Food and Drug Administration (FDA) within the past few years for weight loss. Qsymia, a combination of phentermine and topiramate, produced a 5% weight loss in over 70% of patients after 1 year.¹⁸ Lorcaserin (Belviq), a central serotonin agonist, produced a 5% weight loss in 47% of patients taking the medication.¹⁹

Since medical therapies are almost uniformly ineffective long-term for patients with severe obesity, the severely obese patient tends to continue to gain weight over time. The number and strength of prescribed medications slowly increase as the medical comorbidities become increasingly worse. Unfortunately, for the majority of severely obese patients, this process continues unabated until death results eventually from the comorbidities. Until recently, less than 1% of severely obese patients underwent surgical treatment for obesity annually. That number has now increased, but still is not over 2% of individuals. Even accounting for patients referred for surgery and felt to be poor candidates, it is likely that less than 5% of patients with severe obesity are referred on an annual basis. Part of this issue may be patient aversion to surgical therapy. Primary care physician awareness, patient reticence, and economic concerns about potentially losing employment due to time off required for surgery or its complications have been the primary reasons cited for the lack of increased performance of bariatric and metabolic surgery. Lack of insurance coverage by many patients is also a primary reason for not seeking surgical therapy for the medical problems associated with severe obesity. Disincentives posed by insurance companies, such as required dietary periods that clearly have no scientific or clinical basis of merit, are still used to discourage patients from pursuing surgical therapy. The lack of efficacy and potential harm to patients of such policies has been clearly demonstrated in the literature.^{20,21}

OVERVIEW OF BARIATRIC SURGERY

Bariatric operations produce weight loss through at least two mechanisms and probably many more that are not known. The most common is restriction of intake. Malabsorption of ingested food is the second mechanism. Restrictive operations may include no or only a modest malabsorptive component. Malabsorptive operations may have some restrictive component, but it is secondary to the malabsorptive aspect of the operation.

Table 27-2

Types of commonly performed bariatric operations by mechanism of action**Primarily Restrictive**

Laparoscopic adjustable gastric banding (LAGB)

Sleeve gastrectomy (SG)

Primarily Malabsorptive

Biliopancreatic diversion (BPD)

Duodenal switch (DS)

Combination

Roux-en-Y gastric bypass (RYGB)

Table 27-2 describes the common currently performed operations listed by mechanism of action.

This chapter focuses on the operations listed in Table 27-2, whether they are done via a laparoscopic or an open incision approach. Any other procedures to produce weight loss are so infrequently done that they will not be discussed in detail. Vertical banded gastroplasty (VBG), although still one of the approved operations for the surgical treatment of severe obesity based on the NIH Consensus Conference of 1991,²² is now so infrequently performed and has such poor long-term follow-up results²³ that it is of historic interest only.

Evolution of Bariatric Surgery

During the 1950s, operations were first performed to treat severe hyperlipidemia with associated obesity.²⁴ These were ileocolic bypass operations to limit absorption and were associated with severe nutritional complications and liver failure postoperatively. The jejunioleal bypass was then devised and popularized in the mid-1970s.²⁵ It was also a malabsorptive operation, but bypassed only a portion of the small intestine. Complications after this procedure included severe diarrhea, electrolyte disturbances, protein-calorie malnutrition, renal stones, and liver failure.

In 1969, Mason and Ito performed the first gastric bypass, describing a loop of jejunum connected to a transverse proximal gastric pouch.²⁶ Bile reflux esophagitis was severe postoperatively, causing Griffin and colleagues to describe the Roux-en-Y modification of the gastric bypass in 1977.²⁷ The gastric pouch was altered from transverse to vertical using the upper lesser curvature as well.

During the 1970s, the dismal failure of the jejunioleal bypass resulted in a very bad reputation in general for bariatric surgery among general surgeons who had performed the procedure or cared for patients suffering from its complications. The reputation was not enhanced by the many variations of gastric stapling that then became common during the 1970s and early 1980s. Such operations often consisted of a few rows of staples partially across the upper stomach for restrictive purposes. Since the procedure was easily done, some surgeons performed it in prolific numbers. Staple breakdown predictably occurred months to years later, with subsequent weight regain. These procedures added to the string of failures of bariatric operations.²⁸

In 1980, Mason²⁹ first performed the VBG, which was a restrictive procedure using a stapled proximal gastric pouch of the upper lesser curvature of the stomach with a restrictive band for its outlet to the rest of the stomach. This operation produced excellent initial weight loss (50% of excess weight or more)

with low morbidity and mortality. It rapidly became the most commonly performed bariatric operation in the United States during the 1980s. However, by the early 1990s, it became clear that patients who underwent VBG tended to adopt a diet of high-calorie liquids and regained weight.³⁰ A significant incidence of stenosis at the band was also a problem.³¹ Long-term weight loss was poor,²³ and by the 1990s in the United States, Roux-en-Y gastric bypass (RYGB) became the procedure of choice for bariatric surgery.

In Italy, in the meantime, Scopinaro had developed and popularized the biliopancreatic diversion (BPD) in the early 1980s.³² This procedure, described in more detail later, has been, along with its modification to include duodenal switch (DS),³³ the only major malabsorptive operation to enjoy long-term success. BPD and DS are both still used by a fairly select few surgeons throughout the world and have traditionally represented and continue to represent less than 5% of operations performed in the United States.

Fixed banding of the stomach, besides the VBG, was also described by other surgeons in the 1980s and 1990s. Kuzmak is credited with describing the fixed gastric band procedure, which later led to the development of the adjustable gastric banding operation.³⁴

The laparoscopic alternative to bariatric surgery became available in the 1990s. Belachew performed the first laparoscopic adjustable gastric banding (LAGB) operation in 1994.³⁵ Wittgrove and Clark performed the first laparoscopic RYGB the same year.³⁶ Since the former operation is technically much easier than the latter, it was not surprising that it became very popular and frequently performed in Europe and Australia during the late 1990s. In 2001, LAGB was approved for use in the United States. Its popularity increased annually until 2009, but since then, it has decreased in popularity. Sleeve gastrectomy (SG) has enjoyed a rapid increase in popularity both in the United States and internationally since 2008. Buchwald and Oien³⁷ have recently described the international trends in the performance of bariatric operations.

The Bariatric Revolution

The Bariatric Revolution is a term applied to the 5-year stretch from 1998 to 2003 during which the number of gastric bypass operations performed in the United States, membership in ASMBS, and public recognition and interest and professional respect for the field dramatically increased. Few medical centers in the United States offered a laparoscopic approach to bariatric surgery prior to 1998. Several centers, most notably Schauer and colleagues at Pittsburgh, then began **2▶** numerous programs to teach many bariatric surgeons the procedure. Simultaneous improvement in the laparoscopic instruments for bariatric procedures combined with these programs to allow the performance of laparoscopic Roux-en-Y gastric bypass (LRYGB) in numerous centers over the next few years. The field then literally exploded in terms of growth in the United States. Figure 27-1 illustrates the volume of LRYGBs performed during the years prior to and during the Bariatric Revolution. Operative procedures increased nearly eight-fold. Membership in the American Society for Bariatric Surgery (the name of the ASMBS at that time) tripled during these years. The number of minimally invasive fellowships offered to graduating residents, most of whom included bariatric surgical procedures as a major component of the case load, increased from about 25 to 125 during these years.

Gastric bypass

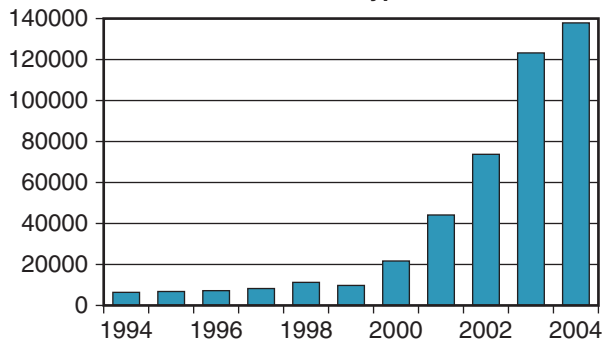


Figure 27-1. Number of Roux-en-Y gastric bypass operations performed in the United States by year. (Data from the Nationwide Inpatient Sample Database.)

Public recognition of the procedure markedly increased due to public figures in the media undergoing bariatric surgery. The widespread availability of the Internet to prospective patients allowed much more information to be relayed. Patients who had or were contemplating surgery were able to communicate via the Internet. Videos of bariatric operations became available via several media outlets including television and the Internet. Many U.S. surgical departments that had previously shunned the field of bariatric surgery recruited bariatric surgeons and established programs. Hospitals without programs recruited surgeons so they could offer the service. Bariatric surgery presentations at national surgical meetings became common instead of rare.

Indications

The indications for performing bariatric surgery remain as described in the NIH Consensus Conference of 1991.²² The only major difference is the procedures that are now recognized as standard procedures. These were defined by the CMS in 2005 as those listed in Table 27-2, with the exception of SG. SG did not receive approval until 2012, when after a controversial initial rejection of coverage, the CMS decided to allow coverage based on the discretion of regional carriers. The standard and somewhat conservative indications for performing bariatric surgery are summarized in Table 27-3.

Contraindications

Of all the reasons a patient who desires bariatric surgery cannot have an operation, insurance coverage, or lack thereof, is the most common reason. This factor, however, is normally beyond surgeon control. Assuming the patient does have coverage or

financial means to qualify for surgery, then application of the NIH criteria is the next consideration. Once a patient qualifies according to those criteria, then consideration of medical, social, and psychological issues can determine reasons to avoid surgical therapy.

The NIH criteria do not set limits for age, and surgeon opinion on this issue varies widely. Surgeons have variable practice patterns as to performance of surgery in the older patient. The philosophy for age restriction is two-fold: A large number of younger patients are interested in and eligible for bariatric surgery, and there is a greater likelihood that a longer period of postoperative benefit in terms of improved quality of life and longevity will occur with a younger patient population. Alternatively, older patients are more likely to have debilitating comorbid conditions and thus have immediate benefit in quality of life but not necessarily enhanced longevity.

Medical issues that preclude patients from being good surgical candidates include American Society of Anesthesiologists class IV disease of a nature that makes surgical therapy extraordinarily high risk. Psychological instability or the inability to understand the implications of the proposed operation and what changes will result from it in terms of the patient's lifestyle are also contraindications. Known and documented drug or alcohol addiction is a contraindication to surgery. Smoking is a relative contraindication, and requirement of cessation of smoking varies by surgical practice. A poorly controlled eating disorder, especially bulimia, is also a contraindication to surgery. Nonambulatory status is a relative contraindication to surgery, especially if the obesity is so severe that the patient cannot normally do self-care or would not likely be able to do so after surgery. Such patients have excessive morbidity in our experience, and placement in care facilities postoperatively after recovery from surgery is often impossible due to their size and limitations of physical ability. Although hard to determine on a single visit, an accumulation of evidence that suggests the patient views the operation as a "magic bullet" for which they must only show up and after which they will not be required to make any substantive changes in eating or lifestyle is a potential valid reason to deny surgery. Finally, lack of sufficient social support, an extremely poor or unsupportive home environment, or hostile spouse or relatives can be contraindications to surgical care, since such supportive environmental factors are important to optimize outcomes once discharged from the hospital. Table 27-4 summarizes potential contraindications for surgery.

Table 27-3

Indications for bariatric surgery

Patient must have:

1. Body mass index ≥ 40 kg/m² with or without comorbid medical conditions associated with obesity
2. Body mass index 35–40 kg/m² with comorbid medical conditions

In addition, it is expected that the patient:

3. Has failed attempt at medically supervised diet
4. Be psychiatrically stable

Table 27-4

Potential contraindications for bariatric surgery

1. Severe medical disease making anesthesia or surgery prohibitively risky (American Society of Anesthesiologists class IV)
2. Mentally incompetent to understand procedure
3. Inability or unwillingness to change lifestyle postoperatively
4. Drug, alcohol, or other addiction
5. Active problem of bulimia or other eating disorder
6. Psychologically unstable
7. Nonambulatory status
8. Unsupportive home environment

PREOPERATIVE ISSUES

Patient Selection

Patient selection for surgery should be based on a multidisciplinary team evaluation. The patient has usually been screened by his or her primary care physician prior to referral, with major medical issues addressed prior to referral. Qualification by NIH criteria and availability of insurance coverage can be handled by office administrators to document and confirm prior to the first appointment.

The preoperative assessment of the patient for bariatric surgery must include input from the nutritionist as an important independent evaluation. Careful assessment of the patient's eating habits, knowledge, self-awareness, and insight are important. An estimation of the patient's motivation to change eating habits is important. The nutritionist should have at least one assessment session with the patient and an educational session preoperatively once the decision to proceed with surgery has been determined. The operation to be performed requires specific nutritional counseling and education.

Psychological assessment is required by most insurance carriers. One major benefit of the psychological assessment is to determine the patient's understanding of the operation and whether he or she has a realistic understanding of the changes that are needed in lifestyle for optimal outcomes. The psychologist or psychiatrist often may diagnose previously unappreciated depression, which is prevalent in nearly 40% of our preoperative patients when carefully screened. Its treatment is felt to improve postoperative outcomes.

Most of the patients referred for surgery who have been screened for qualification by NIH standards will be appropriate candidates for bariatric surgery. Some will decide against the procedure after thorough educational and counseling sessions. Such sessions are imperative for improving outcomes. Providing both written detailed information and a verbal presentation by the multidisciplinary team to educate patients preoperatively regarding bariatric surgical procedures and expected outcomes and potential complications is recommended. Informed and prepared patients will likely be much more compliant with perioperative and postoperative requested behavioral and eating changes. Some patients who decide against the procedure will return in the future after their obesity comorbidities worsen. Reevaluation for continued appropriateness as a good surgical candidate is equally indicated at such time.

Preoperative Preparation

Preoperatively, current comorbid and other medical problems and their optimal therapy are confirmed. Potentially undiagnosed medical problems are sought. Screening for "hidden" diseases such as coronary artery disease in those patients over age 50 is important. For such patients, or those with known cardiovascular disease, a preoperative cardiology consultation is recommended. Such consultation usually then involves electrocardiogram (ECG), echocardiogram, and stress test, with the results of these at times suggesting need for cardiac catheterization. Another condition often underdiagnosed preoperatively in the severely obese patient population is obstructive sleep apnea (OSA). The Epworth Sleepiness Scale, a standard set of questions evaluating daytime sleepiness, is often used as a screening tool for OSA.³⁸ Many institutions are routinely employing it for all surgical patients, given the recognition that OSA increases postoperative morbidity after all operations. Patients who give

a history of loud snoring, morning tiredness on waking, and falling asleep easily while driving or sitting likely have OSA. A diagnostic sleep study is indicated for these individuals. One report suggests that the incidence of sleep apnea in severely obese patients, when all are routinely subjected to sleep studies, may approach 80%.³⁹ Once diagnosed with sleep apnea, patients should use their positive airway pressure appliance as treatment. Use of this system in the immediate postoperative period is especially important to prevent episodes of hypoxia and potentially resulting cardiac arrhythmias. Asthma and hypoventilation syndrome of obesity are other significant pulmonary diseases often requiring preoperative management. Hypoventilation syndrome of obesity is defined as resting arterial partial pressure of oxygen less than 55 mmHg and partial pressure of carbon dioxide greater than 47 mmHg, with accompanying pulmonary hypertension and polycythemia. Pulmonary consultation is indicated for patients with hypoventilation syndrome. Postoperative intensive care unit hospitalization, rarely used after bariatric surgery, may be indicated for these patients.

For patients with active GERD on medication, a preoperative screening upper endoscopy to rule out Barrett's esophagus and to rule out intrinsic lesions of the stomach or duodenum is recommended. This is especially true for patients planning LRYGB, where the distal stomach and duodenum will be precluded from easy inspection postoperatively. Several studies have documented the considerable incidence of preoperative pathology on flexible upper endoscopy for this patient population, as well as a small but not insignificant incidence of pathology resulting in alteration of the originally planned surgical procedure.^{40,41} At Virginia, our experience was that such pathology was present in 4.6% of examinations.⁴² The presence of a hiatal hernia detected on preoperative esophagogastroduodenoscopy will alert the surgeon for the need to perform intraoperative repair.

Patients who are on anticoagulation medication for prosthetic cardiac valves or history of recent venous thromboembolism must have their anticoagulation managed perioperatively. Options include total cessation of oral warfarin therapy 5 days prior to surgery, bridging this time with subcutaneous low-molecular-weight heparin, or, more rarely, preoperative admission for intravenous heparin anticoagulation, which is then stopped 6 hours prior to surgery.

Patients with a strong history of previous venous thromboembolism or who are felt to have multiple risk factors for postoperative venous thromboembolism are potential candidates for preoperative placement of a temporary inferior vena cava filter. Such filters are placed the day prior to surgery by our interventional radiology colleagues and removed 3 to 6 weeks postoperatively. However, a report on a large experience of collected hospitals has shown this procedure has potential complications and morbidity, which may outweigh its use in all but the most high-risk patients.⁴³

Some surgeons routinely perform screening ultrasound of the abdomen for patients planning to undergo LRYGB with an intact gallbladder to rule out the potential presence of gallstones. Should gallstones be discovered, simultaneous laparoscopic cholecystectomy is one option, whereas deferring until after weight loss is another reasonable option. Recent analysis of our experience with simultaneous cholecystectomy at the University of Virginia has shown the average increase in operative time to be approximately 30 minutes for both LRYGB and RYGB with no increase in hospitalization or morbidity.⁴⁴ An earlier study at

Pittsburgh did demonstrate an increased length of hospitalization for patients having simultaneous cholecystectomy.⁴⁵ When a patient does not have gallstones on preoperative ultrasound, use of prophylactic ursodiol in a dose of 300 mg twice a day will decrease the incidence of gallstone formation after RYGB to approximately 4%.⁴⁶ Controversy currently exists as to the proper role of simultaneous laparoscopic cholecystectomy at the time of LAGB. The conservative approach is to not perform such an operation, given the small potential for gallbladder bile spillage resulting in an infection of the prosthesis. However, some reports have shown that this risk may be very low.⁴⁷

Another value of a preoperative ultrasound of the abdomen is the assessment of liver size and composition. An ultrasound that reveals a large fatty liver in a patient planning to undergo either LAGB or LRYGB should alert the surgeon to the high potential for technical difficulty in liver retraction and exposure. We have converted to an open incision and even deferred persisting with the operation altogether when confronted with an excessively large or a tremendously large liver, respectively. Knowledge of this prior to surgery allows the patient to follow a low-calorie diet to shrink the liver preoperatively.

Some surgeons require patients to follow a low-calorie diet in the immediate postoperative period, requiring weight loss prior to proceeding with surgery. Some data exist indicating that preoperative weight loss by patients may improve outcomes.⁴⁸ Such studies suffer from the fact that the patients who are most compliant and lose weight preoperatively may be the most compliant postoperatively, accounting for the improved outcomes. Preoperative weight loss is not necessary to achieve good outcomes from surgery. Requiring preoperative weight loss raises the dilemma of whether patients who do not achieve weight loss should be then denied the benefit of surgical therapy.

Another controversial area is the requirement for cessation of smoking by patients prior to undergoing surgery. Some surgeons make this an absolute requirement, while others do not. Certainly the risk of marginal ulcer after RYGB, which is more difficult to treat and has a higher recurrence rate in smokers,⁴⁹ should be considered as a factor in whether to offer the smoking patient this operation.

Other preparation for bariatric surgery includes the performance of a baseline arterial blood gas measurement. This is especially important in any patients with significant pulmonary disease or hypoventilation syndrome of obesity, since a baseline value of “normal” for the patient must be appreciated if ventilator management postoperatively is necessary.

Baseline evaluation of thyroid function is indicated preoperatively, since hypothyroidism is not uncommon in this patient population. Serum chemistries, liver function tests, and usual screening blood tests are done. Blood tests to determine baseline nutritional parameters are not uncommonly abnormal for low iron and vitamin D levels. The former finding is common in the menstruating female population, obese or not, while the latter has been reported for the population in general but especially for the obese patient population.⁵⁰ The necessity to treat low vitamin D levels preoperatively is unclear in terms of its influence on clinical outcomes. However, the primary reason to correct low vitamin D is improved long-term bone disease health.

Preoperative education is important to reemphasize important points of likely events of the perioperative period, expected postoperative course, and instructions for postoperative activity and diet. Expectations for patients include ambulation on

the day of surgery, following postoperative dietary instructions, taking recommended vitamin and mineral supplements, and following a regular exercise plan.

Anesthesiology Issues

A preoperative anesthesiology assessment is indicated for all patients undergoing bariatric surgery. This assessment confirms the optimal assessment and management of ongoing comorbid medical problems. It also includes the aforementioned cardiopulmonary evaluation to determine any underlying pathology that requires preoperative treatment to decrease perioperative morbidity from cardiopulmonary complications.

It is important that the anesthesiologist be experienced in performing general anesthesia management for the bariatric patient. There is no question that the consistent participation of a few selected and experienced anesthesiologists who specialize in the care of the bariatric patient will minimize morbidity of surgical outcomes. Perioperative and intraoperative communication between the anesthesiology team and the surgical team is particularly important during bariatric operations to facilitate the smooth flow of the operation and avoid complications from the procedure.

Two major difficulties that the anesthesiologist faces when performing a general anesthetic for the severely obese patient are vascular access and airway management. Both are significantly more difficult in the obese patient population than the normal-weight population. Central venous access is at times the only available route for establishment of a reliable intravenous access. Access to both arms during the procedure is standard in our operating rooms; this allows for additional larger bore intravenous access should an episode of intra-abdominal hemorrhage occur. Jugular cannulation is often very difficult due to neck adipose tissue. However, ultrasound guidance can facilitate this procedure. Subclavian access is performed when other central access routes are not feasible.

Management of the severely obese patient airway is often a major challenge for the anesthesiologist and must be done well to avoid potentially significant morbidity. Videotelescopic intubation systems are successfully used in some institutions to manage difficult airway intubation. Fiberoptic laryngoscopy is more commonly used for the difficult airway should standard laryngoscopy provide an inadequate view. For the most difficult class IV or even class III airways, a fiberoptic guided intubation is used. Experience is key in performing smooth intubation of this patient population. Significant preoxygenation for 3 minutes or longer prior to intubation is used for the severely obese patient to provide a longer safe duration for intubation should difficulties be encountered. However, desaturation must be immediately addressed with reestablishment of oxygenated ventilation because this patient group does not tolerate any prolonged desaturation without potential adverse cardiopulmonary consequences.

The anesthesiologist must be adept at understanding and managing alterations in cardiopulmonary function from the use of a pneumoperitoneum during laparoscopic bariatric procedures. These alterations include the effects of carbon dioxide absorption on required minute ventilation, the potential for bradyarrhythmias, and the potential for decreased systemic pH with longer procedures in patients with preexisting cardiopulmonary disease. Arterial monitoring of the latter group of patients may be necessary by the anesthesiology team, and a radial arterial line is standard for such patients.⁵¹

Drug pharmacokinetics differ in severely obese patients as well. Changes in volume of distribution include smaller-than-normal fraction of total body water, greater adipose tissue content, altered protein binding, and increased blood volume. Possible changes in renal function and hepatic function must be considered when administering drugs.

Specific anesthetic drug metabolic alterations in the severely obese include a larger volume distribution of thiopentone, resulting in a prolonged effect of the drug.

Calculation of the dosage should be done by lean body weight. Benzodiazepines also exhibit a prolonged elimination phase, causing persistence of their effects. Increased pseudocholinesterase activity is present in the severely obese patient, requiring increased dosages of pancuronium. Enflurane metabolism is increased over the average-sized person, requiring a lower dosage of this agent.

BARIATRIC SURGICAL PROCEDURES

Laparoscopic versus Open Procedures

The procedures in this section will be described using a laparoscopic approach as the default or typical approach. RYGB, BPD, and DS may still be performed by some surgeons using an open approach, but this has now become the exception. Minimization of the morbidity of the open incision, especially incisional hernias and wound complications, as well as earlier hospital discharge and lower 30-day complication rates have all been clearly shown to favor using a laparoscopic approach when feasible.⁵²⁻⁵⁴ In addition, the logical assumption that avoiding the major tissue trauma associated with a lengthy abdominal wall incision is beneficial to patient recovery has been confirmed. Most importantly, patient interest in bariatric surgery increased dramatically once a laparoscopic approach was available for these procedures, especially RYGB.⁵⁵ In the twenty-first century, most prospective bariatric patients are informed enough about the options for surgery that they seek out a surgeon who does laparoscopic bariatric surgery.

When an open surgical approach is used for any of these procedures, an upper midline incision is the most commonly used approach. Some surgeons have had excellent success with a left subcostal incision for performing RYGB.⁵⁶ Mechanical retractors afford additional exposure for open surgery and are indicated. Wound closure for midline incisions usually is performed using heavy monofilament suture for the midline fascia, but surgeon preferences vary. Any concerning drainage from a postoperative open surgical incision line requires opening of the wound in that area and confirmation that a more severe deep-seated fascial tissue infection does not exist.

Laparoscopic surgery requires a basic core set of knowledge and skills that have now become a standard part of surgical training. Successful completion of the Fundamentals of Laparoscopic Surgery (FLS) unit developed by the Society of American Gastrointestinal and Endoscopic Surgeons (SAGES)⁵⁷ is now mandatory for all surgical residents in the United States.

Laparoscopy begins with the safe creation of a pneumoperitoneum, often a difficult step in the bariatric patient. We have found the use of a tracheostomy hook inserted through a trocar-sized incision to elevate the fascia in the left subcostal region to be of great assistance in facilitating the insertion of a Veress needle into an appropriate location for pneumoperitoneum creation. In general, the use of a Hasson approach for creating a

pneumoperitoneum in the bariatric population is limited by the thick body wall. In the patient with an extremely thick body wall, extra long trocar ports can be used for laparoscopic surgery.

The pneumoperitoneum pressure that is used when performing bariatric surgical procedures is generally in the 15 to 18 mmHg range. A high-flow insufflator is mandatory to maintain the pneumoperitoneum for adequate and safe visualization. An angled telescope is quite helpful. Instrumentation for performing laparoscopic bariatric surgery has dramatically improved in the past 15 years and continues to improve. We now favor using certain laparoscopic instruments, such as the staplers and harmonic scalpel, even if conversion to an open approach occurs.

Conversion to an open incision is appropriate in circumstances where patient safety would potentially be compromised by persisting with a laparoscopic approach. Table 27-5 lists appropriate reasons for conversion to an open incision as well as consideration for beginning with open surgery if certain conditions are known, such as an existing large upper abdominal incisional hernia or known severe intra-abdominal adhesions. Conversion to an open incision should not be viewed as a failure by the surgeon, nor should such an attitude bias the surgeon in favor of persisting with a laparoscopic approach if the operation is not progressing or if a complication is worsening when it could be corrected more quickly using an open approach. Patient safety is the gold standard for determining the timing and appropriateness of conversion. Usually, if conversion is needed, it is best to do so as early in the course of the operation as possible.

Postoperative Follow-Up

Short-term follow-up is defined as follow-up of up to 2 years. Unfortunately, even in the best of practices in the United States, because of the lack of a centralized health system or registry, 1-year follow-up of 90% or greater is a laudable achievement and rarely reported in most case series. Recommendations for bariatric centers wishing to be COEs are that 75% of patients are followed for 5 years with restrictive operations, and 90% are followed if they have malabsorptive operations. Those recommendations, however, are based on having a system that attempts maximum possible follow-up that should yield such results. Although a system may be in place that generates multiple attempts at having the patient return for postoperative check-ups, without patient compliance, all such systems are fallible.

The goals of short-term follow-up are to maximize care of the patient in the postoperative period; assist in adjustment to

Table 27-5

Indications for conversion from laparoscopic to open surgery

1. Failure to establish an adequate pneumoperitoneum
2. Hemodynamic adverse reaction to pneumoperitoneum
3. Intra-abdominal adhesions precluding safe access or presenting excessive difficulty to access abdomen
4. Hepatomegaly such that retraction is not feasible or, even with retraction, organ visualization is obscured
5. Intraoperative complications such as hemorrhage that are best managed with an open approach
6. Exceedingly thick body wall precluding adequate trocar access or manipulation
7. Existing large upper abdominal wall hernia that optimally can be repaired simultaneously using the same incision

new eating, exercise, and lifestyle patterns; be on the alert for and treat postoperative complications; and recommend measures to limit such complications. Objective data that should be obtained after all bariatric operations include weight loss, change in BMI, resolution or improvement in medical comorbidities, and any adverse events or complications that occur. Optimally, assessment of quality of life can help gauge efficacy as well, with the Short Form-36 (SF36) questionnaire being one standard, frequently used example. Short-term follow-up data do give a good reflection of the safety of the procedure, but only an estimate of the efficacy regarding weight loss and effect on resolution of medical comorbidities.

Medium-term follow-up is defined as that from 2 to 5 years. Medium- and long-term follow-up, defined as greater than 5 years, are the only means by which the true long-term efficacy of bariatric surgical operations can be assessed. Operations that initially appear quite promising, such as the VBG or even the jejunioleal bypass, were shown with long- and medium-term follow-up, respectively, to have significant deficiencies in efficacy for the VBG²³ and safety²⁵ for the jejunioleal bypass. Other stapled gastroplasties similarly did not demonstrate efficacy on medium-term follow-up.²⁵

Unfortunately, to date, there has been no conventional method of reporting outcomes after bariatric surgery. The ideal publication includes quantitation of number of patients, a description of the operative technique, incidence of conversion to open if applicable, number of patients included in follow-up data per year, percentage of patients lost to follow-up, weight loss usually expressed as percentage of excess weight, initial and subsequent BMI, complications, mortality, resolution of medical comorbidities, and any quality of life data. Few publications have met these criteria. There are also only a few studies in which a prospective randomized comparison either between bariatric surgery and medical management or between different bariatric surgical operations or approaches (laparoscopic vs. open) have been performed. Improvement in study design and more complete data in future publications are indicated.

A multidisciplinary team approach to follow-up is as essential, if not more so, postoperatively than preoperatively. Regular counseling sessions with the nutritionist are always helpful. Psychological support should be available as needed to assist the patient in adjustment to major life changes. All programs should offer a frequent support group forum for patients to discuss issues on a less formal basis and receive encouragement from other patients as well as staff.

Experience of performing bariatric surgery for several decades between the co-authors has led us to conclude that *whatever the operation performed, its long-term success is only achieved by patients if they embrace the eating and lifestyle changes the operation allows them to adopt.* Continuation of exercise as part of the daily lifestyle is associated with a high incidence of preservation of weight loss. Diligence to avoid snacking and returning to other poor eating habits is also important. The majority of patients do embrace the metamorphosis their bariatric operation produces such that they maintain their new eating, lifestyle, and exercise habits to the benefit of their continued improved health, self-image, and well-being.

Laparoscopic Adjustable Gastric Banding

Background. LAGB involves placement of an inflatable silicone band around the proximal stomach. The band is attached

to a reservoir system that allows adjustment of the tightness of the band. This reservoir system is accessed through a subcutaneously placed port, similar in concept to ports used for chemotherapy via central venous catheters. Figure 27-2 shows the LAGB apparatus in place.

Two major types of bands have been used for this procedure. The original Lap-Band, most recently marketed by Apollo Endosurgery, has been used most frequently. The Swedish Band, now remarketed as the Realize Band by Ethicon, is slightly wider than the Lap-Band.⁵⁸ The port systems have differences as to profile and methods of attachment to the fascia.

Technique. Port placement for LAGB has varied among surgeons. Figure 27-2 shows a common configuration used. Usually some combination of two ports for the surgeon's hands, one or two for the assistant, a port for the telescope, and a liver retractor site are needed.

With the patient placed in reverse Trendelenburg position, the procedure begins with division of the peritoneum at the angle of His and then division of the gastrohepatic ligament in its avascular area (the *pars flaccida*) to expose the base of the right crus of the diaphragm. If a hiatal hernia is present, it must be repaired at this point, using a standard posterior esophageal dissection to expose the crura and perform suture repair. A grasper (Lap-Band) or specially devised instrument (Realize Band) is inserted along the base of the anterior surface of the diaphragmatic crura, from right to left, emerging at the angle of

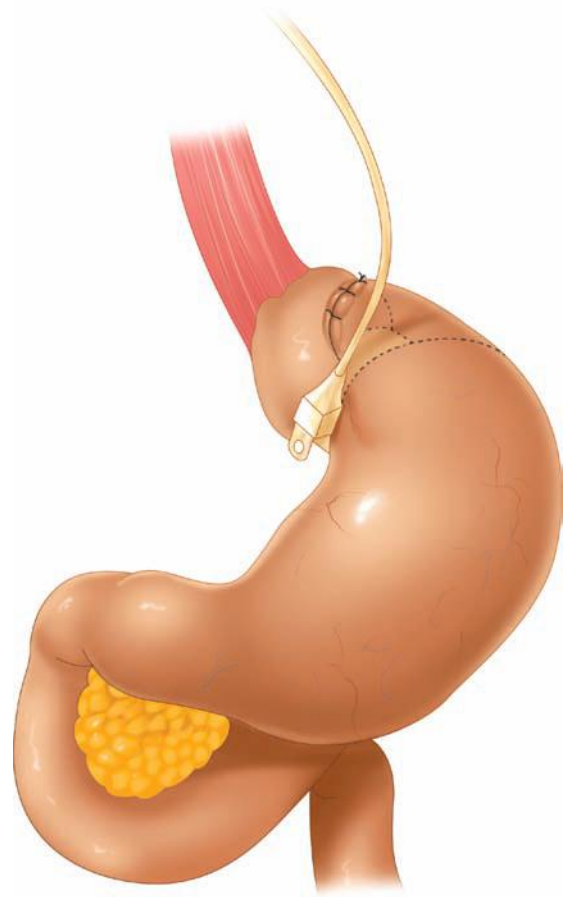


Figure 27-2. Laparoscopic adjustable band overall scheme. (From Schauer PR, et al, eds. *Minimally Invasive Bariatric Surgery*, 1st ed. New York: Springer; 2007. Reprinted with permission, Cleveland Clinic Center for Medical Art & Photography © 2005-2009. All rights reserved.)

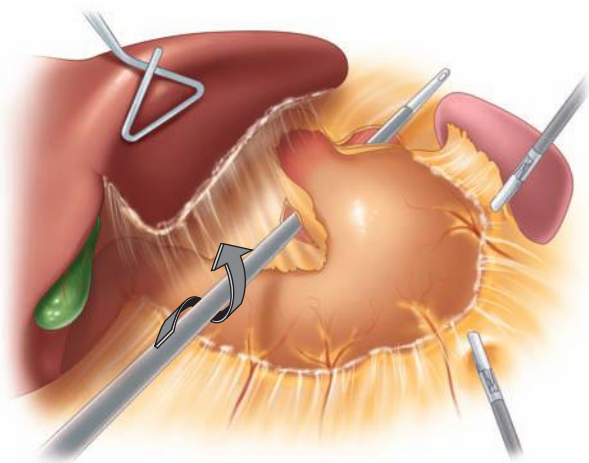
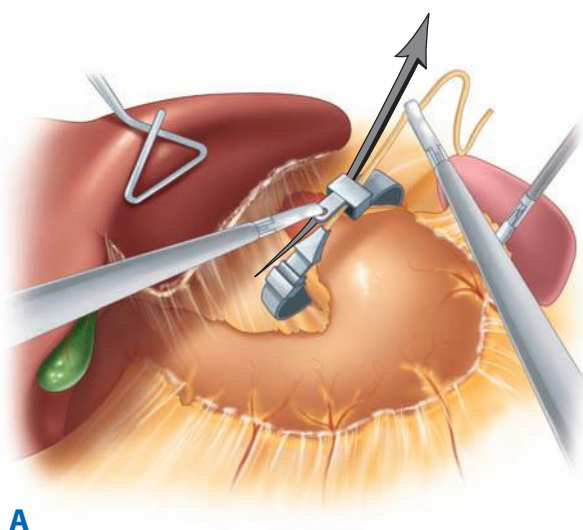


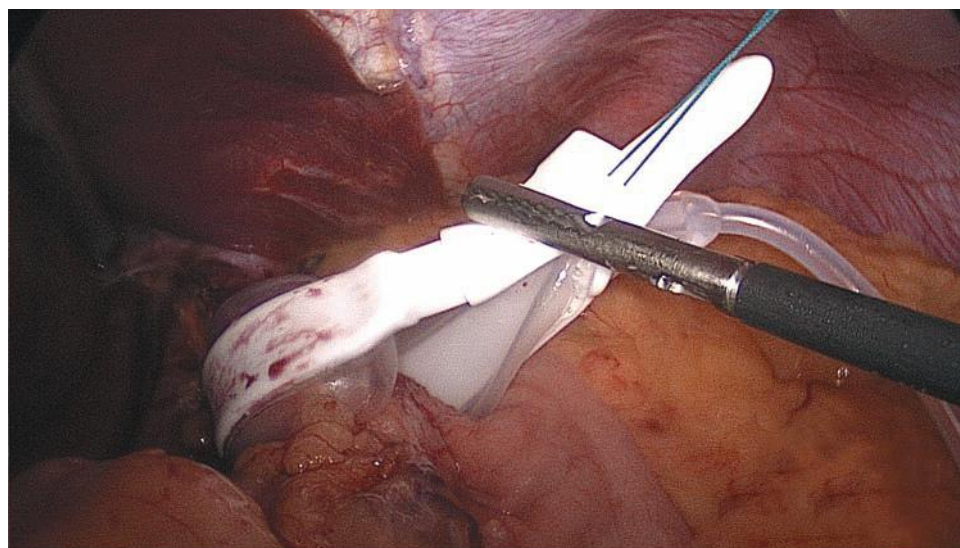
Figure 27-3. Grasper being passed through under stomach to grasp tubing during placement. (From Schauer PR, et al, eds. *Minimally Invasive Bariatric Surgery, 1st ed.* New York: Springer; 2007. Reprinted with permission, Cleveland Clinic Center for Medical Art & Photography © 2005-2009. All rights reserved.)

His in the area of the divided peritoneum (Fig. 27-3). The device is then used to pull the band underneath the posterior surface of the gastroesophageal junction. This technique, by passing the band through some fibrous tissue in this plane, serves to anchor the band more securely posteriorly. During the initial years of band placement, a retrogastric location of the posterior half of the band in the free space of the lesser sac caused an unacceptably high incidence of slippage and prolapse of the band. The adoption of the *pars flaccida* technique decreased the incidence of such slippage.⁵⁹

Once the band is passed around the proximal stomach, it is locked into its ring configuration through its own self-locking mechanism. This involves the tubing end being passed through the orifice of the buckle for the Lap-Band and the suture on the end of the flanged end of the band site being passed through for the Realize Band. Once the band is securely locked in place, the buckle portion of the band is located on the lesser curvature of the stomach (Fig. 27-4A,B). Now the anterior surface of the fundus and proximal stomach is imbricated over the band using several sutures (Fig. 27-5).



A



B

Figure 27-4. A. Lap-Band in place around stomach. (From Schauer PR, et al, eds. *Minimally Invasive Bariatric Surgery, 1st ed.* New York: Springer; 2007. Reprinted with permission, Cleveland Clinic Center for Medical Art & Photography © 2005-2009. All rights reserved. B. Realize (Swedish) Band around stomach.

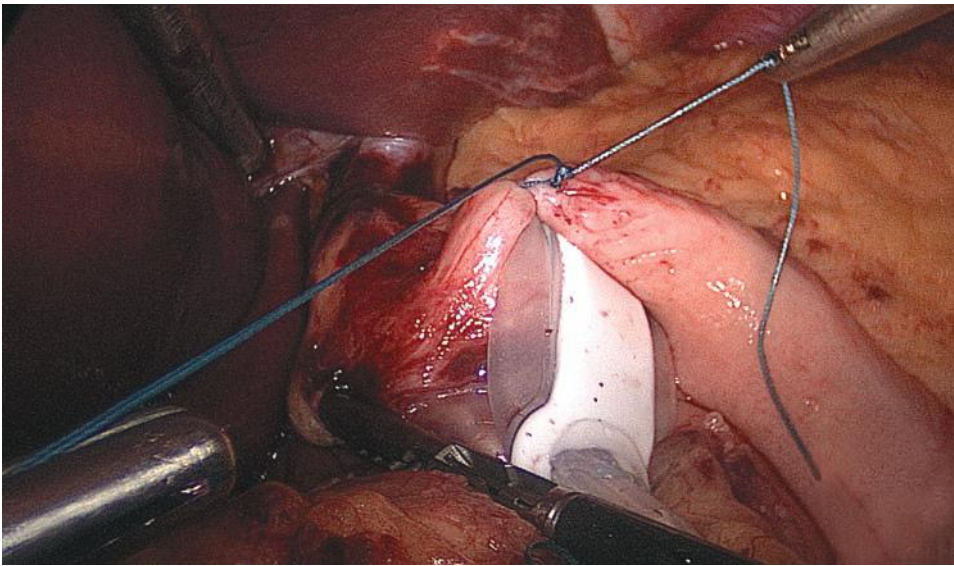


Figure 27-5. Stomach imbricated over band.

The tubing of the band system is brought out through the desired site for placement of the port portion of the system. Usually this is a trocar site near the upper abdomen or xiphoid region to place the port most superficially such that it can be palpated postoperatively. The port is secured to the anterior abdominal wall fascia. Access to the port for subsequent addition of fluid to the band system is percutaneously achieved using a Huber or noncutting type needle. The band is initially placed empty of fluid in most circumstances.

Patient Selection and Preparation. Most LAGB procedures are done on an outpatient basis. Technically the operation is not as difficult as the other operations described later. Because the gastrointestinal tract is not violated, the relative risk of the procedure is lower than most other bariatric operations, making this procedure more amenable to offer to older, more medically ill, or higher risk patient populations. However, efficacy of the operation in the superobese (BMI >50 kg/m²) is less impressive, with average BMI remaining over 40 kg/m² after 5 to 8 years of follow-up.⁶⁰ It has been our impression that optimal results occur with this operation in a patient population who is motivated, needs to lose less than 50 kg to achieve a BMI less than 30 kg/m², is willing and able to exercise regularly, is amenable to changing eating patterns as recommended, and is within a geographically close enough area for ease of follow-up. Patients who are impatient to lose weight, immobile, unable or unwilling to exercise, or confirmed “grazers” or “nibblers” on high-calorie sweets who expect to be able to continue their dietary habits without great alteration are not good candidates for this operation. Similarly, patients who have had previous upper gastric surgery, such as a Nissen fundoplication, are relatively poor candidates for LAGB due to the potential tissue compromise in taking down the wrap to place the band.

Important points of preoperative preparation specific to the procedure include being nil per os (NPO), receiving preoperative appropriate venous thromboembolism prophylaxis, appropriate broad-spectrum intravenous antibiotics, and having appropriate intravenous access and monitoring. An orogastric tube is inserted into the stomach. These preoperative measures are recommended in all the procedures described later as well.

Postoperative Care and Follow-Up. The majority of LAGB procedures are performed on an outpatient basis. Insurance

requirement and pre-existing medical issues are usually the only reason for overnight hospitalization. Diet instructions, wound care, pain medications, and instructions on time schedule of resuming other preoperative medications should all be explained to the patient as well as to a family member (who has not just undergone general anesthesia) prior to discharge. Arrangements for a postoperative follow-up visit, phone numbers to call for emergencies, and indications to call should all be explained as well.

The first postoperative evaluation after LAGB generally occurs 2 to 3 weeks after surgery. By this time, patients have begun to tire of the blenderized diet recommended, are often eager to return to work if they have not done so, and are amenable to discussions of an exercise plan and diet progression plan. Wounds are assessed, as are medical problems, oral intake, and adherence to diet. Since LAGB does not preclude absorption of any specific nutrients, we only recommend a multivitamin for patients whose preoperative lab values are normal. Use of ursodiol (300 mg twice a day) for gallstone prophylaxis after LAGB is variable from surgeon to surgeon. Weight loss after LAGB often does not occur as rapidly as after gastric bypass, and data regarding gallstone formation after LAGB are lacking. However, rapid weight loss after LAGB will occur in some patients justifying prophylaxis with ursodiol.

Band adjustments and postoperative support group sessions are extremely important for good outcomes after LAGB.⁶¹ Band adjustments are paramount as part of the operation. The actual performance of the LAGB procedure is really only a small part of the care of the patient. Frequent postoperative visits, band adjustments as necessary, and participation in an appropriate exercise program are all important for postoperative success for these patients. Recommendations for timing of band adjustments vary from practice to practice. In general, there is agreement that losing less than 2 lb per week is an indication to increase the restriction of the band by adding fluid. Patients who can easily eat most solid foods and have little satiety and a fairly pronounced appetite need additional restriction from the band.

Band fills usually are accomplished in the outpatient clinic setting. Occasionally fluoroscopic radiology is needed to assist in accessing the port, based on the depth of the port from the skin and its ease of palpation. Experience by the person doing the band fill is an important factor in increasing the percentage

of patients able to be accessed in clinic without radiology assistance. A careful record should be maintained of the amount of fluid in each patient's band. Some surgeons will withdraw all the fluid at each fill, reinserting the desired amount. Many will just add additional fluid as indicated. The amount of fluid added is based on hunger, weight loss, and ability to eat meat or bread. Figure 27-6 shows an in-office algorithm adjustment scheme used by Ren and colleagues at New York University.⁶² Ideally, adjustments are performed over approximately a 2-year period after surgery. However, changing life and clinical circumstances can require adjustments at any time thereafter.

An optimal situation for LAGB success is a program whose patients all live within an easy drive of the center, will and do participate in frequently available support groups and use exercise facilities supplied by the program, have access to band adjustment visits as needed, and are carefully selected for appropriateness and motivation for the procedure preoperatively.

Outcomes. Medium- to long-term (8-year follow-up) outcomes have been reported for LAGB from Weiner et al.⁶³ At

5 and 7 years after LAGB, an average of published studies in the literature showed that patients lost 60% and 58% of excess weight, respectively.⁶⁴ Resolution of comorbidities after LAGB has been reported as overall very good, with hypertension resolving in 55% at 1 year,⁶⁴ observed sleep apnea decreasing from 33% to 2%,⁶⁵ GERD improving in over 50% of cases,⁶⁶ and asthma,⁶⁷ depression,⁶⁸ and quality of life⁶⁹ improving for patients after LAGB. Dixon and colleagues⁷⁰ published a landmark article describing the vastly superior results of managing patients with diabetes using LAGB versus optimal medical management. Resolution of diabetes was 13% in the medical group versus 73% in the surgical group after a 2-year follow-up.

Large institutional series of LAGB results have been published from centers in Europe and Australia, with good results^{71,72} for the Lap-Band. Similarly excellent results have been published for the Swedish adjustable band.⁷³ Buchwald and colleagues⁷⁴ performed a meta-analysis of all bariatric surgical papers published from 1990 to 2003. Overall mortality for LAGB was given as 0.1%. Table 27-6 shows the data from this paper and another meta-analysis⁷⁵ for weight loss,

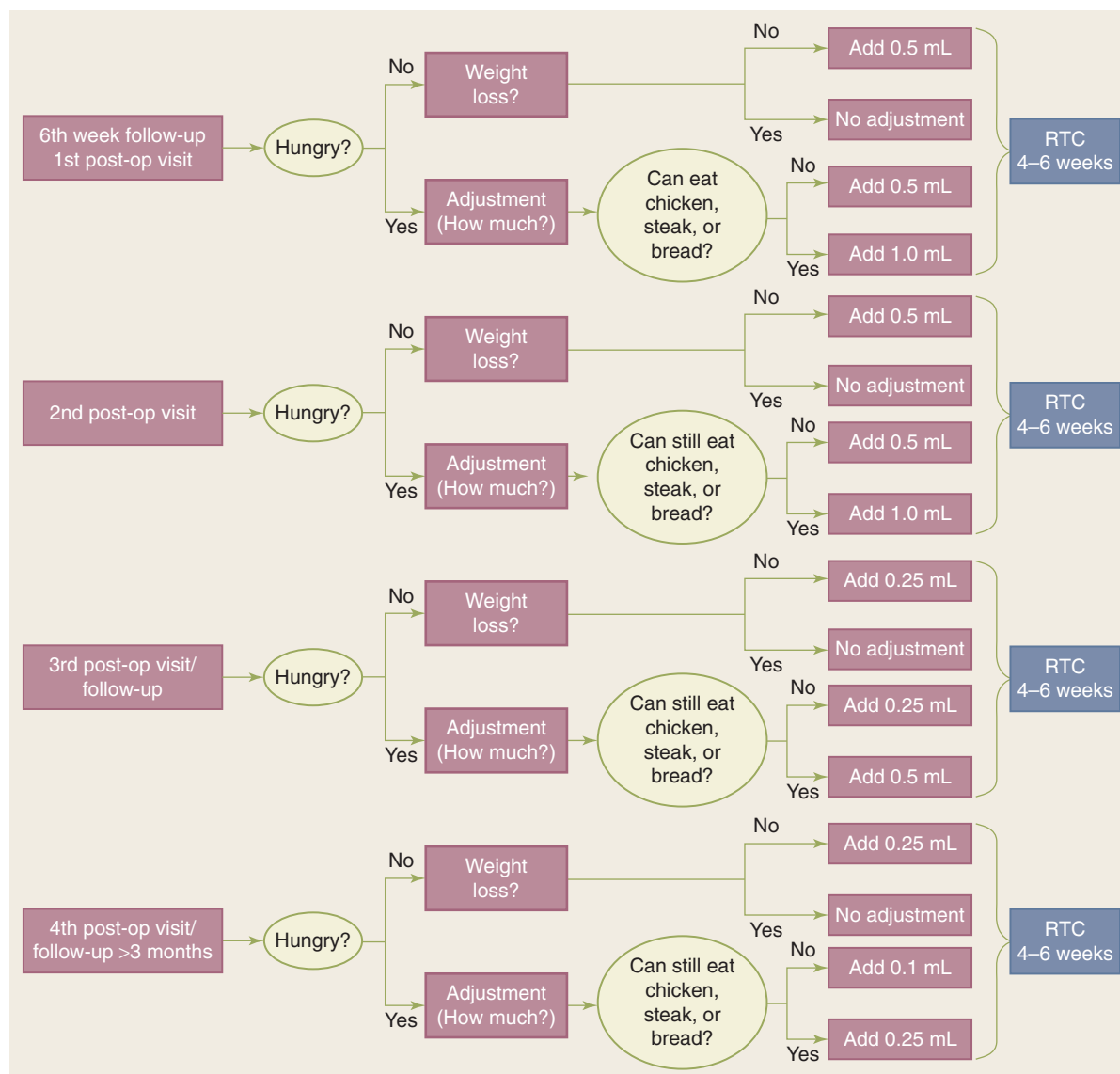


Figure 27-6. Algorithm for postoperative band adjustment. RTC = return to clinic. (Reproduced with permission from Ren CJ. *Laparoscopic adjustable gastric banding: postoperative management and nutritional evaluation*. In: Schauer PR, et al, eds. *Minimally Invasive Bariatric Surgery*. 1st ed. New York: Springer; 2007:200. With kind permission of Springer Science + Business Media.)

Table 27-6

Outcomes for bariatric operations

	LAGB	RYGB	BPD/DS
% Excess weight loss	47.5	61.6	70.1
% Mortality	0.1	0.5	1.1
% Morbidity	10–25	13–38	27–33
% Nutritional morbidity	0–10	15–25	40–77

Source: Buchwald and colleagues.⁷⁴

morbidity, and mortality for LAGB compared with RYGB and the malabsorptive procedures. Table 27-7 also shows data also from Buchwald and colleagues⁷⁴ regarding the percentage of resolution of four major comorbidities associated with obesity after the most common types of bariatric operations, including LAGB.

Specific complications that may occur after LAGB include prolapse, slippage, erosion, and port and tubing complications. In addition, just plain failure to lose weight is more commonly seen with this procedure than with other common bariatric procedures.

Prolapse is perhaps the most common emergent complication that requires reoperation after LAGB. The incidence of reoperation is generally around 3%. Postoperative vomiting predisposes to this problem. The lower stomach is pushed upward and trapped within the lumen of the band. Typical patient symptoms include immediate dysphagia, vomiting, and inability to take oral food or liquid. Either anterior or posterior prolapse may occur.⁷⁶ The initial evaluation for prolapse involves obtaining a plain film radiograph. If the band is in a horizontal position, prolapse must be strongly suspected. This orientation differs from the normal angulation of the band in the 1 to 2 o'clock and 7 to 8 o'clock positions of the two ends of the band on plain radiograph. Initial treatment for a prolapse is to remove all the fluid from the system. This often allows reduction of the prolapse and resolution of symptoms. If symptoms resolve, the necessity of performing an upper gastrointestinal series is lessened. If they do not, an upper gastrointestinal series is indicated, and if prolapse persists, then reoperation laparoscopically to reduce the prolapse and resuture the band in place is indicated.

Slippage has been greatly reduced by the *pars flaccida* technique, and operative need for repair now occurs in about 3% of cases in most series of short-term follow-up. Longer-term follow-up rates may show higher rates of prolapse. In our

Table 27-7

Effect of bariatric surgery on comorbid medical conditions

CONDITION	% RESOLVED	% IMPROVED
Diabetes	76.8	85.4
Hypertension	61.7	78.5
Sleep apnea	83.6	85.7
Hyperlipidemia	70.0	96.9

Source: Buchwald and colleagues.⁷⁴

experience, a symptom-related need for band deflation, with suspected prolapse, occurs in 10% of patients.

Band erosion is uncommon, reported in 1% to 2% of most series. The patient usually becomes ill but not floridly ill, developing either a port site infection or systemic fever and a low-grade abdominal inflammatory sepsis. Endoscopy can be diagnostic. The presence of otherwise unexplained free air on computed tomography (CT) scan should alert the surgeon to this diagnosis as well. Laparoscopic removal of the band is indicated, with repair of any gastric perforation. Often the perforation is already sealed by an inflammatory process, but if not, appropriate management of a gastric perforation must be followed.⁷⁶

Port and tubing problems occur in approximately 5% of patients undergoing LAGB. These require revision of the port/tubing system due to perforation, leaking, or kinking of the tubing or turning of the port such that access to the surface of the port for adding fluid is precluded. Usually a procedure under local anesthesia is all that is required to repair or realign the tubing or port.

The incidence of band removal for patient dissatisfaction or lack of weight loss is difficult to assess, since this number is increasing annually at a not small rate. The figure also is likely related to patient follow-up and may be artificially low if the patient seeks a second surgeon to remove a band. The true incidence probably varies widely. Angrisani et al⁷⁷ reported a 40.9% incidence of band removal after 10-year follow-up.

One of the positive outcomes of LAGB is the safety of the procedure. While complications are not rare, most of them involve non-life-threatening events. Nutritional complications are uncommon and easily treated. Based on worldwide data, the results appear to be optimal in those practices and centers where continued optimal follow-up and encouragement of appropriate behavioral lifestyle changes occur.

The Lap-Band also has its limitations, which may be the cause of its reduced popularity. It is often ineffective in producing adequate weight loss. Restriction of high-caloric liquids, easily digested snacks, and other foods that tend to negate dietary efforts is not adequately achieved with the Lap-Band. Patients must have enough willpower to avoid such foods. If weight loss remains poor, patient frustration and dissatisfaction increase as time passes postoperatively. In centers where suboptimal conditions exist for support and follow-up, the rate of band failure in terms of poor overall weight loss is significant. Reports in the literature tend to only include patients who still have their bands in place and exclude patients who have had bands removed for failure to lose weight. While the latter group of patients probably varies widely from center to center, the trend in many centers to now perform more LRYGB or SG and less LAGB than 5 years ago suggests that LAGB outcomes may rest as much on the postoperative support setting as the operation itself. Centers should reassess their ability to provide optimal follow-up and should do so if possible for optimal long-term results after LAGB.

Laparoscopic Roux-en-Y Gastric Bypass

Background. LRYGB was first described in 1994,²⁵ but by 1998, only a few centers had accumulated any significant experience with the procedure. The University of Pittsburgh was one of those centers, with Schauer and colleagues performing the procedure, and instituted a large number of training courses from 1998 to 2001, which trained many of the bariatric surgeons who adopted the laparoscopic approach. By 2003, over 130,000 gastric

bypasses were done in the United States, with more than half of them being done laparoscopically. Currently over 90% of gastric bypass operations nationally are performed laparoscopically.

Figure 27-7 depicts the configuration of the LRYGB. The major feature of the operation is a proximal gastric pouch of small size (often <20 mL) that is totally separated from the distal stomach. A Roux limb of proximal jejunum is brought up and anastomosed to the pouch. The pathway of that limb can be anterior to the colon and stomach, posterior to both, or posterior to the colon and anterior to the stomach. The length of the biliopancreatic limb from the ligament of Treitz to the distal enteroenterostomy is 20 to 50 cm, and the length of the Roux limb is 75 to 150 cm. Longer Roux limb lengths are performed but considered to have more malabsorption than the standard gastric bypass.

Experience has resolved several controversies about gastric bypass, but others are still debated. It is clear that creating the proximal gastric pouch by totally dividing it from the distal stomach is superior to simply stapling the stomach, since the latter is associated with a high incidence of staple breakdown.⁷⁸ The size of the proximal gastric pouch must be small to create adequate restriction and should be based on the lesser curvature of the stomach to prevent dilation over time. Length of the Roux limb is associated with higher short-term weight loss for longer length limbs,⁷⁹ but this difference becomes less on long-term follow-up.⁸⁰ Some surgeons doing LRYGB will create a longer

(150 cm) Roux limb for patients with a BMI over 60 or even 50 kg/m². Antecolic position of the Roux limb is associated with a lower incidence of internal hernias leading to obstruction in most series with short-term follow-up.⁸¹ However, reports with longer follow-up suggest later internal hernia incidence may increase with an antecolic approach.⁸² Despite the plethora of enthusiasm for reoperative endoscopic narrowing of the gastrojejunostomy opening,⁸³⁻⁸⁵ good long-term data do not yet exist to confirm that size of the gastrojejunostomy can be related to weight loss. The gastrojejunal anastomosis can be constructed in a variety of ways. Smaller diameter circular staplers are associated with a higher incidence of postoperative stenosis, and linear stapling is associated with a lower incidence of stenosis compared to circular stapling.^{86,87}

Technique. The operation generally is performed using five ports plus a liver retractor. Both the surgeon, who stands on the patient's right, and the first assistant, who stands on the patient's left, have two ports for instruments. The telescope requires a port, usually in the supraumbilical region. The assistant's ports are in the left subcostal and flank areas, while the surgeon may have both ports in the right upper quadrant (Cleveland approach) or one on each side of the camera (Virginia approach, Fig. 27-8). Division of the proximal jejunum at 40 to 50 cm distal to the ligament of Treitz is performed with the linear stapler, using the

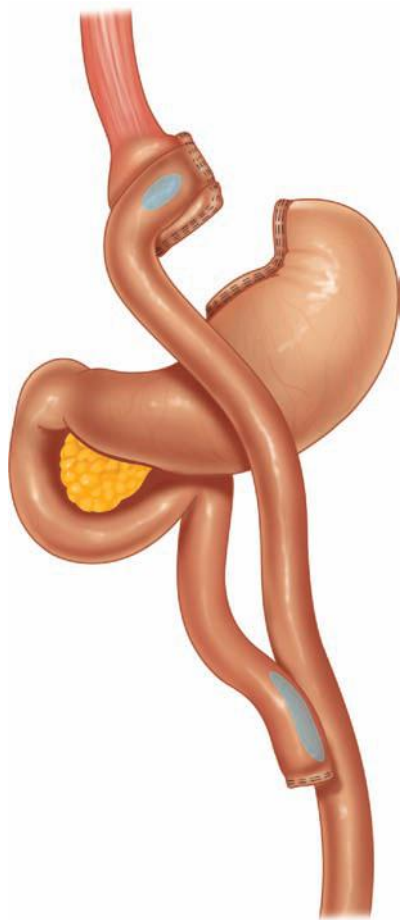

Figure 27-7. Configuration of laparoscopic gastric bypass. (From Schauer PR, et al, eds. *Minimally Invasive Bariatric Surgery, 1st ed.* New York: Springer; 2007. Reprinted with permission, Cleveland Clinic Center for Medical Art & Photography © 2005-2009. All rights reserved.)

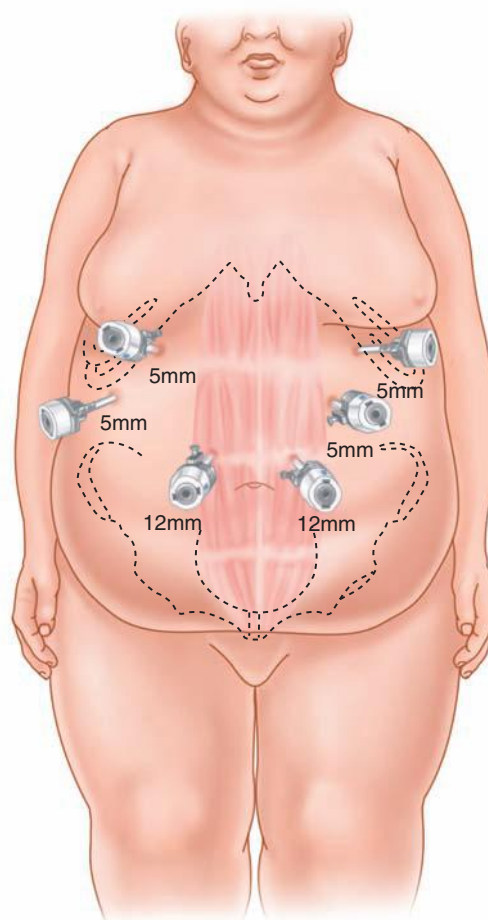


Figure 27-8. Port scheme for laparoscopic gastric bypass. (From Schauer PR, et al, eds. *Minimally Invasive Bariatric Surgery, 1st ed.* New York: Springer; 2007. Reprinted with permission, Cleveland Clinic Center for Medical Art & Photography © 2005-2009. All rights reserved.)

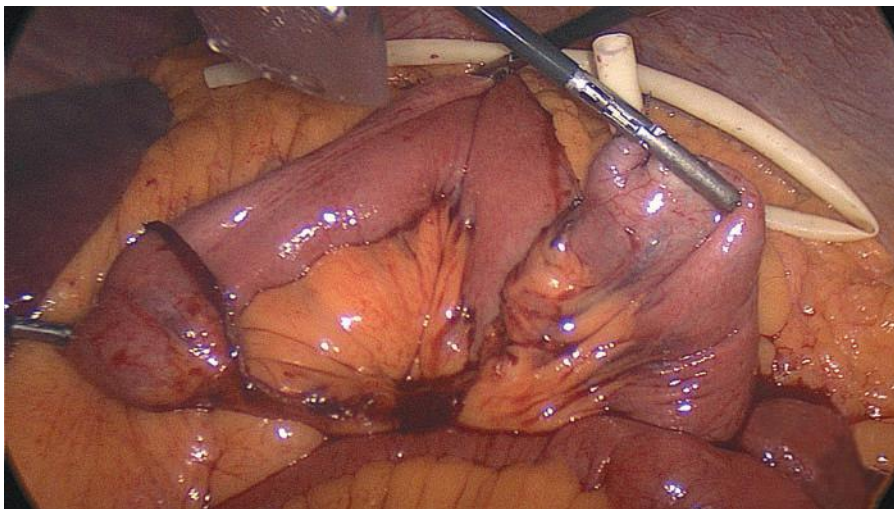


Figure 27-9. Creating Roux limb during laparoscopic gastric bypass.

white stapler cartridge. Further division of the mesentery at that location is performed either with the stapler or harmonic scalpel, such that adequate mobilization of the Roux limb is achieved. A Penrose drain or suture is sutured to the proximal Roux limb (Fig. 27-9) for identification and facilitation of advancement to the gastric pouch.

The length of the Roux limb (usually 100–150 cm) to be created is now measured. A jejunojejunostomy is then created to the proximal end of the biliopancreatic limb at the above-determined location along the Roux limb. A side-to-side stapled anastomosis is performed (Fig. 27-10). Either single- or double-fired staple technique (the latter using a stapler fired in each direction) is used. The stapler defect is optimally closed with sutures but can be closed with a stapler if great care is taken not to narrow the lumen of the alimentary tract at this location. Once the stapler defect is closed, the mesenteric defect is then also closed with running permanent suture.

Passage of the Roux limb toward the stomach is now performed. If an antecolic route is to be used, the end of the Roux limb is brought up so as to confirm its ability to reach the stomach. If a retrocolic route is to be used, a defect is made in the transverse colon mesentery just to the left and slightly above the ligament of Treitz. The Penrose drain and the proximal end of the Roux limb are placed into the retrogastric space (Fig. 27-11).

The left lobe of the liver is now retracted using any one of several retractor types. The patient is moved to a reverse Trendelenburg position. The harmonic scalpel divides the peritoneum in the area of the angle of His. Then it is used to open an area along the lesser curvature of the stomach approximately 3 cm down from the gastroesophageal junction. Another approach for creating access to the lesser curvature of the stomach is to use a white or gray load (vascular load) of the stapler and divide the lesser curvature vessels up to the surface of the stomach. Then a blue load of the stapler is fired one time transversely from the lesser curvature side partially across the stomach, followed by multiple subsequent firings of the stapler upward in the direction of the angle of His, to completely separate the proximal gastric pouch from the remainder of the stomach (Fig. 27-12). Use of an Ewald tube passed by the anesthesiologist and maneuvered to lie against the lesser curvature of the proximal stomach can help calibrate the pouch size.

Once the pouch is created, the Roux limb is brought up to the proximal gastric pouch. For the linear stapled anastomosis, the proximal end of the Roux limb is aligned with the distal gastric pouch end, and the sides of the organs are sutured together to maintain their side-by-side position. A blue load of the stapler is introduced through a gastrotomy and an enterotomy for the two legs of the stapler, and the anastomosis is created (Fig. 27-13).

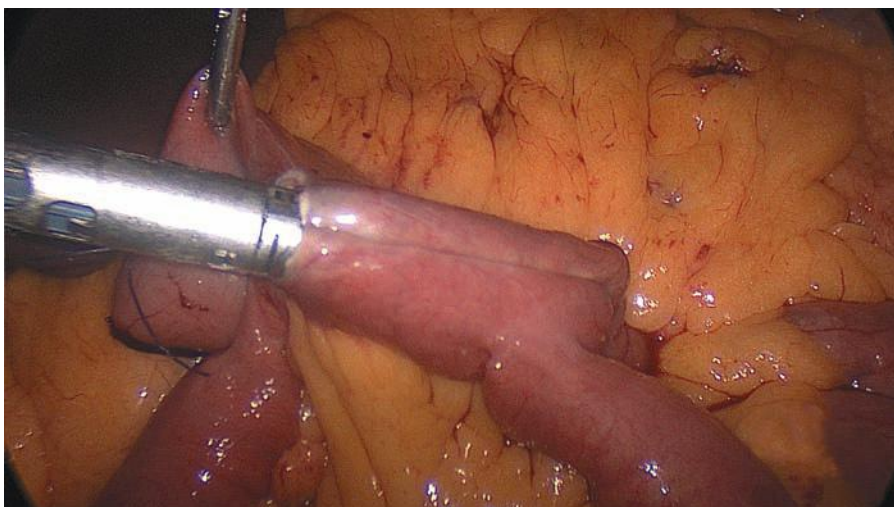


Figure 27-10. Enteroenterostomy of laparoscopic Roux-en-Y gastric bypass.

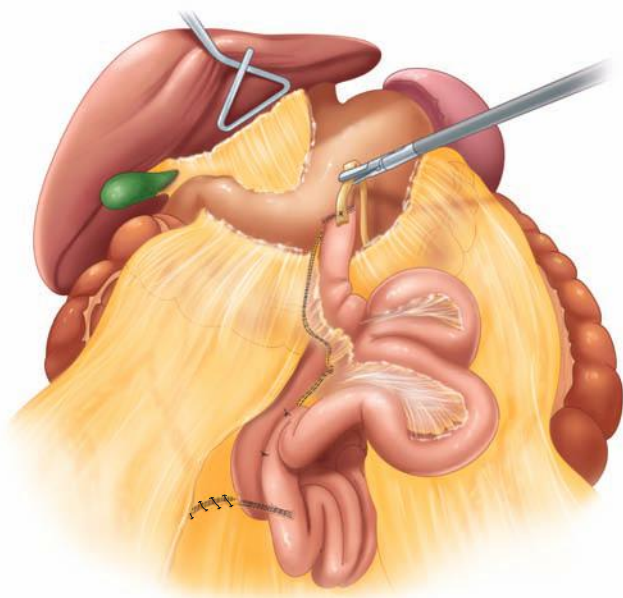


Figure 27-11. Passage of Roux limb. (From Schauer PR, et al, eds. *Minimally Invasive Bariatric Surgery, 1st ed.* New York: Springer; 2007. Reprinted with permission, Cleveland Clinic Center for Medical Art & Photography © 2005-2009. All rights reserved.)

The stapler defect is closed with sutures and often reinforced with a second layer of sutures. At this point, the gastrojejunostomy is tested for security by using either methylene blue injected under pressure through the Ewald tube or a flexible upper endoscopy intraoperatively to test for air leakage from the anastomosis. The latter technique has been shown to decrease the incidence and seriousness of anastomotic leaks postoperatively.⁸⁸ The final step of the operation involves suture closure of all mesenteric defects using permanent suture.

Circular anastomosis for the gastrojejunostomy is accomplished through placement of the anvil of the stapler through the anterior wall of the proximal gastric pouch. This is accomplished by pulling the anvil transorally via an endoscopically placed

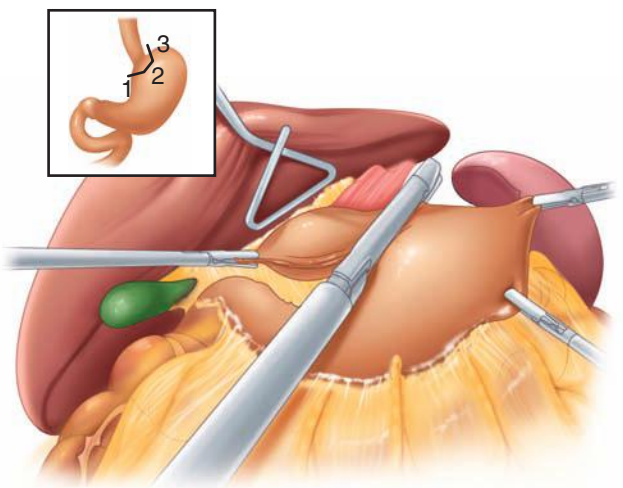


Figure 27-12. Creation of gastric pouch for laparoscopic Roux-en-Y gastric bypass. (From Schauer PR, et al, eds. *Minimally Invasive Bariatric Surgery, 1st ed.* New York: Springer; 2007. Reprinted with permission, Cleveland Clinic Center for Medical Art & Photography © 2005-2009. All rights reserved.)

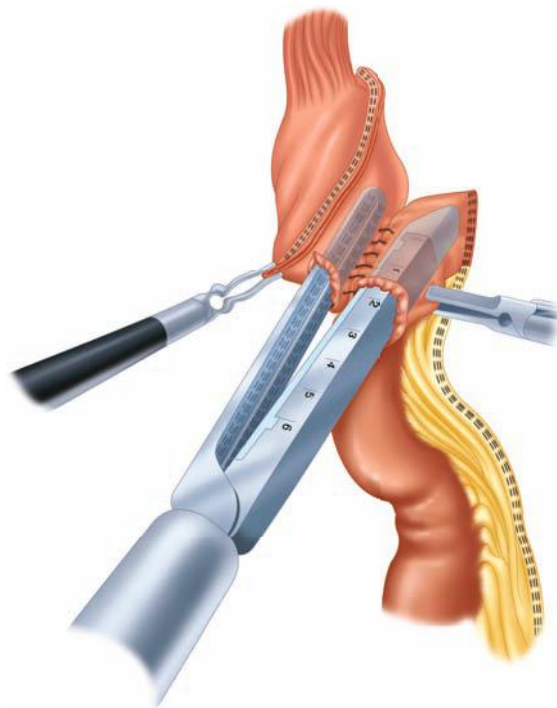


Figure 27-13. Gastrojejunostomy in laparoscopic Roux-en-Y gastric bypass. (From Schauer PR, et al, eds. *Minimally Invasive Bariatric Surgery, 1st ed.* New York: Springer; 2007. Reprinted with permission, Cleveland Clinic Center for Medical Art & Photography © 2005-2009. All rights reserved.)

guidewire (Fig. 27-14), making a gastrotomy in the pouch that is later closed, or making a gastrotomy in the lower stomach before completing gastric division to create the pouch, allowing the anvil to be placed into the lumen of the stomach and then be brought through the anterior stomach in an area that is subsequently included in the proximal gastric pouch (Fig. 27-15).

Hand-sewn gastrojejunostomy is usually created using two layers of absorbable suture to anastomose an approximately 1-cm gastrotomy and enterotomy.

Patient Selection and Preparation. LRYGB is an appropriate operation for consideration for most patients eligible for bariatric surgery. Relative contraindications to LRYGB include previous gastric surgery, previous antireflux surgery, severe iron deficiency anemia, distal gastric or duodenal lesions that require ongoing future surveillance, and Barrett's esophagus with severe dysplasia. Contraindications to a laparoscopic approach to RYGB should cause the surgeon to choose an open RYGB or other open procedure instead.

Preoperative flexible upper endoscopy is indicated in all patients contemplating undergoing RYGB to rule out lesions of the stomach or duodenum noted earlier.⁴² Preoperative low-calorie diet for patients with hepatomegaly can decrease liver size and thus improve the chances of completing the operation laparoscopically. We use a mechanical bowel prep to decrease bowel weight and the chance of an inadvertent tear with handling using the laparoscopic graspers.

Postoperative Care and Follow-Up. LRYGB patients are usually hospitalized for 2 to 3 days. Major concerns on the night of surgery include adequate analgesia, adequate fluid resuscitation to provide adequate urine output, and early ambulation. We still routinely employ a postoperative oral contrast study

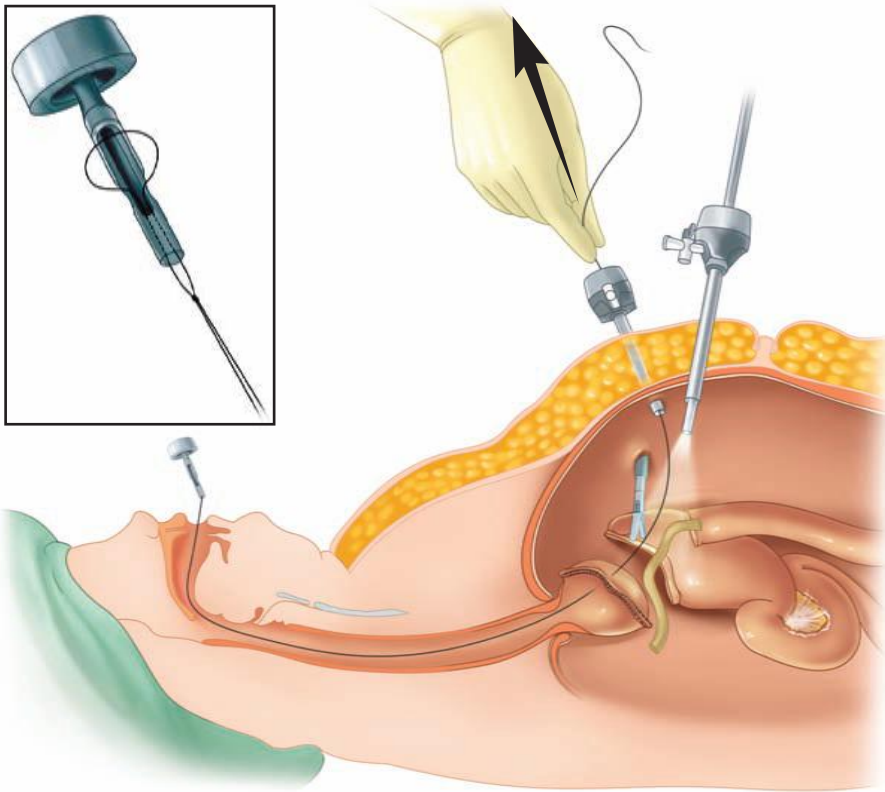


Figure 27-14. Oral passage of EEA circular stapler to create gastrojejunostomy for laparoscopic Roux-en-Y gastric bypass. (From Schauer PR, et al, eds. *Minimally Invasive Bariatric Surgery, 1st ed.* New York: Springer; 2007. Reprinted with permission, Cleveland Clinic Center for Medical Art & Photography © 2005-2009. All rights reserved.)

on the first postoperative day. Numerous studies have advocated abandoning this practice due to its lack of accuracy and cost-effectiveness.^{89,90} The study's value to us has been to alert us to edema or stenosis of the enteroenterostomy or any other obstructive pattern of the proximal bowel. Obstruction of the enteroenterostomy or beyond can result in distal gastric dilatation over just a period of several hours, which, if untreated, can cause distal gastric staple line rupture with fatal consequences.

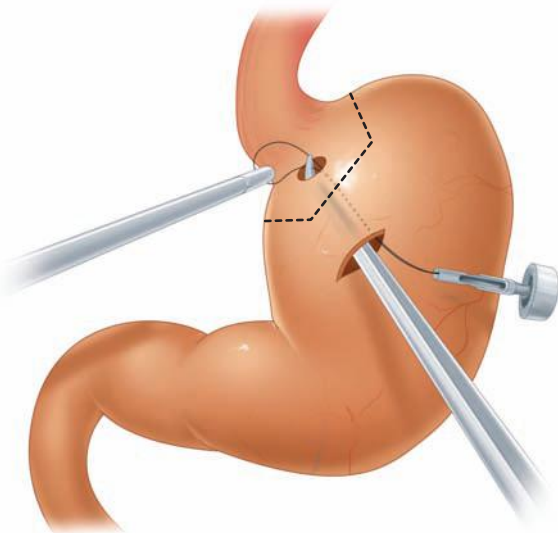


Figure 27-15. Transgastric passage of circular EEA stapler to create gastrojejunostomy for laparoscopic Roux-en-Y gastric bypass. (Reproduced with permission from Schneider BE, et al. *Circular stapled transabdominal technique.* In: Schauer PR, et al, eds. *Minimally Invasive Bariatric Surgery, 1st ed.* New York: Springer; 2007:248. With kind permission of Springer Science + Business Media.)

Aside from early ambulation, postoperative prophylaxis against venous thromboembolism includes compression shoes and low-molecular-weight subcutaneous heparin. Discharge on a blenderized diet is standard for our practice.

Diet advancement occurs after the first clinic visit, usually approximately 3 weeks after surgery. At that time, an exercise plan is initiated if not already started.

Patients on insulin for type 2 diabetes and on antihypertensive medications should be monitored to determine whether reduction of their medication is indicated. Subsequent follow-up visits are usually scheduled for 3 months, 6 months, and 1 year after surgery, and then annually thereafter. The focus of later postoperative visits is documentation of outcomes and testing for postoperative nutritional deficiencies.

Outcomes. Patients undergoing LRYGB usually lose between 60% and 70% of excess body weight during the first year after surgery. This has held true since the earliest large series of this operation was reported.⁹¹ Resolution of comorbidities varies, but is over 90% for GERD and venous stasis ulcers and over 80% for patients with type 2 diabetes of less than 5 years in duration. Hyperlipidemias are almost always improved and resolve totally in about 70% of cases. Hypertension resolves in 50% to 65% of cases (see Table 27-7). Even superobese patients who do not achieve an ultimate BMI of less than 35 kg/m² can experience significant improvements in comorbidities after LRYGB or open RYGB.⁹²

Mortality after LRYGB is now consistently less than 0.5% in most large reported series. Recent data from centers applying to be centers of bariatric surgery excellence showed a mortality rate of approximately 0.3% overall. The Bariatric Surgery Center Network (BSCN) of the ACS database showed a mortality of 0.14% at 30 days.⁹³

Overall morbidity after LRYGB has been acceptably low. In the BOLD database of the ASMBS, it was 14.87% for 30,864 gastric bypass procedures.⁹⁴ In the BSCN database, the 30-day

Table 27-8

Complications for which laparoscopic Roux-en-Y gastric bypass patients require urgent surgical intervention

Small bowel obstruction
Early postoperative vomiting with obstructive picture
Early postoperative hematemesis with obstructive picture
Intestinal leak
Bleeding

morbidity rate was 5.91% for 14,491 LRYGB procedures.⁹³ LRYGB avoids most wound and incisional hernia problems. Complications that do occur include a 0.3% incidence of anastomotic leak,⁹⁵ 0.33% incidence of venous thromboembolism,⁹⁶ a 3% to 5% incidence of wound infections or problems,⁹³ a 3% to 15% incidence of marginal ulcers,⁹⁷ an approximately 7% incidence of bowel obstruction,⁹⁸ a 4% incidence of postoperative transfusion,⁹⁹ and a 1% to 19% incidence of anastomotic stenosis,⁸⁷ based on the type of anastomosis created.

Postoperative nutritional complications after LRYGB include a 66% incidence of iron deficiency, a 5% incidence of iron deficiency anemia, a 50% incidence of vitamin B₁₂ deficiency,¹⁰⁰ and an at least 15% incidence of vitamin D deficiency,¹⁰¹ which usually is present preoperatively.

Several complications that are specific to LRYGB must be emphasized. One of the most important is small bowel obstruction. This complication must be treated differently than in the average general surgery patient, whose complication is usually from adhesions and often will resolve with conservative, non-operative therapy. Patients who have had LRYGB who present with obstructive symptoms generally **require surgical therapy** **4▶ on an emergent basis (Table 27-8)**. This is because the etiology of the bowel obstruction after LRYGB is often an internal hernia from inadequate or nonclosure of the mesenteric defects by the surgeon at the time of operation. Thus, treatment for these patients differs from most patients with small bowel obstruction. One of the **most important points** of this chapter is to emphasize to general surgeons to be aware of the need to emergently operate on patients after LRYGB who present with

small bowel obstruction. Currently, centers that perform small bowel transplantation are seeing patient referral for that procedure after small bowel obstruction after LRYGB, where patients developed infarction of most of the bowel from an internal hernia and have short gut syndrome.¹⁰² Other patients, for whom surgery is delayed and the bowel infarcts, do not survive. When the surgeon does encounter bowel obstruction after LRYGB, he or she can expect to see proximally dilated bowel. Cutoff of passage of contrast on CT scan at the enteroenterostomy is particularly suggestive of this diagnosis (Fig. 27-16). The surgical treatment of this particular problem can, if addressed early in the course of the obstruction, be treated laparoscopically. The surgeon must place a trocar for the telescope low enough in the abdomen to adequately survey most of the small intestine. The cecum and terminal ileum are identified, and the bowel is followed retrograde from the terminal ileum to determine the anatomy. Often much of the small bowel is herniated through a mesenteric defect, and only this technique allows the surgeon to reliably identify the bowel and decompress it appropriately. If the bowel is viable, suturing the mesenteric defect is all that is needed for treatment. It should be emphasized that either an antecolic or retrocolic placement of the Roux limb can result in this complication, as internal hernias can arise from either approach.

Marginal ulcers are another complication relatively specific to RYGB, either LRYGB or open RYGB. The patient presents with pain in the epigastric region that is not altered by eating. Diagnosis is by endoscopy. Treatment is medical with proton pump inhibitors, which are effective in 90% of cases. Only those with a gastrogastric fistula to the distal stomach, severe stenosis of the lumen of the gastrojejunostomy, or acute perforation require surgical therapy.

Stenosis of the gastrojejunostomy has been remarkably reduced by the use of a linear stapling technique in our experience.⁸⁶ Stenosis symptoms usually appear from 6 to 12 weeks postoperatively, but less commonly can occur later. Diagnosis is by upper endoscopy. Treatment is balloon dilatation. Resolution normally occurs with one or two treatments. Less than 10% of patients require reoperation, and those are almost always associated with concurrent marginal ulcers.¹⁰³

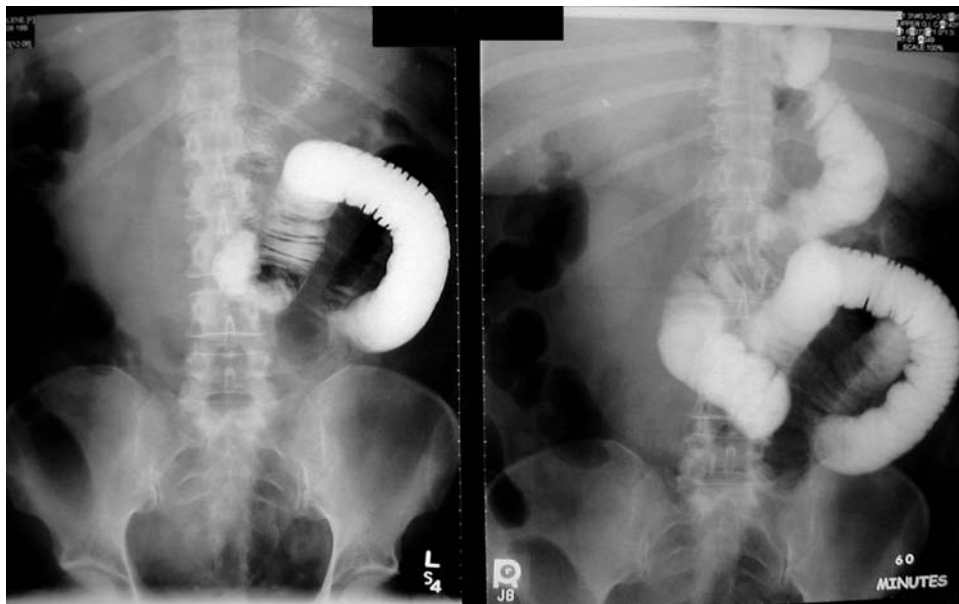


Figure 27-16. Obstruction of contrast at enteroenterostomy with small bowel obstruction from internal hernia after laparoscopic Roux-en-Y gastric bypass.

In the immediate postoperative period, anastomotic leak is the single most feared complication after RYGB, either open or laparoscopic. Careful vigilance and a high index of suspicion for this problem are the only appropriate approach, since its presentation may be insidious and the patient's demise, if untreated, sudden and complete. Tachycardia, tachypnea, fever, and oliguria are the most common symptoms that arouse suspicion for this problem. The treatment is surgical except in rare circumstances where a drain is already in place, no hemodynamic or clinical deterioration is present, and the leak is contained.¹⁰⁴ Usual surgical treatment involves repair as feasible, drainage, and creation of a reliable feeding access through a distal Stamm gastrostomy.

In the first few hours or day after surgery, hematemesis indicates bleeding from the gastrojejunostomy unless proven otherwise. The dangers to the patient include aspiration, life-threatening hemorrhage, or more commonly intraluminal hematoma of the Roux limb and enteroenterostomy, which then causes an obstruction of the biliopancreatic limb leading to distal gastric staple line rupture. In fact, any obstructive symptoms in the first few weeks after surgery or any signs of obstruction of the biliopancreatic limb on postoperative swallow studies due to stenosis of the enteroenterostomy require immediate surgical intervention to prevent rupture of the distal gastric staple line. Some reports show that percutaneous decompression of the distal stomach can ameliorate the danger.¹⁰⁵ Alternatively, operative therapy to decompress the stomach and treat the obstructive problem is also a reasonable option.

Overall, LRYGB has the significant advantages over open RYGB of avoiding incisional hernias and severe wound infections. Table 27-9 shows the data on these problems, comparing outcomes for laparoscopic versus open procedures at the University of Virginia. Compared with other bariatric surgical procedures, the LRYGB offers a reliable and powerful operation to allow the severely obese patient to lose weight. Although more reliable and greater, this weight loss does come at a slightly higher complication rate compared with LAGB and SG. However, these complication rates, as well as mortality, have been steadily decreasing for LRYGB in the past decade.

Open Roux-en-Y Gastric Bypass

Background. As described earlier in the chapter, Mason and Itoh²⁶ first described gastric bypass, and Griffin and colleagues²⁷ first described its Roux limb modification. It has been the most time-tested and proven of all bariatric operations. The procedure

is now done virtually the same as LRYGB, with the only difference being the access route to perform it. Experienced bariatric surgeons who do not perform laparoscopic surgery still perform this operation with excellent overall outcomes,⁵⁶ but their numbers are diminishing. RYGB was the most popular operation performed in the United States in the 1990s, but is now far exceeded by LRYGB and LAGB in terms of volume due to the preference of patients to undergo a laparoscopic rather than open procedure. However, for the patient for whom a laparoscopic approach fails, RYGB must be an operation that the bariatric surgeon can perform with skill.

Technique. RYGB is performed essentially the same as LRYGB. Some surgeons who use an open approach prefer to perform creation of the gastric pouch as the first part of the procedure, but in essence, the net procedure is the same. Access for open RYGB is usually through an upper midline incision, although a left subcostal incision has been reported to furnish adequate access as well. Closure of the midline wound is performed using a running monofilament suture. Subcutaneous tissues are thoroughly irrigated, and skin is closed with a skin stapler.

Patient Selection and Preparation. Patient selection is essentially the same as for LRYGB, since the operation is the same. Extraordinarily large patients or those with multiple previous abdominal operations, particularly previous gastric surgery, left colectomy, and splenectomy, often require an open incision to perform RYGB. Abdominal wall thickness and liver size are other factors that may require an open incision approach. Patients who have an existing large midline incisional hernia are also candidates for an open approach.

Preparation for open RYGB is identical to LRYGB.

Postoperative Care and Follow-Up. The postoperative care of the patient undergoing open RYGB is very similar to that of the patient undergoing LRYGB. Larger volumes of fluid resuscitation and often more narcotic analgesics are required the day of surgery and often the next as well. Greater attention must be paid to the incision site for potential infection, since an inadequately treated wound infection in these patients can extend easily to the fascial level and cause significant tissue loss before it is fully diagnosed. The perioperative care of open RYGB patients is usually more intense, often because such patients are very large, and concurrently have severe comorbidities, making them higher risk overall for complications of all types. It is interesting, though, that since the era of LRYGB,

Table 27-9

Outcomes for laparoscopic versus open Roux-en-Y gastric bypass (University of Virginia 1994–2004)

CHARACTERISTICS	LRYGB	ORYGB	P VALUE
Preoperative body mass index (kg/m ²)	50.9 ± 0.3	57.5 ± 0.5	<.001
Number of comorbidities	2.7 ± 0.1	3.6 ± 0.1	<.001
30-day mortality	2 (0.3%)	6 (1.7%)	<.02
Overall complications	111 (14.5 %)	208 (57.3%)	<.001
Reoperation	67 (8.8%)	150 (41.3%)	<.001
Incisional hernia	13 (1.7%)	123 (33.9%)	<.001
Wound infection	14 (1.8%)	27 (7.4%)	<.001

LRYGB = laparoscopic Roux-en-Y gastric bypass; ORYGB = open Roux-en-Y gastric bypass.

patients who still undergo open RYGB (usually due to intraoperative conversion) in our practice often are discharged within 1 day of the laparoscopic patients. Our overall length of stay has decreased for RYGB patients based on postoperative pathways geared toward LRYGB.

Postoperative follow-up visits are similar to those of LRYGB patients, with the first visit being timed to appropriately remove skin staples. Other visits, follow-up schedule, and blood testing are identical to LRYGB.

Outcomes. The weight loss statistics and patterns for RYGB are comparable to those of LRYGB, as would be expected. Postoperative deaths are slightly higher for RYGB, but this is almost certainly due to the patient population, which is often among the most severely medically compromised preoperatively. Flum and Dellinger¹⁰⁶ showed that for a patient population on Medicare insurance, and hence largely disabled, RYGB had an across-the-board mortality rate of 2.0%. This rate is considerably higher than the 0.3% to 0.4% incidence that was reported for programs applying at that time as bariatric COEs and is in large part due to the patient population. Interestingly, in the report by Flum and Dellinger, surgeons with the most experience had a mortality rate of less than 1.0% for this patient population, suggesting that surgeon experience and patient selection by experienced surgeons influence mortality for RYGB.

One of the most important population studies showing the benefit of bariatric surgery was done in patients undergoing RYGB. Christou and colleagues¹⁰⁷ showed a lower incidence of mortality (0.68% vs. 6.17%) in the 5-year follow-up of over 1000 patients undergoing RYGB versus over 5000 severely obese individuals who did not have surgery. This was a reduction of 89% in the death rate.

The incidence of postoperative complications for RYGB is higher than that of LRYGB, due largely to increased morbidity from incisional hernias and other wound-related problems (see Table 27-9). Other than incisional hernias, the long-term results of patients undergoing RYGB are similar to those undergoing LRYGB, including nutritional issues, weight loss, and overall resolution of comorbidities.

Biliopancreatic Diversion and Duodenal Switch

Background. BPD was first described by, and remains championed by, Scopinaro in Italy.³² The operation, which is shown in Fig. 27-17, involves resection of the distal half to two-thirds of the stomach and creation of an alimentary tract of the most distal 200 cm of ileum, which is anastomosed to the stomach. The biliopancreatic limb is anastomosed to the alimentary tract either 75 or 100 cm proximal to the ileocecal valve, depending on the protein content of the patient's diet. This operation met with limited international popularity, due to the technical difficulty to perform it combined with the significant percentage of nutritional complications that arise postoperatively. However, the procedure did develop a devoted following among a few bariatric surgeons.

One complication that plagued the BPD was the development of a high incidence of marginal ulcers postoperatively. Hess and Hess³³ and Marceau and colleagues¹⁰⁸ separately described the adaptation of the DS operation, originally proposed by DeMeester and colleagues¹⁰⁹ for treatment of bile reflux gastritis, to replace the gastric portion of the BPD. This new procedure was originally called BPD with DS. For ease of description, we now simply use the term *duodenal switch* (DS) to describe this procedure. It is illustrated in Fig. 27-18.

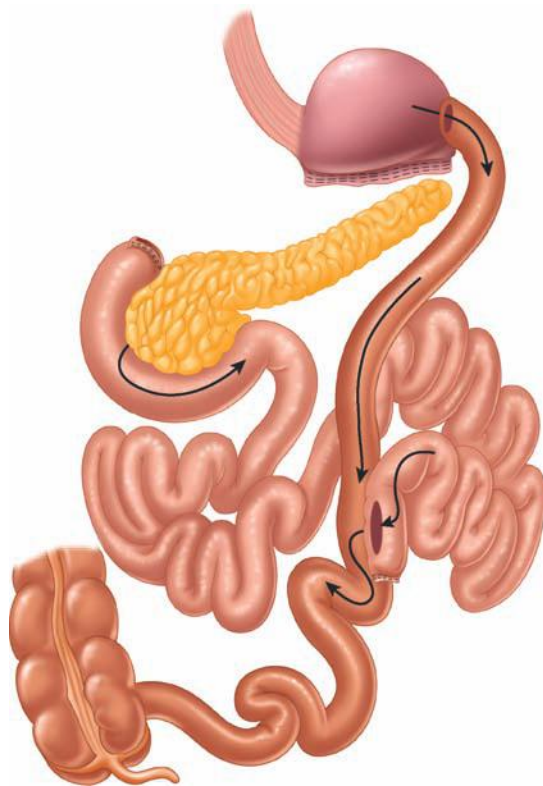


Figure 27-17. Diagram of biliopancreatic diversion. (From Schauer PR, et al, eds. *Minimally Invasive Bariatric Surgery, 1st ed.* New York: Springer; 2007. Reprinted with permission, Cleveland Clinic Center for Medical Art & Photography © 2005-2009. All rights reserved.)

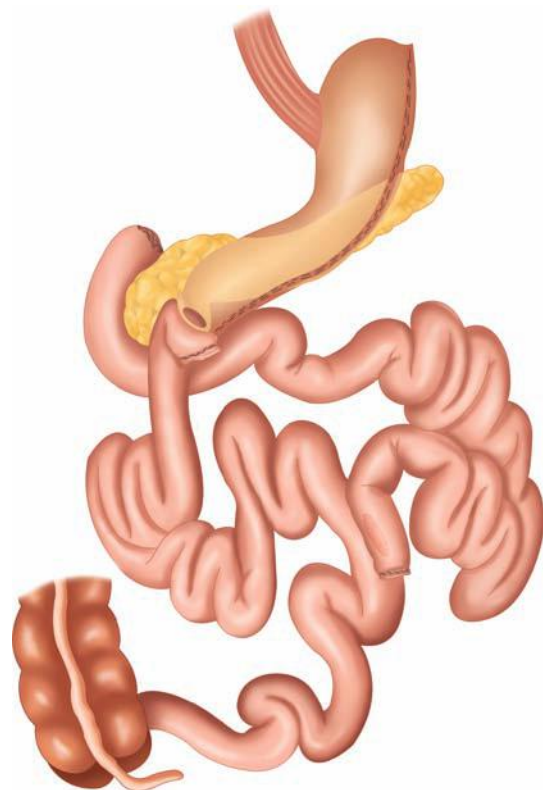


Figure 27-18. Diagram of duodenal switch. (From Schauer PR, et al, eds. *Minimally Invasive Bariatric Surgery, 1st ed.* New York: Springer; 2007. Reprinted with permission, Cleveland Clinic Center for Medical Art & Photography © 2005-2009. All rights reserved.)

Currently BPD and DS represent together less than 3% of bariatric operations performed in the United States, and this rate could be as low as 1% to 2%. The lack of a significant number of surgeons offering the operation, especially via a laparoscopic approach, probably has a great deal to do with that statistic. BPD and DS are, however, recognized as standard bariatric operations and approved for coverage by most insurance companies at this time.

Technique. The technique for BPD will be described for the open approach, but the laparoscopic approach essentially reproduces what is done with the open approach, using different access. Laparoscopic BPD and DS are very technically challenging operations, perhaps another contributing factor to the relatively low numbers of surgeons offering these operations.¹¹⁰

The BPD operation begins with performance of a distal subtotal gastrectomy. A residual 200-mL gastric pouch is created for superobese patients, or a slightly larger pouch is created for patients with a BMI under 50 kg/m². The terminal ileum is identified and divided 250 cm proximal to the ileocecal valve. The distal end of that divided ileum is then anastomosed to the stomach, creating a 2- to 3-cm stoma. The proximal end of the ileum is then anastomosed side-to-side to the terminal ileum approximately 100 cm proximal to the ileocecal valve. Some surgeons perform the anastomosis only 50 cm proximal to the valve, but in these patients, the likelihood of good protein intake postoperatively should be high. Prophylactic cholecystectomy is performed due to the high incidence of gallstone formation with the malabsorption of bile salts.

The DS procedure differs from the BPD only in the proximal gut portion of the operation. Instead of a distal gastrectomy, resection of all the stomach except for a narrow lesser curvature tube of the stomach is performed. The diameter of this tube is calibrated with a dilator and, if limited to a 32- to 40-French diameter, produces the optimal amount of weight loss while still allowing adequate oral intake. The duodenum is now divided in its first portion, leaving an approximately 2-cm length of duodenum intact beyond the pylorus. This end of the duodenum is then anastomosed to the distal 250 cm of ileum. This anastomosis is often done in an end-to-end fashion with a circular stapler. It is the most difficult portion of the DS procedure, and leak rates are slightly higher than with other anastomoses. The distal bowel configuration and cholecystectomy are similar to BPD.

Patient Selection and Preparation. Patients who undergo either BPD or DS must be prepared for the consequences of a malabsorptive operation. Frequent and large-quantity bowel movement after any large amount of oral intake is common. Patients who have this procedure must be willing to accept frequent, voluminous bowel movements and will also usually modify their eating pattern to restrict intake if access to a bathroom will prove difficult. Patients who undergo either operation must agree to close follow-up preferably *by the surgeon*. Internists and family physicians may not appreciate the issues related to protein-calorie malabsorption if they occur and treat the patients instead for congestive heart failure. Disastrous results may then occur. Patients must also have the financial means to afford the large number of vitamin and mineral supplements that must be taken to avoid nutritional problems in this patient population.

Given the increased incidence of postoperative nutritional and other complications relative to any of the restrictive operations, BPD and DS usually are recommended only for patients who have superobesity or for whom it is reasonable to believe

they will not succeed with the diet and exercise requirements that form the basis for long-term success with restrictive operations. Patients who have failed a restrictive operation and are considering reoperation are candidates for these procedures.

Contraindications to the procedure include geographic distance from the surgeon, lack of financial means to afford supplements, and preexisting calcium, iron, or other nutrient deficiencies.

Postoperative Care and Follow-Up. Patients undergoing BPD or DS must be followed closely and with absolute completeness for nutritional issues long term. Postoperatively, BPD and DS patients face the same potential complications as seen after RYGB. Anastomotic leaks, pulmonary compromise and complications, gastrointestinal bleeding, anastomotic stenosis or obstruction, and infections are all potential concerns during the index hospitalization. The long gastric staple line and the duodenoileostomy of the DS and the duodenal stump and gastroileostomy of the BPD are all areas of anatomic concern postoperatively. Distal anastomotic problems can occur with either procedure as well. Thorough preoperative and postoperative counseling by a nutritionist versed in the operation and potential nutritional deficiencies is essential. Vitamin and mineral supplements must be taken regularly on follow-up, including oral supplements for iron, calcium, and vitamin B₁₂ and a multivitamin. Fat-soluble vitamins must be supplemented in parenteral form. Careful monitoring of protein intake and serum albumin is necessary. More frequent follow-up than with RYGB is needed; checkups at 2-month intervals for the first year and semi-annual or more frequent visits thereafter are appropriate.

Outcomes. Weight loss results with BPD or DS are both excellent and comparable. They also are very durable. One 18-year follow-up study after BPD showed a mean excess weight loss of 70% persisting for that duration of time.¹¹¹

Although most of the results of BPD or DS are after open operations, one report of laparoscopic DS showed that for 40 patients with an average BMI of 60 kg/m² the mean hospital stay was 4 days, average operation room time was 3.5 hours, and mean excess weight loss at 9 months was 58%.¹¹²

Buchwald and colleagues⁷⁴ showed that the average weight loss after BPD and DS in the literature was over 70%, with mortality rate of 1.1%, complication rate of 27% to 33%, and nutritional complication rate of 40% to 77% (see Table 27-6).

Complications that occur after the BPD include those seen after RYGB, where intestinal anastomoses and gastric division create potential problems. Scopinaro and colleagues¹¹¹ reported obstruction in 1.2%, wound infections in a similar rate, and marginal ulcer in 2.8% of patients. However, others found the incidence of marginal ulcer to be higher after BPD, causing the adoption of the DS. Preservation of the pylorus drastically reduces the significant incidence of dumping (poorly quantitated in most series) after BPD. The duodenoileostomy of DS also has a very low rate of stomal ulcer, unlike the gastroileostomy of BPD.

Nutritional complications are by far the most frequent and concerning after both of these operations, particularly on long-term follow up. Scopinaro and colleagues¹¹¹ reported a protein malnutrition rate of 7%, iron deficiency anemia rate of less than 5%, and bone demineralization at 5 years of 53%. Other problems that may arise include alopecia from inadequate protein absorption, night blindness from a lack of vitamin A, and

gallstones if the gallbladder is not removed. However, of all these nutritional complications, protein-calorie malnutrition is the most severe and life-threatening. When it is diagnosed, the treatment is parenteral nutrition. Two episodes of required parenteral nutrition are usually considered adequate indication to lengthen the “common channel” of ileum—the ileum between the ileoileostomy of the biliopancreatic limb to the alimentary tract and the ileocecal valve. The amount that the surgeon should lengthen it is poorly documented, but most surgeons will favor making it long enough to be certain to avoid recurrence of the problem, such as doubling the length of the common channel, even if it decreases weight loss somewhat.

It cannot be emphasized enough that patients who undergo either BPD or DS should be impressed with the fact that lifetime nutritional supplements and lifetime follow-up are essential to preserve good health after these operations.

Laparoscopic Sleeve Gastrectomy

Laparoscopic sleeve gastrectomy has taken the bariatric surgical scene by storm over the past 5 to 10 years. It is rapidly increasing in popularity, and by the time this book is published, it may be, in some countries and areas, the most popular bariatric and metabolic operation performed. Its rapid rise in popularity coupled with good initial results suggest that it will be a major component of patient care for the treatment of morbid obesity and its comorbid medical problems for years to come in the future.

Since sleeve gastrectomy is performed almost exclusively using a laparoscopic approach, the remainder of this text will use the simple term sleeve gastrectomy (SG) to describe the procedure, with the understanding that it is routinely performed using a laparoscopic approach. SG had its origins in the early days of laparoscopic bariatric surgery. The procedure represents the gastric portion of the DS procedure.³³ Ren and colleagues¹¹² reported an initial experience of performing DS using a laparoscopic approach that had relatively higher mortality than seen with gastric bypass or other treatment options being performed laparoscopically. This was in part due to the fact that patients selected to receive DS often were significantly larger and had more numerous and more severe comorbid medical problems. Gagner began to perform the gastric resection portion of the DS operation as a first-stage procedure. After patients had lost weight, the malabsorptive component of the procedure was then performed. However, many of the patients had such good results after the first stage of the procedure that they refused to proceed to the second portion.¹¹³ Thus, the concept of performing SG as a primary procedure was born.

Until 2009, SG was considered an “experimental” procedure by insurance carriers. That year, the ASMBS reviewed the data on the procedure and published a statement in January of 2010 recognizing the procedure had adequate data and results to support its use as a primary bariatric operation for carefully selected patients.¹¹⁴ Shortly thereafter, SG received a designated Common Procedural Terminology (CPT) code. Since that time, insurance carriers have recognized the procedure as being appropriate for treating severe obesity and its comorbid problems. The final carrier, Medicare and Medicaid in the United States, issued a statement in April 2012 that left the determination of coverage of this procedure to the regional insurance carriers administering Medicare. This happened only after a hearing to determine coverage in which a great deal of data was presented in favor of the procedure. The initial conclusion of that panel was that SG should be reimbursed if performed in the setting of a prospective randomized trial. However, subsequent public opinion and data caused CMS to revise its decision to allow regional carriers to determine coverage.

SG has the advantage of being a technically easier operation to perform than gastric bypass, while achieving better efficacy in treating comorbid medical problems and producing superior weight loss than LAGB. Once the results of the procedure began to be published, understood, and accepted, its popularity rose dramatically. In the United States, the incidence of performing SG has risen rapidly since 2008, as shown in Fig. 27-19. The incidence of SG is increasing at a rate that suggests that within the next 2 years it may pass LRYGB as the most popular bariatric operation performed in the United States.

Throughout the rest of the world, the popularity of SG has also risen dramatically in the past 5 to 8 years. In Asia, where there is a high incidence of gastric cancer in countries such as Japan, SG makes more sense anatomically as an appropriate treatment for severe obesity. In India, where the high incidence of diabetes in the obese population makes metabolic and bariatric surgery a desirable option, SG has gained popularity once its effectiveness in treating diabetes was shown. Figure 27-20 shows the trend in performance of several bariatric operations in Asia from 2003 to 2011, during which the totals of those procedures from surgeons surveyed increased over 500%.³⁷ This rise in bariatric and metabolic surgery was comparable to the same increase in percentage of cases performed seen in the United States from 1998 to 2003. In Europe, the past few years have seen a clear trend away from performing LAGB and a higher incidence of performing both SG and LRYGB.³⁷

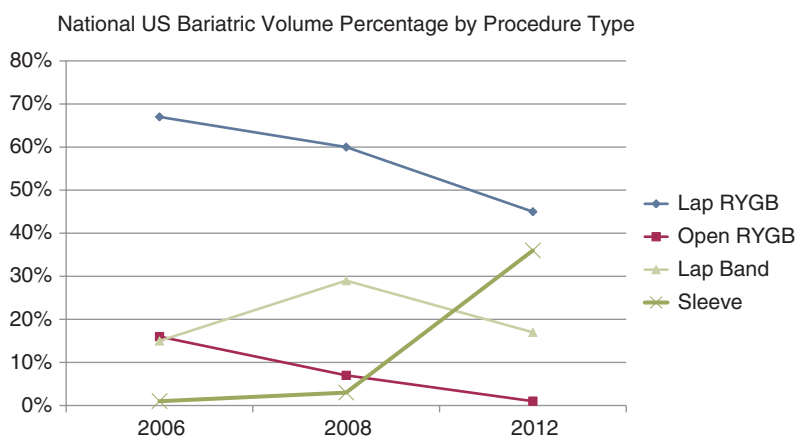


Figure 27-19. National U.S. Bariatric Volume Percentage by Procedure Type. (Reproduced with permission from Buchwald H, Oien DM: *Metabolic/bariatric surgery worldwide 2011*. *Obes Surg*. 2013;23:427. With kind permission of Springer Science+Business Media.)

TRENDS: 2003 to 2008 to 2011
ASIA/PACIFIC

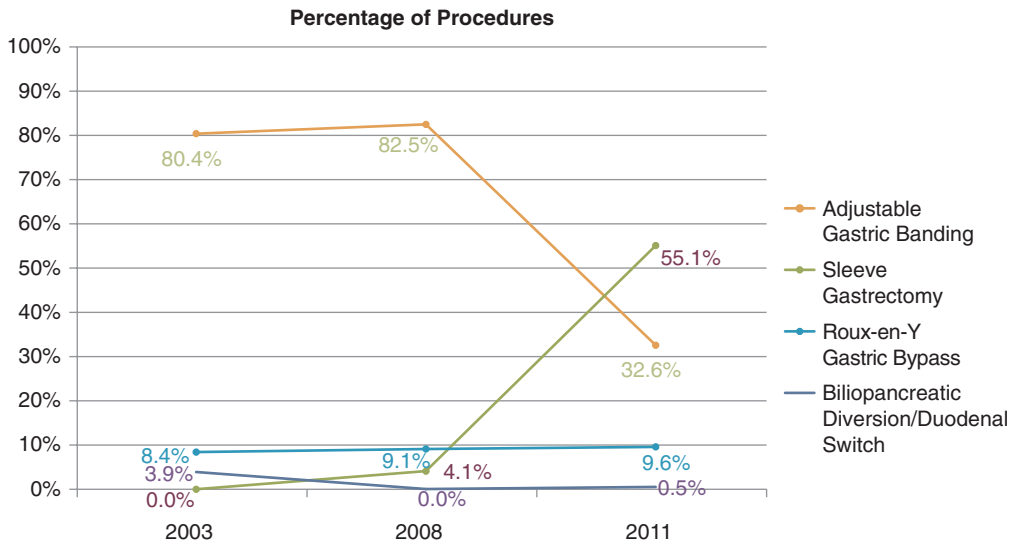


Figure 27-20. Asia/Pacific Bariatric Volume Percentage by Procedure Type. (Reproduced with permission from Buchwald H, Oien DM: *Metabolic/bariatric surgery worldwide 2011*. *Obes Surg*. 2013;23:427. With kind permission of Springer Science+Business Media.)

Indications. Patient selection for SG is comparable to that for other bariatric and metabolic operations with a few notable exceptions. SG was originally introduced as the first of a two-stage operative treatment for patients with super obesity (BMI >60 kg/m²).¹¹⁵ It remains an effective first- or second-stage treatment for such patients. Whether a second stage is indicated depends on the effectiveness of the SG. SG has been shown to be safe and effective in adolescent obese patients.¹¹⁶ It has also been shown to be an acceptable procedure for the elderly obese patient.¹¹⁷ SG effectively treats most of the comorbid medical problems associated with obesity. The one exception is GERD. Patients with GERD experience less resolution of their symptoms after SG than do patients with LAGB, even when the LAGB patients lost less weight overall.⁹³ Patients who have longstanding severe GERD may not be good candidates for SG. Barrett's esophagus is considered a relative contraindication for performing SG, since the potential for future esophagectomy and the need for an available intact stomach for reconstruction outweigh the potential advantages of the procedure.

Technique. The patient is positioned supine, with foot support to allow reverse Trendelenburg positioning. The surgeon stands to the patient's right along with the camera driver, while the assistant stands to the patient's left. Port placement may vary from institution to institution, but our recommended port placement is shown in Fig. 27-21. The 15-mm port, helpful for removal of the stomach, is located in either the camera (just to the patient's left of the umbilicus) or surgeon's right hand (right upper quadrant near the midline) location. The other of these ports is a 12-mm port. The assistant has two 5-mm ports available in the left upper quadrant laterally, and the surgeon's left hand port is a 5-mm port more lateral and superior in the right upper quadrant. A liver retractor is placed in the epigastric region. This can be a Nathanson or T-Boone retractor.

The operation begins by devascularizing the greater curvature of the stomach, beginning 3 to 5 cm proximal to the pylorus. The harmonic scalpel works nicely to perform this tissue division. The division of all vessels adjacent to the greater curvature is continued up to the left crus of the diaphragm. A complete mobilization of the fundus in this area and division of posterior

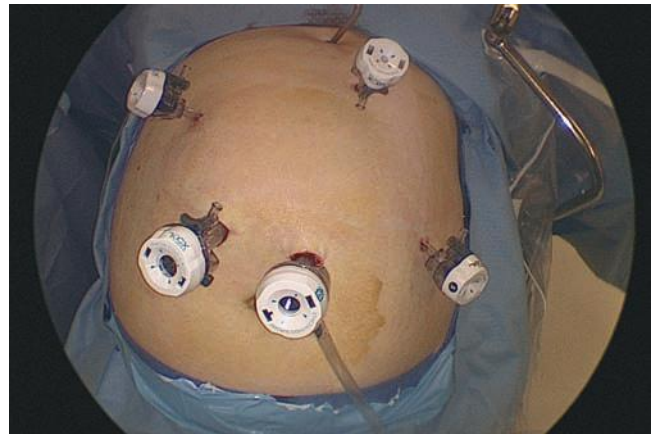


Figure 27-21. Port scheme for Laparoscopic sleeve gastrectomy.

fibrous attachments to the antrum and body of the stomach are then performed such that the stomach is attached solely by the lesser curvature blood supply and the pyloric and esophageal regions. Stapled division of the stomach now follows. The first firing of the stapler occurs from the point of devascularization of the greater curvature at an angle pointing toward a point about 2 cm lateral to the incisura. The antrum of the stomach is at its thickest here, and so it is important to be certain the stapler load used is sufficiently large enough to allow good approximation and closure of the divided stomach. We have favored use of the black load (2.5-mm staple height) in all males with a BMI over 45 kg/m², females with a BMI over 55 kg/m², or anyone whose stomach looks particularly thick. A green load (staple height of 2 mm when closed) is used for less thick stomachs or smaller individuals. We continue the use of this color load for the first two firings, which takes the gastric division to past the incisura. After the first staple firing, some surgeons will engage the anesthesiologist to pass a 32- to 36-French bougie and position it along the lesser curvature of the stomach. This bougie then serves as a guide for further gastric division. Alternatively, some surgeons will insert the endoscope instead of the bougie as a guide for gastric division. It can also be used to test for air

leaks, bleeding, or obstruction as it is withdrawn after gastric division. Dividing the stomach adjacent to the bougie or endoscope will produce the desired diameter of the gastric sleeve. It is most important **not to narrow the stomach lumen at the incisura**. During the second and third firing of the stapler to divide the stomach, it is critical to confirm by visualization of both the anterior and posterior surfaces of the stomach that the incisura area is not narrowed. By the third firing of the stapler, usually the angle of the gastric division is now pointed directly toward the angle of His, parallel to the bougie (Fig. 27-22). At this point, changing staple loads to lower staple height is advisable. We usually switch to gold then blue staple loads as we progress proximally in dividing the stomach. It is essential that with each firing of the stapler, adequate time (10–20 seconds) is allowed for tissue compression to allow optimal staple closure and security of the divided tissue.

Once the stomach is completely divided up to the angle of His, the staple line is inspected for hemostasis and integrity. Some surgeons will reinforce the staple line with a buttress material, while others will invaginate the staple line with a running serosa to serosa suture. Some surgeons will exchange the bougie at this point for a 32-French Ewald tube and perform a methylene blue leak test. Alternatively, if an endoscope is used, it is withdrawn with insufflation, and the staple line is inspected for air leaks while submerged in saline. The specimen is removed through the 15-mm trocar site, usually with only slight enlargement of the site. Figure 27-23 shows the completed operation.

Controversy still exists as to the optimal size of the bougie used during the procedure. One summary of the literature shows that the stenosis rate is lower if a 40-French bougie is used, and the leak rate may also be lower without compromising weight loss.¹¹⁸ However, individual institutional experiences with smaller-sized bougies have shown the potential for exceptionally good weight loss and no increased incidence of stenosis.¹¹⁹ Another controversial area is that of staple line reinforcement

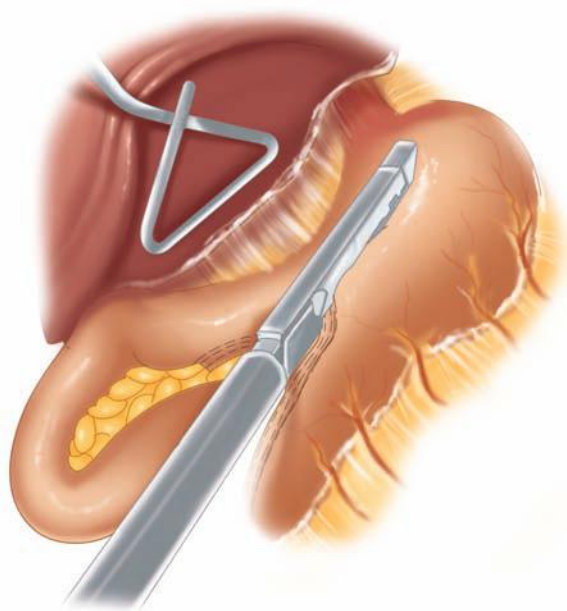


Figure 27-22. Performing sleeve gastrectomy. (From Schauer PR, et al, eds. *Minimally Invasive Bariatric Surgery, 1st ed.* New York: Springer; 2007. Reprinted with permission, Cleveland Clinic Center for Medical Art & Photography © 2005-2009. All rights reserved.)

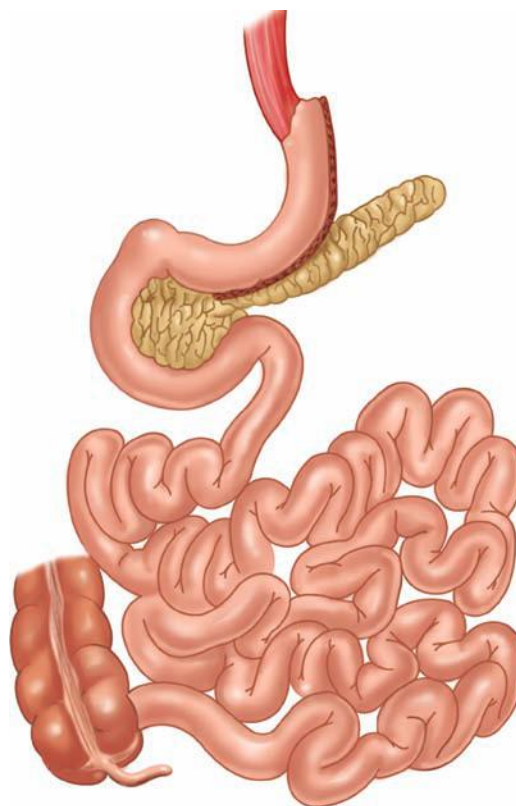


Figure 27-23. Completed sleeve gastrectomy. (From Schauer PR, et al, eds. *Minimally Invasive Bariatric Surgery, 1st ed.* New York: Springer; 2007. Reprinted with permission, Cleveland Clinic Center for Medical Art & Photography © 2005-2009. All rights reserved.)

with staple buttressing material. Some surgeons advocate routine staple line reinforcement, whereas others advocate none. Still others advocate oversewing of the staple line in areas of bleeding or in selected cases that show a predilection for bleeding intraoperatively. Other experts advocate routine oversewing of the entire staple line.¹²⁰ At this time, there is no preponderance of data to support one approach as being superior to others.

Postoperative Care and Follow-Up. SG usually is performed with an overnight stay of 2 nights after surgery. Longer hospitalizations are indicated for patients with more severe medical problems. Absence of signs of bleeding and a documented intact staple line with good gastric emptying are required prior to discharge. Routine Gastrografin swallow on the first day after surgery is used by many surgeons, but its efficacy and cost-effectiveness have yet to be clearly documented. Follow-up is similar to that after LRYGB. Few nutritional complications occur unless the patient has difficulty taking in enough nutrients or protein or vitamins due to edema or tightness of the sleeve lumen. Most surgeons advocate routine vitamin B₁₂. Iron supplementation may be required as well since iron in the diet is usually drastically restricted by elimination of many foods rich in iron. It is unclear whether the same need for vitamin D supplementation seen after LRYGB is also needed after SG, since there is a high incidence of low 25-hydroxyvitamin D levels preoperatively in patients undergoing SG.¹²¹ Routine multivitamins are usually prescribed to avert any potential other shortages from dietary vagaries.

The other aspect of weight loss that must be considered in the nutritional aspects of postoperative care and follow-up after SG is that patients are at risk of losing significant lean body

mass while they are also losing weight. Damms-Machado and colleagues¹²¹ showed that SG patients' lean body mass decreased from 74.8 kg to 62.3 kg at 1 year after SG. This emphasizes the need for high protein content in the postoperative diet of SG patients to maintain lean body mass.

Outcomes and Complications. Reports in the literature of the success and excellent weight loss after SG have been accumulating since 2006.^{122,123} The first very large series from a single institution reported 750 patients undergoing SG as a primary weight loss procedure. Five-year follow-up of some patients was available, and a hospital stay averaging 1.7 days, a major complication rate under 5%, an operative time under 80 minutes, and no conversions or mortality were reported.¹²⁴

Brethauer and colleagues¹²⁵ published an excellent review of the early data on SG through 2009. For the collected number of patients treated with SG (2750 patients), the excess weight loss rate was 55.4%. Studies with 5-year follow-up for SG are not yet common. One highly successful series was recently reported by Rawlins and colleagues¹¹⁹ for 49 patients followed for 5 years after SG with an average weight loss of 86% of excess weight and a decrease in average BMI from 65 to 35 kg/m². One of the longest follow-up studies for SG by Eid and colleagues¹²⁶ demonstrated an average excess weight loss of 48% and BMI decrease from 66 to 46 kg/m² in 74 superobese patients with 6- to 8-year follow-up.

Prospective randomized trials comparing SG with other procedures have shown that SG is superior to LAGB for excess weight loss at 3 years (66% vs. 48%).¹²⁷ One study reported that SG achieved a superior excess weight loss compared with LRYGB (69.7% vs. 60.5%) at 1 year after surgery. This study also found greater appetite suppression and a lower serum ghrelin level for SG.¹²⁸

SG has been included in the results of large databases showing outcomes after bariatric surgery. Data from the ACS BSCN showed that SG was positioned between LAGB and LRYGB for efficacy of weight loss and resolution of comorbid medical problems and for morbidity and mortality.⁹³

As noted earlier, controversy exists as to whether the use of buttress materials with the stapling of the stomach improves outcomes. The overall bleeding rate for the staple line after SG is generally cited as about 2% in collected series.¹²⁵ There have been no studies that have shown a definitive decrease in this bleeding rate with the use of buttress materials; however, a panel of experts has voiced support for a decreased incidence of bleeding from the staple line if buttress material is used.¹²⁰

Measures to prevent staple line leakage are similarly controversial with respect to buttress materials and other measures. It is certain that appropriate stapling technique in dividing the stomach is important. Using an adequately high staple height for the tissue to be divided and allowing an adequate amount of time for tissue decompression within the stapler jaws before firing are essential to minimize the likelihood of a staple line leak. Failure to perform gastric division appropriately in this fashion will lead to an early staple line leak after surgery. Whether buttress materials do decrease the leak rate with SG is very controversial. One meta-analysis did show that there is evidence to suggest buttress materials may decrease this rate.¹²⁹ Other prospective randomized studies have failed to show a benefit of buttress materials.¹³⁰ To date, the literature has not clearly shown a benefit for using buttress materials in terms of leak prevention.

Perhaps the major factor that is different in SG than other gastric stapling procedures is that SG creates a high-pressure gastric tube. This increased intraluminal pressure places the staple line at risk for leakage. If there is a relative obstruction or stenosis of the sleeve, which most often may occur at the incisura due to narrowing there during formation of the sleeve, pressure above the level of the obstruction will be even more elevated and create an increased risk for staple line leak. Leaks of the proximal staple line are the most frequent type seen after SG and often are felt to be related to increased intraluminal pressure distally. They may also be related to stapling too close to the angle of His, with resultant instability of the tissue directly adjacent to the esophagus in this area. It is important not to staple too close to the angle of His during the final stapling division portion of the stomach so as to not further weaken the staple line in this area. Proximal staple line leaks may also present as late leaks. Late leaks are generally felt to be those that occur 6 weeks or longer after surgery. Late leaks are rare in other bariatric procedures, but are seen with SG. The increased pressure of the system may be a reason SG is associated with late leaks. Confirmation and treatment of stenosis symptoms early after SG may prevent such leaks.

Distal staple line leaks are different than proximal staple line leaks, and are usually associated with earlier presentation and related to mechanical failure of the staple line to securely approximate the thicker distal gastric tissue. These leaks are more amenable to successful repair with a reoperation, whereas proximal leaks may not improve with oversewing at a reoperation unless the mechanics of the relative distal obstruction and high intraluminal pressure of the sleeve are also treated. Endoscopic intervention to dilate stenotic areas as well may be beneficial in the setting of a stenosis with or without a proximal leak. Care must be taken by the endoscopist to not excessively dilate the tract beyond the original size of the bougie used. Another factor that may influence stenosis at the incisura is that there may be a relative twisting of the stomach at this location, with the antrum being partially twisted away from the upper portion of the sleeve. Endoscopic treatment can help straighten and markedly alleviate the obstruction in such cases. Thus relatively early endoscopic intervention is appropriate in the patient with a stenosis at the incisura. One study has shown that endoscopic dilation is usually successful in treating stenosis after SG, with a mean of 1.6 dilatations being done an average of 48 days postoperatively.¹³¹

The patient with the proximal gastric staple line leak due to mechanical factors may experience a persistence of the leak for months. Such cases are now only recently being published and discussed in the literature. It is unclear how long one should optimally treat such a leak conservatively with the likelihood it will close. Reports of such leaks persisting for multiple months postoperatively exist. Our own experience has been that eventual closure of such a leak is possible even 4 months postoperatively. However, longer duration leaks are less likely to close. Some experts have now advocated conversion of the patient with a longstanding leak after SG to a RYGB to provide a low-pressure anastomosis above the site of the stenosis. Similarly, persistent stenosis of the sleeve despite conservative therapy and endoscopic dilatation also is an indication for conversion to LRYGB.

Physiology of Weight Loss. SG is a fairly simple technical operation, amenable to performance by many surgeons. The results of the operation for weight loss have been excellent

and dramatic. However, the mechanisms of the resolution of comorbidities, such as diabetes, are still not totally clear. While weight loss alone may provide the majority of the physiologic changes that improve comorbid problems such as diabetes and hypertension, it is also possible that other factors may be involved. Certainly SG, through gastric resection, eliminates much of the ghrelin-producing portion of the stomach. The resolution of type 2 diabetes after SG is remarkable, although not as good as that seen after RYGB. The reasons for this are as yet unclear, since lap RYGB has been shown to have independent factors influencing glucose metabolism separate from weight loss alone. The hormonal and peptidergic changes produced by SG in terms of appetite suppression, glucose metabolism, and other metabolic pathways have yet to be clarified. A recent hypothesis summarized by Ed Mason¹³² is that the rapid emptying of the stomach after SG creates a similar exaggerated release of GLP-1 as seen after LRYGB, and this results in the improved carbohydrate metabolism and improvement of type 2 diabetes seen after SG, as after LRYGB.¹³³

There is some concern among the bariatric surgical community that SG, because it is technically not that difficult, could become a procedure performed by surgeons without a full support system and follow-up mechanism for bariatric patients. The bariatric surgery community feels strongly that this procedure should remain a procedure done within the confines of the COE framework. This will ensure optimal patient outcomes.

SPECIAL ISSUES RELATING TO THE BARIATRIC PATIENT

Bariatric Procedures in Adolescent and Elderly Patients

The incidence of obesity in the U.S. population has risen dramatically during the past two decades. This increase has included children and adolescents as well. The incidence of obesity (BMI >30 kg/m²) is estimated to exceed 25% in the adolescent population. Factors felt to contribute to this include decreased participation in physical sports and activities, increased time playing computer and screen games, and increased consumption of fast food and processed foods.

Obese adolescents have a high likelihood of being obese adults. In one study, 75% of adolescents above the 85th percentile were obese as adults.¹³⁴ The social stigmatization of the severely obese adolescent is often brutal. Comorbid medical problems may already be present in severely obese adolescents, including hypertension and type 2 diabetes. The overwhelming likelihood of a severely obese adolescent facing a lifetime of severe obesity as an adult also implies that an average of 12 years of life for males and 9 years of life for females will be lost due to this medical problem.

The major controversy with regard to adolescents undergoing bariatric surgery includes the general aversion of subjecting an adolescent to surgery as well as the concern of the secondary side effects of bariatric surgery on remaining growth and development. Clearly the younger the patient, the more relevant the latter concern becomes.

The literature to date on the results of outcomes from bariatric surgery on adolescents is generally quite favorable. However, it is still limited. Sugerman and colleagues¹³⁵ reported on results for 33 adolescents, 30 of whom had RYGB (mostly open RYGB). There were two late deaths at 2 and 6 years of

follow-up unrelated to surgery. There were 20 early and late complications, including six incisional hernias and five wound infections. Significant weight loss was maintained in the majority of patients for up to 14 years after surgery. Most comorbidities resolved at 1 year after surgery. Self-image was greatly enhanced and social stigmatization greatly decreased. Capella and Capella¹³⁶ reported on 19 adolescent patients treated with a modified version of open RYGB in which a vertical band was added to the pouch. After an average 5.5-year follow-up, average BMI for the group was 28 kg/m². No deaths occurred, but two patients required revisional surgery. No mortality or morbidity was reported, and all comorbidities resolved. Abu-Abeid and colleagues¹³⁷ treated 11 adolescents with LAGB. No late complications occurred, and after a 4-year follow-up, BMI average went from 46.4 to 32.1 kg/m².

A meta-analysis involving 131 adolescents undergoing bariatric surgery demonstrated a 17.8 to 22.3 kg/m² decrease in BMI after RYGB.¹³⁸ They also observed improvement of hypertension in more than half the patients and sleep apnea resolution in all 131 patients. There were four mortalities in this cohort, but only one of them was potentially associated with the procedure (*Clostridium difficile* colitis 9 months after operation). Morbidity in the adolescent literature ranges from 0% to 38% and tends to be minor in most cases. The most common complication in the meta-analysis was nutrient deficiencies. The weight of the evidence supports adolescent bariatric surgery as a safe and effective treatment of severe obesity in adolescents. The ASMBS pediatric guidelines suggest using BMI criteria similar to the adult population but with some modifications to comorbidity thresholds.¹³⁹ They recommend considering surgery in patients with a BMI of 35 kg/m² or greater with major comorbidities (e.g., type 2 diabetes, severe nonalcoholic fatty liver disease, OSA) or a BMI of 40 kg/m² or greater with minor comorbidities (e.g., hypertension, dyslipidemia, insulin resistance).

The elderly patient population certainly suffers from severe obesity. However, data on the effect of nonsurgical therapies in treating this patient population are lacking. Similarly, it is likely that the patient who becomes obese late in life has a significantly different prognosis than the individual who has been severely obese and does manage to survive to an older age despite the resulting comorbidities.

There has been an increasing tendency to offer bariatric surgery to patients over the age of 60. Studies have documented that this patient population can have the same good outcomes and resolution of comorbidities as younger patients.¹⁴⁰ Nehoda and colleagues¹⁴¹ reported equally excellent results for LAGB in patients over age 50 compared with those under age 50. Excess weight loss of 68%, reoperation rate of 10%, and 97% improvement in comorbidities were reported for this age group. A recent retrospective review of 42 carefully selected bariatric surgery patients over 70 years old looked at the outcomes up to 1 year after surgery. Of these patients, 22 patients (52.4%) underwent laparoscopic gastric banding, 12 patients (28.6%) underwent laparoscopic SG, and 8 patients (19%) underwent LRYGB. They safely achieved a mean weight loss of 47.7% with no mortality and modest improvement in obesity-associated comorbidities.¹⁴² SG for elderly patients is also gaining popularity. In 35 patients ≥60 years of age, Soto and colleagues¹⁴³ demonstrated greater than 60% excess weight loss at 48 months with low morbidity (8.4%) and no mortality with SG.

Although these data show that in selected older patients excellent results can be obtained, surgeons must be cautious to

determine which patients have been severely obese for decades and therefore have essentially end-stage organ function in many cases as a result of the comorbid medical conditions that have been present for decades. Flum and Dellinger¹⁰⁶ showed that the older patient population, especially those few patients older than age 70 undergoing bariatric surgery, did have an increased incidence of mortality and morbidity after RYGB.

The concept that bariatric surgery confers an improved quality of life, a longer life, and a life without as many associated medical problems leads to the logical conclusion that the benefits of an operation will be more fully realized in the younger patient. This philosophy, in view of the large number of unserved patients, does justify age limits for individual surgeon practices. While some surgeons do have such limits, patients near or just over the age limit are often reviewed on an individual basis to determine their appropriateness for surgery. However, some surgeons will base their decision on “physiologic” age rather than chronologic age because many elderly patients may be reasonably low risk for major complications. Accumulation of data may also change these limits in the future.

The Female Patient: Pregnancy and Gynecologic Issues in the Bariatric Surgery Patient

Hormonal levels in female patients are related to body weight. Obesity alters the levels of estrogen and progesterone available for normal ovulation, resulting in abnormal ovulation patterns, amenorrhea, and difficulty conceiving. Should an obese woman become pregnant, the increased chances of gestational diabetes and hypertension make the pregnancy high risk. Macrosomia is increased. There is a two- to three-fold increase in the rate of cesarean sections, with more complications. Fetal mortality does not appear to be changed when maternal weight gain is limited.¹⁴⁴ With obesity, there is an increased risk for breast and endometrial cancer in the postpartum mother.

Infertility compounds the difficulties of the obese woman who wishes to have an uncomplicated pregnancy and delivery. The same hormonal alterations that cause an increased incidence of cancer (i.e., increased circulating estrogen levels) also cause infertility. If a severely obese woman becomes pregnant, the pregnancy management is made more difficult by the body habitus and the need for more frequent ultrasounds as opposed to physical examination, which yields limited information.

Women who become pregnant soon after undergoing bariatric surgery can be at risk due to the ongoing weight loss produced by the operation. However, if the pregnancy is quickly recognized and appropriately managed, patients after bariatric surgery may actually have a better prognosis than if they had not had surgery. Wittgrove and colleagues¹⁴⁵ showed that patients who had undergone RYGB had a decreased incidence of diabetes, macrosomia, and cesarean section than those who had not had surgery. However, iron replacement was cited as a critical need for these pregnant women. Despite these good results, there are issues for the female patient who undergoes RYGB and becomes pregnant during the rapid weight loss phase after surgery. Special attention is needed to assure adequate intake of vitamins and essential nutrients during what otherwise would be a period of rapid weight loss. Although no clear consensus exists regarding management of pregnancy after bariatric surgery, Beard and colleagues¹⁴⁶ provide the following sound advice: (a) promotion of reliable contraception for 12 to 18 months after

surgery; (b) close nutritional and weight monitoring during and after pregnancy; (c) supplementation to include daily prenatal vitamin, folate 400 µg, iron 50 to 100 mg, calcium 1000 mg, and protein 60 g; and (d) collaboration with high-risk obstetrical colleagues as needed.

Patients who become pregnant after LAGB would seem to have even less likelihood of significant risk to their pregnancy, since the band can be adjusted to allow more food intake during the pregnancy but similarly limit weight gain to a healthy amount. Dixon and colleagues¹⁴⁷ wrote that morbidly obese women do have higher risks during pregnancy, but LAGB allows weight loss, which reduces such risk. The adjustability of the band provides a potential advantage for the pregnant woman.

Weight loss after bariatric surgery can correct the high incidence of gynecologic problems that may exist as a result of severe obesity. Deitel and colleagues¹⁴⁸ found menstrual irregularities in over 40% of patients preoperatively, which became normal in over 95% of patients postoperatively. Infertility problems were present preoperatively in 29% of patients, and medical problems were frequent during previous pregnancies including hypertension in 26.7%, preeclampsia in 12.8%, diabetes in 7%, and deep vein thrombosis in 7%. These problems were virtually eliminated after weight loss. Stress urinary incontinence in the female patients in that study decreased from 61.2% to 11.6% after bariatric surgery.

Polycystic ovary syndrome (PCOS) is another common hormonal dysfunction associated with severe obesity. It is associated with obesity, infertility, hyperandrogenism, dyslipidemia, anovulation, insulin resistance, and abnormal menses.¹⁴⁹ Bariatric surgery improves not only metabolic disease but also menstrual irregularity, hirsutism, and infertility associated with PCOS.^{150,151}

Stress urinary incontinence is a frequent problem of the severely obese woman, which must be specifically solicited on history. The increased intra-abdominal pressure from severe obesity contributes to the high incidence of this problem in the severely obese population. Obesity may also alter the neuromuscular function of the genitourinary tract, contributing to incontinence. Studies have confirmed the increased incidence of obesity in patients with both true stress incontinence and detrusor instability.¹⁵² Weight loss alone relieves symptoms in many patients with obesity. A recent study involving 72 patients who had bariatric surgery (90% RYGB) showed a nearly 50% reduction in prevalence and severity of urinary incontinence after surgery based on objective urodynamic testing.¹⁵³ A significant improvement in subjective quality of life and sexual function was also achieved.

Metabolic Surgery

Advances in the role of metabolic surgery to treat type 2 diabetes mellitus (T2DM) and increases in the understanding of how surgery improves or resolves T2DM continue to represent the single most prominent change in the field of bariatric surgery since the last edition of this text. Nearly all international bariatric surgery societies have added “metabolic” to their name, including the American Society for Metabolic and Bariatric Surgery (ASMBS), which was formerly the American Society for Bariatric Surgery (ASBS). International meetings on the topic of bariatric surgery and its effects on diabetes have convened during the last 5 years to establish new guidelines regarding indications for metabolic surgery for T2DM as well as research priorities.¹⁵⁴ The entire field of bariatric surgery is now much more focused on the metabolic effects and benefits of bariatric surgery.

Although many comorbidities are improved by bariatric surgery and its resultant weight loss, the metabolic diseases that are most particularly affected are T2DM and the hyperlipidemias and metabolic syndrome. Hypertension and cardiovascular disease are also improved indirectly through metabolic benefits as well as directly through weight loss effects.

Type 2 Diabetes. There has been a dramatic increase in the potential application of surgical therapy to treat T2DM. Much of this stems from the original observations of surgeons performing RYGB concerning the improvement or near resolution of T2DM well before patients who had undergone the operation had achieved maximum weight loss. Pories and colleagues¹⁵⁵ championed these observations in a landmark paper that confirmed RYGB as an effective treatment for T2DM, resolving the condition in 85% of patients who had developed it within the 5 years prior to surgery. MacDonald and colleagues,¹⁵⁶ also from the same institution, showed that treatment with RYGB of patients with T2DM resulted in longer life span. Schauer and colleagues¹⁵⁷ showed that improvement in T2DM after LRYGB is comparable to that seen in Pories' original work, with fasting insulin levels and glycosylated hemoglobin levels returned to normal levels in 83% of patients and markedly improved in 17% of patients. RYGB has been shown to decrease overall long-term mortality related to diabetes in several large population studies.^{158,159}

These results and studies, as well as the observation that T2DM resolved quickly after RYGB, led to the general belief that there is an important contribution of the enteric hormonal component of glucose metabolism influencing the disease. Rubino and Marescaux¹⁶⁰ reported the resolution of diabetes in the obese rat model with surgical diversion of the food stream from the duodenum and proximal jejunum. Reversal of the operation led to return of the disease state. The extension of the findings of Rubino and Marescaux to humans has occurred; a duodenojejunal exclusion operation has been performed and shows initial safety and efficacy in a small group of patients.¹⁶¹ Although the majority of patients who have T2DM are obese, approximately 10% of patients with T2DM are not obese, and these data from Brazil may confirm that the resolution of the disease through enteric diversion is not based on associated weight loss.¹⁶²

Surgical therapy that does produce weight loss without diversion of the enteric stream also can be quite effective in resolving T2DM. Dixon and colleagues⁷⁰ reported, in the first randomized controlled trial comparing surgical versus medical treatment of diabetes, that 73% of patients undergoing LAGB and followed for 2 years achieved resolution of T2DM versus 13% of medically treated patients in the control group. An accompanying editorial to Dixon's article advocated that the treatment for diabetes be reshaped to include consideration of surgical therapy as an option for patients, especially severely obese patients.¹⁶³

Despite these data in the literature, there has been resistance from endocrinologists and internists specializing in the medical treatment of diabetes to accept the use of surgical therapy as an optimal treatment for the disease.¹⁶⁴ One major criticism pertaining to the quality of outcome studies for diabetes surgery has been that except for the Dixon study, none have been randomized controlled trials. In the last few years, however, three additional randomized controlled trials have been published in high-impact medical journals. Schauer and colleagues (n = 150) showed superior glycemic control

(defined as hemoglobin A1c [HbA1c] <6% with or without medications) after RYGB (42%) and SG (37%) compared to intense medical therapy (12%) at 1 year ($P < .001$) in patients with mild to moderate obesity (BMI 27–43 kg/m²) and poorly controlled T2DM (average HbA1c 9%).¹⁶⁵ Gastric bypass and SG resulted in greater improvement in other cardiovascular risk factors such as BMI, triglycerides, high-density lipoprotein, and C-reactive protein compared with intense medical therapy. The surgical patients also significantly reduced their dependency on diabetes medications, while medical patients had increased dependency on diabetes medications. Mingrone and colleagues (n = 60) demonstrated that diabetes remission rates (HbA1c <6.5% without medications) were superior after BPD (95%) and RYGB (75%) compared to conventional medical therapy (0%) at 2 years ($P < .001$) in patients with severe obesity (average BMI 45 kg/m²) and poorly controlled T2DM (average HbA1c 9%).¹⁶⁶ Ikramuddin and colleagues (n = 120) found that RYGB (49%) was superior ($P < .001$) to intense medical therapy (19%) in achieving the American Diabetes Association goal of therapy (HbA1c <7%, low-density lipoprotein cholesterol <100 mg/dL, systolic blood pressure <130 mmHg) in patients with obesity (BMI 30 to 40 kg/m²) and poorly controlled T2DM (average HbA1c 9.6%).¹⁶⁷ All four randomized controlled trials to date have shown that surgery in the short term (1–2 years) was well tolerated, with few major complications (two serious cases of sepsis), no cardiovascular events, and no operative mortality, and that surgery resulted in both superior glycemic control and greater improvements in cardiovascular risk factors compared to medical treatment alone.

Adoption of metabolic surgery by endocrinologists, internists, and primary care physicians as a treatment of T2DM has gradually increased over the last 5 years. The Diabetes Surgery Summit in 2007 published the first consensus guidelines for the use and study of metabolic surgery.¹⁵⁴ Since 2009, the American Diabetes Association has included bariatric surgery in their position statement on standards of medical care in T2DM. The guideline indicates that “bariatric surgery should be considered for adults with BMI ≥ 35 kg/m² and T2DM, especially if the diabetes is difficult to control with lifestyle and pharmacological therapy.”¹⁶⁸ In 2011, the International Diabetes Federation (IDF) released its position statement on the role of surgery and other gastrointestinal interventions in the management of T2DM.¹⁶⁹ At this time, the IDF guidelines are the most useful summaries, from the evidence available, for healthcare providers who manage patients with T2DM. The IDF guidelines are the first to recommend that metabolic surgery be considered for patients with a BMI as low as 30 kg/m² if they are not in good glycemic control on optimal medical therapy.

Metabolic Syndrome. The metabolic syndrome is characterized by central obesity, glucose intolerance, dyslipidemia, and hypertension. This is a common finding in patients with severe obesity, occurring in 52% of individuals in one report.¹⁷⁰ All the associated metabolic problems of the metabolic syndrome respond to surgical therapy to produce weight loss. Basic scientists attribute the occurrence of this associated array of diseases to an enhanced inflammatory state in the body resulting from the increased production of cytokines by the adipocyte. These cytokines in turn produce a mild inflammatory reaction that promotes the production of these diseases.

Diabetes and glucose tolerance are effectively treated by bariatric operations as discussed earlier. These operations also are effective in treating the other components of metabolic syndrome.

RYGB produced a 98% resolution of the metabolic syndrome in patients 1 year after surgery.¹⁷¹

Dyslipidemias improve in over 70% of patients undergoing RYGB. Improvement is 100% and resolution is greater than 90% after any of the malabsorptive operations (see Table 27-7). Overall lipid profiles are improved, and the degree to which this occurs is in part related to exercise levels of the individual as well as genetic components of the disease.

Cardiovascular Disease. Hypertension, a component of the metabolic syndrome, is one of the cardiovascular diseases that are increased in the setting of obesity. Elevated arterial pressure in patients with obesity-related hypertension is associated with increased cardiac output and total peripheral resistance. The elevated output is related to expanded intravascular volume that increases cardiopulmonary volume, venous return, and left ventricular preload; the elevated pressure and total peripheral resistance increase afterload. This dual ventricular overload promotes a dimorphic, concentric, and eccentric hypertrophy in response to the volume and pressure overload. Increased myocardial oxygen demand results from the elevated tension in the left ventricular wall, reflecting its increased diameter and pressure, and provides a physiologic rationale for the greater potential of coronary arterial insufficiency and cardiac failure. There is greater renal blood flow and lower renal vascular resistance in patients with obesity-related hypertension at any level of arterial pressure. This may be offset by an increased renal filtration fraction that may favor protein deposition and glomerulosclerosis.¹⁷⁰

Weight loss results in decreased intravascular volume, decreased cardiac output, and decreased arterial pressure. These manifestations occur after all the various bariatric operations that produce weight loss.

Heart failure also is increased in the setting of severe obesity. Much of the risk is secondary to the processes mentioned earlier, which produce hypertension and cardiac hypertrophy. Hypertension and obesity have significant independent associations with left ventricular hypertrophy and cardiac wall thickness. Obesity is particularly strongly associated with left ventricular internal diameter.¹⁷²

Much data now exists regarding the effect of bariatric surgery on cardiovascular disease. A recent systematic review of long-term cardiovascular risk factor reduction after bariatric surgery involved 73 studies and 19,543 subjects with a mean age of 42 years; 76% of subjects were female, and 44%, 24%, and 44% had a baseline hypertension, diabetes, and hyperlipidemia, respectively.¹⁷³ At a mean follow-up of 57.8 months, the average excess weight loss for all bariatric procedures was 54%, and remission/improvement was 63% for hypertension, 73% for T2DM, and 65% for hyperlipidemia. Echocardiographic results from 713 subjects showed statistically significant improvements in left ventricular mass, E/A ratio, and isovolumic relaxation time postoperatively.

Thus far, there are no long-term randomized controlled trials comparing bariatric surgery with nonsurgical medical treatment of obesity that evaluate cardiovascular endpoints and mortality. However, 12 cohort-matched studies comparing bariatric surgery with nonsurgical controls have recently been reviewed.¹⁷⁴ Collectively, all but two of these studies support a reduced cardiovascular event rate and all-cause mortality rate conferred by bariatric surgery. Of these studies, the Swedish Obesity Subjects (SOS) study has the longest outcomes follow-up at a median of 14.7 years.¹⁵⁸ Cardiovascular mortality in the surgical group was significantly lower than for control subjects (adjusted hazard ratio, 0.47; 95% confidence interval, 0.29–0.76; $P = .002$) despite the

greater prevalence of smoking and higher baseline weights and blood pressures in the surgical cohort. The SOS study has formed the basis of much of our current understanding of medium- and long-term outcomes after bariatric surgery despite the fact that the majority of their surgical cohort received vertical-banded gastroplasty (>70%), a gastric volume reduction procedure that is now rarely performed in the United States.

Resolution of Other Comorbid Medical Problems

Bariatric surgery can produce resolution of many, if not all, of the comorbid medical problems associated with obesity and present at the time of surgery. This is true to some extent for all bariatric procedures, although some are more efficient at reversing specific comorbid problems than others.

GERD is symptomatically present in approximately half of patients with severe obesity and has been objectively proven to be present in 21%.⁹² Unfortunately, obese patients with GERD have a higher chance of failing to obtain symptomatic relief from standard antireflux surgery. The recurrence of symptoms is higher, likely due to a higher incidence of wrap herniation into the mediastinum and other mechanical failure of the fundoplication, which in turn is likely affected by the increased intra-abdominal pressure of the obese condition. The patient with a BMI over 35 kg/m² who has GERD has a better chance of elimination of symptoms by undergoing LRYGB, which is >90% effective in the elimination of GERD.¹⁷⁵ LRYGB creates such a small gastric pouch that it has a very limited volume for acid production. LAGB improves GERD but to a considerably lesser extent than RYGB. A recent prospective analysis of 558 consecutive laparoscopic SG ($n = 200$) and LRYGB ($n = 358$) patients demonstrated significantly improved subjective GERD symptoms in the bypass cohort when compared to the SG patients at 1 year ($P < .001$).¹⁷⁶ In fact, some studies suggest that SG can increase GERD symptoms postoperatively. Zhang and colleagues¹⁷⁷ reported new reflux seen on upper gastrointestinal series in 18% of their 28 patients after SG.

OSA is a disturbance of sleep associated with obesity. It is a measurable problem, quantitated by polysomnography. In one recent study of 349 patients considering bariatric surgery who were referred and tested, only 17% had no sleep apnea, whereas 32% had mild, 18% moderate, and 33% severe sleep apnea.¹⁷⁸ At a mean time of 11 months after RYGB, the mean Respiratory Disturbance Index for all patients decreased from 51 to 15 ($P < 0.01$). Of 83 patients using continuous positive airway pressure or bilevel positive airway pressure preoperatively, only 31 still required it, and they had decreased setting requirements. A recent systematic review of 13,900 patients (69 studies) showed significant improvement or resolution of sleep apnea in more than 75% of bariatric surgery patients.¹⁷⁹ Comparison of outcomes between procedures demonstrated the most benefit with BPD and gastric bypass and the least with LAGB. However, a recent randomized control trial comparing the effect of medical and surgical weight loss (LAGB) on sleep apnea found no significant difference in apnea events despite major differences in weight loss. The findings suggested that much of the improvement achieved was in the mild to moderate weight loss range, with little benefit of further weight loss.¹⁸⁰

Another pulmonary symptom that commonly occurs in severely obese patients is asthma. Dixon and colleagues¹⁸¹ studied 23 asthmatic patients who underwent bariatric surgery and found a significant improvement in asthma control (e.g., forced expiratory

volume in 1 second, forced vital capacity), asthma-related quality of life, and responsiveness to methacholine. Boulet and colleagues¹⁸² found similar results in their cohort of 12 patients with asthma who experienced significant weight loss after bariatric surgery.

Nonalcoholic fatty liver disease (NAFLD) is a metabolically related problem associated with obesity. The disease is a spectrum of liver abnormalities including steatosis, steatohepatitis, fibrosis, and cirrhosis of the liver. It is estimated that 20% of U.S. adults have NAFLD, largely because of the high incidence of obesity. NAFLD is present in an estimated 85% of patients with severe obesity.¹⁸³ Due to the high incidence of this disease, some authorities have advocated routine liver biopsy at the time of bariatric operations. However, since the treatment of the disease is weight loss, patients with mild forms of the disease need no further treatment or follow-up. Biopsy reports showing any degree of fibrosis should be further followed up by a hepatologist. Weight loss after RYGB decreases metabolic disease, hepatic steatosis, inflammation, and in some cases even fibrosis.¹⁸⁴ Although further research is needed to accurately assess the role of bariatric surgery as a potential treatment for NAFLD, there are numerous reports that support its use. A recent systematic review of the available literature found many retrospective and prospective observational cohort studies, but no randomized control trials or case-control series.¹⁸⁵ There did appear to be significant histologic regression of NAFLD in most of these studies; however, steatohepatitis and fibrosis were also observed in rare cases postoperatively. In one prospective study with before and after liver biopsies, residual steatohepatitis did not appear to be associated with the various bariatric approaches; rather, it was related to higher baseline BMI, degree of previous steatosis/fibrosis, NAFLD activity score, ballooning, degree of inflammation, and insulin resistance.¹⁸⁶ The role of bariatric surgery in the treatment in NAFLD remains to be seen.

Musculoskeletal problems, especially degenerative joint disease and low back pain, are among the most common complaints and associated comorbid problems of the severely obese population. Quantitation of their severity, however, is often difficult, making resolution or improvement equally difficult. Symptoms often resolve and usually improve in patients who experience significant weight loss. This is likely a combined effect of the direct lessened work load as well as some secondary resolution of the inflammatory process of the joints brought on directly and indirectly by obesity. A prospective cohort of 50 obese females age 20 to 74 years were followed for 1 year after RYGB using the timed-get-up-and-go (TGUG) and health survey Short Form-36 (SF-36).¹⁸⁷ The results showed a significant improvement in musculoskeletal function and likely enhanced ability to progress in rehabilitation. Patients with osteoarthritis of the neck, shoulder, spine, hip, knee, ankle, wrist, and hand have been shown to have improved or resolved joint pain after bariatric surgery. Reduction in BMI values of 6.2 to 14.7 kg/m² has corresponded with back and knee pain resolution in 5% to 100% of patients, whereas pain severity was reduced in 31% to 94% of patients depending on the joint and study.¹⁸⁸

Plastic Surgery after Weight Loss

Patients who have undergone bariatric surgery are often left with large amounts of hanging skin or rolls of skin and subcutaneous tissue as a result of the weight loss. Additional problems include skin rashes; maceration under folds in the pannus, thighs, and breasts; body odor; and poorly fitting clothes. Excess skin can be a limiting factor in exercise and sexual activity.

Many patients desire to be rid of the extra skin and its associated problems. The major problem they face, however, in accomplishing this is obtaining insurance approval for surgical removal of the excess skin. Most insurance companies consider this “cosmetic” surgery and will not authorize coverage. A few, with appropriate documentation of the conditions and problems from excess skin, do provide coverage for surgery. Plastic surgeons who are experienced in abdominoplasty and body contouring can offer these patients an excellent surgical treatment for the problems of excessive skin.

Reconstructive surgery requires careful preoperative planning and is based on the patient’s deformities and priorities. Excess tissue of the lower torso is the most common deformed area for which patients undergo surgical intervention. A standard abdominoplasty to remove this excessive tissue is performed. More radical body contouring can include a circumferential abdominoplasty and lower body lift.¹⁸⁹ This procedure involves excision of tissue from the buttocks and lateral thighs, with skin undermining down the thighs. Circumferential abdominoplasty removes redundant skin of the lower abdomen, flattens the abdomen, and incorporates the lower body lift. It requires central undermining to the xiphoid and minimal lateral undermining of the superior flap. The central abdominal fascia often requires imbrication. If simultaneous abdominal hernia repair is performed, this performs the function of fascial imbrication by creating a repair with some degree of fascial tension. The closure of the superior flap to the inferior skin edge incorporates lateral tension to narrow the waist and advance the anterolateral thighs. Medial thighplasty also may be needed for patients with significant excess medial thigh skin. This is done transversely.

Excess skin redundancy distal to the mid-thighs requires long vertical medial excision of skin. Mid-back and epigastric rolls, along with sagging breasts, are corrected with an upper body lift. The upper body lift is a reverse abdominoplasty, removal of mid-torso excessive skin, and reshaping of the breasts. For highly selected individuals, and with a well-organized team, a single-stage total body lift, which includes a circumferential abdominoplasty, lower body lift, medial thighplasty, an upper body lift, and breast reshaping, can be performed safely in under 8 hours (Figs. 27-24 and 27-25).¹⁹⁰ While many bariatric surgery programs do not have the accompanying volume, experience, and interest to offer such an extensive single-stage operation, most programs do offer availability of plastic surgery expertise for abdominoplasty and removal of excess skin of the extremities as separate procedures. Increasing numbers of patients undergoing bariatric surgery have provided an increased flow of patients requesting such services, which in turn should lead to improved outcomes with increasing experience for surgeons performing these procedures. One matched control study suggests that plastic surgery after bariatric surgery may actually improve long-term weight loss.¹⁹¹

Endoscopic, Electric, and Other Experimental Procedures

Bariatric surgery has been a field of constant succession of procedures in an attempt to improve safety, minimize invasiveness, and offer better outcomes. Recent experimental procedures in electrical stimulation of the stomach and vagus nerves have been performed to produce weight loss.

The implantable gastric stimulation device, initially marketed by Trasneuronix, Inc., in the early part of the twenty-first century, was a dual-lead implantable gastric electrical

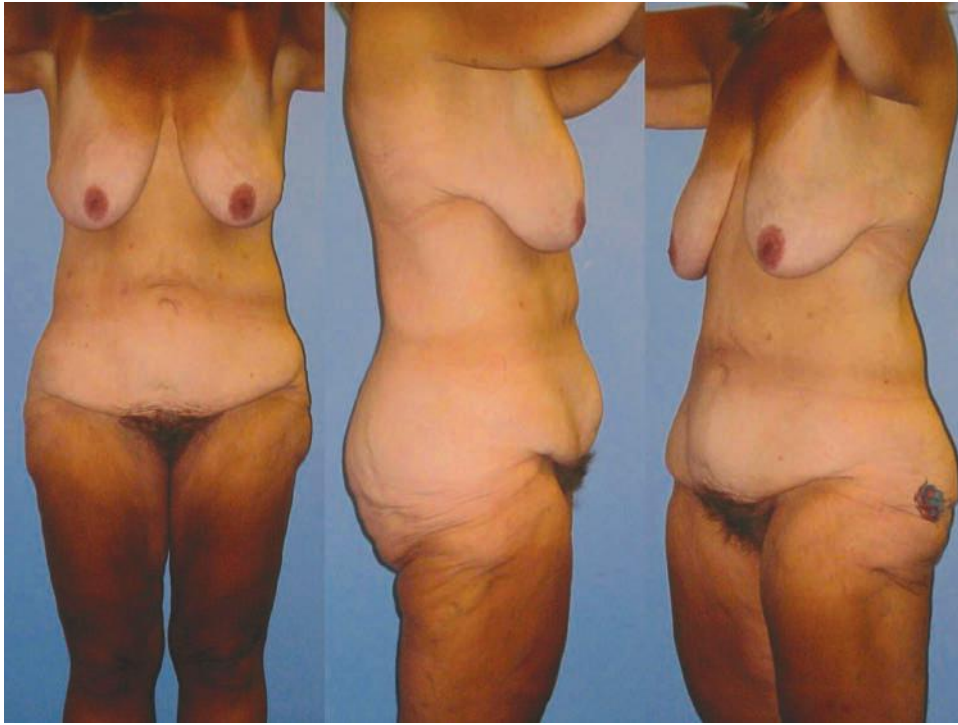


Figure 27-24. Preoperative frontal, right lateral, and left anterior oblique views of a 36-year-old, 150-lb, 5'6" woman who lost 120 lb 2 years after laparoscopic Roux-en-Y bypass procedure. She desired a one-stage total body lift and bilateral brachioplasties, which were performed in the manner described in the text. (Courtesy of Dennis Hurwitz, MD, Clinical Professor of Plastic Surgery, University of Pittsburgh.)

stimulator that theoretically interfered with the stomach's innate myoelectric pattern, causing decreased gastric emptying and nausea. A mean excess weight loss of 23% was reported at 16-month follow-up for the second U.S. trial.¹⁹² Longer-term follow-up for the first European study showed a 25% excess weight loss in 91 patients over a 2-year follow-up.¹⁹³ The

disappointing aspect of this treatment is that a significant number of the patients lose little weight, whereas a smaller group seem to respond well to the treatment. The ability to select patients who will respond remains a challenge for this technology, which is still in the status of only a proposed potential operation for weight loss.

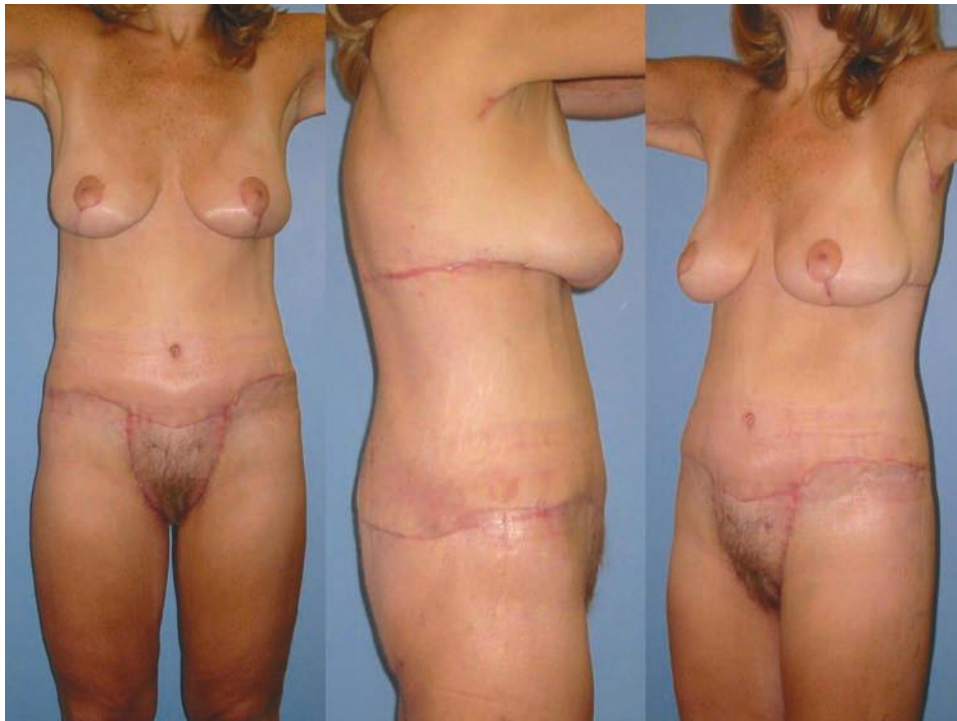

Figure 27-25. Frontal, right lateral, and left anterior oblique views 6 weeks after surgery for the woman in Fig. 27-24. The scars indicate the circumferential abdominoplasty, lower body lift, upper body lift, breast reshaping, and autoaugmentation through a keyhole pattern and bilateral brachioplasties. All redundant skin has been removed, leaving well-positioned scars and feminine features. (Courtesy of Dennis Hurwitz, MD, Clinical Professor of Plastic Surgery, University of Pittsburgh.)

Vagal stimulation/blockade has recently been proposed as a means of stimulating the neural input to the stomach to achieve decrease in appetite, early satiety, at times nausea, and weight loss. Data to date have been sparse and very preliminary in showing any merits of the potential efficacy of this approach.¹⁹⁴

Endoscopic procedures to decrease gastric pouch size and to limit gastrojejunostomy anastomotic size are currently being performed at several medical centers.^{84,195} These are currently reoperative procedures, not initial procedures for weight loss. Long-term weight loss of significant magnitude has yet to be demonstrated by these revisional endoscopic procedures.

Intragastric balloon placement has resurfaced on the bariatric scene in the past few years. The Garren-Edwards bubble of the late 1980s era¹⁹⁶ was prone to migration and bowel obstruction, which led to its early demise. Now this concept has resurfaced as a short-term bridge to weight loss to be followed by a more definitive procedure. While there may be some limited application of this device for such purposes,¹⁹⁷ its ability to produce durable weight loss is unproven. It may have potential use only as a preliminary procedure prior to a more definitive one.

Prototype procedures undergoing trial include one that uses an endoscopically placed sleeve to limit absorption. A small randomized control study out of the Netherlands compared an endoscopically placed intraluminal sleeve extending from the duodenum to the jejunum (EndoBarrier) to a diet modification control group.¹⁹⁸ They successfully placed 26 devices, but were unable to do so in 4 cases. Four implants had to be removed before the end of the study due to migration, obstruction, and continuous epigastric pain. Mean weight loss at 3 months was 19.0% in the study group and 6.9% in the control group. HbA1c was significantly improved after EndoBarrier placement in seven of eight patients with T2DM. An FDA trial is currently under way to determine the long-term safety and efficacy of this experimental gastrointestinal liner.

The eventual ability to endoscopically create a stapled or sutured gastric pouch and hence a completely endoscopically performed restrictive operation is being envisioned. While these proposed procedures speak to the energy and innovation of today's bariatric surgery community, their implementation into clinical practice has yet to occur. Endoscopic procedures and devices such as the transoral gastroplasty (TOGA) and the transoral endoscopic restrictive implant system (TERIS) did not initially achieve sufficient weight loss to satisfy FDA requirements and thus have been withheld from further development at this time.^{199,200}

Other investigational procedures under development and performed laparoscopically include the duodenal-jejunal bypass and ileal transposition. These procedures are intended to improve T2DM without intentional weight loss.^{201,202} Gastric plication is also a new laparoscopic procedure intended to mimic results of SG but without requiring stapling or stomach removal.²⁰³ Further studies with long-term safety and efficacy data are required before these investigational procedures can be considered for routine clinical use.

REFERENCES

Entries highlighted in bright blue are key references.

1. Dimick JB, Nicholas LH, Ryan AM, et al. Bariatric surgery complications before vs. after implementation of a national policy restricting coverage to centers of excellence. *JAMA*. 2013;309:792-799.
2. Shimizu H, Timratana P, Schauer PR, Rogula T. Review of metabolic surgery for type 2 diabetes in patients with a BMI < 35 kg/m². *J Obes*. 2012;2012:147256.
3. Hellmich N. Medical group recognizes obesity as a disease. *USA TODAY*, June 19, 2013.
4. Centers for Medicare and Medicaid Services. Medicare National Coverage Determinations Manual Chapter 1, Part 2, Section 100.1. Available at: http://www.cms.gov/Regulations-and-Guidance/Guidance/Manuals/downloads/ncd103c1_part2.pdf. Accessed November 24, 2013.
5. Centers for Disease Control and Prevention. Adult obesity facts. Available at: <http://www.cdc.gov/obesity/data/adult.html>. Accessed November 24, 2013.
6. Stunkard AJ, Foch TT, Hrubec Z. A twin study of human obesity. *JAMA*. 1986;256:51-54.
7. Sweeney TM, Morton JM. The human gut microbiome: a review of the effect of obesity and surgically induced weight loss. *JAMA Surg*. 2013;148:563-569.
8. Timar O, Sestier F, Levy E. Metabolic syndrome X: a review. *Can J Cardiol*. 2000;16:779-789.
9. Garfinkel L. Overweight and cancer. *Ann Intern Med*. 1985;103:1034-1036.
10. Dreick EJ, Bale GS, Seltzer F, et al. Excessive mortality and causes of death in morbidly obese men. *JAMA*. 1980;243:443-445.
11. Wadden TA, Foster GD, Letizia KA. One-year behavioral treatment of obesity: comparison of moderate and severe caloric restriction and the effects of weight maintenance therapy. *J Consult Clin Psychol*. 1994;62:165-171.
12. Wood PD, Stefanick ML, Dreon DM, et al. Changes in plasma lipids and lipoproteins in overweight men during weight loss through dieting as compared with exercise. *N Engl J Med*. 1988;319:1173-1179.
13. Wing RR. Behavioral strategies to improve long-term weight loss and maintenance. *Med Health RI*. 1999;82:123.
14. Miller WC, Koxeja DM, Hamilton EJ. A meta-analysis of the past 25 years of weight loss research using diet, exercise or diet plus exercise intervention. *Int J Obes Relat Metab Disord*. 1987;21:941-947.
15. Eriksson KF, Lindgarde F. Prevention of type 2 (non-insulin-dependent) diabetes by diet and physical exercise. The 6-year Malmo feasibility study. *Diabetologia*. 1991;34:891-898.
16. Scheen AJ, Ernest P. New antiobesity agents in type 2 diabetes. Overview of clinical trials with sibutramine and orlistat. *Diabetes Metab*. 2002;28:437-445.
17. Bray GA. Drug treatment of obesity. *Rev Endocr Metab Disord*. 2001;2:403-418.
18. Gadde KM, Allison DB, Ryan DH, et al. Effects of low-dose, controlled-release, phentermine plus on weight and associated comorbidities in overweight and obese adults (CONQUER): a randomised, placebo-controlled, phase 3 trial. *Lancet*. 2011;377:134-152.
19. Fidler MC, Sanchez M, Raether B, et al. A one-year randomized trial of lorcaserin for weight loss in obese and overweight adults: the BLOSSOM trial. *J Clin Endocrinol Metab*. 2011;96:3067-3077.
20. Harnisch MC, Portenier DD, Pryor AD, et al. Preoperative weight gain does not predict failure of weight loss or comorbidity resolution of laparoscopic Roux-en-Y gastric bypass for morbid obesity. *Surg Obes Relat Dis*. 2008;4:445-450.
21. Cassie S, Menezes C, Birch DW, et al. Effect of preoperative weight loss in bariatric surgical patients: a systematic review. *Surg Obes Relat Dis*. 2011;7:760-767.
22. National Institutes of Health Consensus Conference. Gastrointestinal surgery for severe obesity. Consensus Development Conference Panel. *Ann Intern Med*. 1991;115:956-961.
23. Balsinger BM, Poggio JL, Mai J, et al. Ten and more years after vertical banded gastroplasty as primary operation for morbid obesity. *J Gastrointest Surg*. 2000;4:598-605.
24. Kremen AJ, Linner JH, Nelson CH. An experimental evaluation of the nutritional importance of proximal and distal small intestine. *Ann Surg*. 1954;140:439-448.

25. Deitel M. Overview of operations for morbid obesity. *World J Surg.* 1998;22:913-918.
26. Mason EE, Ito C. Gastric bypass in obesity. *Surg Clin N Am.* 1969;47:1345-1351.
27. Griffin WO, Young VL, Stevenson CC. A prospective comparison of gastric and jejunoileal bypass procedures for morbid obesity. *Ann Surg.* 1977;186:500-509.
28. Mason EE, Doherty C, Cullen JJ, et al. Vertical gastroplasty: evolution of vertical banded gastroplasty. *World J Surg.* 1998;22:919-924.
29. Mason EE. Vertical banded gastroplasty for obesity. *Arch Surg.* 1982;117:701-706.
30. Brolin RE, Robertson LB, Kenler HA, et al. Weight loss and dietary intake after vertical banded gastroplasty and Roux-en-Y gastric bypass. *Ann Surg.* 1994;220:782-790.
31. Waaddegaard P, Clemesen T, Jess P. Vertical gastric banding for morbid obesity: a long-term follow-up study. *Eur J Surg.* 2002;168:220-222.
32. Scopinaro N, Gianetta E, Civalleri D, et al. Bilio-pancreatic bypass for obesity: II. Initial experience in man. *Br J Surg.* 1979;66:618-620.
33. Hess DS, Hess DW. Biliopancreatic diversion with a duodenal switch. *Obes Surg.* 1998;8:267-282.
34. Kuzmak LI. A review of seven years experience with silicone gastric banding. *Obes Surg.* 1991;1:403-408.
35. Belachew M, Legrand MJ, Defechereux TH, et al. Laparoscopic adjustable silicone gastric banding in the treatment of morbid obesity. A preliminary report. *Surg Endosc.* 1994;8:1354-1356.
36. Wittgrove AC, Clark WG, Tremblay LJ. Laparoscopic gastric bypass, Roux-en-Y: preliminary report of five cases. *Obes Surg.* 1994;4:353-357.
37. Buchwald H, Oien DM. Metabolic/bariatric surgery worldwide 2011. *Obes Surg.* 2013;23:427-436.
38. Sil A, Barr G. Assessment of predictive ability of Epworth scoring in screening of patients with sleep apnoea. *J Laryngol Otol.* 2012;126:372-379.
39. O'Keefe T, Patterson EJ. Evidence supporting routine polysomnography before bariatric surgery. *Obes Surg.* 2004;14:23-26.
40. Sharaf RN, Weinschel EH, Bini EJ, et al. Endoscopy plays an important preoperative role in bariatric surgery. *Obes Surg.* 2004;14:1367-1372.
41. Verset D, Houben J-J, Gay F, et al. The place of upper gastrointestinal tract endoscopy before and after vertical banded gastroplasty for morbid obesity. *Dig Dis Sci.* 1997;42:2333-2337.
42. Schirmer B, Erenoglu C, Miller A. Flexible endoscopy in the management of patients undergoing Roux-en-Y gastric bypass. *Obes Surg.* 2002;12:634-638.
43. Birkmeyer NJ, Finks JF, English WJ, et al. Risks and benefits of prophylactic inferior vena cava filters in patients undergoing bariatric surgery. *J Hosp Med.* 2013;8:173-177.
44. Kim JJ, Schirmer B. Safety and efficacy of simultaneous cholecystectomy at the time of Roux-en-Y gastric bypass. *Surg Obes Relat Dis.* 2009;5:48-53.
45. Hamad GG, Ikramuddin S, Gourash WF, Schauer PR. Elective cholecystectomy during laparoscopic Roux-en-Y gastric bypass. Is it worth the wait? *Obes Surg.* 2003;13:76-81.
46. Sugerman HJ, Brewer WH, Shiffman ML, et al. A multicenter, placebo-controlled, randomized, double-blind prospective trial of prophylactic ursodiol for the prevention of gallstone formation following gastric-bypass-induced rapid weight loss. *Am J Surg.* 1995;169:91-97.
47. De Waelle B, Lauwers M, Van Nieuwenhove Y, Delvaux G. Outpatient laparoscopic gastric banding: initial experience. *Obes Surg.* 2004;14:1108-1110.
48. Collins J, McCloskey C, Titchner R, et al. Preoperative weight loss in high-risk superobese bariatric patients: a computed tomography-based analysis. *Surg Obes Relat Dis.* 2011;7:480-485.
49. Patel RA, Brolin RE, Gandhi A. Revisional operations for marginal ulcer after Roux-en-Y gastric bypass. *Surg Obes Relat Dis.* 2009;5:317-322.
50. Buffington C, Walker B, Cowan GS Jr, et al. Vitamin D deficiency in the morbidly obese. *Obes Surg.* 1993;3:421-424.
51. Bogdonoff DL, Schirmer B. Laparoscopic surgery. In: Stone DJ, Bogdonoff DL, Leisure GS, Mathes DD, Spiekermann BF, eds. *Perioperative Care: Anesthesia, Medicine and Surgery.* 1st ed. St. Louis: Mosby; 1998:547-558.
52. Nguyen NT, Goldman C, Rosenquist CJ, et al. Laparoscopic versus open gastric bypass: a randomized study of outcomes, quality of life, and costs. *Ann Surg.* 2001;234:279-289.
53. Hutter M, Randall S, Khuri SF, et al. Laparoscopic versus open gastric bypass for morbid obesity. A multicenter, prospective, risk-adjusted analysis from the National Surgical Quality Improvement Program. *Ann Surg.* 2006;243:657-666.
54. Lujan JA, Frutos MD, Hernandez Q, et al. Laparoscopic versus open gastric bypass in the treatment of morbid obesity. *Ann Surg.* 2004;239:433-437.
55. Schirmer B. Laparoscopic bariatric surgery. *Surg Endosc.* 2006;20(Suppl):S450-S455.
56. Jones KB Jr, Affram JD, Benotti PM, et al. Open versus laparoscopic Roux-en-Y gastric bypass: a comparative study of over 25,000 open cases and the major laparoscopic bariatric reported series. *Obes Surg.* 2006;16:721-727.
57. Swanstrom LL, Fried GM, Hoffman KI, et al. Beta test results of a new system assessing competence in laparoscopic surgery. *J Am Coll Surg.* 2006;202:62-69.
58. Wright TA, Kow L, Wilson T, et al. Early results of laparoscopic Swedish adjustable gastric banding for morbid obesity. *Br J Surg.* 2000;87:362-373.
59. Dargent J. Laparoscopic adjustable gastric banding: lessons from the first 500 patients in a single institution. *Obes Surg.* 1999;9:446-452.
60. Favretti F, Segato G, DeLuca M, Busetto L. Laparoscopic adjustable gastric banding: revisional surgery. In: Schauer PR, Schirmer BD, Brethauer SA, eds. *Minimally Invasive Bariatric Surgery.* New York: Springer; 2007:213-230.
61. Weichman K, Ren C, Kurian M, et al. The effectiveness of adjustable gastric banding: a retrospective 6-year U.S. follow-up study. *Surg Endosc.* 2011;25:397-403.
62. Ren C. Laparoscopic adjustable gastric banding: postoperative management and nutritional evaluation. In: Schauer PR, Schirmer BD, Brethauer SA, eds. *Minimally Invasive Bariatric Surgery.* New York: Springer; 2007:200.
63. Weiner R, Blanco-Engert R, Weiner S, et al. Outcome after laparoscopic adjustable gastric banding—8 years experience. *Obes Surg.* 2003;13:427-434.
64. Dixon JB, O'Brien PE. Laparoscopic adjustable gastric banding: outcomes. In: Schauer PR, Schirmer BD, Brethauer SA, eds. *Minimally Invasive Bariatric Surgery.* New York: Springer; 2007:189-196.
65. Dixon JB, Schachter LM, O'Brien PE. Predicting sleep apnea and excessive day sleepiness in the severely obese: indicators for polysomnography. *Chest.* 2003;123:1134-1141.
66. Angrisani L, Iovino P, Lorenzo M, et al. Treatment of morbid obesity and gastroesophageal reflux with hiatal hernia by Lap-Band. *Obes Surg.* 1999;9:396-398.
67. Dixon JB, Chapala L, O'Brien PE. Marked improvement in asthma after Lap-Band surgery for morbid obesity. *Obes Surg.* 1999;9:15-21.
68. Dixon JB, Dixon ME, O'Brien PE. Depression in association with severe obesity: changes in weight loss. *Arch Intern Med.* 2003;163:2058-2065.
69. Schok M, Geenen R, van Antwerpen T, et al. Quality of life after laparoscopic adjustable gastric banding for severe obesity: postoperative and retrospective preoperative evaluations. *Obes Surg.* 2000;10:502-508.

70. Dixon JB, O'Brien PE, Playfair J, et al. Adjustable gastric banding and conventional therapy for type 2 diabetes. A randomized controlled trial. *JAMA*. 2008;299:316-323.
71. Favretti F, Cadiere GB, Segato G, et al. Laparoscopic banding: selection and technique in 830 patients. *Obes Surg*. 2002;12:385-390.
72. Dixon JB, O'Brien PE. Changes in comorbidities and improvements in quality of life after LAP-BAND placement. *Am J Surg*. 2002;184:S51-S54.
73. Ceelen W, Walder J, Cardon A, et al. Surgical treatment of severe obesity with a low-pressure adjustable gastric band. Experimental data and clinical results in 625 patients. *Ann Surg*. 2003;237:10-16.
74. Buchwald H, Avidor Y, Braunwald E, et al. Bariatric surgery. A systematic review and meta-analysis. *JAMA*. 2004;292:1724-1737.
75. Maggard MA, Shugarman LR, Suttrop M, et al. Meta-analysis: surgical treatment of obesity. *Ann Intern Med*. 2005;142:547-559.
76. Allen JW, Lagardere AO. Laparoscopic adjustable gastric banding: complications. In: Schauer PR, Schirmer BD, Brethauer SA, eds. *Minimally Invasive Bariatric Surgery*. New York: Springer; 2007:205-212.
77. Angrisani L, Cutolo PP, Formisano G, et al. Laparoscopic adjustable gastric banding versus Roux-en-Y gastric bypass: 10-year results of a prospective, randomized trial. *Surg Obes Relat Dis*. 2013;9:405-416.
78. MacLean LD, Rhode BM, Nohr CW. Late outcome of isolated gastric bypass. *Ann Surg*. 2000;231:524-528.
79. Brolin RE. Long-limb gastric bypass in the super-obese. A prospective randomized trial. *Ann Surg*. 1992;215:387-395.
80. Choba PS, Flancbaum L. The effect of Roux limb lengths on outcome after Roux-en-Y gastric bypass: a prospective randomized clinical trial. *Obes Surg*. 2002;12:540-545.
81. Champion JK, Williams M. Small bowel obstruction and internal hernias after laparoscopic Roux-en-Y gastric bypass. *Obes Surg*. 2003;13:596-600.
82. Carmody B, DeMaria EJ, Jamal M, et al. Internal hernia after laparoscopic Roux-en-Y gastric bypass. *Surg Obes Relat Dis*. 2005;1:543-548.
83. Schweitzer M. Endoscopic intraluminal suture placement of the gastric pouch and stoma in postoperative Roux-en-Y gastric bypass patients. *J Laparoendosc Adv Surg Tech A*. 2004;14:223-226.
84. Thompson CC. Perioral endoscopic reduction of dilated gastrojejunal anastomosis following Roux-en-Y gastric bypass: a possible new option for patients with weight regain. *Surg Obes Relat Dis*. 2005;1:223.
85. Mikami D, Needleman B, Narula V, et al. Natural orifice surgery: initial U.S. experience utilizing the StomaphyX device to reduce gastric pouches after Roux-en-Y gastric bypass. *Surg Endosc*. 2010;24:223-228.
86. Schirmer BD, Lee SK, Northup CJ, et al. Gastrojejunal anastomosis stenosis is lower using linear rather than circular stapling during Roux-en-Y gastric bypass. Presented at SAGES 2006 Scientific session, April 2006.
87. Gonzalez R, Lin E, Venkatesh KR, et al. Gastrojejunostomy during laparoscopic gastric bypass: analysis of 3 techniques. *Arch Surg*. 2003;138:181-184.
88. Sekhar N, Torquati A, Lufti R, Richards WO. Endoscopic evaluation of the gastrojejunostomy in laparoscopic gastric bypass. A series of 340 patients without postoperative leak. *Surg Endosc*. 2006;20:199-201.
89. Singh R, Fisher BL. Sensitivity and specificity of postoperative upper GI series following gastric bypass. *Obes Surg*. 2003;13:73-75.
90. Ganci-Cerrud G, Herrera MF. Role of radiologic contrast studies in the early postoperative period after bariatric surgery. *Obes Surg*. 1999;9:532-534.
91. Schauer PR, Ikramuddin S, Gourash W, et al. Outcomes after laparoscopic Roux-en-Y gastric bypass for morbid obesity. *Ann Surg*. 2000;232:515-529.
92. Bennett JC, Wang H, Schirmer BD, Northup CJ. Quality of life and resolution of comorbidities in super-obese patients remaining morbidly obese after Roux-en-Y gastric bypass. *Surg Obes Relat Dis*. 2007;3:387-391.
93. Hutter MM, Schirmer BD, Jones DB, et al. First report of the American College of Surgeons Bariatric Surgery Center Network: laparoscopic sleeve gastrectomy has morbidity and effectiveness positioned between the band and the bypass. *Ann Surg*. 2011;254:410-422.
94. DeMaria EJ, Pate V, Warthen M, Winegar DA. Baseline data from American Society for Metabolic and Bariatric Surgery-designated Bariatric Surgery Centers of Excellence using the Bariatric Outcomes Longitudinal Database. *Surg Obes Relat Dis*. 2010;6:347-355.
95. Masoomi H, Kim H, Reavis K, et al. Analysis of factors predictive of gastrointestinal tract leak in laparoscopic and open gastric bypass. *Arch Surg*. 2011;146:1048-1051.
96. Finks JF, English WJ, Carlin AM, et al. Predicting risk for venous thromboembolism with bariatric surgery: results from the Michigan Bariatric Surgery Collaborative. *Ann Surg*. 2012;255:1100-1104.
97. Gumbs AA, Duffy AJ, Bell RL. Incidence and management of marginal ulceration after laparoscopic Roux-Y gastric bypass. *Surg Obes Relat Dis*. 2006;2:460-463.
98. Parakh S, Soto E, Merola S. Diagnosis and management of internal hernias after laparoscopic gastric bypass. *Obes Surg*. 2007;17:1498-1502.
99. Nguyen NT, Rivers R, Wolfe BM. Early gastrointestinal hemorrhage after laparoscopic gastric bypass. *Obes Surg*. 2003;13:62-65.
100. Aarts EO, van Wagenhingen B, Janssen IM, Berends FJ. Prevalence of anemia and related deficiencies in the first year following laparoscopic gastric bypass for morbid obesity. *J Obes*. 2012;2012:193705.
101. Clements RH, Yellumhanthi K, Wesley M, et al. Hyperparathyroidism and vitamin D deficiency after laparoscopic gastric bypass. *Am Surg*. 2008;74:469-475.
102. McBride CL, Petersen A, Sudan D, Thompson J. Short bowel syndrome following bariatric surgical procedures. *Am J Surg*. 2006;192:828-832.
103. Vance PL, de Lange EE, Shaffer HA Jr, Schirmer B. Gastric outlet obstruction following surgery for morbid obesity: effect of fluoroscopically guided balloon dilation. *Radiology*. 2002;222:70-72.
104. Thodiyil PA, Yenumula P, Rogula T, et al. Selective non-operative management of leaks after gastric bypass: lessons learned from 2675 consecutive patients. *Ann Surg*. 2008;248:782-792.
105. Hamoui N, Crookes PF, Kaufman HS. Percutaneous gastric drainage as a treatment for small bowel obstruction after gastric bypass. *Obes Surg*. 2007;17:1411-1412.
106. Flum DR, Dellinger EP. Impact of gastric bypass operation on survival: a population-based analysis. *J Am Coll Surg*. 2004;199:543-551.
107. Christou NV, Sampalis JS, Liberman M, et al. Surgery decreases long-term mortality, morbidity, and health care use in morbidly obese patients. *Ann Surg*. 2004;240:416-424.
108. Marceau P, Hould FS, Simard S, et al. Biliopancreatic diversion with a duodenal switch. *World J Surg*. 1998; 22:947-954.
109. DeMeester TR, Fuchs KH, Ball CS, et al. Experimental and clinical results with proximal end-to-end duodenojejunostomy for pathologic duodenogastric reflux. *Ann Surg*. 1987;206:414-426.
110. Sudan R, Bennett KM, Jacobs DO, Sudan DL. Multifactorial analysis of the learning curve for robotic-assisted laparoscopic

- biliopancreatic diversion with duodenal switch. *Ann Surg.* 2012;255:940-945.
111. Scopinaro N, Scopinaro N, Gianetta E, Adami GF, et al. Biliopancreatic diversion for obesity at eighteen years. *Surgery.* 1996;119:261-268.
 112. Ren CJ, Patterson E, Gagner M. Early results of laparoscopic biliopancreatic diversion with duodenal switch: a case series of 40 consecutive patients. *Obes Surg.* 2000;10:514-524.
 113. Gumbs AA, Gagner M, Dakin G, Pomp A. Sleeve gastrectomy for morbid obesity. *Obes Surg.* 2007;17:962-969.
 114. Clinical Issues Committee of the American Society for Metabolic and Bariatric Surgery. Updated position statement on sleeve gastrectomy as a bariatric procedure. *Surg Obes Relat Dis.* 2010;6:1-5.
 115. Almqvist G, Crookes PF, Anthonie GJ. Longitudinal gastrectomy as a treatment for the high-risk super-obese patient. *Obes Surg.* 2004;14:492-497.
 116. Boza C, Viscido G, Salinas J, et al. Laparoscopic sleeve gastrectomy in obese adolescents: results in 51 patients. *Surg Obes Rel Dis.* 2012;8:133-139.
 117. Ramirez A, Roy M, Hidalgo JE, et al. Outcomes of bariatric surgery in patients > 70 years old. *Surg Obes Relat Dis.* 2012;8:458-462.
 118. Parikh M, Issa R, McCrillis A, et al. Surgical strategies that may decrease leak after laparoscopic sleeve gastrectomy: a systematic review and meta-analysis of 9991 cases. *Ann Surg.* 2013;257:231-237.
 119. Rawlins L, Rawlins MP, Brown CC, Schumacher DL. Sleeve gastrectomy: 5-year outcomes of a single institution. *Surg Obes Relat Dis.* 2013;9:21-25.
 120. Rosenthal R, International Sleeve Gastrectomy Expert Panel, Diaz AA, et al. International Sleeve Gastrectomy Expert Panel Consensus Statement: best practice guidelines based on experience of > 12,000 cases. *Surg Obes Relat Dis.* 2012;8:8-19.
 121. Damms-Machado A, Friedrich A, Kramer KM, et al. Pre- and postoperative nutritional deficiencies in obese patients undergoing laparoscopic sleeve gastrectomy. *Obes Surg.* 2012;22:881-889.
 122. Cottam D, Qureshi FG, Mattar SG, et al. Laparoscopic sleeve gastrectomy as an initial weight-loss procedure for high-risk patients with morbid obesity. *Surg Endosc.* 2006;20:859-863.
 123. Baltasar A, Serra C, Perez N, et al. Laparoscopic sleeve gastrectomy: a multi-purpose bariatric operation. *Obes Surg.* 2005;15:1124-1128.
 124. Lee CM, Cirangle PT, Jossart GH. Laparoscopic vertical sleeve gastrectomy for morbid obesity: a report of a five-year experience with 750 patients. Presented at 49th Annual Meeting of the Society for Surgery of the Alimentary Tract, San Diego, CA, May 19, 2008.
 125. Brethauer SA, Hammel JP, Schauer PR. Systematic review of sleeve gastrectomy as staging and primary bariatric procedure. *Surg Obes Relat Dis.* 2009;5:469-475.
 126. Eid GM, Brethauer S, Mattar SG, Titchner RL, Gourash W, Schauer PR. Laparoscopic sleeve gastrectomy for super obese patients: forty-eight percent excess weight loss after 6 to 8 years with 93% follow-up. *Ann Surg.* 2012;256:262-265.
 127. Himpens J, Dapri G, Cadiere GB. A prospective randomized study between laparoscopic gastric banding and laparoscopic isolated sleeve gastrectomy: results after 1 and 3 years. *Obes Surg.* 2006;16:1450-1456.
 128. Karamanakos SN, Vagenas K, Kalfarentzos F, Alexandrides TK. Weight loss, appetite suppression, and changes in fasting and postprandial ghrelin and peptide-YY levels after Roux-en-Y gastric bypass and sleeve gastrectomy: a prospective, double blind study. *Ann Surg.* 2008;247:401-407.
 129. Choi YY, Bae J, Hur KY, et al. Reinforcing the staple line during laparoscopic sleeve gastrectomy: does it have advantages? A meta-analysis. *Obes Surg.* 2012;22:1206-1213.
 130. Albanopoulos K, Alevizos L, Flessas J, et al. Reinforcing the staple line during laparoscopic sleeve gastrectomy: prospective randomized clinical study comparing two different techniques. Preliminary results. *Obes Surg.* 2012;22:42-46.
 131. Parikh A, Alley JB, Peterson RM, et al. Management options for symptomatic stenosis after laparoscopic vertical sleeve gastrectomy in the morbidly obese. *Surg Endosc.* 2012;26:738-746.
 132. Martinez T. Ed Mason at Large—July 2012. *Bariatric Times.* July 2012.
 133. Falken Y, Hellstrom PM, Holst JJ, et al. Changes in glucose homeostasis after Roux-en-Y gastric bypass surgery at day three, two months, and one year after surgery: role of gut peptides. *J Clin Endocrinol Metab.* 2011;96:2227-2235.
 134. Whitaker RC, Wright JA, Pepe MS, et al. Predicting obesity in young adulthood from childhood and parental obesity. *N Engl J Med.* 1997;337:869-873.
 135. Sugerman HJ, Sugerman EL, DeMaria EJ, et al. Bariatric surgery for severely obese adolescents. *J Gastrointest Surg.* 2003;7:102-107.
 136. Capella JF, Capella RF. Bariatric surgery in adolescence. Is this the best age to operate? *Obes Surg.* 2003;13:826-832.
 137. Abu-Abeid S, Gavert N, Klausner JM, Szold A. Bariatric surgery in adolescence. *J Pediatr Surg.* 2003;38:1379-1382.
 138. Treadwell JR, Sun F, Schoelles K. Systematic review and meta-analysis of bariatric surgery for pediatric obesity. *Ann Surg.* 2008;248:763-776.
 139. Michalsky M, Reichard K, Inge T, Pratt J, Lenders C, American Society for Metabolic and Bariatric Surgery. ASMBS pediatric committee best practice guidelines. *Surg Obes Relat Dis.* 2012;8:1-7.
 140. Rossner S. Obesity in the elderly—a future matter of concern? *Obes Rev.* 2001;2:183-188.
 141. Nehoda H, Hourmont K, Sauper T, et al. Laparoscopic gastric banding in older patients. *Arch Surg.* 2001;136:1171-1176.
 142. Ramirez A, Roy M, Hidalgo JE, Szomstein S, Rosenthal RJ. Outcomes of bariatric surgery in patients >70 years old. *Surg Obes Relat Dis.* 2012;8:458-462.
 143. Soto FC, Gari V, de la Garza JR, Szomstein S, Rosenthal RJ. Sleeve gastrectomy in the elderly: a safe and effective procedure with minimal morbidity and mortality. *Obes Surg.* 2013;23:1445-1449.
 144. Bongain A, Isnard V, Gillet JY. Obesity in obstetrics and gynecology. *Eur J Obstet Gynecol Reprod Biol.* 1998;77:217-228.
 145. Wittgrove AC, Jester L, Wittgrove P, Clark GW. Pregnancy following gastric bypass for morbid obesity. *Obes Surg.* 1998;8:461-465.
 146. Beard JH, Bell RL, Duffy AJ. Reproductive considerations and pregnancy after bariatric surgery: current evidence and recommendations. *Obes Surg.* 2008;18:1023-1027.
 147. Dixon JB, Dixon ME, O'Brien PE. Pregnancy after Lap-Band surgery: management of the band to achieve healthy weight outcomes. *Obes Surg.* 2001;11:59-65.
 148. Deitel M, Stone E, Kassam HA, et al. Gynecologic-obstetric changes after loss of massive excess weight following bariatric surgery. *J Am Coll Nutr.* 1988;7:147-153.
 149. Gonzalez CA, Hernandez MI, Mendoza R, et al. Polycystic ovarian disease: clinical and biochemical expression *J Gynecol Obstet Mex.* 2003;71:253.
 150. Eid GM, Cottam DR, Schauer PR, et al. Effective treatment of polycystic ovarian syndrome with Roux-en-Y gastric bypass. *SOARD.* 2005;1:77-80.
 151. Jamal M, Gunay Y, Capper A, Eid A, Heitshusen D, Samuel I. Roux-en-Y gastric bypass ameliorates polycystic ovary syndrome and dramatically improves conception rates: a 9-year analysis. *Surg Obes Relat Dis.* 2012;8:440-444.
 152. Subak LL, Johnson C, Whitcomb E, et al. Does weight loss improve incontinence in moderately obese women? *Int Urogynecol J Pelvic Floor Dysfunct.* 2002;13:40-43.

153. Romero Talamas H, Aminian A, Batayyah E, et al. Comprehensive evaluation of the effect of bariatric surgery on pelvic floor disorders. Presented at ASMBS 2013.
154. Rubino F, Kaplan L, Schauer PR, Cummings DE. The Diabetes Surgery Summit consensus conference: recommendations for the evaluation and use of gastrointestinal surgery to treat type 2 diabetes mellitus. *Ann Surg.* 2010;251:399-405.
155. Hickey MS, Pories WJ, MacDonald KG Jr, et al. A new paradigm for type 2 diabetes mellitus. Could it be a disease of the foregut? *Ann Surg.* 1998;227:637-643.
156. MacDonald KG Jr, Long SD, Swanson MS, et al. The gastric bypass operation reduces the progression and mortality of non-insulin-dependent diabetes mellitus. *J Gastrointest Surg.* 1997;1:213-220.
157. Schauer PR, Burguera B, Ikramuddin S, et al. Effect of laparoscopic Roux-en-Y gastric bypass on type 2 diabetes mellitus. *Ann Surg.* 2003;238:467-485.
158. Sjostrom L, Narbro K, Sjostrom CD, et al. Effects of bariatric surgery on mortality in Swedish obese subjects. *N Engl J Med.* 2007;357:741-752.
159. Adams TD, Gress RE, Smith SC, et al. Long-term mortality after gastric bypass surgery. *N Engl J Med.* 2007;357:753-761.
160. Rubino F, Marescaux J. Effect of duodenal-jejunal exclusion in a nonobese animal model of type 2 diabetes: a new perspective for an old disease. *Ann Surg.* 2004;239:1-11.
161. Tarnoff M, Rodriguez L, Escalona A, et al. Open label, prospective, randomized controlled trial of an endoscopic duodenal-jejunal bypass sleeve versus low calorie diet for pre-operative weight loss in bariatric surgery. *Surg Endosc.* 2009;23:650-656.
162. Cohen RV, Schiavon CA, Pinheiro JS, et al. Duodenal-jejunal bypass for treatment of type 2 diabetes in patients with body mass index of 22-34 kg/m²: a report of two cases. *Surg Obes Relat Dis.* 2007;3:195-197.
163. Cummings DE, Flum DR. Gastrointestinal surgery as a treatment for diabetes. *JAMA.* 2008;299:341-343.
164. Dixon JB, Pories WJ, O'Brien PE, et al. Surgery as an effective early intervention for diabetes: why the reluctance? *Diabetes Care.* 2005;28:472-474.
165. Schauer PR, Kashyap SR, Wolski K, et al. Bariatric surgery versus intensive medical therapy in obese patients with diabetes. *N Engl J Med.* 2012;366:1567-1576.
166. Mingrone G, Panunzi S, De Gaetano A, et al. Bariatric surgery versus conventional medical therapy for type 2 diabetes. *N Engl J Med.* 2012;366:1577-1585.
167. Ikramuddin S, Korner J, Lee W, et al. Roux-en-Y gastric bypass vs intensive medical management for the control of type 2 diabetes, hypertension, and hyperlipidemia: the Diabetes Surgery Study randomized clinical trial. *JAMA.* 2013;309:2240-2249.
168. American Diabetes Association. Standards of medical care in diabetes—2009. *Diabetes Care.* 2009;32(Suppl 1):S13-S61.
169. Dixon JB, Zimmet P, Alberti KG, et al. Bariatric surgery: an IDF statement for obese type 2 diabetes. *Surg Obes Relat Dis.* 2011;7:433-447.
170. Frohlich ED. Obesity and hypertension. Hemodynamic aspects. *Ann Epidemiol.* 1991;1:287-293.
171. Lee W-J, Huang, M-T, Wang W, et al. Effects of obesity surgery on the metabolic syndrome. *Arch Surg.* 2004;139:1088-1092.
172. Lauer MS, Anderson KM, Levy D. Separate and joint influences of obesity and mild hypertension on left ventricular mass and geometry: the Framingham Heart Study. *J Am Coll Cardiol.* 1992;19:130-134.
173. Vest AR, Heneghan HM, Agarwal S, Schauer PR, Young JB. Bariatric surgery and cardiovascular outcomes: a systematic review. *Heart.* 2012;98:1763-1777.
174. Vest AR, Heneghan HM, Schauer PR, Young JB. Surgical management of obesity and the relationship to cardiovascular disease. *Circulation.* 2013;127:945-959.
175. Frezza EE, Ikramuddin S, Gourash W, et al. Symptomatic improvement in gastroesophageal reflux disease (GERD) following laparoscopic Roux-en-Y gastric bypass. *Surg Endosc.* 2002;16:1027-1031.
176. Zhang N, Maffei A, Cerabona T, Pahuja A, Omana J, Kaul A. Reduction in obesity-related comorbidities: is gastric bypass better than sleeve gastrectomy? *Surg Endosc.* 2013;27:1273-1280.
177. Zhang N, Maffei A, Cerabona T, Pahuja A, Omana J, Kaul A. Gastroesophageal reflux after sleeve gastrectomy in morbidly obese patients. *Surg Obes Relat Dis.* 2011;7:709-713.
178. Haines KL, Nelson LG, Gonzalez R, et al. Objective evidence that bariatric surgery improves obesity-related obstructive sleep apnea. *Surgery.* 2007;141:354-358.
179. Sarkhosh Switzer NJ, El-Hadi M, Birch DW, Shi X, Karmali S. The impact of bariatric surgery on obstructive sleep apnea: a systematic review. *Obes Surg.* 2013;23:414-423.
180. Dixon JB, Schachter LM, O'Brien PE, et al. Surgical vs. conventional therapy for weight loss treatment of obstructive sleep apnea: a randomized controlled trial. *JAMA.* 2012;308:1142-1149.
181. Dixon AE, Pratley RE, Forgione PM, et al. Effects of obesity and bariatric surgery on airway hyperresponsiveness, asthma control and inflammation. *J Allergy Clin Immunol.* 2011;128:508-515.
182. Boulet LP, Turcotte H, Martin J, Poirier P. Effect of bariatric surgery on airway response and lung function in obese subjects with asthma. *Respir Med.* 2012;106:651-660.
183. Beymer C, Kowdley KV, Larson A, et al. Prevalence and predictors of asymptomatic liver disease in patients undergoing gastric bypass surgery. *Arch Surg.* 2003;138:1240-1244.
184. Mattar SG, Velcu LM, Rebinovitz M, et al. Surgically-induced weight loss significantly improves nonalcoholic fatty liver disease and the metabolic syndrome. *Ann Surg.* 2005;242:610-620.
185. Rabl C, Campos G. The impact of bariatric surgery on nonalcoholic steatohepatitis (review). *Semin Liver Dis.* 2012;32:80-91.
186. Mathurin P, Hollebecque A, Arnalsteen L, et al. Prospective study of the long-term effects of bariatric surgery in patients without advanced disease. *Gastroenterology.* 2009;137:532-540.
187. Iossi MF, Konstantakos EK, Teel DD II, et al. Musculoskeletal function following bariatric surgery. *Obesity.* 2013;21:1104-1110.
188. Vincent HK, Heywood K, Connelly J, Hurley RW. Weight loss and obesity in the treatment and prevention of osteoarthritis. *PM R.* 2012;4(5 Suppl):S59-S67.
189. Hurwitz DJ. Body contouring surgery in the bariatric surgical patient. In: *Operative Techniques in Plastic Surgery and Reconstructive Surgery.* New York: Elsevier; 2002:87
190. Hurwitz DJ. Single-staged total body lift after massive weight loss. *Ann Plast Surg.* 2004;52:435-441.
191. Balagué N, Combescure C, Huber O, Pittet-Cuénod B, Modarressi A. Plastic surgery improves long-term weight control after bariatric surgery. *Plast Reconstr Surg.* 2013;132:826-833.
192. Shikora SA. Implantable gastric stimulation for weight loss. *J Gastrointest Surg.* 2004;8:408-412.
193. Miller K, Hoeller E, Aigner F. The implantable gastric stimulator for obesity: an update of the European Experience in the LOSS (Laparoscopic Obesity Stimulation Survey) Study. *Treat Endocrinol.* 2006;5:53-58.
194. Toouli J, Kow L, Kulseng B, et al. Vagal blocking for obesity control (VBLOCTM): ongoing comparison of weight loss with two generations of an active, implantable medical device. Presented at 25th Annual Meeting of the ASMBS, Washington, DC, June 19, 2008.
195. Thompson CC, Slattery J, Bundga ME, Lautz DB. Peroral endoscopic reduction of dilated gastrojejunal anastomosis after Roux-en-Y gastric bypass: a possible new option

- for patients with weight regain. *Surg Endosc.* 2006;20:1744-1748.
196. Garren L. Garren gastric bubble. *Bariatr Surg.* 1985;3:14-15.
197. Genco A, Brui T, Doldi SB, et al. BioEnterics intragastric balloon: the Italian experience with 2515 patients. *Obes Surg.* 2005;15:1161-1164.
198. Schouten R, Rijs CS, Bouvy ND, et al. A multicenter, randomized efficacy study of the EndoBarrier Gastrointestinal Liner for presurgical weight loss prior to bariatric surgery. *Ann Surg.* 2010;251:236-243.
199. Familiari P, Costamagna G, Bléro D, et al. Transoral gastroplasty for morbid obesity: a multicenter trial with a 1-year outcome. *Gastrointest Endosc.* 2011;74:1248-1258.
200. Stimac D, Majanovic SK. The position of endoscopic procedures in the treatment of obesity. *Curr Clin Pharmacol.* 2013;8:238-246.
201. Cohen R, Caravatto PP, Correa JL, et al. Glycemic control after stomach-sparing duodenal-jejunal bypass surgery in diabetic patients with low body mass index. *Surg Obes Relat Dis.* 2012;8:375-380.
202. Gaitonde S, Kohli R, Seeley R. The role of the gut hormone GLP-1 in the metabolic improvements caused by ileal transposition. *J Surg Res.* 2012;178:33-39.
203. Niazi M, Maleki AR, Talebpour M. Short-term outcomes of laparoscopic gastric plication in morbidly obese patients: importance of postoperative follow-up. *Obes Surg.* 2013;23:87-92.
204. WHO. Appropriate body mass index for Asian populations and its implications for policy and intervention strategies. *Lancet* 2004; 363: 157-163.
205. WHO. Obesity: preventing and managing the global epidemic. Report of a WHO consultation. *World Health Organ Tech Rep Ser* 2000; 894: 1-253.

28 chapter

Small Intestine

Ali Tavakkoli, Stanley W. Ashley, and
Michael J. Zinner

Introduction	1137	Therapy / 1152	Outcomes / 1163	
Gross Anatomy	1137	Crohn's Disease	Prevention / 1163	
Histology	1138	Pathophysiology / 1153	Meckel's Diverticulum	1163
Development	1139	Clinical Presentation / 1154	Pathophysiology / 1164	
Physiology	1140	Diagnosis / 1154	Clinical Presentation / 1164	
Digestion and Absorption / 1140		Therapy / 1155	Diagnosis / 1164	
Barrier and Immune Function / 1143		Outcomes / 1157	Therapy / 1164	
Motility / 1144		Intestinal Fistulas	1165	
Endocrine Function / 1145		Pathophysiology / 1158	Pathophysiology / 1165	
Intestinal Adaptation / 1145		Clinical Presentation / 1158	Clinical Presentation / 1166	
Small Bowel Obstruction	1146	Diagnosis / 1158	Diagnosis / 1167	
Epidemiology / 1146		Therapy / 1158	Therapy / 1167	
Pathophysiology / 1147		Outcomes / 1158	Mesenteric Ischemia	1167
Clinical Presentation / 1147		Small Bowel Neoplasms	1159	
Diagnosis / 1147		Pathophysiology / 1159	Miscellaneous Conditions	1167
Therapy / 1149		Clinical Presentation / 1160	Obscure Gastrointestinal Bleeding / 1167	
Outcomes / 1151		Diagnosis / 1161	Small Bowel Perforation / 1168	
Prevention / 1151		Therapy / 1161	Chylous Ascites / 1169	
Ileus and Other Disorders of Intestinal Motility	1151	Outcomes / 1162	Intussusception / 1170	
Pathophysiology / 1151		Radiation Enteritis	Pneumatosis Intestinalis / 1170	
Clinical Presentation / 1152		Pathophysiology / 1162	Short Bowel Syndrome	1171
Diagnosis / 1152		Clinical Presentation / 1162	Pathophysiology / 1171	
		Diagnosis / 1162	Therapy / 1171	
		Therapy / 1163	Outcomes / 1172	

INTRODUCTION

The small intestine is the *raison d'être* of the gastrointestinal tract as it is the principle site of nutrient digestion and absorption.¹ The small intestine is also the body's largest reservoir of immunologically active and hormone-producing cells and hence can be conceptualized as the largest organ of the immune and endocrine systems, respectively. It achieves this diversity of action through unique anatomic features, which provide it with a massive surface area, a diversity of cell types, and a complex neural network to coordinate these functions.

Despite its size and importance, diseases of the small intestine are relatively infrequent and present diagnostic and therapeutic challenges. Treatments for common conditions such as postoperative ileus are hardly more effective than those used at the dawn of the last century. Mortality rates associated with acute mesenteric ischemia have not improved during the past 50 years.

Despite introduction of novel imaging techniques such as capsule endoscopy and double balloon endoscopy, diagnostic tests lack sufficient predictive power to definitively guide clinical decision making for individual patients. Furthermore, few high-quality, controlled data on the efficacy of surgical therapies for small bowel diseases are available.

Therefore, sound clinical judgment and a thorough understanding of anatomy, physiology, and pathophysiology remain essential to the care of patients with intestinal disorders.

GROSS ANATOMY

The small intestine is a tubular structure that extends from the pylorus to the cecum. The estimated length of this structure varies depending on whether radiologic, surgical, or autopsy measurements are made. In the living, it is thought to measure 4 to 6 m.² The small intestine consists of three segments lying in series: the duodenum, the jejunum, and the ileum.

Key Points

- ▶ The small intestine performs a diverse set of functions.
- ▶ Small bowel obstruction is one of the most common surgical diagnoses.
- ▶ Most cases of small bowel obstruction are due to adhesions from previous surgery and resolve with conservative management.
- ▶ Tumors and malignancies of the small bowel are rare and difficult to diagnose.
- ▶ Small bowel may be the source of gastrointestinal bleeding, which may be difficult to diagnose.
- ▶ If following surgical resection, less than 200 cm of small bowel remains, patients are at risk of developing short bowel syndrome.

The duodenum, the most proximal segment, lies in the retroperitoneum immediately adjacent to the head and inferior border of the body of the pancreas. The duodenum is demarcated from the stomach by the pylorus and from the jejunum by the ligament of Treitz. The jejunum and ileum lie within the peritoneal cavity and are tethered to the retroperitoneum by a broad-based mesentery. No distinct anatomic landmark demarcates the jejunum from the ileum; the proximal 40% of the jejunoileal segment is arbitrarily defined as the jejunum and the distal 60% as the ileum. The ileum is demarcated from the cecum by the ileocecal valve.

The small intestine contains internal mucosal folds known as *plicae circulares* or *valvulae conniventes* that are visible upon gross inspection. These folds are also visible radiographically and help in the distinction between small intestine and colon, which does not contain them, on abdominal radiographs. These folds are more prominent in the proximal intestine than in the distal small intestine. Other features evident on gross inspection that are more characteristic of the proximal than distal small intestine include larger circumference, thicker wall, less fatty mesentery, and longer vasa recta (Fig. 28-1). Gross examination of the small-intestinal mucosa also reveals aggregates of lymphoid follicles. Those follicles, located in the ileum, are the most prominent and are designated *Peyer's patches*.

Most of the duodenum derives its arterial blood from branches of both the celiac and the superior mesenteric arteries. The distal duodenum, the jejunum, and the ileum derive their arterial blood from the superior mesenteric artery. Their venous drainage occurs via the superior mesenteric vein. Lymph drainage occurs through lymphatic vessels coursing parallel to corresponding arteries. This lymph drains through mesenteric lymph nodes to the cisterna chyli, then through the thoracic duct, and ultimately into the left subclavian vein. The parasympathetic and sympathetic innervation of the small intestine is derived from the vagus and splanchnic nerves, respectively.

HISTOLOGY

The wall of the small intestine consists of four distinct layers: mucosa, submucosa, muscularis propria, and serosa (Fig. 28-2).

The mucosa is the innermost layer, and it consists of three layers: epithelium, lamina propria, and muscularis mucosae. The epithelium is exposed to the intestinal lumen and is the surface through which absorption from and secretion into the lumen occurs. The lamina propria is located immediately external to the epithelium and consists of connective tissue and a heterogeneous population of cells. It is demarcated from the more external submucosa by the muscularis mucosae, a thin sheet of smooth muscle cells.

The mucosa is organized into villi and crypts (crypts of Lieberkuhn). *Villi* are finger-like projections of epithelium and underlying lamina propria that contain blood and lymphatic (lacteals) vessels that extend into the intestinal lumen. Intestinal, epithelial cellular proliferation is confined to the *crypts*, each of which carries 250 to 300 cells. All epithelial cells in each crypt are derived from an unknown number of multipotent stem cells located at or near the crypt's base. Our understanding of these crypt cells is rapidly expanding. It appears that there are two subgroups of intestinal stem cells, with specific cell markers. Bmi1-positive cells are usually quiescent, radiation-resistant cells that are induced by injury, whereas LGR5-positive cells facilitate homeostatic vs. injury-induced regeneration and are radiation sensitive.³

The stem cells can differentiate along one of four pathways that ultimately yield *enterocytes* and *goblet*, *enteroendocrine*, and *Paneth* cells. With the exception of Paneth cells, these lineages complete their terminal differentiation during an upward migration from each crypt to adjacent villi. The journey from the crypt to the villus tip is completed in 2 to 5 days and terminates with cells being removed by apoptosis and/or exfoliation. Thus, the small-intestinal epithelium undergoes

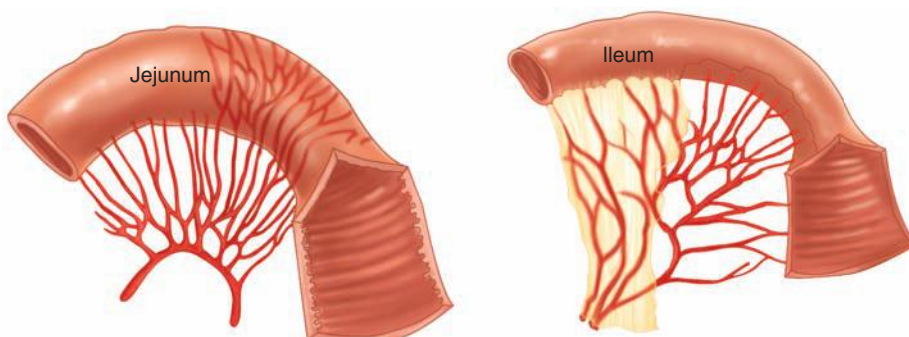


Figure 28-1. Gross features of jejunum contrasted with those of ileum. Relative to the ileum, the jejunum has a larger diameter, a thicker wall, more prominent plicae circulares, a less fatty mesentery, and longer vasa recta.

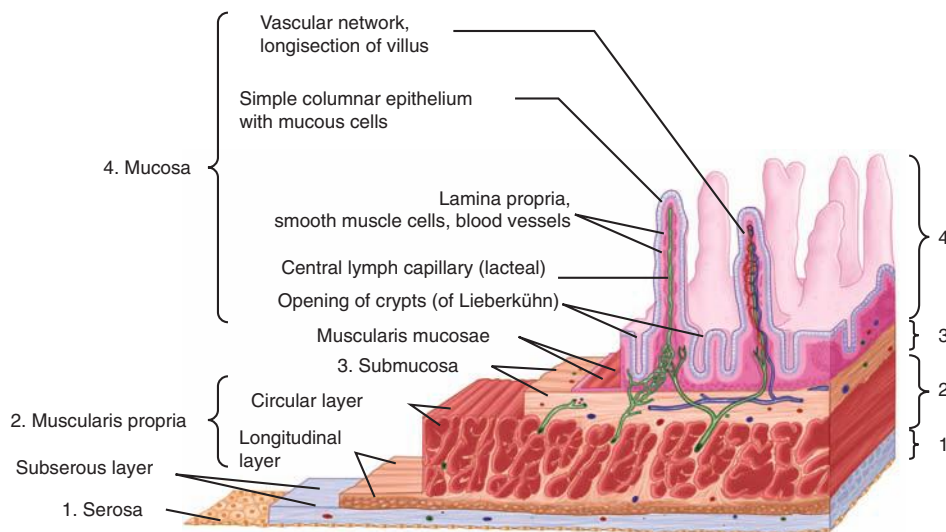


Figure 28-2. Layers of wall of the small intestine. The individual layers and their prominent features are represented schematically.

continuous renewal, making it one of the body's most dynamic tissues. The high cellular turnover rate contributes to mucosal resiliency but also makes the intestine uniquely susceptible to certain forms of injury such as that induced by radiation and chemotherapy.

Enterocytes are the predominant absorptive cell of the intestinal epithelium. Their apical (lumen-facing) cell membrane contains specialized digestive enzymes, transporter mechanisms, and microvilli that are estimated to increase the absorptive surface area of the small intestine by up to 40-fold. *Goblet cells* produce mucin believed to play a role in mucosal defense against pathogens. *Enteroendocrine cells* are characterized by secretory granules containing regulatory agents and are discussed in greater detail later in the Endocrine Function section. *Paneth cells* are located at the base of the crypt and contain secretory granules containing growth factors, digestive enzymes, and antimicrobial peptides. In addition, the intestinal epithelium contains M cells and intraepithelial lymphocytes. These two components of the immune system are discussed later.

The submucosa consists of dense connective tissue and a heterogeneous population of cells, including leukocytes and fibroblasts. The submucosa also contains an extensive network of vascular and lymphatic vessels, nerve fibers, and ganglion cells of the submucosal (Meissner's) plexus.

The muscularis propria consists of an outer, longitudinally oriented layer and an inner, circularly oriented layer of smooth muscle fibers. Located at the interface between these two layers are ganglion cells of the myenteric (Auerbach's) plexus.

The serosa consists of a single layer of mesothelial cells and is a component of the visceral peritoneum.

DEVELOPMENT

The first recognizable precursor of the small intestine is the embryonic gut tube, formed from the endoderm during the fourth week of gestation. The gut tube is divided into foregut, midgut, and hindgut. Other than duodenum, which is a foregut structure, the rest of the small intestine is derived from the midgut. The gut tube initially communicates with the yolk sac; however, the communication between these two structures narrows by the sixth week to form the vitelline duct. The yolk sac and vitelline duct usually undergo obliteration by the end

of gestation. Incomplete obliteration of the vitelline duct results in the spectrum of defects associated with Meckel's diverticulum.

Also during the fourth week of gestation, the mesoderm of the embryo splits. The portion of mesoderm that adheres to the endoderm forms the visceral peritoneum, while the portion that adheres to the ectoderm forms the parietal peritoneum. This mesodermal division results in the formation of a coelomic cavity that is the precursor of the peritoneal cavity.

At approximately the fifth week of gestation, the bowel begins to lengthen to an extent greater than that which can be accommodated by the developing abdominal cavity, resulting in the extracoelomic herniation of the developing bowel. The bowel continues to lengthen during the subsequent weeks and is retracted back into the abdominal cavity during the tenth week of gestation. Subsequently, the duodenum becomes a retroperitoneal structure. Coincident with extrusion and retraction, the bowel undergoes a 270° counterclockwise rotation relative to the posterior abdominal wall. This rotation accounts for the usual locations of the cecum in the right lower quadrant and the duodenojejunal junction to the left of midline (Fig. 28-3).

The celiac and superior mesenteric arteries and veins are derived from the vitelline vascular system, which in turn is derived from blood vessels formed within the splanchnopleuric mesoderm during the third week of gestation. Neurons found in the small intestine are derived from neural crest cells that begin to migrate away from the neural tube during the third week of gestation. These neural crest cells enter the mesenchyme of the primitive foregut and subsequently migrate to the remainder of the bowel.

During the sixth week of gestation, the lumen of the developing bowel becomes obliterated as bowel epithelial proliferation accelerates. Vacuoles form within the bowel substance during the subsequent weeks and coalesce to form the intestinal lumen by the ninth week of gestation. Errors in this recanalization may account for defects such as intestinal webs and stenoses. Most intestinal atresias, however, are believed to be related to ischemic episodes occurring after organogenesis has been completed rather than to errors in recanalization.

During the ninth week of gestation, the intestinal epithelium develops intestine-specific features such as crypt-villus architecture. Organogenesis is complete by approximately the twelfth week of gestation.

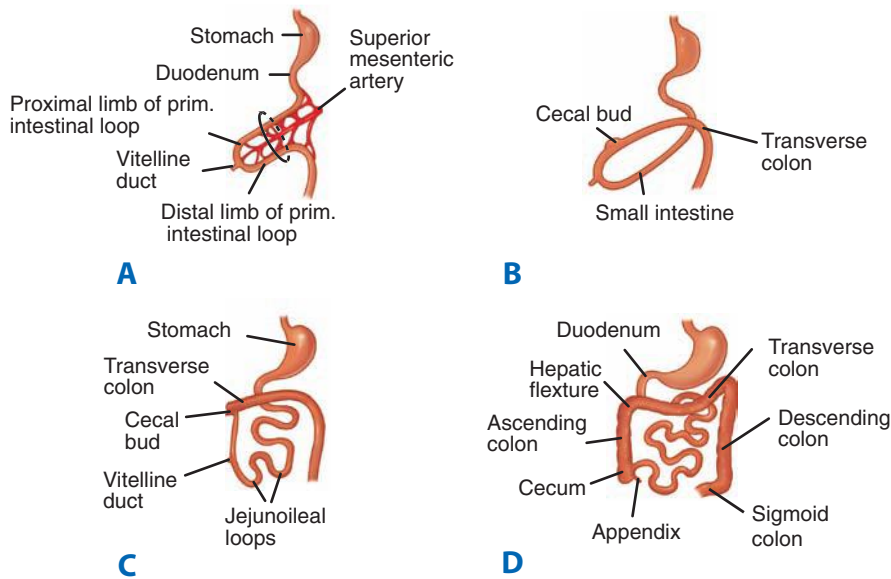


Figure 28-3. Developmental rotation of the intestine. **A.** During the fifth week of gestation, the developing intestine herniates out of the coelomic cavity and begins to undergo a counterclockwise rotation about the axis of the superior mesenteric artery. **B** and **C.** Intestinal rotation continues, as the developing transverse colon passes anterior to the developing duodenum. **D.** Final positions of the small intestine and colon resulting from a 270° counterclockwise rotation of the developing intestine and its return into the abdominal cavity.

PHYSIOLOGY

Digestion and Absorption

The intestinal epithelium is the interface through which absorption and secretion occur. It has features characteristic of absorptive epithelia in general including epithelial cells with cellular membranes possessing distinct apical (luminal) and basolateral (serosal) domains demarcated by intercellular tight junctions and an asymmetric distribution of transmembrane transporter mechanisms that promotes vectorial transport of solutes across the epithelium.

Solutes can traverse the epithelium by active or passive transport. Passive transport of solutes occurs through diffusion or convection and is driven by existing electrochemical gradients. *Active transport* is the energy-dependent net transfer of solutes in the absence of or against an electrochemical gradient.

Active transport occurs through transcellular pathways (through the cell), whereas passive transport can occur through either transcellular or paracellular pathways (between cells through the tight junctions). Transcellular transport requires solutes to traverse the cell membranes through specialized membrane proteins, such as channels, carriers, and pumps. The molecular characterization of transporter proteins is evolving rapidly, with different transporter families, each containing many individual genes encoding specific transporters, now identified. Similarly, understanding of the paracellular pathway is evolving. In contrast to what was once believed, it is becoming apparent that paracellular permeability is substrate-specific, dynamic, and subject to regulation by specific tight junction proteins.

Water and Electrolyte Absorption and Secretion. Eight to nine L of fluid enters the small intestine daily. Most of this volume consists of salivary, gastric, biliary, pancreatic, and intestinal secretions. Under normal conditions, the small intestine absorbs over 80% of this fluid, leaving approximately 1.5 L that enters the colon (Fig. 28-4). Small-intestinal absorption and secretion are tightly regulated; derangements in water and electrolyte homeostasis characteristic of many of the disorders discussed in this chapter play an important role in contributing to their associated clinical features.

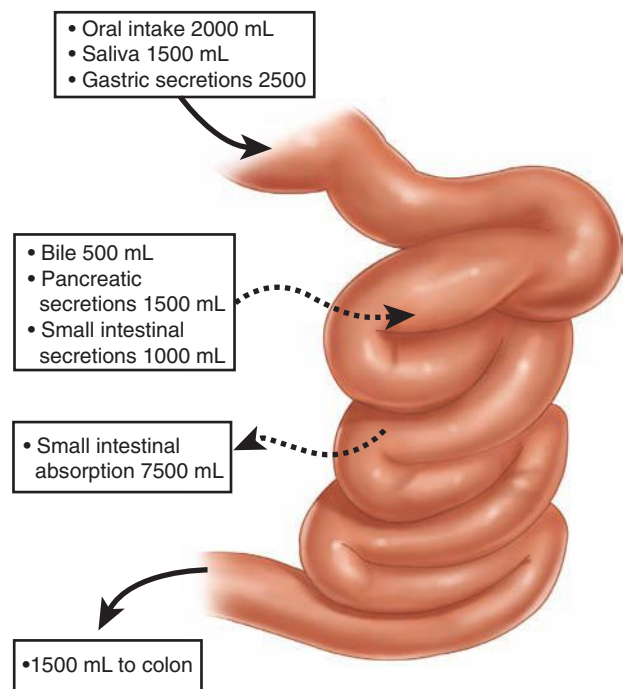


Figure 28-4. Small intestinal fluid fluxes. Typical quantities (in volume per day) of fluid entering and leaving the small intestinal lumen in a healthy adult are shown.

Gut epithelia have two pathways for water transport: (a) the paracellular route, which involves transport through the spaces between cells, and (b) the transcellular route, through apical and basolateral cell membranes. Although most water absorption was thought to occur through the paracellular pathway, it is now well documented that most intestinal water transport occurs through the transcellular pathway.⁴ The specific transport mechanisms mediating this transcellular transport are not completely characterized and may involve passive diffusion through the phospholipid bilayer, cotransport with other ions and nutrients, or diffusion through water channels called aquaporins. Many different types of aquaporins have been identified;

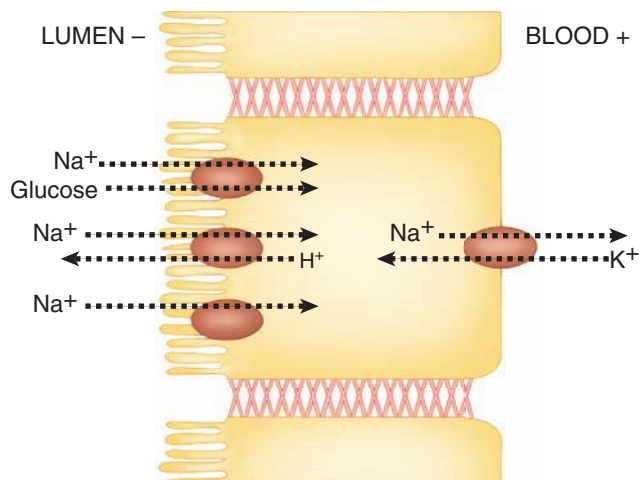


Figure 28-5. Model of transepithelial sodium (Na^+) absorption. Na^+ traverses the apical membrane of enterocytes through a variety of mechanisms, including nutrient-coupled Na^+ transport, Na^+/H^+ exchange, and Na^+ channels. Activity of the Na^+/K^+ ATPase located on the basolateral membrane generates the electrochemical gradient that provides the driving force for Na^+ absorption.

however, their contribution to overall intestinal water absorption appears to be relatively minor.⁵

The prevailing model for intestinal epithelial Na^+ absorption is shown in Fig. 28-5. Activity of the Na^+/K^+ ATPase enzyme, which is located in the basolateral membrane and exchanges three intracellular Na^+ for every two extracellular K^+ in an energy-dependent process, generates the electrochemical gradient that drives the transport of Na^+ from the intestinal lumen into the cytoplasm of enterocytes. Na^+ ions traverse the apical membrane through several distinct transporter mechanisms including nutrient-coupled sodium transport (e.g., sodium glucose cotransporter-1 [SGLT1]), sodium channels, and sodium-hydrogen exchangers (NHEs). Absorbed Na^+ ions are then extruded from enterocytes through the Na^+/K^+ ATPase located in the basolateral membrane. Similar mechanistic models that account for the transport of other common ions such as K^+ and HCO_3^- also exist.

Substantial heterogeneity, with respect to both crypt-villus and craniocaudal axes, exists for intestinal epithelial transport mechanisms. This spatial distribution pattern is consistent with a model in which absorptive function resides primarily in the villus and secretory function in the crypt.

Intestinal absorption and secretion are subject to modulation under physiologic and pathophysiologic conditions by a wide array of hormonal, neural, and immune regulatory mediators (Table 28-1).

Carbohydrate Digestion and Absorption. Approximately 45% of energy consumption in the average Western diet consists of carbohydrates, approximately one half of which is in the form of starch (linear or branched polymers of glucose) derived from cereals and plants. Other major sources of dietary carbohydrates include sugars derived from milk (lactose), fruits and vegetables (fructose, glucose, and sucrose), or purified from sugar cane or beets (sucrose). Processed foods contain a variety of sugars including fructose, oligosaccharides, and polysaccharides. Glycogen derived from meat contributes only a small fraction of dietary carbohydrate.

Table 28-1

Regulation of intestinal absorption and secretion

Agents that stimulate absorption or inhibit secretion of water

- Aldosterone
- Glucocorticoids
- Angiotensin
- Norepinephrine
- Epinephrine
- Dopamine
- Somatostatin
- Neuropeptide Y
- Peptide YY
- Enkephalin

Agents that stimulate secretion or inhibit absorption of water

- Secretin
- Bradykinin
- Prostaglandins
- Acetylcholine
- Atrial natriuretic factor
- Vasopressin
- Vasoactive intestinal peptide
- Bombesin
- Substance P
- Serotonin
- Neurotensin
- Histamine

Pancreatic amylase is the major enzyme of starch digestion, although salivary amylase initiates the process. The terminal products of amylase-mediated starch digestion are oligosaccharides, maltotriose, maltose, and α -limit dextrans (Fig. 28-6). These products, as well as the major disaccharides in the diet (sucrose and lactose), are unable to undergo absorption in this form. They must first undergo hydrolytic cleavage into their constituent monosaccharides; these hydrolytic reactions are catalyzed by specific brush border membrane hydrolases that are expressed most abundantly in the villi of the duodenum and jejunum. The three major monosaccharides that represent the terminal products of carbohydrate digestion are glucose, galactose, and fructose.

Under physiologic conditions, most of these sugars are absorbed through the epithelium via the transcellular route. Glucose and galactose are transported through the enterocyte brush border membrane via intestinal Na^+ -glucose cotransporter, SGLT1 (Fig. 28-7). Fructose is transported through the brush border membrane by facilitated diffusion via GLUT5 (a member of the facilitative glucose transporter family). All three monosaccharides are extruded through the basolateral membrane by facilitated diffusion using GLUT2 and GLUT5 transporters. Extruded monosaccharides diffuse into venules and ultimately enter the portal venous system.

There is evidence of overexpression of hexose transporters, specifically SGLT1, in disease states such as diabetes.⁶ Several approaches aimed at downregulation of intestinal glucose transporter are being investigated as a novel therapy for disease states such as diabetes and obesity.⁷

Protein Digestion and Absorption. Ten to fifteen percent of energy consumption in the average Western diet consists of proteins. In addition to dietary proteins, approximately one half of the protein load that enters the small intestine is derived from

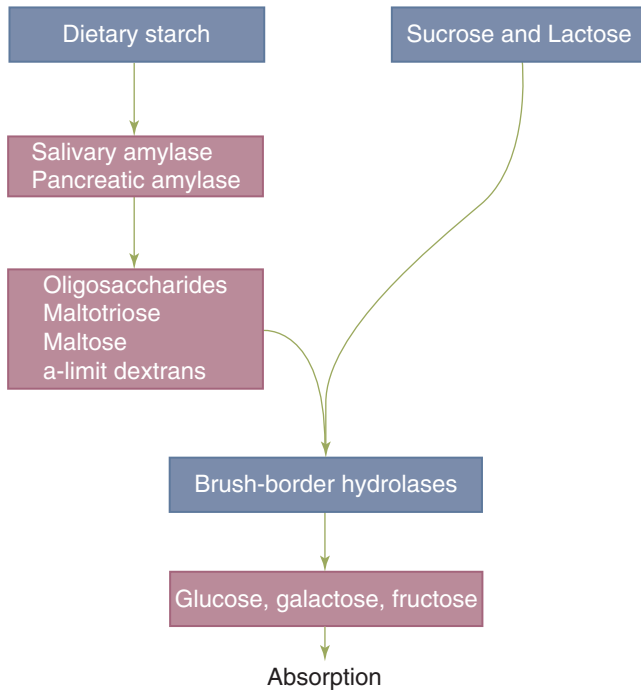


Figure 28-6. Carbohydrate digestion. Dietary carbohydrates, including starch and the disaccharides sucrose and lactose, must undergo hydrolysis into constituent monosaccharides glucose, galactose, and fructose before being absorbed by the intestinal epithelium. These hydrolytic reactions are catalyzed by salivary and pancreatic amylase and by enterocyte brush border hydrolases.

endogenous sources including salivary and gastrointestinal secretions and desquamated intestinal epithelial cells. Protein digestion begins in the stomach with action of pepsins. This is not, however, an essential step, since surgical patients who are achlorhydric or who have lost part or all their stomach are still able to successfully digest proteins. Digestion continues in the duodenum with the actions of a variety of pancreatic peptidases.

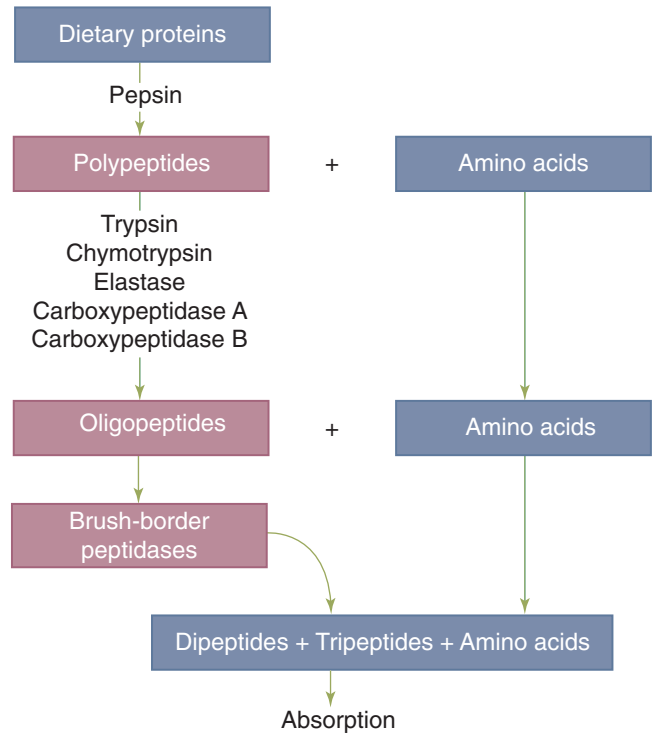


Figure 28-8. Protein digestion. Dietary proteins must undergo hydrolysis into constituent single amino acids and di- and tripeptides before being absorbed by the intestinal epithelium. These hydrolytic reactions are catalyzed by pancreatic peptidases (e.g., trypsin) and by enterocyte brush border peptidases.

These enzymes are secreted as inactive proenzymes. This is in contrast to pancreatic amylase and lipase, which are secreted in their active forms. In response to the presence of bile acids, enterokinase is liberated from the intestinal brush border membrane to catalyze the conversion of trypsinogen to active trypsin; trypsin in turn activates itself and other proteases. The final products of intraluminal protein digestion consist of neutral and basic amino acids and peptides two to six amino acids in length (Fig. 28-8). Additional digestion occurs through the actions of peptidases that exist in the enterocyte brush border and cytoplasm. Epithelial absorption occurs for both single amino acids and di- or tripeptides via specific membrane-bound transporters. Absorbed amino acids and peptides then enter the portal venous circulation.

Of all amino acids, glutamine appears to be a unique, major source of energy for enterocytes. Active glutamine uptake into enterocytes occurs through both apical and basolateral transport mechanisms.

Fat Digestion and Absorption. Approximately 40% of the average Western diet consists of fat. Over 95% of dietary fat is in the form of long-chain triglycerides; the remainder includes phospholipids such as lecithin, fatty acids, cholesterol, and fat-soluble vitamins. Over 94% of the ingested fats are absorbed in the proximal jejunum.

Since fats are normally water insoluble, key to successful digestion of ingested fats is solubilization of them into an emulsion by the mechanical actions of mastication and antral peristalsis. Although lipolysis of triglycerides to form fatty acids and monoglycerides is initiated in the stomach by gastric lipase, its principal site is the proximal intestine, where pancreatic lipase is the catalyst (Fig. 28-9).

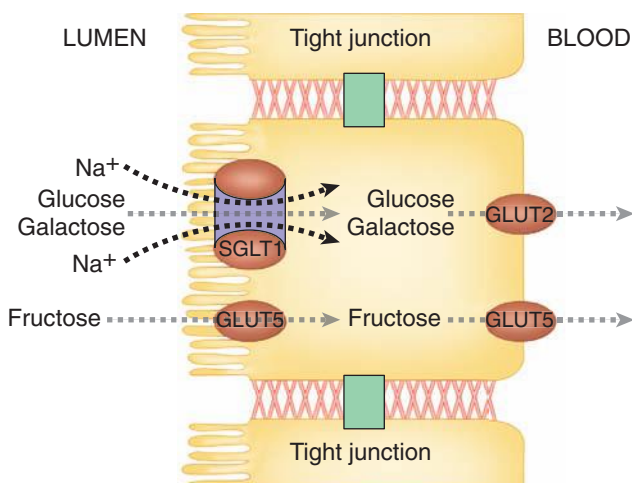


Figure 28-7. Hexose transporters. Glucose and galactose enter the enterocyte through secondary active transport via the sodium-glucose cotransporter (SGLT1) located on the apical (brush border) membrane. Fructose enters through facilitated diffusion via glucose transporter 5 (GLUT5). Glucose and galactose are extruded basolaterally through facilitated diffusion via glucose transporter 2 (GLUT2). Fructose is extruded basolaterally via GLUT5.

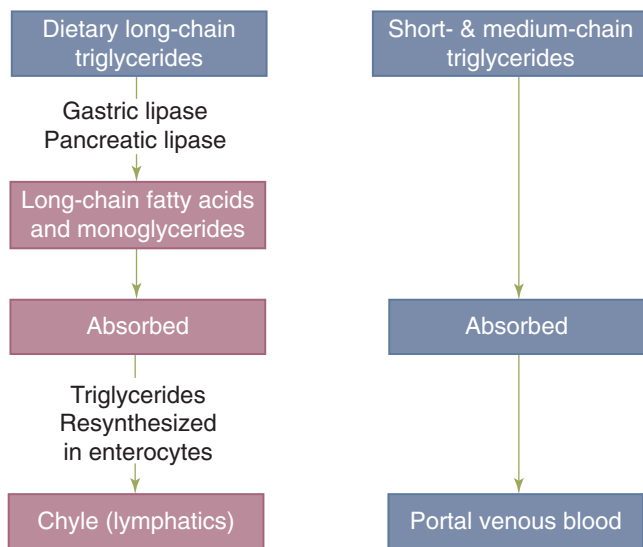


Figure 28-9. Fat digestion. Long-chain triglycerides, which constitute the majority of dietary fats, must undergo lipolysis into constituent long-chain fatty acids and monoglycerides before being absorbed by the intestinal epithelium. These reactions are catalyzed by gastric and pancreatic lipases. The products of lipolysis are transported in the form of mixed micelles to enterocytes, where they are resynthesized into triglycerides, which are then packaged in the form of chylomicrons that are secreted into the intestinal lymph (chyle). Triglycerides composed of short- and medium-chain fatty acids are absorbed by the intestinal epithelium directly, without undergoing lipolysis, and are secreted into the portal venous circulation.

Bile acids act as detergents that help in solubilization of the lipolysis by forming mixed micelles. These micelles are polymolecular aggregates with a hydrophobic core of fat and a hydrophilic surface that act as shuttles, delivering the products of lipolysis to the enterocyte brush border membrane, where they are absorbed. The bile salts, however, remain in the bowel lumen and travel to the terminal ileum, where they are actively resorbed. They enter the portal circulation and are resecreted into bile, thus completing the enterohepatic circulation.

Dissociation of lipids from the micelles occurs in a thin layer of water (50–500 μm thick) with an acidic microenvironment immediately adjacent to the brush border called the *unstirred water layer*. Most lipids are absorbed in the proximal jejunum, whereas bile salts are absorbed in the distal ileum through an active process. Fatty acid binding proteins (FABPs) are a family of proteins located on the brush border membrane, facilitating diffusion of long-chain fatty acids across the brush border membrane. Cholesterol crosses the brush border membrane through an active process that is yet to be completely characterized. Within the enterocytes, triglycerides are resynthesized and incorporated into chylomicrons that are secreted into the intestinal lymphatics and ultimately enter the thoracic duct. In these chylomicrons, lipoproteins serve a detergent-like role similar to that served by bile salts in the mixed micelles.

The steps described above are required for the digestion and absorption of triglycerides containing long-chain fatty acids. However, triglycerides containing short- and medium-chain fatty acids are more hydrophilic and are absorbed without undergoing intraluminal hydrolysis, micellar solubilization, mucosal re-esterification, and chylomicron formation. Instead, they are directly absorbed and enter the portal venous circulation

rather than the lymphatics. This information provides the rationale for administering nutritional supplements containing medium-chain triglycerides to patients with gastrointestinal diseases associated with impaired digestion and/or malabsorption of long-chain triglycerides.

Vitamin and Mineral Absorption. Vitamin B₁₂ (cobalamin) malabsorption can result from a variety of surgical manipulations. The vitamin is initially bound by saliva-derived R protein. In the duodenum, R protein is hydrolyzed by pancreatic enzymes, allowing free cobalamin to bind to gastric parietal cell-derived intrinsic factor. The cobalamin-intrinsic factor complex is able to escape hydrolysis by pancreatic enzymes, allowing it to reach the terminal ileum, which expresses specific receptors for intrinsic factor. Subsequent events in cobalamin absorption are poorly characterized, but the intact complex probably enters enterocytes through translocation. Because each of these steps is necessary for cobalamin assimilation, gastric resection, gastric bypass, and ileal resection can each result in vitamin B₁₂ insufficiency.

Other water-soluble vitamins for which specific carrier-mediated transport processes have been characterized include ascorbic acid, folate, thiamine, riboflavin, pantothenic acid, and biotin. Fat-soluble vitamins A, D, and E appear to be absorbed through passive diffusion. Vitamin K appears to be absorbed through both passive diffusion and carrier-mediated uptake.

Calcium is absorbed through both transcellular transport and paracellular diffusion. The duodenum is the major site for transcellular transport; paracellular transport occurs throughout the small intestine. A key step in transcellular calcium transport is mediated by calbindin, a calcium-binding protein located in the cytoplasm of enterocytes. Regulation of calbindin synthesis is the principle mechanism by which vitamin D regulates intestinal calcium absorption. Abnormal calcium levels are increasingly seen in surgical patients who have undergone a gastric bypass. Although usual calcium supplementation is often in the form of calcium carbonate, which is cheap, in such patients with low acid exposure, calcium citrate is a better formulation for supplemental therapy.

Iron and magnesium are each absorbed through both transcellular and paracellular routes. A divalent metal transporter capable of transporting Fe²⁺, Zn²⁺, Mn²⁺, Co²⁺, Cd²⁺, Cu²⁺, Ni²⁺, and Pb²⁺ that has recently been localized to the intestinal brush border may account for at least a portion of the transcellular absorption of these ions.⁸

Barrier and Immune Function

Although the intestinal epithelium allows for the efficient absorption of dietary nutrients, it must discriminate between pathogens and harmless antigens such as food proteins and commensal bacteria, and it must resist invasion by pathogens. Factors contributing to epithelial defense include immunoglobulin A (IgA), mucins, and the relative impermeability of the brush border membrane and tight junctions to macromolecules and bacteria. Recently described factors likely to play important roles in intestinal mucosal defense include antimicrobial peptides such as the defensins.⁹ The intestinal component of the immune system, known as the gut-associated lymphoid tissue (GALT), contains over 70% of the body's immune cells.

The GALT is conceptually divided into inductive and effector sites.¹⁰ Inductive sites include Peyer's patches, mesenteric lymph nodes, and smaller isolated lymphoid follicles scattered throughout the small intestine (Fig. 28-10).

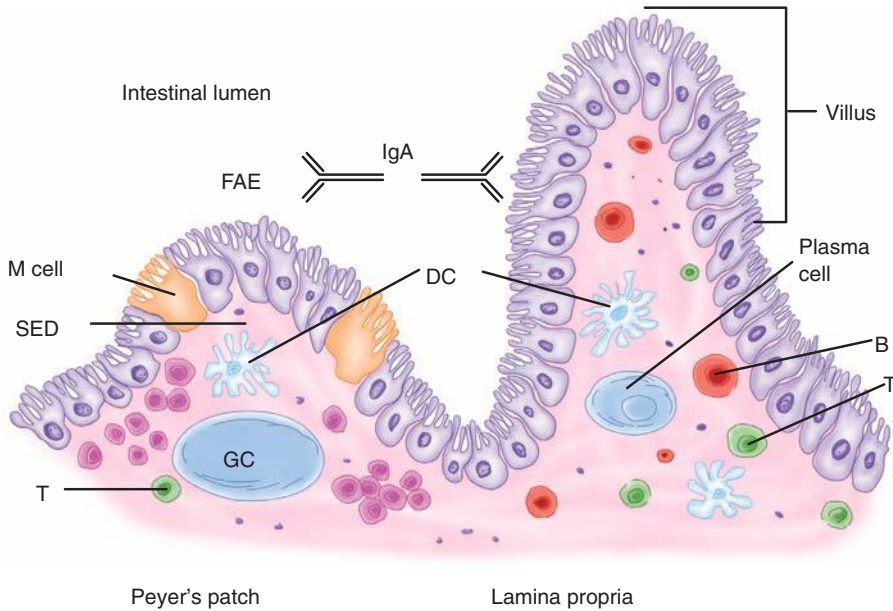


Figure 28-10. Gut-associated lymphoid tissue. Select components of the gut-associated lymphoid tissue (GALT) are schematically represented. Peyer's patches consist of a specialized follicle-associated epithelium (FAE) containing M cells, a subepithelial dome (SED) rich in dendritic cells, and B-cell follicle-containing germinal centers (GC). Plasma cells in the lamina propria produce immunoglobulin A (IgA), which is transported to the intestinal lumen where it serves as the first line of defense against pathogens. Other components of GALT include isolated lymphoid follicles, mesenteric lymph nodes, and regulatory and effector lymphocytes.

Peyer's patches are macroscopic aggregates of B-cell follicles and intervening T-cell areas found in the lamina propria of the small intestine, primarily the distal ileum. Overlying Peyer's patches are a specialized epithelium containing microfold (M) cells. These cells possess an apical membrane with microfolds rather than microvilli, which is characteristic of most intestinal epithelial cells. Using transepithelial vesicular transport, M cells transfer microbes to underlying professional antigen-presenting cells (APCs), such as dendritic cells. Dendritic cells, in addition, may sample luminal antigens directly through their dendrite-like processes that extend through epithelial tight junctions. APCs interact with and prime naïve lymphocytes, which then exit through the draining lymphatics to enter the mesenteric lymph nodes where they undergo differentiation. These lymphocytes then migrate into the systemic circulation via the thoracic duct and ultimately accumulate in the intestinal mucosa at effector sites. Alternative induction mechanisms, such as antigen presentation within mesenteric lymph nodes, are also likely to exist.

Effector lymphocytes are distributed into distinct compartments. IgA-producing plasma cells are derived from B cells and are located in the lamina propria. $CD4^+$ T cells are also located in the lamina propria. $CD8^+$ T cells migrate preferentially to the epithelium, but are also found in the lamina propria. These T cells are central to immune regulation; in addition, the $CD8^+$ T cells have potent cytotoxic (CTL) activity. IgA is transported through the intestinal epithelial cells into the lumen, where it exists in the form of a dimer complexed with a secretory component. This configuration renders IgA resistant to proteolysis by digestive enzymes. IgA is believed to both help prevent the entry of microbes through the epithelium and to promote excretion of antigens or microbes that have already penetrated into the lamina propria.

It has been increasingly recognized that the gastrointestinal tract is colonized with many bacteria that are essential for health. Communication between the microbiota and the host defense allows for protective immune responses against pathogens while preventing adverse inflammatory responses to harmless commensal microbes, which could lead to chronic

inflammatory disorders such as celiac disease and Crohn's disease.¹¹

Motility

Myocytes of the intestinal muscle layers are electrically and mechanically coordinated in the form of syncytia. Contractions of the muscularis propria are responsible for small-intestinal peristalsis. Contraction of the outer longitudinal muscle layer results in bowel shortening; contraction of the inner circular layer results in luminal narrowing. Contractions of the muscularis mucosa contribute to mucosal or villus motility, but not to peristalsis.

Several distinctive patterns of muscularis propria activity have been observed to occur in the small intestine. These patterns include *ascending excitation and descending inhibition* in which muscular contraction occurs proximal to a stimulus, such as the presence of a bolus of ingested food, and muscular relaxation occurs distal to the stimulus (Fig. 28-11). These two

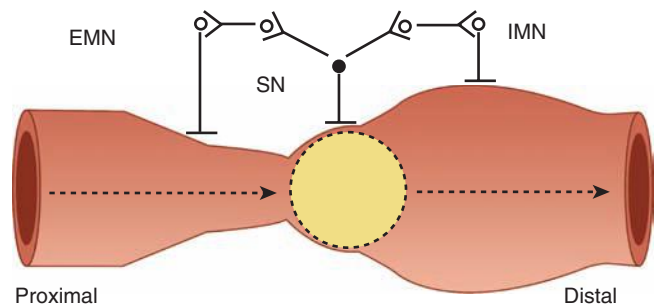


Figure 28-11. Ascending excitation and descending inhibition. The presence of a food bolus within the intestinal lumen is sensed by a sensory neuron (SN) that relays signals to (a) excitatory motor neurons (EMN) that have projections to intestinal muscle cells located proximal to the food bolus and (b) inhibitory motor neurons (IMN) that have projections to intestinal muscle cells located distal to the food bolus. This stereotypical motor reflex is controlled by the enteric nervous system and occurs in the absence of extraintestinal innervations. It contributes to peristalsis.

reflexes are present even in the absence of any extrinsic innervation to the small intestine and contribute to peristalsis when they are propagated in a coordinated fashion along the length of the intestine. The *fed or postprandial pattern* begins within 10 to 20 minutes of meal ingestion and abates 4 to 6 hours afterward. *Rhythmic segmentations* or pressure waves traveling only short distances also are observed. This segmenting pattern is hypothesized to assist in mixing intraluminal contents and in facilitating their contact with the absorptive mucosal surface. The *fasting pattern or interdigestive motor cycle (IDMC)* consists of three phases. Phase I is characterized by motor quiescence, phase II by seemingly disorganized pressure waves occurring at submaximal rates, and phase III by sustained pressure waves occurring at maximal rates. This pattern is hypothesized to expel residual debris and bacteria from the small intestine. The median duration of the IDMC ranges from 90 to 120 minutes. At any given time, different portions of the small intestine can be in different phases of the IDMC.

The regulatory mechanisms driving small-intestinal motility consist of both pacemakers intrinsic to the small intestine and external neurohumoral modulatory signals. The interstitial cells of Cajal are pleomorphic mesenchymal cells located within the muscularis propria of the intestine that generate the electrical slow wave (basic electrical rhythm or pacesetter potential) that plays a pacemaker role in setting the fundamental rhythmicity of small-intestinal contractions. The frequency of the slow wave varies along the longitudinal axis of the intestine: it ranges from 12 waves per minute in the duodenum to 7 waves per minute in the distal ileum. Smooth muscle contraction occurs only when an electrical action potential (spike burst) is superimposed on the slow wave. Thus, the slow wave determines the maximum frequency of contractions; however, not every slow wave is associated with a contraction.

This intrinsic contractile mechanism is subject to neural and hormonal regulation. The enteric nervous system (ENS) provides both inhibitory and excitatory stimuli. The predominant excitatory transmitters are acetylcholine and substance P, and the inhibitory transmitters include nitric oxide, vasoactive intestinal peptide, and adenosine triphosphate. In general, the sympathetic motor supply is inhibitory to the ENS; therefore, increased sympathetic input into the intestine leads to decreased intestinal smooth muscle activity. The parasympathetic motor supply is more complex, with projections to both inhibitory and excitatory ENS motor neurons. Correspondingly, the effects of parasympathetic inputs into intestinal motility are more difficult to predict.

Endocrine Function

Endocrinology as a discipline was born with the discovery of secretin, an intestinal regulatory peptide that was the first hormone to be identified. Our improving understanding of the physiology of the small intestine has led to identification of many additional intestinal-derived hormones that make this the largest hormone-producing organ in the body. Over 30 peptide hormone genes have been identified as being expressed in the gastrointestinal tract. Because of differential posttranscriptional and posttranslational processing, over 100 distinct regulatory peptides are produced. In addition, monoamines, such as histamine and dopamine, and eicosanoids with hormone-like activities are produced in the intestine.

“Gut hormones” were previously conceptualized as peptides produced by the enteroendocrine cells of the intestinal

mucosa that are released into the systemic circulation to reach receptors in target sites in the gastrointestinal tract. Now it is clear that “gut hormone” genes are widely expressed throughout the body, not only in endocrine cells, but also in central and peripheral neurons. The products of these genes are general intercellular messengers that can act as endocrine, paracrine, autocrine, or neurocrine mediators. Thus, they may act as true blood-borne hormones as well as through local effects.

There are notable homology patterns among individual regulatory peptides found in the gastrointestinal tract. Based on these homologies, approximately one half of the known regulatory peptides can be classified into families.¹² For example, the secretin family includes secretin, glucagon, and glucagon-like peptides, glucose-dependent insulinotropic peptide, vasoactive intestinal polypeptide, peptide histidine isoleucine, growth hormone–releasing hormone, and pituitary adenylyl cyclase–activating peptide. Other peptide families include those named for insulin, epidermal growth factor, gastrin, pancreatic polypeptide, tachykinin, and somatostatin.

Receptor subtype multiplicity and cell-specific expression patterns for these receptor subtypes that are characteristic of these regulatory mediators make definition of their actions complex. Detailed description of these actions is beyond the scope of this chapter; however, examples of regulatory peptides produced by enteroendocrine cells of the small-intestinal epithelium and their most commonly ascribed functions are summarized in Table 28-2. Some of these peptides, or their analogues, are used in routine clinical practice. For example, therapeutic applications of octreotide, a long-acting analogue of somatostatin, include the amelioration of symptoms associated with neuroendocrine tumors (e.g., carcinoid syndrome), post-gastrectomy dumping syndrome, enterocutaneous fistulas, and the initial treatment of acute hemorrhage due to esophageal varices. The gastrin secretory response to secretin administration forms the basis for the standard test used to establish the diagnosis of Zollinger-Ellison syndrome. Cholecystokinin is used in evaluations of gallbladder ejection fraction, a parameter that may have utility in patients who have symptoms of biliary colic but are not found to have gallstones. Of the peptides listed in Table 28-2, glucagon-like peptide-2 (GLP-2) has been identified as a specific and potent intestinotrophic hormone and is currently under clinical evaluation as an intestinotrophic agent in patients suffering from the short bowel syndrome, as discussed in the later Short Bowel Syndrome section.

Intestinal Adaptation

The small intestine has the capacity to adapt in response to varying demands imposed by physiologic and pathologic conditions. Of particular relevance to many of the diseases discussed in this chapter is the adaptation that occurs in the remnant intestine following surgical resection of a large portion of the small intestine (massive small bowel resection). Postresection intestinal adaptation has been studied extensively using animal models. Within a few hours after bowel resection, the remnant small intestine displays evidence of epithelial cellular hyperplasia. With additional time, villi lengthen, intestinal absorptive surface area increases, and digestive and absorptive functions improve. Postresection intestinal adaptation in human patients is less well studied, but seems to follow similar steps as those seen in experimental models, and takes 1 to 2 years to complete.¹³

The mechanisms responsible for inducing postresection intestinal adaptation are under active investigation.

Table 28-2

Representative regulatory peptides produced in the small intestine

HORMONE	SOURCE ^a	ACTIONS
Somatostatin	D cell	Inhibits gastrointestinal secretion, motility, and splanchnic perfusion
Secretin	S cell	Stimulates exocrine pancreatic secretion, stimulates intestinal secretion
Cholecystokinin	I cell	Stimulates pancreatic exocrine secretion, stimulates gallbladder emptying, inhibits sphincter of Oddi contraction
Motilin	M cell	Stimulates intestinal motility
Peptide YY	L cell	Inhibits intestinal motility and secretion
Glucagon-like peptide 2	L cell	Stimulates intestinal epithelial proliferation
Neurotensin	N cell	Stimulates pancreatic and biliary secretion, inhibits small bowel motility, stimulates intestinal mucosal growth

^aThis table indicates which enteroendocrine cell types located in the intestinal epithelium produce these peptides. These peptides are also widely expressed in nonintestinal tissues.

Several classes of effectors that stimulate intestinal growth include specific nutrients, peptide hormones and growth factors, pancreatic secretions, and some cytokines. Nutritional components with intestinal growth-stimulating effects include fiber, fatty acids, triglycerides, glutamine, polyamines, and lectins.

Postresection adaptation serves to compensate for the function of intestine that has been resected. Jejunal resection is generally better tolerated, as ileum shows better capacity to compensate. However, the magnitude of this response is limited. If enough small intestine is resected, a devastating condition known as the short bowel syndrome results. This condition is discussed in the Short Bowel Syndrome section at the end of this chapter.

SMALL BOWEL OBSTRUCTION

Epidemiology

Mechanical small bowel obstruction is the most frequently encountered surgical disorder of the small intestine. **2▶** Although a wide range of etiologies for this condition exists, the obstructing lesion can be conceptualized according to its anatomic relationship to the intestinal wall as:

1. *Intraluminal* (e.g., foreign bodies, gallstones, or meconium)
2. *Intramural* (e.g., tumors, Crohn's disease–associated inflammatory strictures)
3. *Extrinsic* (e.g., adhesions, hernias, or carcinomatosis)

Intra-abdominal adhesions related to prior abdominal surgery account for up to 75% of cases of small bowel obstruction.

3▶ Over 300,000 patients are estimated to undergo surgery to treat adhesion-induced small bowel obstruction in the United States annually. A 20-year trend analysis between 1988 and 2007 has documented no decrease in this rate during this time period, highlighting the ongoing problem with this “old” disease.¹⁴

Less prevalent etiologies for small bowel obstruction include hernias, malignant bowel obstruction, and Crohn's disease. The frequency with which obstruction related to these conditions is encountered varies according to the patient population and practice setting. Cancer-related small bowel

obstructions are commonly due to extrinsic compression or invasion by advanced malignancies arising in organs other than the small bowel; few are due to primary small bowel tumors. The most commonly encountered etiologies of small bowel obstruction are summarized in Table 28-3. Although **4▶** congenital abnormalities capable of causing small bowel obstruction usually become evident during childhood, they sometimes elude detection and are diagnosed for the first time in adult patients presenting with abdominal symptoms. For example, intestinal malrotation and mid-gut volvulus should not be forgotten when considering the differential

Table 28-3

Small bowel obstruction: common etiologies

Adhesions
Neoplasms
Primary small bowel neoplasms
Secondary small bowel cancer (e.g., melanoma-derived metastasis)
Local invasion by intra-abdominal malignancy (e.g., desmoid tumors)
Carcinomatosis
Hernias
External (e.g., inguinal and femoral)
Internal (e.g., following Roux-en-Y gastric bypass surgery)
Crohn's disease
Volvulus
Intussusception
Radiation-induced stricture
Postischemic stricture
Foreign body
Gallstone ileus
Diverticulitis
Meckel's diverticulum
Hematoma
Congenital abnormalities (e.g., webs, duplications, and malrotation)

diagnosis of adult patients with acute or chronic symptoms of small bowel obstruction, especially those without a history of prior abdominal surgery. A rare etiology of obstruction is the superior mesenteric artery syndrome, characterized by compression of the third portion of the duodenum by the superior mesenteric artery as it crosses over this portion of the duodenum. This condition should be considered in young asthenic individuals who have chronic symptoms suggestive of proximal small bowel obstruction.

Pathophysiology

With onset of obstruction, gas and fluid accumulate within the intestinal lumen proximal to the site of obstruction. The intestinal activity increases in an effort to overcome the obstruction, accounting for the colicky pain and the diarrhea that some experience even in the presence of complete bowel obstruction. Most of the gas that accumulates originates from swallowed air, although some is produced within the intestine. The fluid consists of swallowed liquids and gastrointestinal secretions (obstruction stimulates intestinal epithelial water secretion). With ongoing gas and fluid accumulation, the bowel distends and intraluminal and intramural pressures rise. The intestinal motility is eventually reduced with fewer contractions. With obstruction, the luminal flora of the small bowel, which is usually sterile, changes, and a variety of organisms have been cultured from the contents. Translocation of these bacteria to regional lymph nodes has been demonstrated, although the significance of this process is not well understood. If the intramural pressure becomes high enough, intestinal microvascular perfusion is impaired, leading to intestinal ischemia and, ultimately, necrosis. This condition is termed *strangulated bowel obstruction*.

With *partial small bowel obstruction*, only a portion of the intestinal lumen is occluded, allowing passage of some gas and fluid. The progression of pathophysiologic events described earlier tends to occur more slowly than with *complete small bowel obstruction*, and development of strangulation is less likely.

A particularly dangerous form of bowel obstruction is *closed-loop obstruction* in which a segment of intestine is obstructed both proximally and distally (e.g., with volvulus). In such cases, the accumulating gas and fluid cannot escape either proximally or distally from the obstructed segment, leading to a rapid rise in luminal pressure and a rapid progression to strangulation.

Clinical Presentation

The symptoms of small bowel obstruction are colicky abdominal pain, nausea, vomiting, and obstipation. Vomiting is a more prominent symptom with proximal obstructions than distal. The character of vomitus is important because with bacterial overgrowth, the vomitus is more feculent, suggesting a more established obstruction. Continued passage of flatus and/or stool beyond 6 to 12 hours after onset of symptoms is characteristic of partial rather than complete obstruction. The signs of small bowel obstruction include abdominal distention, which is most pronounced if the site of obstruction is in the distal ileum and may be absent if the site of obstruction is in the proximal small intestine. Bowel sounds may be hyperactive initially, but in late stages of bowel obstruction, minimal bowel sounds may be heard. Laboratory findings reflect intravascular volume depletion and consist of hemoconcentration and electrolyte abnormalities. Mild leukocytosis is common.

Features of strangulated obstruction include abdominal pain often disproportionate to the degree of abdominal findings, suggestive of intestinal ischemia. Patients often have tachycardia, localized abdominal tenderness, fever, marked leukocytosis, and acidosis. Any of these findings should alert the clinician to the possibility of strangulation and need for early surgical intervention.

Diagnosis

The diagnostic evaluation should focus on the following goals: (a) distinguish mechanical obstruction from ileus, (b) determine the etiology of the obstruction, (c) discriminate partial from complete obstruction, and (d) discriminate simple from strangulating obstruction.

Important elements to obtain on history include prior abdominal operations (suggesting the presence of adhesions) and the presence of abdominal disorders (e.g., intra-abdominal cancer or inflammatory bowel disease) that may provide insights into the etiology of obstruction. Upon examination, a meticulous search for hernias (particularly in the inguinal and femoral regions) should be conducted.

The diagnosis of small bowel obstruction is usually confirmed with radiographic examination. The *abdominal series* consists of (a) a radiograph of the abdomen with the patient in a supine position, (b) a radiograph of the abdomen with the patient in an upright position, and (c) a radiograph of the chest with the patient in an upright position. The finding most specific for small bowel obstruction is the triad of dilated small bowel loops (>3 cm in diameter), air-fluid levels seen on upright films, and a paucity of air in the colon. The sensitivity of abdominal radiographs in the detection of small bowel obstruction ranges 70% to 80%.¹⁵ Specificity is low, because ileus and colonic obstruction can be associated with findings that mimic those observed with small bowel obstruction. False-negative findings on radiographs can result when the site of obstruction is located in the proximal small bowel and when the bowel lumen is filled with fluid but no gas, thereby preventing visualization of air-fluid levels or bowel distention. The latter situation is associated with closed-loop obstruction. Despite these limitations, abdominal radiographs remain an important study in patients with suspected small bowel obstruction because of their widespread availability and low cost (Fig. 28-12).

Computed tomography (CT) scanning is 80% to 90% sensitive and 70% to 90% specific in the detection of small bowel obstruction.¹⁵ The findings of small bowel obstruction include a discrete transition zone with dilation of bowel proximally, decompression of bowel distally, intraluminal contrast that does not pass beyond the transition zone, and a colon containing little gas or fluid (Figs. 28-13 and 28-14). CT scanning may also provide evidence for the presence of closed-loop obstruction and strangulation. Closed-loop obstruction is suggested by the presence of a U-shaped or C-shaped dilated bowel loop associated with a radial distribution of mesenteric vessels converging toward a torsion point. Strangulation is suggested by thickening of the bowel wall, pneumatosis intestinalis (air in the bowel wall), portal venous gas, mesenteric haziness, and poor uptake of intravenous contrast into the wall of the affected bowel (Fig. 28-15). CT scanning also offers a global evaluation of the abdomen and may therefore reveal the etiology of obstruction. This feature is important in the acute setting when intestinal obstruction represents only one of many diagnoses in patients presenting with acute abdominal conditions.

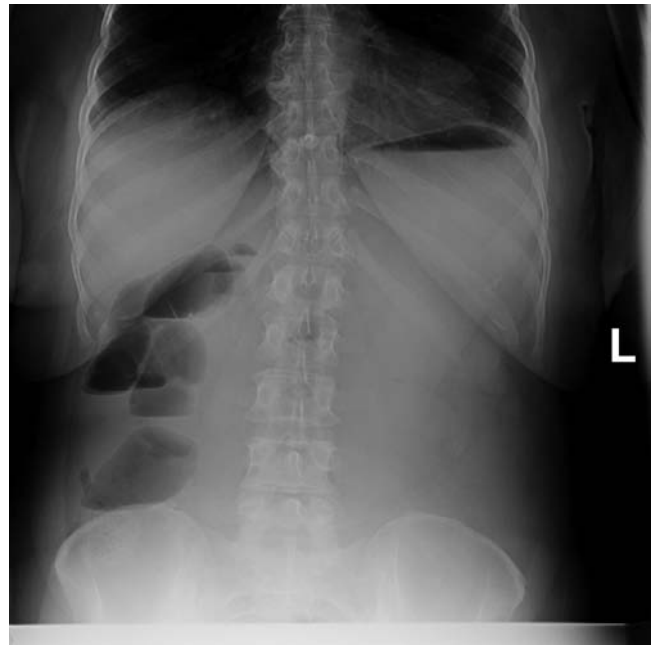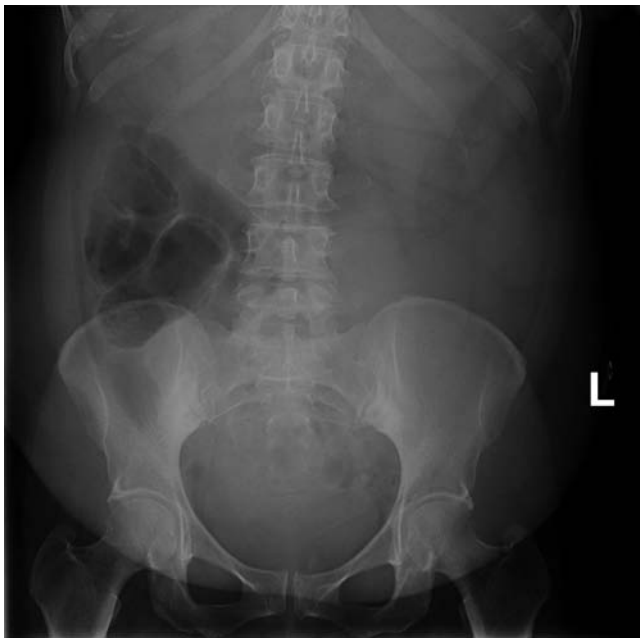


Figure 28-12. Small bowel obstruction. Plain radiographs (A) supine, which show dilated loops of small bowel in the right upper quadrant, and (B) erect, which confirm the presence of air-fluid level in the loops of small bowel as well as the stomach, consistent with small bowel obstruction.

The CT scan is usually performed after administration of oral water-soluble contrast or diluted barium. The water-soluble contrast has been shown to have prognostic and therapeutic value too. Several studies and a subsequent meta-analysis have shown that appearance of the contrast in the colon within 24 hours is predictive of nonsurgical resolution of bowel obstruction.¹⁶ Although use of oral contrast did not alter the rate of surgical intervention, it did reduce the overall length of hospital stay in those presenting with small bowel obstruction.

A limitation of CT scanning is its low sensitivity (<50%) in the detection of low-grade or partial small bowel obstruction. A subtle transition zone may be difficult to identify in the axial images obtained during CT scanning. In such cases, contrast

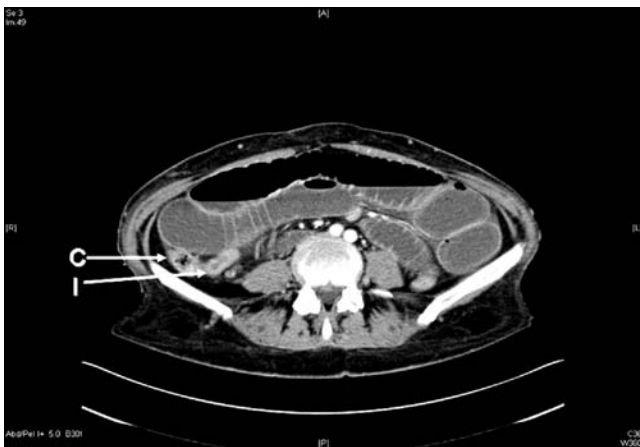

Figure 28-13. Small bowel obstruction. A computed tomography scan of a patient presenting with signs and symptoms of bowel obstruction. Image shows grossly dilated loops of small bowel, with decompressed terminal ileum (I) and ascending colon (C), suggesting a complete distal small bowel obstruction. At laparotomy, adhesive bands from a previous surgery were identified and divided.

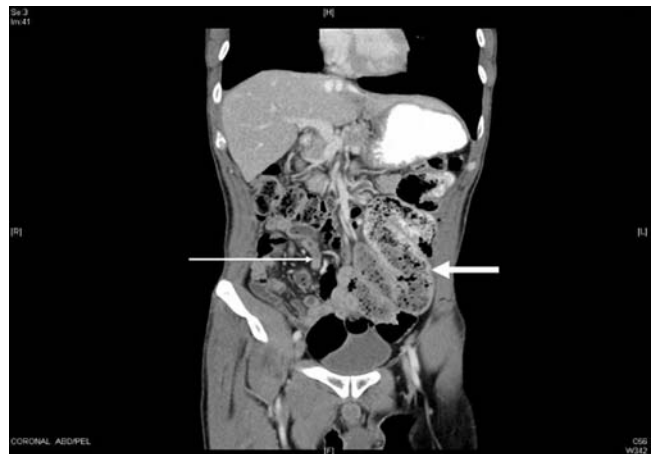

Figure 28-14. Chronic partial small bowel obstruction. This patient presented with a several-month history of chronic abdominal pain and intermittent vomiting. The coronal computed tomography image shows grossly dilated loops of proximal small bowel on the left side (*wide arrow*), with decompressed loops of small bowel on the right side (*narrow arrow*). The dilated segment shows evidence of fecalization of bowel contents, consistent with the chronic nature of the obstruction. Patient's vomitus had characteristic feculent smell and quality. At exploratory laparotomy, adhesive band were identified and divided.

examinations of the small bowel, either *small bowel series* (small bowel follow-through) or *enteroclysis*, can be helpful. For standard small bowel series, contrast is swallowed or instilled into the stomach through a nasogastric tube. Abdominal radiographs are then taken serially as the contrast travels distally in the intestine. Although barium can be used, water-soluble contrast agents, such as Gastrografin, should be used if the possibility of intestinal perforation exists. These examinations are more labor-intensive and less rapidly performed than

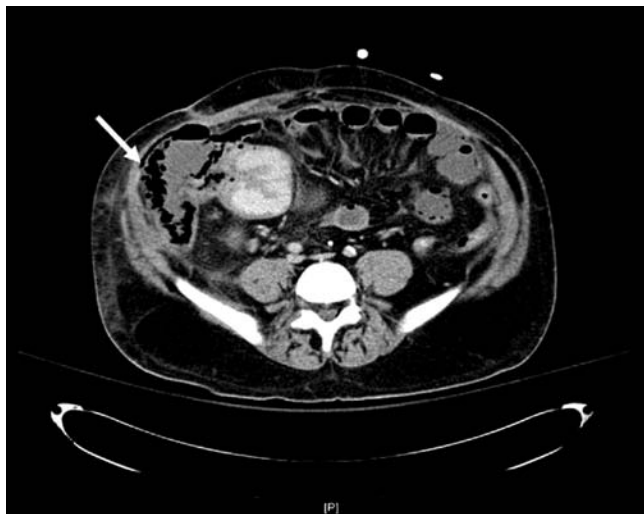


Figure 28-15. Intestinal pneumatosis. This computed tomography scan shows intestinal pneumatosis (*arrow*). The cause of this radiologic finding was intestinal ischemia. Patient was taken emergently to the operating room and underwent resection of an infarcted segment of small bowel.

CT scanning but may offer greater sensitivity in the detection of luminal and mural etiologies of obstruction, such as primary intestinal tumors. For enteroclysis, 200 to 250 mL of barium followed by 1 to 2 L of a solution of methylcellulose in water are instilled into the proximal jejunum via a long nasoenteric catheter. The double-contrast technique used in enteroclysis permits a better assessment of mucosal surface and detection of relatively small lesions, even through overlapping small bowel loops. Enteroclysis is rarely performed in the acute setting but offers greater sensitivity than small bowel series in the detection of lesions that may be causing partial small bowel obstruction. Recently, CT enteroclysis has been used and reported to be superior to plain x-ray small bowel contrast studies.

Therapy

Small bowel obstruction is usually associated with a marked depletion of intravascular volume due to decreased oral intake, vomiting, and sequestration of fluid in bowel lumen and wall. Therefore, fluid resuscitation is integral to treatment. Isotonic fluid should be given intravenously, and an indwelling bladder catheter may be placed to monitor urine output. Central venous or pulmonary artery catheter monitoring may be necessary to assist with fluid management in patients with underlying cardiac disease and severe dehydration. Broad-spectrum antibiotics are given by some because of concerns that bacterial translocation may occur in the setting of small bowel obstruction; however, there are no data to support this approach.

The stomach should be continuously evacuated of air and fluid using a nasogastric (NG) tube. Effective gastric decompression decreases nausea, distention, and the risk of vomiting and aspiration. Longer nasoenteric tubes, with tips placed into the jejunum or ileum, were favored in the past but are rarely used today, as they are associated with higher complication rates than NG tubes, with no proven greater efficacy in several studies.

The standard therapy for *complete* small bowel obstruction has generally been expeditious surgery, with the dictum that “the sun should never rise and set on a complete bowel obstruction.”

Recently, however, some have advocated nonoperative approaches in management of these patients, provided closed-loop obstruction is ruled out and there is no evidence of intestinal ischemia. Such patients need to be observed closely and undergo serial exams. The rationale for those favoring early surgical intervention is to minimize the risk for bowel strangulation, which is associated with an increased risk for morbidity and mortality. Clinical signs and currently available laboratory tests and imaging studies do not reliably permit the distinction between patients with simple obstruction and those with strangulated obstruction prior to the onset of irreversible ischemia. Therefore, the goal is to operate before the onset of irreversible ischemia. Others note, however, that a period of observation and nasogastric decompression, provided no tachycardia, tenderness, or an increase in white cell count is noted, are appropriate (see Fig. 28-16 for a proposed management algorithm).

However, conservative therapy, in the form of NG decompression and fluid resuscitation, is commonly recommended in the initial recommendation for:

1. Partial small bowel obstruction
2. Obstruction occurring in the early postoperative period
3. Intestinal obstruction due to Crohn’s disease
4. Carcinomatosis

In *partial obstruction*, progression to strangulation is unlikely to occur, and an attempt at nonoperative resolution is warranted. Nonoperative management has been documented to be successful in 65% to 81% of patients with partial small bowel obstruction. Of those successfully treated nonoperatively, only 5% to 15% have been reported to have symptoms that were not substantially improved within 48 hours after initiation of therapy.¹⁷ Therefore, most patients with partial small bowel obstruction whose symptoms do not improve within 48 hours after initiation of nonoperative therapy should undergo surgery. In a recent study, using the National Inpatient Sample, this principle was further highlighted. The authors concluded that a 2-day limit of watchful waiting before surgery is not associated with an increase in mortality or postoperative morbidity, although inpatient costs were higher.¹⁸

Patients undergoing nonoperative therapy should be closely monitored for signs suggestive of peritonitis, the development of which would mandate urgent surgery. As stated before, the administration of hypertonic water-soluble contrast agents, such as Gastrografin used in upper gastrointestinal (GI) and small bowel follow-through examinations, causes a shift of fluid into the intestinal lumen, thereby increasing the pressure gradient across the site of obstruction. This effect may accelerate resolution of partial small bowel obstruction; however, there is less evidence that administration of water-soluble contrast agents increases the probability that an episode of bowel obstruction will be successfully managed nonoperatively.¹⁶

Obstruction presenting in the *early postoperative period* has been reported to occur in 0.7% patients undergoing laparotomy.¹⁹ Patients undergoing pelvic surgery, especially colorectal procedures, have the greatest risk for developing early postoperative small bowel obstruction. The presence of obstruction should be considered if symptoms of intestinal obstruction occur after the initial return of bowel function or if bowel function fails to return within the expected 3 to 5 days after abdominal surgery. Plain radiographs may demonstrate dilated loops of small intestine with air-fluid levels but are interpreted as normal

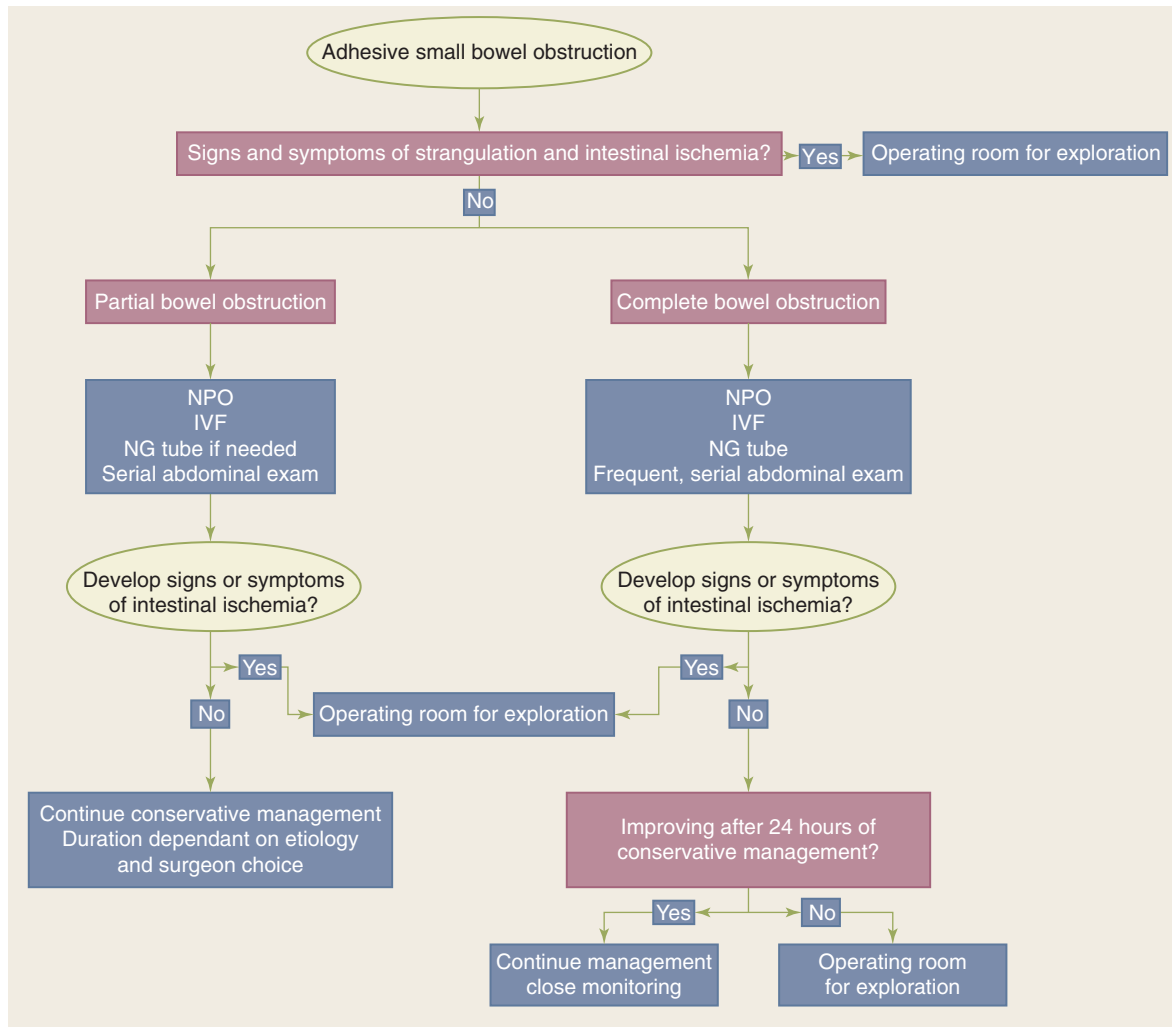


Figure 28-16. Management algorithm of small bowel obstruction. IVF = intravenous fluid; NG = nasogastric; NPO = nothing by mouth.

or nonspecific in up to a third of patients with early postoperative obstruction. CT scanning or a small bowel series is often required to make the diagnosis. Obstruction that occurs in the early postoperative period is usually partial and only rarely is associated with strangulation. Therefore, a period of extended nonoperative therapy (2–3 weeks) consisting of bowel rest, hydration, and total parental nutrition (TPN) administration is usually warranted. However, if complete obstruction is demonstrated or if signs suggestive of peritonitis are detected, expeditious reoperation should be undertaken without delay.

Crohn's disease as a cause of small bowel obstruction is discussed in more detail later in the Crohn's Disease section.

Twenty-five to thirty-three percent of patients with a history of cancer who present with small bowel obstruction have adhesions as the etiology of their obstruction and therefore should not be denied appropriate therapy.²⁰ Even in cases in which the obstruction is related to recurrent malignancy, palliative resection or bypass can be performed. Patients with obvious carcinomatosis pose a difficult challenge, given their limited prognosis. Management must be tailored to an individual patient's prognosis and desires, and relief of the obstruction may be best achieved by a bypass procedure, avoiding a potentially difficult bowel resection.

The operative procedure performed for small bowel obstruction varies according to the etiology of the obstruction. For example, adhesions are lysed, tumors are resected,

and hernias are reduced and repaired. Regardless of the etiology, the affected intestine should be examined, and nonviable bowel resected. Criteria suggesting viability are normal color, peristalsis, and marginal arterial pulsations. Usually, visual inspection alone is adequate in judging viability. In borderline cases, a Doppler probe may be used to check for pulsatile flow to the bowel, and arterial perfusion can be verified by visualizing intravenously administered fluorescein dye in the bowel wall under ultraviolet illumination. However, neither technique has been found to be superior to clinical judgment. In general, if the patient is hemodynamically stable, short lengths of bowel of questionable viability should be resected and primary anastomosis of the remaining intestine performed. However, if the viability of a large proportion of the intestine is in question, a concerted effort to preserve intestinal tissue should be made. In such situations, the bowel of uncertain viability should be left intact and the patient re-explored in 24 to 48 hours in a "second-look" operation. At that time, definitive resection of nonviable bowel is completed.

Successful laparoscopic surgery for bowel obstruction is being reported with greater frequency.^{22,23} Those who undergo successful laparoscopic procedure have a quicker recovery, less complications, and lower costs. Since distended loops of bowel can interfere with adequate visualization, early cases of proximal small bowel obstruction that are likely due to a single

adhesive band are best suited for this approach. Presence of bowel distention and multiple adhesions can cause these procedures to be difficult and potentially hazardous. Conversion rate to open surgery is between 17% and 33%.²¹⁻²³

Outcomes

Prognosis is related to the etiology of obstruction. The majority of patients who are treated conservatively for adhesive small bowel obstruction do not require future readmissions; less than 20% of such patients will have a readmission over the subsequent 5 years with another episode of bowel obstruction.²³

The perioperative mortality rate associated with surgery for nonstrangulating small bowel obstruction is less than 5%, with most deaths occurring in elderly patients with significant comorbidities. Mortality rates associated with surgery for strangulating obstruction range from 8% to 25%.

Considering the frequency of small bowel obstruction and the varied degree of clinical severity and presentation, there is often no consistency as to whether the patient is admitted to the medical or surgical service, and further variability in whether and when surgery is consulted. Recent studies have shown that a standard hospital-wide policy can help improve care of patients with bowel obstruction, reducing their time to surgery and shortening their length of hospital stay.²⁴

Prevention

With adhesive small bowel obstruction representing a large therapeutic burden, prevention of postoperative adhesions has become an area of great interest. Good surgical technique, careful handling of tissue, and minimal use and exposure of peritoneum to foreign bodies form the cornerstone of adhesion prevention. These measures alone are often inadequate. In patients undergoing colorectal or pelvic surgery, hospital readmission rates of greater than 30% over the subsequent 10 years have been reported for adhesive small bowel obstruction.²⁵

Use of laparoscopic surgery, when possible, has been strongly promoted. A recent study using the Swedish Inpatient Register has shown that, compared to laparoscopy, open surgery is associated with a four-fold increase in risk of small bowel obstruction within 5 years of the index procedure even after accounting for other risk factors such as age, comorbidity, and previous abdominal surgery.²⁶

In those undergoing open surgery, several strategies for adhesion prevention have been tried; however, the only therapy that has shown some success has been the use of hyaluronan-based agents, such as Seprafilm. The use of this barrier has been clearly shown to reduce the incidence of postoperative bowel adhesions; however, its effect in actually reducing the incidence of small bowel obstruction remains less well defined.²⁷ The use of these products is often left to the discretion of the surgeon and the clinical context. Wrapping of an intestinal anastomosis with the material may be associated with increased leak rates and is generally discouraged.²⁸

ILEUS AND OTHER DISORDERS OF INTESTINAL MOTILITY

Ileus and intestinal pseudo-obstruction designate clinical syndromes caused by impaired intestinal motility and are characterized by symptoms and signs of intestinal obstruction in the absence of a lesion-causing mechanical obstruction. Ileus is a major cause of morbidity in hospitalized patients. Postoperative ileus is

the most frequently implicated cause of delayed discharge following abdominal operations; its economic impact has been estimated to be between \$750 million and \$1 billion annually in the United States.²⁹

Ileus is a temporary motility disorder that is reversed with time as the inciting factor is corrected. In contrast, chronic intestinal pseudo-obstruction comprises a spectrum of specific disorders associated with irreversible intestinal dysmotility.

Pathophysiology

Numerous factors capable of impairing intestinal motility, and thus inciting ileus, have been described (Table 28-4). The most frequently encountered factors are abdominal operations, infection and inflammation, electrolyte abnormalities, and drugs.

Following most abdominal operations or injuries, the motility of the GI tract is transiently impaired. Among the proposed mechanisms responsible for this dysmotility are surgical stress-induced sympathetic reflexes, inflammatory response mediator release, and anesthetic/analgesic side effects, each of which can inhibit intestinal motility.³⁰ The return of normal motility generally follows a characteristic temporal sequence, with small-intestinal motility returning to normal within the first 24 hours after laparotomy and gastric and colonic motility returning to normal by 48 hours and 3 to 5 days, respectively. Because small bowel motility is returned before colonic and gastric motility, listening for bowel sounds is not a reliable indicator that ileus has fully resolved. Functional evidence of coordinated GI motility in the form of passing flatus or a bowel movement is a more useful indicator. Resolution of ileus may be delayed in the presence of other factors capable of inciting ileus such as the presence of intra-abdominal abscesses or electrolyte abnormalities.

Chronic intestinal pseudo-obstruction can be caused by a large number of specific abnormalities affecting intestinal

Table 28-4

Ileus: common etiologies

Abdominal surgery
Infection
Sepsis
Intra-abdominal abscess
Peritonitis
Pneumonia
Electrolyte abnormalities
Hypokalemia
Hypomagnesemia
Hypermagnesemia
Hyponatremia
Medications
Anticholinergics
Opiates
Phenothiazines
Calcium channel blockers
Tricyclic antidepressants
Hypothyroidism
Ureteral colic
Retroperitoneal hemorrhage
Spinal cord injury
Myocardial infarction
Mesenteric ischemia

TABLE 28-5

Chronic intestinal pseudo-obstruction: etiologies**Primary Causes**

- Familial types
 - Familial visceral myopathies (types I, II, and III)
 - Familial visceral neuropathies (types I and II)
 - Childhood visceral myopathies (types I and II)
- Sporadic types
 - Visceral myopathies
 - Visceral neuropathies

Secondary Causes

- Smooth muscle disorders
 - Collagen vascular diseases (e.g., scleroderma)
 - Muscular dystrophies (e.g., myotonic dystrophy)
 - Amyloidosis
- Neurologic disorders
 - Chagas disease, Parkinson's disease, spinal cord injury
- Endocrine disorders
 - Diabetes, hypothyroidism, hypoparathyroidism
- Miscellaneous disorders
 - Radiation enteritis
- Pharmacologic causes
 - E.g., phenothiazines and tricyclic antidepressants
- Viral infections

smooth muscle, the myenteric plexus, or the extraintestinal nervous system (Table 28-5). Visceral myopathies constitute a group of diseases characterized by degeneration and fibrosis of the intestinal muscularis propria. Visceral neuropathies encompass a variety of degenerative disorders of the myenteric and submucosal plexuses. Both sporadic and familial forms of visceral myopathies and neuropathies exist. Systemic disorders involving the smooth muscle, such as progressive systemic sclerosis and progressive muscular dystrophy, and neurologic diseases, such as Parkinson's disease, can also be complicated by chronic intestinal pseudo-obstruction. In addition, viral infections, such as those associated with cytomegalovirus and Epstein-Barr virus, can cause intestinal pseudo-obstruction.

Clinical Presentation

The clinical presentation of ileus resembles that of small bowel obstruction. Inability to tolerate liquids and solids by mouth, nausea, and lack of flatus or bowel movements are the most common symptoms. Vomiting and abdominal distension may occur. Bowel sounds are characteristically diminished or absent, in contrast to the hyperactive bowel sounds that usually accompany mechanical small bowel obstruction. The clinical manifestations of chronic intestinal pseudo-obstruction include variable degrees of nausea and vomiting and abdominal pain and distention.

Diagnosis

Routine postoperative ileus should be expected and requires no diagnostic evaluation. If ileus persists beyond 3 to 5 days postoperatively or occurs in the absence of abdominal surgery, diagnostic evaluation to detect specific underlying factors capable of inciting ileus and to rule out the presence of mechanical obstruction is warranted.

Patient medication lists should be reviewed for the presence of drugs, especially opiates, known to be associated with

impaired intestinal motility. Measurement of serum electrolytes may demonstrate electrolyte abnormalities commonly associated with ileus. Abdominal radiographs are often obtained, but the distinction between ileus and mechanical obstruction may be difficult based on this test alone. In the postoperative setting, CT scanning is the test of choice because it can demonstrate the presence of an intra-abdominal abscess or other evidence of peritoneal sepsis that may be causing ileus and can exclude the presence of complete mechanical obstruction. Distinction of postoperative ileus from early postoperative obstruction can be difficult but is helpful in developing the appropriate management plan.

The diagnosis of chronic pseudo-obstruction is suggested by clinical features and confirmed by radiographic and manometric studies. Diagnostic laparotomy or laparoscopy with full-thickness biopsy of the small intestine may be required to establish the specific underlying cause.

Therapy

The management of ileus consists of limiting oral intake and correcting the underlying inciting factor. If vomiting or abdominal distention is prominent, the stomach should be decompressed using a nasogastric tube. Fluid and electrolytes should be administered intravenously until ileus resolves. If the duration of ileus is prolonged, TPN may be required.

Given the frequency of postoperative ileus and its financial impact, a large number of investigations have been conducted to define strategies to reduce its duration. Although often recommended, the use of early ambulation and routine nasogastric intubation has not been demonstrated to be associated with earlier resolution of postoperative ileus. There is some evidence that early postoperative feeding protocols and are generally well tolerated, reduce postoperative ileus, and can result in a shorter hospital stay.³¹ The administration of nonsteroidal anti-inflammatory drugs such as ketorolac and concomitant reductions in opioid dosing have been shown to reduce the duration of ileus in most studies. Similarly, the use of perioperative thoracic epidural anesthesia/analgesia with regimens containing local anesthetics combined with limitation or elimination of systemically administered opioids has been shown to reduce duration of postoperative ileus, although they have not reduced the overall length of hospital stay.³² Interestingly, recent data have suggested that limiting intra- and postoperative fluid administration can also result in reduction of postoperative ileus and shortened hospital stay.³³ Table 28-6 summarizes some of the measures used to minimize postoperative ileus.

Most other pharmacologic agents, including prokinetic agents, are associated with efficacy-toxicity profiles that are

Table 28-6

Measures to reduce postoperative ileus**Intraoperative measures**

- Minimize handling of the bowel
- Laparoscopic approach, if possible
- Avoid excessive intraoperative fluid administration

Postoperative measures

- Early enteral feeding
- Epidural anesthesia, if indicated
- Avoid excessive intravenous fluid administration
- Correct electrolyte abnormalities
- Consider mu-opioid antagonists

too unfavorable to warrant routine use. Recently, administration of alvimopan, a novel peripherally active mu-opioid receptor antagonist with limited oral absorption, has been shown to reduce duration of postoperative ileus, hospital stay, and rate of readmissions in several prospective, randomized, placebo-controlled trials and a subsequent meta-analysis.³⁴ However, any cost savings associated with the use of this drug outside of a clinical trial have been debated.³⁵

Surgical interest in minimizing postoperative ileus has led to exploration of other potential avenues. Experiments in rodents have shown reduced postoperative ileus with enteral administration of lipid-rich nutrition, which is believed to work through a CCK-dependent vagovagal reflex.³⁶

Therapy of patients with chronic intestinal pseudo-obstruction focuses on palliation of symptoms as well as fluid, electrolyte, and nutritional management. Surgery should be avoided if at all possible. No standard therapies are curative or delay the natural history of any of the specific disorders causing intestinal pseudo-obstruction. Prokinetic agents, such as metoclopramide and erythromycin, are associated with poor efficacy. Cisapride has been associated with palliation of symptoms; however, because of cardiac toxicity and reported deaths, this agent is restricted to compassionate use in the United States.

Patients with refractory disease may require strict limitation of oral intake and long-term TPN administration. Despite these measures, some patients will continue to have severe abdominal pain or such copious intestinal secretions that vomiting and fluid and electrolyte losses remain substantial. These patients may require a decompressive gastrostomy or an extended small bowel resection to remove abnormal intestine. Small-intestinal transplantation has been applied in these patients with increasing frequency; the ultimate role of this modality remains to be defined.

CROHN'S DISEASE

Crohn's disease is a chronic, idiopathic transmural inflammatory disease with a propensity to affect the distal ileum, although any part of the alimentary tract can be involved. Estimates of the incidence of Crohn's disease in the United States have ranged from 3.6 to 8.8 per 100,000, with recent studies suggesting a prevalence of about 200 cases per 100,000.³⁷ A dramatic increase in incidence in the United States was observed to occur from the mid-1950s through the early 1970s. Incidence rates have been stable since the 1980s. Substantial regional variations in incidence have been observed, with the highest incidences reported to exist in northern latitudes. The incidence of Crohn's disease varies among ethnic groups within the same geographic region. For example, members of Eastern European Ashkenazi Jewish population are at two- to four-fold higher risk of developing Crohn's disease than members of other populations living in the same location. In countries such as China, the prevalence of Crohn's disease is estimated at 1.38 cases per 100,000, substantially below that seen in the West, but the rates have been on a rapid increase recently.³⁸

Most studies suggest that Crohn's disease is slightly more prevalent in females than in males. The mean age at which patients are diagnosed with Crohn's disease falls in the third decade of life years, with a second smaller peak in the sixth decade of life, giving it a bimodal distribution. However, the age at diagnosis can range from early childhood through the entire lifespan.

Both genetic and environmental factors appear to influence the risk for developing Crohn's disease. The relative risk among first-degree relatives of patients with Crohn's disease is 14 to 15 times higher than that of the general population. Approximately one in five patients with Crohn's disease will report having at least one affected relative. The concordance rate among monozygotic twins is as high as 67%; however, Crohn's disease is not associated with simple Mendelian inheritance patterns. Although there is a tendency within families for either ulcerative colitis or Crohn's disease to be present exclusively, mixed kindreds also occur, suggesting the presence of some shared genetic traits as a basis for both diseases.

Higher socioeconomic status is associated with an increased risk of Crohn's disease. Most studies have found breastfeeding to be protective against the development of Crohn's disease. Crohn's disease is more prevalent among smokers. Furthermore, smoking is associated with the increased risk for both the need for surgery and the risk of relapse after surgery for Crohn's disease.

Pathophysiology

Crohn's disease is characterized by sustained inflammation. Whether this inflammation represents an appropriate response to a yet unrecognized pathogen or an inappropriate response to a normally innocuous stimulus is unknown. Various hypotheses on the roles of environmental and genetic factors in the pathogenesis of Crohn's disease have been proposed. Many infectious agents have been suggested to be the causative organism of Crohn's disease. Candidate organisms have included chlamydia, *Listeria monocytogenes*, *Pseudomonas* species, reovirus, *Mycobacterium paratuberculosis*, and many others. There is no conclusive evidence that any of these organisms is the causative agent. Studies using animal models suggest that in a genetically susceptible host, nonpathogenic, commensal enteric flora are sufficient to induce a chronic inflammatory response resembling that associated with Crohn's disease. In these models, the sustained intestinal inflammation is the result of either abnormal epithelial barrier function or immune dysregulation. Poor barrier function is hypothesized to permit inappropriate exposure of lamina propria lymphocytes to antigenic stimuli derived from the intestinal lumen. In addition, a variety of defects in immune regulatory mechanisms (e.g., overresponsiveness of mucosal T cells to enteric flora-derived antigens) can lead to defective immune tolerance and sustained inflammation.

Specific genetic defects associated with Crohn's disease in human patients are beginning to be defined. For example, the presence of a locus on chromosome 16 (the so-called IBD1 locus) has been linked to Crohn's disease. The IBD1 locus has been identified as the *NOD2* gene. Persons with allelic variants on both chromosomes have a 40-fold relative risk of Crohn's disease compared to those without variant *NOD2* genes. The relevance of this gene to the pathogenesis of Crohn's disease is biologically plausible, as the protein product of the *NOD2* gene mediates the innate immune response to microbial pathogens. Other putative IBD loci have been identified on other chromosomes (IBD2 on chromosome 12q and IBD3 on chromosome 6) and are under investigation.

Although the pathologic hallmark of Crohn's disease is focal, transmural inflammation of the intestine, a spectrum of pathologic lesions can be present. The earliest lesion characteristic of Crohn's disease is the aphthous ulcer. These superficial ulcers are up to 3 mm in diameter and are surrounded by a halo

of erythema. In the small intestine, aphthous ulcers typically arise over lymphoid aggregates. Granulomas are highly characteristic of Crohn's disease and are reported to be present in up to 70% of intestinal specimens obtained during surgical resection. These granulomas are noncaseating and can be found in both areas of active disease and apparently normal intestine, in any layer of the bowel wall, and in mesenteric lymph nodes.

As disease progresses, aphthae coalesce into larger, stellate-shaped ulcers. Linear or serpiginous ulcers may form when multiple ulcers fuse in a direction parallel to the longitudinal axis of the intestine. With transverse coalescence of ulcers, a cobblestoned appearance of the mucosa may arise.

With advanced disease, inflammation can be transmural. Serosal involvement results in adhesion of the inflamed bowel to other loops of bowel or other adjacent organs. Transmural inflammation can also result in fibrosis with stricture formation, intra-abdominal abscesses, fistulas, and, rarely, free perforation. Inflammation in Crohn's disease can affect discontinuous portions of intestine—so-called “skip lesions” that are separated by intervening normal-appearing intestine.

A feature of Crohn's disease that is grossly evident and helpful in identifying affected segments of intestine during surgery is the presence of *fat wrapping*, which represents encroachment of mesenteric fat onto the serosal surface of the bowel (Fig. 28-17). This finding is virtually pathognomonic of Crohn's disease. The presence of fat wrapping correlates well with the presence of underlying acute and chronic inflammation.

Features that allow for differentiation between Crohn's disease of the colon and ulcerative colitis include the layers of the bowel wall affected (inflammation in ulcerative colitis is limited to the mucosa and submucosa but may involve the full thickness of the bowel wall in Crohn's disease) and the longitudinal extent of inflammation (inflammation is continuous and characteristically affects the rectum in ulcerative colitis but may be discontinuous and spare the rectum in Crohn's disease). In the absence of full expression of features of advanced disease, Crohn's colitis can sometimes be difficult to distinguish from ulcerative colitis. It is also important to remember that although ulcerative colitis is a disease of the colon, it can be associated with inflammatory changes in the distal ileum (backwash ileitis).

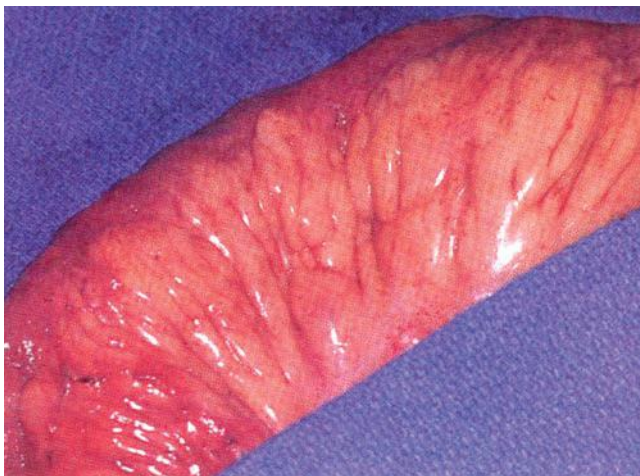

Figure 28-17. Crohn's disease. This intraoperative photograph demonstrates encroachment of mesenteric fat onto the serosal surface of the intestine (“fat wrapping”) that is characteristic of intestinal segments affected by active Crohn's disease.

Clinical Presentation

The most common symptoms of Crohn's disease are abdominal pain, diarrhea, and weight loss. However, the clinical features are highly variable among individual patients and depend on which segment(s) of the GI tract is (are) predominantly affected, the intensity of inflammation, and the presence or absence of specific complications. Patients with Crohn's disease can be classified by their predominant clinical manifestation as having primarily (a) fibrostenotic disease, (b) fistulizing disease, or (c) aggressive inflammatory disease. There is substantial overlap among these disease patterns in individual patients, however. The onset of symptoms is insidious, and once present, their severity follows a waxing and waning course. Constitutional symptoms, particularly weight loss and fever, or growth retardation in children, may also be prominent and are occasionally the sole presenting features of Crohn's disease.

The disease affects the small bowel in 80% of cases and the colon alone in 20%. In those with small bowel disease, the majority have ileocecal disease. The small bowel alone is affected in 15% to 30% of patients. Isolated perineal and anorectal disease occurs in 5% to 10% of affected patients. Uncommon sites of involvement include the esophagus, stomach, and duodenum.

An estimated one fourth of all patients with Crohn's disease will have an extraintestinal manifestation of their disease. One fourth of those affected will have more than one manifestation. Many of these complications are common to both Crohn's disease and ulcerative colitis, although as a whole, they are more prevalent among patients with Crohn's disease than those with ulcerative colitis. The most common extraintestinal manifestations are listed in Table 28-7. The clinical severity of some of these manifestations, such as erythema nodosum and peripheral arthritis, are correlated with the severity of intestinal inflammation. The severity of other manifestations, such as pyoderma gangrenosum and ankylosing spondylitis, bear no apparent relationship to the severity of intestinal inflammation.

Diagnosis

The diagnosis is usually established with endoscopic findings in a patient with a compatible clinical history. The diagnosis should be considered in those presenting with acute or chronic abdominal pain, especially when localized to the right lower quadrant, chronic diarrhea, evidence of intestinal inflammation on radiography or endoscopy, the discovery of a bowel stricture or fistula arising from the bowel, and evidence of inflammation or granulomas on intestinal histology. Disorders associated with clinical presentations that resemble those of Crohn's disease include ulcerative colitis, functional bowel disorders such as irritable bowel syndrome, mesenteric ischemia, collagen vascular diseases, carcinoma and lymphoma, diverticular disease, and infectious enteritides. These infectious enteritides are most frequently diagnosed in immunocompromised patients but can also occur in patients with normal immune function. Acute ileitis caused by *Campylobacter* and *Yersinia* species can be difficult to distinguish from that caused by an acute presentation of Crohn's disease. Typhoid enteritis caused by *Salmonella typhosa* can lead to overt intestinal bleeding and perforation, most often affecting the terminal ileum. The distal ileum and cecum are the most common sites of intestinal involvement by infection due to *Mycobacterium tuberculosis*. This condition can result in intestinal inflammation, strictures, and fistula formation, similar to those seen in Crohn's disease.

Table 28-7

Extraintestinal manifestations of Crohn's disease

Dermatologic
Erythema nodosum
Pyoderma gangrenosum
Rheumatologic
Peripheral arthritis
Ankylosing spondylitis
Sacroiliitis
Ocular
Conjunctivitis
Uveitis/iritis
Episcleritis
Hepatobiliary
Hepatic steatosis
Cholelithiasis
Primary sclerosing cholangitis
Pericholangitis
Urologic
Nephrolithiasis
Ureteral obstruction
Miscellaneous
Thromboembolic disease
Vasculitis
Osteoporosis
Endocarditis, myocarditis, pleuropericarditis
Interstitial lung disease
Amyloidosis
Pancreatitis

Cytomegalovirus (CMV) can cause intestinal ulcers, bleeding, and perforation.

No single symptom, sign, or diagnostic test establishes the diagnosis of Crohn's disease. Instead, the diagnosis is based on a complete assessment of the clinical presentation with confirmatory findings derived from radiographic, endoscopic, and in most cases pathologic tests. Colonoscopy with intubation of terminal ileum is the main diagnostic tool and can reveal focal ulcerations adjacent to areas of normal-appearing mucosa along with polypoid mucosal changes that give a "cobblestone appearance." Skip areas of involvement are typical, with segments of normal-appearing bowel interrupted by large areas of obvious disease; this pattern is different from the continuous involvement in ulcerative colitis. Pseudopolyps, as seen in ulcerative colitis, are also often present. Contrast examinations of the small bowel and colon may reveal strictures or networks of ulcers and fissures. CT scanning may reveal intra-abdominal abscesses and is useful in acute presentations to rule out the presence of other intra-abdominal disorders. Esophagogastroduodenoscopy (EGD) is done for disease of the proximal alimentary tract. Because Crohn's disease often affects the small bowel, which is difficult to image, capsule endoscopy has been increasingly used to make this diagnosis (Fig. 28-18).³⁹

Several antibodies have also been identified in patients with inflammatory bowel disease, which may have diagnostic value. The most commonly tested antibodies are antineutrophil cytoplasmic antibody (pANCA) and anti-*Saccharomyces cerevisiae* antibody (ASCA). ASCA +/pANCA- is associated with a diagnosis of Crohn's disease, while ASCA-/pANCA+ correlates with ulcerative colitis. Although these antibody tests

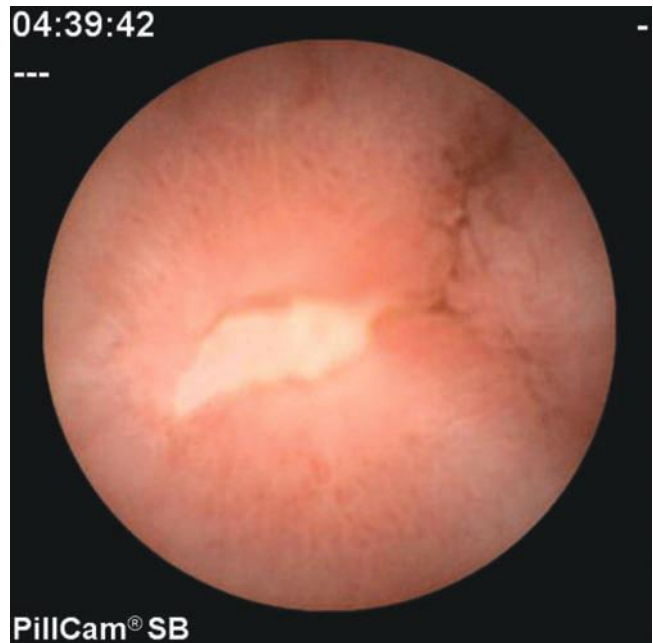


Figure 28-18. Crohn's disease. This image was captured by a wireless capsule endoscope as it was traveling through the small intestine. It demonstrates a superficial ulceration in the small bowel consistent with Crohn's disease. (Used with permission from Dr. Anne C. Travis, Division of Gastroenterology, Brigham and Women's Hospital, Boston, MA.)

are commercially available, their widespread use has been hampered by low test sensitivities.

Because of the insidious, and often nonspecific, presentation, the diagnosis of Crohn's disease is typically made only after symptoms have been present for several years. However, in acute presentations, the diagnosis is sometimes made intraoperatively or during surgical evaluation. The initial manifestation of Crohn's disease can consist of right lower quadrant abdominal mimicking the presentation of acute appendicitis. In patients with this presentation, Crohn's disease can be discovered for the first time during laparotomy or laparoscopy performed for presumed appendicitis. In some patients, the initial manifestation of Crohn's disease is an acute abdomen related to small bowel obstruction, intra-abdominal abscess, or free intestinal perforation. In other patients, perianal abscesses and fistulas requiring surgical therapy may be the first manifestation of Crohn's disease.

Therapy

Because no curative therapies are available for Crohn's disease, the goal of treatment is to palliate symptoms rather than to achieve cure. Medical therapy is used to induce and maintain disease remission. Surgery is reserved for specific indications described later. In addition nutritional support in the form of aggressive enteral regimens or, if necessary, parenteral nutrition is used to manage the malnutrition that is common in patients with Crohn's disease.

Medical Therapy. Pharmacologic agents used to treat Crohn's disease include antibiotics, aminosalicylates, corticosteroids, and immunomodulators. Antibiotics have an adjunctive role in the treatment of infectious complications associated with Crohn's disease. They are also used to treat patients with perianal disease, enterocutaneous fistulas, and active colonic disease.

Most studies have shown oral 5-aminosalicylic acid (5-ASA) drugs (e.g., mesalamine) to be superior to placebo in inducing disease remission. Their efficacy in the maintenance of remission is less clear. Aminosaliculates are associated with minimal toxicity and are available in a variety of formulations that allow for their delivery to specific regions of the alimentary tract. In Crohn's disease, sulfasalazine, the parent compound of 5-ASA and widely used in ulcerative colitis, has been shown to be less effective than 5-ASA.

Orally administered glucocorticoids are used to treat patients with mildly to moderately severe disease that does not respond to aminosaliculates. Patients with severe active disease usually require intravenous administration of glucocorticoids. Although glucocorticoids are effective in inducing remission, they are ineffective in preventing relapse, and their adverse effect profile makes long-term use hazardous. Therefore, they should be tapered once remission is achieved. Some patients are unable to undergo glucocorticoid tapering without suffering recurrence of symptoms. Such patients are said to have steroid dependence. In these patients, along with those who do not respond to steroids at all (steroid resistant), use of immune modulators should be considered.

The thiopurine antimetabolites azathioprine and its active metabolite, 6-mercaptopurine, have demonstrated efficacy in inducing remission, in maintaining remission, and in allowing for glucocorticoid tapering in glucocorticoid-dependent patients. A response to these medications is usually observed in 3 to 6 months. There is also some evidence that they decrease the risk of relapse after intestinal resection for Crohn's disease. These agents are relatively safe but can induce bone marrow suppression and promote infectious complications. For patients who do not respond to the thiopurines, methotrexate is an alternative that is usually given intramuscularly before switching to an oral form after achieving symptomatic control. There is little role for cyclosporine in Crohn's disease; its efficacy/toxicity profile in this disease is poor.

The successful introduction of infliximab (Remicade), an anti-tumor necrosis factor- α (TNF- α) antibody, heralded the era of biologic therapies for inflammatory bowel disease. Infliximab is a chimeric monoclonal anti-TNF α antibody that has been shown to have efficacy in inducing remission and in promoting closure of enterocutaneous fistulae. It is generally used for patients resistant to standard therapy, in order to help taper steroid dosage. Infliximab is generally well tolerated but should not be used in patients with ongoing septic processes, such as undrained intra-abdominal abscesses. Whereas infliximab is a mouse-human chimeric antibody, the newer drugs in this group include adalimumab (Humira), which is a fully human antibody. Antibodies against other targets in this inflammatory pathway have also been developed and are in various stages of clinical evaluation. Recent studies have shown that these biologic therapies can be used safely after surgery for Crohn's disease. In a randomized study of 24 patients, those receiving infliximab starting 4 weeks after ileal resection had improved endoscopic and histologic scores at 1-year follow-up compared to those receiving placebo.⁴⁰

For patients with perianal disease, antibiotic therapy with metronidazole or ciprofloxacin is the primary step. Two to 4 weeks of therapy is needed before improvements are seen, and often long-term therapy is required to prevent relapse. In cases of relapse, azathioprine can be considered. In patients with fistulas, infliximab and azathioprine are drugs of choice.

Surgical Therapy. Fifty to seventy percent of patients with Crohn's disease will ultimately require at least one surgical intervention for their disease.^{41,42} Surgery is generally reserved for patients whose disease is unresponsive to aggressive medical therapy or who develop complications of their disease (Table 28-8). Failure of medical management may be the indication for surgery if symptoms persist despite aggressive therapy for several months or if symptoms recur whenever aggressive therapy is tapered. Surgery should be considered if medication-induced complications arise, specifically corticosteroid-related complications, such as cushingoid features, cataracts, glaucoma, systemic hypertension, compression fractures, or aseptic necrosis of the femoral head. Growth retardation constitutes an indication for surgery in 30% of children with Crohn's disease.

One of the most common indications for surgical intervention is intestinal obstruction. Abscesses and fistulas are frequently encountered during operations performed for intestinal obstruction in these patients, but are rarely the only indication for surgery. Most abscesses are amenable to percutaneous drainage, and fistulas, unless associated with symptoms or metabolic derangements, do not require surgical intervention. Less common complications that require surgical intervention are acute GI hemorrhage, perforations, and development of cancer.

Although most commonly, surgery for Crohn's disease is planned, an uncommon, but not rare, scenario is the intraoperative discovery of inflammation limited to the terminal ileum during operations performed for presumed appendicitis. This scenario can result from an acute presentation of Crohn's disease or from acute ileitis caused by bacteria such as *Yersinia* or *Campylobacter*. Both conditions should be treated medically; ileal resection is not generally indicated. However, the appendix, even if normal appearing, should be removed (unless the cecum is inflamed, increasing the potential morbidity of this procedure) in order to eliminate appendicitis from the differential diagnosis of abdominal pain in these patients, particularly those with Crohn's disease who may be destined to have recurring symptoms.

When the diagnosis of Crohn's disease is known and surgery planned, thorough examination of the entire intestine should be performed. The presence of active disease is suggested by thickening of the bowel wall, narrowing of the lumen, serosal inflammation and coverage by creeping fat, and thickening of the mesentery. Skip lesions are present in approximately

Table 28-8

Indications for surgical intervention in Crohn's disease

Acute onset of severe disease:

Crohn's colitis +/- toxic megacolon (rare)

Failure of medical therapy:

Persistent symptoms despite long-term steroid use

Recurrence of symptoms when high-dose steroids are tapered

Drug-induced complications (Cushing's disease, hypertension)

Development of disease complications:

Obstruction

Perforation

Complicated fistulas

Hemorrhage

Malignancy risk

20% of cases and should be sought. The length of uninvolved small intestine should be noted.

Segmental intestinal resection of grossly evident disease followed by primary anastomosis is the usual procedure of choice. Microscopic evidence of Crohn's disease at the resection margins does not compromise a safe anastomosis, and frozen-section analysis of resection margins is unnecessary. In a randomized prospective trial, the effects of achieving 2-cm resection margins beyond grossly evident disease were compared with achieving 12-cm resection margins.⁴³ There were no evident differences with respect to clinical recurrence rates or anastomotic recurrences. Recurrence rates were similar whether margins were histologically free of or involved with Crohn's disease. An area of controversy in surgical management of Crohn's disease has been the ideal anastomotic technique for the bowel after intestinal resection. This issue was addressed in a randomized study of 139 patients undergoing an ileocolic resection for Crohn's disease, with a mean follow-up of 11.9 months. There were no differences in endoscopic or symptomatic disease recurrence between the groups reconstructed using end-to-end sutured (2-0 PDS) anastomosis vs. those with side-to-side staples anastomosis.⁴⁴

An alternative to segmental resection for obstructing lesions is stricturoplasty (Fig. 28-19). This technique allows for preservation of intestinal surface area and is especially well suited to patients with extensive disease and fibrotic strictures who may have undergone previous resection and are at risk for developing short bowel syndrome. In this technique, the bowel

is opened longitudinally to expose the lumen. Any intraluminal ulcerations should be biopsied to rule out the presence of neoplasia. Depending on the length of the stricture, the reconstruction can be fashioned in a manner similar to the Heinecke-Mickulicz pyloroplasty (for strictures <12 cm in length) or the Finney pyloroplasty (for longer strictures as much as 25 cm in length). For longer strictures, variations on the standard stricturoplasty, namely the side-to-side isoperistaltic enteroenterostomy, have been advocated and used for strictures with mean lengths of 50 cm.⁴⁵ Stricturoplasty sites should be marked with metallic clips to facilitate their identification on radiographs and during subsequent operations. Stricturoplasty is associated with recurrence rates that are no different from those associated with segmental resection. Because the affected bowel is left in situ rather than resected, there is the potential for cancer developing at the stricturoplasty site. However, as data on this complication are limited to anecdotes, this risk remains a theoretical one. Stricturoplasty is contraindicated in patients with intra-abdominal abscesses or intestinal fistulas. The presence of a solitary stricture relatively close to a segment for which resection is planned is a relative contraindication. In general, stricturoplasty is performed in cases where single or multiple strictures are identified in diffusely involved segments of bowel or where previous resections have been performed and maintenance of intestinal length is of great importance.

Intestinal bypass procedures are sometimes required in the presence of intramesenteric abscesses or if the diseased bowel is coalesced in the form of a dense inflammatory mass, making its mobilization unsafe. Bypass procedures (gastrojejunostomy) are also used in the presence of duodenal strictures, for which stricturoplasty and segmental resection can be technically difficult.

Since the 1990s, laparoscopic surgical techniques have been applied to patients with Crohn's disease. The inflammatory changes associated with Crohn's disease such as thickened and foreshortened mesentery, obliterated tissue planes, and friable tissues with engorged vasculature can make the laparoscopic approach challenging. Randomized studies and a meta-analysis have confirmed that laparoscopic surgery for Crohn's disease is associated with less postoperative pain, shorter duration of ileus, and a shorter hospital stay. The rates of disease recurrence were similar between the two groups.⁴⁶

Outcomes

Overall complication rates following surgery for Crohn's disease range from 15% to 30%. Wound infections, postoperative intra-abdominal abscesses, and anastomotic leaks account for most of these complications.

Most patients whose disease is resected eventually develop recurrence. If recurrence is defined endoscopically, 70% recur within 1 year of a bowel resection and 85% by 3 years.⁴⁷ Clinical recurrence, defined as the return of symptoms confirmed as being due to Crohn's disease, affects 60% of patients by 5 years and 94% by 15 years after intestinal resection. Reoperation becomes necessary in approximately one third of patients by 5 years after the initial operation, with a median time to reoperation of 7 to 10 years.⁴⁸

INTESTINAL FISTULAS

A *fistula* is defined as an abnormal communication between two epithelialized surfaces. The communication occurs between two parts of the GI tract or adjacent organs in an *internal fistula* (e.g., enterocolonic fistula or colovesicular fistula). An *external*

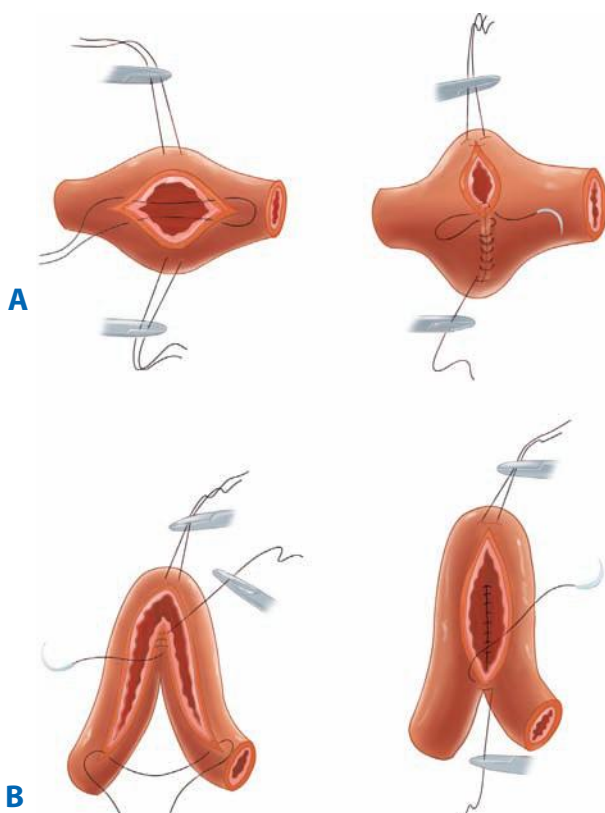


Figure 28-19. Stricturoplasty. The wall of the strictured bowel is incised longitudinally. Reconstruction is performed by closing the defect transversely in a manner similar to the Heinecke-Mickulicz pyloroplasty for short strictures (A), or the Finney pyloroplasty for longer strictures (B).

fistula (e.g., enterocutaneous fistula or rectovaginal fistula) involves the skin or another external surface epithelium. Enterocutaneous fistulas that drain less than 200 mL of fluid per day are known as *low-output fistulas*, whereas those that drain more than 500 mL of fluid per day are known as *high-output fistulas*.

Over 80% of enterocutaneous fistulas represent iatrogenic complications that occur as the result of enterotomies or intestinal anastomotic dehiscences. Fistulas that arise spontaneously without antecedent iatrogenic injury are usually manifestations of progression of underlying Crohn's disease or cancer.

Pathophysiology

The manifestations of fistulas depend on which structures are involved. Low-resistance enteroenteric fistulas, which allow luminal contents to bypass a significant proportion of the small intestine, may result in clinically significant malabsorption. Enterovesicular fistulas often cause recurrent urinary tract infections. The drainage emanating from enterocutaneous fistulas are irritating to the skin and cause excoriation. The loss of enteric luminal contents, particularly from high-output fistulas originating from the proximal small intestine, results in dehydration, electrolyte abnormalities, and malnutrition.

Fistulas have the potential to close spontaneously. Factors inhibiting spontaneous closure, however, include malnutrition, sepsis, inflammatory bowel disease, cancer, radiation, obstruction of the intestine distal to the origin of the fistula, foreign bodies, high output, short fistulous tract (<2 cm) and epithelialization of the fistula tract (Table 28-9).

Clinical Presentation

Iatrogenic enterocutaneous fistulas usually become clinically evident between the fifth and tenth postoperative days. Fever, leukocytosis, prolonged ileus, abdominal tenderness, and wound infection are the initial signs. The diagnosis becomes obvious when drainage of enteric material through the abdominal wound or through existing drains occurs. These fistulas are often associated with intra-abdominal abscesses.

Diagnosis

CT scanning following the administration of enteral contrast is the most useful initial test. Leakage of contrast material from the intestinal lumen can be observed. Intra-abdominal abscesses

should be sought and drained percutaneously. If the anatomy of the fistula is not clear on CT scanning, a small bowel series or enteroclysis examination can be obtained to demonstrate the fistula's site of origin in the bowel. This study is also useful to rule out the presence of intestinal obstruction distal to the site of origin. Occasionally, contrast administered into the intestine does not demonstrate the fistula tract. A *fistulogram*, in which contrast is injected under pressure through a catheter placed percutaneously into the fistula tract, may offer greater sensitivity in localizing the fistula origin.

Therapy

The treatment of enterocutaneous fistulas should proceed through an orderly sequence of steps.⁴⁹

1. **Stabilization.** Fluid and electrolyte resuscitation is begun. Nutrition is provided, usually through the parenteral route initially. Sepsis is controlled with antibiotics and drainage of abscesses. The skin is protected from the fistula effluent with ostomy appliances or fistula drains.
2. **Investigation.** The anatomy of the fistula is defined using the studies described earlier.
3. **Decision.** The available treatment options are considered, and a timeline for conservative measures is determined.
4. **Definitive management.** This entails the surgical procedure and requires appropriate preoperative planning and surgical experience.
5. **Rehabilitation.**

The overall objective is to increase the probability of spontaneous closure. Nutrition and time are the key components of this approach. Most patients will require TPN; however, a trial of oral or enteral nutrition should be attempted in patients with low-output fistulas originating from the distal intestine. The somatostatin analogue octreotide is a useful adjunct, particularly in patients with high-output fistulas; its administration reduces the volume of fistula output, thereby facilitating fluid and electrolyte management. Further, octreotide may accelerate the rate at which fistulas close; however, its administration has not clearly been demonstrated to increase the probability of spontaneous closure.

Timing of Surgical Intervention. Most surgeons would pursue 2 to 3 months of conservative therapy before considering surgical intervention. This approach is based on evidence that 90% of fistulas that are going to close do so within 5 weeks and also that surgical intervention after this time period is associated with better outcomes and lower morbidity.⁵⁰

If the fistula fails to resolve during this period, surgery may be required during which the fistula tract, together with the segment of intestine from which it originates, should be resected. Simple closure of the opening in the intestine from which the fistula originates is associated with high recurrence rates. Patients with intestinal fistulas typically have extensive and dense intra-abdominal adhesions. As a result, operations performed for nonhealing fistulas can present formidable challenges. Successful applications of alternative therapies to close intestinal fistulas such as the use of biologic sealants have been reported. The indications for their use remain to be defined.

Outcomes

Over 50% of intestinal fistulas close spontaneously. A useful mnemonic designates factors that inhibit spontaneous closure of

Table 28-9

Factors negatively impacting enteric fistula closure

Patient factors
Poor nutrition
Medications such as steroids
Etiologic factors
Malignant fistula
Fistula related to Crohn's disease
Fistula in radiated fields
Fistula site
Gastric
Duodenal
Local factors
Persistence of local inflammation and sepsis
Presence of a foreign body (e.g., meshes or sutures)
Epithelialization of fistula tract
Fistula tract <2 cm
Distal obstruction to the fistula site

Table 28-10

Features of small-intestinal malignancies

TUMOR TYPE	CELL OF ORIGIN	FREQUENCY ^a	PREDOMINANT SITE
Adenocarcinoma	Epithelial cell	35%–50%	Duodenum
Carcinoid	Enterochromaffin cell	20%–40%	Ileum
Lymphoma	Lymphocyte	10%–15%	Ileum
GIST	?Interstitial cell of Cajal	10%–15%	—

^aFrequencies given as percentages of small intestinal malignancies comprised by each of the tumor types. Gastrointestinal stromal tumors (GISTs) display no regional variation in prevalence within the small intestine.

intestinal fistulas: “FRIEND” (Foreign body within the fistula tract, Radiation enteritis, Infection/Inflammation at the fistula origin, Epithelialization of the fistula tract, Neoplasm at the fistula origin, Distal obstruction of the intestine) (Table 28-10).

In a recent 23-year old retrospective review of 153 cases of enterocutaneous fistulas that were treated surgically, the majority of fistulas were found to originate from the small bowel and be iatrogenic in nature, with patients having undergone five or more previous abdominal surgeries. Operative repair was associated with a 30-day mortality of approximately 4% and a 1-year mortality of 15%. Morbidity was over 80%. First attempt at surgical repair was successful in 70% of cases, with an overall closure rate of 84% and some patients requiring up to three attempts at surgical repair. The authors identified closure of the abdominal fascia as an important factor in reducing rates of refistulization and postoperative mortality.⁵¹ In another similar study, fistula recurrence rates of 30% were again documented and were independently associated with high-output fistulas and the type of surgical treatment: operations not involving resection of the fistula had a much higher rate of recurrence.⁵²

SMALL BOWEL NEOPLASMS

Adenomas are the most common benign neoplasm of the small intestine. Other benign tumors include fibromas, lipomas, hemangiomas, lymphangiomas, and neurofibromas. The prevalence of small bowel tumors identified at autopsy is 0.2% to 0.3%, which is significantly higher than the rate of operation for small bowel tumors. This suggests that the majority of small bowel tumors are asymptomatic. These lesions are most frequently encountered in the duodenum as incidental findings during esophagogastroduodenoscopic (EGD) examinations (Fig. 28-20). The reported prevalence of duodenal polyps, as detected during EGD performed for other reasons, ranges from 0.3% to 4.6%.⁵³

Benign neoplasms account for 30% to 50% of small bowel tumors and include adenomas, lipomas, hamartomas, and hemangiomas. Primary small bowel cancers are rare, with an estimated incidence of 5300 cases per year in the United States.⁵⁴ Among small bowel cancers, adenocarcinomas comprise 35% to 50% of all cases, carcinoid tumors comprise 20% to 40%, and lymphomas comprise approximately 10% to 15%. In a retrospective review of a large U.S. database (Surveillance, Epidemiology, and End Results) between 1992 and 2006, of a total of 10,945 small intestine cancers, 4315 were neuroendocrine in origin, 3412 were carcinomas, 2023 were lymphomas, and 1084 were sarcomas.⁵⁵ GI stromal tumors (GISTs) are the most common mesenchymal tumors arising in the small intestine and

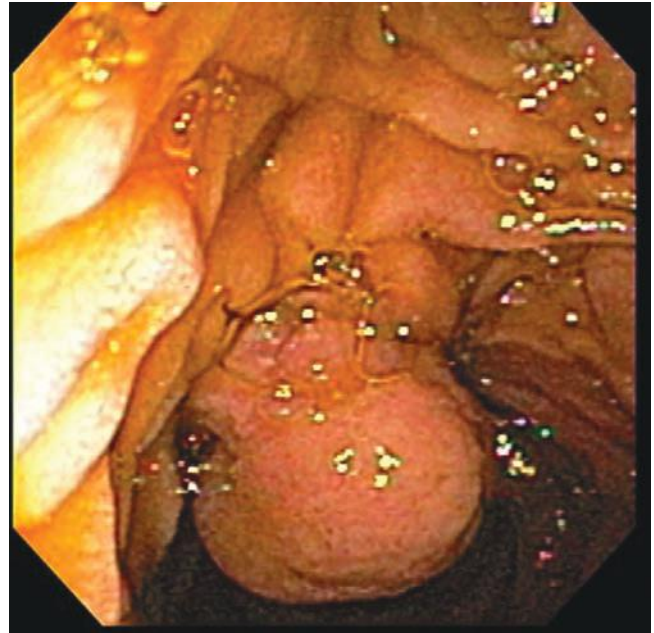


Figure 28-20. Duodenal polyp. This polyp was incidentally encountered during esophagogastroduodenoscopy. It was biopsied and found to be an adenoma.

comprise the vast majority of tumors that were formerly classified as leiomyomas, leiomyosarcomas, and smooth muscle tumors of the intestine. The small intestine is frequently affected by metastases from or local invasion by cancers originating at other sites. Melanoma, in particular, is associated with a propensity for metastasis to the small intestine.

Most patients with small-intestinal cancers are in their fifth or sixth decade of life. Reported risk factors for developing small-intestinal cancers include consumption of red meat, ingestion of smoked or cured foods, Crohn’s disease, celiac sprue, hereditary nonpolyposis colorectal cancer (HNPCC), familial adenomatous polyposis (FAP), and Peutz-Jeghers syndrome.

Pathophysiology

The small intestine contains over 90% of the mucosal surface area of the GI tract, but only 1.1% to 2.4% of all GI malignancies. Proposed explanations for the low frequency of small-intestinal neoplasms include (a) dilution of environmental carcinogens in the liquid chyme present in the small-intestinal lumen, (b) rapid transit of chyme, limiting the contact time between carcinogens and the intestinal mucosa, (c) a relatively

low concentration of bacteria in small-intestinal chyme and, therefore, a relatively low concentration of carcinogenic products of bacterial metabolism, (d) mucosal protection by secretory IgA and hydrolases such as benzpyrene hydroxylase that may render carcinogens less active, and (e) efficient epithelial cellular apoptotic mechanisms that serve to eliminate clones harboring genetic mutations.

Recent advances have begun to clarify the molecular pathogenesis of small-intestinal adenocarcinomas and GISTs; there has been less progress with respect to the pathogenesis of the other small-intestinal malignancies (see Table 28-10). Small-intestinal adenocarcinomas are believed to arise from pre-existing adenomas through a sequential accumulation of genetic abnormalities in a model similar to that described for the pathogenesis of colorectal cancer. Adenomas are histologically classified as tubular, villous, and tubulovillous. Tubular adenomas have the least aggressive features. Villous adenomas have the most aggressive features and tend to be large, sessile, and located in the second portion of the duodenum. Malignant degeneration has been reported to be present in up to 45% of villous adenomas by the time of diagnosis. Patients with FAP have a nearly 100% cumulative lifetime risk of developing duodenal adenomas that have the potential to undergo malignant transformation. The risk of duodenal cancer in these patients is over 100-fold that in the general population. Indeed, duodenal cancer is the leading cause of cancer-related death among patients with FAP who have undergone colectomy. Patients with Peutz-Jeghers syndrome develop hamartomatous polyps; however, these polyps can contain adenomatous foci that can undergo malignant transformation (Fig. 28-21).

A defining feature of GISTs is their gain-of-function mutation of proto-oncogene KIT, a receptor tyrosine kinase. Pathologic KIT signal transduction is believed to be a central event in GIST pathogenesis. The majority of GISTs have

activating mutations in the *c-kit* protooncogene, which cause KIT to become constitutively activated, presumably leading to persistence of cellular growth or survival signals. Because the interstitial cells of Cajal normally express KIT, these cells have been implicated as the cell of origin for GISTs. KIT expression is assessed by staining the tissues for CD117 antigen, which is part of the KIT receptor, and present in 95% of GISTs.

Clinical Presentation

Most small-intestinal neoplasms are asymptomatic until they become large. Partial small bowel obstruction, with associated symptoms of crampy abdominal pain and distention, nausea, and vomiting, is the most common mode of presentation. Obstruction can be the result of either luminal narrowing by the tumor itself or intussusception, with the tumor serving as the lead point. Hemorrhage, usually indolent, is the second most common mode of presentation.

Physical examination may be unrevealing. Up to 25% of patients with small-intestinal malignancies are reported to have a palpable abdominal mass. Findings of intestinal obstruction are reported to be present in 25% of patients. Fecal occult blood test may be positive. Jaundice secondary to biliary obstruction or hepatic metastasis may be present. Cachexia, hepatomegaly, and ascites may be present with advanced disease.

Although the clinical presentation is usually not specific for tumor type, some general comments are appropriate. Adenocarcinomas, as well as adenomas (from which most are believed to arise), are most commonly found in the duodenum, except in patients with Crohn's disease, in whom most are found in the ileum. Lesions in the periampullary location can cause obstructive jaundice or pancreatitis. Adenocarcinomas located in the duodenum tend to be diagnosed earlier in their progression than those located in the jejunum or ileum, which are rarely diagnosed prior to the onset of locally advanced or metastatic disease.

Carcinoid tumors of the small intestine are also usually diagnosed after the development of metastatic disease. These tumors are associated with a more aggressive behavior than the more common appendiceal carcinoid tumors. Approximately 25% to 50% of patients with carcinoid tumor-derived liver metastases will develop manifestations of the carcinoid syndrome. These manifestations include diarrhea, flushing, hypotension, tachycardia, and fibrosis of the endocardium and valves of the right heart. Candidate tumor-derived mediators of the carcinoid syndrome such as serotonin, bradykinin, and substance P undergo nearly complete metabolism during first passage through the liver. As a result, symptoms of carcinoid syndrome are rare in the absence of liver metastases.

Lymphoma may involve the small intestine primarily or as a manifestation of disseminated systemic disease. Primary small-intestinal lymphomas are most commonly located in the ileum, which contains the highest concentration of lymphoid tissue in the intestine. Although partial small bowel obstruction is the most common mode of presentation, 10% of patients with small-intestinal lymphoma present with bowel perforation.

Sixty to seventy percent of GISTs are located in the stomach. The small intestine is the second most common site, containing 25% to 35% of GISTs. There appears to be no regional variation in the prevalence of GISTs within the small intestine. GISTs have a greater propensity to be associated with overt hemorrhage than the other small-intestinal malignancies (Fig. 28-22).

Metastatic tumors involving the small intestine can induce intestinal obstruction and bleeding.

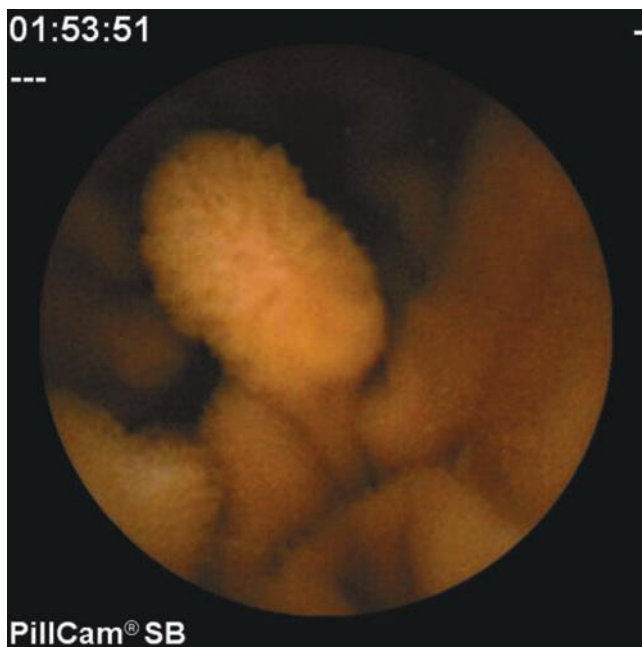

Figure 28-21. Small bowel polyp in Peutz-Jeghers syndrome. This image was captured by a wireless capsule endoscope as it was traveling through the small intestine. (Used with permission from Dr. Anne C. Travis, Division of Gastroenterology, Brigham and Women's Hospital, Boston, MA.)

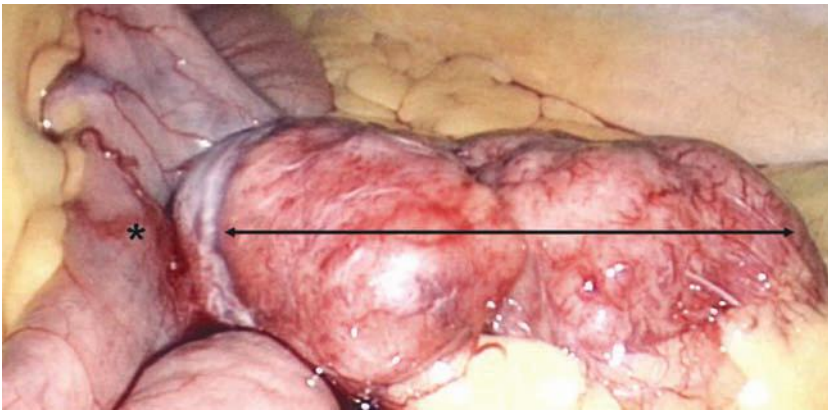


Figure 28-22. Jejunal gastrointestinal (GI) stromal tumor (GIST). This patient presented with overt obscure GI bleeding and was found to have a 7-cm jejunal GIST. The picture represents the laparoscopic view of the mass (*black arrow*), arising from the antimesenteric side of the small bowel (*). He underwent a successful laparoscopic resection.

Diagnosis

Because of the absent or nonspecific symptoms associated with most small-intestinal neoplasms, these lesions are rarely diagnosed preoperatively. Laboratory tests are nonspecific, with the exception of elevated serum 5-hydroxyindole acetic acid (5-HIAA) levels in patients with the carcinoid syndrome. Elevated carcinoembryonic antigen (CEA) levels are associated with small-intestinal adenocarcinomas, but only in the presence of liver metastases.

Contrast radiography of the small intestine may demonstrate benign and malignant lesions. Enteroclysis is reported to have a sensitivity of over 90% in the detection of small bowel tumors and is the test of choice, particularly for tumors located in the distal small bowel. Upper GI with small bowel follow-through examinations have reported sensitivities ranging from only 30% to 44%.⁵⁵ CT scanning has low sensitivity for detecting mucosal or intramural lesions but can demonstrate large tumors and is useful in the staging of intestinal malignancies. Tumors associated with significant bleeding can be localized with angiography or radioisotope-tagged red blood cell (RBC) scans.

Tumors located in the duodenum can be visualized and biopsied on EGD. In addition, endoscopic ultrasonography (EUS) can offer additional information such as the layers of the intestinal wall involved by the lesion. Occasionally, the distal ileum can be successfully visualized during colonoscopy. Intraoperative enteroscopy can be used to directly visualize small-intestinal tumors beyond the reach of standard endoscopic techniques. Recently, capsule endoscopy and double-balloon endoscopy have been used to evaluate small bowel.

Therapy

Benign neoplasms of the small intestine that are symptomatic should be surgically resected or removed endoscopically, if feasible. Tumors located in the duodenum, including asymptomatic lesions incidentally found during EGD, can pose the greatest therapeutic challenges. These lesions should be biopsied; symptomatic tumors and adenomas, because of their malignant potential, should be removed. In general, duodenal tumors less than 1 cm in diameter are amenable to endoscopic polypectomy. Lesions greater than 2 cm in diameter are technically difficult to remove endoscopically and may need to be removed surgically. Surgical options include transduodenal polypectomy and segmental duodenal resection. Tumors located in the second portion of the duodenum near the ampulla of Vater may require pancreaticoduodenectomy. EUS may offer utility for duodenal tumors ranging in size between 1 and 2 cm in diameter,

with those limited to the mucosa being amenable to endoscopic polypectomy. Recent studies have shown that endoscopic resection of biopsy-proven benign duodenal periampullary adenomas leads to equivalent efficacy to surgery but with lower morbidity. Adenomas can recur; therefore, surveillance endoscopy is required after these procedures.⁵⁶

Duodenal adenomas occurring in the setting of FAP require an especially aggressive approach to management. Patients with FAP should undergo screening EGD starting sometime during their second or third decade of life. Adenomas detected should be removed endoscopically, if possible, followed by surveillance endoscopy in 6 months and yearly thereafter, in the absence of recurrence. If surgery is required, pancreaticoduodenectomy is generally necessary because adenomas in patients with FAP tend to be multiple and sessile, with a predilection for the periampullary region. Further, localized resections are complicated by high recurrence rates. Given the potential for recurrences in the duodenal remnant following pylorus-preserving pancreaticoduodenectomy, there is rationale for recommending the application of standard pancreaticoduodenectomy in these patients. However, recurrences have been reported even following this procedure; therefore, continuing surveillance is necessary. For most adenocarcinomas of the duodenum, except those in the third or fourth portion of the duodenum where a local resection could be considered, pancreaticoduodenectomy is required.

The surgical therapy of jejunal and ileal malignancies usually consists of wide local resection of the intestine harboring the lesion. For adenocarcinomas, a wide excision of corresponding mesentery is done to achieve regional lymphadenectomy, as is done for adenocarcinomas of the colon. In the presence of locally advanced or metastatic disease, palliative intestinal resection or bypass is performed. Chemotherapy has no proven efficacy in the adjuvant or palliative treatment of small-intestinal adenocarcinomas.

The goal of surgical therapy for carcinoids is resection of all visible disease. Localized small-intestinal carcinoid tumors should be treated with segmental intestinal resection and regional lymphadenectomy. Nodal metastases are unusual with tumors less than 1 cm in diameter but are present with 75% to 90% of tumors larger than 3 cm in diameter. In approximately 30% of cases, multiple small-intestinal carcinoid tumors are present. Therefore, the entire small intestine should be examined before planning extent of resection. In the presence of metastatic disease, tumor debulking should be conducted as it can be associated with long-term survival and amelioration of symptoms of the carcinoid syndrome. Response rates of 30% to 50% have been reported with chemotherapy regimens based on

agents such as doxorubicin, 5-fluorouracil, and streptozocin. However, none of these regimens is associated with a clearly demonstrable impact on the natural history of disease. Octreotide is the most effective pharmacologic agent for management of symptoms of carcinoid syndrome.

Localized small-intestinal lymphoma should be treated with segmental resection of the involved intestine and adjacent mesentery. If the small intestine is diffusely affected by lymphoma, chemotherapy rather than surgical resection should be the primary therapy. The value to adjuvant chemotherapy after resection of localized lymphoma is controversial.

Small-intestinal GISTs should be treated with segmental intestinal resection. If the diagnosis is known prior to resection, wide lymphadenectomy can be avoided as GISTs are rarely associated with lymph node metastases. GISTs are resistant to conventional chemotherapy agents. Imatinib (Gleevec) is a tyrosine kinase inhibitor with potent activity against the tyrosine kinase KIT and is used in those with metastatic disease. Clinical trials have shown that 80% of patients with unresectable or metastatic GISTs derive clinical benefit from the administration of imatinib, with 50% to 60% having objective evidence of reduction in tumor volume.⁵⁷ Imatinib has shown great promise as a neoadjuvant and adjuvant therapy of GISTs. Studies have emphasized the potential for development of tumor resistance to this agent. In this setting, an alternative tyrosine kinase inhibitor, sunitinib, has been used with good results.⁵⁷

Metastatic cancers affecting the small intestine that are symptomatic should be treated with palliative resection or bypass except in the most advanced cases. Systemic therapy may be offered if effective chemotherapy exists for the primary cancer.

Outcomes

Complete resection of duodenal adenocarcinomas is associated with postoperative 5-year survival rates ranging from 50% to 60%. Complete resection of adenocarcinomas located in the jejunum or ileum is associated with 5-year survival rates of 20% to 30%.⁵⁸ Five-year survival rates of 75% to 95% following resection of localized small-intestinal carcinoid tumors have been reported. In the presence of carcinoid tumor–derived liver metastases, 5-year survival rates of 19% to 54% have been reported. The overall 5-year survival rate for patients diagnosed with intestinal lymphoma ranges from 20% to 40%. For patients with localized lymphoma amenable to surgical resection, the 5-year survival rate is 60%.

The recurrence rate after resection of GISTs averages 35%. The 5-year survival rate after surgical resection has been reported to range from 35% to 60%. Both tumor size and mitotic index are independently correlated with prognosis. Low-grade tumors (mitotic index <10 per high-power field) measuring less than 5 cm in diameter are associated with excellent prognosis.

RADIATION ENTERITIS

Radiation therapy is a component of multimodality therapy for many intra-abdominal and pelvic cancers such as those of the cervix, endometrium, ovary, bladder, prostate, and rectum. An undesired side effect of radiation therapy is radiation-induced injury to the small intestine, which can present clinically as two distinct syndromes: acute and chronic radiation enteritis. Acute radiation enteritis is a transient condition that occurs in approximately 75% of patients undergoing radiation therapy for

abdominal and pelvic cancers. Chronic radiation enteritis is inexorable and develops in approximately 5% to 15% of these patients.

Pathophysiology

Radiation induces cellular injury directly and through the generation of free radicals. The principal mechanism of radiation-induced cell death is believed to be apoptosis resulting from free radical–induced breaks in double-stranded DNA. Because radiation has its greatest impact on rapidly proliferating cells, the small-intestinal epithelium is acutely susceptible to radiation-induced injury. Pathologic correlates of this acute injury include villus blunting and a dense infiltrate of leukocytes and plasma cells within the crypts. With severe cases, mucosal sloughing, ulceration, and hemorrhage are observed. The intensity of injury is related to the dose of radiation administered, with most cases occurring in patients who have received *at least* 4500 cGy. Risk factors for acute radiation enteritis include conditions that may limit splanchnic perfusion such as hypertension, diabetes mellitus, coronary artery disease, and restricted mobility of the small intestine due to adhesions. Injury is potentiated by concomitant administration of chemotherapeutic agents such as doxorubicin, 5-fluorouracil, dactinomycin, and methotrexate that act as radiation sensitizers. Because of the intestinal epithelium's capacity for regeneration, the mucosal injury that is characteristic of acute radiation enteritis resolves after the cessation of radiation therapy.

In contrast, chronic radiation enteritis is characterized by a progressive occlusive vasculitis that leads to chronic ischemia and fibrosis that affects all layers of the intestinal wall, rather than the mucosa alone. These changes can lead to strictures, abscesses, and fistulas, which are responsible for the clinical manifestations of chronic radiation enteritis.

Clinical Presentation

The most common manifestations of acute radiation enteritis are nausea, vomiting, diarrhea, and crampy abdominal pain. Symptoms are generally transient and subside after the discontinuation of radiation therapy. Because the diagnosis is usually obvious, given the clinical context, no specific diagnostic tests are required. However, if patients develop signs suggestive of peritonitis, CT scanning should be performed to rule out the presence of other conditions capable of causing acute abdominal syndromes.

The clinical manifestations of chronic radiation enteritis usually become evident within 2 years of radiation administration, although they can begin as early as several months or as late as decades afterward. The most common clinical presentation is one of partial small bowel obstruction, with nausea, vomiting, intermittent abdominal distention, crampy abdominal pain, and weight loss being the most common symptoms. The terminal ileum is the most frequently affected segment. Other manifestations of chronic radiation enteritis include complete bowel obstruction, acute or chronic intestinal hemorrhage, and abscess or fistula formation.

Diagnosis

Evaluation of patients suspected of having chronic radiation enteritis should include review of the records of their radiation treatments for information on total radiation dose administered, fractionation, and volume of treatment. Areas that received high doses should be noted, as lesions subsequently found in imaging studies usually localize to areas that had received high

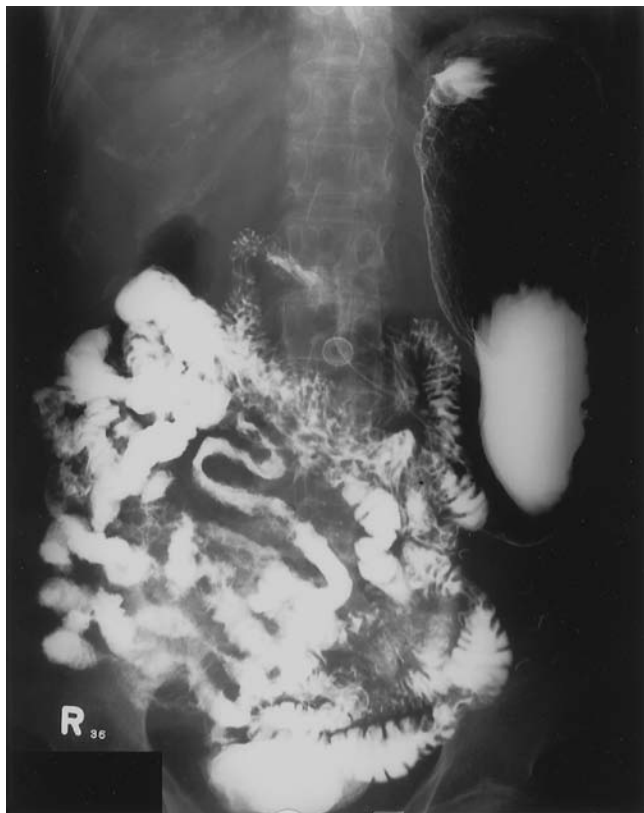


Figure 28-23. Radiation enteritis. This contrast radiograph reveals widely separated loops of small bowel with luminal narrowing, loss of mucosal folds, and ulceration. This patient had received radiation therapy for a pelvic malignancy 8 years before this examination.

radiation doses. Enteroclysis is the most accurate imaging test for diagnosing chronic radiation enteritis, with reported sensitivities and specificities of over 90% (Fig. 28-23). CT scan findings are neither very sensitive nor specific for chronic radiation enteritis. However, CT scanning should be obtained to rule out the presence of recurrent cancer since its clinical manifestations may overlap with those of chronic radiation enteritis.

Therapy

Most cases of acute radiation enteritis are self-limited. Supportive therapy, including the administration of antiemetics, is usually sufficient. Patients with diarrhea-induced dehydration may require hospital admission and parenteral fluid administration. Rarely are symptoms severe enough to necessitate reduction in or cessation of radiation therapy.

In contrast, the treatment of chronic radiation enteritis represents a formidable challenge. Surgery for this condition is difficult, is associated with high morbidity rates, and should be avoided in the absence of specific indications such as high-grade obstruction, perforation, hemorrhage, intra-abdominal abscesses, and fistulas. The goal of surgery is limited resection of diseased intestine with primary anastomosis between healthy bowel segments. However, the characteristically diffuse nature of fibrosis and dense adhesions among bowel segments can make limited resection difficult to achieve. Further, it is difficult to distinguish between normal and irradiated intestine intraoperatively by either gross inspection or even frozen section analysis. This distinction is important as anastomoses between irradiated segments of intestine have been associated with leak

rates as high as 50%.⁵⁹ If limited resection is not achievable, an intestinal bypass procedure may be an option, except in cases for which hemorrhage is the surgical indication. There remain cases in which resections extensive enough to cause short bowel syndrome are unavoidable. This condition is discussed in detail later in the Short Bowel Syndrome section.

Outcomes

Acute radiation injury to the intestine is self-limited; its severity is not correlated with the probability of chronic radiation enteritis developing. Surgery for chronic radiation enteritis is associated with high morbidity rates and reported mortality rates averaging 10%.

Prevention

In view of significant morbidity associated with radiation enteritis, groups have studied possible measures to reduce or prevent such side effects. Keeping radiation exposure to below 5000 cGy is associated with minimal long-term side effects and recommended where clinically possible.

Multi-beam radiation techniques to minimize the area of maximal radiation exposure and tilt tables to move the bowel out of the pelvis during radiation are increasingly used. Few small studies have suggested that oral sulfasalazine may help reduce the incidence of acute radiation-induced enteritis.⁶⁰

In patients undergoing pelvic surgery who are likely to require postoperative radiation therapy, surgical techniques that keep the small bowel out of the pelvis have been recommended. These measures include use of absorbable mesh sling to separate the pelvis from the true abdominal cavity and prevent the small bowel from being exposed to pelvic radiation.⁶¹

MECKEL'S DIVERTICULUM

Meckel's diverticulum is the most prevalent congenital anomaly of the GI tract, affecting approximately 2% of the general population. Meckel's diverticula are designated *true diverticula* because their walls contain all of the layers found in normal small intestine. Their location varies among individual patients, but they are usually found in the ileum within 100 cm of the ileocecal valve (Fig. 28-24). Approximately 60% of Meckel's diverticula contain heterotopic mucosa, of which over 60% consist of

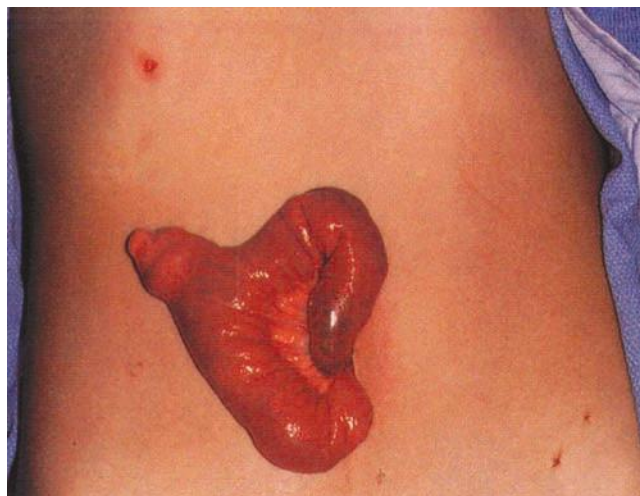


Figure 28-24. Meckel's diverticulum. This intraoperative photograph shows Meckel's diverticulum in ileum that has been eviscerated.

gastric mucosa. Pancreatic acini are the next most common; others include Brunner's glands, pancreatic islets, colonic mucosa, endometriosis, and hepatobiliary tissues. A useful, although crude, mnemonic describing Meckel's diverticula is the "rule of two's": 2% prevalence, 2:1 male predominance, location 2 feet proximal to the ileocecal valve in adults, and half of those who are symptomatic are under 2 years of age.

Pathophysiology

During the eighth week of gestation, the omphalomesenteric (vitelline) duct normally undergoes obliteration. Failure or incomplete vitelline duct obliteration results in a spectrum of abnormalities, the most common of which is Meckel's diverticulum. Other abnormalities include omphalomesenteric fistula, enterocyst, and a fibrous band connecting the intestine to the umbilicus. A remnant of the left vitelline artery can persist to form a mesodiverticular band tethering a Meckel's diverticulum to the ileal mesentery.

Bleeding associated with Meckel's diverticulum is usually the result of ileal mucosal ulceration that occurs adjacent to acid-producing, heterotopic gastric mucosa located within the diverticulum. Intestinal obstruction associated with Meckel's diverticulum can result from several mechanisms:

1. Volvulus of the intestine around the fibrous band attaching the diverticulum to the umbilicus
2. Entrapment of intestine by a mesodiverticular band (Fig. 28-25)
3. Intussusception with the diverticulum acting as a lead point
4. Stricture secondary to chronic diverticulitis

Meckel's diverticula can be found in inguinal or femoral hernia sacs (known as Littre's hernia). These hernias, when incarcerated, can cause intestinal obstruction.

Clinical Presentation

Meckel's diverticula are asymptomatic unless associated complications arise. The lifetime incidence rate of complications arising in patients with Meckel's diverticula has been estimated to be approximately 4% to 6%.^{62,63} Although initial data had suggested that the risk of developing a complication related to Meckel's diverticulum decreases with age, this has been now questioned. In a population-based review at Olmsted County, MN, Cullen and colleagues showed that the risk of developing Meckel's-related complications does not change with age.⁶³

The most common presentations associated with symptomatic Meckel's diverticula are bleeding, intestinal obstruction, and diverticulitis. Bleeding is the most common presentation in children with Meckel's diverticula, representing over 50% of Meckel's diverticulum-related complications among patients less than 18 years of age. Bleeding associated with Meckel's diverticula is rare among patients older than 30 years of age.

Intestinal obstruction is the most common presentation in adults with Meckel's diverticula. Diverticulitis, present in 20% of patients with symptomatic Meckel's diverticula, is associated with a clinical syndrome that is indistinguishable from acute appendicitis. Neoplasms, most commonly carcinoid tumors, are present in 0.5% to 3.2% of symptomatic Meckel's diverticula that are resected.⁵⁶

Diagnosis

Most Meckel's diverticula are discovered incidentally on radiographic imaging, during endoscopy, or at the time of surgery. In the absence of bleeding, Meckel's diverticula rarely are diagnosed prior to the time of surgical intervention. For those presenting with symptoms suggestive of a Meckel's diverticulum, confirmatory imaging can be challenging. The sensitivity of CT scanning for the detection of Meckel's diverticula is too low to be clinically useful. Enteroclysis is associated with an accuracy of 75% but is usually not applicable during acute presentations of complications related to Meckel's diverticula. Radionuclide scans (^{99m}Tc-pertechnetate) can be helpful in the diagnosis of Meckel's diverticulum; however, this test is positive only when the diverticulum contains associated ectopic gastric mucosa that is capable of uptake of the tracer (Fig. 28-26). The accuracy of radionuclide scanning is reported to be 90% in pediatric patients but less than 50% in adults. Angiography can localize the site of bleeding during acute hemorrhage related to Meckel's diverticula.

Therapy

The surgical treatment of symptomatic Meckel's diverticula should consist of diverticulectomy with removal of associated bands connecting the diverticulum to the abdominal wall or intestinal mesentery. If the indication for diverticulectomy is bleeding, segmental resection of ileum that includes both the diverticulum and the adjacent ileal peptic ulcer should be performed. Segmental ileal resection may also be necessary if the diverticulum contains a tumor or if the base of the diverticulum is inflamed or perforated.

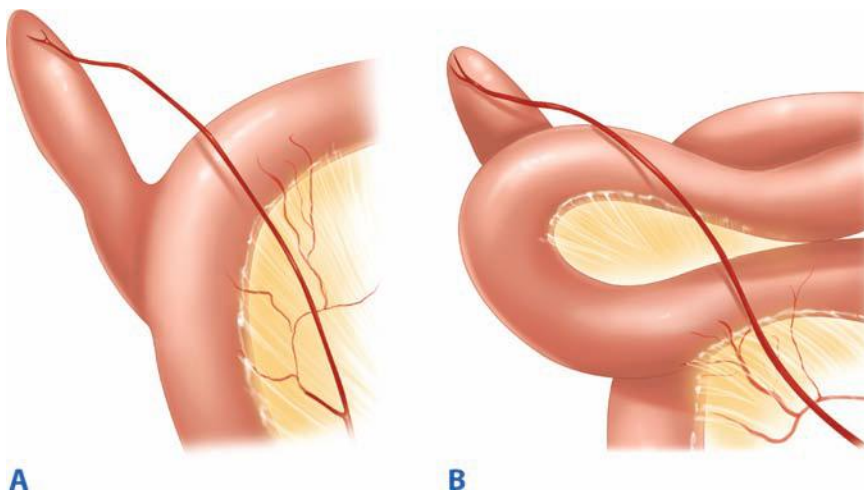


Figure 28-25. A. Meckel's diverticulum with mesodiverticular band. B. One mechanism by which Meckel's diverticula can cause small bowel obstruction is entrapment of the intestine by a mesodiverticular band.

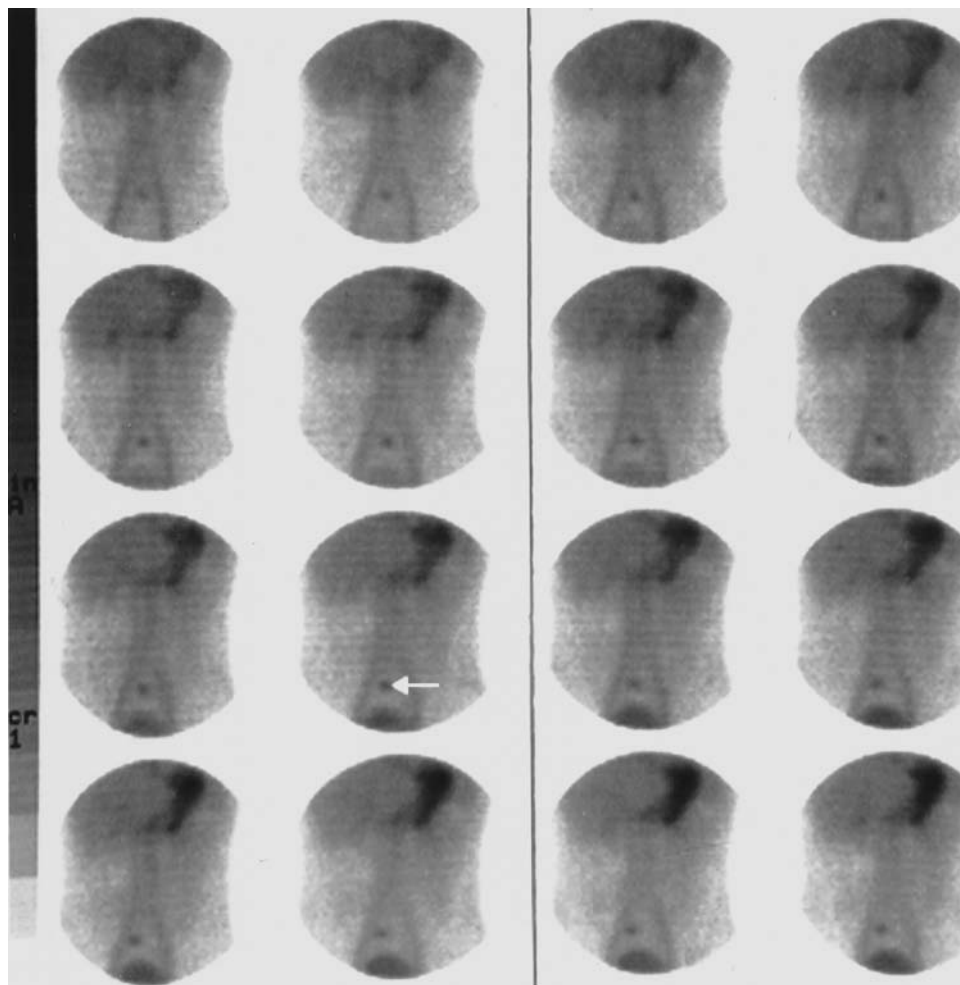


Figure 28-26. Meckel's diverticulum with ectopic gastric tissue. The diagnosis was made in this patient using ^{99m}Tc -pertechnetate scintigraphy. The study revealed an abnormal focus of radiotracer accumulation in the right lower quadrant (*arrow*).

The management of incidentally found (asymptomatic) Meckel's diverticula is controversial. Until recently, most authors recommended against prophylactic removal of asymptomatic Meckel's diverticula, given the low lifetime incidence of complications. More recently, greater enthusiasm for prophylactic diverticulectomy has appeared in the literature.⁶³ Proponents of this approach cite the minimal morbidity associated with removing Meckel's diverticula and the possibility that previous estimates of the lifetime incidence of complications related to Meckel's diverticula may be erroneously low. Other authors have advocated a selective approach, with a recommendation to remove diverticula attached by bands and those with narrow bases, on the assumption that these diverticula are more likely to develop complications. No controlled data supporting or refuting these recommendations exist.

ACQUIRED DIVERTICULA

Acquired diverticula are designated *false diverticula* because their walls consist of mucosa and submucosa but lack a complete muscularis. Acquired diverticula are more common in the duodenum and tend to be located near the ampulla; such diverticula are known as *periampullary*, *juxtapapillary*, or *perivaterian diverticula*. Approximately 75% of juxtapapillary diverticula arise on the medial wall of the duodenum. Acquired diverticula

in the jejunum or ileum are known as *jejunoileal diverticula*. Eighty percent of jejunoileal diverticula are localized to the jejunum, 15% to the ileum, and 5% to both jejunum and ileum. Diverticula in the jejunum tend to be large and accompanied by multiple other diverticula, whereas those in the ileum tend to be small and solitary.

The prevalence of duodenal diverticula, as detected on upper GI examinations (Fig. 28-27), has been reported to range from 0.16% to 6%.⁶⁴ Their prevalence, as detected during endoscopic retrograde cholangiography (ERCP) examinations, has been reported to range from 5% to 27%. A 23% prevalence rate has been reported in an autopsy series. The prevalence of duodenal diverticula increases with age; they are rare in patients under the age of 40 years. The mean age of diagnosis ranges from 56 to 76 years.

The prevalence of jejunoileal diverticula (Fig. 28-28) has been estimated to range from 1% to 5%.⁶⁵ Their prevalence increases with age; most patients diagnosed with these diverticula are in the sixth and seventh decades of life.

Pathophysiology

The pathogenesis of acquired diverticula is hypothesized to be related to acquired abnormalities of intestinal smooth muscle or dysregulated motility, leading to herniation of mucosa and submucosa through weakened areas of muscularis.

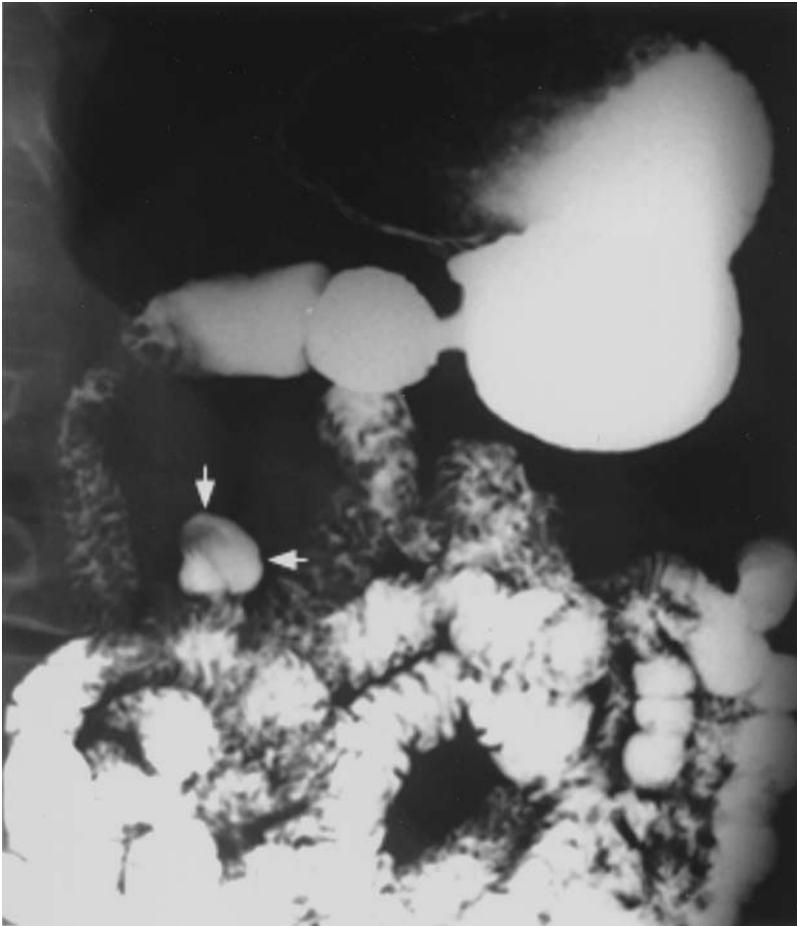

Figure 28-27. Duodenal diverticulum. This contrast radiograph demonstrates a duodenal diverticulum (*arrows*) that extends medially into the substance of the head of the pancreas.

Acquired diverticula can be associated with bacterial overgrowth, leading to vitamin B₁₂ deficiency, megaloblastic anemia, malabsorption, and steatorrhea. Periapillary duodenal diverticula have been described to become distended with intraluminal debris and to compress the common bile duct or pancreatic duct, thus causing obstructive jaundice or pancreatitis, respectively. Jejunioleal diverticula can also cause intestinal obstruction through intussusception or compression of adjacent bowel.

Clinical Presentation

Acquired diverticula are asymptomatic unless associated complications arise. Such complications are estimated to occur in 6% to 10% of patients with acquired diverticula and include intestinal obstruction, diverticulitis, hemorrhage, perforation, and malabsorption. Periapillary duodenal diverticula may be associated with choledocholithiasis, cholangitis, recurrent pancreatitis, and sphincter of Oddi dysfunction. However, a clear link between the presence of the diverticula and the development of these

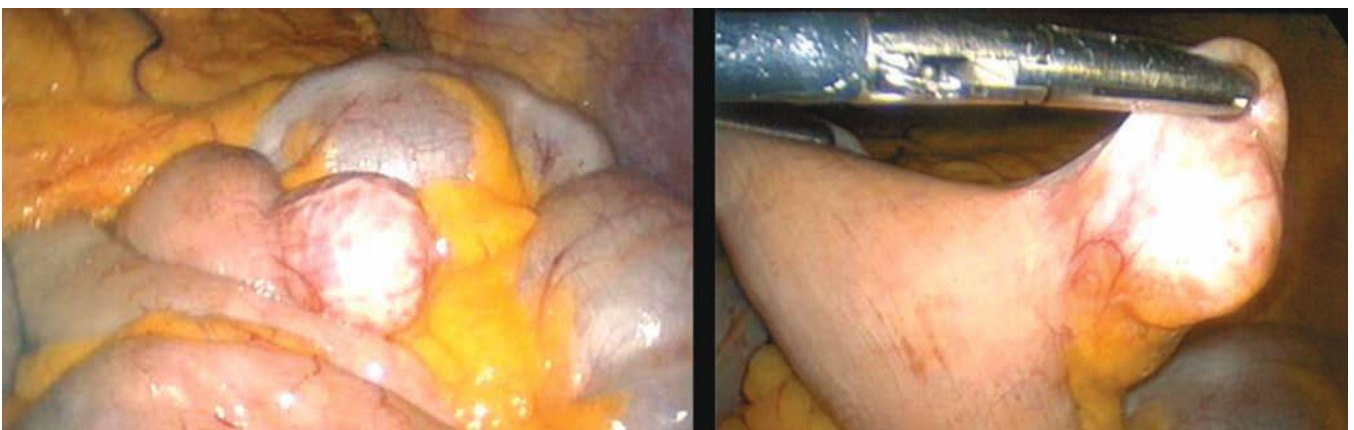


Figure 28-28. Jejunioleal diverticula. This picture demonstrates incidental jejunal diverticula identified during a laparoscopic cholecystectomy. The diverticula are typically located on the mesenteric aspect of the jejunum. Resection was not indicated because the diverticula were asymptomatic.

conditions has not been demonstrated. Symptoms such as intermittent abdominal pain, flatulence, diarrhea, and constipation are reported to be present in 10% to 30% of patients with jejunoileal diverticula. The relationship between these symptoms and the presence of diverticula is similarly unclear.

Diagnosis

Most acquired diverticula are discovered incidentally on radiographic imaging, during endoscopy, or at the time of surgery. On ultrasound and CT scanning, duodenal diverticula may be mistaken for pancreatic pseudocysts and fluid collections, biliary cysts, and periampullary neoplasms. These lesions can be missed on endoscopy, particularly with forward-viewing endoscopes, and are best diagnosed on upper GI radiographs. Enteroclysis is the most sensitive test for detecting jejunoileal diverticula.

Therapy

Asymptomatic acquired diverticula should be left alone. Bacterial overgrowth associated with acquired diverticula is treated with antibiotics. Other complications, such as bleeding and diverticulitis, are treated with segmental intestinal resection for diverticula located in the jejunum or ileum.

Bleeding and obstruction related to lateral duodenal diverticula are generally treated with diverticulectomy alone. These procedures can be technically difficult for medial duodenal diverticula that penetrate into the substance of the pancreas. Complications related to these medial duodenal diverticula should be managed nonoperatively, if possible, using endoscopy. In emergent situations, bleeding related to medial duodenal diverticula can be controlled using a lateral duodenotomy and oversewing of the bleeding vessel. Similarly, perforation can be managed with wide drainage rather than complex surgery. Whether diverticulectomy should be done in patients with biliary or pancreatic symptoms is controversial and is not routinely recommended.⁵⁸

MESENTERIC ISCHEMIA

Mesenteric ischemia can present as one of two distinct clinical syndromes: acute mesenteric ischemia and chronic mesenteric ischemia.

Four distinct pathophysiologic mechanisms can lead to *acute mesenteric ischemia*:

1. Arterial embolus
2. Arterial thrombosis
3. Vasospasm (also known as nonocclusive mesenteric ischemia [NOMI])
4. Venous thrombosis

Embolus is the most common cause of acute mesenteric ischemia and is responsible for over 50% of cases. The embolic source is usually in the heart, most often the left atrial or ventricular thrombi or valvular lesions. Indeed, up to 95% of patients with acute mesenteric ischemia due to emboli will have a documented history of cardiac disease. Embolism to the superior mesenteric artery accounts for 50% of cases; most of these emboli become wedged and cause occlusion at branch points in the mid to distal superior mesenteric artery, usually distal to the origin of the middle colic artery. In contrast, acute occlusions due to thrombosis tend to occur in the proximal mesenteric arteries, near their origins. Acute thrombosis is usually

superimposed on pre-existing atherosclerotic lesions at these sites. NOMI is the result of vasospasm and is usually diagnosed in critically ill patients receiving vasopressor agents.

Mesenteric venous thrombosis accounts for 5% to 15% of cases of acute mesenteric ischemia and involves the superior mesenteric vein in 95% of cases.⁶⁶ The inferior mesenteric vein is only rarely involved. Mesenteric venous thrombosis is classified as primary if no etiologic factor is identifiable or as secondary if an etiologic factor, such as heritable or acquired coagulation disorders, is identified.

Regardless of the pathophysiologic mechanism, acute mesenteric ischemia can lead to intestinal mucosal sloughing within 3 hours of onset and full-thickness intestinal infarction by 6 hours.

In contrast, *chronic mesenteric ischemia* develops insidiously, allowing for development of collateral circulation, and, therefore, rarely leads to intestinal infarction. Chronic mesenteric arterial ischemia results from atherosclerotic lesions in the main splanchnic arteries (celiac, superior mesenteric, and inferior mesenteric arteries). In most patients with symptoms attributable to chronic mesenteric ischemia, at least two of these arteries are either occluded or severely stenosed. A chronic form of mesenteric venous thrombosis can involve the portal or splenic veins and may lead to portal hypertension, with resulting esophagogastric varices, splenomegaly, and hypersplenism.

Severe abdominal pain, out of proportion to the degree of tenderness on examination, is the hallmark of acute mesenteric ischemia, regardless of the pathophysiologic mechanism. The pain is typically perceived to be colicky and most severe in the mid-abdomen. Associated symptoms can include nausea, vomiting, and diarrhea. Physical findings are characteristically absent early in the course of ischemia. With the onset of bowel infarction, abdominal distension, peritonitis, and passage of bloody stools occur.

Chronic mesenteric ischemia presents insidiously. Postprandial abdominal pain is the most prevalent symptom, producing a characteristic aversion to food ("food fear") and weight loss. These patients are often thought to have a malignancy and suffer a prolonged period of symptoms before the correct diagnosis is made.

Most patients with chronic mesenteric venous thrombosis are asymptomatic because of the presence of extensive collateral venous drainage routes; this condition is usually discovered as an incidental finding on imaging studies. However, some patients with chronic mesenteric venous thrombosis present with bleeding from esophagogastric varices.

The diagnosis and management of these disorders, which are of primary vascular origin, are discussed in the section on mesenteric artery occlusive disease in the chapter on arterial disease.

MISCELLANEOUS CONDITIONS

Obscure Gastrointestinal Bleeding

Up to 90% of lesions responsible for GI bleeding are within the reach of EGD and colonoscopy. *Obscure GI bleeding* refers to GI bleeding for which no source has been identified by routine endoscopic studies (EGD and colonoscopy). *Overt GI bleeding* refers to the presence of hematemesis, melena, or hematochezia. In contrast, *occult GI bleeding* occurs in the absence of overt bleeding and is identified on laboratory tests (e.g., iron-deficiency anemia) or examination of the stool (e.g., positive guaiac test). Obscure GI bleeding is occult in 20% of cases.⁶⁷

Obscure bleeding can be frustrating for both the patient and the clinician, and this is particularly true for obscure-overt bleeding, which cannot be localized despite aggressive diagnostic measures. One study from a tertiary referral center reported that the typical patient with obscure-overt bleeding had suffered intermittent episodes of hemorrhage for 26 months, had undergone up to 20 diagnostic tests, and had received an average of 20 units of blood before reaching a diagnosis.⁶⁸ Most of the small bowel is beyond the reach of these examinations

and, hence, contains most lesions responsible for obscure GI bleeding. Small-intestinal angiodysplasias account for approximately 75% of cases in adults, and neoplasms account for approximately 10%. Meckel's diverticulum is the most common etiology of obscure GI bleeding in children. Other etiologies of obscure GI bleeding include Crohn's disease, infectious enteritides, nonsteroidal anti-inflammatory drug (NSAID)-induced ulcers and erosions, vasculitis, ischemia, varices, diverticula, and intussusception.

The diagnostic evaluation of patients with obscure GI bleeding should be tailored to the severity of bleeding and to the availability of technology and expertise. Enteroscopy is playing an increasingly important role. Several endoscopic techniques for visualizing the small intestine are available: push enteroscopy, Sonde enteroscopy, intraoperative enteroscopy, double-balloon enteroscopy, and wireless capsule enteroscopy.

Push enteroscopy entails advancing a long endoscope (such as a pediatric or adult colonoscope or a specialized instrument) beyond the ligament of Treitz into the proximal jejunum. This procedure can allow for visualization of approximately 60 cm of the proximal jejunum. Diagnostic yield in patients with obscure GI bleeding ranges from 3% to 65%. In addition to diagnosis, push enteroscopy allows for cauterization of bleeding sites.

In Sonde enteroscopy, a long, thin fiberoptic instrument is propelled through the intestine by peristalsis following inflation of a balloon at the instrument's tip. Visualization is done during instrument withdrawal; approximately 50% to 75% of the small-intestinal mucosa can be examined. However, this instrument lacks biopsy or therapeutic capability. Further, it lacks tip deflection capability, limiting complete mucosal visualization, and has therefore been abandoned in favor of capsule endoscopy.

Wireless capsule enteroscopy relies on a radiotelemetry capsule endoscope that is small enough to swallow and has no external wires, fiberoptic bundles, or cables. While the capsule is being propelled through the intestine by peristalsis, video images are transmitted using radiotelemetry to an array of detectors attached to the patient's body. These detectors capture the images and permit continuous triangulation of the capsule location in the abdomen, facilitating the localization of lesions detected. The entire system is portable, allowing the patient to be ambulatory during the entire examination. Capsule endoscopy is an excellent tool in the patient who is hemodynamically stable but continues to bleed. This technique has reported success rates as high as 90% in identifying a small bowel pathology. Although many studies have shown an improved diagnostic yield for small bowel lesions with capsule endoscopy, the impact of this new imaging modality on actual patient outcomes was not studied until recently. In a randomized study of patients with obscure GI bleeding, evaluation with capsule endoscopy vs. small bowel contrast study had a much higher diagnostic yield (30% vs. 7%, respectively); however, this

did not translate into an improvement in outcomes. The rates of rebleeding, hospitalization, need for blood transfusion, and therapeutic interventions were similar between the two arms.

The inability to perform biopsies or carry out any therapeutic interventions of capsule endoscope likely prevents the improved diagnostic yield of the test from translating into improved patient outcomes and highlights the continuing challenge with evaluation of the small bowel.⁶⁹

For patients in whom bleeding from an obscure GI source has apparently stopped, push enteroscopy or capsule enteroscopy is a reasonable initial study. If these examinations do not reveal a potential source of bleeding, then enteroclysis should be performed. Standard small bowel follow-through examinations are associated with a low diagnostic yield in this setting and should be avoided. If still no diagnosis has been made, a "watch-and-wait" approach is reasonable, although angiography should be considered if the prior episode of bleeding was overt. Angiography can reveal angiodysplasia and vascular tumors in the small intestine even in the absence of ongoing bleeding.

For persistent mild bleeding from an obscure GI source, push and capsule enteroscopy can be used. If these examinations are nondiagnostic, then ^{99m}Tc-labeled RBC scanning should be performed and, if positive, followed by angiography to localize the source of bleeding. ^{99m}Tc-pertechnetate scintigraphy to diagnose Meckel's diverticulum should be considered, although its yield in patients older than 40 years of age is extremely low. Patients who remain undiagnosed but continue to bleed and those with recurrent episodic bleeding significant enough to require blood transfusions should then undergo exploration with intraoperative enteroscopy.

Patients with persistent severe bleeding from an obscure source should undergo angiography to help localize the bleeding source. Therapy can be tailored based on the source. Push enteroscopy can also be attempted, but capsule enteroscopy is too slow to be applicable in this setting. If these examinations fail to localize the source of bleeding, exploratory laparoscopy or laparotomy with intraoperative enteroscopy is indicated. Intraoperative enteroscopy can be done during either laparotomy or laparoscopy. An endoscope (usually a colonoscope) is inserted into the small bowel through peroral intubation or through an enterotomy made in the small bowel or cecum. The endoscope is advanced by successively telescoping short segments of intestine onto the end of the instrument. In addition to the endoscopic image, the transilluminated bowel should be examined externally with the operating room lights dimmed, as this maneuver may facilitate the identification of angiodysplasias. Identified lesions should be marked with a suture placed on the serosal surface of the bowel; these lesions can be resected after completion of endoscopy. Examination should be performed during instrument insertion rather than withdrawal because instrument-induced mucosal trauma can be confused with angiodysplasias.

Fig. 28-29 provides a diagnostic and management algorithm for patients with obscure GI bleeding.

Small Bowel Perforation

Prior to the 1980s, duodenal perforation due to peptic ulcer disease was the most common form of small bowel perforation. Today, iatrogenic injury incurred during GI endoscopy is the most common cause of small bowel perforation. Other etiologies of small bowel perforation include infections (especially tuberculosis, typhoid, and CMV), Crohn's disease, ischemia, drugs (e.g., potassium- and NSAID-induced ulcers), radiation-induced

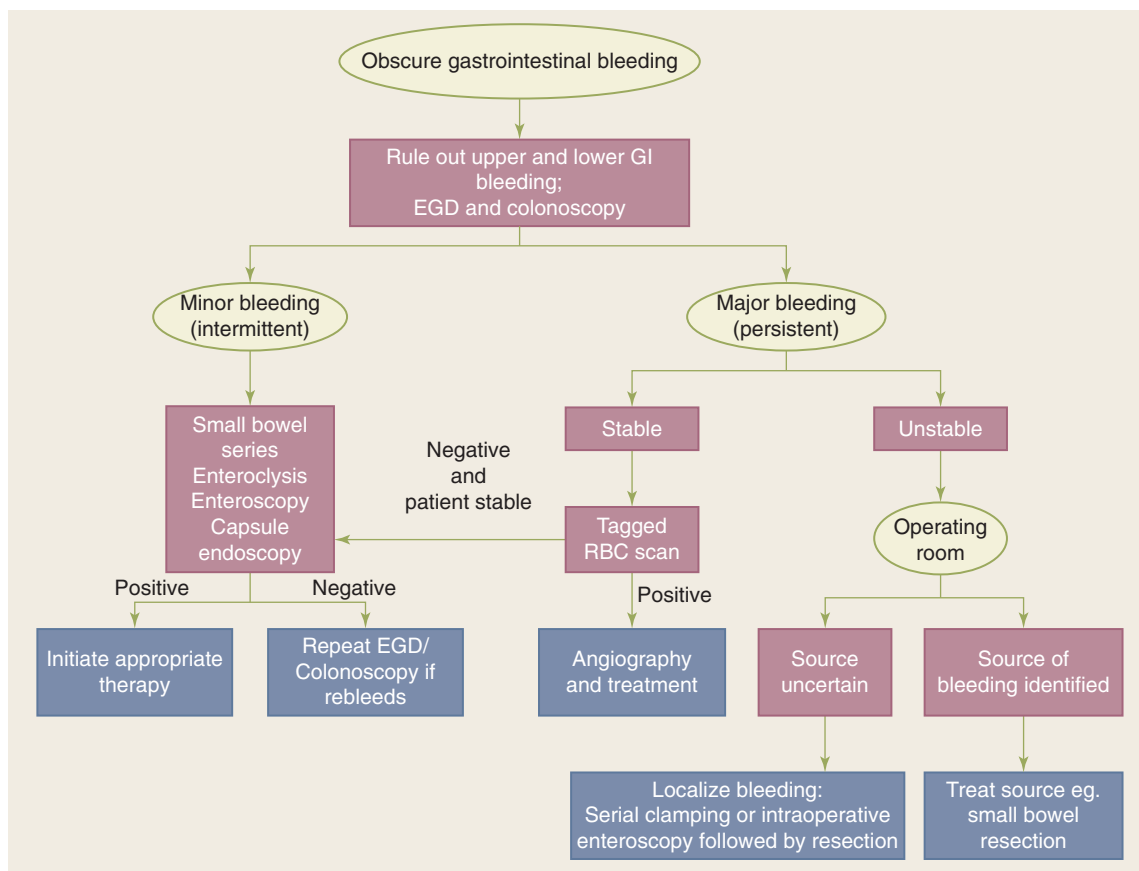


Figure 28-29. Diagnostic and management algorithm for obscure gastrointestinal (GI) bleeding. EGD = esophagogastroduodenoscopy; RBC = red blood cell.

injury, Meckel's and acquired diverticula, neoplasms (especially lymphoma, adenocarcinoma, and melanoma), and foreign bodies.

Among iatrogenic injuries, duodenal perforation during ERCP with endoscopic sphincterotomy (ES) is the most common. This complication occurs in 0.3% to 2.1% of cases. Patients who have undergone Billroth II gastrectomy are at increased risk of duodenal perforations as well as free jejunal perforations during ERCP. Although ERCP-related duodenal perforations can result in a free perforation, most are retroperitoneal. Manifestations of such contained duodenal perforations following ERCP can resemble those of ERCP-induced pancreatitis, including hyperamylasemia.

CT scanning is the most sensitive test for diagnosing duodenal perforations; positive findings include pneumoperitoneum for free perforations, but more commonly retroperitoneal air, contrast extravasation, and paraduodenal fluid collections. If all patients undergoing a therapeutic ERCP are imaged with a CT scan following the procedure, up to 30% will have evidence of air in the retroperitoneum, but the majority are asymptomatic. These patients do not require any specific therapy.⁷⁰

True cases of retroperitoneal perforations of the duodenum can be managed nonoperatively, in the absence of progression and sepsis. However, intraperitoneal duodenal perforations require surgical repair with pyloric exclusion and gastrojejunostomy or tube duodenostomy. Iatrogenic small bowel perforation incurred during endoscopy, if immediately recognized, can sometimes be repaired using endoscopic techniques.

Perforation of the jejunum and ileum occurs into the peritoneal cavity and usually causes overt symptoms and signs, such as abdominal pain, tenderness, and distention accompanied by

fever and tachycardia. Plain abdominal radiographs may reveal free intraperitoneal air if intraperitoneal perforation has occurred. If perforation is suspected but not clinically obvious, CT scanning should be performed. Jejunal and ileal perforations require surgical repair or segmental resection.

Chylous Ascites

Chylous ascites refers to the accumulation of triglyceride-rich peritoneal fluid with a milky or creamy appearance, caused by the presence of intestinal lymph in the peritoneal cavity. Chylomicrons, produced by the intestine and secreted into lymph during the absorption of long-chain fatty acids, account for the characteristic appearance and triglyceride content of chyle.

The most common etiologies of chylous ascites in Western countries are abdominal malignancies and cirrhosis. In Eastern and developing countries, infectious etiologies, such as tuberculosis and filariasis, account for most cases. Chylous ascites can also develop as a complication of abdominal and thoracic operations and trauma. Operations particularly associated with this complication include abdominal aortic aneurysm repair, retroperitoneal lymph node dissection, inferior vena cava resection, and liver transplantation. Other etiologies of chylous ascites include congenital lymphatic abnormalities (e.g., primary lymphatic hypoplasia), radiation, pancreatitis, and right-sided heart failure.

Three mechanisms have been postulated to cause chylous ascites: (a) exudation of chyle from dilated lymphatics on the wall of the bowel and in the mesentery caused by obstruction of lymphatic vessels at the base of the mesentery or the cisterna chylifera (e.g., by malignancies); (b) direct leakage of chyle through

a lymphoperitoneal fistula (e.g., those that develop as a result of trauma or surgery); and (c) exudation of chyle through the wall of dilated retroperitoneal lymphatic vessels (e.g., in congenital lymphangiectasia or thoracic duct obstruction).

Patients with chylous ascites develop abdominal distention over a period of weeks to months. Postoperative chylous ascites can present acutely during the first postoperative week. Delayed presentations following surgery can occur if the mechanism of ascites formation is adhesion-induced lymphatic obstruction rather than lymphatic vessel disruption. Dyspnea may result if abdominal distention is severe enough.

Paracentesis is the most important diagnostic test. Chyle typically has a cloudy and turbid appearance; however, it may be clear in fasting patients (such as those in the immediate postoperative period). Fluid triglyceride concentrations above 110 mg/dL are diagnostic. CT scanning may be useful in identifying pathologic intra-abdominal lymph nodes and masses and in identifying extent and localization of fluid. Lymphangiography and lymphoscintigraphy may help localize lymph leaks and obstruction; this information is particularly useful for surgical planning.

There are few data on optimal management of patients with chylous ascites. The general approach is to focus on evaluating and treating the underlying causes, especially for patients with infectious, inflammatory, or hemodynamic etiologies for this condition.

Most patients respond to administration of a high-protein and low-fat diet supplemented with medium-chain triglycerides. This regimen is designed to minimize chyle production and flow. Medium-chain triglycerides are absorbed by the intestinal epithelium and are transported to liver through the portal vein; they do not contribute to chylomicron formation.

Patients who do not respond to this approach should be fasted and placed on TPN. Octreotide can further decrease lymph flow. Paracentesis is indicated for respiratory difficulties related to abdominal distention. Overall, two thirds of patients will respond to conservative therapy. However, one third of patients will require surgical therapy for chylous ascites. In general, postoperative and trauma-related cases that fail to respond to initial nonoperative therapy are best managed by surgical repair. Lymphatic leaks are localized and repaired with fine nonabsorbable sutures. If extravasation of chyle is localized

to the periphery of the small bowel mesentery, then a limited small bowel resection can be performed instead. For patients who are poor surgical candidates and do not respond to prolonged conservative therapy, peritoneovenous shunting may be an option. However, these shunts are associated with high rates of complications, including sepsis and disseminated intravascular coagulation. Because of the viscosity of chyle, these shunts are associated with a high occlusion rate.

Intussusception

Intussusception refers to a condition where one segment of the intestine becomes drawn in to the lumen of the proximal segment of the bowel. It is usually seen in the pediatric population, where the cecum intussuscepts into the ileum (ileocolic intussusception). In children, it is often an idiopathic condition and treated nonsurgically by radiologic reduction.

Adult intussusceptions are far less common and usually have a distinct pathologic lead point, which can be malignant in up to one half of cases.⁷¹ They commonly present with a history of intermittent abdominal pain and signs and symptoms of bowel obstruction. CT scan is the investigation of choice, where a “target sign” may be seen (Fig. 28-30). Treatment is surgical resection of the involved segment and the lead point, which needs to undergo pathologic evaluation to rule out an underlying malignancy.

With increasing use of CT imaging, target signs are sometimes seen on CT scans of patients who do not have a clinical presentation indicative of bowel obstruction. In such cases, the finding is of little clinical significance and is probably related to normal peristalsis.

In patients who have undergone a Roux-en-Y gastric bypass surgery, an atypical form of intussusception has been increasingly described. In these cases, the proximal bowel is drawn in to the lumen of the distal bowel (retrograde intussusception). These intussusceptions are usually not associated with a lead point and may represent a motility disorder of the bowel following the Roux-en-Y reconstruction. Surgical reductions without resection have been successfully reported in these patients.⁷²

Pneumatosis Intestinalis

Pneumatosis intestinalis indicates the presence of gas within the bowel wall. It may affect any region of the GI tract, but is most

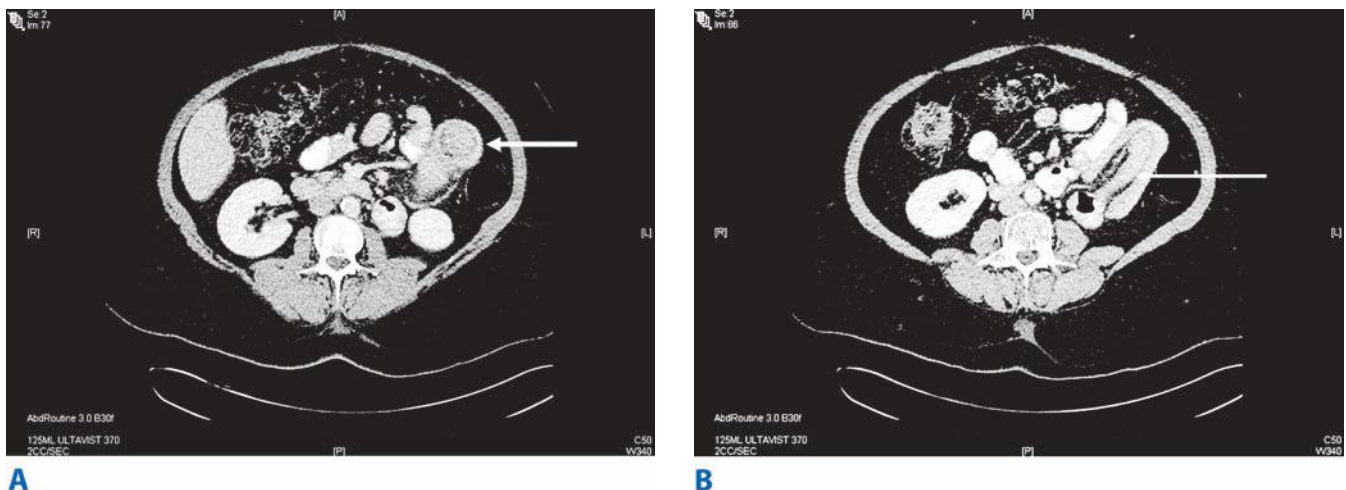


Figure 28-30. Small bowel intussusception. Panel **A** demonstrate the target sign seen on computed tomography scans in patients with small bowel intussusception (*arrow*). Panel **B** demonstrates the distal bowel clearly within the lumen of the proximal bowel (*arrow*).

commonly seen in the jejunum. Pneumatosis intestinalis is not a disease but merely a sign that can be idiopathic or associated with many intestinal or nonintestinal disorders such as obstructive pulmonary disease and asthma. Most cases of pneumatosis intestinalis are secondary to an identifiable cause, and 15% are idiopathic. The pathogenesis of pneumatosis intestinalis is not fully understood.

The surgical interest in this finding is the association of it with bowel ischemia and infarction, both of which necessitate emergent surgical intervention (see Fig. 28-15). Thus, patients with this radiologic finding need to be fully evaluated and monitored closely to rule out such intra-abdominal catastrophes.

SHORT BOWEL SYNDROME

Intestinal resection is performed for many of the diseases discussed in this chapter and generally is associated with minimal morbidity. However, when extent of resection is great enough, a devastating condition known as short bowel syndrome may result. *Short bowel syndrome* has been arbitrarily defined as the presence of less than 200 cm of residual small bowel in adult

patients.⁷³ A functional definition, in which insufficient intestinal absorptive capacity results in the clinical manifestations of diarrhea, dehydration, and malnutrition, is more broadly applicable.

In adults, the most common etiologies of short bowel syndrome are acute mesenteric ischemia, malignancy, and Crohn's disease. Seventy-five percent of cases result from resection of a large amount of small bowel at a single operation. Twenty-five percent of cases result from the cumulative effects of multiple operations during which small intestine is resected. This latter pattern is typical of patients with Crohn's disease who develop short bowel syndrome; the former is typical of patients with acute mesenteric ischemia who develop intestinal infarction. In pediatric patients, intestinal atresias, volvulus, and necrotizing enterocolitis are the most common etiologies of short bowel syndrome.

The prevalence of short bowel syndrome is hard to estimate. The most recent available data on chronic home total TPN administration were obtained in 1992. At that time, approximately 40,000 patients were receiving TPN chronically at home. The most prevalent indication for TPN among these patients was short bowel syndrome; however, this estimate does not include patients with short bowel syndrome not receiving TPN at home. It also fails to include those who have been weaned off of TPN.⁷⁴

Pathophysiology

Resection of less than 50% of the small intestine is generally well tolerated. However, clinically significant malabsorption occurs when greater than 50% to 80% of the small intestine has been resected. Among adult patients who lack a functional colon, lifelong TPN dependence is likely to persist if there is less than 100 cm of residual small intestine. Among adult patients who have an intact and functional colon, lifelong TPN dependence is likely to persist if there is less than 60 cm of residual small intestine. Among infants with short bowel syndrome, weaning from TPN dependence has been achieved with as little as 10 cm of residual small intestine.

Residual bowel length is not the only factor predictive of achieving independence from TPN (enteral autonomy), however. Other determinants of the severity of malabsorption

Table 28-11

Risk factors for development of short bowel syndrome after massive small bowel resection

Small bowel length <200 cm
Absence of ileocecal valve
Absence of colon
Diseased remaining bowel (e.g., Crohn's disease)
Ileal resection

include the presence or absence of an intact colon, as indicated earlier. The colon has the capacity to absorb large fluid and electrolyte loads. In addition, the colon can play an important, albeit small, role in nutrient assimilation by absorbing short-chain fatty acids. Second, an intact ileocecal valve is believed to be associated with decreased malabsorption. The ileocecal valve delays transit of chyme from the small intestine into the colon, thereby prolonging the contact time between nutrients and the small-intestinal absorptive mucosa. Third, healthy, rather than diseased, residual small intestine is associated with decreased severity of malabsorption. Fourth, resection of jejunum is better tolerated than resection of ileum, as the capacity for bile salt and vitamin B₁₂ absorption is specific to the ileum (Table 28-11).

During the first 1 to 2 years following massive small bowel resection, the remaining intestine undergoes compensatory adaptation, as discussed earlier. Clinically, the period of adaptation is associated with reductions in volume and frequency of bowel movements, increases in the capacity for enteral nutrient assimilation, and reductions in TPN requirements. As this process completes, some patients are successfully weaned off TPN. Understanding the mechanisms mediating intestinal adaptation may suggest strategies for enhancing adaptation in patients with short bowel syndrome who are unable to achieve independence from TPN. To date, the phenomenon of intestinal adaptation in patients remains poorly understood.¹³

Malabsorption in patients who have undergone massive small bowel resection is exacerbated by a characteristic hypergastrinemia-associated gastric acid hypersecretion that persists for 1 to 2 years postoperatively. The increased acid load delivered to the duodenum inhibits absorption by a variety of mechanisms, including the inhibition of digestive enzymes, most of which function optimally under alkaline conditions.

Therapy

Medical Therapy. For patients having undergone massive small bowel resection, the initial treatment priorities include management of the primary condition precipitating the intestinal resection and the repletion of fluid and electrolytes lost in the severe diarrhea that characteristically occurs. Most patients will require TPN, at least initially. Enteral nutrition should be gradually introduced, once ileus has resolved. High-dose histamine-2 receptor antagonists or proton pump inhibitors should be administered to reduce gastric acid secretion. Antimotility agents, such as loperamide hydrochloride or diphenoxylate, may be administered to delay small-intestinal transit. Octreotide can be administered to reduce the volume of GI secretions, although in animal models, its use is associated with an inhibition of intestinal adaptation.

During the period of adaptation, generally lasting 1 to 2 years postoperatively, TPN and enteral nutrition are titrated

in an attempt to allow for independence from TPN. Patients who remain dependent on TPN face substantial TPN-associated morbidities including catheter sepsis, venous thrombosis, liver and kidney failure, and osteoporosis. Liver failure is a significant source of morbidity and often leads to liver transplantation (always in combination with small bowel transplantation). Due to these complications, patients with short bowel syndrome on TPN have a reduced life expectancy, with 5-year survival rates of 50% to 75%. Costs associated with chronic TPN administration are estimated to be as high as \$150,000 per patient annually. Because of these problems, alternative therapies for short bowel syndrome are under investigation.

Nontransplant Surgical Therapy. Among patients with stomas, restoration of intestinal continuity should be performed whenever possible to capitalize on the absorptive capacity of all residual intestine. Other forms of nontransplant surgery designed to improve intestinal absorption are associated with unclear efficacy and/or substantial morbidities and therefore should not be applied routinely.

The goal of these operations is to increase nutrient and fluid absorption by either slowing intestinal transit or increasing intestinal length. Operations designed to slow intestinal transit include segmental reversal of the small bowel, interposition of a segment of colon between segments of small bowel, construction of small-intestinal valves, and electrical pacing of the small intestine. Reported experience with these procedures is limited to case reports or series of a few cases. Objective evidence of increased absorption is lacking; further, these procedures are frequently associated with intestinal obstruction.

The intestinal lengthening operation that has the longest history is the longitudinal intestinal lengthening and tailoring (LILT) procedure, first described by Bianchi in 1980.⁷⁵ The procedure entails separation of the dual vasculature of the small intestine, followed by longitudinal division of the bowel with subsequent isoperistaltic end-to-end anastomosis. This procedure has the potential to double the length of small intestine to which it is applied. This procedure has generally been used for pediatric patients with *dilated* residual small bowel.

An alternative surgical approach to lengthening the small bowel is the serial transverse enteroplasty procedure (STEP). This procedure is designed to accomplish lengthening of dilated

small intestine without the need for separating its dual vasculature (Fig. 28-31). A recent report from an international registry of 111 patients showed that 47% of patients achieved enteral autonomy at a median follow-up of 21 months.⁷⁶

Intestinal Transplantation. This complex procedure is being increasingly performed to treat patients with short bowel syndrome. Approximately 1850 patients worldwide had undergone this procedure by 2009.⁷⁷ The currently accepted indication for intestinal transplantation is the presence of life-threatening complications attributable to intestinal failure and/or long-term TPN therapy. Specific complications for which intestinal transplantation is indicated include (a) impending or overt liver failure, (b) thrombosis of major central veins, (c) frequent episodes of catheter-related sepsis, and (d) frequent episodes of severe dehydration.

Of the transplants involving the intestine, 37% were intestine-alone transplants, 30% included intestine + liver + pancreas, and 24% were intestine + liver.⁷⁷

Isolated intestinal transplantation is used for patients with intestinal failure who have no significant liver disease or failure of other organs. Combined intestine/liver transplantation is used for patients with both intestinal and liver failure. Multivisceral transplantation has been used for patients with giant desmoid tumors involving the vascular supply of the liver and pancreas as well as that of the intestine, for diffuse GI motility disturbances, and for diffuse splanchnic thrombosis.

Nearly 80% of survivors have full intestinal graft function with no need for TPN. However, morbidities associated with intestinal transplantation are substantial and include acute and chronic rejection, CMV infection, and posttransplant lymphoproliferative disease.

Alternative Therapies. Pharmacologic and biologic therapies designed to expand intestinal mucosal surface area or to enhance the efficiency of intestinal absorption are beginning to undergo clinical evaluation. Promising regimens include GLP-2 and the combination of glutamine and growth hormone with a modified, high-carbohydrate diet.

Outcomes

Approximately 50% to 70% of patients with short bowel syndrome who initially require TPN are ultimately able to

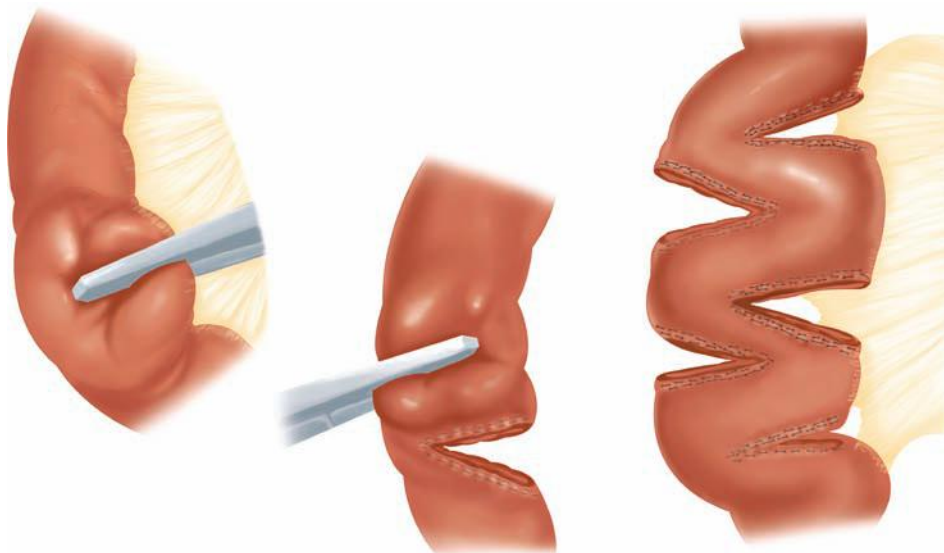


Figure 28-31. This figure depicts the serial transverse enteroplasty (STEP) procedure. Lengthening of dilated small intestine is accomplished by serial applications of an intestinal stapling device, with firings oriented perpendicular to the long axis of the intestine. (Used with permission from Patrick Javid, MD, and Tom Jaksic, MD, Department of Surgery, Children's Hospital, Boston, MA).

achieve independence from TPN.⁷³ Prognosis for achieving enteral autonomy is better among pediatric patients than among adults.

Information on survival among patients with short bowel syndrome is limited. In a recently reported study of 124 adults with short bowel syndrome due to nonmalignant etiologies, the survival rates at 2 and 5 years of follow-up were 86% and 45%, respectively.⁷⁸ Patients with end-enterostomies and those having less than 50 cm of residual small intestine had significantly worse survivals than those without these features.

No randomized trials comparing intestinal transplantation to chronic TPN administration among patients with short bowel syndrome have been reported. One-, 5-, and 10-year graft survival rates of intestine-alone recipients were 80%, 44%, and 26%; whereas the rates for intestine + liver and intestine + liver + pancreas were 62%, 45%, and 36% and 69%, 48%, and 33%, respectively.⁷⁷

REFERENCES

Entries highlighted in bright blue are key references.

1. Tavakkolizadeh A, Whang EE, Ashley SW, Zinner MJ. Small intestine. In: Brunicaardi F, Andersen D, Billiar T, et al, eds. *Principles of Surgery*. 9th ed. New York: McGraw-Hill; 2004:28-1.
2. McMinn RMH. *Last's Anatomy: Regional and Applied*. 9th ed. Singapore: Churchill Livingstone; 1994:337.
3. Yan KS, Chia LA, Li X, et al. The intestinal stem cell markers Bmi1 and Lgr5 identify two functionally distinct populations. *Proc Natl Acad Sci U S A*. 2012;109:466.
4. Thomson ABR, Keelan M, Thiesen A, et al. **Small bowel review: normal physiology part 2.** *Dig Dis Sci*. 2001;46:2588.
5. Laforenza U. Water channel proteins in the gastrointestinal tract. *Mol Aspects Med*. 2012;33:642.
6. Dyer J, Wood IS, Palejwala A, Ellis A, Shirazi-Beechy SP. Expression of monosaccharide transporters in intestine of diabetic humans. *Am J Physiol*. 2002;282:G241.
7. Powell DR, DaCosta CM, Gay J, et al. Improved glycemic control in mice lacking Sglt1 and Sglt2. *Am J Physiol Endocrinol Metab*. 2013;304:E117.
8. Rolfs A, Hediger MA. Intestinal metal ion absorption: an update. *Curr Opin Gastroenterol*. 2001;17:177.
9. Nagler-Anderson C. Man the barrier! Strategic defenses in the intestinal mucosa. *Nat Rev Immunol*. 2001;1:59.
10. Mowat AM. Anatomical basis of tolerance and immunity to intestinal antigens. *Nat Rev Immunol*. 2003;3:331.
11. Jarchum I, Pamer EG. Regulation of innate and adaptive immunity by the commensal microbiota. *Curr Opin Immunol*. 2011;23:353.
12. Rehfeld JF. The new biology of gastrointestinal hormones. *Physiol Rev*. 1998;78:1087.
13. Tavakkolizadeh A, Whang EE. Understanding and augmenting human intestinal adaptation: a call for more clinical research. *JPEN J Parenter Enteral Nutr*. 2002;26:251.
14. Scott FI, Osterman MT, Mahmood NN, Lewis JD. Secular trends in small-bowel obstruction and adhesiolysis in the United States: 1988-2007. *Am J Surg*. 2012;204:315.
15. Maglinte DD, Heitkamp DE, Howard TJ. Current concepts in imaging of small bowel obstruction. *Radiol Clin N Am*. 2003;41:263.
16. Abbas S, Bissett IP, Parry BR. Oral water soluble contrast for the management of adhesive small bowel obstruction. *Cochrane Database Syst Rev*. 2007;3:CD004651.
17. Brodin RE, Krasna MJ, Mast BA. Use of tubes and radiographs in the management of small bowel obstruction. *Ann Surg*. 1987;206:126.
18. Chu DI, Gainsbury ML, Howard LA, Stucchi AF, Becker JM. Early versus late adhesiolysis for adhesive-related intestinal obstruction: a nationwide analysis of inpatient outcomes. *J Gastrointest Surg*. 2013;17:288.
19. Stewart RM, Page CP, Brender J, et al. The incidence and risk of early postoperative small bowel obstruction: a cohort study. *Am J Surg*. 1987;154:643.
20. Krouse RS, McCahill LE, Easson A, et al. When the sun can set on an unoperated bowel obstruction: management of malignant bowel obstruction. *J Am Coll Surg*. 2002;195:117.
21. Mancini GJ, Petroski GF, Lin WC, Sporn E, Miedema BW, Thaler K. Nationwide impact of laparoscopic lysis of adhesions in the management of intestinal obstruction in the US. *J Am Coll Surg*. 2008;207:520.
22. Ghosheh B, Salameh JR. Laparoscopic approach to acute small bowel obstruction: review of 1061 cases. *Surg Endosc*. 2007;21:1945.
23. Foster NM, McGory ML, Zingmond DS, Ko CY. **Small bowel obstruction: a population-based appraisal.** *J Am Coll Surg*. 2006;203:170.
24. Wahl WL, Wong SL, Sonnenday CJ, et al. Implementation of a small bowel obstruction guideline improves hospital efficiency. *Surgery*. 2012;152:626.
25. Ellis H, Moran BJ, Thompson JN, et al. Adhesion-related hospital readmissions after abdominal and pelvic surgery: a retrospective cohort study. *Lancet*. 1999;353:1476.
26. Angenete E, Jacobsson A, Gellerstedt M, Haglund E. Effect of laparoscopy on the risk of small-bowel obstruction: a population-based register study. *Arch Surg*. 2012;147:359.
27. Fazio VW, Cohen Z, Fleshman JW, et al. Reduction in adhesive small-bowel obstruction by Seprafilm adhesion barrier after intestinal resection. *Dis Colon Rectum*. 2006;49:1.
28. Kumar S, Wong PF, Leaper DJ. Intra-peritoneal prophylactic agents for preventing adhesions and adhesive intestinal obstruction after non-gynaecological abdominal surgery. *Cochrane Database Syst Rev*. 2009;CD005080.
29. Lucky A, Livingstone E, Tache Y. Mechanisms and treatment of postoperative ileus. *Arch Surg*. 2003;138:206.
30. Doorly MG, Senagore AJ. Pathogenesis and clinical and economic consequences of postoperative ileus. *Surg Clin North Am*. 2012;92:259.
31. Charoenkwan K, Phillipson G, Vutyavanich T. Early versus delayed oral fluids and food for reducing complication after major abdominal gynecological surgery. *Cochrane Database Syst Rev*. 2007;4:CD004508.
32. Gendall KA, Kennedy RR, Watson AJ, Frizelle FA. The effect of epidural analgesia on postoperative outcome after colorectal surgery. *Colorectal Dis*. 2007;9:584.
33. Noblett SE, Snowden CP, Shenton BK, Horgan AF. Randomized clinical trial assessing the effect of Doppler-optimized fluid management on outcome after elective colorectal resection. *Br J Surg*. 2006;93:1069.
34. Tan EK, Cornish J, Darzi AW, Tekkis PP. Meta-analysis: alvimopan vs. placebo in the treatment of post-operative ileus. *Aliment Pharmacol Ther*. 2007;25:47.
35. Gaines SL, Giroux K, Thomas S, Gregory JS. Real world efficacy of alvimopan on elective bowel resection patients: an analysis of statistical versus clinical significance. *Am J Surg*. 2012;203:308.
36. Lubbers T, Luyer MD, de Haan JJ, Hadfoune M, Buurman WA, Greve JW. Lipid-rich enteral nutrition reduces postoperative ileus in rats via activation of cholecystokinin-receptors. *Ann Surg*. 2009;249:481.
37. Loftus EV Jr, Schoenfeld P, Sandborn WJ. The epidemiology and natural history of Crohn's disease in population-based patient cohorts from North America: a systematic review. *Aliment Pharmacol Ther*. 2002;16:51.

38. Zheng JJ, Zhu XS, Huangfu Z, Gao ZX, Guo ZR, Wang Z. Crohn's disease in mainland China: a systematic analysis of 50 years of research. *Chin J Dig Dis*. 2005;6:175.
39. Nikolaus S, Schreiber S. Diagnosis of inflammatory bowel disease. *Gastroenterology*. 2007;133:1670.
40. Regueiro M, Schraut W, Baidoo L, et al. Infliximab prevents Crohn's disease recurrence after ileal resection. *Gastroenterology*. 2009;136:441.
41. Gardiner KR, Dasari BV. Operative management of small bowel Crohn's disease. *Surg Clin North Am*. 2007;87:587.
42. Solberg IC, Vatn MH, Hoie O, et al. Clinical course of Crohn's disease: result of a Norwegian population-based ten-year follow up study. *Clin Gastroenterol Hepatol*. 2007;5:1430.
43. Fazio VW, Marchetti F, Church JM, et al. Effect of resection margins on the recurrence of Crohn's disease of the small bowel. *Ann Surg*. 1996;224:563.
44. McLeod RS, Wolff BG, Ross S, Parkes R, McKenzie M. Recurrence of Crohn's disease after ileocolic resection is not affected by anastomotic type: results of a multicenter, randomized, controlled trial. *Dis Colon Rectum*. 2009;52:919.
45. Michelassi F, Upadhyay GA. Side-to-side isoperistaltic strictureplasty in the treatment of extensive Crohn's disease. *J Surg Res*. 2004;117:71.
46. Tan JJ, Tjandra JJ. Laparoscopic surgery for Crohn's disease: a meta-analysis. *Dis Colon Rectum*. 2007;50:576.
47. Delaney CP, Fazio VW. Crohn's disease of the small bowel. *Surg Clin N Am*. 2001;81:137.
48. Penner RM, Madsen KL, Fedorak RN. Postoperative Crohn's disease. *Inflamm Bowel Dis*. 2005;11:765.
49. Evenson AR, Shrikhande G, Fischer JE. Abdominal abscess and enteric fistula. In: Zinner MJ, Ashley SW, eds. *Maingot's Abdominal Operations*. 11th ed. New York: McGraw Hill; 2007:184.
50. Fazio VW, Coutsoftides T, Steiger E. Factors influencing the outcome of treatment of small bowel cutaneous fistula. *World J Surg*. 1983;7:481.
51. Owen RM, Love TP, Perez SD, et al. Definitive surgical treatment of enterocutaneous fistula: outcomes of a 23-year experience. *Arch Surg*. 2012;15:1.
52. Martinez JL, Luque-de-Leon E, Ballinas-Oseguera G, Mendez JD, Juarez-Oropeza MA, Roman-Ramos R. Factors predictive of recurrence and mortality after surgical repair of enterocutaneous fistula. *J Gastrointest Surg*. 2012;16:156.
53. Jepsen JM, Persson M, Jakobsen NO, et al. Prospective study of prevalence and endoscopic and histopathologic characteristics of duodenal polyps in patients submitted to upper endoscopy. *Scand J Gastroenterol*. 1994;29:483.
54. Jemal A, Murray T, Samuels A, et al. Cancer statistics, 2003. *CA Cancer J Clin*. 2003;53:5.
55. Qubaiah O, Devesa SS, Platz CE, Huycke MM, Dores GM. Small intestinal cancer: a population-based study of incidence and survival patterns in the United States, 1992 to 2006. *Cancer Epidemiol Biomarkers Prev*. 2010;19:1908.
56. Ceppa EP, Burbridge RA, Rialon KL, et al. Endoscopic versus surgical ampullectomy: an algorithm to treat disease of the ampulla of Vater. *Ann Surg*. 2013;257:315.
57. Judson I, Demetri G. Advances in the treatment of gastrointestinal stromal tumors. *Ann Oncol*. 2007;18:S20.
58. Agrawal S, McCarron EC, Gibbs JF, Nava HR, Wilding GE, Rajput A. Surgical management and outcome in primary adenocarcinoma of the small bowel. *Ann Surg Oncol*. 2007;14:2263.
59. Girvent M, Carlson GL, Anderson I, et al. Intestinal failure after surgery for complicated radiation enteritis. *Ann R Coll Surg Engl*. 2000;82:198.
60. Kiliç D, Egehan I, Ozenirler S, Dursun A. Double-blinded, randomized, placebo-controlled study to evaluate the effectiveness of sulphasalazine in preventing acute gastrointestinal complications due to radiotherapy. *Radiother Oncol*. 2000;57:125.
61. Waddell BE, Lee RJ, Rodriguez-Bigas MA, Weber TK, Petrelli NJ. Absorbable mesh sling prevents radiation-induced bowel injury during "sandwich" chemoradiation for rectal cancer. *Arch Surg*. 2000;135:1212.
62. Yahouchy EK, Marano AF, Etienne JC, et al. Meckel's diverticulum. *J Am Coll Surg*. 2001;192:654.
63. Cullen JJ, Kelly KA, Moir CR, et al. Surgical management of Meckel's diverticulum. An epidemiologic, population-based study. *Ann Surg*. 1994;220:564.
64. Lobo DN, Balfour TW, Iftikhar SY, et al. Periapillary diverticula and pancreaticobiliary disease. *Br J Surg*. 1999;86:588.
65. Chow DC, Babaian M, Taubin HL. Jejunoileal diverticula. *Gastroenterologist*. 1997;5:78.
66. Kumar S, Sarr MG, Kamath PS. Mesenteric venous thrombosis. *N Engl J Med*. 2001;345:1683.
67. Gralnek IM. Obscure-overt gastrointestinal bleeding. *Gastroenterology*. 2005;128:1424.
68. Szold A, Katz LB, Lewis BS. Surgical approach to occult gastrointestinal bleeding. *Am J Surg*. 1992;163:90.
69. Laine L, Sahota A, Shah A. Does capsule endoscopy improve outcomes in obscure gastrointestinal bleeding? Randomized trial versus dedicated small bowel radiography. *Gastroenterology*. 2010;138:1673.
70. Genzlinger JL, McPhee MS, Fisher JK, et al. Significance of retroperitoneal air after endoscopic retrograde cholangiopancreatography with sphincterotomy. *Am J Gastroenterol*. 1999;94:1267.
71. Varban O, Ardestani A, Azagury D, et al. Contemporary management of adult intussusception: who needs a resection? *World J Surg*. 2013;37:1872.
72. Varban O, Ardestani A, Azagury D, et al. Resection or reduction? The dilemma of managing retrograde intussusception after Roux-en-Y gastric bypass. *Surg Obes Relat Dis*. 2013;9:725.
73. Buchman AL, Solapio J, Fryer J. AGA technical review on short bowel syndrome and intestinal transplantation. *Gastroenterology*. 2003;124:1111.
74. Thompson JS, Langnas AN. Surgical approaches to improving intestinal function in the short-bowel syndrome. *Arch Surg*. 1999;134:706.
75. Bianchi A. Intestinal loop lengthening: a technique for increasing small-intestinal length. *J Pediatr Surg*. 1980;15:145.
76. Jones BA, Hull MA, Potanos KM, et al. Report of 111 consecutive patients enrolled in the International Serial Transverse Enteroplasty (STEP) data registry: a retrospective observational study. *J Am Coll Surg*. 2013;216:438.
77. Cai J. Intestine and multivisceral transplantation in the United States: a report of 20-year national registry data (1990-2009). *Clin Transpl*. 2009;83.
78. Messing B, Crenn P, Beau P, et al. Long-term survival and parenteral nutrition dependence in adult patients with short bowel syndrome. *Gastroenterology*. 1999;117:1043.

29 chapter

Colon, Rectum, and Anus

Kelli M. Bullard Dunn and David A. Rothenberger

Embryology and Anatomy / 1175		
Embryology / 1175		
Anatomy / 1176		
Congenital Anomalies / 1179		
Normal Physiology / 1179		
Fluid and Electrolyte Exchanges / 1179		
Short-Chain Fatty Acids / 1179		
Colonic Microflora and Intestinal Gas / 1179		
Motility, Defecation, and Continence / 1180		
Clinical Evaluation / 1180		
Clinical Assessment / 1180		
Endoscopy / 1180		
Imaging / 1181		
Physiologic and Pelvic Floor Investigations / 1181		
Laboratory Studies / 1182		
Evaluation of Common Symptoms / 1183		
General Surgical Considerations / 1185		
Resections / 1185		
Anastomoses / 1189		
Ostomies and Preoperative Stoma Planning / 1191		
Functional Results / 1193		
Anesthesia Considerations / 1194		
Operative Preliminaries / 1194		
Inflammatory Bowel Disease / 1195		
General Considerations / 1195		
Ulcerative Colitis / 1197		
Crohn's Disease / 1198		
Indeterminate Colitis / 1201		
Diverticular Disease / 1201		
Inflammatory Complications (Diverticulitis) / 1201		
Hemorrhage / 1203		
Giant Colonic Diverticulum / 1203		
Right-Sided Diverticula / 1203		
Adenocarcinoma and Polyps / 1203		
Incidence / 1203		
Epidemiology (Risk Factors) / 1203		
Pathogenesis of Colorectal Cancer / 1204		
Polyps / 1205		
Inherited Colorectal Carcinoma / 1206		
Prevention: Screening and Surveillance / 1208		
Routes of Spread and Natural History / 1209		
Staging and Preoperative Evaluation / 1209		
Therapy for Colonic Carcinoma / 1212		
Therapy for Rectal Carcinoma / 1213		
Follow-Up and Surveillance / 1215		
Treatment of Recurrent Colorectal Carcinoma / 1215		
Minimally Invasive Techniques For Resection / 1216		
Other Neoplasms / 1216		
Rare Colorectal Tumors / 1216		
Retrorectal/Presacral Tumors / 1217		
Anal Canal and Perianal Tumors / 1217		
Other Benign Colorectal Conditions / 1218		
Rectal Prolapse and Solitary Rectal Ulcer Syndrome / 1218		
Volvulus / 1219		
Megacolon / 1220		
Colonic Pseudo-obstruction (Ogilvie's Syndrome) / 1221		
Ischemic Colitis / 1221		
Infectious Colitis / 1222		
Anorectal Diseases / 1222		
Hemorrhoids / 1222		
Anal Fissure / 1225		
Anorectal Sepsis and Cryptoglandular Abscess / 1227		
Perianal Abscess / 1228		
Ischiorectal Abscess / 1228		
Intersphincteric Abscess / 1228		
Supralelevator Abscess / 1229		
Perianal Sepsis in the Immunocompromised Patient / 1229		
Necrotizing Soft Tissue Infection of the Perineum / 1229		
Fistula In Ano / 1229		
Rectovaginal Fistula / 1231		
Perianal Dermatitis / 1231		
Sexually Transmitted Diseases / 1232		
Pilonidal Disease / 1233		
Hidradenitis Suppurativa / 1233		
Trauma / 1233		
Penetrating Colorectal Injury / 1233		
Blunt Colorectal Injury / 1234		
Iatrogenic Injury / 1234		
Anal Sphincter Injury and Incontinence / 1235		
Foreign Body / 1235		
The Immunocompromised Patient / 1235		
Human Immunodeficiency Virus / 1235		
Immunosuppression for Transplantation / 1236		
The Neutropenic Patient / 1236		

EMBRYOLOGY AND ANATOMY

Embryology

The embryonic gastrointestinal tract begins developing during the fourth week of gestation. The primitive gut is derived from the endoderm and divided into three segments: *foregut*, *midgut*, and *hindgut*. Both *midgut* and *hindgut* contribute to the colon, rectum, and anus.

The *midgut* develops into the small intestine, ascending colon, and proximal transverse colon, and receives blood supply from the superior mesenteric artery. During the sixth week of gestation, the *midgut* herniates out of the abdominal cavity, and then rotates 270° counterclockwise around the superior mesenteric artery to return to its final position inside the abdominal cavity during the tenth week of gestation. The *hindgut* develops into the distal transverse colon, descending colon, rectum, and

Key Points

- 1▶ Resection principles: The mesenteric clearance technique dictates the extent of resection and is determined by the nature of the primary pathology, the intent of resection, the location of the lesion, and the condition of the mesentery.
- 2▶ Function after resection: Bowel function is often compromised after colorectal resection, especially after low anterior resection. For this reason, it is important to obtain a history of prior anorectal trauma and/or incontinence before considering a low anastomosis.
- 3▶ Ostomies: Preoperative marking for a planned stoma is critical for a patient's quality of life. Ideally, a stoma should be located within the rectus muscle, in a location where the patient can easily see and manipulate the appliance, and away from previous scars, bony prominences, or abdominal creases.
- 4▶ Inflammatory bowel disease: Both Crohn's disease and ulcerative colitis are associated with an increased risk of colorectal carcinoma. Risk depends on the amount of colon involved and the duration of disease.
- 5▶ Pathogenesis of colorectal cancer: A variety of mutations have been identified in colorectal cancer. Mutations may cause activation of oncogenes (*K-ras*) and/or inactivation of tumor suppressor genes (adenomatous polyposis coli [*APC*], deleted in colorectal carcinoma [*DCC*], *p53*).
- 6▶ Minimally invasive resection: Laparoscopy and HAL have been shown to be both safe and efficacious for colorectal resection.
- 7▶ Anal epidermoid carcinoma: Unlike rectal adenocarcinoma, anal epidermoid carcinoma is treated primarily with chemoradiation. Surgery is reserved for patients with persistent or recurrent disease.
- 8▶ Rectal prolapse: Rectal prolapse occurs most commonly in elderly women. Transabdominal repair (rectopexy with or without resection) offers more durability than perineal proctosigmoidectomy, but carries greater operative risk.
- 9▶ Hemorrhoids: Hemorrhoids are cushions of submucosal tissue containing venules, arterioles, and smooth muscle fiber. They are thought to play a role in maintaining continence. Resection is only indicated for refractory symptoms.
- 10▶ Fistula in ano: Treatment of fistula in ano depends on the location of the fistula, amount of anal sphincter involved in the fistula, and the underlying disease process.

proximal anus, all of which receive their blood supply from the inferior mesenteric artery. During the sixth week of gestation, the distal-most end of the hindgut, the *cloaca*, is divided by the urorectal septum into the urogenital sinus and the rectum.

The distal anal canal is derived from ectoderm and receives its blood supply from the internal pudendal artery. The dentate line divides the endodermal hindgut from the ectodermal distal anal canal.

Anatomy

The large intestine extends from the ileocecal valve to the anus. It is divided anatomically and functionally into the *colon*, *rectum*, and *anal canal*. The wall of the colon and rectum comprise five distinct layers: mucosa, submucosa, inner circular muscle, outer longitudinal muscle, and serosa. In the colon, the outer longitudinal muscle is separated into three *teniae coli*, which converge proximally at the appendix and distally at the rectum, where the outer longitudinal muscle layer is circumferential. In the distal rectum, the inner smooth muscle layer coalesces to form the internal anal sphincter. The intraperitoneal colon and proximal one-third of the rectum are covered by serosa; the mid and lower rectum lack serosa.

Colon Landmarks. The colon begins at the junction of the terminal ileum and cecum and extends 3 to 5 feet to the rectum. The rectosigmoid junction is found at approximately the level of the sacral promontory and is arbitrarily described as the point at which the three *teniae coli* coalesce to form the outer longitudinal smooth muscle layer of the rectum. The *cecum* is the widest diameter portion of the colon (normally 7.5–8.5 cm) and has the thinnest muscular wall. As a result, the cecum is most vulnerable to perforation and least vulnerable to obstruction. The ascending colon is usually fixed to the retroperitoneum. The hepatic flexure marks the transition to the transverse colon.

The intraperitoneal transverse colon is relatively mobile, but is tethered by the gastrocolic ligament and colonic mesentery. The greater omentum is attached to the anterior/superior edge of the transverse colon. These attachments explain the characteristic triangular appearance of the transverse colon observed during colonoscopy. The splenic flexure marks the transition from the transverse colon to the descending colon. The attachments between the splenic flexure and the spleen (the lienocolic ligament) can be short and dense, making mobilization of this flexure during colectomy challenging. The descending colon is relatively fixed to the retroperitoneum. The sigmoid colon is the narrowest part of the large intestine and is extremely mobile. Although the sigmoid colon is usually located in the left lower quadrant, redundancy and mobility can result in a portion of the sigmoid colon residing in the right lower quadrant. This mobility explains why volvulus is most common in the sigmoid colon and why diseases affecting the sigmoid colon, such as diverticulitis, may occasionally present as right-sided abdominal pain. The narrow caliber of the sigmoid colon makes this segment of the large intestine the most vulnerable to obstruction.

Colon Vascular Supply. The arterial supply to the colon is highly variable (Fig. 29-1). In general, the *superior mesenteric artery* branches into the *ileocolic artery* (absent in up to 20% of people), which supplies blood flow to the terminal ileum and proximal ascending colon; the *right colic artery*, which supplies the ascending colon; and the *middle colic artery*, which supplies the transverse colon. The *inferior mesenteric artery* branches into the *left colic artery*, which supplies the descending colon; several *sigmoidal branches*, which supply the sigmoid colon; and the *superior rectal artery*, which supplies the proximal rectum. The terminal branches of each artery form anastomoses with the terminal branches of the adjacent artery and communicate

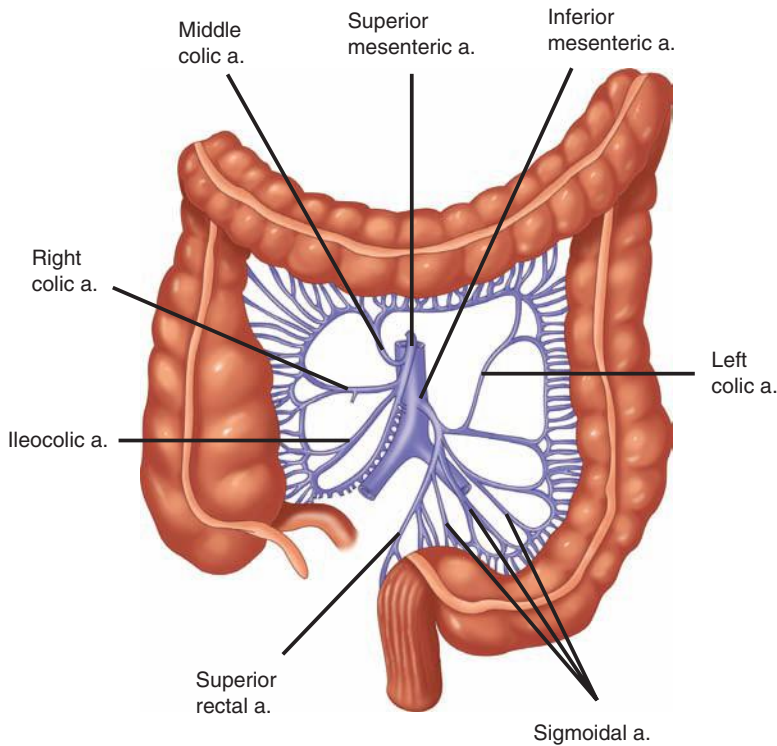


Figure 29-1. Arterial blood supply to the colon. a. = artery.

via the *marginal artery of Drummond*. This arcade is complete in only 15% to 20% of people.

Except for the *inferior mesenteric vein*, the veins of the colon parallel their corresponding arteries and bear the same terminology (Fig. 29-2). The inferior mesenteric vein ascends in the retroperitoneal plane over the psoas muscle and continues posteriorly to join the splenic vein. During a colectomy, this vein is often mobilized independently and ligated at the inferior edge of the pancreas.

Colon Lymphatic Drainage. The lymphatic drainage of the colon originates in a network of lymphatics in the muscularis mucosa. Lymphatic vessels and lymph nodes follow the

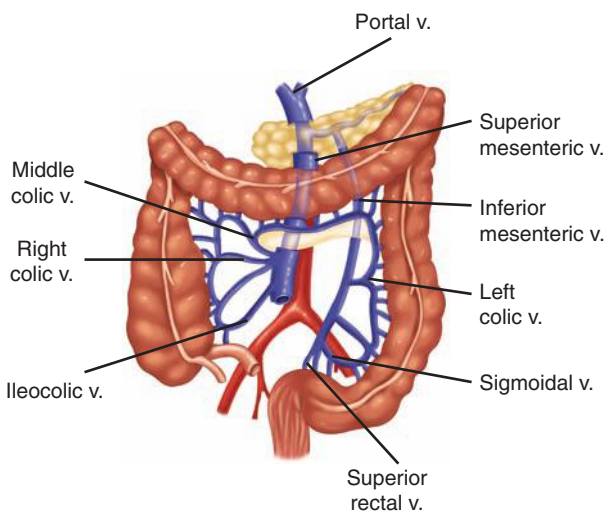


Figure 29-2. Venous drainage of the colon. v. = vein. (Reproduced with permission from Bell RH, Rikkers LF, Mulholland M, eds. *Digestive Tract Surgery: A Text and Atlas*. Philadelphia: Lippincott Williams & Wilkins; 1996:1459.)

regional arteries. Lymph nodes are found on the bowel wall (epicolic), along the inner margin of the bowel adjacent to the arterial arcades (paracolic), around the named mesenteric vessels (intermediate), and at the origin of the superior and inferior mesenteric arteries (main). The *sentinel lymph nodes* are the first one to four lymph nodes to drain a specific segment of the colon and are thought to be the first site of metastasis in colon cancer. The utility of sentinel lymph node dissection and analysis in colon cancer remains controversial.

Colon Nerve Supply. The colon is innervated by both *sympathetic* (inhibitory) and *parasympathetic* (stimulatory) nerves, which parallel the course of the arteries. Sympathetic nerves arise from T6-T12 and L1-L3. The parasympathetic innervation to the right and transverse colon is from the vagus nerve; the parasympathetic nerves to the left colon arise from sacral nerves S2-S4 to form the *nervi erigentes*.

Anorectal Landmarks. The rectum is approximately 12 to 15 cm in length. Three distinct submucosal folds, the *valves of Houston*, extend into the rectal lumen. Posteriorly, the *preseacral fascia* separates the rectum from the presacral venous plexus and the pelvic nerves. At S4, the *rectosacral fascia (Waldeyer's fascia)* extends forward and downward and attaches to the fascia propria at the anorectal junction. Anteriorly, *Denonvilliers' fascia* separates the rectum from the prostate and seminal vesicles in men and from the vagina in women. The *lateral ligaments* support the lower rectum.

The *anatomic anal canal* extends from the dentate or pectinate line to the anal verge. The *dentate or pectinate line* marks the transition point between columnar rectal mucosa and squamous anoderm. The *anal transition zone* includes mucosa proximal to the dentate line that shares histologic characteristics of columnar, cuboidal, and squamous epithelium. Although the anal transition zone was long thought to extend only 1 to 2 cm proximal to the dentate line, it is known that the proximal extent of this zone is highly variable and can be as far as 15 cm proximal to

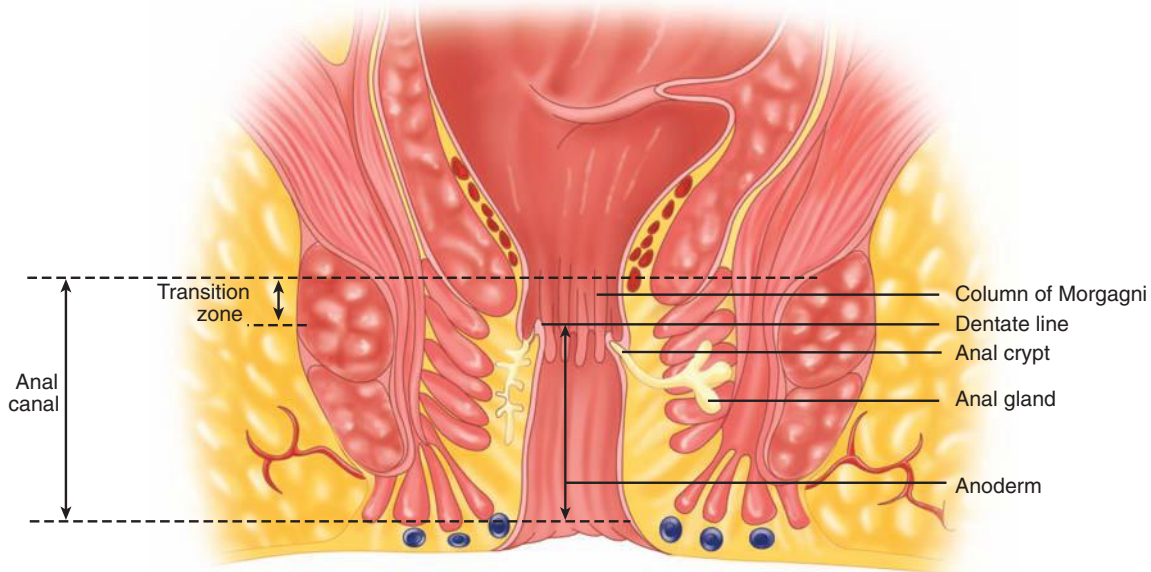


Figure 29-3. The lining of the anal canal. (From Goldberg SM, Gordon PH, Nivatvongs S, eds. *Essentials of Anorectal Surgery*. Philadelphia: J.B. Lippincott Company; 1980:4. Reproduced with permission from Stanley M. Goldberg, MD.)

the dentate line. The dentate line is surrounded by longitudinal mucosal folds, known as the *columns of Morgagni*, into which the anal crypts empty. These crypts are the source of cryptoglandular abscesses (Fig. 29-3). In contrast to the anatomic anal canal, the surgical anal canal begins at the anorectal junction and terminates at the anal verge. The surgical anal canal measures 2 to 4 cm in length and is generally longer in men than in women. It begins at the anorectal junction and terminates at the anal verge.

In the distal rectum, the inner smooth muscle is thickened and comprises the *internal anal sphincter* that is surrounded by the *subcutaneous, superficial, and deep external sphincter*. The *deep external anal sphincter* is an extension of the *puborectalis* muscle. The *puborectalis, iliococcygeus, and pubococcygeus* muscles form the *levator ani* muscle of the pelvic floor (Fig. 29-4).

Anorectal Vascular Supply. The *superior rectal artery* arises from the terminal branch of the inferior mesenteric artery and

supplies the upper rectum. The *middle rectal artery* arises from the internal iliac; the presence and size of these arteries are highly variable. The *inferior rectal artery* arises from the internal pudendal artery, which is a branch of the internal iliac artery. A rich network of collaterals connects the terminal arterioles of each of these arteries, thus making the rectum relatively resistant to ischemia (Fig. 29-5).

The venous drainage of the rectum parallels the arterial supply. The *superior rectal vein* drains into the portal system via the inferior mesenteric vein. The *middle rectal vein* drains into the internal iliac vein. The *inferior rectal vein* drains into the internal pudendal vein, and subsequently into the internal iliac vein. A submucosal plexus deep to the columns of Morgagni forms the *hemorrhoidal plexus* and drains into all three veins.

Anorectal Lymphatic Drainage. Lymphatic drainage of the rectum parallels the vascular supply. Lymphatic channels in the upper and middle rectum drain superiorly into the inferior

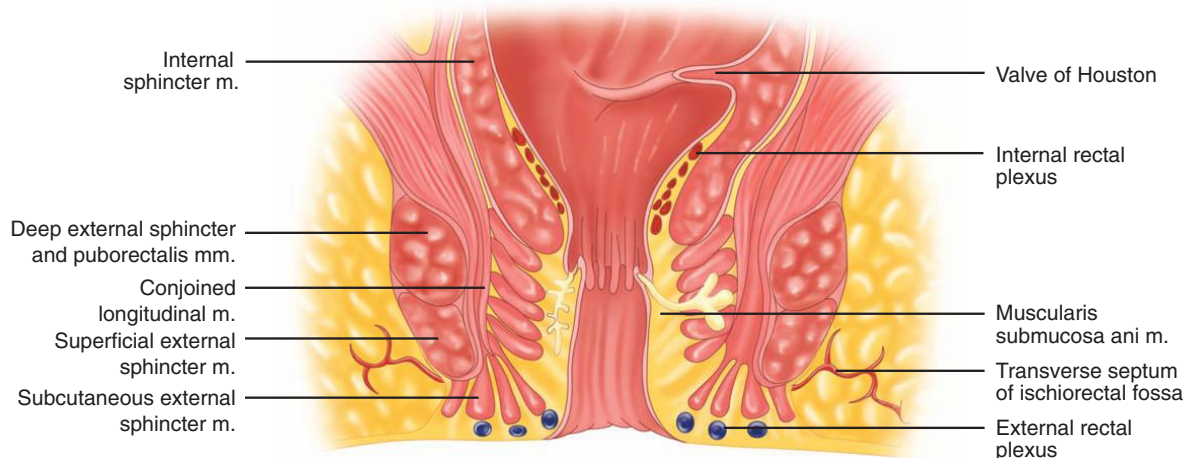


Figure 29-4. The distal rectum and anal canal. m. = muscle.

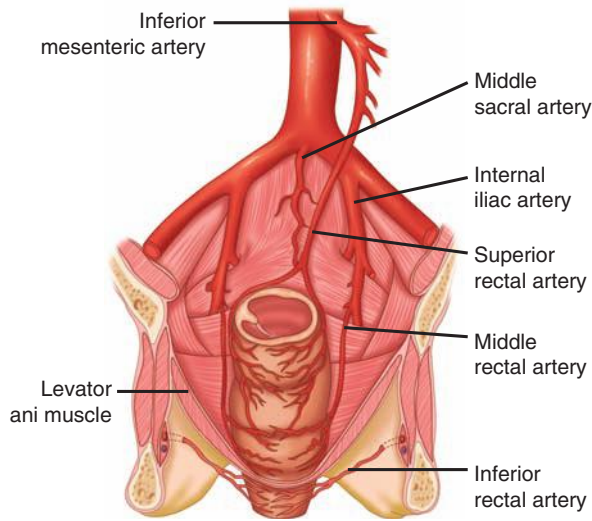


Figure 29-5. Arterial supply to the rectum and anal canal.

mesenteric lymph nodes. Lymphatic channels in the lower rectum drain both superiorly into the inferior mesenteric lymph nodes and laterally into the internal iliac lymph nodes. The anal canal has a more complex pattern of lymphatic drainage. Proximal to the dentate line, lymph drains into both the inferior mesenteric lymph nodes and the internal iliac lymph nodes. Distal to the dentate line, lymph primarily drains into the inguinal lymph nodes, but can also drain into the inferior mesenteric lymph nodes and internal iliac lymph nodes.

Anorectal Nerve Supply. Both sympathetic and parasympathetic nerves innervate the anorectum. Sympathetic nerve fibers are derived from L1-L3 and join the preaortic plexus. The preaortic nerve fibers then extend below the aorta to form the *hypogastric plexus*, which subsequently joins the parasympathetic fibers to form the pelvic plexus. Parasympathetic nerve fibers are known as the *nervi erigentes* and originate from S2-S4. These fibers join the sympathetic fibers to form the pelvic plexus. Sympathetic and parasympathetic fibers then supply the anorectum and adjacent urogenital organs.

The internal anal sphincter is innervated by sympathetic and parasympathetic nerve fibers; both types of fibers inhibit sphincter contraction. The external anal sphincter and puborectalis muscles are innervated by the *inferior rectal branch* of the *internal pudendal nerve*. The levator ani receives innervation from both the *internal pudendal nerve* and direct branches of S3 to S5. Sensory innervation to the anal canal is provided by the *inferior rectal branch* of the *pudendal nerve*. While the rectum is relatively insensate, the anal canal below the dentate line is sensate.

Congenital Anomalies

Perturbation of the embryologic development of the midgut and hindgut may result in anatomic abnormalities of the colon, rectum, and anus. Failure of the midgut to rotate and return to the abdominal cavity during the tenth week of gestation results in varying degrees of intestinal malrotation and colonic nonfixation. Failure of canalization of the primitive gut can result in colonic duplication. Incomplete descent of the urogenital septum may result in imperforate anus and associated fistulas to the genitourinary tract. Many infants with congenital anomalies of the hindgut have associated abnormalities in the genitourinary tract.

NORMAL PHYSIOLOGY

Fluid and Electrolyte Exchanges

Water, Sodium, Potassium, Chloride, Bicarbonate, and Ammonia. The colon is a major site for water absorption and electrolyte exchange. Under normal circumstances, approximately 90% of the water contained in ileal fluid is absorbed in the colon (1000–2000 mL/d), but up to 5000 mL of fluid can be absorbed daily. Sodium is absorbed actively via sodium-potassium (Na^+/K^+) ATPase. The colon can absorb up to 400 mEq of sodium per day. Water accompanies the transported sodium and is absorbed passively along an osmotic gradient. Potassium is actively secreted into the colonic lumen and absorbed by passive diffusion. Chloride is absorbed actively via a chloride-bicarbonate exchange.

Bacterial degradation of protein and urea produces ammonia. Ammonia is subsequently absorbed and transported to the liver. Absorption of ammonia depends in part on intraluminal pH. A decrease in colonic bacteria (e.g., due to broad-spectrum antibiotic use) and/or a decrease in intraluminal pH (e.g., due to lactulose administration) will decrease ammonia absorption.

Short-Chain Fatty Acids

Short-chain fatty acids (acetate, butyrate, and propionate) are produced by bacterial fermentation of dietary carbohydrates. Short-chain fatty acids are an important source of energy for the colonic mucosa, and metabolism by colonocytes provides energy for processes such as active transport of sodium. Lack of a dietary source for production of short-chain fatty acids, or diversion of the fecal stream by an ileostomy or colostomy, may result in mucosal atrophy and inflammation, the latter termed “diversion colitis.”

Colonic Microflora and Intestinal Gas

Approximately 30% of fecal dry weight is composed of bacteria (10^{11} – 10^{12} bacteria/g of feces). Anaerobes are the predominant class of microorganism, and *Bacteroides* species are the most common (10^{11} – 10^{12} organisms/mL). *Escherichia coli* are the most numerous aerobes (10^8 – 10^{10} organisms/mL). Endogenous microflora are crucial for the breakdown of carbohydrates and proteins in the colon and participate in the metabolism of bilirubin, bile acids, estrogen, and cholesterol. Colonic bacteria also are necessary for production of vitamin K. Endogenous bacteria also are thought to suppress the emergence of pathogenic microorganisms, such as *Clostridium difficile*, a phenomenon termed “colonization resistance.” However, the high bacterial load of the large intestine may contribute to sepsis in critically ill patients and may contribute to intra-abdominal sepsis, abscess, and wound infection following colectomy.

Intestinal gas arises from swallowed air, diffusion from the blood, and intraluminal production. Nitrogen, oxygen, carbon dioxide, hydrogen, and methane are the major components of intestinal gas. Nitrogen and oxygen are largely derived from swallowed air. Carbon dioxide is produced by the reaction of bicarbonate and hydrogen ions and by the digestion of triglycerides to fatty acids. Hydrogen and methane are produced by colonic bacteria. The production of methane is highly variable. The gastrointestinal tract usually contains between 100 and 200 mL of gas, and 400 to 1200 mL/d are released as flatus, depending on the type of food ingested.

Motility, Defecation, and Continence

Motility. Unlike the small intestine, the large intestine does not demonstrate cyclic motor activity characteristic of the migratory motor complex. Instead, the colon displays intermittent contractions of either low or high amplitude. Low-amplitude, short-duration contractions occur in bursts and appear to move the colonic contents both antegrade and retrograde. It is thought that these bursts of motor activity delay colonic transit and thus increase the time available for absorption of water and exchange of electrolytes. High-amplitude contractions occur in a more coordinated fashion and create “mass movements.” Bursts of “rectal motor complexes” also have been described. In general, cholinergic activation increases colonic motility.

Defecation. Defecation is a complex, coordinated mechanism involving colonic mass movement, increased intra-abdominal and rectal pressure, and relaxation of the pelvic floor. Distention of the rectum causes a reflex relaxation of the internal anal sphincter (the rectoanal inhibitory reflex) that allows the contents to make contact with the anal canal. This “sampling reflex” allows the sensory epithelium to distinguish solid stool from liquid stool and gas. If defecation does not occur, the rectum relaxes and the urge to defecate passes (*accommodation response*). Defecation proceeds by coordination of increasing intra-abdominal pressure via the Valsalva maneuver, increased rectal contraction, relaxation of the puborectalis muscle, and opening of the anal canal.

Continence. The maintenance of fecal continence is at least as complex as the mechanism of defecation. Continence requires adequate rectal wall compliance to accommodate the fecal bolus, appropriate neurogenic control of the pelvic floor and sphincter mechanism, and functional internal and external sphincter muscles. At rest, the puborectalis muscle creates a “sling” around the distal rectum, forming a relatively acute angle that distributes intra-abdominal forces onto the pelvic floor. With defecation, this angle straightens, allowing downward force to be applied along the axis of the rectum and anal canal. The internal and external sphincters are tonically active at rest. The internal sphincter is responsible for most of the resting, involuntary sphincter tone (resting pressure). The external sphincter is responsible for most of the voluntary sphincter tone (squeeze pressure). Branches of the pudendal nerve innervate both the internal and external sphincter. Finally, the hemorrhoidal cushions may contribute to continence by mechanically blocking the anal canal. Thus, impaired continence may result from poor rectal compliance, injury to the internal and/or external sphincter or puborectalis, or nerve damage or neuropathy.

CLINICAL EVALUATION

Clinical Assessment

Obtaining a complete history and performing a physical examination are the starting points for evaluating any patient with suspected disease of the colon, rectum, or anus. Special attention should be paid to the patient’s past medical and surgical history to detect underlying conditions that might contribute to a gastrointestinal problem. If patients have had prior intestinal surgery, it is essential that one understand the resultant gastrointestinal anatomy. A history of anorectal surgery may be critical for patients with either abdominal or anorectal complaints. The obstetrical history in women is essential to detect occult pelvic floor and/or anal sphincter damage. Identifying a family

history of colorectal disease, especially inflammatory bowel disease, polyps, and colorectal cancer, is crucial. In addition to a family history of colorectal disease, a history of other malignancies may suggest the presence of a genetic syndrome. Medication use must be detailed as many drugs cause gastrointestinal symptoms. Before recommending operative intervention, the adequacy of medical treatment must be ascertained. In addition to examining the abdomen, visual inspection of the anus and perineum and careful digital rectal exam are essential.

Endoscopy

Anoscopy. The anoscope is a useful instrument for examination of the anal canal. Anoscopes are made in a variety of sizes and measure approximately 8 cm in length. A larger anoscope provides better exposure for anal procedures such as rubber band ligation or sclerotherapy of hemorrhoids. The anoscope, with obturator in place, should be adequately lubricated and gently inserted into the anal canal. The obturator is withdrawn, inspection of the visualized anal canal is done, and the anoscope should then be withdrawn. It is rotated 90° and reinserted to allow visualization of all four quadrants of the canal. If the patient complains of severe perianal pain and cannot tolerate a digital rectal examination, anoscopy should not be attempted without anesthesia.

Proctoscopy. The rigid proctoscope is useful for examination of the rectum and distal sigmoid colon and is occasionally used therapeutically. The standard proctoscope is 25 cm in length and available in various diameters. Most often, a 15- or 19-mm diameter proctoscope is used for diagnostic examinations. The large (25-mm diameter) proctoscope is useful for procedures such as polypectomy, electrocoagulation, or detorsion of a sigmoid volvulus. A smaller “pediatric” proctoscope (11-mm diameter) is better tolerated by patients with anal stricture. Suction is necessary for an adequate proctoscopic examination.

Flexible Sigmoidoscopy and Colonoscopy. Video or fiberoptic flexible sigmoidoscopy and colonoscopy provide excellent visualization of the colon and rectum. Sigmoidoscopes measure 60 cm in length. Full depth of insertion may allow visualization as high as the splenic flexure, although the mobility and redundancy of the sigmoid colon often limit the extent of the examination. Partial preparation with enemas is usually adequate for sigmoidoscopy, and most patients can tolerate this procedure without sedation. Colonoscopes measure 100 to 160 cm in length and are capable of examining the entire colon and terminal ileum. A complete oral bowel preparation is usually necessary for colonoscopy, and the duration and discomfort of the procedure usually require conscious sedation. Both sigmoidoscopy and colonoscopy can be used diagnostically and therapeutically. Electrocautery should generally not be used in the absence of a complete bowel preparation because of the risk of explosion of intestinal methane or hydrogen gases. Diagnostic colonoscopes possess a single channel through which instruments such as snares, biopsy forceps, or electrocautery can be passed; this channel also provides suction and irrigation capability. Therapeutic colonoscopes possess two channels to allow simultaneous suction/irrigation and the use of snares, biopsy forceps, or electrocautery.

Capsule Endoscopy. Capsule endoscopy is an emerging technology that uses a small ingestible camera. After swallowing the camera, images of the mucosa of the gastrointestinal tract are captured, transmitted by radiofrequency to a belt-held receiver,

and then downloaded to a computer for viewing and analysis. Capsule endoscopy largely has been used to detect small bowel lesions. However, it has been suggested that this technique might also be useful for diagnosing colorectal disease, although utility in the evaluation of colorectal disease remains unproven.¹⁻⁵ Finally, recent advances in the development of maneuverable capsules may improve the sensitivity of this procedure.⁵

Imaging

Plain X-Rays and Contrast Studies. Despite advanced radiologic techniques, plain X-rays and contrast studies continue to play an important role in the evaluation of patients with suspected colon and rectal diseases. Plain X-rays of the abdomen (supine, upright, and diaphragmatic views) are useful for detecting free intra-abdominal air, bowel gas patterns suggestive of small or large bowel obstruction, and volvulus. Contrast studies are useful for evaluating obstructive symptoms, delineating fistulous tracts, and diagnosing small perforations or anastomotic leaks. Although Gastrografin cannot provide the mucosal detail provided by barium, this water-soluble contrast agent is recommended if perforation or leak is suspected. Double-contrast barium enema (use of barium followed by the insufflation of air into the colon) has been reported to be 70% to 90% sensitive for the detection of mass lesions greater than 1 cm in diameter.⁶ Detection of small lesions can be extremely difficult, especially in a patient with extensive diverticulosis. For this reason, a colonoscopy is preferred for evaluating nonobstructing mass lesions in the colon. Double-contrast barium enema has been used as a back-up examination if colonoscopy is incomplete.

Computed Tomography. Computed tomography (CT) commonly is employed in the evaluation of patients with abdominal complaints. Its utility is primarily in the detection of extraluminal disease, such as intra-abdominal abscesses and pericolic inflammation, and in staging colorectal carcinoma, because of its sensitivity in detection of hepatic metastases.⁷

Extravasation of oral or rectal contrast may also confirm the diagnosis of perforation or anastomotic leak. Nonspecific findings such as bowel wall thickening or mesenteric stranding may suggest inflammatory bowel disease, enteritis/colitis, or ischemia. A standard CT scan is relatively insensitive for the detection of intraluminal lesions; however, improved CT technology is increasing the ability to assess bulky rectal tumors and perirectal adenopathy.

Computed Tomography Colonography. CT colonography (virtual colonoscopy) is a radiologic technique that is designed to overcome some of the limitations of traditional CT scanning. This technology uses helical CT and three-dimensional reconstruction to detect intraluminal colonic lesions. Oral bowel preparation, oral and rectal contrast, and colon insufflation have been used to maximize sensitivity. Experience with this technology has shown a sensitivity and specificity for detecting 1 cm or larger polyps of 85% to 90% in most studies, making it comparable to traditional colonoscopy. The addition of “fecal tagging” agents that create a distinct difference in appearance between stool and mucosa during imaging studies holds promise for increasing accuracy and possibly decreasing the need for mechanical bowel preparation.⁸

Magnetic Resonance Imaging. The main use of magnetic resonance imaging (MRI) in colorectal disorders is in evaluation of pelvic lesions. MRI is more sensitive than CT for detecting bony involvement or pelvic sidewall extension of rectal tumors.

MRI accurately determines the extent of spread of rectal cancer into the adjacent mesorectum and can reliably predict difficulty achieving radial margin clearance of a rectal cancer by surgery alone. When the radial margin is threatened, neoadjuvant chemoradiation is generally indicated. MRI also can be helpful in the detection and delineation of complex fistulas in ano. The use of an endorectal coil may increase sensitivity.

Positron Emission Tomography. Positron emission tomography (PET) is used for imaging tissues with high levels of anaerobic glycolysis, such as malignant tumors.⁶ ¹⁸F-fluorodeoxyglucose (FDG) is injected as a tracer; metabolism of this molecule then results in positron emission. PET has been used as an adjunct to CT in the staging of colorectal cancer and may prove useful in discriminating recurrent cancer from fibrosis. By combining PET and CT technology (PET/CT), anatomic correlation between regions of high isotope accumulation (“hot spots”) on PET and abnormalities on CT can be determined. PET/CT increasingly is used to diagnose recurrent and/or metastatic colorectal cancer. However, the efficacy and utility of this technology remains unproven.

Angiography. Angiography is occasionally used for the detection of bleeding within the colon or small bowel. To visualize hemorrhage angiographically, bleeding must be relatively brisk (approximately 0.5 to 1.0 mL per minute). If extravasation of contrast is identified, infusion of vasopressin or angiographic embolization can be therapeutic. If surgical resection is required, the angiographic catheter can be left in place to assist with identification of the bleeding site intraoperatively.

CT and magnetic resonance angiography are also useful for assessing patency of visceral vessels. This technique uses three-dimensional reconstruction to detect vascular lesions. If an abnormality is found, more traditional techniques (angiography, surgery) may then be used to further define and/or correct the problem.

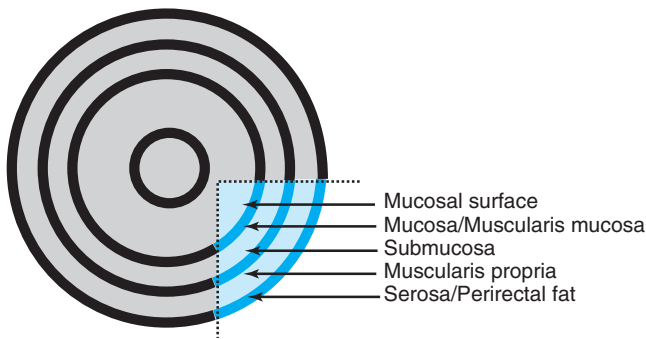
Endorectal and Endoanal Ultrasound. Endorectal ultrasound is primarily used to evaluate the depth of invasion of neoplastic lesions in the rectum. The normal rectal wall appears as a five-layer structure (Fig. 29-6). Ultrasound can reliably differentiate most benign polyps from invasive tumors based on the integrity of the submucosal layer. Ultrasound can also differentiate superficial T1-T2 from deeper T3-T4 tumors. Overall, the accuracy of ultrasound in detecting depth of mural invasion ranges between 81% and 94%.⁹ This modality also can detect enlarged perirectal lymph nodes, which may suggest nodal metastases; accuracy of detection of pathologically positive lymph nodes is 58% to 83%. Ultrasound may also prove useful for early detection of local recurrence after surgery.

Endoanal ultrasound is used to evaluate the layers of the anal canal. Internal anal sphincter, external anal sphincter, and puborectalis muscle can be differentiated. Endoanal ultrasound is particularly useful for detecting sphincter defects and for outlining complex anal fistulas.

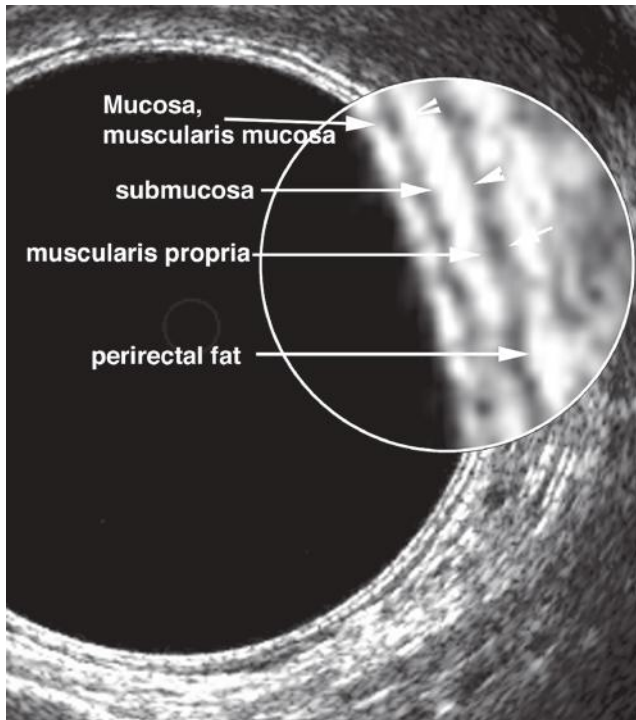
Physiologic and Pelvic Floor Investigations

Anorectal physiologic testing uses a variety of techniques to investigate the function of the pelvic floor. These techniques are useful in the evaluation of patients with incontinence, constipation, rectal prolapse, obstructed defecation, and other disorders of the pelvic floor.

Manometry. Anorectal manometry is performed by placing a pressure-sensitive catheter in the lower rectum. The catheter is



A



B

Figure 29-6. A. Schematic of the layers of the rectal wall observed on endorectal ultrasonography. B. Normal endorectal ultrasonography. (A. Used with permission of Charles O. Finne III, MD, Minneapolis, MN.)

then withdrawn through the anal canal and pressures recorded. A balloon attached to the tip of the catheter also can be used to test anorectal sensation. The *resting pressure* in the anal canal reflects the function of the internal anal sphincter (normal, 40–80 mmHg), whereas the *squeeze pressure*, defined as the maximum voluntary contraction pressure minus the resting pressure, reflects function of the external anal sphincter (normal, 40–80 mmHg above resting pressure). The *high-pressure zone* estimates the length of the anal canal (normal, 2.0–4.0 cm). The *rectoanal inhibitory reflex* can be detected by inflating a balloon in the distal rectum; absence of this reflex is characteristic of Hirschsprung's disease.

Neurophysiology. Neurophysiologic testing assesses function of the pudendal nerves and recruitment of puborectalis muscle fibers. Pudendal nerve terminal motor latency measures the speed of transmission of a nerve impulse through the

distal pudendal nerve fibers (normal, 1.8–2.2 ms); prolonged latency suggests the presence of neuropathy. Electromyographic (EMG) recruitment assesses the contraction and relaxation of the puborectalis muscle during attempted defecation. Normally, recruitment increases when a patient is instructed to “squeeze” and decreases when a patient is instructed to “push.” Inappropriate recruitment is an indication of paradoxical contraction (nonrelaxation of the puborectalis). Needle EMG has been used to map both the pudendal nerves and the anatomy of the internal and external sphincters. However, this examination is painful and poorly tolerated by most patients. Needle EMG has largely been replaced by pudendal nerve motor latency testing to assess pudendal nerve function and endoanal ultrasound to map the sphincters.

Rectal Evacuation Studies. Rectal evacuation studies include the balloon expulsion test and video defecography. Balloon expulsion assesses a patient's ability to expel an intrarectal balloon. Video defecography provides a more detailed assessment of defecation. In this test, barium paste is placed in the rectum, and defecation is then recorded fluoroscopically. Defecography is used to differentiate nonrelaxation of the puborectalis, obstructed defecation, increased perineal descent, rectal prolapse and intussusception, rectocele, and enterocele. The addition of vaginal contrast and intraperitoneal contrast is useful in delineating complex disorders of the pelvic floor.

Laboratory Studies

Fecal Occult Blood Testing. Fecal occult blood testing (FOBT) has been used as a screening test for colonic neoplasms in asymptomatic, average-risk individuals. The efficacy of this test is based on serial testing because the majority of colorectal malignancies will bleed intermittently. FOBT has been a nonspecific test for peroxidase contained in hemoglobin; consequently, occult bleeding from any gastrointestinal source will produce a positive result. Similarly, many foods (red meat, some fruits and vegetables, and vitamin C) will produce a false-positive result. Increased specificity is now possible by using immunochemical FOBT. These tests rely on monoclonal or polyclonal antibodies to react with the intact globin portion of human hemoglobin and are more specific for identifying occult bleeding from the colon or rectum. Any positive FOBT mandates further investigation, usually by colonoscopy.

Stool Studies. Stool studies are often helpful in evaluating the etiology of diarrhea. Wet-mount examination reveals the presence of fecal leukocytes, which may suggest colonic inflammation or the presence of an invasive organism such as invasive *E. coli* or *Shigella* species. Stool cultures can detect pathogenic bacteria, ova, and/or parasites. *C. difficile* colitis is diagnosed by detecting bacterial toxin in the stool.¹⁰ Steatorrhea may be diagnosed by adding Sudan red stain to a stool sample.

Serum Tests. Specific laboratory tests that should be performed will be dictated by the clinical scenario. Preoperative studies generally include a complete blood count and electrolyte panel. The addition of coagulation studies, liver function tests, and blood typing/cross-matching depends on the patient's medical condition and the proposed surgical procedure.

Tumor Markers. Carcinoembryonic antigen (CEA) may be elevated in 60% to 90% of patients with colorectal cancer. Despite this, CEA is not an effective screening tool for this malignancy. Many practitioners follow serial CEA levels after curative-intent surgery in order to detect early recurrence of

colorectal cancer. However, this tumor marker is nonspecific, and no survival benefit has yet been proven. It is also important to note that CEA may be mildly elevated in patients who smoke tobacco. Other biochemical markers (ornithine decarboxylase, urokinase) have been proposed, but none has yet proven sensitive or specific for detection, staging, or predicting prognosis of colorectal carcinoma.¹¹

Genetic Testing. Although familial colorectal cancer syndromes, such as familial adenomatous polyposis (FAP) and hereditary nonpolyposis colon cancer (HNPCC) are rare, information about the specific genetic abnormalities underlying these disorders has led to significant interest in the role of genetic testing for colorectal cancer.¹²

Tests for mutations in the adenomatous polyposis coli (*APC*) gene responsible for FAP and in mismatch repair genes responsible for HNPCC are commercially available and extremely accurate in families with known mutations. However, in the absence of an identified mutation, a negative result is uninformative. For individuals from high-risk families without an identified mutation, increased surveillance is recommended.¹³ Although many of these mutations are also present in sporadic colorectal cancer, the accuracy of genetic testing in average-risk individuals is considerably lower, and these tests are not recommended for screening. Because of the potential psychosocial implications of genetic testing, it is strongly recommended that professional genetic counselors be involved in the care of any patient considering these tests.

Evaluation of Common Symptoms

Pain

Abdominal Pain. Abdominal pain is a nonspecific symptom with myriad causes. Abdominal pain related to the colon and rectum can result from obstruction (either inflammatory or neoplastic), inflammation, perforation, or ischemia. Plain X-rays and judicious use of contrast studies and/or a CT scan can often confirm the diagnosis. Gentle retrograde contrast studies (Gastrografin enema) may be useful in delineating the degree of colonic obstruction. Sigmoidoscopy and/or colonoscopy performed by an experienced endoscopist can assist in the diagnosis of ischemic colitis, infectious colitis, and inflammatory bowel disease. However, if perforation or near complete obstruction is suspected, colonoscopy and/or sigmoidoscopy are generally contraindicated. Evaluation and treatment of abdominal pain from a colorectal source should follow the usual surgical principles of a thorough history and physical examination, appropriate diagnostic tests, resuscitation, and appropriately timed surgical intervention.

Pelvic Pain. Pelvic pain can originate from the distal colon and rectum or from adjacent urogenital structures. Tenesmus may result from proctitis or from a rectal or retrorectal mass. Cyclical pain associated with menses, especially when accompanied by rectal bleeding, suggests a diagnosis of endometriosis. Pelvic inflammatory disease also can produce significant abdominal and pelvic pain. The extension of a peridiverticular abscess or periappendiceal abscess into the pelvis may also cause pain. CT scan and/or MRI may be useful in differentiating these diseases. Proctoscopy (if tolerated) also can be helpful. Occasionally, laparoscopy will yield a diagnosis.

Anorectal Pain. Anorectal pain is most often secondary to an anal fissure, perirectal abscess and/or fistula, or a thrombosed hemorrhoid. Physical examination can usually differentiate these conditions. Other, less common causes of anorectal pain include

anal canal neoplasms, perianal skin infection, and dermatologic conditions. Proctalgia fugax results from levator spasm and may present without any other anorectal findings. Physical exam is critical in evaluating patients with anorectal pain. If a patient is too tender to examine in the office, an examination under anesthesia is necessary. MRI or other imaging studies may be helpful in select cases where the etiology of pain is elusive.

Lower Gastrointestinal Bleeding. The first goal in evaluating and treating a patient with gastrointestinal hemorrhage is adequate resuscitation. The principles of ensuring a patent airway, supporting ventilation, and optimizing hemodynamic parameters apply, and coagulopathy and/or thrombocytopenia should be corrected. The second goal is to identify the source of hemorrhage. Because the most common source of gastrointestinal hemorrhage is esophageal, gastric, or duodenal, nasogastric aspiration should always be performed; return of bile suggests that the source of bleeding is distal to the ligament of Treitz. If aspiration reveals blood or non-bile secretions, or if symptoms suggest an upper intestinal source, esophagogastroduodenoscopy is performed. Anoscopy and/or limited proctoscopy can identify hemorrhoidal bleeding. A technetium-99 (^{99m}Tc)-tagged red blood cell (RBC) scan is extremely sensitive and is able to detect as little as 0.1 mL/h of bleeding; however, localization is imprecise. If the ^{99m}Tc-tagged RBC scan is positive, angiography can then be both diagnostic and potentially therapeutic. If the patient is hemodynamically stable, a rapid bowel preparation (over 4–6 hours) can be performed to allow colonoscopy. Colonoscopy may identify the cause of the bleeding, and cautery or injection of epinephrine into the bleeding site may be used to control hemorrhage. Colectomy may be required if bleeding persists despite these interventions. Intraoperative colonoscopy and/or enteroscopy may assist in localizing bleeding. If colectomy is required, a segmental resection is preferred if the bleeding source can be localized. “Blind” subtotal colectomy may very rarely be required in a patient who is hemodynamically unstable with ongoing colonic hemorrhage of an unknown source. In this setting, just prior to proceeding with a “blind” subtotal colectomy, it is crucial to irrigate the rectosigmoid and re-examine the mucosa of the anal canal and rectum by anoscopy and proctoscopy to ensure the source of ongoing bleeding is not distal to the planned resection margin (Fig. 29-7).

Occult blood loss from the gastrointestinal tract may manifest as iron-deficiency anemia or may be detected with FOBT. Because colon neoplasms bleed intermittently and rarely present with rapid hemorrhage, the presence of occult fecal blood should always prompt a colonoscopy. Unexplained iron-deficiency anemia is also an indication for colonoscopy.

Hematochezia is commonly caused by hemorrhoids or a fissure. Sharp, knife-like pain and bright red rectal bleeding with bowel movements suggest the diagnosis of fissure. Painless, bright red rectal bleeding with bowel movements is often secondary to a friable internal hemorrhoid that is easily detected by anoscopy. In the absence of a painful, obvious fissure, any patient with rectal bleeding should undergo a careful digital rectal examination, anoscopy, and proctosigmoidoscopy. Failure to diagnose a source in the distal anorectum should prompt colonoscopy.

Constipation and Obstructed Defecation. Constipation is an extremely common complaint, affecting more than 4 million people in the United States. Despite the prevalence of this problem, there is lack of agreement about an appropriate definition of constipation. Patients may describe infrequent bowel

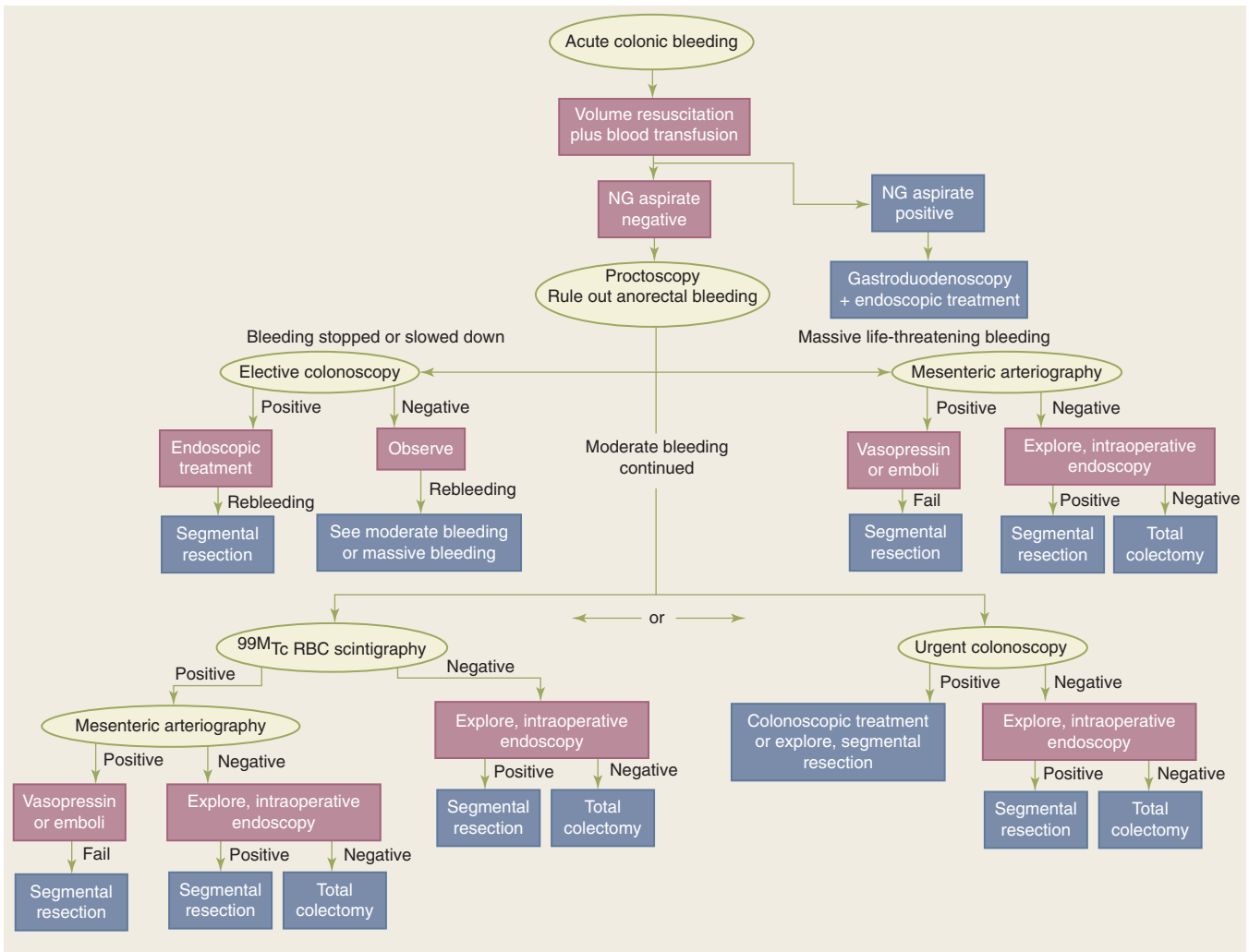


Figure 29-7. Algorithm for treatment of colorectal hemorrhage. NG = nasogastric; ^{99m}Tc = technetium-99; RBC = red blood cell. (Reproduced with permission of Taylor & Francis, LLC from Gordon PH, Nivatvongs S, eds. Principles and Practice of Surgery for the Colon, Rectum, and Anus. 2nd ed. New York: Marcel Dekker, Inc.; 1999:1279. Permission conveyed through Copyright Clearance Center, Inc.)

movements, hard stools, or excessive straining. A careful history of these symptoms often clarifies the nature of the problem.

Constipation has many causes. Underlying metabolic, pharmacologic, endocrine, psychological, and neurologic causes often contribute to the problem. A stricture or mass lesion should be excluded by colonoscopy, barium enema, or CT colonography. After these causes have been excluded, evaluation focuses on differentiating *slow-transit constipation* from *outlet obstruction*. Transit studies, in which radiopaque markers are swallowed and then followed radiographically, are useful for diagnosing slow-transit constipation. Anorectal manometry and EMG can detect nonrelaxation of the puborectalis, which contributes to outlet obstruction. The absence of an anorectal inhibitory reflex suggests Hirschsprung's disease and may prompt a rectal mucosal biopsy. Defecography can identify rectal prolapse, intussusception, rectocele, or enterocele.

Medical management is the mainstay of therapy for constipation and includes fiber, increased fluid intake, and laxatives. Outlet obstruction from nonrelaxation of the puborectalis often responds to biofeedback.¹⁴ Surgery to correct rectocele and rectal prolapse has a variable effect on symptoms of constipation but can be successful in selected patients. Subtotal colectomy is considered only for patients with severe slow-transit constipation

(colonic inertia) refractory to maximal medical interventions. While this operation almost always increases bowel movement frequency, complaints of diarrhea, incontinence, and abdominal pain are not infrequent, and patients should be carefully selected and counseled.¹⁵

Diarrhea and Irritable Bowel Syndrome. Diarrhea is also a common complaint and is usually a self-limited symptom of infectious gastroenteritis. If diarrhea is chronic or is accompanied by bleeding or abdominal pain, further investigation is warranted. Bloody diarrhea and pain are characteristic of colitis; etiology can be an infection (invasive *E. coli*, *Shigella*, *Salmonella*, *Campylobacter*, *Entamoeba histolytica*, or *C. difficile*), inflammatory bowel disease (ulcerative colitis or Crohn's colitis), or ischemia. Stool wet-mount and culture can often diagnose infection. Sigmoidoscopy or colonoscopy can be helpful in diagnosing inflammatory bowel disease or ischemia. However, if the patient has abdominal tenderness, particularly with peritoneal signs, or any other evidence of perforation, endoscopy is contraindicated.

Chronic diarrhea may present a more difficult diagnostic dilemma. Chronic ulcerative colitis, Crohn's colitis, infection, malabsorption, and short gut syndrome can cause chronic

diarrhea. Rarely, carcinoid syndrome and islet cell tumors (vasoactive intestinal peptide–secreting tumor [VIPoma], somatostatinoma, gastrinoma) present with this symptom. Large villous lesions may cause secretory diarrhea. Collagenous colitis can cause diarrhea without any obvious mucosal abnormality. Along with stool cultures, tests for malabsorption, and metabolic investigations, colonoscopy can be invaluable in differentiating these causes. Biopsies should be taken even if the colonic mucosa appears grossly normal.

Irritable bowel syndrome is a particularly troubling constellation of symptoms consisting of crampy abdominal pain, bloating, constipation, and urgent diarrhea. Workup reveals no underlying anatomic or physiologic abnormality. Once other disorders have been excluded, dietary restrictions and avoidance of caffeine, alcohol, and tobacco may help to alleviate symptoms. Antispasmodics and bulking agents may be helpful.

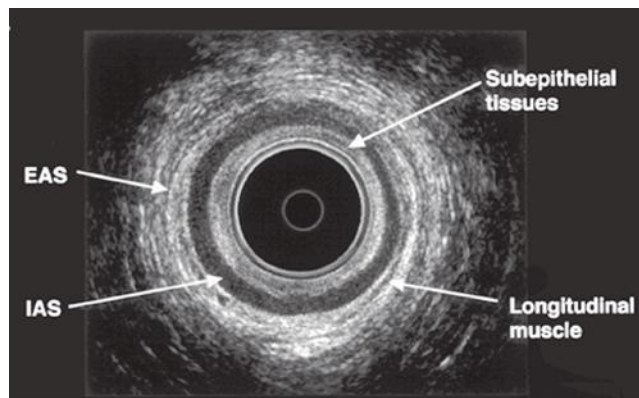
Incontinence. The incidence of fecal incontinence has been estimated to occur in 10 to 13 individuals per 1000 people older than age 65 years. Incontinence ranges in severity from occasional leakage of gas and liquid stool to daily loss of solid stool. The underlying cause of incontinence is often multifactorial, and diarrhea is often contributory. In general, causes of incontinence can be classified as *neurogenic* or *anatomic*. Neurogenic causes include diseases of the central nervous system and spinal cord along with pudendal nerve injury. Anatomic causes include congenital abnormalities, procidentia (rectal prolapse), overflow incontinence secondary to impaction or an obstructing neoplasm, and trauma. The most common traumatic cause of incontinence is injury to the anal sphincter during vaginal delivery. Other causes include anorectal surgery, impalement, and pelvic fracture.

After a thorough medical evaluation to detect underlying conditions that might contribute to incontinence, evaluation focuses on assessment of the anal sphincter and pudendal nerves. Pudendal nerve terminal motor latency testing may detect neuropathy. Anal manometry can detect low resting and squeeze pressures. Physical examination and defecography can detect rectal prolapse. Endoanal ultrasound is invaluable in diagnosing sphincter defects (Fig. 29-8).

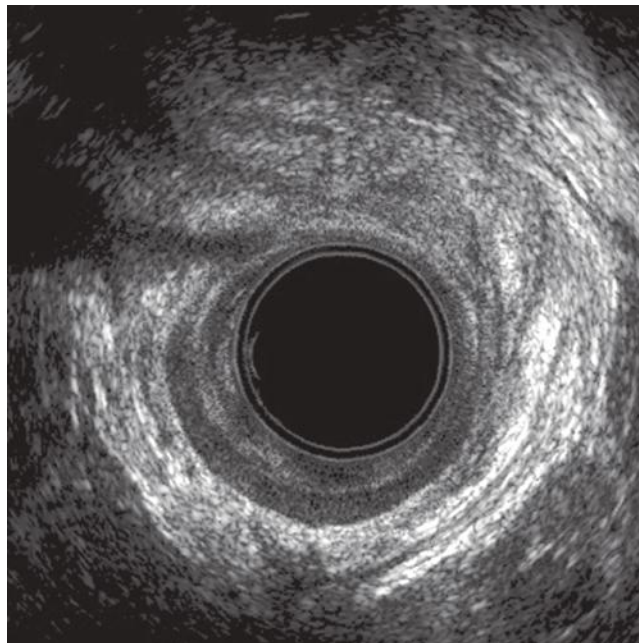
Therapy depends on the underlying abnormality. Diarrhea should be treated medically (fiber, antidiarrheal agents). Even in the absence of frank diarrhea, the addition of dietary fiber may improve continence. Some patients may respond to biofeedback. Many patients with a sphincter defect are candidates for an overlapping sphincteroplasty. Innovative technologies such as sacral nerve stimulation and the artificial bowel sphincter are proving useful in patients who fail other interventions.¹⁶ The delivery of radiofrequency energy to the anal canal (the Secca procedure) appears to be safe and effective in early studies.¹⁷ Injectable bulking agents are also gaining popularity, but long-term efficacy has not yet been proven.¹⁸ Finally, a stoma can provide relief for severely incontinent patients who have failed or are not candidates for other interventions.¹⁹

GENERAL SURGICAL CONSIDERATIONS

Colorectal resections are performed for a wide variety of conditions, including neoplasms (benign and malignant), inflammatory bowel diseases, and other benign conditions. Although the indication and urgency for surgery will alter some of the technical details, the operative principles of colorectal resections, anastomoses, and use of ostomies are well established.



A



B

Figure 29-8. **A.** Endoanal ultrasonography showing the normal layers of the anal canal. **B.** Endoanal ultrasonography with anterior sphincter defect from birthing injury. EAS = external anal sphincter; IAS = internal anal sphincter. (Both images used with permission of Charles O. Finne III, MD, Minneapolis, MN.)

Resections

The mesenteric clearance technique dictates the extent of colonic resection and is determined by the nature of the primary pathology (malignant or benign), the intent of the resection (curative or palliative), the precise location(s) of the primary pathology, and the condition of the mesentery (thin and soft or thick and indurated). In general, a proximal mesenteric ligation will eliminate the blood supply to a greater length of colon and require a more extensive “colectomy.” Curative resection of a colorectal cancer is usually best accomplished by performing a proximal mesenteric vessel ligation and radical mesenteric clearance of the lymphatic drainage basin of the tumor site (Fig. 29-9). Resection of a benign process does not require wide mesenteric clearance.

Emergency Resection. Emergency resection may be required because of obstruction, perforation, or hemorrhage. In this setting, the bowel is almost always unprepared and the patient may

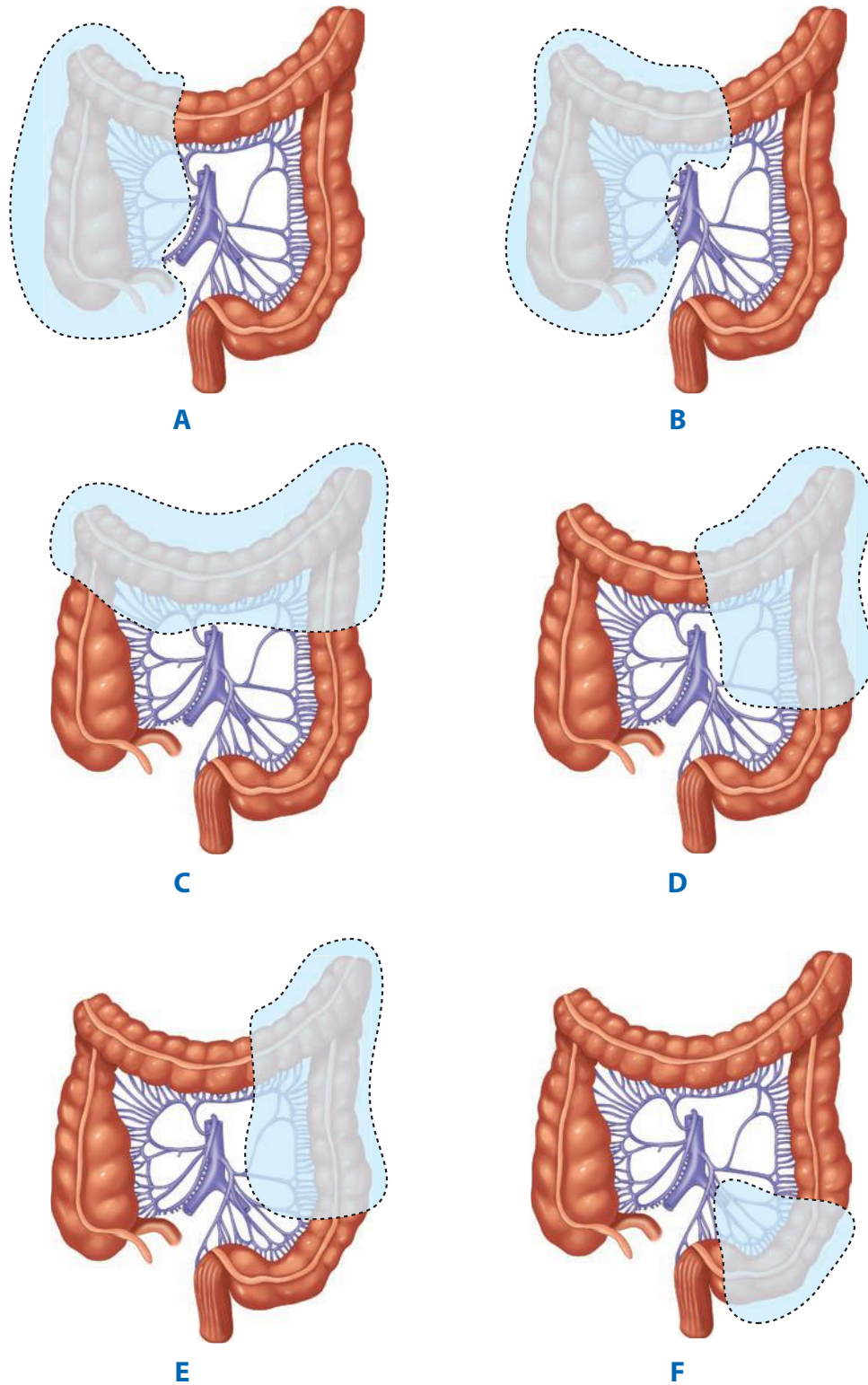


Figure 29-9. Extent of resection for carcinoma of the colon. **A.** Cecal cancer. **B.** Hepatic flexure cancer. **C.** Transverse colon cancer. **D.** Splenic flexure cancer. **E.** Descending colon cancer. **F.** Sigmoid colon cancer.

be unstable. The surgical principles described earlier apply, and an attempt should be made to resect the involved segment along with its lymphovascular supply. If the resection involves the right colon or proximal transverse colon (right or extended right colectomy), a primary ileocolonic anastomosis can usually be performed safely as long as the remaining bowel appears healthy and the patient is stable. For left-sided tumors, the traditional

approach has involved resection of the involved bowel and end colostomy, with or without a mucus fistula. However, there is an increasing body of data to suggest that a primary anastomosis without a bowel preparation or with an on-table lavage, with or without a diverting ileostomy, may be equally safe in this setting. If the proximal colon appears unhealthy (vascular compromise, serosal tears, perforation), a subtotal colectomy can

be performed with a small bowel to rectosigmoid anastomosis. Resection and diversion (ileostomy or colostomy) remain safe and appropriate if the bowel appears compromised or if the patient is unstable, malnourished, or immunosuppressed.

Minimally Invasive Techniques of Resection. With advances in minimally invasive technology, many procedures that previously have required laparotomy can now be performed laparoscopically,^{20,21} with hand-assisted laparoscopy (HAL), or robotically. Potential advantages of minimally invasive surgery include improved cosmetic result, decreased postoperative pain, and earlier return of bowel function. Moreover, some experimental data suggest that minimally invasive operations have less immunosuppressive impact on the patient and thus might improve postoperative outcome and even long-term survival. To date, most studies have demonstrated equivalence between laparoscopic, HAL, and open resection in terms of extent of resection. Return of bowel function and length of hospital stay are highly variable. Long-term outcome has yet to be determined; however, short-term quality of life appears to be improved by laparoscopy.^{22,23} The most recent advances in minimally invasive surgery involve use of *robotics* and *telemanipulation* in which the surgeon operates from a console remote from the patient. These procedures have been rapidly gaining in popularity, especially for pelvic and rectal resections. Early studies suggest equivalence between robotic resections and laparoscopic/HAL resections.²⁴

In addition, some proponents have suggested that robotic procedures may be easier to learn (a shorter “learning curve”) and that robotic surgery may be ergonomically better for the operating surgeon. Nevertheless, long-term superiority, or even equivalence, has yet to be demonstrated, and these advanced technologies are likely to be associated with significant cost.

Colectomy. A variety of terms are used to describe different types of colectomy (Fig. 29-10).

Ileocolic Resection. An ileocolic resection describes a limited resection of the terminal ileum, cecum, and appendix. It is used to remove disease involving these segments of the intestine (e.g., ileocecal Crohn’s disease) and benign lesions or incurable cancers arising in the terminal ileum, cecum, and, occasionally, the appendix. If curable malignancy is suspected, more radical resections, such as a right hemicolectomy, are generally indicated. The ileocolic vessels are ligated and divided. A variable length of small intestine may be resected depending on the disease process. A primary anastomosis is created between the distal small bowel and the ascending colon. It is technically difficult to perform an anastomosis at or just proximal to the ileocecal valve; therefore, if the most distal ileum needs to be resected, the cecum is generally also removed.

Right Colectomy. A right colectomy is used to remove lesions or disease in the right colon and is oncologically the most appropriate operation for curative intent resection of proximal colon carcinoma. The ileocolic vessels, right colic vessels, and right branches of the middle colic vessels are ligated and divided. Approximately 10 cm of terminal ileum are usually included in the resection. A primary ileal-transverse colon anastomosis is almost always possible.

Extended Right Colectomy. An extended right colectomy may be used for curative intent resection of lesions located at the hepatic flexure or proximal transverse colon. A standard right colectomy is extended to include ligation of the middle colic vessels at their base. The right colon and proximal transverse colon are

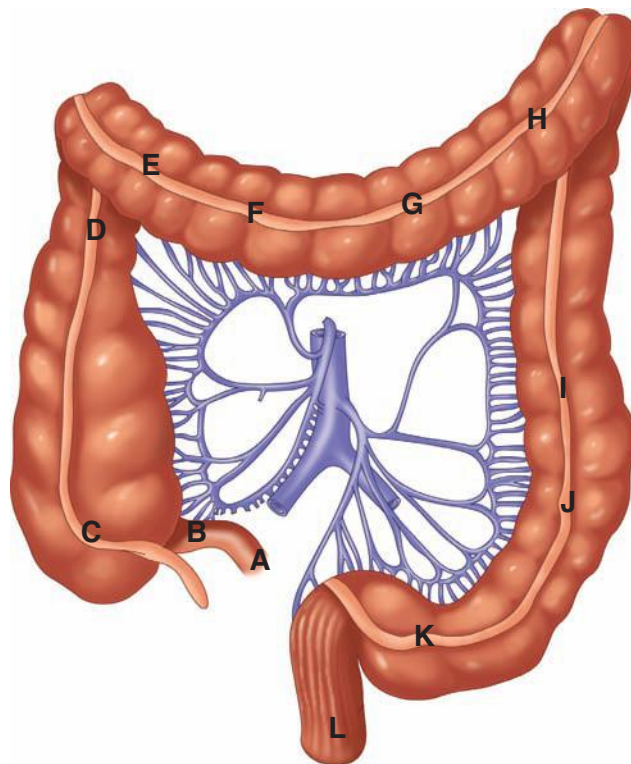


Figure 29-10. Terminology of types of colorectal resections: A→C Ileocectomy; + A + B→D Ascending colectomy; + A + B→F Right hemicolectomy; + A + B→G Extended right hemicolectomy; + E + F→G + H Transverse colectomy; G→I Left hemicolectomy; F→I Extended left hemicolectomy; J + K Sigmoid colectomy; + A + B→J Subtotal colectomy; + A + B→K Total colectomy; + A + B→L Total proctocolectomy. (Reproduced with permission from Fielding LP, Goldberg SM, eds. *Rob & Smith’s Operative: Surgery of the Colon, Rectum, and Anus*. London: Elsevier Science Ltd; 1993:349.)

resected, and a primary anastomosis is created between the distal ileum and distal transverse colon. Such an anastomosis relies on the marginal artery of Drummond. If the blood supply to the distal transverse colon is questionable, the resection is extended distally beyond the splenic flexure to well-perfused descending colon where the ileocolic anastomosis can be performed safely.

Transverse Colectomy. Lesions in the mid and distal transverse colon may be resected by ligating the middle colic vessels and resecting the transverse colon, followed by a colocolonic anastomosis. However, an extended right colectomy with an anastomosis between the terminal ileum and descending colon may be a safer anastomosis with an equivalent functional result.

Left Colectomy. For lesions or disease states confined to the distal transverse colon, splenic flexure, or descending colon, a left colectomy is performed. The left branches of the middle colic vessels, the left colic vessels, and the first branches of the sigmoid vessels are ligated. A colocolonic anastomosis can usually be performed.

Extended Left Colectomy. An extended left colectomy is an option for removing lesions in the distal transverse colon. In this operation, the left colectomy is extended proximally to include the right branches of the middle colic vessels.

Sigmoid Colectomy. Lesions in the sigmoid colon require ligation and division of the sigmoid branches of the inferior mesenteric artery. In general, the entire sigmoid colon should be

resected to the level of the peritoneal reflection and an anastomosis created between the descending colon and upper rectum. Full mobilization of the splenic flexure is often required to create a tension-free anastomosis.

Total and Subtotal Colectomy. Total or subtotal colectomy is occasionally required for patients with fulminant colitis, attenuated FAP, or synchronous colon carcinomas. In this procedure, the ileocolic vessels, right colic vessels, middle colic vessels, and left colic vessels are ligated and divided. The superior rectal vessels are preserved. If it is desired to preserve the sigmoid, the distal sigmoid vessels are left intact, and an anastomosis is created between the ileum and distal sigmoid colon (subtotal colectomy with ileosigmoid anastomosis). If the sigmoid is to be resected, the sigmoidal vessels are ligated and divided, and the ileum is anastomosed to the upper rectum (total abdominal colectomy with ileorectal anastomosis). If an anastomosis is contraindicated, an end ileostomy is created, and the remaining sigmoid or rectum is managed either as a mucus fistula or a Hartmann's pouch.

Proctocolectomy

Total Proctocolectomy. In this procedure, the entire colon, rectum, and anus are removed and the ileum is brought to the skin as a Brooke ileostomy.

Restorative Proctocolectomy (Ileal Pouch–Anal Anastomosis). The entire colon and rectum are resected, but the anal sphincter muscles and a variable portion of the distal anal canal are preserved. Bowel continuity is restored by anastomosis of an ileal reservoir to the anal canal. The original technique included a transanal mucosectomy and hand-sewn ileoanal anastomosis. Proponents of this technique argue that mucosectomy guarantees removal of all of the diseased mucosa, including the anal transition zone, and therefore decreases the risk of ongoing disease, dysplasia, and carcinoma.²⁵ Opponents cite the increased risk of incontinence after mucosectomy and argue that even meticulous technique invariably leaves behind mucosal “islands” that are subsequently hidden under the anastomosis. Moreover, the “double-staple” technique using the circular stapling devices is considerably simpler than mucosectomy and a hand-sewn anastomosis and may be associated with a better functional outcome (Fig. 29-11).²⁶⁻²⁹ Regardless of the anastomotic technique, many surgeons recommend that patients undergo annual surveillance of the anastomosis and/or anal transition zone by digital rectal exam and anoscopy or proctoscopy.

The neorectum is made by anastomosis of the terminal ileum aligned in a “J,” “S,” or “W” configuration. Because functional outcomes are similar and because the J-pouch is the simplest to construct, it has become the most used configuration. With increasing experience in laparoscopic and robotic colectomy, some centers have begun performing total proctocolectomy with ileal pouch–anal reconstruction using minimally invasive surgical techniques.²⁰ Most surgeons perform a proximal ileostomy to divert succus from the newly created pouch in an attempt to minimize the consequences of leak and sepsis, especially in patients who are malnourished or immunosuppressed (Fig. 29-12). The ileostomy is then closed 6 to 12 weeks later, after a contrast study confirms the integrity of the pouch. In low-risk patients, however, there are reports of successful creation of an ileoanal pouch without a diverting stoma.

Anterior Resection. *Anterior resection* is the general term used to describe resection of the rectum from an abdominal approach to the pelvis with no need for a perineal, sacral, or

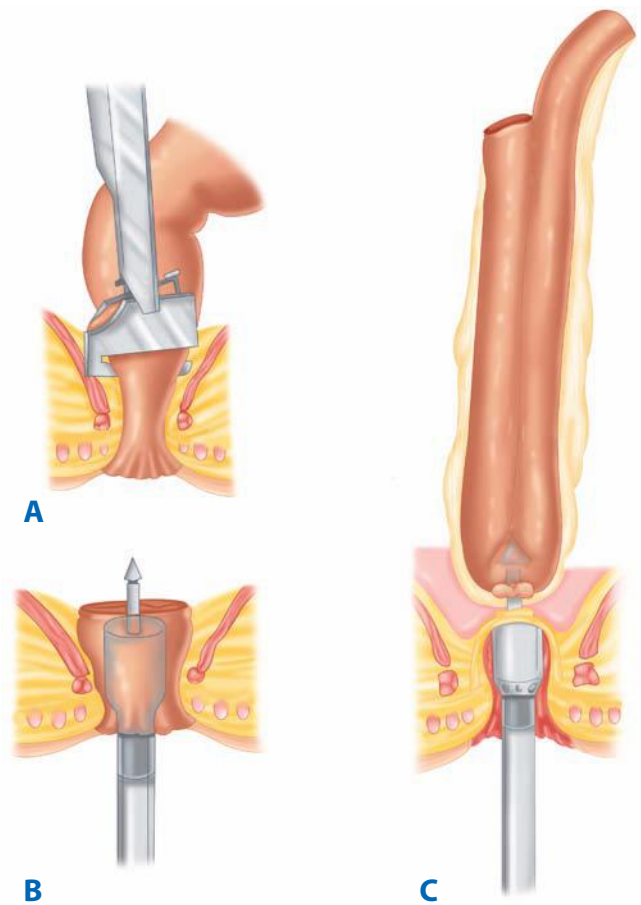


Figure 29-11. After a total colectomy and resection of the rectum (A), the anal canal with a short cuff of transitional mucosa and sphincter muscles is preserved (B). An ileal J-pouch has been constructed and is anastomosed to the anal canal using a double-staple technique (C). (Reproduced with permission from Bell RH, Rikkers LF, Mulholland M, eds. *Digestive Tract Surgery: A Text and Atlas*. Philadelphia: Lippincott Williams & Wilkins; 1996:1527.)

other incision. Three types of anterior resection have been described.

High Anterior Resection. A *high anterior resection* is the term used to describe resection of the distal sigmoid colon and upper rectum and is the appropriate operation for benign lesions and disease at the rectosigmoid junction such as diverticulitis. The upper rectum is mobilized, but the pelvic peritoneum is not divided and the rectum is not mobilized fully from the concavity of the sacrum. The inferior mesenteric artery is ligated at its base, and the inferior mesenteric vein, which follows a different course than the artery, is ligated separately. A primary anastomosis (usually end-to-end) between the colon and rectal stump with a short cuff of peritoneum surrounding its anterior two thirds generally can be performed.

Low Anterior Resection. A *low anterior resection* is used to remove lesions in the upper and mid rectum. The rectosigmoid is mobilized, the pelvic peritoneum is opened, and the inferior mesenteric artery is ligated and divided either at its origin from the aorta or just distal to the takeoff of the left colic artery. The rectum is mobilized from the sacrum by sharp dissection under direct view within the endopelvic fascial plane. The dissection may be performed distally to the anorectal ring, extending posteriorly through the rectosacral fascia to the coccyx and

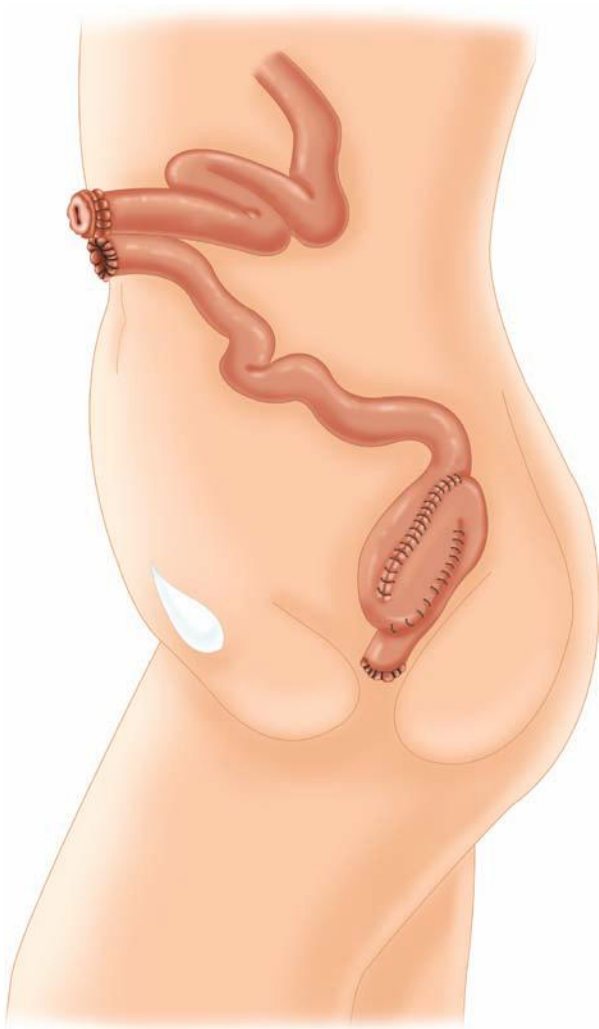


Figure 29-12. Ileal S-pouch anal anastomosis with temporary loop ileostomy. (Reproduced with permission from Bell RH, Rikkers LF, Mulholland M, eds. *Digestive Tract Surgery: A Text and Atlas*. Philadelphia: Lippincott Williams & Wilkins; 1996:1533.)

anteriorly through Denonvilliers' fascia to the vagina in women or the seminal vesicles and prostate in men. The rectum and accompanying mesorectum are divided at the appropriate level, depending on the nature of the lesion. A low rectal anastomosis usually requires mobilization of the splenic flexure and ligation and division of the inferior mesenteric vein just inferior to the pancreas. Circular stapling devices have greatly facilitated the conduct and improved the safety of the colon to extraperitoneal rectal anastomosis.

Extended Low Anterior Resection. An *extended low anterior resection* is necessary to remove lesions located in the distal rectum, but several centimeters above the sphincter. The rectum is fully mobilized to the level of the levator ani muscle just as for a low anterior resection, but the anterior dissection is extended along the rectovaginal septum in women and distal to the seminal vesicles and prostate in men. After resection at this level, a *coloanal anastomosis* can be created using one of a variety of techniques. An end-to-end stapled or hand-sewn anastomosis has traditionally been the procedure of choice. However, the functional consequences of a "straight" anastomosis have led to consideration for creation of a colon J-pouch or transverse coloplasty to increase the capacity of the neorectal reservoir.³⁰

Because the risk of an anastomotic leak and subsequent sepsis is higher when an anastomosis is created in the distal rectum or anal canal, creation of a temporary ileostomy should be considered in this setting.

Although an anastomosis may be technically feasible very low in the rectum or anal canal, it is important to note that postoperative function may be poor. Because the descending colon lacks the distensibility of the rectum, the reservoir function may be compromised. Pelvic radiation, prior anorectal surgery, and obstetrical trauma may cause unsuspected sphincter damage. Finally, a very low anastomosis may involve and compromise the upper sphincter. Creation of a *colon J-pouch* or transverse coloplasty may improve function, but few long-term studies have addressed this issue.^{30,31}

A history of sphincter damage or any degree of incontinence is a relative contraindication for a coloanal anastomosis.

2► In such patients, an end colostomy may be a more satisfactory option.

Hartmann's Procedure and Mucus Fistula. Hartmann's procedure refers to a colon or rectal resection without an anastomosis in which a colostomy or ileostomy is created and the distal colon or rectum is left as a blind pouch. The term is typically used when the left or sigmoid colon is resected and the closed off rectum is left in the pelvis. If the distal colon is long enough to reach the abdominal wall, a *mucus fistula* can be created by opening the defunctioned bowel and suturing the open lumen to the skin.

Abdominoperineal Resection. An abdominoperineal resection (APR) involves removal of the entire rectum, anal canal, and anus with construction of a permanent colostomy from the descending or sigmoid colon. The abdominal-pelvic portion of this operation proceeds in the same fashion as described for an extended low anterior resection. The perineal dissection can be performed with the patient in lithotomy position (often by a second surgeon) or in the prone position after closure of the abdomen and creation of the colostomy. For cancer, the perineal dissection is designed to excise the anal canal with a wide circumferential margin including a cylindrical cuff of the levator muscle. Primary wound closure is usually successful, but a large perineal defect, especially if preoperative radiation has been used, may require a vascularized flap closure in some patients. For benign disease, proctectomy may be performed using an *intersphincteric dissection* between the internal and external sphincters. This approach minimizes the perineal wound, making it easier to close because the levator muscle remains intact.

Anastomoses

Anastomoses may be created between two segments of bowel in a multitude of ways. The geometry of the anastomosis may be *end-to-end*, *end-to-side*, *side-to-end*, or *side-to-side*. The anastomotic technique may be *hand-sewn* or *stapled* (Fig. 29-13). The submucosal layer of the intestine provides the strength of the bowel wall and must be incorporated in the anastomosis to assure healing. The choice of anastomosis depends on the operative anatomy and surgeon preference. Although many surgeons advocate one method over another, none has been proven to be superior. Accurate approximation of two well-vascularized, healthy limbs of bowel without tension in a normotensive, well-nourished patient almost always results in a good outcome. Anastomoses at highest risk of leak or stricture are those that are in the distal rectal or anal canal, involve irradiated or diseased

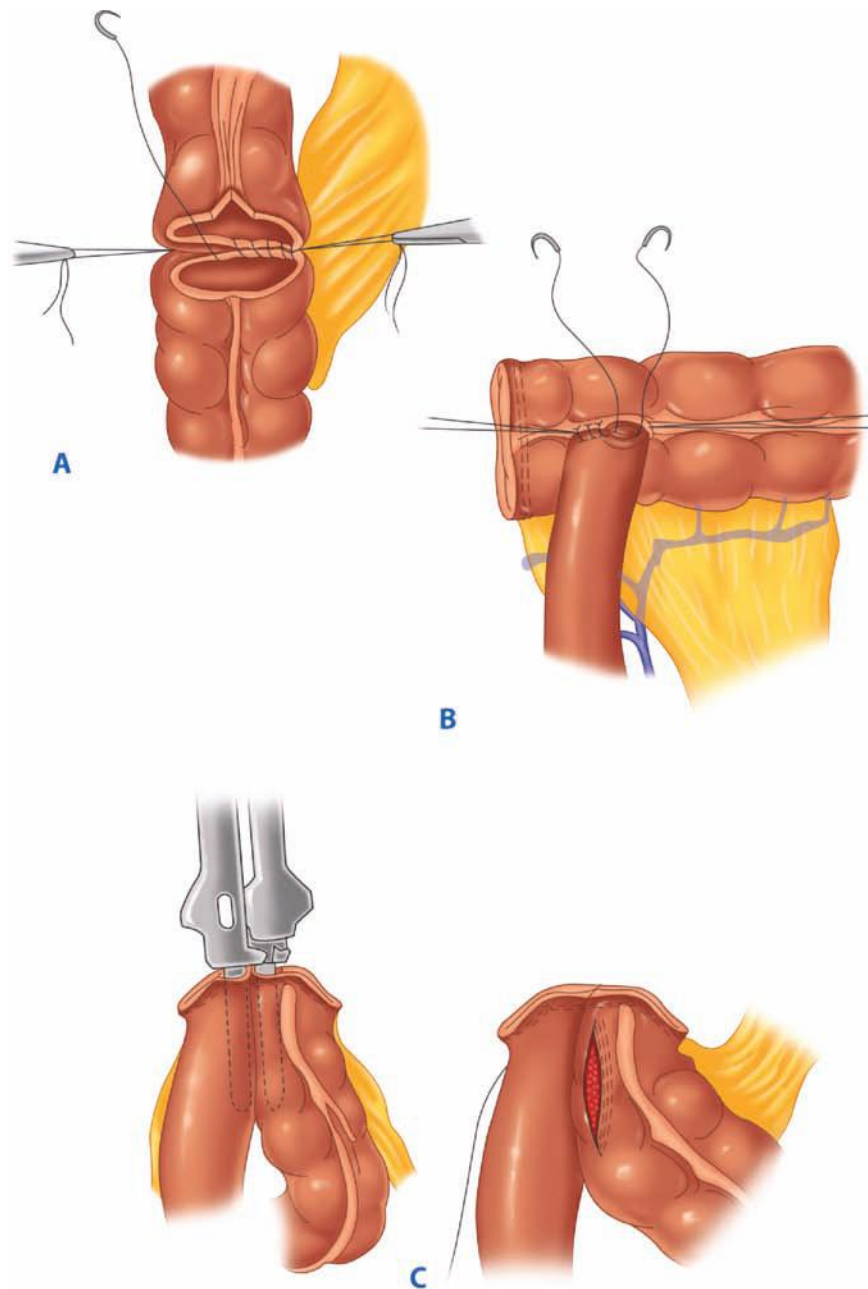


Figure 29-13. **A.** Sutured end-to-end colocolic anastomosis. **B.** Sutured end-to-side ileocolic anastomosis. **C.** Stapled side-to-side, functional end-to-end ileocolic anastomosis. (Reproduced with permission from Bell RH, Rikkers LF, Mulholland M, eds. Digestive Tract Surgery: A Text and Atlas. Philadelphia: Lippincott Williams & Wilkins; 1996:1473, 1475, and 1479.)

intestine including perforation with peritoneal soilage, or are performed in malnourished, immunosuppressed, or ill patients.

Anastomotic Configuration

End-to-End. An end-to-end anastomosis can be performed when two segments of bowel are roughly the same caliber. This technique is most often employed in rectal resections, but may be used for colocolostomy or small bowel anastomoses.

End-to-Side. An end-to-side configuration is useful when one limb of bowel is larger than the other. This most commonly occurs in the setting of chronic obstruction.

Side-to-End. A side-to-end anastomosis is used when the proximal bowel is of smaller caliber than the distal bowel. Ileorectal anastomoses commonly make use of this configuration.

A side-to-end anastomosis may have a less tenuous blood supply than an end-to-end anastomosis.

Side-to-Side. A side-to-side anastomosis allows a large, well-vascularized connection to be created on the antimesenteric side of two segments of intestine. This technique is commonly used in ileocolic and small bowel anastomoses.

Anastomotic Technique

Hand-Sutured Technique. Any of the configurations described earlier may be created using a hand-sutured or stapled technique. Hand-sutured anastomoses may be *single layer*, using either running or interrupted stitches, or *double layer*. A double-layer anastomosis usually consists of a continuous inner layer and an interrupted outer layer. Suture material may be either permanent

or absorbable. After distal rectal or anal canal resection, a trans-anal, hand-sewn coloanal anastomosis may be necessary to restore bowel continuity. This can be done in conjunction with an anal canal mucosectomy to allow the anastomosis to be created at the dentate line.

Stapled Techniques. Linear cutting/stapling devices are used to divide the bowel and to create side-to-side anastomoses. The anastomosis may be reinforced with interrupted sutures if desired. Circular cutting/stapling devices can create end-to-end, end-to-side, or side-to-end anastomoses. These instruments are particularly useful for creating low rectal or anal canal anastomoses where the anatomy of the pelvis makes a hand-sewn anastomosis technically difficult or impossible.

Following resection of the colorectum, a stapled end-to-end colorectal, coloanal canal, or ileal pouch–anal canal anastomosis may be created by one of two techniques. With the *open purse-string technique*, the distal rectal stump purse-string is placed by hand, and the assembled circular stapler is inserted into the anus and guided up to the rectal purse-string. The stapler is opened, and the distal purse-string is tied. A purse-string is placed in the distal end of the proximal colon; the proximal

colon is placed over the anvil and the purse-string tightened. The stapler is closed and fired (Fig. 29-14). With the alternative *double-staple technique*, the distal rectum or anal canal is closed with a transverse staple line. The circular stapler is inserted through the anus without its anvil until the cartridge effaces the transverse staple line. The stapler is opened, causing the trocar to perforate through the rectal stump adjacent to the transverse staple line. The anastomosis is then completed as described earlier (see Fig. 29-11). After firing and removing the stapler, the resulting anastomotic rings should be inspected to ensure that they are intact. A gap in an anastomotic ring suggests that the circular staple line is incomplete and the anastomosis should be reinforced with suture circumferentially, if technically feasible. A temporary proximal ileostomy may be indicated as well. Most surgeons will also *leak test* an anastomosis by instilling water or saline into the pelvis and insufflating the rectum with air via a proctoscope or alternatively instilling methylene blue or beta-dine into the rectum to look for extravasation.

Ostomies and Preoperative Stoma Planning

Depending on the clinical situation, a stoma may be temporary or permanent. It may be end-on or a loop. However, regardless

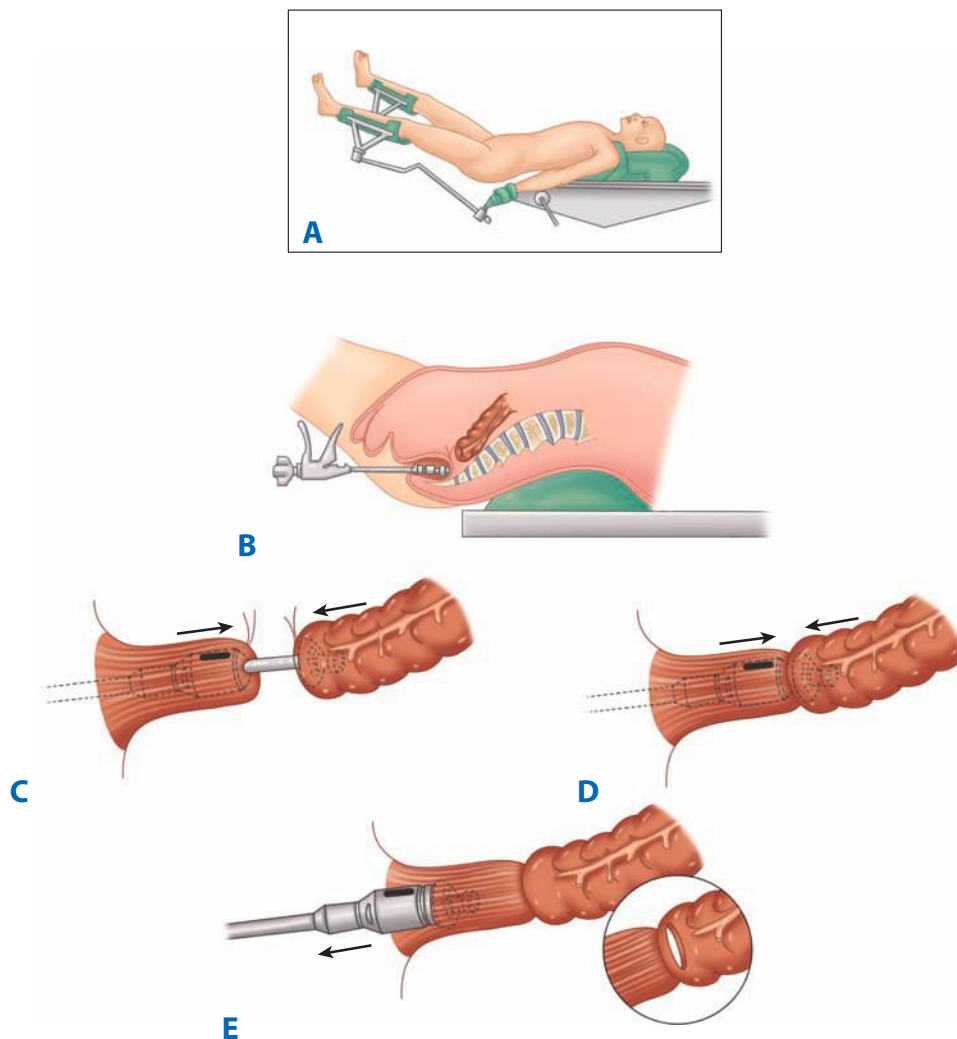


Figure 29-14. Technique of end-to-end colorectal anastomosis using a circular stapler. **A.** The patient is in modified lithotomy position. **B.** After resection of the rectosigmoid and placement of purse-string sutures proximally and distally, the stapler is inserted into the anal canal and opened. **C.** Rectal purse-string suture is tied to secure the rectal stump to the rod of the stapler, and the colonic purse-string is tied to secure the colon to the anvil of the stapler. **D.** The stapler is closed and fired. **E.** The stapler is removed, leaving a circular stapled end-to-end anastomosis.

of the indication for a stoma, placement and construction are crucial for function.

The preoperative preparation of a patient who is expected to require a stoma should include a consultation with an *enterostomal therapy (ET) nurse*. ET nurses are specially trained and credentialed by the Wound, Ostomy and Continence Nurses Society. Preoperative planning includes counseling, education, and stoma siting. Postoperatively, the ET nurse assists with local skin care and pouching. Other considerations in stoma planning include evaluation of other medical conditions that may impact on a patient's ability to manage a stoma (e.g., eyesight, manual dexterity).

Preoperative stoma siting is crucial for a patient's postoperative function and quality of life. A poorly placed stoma can result in leakage and skin breakdown. Ideally, a stoma should be placed in a location that the patient can easily see and manipulate, within the rectus muscle, and below the belt line (see Fig. 29-15). Because the abdominal landmarks in a supine, anesthetized patient may be dramatically different from those in an awake, standing, or sitting patient, the stoma site should always be marked with a tattoo, skin scratch, or permanent marker preoperatively, if possible. In an emergency operation where the stoma site has not been marked, an attempt should be made to place a stoma within the rectus muscle and away from both the costal margin and iliac crest. In emergencies, placement high on the abdominal wall is preferred to a low-lying site.

For all stomas, a circular skin incision is created and the subcutaneous tissue dissected to the level of the anterior rectus sheath. The anterior rectus sheath is incised in a cruciate fashion, the muscle fibers separated bluntly, and the posterior sheath identified and incised. Care should be taken to avoid injuring and causing bleeding from the inferior epigastric artery and

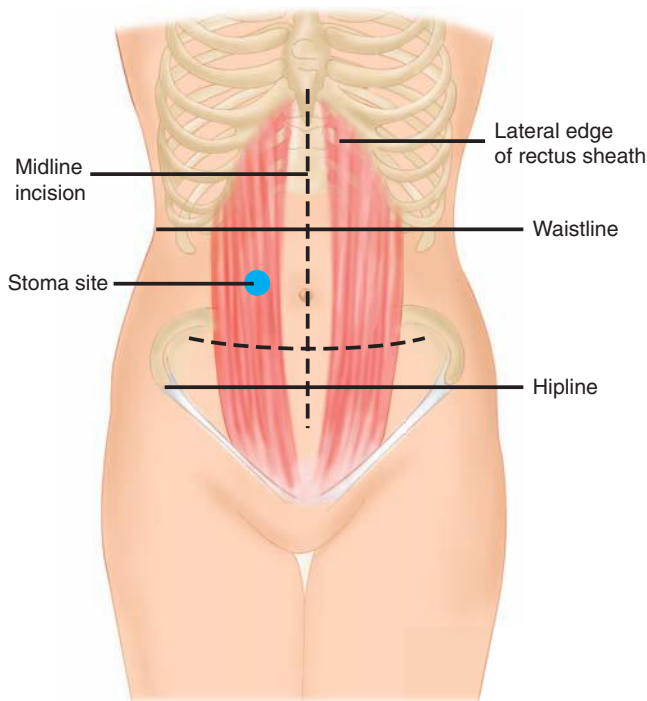


Figure 29-15. Marking of an ideal site for ileostomy. (Reproduced with permission from Bell RH, Rikkers LF, Mulholland M, eds. *Digestive Tract Surgery: A Text and Atlas*. Philadelphia: Lippincott Williams & Wilkins; 1996:1273.)

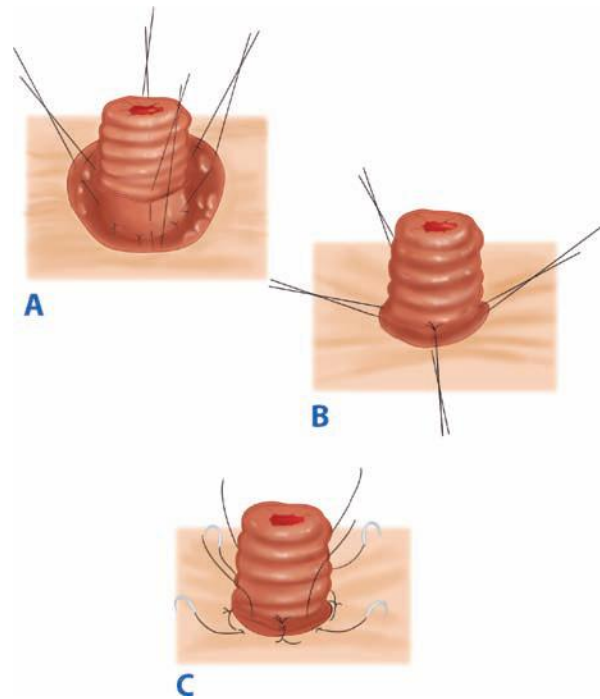


Figure 29-16. Brooke ileostomy. **A.** Four sutures incorporating the cut end of the ileum, the seromuscular layer at the level of the anterior rectus fascia, and the subcuticular edge of the skin are placed at 90° to each other. **B.** The sutures are tied to produce stomal eversion, and **(C)** simple sutures from the cut edge of the bowel to the subcuticular tissue complete the maturation of the ileostomy. (Reproduced with permission from Bell RH, Rikkers LF, Mulholland M, eds. *Digestive Tract Surgery: A Text and Atlas*. Philadelphia: Lippincott Williams & Wilkins; 1996:1278.)

vein. The size of the defect depends on the size of the bowel used to create the stoma, but should be as small as possible without compromising the intestinal blood supply (usually the width of two to three fingers). The bowel is then brought through the defect and secured with sutures. The abdominal incision is usually closed and dressed prior to maturing the stoma to avoid contaminating the wound. In order to make appliance use easier, a protruding nipple is fashioned by everting the bowel. Three or four interrupted absorbable sutures are placed through the edge of the bowel, then through the serosa, approximately 2 cm proximal to the edge, and then through the dermis (Brooke technique). After the stoma is everted, the mucocutaneous junction is sutured circumferentially with interrupted absorbable suture (Fig. 29-16).

Ileostomy

Temporary Ileostomy. A temporary ileostomy is often used to “protect” an anastomosis that is at risk for leakage (low in the rectum, in an irradiated field, in an immunocompromised or malnourished patient, and during some emergency operations). In this setting, the stoma is often constructed as a *loop ileostomy* (see Fig. 29-12). A segment of distal ileum is brought through the defect in the abdominal wall as a loop. An enterotomy is created and the stoma matured as described earlier. The loop may be secured with or without an underlying rod. A *divided loop* may also be created by firing a linear cutting/stapler across the distal limb of the loop flush with the skin followed by maturation of the proximal limb of the loop.

This technique prevents incomplete diversion that occasionally occurs with a loop ileostomy.

The advantage of a loop or divided loop ileostomy is that subsequent closure can often be accomplished without a formal laparotomy. An elliptical incision is created around the stoma and the bowel gently dissected free of the subcutaneous tissues and fascia. A hand-sewn or stapled anastomosis can then be created and the intestine returned to the peritoneal cavity. This avoids a long laparotomy incision and generally is well tolerated. The timing of ileostomy closure should take into account anastomotic healing as well as the patient's overall condition. A flexible endoscopy exam and a contrast enema (Gastrografin) are recommended prior to closure to ensure that the anastomosis has not leaked and is patent. A patient's nutritional status should be optimized. In cancer patients receiving adjuvant chemotherapy, ileostomy closure should be delayed until the chemotherapy is completed.

Permanent Ileostomy. A permanent ileostomy is sometimes required after total proctocolectomy or in patients with obstruction. An *end ileostomy* is the preferred configuration for a permanent ileostomy because a symmetric protruding nipple can be fashioned more easily than with a loop ileostomy (see Fig. 29-16). The end of the small intestine is brought through the abdominal wall defect and matured. Stitches are often used to secure the bowel to the posterior fascia.

Complications of Ileostomy. Stoma necrosis may occur in the early postoperative period and is usually caused by skeletonizing the distal small bowel and/or creating an overly tight fascial defect. Limited mucosal necrosis above the fascia may be treated expectantly, but necrosis below the level of the fascia requires surgical revision. Stoma retraction may occur early or late and may be exacerbated by obesity. Local revision may be necessary. The creation of an ileostomy bypasses the fluid-absorbing capability of the colon, and dehydration with fluid and electrolyte abnormalities is not uncommon. Ideally, ileostomy output should be maintained at less than 1500 mL/d to avoid this problem. Bulk agents and opioids (Lomotil, Imodium, tincture of opium) are useful. The somatostatin analogue, octreotide, has been used with varying success in this setting. Skin irritation can also occur, especially if the stoma appliance fits poorly. Skin-protecting agents and custom pouches can help to solve this problem. Obstruction may occur intra-abdominally or at the site where the stoma exits the fascia. Parastomal hernia is less common after an ileostomy than after a colostomy but can cause poor appliance fitting, pain, obstruction, or strangulation. In general, symptomatic parastomal hernias should be repaired. A variety of techniques to repair these hernias have been described, including local repair (either with or without mesh), laparoscopic repair, and stoma resiting. Prolapse is a rare, late complication and is often associated with a parastomal hernia.

Colostomy. Most colostomies are created as *end colostomies* rather than *loop colostomies* (Fig. 29-17). The bulkiness of the colon makes a loop colostomy awkward for use of an appliance, and prolapse is more likely with this configuration. Most colostomies are created on the left side of the colon. An abdominal wall defect is created and the end of the colon mobilized through it. Because a protruding stoma is considerably easier to pouch, colostomies should also be matured in a Brooke fashion. The distal bowel may be brought through the abdominal wall as a *mucus fistula* or left intra-abdominally as a *Hartmann's pouch*. Tacking the distal end of the colon to the abdominal wall or

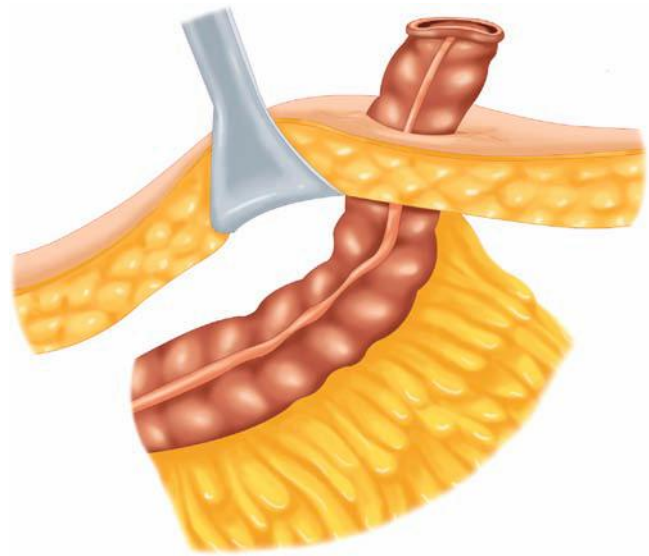


Figure 29-17. Intraperitoneal end colostomy.

tagging it with permanent suture can make identification of the stump easier if the colostomy is closed at a later date. Closure of an end colostomy has traditionally required a laparotomy, but increasingly minimally invasive techniques have been adopted. The stoma is dissected free of the abdominal wall and the distal bowel identified. An end-to-end anastomosis is then created.

Complications of Colostomy. *Colostomy necrosis* may occur in the early postoperative period and results from an impaired vascular supply (skeletonization of the distal colon or a tight fascial defect). Like ileostomy necrosis, limited suprafascial necrosis may be followed expectantly, but necrosis below the fascia requires surgery. *Retraction* may also occur but is less problematic with a colostomy than with an ileostomy because the stool is less irritating to the skin than *succus entericus*. *Obstruction* is unusual, but may also occur. *Parastomal hernia* is the most common late complication of a colostomy and requires repair if it is symptomatic. *Prolapse* occurs rarely, but is more common with a loop colostomy. Interestingly, it is almost always the efferent limb of the loop that prolapses. Dehydration is rare after colostomy, and skin irritation is less common than with ileostomy.

Functional Results

Function following segmental colonic resection and primary anastomosis is generally excellent. A small percentage of patients following subtotal or total colectomy and ileosigmoid or ileorectal anastomosis may experience diarrhea and bowel frequency. This is especially true if the patient is elderly, if significant length of small bowel has been resected, and if residual proctocolitis is poorly controlled. In general, the more distal the anastomosis, the greater is the risk of troublesome diarrhea and frequency. However, some patients develop significant diarrhea after right colectomy due to malabsorption of bile acids; in these cases, bile acid binding resins (e.g., cholestyramine) sometimes can be helpful.

Function following anterior resection is highly dependent on the level of anastomosis, the use of pre- or postoperative pelvic radiation, and underlying sphincter function. Following low anterior or extended low anterior resection, some surgeons

prefer to construct a short (5-cm) colon J-pouch to anastomose to the distal rectum or anal canal or, alternatively, a transverse colectomy to increase the capacity of the neorectum. The reservoirs are thought to lessen urgency, frequency, and incontinence, but some patients have difficulty initiating defecation, and long-term superiority over a “straight” anastomosis has yet to be proven. In addition, these reservoirs can be technically difficult, especially in an obese male with a narrow pelvis.

The physical and psychological problems associated with a permanent Brooke ileostomy led to development of the continent Kock pouch ileostomy. Unfortunately, complications, especially complications related to valve slippage, are common. Despite variations of technique designed to improve the function of the continent ileostomy, most surgeons have abandoned this operation and instead perform restorative proctocolectomy with ileal pouch–anal anastomosis.

Although ileal pouch–anal reconstruction is anatomically appealing, functional outcome is far from perfect.^{6,25} Patients should be counseled to expect 8 to 10 bowel movements per day. Up to 50% have some degree of nocturnal incontinence. Pouchitis occurs in nearly 50% of patients who undergo the operation for chronic ulcerative colitis, and small bowel obstruction is not uncommon. Other less common complications include difficulties with pouch evacuation, pouch–anal and/or pouch–vaginal fistula, and anal stricture. Pouch failure rate averages 5% to 10%. Patients who are subsequently diagnosed with Crohn’s disease have a considerably higher pouch failure rate (approximately 50%), whereas patients with indeterminate colitis have a lower pouch failure rate (15%–20%). Despite these drawbacks, the vast majority of patients are satisfied and prefer ileal pouch–anal reconstruction to permanent ileostomy.

Pouchitis is an inflammatory condition that affects both ileoanal pouches and continent ileostomy reservoirs. The incidence of pouchitis ranges from 30% to 55%. Symptoms include increased diarrhea, hematochezia, abdominal pain, fever, and malaise. Diagnosis is made endoscopically with biopsies. Differential diagnosis includes infection and undiagnosed Crohn’s disease. The etiology of pouchitis is unknown. Some believe pouchitis results from fecal stasis within the pouch, but emptying studies are not confirmatory. Antibiotics (metronidazole ± ciprofloxacin) are the mainstays of therapy, and most patients will respond rapidly to either oral preparations or enemas.^{32,33} Some patients develop chronic pouchitis that necessitates ongoing suppressive antibiotic therapy. Salicylate and corticosteroid enemas have also been used with some success. Reintroduction of normal flora by ingestion of *probiotics* and/or an elemental diet have been suggested as a possible treatment in refractory cases. Occasionally, pouch excision is necessary to control the symptoms of chronic pouchitis.

Anesthesia Considerations

Local Anesthesia. Many anorectal procedures can be performed with local anesthetic alone. Intravenous sedation is often provided to calm the patient. Injection of 0.5% lidocaine (short acting) and 0.25% bupivacaine (long acting) into the perianal skin, sphincter, and area around the pudendal nerves usually provides an adequate block. The addition of dilute epinephrine decreases bleeding and prolongs the anesthetic effect.

Regional Anesthesia. Epidural, spinal, and caudal anesthetics can be used for anorectal procedures and transanal resections. In patients with severe medical comorbidity, regional anesthesia may occasionally be used for laparotomy and colectomy.

Postoperative epidural anesthesia provides excellent pain relief and improves pulmonary function.

General Anesthesia. General anesthesia is required for the vast majority of intra-abdominal procedures. Patients should undergo a thorough preoperative cardiovascular evaluation. In patients with significant comorbid disease, an anesthesia consultation may be appropriate.

Positioning. Most abdominal colectomies can be performed in the supine position. Anterior resection and APR require lithotomy positioning to facilitate the pelvic dissection and mobilization of the splenic flexure. Adequate padding should be provided for the patient’s sacrum, and care should be taken to avoid stirrup pressure on the peroneal nerves.

Anorectal procedures may be performed in lithotomy or in the prone jackknife position. Some surgeons prefer the prone jackknife position because exposure may be better, especially for anterior lesions. Distal posterior lesions can usually be accessed from either position, but more proximal posterior lesions are better accessed in the prone position.

Operative Preliminaries

Bowel Preparation. The rationale for bowel preparation is that decreasing the bacterial load in the colon and rectum will decrease the incidence of postoperative infection. *Mechanical bowel preparation* uses cathartics to rid the colon of solid stool the night before surgery.^{28,29} The most commonly used regimens include polyethylene glycol (PEG) solutions or magnesium citrate. PEG solutions require patients to drink a large volume of fluid and may cause bloating and nausea. Magnesium citrate solutions are generally better tolerated but are more likely to cause fluid and electrolyte abnormalities. Both are equally efficacious in bowel cleansing. Preparatory formulations have been recently introduced in tablet form in an attempt to improve tolerance. However, these methods of bowel cleansing require ingestion of 40 or more tablets with water over several hours. To date, these formulations have not been proven to be superior to the more traditional products.³⁴ *Antibiotic prophylaxis* also is recommended. The addition of oral antibiotics to the preoperative mechanical bowel preparation has been thought to decrease postoperative infection by further decreasing the bacterial load of the colon. However, the regimens used (neomycin, erythromycin, or metronidazole) frequently caused gastrointestinal upset that interfered with the mechanical preparation, and many surgeons have abandoned oral antibiotic prophylaxis. Nevertheless, a recent analysis of the Surgical Care Improvement Project-1 (SCIP-1) suggests that oral antibiotics do reduce postoperative wound infection, especially if a mechanical bowel preparation is not used.³⁵

Prospective randomized trials are needed to better understand the role of oral antibiotic prophylaxis in colorectal surgery. In contrast, longstanding, convincing data support the efficacy of parenteral antibiotic prophylaxis at the time of surgery. Broad-spectrum parenteral antibiotic(s) with activity against aerobic and anaerobic enteric pathogens should be administered just prior to the skin incision and redosed as needed depending on the length of the operation. There is no proven benefit to using antibiotics postoperatively after an uncomplicated colectomy.

Despite widespread use of mechanical bowel preparation, the necessity of bowel cleansing prior to colectomy has been questioned. European surgeons in particular have advocated abandoning this practice. Arguments against mechanical

bowel preparation include dehydration and electrolyte abnormalities that often result from bowel cleansing, as well as the risk of spillage of liquid stool left over from the “prep.” Arguments in favor of mechanical bowel preparation included easier manipulation of an “empty” colon (especially in minimally invasive procedures) and avoidance of a “stool column” above an anastomosis, especially in the pelvis. Interestingly, a recent meta-analysis of 14 randomized controlled trials suggested that mechanical bowel preparation does *not* prevent surgical site infection and should be abandoned in clinical practice.³⁶

Ureteral Stents. Ureteral stents may be useful for identifying the ureters intraoperatively and are placed via cystoscopy after the induction of general anesthesia and removed at the end of the operation. Stents can be invaluable during reoperative pelvic surgery or when there is significant retroperitoneal inflammation (such as complicated diverticulitis), as well as in obese patients. Lighted stents may be helpful in laparoscopic and robotic resections. Patients often have transient hematuria postoperatively, but major complications are rare.

Multidisciplinary Teams. Patients with complex colorectal disease often benefit from a multidisciplinary approach to their care. Patients with pelvic floor disorders (especially incontinence) often require evaluation by both a colorectal surgeon and a urologist or urogynecologist. Preoperative evaluation of cancer patients by a medical oncologist and/or radiation oncologist is crucial for planning either neoadjuvant or adjuvant therapy. Intraoperatively, complex pelvic resections often require the involvement of not only a colorectal surgeon but also a urologist, gynecologic oncologist, neurosurgeon, and/or plastic surgeon. Radiation oncologists should be involved in the operation if brachytherapy catheters are to be placed for intracavitary radiation or if intraoperative radiation therapy is planned. Rarely, psychiatric disorders may manifest as colorectal problems (especially functional disorders and chronic pain), and involvement of a psychiatrist or psychologist may be beneficial.

INFLAMMATORY BOWEL DISEASE

General Considerations

Epidemiology. Inflammatory bowel disease includes *ulcerative colitis*, *Crohn’s disease*, and *indeterminate colitis*. *Ulcerative colitis* occurs in 8 to 15 people per 100,000 in the United States and Northern Europe. The incidence is considerably lower in Asia, Africa, and South America, and among the nonwhite population in the United States. *Ulcerative colitis* incidence peaks during the third decade of life and again in the seventh decade of life. The incidence of *Crohn’s disease* is slightly lower, 1 to 5 people per 100,000. *Crohn’s disease* also affects Northern European and white populations disproportionately. *Crohn’s disease* has a similar bimodal incidence, with most cases occurring between ages 15 to 30 years and ages 55 to 60 years. In 15% of patients with inflammatory bowel disease, differentiation between *ulcerative colitis* and *Crohn’s colitis* is impossible; these patients are classified as having *indeterminate colitis*.

Etiology. Many different etiologies for inflammatory bowel disease have been proposed, but none are proven. The consistent geographic differences in incidence suggest an environmental factor such as diet or infection. Alcohol and oral contraceptive use have also been implicated. Smoking has been implicated in the etiology and exacerbation of *Crohn’s disease* in particular. Family history may play a role because 10% to 30% of patients

with inflammatory bowel disease report a family member with the same disease.^{37,38} Other theories focus on an autoimmune mechanism and/or a defect in the intestinal immune system. While there is general agreement that interaction among the immune system, the mucosal barrier of the gut, and a variety of infectious agents is involved in the pathogenesis of inflammatory bowel disease, the mechanism(s) by which these interactions produce disease is poorly understood. Bacteria, such as *Mycobacterium paratuberculosis* and *Listeria monocytogenes*, and viruses, such as paramyxovirus and measles virus, have been suggested as etiologic agents in *Crohn’s disease*. A defect in the gut mucosal barrier, which increases exposure to intraluminal bacteria, toxins, or proinflammatory substances, also has been suggested. Finally, as noted earlier, an autoimmune mechanism has been postulated. Although there is no clear evidence linking an immunologic disorder to inflammatory bowel disease, the similarity of many of the extraintestinal manifestations to rheumatologic disorders has made this theory attractive. Regardless of the underlying cause of either *ulcerative colitis* or *Crohn’s disease*, both disorders are characterized by intestinal inflammation, and medical therapy is largely based on reducing inflammation.

Pathology and Differential Diagnosis. Although *ulcerative colitis* and *Crohn’s colitis* share many pathologic and clinical similarities, these conditions may be differentiated in 85% of patients. *Ulcerative colitis* is a mucosal process in which the colonic mucosa and submucosa are infiltrated with inflammatory cells. The mucosa may be atrophic, and crypt abscesses are common. Endoscopically, the mucosa is frequently friable and may possess multiple inflammatory pseudopolyps. In longstanding *ulcerative colitis*, the colon may be foreshortened and the mucosa replaced by scar. In quiescent *ulcerative colitis*, the colonic mucosa may appear normal both endoscopically and microscopically. *Ulcerative colitis* may affect the rectum (proctitis), rectum and sigmoid colon (proctosigmoiditis), rectum and left colon (left-sided colitis), or the rectum and entire colon (pancolitis). *Ulcerative colitis* does not involve the small intestine, but the terminal ileum may demonstrate inflammatory changes (“backwash ileitis”). A key feature of *ulcerative colitis* is the continuous involvement of the rectum and colon; rectal sparing or skip lesions suggest a diagnosis of *Crohn’s disease*. Symptoms are related to the degree of mucosal inflammation and the extent of colitis. Patients typically complain of bloody diarrhea and crampy abdominal pain. Proctitis may produce tenesmus. Severe abdominal pain and fever raise the concern of *fulminant colitis* or *toxic megacolon*. Physical findings are nonspecific and range from minimal abdominal tenderness and distention to frank peritonitis. In the nonemergent setting, the diagnosis is typically made by colonoscopy and mucosal biopsy.

In contrast to *ulcerative colitis*, *Crohn’s disease* is a transmural inflammatory process that can affect any part of the gastrointestinal tract from mouth to anus. Mucosal ulcerations, an inflammatory cell infiltrate, and noncaseating granulomas are characteristic pathologic findings. Chronic inflammation may ultimately result in fibrosis, strictures, and fistulas in either the colon or small intestine. The endoscopic appearance of *Crohn’s colitis* is characterized by deep serpiginous ulcers and a “cobblestone” appearance. Skip lesions and rectal sparing are common. Symptoms of *Crohn’s disease* depend on the severity of inflammation and/or fibrosis and the location of inflammation in the gastrointestinal tract. Acute inflammation may

produce diarrhea, crampy abdominal pain, and fever. Strictures may produce symptoms of obstruction. Weight loss is common, both because of obstruction and from protein loss. Perianal Crohn's disease may present with pain, swelling, and drainage from fistulas or abscesses. Physical findings are also related to the site and severity of disease.

In 15% of patients with colitis from inflammatory bowel disease, differentiation of ulcerative colitis from Crohn's colitis is impossible either grossly or microscopically (indeterminate colitis). These patients typically present with symptoms similar to ulcerative colitis. Endoscopic and pathologic findings usually include features common to both diseases. Increasingly, serologic markers have been employed to differentiate ulcerative colitis from Crohn's disease. The anti-Saccharomyces cerevisiae antibody (ASCA) and perinuclear anticytoplasmic antibody (pANCA) may be useful in differentiating these two processes but require prospective study.³⁹

Further differential diagnoses include infectious colitides, especially *Campylobacter jejuni*, *Entamoeba histolytica*, *C. difficile*, *Neisseria gonorrhoeae*, *Salmonella*, and *Shigella* species.

Extraintestinal Manifestations. The liver is a common site of extracolonic disease in inflammatory bowel disease. Fatty infiltration of the liver is present in 40% to 50% of patients, and cirrhosis is found in 2% to 5%. Fatty infiltration may be reversed by medical or surgical treatment of colonic disease, but cirrhosis is irreversible. Primary sclerosing cholangitis is a progressive disease characterized by intra- and extrahepatic bile duct strictures. Forty percent to 60% of patients with primary sclerosing cholangitis have ulcerative colitis. Colectomy will not reverse this disease, and the only effective therapy is liver transplantation.⁴⁰ Pericholangitis is also associated with inflammatory bowel disease and may be diagnosed with a liver biopsy. Bile duct carcinoma is a rare complication of long-standing inflammatory bowel disease. Patients who develop bile duct carcinoma in the presence of inflammatory bowel disease are, on average, 20 years younger than other patients with bile duct carcinoma.

Arthritis also is a common extracolonic manifestation of inflammatory bowel disease, and the incidence is 20 times greater than in the general population. Arthritis usually improves with treatment of the colonic disease. Sacroiliitis and ankylosing spondylitis are associated with inflammatory bowel disease, although the relationship is poorly understood. Medical and surgical treatment of the colonic disease does not impact symptoms.

Erythema nodosum is seen in 5% to 15% of patients with inflammatory bowel disease and usually coincides with clinical disease activity. Women are affected three to four times more frequently than men. The characteristic lesions are raised, red, and predominantly on the lower legs. Pyoderma gangrenosum is an uncommon but serious condition that occurs almost exclusively in patients with inflammatory bowel disease. The lesion begins as an erythematous plaque, papule, or bleb, usually located on the pretibial region of the leg and occasionally near a stoma. The lesions progress and ulcerate, leading to a painful, necrotic wound. Pyoderma gangrenosum may respond to resection of the affected bowel in some patients. In others, this disorder is unaffected by treatment of the underlying bowel disease.

Up to 10% of patients with inflammatory bowel disease will develop ocular lesions. These include uveitis, iritis, episcleritis, and conjunctivitis. They usually develop during an acute exacerbation of the inflammatory bowel disease. The etiology is unknown.

Principles of Nonoperative Management. Medical therapy for inflammatory bowel disease focuses on decreasing inflammation and alleviating symptoms, and many of the agents used are the same for both ulcerative colitis and Crohn's disease. In general, mild to moderate flares may be treated in the outpatient setting. More severe signs and symptoms mandate hospitalization. Pancolitis generally requires more aggressive therapy than limited disease. Because ulcerative proctitis and proctosigmoiditis are limited to the distal large intestine, topical therapy with salicylate and/or corticosteroid suppositories and enemas can be extremely effective. Systemic therapy is rarely required in these patients.

Salicylates. Sulfasalazine (Azulfidine), 5-acetyl salicylic acid (5-ASA), and related compounds are first-line agents in the medical treatment of mild to moderate inflammatory bowel disease. These compounds decrease inflammation by inhibition of cyclooxygenase and 5-lipoxygenase in the gut mucosa. They require direct contact with affected mucosa for efficacy. Multiple preparations are available for administration to different sites in the small intestine and colon (sulfasalazine, mesalamine [Pentasa, Asacol, Rowasa]).

Antibiotics. Antibiotics are often used to decrease the intraluminal bacterial load in Crohn's disease. Metronidazole has been reported to improve Crohn's colitis and perianal disease, but the evidence is weak. Fluoroquinolones may also be effective in some cases. In the absence of fulminant colitis or toxic megacolon, antibiotics are not used to treat ulcerative colitis.

Corticosteroids. Corticosteroids (either oral or parenteral) are a key component of treatment for an acute exacerbation of either ulcerative colitis or Crohn's disease. Corticosteroids are nonspecific inhibitors of the immune system, and 75% to 90% of patients will improve with the administration of these drugs. However, corticosteroids have a number of serious side effects, and use of these agents should be limited to the shortest course possible. In addition, corticosteroids should be used judiciously in children because of the potential adverse effect on growth. Failure to wean corticosteroids is a relative indication for surgery.

Because of the systemic effects of corticosteroids, an effort has been made to develop drugs that act locally and have limited systemic absorption. Agents such as budesonide, beclomethasone dipropionate, and tixocortol pivalate undergo rapid hepatic degradation that significantly decreases systemic toxicity. Budesonide is available as an oral preparation. Corticosteroid enemas provide effective local therapy for proctitis and proctosigmoiditis and have fewer side effects than systemic corticosteroids.

Immunomodulating Agents. Azathioprine and 6-mercaptopurine (6-MP) are antimetabolite drugs that interfere with nucleic acid synthesis and thus decrease proliferation of inflammatory cells. These agents are useful for treating ulcerative colitis and Crohn's disease in patients who have failed salicylate therapy or who are dependent on, or refractory to, corticosteroids. It is important to note, however, that the onset of action of these drugs takes 6 to 12 weeks, and concomitant use of corticosteroids almost always is required.³⁷

Cyclosporine is an immunosuppressive agent that interferes with T-lymphocyte function. While cyclosporine is not routinely used to treat inflammatory bowel disease, up to 80% of patients with an acute flare of ulcerative colitis will improve with its use. However, the majority of these patients will ultimately require colectomy. Cyclosporine is also occasionally

used to treat exacerbations of Crohn's disease, and approximately two-thirds of patients will note some improvement. Improvement is generally apparent within 2 weeks of beginning cyclosporine therapy. Long-term use of cyclosporine is limited by its significant toxicities (e.g., nephrotoxicity, hirsutism, gum hypertrophy).

Methotrexate is a folate antagonist that also has been used to treat inflammatory bowel disease. Although the efficacy of this agent is unproven, there are reports that more than 50% of patients will improve with administration of this drug.⁴¹

Biologic Agents. In an effort to improve treatment for steroid-refractory inflammatory bowel disease, a new class of agents has been developed based on inhibition of tumor necrosis factor alpha (TNF- α). Intravenous infusion of these agents decreases inflammation systemically. Infliximab is a monoclonal antibody directed against TNF- α and was the first biologic agent used to treat Crohn's disease. More than 50% of patients with moderate to severe Crohn's disease will improve with infliximab therapy.⁴² This agent also has been useful in treating patients with perianal Crohn's disease. Recurrence is common, however; and many patients require infusions on a bimonthly basis. Newer anti-TNF- α agents, such as adalimumab and certolizumab pegol, also show promise in treating Crohn's disease.⁴³

The use of anti-TNF- α agents for the treatment of ulcerative colitis has been less well studied, but there are reports of efficacy in this setting, and adalimumab has been approved for treatment of steroid-refractory ulcerative colitis in Europe.^{44,45} Interestingly, anti-TNF- α therapy may also be beneficial in treating the extraintestinal manifestations of inflammatory bowel disease in some patients.⁴⁰

Nutrition. Patients with inflammatory bowel disease are often malnourished. Abdominal pain and obstructive symptoms may decrease oral intake. Diarrhea can cause significant protein loss. Ongoing inflammation produces a catabolic physiologic state. Parenteral nutrition should be strongly considered early in the course of therapy for either Crohn's disease or ulcerative colitis. The nutritional status of the patient also should be considered when planning operative intervention, and nutritional parameters such as serum albumin, prealbumin, and transferrin should be assessed. In extremely malnourished patients, especially those who are also being treated with corticosteroids, creation of a stoma is often safer than a primary anastomosis.

Ulcerative Colitis

Ulcerative colitis is a dynamic disease characterized by remissions and exacerbations. The clinical spectrum ranges from an inactive or quiescent phase to low-grade active disease to fulminant disease. The onset of ulcerative colitis may be insidious, with minimal bloody stools, or the onset can be abrupt, with severe diarrhea and bleeding, tenesmus, abdominal pain, and fever. The severity of symptoms depends on the degree and extent of inflammation. Although anemia is common, massive hemorrhage is rare. Physical findings are often nonspecific.

The diagnosis of ulcerative colitis is almost always made endoscopically. Because the rectum is invariably involved, proctoscopy may be adequate to establish the diagnosis. The earliest manifestation is mucosal edema, which results in a loss of the normal vascular pattern. In more advanced disease, characteristic findings include mucosal friability and ulceration. Pus and mucus may also be present. While mucosal biopsy is often diagnostic in the chronic phase of ulcerative colitis, biopsy in

the acute phase will often reveal only nonspecific inflammation. Evaluation with colonoscopy or barium enema during an acute flare is contraindicated because of the risk of perforation.

Barium enema has been used to diagnose chronic ulcerative colitis and to determine the extent of disease. However, this modality is less sensitive than colonoscopy and may not detect early disease. In long-standing ulcerative colitis, the colon is foreshortened and lacks haustral markings ("lead pipe" colon). Because the inflammation in ulcerative colitis is purely mucosal, strictures are highly uncommon. Any stricture diagnosed in a patient with ulcerative colitis must be presumed to be malignant until proven otherwise.

Indications for Surgery. Indications for surgery in ulcerative colitis may be emergent or elective. Emergency surgery is required for patients with massive life-threatening *hemorrhage*, *toxic megacolon*, or *fulminant colitis* who fail to respond rapidly to medical therapy. Patients with signs and symptoms of fulminant colitis should be treated aggressively with bowel rest, hydration, broad-spectrum antibiotics, and parenteral corticosteroids. Colonoscopy and barium enema are contraindicated, and antidiarrheal agents should be avoided. Deterioration in clinical condition or failure to improve within 24 to 48 hours mandates surgery.

Indications for elective surgery include intractability despite maximal medical therapy and high-risk development of major complications of medical therapy such as aseptic necrosis of joints secondary to chronic steroid use. Elective surgery also is indicated in patients at significant risk of developing colorectal carcinoma. The risk of malignancy increases with pancolonic disease and the duration of symptoms and is approximately 2% after 10 years, 8% after 20 years, and 18% after 30 years. Unlike sporadic colorectal cancers, carcinoma developing in the context of ulcerative colitis is more likely to arise from areas of *flat dysplasia* and may be difficult to diagnose at an early stage. For this reason, it is recommended that patients with long-standing ulcerative colitis undergo colonoscopic surveillance with multiple (40–50), random biopsies to identify dysplasia before invasive malignancy develops. However, the adequacy of this type of screening is controversial. Recently, magnifying chromoendoscopy has been used to improve sensitivity.^{46,47} This technique uses topical dyes that are applied to the colonic mucosa at the time of endoscopy (Lugol's solution, methylene blue, indigo carmine, and others). These dyes highlight contrast between normal and dysplastic epithelium, allowing more precise biopsy of suspicious areas. Surveillance is recommended annually after 8 years in patients with pancolitis, and annually after 15 years in patients with left-sided colitis. Although low-grade dysplasia was long thought to represent minimal risk, more recent studies show that invasive cancer may be present in up to 20% of patients with low-grade dysplasia. For this reason, any patient with dysplasia should be advised to undergo proctocolectomy. Controversy exists over whether prophylactic proctocolectomy should be recommended for patients who have had chronic ulcerative colitis for greater than 10 years in the absence of dysplasia. Proponents of this approach note that surveillance colonoscopy with multiple biopsies samples only a small fraction of the colonic mucosa, and dysplasia and carcinoma are often missed. Opponents cite the relatively low risk of progression to carcinoma (approximately 2.4%) if all biopsies lack dysplasia. Neither approach has been shown definitively to decrease mortality from colorectal cancer.

Emergent Operation. In a patient with fulminant colitis or toxic megacolon, total abdominal colectomy with end ileostomy (with or without a mucus fistula), rather than total proctocolectomy, is recommended. Although the rectum is invariably diseased, most patients improve dramatically after an abdominal colectomy, and this operation avoids a difficult and time-consuming pelvic dissection in a critically ill patient. Rarely, a loop ileostomy and decompressing colostomy may be necessary if the patient is too unstable to withstand colectomy. Definitive surgery may then be undertaken at a later date once the patient has recovered. Complex techniques, such as an ileal pouch–anal reconstruction, generally are contraindicated in the emergent setting. However, massive hemorrhage that includes bleeding from the rectum may necessitate proctectomy and creation of either a permanent ileostomy or an ileal pouch–anal anastomosis.

Elective Operation. Elective resection for ulcerative colitis usually is performed for refractory inflammation and/or the risk of malignancy (dysplasia). Because of the risk of ongoing inflammation, the risk of malignancy, and the availability of restorative proctocolectomy, most surgeons recommend operations that include resection of the rectum. *Total proctocolectomy with end ileostomy* has been the “gold standard” for treating patients with chronic ulcerative colitis. This operation removes the entire affected intestine and avoids the functional disturbances associated with ileal pouch–anal reconstruction. Most patients function well physically and psychologically after this operation. *Total proctocolectomy with continent ileostomy (Kock’s pouch)* was developed to improve function and quality of life after total proctocolectomy, but morbidity is significant, and restorative proctocolectomy is generally preferred today. Since its introduction in 1980, *restorative proctocolectomy with ileal pouch–anal anastomosis* has become the procedure of choice for most patients who require total proctocolectomy but wish to avoid a permanent ileostomy (see Figs. 29-11 and 29-12).⁶ Abdominal colectomy with ileorectal anastomosis may be appropriate for a patient with indeterminate colitis and rectal sparing.

Crohn’s Disease

Similar to ulcerative colitis, Crohn’s disease is characterized by exacerbations and remissions. Crohn’s disease, however, may affect any portion of the intestinal tract, from mouth to anus. Diagnosis may be made by colonoscopy or esophagogastroduodenoscopy or by barium small bowel study or enema, depending on which part of the intestine is most affected. The presence of skip lesions is key in differentiating Crohn’s colitis from ulcerative colitis, and rectal sparing occurs in approximately 40% of patients. The most common site of involvement of Crohn’s disease is the terminal ileum and cecum (*ileocolic Crohn’s disease*), followed by the small bowel, and then by the colon and rectum. Perianal and anal canal Crohn’s disease manifest by complex anal fistulae and/or abscesses, anal ulcers, and large skin tags may be the initial site of presentation in up to 4% of cases.

Indications for Surgery. Because Crohn’s disease can affect any part of the gastrointestinal tract, the therapeutic rationale is fundamentally different from that of ulcerative colitis. Ulcerative colitis may be cured by removal of the affected intestinal segment (the colon and rectum). In Crohn’s disease, it is impossible to remove all the at-risk intestine; therefore, surgical therapy is reserved for complications of the disease.

Crohn’s disease may present as an *acute inflammatory* process or as a *chronic fibrotic* process. During the acute inflammatory phase, patients may present with intestinal inflammation complicated by fistulae and/or intra-abdominal abscesses. Maximal medical therapy should be instituted, including anti-inflammatory medications, bowel rest, and antibiotics. Parenteral nutrition should be considered if the patient is malnourished. Most intra-abdominal abscesses can be drained percutaneously with the use of CT scan guidance. Although the majority of these patients will ultimately require surgery to remove the diseased segment of bowel, these interventions allow the patient’s condition to stabilize, nutrition to be optimized, and inflammation to decrease prior to embarking on a surgical resection. Once an operation is undertaken, fistulae generally require resection of the segment of bowel with active Crohn’s disease; the secondary sites of the fistula are often otherwise normal and do not generally require resection after division of the fistula. Simple closure of the secondary fistula site usually suffices.

Chronic fibrosis may result in strictures in any part of the gastrointestinal tract. Because the fibrotic process is gradual, free perforation proximal to the obstructing stricture is rare. Chronic strictures almost never improve with medical therapy. Optimal timing for surgery should take into account the patient’s underlying medical and nutritional status.

Strictures may be treated with *resection* or *stricturoplasty*. Distal ileal strictures are sometimes amenable to colonoscopic balloon dilatation.

Once an operation is undertaken for Crohn’s disease, several principles should guide intraoperative decision making. In general, a laparotomy for Crohn’s disease should be performed through a *midline incision* because of the possible need for a stoma. *Laparoscopy* is also increasingly used in this setting. Because many patients with Crohn’s disease often will require multiple operations, *the length of bowel removed should be minimized*. Bowel should be resected to an area with *grossly normal margins*; frozen sections are not necessary. Finally, a primary anastomosis may be created safely if the patient is medically stable, nutritionally replete, and taking few immunosuppressive medications. *Creation of a stoma should be strongly considered* in any patient who is hemodynamically unstable, septic, malnourished, or receiving high-dose immunosuppressive therapy and among patients with extensive intra-abdominal contamination.

Ileocolic and Small Bowel Crohn’s Disease. The terminal ileum and cecum are involved in Crohn’s disease in up to 41% of patients; the small intestine is involved in up to 35% of patients. The most common indications for surgery are *internal fistula or abscess* (30%–38% of patients) and *obstruction* (35%–37% of patients). *Psoas abscess* may result from ileocolic Crohn’s disease. Sepsis should be controlled with percutaneous drainage of abscess(es) and antibiotics, if possible. Parenteral nutrition may be necessary in patients with chronic obstruction. The extent of resection depends on the amount of involved intestine. Short segments of inflamed small intestine and right colon should be resected and a primary anastomosis created if the patient is stable, nutrition is adequate, and immunosuppression is minimal. Isolated chronic strictures should also be resected. In patients with multiple fibrotic strictures that would require extensive small bowel resection, *stricturoplasty* is a safe and effective alternative to resection. Short strictures are amenable to a transverse stricturoplasty, while longer strictures may be treated with a side-to-side small bowel anastomosis (Fig. 29-18).

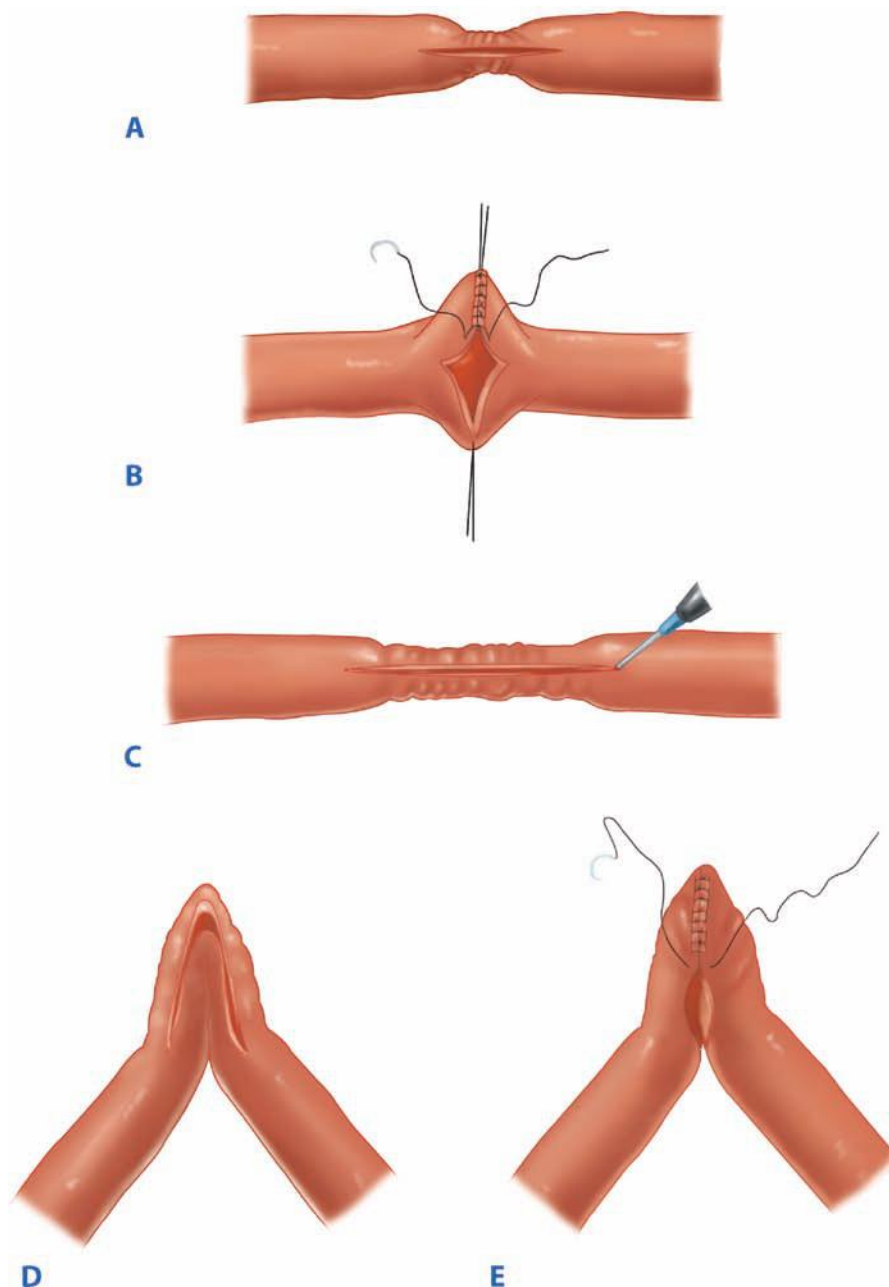


Figure 29-18. Alternative stricturoplasty techniques. **A.** A short stricture is opened along the antimesenteric surface of the bowel wall. **B.** The enterotomy is closed transversely. **C.** A long stricture is opened along the antimesenteric surface of the bowel wall. **D.** The bowel is folded into an inverted “U.” **E.** A side-to-side anastomosis is made. (Reproduced with permission from Corman ML. *Colon & Rectal Surgery*. 2nd ed. Philadelphia: Lippincott Williams & Wilkins; 1989:832.)

Risk of recurrence after resection for ileocolic and small bowel Crohn’s disease is high. More than 50% of patients will experience a recurrence within 10 years, and the majority of these will require a second operation.

Crohn’s Colitis. Crohn’s disease of the large intestine may present as *fulminant colitis* or *toxic megacolon*. In this setting, treatment is identical to treatment of fulminant colitis and toxic megacolon secondary to ulcerative colitis. Resuscitation and medical therapy with bowel rest, broad-spectrum antibiotics, and parenteral corticosteroids should be instituted. If the patient’s condition worsens or fails to rapidly improve, total abdominal colectomy with end ileostomy is recommended. An

elective proctectomy may be required if the patient has refractory Crohn’s proctitis. Alternatively, if the rectum is spared, an ileorectal anastomosis may be appropriate once the patient has recovered.

Other indications for surgery in chronic Crohn’s colitis are *intractability*, *complications of medical therapy*, and *risk of or development of malignancy*. Unlike ulcerative colitis, Crohn’s colitis may be segmental, and rectal sparing is often observed. A segmental colectomy may be appropriate if the remaining colon and/or rectum appear normal. An isolated colonic stricture may also be treated by segmental colectomy. Although it was long thought that Crohn’s disease did not increase the risk of

colorectal carcinoma, it is now recognized that Crohn's colitis (especially pancolitis) carries nearly the same risk for cancer as ulcerative colitis. Annual surveillance colonoscopy with multiple biopsies is recommended for patients with long-standing Crohn's colitis (>7 years in duration). As in ulcerative colitis, dysplasia is an indication for total proctocolectomy. Ileal pouch–anal reconstruction is not recommended in these patients because of the risk for development of Crohn's disease within the pouch and the high risk of complications, such as fistula, abscess, stricture, pouch dysfunction, and pouch failure.

Anal and Perianal Crohn's Disease. Anal and perianal manifestations of Crohn's disease are very common and occur in 35% of all patients with Crohn's disease. Isolated anal Crohn's disease is uncommon, affecting only 3% to 4% of patients. Detection of anal Crohn's disease, therefore, should prompt evaluation of the remainder of the gastrointestinal tract.

The most common perianal lesions in Crohn's disease are *skin tags* that are minimally symptomatic. *Fissures* are also common. Typically, a fissure from Crohn's disease is particularly deep or broad and perhaps better described as an anal ulcer. These fissures are often multiple and located in a lateral position rather than anterior or posterior midline as seen in an idiopathic fissure in ano. A classic-appearing fissure in ano located laterally should raise the suspicion of Crohn's disease. *Perianal abscess* and *fistulas* are common and can be particularly challenging. Fistulas tend to be complex and often have multiple tracts (Fig. 29-19). *Hemorrhoids* are not more common in patients with Crohn's disease than in the general population, although many patients tend to attribute any anal or perianal symptom to "hemorrhoids."

Treatment of anal and perianal Crohn's disease focuses on alleviation of symptoms. Perianal skin irritation from diarrhea often responds to medical therapy directed at small bowel or colonic disease. In general, skin tags and hemorrhoids should not be excised unless they are extremely symptomatic because of the risk of creating chronic, nonhealing wounds. Fissures may respond to local or systemic therapy; sphincterotomy is relatively contraindicated because of the risk of creating a chronic, nonhealing wound and because of the increased risk of incontinence in a patient with diarrhea from underlying colitis or small bowel disease. Anal ulcers associated with Crohn's disease are usually not very painful unless there is an underlying abscess. Thus, in patients with significant anal pain, an examination under anesthesia is indicated to exclude an underlying abscess or fistula and to assess the rectal mucosa. In the absence of active Crohn's proctitis, one can proceed cautiously with a partial internal sphincterotomy if the examination under anesthesia reveals a classic-appearing posterior or anterior fissure and anal stenosis.

Recurrent abscess(es) or complex anal fistulae should raise the possibility of Crohn's disease. Treatment focuses on *control of infection*, *delineation of complex anatomy*, *treatment of underlying mucosal disease*, and *sphincter preservation*. Abscesses often can be drained locally, and mushroom catheters are useful for maintaining drainage. Endoanal ultrasound and pelvic MRI are useful for mapping complex fistulous tracts. Liberal use of setons can control many fistulas and avoid division of the sphincter. Many patients with anal Crohn's disease function well with multiple setons left in place for years. Endoanal advancement flaps may be considered for definitive therapy if the rectal mucosa is uninvolved but will not heal due to rectal

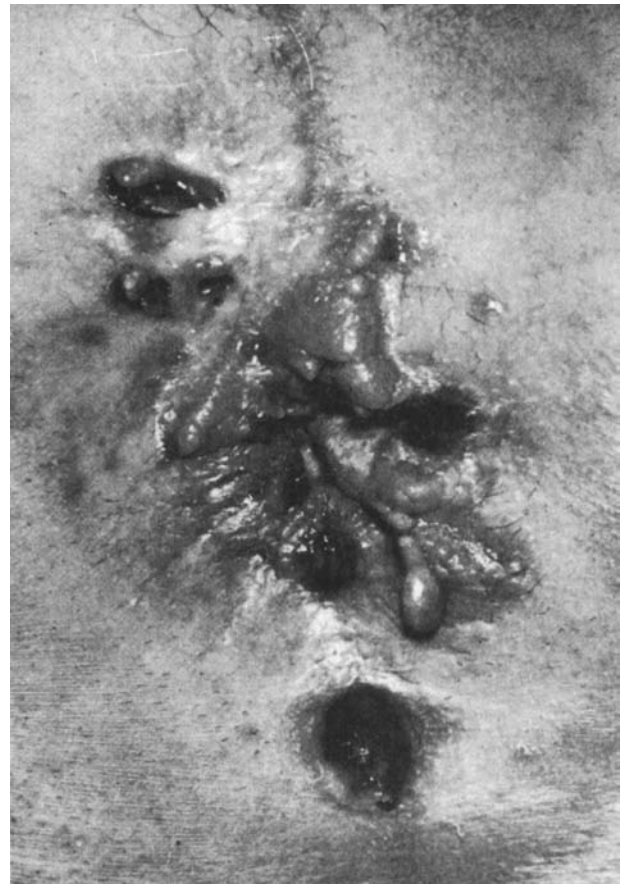


Figure 29-19. Photograph of a patient with multiple perianal fistulas secondary to Crohn's disease. (Reproduced with permission from Hamilton SR, Borson BC. *Crohn's disease: Pathology*. In: Berk JE, ed. *Bockus Gastroenterology*. 4th ed. Philadelphia: Saunders; 1985:2229, Fig. 127-5. Copyright Elsevier.)

inflammation. In 10% to 15% of cases, intractable perianal sepsis requires proctectomy.

Rectovaginal fistula can be a particularly difficult problem in these patients. A rectal or vaginal mucosal advancement flap may be used if the rectal mucosa appears healthy and scarring of the rectovaginal septum is minimal. Occasionally, proctectomy is the best option for women with highly symptomatic rectovaginal fistulae. Although proximal diversion is often employed to protect complex perianal reconstruction, there is no evidence that diversion alone increases healing of anal and perianal Crohn's disease.

Medical treatment of underlying proctitis with salicylate and/or corticosteroid enemas may be helpful; however, control of infection is the primary goal of therapy. Metronidazole has been used with some success in this setting. Anti-TNF- α agents (infliximab and adalimumab) have shown some efficacy in healing chronic fistulas secondary to Crohn's disease. The success of these agents has led to a concerted effort to identify other immunomodulators that might prove useful. Proinflammatory cytokines such as interleukin-12 and interferon- γ are potential targets. Inhibition of immune cell migration has also been suggested as an approach.⁴⁸ However, it is of paramount importance to drain any and all abscesses before initiating immunosuppressive therapy such as corticosteroids or anti-TNF- α monoclonal antibodies.

Indeterminate Colitis

Approximately 15% of patients with inflammatory bowel disease manifest clinical and pathologic characteristics of both ulcerative colitis and Crohn's disease. Endoscopy, barium enema, and biopsy may be unable to differentiate ulcerative colitis from Crohn's colitis in this setting. The indications for surgery are the same as those for ulcerative colitis: *intractability, complications of medical therapy, and risk of or development of malignancy*. In the setting of indeterminate colitis in a patient who prefers a sphincter-sparing operation, a *total abdominal colectomy with end ileostomy* may be the best initial procedure. Pathologic examination of the entire colon may then allow a more accurate diagnosis. If the diagnosis suggests ulcerative colitis, an ileal pouch–anal anastomosis procedure can be performed. If the diagnosis remains in question, the safest surgical option is completion proctectomy with end ileostomy (similar to Crohn's colitis). Ileal pouch–anal reconstruction may also be considered with the understanding that the pouch failure rate is between 15% and 20%.

DIVERTICULAR DISEASE

Diverticular disease is a clinical term used to describe the presence of symptomatic diverticula. *Diverticulosis* refers to the presence of diverticula without inflammation. *Diverticulitis* refers to inflammation and infection associated with diverticula. The majority of colonic diverticula are *false diverticula* in which the mucosa and muscularis mucosa have herniated through the colonic wall. These diverticula occur between the teniae coli, at points where the main blood vessels penetrate the colonic wall (presumably creating an area of relative weakness in the colonic muscle). They are thought to be *pulsion diverticula* resulting from high intraluminal pressure. *Diverticular bleeding* can be massive but usually is self-limited. *True diverticula*, which comprise all layers of the bowel wall, are rare and are usually congenital in origin.

Diverticulosis is extremely common in the United States and Europe. It is estimated that half of the population older than age 50 years has colonic diverticula. The sigmoid colon is the most common site of diverticulosis (Fig. 29-20). Diverticulosis is thought to be an acquired disorder, but the etiology is poorly understood. The most accepted theory is that a lack of dietary fiber results in smaller stool volume, requiring high intraluminal pressure and high colonic wall tension for propulsion. Chronic contraction then results in muscular hypertrophy and development of the process of segmentation in which the colon acts like separate segments instead of functioning as a continuous tube. As segmentation progresses, the high pressures are directed radially toward the colon wall rather than to development of propulsive waves that move stool distally. The high radial pressures directed against the bowel wall create pulsion diverticula. A loss of tensile strength and a decrease in elasticity of the bowel wall with age have also been proposed etiologies. Although none of these theories has been proven, a high-fiber diet does appear to decrease the incidence of diverticulosis. Although diverticulosis is common, most cases are asymptomatic, and complications occur in the minority of people with this condition.

Inflammatory Complications (Diverticulitis)

Diverticulitis refers to inflammation and infection associated with a diverticulum and is estimated to occur in 10% to 25% of people with diverticulosis. Peridiverticular and pericolic

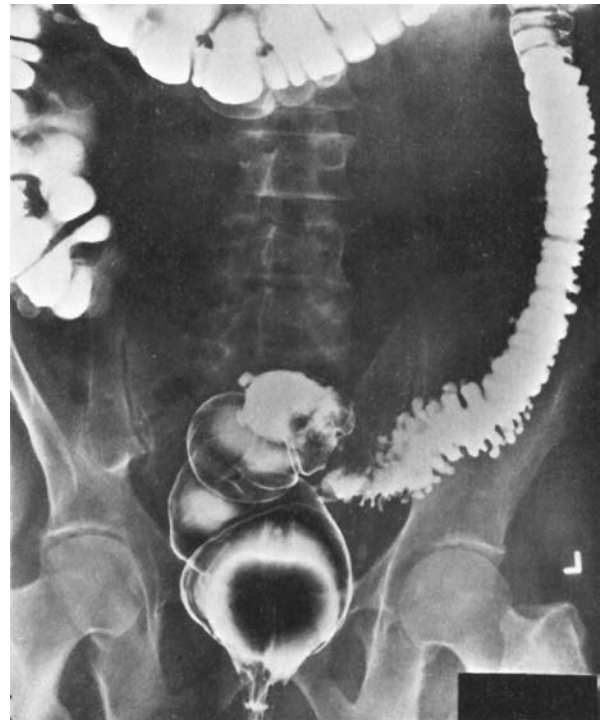

Figure 29-20. Diverticulosis of sigmoid colon on barium enema. (Reproduced with permission from Nivatvongs S, Becker ER. *Colon, rectum, and anal canal*. In: James EC, Corry RJ, Perry JCF Jr, eds. *Basic Surgical Practice*. Philadelphia: Hanley & Belfus; 1987. Copyright Elsevier.)

infection results from a perforation (either macroscopic or microscopic) of a diverticulum, which leads to contamination, inflammation, and infection. The spectrum of disease ranges from mild, uncomplicated diverticulitis that can be treated in the outpatient setting, to free perforation and diffuse peritonitis that requires emergency laparotomy. Most patients present with left-sided abdominal pain, with or without fever, and leukocytosis. A mass may be present. Plain radiographs are useful for detecting free intra-abdominal air. CT scan is extremely useful for defining pericolic inflammation, phlegmon, or abscess. Contrast enemas and/or endoscopy are relatively contraindicated because of the risk of perforation. The differential diagnosis includes malignancy, ischemic colitis, infectious colitis, and inflammatory bowel disease.

Uncomplicated Diverticulitis. *Uncomplicated diverticulitis* is characterized by left lower quadrant pain and tenderness. CT findings include pericolic soft tissue stranding, colonic wall thickening, and/or phlegmon. Most patients with uncomplicated diverticulitis will respond to outpatient therapy with broad-spectrum oral antibiotics and a low-residue diet. Antibiotics should be continued for 7 to 10 days. About 10% to 20% of patients with more severe pain, tenderness, fever, and leukocytosis are treated in the hospital with parenteral antibiotics and bowel rest. Most patients improve within 48 to 72 hours. Failure to improve may suggest abscess formation. CT can be extremely useful in this setting, and many pericolic abscesses can be drained percutaneously (see below). Deterioration in a patient's clinical condition and the development of peritonitis are indications for laparotomy.

Most patients with uncomplicated diverticulitis will recover without surgery, and 50% to 70% will have no further

episodes.⁴⁹ It has long been believed that the risk of complications increases with recurrent disease. For this reason, elective sigmoid colectomy has often been recommended after the second episode of diverticulitis, especially if the patient has required hospitalization. Resection has often been recommended after the first episode in very young patients and is often recommended after the first episode of *complicated diverticulitis*. These general guidelines have been questioned in recent years, and more recent studies suggest that the risk of complications and/or need for emergent resection does *not* increase with recurrent disease.^{49,50}

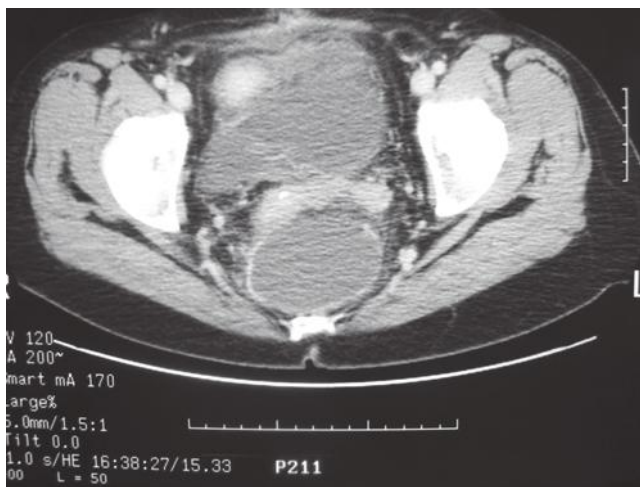Many surgeons now will not advise colectomy even after two documented episodes of diverticulitis assuming the patient is completely asymptomatic and that carcinoma has been excluded by colonoscopy. Immunosuppressed patients are generally still advised to undergo colectomy after a single episode of documented diverticulitis. Medical comorbidities should be considered when evaluating a patient for elective resection, and the risks of recurrent disease should be weighed against the risks of the operation. Because colon carcinoma may present in an identical fashion to diverticulitis (either complicated or uncomplicated), all patients must be evaluated for malignancy after resolution of the acute episode. Colonoscopy is recommended 4 to 6 weeks after recovery. Inability to exclude malignancy is another indication for resection.

In the elective setting, a *sigmoid colectomy with a primary anastomosis* is the procedure of choice. The resection should always be extended to the rectum distally because the risk of recurrence is high if a segment of sigmoid colon is retained. The proximal extent of the resection should include all thickened or inflamed bowel; however, resection of all diverticula is unnecessary. Increasingly, laparoscopy is being used for elective sigmoid colectomy for diverticular disease.

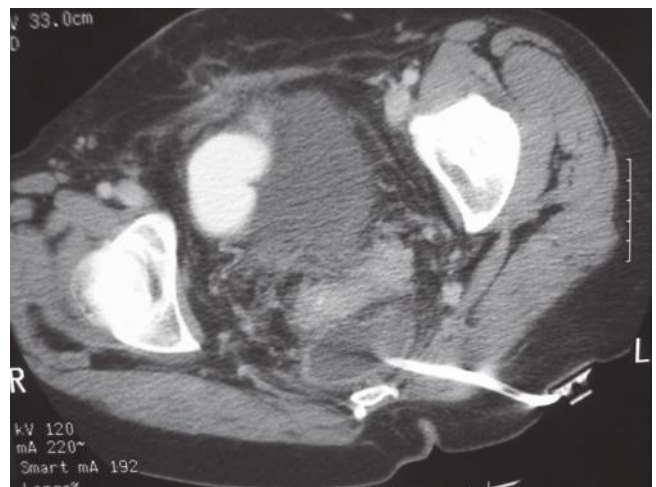Complicated Diverticulitis. *Complicated diverticulitis* includes diverticulitis with abscess, obstruction, diffuse peritonitis (free perforation), or fistulas between the colon and adjacent structures. Colovesical, colovaginal, and coloenteric fistulas are long-term sequelae of complicated diverticulitis.

The *Hinchey staging system* is often used to describe the severity of complicated diverticulitis: Stage I includes colonic inflammation with an associated pericolic abscess; stage II includes colonic inflammation with a retroperitoneal or pelvic abscess; stage III is associated with purulent peritonitis; and stage IV is associated with fecal peritonitis. Treatment depends on the patient's overall clinical condition and the degree of peritoneal contamination and infection. Small abscesses (<2 cm in diameter) may be treated with parenteral antibiotics. Larger abscesses are best treated with CT-guided percutaneous drainage (Fig. 29-21) and antibiotics. Many of these patients will ultimately require resection, but percutaneous drainage may allow a one-stage, elective procedure and may obviate the need for colectomy if full recovery follows the drainage.

Urgent or emergent laparotomy may be required if an abscess is inaccessible to percutaneous drainage, if the patient's condition deteriorates or fails to improve, or if the patient presents with free intra-abdominal air or peritonitis. In almost all cases, an attempt should be made to resect the affected segment of bowel. Patients with small, localized pericolic or pelvic abscesses (Hinchey stages I and II) may be candidates for a sigmoid colectomy with a primary anastomosis (a one-stage operation).⁴⁵ Among patients with larger abscesses, peritoneal soiling, or peritonitis, sigmoid colectomy with end colostomy and Hartmann's pouch is the most commonly used procedure.⁴⁶ Success also has been reported after sigmoid colectomy, primary anastomosis, with or without on-table lavage, and proximal diversion (loop ileostomy). This option may be appropriate in stable patients and offers the great advantage that the subsequent operation to restore bowel continuity is simpler than is takedown of a Hartmann's pouch. The presence of inflammation and phlegmon may increase the risk of ureteral damage during mobilization of the sigmoid colon, and preoperative placement of ureteral catheters can be invaluable. In extremely unstable patients, or in the presence of such severe inflammation that resection would harm adjacent organs, proximal diversion and local drainage have been employed. However, this approach is generally avoided because of high morbidity and mortality



A



B

Figure 29-21. A. Computed tomography scan demonstrating pelvic abscess from perforated diverticular disease. B. Posterolateral computed tomography-guided drainage of abdominal abscess from perforated diverticular disease. (Both images used with permission of Charles O. Finne III, MD, Minneapolis, MN.)

rates, along with the requirement for multiple operations. More recently, several studies have suggested that laparoscopic lavage and drainage without bowel resection may be safe and effective even in the presence of free perforation. Nevertheless, this approach remains controversial and will require additional prospective trials before it can be recommended under most circumstances.

Obstructive symptoms occur in approximately 67% of patients who develop acute diverticulitis, and complete obstruction occurs in 10%. Patients with incomplete obstruction often respond to fluid resuscitation, nasogastric suction, and gentle, low-volume water or Gastrografin enemas. Relief of obstruction allows full bowel preparation and elective resection. A high-volume oral bowel preparation is contraindicated in the presence of obstructive symptoms. Obstruction that does not rapidly respond to medical management mandates laparotomy. Sigmoid colectomy with end colostomy is the safest procedure to perform in this setting. However, colectomy and primary anastomosis, with or without on-table lavage (depending on extent of fecal load in the proximal colon), and proximal diversion may be appropriate if the patient is stable and the proximal and distal bowel appear healthy.

Approximately 5% of patients with complicated diverticulitis develop fistulas between the colon and an adjacent organ. *Colovesical* fistulas are most common, followed by *colovaginal* and *coloenteric* fistulas. *Colocutaneous* fistulas are a rare complication of diverticulitis. Two key points in the evaluation of fistulas are to *define the anatomy of the fistula* and *exclude other diagnoses*. Contrast enema and/or small bowel studies are extremely useful in defining the course of the fistula. CT scan can identify associated abscesses or masses. The differential diagnosis includes *malignancy*, *Crohn's disease*, and *radiation-induced fistulas*. While Crohn's disease and radiation injury may be suspected based on the patient's medical history, colonoscopy or sigmoidoscopy usually is required to rule out malignancy. In addition, in a patient who has received radiation therapy, a fistula must be considered to be recurrent cancer until proven otherwise. Once the anatomy of the fistula has been defined and other diagnoses excluded, operative management should include resection of the affected segment of the colon involved with diverticulitis (usually with a primary anastomosis) and simple repair of the secondarily involved organ. Suspicion of carcinoma may mandate a wider, en bloc resection.

Hemorrhage

Bleeding from a diverticulum results from erosion of the peridiverticular arteriole and may result in massive hemorrhage. Most significant lower gastrointestinal hemorrhage occurs in elderly patients in whom both diverticulosis and angiodysplasia are common. Consequently, the exact bleeding source may be difficult to identify. Fortunately, in 80% of patients, bleeding stops spontaneously. Clinical management should focus on resuscitation and localization of the bleeding site as described for lower gastrointestinal hemorrhage. Colonoscopy may occasionally identify a bleeding diverticulum that may then be treated with epinephrine injection or cautery. Angiography may be diagnostic and therapeutic in this setting. In the rare instance in which diverticular hemorrhage persists or recurs, laparotomy and segmental colectomy may be required.

Giant Colonic Diverticulum

Giant colonic diverticula are extremely rare. Most occur on the antimesenteric side of the sigmoid colon. Patients may be

asymptomatic or may present with vague abdominal complaints such as pain, nausea, or constipation. Plain radiographs may suggest the diagnosis. Barium enema is usually diagnostic. Complications of a giant diverticulum include perforation, obstruction, and volvulus. Resection of the involved colon and diverticulum is recommended.

Right-Sided Diverticula

The cecum and ascending colon infrequently are involved in diverticulosis coli. Even more uncommon is a true solitary diverticulum, which contains all layers of the bowel wall and is thought to be congenital in origin. Right-sided diverticula occur more often in younger patients than do left-sided diverticula and are more common in people of Asian descent than in other populations. Most patients with right-sided diverticula are asymptomatic. However, diverticulitis does occur occasionally. Because patients are young and present with right lower quadrant pain, they are often thought to suffer from acute appendicitis, and the diagnosis of right-sided diverticulitis is subsequently made in the operating room. If there is a single large diverticulum and minimal inflammation, a diverticulectomy may be performed, but an ileocecal resection is usually the preferred operation in this setting. Hemorrhage rarely occurs and should be treated in the same fashion as hemorrhage from a left-sided diverticulum.

ADENOCARCINOMA AND POLYPS

Incidence

Colorectal carcinoma is the most common malignancy of the gastrointestinal tract. Over 140,000 new cases are diagnosed annually in the United States, and more than 50,000 patients die of this disease each year, making colorectal cancer the third most lethal cancer in the United States.⁵¹

The incidence is similar in men and women and has remained fairly constant over the past 20 years; however, the widespread adoption of current national screening programs is gradually decreasing the incidence of this common and lethal disease. Early detection and improvements in medical and surgical care are thought to be responsible for the decreasing mortality of colorectal cancer observed in recent years.

Epidemiology (Risk Factors)

Identification of risk factors for development of colorectal cancer is essential to establish screening and surveillance programs in appropriately targeted populations.

Aging. Aging is the dominant risk factor for colorectal cancer, with incidence rising steadily after age 50 years. More than 90% of cases diagnosed are in people older than age 50 years. This is the rationale for initiating screening tests of asymptomatic patients at average risk of developing colorectal cancer at age 50 years. However, individuals of any age can develop colorectal cancer, so symptoms such as a significant change in bowel habits, rectal bleeding, melena, unexplained anemia, or weight loss require a thorough evaluation.

Hereditary Risk Factors. Approximately 80% of colorectal cancers occur sporadically, while 20% arise in patients with a known family history of colorectal cancer. Advances in the understanding of these familial disorders have led to interest in early diagnosis using genetic testing. Because of the medical, legal, and ethical considerations that are involved in this type

of testing, all patients should be offered genetic counseling if a familial syndrome is suspected.

Environmental and Dietary Factors. The observation that colorectal carcinoma occurs more commonly in populations that consume diets high in animal fat and low in fiber has led to the hypothesis that dietary factors contribute to carcinogenesis. A diet high in saturated or polyunsaturated fats increases risk of colorectal cancer, while a diet high in oleic acid (olive oil, coconut oil, fish oil) does not increase risk. Animal studies suggest that fats may be directly toxic to the colonic mucosa and thus may induce early malignant changes. In contrast, a diet high in *vegetable fiber* appears to be protective. A correlation between alcohol intake and incidence of colorectal carcinoma has also been suggested. Ingestion of calcium, selenium, vitamins A, C, and E, carotenoids, and plant phenols may decrease the risk of developing colorectal cancer. Obesity and sedentary lifestyle dramatically increase cancer-related mortality in a number of malignancies, including colorectal carcinoma. This knowledge is the basis for primary prevention strategies to eliminate colorectal cancer by altering diet and lifestyle.⁵²

Inflammatory Bowel Disease. Patients with long-standing colitis from inflammatory bowel disease are at increased risk for the development of colorectal cancer. It is hypothesized that chronic inflammation predisposes the mucosa to malignant changes, and there is some evidence that degree of inflammation influences risk. In general, the duration and extent of colitis correlate with risk. Other factors thought to increase risk include the presence of primary sclerosing cholangitis and family history of colorectal cancer.

Other Risk Factors. Cigarette smoking is associated with an increased risk of colonic adenomas, especially after more than 35 years of use. Patients with ureterosigmoidostomy are also at increased risk for both adenoma and carcinoma formation.⁵³

Acromegaly, which is associated with increased levels of circulating human growth hormone and insulin-like growth factor-1, increases risk as well. Pelvic irradiation may increase the risk of developing rectal carcinoma. However, it is unclear whether this represents a direct effect of radiation damage or is instead a correlation between the development of rectal cancer and a history of another pelvic malignancy; for example among patients who develop prostate cancer and are treated with radiation, the risk of rectal cancer increases significantly.⁵⁴

Pathogenesis of Colorectal Cancer

Genetic Defects. Over the past two decades, an intense research effort has focused on elucidating the genetic defects and molecular abnormalities associated with the development

and progression of colorectal adenomas and carcinoma. Mutations may cause *activation of oncogenes (K-ras)* and/or *inactivation of tumor suppressor genes (APC, deleted in colorectal carcinoma [DCC], p53)*. Colorectal carcinoma is thought to develop from adenomatous polyps by accumulation of these mutations in what has come to be known as the *adenoma-carcinoma sequence* (Fig. 29-22).

Defects in the *APC* gene were first described in patients with FAP. By investigating these families, characteristic mutations in the *APC* gene were identified. They are now known to be present in 80% of sporadic colorectal cancers as well.

The *APC* gene is a *tumor suppressor gene*. Mutations in both alleles are necessary to initiate polyp formation. The majority of mutations are premature stop codons, which result in a truncated APC protein. In FAP, the site of mutation correlates with the clinical severity of the disease. For example, mutations in either the 3' or 5' end of the gene result in attenuated forms of FAP (AFAP), whereas mutations in the center of the gene result in more virulent disease. Thus, knowledge of the specific mutation in a family may help guide clinical decision making.

APC inactivation alone does not result in a carcinoma. Instead, this mutation sets the stage for the accumulation of genetic damage that results in malignancy. Additional mutations may include activation or inactivation of a variety of genes.

One of the most commonly involved genes in colorectal cancer is *K-ras*. *K-ras*, a signaling molecule in the epidermal growth factor receptor (EGFR) pathway, is classified as a *proto-oncogene* because mutation of only one allele will perturb the cell cycle. The *K-ras* gene product is a G-protein involved in intracellular signal transduction. When active, *K-ras* binds guanosine triphosphate (GTP); hydrolysis of GTP to guanosine diphosphate (GDP) then inactivates the G-protein. Mutation of *K-ras* results in an inability to hydrolyze GTP, thus leaving the G-protein permanently in the active form. It is thought that this then leads to uncontrolled cell division. Other EGFR signaling molecules such as BRAF have also been implicated in colorectal cancer pathogenesis and progression, and ongoing research is focusing on elucidating their roles in this disease.

Another common mutation occurs in the *MYH* gene on chromosome 1p.^{55,56} *MYH* is a base excision repair gene, and biallelic deletion results in changes in other downstream molecules. Since its discovery, *MYH* mutations have been associated with an AFAP phenotype in addition to sporadic cancers.⁵⁵ Unlike *APC* gene mutations that are expressed in an autosomal dominant pattern, the requirement for biallelic mutation in *MYH* results in an autosomal recessive pattern of inheritance.

The tumor suppressor gene *p53* has been well characterized in a number of malignancies. The p53 protein appears

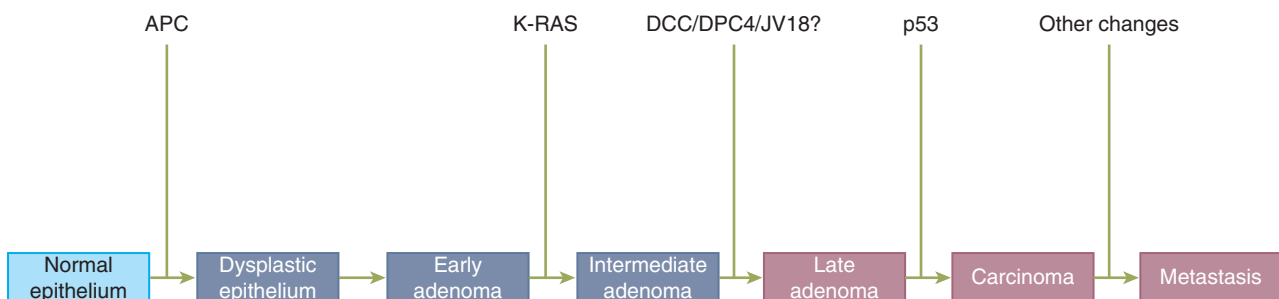


Figure 29-22. Schematic showing progression from normal colonic epithelium to carcinoma of the colon.

to be crucial for initiating apoptosis in cells with irreparable genetic damage. Mutations in *p53* are present in 75% of colorectal cancers.

Deletion of the tumor suppressor phosphatase and tensin homolog (*PTEN*) appears to be involved in a number of hamartomatous polyposis syndromes. Deletions in *PTEN* have been identified in juvenile polyposis, Peutz-Jeghers syndrome, Cowden's syndrome, and *PTEN* hamartoma syndrome, in addition to multiple endocrine neoplasia type IIB.¹²

Genetic Pathways. The mutations involved in colorectal cancer pathogenesis and progression are now recognized to accumulate via one of three major genetic pathways: the *loss of heterozygosity (LOH; chromosomal instability)* pathway, the *microsatellite instability (MSI)* pathway, and the *CpG island methylation (CIMP; serrated methylated)* pathway.

The Loss of Heterozygosity Pathway. The LOH pathway is characterized by chromosomal deletions and tumor aneuploidy. Eighty percent of colorectal carcinomas appear to arise from mutations in the LOH pathway. This pathway was first described in patients with FAP in whom mutations of the *APC* gene were found to be inherited.

Another example of LOH occurs in the region of chromosome 18q. This region has been found to be deleted in up to 70% of colorectal cancers. Two tumor suppressor genes, *DCC* and *SMAD4*, are located in this region, and as such, *deletion of 18q* may result in the loss of one or both of these genes. *DCC* is a tumor suppressor gene, and loss of both alleles is required for malignant degeneration. The main role of this molecule appears to be in the central nervous system, where it is involved in neural differentiation and axonal migration. This observation has led to the hypothesis that *DCC* may be involved in differentiation and cellular adhesion in colorectal cancer, but this theory remains unproven.⁵⁷ *DCC* mutations are present in more than 70% of colorectal carcinomas and may negatively impact prognosis. *SMAD4* functions in the signaling cascade of transforming growth factor beta and beta-catenin (also a downstream effector of the *APC* gene). Loss of either of these genes is thought to promote cancer progression.

The Microsatellite Instability Pathway. Many of the remaining colorectal carcinomas are thought to arise from mutations in the MSI pathway, which is characterized by errors in mismatch repair during DNA replication. These errors in mismatch repair were first described in HNPCC (Lynch's syndrome), but are now recognized to be present in many sporadic tumors as well. A number of genes have been identified that appear to be crucial for recognizing and repairing DNA replication errors. These *mismatch repair genes* include *MSH2*, *MLH1*, *PMS1*, *PMS2*, and *MSH6/GTBP*. A mutation in one of these genes predisposes a cell to mutations, which may occur in proto-oncogenes or tumor suppressor genes. Accumulation of these errors then leads to genomic instability and ultimately to carcinogenesis.

Microsatellites are regions of the genome in which short base-pair segments are repeated several times, regions that are particularly prone to replication error. Consequently, a mutation in a mismatch repair gene produces variable lengths of these repetitive sequences, a finding that has been described as MSI.

Tumors associated with MSI appear to have different biologic characteristics than do tumors that result from the LOH pathway. Tumors with MSI are more likely to be in the right colon and possess diploid DNA and are associated with a better prognosis than tumors that arise from the LOH pathway that are

microsatellite stable. Tumors arising from the LOH pathway tend to occur in the more distal colon, often have chromosomal aneuploidy, and are associated with a poorer prognosis.

CpG Island Methylation Pathway. In the recently described CIMP pathway, genes do not accumulate mutations (deletions or insertions of bases), but instead are activated or inactivated by methylation. This process has been called *epigenetic alteration* to differentiate it from the more traditional genetic alterations or true mutations. In normal cells, methylation is critical for regulation of gene expression. In cancer, aberrant methylation (either hyper- or hypomethylation), usually of a promoter region, results in abnormal activation or inactivation of genes. This gene silencing or, alternatively, activation results in a phenotype similar to that present with a true gene mutation. This pathway has also been called the *serrated methylated pathway* because of the observation that *serrated polyps* often harbor aberrant methylation in contrast to adenomatous polyps that are more often associated with mutations in the *APC* gene (LOH pathway).⁵⁸

Although these classifications are useful for understanding the mechanisms underlying carcinogenesis, they are not mutually exclusive. For example, a mismatch repair gene may be inactivated by methylation. Errors in mismatch repair may then allow mutations to inactivate a tumor suppressor gene. In addition, there is considerable interest in targeting molecules in each of these pathways in order to design better anticancer agents. Finally, ongoing research is focusing on the utility of molecular profiling in predicting prognosis and/or response to treatment.

Polyps

It is now well accepted that the majority of colorectal carcinomas evolve from adenomatous polyps; this sequence of events is the *adenoma-carcinoma sequence*. *Polyp* is a nonspecific clinical term that describes any projection from the surface of the intestinal mucosa regardless of its histologic nature. Colorectal polyps may be classified as *neoplastic (tubular adenoma, villous adenoma, tubulovillous adenomas, serrated adenomas/polyps)*, *hyperplastic, hamartomatous (juvenile, Peutz-Jeghers, Cronkite-Canada)*, or *inflammatory (pseudopolyp, benign lymphoid polyp)*.

Neoplastic Polyps. Adenomatous polyps are common, occurring in up to 25% of the population older than 50 years of age in the United States. By definition, these lesions are dysplastic. The risk of malignant degeneration is related to both the size and type of polyp. Tubular adenomas are associated with malignancy in only 5% of cases, whereas villous adenomas may harbor cancer in up to 40%. Tubulovillous adenomas are at intermediate risk (22%). Invasive carcinomas are rare in polyps smaller than 1 cm; the incidence increases with size. The risk of carcinoma in a polyp larger than 2 cm is 35% to 50%. Although most neoplastic polyps do not evolve to cancer, most colorectal cancers originate as a polyp. It is this fact that forms the basis for secondary prevention strategies to eliminate colorectal cancer by targeting the neoplastic polyp for removal before malignancy develops.

Polyps may be *pedunculated* or *sessile*. Most pedunculated polyps are amenable to colonoscopic snare excision. Removal of sessile polyps is often more challenging. Special colonoscopic techniques, including saline lift, piecemeal snare excision, and endoscopic mucosal resection facilitate successful removal of many sessile polyps. For rectal sessile polyps, transanal operative excision is preferred because it produces an

intact, single pathology specimen that can be used to determine the need for further therapy. Interpretation of the precise depth of invasion of a cancer arising in a sessile polyp after piecemeal excision is often impossible. The site of sessile polypectomies should be marked by injection of India ink to guide follow-up colonoscopy sessions to ensure that the polyp has been completely removed and to facilitate identification of the involved bowel segment should operative resection be necessary. Colectomy is reserved for cases in which colonoscopic removal is impossible, such as large, flat lesions, or if a focus of invasive cancer is confirmed in the specimen.

Complications of polypectomy include *perforation* and *bleeding*. A small perforation (*microperforation*) in a fully prepared, stable patient may be managed with bowel rest, broad-spectrum antibiotics, and close observation. Signs of sepsis, peritonitis, or deterioration in clinical condition are indications for laparotomy. Bleeding may occur immediately after polypectomy or may be delayed. The bleeding will usually stop spontaneously, but colonoscopy may be required to resnare a bleeding stalk or cauterize the lesion. Occasionally angiography and infusion of vasopressin may be necessary. Rarely, colectomy is required.

Hyperplastic Polyps. Hyperplastic polyps are extremely common in the colon. These polyps are usually small (<5 mm) and show histologic characteristics of hyperplasia without any dysplasia. They are not considered premalignant, but cannot be distinguished from adenomatous polyps colonoscopically and are therefore often removed. In contrast, large hyperplastic polyps (>2 cm) may have a slight risk of malignant degeneration. Moreover, large polyps may harbor foci of adenomatous tissue and dysplasia. *Hyperplastic polyposis* is a rare disorder in which multiple large hyperplastic polyps occur in young adults. These patients are at slightly increased risk for the development of colorectal cancer.

Serrated Polyps. Serrated polyps are a recently recognized, histologically distinct group of neoplastic polyps. These lesions were long thought to be similar to hyperplastic polyps with minimal malignant potential. However, it has become clear that some of these polyps will develop into invasive cancers. In addition, a familial *serrated polyposis syndrome* has recently been described. Serrated polyps should be treated like adenomatous polyps.⁵⁹

Hamartomatous Polyps (Juvenile Polyps). In contrast to adenomatous and serrated polyps, hamartomatous polyps (juvenile polyps) usually are not premalignant. These lesions are the characteristic polyps of childhood but may occur at any age. Bleeding is a common symptom, and intussusception and/or obstruction may occur. Because the gross appearance of these polyps is identical to adenomatous polyps, these lesions should also be treated by polypectomy. In contrast to adenomatous polyposis syndromes, these conditions are often associated with mutation in *PTEN*.

Familial juvenile polyposis is an autosomal dominant disorder in which patients develop hundreds of polyps in the colon and rectum. Unlike solitary juvenile polyps, these lesions may degenerate into adenomas and eventually carcinoma. Annual screening should begin between the ages of 10 and 12 years. Treatment is surgical and depends in part on the degree of rectal involvement. If the rectum is relatively spared, a total abdominal colectomy with ileorectal anastomosis may be performed with subsequent close surveillance of the retained rectum. If the

rectum is carpeted with polyps, total proctocolectomy is the more appropriate operation. These patients are candidates for ileal pouch–anal reconstruction to avoid a permanent stoma.

Peutz-Jeghers syndrome is characterized by polyposis of the small intestine and, to a lesser extent, polyposis of the colon and rectum. Characteristic melanin spots are often noted on the buccal mucosa and lips of these patients. The polyps of Peutz-Jeghers syndrome are generally considered to be hamartomas and are not thought to be at significant risk for malignant degeneration. However, carcinoma may occasionally develop. Because the entire length of the gastrointestinal tract may be affected, surgery is reserved for symptoms such as obstruction or bleeding or for patients in whom polyps develop adenomatous features. Screening consists of a baseline colonoscopy and upper endoscopy at age 20 years, followed by annual flexible sigmoidoscopy thereafter.

Cronkite-Canada syndrome is a disorder in which patients develop gastrointestinal polyposis in association with alopecia, cutaneous pigmentation, and atrophy of the fingernails and toenails. Diarrhea is a prominent symptom, and vomiting, malabsorption, and protein-losing enteropathy may occur. Most patients die of this disease despite maximal medical therapy, and surgery is reserved for complications of polyposis such as obstruction.

Cowden's syndrome is an autosomal dominant disorder with hamartomas of all three embryonal cell layers. Facial trichilemmomas, breast cancer, thyroid disease, and gastrointestinal polyps are typical of the syndrome. Patients should be screened for cancers. Treatment is otherwise based on symptoms.

Inflammatory Polyps (Pseudopolyps). Inflammatory polyps occur most commonly in the context of inflammatory bowel disease, but may also occur after amebic colitis, ischemic colitis, and schistosomal colitis. These lesions are not premalignant, but they cannot be distinguished from adenomatous polyps based on gross appearance and therefore should be removed. Microscopic examination shows islands of normal, regenerating mucosa (the polyp) surrounded by areas of mucosal loss. Polyposis may be extensive, especially in patients with severe colitis, and may mimic FAP.

Inherited Colorectal Carcinoma

Many of the genetic defects originally described in hereditary cancers have subsequently been found in sporadic tumors. Although the majority of colorectal cancer is sporadic, several hereditary syndromes provide paradigms for the study of this disease. Insight gained from studying inherited colorectal cancer syndromes has led to better understanding of the genetics of colorectal carcinoma.

Familial Adenomatous Polyposis. This rare autosomal dominant condition accounts for only about 1% of all colorectal adenocarcinomas. Nevertheless, this syndrome has provided tremendous insight into the molecular mechanisms underlying colorectal carcinogenesis. The genetic abnormality in FAP is a mutation in the *APC* gene, located on chromosome 5q. Of patients with FAP, *APC* mutation testing is positive in 75% of cases. While most patients with FAP will have a known family history of the disease, up to 25% present without other affected family members. Clinically, patients develop hundreds to thousands of adenomatous polyps shortly after puberty. The lifetime risk of colorectal cancer in FAP patients approaches 100% by age 50 years.

Flexible sigmoidoscopy of first-degree relatives of FAP patients beginning at age 10 to 15 years has been the traditional

mainstay of screening. Today, following genetic counseling, *APC* gene testing may be used to screen family members, providing an *APC* mutation has been identified. If *APC* testing is positive in a relative of a patient with a known *APC* mutation, annual flexible sigmoidoscopy beginning at age 10 to 15 years is done until polyps are identified. If *APC* testing is negative, the relative can be screened starting at age 50 years per average-risk guidelines. If *APC* testing is refused or unavailable, or if a mutation cannot be identified, annual flexible sigmoidoscopy beginning at age 10 to 15 years is performed until age 24 years. Screening flexible sigmoidoscopy is then done every 2 years until age 34 years, every 3 years until age 44 years, and then every 3 to 5 years.

FAP patients are also at risk for the development of adenomas anywhere in the gastrointestinal tract, particularly in the duodenum. Periampullary carcinoma is a particular concern. Upper endoscopy is therefore recommended for surveillance every 1 to 3 years beginning at age 25 to 30 years.

Once the diagnosis of FAP has been made and polyps are developing, treatment is surgical. Four factors affect the choice of operation: age of the patient; presence and severity of symptoms; extent of rectal polyposis; and presence and location of cancer or desmoid tumors. Three operative procedures can be considered: total proctocolectomy with an end (Brooke) ileostomy; total abdominal colectomy with ileorectal anastomosis; and restorative proctocolectomy with ileal pouch–anal anastomosis with or without a temporary ileostomy. Most patients elect to have an ileal pouch–anal anastomosis in the absence of a distal rectal cancer, a mesenteric desmoid tumor that prevents the ileum from reaching the anus, or poor sphincter function. Mucosectomy has been advocated in patients with FAP undergoing ileal pouch–anal anastomosis because of the risk of neoplasia in the anal transition zone, but the requirement for this procedure remains controversial. Although patient satisfaction with this procedure remains high, function may not be ideal, and up to 50% of patients experience some degree of incontinence. Total abdominal colectomy with an ileorectal anastomosis is also an option in these patients, but requires vigilant surveillance of the retained rectum for development of rectal cancer. There is increasing data suggesting that the administration of cyclooxygenase-2 (COX-2) inhibitors (celecoxib, sulindac) may slow or prevent the development of polyps.⁶⁰

FAP may be associated with extraintestinal manifestations such as congenital hypertrophy of the retinal pigmented epithelium, desmoid tumors, epidermoid cysts, mandibular osteomas (Gardner's syndrome), and central nervous system tumors (Turcot's syndrome). Desmoid tumors in particular, can make surgical management difficult and are a source of major morbidity and mortality in these patients. Desmoid tumors are often hormone responsive, and growth may be inhibited in some patients with tamoxifen. COX-2 inhibitors and nonsteroidal, anti-inflammatory drugs may also be beneficial in this setting.

Attenuated Familial Adenomatous Polyposis. AFAP is a recognized variant of FAP. Patients present later in life with fewer polyps (usually 10–100) predominantly located in the right colon, when compared to classic FAP. Colorectal carcinoma develops in more than 50% of these patients, but occurs later (average age, 55 years). Patients are also at risk for duodenal polyposis. However, in contrast to FAP, *APC* gene mutations are present in only about 30% of patients with AFAP. When present, these mutations are expressed in an autosomal dominant pattern.

Mutations in *MYH* also result in the AFAP phenotype but are expressed in an autosomal recessive pattern. It has been suggested that *MYH* mutations may be responsible for AFAP in patients who do not have a detectable *APC* gene mutation.⁶¹

Genetic testing is often offered to patients with suspected AFAP. When positive, genetic counseling and testing may be used to screen at-risk family members. If the family mutation is unknown, screening colonoscopy is recommended beginning at age 13 to 15 years, then every 4 years to age 28 years, and then every 3 years. These patients are often candidates for a total abdominal colectomy with ileorectal anastomosis because the limited polyposis in the rectum can usually be treated by colonoscopic snare excision.^{62,63} Prophylaxis with COX-2 inhibitors also may be appropriate. Because of the more subtle phenotype in these patients, it is important to rule out other familial syndromes such as HNPCC (Lynch's syndrome) and the more common familial colorectal cancer.

Hereditary Nonpolyposis Colon Cancer (Lynch's Syndrome). HNPCC (Lynch's syndrome) is more common than FAP, but is still extremely rare (1%–3% of all colon cancers). The genetic defects associated with HNPCC arise from errors in *mismatch repair*, the phenotypic result being MSI. HNPCC is inherited in an autosomal dominant pattern and is characterized by the development of colorectal carcinoma at an early age (average age, 40–45 years). Approximately 70% of affected individuals will develop colorectal cancer. Cancers appear in the proximal colon more often than in sporadic colorectal cancer and have a better prognosis regardless of stage. The risk of synchronous or metachronous colorectal carcinoma is 40%. HNPCC may also be associated with extracolonic malignancies, including endometrial carcinoma, which is most common, and ovarian, pancreas, stomach, small bowel, biliary, and urinary tract carcinomas. The diagnosis of HNPCC is made based on family history. The *Amsterdam criteria* for clinical diagnosis of HNPCC are three affected relatives with histologically verified adenocarcinoma of the large bowel (one must be a first-degree relative of one of the others) in two successive generations of a family with one patient diagnosed before age 50 years. The presence of other HNPCC-related carcinomas should raise the suspicion of this syndrome. In a patient with an established diagnosis of colorectal cancer, tumor testing for presence of mismatch repair gene products (immunohistochemistry) and/or MSI can sometimes serve as screening for this syndrome.^{64,65}

HNPCC results from mutations in mismatch repair genes, and like FAP, specific mutations are associated with different phenotypes. For example, mutations in *PMS2* or *MSH6* result in a more attenuated form of HNPCC when compared to mutations in other genes. *MSH6* inactivation also appears to be associated with a higher risk for endometrial cancer. Further significance of these specific mutations remains to be determined.

Screening colonoscopy is recommended annually for at-risk patients beginning at either age 20 to 25 years or 10 years younger than the youngest age at diagnosis in the family, whichever comes first.⁶⁶ Because of the high risk of endometrial carcinoma, transvaginal ultrasound or endometrial aspiration biopsy is also recommended annually after age 25 to 35 years. Because there is a 40% risk of developing a second colon cancer, total colectomy with ileorectal anastomosis is recommended once adenomas or a colon carcinoma is diagnosed. Annual proctoscopy is necessary because the risk of developing rectal cancer remains high. Similarly, prophylactic hysterectomy and bilateral

salpingo-oophorectomy should be considered in women who have completed childbearing.

Familial Colorectal Cancer. Nonsyndromic familial colorectal cancer accounts for 10% to 15% of patients with colorectal cancer. The lifetime risk of developing colorectal cancer increases with a family history of the disease. The lifetime risk of colorectal cancer in a patient with no family history of this disease (average-risk population) is approximately 6%, but rises to 12% if one first-degree relative is affected and to 35% if two first-degree relatives are affected. Age of onset also impacts risk, and a diagnosis before the age of 50 years is associated with a higher incidence in family members. Screening colonoscopy is recommended every 5 years beginning at age 40 years or beginning 10 years before the age of the earliest diagnosed patient in the pedigree. While there are no specific genetic abnormalities that are associated with familial colorectal cancer, any of the defects found in either the LOH pathway or MSI pathway may be present in these patients.

Prevention: Screening and Surveillance

Because the majority of colorectal cancers are thought to arise from adenomatous polyps, preventive measures focus on identification and removal of these premalignant lesions. In addition, many cancers are asymptomatic, and screening may detect these tumors at an early and curable stage (Table 29-1). Although screening for colorectal cancer decreases the incidence of cancer and cancer-related mortality, the optimal method of screening remains controversial. Screening guidelines are meant for *asymptomatic* patients.^{61,66-68} Any patient with a gastrointestinal complaint (bleeding, change in bowel habits, pain, etc.) requires a complete evaluation, usually by colonoscopy.

Fecal Occult Blood Testing. FOBT is known to reduce colorectal cancer mortality by 33% and metastatic disease by 50%. However, FOBT is relatively insensitive, missing up to 50% of cancers and the majority of adenomas. Its specificity is low because 90% of patients with positive tests do not have colorectal cancer. Compliance with annual testing is low and costs are significant if one includes the colonoscopy examinations done to evaluate patients with positive FOBT. Nonetheless, the direct evidence that FOBT screening is efficacious and decreases both the incidence and mortality of colorectal cancer is so strong that national guidelines recommend annual FOBT screening for asymptomatic, average-risk Americans older than 50 years of age as one of several accepted strategies. Newer immunohistochemical methods for detecting human globin may prove to be more sensitive and specific.⁶⁹ A positive FOBT test should be followed by colonoscopy.

Flexible Sigmoidoscopy. Screening by flexible sigmoidoscopy every 5 years may lead to a 60% to 70% reduction in mortality from colorectal cancer, chiefly by identifying high-risk individuals with adenomas. However, it is important to recognize that lesions in the proximal colon cannot be identified, and for this reason, flexible sigmoidoscopy has often been paired with *air-contrast barium enema* to detect transverse and right colon lesions. Patients found to have a polyp, cancer, or other lesion on flexible sigmoidoscopy will require colonoscopy.⁷⁰

Fecal Occult Blood Testing and Flexible Sigmoidoscopy. Several trials have shown that FOBT screening is least effective at detecting rectosigmoid cancers.^{69,71} This is precisely the area screened by flexible sigmoidoscopy; thus, the combination of the two tests has been suggested as a reasonable screening

Table 29-1

Advantages and disadvantages of screening modalities for asymptomatic individuals

	ADVANTAGES	DISADVANTAGES
Fecal occult blood testing	Ease of use and noninvasive Low cost Good sensitivity with repeat testing	May not detect most polyps Low specificity Colonoscopy required for positive result Poor compliance with serial testing
Sigmoidoscopy	Examines colon most at risk Very sensitive for polyp detection in left colon Does not require full bowel preparation (enemas only)	Invasive Uncomfortable Slight risk of perforation or bleeding May miss proximal lesions Colonoscopy required if polyp identified
Colonoscopy	Examines entire colon Highly sensitive and specific Therapeutic	Most invasive Uncomfortable and requires sedation Requires bowel preparation Risk of perforation or bleeding Costly
Double-contrast barium enema	Examines entire colon Good sensitivity for polyps >1 cm Examines entire colon	Requires bowel preparation Less sensitivity for polyps <1 cm May miss lesions in the sigmoid colon Colonoscopy required for positive result
Computed tomography colonography (virtual colonoscopy)	Noninvasive Sensitivity may be as good as colonoscopy	Requires bowel preparation Insensitive for small polyps Minimal experience and data Colonoscopy required for positive result

strategy. Winawer and colleagues, in a study of 12,479 subjects, showed that the combination of FOBT annually with flexible sigmoidoscopy every 5 years resulted in lower mortality from colorectal cancer and better survival in patients with colorectal cancer.⁷² Such data led to the American Cancer Society recommendations that one of the acceptable screening regimens for average-risk Americans is the combination of FOBT annually and flexible sigmoidoscopy every 5 years; this combination was preferred over either test alone. The addition of air-contrast barium enema to assess the proximal colon may improve sensitivity as well.

Colonoscopy. Colonoscopy is currently the most accurate and most complete method for examining the large bowel. This procedure is highly sensitive for detecting even small polyps (<1 cm) and allows biopsy, polypectomy, control of hemorrhage, and dilation of strictures. However, colonoscopy does require mechanical bowel preparation, and the discomfort associated with the procedure requires conscious sedation in most patients. Colonoscopy is also considerably more expensive than other screening modalities and requires a well-trained endoscopist. The risk of a major complication after colonoscopy (perforation and hemorrhage) is extremely low (0.2%–0.3%). Nevertheless, deaths have been reported.

Air-Contrast Barium Enema. Air-contrast barium enema is also highly sensitive for detecting polyps greater than 1 cm in diameter (90% sensitivity). Unfortunately, there are no studies proving its efficacy for screening large populations. Accuracy is greatest in the proximal colon but may be compromised in the sigmoid colon if there is significant diverticulosis. The major disadvantages of barium enema are the need for mechanical bowel preparation and the requirement for colonoscopy if a lesion is discovered.

Computed Tomography Colonography (Virtual Colonoscopy). Advances in imaging technology have created a number of less invasive, but highly accurate tools for screening. CT colonography makes use of helical CT technology and three-dimensional reconstruction to image the intraluminal colon. A present, patients require a mechanical bowel preparation. The colon is then insufflated with air, a spiral CT is performed, and both two-dimensional and three-dimensional images are generated. In the hands of a qualified radiologist, sensitivity appears to be as good as colonoscopy for colorectal cancers and polyps greater than 1 cm in size.⁷³ Colonoscopy is required if a lesion is identified. CT colonography is also useful for imaging the proximal colon in cases of obstruction or if a colonoscopy cannot be completed. Limitations of this technique include false-positive results from retained stool, diverticular disease, haustral folds, motion artifacts, and an inability to detect flat adenomas.

Guidelines for Screening. Current American Cancer Society guidelines advocate screening for the average-risk population (asymptomatic, no family history of colorectal carcinoma, no personal history of polyps or colorectal carcinoma, no familial syndrome) beginning at age 50 years. Recommended procedures include yearly FOBT, flexible sigmoidoscopy every 5 years, FOBT and flexible sigmoidoscopy in combination, air-contrast barium enema every 5 years, or colonoscopy every 10 years.⁶⁶ Patients with other risk factors should be screened earlier and more frequently (Table 29-2).

Routes of Spread and Natural History

Carcinoma of the colon and rectum arises in the mucosa. The tumor subsequently invades the bowel wall and eventually

adjacent tissues and other viscera. Tumors may become bulky and circumferential, leading to colon obstruction. Local extension (especially in the rectum) may occasionally cause obstruction of other organs such as the ureter.

Regional lymph node involvement is the most common form of spread of colorectal carcinoma and usually precedes distant metastasis or the development of carcinomatosis. The likelihood of nodal metastasis increases with tumor size, poorly differentiated histology, lymphovascular invasion, and depth of invasion. The T stage (depth of invasion) is the single most significant predictor of lymph node spread. Carcinoma in situ (Tis) in which there is no penetration of the muscularis mucosa (basement membrane) has also been called *high-grade dysplasia* and should carry no risk of lymph node metastasis. Small lesions confined to the bowel wall (T1 and T2) are associated with lymph node metastasis in 5% to 20% of cases, whereas larger tumors that invade through the bowel wall or into adjacent organs (T3 and T4) are likely to have lymph node metastasis in more than 50% of cases. The number of lymph nodes with metastases correlates with the presence of distant disease and inversely with survival. Four or more involved lymph nodes predict a poor prognosis. In colon cancer, lymphatic spread usually follows the major venous outflow from the involved segment of the colon. Lymphatic spread from the rectum follows two routes. In the upper rectum, drainage ascends along the superior rectal vessels to the inferior mesenteric nodes. In the lower rectum, lymphatic drainage may course along the middle rectal vessels. Nodal spread along the inferior rectal vessels to the internal iliac nodes or groin is rare unless the tumor involves the anal canal or the proximal lymphatics are blocked with tumor (Fig. 29-23).

The most common site of distant metastasis from colorectal cancer is the liver. These metastases arise from hematogenous spread via the portal venous system. Like lymph node metastasis, the risk of hepatic metastasis increases with tumor size and tumor grade. However, even small tumors may produce distant metastasis. The lung is also a site of hematogenous spread, but this rarely occurs in isolation. Carcinomatosis (diffuse peritoneal metastases) occurs by peritoneal seeding and has a dismal prognosis.

Staging and Preoperative Evaluation

Clinical Presentation. Symptoms of colon and rectal cancers are nonspecific and generally develop when the cancer is locally advanced. The classic first symptoms are a change in bowel habits and rectal bleeding. Abdominal pain, bloating, and other signs of obstruction typically occur with larger tumors and suggest more advanced disease. Because of the caliber of the bowel and the consistency of the stool, left-sided tumors are more likely to cause obstruction than are right-sided tumors. Rectal tumors may cause bleeding, tenesmus, and pain. Alternatively, patients may be asymptomatic and/or present with unexplained anemia, weight loss, or poor appetite.

Staging. Colorectal cancer staging is based on tumor depth and the presence or absence of nodal or distant metastases. Older staging systems, such as the Dukes' Classification and its Astler-Coller modification, have been replaced by the tumor-node-metastasis (TNM) staging system (Table 29-3).⁷⁴ Stage I disease includes adenocarcinomas that are invasive through the muscularis mucosa but are confined to the submucosa (T1) or the muscularis propria (T2) in the absence of nodal metastases. Stage II disease consists of tumors that invade through the

Table 29-2

Screening guidelines for colorectal cancer

POPULATION	INITIAL AGE	RECOMMENDED SCREENING TEST
Average risk	50 y	Annual FOBT or Flexible sigmoidoscopy every 5 y or Annual FOBT and flexible sigmoidoscopy every 5 y or Air-contrast barium enema every 5 y or Colonoscopy every 10 y
Adenomatous polyps	50 y	Colonoscopy at first detection; then colonoscopy in 3 y If no further polyps, colonoscopy every 5 y If polyps, colonoscopy every 3 y Annual colonoscopy for >5 adenomas
Colorectal cancer	At diagnosis	Pretreatment colonoscopy; then at 12 mo after curative resection; then colonoscopy after 3 y; then colonoscopy every 5 y, if no new lesions
Ulcerative colitis, Crohn's colitis	At diagnosis; then after 8 y for pancolitis, after 15 y for left-sided colitis	Colonoscopy with multiple biopsies every 1–2 y
FAP	10–12 y	Annual flexible sigmoidoscopy Upper endoscopy every 1–3 y after polyps appear
Attenuated FAP	20 y	Annual flexible sigmoidoscopy Upper endoscopy every 1–3 y after polyps appear
HNPCC	20–25 y	Colonoscopy every 1–2 y Endometrial aspiration biopsy every 1–2 y
Familial colorectal cancer first-degree relative	40 y or 10 y before the age of the youngest affected relative	Colonoscopy every 5 y Increase frequency if multiple family members are affected, especially before 50 y

FAP = familial adenomatous polyposis; FOBT = fecal occult blood testing; HNPCC = hereditary nonpolyposis colon cancer.
Sources: Data adapted from Smith et al,⁶ Pignone et al,⁶⁸ and Levin et al.⁶⁷

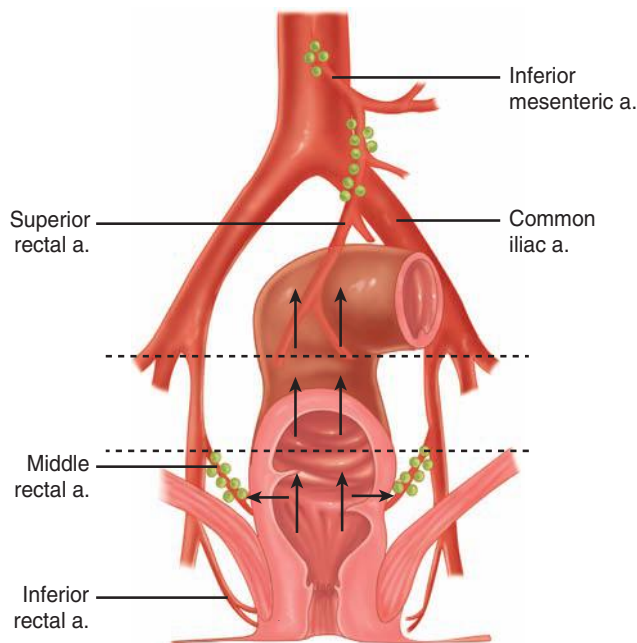


Figure 29-23. Lymphatic drainage of the rectum. a. = artery.

bowel wall into the subserosa or nonperitonealized pericolic or perirectal tissues (T3) or into other organs or tissues or through the visceral peritoneum (T4) without nodal metastases. Stage III disease includes any T stage with nodal metastases, and stage IV disease denotes distant metastases.

The preoperative evaluation usually identifies stage IV disease. In colon cancer, differentiating stages I, II, and III depends on examination of the resected specimen. In rectal cancer, endorectal ultrasound or MRI may predict the stage (ultrasound stage, uTxNx) preoperatively, but the final determination depends on pathologic examination of the resected tumor and adjacent lymph nodes (pathologic stage, pTxNx). Disease stage correlates with 5-year survival. Patients with stages I and II disease can expect excellent survival rates. The presence of nodal metastases (stage III) decreases survival (Table 29-4). The 5-year survival rate with stage IV disease is less than 16%. However, in well-selected patients, metastasectomy, especially of isolated liver or lung lesions, can result in cure. In rectal cancer, staging has been further refined, and outcomes suggest that subgroups of patients within each stage may have very different prognoses (Table 29-5). If the mesorectum around a rectal cancer is involved or threatened (only 1–2 mm of clearance), there is a very high likelihood of local recurrence and a poor

Table 29-3

TNM staging of colorectal carcinoma

	DEFINITION
Tumor stage (T)	
TX	Cannot be assessed
T0	No evidence of cancer
Tis	Carcinoma in situ
T1	Tumor invades submucosa
T2	Tumor invades muscularis propria
T3	Tumor invades through muscularis propria into subserosa or into nonperitonealized pericolic or perirectal tissues
T4	Tumor directly invades other organs or tissues or perforates the visceral peritoneum of specimen
Nodal stage (N)	
NX	Regional lymph nodes cannot be assessed
N0	No lymph node metastasis
N1	Metastasis to one to three pericolic or perirectal lymph nodes
N2	Metastasis to four or more pericolic or perirectal lymph nodes
N3	Metastasis to any lymph node along a major named vascular trunk
Distant metastasis (M)	
MX	Presence of distant metastasis cannot be assessed
M0	No distant metastasis
M1	Distant metastasis present

TNM = tumor-node-metastasis.

Source: Used with the permission of the American Joint Committee on Cancer (AJCC), Chicago, Illinois. The original source for this material is the AJCC Cancer Staging Manual, Seventh Edition (2010) published by Springer Science and Business Media LLC, www.springer.com.

Table 29-4

TNM staging of colorectal carcinoma and 5-year survival

STAGE	TNM	5-Y SURVIVAL (%)
I	T1–2, N0	93.2
IIa	T3, N0	84.7
IIb	T4, N0	72.2
IIIa	T1–2, N1	83.4
IIIb	T3, N1	64.1
IIIc	T3, N2 or T4, N1–2	44.3
IV	Tany, Nany, M1	8.1

TNM = tumor-node-metastasis.

Source: Data from O'Connell et al.⁷⁵

Table 29-5

American Joint Committee on Cancer staging

TNM	STAGE	LOCAL RECURRENT (%)	SURVIVAL (%)
T1–2 N0	I	<5	90
T3 N0	IIA	8	74
T4 N0	IIB	15	65
T1–2 N1	IIIA	6	81
T1–2 N2	IIIB	8	69
T3 N1	IIIB	11	61
T3 N2	IIIC	15	48
T4 N1–2	IIIC	19–22	36

TNM = tumor-node-metastasis.

Source: From Gunderson et al.⁷⁶ Copyright Elsevier.

prognosis. This circumferential or radial margin is probably best assessed preoperatively by MRI. Although nodal involvement is the single most important prognostic factor in colorectal carcinoma, tumor characteristics, such as degree of differentiation, mucinous or signet-ring cell histology, vascular invasion, and DNA aneuploidy, also adversely affect prognosis. Molecular profiling is currently being studied in an effort to further improve prognostic indicators.

Preoperative Evaluation. Once a colon or rectal carcinoma has been diagnosed, a staging evaluation should be undertaken. The colon must be evaluated for synchronous tumors, usually by colonoscopy. Synchronous disease will be present in up to 5% of patients. For rectal cancers, digital rectal examination and rigid or flexible proctoscopy with biopsy should be performed to assess tumor size, location, morphology, histology, and fixation. Endorectal ultrasound or MRI can be invaluable in staging rectal cancer and is used to classify the ultrasound T and N stage of rectal cancers (Fig. 29-24). A chest/abdominal/pelvic

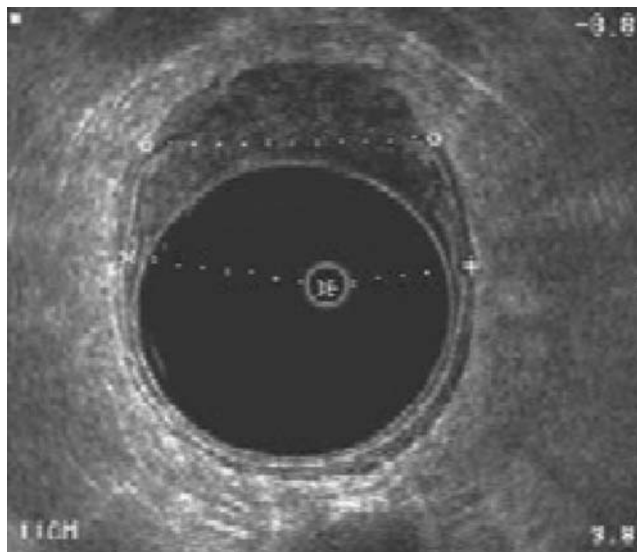


Figure 29-24. Endorectal ultrasonography showing a T3 rectal carcinoma. The dotted line is being used to measure the diameter of the lesion. (Used with permission of Charles O. Finne III, MD, Minneapolis, MN.)

CT scan should be obtained to evaluate for distant metastases. Pelvic CT scan, and sometimes MRI, can be useful in large rectal tumors and in recurrent disease to determine the extent of local invasion. Among patients with obstructive symptoms, a water-soluble contrast study (Gastrografin enema) may be useful for delineating the degree of obstruction. It is important to avoid mechanical bowel preparation (for either colonoscopy or surgery) in a patient who appears to be obstructed. PET scan may be useful in evaluating lesions seen on CT scan and in patients in whom a risky or highly morbid operation is planned (pelvic exenteration, sacrectomy). Preoperative CEA is often obtained and may be useful for postoperative follow-up.

Therapy for Colonic Carcinoma

Principles of Resection. The objective in treatment of carcinoma of the colon is to remove the primary tumor along with its lymphovascular supply. Because the lymphatics of the colon accompany the main arterial supply, the length of bowel resected depends on which vessels are supplying the segment involved with the cancer. Any adjacent organ or tissue, such as the omentum, that has been invaded should be resected en bloc with the tumor. If all of the tumor cannot be removed, a palliative procedure should be considered, although it is important to note that “debulking” is rarely effective in colorectal adenocarcinoma.

The presence of synchronous cancers or adenomas or a strong family history of colorectal neoplasms suggests that the entire colon is at risk for carcinoma (often called a *field defect*), and a subtotal or total colectomy should be considered. Metachronous tumors (a *second primary colon cancer*) identified during follow-up studies should be treated similarly. However, the surgeon must be aware of which mesenteric vessels have been ligated at the initial colectomy because that may influence the choice of procedure.

The number of lymph nodes recovered in the surgical specimen has long served as a proxy for the oncologic adequacy of resection. A number of studies previously have suggested that a minimum of 12 lymph nodes in the resected specimen are necessary for adequate staging. In addition, patients in whom more nodes are harvested have better long-term outcome.^{76,77} As such, a 12-node minimum has been suggested as an appropriate benchmark for assessing quality of care. However, several investigators recently have called this into question, noting that the number of lymph nodes examined does not correlate with staging, use of adjuvant chemotherapy, or patient survival.⁷⁰ Others have suggested that the number of negative lymph nodes and/or the lymph node ratio (positive lymph nodes to total lymph nodes) may further improve staging.⁷⁸⁻⁸⁰

If unexpected metastatic disease is encountered at the time of a laparotomy, the decision about whether to proceed with resection of the primary tumor depends on the volume of distant disease, location and size of the primary tumor, the operation required to remove the primary tumor, and the operative approach. If the metastatic disease is low volume (isolated or potentially resectable liver lesions) and the resection of the primary tumor is straightforward (segmental abdominal colectomy), it is probably reasonable to proceed with resection. On the other hand, if the metastatic disease is high volume (carcinomatosis), especially if the primary tumor is minimally symptomatic, the operation should be aborted in order to facilitate

early systemic chemotherapy. Some centers favor starting the operation with a diagnostic laparoscopy in cases where risk of discovering metastasis is high in order to minimize the magnitude of the operation should surgery be aborted. With recent advances in chemotherapy, many of these patients will never develop a complication from the primary tumor requiring surgical intervention.⁸¹

Other palliative approaches include a bypass or proximal stoma for obstructing lesions.

Stage-Specific Therapy

Stage 0 (Tis, NO, MO). Polyps containing carcinoma in situ (high-grade dysplasia) carry no risk of lymph node metastasis. However, the presence of high-grade dysplasia increases the risk of finding an invasive carcinoma within the polyp. For this reason, these polyps should be excised completely, and pathologic margins should be free of dysplasia. Most pedunculated polyps and many sessile polyps may be completely removed endoscopically. These patients should be followed with frequent colonoscopy to ensure that the polyp has not recurred and that an invasive carcinoma has not developed. In cases where the polyp cannot be removed entirely, a segmental resection is recommended.

Stage I: The Malignant Polyp (T1, NO, MO). Occasionally a polyp that was thought to be benign will be found to harbor invasive carcinoma after polypectomy. Treatment of a *malignant polyp* is based on the risk of local recurrence and the risk of lymph node metastasis.⁶⁴ The risk of lymph node metastases depends primarily on the depth of invasion. Invasive carcinoma in the head of a pedunculated polyp with no stalk involvement carries a low risk of metastasis (<1%) and may be completely resected endoscopically. However, lymphovascular invasion, poorly differentiated histology, or tumor within 1 mm of the resection margin greatly increases the risk of local recurrence and metastatic spread. Segmental colectomy is then indicated. Invasive carcinoma arising in a sessile polyp extends into the submucosa and is usually best treated with segmental colectomy (Fig. 29-25).

Stages I and II: Localized Colon Carcinoma (T1-3, NO, MO). The majority of patients with stages I and II colon cancer will be cured with surgical resection. Few patients with completely resected stage I disease will develop either local or distant recurrence, and adjuvant chemotherapy does not improve

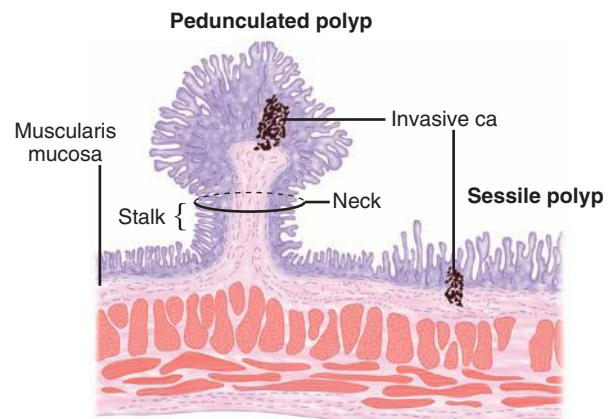


Figure 29-25. Levels of invasive carcinoma in pedunculated and sessile polyps. ca = carcinoma.

survival in these patients. However, up to 46% of patients with completely resected stage II disease will ultimately die from colon cancer. For this reason, adjuvant chemotherapy has been suggested for selected patients with stage II disease (young patients, tumors with “high-risk” histologic findings). It remains controversial as to whether chemotherapy improves survival rates in these patients. Molecular profiling holds promise for improving patient selection in these early cancers.

Stage III: Lymph Node Metastasis (Tany, N1, M0). Patients with lymph node involvement are at significant risk for both local and distant recurrence, and adjuvant chemotherapy has been recommended routinely in these patients. 5-Fluorouracil–based regimens (with leucovorin) and oxaliplatin (FOLFOX) reduce recurrences and improve survival in this patient population.⁶⁹ It is important to note, however, that a subgroup of patients with stage III disease will do well without chemotherapy. MSI status in particular predicts good prognosis. Subset analysis from the CRYSTAL trial has shown that patients with MSI-high stage III disease do not benefit from 5-fluorouracil–based chemotherapy. Molecular profiling, therefore, may be helpful in determining which stage III patients can safely avoid systemic chemotherapy.⁸²

Stage IV: Distant Metastasis (Tany, Nany, M1). Survival is extremely limited in stage IV colon carcinoma. However, unlike many other malignancies, highly selected patients with isolated, resectable metastases may benefit from resection (metastasectomy). The most common site of metastasis is the liver. Of patients with systemic disease, approximately 15% will have metastases limited to the liver. Of these, 20% are potentially resectable for cure. Survival is improved in these patients (20%–40% 5-year survival) when compared to patients who do not undergo resection. Hepatic resection of synchronous metastases from colorectal carcinoma may be performed as a combined procedure or in two stages. All patients require adjuvant chemotherapy. The second most common site of metastasis is the lung, occurring in approximately 20% of patients with colorectal carcinoma. Although very few of these patients will be potentially resectable, among those who are (about 1%–2% of all colorectal cancer patients), long-term survival benefit is approximately 30% to 40%.⁸³ There are limited reports of successful resection of metastases in other sites (ovary and retroperitoneum are most common).

The remainder of patients with stage IV disease cannot be cured surgically, and therefore, the focus of treatment should be palliation.⁸⁴ Methods such as colonic stenting for obstructing lesions of the left colon also provide good palliation. More limited surgical intervention such as a diverting stoma or bypass procedure may be appropriate in patients with stage IV disease who develop obstruction. Hemorrhage in an unresectable tumor can sometimes be controlled with angiographic embolization. External beam radiation also has been used for palliation.

Therapy for Rectal Carcinoma

Principles of Resection. The biology of rectal adenocarcinoma is thought to be identical to the biology of colonic adenocarcinoma, and the operative principles of complete resection of the primary tumor, its lymphatic bed, and any other involved organ apply to surgical resection of rectal carcinoma. However, the anatomy of the pelvis and proximity of other structures (ureters, bladder, prostate, vagina, iliac vessels, and sacrum) make resection more challenging and often require a different approach than for colonic adenocarcinoma. Moreover, it is more difficult to achieve negative radial margins in rectal cancers that

extend through the bowel wall because of the anatomic limitations of the pelvis. Therefore, local recurrence is higher than with similar stage colon cancers. However, unlike the intraperitoneal colon, the relative paucity of small bowel and other radiation-sensitive structures in the pelvis makes it easier to treat rectal tumors with radiation. Therapeutic decisions, therefore, are based on the location and depth of the tumor and its relationship to other structures in the pelvis.

Local Therapy. The distal 10 cm of the rectum are accessible transanally. For this reason, several local approaches have been proposed for treating rectal neoplasms. *Transanal excision* (full thickness or mucosal) is an excellent approach for noncircumferential, benign, villous adenomas of the rectum. *Transanal endoscopic microsurgery (TEM)* and *transanal minimally invasive surgery (TAMIS)* make use of a specially designed proctoscope, magnifying system, and instruments similar to those used in laparoscopy to allow local excision of lesions higher in the rectum (up to 15 cm). Although this technique has been used for selected T1, and some T2, carcinomas, local excision does not allow pathologic examination of the lymph nodes and might therefore understage patients. Moreover, local recurrence rates are high after transanal excision, and salvage surgery, while often curative, is associated with poorer survival than with initial radical surgery. Local excision of any rectal neoplasm should be considered an *excisional biopsy* because final pathologic examination of the specimen may reveal an invasive carcinoma that then mandates more radical therapy.

Ablative techniques, such as electrocautery or endocavitary radiation, also have been used. The disadvantage of these techniques is that no pathologic specimen is retrieved to confirm the tumor stage. Fulguration is generally reserved for extremely high-risk patients with a limited life span who cannot tolerate more radical surgery.

Radical Resection. Radical resection is preferred to local therapy for most rectal carcinomas. Radical resection involves removal of the involved segment of the rectum along with its lymphovascular supply. Although any microscopically negative margin has been suggested to be adequate, most surgeons still attempt to obtain a 2-cm distal mural margin for curative resections.

Total mesorectal excision (TME) is a technique that uses sharp dissection along anatomic planes to ensure complete resection of the rectal mesentery during low and extended low anterior resections. For upper rectal or rectosigmoid resections, a partial mesorectal excision of at least 5 cm distal to the tumor appears adequate. TME both decreases local recurrence rates and improves long-term survival rates. Moreover, this technique is associated with less blood loss and less risk to the pelvic nerves and presacral plexus than is blunt dissection. The principles of TME should be applied to all radical resections for rectal cancer.

Recurrence of rectal cancer generally has a poor prognosis. Extensive involvement of other pelvic organs (usually occurring in the setting of tumor recurrence) may require a *pelvic exenteration*. The rectal and perineal portions of this operation are similar to an APR, but en bloc resection of the ureters, bladder, and prostate or uterus and vagina are also performed. A permanent colostomy and an ileal conduit to drain the urinary tract may be necessary. The sacrum may also be resected if necessary (*sacrectomy*) up to the level of the S2–S3 junction. These operations are best performed in tertiary centers with multidisciplinary teams consisting of a colon and rectal surgeon, urologist, neurosurgeon, and plastic surgeon.

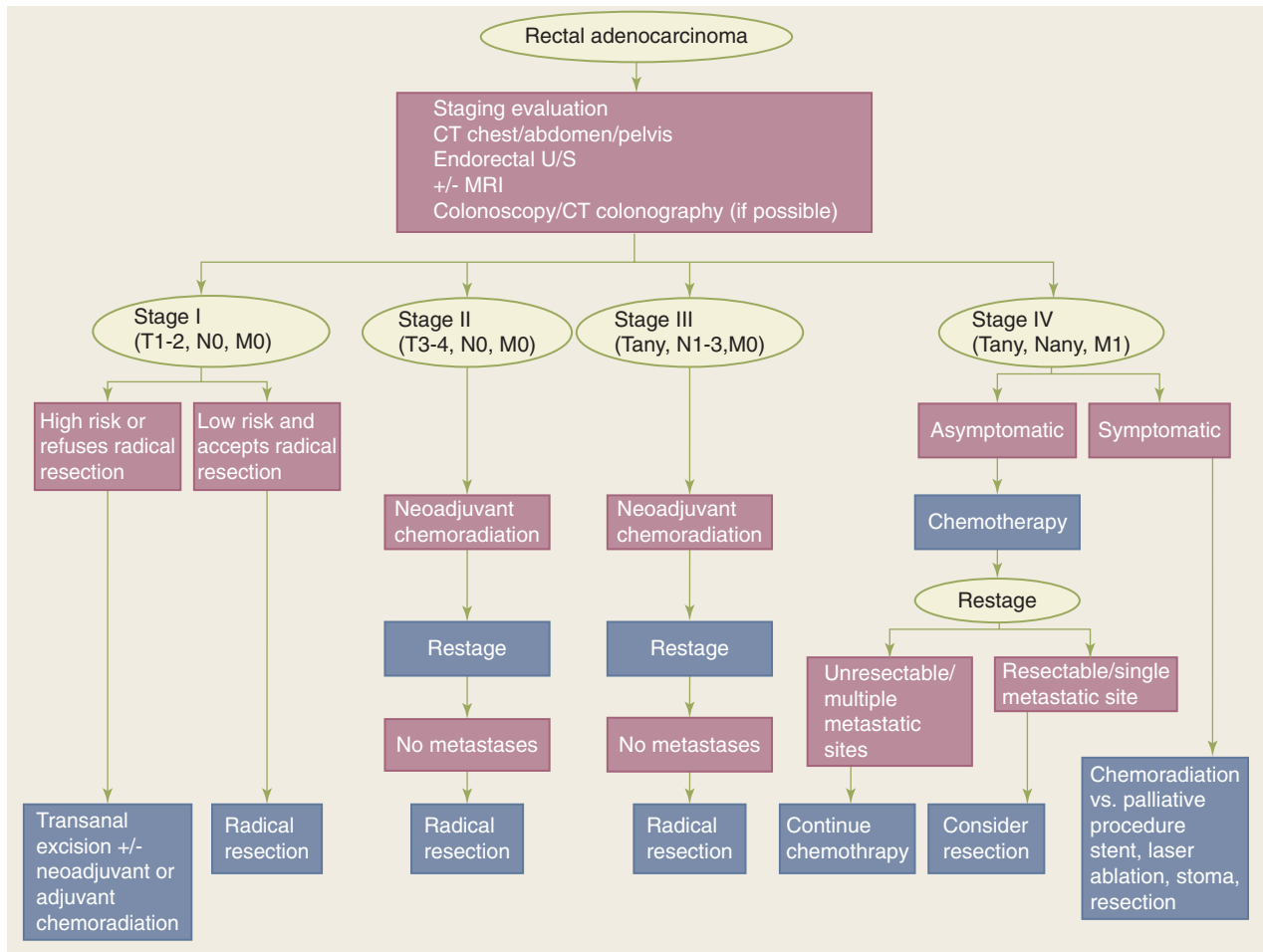


Figure 29-26. Diagnostic algorithm for rectal cancer. CT = computed tomography; MRI = magnetic resonance imaging; U/S = ultrasound.

Stage-Specific Therapy (Fig. 29-26). Pretreatment staging of rectal carcinoma often relies on endorectal ultrasound to determine the T and N status of a rectal cancer. Ultrasound is highly accurate at assessing tumor depth, but less accurate in diagnosing nodal involvement. Ultrasound evaluation can guide choice of therapy in most patients. MRI is useful to assess mesorectal involvement. When the radial margin is threatened or involved, neoadjuvant chemoradiation is recommended.

Stage 0 (Tis, N0, M0). Villous adenomas harboring carcinoma in situ (high-grade dysplasia) are ideally treated with local excision. A 1-cm margin should be obtained. Rarely, radical resection will be necessary if transanal excision is not technically possible (large circumferential lesions).

Stage I: Localized Rectal Carcinoma (T1-2, N0, M0). Although local excision has been used for small, favorable sessile uT1N0 and uT2N0 rectal cancers, local recurrence rates may be as high as 20% and 40%, respectively. For this reason, radical resection is strongly recommended in all good-risk patients. Lesions with unfavorable histologic characteristics and those located in the distal third of the rectum, in particular, are prone to recurrence. In high-risk patients and in patients who refuse radical surgery because of the risk of need for a permanent colostomy, local excision may be adequate, but strong consideration should be given to adjuvant or neoadjuvant chemoradiation to improve local control. The efficacy of adjuvant or neoadjuvant chemoradiation followed by transanal excision in patients who can

tolerate radical surgery has been controversial. Early results from ACOSOG Z6041, in which patients with T2 rectal cancers received neoadjuvant chemoradiation followed by transanal excision, showed a pathologic complete response rate of 44%. Long-term outcomes, however, are not yet known.⁸⁵

Locally Advanced Rectal Cancer (Stages II and III)

Stage II: Localized Rectal Carcinoma (T3-4, N0, M0). Larger rectal tumors, especially if located in the distal rectum, are more likely to recur locally. There are two schools of thought, each differing in their approach to control local recurrences. Advocates of total mesorectal resection suggest that optimization of operative technique will obviate the need for any adjuvant chemoradiation to control local recurrence after resection of stages I, II, and III rectal cancers. The opposing school suggests that stages II and III rectal cancers will benefit from chemoradiation. They argue that such therapy reduces local recurrences and prolongs survival whether given preoperatively or postoperatively. The advantages of preoperative chemoradiation include tumor shrinkage, increased likelihood of resection and of a sphincter-sparing procedure, tumor downstaging by treating locally involved lymph nodes, and decreased risk to the small intestine. Disadvantages include possible overtreatment of early-stage tumors, impaired wound healing, and pelvic fibrosis increasing the risk of operative complications. Postoperative radiation allows accurate pathologic staging of the resected tumor and lymph nodes and avoids the wound healing problems

associated with preoperative radiation. However, bulky tumors, tumors involving adjacent organs, and very low rectal tumors may be much more difficult to resect without preoperative radiation and may require a more extensive operation.

Stage III: Lymph Node Metastasis (Tany, N1, M0). Many surgeons now recommend chemotherapy and radiation either pre- or postoperatively for node-positive rectal cancers. The advantages and disadvantages are similar to those listed for stage II disease, except that the likelihood of overtreating an early-stage lesion is considerably less.

Over the past two decades, a wide variety of studies have addressed the issue of adjuvant and neoadjuvant therapy for locally advanced rectal cancer. Many of these studies demonstrated both improved local control and prolonged survival and resulted in the 1990 National Institutes of Health (NIH) consensus conference recommendation for postoperative chemoradiation therapy in these patients. There is little controversy regarding chemoradiation therapy for stage III (node-positive) disease. However, advances in surgical technique, such as TME, for locally advanced node-negative cancers (T3-4, N0; stage II) have improved local control with surgery alone, prompting some to abandon adjuvant chemoradiation in these patients, especially for those with cancers in the proximal rectum. Although the data from these studies are intriguing, other reports have shown that chemoradiation improves local control and survival even in patients who undergo TME. Thus, most colorectal surgeons in the United States continue to recommend adjuvant or neoadjuvant therapy for patients with locally advanced disease. Many European surgeons now rely heavily on MRI staging to determine the need for neoadjuvant chemoradiation. They use neoadjuvant chemoradiation if the radial margin is threatened or involved by the cancer or if anal sphincter or other local organ invasion is present. In the United States, chemoradiation therapy is still recommended for all patients with stage III disease and the majority of patients with stage II disease. In select patients with T3 tumors, favorable histology, and negative radial margins, chemoradiation may not be necessary, but larger prospective studies are required before this approach can be recommended.

Appropriate timing of chemoradiation for locally advanced rectal cancer has been debated. Historically, preoperative chemoradiation has been advocated based on tumor shrinkage/downstaging, improved resectability, and the possibility of performing a sphincter-sparing operation in some patients. In addition, the absence of small bowel adhesions in the pelvis may decrease toxicity. However, preoperative radiation therapy may increase operative complications and impairs wound healing. Although preoperative endorectal ultrasound and MRI have improved our ability to stage rectal cancer, clinical “overstaging” can be problematic, and neoadjuvant therapy may therefore overtreat patients with pT1-2, N0 tumors. Advocates of postoperative radiation therapy cite more accurate pathologic staging and fewer operative/postoperative complications. However, large, bulky tumors may be unresectable or require a more extensive operation (APR, pelvic exenteration) without preoperative therapy. In addition, postoperative pelvic radiation may compromise function of the neorectum.

Comparisons of perioperative toxicity and oncologic outcome have been addressed by the German CAO/ARO/AIO-94 trial. In this study, pre- and postoperative chemoradiation were associated with equivalent acute toxicity and equivalent postoperative complication rates. Postoperative chemoradiation,

however, doubled the risk of postoperative stricture formation. In addition, preoperative chemoradiation halved the risk of local recurrence (6% vs. 12%). Based on these data, most surgeons consider preoperative chemoradiation to be the most appropriate therapy for locally advanced rectal cancer.⁸⁶

Stage IV: Distant Metastasis (Tany, Nany, M1). Like stage IV colon carcinoma, survival is limited in patients with distant metastasis from rectal carcinoma. Isolated hepatic and/or pulmonary metastases are rare, but when present may be resected for cure in selected patients.⁸³ Some patients will require palliative procedures. Radical resection may be required to control pain, bleeding, or tenesmus, but highly morbid procedures such as pelvic exenteration and sacrectomy should generally be avoided in this setting. Local therapy using cautery, endocavitary radiation, or laser ablation may be adequate to control bleeding or prevent obstruction. Intraluminal stents may be useful in the uppermost rectum but often cause pain and tenesmus lower in the rectum. Occasionally, a proximal diverting colostomy will be required to alleviate obstruction. A mucus fistula should be created if possible to vent the distal colon. It is critical that the morbidity of any procedure be realistically weighed against potential benefit in these patients with limited life expectancy. The assistance of a palliative care team can be invaluable in this setting.⁸⁴

Follow-Up and Surveillance

Patients who have been treated for one colorectal cancer are at risk for the development of recurrent disease (either locally or systemically) or metachronous disease (a second primary tumor). In theory, metachronous cancers should be preventable by using surveillance colonoscopy to detect and remove polyps before they progress to invasive cancer. For most patients, a colonoscopy should be performed within 12 months after the diagnosis of the original cancer (or sooner if the colon was not examined in its entirety prior to the original resection). If that study is normal, colonoscopy should be repeated every 3 to 5 years thereafter.

The optimal method of following patients for recurrent cancer remains controversial. The goal of close follow-up observation is to *detect resectable recurrence* and to *improve survival*. Re-resection of local recurrence and resection of distant metastasis to liver, lung, or other sites are often technically challenging and highly morbid, with only a limited chance of achieving long-term survival. Thus, only selected patients who would tolerate such an approach should be followed intensively. Because most recurrences occur within 2 years of the original diagnosis, surveillance focuses on this time period. Patients who have undergone local resection of rectal tumors probably also should be followed with frequent endoscopic examinations (every 3–6 months for 3 years, then every 6 months for 2 years). CEA is often followed every 3 to 6 months for 2 years. CT scans are often performed annually for 5 years, but there are few data to support this practice. More intensive surveillance is appropriate in high-risk patients such as those with possible HNPCC syndrome or T3, N+ cancers. Although intensive surveillance improves detection of resectable recurrences, it is important to note that a survival benefit has never been proven. Therefore, the risks and benefits of intensive surveillance must be weighed and treatment individualized.

Treatment of Recurrent Colorectal Carcinoma

Between 20% and 40% of patients who have undergone curative intent surgery for colorectal carcinoma will eventually

develop recurrent disease. Most recurrences occur within the first 2 years after the initial diagnosis, but preoperative chemoradiation therapy may delay recurrence. While most of these patients will present with distant metastases, a small proportion will have isolated local recurrence and may be considered for *salvage surgery*. Recurrence after colon cancer resection usually occurs at the local site within the abdomen or in the liver or lungs. Resection of other involved organs may be necessary. Recurrence of rectal cancer can be considerably more difficult to manage because of the proximity of other pelvic structures. If the patient has not received chemotherapy and radiation, then adjuvant therapy should be administered prior to salvage surgery. Radical resection may require extensive resection of pelvic organs (pelvic exenteration with or without sacrectomy). Ideally, the aim of a salvage operation should be to resect all of the tumor with negative margins. However, if the ability to achieve a negative margin is in question, the addition of intraoperative radiation therapy (usually brachytherapy) can help improve local control. Pelvic MRI is useful for identifying tumor extension that would prevent successful resection (extension of tumor into the pelvic sidewall, involvement of the iliac vessels or bilateral sacral nerves, sacral invasion above the S2-S3 junction). Patients should also undergo a thorough preoperative evaluation to identify distant metastases (CT of chest, abdomen, and pelvis, and PET scan) before undergoing such an extensive procedure. Nevertheless, radical salvage surgery can prolong survival in selected patients.

Minimally Invasive Techniques For Resection

Laparoscopic colectomy for cancer has been controversial. Early reports of high port site recurrence dampened enthusiasm for this technique.⁸⁷ The ability to perform an adequate oncologic resection for cancer has also been questioned. Several trials have laid to rest many of these fears. The Clinical 6► Outcomes of Surgical Therapy Study Group (COST), the Colon Carcinoma Laparoscopic or Open Resection (COLOR) trial, and the United Kingdom Medical Research Council Conventional versus Laparoscopic-Assisted Surgery in Colorectal Cancer (CLASSICC) trial all have shown oncologic equivalence between open and laparoscopic techniques. In these multi-institutional studies, the rates of cancer recurrence, survival, and quality of life were similar, suggesting that, in the hands of an appropriately trained surgeon, laparoscopic colectomy is appropriate for cancer.⁸⁸⁻⁹⁰ The recent introduction of robotic surgery offers an additional minimally invasive approach. Early studies suggest that robotic surgery may be the oncologic equivalent to laparoscopic surgery for colorectal cancer. A prospective, randomized, multicenter trial, Robotic versus Laparoscopic Resection for Rectal Cancer (ROLARR) is under way in hopes of answering this question.⁹¹

OTHER NEOPLASMS

Rare Colorectal Tumors

Carcinoid Tumors. Carcinoid tumors occur most commonly in the gastrointestinal tract, and up to 25% of these tumors are found in the rectum. Most small rectal carcinoids are benign, and overall survival is greater than 80%. However, the risk of malignancy increases with size, and more than 60% of tumors greater than 2 cm in diameter are associated with distant metastases. Rectal carcinoids appear to be less likely to secrete vasoactive substances than carcinoids in other locations, and carcinoid

syndrome is uncommon in the absence of hepatic metastases. Small carcinoids can be locally resected transanally. Larger tumors or tumors with obvious invasion into the muscularis require more radical surgery. Carcinoid tumors in the proximal colon are less common and are more likely to be malignant. Size also correlates with risk of malignancy, and tumors less than 2 cm in diameter rarely metastasize. However, the majority of carcinoid tumors in the proximal colon present as bulky lesions, and up to two thirds of patients will have metastatic spread at the time of diagnosis. These tumors should usually be treated with radical resection. Because carcinoid tumors are typically slow growing, patients with distant metastases may expect reasonably long survival. Symptoms of carcinoid syndrome can often be alleviated with somatostatin analogues (octreotide) and/or interferon- α . Tumor debulking can offer effective palliation in selected patients.

Carcinoid Carcinomas. Composite carcinoid carcinomas (adenocarcinoids) have histologic features of both carcinoid tumors and adenocarcinomas. The natural history of these tumors more closely parallels that of adenocarcinomas than carcinoid tumors, and regional and systemic metastases are common. Carcinoid carcinoma of the colon and rectum should be treated according to the same oncologic principles as followed for management of adenocarcinoma.

Lipomas. Lipomas occur most commonly in the submucosa of the colon and rectum. They are benign lesions, but rarely may cause bleeding, obstruction, or intussusception, especially when greater than 2 cm in diameter. Small asymptomatic lesions do not require resection. Larger lipomas should be resected by colonoscopic techniques or by a colotomy and enucleation or limited colectomy.

Lymphoma. Lymphoma involving the colon and rectum is rare but accounts for about 10% of all gastrointestinal lymphomas. The cecum is most often involved, probably as a result of spread from the terminal ileum. Symptoms include bleeding and obstruction, and these tumors may be clinically indistinguishable from adenocarcinomas. Bowel resection is the treatment of choice for isolated colorectal lymphoma. Adjuvant therapy may be given based on the stage of disease.

Leiomyoma and Leiomyosarcoma. Leiomyomas are benign tumors of the smooth muscle of the bowel wall and occur most commonly in the upper gastrointestinal tract. Most patients are asymptomatic, but large lesions can cause bleeding or obstruction. Because it is difficult to differentiate a benign leiomyoma from a malignant leiomyosarcoma, these lesions should be resected. Recurrence is common after local resection, but most small leiomyomas can be adequately treated with limited resection. Lesions larger than 5 cm should be treated with radical resection because the risk of malignancy is high.

Leiomyosarcoma is rare in the gastrointestinal tract. When this malignancy occurs in the large intestine, the rectum is the most common site. Symptoms include bleeding and obstruction. A radical resection is indicated for these tumors.

Gastrointestinal Stromal Tumor. These rare tumors occur most commonly in the stomach and small intestine, but 5% to 10% arise in the colon or rectum. They are often mistaken for leiomyomas. Thirty percent to 50% are malignant; thus all lesions should be resected.

Retrorectal/Presacral Tumors

Tumors occurring in the retrorectal space are rare. This region lies between the upper two thirds of the rectum and the sacrum above the rectosacral fascia. It is bound by the rectum anteriorly, the presacral fascia posteriorly, and the endopelvic fascia laterally (lateral ligaments). The retrorectal space contains multiple embryologic remnants derived from a variety of tissues (neuroectoderm, notochord, and hindgut). Tumors that develop in this space are often heterogeneous.

Congenital lesions are most common, comprising almost two thirds of retrorectal lesions. The remainder are classified as neurogenic, osseous, inflammatory, or miscellaneous lesions. Malignancy is more common in the pediatric population than in adults, and solid lesions are more likely to be malignant than are cystic lesions. Inflammatory lesions may be solid or cystic (abscess) and usually represent extensions of infection either in the perirectal space or in the abdomen.

Developmental cysts constitute the majority of congenital lesions and may arise from all three germ cell layers. Dermoid and epidermoid cysts are benign lesions that arise from the ectoderm. Enterogenous cysts arise from the primitive gut. Anterior meningocele and myelomeningocele arise from herniation of the dural sac through a defect in the anterior sacrum. A “scimitar sign” (sacrum with a rounded, concave border without any bony destruction) is the pathognomonic radiographic appearance of this condition.

Solid lesions include teratomas, chordomas, neurologic tumors, or osseous lesions. Teratomas are true neoplasms and contain tissue from each germ cell layer. They often contain both cystic and solid components. Teratomas are more common in children than in adults, but when found in adults, 30% are malignant. Chordomas arise from the notochord and are the most common malignant tumor in this region. These are slow-growing, invasive cancers that show characteristic bony destruction. Neurogenic tumors include neurofibromas and sarcomas, neurilemmomas, ependymomas, and ganglioneuromas. Osseous lesions include osteomas and bone cysts, as well as neoplasms such as osteogenic sarcoma, Ewing’s tumor, chondromyxosarcoma, and giant cell tumors.

Patients may present with pain (lower back, pelvic, or lower extremity), gastrointestinal symptoms, or urinary tract symptoms. Most lesions are palpable on digital rectal examination. While plain X-rays and CT scans often are used to evaluate these lesions, pelvic MRI is the most sensitive and specific imaging study. Myelogram is occasionally necessary if there is central nervous system involvement. Treatment is almost always surgical resection. The approach depends in part on the nature of the lesion and its location. Lesions high in the pelvis may be approached via a transabdominal route, whereas low lesions may be resected transsacrally. Intermediate lesions may require a combined abdominal and sacral operation. Although survival is excellent after resection of benign lesions, local recurrence is not uncommon. Prognosis after resection of malignant lesions is highly variable and reflects the biology of the underlying tumor.

The role of biopsy in this setting has been controversial. Historically, the recommendation was to *avoid* biopsy because of the risk of infection or needle tract seeding. This recommendation has recently been challenged, especially for large and/or unusual tumors that would be better treated with multimodality neoadjuvant therapy (sarcomas, for example). A recent study confirmed the utility of needle biopsy of solid lesions and refuted concerns about needle tract seeding.⁹² As such, most

solid lesions should be biopsied regardless of resectability. Biopsy of cystic lesions, especially meningoceles, should still be avoided because of the risk of infection.

Anal Canal and Perianal Tumors

Cancers of the anal canal are uncommon and account for approximately 2% of all colorectal malignancies. Neoplasms of the anal canal have traditionally been divided into those affecting the *anal margin* (distal to the dentate line) and those affecting the *anal canal* (proximal to the dentate line) based on lymphatic drainage patterns. Lymphatics from the anal canal proximal to the dentate line drain cephalad via the superior rectal lymphatics to the inferior mesenteric nodes and laterally along both the middle rectal vessels and inferior rectal vessels through the ischiorectal fossa to the internal iliac nodes. Lymph from the anal canal distal to the dentate line usually drains to the inguinal nodes. It can also drain to the superior rectal lymph nodes or along the inferior rectal lymphatics to the ischiorectal fossa if primary drainage routes are blocked with tumor (Fig. 29-27).

A more clinically useful classification divides anal lesions into those that are *perianal* (can be completely visualized with gentle eversion of the buttocks) and those that are *intra-anal* (cannot be completely visualized with gentle eversion of the buttocks). In many cases, therapy depends on whether the tumor is perianal or intra-anal.

Squamous Intraepithelial Lesions. Anal canal and perianal dysplasia have long had a potpourri of nomenclature. Anal intraepithelial neoplasia (AIN), Bowen’s disease, and carcinoma in situ all refer to human papillomavirus (HPV)–induced dysplasia. Because these entities are pathologically identical, there has been a recent effort to standardize nomenclature. *High-grade squamous intraepithelial lesions (HSIL)* include high- and intermediate-grade dysplasia, AIN2 and AIN3, Bowen’s

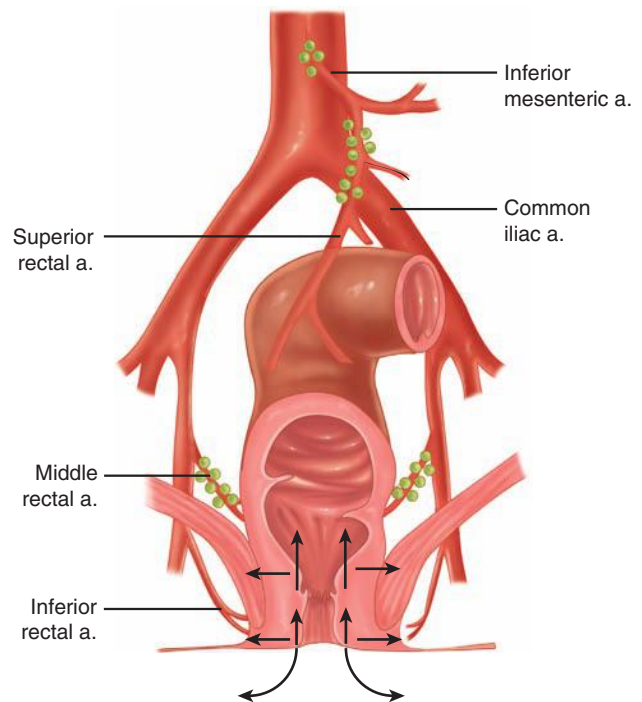


Figure 29-27. Lymphatic drainage of the anal canal. a. = artery.

disease, and carcinoma in situ. *Low-grade squamous intraepithelial lesions (LSIL)* include low-grade dysplasia and AIN1.⁹³

HSIL is a precursor to an invasive squamous cell carcinoma (epidermoid carcinoma). HSIL may appear as a plaque-like lesion or may only be apparent with high-resolution anoscopy and application of acetic acid or Lugol's iodine solution. Both HSIL and LSIL are associated with infection with HPV, especially types 16 and 18. The incidence of both squamous intraepithelial lesions and epidermoid carcinoma of the anus has increased dramatically among human immunodeficiency virus (HIV)-positive, homosexual men. This increase is thought to result from increased rates of HPV infection along with HIV-induced immunosuppression. Treatment of HSIL is *ablation*. Because of a high recurrence and/or reinfection rate, these patients require extremely close surveillance. High-risk patients should be followed with frequent anal Papanicolaou (Pap) smears every 3 to 6 months. An abnormal Pap smear should be followed by an examination under anesthesia and anal mapping using high-resolution anoscopy. High-resolution anoscopy shows areas with abnormal telangiectasias that are consistent with high-grade dysplasia (HSIL). Many centers now consider this technique for repeated ablation of HSIL to be the optimal method for following these patients. It should be noted, however, that the practice has not been universally adopted, and it is unclear whether close surveillance in lower risk (nonimmunosuppressed) patients is necessary. Rarely, extensive disease may require resection with flap closure. Medical therapy for HPV has also been proposed. Topical immunomodulators such as imiquimod (Aldara) have been shown to induce regression in some series.⁹⁴ Topical 5-fluorouracil has also been used in this setting. Finally, the introduction of a vaccine against HPV may help decrease the incidence of this disease in the future.

Epidermoid Carcinoma. Epidermoid carcinoma of the anus includes squamous cell carcinoma, cloacogenic carcinoma, transitional carcinoma, and basaloid carcinoma. The clinical behavior and natural history of these tumors are similar. Epidermoid carcinoma is a slow-growing tumor and usually presents as an intra-anal or perianal mass. Pain and bleeding may be present. Perianal epidermoid carcinoma may be treated in a similar fashion as squamous cell carcinoma of the skin in other locations because wide local excision can usually be achieved without resecting the anal sphincter. Intra-anal epidermoid carcinoma cannot be excised locally, and first-line therapy relies on chemotherapy and radiation (the *Nigro protocol*: 5-fluorouracil, 7▶ mitomycin C, and 30 Gy of external beam radiation). More than 80% of these tumors can be cured by using this regimen. Recurrence usually requires radical resection (APR). Metastasis to inguinal lymph nodes is a poor prognostic sign.

Verrucous Carcinoma (Buschke-Lowenstein Tumor, Giant Condyloma Acuminata). Verrucous carcinoma is a locally aggressive form of condyloma acuminata. Although these lesions do not metastasize, they can cause extensive local tissue destruction and may be grossly indistinguishable from epidermoid carcinoma. Wide local excision is the treatment of choice when possible, but radical resection may sometimes be required. Very large lesions may respond to external beam radiation, but resection is almost always required.

Basal Cell Carcinoma. Basal cell carcinoma of the anus is rare and resembles basal cell carcinoma elsewhere on the skin (raised, pearly edges with central ulceration). This is a slow-growing tumor that rarely metastasizes. Wide local excision

is the treatment of choice, but recurrence occurs in up to 30% of patients. Radical resection and/or radiation therapy may be required for large lesions.

Adenocarcinoma. Adenocarcinoma of the anus is extremely rare and usually represents downward spread of a low rectal adenocarcinoma. Adenocarcinoma may occasionally arise from the anal glands or may develop in a chronic fistula. Radical resection with or without adjuvant chemoradiation is usually required.

Extramammary perianal *Paget's disease* is *adenocarcinoma in situ* arising from the apocrine glands of the perianal area. The lesion is typically plaque-like and may be indistinguishable from HSIL. Characteristic *Paget's cells* are seen histologically. These tumors are often associated with a synchronous gastrointestinal adenocarcinoma, so a complete evaluation of the intestinal tract should be performed. Wide local excision is usually adequate treatment for perianal Paget's disease.

Melanoma. Anorectal melanoma is rare, comprising less than 1% of all anorectal malignancies and 1% to 2% of melanomas. Despite many advances in the treatment of melanoma, prognosis for patients with anorectal disease remains poor. Overall 5-year survival is less than 10%, and many patients present with systemic metastasis and/or deeply invasive tumors at the time of diagnosis. A few patients with anorectal melanoma, however, present with isolated local or locoregional disease that is potentially resectable for cure, and both radical resection (APR) and wide local excision have been advocated. Recurrence is common and usually occurs systemically regardless of the initial surgical procedure. Local resection with free margins does not increase the risk of local or regional recurrence, and APR offers no survival advantage over local excision. Because of the morbidity associated with APR, wide local excision is recommended for initial treatment of localized anal melanoma. In some patients, wide local excision may not be technically feasible, and APR may be required if the tumor involves a significant portion of the anal sphincter or is circumferential. The addition of adjuvant chemotherapy, biochemotherapy, vaccines, or radiotherapy may be of benefit in some patients, but efficacy remains unproven.⁹⁵

OTHER BENIGN COLORECTAL CONDITIONS

Rectal Prolapse and Solitary Rectal Ulcer Syndrome

Rectal Prolapse. Rectal prolapse refers to a circumferential, full-thickness protrusion of the rectum through the anus and has also been called "first-degree" prolapse, "complete" prolapse, or procidentia. Internal prolapse occurs when the rectal wall intussuscepts but does not protrude and is probably more accurately described as internal intussusception. Mucosal prolapse is a partial-thickness protrusion often associated with hemorrhoidal disease and is usually treated with banding or hemorrhoidectomy.

In adults, this condition is far more common among women, with a female-to-male ratio of 6:1. Prolapse becomes more prevalent with age in women and peaks in the seventh 8▶ decade of life. In men, prevalence is unrelated to age. Symptoms include tenesmus, a sensation of tissue protruding from the anus that may or may not spontaneously reduce, and a sensation of incomplete evacuation. Mucus discharge and leakage may accompany the protrusion. Patients also present with a myriad of functional complaints, from incontinence and diarrhea to constipation and outlet obstruction.

A thorough preoperative evaluation, including colonic transit studies, anorectal manometry, tests of pudendal nerve terminal motor latency, EMG, and cinedefecography, may be useful. The colon should be evaluated by colonoscopy, air-contrast barium enema, or CT colonography to exclude neoplasms or diverticular disease. Cardiopulmonary condition should be thoroughly evaluated because comorbidities may influence the choice of surgical procedure.

The primary therapy for rectal prolapse is surgery, and more than 100 different procedures have been described to treat this condition. Operations can be categorized as either *abdominal* or *perineal*. Abdominal operations have taken three major approaches: (a) reduction of the perineal hernia and closure of the cul-de-sac (*Moschowitz repair*); (b) fixation of the rectum, either with a prosthetic sling (*Ripstein* and *Wells rectopexy*) or by *suture rectopexy*; or (c) resection of redundant sigmoid colon (Fig. 29-28). In some cases, resection is combined with rectal fixation (*resection rectopexy*). Abdominal rectopexy with or without resection also is increasingly performed laparoscopically or robotically. Perineal approaches have focused on tightening the anus with a variety of prosthetic materials, reefing the rectal mucosa (*Delorme procedure*), or resecting the prolapsed bowel from the perineum (*perineal rectosigmoidectomy* or *Altemeier procedure*) (Fig. 29-29).

Because rectal prolapse occurs most commonly in elderly women, the choice of operation depends in part on the patient's overall medical condition. Abdominal rectopexy (with or without sigmoid resection) offers the most durable repair, with recurrence occurring in less than 10% of patients. Perineal rectosigmoidectomy avoids an abdominal operation and may be preferable in high-risk patients but is associated with a higher recurrence rate. Reefing the rectal mucosa is effective for patients with limited prolapse. Anal encirclement procedures generally have been abandoned.

Solitary Rectal Ulcer Syndrome. Solitary rectal ulcer syndrome and colitis cystica profunda are commonly associated with internal intussusception. Patients may complain of pain, bleeding, mucus discharge, or outlet obstruction. In solitary rectal ulcer syndrome, one or more ulcers are present in the distal rectum, usually on the anterior wall. In colitis cystica profunda, nodules or a mass may be found in a similar location. Evaluation should include anorectal manometry, defecography, and either colonoscopy or barium enema to exclude other diagnoses. Biopsy of an ulcer or mass is mandatory to exclude malignancy or infection due to cytomegalovirus (CMV) in an immunosuppressed patient. Nonoperative therapy (high-fiber diet, defecation training to avoid straining, and laxatives or enemas)

is effective in the majority of patients. Biofeedback has also been reported to be effective in some patients. Surgery (either abdominal or perineal repair of prolapse as described earlier) is reserved for highly symptomatic patients who have failed all medical interventions.⁷²

Volvulus

Volvulus occurs when an air-filled segment of the colon twists about its mesentery. The sigmoid colon is involved in up to 90% of cases, but volvulus can involve the cecum (<20%) or transverse colon. A volvulus may reduce spontaneously, but more commonly produces bowel obstruction, which can progress to strangulation, gangrene, and perforation. Chronic constipation may produce a large, redundant colon (*chronic megacolon*) that predisposes to volvulus, especially if the mesenteric base is narrow.

The symptoms of volvulus are those of acute bowel obstruction. Patients present with abdominal distention, nausea, and vomiting. Symptoms rapidly progress to generalized abdominal pain and tenderness. Fever and leukocytosis are heralds of gangrene and/or perforation. Occasionally, patients will report a long history of intermittent obstructive symptoms and distention, suggesting intermittent chronic volvulus.

Sigmoid Volvulus. Sigmoid volvulus can often be differentiated from cecal or transverse colon volvulus by the appearance of plain X-rays of the abdomen. Sigmoid volvulus produces a characteristic *bent inner tube* or *coffee bean* appearance, with the convexity of the loop lying in the right upper quadrant (opposite the site of obstruction). Gastrografin enema shows a narrowing at the site of the volvulus and a pathognomonic *bird's beak* (Fig. 29-30).

Unless there are obvious signs of gangrene or peritonitis, the initial management of sigmoid volvulus is resuscitation followed by endoscopic detorsion. Detorsion is usually most easily accomplished by using a rigid proctoscope, but a flexible sigmoidoscope or colonoscope may also be effective. A rectal tube may be inserted to maintain decompression. Although these techniques are successful in reducing sigmoid volvulus in the majority of patients, the risk of recurrence is high (up to 40%). For this reason, an elective sigmoid colectomy should be performed after the patient has been stabilized and undergone an adequate bowel preparation.

Clinical evidence of gangrene or perforation mandates immediate surgical exploration without an attempt at endoscopic decompression. Similarly, the presence of necrotic mucosa, ulceration, or dark blood noted on endoscopy examination suggests strangulation and is an indication for operation.

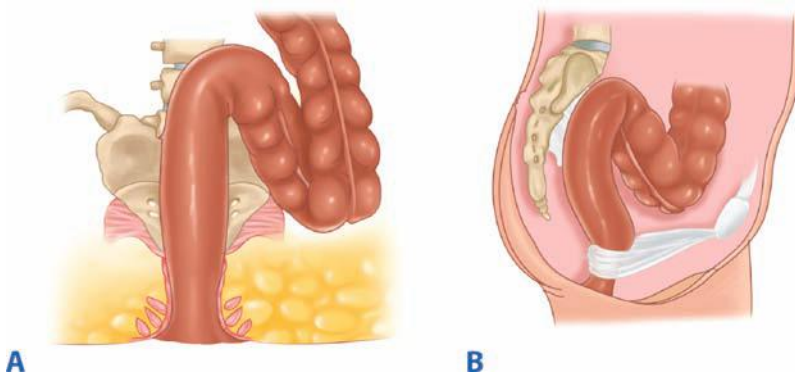


Figure 29-28. Transabdominal proctopexy for rectal prolapse. The fully mobilized rectum is sutured to the presacral fascia. **A.** Anterior view. **B.** Lateral view. If desired, a sigmoid colectomy can be performed concomitantly to resect the redundant colon.

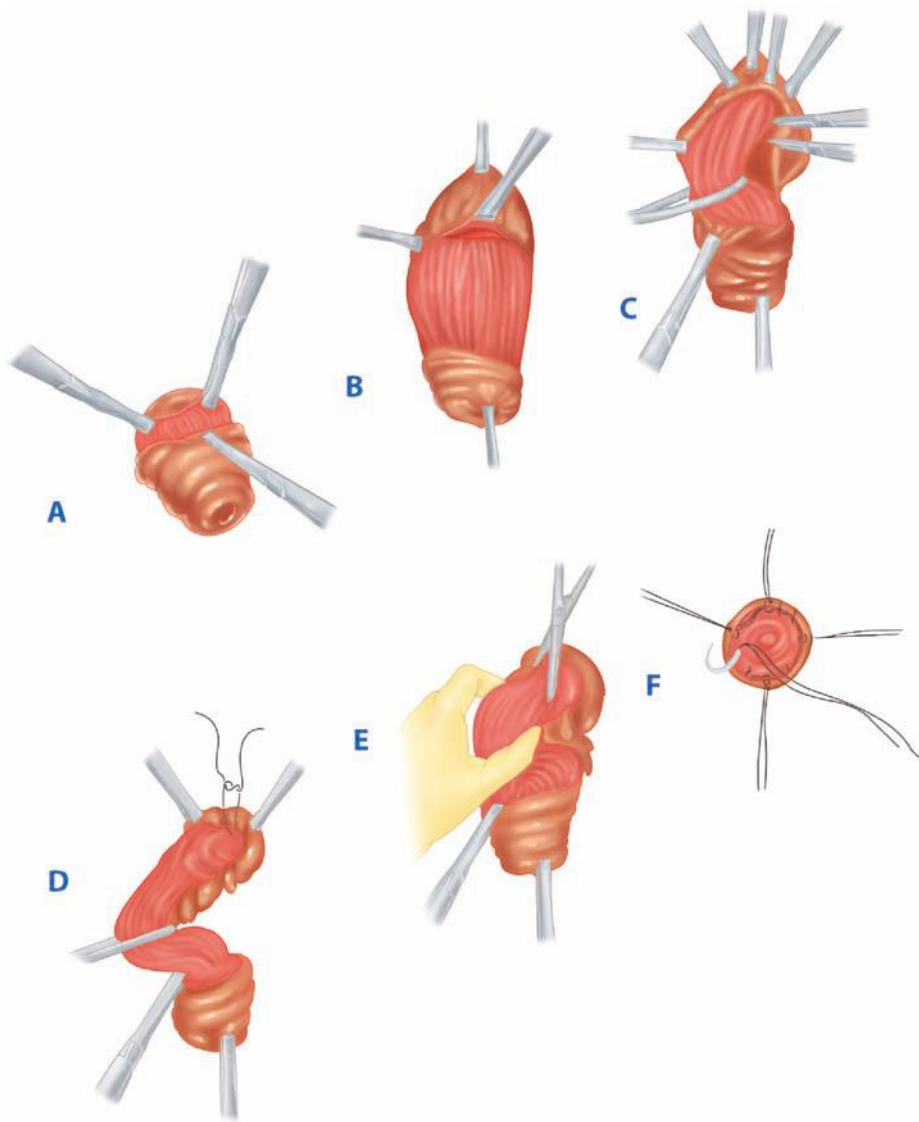


Figure 29-29. Perineal rectosigmoidectomy shown in lithotomy position. **A.** A circular incision is made 2 cm proximal to the dentate line. **B.** The anterior peritoneal reflection is opened. **C.** The mesentery is divided and ligated. **D.** The peritoneum may be sutured to the bowel wall. **E.** The bowel is resected. **F.** A hand-sewn anastomosis is performed.

If dead bowel is present at laparotomy, a sigmoid colectomy with end colostomy (Hartmann's procedure) may be the safest operation to perform.

Cecal Volvulus. Cecal volvulus results from nonfixation of the right colon. In the majority of cases, rotation occurs around the ileocolic blood vessels and vascular impairment occurs early, although 10% to 30% of the cecum folds upon itself (cecal bascule). Plain X-rays of the abdomen show a characteristic kidney-shaped, air-filled structure in the left upper quadrant (opposite the site of obstruction), and a Gastrografin enema confirms obstruction at the level of the volvulus.

Unlike sigmoid volvulus, cecal volvulus can almost never be detorsed endoscopically. Moreover, because vascular compromise occurs early in the course of cecal volvulus, surgical exploration is necessary when the diagnosis is made. Right hemicolectomy with a primary ileocolic anastomosis can usually be performed safely and prevents recurrence. Simple detorsion or detorsion and cecopexy are associated with a high rate of recurrence.

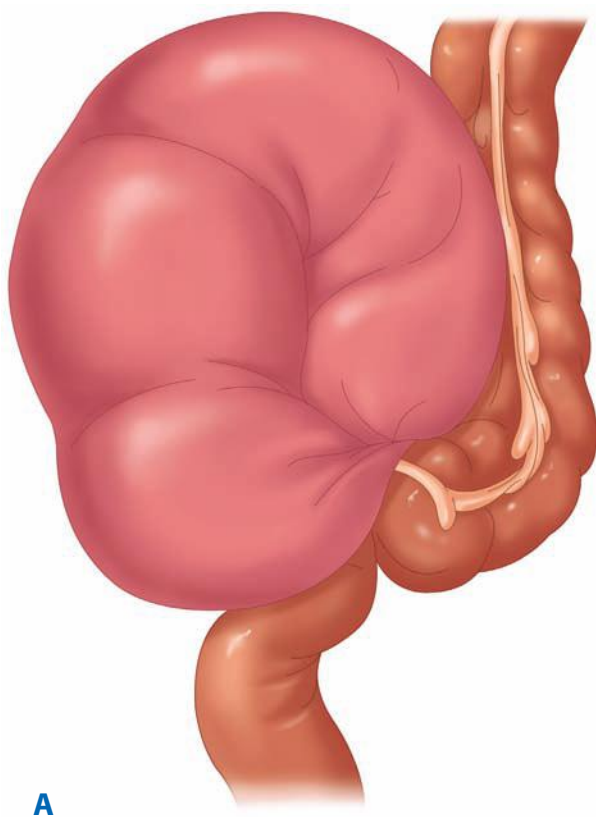
Transverse Colon Volvulus. Transverse colon volvulus is extremely rare. Nonfixation of the colon and chronic constipation with megacolon may predispose to transverse colon volvulus.

The radiographic appearance of transverse colon volvulus resembles sigmoid volvulus, but Gastrografin enema will reveal a more proximal obstruction. Although colonoscopic detorsion is occasionally successful in this setting, most patients require emergent exploration and resection.

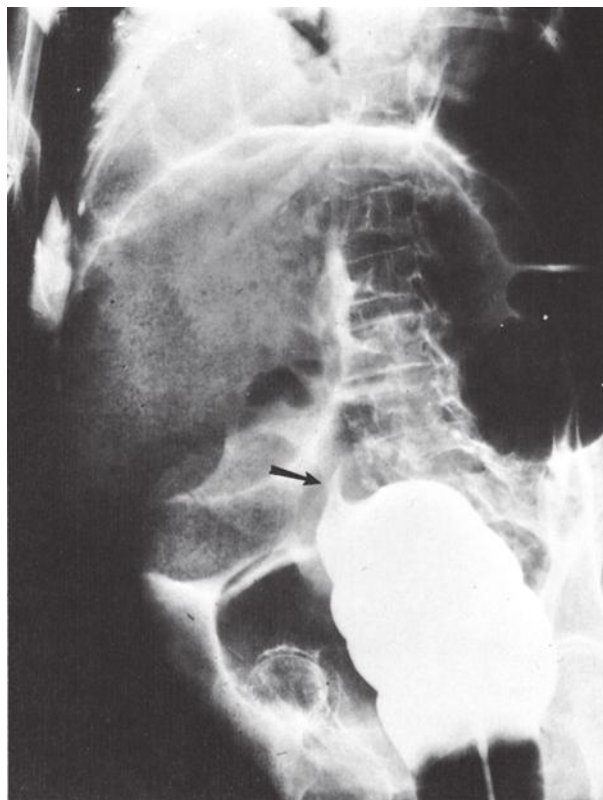
Megacolon

Megacolon describes a chronically dilated, elongated, hypertrophied large bowel. Megacolon may be congenital or acquired and is usually related to chronic mechanical or functional obstruction. In general, the degree of megacolon is related to the duration of obstruction. Evaluation must always include examination of the colon and rectum (either endoscopically or radiographically) to exclude a surgically correctable mechanical obstruction.

Congenital megacolon caused by Hirschsprung's disease results from the failure of migration of neural crest cells to the distal large intestine. The resulting absence of ganglion cells in the distal colon results in a failure of relaxation and causes a functional obstruction. The proximal, healthy bowel becomes progressively dilated. Surgical resection of the aganglionic segment is curative. Although Hirschsprung's disease primarily is a disease of infants and children, it occasionally presents



A



B

Figure 29-30. Sigmoid volvulus: (A) Illustration and (B) Gastrografin enema showing “bird-beak” sign (arrow). (B: Reproduced with permission from Nivatvongs S, Becker ER. *Colon, rectum, and anal canal*. In: James EC, Corry RJ, Perry JCF Jr, eds. *Basic Surgical Practice*. Philadelphia: Hanley & Belfus; 1987. Copyright Elsevier.)

later in adulthood, especially if an extremely short segment of the bowel is affected (*ultrashort-segment Hirschsprung’s disease*).

Acquired megacolon may result from infection or chronic constipation. Infection with the protozoan *Trypanosoma cruzi* (*Chagas’ disease*) destroys ganglion cells and produces both megacolon and megaesophagus. Chronic constipation from slow transit or secondary to medications (especially anticholinergic medications) or neurologic disorders (paraplegia, poliomyelitis, amyotrophic lateral sclerosis, multiple sclerosis) may produce progressive colonic dilatation. Diverting ileostomy or subtotal colectomy with an ileorectal anastomosis is occasionally necessary in these patients.

Colonic Pseudo-obstruction (Ogilvie’s Syndrome)

Colonic pseudo-obstruction (Ogilvie’s syndrome) is a functional disorder in which the colon becomes massively dilated in the absence of mechanical obstruction. Pseudo-obstruction most commonly occurs in hospitalized patients and is associated with the use of narcotics, bed rest, and comorbid disease. Pseudo-obstruction is thought to result from autonomic dysfunction and severe adynamic ileus. The diagnosis is made based on the presence of massive dilatation of the colon (usually predominantly the *right* and *transverse* colon) in the absence of a mechanical obstruction. Initial treatment consists of cessation of narcotics, anticholinergics, or other medications that may contribute to ileus. Strict bowel rest and intravenous hydration are crucial.

Most patients will respond to these measures. In patients who fail to improve, colonoscopic decompression often is effective. However, this procedure is technically challenging, and great care must be taken to avoid causing perforation. Up to 40% of patients recur. Intravenous neostigmine (an acetylcholinesterase inhibitor) also is extremely effective in decompressing the dilated colon and is associated with a low rate of recurrence (20%). However, neostigmine may produce transient but profound bradycardia and may be inappropriate in patients with cardiopulmonary disease. Because the colonic dilatation is typically greatest in the proximal colon, placement of a rectal tube is rarely effective. It is crucial to exclude mechanical obstruction (usually with a Gastrografin enema) prior to medical or endoscopic treatment.

Ischemic Colitis

Intestinal ischemia occurs most commonly in the colon. Unlike small bowel ischemia, colonic ischemia rarely is associated with major arterial or venous occlusion. Instead, most colonic ischemia appears to result from low flow and/or small vessel occlusion. Risk factors include vascular disease, diabetes mellitus, vasculitis, hypotension, and tobacco use. In addition, ligation of the inferior mesenteric artery during aortic surgery predisposes to colonic ischemia. Occasionally, thrombosis or embolism may cause ischemia. Although the splenic flexure is the most common site of ischemic colitis, any segment of the colon may be affected. The rectum is relatively spared because of its rich collateral circulation.

Signs and symptoms of ischemic colitis reflect the extent of bowel ischemia. In mild cases, patients may have diarrhea (usually bloody) without abdominal pain. With more severe ischemia, intense abdominal pain (often out of proportion to the clinical examination), tenderness, fever, and leukocytosis are present. Peritonitis and/or systemic toxicity are signs of full-thickness necrosis and perforation.

The diagnosis of ischemic colitis is often based on the clinical history and physical examination. Plain films may reveal *thumb printing*, which results from mucosal edema and submucosal hemorrhage. CT often shows nonspecific colonic wall thickening and pericolic fat stranding. Angiography is usually not helpful because major arterial occlusion is rare. While sigmoidoscopy may reveal characteristic dark, hemorrhagic mucosa, the risk of precipitating perforation is high. For this reason, *sigmoidoscopy is relatively contraindicated* in any patient with significant abdominal tenderness. Contrast studies (Gastrografin or barium enema) are similarly contraindicated during the acute phase of ischemic colitis.

Treatment of ischemic colitis depends on clinical severity. Unlike ischemia of the small bowel, the majority of patients with ischemic colitis can be treated medically. Bowel rest and broad-spectrum antibiotics are the mainstay of therapy, and 80% of patients will recover with this regimen. Hemodynamic parameters should be optimized, especially if hypotension and low flow appear to be the inciting cause. Long-term sequelae include stricture (10%–15%) and chronic segmental ischemia (15%–20%). Colonoscopy should be performed after recovery to evaluate strictures and to rule out other diagnoses such as inflammatory bowel disease or malignancy. Failure to improve after 2 to 3 days of medical management, progression of symptoms, and deterioration in clinical condition are indications for surgical exploration. In this setting, all necrotic bowel should be resected. Primary anastomosis should be avoided. Occasionally, repeated exploration (a *second-look operation*) may be necessary.

Infectious Colitis

Pseudomembranous Colitis (*Clostridium difficile* Colitis). *Pseudomembranous colitis* is caused by *C. difficile*, a gram-positive anaerobic bacillus. *C. difficile colitis* is extremely common and is the leading cause of nosocomially acquired diarrhea.^{6,88} The spectrum of disease ranges from watery diarrhea to fulminant, life-threatening colitis. *C. difficile* is carried in the large intestine of many healthy adults. Colitis is thought to result from overgrowth of this organism after depletion of the normal commensal flora of the gut with the use of antibiotics. Although clindamycin was the first antimicrobial agent associated with *C. difficile* colitis, almost any antibiotic may cause this disease. Moreover, although the risk of *C. difficile* colitis increases with prolonged antibiotic use, even a single dose of an antibiotic may cause the disease. Immunosuppression, medical comorbidities, prolonged hospitalization or nursing home residence, and bowel surgery increase the risk.

The pathogenic changes associated with *C. difficile* colitis result from production of two toxins: *toxin A* (an enterotoxin) and *toxin B* (a cytotoxin). Diagnosis of this disease was traditionally made by culturing the organism from the stool. Detection of one or both toxins (either by cytotoxic assays or by immunoassays) has proven to be more rapid, sensitive, and specific. The diagnosis may also be made endoscopically by detection of characteristic ulcers, plaques, and pseudomembranes.

Management should include immediate cessation of the offending antimicrobial agent. Patients with mild disease (diarrhea but no fever or abdominal pain) may be treated as outpatients with a 10-day course of oral metronidazole. Oral vancomycin is a second-line agent used in patients allergic to metronidazole or in patients with recurrent disease. More severe diarrhea associated with dehydration and/or fever and abdominal pain is best treated with bowel rest, intravenous hydration, and oral metronidazole or vancomycin. Proctosigmoiditis may respond to vancomycin enemas. Recurrent colitis occurs in up to 20% of patients and may be treated by a longer course of oral metronidazole or vancomycin (up to 1 month) or rifaximin (a rapamycin derivative). Reintroduction of normal flora by ingestion of *probiotics* or *stool transplantation* has been suggested as a possible treatment for recurrent or refractory disease. Fulminant colitis, characterized by septicemia and/or evidence of perforation, requires emergent laparotomy. A total abdominal colectomy with end ileostomy may be lifesaving. Over the past decade, *C. difficile* colitis has increased in prevalence, and new, more virulent strains have appeared, making this disease increasingly challenging to treat.⁹⁶

Other Infectious Colitides. A variety of other infections with bacteria, parasites, fungi, or viruses may cause colonic inflammation. Common bacterial infections include enterotoxigenic *E. coli*, *Campylobacter jejuni*, *Yersinia enterocolitica*, *Salmonella typhi*, *Shigella*, and *N. gonorrhoeae*. Less commonly, *Mycobacterium tuberculosis*, *Mycobacterium bovis*, *Actinomyces israelii*, or *Treponema pallidum* (syphilis) may cause colitis or proctitis. Parasitic infections such as amebiasis, cryptosporidiosis, and giardiasis are also relatively common. Fungal infections (*Candida* species, histoplasmosis) are extremely rare in otherwise healthy individuals. The most common viral infections that produce colitic symptoms are HIV, herpes simplex viruses, and CMV.

Most symptoms are nonspecific and consist of diarrhea (with or without bleeding), crampy abdominal pain, and malaise. A thorough history may offer clues to the etiology (other medical conditions, especially immunosuppression; recent travel or exposures; and ingestions). Diagnosis is usually made by identification of a pathogen in the stool, either by microscopy or culture. Serum immunoassays may also be useful (amebiasis, HIV, CMV). Occasionally, endoscopy with biopsy may be required. Treatment is tailored to the infection.

ANORECTAL DISEASES

Any patient with anal/perianal symptoms requires a careful history and physical, including a digital rectal examination. Other studies such as defecography, manometry, CT scan, MRI, contrast enema, endoscopy, endoanal ultrasound, or exam under anesthesia may be required to arrive at an accurate diagnosis.

Hemorrhoids

Hemorrhoids are cushions of submucosal tissue containing venules, arterioles, and smooth muscle fibers that are located in the anal canal (see Fig. 29-4). Three hemorrhoidal cushions are found in the left lateral, right anterior, and right posterior positions. Hemorrhoids are thought to function as part of the continence mechanism and aid in complete closure of the anal canal at rest. Because hemorrhoids are a normal part of anorectal anatomy, treatment is only indicated if they become symptomatic. Excessive straining, increased abdominal

pressure, and hard stools increase venous engorgement of the hemorrhoidal plexus and cause prolapse of hemorrhoidal tissue. Bleeding, thrombosis, and symptomatic hemorrhoidal prolapse may result.

External hemorrhoids are located distal to the dentate line and are covered with anoderm. Because the anoderm is richly innervated, thrombosis of an external hemorrhoid may cause significant pain. It is for this reason that external hemorrhoids should not be ligated or excised without adequate local anesthetic. A *skin tag* is redundant fibrotic skin at the anal verge, often persisting as the residua of a thrombosed external hemorrhoid. Skin tags are often confused with symptomatic hemorrhoids. External hemorrhoids and skin tags may cause itching and difficulty with hygiene if they are large. Treatment of external hemorrhoids and skin tags is only indicated for symptomatic relief.

Internal hemorrhoids are located proximal to the dentate line and covered by insensate anorectal mucosa. Internal hemorrhoids may prolapse or bleed, but rarely become painful unless they develop thrombosis and necrosis (usually related to severe prolapse, incarceration, and/or strangulation). Internal hemorrhoids are graded according to the extent of prolapse. *First-degree hemorrhoids* bulge into the anal canal and may prolapse beyond the dentate line on straining. *Second-degree hemorrhoids* prolapse through the anus but reduce spontaneously. *Third-degree hemorrhoids* prolapse through the anal canal and require manual reduction. *Fourth-degree hemorrhoids* prolapse but cannot be reduced and are at risk for strangulation.

Combined internal and external hemorrhoids straddle the dentate line and have characteristics of both internal and external hemorrhoids. Hemorrhoidectomy is often required for large, symptomatic, combined hemorrhoids. *Postpartum hemorrhoids* result from straining during labor, which results in edema, thrombosis, and/or strangulation. Hemorrhoidectomy is often the treatment of choice, especially if the patient has had chronic hemorrhoidal symptoms. *Portal hypertension* was long thought to increase the risk of hemorrhoidal bleeding because of the anastomoses between the portal venous system (middle and upper hemorrhoidal plexuses) and the systemic venous system (inferior rectal plexuses). It is now understood that hemorrhoidal disease is no more common in patients with portal hypertension than in the normal population. *Rectal varices*, however, may occur and may cause hemorrhage in these patients. In general, rectal varices are best treated by lowering portal venous pressure. Rarely, suture ligation may be necessary if massive bleeding persists. Surgical hemorrhoidectomy should be avoided in these patients because of the risk of massive, difficult-to-control variceal bleeding.

Treatment

Medical Therapy. Bleeding from first- and second-degree hemorrhoids often improves with the addition of dietary fiber, stool softeners, increased fluid intake, and avoidance of straining. Associated pruritus often may improve with improved hygiene. Many over-the-counter topical medications are desiccants and are relatively ineffective for treating hemorrhoidal symptoms.

Rubber Band Ligation. Persistent bleeding from first-, second-, and selected third-degree hemorrhoids may be treated by rubber band ligation.

Mucosa located 1 to 2 cm proximal to the dentate line is grasped and pulled into a rubber band applicator. After firing

the ligator, the rubber band strangulates the underlying tissue, causing scarring and preventing further bleeding or prolapse (Fig. 29-31). In general, only one or two quadrants are banded per visit. Severe pain will occur if the rubber band is placed at or distal to the dentate line where sensory nerves are located. Other complications of rubber band ligation include *urinary retention*, *infection*, and *bleeding*. Urinary retention occurs in approximately 1% of patients and is more likely if the ligation has inadvertently included a portion of the internal sphincter. *Necrotizing infection* is an uncommon, but life-threatening complication. Severe pain, fever, and urinary retention are early signs of infection and should prompt immediate evaluation of the patient usually with an exam under anesthesia. Treatment includes débridement of necrotic tissue, drainage of associated abscesses, and broad-spectrum antibiotics. *Bleeding* may occur approximately 7 to 10 days after rubber band ligation, at the time when the ligated pedicle necroses and sloughs. Bleeding is usually self-limited, but persistent hemorrhage may require exam under anesthesia and suture ligation of the pedicle.

Infrared Photocoagulation. Infrared photocoagulation is an effective office treatment for small first- and second-degree hemorrhoids. The instrument is applied to the apex of each hemorrhoid to coagulate the underlying plexus. All three quadrants may be treated during the same visit. Larger hemorrhoids and hemorrhoids with a significant amount of prolapse are not effectively treated with this technique.

Sclerotherapy. The injection of bleeding internal hemorrhoids with sclerosing agents is another effective office technique for treatment of first-, second-, and some third-degree hemorrhoids. One to 3 mL of a sclerosing solution (phenol in olive oil, sodium morrhuate, or quinine urea) is injected into the submucosa of each hemorrhoid. Few complications are associated with sclerotherapy, but infection and fibrosis have been reported.

Excision of Thrombosed External Hemorrhoids. Acutely thrombosed external hemorrhoids generally cause intense pain and a palpable perianal mass during the first 24 to 72 hours after thrombosis. The thrombosis can be effectively treated with an elliptical excision performed in the office under local anesthesia. Because the clot is usually loculated, simple incision and drainage is rarely effective. After 72 hours, the clot begins to resorb, and the pain resolves spontaneously. Excision is unnecessary, but sitz baths and analgesics are often helpful.

Operative Hemorrhoidectomy. A number of surgical procedures have been described for elective resection of symptomatic hemorrhoids. All are based on decreasing blood flow to the hemorrhoidal plexuses and excising redundant anoderm and mucosa.

Closed Submucosal Hemorrhoidectomy. The Parks or Ferguson hemorrhoidectomy involves resection of hemorrhoidal tissue and closure of the wounds with absorbable suture. The procedure may be performed in the prone or lithotomy position under local, regional, or general anesthesia. The anal canal is examined and an anal speculum inserted. The hemorrhoid cushions and associated redundant mucosa are identified and excised using an elliptical incision starting just distal to the anal verge and extending proximally to the anorectal ring. It is crucial to identify the fibers of the internal sphincter and carefully brush these away from the dissection in order to avoid injury to the sphincter. The apex of the hemorrhoidal plexus is then ligated and the hemorrhoid excised. The wound is then closed with a running absorbable suture. All three hemorrhoidal cushions may

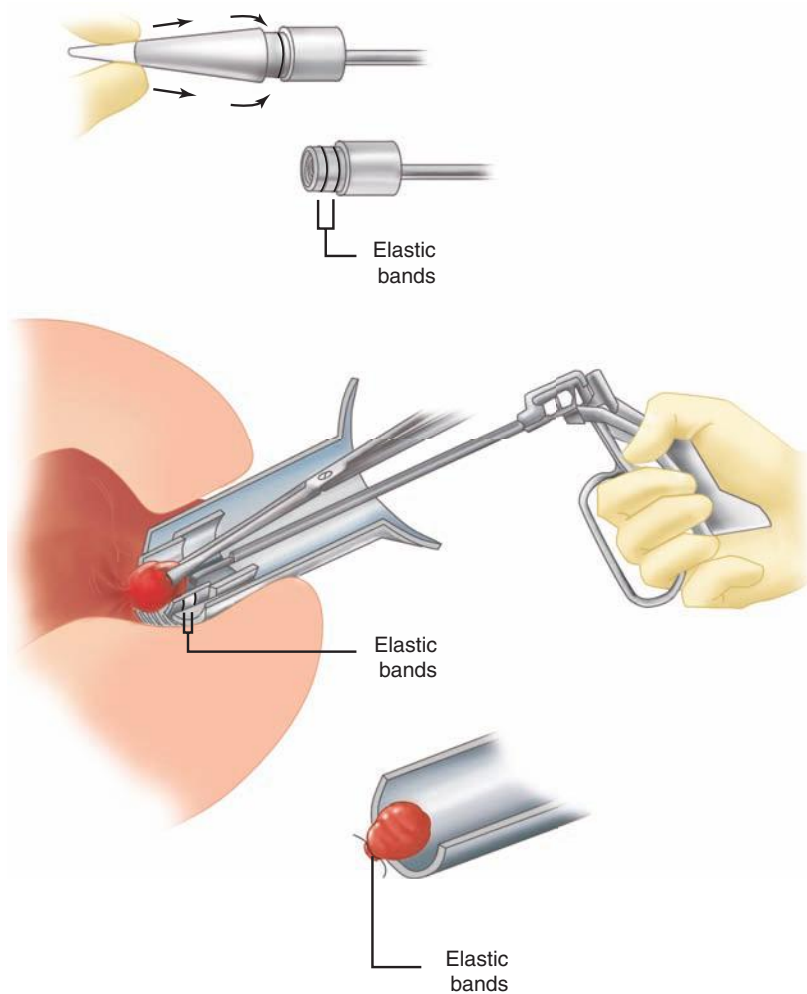


Figure 29-31. Rubber band ligation of internal hemorrhoids. The mucosa just proximal to the internal hemorrhoids is banded.

be removed using this technique; however, care should be taken to avoid resecting a large area of perianal skin in order to avoid postoperative anal stenosis (Fig. 29-32).

Open Hemorrhoidectomy. This technique, often called the Milligan and Morgan hemorrhoidectomy, follows the same principles of excision described earlier, but the wounds are left open and allowed to heal by secondary intention.

Whitehead's Hemorrhoidectomy. Whitehead's hemorrhoidectomy involves circumferential excision of the hemorrhoidal cushions just proximal to the dentate line. After excision, the rectal mucosa is then advanced and sutured to the dentate line. While some surgeons still use Whitehead's hemorrhoidectomy, most have abandoned this approach because of the risk of ectropion (*Whitehead's deformity*).

Procedure for Prolapse and Hemorrhoids/Stapled Hemorrhoidectomy. Procedure for prolapse and hemorrhoids (PPH) has been proposed as an alternative surgical approach. The term PPH has largely replaced stapled hemorrhoidectomy because the procedure does not involve excision of hemorrhoidal tissue, but instead pexes the redundant mucosa above the dentate line. PPH removes a short circumferential segment of rectal mucosa proximal to the dentate line using a circular stapler. This effectively ligates the venules feeding the hemorrhoidal plexus and fixes redundant mucosa higher in the anal canal. Several studies suggest that this procedure is safe and effective, is associated with less postoperative pain and disability, and has an equivalent

risk of postoperative complications when compared to traditional hemorrhoidectomy.^{97,98} Nevertheless, with increased use of this technique, serious and occasionally life-threatening complications have been described.⁹⁹

Doppler-Guided Hemorrhoidal Artery Ligation. Another recent approach to treating symptomatic hemorrhoids is Doppler-guided hemorrhoidal artery ligation (also called transanal hemorrhoidal dearterialization). In this procedure, a Doppler probe is used to identify the artery or arteries feeding the hemorrhoidal plexus. These vessels are then ligated. Early reports have shown promise, but long-term durability remains to be determined.¹⁰⁰

Complications of Hemorrhoidectomy. Postoperative pain following excisional hemorrhoidectomy requires analgesia usually with oral narcotics. Nonsteroidal anti-inflammatory drugs, muscle relaxants, topical analgesics, and comfort measures, including sitz baths, are often useful as well. Urinary retention is a common complication following hemorrhoidectomy and occurs in 10% to 50% of patients. The risk of urinary retention can be minimized by limiting intraoperative and perioperative intravenous fluids and by providing adequate analgesia. Pain can also lead to *fecal impaction*. Risk of impaction may be decreased by preoperative enemas or a limited mechanical bowel preparation, liberal use of laxatives postoperatively, and adequate pain control. While a small amount of *bleeding*, especially with bowel movements, is to be expected, massive hemorrhage can occur after hemorrhoidectomy. Bleeding may occur

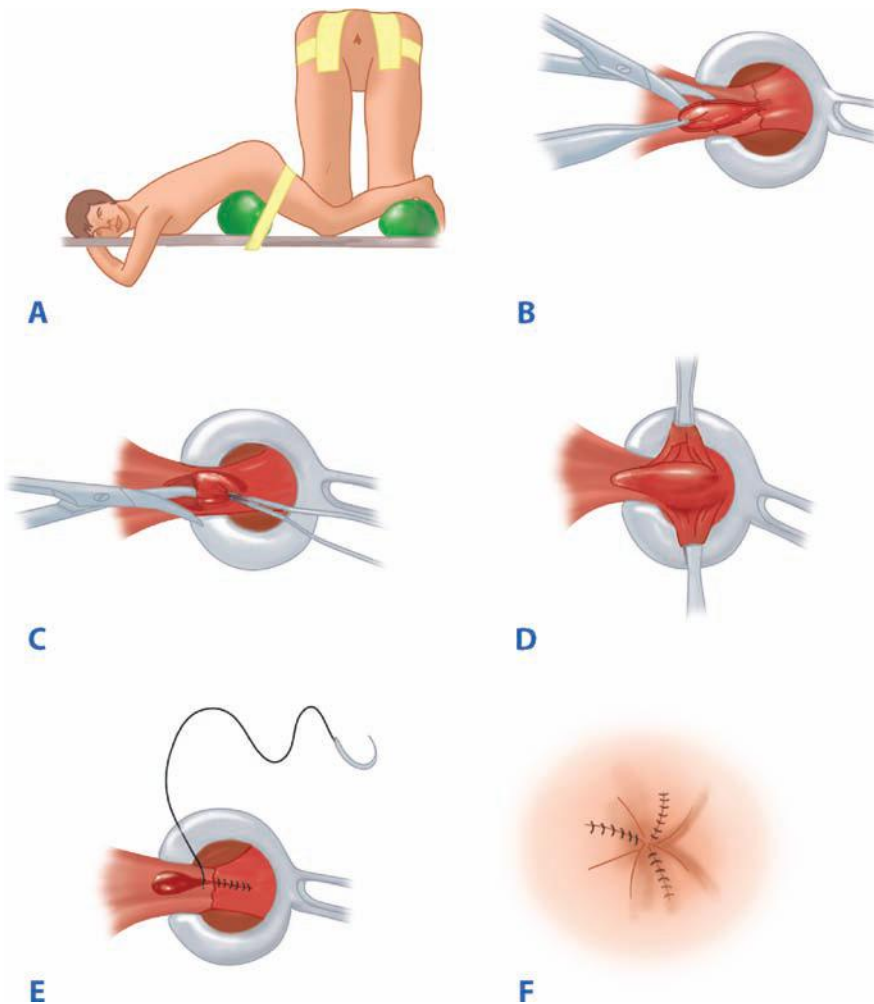


Figure 29-32. Technique of closed submucosal hemorrhoidectomy. **A.** The patient is in prone jackknife position. **B.** A Fansler anoscope is used for exposure. **C.** A narrow ellipse of anoderm is excised. **D.** A submucosal dissection of the hemorrhoidal plexus from the underlying anal sphincter is performed. **E.** Redundant mucosa is anchored to the proximal anal canal, and the wound is closed with a running absorbable suture. **F.** Additional quadrants are excised to complete the procedure.

in the immediate postoperative period (often in the recovery room) as a result of inadequate ligation of the vascular pedicle. This type of hemorrhage mandates an urgent return to the operating room where suture ligation of the bleeding vessel will often solve the problem. Bleeding may also occur 7 to 10 days after hemorrhoidectomy when the necrotic mucosa overlying the vascular pedicle sloughs. While some of these patients may be safely observed, others will require an exam under anesthesia to ligate the bleeding vessel or to oversee the wounds if no specific site of bleeding is identified. *Infection* is uncommon after hemorrhoidectomy; however, necrotizing soft tissue infection can occur with devastating consequences. Severe pain, fever, and urinary retention may be early signs of infection. If infection is suspected, emergent examination under anesthesia, drainage of abscess, and/or débridement of all necrotic tissue are required.

Long-term sequelae of hemorrhoidectomy include *incontinence*, *anal stenosis*, and *ectropion* (*Whitehead's deformity*). Many patients experience transient incontinence to flatus, but these symptoms are usually short-lived, and few patients have permanent fecal incontinence. Anal stenosis may result from scarring after extensive resection of perianal skin. Ectropion may occur after Whitehead's hemorrhoidectomy.

Anal Fissure

A fissure in ano is a tear in the anoderm distal to the dentate line. The pathophysiology of anal fissure is thought to be related

to trauma from either the passage of hard stool or prolonged diarrhea. A tear in the anoderm causes spasm of the internal anal sphincter, which results in pain, increased tearing, and decreased blood supply to the anoderm. This cycle of pain, spasm, and ischemia contributes to development of a poorly healing wound that becomes a *chronic fissure*. The vast majority of anal fissures occur in the posterior midline. Ten percent to 15% occur in the anterior midline. Less than 1% of fissures occur off midline.

Symptoms and Findings. Anal fissure is extremely common. Characteristic symptoms include tearing pain with defecation and hemochezia (usually described as blood on the toilet paper). Patients may also complain of a sensation of intense and painful anal spasm lasting for several hours after a bowel movement. On physical examination, the fissure can often be seen in the anoderm by gently separating the buttocks. Patients are often too tender to tolerate digital rectal examination, anoscopy, or proctoscopy. An *acute fissure* is a superficial tear of the distal anoderm and almost always heals with medical management. *Chronic fissures* develop ulceration and heaped-up edges with the white fibers of the internal anal sphincter visible at the base of the ulcer. There often is an associated external skin tag and/or a hypertrophied anal papilla internally. These fissures are more challenging to treat and may require surgery. A lateral location of a chronic anal fissure may be evidence of an underlying disease such as Crohn's disease, HIV, syphilis, tuberculosis,

or leukemia. If the diagnosis is in doubt or there is suspicion of another cause for the perianal pain such as abscess or fistula, an examination under anesthesia may be necessary.

Treatment. Therapy focuses on breaking the cycle of pain, spasm, and ischemia thought to be responsible for development of fissure in ano. First-line therapy to minimize anal trauma includes bulk agents, stool softeners, and warm sitz baths. The addition of 2% lidocaine jelly or other analgesic creams can provide additional symptomatic relief. Nitroglycerin ointment has been used locally to improve blood flow but often causes severe headaches. Both oral and topical calcium channel blockers (diltiazem and nifedipine) have also been used to heal fissures and may have fewer side effects than topical nitrates.⁹⁷ Newer agents, such as arginine (a nitric oxide donor) and topical bethanechol (a muscarinic agonist), have also been used to treat fissures. Medical therapy is effective in most acute fissures, but will heal only approximately 50% of chronic fissures.

Botulinum toxin (Botox) causes temporary muscle paralysis by preventing acetylcholine release from presynaptic nerve terminals. Injection of botulinum toxin is used in some centers as an alternative to surgical sphincterotomy for chronic fissure. Although there are few long-term complications from the use of botulinum toxin, healing appears to be equivalent to other medical therapies.^{98,101}

Surgical therapy has traditionally been recommended for chronic fissures that have failed medical therapy, and lateral internal sphincterotomy is the procedure of choice. The aim of this procedure is to decrease spasm of the internal sphincter by

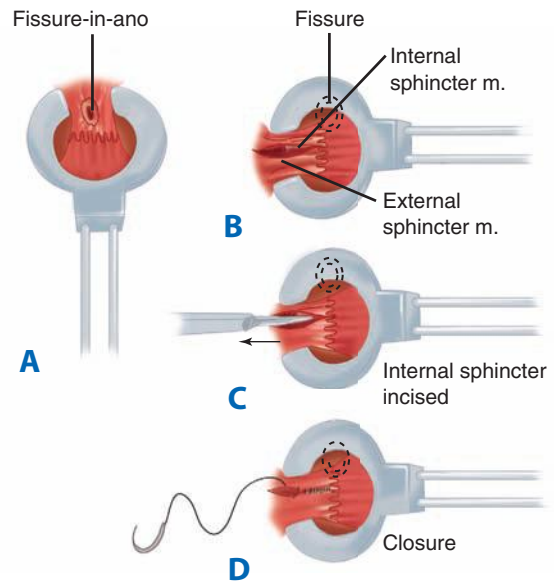


Figure 29-33. A through D. Open lateral internal sphincterotomy for fissure in ano. m = muscle.

dividing a portion of the muscle. Approximately 30% of the internal sphincter fibers are divided laterally by using either an open (Fig. 29-33) or closed (Fig. 29-34) technique. Healing is achieved in more than 95% of patients using this technique,

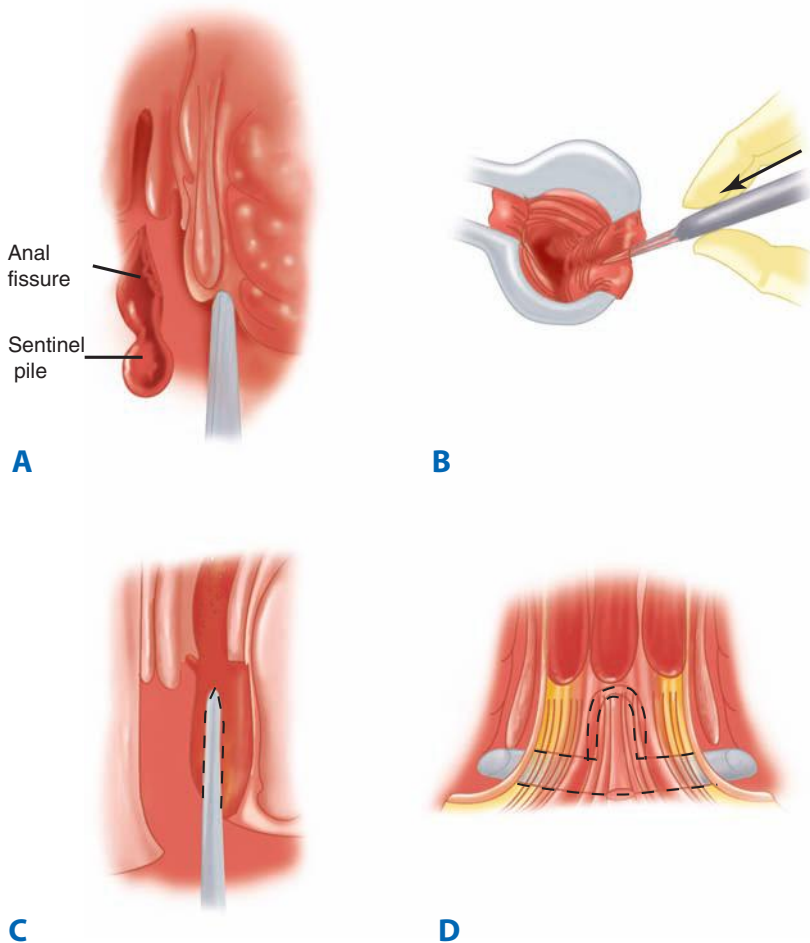


Figure 29-34. A through D. Closed lateral internal sphincterotomy for fissure in ano.

and most patients experience immediate pain relief. Recurrence occurs in less than 10% of patients, and the risk of incontinence (usually to flatus) ranges from 5% to 15%. Advancement flaps (VY) with or without sphincterotomy have also been reported to successfully treat chronic fissures.

Anorectal Sepsis and Cryptoglandular Abscess

Relevant Anatomy. The majority of anorectal suppurative disease results from infections of the anal glands (cryptoglandular infection) found in the intersphincteric plane. Their ducts traverse the internal sphincter and empty into the anal crypts at the level of the dentate line. Infection of an anal gland results in the formation of an abscess that enlarges and spreads along one of several planes in the perianal and perirectal spaces. The *perianal space* surrounds the anus and laterally becomes continuous with the fat of the buttocks. The *intersphincteric space* separates the internal and external anal sphincters. It is continuous with the perianal space distally and extends cephalad into the rectal wall. The *ischioanal space (ischioanal fossa)* is located lateral and posterior to the anus and is bounded medially by the external sphincter, laterally by the ischium, superiorly by the

levator ani, and inferiorly by the transverse septum. The ischioanal space contains the inferior rectal vessels and lymphatics. The two ischioanal spaces connect posteriorly above the anococcygeal ligament but below the levator ani muscle, forming the *deep postanal space*. The *supralelevator spaces* lie above the levator ani on either side of the rectum and communicate posteriorly. The anatomy of these spaces influences the location and spread of cryptoglandular infection (Fig. 29-35).

As an abscess enlarges, it spreads in one of several directions. A *perianal abscess* is the most common manifestation and appears as a painful swelling at the anal verge. Spread through the external sphincter below the level of the puborectalis produces an *ischioanal abscess*. These abscesses may become extremely large and may not be visible in the perianal region. Digital rectal exam will reveal a painful swelling laterally in the ischioanal fossa. *Intersphincteric abscesses* occur in the intersphincteric space and are notoriously difficult to diagnose, often requiring an examination under anesthesia. *Pelvic* and *supralelevator abscesses* are uncommon and may result from extension of an intersphincteric or ischioanal abscess upward or extension of an intraperitoneal abscess downward (Fig. 29-36).

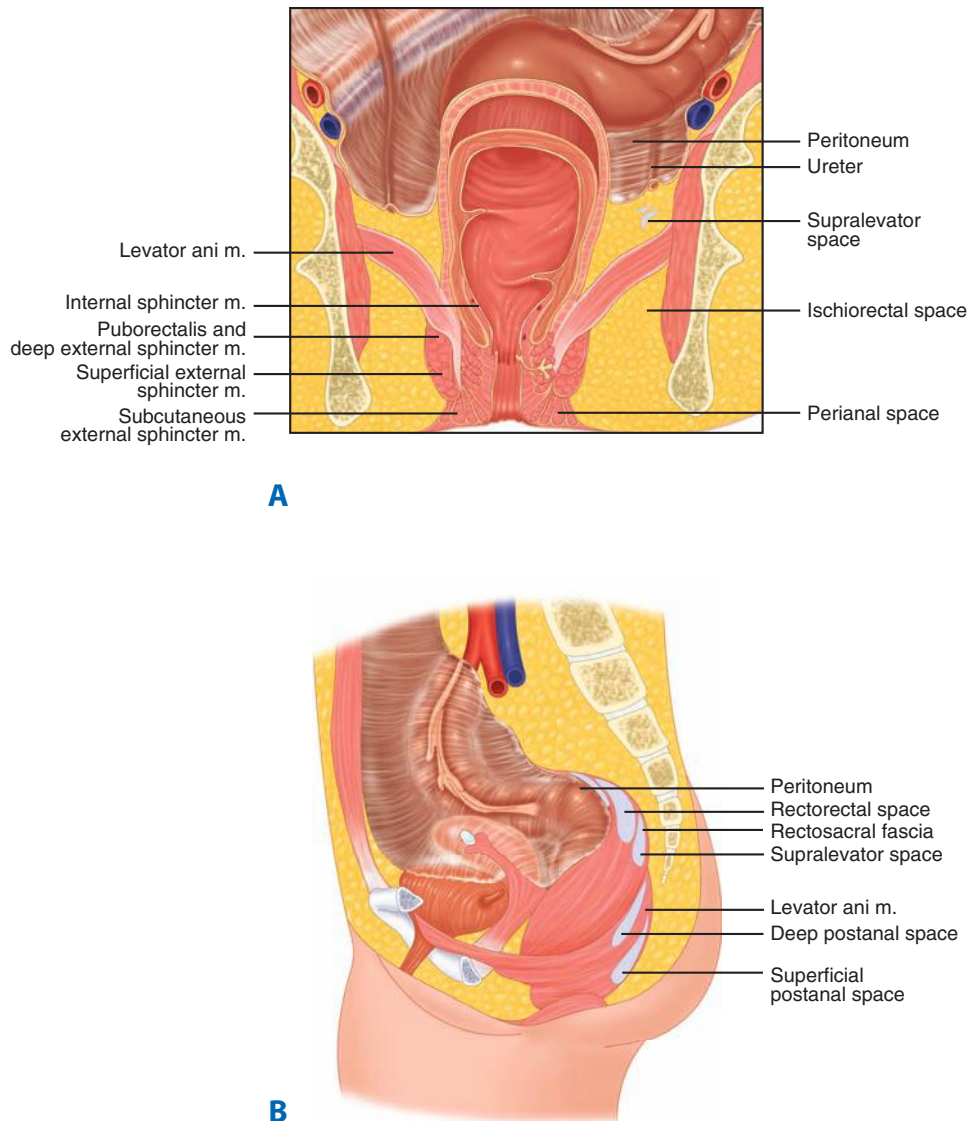


Figure 29-35. Anatomy of perianorectal spaces. (A) Anterior view and (B) lateral view. m = muscle.

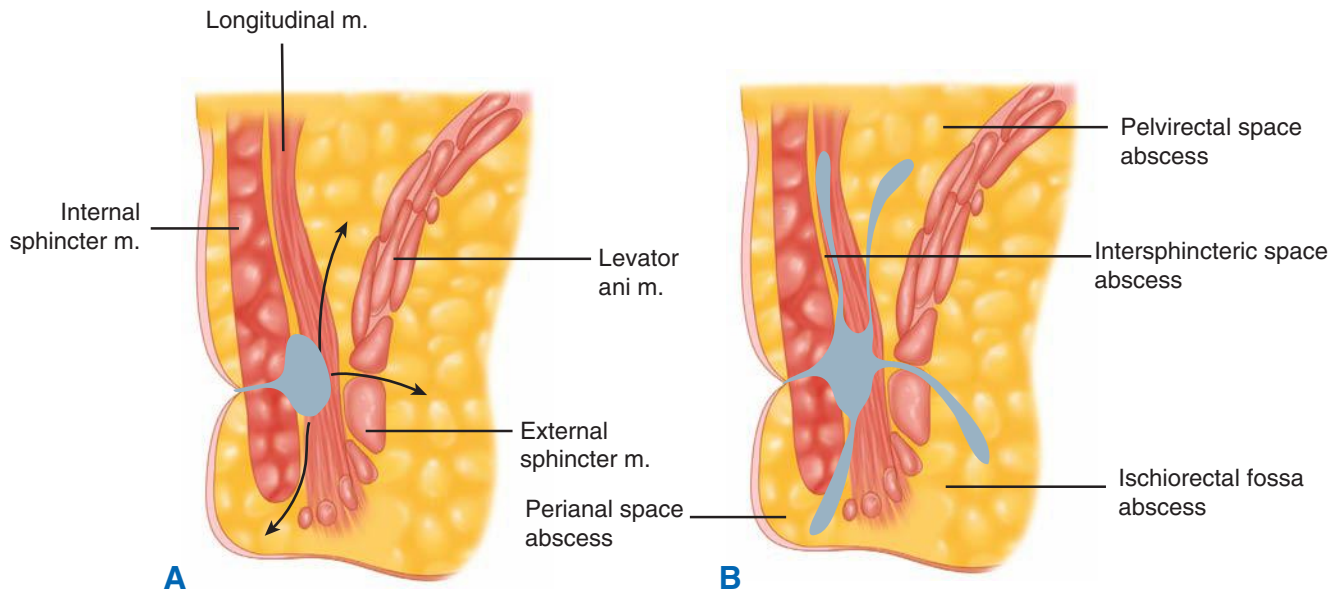


Figure 29-36. A and B. Pathways of anorectal infection in perianal spaces. m = muscle.

Diagnosis. Severe anal pain is the most common presenting complaint. A palpable mass is often detected by inspection of the perianal area or by digital rectal examination. Occasionally, patients will present with fever, urinary retention, or life-threatening sepsis. The diagnosis of a perianal or ischioanal abscess can usually be made with physical exam alone (either in the office or in the operating room). However, complex or atypical presentations may require imaging studies such as CT or MRI to fully delineate the anatomy of the abscess.

Treatment. Anorectal abscesses should be treated by drainage as soon as the diagnosis is established. If the diagnosis is in question, an examination and drainage under anesthesia are often the most expeditious ways both to confirm the diagnosis and to treat the problem. Delayed or inadequate treatment may occasionally cause extensive and life-threatening suppuration with massive tissue necrosis and septicemia. Antibiotics are only indicated if there is extensive overlying cellulitis or if the patient is immunocompromised, has diabetes mellitus, or has valvular heart disease. Antibiotics alone are ineffective at treating perianal or perirectal infection.

Perianal Abscess

Most perianal abscesses can be drained under local anesthesia in the office, clinic, or emergency room. Larger, more complicated abscesses may require drainage in the operating room. A skin incision is created, and a disk of skin excised to prevent premature closure. No packing is necessary, and sitz baths are started the next day (Fig. 29-37).

Ischioanal Abscess

An ischioanal abscess causes diffuse swelling in the ischioanal fossa that may involve one or both sides, forming a “horseshoe” abscess. Simple ischioanal abscesses are drained through an incision in the overlying skin. Horseshoe abscesses require drainage of the deep postanal space and often require counterincisions over one or both ischioanal spaces (Fig. 29-38).

Intersphincteric Abscess

Intersphincteric abscesses are notoriously difficult to diagnose because they produce little swelling and few perianal signs of

infection. Pain is typically described as being deep and “up inside” the anal area and is usually exacerbated by coughing or sneezing. The pain is so intense that it usually precludes a digital rectal examination. The diagnosis is made based on a high index of suspicion and usually requires an examination under anesthesia. Once identified, an intersphincteric abscess can be drained through a limited, usually posterior, internal sphincterotomy.

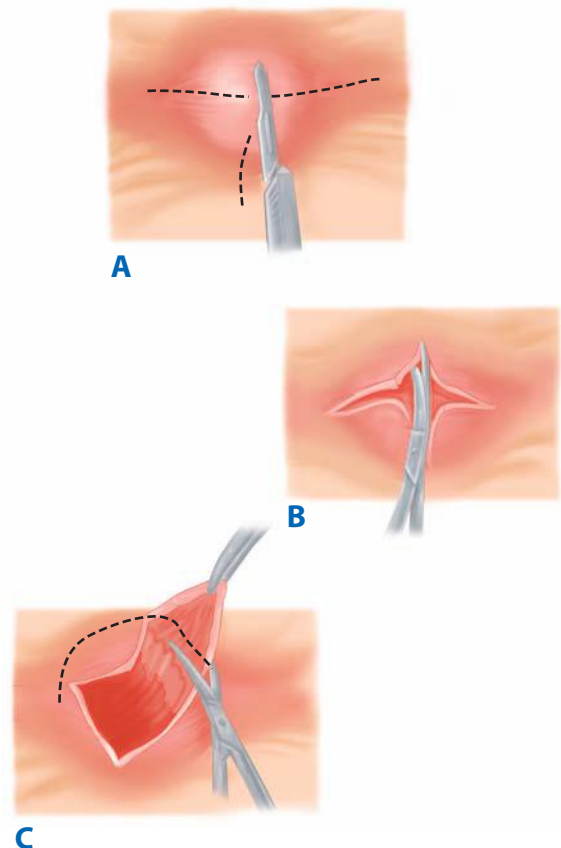


Figure 29-37. A through C. Technique of drainage of perianal abscess.

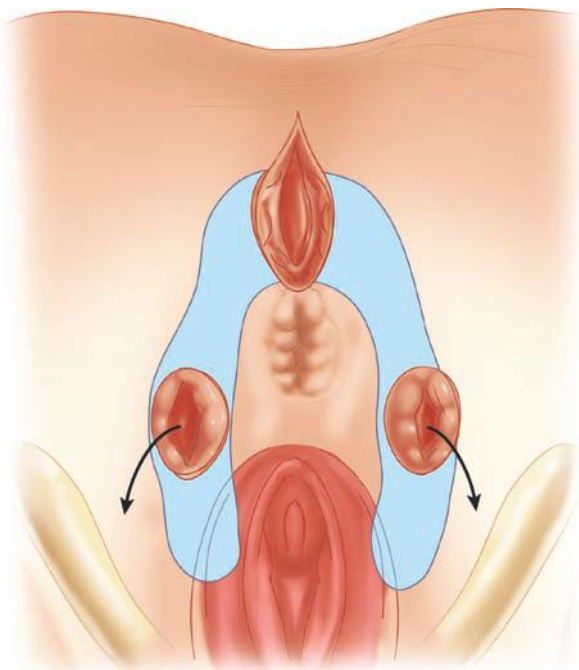


Figure 29-38. Drainage of horseshoe abscess. The deep postanal space is entered, incising the anococcygeal ligament. Counter drainage incisions are made for each limb of the ischioanal space.

Supralelevator Abscess

This type of abscess is uncommon and can be difficult to diagnose. Because of its proximity to the peritoneal cavity, supralelevator abscesses can mimic intra-abdominal conditions. Digital rectal examination may reveal an indurated, bulging mass above the anorectal ring. It is essential to identify the origin of a supralelevator abscess prior to treatment. If the abscess is secondary to an upward extension of an intersphincteric abscess, it should be drained through the rectum. If it is drained through the ischioanal fossa, a complicated, suprasphincteric fistula may result. If a supralelevator abscess arises from the upward extension of an ischioanal abscess, it should be drained through the ischioanal fossa. Drainage of this type of abscess through the rectum may result in an extrasphincteric fistula. If the abscess is secondary to intra-abdominal disease, the primary process requires treatment and the abscess is drained via the most direct route (transabdominally, rectally, or through the ischioanal fossa).

Perianal Sepsis in the Immunocompromised Patient

The immunocompromised patient with perianal pain presents a diagnostic dilemma. Because of leukopenia, these patients may develop serious perianal infection without any of the cardinal signs of inflammation. While broad-spectrum antibiotics may cure some of these patients, an exam under anesthesia should not be delayed because of neutropenia. An increase in pain or fever and/or clinical deterioration mandates an exam under anesthesia. Any indurated area should be incised and drained, biopsied to exclude a leukemic infiltrate, and cultured to aid in the selection of antimicrobial agents.¹⁰²

Necrotizing Soft Tissue Infection of the Perineum

Necrotizing soft tissue infection of the perineum is a rare, but lethal, condition. Most of these infections are polymicrobial and

synergistic. The source of sepsis is commonly an undrained or inadequately drained cryptoglandular abscess or a urogenital infection. Occasionally, these infections may be encountered postoperatively (e.g., after hemorrhoidectomy). Immunocompromised patients and diabetic patients are at increased risk.

Physical examination may reveal necrotic skin, bullae, or crepitus. Patients often have signs of systemic toxicity and may be hemodynamically unstable. A high index of suspicion is necessary because perineal signs of severe infection may be minimal and prompt surgical intervention can be lifesaving.

Surgical débridement of all nonviable tissue is required to treat all necrotizing soft tissue infections. Multiple operations may be necessary to ensure that all necrotic tissue has been resected. Broad-spectrum antibiotics are frequently employed, but adequate surgical débridement remains the mainstay of therapy. Colostomy may be required if extensive resection of the sphincter is required or if stool contamination of the perineum makes wound management difficult. Despite early recognition and adequate surgical therapy, the mortality of necrotizing perineal soft tissue infections remains approximately 50%.

Fistula In Ano

Drainage of an anorectal abscess results in cure for about 50% of patients. The remaining 50% develop a persistent *fistula in ano*. The fistula usually originates in the infected crypt (*internal opening*) and tracks to the *external opening*, usually the site of prior drainage. The course of the fistula can often be predicted by the anatomy of the previous abscess.

While the majority of fistulas are cryptoglandular in origin, trauma, Crohn's disease, malignancy, radiation, or unusual infections (tuberculosis, actinomycosis, and chlamydia) may also produce fistulas. A complex, recurrent, or nonhealing fistula should raise the suspicion of one of these diagnoses.

Diagnosis. Patients present with persistent drainage from the internal and/or external openings. An indurated tract is often palpable. Although the external opening is often easily identifiable, identification of the internal opening may be more challenging. Goodsall's rule can be used as a guide in determining the location of the internal opening (Fig. 29-39). In general, fistulas with an external opening *anteriorly* connect to the internal opening by a *short, radial tract*. Fistulas with an external opening *posteriorly* track in a *curvilinear fashion to the posterior midline*. However, exceptions to this rule often occur if an anterior

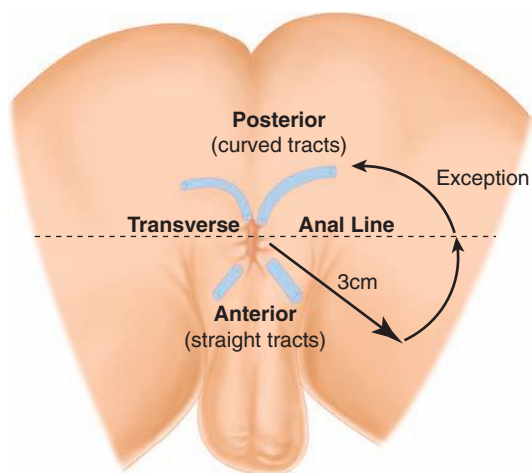


Figure 29-39. Goodsall's rule to identify the internal opening of fistulas in ano.

external opening is greater than 3 cm from the anal margin. Such fistulas usually track to the posterior midline.

Fistulas are categorized based on their relationship to the anal sphincter complex, and treatment options are based on these classifications. An *intersphincteric fistula* tracks through the distal internal sphincter and intersphincteric space to an external opening near the anal verge (Fig. 29-40A). A *transsphincteric fistula* often results from an ischioanal abscess and extends through both the internal and external sphincters (Fig. 29-40B). A *suprasphincteric fistula* originates in the intersphincteric plane and tracks up and around the entire external sphincter (Fig. 29-40C). An *extrasphincteric fistula* originates in the rectal wall and tracks around both sphincters to exit laterally, usually in the ischioanal fossa (Fig. 29-40D).

Treatment. The goal of treatment of fistula in ano is eradication of sepsis without sacrificing continence. Because fistulous

tracks encircle variable amounts of the sphincter complex, surgical treatment is dictated by the location of the internal and external openings and the course of the fistula. The external opening is usually visible as a red elevation of granulation tissue with or without concurrent drainage. The internal opening may be more difficult to identify. Injection of hydrogen peroxide or dilute methylene blue may be helpful. Care must be taken to avoid creating an artificial internal opening (thus often converting a simple fistula into a complex fistula).

Simple intersphincteric fistulas can often be treated by *fistulotomy* (opening the fistulous tract), curettage, and healing by secondary intention (see Fig. 29-40A). “Horseshoe” fistulas usually have an internal opening in the posterior midline and extend anteriorly and laterally to one or both ischioanal spaces by way of the deep postanal space. Treatment of a transsphincteric fistula depends on its location in the sphincter complex.

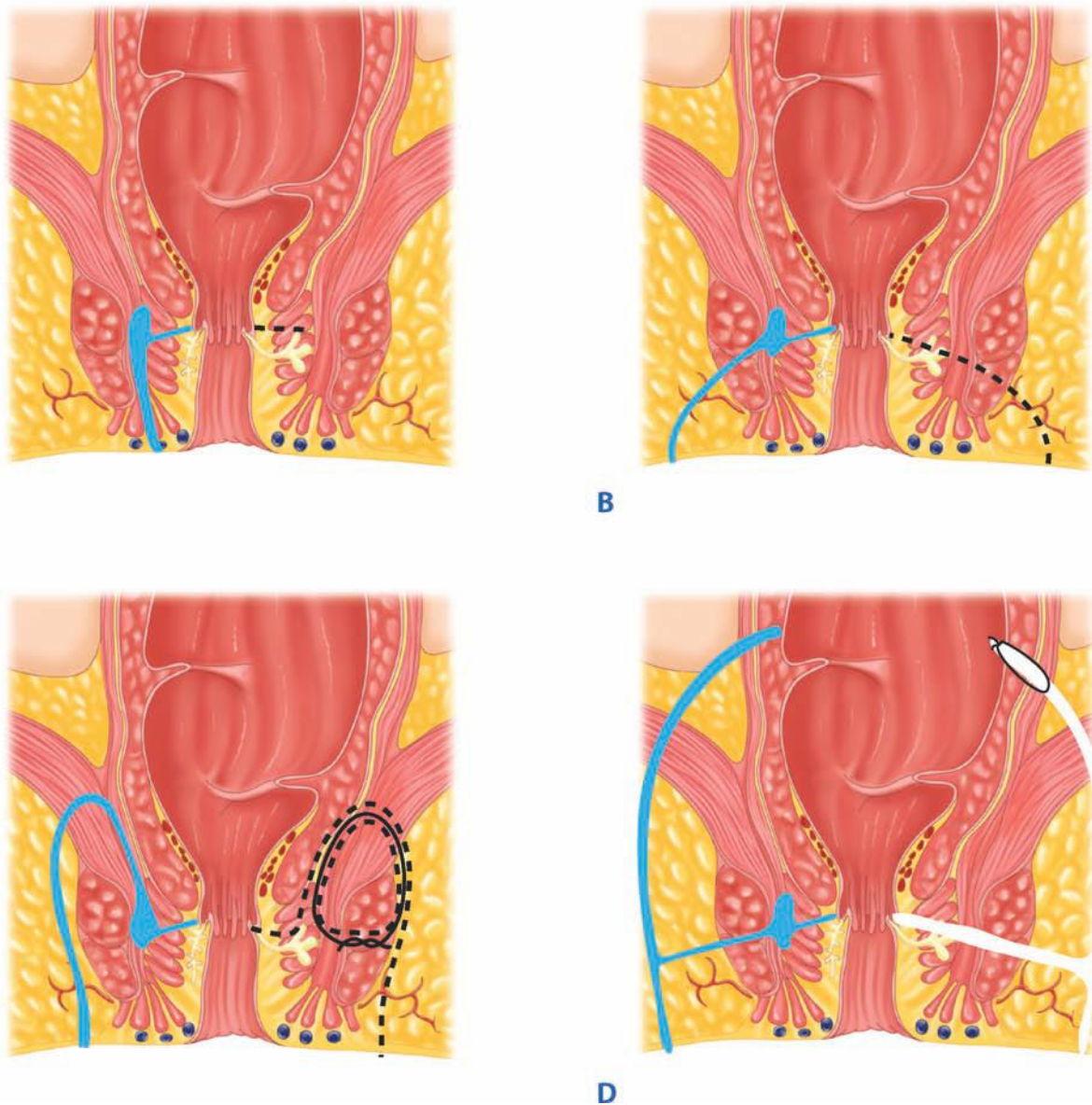


Figure 29-40. The four major categories of fistula in ano (left side of drawings) and the usual operative procedure to correct the fistula (right side of drawings). **A.** Intersphincteric fistula with simple low tract. **B.** Uncomplicated transsphincteric fistula. **C.** Uncomplicated suprasphincteric fistula. **D.** Extrasphincteric fistula secondary to anal fistula. (Data from Gordon PH, Nivatvongs S, eds. Principles and Practice of Surgery for the Colon, Rectum, and Anus. 2nd ed. New York: Marcel Dekker, Inc.; 1999:256-260.)

Fistulas that include less than 30% of the sphincter muscles can often be treated by sphincterotomy without significant risk of major incontinence (see Fig. 29-40B). High transsphincteric fistulas, which encircle a greater amount of muscle, are more safely treated by initial placement of a *seton* (see below). Similarly, suprasphincteric fistulas are usually treated with seton placement (see Fig. 29-40C). Extrasphincteric fistulas are rare, and treatment depends on both the anatomy of the fistula and its etiology. In general, the portion of the fistula outside the sphincter should be opened and drained. A primary tract at the level of the dentate line may also be opened if present. Complex fistulas with multiple tracts may require numerous procedures to control sepsis and facilitate healing. Liberal use of drains and setons is helpful. Failure to heal may ultimately require fecal diversion (see Fig. 29-40D). Complex and/or nonhealing fistulas may result from Crohn's disease, malignancy, radiation proctitis, or unusual infection. Proctoscopy should be performed in all cases of complex and/or nonhealing fistulas to assess the health of the rectal mucosa. Biopsies of the fistula tract should be taken to rule out malignancy.

A *seton* is a drain placed through a fistula to maintain drainage and/or induce fibrosis. *Cutting setons* consist of a suture or a rubber band that is placed through the fistula and intermittently tightened in the office. Tightening the seton results in fibrosis and gradual division of the sphincter, thus eliminating the fistula while maintaining continuity of the sphincter. A *noncutting seton* is a soft plastic drain (often a vessel loop) placed in the fistula to maintain drainage. The fistula tract may subsequently be laid open with less risk of incontinence because scarring prevents retraction of the sphincter. Alternatively, the seton may be left in place for chronic drainage. Higher fistulas may be treated by an *endorectal advancement flap* (see below). *Fibrin glue* and a variety of collagen-based plugs also have been used to treat persistent fistulas with variable results. A more recent technique, *ligation of the intersphincteric fistula tract (LIFT)*, also shows promise. In this procedure, the fistula is identified in the intersphincteric plane (usually by placement of a lacrimal probe), divided, and the two ends ligated. Early reports have shown success with this technique, but long-term outcome is not yet known.^{103,104}

Rectovaginal Fistula

A rectovaginal fistula is a connection between the vagina and the rectum or anal canal proximal to the dentate line. Rectovaginal fistulas are classified as *low* (rectal opening close to the dentate line and vaginal opening in the fourchette), *middle* (vaginal opening between the fourchette and cervix), or *high* (vaginal opening near the cervix). Low rectovaginal fistulas are commonly caused by obstetric injuries or trauma from a foreign body. Mid-rectovaginal fistulas may result from more severe obstetric injury, but also occur after surgical resection of a mid-rectal neoplasm, radiation injury, or extension of an undrained abscess. High rectovaginal fistulas result from operative or radiation injury. Complicated diverticulitis may cause a colovaginal fistula. Crohn's disease can cause rectovaginal fistulas at all levels, as well as colovaginal and enterovaginal fistulas.

Diagnosis. Patients describe symptoms varying from the sensation of passing flatus from the vagina to the passage of solid stool from the vagina. Most patients experience some degree of fecal incontinence. Contamination may result in *vaginitis*. Large fistulas may be obvious on anoscopic and/or vaginal speculum examination, but smaller fistulas may be difficult to locate. Occasionally, a barium enema or vaginogram may identify

these fistulas. Endorectal ultrasound may also be useful. With the patient in the prone position, installation of methylene blue into the rectum while a tampon is in the vagina may confirm the presence of a small fistula.

Treatment. The treatment of rectovaginal fistula depends on the size, location, etiology, and condition of surrounding tissues. Because up to 50% of fistulas caused by obstetric injury heal spontaneously, it is prudent to wait 3 to 6 months before embarking on surgical repair in these patients. If the fistula was caused by a cryptoglandular abscess, drainage of the abscess may allow spontaneous closure.

Low and mid-rectovaginal fistulas are usually best treated with an endorectal advancement flap. The principle of this procedure is based on the advancement of healthy mucosa, submucosa, and circular muscle over the rectal opening (the high-pressure side of the fistula) to promote healing (Fig. 29-41). If a sphincter injury is present, an overlapping sphincteroplasty should be performed concurrently. Fecal diversion is rarely required. High rectovaginal, colovaginal, and enterovaginal fistulas are usually best treated via a transabdominal approach. The diseased tissue, which caused the fistula (upper rectum, sigmoid colon, or small bowel), is resected and the hole in the vagina closed. Healthy tissue, such as omentum or muscle, frequently is interposed between the bowel anastomosis and the vagina to prevent recurrence.

Rectovaginal fistulas caused by Crohn's disease, radiation injury, or malignancy almost never heal spontaneously. In Crohn's disease, treatment is based on adequate drainage of perianal sepsis and nutritional support. An endorectal advancement flap may be performed if the rectum is spared from active Crohn's disease. Fistulas resulting from radiation damage are not amenable to local repair with an advancement flap because of damage to the surrounding rectal and vaginal tissues. Such mid- and high rectovaginal fistulas are occasionally repaired successfully with a transabdominal approach in which healthy tissue (omentum, muscle, or nonradiated bowel) is interposed between the damaged rectum and vagina. Fistulas caused by malignancy should be treated with resection of the tumor. Because differentiating radiation damage from malignancy can be extremely difficult, all fistulas resulting from radiation should be biopsied to rule out the presence of cancer.

Perianal Dermatitis

Pruritus Ani. Pruritus ani (severe perianal itching) is a common problem with a multitude of etiologies. Surgically correctable (anatomic) causes include prolapsing hemorrhoids, ectropion, fissure, fistula, and neoplasms. Perianal infection may also present with pruritus ani. Infections may be caused by fungus (*Candida* species and *Epidermophyton* organisms), parasites (*Enterobius vermicularis* [pinworms], *Pediculus pubis* [a louse], and *Sarcoptes scabiei* [scabies]), bacteria (*Corynebacterium minutissimum* [erythrasma] and *T. pallidum* [syphilis]), or viruses (HPV [condylooma acuminata]). Antibiotic use may also cause itching, usually by precipitating fungal infection. Noninfectious dermatologic causes include seborrhea, psoriasis, and contact dermatitis. Contact dermatitis can be particularly troublesome because many over-the-counter topical agents used by patients to relieve itching may exacerbate the problem. Occasionally, systemic diseases such as jaundice and diabetes may present with pruritus ani.

Despite the myriad of causes, the majority of pruritus ani is idiopathic and probably related to local hygiene, neurogenic, or

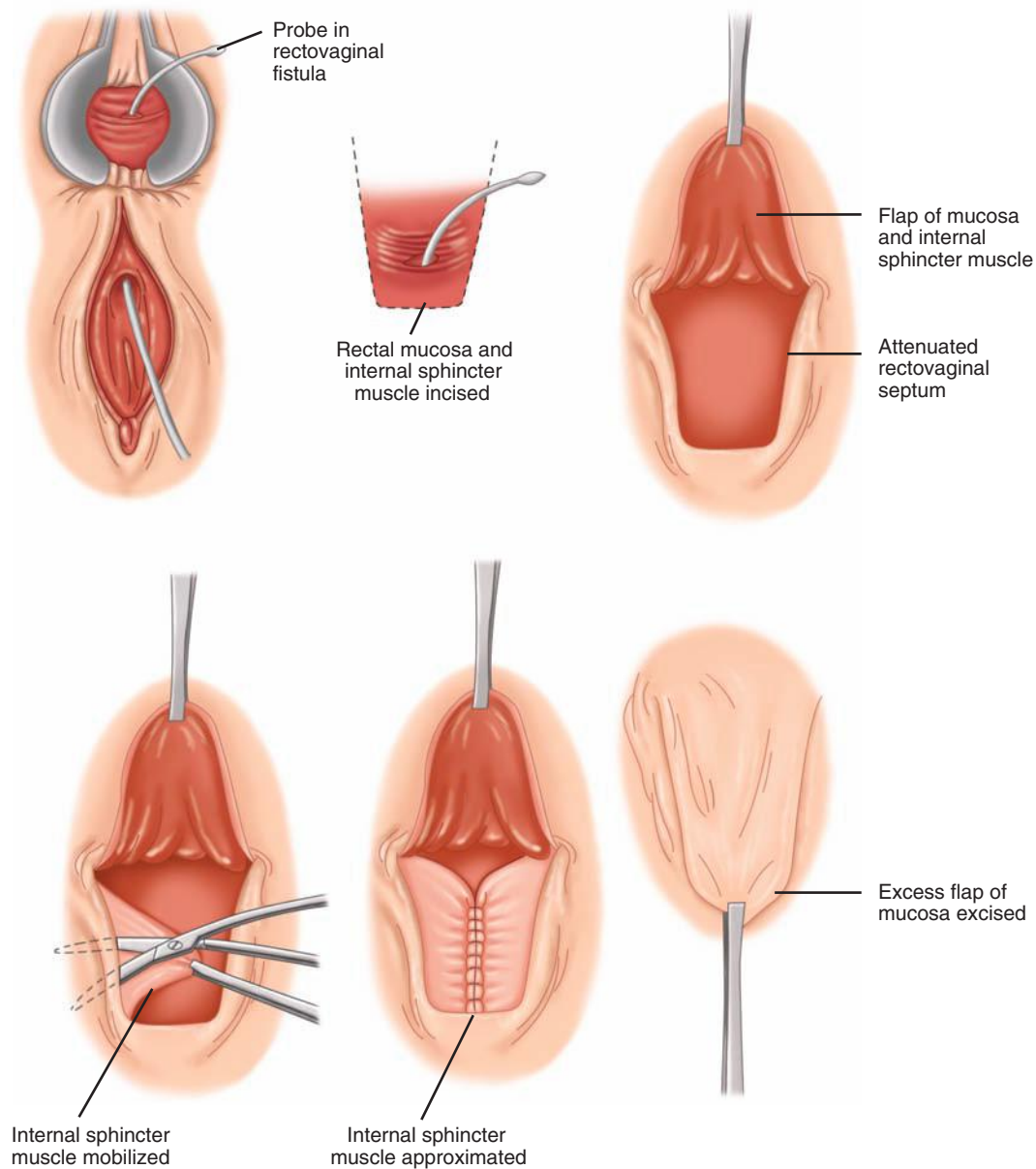


Figure 29-41. Endorectal advancement flap for rectovaginal fistula. (Reproduced with permission of Taylor & Francis, LLC from Gordon PH, Nivatvongs S, eds. *Principles and Practice of Surgery for the Colon, Rectum, and Anus*. 2nd ed. New York: Marcel Dekker, Inc.; 1999:412. Permission conveyed through Copyright Clearance Center, Inc.)

psychogenic causes. Treatment focuses on removal of irritants, improving perianal hygiene, dietary adjustments, and avoiding scratching. Biopsy and/or culture may be required to rule out an infectious or dermatologic cause. Hydrocortisone ointment 0.5% to 1.0% can provide symptomatic relief but should not be used for prolonged periods of time because of the risk of dermal atrophy. Skin barriers such as Calmoseptine can also provide relief. Systemic antihistamines or tricyclic antidepressants have also been used with some success.

Nonpruritic Lesions. Several perianal skin conditions may present with perianal skin changes. Leprosy, amebiasis, actinomycosis, and lymphogranuloma venereum produce characteristic perianal lesions. Neoplasms such as squamous intraepithelial lesions, Paget's disease, and invasive carcinomas may also appear first in the perianal skin. Biopsy can usually distinguish these diagnoses.

Sexually Transmitted Diseases

Bacterial Infections. Proctitis is a common symptom of anorectal bacterial infection. *N. gonorrhoeae* is the most common bacterial cause of proctitis and causes pain, tenesmus, rectal bleeding, and mucus discharge. *Chlamydia trachomatis* infection may be asymptomatic or may produce similar symptoms. *T. pallidum*, the microbe causing syphilis, causes a chancre at the site of inoculation, which may be asymptomatic or may present as an atypical fissure (primary syphilis). Condyloma lata are characteristic of secondary syphilis. Chancroid, caused by *Haemophilus ducreyi*, is a disease manifested by multiple painful, bleeding lesions. Inguinal lymphadenopathy and fluctuant, draining lymph nodes are characteristic. *Donovania granulomatis* infection produces shiny, red masses on the perineum (granuloma inguinale). Diarrheal illnesses caused by organisms such as *Campylobacter* or *Shigella* may also be sexually transmitted.

Treatment consists of antimicrobial agents directed against the infecting organism.

Parasitic Infections. *Entamoeba histolytica* is an increasingly common sexually transmitted disease. Amebas produce ulcerations in the gastrointestinal mucosa and can infect any part of the gut. Symptoms include diarrhea, abdominal pain, and tenesmus. *Giardia lamblia* is also common and produces diarrhea, abdominal pain, and malaise.

Viral Infections

Herpes Simplex Virus. Herpes proctitis is extremely common. Proctitis is usually caused by type 2 herpes simplex virus and less commonly by type 1 herpes simplex virus. Patients complain of severe, intractable perianal pain and tenesmus. Pain often precedes the development of characteristic vesicles, and these patients may require an examination under anesthesia to exclude another diagnosis such as an intersphincteric abscess. Diagnosis is confirmed by viral culture of tissue or vesicular fluid.

Human Papillomavirus. HPV causes condyloma acuminata (anogenital warts) and is associated with squamous intraepithelial lesions and squamous cell carcinoma (see previous section, “Anal Canal and Perianal Tumors”). Condylomas occur in the perianal area or in the squamous epithelium of the anal canal. Occasionally, the mucosa of the lower rectum may be affected. There are approximately 30 serotypes of HPV. As previously mentioned, HPV types 16 and 18, in particular, appear to predispose to malignancy and often cause flat dysplasia in skin unaffected by warts. In contrast, HPV types 6 and 11 commonly cause warts, but do not appear to cause malignant degeneration.

Treatment of anal condyloma depends on the location and extent of disease. Small warts on the perianal skin and distal anal canal may be treated in the office with topical application of bichloroacetic acid or podophyllin. Although 60% to 80% of patients will respond to these agents, recurrence and reinfection are common. Imiquimod (Aldara) is an immunomodulator that was recently introduced for topical treatment of several viral infections, including anogenital condyloma.¹⁰⁵ Initial reports suggest that this agent is highly effective in treating condyloma located on the perianal skin and distal anal canal. Larger and/or more numerous warts require excision and/or fulguration in the operating room. Excised warts should be sent for pathologic examination to rule out dysplasia or malignancy. It is important to note that prior use of podophyllin may induce histologic changes that mimic dysplasia. The recent introduction of a vaccine against HPV holds promise for preventing anogenital condylomas.

Human Immunodeficiency Virus. See later section, “The Immunocompromised Patient.”

Pilonidal Disease

Pilonidal disease (cyst, infection) consists of a hair-containing sinus or abscess occurring in the intergluteal cleft. Although the etiology is unknown, it is speculated that the cleft creates a suction that draws hair into the midline pits when a patient sits. These ingrown hairs may then become infected and present acutely as an abscess in the sacrococcygeal region. Once an acute episode has resolved, recurrence is common.

An acute abscess should be incised and drained as soon as the diagnosis is made. Because these abscesses are usually very superficial, this procedure can often be performed in the office, clinic, or emergency room under local anesthetic.

Because midline wounds in the region heal poorly, some surgeons recommend using an incision *lateral* to the intergluteal cleft. A number of procedures have been proposed to treat a chronic pilonidal sinus. The simplest method involves unroofing the tract, curetting the base, and marsupializing the wound. The wound must then be kept clean and free of hair until healing is complete (often requiring weekly office visits for wound care). Alternatively, a small lateral incision can be created and the pit excised. This method is effective for most primary pilonidal sinuses. In general, extensive resection should be avoided. Complex and/or recurrent sinus tracts may require more extensive resection and closure with a Z-plasty, advancement flap, or rotational flap.

Hidradenitis Suppurativa

Hidradenitis suppurativa is an infection of the cutaneous apocrine sweat glands. Infected glands rupture and form subcutaneous sinus tracts. The infection may mimic complex anal fistula disease, but stops at the anal verge because there are no apocrine glands in the anal canal. Treatment involves incision and drainage of acute abscesses and unroofing of all chronically inflamed fistulas and débridement of granulation tissue. Radical excision and skin grafting are almost never necessary.

TRAUMA

Penetrating Colorectal Injury

Colorectal injury is common following penetrating trauma to the abdomen and has historically been associated with high mortality. In the first half of the twentieth century, the mortality rate from colorectal injury was as high as 90%. The introduction of exteriorization of colonic injuries and fecal diversion during World War II dramatically decreased mortality, and this principle has governed the management of large bowel injury for over 50 years. Recently, however, this practice was challenged, and trauma surgeons are increasingly performing primary repairs in selected patients.

Management of colonic injury depends on the mechanism of injury, the delay between the injury and surgery, the overall condition and stability of the patient, the degree of peritoneal contamination, and the condition of the injured colon. A primary repair may be considered in hemodynamically stable patients with few additional injuries and minimal contamination if the colon appears otherwise healthy. Contraindications to primary repair include shock, injury to more than two other organs, mesenteric vascular damage, and extensive fecal contamination. A delay of greater than 6 hours between the injury and the operation also is associated with increased morbidity and mortality and is a relative contraindication to primary repair. Injuries caused by high-velocity gunshot wounds or blast injuries are often associated with multiple intra-abdominal injuries and tissue loss and therefore are usually treated by fecal diversion after débridement of all nonviable tissue. Patient factors, such as medical comorbidities, advanced age, and the presence of tumor or radiation injury, must also be considered (Table 29-6).

Like injuries to the intraperitoneal colon, penetrating trauma to the rectum traditionally has been associated with high morbidity and mortality. Primary repair of the rectum is more difficult than primary repair of the colon, however, and most rectal injuries are associated with significant contamination. For that reason, the majority of penetrating rectal injuries should be treated with proximal fecal diversion and copious irrigation of

Table 29-6

Criteria for use of an ostomy

Injuring agent factors
High-velocity bullet wounds
Shotgun wounds
Explosive blast wounds
Crush injury
Patient factors
Presence of tumor
Radiated tissue
Medical condition
Advanced age
Injury factors
Inflamed tissue
Advanced infection
Distal obstruction
Local foreign body
Impaired blood supply
Mesenteric vascular damage
Shock with blood pressure <80/60 mmHg
Hemorrhage >1000 mL
More than two organs (especially kidney) injured
Interval to operation >6 h (pancreatic, splenic, hepatic)
Extensive injury requiring resection
Major abdominal wall loss
Thoracoabdominal penetration

Source: Reproduced with permission from Gordon PH, Nivatvongs S, eds. *Principles and Practice of Surgery for the Colon, Rectum, and Anus*. 2nd ed. New York: Marcel Dekker, Inc; 1999:1249.

the rectum (distal rectal washout). Small, clean rectal injuries may be closed primarily without fecal diversion in an otherwise stable patient. Intractable rectal bleeding may require angiographic embolization. Very rarely, hemorrhage or extensive tissue loss (especially if the anal sphincter is severely damaged) may require an emergent APR. However, this operation should be avoided, if at all possible, because of the morbidity associated with an extensive pelvic dissection in a severely injured patient.

Blunt Colorectal Injury

Blunt injury to the colon and rectum is considerably less common than penetrating injury. Nevertheless, blunt trauma can cause colon perforation, and shear injury to the mesentery can devascularize the intestine. Management of these injuries should follow the same principles outlined for management of penetrating injuries. Small perforations with little contamination in a stable patient may be closed primarily; more extensive injury requires fecal diversion. A serosal hematoma alone does not mandate resection, but the bowel should be carefully inspected to ensure that there is not an associated perforation or significant bowel ischemia.

Blunt injury to the rectum may result from significant trauma, such as a pelvic crush injury, or may result from local trauma caused by an enema or foreign body. Crush injuries, especially with an associated pelvic fracture, are often associated with significant rectal damage and contamination. These patients require débridement of all nonviable tissue, proximal fecal diversion, and a distal rectal washout, with or without

drain placement. Blunt trauma from an enema or foreign body may produce a mucosal hematoma, which requires no surgical treatment if the mucosa is intact. Small mucosal tears may be closed primarily if the bowel is relatively clean and there is little contamination.

Iatrogenic Injury

Intraoperative Injury. The colon and rectum are at risk for inadvertent injury during other procedures, especially during pelvic operations. The key to managing these injuries is *early recognition*. The vast majority of iatrogenic colorectal injuries may be closed primarily if there is little contamination and if the patient is otherwise stable. Delayed recognition of colorectal injuries may result in significant peritonitis and life-threatening sepsis. In these cases, fecal diversion is almost always required, and the patient may need repeated exploration for drainage of abscesses.

Injury from Barium Enema. Colorectal injury from a barium enema is an extremely rare complication associated with a high rate of morbidity and mortality. Perforation with spillage of barium, especially above the peritoneal reflection, may result in profound peritonitis, sepsis, and a systemic inflammatory response. If the perforation is recognized early, it may be closed primarily and the abdomen irrigated to remove stool and barium. However, if the patient has developed sepsis, fecal diversion (with or without bowel resection) is almost always required. Rarely, a small mucosal injury to the extraperitoneal rectum may be managed with bowel rest, broad-spectrum antibiotics, and close observation.

Colonoscopic Perforation. Perforation is the most common major complication after either diagnostic or therapeutic colonoscopy. Fortunately, this complication is rare and occurs in less than 1% of procedures. Perforation may result from trauma from the tip of the instrument, from shear forces related to the formation of a “loop” in the colonoscope, or from barotrauma from insufflation. Biopsy or fulguration can also cause perforation. Polypectomy using electrocautery may produce a full-thickness burn, resulting in *postpolypectomy syndrome* in which a patient develops abdominal pain, fever, and leukocytosis without evidence of diffuse peritonitis.

Management of colonoscopic perforation depends on the *size of the perforation*, the *duration of time* since the injury, the *overall condition of the patient*, and the *underlying diagnosis*. A large perforation recognized during the procedure requires surgical exploration. Because the bowel has almost always been prepared prior to the colonoscopy, there is usually little contamination associated with these injuries, and most can be repaired primarily. If there is significant contamination, if there has been a delay in diagnosis with resulting peritonitis, or if the patient is hemodynamically unstable, proximal diversion with or without resection is the safest approach. It is also important to know the indication for and findings at the time of colonoscopy. If the patient has an underlying neoplasm and is stable, definitive resection is best. Occasionally, a patient will develop abdominal pain and localized signs of perforation after what was thought to be an uneventful colonoscopy. Many of these patients will have a “microperforation,” which will resolve with bowel rest, broad-spectrum antibiotics, and close observation. Evidence of peritonitis or any deterioration in clinical condition mandates exploration. Similarly, free retroperitoneal or intra-peritoneal air may be discovered incidentally after colonoscopy.

In a completely asymptomatic patient, this finding is thought to result from barotrauma and dissection of air through tissue planes without a free perforation. Many of these patients can be successfully treated with bowel rest and broad-spectrum antibiotics. Surgical exploration is indicated if any clinical deterioration occurs.

Anal Sphincter Injury and Incontinence

The most common cause of anal sphincter injury is obstetric trauma during vaginal delivery. The risk of sphincter injury is increased by a laceration that extends into the rectum (fourth-degree tear), infection of an episiotomy or laceration repair, prolonged labor, and possibly by use of a midline episiotomy. Sphincter damage may also result from hemorrhoidectomy, sphincterotomy, abscess drainage, or fistulotomy. Patients with incontinence and a suspected sphincter injury can be evaluated with anal manometry, EMG, pudendal nerve motor latency, and endoanal ultrasound. Mild incontinence, even in the presence of a sphincter defect, may respond to dietary changes and/or biofeedback. More severe incontinence may require surgical repair.

The anal sphincter can also be injured by penetrating or blunt mechanisms (impalement, blast injury, crush injuries of the pelvis). Because damage to the anal sphincter is not life-threatening, definitive repair of the sphincter is often deferred until other injuries have been repaired and the patient's clinical condition is stable. Isolated sphincter injuries that do not involve the rectum may be repaired primarily. Rectal injury accompanied by sphincter injury should be treated with fecal diversion and distal rectal washout, with or without drain placement. Significant perineal tissue loss may require extensive débridement and a diverting colostomy.

Surgical Repairs. The most common method of repair of the anal sphincter is a *wrap-around sphincteroplasty* (Fig. 29-42).¹⁰⁶ The procedure involves mobilization of the divided sphincter muscle and reapproximation without tension. The internal and external sphincters may be overlapped together or separately. *Postanal intersphincteric levatorplasty* is less commonly used to repair sphincter defects but may be useful for incontinence caused by prolapse and/or loss of the anorectal angle (see "Continence"). The approach is via the intersphincteric plane posteriorly. It may be performed concomitantly with a perineal repair of rectal prolapse. The levator ani muscle is approximated to restore the anorectal angle, and the puborectalis and external sphincter muscle are tightened with sutures. These elective procedures usually do not require a diverting colostomy.

In cases where there has been significant loss of sphincter muscle or in which prior repairs have failed, more complex techniques, such as *gracilis muscle transposition* with or without chronic, low-frequency electrostimulation, have been used with some success.¹⁰⁷ In this procedure, the gracilis muscle is mobilized from the thigh, detached from its insertion on the tibial tuberosity, tunneled through the perineum, and wrapped around the anal canal. Another alternative in patients who have failed other repairs is the *artificial anal sphincter*. This device consists of an inflatable silastic cuff, a pressure-regulating balloon, and a control pump. Patients deflate the cuff manually to open the anal canal; the cuff then reinflates spontaneously to maintain closure of the anal canal. *Sacral nerve stimulation* via an implanted pulse generator is a technique used for neurogenic incontinence when the sphincter is intact.^{16,27} In some patients, an end stoma provides the best relief for intractable incontinence.¹⁰⁸

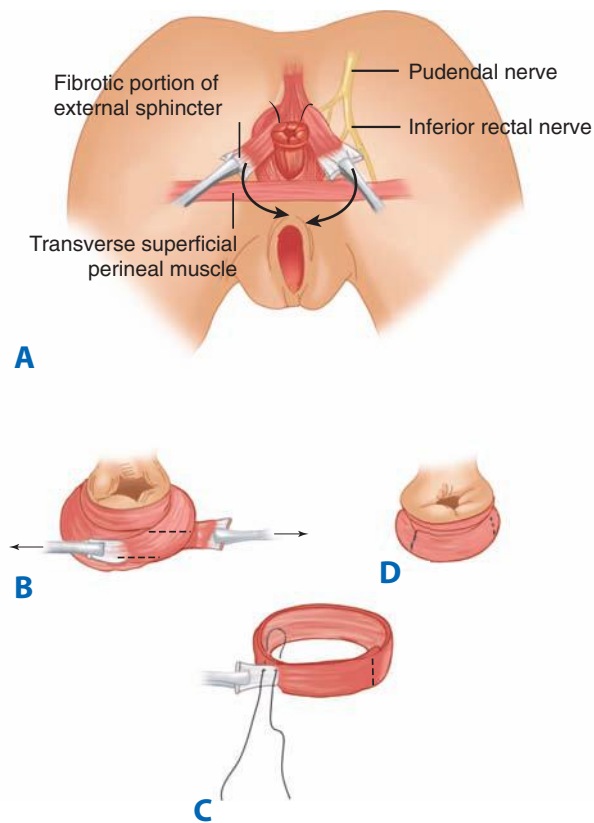


Figure 29-42. Overlapping sphincteroplasty for incontinence from sphincter disruption. **A.** The external sphincter muscle with scar at site of injury is mobilized. **B.** The muscle edges are aligned in an overlapping fashion. **C.** Mattress sutures are used to approximate the muscle. **D.** The completed operation.

Foreign Body

Foreign body entrapment in the rectum is not uncommon. Depending on the level of entrapment, a foreign body may cause damage to the rectum, rectosigmoid, or descending colon. Generalized abdominal pain suggests intraperitoneal perforation. Evaluation of the patient includes inspection of the perineum and a careful abdominal examination to detect any evidence of perforation. Plain films of the abdomen are mandatory to detect free intra-abdominal air.

Foreign bodies lodged low in the rectum may often be removed under conscious sedation with or without a local anesthetic block. Objects impacted higher in the rectum may require regional or general anesthesia for removal. Only rarely will a laparotomy be required to remove the object. After removal of the foreign body, it is crucial to evaluate the rectum and sigmoid colon for injury. Proctoscopy and/or flexible sigmoidoscopy should be performed. A hematoma without evidence of perforation requires no surgical treatment. Perforation of the rectum or sigmoid colon should be managed as described in the preceding sections.

THE IMMUNOCOMPROMISED PATIENT

Human Immunodeficiency Virus

Patients infected with HIV may present with a myriad of gastrointestinal symptoms. Diarrhea, in particular, is extremely common. The severity of gastrointestinal disease depends

in part on the degree of immunosuppression; however, both ordinary and opportunistic pathogens may affect patients at any stage of the disease. Opportunistic infections with bacteria (*Salmonella*, *Shigella*, *Campylobacter*, *Chlamydia*, and *Mycobacterium* species), fungi (histoplasmosis, coccidiosis, *Cryptococcus*), protozoa (toxoplasmosis, cryptosporidiosis, isosporiasis), and viruses (CMV, herpes simplex virus) can cause diarrhea, abdominal pain, and weight loss. CMV in particular may cause severe enterocolitis and is the most common infectious cause of emergency laparotomy in acquired immunodeficiency syndrome (AIDS) patients. *C. difficile colitis* is a major concern in these patients, especially because many patients are maintained on suppressive antibiotic therapy. The incidence of gastrointestinal malignancy is also increased in patients with HIV infection.¹⁰⁹ Kaposi's sarcoma is the most common malignancy in AIDS patients and can affect any part of the gastrointestinal tract. Patients may be asymptomatic or may develop bleeding or obstruction. Gastrointestinal lymphoma (usually non-Hodgkin's lymphoma) is also common. The incidence of colorectal carcinoma may also be increased in this population, although definitive data are lacking.

Perianal disease is extremely common in patients with HIV infection. Because HIV is sexually transmitted, it is common to find concomitant infection with other sexually transmitted diseases such as *Chlamydia*, *herpes simplex virus*, and HPV (anal condyloma). *Anal condyloma* in particular are very common, and the incidence of dysplasia (HSIL) is high in the HIV-infected population.¹¹⁰ Abscesses and fistulas may be more difficult to diagnose in these patients and may be complex. Many patients require an examination under anesthesia with biopsy and cultures to determine the etiology of many of these perianal problems. The introduction of highly active antiretroviral therapy (HAART) has changed the natural history of HIV infection, but it remains to be seen how these medications will affect the incidence and outcome of colorectal disease in this patient population.

IMMUNOSUPPRESSION FOR TRANSPLANTATION

The gastrointestinal tract is a common site for posttransplantation complications that are responsible for significant morbidity and mortality. In these patients, infection and medication are the most common causes of diarrhea. Immunosuppressant medications, in particular, may cause diarrhea. CMV infection is common and may be severe. *C difficile colitis* also occurs commonly. Diverticulitis appears to be more common in some populations of transplant patients and may be more likely to present with abscess or free perforation. Elective resection after recovery from one episode of confirmed diverticulitis may be indicated in the transplant population. Graft-versus-host disease is unique to transplant patients and often requires endoscopy and biopsy to diagnose gastrointestinal involvement. Patients are subject to the same opportunistic infections outlined earlier; however, sexually transmitted infections and Kaposi's sarcoma are somewhat less prevalent. Perianal disease is somewhat less common in the transplant population than in patients infected with HIV; however, similar infections may occur, and immunosuppression often makes diagnosis and treatment challenging.

With increasing long-term survival among transplant recipients, the development of posttransplant malignancy has become a major concern. Posttransplant lymphoproliferative disease is increasingly common and may occur anywhere

in the gastrointestinal tract. The risk of colorectal carcinoma is increased in patients with predisposing conditions such as ulcerative colitis. However, immunosuppression alone does not appear to increase the incidence of colorectal cancer, and current screening recommendations are similar to those for the average risk population. In contrast, the incidence of anal squamous cell carcinoma is dramatically increased in transplant patients, and patients with known HPV infection should undergo more vigorous screening.

THE NEUTROPENIC PATIENT

Neutropenic enterocolitis (typhlitis) is a life-threatening problem with a mortality rate of greater than 50%. This syndrome is characterized by abdominal pain and distention, fever, diarrhea (often bloody), nausea, and vomiting in a patient with fewer than 1000 neutrophils/ μ L blood from any cause (bone marrow transplantation, solid-organ transplantation, or chemotherapy). CT scan of the abdomen often shows a dilated cecum with pericolic stranding. However, a normal-appearing CT scan does not exclude the diagnosis. Some patients will respond to bowel rest, broad-spectrum antibiotics, parenteral nutrition, and granulocyte infusion or colony-stimulating factors. Evidence of perforation, generalized peritonitis, and deterioration in clinical condition are indications for operation.

Neutropenic patients often develop perianal pain, and diagnosis may be difficult because of a lack of inflammatory response to infection. While broad-spectrum antibiotics may cure some of these patients, an examination under anesthesia should not be delayed because of neutropenia. An increase in pain or fever and/or clinical deterioration mandates an exam under anesthesia. Any indurated area should be incised and drained, biopsied to exclude a leukemic infiltrate, and cultured to aid in the selection of antimicrobial agents.

REFERENCES

Entries highlighted in bright blue are key references.

1. Tran K. Capsule colonoscopy: PillCam Colon. *Issues Emerg Health Technol.* 2007;106:1-4.
2. de Franchis R, Rondonotti E, Villa F. Capsule endoscopy—state of the art. *Dig Dis.* 2007;25:249-251.
3. Fireman Z, Kopelman Y. The colon: the latest terrain for capsule endoscopy. *Dig Liver Dis.* 2007;39:895-899.
4. Spada C, De Vincentis F, Cesaro P, et al. Accuracy and safety of second-generation PillCam COLON capsule for colorectal polyp detection. *Ther Adv Gastroenterol.* 2012;5:173-178.
5. Keller J, Fibbe C, Rosien U, et al. Recent advances in capsule endoscopy: development of maneuverable capsules. *Expert Rev Gastroenterol Hepatol.* 2012;6:561-566.
6. Smith RA, von Eschenbach AC, Wender R, et al. American Cancer Society guidelines for the early detection of cancer: update of early detection guidelines for prostate, colorectal, and endometrial cancers. Also: update 2001—testing for early lung cancer detection. *CA Cancer J Clin.* 2001;51:38-75.
7. Bernini A, Spencer MP, Wong WD, et al. Computed tomography-guided percutaneous abscess drainage in intestinal disease: factors associated with outcome. *Dis Colon Rectum.* 1997;40:1009-1013.
8. Mang T, Bogoni L, Salganicoff M, et al. Computer-aided detection of colorectal polyps in CT colonography with and without fecal tagging: a stand-alone evaluation. *Invest Radiol.* 2012;47:99-108.

9. Garcia-Aguilar J, Pollack J, Lee SH, et al. Accuracy of endorectal ultrasonography in preoperative staging of rectal tumors. *Dis Colon Rectum*. 2002;45:10-15.
10. Turgeon DK, Novicki TJ, Quick J, et al. Six rapid tests for direct detection of *Clostridium difficile* and its toxins in fecal samples compared with the fibroblast cytotoxicity assay. *J Clin Microbiol*. 2003;41:667-670.
11. Qiu H, Sirivongs P, Rothenberger M, et al. Molecular prognostic factors in rectal cancer treated by radiation and surgery. *Dis Colon Rectum*. 2000;43:451-459.
12. Offit K. Genetic prognostic markers for colorectal cancer. *N Engl J Med*. 2000;342:124-125.
13. Lynch HT, Lynch JF, Lynch PM, et al. **Hereditary colorectal cancer syndromes: molecular genetics, genetic counseling, diagnosis and management.** *Fam Cancer*. 2008;7:27-39.
14. Dailianas A, Skandalis N, Rimikis MN, et al. Pelvic floor study in patients with obstructive defecation: influence of biofeedback. *J Clin Gastroenterol*. 2000;30:176-180.
15. FitzHarris GP, Garcia-Aguilar J, Parker SC, et al. Quality of life after subtotal colectomy for slow-transit constipation: both quality and quantity count. *Dis Colon Rectum*. 2003;46:433-440.
16. Ganio E, Ratto C, Masin A, et al. Neuromodulation for fecal incontinence: outcome in 16 patients with definitive implant. The initial Italian Sacral Neurostimulation Group (GINS) experience. *Dis Colon Rectum*. 2001;44:965-970.
17. Ruiz D, Pinto RA, Hull TL, et al. Does the radiofrequency procedure for fecal incontinence improve quality of life and incontinence at 1-year follow-up? *Dis Colon Rectum*. 2010;53:1041-1046.
18. Hussain ZI, Lim M, Stojkovic SG. Systematic review of perianal implants in the treatment of faecal incontinence. *Br J Surg*. 2011;98:1526-1536.
19. Tjandra JJ, Dykes SL, Kumar RR, et al. **Practice parameters for the treatment of fecal incontinence.** *Dis Colon Rectum*. 2007;50:1497-1507.
20. Ky AJ, Sonoda T, Milsom JW. One-stage laparoscopic restorative proctocolectomy: an alternative to the conventional approach? *Dis Colon Rectum*. 2002;45:207-210.
21. Lezoche E, Felicciotti F, Paganini AM, et al. Laparoscopic colonic resections versus open surgery: a prospective non-randomized study on 310 unselected cases. *Hepatogastroenterology*. 2000;47:697-708.
22. Heuschen UA, Hinz U, Allemeyer EH, et al. One- or two-stage procedure for restorative proctocolectomy: rationale for a surgical strategy in ulcerative colitis. *Ann Surg*. 2001;234:788-794.
23. Weeks JC, Nelson H, Gelber S, et al. Short-term quality-of-life outcomes following laparoscopic-assisted colectomy vs. open colectomy for colon cancer: a randomized trial. *JAMA*. 2002;287:321-328.
24. deSouza AL, Prasad LM, Ricci J, et al. A comparison of open and robotic total mesorectal excision for rectal adenocarcinoma. *Dis Colon Rectum*. 2011;54:275-282.
25. O'Riordain MG, Fazio VW, Lavery IC, et al. Incidence and natural history of dysplasia of the anal transitional zone after ileal pouch-anal anastomosis: results of a five-year to ten-year follow-up. *Dis Colon Rectum*. 2000;43:1660-1665.
26. Regimbeau JM, Panis Y, Pocard M, et al. Handsewn ileal pouch-anal anastomosis on the dentate line after total proctectomy: technique to avoid incomplete mucosectomy and the need for long-term follow-up of the anal transition zone. *Dis Colon Rectum*. 2001;44:43-50.
27. Vaizey CJ, Kamm MA, Roy AJ, et al. Double-blind crossover study of sacral nerve stimulation for fecal incontinence. *Dis Colon Rectum*. 2000;43:298-302.
28. Farouk R, Pemberton JH, Wolff BG, et al. Functional outcomes after ileal pouch-anal anastomosis for chronic ulcerative colitis. *Ann Surg*. 2000;231:919-926.
29. Bullard KM, Madoff RD, Gemlo BT. Is ileoanal pouch function stable with time? Results of a prospective audit. *Dis Colon Rectum*. 2002;45:299-304.
30. Biondo S, Frago R, Codina Cazador A, et al. Long-term functional results from a randomized clinical study of transverse coloplasty compared with colon J-pouch after low anterior resection for rectal cancer. *Surgery*. 2013;153:383-392.
31. Heah SM, Seow-Choen F, Eu KW, et al. Prospective, randomized trial comparing sigmoid vs. descending colonic J-pouch after total rectal excision. *Dis Colon Rectum*. 2002;45:322-328.
32. Sandborn W, McLeod R, Jewell D. Pharmacotherapy for inducing and maintaining remission in pouchitis. *Cochrane Database Syst Rev*. 2000;2:CD001176.
33. Stocchi L, Pemberton JH. Pouch and pouchitis. *Gastroenterol Clin North Am*. 2001;30:223-241.
34. Zmora O, Pikarsky AJ, Wexner SD. Bowel preparation for colorectal surgery. *Dis Colon Rectum*. 2001;44:1537-1549.
35. Cannon JA, Altom LK, Deierhoi RJ, et al. Preoperative oral antibiotics reduce surgical site infection following elective colorectal resections. *Dis Colon Rectum*. 2012;55:1160-1166.
36. Cao F, Li J, Li F. **Mechanical bowel preparation for elective colorectal surgery: updated systematic review and meta-analysis.** *Int J Colorectal Dis*. 2012;27:803-810.
37. Bonen DK, Cho JH. The genetics of inflammatory bowel disease. *Gastroenterology*. 2003;124:521-536.
38. Yamamoto-Furusho JK. Genetic factors associated with the development of inflammatory bowel disease. *World J Gastroenterol*. 2007;13:5594-5597.
39. Tremaine WJ. Is indeterminate colitis determinable? *Curr Gastroenterol Rep*. 2012;14:162-165.
40. Lakatos PL, Lakatos L, Kiss LS, et al. Treatment of extraintestinal manifestations in inflammatory bowel disease. *Digestion*. 2012;86(Suppl 1):28-35.
41. Alfadhli AA, McDonald JW, Feagan BG. Methotrexate for induction of remission in refractory Crohn's disease. *Cochrane Database Syst Rev*. 2005;1:CD003459.
42. Hanauer SB, Feagan BG, Lichtenstein GR, et al. **Maintenance infliximab for Crohn's disease: the ACCENT I randomized trial.** *Lancet*. 2002;359:1541-1549.
43. Manz M, Vavricka SR, Wanner R, et al. Therapy of steroid-resistant inflammatory bowel disease. *Digestion*. 2012;86(Suppl 1): 11-15.
44. Actis GC, Bruno M, Pinna-Pintor M, et al. Infliximab for treatment of steroid-refractory ulcerative colitis. *Dig Liver Dis*. 2002;34:631-634.
45. Su C, Lewis JD, Deren JJ, et al. Efficacy of anti-tumor necrosis factor therapy in patients with ulcerative colitis. *Am J Gastroenterol*. 2002;97:2577-2584.
46. Matsumoto T, Iwao Y, Igarashi M, et al. Endoscopic and chromoendoscopic atlas featuring dysplastic lesions in surveillance colonoscopy for patients with long-standing ulcerative colitis. *Inflamm Bowel Dis*. 2008;14:259-264.
47. Wong Kee Song LM, Adler DG, Chand B, et al. Chromoendoscopy. *Gastrointest Endosc*. 2007;66:639-649.
48. Bamias G, Cominelli F. Novel strategies to attenuate immune activation in Crohn's disease. *Curr Opin Pharmacol*. 2006;6:401-407.
49. Hall JF, Roberts PL, Ricciardi R, et al. Long-term follow-up after an initial episode of diverticulitis: what are the predictors of recurrence? *Dis Colon Rectum*. 2011;54:283-288.
50. Daniels L, de Korte N, Winter D, et al. Overtreatment of sigmoid diverticulitis: plea for a less aggressive approach. *Dig Dis*. 2012;30:86-91.
51. American Cancer Society. Cancer facts and figures. Available from: <http://www.cancer.org/acs/groups/content/@epidemiology-surveillance/documents/document/acspc-031941.pdf>.

52. Calle EE, Rodriguez C, Walker-Thurmond K, et al. Overweight, obesity, and mortality from cancer in a prospectively studied cohort of U.S. adults. *N Engl J Med*. 2003;348:1625-1638.
53. Woodhouse CR. Guidelines for monitoring of patients with ureterosigmoidostomy. *Gut*. 2002;51(Suppl 5):V15-V16.
54. Baxter NN, Tepper JE, Durham SB, et al. Increased risk of rectal cancer after prostate radiation: a population-based study. *Gastroenterology*. 2005;128:819-824.
55. Al-Tassan N, Chmiel NH, Maynard J, et al. Inherited variants of MYH associated with somatic G:C→T:A mutations in colorectal tumors. *Nat Genet*. 2002;30:227-232.
56. Lefevre JH, Rodrigue CM, Mourra N, et al. Implication of MYH in colorectal polyposis. *Ann Surg*. 2006;244:874-879.
57. Martin M, Simon-Assmann P, Kedinger M, et al. DCC regulates cell adhesion in human colon cancer derived HT-29 cells and associates with ezrin. *Eur J Cell Biol*. 2006;85:769-783.
58. Lao VV, Grady WM. Epigenetics and colorectal cancer. *Nat Rev Gastroenterol Hepatol*. 2011;8:686-700.
59. Rex DK, Ahnen DJ, Baron JA, et al. Serrated lesions of the colorectum: review and recommendations from an expert panel. *Am J Gastroenterol*. 2012;107:1315-1329.
60. Janne PA, Mayer RJ. Chemoprevention of colorectal cancer. *N Engl J Med*. 2000;342:1960-1968.
61. Lieberman DA, Weiss DG, Bond JH, et al. Use of colonoscopy to screen asymptomatic adults for colorectal cancer. Veterans Affairs Cooperative Study Group 380. *N Engl J Med*. 2000;343:162-168.
62. Bulow C, Vasen H, Järvinen H, et al. Ileorectal anastomosis is appropriate for a subset of patients with familial adenomatous polyposis. *Gastroenterology*. 2000;119:1454-1460.
63. Steinbach G, Lynch PM, Phillips RK, et al. The effect of celecoxib, a cyclooxygenase-2 inhibitor, in familial adenomatous polyposis. *N Engl J Med*. 2000;342:1946-1952.
64. Hampel H, Panescu J, Lockman J, et al. Screening for the Lynch syndrome (hereditary nonpolyposis colorectal cancer). *N Engl J Med*. 2005;352:1851-1860.
65. Jarvinen HJ, Aarnio M, Mustonen H, et al. Controlled 15-year trial on screening for colorectal cancer in families with hereditary nonpolyposis colorectal cancer. *Gastroenterology*. 2000;118:829-834.
66. National Quality Forum. Appendix A: Specifications of the National Voluntary Consensus Standards for Breast and Colon Cancer. <http://www.qualityforum.org/pdf/cancer/txbreast-colonAppa-Specsvoting01-18-07clean.pdf>.
67. Levin B, Brooks D, Smith RA, et al. Emerging technologies in screening for colorectal cancer: CT colonography, immunochemical fecal occult blood tests, and stool screening using molecular markers. *CA Cancer J Clin*. 2003;53:44-55.
68. Pignone M, Rich M, Teutsch SM, et al. Screening for colorectal cancer in adults at average risk: a summary of the evidence for the U.S. Preventive Services Task Force. *Ann Intern Med*. 2002;137:132-141.
69. Mandel JS, Church TR, Bond JH, et al. The effect of fecal occult-blood screening on the incidence of colorectal cancer. *N Engl J Med*. 2000;343:1603-1607.
70. Imperiale TF, Wagner DR, Lin CY, et al. Risk of advanced proximal neoplasms in asymptomatic adults according to the distal colorectal findings. *N Engl J Med*. 2000;343:169-174.
71. Hardcastle JD, Armitage NC, Chamberlain J, et al. Fecal occult blood screening for colorectal cancer in the general population. Results of a controlled trial. *Cancer*. 1986;58:397-403.
72. Winawer SJ, Flehinger BJ, Schottenfeld D, et al. Screening for colorectal cancer with fecal occult blood testing and sigmoidoscopy. *J Natl Cancer Inst*. 1993;85:1311-1318.
73. Yee J, Akerkar GA, Hung RK, et al. Colorectal neoplasia: performance characteristics of CT colonography for detection in 300 patients. *Radiology*. 2001;219:685-692.
74. Greene FL, Fleming PD, Fleming ID, et al. *AJCC Cancer Staging Manual*. Springer: New York; 2002.
75. O'Connell JB, Maggard MA, Clifford KY. Colon Cancer Survival Rates with the New American Joint Committee on Cancer Sixth Edition Staging. *J Natl Cancer Inst*. 2004;96(19):1420-1425.
76. Gunderson LL, Sargent DJ, Tepper JE, et al. Impact of T and N substage on survival and disease relapse in adjuvant rectal cancer: a pooled analysis. *Int J Radiat Oncol Biol Phys*. 2002;54:386-396.
77. Johnson PM, Porter GA, Ricciardi R, et al. Increasing negative lymph node count is independently associated with improved long-term survival in stage IIIB and IIIC colon cancer. *J Clin Oncol*. 2006;24:3570-3575.
78. Chang GJ, Rodriguez-Bigas MA, Skibber JM, et al. Lymph node evaluation and survival after curative resection of colon cancer: systematic review. *J Natl Cancer Inst*. 2007;99:433-441.
79. Ricciardi R, Madoff RD, Rothenberger DA, et al. Population-based analyses of lymph node metastases in colorectal cancer. *Clin Gastroenterol Hepatol*. 2006;4:1522-1527.
80. Ricciardi R, Baxter NN. Association versus causation versus quality improvement: setting benchmarks for lymph node evaluation in colon cancer. *J Natl Cancer Inst*. 2007;99:414-415.
81. Puthillath A, Dunn KB, Rajput A, et al. Safety and efficacy of first-line chemotherapy in unresected metastatic colorectal cancer. *Clin Colorectal Cancer*. 2007;6:710-715.
82. Sargent DJ, Marsoni S, Monges G, et al. Defective mismatch repair as a predictive marker for lack of efficacy of fluorouracil-based adjuvant therapy in colon cancer. *J Clin Oncol*. 2010;28:3219-3226.
83. Demmy TL, Dunn KB. Surgical and nonsurgical therapy for lung metastasis: indications and outcomes. *Surg Oncol Clin N Am*. 2007;16:579-605.
84. Francescutti V, Miller A, Satchidanand Y, et al. Management of bowel obstruction in patients with stage IV cancer: predictors of outcome after surgery. *Ann Surg Oncol*. 2013;20:707-714.
85. Garcia-Aguilar J, Shi Q, Thomas CR Jr, et al. A phase II trial of neoadjuvant chemoradiation and local excision for T2N0 rectal cancer: preliminary results of the ACOSOG Z6041 trial. *Ann Surg Oncol*. 2012;19:384-391.
86. Sauer R, Liersch T, Merkel S, et al. Preoperative versus postoperative chemoradiotherapy for rectal cancer. *N Engl J Med*. 2004;351:1731-1740.
87. Berends FJ, Kazemier G, Bonjer HJ, et al. Subcutaneous metastases after laparoscopic colectomy. *Lancet*. 1994;344:58.
88. Jayne DG, Guillou PJ, Thorpe H, et al. Randomized trial of laparoscopic-assisted resection of colorectal carcinoma: 3-year results of the UK MRC CLASICC Trial Group. *J Clin Oncol*. 2007;25:3061-3068.
89. A comparison of laparoscopically assisted and open colectomy for colon cancer. *N Engl J Med*. 2004;350:2050-2059.
90. Hazebroek EJ. COLOR: a randomized clinical trial comparing laparoscopic and open resection for colon cancer. *Surg Endosc*. 2002;16:949-953.
91. Collinson FJ, Jayne DG, Pigazzi A, et al. An international, multicentre, prospective, randomised, controlled, unblinded, parallel-group trial of robotic-assisted versus standard laparoscopic surgery for the curative treatment of rectal cancer. *Int J Colorectal Dis*. 2012;27:233-241.
92. Merchea AL, Hubner M, Wenger D, Rose P, Dozois E. The value of preoperative biopsy in the management of solid presacral tumors. *Dis Colon Rectum*. 2013;56:756-760.
93. Darragh TM, Colgan TJ, Cox JT, et al. The lower anogenital squamous terminology standardization project for HPV-associated lesions: background and consensus recommendations from the College of American Pathologists and the American Society for Colposcopy and Cervical Pathology. *J Low Genit Tract Dis*. 2012;16:205-242.

94. Stanley MA. Imiquimod and the imidazoquinolones: mechanism of action and therapeutic potential. *Clin Exp Dermatol*. 2002;27:571-577.
95. Bullard KM, Tuttle TM, Rothenburger DA, et al. Surgical therapy for anorectal melanoma. *J Am Coll Surg*. 2003;196:206-211.
96. Cecil JA. *Clostridium difficile*: changing epidemiology, treatment and infection prevention measures. *Curr Infect Dis Rep*. 2012;14:612-619.
97. Jonas M, Speake W, Scholefield J. Diltiazem heals glyceryl trinitrate-resistant chronic anal fissures: a prospective study. *Dis Colon Rectum*. 2002;45:1091-1095.
98. Menten BB, Irkörücü O, Akin M, et al. Comparison of botulinum toxin injection and lateral internal sphincterotomy for the treatment of chronic anal fissure. *Dis Colon Rectum*. 2003;46:232-237.
99. Manfredelli S, Montalto G, Leonetti G, et al. Conventional (CH) vs. stapled hemorrhoidectomy (SH) in surgical treatment of hemorrhoids. Ten years experience. *Ann Ital Chir*. 2012;83:129-134.
100. Schuurman JP, Borel Rinkes IH, Go PM. Hemorrhoidal artery ligation procedure with or without Doppler transducer in grade II and III hemorrhoidal disease: a blinded randomized clinical trial. *Ann Surg*. 2012;255:840-845.
101. Nelson RL, Thomas K, Morgan J, et al. Nonsurgical therapy for anal fissure. *Cochrane Database Syst Rev*. 2012;2:CD003431.
102. North JH Jr, Weber TK, Rodriguez-Bigas MA, et al. The management of infectious and noninfectious anorectal complications in patients with leukemia. *J Am Coll Surg*. 1996; 183:322-328.
103. Jacob TJ, Perakath B, Keighley MR. Surgical intervention for anorectal fistula. *Cochrane Database Syst Rev*. 2010;5:CD006319.
104. Shanwani A, Nor AM, Amri N. Ligation of the intersphincteric fistula tract (LIFT): a sphincter-saving technique for fistula-in-ano. *Dis Colon Rectum*. 2010;53:39-42.
105. Gunter J. Genital and perianal warts: new treatment opportunities for human papillomavirus infection. *Am J Obstet Gynecol*. 2003;189(3 Suppl):S3-S11.
106. Buie WD, Lowry AC, Rothenberger DA, et al. Clinical rather than laboratory assessment predicts continence after anterior sphincteroplasty. *Dis Colon Rectum*. 2001;44:1255-1260.
107. Baeten CG, Bailey HR, Bakka A, et al. Safety and efficacy of dynamic graciloplasty for fecal incontinence: report of a prospective, multicenter trial. Dynamic Graciloplasty Therapy Study Group. *Dis Colon Rectum*. 2000;43:743-751.
108. Tan EK, Vaizey C, Cornish J, et al. Surgical strategies for faecal incontinence—a decision analysis between dynamic graciloplasty, artificial bowel sphincter, and end stoma. *Colorectal Dis*. 2008;10:577-586.
109. Cooksley CD, Hwang LY, Waller DK, et al. HIV-related malignancies: community-based study using linkage of cancer registry and HIV registry data. *Int J STD AIDS*. 1999;10:795-802.
110. Palefsky JM. Anal squamous intraepithelial lesions: relation to HIV and human papillomavirus infection. *J Acquir Immune Defic Syndr*. 1999;21(Suppl 1):S42-S48.

This page intentionally left blank

30 chapter

The Appendix

Mike K. Liang, Roland E. Andersson,
Bernard M. Jaffe, and David H. Berger

Historical Background	1241	Operative Interventions for the Appendix	1251	Acute Appendicitis during Pregnancy / 1256	
Embryology, Anatomy, and Physiology	1241	Open Appendectomy / 1251		Postoperative Care and Complications	1257
Embryology / 1241		Laparoscopic Appendectomy / 1252		Surgical Site Infection / 1257	
Anatomy / 1242		Laparoscopic versus Open Appendectomy / 1253		Stump Appendicitis / 1257	
Physiology / 1242		Laparoscopic Single-Incision Appendectomy / 1254		Incidental Appendectomy	1257
Acute Appendicitis	1243	Natural Orifice Transluminal Endoscopic Surgery / 1254		Neoplasms of the Appendix	1257
Epidemiology / 1243		Special Circumstances	1256	Prevalence of Neoplasms / 1257	
Etiology and Pathogenesis / 1243		Acute Appendicitis in the Young / 1256		Carcinoid / 1258	
Microbiology / 1243		Acute Appendicitis in the Elderly / 1256		Adenocarcinoma / 1258	
Natural History / 1243				Mucocele / 1258	
Clinical Presentation / 1243				Pseudomyxoma Peritonei / 1258	
Differential Diagnosis / 1246				Lymphoma 1259	
Initial Management / 1248					

HISTORICAL BACKGROUND

Appendiceal disease is a frequent reason for emergency hospital admission, and appendectomy is one of the most common emergency procedures performed in contemporary medicine. Despite the prevalent role this organ plays in healthcare today, the human appendix was not noted until 1492. Leonardo da Vinci depicted the appendix in his anatomic drawings, but these were not published until the eighteenth century.¹ In 1521, Berengario Da Capri and, in 1543, Andreas Vesalius published drawings recognizing the appendix.²

Credit is given to Jean Fernel for first describing appendiceal disease in a paper published in 1544. He reported on a 7-year-old girl whose diarrhea he treated with doses of quince, an apple-like fruit used in folk remedies. She developed abdominal pain and died. At autopsy, the quince was found to have obstructed the lumen of the appendix, causing necrosis and perforation.³ Lorenz Heister provided the first description of classic appendicitis in 1711.¹

The first known appendectomy was performed in 1736 by Claudius Amyand in London. He operated on an 11-year-old boy with a scrotal hernia and a fecal fistula. Within the hernia sac, Amyand found a perforated appendix surrounded by omentum. The appendix and omentum were amputated. The patient was discharged a month later in good condition.⁴

It would be over a century later before appendicitis was widely recognized as a common cause of right lower quadrant pain and early appendectomy advocated as treatment. Throughout this period, there was extensive discussion of typhlitis and perityphlitis as the common etiologies of right lower quadrant pain. Only sporadic cases of right lower quadrant pain were

treated with appendectomy. In 1886, Reginald H. Fitz presented his findings regarding appendicitis and recommended consideration for operative treatment. In 1889, Charles McBurney published his landmark paper in the *New York State Medical Journal* describing the indications for early laparotomy for the treatment of appendicitis.⁵ During the following decade, the role of surgical treatment was discussed intensely between proponents of early appendectomy and of a more expectant management. It was recognized that most instances of appendicitis could resolve without surgical treatment; but, the problem was how to identify early the patients who had the progressive, often lethal form of the disease.⁶ Eventually, early appendectomy became the accepted standard of care, with broad indications in order to prevent perforation. This change in practice resulted in an enormous increase in the number of appendectomies during the first decades of the twentieth century. However, this had almost no impact on the incidence of perforated appendicitis or on the mortality of appendicitis.⁷ In the 1970s, the negative effects of the large number of appendectomies of uninflamed appendices were noted, and the focus gradually shifted toward a more conservative approach to exploration.⁸

EMBRYOLOGY, ANATOMY, AND PHYSIOLOGY

Embryology

In the sixth week of human embryonic development, the appendix and cecum appear as outpouchings from the caudal limb of the midgut. The appendiceal outpouching, initially noted in the eighth week, begins to elongate at about the fifth month to achieve a vermiform appearance.^{9,10} The appendix maintains

Key Points

- 1▶ Appendicitis is one of the most common surgical emergencies in contemporary medicine, with a yearly incidence rate of about 100 per 100,000 inhabitants. Lifetime risk for appendicitis is 8.6% for males and 6.7% for females, with the highest incidence in the second decade of life.
- 2▶ The natural history of appendicitis is unclear, but it appears that progression to perforation is not predictable and that spontaneous resolution is common, suggesting that nonperforated and perforated appendicitis may, in fact, be different diseases.
- 3▶ Right lower quadrant pain, gastrointestinal symptoms starting after the onset of pain, and a systemic inflammatory response with leukocytosis and neutrophilia, increased C-reactive protein concentration, and fever are considered diagnostic of appendicitis. The Appendicitis Inflammatory Response Score or Alvarado score can help improve diagnostic accuracy.
- 4▶ Computed tomography scan has improved diagnostic accuracy in individual studies. However, in population-wide studies, the rate of misdiagnosis of appendicitis remains constant. Rates of misdiagnosis are highest in female patients of child-bearing age and patients on the extremes of age (i.e., very young and very old).
- 5▶ The role of nonoperative treatment for uncomplicated appendicitis remains controversial. Currently, appendectomy remains the standard of care. Laparoscopic appendectomy has a slight benefit over open appendectomy.
- 6▶ Perforated or complicated appendicitis is more common in the very young (age <5 years) and very old (age >65 years).
- 7▶ Complicated appendicitis without signs of sepsis or generalized peritonitis may benefit from nonoperative management. The role of interval appendectomy in these cases remains controversial.
- 8▶ Single-incision appendectomy provides no obvious advantage over standard laparoscopic appendectomy. Natural orifice transluminal endoscopic surgery remains an investigational procedure.
- 9▶ The incidence of fetal loss following normal appendectomy in pregnant patients is 4%, and the risk of premature delivery is 10%. The greatest opportunity to improve fetal outcomes may be through improving diagnostic accuracy and reducing the rate of negative appendectomy.
- 10▶ Antibiotic prophylaxis is effective in the prevention of postoperative surgical site infection. Postoperative antibiotics are unnecessary following uncomplicated appendicitis. For complicated appendicitis, a treatment duration of 4 to 7 days is recommended.
- 11▶ The role of incidental appendectomy is limited to patients at high risk for misdiagnosis of appendicitis (malrotation, patients unable to respond or react normally), patients at high risk for complications with appendicitis (children ready to undergo chemotherapy), and patients with limited access to modern healthcare.
- 12▶ The prevalence of appendiceal malignancy remains at or below 1% of appendectomies. Carcinoid and mucinous adenocarcinoma remain the most frequent histologic diagnosis.

its position at the tip of the cecum throughout development. The subsequent unequal growth of the lateral wall of the cecum causes the appendix to find its adult position on the posterior medial wall, just below the ileocecal valve. The base of the appendix can be located by following the longitudinally oriented taenia coli to their confluence on the cecum. The tip of the appendix can be located anywhere in the right lower quadrant of the abdomen, pelvis, or retroperitoneum.

In patients with midgut malrotation and situs inversus, the cecum (and thus the appendix) will not reside in the usual right lower quadrant location. With midgut malrotation, the midgut (small bowel and proximal colon) incompletely rotates or fails to rotate around the axis of the superior mesenteric artery during fetal development. In this situation, the appendix will remain in the left upper quadrant of the abdomen. Situs inversus is a rare autosomal recessive congenital defect characterized by the transposition of abdominal and/or thoracic organs. In this situation, the appendix is found in the left lower quadrant of the abdomen.¹¹

Anatomy

In the adult, the average length of the appendix is 6 to 9 cm; however, it can vary in length from <1 to >30 cm. The outer diameter varies between 3 and 8 mm, whereas the luminal diameter varies between 1 and 3 mm.⁹

The appendix receives its arterial supply from the appendicular branch of the ileocolic artery. This artery originates pos-

terior to the terminal ileum, entering the mesoappendix close to the base of the appendix.¹² The lymphatic drainage of the appendix flows into lymph nodes that lie along the ileocolic artery. Innervation of the appendix is derived from sympathetic elements contributed by the superior mesenteric plexus (T10-L1) and afferents from the parasympathetic elements via the vagus nerves.¹²

The histologic features of the appendix are contained within the three following layers: the outer serosa, which is an extension of the peritoneum; the muscularis layer, which is not well defined and may be absent in certain locations; and finally, the submucosa and mucosa. Lymphoid aggregates occur in the submucosal layer and may extend into the muscularis mucosa. Lymphatic channels are prominent in regions underlying these lymphoid aggregates. The mucosa is like that of the large intestine, except for the density of the lymphoid follicles. The crypts are irregularly sized and shaped, in contrast to the more uniform appearance of the crypts in the colon. Neuroendocrine complexes composed of ganglion cells, Schwann cells, neural fibers, and neurosecretory cells are positioned just below the crypts.^{13,14}

Physiology

For many years, the appendix was erroneously believed to be a vestigial organ with no known function. It is now well recognized that the appendix is an immunologic organ that actively participates in the secretion of immunoglobulins, particularly immunoglobulin A.

Although there is no clear role for the appendix in the development of human disease, an inverse association between appendectomy and the development of ulcerative colitis has been reported, suggesting a protecting effect of the appendectomy. However, this association is only seen in patients treated with appendectomy for appendicitis before age 20.¹⁵⁻¹⁷

The association between Crohn's disease and appendectomy is less clear. Although earlier studies suggested that appendectomy increases the risk of developing Crohn's disease, more recent studies that carefully assessed the timing of appendectomy in relationship to the onset of Crohn's disease demonstrated no correlation.¹⁷ A recent meta-analysis demonstrated a significant risk of Crohn's disease early following appendicitis.¹⁸ This risk diminishes later, which suggests that a diagnostic (misidentifying Crohn's disease as appendicitis) rather than a physiologic relationship exists between appendectomy and Crohn's disease.

The appendix may function as a reservoir to recolonize the colon with healthy bacteria. One retrospective study demonstrated that prior appendectomy may have an inverse relationship to recurrent *Clostridium difficile* infections.¹⁹ However, in another retrospective study, prior appendectomy did not affect the rate of *C. difficile* infections.²⁰ The role of the appendix in recolonizing the colon remains to be elucidated.

ACUTE APPENDICITIS

Epidemiology

The lifetime risk of developing appendicitis is 8.6% for males **1▶** and 6.7% for females, with the highest incidence in the second and third decades.²¹ The rate of appendectomy for appendicitis has been decreasing since the 1950s in most countries. In the United States, it reached its lowest incidence rate of about 15 per 10,000 inhabitants in the 1990s.²² Since then, there has been an increase in the incidence rate of nonperforated appendicitis. The reason for this is not clear, but it has been proposed that the increased use of diagnostic imaging has led to a higher detection rate of mild appendicitis that would otherwise resolve undetected.

Etiology and Pathogenesis

The etiology and pathogenesis of appendicitis are not completely understood. Obstruction of the lumen due to fecaliths or hypertrophy of lymphoid tissue is proposed as the main etiologic factor in acute appendicitis. The frequency of obstruction rises with the severity of the inflammatory process. Fecaliths and calculi are found in 40% of cases of simple acute appendicitis,²³ in 65% of cases of gangrenous appendicitis without rupture, and in nearly 90% of cases of gangrenous appendicitis with rupture.²⁴

Traditionally, the belief has been that there is a predictable sequence of events leading to eventual appendiceal rupture. The proximal obstruction of the appendiceal lumen produces a closed-loop obstruction, and continuing normal secretion by the appendiceal mucosa rapidly produces distension. Distension of the appendix stimulates the nerve endings of visceral afferent stretch fibers, producing vague, dull, diffuse pain in the mid-abdomen or lower epigastrium. Distension increases from continued mucosal secretion and from rapid multiplication of the resident bacteria of the appendix. This causes reflex nausea and vomiting, and the visceral pain increases. As pressure in the organ increases, venous pressure is exceeded. Capillaries and venules are occluded but arterial inflow continues, resulting in engorgement and vascular congestion. The inflammatory

process soon involves the serosa of the appendix and in turn the parietal peritoneum. This produces the characteristic shift in pain to the right lower quadrant.

The mucosa of the appendix is susceptible to impairment of blood supply; thus, its integrity is compromised early in the process, which allows bacterial invasion. The area with the poorest blood supply suffers the most: ellipsoidal infarcts develop in the antimesenteric border. As distension, bacterial invasion, compromise of the vascular supply, and infarction progress, perforation occurs, usually on the antimesenteric border just beyond the point of obstruction. This sequence is not inevitable, however, and some episodes of acute appendicitis may resolve spontaneously.

Microbiology

Appendicitis may occur in clusters, suggesting an infectious genesis. However, an association with various contagious bacteria and viruses has only been found in a small proportion of appendicitis patients.²⁵ The flora of the inflamed appendix differs from that of the normal appendix. About 60% of aspirates of inflamed appendices have anaerobes compared to 25% of aspirates from normal appendices.²⁶ Tissue specimens from the inflamed appendix wall (not luminal aspirates) virtually all grow *Escherichia coli* and *Bacteroides* species on culture.^{27,28} *Fusobacterium nucleatum/necrophorum*, which is not present in the normal cecal flora, has been identified in 62% of inflamed appendices.²⁹ In addition to the other usual species (*Peptostreptococcus*, *Pseudomonas*, *Bacteroides splanchnicus*, *Bacteroides intermedius*, *Lactobacillus*), previously unreported fastidious gram-negative anaerobic bacilli have been encountered. Patients with gangrene or perforated appendicitis appear to have more tissue invasion by *Bacteroides*.

Natural History

Because of the current predilection for surgical treatment, the natural history of appendicitis has not been well described. An increasing amount of circumstantial evidence suggests that not all patients with appendicitis will progress to perforation and **2▶** that resolution may be a common event.³⁰ Among the strongest evidence are two randomized trials comparing early laparoscopy with conservative management of patients with acute abdominal pain. These studies found three to five times more patients with appendicitis in the group of patients who were randomized to laparoscopy.^{31,32} Based on epidemiologic differences, it has been proposed that nonperforated and perforated appendicitis may, in fact, be different diseases.²²

Clinical Presentation

The inflammatory process in the appendix presents as pain, which initially is of a diffuse visceral type and later becomes more localized as the peritoneal lining gets irritated (Table 30-1).³³

Symptoms. Appendicitis usually starts with periumbilical and diffuse pain that eventually localizes to the right lower quadrant (sensitivity, 81%; specificity, 53%).³⁴ Although right lower quadrant pain is one of the most sensitive signs of appendicitis, pain in an atypical location or minimal pain will often be the initial presentation. Variations in the anatomic location of the appendix may account for the differing presentations of the somatic phase of pain.

Appendicitis is also associated with gastrointestinal symptoms like nausea (sensitivity, 58%; specificity, 36%), vomiting (sensitivity, 51%; specificity, 45%), and anorexia (sensitivity,

Table 30-1

Signs and symptoms of appendicitis (data from Andersson³³)

	TRUE POSITIVE LIKELIHOOD RATIO	95% CONFIDENCE INTERVAL	TRUE NEGATIVE LIKELIHOOD RATIO	95% CONFIDENCE INTERVAL
Duration of symptoms (hours)				
>9	1.01	0.97–1.05	0.94	0.62–1.42
>12	0.96	0.90–1.04	1.19	0.87–1.63
>24	0.65	0.47–0.90	1.47	1.14–1.90
>48	0.49	0.36–0.67	1.20	1.08–1.34
Fever	1.64	0.89–3.01	0.61	0.49–0.77
Gastrointestinal dysfunction				
Anorexia	1.27	1.14–1.41	0.59	0.45–0.77
Nausea	1.15	1.04–1.36	0.72	0.57–0.91
Vomiting	1.63	1.45–1.84	0.75	0.69–0.80
Pain				
Pain migration	2.06	1.63–2.60	0.52	0.40–0.69
Pain progression	1.39	1.29–1.50	0.46	0.27–0.77
Direct tenderness	1.29	1.06–1.57	0.25	0.12–0.53
Indirect tenderness	2.47	1.38–4.43	0.71	0.65–0.77
Psoas sign	2.31	1.36–3.91	0.85	0.76–0.95
Rebound	1.99	1.61–2.45	0.39	0.32–0.48
Percussion tenderness	2.86	1.95–4.21	0.49	0.37–0.63
Guarding	2.48	1.60–3.84	0.57	0.48–0.68
Rigidity	2.96	2.43–3.59	0.86	0.72–1.02
Temperature (degrees centigrade)				
>37.7	1.57	0.90–2.76	0.65	0.31–1.36
>38.5	1.87	0.66–5.32	0.89	0.71–1.12
White blood cells (10 ⁹ /L)				
≥10	4.20	2.11–8.35	0.20	0.10–0.41
≥15	7.20	4.31–12.00	0.66	0.56–0.78
C-reactive protein (mg/L)				
>10	1.97	1.58–2.45	0.32	0.20–0.51
>20	2.39	1.67–3.41	0.47	0.28–0.81

Conclusions: Individually, disease history, clinical findings, and laboratory tests are weak. But, when combined, they yield high discriminatory power.

68%; specificity, 36%). Gastrointestinal symptoms that develop before the onset of pain suggest a different etiology such as gastroenteritis.³⁴ Many patients complain of a sensation of obstipation prior to the onset of pain and feel that defecation will relieve their abdominal pain. Diarrhea may occur in association with perforation, especially in children.

Signs. Early in presentation, vital signs may be minimally altered. The body temperature and pulse rate may be normal or slightly elevated. Changes of greater magnitude may indicate that a complication has occurred or that another diagnosis should be considered.³⁵

Physical findings are determined by the presence of peritoneal irritation and are influenced by whether the organ has already ruptured when the patient is first examined. Patients with appendicitis usually move slowly and prefer to lie supine due to the peritoneal irritation. On abdominal palpation, there is tenderness with a maximum at or near McBurney's point (Fig. 30-1).⁵ On deep palpation, one can often feel a muscular resistance (guarding) in the right iliac fossa, which may be more evident when compared to the left side. When the pressure of the examining hand is quickly relieved, the patient feels

a sudden pain, the so-called rebound tenderness. Indirect tenderness (Rovsing's sign) and indirect rebound tenderness (i.e., pain in the right lower quadrant when the left lower quadrant is palpated) are strong indicators of peritoneal irritation. Rebound tenderness can be very sharp and uncomfortable for the patient. It is therefore recommended to start with testing for indirect rebound tenderness and direct percussion tenderness.

Anatomic variations in the position of the inflamed appendix lead to deviations in the usual physical findings. With a retrocecal appendix, the abdominal findings are less striking, and tenderness may be most marked in the flank. When the appendix hangs into the pelvis, abdominal findings may be entirely absent, and the diagnosis may be missed. Right-sided rectal tenderness is said to help in this situation, but the diagnostic value is low. Pain with extension of the right leg (psoas sign) indicates a focus of irritation in the proximity of the right psoas muscle. Similarly, stretching of the obturator internus through internal rotation of a flexed thigh (obturator sign) suggests inflammation near the muscle.

Laboratory Findings. Appendicitis is associated with an inflammatory response that is strongly related to the severity of

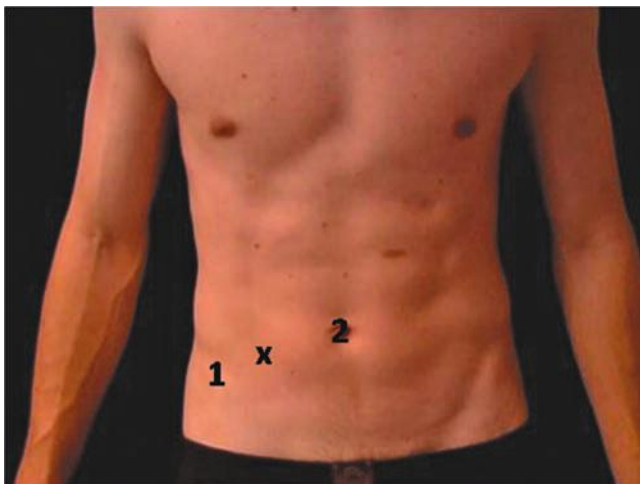


Figure 30-1. McBurney's point (1 = anterior superior iliac spine; 2 = umbilicus; x = McBurney's point).

the disease. Laboratory examinations are therefore an important part of the diagnosis. Mild leukocytosis is often present in patients with acute, uncomplicated appendicitis and is usually accompanied by a polymorphonuclear prominence. It is unusual for the white blood cell count to be $>18,000$ cells/mm³ in uncomplicated appendicitis. Counts above this level raise the possibility of a perforated appendix with or without an abscess. An increased C-reactive protein (CRP) concentration is a strong indicator of appendicitis, especially for complicated appendicitis.³⁶

White blood cell counts can be low due to lymphopenia or septic reaction, but in this situation, the proportion of neutrophils is usually very high. Therefore, all inflammatory variables should be viewed together. Appendicitis is very unlikely if the white blood cell count, proportion of neutrophils, and CRP are

all normal. The inflammatory response in acute appendicitis is a dynamic process. Early in the process, the inflammatory response can be weak. CRP elevation, in particular, can have up to a 12-hour delay. A decreasing inflammatory response may indicate spontaneous resolution.

Urinalysis can be useful to rule out the urinary tract as the source of infection; however, several white or red blood cells can be present from irritation of the ureter or bladder. Bacteriuria is generally not seen.

Clinical Scoring Systems. The clinical diagnosis of appendicitis is a subjective estimate of the probability of appendicitis based on multiple variables that individually are weak discriminators; however, used in conjunction, they possess a high predictive value. This process can be made more objective by the use of clinical scoring systems, which are based on variables with proven discriminating power and assigned a proper weight. The Alvarado score is the most widespread scoring system. It is especially useful for ruling out appendicitis and selecting patients for further diagnostic workup.³⁷ The Appendicitis Inflammatory Response Score resembles the Alvarado score but uses more graded variables and includes CRP (Table 30-2).^{38,39} Studies have shown it to perform better than the Alvarado score in accurately predicting appendicitis.^{38,39} However, clinical scoring systems have not gained widespread acceptance in making the diagnosis of appendicitis.

Imaging Studies. Plain films of the abdomen can show the presence of a fecalith and fecal loading in the cecum associated with appendicitis but are rarely helpful in diagnosing acute appendicitis⁴⁰; however, they may be of benefit in ruling out other pathology. A chest radiograph is helpful to rule out referred pain from a right lower lobe pneumonic process. If the appendix fills on barium enema, appendicitis is unlikely⁴¹; however, this test is not indicated in the acute setting. Technetium-99m-labeled

Table 30-2

Scoring systems

ALVARADO SCORE ³⁷		APPENDICITIS INFLAMMATORY RESPONSE SCORE ^{38,39}	
Findings	Points	Findings	Points
Migratory right iliac fossa pain	1	Vomiting	1
Anorexia	1	Pain in the right inferior fossa	1
Nausea or vomiting	1	Rebound tenderness or muscular defense	
Tenderness: right iliac fossa	2	Light	1
Rebound tenderness right iliac fossa	1	Medium	2
Fever $\geq 36.3^{\circ}\text{C}$	1	Strong	3
Leukocytosis $\geq 10 \times 10^9$ cells/L	2	Body temperature $\geq 38.5^{\circ}\text{C}$	1
Shift to the left of neutrophils	1	Polymorphonuclear leukocytes	
		70%–84%	1
		$\geq 85\%$	2
		White blood cell count	
		10.0–14.9 $\times 10^9$ cells/L	1
		$\geq 15.0 \times 10^9$ cells/L	2
		C-reactive protein concentration	
		10–49 g/L	1
		≥ 50 g/L	2

Score: <3: Low likelihood of appendicitis
4–6: Consider further imaging
 ≥ 7 : High likelihood of appendicitis

Score: 0–4: Low probability. Outpatient follow-up.
5–8: Indeterminate group. Active observation or diagnostic laparoscopy.
9–12: High probability. Surgical exploration.

leukocyte scan has been reported for use in diagnosing appendicitis with good results but has not gained widespread use due to its relative unavailability and impracticality in daily use.⁴²

Ultrasonography and computed tomography (CT) scan are the most commonly used imaging tests in patients with abdominal pain, particularly in evaluation of possible appendicitis. Multiple meta-analyses have been performed comparing the two imaging modalities (Table 30-3).⁴³⁻⁴⁷ Overall, CT scan is more sensitive and specific than ultrasonography in diagnosing appendicitis.

Graded compression ultrasonography is inexpensive, can be performed rapidly, does not require a contrast medium, and can be used in pregnant patients. Sonographically, the appendix is identified as a blind-ending, nonperistaltic bowel loop originating from the cecum. With maximal compression, the diameter of the appendix is measured in the anterior-posterior direction. Thickening of the appendiceal wall and the presence of periappendiceal fluid are highly suggestive of appendicitis. Demonstration of an easily compressible appendix measuring <5 mm in diameter excludes the diagnosis of appendicitis. The sonographic diagnosis of acute appendicitis has a reported sensitivity of 55% to 96% and a specificity of 85% to 98%. Ultrasonography is similarly effective in children and pregnant women, although its application is limited in late pregnancy. Ultrasonography has its limitations, particularly the operator-dependent nature of results. In the adult population, ultrasonography remains limited in its use.

With high-resolution helical CT, the inflamed appendix appears dilated (>5 mm), and the wall is thickened. There is often evidence of inflammation, which can include periappendiceal fat stranding, thickened mesoappendix, periappendiceal phlegmon, and free fluid. Fecaliths can be often visualized; however, their presence is not pathognomonic of appendicitis. CT scanning is also an excellent technique for identifying other inflammatory processes masquerading as appendicitis. Several CT techniques have been used, including focused and nonfocused CT scans and contrast and noncontrast scans. Surprisingly, all of these techniques have yielded essentially identical rates of diagnostic accuracy: 92% to 97% sensitivity, 85% to 94% specificity, 90% to 98% accuracy, 75% to 95% positive predictive value, and 95% to 99% negative predictive value. The additional use of rectal contrast does not improve the results of CT scanning.

A number of studies have documented improvement in diagnostic accuracy with the liberal use of CT scanning in the workup of suspected appendicitis. CT lowered the rate of negative appendectomies from 19% to 12% in one study⁴⁸ and the incidence of negative appendectomies in women from 24% to 5% in another study.⁴⁹ Use of CT altered the care of 24% of patients studied and provided an alternative diagnosis in half of the patients with normal appendices on CT scan.

Despite the potential usefulness of CT, there are significant disadvantages. CT scanning is expensive, exposes the patient to significant radiation, and has limited use during pregnancy. Allergy to iodine or contrast limits the administration of contrast agents in some patients, and others cannot tolerate the oral ingestion of luminal dye.

The role of CT scanning in patients who present with right lower quadrant pain is unclear. One rationale is universal CT scanning. There is, however, an argument that indiscriminate diagnostic imaging can increase the detection of clinically nonsignificant appendicitis that would resolve without treatment.

Alternatively, selective CT scanning based on the likelihood of appendicitis takes advantage of the clinical skills of the surgeon and, when indicated, adds the expertise of the radiologist.

Despite the increased use of ultrasonography and CT, the rate of misdiagnosis of appendicitis has remained constant (15%). The percentage of misdiagnosed cases of appendicitis is significantly higher among women than men (22% vs. 9.3%).^{50,51} The negative appendectomy rate is highest in women of reproductive age.

Differential Diagnosis

The differential diagnosis of acute appendicitis is essentially the diagnosis of acute abdomen. An identical clinical picture can result from a wide variety of acute processes within the peritoneal cavity that produce the same physiologic alterations as acute appendicitis.

The accuracy of preoperative diagnosis should be higher than 85%. If it is consistently less, it is likely that unnecessary operations are being performed and a more rigorous preoperative differential diagnosis is needed.

The most common findings in the case of an erroneous preoperative diagnosis of appendicitis—together accounting for more than 75% of cases—are, in descending order of frequency, acute mesenteric adenitis, no organic pathologic condition, acute pelvic inflammatory disease, twisted ovarian cyst or ruptured graafian follicle, and acute gastroenteritis.

The differential diagnosis of acute appendicitis depends on four major factors: the anatomic location of the inflamed appendix; the stage of the process (uncomplicated or complicated); the patient's age; and the patient's gender.⁵²⁻⁵⁶

Pediatric Patient. Acute mesenteric adenitis is the disease most often confused with acute appendicitis in children. Almost invariably, an upper respiratory tract infection is present or has recently subsided. The pain usually is diffuse, and tenderness is not as sharply localized as in appendicitis. Voluntary guarding is sometimes present, but true rigidity is rare. Generalized lymphadenopathy may be noted. Laboratory procedures are of little help in arriving at the correct diagnosis, although a relative lymphocytosis, when present, suggests mesenteric adenitis. Observation for several hours is appropriate if the diagnosis of mesenteric adenitis is suspected, as it is a self-limited disease.

Elderly Patient. Diverticulitis or perforating carcinoma of the cecum or of a portion of the sigmoid that overlies the right lower abdomen may be impossible to distinguish from appendicitis. These entities should be considered, particularly in older patients. CT scanning is often helpful in making a diagnosis in older patients with right lower quadrant pain and atypical clinical presentations. In patients successfully managed conservatively, interval surveillance of the colon (colonoscopy or barium enema) may be warranted.

Female Patient. Diseases of the female internal reproductive organs that may erroneously be diagnosed as appendicitis are, in approximate descending order of frequency, pelvic inflammatory disease, ruptured graafian follicle, twisted ovarian cyst or tumor, endometriosis, and ruptured ectopic pregnancy. As a result, the rate of misdiagnosis remains higher among female patients.

In pelvic inflammatory disease, the infection is usually bilateral but, if confined to the right tube, may mimic acute appendicitis. Nausea and vomiting are present in patients with appendicitis but in only approximately 50% of those with pelvic

Table 30-3

Meta-analyses comparing CT scan and US outcomes

		AUTHOR					SUMMARY
		TERASAWA	WESTON	DORIA	AL-KHAYAL	VAN RANDEN	
Year		2004	2005	2006	2007	2008	
No. of studies		22	21	57	25	6	
No. of patients	CT	1172	NR	NR	NR	NR	
	US	1516	NR	NR	NR	NR	
	Total	2688	5039	13697	13046	671	
Sensitivity	CT	94% (CI: 91%–95%)	97% (CI: 95%–98%)	94% (CI: 92%–97%)	93% (CI: 92%–95%)	91% (CI: 84%–95%)	CT more sensitive than US in five of five meta-analyses
	US	86% (CI: 83%–88%)	87% (CI: 85%–89%)	88% (CI: 86%–90%)	84% (CI: 82%–85%)	78% (CI: 67%–86%)	
Specificity	CT	95% (CI: 93%–96%)	95% (CI: 93%–96%)	94% (CI: 94%–96%)	93 (CI: 92%–94%)	90% (CI: 85%–94%)	CT more specific than US in four of five meta-analyses
	US	81% (CI: 78%–84%)	93% (CI: 92%–94%)	93% (CI: 90%–96%)	96 (CI: 95%–96%)	83% (CI: 76%–88%)	
Positive predictive value	CT	NR	94% (CI: 92%–95%)	NR	90% (CI: 89%–92%)	NR	CT has superior positive predictive value in one of two meta-analyses
	US	NR	89% (CI: 87%–90%)	NR	90% (CI: 89%–91%)	NR	
Negative predictive value	CT	NR	97% (CI: 96%–98%)	NR	96% (CI: 95%–97%)	NR	CT has superior negative predictive value in both meta-analyses
	US	NR	92% (CI: 91%–93%)	NR	93% (CI: 92%–94%)	NR	
Accuracy	CT	NR	NR	NR	94% (CI: 93%–94%)	NR	CT is more accurate in the one study reporting results
	US	NR	NR	NR	92% (CI: 92%–96%)	NR	

CI = confidence interval; CT = computed tomography; NR = not reported; US = ultrasonography.

inflammatory disease. Pain and tenderness are usually lower, and motion of the cervix is exquisitely painful. Intracellular diplococci may be demonstrable on smear of the purulent vaginal discharge. The ratio of cases of appendicitis to cases of pelvic inflammatory disease is low in females in the early phase of the menstrual cycle and high during the luteal phase. The careful clinical use of these features has reduced the incidence of negative findings on laparoscopy in young women to 15%.

Ovulation commonly results in the spillage of sufficient amounts of blood and follicular fluid to produce brief, mild lower abdominal pain. If the amount of fluid is unusually copious and is from the right ovary, appendicitis may be simulated. Pain and tenderness may be rather diffuse, and leukocytosis and fever minimal or absent. Because this pain occurs at the midpoint of the menstrual cycle, it is often called *mittelschmerz*.

Serous cysts of the ovary are common and generally remain asymptomatic. When right-sided cysts rupture or undergo torsion, the manifestations are similar to those of appendicitis. Patients develop right lower quadrant pain, tenderness, rebound, fever, and leukocytosis. Both transvaginal ultrasonography and CT scanning can be diagnostic.

Torsion requires emergent operative treatment. If the torsion is complete or longstanding, the pedicle undergoes thrombosis, and the ovary and tube become gangrenous and require resection. However, simple detorsion, fenestration of the cyst, and fixation of the ovary as a primary intervention, followed by a laparoscopy a few days later, can be recommended because it is often difficult to preoperatively determine the viability of the ovary.

Blastocysts may implant in the fallopian tube (usually the ampullary portion) and in the ovary. Rupture of right tubal or ovarian pregnancies can mimic appendicitis. Patients may give a history of abnormal menses, either missing one or two periods or noting only slight vaginal bleeding. Unfortunately, patients do not always realize they are pregnant. The development of right lower quadrant or pelvic pain may be the first symptom. The diagnosis of ruptured ectopic pregnancy should be relatively easy. The presence of a pelvic mass and elevated levels of human chorionic gonadotropin are characteristic. Although the leukocyte count rises slightly, the hematocrit level falls as a consequence of the intra-abdominal hemorrhage. Vaginal examination reveals cervical motion and adnexal tenderness, and a more definitive diagnosis can be established by culdocentesis. The presence of blood and particularly decidual tissue is pathognomonic. The treatment of ruptured ectopic pregnancy is emergency surgery.

Immunosuppressed Patient. The incidence of acute appendicitis in patients infected with human immunodeficiency virus (HIV) is reported to be 0.5%. This is higher than the 0.1% to 0.2% incidence reported for the general population.⁵⁷ The presentation of acute appendicitis in HIV-infected patients is similar to that in noninfected patients. The majority of HIV-infected patients with appendicitis have fever, periumbilical pain radiating to the right lower quadrant (91%), right lower quadrant tenderness (91%), and rebound tenderness (74%). HIV-infected patients do not manifest an absolute leukocytosis; however, if a baseline leukocyte count is available, nearly all HIV-infected patients with appendicitis demonstrate a relative leukocytosis.⁵⁷

The risk of appendiceal rupture appears to be increased in HIV-infected patients. In one large series of HIV-infected patients who underwent appendectomy for presumed appendicitis, 43% of

patients were found to have perforated appendicitis at laparotomy.⁵⁸ The increased risk of appendiceal rupture may be related to the delay in presentation seen in this patient population.^{57,58} A low CD4 count is also associated with an increased incidence of appendiceal rupture.⁵⁷

The differential diagnosis of right lower quadrant pain is expanded in HIV-infected patients compared with the general population. In addition to the conditions discussed elsewhere in this chapter, opportunistic infections should be considered as a possible cause of right lower quadrant pain.^{57,58} Neutropenic enterocolitis (typhlitis) should also be considered in the differential diagnosis of right lower quadrant pain in HIV-infected patients.^{57,58}

Initial Management

Uncomplicated Appendicitis

Operative versus Nonoperative Management of Uncomplicated Appendicitis In patients with uncomplicated appendicitis, surgical treatment has been the standard of treatment since McBurney reported his experiences. The concept of nonoperative treatment for uncomplicated appendicitis developed from two lines of observations. First, for patients in an environment where surgical treatment is not available (e.g., submarines, expeditions in remote areas), treatment with antibiotics alone was noted to be effective. Second, many patients with signs and symptoms consistent with appendicitis who did not pursue medical treatment would occasionally have spontaneous resolution of their illness.

A handful of observational studies and controlled trials have reported the outcomes of nonoperative versus operative treatment of presumed uncomplicated appendicitis (Table 30-4).⁵⁹⁻⁶⁴ Overall, there is a reported 9% short-term (<30 days) failure rate with nonoperative management of appendicitis (13% if evaluated per protocol). In patients in whom nonoperative treatment fails, nearly half of patients have complicated (perforated or gangrenous) appendicitis. After 1 month, about 1% of patients in the trials underwent an interval appendectomy, and 13% of patients who initially were successfully treated with nonoperative measures developed recurrent appendicitis, with an 18% rate of complicated appendicitis. Follow-up was not longer than 1 year in any study. In addition, one-third of patients declined or dropped out from nonoperative management of appendicitis.

In comparison, operative appendectomy demonstrated a relatively low dropout rate (2%), lower proportion of complicated appendicitis (25%), small proportion of a normal appendix (5%), and low rates of superficial surgical site infection (3.7%) and intra-abdominal abscess (1.3%).

The results in these studies must be viewed with caution due to unclear selection of patients, incomplete diagnostic workup in the nonoperated patients, unclear gold standard for the operated patients, and high rates of crossover between the treatment arms. The consequences in terms of use of hospital beds, length of hospital stay, morbidity of delayed surgical treatment after failed nonsurgical treatment, delayed diagnosis for patients with an underlying cancer in the appendix or cecum, and risk of increased antibiotic resistance need to be further investigated. Thus, operative treatment of presumed uncomplicated appendicitis still remains the standard of care. Certain subgroups with uncomplicated appendicitis may do well with nonoperative therapy. Patients pursuing nonoperative management should be carefully counseled regarding the risks of treatment failure and recurrent appendicitis.

Table 30-4

Outcomes associated with nonoperative and operative management of acute appendicitis

NONOPERATIVE OUTCOMES

AUTHOR	STUDY TYPE	NO.	MALE	AGE	DROPOUT AFTER RANDOMIZATION	FAILED THERAPY IN 0-30 DAYS	COMPLICATED APPENDICITIS	INTERVAL APPENDECTOMY	FAILED THERAPY IN >30 DAYS	COMPLICATED APPENDICITIS	FOLLOW-UP DURATION IN MONTHS (RANGE)
Vons	PRCT	120 ^a	75	21±9 ^b	3	14	9	NR	30	3	12
Hansson	PRCT	202	103	38±1 ^c	96	9	6/11 ^d	NR	11	4/12 ^d	12
Turhan	PCT	107	65	21 ^c	5	14	0	NR	8	0	NR
Liu	RT	19	8	34±1 ^e	NA	0	0	5	6	1	NR
Styrud	PT	128	128	18-50	79/104 ^f	15	7	NR	16	5	4 (1-10)
Eriksson	PRCT	20	14	28 (18-53)	5 ^g	1	1	NR	7	1	7 (3-12)
Overall		596	393 (66%)	23	188 (33%)	53 (8.9%)	23 (42%)	5 (0.8%)	78 (13%)	14 (17.7%)	<1 year

OPERATIVE OUTCOMES

AUTHOR	STUDY TYPE	NO.	MALE	AGE	DROPOUT AFTER RANDOMIZATION	COMPLICATED APPENDICITIS	NORMAL APPENDIX	SSI, SUPERFICIAL	INTRA-ABDOMINAL ABSCESS
Vons	PRCT	120	70	34±12 ^b	1	21	NR	1	NR
Hansson	PRCT	167	92	38±1 ^c	13	92/250 ^f	30/250 ^f	7	5
Turhan	PCT	183	125	26±1	NR	34	NR	6	2
Liu	RT	151	104	34±1 ^e	NR	47	5	9	0
Styrud	PT	124	124	18-50	NR	7	4	NR	NR
Eriksson	PRCT	20	13	35 (19-85)	NR	9	3	1	0
Overall		765	528 (69%)	33	14 (1.8%)	210 (24.8%)	42 (5.0%)	24 (3.7%)	7 (1.3%)

^aAlthough 123 patients were randomized to nonoperative management and 3 patients dropped out, only 120 patients were included in the intent-to-treat analysis.

^bStandard deviation.

^cStandard error of the mean.

^dStudy only reported pathology results based on the per-protocol group and not the intent-to-treat group.

^eStudy did not report the meaning of these values.

^fStudy did not report the intent-to-treat values; instead, at one institution, 79 of 104 patients declined to be included in the trial.

^gThese patients declined to be included in the study and opted for surgical management.

NA = not applicable; NR = not reported; PCT = prospective controlled trial; PRCT = prospective randomized controlled trial; RT = retrospective trial; SSI = surgical site infection.

Urgent versus Emergent Appendectomy for Uncomplicated Appendicitis

Traditionally, appendicitis has been considered a surgical emergency. Once diagnosed, a patient was emergently taken to the operating room for surgical treatment. However, delays in diagnosis, lack of access to available operating suites, and nonoperative management of appendicitis have challenged the notion that uncomplicated appendicitis is a surgical emergency.

Three retrospective studies have evaluated the role of emergent or urgent surgery for uncomplicated appendicitis; the emergent group had a time from presentation to the operating room of <12 hours, whereas the urgent group had a time from presentation to the operating room of 12 to 24 hours (Table 30-5).⁶⁵⁻⁶⁷ There was no statistically significant increase in the number of complicated appendicitis cases in the urgent group when compared to the emergent group. Similarly, rates of surgical site infection, intra-abdominal abscesses, conversion to an open procedure, or operative time showed no difference between the two groups. While length of stay was longer for the urgent group, it was not statistically or clinically different from the emergent group. Important caveats in consideration of urgent as opposed to emergent surgical care include the patient's clinical examination, time of presentation from onset of symptoms, and duration of "delay" in surgery. Patients with clinical signs of perforation, patients with delayed presentation of greater than 48 hours from onset of symptoms, and patients whose definitive therapy may be delayed for more than 12 hours were beyond the scope of these studies.

Emergent versus urgent operation for uncomplicated appendicitis is dependent on each institution and surgeon. Institutions without readily available operating rooms and staff may

consider performing appendectomy in an urgent fashion as opposed to emergently.

Complicated Appendicitis. Complicated appendicitis typically refers to perforated appendicitis commonly associated with an abscess or phlegmon. The yearly incidence rate of perforated appendicitis is about 2 per 10,000 persons and has remarkable little variance over time, geographic region, and age.^{51,68,69} The proportion of perforated appendicitis, commonly around 25%, is often used as an indicator of quality of care. Differences in this proportion are almost entirely related to differences in the incidence of nonperforated appendicitis. A low proportion of perforations may therefore be the consequence of a higher rate of detection and treatment of early or resolving appendicitis.

Children less than 5 years of age and patients more than 65 years of age have the highest rates of perforation (45% and 6▶ 51%, respectively). The proportion of perforation increases with increasing duration of symptoms. There is, however, no association of in-hospital delay with perforation. This suggests that most perforations occur early, before the patient arrives to hospital. It has also been proposed that the increasing proportion of perforations with time is explained by selection due to spontaneous resolution of noncomplicated appendicitis.

Perforated appendicitis has been suggested to increase the risk of female infertility due to impaired tubal function, but this has not been shown in epidemiologic studies.⁷⁰

Rupture should be suspected in the presence of generalized peritonitis and a strong inflammatory response. In many cases, rupture is contained and patients display localized peritonitis. In 2% to 6% of cases, a palpable mass is detected on physical examination. This could represent a phlegmon, which consists

Table 30-5

Emergent versus urgent surgery

		AUTHOR				
		ABOU-NUKTA	STAHLFELD	INGRAHAM	SUMMARY	
Year		2006	2007	2010		
No. of patients	Emergent Urgent	233 76	53 18	24,647 4934		
Time from presentation to OR (hours)	Emergent Urgent	6.7±2.7 16.7±3.6	3.2±2.4 15.8±5.5	1.5 8.5		
% Complicated	Emergent Urgent	32% 37%	NR	NR	No difference in complicated appendicitis	
Conversion to open, %	Emergent Urgent	NR	15% 7%	NR	No difference in conversion rates	
Operative duration (minutes)	Emergent Urgent	81±31 82±31	54 56	51 50	No difference in operative duration	
SSI, %	Emergent Urgent	1% 1%	7.5% 0%	NR	One study demonstrates increased infections with emergent operation	
Intra-abdominal abscess, %	Emergent Urgent	2% 1%	NR	NR	No difference in intra-abdominal abscess rates	
Length of stay (days)	Emergent Urgent	2.5±2.3 2.9±1.8	2.7 2.1	1.8 1.8	No significant difference in length of stay	

NR = not reported; OR = operating room; SSI = surgical site infection.

of matted loops of bowel adherent to the adjacent inflamed appendix or a periappendiceal abscess. Patients who present with a mass have experienced symptoms for a longer duration, usually 5 to 7 days. Distinguishing acute, uncomplicated appendicitis from acute appendicitis with perforation based on clinical findings is often difficult, but it is important to make the distinction because the treatments may differ. CT scan may be beneficial in establishing a diagnosis and guiding therapy.

Operative versus Nonoperative Management of Complicated Appendicitis Patients who present with signs of sepsis and generalized peritonitis should be taken to the operating room immediately with concurrent resuscitation. The surgical approach is based on the surgeon's level of comfort; however, open appendectomy through a lower midline incision may be necessary to treat these complicated cases.

In patients with complicated appendicitis and a contained abscess or phlegmon but limited peritonitis (focal right lower quadrant pain), the treatment options become more complicated. Often, these patients will require a challenging procedure with a high risk for development of a postoperative intra-abdominal abscess. Options include operative management versus conservative management (antibiotics, bowel rest, fluids, and possible percutaneous drainage).

There have been no prospective randomized controlled studies comparing operative versus conservative management of complicated appendicitis in adults; all studies have been retrospective cohort studies. Two meta-analyses have been performed. In Andersson and Petzold's 2007 analysis of 61 studies evaluating this issue, they noted that initial nonoperative management had superior outcomes.⁷⁰ Nonoperative management included intravenous fluids, minimizing gastrointestinal stimulation, parenteral antibiotics, and percutaneous drainage where deemed appropriate. The morbidity of immediate operative treatment was 36.5%, whereas the morbidity of conservative management was 11%. Of patients undergoing conservative treatment, 7.6% failed conservative treatment and underwent operative management. This subgroup had an overall complication rate of 13.5%. The recurrence rate was 7.4%, which does not necessitate interval appendectomy. The authors concluded that conservative treatment was favored over early operation in complicated appendicitis.³⁰

Simillis and colleagues performed a meta-analysis of 17 studies.⁷¹ They noted that conservative treatment was associated with fewer overall complications (odds ratio, 0.24; 95% confidence interval [CI], 0.13 to 0.44), intra-abdominal abscesses (odds ratio, 0.19; 95% CI, 0.07 to 0.58), bowel obstructions (odds ratio, 0.35; 95% CI, 0.17 to 0.71), and reoperations (odds ratio, 0.17; 95% CI, 0.04 to 0.75).⁷¹ The authors concluded that conservative treatment was favored over early operation in complicated appendicitis.

In the pediatric literature, there have been two prospective randomized controlled trials^{72,73} demonstrating that early operative intervention had equivalent or superior outcomes to conservative management, but these studies included interval appendectomy for all patients in their calculations. St. Peter and colleagues⁷² demonstrated that 20% of patients failed conservative treatment. Early surgical intervention had equivalent results to interval appendectomy. Alternatively, Blakely and colleagues⁷³ noted that interval appendectomy, versus early appendectomy, had a higher incidence of adverse events (50% vs. 30%, $P = .003$), intra-abdominal abscesses (37% vs. 19%, $P = .02$), small bowel obstruction (10.4% vs. 0%, $P = .01$), and readmissions (31% vs. 8%, $P = .06$). In addition, Blakely and

colleagues noted that 9% of the group treated conservatively developed recurrent appendicitis. The authors concluded that immediate surgical treatment was superior to conservative treatment with interval appendectomy.

Interval Appendectomy Following Nonoperative Management of Complicated Appendicitis Interval appendectomy is defined as performing an appendectomy following initial successful nonoperative management in patients with no further symptoms. The major argument against interval appendectomy is that many patients treated conservatively never develop manifestations of appendicitis, and those who do generally can be treated without additional morbidity. The major argument for interval appendectomy is to prevent future attacks of appendicitis or to identify other disease, such as appendiceal malignancy.

There has only been one small prospective randomized controlled trial ($n = 40$) investigating this subject. The literature is largely populated with small case series and retrospective cohort studies; there is no meta-analysis evaluating the subject (Table 30-6).⁷⁴⁻⁸¹ Of the 1434 patients who had presumed complicated appendicitis and were successfully treated conservatively, 8.8% developed recurrent appendicitis with a median follow-up of 35 months. The incidence of complicated appendicitis following recurrence was low (2.4%). Malignancy was noted in 1.3% of cases where pathology was reported. Many of the patients were excluded from these studies due to persistent symptoms, persistent infections, or note of malignancy on screening colonoscopy.

Alternatively, of the 344 patients who had presumed complicated appendicitis, were successfully treated conservatively, and subsequently underwent interval appendectomy, surgical complications occurred in 9.4% of the patients. Most patients underwent interval appendectomy 2 to 4 months after their acute presentation. Although operative and pathologic details were not uniformly reported in these patients, many continued to have evidence of appendicitis or abscess at the time of interval appendectomy; 3.6% of patients had malignancy in cases where pathology was reported.

The role of interval appendectomy following successful management of conservative treatment of complicated appendicitis is unclear. Close clinical follow-up, a complete history searching for persistent symptoms, and screening colonoscopy (when age appropriate) should all be used to help guide the discussion with the patient on the role of interval appendectomy following conservative management of complicated appendicitis.

OPERATIVE INTERVENTIONS FOR THE APPENDIX

Open Appendectomy

Typically performed with a patient under general anesthesia, the patient is placed in supine position. The entire abdomen should be prepped and draped in case a larger incision is needed. For early nonperforated appendicitis, a right lower quadrant incision at McBurney's point (one-third of the distance from the anterior superior iliac spine to the umbilicus) is commonly used. A McBurney (oblique) or Rocky-Davis (transverse) right lower quadrant muscle splitting incision is made. If perforated appendicitis is suspected or the diagnosis is in doubt, a lower midline laparotomy can be considered. Although it has been reported that the position of the base of the appendix can change with pregnancy, prospective studies have demonstrated that pregnancy does not change the proportion of patients with the appendiceal base within 2 cm of McBurney's point.⁸²

Table 30-6

Interval appendectomy following nonoperative management of complicated appendicitis

NO INTERVAL APPENDECTOMY									
AUTHOR	YEAR	STUDY TYPE	NO.	RECURRENT APPENDICITIS	APPENDECTOMY	COMPLICATED	COMPLICATIONS	MALIGNANCY	FOLLOW-UP DURATION (MONTHS)
Youssef	2010	PCT	51	9	7	1	1	NR	24
Tekin	2008	CS	89	15	NR	NR	NR	NR	NR
Lai	2006	RT	94	24	20	NR	NR	2	33
Kaminski	2005	CS	1012	39	39	NR	NR	NR	48
Kumar	2004	PRCT	20	2	2	NR	NR	1	34
Eryilmaz	2004	CS	25	3	3	NR	NR	NR	35
Dixon	2003	RT	116	32	22	0	NR	0	NR
Adalla	1996	CS	27	2	2	NR	NR	NR	NR
Overall			1434	126 (8.8%)	95 (7.1%)	1 (2.4%)	1 (11%)	3 (1.3%)	35
INTERVAL APPENDECTOMY									
AUTHOR	YEAR	STUDY TYPE	NO.	COMPLICATIONS	MALIGNANCY	TIME OF SURGERY (MONTHS)			
Lugo	2010	PT	46	3	2	2			
Youssef	2010	PCT	10	1	NR	3			
Lai	2006	RT	70	NR	2	2			
Kumar	2004	PRCT	20	0	1	3			
Dixon	2004	RCT	114	NR	NR	2			
Friedell	2000	CS	5	0	1	2			
Yamini	1998	CS	41	6	1	2			
Eriksson	1998	CS	38	5	1	4			
Overall			344	15 (9.4%)	8 (3.6%)	3			

CS = case series; NR = not reported; PCT = prospective controlled trial; PRCT = prospective randomized controlled trial; RT = retrospective trial.

Following entry into the abdomen, the patient should be placed in slight Trendelenburg position with rotation of the bed to the patient's left. If the appendix is not easily identified, the cecum should be located. Tracing the taenia libera (anterior taenia), the most visible of the three taeniae coli, distally, the base of the appendix can be identified.

The appendix will often have attachments to the lateral wall or pelvis that can be dissected free. Dividing the mesentery of the appendix first will often allow improved exposure of the base of the appendix. The appendiceal stump can be managed by simple ligation or by ligation and inversion. As long as the stump is clearly visible and the base of the cecum is not involved with the inflammatory process, the stump can be safely ligated. Obliteration of the mucosa with electrocautery with the intention to obviate the development of a mucocele is recommended by some surgeons; however, no data have evaluated the risk or benefit of this surgical maneuver. Inversion of the stump with plication of the cecum has also been described. Placement of surgical drains for both uncomplicated⁸³ and complicated appendicitis,⁸⁴⁻⁸⁷ practiced by many surgeons, has not been supported in clinical trials. Pus in the abdomen should be aspirated, but irrigation in complicated appendicitis is not recommended.⁸⁸

The skin can also be closed primarily in patients with perforated appendicitis.

If appendicitis is not found, a methodical search must be made for an alternative diagnosis. The cecum and mesentery should be inspected. The small bowel should be evaluated in a retrograde fashion beginning at the ileocecal valve. Concerns for Crohn's disease or Meckel's diverticulum should be of priority. In female patients, the reproductive organs should be closely inspected. If purulent or bilious fluid is encountered, it is imperative that the source be identified. For example, Valentino's appendicitis, or a perforated duodenal ulcer presenting as appendicitis, should be excluded in such cases. A medial extension of the incision (Fowler-Weir) or superior extension of the lateral incision is appropriate if further evaluation of the lower abdomen or right colon is warranted. Selective laparoscopy through a right lower quadrant incision has also been described.⁸⁹ If upper abdominal pathology is encountered, a midline incision should be made.

Laparoscopic Appendectomy

The first reported laparoscopic appendectomy was performed in 1983 by Semm; however, the laparoscopic approach did

not come into widespread use until much later, following the success of laparoscopic cholecystectomy. This may be due to the small incision already commonly used with open appendectomy.

Laparoscopic appendectomy is performed under general anesthesia. An oro- or nasogastric tube and urinary catheter are placed. The patient should be placed supine with his or her left arm tucked and securely strapped to the operating table. Both surgeon and assistant should be standing on the patient's left facing the appendix. The laparoscopic screens should be positioned on the patient's right or at the foot of the bed. Standard laparoscopic appendectomy typically uses three ports. Typically, a 10- or 12-mm port is placed at the umbilicus, whereas two 5-mm ports are placed suprapubic and in the left lower quadrant. The patient should be placed in Trendelenburg and tilted to the left (Fig. 30-2).

The appendix should be identified similarly as in open surgery by tracking the taenia libera/coli to the appendiceal base. Through the suprapubic port, the appendix should be grasped securely and elevated to the 10 o'clock position. An "appendiceal critical view" should be obtained where the taenia libera is at the 3 o'clock position, the terminal ileum at the 6 o'clock

position, and the retracted appendix at the 10 o'clock position to allow proper identification of the base of the appendix (Fig. 30-3).⁹⁰ Through the infraumbilical port, the mesentery should be gently dissected from the base of the appendix and a window created. Typically the base of the appendix is stapled, followed by stapling of the mesentery. Alternatively, the mesentery may be divided by an energy device or clipped and the base of the appendix secured with an Endoloop. The stump should be carefully examined to ensure hemostasis, complete transection, and ensure that no stump is left behind. The appendix is removed through the infraumbilical trocar in a retrieval bag.

Laparoscopic versus Open Appendectomy

There have been multiple prospective, randomized controlled trials comparing laparoscopic and open appendectomy outcomes. A number of meta-analyses have been performed evaluating the cumulative outcomes (Table 30-7).⁹¹⁻⁹⁹

Laparoscopic appendectomy is associated with fewer incisional surgical site infections compared to open appendectomy. However, laparoscopic appendectomy may be associated with increased risk of intra-abdominal abscess compared to open appendectomy. There is less pain, shorter length of stay, and

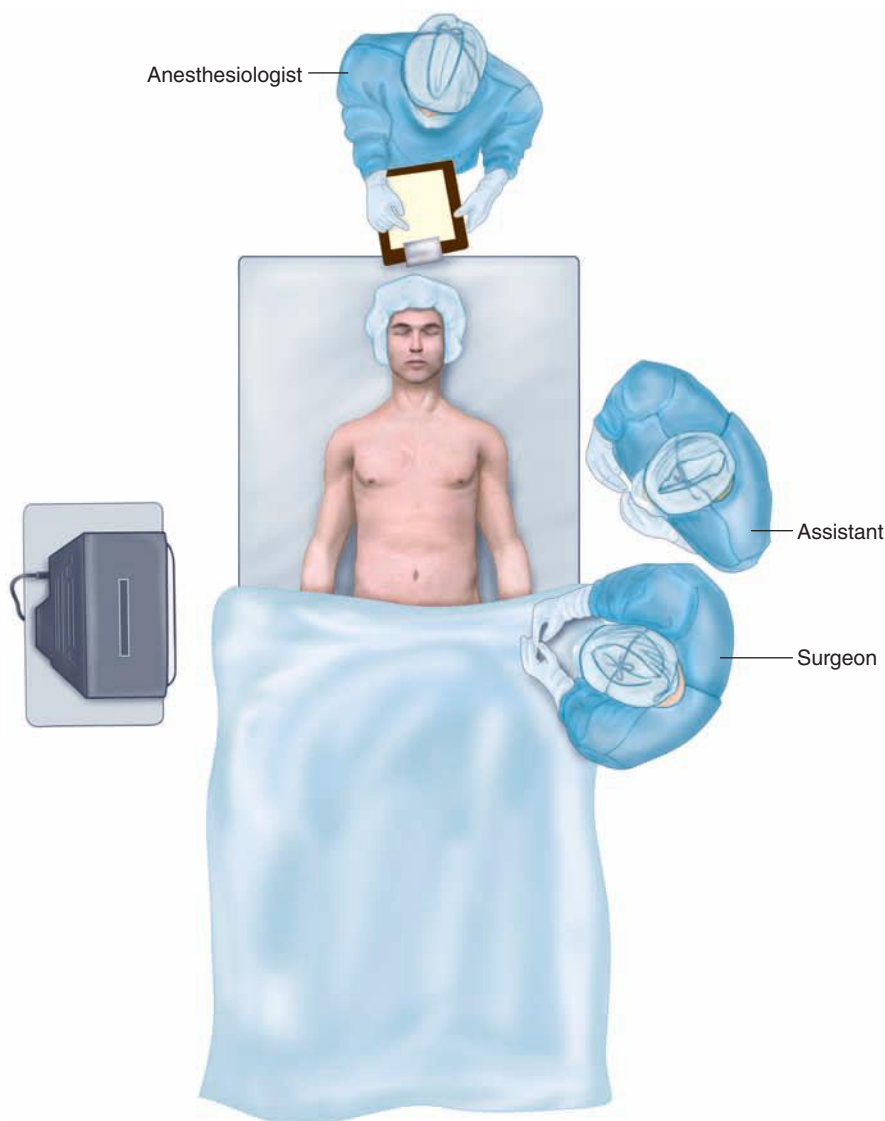


Figure 30-2. Operating room setup.

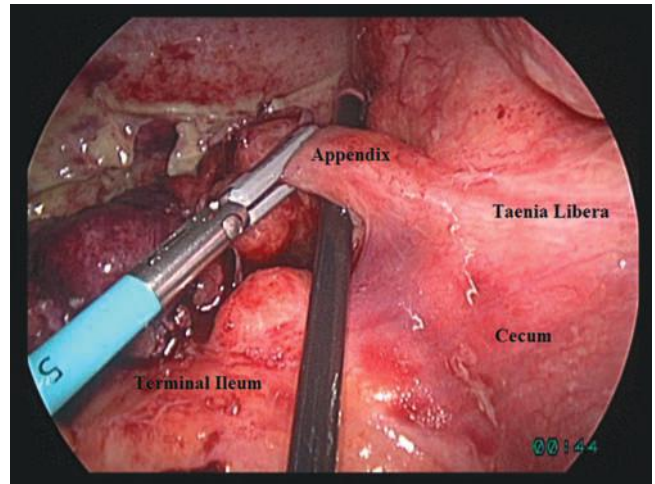
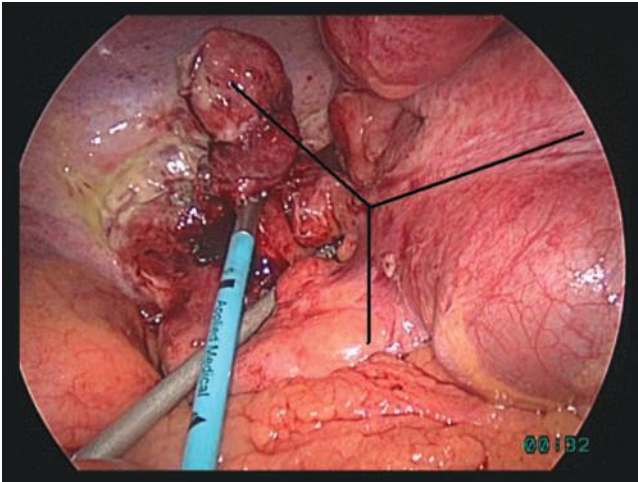


Figure 30-3. A and B. Appendiceal critical view.

quicker return to normal activity with laparoscopic appendectomy when compared to open appendectomy. Laparoscopic appendectomy is associated with increased operative duration and increased operating rooms costs; however, overall costs are likely similar when compared to open appendectomy. Patients tend to have improved satisfaction scores with laparoscopic appendectomy. Many of the differences, while statistically significant, have nominal clinical difference, such as length of stay where differences are measured in hours.⁹¹⁻⁹⁹

In addition, laparoscopic appendectomy may provide a benefit when the diagnosis is in question, such as in female patients of reproductive age, older patients in whom malignancy is suspected, and morbidly obese patients for whom larger open appendectomy incisions may be required.

Laparoscopic Single-Incision Appendectomy

There has been growing interest in laparoscopic single-incision appendectomy. Instead of two or three incisions, a single incision is made, typically periumbilical. The first published laparoscopic-assisted, single-incision appendectomy was reported by Inoue in 1994, where the appendix was identified laparoscopically and grasped and pulled through the laparoscopic incision and the appendectomy completed in an open manner. The first reports of a pure laparoscopic single-incision appendectomy were described in 2009 by multiple surgical groups. By this time, industry had designed multiple options for true single-port access as opposed to makeshift single-incision access.

With laparoscopic single-incision appendectomy, the patient is prepared similarly to laparoscopic appendectomy. Under general anesthesia, the patient is secured in a supine position with the left arm tucked. The surgeon and assistant stand on the left side facing the appendix and the screen. When performing laparoscopic single-incision appendectomy, the surgeon's hands perform the opposite function that they would normally in standard laparoscopic surgery. The surgeon's right hand will grasp the appendix and retract it to the right lower quadrant at the 10 o'clock position.⁹⁰ The surgeon's left hand will dissect the mesenteric window and, upon identifying the appendiceal critical view, staple across the base of the appendix and mesentery. If the base of the appendix cannot be definitively identified or the appendiceal critical view cannot be obtained, additional ports can be placed to perform a "plus one" or even standard

laparoscopic appendectomy. The appendix may be placed in a retrieval bag or removed through the single incision.

There have been multiple small trials evaluating the efficacy of laparoscopic single-incision appendectomy compared to standard appendectomy; however, there has only been one prospective randomized study (in the pediatric population) and one meta-analysis. Gill and colleagues, in 2012, reviewed nine studies for a total of 275 laparoscopic single-incision appendectomies and 348 standard laparoscopic appendectomy procedures. In this meta-analysis, there was no difference in operative time (57 ± 10 vs. 55 ± 13 minutes), complications (11% vs. 8.3%), incisional surgical site infections (5.6% vs. 4.9%), intra-abdominal abscesses (1.8% vs. 1.4%), or length of stay (3 ± 2 vs. 4 ± 1 days). Cases were converted to open or additional ports were placed in 4% of laparoscopic single-incision appendectomies and 0.9% of standard laparoscopic procedures. There was no difference in return to bowel function, postoperative pain, or return to normal activity. There was no difference in overall cost. The incidence of hernia formation following the laparoscopic single-incision appendectomy procedure compared to standard laparoscopy has not been reported.¹⁰⁰

Although further study is needed, it appears that in laparoscopic appendectomy, laparoscopic single-incision appendectomy conveys no discernible advantage or disadvantage with short-term outcomes. Late outcomes and patient quality-of-life outcomes remain to be investigated.

Natural Orifice Transluminal Endoscopic Surgery

Natural orifice transluminal endoscopic surgery (NOTES) is a new surgical procedure using flexible endoscopes in the abdominal cavity. In this procedure, access is gained by way of organs that are reached through a natural, already-existing external orifice. The hoped-for advantages associated with this method include the reduction of postoperative wound pain, shorter convalescence, avoidance of wound infection and abdominal wall hernias, and the absence of scars.

One hundred thirteen NOTES appendectomies in human patients have been reported in the medical literature. Eighty-seven were performed transvaginally, and 26 were performed transgastrically.¹⁰¹ The vast majority of these cases are hybrid procedures (NOTES plus laparoscopic assist port) with only 14 cases of pure NOTES appendectomies (three transvaginal

Table 30-7

Meta-analysis comparing laparoscopic versus open appendectomy outcomes

		AUTHOR									SUMMARY
		WEI	LUI	LI	MARKIDES	BENNET	TEMPLE	GARBUTT	SAUERLAND	GOLUB	
Year		2011	2010	2010	2010	2007	1999	1999	1998	1998	
No. of studies		25	16	44	12	34	8	11	28	16	
No. of patients	LA	2220	1587	2609	NR	2064	730		2877	887	
	OA	2474	1674	2683	NR	2350	653			795	
	Total	4694	3261	5292		4414	1383	1375		1682	
SSI	LA (%)			3.8						2.8	9/9 favor LA 3/9 not SS
	OA (%)			8.4						7.0	
	Odds Ratio*		0.51	0.45	0.43	0.52	0.40	-5.6 to -0.8	06.1 to -2.3		
	95% CI		0.36-0.73	0.34-0.59	0.34-0.55	0.39-0.70	0.24-0.59	-3.2	-4.2	0.19-0.47	
	Pooled effect	0.30-0.56									
IAA	LA (%)		NR							2.0	3/8 LA = OA 7/8 not SS
	OA (%)									0.94	
	Odds Ratio*			1.56	1.24	2.29	1.94				
	95% CI			1.01-2.43	0.84-1.84	1.48-3.53	0.98-5.58	-0.8 to 2.4	-0.4 to 2.3	0.88-6.64	
	Pooled effect	0.93-2.14						0.8	0.52		
Pain	Difference*	-0.52	NR	-0.7	NR	-0.8	NR	-1.19	-0.05	NR	6/6 favor LA 1 not SS
LOS	LA (days)			1.2	1.9	1.4				3.2	9/9 favor LA 3/9 not SS
	OA (days)			1.8	3.0	2.0				3.8	
	Difference ^a	-0.68	-0.82	-0.60	-1.10	-0.62	-0.16	-0.58	-15.0		
Return activity	LA (days)			8.0	NR	7.8				11.9	8/8 favor LA 1/8 not SS
	OA (days)			12.5		10.0				19.0	
	Difference ^a	-3.1	-6.9	-4.5		-2.2	-5.7	-5.5	-6.5	-7.1	
Operative time	LA (min)			24.0	30.0	25.0				69.8	9/9 favor OA
	OA (min)			11.7	17.2	10.4				52.9	
	Difference ^a	10.7	7.6	12.35	12.8	14.6	18.1	16.8	15.7	16.2	
Cost	Difference ^a	11%	NR	NR	NR	NR	NR	NR	NR	-3%	1/3 favors LA 1/3 favors OA 1/3 LA = OA 2/3 not SS
Conversion rate		NR	NR	NR	NR	NR	11%	11%	8%	NR	

^aIndex is open.

IAA = intra-abdominal abscess (specifically organ/space surgical site infection); LA = laparoscopic appendectomy; LOS = length of stay; NR = not reported; OA = open appendectomy; SS = statistically significant; SSI = surgical site infection (specifically superficial and deep).

and 11 transgastric). Although reported complication rates appear low, conversion rates (to hybrid procedures) remain high.

The main concern with NOTES has been complications with closure of the enterotomy. To date, there is no reliable method of closure of the gastrotomy site, and there has been significant morbidity reported with this approach.

Although the transvaginal approach appears to be more promising, in women surveyed on their perception of NOTES, three-quarters were either neutral or unhappy about the prospects of NOTES.¹⁰²

Much work remains to demonstrate whether NOTES is able to provide the theoretical benefits purported. Great care must be taken to prevent significant morbidity or mortality en route to studying these procedures.

SPECIAL CIRCUMSTANCES

Acute Appendicitis in the Young

The establishment of a diagnosis of acute appendicitis is more difficult in young children than in the adult. The inability of young children to give an accurate history, diagnostic delays by both parents and physicians, and the frequency of gastrointestinal distress in children are all contributing factors to the misdiagnosis and delay in diagnosis.¹⁰³ In children, the physical examination findings of maximal tenderness in the right lower quadrant, the inability to walk or walking with a limp, and pain with percussion, coughing, and hopping were found to have the highest sensitivity for appendicitis.¹⁰⁴

The more rapid progression to rupture and the inability of the underdeveloped greater omentum to contain a rupture lead to significant morbidity rates in children. Children <5 years of age have a negative appendectomy rate of 25% and an appendiceal perforation rate of 45%. These rates may be compared with a negative appendectomy rate of <10% and a perforated appendix rate of 20% in children 5 to 12 years of age.^{50,51} The incidence of major complications after appendectomy in children is correlated with appendiceal rupture. The wound infection rate after the treatment of nonperforated appendicitis in children is 2.8%, compared with a rate of 11% after the treatment of perforated appendicitis. The incidence of intra-abdominal abscess also is higher after the treatment of perforated appendicitis than after nonperforated appendicitis (6% vs. 3%).¹⁰⁵ The treatment regimen for perforated appendicitis generally includes immediate appendectomy. Antibiotic coverage is limited to 24 to 48 hours in cases of nonperforated appendicitis. For perforated appendicitis, intravenous antibiotics usually are given until the white blood cell count is normal and the patient is afebrile for 24 hours. Laparoscopic appendectomy has been shown to be safe and effective for the treatment of appendicitis in children.¹⁰⁶

Acute Appendicitis in the Elderly

Compared with younger adults, elderly patients with appendicitis often pose a more difficult diagnostic problem because of the atypical presentation, expanded differential diagnosis, and communication difficulty. These factors may be responsible for the disproportionately high perforation rate seen in the elderly. In the general population, perforation rates range from 20% to 30%, compared with 50% to 70% in the elderly.¹⁰⁷ In addition, the perforation rate appears to increase with age greater than 80 years.¹⁰⁸

Elderly patients usually present with lower abdominal pain, but on clinical examination, localized right lower quadrant tenderness is not as common as in younger patients. A history of periumbilical pain migrating to the right lower quadrant is reported infrequently. Although currently there are no criteria that definitively identify elderly patients with acute appendicitis who are at risk of rupture, prioritization should be given to patients with a temperature of greater than 38°C (100.4°F) and a shift to the left in leukocyte count of more than 76%, especially if they are male, are anorexic, or have had pain of long duration before admission.⁶⁵

As a result of increased comorbidities and an increased rate of perforation, postoperative morbidity, mortality, and hospital length of stay are increased in the elderly compared with younger populations with appendicitis. Although no randomized trials have been conducted, it appears that elderly patients benefit from a laparoscopic approach to treatment of appendicitis. The use of laparoscopy in the elderly has significantly increased in recent years. In general, laparoscopic appendectomy offers elderly patients with appendicitis a shorter length of hospital stay, a reduction in complication and mortality rates, and a greater chance of discharge to home (independent of further nursing care or rehabilitation).¹⁰⁹

Acute Appendicitis during Pregnancy

Appendectomy for presumed appendicitis is the most common surgical emergency during pregnancy. The incidence is approximately 1 in 766 births. Acute appendicitis can occur at any time during pregnancy but is rare in the third trimester.¹¹⁰ The overall negative appendectomy rate during pregnancy is approximately 25% and appears to be higher than the rate seen in nonpregnant women.^{110,111} A higher rate of negative appendectomy is seen in the second trimester, whereas the lowest rate is in the third trimester. The diversity of clinical presentations and the difficulty in making the diagnosis of acute appendicitis in pregnant women are well established. This is particularly true in the late second trimester and the third trimester, when many abdominal symptoms may be considered pregnancy related. In addition, during pregnancy, there are anatomic changes in the appendix and increased abdominal laxity that may further complicate clinical evaluation.

Appendicitis in pregnancy should be suspected when a pregnant woman complains of abdominal pain of new onset. The most consistent sign encountered in acute appendicitis during pregnancy is pain in the right side of the abdomen. Seventy-four percent of patients report pain located in the right lower abdominal quadrant, with no difference between early and late pregnancy. Only 57% of patients present with the classic history of diffuse periumbilical pain migrating to the right lower quadrant. Laboratory evaluation is not helpful in establishing the diagnosis of acute appendicitis during pregnancy. The physiologic leukocytosis of pregnancy has been defined as high as 16,000 cells/mm³. In one series, only 38% of patients with appendicitis had a white blood cell count of more than 16,000 cells/mm³.¹¹⁰ Recent data suggest that the incidence of perforated or complex appendicitis is not increased in pregnant patients.¹¹¹

When the diagnosis is in doubt, abdominal ultrasound may be beneficial. Another option is magnetic resonance imaging, which has no known deleterious effects on the fetus. The American College of Radiology recommends the use of nonionizing radiation techniques for front-line imaging in

pregnant women.⁷⁰ Laparoscopy has been advocated in equivocal cases, especially early in pregnancy; however, laparoscopic appendectomy may be associated with an increase in pregnancy-related complications. In an analysis of outcomes in California using administrative databases, laparoscopy was found to be associated with a 2.31 times increased risk of fetal loss compared with open surgery.¹¹¹

The overall incidence of fetal loss after appendectomy is 4%, and the risk of early delivery is 7%. Rates of fetal loss are considerably higher in women with complicated appendicitis than in those with a negative appendectomy or with simple appendicitis. It is important to note that a negative appendectomy is not a benign procedure. Removing a normal appendix is associated with a 4% risk of fetal loss and 10% risk of early delivery.

9▶ Maternal mortality after appendectomy is extremely rare (0.03%). Because the incidence of complicated appendix is similar in pregnant and nonpregnant women and because maternal mortality is so low, it appears that the greatest opportunity to improve fetal outcomes is by improving diagnostic accuracy and reducing the rate of negative appendectomy.¹¹⁰⁻¹¹³

POSTOPERATIVE CARE AND COMPLICATIONS

Following uncomplicated appendectomy, complication rates are low,¹¹⁴ and most patients can quickly be started on a diet and discharged home the same day or the following day.¹¹⁵ Postoperative antibiotic therapy is unnecessary.¹¹⁶

Alternatively, with complicated appendectomy, complication rates are increased compared to uncomplicated appendicitis.¹¹⁴ Patients should be continued on broad-spectrum antibiotics for 4 to 7 days.^{117,118} Postoperative ileus may occur, so diet should be started based on daily clinical evaluation. These patients are at increased risk for surgical site infections.

Surgical Site Infection

In patients with incisional (superficial or deep) surgical site infection, treatment should be opening of the incision and obtaining a culture. Following laparoscopic appendectomy, the extraction port site is the most common site of surgical site infection. Patients with cellulitis can be started on antibiotics. The cultured organisms are typically bowel flora, as opposed to skin flora.¹¹⁹

Patients with postoperative intra-abdominal abscesses can present in a variety of ways. Although fever, leukocytosis, and abdominal pain are common presentations, patients with ileus, bowel obstruction, diarrhea, and tenesmus may also harbor intra-abdominal abscesses. Small abscesses can be simply treated with antibiotics; however, larger abscesses require drainage. Most commonly, percutaneous drainage with CT or ultrasound guidance is effective. For abscesses not amenable to percutaneous drainage, laparoscopic abscess drainage is a viable option.

Stump Appendicitis

Incomplete appendectomy represents a failure of removing the entire appendix on the initial procedure. A review of literature has revealed only 60 reports of this phenomenon. Likely, incomplete appendectomy is underreported, and the true prevalence is much higher. Reported as “stump appendicitis,” patients typically present with recurrent symptoms of appendicitis approximately 9 years after their initial surgery. There was no difference in initial surgery between laparoscopic and open procedures. However, there were more complicated appendectomies on

initial surgery. Patients presenting with stump appendicitis are more likely to have complicated appendicitis, have an open procedure, and undergo colectomy.

The key to avoiding stump appendicitis is prevention. Use of the “appendiceal critical view” (appendix placed at 10 o’clock, taenia coli/libera at 3 o’clock, and terminal ileum at 6 o’clock) and identification of where the taenia coli merge and disappear is paramount to identifying and ligating the base of the appendix during the initial operation. The remaining stump should be no longer than 0.5 cm, as stump appendicitis has only been noted in stumps ≥ 0.5 cm in the literature.

In patients who have had prior appendectomy, a low index of suspicion is important to prevent delay in diagnosis and complications. Prior appendectomy should not be an absolute criterion in ruling out acute appendicitis.

INCIDENTAL APPENDECTOMY

Decisions regarding the efficacy of incidental appendectomy should be based on the epidemiology of appendicitis. The best data were published by the Centers for Disease Control and Prevention based on the period from 1979 to 1984.¹²⁰ During this period, an average of 250,000 cases of appendicitis and 310,000 incidental appendectomies occurred annually in the United States. It was estimated that 36 incidental appendectomies had to be performed to prevent one patient from developing appendicitis.¹²¹ In view of the added costs and risk of morbidity for each extension of a surgical intervention, this does not seem to justify incidental appendectomy.

The financial aspects of the decision to perform incidental appendectomy were assessed.¹²² For open appendectomy, there was a financial disincentive to perform incidental appendectomy. On an annual basis, \$20,000,000 had to be spent to save the \$6,000,000 cost of appendicitis. With the laparoscopic approach, it was cost-effective to perform incidental appendectomy only in patients less than 25 years of age and only if the reimbursement for surgeons was 10% of the usual and customary charges. At a higher rate of reimbursement, incidental appendectomy was not cost-effective in any age group.

Although incidental appendectomy is generally neither clinically nor economically appropriate, there are some special patient groups in whom it should be performed during laparotomy or laparoscopy for other indications. These include children about to undergo chemotherapy, the disabled who cannot describe symptoms or react normally to abdominal pain, patients with Crohn’s disease in whom the cecum is free of macroscopic disease, and

11▶ individuals who are about to travel to remote places where there is no access to medical or surgical care.¹²³

Appendectomy is routinely carried out during the performance of Ladd’s procedure for malrotation because displacement of the cecum into the left upper quadrant would complicate the diagnosis of subsequent appendicitis.

NEOPLASMS OF THE APPENDIX

Prevalence of Neoplasms

Multiple studies have evaluated the prevalence of mass lesions present in appendectomy specimens (Table 30-8).¹²⁴⁻¹³² The prevalence of identifying a mass within the appendix is less than 1%. Appendiceal carcinoid and appendiceal adenomas are the

12▶ most common lesions identified. There is no clear age relationship associated with the identification of these masses.

Table 30-8

Prevalence of malignancy associated with appendix specimens

AUTHOR	NO.	MALE GENDER	AGE (MEAN)	AGE (RANGE)	ADENOMA	CARCINOID	OTHER	OVERALL
Ozer	2376	22 (81.5%)	26.7	NR	NR	27 (1.13%)	NR	27 (1.13%)
Lee	3744	NR	NR	NR	14 (0.35%)	9 (0.24%)	5 (0.12%)	28 (0.7%)
Sieren	141	6 (60%)	47	NR	NR	NR	NR	10 (7.1%)
Debnath	1941	11 (69%)	41.8	NR	NR	16 (0.82%)	NR	16 (0.82%)
In't Hof	1485	4 (57%)	32.7	20–59	NR	7 (0.47%)	NR	7 (0.47%)
Smeenck	167,744	608 (41%)	61	7–93	NR	NR	NR	1482 (0.9%)
O'Donnell	2154	8 (36%)	30	14–83	NR	11 (0.5%)	11 (0.5%)	22 (1.02%)
Marudanayagam	2660	NR	NR	NR	16 (0.6%)	14 (0.52%)	10 (0.39%)	40 (1.50%)
Overall	184,118				30 (0.47%)	57 (0.54%)	26 (0.30%)	1558 (0.89%)
Lai ^a	1873	11 (69%)	69	42–89	NR	NR	16 (0.85%)	16 (0.85%)

^aLai reported only the incidence of colon cancer presenting as appendicitis. NR = not reported.

In older patients, the prevalence of identifying colon cancer appearing as appendicitis has been reported in a single study with a prevalence of less than 1%. The mean age in this case series was 69 years (range, 42 to 89 years).

Carcinoid

The finding of a firm, yellow, bulbar mass in the appendix should raise the suspicion of an appendiceal carcinoid. The appendix is the most common site of gastrointestinal carcinoid, followed by the small bowel and rectum. Carcinoid syndrome is rarely associated with appendiceal carcinoid unless widespread metastases are present, which occur in 2.9% of cases. Symptoms attributable directly to the carcinoid are rare, although the tumor can occasionally obstruct the appendiceal lumen much like a fecalith and result in acute appendicitis.^{131,133,134}

The majority of carcinoids are located in the tip of the appendix. Malignant potential is related to size, with tumors <1 cm rarely resulting in extension outside of the appendix or adjacent to the mass. The mean tumor size for carcinoids is 2.5 cm.¹³³ Carcinoid tumors usually present with localized disease (64%). Treatment for tumors ≤1 cm is appendectomy. For tumors larger than 1 to 2 cm located at the base, involving the mesentery, or with lymph node metastases, right hemicolectomy is indicated. Despite these recommendations, surveillance, epidemiology, and end results data indicate that proper surgery for carcinoids is not performed at least 28% of the time.¹³³

Adenocarcinoma

Primary adenocarcinoma of the appendix is a rare neoplasm with three major histologic subtypes: mucinous adenocarcinoma, colonic adenocarcinoma, and adenocarcinoid.¹³⁵ The most common mode of presentation for appendiceal carcinoma is that of acute appendicitis. Patients also may present with ascites or a palpable mass, or the neoplasm may be discovered during an operative procedure for an unrelated cause. The recommended treatment for all patients with adenocarcinoma of the appendix is a formal right hemicolectomy. Appendiceal adenocarcinomas have a propensity for early perforation, although they are not clearly associated with a worsened prognosis.¹³⁴ Overall 5-year survival is 55% and varies with stage and grade. Patients with

appendiceal adenocarcinoma are at significant risk for both synchronous and metachronous neoplasms, approximately half of which will originate from the gastrointestinal tract.¹³⁵

Mucocele

A mucocele of the appendix is an obstructive dilatation by intraluminal accumulation of mucoid material. Mucoceles may be caused by one of four processes: retention cysts, mucosal hyperplasia, cystadenomas, and cystadenocarcinomas. The clinical presentation of a mucocele is nonspecific, and often it is an incidental finding at operation for acute appendicitis. An intact mucocele presents no future risk for the patient; however, the opposite is true if the mucocele has ruptured and epithelial cells have escaped into the peritoneal cavity. As a result, when a mucocele is visualized at the time of laparoscopic examination, conversion to open laparotomy is recommended. Conversion from a laparoscopic approach to a laparotomy ensures that a benign process will not be converted to a malignant one through mucocele rupture. In addition, laparotomy allows for thorough abdominal exploration to rule out the presence of mucoid fluid accumulations.¹³⁵

The presence of a mucocele of the appendix does not mandate performance of a right hemicolectomy. The principles of surgery include resection of the appendix, wide resection of the mesoappendix to include all the appendiceal lymph nodes, collection and cytologic examination of all intraperitoneal mucus, and careful inspection of the base of the appendix. Right hemicolectomy or, preferably, ileocecectomy is reserved for patients with a positive margin at the base of the appendix or positive periappendiceal lymph nodes. Recently, a more aggressive approach to ruptured appendiceal neoplasms has been advocated. This approach includes a thorough but minimally aggressive approach at initial laparotomy, as described earlier, with subsequent referral to a specialized center for consideration of reexploration and hyperthermic intraperitoneal chemotherapy.¹³⁴

Pseudomyxoma Peritonei

Pseudomyxoma peritonei is a rare condition in which diffuse collections of gelatinous fluid are associated with mucinous

implants on peritoneal surfaces and omentum. Pseudomyxoma is two to three times more common in females than in males. Recent immunocytologic and molecular studies suggest that the appendix is the site of origin for the overwhelming majority of cases of pseudomyxoma. Pseudomyxoma is invariably caused by neoplastic mucus-secreting cells within the peritoneum. These cells may be difficult to classify as malignant because they may be sparse, widely scattered, and have a low-grade cytologic appearance. Patients with pseudomyxoma usually present with abdominal pain, distention, or a mass. Primary pseudomyxoma usually does not cause abdominal organ dysfunction. However, ureteral obstruction and obstruction of venous return can be seen.¹³⁶ Pseudomyxoma is a disease that progresses slowly and in which recurrences may take years to develop or become symptomatic.¹³⁶ In a series from the Mayo Clinic, 76% of patients developed recurrences within the abdomen.¹³⁷ Lymph node metastasis and distant metastasis are uncommon.

The use of imaging before surgery is advantageous to plan surgery. CT scanning is the preferred imaging modality. At surgery, a variable volume of mucinous ascites is found together with tumor deposits involving the right hemidiaphragm, right retrohepatic space, left paracolic gutter, ligament of Treitz, and the ovaries in women. Peritoneal surfaces of the bowel are usually free of tumor. Thorough surgical debulking is the mainstay of treatment. All gross disease and the omentum should be removed. If not done previously, appendectomy is routinely performed. Hysterectomy with bilateral salpingo-oophorectomy is performed in women. Survival is better in patients who undergo R0 or R1 resection than in patients who undergo R2 resection (visible gross disease remaining).¹³⁸ Because 5-year survival of mucinous appendiceal neoplasms is only 30%, adjuvant intraperitoneal hyperthermic chemotherapy is advocated as a standard adjunct to radical cytoreductive surgery.¹³⁹ Cytoreductive surgery with intraperitoneal hyperthermic chemotherapy is a long, tedious procedure with operative times of 300 to 1020 minutes reported. In addition, morbidity (38%) and mortality (6%) are high. Cytoreductive surgery with intraperitoneal hyperthermic chemotherapy is associated with a 5-year survival rate of 53% to 78%. Survival is associated with initial patient performance status.¹³⁸⁻¹⁴⁰

Any recurrence should be investigated completely. Recurrences are usually treated by additional surgery. It is important to note that surgery for recurrent disease is usually difficult and is associated with an increased incidence of enterotomies, anastomotic leaks, and fistulas.^{136,137}

Lymphoma

Lymphoma of the appendix is extremely uncommon. The gastrointestinal tract is the most frequently involved extranodal site for non-Hodgkin's lymphoma.¹⁴¹ Other types of appendiceal lymphoma, such as Burkitt's lymphoma, as well as leukemia, have also been reported.¹⁴² Primary lymphoma of the appendix accounts for 1% to 3% of gastrointestinal lymphomas. Appendiceal lymphoma usually presents as acute appendicitis and is rarely suspected preoperatively. Findings on CT scan of an appendiceal diameter ≥ 2.5 cm or surrounding soft tissue thickening should prompt suspicion of an appendiceal lymphoma. The management of appendiceal lymphoma confined to the appendix is appendectomy. Right hemicolectomy is indicated if tumor extends beyond the appendix onto the cecum or mesentery. A postoperative staging workup is indicated before

initiating adjuvant therapy. Adjuvant therapy is not indicated for lymphoma confined to the appendix.^{142,143}

REFERENCES

Entries highlighted in bright blue are key references.

1. Williams RG. Presidential address: a history of appendicitis. *Ann Surg.* 1983;197:495-506.
2. Deaver JB. *Appendicitis*. 3rd ed. Philadelphia: P Blakiston's Son & Co; 1905.
3. Fernal J. *Universal Medicina, 1554. Classic Description of Disease*. U.S.: Springfield; 1932:614-615.
4. Ellis H. Appendix. In: Schwartz SI, ed. *Maingot's Abdominal Operations*. 8th ed., vol. 2. Norwalk: Appleton-Century-Crofts; 1985:1255.
5. McBurney C. Experience with early operative interference in cases of disease of the vermiform appendix. *N Y State Med J.* 1889;50:676.
6. Power D. The prognosis and modern treatment of appendicitis. *Br Med J.* 1899;2:1467-1470.
7. Loveland JE. Reginald Heber Fitz. The exponent of appendicitis. *Yale J Biol Med.* 1937;9:509-520.
8. Lichtner S, Pflanz M. Appendectomy in the Federal Republic of Germany: epidemiology and medical care patterns. *Med Care.* 1971;9:311-330.
9. Williams RA, Myers P. *Pathology of the Appendix*. New York: Chapman and Hall Medical; 1994:1-7.
10. Kelly HA, Hurdon E. *The Vermiform Appendix and Its Diseases*. Philadelphia: W.B. Saunders; 1905:55-74.
11. Akbulut S, Ulku A, Senol A, Tas M, Yagmur Y. Left-sided appendicitis: review of 95 published cases and a case report. *World J Gastroenterol.* 2010;16:5598-5602.
12. Meyers S, Miller TA. *Acute Abdominal Pain: Physiology of the Acute Abdomen*. In: Miller TA, ed. St. Louis: Quality Medical; 1998:641-667.
13. Dhillon AP, Rode J. Serotonin and its possible role in the painful non-inflamed appendix. *Diagn Histopathol.* 1983;6:239-246.
14. Dhillon AP, Williams RA, Rode J. Age, site, and distribution of subepithelial neurosecretory cells in the appendix. *Pathology.* 1992;24:56-59.
15. Andersson RE, Olaison G, Tysk C, Ekbohm A. Appendectomy and protection against ulcerative colitis. *N Engl J Med.* 2001;344:808-814.
16. Frisch M, Pedersen BV, Andersson RE. Appendicitis, mesenteric lymphadenitis, and subsequent risk of ulcerative colitis: cohort studies in Sweden and Denmark. *BMJ.* 2009;338:b716.
17. Radford-Smith GL, Edwards JE, Purdie DM, et al. Protective role of appendectomy on onset and severity of ulcerative colitis and Crohn's disease. *Gut.* 2002;51:808-813.
18. Kaplan GG, Jackson T, Sands BE, Frisch M, Andersson RE, Korzenik J. The risk of developing Crohn's disease after an appendectomy: a meta-analysis. *Am J Gastroenterol.* 2008;103:2925-2931.
19. Merchant R, Mower WR, Ourian A, et al. Association between appendectomy and *Clostridium difficile* infection. *J Clin Med Res.* 2012;4:17-19.
20. Im GY, Modayil RJ, Lin CT, et al. The appendix may protect against *Clostridium difficile* recurrence. *Clin Gastroenterol Hepatol.* 2011;9:1072-1077.
21. Addiss DG, Shaffer N, Fowler BS, Tauxe RV. The epidemiology of appendicitis and appendectomy in the United States. *Am J Epidemiol.* 1990;132:910-925.
22. Livingston EH, Woodward WA, Sarosi GA, Haley RW. Disconnect between incidence of nonperforated and perforated appendicitis: implications for pathophysiology and management. *Ann Surg.* 2007;245:886-892.
23. Raahave D, Christensen E, Moeller H, Kirkeby LT, Loud FB, Knudsen LL. Origin of acute appendicitis: fecal retention in

- colonic reservoirs: a case control study. *Surg Infect (Larchmt)*. 2007;8:55-62.
24. Nitecki S, Karmeli R, Sarr MG. Appendiceal calculi and fecaliths as indications for appendectomy. *Surg Gynecol Obstet*. 1990;171:185-188.
 25. Lamps LW. Appendicitis and infections of the appendix. *Semin Diagn Pathol*. 2004;21:86-97.
 26. Thadepalli H, Mandal AK, Chuah SK, Lou MA. Bacteriology of the appendix and the ileum in health and appendicitis. *Am Surg*. 1991;57:317-322.
 27. Pieper R, Kager L, Weintraub A, Lindberg AA, Nord CE. The role of *Bacteroides fragilis* in the pathogenesis of acute appendicitis. *Acta Chir Scand*. 1982;148:39-44.
 28. Bennon RS, Baron EJ, Thompson JE, et al. The bacteriology of gangrenous and perforated appendicitis-revisited. *Ann Surg*. 1990;211:165-171.
 29. Swidsinski A, Dörffel Y, Loening-Baucke V, et al. Acute appendicitis is characterised by local invasion with *Fusobacterium nucleatum/necrophorum*. *Gut*. 2011;60:34-40.
 30. Andersson RE. The natural history and traditional management of appendicitis revisited: spontaneous resolution and predominance of prehospital perforations imply that a correct diagnosis is more important than an early diagnosis. *World J Surg*. 2007;31:86-92.
 31. Decadt B, Sussman L, Lewis MP, et al. Randomized clinical trial of early laparoscopy in the management of acute non-specific abdominal pain. *Br J Surg*. 1999;86:1383-1386.
 32. Morino M, Pellegrino L, Castagna E, Farinella E, Mao P. Acute nonspecific abdominal pain: a randomized, controlled trial comparing early laparoscopy versus clinical observation. *Ann Surg*. 2006;244:881-886.
 33. Andersson RE. Meta-analysis of the clinical and laboratory diagnosis of appendicitis. *Br J Surg*. 2004;91:28-37.
 34. Wagner JM, McKinney WP, Carpenter JL. Does this patient have appendicitis? *JAMA*. 1996;276:1589-1593.
 35. Berry J, Malt RA. Appendicitis near its centenary. *Ann Surg*. 1984;200:567-575.
 36. Bower RJ, Bell MJ, Temberg JL. Diagnostic value of the white blood count and neutrophil percentage in the evaluation of abdominal pain in children. *Surg Gynecol Obstet*. 1981;152:424-426.
 37. Ohle R, O'Reilly F, O'Brien KK, Fahey T, Dimitrov BD. The Alvarado score for predicting acute appendicitis: a systematic review. *BMC Med*. 2011;9:139.
 38. Andersson M, Andersson RE. The appendicitis inflammatory response score: a tool for the diagnosis of acute appendicitis that outperforms the Alvarado score. *World J Surg*. 2008;32:1843-1849.
 39. de Castro SM, Ünlü C, Steller EP, van Wagenveld BA, Vrouwenraets BC. Evaluation of the appendicitis inflammatory response score for patients with acute appendicitis. *World J Surg*. 2012;36:1540-1545.
 40. Petroianu A, Alberti LR. Accuracy of the new radiographic sign of fecal loading in the cecum for differential diagnosis of acute appendicitis in comparison with other inflammatory diseases of right abdomen: a prospective study. *J Med Life*. 2012;5:85-91.
 41. el Ferzli G, Ozuner G, Davidson PG, Isenberg JS, Redmond P, Worth MH Jr. Barium enema in the diagnosis of acute appendicitis. *Surg Gynecol Obstet*. 1990;171:40-42.
 42. Rypins EB, Kipper SL. Scintigraphic determination of equivocal appendicitis. *Am Surg*. 2000;66:891-895.
 43. Terasawa T, Blackmore CC, Bent S, Kohlwes RJ. Systematic review: computed tomography and ultrasonography to detect acute appendicitis in adults and adolescents. *Ann Intern Med*. 2004;141:537-546.
 44. Weston AR, Jackson TJ, Blamey S. Diagnosis of appendicitis in adults by ultrasonography or computed tomography: a systematic review and meta-analysis. *Int J Technol Assess Health Care*. 2005;21:368-379.
 45. Doria AS, Moineddin R, Kellenberger CJ, et al. US or CT for diagnosis of appendicitis in children and adults? A meta-analysis. *Radiology*. 2006;241:83-94.
 46. Al-Khayal KA, Al-Omran MA. Computed tomography and ultrasonography in the diagnosis of equivocal acute appendicitis. A meta-analysis. *Saudi Med J*. 2007;28:173-180.
 47. van Randen A, Bipat S, Zwinderman AH, Ubbink DT, Stoker J, Boermeester MA. Acute appendicitis: meta-analysis of diagnostic performance of CT and graded compression US related to prevalence of disease. *Radiology*. 2008;249:97-106.
 48. Weyant MJ, Eachempati SR, Maluccio MA, et al. Interpretation of computed tomography does not correlate with laboratory or pathologic findings in surgically confirmed acute appendicitis. *Surgery*. 2000;128:145-153.
 49. Fuchs JR, Schlamberger JS, Shortleeve MJ, Schuler JG. Impact of abdominal CT imaging on the management of appendicitis: an update. *J Surg Res*. 2002;106:131-136.
 50. Flum DR, Morris A, Koepsell T, Dellinger EP. Has misdiagnosis of appendicitis decreased over time? A population-based analysis. *JAMA*. 2001;286:1748-1753.
 51. Flum DR, Koepsell T. The clinical and economic correlates of misdiagnosed appendicitis: nationwide analysis. *Arch Surg*. 2002;137:799-804.
 52. Bongard F, Landers DV, Lewis F. Differential diagnosis of appendicitis and pelvic inflammatory disease. A prospective analysis. *Am J Surg*. 1985;150:90-96.
 53. Jepsen OB, Korner B, Lauritsen KB, et al. *Yersinia enterocolitica* infection in patients with acute surgical abdominal disease. A prospective study. *Scand J Infect Dis*. 1976;8:189-194.
 54. Knight PJ, Vassy LE. Specific diseases mimicking appendicitis in childhood. *Arch Surg*. 1981;116:744-746.
 55. McDonald JC. Nonspecific mesenteric lymphadenitis: collective review. *Surg Gynecol Obstet*. 1963;116:409.
 56. Morrison JD. *Yersinia* and viruses in acute non-specific abdominal pain and appendicitis. *Br J Surg*. 1981;68:284-286.
 57. Flum DR, Steinberg SD, Sarkis AY, Wallack MK. Appendicitis in patients with acquired immunodeficiency syndrome. *J Am Coll Surg*. 1997;184:481-486.
 58. Bova R, Meagher A. Appendicitis in HIV-positive patients. *Aust N Z J Surg*. 1998;68:337-339.
 59. Vons C, Barry C, Maitre S, et al. Amoxicillin plus clavulanic acid versus appendicectomy for treatment of acute uncomplicated appendicitis: an open-label, non-inferiority, randomised controlled trial. *Lancet*. 2011;377:1573-1579.
 60. Hansson J, Körner U, Khorram-Manesh A, Solberg A, Lundholm K. Randomized clinical trial of antibiotic therapy versus appendicectomy as primary treatment of acute appendicitis in unselected patients. *Br J Surg*. 2009;96:473-481.
 61. Turhan AN, Kapan S, Kütükçü E, Yiğitbaş H, Hatipoğlu S, Aygün E. Comparison of operative and non operative management of acute appendicitis. *Ulus Travma Acil Cerrahi Derg*. 2009;15:459-462.
 62. Liu K, Ahanchi S, Pisaneschi M, Lin I, Walter R. Can acute appendicitis be treated by antibiotics alone? *Am Surg*. 2007;73:1161-1165.
 63. Styrd J, Eriksson S, Nilsson I, et al. Appendectomy versus antibiotic treatment in acute appendicitis: a prospective multicenter randomized controlled trial. *World J Surg*. 2006;30:1033-1037.
 64. Eriksson S, Granström L. Randomized controlled trial of appendicectomy versus antibiotic therapy for acute appendicitis. *Br J Surg*. 1995;82:166-169.
 65. Abou-Nukta F, Bakhos C, Arroyo K, et al. Effects of delaying appendectomy for acute appendicitis for 12 to 24 hours. *Arch Surg*. 2006;141:504-506.
 66. Stahlfeld K, Hower J, Homitsky S, Madden J. Is acute appendicitis a surgical emergency? *Am Surg*. 2007;73:626-629; discussion 629-630.

67. Ingraham AM, Cohen ME, Bilimoria KY, et al. Effect of delay to operation on outcomes in adults with acute appendicitis. *Arch Surg*. 2010;145:886-892.
68. Burkitt DP. The aetiology of appendicitis. *Br J Surg*. 1971;58:695-699.
69. Owings MF, Kozak LJ. Ambulatory and inpatient procedures in the United States, 1996. National Center for Health Statistics Series 13, No. 139. Hyattsville: Department of Health and Human Services, Centers for Disease Control and Prevention, National Center for Health Statistics; 2004.
70. Andersson RE, Petzold MG. Nonsurgical treatment of appendiceal abscess or phlegmon: a systematic review and meta-analysis. *Ann Surg*. 2007;246(5):741-8.
71. Simillis C, Symeonides P, Shorthouse AJ, Tekkis PP. A meta-analysis comparing conservative treatment versus acute appendectomy for complicated appendicitis (abscess or phlegmon). *Surgery*. 2010;147:818-829.
72. St. Peter SD, Aguayo P, Fraser JD, et al. Initial laparoscopic appendectomy versus initial nonoperative management and interval appendectomy for perforated appendicitis with abscess: a prospective, randomized trial. *J Pediatr Surg*. 2010;45:236-240.
73. Blakely ML, Williams R, Dassinger MS, et al. Early vs interval appendectomy for children with perforated appendicitis. *Arch Surg*. 2011;146:660-665.
74. Youssef T, Badrawy A. Prospective evaluation of the necessity of interval appendectomy after resolution of appendiceal mass. *Egyptian J Surg*. 2010;29:2.
75. Tekin A, Kurtoğlu HC, Can I, Oztan S. Routine interval appendectomy is unnecessary after conservative treatment of appendiceal mass. *Colorectal Dis*. 2008;10:465-468.
76. Lai HW, Loong CC, Chiu JH, Chau GY, Wu CW, Lui WY. Interval appendectomy after conservative treatment of an appendiceal mass. *World J Surg*. 2006;30:352-357.
77. Kaminski A, Liu IL, Applebaum H, Lee SL, Haigh PI. Routine interval appendectomy is not justified after initial nonoperative treatment of acute appendicitis. *Arch Surg*. 2005;140:897-901.
78. Kumar S, Jain S. Treatment of appendiceal mass: prospective, randomized clinical trial. *Indian J Gastroenterol*. 2004;23:165-167.
79. Eryilmaz R, Sahin M, Savas MR. Is interval appendectomy necessary after conservative treatment of appendiceal masses? *Ulus Travma Derg*. 2004;10:185-188.
80. Dixon MR, Haukoos JS, Park IU, et al. An assessment of the severity of recurrent appendicitis. *Am J Surg*. 2003;186:718-722; discussion 722.
81. Adalla SA. Appendiceal mass: interval appendectomy should not be the rule. *Br J Clin Pract*. 1996;50:168-169.
82. Hodjati H, Kazerooni T. Location of the appendix in the gravid patient: a re-evaluation of the established concept. *Int J Gynecol Obstet*. 2003;81:245-247.
83. Tander B, Pektas O, Bulut M. The utility of peritoneal drains in children with uncomplicated perforated appendicitis. *Pediatr Surg Int*. 2003;19:548-550.
84. Narci A, Karaman I, Karaman A, et al. Is peritoneal drainage necessary in childhood perforated appendicitis? A comparative study. *J Pediatr Surg*. 2007;42:1864-1868.
85. Toki A, Ogura K, Horimi T, et al. Peritoneal lavage versus drainage for perforated appendicitis in children. *Surg Today*. 1995;25:207-210.
86. Dandapat MC, Panda C. A perforated appendix: should we drain? *J Indian Med Assoc*. 1992;90:147-148.
87. Greenall MJ, Evans M, Pollock AV. Should you drain a perforated appendix? *Br J Surg*. 1978;65:880-882.
88. St Peter SD, Adibe OO, Iqbal CW, et al. Irrigation versus suction alone during laparoscopic appendectomy for perforated appendicitis: a prospective randomized trial. *Ann Surg*. 2012;256:581-585.
89. Giri SK, Shaikh FM, Sil D, Drumm J, Naqvi SA. Our experience with selective laparoscopy through an open appendectomy incision in the management of suspected appendicitis. *Am J Surg*. 2007;194:231-233.
90. Subramanian A, Liang MK. A 60-year literature review of stump appendicitis: the need for a critical view. *Am J Surg*. 2012;203:503-507.
91. Wei B, Qi CL, Chen TF, et al. Laparoscopic versus open appendectomy for acute appendicitis: a meta-analysis. *Surg Endosc*. 2011;25:1199-1208.
92. Liu Z, Zhang P, Ma Y, et al. Laparoscopy or not: a meta-analysis of the surgical effects of laparoscopic versus open appendectomy. *Surg Laparosc Endosc Percutan Tech*. 2010;20:362-370.
93. Li X, Zhang J, Sang L, et al. Laparoscopic versus conventional appendectomy—a meta-analysis of randomized controlled trials. *BMC Gastroenterol*. 2010;10:129.
94. Markides G, Subar D, Riyad K. Laparoscopic versus open appendectomy in adults with complicated appendicitis: systematic review and meta-analysis. *World J Surg*. 2010;34:2026-2040.
95. Bennett J, Boddy A, Rhodes M. Choice of approach for appendicectomy: a meta-analysis of open versus laparoscopic appendicectomy. *Surg Laparosc Endosc Percutan Tech*. 2007;17:245-255.
96. Temple LK, Litwin DE, McLeod RS. A meta-analysis of laparoscopic versus open appendectomy in patients suspected of having acute appendicitis. *Can J Surg*. 1999;42:377-383.
97. Garbutt JM, Soper NJ, Shannon WD, Botero A, Littenberg B. Meta-analysis of randomized controlled trials comparing laparoscopic and open appendectomy. *Surg Laparosc Endosc*. 1999;9:17-26.
98. Sauerland S, Lefering R, Holthausen U, Neugebauer EA. Laparoscopic vs conventional appendectomy—a meta-analysis of randomised controlled trials. *Langenbecks Arch Surg*. 1998;383:289-295.
99. Golub R, Siddiqui F, Pohl D. Laparoscopic versus open appendectomy: a metaanalysis. *J Am Coll Surg*. 1998;186:545-553.
100. Gill RS, Shi X, Al-Adra DP, Birch DW, Karmali S. Single-incision appendectomy is comparable to conventional laparoscopic appendectomy: a systematic review and pooled analysis. *Surg Laparosc Endosc Percutan Tech*. 2012;22:319-327.
101. Coomber RS, Sodergren MH, Clark J, Teare J, Yang GZ, Darzi A. Natural orifice transluminal endoscopic surgery applications in clinical practice. *World J Gastrointest Endosc*. 2012;4:65-74.
102. Strickland AD, Norwood MG, Behnia-Willison F, Olakkengil SA, Hewett PJ. Transvaginal natural orifice transluminal endoscopic surgery (NOTES): a survey of women's views on a new technique. *Surg Endosc*. 2010;24:2424-2431.
103. Bundy DG, Byerley JS, Liles EA, et al. Does this child have appendicitis? *JAMA*. 2007;298:438-451.
104. Colvin JM, Bachur R, Kharbanda A. The presentation of appendicitis in preadolescent children. *Pediatr Emerg Care*. 2007;23:849-855.
105. Andersen BR, Kallehave FL, Andersen HK. Antibiotics versus placebo for prevention of postoperative infection after appendicectomy. *Cochrane Database Syst Rev*. 2005;3:CD001439.
106. Sauerland S, Lefering R, Neugebauer EA. Laparoscopic versus open surgery for suspected appendicitis. *Cochrane Database Syst Rev*. 2004;4:CD001546.
107. Sheu BF, Chiu TE, Chen JC, Tung MS, Chang MW, Young YR. Risk factors associated with perforated appendicitis in elderly patients presenting with signs and symptoms of acute appendicitis. *ANZ J Surg*. 2007;77:662-666.
108. Young YR, Chiu TF, Chen JC, et al. Acute appendicitis in the octogenarians and beyond: a comparison with younger geriatric patients. *Am J Med Sci*. 2007;334:255-259.

109. Harrell AG, Lincourt AE, Novitsky YW, et al. Advantages of laparoscopic appendectomy in the elderly. *Am Surg.* 2006;72:474-480.
110. Andersen B, Nielsen TF. Appendicitis in pregnancy: diagnosis, management and complications. *Acta Obstet Gynecol Scand.* 1999;78:758-762.
111. McGory ML, Zingmond DS, Tillou A, Hiatt JR, Ko CY, Cryer HM. Negative appendectomy in pregnant women is associated with a substantial risk of fetal loss. *J Am Coll Surg.* 2007;205:534-540.
112. Bree RL, Ralls PW, Baffle DM, et al. Evaluation of patients with acute right upper quadrant pain. American College of Radiology. ACR Appropriateness Criteria. *Radiology.* 2000;215(Suppl):153.
113. Bailey LE, Finley RK Jr., Miller SF, Jones LM. Acute appendicitis during pregnancy. *Am Surg.* 1986;52:218-221.
114. Masoomi H, Nguyen NT, Stamos MJ, Smith BR. Overview of outcomes of laparoscopic and open Roux-en-Y gastric bypass in the United States. *Surg Technol Int.* 2012;22:72-76.
115. Cash C, Frazee R. Improvements in laparoscopic treatment for complicated appendicitis. *J Laparoendosc Adv Surg Tech A.* 2012;22:581-583.
116. Mui LM, Ng CS, Wong SK, et al. Optimum duration of prophylactic antibiotics in acute non-perforated appendicitis. *ANZ J Surg.* 2005;75:425-428.
117. Hoelzer DJ, Zabel DD, Zern JT. Determining duration of antibiotic use in children with complicated appendicitis. *Pediatr Infect Dis J.* 1999;18:979-982.
118. Taylor E, Berjis A, Bosch T, Hoehne F, Ozaeta M. The efficacy of postoperative oral antibiotics in appendicitis: a randomized prospective double-blinded study. *Am Surg.* 2004;70:858-862.
119. Hamzaoglu I, Baca B, Böler DE, Polat E, Ozer Y. Is umbilical flora responsible for wound infection after laparoscopic surgery? *Surg Laparosc Endosc Percutan Tech.* 2004;14:263-267.
120. Addiss DG, Shaffer N, Fowler BS, Tauxe RV. The epidemiology of appendicitis and appendectomy in the United States. *Am J Epidemiol.* 1990;132:910-925.
121. Wang HT, Sax HC. Incidental appendectomy in the era of managed care and laparoscopy. *J Am Coll Surg.* 2001;192:182-188.
122. Sugimoto T, Edwards D. Incidence and costs of incidental appendectomy as a preventive measure. *Am J Public Health.* 1987;77:471-475.
123. Fisher KS, Ross DS. Guidelines for therapeutic decision in incidental appendectomy. *Surg Gynecol Obstet.* 1990;171:95-98.
124. Ozer MT, Demirbas S, Celik E, et al. Natural behavior and surgical treatment of appendiceal carcinoids: an analysis of 2,376 consecutive emergency appendectomies. *Bratisl Lek Listy.* 2011;112:619-622.
125. Lee WS, Choi ST, Lee JN, Kim KK, Park YH, Baek JH. A retrospective clinicopathological analysis of appendiceal tumors from 3,744 appendectomies: a single-institution study. *Int J Colorectal Dis.* 2011;26:617-621.
126. Sieren LM, Collins JN, Weireter LJ, et al. The incidence of benign and malignant neoplasia presenting as acute appendicitis. *Am Surg.* 2010;76:808-811.
127. Debnath D, Rees J, Myint F. Are we missing diagnostic opportunities in cases of carcinoid tumours of the appendix? *Surgon.* 2008;6:266-272.
128. In't Hof KH, van der Wal HC, Kazemier G, Lange JF. Carcinoid tumour of the appendix: an analysis of 1,485 consecutive emergency appendectomies. *J Gastrointest Surg.* 2008;12:1436-1438.
129. Smeenk RM, van Velthuysen ML, Verwaal VJ, Zoetmulder FA. Appendiceal neoplasms and pseudomyxoma peritonei: a population based study. *Eur J Surg Oncol.* 2008;34:196-201.
130. O'Donnell M, Badger SA, Beattie GC, Carson J, Garstin WIH. Malignant neoplasms of the appendix. *Int J Colorectal Dis.* 2007;22:1239-1248.
131. Marudanayagam R, Williams GT, Rees BI. Review of the pathological results of 2660 appendicectomy specimens. *J Gastroenterol.* 2006;41:745-749.
132. Lai HW, Loong CC, Tai LC, Wu CW, Lui WY. Incidence and odds ratio of appendicitis as first manifestation of colon cancer: a retrospective analysis of 1873 patients. *J Gastroenterol Hepatol.* 2006;21:1693-1696.
133. McGory ML, Maggard MA, Kang H, O'Connell JB, Ko CY. Malignancies of the appendix: beyond case series reports. *Dis Colon Rectum.* 2005;48:2264-2271.
134. Dhage-Ivatury S, Sugarbaker PH. Update on the surgical approach to mucocele of the appendix. *J Am Coll Surg.* 2006;202:680-684.
135. McCusker ME, Cote TR, Clegg LX, Sobin LH. Primary malignant neoplasms of the appendix: a population-based study from the Surveillance, Epidemiology and End Results program, 1973-1998. *Cancer.* 2002;94:3307-3312.
136. Hinson FL, Ambrose NS. Pseudomyxoma peritonei. *Br J Surg.* 1998;85:1332-1339.
137. Gough DB, Donohue JH, Schutt AJ, et al. Pseudomyxoma peritonei. Long-term patient survival with an aggressive regional approach. *Ann Surg.* 1994;219:112-119.
138. Stewart JH IV, Shen P, Russell GB, et al. Appendiceal neoplasms with peritoneal dissemination: outcomes after cytoreductive surgery and intraperitoneal hyperthermic chemotherapy. *Ann Surg Oncol.* 2006;13:624-634.
139. Sugarbaker PH. New standard of care for appendiceal epithelial neoplasms and pseudomyxoma peritonei syndrome? *Lancet Oncol.* 2006;7:69-76.
140. McQuellon RP, Russell GB, Shen P, et al. Survival and health outcomes after cytoreductive surgery with intraperitoneal hyperthermic chemotherapy for disseminated peritoneal cancer of appendiceal origin. *Ann Surg Oncol.* 2008;15:125-133.
141. Crump M, Gospodarowicz M, Shepherd FA. Lymphoma of the gastrointestinal tract. *Semin Oncol.* 1999;26:324-337.
142. Pickhardt PJ, Levy AD, Rohrmann CA Jr, Abbondanzo SL, Kende AL. Non-Hodgkin's lymphoma of the appendix: clinical and CT findings with pathologic correlation. *AJR Am J Roentgenol.* 2002;178:1123-1127.
143. Muller G, Dargent JL, Duwel V, et al. Leukaemia and lymphoma of the appendix presenting as acute appendicitis or acute abdomen. Four case reports with a review of the literature. *J Cancer Res Clin Oncol.* 1997;123:560-564.

31 chapter

Liver

Elaine Y. Cheng, Ali Zarrinpar, David A. Geller,
John A. Goss, and Ronald W. Busuttil

History of Liver Surgery	1264	Liver Biopsy / 1279	
Liver Anatomy	1264	Hepatic Reserve and Assessment of Surgical Risk in the Cirrhotic Patient / 1279	
Segmental Anatomy / 1265		Child-Turcotte-Pugh Score / 1280	
Hepatic Artery / 1266		Model for End-Stage Liver Disease Scoring System / 1280	
Portal Vein / 1267		Portal Hypertension / 1280	
Hepatic Veins and Inferior Vena Cava / 1267		Imaging of the Portal Venous System and Measurement of Portal Venous Pressure / 1280	
Bile Duct and Hepatic Ducts / 1268		Etiology and Clinical Features of Portal Hypertension / 1281	
Neural Innervation and Lymphatic Drainage / 1268		Management of Gastroesophageal Varices / 1281	
Liver Physiology	1269	Prevention of Variceal Bleeding / 1281	
Bilirubin Metabolism / 1270		Management of Acute Variceal Hemorrhage / 1282	
Formation of Bile / 1270		Luminal Tamponade / 1282	
Drug Metabolism / 1270		Transjugular Intrahepatic Portosystemic Shunt / 1282	
Liver Function Tests / 1270		Balloon-Occluded Retrograde Transvenous Obliteration / 1282	
Hepatocellular Injury / 1270		Surgical Shunting / 1282	
Abnormal Synthetic Function / 1271		Nonshunt Surgical Management of Refractory Variceal Bleeding / 1283	
Cholestasis / 1271		Hepatic Transplantation / 1283	
Jaundice / 1271		Budd-Chiari Syndrome / 1283	
Radiologic Evaluation of the Liver	1272	Infections of the Liver	1284
Ultrasound / 1272		Pyogenic Liver Abscesses / 1284	
Computed Tomography / 1273		Amebic Abscesses / 1285	
Magnetic Resonance Imaging / 1274		Hydatid Disease / 1285	
Positron Emission Tomography / 1275		Ascariasis / 1286	
Acute Liver Failure	1275	Schistosomiasis / 1286	
Etiology / 1276		Viral Hepatitis / 1286	
Clinical Presentation / 1276		Evaluation of an Incidental Liver Mass	1287
Diagnosis and Clinical Management / 1276		Hepatic Cysts	1288
Prognosis / 1277		Congenital Cysts / 1288	
Liver Transplantation / 1277		Biliary Cystadenoma / 1288	
Emerging Technologies / 1277		Polycystic Liver Disease / 1288	
Cirrhosis and Portal Hypertension	1277	Caroli's Disease / 1289	
Morphologic Classification of Cirrhosis / 1277			
Etiology of Cirrhosis / 1278			
Clinical Manifestations of Cirrhosis / 1279			
Laboratory Findings Associated with Cirrhosis / 1279			
		Benign Liver Lesions	1289
		Cyst / 1289	
		Hemangioma / 1289	
		Adenoma / 1290	
		Focal Nodular Hyperplasia / 1291	
		Bile Duct Hamartoma / 1291	
		Malignant Liver Tumors	1291
		Hepatocellular Carcinoma / 1291	
		Cholangiocarcinoma / 1291	
		Gallbladder Cancer / 1293	
		Metastatic Colorectal Cancer / 1293	
		Neuroendocrine Tumors / 1294	
		Other Metastatic Tumors / 1294	
		Treatment Options for Liver Cancer	1294
		Hepatic Resection / 1294	
		Liver Transplantation / 1295	
		Radiofrequency Ablation / 1295	
		Ethanol Ablation, Cryosurgery, and Microwave Ablation / 1295	
		Chemoembolization and Hepatic Artery Pump Chemoperfusion / 1295	
		Yttrium-90 Microspheres / 1296	
		Stereotactic Radiosurgery and Intensity-Modulated Radiation Therapy / 1296	
		Downstaging / 1296	
		Systemic Chemotherapy / 1296	
		Hepatic Resection Surgical Techniques	1296
		Nomenclature / 1296	
		Techniques and Devices for Dividing the Hepatic Parenchyma / 1296	
		Steps in Commonly Performed Hepatic Resections / 1297	
		Pringle and Ischemic Preconditioning / 1300	
		Preoperative Portal Vein Embolization / 1300	
		Staged Hepatectomy and Repeat Hepatic Resection for Recurrent Liver Cancer / 1301	
		Laparoscopic Liver Resection / 1301	

Key Points

- ▶ When operating on the liver, gallbladder, pancreas, or adjacent organs, recognition of the normal or variant vascular and biliary anatomy is essential to avoiding surgical complications.
- ▶ The liver is the largest gland in the body and performs a diverse spectrum of functions.
- ▶ Computed tomography and magnetic resonance imaging with contrast enhancement constitute the mainstays for the radiologic evaluation of the liver.
- ▶ Acute liver failure rapidly progresses to hepatic coma and death even with maximal medical therapy. The only definitive treatment is orthotopic liver transplantation.
- ▶ Cirrhosis is the end result of chronic hepatic insult, and further deterioration can lead to the development of end-stage liver disease, which carries a high mortality rate.
- ▶ Acute variceal bleeding should be managed with aggressive resuscitation and prompt endoscopic diagnosis with hemorrhage control. The transjugular intrahepatic portosystemic shunt procedure can be considered for cases refractory to medical treatment.
- ▶ Common benign lesions of the liver include cysts, hemangiomas, focal nodular hyperplasia, and hepatocellular adenomas. In most instances, these lesions can be reliably diagnosed by their characteristic features on imaging.
- ▶ Many options exist for the treatment of hepatocellular carcinomas, and these cases are best managed by a multidisciplinary liver transplant team.
- ▶ Surgical resection is the treatment of choice for hilar cholangiocarcinoma. Under a protocol with strict eligibility criteria, patients with unresectable tumors can be considered for liver transplantation following neoadjuvant chemoradiation, with survival rates that compare favorably with the rates for resection.
- ▶ The resectability of colorectal cancer metastases to the liver is primarily determined by the volume of the future liver remnant and the health of the background liver and not actual tumor number.
- ▶ Laparoscopic liver resections can be performed safely by experienced surgeons in selected patients and have been shown to produce comparable morbidity and mortality rates to open resections.

HISTORY OF LIVER SURGERY

The ancient Greek myth of Prometheus reminds us that the liver is the only organ that regenerates. According to Greek mythology, Zeus was furious with the Titan Prometheus because he gave fire to mortals. In return, Zeus chained Prometheus to Mount Caucasus and sent his giant eagle to eat his liver during the day, only to have it regenerate at night. Although this is folklore, the principles are correct that after hepatic resection, the remnant liver will hypertrophy over weeks to months to regain most of its original liver mass. It is interesting to note that the ancient Greeks seem to have been aware of this fact, because the Greek word for the liver, *hēpar*, derives from the verb *hēpaomai*, which means “mend” or “repair.” Hence *hēpar* roughly translates as “repairable.”¹ The importance of the liver dates back to even biblical times, for the Babylonians (c. 2000 B.C.) considered the liver to be the seat of the soul. There are scattered reports of liver surgery for battlefield injuries, but the first recorded elective hepatic resection was done in 1888 in Germany by Langenbuch. There followed reports of liver resections in the United States (Tiffany, 1890) and Europe (Lucke, 1891), as well as the first large series of hepatic resections by Keen in 1899.^{2,3} In 1908, Pringle described in *Annals of Surgery* the “arrest of hepatic hemorrhage due to trauma” by compression of the porta hepatis, a maneuver that now bears his name.⁴ Possibly due to the potential for massive hemorrhage during liver surgery, very little progress in surgical techniques was recorded for the next half-century. Work by Rex, Cantlie, and others laid the groundwork for experimental and clinical reports in the 1950s by Couinaud, Hjortsjo, Healey, Lortat-Jacob, and Starzl.^{5,6} These seminal contributions paved the way for the modern era of hepatic resection surgery.

LIVER ANATOMY

The liver is the largest organ in the body, weighing approximately 1500 g. It resides in the right upper abdominal cavity beneath the diaphragm and is protected by the rib cage. It is reddish brown and is surrounded by a fibrous sheath known as *Glisson’s capsule*. The liver is held in place by several ligaments (Fig. 31-1). The round ligament is the remnant of the obliterated umbilical vein and enters the left liver hilum at the front edge of the falciform ligament. The falciform ligament separates the left lateral and left medial segments along the umbilical fissure and anchors the liver to the anterior abdominal wall. Deep in the plane between the caudate lobe and the left lateral segment is the fibrous ligamentum venosum (Arantius’ ligament), which is the obliterated ductus venosus and is covered by the plate of Arantius. The left and right triangular ligaments secure the two sides of the liver to the diaphragm. Extending from the triangular ligaments anteriorly on the liver are the coronary ligaments. The right coronary ligament also extends from the right undersurface of the liver to the peritoneum overlying the right kidney, thereby anchoring the liver to the right retroperitoneum. These ligaments (round, falciform, triangular, and coronary) can be divided in a bloodless plane to fully mobilize the liver to facilitate hepatic resection. Centrally and just to the left of the gallbladder fossa, the liver attaches via the hepatoduodenal and the gastrohepatic ligaments (Fig. 31-2). The hepatoduodenal ligament is known as the *porta hepatis* and contains the common bile duct, the hepatic artery, and the portal vein. From the right side and deep (dorsal) to the porta hepatis is the foramen of Winslow, also known as the *epiploic foramen* (see Fig. 31-2). This passage connects directly to the lesser sac and allows complete vascular inflow control to the liver when the hepatoduodenal ligament is clamped using the Pringle maneuver.

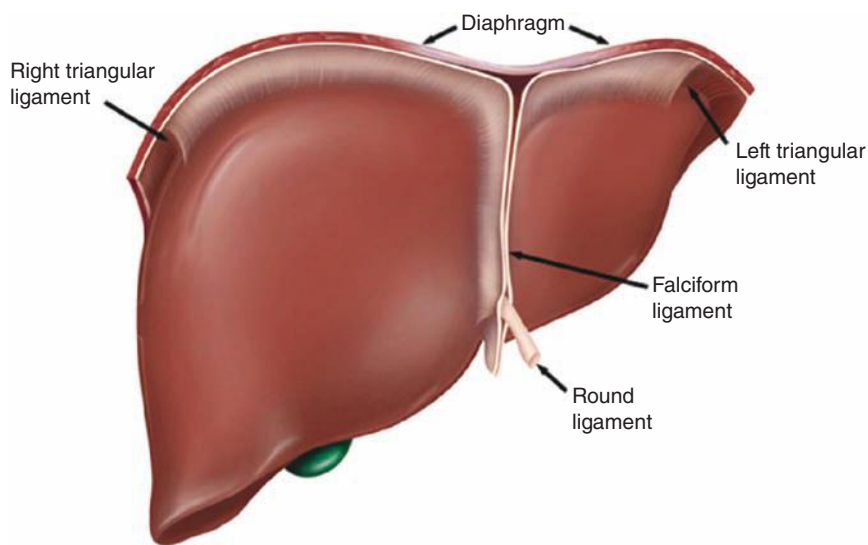


Figure 31-1. Hepatic ligaments suspending the liver to the diaphragm and anterior abdominal wall.

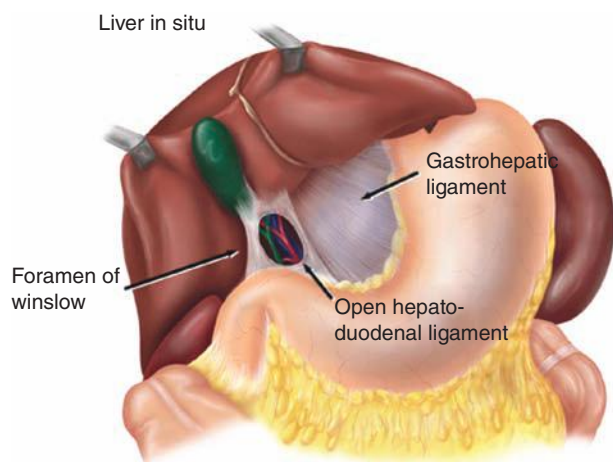


Figure 31-2. In situ liver hilar anatomy with hepatoduodenal and gastrohepatic ligaments. Foramen of Winslow is depicted.

Segmental Anatomy

The liver is grossly separated into the right and left lobes by the plane from the gallbladder fossa to the inferior vena cava (IVC), known as *Cantlie's line*.⁵ The right lobe typically accounts for 60% to 70% of the liver mass, with the left lobe (and caudate lobe) making up the remainder. The caudate lobe lies to the left and anterior of the IVC and contains three subsegments: the Spiegel lobe, the paracaval portion, and the caudate process.⁷ The falciform ligament does not separate the right and left lobes, but rather it divides the left lateral segment from the left medial segment. The left lateral and left medial segments also are referred to as *sections* as defined in the Brisbane 2000 terminology, which is outlined later in the section titled "Hepatic Resection." A significant advance in our understanding of liver anatomy came from the cast work studies of the French surgeon and anatomist Couinaud in the early 1950s. Couinaud divided the liver into eight segments, numbering them in a clockwise direction beginning with the caudate lobe as segment I.⁶ Segments II and III comprise the left lateral segment, and segment IV is the left medial segment (Fig. 31-3). Thus, the left lobe is made up of the left lateral segment (Couinaud's segments II and III) and the left medial segment (segment IV). Segment IV can be subdivided into segment IVA and segment IVB. Segment IVA is cephalad and just below the diaphragm, spanning from segment VIII to the falciform liga-

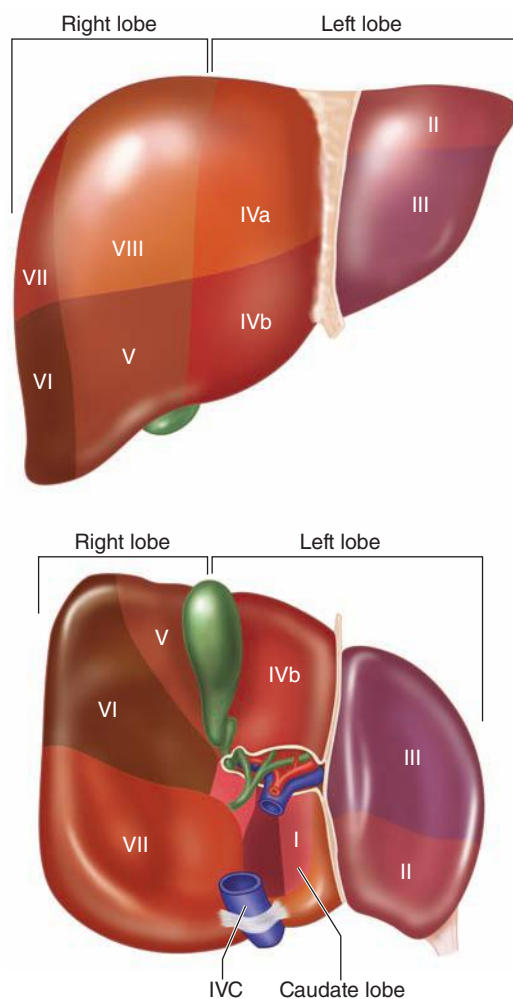


Figure 31-3. Couinaud's liver segments (I through VIII) numbered in a clockwise manner. The left lobe includes segments II to IV, the right lobe includes segments V to VIII, and the caudate lobe is segment I. IVC = inferior vena cava.

ment adjacent to segment II. Segment IVB is caudad and adjacent to the gallbladder fossa. Many anatomy textbooks also refer to segment IV as the *quadrate lobe*. *Quadrate lobe* is an outdated term, and the preferred term is *segment IV* or *left medial segment*. Most surgeons still refer to segment I as the *caudate lobe*, rather than segment I. The right lobe is comprised of segments V, VI, VII, and

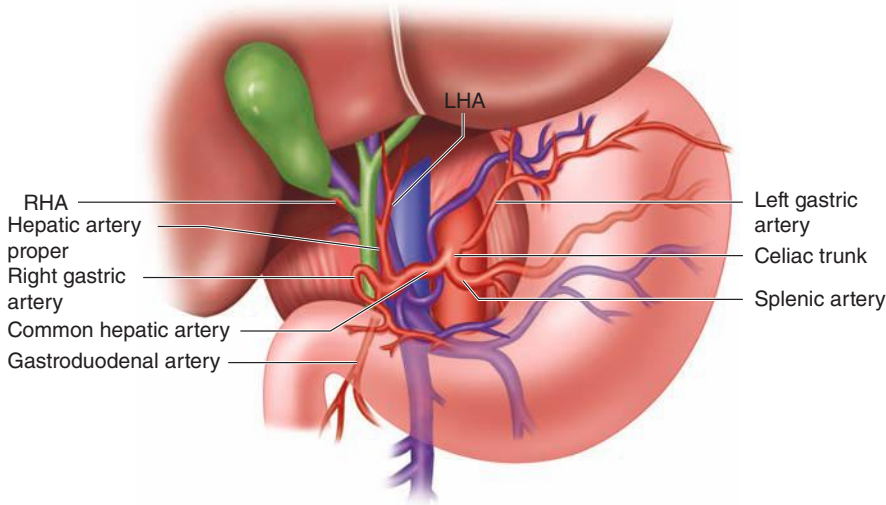


Figure 31-4. Arterial anatomy of the upper abdomen and liver, including the celiac trunk and hepatic artery branches. a. = artery; LHA = left hepatic artery; RHA = right hepatic artery.

VIII, with segments V and VIII making up the right anterior lobe, and segments VI and VII the right posterior lobe.

Additional functional anatomy was highlighted by Bismuth based on the distribution of the hepatic veins. The three hepatic veins run in corresponding scissura (fissures) and divide the liver into four sectors.⁸ The right hepatic vein runs along the right scissura and separates the right posterolateral sector from the right anterolateral sector. The main scissura contains the middle hepatic vein and separates the right and left livers. The left scissura contains the course of the left hepatic vein and separates the left posterior and left anterior sectors.

Hepatic Artery

The liver has a dual blood supply consisting of the hepatic artery and the portal vein. The hepatic artery delivers approximately

25% of the blood supply, and the portal vein approximately 75%. The hepatic artery arises from the celiac axis (trunk), which gives off the left gastric, splenic, and common hepatic arteries (Fig. 31-4). The common hepatic artery then divides into the gastroduodenal artery and the hepatic artery proper. The right gastric artery typically originates off of the hepatic artery proper, but this is variable. The hepatic artery proper divides into the right and left hepatic arteries. This “classic” or standard arterial anatomy is present in only approximately 76% of cases, with the remaining 24% having variable anatomy. It is critical to **1▶** understand the arterial (and biliary) anatomic variants to avoid surgical complications when operating on the liver, gallbladder, pancreas, or adjacent organs.

The most common hepatic arterial variants are shown (Fig. 31-5). Approximately 10% to 15% of the time, there is a

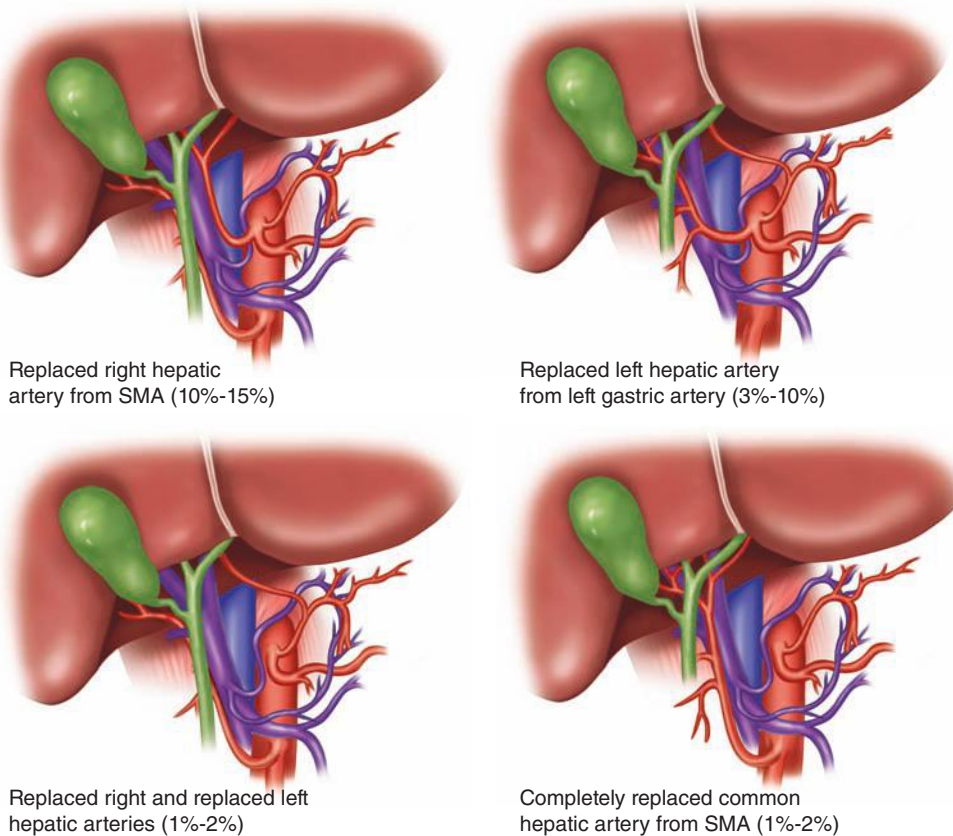


Figure 31-5. Common hepatic artery anatomic variants. SMA = superior mesenteric artery.

replaced or accessory right hepatic artery arising from the superior mesenteric artery (SMA). When there is a replacement or accessory right hepatic artery, it travels posterior to the portal vein and then takes up a right lateral position before diving into the liver parenchyma. This can be recognized visually on a preoperative computed tomography (CT) or magnetic resonance imaging (MRI) scan, and confirmed by palpation in the hilum where a separate right posterior pulsation is felt distinct from that of the hepatic artery proper that lies anteriorly in the hepatoduodenal ligament to the left of the common bile duct. In approximately 3% to 10% of cases, there exists a replacement (or accessory) left hepatic artery coming off of the left gastric artery and running obliquely in the gastrohepatic ligament anterior to the caudate lobe before entering the hilar plate at the base of the umbilical fissure. Other less common variants (approximately 1% to 2% each) are the presence of both replaced right and replaced left hepatic arteries, as well as a completely replaced common hepatic artery coming off the SMA (see Fig. 31-5). Although not well demonstrated in the illustration, the clue for a completely replaced common hepatic artery coming off the SMA is the presence of a strong arterial pulsation to the right of and posterior to the common bile duct, rather than the left side and anterior, in the porta hepatis. Another important point is that the right hepatic artery passes deep and posterior to the common bile duct approximately 88% of the time but crosses anterior to the common bile duct in approximately 12% of cases. The cystic artery feeding the gallbladder usually arises from the right hepatic artery in Calot's triangle.

Portal Vein

The portal vein is formed by the confluence of the splenic vein and the superior mesenteric vein. The inferior mesenteric vein usually drains into the splenic vein upstream from the confluence (Fig. 31-6). The main portal vein traverses the porta hepatis before dividing into the left and right portal vein branches. The left portal vein typically branches from the main portal vein outside of the liver with a sharp bend to the left and consists of the transverse portion followed by a 90° turn at the base of the umbilical fissure to become the umbilical portion before entering the liver parenchyma (Fig. 31-7). The left portal vein then

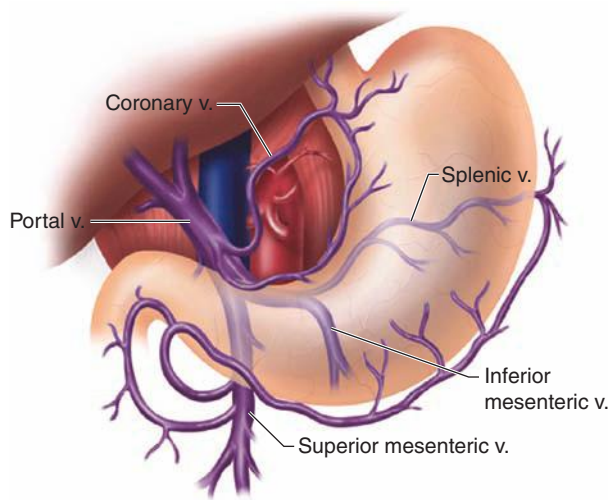


Figure 31-6. Portal vein anatomy. The portal vein is formed by the confluence of the splenic and superior mesenteric veins. The inferior mesenteric vein drains into the splenic vein. The coronary (left gastric) vein drains into the portal vein in the vicinity of the confluence. v. = vein.

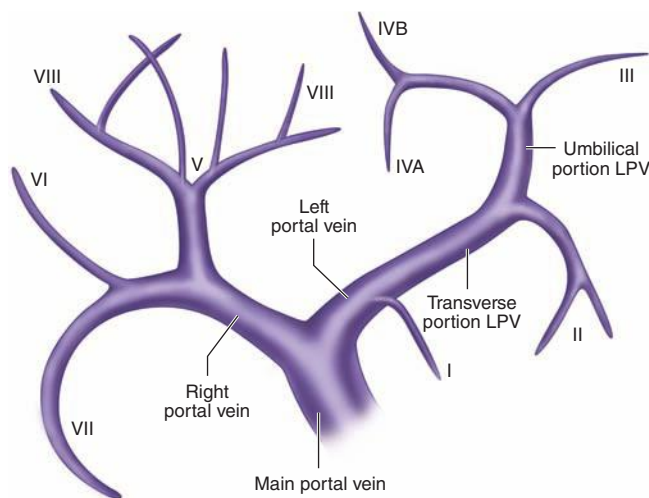


Figure 31-7. Anatomy of the left portal vein (LPV). Cadaver cast shows the transverse and umbilical portions of the LPV.

divides to give off the segment II and III branches to the left lateral segment, as well as the segment IV branches that supply the left medial segment. The left portal vein also provides the dominant inflow branch to the caudate lobe (although branches can arise from the main and right portal veins also), usually close to the bend between the transverse and umbilical portions. The division of the right portal vein is usually higher in the hilum and may be close to (or inside) the liver parenchyma at the hilar plate. Twenty percent to thirty-five percent of individuals have aberrant portal venous anatomy, with portal vein trifurcation or an aberrant branch from the left portal vein supplying the right anterior lobe being the most frequent.

The portal vein drains the splanchnic blood from the stomach, pancreas, spleen, small intestine, and majority of the colon to the liver before returning to the systemic circulation. The portal vein pressure in an individual with normal physiology is low at 3 to 5 mmHg. The portal vein is valveless, however, and in the setting of portal hypertension, the pressure can be quite high (20 to 30 mmHg). This results in decompression of the systemic circulation through portocaval anastomoses, most commonly via the coronary (left gastric) vein, which produces esophageal and gastric varices with a propensity for major hemorrhage. Another branch of the main portal vein is the superior pancreaticoduodenal vein (which comes off low in an anterior lateral position and is divided during pancreaticoduodenectomy). Closer to the liver, the main portal vein typically gives off a short branch (posterior lateral) to the caudate process on the right side. It is important to identify this branch and ligate it during hilar dissection for anatomic right hemihepatectomy to avoid avulsion.

Hepatic Veins and Inferior Vena Cava

There are three hepatic veins (right, middle, and left) that pass obliquely through the liver to drain the blood to the suprahepatic IVC and eventually the right atrium (Fig. 31-8). The right hepatic vein drains segments V through VIII; the middle hepatic vein drains segment IV as well as segments V and VIII; and the left hepatic vein drains segments II and III. The caudate lobe is unique because its venous drainage feeds directly into the IVC. In addition, the liver usually has a few small, variable short hepatic veins that directly enter the IVC from the undersurface of the liver. The left and middle hepatic veins form a common trunk approximately 95% of the time before entering the IVC, whereas the right hepatic vein inserts separately (in an oblique orientation) into the IVC.

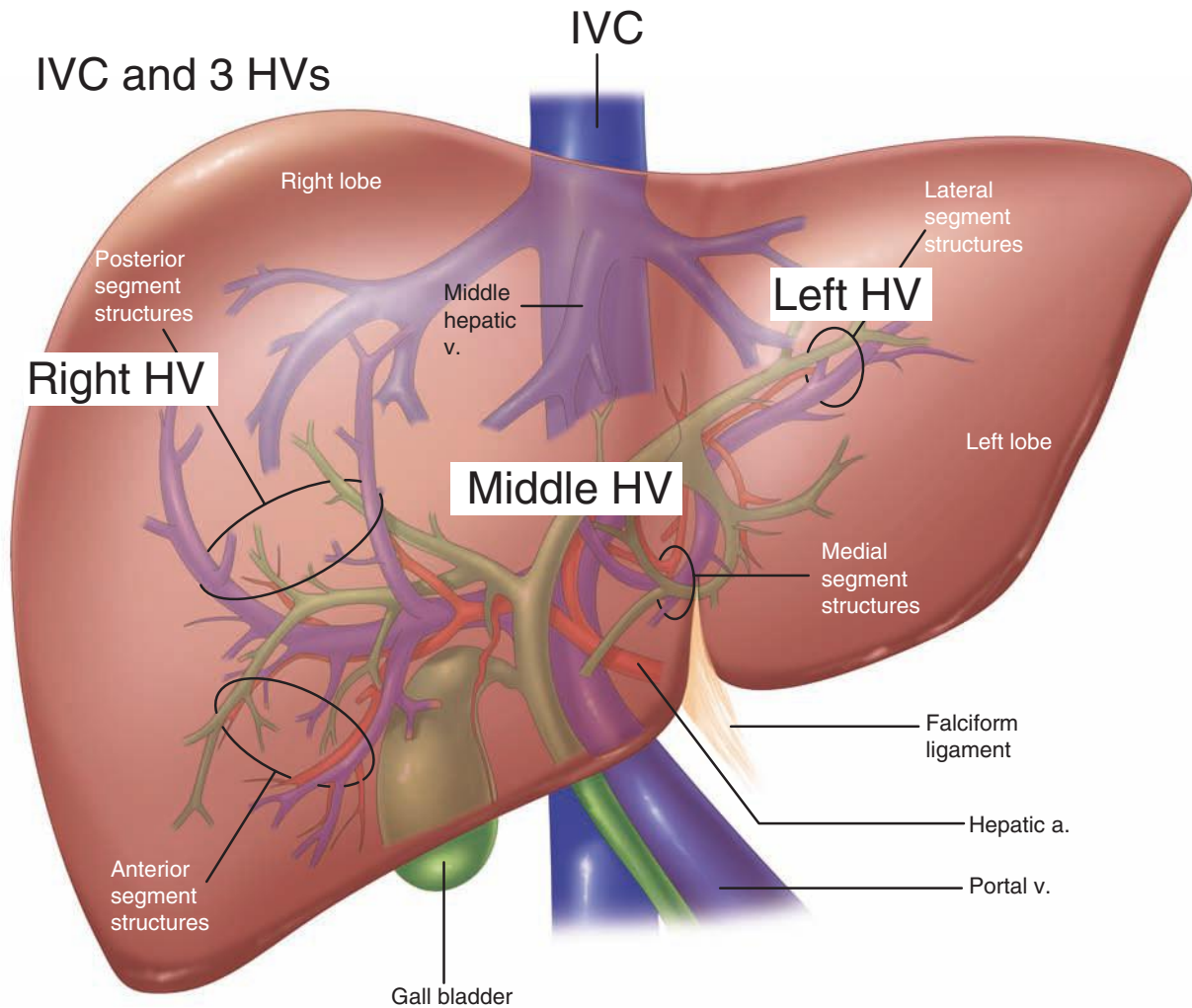


Figure 31-8. Confluence of the three hepatic veins (HVs) and the inferior vena cava (IVC). Note that the middle and left HVs drain into a common trunk before entering the IVC. a. = artery; v. = vein. (Adapted with permission from Cameron JL, ed. *Atlas of Surgery*. Vol. I, Gallbladder and Biliary Tract, the Liver, Portosystemic Shunts, the Pancreas. Toronto: BC Decker; 1990:153.)

There is a large inferior accessory right hepatic vein in 15% to 20% of cases that runs in the hepatocaval ligament. This can be a source of torrential bleeding if control of it is lost during right hepatectomy. The hepatic vein branches bisect the portal branches inside the liver parenchyma (i.e., the right hepatic vein runs between the right anterior and posterior portal veins; the middle hepatic vein passes between the right anterior and left portal vein; and the left hepatic vein crosses between the segment II and III branches of the left portal vein).

Bile Duct and Hepatic Ducts

Within the hepatoduodenal ligament, the common bile duct lies anteriorly and to the right. It gives off the cystic duct to the gallbladder and becomes the common hepatic duct before dividing into the right and left hepatic ducts. In general, the hepatic ducts follow the arterial branching pattern inside the liver. The right anterior hepatic duct usually enters the liver above the hilar plate, whereas the right posterior duct dives behind the right portal vein and can be found on the surface of the caudate process before entering the liver. The left hepatic duct typically has a longer extrahepatic course before giving off segmental branches behind the left portal vein at the base of the umbilical fissure. Considerable variation exists, and in 30% to 40% of

cases, there is a nonstandard hepatic duct confluence with accessory or aberrant ducts (Fig. 31-9). The cystic duct itself also has a variable pattern of drainage into the common bile duct. This can lead to potential injury or postoperative bile leakage during cholecystectomy or hepatic resection, and the surgeon needs to expect these variants. The gallbladder sits adherent to hepatic segments IVB (left lobe) and V (right lobe).

Neural Innervation and Lymphatic Drainage

The parasympathetic innervation of the liver comes from the left vagus, which gives off the anterior hepatic branch, and the right vagus, which gives off the posterior hepatic branch. The sympathetic innervation involves the greater thoracic splanchnic nerves and the celiac ganglia, although the function of these nerves is poorly understood. The denervated liver after hepatic transplantation seems to function with normal capacity. A common source of referred pain to the right shoulder and scapula as well as the right side or back is the right phrenic nerve, which is stimulated by tumors that stretch Glisson's capsule or by diaphragmatic irritation.

Lymph is produced within the liver and drains via the perisinusoidal space of Disse and periportal clefts of Mall to larger lymphatics that drain to the hilar cystic duct lymph node

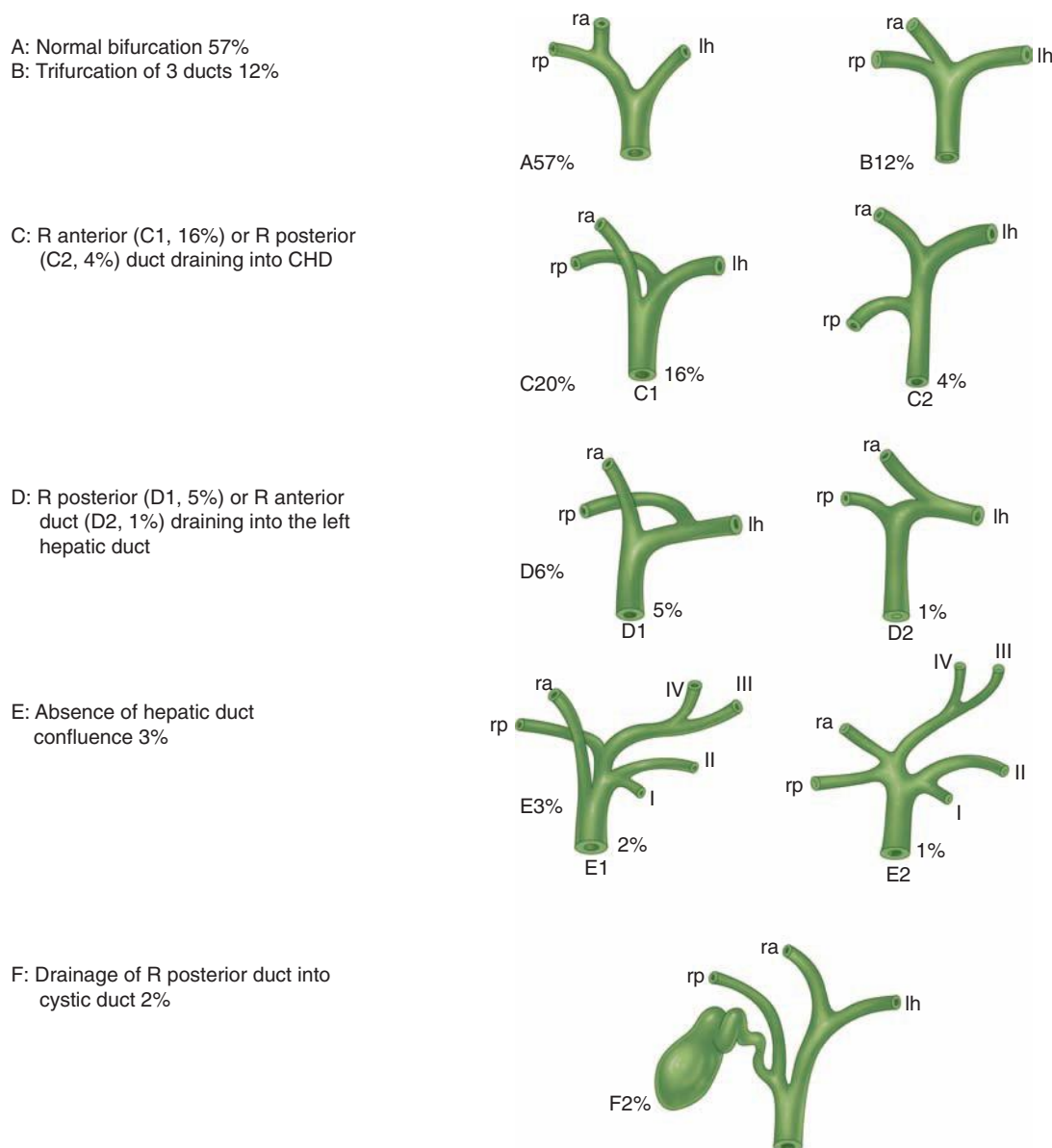


Figure 31-9. Main variations of hepatic duct confluence. As described by Couinaud in 1957, the bifurcation of the hepatic ducts has a variable pattern in approximately 40% of cases. CHD = common hepatic duct; lh = left hepatic; R = right; ra = right anterior; rp = right posterior. (Reproduced with permission from Blumgart LH, Fong Y, eds. *Surgery of the Liver and Biliary Tract*. 3rd ed, Vol. I. London: Elsevier Science; 2000. Copyright © Elsevier Science.)

(Calot's triangle node), as well as the common bile duct, hepatic artery, and retropancreatic and celiac lymph nodes. This is particularly important for resection of hilar cholangiocarcinoma, which has a high incidence of lymph node metastases. The hepatic lymph also drains cephalad to the cardiophrenic lymph nodes, and the latter can be pathologically identified on a staging CT or MRI scan.

LIVER PHYSIOLOGY

The liver is the largest gland in the body and has an extraordinary spectrum of functions. These include processes such as storage, metabolism, production, and secretion. One crucial role is the processing of absorbed nutrients through the metabolism of glucose, lipids, and proteins. The liver maintains glucose concentrations in a normal range over both short and long periods by performing several important roles in carbohydrate metabolism.

In the fasting state, the liver ensures a sufficient supply of glucose to the central nervous system. The liver can produce glucose by breaking down glycogen through glycogenolysis and by de novo synthesis of glucose through gluconeogenesis from noncarbohydrate precursors such as lactate, amino acids, and glycerol. In the postprandial state, excess circulating glucose is removed by glycogen synthesis or glycolysis and lipogenesis. The liver also plays a central role in lipid metabolism through the formation of bile and the production of cholesterol and fatty acids. Protein metabolism occurs in the liver through amino acid deamination, resulting in the production of ammonia as well as the production of a variety of amino acids. In addition to metabolism, the liver also is responsible for the synthesis of most circulating plasma proteins. Among these proteins are albumin, factors of the coagulation and fibrinolytic systems, and compounds of the complement cascade. Furthermore, the detoxification of many substances through drug metabolism occurs in the

liver, as do immunologic responses through the many immune cells found in its reticuloendothelial system.⁹

Bilirubin Metabolism

Bilirubin is the breakdown product of normal heme catabolism. Bilirubin is bound to albumin in the circulation and sent to the liver. In the liver, it is conjugated to glucuronic acid to form bilirubin diglucuronide in a reaction catalyzed by the enzyme glucuronyl transferase, making it water soluble. This glucuronide is then excreted into the bile canaliculi. A small amount dissolves in the blood and is then excreted in the urine. The majority of conjugated bilirubin is excreted in the intestine as waste, because the intestinal mucosa is relatively impermeable to conjugated bilirubin. However, it is permeable to unconjugated bilirubin and urobilinogens, a series of bilirubin derivatives formed by the action of bacteria. Thus, some of the bilirubin and urobilinogens are reabsorbed in the portal circulation; they are again excreted by the liver or enter the circulation and are excreted in the urine.¹⁰

Formation of Bile

Bile is a complex fluid containing organic and inorganic substances dissolved in an alkaline solution that flows from the liver through the biliary system and into the small intestine. The main components of bile are water, electrolytes, and a variety of organic molecules including bile pigments, bile salts, phospholipids (e.g., lecithin), and cholesterol. The two fundamental roles of bile are to aid in the digestion and absorption of lipids and lipid-soluble vitamins and to eliminate waste products (bilirubin and cholesterol) through secretion into bile and elimination in feces. Bile is produced by hepatocytes and secreted through the biliary system. In between meals, bile is stored in the gallbladder and concentrated through the absorption of water and electrolytes. Upon entry of food into the duodenum, bile is released from the gallbladder to aid in digestion. The human liver can produce about 1 L of bile daily.

Bile salts, in conjunction with phospholipids, are responsible for the digestion and absorption of lipids in the small intestine. Bile salts are sodium and potassium salts of bile acids conjugated to amino acids. The bile acids are derivatives of cholesterol synthesized in hepatocytes. Cholesterol, ingested from the diet or derived from hepatic synthesis, is converted into the bile acids cholic acid and chenodeoxycholic acid. These bile acids are conjugated to either glycine or taurine before secretion into the biliary system. Bacteria in the intestine can remove glycine and taurine from bile salts. They can also convert some of the primary bile acids into secondary bile acids by removing a hydroxyl group, producing deoxycholic acid from cholic acid and lithocholic acid from chenodeoxycholic acid.

Bile salts secreted into the intestine are efficiently reabsorbed and reused. Approximately 90% to 95% of the bile salts are absorbed from the small intestine at the terminal ileum. The remaining 5% to 10% enter the colon and are converted to the secondary salts, deoxycholic acid and lithocholic acid. The mixture of primary and secondary bile salts and bile acids is absorbed primarily by active transport in the terminal ileum. The absorbed bile salts are transported back to the liver in the portal vein and re-excreted in the bile. Those lost in the stool are replaced by synthesis in the liver. The continuous process of secretion of bile salts in the bile, their passage through the intestine, and their subsequent return to the liver is termed the *enterohepatic circulation*.¹⁰

Drug Metabolism

The liver plays an important role in providing mechanisms for ridding the body of foreign molecules (xenobiotics) that are absorbed from the environment. In most cases, a drug is relatively lipophilic to ensure good absorption. The liver participates in the elimination of these lipid-soluble drugs by transforming them into more readily excreted hydrophilic products. There are two main reactions important for drug metabolism. Phase I reactions include oxidation, reduction, and hydrolysis of molecules. These result in metabolites that are more hydrophilic than the original chemicals. The cytochrome P450 system is a family of hemoproteins important for oxidative reactions involving drugs and toxic substances. Phase II reactions, also known as *conjugation reactions*, are synthetic reactions that involve addition of subgroups to the drug molecule. These subgroups include glucuronate, acetate, glutathione, glycine, sulfate, and methyl groups. These drug reactions occur mainly in the smooth endoplasmic reticulum of hepatocytes.

Many factors can affect drug metabolism in the liver. When the rate of metabolism of a drug is increased (i.e., enzyme induction), the duration of the drug action will decrease. However, when the metabolism of a drug is decreased (i.e., enzyme inhibition), then the drug will circulate for a longer period of time. It is important to note that some drugs may be converted to active products by metabolism in the liver. An example is acetaminophen when taken in larger doses. Normally, acetaminophen is conjugated by the liver to harmless glucuronide and sulfate metabolites that are water soluble and eliminated in the urine. During an overdose, the normal metabolic pathways are overwhelmed, and some of the drug is converted to a reactive and toxic intermediate by the cytochrome P450 system. Glutathione normally reacts with this intermediate, leading to the production and subsequent excretion of a harmless product. However, as glutathione stores are diminished, the reactive intermediate cannot be detoxified and it combines with lipid membranes of hepatocytes, which results in cellular necrosis. Thus, treatment of acetaminophen overdoses consists of replenishing glutathione stores by supplementing with sulfhydryl compounds such as acetylcysteine.

Liver Function Tests

Liver function tests is a term frequently used to refer to measurement of the levels of a group of serum markers for evaluation of liver dysfunction. Most commonly, levels of aspartate transaminase (AST), alanine transaminase (ALT), alkaline phosphatase (AP), γ -glutamyltranspeptidase (GGT), and bilirubin are included in this panel. This term is a misnomer, however, because most of these tests measure not liver function but rather cell damage. More accurate measurement of the liver's synthetic function is provided by serum albumin levels and prothrombin time (PT). Although measuring liver enzyme levels is important in the assessment of a patient's liver disease, these test results can be nonspecific. Thus, evaluation of patients with suspected liver disease should always involve careful interpretation of abnormalities in these liver test results in the context of a thorough history and physical examination. The approach to evaluating abnormal laboratory values also can be simplified by categorizing the type of abnormality that predominates (hepatocellular damage, abnormal synthetic function, or cholestasis).

Hepatocellular Injury

Hepatocellular injury of the liver is usually indicated by abnormalities in levels of the liver aminotransferases AST and ALT.

These enzymes participate in gluconeogenesis by catalyzing the transfer of amino groups from aspartic acid or alanine to ketoglutaric acid to produce oxaloacetic acid and pyruvic acid, respectively (these enzymes are also referred to as *serum glutamic-oxaloacetic transaminase [SGOT]* and *serum glutamic-pyruvic transaminase [SGPT]*). AST is found in liver, cardiac muscle, skeletal muscle, kidney, brain, pancreas, lungs, and red blood cells and thus is less specific for disorders of the liver. ALT is predominately found in the liver and thus is more specific for liver disease. Hepatocellular injury is the trigger for release of these enzymes into the circulation. Common causes of elevated aminotransferase levels include viral hepatitis, alcohol abuse, medications, genetic disorders (Wilson's disease, hemochromatosis, α_1 -antitrypsin deficiency), and autoimmune diseases.

The extent of serum aminotransferase elevations can suggest certain etiologies of the liver injury. However, the levels of the enzymes in these tests correlate poorly with the severity of hepatocellular necrosis, because they may not be significantly elevated in conditions of hepatic fibrosis or cirrhosis. In alcoholic liver disease, an AST:ALT ratio of $>2:1$ is common. Mild elevations of transaminase levels can be found in nonalcoholic fatty liver disease, chronic viral infection, or medication-induced injury. Moderate increases in the levels of these enzymes are common in acute viral hepatitis. In conditions of ischemic insults, toxin ingestions (i.e., acetaminophen), and fulminant hepatitis, AST and ALT levels can be elevated to the thousands.

Abnormal Synthetic Function

Albumin synthesis is an important function of the liver and thus can be measured to evaluate the liver's synthetic function. The liver produces approximately 10 g of albumin per day. However, albumin levels are dependent on a number of factors such as nutritional status, renal dysfunction, protein-losing enteropathies, and hormonal disturbances. In addition, level of albumin is not a marker of acute hepatic dysfunction due to albumin's long half-life of 15 to 20 days.

Most clotting factors (except factor VIII) are synthesized exclusively in the liver, and thus their levels can also be used as a measure of hepatic synthetic function. Measurements of the prothrombin time (PT) and international normalized ratio (INR) are some of the best tests of hepatic synthetic function. PT measures the rate of conversion of prothrombin to thrombin. To standardize the reporting of PT and avoid interlaboratory variability, the INR was developed. The INR is the ratio of the patient's PT to the mean control PT. Because vitamin K is involved in the γ -carboxylation of factors used to measure PT (factors II, VII, IX, and X), values also may be prolonged in other conditions such as vitamin K deficiency and warfarin therapy.

Cholestasis

Cholestasis is a condition in which bile flow from the liver to the duodenum is impaired. Disturbances in bile flow may be due to intrahepatic causes (hepatocellular dysfunction) or extrahepatic causes (biliary tree obstruction). Cholestasis often results in the release of certain enzymes and thus can be detected by measuring the serum levels of bilirubin, AP, and GGT. Bilirubin is a breakdown product of hemoglobin metabolism. Unconjugated bilirubin is insoluble and thus is transported to the liver bound to albumin. In the liver, it is conjugated to allow excretion

in bile. Measured total bilirubin levels can be normal or high in patients with significant liver disease because of the liver's ability to conjugate significant amounts of bilirubin. Thus, to help aid in the diagnosis of hyperbilirubinemia, fractionation of total bilirubin is usually performed to distinguish between conjugated (direct) and unconjugated (indirect) bilirubin. *Indirect bilirubin* is a term frequently used to refer to unconjugated bilirubin in the circulation because the addition of another chemical is necessary to differentiate this fraction from the whole. Normally, $>90\%$ of serum bilirubin is unconjugated. The testing process for conjugated bilirubin, in contrast, is direct without the addition of other agents. The direct bilirubin test measures the levels of conjugated bilirubin and δ bilirubin (conjugated bilirubin bound to albumin).

The patterns of elevation of the different fractions of bilirubin provide important diagnostic clues as to the cause of cholestasis. In general, an elevated indirect bilirubin level suggests intrahepatic cholestasis, and an elevated direct bilirubin level suggests extrahepatic obstruction. Mechanisms that can result in increases in unconjugated bilirubin levels include increased bilirubin production (hemolytic disorders and resorption of hematomas) or defects (inherited or acquired) in hepatic uptake or conjugation. The rate-limiting step in bilirubin metabolism is the excretion of bilirubin from hepatocytes, so conjugated hyperbilirubinemia can be seen in inherited or acquired disorders of intrahepatic excretion or extrahepatic obstruction. Conjugated bilirubin that cannot be excreted accumulates in hepatocytes, which results in its secretion into the circulation. Because conjugated bilirubin is water soluble, it can be found in the urine of patients with jaundice.

AP is an enzyme with a wide tissue distribution but is found primarily in the liver and bones. In the liver, it is expressed by the bile duct epithelium. In conditions of biliary obstruction, levels rise as a result of increased synthesis and release into the serum. Because the half-life of serum AP is approximately 7 days, it may take several days for levels to normalize even after resolution of the biliary obstruction.

GGT is another enzyme found in hepatocytes and released from the bile duct epithelium. Elevation of GGT is an early marker and also a sensitive test for hepatobiliary disease. Like AP elevation, however, it is nonspecific and can be produced by a variety of disorders in the absence of liver disease. Increased levels of GGT can be induced by certain medications, alcohol abuse, pancreatic disease, myocardial infarction, renal failure, and obstructive pulmonary disease. For this reason, elevated GGT levels are often interpreted in conjunction with other enzyme abnormalities. For example, a raised GGT level with increased AP level supports a liver source.

Jaundice

Jaundice refers to the yellowish staining of the skin, sclera, and mucous membranes with the pigment bilirubin. Hyperbilirubinemia usually is detectable as jaundice when blood levels rise above 2.5 to 3 mg/dL. Jaundice can be caused by a wide range of benign and malignant disorders. However, when present, it may indicate a serious condition, and thus knowledge of the differential diagnosis of jaundice and a systematic approach to the workup of the patient is necessary. Workup of a patient with jaundice is simplified by organizing the possible causes of the disorder into groups based on the location of bilirubin metabolism. As mentioned previously, bilirubin metabolism can take place in three phases: prehepatic, intrahepatic, and posthepatic.

The prehepatic phase includes the production of bilirubin from the breakdown of heme products and its transport to the liver. The majority of the heme results from red blood cell metabolism and the rest from other heme-containing organic compounds such as myoglobin and cytochromes. In the liver, the insoluble unconjugated bilirubin is then conjugated to glucuronic acid to allow for solubility in bile and excretion. The posthepatic phase of bilirubin metabolism consists of excretion of soluble bilirubin through the biliary system into the duodenum. Dysfunction in any of these phases can lead to jaundice.¹⁰

Prehepatic. Jaundice as a result of elevated levels of unconjugated bilirubin occurs from faulty prehepatic metabolism and usually arises from conditions that interfere with proper conjugation of bilirubin in the hepatocyte. Insufficient conjugation is often seen in processes that result in excessive heme metabolism. Subsequently, the conjugation system is overwhelmed, which results in unconjugated hyperbilirubinemia. Causes of hemolysis include inherited and acquired hemolytic anemias. Inherited hemolytic anemias include genetic disorders of the red blood cell membrane (hereditary spherocytosis and elliptocytosis), enzyme defects (glucose-6-phosphate dehydrogenase deficiency), and defects in hemoglobin structure (sickle cell anemia and thalassemias). Hemolytic anemias can also be acquired, and these can be further divided into those with immune-mediated and those with non-immune-mediated causes. Immune-mediated hemolytic anemias result in a positive finding on a direct Coombs' test and have a variety of autoimmune and drug-induced causes. In contrast, direct Coombs' test results are negative in nonimmune hemolytic anemias. The causes in this latter category are varied and include drugs and toxins that directly damage red blood cells, mechanical trauma (heart valves), microangiopathy, and infections. Prehepatic dysfunction of bilirubin metabolism also can result from failure in the transport of unconjugated bilirubin to the liver by albumin in any condition that leads to plasma protein loss. A poor nutritional state or excess protein loss as seen in burn patients can lead to elevated levels of unconjugated bilirubin in the circulation and jaundice.

Intrahepatic. Intrahepatic causes of jaundice involve the intracellular mechanisms for conjugation and excretion of bile from the hepatocyte. The enzymatic processes in hepatocytes can be affected by any condition that impairs hepatic blood flow and subsequent function of the liver (ischemic or hypoxic events). Furthermore, there are multiple inherited disorders of enzyme metabolism that can result in either unconjugated or conjugated hyperbilirubinemia. Gilbert's syndrome is a genetic variant characterized by diminished activity of the enzyme glucuronyltransferase, which results in decreased conjugation of bilirubin to glucuronide. It is a benign condition that affects approximately 4% to 7% of the population. Typically, the disease results in transient mild increases in unconjugated bilirubin levels and jaundice during episodes of fasting, stress, or illness. These episodes are self-limited and usually do not require further treatment. Another inherited disorder of bilirubin conjugation is Crigler-Najjar syndrome. It is a rare disease found in neonates and can result in neurotoxic sequelae from bilirubin encephalopathy.

In addition to defects in conjugation, disorders in bilirubin excretion in hepatocytes can also lead to jaundice. Rotor's syndrome and Dubin-Johnson syndrome are two uncommon genetic disorders that disrupt secretion of conjugated bilirubin from the

hepatocyte into the bile and result in conjugated hyperbilirubinemia. There are also multiple acquired conditions that result in inflammation and intrahepatic cholestasis by affecting hepatocyte mechanisms for conjugation and excretion of bile. Viruses, alcohol abuse, sepsis, and autoimmune disorders all can result in inflammation in the liver with subsequent disruption of bilirubin transport in the liver. In addition, jaundice can also occur from the cytotoxic effects of many medications, including acetaminophen, oral contraceptives, and anabolic steroids.

Posthepatic. Posthepatic causes of jaundice are usually the result of intrinsic or extrinsic obstruction of the biliary duct system that prevents the flow of bile into the duodenum. There is a wide spectrum of pathologies that may present with obstructive jaundice. Intrinsic obstruction can occur from biliary diseases, including cholelithiasis, choledocholithiasis, benign and malignant biliary strictures, cholangiocarcinoma, cholangitis, and disorders of the papilla of Vater. Extrinsic compression of the biliary tree is commonly due to pancreatic disorders. Patients with pancreatitis, pseudocysts, and malignancies can present with jaundice due to external compression of the biliary system. Finally, with the growing armamentarium of endoscopic tools and minimally invasive surgical approaches, surgical complications are becoming more frequent causes of extrahepatic cholestasis. Misadventures with surgical clips, retained stones, and inadvertent ischemic insults to the biliary system can result in obstructive jaundice recognized at any time from immediately postoperatively to many years later.

RADIOLOGIC EVALUATION OF THE LIVER

Ultrasound

Abdominal ultrasound is a commonly applied imaging modality used to evaluate abdominal symptoms. Ultrasound technology is based on the pulse-echo principle. The ultrasound transducer converts electrical energy to high-frequency sound energy that is transmitted into tissue. Although some of the ultrasound waves are transmitted through the tissue, some are reflected back, and the ultrasound image is produced when the ultrasound receiver detects those reflected waves. This real-time gray scale (B-mode) imaging is augmented by Doppler flow imaging. Doppler ultrasound not only can detect the presence of blood vessels but also can determine the direction and velocity of blood flow. Ultrasonography is a useful initial imaging test of the liver because it is inexpensive, widely available, involves no radiation exposure, and is well tolerated by patients. It is excellent for diagnosing biliary pathology and focal liver lesions. In addition, liver injury can be evaluated in trauma patients using the focused abdominal sonography for trauma examination. Limitations of ultrasound include incomplete imaging of the liver, most often at the dome or beneath ribs on the surface, and incomplete visualization of lesion boundaries. Moreover, obesity and overlying bowel gas also can interfere with image quality. Thus, ultrasonographically detected masses usually require further evaluation by other imaging modalities due to the lower sensitivity and specificity of ultrasound compared with CT and MRI.

The advent of contrast-enhanced ultrasound has improved the ability of this modality to differentiate among benign and malignant lesions. The injection of gas microbubble agents can increase the sensitivity and specificity of ultrasound in detecting and diagnosing liver lesions. Microbubbles are <10 μm

and, when given intravenously, allow for more effective echo enhancement. Contrast-enhanced ultrasound imaging of the liver improves delineation of liver lesions through identification of dynamic enhancement patterns and the vascular morphology of the lesion. In addition, some agents exhibit a late liver-specific phase in which the bubbles are taken up by cells in the reticuloendothelial system and accumulate in normal liver parenchyma after the vascular enhancement has faded.

The use of intraoperative ultrasound of the liver has rapidly expanded over the years with the increasing number and complexity of hepatic resections being performed.¹¹ It has the ability to provide the surgeon with real-time accurate information useful for surgical planning. Intraoperative ultrasound is considered the gold standard for detecting liver lesions, and studies have shown that it can identify 20% to 30% more lesions than other preoperative imaging modalities. Importantly, it has been shown to influence surgical management in almost 50% of planned liver resections for malignancies. Applications for intraoperative ultrasound of the liver include tumor staging, visualization of intrahepatic vascular structures (Fig. 31-10), and guidance of resection plane by assessment of the relationship of a mass to the vessels. In addition, biopsy of lesions and ablation of tumors can be guided by intraoperative ultrasound.

Ultrasound elastography, also referred to as transient elastography, can be used to assess the degree of fibrosis or cirrhosis in the liver. Low-frequency vibrations transmitted through the liver induce an elastic shear wave that is detected by pulse-echo ultrasonography as the wave propagates through the liver. The velocity of the wave correlates with the stiffness of the organ—the wave travels faster through fibrotic or cirrhotic tissues. Ultrasound elastography has been found in large cohorts of individuals to have a sensitivity of 87% and a specificity of 91% for the diagnosis of cirrhosis when compared with liver biopsy.¹² Unlike liver biopsy, ultrasound elastography is non-invasive and can be repeated often without additional risk to the patient. Furthermore, this rapid test can acquire information from a larger area of the tissue relative to needle biopsy, providing a better understanding of the entire hepatic parenchyma and reducing sampling error.

Computed Tomography

CT produces a digitally processed cross-sectional image of the body from a large series of x-ray images. The introduction of helical (spiral) CT has improved the imaging capabilities of this technique compared to earlier conventional axial CT by combining a continuous patient-table motion with continuous rotation of the CT gantry and allowing rapid acquisition of a volume of data within a single breath hold. With the recent advent of multi-detector row CT scanners, high-resolution images can be obtained in submillimeter section thickness within a short scan time, with virtually no penalty in increased radiation dose. Together, these technological advances have led to reduced motion artifacts due to variations in inspiration, facilitated optimal contrast delivery, and allowed for the capability to generate high-resolution reformations in any desired plane. In a single examination, modern-day CT scans provide detailed morphologic information on the number, size, distribution, and vascularity of liver lesions, all of which are vital in guiding the clinical management and therapeutic plan.

Contrast medium is routinely used in CT evaluation of the liver because of the similar densities of most pathologic liver masses and normal hepatic parenchyma. A CT scan with a

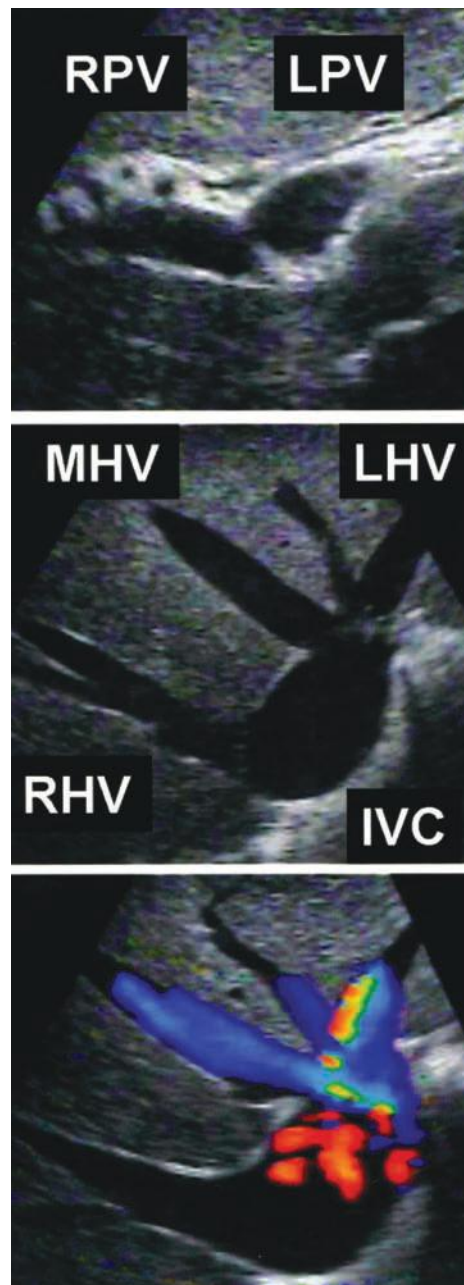


Figure 31-10. Intraoperative liver ultrasound images of the portal veins, hepatic veins, and inferior vena cava (IVC). *Upper panel* shows the portal vein bifurcation with echogenic Glissonian sheath. The confluence of the three hepatic veins (right hepatic vein [RHV], middle hepatic vein [MHV], and left hepatic vein [LHV]) and the IVC is shown in the *middle panel*. An accessory LHV is present in this patient. *Lower panel* is a color Doppler image showing flow.

dual- or triple-phase bolus of intravenous contrast agent is performed to achieve the greatest enhancement of contrast between normal and pathologic tissues.¹³ Ideally, contrast media should be selectively delivered to either the tumor or the liver, but not both. Radiologists use the dual blood supply of the liver and the hemodynamics of hepatic tumors to achieve this goal. The liver is unique in that it has a dual blood supply. As previously noted, the portal vein supplies approximately 75% of the blood flow and the hepatic artery the remaining 25%. However, many liver tumors receive the majority of their blood supply from the hepatic artery. After injection of the contrast agent, the rapid

scan time of helical CT allows for CT sections through the liver in both the arterial dominant phase (20 to 30 seconds after the beginning of contrast delivery) and venous or portal dominant phase (60 to 70 seconds after contrast injection) (Fig. 31-11). Thus, many hepatic tumors that derive the majority of their blood supply from the hepatic artery as well as other hypervascular lesions are well delineated in the arterial phase. On the other hand, the portal phase provides optimal enhancement of the normal liver parenchyma because the majority of its blood supply is derived from the portal vein. This allows for detection of hypovascular lesions because they will appear hypoattenuated in relation to the brighter normal liver parenchyma.³ Furthermore, the arterial and portal phase images allow for

noninvasive mapping of the hepatic arterial and venous anatomy, information that is crucial in the preoperative planning for patients undergoing liver surgery.

CT cholangiography has emerged as a new imaging modality for biliary disease. This technique usually involves the use of contrast agents, which are excreted by hepatocytes into the bile ducts. CT cholangiography, therefore, provides information on hepatocyte function and bile flow, in addition to high-resolution depiction of the biliary tree. It has compared well to endoscopic retrograde cholangiopancreatography (ERCP) in identifying obstructive biliary disease.¹⁴ One of the major advantages of CT cholangiography over other imaging modalities is the ability to depict small nondilated peripheral biliary radicals. This technique may be useful in the context of live liver donation or complex biliary surgery to aid in the preoperative depiction of biliary anatomy. It also may be applicable in the postoperative setting for the detection of biliary leakage or obstruction. A limitation of CT cholangiography is that the biliary tree may not be well visualized in patients with excessively dilated bile ducts or in those with hyperbilirubinemia, as bilirubin excretion is impaired in these cases.

Magnetic Resonance Imaging

MRI is a technique that produces images based on magnetic fields and radio waves. The MRI scanner creates a powerful magnetic field that aligns the hydrogen atoms in the body, and radio waves are used to alter the alignment of this magnetization. Different tissues absorb and release radio wave energy at different rates, and this information is used to construct an image of the body. Most tissues can be differentiated by differences in their characteristic T1 and T2 relaxation times. T1 is a measure of how quickly a tissue can become magnetized, and T2 measures how quickly it loses its magnetization. As with CT technology, advances in MRI now provide the opportunity to perform single-breath T1-weighted imaging and respiration-triggered T2-weighted imaging. The development of breath-hold imaging techniques has eliminated many of the motion artifacts that previously limited the sensitivity and application of MRI for imaging of the liver. Compared with CT scanning, the major advantages of MRI pertain to higher soft tissue contrast resolution and excellent depiction of fluid-containing structures, while obviating the need for ionizing radiation.

As with the iodinated contrast media use in CT scanning, multiple contrast agents have been developed for MRI to increase the difference in signal intensity between normal liver and pathologic lesions. Various gadolinium-based compounds have been used as MRI contrast agents that behave in a manner very similar to iodine in CT. Liver-specific MRI contrast agents also have been developed that rely either on excretion by Kupffer cells, such as ferumoxide (Feridex, Advanced Magnetics, Cambridge, MA), or on secretion in bile by hepatocytes, including gadoxetate (Eovist or Primovist, Bayer-Schering, Berlin, Germany). These agents combine the information obtained during a standard MRI with additional functional data, which in turn yields improved detection and characterization of lesions within the liver.¹⁵

Just as ultrasound elastography is useful in the diagnosis of hepatic fibrosis and cirrhosis, magnetic resonance (MR) elastography appears promising as an imaging modality in reducing the need for liver biopsy. In this technique, a vibration device is used to induce a shear wave in the liver. A modified MRI machine detects the shear wave, then generates a color-coded image that

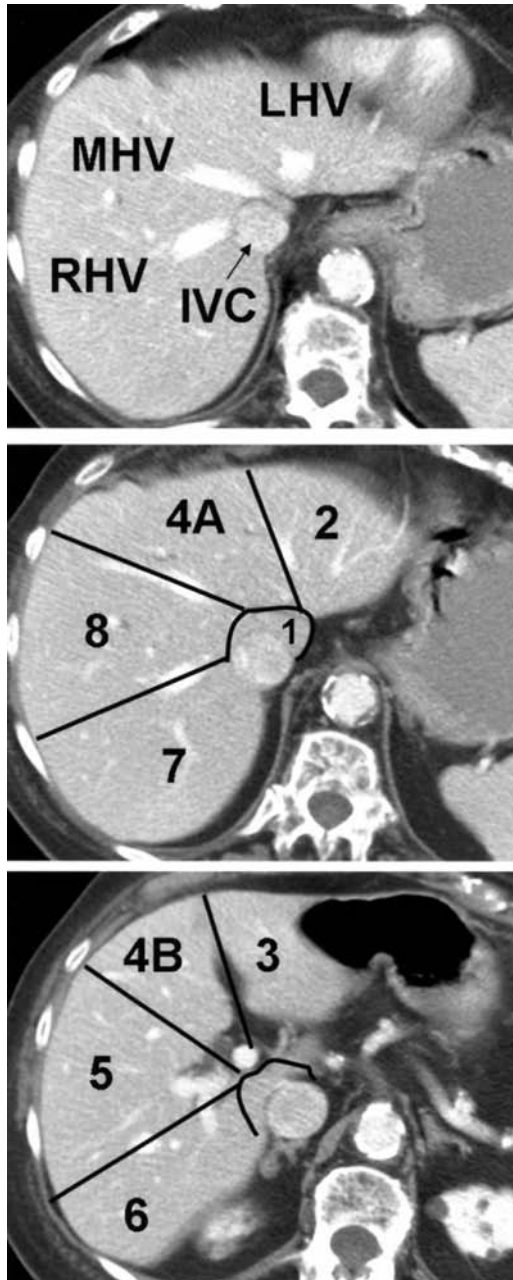


Figure 31-11. Computed tomographic (CT) images of hepatic veins and Couinaud's liver segments. The images show the three hepatic veins and inferior vena cava (IVC) (*upper panel*), as well as Couinaud's liver segments (*lower panels*). LHV = left hepatic vein; MHV = middle hepatic vein; RHV = right hepatic vein.

depicts the wave velocity, and hence stiffness, throughout the organ. Although preliminary studies have shown that MR elastography can detect cirrhosis with a high degree of accuracy, the clinical utility of this modality, especially given its relatively high cost, remains to be determined.

Magnetic resonance cholangiopancreatography (MRCP) enables rapid, noninvasive depiction of both the biliary tree and the pancreatic duct without the use of ionizing radiation or intravenous contrast media. One of the most common clinical indications for MRCP is biliary obstruction. MRCP provides visualization of dilated bile ducts, and the high spatial and contrast resolution often enables accurate assessment of the level of occlusion in the biliary tree. MRCP also can be enhanced with liver-specific MRI contrast agents that are actively secreted into the bile, but the clinical indications for such studies are still a matter of intensive investigation.¹⁶

Positron Emission Tomography

Positron emission tomography (PET) is a nuclear medicine test that produces images of metabolic activity in tissues by detecting gamma rays emitted by a radioisotope incorporated into a metabolically active molecule. Fluorodeoxyglucose (FDG) is the most common metabolic molecule used in PET imaging. Although traditional imaging such as CT, ultrasound, and MRI provide anatomic information, PET offers functional imaging of tissues with high metabolic activity, including most types of metastatic tumors. PET imaging increasingly is used as a tool in the diagnostic evaluation of a patient with potentially resectable hepatic disease. In nonrandomized trials, PET demonstrated better sensitivity and specificity than CT scanning for the detection of both intrahepatic and extrahepatic disease.¹⁷ Integrated PET/CT improves diagnostic accuracy over standard PET or CT alone and has been shown to be sensitive in the detection of liver metastases derived from a wide range of cancers, including colorectal (Fig. 31-12), breast, or lung primaries.¹⁷

More than 20% of patients with colorectal cancer initially present with hepatic metastasis, and a large percentage of patients undergoing resection for their primary colorectal cancer eventually experience disease recurrence in the liver. The role of FDG-PET/CT in colorectal cancers lies predominantly in tumor staging and follow-up, particularly in the detection of occult intrahepatic metastases or extrahepatic disease. Although hepatic resection of colorectal metastases provides survival

rates nearing 50%, the presence of extrahepatic disease is a poor prognosticator and usually precludes aggressive surgical intervention. Thus, accurate information regarding the extent of the disease is necessary for management of patients with colorectal metastases. PET/CT has also been shown to be more accurate than contrast-enhanced CT in tumor surveillance after radio-frequency ablation.¹⁸ The sensitivity of FDG-PET, however, is lowered by neoadjuvant chemotherapy, most likely secondary to reduced metabolic activity within the tumor.

Although the role of PET/CT in the clinical management of liver metastases has been well-established, its utility in the diagnostic workup of primary liver tumors is still debated. In hepatocellular carcinoma (HCC), FDG uptake correlates with the degree of differentiation—high-grade HCC lesions have increased FDG uptake compared to low-grade HCCs. As a result, the overall sensitivity of FDG-PET/CT in the detection of HCCs is reported to be only 50% to 65%, rendering this modality insufficient when used alone in the diagnosis of primary HCCs. For this reason, dual-tracer PET has been introduced to improve sensitivity in detecting all HCC. This modality combines the use of FDG, which accumulates in poorly differentiated tumors, with ¹¹C-acetate, a tracer preferentially accumulated by well-differentiated HCC lesions. Although the clinical benefits of dual-tracer PET/CT have yet to be fully established, this combined modality has the potential to become a valuable tool in the diagnosis and staging of HCC. In cholangiocarcinoma tumors, FDG avidity depends on the morphologic characteristics and location of the lesion. Therefore, FDG-PET and FDG-PET/CT have not been shown to be highly beneficial in the diagnosis of primary cholangiocarcinoma, but they may be beneficial in the detection of regional and distal metastases, which can affect clinical decision making and patient management.

ACUTE LIVER FAILURE

Acute liver failure (ALF) occurs when the rate and extent of hepatocyte death exceeds the liver's regenerative capabilities. It was initially described as a specific disease entity in the 1950s. It also has been referred to as *fulminant hepatic failure*. ALF is a rare disorder affecting approximately 2000 patients annually in the United States. ALF is defined by the development of hepatic encephalopathy occurring within 26 weeks of severe liver injury in a patient without a history of previous liver disease or portal

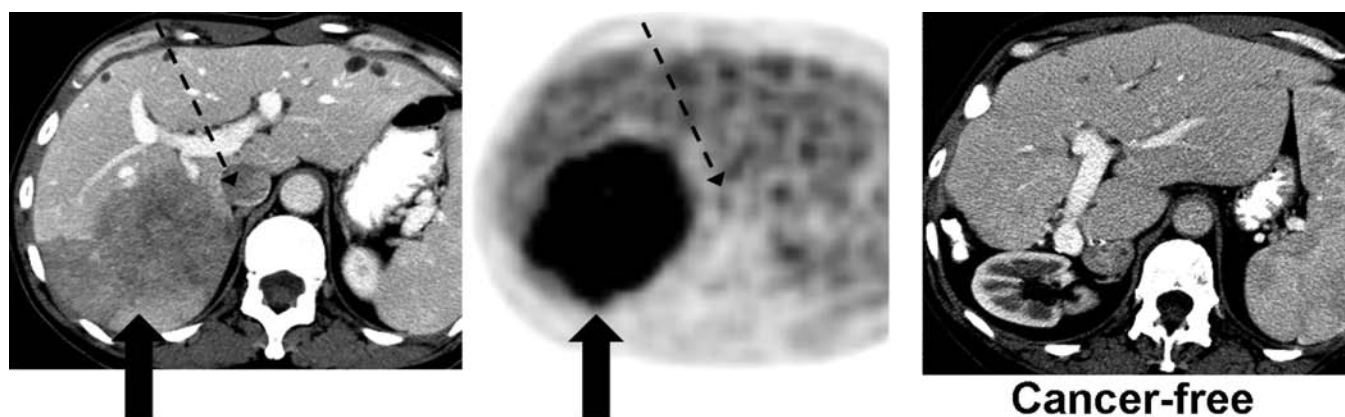


Figure 31-12. Computed tomography (CT)–positron emission tomography (PET) scans before and after resection of liver metastasis from colorectal cancer in a 54-year-old patient. CT scan shows large 10-cm right lobe liver metastasis (*left panel*), and PET scan findings are strongly positive (*middle panel*). Two years after right hepatectomy, the patient has no evidence of recurrence and significant hypertrophy of the left lobe (*right panel*).

hypertension.¹⁹ The manifestations of ALF may include cerebral edema, hemodynamic instability, increased susceptibility to bacterial and fungal infections, renal failure, coagulopathy, and metabolic disturbances. Even with current medical care, ALF can progress rapidly to hepatic coma and death. The most common cause of death is intracranial hypertension due to cerebral edema, followed by sepsis and multisystem organ failure. **4▶** The causes of ALF, which are the most important variables in determining outcome, are numerous and can include viral infection as well as drug overdose, reaction, and toxicity. It has been determined that the etiologic factor leading to ALF varies according to geographic location.²⁰ Before the introduction of orthotopic liver transplantation (OLT), the chance for survival was <20%. Currently, most series report 5-year survival rates of >70% for affected patients.²¹

Etiology

Differences in etiology, management, and patient outcomes have been described for various regions of the globe. In the East and developing portions of the world, the most common causes of ALF are viral infections, primarily hepatitis B, A, and E.²⁰ In these areas, there are a relatively small number of drug-induced cases. In contrast, 65% of cases of ALF in the West are thought to be due to drugs and toxins, with acetaminophen (paracetamol) being the most common etiologic agent in the United States, Australia, United Kingdom, and most of Europe. In France and Spain, where acetaminophen sales are restricted, the rate of acetaminophen-induced ALF is quite low.²² Acetaminophen-induced ALF is also uncommon in South America. The U.S. Acute Liver Failure Study Group identified several other causes of ALF, including autoimmune hepatitis, hypoperfusion of the liver (in cardiomyopathy or cardiogenic shock), pregnancy-related conditions, and Wilson's disease.²³ Even with exhaustive efforts to identify a cause, approximately 20% of all cases of ALF remain indeterminate in origin.

Clinical Presentation

In a multicenter study involving 17 tertiary care centers and 308 patients in the United States, 73% of all patients with ALF were female, with a median age of 38 years.²⁴ The most common ethnic group affected was whites (74%), followed by Hispanics (9%) and African Americans (3%). Patients were ill for a median of 6 days before the onset of encephalopathy and had a median of 2 days between the onset of jaundice and the development of encephalopathy. Hepatic coma grade at presentation was approximately equally distributed across grades I to IV. Eighty-four percent of the patients in the study were referred from outside hospitals, 40% had a serum creatinine level exceeding 2.0 mg/dL, and 14% had an arterial pH of <7.30. In addition, 44% of the patients acquired a culture-proven infection.

Diagnosis and Clinical Management

When the medical history is obtained, it is important to address the possibility of exposure to viral infections, medications, and other possible toxins. The possibility of previous liver disease needs to be explored. The physical examination must assess and document the patient's mental status as well as attempt to identify findings of chronic liver disease. The initial laboratory examination must evaluate the severity of the ALF as well as attempt to identify the cause (Table 31-1). A liver biopsy should be performed if certain disease entities such as autoimmune hepatitis or lymphoma are a possibility. Because of the associated coagulopathy, if a liver biopsy is needed, it is usually

Table 31-1

Acute liver failure laboratory evaluation

Complete blood count
Complete metabolic panel
Amylase and lipase levels
Liver function tests
Prothrombin time/international normalized ratio
Factor V level
Factor VII level
Arterial blood gas concentrations
Arterial serum ammonia level
ABO typing
Acute hepatitis panel
Autoimmune marker levels
Ceruloplasmin level
Toxicology screening
Acetaminophen level
HIV screening
Pregnancy test (females)

HIV = human immunodeficiency virus.

safest to obtain the tissue via a transjugular approach. Patients with ALF should be admitted to the hospital and monitored frequently. Due to the rapidity with which this disease process may progress, a liver transplant center should be contacted and the affected patient transferred to the center early in the evaluation period.

If acetaminophen overdose is suspected to have occurred within a few hours of presentation, administration of activated charcoal may be useful to reduce the volume of acetaminophen present in the gastrointestinal (GI) tract. *N*-acetylcysteine (NAC), the clinically effective antidote for acetaminophen overdose, should be administered as early as possible to any patient with suspected acetaminophen-associated ALF.²⁵ NAC also should be administered to patients with ALF of unclear etiology, because replenishing glutathione may be beneficial in this patient population as well.²⁶ NAC can be administered either orally (140 mg/kg initial dose, followed by 70 mg/kg every 4 hours × 17 doses) or via the intravenous route (loading dose of 150 mg/kg, followed by a maintenance dose of 50 mg/kg every 4 hours × 12 doses). For patients who are suspected of having drug-induced hepatotoxicity, it is important to obtain details regarding all prescription and nonprescription drugs, herbs, and dietary supplements that may have been taken in the previous year. Most instances of drug-induced hepatotoxicity occur in the first 6 months after drug initiation. Any suspected offending agent must be discontinued, and an attempt should be made to administer only essential medications.

The majority of patients with ALF need to be monitored in the intensive care unit (ICU) setting, and specific attention needs to be given to fluid management, ulcer prophylaxis, hemodynamic monitoring, electrolyte management, and surveillance for and treatment of infection. Surveillance cultures should be performed to identify bacterial and fungal infections as early as possible. Serum phosphorus levels need to be monitored. Hypophosphatemia, a sign of hepatic regeneration, may indicate a higher likelihood of spontaneous recovery and needs to be corrected via intravenous (IV) administration of phosphate. Sedation should be avoided, and the head of the bed should be elevated at least 30°. Neurologic examinations

should be performed frequently. Intracranial pressure monitoring is reserved for patients in whom a neurologic examination is no longer reliable. CT scans of the head should be performed to rule out mass lesion or hemorrhage, but they provide only limited information regarding increased intracranial pressure. The administration of blood products for thrombocytopenia and prolonged PT is recommended only in the setting of hemorrhage or before invasive procedures. Acute renal failure is a frequent complication in patients with ALF, and efforts should be made to protect renal function by maintaining sufficient perfusion and avoiding nephrotoxic medications. Should renal replacement therapy become necessary, continuous venovenous hemodialysis should be used rather than intermittent hemodialysis, because continuous venovenous hemodialysis provides better hemodynamic and intracranial pressure stability. The most severely affected patients have a poor prognosis with medical management alone and require liver transplantation. Identifying these patients early in the clinical course is important both to maximize the time available to obtain a donor liver allograft for those in need and to avoid transplant in those who will recover without it.

Prognosis

Accurate identification of ALF patients who will recover spontaneously is important because of the severe shortage of donor liver allografts and the potential complications of life-long nonspecific immunosuppression. The most widely applied prognostic scoring system is the King's College Hospital ALF criteria.²⁷ This scoring system has separate criteria predicting a poor medical management outcome for acetaminophen-related and non-acetaminophen-related forms of ALF (Table 31-2). Many other prognostic models exist such as the Acute Physiology and Chronic Health Evaluation II (APACHE II) score, the Clichy criteria,²⁸ and actin-free Gc-globulin serum concentration.²⁹ Overall, prognostic scoring systems have proven to have acceptable specificity but low sensitivity in determining patient

outcome and therefore should not replace the judgment of an experienced clinician.³⁰

Liver Transplantation

Despite advances in medical management, OLT remains the only definitive therapy for patients unable to regenerate sufficient hepatocyte mass in a timely manner. The advent of OLT has coincided with a rise in overall ALF survival rates from approximately 20% in the pretransplantation era to >70% at the present time. One-year posttransplantation survival for patients with ALF has been reported to be as high as 80% to 90%.²¹ Although these improvements in survival rates are impressive, it should be noted that 10% of patients still die while awaiting OLT, which confirms that the potential for improved patient outcome still has not been realized because of the ongoing liver allograft shortage.

Emerging Technologies

As mentioned earlier, patient survival could be improved if additional time could be gained for the patient while awaiting liver replacement or hepatocyte regeneration. The development of a support device to replace the acutely failing liver has been a highly sought after (and elusive) goal. Several systems have been tested without definitive evidence of efficacy. Transient improvement in hepatic encephalopathy has been observed in several trials, but improvement in hepatocyte function and long-term benefit have not been realized.³¹ Liver support trials are difficult to perform due to access to liver replacement, the rarity of affected patients, and the heterogeneous causes and varying levels of disease severity. Therefore, additional data are necessary, and liver support systems should be used only as part of an approved clinical trial. Focus has now shifted toward xenotransplantation,³² organ engineering, and cell transplantation.³³ In the meantime, living donation and auxiliary liver transplantation can help overcome the organ shortage.³⁴

CIRRHOSIS AND PORTAL HYPERTENSION

Cirrhosis, the final sequela of chronic hepatic insult, is characterized by the presence of fibrous septa throughout the liver subdividing the parenchyma into hepatocellular nodules (Fig. 31-13).³⁵ Cirrhosis is the consequence of sustained wound healing in response to chronic liver injury. Approximately 40% of cirrhotic patients are asymptomatic, but progressive deterioration leading to the need for liver transplantation or death is typical after the development of end-stage liver disease (ESLD). The complications of ESLD include progressive hyperbilirubinemia, malnutrition, decreased synthetic function of the liver, coagulopathy, portal hypertension (i.e., ascites and variceal bleeding), hepatic encephalopathy, and life-limiting fatigue. ESLD carries a 5-year mortality of 50%, with 70% of deaths due to liver failure.³⁶ In the United States, cirrhosis accounts for 30,000 deaths per year and is the most common nonneoplastic cause of death among patients with hepatobiliary and digestive diseases. An additional 10,000 to 12,000 deaths occur annually due to HCC, the most rapidly increasing neoplasm in the United States.³⁶

Morphologic Classification of Cirrhosis

Morphologically, cirrhosis can be described as micronodular, macronodular, or mixed. Micronodular cirrhosis is characterized by thick regular septa, small uniform regenerative nodules, and involvement of virtually every hepatic lobule. Macronodular cirrhosis frequently has septa and regenerative nodules of

Table 31-2

King's College selection criteria for liver transplantation in acute liver failure

CAUSE	SELECTION CRITERIA
Acetaminophen	Arterial pH <7.30 irrespective of hepatic coma grade <i>Or</i> Prothrombin time >100 s + serum creatinine level >3.4 mg/dL + grade III or IV hepatic coma
Not acetaminophen	Prothrombin time >100 s irrespective of hepatic coma grade <i>Or</i> Any three of the following, irrespective of hepatic coma grade: Cryptogenic or drug-induced hepatitis Jaundice to coma interval >7 d Prothrombin time >50 s Serum bilirubin level >17.5 mg/dL Age <10 y or >40 y

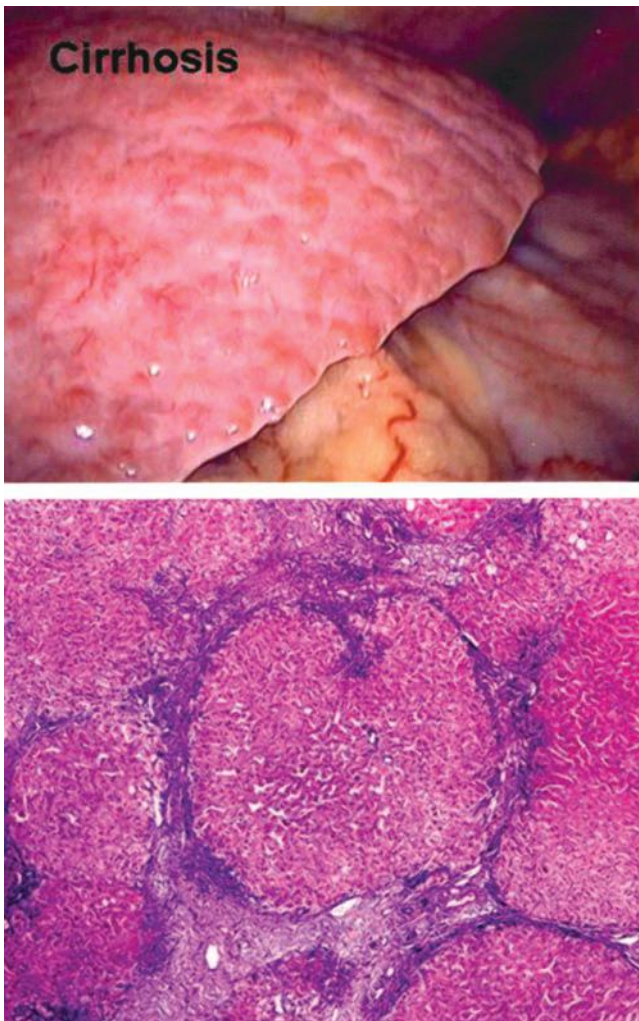


Figure 31-13. Histology of cirrhotic liver with regenerating macronodules. *Upper panel:* Grossly cirrhotic liver. *Lower panel:* Regenerative nodules and bridging fibrosis representative of cirrhosis seen on standard light microscopy (hematoxylin and eosin stain).

varying sizes. The regenerative nodules consist of irregularly sized hepatocytes with large nuclei and cell plates of varying thickness. Mixed cirrhosis is present when regeneration is occurring in a micronodular liver and over time converts to a macronodular pattern. This morphologic categorization is limited, and cirrhosis is a dynamic process in which nodule size varies over time. The three patterns correlate poorly with etiology, and the same pattern can result from a variety of disease processes. Conversely, a single disease process can demonstrate several morphologic patterns. Irrespective of etiology and morphologic pattern, the cirrhotic liver frequently demonstrates right hepatic lobe atrophy, caudate lobe and left lateral segment hypertrophy, recanalization of the umbilical vein, a nodular surface contour, dilatation of the portal vein, gastroesophageal varices, and splenomegaly on radiographic evaluation.

Etiology of Cirrhosis

Cirrhosis can result from a wide range of disease processes, including viral, autoimmune, drug-induced, cholestatic, and metabolic diseases (Table 31-3). In the diagnosis of alcoholic liver disease, documentation of chronic alcohol abuse is imperative. Liver biopsy will reveal the typical findings of alcoholic

Table 31-3

Etiology of cirrhosis

Viral hepatitis (hepatitis B, C, and D)
Cryptogenic
Alcohol abuse
Metabolic abnormalities
Iron overload (hemochromatosis)
Copper overload (Wilson's disease)
α_1 -Antitrypsin deficiency
Glycogen storage disease (types IA, III, and IV)
Tyrosinemia
Galactosemia
Cholestatic liver disease
Hepatic vein outflow abnormalities
Budd-Chiari syndrome
Cardiac failure
Autoimmune hepatitis
Toxins and drugs

hepatitis, including hepatocyte necrosis, Mallory bodies, neutrophil infiltration, and perivenular inflammation. Patients with nonalcoholic steatohepatitis (NASH) often endorse a history of diabetes mellitus or metabolic syndrome. The diagnosis of NASH requires the demonstration of steatohepatitis on biopsy, the lack of a history of significant alcohol consumption, and exclusion of other causes of hepatic steatosis. Although cryptogenic cirrhosis, or cirrhosis without an apparent cause, accounted for a third of all cases in the past, this proportion has declined over time as it becomes increasingly apparent that many of such patients may actually have unrecognized NASH.

Chronic hepatitis C infection is the most common cause of chronic liver disease and the most frequent indication for liver transplantation in the United States. The identification of chronic hepatitis C infection is facilitated by serologic assays that detect antibody to hepatitis C and molecular assays that quantify hepatitis C viral RNA. Chronic hepatitis B, on the other hand, can be diagnosed based on the detection of hepatitis B surface antigen (HBsAg) more than 4 to 6 months after initial infection. Additional tests of hepatitis B viral replication, such as the hepatitis B e antigen (HBeAg) and hepatitis B viral DNA, can be used to confirm ongoing infection and to guide appropriate antiviral therapy.

Autoimmune causes of cirrhosis include primary biliary cirrhosis, primary sclerosing cholangitis, and autoimmune hepatitis. Patients with primary biliary cirrhosis may be asymptomatic or may present with a history of fatigue, pruritus, and skin hyperpigmentation that is not related to jaundice. Antimitochondrial antibodies will test positive in the vast majority of cases. Affected patients also may have marked elevations in serum cholesterol, while hyperbilirubinemia is seen late in the course of the disease. Primary sclerosing cholangitis is a chronic cholestatic disease of the liver associated with ulcerative colitis and Crohn's disease. The clinical presentation can include pruritus, steatorrhea, fat-soluble vitamin deficiencies, and metabolic bone disease. The diagnosis is often established by imaging of the biliary tree, which reveals a characteristic picture of diffuse, multifocal strictures with focal dilation of the bile ducts resulting in a beaded appearance. Complications are common and can include biliary strictures, cholangitis, cholelithiasis, and

cholangiocarcinoma. Autoimmune hepatitis is often accompanied by an elevation in serum globulins, particularly gamma globulins. Liver biopsy will show nonspecific changes such as a portal mononuclear cell infiltrate with the characteristic presence of plasma cells. Many patients with autoimmune hepatitis will respond to treatment with prednisone with or without azathioprine.

Hereditary hemochromatosis is the most common metabolic disorder causing cirrhosis. This entity should be suspected if the patient's clinical presentation includes skin hyperpigmentation, diabetes mellitus, pseudogout, cardiomyopathy, or a family history of cirrhosis. Elevated plasma ferritin and increased iron saturation levels suggest the presence of iron overload, but these findings also can be seen in other diseases of the liver. Confirmatory testing can be achieved by means of genetic testing, liver biopsy, or by assessing the response to phlebotomy. Other uncommon metabolic disorders leading to cirrhosis include Wilson's disease and α_1 -antitrypsin deficiency.

Clinical Manifestations of Cirrhosis

The clinical history associated with cirrhosis can include fatigue, anorexia, weight loss, jaundice, abdominal pain, peripheral edema, ascites, GI bleeding, and hepatic encephalopathy. On physical examination, a number of findings have been described in patients with cirrhosis. Spider angiomas and palmar erythema are believed to be caused by alterations in sex hormone metabolism. Finger clubbing may be a consequence of hypoalbuminemia, while the pathogenesis of white nail beds and Dupuytren's contractures are less well understood. Males may develop features of feminization such as gynecomastia, loss of chest and axillary hair, and testicular atrophy. Splenomegaly is common, whereas the cirrhotic liver itself may be enlarged, normal sized, or small. Ascites and pleural effusion can be seen with fluid accumulation. Portal hypertension can manifest as caput medusae and/or the presence of the Cruveilhier-Baumgarten murmur, a venous hum that can be auscultated in the epigastrium resulting from collaterals between the portal system and the remnant of the umbilical vein. Jaundice usually does not appear until the bilirubin rises above 2 to 3 mg/dL. Asterixis can be detected in patients with hepatic encephalopathy. Other manifestations include fetor hepaticus, as well as features suggestive of malnutrition such as weakness, weight loss, and temporal muscle wasting.

Although fat stores and muscle mass are reduced, resting energy expenditure is increased. Muscle cramps occur frequently in the cirrhotic patient and are felt to correlate with ascites, low mean arterial pressure, and plasma renin activity. Abdominal hernias are common with ascites and should be electively repaired only in patients with well-compensated cirrhosis; otherwise, the hernia should be repaired at the time of or after hepatic transplantation. HCC can occur in all forms of cirrhosis, and every cirrhotic patient should undergo screening for the development of HCC every 6 months via imaging and measurement of a serum α -fetoprotein (AFP) level. Cirrhosis is associated with increased cardiac output and heart rate as well as decreased systemic vascular resistance and blood pressure. Patients with cirrhosis are more prone to infections due to impaired phagocytic activity of the reticuloendothelial system. Bacterial infections, often of intestinal origin, are common and must be suspected in a patient with unexplained pyrexia or clinical deterioration. Spontaneous bacterial peritonitis also is seen in cases of cirrhosis with ascites. Intrinsic drug metabolism is

reduced in the cirrhotic liver, and this fact needs to be recognized when prescribing medications.

Laboratory Findings Associated with Cirrhosis

Laboratory findings vary in the cirrhotic patient depending on the degree of compensation; however, in general, a number of trends are seen. The cirrhotic patient usually has a mild normocytic normochromic anemia. The white blood cell and platelet counts are reduced, and the bone marrow is macro-normoblastic. The PT is prolonged and does not respond to vitamin K therapy, and the serum albumin level is depressed. Urobilinogen is present and urinary sodium excretion is diminished in the presence of ascites. The serum levels of bilirubin, transaminases, and alkaline phosphatase may all be elevated. However, normal liver function test results do not eliminate the possibility of cirrhosis.

Liver Biopsy

The diagnosis of cirrhosis can be made in many cases from a constellation of clinical features, laboratory values, and radiographic findings. Histopathologic examination of liver tissue is occasionally needed to confirm the diagnosis of cirrhosis and in determining disease etiology, activity, and progression. Liver biopsy can be performed via a percutaneous, transjugular, or laparoscopic approach. If needed, ultrasound or CT guidance can be helpful in obtaining an adequate sample and avoiding other viscera.

Various serologic markers of hepatic fibrosis are currently being investigated to help predict the presence of cirrhosis without the need for liver biopsy. However, no currently available marker is sufficiently accurate for clinical use. Ultrasound elastography, which measures the stiffness of the liver by inducing an elastic shear wave that propagates through the tissue, shows promise as a noninvasive test in identifying patients with advanced fibrosis and cirrhosis. (See earlier section, "Radiologic Evaluation of the Liver.")

Hepatic Reserve and Assessment of Surgical Risk in the Cirrhotic Patient

Assessing the hepatic reserve of the cirrhotic patient is important, because cirrhosis and portal hypertension can have a negative impact on the outcome of nontransplant surgical procedures. Patients with liver disease undergoing surgery are at increased risk for surgical and anesthesia-related complications. The actual risk depends on the type of anesthetic used, the specific surgical procedure performed, and the severity of liver disease. Previous studies have demonstrated that emergency operations, cardiac surgery, hepatic resections, and abdominal surgery, particularly cholecystectomy, gastric resection, and colectomy, generate the highest operative risk among cirrhotic patients. Additionally, preoperative patient characteristics such as anemia, ascites, encephalopathy, malnutrition, hypoalbuminemia, hypoxemia, infection, jaundice, portal hypertension, and prolonged PT have also been associated with inferior outcomes after surgery. Nontransplant surgical procedures are contraindicated in patients with acute fulminant hepatitis and those with severe decompensated chronic hepatitis.

A number of laboratory tests have been used to assess hepatic reserve in patients with cirrhosis. Tests of indocyanine green, sorbitol, and galactose elimination capacity as well as the carbon-13 galactose breath test and carbon-13 aminopyrine breath test have all been disappointing clinically due to their

dependence on flow to the liver as well as the unavailability and complexity of the tests. The monoethylglycinexylidide (MEGX) test, which measures MEGX formation after the administration of lidocaine, has been shown to be approximately 80% sensitive and specific in diagnosing cirrhosis. However, this test loses both sensitivity and specificity as the serum bilirubin level rises and interferes with the fluorescent readout system.

Child-Turcotte-Pugh Score

The Child-Turcotte-Pugh (CTP) score was originally developed to evaluate the risk of portocaval shunt procedures performed for portal hypertension and subsequently has been shown to be useful in predicting surgical risks of other intra-abdominal operations on cirrhotic patients (Table 31-4). Numerous studies have demonstrated overall surgical mortality rates of 10% for patients with class A cirrhosis, 30% for those with class B cirrhosis, and 75% to 80% for those with class C cirrhosis.³⁷ The CTP score is derived from five variables as shown in Table 31-4. The problems with the CTP score are the presence of subjective variables (encephalopathy and ascites), its narrow range (5 to 15 points), and the equal weighting given to each variable. Multiple retrospective studies have demonstrated that perioperative mortality and morbidity rates correlate well with the CTP score, and for over 30 years, this measure had been used as the principal predictor of operative risk.

Model for End-Stage Liver Disease Scoring System

The Model for End-Stage Liver Disease (MELD) is a linear regression model based on objective laboratory values (INR, bilirubin level, and creatinine level). It was originally developed as a tool to predict mortality after transjugular intrahepatic portosystemic shunt (TIPS) but has been validated and used as the sole method of liver transplant allocation in the United States since 2002. The MELD formula is as follows:

$$\text{MELD Score} = 9.57 \text{ Ln}(\text{SCr}) + 3.78 \text{ Ln}(\text{Tbil}) + 11.2 \text{ Ln}(\text{INR}) + 6.43$$

where Ln represents natural logarithm, SCr is serum creatinine level (in milligrams per deciliter), and Tbil is serum bilirubin level (in milligrams per deciliter).

A number of studies have examined the relative values of MELD and CTP scores in predicting postoperative mortality in

cirrhotic patients undergoing nontransplant surgical procedures. Northup and colleagues demonstrated that MELD score was the only statistically significant predictor of 30-day mortality.³⁸ In this study, mortality increased by approximately 1% for each MELD point up to a score of 20 and by 2% for each MELD point above 20. A comparison of the MELD model with the CTP classification showed good correlation between the two measures in predicting mortality, especially in the setting of emergency surgery.³⁹ In these studies, the relative risk of mortality increased by 14% for each 1-point increase in MELD score. As a result, it has been proposed that patients with a MELD score below 10 can safely undergo elective surgery, those with MELD between 10 and 15 may undergo surgery with caution, while those with MELD scores in excess of 15 should not be subjected to elective surgical procedures.⁴⁰

Portal Hypertension

The portal venous system contributes approximately 75% of the blood and 72% of the oxygen supplied to the liver. In the average adult, 1000 to 1500 mL/min of portal venous blood is supplied to the liver. However, this amount can be significantly increased in the cirrhotic patient. The portal venous system is without valves and drains blood from the spleen, pancreas, gallbladder, and abdominal portion of the alimentary tract into the liver. Tributaries of the portal vein communicate with veins draining directly into the systemic circulation. These collateral communications occur at the gastroesophageal junction, anal canal, falciform ligament, splenic venous bed and left renal vein, and retroperitoneum (Fig. 31-14). The normal portal venous pressure is 5 to 10 mmHg, and at this pressure, very little blood is shunted from the portal venous system into the systemic circulation. As portal venous pressure increases, however, the collateral communications with the systemic circulation dilate, and a large amount of blood may be shunted around the liver and into the systemic circulation.

Imaging of the Portal Venous System and Measurement of Portal Venous Pressure

The patency of the portal vein and the nature of the collateral circulation should be established. An understanding of portal vein patency and anatomy is crucial before undertaking portosystemic shunts, hepatic resection, or hepatic transplantation. The simplest initial investigation is abdominal ultrasonography. A large portal vein suggests portal hypertension but is not diagnostic. Doppler ultrasound is capable of outlining the anatomy of the portal vein, excluding the presence of thrombosis, and identifying the direction of portal venous blood flow. Doppler ultrasound also is useful in evaluating blood flow through surgical shunts and TIPS. Abdominal CT and magnetic resonance angiography both are capable of revealing portal vein anatomy as well as patency. Visceral angiography and portal venography are reserved for cases that cannot be evaluated satisfactorily by noninvasive methods and require further clarification of portal patency or anatomy.

The most accurate method of determining portal hypertension is hepatic venography. The most commonly used procedure involves placing a balloon catheter directly into the hepatic vein and measuring the free hepatic venous pressure (FHVP) with the balloon deflated and the wedged hepatic venous pressure (WHVP) with the balloon inflated to occlude the hepatic vein. The hepatic venous pressure gradient (HVPG) is then calculated by subtracting the free from the wedged venous pressure

Table 31-4

Child-Turcotte-Pugh (CTP) score

VARIABLE	1 POINT	2 POINTS	3 POINTS
Bilirubin level	<2 mg/dL	2–3 mg/dL	>3 mg/dL
Albumin level	>3.5 g/dL	2.8–3.5 g/dL	<2.8 g/dL
International normalized ratio	<1.7	1.7–2.2	>2.2
Encephalopathy	None	Controlled	Uncontrolled
Ascites	None	Controlled	Uncontrolled

Child-Turcotte-Pugh class

Class A = 5–6 points
Class B = 7–9 points
Class C = 10–15 points

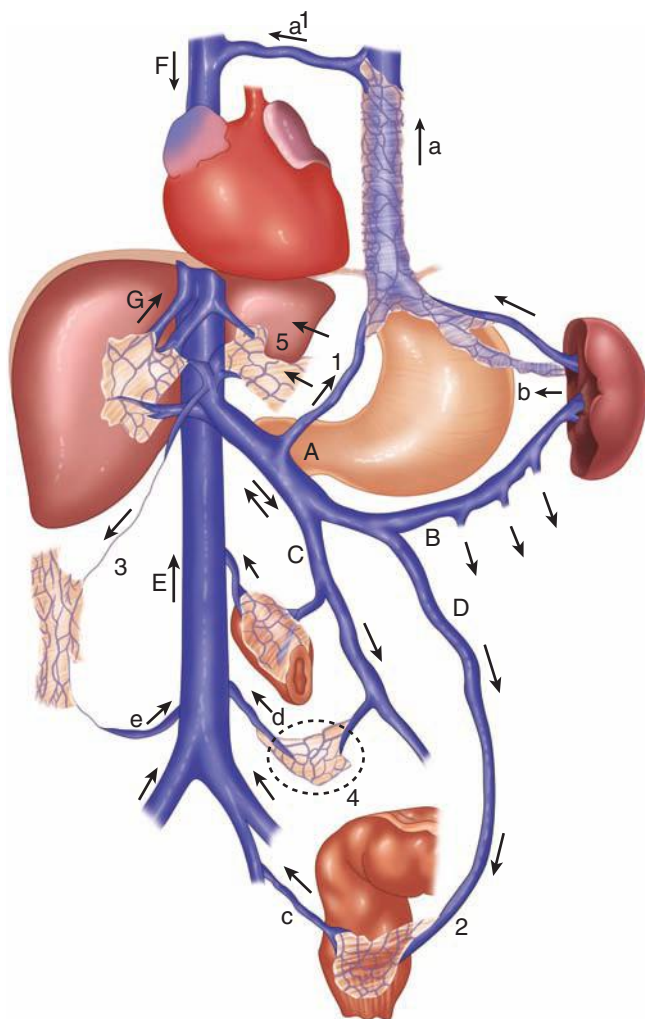


Figure 31-14. Intra-abdominal venous flow pathways leading to engorged veins (varices) from portal hypertension. 1, Coronary vein; 2, superior hemorrhoidal veins; 3, paraumbilical veins; 4, Retzius' veins; 5, veins of Sappey; A, portal vein; B, splenic vein; C, superior mesenteric vein; D, inferior mesenteric vein; E, inferior vena cava; F, superior vena cava; G, hepatic veins; a, esophageal veins; a', azygos system; b, vasa brevia; c, middle and inferior hemorrhoidal veins; d, intestinal; e, epigastric veins.

(HVPG = WHVP – FHVP). The HVPG represents the pressure in the hepatic sinusoids and portal vein and is a measure of portal venous pressure. Clinically significant portal hypertension is evident when HVPG exceeds 10 mmHg.

Etiology and Clinical Features of Portal Hypertension

The causes of portal hypertension can be divided into three major groups: presinusoidal, sinusoidal, and postsinusoidal.⁴¹ Although multiple disease processes can result in portal hypertension (Table 31-5), in the United States, the most common cause of portal hypertension is usually an intrahepatic one, namely, cirrhosis. The most significant clinical finding associated with portal hypertension is the development of gastroesophageal varices, which are mainly supplied by the anterior branch of the left gastric (coronary) vein.

Portal hypertension also results in splenomegaly with enlarged, tortuous, and even aneurysmal splenic vessels. Splenomegaly is frequently associated with functional hypersplenism,

Table 31-5

Etiology of portal hypertension

Presinusoidal

Sinistral/extrahepatic

- Splenic vein thrombosis
- Splenomegaly
- Splenic arteriovenous fistula

Intrahepatic

- Schistosomiasis
- Congenital hepatic fibrosis
- Nodular regenerative hyperplasia
- Idiopathic portal fibrosis
- Myeloproliferative disorder
- Sarcoid
- Graft-versus-host disease

Sinusoidal

Intrahepatic

- Cirrhosis
 - Viral infection
 - Alcohol abuse
 - Primary biliary cirrhosis
 - Autoimmune hepatitis
 - Primary sclerosing cholangitis
 - Metabolic abnormality

Postsinusoidal

Intrahepatic

- Vascular occlusive disease

Posthepatic

- Budd-Chiari syndrome
- Congestive heart failure
- Inferior vena caval web
- Constrictive pericarditis

causing leukopenia, thrombocytopenia, and anemia. Ascites occurs in the setting of severe portal hypertension in combination with hepatocyte dysfunction. The umbilical vein may recannulate and dilate, leading to visible collaterals on the abdominal wall. Anorectal varices are present in approximately 45% of cirrhotic patients and must be distinguished from hemorrhoids, which do not communicate with the portal system and are not present at increased incidence in patients with portal hypertension. Large spontaneous venous shunts may form between the portal venous system and the left renal vein or the IVC, but these shunts are ineffective in reducing portal venous pressures and preventing bleeding from gastroesophageal varices.

Management of Gastroesophageal Varices

The most significant manifestation and the leading cause of morbidity and mortality related to portal hypertension is variceal bleeding. Approximately 30% of patients with compensated cirrhosis and 60% of patients with decompensated cirrhosis have esophageal varices. One third of all patients with varices will experience variceal bleeding. Each episode of bleeding is associated with a 20% to 30% risk of mortality. If left untreated, 70% of patients who survive the initial bleed will experience recurrent variceal hemorrhage within 2 years of the index hemorrhage.

Prevention of Variceal Bleeding

Current measures aimed at preventing variceal bleeding include the administration of nonselective β -blockers and prophylactic

endoscopic surveillance with variceal band ligation. Meta-analyses have demonstrated that nonselective β -blockers such as propranolol and nadolol reduce the index variceal bleed by approximately 45% and decrease bleeding mortality by 50%.⁴² However, approximately 20% of patients do not respond to β -blockade, and another 20% cannot tolerate β -blockade due to medication side effects. Endoscopic surveillance with prophylactic variceal band ligation has been associated with a lower incidence of a first variceal bleed.⁴³ Variceal band ligation is recommended for patients with medium to large varices, performed every 1 to 2 weeks until obliteration, followed by esophagogastroduodenoscopy (EGD) 1 to 3 months later and surveillance EGD every 6 months to monitor for recurrence of varices.

Management of Acute Variceal Hemorrhage

Patients with acute variceal hemorrhage should be admitted to an ICU for resuscitation and management. Blood resuscitation should be performed carefully to reach a hemoglobin level of approximately 8 g/dL. Overzealous replacement of blood products and administration of saline can lead to both rebleeding and increased mortality. Administration of fresh frozen plasma and platelets can be considered in patients with severe coagulopathy. Use of recombinant factor VIIa has not been shown to be more beneficial than standard therapy and therefore is not recommended at this time. Cirrhotic patients with variceal bleeding have a high risk of developing bacterial infections, which are associated with increased risks of rebleeding and mortality. Spontaneous bacterial peritonitis accounts for approximately half of these infections, with urinary tract infections and pneumonias comprising the remainder. The use of short-term prophylactic antibiotics (e.g., ceftriaxone 1 g/d intravenously) has been shown both to decrease the rate of bacterial infections and to increase survival.

Vasoactive medications decrease blood flow to the gastroesophageal varices and can be initiated as soon as the diagnosis of variceal bleeding is made. Although vasopressin is the most potent available vasoconstrictor, its use is limited by its systemic vasoconstrictive effects that can produce hypertension, myocardial ischemia, arrhythmias, ischemic abdominal pain, and limb gangrene. Octreotide, a somatostatin analog, has the advantage that it can be administered for 5 days or longer, and it is currently the preferred pharmacologic agent for initial management of acute variceal bleeding. In addition to pharmacologic therapy, endoscopy with variceal band ligation should be carried out as soon as possible. This combination of pharma-

6 ► cologic and endoscopic therapy has been shown both to improve the initial control of bleeding and to increase the 5-day hemostasis rate.⁴³

Luminal Tamponade

When medical and endoscopic measures fail to control variceal hemorrhage, balloon tamponade using a Sengstaken-Blakemore tube will control refractory bleeding in up to 90% of patients. However, its application is limited due to the potential for complications, which include aspiration, airway obstruction, and esophageal perforation due to overinflation or pressure necrosis. Therefore, the use of a Sengstaken-Blakemore tube should not exceed 36 hours to avoid tissue necrosis, and this treatment modality should only be considered a temporary bridge to more definitive measures of variceal hemorrhage control.

Transjugular Intrahepatic Portosystemic Shunt

The TIPS procedure involves implantation of a metallic stent between an intrahepatic branch of the portal vein and a hepatic

vein radicle. The needle track is dilated until a portal pressure gradient of ≤ 12 mmHg is achieved. TIPS can be performed in 95% of patients by an experienced interventional radiologist, controls variceal bleeding in $>90\%$ of cases refractory to medical treatment, and should not affect subsequent hepatic transplantation. Possible complications include bleeding either intra-abdominally or via the biliary tree, infections, renal failure, decreased hepatic function, and hepatic encephalopathy, which occur in 25% to 30% of patients after the TIPS procedure. A high rate of thrombosis is seen and can be attributed to intimal hyperplasia of the metallic stent. Frequent follow-up with repeated interventions such as dilation or restenting often are needed to maintain TIPS patency.

Balloon-Occluded Retrograde Transvenous Obliteration

The balloon-occluded retrograde transvenous obliteration (BRTO) procedure has been used for the specific management of bleeding gastric varices in patients with spontaneous gastrorenal or splenorenal shunts shown on contrast-enhanced cross-sectional imaging. Using a transjugular or transfemoral approach, a balloon-occlusion catheter is directed through the left renal vein into the spontaneous shunt, which is then obliterated with the use of a sclerosing agent. BRTO effectively controls hemorrhage from gastric varices and preserves portal flow to the liver, thereby reducing the risk of hepatic encephalopathy relative to TIPS. The occlusion of spontaneous shunts, however, can theoretically exacerbate portal hypertension, precipitate hemorrhage from esophageal varices, and exacerbate the accumulation of ascites.

Surgical Shunting

The need for surgical shunts has been reduced since the introduction of the TIPS procedure and hepatic transplantation. At this time, the recommendation is that surgical shunts be considered only in patients who have MELD scores of <15 , who are not candidates for hepatic transplantation, or who have limited access to TIPS therapy and the necessary follow-up. The aim of the surgical shunt is to reduce portal venous pressure, maintain total hepatic and portal blood flow, and avoid the high incidence of complicating hepatic encephalopathy. Patient survival is determined by hepatic reserve.

The portacaval shunt, as first described by Eck in 1877, either joins the portal vein to the IVC in an end-to-side fashion and completely disrupts portal vein flow to the liver, or joins it in a side-to-side fashion and thereby maintains partial portal venous flow to the liver. Currently this shunt is rarely performed due to the high incidence of hepatic encephalopathy and decreased liver function resulting from the reduction of portal perfusion. The Eck fistula also makes subsequent hepatic transplantation much more technically difficult.

The mesocaval shunt uses an 8- or 10-mm polytetrafluoroethylene (PTFE) graft to connect the superior mesenteric vein to the IVC. The mesocaval shunt is technically easier to perform and can be easily ligated during subsequent hepatic transplantation. The smaller caliber of the shunt avoids the deleterious effects of portal blood flow deprivation on hepatic function. Small-diameter portosystemic shunts have been reported to reduce the incidence of encephalopathy but at the expense of increased risks of shunt thrombosis and rebleeding.

The surgical shunt currently used most often is the distal splenorenal or Warren shunt (Fig. 31-15). This shunt is technically

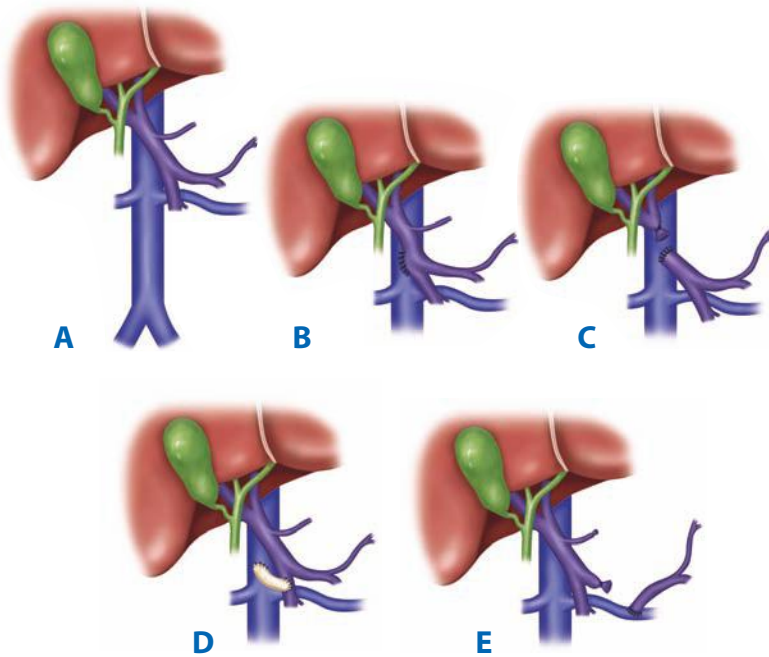


Figure 31-15. Surgical shunts for portal hypertension. Types of portacaval anastomoses. **A.** Normal anatomy. **B.** Side-to-side portacaval shunt. **C.** End-to-side portacaval shunt. **D.** Mesocaval shunt. **E.** Distal splenorenal (Warren) shunt. (Reproduced with permission from Doherty GM, Way LW, eds. *Current Surgical Diagnosis and Treatment*. 12th ed. New York: McGraw-Hill; 2006). Copyright © The McGraw-Hill Companies, Inc.

the most difficult to perform. It requires division of the gastroesophageal collaterals and allows venous drainage of the stomach and lower esophagus through the short gastrosplenic veins into the spleen, and ultimately decompresses the left upper quadrant by allowing the splenic vein to drain directly into the left renal vein via an end-to-side splenic to left renal vein anastomosis. This shunt has the advantages of being associated with a lower rate of hepatic encephalopathy and decompensation and not interfering with subsequent liver transplantation.

Nonshunt Surgical Management of Refractory Variceal Bleeding

In the patient with extrahepatic portal vein thrombosis and refractory variceal bleeding, the Sugiura procedure may be considered. The Sugiura procedure consists of extensive devascularization of the stomach and distal esophagus along with transection of the esophagus, splenectomy, truncal vagotomy, and pyloroplasty. As with performance of surgical shunts, patient survival is dependent on hepatic reserve at the time of the surgical procedure. Experience in Western countries is somewhat limited, and a number of modifications have been made to the original Sugiura procedure over time.

Hepatic Transplantation

Patients with cirrhosis, portal hypertension, and variceal bleeding usually die as a result of hepatic failure and not acute blood loss. Therefore, hepatic transplantation must be considered in the patient with ESLD, because it represents the patient's only chance for definitive therapy and long-term survival. Hepatic transplantation also can be considered for the patient with variceal bleeding refractory to all other forms of management. Survival after hepatic transplantation is not affected adversely by the previous performance of endoscopic variceal band ligation, TIPS, or splenorenal or mesocaval shunts. Previous creation of an Eck fistula, however, does make hepatic transplantation much more technically difficult, and therefore this procedure should be avoided in the transplant candidate. In addition to saving the patient's life, hepatic transplantation reverses most

of the hemodynamic and humoral changes associated with cirrhosis.

Budd-Chiari Syndrome

Budd-Chiari syndrome (BCS) is an uncommon congestive hepatopathy characterized by the obstruction of hepatic venous outflow. The incidence of BCS is 1 in 100,000 of the general population worldwide.⁴⁴ Patients may present with acute signs and symptoms of abdominal pain, ascites, and hepatomegaly or more chronic symptoms related to long-standing portal hypertension. BCS is defined as primary when the obstructive process involves an endoluminal venous thrombosis. BCS is considered as a secondary process when the veins are compressed or invaded by a neighboring lesion originating outside the vein.

A thorough evaluation demonstrates one or more thrombotic risk factors in approximately 75% to 90% of patients with primary BCS.⁴⁴ Primary myeloproliferative disorders, such as essential thrombocythemia or polycythemia rubra, account for approximately 35% to 50% of the primary cases of BCS. All known inherited thrombophilias also have been implicated in the development of BCS. Activated protein C resistance, generally related to factor V Leiden mutation, is present in approximately 25% of patients. Anticardiolipin antibodies, hyperhomocysteinemia, and oral contraceptive use all have been shown to be risk factors for BCS.⁴⁴

Clinically significant BCS is usually the result of obstruction of two or more of the major hepatic veins. The obstruction results in hepatomegaly, liver congestion, and right upper quadrant pain. In addition, liver perfusion via the portal vein may be decreased, and 70% of affected patients have noninflammatory centrilobular necrosis on biopsy. Although ALF is rare, most patients will go on to develop chronic portal hypertension and ascites. Caudate lobe hypertrophy occurs in approximately 50% of cases and is due to the fact that the caudate lobe has direct venous drainage into the IVC. This caudate lobe hypertrophy, in turn, can result in further obstruction of the IVC.

Abdominal ultrasonography is the initial investigation of choice and can demonstrate the absence of hepatic vein flow, spider web hepatic veins, and collateral hepatic veins.⁴⁵ CT or MRI of the abdomen also is capable of demonstrating hepatic vein thrombosis and evaluating the IVC but is limited in that it cannot show direction of blood flow. The definitive radiographic study to evaluate BCS is hepatic venography to determine the presence and extent of hepatic vein thrombus as well as measure IVC pressures.

Initial treatment consists of diagnosing and medically managing the underlying disease process and preventing extension of the hepatic vein thrombosis through systemic anticoagulation. The BCS-associated portal hypertension and ascites can be medically managed in a manner similar to that in most cirrhotic patients. Radiologic and surgical intervention should be reserved for patients whose condition is nonresponsive to medical therapy. Percutaneous angioplasty and TIPS, in combination with thrombolytic therapy, are the preferred strategies to restore the outflow of blood from the liver. Thrombolytic therapy alone may be attempted for acute thrombosis. Surgical shunting, namely with the side-to-side portacaval shunt, essentially turns the portal vein into a hepatic outflow tract. Most patients with a portacaval shunt show improvement in hepatic function and fibrosis at 1 year without significant hepatic encephalopathy.⁴⁵ However, the enthusiasm for this procedure has been curbed due to the relatively high rate of operative mortality and shunt dysfunction. Patients with progressive BCS and manifestations of ESLD will ultimately require hepatic transplantation.

INFECTIONS OF THE LIVER

The liver contains the largest portion of the reticuloendothelial system in the human body and is therefore able to handle the continuous low-level exposure to enteric bacteria that it receives through the portal venous system. Due to the high level of reticuloendothelial cells in the liver, nonviral infections are unusual.

Pyogenic Liver Abscesses

Pyogenic liver abscesses are the most common liver abscesses seen in the United States. They may be single or multiple and are more frequently found in the right lobe of the liver.⁴⁶ The abscess cavities are variable in size and, when multiple, may coalesce to give a honeycomb appearance. Approximately 40% of abscesses are monomicrobial, an additional 40% are polymicrobial, and 20% are culture-negative. The most common infecting agents are gram-negative bacteria; *Escherichia coli* is found in two thirds of cases, and other common organisms include *Streptococcus faecalis*, *Klebsiella*, and *Proteus vulgaris*. Anaerobic organisms such as *Bacteroides fragilis* also are seen frequently. In patients with endocarditis and infected indwelling catheters, *Staphylococcus* and *Streptococcus* species are more commonly found.

In the past, pyogenic liver abscesses often resulted from infections of the intestinal tract such as acute appendicitis and diverticulitis, which then spread to the liver via the portal circulation. With improved imaging modalities and earlier diagnosis of these intra-abdominal infections, this particular etiology of pyogenic liver abscesses has become less common. Pyogenic liver abscesses also occur as a result of impaired biliary drainage, subacute bacterial endocarditis, infected indwelling catheters, dental work, or the direct extension of infections such as diverticulitis or Crohn's disease into the liver. There appears

to be an increasing incidence due to infection by opportunistic organisms among immunosuppressed patients, including transplant and chemotherapy recipients as well as patients with acquired immunodeficiency syndrome (AIDS).

Patients commonly present with right upper quadrant pain and fever. Jaundice occurs in up to one third of affected patients. A thorough history and physical examination are usually helpful in identifying the underlying cause of the liver abscess. Leukocytosis, an elevated sedimentation rate, and an elevated AP level are the most common laboratory findings. Significant abnormalities in the results of the remaining liver function tests are unusual. Blood cultures will only reveal the causative organism in approximately 50% of cases. Ultrasound examination of the liver reveals pyogenic abscesses as round or oval hypoechoic lesions with well-defined borders and a variable number of internal echoes. CT scan is highly sensitive in the localization of pyogenic liver abscesses, which appear hypodense with peripheral enhancement and may contain air-fluid levels indicating a gas-producing infectious organism (Fig. 31-16). MRI of the abdomen can also detect pyogenic abscesses with a high level of sensitivity but plays a limited role because of its inability to be used for image-guided diagnosis and therapy.

The current cornerstones of treatment include correction of the underlying cause and IV antibiotic therapy. Empiric antibiotic therapy should cover gram-negative and anaerobic organisms; percutaneous needle aspiration and culture of the aspirate may be useful in guiding subsequent antibiotic therapy. IV antibiotic therapy should be continued for at least 8 weeks and can be expected to be effective in 80% to 90% of patients. Placement of a percutaneous drainage catheter is beneficial only for a minority of patients, as most pyogenic abscesses are quite viscous and catheter drainage is often ineffective.

Surgical drainage either via the laparoscopic or open approach may become necessary if initial therapies fail. Anatomic surgical resection can be performed in patients with recalcitrant abscesses. It must be kept in mind throughout the evaluation and treatment of the presumed pyogenic abscess that a necrotic hepatic malignancy must not be mistaken for a hepatic abscess. Therefore, early diagnosis and progression to

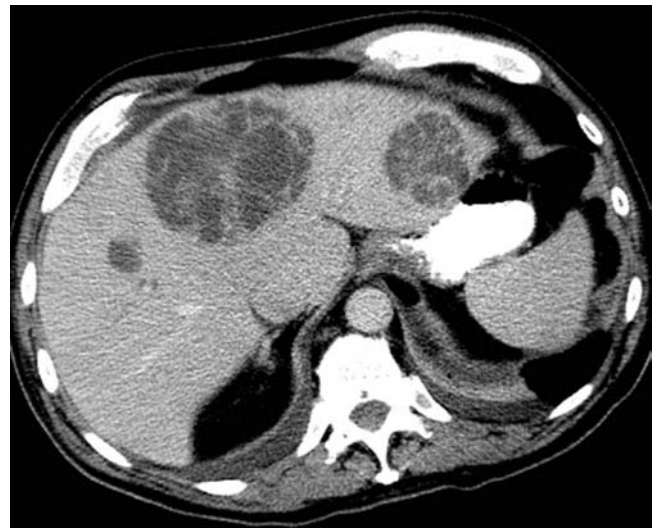

Figure 31-16. Computed tomographic scan of pyogenic liver abscesses. Multiple hepatic abscesses are seen in a patient after an episode of diverticulitis. Note the loculated large central abscess as well as the left lateral segment abscess.

surgical resection should be advocated for patients who do not respond to initial antibiotic therapy.

Amebic Abscesses

Entamoeba histolytica is a parasite that is endemic worldwide, infecting approximately 10% of the world's population. Amebiasis is most common in subtropical climates, especially in areas with poor sanitation. *E. histolytica* exists as cysts in a vegetative form that are capable of surviving outside the human body. The cystic form passes through the stomach and small bowel unharmed and then transforms into a trophozoite in the colon. Here it invades the colonic mucosa forming typical flask-shaped ulcers, enters the portal venous system, and is carried to the liver. Occasionally, the trophozoite will pass through the hepatic sinusoid and into the systemic circulation, which results in lung and brain abscesses.

Amebae multiply and block small intrahepatic portal radi- cles with consequent focal infarction of hepatocytes. They contain a proteolytic enzyme that also destroys liver parenchyma. The abscesses formed are variable in size and can be single or multiple. The amebic abscess is most commonly located in the superior-anterior aspect of the right lobe of the liver near the diaphragm and has a necrotic central portion that contains a thick, reddish brown, pus-like material. This material has been likened to anchovy paste or chocolate sauce. Amebic abscesses are the most common type of liver abscesses worldwide.

Amebiasis should be considered in patients who have trav- eled to an endemic area and present with right upper quadrant pain, fever, hepatomegaly, and hepatic abscess.⁴⁶ Leukocytosis is common, whereas elevated transaminase levels and jaundice are unusual. The most common biochemical abnormality is a mildly elevated AP level. Even though this disease process is secondary to a colonic infection, the presence of diarrhea is unusual. Most patients have a positive fluorescent antibody test for *E. histolytica*, and test results can remain positive for some time after a clinical cure. This serologic test has a high sensi- tivity, and therefore amebiasis is unlikely if the test results are negative.

Ultrasound and CT scanning of the abdomen are both very sensitive but nonspecific for the detection of amebic abscesses.⁴⁶ Amebic abscesses usually appear on CT as well- defined low-density round lesions that have enhancement of the wall, somewhat ragged in appearance with a peripheral zone of edema. The central cavity may have septations as well as fluid levels. CT scanning is also useful in the detection of extrahe- patic involvement.

Metronidazole 750 mg three times a day for 7 to 10 days is the treatment of choice and is successful in 95% of cases. Defervescence usually occurs in 3 to 5 days, but the time nec- essary for the abscess to resolve depends on the initial size at presentation and varies from 30 to 300 days.⁴⁶ Both ultrasound and CT of the liver can be used as follow-up after the initiation of medical therapy. Aspiration of the abscess rarely is needed and should be reserved for patients with large abscesses, those who do not respond to medical therapy, or those who appear to be superinfected. Furthermore, abscesses of the left lobe of the liver at risk for rupture into the pericardium should be treated with aspiration and drainage.

Hydatid Disease

Hydatid disease is due to infection by the tapeworm *Echinococ- cus granulosus* in its larval or cyst stage.⁴⁷ The tapeworm lives

in canids, which are infected by eating the viscera of sheep that contain hydatid cysts. Scolices, contained in the cysts, adhere to the small intestine of dogs and become adult taenia, which attach to the intestinal wall. Each worm sheds approximately 500 ova into the bowel. The infected ova-containing feces of dogs contaminate grass and farmland, and the ova are ingested by intermediate hosts such as sheep, cattle, pigs, and humans. The ova have chitinous envelopes that are dissolved by gastric juice. The liberated ovum then burrows through the intestinal mucosa and is carried by the portal vein to the liver, where it develops into an adult cyst. Most cysts are caught in the hepatic sinusoids, and therefore 70% of hydatid cysts form in the liver. A few ova pass through the liver and are held up in the pul- monary capillary bed or enter the systemic circulation, forming cysts in the lung, spleen, brain, or bones.

Hydatid disease is most common in sheep-raising areas, where dogs have access to infected offal. These include South Australia, New Zealand, Africa, Greece, Spain, and the Middle East. Hydatid cysts commonly involve the right lobe of the liver, usually the anterior-inferior or posterior-inferior segments. The uncomplicated cyst may be silent and found only incidentally or at autopsy. Occasionally, the affected patient presents with symptoms such as dull right upper quadrant pain or abdomi- nal distention. Cysts may become secondarily infected, involve other organs, or even rupture, which leads to an allergic or ana- phylactic reaction.

The diagnosis of hydatid disease is based on the findings of an enzyme-linked immunosorbent assay (ELISA) for echino- cocal antigens, and results are positive in approximately 85% of infected patients.⁴⁷ The ELISA results may be negative in an infected patient if the cyst has not leaked or does not contain scolices or if the parasite is no longer viable. Eosinophilia is seen in approximately 30% of infected patients. Ultrasonog- raphy and CT scanning of the abdomen are both quite sensi- tive for detecting hydatid cysts. The appearance of the cysts on images depends on the stage of cyst development. Typically, hydatid cysts are well-defined hypodense lesions with a dis- tinct wall. Ring-like calcifications of the pericysts are present in 20% to 30% of cases. As healing occurs, the entire cyst calci- fies densely, and a lesion with this appearance is usually dead or inactive. Daughter cysts generally occur in a peripheral loca- tion within the main cyst and are typically slightly hypodense compared with the mother cyst. MRI of the abdomen may be useful to evaluate the pericyst, cyst matrix, and daughter cyst characteristics.

Unless the cysts are small or the patient is not a suitable candidate for surgical resection, the treatment of hydatid disease is surgically based because of the high risk of secondary infec- tion and rupture. Medical treatment with albendazole relies on drug diffusion through the cyst membrane. The concentration of drug achieved in the cyst is uncertain but is better than that of mebendazole, and albendazole can be used as initial treat- ment for small, asymptomatic cysts. For most cysts, surgical resection involving laparoscopic or open complete cyst removal with instillation of a scolicidal agent is preferred and usually is curative. If complete cystectomy is not possible, then formal anatomic liver resection can be undertaken. During surgical resection, caution must be exercised to avoid rupture of the cyst with release of protoscolices into the peritoneal cavity. Perito- neal contamination can result in an acute anaphylactic reaction or peritoneal implantation of scolices with daughter cyst forma- tion and inevitable recurrence.

Echinococcus multilocularis occurs in the Northern Hemisphere and can infect the liver in a fashion similar to that described earlier, although the cysts are multilocular. Infection of the lung also is common (alveolar echinococcosis). Canine species such as wolves, foxes, and dogs ingest infected viscera of an intermediate host (e.g., rodents, moose) and become infected; humans become infected incidentally by ingesting contaminated food or water. Treatment consists of albendazole; however, infection in the lung produces a more generalized granulomatous reaction, can present in a manner similar to that of a malignancy, and often requires resection.

Ascariasis

Ascaris infection is particularly common in the Far East, India, and South Africa. Ova of the roundworm *Ascaris lumbricoides* arrive in the liver by retrograde locomotion in the bile ducts from the GI tract. The adult worm is 10 to 20 cm long and may lodge in the common bile duct, causing partial bile duct obstruction and secondary cholangitic abscesses. The *Ascaris* may serve as a nidus for the development of intrahepatic gallstones. The clinical presentation in an affected patient may include biliary colic, acute cholecystitis, acute pancreatitis, or hepatic abscesses.⁴⁸ Plain abdominal radiographs, abdominal ultrasound, and ERCP can demonstrate the *Ascaris* as linear filling defects within the bile ducts. Occasionally, worms can be seen moving into and out of the biliary tree from the duodenum. Treatment consists of the administration of piperazine citrate, mebendazole, or albendazole in combination with endoscopic extraction of the worms. Surgical intervention may become necessary if the *Ascaris* cannot be removed via ERCP.

Schistosomiasis

Schistosomiasis affects >200 million people in 74 countries. Hepatic schistosomiasis occurs when emboli of the ova in the intestines reach the liver via the mesenteric venous system. Eggs excreted in the feces hatch in water to release free-swimming embryos, which enter snails and develop into fork-tailed cercariae. They then re-enter human skin during contact with infected water. They burrow down to the capillary bed and enter the bloodstream, leading to widespread hematogenous dissemination. Those entering the intrahepatic portal system grow rapidly, resulting in a granulomatous reaction. The degree of consequent portal fibrosis is related to the adult worm load.

Schistosomiasis has three stages of clinical symptomatology: the first includes itching after the entry of cercariae through the skin; the second includes fever, urticaria, and eosinophilia; and the third involves hepatic fibrosis followed by presinusoidal portal hypertension. During this third phase, the liver shrinks, the spleen enlarges, and the patient may develop complications of portal hypertension while hepatic function is maintained. Active infection is detected by stool examination. Serologic tests indicate past exposure but do not provide information regarding the timing of infection. A negative serologic test result excludes the presence of schistosomal infection. Serum levels of transaminases are usually normal, but the AP level may be mildly elevated. A decreased serum albumin level is usually the result of frequent GI bleeds and malnutrition.

Medical treatment of schistosomiasis includes education on hygiene and the avoidance of infected water. Treatment with praziquantel 40 to 75 mg/kg as a single dose is the treatment of choice for all forms of schistosomiasis and produces few side effects. GI bleeding usually is controlled by endoscopic variceal ligation.

However, in a patient with refractory GI portal hypertensive bleeding, distal splenorenal shunt or gastric devascularization and splenectomy may be considered.

Viral Hepatitis

The role of the surgeon in the management of viral hepatitis is somewhat limited. However, the disease entities of hepatitis A, B, and C need to be kept in mind during any evaluation for liver disease. Hepatitis A usually results in an acute self-limited illness and only rarely leads to fulminant hepatic failure. Patients can present with fatigue, malaise, nausea, vomiting, anorexic fever, and right upper quadrant abdominal pain. The most common physical findings are jaundice and hepatomegaly. Because the disease is self-limited, the treatment is usually supportive. Patients who develop fulminant infection require aggressive therapy and should be transferred to a center capable of performing liver transplantation.

Hepatitis B and C, on the other hand, can both lead to chronic liver disease, cirrhosis, and HCC. The prevalence of chronic hepatitis B infection in the U.S. population is estimated to be 0.27%, but hepatitis B remains a major burden in resource-limited countries, accounting for 30% of cirrhosis and 53% of HCC cases. The ultimate goal of treatment for chronic hepatitis B is viral suppression, thereby preventing the development of clinical outcomes such as cirrhosis, liver failure, and HCC. The cornerstone of current antiviral therapy includes pegylated interferon and nucleoside analogs such as tenofovir or entecavir.⁴⁹ These agents have been proven to reduce complications of cirrhosis and HCC and perhaps reverse previous damage to the liver. Interferon therapy produces various side effects including fatigue, flu-like symptoms, mood changes, bone marrow suppression, and stimulation of autoimmunity. On the other hand, the nucleoside analogs are generally well-tolerated by patients. Compared with lamivudine, the nucleoside analogs are less likely to produce resistance and are more likely to be clinically effective. Despite its high rate of viral resistance, lamivudine may be the preferred treatment in some countries because of its relatively low cost.

Acute hepatitis C viral (HCV) infection typically develops 2 to 26 weeks after exposure to the virus, and presenting symptoms can include jaundice, nausea, dark urine, and right upper quadrant abdominal pain. Diagnosis is confirmed by testing for the presence of HCV RNA and anti-HCV antibodies in the serum; viral RNA is first detectable in the serum by polymerase chain reaction (PCR) within days to weeks following the exposure, whereas antibodies will not appear until 2 to 6 months after. If the diagnosis of acute hepatitis is established and the virus is not spontaneously cleared within 12 weeks, patients should generally be treated with pegylated interferon monotherapy. High rates of sustained viral response, in excess of 80%, have been achieved with the early treatment of acute HCV infection.⁵⁰ Unfortunately patients with acute HCV infection are typically asymptomatic, and the vast majority of cases go undetected. Untreated, most of these patients will eventually develop chronic infection.

Chronic HCV infection often follows a progressive course over many years and can ultimately result in cirrhosis, HCC, and the need for liver transplantation. Cirrhosis secondary to hepatitis C remains the leading indication for liver transplantation in the United States, Europe, and Japan. The decision to treat a patient with chronic HCV infection is complex and involves consideration of multiple factors including the natural history of

the disease, stage of fibrosis, and the efficacy and adverse effects related to the treatment regimen. Patients with genotype 1 are now treated with triple-agent therapy including pegylated interferon, ribavirin, and a protease inhibitor. The protease inhibitors telaprevir and boceprevir were recently approved for the treatment of chronic HCV genotype 1 infection, and their addition to the treatment regimen has been shown to increase the rate of sustained viral response from 40% to 70%. These protease inhibitors do not exhibit significant antiviral activity against other HCV genotypes, and therefore genotypes 2, 3, and 4 are treated with interferon and ribavirin alone. Genotypes 2 and 3 are generally more responsive to treatment than genotypes 1 and 4, but the therapeutic response also is dependent on other factors such as baseline viral load, ethnicity, and the patient's genetic background and compliance with the regimen.

EVALUATION OF AN INCIDENTAL LIVER MASS

A liver mass often is identified incidentally during a radiologic imaging procedure performed for another indication. For example, a liver mass may be discovered during evaluation for

gallbladder disease or kidney stones. In addition, with advances in imaging technology, previously undetected lesions not infrequently are now identified. Although many of these lesions are benign and will require no further treatment, the concern for malignancy requires a thorough evaluation. Thus, an orderly approach should be taken to the workup of an incidental liver lesion to minimize unnecessary testing.⁵¹

The evaluation of an incidental liver mass begins with a history and physical examination (Fig. 31-17). The patient should be asked about abdominal pain, weight loss, previous liver disease, cirrhosis, alcohol use, viral hepatitis, blood transfusions, tattoos, oral contraceptive use (in women), and personal or family history of cancer. On physical examination, jaundice, scleral icterus, hepatomegaly, splenomegaly, palpable mass, or stigmata of portal hypertension should be noted. After completion of the history and physical examination, blood work should be performed, including complete blood count; platelet count; measurement of levels of electrolytes, blood urea nitrogen, creatinine, glucose, and albumin; liver function tests; serum ammonia level; coagulation studies; hepatitis screen; and measurement of levels of the

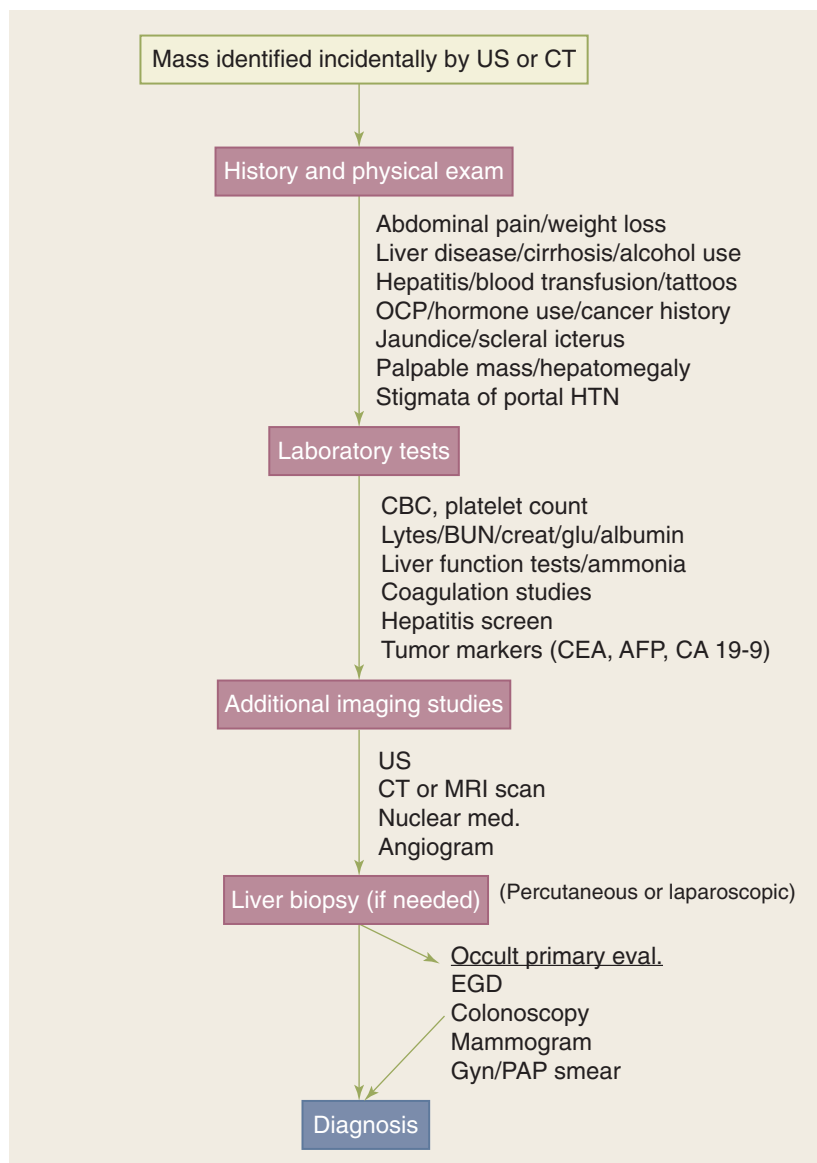


Figure 31-17. Algorithm for diagnostic workup of an incidental liver lesion. The evaluation includes history and physical examination, blood work, imaging studies, and liver biopsy (if needed). AFP = α -fetoprotein; BUN = blood urea nitrogen; CA 19-9 = cancer antigen 19-9; CBC = complete blood count; CEA = carcinoembryonic antigen; creat = creatinine; CT = computed tomography; EGD = esophagogastroduodenoscopy; glu = glucose; Gyn = gynecologic; HTN = hypertension; MRI = magnetic resonance imaging; OCP = oral contraceptive pill; PAP = Papanicolaou; US = ultrasound.

Table 31-6

Classification of liver lesions

Benign
Cyst
Hemangioma
Focal nodular hyperplasia
Adenoma
Biliary hamartoma
Abscess
Malignant
Hepatocellular carcinoma
Cholangiocarcinoma (bile duct cancer)
Gallbladder cancer
Metastatic colorectal cancer
Metastatic neuroendocrine cancer (carcinoid)
Other metastatic cancers

tumor markers carcinoembryonic antigen, AFP, and cancer antigen 19-9.

The differential diagnosis for an incidental liver mass includes cysts, benign solid lesions, and primary or metastatic cancers (Table 31-6). Ultrasound or CT is commonly performed to evaluate respiratory or abdominal symptoms, and these imaging studies usually lead to the discovery of an incidental liver lesion. Further radiologic evaluation by dual- or triple-phase CT scan or MRI is often necessary to fully characterize the extent and nature of the lesion. Different types of liver masses have distinct appearances and patterns of contrast enhancement on these studies, facilitating the clinician in the diagnosis and formulation of the treatment plan. The use of liver-specific contrast agents in MRI provides information on hepatocyte function in combination with the structural data obtained during a standard MRI, and yields improved detection and characterization of liver lesions. CT cholangiography or MRCP can be obtained, particularly when visualization of the biliary tract is desired. These modalities may be useful in the depiction of benign or malignant strictures resulting in biliary obstruction. In the evaluation of metastases to the liver from a variety of primary cancers, FDG-PET/CT has emerged as an indispensable tool in disease staging and in the follow-up after treatment. The techniques available for imaging of liver lesions are described in detail earlier in the section “Radiologic Evaluation of the Liver.”

Liver biopsy is indicated when biochemical analysis and diagnostic imaging fail to lead to a definitive diagnosis. Percutaneous liver biopsy with ultrasound or CT guidance is the simplest, fastest, and most commonly performed approach to obtain hepatic tissue for histologic examination. Absolute contraindications to percutaneous liver biopsy include significant coagulopathy (as in patients with decompensated cirrhosis), biliary dilatation, and suspicion for hemangioma or echinococcal cyst. Obesity and the presence of ascites are relative contraindications that can present a challenge to the percutaneous approach. In these patients, laparoscopic liver biopsy can be considered. The laparoscopic technique is likely to have a higher diagnostic yield in cirrhotic patients with ascites and/or coagulopathy, in whom bleeding risk is excessive by the percutaneous route. Laparoscopy also offers the opportunity to stage the extent of disease in patients with various intra-abdominal malignancies.

HEPATIC CYSTS

Congenital Cysts

The majority of hepatic cysts are asymptomatic. Hepatic cysts are usually identified incidentally and can occur at any time throughout life. The most common benign lesion found in the liver is the congenital or simple cyst. The exact prevalence of simple hepatic cysts in the U.S. population is not known, but the female:male ratio is approximately 4:1, and the prevalence is approximately 2.8% to 3.6%.⁵² Simple cysts are the result of excluded hyperplastic bile duct rests. Simple cysts usually are identified in hepatic imaging studies as thin-walled, homogeneous, fluid-filled structures with few to no septations. The cyst epithelium is cuboidal and secretes a clear nonbilious serous fluid. With the exception of large cysts, simple cysts are usually asymptomatic. Large simple cysts may cause abdominal pain, epigastric fullness, and early satiety. Occasionally the affected patient presents with an abdominal mass.

Asymptomatic simple cysts are best managed conservatively. The preferred treatment for symptomatic cysts is ultrasound- or CT-guided percutaneous cyst aspiration followed by sclerotherapy. This approach is approximately 90% effective in controlling symptoms and ablating the cyst cavity. If percutaneous treatment is unavailable or ineffective, treatment may include either laparoscopic or open surgical cyst fenestration. The laparoscopic approach is being used more frequently and is 90% effective. The excised cyst wall is sent for pathologic analysis to exclude the presence of carcinoma, and the remaining cyst wall must be carefully inspected for evidence of neoplastic change. If such change is present, complete resection is required, either by enucleation or formal hepatic resection.

Biliary Cystadenoma

Biliary cystadenomas are slow-growing, unusual, benign lesions that most commonly present as large lesions in the right lobe of the liver. Although these lesions are usually benign, they can undergo malignant transformation. Patients with biliary cystadenomas commonly present with abdominal pain. An abdominal mass occasionally can be identified on physical examination. In contrast to simple cysts, biliary cystadenomas have walls that appear thicker with soft tissue nodules and septations that usually enhance. The protein content of the fluid can be variable and can affect the radiographic images on CT and MRI. Surgical resection is the preferred mode of treatment.

Polycystic Liver Disease

Adult polycystic liver disease (PCLD) occurs as an autosomal dominant disease and usually presents in the third decade of life. Approximately 44% to 76% of affected families are found to have mutations of *PKD1*, and approximately 75% have mutations of *PKD2*.⁵³ The prevalence and number of hepatic cysts are higher in females and increase with advancing age and with increasing severity of renal cystic disease and renal dysfunction. Patients with a small number of cysts or with small cysts (<2 cm) usually remain asymptomatic. In contrast, patients who develop many or large cysts, with a cyst-to-parenchymal volume ratio of >1, usually develop clinical symptoms, including abdominal pain, distension, shortness of breath, and early satiety. Disease progression often results in renal failure and the need for hemodialysis. In most patients, the liver parenchymal volume and synthetic function are preserved despite extensive cystic disease. Hepatic decompensation, variceal hemorrhage, ascites,

and encephalopathy develop rarely in patients with PCLD and only in those with massive cystic disease. The most common liver-specific complications associated with PCLD are intracystic hemorrhage, infection, and posttraumatic rupture. The most common abnormal biochemical test finding is a modestly elevated γ -glutamyltransferase level, and the most useful imaging tests are CT or MRI of the abdomen, which will demonstrate the characteristic polycystic appearance. Other conditions that may be associated with PCLD include cerebral aneurysm, diverticulosis, mitral valve prolapse, and inguinal hernia.

The principal aim of treatment for PCLD is to ameliorate symptoms by decreasing liver volume. Medical therapy options for PCLD remain experimental at this time. Somatostatin analogs such as octreotide and lanreotide have been shown to modestly reduce liver volume and are generally well tolerated. Sirolimus and other mammalian target of rapamycin (mTOR) inhibitors possess antiproliferative effects and thus have been postulated to slow disease progression. The effectiveness of these medical measures in relieving symptoms among patients with PCLD, however, remains to be proven.⁵⁴

Cyst aspiration and sclerotherapy entail puncture of a cyst with an aspiration needle followed by injection of a sclerosing agent that causes destruction of the epithelial lining thereby inhibiting fluid production. Common agents used for sclerosis include ethanol, minocycline, and tetracycline. This technique may be considered if the patient has one or a few dominant cysts, each measuring over 5 cm. Appropriate candidates for sclerotherapy can experience a complete resolution of symptoms, but patients with numerous cysts often do not improve when this technique is used. This procedure is generally well tolerated, with the most common complication being pain from the instillation of ethanol.

Cyst fenestration, or surgical unroofing of the cyst, can be performed via an open or laparoscopic approach in symptomatic patients.⁵⁵ This approach allows multiple cysts to be treated during a single procedure, but carries the risk of potential surgical complications, including ascites, pleural effusion, hemorrhage, and biliary leakage. Immediate symptom relief can be achieved in up to 92% of cases, but 22% of patients eventually develop recurrence of their symptoms.

Hepatic resection can be considered for PCLD patients with massive hepatomegaly, when fenestration alone is unlikely to significantly reduce liver volume. Appropriate candidates are those with portions of liver that harbor numerous cysts, but have at least one spared segment with predominantly normal liver parenchyma. Because the intrahepatic vascular and biliary anatomy can be distorted by the cysts, PCLD patients undergoing hepatic resection are at increased risk for hemorrhagic and biliary complications. Furthermore, adhesion formation after liver resection can increase the technical complexity of future OLT. Significant symptom relief has been reported in up to 86% of PCLD patients following hepatic resection.

OLT represents the only definitive therapy for patients with symptomatic PCLD. This therapeutic option is indicated in patients with severely disabling symptoms that lead to a poor quality of life or in those who have developed untreatable complications such as portal hypertension and nutritional deprivation. If the patient has severe renal insufficiency from polycystic kidney disease, consideration should be given to combined liver-kidney transplantation. Because of the genetic basis of PCLD, living-donor transplantation should be considered only if the presence of PCLD in the donor can be ruled out.

Caroli's Disease

Caroli's disease is a syndrome of congenital ductal plate malformations of the intrahepatic bile ducts and is characterized by segmental cystic dilatation of the intrahepatic biliary radicals.⁵⁶ Caroli's disease also is associated with an increased incidence of biliary lithiasis, cholangitis, and biliary abscess formation. Caroli's disease usually occurs in the absence of cirrhosis and is associated with cystic renal disease.⁵⁶ The most common presenting symptoms include fever, chills, and abdominal pain. Most patients present by the age of 30 years, and males and females are affected equally. Rarely, patients can present later in life with complications secondary to portal hypertension. Approximately 33% of affected patients develop biliary lithiasis and 7% develop cholangiocarcinoma. The diagnosis of Caroli's disease is made based on imaging studies. Magnetic resonance cholangiopancreatography, ERCP, and percutaneous transhepatic cholangiography provide more detailed imaging of the biliary tree and confirm communication of the intrahepatic cysts with the biliary tree, which is necessary to solidify the diagnosis. Treatment consists of biliary drainage, with ERCP and percutaneous transhepatic cholangiography serving as first-line therapeutic modalities. If the disease is limited to a single lobe of the liver, hepatic resection can be beneficial. Liver resection can be considered in the patient with hepatic decompensation or unresponsive recurrent cholangitis and possibly in the patient with a small (T1 or T2) cholangiocarcinoma.

BENIGN LIVER LESIONS

The liver is an organ that is commonly involved either primarily or secondarily with vascular, metabolic, infectious, and malignant processes. Many classification schemes are used to help narrow the differential diagnosis of liver lesions: solid or cystic, single or multiple, cell of origin (hepatocellular, cholangiocellular, or mesenchymal), and benign or malignant. Benign liver lesions occur in up to 20% of the general population and are much more common than malignant tumors. The most common benign lesions are cysts, hemangiomas, focal nodular hyperplasia (FNH), and hepatocellular adenomas (see Table 31-6). Many of these lesions have typical features in imaging studies that help confirm the diagnosis.

Cyst

Hepatic cysts are the most frequently encountered liver lesion overall and are described in detail in the section "Hepatic Cysts." Cystic lesions of the liver can arise primarily (congenital) or secondarily from trauma (seroma or biloma), infection (pyogenic or parasitic), or neoplastic disease. Congenital cysts are usually simple cysts containing thin serous fluid and are reported to occur in 5% to 14% of the population, with higher prevalence in women. In most cases, congenital cysts are differentiated from secondary cysts (infectious or neoplastic origin) in that they have a well-defined thin wall and no solid component and are filled with homogeneous, clear fluid. For benign solid liver lesions, the differential diagnosis includes hemangioma, adenoma, FNH, and bile duct hamartoma.

Hemangioma

Hemangiomas (also referred to as *hemangiomata*) are the most common solid benign masses that occur in the liver. They consist of large endothelial-lined vascular spaces and represent

congenital vascular lesions that contain fibrous tissue and small blood vessels that eventually grow. They are predominantly seen in women and occur in 2% to 20% of the population. They can range from small (≤ 1 cm) to giant cavernous hemangiomas (10 to 25 cm). Most hemangiomas are discovered incidentally with little clinical consequence. However, large lesions can cause symptoms as a result of compression of adjacent organs or intermittent thrombosis, which in turn results in further expansion of the lesion. Spontaneous rupture (bleeding) is rare, but surgical resection can be considered if the patient is symptomatic. Resection can be accomplished by enucleation or formal hepatic resection, depending on the location and involvement of intrahepatic vascular structures and hepatic ducts.

The majority of hemangiomas can be diagnosed by liver imaging studies. On biphasic contrast CT scan, large hemangiomas show asymmetrical nodular peripheral enhancement that is isodense with large vessels and exhibit progressive centripetal enhancement fill-in over time (Fig. 31-18). On MRI, hemangiomas are hypointense on T1-weighted images and hyperintense on T2-weighted images.⁵⁷ With gadolinium enhancement, hemangiomas show a pattern of peripheral nodular enhancement similar to that seen on contrast CT scans. Caution should be exercised in ordering a liver biopsy if the suspected diagnosis

is hemangioma because of the risk of bleeding from the biopsy site, especially if the lesion is at the edge of the liver.

Adenoma

Hepatic adenomas are benign solid neoplasms of the liver. They are most commonly seen in premenopausal women older than 30 years of age and are typically solitary, although multiple adenomas also can occur. Prior or current use of estrogens (oral contraceptives) is a clear risk factor for development of liver adenomas, although they can occur even in the absence of oral contraceptive use. On gross examination, they appear soft and encapsulated and are tan to light brown. Histologically, adenomas lack bile duct glands and Kupffer cells, have no true lobules, and contain hepatocytes that appear congested or vacuolated due to glycogen deposition. On CT scan, adenomas usually have sharply defined borders and can be confused with metastatic tumors. With venous phase contrast, they can look hypodense or isodense in comparison with background liver, whereas on arterial phase contrast, subtle hypervascular enhancement often is seen (see Fig. 31-18). On MRI scans, adenomas are hyperintense on T1-weighted images and enhance early after gadolinium injection. With the use of liver-specific MRI contrast agents such as gadoxetate (Eovist or Primovist, Bayer-Schering, Berlin, Germany), hepatic adenomas can be

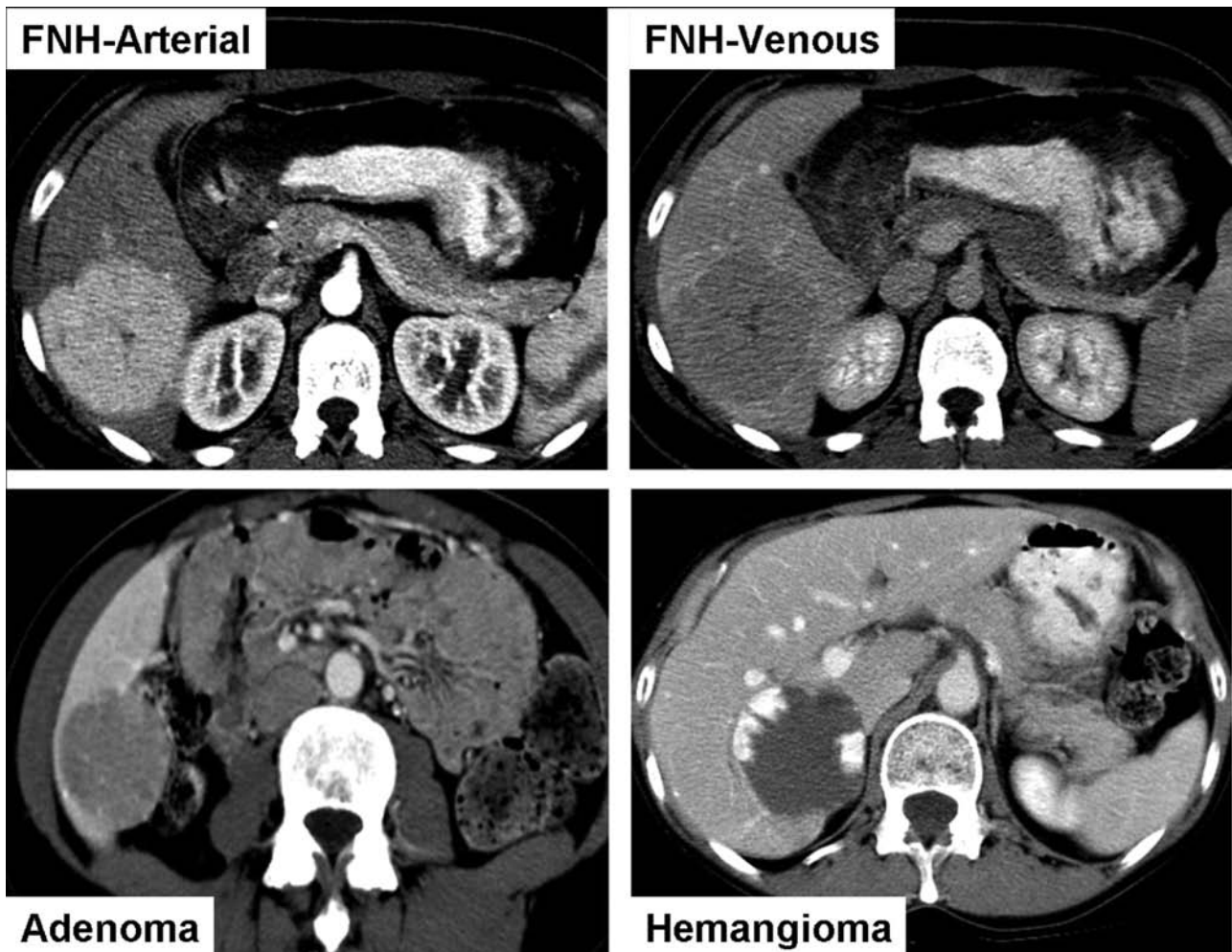


Figure 31-18. Computed tomographic scans showing classic appearance of benign liver lesions. Focal nodular hyperplasia (FNH) is hypervascular on arterial phase, isodense to liver on venous phase, and has a central scar (*upper panels*). Adenoma is hypovascular (*lower left panel*). Hemangioma shows asymmetrical peripheral enhancement (*lower right panel*).

better distinguished from FNH by their enhancement characteristics during the hepatobiliary phase of imaging. The new MRI contrast agent, gadobenate dimeglumine (MultiHance, Bracco Diagnostics, Milan, Italy), is eliminated through both renal and biliary excretion. Therefore, liver lesions that contain hepatocytes with intact biliary excretion mechanism will take up this contrast agent and be easily distinguished from lesions that do not. This contrast agent has improved our ability to differentiate hepatic adenoma from FNH with a high degree of accuracy.

Hepatic adenomas carry a significant risk of spontaneous rupture with intraperitoneal bleeding. The clinical presentation may be abdominal pain, and in 10% to 25% of cases, hepatic adenomas present with spontaneous intraperitoneal hemorrhage. Hepatic adenomas also have a risk of malignant transformation to a well-differentiated HCC. Therefore, it usually is recommended that a hepatic adenoma (once diagnosed) be surgically resected.

Focal Nodular Hyperplasia

FNH is a solid, benign lesion of the liver believed to be a hyperplastic response to an anomalous artery. Similar to adenomas, they are more common in women of childbearing age, although the link to oral contraceptive use is not as clear as with adenomas. A good-quality biphasic CT scan usually is diagnostic of FNH, on which such lesions appear well circumscribed with a typical central scar (see Fig. 31-18). They show intense homogeneous enhancement on arterial phase contrast images and are often isodense or invisible compared with background liver on the venous phase. On MRI scans, FNH lesions are hypointense on T1-weighted images and isointense to hyperintense on T2-weighted images. After gadolinium administration, lesions are hyperintense but become isointense on delayed images. The fibrous septa extending from the central scar are also more readily seen with MRI. Unlike adenomas, FNH lesions usually do not rupture spontaneously and have no significant risk of malignant transformation. Therefore, the management of FNH is usually reassurance and prospective observation irrespective of size. Surgical resection can be recommended, however, when patients are symptomatic or when hepatic adenoma or HCC cannot be definitively excluded. Oral contraceptive or estrogen use should be stopped when either FNH or adenoma is diagnosed.

Bile Duct Hamartoma

Bile duct hamartomas are typically small liver lesions, 2 to 4 mm in size, visualized on the surface of the liver at laparotomy. They are firm, smooth, and whitish yellow in appearance. They can be difficult to differentiate from small metastatic lesions, and excisional biopsy often is required to establish the diagnosis.

MALIGNANT LIVER TUMORS

Malignant tumors in the liver can be classified as primary (cancers that originate in the liver) or metastatic (cancers that spread to the liver from an extrahepatic primary site) (see Table 31-6). Primary cancers in the liver that originate from hepatocytes are known as *hepatocellular carcinomas* (HCCs or hepatomas), whereas cancers arising in the bile ducts are known as *cholangiocarcinomas*.

In the United States, approximately 150,000 new cases of colorectal cancer are diagnosed each year, and the majority of patients (approximately 60%) will develop hepatic metastases over their lifetime. Hence, the most common tumor seen in the liver is metastatic colorectal cancer. This compares with approximately 18,000 new cases of HCC diagnosed annually in

the United States. Interestingly, in a Western series of 1000 consecutive new liver cancer patients seen at a university medical center, 47% had HCC, 17% had colorectal cancer metastases, 11% had cholangiocarcinomas, 7% had neuroendocrine metastases, and 18% had other tumors.⁵⁸ Although these figures do not reflect the incidence or prevalence of these liver cancers, they are indicative of referral patterns in a tertiary academic medical center with a large liver transplantation team and active hepatology clinic.

Hepatocellular Carcinoma

HCC is the fifth most common malignancy worldwide, with an estimated 750,000 new cases diagnosed annually. Because of its high fatality, it is the third most common cause of cancer death worldwide.⁵⁹ Major risk factors are viral hepatitis (B or C), alcoholic cirrhosis, hemochromatosis, and NASH. In Asia, the risk is as high as 35 to 117 per 100,000 persons per year, whereas in the United States, the risk is only 7 per 100,000 persons per year.⁵⁹ Although cirrhosis is not present in all cases, it has been estimated to be present 70% to 90% of the time. In a person with cirrhosis, the annual conversion rate to HCC is 2% to 6%.⁶⁰ In patients with chronic HCV infection, cirrhosis usually is present before the HCC develops; however, in cases of hepatitis B virus infection, HCC tumors can occur before the onset of cirrhosis. HCCs are typically hypervascular with blood supplied predominantly from the hepatic artery. Thus, the lesion often appears hypervascular during the arterial phase of CT studies (Fig. 31-19) and relatively hypodense during the delayed phases due to early washout of the contrast medium by the arterial blood. MRI imaging also is effective in characterizing HCC. HCC is variable on T1-weighted images and usually hyperintense on T2-weighted images. As with contrast CT, HCC enhances in the arterial phase after gadolinium injection because of its hypervascularity and becomes hypointense in the delayed phases due to contrast washout. HCC has a tendency to invade the portal vein, and the presence of an enhancing portal vein thrombus is highly suggestive of HCC.

The treatment of HCC is complex and is best managed by a multidisciplinary liver transplant team. A complete algorithm for the evaluation and management of HCC is shown **8▶** (Fig. 31-20). For patients without cirrhosis who develop HCC, resection is the treatment of choice. For patients with Child's class A cirrhosis with preserved liver function and no portal hypertension, resection also is considered. If resection is not possible because of poor liver function and the HCC meets transplant criteria (discussed later), liver transplantation is the treatment of choice.^{61,62}

The Barcelona-Clinic Liver Cancer Group has refined its HCC management strategy and has developed the American Association for the Study of Liver Diseases Practice Guidelines.⁶³ Management guidelines vary slightly in Asia, Europe, the United States, and other countries based in part on availability of organ donors for liver transplantation. Living donor liver transplantation also is an alternative for patients with HCC awaiting transplantation to avoid dropout as a candidate for cadaveric donor liver transplantation due to tumor progression.⁶² Specific treatment options are described in the next section.

Cholangiocarcinoma

Cholangiocarcinoma, or bile duct cancer, is the second most common primary malignancy of the liver. Cholangiocarcinoma is an adenocarcinoma of the bile ducts; it forms in the biliary epithelial cells and can be subclassified into peripheral

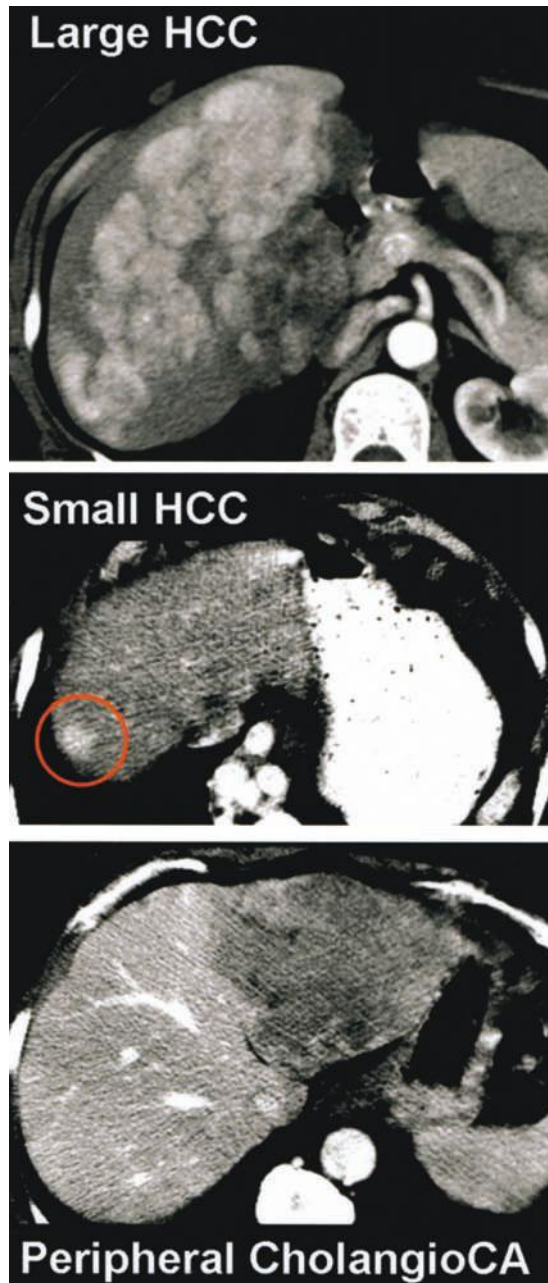


Figure 31-19. Computed tomographic (CT) images of hepatocellular carcinoma (HCC) and peripheral cholangiocarcinoma. CT scans reveal a large (*upper panel*) and small (*middle panel*) hypervascular HCC. A hypovascular left lobe peripheral cholangiocarcinoma (CholangioCA) is also shown (*lower panel*).

(intrahepatic) bile duct cancer and central (extrahepatic) bile duct cancer. Extrahepatic bile duct cancer can be located distally or proximally. When proximal, it is referred to as a *hilar cholangiocarcinoma* (Klatskin's tumor). Hilar cholangiocarcinoma originates in the wall of the bile duct at the hepatic duct confluence and usually presents with obstructive jaundice rather than an actual liver mass. In contrast, a peripheral (or intrahepatic) cholangiocarcinoma represents a tumor mass within a hepatic lobe or at the periphery of the liver. A biopsy specimen from the cholangiocarcinoma will show adenocarcinoma, but pathologists are often unable to differentiate metastatic adenocarcinoma to the liver from primary bile duct adenocarcinoma. Therefore, a search for a primary site should

be undertaken in cases in which an incidentally discovered liver lesion is proven to be an adenocarcinoma on biopsy.

Hilar cholangiocarcinoma is difficult to diagnose and typically presents as a stricture of the proximal hepatic duct causing painless jaundice. It preferentially grows along the length of the bile ducts, often involving the periductal lymphatics with frequent lymph node metastases. Surgical resection offers the only chance for cure of cholangiocarcinoma.⁶⁴ The location and extent of tumor dictate the operative approach. In one series of 225 patients with hilar cholangiocarcinoma, 65 (29%) were deemed to have unresectable tumors by initial imaging.⁶⁵ Of the remaining 160 patients who underwent exploratory surgery with curative intent, 80 (50%) were found to have inoperable tumors. Histologically negative margins, concomitant hepatic resection, and well-differentiated tumor histology were associated with improved outcome after resection. In another series of 61 patients undergoing surgical exploration for hilar cholangiocarcinoma, the 5-year actuarial survival rates for an R0 or R1 resection were 45% and 26%, respectively.⁶⁶ In a large series reported by Nagino and colleagues, 132 patients with hilar cholangiocarcinoma underwent hepatectomy with resection of the caudate lobe and extrahepatic bile duct, and/or portal vein resection (n = 63) after portal vein embolization.⁶⁷ The 3- and 5-year survival rates were 41.7% and 26.8%, respectively.

In the absence of associated primary sclerosing cholangitis (PSC), surgical resection is the treatment of choice for hilar cholangiocarcinoma. However, approximately 10% of patients with cholangiocarcinoma have PSC.⁶⁸ Furthermore, cholangiocarcinoma in the setting of PSC is frequently multicentric and often is associated with underlying liver disease, with eventual cirrhosis and portal hypertension. As a result, experience has shown that resection of cholangiocarcinoma in patients with PSC yields dismal results. This led transplant centers to consider OLT for patients with hilar cholangiocarcinoma. The initial results of transplantation were disappointing, however, with high recurrence and overall 3-year survival rates of <30%.⁶⁹

Because the growth of hilar cholangiocarcinoma indicates that this disease spreads in a locoregional manner, a rationale for the use of neoadjuvant chemoradiation was developed by the transplant team at the University of Nebraska in the late 1980s. This was adapted in 1993 by the transplant team at the Mayo Clinic, which led to the current Mayo Clinic protocol.⁷⁰ The pretransplant Mayo protocol consists of external-beam radiation therapy plus a protracted course of intravenous 5-fluorouracil followed by iridium-192 brachytherapy.⁷¹ Patients then undergo an abdominal exploration with staging. If findings are negative, patients are given capecitabine for 2 of every 3 weeks until transplantation. Even after restaging with CT/MRI and endoscopic ultrasonography, approximately 15% to 20% of patients will have positive findings for tumor on abdominal exploration.^{68,71} The 5-year survival rate for those undergoing transplantation for cholangiocarcinoma at the Mayo Clinic is approximately 70% and compares favorably with the rate for resection.^{68,71} Current eligibility criteria for this Mayo Clinic protocol include unresectable hilar cholangiocarcinoma or hilar cholangiocarcinoma with PSC. The tumor must have a radial dimension of ≤ 3 cm with

- 9▶ no intrahepatic or extrahepatic metastases, and the patient must not have undergone prior radiation therapy or transperitoneal biopsy.⁷¹ Many centers have adopted similar protocols with comparable results.⁷²

Peripheral, or intrahepatic, cholangiocarcinoma is less common than hilar cholangiocarcinoma. In a series of 53 patients

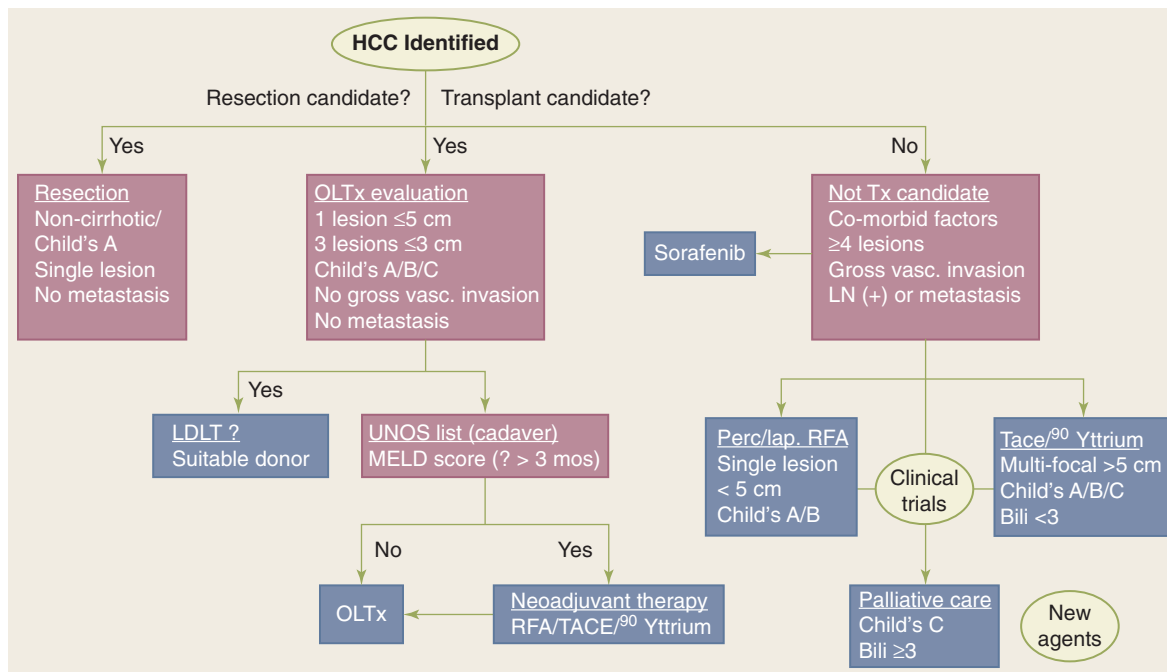


Figure 31-20. Algorithm for the management of hepatocellular carcinoma (HCC). The treatment algorithm for HCC begins with determining whether the patient is a resection candidate or liver transplant candidate. Bili = bilirubin level (in milligrams per deciliter); Child's = Child-Turcotte-Pugh class; lap = laparoscopic; LDLT = living-donor liver transplantation; LN = lymph node; MELD = Model for End-Stage Liver Disease; OLTx = orthotopic liver transplantation; Perc = percutaneous; RFA = radiofrequency ablation; TACE = transarterial chemoembolization; Tx = transplantation; UNOS = United Network for Organ Sharing; vasc. = vascular.

at Memorial Sloan-Kettering Cancer Center who underwent surgical exploration for a diagnosis of intrahepatic cholangiocarcinoma, 33 (62%) were found to have resectable tumors.⁷³ Actuarial 3-year survival for patients undergoing resection was 55%. Factors predictive of poor survival included vascular invasion, histologically positive margins, and multiple tumors. In a large series in Taiwan, 373 patients with peripheral cholangiocarcinoma underwent surgical treatment from 1977 to 2001. Absence of mucobilia, nonpapillary tumor type, tumor of advanced stage, nonhepatectomy, and lack of postoperative chemotherapy were five independent prognostic factors that adversely affected overall survival.⁷⁴ Liver transplantation has been performed for peripheral cholangiocarcinoma⁷⁵; however, currently all but one center in the United States have eschewed this approach because of organ shortages and relatively high recurrence rates.

Gallbladder Cancer

Gallbladder cancer is a rare aggressive tumor with a very poor prognosis. Over 90% of patients have associated cholelithiasis. In one study examining the mode of presentation over a 10-year period from 1990 to 2000 in 44 patients diagnosed with gallbladder cancer, the diagnosis was found to be made preoperatively in 57%, intraoperatively in 11%, and incidentally after cholecystectomy in 32%.⁷⁶ Surgical approaches can be classified into (a) reoperation for an incidental finding of gallbladder cancer after cholecystectomy, and (b) radical resection in patients with advanced disease. The results are dismal for radical resection in patients with advanced disease and positive hilar lymph nodes.^{77,78} For incidental gallbladder cancer beyond stage T1, reoperation with central liver resection, hilar lymphadenectomy, and evaluation of cystic duct stump is most commonly performed.^{79,80} The role of formal lobectomy or extended lobectomy as well as common bile duct resection

is more controversial. In a single-center study of 23 patients undergoing attempted curative treatment by surgical resection, survival was 85% at 1 year, 63% at 2 years, and 55% at 3 years.⁸⁰ In a multicenter study encompassing 115 patients with incidentally discovered gallbladder cancer who underwent re-resection,⁷⁹ residual disease in the liver was identified in 46% of patients (0% of those with stage T1 disease, 10% of those with T2 tumors, and 36% of those with T3 disease). T stage also was associated with the risk of metastasis to locoregional lymph nodes (lymph node metastasis for T1 of 13%; for T2, 31%; and for T3, 46%). In another study, a German registry of incidental gallbladder cancer identified 439 patients. Patients with tumors staged as T2 or T3 after cholecystectomy had better survival if they underwent reoperation than if they were managed with observation.⁸¹ Hence, reoperation should be considered for all patients who have T2 or T3 tumors or for whom the accuracy of staging is in question.

Metastatic Colorectal Cancer

Over 50% to 60% of patients diagnosed with colorectal cancer will develop hepatic metastases during their lifetime. Resection for hepatic metastases has been a routine part of treatment for colorectal cancer since the publication of a large single-center experience demonstrating its safety and efficacy.⁸² Predictors of poor outcome in that study included node-positive primary, disease-free interval <12 months, more than one tumor, tumor size >5 cm, and carcinoembryonic antigen level >200 ng/mL. Traditional teaching suggested that hepatic resection for metastatic colorectal cancer to the liver, if technically feasible, should be performed only for fewer than four metastases.⁸³ However, later studies challenged this paradigm. In a series of 235 patients who underwent hepatic resection for metastatic colorectal cancer, the 10-year survival rate of patients with four or more nodules was 29%, nearly comparable to the 32% survival rate of patients

with only a solitary tumor metastasis.⁸⁴ In the Memorial Sloan-Kettering Cancer Center series of 98 patients with four or more colorectal hepatic metastases who underwent resection between 1998 and 2002, the 5-year actuarial survival was 33%.⁸⁵ Furthermore, improved chemotherapeutic regimens and surgical techniques have produced aggressive strategies for the management of this disease. Many groups now consider volume of future liver remnant and the health of the background liver, and not actual tumor number, as the primary determinants in selection for an operative approach.^{86,87} Hence, resectability is no longer defined by what is actually removed, but indications

10▶ for hepatic resection now center on what will remain after resection.⁸⁸ Use of neoadjuvant chemotherapy, portal vein embolization, two-stage hepatectomy, simultaneous ablation, and resection of extrahepatic tumor in select patients have increased the number of patients eligible for a surgical approach.^{89,90}

Neuroendocrine Tumors

Hepatic metastases from neuroendocrine tumors have a protracted natural history and commonly are associated with debilitating endocrinopathies. Several groups have advocated an aggressive surgical approach of debulking surgery, both to control symptoms and to extend survival.^{91,92} In a series of 170 patients undergoing resection of hepatic metastases from neuroendocrine tumors between 1977 and 1998 at the Mayo Clinic, overall survival was 61% and 35% at 5 and 10 years, respectively.⁹³ There was no difference in survival between patients with carcinoid tumors and those with islet cell tumors. Major hepatectomy was performed in 91 patients (54%), and recurrence rate was 84% at 5 years. Belghiti's group has described a two-stage strategy used in 41 patients with a primary neuroendocrine tumor and synchronous bilobar liver metastases.⁹⁴ In the first stage, the primary tumor is resected and limited resection of metastases in the left hemiliver, combined with right portal vein ligation, is performed. After 8 weeks of hypertrophy, a right hepatectomy or extended right hepatectomy (also referred to as a right trisectionectomy; resection of Couinaud's segments IV, V, VI, VII, and VIII of the liver) is performed.⁹⁴ In patients treated using this strategy, the 2-, 5-, and 8-year Kaplan-Meier overall survival rates were 94%, 94%, and 79%, respectively, and disease-free survival rates were 85%, 50%, and 26%, respectively. Because systemic therapy has had little success in the treatment of advanced tumors, a broader approach using multimodal therapy has been used to increase survival and improve hormone-related symptoms. These therapies include radiofrequency or microwave ablation and intra-arterial therapy with chemoembolization or radioembolization (yttrium-90). Some centers perform liver transplantation for selected patients (carcinoid histology; primary tumor removed with curative resection; primary tumor drained by portal system; ≤50% hepatic parenchyma involved; good response or stable disease for at least 6 months during pretransplantation period; and age 55 years or younger), although this is not routine.⁹⁵

Other Metastatic Tumors

Nearly every cancer has the propensity to metastasize to the liver. Historically, enthusiasm was low for resecting metastases other than those from a colorectal cancer primary. This was due in part to the recognition that many other primary cancers (such as breast cancer) represent a systemic disease when liver metastases are present. However, more recent studies have shown

acceptable 5-year survival rates in the 20% to 40% range for resection of hepatic metastases from breast, renal, and other GI tumors.^{96,97} In a large study of hepatic resection for noncolorectal, nonendocrine liver metastases in 1452 patients, negative prognostic factors were nonbreast origin, age >60 years, disease-free interval of <12 months, need for major hepatectomy, performance of R2 resection, and presence of extrahepatic metastases.⁹⁶

TREATMENT OPTIONS FOR LIVER CANCER

In general, the major treatment options for liver cancer can be categorized as shown in Table 31-7. The decision making for any given patient is complex and is best managed by a multidisciplinary liver tumor board. The treatments listed in Table 31-7 are not mutually exclusive; the important point is to select the most appropriate initial treatment after a complete evaluation. In general, surveillance imaging (CT or MRI) is performed every 3 to 4 months during the first year after diagnosis to observe for response, progression, or recurrence. The treatment plan is individualized and modified according to the response of the patient.

Hepatic Resection

For primary liver cancers or hepatic metastases, hepatic resection is the gold standard and treatment of choice. Although there are anecdotal reports of long-term survival after ablation and other regional liver therapies, liver resection remains the only real option for cure. For HCC in the setting of cirrhosis, liver transplantation also offers the potential for long-term survival, albeit with the consequences of immunosuppression. Hepatic resection also has been advocated for HCC in select patients with cirrhosis before secondary liver transplantation, although not without some controversy.⁹⁸ Many large series of patients undergoing major hepatectomy now report mortality rates of <5%.⁹⁹⁻¹⁰² Previously, a 1-cm tumor margin was considered desirable; however, recent studies have reported comparable survival rates with smaller margins.¹⁰³⁻¹⁰⁵ Technical innovation in liver surgery and a better understanding of perioperative care have even allowed surgeons to perform resections in cases with IVC involvement

Table 31-7

Treatment options for liver cancer

Hepatic resection
Liver transplantation
Ablation techniques
<ul style="list-style-type: none"> • Radiofrequency ablation • Ethanol ablation • Cryoablation • Microwave ablation
Regional liver therapies
<ul style="list-style-type: none"> • Chemoembolization/embolization • Hepatic artery pump chemoperfusion • Internal radiation therapy (yttrium-90 internal radiation)
External-beam radiation therapy
<ul style="list-style-type: none"> • Stereotactic radiosurgery (CyberKnife, Trilogy, Synergy) • Intensity-modulated radiation therapy
Systemic chemotherapy
Multimodality approach

with extracorporeal liver surgery.¹⁰⁶ The technical aspects of anatomic hepatic lobectomies are described later.

Liver Transplantation

The rationale supporting OLT for HCC includes the fact that most HCCs (>80%) arise in the setting of cirrhosis.^{69,107} The cirrhotic liver often does not have enough reserve to tolerate a formal resection. Also, HCC tumors are commonly multifocal and are underestimated by current CT or MRI imaging.¹⁰⁸ Furthermore, recurrence rates are high at 5 years after resection (>50%). Hence, OLT is an appealing treatment, because it removes both the cancer and the cirrhotic liver that leads to cancer. More than 6000 liver transplantations are performed each year in the United States, with 1-year survival rates approaching 90%. In June 2013, approximately 15,800 patients were on the waiting list for liver transplantation.¹⁰⁹

Initial series of OLT for HCC reported in the 1990s included advanced cases of HCC, and the 5-year survival rates were only 20% to 50%.⁶⁹ This compared poorly with overall 5-year survival rates of 70% to 75% for OLT in the Organ Procurement and Transplantation Network/United Network for Organ Sharing (OPTN/UNOS) database. Mazzaferro and colleagues at Milan subsequently showed that survival rates were markedly improved when OLT was limited to patients with early-stage HCC (stage I or stage II) with one tumor ≤5 cm, or up to three tumors no larger than 3 cm, along with the absence of gross vascular invasion or extrahepatic spread.¹¹⁰ Multiple studies have validated these findings, and many groups have proposed an expansion of the Milan criteria.⁶²

As noted previously, the 6- to 40-point MELD score was adopted by OPTN/UNOS in 2002 for allocation of deceased donor liver organs in the United States. In an attempt to prioritize patients with preserved liver function and progressive HCC, patients with stage I or stage II HCC are allocated exception points (currently 22 MELD points, increasing every 3 months as long as they continue to meet transplant criteria). This allocation has had a positive effect for HCC liver transplant candidates, leading to decreased waiting list dropout and increased transplant rates with excellent long-term outcomes.¹¹¹ The goal is to better equate death rates on the liver transplant waiting list for patients with stage I or stage II HCC with rates for patients with chronic liver disease without HCC. Although indications for liver transplantation have increased, the supply of donor livers has failed to keep pace with the numbers of potential recipients. A partial solution has been the use of living donor grafts. This is especially true in Asia where the incidence of HCC is high and the rate of cadaveric donation is low. Living donor grafts include right and left lobes, as well as dual grafts from separate donors to provide adequate hepatic mass to the recipient. The use of living donor grafts also allows for transplant programs to push the boundaries by accepting patients beyond the Milan criteria with good results.¹¹²

Radiofrequency Ablation

In 1891, d'Arsonval discovered that radiofrequency (RF) waves delivered as an alternating electric current (>10 kHz) could pass through living tissue without causing pain or neuromuscular excitation. The resistance of the tissue to the rapidly alternating current produced heat. This discovery contributed to the development of the surgical application of electrocautery. In 1908, Beer used RF coagulation to destroy urinary bladder tumors. Cushing and Bovie later applied RF ablation to intracranial tumors. In 1961, Lounsberry studied the histologic changes of the liver after RF

ablation (RFA) in animal models. He found that RF caused local tissue destruction with uniform necrosis. In the early 1990s, two groups proposed that RFA can be an effective method for destroying unresectable malignant liver tumors.^{113,114} Both groups found that RFA produced lesions with well-demarcated areas of necrosis without viable tumor cells present. Clinical reports after short-term follow-up suggested that RFA was safe and effective in the treatment of liver tumors.¹¹⁵⁻¹¹⁷ However, Abdalla and colleagues examined data for 358 consecutive patients with colorectal liver metastases treated with curative intent over a 10-year period (1992 to 2002).¹¹⁸ Liver-only recurrence after RFA was four times the rate after resection (44% vs. 11% of patients), and RFA alone or in combination with resection did not provide survival rates comparable to those with resection alone. Other studies have corroborated this trend.¹¹⁹ Nonetheless, RFA remains a common procedure that can be performed by a percutaneous, minimally invasive laparoscopic, or open approach.^{120,121} It also has been used successfully to ablate small HCCs as a bridge to liver transplantation.¹²² Recently, results were reported for the first randomized clinical trial involving RFA treatment for HCC in 291 Chinese patients with three or fewer HCC tumors ranging in size from 3 to 7.5 cm.¹²³ Patients were randomly assigned to treatment arms of RFA alone (n = 100), transarterial chemoembolization (TACE) alone (n = 95), or combined TACE plus RFA (n = 96). At a median follow-up of 28.5 months, median survival was 22 months in the RFA group, 24 months in the TACE group, and 37 months in the TACE plus RFA group. Patients treated with TACE plus RFA had significantly better overall survival than those treated with TACE alone ($P < .001$) or RFA alone ($P < .001$).

Ethanol Ablation, Cryosurgery, and Microwave Ablation

Percutaneous ethanol injection has been shown to be a safe and effective treatment for small HCCs.¹⁰⁷ The ethanol usually is delivered by percutaneous injection under ultrasound or CT guidance. Percutaneous ethanol injection also is used to treat small HCC tumors as a bridge to liver transplantation in some centers to avoid patient dropout.⁶¹ Although cryosurgery was used in the late 1980s and 1990s for ablation of liver tumors, many have abandoned this approach in favor of RFA because of the latter's fewer side effects and ease of use. Microwave ablation is a thermal ablative technique used in the management of unresectable liver tumors to produce a coagulation necrosis. In a multicenter phase II U.S. trial using a 915-MHz microwave generator, 87 patients underwent 94 ablation procedures for 224 hepatic tumors.¹²⁴ Forty-five percent of the procedures were performed using an open approach, 7% laparoscopically, and 48% percutaneously. The average tumor size was 3.6 cm (range, 0.5 to 9.0 cm). At a mean follow-up of 19 months, 47% of the patients were alive with no evidence of disease. Local recurrence at the ablation site occurred in 2.7% of tumors, and regional recurrence occurred in 43% of patients. There were no procedure-related deaths. Further studies are required to define the role of this technology in relation to the other ablation options available.

Chemoembolization and Hepatic Artery Pump Chemoperfusion

Chemoembolization is the process of injecting chemotherapeutic drugs combined with embolization particles into the hepatic artery that supplies the liver tumor using a percutaneous, transfemoral approach. It is most commonly used for treatment of unresectable HCC. Three randomized trials and a meta-analysis

have shown a survival benefit with chemoembolization.¹²⁵⁻¹²⁸ In a study by Lo and colleagues, 80 Asian patients were randomly assigned to receive either chemoembolization with cisplatin in lipiodol or symptomatic treatment only.¹²⁵ Chemoembolization resulted in a marked tumor response, and the actuarial survival was significantly better in the chemoembolization group (1- and 3-year survival of 57% and 26%, respectively) than in the control group (1- and 3-year survival of 32% and 3%, respectively). In another randomized trial, a Barcelona group compared chemoembolization with doxorubicin versus supportive care and showed that chemoembolization significantly improved survival.¹²⁶ Finally, in a large prospective cohort study of 8510 patients with unresectable HCC in Japan who received transcatheter arterial lipiodol chemoembolization, the 5-year survival rate was 26% and median survival time was 34 months.¹²⁷ The TACE-related mortality rate after the initial therapy was 0.5%. Complications of TACE include liver dysfunction or liver failure, hepatic abscess, and hepatic artery thrombosis. Multiple studies also have shown promising results for chemoembolization with drug-eluting beads in treatment of HCC.¹²⁹

In the 1990s, hepatic artery pump chemoperfusion with floxuridine for colorectal cancer metastases to the liver was used both for treatment of inoperable disease and in the adjuvant setting.¹³⁰ However, in the modern era of improved chemotherapeutic options, this treatment modality is seldom used outside of a clinical trial.

Yttrium-90 Microspheres

Selective internal radioembolization or transarterial radioembolization (TARE) is a promising new treatment modality for patients with inoperable primary or metastatic liver tumors. The treatment is a minimally invasive transcatheter therapy in which radioactive microspheres are infused into the hepatic arteries via a transfemoral percutaneous approach. The yttrium-90 microspheres are directly injected into the hepatic artery branches that supply the tumor. Once infused, the microspheres deliver doses of high-energy, low-penetration radiation selectively to the tumor. The main indications are inoperable HCC¹³¹ and colorectal cancer hepatic metastases for which systemic chemotherapy has failed.^{132,133} In a recent study involving 137 patients with unresectable chemorefractory liver metastases treated with radioembolization, there was a response rate of 42.8% (2.1% complete response, 40.7% partial response) according to World Health Organization criteria.¹³³ One-year survival rate was 47.8%, and 2-year survival rate was 30.9%. Median survival was 457 days for patients with colorectal tumor metastases, 776 days for those with neuroendocrine tumor metastases, and 207 days for those with noncolorectal, nonneuroendocrine tumor metastases. The two products available in the United States are SIR-Spheres (Sirtex, Sydney, Australia) and TheraSphere (Nordian, Ottawa, Canada).

Stereotactic Radiosurgery and Intensity-Modulated Radiation Therapy

Although stereotactic radiosurgery (with CyberKnife and other systems) is in widespread use for brain and spinal tumors, body application to HCC or metastatic liver tumors has only recently occurred. In a phase I study, 31 patients with unresectable HCCs and 10 with unresectable cholangiocarcinomas completed a six-fraction course of stereotactic body radiotherapy.¹³⁴ The treatment was well tolerated, and median survival was 11.7 and 15.0 months for the two groups, respectively. A similar safety profile was observed in a study in the Netherlands.¹³⁵ Further clinical

trials are required to define the future role of stereotactic radiosurgery in treatment of HCC and metastatic tumors. Intensity-modulated radiation therapy (IMRT) is another technologic advancement that facilitates the targeted delivery of external-beam radiation. Early clinical data suggested favorable outcomes with IMRT for the treatment of patients with unresectable HCC, and ongoing trials are further examining the role of IMRT for these locally advanced tumors.

Downstaging

In more advanced-stage patients not eligible for MELD exception points, hepatic-directed therapy including TACE and tumor ablation with radiofrequency, microwave, and ethanol ablation have been found to be effective in shrinking tumors to meet Milan criteria (downstaging). Multiple centers have used downstaging to allow for OLT in patients whose tumors responded and shrank to meet eligibility criteria.^{136,137}

Systemic Chemotherapy

Chemotherapy has not demonstrated great efficacy in patients with HCC, especially in patients with significant cirrhosis. For treatment of HCC, the multikinase inhibitor sorafenib has shown some efficacy in a phase III randomized international multicenter trial. The SHARP trial (Sorafenib HCC Assessment Randomized Protocol) enrolled 602 patients with Child's class A cirrhosis and inoperable HCC. At interim analysis, the trial was discontinued because a survival benefit was found in the treatment group. The median overall survival for patients receiving sorafenib was 10.7 months versus 7.9 months for patients in the control arm. Based on these findings, sorafenib received accelerated Food and Drug Administration approval for the treatment of advanced unresectable HCC.¹³⁸ Future studies will likely examine the role of other molecularly targeted agents and combinations of sorafenib with other treatment modalities.

HEPATIC RESECTION SURGICAL TECHNIQUES

Nomenclature

Due to the confusion in language with regard to anatomic descriptions of hepatic resections, a common nomenclature was introduced at the International Hepato-Pancreato-Biliary Association meeting in Brisbane, Australia, in 2000 (Table 31-8).^{139,140} The goal was to provide universal terminology for liver anatomy and hepatic resections, because there was much overlap among the designations for hepatic lobes, sections, sectors, and segments used by surgeons worldwide (Fig. 31-21). The most common or prevailing anatomic pattern was used as the basis for naming liver anatomy, and the surgical procedure nomenclature adopted for hepatic resections was based on the assigned anatomic terminology.¹⁴¹ Adoption of a common language should enable hepatic surgeons to better understand and interpret liver surgery publications from different continents and disseminate their knowledge to the next generation of hepatobiliary surgeons. Nonetheless, even today, the literature is full of both old and new liver resection terminology, so the surgeon in training must be familiar with all the various classifications.

Techniques and Devices for Dividing the Hepatic Parenchyma

Hepatic resection surgery has evolved over the past 50 years. A better understanding of liver anatomy and physiology, coupled with improved anesthesia techniques and widespread use of

Table 31-8

Brisbane 2000 liver terminology

OLDER HEPATIC RESECTION TERMINOLOGY	BRISBANE 2000 HEPATIC RESECTION TERMINOLOGY
Right hepatic lobectomy	Right hepatectomy or right hemihepatectomy (V, VI, VII, VIII)
Left hepatic lobectomy	Left hepatectomy or left hemihepatectomy (II, III, IV)
Right hepatic trisegmentectomy	Right trisectionectomy or extended right hepatectomy (or hemihepatectomy, IV, V, VI, VII, VIII)
Left hepatic trisegmentectomy	Left trisectionectomy or extended left hepatectomy (or hemihepatectomy, II, III, IV, V, VIII)
Left lateral segmentectomy	Left lateral sectionectomy or bisegmentectomy (II, III)
Right posterior lobectomy	Right posterior sectionectomy (VI, VII)
Caudate lobectomy	Caudate lobectomy or segmentectomy (I)
	ALTERNATIVE "SECTOR" TERMINOLOGY
	Right anterior sectorectomy
	Right posterior sectorectomy or right lateral sectorectomy
	Left medial sectorectomy or left paramedian sectorectomy (bisegmentectomy, III, IV)
	Left lateral sectorectomy (segmentectomy, II)

intraoperative ultrasound, has led to virtually "bloodless" liver surgery in the modern era (the year 2000 to the present). Innovations in technology have expanded the list of liver parenchymal transection devices¹⁴²⁻¹⁴⁴ and hemostatic agents (Table 31-9). Use of each device or agent has a learning curve, and undoubtedly every experienced hepatic surgeon has his or her personal preferences.

One major trend has been the application of vascular stapling devices for division of the hepatic and portal veins.¹⁴⁵⁻¹⁴⁷ Based on early reports of successful stapling of extrahepatic vessels, stapling devices are now being used in the parenchymal transection phase, which remains a source of potential blood loss due to back bleeding from the middle hepatic vein.^{148,149} One advantage of the stapling technique is the speed with which the transection can be performed, which minimizes surface bleeding and period of ischemia for the remnant liver.

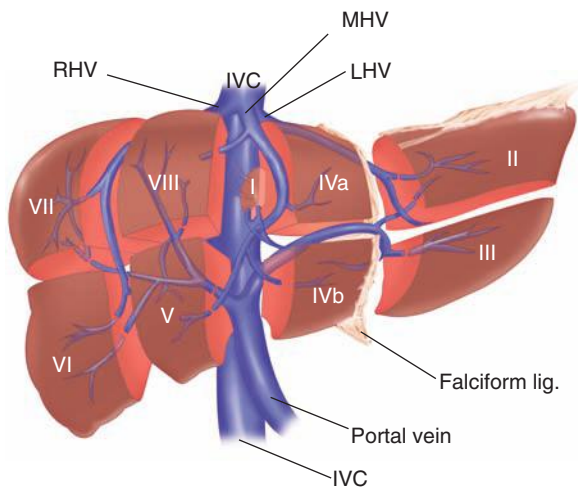


Figure 31-21. Hepatic anatomy. Hepatic segments removed in the formal major hepatic resections are indicated. IVC = inferior vena cava; LHV = left hepatic vein; MHV = middle hepatic vein; RHV = right hepatic vein.

Table 31-9

Techniques and devices for dividing liver parenchyma and achieving hemostasis

Blunt fracture and clips
Monopolar cautery (Bovie)
Bipolar cautery
Argon beam coagulator
CUSA ultrasonic dissector
Hydro-Jet water-jet dissector
Harmonic Scalpel, AutoSonix ultrasonic transector-coagulator
LigaSure tissue fusion system
SurgRx EnSeal tissue sealing and transection system
Gyrus PK cutting forceps
Endovascular staplers
TissueLink sealing devices
Habib 4X Laparoscopic sealer
InLine bipolar linear coagulator
Topical agents (fibrin glues, Surgicel, Gelfoam, Avitene, Tisseel, Floseal, Crosseal)

However, a major disadvantage of the stapling technique is the cost of multiple stapler cartridges. This is balanced by the decreased expenses reported with avoidance of ICU admission and blood transfusion, as well as shortened operating room time. Another consideration in the use of staplers for parenchymal transection is the potential for bile leaks. However, in a large series of 101 consecutive right hemihepatectomies performed using the stapling technique, there was only one reported bile leak (1%), which sealed after ERCP.¹⁴⁹

Steps in Commonly Performed Hepatic Resections

A fundamental understanding of hepatic anatomy is vital for any surgeon with the desire to perform hepatobiliary surgery. Each hepatic resection surgery can be broken down into a

series of orderly steps. The key to being a proficient hepatic surgeon is not to operate swiftly but rather to accomplish the operation by completing the steps in an orchestrated fashion. Mastery of the operative steps coupled with knowledge of liver anatomy and the common anatomic variants provides the foundation for safe hepatic surgery. There are many different techniques and sequences for accomplishing each of the anatomic (and nonanatomic) hepatic operations. The authors present their preferred approach in a stepwise fashion for right hepatic lobectomy (right hemihepatectomy), left hepatic lobectomy (left hemihepatectomy), and left lateral segmentectomy (left lateral sectionectomy). Provision of a detailed approach for every type of liver resection is beyond the scope of this chapter, and readers are referred to several excellent descriptions.¹⁵⁰

Steps Common to All Open Major Hepatic Resections

1. Make the skin incision—right subcostal with or without a partial or complete left subcostal extension across the midline, depending on the patient's habitus and liver/tumor anatomy.
2. Open and explore the abdomen, and place a fixed table retractor (e.g., Thompson or Bookwalter).
3. Examine the liver with bimanual palpation. Perform liver ultrasound, and confirm the operation to be performed.
4. Take down the round and falciform ligaments, and expose the anterior surface of the hepatic veins.
5. For a left hepatectomy, divide the left triangular ligament; for a right hepatectomy, mobilize the right lobe from the right coronary and triangular ligaments.
6. Open the gastrohepatic ligament, palpate the porta hepatis, and assess for accessory or replaced hepatic arteries.
7. Perform a cholecystectomy; leave the gallbladder with the cystic duct intact if the gallbladder is involved by the tumor.

Right Hepatic Lobectomy (Right Hepatectomy or Hemihepatectomy)

8. Mobilize the liver from the anterior aspect of the IVC in "piggyback" fashion; ligate the short hepatic veins up to the right hepatic vein (RHV).
9. Perform a right hilar dissection—gently lower the hilar plate, then doubly ligate and divide the right hepatic artery (RHA), superior to the right side of the common bile duct.
10. Doubly ligate and divide a replaced or accessory RHA if present.
11. Expose the portal vein, identifying its right and left branches. There is a small lateral portal vein branch off the right portal vein (RPV) to the caudate lobe that should be controlled and ligated to allow the exposure of additional length on the RPV. Divide the RPV either with a vascular stapler or between vascular clamps.
12. Dissect the avascular tissue along the suprahepatic vena cava between the right and middle hepatic veins. Pass a silastic tube of a Jackson-Pratt drain through this gap.
13. Notch or divide the caudate process crossing to the right hepatic lobe, and bring the drain up and through this notch.
14. Hang the liver over the drain by pulling up as you divide through the liver parenchyma.
15. Repeat ultrasound and confirm the transection plane, staying just to the right of the middle hepatic vein (MHV) unless the tumor extends over it.

16. Cauterize approximately 1 cm into the liver parenchyma, then switch to a hydro-jet dissection device in combination with Bovie electrocautery and suture ligation.
17. Continue parenchymal division until the RHV is encountered. During this division, identification, control, ligation, and transection of the right hepatic duct (RHD) are obtained late in the parenchymal transection process.
18. Divide the RHV between vascular clamps and suture ligate the RHV.
19. Examine the transected liver edge for bleeding; place a figure-of-eight ligating vascular suture if bleeding is encountered.
20. Ensure hemostasis of the transected liver edge with an argon beam coagulator and suture ligation.
21. Inspect the transection surface for bile leaks. These should be clipped or suture ligated. Applying a dilute solution of hydrogen peroxide can facilitate the visualization of bile leaks.
22. Inspect the IVC and right retroperitoneal space for hemostasis.
23. Perform completion ultrasound to confirm left portal vein (LPV) inflow and outflow in the remaining hepatic veins.
24. Fix the proximal falciform ligament back to the diaphragm side with figure-of-eight sutures.
25. Apply tissue sealant to the cut surface of the liver, and place a Jackson-Pratt drain in the right subphrenic space and close the abdomen (Fig. 31-22).

Comments Although some liver surgeons advocate a one-step division of the entire intrahepatic Glissonian pedicle as described by Launois and Jamieson,¹⁵¹ it is the authors' preference to divide the RHA, RHD, and RPV in an extrahepatic fashion. As for the transection plane, the key is to perform

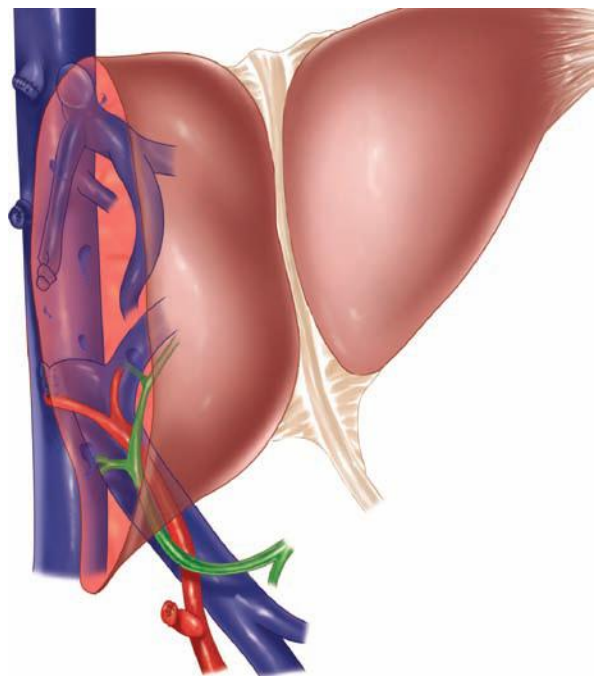


Figure 31-22. Completed right hepatic lobectomy (right hepatectomy) with the right portal vein, right hepatic artery, and right bile duct ligated and divided. The right hepatic vein is ligated and divided. Middle hepatic vein branches inside the liver are divided.

accurate ultrasound visualization and mapping of the MHV and to stay just to the right of it. Weaving in and out or bisecting the MHV can lead to torrential back bleeding. Also, for bulky right lobe tumors adherent to the diaphragm or retroperitoneum, an anterior approach with division of the parenchyma can be performed before right lobe mobilization.^{152,153}

Left Hepatic Lobectomy (Left Hepatectomy or Hemihepatectomy)

8. Widely open the gastrohepatic ligament flush with the undersurface of the left lateral section and the caudate lobe.
9. Doubly ligate and divide a replaced or accessory left hepatic artery (LHA) if present.
10. Clamp the round ligament (ligament teres) and pull it anteriorly as a handle to expose the left hilum.
11. Divide any existing parenchymal bridge between segments III and IVB.
12. Dissect the left hilum at the base of the umbilical fissure and lower the hilar plate anterior to the left portal pedicle.
13. Incise the peritoneum overlying the hilum from the left side, and doubly ligate the LHA (after test clamping and confirming a palpable pulse in the RHA).
14. Dissect the portal vein at the base of the umbilical fissure (it will take a nearly 90° bend from the transverse to the umbilical portion).
15. Expose the portal vein, identifying the right and left branches. Control the small portal vein branch off the LPV to the caudate lobe to allow the exposure of additional length. Divide the LPV either with a vascular stapler or between vascular clamps.
16. Ligate and divide the ligamentum venosum caudally.
17. Identify the long extrahepatic course of the left hepatic duct (LHD) behind the portal vein. Ligate and divide the LHD at the umbilical fissure.
18. Fold the left lateral segment up and back to the right, exposing the window at the base of the left hepatic vein (LHV) as it enters the IVC. This is facilitated by dividing any loose areolar tissue overlying the ligamentum venosum, which is divided proximally.
19. Pass a large, blunt right-angle clamp in the window between the RHV and the MHV, and hug the back of the MHV, aiming for the deep edge of the LHV. *Do not force it or perforate the IVC or MHV.*
20. Pass the silastic tube of a Jackson-Pratt drain through this window.
21. Notch or divide the caudate process crossing to the left hepatic lobe and bring the drain up and through this notch.
22. Hang the liver over the drain by pulling up as you divide through the liver parenchyma.
23. Repeat ultrasound and confirm the transection plane on the anterior surface, staying close to the demarcated line. Do not bisect the MHV as it passes tangentially from the left to the right lobe.
24. Cauterize down approximately 1 cm in the liver parenchyma, then switch to a hydro-jet dissection device in combination with Bovie electrocautery and suture ligation.
25. Continue parenchymal division until the left/middle hepatic veins are encountered.
26. Divide the LHV and MHV between vascular clamps and suture ligate the LHV/MHV.

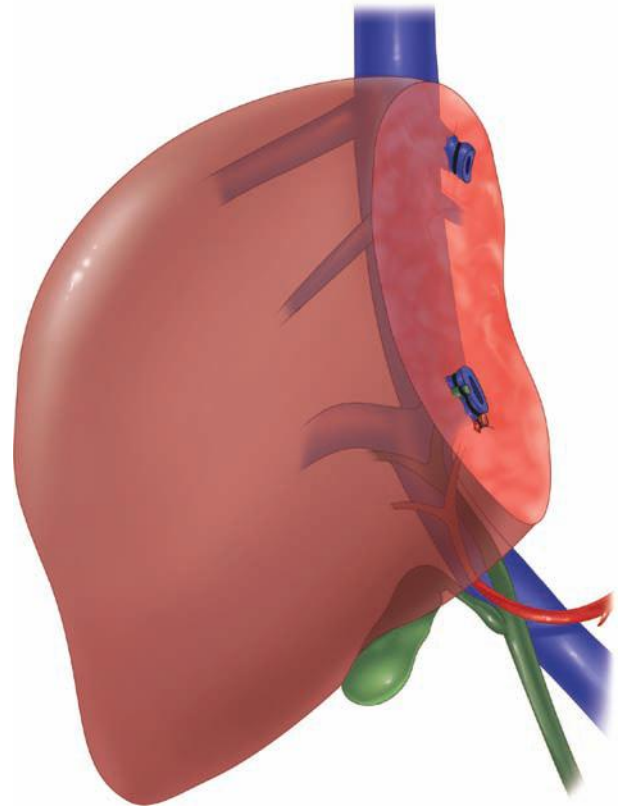


Figure 31-23. Completed left hepatic lobectomy (left hepatectomy) resecting segments II, III, and IV.

27. Check the transected edge of the liver for surgical bleeding; ensure hemostasis of the transected edge with an argon beam coagulator and suture ligation.
28. Inspect the transection surface for bile leaks. These should be clipped or suture ligated. Apply dilute solution of hydrogen peroxide to facilitate the visualization of bile leaks.
29. Perform completion ultrasound to confirm RPV inflow and RHV outflow.
30. Apply tissue sealant to the transected surface of the liver. Place a Jackson-Pratt drain in the left subphrenic space and close the abdomen (Fig. 31-23).

Comments Because the right posterior duct arises from the left hepatic duct (LHD) in approximately 20% of cases (see Fig. 31-9) and the right anterior duct comes off the LHD in approximately 5% of cases,⁶ it is vital to divide the LHD at the base of the umbilical fissure and not more centrally in the hilum as it bifurcates. If the LHD were divided as it appears to bifurcate from the right hepatic duct, then approximately 20% to 25% of the time, either the right posterior or right anterior duct would be transected. After the LHD is divided as described earlier (Step 17), the liver parenchyma is scored and divided horizontally approximately 1 cm above the left hilum; the surgeon thus assumes that an aberrant right anterior or posterior duct is coming off the LHD in the hilum and preserves it. Then as the parenchymal transection reaches the left side of the gallbladder fossa, the transection plane turns vertical to run parallel to Cantlie's line (or the left edge of the gallbladder bed). The left lobe of the liver will be well demarcated at this point (after the vascular inflow has been divided), which guides the transection plane on the anterior surface. In general, the transection plane should be close to the demarcation line to minimize the amount

of devascularized liver remaining. When dividing the LHV and MHV, the surgeon should keep in mind that they have a common trunk approximately 90% of the time. If it is not easy to open the window deep to the MHV and LHV, then division of the MHV and LHV can be accomplished after the parenchymal transection.

Left Lateral Segmentectomy (Left Lateral Sectionectomy)

8. Widely open the gastrohepatic ligament flush with the undersurface of the left lateral section and the caudate lobe.
9. Doubly ligate and divide a replaced or accessory LHA if present.
10. Clamp the round ligament and pull it anteriorly as a handle to expose the left hilum.
11. Divide any existing parenchymal bridge between segments III and IVB.
12. Carry the dissection down from the end of the round ligament, and the segment III pedicle will be encountered.
13. Incise the peritoneal reflection on the left side of the round ligament as it inserts into the umbilical fissure. This will facilitate encircling the segment III and II pedicles, which can be divided separately. When encircling the segment II pedicle, take care to avoid injury to the caudate inflow vessels coming off the LPV.
14. Divide the liver parenchyma, staying flush on the left side of the falciform ligament using Bovie electrocautery.
15. Divide the LHV as the parenchymal transection is complete.
16. A Pringle maneuver usually is not required for a left lateral sectionectomy because complete devascularization occurs before transection and little back bleeding is encountered.

Comments If the segment III and II LHA branches are large, they can be individually ligated in the left hilum before the pedicles (with portal vein and hepatic duct branches) are taken. If the tumor is more peripheral in the left lateral segment, then the segment III and II pedicles can be divided with a vascular stapler inside the liver during the parenchymal transection.

Pringle and Ischemic Preconditioning

Pringle described clamping of the portal triad a century ago in the landmark paper “Notes on the Arrest of Hepatic Hemorrhage Due to Trauma.”⁷⁴ Although the Pringle maneuver was initially described for controlling bleeding due to traumatic liver injury, it is commonly used during elective hepatic resections.^{154,155} The goal is to minimize blood loss and hypotension, which add significant morbidity to the operation. Furthermore, intraoperative blood transfusion has been shown to be an independent risk factor for increased postoperative infection as well as worse patient survival in some studies. Therefore, all efforts should be made to minimize blood loss during hepatic resection.

Although the liver has been shown to tolerate up to 1 hour of warm ischemia, some technical variations of the Pringle maneuver include intermittent vascular occlusion with cycles of approximately 15 minutes on and 5 minutes off. Experimental and clinical studies have demonstrated the efficacy of intermittent vascular occlusion in decreasing ischemia/reperfusion injury compared with continuous vascular occlusion, with less elevation of postoperative liver enzyme levels.¹⁵⁶ Another variation is selective hemihepatic vascular occlusion, which can reduce the severity of visceral congestion and total liver ischemia. In one prospective trial of total versus selective portal triad clamping, both techniques of inflow clamping were

found to be equally effective for patients with normal livers, but greater liver damage was observed with total inflow occlusion in patients with cirrhotic livers.¹⁵⁷

In an attempt to decrease the ischemic damage associated with inflow occlusion, some hepatic surgeons have advocated the use of ischemic preconditioning.¹⁵⁸ *Ischemic preconditioning* refers to the brief interruption of blood flow to an organ, followed by a short reperfusion period, and then a more prolonged period of ischemia. In a randomized clinical trial involving 100 patients undergoing major hepatic resection, Clavien and colleagues reported significantly less liver injury in the group who received ischemic preconditioning with a 10-minute clamp, a 10-minute reperfusion, and then a 30-minute clamp than in those who received a 30-minute clamp alone.¹⁵⁹ Patients with steatosis also were especially protected by ischemic preconditioning, and the mechanism was shown to be related in part to preservation of the adenosine triphosphate content of liver tissue.

Preoperative Portal Vein Embolization

The observation that tumor thrombosis of a major portal vein branch induced ipsilateral lobar atrophy and contralateral lobe hypertrophy led to the concept of intentional preoperative portal vein embolization (PVE) to induce compensatory hypertrophy of the remnant liver. This procedure was first described in the 1980s and is accomplished via a percutaneous, transhepatic route.^{160,161} Numerous studies have subsequently confirmed that PVE is effective in inducing hypertrophy of nonembolized hepatic segments.^{67,162} PVE usually is performed in the setting of a planned right trisectionectomy or extended left hepatectomy (also referred to as a left trisectionectomy; resection of Couinaud’s segments II, III, IV, V, and VIII of the liver) or extended hepatic lobectomy when it is thought that the patient’s remnant liver will be too small to support liver function. The future liver remnant volume (e.g., the volume of segments II, III, and I) in a patient undergoing a planned right trisectionectomy can be directly measured by helical CT and then divided by the total estimated liver volume to calculate the percentage of the future liver remnant. If the future liver remnant is thought to be too small, then PVE should be considered to increase the size of the future liver remnant.¹⁶³ In general, surgery is planned approximately 4 weeks after PVE to allow adequate time for hypertrophy.

There is no universal agreement on what constitutes a future liver remnant adequate to avoid postoperative liver failure. It is thought that 25% to 30% of the total liver volume is adequate in patients with a normal liver.¹⁶⁴ Vauthey and associates reported that major postoperative complications were increased when the estimated future liver remnant was <25%.¹⁶⁵ Farges and colleagues conducted a prospective study to assess the benefits of PVE before right hepatectomy. They demonstrated that PVE had no beneficial effect on the postoperative course in patients with normal livers but significantly reduced postoperative complications in patients with chronic liver diseases.¹⁶⁶ A larger remnant may be necessary even in patients with normal livers when a complex hepatectomy is planned or when the background liver is steatotic.¹⁶⁷ This is especially relevant with the increased incidence of fatty liver disease. A larger remnant may also be needed when patients have received preoperative chemotherapy. Some have suggested that 40% of the total hepatic volume should remain to minimize postoperative complications in patients who have underlying liver disease or who have received preoperative chemotherapy for colorectal cancer metastases.^{168,169} In a recent study encompassing

112 patients who underwent PVE, major complications, hepatic insufficiency, length of hospital stay, and 90-day mortality rate were significantly greater in patients with a standardized future liver remnant of $\leq 20\%$ or a degree of hypertrophy of $< 5\%$ than in patients with higher values.¹⁷⁰ In another study, the authors performed PVE during neoadjuvant chemotherapy for colorectal cancer metastases. After a median wait of 30 days after PVE, patients receiving neoadjuvant chemotherapy showed median liver growth of 22% in the contralateral (nonembolized) lobe compared with 26% for those not receiving chemotherapy (not a statistically significant difference), which indicated that liver growth occurs after PVE even when cytotoxic chemotherapy is administered.¹⁷¹ PVE-related complications occur at a relatively low rate and include bleeding, hemobilia, liver abscess, incomplete embolization, and small bowel obstruction. To augment the ability to increase liver function reserve in patients who have undergone PVE, some groups have added ipsilateral hepatic artery embolization and ipsilateral hepatic vein embolization.¹⁷²

Staged Hepatectomy and Repeat Hepatic Resection for Recurrent Liver Cancer

A two-stage hepatectomy is a sequential resection strategy to remove all metastatic liver tumors when it is impossible to resect all disease in a single operative procedure. The first-stage hepatectomy usually consists of clearance of the left hemiliver by nonanatomic resection, followed by right portal vein ligation or embolization to induce left lobe hypertrophy.^{173,174} This is followed by a second-stage major right hepatectomy or extended right hepatectomy to resect the right liver metastases. This approach is most commonly used in cases of initially unresectable colorectal hepatic metastases and has yielded very good results.¹⁷⁴ Another possibility is to potentiate the effect of PVE on increasing future liver remnant by performing an in situ liver transection along the future line of resection leaving the arterial and hepatic vein branches intact.¹⁷⁵

The majority of patients undergoing hepatic resection for colorectal cancer metastases experience a recurrence. For those with limited disease recurrence confined to the liver, repeat hepatectomy is a reasonable option and can be performed with low morbidity and mortality in experienced hands.¹⁷⁶ In one study, 126 patients who underwent a second liver resection for colorectal cancer metastases had 1-, 3-, and 5-year survival rates of 86%, 51%, and 34%, respectively. By multivariate analysis, the presence of more than one lesion and a tumor size of > 5 cm were independent prognostic indicators of reduced survival.¹⁷⁷ In another study, 40 patients underwent a second hepatectomy for liver metastases from colorectal cancer and experienced a survival benefit similar to that from the first hepatectomy; however, the results suggested that this approach should be limited to those patients who do not have extrahepatic disease and for whom > 1 year has elapsed since the first operation.¹⁷⁸ A meta-analysis of 21 studies examining clinical outcomes after first and second liver resections for colorectal cancer metastases showed that repeat hepatectomy was safe and provided a survival benefit equal to that from the first liver resection.¹⁷⁹

Repeat hepatectomy also has been performed in patients with HCC. Nakajima and colleagues reported on follow-up of 94 patients who underwent curative liver resection for HCC from 1991 to 1996.¹⁸⁰ Of these, 57 patients had isolated recurrent disease in the liver. Twelve of these 57 patients underwent repeat hepatic resection, whereas the other 45 patients received ablation therapy. The overall survival rate in those undergoing a

second hepatectomy was 90% at 2 years; however, the disease-free survival rate was only 31% at 2 years, significantly lower than the 62% rate after initial hepatectomy. Likewise, in another group of 84 patients who underwent second hepatectomy for recurrent HCC, the overall 5-year survival rate was 50%, but the recurrence-free survival rate was only 10%.¹⁸¹ In a report of 67 patients undergoing a second resection for HCC, overall 1-, 3-, and 5-year survival rates were 93%, 70%, and 56%, respectively.¹⁸² Multivariate analysis showed that absence of portal invasion at the second resection, single HCC at primary hepatectomy, and disease-free interval of ≥ 1 year after primary hepatectomy were independent prognostic factors after the second resection.

LAPAROSCOPIC LIVER RESECTION

Cherqui and colleagues first reported in 2000 that laparoscopic hepatic surgery was feasible.¹⁸³ Since this initial report, laparoscopic liver surgery has expanded from the simple unroofing of hepatic cysts to resection of peripheral benign lesions to formal anatomic lobectomies for malignancy and laparoscopic hepatectomy for living donor liver transplantation. While minimally invasive approaches have been widely adopted in other areas of abdominal surgery, there was initial apprehension regarding laparoscopic liver resection (LLR), hampering its widespread adoption.¹⁸⁴ First, the elementary maneuvers of open hepatic surgery, such as manual palpation, organ mobilization, vascular control, and parenchymal transection, were thought to be difficult to reproduce laparoscopically. Second, there was concern that hemorrhage may be more difficult to control laparoscopically and that the risk of gas embolism may be increased by the use of pneumoperitoneum. Third, there was apprehension concerning the possibility of oncologic inadequacy and tumor seeding, but data regarding long-term oncologic outcomes were lacking at the time.

Because of the increased technical demands in LLR, stringent criteria based on surgeon experience and lesion size and location must be used. Surgeons should have an advanced understanding of liver anatomy, extensive experience in open liver surgery, and the technical skills to control major vascular and biliary structures laparoscopically before embarking on LLR. Familiarity with laparoscopic ultrasonography is needed to help confirm the number and size of lesions, demarcate transection planes, and define relationships to major intrahepatic and extrahepatic structures intraoperatively. Smaller, more peripheral lesions, particularly those located in the anterolateral segments (segments II to VI) are most amenable to LLR. Several centers have reported large series consisting of laparoscopic resections of the left lateral and anterior hepatic segments. Laparoscopic major hepatectomy, such as lobectomies, trisegmentectomies, and the resection of difficult posterior segments, has been described and can be performed by expert centers, but should not be considered standard practice at the current time.

As in open hepatic resections, various different technical approaches for performing major laparoscopic liver resection have been described. Hepatic resection can be achieved using either electro-surgical devices to transect the parenchyma, reserving staplers for larger vascular and biliary structures, or staplers alone to divide parenchyma and major structures without the aid of portal triad clamping. As in open liver surgery, no single method of parenchymal transection has been shown to be superior.

Three general techniques have been used for laparoscopic hepatectomy. The pure laparoscopic method is suitable for experienced surgeons to achieve better cosmetic outcomes, whereas the hand-assisted method has been associated with a reduced conversion rate to open procedures. The addition of the assisting hand allows for tactile feedback while palpating the liver and may help in abdominal exploration, parenchymal transection, mobilization of the liver, and providing gentle retraction. Additionally, in cases when significant bleeding is encountered, hand compression allows for easier hemostasis. The specimen is then removed from the hand-port incision. Hand assistance allows the laparoscopic approach to be extended to lesions in posterosuperior segments. Finally, the laparoscopic-assisted method, or the hybrid procedure, is used by surgeons for difficult or unique resections such as resection in cirrhotic livers, laparoscopic resection of tumors in unfavorable locations, and living donor hepatectomies.¹⁸⁵ With the hybrid procedure, the liver is first mobilized laparoscopically, and the hilar dissection and parenchymal transection are then carried out under direct vision through an 8- to 12-cm midline or subcostal incision, through which the specimen is removed.

Results with laparoscopic liver resections have been excellent. Advantages of laparoscopic liver resection include reduced operative blood loss and need for portal triad clamping, decreased postoperative pain and narcotic requirements, faster return of bowel function, and shorter length of hospital stay.¹⁸⁶ The actual occurrence of gas embolism in clinical practice has proven to be extremely low. Carbon dioxide pneumoperitoneum minimizes the risk of gas embolism as compared to air, and lowered pneumoperitoneum pressures further reduce its incidence. The occurrence of gas embolism has been also related to argon beam coagulation, which increases intra-abdominal pressure, leading to an increased risk of gas embolism.

Comparative studies between open resection and LLR for malignant lesions have revealed no difference in overall or disease-free survival after short- and medium-term follow-up, and no difference in the width of resection margins. Some series have even reported fewer positive resection margins with LLR compared to open resection for malignant lesions.¹⁸⁷ No port site recurrences or tumor seeding has been reported to date after LLR. It has been proposed that LLR may allow for more timely start of adjuvant chemotherapy because of a quicker postoperative recovery and fewer wound-related complications.

In particular to LLR for HCC, hypothesized advantages include avoidance of collateral vessel ligation, resulting in reduced portal hypertension, decreased need for intravenous fluids, and improved reabsorption of ascites. The reduced occurrence of postoperative ascites and hepatic insufficiency in cirrhotic patients has led to decreased morbidity in these high-risk patients operated through a laparoscopic approach. The persisting underlying liver disease in these patients, however, dictates that HCC will recur in 40% to 90% of this population after resection, necessitating salvage liver transplantation.¹⁸⁸ Laurent and colleagues¹⁸⁹ reported that prior LLR for HCC compared to open resection facilitated subsequent salvage liver transplantation with decreased morbidity. In this study, patients with previous LLR had shorter hepatectomy and total operative times, less blood loss, and reduced need for blood transfusions after liver transplantation, possibly due to less arduous adhesiolysis.

Zhou and colleagues¹⁹⁰ published a meta-analysis of 10 nonrandomized controlled studies to compare surgical and oncologic outcomes following LLR or open resection for HCC.

Compared with perioperative results of open liver resection, reports of LLR demonstrate advantageous outcomes related to blood loss, transfusion requirements, postoperative morbidity, and hospital length of stay. There were significantly lower rates of cirrhotic decompensation and ascites, as well as a trend toward lower rates of postoperative liver failure following LLR. There were no differences in operative time or postoperative mortality. With regard to specific oncologic outcomes, there were no differences in pathologic resection margin or in 3- and 5-year overall and disease-free survival. There were no reported cases of port site recurrences or peritoneal dissemination. This meta-analysis suggests that LLR is comparable, and in some parameters superior, to open resection for HCC.

Regarding LLR for metastatic colorectal cancer, multiple retrospective series have reported the safety, feasibility, and oncologic integrity of the laparoscopic approach. Castaing and colleagues¹⁹¹ reported a matched prospective comparison in patients undergoing resection of colorectal cancer liver metastases via laparoscopic and open approaches. There were no differences in resection margins, whereas the incidence of positive margins was greater in the open group. There were no differences in 1- or 3-year overall, recurrence-free, and disease-free survival, indicating that equivalent oncologic outcomes can be achieved with LLR in selected patients.

Initial experience with laparoscopic living-donor hepatectomy for transplantation was with left lateral segmentectomy during liver allograft procurement for pediatric transplants. With continued advances in laparoscopic liver surgery, this approach has been applied to adult-to-adult donor right hepatectomy using the hybrid procedure. Complication rates are comparable to those reported for open living-donor hepatectomies.

Laparoscopic liver resection can now be performed safely by experienced surgeons in selected patients. Benefits of the laparoscopic approach include less operative blood loss, reduced postoperative pain and narcotic requirements, a shorter length of hospital stay, and comparable postoperative morbidity and mortality rates to open liver resection. Although small peripheral lesions in anterolateral segments are most amenable to laparoscopic resection, surgeons with extensive experience can embark on major hepatic resections using the laparoscopic approach. Comparative studies have identified similar oncologic outcomes for laparoscopic and open resections for malignant lesions such as HCC and colorectal liver metastases.

REFERENCES

Entries highlighted in bright blue are key references.

1. Wikipedia. Prometheus. Available at: <http://en.wikipedia.org/wiki/Prometheus>. Accessed June 7, 2013.
2. Keen WW IV. Report of a case of resection of the liver for the removal of a neoplasm, with a table of seventy-six cases of resection of the liver for hepatic tumors. *Ann Surg*. 1899;30(3):267.
3. Fortner JG, Blumgart LH. A historic perspective of liver surgery for tumors at the end of the millennium. *J Am Coll Surg*. 2001;193(2):210.
4. Pringle JH V. Notes on the arrest of hepatic hemorrhage due to trauma. *Ann Surg*. 1908;48(4):541.
5. Cantlie J. On a new arrangement of the right and left lobes of the liver. *Proc Anat Soc Great Britain Ireland*. 1897;32:4.
6. Couinaud C. Lobes de segments hepatiques: notes sur l'architecture anatomique et chirurgicale de foie. *Presse Med*. 1954;62(33):709.

7. Abdalla EK, Vauthey JN, Couinaud C. The caudate lobe of the liver: implications of embryology and anatomy for surgery. *Surg Oncol Clin N Am.* 2002;11(4):835.
8. Bismuth H. Surgical anatomy and anatomical surgery of the liver. *World J Surg.* 1982;6(1):3.
9. Nordlie RC, Foster JD, Lange AJ. Regulation of glucose production by the liver. *Annu Rev Nutr.* 1999;19:379.
10. Merriman R. Approach to the patient with jaundice. In: Yamada T, ed. *Textbook of Gastroenterology.* 4th ed. Philadelphia: Lippincott Williams & Williams; 2003:911.
11. Kruskal JB, Kane RA. Intraoperative US of the liver: techniques and clinical applications. *Radiographics.* 2006;26(4):1067.
12. Martinez SM, Crespo G, Navasa M, Forns X. Noninvasive assessment of liver fibrosis. *Hepatology.* 2011;53(1):325.
13. Federle MP, Blachar A. CT evaluation of the liver: principles and techniques. *Semin Liver Dis.* 2001;21(2):135.
14. Hyodo T, Kumano S, Kushihata F, et al. CT and MR cholangiography: advantages and pitfalls in perioperative evaluation of biliary tree. *Br J Radiol.* 2012;85(1015):887.
15. Ros PR, Davis GL. The incidental focal liver lesion: photon, proton, or needle? *Hepatology.* 1998;27(5):1183.
16. Wald C, Scholz FJ, Pinkus E, Wise RE, Flacke S. An update on biliary imaging. *Surg Clin North Am.* 2008;88(6):1195.
17. Wiering B, Krabbe PF, Jager GJ, Oyen WJ, Ruers TJ. The impact of fluor-18-deoxyglucose-positron emission tomography in the management of colorectal liver metastases. *Cancer.* 2005;104(12):2658.
18. Sacks A, Peller PJ, Surasi DS, Chatburn L, Mercier G, Subramaniam RM. Value of PET/CT in the management of liver metastases, part 1. *AJR Am J Roentgenol.* 2011;197(2):W256.
19. Bernal W, Auzinger G, Dhawan A, Wendon J. Acute liver failure. *Lancet.* 2010;376(9736):190.
20. Polson J, Lee WM. Etiologies of acute liver failure: location, location, location! *Liver Transpl.* 2007;13(10):1362.
21. Agopian V, Petrowsky H, Kaldas FM, et al. The evolution of liver transplantation during three decades: analysis of 5347 consecutive liver transplants at a single center. *Ann Surg.* 2013;258:409.
22. Escorsell A, Mas A, de la Mata M, Spanish Group for the Study of Acute Liver F. Acute liver failure in Spain: analysis of 267 cases. *Liver Transpl.* 2007;13(10):1389.
23. Larson AM, Polson J, Fontana RJ, et al. Acetaminophen-induced acute liver failure: results of a United States multicenter, prospective study. *Hepatology.* 2005;42(6):1364.
24. Ostapowicz G, Fontana RJ, Schiødt FV, et al. Results of a prospective study of acute liver failure at 17 tertiary care centers in the United States. *Ann Intern Med.* 2002;137(12):947.
25. Hodgman MJ, Garrard AR. A review of acetaminophen poisoning. *Crit Care Clin.* 2012;28(4):499.
26. Kortsalioudaki C, Taylor RM, Cheeseman P, Bansal S, Mieli-Vergani G, Dhawan A. Safety and efficacy of N-acetylcysteine in children with non-acetaminophen-induced acute liver failure. *Liver Transpl.* 2008;14(1):25.
27. O'Grady JG, Alexander GJ, Hayllar KM, Williams R. Early indicators of prognosis in fulminant hepatic failure. *Gastroenterology.* 1989;97(2):439.
28. Bismuth H, Samuel D, Castaing D, et al. Orthotopic liver transplantation in fulminant and subfulminant hepatitis. The Paul Brousse experience. *Ann Surg.* 1995;222(2):109.
29. Antoniadis CG, Berry PA, Bruce M, et al. Actin-free Gc globulin: a rapidly assessed biomarker of organ dysfunction in acute liver failure and cirrhosis. *Liver Transpl.* 2007;13(9):1254.
30. Renner EL. How to decide when to list a patient with acute liver failure for liver transplantation? Clichy or King's College criteria, or something else? *J Hepatol.* 2007;46(4):554.
31. Faybik P, Krenn CG. Extracorporeal liver support. *Curr Opin Crit Care.* 2013;19(2):149.
32. Ekser B, Gridelli B, Tector AJ, Cooper DK. Pig liver xenotransplantation as a bridge to allotransplantation: which patients might benefit? *Transplantation.* 2009;88(9):1041.
33. Yu Y, Fisher JE, Lillegard JB, Rodysill B, Amiot B, Nyberg SL. Cell therapies for liver diseases. *Liver Transpl.* 2012;18(1):9.
34. Faraj W, Dar F, Bartlett A, et al. Auxiliary liver transplantation for acute liver failure in children. *Ann Surg.* 2010;251(2):351.
35. Wanless IR, Nakashima E, Sherman M. Regression of human cirrhosis. Morphologic features and the genesis of incomplete septal cirrhosis. *Arch Pathol Lab Med.* 2000;124(11):1599.
36. Fattovich G, Giustina G, Degos F, et al. Morbidity and mortality in compensated cirrhosis type C: a retrospective follow-up study of 384 patients. *Gastroenterology.* 1997;112(2):463.
37. Doberneck RC, Sterling WA Jr, Allison DC. Morbidity and mortality after operation in nonbleeding cirrhotic patients. *Am J Surg.* 1983;146(3):306.
38. Northup PG, Wanamaker RC, Lee VD, Adams RB, Berg CL. Model for End-Stage Liver Disease (MELD) predicts non-transplant surgical mortality in patients with cirrhosis. *Ann Surg.* 2005;242(2):244.
39. Farnsworth N, Fagan SP, Berger DH, Awad SS. Child-Turcotte-Pugh versus MELD score as a predictor of outcome after elective and emergent surgery in cirrhotic patients. *Am J Surg.* 2004;188(5):580.
40. Hanje AJ, Patel T. Preoperative evaluation of patients with liver disease. *Nat Clin Pract Gastroenterol Hepatol.* 2007;4(5):266.
41. Shah V. Cellular and molecular basis of portal hypertension. *Clin Liver Dis.* 2001;5(3):629.
42. Poynard T, Cales P, Pasta L, et al. Beta-adrenergic-antagonist drugs in the prevention of gastrointestinal bleeding in patients with cirrhosis and esophageal varices. An analysis of data and prognostic factors in 589 patients from four randomized clinical trials. Franco-Italian Multicenter Study Group. *N Engl J Med.* 1991;324(22):1532.
43. Garcia-Pagan JC, Bosch J. Endoscopic band ligation in the treatment of portal hypertension. *Nat Clin Pract Gastroenterol Hepatol.* 2005;2(11):526.
44. Valla DC. The diagnosis and management of the Budd-Chiari syndrome: consensus and controversies. *Hepatology.* 2003;38(4):793.
45. Henderson JM, Warren WD, Millikan WJ Jr, et al. Surgical options, hematologic evaluation, and pathologic changes in Budd-Chiari syndrome. *Am J Surg.* 1990;159(1):41.
46. Barnes PF, De Cock KM, Reynolds TN, Ralls PW. A comparison of amebic and pyogenic abscess of the liver. *Medicine (Baltimore).* 1987;66(6):472.
47. Pedrosa I, Saiz A, Arrazola J, Ferreiros J, Pedrosa CS. Hydatid disease: radiologic and pathologic features and complications. *Radiographics.* 2000;20(3):795.
48. Khuroo MS, Zargar SA, Mahajan R. Hepatobiliary and pancreatic ascariasis in India. *Lancet.* 1990;335(8704):1503.
49. Scaglione SJ, Lok AS. Effectiveness of hepatitis B treatment in clinical practice. *Gastroenterology.* 2012;142(6):1360.
50. Corey KE, Mendez-Navarro J, Gorospe EC, Zheng H, Chung RT. Early treatment improves outcomes in acute hepatitis C virus infection: a meta-analysis. *J Viral Hepat.* 2010;17(3):201.
51. Tsung A, Geller DA. Workup of the incidental liver lesion. *Adv Surg.* 2005;39:331.
52. Caremani M, Vincenti A, Benci A, Sassoli S, Tacconi D. Ecographic epidemiology of non-parasitic hepatic cysts. *J Clin Ultrasound.* 1993;21(2):115.
53. Tahvanainen P, Tahvanainen E, Reijonen H, Halme L, Kaariainen H, Hockerstedt K. Polycystic liver disease is genetically heterogeneous: clinical and linkage studies in eight Finnish families. *J Hepatol.* 2003;38(1):39.

54. Drenth JP, Chrispijn M, Nagorney DM, Kamath PS, Torres VE. Medical and surgical treatment options for polycystic liver disease. *Hepatology*. 2010;52(6):2223.
55. Robinson TN, Stiegmann GV, Everson GT. Laparoscopic palliation of polycystic liver disease. *Surg Endosc*. 2005;19(1):130.
56. Caroli J. Disease of the intrahepatic biliary tree. *Clin Gastroenterol*. 1972;2:147.
57. Yoon SS, Charny CK, Fong Y, et al. Diagnosis, management, and outcomes of 115 patients with hepatic hemangioma. *J Am Coll Surg*. 2003;197(3):392.
58. Geller DA, Tsung A, Marsh JW, Dvorchik I, Gamblin TC, Carr BI. Outcome of 1000 liver cancer patients evaluated at the UPMC Liver Cancer Center. *J Gastrointest Surg*. 2006;10(1):63.
59. International Agency for Research on Cancer. GLOBOCAN 2008. Available at: <http://globocan.iarc.fr/>. Accessed June 7, 2013.
60. Liaw YF, Tai DI, Chu CM, et al. Early detection of hepatocellular carcinoma in patients with chronic type B hepatitis. A prospective study. *Gastroenterology*. 1986;90(2):263.
61. Schwartz M, Roayaie S, Uva P. Treatment of HCC in patients awaiting liver transplantation. *Am J Transplant*. 2007;7(8):1875.
62. Zarrinpar A, Kaldas F, Busuttil RW. Liver transplantation for hepatocellular carcinoma: an update. *Hepatobiliary Pancreat Dis Int*. 2011;10(3):234.
63. Bruix J, Sherman M, American Association for the Study of Liver Disease. Management of hepatocellular carcinoma: an update. *Hepatology*. 2011;53(3):1020.
64. DeOliveira ML, Kambakamba P, Clavien PA. Advances in liver surgery for cholangiocarcinoma. *Curr Opin Gastroenterol*. 2013;29(3):293.
65. Jarnagin WR, Fong Y, DeMatteo RP, et al. Staging, resectability, and outcome in 225 patients with hilar cholangiocarcinoma. *Ann Surg*. 2001;234(4):507.
66. Hidalgo E, Asthana S, Nishio H, et al. Surgery for hilar cholangiocarcinoma: the Leeds experience. *Eur J Surg Oncol*. 2008;34(7):787.
67. Nagino M, Kamiya J, Nishio H, Ebata T, Arai T, Nimura Y. Two hundred forty consecutive portal vein embolizations before extended hepatectomy for biliary cancer: surgical outcome and long-term follow-up. *Ann Surg*. 2006;243(3):364.
68. Gores GJ, Nagorney DM, Rosen CB. Cholangiocarcinoma: is transplantation an option? For whom? *J Hepatol*. 2007;47(4):455.
69. Marsh JW, Geller DA, Finkelstein SD, Donaldson JB, Dvorchik I. Role of liver transplantation for hepatobiliary malignant disorders. *Lancet Oncol*. 2004;5(8):480.
70. Rea DJ, Heimbach JK, Rosen CB, et al. Liver transplantation with neoadjuvant chemoradiation is more effective than resection for hilar cholangiocarcinoma. *Ann Surg*. 2005;242(3):451.
71. Hassoun Z, Gores GJ, Rosen CB. Preliminary experience with liver transplantation in selected patients with unresectable hilar cholangiocarcinoma. *Surg Oncol Clin N Am*. 2002;11(4):909.
72. Darwish Murad S, Kim WR, Harnois DM, et al. Efficacy of neoadjuvant chemoradiation, followed by liver transplantation, for perihilar cholangiocarcinoma at 12 US centers. *Gastroenterology*. 2012;143(1):88.
73. Weber SM, Jarnagin WR, Klimstra D, DeMatteo RP, Fong Y, Blumgart LH. Intrahepatic cholangiocarcinoma: resectability, recurrence pattern, and outcomes. *J Am Coll Surg*. 2001;193(4):384.
74. Jan YY, Yeh CN, Yeh TS, Chen TC. Prognostic analysis of surgical treatment of peripheral cholangiocarcinoma: two decades of experience at Chang Gung Memorial Hospital. *World J Gastroenterol*. 2005;11(12):1779.
75. Hong JC, Jones CM, Duffy JP, et al. Comparative analysis of resection and liver transplantation for intrahepatic and hilar cholangiocarcinoma: a 24-year experience in a single center. *Arch Surg*. 2011;146(6):683.
76. Smith GC, Parks RW, Madhavan KK, Garden OJ. A 10-year experience in the management of gallbladder cancer. *HPB (Oxford)*. 2003;5(3):159.
77. Bartlett DL, Fong Y, Fortner JG, Brennan MF, Blumgart LH. Long-term results after resection for gallbladder cancer. Implications for staging and management. *Ann Surg*. 1996;224(5):639.
78. Shoup M, Fong Y. Surgical indications and extent of resection in gallbladder cancer. *Surg Oncol Clin N Am*. 2002;11(4):985.
79. Pawlik TM, Gleisner AL, Vigano L, et al. Incidence of finding residual disease for incidental gallbladder carcinoma: implications for re-resection. *J Gastrointest Surg*. 2007;11(11):1478.
80. Chan SY, Poon RT, Lo CM, Ng KK, Fan ST. Management of carcinoma of the gallbladder: a single-institution experience in 16 years. *J Surg Oncol*. 2008;97(2):156.
81. Goetze TO, Paolucci V. Benefits of reoperation of T2 and more advanced incidental gallbladder carcinoma: analysis of the German registry. *Ann Surg*. 2008;247(1):104.
82. Fong Y, Fortner J, Sun RL, Brennan MF, Blumgart LH. Clinical score for predicting recurrence after hepatic resection for metastatic colorectal cancer: analysis of 1001 consecutive cases. *Ann Surg*. 1999;230(3):309.
83. Poston G, Adam R, Vauthey JN. Downstaging or downsizing: time for a new staging system in advanced colorectal cancer? *J Clin Oncol*. 2006;24(18):2702.
84. Minagawa M, Makuuchi M, Torzilli G, et al. Extension of the frontiers of surgical indications in the treatment of liver metastases from colorectal cancer: long-term results. *Ann Surg*. 2000;231(4):487.
85. Kornprat P, Jarnagin WR, Gonen M, et al. Outcome after hepatectomy for multiple (four or more) colorectal metastases in the era of effective chemotherapy. *Ann Surg Oncol*. 2007;14(3):1151.
86. Charnsangavej C, Clary B, Fong Y, Grothey A, Pawlik TM, Choti MA. Selection of patients for resection of hepatic colorectal metastases: expert consensus statement. *Ann Surg Oncol*. 2006;13(10):1261.
87. Abdalla EK, Adam R, Bilchik AJ, Jaeck D, Vauthey JN, Mahvi D. Improving resectability of hepatic colorectal metastases: expert consensus statement. *Ann Surg Oncol*. 2006;13(10):1271.
88. Pawlik TM, Schulick RD, Choti MA. Expanding criteria for resectability of colorectal liver metastases. *Oncologist*. 2008;13(1):51.
89. Clavien PA, Petrowsky H, DeOliveira ML, Graf R. Strategies for safer liver surgery and partial liver transplantation. *N Engl J Med*. 2007;356(15):1545.
90. Adam R, Wicherts DA, de Haas RJ, et al. Patients with initially unresectable colorectal liver metastases: is there a possibility of cure? *J Clin Oncol*. 2009;27(11):1829.
91. Que FG, Nagorney DM, Batts KP, Linz LJ, Kvolts LK. Hepatic resection for metastatic neuroendocrine carcinomas. *Am J Surg*. 1995;169(1):36.
92. Touzios JG, Kiely JM, Pitt SC, et al. Neuroendocrine hepatic metastases: does aggressive management improve survival? *Ann Surg*. 2005;241(5):776.
93. Sarmiento JM, Heywood G, Rubin J, Ilstrup DM, Nagorney DM, Que FG. Surgical treatment of neuroendocrine metastases to the liver: a plea for resection to increase survival. *J Am Coll Surg*. 2003;197(1):29.
94. Kianmanesh R, Sauvanet A, Hentic O, et al. Two-step surgery for synchronous bilobar liver metastases from digestive endocrine tumors: a safe approach for radical resection. *Ann Surg*. 2008;247(4):659.
95. Mazzaferro V, Pulvirenti A, Coppa J. Neuroendocrine tumors metastatic to the liver: how to select patients for liver transplantation? *J Hepatol*. 2007;47(4):460.

96. Adam R, Aloia T, Krissat J, et al. Is liver resection justified for patients with hepatic metastases from breast cancer? *Ann Surg.* 2006;244(6):897.
97. Abbott DE, Brouquet A, Mittendorf EA, et al. Resection of liver metastases from breast cancer: estrogen receptor status and response to chemotherapy before metastasectomy define outcome. *Surgery.* 2012;151(5):710.
98. Jarnagin W, Chapman WC, Curley S, et al. Surgical treatment of hepatocellular carcinoma: expert consensus statement. *HPB (Oxford).* 2010;12(5):302.
99. Belghiti J, Hiramatsu K, Benoist S, Massault P, Sauvanet A, Farges O. Seven hundred forty-seven hepatectomies in the 1990s: an update to evaluate the actual risk of liver resection. *J Am Coll Surg.* 2000;191(1):38.
100. Jarnagin WR, Gonen M, Fong Y, et al. Improvement in perioperative outcome after hepatic resection: analysis of 1,803 consecutive cases over the past decade. *Ann Surg.* 2002;236(4):397.
101. Imamura H, Seyama Y, Kokudo N, et al. One thousand fifty-six hepatectomies without mortality in 8 years. *Arch Surg.* 2003;138(11):1198.
102. Mullen JT, Ribero D, Reddy SK, et al. Hepatic insufficiency and mortality in 1,059 noncirrhotic patients undergoing major hepatectomy. *J Am Coll Surg.* 2007;204(5):854.
103. Hamady ZZ, Cameron IC, Wyatt J, Prasad RK, Toogood GJ, Lodge JP. Resection margin in patients undergoing hepatectomy for colorectal liver metastasis: a critical appraisal of the 1 cm rule. *Eur J Surg Oncol.* 2006;32(5):557.
104. Pawlik TM, Vauthey JN. Surgical margins during hepatic surgery for colorectal liver metastases: complete resection not millimeters defines outcome. *Ann Surg Oncol.* 2008;15(3):677.
105. Andreou A, Aloia TA, Brouquet A, et al. Margin status remains an important determinant of survival after surgical resection of colorectal liver metastases in the era of modern chemotherapy. *Ann Surg.* 2013;257(6):1079.
106. Hemming AW, Mekeel KL, Zendejas I, Kim RD, Sicklick JK, Reed AI. Resection of the liver and inferior vena cava for hepatic malignancy. *J Am Coll Surg.* 2013;217:115.
107. **Schwartz M, Roayaie S, Konstadoulakis M. Strategies for the management of hepatocellular carcinoma. *Nat Clin Pract Oncol.* 2007;4(7):424.**
108. Duffy JP, Vardanian A, Benjamin E, et al. Liver transplantation criteria for hepatocellular carcinoma should be expanded: a 22-year experience with 467 patients at UCLA. *Ann Surg.* 2007;246(3):502.
109. Organ Procurement and Transplantation Network. Available at: <http://www.optn.org>. Accessed June 4, 2013.
110. **Mazzaferro V, Regalia E, Doci R, et al. Liver transplantation for the treatment of small hepatocellular carcinomas in patients with cirrhosis. *N Engl J Med.* 1996;334(11):693.**
111. Wiesner RH, Freeman RB, Mulligan DC. Liver transplantation for hepatocellular cancer: the impact of the MELD allocation policy. *Gastroenterology.* 2004;127(5 Suppl 1):S261.
112. de Villa V, Lo CM. Liver transplantation for hepatocellular carcinoma in Asia. *Oncologist.* 2007;12(11):1321.
113. McGahan JP, Browning PD, Brock JM, Tesluk H. Hepatic ablation using radiofrequency electrocautery. *Invest Radiol.* 1990;25(3):267.
114. Rossi S, Fornari F, Pathies C, Buscarini L. Thermal lesions induced by 480 KHz localized current field in guinea pig and pig liver. *Tumori.* 1990;76(1):54.
115. Curley SA, Izzo F, Delrio P, et al. Radiofrequency ablation of unresectable primary and metastatic hepatic malignancies: results in 123 patients. *Ann Surg.* 1999;230(1):1.
116. Bilchik AJ, Wood TF, Allegra D, et al. Cryosurgical ablation and radiofrequency ablation for unresectable hepatic malignant neoplasms: a proposed algorithm. *Arch Surg.* 2000;135(6):657.
117. Poon RT, Ng KK, Lam CM, et al. Learning curve for radiofrequency ablation of liver tumors: prospective analysis of initial 100 patients in a tertiary institution. *Ann Surg.* 2004;239(4):441.
118. Abdalla EK, Vauthey JN, Ellis LM, et al. Recurrence and outcomes following hepatic resection, radiofrequency ablation, and combined resection/ablation for colorectal liver metastases. *Ann Surg.* 2004;239(6):818.
119. Weng M, Zhang Y, Zhou D, et al. Radiofrequency ablation versus resection for colorectal cancer liver metastases: a meta-analysis. *PLoS One.* 2012;7(9):e45493.
120. Sutherland LM, Williams JA, Padbury RT, Gotley DC, Stokes B, Maddern GJ. Radiofrequency ablation of liver tumors: a systematic review. *Arch Surg.* 2006;141(2):181.
121. Berber E, Siperstein AE. Perioperative outcome after laparoscopic radiofrequency ablation of liver tumors: an analysis of 521 cases. *Surg Endosc.* 2007;21(4):613.
122. Martin AP, Goldstein RM, Dempster J, et al. Radiofrequency thermal ablation of hepatocellular carcinoma before liver transplantation—a clinical and histological examination. *Clin Transplant.* 2006;20(6):695.
123. Cheng BQ, Jia CQ, Liu CT, et al. Chemoembolization combined with radiofrequency ablation for patients with hepatocellular carcinoma larger than 3 cm: a randomized controlled trial. *JAMA.* 2008;299(14):1669.
124. Iannitti DA, Martin RC, Simon CJ, et al. Hepatic tumor ablation with clustered microwave antennae: the US Phase II trial. *HPB (Oxford).* 2007;9(2):120.
125. Lo CM, Ngan H, Tso WK, et al. Randomized controlled trial of transarterial lipiodol chemoembolization for unresectable hepatocellular carcinoma. *Hepatology.* 2002;35(5):1164.
126. Llovet JM, Real MI, Montana X, et al. Arterial embolisation or chemoembolisation versus symptomatic treatment in patients with unresectable hepatocellular carcinoma: a randomised controlled trial. *Lancet.* 2002;359(9319):1734.
127. Takayasu K, Arii S, Ikai I, et al. Prospective cohort study of transarterial chemoembolization for unresectable hepatocellular carcinoma in 8510 patients. *Gastroenterology.* 2006;131(2):461.
128. Sotiropoulos GC, Druhe N, Sgourakis G, et al. Liver transplantation, liver resection, and transarterial chemoembolization for hepatocellular carcinoma in cirrhosis: which is the best oncological approach? *Dig Dis Sci.* 2009;54(10):2264.
129. Lewandowski RJ, Geschwind JF, Liapi E, Salem R. Transcatheter intraarterial therapies: rationale and overview. *Radiology.* 2011;259(3):641.
130. Kemeny N, Huang Y, Cohen AM, et al. Hepatic arterial infusion of chemotherapy after resection of hepatic metastases from colorectal cancer. *N Engl J Med.* 1999;341(27):2039.
131. Ibrahim SM, Lewandowski RJ, Sato KT, et al. Radioembolization for the treatment of unresectable hepatocellular carcinoma: a clinical review. *World J Gastroenterol.* 2008;14(11):1664.
132. Gulec SA, Fong Y. Yttrium 90 microsphere selective internal radiation treatment of hepatic colorectal metastases. *Arch Surg.* 2007;142(7):675.
133. Sato KT, Lewandowski RJ, Mulcahy MF, et al. Unresectable chemorefractory liver metastases: radioembolization with 90Y microspheres—safety, efficacy, and survival. *Radiology.* 2008;247(2):507.
134. Tse RV, Hawkins M, Lockwood G, et al. Phase I study of individualized stereotactic body radiotherapy for hepatocellular carcinoma and intrahepatic cholangiocarcinoma. *J Clin Oncol.* 2008;26(4):657.
135. Mendez Romero A, Wunderink W, Hussain SM, et al. Stereotactic body radiation therapy for primary and metastatic liver tumors: a single institution phase I-II study. *Acta Oncol.* 2006;45(7):831.

136. Chapman WC, Majella Doyle MB, Stuart JE, et al. Outcomes of neoadjuvant transarterial chemoembolization to downstage hepatocellular carcinoma before liver transplantation. *Ann Surg.* 2008;248(4):617.
137. Yao FY, Kerlan RK Jr, Hirose R, et al. Excellent outcome following down-staging of hepatocellular carcinoma prior to liver transplantation: an intention-to-treat analysis. *Hepatology.* 2008;48(3):819.
138. Llovet JM, Ricci S, Mazzaferro V, et al. Sorafenib in advanced hepatocellular carcinoma. *N Engl J Med.* 2008;359(4):378.
139. American Hepato-Pancreato-Biliary Association. IHPBA Brisbane liver terminology. Available at: <http://www.ahpba.org/resources/liver.asp>. Accessed June 4, 2013.
140. Pang YY. The Brisbane 2000 terminology of liver anatomy and resections. *HPB (Oxford).* 2002;4(2):99; author reply 99.
141. Strasberg SM. Nomenclature of hepatic anatomy and resections: a review of the Brisbane 2000 system. *J Hepatobiliary Pancreat Surg.* 2005;12(5):351.
142. Weber JC, Navarra G, Jiao LR, Nicholls JP, Jensen SL, Habib NA. New technique for liver resection using heat coagulative necrosis. *Ann Surg.* 2002;236(5):560.
143. Geller DA, Tsung A, Maheshwari V, Rutstein LA, Fung JJ, Marsh JW. Hepatic resection in 170 patients using saline-cooled radiofrequency coagulation. *HPB (Oxford).* 2005;7(3):208.
144. Saiura A, Yamamoto J, Koga R, et al. Usefulness of LigaSure for liver resection: analysis by randomized clinical trial. *Am J Surg.* 2006;192(1):41.
145. McEntee GP, Nagorney DM. Use of vascular staplers in major hepatic resections. *Br J Surg.* 1991;78(1):40.
146. Jurim O, Colonna JO II, Colquhoun SD, Shaked A, Busuttill RW. A stapling technique for hepatic resection. *J Am Coll Surg.* 1994;178(5):510.
147. Kaneko H, Otsuka Y, Takagi S, Tsuchiya M, Tamura A, Shiba T. Hepatic resection using stapling devices. *Am J Surg.* 2004;187(2):280.
148. Schemmer P, Friess H, Hinz U, et al. Stapler hepatectomy is a safe dissection technique: analysis of 300 patients. *World J Surg.* 2006;30(3):419.
149. Bala FK, Gambin TC, Tsung A, Marsh JW, Geller DA. Right hepatic lobectomy using the staple technique in 101 patients. *J Gastrointest Surg.* 2008;12(2):338.
150. Blumgart L. Liver resection for benign disease and for liver and biliary disease. In: Blumgart L, ed. *Surgery of the Liver and Biliary Tract.* 3rd ed. London: WB Saunders; 2000:1639.
151. Launois B, Jamieson GG. The importance of Glisson's capsule and its sheaths in the intrahepatic approach to resection of the liver. *Surg Gynecol Obstet.* 1992;174(1):7.
152. Azoulay D, Marin-Hargreaves G, Castaing D, Adam R, Savier E, Bismuth H. The anterior approach: the right way for right massive hepatectomy. *J Am Coll Surg.* 2001;192(3):412.
153. Liu CL, Fan ST, Cheung ST, Lo CM, Ng IO, Wong J. Anterior approach versus conventional approach right hepatic resection for large hepatocellular carcinoma: a prospective randomized controlled study. *Ann Surg.* 2006;244(2):194.
154. Makuuchi M, Mori T, Gunven P, Yamazaki S, Hasegawa H. Safety of hemihepatic vascular occlusion during resection of the liver. *Surg Gynecol Obstet.* 1987;164(2):155.
155. Man K, Fan ST, Ng IO, Lo CM, Liu CL, Wong J. Prospective evaluation of Pringle maneuver in hepatectomy for liver tumors by a randomized study. *Ann Surg.* 1997;226(6):704.
156. Belghiti J, Noun R, Malafosse R, et al. Continuous versus intermittent portal triad clamping for liver resection: a controlled study. *Ann Surg.* 1999;229(3):369.
157. Figueras J, Llado L, Ruiz D, et al. Complete versus selective portal triad clamping for minor liver resections: a prospective randomized trial. *Ann Surg.* 2005;241(4):582.
158. Clavien PA, Yadav S, Sindram D, Bentley RC. Protective effects of ischemic preconditioning for liver resection performed under inflow occlusion in humans. *Ann Surg.* 2000;232(2):155.
159. Clavien PA, Selzner M, Rudiger HA, et al. A prospective randomized study in 100 consecutive patients undergoing major liver resection with versus without ischemic preconditioning. *Ann Surg.* 2003;238(6):843.
160. Kinoshita H, Sakai K, Hirohashi K, Igawa S, Yamasaki O, Kubo S. Preoperative portal vein embolization for hepatocellular carcinoma. *World J Surg.* 1986;10(5):803.
161. Makuuchi M, Thai BL, Takayasu K, et al. Preoperative portal embolization to increase safety of major hepatectomy for hilar bile duct carcinoma: a preliminary report. *Surgery.* 1990;107(5):521.
162. Abdalla EK, Hicks ME, Vauthey JN. Portal vein embolization: rationale, technique and future prospects. *Br J Surg.* 2001;88(2):165.
163. Chun YS, Ribero D, Abdalla EK, et al. Comparison of two methods of future liver remnant volume measurement. *J Gastrointest Surg.* 2008;12(1):123.
164. Abdalla EK, Barnett CC, Doherty D, Curley SA, Vauthey JN. Extended hepatectomy in patients with hepatobiliary malignancies with and without preoperative portal vein embolization. *Arch Surg.* 2002;137(6):675.
165. Vauthey JN, Chaoui A, Do KA, et al. Standardized measurement of the future liver remnant prior to extended liver resection: methodology and clinical associations. *Surgery.* 2000;127(5):512.
166. Farges O, Belghiti J, Kianmanesh R, et al. Portal vein embolization before right hepatectomy: prospective clinical trial. *Ann Surg.* 2003;237(2):208.
167. Hemming AW, Reed AI, Howard RJ, et al. Preoperative portal vein embolization for extended hepatectomy. *Ann Surg.* 2003;237(5):686.
168. Azoulay D, Castaing D, Smail A, et al. Resection of nonresectable liver metastases from colorectal cancer after percutaneous portal vein embolization. *Ann Surg.* 2000;231(4):480.
169. Kubota K, Makuuchi M, Kusaka K, et al. Measurement of liver volume and hepatic functional reserve as a guide to decision-making in resectional surgery for hepatic tumors. *Hepatology.* 1997;26(5):1176.
170. Ribero D, Abdalla EK, Madoff DC, Donadon M, Loyer EM, Vauthey JN. Portal vein embolization before major hepatectomy and its effects on regeneration, resectability and outcome. *Br J Surg.* 2007;94(11):1386.
171. Covey AM, Brown KT, Jarnagin WR, et al. Combined portal vein embolization and neoadjuvant chemotherapy as a treatment strategy for resectable hepatic colorectal metastases. *Ann Surg.* 2008;247(3):451.
172. Hwang S, Lee SG, Ko GY, et al. Sequential preoperative ipsilateral hepatic vein embolization after portal vein embolization to induce further liver regeneration in patients with hepatobiliary malignancy. *Ann Surg.* 2009;249(4):608.
173. Jaeck D, Oussoultzoglou E, Rosso E, Greget M, Weber JC, Bachellier P. A two-stage hepatectomy procedure combined with portal vein embolization to achieve curative resection for initially unresectable multiple and bilobar colorectal liver metastases. *Ann Surg.* 2004;240(6):1037.
174. Adam R, Miller R, Pitombo M, et al. Two-stage hepatectomy approach for initially unresectable colorectal hepatic metastases. *Surg Oncol Clin N Am.* 2007;16(3):525.
175. Schnitzbauer AA, Lang SA, Goessmann H, et al. Right portal vein ligation combined with in situ splitting induces rapid left lateral liver lobe hypertrophy enabling 2-staged extended right hepatic resection in small-for-size settings. *Ann Surg.* 2012;255(3):405.
176. Adam R, Bismuth H, Castaing D, et al. Repeat hepatectomy for colorectal liver metastases. *Ann Surg.* 1997;225(1):51.

177. Petrowsky H, Gonen M, Jarnagin W, et al. Second liver resections are safe and effective treatment for recurrent hepatic metastases from colorectal cancer: a bi-institutional analysis. *Ann Surg.* 2002;235(6):863.
178. Sa Cunha A, Laurent C, Rault A, Couderc P, Rullier E, Saric J. A second liver resection due to recurrent colorectal liver metastases. *Arch Surg.* 2007;142(12):1144.
179. Antoniou A, Lovegrove RE, Tilney HS, et al. Meta-analysis of clinical outcome after first and second liver resection for colorectal metastases. *Surgery.* 2007;141(1):9.
180. Nakajima Y, Ko S, Kanamura T, et al. Repeat liver resection for hepatocellular carcinoma. *J Am Coll Surg.* 2001;192(3):339.
181. Itamoto T, Nakahara H, Amano H, et al. Repeat hepatectomy for recurrent hepatocellular carcinoma. *Surgery.* 2007;141(5):589.
182. Minagawa M, Makuuchi M, Takayama T, Kokudo N. Selection criteria for repeat hepatectomy in patients with recurrent hepatocellular carcinoma. *Ann Surg.* 2003;238(5):703.
183. Cherqui D, Husson E, Hammoud R, et al. Laparoscopic liver resections: a feasibility study in 30 patients. *Ann Surg.* 2000;232(6):753.
184. Reddy SK, Tsung A, Geller DA. Laparoscopic liver resection. *World J Surg.* 2011;35(7):1478.
185. Lin NC, Nitta H, Wakabayashi G. Laparoscopic major hepatectomy: a systematic literature review and comparison of 3 techniques. *Ann Surg.* 2013;257(2):205.
186. Koffron AJ, Auffenberg G, Kung R, Abecassis M. Evaluation of 300 minimally invasive liver resections at a single institution: less is more. *Ann Surg.* 2007;246(3):385.
187. Rao A, Rao G, Ahmed I. Laparoscopic vs. open liver resection for malignant liver disease. A systematic review. *Surgeon.* 2012;10(4):194.
188. Buell JF, Cherqui D, Geller DA, et al. **The international position on laparoscopic liver surgery: The Louisville Statement, 2008.** *Ann Surg.* 2009;250(5):825.
189. Laurent A, Tayar C, Andreoletti M, Lauzet JY, Merle JC, Cherqui D. Laparoscopic liver resection facilitates salvage liver transplantation for hepatocellular carcinoma. *J Hepatobiliary Pancreat Surg.* 2009;16(3):310.
190. Zhou YM, Shao WY, Zhao YF, Xu DH, Li B. Meta-analysis of laparoscopic versus open resection for hepatocellular carcinoma. *Dig Dis Sci.* 2011;56(7):1937.
191. Castaing D, Vibert E, Ricca L, Azoulay D, Adam R, Gayet B. Oncologic results of laparoscopic versus open hepatectomy for colorectal liver metastases in two specialized centers. *Ann Surg.* 2009;250(5):849.

This page intentionally left blank

32 chapter

Gallbladder and the Extrahepatic Biliary System

Thai H. Pham and John G. Hunter

Anatomy	1309	Magnetic Resonance Imaging / 1315	Transduodenal Sphincterotomy / 1327
Gallbladder / 1309		Endoscopic Retrograde Cholangiopancreatography / 1315	Other Benign Diseases and Lesions
Bile Ducts / 1310		Endoscopic Ultrasound / 1316	1327
Anomalies / 1312		Gallstone Disease	Acalculous Cholecystitis / 1327
Physiology	1312	Prevalence and Incidence / 1316	Biliary Cysts / 1330
Bile Formation and Composition / 1312		Natural History / 1317	Sclerosing Cholangitis / 1331
Gallbladder Function / 1313		Gallstone Formation / 1318	Stenosis of the Sphincter of Oddi / 1331
Sphincter of Oddi / 1313		Symptomatic Gallstones / 1319	Bile Duct Strictures / 1331
Diagnostic Studies	1313	Cholangiohepatitis / 1324	Injury to the Biliary Tract
Blood Tests / 1314		Operative Interventions for Gallstone Disease	1331
Ultrasonography / 1314		Cholecystostomy / 1324	Gallbladder / 1331
Oral Cholecystography / 1314		Cholecystectomy / 1324	Extrahepatic Bile Ducts / 1332
Biliary Radionuclide Scanning (HIDA Scan) / 1315		Common Bile Duct Exploration / 1325	Tumors
Computed Tomography / 1315		Common Bile Duct Drainage Procedures / 1327	1334
Percutaneous Transhepatic Cholangiography / 1315			Carcinoma of the Gallbladder / 1334
			Bile Duct Carcinoma / 1335

ANATOMY

Gallbladder

The gallbladder is a pear-shaped sac, about 7 to 10 cm long, with an average capacity of 30 to 50 mL. When obstructed, the gallbladder can distend markedly and contain up to 300 mL.¹ The gallbladder is located in a fossa on the inferior surface of the liver. A line from this fossa to the inferior vena cava divides the liver into right and left liver lobes. The gallbladder is divided into four anatomic areas: the fundus, the corpus (body), the infundibulum, and the neck. The fundus is the rounded, blind end that normally extends 1 to 2 cm beyond the liver's margin. It contains most of the smooth muscles of the organ, in contrast to the body, which is the main storage area and contains most of the elastic tissue. The body extends from the fundus and tapers into the neck, a funnel-shaped area that connects with the cystic duct. The neck usually follows a gentle curve, the convexity of which may be enlarged to form the infundibulum or Hartmann's pouch. The neck lies in the deepest part of the gallbladder fossa and extends into the free portion of the hepatoduodenal ligament (Fig. 32-1).

The same peritoneal lining that covers the liver covers the fundus and the inferior surface of the gallbladder. Occasionally, the gallbladder has a complete peritoneal covering and is suspended in a mesentery off the inferior surface of the liver, and rarely, it is embedded deep inside the liver parenchyma (an intrahepatic gallbladder).

The gallbladder is lined by a single, highly folded, tall columnar epithelium that contains cholesterol and fat globules. The mucus secreted into the gallbladder originates in the tubuloalveolar glands found in the mucosa lining the infundibulum and neck of the gallbladder, but are absent from the body and fundus. The epithelial lining of the gallbladder is supported by a lamina propria. The muscle layer has circular longitudinal and oblique fibers, but without well-developed layers. The perimuscular subserosa contains connective tissue, nerves, vessels, lymphatics, and adipocytes. It is covered by the serosa except where the gallbladder is embedded in the liver. The gallbladder differs histologically from the rest of the gastrointestinal (GI) tract in that it lacks a muscularis mucosa and submucosa.

The cystic artery that supplies the gallbladder is usually a branch of the right hepatic artery (>90% of the time). The course of the cystic artery may vary, but it nearly always is found within the hepatocystic triangle, the area bound by the cystic duct, common hepatic duct, and the liver margin (triangle of Calot). When the cystic artery reaches the neck of the gallbladder, it divides into anterior and posterior divisions. Venous return is carried either through small veins that enter directly into the liver or, rarely, to a large cystic vein that carries blood back to the portal vein. Gallbladder lymphatics drain into nodes at the neck of the gallbladder. Frequently, a visible lymph node overlies the insertion of the cystic artery into the gallbladder wall. The nerves of the gallbladder arise from the vagus and from sympathetic branches that pass through the celiac plexus.

Key Points

- 1▶ The physiology of the gallbladder and sphincter of Oddi is regulated by a complex interplay of hormones and neuronal inputs designed to coordinate bile release with food consumption. Dysfunctions related to this activity are linked to the development of gallbladder pathologies described in this chapter.
- 2▶ In Western countries, the most common type of gallstones are cholesterol stones. The pathogenesis of these stones relates to supersaturation of bile with cholesterol and subsequent precipitation.
- 3▶ Laparoscopic cholecystectomy has been demonstrated to be a safe and effective alternative to open cholecystectomy and has become the treatment of choice for symptomatic gallstones. Knowledge of the various anatomic anomalies of the cystic duct and artery is helpful in guiding the dissection of these structures as well as avoiding injury to the common bile duct during cholecystectomy.
- 4▶ Common bile duct injuries, although uncommon, can be devastating to patients. Proper exposure of Calot's triangle and careful identification of the anatomic structures are keys to avoiding these injuries. Once a bile duct injury is diagnosed, the best outcomes are seen at large referral centers with experienced biliary surgeons.
- 5▶ The main risk factor for gallbladder disease in Western countries is cholelithiasis. The main complications include cholecystitis, choledocholithiasis, cholangitis, and biliary pancreatitis. In addition, cholelithiasis plays the role as the major risk factor for the development of gallbladder cancer.
- 6▶ Carcinoma of the gallbladder and bile duct generally have a poor prognosis because patients usually present late in the disease process and have poor response to chemotherapy and radiation therapy. Surgery offers the best chance for survival and has good long-term survival in patients with early-stage disease.

The preganglionic sympathetic level is T8 and T9. Impulses from the liver, gallbladder, and the bile ducts pass by means of sympathetic afferent fibers through the splanchnic nerves and mediate the pain of biliary colic. The hepatic branch of the vagus nerve supplies cholinergic fibers to the gallbladder, bile ducts, and liver. The vagal branches also have peptide-containing

nerves containing agents such as substance P, somatostatin, enkephalins, and vasoactive intestinal polypeptide.²

Bile Ducts

The extrahepatic bile ducts consist of the right and left hepatic ducts, the common hepatic duct, the cystic duct, and the common bile duct or choledochus. The common bile duct enters the second portion of the duodenum through a muscular structure, the sphincter of Oddi.³

The left hepatic duct is longer than the right and has a greater propensity for dilatation as a consequence of distal obstruction. The two ducts join to form a common hepatic duct, close to their emergence from the liver. The common hepatic duct is 1 to 4 cm in length and has a diameter of approximately 4 mm. It lies in front of the portal vein and to the right of the hepatic artery. The common hepatic duct is joined at an acute angle by the cystic duct to form the common bile duct.

The length of the cystic duct is quite variable. It may be short or absent and have a high union with the hepatic duct, or long and run parallel, behind, or spiral to the main hepatic duct before joining it, sometimes as far as at the duodenum. Variations of the cystic duct and its point of union with the common hepatic duct are surgically important (Fig. 32-2). The segment of the cystic duct adjacent to the gallbladder neck bears a variable number of mucosal folds called the *spiral valves of Heister*. They do not have any valvular function but may make cannulation of the cystic duct difficult.

The common bile duct is about 7 to 11 cm in length and 5 to 10 mm in diameter. The upper third (supraduodenal portion) passes downward in the free edge of the hepatoduodenal ligament, to the right of the hepatic artery and anterior to the portal vein. The middle third (retroduodenal portion) of the common bile duct curves behind the first portion of the duodenum and diverges laterally from the portal vein and the hepatic arteries. The lower third (pancreatic portion) curves behind the head of the pancreas in a groove, or traverses through it and enters the second part of the duodenum. There, the pancreatic duct frequently joins it. The common bile duct runs obliquely downward

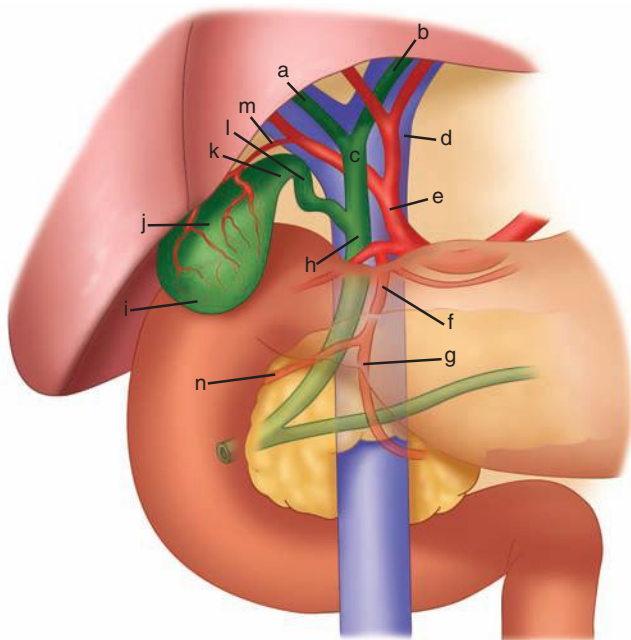


Figure 32-1. Anterior aspect of the biliary anatomy. a = right hepatic duct; b = left hepatic duct; c = common hepatic duct; d = portal vein; e = hepatic artery; f = gastroduodenal artery; g = left gastric artery; h = common bile duct; i = fundus of the gallbladder; j = body of gallbladder; k = infundibulum; l = cystic duct; m = cystic artery; n = superior pancreaticoduodenal artery. Note the situation of the hepatic bile duct confluence anterior to the right branch of the portal vein, and the posterior course of the right hepatic artery behind the common hepatic duct.

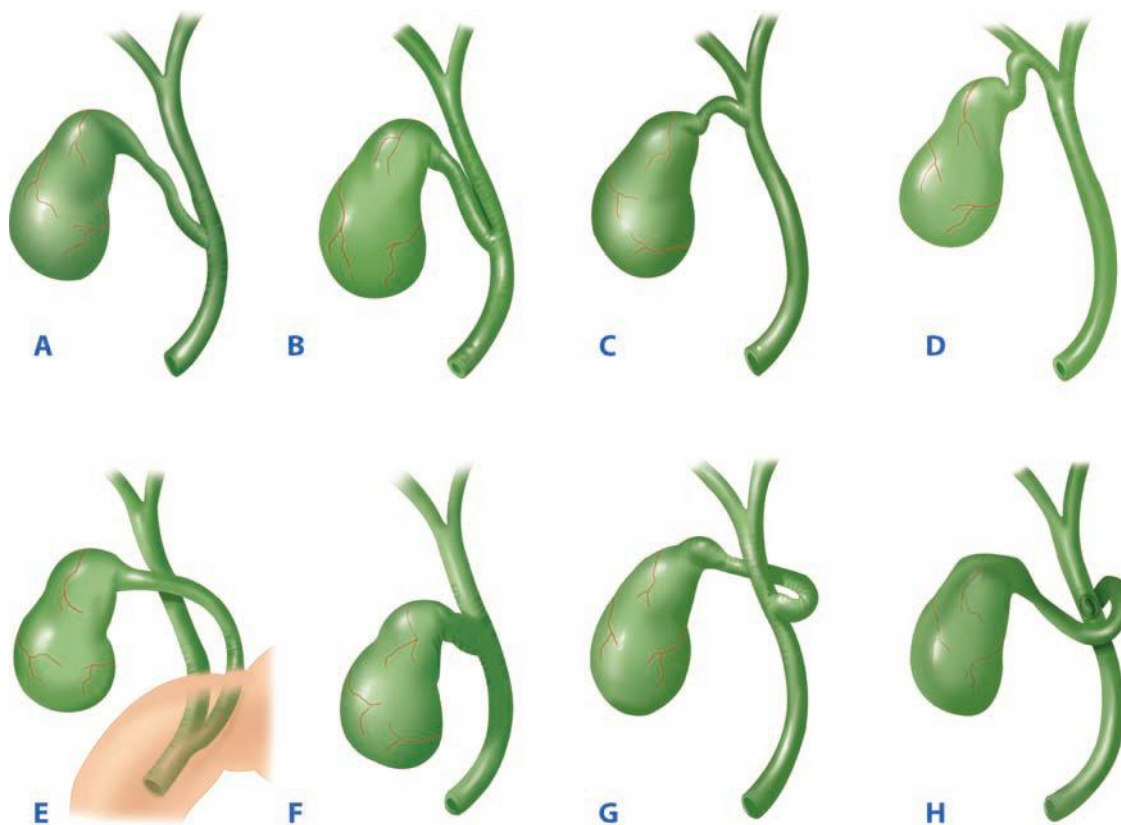


Figure 32-2. Variations of the cystic duct anatomy. **A.** Low junction between the cystic duct and common hepatic duct. **B.** Cystic duct adherent to the common hepatic duct. **C.** High junction between the cystic and the common hepatic duct. **D.** Cystic duct drains into right hepatic duct. **E.** Long cystic duct that joins common hepatic duct behind the duodenum. **F.** Absence of cystic duct. **G.** Cystic duct crosses posterior to common hepatic duct and joins it anteriorly. **H.** Cystic duct courses anterior to common hepatic duct and joins it posteriorly.

within the wall of the duodenum for 1 to 2 cm before opening on a papilla of mucous membrane (ampulla of Vater), about 10 cm distal to the pylorus. The union of the common bile duct and the main pancreatic duct follows one of three configurations. In about 70% of people, these ducts unite outside the duodenal wall and traverse the duodenal wall as a single duct. In about 20%, they join within the duodenal wall and have a short or no common duct, but open through the same opening into the duodenum. In about 10%, they exit via separate openings into the duodenum. The sphincter of Oddi, a thick coat of circular smooth muscle, surrounds the common bile duct at the ampulla of Vater (Fig. 32-3). It controls the flow of bile, and in some cases pancreatic juice, into the duodenum.

The extrahepatic bile ducts are lined by a columnar mucosa with numerous mucous glands in the common bile duct. A fibroareolar tissue containing scant smooth muscle cells surrounds the mucosa. A distinct muscle layer is not present in the human common bile duct. The arterial supply to the bile ducts is derived from the gastroduodenal and the right hepatic arteries, with major trunks running along the medial and lateral walls of the common duct (sometimes referred to as 3 o'clock and 9 o'clock). These arteries anastomose freely within the duct walls. The density of nerve fibers and ganglia increases near the sphincter of Oddi, but the nerve supply to the common bile duct and the sphincter of Oddi is the same as for the gallbladder.^{1,2}

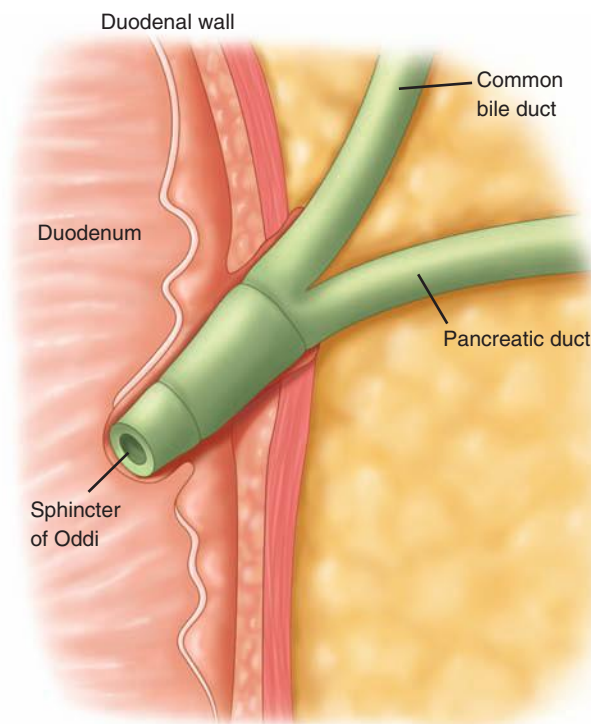


Figure 32-3. The sphincter of Oddi.

The classic description of the extrahepatic biliary tree and its arteries applies only in about one third of patients.⁴ The gallbladder may have abnormal positions, be intrahepatic, be rudimentary, have anomalous forms, or be duplicated. Isolated congenital absence of the gallbladder is very rare, with a reported incidence of 0.03%. Before the diagnosis is made, the presence of an intrahepatic bladder or anomalous position must be ruled out. Duplication of the gallbladder with two separate cavities and two separate cystic ducts has an incidence of about one in every 4000 persons. This occurs in two major varieties: the more common form in which each gallbladder has its own cystic duct that empties independently into the same or different parts of the extrahepatic biliary tree, and as two cystic ducts that merge before they enter the common bile duct. Duplication is only clinically important when some pathologic processes affect one or both organs. A left-sided gallbladder with a cystic duct emptying into the left hepatic duct or the common bile duct and a retrodisplacement of the gallbladder are both extremely rare. A partial or totally intrahepatic gallbladder is associated with an increased incidence of cholelithiasis.

Small ducts (of Luschka) may drain directly from the liver into the body of the gallbladder. If present, but not recognized at the time of a cholecystectomy, a bile leak with the accumulation of bile (biloma) may occur in the abdomen. An accessory right hepatic duct occurs in about 5% of cases. Variations of how the common bile duct enters the duodenum are described in earlier, in the Bile Ducts section.

Anomalies of the hepatic artery and the cystic artery are quite common, occurring in as many as 50% of cases.⁵ In about 5% of cases, there are two right hepatic arteries, one from the common hepatic artery and the other from the superior mesenteric artery. In about 20% of patients, the right hepatic artery comes off the superior mesenteric artery. The right hepatic artery may course anterior to the common duct. The right hepatic artery may be vulnerable during surgical procedures, in particular when it runs parallel to the cystic duct or in the mesentery of the gallbladder. The cystic artery arises from the right hepatic artery in about 90% of cases, but may arise from the left hepatic, common hepatic, gastroduodenal, or superior mesenteric arteries (Fig. 32-4).

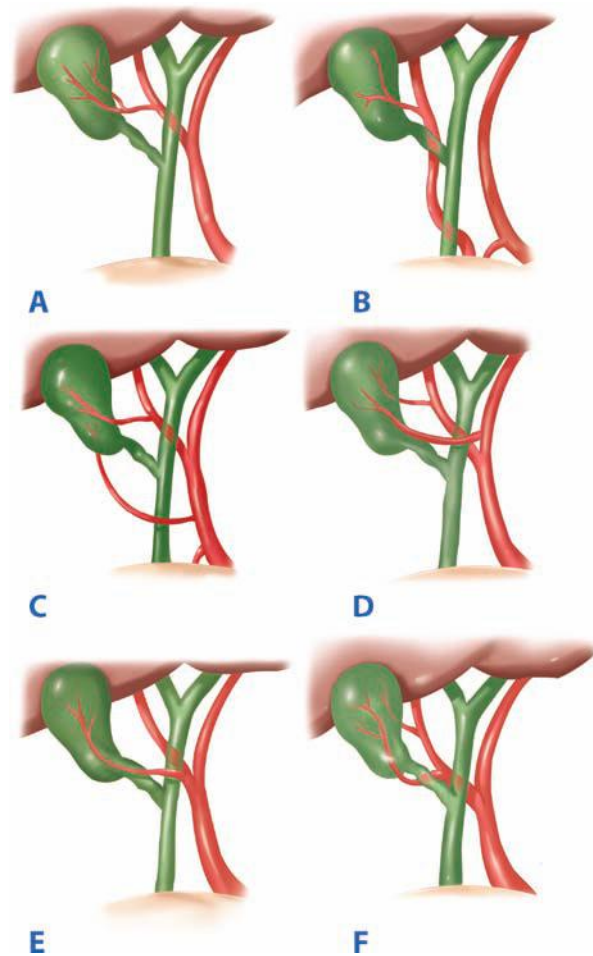


Figure 32-4. Variations in the arterial supply to the gallbladder. **A.** Cystic artery from right hepatic artery, about 80% to 90%. **B.** Cystic artery from right hepatic artery (accessory or replaced) from superior mesenteric artery, about 10%. **C.** Two cystic arteries, one from the right hepatic, the other from the common hepatic artery, rare. **D.** Two cystic arteries, one from the right hepatic, the other from the left hepatic artery, rare. **E.** The cystic artery branching from the right hepatic artery and running anterior to the common hepatic duct, rare. **F.** Two cystic arteries arising from the right hepatic artery, rare.

PHYSIOLOGY

Bile Formation and Composition

The liver produces bile continuously and excretes it into the bile canaliculi. The normal adult consuming an average diet produces within the liver 500 to 1000 mL of bile a day. The secretion of bile is responsive to neurogenic, humoral, and chemical stimuli. Vagal stimulation increases secretion of bile, whereas splanchnic nerve stimulation results in decreased bile flow. Hydrochloric acid, partly digested proteins, and fatty acids in the duodenum stimulate the release of secretin from the duodenum that, in turn, increases bile production and bile flow. Bile flows from the liver through to the hepatic ducts, into the common hepatic duct, through the common bile duct, and finally into the duodenum. With an intact sphincter of Oddi, bile flow is directed into the gallbladder.

Bile is mainly composed of water, electrolytes, bile salts, proteins, lipids, and bile pigments. Sodium, potassium, calcium, and chlorine have the same concentration in bile as in plasma

or extracellular fluid. The pH of hepatic bile is usually neutral or slightly alkaline, but varies with diet; an increase in protein shifts the bile to a more acidic pH. The primary bile salts, cholate and chenodeoxycholate, are synthesized in the liver from cholesterol. They are conjugated there with taurine and glycine and act within the bile as anions (bile acids) that are balanced by sodium. Bile salts are excreted into the bile by the hepatocyte and aid in the digestion and absorption of fats in the intestines.⁶ In the intestines, about 80% of the conjugated bile acids are absorbed in the terminal ileum. The remainder is dehydroxylated (deconjugated) by gut bacteria, forming secondary bile acids deoxycholate and lithocholate. These are absorbed in the colon, transported to the liver, conjugated, and secreted into the bile. Eventually, about 95% of the bile acid pool is reabsorbed and returned via the portal venous system to the liver, the so-called *enterohepatic circulation*. Five percent is excreted in the stool, leaving the relatively small amount of bile acids to have maximum effect.

Cholesterol and phospholipids synthesized in the liver are the principal lipids found in bile. The synthesis of phospholipids and cholesterol by the liver is, in part, regulated by bile acids. The color of the bile is due to the presence of the pigment bilirubin diglucuronide, which is the metabolic product from the breakdown of hemoglobin and is present in bile in concentrations 100 times greater than in plasma. Once in the intestine, bacteria convert it into urobilinogen, a small fraction of which is absorbed and secreted into the bile.

Gallbladder Function

The gallbladder, the bile ducts, and the sphincter of Oddi act together to store and regulate the flow of bile. The main function of the gallbladder is to concentrate and store hepatic bile and to deliver bile into the duodenum in response to a meal.

Absorption and Secretion. In the fasting state, approximately 80% of the bile secreted by the liver is stored in the gallbladder. This storage is made possible because of the remarkable absorptive capacity of the gallbladder, as the gallbladder mucosa has the greatest absorptive power per unit area of any structure in the body. It rapidly absorbs sodium, chloride, and water against significant concentration gradients, concentrating the bile as much as 10-fold and leading to a marked change in bile composition. This rapid absorption is one of the mechanisms that prevent a rise in pressure within the biliary system under normal circumstances. Gradual relaxation as well as emptying of the gallbladder during the fasting period also plays a role in maintaining a relatively low intraluminal pressure in the biliary tree.

The epithelial cells of the gallbladder secrete at least two important products into the gallbladder lumen: glycoproteins and hydrogen ions. The mucosal glands in the infundibulum and the neck of the gallbladder secrete mucus glycoproteins that are believed to protect the mucosa from the lytic action of bile and to facilitate the passage of bile through the cystic duct. This mucus makes up the colorless “white bile” seen in hydrops of the gallbladder resulting from cystic duct obstruction. The transport of hydrogen ions by the gallbladder epithelium leads to a decrease in the gallbladder bile pH. The acidification promotes calcium solubility, thereby preventing its precipitation as calcium salts.⁶

Motor Activity. Gallbladder filling is facilitated by tonic contraction of the sphincter of Oddi, which creates a pressure gradient between the bile ducts and the gallbladder. During fasting, the gallbladder does not simply fill passively. In association with phase II of the interdigestive migrating myenteric motor complex in the gut, the gallbladder repeatedly empties small volumes of bile into the duodenum. This process is mediated at least in part by the hormone motilin. In response to a meal, the gallbladder empties by a coordinated motor response of gallbladder contraction and sphincter of Oddi relaxation. One of the main stimuli to gallbladder emptying is the hormone cholecystokinin (CCK). CCK is released endogenously from the duodenal mucosa in response to a meal.⁷ When stimulated by eating, the gallbladder empties 50% to 70% of its contents within 30 to 40 minutes. Over the following 60 to 90 minutes, the gallbladder gradually refills. This is correlated with a reduced CCK level. Other hormonal and neural pathways also are involved in the coordinated action of the gallbladder and the sphincter of Oddi. Defects in the motor activity of the gallbladder are thought to play a role in cholesterol nucleation and gallstone formation.⁸

Neurohormonal Regulation. The vagus nerve stimulates contraction of the gallbladder, and splanchnic sympathetic

stimulation is inhibitory to its motor activity. Parasympathomimetic drugs contract the gallbladder, whereas atropine leads to relaxation. Neurally mediated reflexes link the sphincter of Oddi with the gallbladder, stomach, and duodenum to coordinate the flow of bile into the duodenum. Antral distention of the stomach causes both gallbladder contraction and relaxation of the sphincter of Oddi.

Hormonal receptors are located on the smooth muscles, vessels, nerves, and epithelium of the gallbladder. CCK is a peptide that comes from epithelial cells of the upper GI tract and is found in the highest concentrations in the duodenum. CCK is released into the bloodstream by acid, fat, and amino acids in the duodenum.⁹ CCK has a plasma half-life of 2 to 3 minutes and is metabolized by both the liver and the kidneys. CCK acts directly on smooth muscle receptors of the gallbladder and stimulates gallbladder contraction. It also relaxes the terminal bile duct, the sphincter of Oddi, and the duodenum. CCK stimulation of the gallbladder and the biliary tree also is mediated by cholinergic vagal neurons. In patients who have had a vagotomy, the response to CCK stimulation is diminished and the size and the volume of the gallbladder are increased.

Vasoactive intestinal polypeptide inhibits contraction and causes gallbladder relaxation. Somatostatin and its analogues are potent inhibitors of gallbladder contraction. Patients treated with somatostatin analogues and those with somatostatinoma have a high incidence of gallstones, presumably due to the inhibition of gallbladder contraction and emptying. Other hormones such as substance P and enkephalin affect gallbladder motility, but the physiologic role is unclear.⁷

Sphincter of Oddi

The sphincter of Oddi regulates flow of bile (and pancreatic juice) into the duodenum, prevents the regurgitation of duodenal contents into the biliary tree, and diverts bile into the gallbladder. It is a complex structure that is functionally independent from the duodenal musculature and creates a high-pressure zone between the bile duct and the duodenum. The sphincter of Oddi is about 4 to 6 mm in length and has a basal resting pressure of about 13 mmHg above the duodenal pressure. On manometry, the sphincter shows phasic contractions with a frequency of about four per minute and an amplitude of 12 to 140 mmHg.⁸ The spontaneous motility of the sphincter of Oddi is regulated by the interstitial cells of Cajal through intrinsic and extrinsic **1▶** inputs from hormones and neurons acting on the smooth muscle cells.¹⁰ Relaxation occurs with a rise in CCK, leading to diminished amplitude of phasic contractions and reduced basal pressure, allowing increased flow of bile into the duodenum (Fig. 32-5). During fasting, the sphincter of Oddi activity is coordinated with the periodic partial gallbladder emptying and an increase in bile flow that occurs during phase II of the migrating myoelectric motor complexes.¹¹

DIAGNOSTIC STUDIES

A variety of diagnostic modalities are available for the patient with suspected disease of the gallbladder and the bile ducts. In 1924, the diagnosis of gallstones was improved significantly by the introduction of oral cholecystography by Graham and Cole. For decades, it was the mainstay of investigation for gallstones. In the 1950s, biliary scintigraphy was developed, as well as intrahepatic and endoscopic retrograde cholangiography (ERC), allowing imaging of the biliary tract. Later ultrasonography,

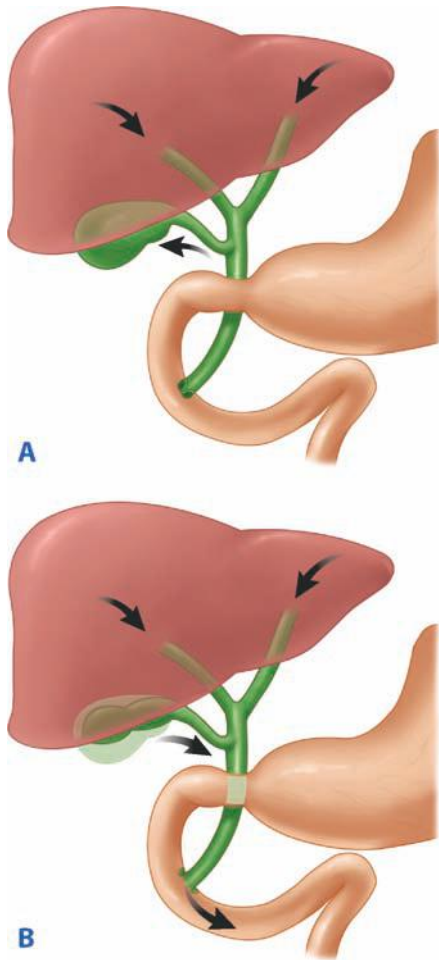


Figure 32-5. The effect of cholecystikinin on the gallbladder and the sphincter of Oddi. **A.** During fasting, with the sphincter of Oddi contracted and the gallbladder filling. **B.** In response to a meal, the sphincter of Oddi relaxed and the gallbladder emptying.

computed tomography (CT), and magnetic resonance imaging (MRI) vastly improved the ability to image the biliary tract.¹²

Blood Tests

When patients with suspected diseases of the gallbladder or the extrahepatic biliary tree are evaluated, a complete blood count and liver function tests are routinely requested. An elevated white blood cell (WBC) count may indicate or raise suspicion of cholecystitis. If associated with an elevation of bilirubin, alkaline phosphatase, and aminotransferase, cholangitis should be suspected. Cholestasis, an obstruction to bile flow, is characterized by an elevation of bilirubin (i.e., the conjugated form) and a rise in alkaline phosphatase. Serum aminotransferases may be normal or mildly elevated. In patients with biliary colic or chronic cholecystitis, blood tests will typically be normal.

Ultrasonography

An ultrasound is the initial investigation of any patient suspected of disease of the biliary tree.¹³ It is noninvasive, painless, does not submit the patient to radiation, and can be performed on critically ill patients. It is dependent upon the skills and the experience of the operator, and it is dynamic (i.e., static images do not give the same information as those obtained during the ultrasound investigation itself). Adjacent organs can frequently be examined at the same time. Obese patients, patients with

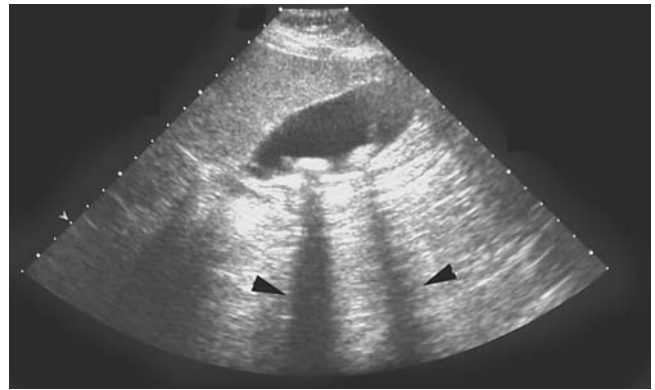


Figure 32-6. An ultrasonography of the gallbladder. Arrows indicate the acoustic shadows from stones in the gallbladder.

ascites, and patients with distended bowel may be difficult to examine satisfactorily with an ultrasound.

Ultrasound will show stones in the gallbladder with sensitivity and specificity of >90%. Stones are acoustically dense and reflect the ultrasound waves back to the ultrasonic transducer. Because stones block the passage of sound waves to the region behind them, they also produce an acoustic shadow (Fig. 32-6). Stones move with changes in position. Polyps may be calcified and reflect shadows, but do not move with change in posture. Some stones form a layer in the gallbladder; others a sediment or sludge. A thickened gallbladder wall and local tenderness indicate cholecystitis. The patient has acute cholecystitis if a layer of edema is seen within the wall of the gallbladder or between the gallbladder and the liver in association with localized tenderness. When a stone obstructs the neck of the gallbladder, the gallbladder may become very large, but thin walled. A contracted, thick-walled gallbladder is indicative of chronic cholecystitis.

The extrahepatic bile ducts are also well visualized by ultrasound, except for the retroduodenal portion. Dilation of the ducts in a patient with jaundice establishes an extrahepatic obstruction as a cause for the jaundice. Frequently, the site and, sometimes, the cause of obstruction can be determined by ultrasound. Small stones in the common bile duct frequently get lodged at the distal end of it, behind the duodenum, and are, therefore, difficult to detect. A dilated common bile duct on ultrasound, small stones in the gallbladder, and the clinical presentation allow one to assume that a stone or stones are causing the obstruction. Periapillary tumors can be difficult to diagnose on ultrasound, but beyond the retroduodenal portion, the level of obstruction and the cause may be visualized quite well. Ultrasound can be helpful in evaluating tumor invasion and flow in the portal vein, an important guideline for resectability of periampullary and pancreatic head tumors.¹⁴

Oral Cholecystography

Once considered the diagnostic procedure of choice for gallstones, oral cholecystography has largely been replaced by ultrasonography. It involves oral administration of a radiopaque compound that is absorbed, excreted by the liver, and passed into the gallbladder. Stones are noted on a film as filling defects in a visualized, opacified gallbladder. Oral cholecystography is of no value in patients with intestinal malabsorption, vomiting, obstructive jaundice, and hepatic failure.

Biliary Radionuclide Scanning (HIDA Scan)

Biliary scintigraphy provides a noninvasive evaluation of the liver, gallbladder, bile ducts, and duodenum with both anatomic and functional information. ^{99m}Tc -labeled derivatives of dimethyl iminodiacetic acid (HIDA) are injected intravenously, cleared by the Kupffer cells in the liver, and excreted in the bile. Uptake by the liver is detected within 10 minutes, and the gallbladder, the bile ducts, and the duodenum are visualized within 60 minutes in fasting subjects. The primary use of biliary scintigraphy is in the diagnosis of acute cholecystitis, which appears as a nonvisualized gallbladder, with prompt filling of the common bile duct and duodenum. Evidence of cystic duct obstruction on biliary scintigraphy is highly diagnostic for acute cholecystitis. The sensitivity and specificity for the diagnosis are about 95% each. False-positive results are increased in patients with gallbladder stasis, as in critically ill patients and in patients receiving parenteral nutrition. Filling of the gallbladder and common bile duct with delayed or absent filling of the duodenum indicates an obstruction at the ampulla. Biliary leaks as a complication of surgery of the gallbladder or the biliary tree can be confirmed and frequently localized by biliary scintigraphy.¹⁵

Computed Tomography

Abdominal CT scans are inferior to ultrasonography in diagnosing gallstones. The major application of CT scans is to define the course and status of the extrahepatic biliary tree and adjacent structures. It is the test of choice in evaluating the patient with suspected malignancy of the gallbladder, the extrahepatic biliary system, or nearby organs, in particular, the head of the pancreas. Use of CT scan is an integral part of the differential diagnosis of obstructive jaundice (Fig. 32-7). Spiral CT scanning provides

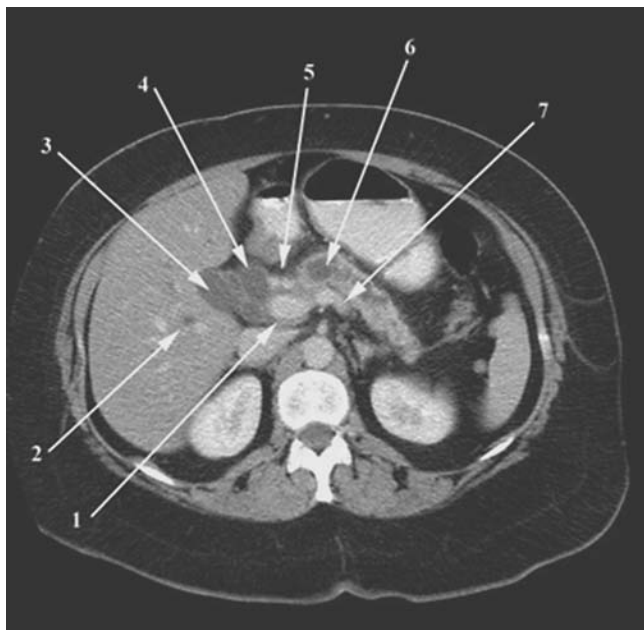

Figure 32-7. Computed tomography scan of the upper abdomen from a patient with cancer of the distal common bile duct. The cancer obstructs the common bile duct as well as the pancreatic duct. 1 = the portal vein; 2 = a dilated intrahepatic bile duct; 3 = dilated cystic duct and the neck of the gallbladder; 4 = dilated common hepatic duct; 5 = the bifurcation of the common hepatic artery into the gastroduodenal artery and the proper hepatic artery; 6 = dilated pancreatic duct; 7 = the splenic vein.

additional staging information, including vascular involvement in patients with periampullary tumors.¹⁶

Percutaneous Transhepatic Cholangiography

Intrahepatic bile ducts are accessed percutaneously with a small needle under fluoroscopic guidance. Once the position in a bile duct has been confirmed, a guidewire is passed, and subsequently, a catheter is passed over the wire (Fig. 32-8). Through the catheter, a cholangiogram can be performed and therapeutic interventions done, such as biliary drain insertions and stent placements. Percutaneous transhepatic cholangiography (PTC) has little role in the management of patients with uncomplicated gallstone disease but is particularly useful in patients with bile duct strictures and tumors, as it defines the anatomy of the biliary tree proximal to the affected segment. As with any invasive procedure, there are potential risks. For PTC, these are mainly bleeding, cholangitis, bile leak, and other catheter-related problems.¹⁵

Magnetic Resonance Imaging

Available since the mid-1990s, MRI provides anatomic details of the liver, gallbladder, and pancreas similar to those obtained from CT. Many MRI techniques (i.e., heavily T2-weighted sequences, pulse sequences with or without contrast materials) can generate high-resolution anatomic images of the biliary tree and the pancreatic duct. It has a sensitivity and specificity of 95% and 89%, respectively, at detecting choledocholithiasis.¹⁷ MRI with magnetic resonance cholangiopancreatography (MRCP) offers a single noninvasive test for the diagnosis of biliary tract and pancreatic disease¹⁸ (Fig. 32-9). In many centers, MRCP is first performed for diagnosis of biliary and pancreatic duct pathology, reserving endoscopic retrograde cholangiopancreatography (ERCP) for therapeutic purposes only.

Endoscopic Retrograde Cholangiopancreatography

Using a side-viewing endoscope, the common bile duct can be cannulated and a cholangiogram performed using fluoroscopy (Fig. 32-10). The procedure requires intravenous (IV) sedation for the patient. The advantages of ERC include direct visualization of the ampullary region and direct access to the distal common bile duct, with the possibility of therapeutic intervention. The test is rarely needed for uncomplicated gallstone disease, but for stones in the common bile duct, in particular, when associated with obstructive jaundice, cholangitis, or gallstone pancreatitis, ERC is the diagnostic and often therapeutic procedure of choice. Once the endoscopic cholangiogram has shown ductal stones, sphincterotomy and stone extraction can be performed, and the common bile duct cleared of stones. In the hands of experts, the success rate of common bile duct cannulation and cholangiography is >90%. Complications of diagnostic ERC include pancreatitis and cholangitis and occur in up to 5% of patients.¹⁹ The development of small fiber-optic cameras that can be threaded through endoscopes used for endoscopic retrograde cholangiopancreatography (ERCP) has facilitated the development of intraductal endoscopy. By providing direct visualization of the biliary and pancreatic ducts, this technology has been shown to increase the effectiveness of ERCP in the diagnosis of certain biliary and pancreatic diseases.^{20,21} Intraductal endoscopy has been shown to have therapeutic applications that include biliary stone lithotripsy and extraction in high-risk surgical patients.²² As with most endoscopic procedures, intraductal endoscopy generally is considered safe, but

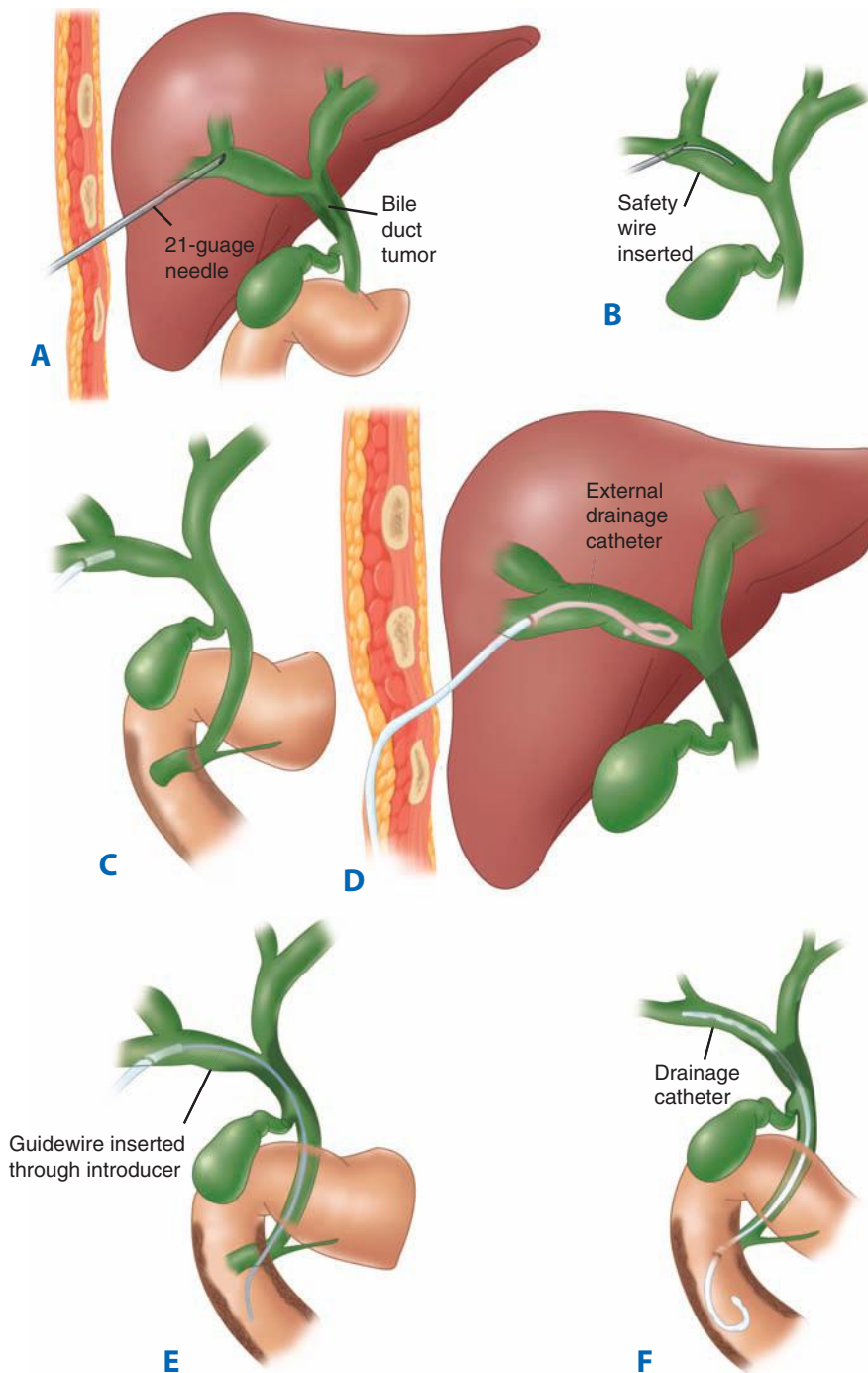


Figure 32-8. Schematic diagram of percutaneous transhepatic cholangiogram and drainage for obstructing proximal cholangiocarcinoma. **A.** Dilated intrahepatic bile duct is entered percutaneously with a fine needle. **B.** Small guidewire is passed through the needle into the duct. **C.** A plastic catheter has been passed over the wire, and the wire is subsequently removed. A cholangiogram is performed through the catheter. **D.** An external drainage catheter is in place. **E.** Long wire placed via the catheter and advanced past the tumor and into the duodenum. **F.** Internal stent has been placed through the tumor.

there are no large trials that specifically address this issue. Typical complications such as bile duct perforation, minor bleeding from sphincterotomy or lithotripsy, and cholangitis have been described.²³ Further refinement of this technology will enhance ERCP as a diagnostic and therapeutic tool.

Endoscopic Ultrasound

Endoscopic ultrasound requires a special endoscope with an ultrasound transducer at its tip. The results are operator dependent, but offer noninvasive imaging of the bile ducts and adjacent structures. It is of particular value in the evaluation of tumors and their resectability. The ultrasound endoscope has a biopsy channel, allowing needle biopsies of a tumor under

ultrasonic guidance. Endoscopic ultrasound also has been used to identify bile duct stones, and although it is less sensitive than ERC, the technique is less invasive as cannulation of the sphincter of Oddi is not necessary for diagnosis of choledocholithiasis.

GALLSTONE DISEASE

Prevalence and Incidence

Gallstone disease is one of the most common problems affecting the digestive tract. Autopsy reports have shown a prevalence of gallstones from 11% to 36%.²⁴ The prevalence of gallstones is related to many factors, including age, gender,

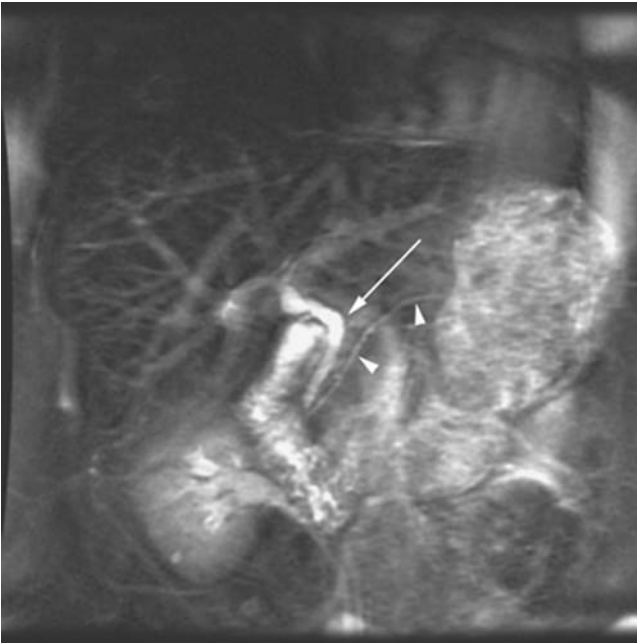

Figure 32-9. Magnetic resonance cholangiopancreatography. This view shows the course of the extrahepatic bile ducts (*arrow*) and the pancreatic duct (*arrowheads*).

and ethnic background. Certain conditions predispose to the development of gallstones. Obesity, pregnancy, dietary factors, Crohn's disease, terminal ileal resection, gastric surgery, hereditary spherocytosis, sickle cell disease, and thalassemia are all associated with an increased risk of developing gallstones.⁸ Women are three times more likely to develop gallstones than

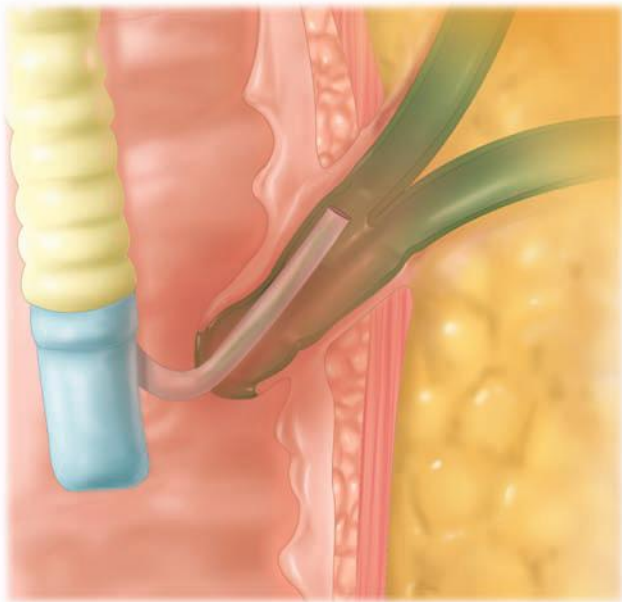
men, and first-degree relatives of patients with gallstones have a twofold greater prevalence.²⁵

Natural History

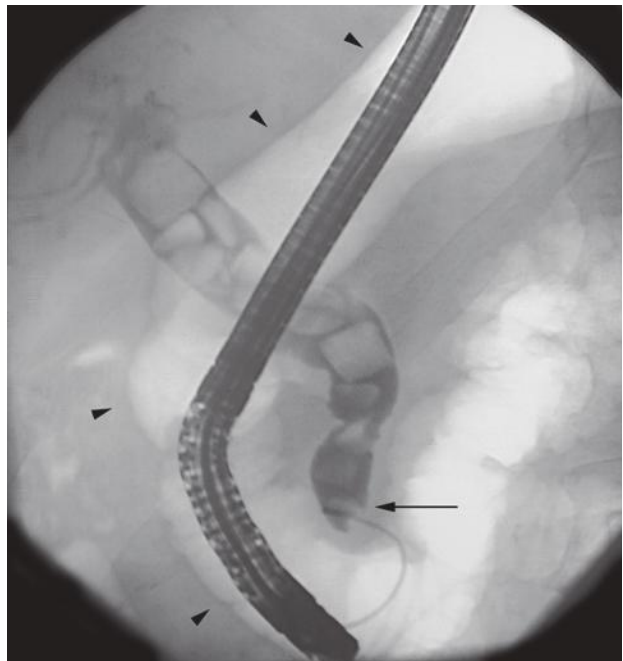
Most patients will remain asymptomatic from their gallstones throughout life. For unknown reasons, some patients progress to a symptomatic stage, with biliary colic caused by a stone obstructing the cystic duct. Symptomatic gallstone disease may progress to complications related to the gallstones.²⁶ These include acute cholecystitis, choledocholithiasis with or without cholangitis, gallstone pancreatitis, cholecystocholedochal fistula, cholecystoduodenal or cholecystoenteric fistula leading to gallstone ileus, and gallbladder carcinoma. Rarely, complication of gallstones is the presenting picture.

Gallstones in patients without biliary symptoms are commonly diagnosed incidentally on ultrasonography, CT scans, or abdominal radiography or at laparotomy. Several studies have examined the likelihood of developing biliary colic or developing significant complications of gallstone disease. Approximately 3% of asymptomatic individuals become symptomatic per year (i.e., develop biliary colic). Once symptomatic, patients tend to have recurring bouts of biliary colic. Complicated gallstone disease develops in 3% to 5% of symptomatic patients per year. Over a 20-year period, about two thirds of asymptomatic patients with gallstones remain symptom free.²⁷

Because few patients develop complications without previous biliary symptoms, prophylactic cholecystectomy in asymptomatic persons with gallstones is rarely indicated. For elderly patients with diabetes, for individuals who will be isolated from medical care for extended periods of time, and in populations with increased risk of gallbladder cancer, a prophylactic cholecystectomy may be advisable. Porcelain gallbladder, a rare premalignant condition in which the wall of the



A



B

Figure 32-10. Endoscopic retrograde cholangiography. **A.** A schematic picture showing the side-viewing endoscope in the duodenum and a catheter in the common bile duct. **B.** An endoscopic cholangiography showing stones in the common bile duct. The catheter has been placed in the ampulla of Vater (*arrow*). Note the duodenal shadow indicated with *arrowheads*.

gallbladder becomes calcified, is an absolute indication for cholecystectomy.

Gallstone Formation

Gallstones form as a result of solids settling out of solution. The major organic solutes in bile are bilirubin, bile salts, phospholipids, and cholesterol. Gallstones are classified by their cholesterol content as either cholesterol stones or pigment stones. Pigment stones can be further classified as either black or brown. In Western countries, about 80% of gallstones are cholesterol stones and about 15% to 20% are black pigment stones.²⁸ Brown pigment stones account for only a small percentage. Both types of pigment stones are more common in Asia.

Cholesterol Stones. Pure cholesterol stones are uncommon and account for <10% of all stones. They usually occur as single large stones with smooth surfaces. Most other cholesterol stones contain variable amounts of bile pigments and calcium, but are always >70% cholesterol by weight. These stones are usually multiple, of variable size, and may be hard and faceted or irregular, mulberry-shaped, and soft (Fig. 32-11). Colors range from whitish yellow and green to black. Most cholesterol stones are radiolucent; <10% are radiopaque. Whether pure or of mixed nature, the common primary event in the formation of cholesterol stones is supersaturation of bile with cholesterol. Therefore, high bile cholesterol levels and cholesterol gallstones are considered as one disease. Cholesterol is highly nonpolar and insoluble in water and bile. Cholesterol solubility depends on the relative concentration of cholesterol, bile salts, and lecithin (the main phospholipid in bile). Supersaturation almost always is caused by cholesterol hypersecretion rather than by a reduced secretion of phospholipid or bile salts.²

Cholesterol is secreted into bile as cholesterol-phospholipid vesicles. Cholesterol is held in solution by micelles, a conjugated bile salt-phospholipid-cholesterol complex, as well as by the cholesterol-phospholipid vesicles. The presence of vesicles and micelles in the same aqueous compartment allows the movement of lipids between the two. Vesicular maturation occurs when vesicular lipids are incorporated into micelles. Vesicular phospholipids are incorporated into micelles more readily than vesicular cholesterol. Therefore, vesicles may become enriched

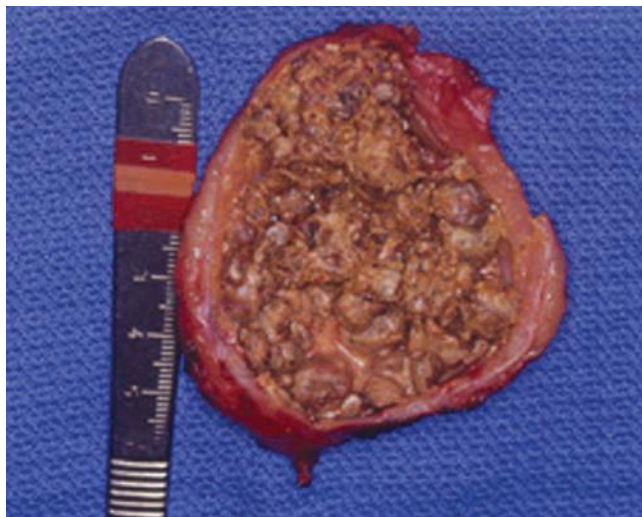


Figure 32-11. Gallbladder with cholesterol stones. Note the different shapes and sizes.

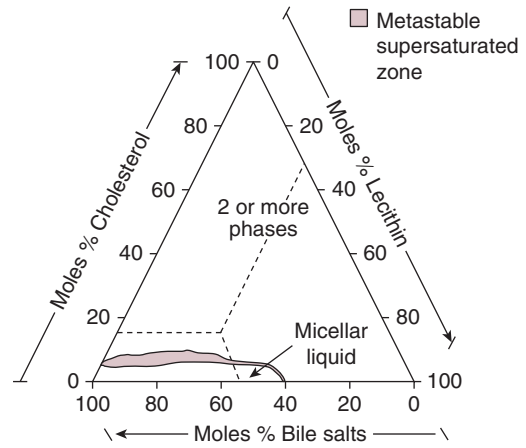


Figure 32-12. The three major components of bile plotted on triangular coordinates. A given point represents the relative molar ratios of bile salts, lecithin, and cholesterol. The area labeled “micellar liquid” shows the range of concentrations found consistent with a clear micellar solution (single phase), where cholesterol is fully solubilized. The shaded area directly above this region corresponds to a metastable zone, supersaturated with cholesterol. Bile with a composition that falls above the shaded area has exceeded the solubilization capacity of cholesterol and precipitation of cholesterol crystals occurs. (Reproduced with permission from Holzbach RT. *Pathogenesis and medical treatment of gallstones*. In: Slesinger MH, Fordtran JS, eds. *Gastrointestinal Diseases*. Philadelphia: WB Saunders; 1989:1672.)

in cholesterol, become unstable, and then nucleate cholesterol crystals. In unsaturated bile, cholesterol enrichment of vesicles is inconsequential. In the supersaturated bile, cholesterol-dense zones develop on the surface of the cholesterol-enriched vesicles, leading to the appearance of cholesterol crystals. About one third of biliary cholesterol is transported in micelles, but the cholesterol-phospholipid vesicles carry the majority of biliary cholesterol²⁹ (Fig. 32-12).

Pigment Stones. Pigment stones contain <20% cholesterol and are dark because of the presence of calcium bilirubinate. Otherwise, black and brown pigment stones have little in common and should be considered as separate entities.

Black pigment stones are usually small, brittle, black, and sometimes spiculated. They are formed by supersaturation of calcium bilirubinate, carbonate, and phosphate, most often secondary to hemolytic disorders such as hereditary spherocytosis and sickle cell disease, and in those with cirrhosis. Like cholesterol stones, they almost always form in the gallbladder. Unconjugated bilirubin is much less soluble than conjugated bilirubin in bile. Deconjugation of bilirubin occurs normally in bile at a slow rate. Excessive levels of conjugated bilirubin, as in hemolytic states, lead to an increased rate of production of unconjugated bilirubin. Cirrhosis may lead to increased secretion of unconjugated bilirubin. When altered conditions lead to increased levels of deconjugated bilirubin in bile, precipitation with calcium occurs. In Asian countries such as Japan, black stones account for a much higher percentage of gallstones than in the Western hemisphere.

Brown stones are usually <1 cm in diameter, brownish-yellow, soft, and often mushy. They may form either in the gallbladder or in the bile ducts, usually secondary to bacterial

infection caused by bile stasis. Precipitated calcium bilirubinate and bacterial cell bodies compose the major part of the stone. Bacteria such as *Escherichia coli* secrete β -glucuronidase that enzymatically cleaves bilirubin glucuronide to produce the insoluble unconjugated bilirubin. It precipitates with calcium, and along with dead bacterial cell bodies, forms soft brown stones in the biliary tree.

Brown stones are typically found in the biliary tree of Asian populations and are associated with stasis secondary to parasite infection. In Western populations, brown stones occur as primary bile duct stones in patients with biliary strictures or other common bile duct stones that cause stasis and bacterial contamination.^{2,30}

Symptomatic Gallstones

Chronic Cholecystitis (Biliary Colic). About two thirds of patients with gallstone disease present with chronic cholecystitis characterized by recurrent attacks of pain, often inaccurately labeled *biliary colic*. The pain develops when a stone obstructs the cystic duct, resulting in a progressive increase of tension in the gallbladder wall. The pathologic changes, which often do not correlate well with symptoms, vary from an apparently normal gallbladder with minor chronic inflammation in the mucosa, to a shrunken, nonfunctioning gallbladder with gross transmural fibrosis and adhesions to nearby structures. The mucosa is initially normal or hypertrophied, but later becomes atrophied, with the epithelium protruding into the muscle coat, leading to the formation of the so-called *Aschoff-Rokitansky sinuses*.

Clinical Presentation The chief symptom associated with symptomatic gallstones is pain. The pain is constant and increases in severity over the first half hour or so and typically lasts 1 to 5 hours. It is located in the epigastrium or right upper quadrant and frequently radiates to the right upper back or between the scapulae (Fig. 32-13). The pain is severe and comes on abruptly, typically during the night or after a fatty meal. It often is associated with nausea and sometimes vomiting. The pain is episodic. The patient suffers discrete attacks of pain, between which they feel well. Physical examination may reveal mild right upper quadrant tenderness during an episode of pain. If the patient is pain free, the physical examination is usually unremarkable. Laboratory values, such as WBC count and liver function tests, are usually normal in patients with uncomplicated gallstones.

Atypical presentation of gallstone disease is common. Association with meals is present in only about 50% of patients. Some patients report milder attacks of pain, but relate it to meals. The pain may be located primarily in the back or the left upper or lower right quadrant. Bloating and belching may be present and associated with the attacks of pain. In patients with atypical presentation, other conditions with upper abdominal pain should be sought out, even in the presence of gallstones. These include peptic ulcer disease, gastroesophageal reflux disease, abdominal wall hernias, irritable bowel disease, diverticular disease, liver diseases, renal calculi, pleuritic pain, and myocardial pain. Many patients with other conditions have gallstones.

When the pain lasts >24 hours, an impacted stone in the cystic duct or acute cholecystitis (see later Acute Cholecystitis section) should be suspected. An impacted stone without cholecystitis will result in what is called *hydrops of the gallbladder*. The bile gets absorbed, but the gallbladder epithelium continues to secrete mucus, and the gallbladder becomes distended with mucinous material. The gallbladder may be palpable but usually

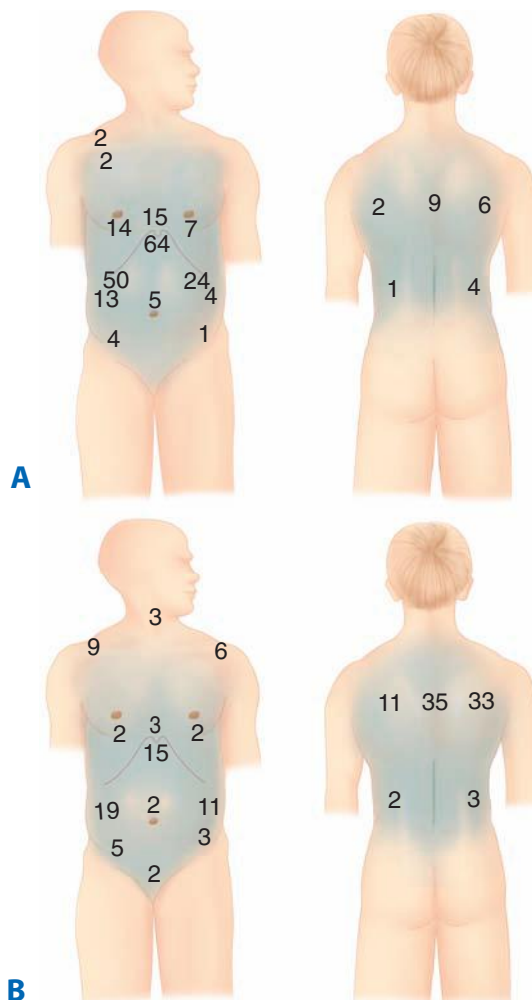


Figure 32-13. A. Sites of the most severe pain during an episode of biliary pain in 107 patients with gallstones (% values add up to >100% because of multiple responses). The subxiphoid and right subcostal areas were the most common sites; note that the left subcostal area was not an unusual site of pain. B. Sites of pain radiation (%) during an episode of biliary pain in the same group of patients. (Reprinted from Gunn A, Keddie N. *Some clinical observations on patients with gallstones*. *Lancet*. 1972;300(7771):239-241, Copyright 1972, with permission from Elsevier.)

is not tender. Hydrops of the gallbladder may result in edema of the gallbladder wall, inflammation, infection, and perforation. Although hydrops may persist with few consequences, early cholecystectomy is generally indicated to avoid complications.

Diagnosis The diagnosis of symptomatic gallstones or chronic calculous cholecystitis depends on the presence of typical symptoms and the demonstration of stones on diagnostic imaging. An abdominal ultrasound is the standard diagnostic test for gallstones (see earlier Ultrasonography section).³¹ Gallstones are occasionally identified on abdominal radiographs or CT scans. In these cases, if the patient has typical symptoms, an ultrasound of the gallbladder and the biliary tree should be added before surgical intervention. Stones diagnosed incidentally in patients without symptoms should be left in place as discussed previously in the Natural History section. Occasionally, patients with typical attacks of biliary pain have no evidence of stones on ultrasonography. Sometimes only sludge in the gallbladder

is demonstrated on ultrasonography. If the patient has recurrent attacks of typical biliary pain and sludge is detected on two or more occasions, cholecystectomy is warranted. In addition to sludge and stones, cholesterosis and adenomyomatosis of the gallbladder may cause typical biliary symptoms and may be detected on ultrasonography. Cholesterosis is caused by the accumulation of cholesterol in macrophages in the gallbladder mucosa, either locally or as polyps. It produces the classic macroscopic appearance of a “strawberry gallbladder.” Adenomyomatosis or cholecystitis glandularis proliferans is characterized on microscopy by hypertrophic smooth muscle bundles and by the ingrowths of mucosal glands into the muscle layer (epithelial sinus formation). Granulomatous polyps develop in the lumen at the fundus, and the gallbladder wall is thickened and septae or strictures may be seen in the gallbladder. In symptomatic patients, cholecystectomy is the treatment of choice for patients with these conditions.³²

Management Patients with symptomatic gallstones should be advised to have elective laparoscopic cholecystectomy. While waiting for surgery, or if surgery has to be postponed, the patient should be advised to avoid dietary fats and large meals. Diabetic patients with symptomatic gallstones should have a cholecystectomy promptly, as they are more prone to develop acute cholecystitis that is often severe. Pregnant women with symptomatic gallstones who cannot be managed expectantly with diet modifications can safely undergo laparoscopic cholecystectomy during the second trimester. Laparoscopic cholecystectomy is safe and

3▶ effective in children as well as in the elderly.^{33,34} Cholecystectomy, open or laparoscopic, for patients with symptomatic gallstones offers excellent long-term results. About 90% of patients with typical biliary symptoms and stones are rendered symptom free after cholecystectomy. For patients with atypical symptoms or dyspepsia (flatulence, belching, bloating, and dietary fat intolerance), the results are not as favorable.

Acute Cholecystitis

Pathogenesis Acute cholecystitis is secondary to gallstones in 90% to 95% of cases. Acute acalculous cholecystitis is a condition that typically occurs in patients with other acute systemic diseases (see later Acalculous Cholecystitis section). In <1% of acute cholecystitis, the cause is a tumor obstructing the cystic duct. Obstruction of the cystic duct by a gallstone is the initiating event that leads to gallbladder distention, inflammation, and edema of the gallbladder wall. Why inflammation develops only occasionally with cystic duct obstruction is unknown. It is probably related to the duration of obstruction of the cystic duct. Initially, acute cholecystitis is an inflammatory process, probably mediated by the mucosal toxin lysolecithin, a product of lecithin, as well as bile salts and platelet-activating factor. Increase in prostaglandin synthesis amplifies the inflammatory response. Secondary bacterial contamination is documented in 15% to 30% of patients undergoing cholecystectomy for acute uncomplicated cholecystitis. In acute cholecystitis, the gallbladder wall becomes grossly thickened and reddish with subserosal hemorrhages. Pericholecystic fluid often is present. The mucosa may show hyperemia and patchy necrosis. In severe cases, about 5% to 10%, the inflammatory process progresses and leads to ischemia and necrosis of the gallbladder wall. More frequently, the gallstone is dislodged and the inflammation resolves.³⁵

When the gallbladder remains obstructed and secondary bacterial infection supervenes, an acute gangrenous cholecystitis develops, and an abscess or empyema forms within

the gallbladder. Rarely, perforation of ischemic areas occurs. The perforation is usually contained in the subhepatic space by the omentum and adjacent organs. However, free perforation with peritonitis, intrahepatic perforation with intrahepatic abscesses, and perforation into adjacent organs (duodenum or colon) with cholecystoenteric fistula occur. When gas-forming organisms are part of the secondary bacterial infection, gas may be seen in the gallbladder lumen and in the wall of the gallbladder on abdominal radiographs and CT scans, an entity called an *emphysematous gallbladder*.

Clinical Manifestations About 80% of patients with acute cholecystitis give a history compatible with chronic cholecystitis. Acute cholecystitis begins as an attack of biliary colic, but in contrast to biliary colic, the pain does not subside; it is unremitting and may persist for several days. The pain is typically in the right upper quadrant or epigastrium and may radiate to the right upper part of the back or the interscapular area. It is usually more severe than the pain associated with uncomplicated biliary colic. The patient is often febrile, complains of anorexia, nausea, and vomiting, and is reluctant to move, as the inflammatory process affects the parietal peritoneum. On physical examination, focal tenderness and guarding are usually present in the right upper quadrant. A mass, the gallbladder and adherent omentum, is occasionally palpable; however, guarding may prevent this. A Murphy’s sign, an inspiratory arrest with deep palpation in the right subcostal area, is characteristic of acute cholecystitis.

A mild to moderate leukocytosis (12,000–15,000 cells/mm³) is usually present. However, some patients may have a normal WBC. A high WBC count (above 20,000) is suggestive of a complicated form of cholecystitis such as gangrenous cholecystitis, perforation, or associated cholangitis. Serum liver chemistries are usually normal, but a mild elevation of serum bilirubin, <4 mg/mL, may be present along with mild elevation of alkaline phosphatase, transaminases, and amylase.³¹ Severe jaundice is suggestive of common bile duct stones or obstruction of the bile ducts by severe pericholecystic inflammation secondary to impaction of a stone in the infundibulum of the gallbladder that mechanically obstructs the bile duct (Mirizzi’s syndrome). In elderly patients and in those with diabetes mellitus, acute cholecystitis may have a subtle presentation resulting in a delay in diagnosis. The incidence of complications is higher in these patients, who also have approximately 10-fold the mortality rate compared to that of younger and healthier patients.

The differential diagnosis for acute cholecystitis includes a peptic ulcer with or without perforation, pancreatitis, appendicitis, hepatitis, perihepatitis (Fitz-Hugh–Curtis syndrome), myocardial ischemia, pneumonia, pleuritis, and herpes zoster involving the intercostal nerve.

Diagnosis Ultrasonography is the most useful radiologic test for diagnosing acute cholecystitis. It has a sensitivity and specificity of 95%. In addition to being a sensitive test for documenting the presence or absence of stones, it will show the thickening of the gallbladder wall and the pericholecystic fluid (Fig. 32-14). Focal tenderness over the gallbladder when compressed by the sonographic probe (sonographic Murphy’s sign) also is suggestive of acute cholecystitis. Biliary radionuclide scanning (HIDA scan) may be of help in the atypical case. Lack of filling of the gallbladder after 4 hours indicates an obstructed cystic duct and, in the clinical setting of acute cholecystitis, is highly sensitive and specific for acute cholecystitis. A normal

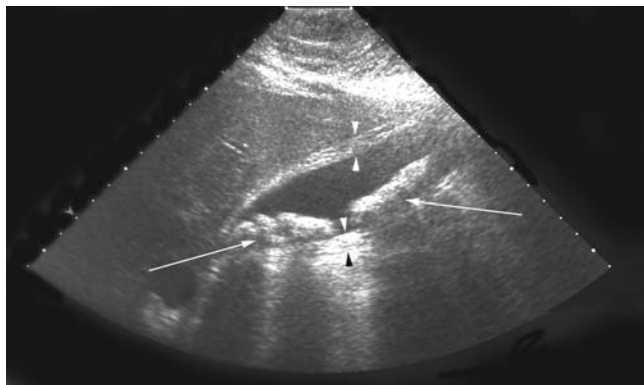

Figure 32-14. Ultrasonography from a patient with acute cholecystitis. The *arrowheads* indicate the thickened gallbladder wall. There are several stones in the gallbladder (*arrows*) throwing acoustic shadows.

HIDA scan excludes acute cholecystitis. CT scan is frequently performed on patients with acute abdominal pain. It demonstrates thickening of the gallbladder wall, pericholecystic fluid, and the presence of gallstones as well as air in the gallbladder wall, but is less sensitive than ultrasonography.

Treatment Patients who present with acute cholecystitis will need IV fluids, antibiotics, and analgesia. The antibiotics should cover gram-negative aerobes as well as anaerobes. A third-generation cephalosporin with good anaerobic coverage or a second-generation cephalosporin combined with metronidazole is a typical regimen. For patients with allergies to cephalosporins, an aminoglycoside with metronidazole is appropriate. Although the inflammation in acute cholecystitis may be sterile in some patients, more than one half will have positive cultures from the gallbladder bile. It is difficult to know who is secondarily infected; therefore, antibiotics have become a part of the management in most medical centers.

Cholecystectomy is the definitive treatment for acute cholecystitis.³⁶ In the past, the timing of cholecystectomy has been a matter of debate. Early cholecystectomy performed within 2 to 3 days of the illness is preferred over interval or delayed cholecystectomy that is performed 6 to 10 weeks after initial medical treatment and recuperation. Several studies have shown that unless the patient is unfit for surgery, early cholecystectomy should be recommended, as it offers the patient a definitive solution in one hospital admission, quicker recovery times, and an earlier return to work.³⁷

Laparoscopic cholecystectomy is the procedure of choice for acute cholecystitis. The conversion rate to an open cholecystectomy is higher (10%–15%) in the setting of acute cholecystitis than with chronic cholecystitis. The procedure is more tedious and takes longer than in the elective setting. However, when compared to the delayed operation, early operation carries a similar complication rate.

When patients present late, after 3 to 4 days of illness, or if they are unfit for surgery, they can be treated with antibiotics with laparoscopic cholecystectomy scheduled for approximately 2 months later. Approximately 20% of patients will fail to respond to initial medical therapy and require an intervention. Laparoscopic cholecystectomy could be attempted, but the conversion rate is high and some prefer to go directly for an open cholecystectomy. For those unfit for surgery, a percutaneous

cholecystostomy or an open cholecystostomy under local analgesia can be performed. Failure to improve after cholecystostomy usually is due to gangrene of the gallbladder or perforation. For these patients, surgery is unavoidable. For those who respond after cholecystostomy, the tube can be removed once cholangiography through it shows a patent ductus cysticus. Laparoscopic cholecystectomy may then be scheduled in the near future.³⁸ For the rare patients who can't tolerate surgery, the stones can be extracted via the cholecystostomy tube before its removal.³⁹

Choledocholithiasis. Common bile duct stones may be small or large and single or multiple, and are found in 6% to 12% of patients with stones in the gallbladder. The incidence increases with age. About 20% to 25% of patients above the age of 60 with symptomatic gallstones have stones in the common bile duct as well as in the gallbladder.⁴⁰ The vast majority of ductal stones in Western countries are formed within the gallbladder and migrate down the cystic duct to the common bile duct. These are classified as secondary common bile duct stones, in contrast to the primary stones that form in the bile ducts. The secondary stones are usually cholesterol stones, whereas the primary stones are usually of the brown pigment type. The primary stones are associated with biliary stasis and infection and are more commonly seen in Asian populations. The causes of biliary stasis that lead to the development of primary stones include biliary stricture, papillary stenosis, tumors, or other (secondary) stones.

Clinical Manifestations Choledochal stones may be silent and often are discovered incidentally. They may cause obstruction, complete or incomplete, or they may manifest with cholangitis or gallstone pancreatitis. The pain caused by a stone in the bile duct is very similar to that of biliary colic caused by impaction of a stone in the cystic duct. Nausea and vomiting are common. Physical examination may be normal, but mild epigastric or right upper quadrant tenderness as well as mild icterus are common. The symptoms may also be intermittent, such as pain and transient jaundice caused by a stone that temporarily impacts the ampulla but subsequently moves away, acting as a ball valve. A small stone may pass through the ampulla spontaneously with resolution of symptoms. Finally, the stones may become completely impacted, causing severe progressive jaundice. Elevation of serum bilirubin, alkaline phosphatase, and transaminases are commonly seen in patients with bile duct stones. However, in about one third of patients with common bile duct stones, the liver chemistries are normal.

Commonly, the first test, ultrasonography, is useful for documenting stones in the gallbladder (if still present), as well as determining the size of the common bile duct. As stones in the bile ducts tend to move down to the distal part of the common duct, bowel gas can preclude their demonstration on ultrasonography. A dilated common bile duct (>8 mm in diameter) on ultrasonography in a patient with gallstones, jaundice, and biliary pain is highly suggestive of common bile duct stones. Magnetic resonance cholangiography (MRC) provides excellent anatomic detail and has a sensitivity and specificity of 95% and 89%, respectively, at detecting choledocholithiasis >5 mm in diameter.¹⁸ Endoscopic cholangiography is the gold standard for diagnosing common bile duct stones. It has the distinct advantage of providing a therapeutic option at the time of diagnosis. In experienced hands, cannulation of the ampulla of Vater and diagnostic cholangiography are achieved in >90% of cases, with

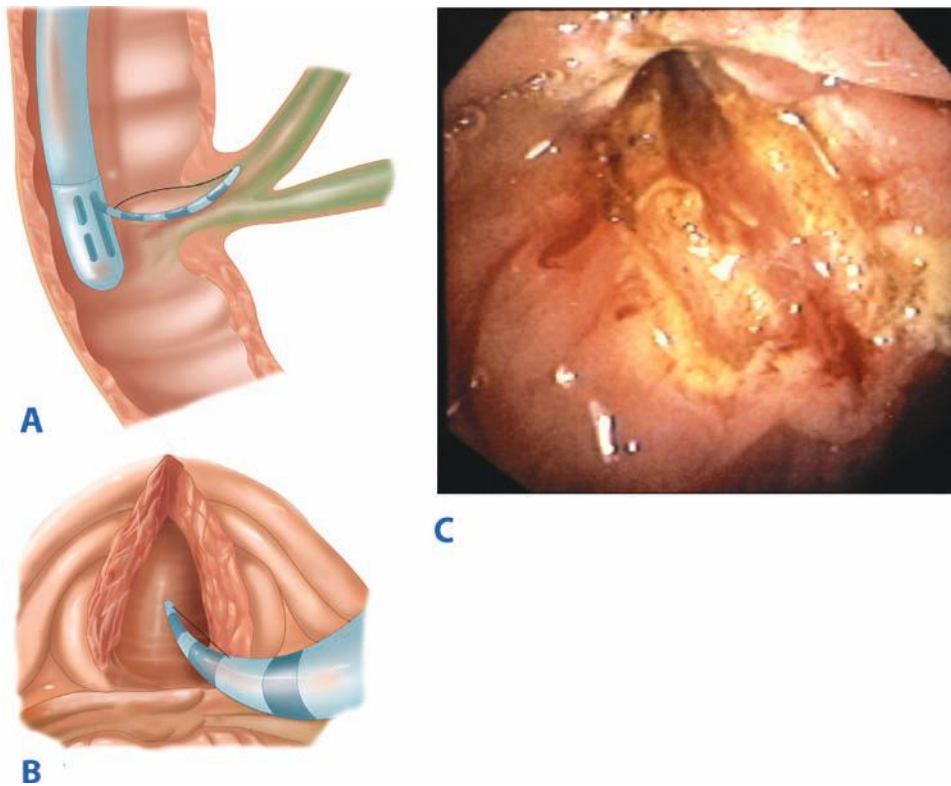


Figure 32-15. An endoscopic sphincterotomy. **A.** The sphincterotome in place. **B.** Completed sphincterotomy. **C.** Endoscopic picture of completed sphincterotomy.

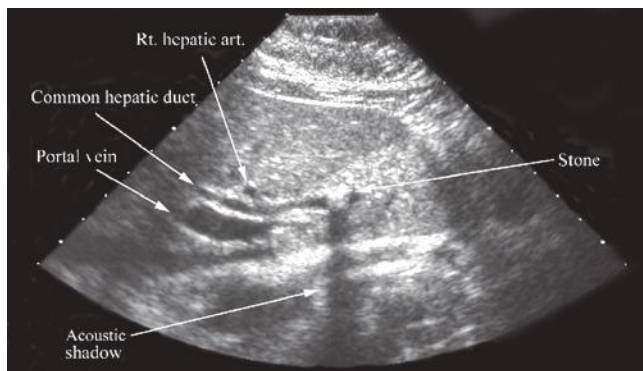
associated morbidity of <5% (mainly cholangitis and pancreatitis). Endoscopic ultrasound has been demonstrated to be as good as ERCP for detecting common bile duct stones (sensitivity of 91% and specificity of 100%), but it lacks therapeutic intervention and requires expertise, making it less available.⁴¹ PTC is rarely needed in patients with secondary common bile duct stones but is frequently performed for both diagnostic and therapeutic reasons in patients with primary bile duct stones.

Treatment For patients with symptomatic gallstones and suspected common bile duct stones, either preoperative endoscopic cholangiography or an intraoperative cholangiogram will document the bile duct stones.⁴² If an endoscopic cholangiogram reveals stones, sphincterotomy and ductal clearance of the stones is appropriate, followed by a laparoscopic cholecystectomy. An intraoperative cholangiogram at the time of cholecystectomy will also document the presence or absence of bile duct stones⁴³ (Fig. 32-15). Laparoscopic common bile duct exploration via the cystic duct or with formal choledochotomy allows the stones to be retrieved in the same setting (see Choledochal Exploration section). If the expertise and/or the instrumentation for laparoscopic common bile duct exploration are not available, a drain should be left adjacent to the cystic duct and the patient scheduled for endoscopic sphincterotomy the following day. An open common bile duct exploration is an option if the endoscopic method has already been tried or is, for some reason, not feasible. If a choledochotomy is performed, a T tube is left in place. Stones impacted in the ampulla may be difficult for both endoscopic ductal clearance as well as common bile duct exploration (open or laparoscopic). In these cases the common bile duct is usually quite dilated (about 2 cm in diameter). A choledochoduodenostomy or a Roux-en-Y choledochojejunostomy may be the best option under this circumstance.⁴⁴

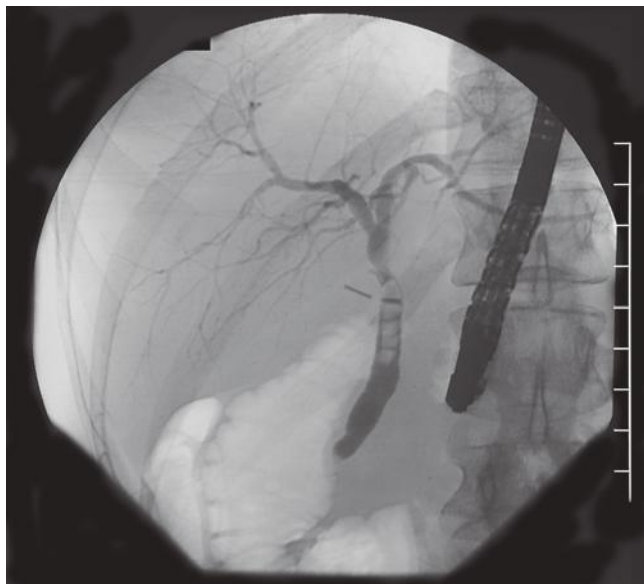
Retained or recurrent stones following cholecystectomy are best treated endoscopically (Fig. 32-16). If the stones were

deliberately left in place at the time of surgery or diagnosed shortly after the cholecystectomy, they are classified as *retained*; those diagnosed months or years later are termed *recurrent*. If a common bile duct exploration was performed and a T tube left in place, a T-tube cholangiogram is obtained before its removal. Retained stones can be retrieved either endoscopically or via the T-tube tract once it has matured (2–4 weeks). The T tube is then removed and a catheter passed through the tract into the common bile duct. Under fluoroscopic guidance, the stones are retrieved with baskets or balloons. Recurrent stones may be multiple and large. A generous endoscopic sphincterotomy will allow stone retrieval as well as spontaneous passage of retained and recurrent stones. Patients >70 years old presenting with bile duct stones should have their ductal stones cleared endoscopically. Studies comparing surgery to endoscopic treatment have documented less morbidity and mortality for endoscopic treatment in this group of patients.⁴⁵ They do not need to be submitted for a cholecystectomy, as only about 15% will become symptomatic from their gallbladder stones, and such patients can be treated as the need arises by a cholecystectomy.⁴⁶

Cholangitis. Cholangitis is one of the two main complications of choledochal stones, the other being gallstone pancreatitis. Acute cholangitis is an ascending bacterial infection in association with partial or complete obstruction of the bile ducts. Hepatic bile is sterile, and bile in the bile ducts is kept sterile by continuous bile flow and by the presence of antibacterial substances in bile, such as immunoglobulin. Mechanical hindrance to bile flow facilitates bacterial contamination. Positive bile cultures are common in the presence of bile duct stones as well as with other causes of obstruction. Biliary bacterial contamination alone does not lead to clinical cholangitis; the combination of both significant bacterial contamination and biliary obstruction is required for its development. Gallstones are the most common cause of obstruction in cholangitis; other causes are benign



A



B

Figure 32-16. Retained common bile duct stones. The patient presented 3 weeks after laparoscopic cholecystectomy. **A.** An ultrasound shows a normal or mildly dilated common bile duct with a stone. Note the location of the right hepatic artery anterior to the common hepatic duct (an anatomic variation). **B.** An endoscopic retrograde cholangiography from the same patient shows multiple stones in the common bile duct. Only the top one showed on ultrasound as the other stones lie in the distal common bile duct behind the duodenum.

and malignant strictures, parasites, instrumentation of the ducts and indwelling stents, and partially obstructed biliary-enteric anastomosis. The most common organisms cultured from bile in patients with cholangitis include *Escherichia coli*, *Klebsiella pneumoniae*, *Streptococcus faecalis*, *Enterobacter*, and *Bacteroides fragilis*.⁴⁷

Clinical Presentation Cholangitis may present as anything from a mild, intermittent, and self-limited disease to a fulminant, potentially life-threatening septicemia. The patient with gallstone-induced cholangitis is typically older and female. The most common presentation is fever, epigastric or right upper quadrant pain, and jaundice. These classic symptoms, well known as *Charcot's triad*, are present in about two thirds of patients. The illness may progress rapidly with septicemia and disorientation, known as *Reynolds' pentad* (e.g., fever, jaundice, right upper quadrant pain, septic shock, and mental status changes).

However, the presentation may be atypical, with little if any fever, jaundice, or pain. This occurs most commonly in the elderly, who may have unremarkable symptoms until they collapse with septicemia. Patients with indwelling stents rarely become jaundiced. On abdominal examination, the findings are indistinguishable from those of acute cholecystitis.⁴⁸

Diagnosis and Management Leukocytosis, hyperbilirubinemia, and elevation of alkaline phosphatase and transaminases are common and, when present, support the clinical diagnosis of cholangitis. Ultrasonography is helpful, as it will document the presence of gallbladder stones, demonstrate dilated ducts, and possibly pinpoint the site of obstruction; however, rarely will it elucidate the exact cause. The definitive diagnostic test is ERC. In cases in which ERC is not available, PTC is indicated. Both ERC and PTC will show the level and the reason for the obstruction, allow culture of the bile, possibly allow the removal of stones if present, and allow drainage of the bile ducts with drainage catheters or stents. CT scanning and MRI will show pancreatic and periampullary masses, if present, in addition to the ductal dilatation.

The initial treatment of patients with cholangitis includes IV antibiotics and fluid resuscitation. These patients may require intensive care unit monitoring and vasopressor support. Most patients will respond to these measures. However, the obstructed bile duct must be drained as soon as the patient has been stabilized. About 15% of patients will not respond to antibiotics and fluid resuscitation, and an emergency biliary decompression may be required. Biliary decompression may be accomplished endoscopically, via the percutaneous transhepatic route, or surgically. The selection of procedure should be based on the level and the nature of the biliary obstruction. Patients with choledocholithiasis or periampullary malignancies are best approached endoscopically, with sphincterotomy and stone removal, or by placement of an endoscopic biliary stent.⁴⁹ In patients in whom the obstruction is more proximal or perihilar, or when a stricture in a biliary-enteric anastomosis is the cause or the endoscopic route has failed, percutaneous transhepatic drainage is used. When neither ERC nor PTC is available, an emergent operation for decompression of the common bile duct with a T tube may be necessary and lifesaving. Definitive operative therapy should be deferred until the cholangitis has been treated and the proper diagnosis established. Patients with indwelling stents and cholangitis usually require repeated imaging and exchange of the stent over a guidewire.

Acute cholangitis is associated with an overall mortality rate of approximately 5%. When associated with renal failure, cardiac impairment, hepatic abscesses, and malignancies, the morbidity and mortality rates are much higher.

Biliary Pancreatitis. Gallstones in the common bile duct are associated with acute pancreatitis. Obstruction of the pancreatic duct by an impacted stone or temporary obstruction by a stone passing through the ampulla may lead to pancreatitis. The exact mechanism by which the obstruction of the pancreatic duct leads to pancreatitis is still not clear. An ultrasonogram of the biliary tree in patients with pancreatitis is essential. If gallstones are present and the pancreatitis is severe, an ERC with sphincterotomy and stone extraction may abort the episode of pancreatitis. Once the pancreatitis has subsided, the gallbladder should be removed during the same admission. When gallstones are present and the pancreatitis is mild and self-limited, the stone has probably passed. For these patients, a cholecystectomy and an intraoperative cholangiogram or a preoperative ERC is indicated.

Cholangiohepatitis

Cholangiohepatitis, also known as *recurrent pyogenic cholangitis*, is endemic to the Orient. It also has been encountered in the Chinese population in the United States, as well as in Europe and Australia. It affects both sexes equally and occurs most frequently in the third and fourth decades of life. Cholangiohepatitis is caused by bacterial contamination (commonly *E. coli*, *Klebsiella* species, *Bacteroides* species, or *Enterococcus faecalis*) of the biliary tree, and often is associated with biliary parasites such as *Clonorchis sinensis*, *Opisthorchis viverrini*, and *Ascaris lumbricoides*. Bacterial enzymes cause deconjugation of bilirubin, which precipitates as bile sludge. The sludge and dead bacterial cell bodies form brown pigment stones. The nucleus of the stone may contain an adult *Clonorchis* worm, an ovum, or an ascarid. These stones are formed throughout the biliary tree and cause partial obstruction that contributes to the repeated bouts of cholangitis. Biliary strictures form as a result of recurrent cholangitis and lead to further stone formation, infection, hepatic abscesses, and liver failure (secondary biliary cirrhosis).⁵⁰

The patient usually presents with pain in the right upper quadrant and epigastrium, fever, and jaundice. Recurrence of symptoms is one of the most characteristic features of the disease. The episodes may vary in severity but, without intervention, will gradually lead to malnutrition and hepatic insufficiency. An ultrasound will detect stones in the biliary tree, pneumobilia from infection due to gas-forming organisms, liver abscesses, and, occasionally, strictures. The gallbladder may be thickened but is inflamed in about 20% of patients and rarely contains stones. MRCP and PTC are the mainstays of biliary imaging for cholangiohepatitis. They can detect obstructions, define strictures and stones, and allow emergent decompression of the biliary tree in the septic patient. Hepatic abscesses may be drained percutaneously. The long-term goal of therapy is to extract stones and debris and relieve strictures. It may take several procedures and require a Roux-en-Y hepaticojejunostomy to establish biliary-enteric continuity. Occasionally, resection of involved areas of the liver may offer the best form of treatment. Recurrences are common and the prognosis is poor once hepatic insufficiency has developed.⁵¹

OPERATIVE INTERVENTIONS FOR GALLSTONE DISEASE

Cholecystostomy

A cholecystostomy decompresses and drains the distended, inflamed, hydroptic, or purulent gallbladder. It is applicable if the patient is not fit to tolerate an abdominal operation.⁵² Ultrasound-guided percutaneous drainage with a pigtail catheter is the procedure of choice. The catheter is inserted over a guidewire that has been passed through the abdominal wall, the liver, and into the gallbladder (Fig. 32-17). By passing the catheter through the liver, the risk of bile leak around the catheter is minimized.⁵³ The catheter can be removed when the inflammation has resolved and the patient's condition improved. The gallbladder can be removed later, if indicated, usually by laparoscopy. Surgical cholecystostomy with a large catheter placed under local anesthesia is rarely required today.

Cholecystectomy

Cholecystectomy is the most common major abdominal procedure performed in Western countries. Carl Langenbuch performed the

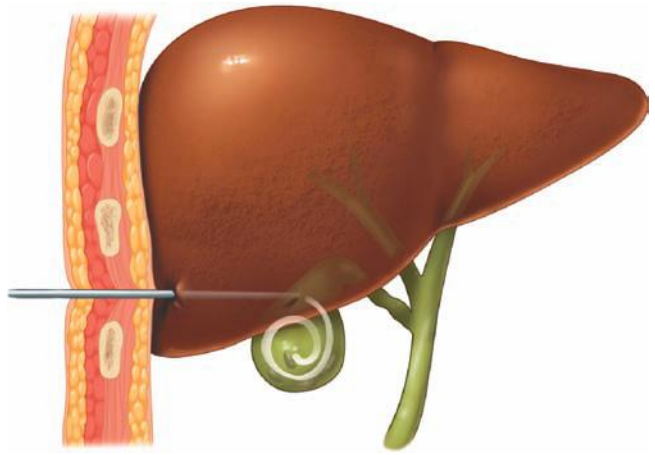


Figure 32-17. Percutaneous cholecystostomy. A pigtail catheter has been placed through the abdominal wall, the right lobe of the liver, and into the gallbladder.

first successful cholecystectomy in 1882, and for >100 years, it was the standard treatment for symptomatic gallbladder stones. Open cholecystectomy was a safe and effective treatment for both acute and chronic cholecystitis. In 1987, laparoscopic cholecystectomy was introduced by Philippe Mouret in France and quickly revolutionized the treatment of gallstones. It not only supplanted open cholecystectomy, but also more or less ended attempts for noninvasive management of gallstones, such as extracorporeal shock wave and bile salt therapy. Laparoscopic cholecystectomy offers a cure for gallstones with a minimally invasive procedure, minor pain and scarring, and early return to full activity. Today, laparoscopic cholecystectomy is the treatment of choice for symptomatic gallstones.

Absolute contraindications for the procedure are uncontrolled coagulopathy and end-stage liver disease. In the latter instance, liver transplantation, with cholecystectomy, may be used for treatment of severe recurrent gallstone disease. Rarely, patients with severe obstructive pulmonary disease or congestive heart failure (e.g., cardiac ejection fraction <20%) may not tolerate pneumoperitoneum with carbon dioxide and require open cholecystectomy. Conditions formerly believed to be relative contraindications such as acute cholecystitis, gangrene and empyema of the gallbladder, biliary-enteric fistulae, obesity, pregnancy, ventriculoperitoneal shunt, cirrhosis, and previous upper abdominal procedures are now considered risk factors for a potentially difficult laparoscopic cholecystectomy. When important anatomic structures cannot be clearly identified or when no progress is made over a set period of time, a conversion to an open procedure is usually indicated. In the elective setting, conversion to an open procedure is needed in about 5% of patients.⁵⁴ Emergent procedures may require more skill on the part of the surgeon and be needed in patients with complicated gallstone disease; the incidence of conversion is 10% to 30%. Conversion to an open procedure is not a failure, and the possibility should be discussed with the patient preoperatively.

Serious complications are rare. The mortality rate for laparoscopic cholecystectomy is about 0.1%. Wound infection and cardiopulmonary complication rates are considerably lower following laparoscopic cholecystectomy than are those for an open procedure. However, laparoscopic cholecystectomy is associated with a higher injury rate to the bile ducts (see later section, Injury to the Biliary Tract).⁵⁵

Patients undergoing cholecystectomy should have a complete blood count and liver function tests preoperatively. Prophylaxis against deep venous thrombosis with either low molecular weight heparin or compression stockings is indicated. The patient should be instructed to empty their bladder before coming to the operating room. Urinary catheters are rarely needed. An orogastric tube is placed if the stomach is distended with gas and is removed at the end of the operation.

Laparoscopic Cholecystectomy. The patient is placed supine on the operating table with the surgeon standing at the patient's left side. Some surgeons prefer to stand between the patient's legs while doing laparoscopic procedures in the upper abdomen. The pneumoperitoneum is created with carbon dioxide gas, either with an open technique or by closed needle technique. Initially, a small incision is made in the upper edge of the umbilicus. With the closed technique, a special hollow insufflation needle (Veress needle) that is spring-loaded with a retractable cutting outer sheath is inserted into the peritoneal cavity and used for insufflation. Once an adequate pneumoperitoneum is established, a 10-mm trocar is inserted through the supraumbilical incision. With the open technique, the supraumbilical incision is carried through the fascia and into the peritoneal cavity. A special blunt cannula (Hasson cannula) is inserted into the peritoneal cavity and anchored to the fascia. The laparoscope with the attached video camera is passed through the umbilical port and the abdomen inspected. Three additional ports are placed under direct vision (Fig. 32-18). A 10-mm port is placed in the epigastrium, a 5-mm port in the middle of the clavicular line, and a 5-mm port in the right flank, in line with the gallbladder fundus. Occasionally, a fifth port is required for better visualization in patients recovering from pancreatitis or those with semi-acute cholecystitis, as well as in very obese patients.

Through the lateral-most port, a grasper is used to grasp the gallbladder fundus. It is retracted over the liver edge upward and toward the patient's right shoulder to expose the proximal gallbladder and the hilar area. Exposure of the hilar area may be facilitated by placing the patient in reverse Trendelenburg position with slight tilting of the table to bring the right side up. Through the midclavicular port a second grasper is used to grasp the gallbladder infundibulum and retract it laterally to expose the triangle of Calot. Before this, it may be necessary to take down any adhesions between the omentum, duodenum, or colon, and the gallbladder. Most of the dissection is carried out through the epigastric port using a dissector, hook cautery, or scissors.

The dissection starts at the junction of the gallbladder and the cystic duct. A helpful anatomic landmark is the cystic artery lymph node. The peritoneum, fat, and loose areolar tissue around the gallbladder and the cystic duct–gallbladder junction is dissected off toward the bile duct. This is continued until the gallbladder neck and the proximal cystic duct are clearly identified. The next step is the identification of the cystic artery, which usually runs parallel to and somewhat behind the cystic duct. A hemoclip is placed on the proximal cystic duct. If an intraoperative cholangiogram is to be performed, a small incision is made on the anterior surface of the cystic duct, just proximal to the clip, and a cholangiogram catheter is passed into the cystic duct. Once the cholangiogram is completed, the catheter is removed and two clips are placed proximal to the incision, and the cystic duct is divided. A wide cystic duct may be too big for clips, requiring the placement of a pre-tied loop ligature to close. The cystic artery is then clipped and divided.

Finally, the gallbladder is dissected out of the gallbladder fossa, using either a hook or scissors with electrocautery. Before the gallbladder is removed from the liver edge, the operative field is carefully searched for bleeding points, and the placement of the clips on the cystic duct and cystic artery is inspected. The gallbladder is removed through the umbilical incision. The fascial defect and skin incision may need to be enlarged if the stones are large. If the gallbladder is acutely inflamed or gangrenous, or if the gallbladder is perforated, it is placed in a retrieval bag before it is removed from the abdomen. Any bile or blood that has accumulated during the procedure is sucked away, and if stones were spilled, they are retrieved, placed inside a retrieval bag, and removed. If the gallbladder was severely inflamed or gangrenous or if any bile or blood is expected to accumulate, a closed-suction drain can be placed through one of the 5-mm ports and left underneath the right liver lobe close to the gallbladder fossa.

Open Cholecystectomy. The same surgical principles apply for laparoscopic and open cholecystectomies. Open cholecystectomy has become an uncommon procedure, usually performed either as a conversion from laparoscopic cholecystectomy or as a second procedure in patients who require laparotomy for another reason. After the cystic artery and cystic duct have been identified, the gallbladder is dissected free from the liver bed, starting at the fundus. The dissection is carried proximally toward the cystic artery and the cystic duct, which are then ligated and divided.

Intraoperative Cholangiogram or Ultrasound. The bile ducts are visualized under fluoroscopy by injecting contrast through a catheter placed in the cystic duct (Fig. 32-19A). Their size can then be evaluated, the presence or absence of common bile duct stones assessed, and filling defects confirmed, as the dye passes into the duodenum. Routine intraoperative cholangiography will detect stones in approximately 7% of patients, as well as outlining the anatomy and detecting injury^{56,57} (Fig. 32-19B). A selective intraoperative cholangiogram can be performed when the patient has a history of abnormal liver function tests, pancreatitis, jaundice, a large duct and small stones, a dilated duct on preoperative ultrasonography, and if preoperative endoscopic cholangiography for the above reasons was unsuccessful. Laparoscopic ultrasonography is as accurate as intraoperative cholangiography in detecting common bile duct stones, and it is less invasive; however, it requires more skill to perform and interpret.^{58,59}

Common Bile Duct Exploration

Common bile duct stones that are detected intraoperatively on intraoperative cholangiography or ultrasonography may be managed with laparoscopic choledochal exploration as a part of the laparoscopic cholecystectomy procedure. Patients with common bile duct stones detected preoperatively, but in whom endoscopic clearance was either not available or unsuccessful, should also have their ductal stones managed during the cholecystectomy.

If the stones in the duct are small, they may sometimes be flushed into the duodenum with saline irrigation via the cholangiography catheter after the sphincter of Oddi has been relaxed with glucagon. If irrigation is unsuccessful, a balloon catheter may be passed via the cystic duct and down the common bile duct, where it is inflated and withdrawn to retrieve the stones. The next attempt is usually made with a wire basket passed

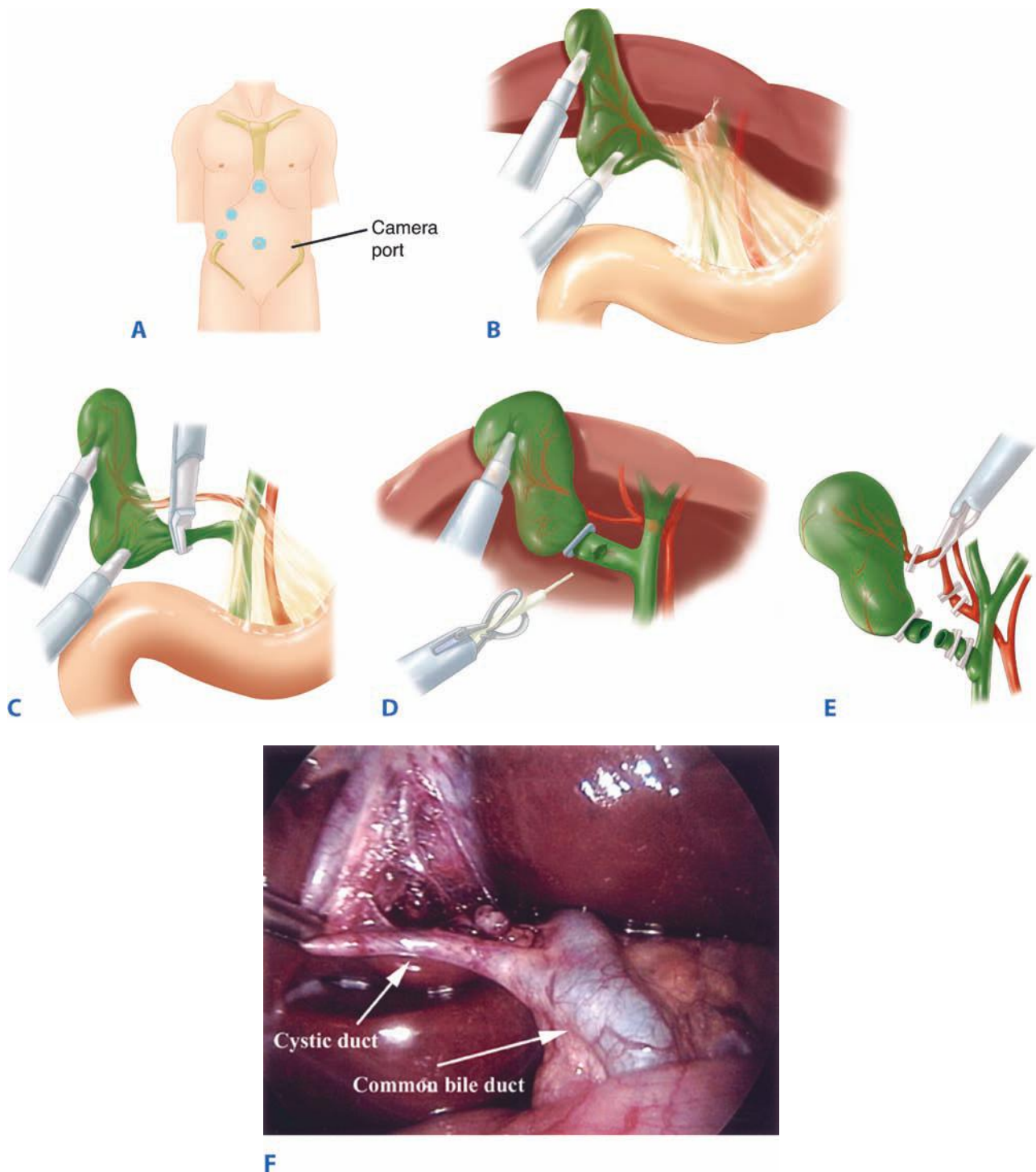


Figure 32-18. Laparoscopic cholecystectomy. **A.** The trocar placement. **B.** The fundus has been grasped and retracted cephalad to expose the proximal gallbladder and the hepatoduodenal ligament. Another grasper retracts the gallbladder infundibulum posterolaterally to better expose the triangle of Calot (hepatocystic triangle bound by the common hepatic duct, cystic duct, and liver margin). **C.** The triangle of Calot has been opened and the neck of the gallbladder and part of the cystic duct dissected free. A clip is being placed on the cystic duct–gallbladder junction. **D.** A small opening has been made into the cystic duct, and a choledochogram catheter is to be inserted. **E.** The cystic duct has been divided, and the cystic artery is being divided. **F.** An intraoperative picture showing a grasper pulling the infundibulum of the gallbladder laterally, exposing the triangle of Calot that has been dissected. The cystic artery can be seen crossing the dissected area upward and to the left.

under fluoroscopic guidance to catch the stones (Fig. 32-20). If needed, a flexible choledochoscope is the next step. The cystic duct may have to be dilated to allow its passage. Once in the common bile duct, the stones may be caught into a wire basket under direct vision or pushed into the duodenum. When the

duct has been cleared, the cystic duct is ligated and cut and the cholecystectomy completed. Occasionally, a choledochotomy, an incision into the common bile duct itself, is necessary. The flexible choledochoscope is then passed into the duct for visualization and clearance of stones. The choledochotomy is sutured

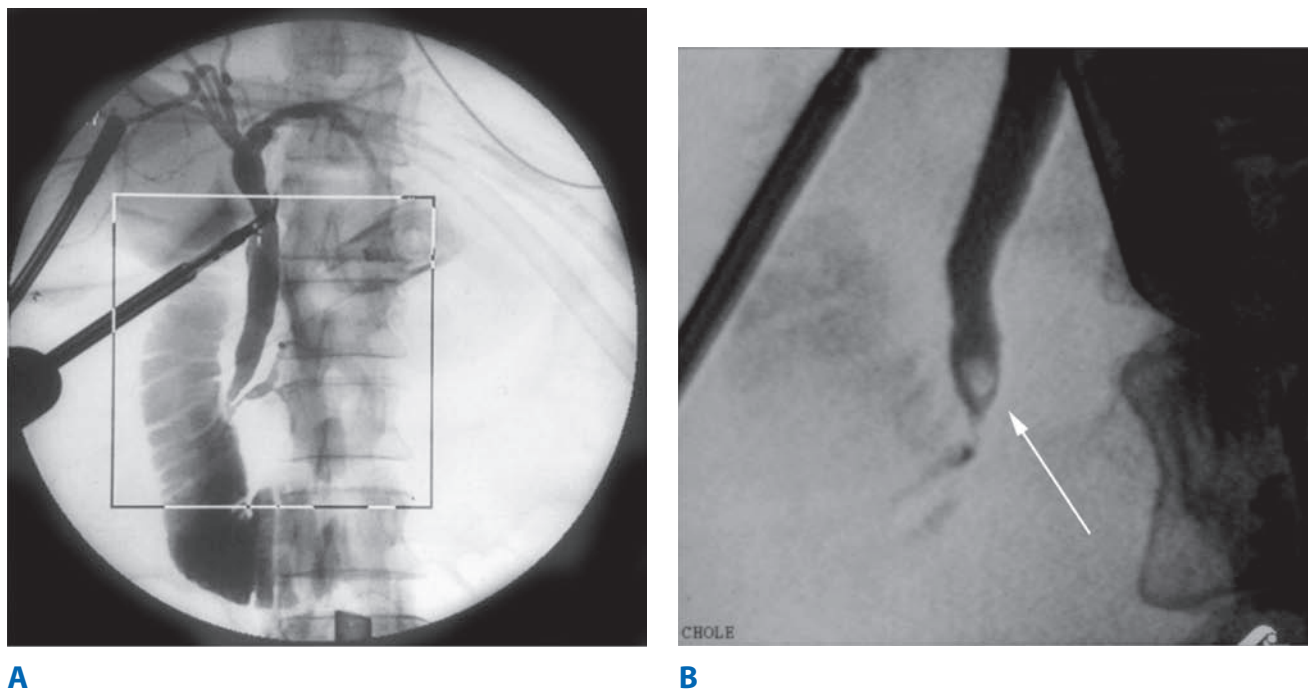


Figure 32-19. **A.** An intraoperative cholangiogram. The bile ducts are of normal size, with no intraluminal filling defects. The left and the right hepatic ducts are visualized, the distal common bile duct tapers down, and the contrast empties into the duodenum. Cholangiography grasper that holds the catheter and the cystic duct stump partly projects over the common hepatic duct. **B.** An intraoperative cholangiogram showing common bile duct stone (*arrow*). A small amount of contrast has passed into the duodenum.

with a T tube left in the common bile duct with one end taken out through the abdominal wall for decompression of the bile ducts. By managing common bile duct stones at the time of the cholecystectomy, the patients can have all of their gallstone disease treated with one invasive procedure. It does, however, depend on the available surgical expertise.⁶⁰

Common Bile Duct Drainage Procedures

Rarely, when the stones cannot be cleared and/or when the duct is very dilated (>1.5 cm in diameter), a choledochal drainage procedure is performed (Fig. 32-21). Choledochoduodenostomy is performed by mobilizing the second part of the duodenum (a Kocher maneuver) and anastomosing it side to side with the common bile duct.

A choledochojejunostomy is done by bringing up a 45-cm Roux-en-Y limb of jejunum and anastomosing it end to side to the common bile duct.

Choledochojejunostomy or, more often, a hepaticojejunostomy, also can be used to repair common bile duct strictures or as a palliative procedure for malignant obstruction in the periampullary region. If the common bile duct has been transected or injured, it can be managed by an end-to-end choledochojejunostomy.

Transduodenal Sphincterotomy

In the majority of cases, endoscopic sphincterotomy has replaced open transduodenal sphincterotomy. If an open procedure for common bile duct stones is being done in which the stones are impacted, recurrent, or multiple, the transduodenal approach may be feasible. The duodenum is incised transversely. The sphincter then is incised at the 11 o'clock position to avoid injury to the pancreatic duct. The impacted stones are removed, as are large stones from the duct. There is no need to

fully clear the duct of stones, as they can pass spontaneously through the cut sphincter.

OTHER BENIGN DISEASES AND LESIONS

Acalculous Cholecystitis

Acute inflammation of the gallbladder can occur without gallstones. Acalculous cholecystitis typically develops in critically ill patients in the intensive care unit. Patients on parenteral nutrition with extensive burns, sepsis, major operations, multiple trauma, or prolonged illness with multiple organ system failure are at risk for developing acalculous cholecystitis. The cause is unknown, but gallbladder distention with bile stasis and ischemia has been implicated as causative factors. Pathologic examination of the gallbladder wall reveals edema of the serosa and muscular layers, with patchy thrombosis of arterioles and venules.^{61,62}

The symptoms and signs depend on the condition of the patient, but in the alert patient, they are similar to acute calculous cholecystitis, with right upper quadrant pain and tenderness, fever, and leukocytosis. In the sedated or unconscious patient, the clinical features are often masked, but fever and elevated WBC count, as well as elevation of alkaline phosphatase and bilirubin, are indications for further investigation.

Ultrasonography is usually the diagnostic test of choice, as it can be done bedside in the intensive care unit. It can demonstrate the distended gallbladder with thickened wall, biliary sludge, pericholecystic fluid, and the presence or absence of abscess formation. Abdominal CT scan can aid in the diagnosis of acalculous cholecystitis and additionally allows imaging of the abdominal cavity and chest to rule out other sources of infection. A HIDA scan can be useful and will show nonvisualization of

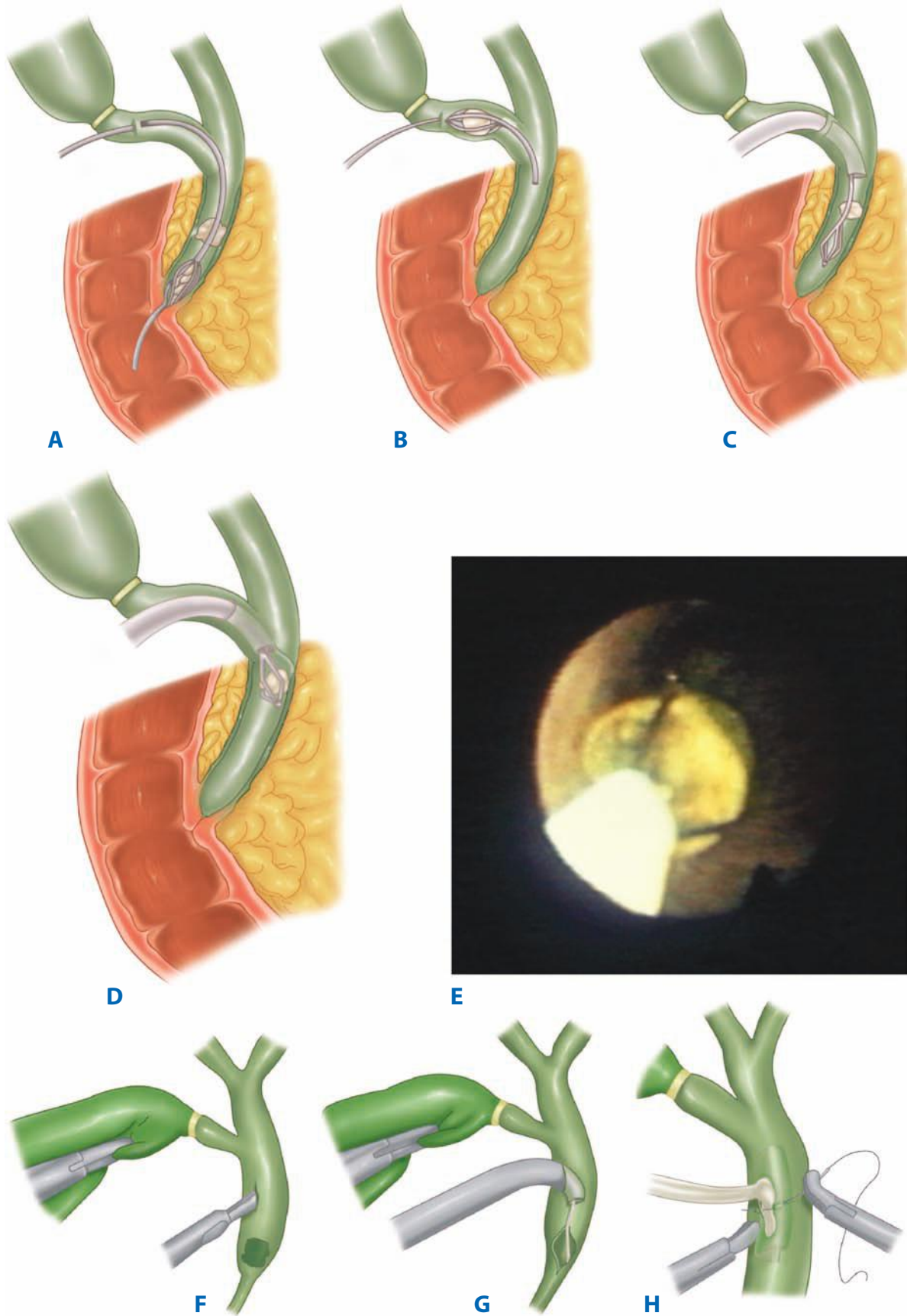


Figure 32-20. Laparoscopic bile duct exploration. I. Transcystic basket retrieval using fluoroscopy. **A.** The basket has been advanced past the stone and opened. **B.** The stone has been entrapped in the basket, and together, they are removed from the cystic duct. II. Transcystic choledochoscopy and stone removal. **C.** The basket has been passed through the working channel of the scope, and the stone is entrapped under direct vision. **D.** Entrapped stone. **E.** A view from the choledochoscope. III. Choledochotomy and stone removal. **F.** A small incision is made in the common bile duct. **G.** The common bile duct is cleared of stones. **H.** A T tube left in the common bile duct with one end taken out through the abdominal wall for decompression of the bile ducts.

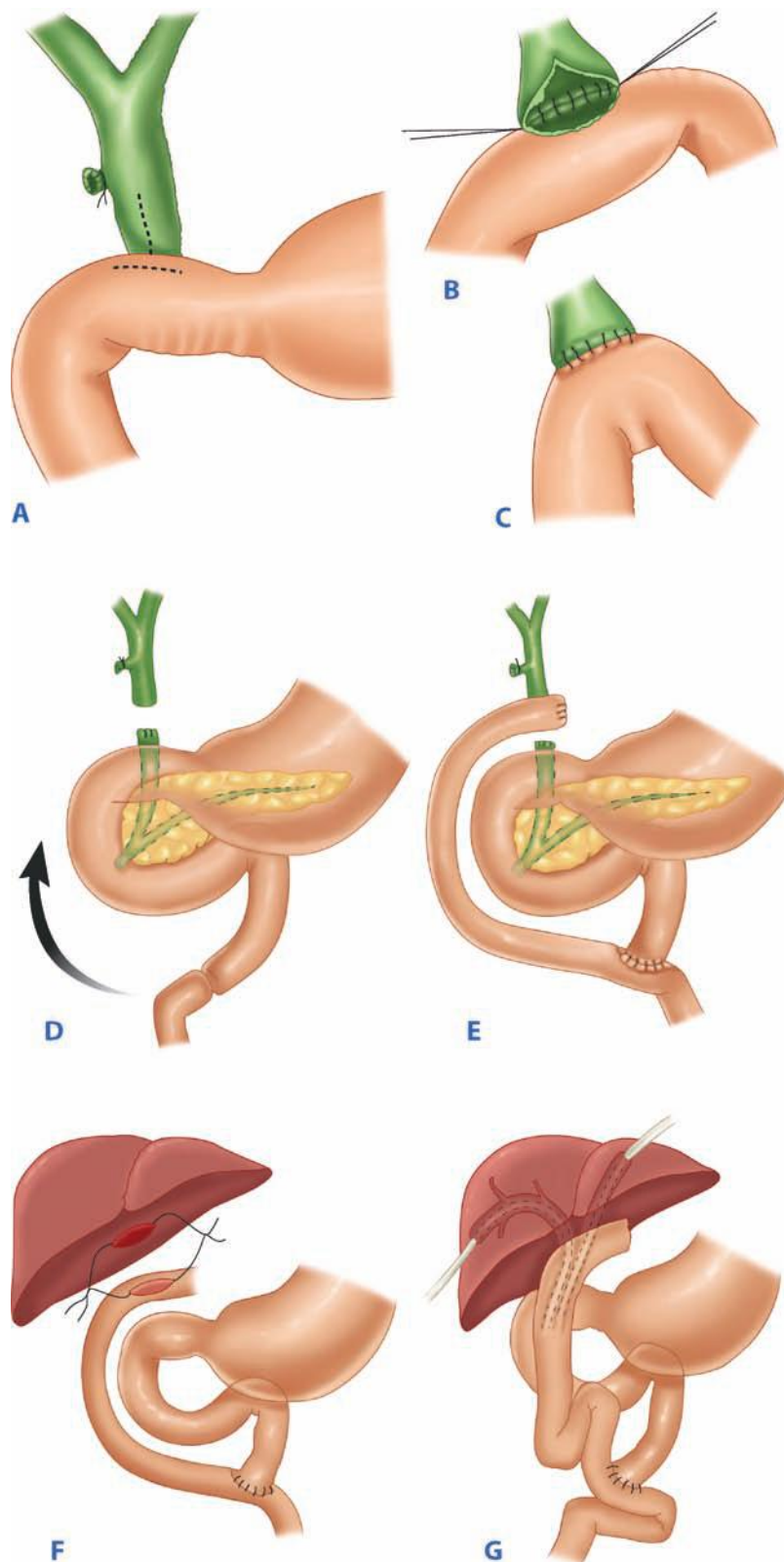


Figure 32-21. Biliary enteric anastomoses. There are three types. I. Choledochoduodenostomy. **A.** The distal common bile duct is opened longitudinally, as is the duodenum. **B.** Interrupted sutures are placed between the common bile duct and the duodenum. **C.** Completed choledochoduodenostomy. II. Choledochojejunostomy. **D.** The common bile duct and small bowel are divided. **E.** A Roux-en-Y limb of jejunum is anastomosed to the choledochus. III. Hepaticojejunostomy. **F.** The entire extrahepatic biliary tree has been resected and the reconstruction done with a Roux-en-Y limb of jejunum. **G.** Percutaneous transhepatic stents are placed across hepaticojejunostomy.

the gallbladder, but it is a less sensitive test with high false-positive rates in patients who are fasting, on total parenteral nutrition, or have liver disease.⁶³ Acalculous cholecystitis requires urgent intervention. Percutaneous ultrasound- or CT-guided cholecystostomy is the treatment of choice for these patients, as they are usually unfit for surgery (see Fig. 32-17). If the diagnosis is uncertain, percutaneous cholecystostomy is both diagnostic and therapeutic. About 90% of patients will improve with the percutaneous cholecystostomy. However, if they do not improve, other steps, such as open cholecystostomy or cholecystectomy, may be required. If needed, cholecystectomy is performed after the patient has recovered from the underlying disease.

Biliary Cysts

Choledochal cysts are congenital cystic dilatations of the extrahepatic and/or intrahepatic biliary tree. They are rare—the incidence is between 1:100,000 and 1:150,000 in populations of Western countries—but are more commonly seen in populations of Eastern countries. Choledochal cysts affect females three to eight times more often than males. Although frequently diagnosed in infancy or childhood, as many as one half of the patients have reached adulthood when diagnosed. The cause is unknown. Weakness of the bile duct wall and increased pressure secondary to partial biliary obstruction are required for biliary

cyst formation. More than 90% of patients have an anomalous pancreaticobiliary duct junction, with the pancreatic duct joining the common bile duct >1 cm proximal to the ampulla. This results in a long common channel that may allow free reflux of pancreatic secretions into the biliary tract, leading to inflammatory changes, increased biliary pressure, and cyst formation. Choledochal cysts are classified into five types (Fig. 32-22). The cysts are lined with cuboidal epithelium and can vary in size from 2 cm in diameter to giant cysts.

Adults commonly present with jaundice or cholangitis. Less than one half of patients present with the classic clinical triad of abdominal pain, jaundice, and a mass. Ultrasonography or CT scanning will confirm the diagnosis, but endoscopic cholangiography, transhepatic cholangiography, or MRC is required to assess the biliary anatomy and to plan the appropriate surgical treatment. For types I, II, and IV, excision of the extrahepatic biliary tree, including cholecystectomy, with a Roux-en-Y hepaticojejunostomy is ideal. In type IV, additional segmental resection of the liver may be appropriate, particularly if intrahepatic stones, strictures, or abscesses are present or if the dilata-tions are confined to one lobe. The risk of cholangiocarcinoma developing in choledochal cysts is as high as 15% in adults and supports complete excision when they are diagnosed. For type III, sphincterotomy is recommended.⁶⁴

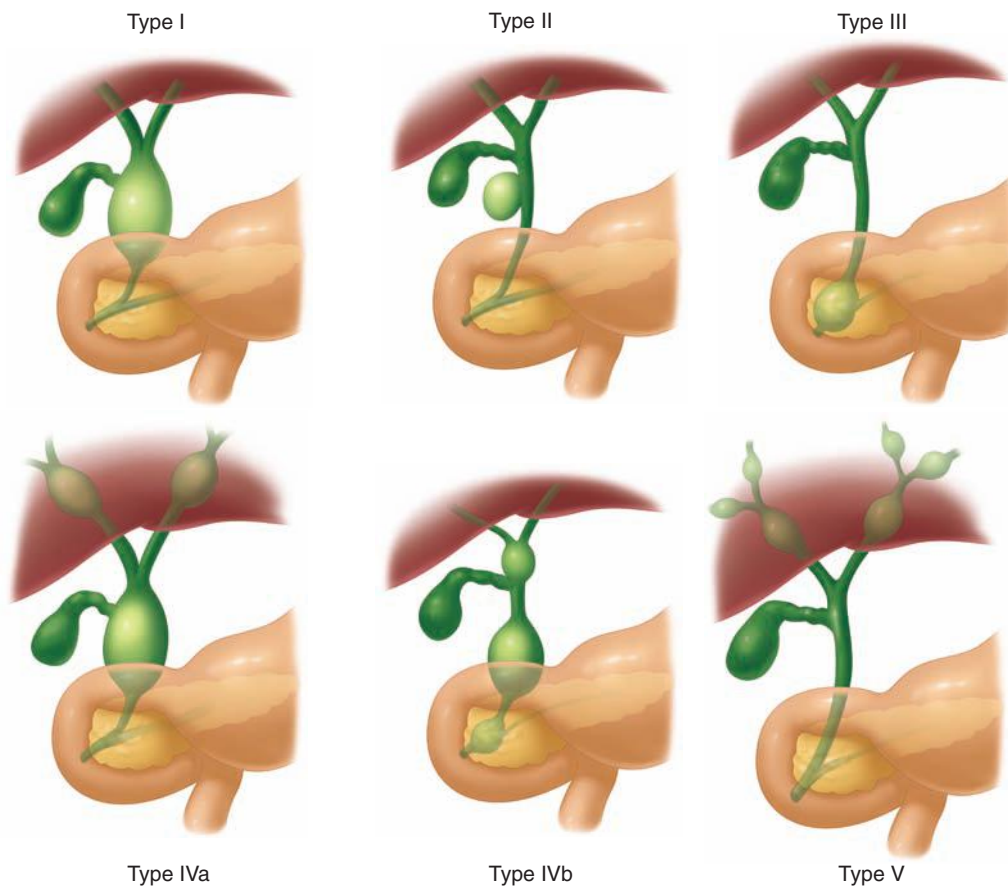


Figure 32-22. Classification of choledochal cysts. Type I, fusiform or cystic dilations of the extrahepatic biliary tree, is the most common type, making up >50% of the choledochal cysts. Type II, saccular diverticulum of an extrahepatic bile duct. Rare, <5% of choledochal cysts. Type III, bile duct dilatation within the duodenal wall (choledochoceles), makes up about 5% of choledochal cysts. Types IVa and IVb, multiple cysts, make up 5% to 10% of choledochal cysts. Type IVa affects both extrahepatic and intrahepatic bile ducts, whereas type IVb cysts affect the extrahepatic bile ducts only. Type V, intrahepatic biliary cysts, is very rare and makes up 1% of choledochal cysts.

Sclerosing Cholangitis

Sclerosing cholangitis is an uncommon disease characterized by inflammatory strictures involving the intrahepatic and extrahepatic biliary tree. It is a progressive disease that eventually results in secondary biliary cirrhosis. Sometimes, biliary strictures are clearly secondary to bile duct stones, acute cholangitis, previous biliary surgery, or toxic agents, and are termed *secondary sclerosing cholangitis*. However, primary sclerosing cholangitis is a disease entity of its own, with no known attributing cause. It is associated with ulcerative colitis in about two thirds of patients. Other diseases associated with sclerosing cholangitis include Riedel's thyroiditis and retroperitoneal fibrosis. Autoimmune reaction, chronic low-grade bacterial or viral infection, toxic reaction, and genetic factors have all been suggested to play a role in its pathogenesis. The human leukocyte antigen haplotypes HLA-B8, -DR3, -DQ2, and -DRw52A, commonly found in patients with autoimmune diseases, also are more frequently seen in patients with sclerosing cholangitis than in controls. Patients with sclerosing cholangitis are at risk for developing cholangiocarcinoma. Eventually, 10% to 20% of the patients will develop cancer. Cholangiocarcinoma can present at any time during the disease process and does not correlate with the extent of sclerosing cholangitis or the development of liver failure, but frequently follows an aggressive course.

The mean age of presentation is 30 to 45 years, and men are affected twice as commonly as women. The usual presentation is intermittent jaundice, fatigue, weight loss, pruritus, and abdominal pain. Symptoms of acute cholangitis are rare, without preceding biliary tract intervention or surgery. More than one half of patients are symptomatic when diagnosed. In several patients with ulcerative colitis, abnormal liver function tests found on routine testing lead to the diagnosis. The clinical course in sclerosing cholangitis is highly variable, but cyclic remissions and exacerbations are typical. However, some patients remain asymptomatic for years, while others progress rapidly with the obliterative inflammatory changes leading to secondary biliary cirrhosis and liver failure. In patients with associated ulcerative colitis, the course of each disease seems independent of the other. Colectomy for the colitis makes no difference to the course of primary sclerosing cholangitis. The median survival for patients with primary sclerosing cholangitis from the time of diagnosis ranges from 10 to 12 years, and most die from hepatic failure.⁶⁵

The clinical presentation and elevation of alkaline phosphatase and bilirubin may suggest the diagnosis, but ERC, revealing multiple dilatations and strictures (beading) of both the intra- and extrahepatic biliary tree, confirms it. The hepatic duct bifurcation is often the most severely affected segment. A liver biopsy may not be diagnostic, but is important to determine the degree of hepatic fibrosis and the presence of cirrhosis. Sclerosing cholangitis is followed by ERC and liver biopsies to provide appropriate management.

There is no known effective medical therapy for primary sclerosing cholangitis and no known curative treatment. Corticosteroids, immunosuppressants, ursodeoxycholic acid, and antibiotics have been disappointing. Biliary strictures can be dilated and stented either endoscopically or percutaneously. These measures have given short-term improvements in symptoms and serum bilirubin levels and long-term improvements in only less than one half of the patients. Surgical management with resection of the extrahepatic biliary tree and hepaticojejunostomy has produced reasonable results in patients with

extrahepatic and bifurcation strictures, but without cirrhosis or significant hepatic fibrosis.⁶⁶ In patients with sclerosing cholangitis and advanced liver disease, liver transplantation is the only option. It offers excellent results, with overall 5-year survival as high as 85%. Primary sclerosing cholangitis recurs in 10% to 20% of patients and may require retransplantation.^{67,68}

Stenosis of the Sphincter of Oddi

A benign stenosis of the outlet of the common bile duct is usually associated with inflammation, fibrosis, or muscular hypertrophy. The pathogenesis is unclear, but trauma from the passage of stones, sphincter motility disorders, and congenital anomalies have been suggested. Episodic pain of the biliary type with abnormal liver function tests is a common presentation. However, recurrent jaundice or pancreatitis also may play a role. A dilated common bile duct that is difficult to cannulate with delayed emptying of the contrast are useful diagnostic features. Ampullary manometry and special provocation tests are available in specialized units. If the diagnosis is well established, endoscopic or operative sphincterotomy will yield good results.⁶⁹

Bile Duct Strictures

Benign bile duct strictures can have numerous causes. However, the vast majority were caused by operative injury, most commonly by laparoscopic cholecystectomy (see later section, Injury to the Biliary Tract). Other causes include fibrosis due to chronic pancreatitis, common bile duct stones, acute cholangitis, biliary obstruction due to cholelithiasis (Mirizzi's syndrome), sclerosing cholangitis, cholangiohepatitis, and strictures of a biliary-enteric anastomosis. Bile duct strictures that go unrecognized or are improperly managed may lead to recurrent cholangitis, secondary biliary cirrhosis, and portal hypertension.⁷⁰

Patients with bile duct strictures most commonly present with episodes of cholangitis. Less commonly, they may present with jaundice without evidence of infection. Liver function tests usually show evidence of cholestasis. An ultrasound or a CT scan will show dilated bile ducts proximal to the stricture, as well as provide some information about the level of the stenosis. MRC will also provide good anatomic information about the location and the degree of dilatation. In patients with intrahepatic ductal dilatation, a percutaneous transhepatic cholangiogram will outline the proximal biliary tree, define the stricture and its location, and allow decompression of the biliary tree with transhepatic catheters or stents (Fig. 32-23). An endoscopic cholangiogram will outline the distal bile duct. Treatment depends on the location and the cause of the stricture. Percutaneous or endoscopic dilatation and/or stent placement give good results in more than one half of patients. Surgery with Roux-en-Y choledochojejunostomy or hepaticojejunostomy is the standard of care with good or excellent results in 80% to 90% of patients.⁷¹ Choledochoduodenostomy may be a choice for strictures in the distal-most part of the common bile duct.

INJURY TO THE BILIARY TRACT

Gallbladder

Injuries to the gallbladder are uncommon. Penetrating injuries are usually caused by gunshot wounds or stab wounds, and rarely by a needle biopsy procedure of the liver. Nonpenetrating trauma is extremely rare. These types of injury to the gallbladder include contusion, avulsion, laceration, rupture, and

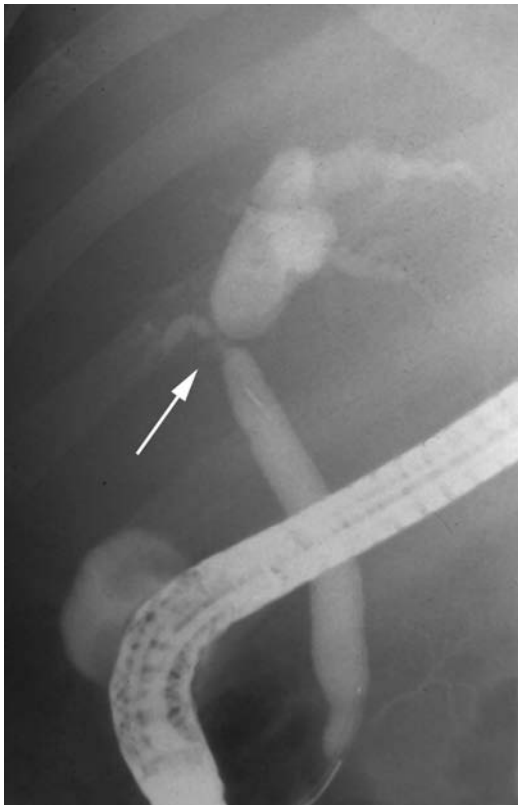


Figure 32-23. An endoscopic retrograde cholangiography showing stricture of the common hepatic duct (*arrow*). The patient had recently had a laparoscopic cholecystectomy; clips from the operation can be seen projected over the common bile duct.

traumatic cholecystitis. The treatment of choice is cholecystectomy, and the prognosis is directly related to the type and incidence of associated injury.

Extrahepatic Bile Ducts

Penetrating trauma to the extrahepatic bile ducts is rare and is usually associated with trauma to other viscera. The great majority of injuries of the extrahepatic biliary duct system are iatrogenic, occurring in the course of laparoscopic or open cholecystectomies.⁷² Less commonly, biliary injury is associated with common bile duct exploration, division or mobilization of the duodenum during gastrectomy, and dissection of the hepatic hilum during liver resections. The exact incidence of bile duct injury during cholecystectomy is unknown, but data suggest that during open cholecystectomy, the incidence is relatively low (about 0.1% to 0.2%). However, the incidence during laparoscopic cholecystectomy, as derived from state and national databases, estimates the rate of major injury to range between 0.1% to 0.55%, and the incidence of minor injuries and bile leaks to be about 0.3%, a total of 0.85%. Limited view, difficult orientation and assessment of depth on a two-dimensional image, and the lack of tactile sensation and unusual manual skills that are needed have led to the rise in bile duct injury during laparoscopic cholecystectomy.⁷³

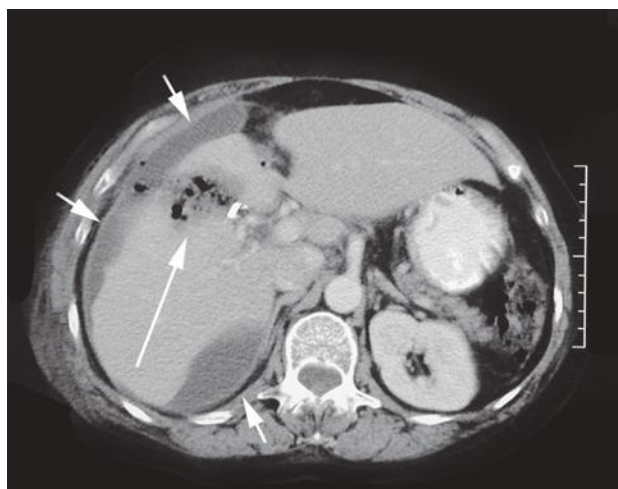
A number of different factors are associated with bile duct injury during laparoscopic cholecystectomy. These include acute or chronic inflammation, obesity, anatomic variations, and bleeding. Surgical technique with inadequate exposure and failure to identify structures before ligating or dividing them are the

most common cause of significant biliary injury. The bile ducts may be narrow and can be mistaken for the cystic duct. The cystic duct may run along side the common bile duct before joining it, leading the surgeon to the wrong place. Additionally, the cystic duct may enter the right hepatic duct, and the right hepatic duct may run aberrantly, coursing through the triangle of Calot and entering the common hepatic duct. A number of intraoperative technical factors have been implicated in biliary injuries. Excessive cephalad retraction of the gallbladder may align the cystic duct with the common bile duct, and the latter is then mistaken for the cystic duct and clipped and divided. The use of an angled laparoscope instead of an end-viewing one will help visualize the anatomic structures, in particular those around the triangle of Calot. An angled scope also will aid in the proper placement of clips. Careless use of electrocautery may lead to thermal injury. Dissection deep into the liver parenchyma may cause injury to intrahepatic ducts, and poor clip placement close to the hilar area or to structures not well visualized can result in a clip across a bile duct.^{74,75}

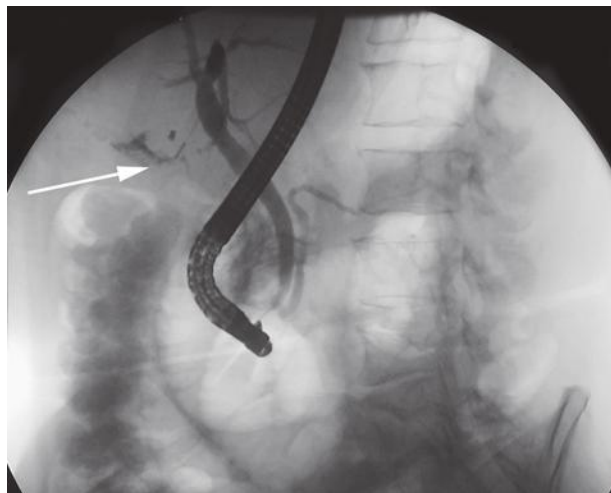The routine use of intraoperative fluoroscopic cholangiography to prevent bile duct injury is controversial.⁷⁶ Routine use may limit the extent of injury but does not seem to prevent it entirely. Nonetheless, the frequency of bile duct injuries is cut by 50% when an intraoperative cholangiogram is performed. Critical to the successful use of cholangiography is accurate interpretation of the imaging. It is important to check that the whole biliary system fills with contrast, including both major ducts on the right and the left hepatic duct, and that there is no extravasation of contrast.

Diagnosis. Only about 25% of major bile duct injuries (common bile duct or hepatic duct) are recognized at the time of operation. Most commonly, intraoperative bile leakage, recognition of the correct anatomy, and an abnormal cholangiogram lead to the diagnosis of a bile duct injury. More than half of patients with biliary injury will present within the first postoperative month. The remainder will present months or years later, with recurrent cholangitis or cirrhosis from a remote bile duct injury. In the early postoperative period, patients present either with progressive elevation of liver function tests due to an occluded or a stenosed bile duct, or with a bile leak from an injured duct. Bile leak, most commonly from the cystic duct stump, a transected aberrant right hepatic duct, or a lateral injury to the main bile duct, usually presents with pain, fever, and a mild elevation of liver function tests. A CT scan or an ultrasound will show either a collection (biloma) in the gallbladder area or free fluid (bile) in the peritoneum (Fig. 32-24). Bilious drainage through operatively placed drains or through the wounds is abnormal. The site of the bile leak can be confirmed noninvasively with a HIDA scan. In patients with a surgical drain or a percutaneously placed catheter, injection of water-soluble contrast media through the drainage tract (sinogram) can often define the site of leakage and the anatomy of the biliary tree.⁷⁷

CT scan and ultrasound also are important in the initial evaluation of the jaundiced patient, as they can demonstrate the dilated part of the biliary tree proximal to the stenosis or obstruction, and may identify the level of the extrahepatic bile duct obstruction. In the jaundiced patient with dilated intrahepatic ducts, a percutaneous cholangiogram will outline the anatomy and the proximal extent of the injury and allow decompression of the biliary tree with catheter or stent placements. An endoscopic cholangiogram demonstrates the anatomy distal to the injury and may allow the placement of stents across a stricture to



A



B

Figure 32-24. A. Computed tomographic scan of a patient with bile leak after cholecystectomy. The *short arrows* indicate the intraperitoneal collections. Both air and bile are seen in the gallbladder bed (*long arrow*) as well as a surgical clip. B. An endoscopic retrograde cholangiography from the same patient showing a leak from the cystic duct stump (*arrow*). Note the filling of the pancreatic duct.

relieve an obstruction (see Fig. 32-23). MRI cholangiography, if available, provides an excellent, noninvasive delineation of the biliary anatomy both proximal and distal to the injury.

Management. The management of bile duct injuries depends on the type, extent, and level of injury, and the time of its diagnosis. Initial proper treatment of bile duct injury diagnosed during the cholecystectomy can avoid the development of a bile duct stricture. If a major injury is discovered and an experienced biliary surgeon is not available, an external drain and, if necessary, transhepatic biliary catheters are placed, and the patient is transferred to a referral center.⁷³

Transected bile ducts <3 mm or those draining a single hepatic segment can safely be ligated. If the injured duct is ≥ 4 mm, it is likely to drain multiple segments or an entire lobe, and thus needs to be reimplemented. Lateral injury to the common bile duct or the common hepatic duct, recognized at the time of surgery, is best managed with a T-tube placement. If the injury is a small incision in the duct, the T tube may be placed through it as if it were a formal choledochotomy. In more extensive lateral injuries, the T tube should be placed through a separate choledochotomy and the injury closed over the T-tube end to minimize the risk of subsequent stricture formation.

Major bile duct injuries such as transection of the common hepatic or common bile duct are best managed at the time of injury. In many of these major injuries, the bile duct has not only been transected, but a variable length of the duct removed. This injury usually requires a biliary enteric anastomosis with a jejunal loop. Either an end-to-side Roux-en-Y choledochojejunostomy or, more commonly, a Roux-en-Y hepaticojejunostomy should be performed. Transhepatic biliary catheters are placed through the anastomosis to stent it and to provide access to the biliary tract for drainage and imaging. Although rare, when the injury is to the distal common bile duct, a choledochoduodenostomy can be performed. If there is no or minimal loss of ductal length, a duct-to-duct repair may be done over a T tube that is placed through a separate incision. It is critical to perform a tension-free anastomosis to minimize the high risk of postoperative stricture formation.⁶⁶

Cystic duct leaks can usually be managed with percutaneous drainage of intra-abdominal fluid collections followed by an endoscopic biliary stenting (see Fig. 32-24).

Major injuries diagnosed postoperatively require transhepatic biliary catheter placement for biliary decompression as well as percutaneous drainage of intra-abdominal bile collections, if any. When the acute inflammation has resolved 6 to 8 weeks later, operative repair is performed.

Patients with bile duct stricture from an injury or as a sequela of previous repair usually present with either progressive elevation of liver function tests or cholangitis. The initial management usually includes transhepatic biliary drainage catheter placement for decompression as well as for defining the anatomy and the location and the extent of the damage. These catheters will also serve as useful technical aids during subsequent biliary enteric anastomosis. An anastomosis is performed between the duct proximal to the injury and a Roux loop of jejunum. Balloon dilatation of a stricture usually requires multiple attempts and rarely provides adequate long-term relief. Self-expanding metal or plastic stents, placed either percutaneously or endoscopically across the stricture, can provide temporary drainage and, in the high-risk patient, permanent drainage of the biliary tree.

Outcome. Good results can be expected in 70% to 90% of patients with bile duct injuries.⁷⁸ The best results are obtained when the injury is recognized during the cholecystectomy and repaired by an experienced biliary tract surgeon. The operative mortality rate varies from 0% to almost 30% in various series, but commonly is about 5% to 8%. Common complications that are specific for bile duct repairs include cholangitis, external biliary fistula, bile leak, subhepatic and subphrenic abscesses, and hemobilia. Restenosis of a biliary enteric anastomosis occurs in about 10% of patients, and may manifest up to 20 years after the initial procedure. Approximately two thirds of recurrent strictures become symptomatic within 2 years after repair. The more proximal strictures are associated with a lower success rate than are distal ones. The worst results are in patients with many operative revisions and in those who have evidence of

liver failure and portal hypertension. However, previous repair does not preclude successful outcome of repeated attempts, particularly in patients with good liver function. Patients with deteriorating liver function are candidates for liver transplants.

TUMORS

Carcinoma of the Gallbladder

Cancer of the gallbladder is a rare malignancy that occurs predominantly in the elderly. It is an aggressive tumor, with poor prognosis except when incidentally diagnosed at an early stage after cholecystectomy for cholelithiasis. The overall reported 5-year survival rate is about 5%.⁷⁹

5 ▶ Incidence. Gallbladder cancer is the fifth most common GI malignancy in Western countries. However, it accounts for only 2% to 4% of all malignant GI tumors, with about 5000 new cases diagnosed annually in the United States. It is two to three times more common in females than males, and the peak incidence is in the seventh decade of life. Its occurrence in random autopsy series is about 0.4%, but approximately 1% of patients undergoing cholecystectomy for gallstone disease are found incidentally to have gallbladder cancer. The incidence of gallbladder cancer is particularly high in native populations of the United States, Mexico, and Chile. The annual incidence in Native American females with gallstones approaches 75 per 100,000, compared with the overall incidence of gallbladder cancer of 2.5 cases per 100,000 residents in the United States.⁸⁰

Etiology. Cholelithiasis is the most important risk factor for gallbladder carcinoma, and up to 95% of patients with carcinoma of the gallbladder have gallstones.⁸¹ However, the 20-year risk of developing cancer for patients with gallstones is <0.5% for the overall population and 1.5% for high-risk groups. The pathogenesis has not been defined but is probably related to chronic inflammation. Larger stones (>3 cm) are associated with a 10-fold increased risk of cancer.⁸² The risk of developing cancer of the gallbladder is higher in patients with symptomatic than asymptomatic gallstones.

Polypoid lesions of the gallbladder are associated with increased risk of cancer, particularly in polyps >10 mm.⁸³ The calcified “porcelain” gallbladder is associated with >20% incidence of gallbladder carcinoma. These gallbladders should be removed, even if the patients are asymptomatic. Patients with choledochal cysts have an increased risk of developing cancer anywhere in the biliary tree, but the incidence is highest in the gallbladder. Sclerosing cholangitis, anomalous pancreaticobiliary duct junction, and exposure to carcinogens (azotoluene, nitrosamines) also are associated with cancer of the gallbladder.

Pathology. Between 80% and 90% of the gallbladder tumors are adenocarcinomas. Squamous cell, adenosquamous, oat cell, and other anaplastic lesions occur rarely. The histologic subtypes of gallbladder adenocarcinomas include papillary, nodular, and tubular. Less than 10% are of the papillary type, but these are associated with an overall better outcome, as they are most commonly diagnosed while localized to the gallbladder. Cancer of the gallbladder spreads through the lymphatics, with venous drainage, and with direct invasion into the liver parenchyma. Lymphatic flow from the gallbladder drains first to the cystic duct node (Calot’s), then the pericholedochal and hilar nodes, and finally the peripancreatic, duodenal, periportal, celiac, and superior mesenteric artery nodes. The gallbladder veins drain directly into the adjacent liver, usually segments

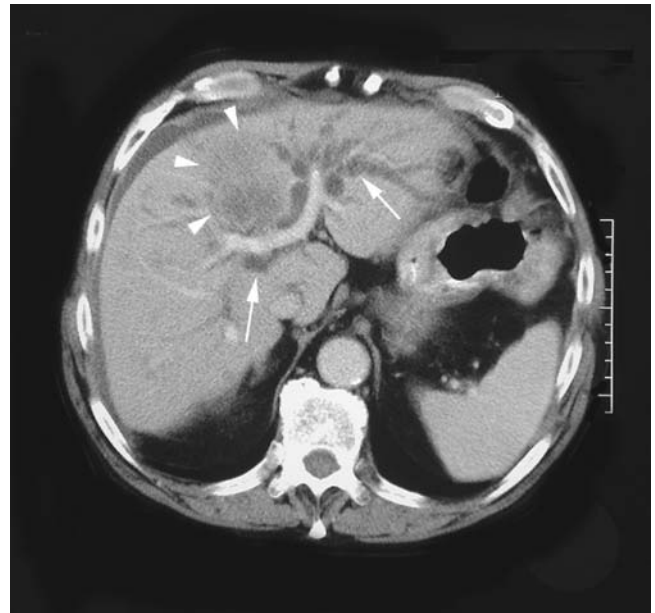

Figure 32-25. Computed tomography scan of a patient with gallbladder cancer. The image shown is at the level of the liver hilum. The portal vein is bifurcating into the left and right portal branch. The tumor has invaded segment IV of the liver (*arrowheads*) and obstructed the common hepatic duct, resulting in intrahepatic ductal dilatation (*arrows*).

IV and V, where tumor invasion is common (Fig. 32-25). The gallbladder wall differs histologically from the intestines in that it lacks a muscularis mucosa and submucosa. Lymphatics are present in the subserosal layer only. Therefore, cancers invading but not growing through the muscular layer have minimal risk of nodal disease. When diagnosed, about 25% of gallbladder cancers are localized to the gallbladder wall, 35% have regional nodal involvement and/or extension into adjacent liver, and approximately 40% have distant metastasis.⁸⁴

Clinical Manifestations and Diagnosis. Signs and symptoms of carcinoma of the gallbladder are generally indistinguishable from those associated with cholecystitis and cholelithiasis. These include abdominal discomfort, right upper quadrant pain, nausea, and vomiting. Jaundice, weight loss, anorexia, ascites, and abdominal mass are less common presenting symptoms. More than one half of gallbladder cancers are not diagnosed before surgery. Common misdiagnoses include chronic cholecystitis, acute cholecystitis, choledocholithiasis, hydrops of the gallbladder, and pancreatic cancer. Laboratory findings are not diagnostic but, if abnormal, are most often consistent with biliary obstruction. Ultrasonography often reveals a thickened, irregular gallbladder wall or a mass replacing the gallbladder. Ultrasonography may visualize tumor invasion of the liver, lymphadenopathy, and a dilated biliary tree. The sensitivity of ultrasonography in detecting gallbladder cancer ranges from 70% to 100%. A CT scan is an important tool for staging and may identify a gallbladder mass or local invasion into adjacent organs. In addition, a spiral CT scan can demonstrate vascular invasion; however, CT scan is a poor method for identifying nodal spread. In jaundiced patients, a percutaneous transhepatic or endoscopic cholangiogram may be helpful to delineate the extent of biliary tree involvement, and typically shows a long stricture of the common bile duct. With newer MRI techniques,

MRCP has evolved into a single noninvasive imaging method that allows complete assessment of biliary, vascular, nodal, hepatic, and adjacent organ involvement.⁸⁵ If diagnostic studies suggest that the tumor is unresectable, a CT scan or ultrasound-guided biopsy of the tumor can be obtained to provide a pathologic diagnosis.

Treatment. Surgery remains the only curative option for gallbladder cancer as well as for cholangiocarcinoma. However, 6▶ palliative procedures for patients with unresectable cancer and jaundice or duodenal obstruction remain the most frequently performed surgery for gallbladder cancers. Today, patients with obstructive jaundice can frequently be managed with either endoscopic or percutaneously placed biliary stents. There are no proven effective options for adjuvant radiation or chemotherapy for patients with gallbladder cancer.

The pathologic stage of gallbladder cancer determines the operative treatment for patients with localized gallbladder cancer. Patients without evidence of distant metastasis warrant exploration for tissue diagnosis, pathologic staging, and possible curative resection.

Tumors limited to the muscular layer of the gallbladder (T1) are usually identified incidentally, after cholecystectomy for gallstone disease. There is near universal agreement that simple cholecystectomy is an adequate treatment for T1 lesions and results in a near 100% overall 5-year survival rate. When the tumor invades the perimuscular connective tissue without extension beyond the serosa or into the liver (T2 tumors), an extended cholecystectomy should be performed.⁸⁶ That includes resection of liver segments IVB and V, and lymphadenectomy of the cystic duct and pericholedochal, portal, right celiac, and posterior pancreaticoduodenal lymph nodes. One half of patients with T2 tumors are found to have nodal disease on pathologic examination. Therefore, regional lymphadenectomy is an important part of surgery for T2 cancers.⁸⁷ For tumors that grow beyond the serosa or invade the liver or other organs (T3 and T4 tumors), there is a high likelihood of intraperitoneal and distant spread. If no peritoneal or nodal involvement is found, complete tumor excision with an extended right hepatectomy (segments IV, V, VI, VII, and VIII) must be performed for adequate tumor clearance. An aggressive approach in patients who will tolerate surgery has resulted in an increased survival for T3 and T4 lesions.

Prognosis. Most patients with gallbladder cancer have unresectable disease at the time of diagnosis. The 5-year survival rate of all patients with gallbladder cancer is <5%, with a median survival of 6 months.⁸⁸ Patients with T1 disease treated with cholecystectomy have an excellent prognosis (85%–100% 5-year survival rate). The 5-year survival rate for T2 lesions treated with an extended cholecystectomy and lymphadenectomy compared with simple cholecystectomy is >70% vs. 25% to 40%, respectively. Patients with advanced but resectable gallbladder cancer are reported to have 5-year survival rates of 20% to 50%. However, the median survival for patients with distant metastasis at the time of presentation is only 1 to 3 months.

Recurrence after resection of gallbladder cancer occurs most commonly in the liver or the celiac or retropancreatic nodes. The prognosis for recurrent disease is very poor. Death occurs most commonly secondary to biliary sepsis or liver failure. The main goal of follow-up is to provide palliative care. The most common problems are pruritus and cholangitis associated with obstructive jaundice, bowel obstruction secondary to carcinomatosis, and pain.

Bile Duct Carcinoma

Cholangiocarcinoma is a rare tumor arising from the biliary epithelium and may occur anywhere along the biliary tree. About two thirds are located at the hepatic duct bifurcation. Surgical resection offers the only chance for cure; however, many patients have advanced disease at the time of diagnosis. Therefore, palliative procedures aimed to provide biliary drainage to prevent liver failure and cholangitis are often the only therapeutic possibilities. Most patients with unresectable disease die within 1 year of diagnosis.⁸⁹

Incidence. The autopsy incidence of bile duct carcinoma is about 0.3%. The overall incidence of cholangiocarcinoma in the United States is about 1.0 per 100,000 people per year, with about 3000 new cases diagnosed annually. The male-to-female ratio is 1.3:1, and the average age of presentation is between 50 and 70 years.

Etiology. Risk factors associated with cholangiocarcinoma include primary sclerosing cholangitis, choledochal cysts, ulcerative colitis, hepatolithiasis, biliary-enteric anastomosis, and biliary tract infections with *Clonorchis* or in chronic typhoid carriers. Features common to most risk factors include biliary stasis, bile duct stones, and infection. Other risk factors associated with cholangiocarcinoma are liver flukes, dietary nitrosamines, Thorotrast, and exposure to dioxin.^{90,91}

Pathology. Over 95% of bile duct cancers are adenocarcinomas. Morphologically, they are divided into nodular (the most common type), scirrhous, diffusely infiltrating, or papillary. Anatomically, they are divided into distal, proximal, or perihilar tumors. Intrahepatic cholangiocarcinomas occur, but they are treated like hepatocellular carcinoma, with hepatectomy when possible. About two thirds of cholangiocarcinomas are located in the perihilar location. Perihilar cholangiocarcinomas, also referred to as Klatskin tumors, are further classified based on anatomic location by the Bismuth-Corlette classification (Fig. 32-26). Type I tumors are confined to the common

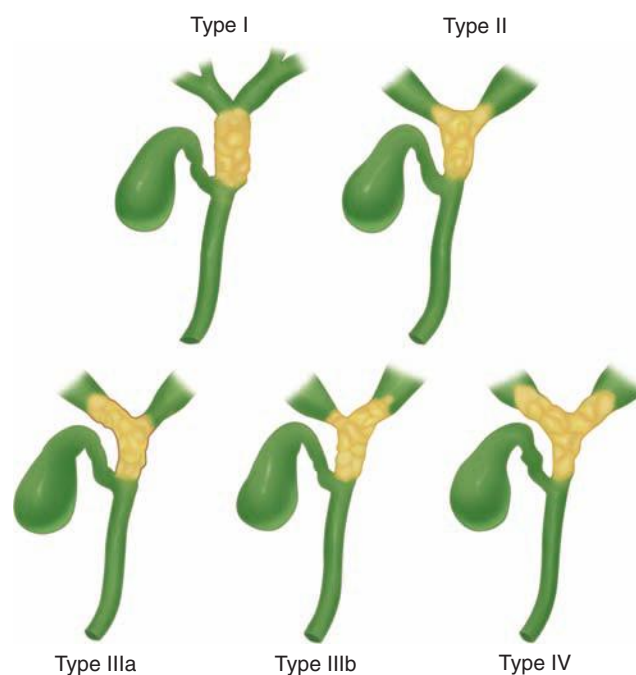


Figure 32-26. Bismuth-Corlette classification of bile duct tumors.

hepatic duct, but type II tumors involve the bifurcation without involvement of the secondary intrahepatic ducts. Type IIIa and IIIb tumors extend into the right and left secondary intrahepatic ducts, respectively. Type IV tumors involve both the right and left secondary intrahepatic ducts.

Clinical Manifestations and Diagnosis. Painless jaundice is the most common presentation. Pruritus, mild right upper quadrant pain, anorexia, fatigue, and weight loss also may be present. Cholangitis is the presenting symptom in about 10% of patients, but occurs more commonly after biliary manipulation in these patients. Except for jaundice, physical examination is usually normal in patients with cholangiocarcinoma. Occasionally, asymptomatic patients are found to have cholangiocarcinoma while being evaluated for elevated alkaline phosphatase and γ -glutamyltransferase levels. Tumor markers such as CA 125 and carcinoembryonic antigen can be elevated in cholangiocarcinoma but tend to be nonspecific because they also increase in other GI and gynecologic malignancies or cholangiopathologies. The tumor marker most commonly used to aid the diagnosis of cholangiocarcinoma is CA 19-9, which has a sensitivity of 79% and specificity of 98% if the serum value is >129 U/mL.⁹² However, mild elevations in CA 19-9 can be seen in cholangitis, other GI and gynecologic neoplasms, and patients who lack the Lewis blood type antigen.⁹³

The initial tests are usually ultrasound or CT scan. A perihilar tumor causes dilatation of the intrahepatic biliary tree, but normal or collapsed gallbladder and extrahepatic bile ducts distal to the tumor. Distal bile duct cancer leads to dilatation of the extra- and intrahepatic bile ducts as well as the gallbladder. Ultrasound can establish the level of obstruction and rule out the presence of bile duct stones as the cause of the obstructive jaundice (Fig. 32-27). It is usually difficult to visualize the tumor itself on ultrasound or on a standard CT scan. Either ultrasound or spiral CT can be used to determine portal vein patency. The biliary anatomy is defined by cholangiography. PTC defines

the proximal extent of the tumor, which is the most important factor in determining resectability. ERC is used, particularly in the evaluation of distal bile duct tumors. For the evaluation of vascular involvement, celiac angiography may be necessary. With the newer types of MRI, a single noninvasive test has the potential of evaluating the biliary anatomy, lymph nodes, and vascular involvement, as well as the tumor growth itself.⁹⁴

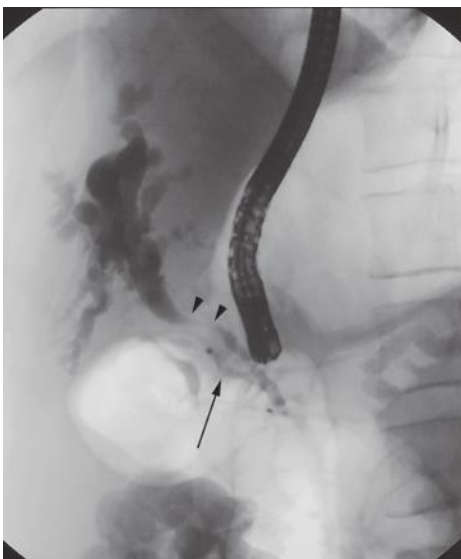Tissue diagnosis may be difficult to obtain nonoperatively except in advanced cases. Percutaneous fine-needle aspiration biopsy, biliary brush or scrape biopsy, and cytologic examination have a low sensitivity in detecting malignancy. Patients with potentially resectable disease should, therefore, be offered surgical exploration based on radiographic findings and clinical suspicion.⁹⁵

Treatment. Surgical excision is the only potentially curative treatment for cholangiocarcinoma. In the past one to two decades, improvements in surgical techniques have resulted in lower mortality and better outcome for patients undergoing aggressive surgical excision for cholangiocarcinoma.⁹⁶

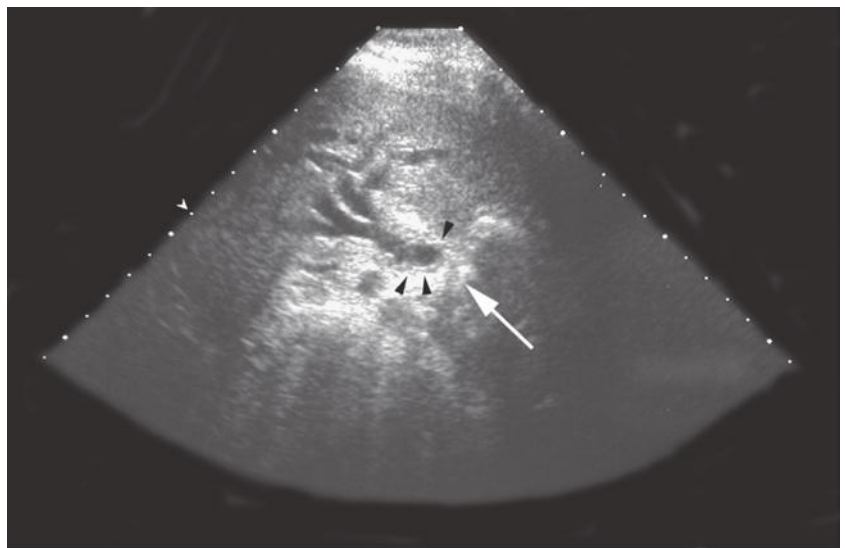
Patients should undergo surgical exploration if they have no signs of metastasis or locally unresectable disease. However, despite improvements in ultrasonography, CT scanning, and MRI, more than one half of patients who are explored are found to have peritoneal implants, nodal or hepatic metastasis, or locally advanced disease that precludes resection. For these patients, surgical bypass for biliary decompression and cholecystectomy to prevent the occurrence of acute cholecystitis should be performed.⁹⁷

For unresectable perihilar cholangiocarcinoma, Roux-en-Y cholangiojejunostomy to either segment II or III bile ducts or to the right hepatic duct can be performed.

For curative resection, the location and local extension of the tumor dictates the extent of the resection. Perihilar tumors involving the bifurcation or proximal common hepatic duct (Bismuth-Corlette type I or II) with no signs of vascular



A



B

Figure 32-27. **A.** An endoscopic retrograde cholangiography from a patient with cancer of the common hepatic duct (*arrowheads*). The common bile duct is of normal size, as is the cystic duct (*arrow*), but the proximal biliary tree is dilated. The gallbladder is not visualized because of tumor obstructing its neck. **B.** An ultrasound from the same patient showing dilated ducts and tumor obstructing the common hepatic duct (*arrow*). The walls of the bile ducts adjacent to the obstruction are thickened by tumor infiltration (*arrowheads*).

involvement are candidates for local tumor excision with portal lymphadenectomy, cholecystectomy, common bile duct excision, and bilateral Roux-en-Y hepaticojejunostomies. If the tumor involves the right or left hepatic duct (Bismuth-Corlette type IIIa or IIIb), right or left hepatic lobectomy, respectively, should also be performed. Frequently, resection of the adjacent caudate lobe is required because of direct extension into caudate biliary radicals or parenchyma.⁹⁵

Distal bile duct tumors are more often resectable. They are treated with pylorus-preserving pancreatoduodenectomy (Whipple procedure). For patients with distal bile duct cancer found to be unresectable on surgical exploration, Roux-en-Y hepaticojejunostomy, cholecystectomy, and gastrojejunostomy to prevent gastric outlet obstruction should be performed.

Nonoperative biliary decompression is performed for patients with unresectable disease on diagnostic evaluation. Percutaneous placement of expandable metal stents or drainage catheters is usually the appropriate approach for proximal tumors. However, for distal bile duct tumors, endoscopic placement is often the preferred approach (Fig. 32-28). There is a significant risk of cholangitis with internal and external drainage, and stent occlusion is not uncommon. However, although surgical bypass offers improved patency and fewer episodes of cholangitis, an operative intervention is not warranted in patients with metastatic disease.⁹⁸

There is no proven role for adjuvant chemotherapy in the treatment of cholangiocarcinoma. Adjuvant radiation therapy has also not been shown to increase either quality of life or survival in resected patients. Patients with unresectable disease

often are offered treatment with 5-fluorouracil alone or in combination with mitomycin C and doxorubicin, but the response rates are low, <10% and <30%, respectively. The combination of radiation and chemotherapy may be more effective than either treatment alone for unresectable disease, but no data from randomized trials are available. Giving chemoradiation to these patients can be difficult because of the high incidence of cholangitis. External-beam radiation has not been shown to be an effective treatment for unresected disease. The use of interstitial (intraoperative) radiation, brachytherapy with iridium-192 via percutaneous or endoscopic stents, and combined interstitial and external-beam radiation for unresectable cholangiocarcinoma has been reported with some encouraging results. However, no randomized, prospective trials have been reported.⁹⁵ A palliative measure that has been shown effective in a multicenter randomized trial is photodynamic therapy. In this trial, patients with a diagnosis of unresectable cholangiocarcinoma were randomized to biliary stenting with photodynamic therapy or stenting alone. The authors found that photodynamic therapy prolonged survival by approximately 400 days and improved quality of life on standardized questionnaire.⁹⁹

Prognosis. Most patients with perihilar cholangiocarcinoma present with advanced, unresectable disease. Patients with unresectable disease have a median survival between 5 and 8 months. The most common causes of death are hepatic failure and cholangitis. The overall 5-year survival rate for patients with resectable perihilar cholangiocarcinoma is between 10% and 30%, but for patients with negative margins, it may be as high as 40%.

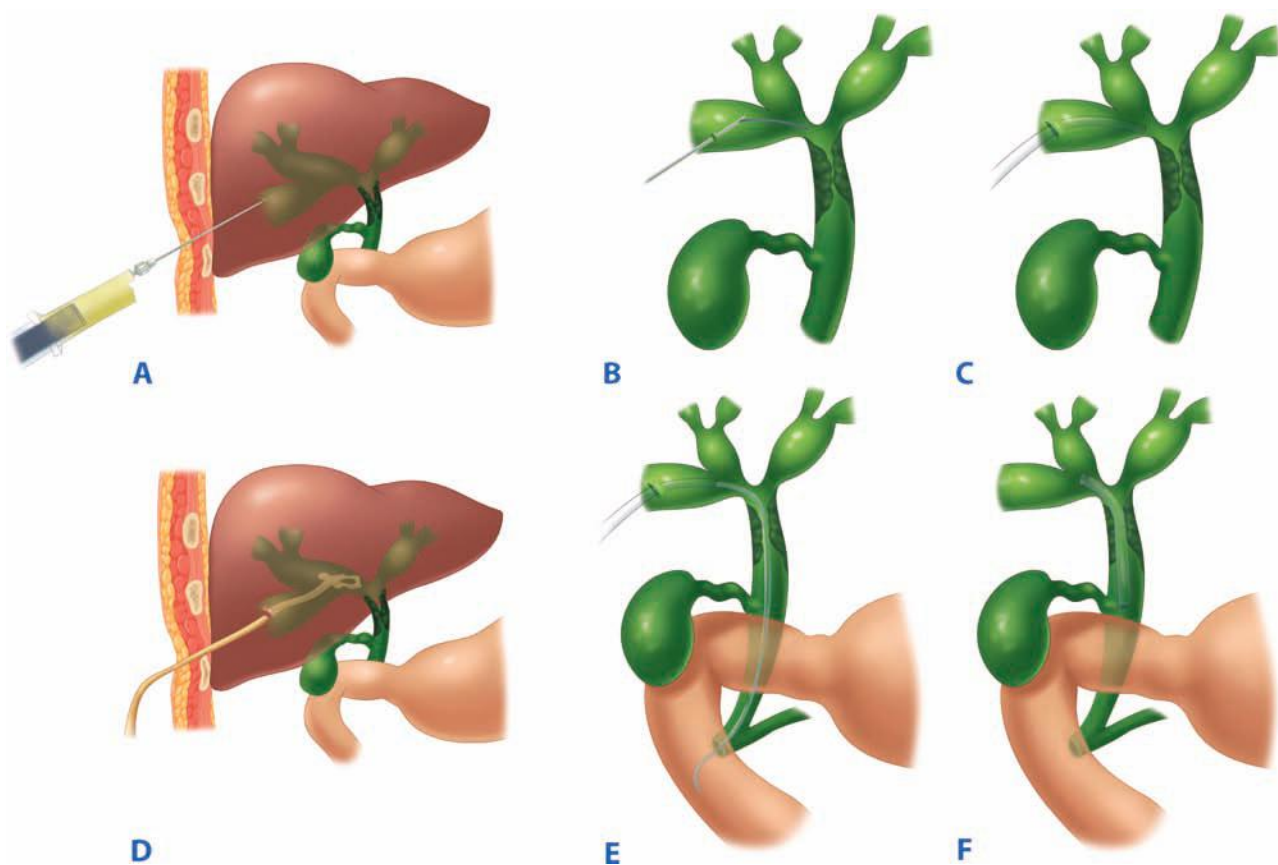


Figure 32-28. A through F. Percutaneous transhepatic cholangiography and placement of a biliary drainage catheter. The catheter has been passed through the tumor area (distal cholangiocarcinoma) that is obstructing the distal common bile duct and into the duodenum.

The operative mortality for perihilar cholangiocarcinoma is 6% to 8%. Patients with distal cholangiocarcinoma are more likely to have resectable disease and improved prognosis compared to perihilar cholangiocarcinoma. The overall 5-year survival rate for resectable disease is 30% to 50%, and the median survival is 32 to 38 months.

The greatest risk factors for recurrence after resection are the presence of positive margins and lymph node–positive tumors. Therapy for recurrent disease is palliation of symptoms. Surgery is not recommended for patients with recurrent disease.⁹⁴

REFERENCES

Entries highlighted in bright blue are key references.

- Clemente CD/ *Gray's Anatomy*. Philadelphia: Lea & Febiger; 1985:132.
- Klein AS, Lillemoed KD, Yeo CJ, et al. Liver, biliary tract, and pancreas. In: O'Leary JP, ed. *Physiologic Basis of Surgery*. Baltimore: Williams & Wilkins; 1996:441.
- Scott-Conner CEH, Dawson DL. *Operative Anatomy*. Philadelphia: JB Lippincott; 1993:388.
- Molmenti EP, Pinto PA, Klein J, et al. Normal and variant arterial supply of the liver and gallbladder. *Pediatr Transplant*. 2003;7:80.
- Chen TH, Shyu JF, Chen CH, et al. Variations of the cystic artery in Chinese adults. *Surg Laparosc Endosc Percutan Tech*. 2000;10:154.
- Boyer J. Bile secretion—models, mechanisms, and malfunctions. A perspective on the development of modern cellular and molecular concepts of bile secretion and cholestasis. *J Gastroenterol*. 1996;31:475.
- Geoghegan J, Pappas TN. Clinical uses of gut peptides. *Ann Surg*. 1997;225:145.
- Al-Jiffry BO, Shaffer EA, Saccone GT, et al. Changes in gallbladder motility and gallstone formation following laparoscopic gastric banding for morbid obesity. *Can J Gastroenterol*. 2003;17:169.
- McDonnell CO, Bailey I, Stumpf T, et al. The effect of cholecystectomy on plasma cholecystokinin. *Am J Gastroenterol*. 2002;97:2189.
- Woods CM, Mawe GM, Saccone GTP. The sphincter of Oddi: understanding its control and function. *Neurogastroenterol Motil*. 2005;17(Suppl 1):31.**
- Yokohata K, Tanaka M. Cyclic motility of the sphincter of Oddi. *J Hepato-Biliary-Pancreatic Surg*. 2000;7:178.
- Ahrendt SA. Biliary tract surgery. *Curr Gastroenterol Rep*. 1999;1:107.
- Lee HJ, Choi BI, Han JK, et al. Three-dimensional ultrasonography using the minimum transparent mode in obstructive biliary diseases: early experience. *J Ultrasound Med*. 2002;21:443.
- Ralls PW, Jeffrey RB Jr, Kane RA, et al. Ultrasonography. *Gastroenterol Clin North Am*. 2002;31:801.
- Wexler RS, Greene GS, Scott M. Left hepatic and common hepatic ductal bile leaks demonstrated by Tc-99m HIDA scan and percutaneous transhepatic cholangiogram. *Clin Nucl Med*. 1994;19:59.
- Breen DJ, Nicholson AA. The clinical utility of spiral CT cholangiography. *Clin Radiol*. 2000;55:733.
- Liu TH, Consorti ET, Kawashima A, et al. Patient evaluation and management with selective use of magnetic resonance cholangiography and endoscopic retrograde cholangiopancreatography before laparoscopic cholecystectomy. *Ann Surg*. 2001;234:33.
- Magnuson TH, Bender JS, Duncan MD, et al. Utility of magnetic resonance cholangiography in the evaluation of biliary obstruction. *J Am Coll Surg*. 1999;189:63.
- Washington M, Ghazi A. Complications of ERCP. In: Scott-Conner CEH, ed. *The SAGES Manual*. New York: Springer-Verlag; 1999:516.
- Tischendorf JJ, Kruger M, Trautwein C, et al. Cholangioscopic characterization of dominant bile duct stenoses in patients with primary sclerosing cholangitis. *Endoscopy*. 2006;38:665.
- Tajiri H, Kobayashi M, Ohtsu A, et al. Peroral pancreatoscopy for the diagnosis of pancreatic diseases. *Pancreas*. 1998;16:408.
- Hui CK, Lai KC, Ng M, et al. Retained common bile duct stones: a comparison between biliary stenting and complete clearance of stones by electrohydraulic lithotripsy. *Aliment Pharmacol Ther*. 2003;17:289.
- Tsuyuguchi T, Saisho H, Ishihara T, et al. Long-term follow-up after treatment of Mirizzi syndrome by peroral cholangioscopy. *Gastrointest Endosc*. 2000;52:639.
- Brett M, Barker DJ. The world distribution of gallstones. *Int J Epidemiol*. 1976;5:335.
- Nakeeb A, Comuzzie AG, Martin L, et al. Gallstones: genetics versus environment. *Ann Surg*. 2002;235:842.
- Brasca A, Berli D, Pezzotto SM, et al. Morphological and demographic associations of biliary symptoms in subjects with gallstones: findings from a population-based survey in Rosario, Argentina. *Dig Liver Dis*. 2002;34:577.
- Attili AF, De Santis A, Capri R, et al. The natural history of gallstones: the GREPCO experience. The GREPCO Group. *Hepatology*. 1995;21:655.
- Bellows CF, Berger DH, Crass RA. Management of gallstones. *Am Fam Physician*. 2005;72:637.
- Strasberg SM. The pathogenesis of cholesterol gallstones: a review. *J Gastrointest Surg*. 1998;2:109.
- Stewart L, Oesterle AL, Erdan I, et al. Pathogenesis of pigment gallstones in Western societies: the central role of bacteria. *J Gastrointest Surg*. 2002;6:891.
- Trowbridge RL, Rutkowski NK, Shojania KG. Does this patient have acute cholecystitis? *JAMA*. 2003;289:80.
- Fletcher DR. Gallstones. Modern management. *Aust Fam Physician*. 2001;30:441.
- Della Corte C, Falchetti D, Nebbia G, et al. Management of cholelithiasis in Italian children: a national multicenter study. *World J Gastroenterol*. 2008;14:1383.
- Weber DM. Laparoscopic surgery: an excellent approach in elderly patients. *Arch Surg*. 2003;138:1083.
- Strasberg SM. Cholelithiasis and acute cholecystitis. *Baillieres Clin Gastroenterol*. 1997;11:643.
- Kiviluoto T, Siren J, Luukkonen P, et al. Randomised trial of laparoscopic versus open cholecystectomy for acute and gangrenous cholecystitis. *Lancet*. 1998;351:321.
- Lo CM, Liu CL, Fan ST, et al. Prospective randomized study of early versus delayed laparoscopic cholecystectomy for acute cholecystitis. *Ann Surg*. 1998;227:461.
- Chikamori F, Kuniyoshi N, Shibuya S, et al. Early scheduled laparoscopic cholecystectomy following percutaneous transhepatic gallbladder drainage for patients with acute cholecystitis. *Surg Endosc*. 2002;16:1704.
- Patel M, Miedema BW, James MA, et al. Percutaneous cholecystostomy is an effective treatment for high-risk patients with acute cholecystitis. *Am Surg*. 2000;66:33.
- Ko C, Lee S. Epidemiology and natural history of common bile duct stones and prediction of disease. *Gastrointest Endosc*. 2002;56:S165.
- Amouyal P, Amouyal G, Levy P, et al. Diagnosis of choledocholithiasis by endoscopic ultrasonography. *Gastroenterology*. 1994;106:1062.
- Tranter S, Thompson M. Comparison of endoscopic sphincterotomy and laparoscopic exploration of the common bile duct. *Br J Surg*. 2002;89:1495.

43. Hamy A, Hennekinne S, Pessaix P, et al. Endoscopic sphincterotomy prior to laparoscopic cholecystectomy for the treatment of cholelithiasis. *Surg Endosc.* 2003;17:872.
44. Lilly MC, Arregui ME. A balanced approach to choledocholithiasis. *Surg Endosc.* 2001;15:467.
45. Ross SO, Forsmark CE. Pancreatic and biliary disorders in the elderly. *Gastroenterol Clin North Am.* 2000;30:531.
46. Lai ECS, Mok FPT, Tan ESY, et al. Endoscopic biliary drainage for severe acute cholangitis. *N Engl J Med.* 1992;326:1582.
47. Lipsett PA, Pitt HA. Acute cholangitis. *Front Biosci.* 2003;8:S1229.
48. Lillemoe KD. Surgical treatment of biliary tract infections. *Am Surg.* 2000;66:138.
49. Rhodes M, Sussman L, Cohen L, et al. Randomised trial of laparoscopic exploration of common bile duct versus postoperative endoscopic retrograde cholangiography for common bile duct stones. *Lancet.* 1998;351:159.
50. Sperling RM, Koch J, Sandhu JS, et al. Recurrent pyogenic cholangitis in Asian immigrants to the United States: natural history and role of therapeutic ERCP. *Dig Dis Sci.* 1997;42:865.
51. Thinh NC, Breda Y, Faucompret S, et al. Oriental biliary lithiasis. Retrospective study of 690 patients treated surgically over 8 years at Hospital 108 in Hanoi (Vietnam). *Med Trop (Mars).* 2001;61:509.
52. Byrne MF, Suhocki P, Mitchell RM, et al. Percutaneous cholecystostomy in patients with acute cholecystitis: experience of 45 patients at a US referral center. *J Am Coll Surg.* 2003;197:206.
53. Akhan O, Akinci D, Ozmen MN. Percutaneous cholecystostomy. *Eur J Radiol.* 2002;43:229.
54. Khaïtan L, Apelgren K, Hunter J, et al. A report on the Society of American Gastrointestinal Endoscopic Surgeons (SAGES) Outcomes Initiative: what have we learned and what is its potential? *Surg Endosc.* 2003;17:365.
55. Richards C, Edwards J, Culver D, et al. Does using a laparoscopic approach to cholecystectomy decrease the risk of surgical site infection? *Ann Surg.* 2003;237:358.
56. Flum DR, Dellinger EP, Cheadle A, et al. Intraoperative cholangiography and risk of common bile duct injury during cholecystectomy. *JAMA.* 2003;289:1639.
57. Hunter JG. Acute cholecystitis revisited: get it while it's hot. *Ann Surg.* 1998;227:468.
58. Biffl W, Moore E, Offner P, et al. Routine intraoperative ultrasonography with selective cholangiography reduces bile duct complications during laparoscopic cholecystectomy. *J Am Coll Surg.* 2001;193:272.
59. Halpin VJ, Dunnegan D, Soper NJ. Laparoscopic intracorporeal ultrasound versus fluoroscopic intraoperative cholangiography: after the learning curve. *Surg Endosc.* 2002;16:336.
60. Barwood NT, Valinsky LJ, Hobbs MS, et al. Changing methods of imaging the common bile duct in the laparoscopic cholecystectomy era in Western Australia: Implications for surgical practice. *Ann Surg.* 2002;235:41.
61. Pelinka LE, Schmidhammer R, Hamid L, et al. Acute acalculous cholecystitis after trauma: a prospective study. *J Trauma-Injury Infect Crit Care.* 2003;55:323.
62. Ryu JK, Ryu KH, Kim KH. Clinical features of acute acalculous cholecystitis. *J Clin Gastroenterol.* 2003;36:166.
63. Yasuda H, Takada T, Kawarada Y, et al. Unusual cases of acute cholecystitis and cholangitis: Tokyo Guidelines. *J Hepatobiliary Pancreat Surg.* 2007;14:98.
64. Lipsett PA, Pitt HA. Surgical treatment of choledochal cysts. *J Hepatobiliary Pancreat Surg.* 2003;10:352.
65. Ahrendt SA, Pitt HA, Nakeeb A, et al. Diagnosis and management of cholangiocarcinoma in primary sclerosing cholangitis. *J Gastrointest Surg.* 1999;3:357.
66. Ahrendt SA, Pitt HA, Kalloo AN, et al. Primary sclerosing cholangitis: resect, dilate, or transplant? *Ann Surg.* 1998;227:412.
67. Goss JA, Shackleton CR, Farmer DG, et al. Orthotopic liver transplantation for primary sclerosing cholangitis. A 12-year single center experience. *Ann Surg.* 1997;225:472.
68. Ahrendt SA, Pitt HA. Surgical treatment for primary sclerosing cholangitis. *J Hepatobiliary Pancreat Surg.* 1999;6:366.
69. Linder JD, Klapow JC, Linder SD, et al. Incomplete response to endoscopic sphincterotomy in patients with sphincter of Oddi dysfunction: evidence for a chronic pain disorder. *Am J Gastroenterol.* 2003;98:1738.
70. Lillemoe KD, Melton GB, Cameron JL, et al. Postoperative bile duct strictures: Management and outcome in the 1990s. *Ann Surg.* 2000;232:430.
71. Melton GB, Lillemoe KD. The current management of postoperative bile duct strictures. *Adv Surg.* 2002;36:193.
72. Archer SB, Brown DW, Smith CD, et al. Bile duct injury during laparoscopic cholecystectomy: results of a national survey. *Ann Surg.* 2001;234:549.
73. Ahrendt SA, Pitt HA. Surgical therapy of iatrogenic lesions of biliary tract. *World J Surg.* 2001;25:1360.
74. Strasberg SM. Avoidance of biliary injury during laparoscopic cholecystectomy. *J Hepatobiliary Pancreat Surg.* 2002;9:543.
75. Way LW, Stewart L, Gantert W, et al. Causes and prevention of laparoscopic bile duct injuries: analysis of 252 cases from a human factors and cognitive psychology perspective [Comment]. *Ann Surg.* 2003;237:460.
76. Flum DR, Flowers C, Veenstra DL. A cost-effectiveness analysis of intraoperative cholangiography in the prevention of bile duct injury during laparoscopic cholecystectomy. *J Am Coll Surg.* 2003;196:385.
77. Lee CM, Stewart L, Way LW. Postcholecystectomy abdominal bile collections. *Arch Surg.* 2000;135:538.
78. Melton GB, Lillemoe KD, Cameron JL, et al. Major bile duct injuries associated with laparoscopic cholecystectomy: effect of surgical repair on quality of life. *Ann Surg.* 2002;235:888.
79. Grobmyer SR, Lieberman MD, Daly JM. Gallbladder cancer in the twentieth century: single institution's experience. *World J Surg.* 2004;28:47.
80. Pandey M, Shukla VK. Diet and gallbladder cancer: a case-control study. *Eur J Cancer Prev.* 2002;11:365.
81. Serra I, Calvo A, Baez S, et al. Risk factors for gallbladder cancer. An international collaborative case control study. *Cancer.* 1996;78:1515.
82. Lowenfels AB, Walker AM, Althaus DP, et al. Gallstone growth, size, and risk of gallbladder cancer: an interracial study. *Int J Epidemiol.* 1998;18:50.
83. Csendes A, Burgos AM, Csendes P, et al. Late follow-up of polypoid lesions of the gallbladder smaller than 10 mm. *Ann Surg.* 2001;234:657.
84. Waghlikar G, Behari A, Krishnani N, et al. Early gallbladder cancer. *J Am Coll Surg.* 2002;194:137.
85. Kim JH, Kim TK, Eun HW. Preoperative evaluation of gallbladder carcinoma: efficacy of combined use of MR imaging, MR cholangiography, and contrast-enhanced dual phase three dimensional MR angiography. *J Magn Reson Imaging.* 2002;16:676.
86. Bartlett DL, Fong Y, Fortner JG, et al. Long-term results after resection for gallbladder cancer. Implications for staging and management. *Ann Surg.* 1996;224:639.
87. Wakai T, Shirai Y, Hatakeyama K. Radical second resection provides survival benefit for patients with T2 gallbladder carcinoma first discovered after laparoscopic cholecystectomy. *World J Surg.* 2002;26:867.
88. Noshiro H, Chijiwa K, Yamaguchi K, et al. Factors affecting surgical outcome for gallbladder carcinoma. *Hepatogastroenterology.* 2003;50:939.

89. Strasberg SM. Resection of hilar cholangiocarcinoma. *HPB Surg.* 1998;10:415.
90. Tocchi A, Mazzoni G, Liotta G, et al. Late development of bile duct cancer in patients who had biliary-enteric drainage for benign disease: a follow-up study of more than 1000 patients. *Ann Surg.* 2001;234:210.
91. Ahrendt SA, Rashid A, Chow JT, et al. p53 overexpression and K-ras gene mutations in primary sclerosing cholangitis-associated biliary tract cancer. *J Hepatobiliary Pancreat Surg.* 2000;7:426.
92. Nehls O, Gregor M, Klump B. Serum and bile markers for cholangiocarcinoma. *Semin Liver Dis.* 2004;24:139.
93. Siqueira E, Schoen RE, Silverman W, et al. Detecting cholangiocarcinoma in patients with primary sclerosing cholangitis. *Gastrointest Endosc.* 2005;56:40.
94. Ahrendt SA, Nakeeb A, Pitt HA. Cholangiocarcinoma. *Clin Liver Dis.* 2001;5:191.
95. Lillemoe KD, Cameron JL. Surgery for hilar cholangiocarcinoma: the Johns Hopkins approach. *J Hepatobiliary Pancreat Surg.* 2000;7:115.
96. Mulholland MW, Yahanda A, Yeo CJ. Multidisciplinary management of perihilar bile duct cancer. *J Am Coll Surg.* 2001;193:440.
97. Vollmer CM, Drebin JA, Middleton WD, et al. Utility of staging laparoscopy in subsets of peripancreatic and biliary malignancies [Comment]. *Ann Surg.* 2002;235:1.
98. Strasberg SM. ERCP and surgical intervention in pancreatic and biliary malignancies. *Gastrointest Endosc.* 2002;56:S213.
99. Ortner ME, Caca K, Berr F, et al. Successful photodynamic therapy for nonresectable cholangiocarcinoma: a randomized prospective study. *Gastroenterology.* 2003;125:1355.

33 chapter

Pancreas

William E. Fisher, Dana K. Andersen,
John A. Windsor, Ashok K. Saluja,
and F. Charles Brunicaudi

Anatomy	1341	Diagnosis / 1355	Chronic Obstructive Pancreatitis / 1365
Gross Anatomy / 1341		Pain Management / 1357	Chronic Inflammatory Pancreatitis / 1366
Regions of the Pancreas / 1341		Predicting Severity / 1357	Tropical (Nutritional) Pancreatitis / 1366
Pancreatic Duct Anatomy / 1344		Classification of the Severity of Acute Pancreatitis / 1357	Asymptomatic Pancreatic Fibrosis / 1367
Vascular and Lymphatic Anatomy / 1344		Determining the Etiology / 1357	Idiopathic Pancreatitis / 1367
Neuroanatomy / 1346		Fluid Resuscitation / 1357	Pathology / 1367
Histology and Physiology	1346	Nutritional Support / 1358	Presentation, Natural History, and Complications / 1371
Exocrine Pancreas / 1347		Cross-sectional Imaging / 1358	Complications / 1375
Endocrine Pancreas / 1348		Therapeutic Endoscopic Retrograde Cholangiopancreatography (ERCP) / 1358	Treatment / 1379
Islet Distribution / 1351		Antibiotics / 1359	Pancreatic Neoplasms
Acute Pancreatitis	1351	Managing Local Complications / 1359	1390
Definition, Incidence, and Epidemiology / 1351		Managing Organ Failure / 1360	Neoplasms of the Endocrine Pancreas / 1390
Etiology / 1351		Cholecystectomy / 1361	Insulinoma / 1391
Gallstones / 1351		Chronic Pancreatitis	Noninsulinoma Hyperinsulinemia Hypoglycemia Syndrome / 1391
Alcohol / 1352		1361	Gastrinoma / 1391
Iatrogenic / 1352		Definition, Incidence, and Prevalence / 1361	Vasoactive Intestinal Peptide-Secreting Tumor / 1392
Hereditary Pancreatitis / 1352		Etiology / 1361	Glucagonoma / 1393
Tumors / 1352		Genetic Causes / 1361	Somatostatinoma / 1393
Hyperlipidemia / 1352		Alcohol / 1362	Nonfunctioning Pancreatic Endocrine Tumors / 1393
Drugs and Miscellaneous Causes / 1353		Hyperparathyroidism / 1365	Neoplasms of the Exocrine Pancreas / 1393
Pathophysiology / 1353		Hyperlipidemia / 1365	
Precipitating Initial Events / 1353		Classification / 1365	
Intrapancreatic Events / 1354		Chronic Calcific (Lithogenic) Pancreatitis / 1365	
Systemic Events / 1355			
Management of the Patient / 1355			

ANATOMY

The pancreas is perhaps the most unforgiving organ in the human body, leading most surgeons to avoid even palpating it unless necessary. Situated deep in the center of the abdomen, the pancreas is surrounded by numerous important structures and major blood vessels. Seemingly minor trauma to the pancreas can result in the release of pancreatic enzymes and cause life-threatening pancreatitis. Therefore, knowledge of the relationships of the pancreas to surrounding structures is critically important for all surgeons to ensure that pancreatic injury is avoided during abdominal surgery.

Gross Anatomy

The pancreas is a retroperitoneal organ that lies in an oblique position, sloping upward from the C-loop of the duodenum to the splenic hilum (Fig. 33-1). In an adult, the pancreas weighs 75 to 100 g and is about 15 to 20 cm long. The fact that the pancreas is situated so deeply in the abdomen and is sealed in the retroperitoneum explains the poorly localized and sometimes

ill-defined nature with which pancreatic pathology presents. Patients with pancreatic cancer without bile duct obstruction usually present after months of vague upper abdominal discomfort, or no antecedent symptoms at all. Due to its retroperitoneal location, pain associated with pancreatitis often is characterized as penetrating through to the back.

Regions of the Pancreas

Surgeons typically describe the location of pathology within the pancreas in relation to four regions: the head, neck, body, and tail. The head of the pancreas is nestled in the C-loop of the duodenum and is posterior to the transverse mesocolon. Just posterior to the head of the pancreas lie the vena cava, the right renal artery, and both renal veins. The neck of the pancreas lies directly anterior to the portal vein. At the inferior border of the neck of the pancreas, the superior mesenteric vein joins the splenic vein and then continues toward the porta hepatis as the portal vein. The inferior mesenteric vein often joins the splenic vein near its junction with the portal vein. Sometimes, the inferior mesenteric

Key Points

- 1▶ Incomplete fusion of the dorsal and ventral pancreatic ducts results in pancreas divisum, but a variety of ductal anomalies can be seen. Magnetic resonance cholangiopancreatography as well as endoscopic retrograde cholangiopancreatography can identify these ductal anomalies, and clarification of the ductal pattern of the pancreas is important before attempts at interventions.
- 2▶ The “replaced right hepatic artery” occurs in 15% of patients and needs to be identified preoperatively to prevent inadvertent injury with resulting hepatic necrosis. Anomalous hepatic arterial anatomy can result in hepatic ischemia during dissection of the porta hepatis as well. “Thin cut” multidetector computed tomographic images are usually able to identify the relevant arterial and venous patterns around the pancreas.
- 3▶ Regardless of the etiology, the management of the early phase of acute pancreatitis is critical to achieve a successful outcome. Aggressive fluid resuscitation and early enteral feeding both reduce the risk of complications. It is no longer considered appropriate to “rest the pancreas” if the patient can tolerate enteral nutrients.
- 4▶ Surgical intervention in acute pancreatitis is reserved for patients with infected collections or infected necrosis only, or to relieve an impacted gallstone in the ampulla if endoscopic or radiologic treatments are unavailable or unsuccessful. Infection is usually confirmed by a pattern of air in the retroperitoneum on computed tomographic scan, or by documentation of bacteria on Gram’s stain or culture from fine-needle aspiration of a suspected infected fluid collection. Fine-needle aspiration of suspicious fluid collections should not be converted to percutaneous drainage unless infection is confirmed, and the consensus decision has been made that percutaneous drainage is appropriate for the individual patient.
- 5▶ The appearance of chronic pancreatitis on computed tomographic scan varies dramatically, and multiple diagnostic studies are usually needed to establish the extent of disease. Calcific pancreatitis is not a marker of alcoholic pancreatitis alone, and rarely indicates autoimmune pancreatitis. Endoscopic ultrasound provides a better assessment of the disease than computed tomography and is useful to disclose indolent or unsuspected cancer, which can occur in up to 10% of patients.
- 6▶ The nidus of inflammation in chronic pancreatitis due to any cause is the head of the gland. Therefore, treatment approaches that address the disease in the head have the best long-term results. The Whipple procedure, the Beger procedure, and the Frey procedure, with or without longitudinal duct drainage, are the best surgical options, as all three approaches remove all or most of the disease in the head of the gland.
- 7▶ The precursor lesion that probably leads to most cases of ductular adenocarcinoma is the ductal epithelial hyperplasia/dysplasia process described by the pancreatic intraepithelial neoplasia classification system. Pancreatic intraepithelial neoplasia 2 and pancreatic intraepithelial neoplasia 3 lesions may be associated with other, nonspecific changes in pancreatic morphology seen on imaging studies, or may only be seen histologically. Resection margins for pancreatic neoplasms should be examined for advanced pancreatic intraepithelial neoplasia stage patterns of ductal hyperplasia to ensure adequate resection status.
- 8▶ Intraductal papillary mucinous neoplasms are small macroscopic polypoid or plaque-like adenomas that develop in the main pancreatic duct or in side-branch ducts, and secrete mucin. They are often silent symptomatically, but cause characteristic appearances of small cyst-like collections of mucus, or diffuse dilatation of the main pancreatic duct with mucus. These premalignant lesions may be multifocal or single and can evolve into invasive adenocarcinoma in a similar pattern as with other adenomatous polypoid lesions of the gastrointestinal tract. They have been diagnosed with increasing frequency, and account for more than one third of pancreatic resections at some centers. Main-duct intraductal papillary mucinous neoplasms are an indication for resection; side-branch intraductal papillary mucinous neoplasms have a lower incidence of malignancy and are sometimes followed with serial imaging surveillance.

vein joins the superior mesenteric vein or merges with the superior mesenteric portal venous junction to form a trifurcation (Fig. 33-2). The superior mesenteric artery lies parallel to and just to the left of the superior mesenteric vein. The uncinate process and the head of the pancreas wrap around the right side of the portal vein and end posteriorly near the space between the superior mesenteric vein and superior mesenteric artery. Venous branches draining the pancreatic head and uncinate process enter along the right lateral and posterior sides of the portal vein. There are usually no anterior venous tributaries, and a plane can usually be developed between the neck of the pancreas and the portal and superior mesenteric veins during pancreatic resection, unless the tumor is invading the vein anteriorly. The common bile duct runs in a deep groove on the posterior aspect of the pancreatic head until it passes through the pancreatic parenchyma to join the main pancreatic duct at the ampulla of Vater. The body and tail of the pancreas lie just anterior to the splenic artery and vein. The vein runs in a

groove on the back of the pancreas and is fed by multiple fragile venous branches from the pancreatic parenchyma. These branches must be divided to perform a spleen-sparing distal pancreatectomy. The splenic artery runs parallel and just superior to the vein along the posterior superior edge of the body and tail of the pancreas. The splenic artery often is tortuous. The anterior surface of the body of the pancreas is covered by peritoneum. Once the gastrocolic omentum is divided, the body and tail of the pancreas can be seen along the floor of the lesser sac, just posterior to the stomach.

Pancreatic pseudocysts commonly develop in this area, and the posterior aspect of the stomach can form the anterior wall of the pseudocyst, allowing drainage into the stomach. The base of the transverse mesocolon attaches to the inferior margin of the body and tail of the pancreas. The transverse mesocolon often forms the inferior wall of pancreatic pseudocysts or inflammatory processes, allowing surgical drainage through the transverse mesocolon. The body of the pancreas is anterior to the

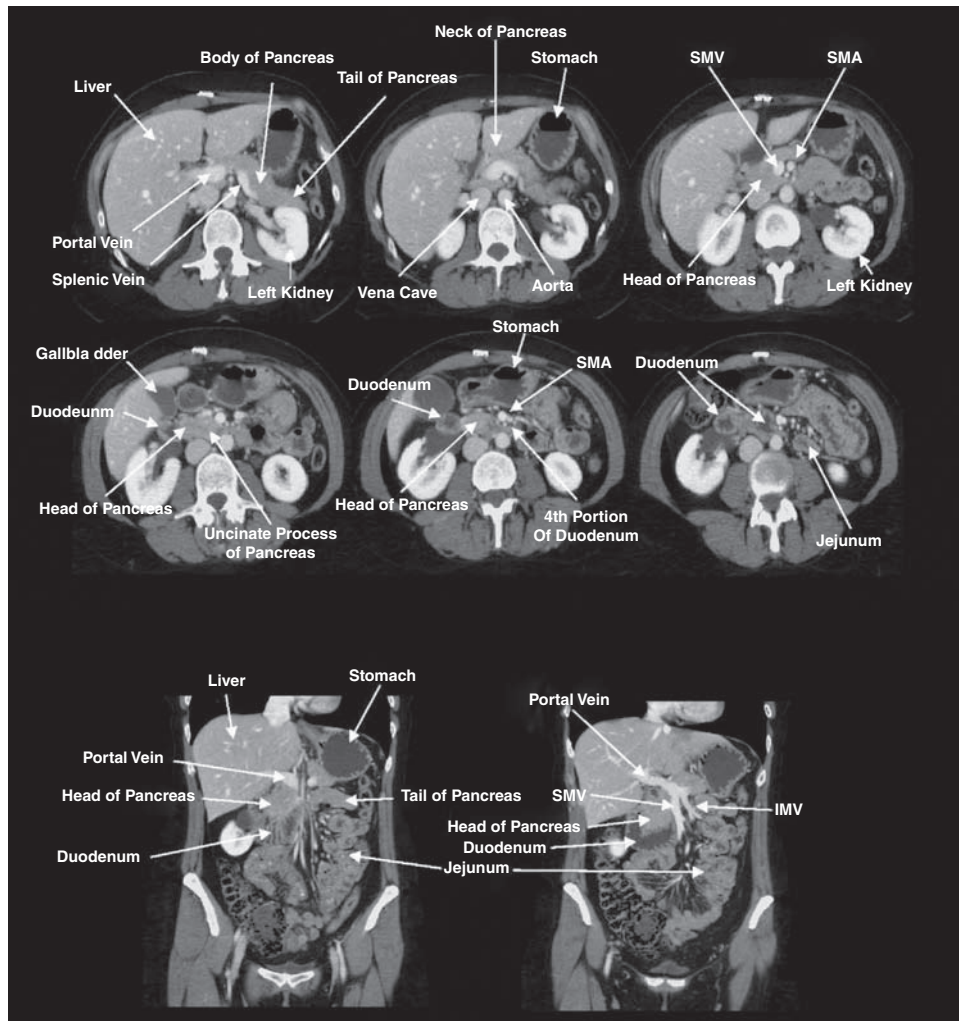

Figure 33-1. Pancreatic anatomy as seen on computed tomography. Knowledge of the relationship of the pancreas with surrounding structures is important to ensure that injury is avoided during abdominal surgery. IMV = inferior mesenteric vein; SMA = superior mesenteric artery; SMV = superior mesenteric vein.

aorta at the origin of the superior mesenteric artery. The neck of the pancreas is anterior to the vertebral body of L1 and L2, and blunt anteroposterior trauma can compress the neck of the pancreas against the spine, causing parenchymal and, sometimes, ductal injury. The neck divides the pancreas into approximately

two equal halves. The small portion of the pancreas anterior to the left kidney is referred to as the *tail* and is nestled in the hilum of the spleen near the splenic flexure of the left colon. Awareness of these anatomic relationships is important to avoid injury to the pancreatic tail during left colectomy or splenectomy.

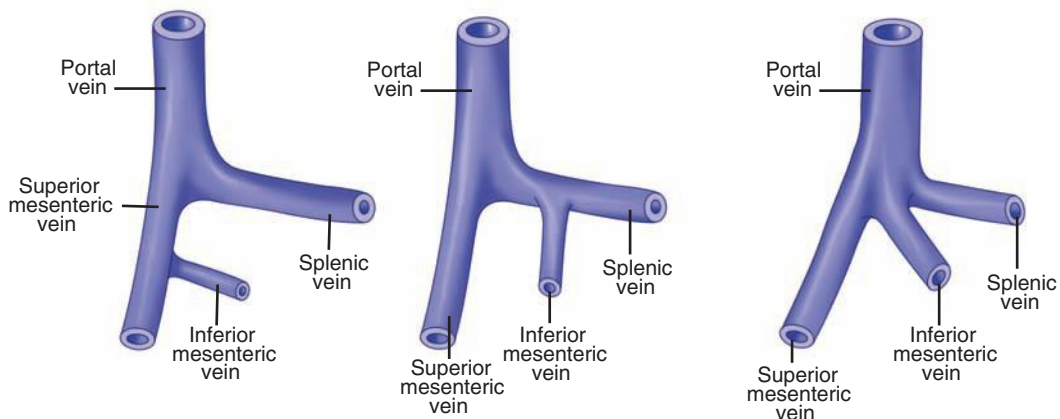


Figure 33-2. Variations in portal venous anatomy. The superior mesenteric vein joins the splenic vein and then continues toward the porta hepatis as the portal vein. The inferior mesenteric vein often joins the splenic vein near its junction with the portal vein, but sometimes joins the superior mesenteric vein; or the three veins merge as a trifurcation to form the portal vein.

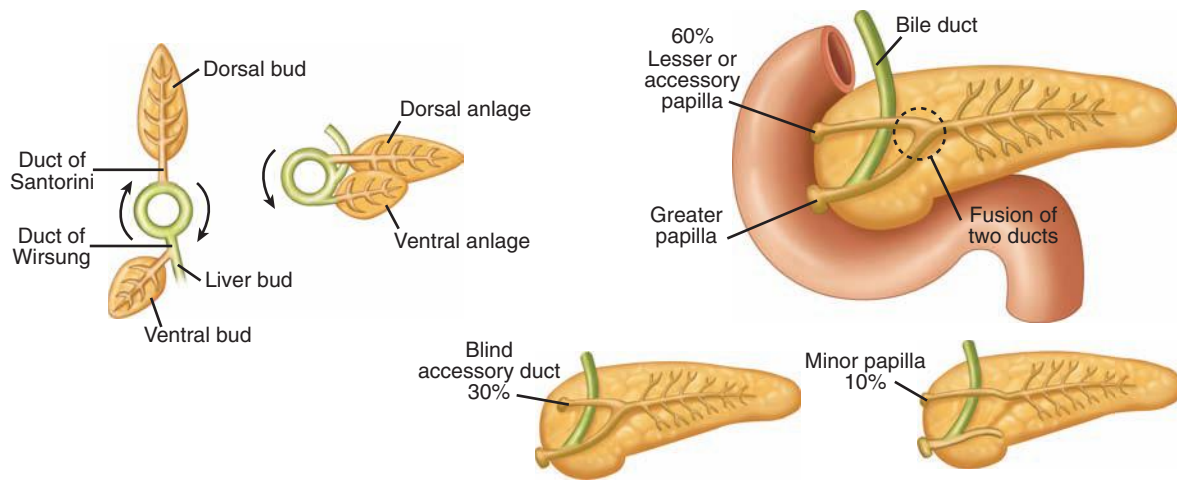


Figure 33-3. Embryology of pancreas and duct variations. The duct of Wirsung from the ventral bud connects to the bile duct, while the duct of Santorini from the larger dorsal bud connects to the duodenum. With gut rotation, the two ducts fuse in most cases such that the majority of the pancreas drains through the duct of Wirsung to the major papilla. The duct of Santorini can persist as a blind accessory duct or drain through the lesser papilla. In a minority of patients, the ducts remain separate, and the majority of the pancreas drains through the duct of Santorini, a condition referred to as *pancreas divisum*.

Pancreatic Duct Anatomy

An understanding of embryology is required to appreciate the common variations in pancreatic duct anatomy. The pancreas is formed by the fusion of a ventral and dorsal bud (Fig. 33-3). The duct from the smaller ventral bud, which arises from the hepatic diverticulum, connects directly to the common bile duct. The duct from the larger dorsal bud, which arises from the duodenum, drains directly into the duodenum. The duct of the ventral anlage becomes the duct of Wirsung, and the duct from the dorsal anlage becomes the duct of Santorini. With gut rotation, the ventral anlage rotates to the right and around the posterior side of the duodenum to fuse with the dorsal bud. The ventral anlage becomes the inferior portion of the pancreatic head and the uncinata process, while the dorsal anlage becomes the body and tail of the pancreas. The ducts from each anlage usually fuse together in the pancreatic head such that most of the pancreas drains through the duct of Wirsung, or main pancreatic duct, into the common channel formed from the bile duct and pancreatic duct. The length of the common channel is variable. In about one third of patients, the bile duct and pancreatic duct remain distinct to the end of the papilla, the two ducts merge at the end of the papilla in another one third, and in the remaining one third, a true common channel is present for a distance of several millimeters. Commonly, the duct from the dorsal anlage, the duct of Santorini, persists as the lesser pancreatic duct, and sometimes drains directly into the duodenum through the lesser papilla just proximal to the major papilla. In approximately 30% of patients, the duct of Santorini ends as a blind accessory duct and does not empty into the duodenum. In 10% of patients,

1▶ the ducts of Wirsung and Santorini fail to fuse.¹ This results in the majority of the pancreas draining through the duct of Santorini and the lesser papilla, while the inferior portion of the pancreatic head and uncinata process drains through the duct of Wirsung and major papilla. This normal anatomic variant, which occurs in one out of 10 patients, is referred to as *pancreas divisum* (Fig. 33-3). In a minority of these patients, the minor papilla can be inadequate to handle the flow of pancreatic juices from the majority of the gland. This relative outflow obstruction can result in pancreatitis and is sometimes treated by sphincteroplasty of the minor papilla.

The main pancreatic duct is usually only 2 to 3 mm in diameter and runs midway between the superior and inferior borders of the pancreas, usually closer to the posterior than to the anterior surface. Pressure inside the pancreatic duct is about twice that in the common bile duct, which is thought to prevent reflux of bile into the pancreatic duct. The main pancreatic duct joins with the common bile duct and empties at the ampulla of Vater or major papilla, which is located on the medial aspect of the second portion of the duodenum. The muscle fibers around the ampulla form the sphincter of Oddi, which controls the flow of pancreatic and biliary secretions into the duodenum. Contraction and relaxation of the sphincter is regulated by complex neural and hormonal factors. When the accessory pancreatic duct or lesser duct drains into the duodenum, a lesser papilla can be identified approximately 2 cm proximal to the ampulla of Vater.

Vascular and Lymphatic Anatomy

The blood supply to the pancreas comes from multiple branches from the celiac and superior mesenteric arteries (Fig. 33-4). The common hepatic artery gives rise to the gastroduodenal artery before continuing toward the porta hepatis as the proper hepatic artery. The right gastric artery branches off the gastroduodenal artery just superior to the duodenum. The gastroduodenal artery then travels inferiorly anterior to the neck of the pancreas and posterior to the duodenal bulb. A posterior ulcer in the duodenal bulb can erode into the gastroduodenal artery in this location. At the inferior border of the duodenum, the gastroduodenal artery then gives rise to the right gastroepiploic artery then continues on as the anterior superior pancreaticoduodenal artery, which branches into the anterior and posterior superior pancreaticoduodenal arteries. As the superior mesenteric artery passes behind the neck of the pancreas, it gives off the inferior pancreaticoduodenal artery at the inferior margin of the neck of the pancreas. This vessel quickly divides into the anterior and posterior inferior pancreaticoduodenal arteries. The superior and inferior pancreaticoduodenal arteries join together within the parenchyma of the anterior and posterior sides of the head of the pancreas along the medial aspect of the C-loop of the duodenum to form arcades that give off numerous branches to the duodenum and head of the pancreas. Therefore, it is impossible to resect the head of the

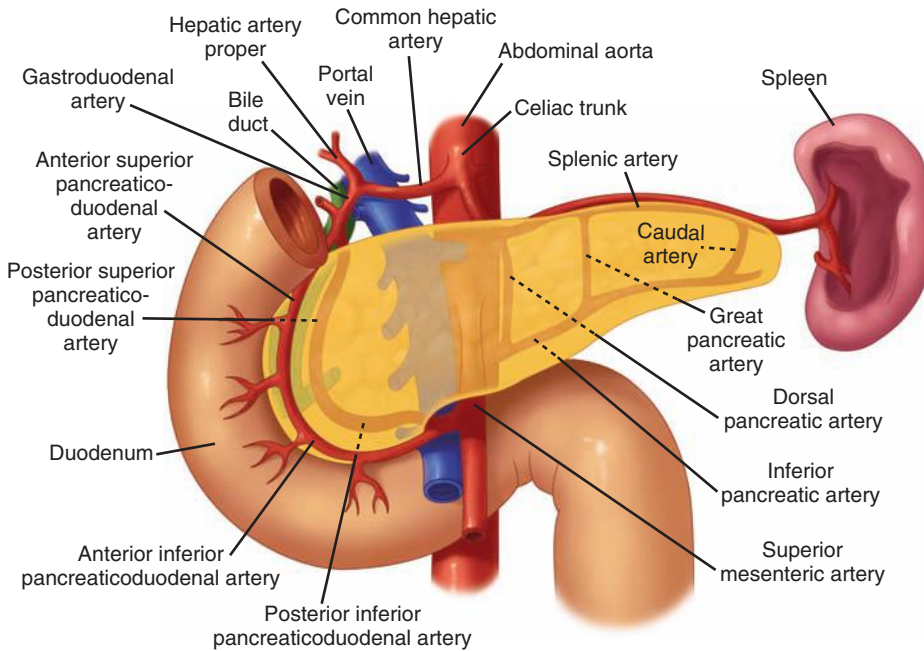


Figure 33-4. Arterial supply to the pancreas. Multiple arcades in the head and body of the pancreas provide a rich blood supply. The head of the pancreas cannot be resected without devascularizing the duodenum unless a rim of pancreas containing the pancreaticoduodenal arcade is preserved.

pancreas without devascularizing the duodenum, unless a rim of pancreas containing the pancreaticoduodenal arcade is preserved. Variations in the arterial anatomy occur in one out of five patients. The right hepatic artery, common hepatic artery, or gastroduodenal arteries can arise from the superior mesenteric artery. In 15% to 20% of patients, the right hepatic artery will arise from the superior mesenteric artery and travel upwards toward the liver along the posterior aspect of the head of the pancreas (referred to as a *replaced right hepatic artery*). It is important to look for this variation on preoperative computed tomographic (CT) scans and in the operating room so the replaced hepatic artery is recognized and injury is avoided. The body and tail of the pancreas are supplied by multiple

branches of the splenic artery. The splenic artery arises from the celiac trunk and travels along the posterior-superior border of the body and tail of the pancreas toward the spleen. The inferior pancreatic artery usually arises from the superior mesenteric artery and runs to the left along the inferior border of the body and tail of the pancreas, parallel to the splenic artery. Three vessels run perpendicular to the long axis of the pancreatic body and tail and connect the splenic artery and inferior pancreatic artery. They are, from medial to lateral, the dorsal, great, and caudal pancreatic arteries. These arteries form arcades within the body and tail of the pancreas, and account for the rich blood supply of the organ.

The venous drainage of the pancreas follows a pattern similar to that of the arterial supply (Fig. 33-5). The veins are usually

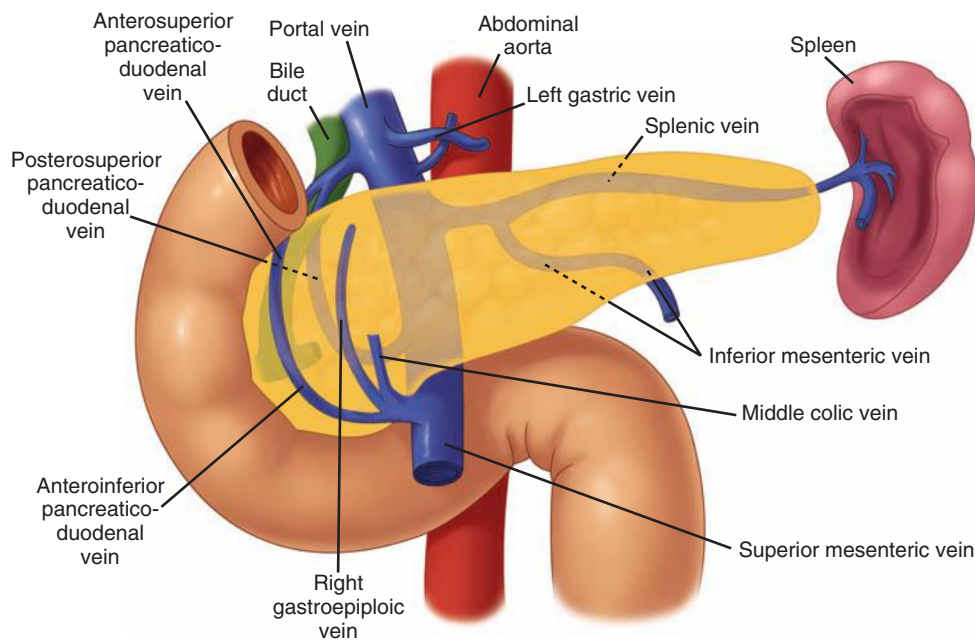


Figure 33-5. Venous drainage from the pancreas. The venous drainage of the pancreas follows a pattern similar to the arterial supply, with the veins usually superficial to the arteries. Anterior traction on the transverse colon can tear fragile branches along the inferior border of the pancreas, which then retract into the parenchyma of the pancreas. Venous branches draining the pancreatic head and uncinate process enter along the right lateral and posterior sides of the portal vein. There are usually no anterior venous tributaries, and a plane can usually be developed between the neck of the pancreas and the portal and superior mesenteric veins.

superficial to the arteries within the parenchyma of the pancreas. There is an anterior and posterior venous arcade within the head of the pancreas. The superior veins drain directly into the portal vein just above the neck of the pancreas. The posterior inferior arcade drains directly into the inferior mesenteric vein at the inferior border of the neck of the pancreas. These venous tributaries must be divided during a Whipple procedure. The anterior inferior pancreaticoduodenal vein joins the right gastroepiploic vein and the middle colic vein to form a common venous trunk, which enters into the superior mesenteric vein. Traction on the transverse colon during colectomy can tear these fragile veins, which then retract into the parenchyma of the pancreas, making control tedious. There also are numerous small venous branches coming from the pancreatic parenchyma directly into the lateral and posterior aspect of the portal vein. Venous return from the body and tail of the pancreas drains into the splenic vein.

The lymphatic drainage from the pancreas is diffuse and widespread (Fig. 33-6). The profuse network of lymphatic vessels and lymph nodes draining the pancreas provides egress to tumor cells arising from the pancreas. This diffuse lymphatic drainage contributes to the fact that pancreatic cancer often presents with positive lymph nodes and a high incidence of local recurrence after resection. Lymph nodes can be palpated along the distal bile duct and posterior aspect of the head of the pancreas in the pancreaticoduodenal groove, where the mesenteric vein passes under the neck of the pancreas, along the inferior border of the body, at the celiac axis and along the hepatic artery ascending into the porta hepatis, and along the splenic artery and vein. The pancreatic lymphatics also communicate with lymph nodes in the transverse mesocolon and mesentery of the proximal jejunum. Tumors in the body and tail of the pancreas often metastasize to these nodes and lymph nodes along the splenic vein and in the hilum of the spleen.

Neuroanatomy

The pancreas is innervated by the sympathetic and parasympathetic nervous systems. The acinar cells responsible for exocrine secretion, the islet cells responsible for endocrine secretion, and the islet vasculature are innervated by both systems.

The parasympathetic system stimulates endocrine and exocrine secretion and the sympathetic system inhibits secretion.²The pancreas is also innervated by neurons that secrete amines and peptides, such as somatostatin, vasoactive intestinal peptide (VIP), calcitonin gene-related peptide (CGRP), and galanin. The exact role of these neurons in pancreatic physiology is uncertain, but they do appear to affect both exocrine and endocrine function. The pancreas also has a rich supply of afferent sensory fibers, which are responsible for the intense pain associated with advanced pancreatic cancer, as well as acute and chronic pancreatitis. These somatic fibers travel superiorly to the celiac ganglia (Fig. 33-7). Interruption of these somatic fibers can stop transmission of pain sensation.

HISTOLOGY AND PHYSIOLOGY

The exocrine pancreas accounts for about 85% of the pancreatic mass; 10% of the gland is accounted for by extracellular matrix, and 4% by blood vessels and the major ducts, whereas only 2% of the gland is comprised of endocrine tissue. The endocrine and exocrine pancreas are sometimes thought of as functionally separate, but these different components of the organ are coordinated to allow an elegant regulatory feedback system for digestive enzyme and hormone secretion. This complex system regulates the type of digestion, its rate, and the processing and distribution of absorbed nutrients. This coordination is facilitated by the physical approximation of the islets and the exocrine pancreas, the presence of specific islet hormone receptors on the plasma membranes of pancreatic acinar cells, and the existence of an islet-acinar portal blood system.

Although patients can live without a pancreas when insulin and digestive enzyme replacement are administered, the loss of this islet-acinar coordination leads to impairments in digestive function. Although only approximately 20% of the normal pancreas is required to prevent insufficiency, in many patients undergoing pancreatic resection, the remaining pancreas is not normal, and pancreatic endocrine and exocrine insufficiency can develop with removal of smaller portions of the gland.

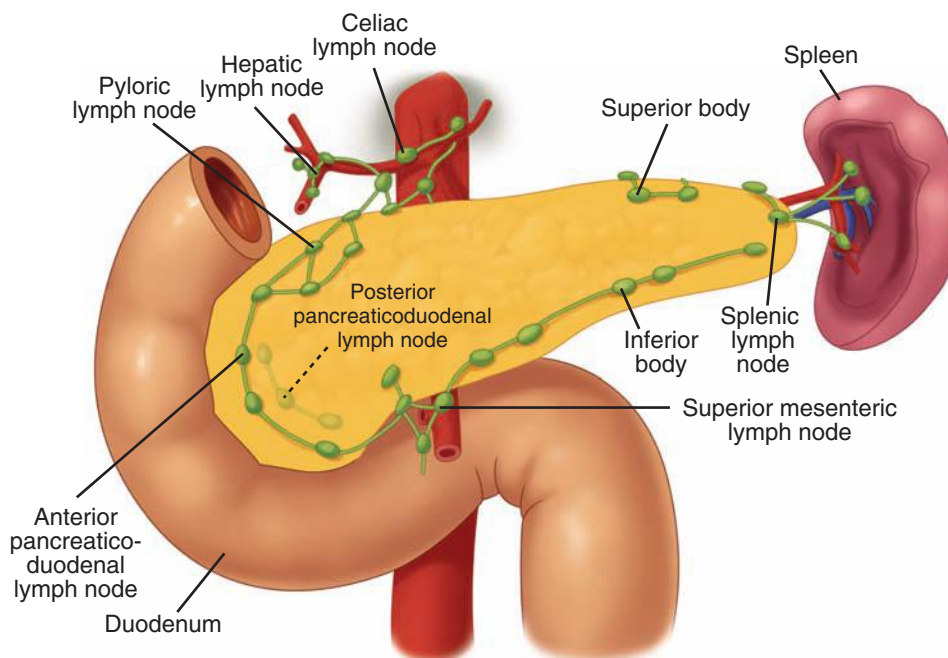


Figure 33-6. Lymphatic supply to the pancreas. The lymphatic drainage from the pancreas is diffuse and widespread, which explains the high incidence of lymph node metastases and local recurrence of pancreatic cancer. The pancreatic lymphatics also communicate with lymph nodes in the transverse mesocolon and mesentery of the proximal jejunum. Tumors in the body and tail of the pancreas are often unresectable because they metastasize to these lymph nodes. (Reproduced with permission from Bell RH Jr: *Atlas of pancreatic surgery*, in Bell RH Jr, Rikkers LF, Mulholland MW (eds): *Digestive Tract Surgery: A Text and Atlas*. Philadelphia: Lippincott-Raven, 1996, p 969.)

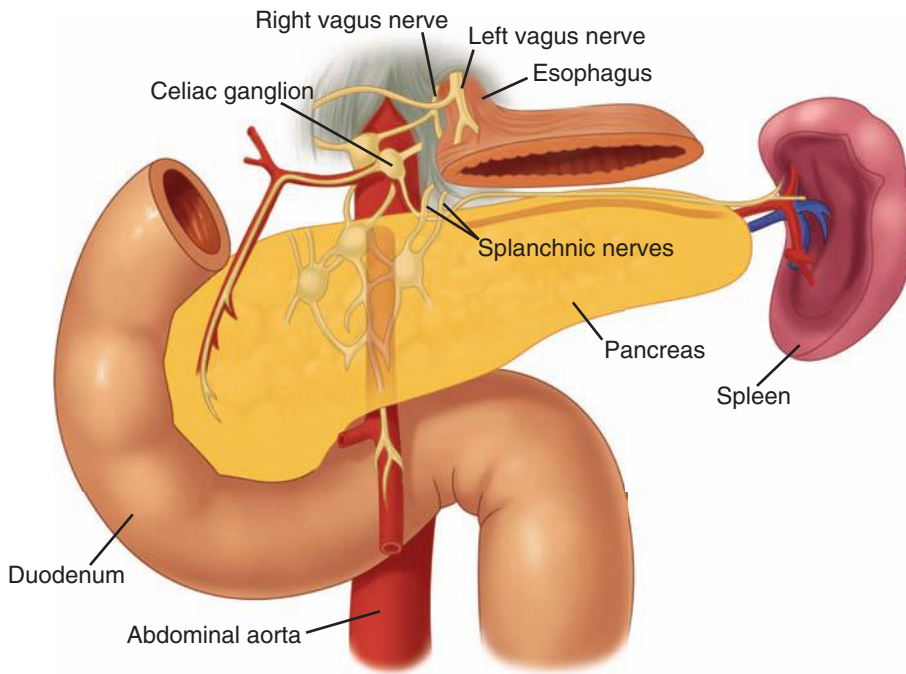


Figure 33-7. Innervation of the pancreas. The pancreas has a rich supply of afferent sensory fibers that travel superiorly to the celiac ganglia. Interruption of these somatic fibers with a celiac plexus block can interfere with transmission of pancreatic pain. (Reproduced with permission from Bell RH Jr: *Atlas of pancreatic surgery*, in Bell RH Jr, Rikkers LF, Mulholland MW [eds]: *Digestive Tract Surgery: A Text and Atlas*. Philadelphia: Lippincott-Raven, 1996, p 969.)

Exocrine Pancreas

The pancreas secretes approximately 500 to 800 mL per day of colorless, odorless, alkaline, isosmotic pancreatic juice. Pancreatic juice is a combination of acinar cell and duct cell secretions. The acinar cells secrete amylase, proteases, and lipases, enzymes responsible for the digestion of all three food types: carbohydrate, protein, and fat. The acinar cells are pyramid-shaped, with their apices facing the lumen of the acinus. Near the apex of each cell are numerous enzyme-containing zymogen granules that fuse with the apical cell membrane (Fig. 33-8). Unlike the endocrine pancreas, where islet cells specialize in the secretion of one hormone type, individual acinar cells secrete all types of enzymes. However, the ratio of the different enzymes released is adjusted to the composition of digested food through nonparallel regulation of secretion.

Pancreatic amylase is secreted in its active form and completes the digestive process already begun by salivary amylase. Amylase is the only pancreatic enzyme secreted in its active form, and it hydrolyzes starch and glycogen to glucose, maltose, maltotriose, and dextrans. These simple sugars are transported across the brush border of the intestinal epithelial cells by active transport mechanisms. Gastric hydrolysis of protein yields peptides that enter the intestine and stimulate intestinal endocrine cells to release cholecystokinin (CCK)-releasing peptide, CCK, and secretin, which then stimulate the pancreas to secrete enzymes and bicarbonate into the intestine.

The proteolytic enzymes are secreted as proenzymes that require activation. Trypsinogen is converted to its active form, trypsin, by another enzyme, enterokinase, which is produced by the duodenal mucosal cells. Trypsin, in turn, activates the other proteolytic enzymes. Trypsinogen activation within the pancreas is prevented by the presence of inhibitors that are also secreted by the acinar cells. A failure to express a normal trypsinogen inhibitor, pancreatic secretory trypsin inhibitor (PSTI), also known as serine protease inhibitor Kazal type 1 (SPINK1), is a cause of familial pancreatitis. Inhibition of trypsinogen activation ensures that the enzymes within the pancreas remain

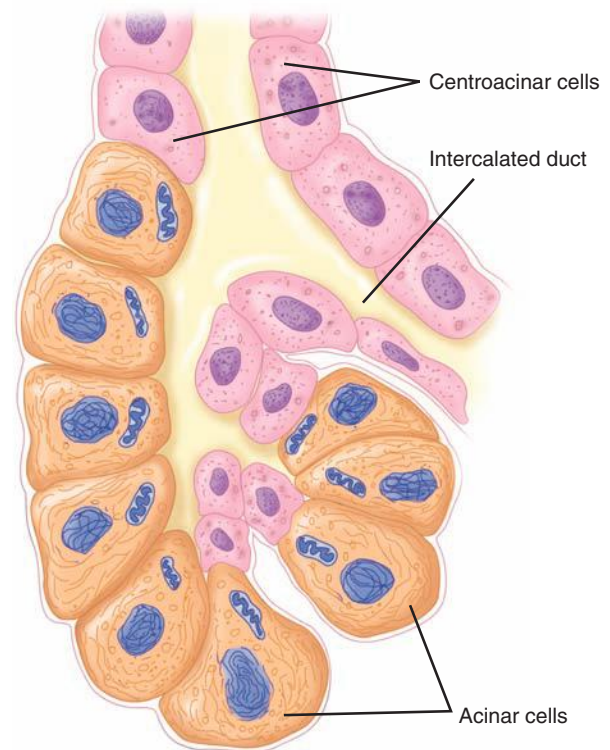


Figure 33-8. Acinar cell. Zymogen granules fuse with the apical membrane and release multiple enzymes to digest carbohydrates, proteins, and fat. (Reproduced with permission from Bloom W, Fawcett DW: *A Textbook of Histology*, 10th ed. Philadelphia: Saunders, 1975, p 738.)

in an inactive precursor state and are activated only within the duodenum. Trypsinogen is expressed in several isoforms, and a missense mutation on the cationic trypsinogen, or *PRSSI*, results in premature, intrapancreatic activation of trypsinogen. This accounts for about two-thirds of cases of hereditary pancreatitis. Chymotrypsinogen is activated to form chymotrypsin.

Elastase, carboxypeptidase A and B, and phospholipase are also activated by trypsin. Trypsin, chymotrypsin, and elastase cleave bonds between amino acids within a target peptide chain, and carboxypeptidase A and B cleave amino acids at the end of peptide chains. Individual amino acids and small dipeptides are then actively transported into the intestinal epithelial cells. Pancreatic lipase hydrolyzes triglycerides to 2-monoglyceride and fatty acid. Pancreatic lipase is secreted in an active form. Colipase is also secreted by the pancreas and binds to lipase, changing its molecular configuration and increasing its activity. Phospholipase A2 is secreted by the pancreas as a proenzyme that becomes activated by trypsin. Phospholipase A2 hydrolyzes phospholipids and, as with all lipases, requires bile salts for its action. Carboxylic ester hydrolase and cholesterol esterase hydrolyze neutral lipid substrates like esters of cholesterol, fat-soluble vitamins, and triglycerides. The hydrolyzed fat is then packaged into micelles for transport into the intestinal epithelial cells, where the fatty acids are reassembled and packaged inside chylomicrons for transport through the lymphatic system into the bloodstream (Table 33-1).

The centroacinar and intercalated duct cells secrete the water and electrolytes present in the pancreatic juice. About 40 acinar cells are arranged into a spherical unit called an *acinus*. Centroacinar cells are located near the center of the acinus and are responsible for fluid and electrolyte secretion. These cells contain the enzyme carbonic anhydrase, which is needed for bicarbonate secretion. The amount of bicarbonate secreted varies with the pancreatic secretory rate, with greater concentrations of bicarbonate being secreted as the pancreatic secretory rate increases. Chloride secretion varies inversely with bicarbonate secretion such that the sum of these two remains constant. In contrast, sodium and potassium concentrations are kept constant throughout the spectrum of secretory rates³ (Fig. 33-9). The hormone secretin is released from cells in the duodenal mucosa in response to acidic chyme passing through

the pylorus into the duodenum. Secretin is the major stimulant for bicarbonate secretion, which buffers the acidic fluid entering the duodenum from the stomach. CCK also stimulates bicarbonate secretion, but to a much lesser extent than secretin. CCK potentiates secretin-stimulated bicarbonate secretion. Gastrin and acetylcholine, both stimulants of gastric acid secretion, are also weak stimulants of pancreatic bicarbonate secretion.⁴ Truncal vagotomy produces a myriad of complex effects on the downstream digestive tract, but the sum effect on the exocrine pancreas is a reduction in bicarbonate and fluid secretion.⁵ The endocrine pancreas also influences the adjacent exocrine pancreatic secretions. Somatostatin, pancreatic polypeptide (PP), and glucagon are all thought to inhibit exocrine secretion.

The acinar cells release pancreatic enzymes from their zymogen granules into the lumen of the acinus, and these proteins combine with the water and bicarbonate secretions of the centroacinar cells. The pancreatic juice then travels into small intercalated ducts. Several small intercalated ducts join to form an interlobular duct. Cells in the interlobular ducts contribute fluid and electrolytes to adjust the final concentrations of the pancreatic fluid. Interlobular ducts then join to form about 20 secondary ducts that empty into the main pancreatic duct. Destruction of the branching ductal tree from recurrent inflammation, scarring, and deposition of stones eventually contributes to destruction of the exocrine pancreas and exocrine pancreatic insufficiency.

Endocrine Pancreas

There are nearly 1 million islets of Langerhans in the normal adult pancreas. They vary greatly in size from 40 to 900 μm . Larger islets are located closer to the major arterioles and smaller islets are embedded more deeply in the parenchyma of the pancreas. Most islets contain 3000 to 4000 cells of five major types: alpha cells that secrete glucagon, β -cells that secrete insulin, delta cells that secrete somatostatin, epsilon cells that secrete ghrelin, and PP cells that secrete PP (Table 33-2).

Table 33-1

Pancreatic enzymes

ENZYME	SUBSTRATE	PRODUCT
Carbohydrate Amylase (active)	Starch, glycogen	Glucose, maltose, maltotriose, dextrins
Protein Endopeptidases Trypsinogen (inactive) $\xrightarrow{\text{Enterokinase}}$ Trypsin (active) Chymotrypsinogen (inactive) $\xrightarrow[\text{Trypsin}]{\text{Enterokinase}}$ Chymotrypsin (active) Proelastase (inactive) $\xrightarrow[\text{Trypsin}]{\text{Enterokinase}}$ Elastase (active) Exopeptidases Procarboxy peptidase A&B (inactive) $\xrightarrow{\text{Enterokinase}}$ Carboxypeptidase A&B (active)	Cleave bonds between amino acids Cleave amino acids from end of peptide chains	Amino acids, dipeptides —
Fat Pancreatic lipase (active) Phospholipase A2 (inactive) $\xrightarrow{\text{Trypsin}}$ Phospholipase A2 (active) Cholesterol esterase	Triglycerides Phospholipase Neutral lipids	2-Monoglycerides, fatty acids — —

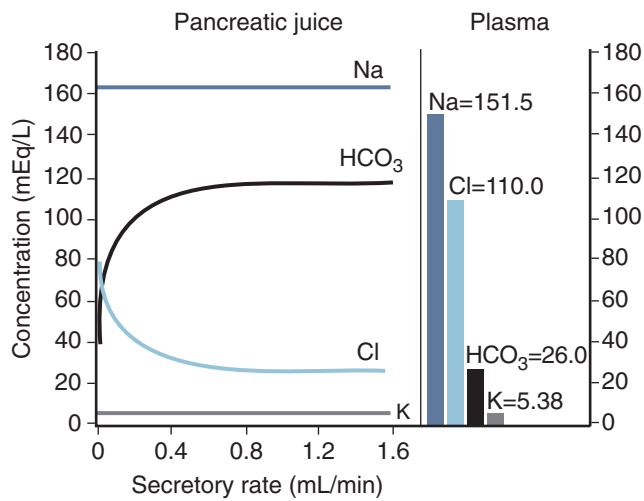


Figure 33-9. Composition of pancreatic exocrine secretions. Greater concentrations of bicarbonate are secreted at higher secretory rates, and chloride secretion varies inversely with bicarbonate secretion. In contrast, sodium and potassium concentrations are independent of the secretory rate. (Reproduced with permission from Bro-Rasmussen F et al: *The composition of pancreatic juice as compared to sweat, parotid saliva, and tears*. Acta Phys Scandinav. 37:97–113, 1956.)

Insulin is the best-studied pancreatic hormone. The discovery of insulin in 1920 by Frederick Banting, an orthopedic surgeon, and Charles Best, a medical student, was recognized with the awarding of the Nobel Prize in Physiology or Medicine. They produced diabetes in dogs by performing total pancreatectomy and then treated them with crude pancreatic extracts from dog and calf pancreata using techniques to prevent the breakdown of insulin by the proteolytic enzymes of the exocrine pancreas.

Insulin was subsequently purified and found to be a 56-amino acid peptide with two chains, an α and a β chain, joined by two disulfide bridges and a connecting peptide, or C-peptide. Pro-insulin is made in the endoplasmic reticulum and then is transported to the Golgi complex, where it is packaged into granules and the C-peptide is cleaved off. There are two phases of insulin secretion. In the first phase, stored insulin is released. This phase lasts about 5 minutes after a glucose challenge. The second phase of insulin secretion is a longer, sustained release due to ongoing production of new insulin. β -cell synthesis of insulin is regulated by plasma glucose levels, neural signals, and the paracrine influence of other islet cells. The diagnosis of diabetes is made by using oral and intravenous (IV) glucose tolerance tests. Oral glucose not only enters the bloodstream but also stimulates the release of enteric hormones such as gastric inhibitory peptide (also known as *glucose-dependent insulinotropic polypeptide* or *GIP*), glucagon-like peptide-1 (GLP-1), and CCK that augment the secretion of insulin, and are therefore referred to as *incretins*. As a result, oral glucose is a more vigorous stimulus to insulin secretion than IV glucose. In the oral glucose tolerance test (OGTT), the patient is fasted overnight, and a basal glucose value is determined. Forty g/m² or 75 g of glucose is given orally over 10 minutes. Blood samples are taken every 30 minutes for 2 hours. Normal values and criteria for diabetes vary by age, but essentially all values should be <200 mg/dL, and the 120-minute value should be <140 mg/dL.

Insulin secretion by the β -cell is also influenced by plasma levels of amino acids such as arginine, lysine, leucine, and free fatty acids. Glucagon, GIP, GLP-1, and CCK stimulate insulin release, while somatostatin, amylin, and pancreastatin inhibit insulin release.⁶ Cholinergic fibers and beta sympathetic fibers stimulate insulin release, while alpha sympathetic fibers inhibit insulin secretion.

Insulin's glucoregulatory function is to inhibit endogenous (hepatic) glucose production and to facilitate glucose transport

Table 33-2

Pancreatic islet peptide products

HORMONES	ISLET CELL	FUNCTIONS
Insulin	β (beta cell)	Decreased gluconeogenesis, glycogenolysis, fatty acid breakdown, and ketogenesis Increased glycogenesis, protein synthesis, and glucose uptake
Glucagon	α (alpha cell)	Opposite effects of insulin; increased hepatic glycogenolysis and gluconeogenesis
Somatostatin	δ (delta cell)	Inhibits GI secretion Inhibits secretion and action of all GI endocrine peptides Inhibits cell growth
Pancreatic polypeptide	PP (PP cell)	Inhibits pancreatic exocrine secretion and secretion of insulin Facilitates hepatic effect of insulin
Amylin (IAPP)	β (beta cell)	Counterregulates insulin secretion and function
Pancreastatin	β (beta cell)	Decreases insulin and somatostatin release Increases glucagon release Decreases pancreatic exocrine secretion
Ghrelin	(epsilon cell)	Decreases insulin release and insulin action

IAPP = islet amyloid polypeptide.

Table 33-3

Clinical and laboratory findings in types of diabetes mellitus

PARAMETER	TYPE 1	TYPE 2	TYPE 3C
	IDDM	NIDDM	Pancreatogenic
Ketoacidosis	Common	Rare	Rare
Hyperglycemia	Severe	Usually Mild	Mild
Hypoglycemia	Common	Rare	Common
Peripheral Insulin Sensitivity	Normal or Increased	Decreased	Increased
Hepatic Insulin Sensitivity	Normal	Normal or Decreased	Decreased
Insulin Levels	Low	High	Low
Glucagon Levels	Normal or High	Normal or High	Low
PP Levels	Normal or Low (late)	High	Low
GIP Levels	Normal or Low	Normal or High	Low
GLP-1 Levels	Normal	Normal or High	Normal or High
Typical Age of Onset	Childhood or adolescence	Adulthood	Any

Abbreviations: IDDM, insulin dependent diabetes mellitus; NIDDM, non-insulin dependent diabetes mellitus; PP, pancreatic polypeptide; GIP, glucose-dependent insulinotropic polypeptide; GLP-1, glucagon-like peptide 1. [Reproduced with permission from Cui YF & Andersen DK. Copyright Elsevier¹⁵⁹]

into cells, thus lowering plasma glucose levels. Insulin also inhibits glycogenolysis, fatty acid breakdown, and ketone formation, and stimulates protein synthesis. There is a considerable amount of functional reserve in insulin secretory capacity. If the remaining portion of the pancreas is healthy, about 80% of the pancreas can be resected without the patient becoming diabetic.⁷ In patients with chronic pancreatitis, or other conditions in which much of the gland is diseased, resection of a smaller fraction of the pancreas can result in pancreatogenic, or type 3c diabetes (Table 33-3).

Insulin receptors are dimeric, tyrosine kinase-containing transmembrane proteins that are located on all cells. Insulin deficiency (seen in type 1 and type 3c diabetes) results in an overexpression or upregulation of insulin receptors, which causes an enhanced sensitivity to insulin in muscle and adipocytes (and therefore increases the risk of insulin-induced hypoglycemia). Type 2 diabetes is associated with a downregulation of insulin receptors and relative hyperinsulinemia, with resulting insulin resistance. Some forms of diabetes are associated with selected impairments of hepatic or peripheral insulin receptors, such as pancreatogenic or type 3c diabetes (T3cDM) or maturity-onset diabetes of the young (MODY).

Glucagon is a 29-amino-acid, single-chain peptide that promotes hepatic glycogenolysis and gluconeogenesis and counteracts the effects of insulin through its hyperglycemic action. Glucose is the primary regulator of glucagon secretion, as it is with insulin, but it has an inhibitory rather than stimulatory effect. Glucagon release is stimulated by hypoglycemia, and by the amino acids arginine and alanine. GLP-1 inhibits glucagon secretion *in vivo*, and insulin and somatostatin inhibit glucagon secretion in a paracrine fashion within the islet. The same neural impulses that regulate insulin secretion also regulate glucagon secretion, so that the two hormones work together in a balance of actions to maintain glucose levels. Cholinergic and beta sympathetic fibers stimulate glucagon release, while alpha sympathetic fibers inhibit glucagon release.⁸ In pancreatogenic or type 3c diabetes, glucagon responsiveness to a fall in blood glucose is lost, thereby increasing the risk for hypoglycemia.

Although originally isolated from the hypothalamus, somatostatin is a peptide that is now known to have a wide anatomic distribution, not only in neurons but also in the pancreas, gut, and other tissues. It is a highly conserved peptide hormone, as it is found in lower vertebrates, and is now realized to be of fundamental importance in regulatory processes throughout the body. One gene encodes for a common precursor that is differentially processed to generate tissue-specific amounts of two bioactive products, somatostatin-14, and somatostatin-28. These peptides inhibit endocrine and exocrine secretion and affect neurotransmission, GI and biliary motility, intestinal absorption, vascular tone, and cell proliferation.

Five different somatostatin receptors (SSTRs) have been cloned and the biologic properties of each are being unraveled.⁹ All five are G-protein-coupled receptors with seven highly conserved transmembrane domains and unique amino and carboxy termini. Phosphorylation sites located within the second and third intracellular loops and in the cytoplasmic C-terminal segment are thought to mediate receptor regulation. Although the naturally occurring peptides bind to all five receptors, somatostatin-28 is relatively selective for SSTR5. The hexapeptide and octapeptide analogues such as octreotide bind only to SSTR2, SSTR3, and SSTR5. These analogues have a longer serum half-life, and their potent inhibitory effect has been used clinically to treat both endocrine and exocrine disorders. For example, octreotide has been shown to decrease fistula output and speed the time it takes for enteric and pancreatic fistulas to close.¹⁰

Endocrine release of somatostatin occurs during a meal. The major stimulant is probably intraluminal fat. Acidification of the gastric and duodenal mucosa also releases somatostatin in isolated perfused organ preparations. Acetylcholine from the cholinergic neurons inhibits somatostatin release.

Pancreatic polypeptide (PP) is a 36-amino-acid, straight-chain peptide discovered by Kimmel in 1968 during the process of insulin purification. Protein is the most potent enteral stimulator of PP release, closely followed by fat, whereas glucose has a weaker effect.¹¹ Hypoglycemia, whether or not it is insulin

induced, strongly stimulates PP secretion through cholinergic stimulation.¹² Phenylalanine, tryptophan, and fatty acids in the duodenum stimulate PP release, probably by inducing CCK and secretin release. In the isolated perfused pancreas, insulin and gastric inhibitory peptide stimulate PP release, while glucagon and somatostatin inhibit it. Vagal stimulation of the pancreas is the most important regulator of PP secretion. In fact, vagotomy eliminates the rise in PP levels usually seen after a meal. This can be used as a test for the completeness of a surgical vagotomy or for the presence of diabetic autonomic neuropathy.

PP has been shown to inhibit choleresis (bile secretion), gallbladder contraction, and secretion by the exocrine pancreas. However, PP's most important role is in glucose regulation through its regulation of hepatic insulin receptor gene expression. A deficiency in PP secretion due to proximal pancreatectomy, severe chronic pancreatitis, or cystic fibrosis, is associated with diminished hepatic insulin sensitivity due to reduced hepatic insulin receptor availability.¹³ This effect is reversed by PP administration.¹⁴

Recent studies have shown that a fifth islet peptide, ghrelin, is secreted from a distinct population of islet cells, called *epsilon cells*.^{15,16} Ghrelin also is present in the gastric fundus in large amounts and stimulates growth hormone secretion via growth hormone releasing hormone release from the pituitary. It is an orexigenic, or appetite-stimulating, peptide the plasma levels of which are increased in obesity. Ghrelin has also been shown to block insulin effects on the liver, and inhibits the β -cell response to incretin hormones and glucose.¹⁷ Therefore, ghrelin secretion from and within the islet may modulate the responses of other islet cells to nutrient and hormonal stimuli.

In addition to the five main peptides secreted by the pancreas, there are a number of other peptide products of the islet cells, including amylin and pancreastatin, as well as neuropeptides such as VIP, galanin, and serotonin. Amylin or islet amyloid polypeptide (IAPP) is a 37-amino-acid polypeptide that is predominantly expressed by the pancreatic β -cells, where it is stored along with insulin in secretory granules.¹⁸ The function of IAPP seems to be the modulation or counterregulation of insulin secretion and function. Pancreastatin is a recently discovered pancreatic islet peptide product that inhibits insulin, and possibly somatostatin release, and augments glucagon release.^{19,20} In addition to this effect on the endocrine pancreas, pancreastatin inhibits pancreatic exocrine secretion.²¹

Islet Distribution

The β -cells are generally located in the central portion of each islet and make up about 70% of the total islet cell mass. The other cell types are located predominantly in the periphery. The delta cells are least plentiful, making up only 5%; the α -cells make up 10%, and the PP cells make up 15%.²² In contrast to the acinar cells that secrete the full gamut of exocrine enzymes, the islet cells seem to specialize in the secretion of predominantly one hormone. However, individual islet cells can secrete multiple hormones. For example, the β -cells secrete both insulin and amylin, which counterregulates the actions of insulin. In reality, more than 20 different hormones are secreted by the islets, and the exact functions of this milieu are very complex. There is diversity among the islets depending on their location within the pancreas. The α - and δ -cells are evenly distributed throughout the pancreas, but islets in the head and uncinata process (ventral anlage) have a higher percentage of PP cells and fewer α -cells, whereas islets in the body and tail (dorsal anlage) contain the majority of

α -cells and few PP cells. This is clinically significant because pancreatoduodenectomy removes 95% of the PP cells in the pancreas. This may partially explain the higher incidence of glucose intolerance after the Whipple procedure compared to a distal pancreatectomy with an equivalent amount of tissue resected. In addition, chronic pancreatitis, which disproportionately affects the pancreatic head, is associated with PP deficiency and pancreatogenic diabetes.²³ The relative preponderance of α -cells in the body and tail of the pancreas explains the typical location of glucagonomas.

ACUTE PANCREATITIS

Definition, Incidence, and Epidemiology

Acute pancreatitis is a common and challenging disease that can develop both local and systemic complications. Its hallmark is acute pancreatic inflammation associated with little or no fibrosis. It ranges from a mild self-limiting inflammation of the pancreas to critical disease characterized by infected pancreatic necrosis, multiple organ failure and a high risk of mortality.²⁴ The clinical outcome has improved over recent decades, even in the absence of specific treatments that target outcome-determining pathophysiology, probably because of a more consistent approach to diagnosis, monitoring and management.

Acute pancreatitis is the most common gastrointestinal discharge diagnosis in the United States (274,119 patients in 2009), an incidence which has increased 30% since 2000, and is associated with the highest aggregate inpatient costs at 2.6 billion dollars per year.²⁵ The crude mortality rate of 1.0/100,000 ranks it as the 14th most fatal illness overall and the ninth most common noncancer gastrointestinal death. Worldwide the incidence of acute pancreatitis ranges from 5 to 80/100,000 population with the highest incidence recorded in Finland and United States.²⁶ The racial incidence of acute pancreatitis also shows significant variation related to the prevalence of etiological factors and ethnicity. The annual incidence of acute pancreatitis in Native Americans is 4 per 100,000 population; in whites it is 5.7 per 100,000 population; and in blacks it is 20.7 per 100,000 population.²⁷ Smoking is an independent risk factor for acute pancreatitis.²⁸

Etiology

Many factors have been causally related to the onset of acute pancreatitis (Table 33-4), but in many instances the mechanism is poorly understood. The most common causes are gallstones and alcohol, accounting for up to 80% of cases, but it is not uncommon to diagnose acute pancreatitis in the absence of these etiological factors. Therefore it is important that a systematic approach is taken to the identification of other, less common, and potentially modifiable, factors. The median age of the onset of acute pancreatitis varies with etiology; alcohol and drug induced pancreatitis typically present in the third or fourth decade compared with gallstone and trauma induced disease in the sixth decade. The gender difference is probably more related to etiology: in males alcohol is more often the cause while in females it is gallstones.

Gallstones

Evidence that passage of a gallstone is related to the onset of acute pancreatitis comes from the characteristic transient derangement of liver function tests and the high retrieval rate

Table 33-4

Etiologies of acute pancreatitis

Alcohol
Biliary tract disease
Hyperlipidemia
Hereditary
Hypercalcemia
Trauma
External
Surgical
Endoscopic retrograde cholangiopancreatography
Ischemia
Hypoperfusion
Atheroembolic
Vasculitis
Pancreatic duct obstruction
Neoplasms
Pancreas divisum
Ampullary and duodenal lesions
Infections
Venom
Drugs
Idiopathic

Source: Reproduced with permission from Yeo CJ, Cameron JL: Exocrine pancreas, in Townsend CM et al (eds): *Sabiston's Textbook of Surgery*. Philadelphia: Saunders, 2000, p 1117. Copyright Elsevier.

of gallstones from feces within 10 days of an attack of acute pancreatitis compared with those without acute pancreatitis (88% vs. 11%).²⁹ The mechanism by which small gallstones migrating down the common bile duct, past the pancreatic duct junction and into the duodenum, cause acute pancreatitis is not clear. Opie made the seminal observation of a gallstone impacted in the sphincter of Oddi in two fatal cases of acute pancreatitis, which lead to the “common channel” hypothesis. It was proposed that a gallstone transiently lodged in the distal common channel of the ampulla of Vater allowed bile to reflux into the pancreatic duct, but this cannot be reliably reproduced in experimental models. Another proposal suggested that transient incompetence caused by the passage of a stone through the sphincter might allow duodenal fluid and bile to reflux into the pancreatic duct, but this is refuted by the usual absence of acute pancreatitis after endoscopic sphincterotomy or surgical sphincteroplasty. A third possibility is that acute pancreatitis is due to a gallstone obstructing the pancreatic duct, leading to ductal hypertension. It has been postulated that this backpressure might lead to minor ductal disruption, extravasation of pancreatic juice into the less alkaline interstitium of the pancreas, and promotion of enzyme activation. When gallstones and other etiological factors cannot be identified there is still the possibility of finding microlithiasis, seen as birefringent crystals, on bile microscopy.³⁰ This occult microlithiasis is probably responsible for up to half of those with idiopathic acute pancreatitis.

Alcohol

Alcohol ingestion is associated with acute pancreatitis and sustained alcohol ingestion is associated with recurrent acute pancreatitis and development of chronic pancreatitis in susceptible individuals who have been drinking for more than a decade. The type of alcohol consumed is less important than the amount

consumed (typically 100 to 150 grams per day) and the pattern of drinking. It is common for patients with alcohol associated acute pancreatitis to have a history of excess alcohol consumption prior to the first attack. There are several mechanisms by which ethanol causes acute pancreatitis. Ethanol is a metabolic toxin to pancreatic acinar cells and causes a brief secretory increase followed by inhibition. The secretory burst coupled with ethanol induced spasm of the sphincter of Oddi is thought to incite acute pancreatitis. Ethanol also induces ductal permeability, which would allow prematurely activated enzymes to cause damage to the pancreatic parenchyma. Ethanol also increases the protein content of pancreatic juice, decreases bicarbonate levels, and trypsin inhibitor concentration. The formation of protein plugs may also contribute by causing an obstructive element to pancreatic outflow.

Iatrogenic

Acute pancreatitis can result from a number of treatments, including pancreatic biopsy, exploration of the extrahepatic biliary tree and ampulla of Vater, distal gastrectomy, splenectomy, colectomy, nephrectomy, aortic aneurysmorrhaphy, and retroperitoneal lymphadenectomy. As the pancreas is susceptible to ischemia it can also occur secondary to splanchnic hypoperfusion with cardio-pulmonary bypass or cardiac transplant. Most commonly, acute pancreatitis occurs as a complication of ERCP in 5% to 10% of procedures, and in many series it is the third most common identified etiological factor. The risk of post-ERCP acute pancreatitis is increased if the contrast agent is infused repeatedly under high pressure by the endoscopist and in patients with sphincter of Oddi dysfunction. Recent evidence demonstrates that the risk can be decreased with prophylactic, rectally administered, nonsteroidal drugs.³¹

Hereditary Pancreatitis

Hereditary pancreatitis is an autosomal dominant disorder usually related to mutations of the cationic trypsinogen gene (PRSS1). Mutations in this gene cause premature activation of trypsinogen to trypsin and cause abnormalities of ductal secretion, both of which promote acute pancreatitis. Mutations in the SPINK1 protein, which blocks the active binding site of trypsin, is also likely to have a role in predisposing to acute pancreatitis. Variations in penetration and phenotype are common and there are many other mutations that may become implicated. Mutant enzymes activated within acinar cells can overwhelm the first line of defense (pancreatic secretory trypsin inhibitor) and resist backup defenses (e.g., proteolytic degradation, enzyme Y, and trypsin itself) allowing activated mutant cationic trypsin to trigger the entire zymogen activation cascade.³²

Tumors

A pancreatic or periampullary tumor should be considered in any patient with idiopathic acute pancreatitis. Approximately 1% to 2% of patients with acute pancreatitis have a pancreatic tumor, and an episode of acute pancreatitis can be the first clinical manifestation of the tumor. If no historical information leads to an etiologic diagnosis, cross sectional pancreatic imaging after the resolution of an unexplained episode of acute pancreatitis is indicated.

Hyperlipidemia

Patients with types I and V hyperlipoproteinemia can experience episodes of abdominal pain, and these often occur in association with marked hypertriglyceridaemia. Lipase is thought to liberate

toxic fatty acids into the pancreatic microcirculation, leading to microcirculatory impairment and ischemia. Dietary modifications to restrict triglycerides are usually effective, but clofibrate may be prescribed in refractory cases of hypertriglyceridemia.

Drugs and Miscellaneous Causes

Many drugs can produce hyperamylasemia and/or abdominal pain, and a drug is considered suspect if the pancreatitis-like illness resolves with its discontinuation. Ethical considerations generally rule out rechallenge with the suspect drug, so the connection often remains vague. However, despite these limitations, certain drugs are known to be capable of causing acute pancreatitis. These include the thiazide diuretics, furosemide, estrogens, azathioprine, l-asparaginase, 6-mercaptopurine, methyl dopa, the sulfonamides, tetracycline, pentamidine, procainamide, nitrofurantoin, dideoxyinosine, valproic acid, and acetylcholinesterase inhibitors. In addition, lipid-based intravenous drugs and solutions, such as propofol, can also cause acute pancreatitis.³³ A history of verified or suspected drug-induced pancreatitis should serve as a contraindication to prescribing that medication again.

Hypercalcemic states arising from hyperparathyroidism can result in both acute and chronic pancreatitis; the mechanism most likely involves hypersecretion and the formation of calcified stones intraductally. Also implicated are infestations by *Ascaris lumbricoides* and the liver fluke *Clonorchis sinensis*, which is endemic to China, Japan, and Southeast Asia. These cause Oriental cholangitis, which is associated with cholangiocarcinoma obstructing the pancreatic duct.

Other implicated factors include azotemia, vasculitis, and the sting of the Trinidadian scorpion *Tityus trinitatis*. This scorpion's venom has been shown to cause neurotransmitter discharge from cholinergic nerve terminals, leading to massive production of pancreatic juice. Poisoning with antiacetylcholinesterase insecticides has a similar effect. Finally, no apparent cause can be ascribed to some episodes of acute pancreatitis, and these constitute the group referred to as idiopathic pancreatitis. Some of these patients are eventually found to have gallstone-related pancreatitis, which calls for caution in labeling any episode "idiopathic."

Pathophysiology

Acute pancreatitis occurs in various degrees of severity, the determinants of which are multifactorial. The generally prevalent belief today is that pancreatitis begins with the activation of digestive zymogens inside acinar cells, which cause acinar cell injury. Studies suggest that the ultimate severity of the resulting pancreatitis may be determined by the events that occur subsequent to acinar cell injury.³⁴ These include inflammatory cell recruitment and activation, as well as generation and release of cytokines and other chemical mediators of inflammation (Fig. 33-10).

Precipitating Initial Events

Acinar Cell Events. Acute pancreatitis is an inflammatory disorder believed to begin in the pancreas and is generally restricted to it; although in some cases its effects can be systemic, diverse and result in multiple organ failure. In 1896, Chiari advanced the understanding of acute pancreatitis by proposing the concept that the pancreatitis is essentially the premature, intrapancreatic activation of digestive enzymes, resulting in auto-digestion of the organ. Since then the intra-acinar activation of zymogens

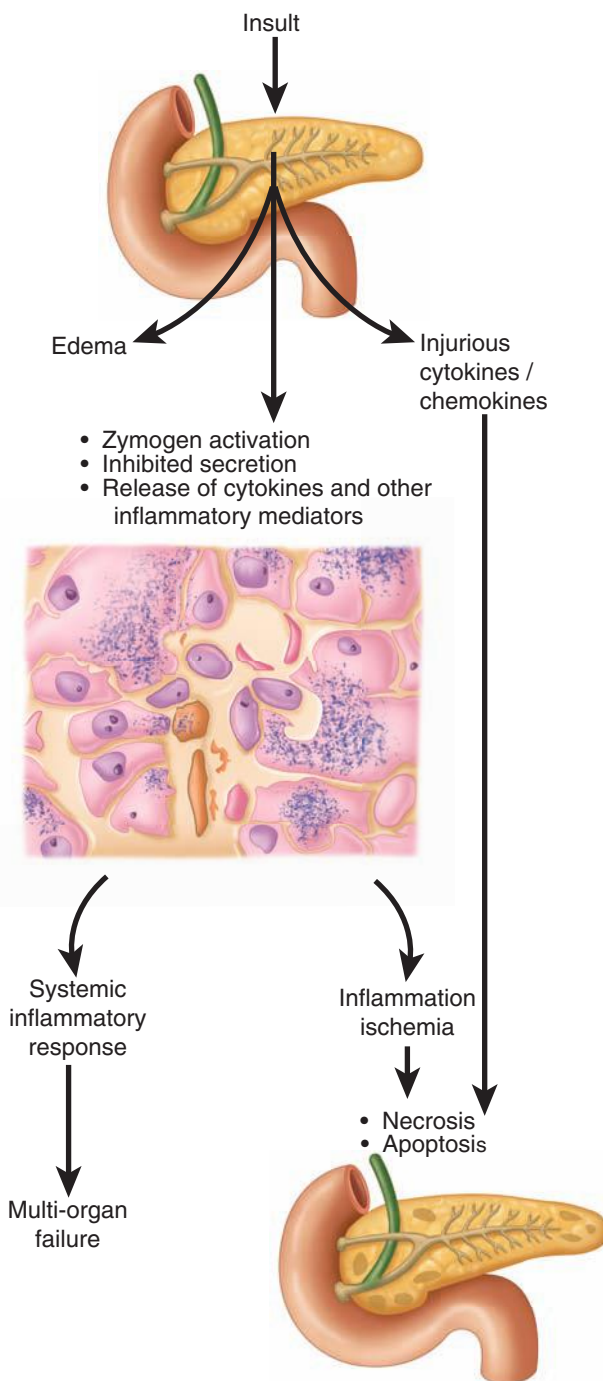


Figure 33-10. Pathophysiology of acute pancreatitis.

has been demonstrated consistently in multiple animal models of acute pancreatitis and is considered a central piece in the puzzle of acute pancreatitis.^{35, 36} The key role of trypsin activation in acute pancreatitis has gained additional support from recent studies showing that mice lacking trypsinogen-7 (the isoform of trypsinogen which is activated during acute pancreatitis in mice) have significantly less pancreatic injury during acute pancreatitis³⁷ and that intra-acinar expression of active trypsin causes pancreatitis in mice.³⁸ The role of trypsin activation in the pathophysiology of acute pancreatitis has also been suggested by clinical studies; e.g., hereditary pancreatitis is associated with mutations that lead to elevated intracellular trypsin activation³⁹ and activation of trypsinogen has been demonstrated in clinical pancreatitis as well.⁴⁰

The mechanisms by which injurious stimuli lead to intracinar activation of trypsinogen and autodigestion of the gland have been the focus of research in pancreatitis for decades. Because the exocrine pancreas produces enzymes that are potentially injurious to it, several protective mechanisms have evolved to prevent autodigestion under normal conditions. Enzymes are synthesized as inactive precursors called proenzymes or zymogens, which are then transported and secreted outside the gland. Their activation occurs safely in the duodenum, where the brush-border enzyme enteropeptidase (or enterokinase) activates the trypsinogen, and the resulting trypsin then activates the other zymogens in a cascade reaction. This separates the site of production of these enzymes from the site of activation and thus the pancreas is insulated against enzymatic attack. Within the acinar cell itself, the potentially harmful digestive enzymes are segregated from the surrounding cytoplasm by being enclosed within membrane-bound organelles referred to as zymogen granules. Another layer of protection is provided by the synthesis of trypsin inhibitors, which are transported and stored along with the digestive enzyme zymogens. These are available to inhibit small amounts of prematurely-activated trypsinogen within the pancreatic acinar cells. It is theorized that acute pancreatitis occurs when this process goes awry and the gland is injured by the erroneously-activated enzymes that it produces. Although the mechanism(s) of erroneous activation are not fully understood, it has been shown that intra-acinar activation of trypsinogen goes hand-in-hand with inhibition of acinar secretion.^{41,42} Furthermore, in the presence of injurious stimuli, the zymogens responsible for initiating the disease are not secreted outside, but are observed to co-localize with cytoplasmic vacuoles that contain lysosomal enzymes such as cathepsin B.⁴³ Data suggest that cathepsin B in these vacuoles activates trypsinogen. Thus, inhibition of cathepsin B by pharmacological inhibitors⁴⁴ or by genetic deletion of cathepsin B eliminates trypsin activation and decreases the severity of pancreatitis in animal models.⁴⁵ What leads to the coming together of zymogens and lysosomal hydrolases is unclear, but injurious stimuli leading to sustained cytosolic calcium increase

have been indicted. Blocking this calcium increase prevents colocalization and activation of trypsin, and decreases injury due to pancreatitis.⁴⁶ Based on these data, pre-ERCP supplementation of magnesium, a natural antagonist of calcium, is currently being evaluated as a strategy to decrease post-ERCP pancreatitis.⁴⁷ How activation of trypsin in the co-localization vacuoles leads to pancreatic damage is also not clear. Recent work has led to the novel hypothesis that the lysosomal hydrolase cathepsin B activates trypsinogen to trypsin within the co-localization vacuoles. Trypsin then permeabilizes these co-localization vacuoles causing the release of cathepsin B into the cytosol. Once in the cytosol, cathepsin B initiates apoptotic cell death by permeabilizing mitochondrial membranes, which allows cytochrome C to be released into the cytosol. This initiates the apoptotic cascade and results in the apoptotic death of the acinar cells (Fig. 33-11).⁴⁸

Intrapancreatic Events

Activated neutrophils are attracted to a focus of tissue injury and after activation release superoxides (the “respiratory burst”) and proteolytic enzymes (cathepsins, elastase and collagenase) which cause further injury. In addition macrophages release cytokines (including tumor necrosis factor-alpha (TNF- α), interleukin (IL)-6, and IL-8) which mediate the local and the systemic inflammatory responses. These inflammatory mediators cause an increased pancreatic vascular permeability, leading to edema, hemorrhage, and microthrombi. Fluid may collect in and around the pancreas. The failure of the pancreatic microcirculation, a feature of more severe acute pancreatitis, results in pancreatic hypoperfusion and necrosis. Acute inflammation of the pancreatic parenchyma and peripancreatic tissues, but without recognizable necrosis is termed interstitial edematous pancreatitis.²⁴ When necrosis is present, and evidenced by pancreatic hypoperfusion with contrast CT, it is termed necrotizing pancreatitis (Fig. 33-12). The updated morphological definitions and the contrast enhanced CT criteria for the diagnosis of the local complications of acute pancreatitis have recently been published in the revised Atlanta statement,⁴⁹ and summarized in Table 33-5.⁵⁰

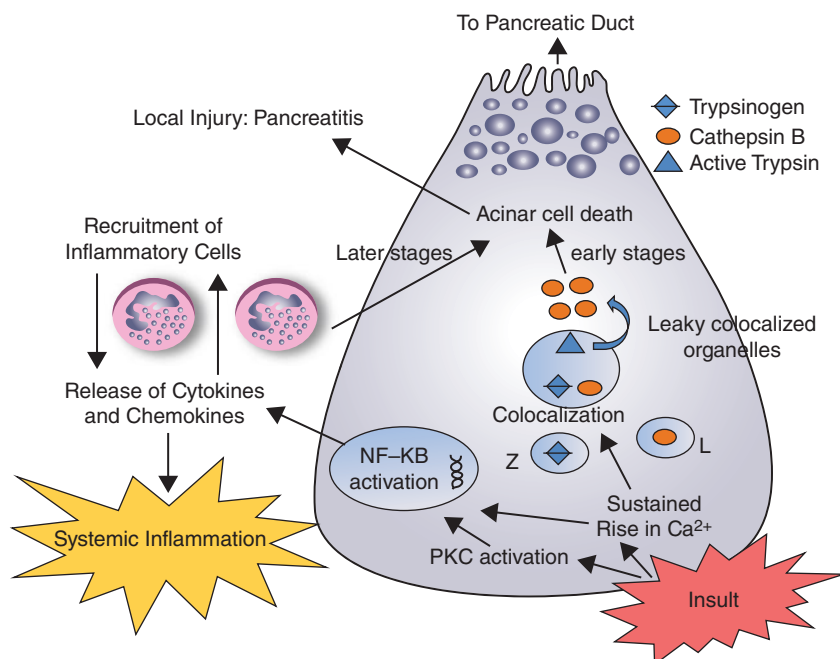


Figure 33-11. Schematic representation of the acinar cell events in acute pancreatitis. When acinar cells are pathologically stimulated, their lysosomal (L) and zymogen (Z) contents colocalize, consequently trypsinogen is activated to trypsin by cathepsin B. Increased cytosolic calcium is required for colocalization. Once trypsin has permeabilized the contents of the cytosol, cathepsin B and other contents of these colocalized organelles are released. Once in the cytosol, cathepsin B activates apoptosis by causing cytochrome c to be released from the mitochondria. Activation of PKC results in a sudden activation of nuclear factor kappa beta (NF- κ B) which in turn triggers the release of cytokines that attract inflammatory response cells which mediate local and systemic inflammation cascades.³⁷

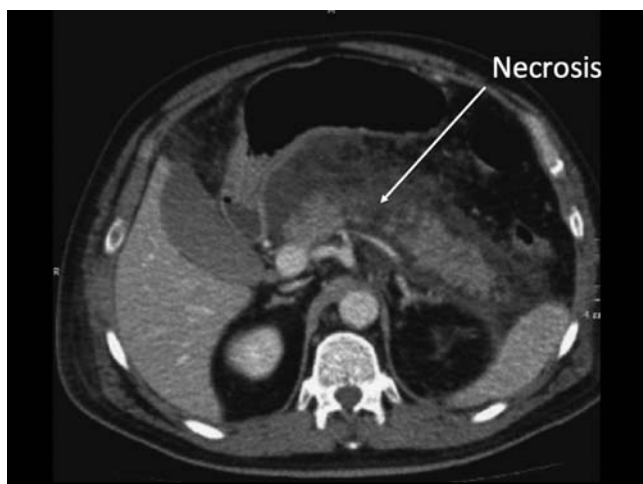


Figure 33-12. CT scan showing well perfused interstitial edematous acute pancreatitis of the neck and tail of the pancreas with a confluent area of necrosis of the pancreatic body. Pancreas surrounded by fluid, inflammation, and possible peripancreatic fat necrosis.

Systemic Events

An important aspect of the pathophysiology of acute pancreatitis is the mechanism by which events occurring in the pancreas induce systemic inflammation and multiorgan failure. The NF κ B-dependent inflammatory pathway is one such key pathway. NF κ B activation parallels trypsin activation in acute pancreatitis but appears to be independent of it. The role of trypsin in NF κ B activation was debated for a long time, but this issue seems to be largely settled following the observation that NF κ B activation still occurs in acini from trypsin knockout mice, which obviously do not have pathologic trypsin activation.³⁷ However, sustained calcium increase, which leads to trypsinogen activation, is critical for NF κ B activation as well, since attenuation of cytosolic calcium also abrogates NF κ B activation.⁵¹ Once activated, NF κ B regulates synthesis of multiple cytokines and chemokines, leading to recruitment of various inflammatory cells that then magnify and propagate systemic inflammation.

Although intra-acinar events initiate acute pancreatitis, events occurring subsequent to acinar cell injury determine the severity of pancreatitis. Once recruited to the pancreas, various inflammatory cells lead to further acinar cell injury and cause an elevation of various pro-inflammatory mediators such as TNF- α ; IL-1, IL-2, IL-6, and other chemokines and anti-inflammatory factors.³⁶ Elucidation of these mediators has encouraged efforts to target their production or activity with an aim to modulate the course of severe acute pancreatitis.

Organ failure can develop at any stage of acute pancreatitis, associated with an overwhelming proinflammatory response

early, or later secondary to the development of infected local complications. The drivers of the systemic response are poorly understood, although factors include the elaboration of proinflammatory cytokines, and it appears that mesenteric lymph, bypassing the liver and containing these constituents, may contribute to the development of organ failure.⁵² The development of pancreatic necrosis, the breakdown of the intestinal barrier and the suppression of the immune response through the compensatory inflammatory response contribute to the development of infected pancreatic necrosis, the incidence of which peaks in the third to fourth week. This is usually associated with deterioration in the patient and may be associated with the late development of the systemic inflammatory response syndrome (SIRS) and multi-organ dysfunction syndrome/failure (MODS/F).

Organ failure is scored using the Marshall or Sequential Organ Failure Assessment (SOFA) systems (Table 33-6). The three organ systems most frequently involved are cardiovascular, respiratory, and renal. Multiple organ failure is defined as two or more organs registering 2 or more points on these scoring systems.⁴⁹ Monitoring organ failure over time and in response to treatment is important in the clinical care of the disease.

Management of the Patient

General Considerations. The management of acute pancreatitis covers a wide spectrum of severity. Patients with suspected acute pancreatitis should be admitted to hospital. Those with mild acute pancreatitis usually remain in hospital for less than a week, while those with severe and critical acute pancreatitis may require many weeks or months of intensive treatment. The risk of mortality reflects this spectrum of severity. The risk is less than 1% for those with mild disease, increasing to around 10% for those with moderate disease, but for severe and critical disease the mortality risk is much higher (20% to 40% and greater than 50%, respectively). The earlier identification of these high-risk categories and the transfer of these patients to specialized centers is an important priority of management.⁵³ Scoring systems such as Ranson's Criteria identify these high-risk patients (Table 33-7). The management of acute pancreatitis should be multidisciplinary and it is important that a coordinated care plan is carefully supervised.

Diagnosis

The diagnosis of acute pancreatitis requires the patient to present with abdominal pain consistent with acute pancreatitis (acute onset of a severe constant epigastric pain which often radiates through to the mid back) and the elevation of serum amylase or lipase (>3 times upper limit of normal). Imaging (usually by contrast enhanced CT scanning) is only required for the diagnosis of acute pancreatitis when these diagnostic criteria are not met.⁴⁹ Because of the many causes of hyperamylasemia,

Table 33-5

Local complications of acute pancreatitis⁵⁰

CONTENT	ACUTE (<4 WEEKS, NO DEFINED WALL)		CHRONIC (>4 WEEKS, DEFINED WALL)	
	NO INFECTION	INFECTION	NO INFECTION	INFECTION
Fluid	Acute pancreatic fluid collection (APFC)	Infected APFC	Pseudocyst	Infected pseudocyst
Solid \pm fluid	Acute necrotic collection (ANC)	Infected ANC	Walled off necrosis (WON)	Infected WON

Source: Reproduced with permission from Windsor JA, Petrov MS: Acute pancreatitis reclassified. Commentary. *Gut*. 2013;62:4. With permission from the BMJ Publishing Group.

Table 33-6

Sequential organ failure assessment (SOFA) score in acute pancreatitis⁴⁹

	0	1	2	3	4
Respiration (PaO ₂ /FIO ₂) (mm Hg)	>400	≤400	≤300	≤200 with respiratory support	≤100 with respiratory support
Coagulation Platelets (x10 ¹ per μL)	>150	≤150	≤100	≤50	≤20
Liver Bilirubin (μmol/L)	<20	20–32	33–101	102–204	>204
Cardiovascular Hypotension	No hypotension	MAP <70mm Hg	Dopamine ≤5 or dobutamine (any dose)*	Dopamine >5 or epi ≤0.1* or norepi ≤0.1*	Dopamine >15 or epi >0.1* or norepi >0.1*
Central nervous system Glasgow coma score	15	13–14	10–12	6–9	<6
Kidney Creatinine (μmol/L) or urine output	<110	110–170	171–299	300–440 or <500 ml/day	>440 or <200 ml/day

MAP = mean arterial pressure. Epi = epineptvine. Norepi = norepinephrine. *Adrenergic agents administered for at least 1 h (doses given in μg/kg per min). A score of 2 or more in any two systems indicates the presence of multiple organ failure.

Table 33-7

Ranson's prognostic signs of pancreatitis

Criteria for acute pancreatitis not due to gallstones

At admission	During the initial 48 h
Age >55 y	Hematocrit fall >10 points
WBC >16,000/mm ³	BUN elevation >5 mg/dL
Blood glucose >200 mg/dL	Serum calcium <8 mg/dL
Serum LDH >350 IU/L	Arterial PO ₂ <60 mm Hg
Serum AST >250 U/dL	Base deficit >4 mEq/L
	Estimated fluid sequestration >6 L

Criteria for acute gallstone pancreatitis

At admission	During the initial 48 h
Age >70 y	Hematocrit fall >10 points
WBC >18,000/mm ³	BUN elevation >2 mg/dL
Blood glucose >220 mg/dL	Serum calcium <8 mg/dL
Serum LDH >400 IU/L	Base deficit >5 mEq/L
Serum AST >250 U/dL	Estimated fluid sequestration >4 L

AST = aspartate transaminase; BUN = blood urea nitrogen; LDH = lactate dehydrogenase; PO₂ = partial pressure of oxygen; WBC = white blood cell count.

Note: Fewer than 3 positive criteria predict mild, uncomplicated disease whereas more than 6 positive criteria predict severe disease with a mortality risk of 50%.

Sources: Data from Ranson JHC: Etiological and prognostic factors in human acute pancreatitis: A review. *Am J Gastroenterol* 77:633, 1982, and From Ranson JH, Rifkind KM, Roses DF, et al. Prognostic signs and the role of operative management in acute pancreatitis. *Surg Gynecol Obstet* 139:69, 1974.

it is important to measure either the pancreatic isoenzyme of amylase or lipase.

The serum amylase concentration increases almost immediately with the onset of disease and peaks within several hours.⁵⁴ It remains elevated for 3 to 5 days before returning to normal. There is no significant correlation between the magnitude of serum amylase elevation and severity of pancreatitis; in fact, a milder form of acute pancreatitis is often associated with higher levels of serum amylase compared with that in a more severe form of the disease.

It is important to note that hyperamylasemia can also occur as a result of conditions not involving pancreatitis. For example, hyperamylasemia can occur in a patient with small bowel obstruction, perforated duodenal ulcer, or other intra-abdominal inflammatory conditions. In contrast, a patient with acute pancreatitis may have a normal serum amylase level, which could be due to several reasons. In patients with hyperlipidemia, values might appear to be normal because of interference by lipids with chemical determination of serum amylase. In many cases, urinary clearance of pancreatic enzymes from the circulation increases during pancreatitis; therefore, urinary levels may be more sensitive than serum levels. For these reasons, it is recommended that amylase concentrations also be measured in the urine. Urinary amylase levels usually remain elevated for several days after serum levels have returned to normal. In patients with severe pancreatitis associated with significant necrotic damage, the pancreas may not release large amounts of enzymes into the circulation.

With increasing severity of disease, the intravascular fluid loss may become life-threatening as a result of sequestration of edematous fluid in the retroperitoneum. Hemoconcentration then results in an elevated hematocrit. However, there also may be bleeding into the retroperitoneum or the peritoneal cavity. In some patients (about 1%), the blood from necrotizing pancreatitis may dissect through the soft tissues and manifest itself as a bluish discoloration around the umbilicus (Cullen's sign) or in the flanks

(Grey Turner's sign). The severe fluid loss may lead to prerenal azotemia with elevated blood urea nitrogen and creatinine levels. There also may be hyperglycemia, hypoalbuminemia, and hypocalcemia sufficient in some cases to produce tetany.

Pain Management

Pain is the cardinal symptom of acute pancreatitis and its relief is a clinical priority. There is a lack of high quality evidence to guide the choice of analgesic. Because of unpredictable absorption analgesia should be administered intravenously, at least at the outset and before oral intake has been established. Those with mild pain can usually be managed with a nonsteroidal anti-inflammatory drug (e.g., metamizole 2g/8h IV) while those with more severe pain are best managed with opioid analgesia (e.g., buprenorphine 0.3mg/4h IV). Administration of buprenorphine, pentazocine, procaine hydrochloride, and meperidine are all of value in controlling abdominal pain. Morphine is to be avoided, due to its potential to cause sphincter of Oddi spasm.

Predicting Severity

Where classification relates to the present or past severity of acute pancreatitis, prediction is about the future and ultimate severity and outcome of the patient. Accurately predicting acute pancreatitis severity is important in making triage decisions about whether a patient should be transferred to a tertiary hospital, or admitted to an intensive care unit, and in making decisions about fluid therapy, whether an ERCP is indicated, and other issues. There is a long history of attempts to find prognostic or predictive markers that accurately stratify the risk, with the most widely used being the Ranson's criteria (Table 33-7) or modified Glasgow criteria. Both use clinical and biochemical parameters scored over the first 48 hours of admission. When there are 3 or more positive criteria, the disease is considered "predicted severe." There are many other approaches to predicting severity. At 24 hours after admission an APACHE II score of 8 or more or a serum C-reactive protein level of >150mg/dl has a similar accuracy in predicting severity as Ranson's criteria.⁵⁴ The more recently proposed Bedside Index for Severity of Acute Pancreatitis (BISAP) is calculated from blood urea nitrogen (> 25 mg/dl), impaired mental status (GCS <15), presence of systemic inflammatory response syndrome (SIRS), age >60 years, and pleural effusion. Although it has the advantage of simplicity and can be performed within the first 24 hours of admission it has performed no better than other predictors in comparison studies.⁵⁵ The presence of SIRS also has prognostic significance.⁵⁶ There remains some controversy as to the importance of obesity as a risk factor for severe and critical acute pancreatitis.⁵⁷ Another approach has been taken in seeking

to predict those with 'harmless' acute pancreatitis⁵⁸ using three factors that can be determined on admission; absence of rebound tenderness or guarding, normal hematocrit, and normal serum creatinine. The accuracy of this approach appears to be over 90%, and triages most patients with acute pancreatitis away from intensive care.

Unfortunately these and many other single and combined predictors of severity have an accuracy of only around 70%.⁵⁴ This means that there is misclassification error of 30% that limits the value in predicting the severity of acute pancreatitis in individual patients. In the absence of any new biomarkers of ultimate disease severity, making better use of existing predictors through sequencing tests, combining tests or using artificial neural network methodologies has shown promise.⁵⁹

Classification of the Severity of Acute Pancreatitis

Accurately classifying or staging acute pancreatitis severity is important for clinical decision-making, communication, and enrollment into trials. The wide spectrum of pancreatitis severity has not been captured in the previous binary classifications (mild or severe). A four-category classification of severity (mild, moderate, severe, critical) (Table 33-8) has been developed on the principle of casual inference, derived by meta-analysis, refined by an international multidisciplinary process and independently validated.⁶⁰ The key determinants of severity are local complications (absent, sterile or infected) and systemic complications (absent, transient organ failure, or persistent organ failure).⁶¹ The tracking of patient severity is important in delineating the clinical trajectory of a patient, and this classification of severity can be applied on a frequent basis. It can also be used in retrospect for audit purposes.

Determining the Etiology

A history of alcohol ingestion must be ascertained and preferably confirmed with blood ethanol levels. Gallstones should be investigated by ultrasonography. A gallstone etiology is more likely in females over the age of 50 with an elevation of alkaline phosphatase (>300 IU/L), alanine transferase (>100 IU/L) and amylase (>4000 IU/L). In the absence of gallstones and alcohol, a systematic approach to the identification of another factor will include taking a history for drug use, trauma, ERCP, infection, and measuring serum triglycerides, calcium, and others (Table 33-4).

Fluid Resuscitation

Fluid therapy to restore and maintain circulating blood volume is the most important intervention in the early management of acute pancreatitis.⁶² A recent systematic review has shown that

Table 33-8

Four categories of acute pancreatitis severity based on organ failure and local complications⁶¹

DETERMINANTS	NO LOCAL COMPLICATIONS	STERILE LOCAL COMPLICATIONS	INFECTED LOCAL COMPLICATIONS
NO ORGAN FAILURE	MILD	MODERATE	SEVERE
TRANSIENT ORGAN FAILURE	MODERATE	MODERATE	SEVERE
PERSISTENT ORGAN FAILURE	SEVERE	SEVERE	CRITICAL

the evidence base for fluid therapy is scant, however.⁶³ It is not known which fluid to give, how aggressively to administer it or what goal to use as a guide or to monitor the response to it. While there are proponents for aggressive fluid therapy and for specific resuscitation goals, it is probably best to resuscitate with a balanced crystalloid and to restore normal blood volume, blood pressure, and urine output. On the basis of recent data it appears that lactated Ringer's solution may be superior to normal saline in reducing the systemic inflammatory response.⁶⁴ Caution needs to be exercised in those with cardiac and renal disease and in the elderly.

Nutritional Support

In contrast to analgesia and fluid therapy there is a sound evidence base for nutritional support in acute pancreatitis.⁶⁵ It is no longer acceptable to "rest the pancreas" by avoiding enteral nutrition, and parenteral nutrition should only be offered if the patient's calculated nutritional requirements cannot be achieved by the enteral route. Enteral nutrition should be commenced after initial fluid resuscitation and within the first 24 hours of admission. It can be introduced through a nasogastric tube and increased in step-wise fashion over 2 to 3 days.⁶⁶ The tube can be advanced to the jejunum, by endoscopy or fluoroscopy, if there is evidence of feeding intolerance. A delay in commencing enteral nutrition may contribute to the development of intestinal ileus and feeding intolerance. Aggressive early enteral feeding, particularly prior to adequate resuscitation, may put the patient at risk of nonocclusive mesenteric ischemia. There is no evidence to support the use of elemental or immune-enhancing formulas over standard polymeric formulas.⁶⁷

3▶ In predicted mild acute pancreatitis the transition from oral fluids to food is usually timed to when the patient's abdominal pain has resolved, but the trend is toward allowing patients to resume intake ad libitum (i.e., patient controlled nutrition).

Cross-sectional Imaging

It may be necessary to perform a CT scan to diagnose acute pancreatitis in patients who are severely ill, or in those presenting with undifferentiated abdominal pain. But there is no advantage in using CT findings, or a "CT Severity Index," over other methods in predicting the severity of acute pancreatitis.⁵⁴ The primary purpose of cross sectional imaging is the diagnosis of local complications, in particular the development and extent of pancreatic necrosis or the presence of different fluid collections. CT scanning is important to guide the insertion of percutaneous drains in the management of local complications. MR is superior to CT scanning in detecting any solid content within collections (Fig. 33-13). When bleeding is suspected in association with a local complication, an arterial phase CT scan (CTa) is useful in detecting a pseudoaneurysm, active bleeding, and/or hematoma.

Therapeutic Endoscopic Retrograde Cholangiopancreatography (ERCP)

Randomized trials have demonstrated that early ERCP (within 24 or 48 hours of admission) reduces complications, but not mortality, in patients with predicted severe gallstone-associated acute pancreatitis. The benefits of this invasive modality (release of the presumed impacted stone) may be offset, however, but the risks of the procedure, which include an increase in the severity of pancreatitis, bleeding, cholangitis, and duodenal perforation. More recent evidence has suggested that early ERCP confers no benefit in the absence of concomitant cholangitis, as the offending common duct stone usually passes before ERCP can be performed.⁶⁸ If symptoms and chemical abnormalities persist or increase after initial presentation, magnetic resonance cholangio-pancreatography (MRCP) can detect a filling defect in the distal common bile duct, and may be used as prerequisite for attempted ERCP.⁶⁹ Persistent cholestasis without cholangitis may require an ERCP but is rarely indicated in the acute setting.

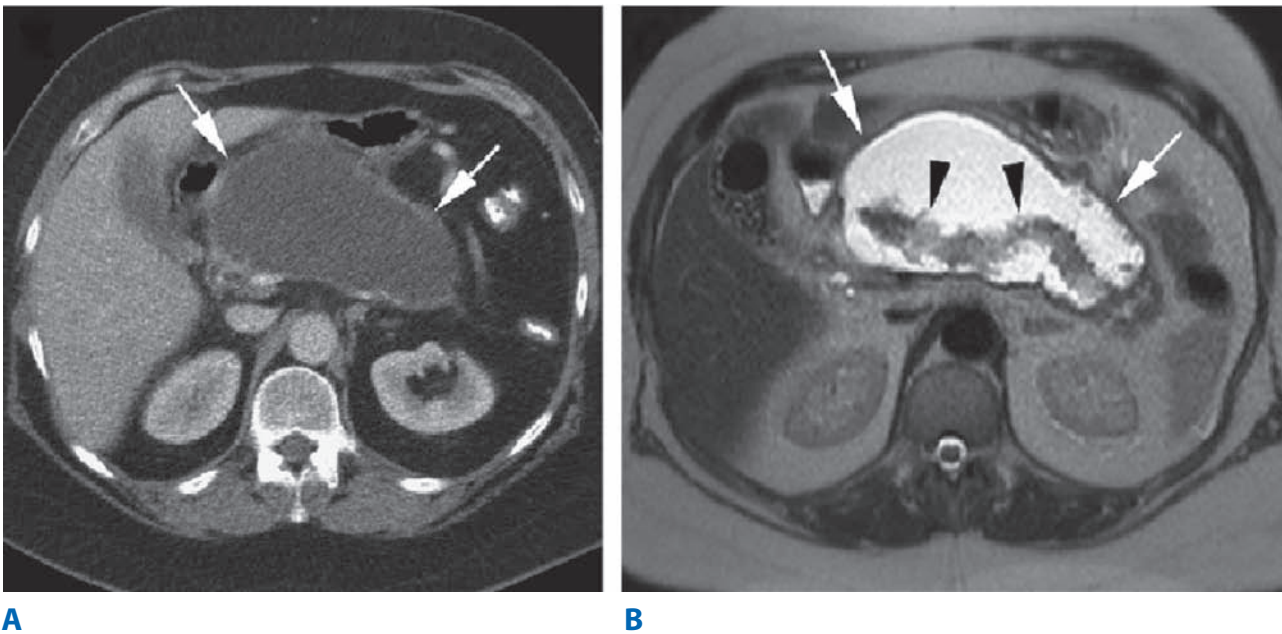


Figure 33-13. Corresponding CT (A) and MR (B) images of a patient with a symptomatic pseudocyst. CT image reveals a well circumscribed homogenous collection (arrows) exerting mass effect on antrum of stomach. The T2-weighted MR image clearly distinguishes necrotic pancreas (black arrows) from fluid (white arrows). (Reproduced with permission from Bollen TL et al. *Imaging of acute pancreatitis: Update of the revised Atlanta Classification*. Radiol Clin North Am. 2012;50:429. Copyright Elsevier.)

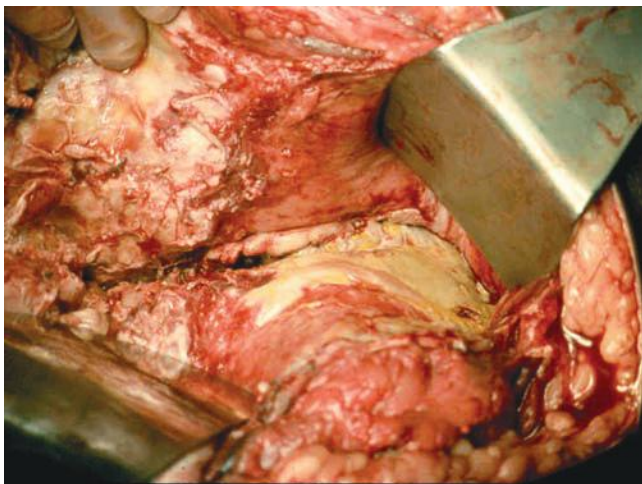


Figure 33-14. Operative view of infected acute pancreatitis. Peripancreatic infection, characterized by mucopurulent exudate, extends far beyond the boundaries of the pancreas in the retroperitoneum.

Antibiotics

Although the use of broad-spectrum antibiotics to treat established infection in acute pancreatitis is a well-established practice, there has been considerable controversy surrounding the use of prophylactic antibiotics. The overuse of antibiotics has been associated with a documented rise in fungal infections and resistant organisms. Overall, it appears that the most recent and generally better designed studies do not support the use of prophylactic antibiotics to reduce the frequency of pancreatic infectious complications, surgical intervention, and death.⁷⁰

Managing Local Complications

Vigilance is required for the timely and accurate diagnosis of local complications. The decisions regarding how and when

to intervene are often difficult. While guided by the information gained by cross-sectional imaging, the decision to intervene is based on the clinical status and trajectory of the patient and the poor response to maximal intensive care support. This means close monitoring of the patient by serial examination, supplemented by regular measurement of inflammatory markers (e.g., C reactive protein) and a pancreatic protocol CT scan if a local complication is suspected and intervention considered warranted. In practice, intervention is delayed in order to allow demarcation of necrosis, and a reduced the risk of bleeding, disseminated infection and collateral damage to adjacent organs by an intervention (Fig. 33-14). Appreciation of this has resulted in a notable trend toward delayed intervention, now uncommon before 3 to 4 weeks from the onset of symptoms. An important emerging approach is the increasing use of percutaneous catheter drainage in patients with suspected infected complications.⁷¹ Fine needle aspiration is now rarely used to confirm infection because the insertion of a needle at the time of planned drainage allows confirmation of the suspected infection. Pre-emptive drainage with one or more catheters often produces improvement or stabilization of the patient's overall clinical status.⁷² In this way drainage “buys time” and allows the lesion to become more walled off and safer to treat. Recent data suggest that primary percutaneous catheter drainage may be the only intervention required in a third to a half of patients and that this proportion might increase further if there were a standard protocol of regular catheter exchange, upsizing and irrigation.⁷² A proportion of patients do however require further treatment when they fail to respond (the so-called “step up approach”) and there is a wide array of minimally invasive options to choose from⁷³(Fig. 33-15). These interventions can be classified on the basis of the method of visualization, route taken to the lesion and the purpose of the intervention.⁷⁴ In practice the approach taken will depend on local expertise and equipment as well as

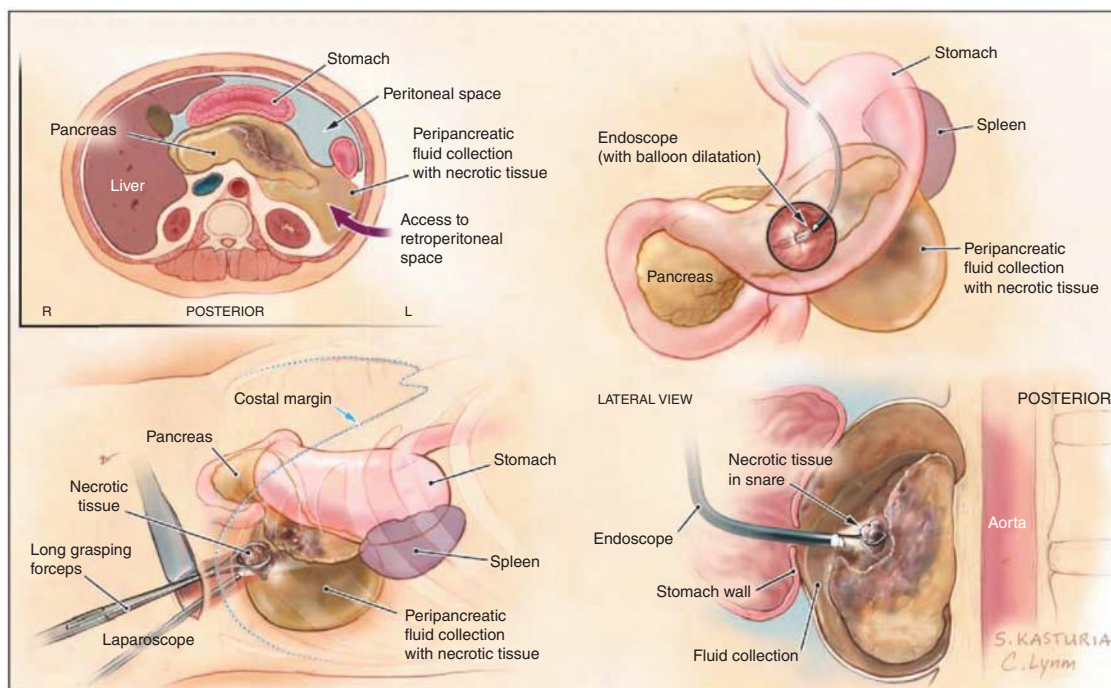


Figure 33-15. Two minimally invasive interventions for local complications of acute pancreatitis: **A.** video-assisted retroperitoneal debridement and **B.** endoscopic transgastric necrosectomy⁷⁶. (Reproduced with permission from Bakker OJ et al. Endoscopic transgastric vs surgical necrosectomy for infected necrotizing pancreatitis: A randomized trial. JAMA. 2012;307(10):1053. Copyright © 2012 American Medical Association. All rights reserved.)

the location and type of the specific local complication. A large Dutch randomized trial has shown that open surgical techniques should only be considered in those who fail to respond to the step-up approach, that is prior percutaneous drainage and minimally invasive intervention.⁷⁵ The exception is to be found in the rare situation where an abdominal compartment syndrome requires open decompression, but this is usually earlier than the optimal time to intervene for local complications. A recent landmark randomized trial has compared two minimally invasive techniques, endoscopic transgastric drainage and the videoscope assisted retroperitoneal debridement through a flank incision (Fig. 33-15). The data show that the former approach is superior, although the latter has a role when the walled off necrosis is remote from the stomach or duodenum, as in the left flank.⁷⁶

The management of an acute noninfected pseudocyst is usually conservative, as about half of these will resolve spontaneously. When symptoms of pain or inability to eat persist or infection occurs, intervention is required. Pseudocysts persist because of communication with the main pancreatic duct and/or distal ductal stenosis. Percutaneous drainage should be

avoided in this situation because of the risk of external pancreatic fistula.⁷⁷ EUS guided internal drainage into stomach, duodenum, or transpapillary pancreatic duct stenting is the preferred approach.

Managing Organ Failure

The specific management of multiple organ failure is beyond the scope of this chapter. The early identification of organ dysfunction and failure is important because it is a key determinant of severity and outcome and to facilitate the timely transfer of the patient to an intensive care unit to optimize management, provide organ support, and allow more intensive monitoring. The severity of organ failure can be scored (Table 33-6). The responsiveness of organ failure to resuscitation over the first 48 hours is an important prognostic clue; those that respond have transient organ failure and have a better outlook than those who do not respond and have persistent organ failure.⁷⁸ Organ failure that develops later in the disease course is usually secondary to infection of a local complication and should be managed accordingly (Table 33-9).

Table 33-9

Algorithm for the evaluation and management of acute pancreatitis

1. Diagnosis
 - History of abdominal pain consistent with acute pancreatitis
 - >3x elevation of pancreatic enzymes
 - CT scan if required to confirm diagnosis
2. Initial assessment / management (first 4 hrs)
 - Analgesia
 - Fluid resuscitation
 - Predict severity of pancreatitis
 - Ranson's criteria
 - HAPS score
 - Assess systemic response
 - SIRS score
 - SOFA (organ failure)
3. Reassessment / management (4 to 6 hrs)
 - Assess response to fluid resuscitation
 - mean arterial pressure
 - heart rate
 - urine output
 - hematocrit
 - Determine etiology
 - Ultrasound for gallstones/sludge
 - History of alcohol consumption
 - Laboratory evaluation of other causes
 - MRCP and/or Urgent ERCP if concomitant cholangitis is present
 - not for cholestasis or predicted severe disease per se
 - Transfer to ICU or specialist center as needed
 - Deterioration or failure to respond to initial management
 - Intensive support for persistent organ failure
 - Commence enteral nutrition
 - Once normovolemia restored (usually after 6 hours)
 - Commence via NG tube if no gastric stasis
 - No prophylactic antibiotics or probiotics
4. Conservative management and monitoring (at least daily)
 - Clinical evaluation
 - Assess cardiovascular, respiratory, and renal function
 - Detect peritonitis and abdominal compartment syndrome
 - Daily C-Reactive Protein
 - Classify severity (mild, moderate, severe, critical)
 - Detect intolerance of NG EN
 - Advance tube for NJ feeding if needed
 - Consider supplemental Parenteral Nutrition by day 4
5. Indications for "pancreatic protocol CT scan" (rarely in 1st week)
 - For significant clinical deterioration and elevated CRP
 - For suspicion of local pancreatic complications
 - For suspected bowel ischemia
 - For acute bleeding (CTa) (if stable enough & consider embolization)
 - For abdominal compartment syndrome
6. Invasive intervention
 - For deteriorating patient with suspected infected local complication
 - "Step up approach" with initial drain guided by current CT scan (percutaneous or endoscopic drainage)
 - Delay for 3 to 4 weeks with intensive care support, if possible
 - If failure to respond or secondary deterioration, repeat CT scan, and select appropriate minimally invasive technique based on available expertise and equipment
 - Video-assisted retroperitoneal debridement or percutaneous nephroscopic debridement
 - Endoscopic transluminal debridement
 - Ongoing large bore drainage and irrigation
7. Indication for laparotomy
 - Failed "step-up approach" for further debridement/drainage
 - Acute abdomen (perforation or ischemia)
 - Severe abdominal compartment syndrome (rarely)

Cholecystectomy

While it is widely accepted that cholecystectomy is essential to prevent gallstone pancreatitis recurrence, the timing of cholecystectomy is important. Index cholecystectomy, done in the same admission and prior to discharge, appears safe and can almost always be accomplished laparoscopically.⁷⁹ But index cholecystectomy is not suitable for all patients, particularly some who have had local pancreatic complications which includes a large phlegmon which extends into the porta

Table 33-10

Complications of acute pancreatitis

- I. Local
 - A. Pancreatic phlegmon
 - B. Pancreatic abscess
 - C. Pancreatic pseudocyst
 - D. Pancreatic ascites
 - E. Involvement of adjacent organs, with hemorrhage, thrombosis, bowel infarction, obstructive jaundice, fistula formation, or mechanical obstruction
- II. Systemic
 - A. Pulmonary
 - 1. Pneumonia, atelectasis
 - 2. Acute respiratory distress syndrome
 - 3. Pleural effusion
 - B. Cardiovascular
 - 1. Hypotension
 - 2. Hypovolemia
 - 3. Sudden death
 - 4. Nonspecific ST-T wave changes
 - 5. Pericardial effusion
 - C. Hematologic
 - 1. Hemoconcentration
 - 2. Disseminated intravascular coagulopathy
 - D. GI hemorrhage
 - 1. Peptic ulcer
 - 2. Erosive gastritis
 - 3. Portal vein or splenic vein thrombosis with varices
 - E. Renal
 - 1. Oliguria
 - 2. Azotemia
 - 3. Renal artery/vein thrombosis
 - F. Metabolic
 - 1. Hyperglycemia
 - 2. Hypocalcemia
 - 3. Hypertriglyceridemia
 - 4. Encephalopathy
 - 5. Sudden blindness (Purtscher's retinopathy)
 - G. Central nervous system
 - 1. Psychosis
 - 2. Fat emboli
 - 3. Alcohol withdrawal syndrome
 - H. Fat necrosis
 - 1. Intra-abdominal saponification
 - 2. Subcutaneous tissue necrosis

Source: Reproduced with permission from Greenberger NJ, Toskes PP, Isselbacher KJ: Acute and chronic pancreatitis, in Isselbacher KJ et al (eds): *Harrison's Principles of Internal Medicine*, 13th ed. New York: McGraw-Hill, 1994, p 1524. Copyright © The McGraw-Hill Companies, Inc.

hepatitis. These patients may require an interval cholecystectomy after resolution of the inflammatory process. If surgery is required for the management of local complications, then a cholecystectomy is often performed at that time.

The management of acute pancreatitis remains a formidable challenge due to the variety and severity of many associated complications (Table 33-10), and continues to evolve. Although specific treatments for acute pancreatitis remain elusive, progress has been made in the management of pain, fluid resuscitation, antibiotic prophylaxis, enteral nutrition, therapeutic ERCP, and cholecystectomy. Progress has also been made in the intensive care management of systemic complications and in the development of less invasive interventions for the treatment of local complications, particularly infected pancreatic necrosis.

CHRONIC PANCREATITIS

Definition, Incidence, and Prevalence

Chronic pancreatitis is an incurable, chronic inflammatory condition that is multifactorial in its etiology, highly variable in its presentation, and a challenge to treat successfully. Autopsy studies indicate that evidence of chronic inflammation, such as fibrosis, duct ectasia, and acinar atrophy is seen in up to 5% of the population,⁸⁰ although these data are difficult to interpret because many of these changes are also present in asymptomatic elderly patients.⁸¹ Population studies suggest a prevalence that ranges from 5 to 40 persons per 100,000 population, with considerable geographic variation.⁸² Differences in diagnostic criteria, regional nutrition, alcohol consumption, and medical access account for variations in the frequency of the diagnosis, but the overall incidence of the disease has risen progressively over the past 50 years.

Etiology

There are multiple etiologies of chronic pancreatitis, including genetic mutations, alcohol exposure, duct obstruction due to trauma, gallstones, and tumors, metabolic diseases such as hyperlipidemia and hyperparathyroidism, and auto-immune disease. In addition, nutritional causes include so-called "tropical pancreatitis," which has been thought to result from ingestion of certain starches. A significant number of patients have no discernible cause of the disease despite extensive testing, and are said to have idiopathic chronic pancreatitis.

Genetic Causes

In 1952, Comfort and Steinberg reported a kindred of "hereditary chronic relapsing pancreatitis" after treating the proband, a 24-year-old woman, at the Mayo Clinic.⁸³ Subsequently, familial patterns of chronic, nonalcoholic pancreatitis have been described worldwide, and a familial pattern has emerged. Typically, patients first present in childhood or adolescence with abdominal pain and are found to have chronic calcific pancreatitis on imaging studies. Progressive pancreatic dysfunction is common, and many patients present with symptoms due to pancreatic duct obstruction. The risk of subsequent carcinoma formation is increased, reaching a prevalence, in some series, of 40%, but the age of onset for carcinoma is typically >50 years old.⁸⁴ The disorder is characterized by an autosomal dominant pattern of inheritance, with 80% penetrance and variable expression. The incidence is equal in both sexes.

Whitcomb and colleagues,⁸⁵ and separately LeBodic and associates,⁸⁶ performed gene linkage analysis and identified a linkage for hereditary pancreatitis to chromosome 7q35. Subsequently, the region was sequenced and revealed eight trypsinogen genes. Mutational analysis revealed a missense mutation resulting in an Arg to His substitution at position 117 of the cationic trypsinogen gene, or PRSS1, one of the primary sites for proteolysis of trypsin. This gain-of-function mutation results in an excess production of trypsinogen, which results in persistent and uncontrolled proteolytic activity and autodestruction within the pancreas.⁸⁷ The position 117 mutation of PRSS1 and an additional mutation, now known collectively as the R122H and N291 mutations of PRSS1, account for about two-thirds of cases of hereditary pancreatitis. Recently, Masson and associates described a gain-of-function mutation in the anionic trypsinogen gene, PRSS2, that is also present in some cases.⁸⁸

Similarly, SPINK1, an inflammation-induced trypsin inhibitor secreted in acinar cells, has been found to have a role in hereditary pancreatitis. SPINK1 specifically inhibits trypsin action by competitively blocking the active site of the enzyme. Witt and colleagues investigated 96 unrelated children with chronic pancreatitis in Germany and found a variety of SPINK1 mutations in 23% of the patients.⁸⁹ Several studies have now confirmed an association of loss-of-function SPINK1 mutations with familial and idiopathic forms of chronic pancreatitis, as well as so-called tropical pancreatitis.^{90,91} SPINK1 mutations are common in the general population as well, and the frequency of these mutations varies in different cohorts of idiopathic chronic pancreatitis, from 6.4% in France⁹² to 25.8% in the United States.⁹³ Thus, hereditary pancreatitis results from one or more mutational defects that incapacitate an auto-protective process that normally prevents proteolysis within the pancreas.

Cystic fibrosis, originally termed cystic fibrosis of the pancreas, results from a variety of mutations of the cystic fibrosis transmembrane receptor (CFTR). The CFTR is present in pancreatic duct cells, and controls the amount of chloride and bicarbonate secreted into the normally alkaline pancreatic juice. The CFTR gene contains over 4300 nucleotides, divided into 24 exons, which encode a 1480-amino acid protein. Over 1000 polymorphisms have been reported, and many are common.³² The CFTR mutation associated with the classic pulmonary disease, F508, is rarely observed in chronic pancreatitis. But other CFTR mutations have been noted to be associated with chronic idiopathic pancreatitis and auto-immune pancreatitis in which the pulmonary, intestinal, and cutaneous manifestations of the disease are silent.⁹⁴

Many studies have been undertaken to determine whether specific genetic abnormalities are associated with alcoholic chronic pancreatitis, and which might confer susceptibility to the disease. A 5.8% rate of SPINK1 mutations in patients with alcoholic pancreatitis has been shown, compared to a 0.8% rate in the control population, and studies of the known mutations of the CFTR gene have failed to demonstrate a strong association with alcoholic chronic pancreatitis.⁸⁹

In 2012, a landmark study by Whitcomb and associates demonstrated a likely genetic cause of the predisposition to alcohol-induced chronic pancreatitis in men⁹⁵. In a genome-wide association study of more than 2000 patients, these researchers discovered that a common DNA variant on the X chromosome is present in 26% of men without pancreatitis, but jumps to nearly 50% of men diagnosed with alcoholic pancreatitis. The variant involves the claudin 2 (CLDN2) gene, which

encodes a tight junction protein normally present in ductal cells. In cases of chronic pancreatitis, the CLDN2 protein is abnormally expressed in acinar cells, and may alter the secretory dynamics of enzyme release. The abnormality does not appear to cause pancreatitis but if pancreatitis occurs for any reason in a person with the CLDN2 variant, it is more likely that the person will develop chronic pancreatitis; the risk is increased even further among alcohol users. Only 10% of women have the X chromosome-linked variant on both X chromosomes, and most women with the CLDN2 variant on one X chromosome appear to be protected from alcoholic chronic pancreatitis by the other X chromosome, if it is normal. Men, with only one X chromosome, have no protection if they inherit a CLDN2 mutation. This helps to explain the high prevalence of alcoholic chronic pancreatitis among men, although the mechanism remains unclear. This study does not demonstrate a genetic cause for all cases of alcohol-related chronic pancreatitis, but shows that a genetic element contributes to many patients with the disease (Fig. 33-16).

Alcohol

In 1878, Friedreich proposed that “a general chronic interstitial pancreatitis may result from excessive alcoholism (drunkard’s pancreas).”⁹⁶ Since that observation, numerous studies have shown that a causal relationship exists between alcohol and chronic pancreatitis, but the prevalence of alcohol as the etiology of the disease in Western countries ranges widely, from 38% to 94%⁹⁷ (Fig. 33-17).

There is a linear relationship between exposure to alcohol and the development of chronic pancreatitis.⁹⁸ The risk of disease is present in patients with even a low or occasional exposure to alcohol (1 to 20 g/d), perhaps due to the CLDN2 gene mutation described above, so there is no threshold level of alcohol exposure below which there is no risk of developing chronic pancreatitis. Furthermore, although the risk of disease is dose related, and highest in heavy (>150 g/d) drinkers, the prevalence of chronic pancreatitis among confirmed alcohol abusers is only 5% to 15%.⁹⁹ However, the duration of alcohol consumption is definitely associated with the development of pancreatic disease. The onset of disease typically occurs between ages 35 to 40 years, after 16 to 20 years of heavy alcohol consumption. Recurrent episodes of acute pancreatitis are typically followed by chronic symptoms after 4 or 5 years.¹⁰⁰

Although the pattern of disease presentation is well known in those alcohol users who develop pancreatic disease, the pathophysiology of alcohol-induced pancreatic disease is still an area of active investigation. In their 1946 classic study, Comfort, Gambrill, and Baggenstoss proposed that chronic pancreatitis was the result of multiple episodes of acute inflammation, with residual and progressively increasing chronic inflammation.¹⁰¹ Subsequently, other investigators proposed that initial acute inflammation was not necessarily linked to chronic changes in the pancreas,¹⁰² and Kondo and associates showed that other, additional factors were necessary for repeated exposure to alcohol to cause chronic pancreatitis.¹⁰³ Regardless of the requirement for other predisposing or facilitative factors, the concept that multiple episodes (or a prolonged course) of pancreatic injury ultimately leads to chronic disease is widely accepted as the pathophysiologic sequence¹⁰⁴ (Fig. 33-18).

Although direct alcohol exposure to the pancreatic ductal system, or elevated levels of alcohol in the bloodstream, has

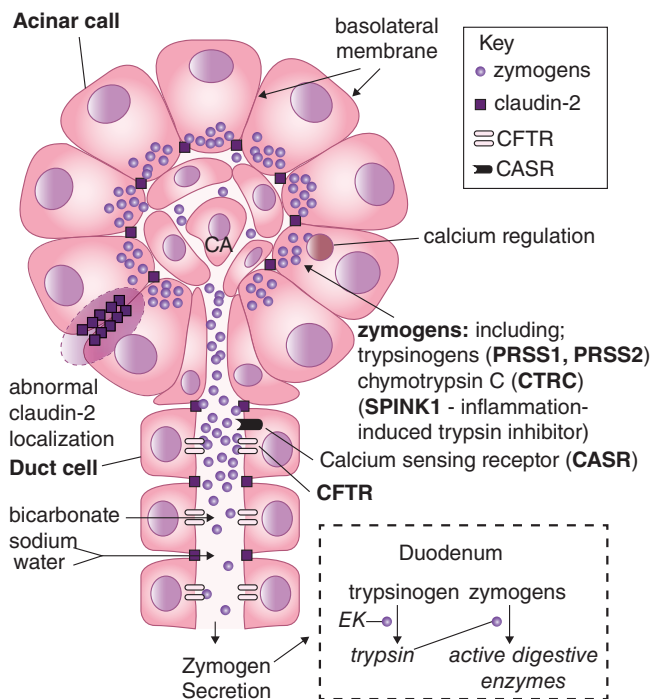


Figure 33-16. Schematic model of genetic causes of chronic pancreatitis. A pancreatic acinus is portrayed showing the pathway for digestive enzymes (**zymogens**) to be secreted by the **acinar cell** into the ductal system where water, sodium, and bicarbonate are secreted by the **duct and centroacinar (CA) cells**. Mutations in at least five genes have been identified as risk factors for chronic pancreatitis: gain-of function mutations in the cationic trypsinogen genes (**PRSS1, PRSS2**) cause hereditary pancreatitis. Cationic and anionic trypsinogen are normally active in the duodenum by enterokinase (**EK**). Premature activation of the trypsin in the acinar cell leads to zymogen activation, local cellular injury, and inflammation. Mutations of the trypsin inhibitors **SPINK1** or chymotrypsin C (**CTRC**), or of the calcium sensing receptor **CASR**, result in premature activation of trypsinogen. Mutations in the cystic fibrosis transmembrane receptor **CFTR** results in trypsinogen stasis within the ducts due to insufficient secretion by duct cells. A Mutation in claudin-2 (**CLDN2**) results in abnormal expression in acinar cells, instead of its normal location between duct cells, and is associated with the accelerated development of chronic pancreatitis in alcohol abusers. (Adapted with permission from Macmillan Publishers, Ltd. Whitcomb DC et al: *Common genetic variants in the CLDN2 and PRSS1-PRSS2 loci alter risk for alcohol-related and sporadic pancreatitis*. Nat Genet. 2012;44:1349. Copyright © 2012.)

been shown to alter the integrity and function of pancreatic ducts and acini directly,¹⁰⁵ most investigators believe that alcohol metabolites such as acetaldehyde, combined with oxidant injury, result in local parenchymal injury that is preferentially targeted to the pancreas in predisposed individuals. Repeated or severe episodes of toxin-induced injury activate a cascade of cytokines, which, in turn, induces pancreatic stellate cells (PSCs) to produce collagen and cause fibrosis (Fig. 33-19). It remains to be determined whether alcohol sensitizes the pancreas of susceptible individuals to another cause of acute inflammation, or whether genetic or other factors predispose to direct alcohol-related injury.¹⁰⁴

Alcohol may interfere with the intracellular transport and discharge of digestive enzymes, and may contribute to the colo-

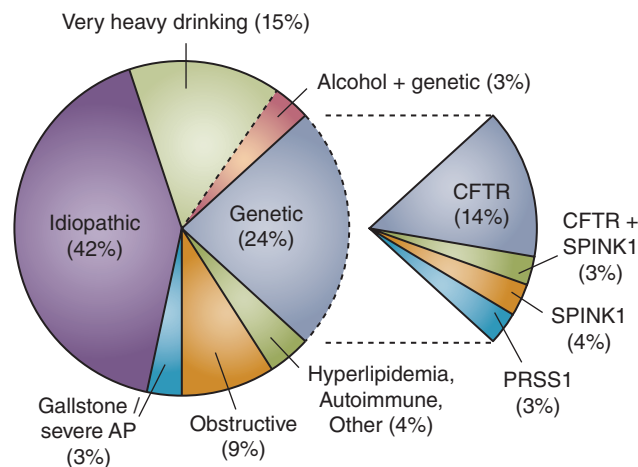


Figure 33-17. Etiologies of chronic pancreatitis. (Reproduced with permission from Whitcomb DC. Acad Med. 86:1353,2011.)

calization of digestive enzymes and lysosomal hydrolase within acinar cells, leading to autodigestion^{106, 107} (see section on Acute Pancreatitis). A high-protein, low-bicarbonate, low-volume secretory output is seen after chronic alcohol exposure which may contribute to the precipitation of proteins in secondary ducts in the early stages of chronic pancreatitis.¹⁰⁸ Calcium is complexed to protein plugs in small ductules, secondary ducts, and, eventually, in the main ductal system, which causes ductal cell injury and obstruction of the secretory system, which further promotes an inflammatory response.

Cigarette smoking has been strongly associated with chronic pancreatitis,¹⁰⁹ but until recently it was unclear whether this was a causative risk factor. Studies have now shown that smoking actually accelerates the development of alcoholic pancreatitis,¹¹⁰ and the risk of cancer in chronic pancreatitis is increased significantly by smoking. In hereditary pancreatitis, smoking has been found to lower the age of onset of carcinoma

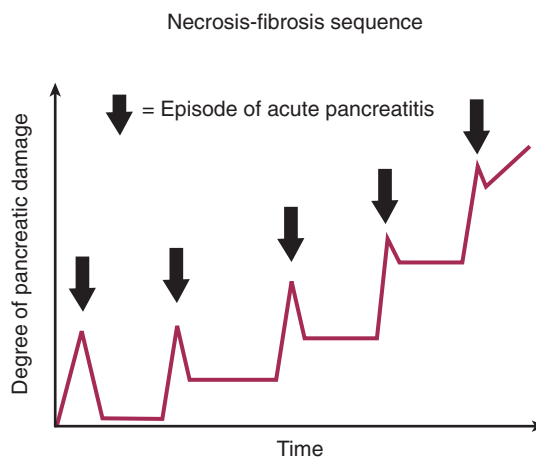


Figure 33-18. “Multiple hit” theory of the etiology of chronic pancreatitis. Multiple episodes of acute pancreatitis cause progressively more organized inflammatory changes that ultimately result in chronic inflammation and scarring. [Reproduced with permission from Apte et al.¹⁰⁴ Copyright Elsevier.]

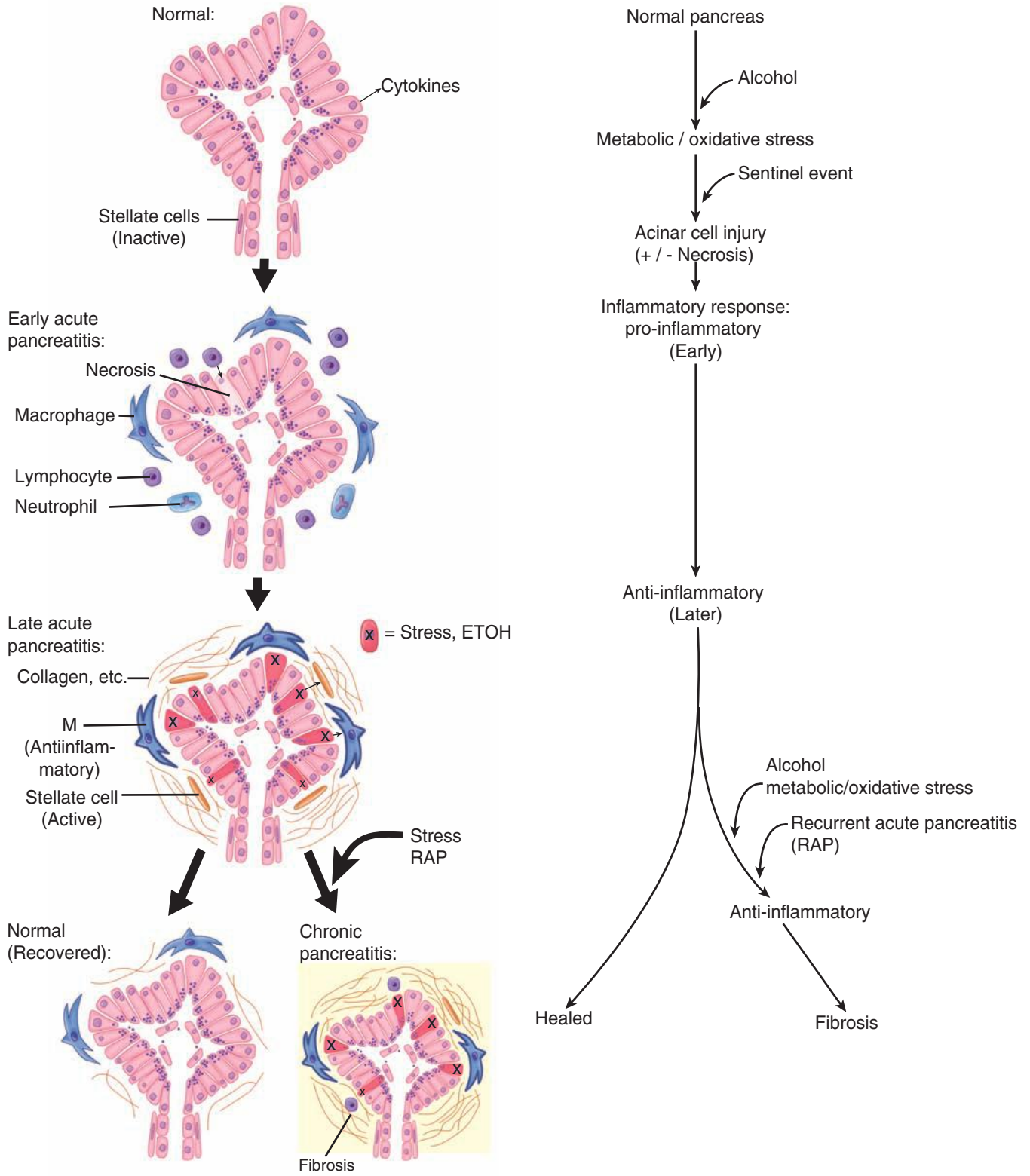


Figure 33-19. The sentinel acute pancreatitis event (SAPE) hypothesis for the development of chronic pancreatitis. A critical episode of acute pancreatitis activates cytokine-induced transformation of pancreatic stellate cells, which results in collagen production and fibrosis. ETOH = ethyl alcohol. (Reproduced with permission from Schneider et al.¹³⁵ Copyright Elsevier.)

by about 20 years.¹¹¹ Smoking therefore appears to be an independent risk factor for the late complications of alcoholic pancreatitis, if not an early cofactor for the development of fibrosis.

Hyperparathyroidism

Hypercalcemia is a known cause of pancreatic hypersecretion,¹¹² and chronic hypercalcemia caused by untreated hyperparathyroidism is associated with chronic calcific pancreatitis.¹¹³ Hypercalcemia is also a stimulant for pancreatic calcium secretion, which contributes to calculus formation and obstructive pancreatopathy. The treatment is correction of the hyperparathyroidism and assessment of any additional endocrinopathies.

Hyperlipidemia

In addition to the risk of acute pancreatitis, hyperlipidemia and hypertriglyceridemia predispose women to chronic pancreatitis when they receive estrogen replacement therapy.¹¹⁴ Fasting triglyceride levels <300 mg/dL are below the threshold for this to occur, and the mechanism of estrogen potentiation of hyperlipidemia-induced chronic pancreatitis is unknown. It is assumed that chronic changes occur after repeated subclinical episodes of acute inflammation. Aggressive therapy of hyperlipidemia is therefore important in peri- or postmenopausal patients who are candidates for estrogen therapy.

Classification

A major impediment to a better understanding of the etiology, frequency and severity of chronic pancreatitis has been the difficulty with which investigators and clinicians have struggled to identify a useful classification system. Multiple classification systems have been proposed. The TIGAR-O scheme categorizes chronic pancreatitis according to risk factors and etiologies, such as a) toxic-metabolic, b) idiopathic, c) genetic, d) auto-immune, e) recurrent and severe acute pancreatitis, or f) obstructive.¹¹⁵ A recent classification system based on his-

topathology as well as etiology, as delineated by Singer and Chari,¹¹⁶ is shown in Table 33-11.

Chronic Calcific (Lithogenic) Pancreatitis

This type is the largest subgroup in the classification scheme proposed by Singer and Chari, and includes patients with calcific pancreatitis of most etiologies. Although the majority of patients with calcific pancreatitis have a history of alcohol abuse, stone formation and parenchymal calcification can develop in a variety of etiologic subgroups; hereditary pancreatitis and tropical pancreatitis are particularly noteworthy for the formation of stone disease. The clinician should therefore avoid the assumption that calcific pancreatitis confirms the diagnosis of alcohol abuse.

Chronic Obstructive Pancreatitis

This refers to chronic inflammatory changes that are caused by the compression or occlusion of the proximal ductal system by tumor, gallstone, posttraumatic scar, or inadequate duct caliber (as in pancreas divisum). Obstruction of the main pancreatic duct by inflammatory (posttraumatic) or neoplastic processes can result in diffuse fibrosis, dilated main and secondary pancreatic ducts, and acinar atrophy. The patient may have little in the way of pain symptoms or may present with signs of exocrine insufficiency. Intraductal stone formation is rare, and both functional and structural abnormalities may improve when the obstructive process is relieved or removed. Trauma to the pancreas frequently results in duct injury and leakage, which may result in pseudocyst formation as well as local scar formation. Inadequately treated pancreatic trauma may result in persistent inflammatory changes in the distal gland.¹¹⁷

Pancreas divisum represents a special case of obstructive pancreatitis. It is the most common congenital anomaly involving the pancreas and occurs in up to 10% of children. It is thought to predispose the pancreas to recurrent acute pancreatitis and chronic pancreatitis, due to functional obstruction of a diminutive duct of Santorini that fails to communicate with

Table 33-11

Classification of chronic pancreatitis based on etiologic causes

CHRONIC CALCIFIC PANCREATITIS	CHRONIC OBSTRUCTIVE PANCREATITIS	CHRONIC INFLAMMATORY PANCREATITIS	CHRONIC AUTOIMMUNE PANCREATITIS	ASYMPTOMATIC PANCREATIC FIBROSIS
Alcohol	Pancreatic tumors	Unknown	Associated with autoimmune disorders (e.g., primary sclerosing cholangitis)	Chronic alcoholic
Hereditary	Ductal stricture			Endemic in asymptomatic residents in tropical climates
Tropical	Gallstone- or trauma-induced or pancreas divisum			
Hyperlipidemia			Sjögren's syndrome	
Hypercalcemia			Primary biliary cirrhosis	
Drug-induced				
Idiopathic				

Source: Reproduced with permission from Wiley-Blackwell. From Singer et al.¹¹⁶

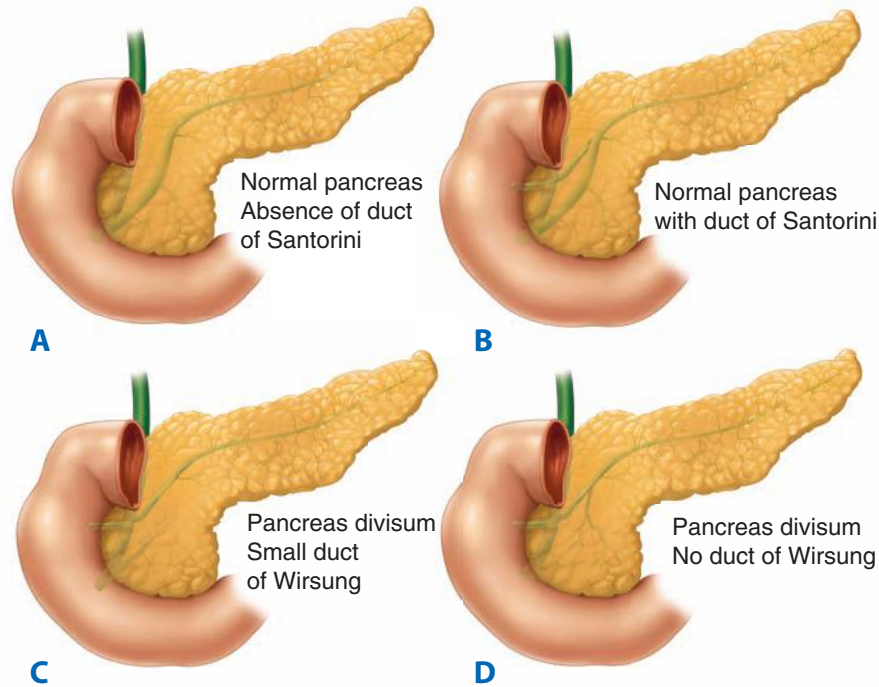


Figure 33-20. Pancreas divisum. Normal pancreatic duct anatomy and the variations of partial or complete pancreas divisum are shown. (Reproduced with permission of Wiley-Blackwell. From *Warsaw*.¹¹⁸)

Wirsung's duct (Fig. 33-20). However, the classic picture of obstructive pancreatopathy with a dilated dorsal duct is unusual in pancreas divisum, so a decompressive operation or a lesser papilla sphincteroplasty is frequently not feasible or unsuccessful. Endoscopic stenting through the lesser papilla may result in temporary relief of symptoms, and this response would increase the possibility that a permanent surgical or endoscopic intervention will be successful. Although some authors emphasize the pathologic implications of pancreas divisum,¹¹⁸ others express skepticism that it represents a true risk to pancreatic secretory capacity or contributes to the development of chronic pancreatitis.^{119, 120} A recent French study reveals that pancreas divisum is equally prevalent among patients with idiopathic chronic pancreatitis and normal controls (7%), and is minimally increased in patients with PRSS1 and SPINK1 mutations. It is accompanied by CFTR mutations in 47% of patients, however, suggesting that the presence of pancreas divisum together with mutational events may increase the susceptibility to pancreatitis.¹²¹

Chronic Inflammatory Pancreatitis

Chronic inflammatory pancreatitis is characterized by diffuse fibrosis and a loss of acinar elements with a predominant mononuclear cell infiltration throughout the gland.

A variant of chronic pancreatitis is a nonobstructive, diffusely infiltrative disease associated with fibrosis, a mononuclear cell (lymphocyte, plasma cell, or eosinophil) infiltrate, and an increased titer of one or more autoantibodies.¹²² This type, referred to as *autoimmune pancreatitis* (AIP), is associated with a variety of illnesses with suspected or proven autoimmune etiology, such as Sjögren's syndrome, rheumatoid arthritis, and type I diabetes mellitus. AIP has been characterized as either type I, with accompanying systemic or multiorgan dysfunction, or type II, which is restricted to the pancreas.

Compressive stenosis of the intrapancreatic portion of the common bile duct is frequently seen in both types of AIP,

along with symptoms of obstructive jaundice. Increased levels of serum β -globulin or immunoglobulin G4 are also present. Steroid therapy is uniformly successful in ameliorating the disease, including any associated bile duct compression.¹²³ CFTR mutations which result in dislocation of the transmembrane protein have been found in AIP, and steroid therapy results in a normalization of the CFTR localization, and a resumption of normal chloride and bicarbonate secretion.¹²⁴ The differential diagnosis includes lymphoma, plasmacytoma ("pseudotumor" of the pancreas), and diffuse infiltrative carcinoma. Although the diagnosis is confirmed on pancreatic biopsy, presumptive treatment with steroids is usually undertaken, especially when clinical and laboratory findings, such as an elevation in IgG4 levels, support the diagnosis. Failure to obtain a cytologic specimen may lead to an unnecessary resectional procedure, and an untreated inflammatory component may cause sclerosis of the extrahepatic or intrahepatic bile ducts, with eventual liver failure.¹²⁵

Tropical (Nutritional) Pancreatitis

Chronic pancreatitis is highly prevalent among adolescents and young adults in Indonesia, southern India, and tropical Africa. Abdominal pain develops in adolescence, followed by the development of a brittle form of pancreatogenic diabetes. Parenchymal and intraductal calcifications are seen, and the pancreatic duct stones may be quite large.¹²⁶ Many of the patients appear malnourished, some present with extreme emaciation, and a characteristic cyanotic coloration of the lips may be seen.¹²⁷ In addition to protein-caloric malnutrition, toxic products of some indigenous foodstuffs have also been thought to contribute to the disease. Because of the geographic concentration of this early-onset form of chronic pancreatitis, it has been termed "*tropical pancreatitis*," although the exact etiology remains unclear.

Clinically, tropical pancreatitis presents much like hereditary pancreatitis, and a familial pattern among cases is not unusual.

SPINK1 mutations have been documented in 20% to 55% of patients with tropical pancreatitis, and CFTR mutations have been reported as well.^{90,91} The accelerated deterioration of endocrine and exocrine function, the chronic pain due to obstructive disease, and the recurrence of symptoms despite decompressive procedures characterize the course of disease. As immigrants from the tropical regions increasingly find their way to all parts of the world, an awareness of this severe form of chronic pancreatitis is helpful for those who treat patients with pancreatic disease.

Asymptomatic Pancreatic Fibrosis

Pancreatic fibrosis is seen in some asymptomatic elderly patients, in tropical populations, or in asymptomatic alcohol users. There is diffuse perilobar fibrosis and a loss of acinar cell mass, but without a main ductular component.

A shortcoming of these clinical classification systems is the lack of histologic criteria of chronic inflammation due to the usual absence of a biopsy specimen. The differentiation of recurrent acute pancreatitis from chronic pancreatitis with exacerbations of pain can be difficult to establish and is not facilitated by the current system. Similarly, cystic fibrosis is known to cause fibrosis and acinar dysfunction but is not included in the classification despite increasing evidence for its possible role in idiopathic chronic pancreatitis.¹²⁸ Therefore, further refinements in the classification system for chronic pancreatitis are needed to allow a better prediction of its clinical course and a more accurate diagnosis of a likely etiologic agent.

Idiopathic Pancreatitis

When a definable cause for chronic pancreatitis is lacking, the term *idiopathic* is used to categorize the illness. Classically, the idiopathic group includes young adults and adolescents who lack a family history of pancreatitis but who may represent individuals with spontaneous gene mutations encoding regulatory proteins in the pancreas. A variable percentage of SPINK1 and CFTR mutations have been described in various studies. In addition, the idiopathic group has included a large number of older patients for whom no obvious cause of recurrent or chronic pancreatitis can be found.¹²⁹ However, because the prevalence of biliary calculi increases steadily with age, it is not surprising that, as methods of biliary stone detection have improved, many elderly “idiopathic” pancreatitis patients are found to have biliary tract disease.¹³⁰

As previously noted, an increasing number of mutations of the SPINK1 and CFTR genes have been identified in association with various forms of chronic pancreatitis. However, the role of genetic analysis in the management of these patients remains unclear, as guidelines have yet to be developed to allow physicians to use the data consistently.³² The clinical management of patients who harbor a minor CFTR mutation and chronic pancreatitis, for example, is still dictated by the clinical manifestations of the pancreatitis.

Pathology

Histology. In early chronic pancreatitis, the histologic changes are unevenly distributed and are characterized by induration, nodular scarring, and lobular regions of fibrosis (Fig. 33-21). As the disease progresses, there is a loss of normal lobulation, with thicker sheets of fibrosis surrounding a reduced acinar cell mass, and dilatation of ductular structures (Fig. 33-22). The ductular epithelium is usually atypical and may display features of dysplasia, as evidenced by cuboidal cells with hyperplastic features, accompanied by areas of mononuclear cell infiltrates or patchy

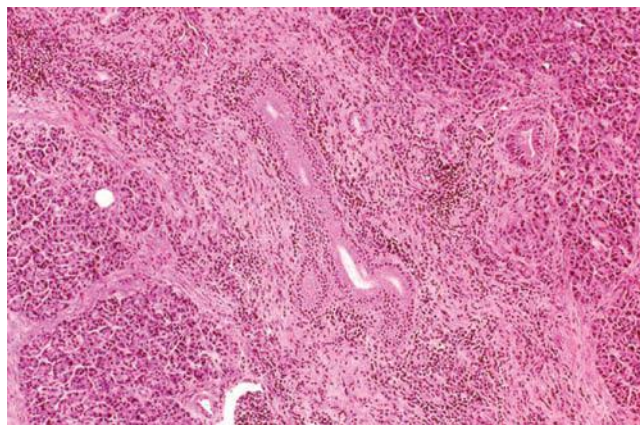


Figure 33-21. Histology of early chronic pancreatitis. High-power microscopic (40x) histology of chronic pancreatitis shows an infiltration of mononuclear inflammatory cells throughout the interstitium of the pancreas, with little fibrosis. (Courtesy of Rhonda Yantiss, Weill Cornell Medical College.)

areas of necrosis. Cystic changes may be seen, but areas of relatively intact acinar elements and normal-appearing islets persist. In severe chronic pancreatitis, there is considerable replacement of acinar tissue by broad, coalescing areas of fibrosis, and the islet size and number are reduced (Fig. 33-23). Small arteries appear thickened and neural trunks become prominent.¹³¹

Tropical pancreatitis and hereditary pancreatitis are histologically indistinguishable from chronic alcoholic pancreatitis. In obstructive chronic pancreatitis, calculi are absent, although periacinar fibrosis and dilated ductular structures are prominent. In pancreatic lobular fibrosis seen in elderly subjects, small ducts are dilated, sometimes with small calculi trapped within. Hypertrophy of ductular epithelia is thought to cause this small-duct disease, which is accompanied by perilobular fibrosis.¹³²

Fibrosis. A common feature of all forms of chronic pancreatitis is the perilobular fibrosis that forms surrounding individual acini, then propagates to surround small lobules, and eventually coalesces to replace larger areas of acinar tissue. The pathogenesis of this process involves the activation of pancreatic

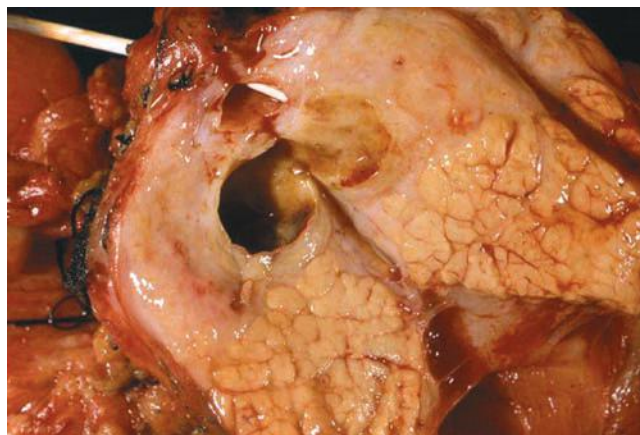


Figure 33-22. Gross appearance of chronic pancreatitis. Areas of fibrosis and scarring are seen adjacent to other areas within the gland in which the lobar architecture is grossly preserved. A dilated pancreatic duct indicates the presence of downstream obstruction in this specimen removed from a patient with chronic pancreatitis. (Courtesy of Rhonda Yantiss, Weill Cornell Medical College.)

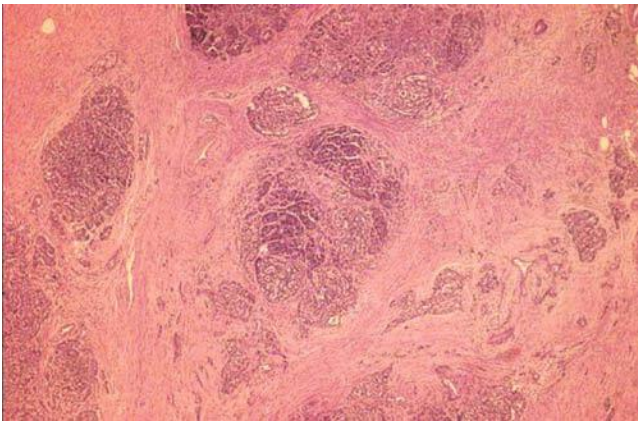


Figure 33-23. Histology of severe chronic pancreatitis. High-power microscopic (40 \times) histologic appearance of advanced chronic pancreatitis shows extensive sheets of fibrosis and loss of acinar tissue, with preservation of islet tissue in scattered areas. (Courtesy of Rhonda Yantiss, Weill Cornell Medical College.)

stellate cells (PSCs) that are found adjacent to acini and small arteries.¹³³ The extended cytoplasmic processes of PSCs encircle the acini but appear quiescent in the normal gland, where they contain lipid vacuoles and cytoskeletal proteins. In response to pancreatic injury, the PSCs become activated and proliferate (similarly to hepatic stellate cells), lose their lipid vesicles, and transform into myofibroblast-like cells. These cells respond to proliferative factors such as transforming growth factor beta, platelet-derived growth factor, and proinflammatory cytokines and synthesize and secrete type I and III collagen and fibronectin. Studies indicate that vitamin A metabolites, similar to those present in quiescent PSCs, can inhibit the collagen production of activated cultured PSCs.¹³⁴ This raises the possibility that early intervention may be possible to interrupt or prevent the fibrosis resulting from ongoing activation of PSCs.

The overall pathogenic sequence proposed by Schneider and Whitcomb¹³⁵ whereby alcohol induces acute pancreatitis and, with ongoing exposure, promotes the development of chronic fibrosis, is summarized in Fig. 33-19. PSCs surrounding the acinus are activated in acute pancreatitis but may be inactivated by anti-inflammatory cytokines and, in the absence of further injury, may revert to a quiescent state. The role of proinflammatory macrophages, cytokines, and PSCs in models of acute and chronic pancreatitis represents an important area of current research.

Stone Formation. Pancreatic stones are composed largely of calcium carbonate crystals trapped in a matrix of fibrillar and other material. The fibrillar center of most stones contains no calcium but rather a mixture of other metals. This suggests that stones form from an initial noncalcified protein precipitate, which serves as a focus for layered calcium carbonate precipitation. The same low-molecular-weight protein is present in stones and protein plugs and was initially named *pancreatic stone protein*, or PSP.¹³⁶ PSP was found to be a potent inhibitor of calcium carbonate crystal growth and has subsequently been renamed *lithostathine*.¹³⁷ Independently, a 15-kDa fibrillar protein isolated from the pancreas was named *pancreatic thread protein*, and it has been shown to be homologous with lithostathine. Finally, a protein product of the *reg* gene, so named because it is expressed in association with regenerating islets in models of pancreatic injury, was isolated and called *reg* protein, and was subsequently

found to be homologous with lithostathine.¹³⁸ No overall homology has been found between lithostathine and other pancreatic proteins. The PSP/pancreatic thread protein/*reg*/lithostathine gene encodes for a 166-amino acid product that undergoes post-translational modification to produce isoforms present in pancreatic juice. The protein is expressed in all rodents and mammals, both in the pancreas as well as in brain tissue, where it is found in particularly high concentrations in pyramidal neurons in Alzheimer's disease and Down syndrome. It is also found in the renal tubules, which is consistent with its biologic action of preventing calcium carbonate precipitation.

Calcium and bicarbonate ions are normally present in pancreatic juice in high concentrations, and the solubility product of calcium carbonate is greatly exceeded under normal conditions. Microcrystals of calcium carbonate can be seen in normal pancreatic juice but are usually clinically silent. Lithostathine is a potent inhibitor of calcium carbonate crystal formation, at a concentration of only 0.1 $\mu\text{mol/L}$. However, lithostathine concentrations in normal pancreatic juice are in the range of 20 to 25 $\mu\text{mol/L}$, so a constant suppression of calcium carbonate crystal formation is present in the normal pancreas.

In alcoholics and in patients with alcoholic chronic pancreatitis, lithostathine expression and secretion are dramatically inhibited¹³⁹ (Fig. 33-24). In addition, elevated levels of precipitated lithostathine in the duct fluid in chronic pancreatitis patients suggests that the availability of the protein may be further reduced by the action of increased proteases and other proteins present in the duct fluid of alcoholic patients. Increased pancreatic juice protein levels in alcoholic men are reversible by abstinence from alcohol,¹⁴⁰ so the availability and effectiveness of lithostathine may be restored in patients with early-stage disease by timely intervention. Nevertheless, calcific stone formation represents an advanced stage of disease, which can further promote injury or symptoms due to mechanical damage to duct epithelium or obstruction of the ductular network.

Duct Distortion. Although calcific stone disease is normally a marker for an advanced stage of disease, parenchymal and

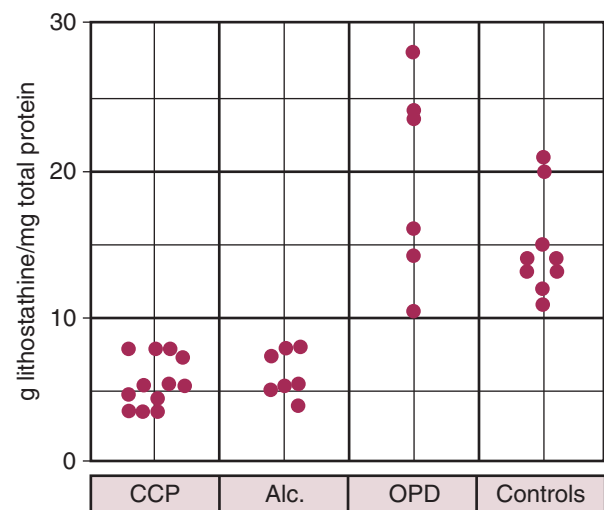


Figure 33-24. Lithostathine levels in chronic calcific pancreatitis (CCP) patients, patients with alcohol abuse (Alc.), patients with other pancreatic disease (OPD), and controls. (Reproduced with permission of Wiley-Blackwell. From Goggin et al.¹⁴⁰)

ductular calcifications do not always correlate with symptoms. Obstructing main duct stones are commonly observed and are thought to be an indication for endoscopic or surgical removal. The ball-valve effect of a stone in a secreting system produces inevitable episodes of duct obstruction, usually accompanied by pain. But some patients with complete duct obstruction have prolonged periods of painlessness. Ductular hypertension has been documented in patients with proximal stenosis of the main pancreatic duct, and prolonged ductular distention after secretin administration is taken as a sign of ductular obstruction.¹⁴¹ Although calculus disease and duct enlargement appear together as late stages of chronic pancreatitis, controversy persists over whether they are associated, are independent events, or are causally related.

Radiology. Radiologic imaging of chronic pancreatitis assists in four areas: (a) diagnosis, (b) the evaluation of severity of disease, (c) detection of complications, and (d) assistance in determining treatment options.¹⁴² With the advent of cross-sectional imaging techniques such as CT and magnetic resonance imaging (MRI), the contour, content, ductal pattern, calcifications, calculi, and cystic disease of the pancreas are all readily discernible. Transabdominal ultrasonography is frequently used as a screening method for patients with abdominal symptoms or trauma, and the extension of ultrasonic imaging to include endoscopic ultrasound (EUS) and laparoscopic US have resulted in the highest-resolution images that are capable of detecting very small (<1 cm) abnormalities in the pancreas. EUS is now frequently used as a preliminary step in the evaluation of patients with pancreatic disease, and magnetic resonance cholangiopancreatography (MRCP) is increasingly being used to select patients who are candidates for the most invasive imaging method, ERCP. The staging of disease is important in the care of patients, and a combination of imaging methods is usually used (Table 33-12).

Ultrasonography is frequently used as an initial imaging method in patients with abdominal symptoms, and changes consistent with pancreatic duct dilatation, intraductal filling defects, cystic changes, and a heterogeneous texture are seen in chronic pancreatitis (Fig. 33-25). The sensitivity of transabdominal ultrasonography ranges from 48% to 96%, and is operator dependent.¹⁴³ However, the contour, texture, and ductal pattern are usually quite discernible, and it is a reliable method for periodic re-examination to determine the efficacy of treatment.

EUS has heavily impacted the evaluation and management of patients with chronic pancreatitis. Although it is more operator dependent and less widely available than transabdominal ultrasonography, EUS provides not only imaging capability but adds the capacity to obtain cytologic and chemical samples of tissue and fluid aspirated with linear array monitoring (Fig. 33-26). EUS images obtained through a high-frequency (7.5- to 12.5-mHz) transducer are able to evaluate subtle changes in 2- to 3-mm structures within the pancreas and can detect indolent neoplasms in the setting of chronic inflammation. Small intraductal lesions, intraductal mucus, cystic lesions, and subtle ductular abnormalities are recognizable by EUS (Table 33-13). This allows ERCP to be reserved for these patients who require therapeutic maneuvers, or for the evaluation of more complex problems. EUS is comparable to ERCP in the detection of advanced changes in chronic pancreatitis and may be more sensitive than ERCP in the detection of mild disease.¹⁴⁴

CT scanning has affected the diagnosis of pancreatic disease more broadly than any other method. With the advent of faster helical CT scanning and CT angiography, visualization of the nature, extent, location, and relative relationships of pancreatic structures and lesions is possible with great clarity. Duct dilatation, calculous disease, cystic changes, inflammatory events, and anomalies are all detectable with a resolution of 3 to 4 mm (Fig. 33-27). CT scanning has a false-negative rate of <10% for chronic pancreatitis, but early or mild chronic

Table 33-12

Cambridge classification of pancreatic morphology in chronic pancreatitis

CLASSIFICATION	ERCP FINDINGS	CT AND US FINDINGS
Normal	No abnormal SBDs	Normal gland size, shape; homogeneous parenchyma
Equivocal	MPD normal	One of the following: less than three abnormal SBDs; MPD 2–4 mm; gland enlarged more than two times normal size; heterogeneous parenchyma
Mild	MPD normal	Two or more of the following: less than three abnormal SBDs; MPD 2–4 mm; slight gland enlargement; heterogeneous parenchyma
Moderate	MPD changes	Small cysts <10 mm; MPD irregularity
	SBD changes	Focal acute pancreatitis; increased echogenicity of MPD walls; gland-contour irregularity
Severe	Any of the above changes plus one or more of the following: Cysts <10 mm; intraductal filling defects; calculi; MPD obstruction or stricture; severe MPD irregularity; contiguous organ invasion	—

CT = computed tomography; ERCP = endoscopic retrograde cholangiopancreatography; MPD = main pancreatic duct; SBD = side-branch duct; US = ultrasound.

Source: Reproduced with permission from Wiley-Blackwell. From Freeny.¹⁴²

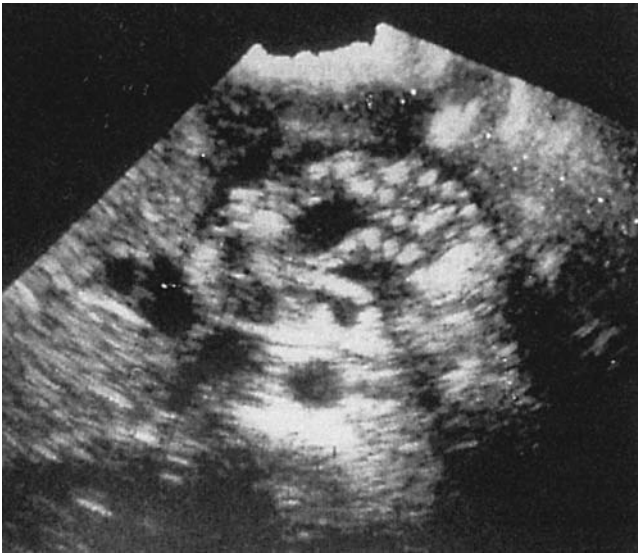


Figure 33-25. Sonography in chronic pancreatitis. Transabdominal sonogram of patient with chronic pancreatitis demonstrates heterogeneity of the pancreatic parenchyma, dilated ductal systems, and cyst formation. (Reproduced with permission from Bolondi et al. *Radiol Clin North Am.* 27: 815, 1989.)

disease may go undetected by CT imaging. The earliest changes are dilatation of secondary ducts and heterogeneous parenchymal changes, which are detectable by EUS and ERCP. Another drawback of CT scanning is its lower sensitivity for detecting small neoplasms, which are seen with increased frequency in chronic pancreatitis and may be invisible to all modalities except EUS.

An MRI, in both the cross-sectional mode and the coronally oriented heavily weighted T2 or high spin ratio imaging (MRCP) that can disclose fluid-filled ducts and cystic lesions, has added greatly to the imaging options for chronic pancreatitis (Fig. 33-28). The resolution of cross-sectional MRI scanning is now approaching that of CT scanning, although the availability of MRI scanners and the complexity of the images produced have limited their large-scale use for routine imaging of the pancreas. MRCP has been shown to be an effective screening technique for disclosing ductal abnormalities that correlates closely with

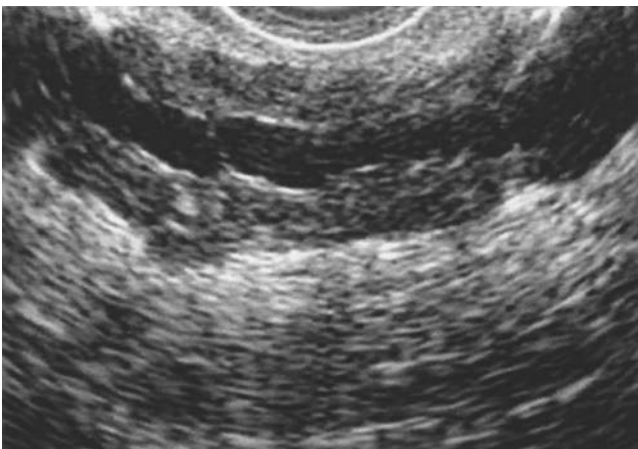

Figure 33-26. Endoscopic ultrasound of chronic pancreatitis. The endoscopic ultrasound appearance of the parenchyma is heterogeneous, and dilated ducts are seen, indicating early obstructive pancreatopathy. (Courtesy of Mark Topazian, Division of Digestive Diseases, Department of Medicine, Mayo Clinic.)

Table 33-13

Endoscopic ultrasound features of chronic pancreatitis

ENDOSCOPIC ULTRASOUND FEATURE	IMPLICATION
Ductal changes	
Duct size >3 mm	Ductal dilation
Tortuous pancreatic duct	Ductal irregularity
Intraductal echogenic foci	Stones or calcification
Echogenic duct wall	Ductal fibrosis
Side-branch ectasia	Periductal fibrosis
Parenchymal changes	
Inhomogeneous echo pattern	Edema
Reduced echogenic foci (1–3 mm)	Edema
Enhanced echogenic foci	Calcifications
Prominent interlobular septae	Fibrosis
Lobular outer gland margin	Fibrosis, glandular atrophy
Large, echo-poor cavities (>5 mm)	Pseudocyst

Source: Reproduced with permission from Catalano et al.¹⁴³ Copyright Elsevier.

the contrast-filled ducts imaged by ERCP.¹⁴⁵ The advantages of MRCP include its noninvasive methodology and its ability to image obstructed ducts that are not opacified by ERCP injection. It is therefore a useful screening study to detect duct abnormalities and to confirm the need for interventional procedures. Oral, IV, and intraductal contrast are unnecessary for MRCP, and its lack of ionizing radiation makes this the safest method to image the ductal system in high-risk patients.

For the diagnosis and staging of chronic pancreatitis, ERCP is considered to be the gold standard. It also serves as a vehicle that enables other diagnostic and therapeutic maneuvers, such as

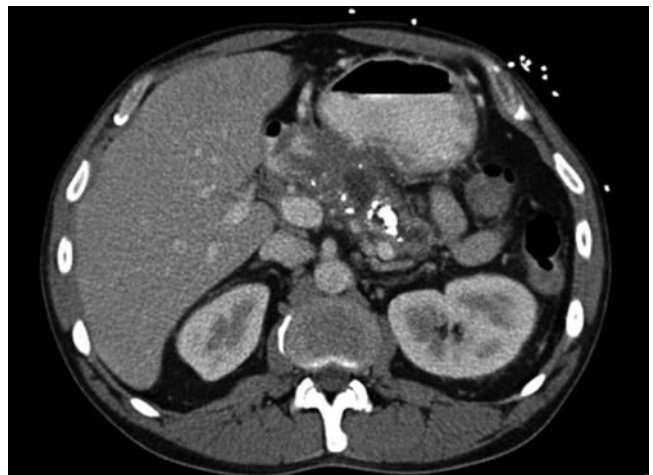


Figure 33-27. Computed tomographic imaging of chronic pancreatitis. A dilated pancreatic duct is seen, with evidence of intraductal stones and parenchymal calcification. (Reproduced with permission from Forsmark CE.²⁰¹ *Management of pancreatitis.* *Gastroenterol.* 2013;144:1282. © 2013 AGA Institute. Published by Elsevier, Inc. All rights reserved.)

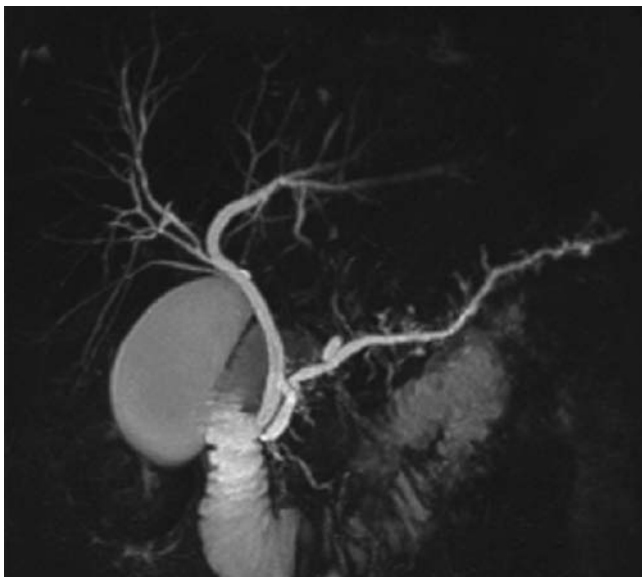


Figure 33-28. Coronal T2-weighted magnetic resonance image showing evidence of chronic pancreatitis, including a pancreatic duct dilatation and side-branch clubbing. (Reproduced with permission of Mellena Bridges, MD, Mayo Clinic Jacksonville, Department of Radiology.)

biopsy or brushing for cytology, or the use of stents to relieve obstruction or drain a pseudocyst (Fig. 33-29). Unfortunately, ERCP also carries a risk of procedure-induced pancreatitis that occurs in approximately 5% of patients.^{31,145} Patients at increased risk include those with sphincter of Oddi dysfunction and those with a previous history of post-ERCP pancreatitis. Post-ERCP pancreatitis occurs after uncomplicated procedures, as well as after those that require prolonged manipulation. Severe pancreatitis and deaths have occurred after ERCP. It should be reserved for patients in whom the diagnosis is unclear despite the use of other imaging methods, or in whom a diagnostic or therapeutic maneuver is specifically indicated.

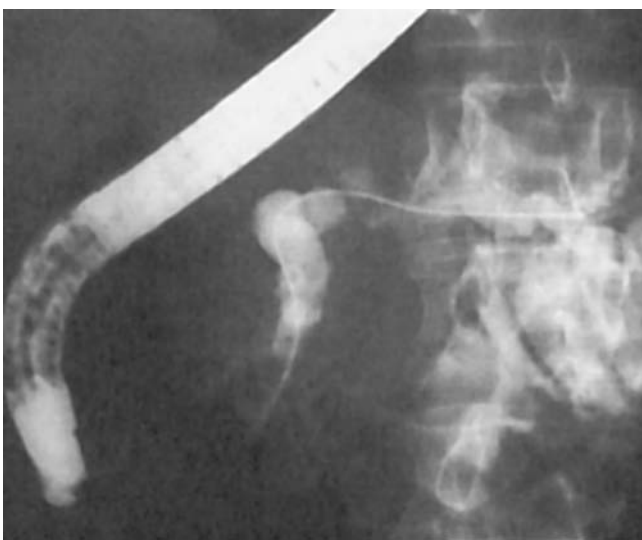

Figure 33-29. Pancreatic duct stenting. At endoscopic retrograde cholangiopancreatography, a stent is placed in the proximal pancreatic duct to relieve obstruction and reduce symptoms of pain. Pancreatic duct stents are left in place for only a limited time to avoid further inflammation.

Presentation, Natural History, and Complications

Presenting Signs and Symptoms. Pain is the most common symptom of chronic pancreatitis. It is usually midepigastic in location but may localize or involve either the left or right upper quadrant of the abdomen. Occasionally, it is perceived in the lower midabdomen but is frequently described as penetrating through to the back (Fig. 33-30). The pain is typically steady and boring, but not colicky. It persists for hours or days and may be chronic with exacerbations caused by eating or drinking alcohol. Chronic alcoholics also describe a steady, constant pain that is temporarily relieved by alcohol, followed by a more severe recurrence hours later.

Patients with chronic pancreatic pain typically flex their abdomen and either sit or lie with their hips flexed, or lie on their side in a fetal position. Unlike ureteral stone pain or biliary colic, the pain causes the patient to be still. Nausea or vomiting may accompany the pain, but anorexia is the most common associated symptom.

Pain from chronic pancreatitis has been ascribed to three possible etiologies. Ductal hypertension, due to strictures or stones, may predispose to pain that is initiated or exacerbated by eating. Chronic pain without exacerbation may be related to parenchymal disease or retroperitoneal inflammation with persistent neural involvement. Acute exacerbations of pain in the setting of chronic pain may be due to acute increases in duct pressure or recurrent episodes of acute inflammation in the setting of chronic parenchymal disease. Nealon and Matin have described these various pain syndromes as being predictive of the response to various surgical procedures.¹⁴⁶ Pain that is found in association with ductal hypertension is most readily relieved by pancreatic duct decompression, through endoscopic stenting or surgical decompression.

The surgical relief of pain due to obstructive pancreatopathy may be dependent on the degree of underlying fibrosis rather than the presence of ductal obstruction, per se, according to a recent study from Johns Hopkins by Cooper et al.¹⁴⁷ About 35 patients with chronic pain associated with evidence of duct obstruction were treated with Local Resection of the pancreatic head and Longitudinal Pancreatico-Jejunostomy (LR-LPJ), or Frey

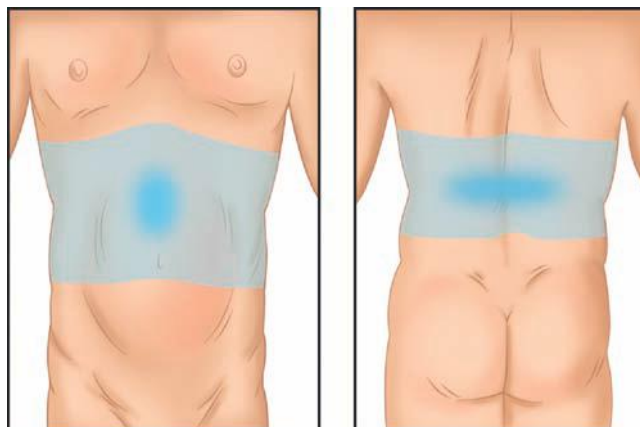


Figure 33-30. Pain location in chronic pancreatitis. (Reproduced with permission from Murayama KM, Jochl RJ. *Chronic pancreatitis*, in Greenfield LJ et al (eds): *Surgery, Scientific Principles and Practice*, 3rd ed. Philadelphia: Lippincott Williams & Wilkins, 2001, p 969.)

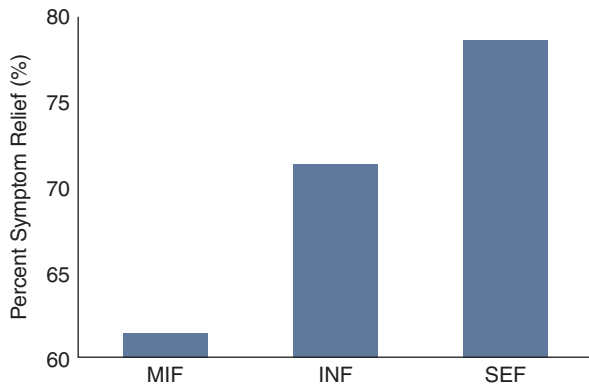


Figure 33-31. Pain relief from chronic pancreatitis treated with the Frey procedure correlates with the degree of underlying fibrosis. Percent of patients with pain relief for those with mild or minimal fibrosis (MIF, $n=13$), intermediate fibrosis (INF, $n=7$), and severe or extensive fibrosis (SEF, $n=14$). $P<0.05$ for MIF vs. SEF by chi-square analysis. (From Cooper M et al: *Extent of pancreatic fibrosis as a determinant of symptom resolution after the Frey procedure: A clinico-pathologic analysis.* J Gastrointest Surg. 2013;17:682. With kind permission from Springer Science+Business Media.)

procedure, and the degree of pain resolution after surgery was compared to the degree of underlying parenchymal fibrosis. After a follow-up that averaged 22 months, patients with more than 80% fibrosis had 100% pain relief, whereas only 60% patients with less than 10% fibrosis experienced substantial or complete pain relief (Fig. 33-31). These findings suggest that minimal fibrosis, or “minimal change chronic pancreatitis,” may produce chronic pain due to extrapancreatic or “peri-pancreatic” inflammatory events which are not ameliorated by decompression.

The pain of chronic pancreatitis may decrease or disappear completely over a period of years, as symptoms of exocrine and endocrine deficiency become apparent.¹⁴⁸ This is referred to as *burned outpancreatitis* and correlates with the progression of disease from a mild or moderate stage to severe destruction of the pancreas. Although this evolution of painful to nonpainful disease is sometimes used as a justification to avoid intervention in painful chronic pancreatitis, noninterventional approaches to the treatment of chronic pancreatitis are inevitably accompanied by the development of narcotic addiction, inability to work, and the sequelae of chronic illness.

Although increased ductal pressure, and therefore parenchymal pressure, is thought to be the cause of pain in chronic obstructive pancreatitis, the role of chronic inflammation per se, and the development of actual nerve damage in the diseased gland, are also thought to contribute to pain.¹⁴⁹ Chronic inflammation results in the infiltration of tissue by macrophages, which secrete prostaglandins and other nociceptive agents that cause chronic stimulation of afferent neural fibers. Inflammatory damage to the perineurial layers surrounding the unmyelinated pancreatic nerves and a focal infiltration of inflammatory cells around nerves suggest that neural fibers are a target for the cellular response to inflammation in the pancreas.¹⁵⁰

Strategies to relieve pain are therefore based on three approaches: (a) reducing secretion and/or decompress the secretory compartment, (b) resecting the focus of chronic inflammatory change, or (c) interrupting the transmission of afferent neural impulses through neural ablative procedures. A trial of antisecretory therapy or endoscopic duct drainage may select those patients who will benefit preferentially from a decompressive procedure.

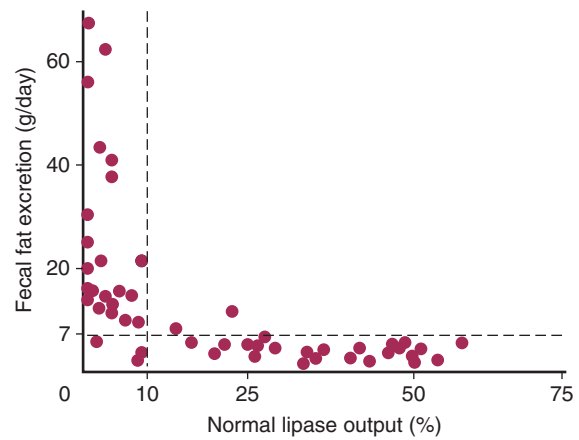


Figure 33-32. Relationship of lipase output to fat malabsorption. Excess fecal fat appears when the pancreatic lipase output falls below 10% of normal secretory values. (Data from DiMagno et al.¹⁵¹)

Malabsorption and Weight Loss. When pancreatic exocrine capacity falls below 10% of normal, diarrhea and steatorrhea develop¹⁵¹ (Fig. 33-32). Patients describe a bulky, foul-smelling, loose (but not watery) stool that may be pale in color and float on the surface of toilet water. Frequently, patients will describe a greasy or oily appearance to the stool, or may describe an “oil slick” on the water’s surface. In severe steatorrhea, an orange, oily stool is often reported. As exocrine deficiency increases, symptoms of steatorrhea are often accompanied by weight loss. Patients may describe a good appetite despite weight loss, or diminished food intake due to abdominal pain.

In severe symptomatic chronic pancreatitis, anorexia or nausea may occur with or separate from abdominal pain. The combination of decreased food intake and malabsorption of nutrients usually results in chronic weight loss. As a result, many patients with severe chronic pancreatitis are below ideal body weight.

Lipase deficiency tends to manifest itself before trypsin deficiency, so the presence of steatorrhea may be the first functional sign of pancreatic insufficiency.¹⁵² As pancreatic exocrine function deteriorates further, the secretion of bicarbonate into the duodenum is reduced, which causes duodenal acidification and further impairs nutrient absorption.¹⁵³ Pancreatic exocrine insufficiency is frequently asymptomatic, however, and pancreatic exocrine function is difficult to measure, so a diagnosis of chronic pancreatitis is sufficient to justify a trial of pancreatic enzyme supplements. Each meal should be followed by 90,000 United States Pharmacopeia units of lipase, and the metabolic and symptomatic status of the patients should be followed.¹⁵⁴

Pancreatogenic Diabetes. The islets comprise only 2% of the mass of the pancreas, but they are preferentially conserved when pancreatic inflammation occurs. In chronic pancreatitis, acinar tissue loss and replacement by fibrosis is greater than the degree of loss of islet tissue, although islets are typically smaller than normal and may be isolated from their surrounding vascular network by the fibrosis. With progressive destruction of the gland, endocrine insufficiency commonly occurs. Frank diabetes is seen initially in about 20% of patients with chronic pancreatitis, and impaired glucose metabolism can be detected in up to 70% of patients. In a study of 500 patients with predominantly

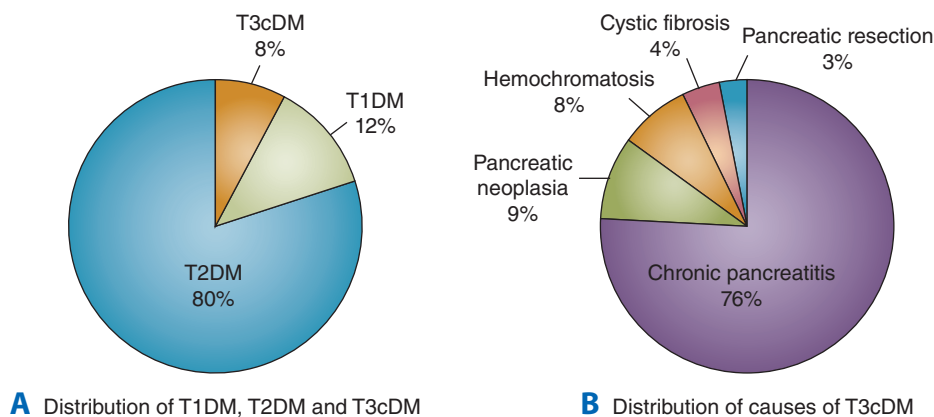


Figure 33-33. Distribution of types of diabetes (A) and causes of type 3c (pancreatogenic) diabetes (B) based on studies of 1922 diabetic patients referred to an academic medical center as reported by Hardt et al.¹⁵⁷ (Reproduced from Cui YF and Andersen DK¹⁵⁹ with permission. Copyright Elsevier.)

alcoholic chronic pancreatitis, diabetes developed in 83% within 25 years of the clinical onset of chronic pancreatitis, and more than half of the diabetic patients required insulin treatment.¹⁵⁵ Ketoacidosis and diabetic nephropathy are relatively uncommon in pancreatogenic diabetes (Table 33-3), but retinopathy and neuropathy are seen to occur with a similar frequency as in type 1 and type 2 diabetes.¹⁵⁶

Pancreatogenic diabetes is most common in cases of chronic pancreatitis, and is often seen after surgical resection for benign or malignant disease^{157,158} (Fig. 33-33). Distal pancreatectomy and Whipple procedures have a higher incidence of diabetes than do drainage procedures, and the severity of diabetes is usually worse after subtotal or total pancreatectomy. Pancreatogenic, or type 3c diabetes (T3cDM), is seen in cystic fibrosis, in association with pancreatic cancer, and in cases of severe hemochromatosis.¹⁵⁹

The etiology and pathophysiology of pancreatogenic diabetes is distinct from that of either autoimmune (type 1) or obesity-related (type 2) diabetes. In type 3c diabetes, the loss of functioning pancreatic tissue by disease or surgical removal results in a global deficiency of all three glucoregulatory islet cell hormones: insulin, glucagon, and PP. In addition, there is a paradoxical combination of enhanced peripheral sensitivity to insulin and decreased hepatic sensitivity to insulin.¹⁶⁰ As a result, insulin therapy is frequently difficult; patients are hyperglycemic when insulin replacement is insufficient (due to unsuppressed hepatic glucose production) or hypoglycemic when insulin replacement is barely excessive (due to enhanced peripheral insulin sensitivity and a deficiency of pancreatic glucagon secretion to counteract the hypoglycemia). This form of diabetes is referred to as *brittle* diabetes and requires special attention.

PP deficiency correlates with the severity of chronic pancreatitis, and impairments in the hepatic action of insulin are reversed in PP-deficient chronic pancreatitis patients by administration of PP¹⁶¹. In addition, a recent study of type 1 and type 3c diabetic patients on insulin pump therapy revealed that the addition of a continuous subcutaneous infusion of PP reduced the insulin requirements needed for glycemic control.¹⁶² This suggests that the treatment of pancreatogenic diabetes may be improved by the use of a clinically suitable PP analog or PP receptor agonist.

Laboratory Studies. The diagnosis of chronic pancreatitis depends on the clinical presentation, a limited number of indirect measurements that correlate with pancreatic function, and selected imaging studies (Table 33-14). The direct measurement

Table 33-14

Tests for chronic pancreatitis

I. Measurement of pancreatic products in blood

- A. Enzymes
- B. Pancreatic polypeptide

II. Measurement of pancreatic exocrine secretion

- A. Direct measurements
 1. Enzymes
 2. Bicarbonate
- B. Indirect measurement
 1. Bentiromide test
 2. Schilling test
 3. Fecal fat, chymotrypsin, or elastase concentration
 4. [¹⁴C]-olein absorption

III. Imaging techniques

- A. Plain film radiography of abdomen
- B. Ultrasonography
- C. Computed tomography
- D. Endoscopic retrograde cholangiopancreatography
- E. Magnetic resonance cholangiopancreatography
- F. Endoscopic ultrasonography

of pancreatic enzymes (e.g., lipase and amylase) by blood test is highly sensitive and fairly specific in acute pancreatitis but is seldom helpful in the diagnosis of chronic pancreatitis. The pancreatic endocrine product that correlates most strongly with chronic pancreatitis is the PP response to a test meal (Fig. 33-34). Severe chronic pancreatitis is associated with a blunted or absent PP response to feeding but, as with many other tests, a normal PP response does not rule out the presence of early disease.¹⁴

The measurement of pancreatic exocrine secretion requires aspiration of pancreatic juice from the duodenum after nutrient (Lundh test meal) or hormonal (CCK or secretin) stimulation.^{163,164} Direct aspiration of pancreatic juice by endoscopic cannulation of the duct is performed in some centers, but is not risk free, comfortable for the patient, or more sensitive than luminal intubation methods.¹⁶⁵

Indirect tests of pancreatic exocrine function are based on the measurement of metabolites of compounds that are altered

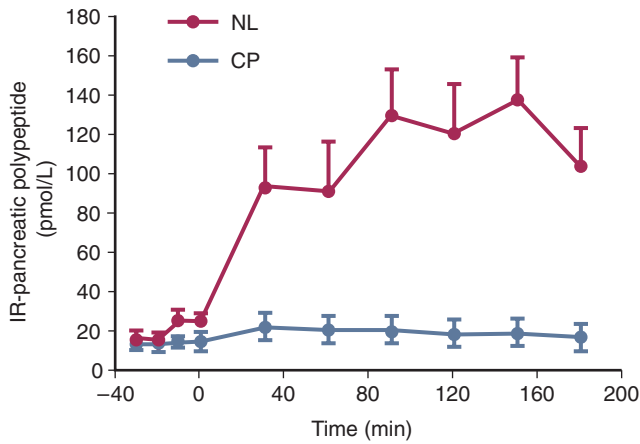


Figure 33-34. Pancreatic polypeptide (PP) response to a test meal. Immunoreactive PP (IR-PP) responses in control subjects (NL, $n = 6$) and patients with severe chronic pancreatitis (CP) accompanied by PP deficiency (CP, $n = 5$) are shown. A test meal was administered at 0 minutes. Means \pm standard error of the mean are shown. (Reproduced with permission from Brunicaudi et al.¹⁶¹ Copyright 1996 The Endocrine Society.)

(“digested”) by pancreatic exocrine products and can be quantified by serum or urine measurements. A commonly used indirect test is the bentiromide test, in which *N*-benzoyl-L-tyrosyl-p-aminobenzoic acid is ingested by the subject, and the urinary excretion of the proteolytic metabolite p-aminobenzoic acid (PABA) is measured.¹⁶⁶ Although the sensitivity of the test is as high as 100% in patients with severe chronic pancreatitis, it identifies only 40% to 50% of patients with mild disease, and reduced PABA excretion is found in patients with a variety of other GI, hepatic, and renal diseases. The quantification of stool fat has also been used as a measure of pancreatic lipase secretion, either through the direct measurement of total fecal fat levels while the subject consumes a diet of known fat content, or by the measurement of exhaled ¹⁴CO₂ after ingestion of [¹⁴C]-triolein or [¹⁴C]-olein. This so-called triolein breath test is less cumbersome than intubation methods, and avoids the necessity of stool collections and analysis, but also has a high false-negative rate.¹⁶⁷

Fecal levels of chymotrypsin¹⁶⁸ and elastase¹⁶⁹ have been proposed as simpler, less expensive tests of exocrine function and correlate well with loss of pancreatic function. As with other test methods, however, these tests lose their sensitivity in patients with mild to moderate chronic pancreatitis and may be more sensitive for other causes of pancreatic dysfunction, including cystic fibrosis. Fecal elastase C1 measurements have become widespread in their use, and levels above 200 μ g/g are considered normal, whereas levels below 100 μ g/g are indicative of pancreatic exocrine insufficiency.¹⁷⁰ The sensitivity and specificity of fecal elastase C1 measurements fall short of those needed for definitive diagnosis of pancreatic exocrine insufficiency, however.¹⁷¹

Radiologic imaging has become the principal method of diagnosis of chronic pancreatitis, with the codification of classification systems that correlate with proven disease. ERCP has been considered the most sensitive radiologic test for the diagnosis of chronic pancreatitis, with specific ERCP findings that are highly correlative with the degree or stage of chronic disease¹⁷² (Table 33-15). CT scanning is sensitive for the diagnosis of chronic pancreatitis when calcification, duct dilatation, or

Table 33-15

Cambridge classification of chronic pancreatitis by endoscopic retrograde cholangiopancreatography

GRADE	MAIN PANCREATIC DUCT	SIDE BRANCHES
Normal	Normal	Normal
Suggestive	Normal	<3 Abnormal
Mild	Normal	≥ 3 Abnormal
Moderate	Abnormal	>3 Abnormal
Severe	Abnormal plus at least one of the following: Large cavity, Duct obstruction, Dilatation or duct irregularity, Intraductal filling defects	

Source: Reproduced with permission from Axon ATR et al. Pancreatography in chronic pancreatitis: International definitions. *Gut* 25:1107, 1984. With permission from the BMJ Publishing Group.

cystic disease is present, but is not accurate in the absence of these findings. CT is helpful as a screening study to guide interventional therapy or other diagnostic modalities,¹⁴² although EUS has become the preferred method for the diagnosis of pancreatic disease and offers the advantage of very-high-resolution images of the pancreatic parenchyma, the main and secondary ductal systems, cystic lesions, and calcific changes. EUS findings may be inconclusive in mild or “minimal change” pancreatitis, however, and improved criteria for an EUS-based diagnosis are still a work in progress. Most importantly, EUS is highly reliable in ruling out pancreatic carcinoma when CT findings are normal or equivocal.¹⁷³

Prognosis and Natural History. The prognosis for patients with chronic pancreatitis is dependent on the etiology of the disease, the development of complications, and on the age and socioeconomic status of the patient. The influence of treatment is less evident in long-term studies, although the general absence of randomized, prospective trials clouds the issue of whether specific forms of therapy alter the long-term outlook for patients with the disease.

Several studies have demonstrated that, although symptoms of pain decrease over time in about half of the patients, this decline is also accompanied by a progression of exocrine and endocrine insufficiency.¹⁷⁴ In general, the likelihood of eventual pain relief is dependent upon the stage of disease at diagnosis, and the persistence of alcohol use in patients with alcoholic chronic pancreatitis. Miyake and colleagues found that pain relief was achieved in 60% of alcoholic patients who successfully discontinued drinking, but in only 26% who did not.¹⁷⁵

The long-term survival of patients with chronic pancreatitis is less than for patients without pancreatitis. In an international multicenter study of >2000 patients, Lowenfels and colleagues found that the 10- and 20-year survival rates for patients with chronic pancreatitis were 70% and 45%, respectively, compared to 93% and 65% for patients without pancreatitis.¹⁷⁴ The mortality risk was found to be 1.6-fold higher in patients who continued to abuse alcohol, compared to those who did not. Continued alcohol abuse has a similar effect on the response to surgical treatment (Fig. 33-35), and results in a twofold increase in mortality over a 10- to 14-year follow-up period.¹⁷⁶

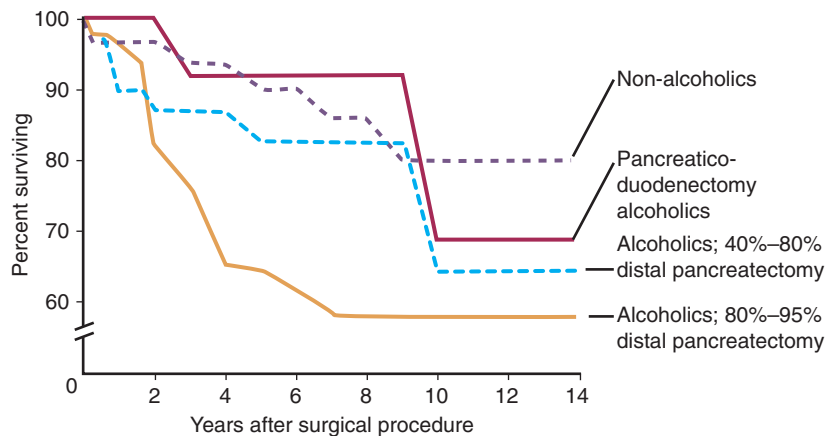


Figure 33-35. Effect of alcohol use on survival after surgical procedures. The cumulative survival of patients with chronic pancreatitis following pancreaticoduodenectomy or distal pancreatectomy is shown for nonalcoholic and alcoholic patients. (Reproduced with permission from Frey et al.¹⁷⁶)

In addition to progressive endocrine and exocrine dysfunction, and the risk of the specific complications outlined below and in Table 33-16, the other significant long-term risk for the patient with chronic pancreatitis is the development of pancreatic carcinoma.¹⁷⁸ There is a progressive, cumulative increased risk of carcinoma development in patients with chronic pancreatitis, which continues throughout the subsequent lifetime of the patient (Fig. 33-36). The incidence of carcinoma in patients with chronic pancreatitis ranges from 1.5% to 6%,¹⁷⁷ which is at least 10-fold greater than that of patients of similar age seen in a hospital setting. In a recent study, the risk of carcinoma among patients with chronic pancreatitis accompanied by diabetes was found to be increased 33-fold compared to healthy, comparably aged controls.¹⁷⁸ In patients with advanced chronic pancreatitis referred for surgical therapy, indolent, undiagnosed carcinoma can be seen in as many as 10% of patients.¹⁷⁹

The development of carcinoma in the setting of chronic pancreatitis is no doubt related to the dysregulation of cellular proliferation and tissue repair processes in the setting of chronic inflammation, as is seen throughout the alimentary tract

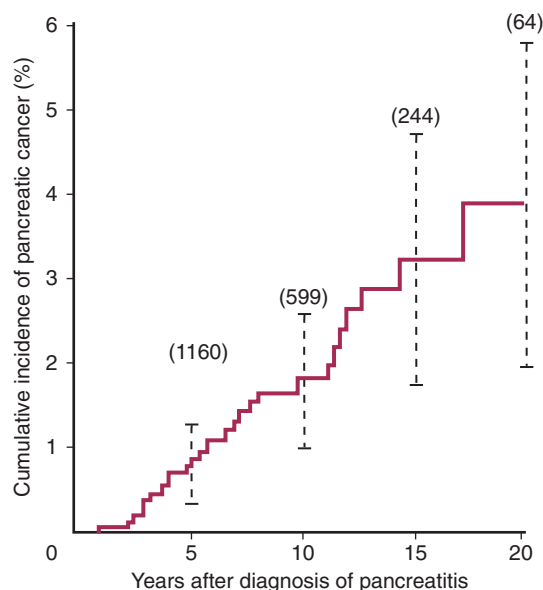


Figure 33-36. Cumulative risk of pancreatic cancer in patients with chronic pancreatitis. The number of patients evaluated at different time intervals is shown in parentheses. (Reproduced with permission from Lowenfels AB et al. Copyright © 1993 Massachusetts Medical Society. All rights reserved.¹⁷⁷)

Table 33-16

Complications of chronic pancreatitis

Intrapancreatic complications

Pseudocysts

Duodenal or gastric obstruction

Thrombosis of splenic vein

Abscess

Perforation

Erosion into visceral artery

Inflammatory mass in head of pancreas

Bile duct stenosis

Portal vein thrombosis

Duodenal obstruction

Duct strictures and/or stones

Ductal hypertension and dilatation

Pancreatic carcinoma

Extrapancreatic complications

Pancreatic duct leak with ascites or fistula

Pseudocyst extension beyond lesser sac into mediastinum, retroperitoneum, lateral pericolic spaces, pelvis, or adjacent viscera

and elsewhere. In the setting of chronic pancreatitis, carcinoma development can be especially cryptic, and the diagnosis of early-stage tumors is particularly difficult. Awareness of this risk justifies close surveillance for cancer in patients with chronic pancreatitis. Periodic measurement of tumor markers such as CA19-9, and periodic imaging of the pancreas with CT scan and EUS seem logical in order to detect the development of carcinoma in the patient with chronic pancreatitis, although no evidence exists to indicate that this alters the outcome of patients who develop pancreatic cancer. Surgical procedures performed for presumed chronic pancreatitis should always include biopsy of the tissue to exclude the diagnosis of malignancy.

Complications

Pseudocyst. A chronic collection of pancreatic fluid surrounded by a nonepithelialized wall of granulation tissue and fibrosis is referred to as a *pseudocyst*. Pseudocysts occur in up to 10% of patients with acute pancreatitis, and in 20% to 38%

Table 33-17

Definitions of pancreatic fluid collections

TERM	DEFINITION
Peripancreatic fluid collection	A collection of enzyme-rich pancreatic juice that occurs early in the course of acute pancreatitis, or that forms after a pancreatic duct leak; located in or near the pancreas; it lacks a well-organized wall of granulation or fibrous tissue
Early pancreatic (sterile) necrosis	A focal or diffuse area of nonviable pancreatic parenchyma, typically occupying >30% of the gland and containing liquefied debris and fluid
Late pancreatic (sterile) necrosis	An organized collection of sterile necrotic debris and fluid with a well-defined margin or wall within the normal domain of the pancreas
Acute pseudocyst	A collection of pancreatic juice enclosed within a perimeter of early granulation tissue, usually as a consequence of acute pancreatitis that has occurred within the preceding 3–4 wk
Chronic pseudocyst	A collection of pancreatic fluid surrounded by a wall of normal granulation and fibrous tissue, usually persisting for >6 wk
Pancreatic abscess	Any of the above in which gross purulence (pus) is present, with bacterial or fungal organisms documented to be present

Source: Modified with permission from Baron et al.¹⁸⁶ Copyright Elsevier.

of patients with chronic pancreatitis, and thus, they comprise the most common complication of chronic pancreatitis.¹⁸⁰⁻¹⁸² The identification and treatment of pseudocysts requires definition of the various forms of pancreatic fluid collections that occur (Table 33-17). In chronic pancreatitis, a pancreatic duct leak with extravasation of pancreatic juice results in a peri-pancreatic fluid collection (PPFC). Over a period of 3 to 4 weeks, the PPFC is sealed by an inflammatory reaction that leads to development of a wall of acute granulation tissue without much fibrosis. This is referred to as an *acute pseudocyst*. Acute pseudocysts may resolve spontaneously in up to 50% of cases, over a course of 6 weeks or longer.¹⁸³ Pseudocysts >6 cm resolve less frequently than smaller ones but may regress over a period of weeks to months. Pseudocysts are multiple in 17% of patients,¹⁸² or may be multilobulated. They may occur intrapancreatically or extend beyond the region of the pancreas into other cavities or compartments (Fig. 33-37).

Pseudocysts may become secondarily infected, in which case they become abscesses. They can compress or obstruct adjacent organs or structures, leading to superior mesenteric-portal vein thrombosis or splenic vein thrombosis.¹⁸⁴ They can erode into visceral arteries and cause intracystic hemorrhage or pseudoaneurysms (Fig. 33-38). They also can perforate and cause peritonitis or intraperitoneal bleeding.¹⁸⁵

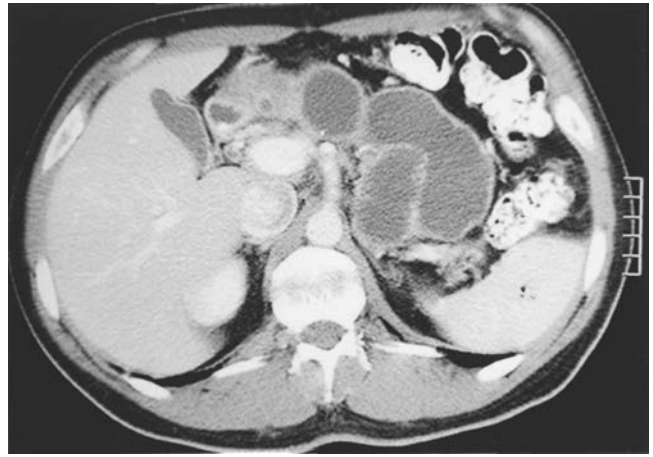

Figure 33-37. Extensive pseudocyst disease. A computed tomographic scan in a patient with alcoholic chronic pancreatitis demonstrates multiloculated pseudocyst disease.

Pseudocysts usually cause symptoms of pain, fullness, or early satiety. Asymptomatic pseudocysts can be managed expectantly and may resolve spontaneously or persist without complication.¹⁸¹ Symptomatic or enlarging pseudocysts require treatment, and any presumed pseudocyst without a documented antecedent episode of acute pancreatitis requires investigation to determine the etiology of the lesion.¹⁸³ Although pseudocysts comprise roughly two thirds of all pancreatic cystic lesions, they resemble cystadenomas and cystadenocarcinoma radiographically. An incidentally discovered cystic lesion should be examined by EUS and aspirated to determine whether it is a true neoplasm or a pseudocyst.

The timing and method of treatment requires careful consideration. Pitfalls in the management of pseudocysts result from the incorrect (presumptive) diagnosis of a cystic neoplasm masquerading as a pseudocyst, a failure to appreciate the solid or debris-filled contents of a pseudocyst that appears to be fluid filled on CT scan, and a failure to document true adherence with

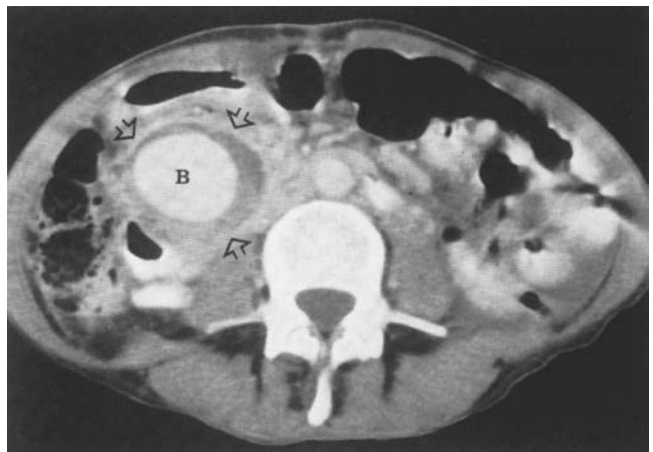


Figure 33-38. Pseudoaneurysm of the gastroduodenal artery. A pseudocyst can erode into an adjacent artery, which results in contained hemorrhage otherwise known as a *pseudoaneurysm*. A contrast-injected computed tomographic scan reveals active bleeding (area marked B) into a pseudocyst (arrows) as a result of this process. (Reproduced with permission from Balthazar EJ: *CT diagnosis and staging of acute pancreatitis*. Radiol Clin North Am. 1989;27:19. Copyright Elsevier.)

an adjacent portion of the stomach before attempting transgastric internal drainage.

If infection is suspected, the pseudocyst should be aspirated (not drained) by CT- or US-guided FNA, and the contents examined for organisms by Gram's stain and culture.¹⁸⁵ If infection is present, and the contents resemble pus, external drainage is employed, using either surgical or percutaneous techniques.

If the pseudocyst has failed to resolve with conservative therapy, and symptoms persist, internal drainage is usually preferred to external drainage, to avoid the complication of a pancreaticocutaneous fistula. Pseudocysts communicate with the pancreatic ductal system in up to 80% of cases,¹⁸⁶ so external drainage creates a pathway for pancreatic duct leakage to and through the catheter exit site. Internal drainage may be performed with either percutaneous catheter-based methods (transgastric puncture and stent placement to create a cystogastrostomy), endoscopic methods (transgastric or transduodenal puncture and multiple stent placements, with or without a nasocystic irrigation catheter), or surgical methods (a true cystoenterostomy, biopsy of cyst wall, and evacuation of all debris and contents). Surgical options include a cystogastrostomy (Fig. 33-39), a Roux-en-Y cystojejunostomy, or a cystoduodenostomy. Cystojejunostomy is the most versatile method, and it can be applied to pseudocysts that penetrate into the transverse mesocolon, the paracolic gutters, or the lesser sac. Cystogastrostomy can be performed endoscopically¹⁸⁷ (Fig. 33-40), laparoscopically,¹⁸⁸ or by a combined laparoscopic-endoscopic method.¹⁸⁹

Because pseudocysts often communicate with the pancreatic ductal system, two newer approaches to pseudocyst management are based on main duct drainage, rather than pseudocyst drainage per se. Transpapillary stents inserted at the time of ERCP may be directed into a pseudocyst through the ductal communication itself (Fig. 33-41), or can be left across the area of suspected duct leakage to facilitate decompression and cyst drainage, analogous to the use of common bile duct stents in the setting of a cystic duct leak.¹⁸⁶ In a surgical series of patients with chronic pancreatitis, ductal dilatation, and a coexisting pseudocyst, Nealon and Walser showed that duct drainage alone, without a separate cystoenteric anastomosis, was as successful as a combined drainage procedure.¹⁹⁰ Furthermore, the "duct drainage only" group enjoyed a shorter hospital stay and fewer complications than the group who underwent a separate

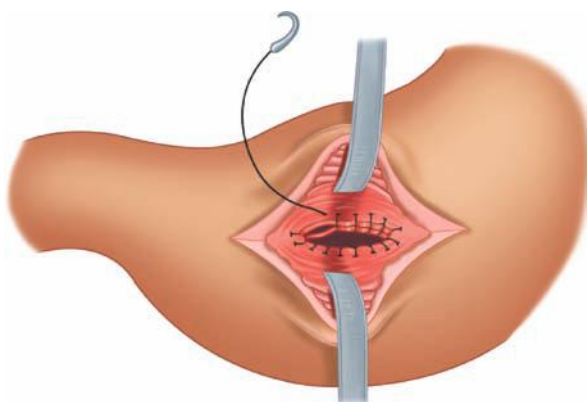


Figure 33-39. Cystogastrostomy drainage of a retrogastric pancreatic pseudocyst. A larger opening is made through the common wall of a retrogastric pseudocyst, and a portion of the pseudocyst wall is submitted for histologic confirmation of the diagnosis. Suture reinforcement of the communication is performed to avoid the complication of bleeding. (Reproduced with permission from Bell.¹⁸⁸)

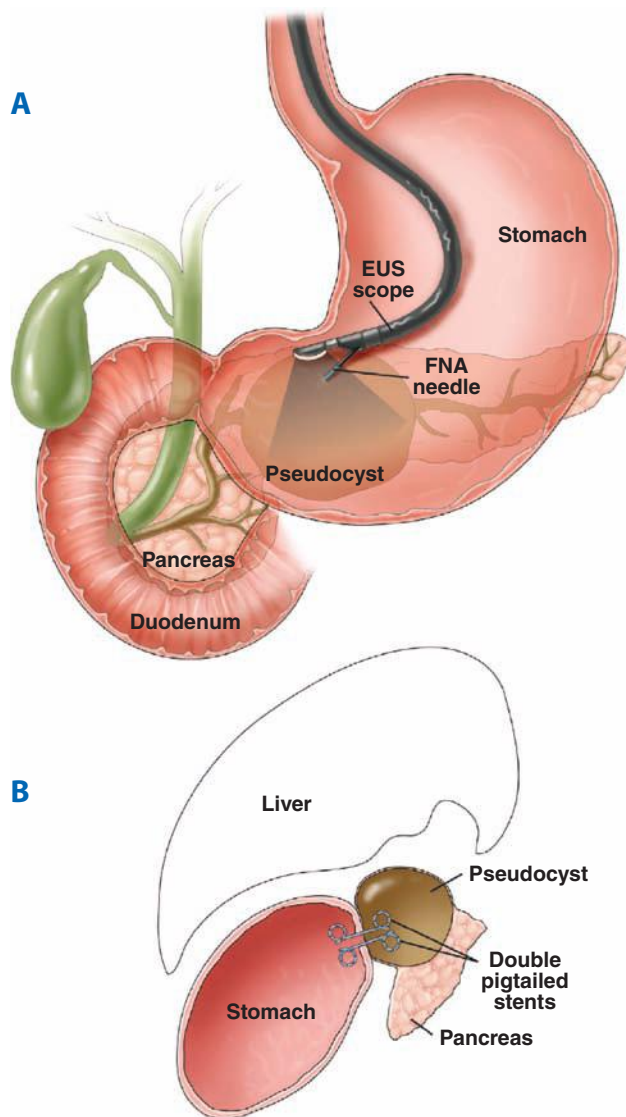
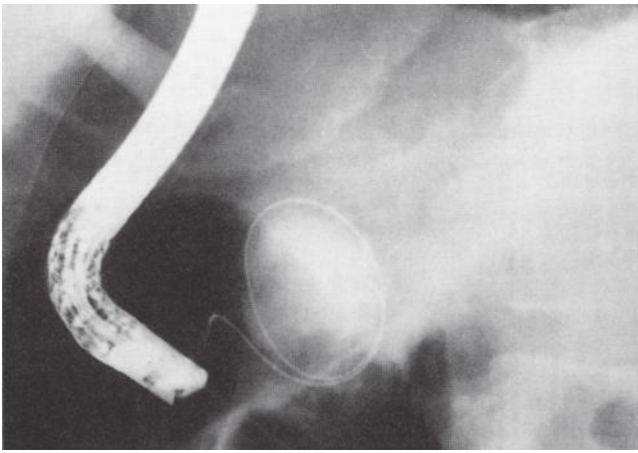


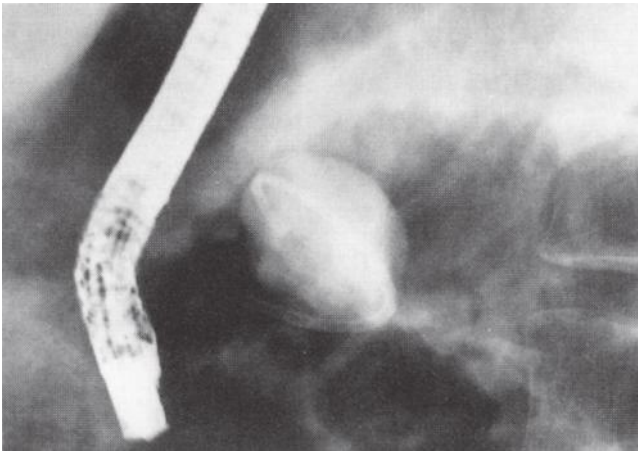
Figure 33-40. Technique of endoluminal cystogastrostomy. **A.** Endoscopic ultrasound (EUS)-guided transgastric puncture of pancreatic pseudocyst. **B.** Transgastric stents placed across fused posterior wall of stomach and anterior wall of pseudocyst. (Reproduced with permission from Chauhan SS, Forsmark CE. Evidence-based treatment of pancreatic pseudocysts. *Gastroenterol* 2013; 145: 512 Copyright Elsevier.)

cystoenterostomy. These observations suggest that transductal drainage may be a safe and effective approach to the management of pseudocystic disease.

The complications of endoscopic or radiologic drainage of pseudocysts often require surgical intervention. Bleeding from the cystoenterostomy, and inoculation of a pseudocyst with failure of resolution and persistence of infection, may require surgical treatment. Bleeding risks may be lessened by the routine use of EUS in the selection of the site for transluminal stent placement.¹⁹¹ Percutaneous and endoscopic treatment of pseudocysts requires large-bore catheters, multiple stents, and an aggressive approach to management for success to be achieved. Failure of nonsurgical therapy, with subsequent salvage procedures to remove infected debris and establish complete drainage, is associated with increased risks for complications and death.¹⁹² The most experienced therapeutic endoscopists report a complication rate of 17% to 19% for the treatment of sterile



A



B

Figure 33-41. Transpapillary drainage of a pancreatic pseudocyst. **A.** Endoscopic passage of a flexible wire through the major papilla, through the pancreatic duct, and into a communicating pseudocyst. **B.** Placement of a stent over the wire into the pseudocyst with transpapillary drainage. (Reproduced with permission from Kozarek *et al.*¹⁸⁷)

pseudocysts, and deaths as a result of endoscopic therapy have occurred.¹⁹³ Therefore, the use of endoscopic methods to treat sterile or infected pancreatic necrosis has a higher complication rate and is limited to specialized centers.

Resection of a pseudocyst is sometimes indicated for cysts located in the pancreatic tail, or when a midpancreatic duct disruption has resulted in a distally located pseudocyst. Distal pancreatectomy for removal of a pseudocyst, with or without splenectomy, can be a challenging procedure in the setting of prior pancreatitis. An internal drainage procedure of the communicating duct or of the pseudocyst itself should be considered when distal resection is being contemplated.

Pancreatic Ascites. When a disrupted pancreatic duct leads to pancreatic fluid extravasation that does not become sequestered as a pseudocyst, but drains freely into the peritoneal cavity, pancreatic ascites occurs. Occasionally, the pancreatic fluid tracks superiorly into the thorax, and a pancreatic pleural effusion occurs. Referred to as *internal pancreatic fistulae*, both complications are seen more often in patients with chronic pancreatitis rather than after acute pancreatitis. Pancreatic ascites and pleural effusion occur together in 14% of patients, and 18% have a pancreatic pleural effusion alone.¹⁹⁴

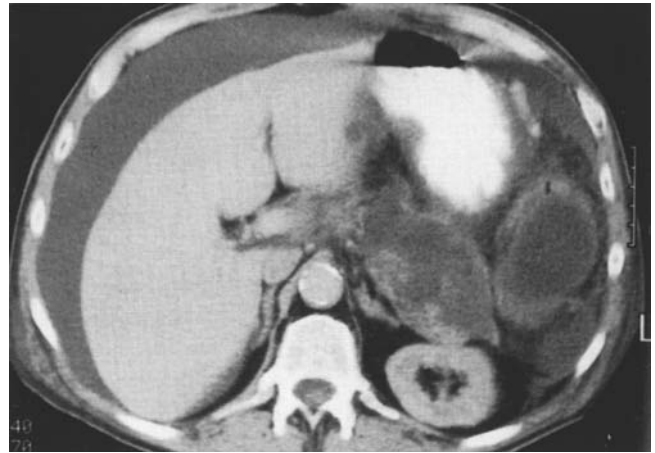


Figure 33-42. Pancreatic ascites. Computed tomographic scan of a patient with a ruptured pancreatic pseudocyst resulting in intraperitoneal pancreatic fluid. (Reproduced with permission from Cameron JL, Cameron AM (eds): *Current Surgical Therapy*, 11th ed. Philadelphia: Elsevier, 2014, p 458. Copyright Elsevier.)

Patients demonstrate the general demographics of chronic pancreatitis and usually present with a subacute or recent history of progressive abdominal swelling despite weight loss. Pain and nausea are rarely present. The abdominal CT scan discloses ascites and the presence of chronic pancreatitis or a partially collapsed pseudocyst (Fig. 33-42). Paracentesis or thoracentesis reveals noninfected fluid with a protein level >25 g/L and a markedly elevated amylase level. Serum amylase may also be elevated, presumably from reabsorption across the parietal membrane. Serum albumin may be low, and patients may have coexisting liver disease. Paracentesis is therefore critical to differentiate pancreatic from hepatic ascites.

ERCP is most helpful to delineate the location of the pancreatic duct leak and to elucidate the underlying pancreatic ductal anatomy. Pancreatic duct stenting may be considered at the time of ERCP, but if nonsurgical therapy is undertaken and then abandoned, repeat imaging of the pancreatic duct is appropriate to guide surgical treatment.

Antisecretory therapy with the somatostatin analogue octreotide acetate, together with bowel rest and parenteral nutrition, is successful in more than half of patients.¹⁹⁵ Reapposition of serosal surfaces to facilitate closure of the leak is considered a part of therapy, and this is accomplished by complete paracentesis. For pleural effusions, a period of chest tube drainage may facilitate closure of the internal fistula.¹⁹⁵ Surgical therapy is reserved for those who fail to respond to medical treatment. If the leak originates from the central region of the pancreas, a Roux-en-Y pancreaticojejunostomy is performed to the site of duct leakage (Fig. 33-43). If the leak is in the tail, a distal pancreatectomy may be considered, or an internal drainage procedure can be performed. The results of surgical treatment are usually favorable if the ductal anatomy has been carefully delineated preoperatively.

Pancreatic-Enteric Fistula. The erosion of a pancreatic pseudocyst into an adjacent hollow viscus can result in a pancreatic-enteric fistula. The most common site of communication is the transverse colon or splenic flexure. The fistula usually presents with evidence of GI or colonic bleeding and sepsis. If the fistula communicates with the stomach or duodenum, it may close spontaneously or persist as a pancreatic-enteric fistula. When the fistula involves the colon, operative correction is usually required.¹⁹⁶

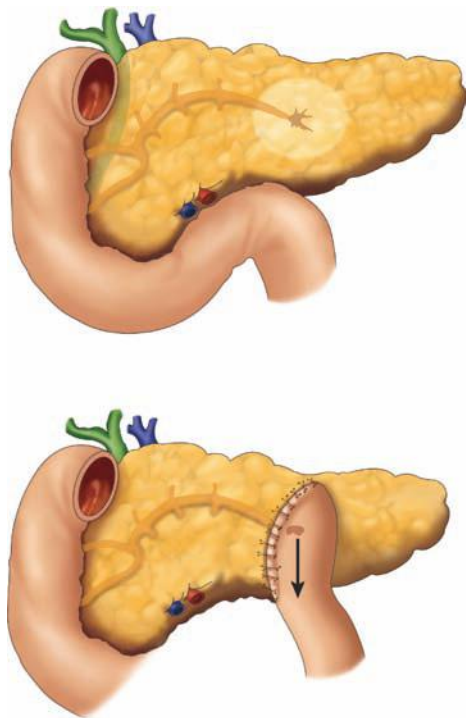


Figure 33-43. Internal drainage for leaking pancreatic duct. A Roux-en-Y pancreaticojejunostomy is performed at the site of duct rupture to accomplish internal drainage of the pancreatic duct leak. (Reproduced with permission from Lipsett.¹⁹⁶)

Head-of-Pancreas Mass. In up to 30% of patients with advanced chronic pancreatitis, an inflammatory mass develops in the head of the pancreas.¹⁹⁷ The clinical presentation includes severe pain, and frequently includes stenosis of the distal common bile duct, duodenal stenosis, compression of the portal vein, and stenosis of the proximal main pancreatic duct (Table 33-18). Mutations and polymorphisms of p53 have been found in these patients, and a focus of ductular carcinoma was found in 3.7% of patients with pancreatic head enlargement in one series.¹⁹⁸ It was concluded that an accelerated transformation from hyperplasia to dysplasia exists in patients with pancreatic head enlargement, although the etiology for this process remains unclear.

Splenic and Portal Vein Thrombosis. Vascular complications of chronic pancreatitis are fortunately infrequent, because

they are difficult to treat successfully. Portal vein compression and occlusion can occur as a consequence of an inflammatory mass in the head of the pancreas, and splenic vein thrombosis occurs in association with chronic pancreatitis in 4% to 8% of cases.¹⁹⁹ Variceal formation can occur as a consequence of either portal or splenic venous occlusion, and splenic vein thrombosis with gastric variceal formation is referred to as *left-sided* or *sinistral portal hypertension*. Although bleeding complications are infrequent, the mortality risk of bleeding is >20%. When gastroesophageal varices are caused by splenic vein thrombosis, the addition of splenectomy to prevent variceal hemorrhage is prudent when surgery is otherwise indicated to correct other problems.

Treatment

Medical Therapy. The medical treatment of chronic or recurrent pain in chronic pancreatitis requires the use of analgesics, a cessation of alcohol use, oral enzyme therapy, and the selective use of antisecretory therapy. Interventional procedures to block visceral afferent nerve conduction or to treat obstructions of the main pancreatic duct are also an adjunct to medical treatment.

Analgesia. Oral analgesics are prescribed as needed, alone or with analgesia-enhancing agents such as gabapentin. Adequate pain control usually requires the use of narcotics, but these should be titrated to achieve pain relief with the lowest effective dose. Opioid addiction is common, and the use of long-acting analgesics by transdermal patch together with oral agents for pain exacerbations slightly reduces the sedative effects of high-dose oral narcotics.

It is essential for patients to abstain from alcohol. In addition to removing the causative agent, alcohol abstinence results in pain reduction or relief in 60% to 75% of patients with chronic pancreatitis.²⁰⁰ Despite this benefit, roughly half of alcoholic chronic pancreatitis patients continue to abuse alcohol.

Enzyme Therapy. Pancreatic enzyme administration serves to reverse the effects of pancreatic exocrine insufficiency. Adequate pancreatic enzyme replacement reverses the exocrine insufficiency seen in most patients, and prevents secondary complications such as metabolic bone disease due to inadequate absorption of the fat-soluble vitamins A, D, E, and K. In addition, pancreatic enzyme replacement may reduce or alleviate the pain experienced by patients. The choice of enzyme supplement and the dose should be selected based on whether malabsorption or pain (or both) are the indications for therapy²⁰¹ (Table 33-19). Conventional (nonenteric-coated) enzyme preparations are partially degraded by gastric acid but are available within the duodenal and jejunal regions to bind to CCK-releasing peptide, and downregulate the release of CCK. This theoretically reduces the enteric signal for pancreatic exocrine secretion, which reduces the pressure within a partially or completely obstructed pancreatic duct.²⁰² Enteric-coated preparations result in little to no pain relief, presumably due to their reduced bioavailability in the proximal gut. Due to the loss of pancreatic enzymes by acid hydrolysis and proteolysis, relatively large doses are required to achieve effective levels of enzyme within the proximal small bowel. Enteric-coated preparations are protected from acid degradation but are presumably not released in the critical proximal gut in sufficient quantity to inhibit the stimulus for endogenous pancreatic enzyme secretion. Nonalcoholic patients may experience more effective pain relief than alcoholic patients, but it is recommended that all patients with chronic pancreatitis pain

Table 33-18

Signs and symptoms of chronic pancreatitis with and without a pancreatic head mass

SIGNS AND SYMPTOMS	WITH HEAD ENLARGEMENT (n = 138) (%)	WITHOUT HEAD ENLARGEMENT (n = 141) (%)
Daily severe pain	67	40
Cholestasis	46	11
Duodenal obstruction	30	7
Diabetes mellitus	18	30
Vascular involvement	15	8

Source: Reproduced with permission from Wiley-Blackwell. From Beger et al.¹⁹⁷

Table 33-19

Pancreatic enzyme preparations

PRODUCT	FORMULATION	MANUFACTURER	LIPASE CONTENT (USP)/PILL OR CAPSULE
Zenpep	Enteric-coated porcine	Aptalis	3000, 5000, 10,000, 15,000, 20,000
Creon	Enteric-coated porcine	Abbott	3000, 6000, 12,000, 24,000
Pancreaze	Enteric-coated porcine	Ortho-McNeil-Janssen	4200, 10,500, 16,800, 21,000
Pertzye	Enteric-coated porcine mixed with bicarbonate granules	Digestive Care	8000, 16,000
Ultresa	Enteric-coated porcine	Aptalis	13,800, 20,700, 23,000
Viokace	Tablet non-enteric-coated porcine	Aptalis	10,440, 20,880

USP: United States Pharmacopeia, the standard for lipase content in the United States. An average meal requires roughly 90,000 USP units of lipase for fat digestion. Enzyme therapy of exocrine deficiency typically begins with a dose of 50,000 USP units per meal with subsequent adjustment.

(Reproduced with permission from Forsmark CE. Management of chronic pancreatitis. *Gastroenterol* 2013; 144: 1282. © 2013 AGA Institute. Published by Elsevier, Inc. All rights reserved.)

begin a trial of nonenteric-coated enzyme supplements together with an acid-suppressive medication for 1 month. If pain relief is achieved, therapy is continued. If enzyme therapy fails, further investigation of the pancreatic ductal system by ERCP guides the therapy based on specific anatomical findings (Fig. 33-44).

Antisecretory Therapy. Somatostatin administration has been shown to inhibit pancreatic exocrine secretion and CCK release.²⁰³ The somatostatin analogue octreotide acetate has therefore been investigated for pain relief in patients with chronic pancreatitis. In a double-blind, prospective, randomized 4-week trial, 65% of patients who received 200 µg of octreotide acetate subcutaneously three times daily reported pain relief, compared with 35% of placebo-treated subjects²⁰⁴. Patients who had the best results were patients with chronic abdominal pain, suggestive of obstructive pancreatopathy. However, in another trial that used a 3-day duration of treatment, no significant pain relief was observed.²⁰⁵ Anecdotal reports suggest that severe pain exacerbations in chronic pancreatitis can benefit from a combination of octreotide therapy and TPN, and a pilot study of the effectiveness of the sustained-release form of octreotide suggested that it was as effective as three-times-per-day administration of the short-acting form of the drug²⁰⁶.

Neurolytic Therapy. Celiac plexus neurolysis with alcohol injection has been an effective form of analgesic treatment in patients with pancreatic carcinoma. However, the use of radiologically- or endoscopically-guided celiac plexus blockade in chronic pancreatitis has been disappointing. Due to the risk of alcohol injury and the need for repeated injections, celiac plexus blockade in chronic pancreatitis has used short-acting analgesics or other drugs rather than 50% alcohol. A trial of EUS-guided celiac plexus blockade revealed successful pain relief in 55% of patients, but the benefit lasted beyond 6 months in only 10% of patients.²⁰⁷ The procedure therefore appears safe, but the effect is short lived in those patients who obtain pain relief.

Endoscopic Management. The techniques of endoscopic treatment of pancreatic duct obstruction, stone disease, pseudocyst formation, pancreatic duct leak, and for the diagnosis and management of associated pancreatic tumors have expanded greatly over the past 10 years. Newer endoscopes with expanded therapeutic capabilities have been introduced,

and the role of EUS and EUS-guided needle and catheter insertion has expanded the ability of the therapeutic endoscopist in the diagnosis and treatment of chronic pancreatitis and its complications.²⁰⁸

Pancreatic duct stenting is used for treatment of proximal pancreatic duct stenosis, decompression of a pancreatic duct leak, and for drainage of pancreatic pseudocysts that can be catheterized through the main pancreatic duct. Pancreatic duct stents can induce an inflammatory response within the duct, so prolonged stenting is usually avoided. Patients with sphincter of Oddi dyskinesia are at high risk for developing post-ERCP pancreatitis after biliary sphincterotomy, and the prophylactic placement of a pancreatic duct stent reduces the amylase level and development of pancreatitis after biliary sphincterotomy.²⁰⁹ Pancreatic duct leaks are seen in 37% of patients with acute pancreatitis, and pancreatic duct stenting appear to facilitate the resolution of the leak.²¹⁰ Similarly, pancreatic duct stenting has been used to treat postsurgical pancreatic duct leaks and post-traumatic leaks.²¹⁰⁻²¹²

Pancreas divisum (see Fig. 33-3) is thought to cause pain and chronic pancreatitis due to functional or mechanical obstruction of the dorsal duct draining exclusively, or predominantly, through the lesser papilla. A study from Marseille reported good long-term results in 24 patients after minor papilla sphincterotomy and dorsal duct stenting.²¹³ The number of patients with chronic pain decreased from 83% before stenting to 29% after stenting, but pancreatitis or recurrent papillary stenosis occurred in 38%. Patients that responded best were those with intermittent pain, and this subset may be preferentially treated with endoscopic therapy.

Idiopathic pancreatitis patients have been treated with endoscopic stenting, pancreatic duct sphincterotomy, and endoscopic stone removal with good results. In a prospective randomized trial, 53% of idiopathic recurrent pancreatitis patients in the control group experienced continued episodes of pancreatitis, although only 11% of the treated patients had continued symptoms.²¹⁴

Extracorporeal shock wave lithotripsy (ESWL) has been used for pancreatic duct stones, together with endoscopic stenting and stone removal.²¹⁵ A single ESWL session was used in 35 patients with pancreatic duct stones, together with 86 ERCP sessions to complete the stone removal process. After 2.4 years,

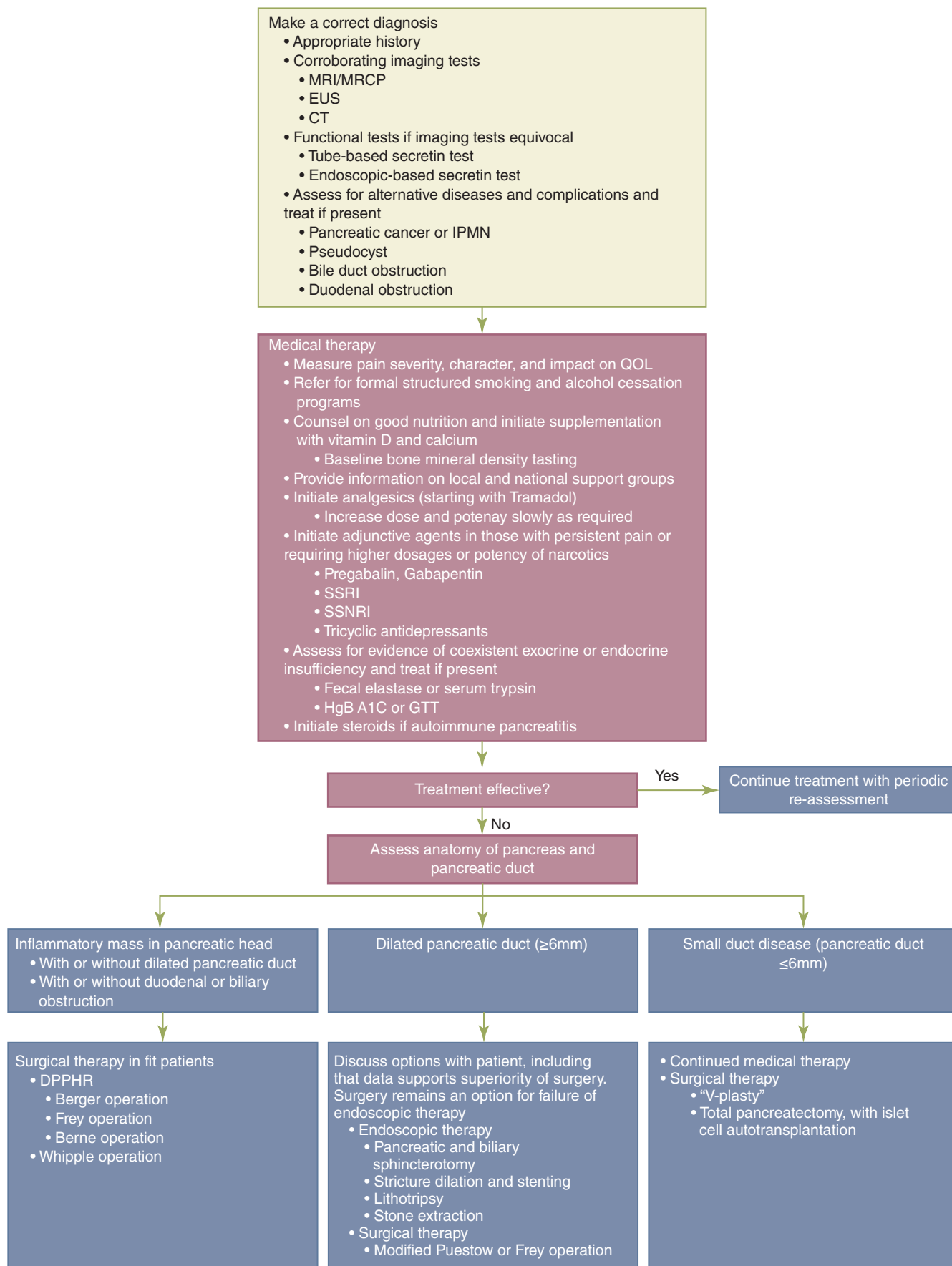
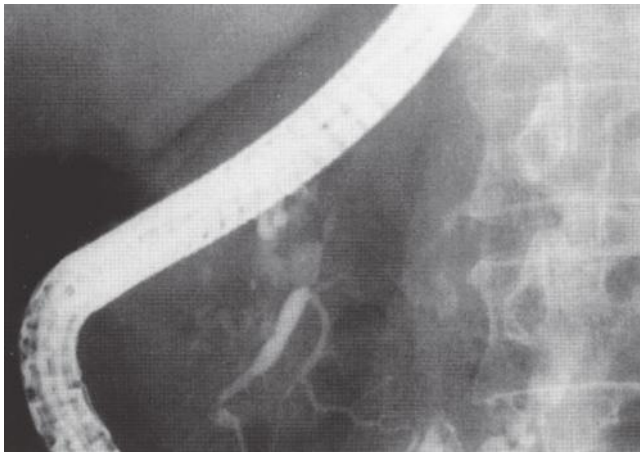
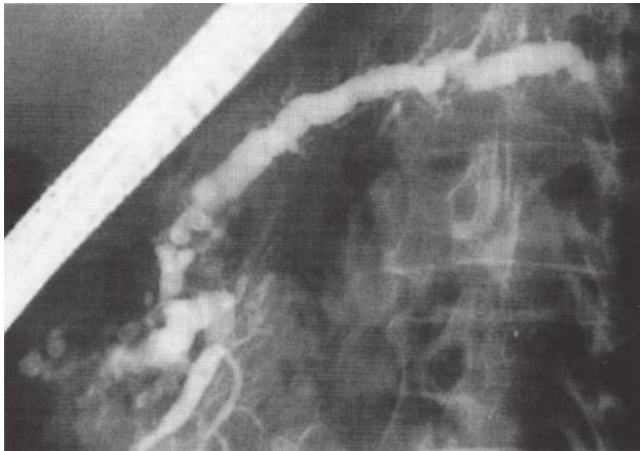


Figure 33-44. Management algorithm for chronic pancreatitis. IPMN – intraductal papillary mucinous neoplasm; QOL – quality of life; SSRI – selective serotonin reuptake inhibitor; SSNRI – selective serotonin-norepinephrine reuptake inhibitor; GTT – glucose tolerance test. (Reproduced with permission from Forsmark CE: *Management of pancreatitis*. *Gastroenterol*. 2013;144:1282. © 2013 AGA Institute. Published by Elsevier, Inc. All rights reserved.)



A



B

Figure 33-45. Extracorporeal shock wave lithotripsy treatment of pancreatic duct stones. The endoscopic retrograde cholangiopancreatography images are shown (A) before and (B) after extracorporeal shock wave lithotripsy therapy of pancreatic duct obstruction due to calculus formation. (Reproduced with permission from Kozarek *et al.*²¹⁵)

80% of patients had significant relief of symptoms (Fig. 33-45). However, due to the tendency for recurrent stone formation, the use of ESWL for long-term management of calcific pancreatitis remains uncertain.

Surgical Therapy

Indications and History The traditional approach to surgical treatment of chronic pancreatitis and its complications has maintained that surgery should be considered only when the medical therapy of symptoms has failed. Nealon and Thompson published a landmark study in 1993, however, that showed that the progression of chronic obstructive pancreatitis could be delayed or prevented by pancreatic duct decompression.²¹⁶ No other therapy has been shown to prevent the progression of chronic pancreatitis, and this study demonstrated the role of surgery in the early management of the disease (Table 33-20). Small-duct disease or “minimal change chronic pancreatitis” are causes for uncertainty over the choice of operation, however. Major resections have a high complication rate, both early and late, in chronic alcoholic pancreatitis, and lesser procedures often result in symptomatic recurrence. So the choice of operation and the timing of surgery are based on each patient’s pancreatic anatomy, the likelihood

Table 33-20

Effect of surgical drainage on progression of chronic pancreatitis

TREATMENT GROUP	24-MONTH EVALUATION
Operated ($n = 47$)	Mild to moderate 48 (87%); severe 6 (13%)
Nonoperated ($n = 36$)	Mild to moderate 8 (22%); severe 28 (78%)

Eighty-three patients with chronic pancreatitis were evaluated by exocrine, endocrine, nutritional, and endoscopic retrograde cholangiopancreatography studies, and all had mild to moderate disease and dilated pancreatic ducts. A Puestow-type duct decompression procedure was performed in 47 patients, and all subjects were restaged by the same methods 24 months later. Source: Reproduced with permission from Nealon *et al.*²¹⁶

(or lack thereof) that further medical and endoscopic therapy will halt the symptoms of the disease, and the chance that a good result will be obtained with the lowest risk of morbidity and mortality. Finally, preparation for surgery should include restoration of protein-caloric homeostasis, abstinence from alcohol and tobacco, and a detailed review of the risks and likely outcomes to establish a bond of trust and commitment between the patient and the surgeon.

Historically, the surgery for chronic pancreatitis before the second half of the twentieth century was a true demonstration of trial and error.²¹⁷ Obtaining good surgical outcomes before the availability of CT scans and ERCP was either the result of serendipity or due to the skill and creativity of the surgeon. In 1911, Link described an operation he devised on the spot, when a laparotomy in a young woman with abdominal pain revealed a fluctuant, obstructed pancreatic duct. After performing a dochootomy and evacuating multiple stones, he inserted a rubber tube, and exteriorized the pancreatostomy just above her navel.²¹⁸ He later described the operation as having been a success for the next 30 years of the patient’s life, during which the patient managed the care of the drainage tube without apparent problems.²¹⁹

With the demonstration in 1942 by Priestley that total pancreatectomy was technically feasible,²²⁰ and the report in 1946 by Whipple that proximal pancreatic resection was beneficial in (three) patients with chronic pancreatitis,²²¹ the option of surgical resection as treatment for chronic pancreatitis was established. By the mid 1950s, however, growing disappointment with the high risk of resection and the lack of long-term benefit overshadowed the surgical treatment of chronic pancreatitis. The choice of resection vs. drainage was largely based on surgeon preference until the 1970s, when the widespread adoption of ERCP and CT scans provided the ability to preoperatively diagnose obstructive and sclerotic disease, and this resulted in the rational selection of operative procedures. During this period, the major drawbacks to surgical therapy remained the recurrence of symptoms despite surgery, the corresponding development of an inflammatory (or malignant) mass in the undrained pancreatic head (Fig. 33-46), or the high morbidity and mortality of major resectional procedures that seemed to predispose the patients to a cascade of metabolic problems.²²²

Sphincteroplasty The sphincter of Oddi and the pancreatic duct sphincter serve as gatekeepers for the passage of pancreatic juice into the duodenum (Fig. 33-47). Stenosis of either sphincter

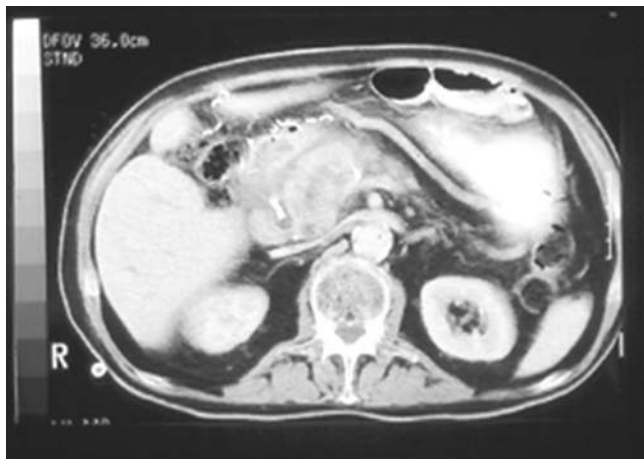


Figure 33-46. Head-of-pancreas mass after Puestow procedure. The computed tomographic appearance of an inflammatory mass occupying the head of the pancreas, which developed 2 years after Puestow decompression of the body and tail of pancreas.

(sclerosing papillitis), due to scarring from pancreatitis or from the passage of gallstones, may result in obstruction of the pancreatic duct and chronic pain.²²³ As gallstone pancreatitis became a popular diagnosis in the 1940s and 1950s, attention was focused on the ampullary region as a possible cause of chronic symptoms, and surgical sphincteroplasty was advocated. Although endoscopic techniques are now used routinely to perform sphincterotomy of either the common bile duct or pancreatic duct, a true (permanent) sphincteroplasty can only be performed surgically. Transduodenal sphincteroplasty with incision of the septum between the pancreatic duct and common bile duct appears to offer significant relief for patients with obstruction and inflammation isolated to this region (Fig. 33-48).

Drainage Procedures After the early reports of success with pancreaticostomy for the relief of symptoms of chronic pancreatitis,²¹⁹ Cattell described pancreaticojejunostomy for relief of pain in

unresectable pancreatic carcinoma.²²⁴ Shortly thereafter, Duval,²²⁵ and separately, Zollinger and associates,²²⁶ described the caudal Roux-en-Y pancreaticojejunostomy for the treatment of chronic pancreatitis in 1954 (Fig. 33-49). The so-called Duval procedure was used for decades by some surgeons, but it almost invariably failed due to restenosis and segmental obstruction of the pancreas due to progressive scarring. In 1958, Puestow and Gillesby described these segmental narrowings and dilatations of the ductal system as a “chain of lakes,” and proposed a longitudinal decompression of the body and tail of the pancreas into a Roux limb of jejunum²²⁷ (Fig. 33-50). Four of Puestow and Gillesby’s 21 initial cases were side-to-side anastomoses, and 2 years after their report, Partington and Rochelle described a much simpler version of the longitudinal, or side-to-side Roux-en-Y pancreaticojejunostomy that became universally known as the Puestow procedure²²⁸ (Fig. 33-51).

The effectiveness of decompression of the pancreatic duct is dependent on the extent to which ductal hypertension is the etiologic agent for the disease. Thus, the diameter of the pancreatic duct is a surrogate for the degree of ductal hypertension, and the Puestow procedure has been shown to be effective for pain relief when the maximum duct diameter is 6 mm. Results are less impressive in glands with smaller caliber ducts, although Izbicki and associates have described good results with a conization method that allows a longitudinal decompression of more normal caliber ducts.²²⁹ Successful pain relief after the Puestow-type decompression procedure has been reported in 75% to 85% of patients for the first few years after surgery, but pain recurs in >20% of patients after 5 years,¹⁴⁸ even in patients who are abstinent from alcohol.

With the advent of therapeutic endoscopy and techniques for transluminal stone removal and lithotripsy, multiple series have reported the successful endoscopic treatment of pancreatic duct calculi, although the long-term outcomes of these efforts has been uneven.^{230–233} Endoscopic removal of pancreatic duct stones is usually coupled to prolonged pancreatic duct stenting, which carries the risk of further inflammation.^{234,235} Despite the risk of perioperative

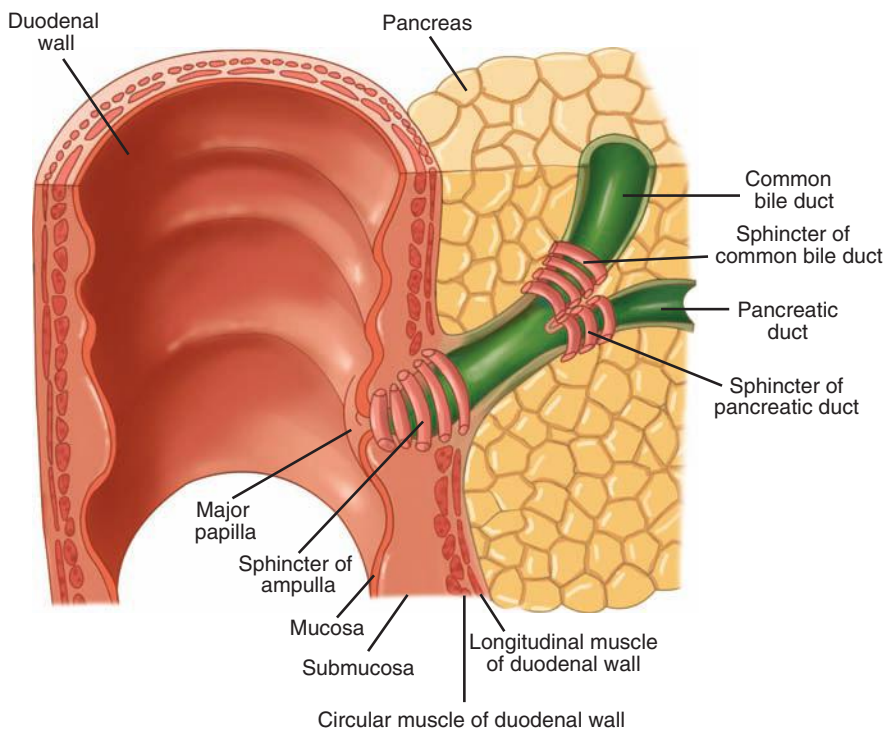


Figure 33-47. Schematic diagram of the ampullary, biliary, and pancreatic duct sphincters. The point of merger of the bile duct and pancreatic duct is highly variable, and a true sphincter of the pancreatic duct may be poorly developed. (Redrawn with permission from Welling TH, Simeone DM: Gallbladder and biliary tract, in Yamada T et al (eds): *Textbook of Gastroenterology*, 5th ed. Oxford: Wiley-Blackwell, 2009, p 1940.)

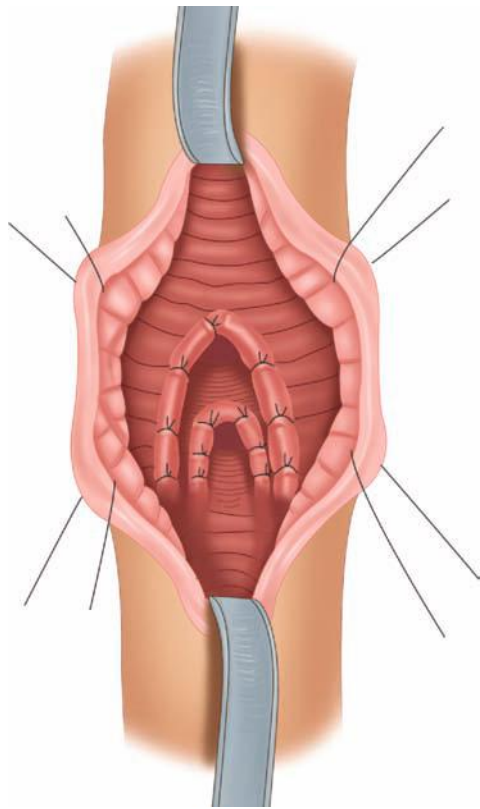


Figure 33-48. Operative sphincteroplasty of the biliary and pancreatic duct. The ampullary and bile duct sphincters are divided, as is the pancreatic duct sphincter, with suture apposition of the mucosal edges of the incision. (Data from Moody *et al.*²²³)

complications, the surgical management of pancreatic duct stones and stenosis has been shown to be superior to endoscopic treatment in randomized clinical trials in which the long, side-to-side technique of pancreaticojejunostomy is used.^{236,237}

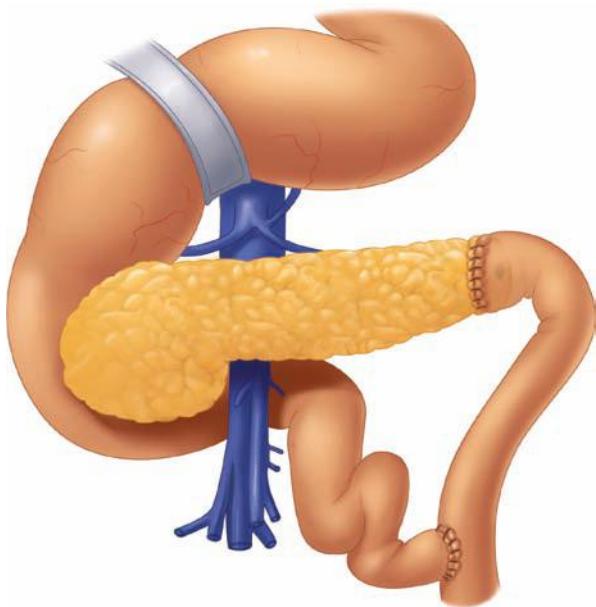


Figure 33-49. Duval's caudal pancreaticojejunostomy. (Reproduced with permission from Greenlee HB: *The role of surgery for chronic pancreatitis and its complications*, in Nyhus LM (ed): *Surg Annu*, Vol 15. Norwalk: Appleton-Century-Crofts, 1983, p 289. Copyright © The McGraw-Hill Companies, Inc.)

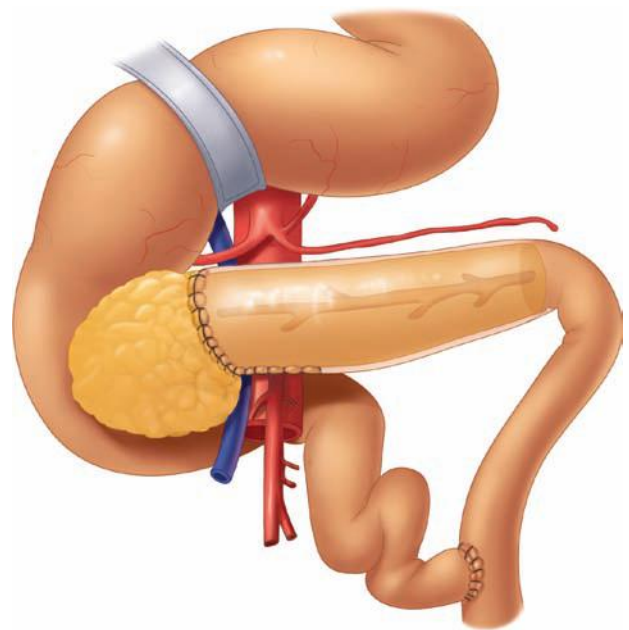


Figure 33-50. Puestow and Gillesby's longitudinal pancreaticojejunostomy. Originally described as an invaginating anastomosis that drained the entire body and tail, the anastomosis was created after amputating the tail of the gland and opening the duct along the long axis of the gland. (Reproduced with permission from Greenlee HB: *The role of surgery for chronic pancreatitis and its complications*, in Nyhus LM (ed): *Surg Annu*, Vol 15. Norwalk: Appleton-Century-Crofts, 1983, p 290. Copyright © The McGraw-Hill Companies, Inc.)

Resectional Procedures

Distal Pancreatectomy For patients with focal inflammatory changes localized to the body and tail, or in whom no significant ductal dilatation exists, the technique of partial (40%–80%) distal pancreatectomy has been advocated (Fig. 33-52). Although distal pancreatectomy is less morbid than more extensive resectional procedures, the operation leaves untreated a major portion of the gland, and is therefore associated with a significant risk of symptomatic recurrence. It has been a more popular operation in British centers, where its success seems to be greater, perhaps due to the lower incidence of alcoholic chronic pancreatitis.²³⁸ However, long-term outcomes reveal good pain relief in only 60% of patients, with completion pancreatectomy required for pain relief in 13% of patients.

Laparoscopic distal pancreatectomy has been shown to be feasible for the removal of focal lesions of the distal pancreas²³⁹ but is more difficult in the setting of chronic pancreatitis.

Ninety-Five Percent Distal Pancreatectomy In 1965, Fry and Child proposed the more radical 95% distal pancreatectomy, which was intended for patients with sclerotic (small duct) disease, and which attempted to avoid the morbidity of total pancreatectomy by preserving the rim of pancreas in the pancreaticoduodenal groove, along with its associated blood vessels and distal common bile duct.²²² The operation was found to be associated with pain relief in 60% to 77% of patients long term, but is accompanied by a high risk of brittle diabetes, hypoglycemic coma, and malnutrition.²⁴⁰ Although the operation was the first attempt to resect the pancreatic head while preserving the duodenum and distal bile duct, the extensive degree of pancreatic removal led to its failure as viable treatment for the symptoms of pancreatic sclerosis.

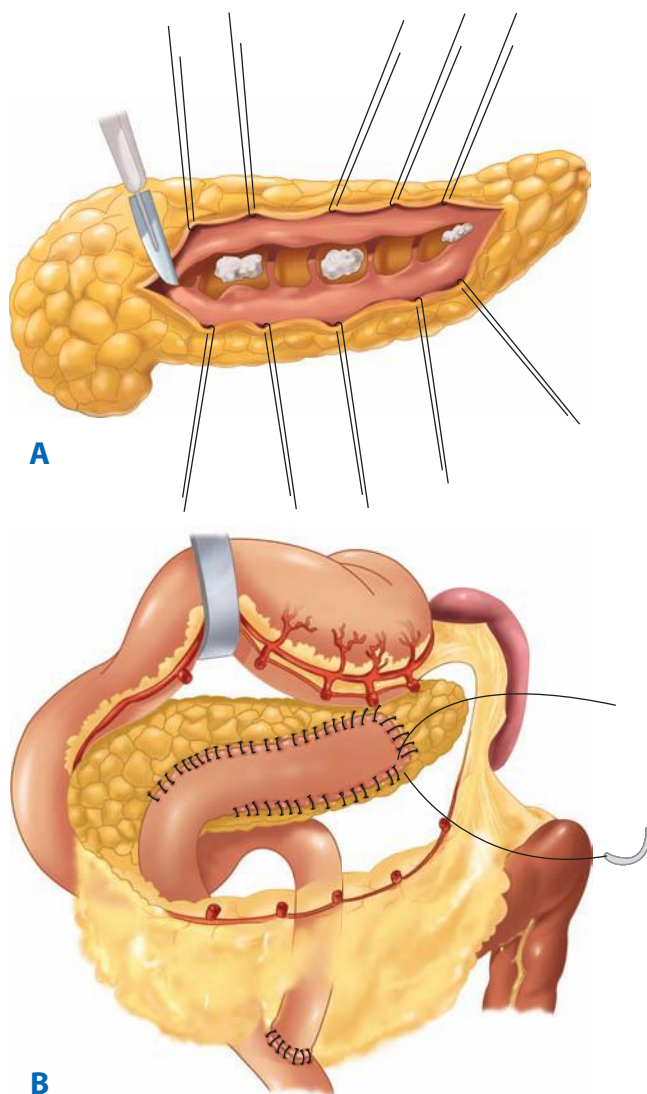


Figure 33-51. Longitudinal doctomy in obstructing calcific pancreatitis. A longitudinal pancreatotomy typically discloses segmental stenosis of the pancreatic duct and the presence of intraductal calculi in a patient with chronic calcific pancreatitis (A). Following mobilization of a Roux limb of jejunum, a longitudinal pancreaticojejunostomy is performed to permit extensive drainage of the pancreatic duct system (B). This technique, described by Partington and Rochelle, is the typical method used for the Puestow procedure. (Data from Partington *et al.*²²⁸)

Proximal Pancreatectomy In 1946, Whipple reported a series of five patients treated with either pancreaticoduodenectomy or total pancreatectomy for symptomatic chronic pancreatitis, with one operative death.²²¹ Subsequently, proximal pancreatectomy or pancreaticoduodenectomy, with or without pylorus preservation (Fig. 33-53), has been widely used for the treatment of chronic pancreatitis.^{217,241} In the three largest modern (circa 2000) series of the treatment of chronic pancreatitis by the Whipple procedure, pain relief 4 to 6 years after operation was found in 71% to 89% of patients. However, mortality ranged from 1.5% to 3%, and major complications occurred in 25% to 38% of patients at the Johns Hopkins Hospital,²⁴² the Mayo Clinic,²⁴³ and the Massachusetts General Hospital.²⁴⁴ In follow-up, 25% to 48% of patients developed diabetes, and about the same percentage required exocrine therapy. Advocates of the

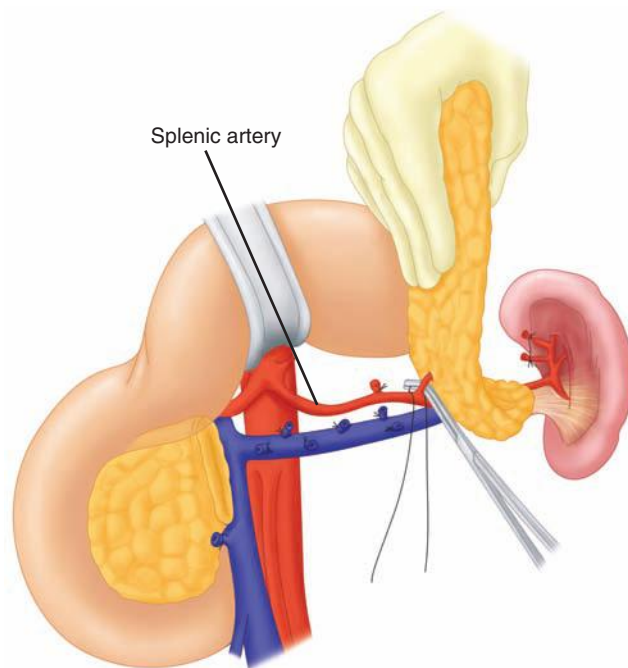


Figure 33-52. Distal (spleen-sparing) pancreatectomy. A distal pancreatectomy for chronic pancreatitis is usually performed with en bloc splenectomy, using either an open or laparoscopic technique. In the presence of minimal inflammation, a spleen-sparing version can be performed, as shown here.

Whipple procedure uniformly suggest that the high rate of symptomatic relief outweighs the metabolic consequences and the mortality risk of the procedure.

Total Pancreatectomy Priestley and associates first described successful total pancreatectomy in 1944 in a patient with hyperinsulinism,²²⁰ and two of Whipple's original five cases of chronic pancreatitis reported in 1946 were treated with total pancreatectomy.²²¹ Subsequently, surgeons who used total pancreatectomy found that the operation produces no better pain relief for their patients than pancreaticoduodenectomy (about 80%–85%). Moreover, the metabolic consequences of total pancreatectomy in the absence of islet cell transplantation are profound and life-threatening. The patients have a “brittle” form of diabetes in which avoidance of hyper- and hypoglycemia is problematic.^{245–247} In addition, lethal episodes of hypoglycemia are common in severe apancreatic diabetes. These are due to hypoglycemic unresponsiveness, due to the absence of pancreatic glucagon, and to hypoglycemia unawareness, despite an ongoing need to treat with exogenous insulin.²⁴⁸ In a series of >100 patients treated with total pancreatectomy, Gall and colleagues showed that half of all the late deaths after this operation were due to (iatrogenic) hypoglycemia.²⁴⁹ Despite newer forms of insulin, insulin delivery systems, and blood glucose monitoring, severe pancreatogenic diabetes remains an adverse outcome, as complete prevention of the physiologic consequences of total pancreatectomy remains an unfulfilled goal. With the growing acceptance of islet auto-transplantation as an adjunct to the procedure (see below), total pancreatectomy itself is now used only rarely for the treatment of refractory chronic pancreatitis.

Hybrid Procedures In 1980, Beger and associates described the Duodenum-preserving Pancreatic Head Resection or DPPHR²⁵⁰

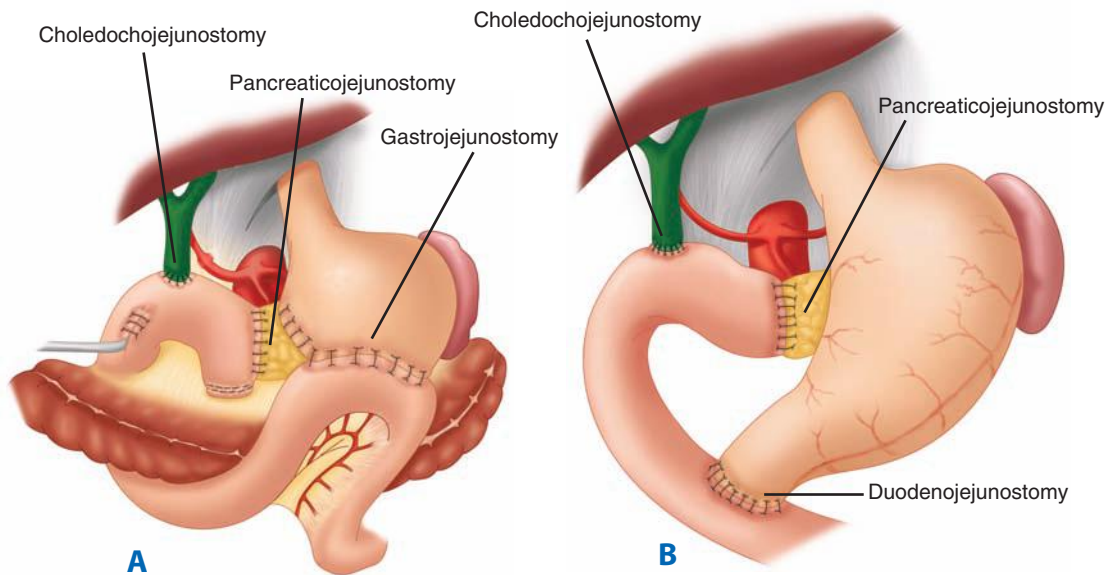


Figure 33-53. The pancreaticoduodenectomy (Whipple procedure) can be performed either with the standard technique, which includes distal gastrectomy (A), or with preservation of the pylorus (B). The pylorus-sparing version of the procedure is used most commonly. (*Reproduced from Gaw JU, Andersen DK: Pancreatic surgery, in Wu GY, Aziz K, Whalen GF (eds): An Internist's Illustrated Guide to Gastrointestinal Surgery. Totowa: Humana Press, 2003, p 229, with permission.*)

(Fig. 33-54), and published long-term results with DPPHR for the treatment of chronic pancreatitis in 1985,²⁵¹ and again in 1999.²⁵² In 388 patients who were followed for an average of 6 years after DPPHR, pain relief was reportedly maintained in 91%, mortality was <1%, and diabetes developed in 21%, with 11% demonstrating a reversal of their preoperative diabetic status. These authors also compared the DPPHR procedure with the pylorus-sparing Whipple procedure in a randomized trial of 40 patients with chronic pancreatitis.²⁵³ The mortality was reportedly zero in both groups, and the morbidity was also comparable. Pain relief (over 6 months) was seen in 94% of DPPHR patients, but in only 67% of Whipple patients. Furthermore, the insulin secretory capacity and glucose tolerance were noted to deteriorate in the Whipple group, but actually improved in the DPPHR patients.

The DPPHR requires the careful dissection of the gastroduodenal artery and the creation of two anastomoses (Fig. 33-55), and carries a similar complication risk as the Whipple procedure due to the risk of pancreatic leakage and intra-abdominal fluid collections.

In 1987, Frey and Smith described the local resection of the pancreatic head with longitudinal pancreaticojejunostomy (LR-LPJ), which included excavation of the pancreatic head, including the ductal structures in continuity with a long dichotomy of the dorsal duct²⁵⁴ (Fig. 33-56). The Frey procedure provides thorough decompression of the pancreatic head as well as the body and tail of the gland, and a long-term follow-up suggested that improved outcomes are associated with this more extensive decompressive procedure. Frey and Amikura reported their results in 50 patients followed for >7 years, and found complete or substantial pain relief in 87% of patients. There was no operative mortality, but 22% of patients developed postoperative complications.²⁵⁵

Key steps in the performance of the LR-LPJ include preservation of the pancreatic neck as well as the capsule of the posterior pancreatic head. In the pancreaticoduodenectomy and the DPPHR, the pancreatic neck is freed up from the portal and

superior mesenteric vein confluence and divided. In the LR-LPJ, the neck of the pancreas is preserved intact as are the body and tail of the pancreas. Not having to divide the pancreatic neck, as in the pancreaticoduodenectomy or DPPHR, reduces the risk of the operation, as it avoids intraoperative problems with the venous structures lying posterior to the gland. To reduce the risk of penetrating the posterior capsule of the head, Frey recommended in his 1994 report that the posterior limit of resection be the back wall of the opened duct of Wirsung and duct to the uncinete (Fig. 33-57).

Subsequent to Frey's own modification of the technique, other surgeons have described modifications of the extent or technique of the LR-LPJ. Andersen and Topazian advocated performing the LR-LPJ as it was originally described, in which the entirety of the ducts are excised from the head (Fig. 33-58), and described the use of the ultrasonic aspirator and dissector for this purpose.²⁵⁶ The use of this device permits precise removal of the ducts and adjacent tissue with good visualization and without complications. There is little pancreatic tissue behind these ducts and the pancreatic capsule is continuously palpated as the dissection proceeds to ensure a safe margin of resection. The intrapancreatic portion of the common bile duct is usually exposed, and avoiding injury to it is enhanced by the ultrasonic aspirator. The majority of the parenchyma of the uncinete process is spared, and the excavation of the pancreatic head is made contiguous with a generous dichotomy of the dorsal duct. Whether merely unroofing as opposed to removal of the proximal ducts contributes to better pain relief is not known and awaits a randomized trial to compare the two versions of the LR-LPJ. Izbicki and colleagues at the University of Hamburg also recommend a more extensive excavation of the pancreatic head, and use a technique that they refer to as the *Hamburg modification* of the LR-LPJ²⁵⁷ (Fig. 33-59). This wider excavation of the pancreatic head is created in continuity with the dorsal dichotomy, and is followed by a single, side-to-side pancreaticojejunostomy.

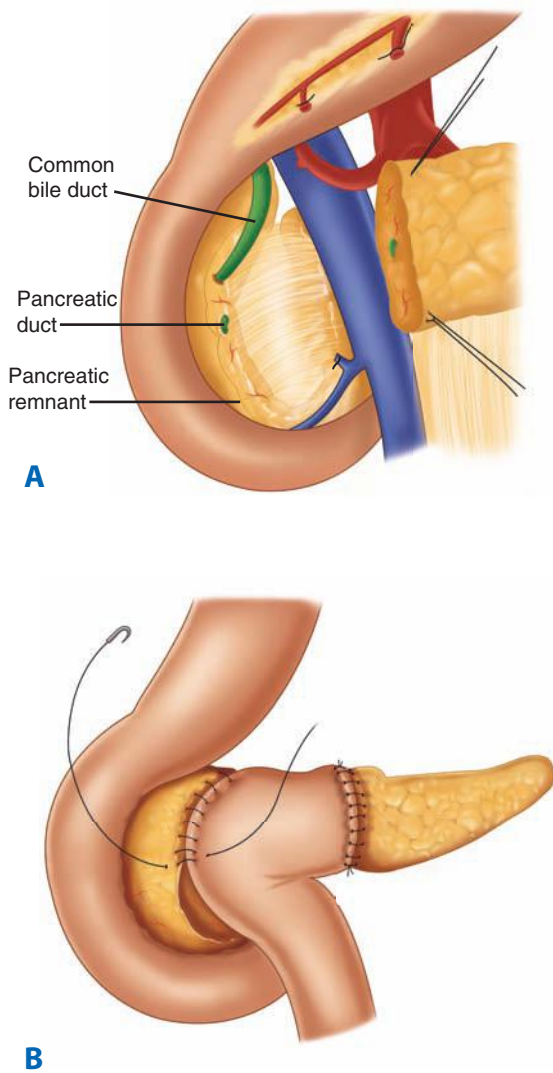


Figure 33-54. The duodenum-preserving pancreatic head resection described by Beger and colleagues. **A.** The completed resection after transection of the pancreatic neck, and subtotal removal of the pancreatic head, with preservation of the distal common bile duct and duodenum. **B.** Completion of the reconstruction with anastomosis to the distal pancreas and to the proximal pancreatic rim by the same Roux limb of jejunum. (Reproduced with permission from Bell.¹⁸⁸)

In 2001, Ho and Frey subsequently described merely excavating the core of the pancreatic head, and draining the excavation with a Roux-en-Y pancreaticojejunostomy, but without any effort to include the dorsal duct^{258,259} (Fig. 33-60). In 2003, Farkas and colleagues described a similar excavation of the central portion of the pancreatic head without any effort to include the duct of the body in the lateral pancreaticojejunostomy,²⁶⁰ and reported excellent results with what they termed an *organ-preserving pancreatic head resection* (OPPHR) in a randomized comparison to the pylorus-preserving pancreaticoduodenectomy (PPPD).²⁶¹

This approach was advocated by Gloor and associates in Bern as an alternative to the DPPHR procedure in patients with portal hypertension,²⁶² and was described as the *Berne modification of the DPPHR* (Fig. 33-61). Königer and colleagues in Heidelberg subsequently published a randomized, controlled trial of the “Berne” version of the excavation method compared

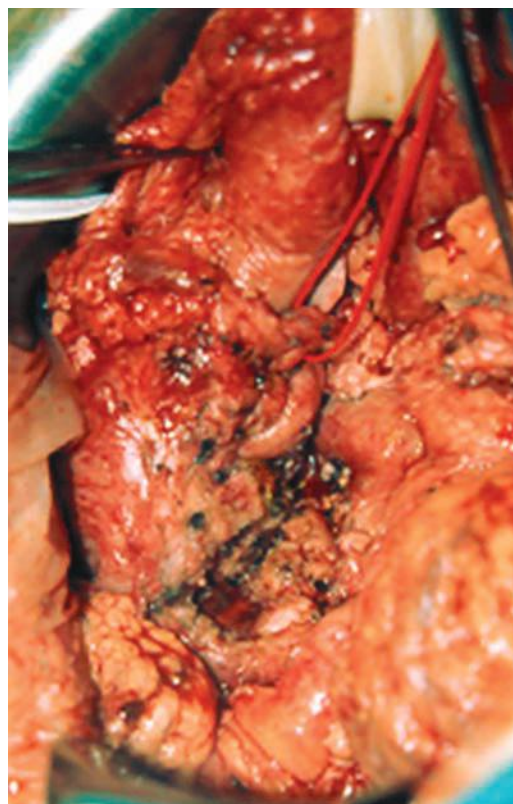


Figure 33-55. Intraoperative view of the Beger procedure. The gastroduodenal artery is encircled by a vessel loop. Just below, the intrapancreatic portion of the common bile duct is exposed as it courses toward the ampulla. A rim of well-vascularized pancreatic tissue remains in the duodenal C-loop. Preservation of the posterior branch of the gastroduodenal artery is essential to preserve viability of these structures.

to the “classic” Beger procedure.²⁶³ Operative times and length of stay were shorter in the group undergoing excavation of the pancreatic head, while long-term outcomes and quality-of-life scores were identical over 2 years postoperatively.

The common element of these variations on the theme of LR-LPJ remains the excavation or “coring out” of the central portion of the pancreatic head. It remains uncertain, however, whether and to what degree the dichotomy needs to be extended **6** into the body and tail. The logical conclusion of all of these efforts is that the head of the pancreas is the nidus of the chronic inflammatory process in chronic pancreatitis, and that removal of the central portion of the head of the gland is the key to the successful resolution of pain long-term.

Complications Initial and long-term results of the LR-LPJ demonstrate pain relief that is equivalent to that of pancreaticoduodenectomy and the DPPHR.^{264,265} The observed mortality rate has been virtually zero, and therefore, less than with the Whipple procedure. Major complications were less with the LR-LPJ (16%) than with pancreaticoduodenectomy (40%) or DPPHR (25%) in one single-site series, and the incidence of new postoperative diabetes after LR-LPJ was 8% with an average follow-up of 3 years.¹⁷⁹

Comparisons of the three operative procedures: Pancreaticoduodenectomy (Whipple procedure), DPPHR (Beger procedure), and LR-LPJ (Frey procedure). There has been considerable interest to apply evidence-based methods to the study of the three operations currently advocated for the treatment of

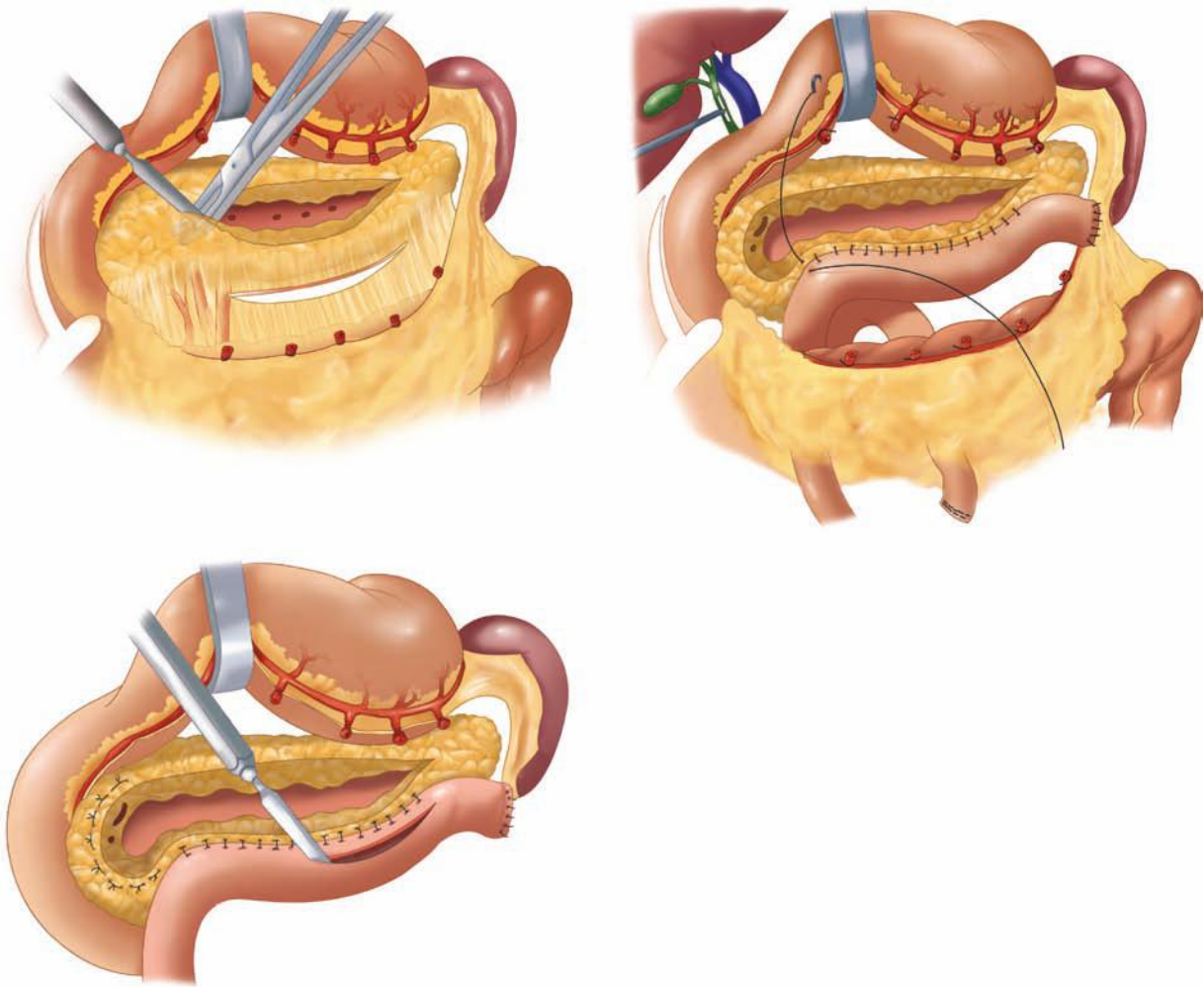


Figure 33-56. Frey procedure. The local resection of the pancreatic head with longitudinal pancreaticojejunostomy (LR-LPJ) provides complete decompression of the entire pancreatic ductal system. Reconstruction is performed with a side-to-side Roux-en-Y pancreaticojejunostomy. (Reproduced with permission from Bell.¹⁸⁸)

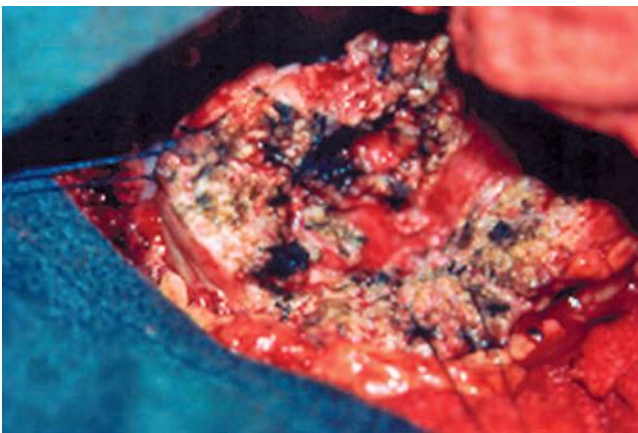


Figure 33-57. Operative view of excavated head of the pancreas during the Frey procedure. The main pancreatic duct is opened widely down to the level of the ampulla, and the head of the pancreas is excavated in a conical fashion so as to allow complete decompression of the chronically obstructed and inflamed pancreatic ducts. (Reproduced with permission from Aspelund G et al: Improved outcomes for benign disease with limited pancreatic head resection. *J Gastrointest Surg.* 9:400, 2005. With kind permission from Springer Science + Business Media.)

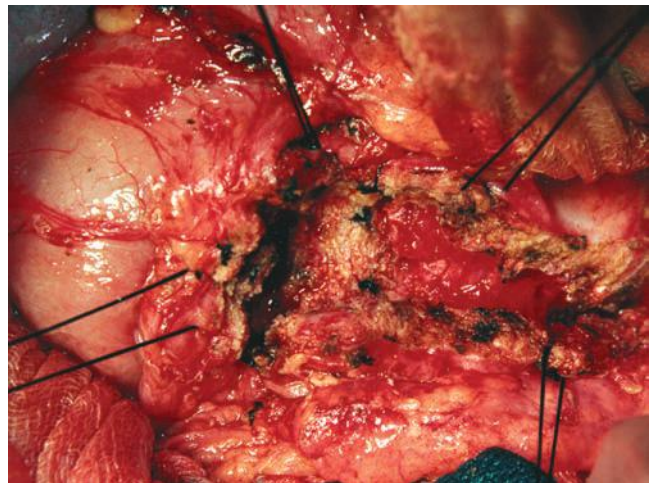


Figure 33-58. Complete excavation of the pancreatic head and distal pancreaticochotomy. A true excavation and removal of the proximal ductal system is combined with a distal pancreaticochotomy. Reconstruction is performed with a single side-to-side Roux-en-Y pancreaticojejunostomy. (Reproduced with permission from Andersen DK, Topazian MD: Pancreatic head excavation: A variation on the theme of duodenum-preserving pancreatic head resection. *Arch Surg.* 139:375, 2004. Copyright © 2004 American Medical Association. All rights reserved.)

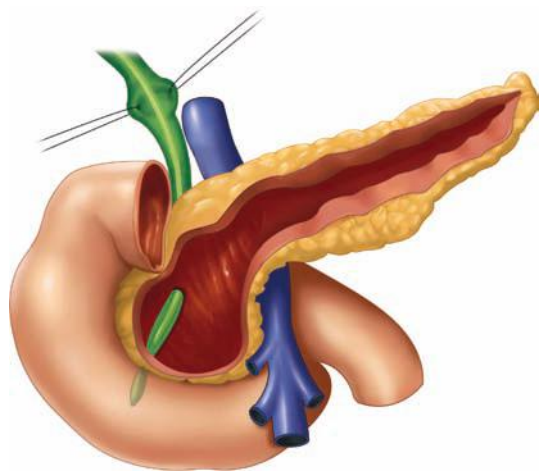


Figure 33-59. The Hamburg modification of the local resection of the pancreatic head with longitudinal pancreaticojejunostomy. (Reproduced with permission from Izbicki JR, Yekebas EF, Mann O: *Chronic pancreatitis*, in Yeo CJ et al (eds): Shackelford's Surgery of the Alimentary Tract. New York: Saunders, 2007, p 1310. Copyright Elsevier.)

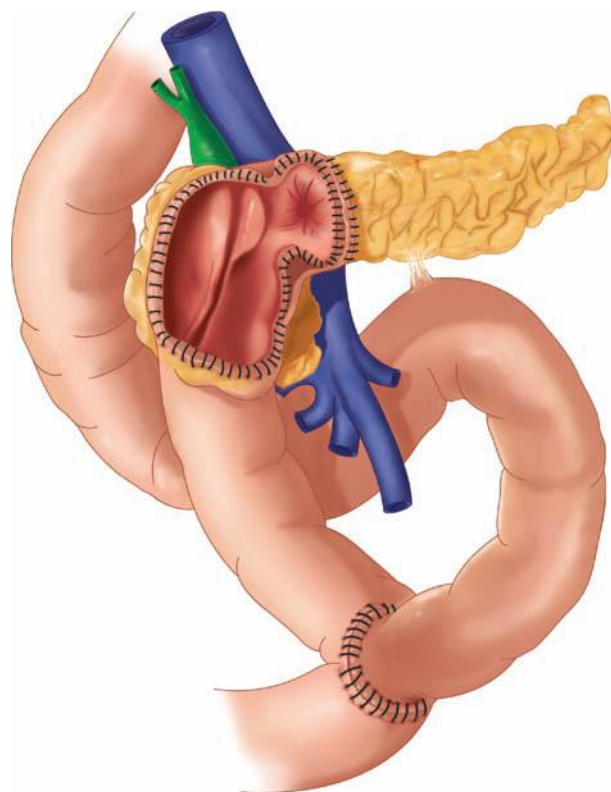


Figure 33-61. The Berne modification of the local resection of the pancreatic head with longitudinal pancreaticojejunostomy. (From Gloor B, Friess H, Uhl W, et al: *A modified technique of the Beger and Frey procedure in patients with chronic pancreatitis*. *Dig Surg*. 18:21, 2001. Copyright © 2001, Karger Publishers.)

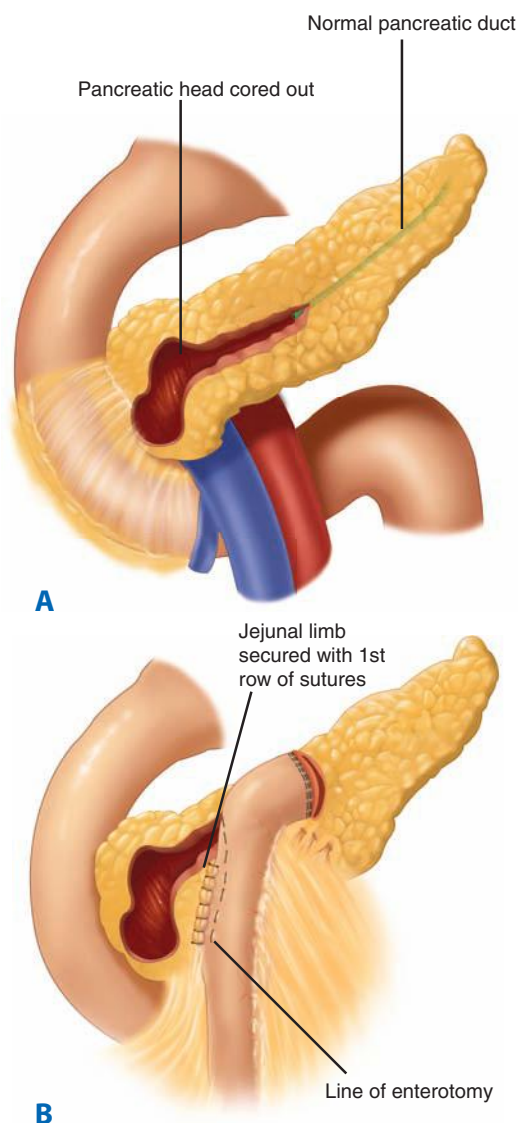


Figure 33-60. Excavation of pancreatic head without longitudinal pancreaticojejunostomy. (Data from Ho HS, Frey CF.²⁵⁹)

chronic pancreatitis. The best studies, or level 1 data by the Strength of Recommendation Taxonomy, are prospective, randomized controlled trials comparing two or more operations from a single or multi-institutional study. Retrospective, cohort-based studies are regarded as level 2 data by the Strength of Recommendation Taxonomy criteria.

To date, six published level 1 studies and three level 2 studies have examined various comparisons between these three operations. In the level 1 study of 43 patients by Klempa and colleagues,²⁶⁶ DPPHR patients had a shorter hospital stay, greater weight gain, less postoperative diabetes, and exocrine dysfunction than standard Whipple patients over a 3- to 5-year follow-up. Pain control was similar between the two procedures. This was confirmed in a level 1 study of 40 patients by Buchler and associates,²⁶⁷ in which DPPHR patients reported better pain relief, glucose tolerance, and weight gain compared to pylorus-preserving pancreaticoduodenectomy (PPPD) patients; however, the follow-up averaged <1 year. Similar results were observed in a recent level 2 retrospective study of 123 patients.²⁶⁸

In a level 1 study of 61 patients randomized to PPPD or LR-LPJ, Izbicki and colleagues found a lower postoperative complication rate associated with the Frey procedure (19%) compared to the PPPD group (53%), and better global quality-of-life scores (71% vs. 43%, respectively).²⁶⁴ Both operations were equally effective in controlling pain over a 2-year follow-up. More recently, the level 1 study by Farkas and associates²⁶¹ examined 40 patients randomized to PPPD or the method of excavation of the pancreatic head that their group described as an *organ-preserving pancreatic head resection* (OPPHR), and found that OPPHR was associated with a shorter operating time,

less postoperative morbidity, shorter hospital stay, and better quality of life than PPPD. The degree of pain relief was equal over a 1- to 3-year follow-up. Operation times have been shown to be shorter with the LR-LPJ and DPPHR compared to the PPPD, and intraoperative blood loss and perioperative transfusion requirements are less with LR-LPJ and DPPHR procedures.

Late Morbidity and Mortality In 2005, Izbicki's group reported on a level 1 study of 74 patients randomized to the DPPHR or LR-LPJ who were then followed for an average of 8.5 years.²⁶⁹ There were no significant differences between the groups with regard to global quality of life, pain scores, late mortality, and exocrine or endocrine insufficiency. The level 1 study by Königer, which compared the classic DPPHR with excavation of the pancreatic head, showed identical outcomes at 2 years after an initial reduction in morbidity associated with the excavation procedure.²⁶³ These results were echoed in the level 2 study by Aspelund and associates, which demonstrated fewer complications with both the DPPHR and LR-LPJ procedures compared to pancreaticoduodenectomy, a lower incidence of new diabetes (8%) for both DPPHR and LR-LPJ compared to the Whipple procedure (25%), but no significant differences in outcomes or pain relief between DPPHR and LR-LPJ.¹⁷⁹ Finally, level 2 data support the efficacy of both DPPHR and LR-LPJ in patients with dilated as well as nondilated ducts.²⁷⁰⁻²⁷²

Long-term exocrine and/or endocrine insufficiency in chronic pancreatitis patients treated surgically is a product of the surgical intervention as well as the progression of the underlying disease. Although the short-term (3-year) incidence of new diabetes after operation appears less with the LR-LPJ and DPPHR than with the PPPD, the late incidence of diabetes appears similar in all groups. After an average of 7 years of follow-up after LR-LPJ or PPPD, survival, pain relief, and pancreatic function were similar in both groups. The rate of diabetes was slightly lower after LR-LPJ (61%) than after PPPD (65%), but these had both more than doubled from their preoperative status.²⁶⁰⁻²⁶⁶ Therefore, although the limited pancreatic procedures of DPPHR and LR-LPJ have a lower initial rate of endocrine dysfunction, the long-term risk of diabetes is more related to the progression of the underlying disease than to the effects of operation.

The decreased incidence of postoperative diabetes in the near-term after the duodenum-sparing operations may be the result of a preserved β -cell mass in the more conservative resections, and may also be due to the conservation of the PP-secreting cells localized to the posterior head and uncinat process. Preservation of near-normal glucose metabolism and the avoidance of pancreatogenic diabetes is therefore a significant but time-limited benefit of the newer operative procedures.

Total Pancreatectomy with Islet Auto-Transplantation Islet cell transplantation for the treatment of diabetes is an attractive adjunct to pancreatic surgery in the treatment of benign pancreatic disease, but problems due to rejection of allotransplanted islets have plagued this method since its initial clinical application in the early 1970s. However, despite the difficulties in recovering islets from a chronically inflamed gland, Najarian and associates demonstrated the utility of autotransplantation of islets in patients with chronic pancreatitis in 1980.²⁷³ Subsequently, through refinements in the methods of harvesting and gland preservation, and through standardization of the methods by which islets are infused into the portal venous circuit for intrahepatic engraftment, the success of total pancreatectomy combined with islet auto-transplantation has steadily increased

to achieve insulin independence in the majority of patients treated in recent series.^{274,275} Although 2 to 3 million islets are required for successful engraftment in an allogeneic recipient, the auto-transplant recipient can usually achieve long-term, insulin-independent status after engraftment of only 300,000 to 400,000 islets.²⁷⁶

The ability to recover a sufficient quantity of islets from a sclerotic gland is dependent on the degree of fibrotic disease present, so the selection of patients as candidates for autologous islet transplantation is important. The impressive improvement in quality of life measures and pain relief seen after total pancreatectomy with islet auto-transplantation (TP-IAT) indicate that it is a highly successful form of therapy for some patients. The significant morbidity risk of TP-IAT, and the likelihood of unsuccessful recovery of sufficient numbers of islets due to advanced disease, however, suggest that further definition is needed regarding criteria for considering TP-IAT vs. hybrid or resectional procedures for patients with persistent symptoms. The recent study which compared degree of fibrosis with the extent of pain relief after the LR-LPJ procedure suggests that the extent of pancreatic fibrosis may be a useful guide to the selection of surgical therapy for refractory symptomatic chronic pancreatitis.¹⁴⁷ Further studies will require accurate methods to quantify the extent of fibrosis preoperatively.

PANCREATIC NEOPLASMS

Neoplasms of the Endocrine Pancreas

Neoplasms of the endocrine pancreas are relatively uncommon but do occur with enough frequency (five cases per million population) that most surgeons will encounter them in an urban practice. The cells of the endocrine pancreas, or islet cells, originate from neural crest cells, also referred to as *amine precursor uptake and decarboxylation cells*. Multiple endocrine neoplasia (MEN) syndromes occur when these cells cause tumors in multiple sites. The MEN1 syndrome involves pituitary tumors, parathyroid hyperplasia, and pancreatic neoplasms. Some pancreatic endocrine neoplasms are functional, secreting peptide products that produce interesting clinical presentations. Neoplasms of the endocrine pancreas that are not associated with excess hormone levels and a recognizable clinical syndrome are considered nonfunctional. Special immunohistochemical stains allow pathologists to confirm the peptide products being produced within the cells of a pancreatic endocrine tumor. However, the histologic characteristics of these neoplasms do not predict their clinical behavior, and malignancy is usually determined by the presence of local invasion and lymph node or hepatic metastases. Unfortunately, most pancreatic endocrine tumors are malignant, but the course of the disease is far more favorable than that seen with pancreatic exocrine cancer. The key to diagnosing these rare tumors is recognition of the classic clinical syndrome; confirmation is achieved by measuring serum levels of the elevated hormone. Localization of the tumor can be a challenging step, but once accomplished, the surgery is relatively straightforward. The goals of surgery range from complete resection, often accomplished with insulinomas, to controlling symptoms with debulking procedures. Unresectable disease in the liver is often addressed with chemoembolization.

As with pancreatic exocrine tumors, the initial diagnostic imaging test of choice for pancreatic endocrine tumors is a multidetector CT scan with four phases of contrast and fine cuts through the pancreas and liver. Neuroendocrine tumors of the

pancreas often enhance with contrast. EUS also can be valuable in localizing these tumors, which can produce dramatic symptoms despite their small (<1 cm) size. In contrast to pancreatic exocrine tumors, many of the endocrine tumors have somatostatin receptors (SSTRs) that allow them to be detected by a radio-labeled octreotide scan. A radioactive somatostatin analogue is injected intravenously, followed by whole-body radionuclide scanning (Fig. 33-62). The success of this modality in localizing tumors and detecting metastases has decreased the use of older techniques such as angiography and selective venous sampling.

Insulinoma

Insulinomas are the most common functional pancreatic endocrine neoplasms and present with a typical clinical syndrome known as Whipple's triad. The triad consists of symptomatic fasting hypoglycemia, a documented serum glucose level <50 mg/dL, and relief of symptoms with the administration of glucose. Patients can present with a profound syncopal episode or less severe symptoms that are averted by frequent eating. Common symptoms include palpitations, trembling, diaphoresis, confusion or obtundation, and seizure, and family members may report that the patient has undergone a personality change.

Routine laboratory studies will uncover a low blood sugar, the cause of all of these symptoms. Serum insulin levels are elevated. C-peptide levels should also be elevated and rule out the unusual case of surreptitious administration of insulin or oral hypoglycemic agents, because excess endogenous

insulin production leads to excess C-peptide. The diagnosis can be clinched with a monitored fast in which blood is sampled every 4 to 6 hours for glucose and insulin levels until the patient becomes symptomatic. However, this can be dangerous and must be done with close supervision.

Insulinomas are usually localized with CT scanning and EUS. Technical advances in EUS have led to preoperative identification of >90% of insulinomas.²⁷⁷ Visceral angiography with venous sampling is rarely required to accurately localize the tumor. Insulinomas are evenly distributed throughout the head, body, and tail of the pancreas.²⁷⁸

Unlike most endocrine pancreatic tumors, the majority (90%) of insulinomas are benign and solitary, and only 10% are malignant. They are typically cured by simple enucleation. However, tumors located close to the main pancreatic duct and large (>2 cm) tumors may require a distal pancreatectomy or pancreaticoduodenectomy. Intraoperative US is useful to determine the tumor's relation to the main pancreatic duct and guides intraoperative decision making. Enucleation of solitary insulinomas and distal pancreatectomy for insulinoma can sometimes be performed using a minimally invasive technique.

Approximately 90% of insulinomas are sporadic, and 10% are associated with the MEN1 syndrome. Insulinomas associated with the MEN1 syndrome are more likely to be multifocal and have a higher rate of recurrence.

Noninsulinoma Hyperinsulinemia Hypoglycemia Syndrome

A syndrome of noninsulinoma pancreatogenous hypoglycemia was described by Service et al. in 1999.²⁷⁹ The syndrome is associated with beta-cell hypertrophy, islet hyperplasia and increased beta-cell mass. When these findings are accompanied by ectopic islet tissue, multilobulated islets, and ductulo-insular complexes, the definition of nesideoblastosis is met. Nesideoblastosis accompanied by hyperinsulinism was previously considered a disease of neonates, where subtotal or total pancreatectomy was required to correct potentially fatal neonatal hyperinsulinism. However, dozens of cases of nesideoblastosis associated with hyperinsulinism have now been reported in patients 2 to 5 years after Roux-en-Y gastric bypass.²⁸⁰ Many of these patients have undergone partial or total pancreatectomy to prevent potentially fatal hypoglycemia. The illness in former bariatric surgery patients appears to result from an idiosyncratically-prolonged hypersecretion of the incretin hormones GIP and GLP-1 after the gastric bypass. GLP-1 is a potent stimulant of the expression of the transcription factor PDX-1, which normally regulates beta-cell development and growth. Conversion of the gastric bypass to a form of bariatric procedure which restores normal intestinal flow of nutrients, such as the gastric sleeve, or the addition of a restriction element such as an adjustable gastric band, appears to prevent episodes of hypoglycemia in these patients. Pancreatic resection without conversion of the Roux-en-Y gastric bypass allows the abnormal entero-insular relationship to continue, and hyperinsulinemia persists or recurs after partial pancreatectomy.

Gastrinoma

Zollinger-Ellison syndrome (ZES) is caused by a *gastrinoma*, an endocrine tumor that secretes gastrin, leading to acid hypersecretion and peptic ulceration. Many patients with ZES present with abdominal pain, peptic ulcer disease, and severe esophagitis. However, in the era of effective antacid therapy, the presentation can be less dramatic. Although most of the ulcers

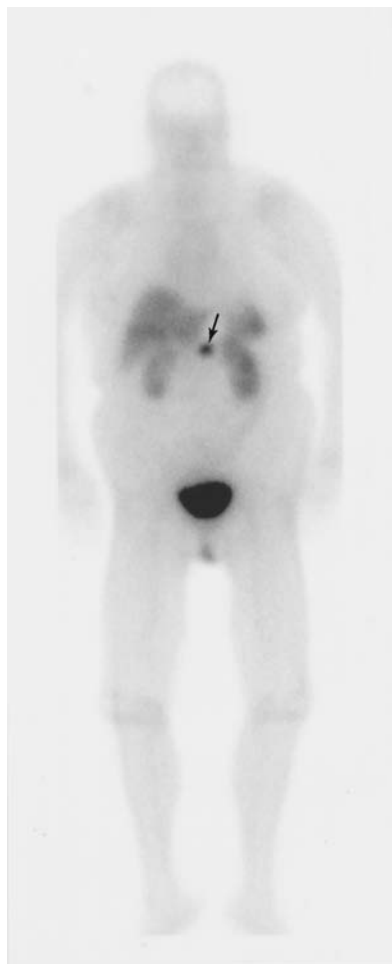


Figure 33-62. Radioactive octreotide scan demonstrating pancreatic endocrine tumor in the body of the pancreas (arrow).

are solitary, multiple ulcers in atypical locations that fail to respond to antacids should raise suspicion for ZES and prompt a work-up. At the time of diagnosis, 21% of patients with gastrinoma have diarrhea.

The diagnosis of ZES is made by measuring the serum gastrin level. It is important that patients stop taking proton pump inhibitors for this test. In most patients with gastrinomas, the level is >1000 pg/mL. Gastrin levels can be elevated under conditions other than ZES. Common causes of hypergastrinemia include pernicious anemia, treatment with proton pump inhibitors, renal failure, G-cell hyperplasia, atrophic gastritis, retained or excluded antrum, and gastric outlet obstruction. In equivocal cases, when the gastrin level is not markedly elevated, a secretin stimulation test is helpful.

In 70% to 90% of patients, the primary gastrinoma is found in Passaro's triangle, an area defined by a triangle with points located at the junction of the cystic duct and common bile duct, the second and third portion of the duodenum, and the neck and body of the pancreas (Fig. 33-63). However, because gastrinomas can be found almost anywhere, whole-body imaging is required. The test of choice is SSTR (octreotide) scintigraphy in combination with CT. The octreotide scan is more sensitive than CT, locating about 85% of gastrinomas and detecting tumors <1 cm. With the octreotide scan, the need for tedious and technically demanding selective angiography and measurement of gastrin gradients has declined. EUS is another modality that assists in the preoperative localization of gastrinomas. It is particularly helpful in localizing tumors in the pancreatic head or duodenal wall, where gastrinomas are usually <1 cm in size. A combination of octreotide scan and EUS detects $>90\%$ of gastrinomas.

It is important to rule out MEN1 syndrome by checking serum calcium levels before surgery because resection of the gastrinoma(s) in these patients rarely results in normalization of serum gastrin concentrations or a prolongation of survival. Only one fourth of gastrinomas occur in association with the MEN1 syndrome. One half of patients with gastrinomas will have solitary tumors while the remainder will have multiple gastrinomas. Multiple tumors are more common in patients with

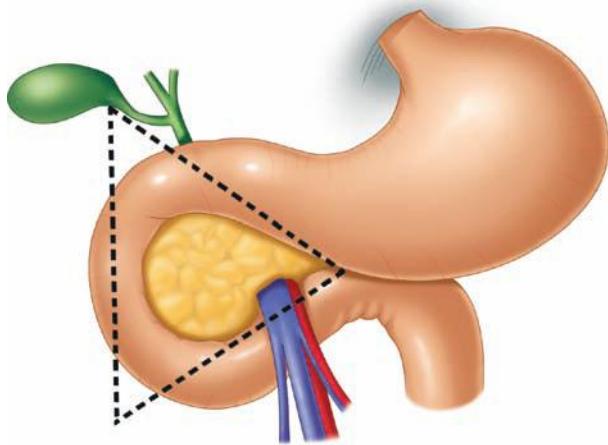


Figure 33-63. Passaro's triangle. The typical location of a gastrinoma is described by this anatomic region, including the head of the pancreas, duodenum, and the lymphatic bed posterior and superior to the duodenum, as originally described by E. Passaro. (Reproduced with permission from Stable BE, Morrow DJ, Passaro E: *The gastrinoma triangle: operative implications*. Am J Surg. 1984;147:25. Copyright Elsevier.)

MEN1 syndrome. Aggressive surgical treatment is justified in patients with sporadic gastrinomas. If patients have MEN1 syndrome, the parathyroid hyperplasia is addressed with total parathyroidectomy and implantation of parathyroid tissue in the forearm.

Approximately 50% of gastrinomas metastasize to lymph nodes or the liver, and are therefore considered malignant. Patients who meet criteria for operability should undergo exploration for possible removal of the tumor. Although the tumors are submucosal, a full-thickness excision of the duodenal wall is performed if a duodenal gastrinoma is found. All lymph nodes in Passaro's triangle are excised for pathologic analysis. If the gastrinoma is found in the pancreas and does not involve the main pancreatic duct, it is enucleated. Pancreatic resection is justified for solitary gastrinomas with no metastases. A highly selective vagotomy can be performed if unresectable disease is identified or if the gastrinoma cannot be localized. This may reduce the amount of expensive proton pump inhibitors required. In cases in which hepatic metastases are identified, resection is justified if the primary gastrinoma is controlled and the metastases can be safely and completely removed. Debulking or incomplete removal of multiple hepatic metastases is probably not helpful, especially in the setting of MEN1. The application of new modalities such as radiofrequency ablation seems reasonable, but data to support this approach are limited.²⁸¹ Postoperatively, patients are followed with fasting serum gastrin levels, secretin stimulation tests, octreotide scans, and CT scans. In patients found to have inoperable disease, chemotherapy with streptozocin, doxorubicin, and 5-fluorouracil (5-FU) is used. Other approaches such as somatostatin analogues, interferon, and chemoembolization also have been used in gastrinoma with some success.

Unfortunately, a biochemical cure is achieved in only about one-third of the patients operated on for ZES. Despite the lack of success, long-term survival rates are good, even in patients with liver metastases. The 15-year survival rate for patients without liver metastases is about 80%, while the 5-year survival rate for patients with liver metastases is 20% to 50%. Pancreatic tumors are usually larger than tumors arising in the duodenum, and more often have lymph node metastases. In gastrinomas, liver metastases decrease survival rates, but lymph node metastases do not. The best results are seen after complete excision of small sporadic tumors originating in the duodenum. Large tumors associated with liver metastases, located outside of Passaro's triangle, have the worst prognosis.

Vasoactive Intestinal Peptide-Secreting Tumor

In 1958, Verner and Morrison first described the syndrome associated with a pancreatic neoplasm secreting VIP. The classic clinical syndrome associated with this pancreatic endocrine neoplasm consists of severe intermittent watery diarrhea leading to dehydration, and weakness from fluid and electrolyte losses. Large amounts of potassium are lost in the stool. The *vasoactive intestinal peptide-secreting tumor (VIPoma) syndrome* is also called the *WDHA syndrome* due to the presence of watery diarrhea, hypokalemia, and achlorhydria. The massive (5 L/d) and episodic nature of the diarrhea associated with the appropriate electrolyte abnormalities should raise suspicion of the diagnosis. Serum VIP levels must be measured on multiple occasions because the excess secretion of VIP is episodic and single measurements might be normal and misleading. ACT scan localizes most VIPomas, although as with all islet cell tumors, EUS is the most sensitive imaging method. Electrolyte and fluid balance

is sometimes difficult to correct preoperatively and must be pursued aggressively. Somatostatin analogues are helpful in controlling the diarrhea and allowing replacement of fluid and electrolytes. VIPomas are more commonly located in the distal pancreas and most have spread outside the pancreas. Palliative debulking operations can sometimes improve symptoms for a period, along with somatostatin analogues. Hepatic artery embolization also has been reported as a potentially beneficial treatment.²⁸²

Glucagonoma

Diabetes in association with dermatitis should raise the suspicion of a glucagonoma. The diabetes usually is mild. The classic necrolytic migratory erythema manifests as cyclic migrations of lesions with spreading margins and healing centers typically on the lower abdomen, perineum, perioral area, and feet. Patients also complain of an enlarged, sensitive tongue. The diagnosis is confirmed by measuring serum glucagon levels, which are usually >500 pg/mL. Glucagon is a catabolic hormone, and most patients present with malnutrition. The rash associated with glucagonoma is thought to be caused by low levels of amino acids. Preoperative treatment usually includes control of the diabetes, parenteral nutrition, and octreotide. Like VIPomas, glucagonomas are more often in the body and tail of the pancreas and tend to be large tumors with metastases. Again, debulking operations are recommended in good operative candidates to relieve symptoms.

Somatostatinoma

Because somatostatin inhibits pancreatic and biliary secretions, patients with a somatostatinoma present with gallstones due to bile stasis, diabetes due to inhibition of insulin secretion, and steatorrhea due to inhibition of pancreatic exocrine secretion and bile secretion. Most somatostatinomas originate in the proximal pancreas or the pancreatoduodenal groove, with the ampulla and periampullary area as the most common site (60%). The most common presentations are abdominal pain (25%), jaundice (25%), and cholelithiasis (19%).²⁸³ This rare type of pancreatic endocrine tumor is diagnosed by confirming elevated serum somatostatin levels, which are usually >10 ng/mL. Although most reported cases of somatostatinoma involve metastatic disease, an attempt at complete excision of the tumor and cholecystectomy is warranted in fit patients.

Nonfunctioning Pancreatic Endocrine Tumors

Although some pancreatic endocrine neoplasms secrete one or more hormones and are associated with interesting characteristic clinical syndromes, most are not associated with elevated serum hormone levels that cause symptoms. Pancreatic endocrine tumors are considered functional if they are associated with a clinical syndrome and nonfunctioning if not associated with clinical symptoms. The majority of pancreatic endocrine tumors (PET), also called pancreatic neuroendocrine tumors (PNET), are malignant because they have the potential for uncontrolled growth and metastasis. Immunohistochemical markers such as synaptophysin, chromogranin A (CgA), and neuron-specific enolase can be helpful in the diagnosis but the gross histology is not a reliable predictor of biologic behavior. CgA is used by some as a serum marker to monitor patients for disease recurrence or response to treatment but the test performs poorly for this purpose. Patients often present similar to patients with pancreatic adenocarcinoma with vague pain, or weight loss but PNETs are increasingly discovered incidentally when imaging is performed for another reason. The tumor frequently

enhances with arterial contrast.(Fig. 33-64) Sometimes a cystic component is seen due to central necrosis. Octreoscan (somatostatin receptor scintigraphy) can be helpful to stage the disease. Surgical resection is always recommended in fit patients in the absence of metastatic disease. Adjuvant treatment after resection is withheld in the absence of radiographically demonstrable metastatic disease even if CgA levels remain elevated. Although these tumors have a slow growth pattern compared to pancreatic ductal adenocarcinoma, many patients with PNETs will die of their disease even after an apparent complete resection. Incomplete resection (debulking) for locally advanced or metastatic PNETs of the pancreas is controversial because of the favorable survival duration of patients without surgery. However, in carefully selected fit patients with a PNET in the head of the pancreas and minimal disease in the liver, a pancreaticoduodenectomy with wedge resection of the liver metastasis might be appropriate because this avoids the morbidity of gastrointestinal hemorrhage, biliary and gastric outlet obstruction before death from the metastatic disease. Recently molecular analysis has shown that PNETs have activation of mammalian target of rapamycin (mTOR) and the VEGF pathway. Antitumor activity has been demonstrated in recent clinical trials with Everolimus, an mTOR inhibitor in combination with temozolomide and sunitinib.^{284,285} In addition, some centers are combining resection with transarterial chemoembolization (TACE) of metastatic disease in the liver.

Neoplasms of the Exocrine Pancreas

Epidemiology and Risk Factors. It is estimated that in 2012, 43,920 Americans were diagnosed with pancreatic cancer and 37,390 died from the disease. Worldwide, over 265,000 people contract this disease annually, of which 74% of patients die within the first year after diagnosis.^{286,287} Overall, pancreatic cancer has the worst prognosis of all malignancies with a 5-year survival rate of only 6%.²⁸⁸ The incidence of pancreatic cancer continues to increase, perhaps related to the increased incidence of risk factors such as obesity and diabetes,²⁸⁹ and as a result, it is predicted that pancreatic cancer will become the leading cause of cancer deaths in the United States by 2050.²⁸⁷ Despite its ubiquity, this disease is extremely difficult to treat, and its exact cause is unknown. However, epidemiologic studies linking various environmental and host factors provide some clues. Recent discoveries using modern molecular biologic techniques have also improved our understanding of the causes of pancreatic cancer. The etiology of pancreatic cancer likely involves a complex interaction of genetic and environmental factors. These factors will become more fully understood as better diagnostic tools such as DNA sequencing become clinically available to screen populations at risk for developing pancreatic cancer.

Pancreatic cancer is more common in the elderly with most patients being >60 years old. Pancreatic cancer is more common in African Americans and slightly more common in men than women. The risk of developing pancreatic cancer is two to three times higher if a parent or sibling had the disease. Another risk factor that is consistently linked to pancreatic cancer is cigarette smoking. Smoking increases the risk of developing pancreatic cancer by at least twofold due to the carcinogens in cigarette smoke.²⁹⁰ Coffee and alcohol consumption have been investigated as possible risk factors, but the data are inconsistent. As in other GI cancers, diets high in fat and low in fiber, fruits, and vegetables are thought to be associated with an increased risk of pancreatic cancer.

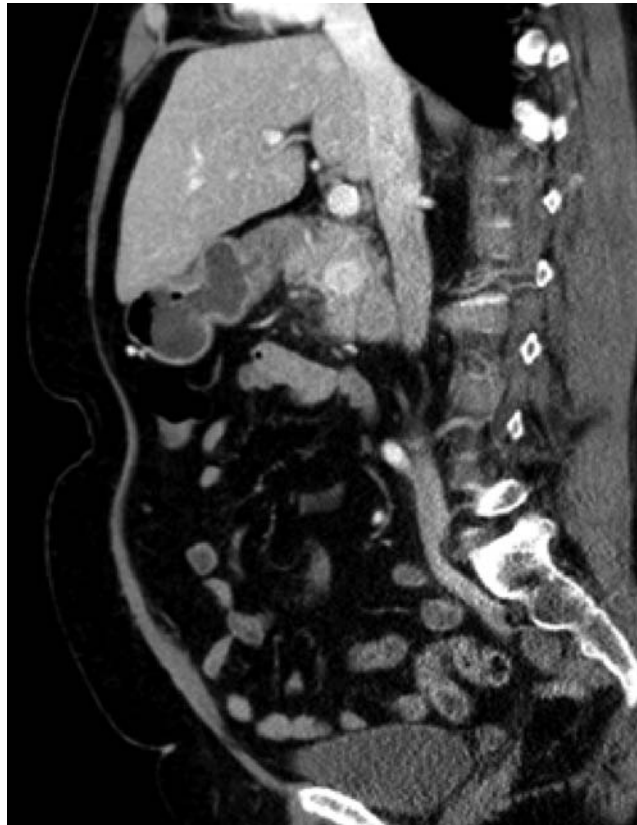
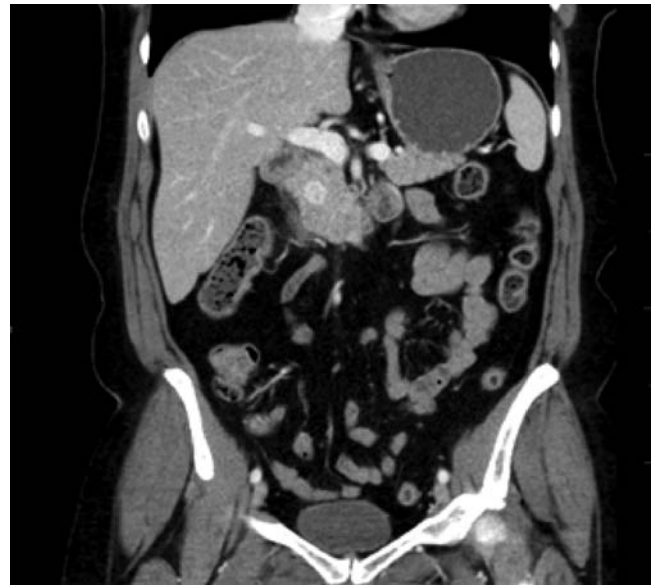
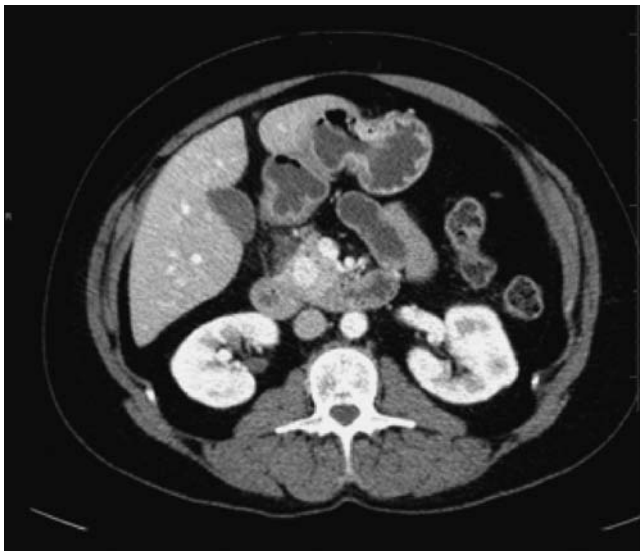
Figure 33-64. Pancreatic neuroendocrine tumor (PNET) demonstrating enhancement during arterial phase of CT scan. Pancreatic head PNET seen in (*left*) sagittal, (*middle*) coronal, and (*right*) lateral views of the abdomen.

Diabetes has been known to be associated with pancreatic cancer for many years. In fact, glucose intolerance is present in 80% of patients with pancreatic cancer, and approximately 50% have overt diabetes, a much greater incidence than would be expected to occur by chance. Pre-existing type 2 diabetes increases the risk for development of pancreatic cancer by about twofold.²⁹¹ The new onset of diabetes also can be an early manifestation of otherwise occult pancreatic cancer. Thus, the new onset of diabetes, or a sudden increase in insulin requirement in an elderly patient with pre-existing diabetes, should provoke concern for the presence of pancreatic cancer.

Recent epidemiologic studies have confirmed the fact that patients with chronic pancreatitis, especially familial pancreatitis, have an increased risk of developing pancreatic cancer.^{111,177,178} Large, retrospective cohort studies of patients with pancreatitis have revealed up to a 20-fold increase in risk for pancreatic cancer. This increased risk seems to be independent of the type of pancreatitis, a finding consistent with the fact that most studies have shown little effect of alcohol ingestion per se on the risk of pancreatic carcinoma. The mechanisms involved in carcinogenesis in patients with pre-existing pancreatitis are unknown. However, the mutated *K-ras* oncogene, which is present in most

cases of pancreatic cancer, has been detected in the ductal epithelium of some patients with chronic pancreatitis.

Genetics of Pancreatic Cancer. Pancreatic carcinogenesis probably involves multiple mutations that are inherited and acquired throughout aging. The *K-ras* oncogene is currently thought to be the most commonly mutated gene in pancreatic cancer, with approximately 90% of tumors having a mutation.²⁹³ This prevalent mutation is present in precursor lesions and is therefore thought to occur early and be essential to pancreatic cancer development. *K-ras* mutations can be detected in DNA from serum, stool, pancreatic juice, and tissue aspirates of patients with pancreatic cancer, suggesting that the presence of this mutation may provide the basis for diagnostic testing in select individuals. The *HER-2/neu* oncogene, homologous to the epidermal growth factor receptor (EGFr), is overexpressed in pancreatic cancers.²⁹² This receptor is involved in signal transduction pathways that lead to cellular proliferation. Multiple tumor-suppressor genes are deleted and/or mutated in pancreatic cancer, including *p53*, *p16*, and *DPC4* (*Smad 4*), and in a minority of cases, *BRCA2*.²⁹³ Most pancreatic cancers have three or more of the above mutations.

With the completion of the human genome project, comparison of the normal genome and the results of DNA sequencing of pancreatic and other cancers is an active area of research. The genetic landscape of pancreatic adenocarcinoma has recently been investigated using exome capture technology combined with the SOLiD or Illumina next generation sequencing platforms and copy number analysis. Detailed analysis of 99 tumors reaffirmed the importance of the already known mutations such as *KRAS*, *TP53*, *CDKN2A*, *SMAD4*, *MLL3*, *TGFBR2*, *ARID1A*, and *SF3B1* in pancreatic cancer and identified 8 novel significantly mutated genes involved in chromatin modification (*EPC1* and *ARID2*), DNA damage repair (*ATM*) and other mechanisms (*ZIM2*, *MAP2K4*, *NALCN*, *SLC16A4*, and *MAGEA6*). Pathway-based analysis of recurrently altered genes also revealed the involvement of axon-guidance genes, particularly *SLIT/ROBO* signaling, in pancreatic carcinogenesis.²⁹⁴ Rapid and sensitive sequencing techniques will hopefully lead to better diagnostic and therapeutic approaches for pancreatic cancer. It is estimated that up to 10% of pancreatic cancers occur as a result of an inherited genetic predisposition. A family history of pancreatic cancer in a first-degree relative increases the risk of pancreatic cancer by about twofold.²⁹³ Rare familial cancer syndromes that are associated with an increased risk of pancreatic cancer include *BRCA2*, the familial atypical multiple mole–melanoma syndrome, hereditary pancreatitis, familial adenomatous polyposis (FAP), hereditary nonpolyposis colorectal cancer, Peutz-Jeghers syndrome, and ataxia-telangiectasia.²⁹³

In addition to mutations in oncogenes and tumor-suppressor genes, pancreatic cancers also are known to have aberrations in the expression of growth factors and their receptors. These growth factors include epidermal growth factor, fibroblast growth factor, transforming growth factor beta, insulin-like growth factor, hepatocyte growth factor, and vascular endothelial growth factor.²⁹²

The fact that many GI hormones and growth factors affect the growth of the normal exocrine pancreas suggests that these peptides also could affect the growth of pancreatic cancer, and some studies in cell culture and laboratory animals have supported this hypothesis.²⁹⁵ Newer drugs such as erlotinib (Tarceva) and cetuximab (Erbix), EGFr inhibitors, and bevacizumab (Avastin), a vascular endothelial growth factor inhibitor, and other drugs aimed at manipulation of growth

factors, their receptors, and secondary messengers are the subject of ongoing clinical research. However, the combination of these drugs with standard chemotherapy in recent trials has not resulted in dramatic improvements in overall survival in pancreatic cancer.

Pathology. Pancreatic cancer probably arises through a stepwise progression of cellular changes, just as colon cancer progresses by stages from hyperplastic polyp to invasive cancer. Systematic histologic evaluation of areas surrounding pancreatic cancers has revealed the presence of precursor lesions that have been named *pancreatic intraepithelial neoplasia* (Fig. 33-65). Three stages of pancreatic intraepithelial neoplasia have been defined. These lesions demonstrate the same oncogene mutations and loss of tumor-suppressor genes found in invasive cancers, the frequency of these abnormalities increasing with progressive cellular atypia and architectural disarray.²⁹⁶ The ability to detect these precursor lesions in humans at a stage where the cancer can still be prevented or cured is an important goal of current pancreatic cancer research.

▶ About two-thirds of pancreatic adenocarcinomas arise within the head or uncinate process of the pancreas; 15% are in the body, and 10% in the tail, with the remaining tumors demonstrating diffuse involvement of the gland. Tumors in the pancreatic body and tail are generally larger at the time of diagnosis, and therefore, less commonly resectable. Tumors in the head of the pancreas are typically diagnosed earlier because they cause obstructive jaundice. Ampullary carcinomas, carcinomas of the distal bile duct, and periampullary duodenal adenocarcinomas present in a similar fashion to pancreatic head cancer but have a slightly better prognosis, probably because early obstruction of the bile duct and jaundice leads to the diagnosis.

In addition to ductal adenocarcinoma, which makes up about 75% of nonendocrine cancers of the pancreas, there are a variety of less common types of pancreatic cancer. Adenosquamous carcinoma is a variant that has both glandular and squamous differentiation. The biologic behavior of this lesion is unfortunately no better than the typical ductal adenocarcinoma.²⁹⁷ Acinar cell carcinoma is an uncommon type of pancreatic cancer that usually presents as a large tumor, often 10 cm in diameter or more, but the prognosis of patients with these tumors may be better than with ductal cancer.

Diagnosis and Staging. Exact pathologic staging of pancreatic cancer is important because it allows accurate quantitative assessment of results and comparisons between institutions. The tumor-node-metastasis (TNM) staging of pancreatic cancer is shown in Table 33-21.

T1 lesions are ≤ 2 cm in diameter and are limited to the pancreas. T2 lesions also are limited to the pancreas, but are > 2 cm. T3 lesions extend beyond the pancreas but do not involve the celiac axis or superior mesenteric artery. T4 lesions involve the celiac axis or superior mesenteric artery and are not resectable. T1 and T2 tumors with no lymph node involvement are considered stage I disease (stage IA and IB). More extensive invasion, such as that associated with T3 tumors, indicates stage IIA disease. Any lymph node involvement indicates stage IIB disease. Locally advanced unresectable tumors (T4) without metastatic disease are considered stage III while patients with metastases to distant sites such as the liver or lungs are stage IV.

Eight percent of pancreas cancer cases are diagnosed while the cancer is still confined to the primary site (localized stage); 27% are diagnosed after the cancer has spread to regional lymph

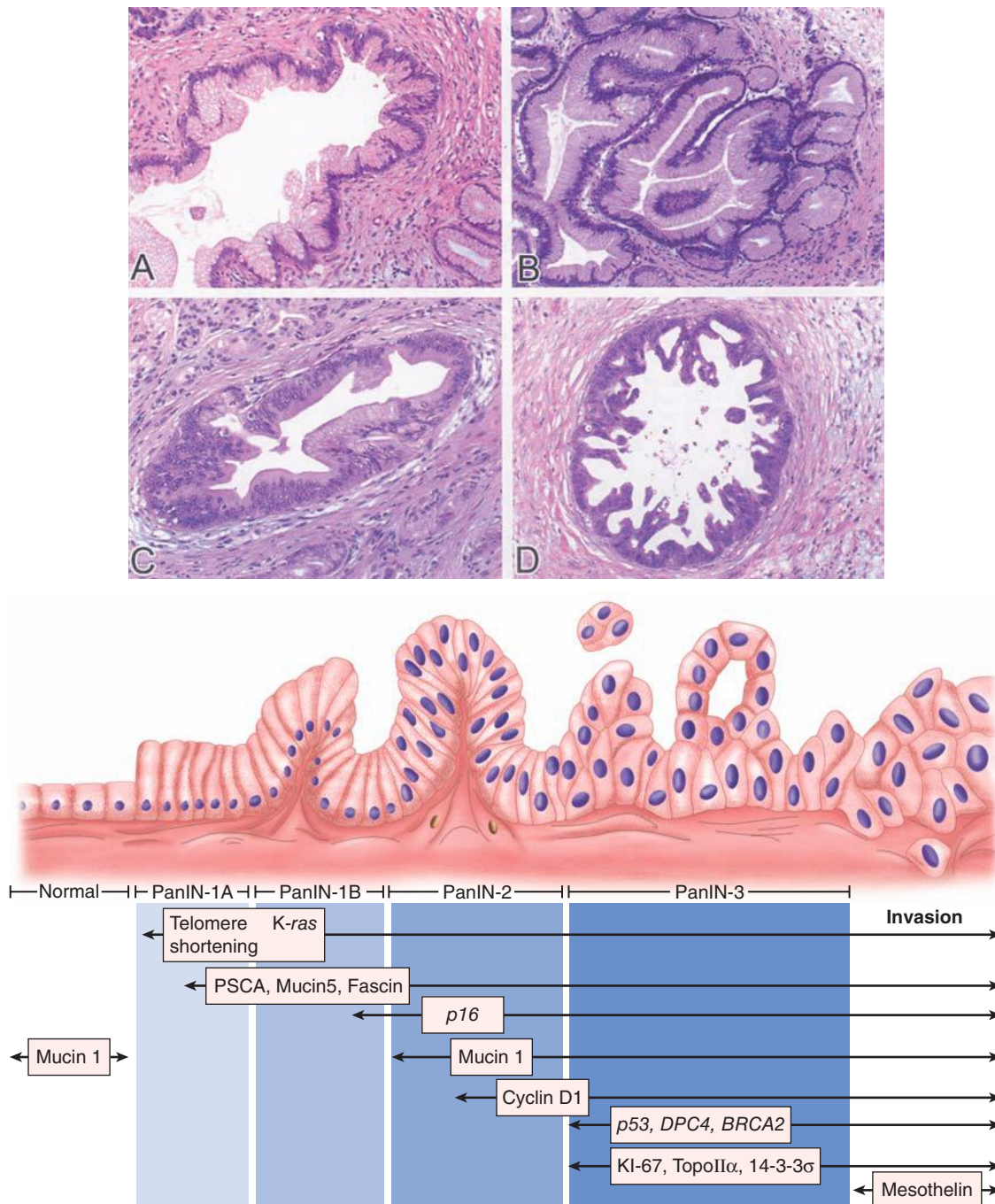


Figure 33-65. Pancreatic intraepithelial neoplasia (PanIN). Histology (*top panel*) showing grades PanIN-1A (A), PanIN-1B (B), PanIN-2 (C), and PanIN-3 (D), and schema of correlation of histology with mutational events (*bottom panel*) showing cumulative abnormalities of tumor-promoter and tumor suppressor factors such as kRAS, p53, etc., and their corresponding cellular phenotype. (From Hruban RH, Takaori K, Klimstra DS, et al: *An illustrated consensus on the classification of pancreatic intraepithelial neoplasia and intraductal papillary mucinous neoplasms*. *Am J Surg Pathol*. 28:977, 2004.)

nodes or directly beyond the primary site; 53% are diagnosed after the cancer has already metastasized (distant stage); and for the remaining 12%, the staging information was unknown. The corresponding 5-year relative survival rates were: 23.3% for localized, 8.9% for regional, 1.8% for distant, and 3.9% for unstaged. The overall 5-year relative survival rate for patients with pancreatic cancer for 2002 to 2008 from 18 Surveillance, Epidemiology and End Results (SEER) geographic areas was 5.8%.²⁹⁸

The most critical deficit in the ability to treat pancreatic cancer effectively is the lack of tools for early diagnosis. The pancreas is situated deep within the abdomen, and the early

symptoms of pancreatic cancer often are too vague to raise suspicion of the disease. Ultimately, the majority of patients present with pain and jaundice. On physical examination, weight loss is evident and the skin is icteric; a distended gallbladder is palpable in about one-fourth of patients. More fortunate patients have tumors situated such that biliary obstruction and jaundice occurs early and prompts diagnostic tests. Unfortunately, however, the vast majority of patients are not diagnosed until weight loss has occurred—a sign of advanced disease.

Although it is often taught that carcinoma of the pancreas presents with painless jaundice (to help distinguish it

Table 33-21

Staging of pancreatic cancer

Tumor (T)

TX: Primary tumor cannot be assessed

T0: No evidence of primary tumor

Tis: Carcinoma in situ

T1: Tumor is limited to the pancreas and is ≤ 2 cm in greatest dimensionT2: Tumor is limited to the pancreas and is > 2 cm in greatest dimension

T3: Tumor extends beyond the pancreas but without involvement of the celiac axis or the superior mesenteric artery

T4: Tumor involves the celiac axis or the superior mesenteric artery (unresectable primary tumor)

Regional lymph nodes (N)

NX: Regional lymph nodes cannot be assessed

N0: No regional lymph node metastasis

N1: Regional lymph node metastasis

Distant metastasis (M)

MX: Distant metastasis cannot be assessed

M0: No distant metastasis

M1: Distant metastasis

Stage	T	N	M	Description
IA	1	0	0	Limited to pancreas ≤ 2 cm
IB	2	0	0	Limited to pancreas > 2 cm
IIA	3	0	0	Extends beyond pancreas but does not involve arteries
IIB	1-3	1	0	Any tumor without artery involvement with lymph node involvement
III	4	Any	0	Tumor involves arteries (unresectable)
IV	Any	Any	1	Any tumor with distant metastases

Used with the permission of the American Joint Committee on Cancer (AJCC), Chicago, Illinois. The original source for this material is the *AJCC Cancer Staging Manual*, Seventh Edition (2010) published by Springer Science and Business Media LLC, www.springer.com.

from choledocholithiasis), this aphorism is not accurate. Most patients do experience pain as part of the symptom complex of pancreatic cancer, and it is often the first symptom. Therefore, awareness of the way pancreatic pain is perceived may help clinicians suspect pancreatic cancer. The pain associated with pancreatic cancer is usually perceived in the epigastrium but can occur in any part of the abdomen, and often, but not always, penetrates to the back. When questioned in retrospect, patients often recall mild and vague pain for many months before diagnosis. A low threshold for ordering a CT scan with “pancreatic protocol” should be maintained for elderly patients with unexplained, persistent, although vague, abdominal pain. As mentioned above, new-onset diabetes in an elderly patient, especially if combined with vague abdominal pain, should prompt a search for pancreatic cancer.

Unfortunately, at this time there is no sensitive and specific serum marker to assist in the timely diagnosis of pancreatic cancer. With jaundice, direct hyperbilirubinemia and elevated alkaline phosphatase are expected but do not serve much of a diagnostic role other than to confirm the obvious. With long-standing biliary obstruction, the prothrombin time will be prolonged due to a depletion of vitamin K, a fat-soluble vitamin dependent on bile flow for absorption. CA19-9 is a mucin-associated carbohydrate antigen that can be detected in the serum of patients with pancreatic cancer. Serum levels are elevated in about 75% of patients with pancreatic cancer. However, CA19-9 is also elevated in about 10% of patients with benign diseases of the pancreas, liver, and bile ducts.²⁹⁹ CA19-9 is thus neither sufficiently sensitive nor specific to allow an early diagnosis of pancreatic cancer. Despite the fact that many tumor markers such as CA19-9 have been

studied, there are still no effective screening tests for pancreatic cancer. Research taking advantage of recent advances in genomics, gene expression analysis, and proteomics has demonstrated thousands of genes and corresponding proteins that are differentially expressed in pancreatic tumors that have potential for early detection of pancreatic cancer.³⁰⁰ Some of these proteins would be expected to be expressed at the cell surface or in pancreatic juice and may become useful as biomarkers for pancreatic cancer in the future.

In patients presenting with jaundice, a reasonable first diagnostic imaging study is abdominal ultrasound. If bile duct dilation is not seen, hepatocellular disease is likely. Demonstration of cholelithiasis and bile duct dilation suggests a diagnosis of choledocholithiasis, and the next logical step would be ERCP to clear the bile duct. In the absence of gallstones, malignant obstruction of the bile duct is likely, and a CT scan rather than ERCP would be the next logical step. For patients suspected of having pancreatic cancer who present without jaundice, a CT scan should be the first test.

The current diagnostic and staging test of choice for pancreatic cancer is a multidetector, dynamic, contrast-enhanced CT scan, and the techniques for obtaining high-quality images are constantly improving (Fig. 33-66). The accuracy of CT scanning for predicting unresectable disease is about 90% to 95%.³⁰¹ In contrast, CT scanning is less accurate in predicting resectable disease. CT scanning will miss small liver metastases, and predicting arterial involvement is sometimes difficult. CT findings that indicate a tumor is unresectable include involvement of ≥ 180 degrees of the celiac axis, hepatic or superior mesenteric artery, enlarged lymph nodes outside the boundaries of resection,

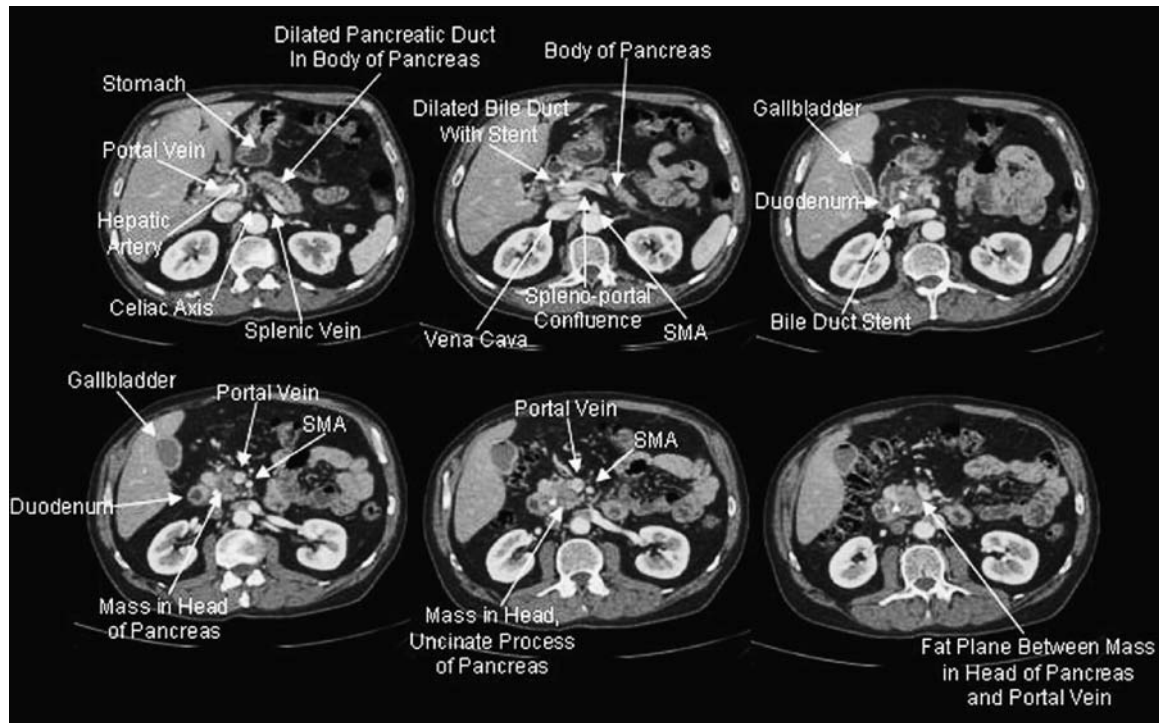


Figure 33-66. Computed tomography scan demonstrating resectable pancreatic cancer. SMA = superior mesenteric artery.

ascites, and distant metastases (e.g., liver). Invasion of the superior mesenteric vein or portal vein is not in itself a contraindication to resection as long as the veins are patent. Tumors are considered “borderline resectable” if there is abutment of ≤ 180 degrees of the circumference of the SMA, celiac axis, or hepatic artery or if there is a short segment of vein occlusion. Also, patients with CT findings suspicious for metastatic disease, like 1 mm liver lesions too small to characterize or biopsy, are considered “borderline resectable” as are patients with multiple comorbidities or marginal performance status. There is growing consensus that neoadjuvant treatment should be considered in all patients with any radiographic evidence of extension to adjacent vascular structures.

Currently, CT is probably the single most versatile and cost-effective tool for the diagnosis and staging of pancreatic cancer. Abdominal MRI is rapidly evolving but currently provides essentially the same information as CT scanning. Positron emission tomography scanning is becoming more widely available and may help distinguish chronic pancreatitis from pancreatic cancer. EUS can be used to detect small pancreatic masses that could be missed by CT scanning and is commonly used when there is a high suspicion for pancreatic cancer but no mass is identified by the CT scan. EUS has the added advantage of providing the opportunity for transluminal biopsy of pancreatic masses, although a tissue diagnosis before pancreaticoduodenectomy is not required. However, in specific patients a histologic diagnosis may be necessary such as for those in a neoadjuvant clinical trial or before chemotherapy in advanced tumors. EUS is a sensitive test for portal/superior mesenteric vein invasion, although it is somewhat less effective at detecting superior mesenteric artery invasion. When all of the current staging modalities are used, their accuracy in predicting resectability is reported to be about 80%, meaning that one in five patients brought to the operating room with the intent of a curative resection will be found at the time of surgery to have unresectable disease.³⁰²

In an attempt to avoid such futile laparotomies, preliminary laparoscopy has been advocated for patients with disease felt to be resectable by CT imaging (Fig. 33-67). Diagnostic laparoscopy with the use of US is reported to improve the accuracy of predicting resectability to about 98%.³⁰² The technique involves more than simple visualization with the scope and requires the placement of multiple ports and manipulation of the tissues. A general exploration of the peritoneal surfaces is carried out. The ligament of Treitz and the base of the transverse mesocolon are examined for tumor. The gastrocolic ligament is incised, and the lesser sac is examined. The US probe is used to examine the liver, porta hepatis, and the portal vein and superior mesenteric artery.

The percentage of patients in whom a positive laparoscopy helps avoid a nontherapeutic laparotomy varies from 10% to 30% in carcinoma of the head of the pancreas but may be as high as 50% in patients with tumors in the body and tail of the gland. As the quality of CT scanning has improved, the value

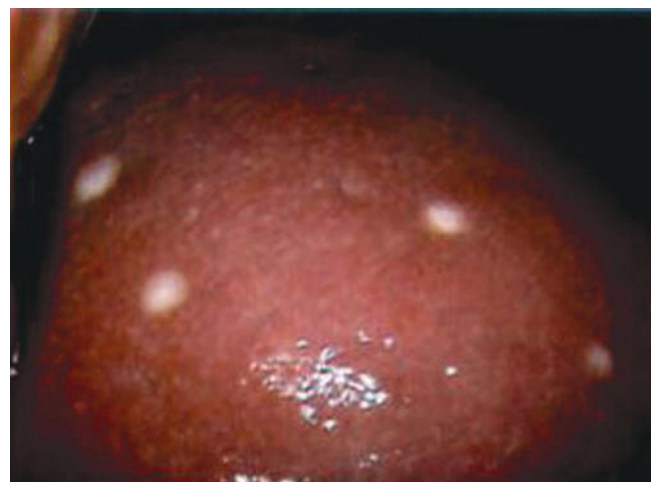

Figure 33-67. Liver metastases identified at diagnostic laparoscopy.

of routine diagnostic laparoscopy has decreased. However, the morbidity of diagnostic laparoscopy is less than that of laparotomy, and the procedure can be performed on an outpatient basis. Patients who are found to have unresectable disease recover more rapidly from a laparoscopy than a laparotomy and can receive palliative chemotherapy and radiation sooner. The potential immunosuppressive effects of a major surgical procedure also are avoided, as well as the negative psychologic impact of a major painful operation with little benefit.

Biliary obstruction can be relieved with an endoscopic approach in almost all cases. When large (10F) plastic stents are used, most patients do not require replacement for about 3 months. Metallic wall stents last about 5 months on average and usually fail only with tumor ingrowth.³⁰³ Keeping in mind that patients with unresectable pancreatic cancer usually live <1 year, the requirement for numerous stent changes is unlikely.

Diagnostic laparoscopy is possibly best applied to patients with pancreatic cancer on a selective basis. Diagnostic laparoscopy will have a higher yield in patients with large tumors (>4 cm), tumors located in the body or tail, patients with equivocal findings of metastasis or ascites on CT scan, and patients with other indications of advanced disease such as marked weight loss or markedly elevated CA19-9 (>1000 U/mL). An algorithm for the diagnosis, staging, and treatment of pancreatic cancer is shown in Fig. 33-68.

Palliative Surgery and Endoscopy. For the 85% to 90% of patients with pancreatic cancer who have disease that precludes surgical resection, appropriate and effective palliative treatment is critical to the quality of their remaining life. Because of the poor prognosis of the disease, it is not appropriate to use invasive and toxic regimens in patients with extremely advanced disease and poor performance status. When patients do desire antineoplastic therapy, it is important to encourage them to enroll in clinical trials so that therapeutic advances can be

made. In general, there are three clinical problems in advanced pancreatic cancer that require palliation: pain, jaundice, and duodenal obstruction. The mainstay of pain control is oral narcotics. Sustained-release preparations of morphine sulfate are frequently used. Invasion of retroperitoneal nerve trunks accounts for the severe pain experienced by patients with advanced pancreatic cancer. A celiac plexus nerve block can control pain effectively for a period of months, although the procedure sometimes needs to be repeated.³⁰⁴

Jaundice is present in the majority of patients with pancreatic cancer, and the most troublesome aspect for the patient is the accompanying pruritus. Biliary obstruction may also lead to cholangitis, coagulopathy, digestive symptoms, and hepatocellular failure. In the past, surgeons traditionally performed a biliary bypass when unresectable disease was found at laparotomy. As many patients today already have a bile duct stent in place by the time of operation, it is not clear that operative biliary bypass is required. If an operative bypass is performed, choledochojejunostomy is the preferred approach. Although an easy procedure to perform, choledochooduodenostomy is felt to be unwise because of the proximity of the duodenum to tumor. Some have discouraged the use of the gallbladder for biliary bypass³⁰⁵; however, it is suitable as long as the cystic duct clearly enters the common duct well above the tumor.

Duodenal obstruction is usually a late event in pancreatic cancer and occurs in only about 20% of patients.³⁰⁵ Therefore, in the absence of signs or symptoms of obstruction, such as a tumor that is already encroaching on the duodenum at the time of surgery, the routine use of prophylactic gastrojejunostomy when exploration reveals unresectable tumor is controversial. Although anastomotic leaks are uncommon, gastrojejunostomy is sometimes associated with delayed gastric emptying, the very symptom the procedure is designed to treat.

Whether performing both a biliary and enteric bypass or just a biliary bypass, the jejunum is brought anterior to

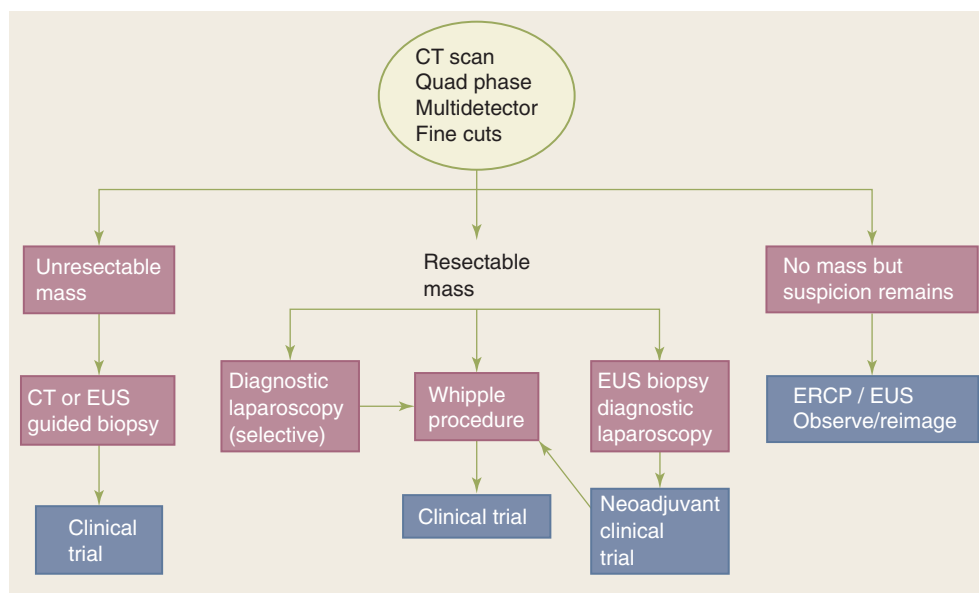


Figure 33-68. Diagnostic and treatment algorithm for pancreatic cancer. If computed tomography (CT) scan demonstrates a potentially resectable tumor, patients are offered participation in a clinical trial after histologic confirmation by CT or endoscopic ultrasound (EUS)-guided biopsy. If CT scan demonstrates resectable disease, diagnostic laparoscopy is used selectively in patients with tumors in the body/tail, equivocal findings of metastasis or CT scan, ascites, high CA19-9, or marked weight loss. Patients also have diagnostic laparoscopy if they elect to participate in a neoadjuvant clinical trial. In cases where no mass is demonstrated on CT scan, but suspicion of cancer remains, EUS or endoscopic retrograde cholangiopancreatography (ERCP) with brushings are performed, and the CT may be repeated after an interval of observation.

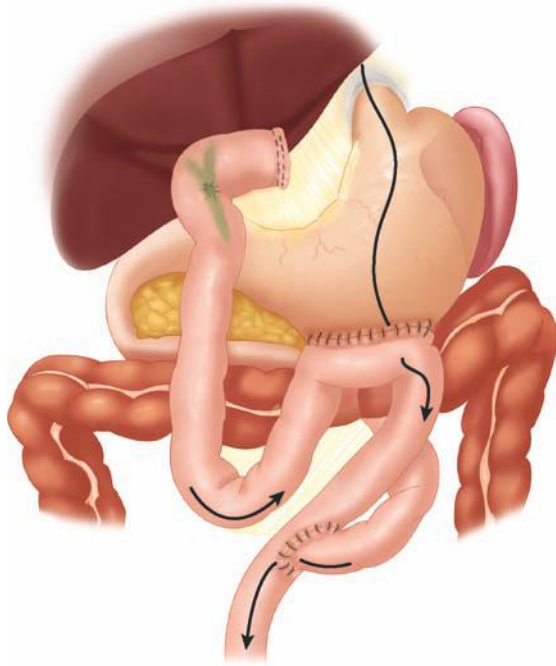


Figure 33-69. Biliary-enteric bypass to palliate unresectable pancreatic cancer. (Reproduced with permission from Bell RH Jr: *Atlas of pancreatic surgery*, in Bell RH Jr, Rikkers LF, Mulholland MW (eds): *Digestive Tract Surgery: A Text and Atlas*. Philadelphia: Lippincott-Raven, 1996, p 1074.)

the colon, if possible, rather than retrocolic, where the tumor potentially would invade the bowel sooner. Some surgeons use a loop of jejunum with a jejunojejunostomy to divert the enteric stream away from the biliary-enteric anastomosis. Others use a Roux-en-Y limb with the gastrojejunostomy located 50 cm downstream from the hepaticojejunostomy (Fig. 33-69). Potential advantages of the defunctionalized Roux-en-Y limb include the ease with which it will reach up to the hepatic hilum, probable decreased risk of cholangitis, and easier management of biliary anastomotic leaks. If a gastrojejunostomy is performed, it should be placed dependently and posterior along the greater curvature to improve gastric emptying, and a vagotomy should not be performed. If patients are explored laparoscopically and found to have unresectable disease, palliation of jaundice can be achieved in a minimally invasive fashion with ERCP and placement of a coated, expandable metallic endoscopic biliary stent

(Fig. 33-70). Endoscopic stents are definitely not as durable as a surgical bypass. Recurrent obstruction and cholangitis is more common with stents and results in inferior palliation. However, this minimally invasive approach is associated with considerably less initial morbidity and mortality than surgical bypass. Newer, expandable metallic wall stents demonstrate improved patency and provide better palliation than plastic stents.

If an initial diagnostic laparoscopy reveals a contraindication to the Whipple procedure, such as liver metastases, it is not appropriate to perform a laparotomy simply to create a biliary bypass. In such a patient, it is better to place an endoscopic stent. In contrast, if a laparotomy has already been performed as part of the assessment of resectability and the Whipple procedure is not possible, a surgical bypass is usually performed. However, if the patient has a functioning endoscopic stent already in place, it may be reasonable to forego surgical bypass.

Palliative Chemotherapy and Radiation. For patients with locally advanced unresectable disease are treated with chemotherapy and possibly radiation and patients with Stage IV metastatic disease are treated with systemic chemotherapy. Gemcitabine (Gemzar[®]) was approved by the U.S. Food and Drug Administration (FDA) for use in pancreatic cancer in 1996. In patients with unresectable pancreatic cancer, gemcitabine results in symptomatic improvement, improved pain control and performance status, and weight gain.³⁰⁶ However, survival is improved by only 1 to 2 months. Erlotinib (Tarceva[®]) was approved in 2005 based on very minimal improvement in overall survival in combination with gemcitabine. Frequently 5-fluorouracil (5-FU) and capecitabine (Xeloda[®]) are used as a radiosensitizer in patients receiving radiation therapy. FOLFIRINOX (5-fluorouracil, leucovorin, irinotecan, and oxaliplatin) is an aggressive chemotherapy regimen that was recently shown to improve objective response rate from 9% to 32% and median overall survival of patients with metastatic pancreatic cancer from 7 to 11 months but the improvement is associated with increased toxicity so patient selection is important.³⁰⁷ Although these results may warrant treatment in patients who understand the benefits and risks, the lack of significant survival advantage should encourage physicians to refer motivated patients for experimental protocols, because it is only through continued clinical research that more meaningful treatments for pancreatic cancer will be developed.

Ablation for Locally Advanced Unresectable Disease. Persistent arterial vascular encasement after neoadjuvant therapy contraindicates resection. Irreversible electroporation using

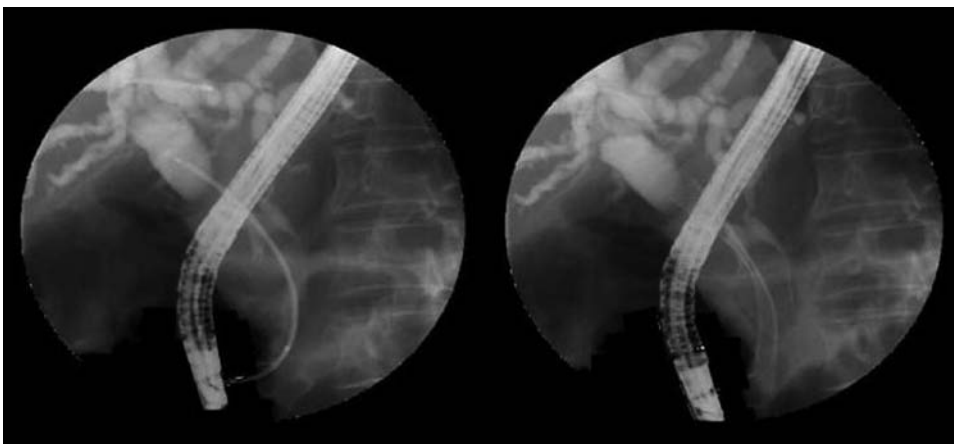


Figure 33-70. Expandable metallic biliary stent. After ERCP cannulation of the distal bile duct (left) the stent is advanced over the cannula and placed across the obstruction in the distal bile duct (right).

the Nanoknife® is reported to enable treatment of pancreatic tumors abutting vascular structures without compromise of the vessels or concern for the heat sink effect of nearby blood flow.³⁰⁸ This modality is new but early reports with limited numbers of patients indicate it may be safe in combination with chemotherapy. Randomized prospective trials are needed. However, these early results are of particular interest because of the potential to down stage and offer surgery to patients initially diagnosed with locally advanced unresectable disease.

Surgical Resection: Pancreaticoduodenectomy. In a patient with appropriate clinical and/or imaging indications of pancreatic cancer, a tissue diagnosis before performing a pancreaticoduodenectomy is not essential. Although percutaneous CT-guided biopsy is usually safe, complications such as hemorrhage, pancreatitis, fistula, abscess, and even death can occur. Tumor seeding along the subcutaneous tract of the needle is uncommon. Likewise, FNA under EUS guidance is safe and well tolerated. The problem with preoperative or even intraoperative biopsy is that many pancreatic cancers are not very cellular and contain a significant amount of fibrous tissue, so a biopsy may be misinterpreted as showing chronic pancreatitis if it does not contain malignant glandular cells. In the face of clinical and radiologic preoperative indications of pancreatic cancer, a negative biopsy should not preclude resection. In patients who are not candidates for resection because of metastatic disease, biopsy for a tissue diagnosis becomes important because these patients may be candidates for palliative chemotherapy trials. It is especially important to make an aggressive attempt at tissue diagnosis before surgery in patients whose clinical presentation and imaging studies are more suggestive of alternative diagnoses such as pancreatic lymphoma or pancreatic islet cell tumors. These patients might avoid surgery altogether in the case of lymphoma or warrant an aggressive approach in the case of islet cell carcinoma.

Pancreaticoduodenectomy can be performed through a midline incision from xiphoid to umbilicus or through a bilateral subcostal incision. The initial portion of the procedure is an assessment of resectability. The liver and visceral and parietal peritoneal surfaces are thoroughly assessed. The gastrohepatic omentum is opened, and the celiac axis area is examined for enlarged lymph nodes. The base of the transverse mesocolon to the right of the middle colic vessels is examined for tumor involvement.

The ascending and hepatic flexure of the colon are mobilized off the duodenum and head of the pancreas and reflected medially. A Kocher maneuver is performed by dissecting behind the head of the pancreas. The superior mesenteric vein is identified early in the case and dissected up toward the inferior border of the neck of the pancreas. The gastroepiploic vein and artery are ligated to prevent any traction injury. The relation of the tumor to the superior mesenteric vein and artery cannot be accurately assessed by palpation at this point and is not completely determined until later in the operation when the neck of the pancreas is divided and the surgeon is committed to resection. Mesenteric vascular involvement is best determined by a high quality preoperative CT scan.

It is important to assess for an aberrant right hepatic artery, which is present in 20% of patients. The aberrant artery arises from the superior mesenteric artery posterior to the pancreas and ascends parallel and adjacent to the superior mesenteric and portal veins. The presence of an aberrant right hepatic artery should be apparent on the preoperative CT scan and can be identified intraoperatively by palpation on the back side of the hepatoduodenal

Table 33-22

Findings at exploration

Findings contraindicating resection
Liver metastases (any size)
Celiac lymph node involvement
Peritoneal implants
Hepatic hilar lymph node involvement
Findings not contraindicating resection
Invasion at duodenum or distal stomach
Involved peripancreatic lymph nodes
Involved lymph nodes along the porta hepatis that can be swept down with the specimen

ligament, where a prominent pulse will be felt posterior and to the right of the portal vein.

The porta hepatis is examined. Enlarged or firm lymph nodes that can be swept down toward the head of the pancreas with the specimen do not preclude resection. If the assessment phase reveals no contraindications to the Whipple procedure (Table 33-22), the resection phase commences.

If the pylorus is to be preserved, the stomach and proximal duodenum are mobilized off the pancreas, preserving the gastroepiploic vessels down to the pylorus. The proximal hepatic artery is identified usually by removing a lymph node that commonly lies just anterior to the artery. The hepatic artery is dissected and traced toward the porta hepatis. Small vessels in this area can be ligated with 3-0 or 4-0 silk ligatures to prevent bothersome hemorrhage later in the case that makes subsequent dissection more tedious. The gastroduodenal branch of the hepatic artery is identified. A test clamping is performed to ensure that a strong pulse remains in the proper hepatic artery before division of the gastroduodenal artery. Once the gastroduodenal artery is divided, the hepatic artery is retracted medially and the common bile duct is retracted laterally to reveal the anterior surface of the portal vein behind them. Dissection is performed only on the anterior surface of the vein. If there is no tumor involvement, the neck of the pancreas will separate from the vein easily. A large, blunt-tipped clamp is a safe instrument to use for this dissection. The tunnel under the neck of the pancreas can then be completed mostly under direct vision from inferior and superior.

The gallbladder is then mobilized from the liver, the cystic duct and artery are ligated, and the gallbladder is removed. The common hepatic duct is circumferentially dissected. Either the duodenum is divided 2 cm distal to the pylorus (which defines the procedure as a pylorus-preserving pancreaticoduodenectomy, or PPPD) or the antrum is divided, as classically described by Whipple. The jejunum is divided beyond the ligament of Treitz, and the mesentery is ligated until the jejunum can be delivered posterior to the superior mesenteric vessels from left to right.

The common hepatic duct is then divided just above the entrance of the cystic duct, and the duct is dissected down to the superior margin of the duodenum. Inferior traction on the distal bile duct opens the plane to make visible the anterior portion of the portal vein. The pancreatic neck is divided anterior to the portal vein (Fig. 33-71). The pancreatic head and uncinate process then are dissected off of the right lateral aspect of the superior mesenteric vein, ligating the fragile branches draining the head and uncinate process into the portal vein (Fig. 33-72).

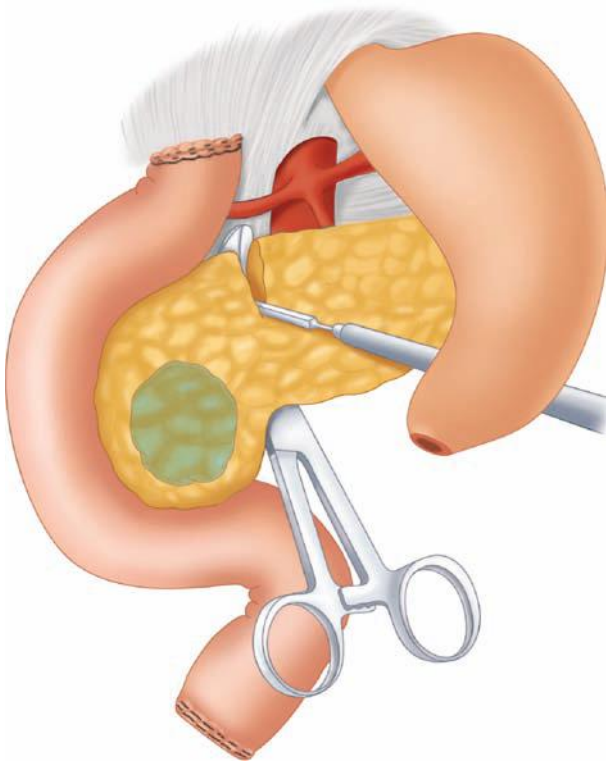


Figure 33-71. Division of the pancreatic neck. The pancreatic neck is separated from the anterior surface of the portal vein and then divided. If there is no tumor involvement, the neck of the pancreas will separate from the vein easily. A large, blunt-tipped clamp is a safe instrument to use for this dissection. (Reproduced with permission from Bell RH Jr: *Atlas of pancreatic surgery*, in Bell RH Jr, Rikkers LF, Mulholland MW (eds): *Digestive Tract Surgery: A Text and Atlas*. Philadelphia: Lippincott-Raven, 1996, p 1054.)

The uncinate process is then dissected off of the posterior and lateral aspect of the superior mesenteric artery. This can be the most tedious portion of the operation, but thoroughly clearing all tissue from the mesenteric vessels helps avoid incomplete resection. The wound is irrigated and meticulous hemostasis is assured at this point because the view of the portal vein area and retroperitoneum is more difficult after the reconstruction phase is completed.

The reconstruction involves anastomoses of the pancreas first, then the bile duct, and, finally, the duodenum or stomach. There are various techniques for the pancreatic anastomoses, and all have equivalent outcomes. After the pancreatic anastomosis is completed, the choledochojejunostomy is performed about 10 cm down the jejunal limb from the pancreatic anastomosis. This is usually performed in an end-to-side fashion with one layer of interrupted sutures. The duodenojejunostomy or gastrojejunostomy is performed another 10 to 15 cm downstream from the biliary anastomosis, using a two-layer technique.

Pancreaticoduodenectomy with Vascular Resection.

Accurate staging of pancreatic cancer with a high-quality preoperative CT scan is extremely important. Involvement of the superior mesenteric artery, the celiac axis, or hepatic artery indicate a T4/Stage 3 tumor that is locally advanced and unresectable. However, involvement of the portal vein or superior mesenteric vein does not necessarily preclude resection as long as there is a patent superior mesenteric vein-portal vein confluence. Reconstruction can often be accomplished with a primary

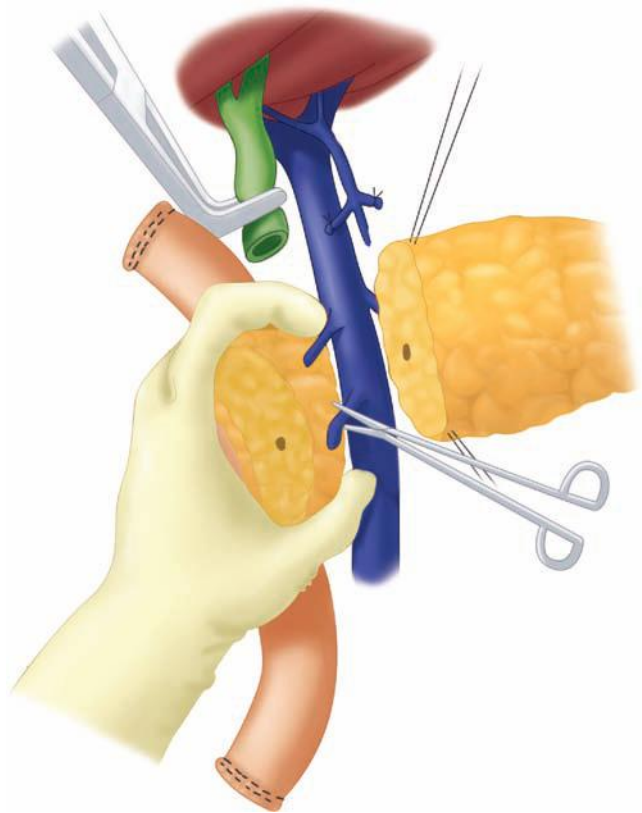


Figure 33-72. Dissection of the pancreatic head and uncinate process. The pancreatic head and uncinate process are dissected off of the right lateral aspect of the superior mesenteric vein and portal vein by ligating the fragile venous branches. (Reproduced with permission from Bell RH Jr: *Atlas of pancreatic surgery*, in Bell RH Jr, Rikkers LF, Mulholland MW (eds): *Digestive Tract Surgery: A Text and Atlas*. Philadelphia: Lippincott-Raven, 1996, p 1056.)

anastomosis of the vein. When resection of more than 2 cm of vein is required, an interposition graft such as the internal jugular vein, can be used for a tension-free reconstruction. During the last decade, studies have been published evaluating mortality rates and long-term survival after partial and segmental portal/mesenteric vein resection with mortality rates below 5%, similar to those of standard pancreaticoduodenectomy. When performed in expert centers, the surgical and oncologic outcome of pancreaticoduodenectomy without and with venous resection appear to be similar.^{309,310}

Minimally Invasive Pancreatectomy. Laparoscopic distal pancreatectomy has been proven to be safe and is appropriate for essentially all indications for pancreatectomy. This approach is associated with decreased blood loss and quicker recovery. Centrally located lesions near the splenoportal confluence must be approached laparoscopically with caution. Robotic technology such as the da Vinci[®] Surgical System may make dissection and control of major vessels in this area easier and perhaps more safe. Interest in laparoscopic pancreaticoduodenectomy is increasing throughout the United States with some early adopters reporting excellent outcomes comparable to the open procedure in single-institution series.³¹¹ Early results indicate this technique is feasible but considerable expertise is required in both open pancreatic resection as well as advanced laparoscopic techniques to achieve these outcomes. Whether the advantages seen in other areas of minimally invasive surgery apply to the Whipple procedure is an area of current investigation.

Variations and Controversies. The preservation of the pylorus has several theoretical advantages, including prevention of reflux of pancreaticobiliary secretions into the stomach, decreased incidence of marginal ulceration, normal gastric acid secretion and hormone release, and improved gastric function. Patients with pylorus-preserving resections have appeared to regain weight better than historic controls in some studies. Return of gastric emptying in the immediate postoperative period may take longer after the pylorus-preserving operation, and it is controversial whether there is any significant improvement in long-term quality of life with pyloric preservation.^{312,313}

Techniques for the pancreaticojejunostomy include end-to-side or end-to-end and duct-to-mucosa sutures or invagination (Fig. 33-73). Pancreaticogastrostomy has also been investigated.

Some surgeons use stents, glue to seal the anastomosis, or octreotide to decrease pancreatic secretions. No matter what combination of these techniques is used, the pancreatic leakage rate is always about 10%. Therefore, the choice of techniques depends more on the surgeon's personal experience.

Traditionally, most surgeons place drains around the pancreatic and biliary anastomoses because disruption of

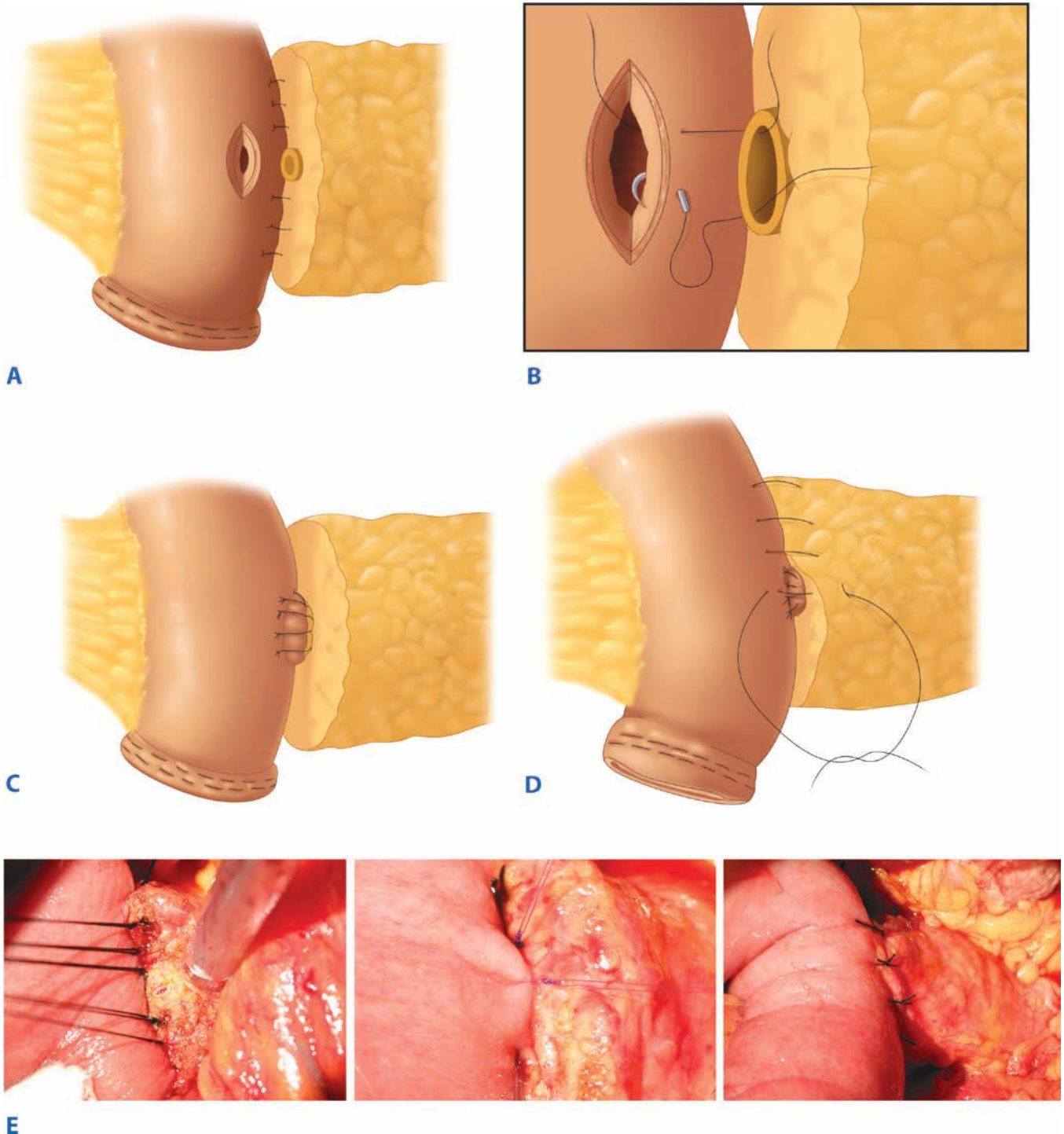


Figure 33-73. Techniques for pancreaticojejunostomy. **A to D.** Duct-to-mucosa, end-to-side **E.** Intraoperative photographs of end-to-side pancreaticojejunostomy. **F to J.** End-to-end invagination. **K to O.** End-to-side invagination.

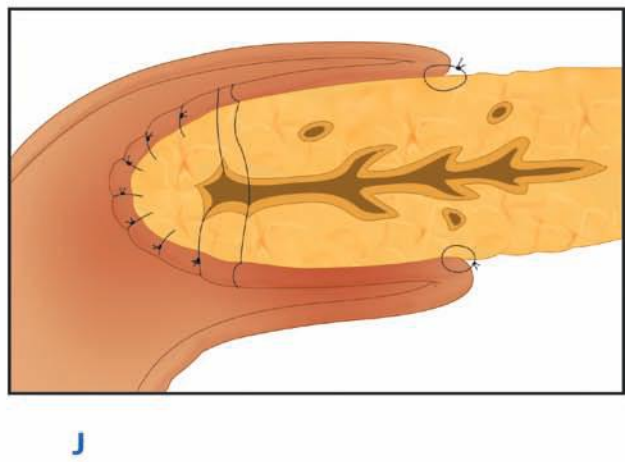
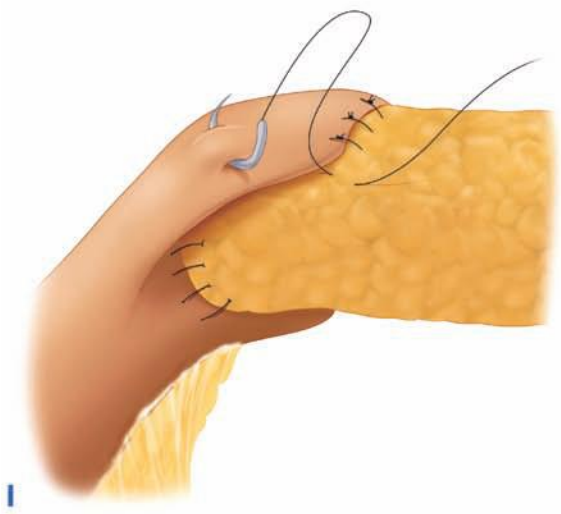
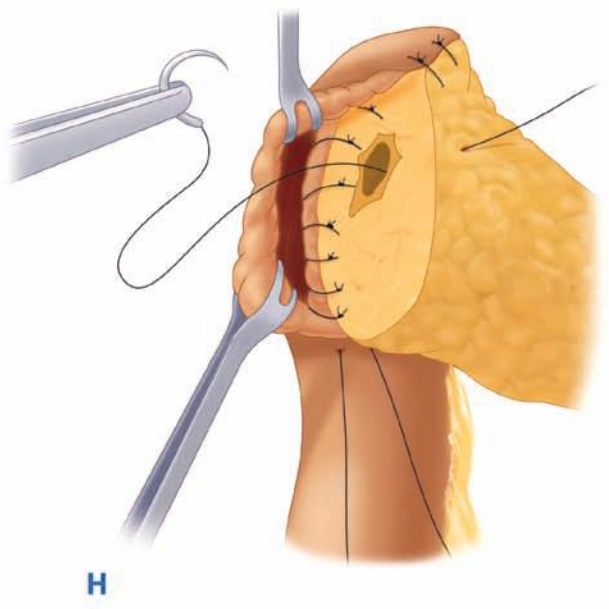
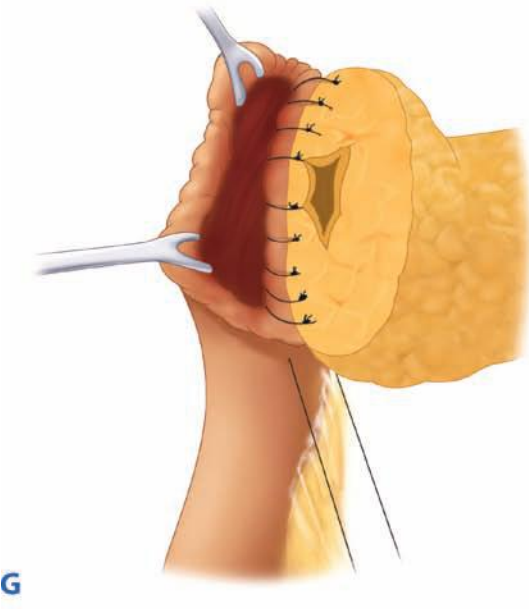
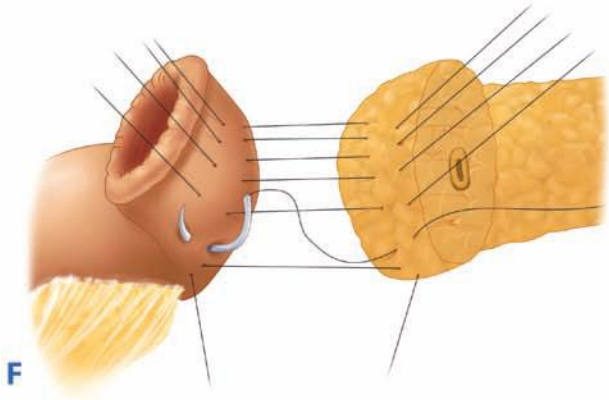


Figure 33-73. (Continued)

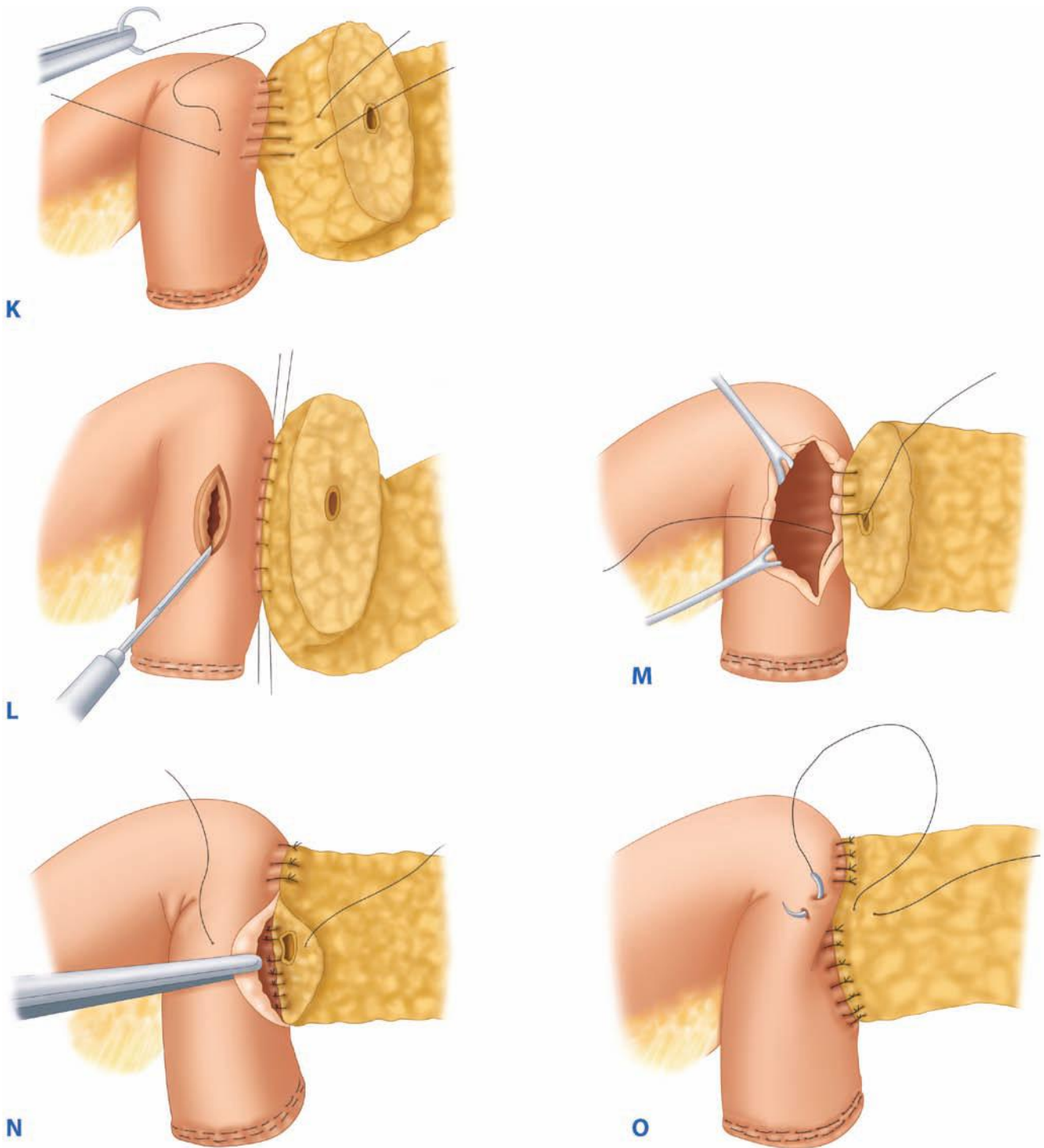


Figure 33-73. (Continued)

the pancreaticojejunostomy cannot be avoided in one out of 10 patients. This complication can lead to the development of an upper abdominal abscess or can present as an external pancreatic fistula. Usually, a pure pancreatic leak is controlled by the drains and will eventually seal spontaneously. Combined pancreatic and biliary leaks are cause for concern because bile will activate the pancreatic enzymes. In its most virulent form, disruption leads to necrotizing retroperitoneal infection, which can erode major arteries and veins of the upper abdomen, including the exposed portal vein and its branches or the stump of the gastroduodenal artery. Impending catastrophe is often preceded by

a small herald bleed from the drain site. Depending on the clinical situation, such an event is an indication to perform an angiogram or return the patient to the operating room to widely drain the pancreaticojejunostomy and to repair the involved blood vessel. Open packing may be necessary to control diffuse necrosis and infection. Some studies have questioned the practice of routine drain placement after pancreaticoduodenectomy. These studies indicated that most pancreatic leaks can be managed with percutaneous drainage.³¹⁴ The practice of routine drainage after pancreatic resection is currently being investigated in a randomized multicenter clinical trial. Many patients with

pancreatic cancer are malnourished preoperatively and suffer from gastroparesis in the immediate postoperative period. Routine placement of a feeding jejunostomy tube and gastrostomy tube has become less common, and most surgeons use these tubes selectively. Gastrostomy tubes may decrease the length of stay in patients who might be predicted to have severe gastroparesis. Jejunostomy tubes are certainly not benign and can result in leaks and intestinal obstruction. However, parenteral nutrition is also associated with serious complications such as line sepsis, loss of gut mucosal integrity, and hepatic dysfunction.

Because of the high incidence of direct retroperitoneal invasion and regional lymph node metastasis at the time of surgery, it has been argued that the scope of resection for pancreatic cancer should be enlarged to include a radical regional lymphadenectomy and resection of areas of potential retroperitoneal invasion. The “radical pancreaticoduodenectomy” includes extension of the pancreatic resection to the middle body of the pancreas, segmental resection of the portal vein, if necessary, resection of retroperitoneal tissue along the right perinephric area, and lymphadenectomy to the region of the celiac plexus. In the hands of experienced surgeons, these techniques are associated with greater blood loss but no increase in mortality; however, improved survival has not been demonstrated. Total pancreatectomy has also been considered in the past. Although pancreatic leaks are eliminated, major morbidity from brittle diabetes and exocrine insufficiency outweigh any theoretical benefit.

Pancreatic cancer can recur locally after pancreaticoduodenectomy. Intraoperative radiotherapy (IORT) delivers a full therapeutic dose of radiation to the operative bed at the time of resection. Radiation to surrounding normal areas is minimized, but the radiation is delivered all in one setting, usually about 15 minutes, rather than in fractionated doses over time. IORT is best performed in a shielded, dedicated, operating room suite rather than by transporting the patient in the middle of an already long and complicated operation. IORT may improve local control and palliate symptoms after pancreaticoduodenectomy. However, IORT has not been shown to be superior to standard external beam radiation therapy, and further randomized trials are needed to determine how this modality should be utilized.³¹⁵

Complications of Pancreaticoduodenectomy. The operative mortality rate for pancreaticoduodenectomy has decreased to <5% in “high volume” centers (where individual surgeons perform more than fifteen cases per year), suggesting that patients in rural areas would benefit from referral to large urban centers.^{316,317} The most common causes of death are sepsis, hemorrhage, and cardiovascular events. Postoperative complications are unfortunately still very common, and include delayed gastric emptying, pancreatic fistula, and hemorrhage.

Delayed gastric emptying is common after pancreaticoduodenectomy and is treated conservatively as long as complete gastric outlet obstruction is ruled out by a contrast study. In the acute phase, IV erythromycin may help but the problem usually improves with time.

Considerable attention has been focused on the prevention of pancreatic leak after pancreas resection. Modifications of the anastomotic technique (end-to-side or end-to-end, duct-to-mucosa, or invaginated), the use of jejunum or the stomach for drainage, the use of pancreatic duct stents, the use of octreotide, and various sealants have all been evaluated. Octreotide, a synthetic analogue of somatostatin with a longer half-life, has been evaluated as a pharmacologic therapy to reduce pancreatic secretion and the rate of pancreatic fistula after pancreatic resection. European studies

advocate the routine use of octreotide while North American trials conclude that octreotide is useless. European studies have demonstrated a significant reduction in the rate of postoperative pancreatic fistula with prophylactic preoperative octreotide injection.^{318–320} However, randomized prospective studies in the United States showed that octreotide did not prevent postoperative pancreatic fistula when used following pancreatic resection.^{321–325} However, a subgroup analysis done by Suc and colleagues³²⁶ suggested that there may be a benefit to using octreotide in a high-risk group of patients undergoing pancreaticoduodenectomy who have a pancreatic duct measuring <3 mm. Some studies suggest a higher rate of complications^{321,323} in patients who receive octreotide even though the difference was not statistically significant, while others report a significantly lower rate of complications with the use of octreotide.^{319,320} Finally, the optimal dose, route (IV drip vs. subcutaneous injection), and timing (preoperative, intraoperative, or postoperative) of octreotide use is unclear.

Many technical modifications to the classic pancreaticoduodenectomy have been described. However, >70 technical variations to the pancreaticoenteric anastomosis have not clearly demonstrated an objective method to consistently decrease the rate of fistula, which varies from 0% to 40% depending on the definition of fistula.^{321,322,327–335} Yeo compared the incidence of pancreatic fistula in patients who had a pancreaticoduodenectomy with reconstruction via a pancreaticogastrostomy or pancreaticojejunostomy.³³⁵ There was no significant difference between the two techniques in the incidence of pancreatic fistula. A recent meta-analysis summarized the results of 16 trials comparing pancreaticogastrostomy to pancreaticojejunostomy. All of the observational clinical studies reported superiority of pancreaticogastrostomy over pancreaticojejunostomy, most likely influenced by publication bias. In contrast, all randomized prospective trials failed to show advantage of a particular technique, suggesting both techniques provide equally good results.³³⁶

Other options to consider when performing the pancreatic anastomosis are the duct-to-mucosa vs. the invagination techniques. Many surgeons choose the technique at the time of operation, depending on the size of the pancreatic duct and the texture of pancreas.³³⁷ The duct-to-mucosa anastomosis results in a low pancreatic fistula rate³³⁸ in patients with a large pancreatic duct and a fibrotic pancreas. However, the end-to-end invagination technique may be more secure in patients with a small duct and soft pancreas.

Even though there has been little convincing evidence for the use of a pancreatic duct stent, proponents suggest that a stent may discourage a pancreatic leak and aid in technical precision.^{339,340} Both internal stenting as well as external stenting have been shown to reduce the incidence of pancreatic fistula in some clinical studies.³³⁸

Some studies^{333,341} suggest that an isolated Roux-en-Y pancreaticoenteric anastomosis may be associated with a lower rate of postoperative pancreatic leak. The logic behind this technical modification is that the use of separate Roux-en-Y limbs for biliary and pancreatic secretions may protect the pancreatic anastomosis from activated pancreatic enzymes.

Avoiding the pancreatic anastomosis altogether by ductal ligation or occlusion has also been evaluated as a potential technique to reduce the rate of postoperative pancreatic fistula.³⁴² Ductal occlusion with neoprene or prolamine, which are nonresorbable glues, has been abandoned due to pancreatic atrophy

and loss of exocrine function.³⁴³ Tran and associates examined duct occlusion in pancreaticojejunostomy and showed that duct occlusion significantly increases the risk of endocrine insufficiency without a decrease in the postoperative complication rate.³⁴⁴ To avoid long-term loss of function, absorbable glues, such as fibrin glue, have been evaluated to limit the action of pancreatic enzymes until the anastomosis is healed. Fibrin glue has been used for both duct occlusion and has also been applied to the surface of the pancreatic stump and anastomotic site without clear improvement in pancreatic fistula rate. The effect of BioGlue[™] applied to the anastomotic surface after the Whipple procedure and pancreatic stump after distal pancreatectomy was recently evaluated in a retrospective cohort study. There were no statistically significant differences in the incidence or severity grades of postoperative pancreatic fistulas.³⁴⁵

If not combined with a biliary leak, pancreatic fistula, although serious, can usually be managed conservatively. In about 95% of cases, reoperation is not indicated and prolonged drainage, using drains placed in the original operation or percutaneously after resection, results in spontaneous closure of the fistula.³⁴⁶

Hemorrhage can occur either intraoperatively or postoperatively. Intraoperative hemorrhage typically occurs during the dissection of the portal vein. A major laceration of the portal vein can occur at a point in the operation at which the portal vein is not yet exposed. Temporary control of hemorrhage is generally possible in this situation by compressing the portal vein and superior mesenteric vein against the tumor with the surgeon's left hand behind the head of the pancreas. An experienced assistant is needed to divide the neck of the pancreas to the left of the portal vein and achieve proximal and distal control. Sometimes, the vein can be sutured closed with minimal narrowing. Other times, a segmental resection and interposition graft (internal jugular vein) may be needed.

Postoperative hemorrhage can occur from inadequate ligation of any one of numerous blood vessels during the procedure. Hemorrhage can also occur due to digestion of retroperitoneal blood vessels due to a combined biliary-pancreatic leak. Uncommonly, a stress ulcer, or later, a marginal ulcer, can result in GI hemorrhage. Typically, a vagotomy is not performed when pancreaticoduodenectomy is performed for pancreatic cancer, but patients are placed on proton pump inhibitors.

Outcome and Value of Pancreaticoduodenectomy for Cancer. Survival figures indicate that perhaps few patients are cured indefinitely of pancreatic cancer with pancreaticoduodenectomy. Survival rates vary according to the stage of disease at diagnosis, and most patients have evidence of locally advanced disease at the time of surgery. The tumor tends to recur locally with retroperitoneal and regional lymphatic disease. In addition, most patients also develop hematogenous metastases, usually in the liver. Malignant ascites, peritoneal implants, and malignant pleural effusions are all common. Median survival after pancreaticoduodenectomy is about 22 months. Even long-term (5-year) survivors often eventually die due to pancreatic cancer as late recurrence is common. Although pancreaticoduodenectomy may be performed with the hope of the rare cure in mind, the operation more importantly provides better palliation than any other treatment, and is the only modality that offers any meaningful improvement in survival. If the procedure is performed without major complications, many months of palliation are usually achieved. It is the surgeon's duty to make sure patients and their families have a realistic understanding

of the true goals of pancreaticoduodenectomy in the setting of pancreatic cancer.

Adjuvant Chemotherapy and Radiation. Small studies in the 1980s suggested that adjuvant chemotherapy with 5-FU combined with radiation improves survival by about 9 months after pancreatic resection for pancreatic adenocarcinoma.³⁴⁷ Subsequent, noncontrolled studies have reinforced that concept; however, the data have been criticized due to the low number of patients and low dose of radiation therapy that was given. In addition, gemcitabine has replaced 5-FU as standard therapy in pancreatic cancer but is thought to be too toxic when given with radiotherapy at current doses. However, a recent large European multicenter trial concluded that there was no value to chemoradiotherapy, although the study suggested the possibility that chemotherapy alone might have survival benefit.³⁴⁸ In contrast to that study, remarkable results in adjuvant therapy have been reported by the Virginia Mason Clinic with combination 5-FU, cisplatin, interferon- α , and external beam radiation. Although the toxicity is high (42% hospitalized for GI toxicity), the promising results prompted larger confirmatory studies. Unfortunately, one such study was stopped due to toxicity and this protocol has not been widely adopted. Results with FOLFIRINOX in the setting of metastatic disease have encouraged some oncologists, despite a lack of data, to offer this aggressive treatment in the adjuvant or neoadjuvant setting. Nevertheless, pending further study, it is typical in the United States for patients with acceptable functional status to receive some form of adjuvant chemotherapy and radiotherapy after surgery.

Neoadjuvant Treatment. There are several potential advantages to the use of chemoradiation before an attempt at surgical resection. For example, it avoids the risk that adjuvant treatment is delayed by complications of surgery. Neoadjuvant treatment also may decrease the tumor burden at operation, increasing the rate of resectability and killing some tumor cells before they can be spread intraoperatively. Another potential advantage is that it allows patients with occult metastatic disease to avoid the morbidity of pancreatic resection. As many as 20% of patients treated with neoadjuvant chemoradiation develop metastatic disease detected by restaging CT and do not go on to surgery. This approach may separate patients into a subset likely to benefit from resection and a subset in whom surgery would be unlikely to provide clinical benefit. Preoperative chemoradiation has been shown not to increase the perioperative morbidity or mortality of pancreaticoduodenectomy. It may even decrease the incidence of pancreatic fistula. Prospective randomized trials investigating this concept are ongoing but are difficult to complete due to the high number of patients who fail to complete or receive a full course of either therapy. Recent studies have shown that neoadjuvant therapy is associated with a lower rate of lymph node positivity and improved overall survival and should be considered an acceptable alternative to surgery followed by adjuvant therapy for resectable pancreatic cancer. Patients should be encouraged to consider available clinical trials of neoadjuvant therapy for resectable pancreatic cancer.³⁴⁹

Postoperative Surveillance. Recurrence after successful resection usually manifests as hepatic metastases. After adjuvant chemoradiation with 5-FU and external beam radiation, gemcitabine is usually administered on a weekly basis for 6

months. During this time period, patients are monitored with frequent physical examinations and laboratory tests, including CA19-9. CT scans are typically ordered every 3 months in the first two years after resection or when a rising CA19-9 or new symptoms suggest recurrence. Surgical therapy for recurrent disease is usually reserved for patients who remain reasonable operative candidates who develop symptomatic gastric outlet or bowel obstruction.

Future Therapy. The most needed advance in pancreatic cancer therapy is the ability to diagnose the disease at earlier stages. Recent developments in genomics and proteomics using high-throughput sequencing techniques and global expression methodologies may make this possible. Gene therapy is also under investigation using different strategies, including immunotherapeutic gene therapy, replacement of tumor suppressor gene function, inactivation of oncogenes, and suicide gene therapy.³⁵⁰ With immunotherapeutic gene therapy, the goal is to assist the immune system in recognizing the cancer cells. Cancer cells have been forced to express tumor-specific antigens and cytokines that activate the immune system and that may have antitumor effects. Because pancreatic cancer is a disease with multiple genetic aberrations, inactivated tumor suppressor genes have been replaced, and mutated oncogenes have been inactivated with gene therapy. In suicide gene therapy, a transgene is introduced that converts an inactive nontoxic drug into an active cytotoxic agent. The herpes simplex virus-thymidine kinase system has been the most extensively studied.³⁵⁰ Various delivery systems, including viral vectors, liposomes, and protein-conjugated DNA, exist. With each of these strategies and delivery systems, tumor cell-specific delivery would be extremely desirable but awaits the discovery of effective tumor-specific promoters. Cancer vaccines and immunotherapy are intriguing because immunotherapy has the potential to specifically target tumor cells and limit toxicities compared to chemotherapy. With recent sequencing of the pancreatic cancer genome, more candidate immune targets will be identified to serve as immunogens and insights into overcoming the immunosuppressive tumor microenvironment could possibly follow. Clinical trials for pancreatic cancer are ongoing and offer hope for more meaningful treatment.

Ampullary and Periapillary Cancer. Ampullary cancers need to be distinguished from periampullary cancers. The ampulla is the junction of the biliary and pancreatic ducts within the duodenum. Periapillary cancer includes tumors arising from the distal bile duct, duodenal mucosa, or pancreas just adjacent to the ampulla, and the ampulla can be overgrown by cancers that arise from these adjacent areas, making it impossible to determine the true site of origin. Clinically, the term *periapillary cancer* is, therefore, a nonspecific term used to refer to a variety of tumors arising at the intersection of these four sites. The term *ampullary cancer* is more specific and is reserved for tumors that arise at the ampulla. Based on their location, ampullary cancers are usually detected relatively early due to the appearance of jaundice and have a more favorable prognosis. The ampulla of Vater is lined by an epithelial layer that transitions from pancreatic and biliary ductal epithelium to duodenal mucosal epithelium. Ampullary adenocarcinomas can therefore have an intestinal and/or pancreaticobiliary histologic morphology, with the former having a better prognosis. Patients with ampullary cancer have a 10-year survival of about 35%, which is a much better prognosis than patients with

pancreatic adenocarcinoma. The difference in survival is not entirely explained by an earlier presentation and lower incidence of lymph node metastases. There are probably biologic, particularly molecular, differences between ampullary and pancreatic adenocarcinoma of the pancreas. Intestinal type ampullary cancers have a lower incidence of EGFr and mutant p53 overexpression, and fewer activating *K-ras* mutations. These tumors are more likely to have genetic changes similar to colon cancer such as microsatellite instability and adenomatous polyposis coli mutations.

Management of Periapillary Adenomas. Benign tumors such as ampullary adenomas can also originate at the ampulla. The accuracy of endoscopic biopsy in distinguishing ampullary cancer from benign adenoma is poor with false-negative rates from 25% to 56% even if sphincterotomy precedes the biopsy. However, benign villous adenomas of the ampullary region can be excised locally. This technique is applicable only for small tumors (approximately 2 cm or less) with no evidence of malignancy upon biopsy. EUS may help to accurately determine if there is invasion into the duodenal wall. In the absence of invasion, adenomas may be amenable to an endoscopic or transduodenal excision. A longitudinal duodenotomy is made and the tumor is excised with a 2- to 3-mm margin of normal duodenal mucosa. In some centers, small periampullary adenomas can also be removed endoscopically. A preoperative diagnosis of cancer is a contraindication to transduodenal excision, and pancreaticoduodenectomy should be performed. Likewise, if final pathologic examination of a locally excised tumor reveals invasive cancer, the patient should be returned to the operating room for a pancreaticoduodenectomy. An important subset of patients are those with FAP, who develop periampullary or duodenal adenomas. These lesions have a high incidence of harboring carcinoma, and frequently recur unless the mucosa at risk is resected. A standard (not pylorus-sparing) Whipple is the procedure of choice in FAP patients with periampullary lesions.

Cystic Neoplasms of the Pancreas. A cystic neoplasm needs to be considered when a patient presents with a fluid-containing pancreatic lesion (Fig. 33-74). Cystic neoplasms of the pancreas may be more frequent than previously recognized and are being identified with increasing frequency as the use of abdominal

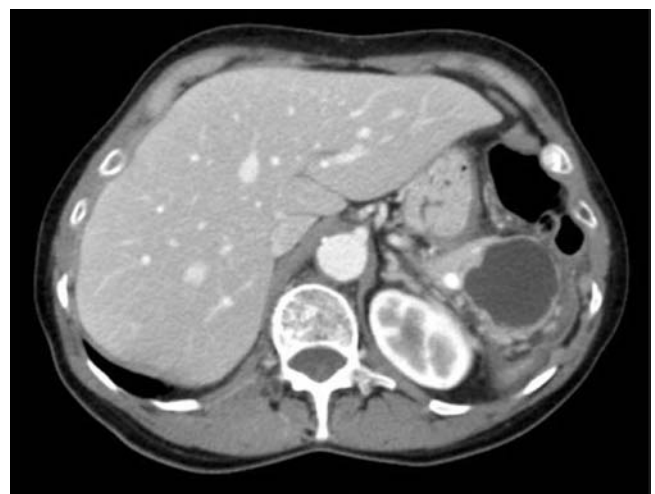


Figure 33-74. Mucinous cystic neoplasm in tail of pancreas.

CT scanning has increased. Most of these lesions are benign or slow growing, and the prognosis is significantly better than with pancreatic adenocarcinoma. However, some of these neoplasms slowly undergo malignant transformation and thus represent an opportunity for surgical cure, which is exceedingly uncommon in the setting of pancreatic adenocarcinoma. The dilemma for the surgeon is an accurate assessment of the risk-benefit ratio of resection vs. observation of these lesions in individual patients. Radiologic features including the size of the lesion and its growth rate, the density of the lesion, characteristics of the wall such as nodules, septations, or calcifications, and the relationship between the lesion and the pancreatic duct can help categorize these lesions. Although a thorough history and radiographic findings often suggest a particular diagnosis, EUS-guided FNA and analysis of cyst fluid or ERCP provide useful additional information to guide clinical decision making. Cysts that contain thick fluid with mucin, elevated carcinoembryonic antigen (CEA), or atypical cells must be treated as potentially malignant³⁵¹ (Fig. 33-75).

Pseudocysts. The most common cystic lesion of the pancreas is the pseudocyst, which, of course, has no epithelial lining

and is a nonneoplastic complication of pancreatitis or pancreatic duct injury. As discussed in “Complications of Chronic Pancreatitis,” the diagnosis is usually straightforward from the clinical history. Although not usually necessary, analysis of pseudocyst fluid would reveal a high amylase content. The danger comes in mistaking a cystic pancreatic neoplasm for a pseudocyst and incorrectly draining a cystic neoplasm into the GI tract rather than resecting the neoplasm. For this reason, biopsy of the pseudocyst wall is a common step in the management of pancreatic pseudocysts.

Cystadenoma. Serous cystadenomas are essentially considered benign tumors without malignant potential. Serous cystadenocarcinoma has been reported very rarely (<1%). Therefore, malignant potential should not be used as an argument for surgical resection, and the majority of these lesions can be safely observed in the absence of symptoms due to mass effect or rapid growth. The average rate of growth is about 0.45 cm/year. About 50% of cystadenomas are asymptomatic and detected as an incidental finding. Most symptomatic patients have mild upper abdominal pain, epigastric fullness, or

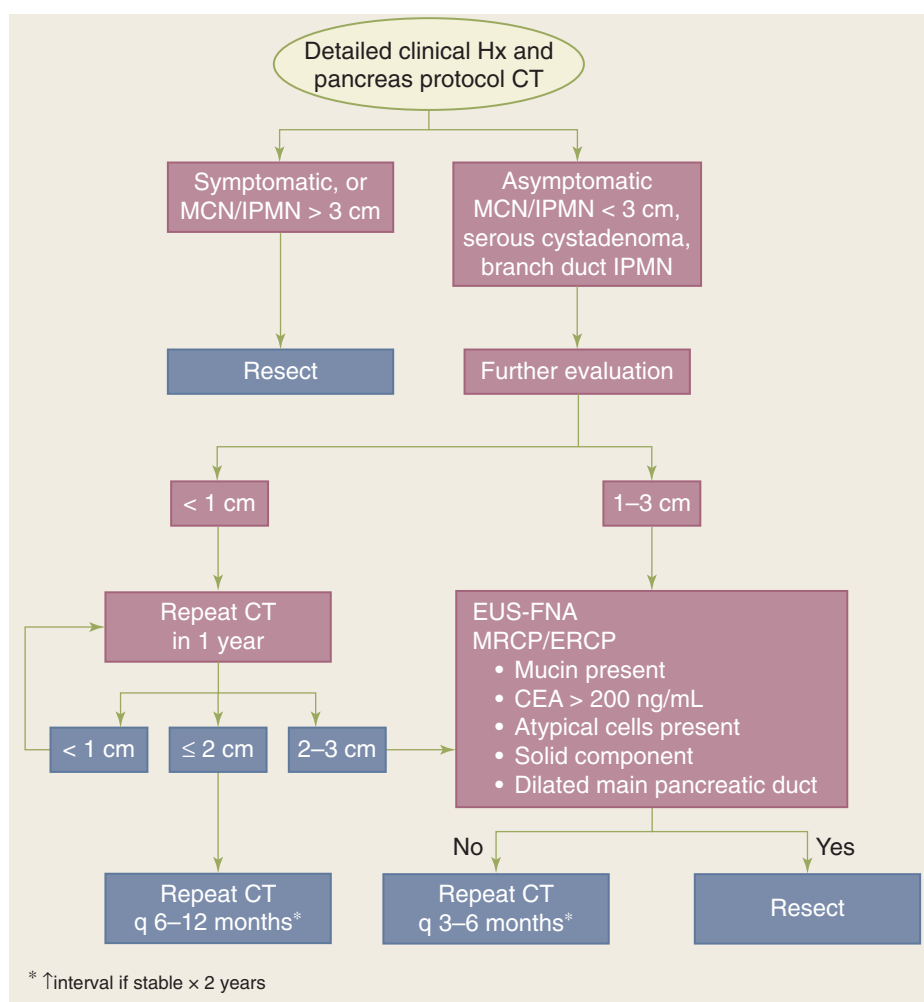


Figure 33-75. Algorithm for management of pancreatic cystic neoplasms. CEA = carcinoembryonic antigen; CT = computed tomography; ERCP = endoscopic retrograde cholangiopancreatography; EUS = endoscopic ultrasound; FNA = fine-needle aspiration; Hx = history; IPMN = intraductal papillary mucinous neoplasm of the pancreas; MCN = mucinous cystic neoplasm; MRCP = magnetic resonance cholangiopancreatography.

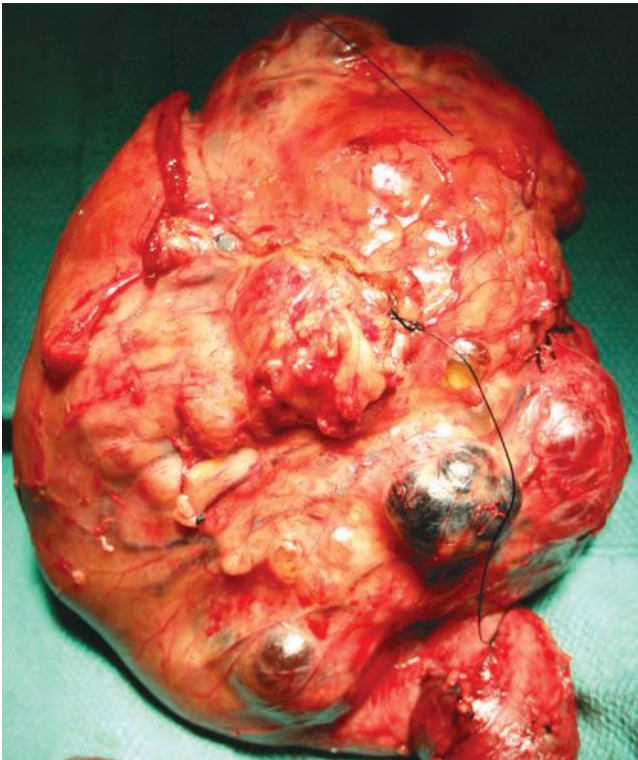
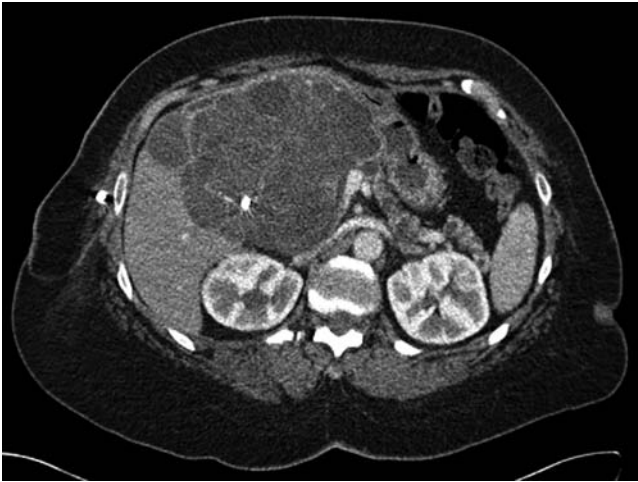


Figure 33-76. Computed tomography appearance of massive multiseptated serous cystadenoma in head of pancreas with central stellate scar (*left*) and resected specimen (*right*).

moderate weight loss. Occasionally, cystadenomas can grow to a size capable of producing jaundice or GI obstruction due to mass effect (Fig. 33-76). For symptomatic patients with serous cystadenoma, surgical resection is indicated. For lesions in the tail, splenectomy is not necessary, given the benign nature of the tumor. In appropriate candidates, a laparoscopic approach to distal pancreatectomy can be considered.³⁵² These cysts are frequently found in older women in which pancreatic resection for a benign neoplasm should be avoided in the absence of significant symptoms. All regions of the pancreas are affected, with half in the head/uncinate process, and half in the neck, body, or tail of the pancreas. They have a spongy appearance, and multiple small cysts (microcystic) are more common than

Table 33-23.

World Health Organization classification of primary tumors of the exocrine pancreas

A. Benign

1. Serous cystadenoma (16%)
2. Mucinous cystadenoma (45%)
3. Intraductal papillary-mucinous adenoma (32%)
4. Mature cystic teratoma

B. Borderline

1. Mucinous cystic tumor with moderate dysplasia
2. Intraductal papillary mucinous tumor with moderate dysplasia
3. Solid pseudopapillary tumor

C. Malignant

1. Ductal adenocarcinoma
2. Serous/mucinous cystadenocarcinoma (29%)
3. Intraductal mucinous papillary tumor

larger cysts (macrocytic or oligocystic). These lesions contain thin serous fluid that does not stain positive for mucin and is low in CEA (<200 ng/mL). Typical imaging characteristics include a well-circumscribed cystic mass, small septations, fluid close to water density, and sometimes, a central scar with calcification. If a conservative management is adopted, it is important to be sure of the diagnosis. EUS-FNA should yield nonviscous fluid with low CEA and amylase levels, and if cells are obtained, which is rare, they are cuboidal and have a clear cytoplasm.

Mucinous Cystadenoma and Cystadenocarcinoma. Mucinous cystic neoplasms (MCNs) encompass a spectrum ranging from benign but potentially malignant to carcinoma with a very aggressive behavior (Table 33-23). There is often heterogeneity within the lesions with benign and malignant-appearing regions, making it impossible to exclude malignancy with biopsy. MCNs are commonly seen in perimenopausal women, and about two-thirds are located in the body or tail of the pancreas. Like cystadenomas, most MCNs are now incidental findings identified during imaging performed for other reasons. When symptoms are present, they are usually nonspecific and include upper abdominal discomfort or pain, early satiety, and weight loss. On imaging studies, the cysts have thick walls and do not communicate with the main pancreatic duct (see Fig. 33-74). There may be nodules or calcifications within the wall of the cyst. The cysts are lined by tall columnar epithelium that fills the cyst with viscous mucin. The submucosal layer consists of a highly cellular stroma of spindle cells with elongated nuclei similar to the “ovarian stroma,” which is a key pathologic feature distinguishing these lesions. Elevated CEA levels in the fluid (>200 ng/mL) may suggest malignant transformation. Solid areas may contain atypical cells or invasive cancer, and extensive sampling of the specimen is necessary to accurately predict prognosis. Resection is the treatment of choice for most mucin-producing cystic tumors. Malignancy cannot be ruled out without removal and extensive sampling of the tumor. Malignancy has been reported in 6% to 36% of MCNs. Current thinking is that all of these tumors will eventually evolve into cancer if left untreated. Malignant transformation is more common with larger tumors, and older

patients, and there appears to be a stepwise accumulation of mutations (*K-ras*, p53). Because most MCNs are located in the body and tail of the pancreas, distal pancreatectomy is the most common treatment. For small lesions, it may be appropriate to preserve the spleen but splenectomy ensures removal of the lymph node basin that can potentially be involved. It is very important not to rupture the cyst during resection and the tumor should be removed intact, not morselized. Therefore, a laparoscopic approach may not be appropriate for larger lesions. Completely resected MCNs without atypia are usually cured especially if small (<3 cm). Even patients with moderate dysplasia or carcinoma in situ are usually cured by complete resection. In the presence of invasive carcinoma, mucinous cystadenocarcinoma, the prognosis is dismal, similar to typical ductal adenocarcinoma of the pancreas.

Intraductal Papillary Mucinous Neoplasm. Intraductal papillary mucinous neoplasms (IPMNs) usually occur within the head of the pancreas and arise within the pancreatic ducts. The ductal epithelium forms a papillary projection into the duct, and mucin production causes intraluminal cystic dilation of the pancreatic ducts. (Fig. 33-77). Imaging studies demonstrate diffuse dilation of the pancreatic duct, and the pancreatic parenchyma is often atrophic due to chronic duct obstruction. However, classic features of chronic pancreatitis, such as calcification and a beaded appearance of the duct, are not present. At ERCP, mucin can be seen extruding from the ampulla of Vater, a so-called *fish-eye lesion* that is virtually diagnostic of IPMN (Fig. 33-78). Initial reports suggested a male predominance, but more recent series indicate an equal distribution. Patients are usually in their seventh to eighth decade of life and present with abdominal pain or recurrent pancreatitis, thought to be caused by obstruction of the pancreatic duct by thick mucin. Some patients (5%–10%) have steatorrhea, diabetes, and weight loss secondary to pancreatic insufficiency. Some IPMNs primarily involve the main pancreatic duct, while others involve the branch ducts (Fig. 33-79). Malignant transformation is found in main duct IPMNs in 57% to 92% of cases and all main duct IPMNs should

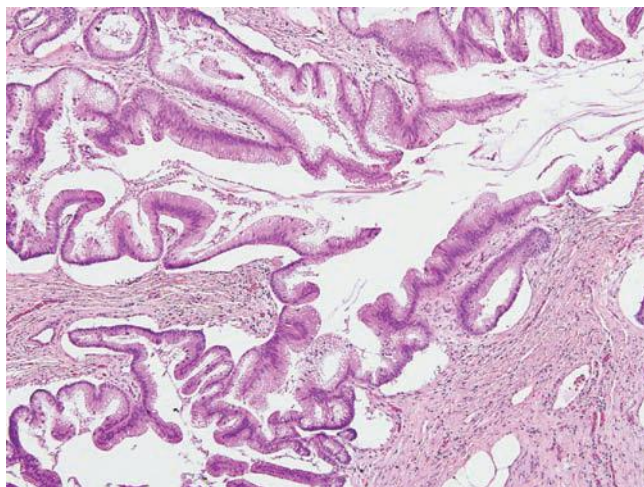


Figure 33-77. Intraductal papillary mucinous neoplasm histology. Papillary projections of ductal epithelium resemble villous morphology and contain mucin-filled vesicles. (From Asiyabola B, Andersen DK: IPMN. Editorial Update. *Access Surgery*, McGraw-Hill, 2008, with permission. Copyright © The McGraw-Hill Companies, Inc.)

be resected in fit surgical candidates. Branch-duct type IPMNs are often found in the uncinate process, are sometimes asymptomatic, and are less frequently associated with malignant transformation (6%–46%). Asymptomatic branch-duct IPMNs less than 1 cm can be observed with annual imaging.³⁵³ Lesions 1 to 2 cm should be evaluated with EUS-FNA to rule out high-risk features such as mural nodules, a dilated main duct, positive cytology or cyst fluid CEA >200. In the absence of these features, continued observation with serial imaging (1–2 cm; every 6–12 months/2–3 cm; every 3–6 months) is appropriate. Branch-duct IPMNs >3cm should be resected³⁵³.

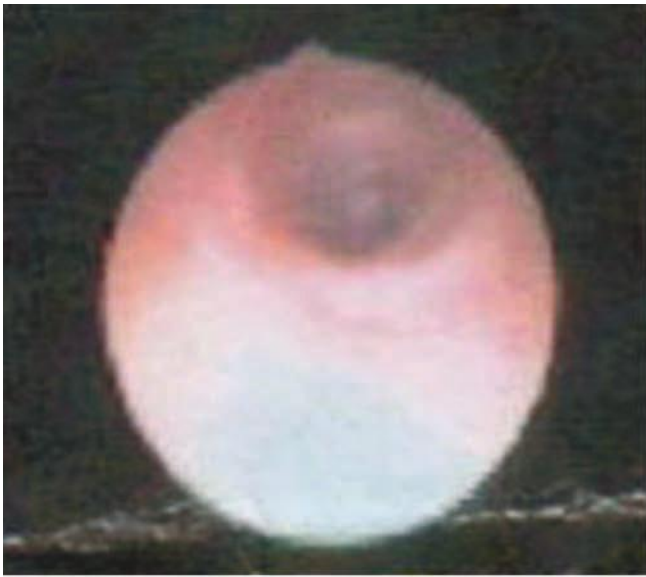
The surgical management of IPMNs is complicated by the fact that the lesion itself is small and preoperative imaging studies show a dilated pancreatic duct but not necessarily the mass. Mucus can dilate the duct proximal and distal to the lesion. Furthermore, these lesions can spread microscopically along the duct, and there can be skip areas of normal duct between the diseased portions. Therefore, thorough preoperative imaging including EUS, MRCP, or ERCP, and sometimes pancreatic ductoscopy, which can also be repeated intraoperatively, is useful (see Fig. 33-78). The surgeon needs to be prepared to extend the resection, if necessary, based on intraoperative findings and frozen section of the margin. Extending the resection to the point of total pancreatectomy is controversial due to the morbidity of this operation. Like MCNs, the IPMNs require careful histologic examination of the entire specimen for an invasive cancer, which if carefully sought, is found in 35% to 40% of cases.

Survival of patients with IPMN, even when malignant and invasive, can be quite good. As with MCN, patients with borderline tumors or carcinoma in situ are usually cured. In IPMN associated with invasive carcinoma, the 5- and 10-year survival is 60% and 50%, which is much better than typical pancreatic adenocarcinoma.³⁵⁶

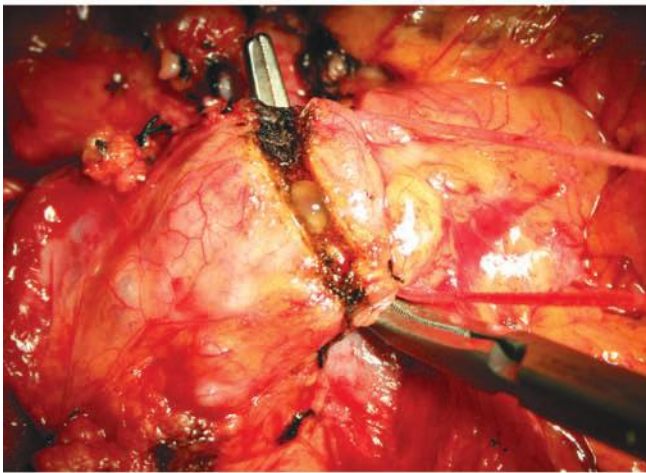
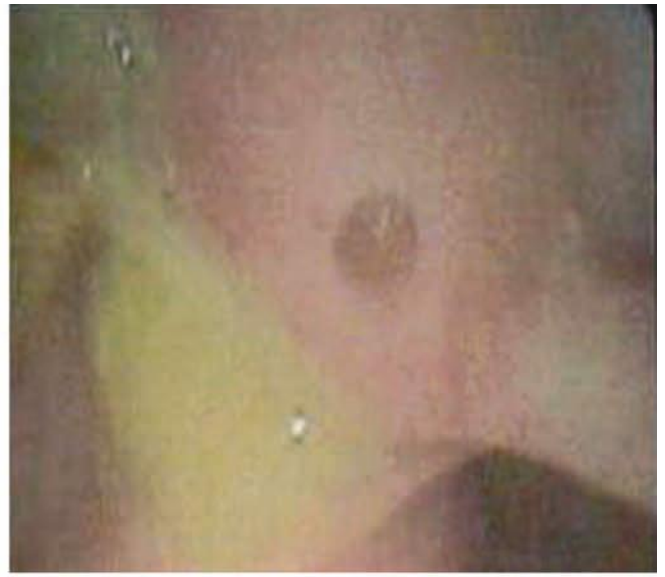For this reason, if recurrence occurs in the remaining pancreas, further resection is warranted because several series have shown that some of these cases are salvageable. Patients with IPMN are also at risk for other malignancies and should undergo colonoscopy and close surveillance.

Solid-Pseudopapillary Tumor. Solid-pseudopapillary tumors are rare and typically occur in young women. Previous names for this entity include, *solid and cystic*, *solid and papillary*, *cystic and papillary*, and *papillary-cystic tumor*. They are typically well circumscribed on CT (Fig. 33-80). The cysts are not true epithelial-lined cysts but rather represent a necrotic/degenerative process. Histology may be similar to neuroendocrine tumors, but they do not stain positive for neuroendocrine markers such as chromogranin. Most are cured by resection but liver and peritoneal metastasis has been reported.

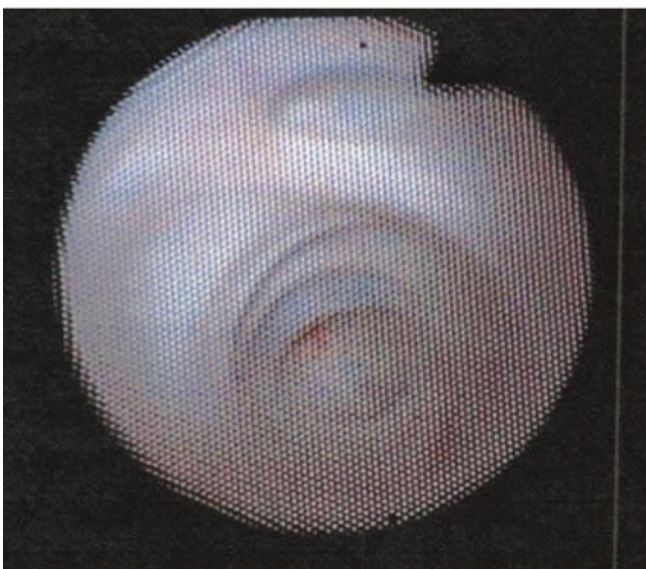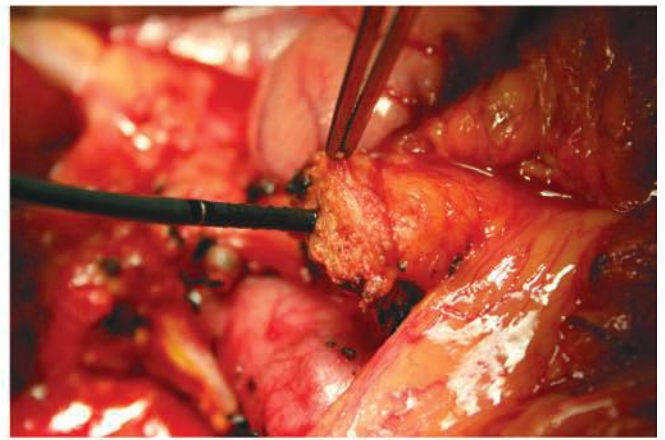
Other Cystic Neoplasms. Rarely, typical ductal adenocarcinoma of the pancreas may undergo cystic degeneration due to central necrosis. Occasionally, this will create difficulty in the proper preoperative diagnosis and should be kept in mind when deciding to conservatively follow a cystic pancreatic neoplasm. It is more common, 5% to 10%, for neuroendocrine tumors of the pancreas to contain cysts. These cysts are filled with serosanguineous fluid rather than necrotic debris. Lymphoepithelial cysts of the pancreas usually occur in men in their fifth to sixth decade. These benign lesions may be unilocular or multilocular and vary widely in size. The contents of the cyst are also variable and may be thin serous fluid or cheesy/caseous



A



B



C

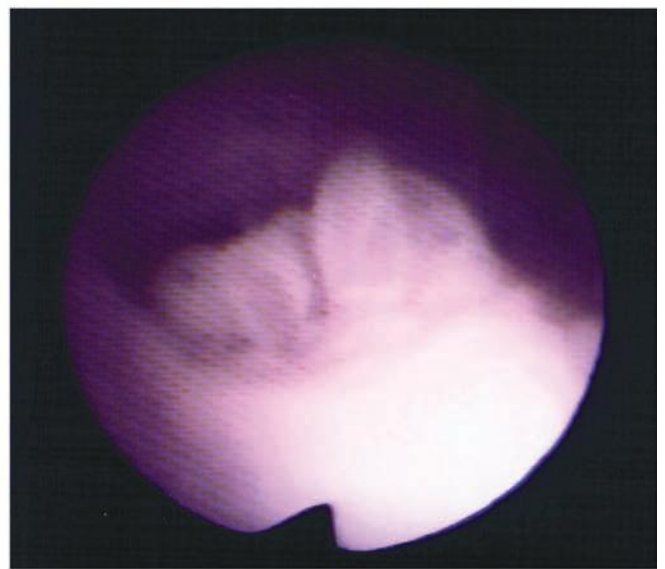


Figure 33-78. Intraductal papillary mucinous neoplasm (IPMN). **A.** Examples of “fish-eye deformity” of IPMN. Mucin is seen extruding from the ampulla. **B.** Mucin coming from pancreatic duct when neck of pancreas is transected during Whipple procedure (*left*). Intraoperative pancreatic ductoscopy to assess the pancreatic tail (*right*). **C.** Views of pancreatic duct during ductoscopy; normal (*left*) and IPMN (*right*).

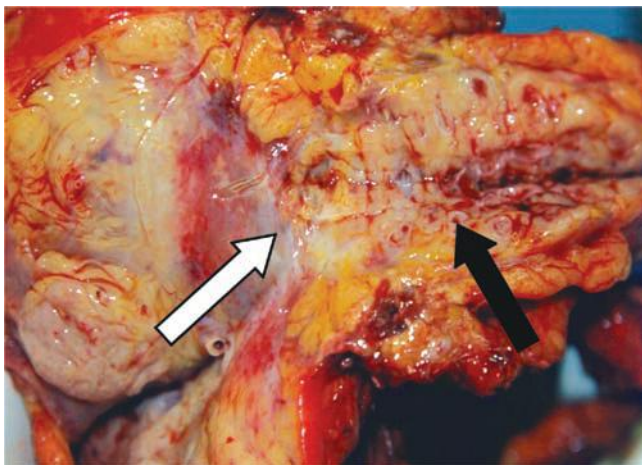


Figure 33-79. Operative specimen of pancreas with multifocal intraductal papillary mucinous neoplasms (*black arrow*) and a focus of invasive adenocarcinoma (*white arrow*). (From Asiyanbola B, Andersen DK: *IPMN. Editorial Update. Access Surgery, McGraw-Hill, 2008, with permission. Copyright © The McGraw-Hill Companies, Inc.*)

material if there is increased keratin formation. A substantial number of patients with von Hippel-Lindau syndrome develop pancreatic cysts that resemble serous cystadenomas. There may be multiple lesions scattered throughout the pancreas. Patients with polycystic kidney and hepatic disease may also develop benign pancreatic cysts (cystadenomas). With all of these rare cystic neoplasms, careful clinical history, high-quality pancreatic imaging, and sampling of the cyst fluid for analysis will guide proper treatment.

Pancreatic Lymphoma. Lymphoma can affect the pancreas. Primary involvement of the pancreas with no disease outside the pancreas also occurs. The clinical presentation often is similar to pancreatic adenocarcinoma, with vague abdominal pain and weight loss. Identification of a large mass often involving the head and body of the pancreas should raise suspicion. Percutaneous or EUS-guided biopsy will confirm the diagnosis in most cases. If the diagnosis cannot be confirmed preoperatively, laparoscopic exploration and biopsy are indicated.³⁵⁴ There is no role for resection in the management of pancreatic lymphoma. Endoscopic stenting to relieve jaundice followed by chemotherapy is the standard treatment, and long-term remission is often achieved.

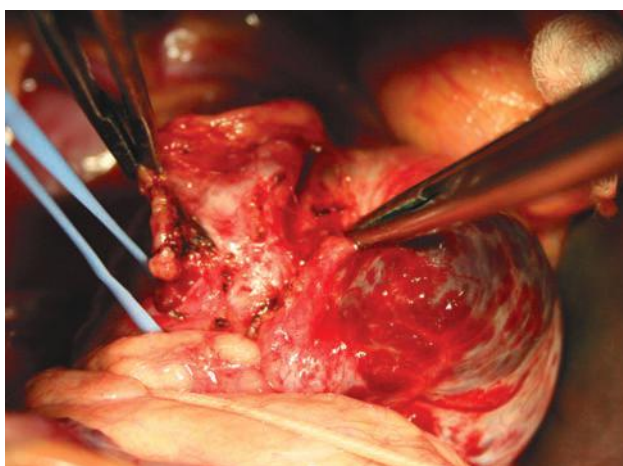
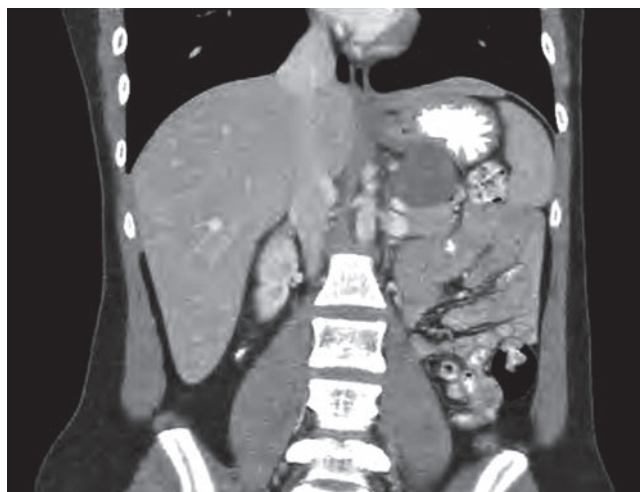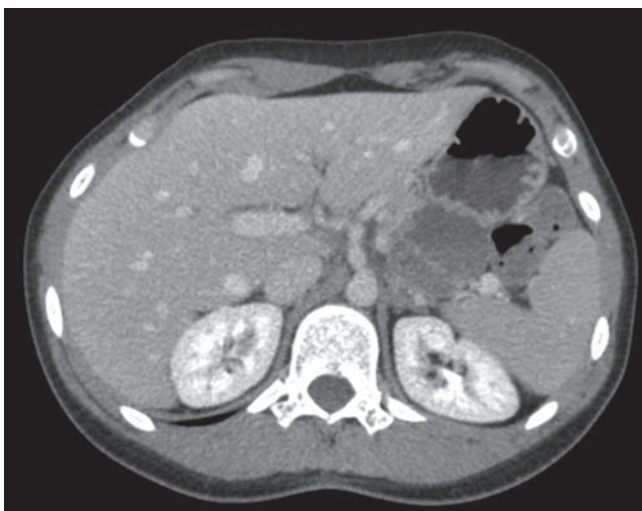


Figure 33-80. Abdominal computed tomographic scan of a 25-year-old woman demonstrating a well-circumscribed cystic lesion with septation in body/tail of pancreas. At surgery, the tumor was adherent to the splenic artery. Pathologic diagnosis was solid-pseudopapillary carcinoma.

Entries highlighted in bright blue are key references.

1. Silen W. Surgical anatomy of the pancreas. *Surg Clin North Am.* 1964;44:1253.
2. Havel PJ, Taborsky GJ Jr. The contribution of the autonomic nervous system to changes of glucagon and insulin secretion during hypoglycemic stress. *Endocr Rev.* 1989;10:332-350.
3. Davenport HW: Pancreatic secretion. In Davenport HN, ed: *Physiology of the Digestive Tract*, 5th ed. Chicago: Year Book Medical Publishers; 1982:143.
4. Valenzuela JE, Weiner K, Saad C. Cholinergic stimulation of human pancreatic secretion. *Dig Dis Sci.* 1986;31:615-619.
5. Konturek SJ, Becker HD, Thompson JC. Effect of vagotomy on hormones stimulating pancreatic secretion. *Arch Surg.* 1974;108:704-708.
6. Ebert R, Creutzfeldt W. Gastrointestinal peptides and insulin secretion. *Diabetes Metab Rev.* 1987;3:1-26.
7. Leahy JL, Bonner-Weir S, Weir GC. Abnormal glucose regulation of insulin secretion in models of reduced B-cell mass. *Diabetes.* 1984; 33:667-673.
8. Brunicaudi FC, Sun YS, Druck P, et al. Splanchnic neural regulation of insulin and glucagon secretion in the isolated perfused human pancreas. *Am J Surg.* 1987;153:34-40.
9. Yamada Y, Post SR, Wang K, et al. Cloning and functional characterization of a family of human and mouse somatostatin receptors expressed in brain, gastrointestinal tract, and kidney. *Proc Natl Acad Sci U S A.* 1992;89:251-255.
10. Voss M, Pappas T. Pancreatic fistula. *Curr Treat Options Gastroenterol.* 2002;5:345-353.
11. Floyd JC Jr, Fajans SS, Pek S. Regulation in healthy subjects of the secretion of human pancreatic polypeptide, a newly recognized pancreatic islet polypeptide. *Trans Assoc Am Physicians.* 1976;89:146-158.
12. Adrian TE, Bloom SR, Besterman HS, et al. Mechanism of pancreatic polypeptide release in man. *Lancet.* 1977;1:161-163.
13. Kono T, XP Wang, WE Fisher, DK Andersen, FC Brunicaudi. Pancreatic Polypeptide (PP). In: L Martini, ed., *Encyclopedia of Endocrine Diseases Volume 3*, Elsevier. 2004; 488-496.
14. Andersen DK. Mechanisms and emerging treatments of the metabolic complications of chronic pancreatitis. *Pancreas.* 2007;35: 1-5.
15. Wierup N, Svensson H, Mulder H, Sundler F. The ghrelin cell: a novel developmentally regulated islet cell in the human pancreas. *Regul Pept.* 2002;107:63-69.
16. Prado CL, Pugh-Bernard AE, Elghazi L, Sosa-Pineda B, Sussel L. Ghrelin cells replace insulin-producing beta cells in two mouse models of pancreas development. *Proc Natl Acad Sci U S A.* 2004;101:2924-2429.
17. Sun Y, Asnicar M, Saha PK, Chan L, Smith RG. Ablation of ghrelin improves the diabetic but not obese phenotype of ob/ob mice. *Cell Metab.* 2006;3:379-386.
18. Westermark P, Wilander E, Westermark GT, et al. Islet amyloid polypeptide-like-immunoreactivity in the islet β -cells of type II (non-insulin-dependent) diabetic and non-diabetic individuals. *Diabetologia.* 1987;30:887-892.
19. Tatemoto K, Efendic S, Mutt V, Makk G, Feistner GJ, Barchas JD. Pancreastatin, a novel pancreatic peptide that inhibits insulin secretion. *Nature.* 1986;324:476-478.
20. Efendic S, Tatemoto K, Mutt V, Quan C, Chang D, Ostenson CG. Pancreastatin and islet hormone release. *Proc Natl Acad Sci U S A.* 1987;84:7257-7260.
21. Funakoshi A, Miyasaka K, Nakamura R, Kitani K, Tatemoto K. Inhibitory effect of pancreastatin on pancreatic exocrine secretion in the conscious rat. *Reg Peptides.* 1989;25:157-166.
22. Gorelick FS, Jamieson JD. Structure-function relationship of the pancreas. In: Johnson LR, ed: *Physiology of the Gastrointestinal Tract*. New York: Raven Press; 1981:773.
23. Kennedy FP. Pathophysiology of pancreatic polypeptide secretion in human diabetes mellitus. *Diabetes Nutr Metab.* 1990;2:155.
24. Petrov MS, Shanbhag S, Chakraborty M, Phillips AR, Windsor JA. Organ failure and infection of pancreatic necrosis as determinants of mortality in patients with acute pancreatitis. *Gastroenterology.* 2010;139: 813-820.
25. Peery AF, Dellon ES, Lund J, et al. Burden of gastrointestinal disease in the United States: 2012 update. *Gastroenterology.* 2012;143(5): 1179-1187.
26. Banks PA. Epidemiology, natural history, and predictors of disease outcome in acute and chronic pancreatitis. *Gastrointestinal Endoscopy.* 2002;56(6 Suppl):S226-S230.
27. Akhtar AJ, Shaheen M. Extrapancratic manifestations of acute pancreatitis in African-American and Hispanic patients. *Pancreas.* 2004; 29(4): 291-297.
28. Lowenfels AB, Maisonneuve P. Acute pancreatitis: is smoking a risk factor for acute pancreatitis. *Nat Rev Gastroenterol Hepatol.* 2011; 8(11): 603-604.
29. Acosta JM, Ledesma CL. Gallstone migration as a cause of acute pancreatitis. *N Engl J Med.* 1974;290:484-487.
30. Lee SP, Nicholls JF, Park HZ. Biliary sludge as a cause of acute pancreatitis. *N Engl J Med.* 1992; 326(9): 589-593.
31. Elmunzer BJ, Schelman JM, Lehman GA, et al. A randomized trial of rectal indomethacin to prevent post-ERCP pancreatitis. *N Engl J Med.* 2012; 366:1414-1422.
32. Whitcomb DC. Genetics of alcoholic and nonalcoholic pancreatitis. *Curr Opin Gastroenterol.* 2012;28(5): 501-506.
33. Muniraj TT, Aslanian HR. Hypertriglyceridemia independent propofol-induced pancreatitis. *J Pancreas.* 2012;13: 451-453.
34. Saluja A, Steer M. Pathophysiology of pancreatitis. Role of cytokines and other mediators of inflammation. *Digestion.* 1999;60:27-33.
35. Hofbauer B, Saluja AK, Lerch MM, et al. Intra-acinar cell activation of trypsinogen during caerulein-induced pancreatitis in rats. *Am J Physiol.* 1998;275(2 Pt 1): G352-G362.
36. Saluja AK, Lerch MM, Phillips PA, Dudeja V. Why does pancreatic overstimulation cause pancreatitis? *Annu Rev Physiol.* 2007;69: 249-269.
37. Dawra R, Sah RP, Dudeja V, et al. Intra-acinar trypsinogen activation mediates early stages of pancreatic injury but not inflammation in mice with acute pancreatitis. *Gastroenterol.* 2011;141(6): 2210-2217 e2212.
38. Gaiser S, Daniluk J, Liu Y, et al. Intracellular activation of trypsinogen in transgenic mice induces acute but not chronic pancreatitis. *Gut.* 2011;60(10): 1379-1388.
39. Whitcomb DC, Gorry MC, Preston RA, et al. Hereditary pancreatitis is caused by a mutation in the cationic trypsinogen gene. *Nat Genet.* 1996;14(2): 141-145.
40. Kloppel G, Dreyer T, Willemer S, et al. Human acute pancreatitis: its pathogenesis in the light of immunocytochemical and ultrastructural findings in acinar cells. *Virchows Arch A Pathol Anat Histopathol.* 1986;409(6): 791-803.
41. Saluja A, Saluja M, Villa A, et al. Pancreatic duct obstruction in rabbits causes digestive zymogen and lysosomal enzyme colocalization. *J Clin Invest.* 1989;84(4): 1260-1266.
42. Saluja AK, Saluja M, Printz H, Zaverchnik A, Sengupta A, Steer ML. Experimental pancreatitis is mediated by low-affinity cholecystokinin receptors that inhibit digestive enzyme secretion. *Proc Natl Acad Sci.* 1989;86(22): 8968-8971.
43. Saluja A, Hashimoto S, Saluja M, et al. Subcellular redistribution of lysosomal enzymes during caerulein-induced pancreatitis. *Am J Physiol.* 1987;253(4 Pt 1): G508-G516.
44. Van Acker GJ, Saluja AK, Bhagat L, et al. Cathepsin B inhibition prevents trypsinogen activation and reduces pancreatitis severity. *Am J Physiol Gastrointest Liver Physiol.* 2002;283(3): G794-G800.

45. Halangk W, Lerch MM, Brandt-Nedelev B, et al. Role of cathepsin B in intracellular trypsinogen activation and the onset of acute pancreatitis. *J Clin Invest.* 2000;106(6): 773-781.
46. Saluja AK, Bhagat L, Lee HS, et al. Secretagogue-induced digestive enzyme activation and cell injury in rat pancreatic acini. *Am J Physiol.* 1999;276(4 Pt 1): G835-G842.
47. Fluhr G, Mayerle J, Weber E, et al. Pre-study protocol Mag-PEP: amulticentre randomized controlled trial of magnesium sulphate in the prevention of post-ERCP pancreatitis. *BMC Gastroenterol.* 2013;13(1): 11.
48. Dudeja V, Phillips P, Mujumdar N, et al: **Heat shock protein 70 inhibits apoptosis in cancer cells by two simultaneous but independent mechanisms.** *Gastroenterology.* 2009; 136: 1772-1782.
49. Banks PA, Bollen TL, Dervenis C, et al. Classification of acute pancreatitis – 2012: revision of the Atlanta classification and definitions by international consensus. *Gut.* 2013; 62(1): 102-111.
50. Windsor JA, Petrov MS. Acute pancreatitis reclassified. Commentary. *Gut.* 2013; 62(1): 4-5.
51. Hietaranta AJ, Singh VP, Bhagat L, et al. Water immersion stress prevents caerulein-induced pancreatic acinar cell nf-kappa b activation by attenuating caerulein-induced intracellular Ca²⁺ changes. *J Biol Chem.* 2001;276(22): 18742-18747.
52. Fanous MYZ, Phillips AJP, Windsor JA. Mesenteric lymph: the bridge to future management of critical illness. *J Pancreas.* 2007; 8(4): 374-399.
53. Working Party of British Society of Gastroenterology, Association of Surgeons of Great Britain and Ireland, Pancreatic Society of Great Britain and Ireland, Association of Upper GI Surgeons of Great Britain and Ireland. UK guidelines for the management of acute pancreatitis. *Gut.* 2005; 54 Suppl 3: iii1-iii9.
54. Whitcomb DC. Acute pancreatitis. *N Engl J Med.* 2006; 354:2142-2150.
55. Papachristou GI, Muddana V, Yadav D, et al. The bedside index for severity of acute pancreatitis (BISAP). *Am J Gastroenterol.* 2010; 105(2): 435-441.
56. Mofidi R, Duff MD, Wigmore SJ, et al. Association between early systemic inflammatory response, severity of multiorgan dysfunction and death in acute pancreatitis. *Br J Surg.* 2006; 93: 738-744.
57. Chen SM, Xiong GS, Wu SM. Is obesity an indicator of complications and mortality in acute pancreatitis? An updated meta-analysis. *J Dig Dis.* 2012; 13: 244-251.
58. Lankisch PG, Weber-Dany B, Hebel K, et al. The harmless acute pancreatitis score: a clinical algorithm for rapid initial stratification of non-severe disease. *Clin Gastroenterol Hepatol.* 2009; 7: 702-705.
59. Windsor JA. Assessment of the severity of acute pancreatitis: no room for complacency. *Pancreatol.* 2008; 8(2): 105-109.
60. Dellinger EP, Forsmark CE, Layer P, et al. Determinants-based classification of acute pancreatitis severity: an international multidisciplinary consultation. *Ann Surg.* 2012; 256: 875-880.
61. Petrov MS, Windsor JA. **Classification of the severity of acute pancreatitis: how many categories make sense?** *Am J Gastroenterol.* 2010;105 (1):74-77.
62. Gardner TB, Vege, SS, Pearson RK, Chari ST. Fluid resuscitation in acute pancreatitis. *Clin Gastroenterol Hepatol.* 2008; 6: 1070-1076.
63. Haydock M, Mittal A, Petrov M, Windsor JA. Fluid therapy in acute pancreatitis—anybody’s guess. *Ann Surg.* 2012; doi: 10.1097/SLA.0b013e31827773ff.
64. Wu BU, Hwang JQ, Gardner TH, et al. **Lactated Ringer’s solution reduces systemic inflammation compared with saline in patients with acute pancreatitis.** *Clin Gastroenterol Hepatol.* 2011;9: 710-717.
65. Al-Omran M, Albalawi ZH, Tashkandi MF, Al-Ansary LA. Enteral versus parenteral nutrition for acute pancreatitis. *Cochrane Database Systematic Reviews* 2010; 20(1): CD002837. doi: 10.1002/14651858
66. Singh N, Sharma B, Sharma M, et al. **Evaluation of early enteral feeding through nasogastric and nasojejunal tube in severe acute pancreatitis: a noninferiority randomized controlled trial.** *Pancreas.* 2012; 41(1): 153-159.
67. Petrov MS, Loveday BP, Pylypchuk RD, et al. Systematic review and meta-analysis of enteral nutrition formulations in acute pancreatitis. *Br J Surg.* 2009;96:1243-1252.
68. Petrov MS, van Santvoort HC, Besselink MG, et al. Early endoscopic retrograde cholangiopancreatography versus conservative management in acute biliary pancreatitis without cholangitis: a meta-analysis of randomized trials. *Ann Surg.* 2008;247(2)250-257.
69. Kraft M, Lerch MM: Gallstone pancreatitis: when is endoscopic retrograde cholangiopancreatography truly necessary? *Curr Gastroenterol Rep.* 2003;5:125-132.
70. Wittau M, Mayer B, Scheele J, et al. **Systematic review and meta-analysis of antibiotic prophylaxis in severe acute pancreatitis.** *Scand J Gastroenterol.* 2011; 46(3): 261-270.
71. Windsor JA. Infected pancreatic necrosis: drain first, but do it better. *HPB (Oxford).* 2011; 13(6): 367-368.
72. Van Baal MC, van Santvoort HC, Bollen TL, et al. Systematic review of percutaneous catheter drainage as primary treatment for necrotizing pancreatitis. *Br J Surg.* 2011; 98(1): 18-27.
73. Freeman M, Werner J, van Santvoort HC, et al. **Interventions for necrotizing pancreatitis: summary of a multidisciplinary consensus conference.** *Pancreas.* 2012;41:1176-1194.
74. Loveday BP, Petrov MS, Connor S, et al. A comprehensive classification of invasive procedures for treating the local complications of acute pancreatitis based on visualization, route, and purpose. *Pancreatol.* 2011; 11(4): 406-413.
75. Van Santvoort HC, Besselink MG, Bakker OJ, et al. **A step-up approach or open necrosectomy for necrotizing pancreatitis.** *N Engl J Med.* 2010; 362(16): 1491-1502.
76. Bakker OJ, van Santvoort HC, van Brunschot S, et al. Endoscopic transgastric versus surgical necrosectomy for infected necrotizing pancreatitis: a randomized trial. *JAMA.* 2012; 307: 1053-1061.
77. Nealon WH, Walser E. Main pancreatic ductal anatomy can direct choice of modality for treating pancreatic pseudocysts (surgery versus percutaneous drainage). *Ann Surg.* 2002; 235(6): 751-758.
78. Johnson CD, Abu-Hilal M. Persistent organ failure during the first week as a marker of fatal outcome in acute pancreatitis. *Gut.* 2004; 53: 1340-1344.
79. Van Baal MC, Besselink MG, Bakker OJ, et al. Timing of cholecystectomy after mild biliary pancreatitis: a systematic review. *Ann Surg.* 2012; 255(5): 860-866.
80. Skyhoj J, Olsen T: The incidence and clinical relevance of chronic inflammation in the pancreas in autopsy material. *Acta Pathol Microbiol Scand.* 1978;86:361-365.
81. Zdankiewicz PD, Andersen DK. Pancreatitis in the elderly. In: Rosenthal R, Katlic M, Zenilman ME, eds: *Principles and Practice of Geriatric Surgery.* New York: Springer-Verlag; 2001:740.
82. Worning H. Incidence and prevalence of chronic pancreatitis. In: Beger HG, Buchler M, Ditschuneit H, eds. *Chronic Pancreatitis.* Berlin: Springer-Verlag; 1990:8.
83. Comfort MW, Steinberg AG. Pedigree of a family with hereditary chronic relapsing pancreatitis. *Gastroenterol.* 1952;21:54-63.
84. Tomsik H, Gress T, Adler G: Hereditary pancreatitis. In: Beger HG, et al, eds. *The Pancreas.* London: Blackwell-Science; 1998:355.
85. Whitcomb DC, Preston RA, Aston CE, et al. A gene for hereditary pancreatitis maps to chromosome 7q35. *Gastroenterology.* 1996;110:1975-1980.

86. Le Bodic L, Bignon JD, Ragueneas O, et al. The hereditary pancreatitis gene maps to long arm of chromosome 7. *Hum Mol Genet.* 1996; 5:549-554.
87. Whitcomb DC: Hereditary diseases of the pancreas. In: Yamada T, Alpers DH, Laine L, et al, eds. *Textbook of Gastroenterology.* 4th ed. Philadelphia: Lippincott Williams & Wilkins; 2002:2147.
88. Masson E, Le Marechal C, Delcenserie R, et al. Hereditary pancreatitis caused by a double gain-of-function trypsinogen mutation. *Hum Genet.* 2008;123:521-529.
89. Witt H, Luck W, Hennies HC, et al. Mutations in the gene encoding the serine protease inhibitor, Kazal type 1 are associated with chronic pancreatitis. *Nat Genet.* 2000;25:213-216.
90. Hassan Z, Mohan V, Ali L, et al. SPINK1 is a susceptibility gene for fibrocalculous pancreatic diabetes in subjects from the Indian subcontinent. *Am J Hum Genet.* 2002;71:964-968.
91. Schneider A, Suman A, Rossi L, et al. SPINK1/PSTI mutations are associated with tropical pancreatitis and type II diabetes mellitus in Bangladesh. *Gastroenterol.* 2002;123:1026-1030.
92. Chen JM, Mercier B, Audrezet MP, et al. Mutational analysis of the human pancreatic secretory trypsin inhibitor (PSTI) gene in hereditary and sporadic chronic pancreatitis. *J Med Genet.* 2000;37:67.
93. Pfutzer RH, Barmada MM, Brunskill AP, et al. SPINK1/PSTI polymorphisms act as disease modifiers in familial and idiopathic chronic pancreatitis. *Gastroenterol.* 2000;119:615-623.
94. Cohn JA, Friedman KJ, Noone PG, Knowles MR, Silverman LM, Jowell PS. Relation between mutations of the cystic fibrosis gene and idiopathic pancreatitis. *N Engl J Med.* 1998;339:653-658.
95. Whitcomb DC, LaRusch J, Krasinskas AM, et al. **Common genetic variants in the CLDN2 and PRSS1-PRSS2 loci alter risk for alcohol-related and sporadic pancreatitis.** *Nat Genet.* 2012; 44: 1349-1356.
96. Friedreich N. Disease of the pancreas. In: Ziemssen H, ed. *Cyclopedia of the Practice of Medicine.* New York: William Wood; 1878:549.
97. Worning H. Alcoholic chronic pancreatitis. In: Beger HG, et al eds. *The Pancreas.* London:Blackwell Sciences; 1998:672.
98. Durbec JP, Sarles H. Multicenter survey of the etiology of pancreatic diseases. Relationship between the relative risk of developing chronic pancreatitis and alcohol, protein, and lipid consumption. *Digestion.* 1978;18:337-350.
99. Lankisch PG, Lowenfels AB, Maisonneuve P. What is the risk of alcoholic pancreatitis in heavy drinkers? *Pancreas.* 2002;25:411-412.
100. Layer P, Yamamoto H, Kalthoff L, Clain JE, Bakken LJ, DiMagno EP. The different courses of early- and late-onset idiopathic and alcoholic chronic pancreatitis. *Gastroenterol.* 1994;107:1481-1487.
101. Comfort MW, Gambrill EE, Baggenstoss AH. Chronic relapsing pancreatitis. A study of twenty-nine cases without associated disease of the biliary or gastro-intestinal tract. *Gastroenterology.* 1968;4:760-765.
102. Ammann RW, Muellhaupt B, Meyenberger C, Heitz PU. Alcoholic nonprogressive chronic pancreatitis: prospective long-term study of a large cohort with alcoholic acute pancreatitis (1976-1992). *Pancreas.* 1994;9:365-373.
103. Kondo T, Hayakawa T, Shibata T, et al. Aberrant pancreas is not susceptible to alcoholic pancreatitis. *Int J Pancreatol.* 1991;8:245-252.
104. Apte MV, Wilson JS. Alcohol-induced pancreatic injury. *Best Pract Res Clin Gastroenterol.* 2003; 17: 593-612.
105. Niebergall-Roth E, Harder H, Singer MV. A review: acute and chronic effects of ethanol and alcoholic beverages on the pancreatic exocrine secretion in vivo and in vitro. *Alcohol Clin Exp Res.* 1998;22:1570-1583.
106. Lerch MM, Albrecht E, Ruthenburger M, Mayerle J, Halangk W, Krüger B. Pathophysiology of alcohol-induced pancreatitis. *Pancreas.* 2003;27:291.
107. Gorelick FS. Alcohol and zymogen activation in the pancreatic acinar cell. *Pancreas.* 2003;27:305-310.
108. Sarles H, Bernard JP, Johnson C. Pathogenesis and epidemiology of chronic pancreatitis. *Annu Rev Med.* 1989;40:453-468.
109. Imoto M, DiMagno EP. Cigarette smoking increases the risk of pancreatic calcification in late-onset but not early-onset idiopathic chronic pancreatitis. *Pancreas.* 2000;21:115-119.
110. **Rebours V, Vullierme MP, Hentic O, et al. Smoking and the course of recurrent acute and chronic alcoholic pancreatitis: adose-dependent relationship.** *Pancreas.* 2012; 41: 1219-1224.
111. Lowenfels AB, Maisonneuve P, Whitcomb DC. Risk factors for cancer in hereditary pancreatitis. International Hereditary Pancreatitis Study Group. *Med Clin North Am.* 2000;84:565-575.
112. Goebell H, Steffen C, Baltzer G, et al. Stimulation of pancreatic secretion of enzymes by acute hypercalcaemia in man. *Eur J Clin Invest.* 1973;3:98-104.
113. Bess MA, Edis AJ, van Heerden JA: Hyperparathyroidism and pancreatitis. Chance or a causal association? *JAMA.* 1980;243:246-247.
114. Glueck CJ, Lang J, Hamer T, et al: Severe hypertriglyceridemia and pancreatitis when estrogen replacement therapy is given to hypertriglyceridemic women. *J Lab Clin Med.* 1994;123:59-64.
115. Etemad B, Whitcomb DC. Chronic pancreatitis: Diagnosis, classification, and new genetic developments. *Gastroenterol.* 2001; 120: 682-707.
116. Singer MV, Chari ST: Classification of chronic pancreatitis. In: Beger HG, et al, eds. *The Pancreas.* London: Blackwell-Science; 1998:665.
117. Othersen HB Jr., Moore FT, Boles ET: Traumatic pancreatitis and pseudocyst in childhood. *J Trauma.* 1968;8:535-546.
118. Warsaw AL: Pancreas divisum and pancreatitis. In: Beger HG, et al, eds. *The Pancreas.* London: Blackwell-Science; 1998:364.
119. Delhaye M, Engelholm L, Cremer M: Pancreas divisum: congenital anatomic variant or anomaly? Contribution of endoscopic retrograde dorsal pancreatography. *Gastroenterol.* 1985;89:951-958.
120. Sugawa C, Walt AJ, Nunez DC, et al: Pancreas divisum: is it a normal anatomic variant? *Am J Surg.* 1987;153:62-67.
121. **Bertin C, Pellitier AL, Vullierme MP, et al. Pancreas divisum is not a cause of pancreatitis itself but acts as a partner of genetic mutations.** *Am J Gastroenterol.* 2012; 107: 311-317.
122. Yoshida K, Toki F, Takeuchi T, Watanabe S, Shiratori K, Hayashi N. Chronic pancreatitis caused by an autoimmune abnormality. Proposal of the concept of autoimmune pancreatitis. *Dig Dis Sci.* 1995;40:1561-1568.
123. Ito T, Nakano I, Koyanagi S, et al. Autoimmune pancreatitis as a new clinical entity. Three cases of autoimmune pancreatitis with effective steroid therapy. *Dig Dis Sci.* 1997; 42:1458-1468.
124. **Ko SB, Mizuno M, Yatabe Y, et al. Corticosteroids correct aberrant CFTR localization in the duct and generate acinar cells in auto-immune pancreatitis.** *Gastroenterol.* 2010; 138: 1988-1996.
125. Stathopoulos G, Nourmand AD, Blackstone M, et al. Rapidly progressive sclerosing cholangitis following surgical treatment of pancreatic pseudotumor. *J Clin Gastroenterol.* 1995;21:143-148.
126. Mohan V, Pitchumoni CS: Tropical chronic pancreatitis. In: Beger HG, et al, eds. *The Pancreas.* London: Blackwell-Science; 1998:688.
127. Pitchumoni CS, Jain NK, Lowenfels AB, DiMagno EP. Chronic cyanide poisoning: unifying concept for alcoholic and tropical pancreatitis. *Pancreas.* 1988;3:220-222.

128. Cohn JA, Bornstein JD, Jowell PS. Cystic fibrosis mutations and genetic predisposition to idiopathic chronic pancreatitis. *Med Clin North Am.* 2000;84:621-631.
129. Layer P, Kalthoff L, Clain JE, et al. Nonalcoholic chronic pancreatitis: two diseases? *Dig Dis Sci.* 1985;30:980.
130. Ammann RW. Chronic pancreatitis in the elderly. *Gastroenterol Clin North Am.* 1990;19:905-914.
131. Kloppel G, Maillet B. Pathology of chronic pancreatitis. In: Beger HG, et al, eds. *The Pancreas.* London: Blackwell-Science;1998:720.
132. Nagai H, Ohtsubo K. Pancreatic lithiasis in the aged. Its clinicopathology and pathogenesis. *Gastroenterol.* 1984;86:331-338.
133. Apte MV, Wilson JS. Stellate cell activation in alcoholic pancreatitis. *Pancreas.* 2003;27:316-320.
134. McCarroll J, Phillips P, Santucci N, et al. Vitamin A induces quiescence in culture-activated pancreatic stellate cells—potential as an antifibrotic agent. *Pancreas.* 2003;27:396 (abstr).
135. Schneider A, Whitcomb DC. Hereditary pancreatitis: a model for inflammatory diseases of the pancreas. *Best Pract Res Clin Gastroenterol.* 2002;16:347-363.
136. Guy O, Robles-Diaz G, Adrich Z, Sahel J, Sarles H. Protein content of precipitates present in pancreatic juice of alcoholic subjects and patients with chronic calcifying pancreatitis. *Gastroenterology.* 1983;84:102-107.
137. Sarles H, Dagorn JC, Giorgi D, Bernard JP. Renaming pancreatic stone protein as “lithostathine.” *Gastroenterol.* 1990;99:900-901.
138. Watanabe T, Yonekura H, Terazono K, Yamamoto H, Okamoto H. Complete nucleotide sequence of human reg gene and its expression in normal and tumoral tissues. The reg protein, pancreatic stone protein, and pancreatic thread protein are one and the same product of the gene. *J Biol Chem.* 1990;265:7432-7439.
139. Giorgi D, Bernard JP, Rouquier S, Iovanna J, Sarles H, Dagorn JC. Secretory pancreatic stone protein messenger RNA. Nucleotide sequence and expression in chronic calcifying pancreatitis. *J Clin Invest.* 1989;84:100-106.
140. Goggin P, Johnson P. Pancreatic stones. In: Beger HG, et al, eds. *The Pancreas.* London: Blackwell-Science; 1998:711.
141. Warshaw AL, Simeone J, Schapiro RH, Hedberg SE, Mueller PE, Ferrucci JT Jr. Objective evaluation of ampullary stenosis with ultrasonography and pancreatic stimulation. *Am J Surg.* 1985;149:65-72.
142. Freeny P. Radiology. In: Beger HG, et al, eds. *The Pancreas.* London: Blackwell-Science; 1998:728.
143. Catalano MF, Lahoti S, Geenen JE, et al. Prospective evaluation of endoscopic ultrasonography, endoscopic retrograde pancreatography, and secretin test in the diagnosis of chronic pancreatitis. *Gastrointest Endosc.* 1998;48:11-17.
144. Kahl S, Glasbrenner B, Leodolter A, Pross M, Schulz HU, Malfertheiner P. EUS in the diagnosis of early chronic pancreatitis: a prospective follow-up study. *Gastrointest Endosc.* 2002;55:507-511.
145. Freeman ML, DiSario JA, Nelson DB, et al: Risk factors for post-ERCP pancreatitis: a prospective, multicenter study. *Gastrointest Endosc.* 2001;54:425-434.
146. Nealon WH, Matin S. Analysis of surgical success in preventing recurrent acute exacerbations in chronic pancreatitis. *Ann Surg.* 2001;233:793
147. Cooper M, Makary MA, Ng Y, et al. Extent of pancreatic fibrosis as a determinant of symptom resolution after the Frey procedure: A clinico-pathologic analysis. *J Gastrointest Surg.* 2013;17: 682-687.
148. Ammann RW, Akovbiantz A, Largiader F, et al. Course and outcome of chronic pancreatitis. Longitudinal study of a mixed medical-surgical series of 245 patients. *Gastroenterol.* 1984;86:820-828.
149. Bockman DE, Buchler M, Malfertheiner P, et al. Analysis of nerves in chronic pancreatitis. *Gastroenterol.* 1988;94:1459-1469.
150. Anaparthi R, Pasricha PJ. Pain and chronic pancreatitis: is it the plumbing or the wiring? *Curr Gastroenterol Rep.* 2008; 10: 101-106.
151. DiMagno EP, Go VL, Summerskill WH. Relations between pancreatic enzyme outputs and malabsorption in severe pancreatic insufficiency. *N Engl J Med.* 1973;288:813-815.
152. Rothenbacher D, Low M, Hardt PD, et al. Prevalence and determinants of exocrine pancreatic insufficiency among older adults: results of a population-based study. *Scand J Gastroenterol.* 2005; 40: 697-704.
153. Dutta SK, Russell RM, Iber FL. Influence of exocrine pancreatic insufficiency on the intraluminal pH of the proximal small intestine. *Dig Dis Sci.* 1979;24:529-534.
154. DiMagno MJ, DiMagno EP. Chronic pancreatitis. *Curr Opin Gastroenterol.* 2012;28: 523-531.
155. Malka D, Hammel P, Sauvanet A, et al: Risk factors for diabetes mellitus in chronic pancreatitis. *Gastroenterol.* 2000; 119:1324.
156. Couet C, Genton P, Pointel JP, et al. The prevalence of retinopathy is similar in diabetes mellitus secondary to chronic pancreatitis with or without pancreatectomy and in idiopathic diabetes mellitus. *Diabetes Care.* 1985;8:323-328.
157. Hardt P, Brendel MD, Kloer HU, Bretzel RG. Is pancreatic diabetes (type 3c diabetes) underdiagnosed and misdiagnosed? *Diabetes Care.* 2008; 31 Suppl 2: S165-S169.
158. Slezak LA, Andersen DK. Pancreatic resection: effects on glucose metabolism. *World J Surg.* 2001;25:452-460.
159. Cui Y, Andersen DK. Pancreatogenic diabetes: special considerations for management. *Pancreatol.* 2011; 11: 279-294.
160. Seymour NE, Volpert AR, Lee EL, Andersen DK, Hernandez C. Alterations in hepatocyte insulin binding in chronic pancreatitis: effects of pancreatic polypeptide. *Am J Surg.* 1995;169:105-109, discussion 110.
161. BrunCARDI FC, Chaiken RL, Ryan AS, et al. Pancreatic polypeptide administration improves abnormal glucose metabolism in patients with chronic pancreatitis. *J Clin Endocrinol Metab.* 1996;81:3566-3572.
162. Rabiee A, Galiatsatos P, Salas-Carrillo R, et al. Pancreatic polypeptide administration enhances insulin sensitivity and reduces the insulin requirement of patients on insulin pump therapy. *J Diabetes Sci Technol.* 2011; 5: 1521-1528.
163. Gyr K, Agrawal NM, Felsenfeld O, Font RG. Comparative study of secretin and Lundh tests. *Am J Dig Dis.* 1975;20:506.
164. Somogyi L, Cintron M, Toskes PP. Synthetic porcine secretin is highly accurate in pancreatic function testing in individuals with chronic pancreatitis. *Pancreas.* 2000;21:262-265.
165. Denyer ME, Cotton PB: Pure pancreatic juice studies in normal subjects and patients with chronic pancreatitis. *Gut.* 1979;20:89-97.
166. Tanner AR, Fisher D, Ward C, et al: An evaluation of the one-day NBT-PABA/14C-PABA in the assessment of pancreatic exocrine insufficiency. *Digestion.* 1984;29:42-46.
167. Brugge W, Goff JS, Allen N: Development of a dual label Schilling test for pancreatic exocrine function based on the differential absorption of cobalamin malabsorption in pancreatic insufficiency. *J Clin Invest.* 1978;61:47.
168. Haverback B, Dyce B, Gutentag P. Measurement of trypsin and chymotrypsin in stool: a diagnostic test for pancreatic exocrine function. *Gastroenterology.* 1986;44:588.
169. Gullo L, Ventrucchi M, Tomassetti P, Migliori M, Pezzilli R. Fecal elastase 1 determination in chronic pancreatitis. *Dig Dis Sci.* 1999;44:210-213.
170. Hardt PD, Hauenschild A, Nalop J, et al. High prevalence of exocrine pancreatic insufficiency in diabetes mellitus. A multicenter study screening fecal elastase 1 concentrations in 1,021 diabetic patients. *Pancreatol.* 2003;3:395-402.

171. DiMagno MJ, DiMagno EP. Chronic pancreatitis. *Curr Opin Gastroenterol.* 2010;26:490-498.
172. Axon AT, Classen M, Cotton PB, et al. Pancreatography in chronic pancreatitis: international definitions. *Gut.* 1984;25:1107-1112.
173. Catanzaro A, Richardson S, Veloso H, et al: Long-term follow-up of patients with clinically indeterminate suspicion of pancreatic cancer and normal EUS. *Gastrointest Endosc.* 2003;58:836-840.
174. Lowenfels AB, Maisonneuve P, Cavallini G, et al. Prognosis of chronic pancreatitis: an international multicenter study. International Pancreatitis Study Group. *Am J Gastroenterol.* 1994;89:1467-1471.
175. Miyake H, Harada H, Kunichika K, Ochi K, Kimura I. Clinical course and prognosis of chronic pancreatitis. *Pancreas.* 1987;2:378-385.
176. Frey CF, Child CG, Fry W. Pancreatectomy for chronic pancreatitis. *Ann Surg.* 1976;184:403-413.
177. Lowenfels AB, Maisonneuve P, Cavallini G, et al. Pancreatitis and the risk of pancreatic cancer. International Pancreatitis Study Group. *N Engl J Med.* 1993;328:1433-1437.
178. Liao KF, Lai SW, Li CI, Chen WC. Diabetes mellitus correlates with increased risk of pancreatic cancer: a population-based cohort study in Taiwan. *J Gastroenterol Hepatol.* 2012;27:709-713.
179. Aspelund G, Topazian MD, Lee JH, Andersen DK. Improved outcomes for benign disease with limited pancreatic head resection. *J Gastrointest Surg.* 2005;9:400-409.
180. Sankaran S, Walt AJ. The natural and unnatural history of pancreatic pseudocysts. *Br J Surg.* 1975;62:37-44.
181. Yeo CJ, Bastidas JA, Lynch-Nyhan A, Fishman EK, Zinner MJ, Cameron JL. The natural history of pancreatic pseudocysts documented by computed tomography. *Surg Gynecol Obstet.* 1990;170:411.
182. Goulet RJ, Goodman J, Schaffer R, Dallemand S, Andersen DK. Multiple pancreatic pseudocyst disease. *Ann Surg.* 1984;199:6-13.
183. Vitas GJ, Sarr MG. Selected management of pancreatic pseudocysts: operative versus expectant management. *Surgery.* 1992;111:123-130.
184. Warshaw AL, Jin GL, Ottinger LW: Recognition and clinical implications of mesenteric and portal vein obstruction in chronic pancreatitis. *Arch Surg.* 1987;122:410-415.
185. Warshaw AL, Rattner DW: Timing of surgical drainage for pancreatic pseudocyst. Clinical and chemical criteria. *Ann Surg.* 1985;202:720-724.
186. Baron TH, Harewood GC, Morgan DE, et al. Outcome differences after endoscopic drainage of pancreatic necrosis, acute pancreatic pseudocysts, and chronic pancreatic pseudocysts. *Gastrointest Endosc.* 2002;56:7-17.
187. Kozarek RA, Brayko CM, Harlan J, et al. Endoscopic drainage of pancreatic pseudocysts. *Gastrointest Endosc.* 1985;31:322-327.
188. Bell RH Jr. Atlas of pancreatic surgery. In: Bell RH Jr, Rikkers LF, Mulholland MW, eds. *Digestive Tract Surgery. A Text and Atlas.* Philadelphia: Lippincott-Raven; 1996:963.
189. Park AE, Heniford BT: Therapeutic laparoscopy of the pancreas. *Ann Surg.* 2002;236:149.
190. Nealon WH, Walser. Duct drainage alone is sufficient in the operative management of pancreatic pseudocyst in patients with chronic pancreatitis. *Ann Surg.* 2003;237:614-620, discussion 620-622.
191. Hawes RH. Endoscopic management of pseudocysts. *Rev Gastroenterol Disord.* 2003;3:135-141.
192. Heider R, Meyer AA, Galanko JA, et al: Percutaneous drainage of pancreatic pseudocysts is associated with a higher failure rate than surgical treatment in unselected patients. *Ann Surg.* 1999;229:781-787.
193. Rao R, Fedorak I, Prinz RA. Effect of failed computed tomography-guided and endoscopic drainage on pancreatic pseudocyst management. *Surgery.* 1993;114:843-847, discussion 847-849.
194. Lipsett PA, Cameron JL. Internal pancreatic fistula. *Am J Surg.* 1992;163:216-220.
195. Uchiyama T, Suzuki T, Adachi A, et al. Pancreatic pleural effusion: case report and review of 113 cases in Japan. *Am J Gastroenterol.* 1992;87:387-391.
196. Lipsett PA, Cameron JL. Treatment of ascites and fistulas. In: Beger HG et al, eds. *The Pancreas.* London: Blackwell-Science; 1998:788.
197. Beger H, Schlosser W, Poch B, et al. Inflammatory mass in the head of the pancreas. In: Beger HG et al, eds. *The Pancreas.* London: Blackwell-Science; 1998:757.
198. Friess H, Yamanaka Y, Buchler M, et al. A subgroup of patients with chronic pancreatitis overexpress the c-erb B-2 protooncogene. *Ann Surg.* 1994;220:183-192.
199. Sakorafas GH, Sarr MG, Farley DR, et al: The significance of sinistral portal hypertension complicating chronic pancreatitis. *Am J Surg.* 2000;179:129.
200. Amann ST, Toskes PP. Analgesic treatment. In: Beger HG et al, eds. *The Pancreas.* London: Blackwell-Science; 1998:766.
201. Forsmark CE. Management of chronic pancreatitis. *Gastroenterol.* 2013; 144: 1282-1291.
202. Halgreen H, Pedersen NT, Worning H. Symptomatic effect of pancreatic enzyme therapy in patients with chronic pancreatitis. *Scand J Gastroenterol.* 1986;21:104-108.
203. Hildebrand P, Ensink JW, Gyr K, et al: Evidence for hormonal inhibition of exocrine pancreatic function by somatostatin 28 in humans. *Gastroenterol.* 1992;103:240-247.
204. Toskes PP, Forsmark CE, DeMeo MT, et al. A multicenter controlled trial of octreotide for pain of chronic pancreatitis. *Pancreas* 8. 1993; A774.
205. Malfertheiner P, Mayer D, Buchler M, et al. Treatment of pain in chronic pancreatitis by inhibition of pancreatic secretion with octreotide. *Gut.* 1995;36:450-454.
206. Lieb JG, Shuster JJ, Theriaque D, et al. A pilot study of octreotide LAR vs. octreotide tid for pain and quality of life in chronic pancreatitis. *J Pancreas.* 2009; 10: 518-522.
207. Gress F, Schmitt C, Sherman S, et al. Endoscopic ultrasound-guided celiac plexus block for managing abdominal pain associated with chronic pancreatitis: a prospective single center experience. *Am J Gastroenterol.* 2001;96:409-416.
208. Jacob L, Geenen JE, Catalano MF, Geenen DJ. Prevention of pancreatitis in patients with idiopathic recurrent pancreatitis: a prospective nonblinded randomized study using endoscopic stents. *Endoscopy.* 2001;33:559-552.
209. Aizawa T, Ueno N. Stent placement in the pancreatic duct prevents pancreatitis after endoscopic sphincter dilation for removal of bile duct stones. *Gastrointest Endosc.* 2001;54:209-213.
210. Lau ST, Simchuk EJ, Kozarek RA, et al. A pancreatic ductal leak should be sought to direct treatment in patients with acute pancreatitis. *Am J Surg.* 2001;181:411-415.
211. Canty TG Sr, Weinman D. Management of major pancreatic duct injuries in children. *J Trauma.* 2001;50:1001-1007.
212. Kim HS, Lee DK, Kim IW, et al. The role of endoscopic retrograde pancreatography in the treatment of traumatic pancreatic duct injury. *Gastrointest Endosc.* 2001;54:49-55.
213. Heyries L, Barthet M, Delvasto C, et al. Long-term results of endoscopic management of pancreas divisum with recurrent acute pancreatitis. *Gastrointest Endosc.* 2002;55:376-381.
214. Gabbriellini A, Mutignani M, Pandolfi M, et al. Endotherapy of early onset idiopathic chronic pancreatitis: Results with long-term follow-up. *Gastrointest Endosc.* 2002;55:488.
215. Kozarek RA, Brandabur JJ, Ball TJ, et al. Clinical outcomes in patients who undergo extracorporeal shock wave lithotripsy for chronic calcific pancreatitis. *Gastrointest Endosc.* 2002;56:496-500.

216. Nealon WH, Thompson JC. Progressive loss of pancreatic function in chronic pancreatitis is delayed by main pancreatic duct decompression. A longitudinal prospective analysis of the modified puestow procedure. *Ann Surg.* 1993;217:458-466, discussion 466-468.
217. Andersen DK, Frey CF. The evolution of the surgery for chronic pancreatitis. *Ann Surg.* 2010; 251: 18-32.
218. Link G. The treatment of chronic pancreatitis by pancreatotomy: a new operation. *Ann Surg.* 1911;53:768-782.
219. Link G. Long term outcome of pancreatotomy for chronic pancreatitis. *Ann Surg.* 1935;101:287.
220. Priestley JT, Comfort MW, Radcliffe J. Total pancreatectomy for hyperinsulinism due to an islet-cell adenoma: Survival and cure at sixteen months after operation presentation of metabolic studies. *Ann Surg.* 1944;119:211-221.
221. Whipple AO. Radical surgery for certain cases of pancreatic fibrosis associated with calcareous deposits. *Ann Surg.* 1946;124:991-1008.
222. Fry WJ, Child CG III. Ninety-five per cent distal pancreatectomy for chronic pancreatitis. *Ann Surg.* 1965;162:543-549.
223. Moody FG, Calabuig R, Vecchio R, et al. Stenosis of the sphincter of Oddi. *Surg Clin North Am.* 1990;70:1341-1354.
224. Cattell RB. Anastomosis of the duct of Wirsung in palliative operation for carcinoma of the head of the pancreas. *Surg Clin North Am.* 1947;27:636-643.
225. Duval MK Jr. Caudal pancreatico-jejunosotomy for chronic relapsing pancreatitis. *Ann Surg.* 1954;140:775-785.
226. Zollinger RM, Keith LM Jr, Ellison EH. Pancreatitis. *N Engl J Med.* 1954;251:497-502.
227. Puestow CB, Gillesby WJ. Retrograde surgical drainage of pancreas for chronic relapsing pancreatitis. *AMA Arch Surg.* 1958;76:898-907.
228. Partington PF, Rochelle RE. Modified Puestow procedure for retrograde drainage of the pancreatic duct. *Ann Surg.* 1960;152:1037-1043.
229. Izbicki JR, Bloechle C, Broering DC, et al. Longitudinal V-shaped excision of the ventral pancreas for small duct disease in severe chronic pancreatitis: prospective evaluation of a new surgical procedure. *Ann Surg.* 1998;227:213-219.
230. Eleftheriadis N, Dinu F, Delhaye M. Long-term outcome after pancreatic stenting in severe chronic pancreatitis. *Endoscopy.* 2005;37:223-230.
231. Gabbriellini A, Pandolfi M, Mutignani M, et al. Efficacy of main pancreatic-duct endoscopic drainage in patients with chronic pancreatitis, continuous pain, and dilated duct. *Gastrointest Endosc.* 2009;61:576-581.
232. Morgan DE, Smith JK, Hawkins K, Wilcox CM. Endoscopic stent therapy in advanced chronic pancreatitis: relationships between ductal changes, clinical response, and stent patency. *Am J Gastroenterol.* 2003;98:821-826.
233. Rosch T, Daniel S, Scholz M, et al. Endoscopic treatment of chronic pancreatitis: a multicenter study of 1000 patients with long-term follow-up. *Endoscopy.* 2002;34:765-771.
234. Ponchon T, Bory RM, Hedelius F, et al. Endoscopic stenting for pain relief in chronic pancreatitis: results of a standardized protocol. *Gastrointest Endosc.* 1995;42:452-456.
235. Vitale GC, Cothron K, Vitale EA, et al. Role of pancreatic duct stenting in the treatment of chronic pancreatitis. *Surg Endosc.* 2004;18:1431.
236. Bradley EL III. Long-term results of pancreatojejunostomy in patients with chronic pancreatitis. *Am J Surg.* 1987;153:207.
237. Cahen DL, Gouma DJ, Nio Y, et al. Endoscopic versus surgical drainage of the pancreatic duct in chronic pancreatitis. *N Engl J Med.* 2007;356:676.
238. Aldridge MC, Williamson RC. Distal pancreatectomy with and without splenectomy. *Br J Surg.* 1991;78:976.
239. Khanna A, Koniaris LG, Nakeeb A, et al. Laparoscopic spleen-preserving distal pancreatectomy. *J Gastrointest Surg.* 2005;9:733.
240. Hess W. Surgical tactics in chronic pancreatitis. In: Hess W, Berci G, eds. *Textbook of Bilio-Pancreatic Diseases*, Vol. 4. Puaa: Piccin Nuova Libraria; 1997:2299.
241. Traverso LW, Longmire WP Jr: Preservation of the pylorus in pancreaticoduodenectomy. *Surg Gynecol Obstet.* 1978; 146:959.
242. Huang JJ, Yeo CJ, Sohn TA, et al. Quality of life and outcomes after pancreaticoduodenectomy. *Ann Surg.* 2000;231:890.
243. Sakorafas GH, Farnell MB, Nagorney DM, et al. Pancreatoduodenectomy for chronic pancreatitis: Long-term results in 105 patients. *Arch Surg.* 2000;135:517, discussion 523.
244. Jimenez RE, Fernandez-del Castillo C, Rattner DW, et al. Outcome of pancreaticoduodenectomy with pylorus preservation or with antrectomy in the treatment of chronic pancreatitis. *Ann Surg.* 2000;231:293.
245. Braasch JW, Vito L, Nugent FW. Total pancreatectomy of end-stage chronic pancreatitis. *Ann Surg.* 1978;188:317.
246. Cooper MJ, Williamson RC, Benjamin IS, et al. Total pancreatectomy for chronic pancreatitis. *Br J Surg.* 1987;74:912.
247. Mannell A, Adson MA, McIlrath DC, et al. Surgical management of chronic pancreatitis: Long-term results in 141 patients. *Br J Surg.* 1988;75:467.
248. Alberti M. *Proceedings of the Post EASD International Symposium on Diabetes Secondary to Pancreatopathy*, International Congress Series, Padova, 1987. Amsterdam: Excerpta Medica; 1988:211.
249. Gall FP, Muhe E, Gebhardt C. Results of partial and total pancreaticoduodenectomy in 117 patients with chronic pancreatitis. *World J Surg.* 1981;5:269.
250. Beger HG, Witte C, Krautzberger W, et al. Experiences with duodenum-sparing pancreas head resection in chronic pancreatitis. *Chirurg.* 1980;51:303.
251. Beger HG, Krautzberger W, Bittner R, et al. Duodenum-preserving resection of the head of the pancreas in patients with severe chronic pancreatitis. *Surgery.* 1985;97:467.
252. Beger HG, Schlosser W, Friess HM, et al. Duodenum-preserving head resection in chronic pancreatitis changes the natural course of the disease: A single-center 26-year experience. *Ann Surg.* 1999;230:512, discussion 519.
253. Buchler MW, Friess H, Muller MW, et al. Randomized trial of duodenum-preserving pancreatic head resection versus pylorus-preserving Whipple in chronic pancreatitis. *Am J Surg.* 1995;169:65, discussion 69.
254. Frey CF, Smith GJ. Description and rationale of a new operation for chronic pancreatitis. *Pancreas.* 1987;2:701.
255. Frey CF, Amikura K. Local resection of the head of the pancreas combined with longitudinal pancreaticojejunostomy in the management of patients with chronic pancreatitis. *Ann Surg.* 1994;220:492, discussion 504.
256. Andersen DK, Topazian MD. Pancreatic head excavation: A variation on the theme of duodenum-preserving pancreatic head resection. *Arch Surg.* 2004;139:375.
257. Izbicki JR, Strate T, Yekebas EE, et al. Chronic pancreatitis. In: Yeo CJ, Dempsey DT, Klein AS, et al, eds. *Shackelford's Surgery of the Alimentary Tract*. 6th ed. New York: Saunders; 2007:1218.
258. Ho HS, Frey CF. The Frey procedure: Combined local resection of the head of the pancreas with longitudinal pancreaticojejunostomy. *Operat Tech Gen Surg.* 2001;4:153.
259. Ho HS, Frey CF. The Frey procedure: Local resection of pancreatic head combined with lateral pancreaticojejunostomy. *Arch Surg.* 2001;136:1353.
260. Farkas G, Leindler L, Daroczi M, et al. Organ-preserving pancreatic head resection in chronic pancreatitis. *Br J Surg.* 2003; 90:29.
261. Farkas G, Leindler L, Daroczi M, Farkas G Jr. Prospective randomised comparison of organ-preserving pancreatic head resection with pylorus-preserving pancreaticoduodenectomy. *Langenbecks Arch Surg.* 2006;391:338-342.

262. Gloor B, Friess H, Uhl W, et al. A modified technique of the Beger and Frey procedure in patients with chronic pancreatitis. *Dig Surg*. 2001;18:21-25.
263. Koninger J, Seiler CM, Sauerland S, et al. Duodenum-preserving pancreatic head resection—a randomized controlled trial comparing the original Beger procedure with the Berne modification (ISRCTN No. 50638764). *Surgery*. 2008;143:490-498.
264. Izbicki JR, Bloechle C, Broering DC, et al. Extended drainage versus resection in surgery for chronic pancreatitis: a prospective randomized trial comparing the longitudinal pancreaticojejunostomy combined with local pancreatic head excision with the pylorus-preserving pancreatoduodenectomy. *Ann Surg*. 1998;228:771-779.
265. Strate T, Bachmann K, Busch P, et al. Resection vs. drainage in treatment of chronic pancreatitis: long-term results of a randomized trial. *Gastroenterology*. 2008;134:1406-1411.
266. Klempa I, Spatny M, Menzel J, et al. Pancreatic function and quality of life after resection of the head of the pancreas in chronic pancreatitis. A prospective, randomized comparative study after duodenum preserving resection of the head of the pancreas versus Whipple's operation. *Chirurg*. 1995;66:350-359.
267. Buchler MW, Friess H, Bittner R, et al. Duodenum-preserving pancreatic head resection: long-term results. *J Gastrointest Surg*. 1997;1:13-19.
268. Zheng Z, Xiang G, Tan C, et al. Pancreaticoduodenectomy vs. duodenum-preserving pancreatic head resection for the treatment of chronic pancreatitis. *Pancreas*. 2012;41:147-152.
269. Strate T, Taherpour Z, Bloechle C, et al. Long term follow-up of a randomized trial comparing the Beger and Frey procedures for patients suffering from chronic pancreatitis. *Ann Surg*. 2005;241:591.
270. Riediger H, Adam U, Fischer E, et al. Long-term outcome after resection for chronic pancreatitis in 224 patients. *J Gastrointest Surg*. 2007;11:949-959, discussion 959-960.
271. Ramesh H, Jacob G, Lekha V, Venugopal A. Ductal drainage with head coring in chronic pancreatitis with small-duct disease. *J Hepatobiliary Pancreat Surg*. 2003;10:366-372.
272. Shrikhande SV, Kleff J, Friess H, et al. Management of pain in small duct chronic pancreatitis. *J Gastrointest Surg*. 2006;10:227-233.
273. Najarian JS, Sutherland DE, Baumgartner D, et al. Total or near total pancreatectomy and islet autotransplantation for treatment of chronic pancreatitis. *Ann Surg*. 1980;192:526-542.
274. Sutherland DE, Radosevich DM, Bellin, MA, et al. Total pancreatectomy and islet autotransplantation for chronic pancreatitis. *J Am Coll Surg*. 2012;214:409-426.
275. Robertson RP, Lanz KJ, Sutherland DE, et al. Prevention of diabetes for up to 13 years by autoislet transplantation after pancreatectomy for chronic pancreatitis. *Diabetes*. 2001;50:47-50.
276. Rastellini C. Donor and recipient selection in pancreatic islet transplantation. *Curr Opin Organ Transplant*. 2002;7:196.
277. Richards ML, Gauger PG, Thompson NW, Kloos RG, Giordano T. Pitfalls in the surgical treatment of insulinoma. *Surgery*. 2002;132:1040-1049, discussion 1049.
278. Howard TJ, Stabile BE, Zinner MJ, Chang S, Bhagavan BS, Passaro E Jr. Anatomic distribution of pancreatic endocrine tumors. *Am J Surg*. 1990;159:258-264.
279. Service FJ, Natt N, Thompson GB, et al. Noninsulinoma pancreatogenous hypoglycemia: A novel syndrome of hyperinsulinemic hypoglycemia in adults independent of mutations in Kir6.2 and SUR1 genes. *J Clin Endocrinol Metab*. 1999;84:1582-1589.
280. Cui YF, Elahi D, Andersen DK. Advances in the etiology and management of hyperinsulinemic hypoglycemia after Roux-en-Y gastric bypass. *J Gastrointest Surg*. 2011;15:1879-1888.
281. Deol ZK, Frezza E, DeJong S, Pickleman J. Solitary hepatic gastrinoma treated with laparoscopic radiofrequency ablation. *JLS*. 2003;7:285-289.
282. Case CC, Wirfel K, Vassilopoulou-Sellin R. Vasoactive intestinal polypeptide-secreting tumor (VIPoma) with liver metastases: dramatic and durable symptomatic benefit from hepatic artery embolization, a case report. *Med Oncol*. 2002;19:181-187.
283. Tanaka S, Yamasaki S, Matsushita H, et al. Duodenal somatostatinoma: a case report and review of 31 cases with special reference to the relationship between tumor size and metastasis. *Pathol Int*. 2000;50:146-152.
284. Raymond E et al. Updated results of the phase III trial of sunitinib (SU) versus placebo (PBO) for treatment of advanced pancreatic neuroendocrine tumors (NET). ASCO 2010 Gastrointestinal Cancers Symposium Abstr 127.
285. Kulke M et al. Phase I/II study of everolimus (RAD001) in combination with temozolomide (TMZ) in patients with advanced pancreatic neuroendocrine tumors (NET) ASCO 2010.
286. Jemal A, Bray F, Center MM, et al. Global cancer statistics. *CA: A Cancer Journal for Clinicians*. 2011; 61: 69-90.
287. Seigel R, Naishadham D, Jemal A. Cancer statistics 2012. *CA: A Cancer Journal for Clinicians*. 2012; 62:10-29.
288. <http://seer.cancer.gov/statfacts/html/pancreas.html>: SEER Stat Fact Sheets. [Accessed March 20, 2009.]
289. Cui YF, Andersen DK. Diabetes and pancreatic cancer. *Endocr Rel Cancer*. 2012; 19: F9-F26.
290. Gold EB, Goldin SB: Epidemiology of and risk factors for pancreatic cancer. *Surg Oncol Clin N Am*. 1998;7:67.
291. Fisher WE. Diabetes: Risk factor for the development of pancreatic cancer or manifestation of the disease? *World J Surg*. 2001;25:503.
292. Jean M, Lowy A, Chiao P, et al: *The Molecular Biology of Pancreatic Cancer*. New York: Springer-Verlag; 2002.
293. Berger D, Fischer W. *Inherited Pancreatic Cancer Syndromes*. New York: Springer-Verlag; 2002.
294. Biankin AV, Waddell N, Kassahn KS, et al. Pancreatic cancer genomes reveal aberrations in axon guidance pathway genes. *Nature*. 2012; 491: 399-405.
295. Fisher WE, Muscarella P, Boros LG, et al. Gastrointestinal hormones as potential adjuvant treatment of exocrine pancreatic adenocarcinoma. *Int J Pancreatol*. 1998;24:169-180.
296. Biankin AV, Kench JG, Dijkman FP, et al. Molecular pathogenesis of precursor lesions of pancreatic ductal adenocarcinoma. *Pathology*. 2003;35:14.
297. Wilentz RE, Hruban RH. Pathology of cancer of the pancreas. *Surg Oncol Clin N Am*. 1998;7:43-65.
298. Howlader N, Noone AM, Krapcho M, et al. SEER Cancer statistics review 1975-2009 (Vintage 2009 populations) National Cancer Institute, Bethesda. Available at: http://seer.cancer.gov/csr/1975_2009_pops09/.
299. Ritts R, Pitt H. CA19-9 in pancreatic cancer. *Surg Oncol Clin N Am*. 1998;7:93-101.
300. Iacobuzio-Donahue CA, Maitra A, Olsen M, et al. Exploration of global gene expression patterns in pancreatic adenocarcinoma using cDNA microarrays. *Am J Pathol*. 2003;162:1151-1162.
301. Squillaci E, Fanucco E, Scuito F: Vascular involvement in pancreatic neoplasm: a comparison between spiral CT and DSA. *Dig Dis Sci*. 2003;48:449-458.
302. Kim HJ, Conlon KC: *Laparoscopic Staging*. New York: Springer-Verlag; 2002.
303. Shah RJ, Howell DA, Desilets DJ, et al. Multicenter randomized trial of the spiral Z-stent compared with the Wall-stent for malignant biliary obstruction. *Gastrointest Endosc*. 2003;57:830-836.

304. Lillemoe K, Cameron JL, Kaufman HS, Yeo CJ, Pitt HA, Sauter PK. Chemical splanchnicectomy in patients with unresectable pancreatic cancer. A prospective randomised trial. *Ann Surg.* 1993;217: 447-455.
305. Singh SM, Reber HA. Surgical palliation for pancreatic cancer. *Surg Clin North Am.* 1989;69:599-611.
306. Casper ES, Green MR, Kelsen DP, et al. Phase II trial of gemcitabine (2,2'-difluorodeoxycytidine) in patients with adenocarcinoma of the pancreas. *Invest New Drugs.* 1994;12:29-34.
307. Conroy T, Desseigne F, Ychou M, et al. Folfirinox versus gemcitabine for metastatic pancreatic cancer. *N Engl J Med.* 2011; 364: 1817-1825.
308. Martin RC II, McFarland K, Ellis S, Velanovich V. Irreversible electroporation therapy in the management of locally advanced pancreatic adenocarcinoma. *J Am Coll Surg.* 2012; 215: 361-369.
309. Bachellier P, Nakano H, Oussoultzoglou PD, et al. Is pancreaticoduodenectomy with mesentericoportal venous resection safe and worthwhile? *Am J Surg.* 2001; 182: 120-129.
310. van Geenen RC, ten Kate FJ, de Witt LT, et al. Segmental resection and wedge excision of the portal or superior mesenteric vein during pancreaticoduodenectomy. *Surgery.* 2001; 129: 158-163.
311. Giulianotti PC, Sbrana F, Bianco FM, et al. Robot-assisted laparoscopic pancreatic surgery: single-surgeon experience. *Surg Endosc.* 2010; 24: 1646-1657.
312. Yamaguchi K, Kishinaka M, Nagai E, et al. Pancreatoduodenectomy for pancreatic head carcinoma with or without pylorus preservation. *Hepatogastroenterol.* 2001;48:1479-1485.
313. Ohtsuka T, Yamaguchi K, Ohuchida J, et al. Comparison of quality of life after pylorus-preserving pancreatoduodenectomy and Whipple resection. *Hepatogastroenterol.* 2003; 50:846-850.
314. Fisher WE, Hodges SE, Silbefein EJ, et al. Pancreatic resection without routine intraperitoneal drainage. *HPB (Oxford)* 2011; 13: 503-510.
315. Sindelar WF, Kinsella TJ. Studies of intraoperative radiotherapy in carcinoma of the pancreas. *Ann Oncol.* 1999;10:226-230.
316. Birkmeyer JD, Finlayson SR, Tosteson AN, et al. Effect of hospital volume on in-hospital mortality with pancreaticoduodenectomy. *Surgery.* 1999;125:250.
317. Gordon TA, Bowman HM, Tielsch JM, et al. Statewide regionalization of pancreaticoduodenectomy and its effect on in-hospital mortality. *Ann Surg.* 1998;228:71-78.
318. Buchler M, Friess H, Klempa I, et al. Role of octreotide in the prevention of postoperative complications following pancreatic resection. *Am J Surg.* 1992;163:125-130, discussion 130-131.
319. Montorsi M, Zago M, Mosca F, et al. Efficacy of octreotide in the prevention of pancreatic fistula after elective pancreatic resections: A prospective, controlled, randomized clinical trial. *Surgery.* 117:26-31.
320. Pederzoli P, Bassi C, Falconi M, et al. Efficacy of octreotide in the prevention of complications of elective pancreatic surgery. Italian Study Group. *Br J Surg.* 1994;81:265-269.
321. Barnett SP, Hodul PJ, Creech S, et al. Octreotide does not prevent postoperative pancreatic fistula or mortality following pancreaticoduodenectomy. *Am Surg.* 2004;70:222-226, discussion 227.
322. Hesse UJ, DeDecker C, Houtmeyers P, et al. Prospectively randomized trial using perioperative low-dose octreotide to prevent organ-related and general complications after pancreatic surgery and pancreatico-jejunostomy. *World J Surg.* 29:1325-1328.
323. Lowy AM, Lee JE, Pisters PW, et al. Prospective, randomized trial of octreotide to prevent pancreatic fistula after pancreaticoduodenectomy for malignant disease. *Ann Surg.* 226: 632-641.
324. Moon HJ, Heo JS, Choi SH, et al. The efficacy of the prophylactic use of octreotide after a pancreaticoduodenectomy. *Yonsei Med J.* 2005;46:788-793.
325. Srivastava S, Sikora SS, Pandey CM, et al. Determinants of pancreaticoenteric anastomotic leak following pancreaticoduodenectomy. *ANZ J Surg.* 2001;71:511-515.
326. Suc B, Msika S, Piccinini M, et al. Octreotide in the prevention of intra-abdominal complications following elective pancreatic resection: a prospective, multicenter randomized controlled trial. *Arch Surg.* 2004;139:288-294, discussion 295.
327. Aranha GV, Hodul PJ, Creech S, Jacobs W. Zero mortality after 152 consecutive pancreaticoduodenectomies with pancreaticogastrostomy. *J Am Coll Surg.* 2003;197:223-231, discussion 231-232.
328. Lillemoe KD, Cameron JL, Kim MP, et al. Does fibrin glue sealant decrease the rate of pancreatic fistula after pancreaticoduodenectomy? Results of a prospective randomized trial. *J Gastrointest Surg.* 2004;8:766-772, discussion 772-774.
329. Nakao A, Fujii T, Sugimoto H, et al. Is pancreaticogastrostomy safer than pancreaticojejunostomy? *J Hepatobiliary Pancreat Surg.* 2006;13:202-206.
330. Payne RF, Pain JA. Duct-to-mucosa pancreaticogastrostomy is a safe anastomosis following pancreaticoduodenectomy. *Br J Surg.* 2006;93:73-77.
331. Peng S, Mou Y, Cai X, et al. Binding pancreaticojejunostomy is a new technique to minimize leakage. *Am J Surg.* 2002;183:283-285.
332. Rosso E, Bachellier P, Oussoultzoglou E, et al. Toward zero pancreatic fistula after pancreaticoduodenectomy with pancreaticogastrostomy. *Am J Surg.* 2006;191:726-732, discussion 733-734.
333. Sutton CD, Garcea G, White SA, et al. Isolated Roux-loop pancreaticojejunostomy: A series of 61 patients with zero postoperative pancreaticoenteric leaks. *J Gastrointest Surg.* 2004;8:701-705.
334. Suzuki Y, Kuroda Y, Morita A, et al. Fibrin glue sealing for the prevention of pancreatic fistulas following distal pancreatectomy. *Arch Surg.* 1995;130:952-955.
335. Yeo CJ, Cameron JL, Maher MM, et al. A prospective randomized trial of pancreaticogastrostomy versus pancreaticojejunostomy after pancreaticoduodenectomy. *Ann Surg.* 1995;222:580, discussion 588.
336. Wente MN, Shrikhande SV, Muller MW, et al. Pancreaticojejunostomy vs. pancreaticogastrostomy: Systematic review and meta-analysis. *Am J Surg.* 2007;193:171-183.
337. Suzuki Y, Fujino Y, Tanioka Y, et al. Selection of pancreaticojejunostomy techniques according to pancreatic texture and duct size. *Arch Surg.* 2002;137:1044-1047, discussion 1048.
338. Reid-Lombardo KM, Farnell MB, Crippa S, et al. Pancreatic anastomotic leakage after pancreaticoduodenectomy in 1,507 patients: a report from the Pancreatic Anastomotic Leak Study Group. *J Gastrointest Surg.* 2007;11:1451-1458.
339. Poon RT, Lo SH, Fong D, et al. Prevention of pancreatic anastomotic leakage after pancreaticoduodenectomy. *Am J Surg.* 2002;183:42-52.
340. Okamoto A, Tsuruta K. Fistulation method: simple and safe pancreaticojejunostomy after pancreatoduodenectomy. *Surgery.* 2000;127:433-438.
341. Yang YM, Tian XD, Zhuang Y, et al. Risk factors of pancreatic leakage after pancreaticoduodenectomy. *World J Gastroenterol.* 2005;11:2456-2461.
342. Di Carlo V, Chiesa R, Pontiroli AE, et al. Pancreatoduodenectomy with occlusion of the residual stump by Neoprene injection. *World J Surg.* 1989;13:105-110, discussion 110-111.
343. Buchler MW, Friess H, Wagner M, et al. Pancreatic fistula after pancreatic head resection. *Br J Surg.* 2000;87: 883-889.

344. Tran K, Van Eijck C, Di Carlo V, et al. Occlusion of the pancreatic duct versus pancreaticojejunostomy: a prospective randomized trial. *Ann Surg.* 2002;236:422-428, discussion 428.
345. Fisher WE, Chai C, Hodges SE, Wu MF, Hilsenbeck SG, Brunnicardi FC. Effect of BioGlue on the incidence of pancreatic fistula following pancreas resection. *J Gastrointest Surg.* 2008;12:882-890.
346. Kazanjian KK, Hines OJ, Eibl G, Reber HA. Management of pancreatic fistulas after pancreaticoduodenectomy: results in 437 consecutive patients. *Arch Surg.* 2005;140:849-854, discussion 854-856.
347. Group GTS. Further evidence of effective adjuvant combined radiation and chemotherapy following curative resection of pancreatic cancer. *Cancer.* 1997;59:2006-2010.
348. Neoptolemos JP, Dunn JA, Stocken DD, et al. Adjuvant chemoradiotherapy and chemotherapy in resectable pancreatic cancer: a randomised controlled trial. *Lancet.* 2001;358:1576.
349. Gillen S, Schuster T, Meyer zum Büschenfelde C, et al. Pre-operative neoadjuvant therapy in pancreatic cancer: a systematic review and meta-analysis of response and resection percentages. *PLoS Med.* 7(4): e1000267. Doi:10.1371/journal.pmed.1000267.
350. Yazawa K, Fisher WE, Brunnicardi FC. Current progress in suicide gene therapy for cancer. *World J Surg.* 2002;26:783-789.
351. Kiely JM, Nakeeb A, Komorowski RA, Wilson SD, Pitt HA. Cystic pancreatic neoplasms: enucleate or resect? *J Gastrointest Surg.* 2003;7:890-897.
352. Obermeyer R, Fisher W, Sweeney J, et al. Laparoscopic distal pancreatectomy for serous oligocystic adenoma. *Surg Rounds.* 2003;423.
353. Salvia R, Fernandez-del Castillo C, Bassi C, et al. Main-duct intraductal papillary mucinous neoplasms of the pancreas: clinical predictors of malignancy and long-term survival following resection. *Ann Surg.* 2004;239:678-685, discussion 685-687.
354. Boni L, Benevento A, Dionigi G, Cabrini L, Dionigi R. Primary pancreatic lymphoma. *Surg Endosc.* 2002;16:1107-1108.

34 chapter

Spleen

Adrian E. Park, Eduardo M. Targarona, and
Igor Belyansky

Historical Background	1423	Indications for Splenectomy	1429	Hand-Assisted Splenectomy / 1441	
Embryology and Anatomy	1424	Benign Disorders / 1429		Single-Incision Laparoscopic Surgery Splenectomy / 1443	
Physiology and Pathophysiology	1426	Malignant Conditions / 1434		Robotic Splenectomy / 1443	
Imaging for Evaluation of Size and Pathology	1428	Other Diseases of the Spleen / 1436		Partial Splenectomy / 1443	
Ultrasound / 1428		Preoperative Considerations	1438	Inadvertent Intraoperative Splenic Injury / 1443	
Computed Tomography / 1428		Vaccination and Patient Education / 1438		Splenectomy Outcomes	1443
Plain Radiography / 1428		Deep Vein Thrombosis Prophylaxis / 1439		Complications / 1444	
Magnetic Resonance Imaging / 1429		Splenectomy Techniques	1439	Hematologic Outcomes / 1444	
Angiography / 1429		Patient Preparation / 1439		Overwhelming Postsplenectomy Infection / 1444	
Nuclear Imaging / 1429		Open Splenectomy / 1439			
		Laparoscopic Splenectomy / 1440			

HISTORICAL BACKGROUND

For more than two millennia, the spleen has perhaps been the least understood and most underappreciated major organ. The central role played by the spleen in regulating the immune system as well as influencing metabolic and endocrine functions has only become clear over the past few decades. Our previous notion of the spleen as an utterly dispensable filter of the blood has been dispelled, enlightening our surgical approach to this fascinating organ.

Many of the “founding fathers of medicine” have weighed in on the anatomy and function of the spleen over the centuries. Hippocrates¹⁻³ in the fourth century BC was one of the first to write on the spleen. He taught broadly on the need for balance and equilibrium between the patient and his environment. Illness arose from disharmony in nature, particularly among the patient’s four humors: blood, phlegm, black bile (melancholia), and yellow bile. Hippocrates wrote of a direct connection between the brain and spleen and its particular association with the black bile. These ideas would influence thinking about the role of the spleen for more than 1000 years.²

Aristotle, later in the same era, famously stated that, “Nature makes nothing in vain,” yet held the spleen to be an organ of minor importance whose main role was to counterbalance the liver.⁴ He also described how the “hot character” of the spleen aided in digestion.

Galen, in the second century AD, engaged in more serious anatomic investigation espousing the early belief that function followed structure. His investigations, though pioneering, lacked sufficient rigor, evidenced by his contention that black bile or melancholia flowed from the liver to the spleen and then through the short gastric vessels into the stomach to be excreted. The influence of Galen’s teaching endured for more than 1200 years.

In the early seventeenth century, several physician scientists, Malpighi being the most prominent, began testing hypotheses on splenic function by splenectomizing dogs. He reportedly followed several dogs 5 years postoperatively, noting their healthy survival though apparent ravenous hunger and enhanced sexual appetites. The spleen, still in the era of “balanced humors,” was thus felt to play a role in balancing various appetites as well. In addition to melancholy, the spleen became associated with anger and, paradoxically, was also seen as the “seat of laughter.”⁵

The claim for the first human splenectomy may have predated that of canine splenectomy. Andriano Zaccavello was credited in 1549 with having performed a splenectomy on a middle-aged woman. This claim remains shrouded in controversy, and the indication for the surgery and whether in fact splenectomy was performed have been called into question. The patient apparently survived. Most patients who underwent splenectomy in the three centuries that followed fared badly. The vast majority of splenectomies performed were partial. Most of these patients required surgery for left upper quadrant stab wounds sustained in battles or duels resulting in partial or complete splenic prolapse.⁶

It was in the early eighteenth century that the growing body of anatomic microstructural knowledge began to turn the tide on the long-held theory of health and disease deriving from a balance of the four humors. William Henson believed the spleen to be a ductless vascular gland similar to the thyroid and adrenals. In 1777, he wrote of the lymphatic nature of the spleen and its filtering function and even suggested its role in hematopoiesis.¹³

Rudolf Virchow, one of the first to discover leukemia, implicated the spleen as figuring prominently in all leukemia patients. He suspected that the spleen was responsible for

Key Points

- ▶ The human spleen plays a key immunologic role in defense against a number of organisms, particularly encapsulated bacteria.
- ▶ The spleen can cause significant morbidity and/or hematologic disturbance if it becomes hyperfunctioning (hypersplenism) or hypertrophied (splenomegaly).
- ▶ There is a broad spectrum of nontraumatic diseases for which elective splenectomy can be curative or palliative. They can be broadly categorized as red blood cell disorders and hemoglobinopathies, white blood cell disorders, platelet disorders, bone marrow disorders, infections and abscesses, cysts and tumors, storage diseases and infiltrative disorders, and miscellaneous conditions.
- ▶ Partial splenectomy may be a suitable alternative to total splenectomy for certain conditions of hypersplenism or splenomegaly, particularly in children in whom preservation of splenic immunologic function is especially important.
- ▶ Preoperative splenic artery embolization for elective splenectomy has benefits and disadvantages. It may be most suitable in cases of enlarged spleen. Conclusive evidence is lacking.
- ▶ Laparoscopic splenectomy provides equal hematologic outcomes with decreased morbidity compared with the open operation. The laparoscopic approach has emerged as the standard for elective, nontraumatic splenectomy.
- ▶ Inadvertent intraoperative splenic injury is a scenario for which every abdominal surgeon should be prepared. Availability of a predetermined algorithm, with emphasis on the patient's condition, facilitates intraoperative decision making.
- ▶ Overwhelming postsplenectomy infection (OPSI) is an uncommon but potentially grave disease. Children and those undergoing splenectomy for hematologic malignancy are at elevated risk.
- ▶ Antibiotic prophylactic strategies against OPSI vary widely. Data regarding their use are lacking.
- ▶ Vaccination of the splenectomized patient remains the most effective prevention strategy against OPSI. Preoperative vaccination before elective splenectomy is most prudent.

generating the leukocytes in large quantities in these patients. There soon followed an enthusiastic effort by surgeons to cure leukemia by splenectomy. Dr. Thomas Bryant performed the first splenectomy in 1866 in a patient with leukemia. The patient died, as did all 14 patients who underwent splenectomy for leukemia over the next 15 years. After his second consecutive mortality in this setting, Bryant declared that “the operation is physiologically unsound & surgically unsafe for leukemia and should not be performed.”⁷ In 1908, Johnson reported a series of 99 splenectomies for leukemia with an 85% mortality rate. Unfortunately, it took several decades for his words to be heeded.

In 1916, a medical student from Prague named Paul Kaznelson wrote on the key role played by the spleen in the destruction of platelets leading to the first reported (and successful) splenectomy for a patient with idiopathic thrombocytopenia purpura.²

As surgeons' experience with the procedure grew, the associated morbidity and mortality decreased. By 1920, the Mayo Clinic experience with splenectomy reported a reduced mortality rate of 11%.¹

O'Donnell in 1929 was the first to describe fatal postsplenectomy sepsis in a child who had undergone the surgery for hemolytic anemia.³ It took Springer's 1973 review of almost 2800 postsplenectomy patients and the 2.5% incidence of sepsis-induced mortality (vs. 0.01% in the general population) to reorient surgeons to more conservative splenic procedures.^{2,3}

The advent of minimally invasive surgery and laparoscopic splenectomy in the early 1990s represented a clear advance, benefitting the patient through this evolution of surgical technique. Most large series of laparoscopic splenectomy for benign and malignant indication now report a mortality rate of <1%.^{9,10} As even more contemporary research reveals the spleen to play a central role in immune, metabolic, and endocrine

function, it follows that the surgeon's role going forward will be to preserve this organ and its functions whenever possible.

EMBRYOLOGY AND ANATOMY

Consisting of an encapsulated mass of vascular and lymphoid tissue, the spleen is the largest reticuloendothelial organ in the body. Arising from the primitive mesoderm as an outgrowth of the left side of the dorsal mesogastrium, by the fifth week of gestation, the spleen is evident in an embryo 8 mm long.

Development begins through the formation of the splanchnic mesodermal plate, derived from the mesoderm, at embryonic day 12. The embryonic spleen is first colonized by erythroid and myeloid progenitor cells at 2 weeks of gestation. Following soon thereafter, the hematopoietic stem cells take up residence in the forming spleen.¹¹ The spleen assumes an important hematopoietic role until the fifth month of gestation. After birth, splenic erythropoietic function may persist in some hematologic disorders.¹²

The organ continues its differentiation and migration to the left upper quadrant, where it comes to rest with its smooth, diaphragmatic surface facing posterosuperiorly.⁸

The most common anomaly of splenic embryology is the accessory spleen. Present in up to 20% of the population, one or more accessory spleens may also occur in up to 30% of patients with hematologic disease. Over 80% of accessory spleens are found in the region of the splenic hilum and vascular pedicle. Other locations for accessory spleens in descending order of frequency are the gastrocolic ligament, the pancreas tail, the greater omentum, the stomach's greater curve, the splenocolic ligament, the small and large bowel mesentery, the left broad ligament in women, and the left spermatic cord in men (Fig. 34-1).^{8,13}

The abdominal surface of the diaphragm separates the spleen from the lower left lung and pleura and the ninth to

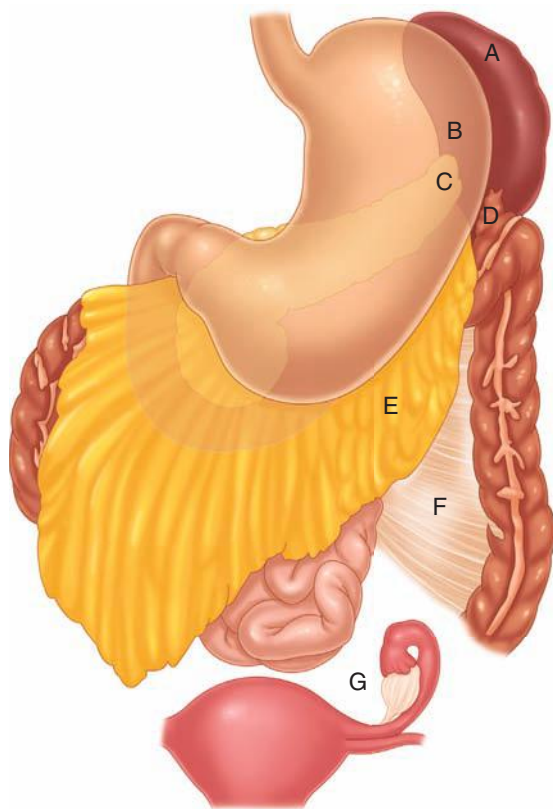


Figure 34-1. Sites where accessory spleens are found in order of importance. A. Hilar region, 54%; B. pedicle, 25%; C. tail of pancreas, 6%; D. splenicocolic ligament, 2%; E. greater omentum, 12%; F. mesentery, 0.5%; G. left ovary, 0.5%.

eleventh ribs. The visceral surface faces the abdominal cavity and contains gastric, colic, renal, and pancreatic impressions. Spleen size and weight vary with age, with both diminishing in the elderly and in those with underlying pathologic conditions. The average adult spleen is 7 to 11 cm in length and weighs 150 g (range, 70 to 250 g).

The spleen's superior border separates the diaphragmatic surface from the gastric impression of the visceral surface and often contains one or two notches, which are particularly pronounced when the spleen is greatly enlarged.

Of particular clinical relevance, the spleen is suspended in position by several ligaments and peritoneal folds to the colon (splenicocolic ligament), the stomach (gastrosplenic ligament), the diaphragm (phrenosplenic ligament), and the kidney, adrenal gland, and tail of the pancreas (splenorenal ligament) (Fig. 34-2). The gastrosplenic ligament contains the short gastric vessels; the remaining ligaments are avascular, with rare exceptions, such as in patients with portal hypertension. The relationship of the pancreas to the spleen also has important clinical implications. In cadaveric anatomic series, the tail of the pancreas has been demonstrated to lie within 1 cm of the splenic hilum 75% of the time and to actually abut the spleen in 30% of patients.²

The spleen derives most of its blood from the splenic artery, the longest and most tortuous of the three main branches of the celiac artery. The splenic artery can be characterized by the pattern of its terminal branches. The *distributed type* of splenic artery is the most common (70%) and is distinguished by a short trunk with many long branches entering over three-

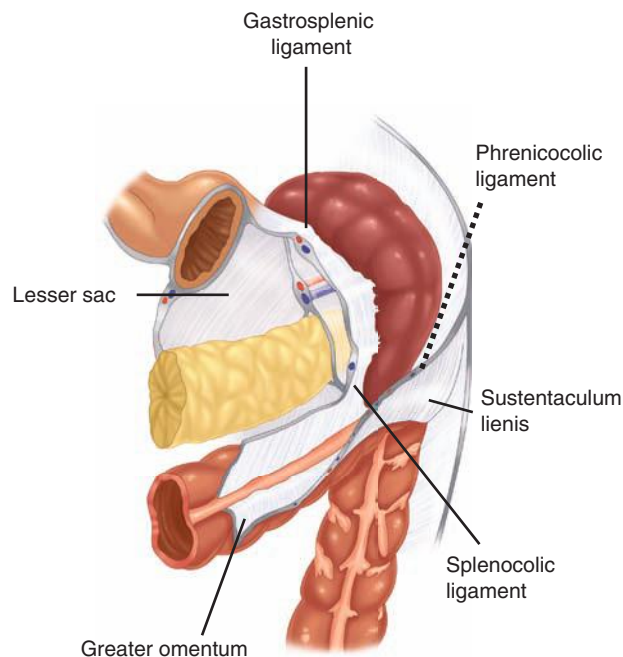


Figure 34-2. Suspensory ligaments of the spleen. (Data from Poulin EC, Thibault C. *The anatomical basis for laparoscopic splenectomy*. Can J Surg. 1993;36:484.)

fourths of the spleen's medial surface. The less common *magistral type* of splenic artery (30%) has a long main trunk dividing near the hilum into short terminal branches, and these enter over 25% to 30% of the spleen's medial surface. The spleen also receives some of its blood supply from the short gastric vessels that branch from the left gastroepiploic artery running within the gastrosplenic ligament. The splenic vein joins the superior mesenteric vein to form the portal vein and accommodates the major venous drainage of the spleen.

When a normal, freshly excised spleen is sectioned, the cut surface is finely granular and predominantly dark red with whitish nodules distributed liberally across its expanse. This gross observation reflects the spleen's microstructure. The splenic parenchyma is composed of two main elements: the red pulp, constituting approximately 75% of total splenic volume, and the white pulp (Fig. 34-3). At the interface between the red and white pulp is the narrow marginal zone.

Blood enters the red pulp through cords comprised of fibroblasts and reticular fibers, which contain many macrophages and lack an endothelial lining. The blood then passes from these "open" cords to venous sinuses, which are surrounded and separated by the same reticulum, and ultimately drains into tributaries of the splenic vein. An understanding of the microanatomy of these sinuses has elucidated the mechanical filtration function of the spleen. Unlike the cords of the red pulp, the sinuses of the red pulp are lined by endothelial cells. These cells contain unique stress fibers that connect the endothelial cells and that contain actin and myosin-like filaments capable of producing a sliding action. When activated, these filaments can create slits or gaps between the endothelial cells through which blood can then pass from the cords.¹¹ Aging erythrocytes with stiffer membranes get stuck trying to pass into the sinus and are phagocytized by macrophages within the red pulp.¹²

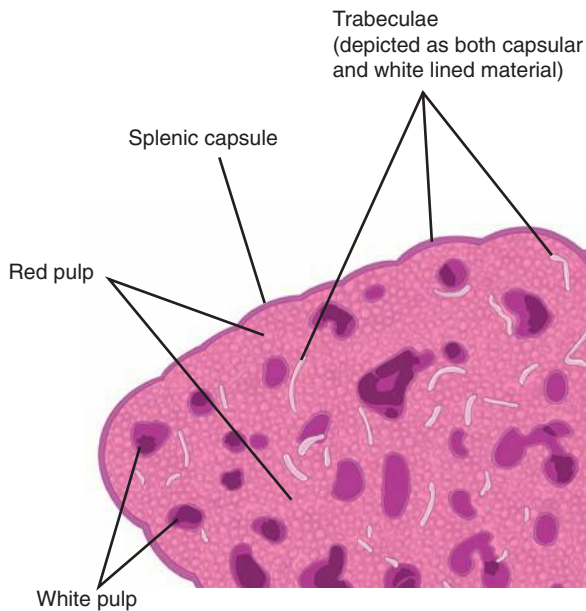


Figure 34-3. Splenic architecture. (Used with permission of Ivan George, University of Maryland School of Medicine.)

The red pulp thus serves as a dynamic filtration system, enabling macrophages to remove microorganisms, cellular debris, antigen-antibody complexes, and senescent erythrocytes from the circulation.

Around the terminal millimeters of splenic arterioles, a *periartericular lymphatic sheath* replaces the native adventitia of the vessel. The sheath is comprised of T lymphocytes and intermittent aggregations of B lymphocytes or lymphoid follicles. When antigenically stimulated, the follicles, serving as centers of lymphocyte proliferation, develop germinal centers, which regress as the stimulus or infection subsides. This white pulp consists of nodules that normally are ≤ 1 mm in size but can increase to several centimeters when nodules coalesce, as occurs in certain lymphoproliferative disorders. At the junction between the white and red pulp is the marginal zone, where lymphocytes are more loosely aggregated.

As well as serving as a transit area, the marginal zone is home to its own unique population of cells. Notably two specific types of macrophages reside there, marginal zone macrophages and marginal zone metallophilic macrophages. The former play an important role in the targeting and clearance of certain bacterial pathogens. The latter have been shown to be the main producers of interferons A and B in response to a viral challenge.¹¹

PHYSIOLOGY AND PATHOPHYSIOLOGY

The spleen is contained by a 1- to 2-mm thick capsule. In humans, the capsule is rich in collagen and contains some elastin fibers. Many mammals have splenic capsules and trabeculae with abundant smooth muscle cells, which upon autonomic stimulation contract to expel large volumes of stored blood into the general circulation. The human splenic capsule and trabeculae, by contrast, contain few or no smooth muscle cells.

Total splenic inflow of blood is approximately 250 to 300 mL/min. Blood flows through successively tapering arteries to arterioles, traverses the white pulp, crosses the marginal zone,

and enters the red pulp. From that entry, the flow rate through the spleen may vary greatly. Animal studies measuring the transit times of isotopically labeled blood through the spleen have revealed three distinct velocities of flow. Humans have long been recognized to have both a fast or closed circulation—with blood passing directly from arterioles into venous sinuses—and a slower or open circulation. Most of the spleen's filtration function occurs via the slower circulation. During open circulation, blood percolates through the reticular space and splenic cords, thus gaining access through gaps or slits in the endothelial cell lining to the sinuses as previously described. Flowing into and out of the venous sinuses through these gaps, the blood is exposed to extensive contact with splenic macrophages. These are responsible for the innate immune response of the spleen, which occurs largely within the marginal zone. The white pulp, by contrast, is involved only in adaptive immunity. In addition, because the passage of plasma through these spaces does not slow in a similar manner, a temporary and unique adhesive contact between blood cells and components of the splenic cord may occur. That there is a selective slowing of blood cell flow versus plasma flow is further evidenced by the fact that within the spleen, the erythrocyte concentration (hematocrit) is twice that of the general circulation. During this contact with splenic macrophages, it is likely that the removal of both cellular debris and senescent blood cells occurs.¹⁴

The process by which the spleen removes erythrocyte inclusions, such as Heinz bodies (intracellular altered hemoglobin), without cell lysis while red blood cells travel through the spleen is not well understood. The spleen acts as the major site for clearance from the blood of damaged or aged red blood cells and, in addition, has a part in the removal of abnormal white blood cells and platelets. A minimum of 2 days of the erythrocyte's 120-day life cycle is spent sequestered in the spleen. Daily, approximately 20 mL of aged red blood cells are removed. Evidence suggests that, as erythrocytes age, previously undetected antigens on their surfaces may attach to auto-antibodies in the circulation; then macrophages may bind to the antibodies and initiate phagocytosis. It is probable that the erythrocyte is damaged over time by multiple passages through the spleen as well as delayed transit through the congested and relatively hypoxic and acidotic environment of the splenic cords.

The spleen can also serve as an extra medullary site for hematopoiesis, if required. Another role played by the spleen is in recycling iron. Erythrocytes in large numbers are destroyed intravascularly throughout the body. The released hemoglobin is then bound to haptoglobin, which is ultimately scavenged from the circulation in the spleen.¹⁵

The spleen plays a vital, although not indispensable, role in host defense evidenced by the healthy survival of splenectomized patients. Both innate and adaptive immune responses (historically categorized as cell-mediated and humoral immunity) occur within the spleen.

In addition to the previously noted activities of the marginal zone macrophages, marginal zone B cells serve to detect circulating pathogens and respond quickly to either differentiate into immunoglobulin M (IgM)-producing plasma cells or to function as antigen-presenting cells (APCs), which facilitate pathogen removal and destruction.

It is APC entry in the white pulp in particular that is key to the initiation of the adaptive immune response. Antigens are thus presented to immunocompetent centers within the lymphoid

follicles. This gives rise to the elaboration of immunoglobulins (predominantly IgM). After an antigen challenge, such an acute IgM response results in the release of opsonic antibodies from the white pulp of the spleen. Antigen clearance is then facilitated by the splenic and hepatic reticuloendothelial systems.

The structure and immunophysiology of the white pulp is very similar to that of lymph nodes, with the notable difference being that material enters the lymph node in the lymph whereas it is delivered to the white pulp in the blood.¹⁶

The spleen also produces opsonins, tuftsin, and properdin. Circulating monocytes are converted within the red pulp into fixed macrophages that account for the spleen's remarkable phagocytic activity.

The spleen also appears to be a major source of the protein properdin, important in the initiation of the alternate pathway of complement activation. The splenic reticuloendothelial system is better able to clear bacteria that are poorly or inadequately opsonized from the circulation than is the hepatic reticuloendothelial system. Encapsulated bacteria generally fit such a profile, hence the risk posed by pneumococcus and *Haemophilus influenzae* to an asplenic patient. There appears to be sufficient physiologic capacity within the complement cascade to withstand the loss of tuftsin and properdin production without an increase in patient vulnerability after splenectomy.¹⁷⁻¹⁹

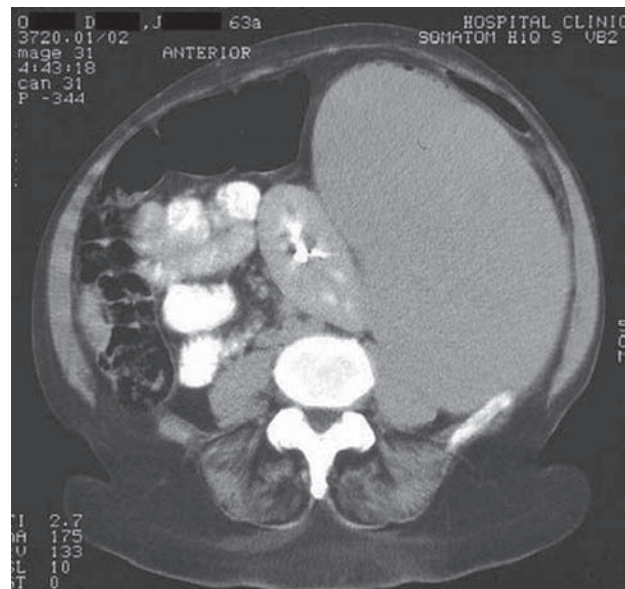
In patients with chronic hemolytic disorders, splenic tissue may become permanently hypertrophied. The reticular spaces of the red pulp become distended with macrophages engorged with the products of erythrocyte breakdown, and splenomegaly can result. It is important to distinguish between *splenomegaly* and *hypersplenism*, two similar but distinct terms that are critical to understand when discussing splenic pathology. *Splenomegaly* refers simply to abnormal enlargement of the spleen. Splenomegaly is described variably within the surgical literature as *moderate*, *massive*, and *hyper*, which reflects a lack of consensus. Most would agree, however, that *splenomegaly* applies to organs weighing ≥ 500 g and/or averaging ≥ 15 cm in length.

Massive splenomegaly similarly lacks a consensus definition but has been described variably as spleens >1 kg in mass or >22 cm in length (Fig. 34-4).⁶ Spleens palpable below the left costal margin are thought to be at least double normal size, with an estimated weight of ≥ 750 g.²⁰

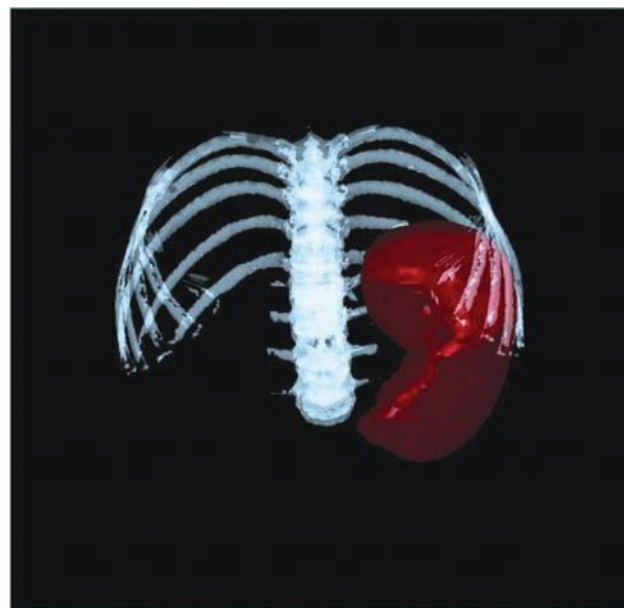
There is not a single, universally accepted standard, but most would agree that an ex vivo mass of >1 kg or a pole-to-pole length of >15 cm generally qualifies as splenomegaly. Hypersplenism often is found in association with splenomegaly but is not synonymous with it. Hypersplenism is defined as the presence of one or more cytopenias in the context of a normally functioning bone marrow.

Disorders causing hypersplenism can be categorized as either (a) those in which increased destruction of abnormal blood cells occurs in an intrinsically normal spleen (e.g., hemolytic anemias) or (b) primary disorders of the spleen resulting in increased sequestration and destruction of normal blood cells (e.g., infiltrative disorders).

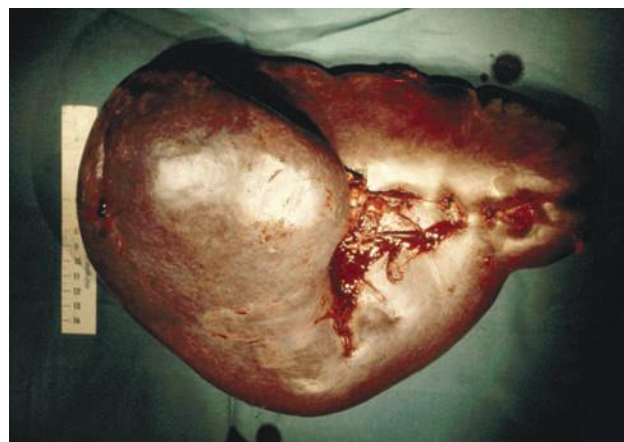The life cycles of cellular elements vary widely in human blood. A neutrophil in circulation has a normal half-life of approximately 6 hours. The spleen's role in the normal clearance of neutrophils is not well established. It is clear that hypersplenism may result in neutropenia through sequestration of normal white blood cells or the removal of abnormal ones. Platelets, on the other hand, generally survive in the circulation for 10 days.



A



B



C

Figure 34-4. Splenomegaly. **A.** Computed tomography (CT) scan. **B.** Three-dimensional reconstruction of CT scan. **C.** Postoperative specimen.

Under normal circumstances, a third of the total platelet pool is sequestered in the spleen. Thrombocytopenia may result from excessive sequestration of platelets as well as accelerated platelet destruction in the spleen. Splenomegaly may result in sequestration of up to 80% of the platelet pool. The spleen may also contribute to the immunologic alteration of platelets, which leads to thrombocytopenia in the absence of splenomegaly (e.g., idiopathic thrombocytopenic purpura [ITP]).²¹

The immunologic functions of the spleen are consistent with those of other lymphoid organs. It is a site of bloodborne antigen presentation and the initiation of T- and B-lymphocyte activities involved in humoral and cellular immune responses. Alteration of splenic immune function often gives rise to antibody production, which results in blood cell destruction.

Although the spleen contributes to the process of erythrocyte maturation, in adult humans there is little evidence of normal hematopoietic function. The spleen does have a minor role in hematopoiesis in the fourth month in the human fetus, and reactivation can occur in childhood if the bone marrow fails to meet the hematologic needs. Splenic hematopoiesis giving rise to abnormal red blood cells is seen in adults with myeloproliferative disorders. In addition, in response to some anemias, elements of the red pulp may revert to hematopoiesis.

IMAGING FOR EVALUATION OF SIZE AND PATHOLOGY

Prior to operation, thorough assessment of anatomic detail and functional status of the spleen is essential for surgical planning. Special preoperative consideration needs to be given to patients with splenomegaly because minimally invasive methods increase in difficulty with increasing size of the spleen. Other indications for splenic imaging include trauma, investigations of left upper quadrant pain, characterization of splenic lesions such as tumors, cysts, and abscesses, and guidance for percutaneous procedures.^{22,23}

Preoperative imaging of the spleen is primarily performed to obtain an accurate assessment of the splenic volume in order to confirm and document splenomegaly as well as to exclude any large splenic lesion that could affect the surgical resection plane. Identification of the presence of accessory spleens in the preoperative setting is also important, although lack of accessory tissue on the imaging should not preclude a thorough intraoperative search.

The guidelines of the European Association for Endoscopic Surgery suggest that all patients should undergo preoperative imaging.²⁰ Some of the common imaging modalities include ultrasound and computed tomography (CT), both enabling measurement of splenic size and volume. When desired, the splenic volume may be calculated using a formula for the volume of a prolate ellipsoid: Volume (cc) = Length (cm) × Width (cm) × Height (cm) × 0.52.⁴³ Other imaging modalities, although not as commonly used, include nuclear medicine studies and magnetic resonance imaging (MRI).

Ultrasound

Ultrasound is the least invasive mode of splenic imaging. It is rapid, easy to perform, and does not expose the patient to ionizing radiation. It is often the first imaging modality applied to the spleen during evaluation and resuscitation of the trauma patient, although questions of sensitivity and specificity remain.^{24,25} In the elective setting, such as for routine diagnostic purposes or

for preoperative planning, it is the least costly modality available, and the sensitivity of ultrasound for detecting textural lesions of the spleen can be quite good in experienced hands.²⁶

When examining a normal spleen, differentiation between red and white pulp is not possible, and a homogeneous acoustic echotexture should be visualized. Splenic artery and vein patency may be assessed using Doppler imaging. Splenic artery anatomy has been classified commonly into two patterns: distributed and magistral. This variability in vascular distribution visualized by Doppler imaging becomes important when there is consideration of performing a partial splenectomy.

Percutaneous ultrasound-guided procedures for splenic disease (e.g., cyst aspiration, biopsy), historically avoided due to the risk of hemorrhage and other complications, are becoming more common as the safety of these procedures is being increasingly demonstrated.^{22,23}

Computed Tomography

CT affords a high degree of resolution and detail of the splenic parenchyma, vasculature, and its relationship to neighboring structures. Modern-day CT is more automated and thus less operator dependent than ultrasound, which makes it the preferred imaging modality for many practitioners. Furthermore, CT has become an invaluable tool in the evaluation and management of the blunt trauma patient, and standardized scoring systems for splenic trauma based on CT images now aid in management decisions.²⁷ In the nontrauma setting, CT is extremely useful for assessment of splenomegaly, identification of solid and cystic lesions, and guidance of percutaneous procedures.³ The use of iodinated contrast material adds diagnostic clarity to CT imaging of the spleen, although at the cost of the small but real risks of renal impairment or allergic reaction. Three-dimensional reconstruction after CT scan may help to predict the difficulty of the procedure and to choose the best surgical approach: open or laparoscopic.^{29,30}

The appearance of normal splenic tissue on a noncontrast CT is uniform parenchymal attenuation. On a contrast-enhanced CT, the appearance of the spleen depends largely on the timing of the intravenous bolus administration of contrast material. Due to the different rates of flow through the red and white pulp, the spleen appears heterogeneously enhancing during the first minute after initiation of intravenous administration of contrast material. The frequency of these artifacts increases with advancing patient age. When evaluating a splenic abscess, a contrast-enhanced CT should be considered.^{28,43}

Three-dimensional CT volumetry is a novel modality that measures the volume of the spleen. This tool may be of some benefit in planning technically challenging cases involving splenomegaly. A recent retrospective review of laparoscopic splenectomy patients who underwent CT volumetry preoperatively demonstrated a higher conversion rate when the spleen was measured to be greater than 2700 cc.²⁹ This information may aid in preoperative planning in determining which patients may benefit from a hand-assisted laparoscopic surgery approach or open approach.⁹⁷

Plain Radiography

Rarely is plain radiography used for primary splenic imaging. Plain films can indirectly provide an outline of the spleen in the left upper quadrant or suggest splenomegaly by revealing displacement of adjacent air-filled structures (e.g., the stomach or splenic flexure of the colon). Plain films may also demonstrate

splenic calcifications. Splenic calcifications often are found in association with splenomegaly but are otherwise a nonspecific finding. Splenic calcifications can indicate a number of benign, neoplastic, or infectious processes, including phlebolith, splenic artery aneurysm, sickle cell changes, tumors (e.g., hemangioma, hemangiosarcoma, lymphoma), echinococcosis, or tuberculosis.²⁶

Magnetic Resonance Imaging

Although MRI offers excellent detail and versatility in abdominal imaging, it is more expensive than CT scanning or ultrasound and offers no obvious advantage for primary imaging of the spleen. MRI can be a valuable adjunct to the more commonly used imaging techniques when splenic disease is suspected but not definitively diagnosed.^{26,28}

Magnetic resonance (MR) signal characteristics of the spleen are related to the relative ratio of red and white pulp and the relationship of the timing of the intravenous (IV) contrast bolus and the time of image acquisition. The spleen will generally have a homogeneous MR signal on noncontrast images. On contrast MRI, the spleen appears to have heterogeneous enhancement during the arterial phase of contrast enhancement.

Angiography

Angiography of the spleen most commonly refers to invasive arterial imaging, and when it is combined with therapeutic splenic arterial embolization (SAE), there are multiple applications for this procedure: localization and treatment of hemorrhage in select trauma patients³¹; delivery of a variety of therapies in patients with cirrhosis or portal and sinistral hypertension and in transplant patients³²; and adjunct (or, more controversially, as an alternative) to splenectomy for treatment of hematologic disorders such as ITP or hypersplenism.³³ Preoperative or intraoperative SAE for elective splenectomy is also a common, although not universal, practice. Few prospective data have been published in the last 5 years on preoperative SAE.³⁴ Preoperative SAE is purported not only to facilitate operation but also possibly to allow a laparoscopic approach in patients whose spleens had previously been considered too large for, or otherwise not amenable to, laparoscopic resection. Limited success in using partial SAE as an alternative to therapeutic splenectomy in chronic ITP has been previously reported.³⁵ Its detractors argue that the need for increased analgesics and occasional extended hospital stay preoperatively, the possibility of pancreatitis, and the well-described risks of invasive arteriography negate any presumed benefits of preoperative SAE.

Nuclear Imaging

Radioscintigraphy with technetium-99m sulfur colloid demonstrates splenic location and size. It may be especially helpful in locating accessory spleens after unsuccessful splenectomy for ITP and has recently proven useful in diagnosing splenosis.^{36,37} Unfortunately, no conclusive outcome benefit has been shown for preoperative technetium scanning before splenectomy.^{38,39} When dealing with diseases of platelet sequestration, indium-labeled autologous platelet scanning (ILAPS) demonstrates whether platelet sequestration is predominantly in the spleen, liver, or both. This becomes important in deciding whether or not a patient will benefit from a splenectomy. ILAPS is a nuclear imaging modality in which autologous platelets are reinfused into the patient after *ex vivo* labeling. Subsequent scintigraphy demonstrates the site(s) of platelet sequestration and clearance. It has been proposed that patients with purely or predominantly splenic sequestration determined by ILAPS may be more likely

to respond to splenectomy than those exhibiting hepatic, mixed, or diffuse patterns.³³

An emerging and novel application for spleen scintigraphy may be as a noninvasive method to diagnose nonalcoholic steatohepatitis (NASH). NASH, which may lead to cirrhosis, can result from nonalcoholic fatty liver disease (NAFLD), the most common cause of steatosis. With the rising prevalence of obesity in the United States, NAFLD is also increasingly prevalent.¹² The diagnosis of progression from NAFLD to NASH has been dependent on histologic assessment of tissue obtained from liver biopsy. Characteristics unique to NASH have been reported, among them the association of splenic enlargement, not seen to a similar degree in NAFLD.¹⁰

In addition, the ratio of liver-to-spleen uptake determined by scintigraphy has been found to be predictably altered in NASH patients. The liver-to-spleen uptake ratio is significantly decreased in NASH patients, but not NAFLD patients, leading some to conclude that technetium-99m-phytate scintigraphy is a reliable tool to differentiate NASH from NAFLD.⁴⁰

INDICATIONS FOR SPLENECTOMY

Splenectomy is therapeutic for a large host of conditions, which can be divided into the following broad categories: (a) benign, including red blood cell disorders, hemoglobinopathies, and platelet disorders; (b) malignant, including white blood cell disorders and bone marrow disorders (myeloproliferative disorders); and (c) other, including cysts and tumors, infections and abscesses, splenic rupture, and a number of miscellaneous disorders and lesions (Table 34-1).

Overall, the most common indication for splenectomy is trauma to the spleen, whether external trauma (blunt or penetrating) or iatrogenic injury (e.g., during operative procedures for other reasons). Inadvertent intraoperative injury to the spleen in the nontrauma patient is discussed in a later section. Management of splenic injury in the trauma patient is beyond the scope of this chapter. The most common indication for elective splenectomy is ITP.

Benign Disorders

Red Blood Cell Disorders

Congenital

Hereditary Spherocytosis. Hereditary spherocytosis (HS) results from an inherited dysfunction or deficiency in one of the erythrocyte membrane proteins (*spectrin*, *ankyrin*, *band 3 protein*, or *protein 4.2*). The resulting destabilization of the membrane lipid bilayer allows a pathologic release of membrane lipids. The red blood cell assumes a more spherical, less deformable shape, and the spherocytic erythrocytes are sequestered and destroyed in the spleen. Hemolytic anemia ensues; in fact, HS is the most common hemolytic anemia for which splenectomy is indicated. HS is inherited primarily in an autosomal dominant fashion; the estimated prevalence in Western populations is 1 in 5000.⁴¹⁻⁴³

Patients with typical HS forms may have mild jaundice. Splenomegaly usually is present on physical examination. Laboratory examination reveals varying degrees of anemia: patients with mild forms of the disease may have no anemia; patients with severe forms may have hemoglobin levels as low as 4 to 6 g/dL. The mean corpuscular volume is typically low to normal or slightly decreased. For screening, a combined elevated

Table 34-1

Indications for and expected response to splenectomy in various diseases and conditions

DISEASE/CONDITION	INDICATIONS FOR SPLENECTOMY	RESPONSE TO SPLENECTOMY
Hereditary spherocytosis	Hemolytic anemia, recurrent transfusions, intractable leg ulcers	Improves or eliminates anemia
Hereditary elliptocytosis	Limited role for splenectomy	—
Pyruvate kinase deficiency	Only in severe cases, recurrent transfusions	Decreased transfusion requirement, palliative only
Glucose-6-phosphate dehydrogenase deficiency	None	—
Warm-antibody autoimmune hemolytic anemia	Failure of medical (steroid) therapy	60%–80% response rate, recurrences common
Sickle cell disease	History of acute sequestration crisis, splenic symptoms, or infarction (consider concomitant cholecystectomy)	Palliative, variable response
Thalassemia	Excessive transfusion requirements, symptomatic splenomegaly, or infarction	Diminished transfusion requirements, relief of symptoms
Acute myeloid leukemia (AML)	Intolerable symptomatic splenomegaly	Relief of abdominal pain and early satiety
Chronic myeloid leukemia	Symptomatic splenomegaly	Relief of abdominal pain and early satiety
Chronic myelomonocytic leukemia	Symptomatic splenomegaly	Relief of abdominal pain and early satiety
Essential thrombocythemia	Only for advanced disease (i.e., transformation to myeloid metaplasia or AML) with severe symptomatic splenomegaly	Relief of abdominal pain and early satiety
Polycythemia vera	Only for advanced disease (i.e., transformation to myeloid metaplasia or AML) with severe symptomatic splenomegaly	Relief of abdominal pain and early satiety
Myelofibrosis (agnogenic myeloid metaplasia)	Severe symptomatic splenomegaly	76% clinical response at 1 y, high risk of hemorrhagic, thrombotic, and infectious complications (26%)
Chronic lymphocytic leukemia	Cytopenias and anemia	75% response rate
Hodgkin's disease	Surgical staging in selected cases	—
Non-Hodgkin's lymphoma	Cytopenias, symptomatic splenomegaly	Improved complete blood count values, relief of symptoms
Idiopathic thrombocytopenic purpura	Failure of medical therapy, recurrent disease	75%–85% rate of long-term response
Thrombotic thrombocytopenic purpura	Excessive plasma exchange requirement	Typically curative
Abscesses of the spleen	Therapy of choice	Curative
Symptomatic parasitic cysts	Therapy of choice	Curative; exercise caution not to spill cyst contents
Symptomatic nonparasitic cysts	Partial splenectomy for small cysts; unroofing for large cysts	Curative
Gaucher's disease	Hypersplenism	Improves cytopenias; does not correct underlying disease
Niemann-Pick disease	Symptomatic splenomegaly	Improves symptoms; does not correct underlying disease
Amyloidosis	Symptomatic splenomegaly	Improves symptoms; does not correct underlying disease
Sarcoidosis	Hypersplenism or symptomatic splenomegaly	Improves symptoms and cytopenias; does not correct underlying disease
Felty's syndrome	Neutropenia	80% durable response rate
Splenic artery aneurysm	Splenectomy best for distal lesions near splenic hilum	Curative
Portal hypertension	Portal or sinistral hypertension due to splenic vein thrombosis	Palliative

mean corpuscular hemoglobin concentration and an elevated erythrocyte distribution width are an excellent predictor. Other laboratory indicators of HS include those providing evidence of rapid red blood cell destruction, including elevated reticulocyte count, elevated lactate dehydrogenase level, and increased level of unconjugated bilirubin. Spherocytes are readily apparent on peripheral blood film.

Risks and benefits should be assessed carefully before splenectomy and cholecystectomy are performed for HS.⁴¹ The main indications are symptomatic hemolytic anemia, growth retardation, skeletal changes, leg ulcers, and extramedullary hemopoietic tumors in young patients. If gallstones coexist with spherocytosis, the gallbladder should be removed, but prophylactic cholecystectomy without gallstones is not recommended. Near total splenectomy is advocated in children. Dramatic clinical improvement—despite persistent hemolysis—usually occurs after splenectomy in patients with severe disease. Because children can be affected with HS, the timing of splenectomy is important and is aimed at reducing the quite small possibility of overwhelming postsplenectomy sepsis. Delaying such an operation until the patient is between the ages of 4 and 6—unless the anemia and hemolysis accelerate—is recommended by most experts.⁴⁴

Hereditary elliptocytosis (HE) merits brief discussion to distinguish it from HS. Both HS and HE are conditions of the red blood cell membrane that result from genetic defects in skeletal membrane proteins. With the HE defect, the red blood cell elongates as it circulates, so that far fewer red blood cells are sequestered or destroyed when transiting the splenic parenchyma. Unless more than 50% of red blood cells are affected (a scenario that could permit development of a clinical syndrome like HS), HE may be considered harmless.

Red Blood Cell Enzyme Deficiencies. Red blood cell enzyme deficiencies associated with hemolytic anemia may be classified into two groups: deficiencies of enzymes involved in glycolytic pathways, such as pyruvate kinase (PK) deficiency, and deficiencies of enzymes needed to maintain a high ratio of reduced to oxidized glutathione in the red blood cell, protecting it from oxidative damage, such as glucose-6-phosphate dehydrogenase (G6PD) deficiency.⁴⁵

Pyruvate Kinase Deficiency The most common red blood cell enzyme deficiency to cause congenital chronic hemolytic anemia is PK deficiency.⁴⁵ Its pathophysiology is unclear. PK deficiency affects people worldwide, with a slight preponderance among those of northern European or Chinese descent. Clinical manifestations of the disease vary widely, from transfusion-dependent severe anemia in early childhood to well-compensated mild anemia in adolescents or adults. Diagnosis is made either by a screening test or by detection of specific mutations at the complementary DNA or genomic level. Splenomegaly is common, and in severe cases, splenectomy can alleviate transfusion requirements.⁵ As with other disorders that cause hemolytic anemia in children, splenectomy should be delayed if possible to at least 4 years of age to reduce the risk of postsplenectomy infection.

Glucose-6-Phosphate Dehydrogenase Deficiency The most common red blood cell enzyme deficiency overall is G6PD deficiency. It is far more prevalent than PK deficiency with more than 400 million people affected worldwide, although most experience only moderate health risks and no longevity reduction.⁴⁶ Clinical manifestations—chronic hemolytic anemia,

acute intermittent hemolytic episodes, or no hemolysis—depend on the variant of G6PD deficiency. The mainstay of therapy is avoidance of drugs known to precipitate hemolysis in patients with G6PD deficiency. Transfusions are given in cases of symptomatic anemia. Conventional wisdom is that splenectomy is not indicated in this disease, and certainly the overwhelming majority of patients with G6PD deficiency will neither require nor benefit from splenectomy. However, one report described a small collection of cases of six symptomatic G6PD deficiency patients who had severe hemolytic anemia and required transfusion, all of whom were identified to share a common mutation at exon 10. All underwent splenectomy. A complete response occurred in four patients (transfusion requirement eliminated), and a partial response occurred in one patient (transfusion requirement reduced); no follow-up data were provided for the remaining patient. This study indicates that for a carefully select group of patients with severe hemolytic anemia attributable to G6PD deficiency, splenectomy may be of benefit, although more data must be collected before such a recommendation can be made.⁴⁶

Acquired

Warm-Antibody Autoimmune Hemolytic Anemia. Autoimmune hemolytic anemias (AIHAs) are characterized by the destruction of red blood cells, whose erythrocyte life span is diminished by autoantibodies leveled against antigens. AIHA is classified as either primary or secondary, depending on whether an underlying cause, such as a disease or toxin, is identified. AIHA is also divided into “warm” and “cold” categories, based on the temperature at which the autoantibodies exert their effect.⁴⁷ In cold-agglutinin disease, severe symptoms are uncommon and splenectomy is almost never indicated; therefore, this entity is not discussed further in this section. However, warm-antibody AIHA has clinical consequences with which the surgeon should be familiar.

Warm-antibody AIHA, although occurring primarily in midlife, can affect individuals at all ages. The disorder is more common among women, and fully half of warm-antibody AIHA cases are idiopathic. Clinical presentation may be acute or gradual. Findings include mild jaundice and symptoms and signs of anemia. One-third to one-half of patients present with splenomegaly. Sometimes in such cases the spleen is palpable on physical examination. The diagnosis relies on demonstrating hemolysis as indicated by anemia, reticulocytosis, and/or products of red blood cell destruction, including bilirubin, in the blood, urine, and stool. A positive result on direct Coombs' test confirms the AIHA diagnosis by distinguishing autoimmune from other forms of hemolytic anemia.

Treatment of AIHA depends on the severity of the disease and whether it is primary or secondary. Severe symptomatic anemia demands prompt attention, often requiring red blood cell transfusion. The mainstay treatment for both primary and secondary forms of symptomatic, unstable AIHA is corticosteroids. Therapy should continue until a response is noted by a rise in hematocrit and fall in reticulocyte count, which generally occurs within 3 weeks.

Clinical response to splenectomy for AIHA varies, and the evidence from a number of small case series is conflicting. For example, one 2004 series reported a favorable response to splenectomy in patients with AIHA secondary to chronic lymphocytic leukemia,⁴⁸ whereas more recent series found no benefit from splenectomy in patients with AIHA secondary to systemic lupus erythematosus or inflammatory bowel disease.⁴⁹

Favorable responses to splenectomy have been reported in patients with warm-antibody AIHA. Transient responses are more common, however, and many patients eventually experience hemolysis again despite splenectomy.^{48,49} The decision regarding splenectomy in the case of AIHA should be individualized based on careful consideration of the clinical history and frank discussion with the patient. It is considered as a third-line therapy after failure of steroids or anti-CD20 antibody administration.⁵⁰

Hemoglobinopathies. Sickle cell disease is an inherited chronic hemolytic anemia that results from the mutant sickle cell hemoglobin (HbS) within the red blood cell and is inherited in an autosomal codominant fashion. Persons who inherit an *HbS* gene from one parent (heterozygous) are carriers; those who inherit an *HbS* gene from both parents (homozygous) have sickle cell anemia.⁵¹

In sickle cell disease, the underlying abnormality is the mutation of adenine to thymine in the sixth codon of the β -globin gene, which results in the substitution of valine for glutamic acid as the sixth amino acid of the β -globin chain. Mutant β chains included in the hemoglobin tetramer create HbS. Deoxygenated HbS is insoluble and becomes polymerized and sickled. The subsequent lack of deformability of the red blood cell, in addition to other processes, results in microvascular congestion, which may lead to thrombosis, ischemia, and tissue necrosis. The disorder is characterized by painful intermittent episodes.

Sequestration occurs in the spleen, with splenomegaly resulting early in the disease course. In most patients, subsequent infarction of the spleen and autosplenectomy occur at some later time. The most frequent indications for splenectomy in sickle cell disease are recurrent acute sequestration crises, hypersplenism, and splenic abscess. The occurrence of one major acute sequestration crisis, characterized by rapid painful enlargement of the spleen and circulatory collapse, generally is considered sufficient grounds for splenectomy. Preoperative preparation should include special attention to adequate hydration and avoidance of hypothermia.

Splenectomy does not affect the sickling process, and therapy for sickle cell anemia remains largely palliative. It is only indicated in cases of massive splenomegaly or frequent sequestration crisis. The patients often have a functional asplenia. Transfusions are indicated for anemia, for moderately severe episodes of acute chest syndrome (i.e., a new infiltrate on chest radiograph associated with new symptoms, such as fever, cough, sputum production, or hypoxia), and preoperatively before splenectomy. Patients experiencing stroke or a severe crisis may require hydration and an exchange transfusion, which may be performed manually or with automated apheresis equipment. Hydroxyurea is an oral chemotherapeutic agent that upregulates fetal hemoglobin, which interferes with polymerization of HbS and thus reduces the sickling process.⁵²

Thalassemia. *Thalassemia* is the term for a group of inherited disorders of hemoglobin synthesis prevalent among people of Mediterranean extraction and classified according to the hemoglobin chain (α , β , or γ) affected. As a group, the thalassemias are the most common genetic diseases known to arise from a single gene defect.^{53,54} Most forms of this disorder are inherited in Mendelian recessive fashion from asymptomatic carrier parents. In the so-called thalassemia belt that extends throughout the shores of the Mediterranean as well as through the Arabian Peninsula, Turkey, Iran, India, and southeastern Asia, the incidence

of thalassemia is between 2.5% and 15%. However, thalassemias have been found in people of all ethnic origins.⁵⁴

In all forms of thalassemia, the primary defect is absent or reduced production of hemoglobin chains. From this abnormality, two significant consequences arise: (a) reduced functioning of hemoglobin tetramers, yielding hypochromia and microcytosis; and (b) unbalanced biosynthesis of individual α and β subunits, which results in insoluble red blood cells that cannot release oxygen normally and may precipitate with cell aging. Both underproduction of hemoglobin and excess production of unpaired hemoglobin subunits contribute to thalassemia-associated morbidity and mortality.

A diagnosis of thalassemia major (homozygous form) is made by demonstrating hypochromic microcytic anemia associated with randomly distorted red blood cells and nucleated erythrocytes (target cells) on peripheral blood smear.⁵ Elevated reticulocyte count and white blood cell count are among the associated findings. Because α chains are needed to form both fetal hemoglobin and adult hemoglobin, α -thalassemia becomes symptomatic in utero or at birth. By contrast, β -thalassemia becomes symptomatic at 4 to 6 months, because β chains are involved only in adult hemoglobin synthesis.

The clinical spectrum of the thalassemias is wide. Heterozygous carriers of the disease are usually asymptomatic. Homozygous individuals, on the other hand, typically present before 2 years of age with pallor, growth retardation, jaundice, and abdominal swelling due to liver and spleen enlargement. Among other characteristics of thalassemia major are intractable leg ulcers, head enlargement, frequent infections, and the need for periodic blood transfusions. Untreated individuals usually die in late infancy or early childhood from severe anemia.⁵

Treatment for thalassemia involves red blood cell transfusions to maintain a hemoglobin level of >9 mg/dL, along with intensive parenteral chelation therapy with deferoxamine. Splenectomy is indicated for patients with excessive transfusion requirements (>200 mL/kg per year), discomfort due to splenomegaly, or painful splenic infarction. Careful assessment of the risk-benefit ratio is essential. Thalassemia patients are at high risk for pulmonary hypertension after splenectomy; the precise etiology of this sequela is under investigation.⁵⁵ The increase in infectious complications is likely to be due to a coexisting immune deficiency, in large part brought about by iron overload, which may be associated both with the thalassemia itself and with transfusions. The disproportionately high rate of overwhelming postsplenectomy infection in thalassemia patients

4► has led some investigators to consider partial splenectomy in children; some success in reducing mortality has been reported.⁵⁶ However, splenectomy should be delayed until after the age of 4 years unless it is absolutely necessary.

Platelet Disorders

Idiopathic Thrombocytopenic Purpura Idiopathic thrombocytopenic purpura (ITP), also called *immune thrombocytopenic purpura*, is an autoimmune disorder characterized by a low platelet count and mucocutaneous and petechial bleeding. The low platelet count stems from premature removal of platelets opsonized by antiplatelet immunoglobulin G autoantibodies produced in the spleen. This clearance occurs through the interaction of platelet autoantibodies with Fc receptors expressed on tissue macrophages, predominantly in the spleen and liver. The estimated incidence of ITP is 100 persons per million annually, about one-half of whom are children.⁵⁷ Adult-onset and

childhood-onset ITP are strikingly different in their clinical course and management.

Patients with ITP typically present with petechiae or ecchymoses, although some experience major bleeding from the outset. Bleeding may occur from mucosal surfaces in the form of gingival bleeding, epistaxis, menorrhagia, hematuria, or even melena. The severity of bleeding frequently corresponds to the deficiency in platelets: Patients with counts greater than 50,000/mm³ usually present with incidental findings; those with counts between 30,000 and 50,000/mm³ often have easy bruising; those with platelet counts between 10,000 and 30,000/mm³ may develop spontaneous petechiae or ecchymoses; and those with counts less than 10,000/mm³ are at risk for internal bleeding.⁵⁷ The incidence of major intracranial hemorrhage is approximately 1%, and it usually occurs early in the disease course. The duration of the bleeding helps to distinguish acute from chronic forms of ITP. Children often present at a young age (peak age of approximately 5 years) with sudden onset of petechiae or purpura several days to weeks after an infectious illness. In contrast, adults experience a more chronic form of disease with an insidious onset. Splenomegaly is uncommon with ITP in both adults and children, and its occurrence should prompt a search for a separate cause of thrombocytopenia. Up to 10% of children, however, have a palpable spleen tip.

Diagnosis of ITP is based on exclusion of other possibilities in the presence of a low platelet count and mucocutaneous bleeding. Other diseases resulting in secondary forms of ITP, such as systemic lupus erythematosus, antiphospholipid syndrome, lymphoproliferative disorders, human immunodeficiency virus (HIV) infection, and hepatitis C, should be identified and treated when present. In addition, any history of use of a drug known to cause thrombocytopenia, such as certain antimicrobials, anti-inflammatories, antihypertensives, and antidepressants, should be sought. In addition to low platelet count, another laboratory finding characteristic of ITP is the presence of large, immature platelets (megakaryocytes) on peripheral blood smear.

The usual first line of therapy is oral prednisone at a dosage of 1.0 to 1.5 mg/kg per day.^{58,59} No consensus exists as to the optimal duration of steroid therapy, but most responses occur within the first 3 weeks. Response rates range from 50% to 75%, but relapses are common. IV immunoglobulin, given at 1.0 g/kg per day for 2 to 3 days, is indicated for internal bleeding when platelet counts remain less than 5000/mm³, when extensive purpura exists, or to preoperatively boost platelets. IV immunoglobulin is thought to impair clearance of immunoglobulin G-coated platelets by competing for binding to tissue macrophage receptors. An immediate response is common, but a sustained remission is not. The medical approach to ITP has been modified with the advent of rituximab⁶⁰ and thrombopoietin receptor agonists. Therapeutic recommendations are summarized in Table 34-2. Splenectomy is selectively indicated for failure of medical therapy, for prolonged use of steroids with undesirable effects, and in selected cases after first relapse.⁵ Prolonged use of steroids can be defined in various ways, but a persistent need for more than 10 to 20 mg/d for 3 to 6 months to maintain a platelet count of greater than 30,000/mm³ generally prompts referral for splenectomy. Splenectomy is an effective option for refractory ITP and provides a permanent response without subsequent need for steroids in 75% to 85% of patients. Two recent reviews and meta-analyses have assessed the global results of splenectomy for ITP, specifically after the use of laparoscopic techniques.

Table 34-2

Second-line treatment options for immune thrombocytopenia

Splenectomy

Advantages

- Effective, time-honored treatment
- Most effective response (overall 88%, partial 22%, complete 66%)

Disadvantages

- Surgical procedure with associated morbidity and mortality
- Risk of overwhelming postsplenectomy infection
- Increased risk of thrombotic events

Rituximab

Advantages

- Nonsurgical
- Good experience since 1999
- Initial response 63%, 31% at 2 years

Disadvantages

- Short follow-up
- Severe toxicity 2%–6%

Thrombopoietin Receptor Agonist

Advantages

- Nonsurgical
- Oral agent self-administered weekly
- 80% response rate

Disadvantages

- Long-term treatment required
- Long-term risk not well known
- Potential toxicity

In 2004, Kojouri and colleagues⁶⁰ reviewed 135 case series from 1966 to 2004, pooling 4955 patients. The long-term platelet count response was assessed, as was the ability to predict response and the incidence of complications. Complete response was achieved in 66% of cases with a follow-up ranging from 1 to 153 months, and complete and partial responses occurred in as many as 88% of patients, regardless of the duration of follow-up. They also analyzed 12 preoperative demographic, clinical, and laboratory parameters and found no predictive capability of platelet response in any of them. Mortality was very low (1%), and morbidity was 10%. Limitations of this review included old case series and a low percentage of laparoscopic splenectomies. In a 2009 systemic review involving 1223 patients, Mikhael and colleagues⁶¹ evaluated the short- and long-term outcomes after laparoscopic splenectomy. The conversion rate to open surgery was 5.6%, and the immediate nonresponder rate was 8.2%; however, eventually a clinical response was achieved in 72% of the patients on long-term follow-up (5 years). The initial concerns regarding the potential for missing accessory spleens, longer operative times, and increased cost related to laparoscopic versus open splenectomy have been resolved. Laparoscopy is now the approach of choice for elective splenectomy for ITP.^{62,63}

In children with ITP, the course is self-limited, with durable and complete remission in greater than 70% of patients regardless of therapy. Because of the good prognosis without treatment, the decision to intervene surgically is controversial and is largely to obviate intracranial hemorrhage discussed

earlier. Thus, children with typical ITP—and certainly those without hemorrhage—are managed principally by observation, with short-term therapy in select cases. Urgent splenectomy, in conjunction with aggressive medical therapy, may play a role in the rare circumstance of severe, life-threatening bleeding in both children and adults.

Thrombotic Thrombocytopenic Purpura. Thrombotic thrombocytopenic purpura (TTP) is a serious disorder characterized by thrombocytopenia, microangiopathic hemolytic anemia, and neurologic complications. Abnormal platelet clumping occurs in arterioles and capillaries, reducing the lumen of these vessels and predisposing the patient to microvascular thrombotic episodes. The reduced lumen size also causes shearing stresses on erythrocytes, which leads to deformed red blood cells subject to hemolysis. Hemolysis may also be due in part to sequestration and destruction of erythrocytes in the spleen. Research has demonstrated that the underlying abnormality is likely related to the persistence of unusually large multimers of von Willebrand factor associated with platelet clumping in the patient's blood.^{64,65}

TTP occurs in approximately 3.7 individuals per million, but this rare disorder's dramatic clinical sequelae and favorable response to early therapy demand an understanding of its clinical presentation to ensure an early diagnosis. Clinical features of the disorder include petechiae, fever, neurologic symptoms, renal failure, and, infrequently, cardiac symptoms such as heart failure or arrhythmias. Petechial hemorrhages in the lower extremities are the most common presenting sign. Along with fever, patients may experience flu-like symptoms, malaise, or fatigue. Neurologic changes range from generalized headaches to altered mental status, seizures, and even coma. Generally, however, the mere presence of petechiae and thrombocytopenia is sufficient to lead to the diagnosis of TTP and consideration of treatment.

The diagnosis is confirmed by the peripheral blood smear, which shows schistocytes, nucleated red blood cells, and basophilic stippling. Although other conditions such as tight aortic stenosis or prosthetic valves may lead to the presence of schistocytes, these conditions generally are not accompanied by thrombocytopenia. TTP may be distinguished from autoimmune causes of thrombocytopenia, such as Evans' syndrome (ITP and autoimmune hemolytic anemia) or systemic lupus erythematosus, by a negative result on Coombs' test.

Plasma exchange is the first-line therapy for TTP. This treatment consists of the daily removal of a single volume of the patient's plasma and its replacement with fresh-frozen plasma until the thrombocytopenia, anemia, and associated symptoms are corrected. Therapy is then tapered over 1 to 2 weeks.⁵¹ Splenectomy plays a key role for patients who experience relapse or who require multiple plasma exchanges to control symptoms, and generally is well tolerated without significant morbidity.⁶⁵

Malignant Conditions

White Blood Cell Disorders. The role of splenectomy in patients with white blood cell disorders varies. As for the myelogenous diseases mentioned previously, splenectomy for white blood cell disorders can be effective therapy for symptomatic splenomegaly and hypersplenism, improving some clinical parameters but generally not altering the course of the underlying disease. Historically, splenectomy has played a role during surgical staging for Hodgkin's disease, although this practice has become obsolete with the advent of imaging technologies (CT scan and 18F-fluorodeoxyglucose positron emission

tomography [18F-FDG PET]).⁶⁶⁻⁶⁸ Careful consideration of the intended benefits of splenectomy must be weighed against the significant perioperative and postsplenectomy risks in this often complex patient population.⁴³

Hairy Cell Leukemia Hairy cell leukemia (HCL) is an uncommon blood disorder, representing only 2% of all adult leukemias. HCL is characterized by splenomegaly, pancytopenia, and large numbers of abnormal lymphocytes in the bone marrow. These lymphocytes contain irregular hair-like cytoplasmic projections identifiable on the peripheral smear. Many HCL patients have few symptoms and require no specific therapy. Splenectomy does not correct the underlying disorder but does return cell counts to normal in 40% to 70% of patients and alleviates symptoms of splenomegaly. However, with the advent of diverse new drugs (e.g., rituximab, pentostatin, cladribine), splenectomy has become rarely indicated.⁶⁹

Hodgkin's Disease Hodgkin's disease (HD) is a disorder of the lymphoid system characterized by the presence of Reed-Sternberg cells (which actually form the minority of the Hodgkin's tumor). More than 90% of patients with HD present with lymphadenopathy above the diaphragm. Lymph nodes can become particularly bulky in the mediastinum, which may result in shortness of breath, cough, or obstructive pneumonia. Lymphadenopathy below the diaphragm is rare on presentation but can arise with disease progression. The spleen is often an occult site of spread, but massive splenomegaly is not common. In addition, large spleens do not necessarily signify involvement.⁶⁷

Four major histologic types exist: lymphocyte predominance type, nodular sclerosis type, mixed cellularity type, and lymphocyte depletion type. The histologic type, along with location of disease and symptomatology, influence survival for patients with HD. Stage I disease is limited to one anatomic region; stage II disease is defined by the presence of two or more contiguous or noncontiguous regions on the same side of the diaphragm; stage III disease involves disease on both sides of the diaphragm, but limited to lymph nodes, spleen, and Waldeyer's ring (the ring of lymphoid tissue formed by the lingual, palatine, and nasopharyngeal tonsils); and stage IV disease includes involvement of the bone marrow, lung, liver, skin, gastrointestinal tract, or any organ or tissue other than the lymph nodes or Waldeyer's ring.⁶⁷

Staging laparotomy for HD is less commonly performed in the current era of minimally invasive surgery and advanced imaging techniques. More liberal use of diagnostic tools (CT scan and 18F-FDG PET) and chemotherapy for patients with HD has drastically reduced the indications for surgical staging. Current indications for surgical staging include clinical suspicion of lymphoma without evidence of peripheral disease or patients requiring restaging for suspicion of failure after chemotherapy.^{67,70}

Non-Hodgkin's Lymphoma Non-Hodgkin's lymphoma (NHL) encompasses all malignancies derived from the lymphoid system except classic HD.⁶⁸ A proliferation of any one of the three predominant lymph cell types—natural killer cells, T cells, or B cells—may be included in the category of NHL. Because of the wide net cast by NHL, the clinical presentations of the disorders under its umbrella vary. The subentities of NHL may be clinically classified into nodal or extranodal, as well as indolent, aggressive, and very aggressive groups. Patients with indolent lymphomas may present with mild or no symptoms and seek medical attention for a swollen lymph node, whereas

the aggressive and very aggressive lymphomas create easily noticeable symptoms, such as pain, swelling due to obstruction of vessels, fever, and night sweats. Surgical staging is no longer indicated for NHL, because the combination of history and physical examination, chest radiograph and abdominal/pelvic CT scan, biopsy of involved lymph nodes (including laparoscopically directed nodal and liver biopsies), and bone marrow biopsy is sufficient.⁶⁸ Splenomegaly exists in some, but not all, forms of NHL. Splenectomy is indicated in cases where a diagnosis cannot be established by obtaining peripheral tissue and clinical suspicion remains^{71,72} or for management of symptoms related to an enlarged spleen as well as for improvement of

5▶ cytopenias. Splenectomy does not alter the natural history of the disease, but related thrombocytopenia may improve in up to 75% of patients.

Chronic Lymphocytic Leukemia Chronic lymphocytic leukemia (CLL) is currently considered a subtype of NHL. The main characteristic of CLL is a progressive accumulation of old and nonfunctional lymphocytes.^{68,73} Symptoms of CLL are nonspecific and include weakness, fatigue, fever without illness, night sweats, and frequent bacterial and viral infections. The most frequent finding is lymphadenopathy. When the spleen is enlarged, it may be massive or barely palpable below the costal margin. Splenectomy is indicated to improve cytopenias and was shown to be 75% effective in a combined group of patients who had either CLL or nonmalignant HD.⁴⁴ Splenectomy may facilitate chemotherapy in patients whose cell counts were prohibitively low before spleen removal. Palliative splenectomy also is indicated for symptomatic splenomegaly.

Bone Marrow Disorders (Myeloproliferative Disorders). The myeloproliferative disorders are characterized by an abnormal growth of cell lines in the bone marrow. They include chronic myeloid leukemia, acute myeloid leukemia, chronic myelomonocytic leukemia, essential thrombocythemia, polycythemia vera, and myelofibrosis, also known as *agnogenic myeloid metaplasia* (see “Myelofibrosis [Agnogenic Myeloid Metaplasia]” later in this chapter). The common underlying problem leading to splenectomy in these disorders is symptomatic splenomegaly. Symptoms due to splenomegaly consist of early satiety, poor gastric emptying, heaviness or pain in the left upper quadrant, and even diarrhea. Hypersplenism, when it occurs in these conditions, usually is associated with splenomegaly. Splenectomy performed in the setting of the myeloproliferative disorders is generally for treatment of the pain, early satiety, and other symptoms of splenomegaly.

Splenomegaly can sometimes be treated nonsurgically by chemotherapeutic agents (busulfan, hydroxyurea, interferon- α) to achieve mild to moderate size reductions and some relief of symptoms, but discontinuation of treatment may result in rapid splenic regrowth. Radiation has been used since 1903 to treat symptomatic splenomegaly, but today it is principally used in situations in which splenectomy is not an option.

Chronic Myeloid Leukemia Chronic myeloid leukemia (CML) is a disorder of the primitive pluripotent stem cells in the bone marrow that results in a significant increase in erythroid, megakaryotic, and pluripotent progenitors in the peripheral blood smear. The genetic hallmark is a transposition between the *bcr* gene on chromosome 9 and the *abl* gene on chromosome 22. CML accounts for 7% to 15% of all leukemias, with an incidence of 1.5 in 100,000 in the United States.⁵⁴ It is often asymptomatic, but CML can cause fatigue, anorexia, sweating,

and left upper quadrant pain and early satiety secondary to splenomegaly. Enlargement of the spleen is found in roughly one-half of patients with CML. Current therapy includes imatinib or allogeneic stem cell transplantation. Splenectomy is indicated to ease pain and early satiety and does not prevent blast crisis.⁵⁵

Acute Myeloid Leukemia Like CML, acute myeloid leukemia (AML) involves the abnormal growth of stem cells in the bone marrow. Unlike CML, AML has a presentation that is more rapid and dramatic. The proliferation and accumulation of hematopoietic stem cells in the bone marrow and blood inhibit the growth and maturation of normal red blood cells, white blood cells, and platelets. Death usually results within weeks to months if AML goes untreated. The incidence of AML is approximately 9200 new cases each year in the United States, and it accounts for 1.2% of all cancer deaths.⁷⁴ Patients with other myeloproliferative disorders, such as polycythemia vera, primary thrombocytosis, or myeloid metaplasia, are at increased risk for leukemic transformation to AML. Presenting signs and symptoms of AML include a viral-like illness with fever, malaise, and frequently bone pain due to the expansion of the medullary space. Standard treatment is combined induction therapy with daunorubicin, cytarabine, and stem cell transplantation. Splenectomy is indicated in AML only in the uncommon circumstance that left upper quadrant pain and early satiety become unbearable. The benefit must be weighed against the heightened risk of post-splenectomy infection in AML patients immunocompromised due to neutropenia and chemotherapy.⁷⁴

Chronic Myelomonocytic Leukemia Like CML and AML, chronic myelomonocytic leukemia (CMML) is characterized by a proliferation of hematopoietic elements in the bone marrow and blood. CMML differs from CML in that it is associated with monocytosis in the peripheral smear ($>1 \times 10^3$ monocytes/mm³) and in the bone marrow. Splenomegaly occurs in one-half of these patients, and splenectomy can result in symptomatic relief.⁷⁵

Essential Thrombocythemia Essential thrombocythemia (ET) represents abnormal growth of the megakaryocyte cell line, resulting in increased levels of platelets in the bloodstream. The diagnosis is made after the exclusion of other chronic myeloid disorders such as CML, polycythemia vera, and myelofibrosis that may also present with thrombocytosis.⁷⁶ Clinical manifestations of ET include vasomotor symptoms, thrombohemorrhagic events, recurrent fetal loss, and the transformation to myelofibrosis with myeloid metaplasia or AML. Hydroxyurea is used to reduce thrombotic events in ET but does not alter transformation to myelofibrosis or leukemia. Splenomegaly occurs in one-third to one-half of patients with ET. Splenectomy is not felt to be helpful in the early stages of ET and is best reserved for the later stages of disease, when myeloid metaplasia has developed.⁷² Even in these circumstances, candidates should be chosen selectively, because significant bleeding has been reported to complicate splenectomy in these patients.

Polycythemia Vera Polycythemia vera (PV) is a clonal, chronic, progressive myeloproliferative disorder characterized by an increase in red blood cell mass, frequently accompanied by leukocytosis, thrombocytosis, and splenomegaly. Patients with PV typically enjoy longer survival than those affected by hematologic malignancies but remain at risk for transformation to myelofibrosis or AML. The disease is rare, with an annual incidence of 5 to 17 cases per million population.^{76,77} Physical findings include ruddy cyanosis, conjunctival plethora,

hepatomegaly, splenomegaly, and hypertension. Treatment should be tailored to the risk status of the patient and ranges from phlebotomy and aspirin administration to the use of chemotherapeutic agents. As in ET, splenectomy is not helpful in the early stages of disease and is best reserved for patients with late-stage disease in whom myeloid metaplasia has developed and splenomegaly-related symptoms are severe.^{76,77}

Myelofibrosis (Agnogenic Myeloid Metaplasia) The term *myelofibrosis* may be used to describe either the generic condition of fibrosis of the bone marrow (which may be associated with a number of benign and malignant disorders) or a specific, chronic, malignant hematologic disease associated with splenomegaly, the presence of red blood cell and white blood cell progenitors in the bloodstream, marrow fibrosis, and extramedullary hematopoiesis, otherwise known as *agnogenic myeloid metaplasia (AMM)*. AMM also can be referred to as *myelosclerosis*, *idiopathic myeloid metaplasia*, and *osteosclerosis*. In this chapter, the term *myelofibrosis* is synonymous with AMM.

In AMM, fibrosis of the bone marrow is believed to be a response to a clonal proliferation of hematopoietic stem cells. Marrow failure is common. The true incidence of AMM is unknown due to the scarcity of epidemiologic data, but one study estimated its U.S. incidence at 1.46 per 100,000 population.⁷⁸⁻⁸⁰ The diagnosis is made by a careful examination of the peripheral blood smear and bone marrow. Nucleated red blood cells and immature myeloid elements in the blood are present in 96% of cases and strongly suggest the diagnosis. Teardrop poikilocytosis is another frequent finding. Care must be taken, however, to exclude a history of a primary neoplasm (such as lymphoma or adenocarcinoma of the stomach, lung, prostate, or breast) or tuberculosis, because patients with these conditions may develop secondary myelofibrosis.

Treatment depends on symptoms: Asymptomatic patients are closely followed, whereas symptomatic patients undergo therapeutic intervention targeted to their symptoms. The only curative therapy is allogeneic bone marrow transplantation in younger, high-risk patients. Supportive therapy for clinically symptomatic anemia includes steroids, danazol, erythropoietin, or blood transfusion.^{78,80} Splenomegaly-related symptoms are best treated with splenectomy. Although some chemotherapeutic agents (busulfan, hydroxyurea, interferon- α) and low-dose radiation can reduce splenic size, their discontinuation usually results in rapid splenic regrowth.

A thorough preoperative workup must precede splenectomy in patients with AMM. The candidate must possess acceptable cardiac, pulmonary, hepatic, and renal reserve for the operation. The coagulation system should be examined; testing should include measurement of coagulation factors V and VIII and fibrin split products, platelet count, and bleeding time. Low platelet counts may require administration of steroids and/or platelet transfusion at the time of surgery. Splenectomy provides durable, effective palliation for nearly all patients with AMM, although postoperative complications are more common in patients with AMM than in those with other hematologic indications. The Mayo Clinic recently published its 30-year experience with 314 myelofibrosis patients who underwent splenectomy. Nearly half of the operations (49%) were performed to alleviate the mechanical symptoms of splenomegaly; the remainder were undertaken to manage anemia, thrombocytopenia, or portal hypertension. Response to splenectomy was 76% overall at 1 year; overall complication rate was 28%, including 21 perioperative deaths.⁸¹ Thrombosis,

hemorrhage, and infection complications were common, with preoperative thrombocytopenia an independent predictor of mortality risk. These data underscore the severity of this malignancy and emphasize need for careful patient selection when considering splenectomy in AMM.⁷⁹

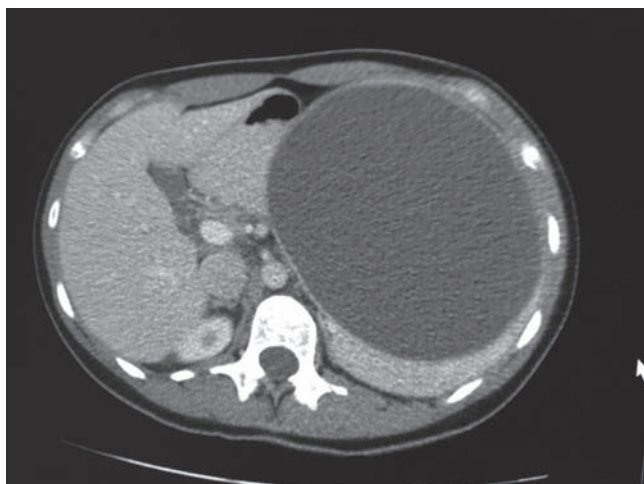
Other Diseases of the Spleen

Infections and Abscesses. Primary infections of the spleen are infrequently reported. However, the potential effects of certain systemic infections on the spleen merit close attention, mostly because of the potential risk of spontaneous splenic rupture. Infectious mononucleosis due to either Epstein-Barr virus or cytomegalovirus infection imparts a small but often-discussed risk of spontaneous splenic rupture in both adults and children. The true incidence may be underreported, however. Recent case reports abound in the literature regarding spontaneous splenic rupture due to a variety of infectious causes (malaria, *Listeria* infection, fungal infections, dengue, and Q fever, to name a few) as well as a variety of neoplastic and other noninfectious causes (lymphoma, angiosarcoma, amyloidosis, pregnancy). The presumed pathophysiologic mechanism is infiltration of the splenic parenchyma with inflammatory cells, which distorts the architecture and fibrous support system of the spleen and thins the splenic capsule.⁸² In this setting, splenic rupture can occur spontaneously or after a seemingly minor external trauma or even a Valsalva maneuver.

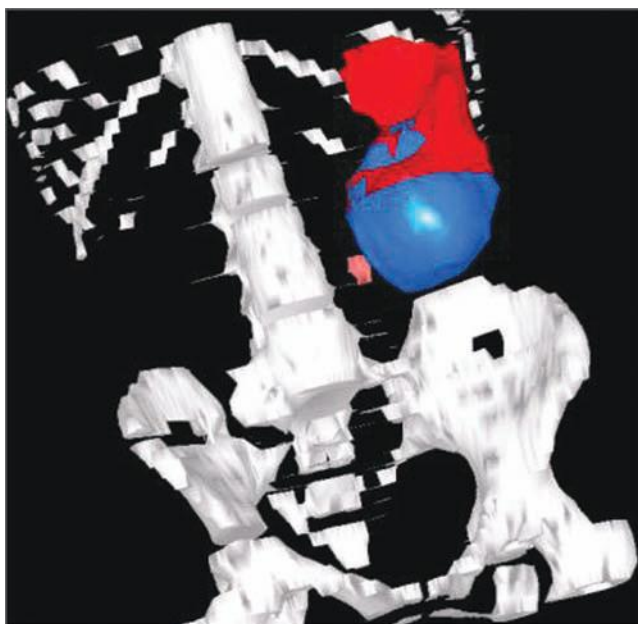
Abscesses of the spleen are uncommon, with an incidence of 0.14% to 0.7% based on autopsy findings.⁸² They occur more frequently in tropical locations, where they are associated with thrombosed splenic vessels and infarction in patients with sickle cell anemia. Five distinct mechanisms of splenic abscess formation have been described: (a) hematogenous infection; (b) contiguous infection; (c) hemoglobinopathy; (d) immunosuppression, including HIV infection and chemotherapy; and (e) trauma. Presentation frequently is delayed, with most patients enduring symptoms for 16 to 22 days before diagnosis. Clinical manifestations include fever, left upper quadrant pain, leukocytosis, and splenomegaly in about one-third of patients. The diagnosis is confirmed by ultrasound or CT scan, which has a 95% sensitivity and specificity. The most common organisms in most series are aerobic microbes (streptococci and *Escherichia coli*), but other microorganisms have also been isolated (*Mycobacterium tuberculosis* and *Salmonella typhi*). Upon discovery of a splenic abscess, broad-spectrum antibiotics should be started, with adjustment to more specific therapy based on culture results and continuation of treatment for 14 days. Splenectomy is the operation of choice, but percutaneous and open drainage are options for patients who cannot tolerate splenectomy. Percutaneous drainage is successful for patients with unilocular disease.

Cysts. Splenic cysts (Fig. 34-5) can be categorized according to a number of criteria; one clinically relevant scheme is to characterize splenic cysts as either parasitic or nonparasitic.

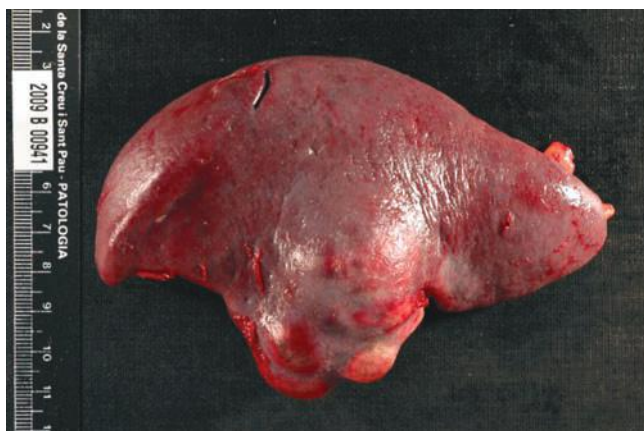Parasitic infection is the most common cause of splenic cysts worldwide, and the majority is due to *Echinococcus* species. Such cysts are more commonly found in areas where the pathogen is endemic. Symptoms, when present, generally are related to the presence of a mass lesion in the left upper quadrant or a lesion that impinges on the stomach. Ultrasound can establish the presence of a cystic lesion and occasionally incidentally detect asymptomatic lesions as well. Serologic testing for echinococcal antibodies can confirm or exclude the cystic lesion as



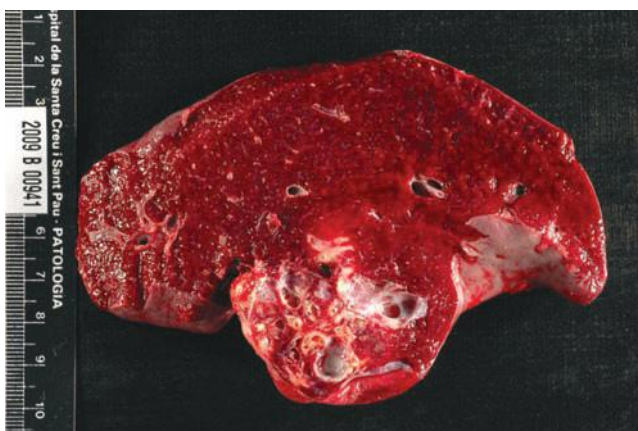A



B



C



D

Figure 34-5. A. Computed tomography (CT) scan of giant splenic cyst. B. Three-dimensional CT reconstruction of splenic cyst. C and D. Macroscopic aspect of a multicystic splenic lesion.

parasitic, an important piece of information when planning operative therapy. Symptomatic parasitic cysts are best treated with splenectomy. Avoidance of spillage of parasitic cyst contents into the peritoneal cavity to avoid the possibility of anaphylactic shock is an important principle in surgical management.

Cysts resulting from trauma are termed *pseudocysts* due to their lack of cellular lining. Less common examples of nonparasitic cysts are dermoid, epidermoid, and epithelial cysts.⁶⁶ The treatment of nonparasitic cysts depends on whether or not they produce symptoms. Asymptomatic nonparasitic cysts may be observed with close follow-up by ultrasound to exclude significant expansion. Patients should be advised of the risk of cyst rupture with even minor abdominal trauma if they elect nonoperative management for large cysts. Small symptomatic nonparasitic cysts may be excised with splenic preservation, and large symptomatic nonparasitic cysts may be unroofed. Both of these operations may be performed laparoscopically.⁶⁶

Tumors and Metastasis. The most common primary tumor of the spleen is sarcoma. Autopsy studies reveal an approximately 0.6% rate of tumor metastasis to the spleen; most of

these metastases are carcinomas. Lung cancer is the tumor that most commonly spreads to the spleen.⁸³⁻⁸⁵

The spleen is an infrequent site for metastatic deposits and usually appears in cases of widely disseminated disease. In some circumstances, colorectal, ovary, and melanoma metastases can be isolated to the spleen. If after a thorough examination, the isolated splenic metastasis is confirmed, a laparoscopic splenectomy with intact spleen retrieval should be considered.^{84,85}

Storage Diseases and Infiltrative Disorders

Gaucher's Disease Gaucher's disease is an inherited lipid storage disorder characterized by the deposition of glucocerebroside in cells of the macrophage-monocyte system. The underlying abnormality is a deficiency in the activity of a lysosomal hydrolyase. Abnormal glycolipid storage results in organomegaly, particularly hepatomegaly and splenomegaly.^{86,87} Patients with Gaucher's disease frequently experience symptoms related to splenomegaly, including early satiety and abdominal discomfort, and to hypersplenism, including thrombocytopenia, normocytic anemia, and mild leukopenia. These latter findings occur as a result of excessive sequestration of formed blood elements

in the spleen. Other symptoms in patients with Gaucher's disease include bone pain, pathologic fractures, and jaundice. Splenectomy alleviates hematologic abnormalities in patients with hypersplenism, but it does not correct the underlying disease process. Partial splenectomy has been shown to be effective in children to correct both hematologic problems and symptoms due to splenomegaly without incurring the risk of overwhelming post-splenectomy sepsis.

Niemann-Pick Disease Niemann-Pick disease is an inherited disorder of abnormal lysosomal storage of sphingomyelin and cholesterol in cells of the macrophage-monocyte system. Four types of the disease (A, B, C, and D) exist, with unique clinical presentations. Types A and B result from a deficiency in lysosomal hydrolase and are the forms most likely to demonstrate splenomegaly with its concomitant symptoms.

Amyloidosis Amyloidosis is a disorder of abnormal extracellular protein deposition. There are multiple forms of amyloidosis, each with its own individual clinical presentation, and the severity of disease may range from asymptomatic to multiorgan failure. Patients with primary amyloidosis, associated with plasma cell dyscrasia, have splenic involvement in approximately 5% of cases. Secondary amyloidosis, associated with chronic inflammatory conditions, also may present with an enlarged spleen. Symptoms of splenomegaly are relieved by splenectomy.

Sarcoidosis Sarcoidosis is an inflammatory disease of young adults characterized by noncaseating granulomas in affected tissues. Signs and symptoms of the disease range in severity and typically are nonspecific, such as fatigue and malaise. Any organ system may be involved. The most commonly involved organ is the lung, followed by the spleen. Splenomegaly occurs in approximately 25% of patients. Massive splenomegaly (>1 kg) is rare.⁶⁹ Other affected tissues include the lymph nodes, eyes, joints, liver, spleen, and heart. When splenomegaly occurs and causes symptoms related to size or hypersplenism, splenectomy effectively relieves symptoms and corrects hematologic abnormalities such as anemia and thrombocytopenia. Spontaneous splenic rupture has been reported in sarcoidosis.⁸⁸

Miscellaneous Disorders and Lesions

Splenic Artery Aneurysm Although splenic artery aneurysm is rare, it is the most common visceral artery aneurysm. Women are four times more likely to be affected than men. The aneurysm usually arises in the middle to distal portion of the splenic artery.^{89,90} Indications for treatment include presence of symptoms, pregnancy, intention to become pregnant, and presence of pseudoaneurysms associated with inflammatory processes. Aneurysm resection or ligation alone is acceptable for amenable lesions in the mid-splenic artery, but distal lesions in close proximity to the splenic hilum should be treated with concomitant splenectomy. An excellent prognosis follows elective treatment. Splenic artery embolization has been used to treat splenic artery aneurysm, but painful splenic infarction and abscess may follow.

Portal Hypertension Portal hypertension can result from numerous causes but is usually due to cirrhosis. Splenomegaly and splenic congestion often accompany portal hypertension, which leads to sequestration and destruction of circulating cells in the spleen. Splenectomy is not indicated for hypersplenism per se in patients with portal as there is no correlation between the degree of pancytopenia and long-term survival in these patients.⁵ In rare circumstances in which splenectomy is required to reduce bleeding from esophageal varices exacerbated by thrombocytopenia, a concomitant splenorenal shunt

procedure should be performed to decompress the portal system.

Portal hypertension secondary to splenic vein thrombosis is potentially curable with splenectomy. Patients with bleeding from isolated gastric varices who have normal liver function test results, especially those with a history of pancreatic disease, should be examined for splenic vein thrombosis and treated with splenectomy if findings are positive.

Felty's Syndrome The triad of rheumatoid arthritis, splenomegaly, and neutropenia is called *Felty's syndrome*. It exists in approximately 3% of all patients with rheumatoid arthritis, two-thirds of whom are women. Immune complexes coat the surface of white blood cells, which leads to their sequestration and clearance in the spleen with subsequent neutropenia. This neutropenia (<2000 neutrophils/mm³) increases the risk for recurrent infections and often drives the decision for splenectomy. The size of the spleen is variable, from nonpalpable in 5% to 10% of patients to massively enlarged in others. In Felty's syndrome the spleen is four times heavier than normal. Corticosteroids, hematopoietic growth factors, methotrexate, and splenectomy have all been used to treat the neutropenia of Felty's syndrome. Responses to splenectomy have been excellent, with >80% of patients showing a durable increase in white blood cell count. More than one-half of patients who had infections before surgery did not have any infections after splenectomy.⁹¹ Besides symptomatic neutropenia, other indications for splenectomy include transfusion-dependent anemia and profound thrombocytopenia.

Wandering Spleen A very uncommon anatomic abnormality is the "wandering spleen." The spleen "floats" inside the abdominal cavity due to an anomaly of embryogenesis. The wandering spleen is not normally attached to adjacent viscera in the splenic fossa. This may lead to splenic torsion and infarction. Spleen removal or splenopexy is indicated.⁹²

PREOPERATIVE CONSIDERATIONS

As part of preoperative discussion prior to splenectomy, patients should be consulted on potential complications associated with this procedure, including overwhelming postsplenectomy sepsis, splenic vein thrombosis, bleeding, arteriothrombosis (myocardial infarction, stroke), deep vein thrombosis, and pulmonary hypertension.

Vaccination and Patient Education

Considering that infection is the most common complication, patient education and vaccinations against encapsulated pathogens are the mainstay of preventive therapy.^{93,61} Although rare, the most feared and extreme infectious complication is overwhelming postsplenectomy sepsis (OPSS). (See later section, "Overwhelming Postsplenectomy Infection," for detailed discussion.) Patients undergoing splenectomy for hematologic or malignant indications have the greatest risk, whereas patients who undergo splenectomy for trauma or iatrogenic injury have the lowest risk. OPSS is more common in the pediatric population, with 4.4% of children less than 16 years of age versus 0.9% of adults developing this life-threatening condition. The risk has been observed to be the greatest in the first 2 years after splenectomy; however, asplenic patients remain at lifelong risk.^{108,109,110} Considering that the spleen is the site for special adaptation of macrophages that target encapsulated organisms, asplenic patients are at higher risk of infection caused by *Streptococcus pneumoniae* (responsible for >50% of OPSS), *H. influenzae* type b, *Neisseria meningitidis*, and *Capnocytophaga canimorsus* (transmitted by dog bites).¹¹¹

In the setting of elective splenectomy, patients should be vaccinated 2 weeks prior to surgery to optimize antigen recognition and processing. If splenectomy is performed emergently, vaccinations can be administered postoperatively and consideration should be given to delaying administration for 2 weeks to avoid the transient immunosuppression associated with surgery. Preoperative and postoperative patient education regarding OPSS is paramount because patients with OPSS may rapidly progress from a febrile illness to circulatory collapse and death within a matter of hours. In one study, 28% of asplenic patients were unaware of the potential infection risks and the main reasons were that correct advice was not given or that that advice was forgotten.^{107,108}

The use of currently available vaccines against pneumococcus and other encapsulated organisms has led to a drop in the overall incidence of OPSI to <1%. The mechanism by which vaccination protects asplenic patients is not entirely understood. Serum antibody titers do not necessarily correspond to clinical immunity. Moreover, antibody levels after pneumococcus vaccination decline steadily within 5 to 10 years. Revaccination is reasonably recommended for these patients, although the efficacy of this measure is not proven.¹⁰⁷⁻¹¹¹

Deep Vein Thrombosis Prophylaxis

Deep vein thrombosis (DVT) after splenectomy is not infrequent, especially in cases involving splenomegaly and myeloproliferative disorders.⁷⁶ The risk of portal vein thrombosis (PVT) may reach 40% for patients presenting with both splenomegaly and myeloproliferative disorders. Postsplenectomy PVT typically presents with anorexia, abdominal pain, leukocytosis, and thrombocytosis. Effective PVT treatment is possible by maintaining a high index of suspicion, achieving early diagnosis with contrast-enhanced CT, and starting anticoagulation immediately. DVT prophylaxis, including use of sequential compression devices and subcutaneous administration of heparin (5000 U), should be initiated for patients undergoing splenectomy.^{8,77} Each patient's risk factors for DVT should be evaluated, and when elevated risk exists (obesity, history of prior venous thromboembolism, known hypercoagulable state, older age), an antithrombotic regimen, including low-molecular-weight heparin, should be pursued.

SPLENECTOMY TECHNIQUES

Patient Preparation

All patients undergoing elective splenectomy should be vaccinated at least 1 week preoperatively with polyvalent pneumococcal, meningococcal, and *Haemophilus* vaccines.⁹³ Assessment of the potential need for transfusion of blood products and optimization of preoperative coagulation status are necessary. It is the authors' practice to order blood typing and antibody screening tests for normosplenic patients undergoing elective splenectomy. Anemic patients should be transfused before surgery to a hemoglobin level of 10 g/dL. In more complex cases, including patients with splenomegaly, at least 2 to 4 units of cross-matched blood should be available at the time of surgery. Thrombocytopenia may be transiently corrected with platelet transfusions. Thrombocytopenic patients preferably should not undergo transfusion before the day of surgery and ideally not before the intraoperative ligation of the splenic artery.

Patients who have been maintained on corticosteroid therapy preoperatively should receive parenteral corticosteroid therapy perioperatively. Bowel preparation is not routinely

performed for patients undergoing elective splenectomy. All splenectomy patients do receive DVT prophylaxis, as discussed previously. After endotracheal intubation, a nasogastric (NG) tube is inserted for stomach decompression.

Open Splenectomy

Although laparoscopic surgery increasingly has achieved acceptance as the standard approach for normosplenic patients requiring splenectomy, open splenectomy (OS) is still widely practiced. Traumatic rupture of the spleen continues as the most common indication for OS. Several other clinical scenarios favor an OS approach, including massive splenomegaly, ascites, portal hypertension, multiple prior operations, extensive splenic irradiation, and possible splenic abscess.

During OS, the patient is placed in the supine position with the surgeon situated at the patient's right. A left subcostal incision paralleling the left costal margin and lying two fingerbreadths below it is preferred for most elective splenectomies. A midline incision is optimal for exposure when the spleen is ruptured or massively enlarged. The spleen is mobilized by dividing ligamentous attachments, usually beginning with the splenocolic ligament (Fig. 34-6). In patients with significant splenomegaly, once lesser sac access has been achieved through either the gastrosplenic or gastrohepatic attachments, ligating the splenic artery in continuity along the superior border of the pancreas may be preferable. This maneuver may serve several purposes: allowing safer manipulation of the spleen and dissection of the splenic hilum, facilitating some shrinkage of the spleen, and providing an autotransfusion of erythrocytes and platelets. Further medial mobilization of the spleen is achieved by incising its lateral peritoneal attachments, most notably the splenophrenic ligament. Then follows individual ligation and sequential division of the short gastric vessels, steps that if carefully executed reduce the risk of these vessels' retracting and bleeding. Splenic hilar dissection then takes place. Whenever possible, care should be taken to dissect and individually ligate the splenic artery and vein (in that order) before dividing

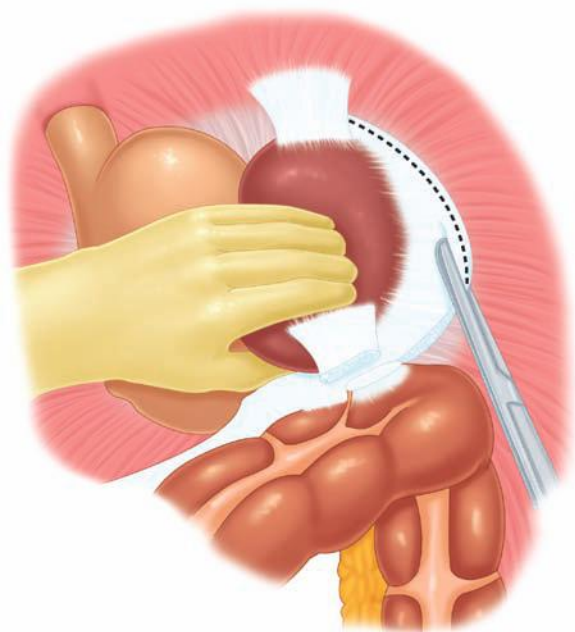


Figure 34-6. Splenocolic ligament is divided at the beginning of open splenectomy.

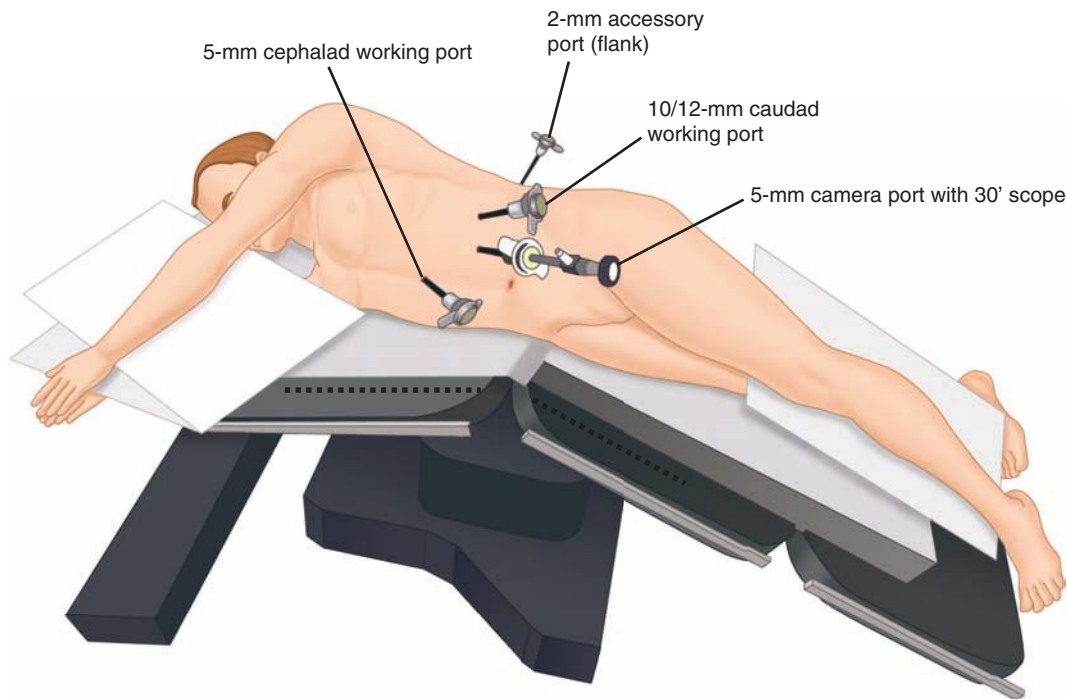


Figure 34-7. Patient positioning and trocar placement for laparoscopic splenectomy.

them. As noted in the discussion of splenic anatomy, the tail of the pancreas lies within 1 cm of the splenic hilum in 75% of patients; therefore, during hilar dissection, great care must be taken to avoid injuring the pancreas.

Once the spleen is excised, hemostasis is secured by irrigating, suctioning, and scrupulously inspecting the bed of dissection. The splenic bed is not routinely drained. A thorough search for accessory spleens must be undertaken when a hematologic disorder has occasioned splenectomy. At the completion of surgery, the nasogastric tube is removed.

Laparoscopic Splenectomy

Laparoscopic splenectomy (LS) has become the procedure of choice over the last two decades, since it has been first described Delaitre and Maignien in 1991.²⁵ In fact, LS is now the gold standard for elective splenectomy in patients with normal-sized spleens. In experienced hands, LS is associated with decreased intraoperative blood loss, shorter hospital length of stay, and lower morbidity rates when compared to OS.^{112,113}

Since the introduction of the lateral approach,⁹⁴ most LS procedures are now performed with the patient in the right lateral decubitus position (Fig. 34-7). A midway “double-access” technique in which the patient is in a 45° right lateral decubitus position has also been advocated. This positioning permits concomitant surgery, such as laparoscopic cholecystectomy, more easily than does the lateral approach. The double-access technique requires the placement of five or six trocars. The lateral approach routinely involves the use of three or four trocars positioned as shown in Fig. 34-7. Use of an angled (30° or 45°) laparoscope (2, 5, or 10 mm) greatly facilitates the procedure. Exposure of the vital anatomy in a manner that allows for a more intuitive sequence of dissection, paralleling that of OS, may be considered an additional advantage of the lateral approach.

Placement of trocars in the left upper quadrant should be performed under laparoscopic visualization, particularly if any degree of splenomegaly exists, because the latter can sig-

nificantly reduce the available operating space. As with OS, the splenocolic ligament and the lateral peritoneal attachments are divided with resultant medial mobilization of the spleen. The short gastric vessels may be divided usually with hemostatic energy sources such as ultrasonic dissection, diathermy, or radiofrequency ablation. With the lower pole of the spleen gently retracted, the splenic hilum is accessible to further applications of clips or an endovascular stapling device. The splenic artery and vein are divided separately when possible. Good long-term outcomes, however, are increasingly being achieved with mass hilar stapling (Fig. 34-8). Using the lateral approach with the spleen thus elevated, the surgeon can easily visualize the tail of the pancreas and avoid injury when placing the endovascular stapler.

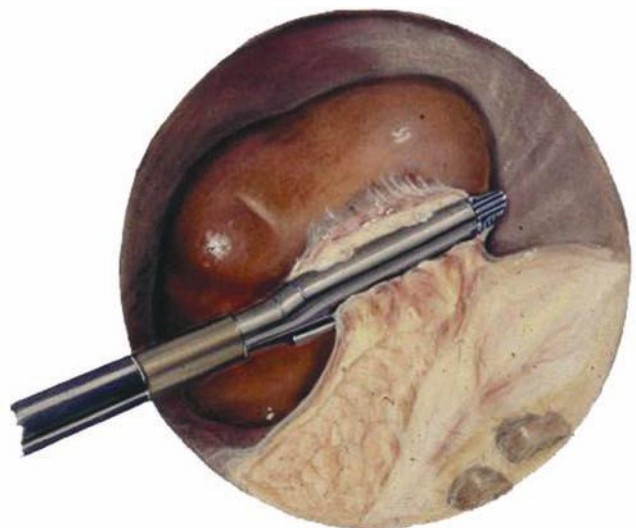
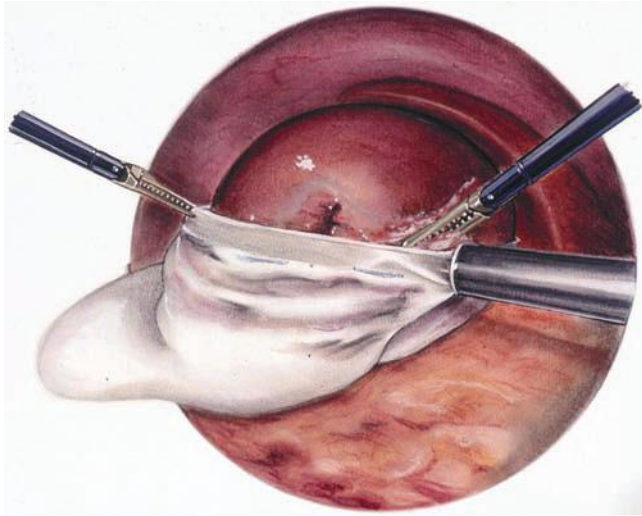
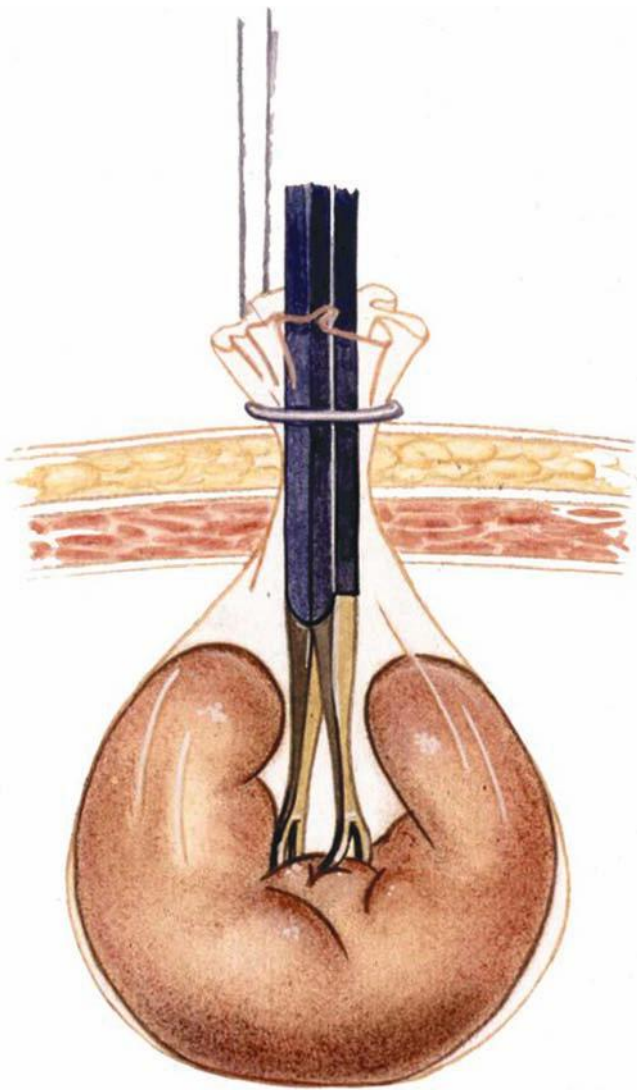


Figure 34-8. Splenic hilum can be divided laparoscopically en masse once the spleen has been rotated medially having been mobilized from its lateral attachments.

Once excised, the spleen is placed in a durable ripstop nylon sack (Fig. 34-9), the neck of which is drawn through one of the 10-mm trocar sites. Morcellation of the spleen takes place



A



B

Figure 34-9. Spleen extraction. **A.** Spleen is placed into a ripstop nylon bag before morcellation. **B.** Splenic morcellation.

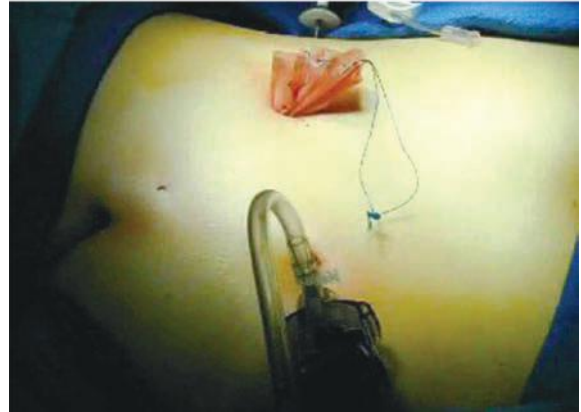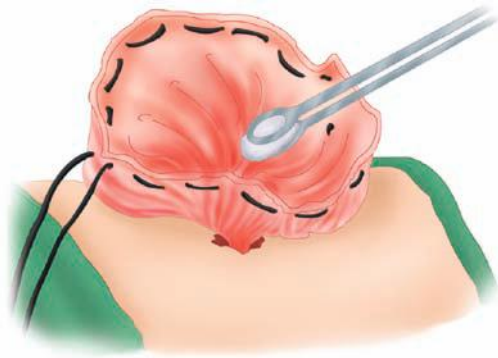


Figure 34-10. Morcellation and extraction of the spleen within nylon sac extending through the 10-mm trocar site. (Illustration is reproduced with permission from Park A et al. *Laparoscopic vs open splenectomy*. *Arch Surg*. 1999;134:1263. Copyright © 1999 American Medical Association. All rights reserved.)

within the sack and allows piecemeal extraction; a blunt instrument should be used to disrupt and remove the spleen to avoid the risk of sack rupture, spillage of contents, and subsequent splenosis (Fig. 34-10).

Hand-Assisted Splenectomy

When LS is performed in patients with splenomegaly, there have been reports of high rates of both complications and conversion to open splenectomy.⁹⁶ Hand-assisted laparoscopic surgery (HALS) has been described as an alternative to the LS approach.^{20,95,97} Spleens greater than 22 cm in craniocaudal length or 19 cm in width may benefit from HALS over a purely laparoscopic approach.⁹⁷ It has been reported that the use of this technique has resulted in a marked reduction in average operative time for patients with massive splenomegaly (146 vs. 295 minutes). Although HALS does require a small incision (7–8 cm) for hand insertion and specimen extraction, no differences in length of stay were observed when comparing these patients to those managed purely laparoscopically.⁹⁷

When performing HALS splenectomy, patient positioning is similar to that of LS (Fig. 34-11). For patients with massive spleens, lateral positioning is altered slightly, such that the patient is placed supine with the left side elevated at 45°. Depending on the hand dominance of the surgeon, the hand-assist device can be placed in either a midline position for right-hand dominant or a subcostal position for left-hand dominant surgeons. A 7- to 8-cm incision should be made 2 to 4 cm caudal to the inferior pole of the enlarged spleen. The hand-assisted technique allows for a tactile feedback and atraumatic manipulation of the enlarged spleen.

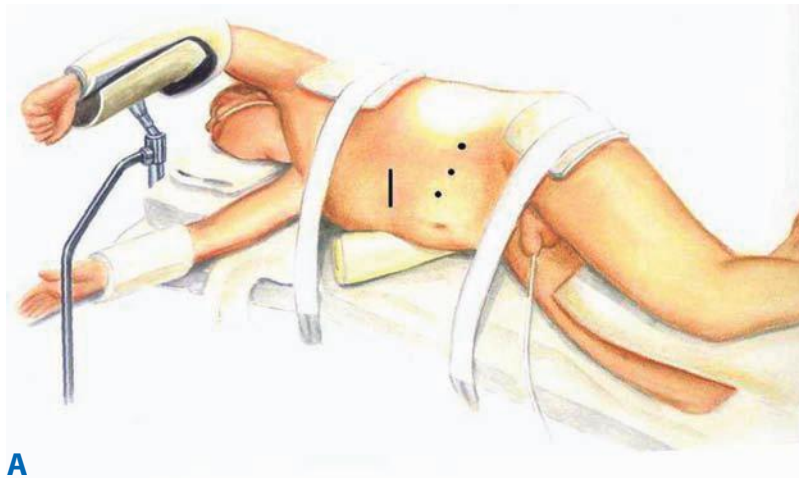
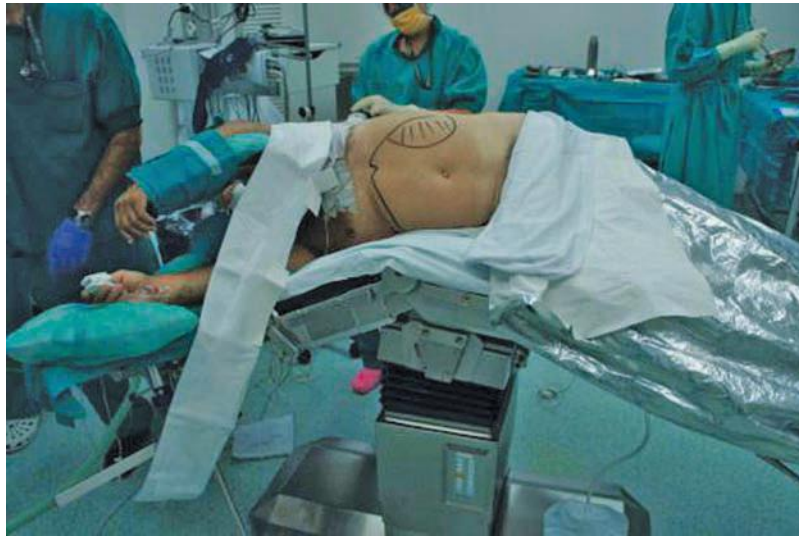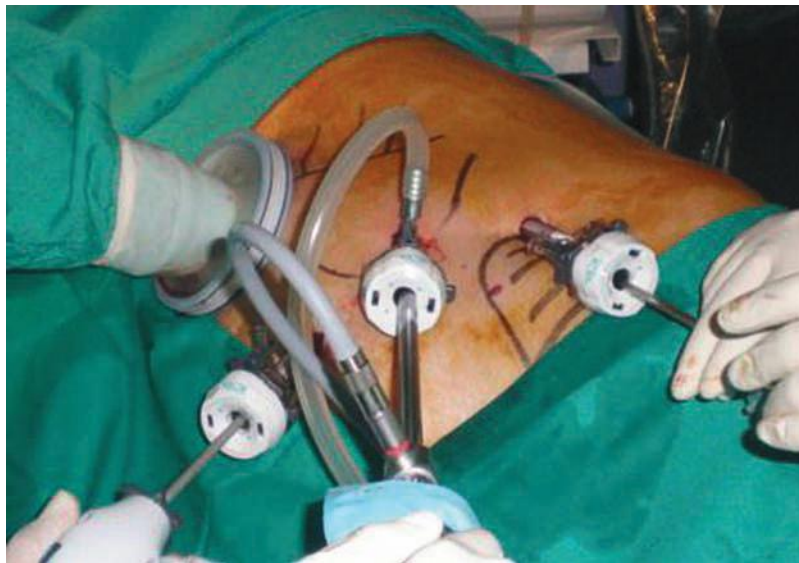**A****B****C**

Figure 34-11. A. Patient table placement for hand-assisted laparoscopic splenectomy (HALS) in case of splenomegaly. B and C. Intraoperative images of HALS.

The nondominant hand provides medial retraction and rotation of the spleen through a hand-assist port, while the dominant hand carries out the dissection using laparoscopic instruments. The anterior and posterior attachments of the spleen are taken down as in the laparoscopic approach, and the hilar pedicle is ligated using an endoscopic vascular stapler.

Single-Incision Laparoscopic Surgery Splenectomy

Single-incision laparoscopic surgery (SILS) splenectomy emphasizes the concept of surgery through one small transabdominal incision rather than the standard multiple trocar sites, with theoretical benefits of less pain and better cosmetics. The incision can be hidden periumbilically and is used as the specimen extraction site at the end of the case. This approach for solid organs poses several technical challenges. Since all instruments are closely aligned together, “fencing” of instruments and the laparoscope and limited degrees of movement are commonly encountered. The spleen, being a solid organ, cannot be grasped, and thus retraction may be more challenging in these cases. Furthermore, it has been reported that periumbilical port position may result in technical challenges when dealing with high body mass index or tall patients, precluding the surgeon from adequately reaching the spleen. Other alternatives to single port placements have been reported, although to date, no proven benefits of SILS splenectomy have been demonstrated.^{98,114,115}

Robotic Splenectomy

The robotic approach does offer a unique three-dimensional visualization of the surgical field. It is also debated that robotic intervention facilitates movement with higher precision than standard laparoscopy. Otherwise the overall surgical approach to splenectomy is very similar to standard laparoscopy, although not as cost effective. To date, no randomized prospective data are available that show a clear benefit of robotic versus laparoscopic splenectomy.^{99,100}

Partial Splenectomy

The past few decades have witnessed ever-widening endorsement for and practice of partial splenectomy. This technique, initially reported in the early eighteenth century, is particularly indicated to minimize the risk of postsplenectomy sepsis in children. Certain lipid storage disorders leading to splenomegaly (e.g., Gaucher’s disease) and some forms of traumatic splenic injury (blunt and penetrating) and spherocytosis in children are amenable to treatment with partial splenectomy. Both the laparoscopic and open approaches for partial splenectomy have been well described. The spleen must be adequately mobilized, and the splenic hilar vessels attached to the targeted segment, ligated, and divided. The devascularized segment of spleen is transected along an obvious line of demarcation. Bleeding from the cut surface of the spleen usually is limited and can be controlled by various methods, including cauterization, argon coagulation, or application of direct hemostatic agents such as cellulose gauze and fibrin glue.

Inadvertent Intraoperative Splenic Injury

Inadvertent intraoperative injury to the spleen is a noted occurrence in the surgical literature, familiar to and dreaded by the abdominal surgeon. The true incidence is unknown. The gravity of such injury is not to be underestimated. Significant short-term morbidity is associated with injury to the

spleen, including increased blood loss, need for transfusion, and prolonged hospital stay.¹⁰²

Intraoperative injury to the spleen has been linked with numerous operations, such as gastric fundoplication, colectomy, paraesophageal hernia repair, nephrectomy, and abdominal and pelvic vascular surgery. There are also reports of splenic injuries after endoscopic procedures, such as colonoscopy.

Improper traction on the spleen against its peritoneal attachments is the most common mechanism of intraoperative injury. Capsular tears are the most common type of injury, but parenchymal lacerations and subcapsular hematomas also occur. The lower pole is more commonly injured, owing to its orientation and the greater concentration of peritoneal attachments found here.

As with all hemorrhage, prompt temporary control of bleeding should be obtained by direct compression of the spleen itself, packing of the left upper quadrant, compression of the vessels at the splenic hilum, or pressure on the splenic artery at the superior pancreatic margin. The spleen should then be mobilized from its peritoneal attachments and the nature of the injury assessed. Overall, the patient’s condition is the primary determinant of whether splenic salvage can be attempted, although hilar injury is best managed by splenectomy. When dealing with capsular tears (most common injury), strong consideration should be given to splenorrhaphy techniques: application of topical hemostatics, suture plication of disrupted parenchyma with or without omental buttress, and the use of bioabsorbable mesh sheets.

The time-honored surgical tenets of liberal exposure and visualization are particularly germane to the avoidance of splenic injury. Incisions and approaches must be tailored to both patient circumstances and surgeon experience. There is some evidence to support the assertion that use of the laparoscopic approach may reduce the incidence of splenic injury for certain operations. As with all hemorrhage, prompt temporary control of bleeding is required. Direct compression of the spleen itself, packing of the left upper quadrant, compression of the vessels at the splenic hilum, or pressure on the splenic artery at the superior pancreatic margin can slow or stop hemorrhage and allow more deliberate consideration of management options.

The spleen is mobilized from its peritoneal attachments and the nature of the injury assessed. Overall, the patient’s condition is the primary determinant of whether splenic salvage can be attempted. The type of injury plays a role as well; it has been suggested that hilar injury is best managed by splenectomy.⁸⁰ Barring these unfavorable circumstances, however, and recalling that the majority of intraoperative splenic injuries are capsular tears, it is reasonable to expect that splenic preservation can be achieved in many appropriately selected situations. Presented with one of these situations, the surgeon has at his or her disposal a number of useful and well-described splenorrhaphy techniques: application of topical hemostatics, suture plication of disrupted parenchyma with or without omental buttress, and the use of bioabsorbable mesh sheets.

SPLENECTOMY OUTCOMES

Changes in blood composition resulting from splenectomy include the appearance of Howell-Jolly bodies and siderocytes. After splenectomy, leukocytosis and increased platelet counts are common as well. Although platelet counts most often rise within 2 days, they may not peak for several weeks in patients

with preoperative thrombocytopenia (see “Hematologic Outcomes” later). Similarly, within 1 day after splenectomy, the white blood cell count typically rises, and such elevation may continue for several months.

Complications

Complications of splenectomy may be classified as pulmonary, hemorrhagic, infectious, pancreatic, and thromboembolic.^{9,103} Left lower lobe atelectasis is the most common complication after OS; pleural effusion and pneumonia also can occur. Hemorrhage can occur intraoperatively or postoperatively, presenting as subphrenic hematoma. Transfusions have become less common since the advent of LS, although the indication for operation influences the likelihood of transfusion as well. Subphrenic abscess and wound infection are among the perioperative infectious complications. The placement of a drain in the left upper quadrant may be associated with postoperative subphrenic abscess and is not routinely recommended. Pancreatitis, pseudocyst, and pancreatic fistula are among the pancreatic complications that may result from intraoperative trauma to the pancreas during dissection of the splenic hilum.

Hematologic Outcomes

The results of splenectomy may be appraised according to the level of hematologic response (e.g., rise in platelet and hemoglobin levels) in those disorders in which the spleen contributes to the hematologic problem. Hematologic responses may be divided into initial and long-term responses. For thrombocytopenia, an initial response typically is defined as a rise in platelet count within several days of splenectomy. Reported series demonstrate the effectiveness of LS in providing a long-term platelet response in approximately 80% of individuals with ITP (Table 34-3). These results are consistent with the long-term success rate associated with OS.

For chronic hemolytic anemias, a rise in hemoglobin levels to >10 g/dL without the need for transfusion signifies a successful response to splenectomy. By this criterion, splenectomy has been reported to be successful for the vast majority of patients with chronic hemolytic anemia. For hemolytic anemia

due to spherocytosis, the success rate is usually higher, ranging from 90% to 100%.

Splenectomy results also may be examined in terms of surgical and postsurgical characteristics, including operative time, recovery time, and morbidity and mortality rates, all of which tend to vary according to hematologic indication⁹ (Tables 34-3 and 34-4).

Results of few prospective, randomized trials comparing LS and OS have been published. However, several recent meta-analyses^{9,94} of published comparative series including 38 papers with more than 2914 patients indicate that the laparoscopic approach typically results in longer operative times, shorter hospital stays, lower morbidity rates, similar blood loss, and similar mortality rates compared with OS. Questions of the cost effectiveness of LS persist, although analysis of this issue is hindered by a lack of universally accepted metrics as well as a paucity of recent objective data. Proponents of LS argue that the generally higher operating room charges are offset by the reduced hospital stay and presumably shorter time of lost productivity. For those institutions with experienced personnel and technical capability, the laparoscopic approach has emerged as the standard for elective, nontraumatic splenectomy.

Overwhelming Postsplenectomy Infection

Asplenic patients bear an increased susceptibility to infection for the remainder of their lives. Although the overwhelming majority of splenectomized patients experience no ill consequence from the absence of the spleen, the potentially catastrophic consequences of overwhelming postsplenectomy infection (OPSI) demand lifelong vigilance and intimate knowledge of the appropriate precautions and preventative measures. All involved—patients, family members, and physicians—need to play an active role.¹⁷

Clinical Features. Sepsis in splenectomized patients is a medical emergency. Therefore, any clinical suggestion of infection, including seemingly isolated fevers, must be viewed with a high index of suspicion and treated empirically as thorough investigation proceeds. OPSI may begin with a relatively

Table 34-3

Outcome after splenectomy

OUTCOME VARIABLE	STUDIES (N)	PATIENTS (N)	POOLED RESULTS AND CI	P
Mortality	38	2914	-0.01 (-0.02, 0)	1
Complications				
Pooled	38	2914	-0.11 (-0.16, -0.05)	<.00001
Minor	36	2914	-0.03 (-0.05, -0.01)	.13
Severe	36	2745	-0.07 (-0.11, -0.03)	<.00001
Thrombosis	35	2695	-0.01 (-0.02, 0.01)	1
Organ injury	34	2639	0.01 (-0, 0.02)	1
Acces. spleen	29	2135	0.02 (-0.01, 0.05)	.87
Operative time	18	1370	57.4 min (43.3, 71.4)	<.00001
Blood loss	10	759	-41 mL (-87, 4.71)	<.00001
Length of stay	20	1566	-2.48 d (-2.89, -2.07)	<.00001

Source: From Bai YN, Jiang H, Prason P. A meta-analysis of perioperative outcomes of laparoscopic splenectomy for hematological diseases. *World J Surg*. 2012;36:2349-2358. With kind permission from Springer Science+Business Media.

Table 34-4

Laparoscopic splenectomy results by hematologic indication

	ITP (N = 151)	TTP (N = 7)	ANEMIA (N = 40)	MALIGNANCY (N = 28)
OR time (min)	128	146	149	165
EBL (mL)	137	96	116	238
LOS (days)	2.2	3.0	2.2	2.6
Conversions from LS to OS	3 (2%)	1 (14%)	1 (3%)	1 (4%)
Complications	14 (9%)	0	1 (3%)	3 (11%)

EBL = estimated blood loss; ITP = idiopathic thrombocytopenic purpura; LOS = length of hospital stay; LS = laparoscopic splenectomy; OR = operating room; OS = open splenectomy; TTP = thrombotic thrombocytopenic purpura.

Source: Data from Park A, McKinlay R. Spleen. In: Brunicaudi FC, Andersen DK, Billiar TR, et al, eds. *Schwartz's Principles of Surgery*. 8th ed. New York: McGraw-Hill; 2005:1312.

mild-appearing prodrome with nonspecific symptoms. In addition to fever, nonspecific symptoms such as malaise, myalgias, headache, vomiting, diarrhea, abdominal pain, and others should be viewed with alarm in the asplenic patient. Absent the spleen, the infectious process signaled by such symptoms can progress rapidly to fulminant bacteremic septic shock, with hypotension, anuria, and disseminated intravascular coagulation. The need for a high index of suspicion, prompt action, and aggressive education of the patient, family, and medical provider cannot be overstated.

The true incidence of OPSI is not precisely known, because defining criteria vary among published series. Overall lifetime risk remains low, ranging from <1% to 5%.^{9,17,106,107} Among those who develop OPSI, some characteristics can be identified that impart greater risk. Reason for splenectomy is the single most influential determinant of OPSI risk. Case series demonstrate that those who undergo splenectomy for hematologic disease (malignancy, myelodysplasia, or hemoglobinopathy) are far more susceptible to OPSI than patients who undergo splenectomy for trauma or iatrogenic reasons. Age is also an important consideration, with children 5 years of age or less and adults 50 years or older being at elevated risk. Finally, time interval from spleen removal must be considered. A large number of OPSI cases occur many years to decades later. This observation underscores both the threat of this lethal disease and the need for lifelong vigilance.

Microbiology and Pathogenesis. Life-threatening infection in the asplenic patient is attributable to three factors: loss of splenic macrophages, diminished tuftsin production, and loss of the spleen's reticuloendothelial screening function. In the normal host, these three factors work in concert to eliminate opsonized bacteria from the bloodstream. This system is particularly suited to the removal of encapsulated bacteria, whose polysaccharide coating is a natural defense against opsonization (*S. pneumoniae*, *H. influenzae*, and *N. meningitidis* are classic examples). Infections with protozoa that invade the red blood cell, such as *Babesia microti* (transmitted by tick bites), *Ehrlichia*, and *Plasmodium*, occur more frequently in splenectomized individuals than in normal hosts. Other potential infectious bacterial sources include group A streptococci, *C. canimorsus* (transmitted by dog bites), group B streptococci, *Enterococcus* species, *Bacteroides* species, *Salmonella* species, and *Bartonella* species.¹¹¹ In the absence of the spleen, elimination of these pathogens from the bloodstream falls solely to the liver, a process that has been demonstrated to be less effective.^{9,107}

Antibiotics and the Asplenic Patient. Antibiotic therapy for the asplenic patient can be considered in three contexts: deliberate therapy for established or presumed infections, prophylaxis in anticipation of invasive procedures (e.g., dental procedures), and general prophylaxis. For the latter two indications, unfortunately, evidence supporting efficacy is scant, and guidelines for antibiotic prophylaxis are not uniform. Optimal duration of chemoprophylaxis in children is unclear. Daily doses of antibiotics until 5 years of age or at least 5 years after splenectomy are commonly recommended,^{108,109} although some advocate continuation into at least young adulthood. Concerns regarding compliance and bacterial resistance have been raised, which have led some authors to suggest that lifelong daily antibiotic prophylaxis be recommended only for those patients whose antibody titers fail to respond appropriately to vaccination or, alternately, that asplenic patients be advised to carry at all times a reserve supply of antibiotic to be self-administered at the earliest sign of infection.¹⁰⁹ Considering the grave consequences of OPSI and its relatively low incidence, controlled trials resulting in meaningful data on this issue seem unlikely to be performed.

Several risk management strategies are commonly recommended to asplenic patients, including wearing a medical bracelet, carrying a laminated medical alert card, possessing a medical letter with specific empiric therapy instructions (including drug names and dosages), and keeping a 5-day supply of standby antibiotics, particularly when travel is anticipated.

REFERENCES

Entries highlighted in bright blue are key references.

- Moynihan B. The surgery of the spleen. *Br J Surg*. 1920;8:307.
- McClusky DA III, Skandalakis LJ, Colborn GL, et al. Tribute to a triad: history of splenic anatomy, physiology, and surgery—part 1. *World J Surg*. 1999;23:311-325.
- McClusky DA III, Skandalakis LJ, Colborn GL, et al. Tribute to a triad: history of splenic anatomy, physiology, and surgery—part 2. *World J Surg*. 1999;23:514-526.
- Aristotle. *De Paribus Animalium [On the Parts of Animals]*. A.L. Peck, translator. Cambridge: Harvard University Press; 1961.
- Malpighi M, quoted in Foster M. *Lectures on the History of Physiology during the Sixteenth, Seventeenth and Eighteenth Centuries*. Cambridge: Cambridge University Press; 1901:164.

6. Morgenstern L. A history of splenectomy. In: Hiatt JR, Philips EH, Morgenstern L, eds. *Surgical Disease of the Spleen*. New York: Springer; 1997.
7. Bryant T. Case of excision of the spleen for an enlargement of the organ, attended with leucocythaemia; with remarks. *Guys Hosp Rep*. 1867;13:412.
8. Morgenstern L, Skandalakis JE. Anatomy and embryology of the spleen. In: Hiatt JR, Phillips EH, Morgenstern L, eds: *Surgical Diseases of the Spleen*. Berlin/Heidelberg: Springer-Verlag; 1997:15.
9. Bickenbach KA, Gonen M, Labow DM, et al. Indications for and efficacy of splenectomy for haematological disorders. *Br J Surg*. 2013;100:794-800.
10. Musallam KM, Khalife M, Sfeir PM, et al. Postoperative outcomes after laparoscopic compared with open splenectomy. *Ann Surg*. 2012;257:1116-1123.
11. Mebius RE, Kraal G. Structure and function of the spleen. *Nat Rev Immunol*. 2005;5:606-616.
12. Tarantino G, Savastano S, Capone D, et al. Spleen: a new role for an old player? *World J Gastroenterol*. 2011;17:3776-3784.
13. Gray H. *On the Structure and Use of the Spleen*. London: John W. Parker and Son; 1854:1-53.
14. Bratosin D, Mazurier J, Tissier JP, et al. Cellular and molecular mechanisms of senescent erythrocyte phagocytosis by macrophages. A review. *Biochimie*. 1998;80:173-195.
15. Knutson M, Wessling-Resnick M. Iron metabolism in the reticuloendothelial system. *Crit Rev Biochem Mol Biol*. 2003;38:61-88.
16. Nolte MA, Belien JA, Schadee-Eestermans I, et al. A conduit system distributes chemokines and small blood-borne molecules through the splenic white pulp. *J Exp Med*. 2003;198:505-512.
17. Di Sabatino A, Carsetti R, Corazza GR. Post-splenectomy and hyposplenic states. *Lancet*. 2011;378:86-97.
18. Spelman D, Buttery J, Daley A, et al. Guidelines for the prevention of sepsis in asplenic and hyposplenic patients. *Intern Med J*. 2008;38:349-356.
19. Davies JM, Lewis MP, Wimperis J, et al. Review of guidelines for the prevention and treatment of infection in patients with an absent or dysfunctional spleen: prepared on behalf of the British Committee for Standards in Haematology by a working party of the Haemato-Oncology Task Force. *Br J Haematol*. 2011;155:308-317.
20. Habermalz B, Sauerland S, Decker G, et al. Laparoscopic splenectomy: the clinical practice guidelines of the European Association for Endoscopic Surgery (EAES). *Surg Endosc*. 2008;22:821-848.
21. Pozo AL, Godfrey EM, Bowles KM. Splenomegaly: investigation, diagnosis and management. *Blood Rev*. 2009;23:105-111.
22. McInnes MD, Kielar AZ, Macdonald DB. Percutaneous image-guided biopsy of the spleen: systematic review and meta-analysis of the complication rate and diagnostic accuracy. *Radiology*. 2011;260:699-708.
23. Singh AK, Shankar S, Gervais DA, Hahn PF, Mueller PR. Image-guided percutaneous splenic interventions. *Radiographics*. 2012;32:523-534.
24. Zarzaur BL, Kozar RA, Fabian TC, Coimbra R. A survey of American Association for the Surgery of Trauma member practices in the management of blunt splenic injury. *J Trauma*. 2011;70:1026-1031.
25. Myers J. Focused assessment with sonography for trauma (FAST): the truth about ultrasound in blunt trauma. *J Trauma*. 2007;62(6 Suppl):S28.
26. Kamaya A, Weinstein S, Desser TS. Multiple lesions of the spleen: differential diagnosis of cystic and solid lesions. *Semin Ultrasound CT MR*. 2006;27:389-403.
27. Thompson BE, Munera F, Cohn SM, et al. Novel computed tomography scan scoring system predicts the need for intervention after splenic injury. *J Trauma*. 2006;60:1083-1086.
28. Karakas HM, Tuncbilek N, Okten OO. Splenic abnormalities: an overview on sectional images. *Diagn Interv Radiol*. 2005;11:152-158.
29. Filicori F, Stock C, Schweitzer AD, et al. Three-dimensional CT volumetry predicts outcome of laparoscopic splenectomy for splenomegaly: retrospective clinical study. *World J Surg*. 2013;37:52-58.
30. Berindoague R, Targarona EM, Balague C, et al. Can we predict immediate outcome after laparoscopic splenectomy for splenomegaly? Multivariate analysis of clinical, anatomic, and pathologic features after 3D reconstruction of the spleen. *Surg Innov*. 2007;14:243-251.
31. Dent D, Alsabrook G, Erickson BA, et al. Blunt splenic injuries: high nonoperative management rate can be achieved with selective embolization. *J Trauma*. 2004;56:1063-1067.
32. Koconis KG, Singh H, Soares G. Partial splenic embolization in the treatment of patients with portal hypertension: a review of the English language literature. *J Trauma*. 2007;18:463-481.
33. Cuker A, Cines DB. Evidence-based mini-review: is indium-labeled autologous platelet scanning predictive of response to splenectomy in patients with chronic immune thrombocytopenia? *Hematology Am Soc Hematol Educ Program*. 2010;2010:385-386.
34. Wu Z, Zhou J, Pankaj P, Peng B. Comparative treatment and literature review for laparoscopic splenectomy alone versus preoperative splenic artery embolization splenectomy. *Surg Endosc*. 2012;26:2758-2766.
35. Mousa A, Armbruster J, Adongay J, Aburahma AF. Splenic artery embolization as a treatment option for chronic pancytopenia secondary to hypersplenism: a case report and review of literature. *Vasc Endovascular Surg*. 2012;46:501-503.
36. Williams G, Rosen MP, Parker JA, et al. Splenic implants detected by SPECT images of Tc-99m labeled damaged red blood cells. *Clin Nucl Med*. 2006;31:467-469.
37. Lui EH, Lau KK. Intra-abdominal splenosis: how clinical history and imaging features averted an invasive procedure for tissue diagnosis. *Australas Radiol*. 2005;49:342-344.
38. Balague C, Vela S, Targarona EM, et al. Predictive factors for successful laparoscopic splenectomy in immune thrombocytopenic purpura: study of clinical and laboratory data. *Surg Endosc*. 2006;20:1208-1213.
39. Mikhael J, Northridge K, Lindquist K, Kessler C, Deuson R, Danese M. Short-term and long-term failure of laparoscopic splenectomy in adult immune thrombocytopenic purpura patients: a systematic review. *Am J Hematol*. 2009;84:743-748.
40. Bolton-Maggs PH, Langer JC, Iolascon A, Tittensor P, King MJ; General Haematology Task Force of the British Committee for Standards in Haematology. Guidelines for the diagnosis and management of hereditary spherocytosis—2011 update. *Br J Haematol*. 2012;156:37-49.
41. Schilling RF. Risks and benefits of splenectomy versus no splenectomy for hereditary spherocytosis—a personal view. *Br J Haematol*. 2009;145:728-732.
42. Perrotta S, Gallagher PG, Mohandas N. Hereditary spherocytosis. *Lancet*. 2008;372:1411-1422.
43. Hollingsworth CL, Rice HE. Hereditary spherocytosis and partial splenectomy in children: review of surgical technique and the role of imaging. *Pediatr Radiol*. 2010;40:1177-1183.
44. Casale M, Perrotta S. Splenectomy for hereditary spherocytosis: complete, partial or not at all? *Expert Rev Hematol*. 2011;4:627-635.
45. Prchal JT, Gregg XT. Red cell enzymopathies. In: Hoffman R, ed. *Hematology: Basic Principles and Practice*. 3rd ed. New York: Churchill Livingstone; 2001:561.

46. Hamilton JW, Jones FGC. Glucose-6-phosphate dehydrogenase Guadalajara—a case of chronic non-spherocytic haemolytic anaemia responding to splenectomy and the role of splenectomy in this disorder. *Hematology*. 2004;9:307-309.
47. Michel M. Classification and therapeutic approaches in autoimmune hemolytic anemia: an update. *Expert Rev Hematol*. 2011;4:607-618.
48. Hill J, Walsh RM, McHam S, et al. Laparoscopic splenectomy for autoimmune hemolytic anemia in patients with chronic lymphocytic leukemia: a case series and review of the literature. *Am J Hematol*. 2004;75:134-138.
49. Plikat K, Rogler G, Scholmerich J. Coombs-positive autoimmune hemolytic anemia in Crohn's disease. *Eur J Gastroenterol Hepatol*. 2005;17:661-666.
50. Rigal D, Meyer F. Autoimmune haemolytic anemia: diagnosis strategy and new treatments. *Transfus Clin Biol*. 2011;18:277-285.
51. Rees DC, Williams TN, Gladwin MT. Sickle-cell disease. *Lancet*. 2010;376:2018-2031.
52. al-Salem AH. Indications and complications of splenectomy for children with sickle cell disease. *J Pediatr Surg*. 2006;41:1909-1915.
53. Rachmilewitz EA, Giardina PJ. How I treat thalassemia. *Blood*. 2011;118:3479-3488.
54. Phrommintikul A, Sukonthasarn A, Kanjanavanit R, et al. Splenectomy: a strong risk factor for pulmonary hypertension in patients with thalassaemia. *Heart*. 2006;92:1467-1472.
55. Sheikh AK, Salih ZT, Kasnazan KH, et al. Prevention of overwhelming postsplenectomy infection in thalassemia patients by partial rather than total splenectomy. *Can J Surg*. 2007;50:382-386.
56. Cines DB, Blanchette VS. Immune thrombocytopenic purpura. *N Engl J Med*. 2002;346:995-1008.
57. George JN. Sequence of treatments for adults with primary immune thrombocytopenia. *Am J Hematol*. 2012;87(Suppl 1): S12-S15.
58. Rodehiero F, Besalduch J, Michel M, Provan D, Grotzinger K, Thompson G. Treatment practices in adults with chronic immune thrombocytopenia—a European perspective. *Eur J Haematol*. 2010;84:160-168.
59. Auger S, Dunny Y, Rossi JF, QUITT P. Rituximab before splenectomy in adults with primary idiopathic thrombocytopenic purpura: a meta-analysis. *Br J Haematol*. 2012;158:386-398.
60. Kojouri K, Vesely SK, Terrell DR, George JN. Splenectomy for adult patients with idiopathic thrombocytopenic purpura: a systematic review to assess long-term platelet count responses, prediction of response, and surgical complications. *Blood*. 2004;104:2623-2634.
61. Mikhael J, Northridge K, Lindquist K, Kessler C, Deuson R, Danese M. Short-term and long-term failure of laparoscopic splenectomy in adult immune thrombocytopenic purpura patients: a systematic review. *Am J Hematol*. 2009;84: 743-748.
62. Szold A, Kais H, Keidar A, et al. Chronic idiopathic thrombocytopenic purpura (ITP) is a surgical disease. *Surg Endosc*. 2002;16:155-158.
63. Keidar A, Feldman M, Szold A. Analysis of outcome of laparoscopic splenectomy for idiopathic thrombocytopenic purpura by platelet count. *Am J Hematol*. 2005;80:95-100.
64. Dubois L, Gray DK. Case series: splenectomy: does it still play a role in the management of thrombotic thrombocytopenic purpura? *Can J Surg*. 2010;53:349-355.
65. Targarona EM. Spleen, hematological disorders. In: Matteotti R, Becker JM, Ashley SM, eds. *Minimally Invasive Surgical Oncology. State-of-the-Art Cancer Management*. New York: Springer Verlag; 2011.
66. Townsend W, Linch D. Hodgkin's lymphoma in adults. *Lancet*. 2012;380:836-847.
67. Shankland KR, Armitage JO, Hancock BW. Non-Hodgkin lymphoma. *Lancet*. 2012;380:848-857.
68. Habermann TM, Rai K. Historical treatments of hairy cell leukemia, splenectomy and interferon: past and current uses. *Leuk Lymphoma*. 2011;52(Suppl 2):18-20.
69. Casaccia M, Torelli P, Cavaliere D, et al. Laparoscopic lymph node biopsy in intra-abdominal lymphoma: high diagnostic accuracy achieved with a minimally invasive procedure. *Surg Laparosc Endosc Percutan Tech*. 2007;17:175-178.
70. Shanshal M, Haddad RY. Chronic lymphocytic leukemia. *Dis Mon*. 2012;58:153-167.
71. Bennett M, Schechter GP. Treatment of splenic marginal zone lymphoma: splenectomy versus rituximab. *Semin Hematol*. 2010;47:143-147.
72. Matutes E, Oscier D, Montalban C, et al. Splenic marginal zone lymphoma proposals for a revision of diagnostic, staging and therapeutic criteria. *Leukemia*. 2008;22:487-495.
73. Ferrara F, Schiffer CA. Acute myeloid leukaemia in adults. *Lancet*. 2013;381:484-495.
74. Jabbour E, Kantarjian H. Chronic myeloid leukemia: 2012 update on diagnosis, monitoring, and management. *Am J Hematol*. 2012;87:1037-1045.
75. Tefferi A. Polycythemia vera and essential thrombocythemia: 2012 update on diagnosis, risk stratification, and management. *Am J Hematol*. 2012;87:285-293.
76. Logan MS, Watson CM, Nottingham JM. Symptomatic splenomegaly in polycythemia vera: a review of the indications for splenectomy and perioperative considerations. *Am Surg*. 2009;75:363-368.
77. Tefferi A. How I treat myelofibrosis. *Blood*. 2011;117: 3494-3504.
78. Mesa R. Myeloproliferative disorder-associated massive splenomegaly. *Clin Adv Hematol Oncol*. 2008;6:278, 281-282.
79. Cervantes F. Myelofibrosis: biology and treatment options. *Eur J Haematol Suppl*. 2007;68:13-17.
80. Mesa RA, Nagarney DS, Schwager S, et al. Palliative goals, patient selection, and perioperative platelet management: outcomes and lessons from three decades of splenectomy for myelofibrosis with myeloid metaplasia at the Mayo Clinic. *Cancer*. 2006;107:361-370.
81. Lee WS, Choi ST, Kim KK. Splenic abscess: a single institution study and review of the literature. *Yonsei Med J*. 2011; 52:288-292.
82. Comitalo JB. Laparoscopic treatment of splenic cysts. *JSLs*. 2001;5:313-316.
83. Gatsby PA, Mudan SS, Wotherspoon AC. Splenectomy for non-hematological metastatic malignant disease. *Langenbecks Arch Surg*. 2011;396:625-638.
84. Lopez Monclova J, Targarona Soler E, Peraza Solis Y, et al. Laparoscopic approach for isolated splenic metastasis: comprehensive literature review and report of 6 cases. *Surg Laparosc Endosc Percutan Tech*. 2013;23:21-24.
85. Cox TM, Aerts JM, Belmatoug N, et al. Management of non-neuronopathic Gaucher disease with special reference to pregnancy, splenectomy, bisphosphonate therapy, use of biomarkers and bone disease monitoring. *J Inherit Metab Dis*. 2008;31:319-336.
86. Guggenbuhl P, Grosbois B, Chalès G. Gaucher disease. *Joint Bone Spine*. 2008;75:116-124.
87. Xiao GQ, Zinberg JM, Unger PD. Asymptomatic sarcoidosis presenting as massive splenomegaly. *Am J Med*. 2002; 113:698-699.
88. Obuchi T, Sasaki A, Nakajima J, Nitta H, Otsuka K, Wakabayashi G. Laparoscopic surgery for splenic artery aneurysm. *Surg Laparosc Endosc Percutan Tech*. 2009;19:338-340.
89. Sadat U, Dar O, Walsh S, Varty K. Splenic artery aneurysms in pregnancy—a systematic review. *Int J Surg*. 2008;6:261-265.

90. Rashba EJ, Rowe JM, Packman CH. Treatment of the neutropenia of Felty syndrome. *Blood Rev.* 1996;10:177-184.
91. Montenovo MI, Ahad S, Oelschlagel BK. Laparoscopic splenectomy for wandering spleen: case report and review of the literature. *Surg Laparosc Endosc Percutan Tech.* 2010;20:e182-e184.
92. Mourtzoukou EG, Pappas G, Peppas G, Falagas ME. Vaccination of asplenic or hyposplenic adults. *Br J Surg.* 2008;95:273-280.
93. Bai YN, Jiang H, Prasoon P. A meta-analysis of perioperative outcomes of laparoscopic splenectomy for hematological disorders. *World J Surg.* 2012;36:2349-2358.
94. Park AE, Gagner M, Pomp A. The lateral approach to laparoscopic splenectomy. *Am J Surg.* 1997;173:126-130.
95. Patel AG, Parker JE, Wallwork B, et al. Massive splenomegaly is associated with significant morbidity after laparoscopic splenectomy. *Ann Surg.* 2003;238:235-240.
96. Pietrabissa A, Morelli L, Peri A, et al. Laparoscopic treatment of splenomegaly: a case for hand-assisted laparoscopic surgery. *Arch Surg.* 2011;146:818-823.
97. Kercher KW, Matthews BD, Walsh RM, et al. Laparoscopic splenectomy for massive splenomegaly. *Am J Surg.* 2002;183:192-196.
98. Monclova JL, Targarona EM, Vidal P, et al. Single incision versus reduced port splenectomy—searching for the best alternative to conventional laparoscopic splenectomy. *Surg Endosc.* 2013;27:895-890.
99. Giulianotti, Buchs NC, Addeo P, et al. Robot-assisted partial and total splenectomy. *Int J Med Robot.* 2011;7:482-488.
100. Bodner J, Kafka-Ritsch R, Lucciarini P, et al. A critical comparison of robotic versus conventional laparoscopic splenectomies. *World J Surg.* 2005;29:982-985; discussion 985-986.
101. Cassar K, Munro A. Iatrogenic splenic injury. *J R Coll Surg Edinb.* 2002;47:731-741.
102. Cadili A, de Gara C. Complications of splenectomy. *Am J Med.* 2008;121:371-375.
103. James AW, Rabl C, Westphalen AC, Fogarty PF, Posselt AM, Campos GM. Portomesenteric venous thrombosis after laparoscopic surgery: a systematic literature review. *Arch Surg.* 2009;144:520-526.
104. Targarona EM. Portal vein thrombosis after laparoscopic splenectomy: the size of the risk. *Surg Innov.* 2008;15:266-270.
105. Wang H, Kopac D, Brisebois R, Sample C, Shapiro AM. Randomized controlled trial to investigate the impact of anticoagulation on the incidence of splenic or portal vein thrombosis after laparoscopic splenectomy. *Can J Surg.* 2011;54: 227-231.
106. Okabayashi T, Hanazaki K. Overwhelming postsplenectomy infection syndrome in adults: a clinically preventable disease. *World J Gastroenterol.* 2008;14:176-179.
107. Taylor MD, Genuit T, Napolitano LM. Overwhelming postsplenectomy sepsis and trauma: time to consider revaccination? *J Trauma.* 2005;59:1482-1485.
108. Jones P, Leder K, Woolley I, et al. Postsplenectomy infection: strategies for prevention in general practice. *Aust Fam Physician.* 2010;39:383-386.
109. Denholm JT, Jones PA, Spelman DW, et al. Spleen registry may help reduce the incidence of overwhelming postsplenectomy infection in Victoria. *Med J Aust.* 2010;192:49-50.
110. Holdsworth RJ, Irwing AD, Cuschia A. Postsplenectomy Sepsis and its Mortality rate: actual versus perceived risks *Br J Surg.* 1991;78(9):1031-1038
111. Waghorn DJ. Overwhelming infection in asplenic patients: current best practice preventive measures are not being followed. *J Clin Pathol.* 2001;54(3):214-218
112. Park A, Maraccio M, Sterbach M, et al. Laparoscopic vs open splenectomy. *Arch Surg.* 1999;134(11):1263-1269
113. Winslow ER, Brunt LM. Perioperative outcomes of laparoscopic versus open splenectomy: a meta-analysis with emphasis on complications. *Surgery.* 2003;134(4):647-653; DISCUSSION 654-655
114. Vantasev C, Ece I, Jr. Single incision laparoscopic splenectomy with double ports. *Surg Laparosc Endosc Percutan Tech.* 2009.19(6):e225-227
115. Barbaros U, Dincag A. Single Incision laparoscopic splenectomy: the first two cases. *J Gastrointest Surg.* 2009;13(8): 1520-1523

35 chapter

Abdominal Wall, Omentum, Mesentery, and Retroperitoneum

Neal E. Seymour and Robert L. Bell

Abdominal Wall

1449

General Considerations / 1449
Surgical Anatomy / 1449
Physiology / 1450
Abdominal Anatomy and Surgical Incisions / 1451
Congenital Abnormalities / 1453
Acquired Abnormalities / 1453

Omentum

1456

Surgical Anatomy / 1456
Physiology / 1457
Omental Infarction / 1457
Omental Cysts / 1457
Omental Neoplasms / 1457

Mesentery

1457

Surgical Anatomy / 1457

Sclerosing Mesenteritis / 1458
Mesenteric Cysts / 1459
Mesenteric Tumors / 1460

Retroperitoneum

1460

Surgical Anatomy / 1460
Retroperitoneal Infections / 1460
Retroperitoneal Fibrosis / 1460

ABDOMINAL WALL

General Considerations

The abdominal wall provides structure, protection, and support for abdominal and retroperitoneal structures and is defined superiorly by the costal margins, inferiorly by the pelvic ring, and posteriorly by the vertebral column. Knowledge of its specific anatomic features is required for management of abdominal wall diseases or during entry into the peritoneal cavity.

Surgical Anatomy

The abdominal wall is an anatomically complex, layered structure with segmentally derived blood supply and innervation (Fig. 35-1). It is mesodermal in origin and develops as bilateral migrating sheets, which originate in the paravertebral region and envelop the future abdominal area. The leading edges of these structures develop into the rectus abdominis muscles, which eventually meet in the anterior midline. The rectus abdominis is longitudinally oriented and encased within an aponeurotic sheath, the layers of which are fused in the midline at the *linea alba*. The rectus insertions are on the pubic bones inferiorly and on the fifth and sixth ribs, as well as the seventh costal cartilages and the xiphoid process superiorly. The lateral border of the rectus muscles has a curved shape identifiable as the surface landmark, the *linea semilunaris*. Three tendinous intersections cross the rectus muscles at the level of the xiphoid process, umbilicus, and about halfway between the xiphoid process and the umbilicus (see Fig. 35-1).

Lateral to the rectus sheath are three muscular layers with oblique fiber orientations relative to one another (Fig. 35-2). These layers are derived from laterally migrating mesodermal tissues during the sixth to seventh week of fetal development. The external oblique muscle runs inferiorly and medially, arising from the margins of the lowest eight ribs and costal cartilages. The external oblique muscles originate on the latissimus dorsi and serratus anterior muscles, as well as on the iliac crest.

Medially, the external obliques form a tendinous aponeurosis, which is contiguous with the anterior rectus sheath. The *inguinal ligament* is the inferior-most edge of the external oblique aponeurosis, reflected posteriorly in the area between the anterior superior iliac spine and pubic tubercle. The internal oblique muscle lies deep to the external oblique and arises from the lateral aspect of the inguinal ligament, the iliac crest, and the thoracolumbar fascia. Its fibers course superiorly and medially and form a tendinous aponeurosis that contributes components to both the anterior and posterior rectus sheath. The lower medial and inferior-most fibers of the internal oblique may fuse with the lower fibers of the transversus abdominis muscle (the *conjoined area*). The inferior-most fibers of the internal oblique muscle are contiguous with the cremasteric muscle in the inguinal canal. These relationships are of critical significance in the management of inguinal hernias. The transversus abdominis muscle is the deepest of the three lateral muscles and runs transversely from the lowest six ribs, the lumbosacral fascia, and the iliac crest, to the lateral border of the rectus abdominis. The *arcuate line* (semicircular line of Douglas) lies roughly at the level of the anterior superior iliac spines (Fig. 35-3). Above the arcuate line, the anterior rectus sheath is formed by the external oblique aponeurosis and the external lamina of the internal oblique aponeurosis, whereas the posterior rectus sheath is formed by the internal lamina of the internal oblique aponeurosis and the transversus abdominis aponeurosis. Below the arcuate line, the anterior rectus sheath is formed by the external oblique aponeurosis, the laminae of the internal oblique aponeurosis, and the transversus abdominis aponeurosis. There is **1▶** no aponeurotic posterior covering of this lower portion of the rectus muscles, although the endoabdominal, or *transversalis*, fascia provides contiguous coverage of the posterior aspect of the abdominal above and below the arcuate line.

The blood supply to the muscles of the anterior abdominal wall is derived mainly from the superior and inferior epigastric arteries (Fig. 35-4). The superior epigastric artery arises from

Key Points

- 1▶ There are important anatomic differences in the rectus sheath structures above and below the arcuate line. The laminae of the internal oblique, which contribute to both the anterior and (along with the transversus abdominis) posterior rectus above the arcuate line, only contribute to the anterior sheath below the arcuate line. There is no aponeurotic posterior covering on the lower portion of the rectus muscles.
- 2▶ Rectus diastasis is associated with abdominal wall bulging consequent to separation of the rectus abdominis muscles in the midline. It does not represent a hernia, and surgical interventions for this condition are of questionable, if any, clinical benefit.
- 3▶ When resection of abdominal wall desmoid tumors is undertaken, it must be recognized that failure to achieve negative margins is associated with an extremely high risk of local recurrence of the tumor.
- 4▶ Primary repair of ventral incisional hernias is associated with unacceptably high failure rates, and repair using other approaches, such as use of prosthetic mesh, is preferred.
- 5▶ The addition of the closed videoscopic technique to components separation procedures has been associated with a significant decrease in the incidence of local wound complications.
- 6▶ Potential benefits of laparoscopic incisional hernia repairs compared to open repairs with mesh include shorter hospitalization, lower risk of wound complications, and better abdominal wall function. A lower recurrence rate benefit remains controversial.
- 7▶ Surgical treatment of sclerosing mesenteritis is most often undertaken to confirm diagnosis and to rule out neoplasm as the cause of a mesenteric mass. Resection possibilities are limited by the extensiveness of the process as well as by the questionable benefit in most cases.
- 8▶ Potential surgical interventions in retroperitoneal fibrosis include operative biopsy to rule out neoplasm, ureteral stent placement, open or laparoscopic ureterolysis, and endovascular interventions for ilio caval occlusion.

the internal thoracic artery, while the inferior epigastric artery arises from the external iliac artery. A collateral network of branches of the subcostal and lumbar arteries also contributes the abdominal wall blood supply. The lymphatic drainage of the abdominal wall is predominantly to the major nodal basins in the superficial inguinal and axillary areas.

Anterior abdominal wall innervation is segmental. Motor nerves to the rectus, oblique, and transversus abdominis muscles run from the anterior rami of spinal nerves at the T6 to T12

levels. The overlying skin is innervated by afferent branches of the T4 through L1 nerve roots, with T10 nerve roots providing sensation around the umbilicus (Fig. 35-5).

Physiology

The rectus muscles, external obliques, and internal obliques work as a unit to flex the trunk anteriorly or laterally. Trunk rotation is achieved by simultaneous contraction of a unilateral external oblique and the contralateral internal oblique (e.g.,

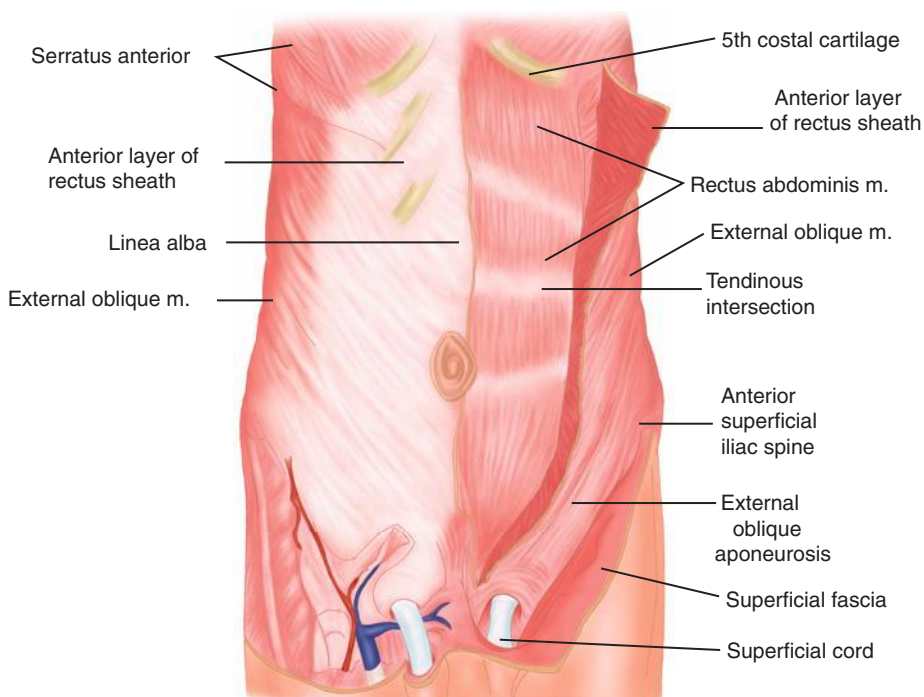


Figure 35-1. Anterior abdominal wall. *Linea alba* is the midline aponeurotic demarcation between the bellies of the rectus abdominis muscles. The rectus abdominis muscle and its tendinous intersections on the left are shown deep to the reflected anterior rectus sheath. (Reproduced with permission from Moore KL, Dalley AF, eds. Clinically Oriented Anatomy. 4th ed. Philadelphia: Lippincott Williams & Wilkins; 1999:181.)

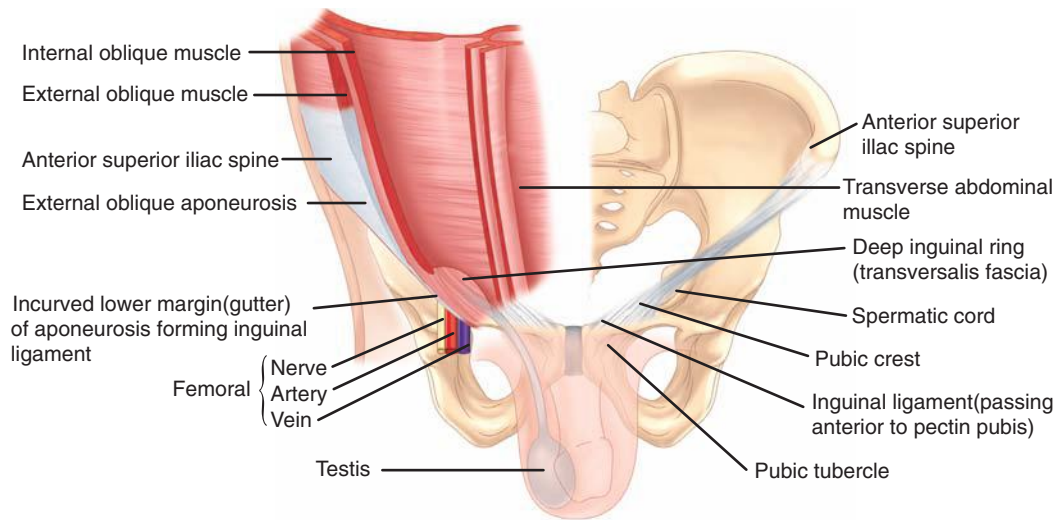


Figure 35-2. The three muscular layers of the abdominal wall lateral to the rectus abdominis are the *external oblique*, *internal oblique*, and *transversus abdominis* muscles, shown here on the low abdomen, where the lower margin of the external oblique reflects posteriorly as the inguinal ligament. (Reproduced with permission from Moore KL, Dalley AF, eds. Clinically Oriented Anatomy. 4th ed. Philadelphia: Lippincott Williams & Wilkins; 1999:181.)

rotation to the right is produced by contraction of the left external oblique muscle and the right internal oblique). All of the truncal muscles are involved in raising intra-abdominal pressure. Abdominal musculature contraction that occurs when the diaphragm is relaxed will result in expiration of air from the lungs, or a cough if this contraction is forceful. If the diaphragm is contracted when the abdominal musculature is contracted (*Valsalva maneuver*), the increased abdominal pressure aids in processes such as micturition, defecation, and childbirth.

Abdominal Anatomy and Surgical Incisions

Surgeons must deal with the abdominal wall to access pre-, intra-, and retroperitoneal sites. This begs practical questions of where and how to make incisions. Incisions for open surgery

are generally located in proximity to the principal operative targets. Laparoscopic port site incisions might be remote from the site of interest and are carefully planned based on the instrument approach angles and working distances both to the operative site and between ports. Orientation of any incision may be determined based on expected quality of exposure, closure considerations including cosmesis, avoidance of previous incision sites, and surgeon preference. In general, incisions for open peritoneal access can be longitudinal (in or off the midline), transverse (lateral to or crossing midline), or oblique (directed either upward or downward toward the flank) (Fig. 35-6). Modifications are numerous and can consist of various extensions to optimize exposure in specific clinical situations. Midline incisions are used for the majority of nonlaparoscopic

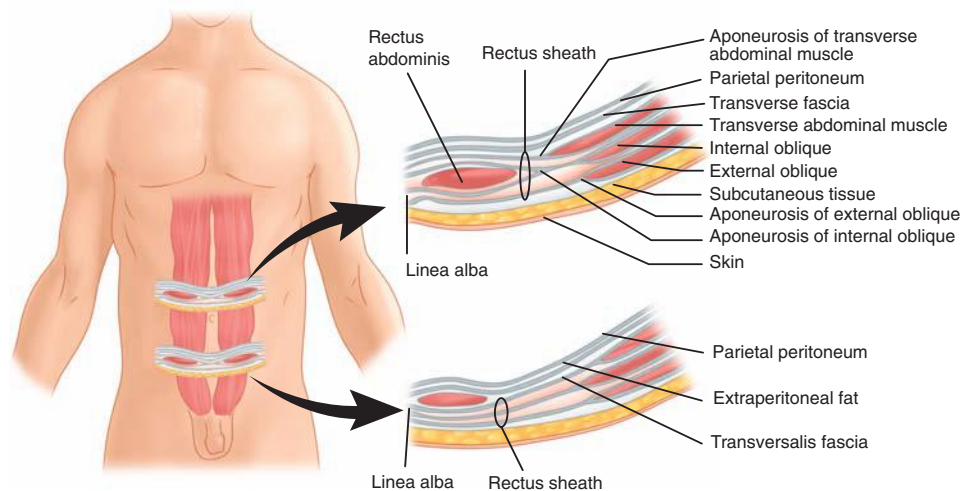


Figure 35-3. Cross-sectional anatomy of the abdominal wall above and below the arcuate line of Douglas. The lower right abdominal wall segment shows clearly the absence of an aponeurotic covering of the posterior aspect of the rectus abdominis muscle inferior to the arcuate line. Superior to the arcuate line, there are both internal oblique and transversus abdominis aponeurotic contributions to the posterior rectus sheath. (Reproduced with permission from Moore KL, Dalley AF, eds. Clinically Oriented Anatomy. 4th ed. Philadelphia: Lippincott Williams & Wilkins; 1999:185.)

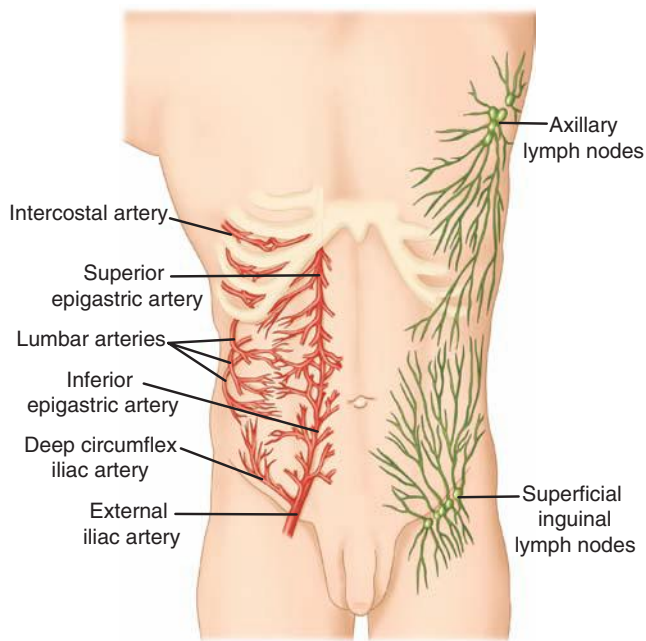


Figure 35-4. The superior and inferior epigastric arteries form an anastomosing network of vessels in and around the rectus sheath, with collateralization to subcostal and lumbar vessels situated more laterally on the abdominal wall. Lymphatic drainage is via axillary or inguinal nodal basins. (Reproduced with permission from Moore KL, Dalley AF, eds. *Clinically Oriented Anatomy*. 4th ed. Philadelphia: Lippincott Williams & Wilkins; 1999:188.)

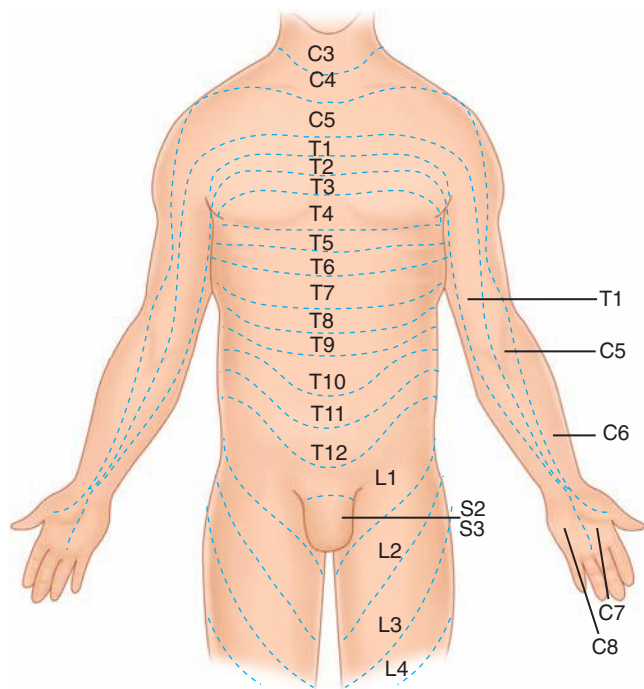


Figure 35-5. Dermatomal sensory innervation of the abdominal wall. (Reproduced with permission from Moore KL, Dalley AF, eds. *Clinically Oriented Anatomy*. 4th ed. Philadelphia: Lippincott Williams & Wilkins; 1999:86.)

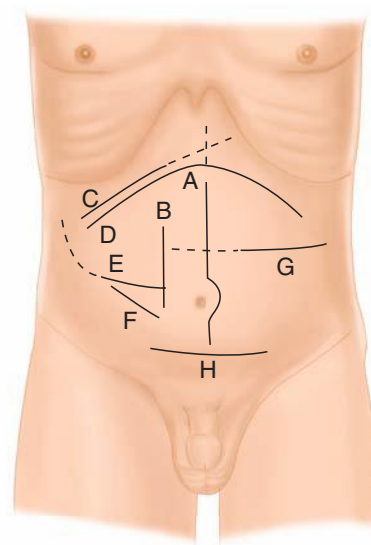


Figure 35-6. Various anterior abdominal wall incisions for exposure of peritoneal structures. A. Midline incision; B. paramedian incision; C. right subcostal incision and “saber slash” extension to costal margin (dashed line); D. bilateral subcostal (also bucket-handle, chevron, gable) incision and “Mercedes Benz” extension (dashed line); E. Rocky-Davis incision and Weir extension (dashed line); F. McBurney incision; G. transverse incision and extension across midline (dashed line); and H. Pfannenstiel incision.

procedures on the gastrointestinal tract. Incising the fused midline aponeurotic tissue of the linea alba is simple and does not injure skeletal muscle. Paramedian incisions through the rectus abdominis sheath structures have largely been abandoned in favor of midline or nonlongitudinal incisions. Incisions lateral to the midline made with transverse or oblique orientations can either divide the successive muscular layers or bluntly separate the fibers. This latter muscle-splitting approach, exemplified by the classic McBurney incision for appendectomy, may be less destructive to tissue but offers more limited exposure. Subcostal incisions on the right (Kocher incision for cholecystectomy) or left (for splenectomy) are archetypal muscle-dividing incisions that result in transection of intervening musculoaponeurotic tissues, including a portion of the rectus abdominis. These incisions are closed in two layers, the more superficial one incorporating the anterior aponeurotic sheath of the rectus medially, transitioning to external oblique muscle and aponeurosis laterally. The posterior, deeper layer consists of internal oblique and transversus abdominis muscle. Similar anatomic considerations are guide closure of transversely oriented muscle-dividing incisions. The Pfannenstiel incision, used commonly for pelvic procedures, is distinguished by transverse skin and anterior rectus sheath incisions, followed by rectus muscle retraction and longitudinal incision of the peritoneum. Irrespective of the incision type, suture apposition of abdominal wall tissues during closure is accomplished without significant tension and with great precision.

Abdominal incisions can lead to short- and long-term complications and patient disability. The question of how large an incision ought to be has no simple answer. In general, it is prudent to make incisions no larger than necessary to safely accomplish the operative goals. Laparoscopic and other minimally invasive surgical methods owe their development in large

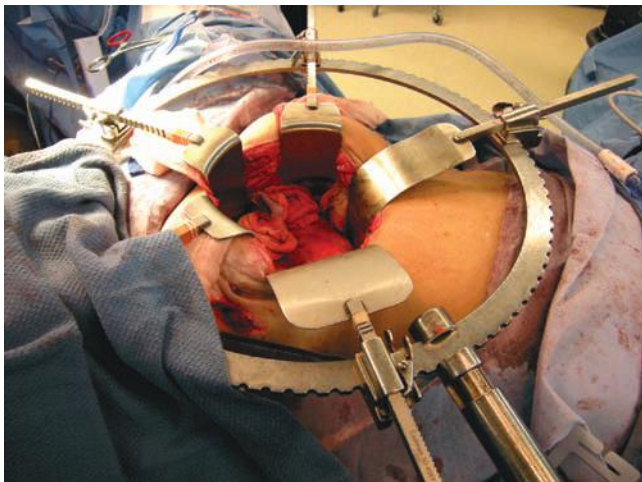


Figure 35-7. Bookwalter™ retractor in use for exposure of peritoneal structures during abdominal surgery. Devices of this type are valuable exposure aids that reduce the physical demands on personnel in the operating room and allow more complete focus on the surgical site of interest.

part to the belief that minimizing surgical injury to the abdominal wall is of significant benefit to the patient. For open surgery, a variety of devices are available to retract the abdominal wall and facilitate peritoneal exposure without subjecting the patient to excessively large incisions or surgical personnel to exhausting retraction tasks (Fig. 35-7). Examples include the Bookwalter™, Omni-Tract®, and Thompson retractors.

Congenital Abnormalities

The abdominal wall layers begin to form within in first weeks following conception. In early embryonic development, there is a large central defect through which pass the vitelline (omphalomesenteric) duct and allantois. The vitelline duct connects the embryonic and fetal midgut to the yolk sac. During the sixth week of development, the abdominal contents grow too large for the abdominal wall to completely contain them, and the embryonic midgut herniates into the umbilical cord. While outside the developing abdomen, it undergoes a 270-degree counterclockwise rotation on the developing mesentery. At the end of the twelfth week, it returns to the abdominal cavity. Defects in abdominal wall closure may lead to omphalocele or gastroschisis. In omphalocele, viscera protrude through an open umbilical ring and are covered by a sac derived from the amnion. In gastroschisis, the viscera protrude through a defect lateral to the umbilicus and no sac is present.

During the third trimester, the vitelline duct regresses. Persistence of a vitelline duct remnant on the ileal border results in a *Meckel's diverticulum*. Complete failure of the vitelline duct to regress results in a *vitelline duct fistula*, which is associated with drainage of small intestinal contents from the umbilicus. If both the intestinal and umbilical ends of the vitelline duct regress into fibrous cords, a central *vitelline duct (omphalomesenteric) cyst* may occur. Persistent vitelline duct remnants between the gastrointestinal tract and the anterior abdominal wall may be associated with small intestinal volvulus in neonates. When diagnosed, vitelline duct fistulas and cysts should be excised along with any accompanying fibrous cord.

The urachus is a fibromuscular tubular extension of the allantois that develops with the descent of the bladder to its

pelvic position. Persistence of urachal remnants can result in cysts as well as fistulas to the urinary bladder with drainage of urine from the umbilicus. These are treated by urachal excision and closure of any bladder defect that may be present.

Acquired Abnormalities

Rectus Abdominis Diastasis. Rectus abdominis diastasis (or diastasis recti) results from a separation of the two rectus abdominis muscle pillars. This results in the characteristic bulging of the abdominal wall in the epigastrium that is sometimes mistaken for a ventral hernia despite the fact that the midline aponeurosis is intact and no hernia defect is present. Diastasis may be congenital, as a result of a more lateral insertion of the rectus muscles to the ribs and costochondral junctions, but is more typically an acquired condition with advancing age, obesity, or following pregnancy. In the postpartum setting, rectus diastasis tends to occur in women of advanced maternal age, after multiple or twin pregnancies, or in women who deliver high-birth-weight infants. Diastasis is usually easily identified on physical examination (Fig. 35-8). Computed tomography (CT) scanning can provide an accurate measure of the distance between the rectus pillars and will differentiate rectus diastasis from a true ventral hernia if clarification is required. Surgical correction of rectus diastasis by plication of the broad midline aponeurosis has been described for cosmetic indications and for

2► disability of abdominal wall muscular function. However, these approaches introduce the risk of an actual ventral hernia and are of questionable value in addressing any actual pathology.

Rectus Sheath Hematoma. Hemorrhage from the network of collateralizing vessels within the rectus sheath and muscles can result in a rectus sheath hematoma. Although a history of trauma might be elicited, other less obvious events including sudden contraction of the rectus muscles with coughing, sneezing, or any vigorous physical activity may also cause this condition. Spontaneous rectus sheath hematomas occur most frequently in the elderly and in those on anticoagulation therapy. Patients frequently describe the sudden onset of unilateral abdominal pain that may be confused with lateralized peritoneal disorders such as appendicitis.

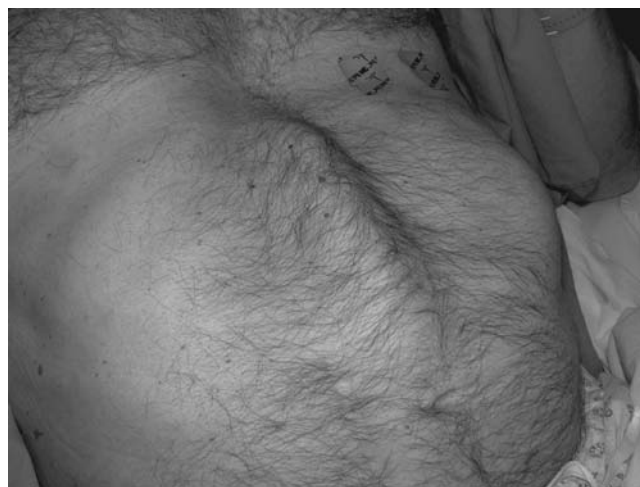

Figure 35-8. Diastasis recti visible in the midepigastrium with Valsalva maneuver. The edges of the rectus abdominis muscle, rigid with voluntary contraction, are palpable along the entire length of the bulging area. This should not be mistaken for a ventral hernia.

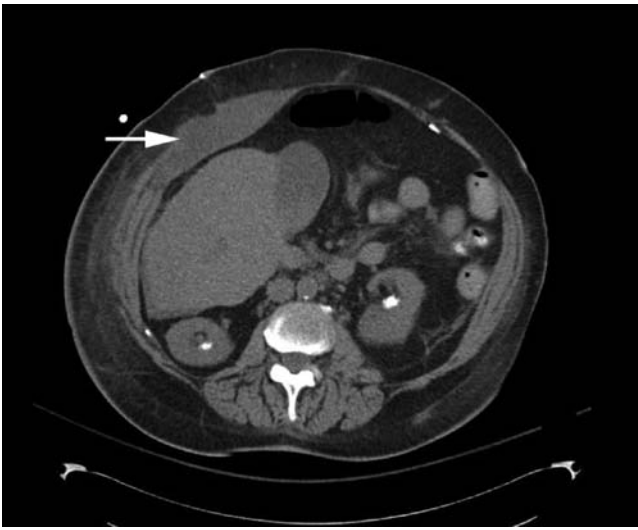


Figure 35-9. Computed tomography scan showing a medium-sized right rectus sheath hematoma. This occurred in an elderly, anticoagulated patient without a clear history of trauma. Because of its size and the patient's slender body habitus, this hematoma was palpable and could be followed clinically.

History and physical examination alone may be diagnostic. Pain typically increases with contraction of the rectus muscles, and a tender mass may be palpated. The ability to appreciate an intra-abdominal mass is ordinarily degraded with contraction of the rectus muscles. *Fothergill's sign* is a palpable abdominal mass that remains unchanged with contraction of the rectus muscles and is classically associated with rectus hematoma. A hemoglobin/hematocrit level and coagulation studies should be obtained. Both ultrasonography and CT (Fig. 35-9) can provide confirmatory imaging information and exclude other disorders.

Specific treatment depends on the severity of the hemorrhage. Small, unilateral, and stable hematomas may be observed without hospitalization. Bilateral or large hematomas will likely require hospitalization, as well as potential resuscitation. Transfusion or coagulation factor replacement may be indicated in some situations. Angiographic embolization is required infrequently, but may be necessary if hematoma enlargement, free bleeding, or clinical deterioration occurs. Surgical therapy is used in the rare situations of failed angiographic treatment or hemodynamic instability that precludes any other options. The operative goals are evacuation of the hematoma and ligation of any bleeding vessel identified. Mortality in this condition is rare, but has been reported in patients requiring surgical treatment and in the elderly.

Desmoid Tumors. Desmoid tumors of the abdominal wall are fibrous neoplasms originating from the musculoaponeurotic structures of the anterior abdomen. They are also referred to collectively as *aggressive fibrosis*, a term that describes their aggressive and infiltrative local behavior. They do not have metastatic potential, and although there is marked cellularity in biopsy specimens, there are no specific histologic characteristics that suggest malignancy, per se. Desmoid tumors of the abdominal wall have a slight female predominance and occur either sporadically or in the setting of familial adenomatous polyposis (FAP), with the greatest risk incurred in Gardner's syndrome. As many as 10% to 15% of FAP patients develop

desmoid tumors of the abdominal wall, abdomen, or retroperitoneum, and this condition can account for patient mortality from complications of aggressive local growth. In non-FAP settings, abdominal wall desmoids occur most frequently in postpartum women or in surgical scars. Radical resection with frozen section margins and immediate mesh reconstruction of any consequent abdominal wall defect is the most commonly recommended treatment. Involvement of margins is associated with recurrence rates as high as 80%. Extensive infiltration and involvement of peritoneal structures frequently makes desmoid resection technically unfeasible. Medical treatment with an antineoplastic agent such as doxorubicin, dacarbazine, or carboplatin can produce remission for variable periods in up to 50% of patients, although the prognosis of advanced desmoids, particularly in FAP, is poor, with a 5-year mortality rate as high as 50% reported. Combined medical treatments and the addition of imatinib have been used with some success in small numbers of patients; radiation therapy has been used in both adjuvant and palliative roles with high response rates.

Other Abdominal Wall Tumors. The abdominal wall may be the site of various benign neoplasms including lipomas and neurofibromas. Surgical treatment is not always mandatory, but local excision is recommended for symptomatic or enlarging lesions. Primary abdominal wall malignancies are exceedingly rare and include subtypes of sarcomas (leiomyosarcoma, malignant fibrous histiocytoma, fibrosarcoma, liposarcoma, and rhabdomyosarcoma), dermatofibrosarcoma protuberans, schwannoma, and melanoma. Magnetic resonance imaging (MRI) or CT is used for tumor staging, and chest CT should be included to rule out pulmonary metastases. These studies define the extent of the tumor and involvement of contiguous structures in anticipation of surgical treatment. Prior to surgery for abdominal wall sarcomas, a core needle biopsy is generally obtained (with image guidance if needed). Once the diagnosis is established, treatment consists of resection with tumor-free margins, applying the same general principles used for extremity sarcoma resection. Meticulous dissection avoiding violation of tumor capsule and maintaining margins greater than 2 cm, if possible, are essential considerations. Extensive resection may leave a considerable abdominal wall defect that will have to be reconstructed. Immediate reconstruction with mesh and/or wound coverage with rotational or free myocutaneous flaps are the best options if primary closure is not feasible. Although these tumors are frequently described as radiation- and chemotherapy-resistant, both modalities have been used in advanced cases in both adjuvant and palliative settings. The very limited experience in these rare conditions makes commentary on the effectiveness of these therapies difficult.

Abdominal wall resection may also be required with contiguous involvement of gastrointestinal or gynecologic malignancies. Primary closure may be feasible, but prosthetic mesh use (even in the setting of bowel resection), absorbable or biologic mesh reinforcement, and myocutaneous flap reconstruction are also options.

Abdominal Wall Hernias. Hernias of the anterior abdominal wall, or *ventral* hernias, represent defects in the parietal abdominal wall fascia and muscle through which intra-abdominal or preperitoneal contents can protrude. Ventral hernias may be congenital or acquired. Acquired hernias may develop via slow architectural deterioration of the musculoaponeurotic tissues, or they may develop from failed healing of an anterior abdominal

wall incision (*incisional hernia*). The most common finding is a mass or bulge, which may increase in size with Valsalva. Ventral hernias may be asymptomatic or cause a considerable degree of discomfort and will generally enlarge over time. Physical examination reveals a bulge on the anterior abdominal wall that may reduce spontaneously, with recumbency, or with manual pressure. A hernia that cannot be reduced is described as *incarcerated* and generally requires surgical correction. Incarceration of an intestinal segment may be accompanied by nausea, vomiting, and significant pain, and is a true surgical emergency. If the blood supply to the incarcerated bowel is compromised, the hernia is described as *strangulated*, and the localized ischemia may lead to infarction and perforation.

Primary ventral hernias (nonincisional) are generally named according to their anatomic location. *Epigastric* hernias are located in the midline between the xiphoid process and the umbilicus. They are generally small and may be multiple, and at elective repair, they are usually found to contain omentum or a portion of the falciform ligament. These may be congenital and due to defective midline fusion of developing lateral abdominal wall elements.

Umbilical hernias occur at the umbilical ring and may be present at birth or develop later in life. Umbilical hernias are present in approximately 10% of all newborns and are more common in premature infants. Most congenital umbilical hernias close spontaneously by 5 years. If closure does not occur, elective surgical repair is usually advised. Adults with small, asymptomatic umbilical hernias should be followed clinically. Surgical treatment is offered if a hernia is observed to enlarge or is associated with symptoms, or if incarceration occurs. Surgical treatment can consist of primary sutured repair or placement of prosthetic mesh for larger defects (>2 cm) using open or laparoscopic methods.

Patients with advanced liver disease, ascites, and umbilical hernia require special consideration. Enlargement of the umbilical ring usually occurs in this clinical situation as a result of increased intra-abdominal pressure from uncontrolled ascites. First line of therapy is aggressive medical correction of the ascites and paracentesis for tense ascites with respiratory compromise. These hernias are usually filled with ascitic fluid, but omentum or bowel may enter the defect after large-volume paracentesis. Uncontrolled ascites may lead to skin breakdown on the protuberant hernia and eventual ascitic leak, which can predispose the patient to bacterial peritonitis. Patients with refractory ascites may be candidates for transjugular intrahepatic portocaval shunt (TIPS) or eventual liver transplantation. Umbilical hernia repair should be deferred until after the ascites is controlled.

Spigelian hernias can occur anywhere along the length of the Spigelian line or zone—an aponeurotic band of variable width at the lateral border of the rectus abdominis. However, the most frequent location of these rare hernias is at or slightly above the level of the arcuate line. These are not always clinically evident as a bulge and may come to medical attention because of pain or incarceration. The largest review of surgical management of these hernias suggests that the risk of incarceration is as high as 17% at the time of diagnosis. This has been cited as a justification for mandatory repair of Spigelian hernias after they have been diagnosed. Repair may be accomplished with either open or laparoscopic procedures.

Incisional Hernias. As many as 10% to 20% of patients may eventually develop hernias at incision sites following open abdominal surgery. The etiology of any given case of incisional

hernia can be difficult to determine. Obesity, primary wound healing defects, multiple prior procedures, prior incisional hernias, and technical errors during repair may all be contributory. Repair of incisional hernias can be technically challenging, and a myriad of methods have been described. The most important distinctions in surgical management of incisional hernias are primary versus mesh repair and open versus laparoscopic repair.

Primary repairs of incisional hernia include both simple suture closure and components separation. Primary repair by simple suture approximation, even for small hernias (defects <3 cm), is associated with high reported hernia recurrence rates. In a randomized prospective study of open primary and open mesh incisional hernia repairs in 200 patients, investigators from the Netherlands found that after 3 years, recurrence rates were 43% and 24%, respectively. Risk factors for recurrence were primary suture repair, postoperative wound infection, prostate problems, and surgery for abdominal aortic aneurysm.

In an effort to decrease suture line tension associated with primary repair, Ramirez described the components separation technique in 1990. This procedure entailed creation of large subcutaneous flaps lateral to the fascial defect followed by bilateral incision of the external oblique aponeuroses and, if necessary, incision of the posterior rectus sheaths bilaterally. The net effect is up to 10 cm of medial mobilization of the rectus muscles allowing for primary apposition of the fascia. Early reports of components separation demonstrated a high wound infection rate (20%) and an 18.2% hernia recurrence rate at 1 year. However, as the technique evolved, an improved understanding of key operative elements, including maximal preservation of the rectus perforator vessels and minimal dissection of the subcutaneous tissues, has led to fewer postoperative wound complications. In recent years, further modifications have included the endoscopic components separation technique as well as the addition of mesh reinforcement to primary fascial edge closure. Using the former closed technique with videoscopic control, effective external oblique division is achieved without creation of extensive subcutaneous flaps. This has been shown to dramatically decrease wound complications associated with the open procedure. The use of either permanent implant or biologic materials with components separation may lead to a hernia recurrence rate as low as 4% at 1 year of follow-up.

Mesh repair has become the standard in the elective management of most incisional hernias. Mesh can be placed as an *underlay* deep to the fascial defect (intra- or preperitoneal), an *interlay* either bridging the gap between the defect edges or within the abdominal wall musculoaponeurotic layers (intraparietal), or an *onlay* (superficial to the fascial defect). Laparoscopic repairs use an underlay technique. Each mesh material type has specific density, porosity, and strength characteristics. Some of the commercially available meshes for incisional hernia repair are listed in Table 35-1. Permanent mesh implants are made of prosthetic materials that do not degrade over time. Their principal advantages are ease of use, relatively low cost, and durability. Absorbable meshes are degraded and eliminated from tissues, gradually losing the structural integrity needed for tissue support. They can be useful for temporary abdominal wall closure in contaminated or infected fields but will eventually leave patients with an incisional hernia. Biologic meshes are prepared from collagen-rich porcine, bovine, or human tissues from which all antigenic cellular materials have been removed. These can also be chemically treated to crosslink collagen molecules, increasing strength and durability at the cost of some

Table 35-1

Commercially available meshes for incisional hernia repair

PROPRIETARY NAME	COMPOSITION
<i>Prosthetic meshes</i>	
Parietex	Polyester/collagen film
Composix	Polypropylene/ePTFE
DualMesh, Dulex, MotifMESH	ePTFE
Prolene, Surgipro, ProLite	Polypropylene
Proceed, Physiomesh	Polypropylene/polydioxanone
Sepramesh IP	Polypropylene/hyaluronate gel
C-Qur	Polypropylene/omega-3 fatty acid
TiMESH	Polypropylene/titanium
<i>Biologic meshes</i>	
Surgis Gold	Porcine small intestine submucosa
AlloDerm	Human dermis
SurgiMend	Fetal bovine dermis
CollaMend	Porcine dermis
AlloMax	Human dermis
Strattice	Porcine dermis
Veritas	Bovine pericardium
<i>Absorbable meshes</i>	
Gore Bio-A	Polyglycolide/trimethylene carbonate
Vicryl	Polyglactin 910
Dexon	Polyglycolic acid

ePTFE = expanded polytetrafluoroethylene.

impairment in host cellular ingrowth. Over time, biologic mesh-derived collagen is incorporated into the host tissue, remodeled, and eventually replaced by host collagen. These characteristics may be useful in the setting of contaminated or infected fields. However, when used to bridge ventral hernia defects, biologic meshes are associated with excessively high hernia recurrence rates and ought to be reserved for tissue reinforcement rather than replacement. Newer prosthetic absorbable mesh materials are now available that share some of the characteristics of biologics (e.g., host tissue ingrowth and replacement with collagen) and can also be used for reinforcement of primary closure at a considerably lower cost.

In recent years, the trend toward use of minimally invasive surgical methods has exerted a great influence on incisional hernia management. However, open repairs continue to be performed extensively, mostly using a mesh underlay technique, often with extensive dissection of a preperitoneal space to accommodate a large sheet of polypropylene or woven polyester mesh. This method isolates mesh from the peritoneal contents. Although the implications of direct mesh contact with peritoneal

structures is somewhat controversial, dense adhesions to intestine may complicate reoperation, and at least anecdotally may predispose to erosion and fistulization even without a concomitant bowel resection. Meshes with adhesion barrier coatings of fish oil, oxidized cellulose, or hyaluronic acid have been offered as solutions for this concern. Expanded polytetrafluoroethylene (ePTFE) prostheses are also used if contact with peritoneal structures is unavoidable because this material tends not to be associated with development of dense adhesions.

Laparoscopic incisional hernia repair was first described by LeBlanc and Booth in 1993. Since that time, numerous studies have examined early and late results compared to open repair. In 2000, data from 407 patients undergoing laparoscopic incisional hernia as part of a multicenter trial revealed a recurrence rate of only 3.4%, with a mean follow-up of more than 2 years. Of the recurrences noted, the vast majority were felt to be secondary to technical errors committed early in the surgeons' experience that were avoided during the later cases. Studies using pooled multicenter data or meta-analyses of published reports have tended to strongly favor laparoscopic incisional hernia repairs based on fewer wound complications, fewer overall complications, and lower recurrence rates when compared to the open technique. Authors speculate that these benefits are achieved by eliminating repeated abdominal incisions and improving detection of unsuspected secondary defects that might not otherwise be appreciated during open repair. However, a recent Cochrane database review of studies totaling 880 cases and including the results from 10 randomized controlled trials concluded that short-term recurrence rates did not differ significantly and laparoscopic repairs were associated with higher in-hospital costs despite generally shorter lengths of stay. The major benefit for laparoscopic repairs compared to open repairs was a consistently lower risk of wound infections. In a recent multicenter randomized trial, in addition to lower infection rates, superior early physical function was also demonstrated very early after laparoscopic repairs compared to open repair.

The technique of laparoscopic incisional hernia repair generally involves laterally placed ports for midline defects and contralaterally placed ports for lateral defects. All adhesions to the anterior abdominal wall are divided, taking great care not to injure the intestine either directly or with thermal or electrical energy. The contents of the hernia sac are completely reduced, but in contrast to open repairs, the sac itself is left in situ. Once the area encompassing all fascial defects is defined, a mesh is fashioned to allow for sufficient overlap (at least 4 cm) under the healthy abdominal wall. After insertion into the abdomen, the mesh is fixed into position with transfascial sutures, placed circumferentially around the mesh, and spiral tacks are placed according to surgeon preference (Fig. 35-10). It has been proposed that transfascial sutures contribute to excessive postoperative pain, and some surgeons have eliminated them from the aforementioned technique, relying solely on spiral tacks for the strength of the repair. LeBlanc reviewed the utility of transfascial sutures and recommended a minimum 5-cm overlap of mesh from defect edge if transfascial sutures are not used.

OMENTUM

Surgical Anatomy

The greater omentum and lesser omentum are fibrofatty aprons that provide support, coverage, and protection of peritoneal contents.




Figure 35-10. Intraperitoneal view of expanded polytetrafluoroethylene mesh used for laparoscopic ventral incisional hernia repair. The mesh is in place on the posterior aspect of the abdominal wall without apparent laxity due to the ongoing carbon dioxide insufflation. Once pneumoperitoneum is released, sufficient laxity is introduced to relieve any pull at the fixation points and to permit good apposition of mesh to the abdominal wall surface.

These structures begin to develop during the fourth week of gestation. The greater omentum develops from the dorsal mesogastrium, which begins as a double-layered structure. The spleen develops in between the two layers, and later in development, the two layers fuse, giving rise to the intraperitoneal spleen and the gastrosplenic ligament. The fused layers then hang from the greater curvature of the stomach and drape over the transverse colon, to which its posterior surface becomes fixed. The gastrocolic ligament and the gastrosplenic ligament are those segments of the greater omental apron that connect the named structures. In the adult, the greater omentum lies in between the anterior abdominal wall and the hollow viscera and usually extends into the pelvis.

The lesser omentum, otherwise known as the hepatoduodenal and hepatogastric ligaments, develops from the mesoderm of the septum transversum, which connects the embryonic liver to the foregut. The common bile duct, portal vein, and hepatic artery are located in the inferolateral margin of the lesser omentum, which also forms the anterior border of the foramen of Winslow.

The blood supply to the greater omentum is derived from the right and left gastroepiploic arteries. The venous drainage parallels the arterial supply to a great extent, with the left and right gastroepiploic veins ultimately draining into the portal system.

Physiology

In the early twentieth century, the British surgeon Rutherford Morison noted that the omentum tended to wall off areas of infection and limit the spread of intraperitoneal contamination. He termed the omentum the “abdominal policeman.” Shortly after his description was published, several reports suggested intrinsic hemostatic characteristics of the omentum. In 1996, researchers from the Netherlands demonstrated that the concentration of tissue factor in omentum is over twice the amount per gram of that found in muscle. This facilitates activation of coagulation at sites of inflammation, ischemia, infection, or trauma

within the peritoneal cavity. The consequent local production of fibrin contributes to the ability of the omentum to adhere to areas of injury or inflammation.

Omental Infarction

Interruption of the blood supply to the omentum is a rare cause of an acute abdomen that may be secondary to torsion of the omentum around its vascular pedicle, thrombosis or vasculitis of the omental vessels, or omental venous outflow obstruction. Fewer than 100 cases have been reported, and the diagnosis is most likely to be made in male adults. Depending on the location of the infarcted omental tissue, this disease process may mimic appendicitis, cholecystitis, diverticulitis, perforated peptic ulcer, or ruptured ovarian cyst, with abdominal pain and tenderness typical at locations typical for these conditions. Abdominal examination may reveal a tender, palpable mass. The diagnosis is generally inferred from abdominal CT or ultrasonography, which shows a localized inflammatory mass of fat density. In patients with convincing imaging who are clinically stable without signs of worsening peritonitis, supportive care is sufficient. However, some cases may be indistinguishable from more worrisome surgical conditions. In these instances, laparoscopic exploration can establish an accurate diagnosis and permit resection of the infarcted tissue, which should result in rapid resolution of symptoms.

Omental Cysts

Cystic lesions of the omentum and mesentery are related disorders, likely resulting from either peritoneal inclusions or degeneration of lymphatic structures. Omental cysts are far less common than mesenteric cysts. Omental cysts may present as an asymptomatic abdominal mass or may cause abdominal pain with or without appreciable mass or distention. Physical examination may reveal a freely mobile intra-abdominal mass. Both CT and abdominal ultrasound reveal a well-circumscribed, cystic-mass lesion arising from the greater omentum. Treatment involves resection of all symptomatic omental cysts. Resection of these benign lesions is readily accomplished using laparoscopic techniques.

Omental Neoplasms

Primary tumors of the omentum are rare. Benign tumors of the omentum include lipomas, myxomas, and desmoid tumors. Primary malignant tumors of the omentum are usually mesodermally derived and may share immunohistochemical characteristics of gastrointestinal stromal tumors including c-kit immunopositivity. Metastatic tumors of the omentum are common, with metastatic ovarian cancer having the highest preponderance of omental involvement. Cancers of any portion of the gastrointestinal tract, as well as melanoma, uterus, and kidney cancer, may also metastasize to the omentum.

MESENTERY

Surgical Anatomy

The small and large intestinal mesenteries serve as the major pathways for arterial, venous, lymphatic, and neural structures to course to and from the bowel. Mesenteric tissues develop from embryonic dorsal mesentery that attaches the foregut, midgut, and hindgut to the posterior abdominal wall. The dorsal mesentery becomes the greater omentum proximally, the small intestinal mesentery in the region of the jejunum and ileum, and

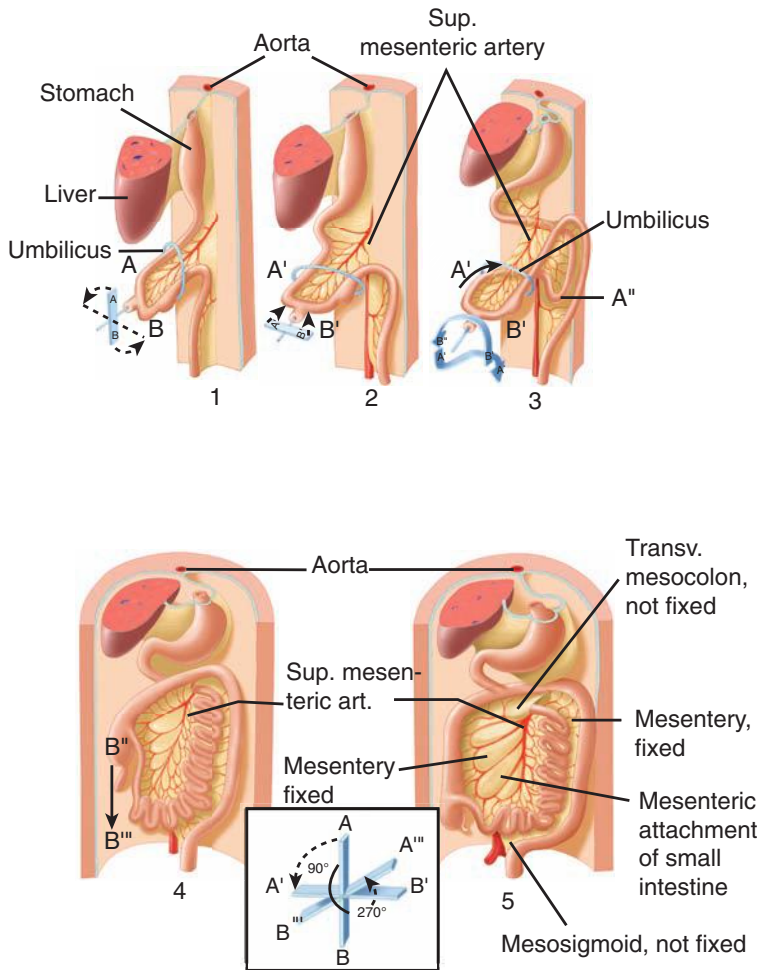


Figure 35-11. Rotational events during gastrointestinal (GI) tract development in the fetus result in the final positioning of the GI tract segments and anatomic relationships of intestinal mesentery to the retroperitoneum. The cecum, designated “B,” can be followed during the course of the 270-degree counterclockwise rotation of the mesentery to its right lower quadrant position. During the course of these events, the duodenum and right and left colon segments and their mesenteries become affixed to the retroperitoneum, leaving the small intestine and sigmoid colon mobile on their respective mesenteries. (Reproduced with permission from Healy JE, Hodge J (eds). *Surgical Anatomy*, 2nd ed. Toronto: BC Decker, 1990:151.)

the mesocolon in the region of the colon. During fetal development, after the herniated and 270-degree rotated midgut returns to its intraperitoneal location, the reduced mesentery achieves its final fixation state. The duodenum and lateral colon segments become fixed to the retroperitoneum, whereas the small intestinal mesentery, transverse colon mesentery, and sigmoid colon mesentery remain mobile (Fig. 35-11). Defects in these normal developmental steps starting with midgut rotation result in the spectrum of disorders associated with midgut malrotation. The related anatomic anomalies of the mesentery include paraduodenal or mesocolic hernias (Fig. 35-12), which can present as chronic or acute intestinal obstruction in children or adults.

Sclerosing Mesenteritis

Sclerosing mesenteritis, also referred to as retractile mesenteritis, mesenteric panniculitis, or mesenteric lipodystrophy, is an inflammatory and fibrotic process involving the intestinal mesentery. There is no gender or race predominance, but the condition is most commonly diagnosed in individuals older than 50 years of age.

The etiology of this process is unknown, but its cardinal feature is increased tissue density within the mesentery. This can be localized and associated with a discrete nonneoplastic mesenteric mass, or it can be more diffuse, sometimes involving large swaths of mesentery without well-defined borders. There may be varying relative degrees of fat tissue degeneration, inflammation, and fibrosis on histologic examination, giving

rise to the various terms used to describe this condition. It is not clear if these variations represent stages in a sequential process or differences in basic pathobiology. Abdominal pain is the most frequent presenting symptom, followed by the presence of

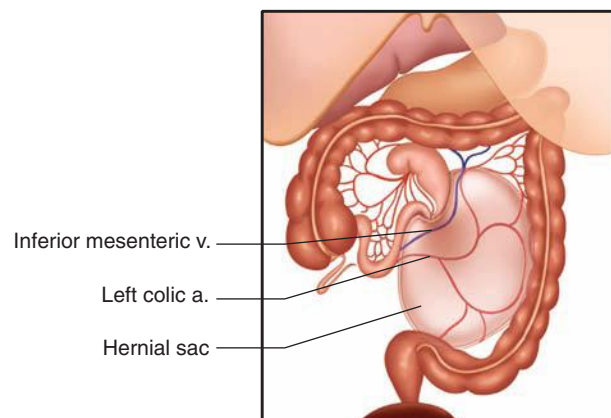


Figure 35-12. Mesocolic hernia of small bowel into a retrocolic hernia sac posterior to the descending colon mesentery. Hernias of this type, as well as hernias into paraduodenal recesses, result from abnormal fixation of mesenteric structures during the course of intestinal rotation. (Reproduced with permission from Healy JE, Hodge J, eds. *Surgical Anatomy*. 2nd ed. Toronto: BC Decker; 1990:153.)

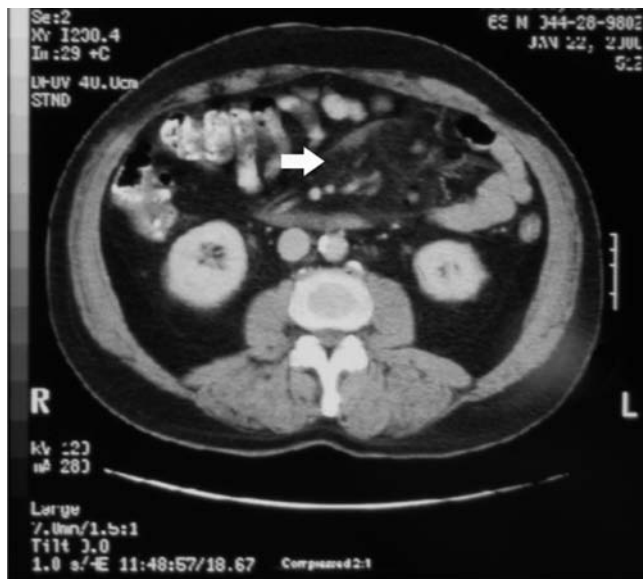

Figure 35-13. Computed tomography scan of sclerosing mesenteritis (mesenteric lipodystrophy). This condition cannot easily be distinguished from a neoplasm of the mesentery on radiologic study. In this case, the study showed “fatty mesenteric tumor with involvement of mesenteric vessels,” and “mesenteric lipodystrophy” was demonstrated by biopsy at exploration. The finding of a “hyperattenuating stripe” around the lesion, as seen in this image, has been associated with the mesenteritis diagnosis.

a mass or, much more rarely, intestinal obstruction. However, many cases are discovered incidentally when imaging studies, most frequently CT scan, are performed for unrelated reasons.

CT of the abdomen shows a mass lesion or an area of the mesentery with a higher density than normal mesenteric tissue. Vascular structures are seen coursing through the affected areas, which sometimes involve in the mesenteric root (Fig. 35-13). Although CT cannot definitively distinguish sclerosing mesenteritis from a mesenteric tumor, identification of a “fat ring sign” or hypodense zone around the mass area has been suggested as a means of distinguishing sclerosing mesenteritis from lymphoma. The presence of a hyperattenuating stripe has also been suggested as radiologic finding that would favor the mesenteritis diagnosis.

Operative findings range from a discrete mesenteric mass (Fig. 35-14) to broad areas of mesenteric nodularity and thickening. Surgical biopsy has frequently been used to confirm the diagnosis and to rule out a neoplastic process. The extent and location of mesenteric involvement define and, in some cases, limit the options for surgical intervention. In addition to simple biopsy, bowel and mesenteric resection can be considered, particularly in cases where this is technically feasible based on mass size and the ability to avoid injury to small intestinal blood supply. Often, however, the involvement of the vascular structures at the mesenteric root makes resection unfeasible. Rarely, an ostomy of some type for fecal diversion in the face of obstruction can be considered. Positron emission tomography with CT scanning has proven effective in ruling out neoplasia for focal mesenteric masses, leaving the sclerosing mesenteritis diagnosis as one of exclusion.

In most cases of sclerosing mesenteritis, the process appears to be self-limited and may even demonstrate regression if followed with interval imaging studies. Clinical symptoms

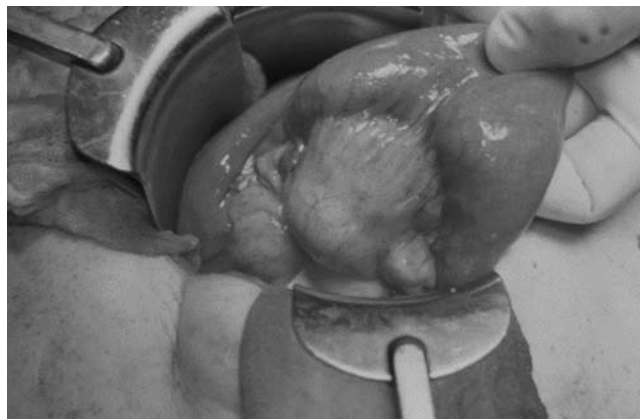


Figure 35-14. Operative findings at the time of resection of what was believed to be a mesenteric tumor but that proved to be a focus of mesenteric lipodystrophy. In this case, the relatively small site of involvement and the peripheral location in the small intestinal mesentery permitted management by resection en bloc with a segment of adjacent small bowel.

are very likely to improve without intervention, and therefore, aggressive surgical treatments are generally not indicated. In clinically problematic cases that are not amenable to resection because of widespread mesenteric involvement or unfavorable location, medical treatment has been given to alleviate severe symptoms. Among the agents that have been used are corticosteroids, colchicine, tamoxifen, and cyclophosphamide.

Mesenteric Cysts

Cysts of the mesentery are benign lesions with an incidence of less than 1 in 100,000. The etiology of such cysts remains unknown, but several theories regarding their development exist, including degeneration of the mesenteric lymphatics or peritoneal inclusions arising as congenital anomalies.

Mesenteric cysts may be asymptomatic or cause acute or chronic symptoms of a mass lesion. Acute pain is generally caused by rupture or torsion of the cyst or from acute hemorrhage into the cyst cavity. Mesenteric cysts may also cause intermittent abdominal pain secondary to compression of adjacent structures or reversible torsion of the cyst. Mesenteric cysts can also be the cause of nonspecific symptoms such as anorexia, nausea, vomiting, fatigue, and weight loss.

Physical examination may reveal a mass lesion that is mobile only from the patient’s right to left or left to right (Tillaux’s sign), in contrast to the findings with omental cysts, which should be freely mobile in all directions. Tillaux was the first to record this physical finding and, in 1850, the first to successfully remove a mesenteric cyst.

CT (Fig. 35-15), ultrasound, and MRI all have been used to evaluate patients with mesenteric cysts. Cysts generally appear unilocular without solid component on imaging. Less frequently, they may be multiple or multilocular or difficult to distinguish from solid mesenteric tumors with cystic components such as a cystic stromal tumor or mesothelioma. Mesenteric cystic lymphangioma may present as numerous, often large cysts in the setting of abdominal pain. These can be difficult to treat and almost invariably recur after excision.

When symptomatic, simple mesenteric cysts are surgically excised either openly or laparoscopically. Cyst unroofing or marsupialization is not recommended because mesenteric cysts

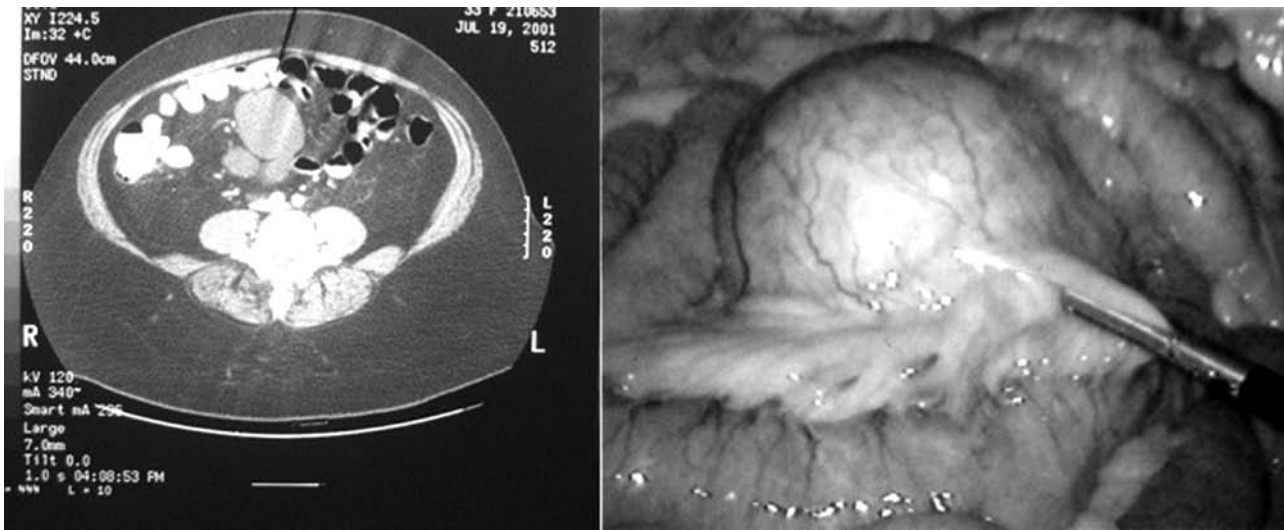


Figure 35-15. Computed tomography (CT) scan of a mesenteric cyst (*left panel*). Unilocular appearance without associated solid component strongly suggests the diagnosis of benign cyst. The operative findings during laparoscopic exploration (*right panel*) confirm the CT diagnosis of unilocular cyst, which is then enucleated from the mesentery in a relatively avascular plane adjacent to mesenteric vessels.

have a high propensity to recur after drainage alone. On rare occasion, adjacent mesentery or bowel may be densely adherent to the cyst, or mesenteric vessels must be sacrificed in order to achieve complete excision. In this case, segmental bowel resection inclusive of the adjacent mesentery is performed.

Mesenteric Tumors

Primary tumors of the mesentery are rare. Benign tumors of the mesentery include lipoma, cystic lymphangioma, and desmoid tumors. Primary malignant tumors of the mesentery are similar to those described for omentum. Liposarcomas, leiomyosarcomas, malignant fibrous histiocytomas, lipoblastomas, and lymphangiosarcomas have all been described. Metastatic small intestinal carcinoid in mesenteric lymph nodes may exceed the bulk of primary disease and compromise blood supply to the bowel. Treatment of mesenteric malignancies involves wide resection of the mass. Because of the proximity to the blood supply to the intestine, such resections may be technically unfeasible or involve loss of substantial lengths of bowel.

RETROPERITONEUM

Surgical Anatomy

The retroperitoneum is defined as the space between the posterior envelopment of the peritoneum and the posterior body wall (Fig. 35-16). The retroperitoneal space is bounded superiorly by the diaphragm, posteriorly by the spinal column and iliopsoas muscles, and inferiorly by the levator ani muscles. Although technically bounded anteriorly by the posterior reflection of the peritoneum, the anterior border of the retroperitoneum is quite convoluted, extending into the spaces in between the mesenteries of the small and large intestine. Because of the rigidity of the superior, posterior, and inferior boundaries, and the compliance of the anterior margin, retroperitoneal tumors tend to expand anteriorly toward the peritoneal cavity.

Retroperitoneal Infections

The posterior reflection of the peritoneum limits the spread of most intra-abdominal infections into the peritoneum. Accordingly,

the source of retroperitoneal infections is usually an organ contained within or abutting the retroperitoneum. Retrocecal appendicitis, contained perforation of duodenal ulcers, iatrogenic perforation with esophagogastroduodenoscopy or endoscopic retrograde cholangiopancreatography, and complicated pancreatitis may all lead to retroperitoneal infection with or without abscess formation. The substantial space and rather nondiscrete boundaries of the retroperitoneum allow some retroperitoneal abscesses to become quite large prior to diagnosis.

Patients with a retroperitoneal abscess usually present with pain and fever, but more worrisome signs of sepsis may also be present depending on clinical severity. The site of pain may be variable and can include the back, pelvis, or thighs. Erythema may be observed around the umbilicus or flank. The diagnosis is best established by CT, which may demonstrate a unilocular or multilocular collection along with retroperitoneal soft tissue stranding (Fig. 35-17).

Management of retroperitoneal infections includes identification and treatment of the underlying condition, intravenous antibiotics, and drainage of all well-defined collections. Image-guided percutaneous drainage is strongly favored, but operative drainage may sometimes be needed for adequate drainage of complex or multiple collections. The mortality rate of retroperitoneal abscess has been reported to be as high as 25%, and even higher in rare cases of necrotizing fasciitis of the retroperitoneum.

Retroperitoneal Fibrosis

Retroperitoneal fibrosis is a class of disorders characterized by hyperproliferation of fibrous tissue in the retroperitoneum. This may be a primary disorder as in idiopathic retroperitoneal fibrosis, also known as Ormond's disease, or a secondary reaction to an inciting inflammatory process, malignancy, or medication. Idiopathic retroperitoneal fibrosis is a rare disorder, usually affecting 0.5 per 100,000 patients annually. Men are twice as likely to be affected as women, with no predilection for any particular ethnic group. The disease primarily affects individuals in the fourth to the sixth decades of life.

Although allergic or autoimmune mechanisms have been postulated, the pathogenesis of this condition remains uncertain.

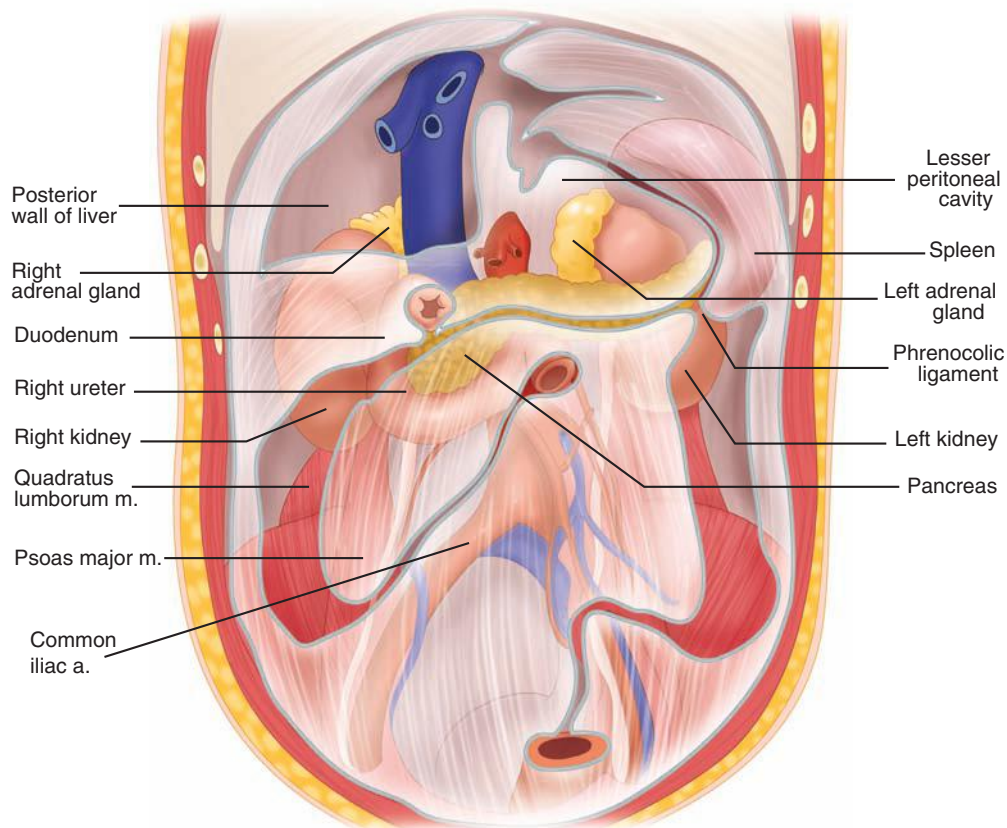


Figure 35-16. Anatomy of the retroperitoneum. (Reproduced with permission from Healy JE, Hodge J, eds. *Surgical Anatomy*. 2nd ed. Toronto: BC Decker; 1990:201.)

In the closely related condition of chronic perioaortitis, an association with the HLA-DRB1*03 allele, which has been linked to autoimmune diseases such as systemic lupus erythematosus, type 1 diabetes mellitus, and myasthenia gravis, is of particular interest

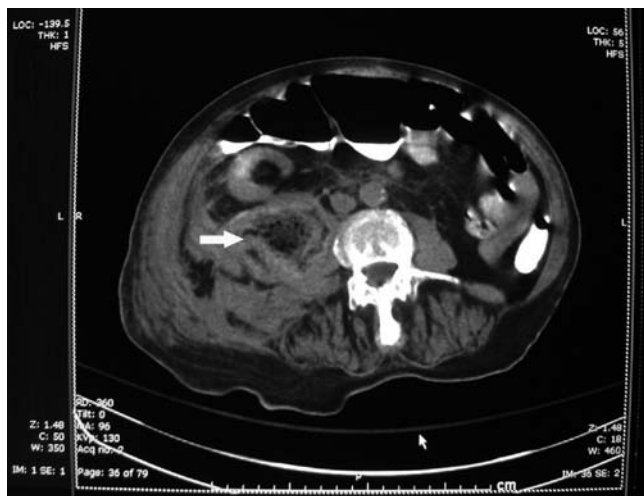

Figure 35-17. Computed tomography scan of retroperitoneal abscess complicating complex, surgically treated retroperitoneal infection that had resulted from ampullary perforation at the time of endoscopic retrograde cholangiopancreatography. This pattern of infection may be difficult to treat and result in multiple interventions such as percutaneous drainage before resolution.

in defining an autoimmune cause of retroperitoneal fibrosis. Circulating antibodies to ceroid, a lipoproteinaceous by-product of vascular atheromatous plaque oxidation, are present in more than 90% of patients with retroperitoneal fibrosis. The relationship of these findings to the occurrence of fibrosis remains uncertain. The early inflammatory reaction is predominated by T-helper cells, plasma cells, and macrophages, but is subsequently replaced by collagen-synthesizing fibroblasts. Microscopically, the infiltrate is indistinguishable from the periaortitis involvement of aortic aneurysmal disease, Reidel's thyroiditis, sclerosing cholangitis, and Peyronie's disease. The fibrotic process begins in the retroperitoneum just below the level of the renal arteries. Fibrosis gradually expands, encasing the ureters, inferior vena cava, aorta, mesenteric vessels, or sympathetic nerves. Bilateral involvement is noted in 67% of cases.

Retroperitoneal fibrosis may also appear secondarily with a variety of inflammatory conditions including abdominal aortic aneurysm, pancreatitis, histoplasmosis, tuberculosis, or actinomycosis. It also is associated with a variety of malignancies, including prostate, pancreas, and gastric cancer, as well as non-Hodgkin's lymphoma, stromal tumors, and carcinoid tumors. Retroperitoneal fibrosis has been described in association with autoimmune disorders including ankylosing spondylitis, systemic lupus erythematosus, Wegener's granulomatosis, and polyarteritis nodosa.

There is strong evidence that methysergide, a semisynthetic ergot alkaloid used in the treatment of migraine headaches, plays a causal role in some cases of retroperitoneal

fibrosis. Other medications that have been linked to retroperitoneal fibrosis include β -blockers, hydralazine, α -methyl dopa, and entacapone, which inhibits catechol-*O*-methyltransferase and is used as an adjunct with levodopa in the treatment of Parkinson's disease. The retroperitoneal fibrosis regresses upon discontinuation of these medications.

Presenting symptoms depend on the structure or structures affected by the fibrotic process. Initially, patients complain of the insidious onset of dull, poorly localized abdominal pain. Sudden-onset or severe abdominal pain may signify acute mesenteric ischemia. Other symptoms of retroperitoneal fibrosis may include unilateral leg swelling, intermittent claudication, oliguria, hematuria, or dysuria.

As with the patient's symptomatology, findings on physical examination vary with the retroperitoneal structure involved. Consequently, findings may include hypertension, the palpation of an abdominal or flank mass, lower-extremity edema (unilateral or bilateral), or diminished lower-extremity pulses (unilateral or bilateral). Laboratory evaluation may reveal elevated blood urea nitrogen and/or creatinine levels. As with many autoimmune inflammatory processes, the erythrocyte sedimentation rate almost always is elevated in patients with retroperitoneal fibrosis.

Many imaging modalities have been used with various sensitivities to diagnose retroperitoneal fibrosis. Abdominal/lower-extremity ultrasonography is the least invasive imaging procedure but is technician dependent. It may be useful if ilio caval compressive or renal symptoms predominate. A lower-extremity ultrasound may show deep venous thrombosis, whereas abdominal ultrasonography may identify a mass lesion or hydronephrosis. Once the diagnostic procedure of choice, intravenous pyelography (IVP) is less commonly used today. If the ureters are involved, IVP findings include ureteral compression, ureteral deviation toward the midline, and hydronephrosis.

Abdominopelvic CT with oral and intravenous contrast is the imaging procedure of choice and will generally allow the extent of the fibrotic process to be determined. If there is diminished renal function, avoidance of the use of intravenous contrast will reduce the ability to characterize retroperitoneal tissue planes. In this case, MRI may be used, since the signal intensity of the fibrotic process is discrete from muscle or fat. Additionally, magnetic resonance angiography will generally provide a good assessment of the degree of ilio caval involvement. Once a mass lesion is identified, the mass should be biopsied to rule out a retroperitoneal malignancy. The specimen may be retrieved using image-guided techniques or surgical retroperitoneal biopsy, which may be performed laparoscopically or during open laparotomy.

Once malignancy, drug-induced, and infectious etiologies are ruled out, treatment of the retroperitoneal fibrotic process is instituted. Corticosteroids, with or without surgery, are the mainstay of medical therapy. Surgical treatment consists primarily of ureterolysis or ureteral stenting and is required in patients who present with significant hydronephrosis. Laparoscopic ureterolysis has been shown to be as efficacious as open the open procedure. Patients with ilio caval thrombosis require anticoagulation, although appropriate duration of therapy is uncertain. Endovascular interventions for ilio caval occlusion have also been shown to be effective in small numbers of patients. **8** Prednisone is initially administered at a relatively high dose (60 mg every other day for 2 months), and then gradually tapered over the next 2 months. Therapeutic efficacy is assessed

based on patient symptoms and interval imaging studies. Cyclosporin, tamoxifen, and azathioprine have also been used to treat patients who respond poorly to corticosteroids.

The overall prognosis in idiopathic retroperitoneal fibrosis is good, with 5-year survival rates of 90% to 100%. Because long-term recurrences have been described, lifelong follow-up is warranted.

BIBLIOGRAPHY

Entries highlighted in bright blue are key references.

General References

- Burt BM, Tavakkolizaden A, Ferzoco SJ. Incisions, closures, and management of the abdominal wound. In: Zinner MJ, Ashley SW, eds. *Maingot's Abdominal Operations*. 11th ed. New York: McGraw Hill; 2007:71-102.
- Flament JB, Avisse C, Delattre JF. Anatomy of the abdominal wall. In: Bendavid R, Abrahamson J, Arregui ME, et al, eds. *Abdominal Wall Hernias: Principles and Management*. 1st ed. New York: Springer-Verlag; 2001:39-63.
- Sauerland S, Walgenbach M, Habermalz B, et al. Laparoscopic versus open surgical techniques for ventral or incisional hernia repair. *Cochrane Database Syst Rev* 16 (3): 2011.**

Abdominal Wall

- Albright E, Diaz D, Davenport D, Roth JS. The component separation technique for hernia repair: a comparison of open and endoscopic techniques. *Am Surg*. 2011;77:839-843.
- Anthony T, Bergen PC, Kim LT, et al. Factors affecting recurrence following incisional herniorrhaphy. *World J Surg*. 2000;24:95-100.
- Bertani E, Chiappa A, Testori A, et al. Desmoid tumors of the anterior abdominal wall: results from a monocentric surgical experience and review of the literature. *Ann Surg Oncol*. 2009;16:1642-1649.
- Blatnik J, Jin J, Rosen M. Abdominal hernia repair with bridging acellular dermal matrix: an expensive hernia sac. *Am J Surg*. 2008;196:47-50.
- de Vries Reilingh TS, Bodegom ME, van Goor H, et al. Autologous tissue repair of large abdominal wall defects. *Br J Surg*. 2007;94:791-803.
- Edlow JA, Juang P, Marglies S, et al. Rectus sheath hematoma. *Ann Emerg Med*. 1999;34:671-675.
- Halm JA, de Wall LL, Steyerberg EW, et al. Intraoperative polypropylene mesh hernia repair complicates subsequent abdominal surgery. *World J Surg*. 2007;31:423-429.
- Harth KC, Rose J, Delaney CP, et al. Open versus endoscopic component separation: a cost comparison. *Surg Endosc*. 2011;25:2865-2870.
- Heniford BT, Park A, Ramshaw BJ, et al. Laparoscopic ventral and incisional hernia repair in 407 patients. *J Am Coll Surg*. 2000;190:645-650.
- Hesselink VJ, Luijendijk R, de Wilt JH, et al. An evaluation of risk factors in incisional hernia recurrence. *Surg Gynecol Obstet*. 1993;176:228-234.
- Jin J, Rosen MJ, Blatnik J, et al. Use of acellular dermal matrix for complicated hernia repair: does technique affect outcome? *J Am Coll Surg*. 2007;205:654-660.
- Klingler PJ, Wetscher G, Glaser K, et al. The use of ultrasound to differentiate rectus sheath hematoma from other acute abdominal disorders. *Surg Endosc*. 1999;13:1129-1134.
- Knechtel G, Stoeger H, Szkandera J, Dorr K, Beham A, Samonigg H. Desmoid tumor treated with polychemotherapy followed by imatinib: a case report and review of the literature. *Case Rep Oncol*. 2010;3:287-293.
- Korenkov M, Sauerland S, Arndt M, et al. Randomized clinical trial of suture repair, polypropylene mesh, or autodermal hernioplasty for incisional hernia. *Br J Surg*. 2002;89:50-56.

- Larson DW, Farley DR. Spigelian hernias: repair and outcome for 81 patients. *World J Surg.* 2002;26:1277-1281.
- LeBlanc KA. Laparoscopic incisional hernia repair: are transfascial sutures necessary? A review of the literature. *Surg Endosc.* 2007;21:508-513.
- LeBlanc KA, Booth WV. Laparoscopic repair of incisional abdominal hernias using expanded polytetrafluorethylene: preliminary findings. *Surg Laparosc Endosc.* 1993;3:39-41.
- Luijendijk RW, Hop WC, van den Tol MP, et al. A comparison of suture repair with mesh repair for incisional hernia. *N Engl J Med.* 2000;343:392-398.
- National Center for Health Statistics. Detailed diagnoses and procedures. *National Hospital Discharge Survey, Series 13, No. 122, 1995.*
- Park A, Birch DW, Lovrics P. Laparoscopic and open incisional hernia repair: a comparison study. *Surgery.* 1998;124:816-821.
- Perry CW, Phillips BJ. Rectus sheath hematoma: review of an uncommon surgical complication. *Hosp Physician.* 2001;56:35-37.
- Pierce RA, Spitler JA, Frisella MM, et al. Pooled data analysis of laparoscopic vs. open ventral hernia repair: 14 years of patient data accrual. *Surg Endosc.* 2007;21:378-386.
- Quintini C, Ward G, Shatnawi A, et al. Mortality of intra-abdominal desmoid tumors in patients with familial adenomatous polyposis: a single center review of 154 patients. *Ann Surg.* 2012;255:511-516.
- Ramirez OM, Ruas E, Dellon AL. "Components separation" method for closure of abdominal-wall defects: an anatomic and clinical study. *Plast Reconstr Surg.* 1990;86:519-526.
- Rogmark P, Petersson U, Bringman S, et al. Short-term outcomes for open and laparoscopic midline incisional hernia repair: a randomized multicenter controlled trial: the ProLOVE (prospective randomized trial on open versus laparoscopic operation of ventral eventrations) trial. *Ann Surg.* 2013;258:37-45.
- Stojadinovic A, Hoos A, Karpoff HM, et al. Soft tissue tumors of the abdominal wall. Analysis of disease patterns and treatment. *Arch Surg.* 2001;136:70-79.
- Stoppa R, Ralaimiamanana F, Henry X, et al. Evolution of large ventral incisional hernia repair: the French contribution to a difficult problem. *Hernia.* 1999;3:1-3.
- Zainea GG, Jordan F. Rectus sheath hematomas: their pathogenesis, diagnosis, and management. *Am Surg.* 1988;54:630-633.
- Omentum**
- Beelen RHJ. The greater omentum: physiology and immunological concepts. *Neth J Surg.* 1991;43:145-149.
- Fukatsu K, Saito H, Han I, et al. The greater omentum is the primary site of neutrophil exudation in peritonitis. *J Am Coll Surg.* 1996;183:450-456.
- Goldsmith HS, ed. *The Omentum: Research and Clinical Applications.* New York: Springer-Verlag; 2000.
- Liebermann-Meffert D. The greater omentum. Anatomy, embryology, and surgical applications. *Surg Clin North Am.* 2000;80:275-293, xii.
- Liebermann-Meffert D, White H, eds. *The Greater Omentum. Anatomy, Physiology, Pathology, Surgery with an Historical Survey.* New York: Springer-Verlag; 1983.
- Logmans A, Schoenmakers CH, Haensel SM, et al. High tissue factor concentration in the omentum, a possible cause of its hemostatic properties. *Eur J Clin Invest.* 1996;26:82-83.
- Morison R. Remarks on some functions of the omentum. *Br Med J.* 1906;1:76.
- Nakagawa M, Akasaka Y, Kanai T, et al. Extragastrointestinal stromal tumor of the greater omentum: case report and review of the literature. *Hepatogastroenterology.* 2003;50:691-695.
- O'Leary DP. Use of the greater omentum in colorectal surgery. *Dis Colon Rectum.* 1999;42:533-539.
- Powers JC, Fitzgerald JF, McAlvanah MJ. The anatomical basis for the surgical detachment of the greater omentum from the transverse colon. *Surg Gynecol Obstet.* 1976;143:105-106.
- Saborido BP, Romero CJ, Medina ME, et al. Idiopathic segmental infarction of the greater omentum as a cause of acute abdomen. Report of two cases and review of the literature. *Hepatogastroenterology.* 2001;48:737-740.
- Schwartz RW, Reames M, McGrath PC, et al. Primary solid neoplasms of the greater omentum. *Surgery.* 2011;15:409-411.
- Mesentery**
- Burkett JS, Pickleman J. The rationale for surgical treatment of mesenteric and retroperitoneal cysts. *Am Surg.* 1994;60:432-435.
- Daskalogiannaki M, Voloudaki A, Prassopoulos P, et al. CT evaluation of mesenteric panniculitis: prevalence and associated diseases. *Am J Roentgenol.* 2000;174:427-431.
- Egozi EI, Ricketts RR. Mesenteric and omental cysts in children. *Am Surg.* 1997;63:287-290.
- Emory T, Monihan J, Carr NJ, et al. Sclerosing mesenteritis, mesenteric panniculitis, and mesenteric lipodystrophy: a single entity? *Am J Surg Pathol.* 1997;21:392-398.
- Genereau T, Bellin MF, Wechsler B, et al. Demonstration of efficacy of combining corticosteroids and colchicine in two patients with idiopathic sclerosing mesenteritis. *Dig Dis Sci.* 1996;41:684-688.
- Hebra A, Brown MF, McGeehin KM, et al. Mesenteric, omental and retroperitoneal cysts in children: a clinical study of 22 cases. *South Med J.* 1993;86:173-176.
- Issa I, Baydoun H. Mesenteric panniculitis: various presentations and treatment regimens. *World J Gastroenterol.* 2009;15:3827-3830.
- Kelly JK, Hwang WS. Idiopathic retractile (sclerosing) mesenteritis and its differential diagnosis. *Am J Surg Pathol.* 1989;13:513-521.
- O'Brien MF, Winter DC, Lee G, et al. Mesenteric cysts—a series of six cases with a review of the literature. *Ir J Med Sci.* 1999;168:233-236.
- Ogden WW, Bradburn DM, Rives JD. Panniculitis of the mesentery. *Ann Surg.* 1960;151:659-668.
- Ros PR, Olmsted WW, et al. Mesenteric and omental cysts: histologic classification with imaging correlation. *Radiology.* 1987;164:327-332.
- Shamiyeh A, Rieger R, Schrenk P, Wayand W. Role of laparoscopic surgery in treatment of mesenteric cysts. *Surg Endosc.* 1999;13:937-939.
- Takiff H, Calabria R, Yin L, et al. Mesenteric cysts and intra-abdominal cystic lymphangiomas. *Arch Surg.* 1985;120:1266-1269.
- Zissen R, Metser U, Hain D, et al. Mesenteric panniculitis in oncologic patients: PET-CT findings. *Br J Radiol.* 2006;79:37-43.
- Retroperitoneum**
- Cerfolio RJ, Morgan AS, Hirvela ER, et al. Idiopathic retroperitoneal fibrosis: is there a role for postoperative steroids? *Curr Surg.* 1990;47:423-427.
- Duchene DA, Winfield HN, Cadeddu JA, et al. Multi-institutional survey of laparoscopic ureterolysis for retroperitoneal fibrosis. *Urology.* 2007;69:1017-1021.
- Gilkeson GS, Allen NB. Retroperitoneal fibrosis. A true connective tissue disease. *Rheum Dis Clin North Am.* 1996;22:23-38.
- Hartung O, Alimi YS, Di Mauro P, et al. Endovascular treatment of ilioacaval occlusion caused by retroperitoneal fibrosis: late results in two cases. *J Vasc Surg.* 2002;36:849-852.
- Higgins PM, Bennett-Jones DN, Naish PF, et al. Non-operative management of retroperitoneal fibrosis. *Br J Surg.* 1990;8:206-222.
- Kardar AH, Kattan S, Lindstedt E, et al. Steroid therapy for idiopathic retroperitoneal fibrosis: dose and duration. *J Urol.* 2002;168:550-555.

- Kottra JJ, Dunnick NR. Retroperitoneal fibrosis. *Radiol Clin North Am.* 1996;34:1259-1275.
- Martorana D, Vaglio A, Greco P, et al. Chronic periaortitis and HLA-DRB1*03: another clue to an autoimmune origin. *Arthritis Rheum.* 2006;55:126-130.
- Marzano A, Trapani A, Leone N, et al. Treatment of idiopathic retroperitoneal fibrosis using cyclosporine. *Ann Rheum Dis.* 2001;60:427-428.
- Ormond JK. Bilateral ureteral obstruction due to envelopment and compression by an inflammatory process. *J Urol.* 1948;59:1072-1079.
- Pryor JP, Piotrowski E, Seltzer CW, et al. Early diagnosis of retroperitoneal necrotizing fasciitis. *Crit Care Med.* 2001;29:1071-1073.

- Rhee RY, Gloviczki P, Luthra HS, et al. Iliocaval complications of retroperitoneal fibrosis. *Am J Surg.* 1994;168:179-183.
- Srinivasan AK, Richstone L, Permpongkosol S, et al. Comparison of laparoscopic with open approach for uterolysis in patients with retroperitoneal fibrosis. *J Urol.* 2008;179:1875-1878.
- Uchida K, Okazaki K, Asada M, et al. Case of chronic pancreatitis involving an autoimmune mechanism that extended to retroperitoneal fibrosis. *Pancreas.* 2003;26:92-94.
- Woodburn KR, Ramsay G, Gillespie G, et al. Retroperitoneal necrotizing fasciitis. *Br J Surg.* 1992;79:342-344.

36 chapter

Soft Tissue Sarcomas

Janice N. Cormier, Alessandro Gronchi, and
Raphael E. Pollock

Introduction	1465	Pathologic Assessment and Classification / 1470	Gastrointestinal Stromal Tumors	1481
Incidence	1465	Staging and Prognostic Factors / 1470	Radiologic Assessment / 1482	
Epidemiology	1466	Treatment of Extremity and Trunk Wall Sarcoma	Management of Localized Disease / 1482	
Radiation Exposure / 1466		1472	Management of Locally Advanced or Metastatic Disease / 1482	
Occupational Chemical Exposure / 1466		Surgery / 1472	Multidisciplinary Treatment / 1483	
Trauma / 1466		Radiation Therapy / 1474	Postoperative Imatinib / 1483	
Chronic Lymphedema / 1466		Systemic Therapy / 1475	Preoperative Imatinib / 1484	
Molecular Pathogenesis	1466	Concurrent Chemoradiation Therapy / 1477	Desmoids	1485
Translocation-Associated Sarcomas / 1467		Posttreatment Surveillance / 1477	Dermatofibrosarcoma Protuberans	1485
Amplification-Associated Sarcomas / 1467		Management of Recurrent Sarcoma / 1478	Pediatric Sarcomas	1485
Oncogenic Mutations / 1467		Special Clinical Situations	Rhabdomyosarcoma / 1485	
Complex Genomic Rearrangements / 1467		1479	Nonrhabdomyosarcoma Soft Tissue Sarcomas / 1486	
Initial Assessment	1468	Myxoid Liposarcoma / 1479	Research Perspectives	1486
Clinical Presentation / 1468		Retroperitoneal Sarcoma / 1479	Conclusions	1486
Diagnostic Imaging / 1468		Gastrointestinal Sarcoma / 1480		
Biopsy Techniques / 1469		Breast Sarcoma / 1481		
		Uterine Sarcoma / 1481		

INTRODUCTION

Sarcomas are a heterogeneous group of neoplasms that arise predominantly from cells of the embryonic mesoderm. While

- ▶ the majority of sarcomas are soft tissue sarcomas, other types of sarcoma include bone sarcomas (osteosarcoma, chondrosarcoma, and rare bone tumors like chordoma, angiosarcoma, and leiomyosarcoma of bone) and Ewing's sarcoma/peripheral primitive neuroectodermal tumor, which can occur either in the bone or in the soft tissues. The primary focus of this chapter is soft tissue sarcomas. Most primary soft tissue sarcomas originate in an extremity (50%–60%); the next most common sites are the trunk (19%), retroperitoneum (15%), and head and neck (9%). The anatomic site of a primary sarcoma influences treatment and outcome.¹

Soft tissue sarcomas include more than 50 histologic subtypes (Table 36-1). Historically, the most common subtypes in adults (excluding Kaposi's sarcoma) were malignant fibrous histiocytoma (28%), liposarcoma (15%), leiomyosarcoma (12%), synovial sarcoma (10%), and malignant peripheral nerve sheath tumor (6%).² Today, malignant fibrous histiocytoma is classified as either leiomyosarcoma, pleomorphic undifferentiated sarcoma, myxofibrosarcoma, or dedifferentiated liposarcoma based on cellular differentiation and genetics. Embryonal/alveolar rhabdomyosarcomas are the most common soft tissue sarcomas of

childhood, whereas pleomorphic rhabdomyosarcoma occurs predominantly in adults, and although it shares part of the name, it has a different biology and should not be treated as a pediatric sarcoma.

- During the past 25 years, patients with extremity sarcomas have been treated with a multimodality approach, which has led to some improvements in survival, local control, and quality of life.³ However, patients with abdominal sarcomas continue to have high rates of recurrence and poor overall survival.⁴ The overall 5-year survival rate for patients with all stages of soft tissue sarcoma is 50% to 60%. Of the patients who die of sarcoma, most succumb to lung metastasis, which 80% of the time occurs within 2 to 3 years after initial diagnosis.

INCIDENCE

In the United States in 2012, approximately 11,280 new cases of soft tissue sarcoma were diagnosed, and 3900 deaths were attributable to this disease.⁵ The true incidence of sarcoma is thought to be higher than reported, and gastrointestinal stromal tumors (GISTs) likely account for an additional 5000 new sarcoma cases per year.¹ Overall, sarcomas affect 5 to 6 individuals per 100,000 inhabitants per year,⁶ accounting for less than 1% of all malignancies in adults and 15% of malignancies in children.⁷

Key Points

- 1▶ Sarcomas are a heterogeneous group of tumors that can occur throughout the body and encompass more than 50 subtypes with distinct histologic lines of differentiation.
- 2▶ Approximately two thirds of soft tissue sarcomas arise in the extremities; the remaining one third is distributed between the retroperitoneum, trunk, abdomen, head, and neck.
- 3▶ Multimodality treatment, including surgical resection, radiation therapy, and, in selected cases, systemic chemotherapy, has been applied to patients with locally advanced, high-grade, extremity sarcomas.
- 4▶ Overall 5-year survival rate for patients with all stages of soft tissue sarcoma is 50% to 60%.
- 5▶ These rare tumors account for less than 1% of cancer in adults (estimated 10,000 cases per year in the United States) and represent 15% of cancers in children.
- 6▶ The treatment algorithm for soft tissue sarcomas depends on tumor stage, site, and histology.
- 7▶ Of the patients who die of sarcoma, most will succumb to metastatic disease in the lungs, which 80% of the time occurs within 2 to 3 years of the initial diagnosis.
- 8▶ Progress in the understanding of soft tissue sarcoma biology is crucial for the development of new treatments.

EPIDEMIOLOGY

Except for malignant peripheral nerve sheath tumors in patients with neurofibromatosis, sarcomas do not seem to result from progression or dedifferentiation of a benign soft tissue tumor. While most sarcomas are of unknown cause, a few sarcoma subtypes have been observed in settings suggesting etiology.

Radiation Exposure

External radiation therapy is a rare but well-established risk factor for soft tissue sarcoma that may be associated with radiation-induced mutations of the *p53* gene.⁸ The incidence of sarcoma among patients who are often treated with radiation for cancer of the breast, cervix, ovary, testes, or lymphatic system is 8 to 50 times the general-population risk.^{9,10} In a review of 160 patients with postirradiation sarcomas, the most common

histologic types were osteogenic sarcoma, malignant fibrous histiocytoma, angiosarcoma, and lymphangiosarcoma.⁹ The risk of developing a sarcoma increased with radiation dose, and the median time between radiation therapy and diagnosis of sarcoma was 10 years.⁹ A recent review of 44 patients with radiation-induced sarcomas identified between 1989 and 2009 noted that the average period from initial radiation treatment to diagnosis was 16 years and that radiation-induced sarcomas occurred most commonly in patients treated for breast cancer (36% of the patients in the series) and lymphoma (34% of the patients in the series).¹¹ The 5-year overall survival rate for patients presenting without metastasis was 44%.

Occupational Chemical Exposure

Exposure to herbicides such as phenoxyacetic acids and to wood preservatives containing chlorophenols has been linked to an increased risk of soft tissue sarcoma.¹² Several chemical carcinogens, including thorium oxide (Thorotrast), vinyl chloride, and arsenic, have been associated with hepatic angiosarcomas.¹³

Trauma

Although patients with sarcoma often report a history of trauma, no causal relationship has been established. More often, a minor injury calls attention to a pre-existing tumor.

Chronic Lymphedema

In 1948, Stewart and Treves first described the association between chronic lymphedema after axillary dissection and subsequent lymphangiosarcoma (Fig. 36-1).¹⁴ Lymphangiosarcoma has been estimated to occur in 0.07% of patients who undergo axillary node dissection.¹⁵ It also has been reported to occur after filarial infections and in the lower extremities of patients with congenital lymphedema.^{16,17} Lymphangiosarcoma is generally an aggressive tumor; average survival of patients with lymphangiosarcoma is 19 months.¹⁸

MOLECULAR PATHOGENESIS

Sarcomas can be broadly classified into three groups according to the genetic events underlying their development: specific translocations or gene amplification, defining oncogenic mutations, and complex genomic rearrangements.¹⁹ In general, sarcomas resulting from identifiable molecular events tend to occur in younger patients with histology suggesting a clear line of differentiation. The identifiable molecular events include point

Table 36-1

Relative frequency of histologic subtypes of soft tissue sarcoma

HISTOLOGIC SUBTYPES	NO.	%
Liposarcoma	188	15
Leiomyosarcoma	148	12
Unclassified sarcoma	140	11
Synovial sarcoma	125	10
Malignant peripheral nerve sheath tumor	72	6
Rhabdomyosarcoma	60	5
Fibrosarcoma	38	3
Ewing sarcoma	25	2
Angiosarcoma	25	2
Osteosarcoma	14	1
Epithelioid sarcoma	14	1
Chondrosarcoma	13	1
Clear cell sarcoma	12	1
Alveolar soft part sarcoma	7	1
Malignant hemangiopericytoma	5	0.4

Source: Data from Coindre et al.²

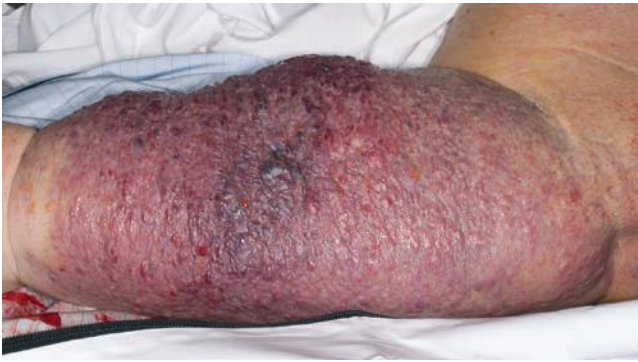

Figure 36-1. A 57-year-old with a chronic, progressive lymphedema of the left upper extremity developed lymphangiosarcoma 10 years after breast cancer treatment.

mutations, translocations causing overexpression of an autocrine growth factor, and oncogenic fusion transcription factor producing a cellular environment prone to malignant transformation. In contrast, sarcomas without identifiable genetic changes or expression profile signatures tend to occur in older patients and exhibit pleomorphic cytology and *p53* dysfunction.²⁰ Improved understanding of the molecular pathogenesis of sarcomas has revealed several potential targets against which investigators are working to develop subtype-specific targeted therapy.

Translocation-Associated Sarcomas

To date, translocations have been identified in 14 subtypes of soft tissue sarcoma, accounting for 20% to 30% of all sarcomas²¹ (Table 36-2). Translocations result in in-frame gene fusion, which in turn results in fused products encoding oncoproteins that function as transcriptional activators or repressors.^{22,23} The best characterized gene fusions are in Ewing's sarcoma (*EWS-FLII*), clear cell sarcoma (*EWS-ATF1*), myxoid/round cell liposarcoma (*TLS-CHOP*), alveolar rhabdomyosarcoma (*PAX3-FKHR*), desmoplastic small round cell tumor (*EWS-WT1*), and synovial sarcoma (*SS18-SSX*). Fusion gene-related sarcomas have been estimated to account for 30% or more of all sarcomas.²⁴

Direct or indirect interactions between fusion transcripts and cell cycle regulators have been elucidated by several investigators and identify these transcripts as potentially promising molecular therapeutic targets.²⁵ However, fusion genes in sarcoma have been successfully targeted in only a few cases, in which fusion resulted in overexpression of a growth factor or growth factor receptor. Several growth factors and their receptors (e.g., epidermal growth factor receptor) previously reported to play an important role in autocrine or paracrine stimulation of carcinoma growth have been associated with high histologic grade and poor prognosis in soft tissue sarcomas.

Amplification-Associated Sarcomas

Oncogenes are genes that can induce malignant transformation and tend to drive cell proliferation. Several oncogenes have been associated with soft tissue sarcomas, including *MDM2*, *N-myc*, *c-erbB2*, and members of the *ras* family. These oncogenes produce specific oncoproteins that either play a role in nuclear function and cellular signal transduction or function as growth factors or growth factor receptors. This typically occurs in dedifferentiated liposarcoma, where the amplification of *MDM2* drives the neoplastic process. Amplification of these genes has been shown to correlate with adverse outcome in several types of soft tissue sarcoma.²²

Table 36-2

Fusion transcripts in soft tissue sarcoma

DIAGNOSIS	CHROMOSOMAL ABNORMALITY	GENES INVOLVED
Alveolar rhabdomyosarcoma	t(2;13)(q35;q14) t(1;13)(p36;q14)	<i>PAX3-FKHR</i> <i>PAX7-FKHR</i>
Alveolar soft part sarcoma	t(X;17) (p11.2;q25)	<i>TFE3-ASPL</i>
Angiomatoid fibrous histiocytoma	t(12;16)(q13;p11)	<i>FUS-ATF1</i>
Clear cell sarcoma	t(12;22)(q13;q12)	<i>EWS-ATF1</i>
Congenital fibrosarcoma/ congenital mesoblastic nephroma	t(12;15)(p13;q25)	<i>ETV6-NTRK3</i>
Dermatofibrosarcoma protuberans	t(17;22)(q22;q13)	<i>PDGFB-COL1A1</i>
Desmoplastic small round cell tumor	t(11;22)(p13;q12)	<i>EWS-WT1</i>
Endometrial stromal sarcoma	t(7;17)(p15;q21)	<i>JAZF1-JJAZ1</i>
Ewing's sarcoma/ peripheral primitive neuroectodermal tumor	t(11;22)(q24;q12) t(21;22)(q22;q12) t(7;22)(p22;q12) t(17;22)(q12;q12) t(2;22)(q33;q12) t(16;21)(p11;q22)	<i>EWS-FLII</i> <i>EWS-ERG</i> <i>EWS-ETV1</i> <i>EWS-FEV</i> <i>EWS-EIAF</i> <i>FUS-ERG</i>
Low-grade fibromyxoid sarcoma	t(7;16)(q33;p11)	<i>FUS-CREB3I2</i>
Inflammatory myofibroblastic tumor	t(1;2)(q22;p23) t(2;19)(p23;p13) t(2;17)(p23;q23)	<i>TPM3-ALK</i> <i>TPM4-ALK</i> <i>CLTC-ALK</i>
Myxoid liposarcoma	t(12;16)(q13;p11) t(12;22)(q13;q12)	<i>TLS-CHOP</i> <i>EWS-CHOP</i>
Myxoid chondrosarcoma	t(9;22)(q22;q12) t(9;15)(q22;q21) t(9;17)(q22;q11)	<i>EWS-CHN</i> <i>TFC12-CHN</i> <i>TAF2N-CHN</i>
Synovial sarcoma	t(x;18)(p11;q11)	<i>SSX1-SYT</i> <i>SSX2-SYT</i> <i>SSX4-SYT</i>

Oncogenic Mutations

GISTs are the classic example of sarcomas in which tumorigenesis is primarily driven by a single activating mutation, in the gene encoding KIT receptor tyrosine kinase or platelet-derived growth factor receptor- α (*PDGFRA*).¹⁹ The majority of GISTs have mutations in exon 11 of *KIT* and respond dramatically to the tyrosine kinase inhibitor imatinib mesylate, although this treatment rarely produces cure.

Complex Genomic Rearrangements

The largest group of sarcomas is the group with complex cytogenetic alterations, which includes high-grade spindle cell sarcomas and pleomorphic sarcomas.¹⁹ Many sarcomas in this group exhibit inactivation of tumor suppressor genes. The two genes most relevant to soft tissue sarcoma are retinoblastoma (*Rb*) and

p53. Mutations or deletions in *Rb* can lead to retinoblastoma, the most common malignant ocular neoplasm of childhood. Survivors of retinoblastoma are at risk for developing soft tissue and bone sarcomas later in life. Patients with germline mutations in *p53* (Li-Fraumeni syndrome) have a high incidence of soft tissue sarcomas. Mutant *p53* expression is thought to correlate with poor overall survival.²² Strategies to target *p53* mutation are being investigated for treatment of some sarcomas.

Neurofibromatosis type 1 (von Recklinghausen's disease) occurs in approximately 1 of every 3000 people and is due to various mutations in the *NF-1* tumor suppressor gene, located on chromosome 17. Patients with neurofibromatosis type 1 have an estimated 3% to 15% additional risk of malignant disease compared with the general population lifetime risk, including malignant peripheral nerve sheath tumors (MPNST) and GIST. In turn, 25% to 50% of patients with MPNST have a mutation in *NF-1*.²⁶

INITIAL ASSESSMENT

The clinical behavior of most soft tissue sarcomas is determined by anatomic location (depth in relation to the investing fascia), histologic subtype and grade of aggressiveness, and size. The dominant pattern of metastasis is hematogenous, primarily to the lungs. Lymph node metastasis is rare (affecting <5% of patients) except in a few histologic subtypes, including epithelioid sarcoma, pediatric rhabdomyosarcoma, clear cell sarcoma, angiosarcoma, and, more rarely, synovial sarcoma and myxofibrosarcoma.²⁷

Clinical Presentation

Soft tissue sarcomas most commonly present as an asymptomatic mass. Extremity sarcomas may present as a deep venous thrombosis, particularly in patients without significant risk factors for thrombosis.²⁸ Tumors in the distal extremities are generally smaller, whereas tumors in the proximal extremities and retroperitoneum can grow quite large before becoming apparent. Tumors often grow centrifugally and can compress surrounding normal structures. Infrequently, tumor impingement on bone or neurovascular bundles produces pain, edema, and swelling. Less frequently, tumors cause obstructive gastrointestinal symptoms or neurologic symptoms related to compression of lumbar or pelvic nerves. Often an extremity mass is discovered after a traumatic event that draws attention to a pre-existing lesion.

The differential diagnosis of a soft tissue mass should include consideration of lipoma (which is 100 times more common than sarcoma), lymphangioma, leiomyoma, neurinoma, primary or metastatic carcinoma, melanoma, and lymphoma. Superficial small lesions (<5 cm) that are new or that are not enlarging as indicated by clinical history can be observed. Enlarging masses and masses larger than 5 cm or deep to the fascia should be evaluated with a history, imaging, and biopsy.²⁹

Diagnostic Imaging

Diagnostic imaging should be performed before any invasive procedure to avoid the possibility of soft tissue swelling or hemorrhage complicating the image interpretation. Pretreatment diagnostic imaging is helpful for defining the size and anatomic location of a tumor and its proximity to adjacent structures; staging disease with respect to regional or metastatic spread; guiding percutaneous biopsy; and establishing whether a tumor is benign or malignant and low grade or high grade.

Radiographs are useful in the evaluation of primary bone tumors but not in the evaluation of soft tissue sarcomas of the extremities unless there is underlying bone involvement from an adjacent soft tissue tumor. Magnetic resonance imaging (MRI) is the preferred imaging technique for soft tissue sarcomas of the extremities, whereas computed tomography (CT) is most useful for evaluating retroperitoneal, intra-abdominal, and truncal sarcomas.³⁰ CT of the chest should be performed to assess for lung metastases in patients with high-grade tumors larger than 5 cm. Abdominal/pelvic CT should be performed in patients with myxoid round cell liposarcomas, leiomyosarcomas, epithelioid sarcomas, or angiosarcomas because of their propensity to metastasize to the abdomen and/or pelvis.¹ MRI of the brain should be considered for patients with alveolar soft part sarcomas and angiosarcomas because of their propensity to metastasize to the brain.

Ultrasonography. Ultrasonography may have a diagnostic role in patients with soft tissue sarcoma who cannot undergo MRI. Ultrasonography can also be a useful adjunct to MRI when findings on MRI are indeterminate and for delineating adjacent vascular structures. Finally, ultrasonography can be used for postoperative surveillance and to guide biopsies.

Computed Tomography. Chest CT should be performed to evaluate for lung metastasis at presentation and before any radical treatment. CT is also the preferred imaging technique for evaluating retroperitoneal sarcomas (Fig. 36-2).³⁰ Current CT techniques can provide a detailed image of the abdomen and pelvis and can delineate adjacent organs and vascular structures. For extremity sarcomas, CT may be useful if MRI is not available or cannot be used. When histologic assessment of an extremity sarcoma reveals a myxoid liposarcoma, CT of the abdomen and pelvis should be done because this subtype is known to metastasize to the abdomen.³¹

Magnetic Resonance Imaging. MRI is the most useful imaging modality for extremity sarcomas because of its superior soft tissue contrast resolution and multiplanar capabilities. MRI accurately delineates muscle groups and distinguishes among bone, vascular structures, and tumor. Sagittal and coronal views allow evaluation of anatomic compartments in three dimensions (Fig. 36-3). Soft tissue sarcomas of the extremities usually present on MRI as a heterogeneous mass. Their signal intensity tends

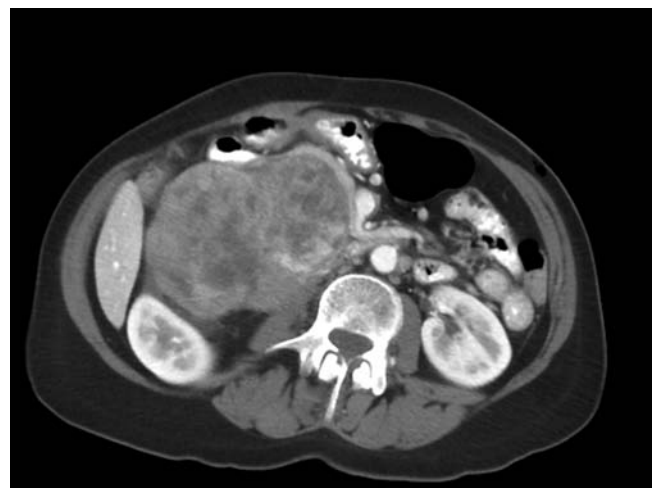


Figure 36-2. A 69-year-old woman with a leiomyosarcoma involving the inferior vena cava.

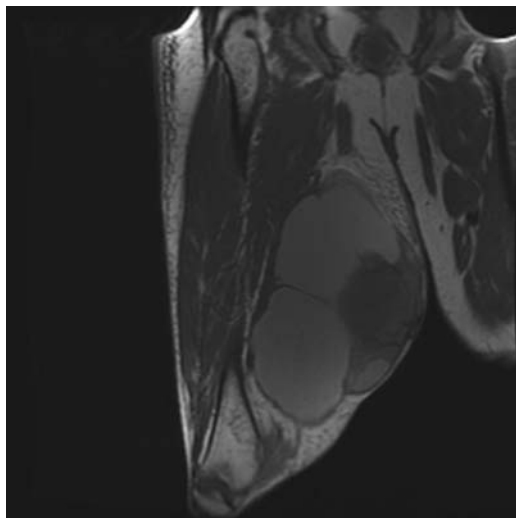


Figure 36-3. A 62-year-old man presented with right thigh pain. Magnetic resonance imaging demonstrated a 20-cm high-grade sarcoma within the medial compartment.

to be equal to or slightly higher than that of adjacent skeletal muscle on T1-weighted images and heterogeneous and high on T2-weighted images. Hemorrhagic, cystic, or necrotic changes may also be observed in the tumor. If adjacent vascular structures must be delineated, special MRI techniques may be performed, including magnetic resonance angiography. MRI may also be an important adjunct to cytologic analysis in distinguishing benign lesions such as lipomas, hemangiomas, schwannomas, neurofibromas, and intramuscular myxomas from their malignant counterparts. In patients undergoing preoperative chemotherapy, contrast-enhanced T1-weighted MRI can be useful in evaluating intratumoral necrosis.

MRI is also valuable for assessing tumor recurrence after surgery. A baseline image is usually obtained 3 months after surgery. Some clinicians forego routine postoperative imaging of the primary extremity tumor site in asymptomatic patients, citing the difficulties in detecting early recurrence in scarred, irradiated tissue.³⁰ Others advocate routine imaging every 3 to 4 months for the first 2 years, every 6 months in years 3 through 5, and then annually.

Positron Emission Tomography. Positron emission tomography (PET) is a functional imaging modality that measures tumor uptake of the glucose analog [¹⁸F] fluorodeoxyglucose (FDG). PET imaging allows evaluation of the entire body. Although PET/CT may be useful in specific circumstances, FDG-PET is not currently recommended for the initial staging of patients with soft tissue sarcoma.

Roberge and colleagues compared FDG-PET/CT versus chest CT alone in the initial staging of 75 patients with soft tissue sarcoma and found that only one patient had disease upstaged as a result of PET, whereas two had false-positive findings and three had indeterminate findings with no subsequent development of metastasis.³² Previous studies that reported a marginal benefit of PET/CT for detecting metastasis at the time of sarcoma staging included patients with more heterogeneous tumors, such as osseous tumors, soft tissue osteosarcomas, Ewing's sarcoma, and rhabdomyosarcoma.³³⁻³⁵

In patients with sarcoma, PET has primarily been used to assist with tumor grading and to assess response to chemotherapy.³⁶⁻³⁹ In 50 patients with resectable high-grade soft

tissue tumors scheduled for preoperative chemotherapy and tumor resection, a 35% or greater reduction in tumor FDG uptake following an initial cycle of chemotherapy was associated with histopathologic tumor response defined as pathologic necrosis in 95% or more of the resected specimen.⁴⁰

Biopsy Techniques

Fine-Needle Aspiration. At centers where cytopathologists have experience with evaluation of mesenchymal tumors, fine-needle aspiration is an acceptable method of diagnosing most soft tissue sarcomas, particularly when the results correlate closely with clinical and radiologic findings.⁴¹ Fine-needle aspiration of primary tumors has a lower diagnostic accuracy rate (60%–90%) than core needle biopsy and is often not sufficient for establishing a specific histologic diagnosis and grade.⁴² However, fine-needle aspiration is the procedure of choice to confirm or rule out the presence of a metastatic focus or local recurrence.⁴³

Although fine-needle aspiration of superficial lesions can often be done in the clinic, fine-needle aspiration of deeper tumors may need to be done by an interventional radiologist under sonographic or CT guidance. Generally, a 21- to 23-gauge needle is introduced into the mass after appropriate cleansing of the skin and injection of local anesthetic. Negative pressure is applied, and the needle is moved back and forth several times in various directions. After the negative pressure is released, the needle is withdrawn, and the contents of the needle are used to prepare smears.⁴⁴ A cytopathologist then examines the slides to determine whether sufficient diagnostic material is present.

Core Needle Biopsy. Core needle biopsy is safe, accurate,^{45,46} and economical⁴⁷ and has become the preferred technique for diagnosing soft tissue lesions. Dupuy and colleagues found that core needle biopsy had an accuracy of 93% in 221 patients with musculoskeletal neoplasms.⁴⁵

Sonography/CT guidance can prevent sampling of nondiagnostic necrotic or cystic areas of the tumor and thus increase the positive yield rate. Sonography/CT guidance also permits biopsy of tumors in otherwise inaccessible locations and tumors located near vital structures.

The tissue sample obtained from core needle biopsy is usually sufficient for several diagnostic tests, such as electron microscopy, cytogenetic analysis, and flow cytometry. The reported complication rate for core needle biopsy is less than 1%.^{45,46}

Incisional Biopsy. Historically, an open surgical biopsy was the gold standard for achieving adequate tissue for definitive and specific histologic diagnosis of bone or soft tissue sarcomas. Contemporary guidelines recommend incisional biopsy when core needle biopsy cannot produce adequate tissue for diagnosis or when findings on core needle biopsy are nondiagnostic.

The disadvantages of incisional biopsy include the need to schedule the procedure, the need for general anesthesia, and high costs. In addition, an inappropriately placed incisions can necessitate more extensive definitive resection to encompass the biopsy site. In a series of 107 patients with soft tissue sarcoma, planned surgical treatments had to be changed because of poorly oriented biopsies in 25% of cases.⁴⁸ Complication rates up to 17% have been reported after incisional biopsies.⁴⁴ Potential complications include hematoma, infection, wound dehiscence, and tumor fungation, any of which can delay definitive treatment.⁴⁴

Incisional biopsies should be performed only by surgeons experienced in the management of soft tissue sarcoma, ideally in a center specializing in the treatment of sarcoma and by the surgeon who will perform the definitive surgery. The biopsy incision should be oriented longitudinally along the extremity to allow a subsequent wide local excision that encompasses the biopsy site, scar, and tumor en bloc. A poorly oriented biopsy incision often necessitates an excessively large surgical defect for a wide local excision, which in turn can result in a larger postoperative radiation therapy field to encompass all tissues at risk. Adequate hemostasis must be achieved at the time of biopsy to prevent dissemination of tumor cells into adjacent tissue planes by hematoma.

Excisional Biopsy. Excisional biopsy can be performed for easily accessible (superficial) extremity or truncal lesions smaller than 3 cm. However, excisional biopsy rarely provides benefits over other biopsy techniques. Excisional biopsies should not be performed for lesions involving the hands and feet because such biopsies may complicate definitive re-excision. For sarcomas with initial diagnosis confirmed with excisional biopsy, microscopic residual disease has been reported in up to 69% of re-excision specimens^{49,50}; without re-excision, the reported rate of local recurrence is 30% to 40% when margins are positive or uncertain.

Wide en bloc excision is seldom performed as a diagnostic procedure. When en bloc excision is done for diagnosis, the margin status is often not adequately evaluated during pathologic assessment of the specimen. Unless detailed descriptions of the surgical procedure and the pathology specimen are provided, the margins should be classified as uncertain or unknown, a classification associated with the same prognosis as resection margins that are positive for tumor cells. In patients with uncertain or unknown margins, re-excision should be performed if possible to ensure negative margins. The biopsy site or tract (if applicable) should be included en bloc with the re-resected specimen.

Pathologic Assessment and Classification

Sarcoma is generally diagnosed by morphologic assessment based on microscopic examination of histologic sections by an experienced sarcoma pathologist. However, even expert sarcoma pathologists disagree on the specific histologic diagnosis and the tumor grade in 25% to 40% of cases.⁵¹

Morphologic assessment can be supported by ancillary techniques, including conventional cytogenetics; immunohistochemistry; and molecular genetic testing, which is useful for classifying soft tissue sarcoma subtypes with multiple genetic aberrations. Other molecular diagnostic techniques include cytogenetic analysis, fluorescence in situ hybridization, and polymerase chain reaction–based methods.⁵² However, molecular genetic techniques are associated with significant technical limitations and should be interpreted in the context of the sarcoma's morphologic features.

Some experts have suggested that pathologic classification of soft tissue sarcomas has more prognostic significance than does tumor grade when other pretreatment variables are taken into account. Tumors with limited metastatic potential include desmoid, atypical lipomatous tumor (also called well-differentiated liposarcoma), dermatofibrosarcoma protuberans, and solitary fibrous tumor. Tumors with an intermediate risk of metastatic spread usually have a large myxoid component and include myxoid liposarcoma, myxofibrosarcoma, and extraskeletal myxoid chondrosarcoma. Among the highly aggressive

tumors with substantial metastatic potential are angiosarcoma, clear cell sarcoma, pleomorphic and dedifferentiated liposarcoma, leiomyosarcoma, MPNST, rhabdomyosarcoma, and synovial sarcoma.

It has recently been noted that malignant fibrous histiocytoma is not associated with a distinct gene cluster, suggesting that malignant fibrous histiocytoma is not a separate tumor entity but rather a common morphologic appearance of various sarcoma subtypes.^{53,54} For example, most tumors initially diagnosed as malignant fibrous histiocytoma in the retroperitoneum have been reclassified using genomic profiling as dedifferentiated liposarcomas,⁵⁵ whereas those in the extremities have been reclassified as leiomyosarcoma, myxofibrosarcoma, or pleomorphic undifferentiated sarcoma.

Guidelines for the pathologic reporting of sarcoma have been established.¹ Included in the report should be the primary diagnosis, anatomic site, depth, size, and histologic grade, presence or absence of necrosis, status of excision margins and lymph nodes, TNM stage, and additional features of the tumor (i.e., mitotic rate and presence or absence of vascular invasion).

Staging and Prognostic Factors

Soft tissue sarcoma is most commonly staged using either the American Joint Committee on Cancer (AJCC) system (generally used in the United States) or the World Health Organization system. A unique aspect of sarcoma staging is the inclusion of tumor grade, which is one of the most important prognostic factors.⁵⁶

The seventh edition of the AJCC staging system for soft tissue sarcomas is based on histologic grade of aggressiveness, tumor size and depth, and the presence of nodal or distant metastases.⁵⁷ This system does not apply to GIST, fibromatosis (desmoid tumor), Kaposi's sarcoma, or infantile fibrosarcoma.

Histologic Grade of Aggressiveness. Histologic grade is the most important prognostic factor for patients with soft tissue sarcoma. For accurate determination of grade, an adequate tissue sample must be appropriately fixed, stained, and reviewed by an experienced sarcoma pathologist. The features that define grade are cellularity, differentiation (good, moderate, or poor/anaplastic), pleomorphism, necrosis (absent, <50%, or ≥50%), and number of mitoses per high-power field (<10, 10–19, or ≥20). Tumor grade has been shown to predict metastasis and overall survival.⁵⁸ Metastasis has been estimated to occur in 5% to 10% of low-grade lesions, 25% to 30% of intermediate-grade lesions, and 50% to 60% of high-grade lesions.

The number of grades varies according to the classification system used. The most common classification systems, those of the National Cancer Institute and the French Federation of Cancer Centers, use three-tier tumor grades.⁵⁹ The National Cancer Institute system is based primarily on histologic subtype, location, and amount of necrosis. The French Federation of Cancer Centers system is based on tumor differentiation (good, moderate, or poor/anaplastic), number of mitoses per high-power field (<10, 10–19, or ≥20), and amount of tumor necrosis (absent, <50%, or ≥50%). A comparative analysis of the two systems suggested that the French Federation of Cancer Centers system has better prognostic capability, predicting 5-year survival rates of 90%, 70%, and 40% for grade 1, 2, and 3 tumors, respectively.⁵⁹

Following the recommendation of the College of American Pathologists, the committee that developed the 2008 AJCC staging system changed the system from a four-grade to a

three-grade system in which the grades are well differentiated (grade 1), moderately differentiated (grade 2), and poorly differentiated (grade 3).⁶⁰ Grade 1 is considered low grade, and grades 2 and 3 are considered high grade.

Tumor Size and Location. Tumor size is an important prognostic variable in soft tissue sarcomas. Sarcomas have classically been stratified into two size groups; T1 lesions are 5 cm or smaller, and T2 lesions are larger than 5 cm. Some authors have suggested adding a third group for tumors larger than 15 cm, because such tumors are associated with a worse prognosis than tumors measuring between 5 and 15 cm.^{61,62}

Anatomic tumor location was incorporated into the AJCC staging system in 1998. Soft tissue sarcomas above the superficial investing fascia of the extremity or trunk are designated “a” lesions within the T category, whereas tumors invading or deep to the fascia and all retroperitoneal, mediastinal, and visceral tumors are designated “b” lesions.

Nodal Metastasis. Overall, lymph node metastases arising from soft tissue sarcomas are rare,²⁷ but the incidence of nodal involvement is higher for epithelioid sarcoma, pediatric rhabdomyosarcoma, clear cell sarcoma, synovial sarcoma, myxofibrosarcoma, and angiosarcoma. In the seventh edition of the AJCC staging system, sarcoma associated with nodal metastases was reclassified as stage III rather than stage IV because several studies reported better survival for patients with isolated regional lymph node metastases treated with radical lymphadenectomy than for patients with distant metastases.^{27, 63-65} Patients with clinically or radiologically suspicious regional nodes should have metastases confirmed or ruled out by fine-needle aspiration before radical lymphadenectomy.

Distant Metastasis. Distant metastases occur most often in the lungs (Fig. 36-4). Selected patients with pulmonary metastases may survive for long periods after surgical resection and chemotherapy. Other potential sites of metastasis include bone (Fig. 36-5), brain (Fig. 36-6), and liver (Fig. 36-7). Visceral and

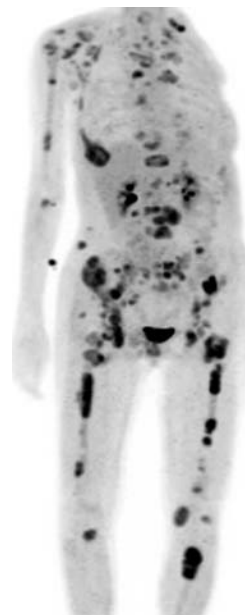


Figure 36-5. A 36-year-old woman with history of multifocal sclerosing osteosarcoma of the humerus developed diffuse bony metastases 2 years after diagnosis.

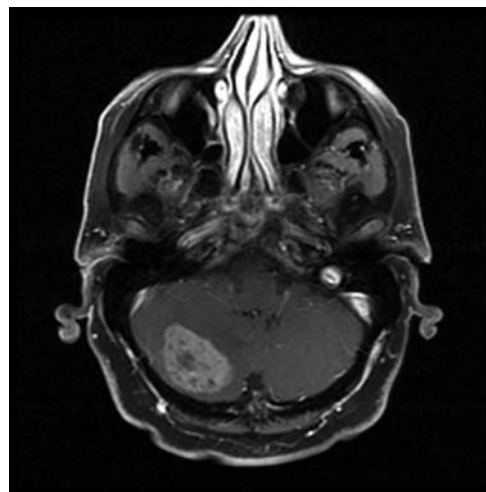


Figure 36-6. A 64-year-old man with a history of a T2 high-grade pleomorphic sarcoma of the thigh who developed brain metastases 14 months after diagnosis.

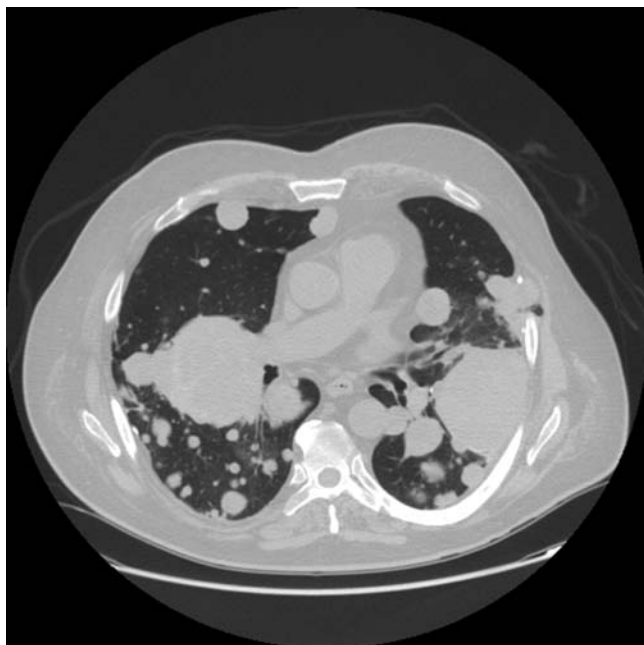


Figure 36-4. A 74-year-old man with a history of an extraskeletal myxoid chondrosarcoma of the gluteal region developed multiple lung metastases.

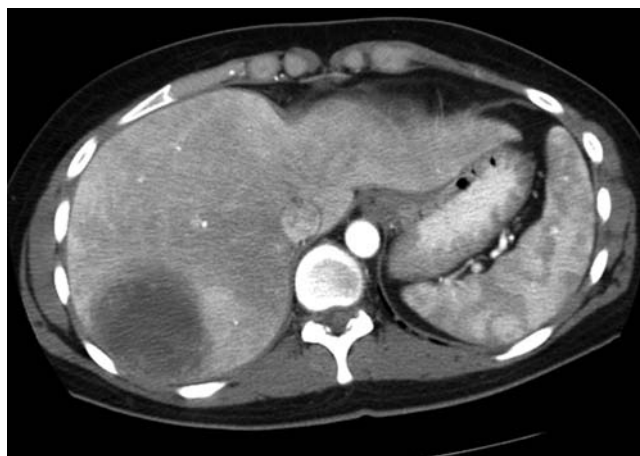

Figure 36-7. A 33-year-old woman with osteosarcoma of the sternum who presented with a liver metastasis 3 years after diagnosis.

retroperitoneal sarcomas have a higher incidence of liver and peritoneal metastases.

Prognostic Factors. Prognostic variables in soft tissue sarcoma include primary tumor size, grade, and depth, all of which are incorporated into the staging system, as well as histology, tumor site, and presentation (local recurrence or initial diagnosis). Patient factors such as older age and gender have also been associated with recurrence and mortality in several studies.⁶⁶ A positive microscopic margin and early recurrence after resection of an extremity sarcoma have been shown to be associated with decreased survival.⁶⁷

Several groups have reported that Ki-67, a proliferation marker, is correlated with a poor clinical outcome in high-grade extremity sarcomas.^{68,69} E-cadherin and catenins, proteins essential for intercellular junctions, have been associated with poor outcome in patients with soft tissue sarcoma.⁶⁸ Similarly, higher CD100 expression has been shown to correlate with higher proliferative potential and poorer outcome.⁶⁹

Prognostic Nomograms. Prognostic nomograms for soft tissue sarcoma have been introduced for use in patient counseling, selecting appropriate surveillance strategies, and selecting patients for clinical trials.⁷⁰ One such nomogram, developed by Kattan and colleagues at Memorial Sloan-Kettering Cancer Center, considers age, histology, grade, location, depth, and size to determine the likelihood of 12-year sarcoma-specific survival.⁷⁰ Two validation studies using the nomogram demonstrated good predictive value.⁷¹ More recently, the same group of investigators developed histology subtype-specific nomograms for patients with liposarcoma, synovial sarcoma, and GIST⁷² and demonstrated that they were accurate in predicting disease-specific survival. Other investigators have just developed a site-specific nomogram for patients with retroperitoneal sarcoma, demonstrating an accurate prediction of survival and disease recurrence.⁷³

TREATMENT OF EXTREMITY AND TRUNK WALL SARCOMA

The goals of treatment of soft tissue sarcoma are to maximize the likelihood of long-term recurrence-free survival while minimizing morbidity and maximizing function. In the past two decades, a multimodality treatment approach with optimal sequencing of treatments for individual patients has been shown to improve survival.⁷⁴ Furthermore, patients with soft tissue sarcoma treated at high-volume centers have been shown to have improved survival and functional outcomes.⁷⁵ Care at such centers is particularly important for patients with high-risk and advanced disease.

The overall 5-year survival rate for patients with all stages of soft tissue sarcoma is 50% to 60%. For patients with extremity sarcomas, a multidisciplinary treatment approach has resulted in local control rates exceeding 90% and 5-year survival rates exceeding 70%. Most patients who die of soft tissue sarcoma die of metastatic disease, which becomes evident within 2 to 3 years of initial diagnosis in 80% of cases.

Recommendations for evaluation and treatment of patients presenting with soft tissue masses are summarized in Table 36-3.

Surgery

Primary tumors with no evidence of distant metastasis are managed with surgery alone or, when wide pathologic margins

Table 36-3

Recommendations for the management of soft tissue masses

1. Soft tissue tumors that are enlarging or greater than 3 cm should be evaluated with radiologic imaging (ultrasonography or computed tomography [CT]), and a tissue diagnosis should be made using core needle biopsy.
2. Once a sarcoma diagnosis is established, obtain imaging (magnetic resonance imaging for extremity lesions and CT for other anatomic locations) and evaluate for metastatic disease with chest CT for intermediate- or high-grade (grade 2 or 3) or large (T2) tumors.
3. A wide local excision with 1- to 2-cm margins is adequate therapy for low-grade lesions and T1 tumors.
4. Radiation therapy plays a critical role in the management of large (T2), intermediate- or high-grade tumors.
5. Patients with locally advanced high-grade sarcomas or distant metastases should be evaluated for chemotherapy.
6. An aggressive surgical approach should be taken in the treatment of patients with an isolated local recurrence or resectable distant metastases.

cannot be achieved because of anatomic constraints and/or the grade is high, surgery plus radiation therapy. The type of surgical resection is determined by several factors, including tumor location, tumor size, depth of invasion, involvement of nearby structures, need for skin grafting or autogenous tissue reconstruction, and the patient's performance status. In 1985, the National Institutes of Health developed a consensus statement recommending limb-sparing surgery for most patients with high-grade extremity sarcomas.⁷⁶ However, for patients with primary or recurrent tumors that cannot be grossly resected with a limb-sparing procedure and preservation of function (<5% of patients), amputation remains the treatment of choice.

Margin status after surgical resection has been shown to be an independent prognostic factor.^{77,78} The goal of surgical resection is to achieve a complete resection because microscopically positive or grossly positive resection margins are associated with increased risk of local recurrence and death.⁷⁹ If an unexpected positive margin is found on pathologic examination of the resection specimen, re-excision should be performed. In patients with a positive margin, particularly in patients with macroscopic residual disease, local control is unlikely even with the addition of postoperative radiation therapy.⁸⁰

Wide Local Excision. The preferred treatment for extremity sarcomas is wide local excision that includes resection of the biopsy site. The goal of wide local excision is to remove the tumor with approximately 1 to 2 cm of surrounding normal soft tissue,⁷⁷ but narrower margins may be necessary to preserve uninvolved critical neurovascular structures and may be adequate for patients undergoing radiation therapy.⁸¹ Dissection should proceed through grossly normal tissue planes not abutting the tumor. Soft tissue sarcomas are generally surrounded by a zone of compressed reactive tissue that forms a pseudocapsule, but this pseudocapsule should not be used to guide resection (enucleation). If the tumor is adjacent to or displacing major neurovascular structures, these do not need to be resected, but the adventitia or perineurium should be removed.¹ For some massive tumors of the extremities, wide local excision entails a

radical or complete anatomic compartment resection. Surgical clips should be placed to delineate the extent of the resection bed for patients likely to require postoperative radiation therapy.

Recent reports demonstrate encouraging results following radical en bloc resection with vascular reconstruction in the lower extremities.^{82,83} While en bloc resection with vascular reconstruction has been associated with increased rates of postoperative complications, reported local recurrence and 5-year survival rates are similar to those for patients not requiring vessel resection.^{84,85} Similarly, studies have shown acceptable functional outcomes with resection of the sciatic, tibial, and peroneal nerves with appropriate reconstruction and rehabilitation.⁸⁶

Bone invasion from extremity soft tissue sarcoma, which can generally be identified using high-quality cross-sectional imaging such as MRI, has been estimated to occur in about 5% of patients and is associated with reduced overall survival.⁸⁷ In cases of bone invasion, bone resection is required to obtain an adequate surgical margin and to achieve local control. Although tumor resection and repair of skeletal defects are possible, the likelihood of postoperative complications may be increased, and functional outcomes may be less favorable. Lin and colleagues⁸⁸ recently analyzed 55 patients with soft tissue sarcomas abutting bone and reported that in the absence of frank cortical bone penetration, periosteum was an adequate surgical margin in patients treated with wide local excision and radiation.

Soft tissue sarcomas arising in the distal extremities, particularly the hands and feet, present unique technical challenges. While distal-extremity tumors are often detected at a smaller size (<5 cm) than proximal-extremity tumors, resection and reconstruction techniques are often more complex for distal-extremity tumors, and preoperative planning is critical to obtain favorable functional outcomes. Identifying the proximity of the tumor to underlying critical structures (e.g., bone, tendon, or neurovascular structures) using MRI is essential for surgical planning. In a reported series of patients with sarcomas of the hands or feet treated with limited surgery only, 32% of patients had local recurrences.⁸⁹ Preservation of function and acceptable recurrence rates with limited surgery and adjuvant radiation therapy for soft tissue sarcomas of the distal extremities have been reported.⁹⁰ For locally advanced tumors, repair of bone defects, vascular reconstruction, tendon transfers, and soft tissue reconstruction using regional or free flaps have resulted in good functional outcomes.⁹¹ Amputation remains a reasonable option for patients with soft tissue sarcomas of the distal extremities when acceptable oncologic or functional outcomes cannot be achieved using available limb salvage techniques.

In an interesting study conducted in Ontario and Quebec, investigators found patients expecting a difficult recovery and patients with uncertain expectations had worse functional outcomes than patients anticipating an easy recovery, indicating that preoperative education including consultation with rehabilitation services may optimize outcomes.⁹² Furthermore, all patients undergoing resection of extremity sarcomas should undergo physical therapy beginning immediately after surgery and continuing until maximum function is achieved.¹

Locoregional Lymphadenectomy. Several studies have reported improved survival for patients with isolated regional lymph node metastases treated with radical lymphadenectomy.^{27, 63-65} Patients with clinically or radiologically suspicious regional nodes should have metastases confirmed before radical lymphadenectomy. At our institution, we perform ultrasound-guided

fine-needle aspiration of lymph nodes in selected patients with suspicious clinical or radiologic findings. The utility of sentinel lymph node biopsy has remained controversial despite the recognition that several histologic subtypes of high-grade sarcoma are known to have a propensity for lymph node metastasis. However, there have been no prospective studies of the sensitivity and specificity of sentinel lymph node biopsy for such tumors.

Amputation. Amputation is the treatment of choice for the 5% of patients with primary or recurrent extremity tumors whose tumors cannot be grossly resected with limb-sparing procedures and preservation of function. Historically, local excision of large, high-grade soft tissue sarcomas resulted in local failure rates of 50% to 70%, even when a margin of normal tissue around the tumor was excised; consequently, radical resection or amputation was recommended. Today, however, the addition of radiation therapy to less radical surgical resection has made limb salvage possible in most cases.

A comparison of amputation versus limb-sparing surgery followed by adjuvant radiation therapy performed by the National Cancer Institute between 1975 and 1981 demonstrated no significant difference between the two groups in local recurrence or overall survival rate.⁹³ Potter and colleagues⁴⁹ later reviewed the entire National Cancer Institute experience with 123 patients treated with conservative surgery plus radiation therapy and 83 treated with amputation. The local recurrence rate was significantly higher in the surgery and adjuvant radiation therapy group: 8% versus 0% in the amputation group. However, survival rates did not differ between the groups. Several large single-institution studies have since also reported favorable local control rates with conservative resection plus radiation therapy.⁹⁴⁻⁹⁶

Isolated Regional Perfusion. Isolated regional perfusion is a limb-sparing technique in which a soft tissue sarcoma is perfused with high concentrations of tumor necrosis factor- α and melphalan under hyperthermic conditions. The technique is generally used for locally advanced, multifocal, or locally recurrent disease; it has also served as a palliative treatment to achieve local control for patients with distant metastases.

Limb perfusion requires isolating the main artery and vein of the perfused limb from the systemic circulation. The anatomic approach is determined by tumor site: external iliac vessels are used for thigh tumors, femoral or popliteal vessels for calf tumors, and axillary vessels for upper extremity tumors. The vessels are dissected, and all collateral vessels are ligated. The main artery and vein are then cannulated and connected to a pump oxygenator similar to that used in cardiopulmonary bypass. Either a tourniquet or an Esmarch band is applied to the limb to achieve complete vascular isolation. Chemotherapeutic agents are then added to the perfusion circuit and circulated for 90 minutes. Systemic leakage from the perfused limb is monitored continuously with ⁹⁹Tc-radiolabeled human serum albumin injected into the perfusate, and radioactivity above the precordial area is recorded with a Geiger counter. During the entire procedure, hyperthermia of the perfused limb is maintained by external heating and by warming the perfusate to 40°C. At the end of the procedure, the limb is washed out, the cannulas are extracted, and the blood vessels are repaired.

Despite the 40-year history of using isolated limb perfusion to treat extremity sarcomas, many questions about this technique remain to be answered. The optimal chemotherapeutic agent in

the perfusion circuit, the benefits of hyperthermia, and the effectiveness of hyperthermic perfusion as neoadjuvant or adjuvant treatment remain to be elucidated. Studies published to date have involved heterogeneous patient groups and various chemotherapeutic agents. Despite these limitations, response rates from 18% to 80% and overall 5-year survival rates from 50% to 70% have been reported.⁹⁷⁻¹⁰¹ However, survival outcomes following isolated limb perfusion have not yet been directly compared with survival outcomes after more conventional treatment approaches.

In the initial report of isolated regional perfusion for extremity sarcomas, published in 1974, McBride reported results in 79 patients with extremity sarcomas who had been treated with isolated limb perfusion during the previous 14 years.⁹⁷ All patients received melphalan and dactinomycin. The overall 5-year survival rate was 57%, and only 13 patients had subsequent amputation for recurrent disease. Over the next 20 years, isolated perfusion for treatment of extremity sarcoma fell out of favor for several reasons. Most notably, improved survival and decreased local recurrence rates could be obtained with less radical therapy, including conservative surgical excision combined with radiation to allow limb sparing in patients who were previously thought to require amputation.

A 1992 report by Lienard and colleagues¹⁰¹ renewed interest in isolated limb perfusion for extremity tumors. Those investigators reported a 100% response rate among patients with extremity melanomas and sarcomas treated with high-dose recombinant tumor necrosis factor- α plus interferon- γ and melphalan in an isolated perfusion circuit. This report led to larger studies geared specifically to patients with sarcoma. The largest of these studies, the European Multicenter Study, was reported by Eggermont and colleagues in 1996.⁹⁹ In that study of 186 patients, the overall tumor response rate was 82%, and the clinical and pathologic complete response rate was 29%. Although all of the study participants were reported to initially be candidates for amputation, the rate of limb salvage following isolated limb perfusion was 82%.⁹⁹ Subsequent studies have shown high local response and limb salvage rates and acceptable local and systemic toxic effects.¹⁰²

However, results in the United States have been inferior to those reported in Europe. In a study by Fraker and colleagues, the complete response rate was 26%, and an additional 30% of patients had a partial response. Fourteen patients (32%) underwent amputation for progressive tumors, while the remaining 30 patients (68%) were able to undergo limb-sparing surgery after isolated limb perfusion.¹⁰⁰ The inferior results in the U.S.-based studies are thought to be due to patient selection biases and the degree of treatment before limb perfusion.

Radiation Therapy

Radiation therapy is part of the standard treatment for high-grade extremity and trunk wall soft tissue sarcomas either in the pre- or postoperative setting. Patients with low-grade tumors or small, superficial high-grade tumors that have been resected with adequate margins may safely avoid radiation therapy.

The evidence supporting adjuvant radiation therapy for patients eligible for conservative surgical resection comes from two randomized trials^{103,104} and three large single-institution reports.¹⁰⁵⁻¹⁰⁷ In a randomized trial by the National Cancer Institute, 91 patients with high-grade extremity tumors were treated with limb-sparing surgery followed by chemotherapy alone or radiation therapy plus chemotherapy. The 10-year local control rate was 98% for patients receiving radiation

therapy compared with 70% for those not receiving radiation therapy ($P = .0001$).¹⁰³ Similarly, in a randomized trial from Memorial Sloan-Kettering Cancer Center, 164 patients underwent conservative surgery followed by observation or brachytherapy. For patients with high-grade tumors, the 5-year local control rate was 66% in the observation group and 89% in the brachytherapy group ($P = .003$).¹⁰⁴ For patients with low-grade tumors, no significant difference was observed between treatment groups.¹⁰⁸

Until recently, the standard treatment guidelines required radiation therapy after surgery for all patients with intermediate- or high-grade tumors of any size. However, small tumors (≤ 5 cm) have not generally been associated with local recurrence, and radiation therapy for such tumors may not be necessary.¹⁰⁴ In a series of 174 patients reported by Geer and colleagues, postoperative radiation therapy did not improve 5-year local recurrence or overall survival rates for patients with small soft tissue sarcomas.¹⁰⁹ Karakousis and colleagues reported a 5-year local recurrence rate of 6% for 80 patients with extremity sarcomas treated with wide local excision and observation, a rate similar to that for the 64 patients who underwent resection with narrower surgical margins and postoperative radiation therapy.¹¹⁰

The optimal mode of radiation therapy (external-beam radiation therapy, brachytherapy, or intensity-modulated radiation therapy [IMRT]) and timing of radiation therapy (preoperative, intraoperative, or postoperative) have yet to be defined. External-beam radiation therapy can be delivered using photons or particle beams (electrons, protons, pions, or neutrons). Conventional fractionation is usually 1.8 to 2 Gy per day. CT is an integral part of radiation therapy, used to define the gross tumor volume and to estimate the margin of tissue at risk for microscopic tumor involvement. The optimal radiation margin is not well defined: a margin of 5 to 7 cm is standard, but some centers advocate wider margins for tumors larger than 15 cm. At most institutions, the typical *preoperative* dose is 50 Gy given in 25 fractions, and resection is performed 4 to 8 weeks after completion of radiation therapy to allow acute radiation changes to subside. *Postoperative* radiation therapy planning is based on tumor site, tumor grade, surgical margins, and institutional preferences. The entire surgical scar and drain sites should be included in the field so that a near-full dose can be administered to the superficial skin. Metallic clips placed in the tumor bed during surgery can help define the limits of the resection and aid in radiation therapy planning. Doses of 60 to 70 Gy are usually necessary for postoperative treatment.

No consensus exists on the optimal sequence of radiation therapy and surgery. The available data come largely from single-institution, nonrandomized studies. Proponents of preoperative radiation therapy note that multidisciplinary planning with radiation oncologists, medical oncologists, and surgeons is easier early in the course of therapy. In addition, for some radiosensitive histologic subtypes, such as myxoid liposarcoma, preoperative radiation therapy may shrink the tumor, facilitating resection with negative margins. Furthermore, a tissue bed undisturbed by resection has better tissue oxygenation and can be successfully treated with lower doses of radiation. In addition, Nielsen and colleagues¹¹¹ demonstrated that preoperative radiation fields are smaller than postoperative radiation fields and that the average number of joints included in the field is lower with preoperative than postoperative radiation therapy, which may result in improved functional outcome. Critics of preoperative radiation therapy cite the difficulty of pathologic

assessment of margins and the increased rate of postoperative wound complications.¹¹² However, reconstructive surgical techniques with advanced tissue transfer procedures are being used more often in these high-risk wounds and reportedly result in better outcomes. The higher doses generally required for postoperative radiation therapy have also been shown to be associated with greater long-term functional impairment.

The only randomized comparison of preoperative and postoperative radiation therapy to date was performed by the National Cancer Institute of Canada Clinical Trials–Canadian Sarcoma Group.¹¹³ This trial was designed to examine complications and functional outcome. The 190 patients enrolled from October 1994 to December 1997 were randomized to preoperative radiation therapy (50 Gy) or postoperative radiation therapy (66 Gy). With a median follow-up time of 3.3 years, the recurrence and progression-free survival rates were similar in the two groups. However, the incidence of wound complications was significantly lower with preoperative radiation therapy (3% vs. 17%), and the incidence of wound complications was significantly higher for tumors of the lower extremity (43%) than for those of the upper extremity (5%).¹¹³ Late radiation toxic effects (e.g., fibrosis, joint stiffness, and edema) were more common with postoperative than preoperative radiation therapy (48% vs. 32%) because of higher postoperative radiation doses and larger treatment field sizes.¹¹⁴

Brachytherapy involves the placement of multiple radioactive seeds through catheters inserted in the tumor resection bed. The primary benefit of brachytherapy is the shorter overall treatment time of 4 to 6 days, compared to the 4 to 6 weeks generally required for preoperative or postoperative radiation therapy regimens. A cost-analysis comparison of adjuvant brachytherapy versus adjuvant external-beam irradiation for soft tissue sarcomas showed that costs were lower with brachytherapy.¹¹⁵ Brachytherapy can also be used for recurrent disease previously treated with external-beam radiation. Guidelines established at Memorial Sloan-Kettering Cancer Center recommend spacing the afterloading catheters in 1-cm increments while leaving a 2-cm margin around the surgical bed.¹⁰⁴ After adequate wound healing is confirmed, usually after the fifth postoperative day, the catheters are loaded with seeds containing iridium-192 that deliver 42 to 45 Gy of radiation to the tumor bed over 4 to 6 days. The primary disadvantage of brachytherapy is that it requires significant expertise, extended inpatient hospital stays, and bed rest.

IMRT delivers radiation more precisely to the tumor than external-beam irradiation while minimizing the volume of surrounding tissues exposed to high radiation doses. The proposed benefits of preoperative IMRT include reduced risk of postoperative wound infections because of minimization of the dose to the skin¹¹⁶ and protection of underlying bone (e.g., femur) as a result of concave dose distributions.¹¹⁷ There have been no prospective randomized trials comparing the long-term outcomes following IMRT versus other types of radiation therapy. In a retrospective analysis of IMRT, patients with negative and positive/close (within 1 mm) margins were found to have 5-year local control rates of 94%.¹¹⁸ In addition, the rates of posttreatment edema and joint stiffness with IMRT were lower than the expected rates with conventional radiation therapy.

Local toxic effects of radiation therapy vary according to radiation dose, field size, and timing (preoperative or postoperative). With preoperative radiation therapy, the most frequent wound complications are wound dehiscence, wound necrosis,

persistent drainage, infection, seroma formation, ulceration, and cellulitis.¹¹³ Postoperative irradiation of free flaps is often associated with wound complications, and patients should be advised that secondary surgical repair may be necessary. Wound complication rates of 13% to 37% have been reported for preoperative radiation therapy, compared to 5% to 20% for postoperative radiation therapy.¹¹⁹ If catheters are loaded after the fifth postoperative day, rates of wound complications after brachytherapy are similar to those after postoperative radiation therapy.

Long-term (chronic) effects of radiation therapy (those occurring >1 year after completion of therapy) are generally related to fibrosis/contractures, lymphedema, neurologic injury, osteitis, and fractures, all of which can cause substantial functional impairment.¹¹⁹ Variables associated with poorer functional outcome after radiation therapy include larger tumors, higher doses of radiation (>63 Gy), longer radiation fields (>35 cm), poor radiation technique, neural sacrifice, postoperative fractures, and wound complications.^{114,120} Additionally, complications of any kind are less likely after treatment for upper extremity sarcoma than after treatment for lower extremity sarcoma.^{112,113}

Definitive radiation therapy that delivers maximal-tissue-tolerance doses of radiation may be appropriate for selected patients with unresectable soft tissue sarcomas. In a study of 112 patients with unresectable soft tissue sarcomas, tumor size and radiation dose were found to influence local control and survival.¹²¹ The local control rate was 51% for tumors smaller than 5 cm and 9% for tumors larger than 10 cm, and patients who received at least 64 Gy had better local control and survival.

Systemic Therapy

Despite improvements in local control rates, metastasis and death remain significant problems for patients with high-risk soft tissue sarcomas. Patients considered at high risk of death from sarcoma include those presenting with metastatic disease, localized sarcomas at nonextremity sites, or sarcomas of intermediate- or high-grade histology larger than 5 cm.^{58,104}

Standard Chemotherapy. For most patients with sarcoma, results of conventional chemotherapy regimens have been poor. The chemosensitivity of soft tissue sarcoma varies by histologic subtype.²⁹ Synovial sarcoma, myxoid/round cell liposarcoma, and uterine leiomyosarcoma are sensitive to chemotherapy,¹²² whereas pleomorphic liposarcoma, myxofibrosarcoma, epithelioid sarcoma, leiomyosarcoma, MPNSTs, angiosarcoma, and desmoplastic round cell tumors have intermediate sensitivity to chemotherapy. Relatively chemoresistant histologic subtypes include clear cell sarcoma, endometrial stromal sarcoma, alveolar soft part sarcoma, and extraskeletal myxoid chondrosarcoma. Considering the variability of responses by histologic subtype, it is not surprising that clinical trials of standard chemotherapy, which often include heterogeneous populations with respect to tumor grade and histology, have demonstrated no overall survival benefit.

Doxorubicin and ifosfamide are the two most active agents against soft tissue sarcoma, with consistently reported response rates of 20% or greater and positive dose-response curves.^{123,124} The European guidelines recommend doxorubicin 75 mg/m² every 3 weeks as first-line treatment for advanced disease.²⁹ Treatment duration is based on response, but a maximum of six cycles is generally recommended because of the risk of cumulative cardiotoxicity. Ifosfamide is the recommended second-line treatment and is recommended for first-line treatment in patients

with cardiac morbidity. The standard dose of ifosfamide is 9 to 10 g/m²; however, single-institution series using higher-dose regimens (>10 g/m²) or standard-dose ifosfamide combined with doxorubicin have shown response rates of 20% to 60%.¹²⁴ Synovial sarcomas have been shown to be particularly sensitive to ifosfamide. Ifosfamide-associated toxic effects include hemorrhagic cystitis, neurotoxicity, and renal tubular acidosis. Historically, combination therapy with doxorubicin plus ifosfamide, dacarbazine, or both has resulted in increased response rates but no improvement in overall survival.¹²⁵ Dacarbazine as a single agent has also demonstrated activity in clinical trials.

Over the past decade, several additional chemotherapeutic agents, including gemcitabine, taxanes, and trabectedin, have been noted to be active against soft tissue sarcomas. Gemcitabine as a single agent was reported to produce responses in 18% of patients with advanced sarcoma.¹²⁶ Gemcitabine combined with docetaxel has been reported to produce response rates as high as 53% in patients with uterine leiomyosarcoma.^{126,127} Gemcitabine combined with vinorelbine has also been associated with clinical benefit in patients with advanced sarcomas.¹²⁸ The taxanes (docetaxel and paclitaxel) have been found to be active against angiosarcomas, particularly of the face and scalp, likely because of their potent antiangiogenic effects.^{129,130}

Novel Chemotherapeutic Agents. Trabectedin, a marine-derived alkaloid that binds DNA, affecting transcription and inducing the formation of DNA double-strand breaks, has shown benefit in the treatment of advanced soft tissue sarcomas, particularly leiomyosarcoma, myxoid liposarcoma, and other translocation-related sarcomas.¹³¹ Trabectedin is generally well tolerated but can be associated with prolonged and severe neutropenia, thrombocytopenia, and hepatic toxic effects.

Palifosfamide is a stabilized formulation of the active metabolite of ifosfamide that has been reported to be better tolerated than ifosfamide.¹³² Early trials have suggested antitumor activity comparable or superior to that of ifosfamide without nephrotoxicity.

Targeted Therapies. Several targeted agents are being investigated for the treatment of soft tissue sarcomas. Among these are tyrosine kinase inhibitors (e.g., imatinib, sunitinib, sorafenib, and dasatinib) that have been developed and approved for treatment of GIST. Clinical data accumulated in phase II trials also support the use of tyrosine kinase inhibitors (e.g., imatinib, sorafenib, and sunitinib) in the management of other advanced sarcomas.¹²⁵ Anti-vascular endothelial growth factor antibodies such as bevacizumab have demonstrated activity in patients with metastatic or unresectable angiosarcoma, solitary fibrous tumor, and epithelioid hemangioendothelioma.¹³³ Pazopanib is an oral angiogenesis inhibitor that targets vascular endothelial growth factor receptors, platelet-derived growth factor receptor (PDGFR), and c-kit. In a recent phase III study, pazopanib showed efficacy against placebo in second or further line of therapy in patients with advanced soft tissue sarcoma.¹³⁴ Inhibitors of the mammalian target of rapamycin pathway, including temsirolimus, everolimus, and ridaforolimus, have also shown activity against some soft tissue sarcomas (i.e., PEComas).¹³⁵

Benefits of Systemic Therapy. The use of adjuvant and neoadjuvant chemotherapy for soft tissue sarcomas remains controversial. More than a dozen individual randomized trials of adjuvant chemotherapy have failed to demonstrate improvement in disease-free or overall survival for patients with soft tissue sarcoma. However, several limitations of these individual

trials may explain the lack of observed improvement. First, the chemotherapy regimens used were suboptimal, consisting of single-agent therapy (most commonly with doxorubicin) and insufficiently intensive dosing schedules. Second, the patient groups were not large enough to reveal clinically significant differences in survival rates. Finally, most studies included patients at low risk of metastasis and death, namely those with small (<5 cm) and low-grade tumors.

The Sarcoma Meta-Analysis Collaboration analyzed 1568 patients from 14 trials of doxorubicin-based adjuvant chemotherapy to evaluate the effect of adjuvant chemotherapy on localized, resectable soft tissue sarcomas.¹³⁶ At a median follow-up time of 9.4 years, doxorubicin-based chemotherapy significantly improved the time to local and distant recurrence and recurrence-free survival rates. However, the absolute benefit in overall survival was only 4%, which was not significant ($P = .12$). In a subset analysis, patients with extremity tumors had a 7% benefit in terms of overall survival ($P = .029$).¹³⁶

After this meta-analysis, randomized controlled trials of more contemporary anthracycline/ifosfamide dosing combinations with relatively small numbers of patients have yielded conflicting results. In an Italian cooperative trial, adjuvant chemotherapy improved median disease-free and overall survival times in patients with high-risk extremity soft tissue sarcomas.¹³⁷ In that study, 104 patients with high-grade tumors 5 cm or larger were randomized to definitive surgery or surgery plus adjuvant chemotherapy consisting of epirubicin (60 mg/m²/d on days 1 and 2) and ifosfamide (1.8 g/m²/d on days 1 through 5) for five cycles. With a median follow-up time of almost 5 years, disease-free survival times were 16 months in the surgery-alone group and 48 months in the combined-treatment group ($P = .04$), and median overall survival times were 46 months in the surgery-alone group and 75 months in the combined-treatment group ($P = .03$).¹³⁷ However, several years later, the surgery-alone and combined-treatment groups had equivalent relapse rates and deaths, which resulted in statistically similar overall survival.¹³⁸

In an effort to further assess the role of chemotherapy in patients with stage III extremity sarcoma, a cohort analysis of the combined databases of The University of Texas MD Anderson Cancer Center and Memorial Sloan-Kettering Cancer Center was performed. Data on 674 patients with stage III extremity sarcoma who received either preoperative or postoperative doxorubicin-based chemotherapy were reviewed. The 5-year disease-specific survival rate was 61%.¹³⁹ Cox regression analysis showed a time-varying effect of chemotherapy with an associated benefit during the first year while receiving chemotherapy. However, the clinical benefits of chemotherapy in patients with stage III sarcomas were not sustained beyond 1 year. Grobmyer and colleagues compared the outcomes of patients treated at two institutions (1990–2001) with surgery only or surgery plus preoperative chemotherapy containing doxorubicin and ifosfamide. In this analysis, chemotherapy was associated with an improvement in the 3-year disease-specific survival rate that was most pronounced in patients with tumors larger than 10 cm (62% for surgery alone vs. 83% for neoadjuvant chemotherapy and surgery).¹⁴⁰

More recently, the European Organization for Research and Treatment of Cancer (EORTC) completed a phase III randomized study (trial EORTC-62931; conducted from 1995 through 2003) comparing surgery alone versus surgery plus adjuvant ifosfamide (5 g/m²) plus doxorubicin (75 mg/m²) with growth factor support (lenograstim) every 21 days for five

cycles in 351 patients with resected grade II or III soft tissue sarcoma at any site. The estimated relapse-free survival rate was 52% in both arms, and the overall survival rate was better in the control arm (69% vs. 64%).¹⁴¹ Although most individual studies are underpowered, data from all of these studies suggest that chemotherapy regimens that incorporate ifosfamide may provide some disease-free survival benefit but do not improve long-term overall survival for the majority of patients with soft tissue sarcoma.

In 2008, two updates to the 1997 Sarcoma Meta-Analysis Collaboration were published.^{142,143} O'Connor and colleagues included all of the trials in the original meta-analysis and added data from four additional trials, for a total of 18 trials with 2170 patients.¹⁴² The results showed a benefit of chemotherapy in terms of disease-free survival at 5 years and recurrence-free survival at 10 years but again failed to demonstrate a benefit in terms of long-term overall survival. The second update, by Pervaiz and colleagues, which did not include the EORTC-62931 trial, showed that adjuvant chemotherapy was associated with a significant decrease in the risk of death (hazard ratio, 0.77; $P = .01$).¹⁴³

Because the evidence regarding adjuvant systemic therapy for stage III soft tissue sarcoma is inconclusive, considerable variation still exists in treatment recommendations even though patients with large, stage II or stage III soft tissue sarcomas are at high risk for recurrence and metastasis. Chemotherapy may be considered to downstage large tumors to enable limb-sparing procedures, particularly for tumors known to be chemosensitive. It is likely that subsets of high-risk patients with extremity soft tissue sarcoma defined on the basis of tumor size or histology derive significant benefit from systemic chemotherapy. For example, retrospective cohort analyses have noted a disease-specific survival benefit in patients with large, high-grade liposarcomas and synovial sarcomas of the extremity treated with ifosfamide plus doxorubicin versus no chemotherapy.¹⁴⁴

Neoadjuvant (Preoperative) Chemotherapy. The use of neoadjuvant (preoperative) chemotherapy for soft tissue sarcomas is based on the belief that only 30% to 50% of patients respond to standard adjuvant (postoperative) chemotherapy. The rationale for using neoadjuvant chemotherapy is that it enables oncologists to identify patients whose disease is sensitive to a particular chemotherapy regimen by assessing response while the primary tumor is in situ. Patients whose tumors do not respond to short courses of neoadjuvant chemotherapy can thus be spared the toxic effects of prolonged adjuvant chemotherapy. Another advantage of neoadjuvant chemotherapy is that it may shrink tumors, enabling less morbid operations. The theoretical disadvantages of neoadjuvant chemotherapy are related to myelosuppression and potential postoperative wound healing complications.

A recent randomized study comparing three preoperative cycles of full-dose anthracycline-ifosfamide-based chemotherapy with three preoperative plus two postoperative cycles of the same regimen in high-risk extremity and trunk wall soft tissue sarcomas showed equivalence between the two approaches, suggesting the possibility of limiting chemotherapy administration to the three preoperative courses, improving the ratio between toxicity and expected benefit.¹⁴⁵

A subanalysis on response showed how tumor attenuation on CT scan and MRI obtained by the administration of such preoperative treatment was associated with a higher percentage of pathologic necrosis¹⁴⁶ and better outcome.¹⁴⁷

Eilber and colleagues examined treatment-induced pathologic necrosis in patients who received neoadjuvant therapy for high-grade extremity sarcomas.¹⁴⁸ The addition of ifosfamide to other agents (doxorubicin alone or doxorubicin and cisplatin) increased the rate of pathologic necrosis to 48% compared to 13% with other combinations. The 5- and 10-year local recurrence rates were significantly lower for patients with 95% or greater pathologic necrosis (6% and 11%, respectively) than for patients with less than 95% pathologic necrosis (17% and 23%, respectively).

Concurrent Chemoradiation Therapy

Treatment approaches that combine systemic chemotherapy with radiosensitizers and concurrent external-beam radiation therapy may improve disease-free survival by treating microscopic disease and enhancing the treatment of macroscopic disease. Concurrent chemoradiation therapy with doxorubicin-based regimens reportedly produces favorable local control rates for patients with sarcoma.¹⁴⁴ Since those findings were published, several groups have evaluated routes of administration, alternative chemotherapeutic agents, and the toxicity of combined therapies.

Theoretical advantages notwithstanding, concurrent chemoradiation therapy decreases the total treatment time for patients with high-risk sarcoma. This decrease represents a substantial advantage over current sequential combined-modality treatment approaches, for which the total duration of radiation therapy, chemotherapy, surgery, and rehabilitation frequently exceeds 6 to 9 months.

Posttreatment Surveillance

Currently, posttreatment surveillance is recommended for all patients with soft tissue sarcomas based on a few reports involving small numbers of patients indicating that local recurrence can be successfully treated with radical re-excision with or without radiation therapy.^{149,150} Similarly, several groups have reported that survival can be prolonged by resection of pulmonary metastases.^{151,152}

The National Comprehensive Cancer Network (NCCN) recommends a history and physical and chest CT or radiography every 3 to 6 months for 2 to 3 years after completion of treatment. Because most cases of distant metastasis occur within 2 to 3 years of initial diagnosis, the NCCN guidelines indicate that follow-up intervals can be lengthened to every 6 months and imaging can be done annually during years 2 through 5.¹ Consideration should also be given to imaging the primary tumor site; most experts recommend that the tumor site be evaluated every 6 months with MRI for extremity tumors or CT for intra-abdominal or retroperitoneal tumors. Guidelines have been established for using MRI to distinguish recurrences from typical postsurgical changes: a discrete nodule with low signal intensity on T1-weighted images and higher signal intensity on T2-weighted images that enhances after administration of intravenous contrast material is strongly suggestive of recurrence and should be biopsied. Ultrasonography may be an alternative to MRI or CT for assessing for recurrence in the extremities.

Recurrence is common after surgery for abdominal soft tissue sarcomas. CT is useful for detecting recurrences at primary and distant anatomic sites in the abdomen and pelvis. After surgery, CT every 3 to 6 months during the first 2 years and every 6 months for 3 years thereafter has been recommended. However, today many experienced surgeons are advocating less aggressive imaging for asymptomatic patients, particularly

after a second recurrence of retroperitoneal sarcoma, arguing that there is insufficient evidence to suggest that survival is improved by earlier detection.

Whooley and colleagues reviewed the efficacy of the surveillance strategy used at Roswell Park Cancer Institute for 174 patients with soft tissue sarcomas of the extremities.¹⁵³ Patients were evaluated every 3 months for the first 2 years, every 4 to 6 months during year 3, and every 6 months during years 4 and 5. Local recurrence occurred in 18% of patients at a median time after completion of treatment of 14 months, and all but one of the recurrences were detected with physical examination alone. Fifty-seven patients had distant recurrences (at a median of 18 months after treatment), of which 36 were asymptomatic and diagnosed by surveillance imaging. The investigators determined that the positive predictive value of chest radiography during follow-up was 92%.¹⁵³ However, evaluation of the primary tumor site by CT or MRI was ineffective in detecting recurrences. The authors recommended that patient characteristics, location of the primary tumor, previous treatment, and physician familiarity with changes after surgery and radiation therapy should all be considered in determining the need for radiographic imaging.

Management of Recurrent Sarcoma

Up to 20% of patients with extremity sarcoma develop locally recurrent disease, which is often accompanied by distant metastases; thus, all patients with recurrent extremity sarcoma should undergo a full staging assessment. Patients with microscopically positive surgical margins are at increased risk of local recurrence. In a series of 179 patients with locally recurrent extremity soft tissue sarcoma at Memorial Sloan-Kettering Cancer Center, the median interval to local recurrence was 16 months; 65% of patients developed a local recurrence by 2 years, and 90% by 4 years.¹⁴⁹ The majority of patients (89%) were treated with additional limb-sparing surgery, and 73% received additional adjuvant therapy; the disease-specific survival after treatment of first local recurrence was 55% at 4 years. Independent prognostic factors for disease-specific survival after local recurrence included tumor grade, local recurrence size, and local recurrence-free interval. These data indicate that an isolated local recurrence should be treated aggressively with resection with negative margins.

For patients with extremity sarcomas, achieving negative margins on resection of recurrent disease frequently requires amputation. However, in some patients with recurrent extremity sarcoma, function-preserving resection combined with additional radiation therapy, with or without chemotherapy, can produce acceptable rates of local control.¹⁵⁴⁻¹⁵⁶ Nori and colleagues reported a local control rate of 69% among 40 patients with recurrent tumors treated with re-excision and brachytherapy to a median dose of 45 Gy.¹⁵⁶ In a similar series, Midis and colleagues reported that limb-sparing surgery was possible in 66% of patients, and the 5-year local recurrence-free survival rate was 72% in those patients.¹⁵⁴

The primary determinant of survival in patients with soft tissue sarcoma is the development of distant metastases. Patients with extremity sarcomas generally develop pulmonary metastases.¹⁵³ Less common sites of metastasis for soft tissue sarcomas include bone (7%), liver (4%),⁴⁹ and lymph nodes (5%–7%).²⁷ Myxoid liposarcoma of the extremity is known to metastasize to the abdomen and pelvis; therefore, staging CT of these regions must be performed before definitive local therapy is administered.³¹

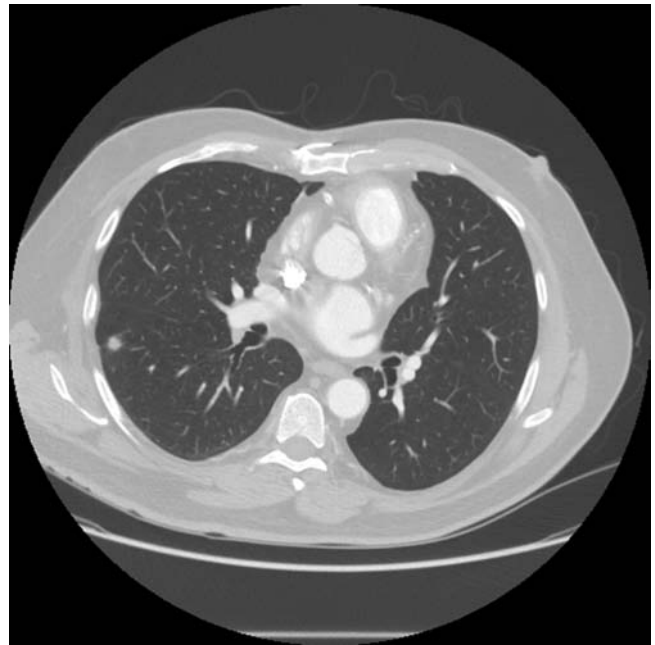


Figure 36-8. A 69-year-old patient with a history of a dedifferentiated liposarcoma of the retroperitoneum developed a solitary lung metastasis 6 years after surgical resection.

Management of Recurrent and Distant Metastatic Sarcoma.

In selected individuals with distant metastatic disease, surgical resection of a primary soft tissue sarcoma may be appropriate as a palliative procedure. The decision should be based on the patient's symptoms, which often include pain; ability to achieve local tumor control; comorbidities; anticipated morbidity of the surgical procedure; and the extent of metastases.

The most common initial site of distant metastasis of soft tissue sarcomas is the lung. Selected patients with a limited number of pulmonary nodules (less than four nodules), long disease-free intervals, and no endobronchial invasion may become long-term survivors after pulmonary resection (Fig. 36-8); 15% to 40% of patients with complete resection of metastatic disease confined to the lung are long-term survivors.^{153,157} In a retrospective multi-institutional study of 255 patients with lung metastases, the 5-year overall survival rate after metastasectomy was 38%.¹⁵¹ Favorable prognostic factors in that study included microscopically tumor-free margins, age younger than 40 years, and grade 1 or 2 tumor.¹⁵¹ For patients who are surgical candidates, pulmonary resection alone can be more cost-effective than watchful waiting, chemotherapy, or chemotherapy plus surgery.¹⁵²

Chemotherapy for Distant Metastatic Sarcoma.

Doxorubicin, either alone or combined with other agents, has been the primary treatment modality for patients with advanced or distant metastatic sarcomas for several decades.¹²⁵ Although most patients with metastatic disease are not curable, some patients with limited disease experience stabilization of disease with multidisciplinary treatment, which often includes surgery and radiation therapy in addition to chemotherapy. Several factors predict better outcome for patients with recurrent metastatic sarcoma undergoing chemotherapy, including good performance status, previous response to chemotherapy, younger age, absence of hepatic metastases, low-grade tumor, and long disease-free interval.¹⁵⁸ Isolated liver metastases, if stable over several months, may be amenable to resection,¹⁵⁹ radiofrequency ablation,¹⁶⁰ or chemoembolization.¹⁶¹

As data accumulate regarding the sensitivity of sarcoma subtypes to particular chemotherapies, it is critical that histology-driven treatment approaches be used. New therapies are also being identified based on the unique molecular signatures of sarcomas.¹²⁵

Palliative Radiation Therapy. Definitive radiation therapy can be considered when no acceptable surgical option is available (e.g., in patients with significant medical comorbidities). In this setting, radiation doses greater than 63 Gy yielded superior tumor control, but doses greater than 68 Gy resulted in increased rates of major complications.¹⁶²

SPECIAL CLINICAL SITUATIONS

Myxoid Liposarcoma

Myxoid liposarcomas belong to the group of soft tissue sarcomas with lipomatous differentiation. However, myxoid liposarcomas differ from the other liposarcoma subtypes with respect to morphology (i.e., myxoid stroma and lipomatous differentiation) and clinical behavior. Myxoid liposarcomas frequently present as slow-growing, deep tumors in the lower extremity and can metastasize to other soft tissue locations, including the retroperitoneum and extremities.^{163,164} For this reason, CT of the chest, abdomen, and pelvis is recommended for adequate staging and surveillance of myxoid liposarcoma.

Retroperitoneal Sarcoma

Most retroperitoneal tumors are malignant, and about one third are soft tissue sarcomas. Also to be considered in the differential diagnosis of a retroperitoneal tumor are primary germ cell tumors, lymphoma, and metastatic testicular cancer. Approximately 1000 new cases of retroperitoneal sarcoma are diagnosed annually in the United States, and these tumors account for 10% to 15% of all adult tissue sarcomas. Approximately two thirds of retroperitoneal sarcomas are high grade (either grade 2 or 3), and liposarcoma and leiomyosarcoma are the most common histologies.

Retroperitoneal sarcomas generally present as large masses: 70% are larger than 10 cm at diagnosis.¹⁶⁵ They typically do not produce symptoms until they grow large enough to compress or invade contiguous structures, although pain, early satiety, and obstructive gastrointestinal symptoms may occur early in the disease course in some patients. Evaluation of a patient with a retroperitoneal mass begins with an accurate history that should exclude signs and symptoms associated with lymphoma (e.g., fever and night sweats). A complete physical examination, with particular attention to all nodal basins and with a testicular examination in men, is critically important. Laboratory assessment can be helpful; elevated lactate dehydrogenase levels may suggest lymphoma, and elevated β -human chorionic gonadotropin levels or α -fetoprotein levels may indicate a germ cell tumor.

Although the general principles of evaluation and management for retroperitoneal sarcomas are similar to those for extremity sarcomas, there are some differences. Contrast-enhanced CT of the abdomen and pelvis is used to define the extent of the tumor and its relationship to surrounding structures, particularly vascular structures, for surgical planning; contrast-enhanced CT can also often distinguish between well-differentiated and dedifferentiated liposarcoma. CT imaging is also done to evaluate the liver for the evidence of metastases, the peritoneal cavity for evidence of discontinuous disease, and

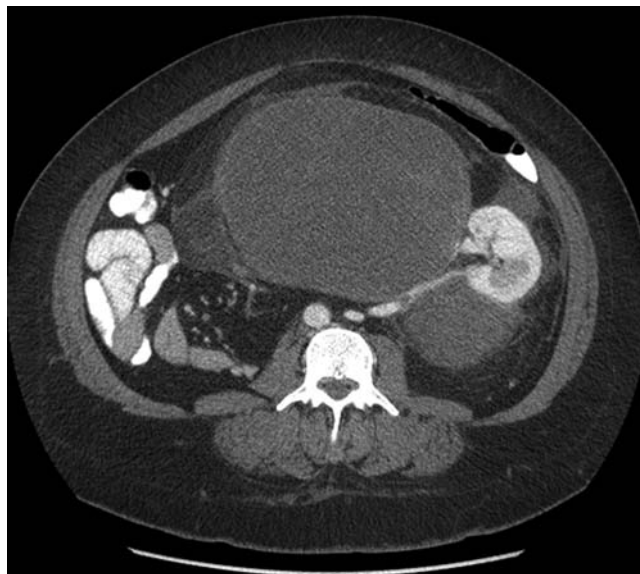


Figure 36-9. A 45-year-old woman with a massive retroperitoneal atypical lipomatous tumor with displacement of the left kidney.

the kidneys for assessment of function. Angiography or magnetic resonance arteriography/venography can also be used to delineate vascular anatomy when involvement of critical vascular structures is suspected. Thoracic CT should be performed to evaluate for potential lung metastases because 11% of patients with retroperitoneal sarcoma present with synchronous metastatic disease. CT-guided core needle biopsy is appropriate to provide a tissue diagnosis; however, negative biopsy findings should not delay operative intervention.

Complete surgical resection is the most effective treatment for primary or recurrent retroperitoneal sarcoma (Fig. 36-9). En bloc resection often necessitates sacrificing contiguous structures such as the colon, kidney, spleen, pancreas, psoas muscle, small bowel, inferior vena cava, and aorta.¹⁶⁶ In a review of 25 patients who underwent resection of retroperitoneal sarcoma with major blood vessel involvement in a 16-year time span, postoperative morbidity and mortality rates were 36% and 4%, respectively. Vessel patency rates were greater than 88% with a median follow-up time of 19.3 months.^{83,167} Local control and survival rates were favorable in patients with tumor-free resection margins. The authors concluded that vascular resection is the treatment of choice in sarcomas that involve major blood vessels in the retroperitoneum.⁸³ Similar considerations were made by other groups reporting specifically on inferior vena cava resection in the context of multi-visceral resection for retroperitoneal sarcoma and on surgical morbidity after extended surgical resection of retroperitoneal sarcoma. Extended procedures, including also vessels, are feasible and safe if carried out in experienced centers. While the goal of sarcoma resection is wide excision, this is unlikely to be achievable in most patients with retroperitoneal sarcomas. Surgery is considered marginal in most cases, even when macroscopically complete, but every attempt should be made to minimize this marginality by liberally resecting surrounding organs when needed. The extension of surgery should then take into consideration a trade-off between expected morbidity and benefit and should be best carried out at high-volume centers, where technical skills and knowledge of the natural history of this very rare disease can be found.

In an analysis of 500 patients with retroperitoneal soft tissue sarcoma treated at Memorial Sloan-Kettering Cancer Center, the median survival time was 103 months for those who underwent complete resection versus 18 months for those who underwent incomplete resection or observation without resection.¹⁶⁵ In general, surgical resection should not be offered unless radiographic evidence indicates the potential for complete resection; however, palliative surgical resection may be considered to reduce symptoms of intestinal obstruction, pain, or bleeding.¹⁶⁸ In particular, in patients with atypical lipomatous tumors, an aggressive surgical approach including incomplete resection or debulking is justified to palliate symptoms and may provide a potential survival benefit.¹⁶⁹ Such an approach is not justified for dedifferentiated liposarcomas or other high-grade retroperitoneal sarcomas because these tumors have high rates of distant metastasis and local recurrence.

Adjuvant Therapy. Most studies have failed to show a survival benefit from adjuvant chemotherapy for retroperitoneal sarcoma.¹⁷⁰⁻¹⁷² Because of the high rates of local recurrence, adjuvant radiation therapy has been proposed for treating microscopic residual disease following surgical resection. However, the optimal technique and timing of radiation therapy have not been established, and the potential benefits of radiation therapy must be weighed against the increased risk of treatment-related toxic effects.

Radiation treatment of retroperitoneal sarcomas is complex because tumors are usually large, which necessitates large treatment fields close to radiosensitive structures (e.g., bowel). Several techniques have been used, including preoperative and postoperative external-beam radiation therapy, intraoperative radiation therapy, and brachytherapy.¹⁷³ Preoperative radiation therapy is feasible and well tolerated. Toxic effects may be less severe with preoperative radiation therapy given that the tumor borders are definable, the tumor displaces radiosensitive viscera away from the treatment field, and effective doses of radiation may be lower preoperatively.¹⁷⁴

Several studies have shown favorable local control rates for intermediate- and high-grade retroperitoneal sarcoma treated with preoperative radiation therapy and complete resection.¹⁷³ However, most studies have failed to show a survival benefit.¹⁷⁵ This situation prompted the initiation of a multicenter, randomized trial sponsored by the American College of Surgeons Oncology Group (ACOSOG) comparing surgery to surgery with preoperative radiation (ACOSOG Z9031). Unfortunately, the study was closed prematurely in 2006 because of low patient accrual. A similar study is now ongoing in Europe, sponsored by the Soft Tissue and Bone Sarcoma Group (STBSG) of the EORTC.

Current recommendations for radiation therapy for patients with retroperitoneal sarcoma at MD Anderson Cancer Center are based on disease characteristics at presentation.¹⁷⁶ For high-risk patients, defined as those with large, high-grade tumors or recurrent low-grade tumors, preoperative radiation therapy to a total dose of 50 Gy followed by surgical resection is considered. Postoperative radiation is discouraged unless the resected tumor bed is clearly away from dose-limiting structures.

Treatment of Recurrence. Retroperitoneal sarcomas recur more often than extremity and trunk wall ones. Retroperitoneal leiomyosarcomas, in addition to recurring locally in the tumor bed and metastasizing to the lungs, frequently spread to the liver. Retroperitoneal sarcomas can also recur diffusely

throughout the peritoneal cavity (sarcomatosis). Resection of recurrent retroperitoneal sarcoma is similar to resection of recurrent extremity sarcoma. However, the likelihood that a recurrent retroperitoneal sarcoma will be resectable declines precipitously with each recurrence. In a large series of patients treated at Memorial Sloan-Kettering Cancer Center, the authors were able to resect recurrent tumors in 57% of patients with a first recurrence but only 20% of patients with a second recurrence and 10% of patients with a third recurrence.⁶⁸ In up to 25% of patients, well-differentiated retroperitoneal liposarcoma recurs in a poorly differentiated form or recurs with areas of dedifferentiation. Dedifferentiated retroperitoneal liposarcoma is more aggressive than its well-differentiated precursor and has a greater propensity for distant metastasis.

Gastrointestinal Sarcoma

Patients with gastrointestinal sarcoma most often present with nonspecific gastrointestinal symptoms that are determined by the site of the primary tumor. In a series from Memorial Sloan-Kettering Cancer Center, early satiety and dyspepsia were noted in patients with tumors of the upper gastrointestinal tract, whereas tenesmus and changes in bowel habits were common in patients with tumors of the lower gastrointestinal tract.¹⁷⁷ In a series of 80 patients with various smooth-muscle tumors of the gastrointestinal tract, Chou and colleagues¹⁷⁸ identified the most common presenting symptoms and signs as gastrointestinal bleeding (44%), abdominal mass (38%), and abdominal pain (21%).

Establishing the diagnosis of a gastrointestinal sarcoma preoperatively is often difficult. Radiologic assessment, including CT of the abdomen or pelvis, is sometimes useful to determine the anatomic location, size, and extent of disease. Patients with localized disease frequently present with a large intra-abdominal mass. However, there is no radiographic evidence of regional lymph node metastases, which would be typical of an adenocarcinoma of similar size and anatomic location. In patients with advanced gastrointestinal sarcoma, CT may demonstrate disseminated intra-abdominal masses with or without concomitant ascites and invasion of tissue planes.

Endoscopy (esophagoduodenoscopy or colonoscopy) has become the mainstay for evaluating symptoms related to the gastrointestinal tract. For tumors involving the stomach, upper endoscopy with endoscopic ultrasonography and biopsy are important diagnostic tests used to distinguish gastrointestinal sarcoma from adenocarcinoma of the stomach. This distinction is clinically significant because the extent of resection (local excision versus gastrectomy) and the role of regional lymphadenectomy differ for these two conditions. For gastrointestinal sarcomas, lymphatic spread is not the primary route of metastasis; consequently, lymphadenectomy is not routinely performed as part of resection. The general recommendation for gastrointestinal sarcoma, based on published data and the primary pattern of distant (vs. local) failure, is to resect the tumor with a 2- to 4-cm margin of normal tissue. However, some cases may be technically challenging because of the tumor's anatomic location or size. For example, for gastric tumors located near the gastroesophageal junction, achieving adequate surgical margins may not be possible without a total or proximal subtotal gastrectomy. Similarly, large leiomyosarcomas arising from the stomach with invasion of adjacent organs should be resected together with the adjacent involved viscera en bloc.

For sarcomas of the small or large intestine, segmental bowel resection is the standard treatment. For sarcomas of the

jejunum, ileum, and colon, the tumor is excised en bloc with the involved segment of intestine and its mesentery; radical mesenteric lymphadenectomy is not attempted. For sarcomas originating in the rectum, the tumor resection technique is based on the anatomic location and size of the tumor. For small, low rectal lesions, clear margins may be achievable with a transanal excision. Large or locally invasive lesions may require more extensive operations for complete tumor extirpation.^{179,180}

Breast Sarcoma

Sarcomas of the breast are rare tumors, accounting for less than 1% of all breast malignancies and less than 5% of all soft tissue sarcomas. A variety of histologic subtypes have been reported within the breast, including angiosarcoma, stromal sarcoma, fibrosarcoma, and malignant fibrous histiocytoma.

Angiosarcoma of the breast accounts for about 50% of all sarcomas of the breast and has increasingly been associated with radiation therapy for treatment of primary breast cancer.¹⁰ The period between radiation therapy and diagnosis of radiation-associated breast sarcoma has been reported to range from 3 to 20 years, with an incidence of 0.3% at 10 years and 0.5% at 15 years.¹⁸¹ In a retrospective study of 55 patients with angiosarcoma of the breast, patients with radiation-associated angiosarcoma were on average 30 years older and were less likely to present with distant metastases than radiation-naïve patients. Clinically, radiation-associated angiosarcoma of the breast may occur in the irradiated chest wall after mastectomy or in the irradiated breast following segmental resection. The findings at presentation of a patient with cutaneous angiosarcoma often include an expanding erythematous patch, red papular eruptions, bluish-black lesions, or bruise-like discoloration overlying an area of induration. Mammography is often nonspecific, and diagnosis requires punch or incisional biopsy.

Cystosarcoma phyllodes are generally not considered to be sarcomas, because these tumors are thought to originate from hormonally responsive stromal cells of the breast and are usually benign. In patients with these tumors, infiltrating tumor margins, severe stromal overgrowth, atypia, and cellularity have all been identified as risk factors for metastases.¹⁸²

As with sarcomas at other anatomic sites, histopathologic grade and tumor size are important prognostic factors for sarcomas of the breast. The likelihood of local recurrence increases as tumor size increases; tumors smaller than 5 cm are associated with better overall survival. Local and distant recurrences are more common in patients with high-grade lesions. Complete excision with negative margins is the primary therapy. Simple mastectomy confers no additional benefit if complete excision can be accomplished by segmental mastectomy. Because of low rates of regional lymphatic spread, axillary dissection is not routinely indicated. Neoadjuvant chemotherapy or radiation therapy may be considered for patients with large, high-risk tumors.

Uterine Sarcoma

Sarcomas account for less than 5% of uterine malignancies. Uterine sarcomas have been classified into four histologic subgroups: uterine leiomyosarcoma, endometrial stromal sarcoma, malignant mixed müllerian tumor (carcinosarcoma), and undifferentiated endometrial sarcoma. Five-year overall survival rates for patients with uterine sarcoma are 30% to 50%.¹⁸³ Total abdominal hysterectomy (TAH) is recommended for localized disease. Bilateral salpingo-oophorectomy is mandatory only in endometrial stromal sarcoma. Because uterine sarcomas are

rare, the benefits of adjuvant therapy (e.g., chemotherapy, hormonal therapy) have not been adequately evaluated. Pelvic postoperative irradiation has been studied instead in a randomized fashion. The results of such study have been reported, showing no benefit in survival in favor of radiation therapy.¹⁸⁴

Uterine leiomyosarcomas are smooth-muscle tumors and account for 35% to 40% of uterine sarcomas. Leiomyosarcoma can affect women in their twenties, although it is more commonly diagnosed between 50 and 60 years of age. Standard treatment is TAH with or without ovarian preservation depending on the patient's wishes and menopausal status. Lymph node metastasis is present in less than 5% of patients at diagnosis, and lymphadenectomy is not recommended. Adjuvant pelvic radiation therapy can be considered for selected high-risk patients. Adjuvant chemotherapy is controversial. Gemcitabine plus docetaxel has been noted to be well tolerated and highly active, with a response rate of 53% in patients with unresectable uterine leiomyosarcoma.¹²⁷ Doxorubicin and trabectedin have also demonstrated activity when used as first- or second-line therapy.

Endometrial stromal sarcomas account for approximately 7% to 10% of uterine sarcomas. Mitotic count is used to classify endometrial stromal sarcomas as low grade (<10 mitoses per 10 high-power fields) or high-grade (>10 mitoses per 10 high-power fields). In general, low-grade tumors demonstrate an indolent clinical course, while high-grade tumors are more aggressive with a poorer prognosis. Unlike other uterine sarcomas subtypes, endometrial stromal sarcomas express progesterone receptors and have been found to be responsive to hormonal manipulation as an adjuvant therapy or for treatment of recurrent disease.^{185,186} Surgical treatment for these tumors includes TAH and bilateral salpingo-oophorectomy in premenopausal women; postoperative hormone replacement therapy is contraindicated.¹⁸⁷ Recurrent or advanced disease may respond to antiestrogen therapy. Tamoxifen is not recommended because it may be proestrogenic in this setting.

Malignant mixed müllerian tumor accounts for 50% of uterine sarcomas and arises predominantly in postmenopausal women. This tumor is regarded as epithelial and is treated not with agents typically used to treat sarcoma but with agents used to treat ovarian and endometrial cancers.

Undifferentiated endometrial sarcoma is an aggressive malignancy that does not express estrogen or progesterone receptors. It is associated with a poor prognosis even in patients presenting with localized disease. TAH with or without preservation of the ovaries is recommended; postoperative pelvic radiation therapy may also be administered. Systemic agents for other soft tissue sarcomas are used for recurrent and/or metastatic disease.

GASTROINTESTINAL STROMAL TUMORS

GISTs, which account for the majority of gastrointestinal sarcomas, have distinctive molecular features that have been characterized over the last decade. These tumors share phenotypic similarities with the intestinal pacemaker cells known as the interstitial cells of Cajal¹⁸⁸; interstitial cells of Cajal and GIST cells express the hematopoietic progenitor cell marker CD34 and the growth factor receptor c-Kit.¹⁸⁹ Expression of the c-Kit gene protein product, CD117, has emerged as an important defining feature of GISTs. Using these diagnostic criteria, the incidence of GIST has been estimated to be 6 to 15 cases per million individuals per year.¹⁹⁰⁻¹⁹² Until recently, systemic

treatment for patients with unresectable or metastatic GIST was of little benefit because these tumors were resistant to conventional chemotherapy. Since the recognition that KIT activation occurs in most GISTs, KIT inhibition has emerged as the primary treatment modality along with surgery.

Approximately 80% of GISTs have a mutation in the gene encoding the KIT receptor tyrosine kinase, and 5% to 10% have a mutation in the gene encoding the related PDGFRA receptor tyrosine kinase; such mutations result in the expression of mutant proteins with constitutive tyrosine kinase activity.¹ The remaining GISTs do not have a detectable mutation, but lack of a mutation does not preclude a diagnosis of GIST if the tumor is morphologically typical of GIST. The presence and type of *KIT* (exon 11 or exon 9) or *PDGFRA* (exon 18) mutation has been found to predict tumor response to imatinib. In a phase II trial, patients with *KIT* exon 11 mutations had better response rates (83.5% vs. 47.8%) and survival than those with *KIT* exon 9 mutations or those without *KIT* or *PDGFRA* mutation.¹⁹³ These findings have subsequently been confirmed in two additional phase III trials conducted by the EORTC–Italian Sarcoma Group–Australasian Gastrointestinal Trials Group (EORTC-62005).^{194,195}

The most common locations for GISTs are the stomach (60%) and small intestine (30%), but GISTs can arise anywhere along the gastrointestinal tract.¹⁹⁶ Gastric GISTs have been shown to be associated with a more favorable prognosis than GISTs at other sites.¹⁹⁷ GISTs are most commonly diagnosed by upper endoscopy and/or CT of the abdomen as an incidental finding in an asymptomatic patient or in a patient being evaluated for symptoms of early satiety, abdominal pain, or gastrointestinal bleeding. GIST most frequently metastasizes to the liver and/or abdominal cavity.

Radiologic Assessment

FDG-PET has been reported to be useful for preoperative staging of GISTs because it may reveal early metastases and establish baseline metabolic activity. PET has been shown to be highly sensitive in detecting early response to imatinib treatment and in predicting long-term response in patients with metastatic GIST. If PET is to be used for monitoring response to therapy, baseline PET should be performed before initiation of treatment. Because PET is still not widely available and because PET fails to detect some lesions because of poor glucose uptake, new CT-based criteria for detection of GIST and for predicting prognosis of GIST have also been proposed.¹⁹⁸

Management of Localized Disease

Complete surgical resection with negative margins is the recommended treatment for localized GISTs. Extended anatomic resection and lymphadenectomy are not required. Resection of even locally advanced tumors is associated with improved survival.¹⁹⁹ The 5-year survival rate for all patients with GISTs ranges from 20% to 44%, and the 5-year survival rate for patients with completely excised early-stage tumors is up to 75%.¹⁹⁹ An analysis of 200 patients by DeMatteo and colleagues found a disease-specific survival rate of 54% for patients with grossly complete resection of primary GIST, and the median survival duration for patients with metastatic disease was only 20 months.⁵⁷

As for other soft tissue sarcomas, tumor size has consistently been identified as an important prognostic factor for GIST. Mitotic activity has also been identified as an important

prognostic factor and is generally categorized as fewer than 5, 5 to 10, or more than 10 mitoses per high-power field. The National Institutes of Health²⁰⁰ and the Armed Forces Institute of Pathology¹⁹⁶ have proposed prognostic criteria for risk stratification of surgically treated, localized primary GIST. Both groups take into account tumor size and mitotic count; the Armed Forces Institute of Pathology also includes tumor site as a prognostic variable. Accurate risk stratification is essential for selecting patients most likely to benefit from adjuvant treatment.

Management of Locally Advanced or Metastatic Disease

Treatment with imatinib mesylate (Gleevec, ST1571), a selective inhibitor of the KIT protein tyrosine kinase, has resulted in impressive clinical responses in a large percentage of patients with unresectable or metastatic GISTs. On the basis of the initial results in a single patient with metastatic GIST, the EORTC Soft Tissue and Bone Sarcoma Group initiated a phase I study to test the safety and efficacy of imatinib.²⁰¹ In that study, 53% of patients with GISTs had confirmed partial responses; investigators concluded that imatinib is safe and effective against this disease.²⁰¹ A multicenter, international trial of imatinib for GIST was begun in July 2000 at four treatment centers: Dana-Farber Cancer Institute, Oregon Health Sciences University, Fox Chase Cancer Center, and University Hospital of Helsinki, Finland.²⁰² A total of 147 patients with unresectable or metastatic GISTs were randomized to 400 or 600 mg of imatinib daily for up to 24 months. Objective response was demonstrated in 79 patients (54%); all had partial responses, and there was no significant difference in response rate between imatinib doses.²⁰³ Fourteen percent of patients experienced disease progression. The toxicity profile was acceptable; the predominant effects were gastrointestinal effects (diarrhea, nausea), periorbital edema, muscle cramps, and fatigue. However, 21% of patients experienced serious (grade 3 or 4) adverse events, including gastrointestinal bleeding in 5% of patients, most likely related to the rapid tumor response of mural lesions.

A phase III randomized Intergroup trial was simultaneously performed to assess the clinical activity of imatinib at two dose levels for patients with unresectable or metastatic GIST expressing the c-Kit tyrosine kinase.²⁰⁴ From December 15, 2000, through September 1, 2001, 746 patients were accrued and randomized to low-dose (400 mg/d) or high-dose (800 mg/d) imatinib. The primary endpoint of the trial was survival. Preliminary toxicity data from 325 patients revealed a 23% incidence of grade 3 or 4 adverse events, including nausea and vomiting, gastrointestinal bleeding, abdominal pain, edema, fatigue, and rash.

In February 2002, the U.S. Food and Drug Administration approved imatinib for treatment of GIST based on the results of these promising clinical trials. Both the Intergroup trial mentioned in the preceding paragraph and a separate phase III trial compared the efficacy of low-dose (400 mg/d) and high-dose (800 mg/d) imatinib in patients with metastatic or unresectable GISTs.^{205,206} Both studies showed equivalent response rates and overall survival for the two doses but increased toxicity for the 800-mg/d dose. Current recommendations include consideration of dose escalation to 800 mg/d for patients who experience disease progression at a dose of 400 mg/d and for patients with advanced GIST and *KIT* exon 9 mutations.^{1,207}

The optimal duration of imatinib treatment, the duration of benefit from imatinib, and the long-term toxicity of imatinib

have not been established. When feasible, imatinib should be continued in the absence of disease progression. A randomized trial reported worse median progression-free survival in patients who stopped imatinib after 1 year than in patients who continued beyond 1 year (progression-free survival of 6 months vs. 18 months).²⁰⁸ Less than 4% of patients with GISTs have experienced serious adverse events with imatinib. Mild gastrointestinal toxicity is the most frequently reported adverse event, but gastrointestinal tract hemorrhage, presumably from rapid tumor necrosis, has also been reported. Thus, all patients with GISTs treated on clinical protocols should be evaluated and followed by a team of medical professionals that includes a surgeon.

Many patients with GIST develop resistance to imatinib. Primary resistance is defined as clinical progression that develops during the first 6 months of treatment and is most commonly seen in patients with *KIT* exon 9 mutation, *PDGFRA* exon 18 mutation, or no mutations.²⁰⁹ Secondary resistance is defined as progression that develops more than 6 months after the start of treatment in a patient with an initial response.²¹⁰ Imatinib resistance should be managed by either dose escalation or transition to treatment with sunitinib.¹

In 2006, sunitinib malate (SU11248, Sutent, Pfizer) emerged as an alternative systemic treatment for patients unable to tolerate imatinib and patients with imatinib-refractory GIST. Sunitinib is a tyrosine kinase inhibitor that targets multiple kinases, including the vascular endothelial growth factor receptors, *PDGFRA*, *KIT*, and *FLt3*. Sunitinib has both antiangiogenic and antiproliferative activity. In a phase III randomized placebo-controlled trial, sunitinib was associated with a significant improvement in median time to progression (27.3 weeks vs. 6.4 weeks with placebo) in patients with imatinib-resistant GIST.¹³¹ In addition, sunitinib therapy was well tolerated; diarrhea, fatigue, and nausea were the most common adverse effects. Sunitinib has also been associated with hand-foot skin reaction, hypertension, cardiotoxicity, and hypothyroidism.²¹¹⁻²¹³ In 2006, sunitinib was approved by the U.S. Food and Drug Administration for treatment of patients with resistance or intolerance to imatinib.

Other tyrosine kinase inhibitors are in development, many of which target more than one family of protein kinases.²¹⁴ Among these are sorafenib, dasatinib, and nilotinib, which are actively being investigated for the treatment of imatinib-resistant GIST.²¹⁵ Everolimus (RAD001) and protein kinase C are being investigated as agents that may maximize the extent and duration of response to imatinib by blocking potential pathways of resistance.

Multidisciplinary Treatment

Although imatinib has improved survival of patients with advanced GIST, most patients with advanced GIST are not cured with imatinib. Some patients develop secondary resistance to imatinib with one or more sites of disease progression after 6 months of clinical response (Fig. 36-10A [before imatinib], Fig. 36-10B [after imatinib]). The mechanisms of imatinib resistance are currently being investigated. Surgery has been shown to be beneficial for selected patients with isolated disease progression during imatinib therapy.²¹⁶⁻²¹⁹ Surgical resection of residual metastatic disease responding to imatinib-sensitive GIST has also been shown to result in progression-free survival in 70% to 96% of patients with imatinib- or sunitinib-sensitive GISTs.²¹⁸⁻²²⁰ The optimal timing of surgery in relation to imatinib therapy for patients with metastatic disease remains to be

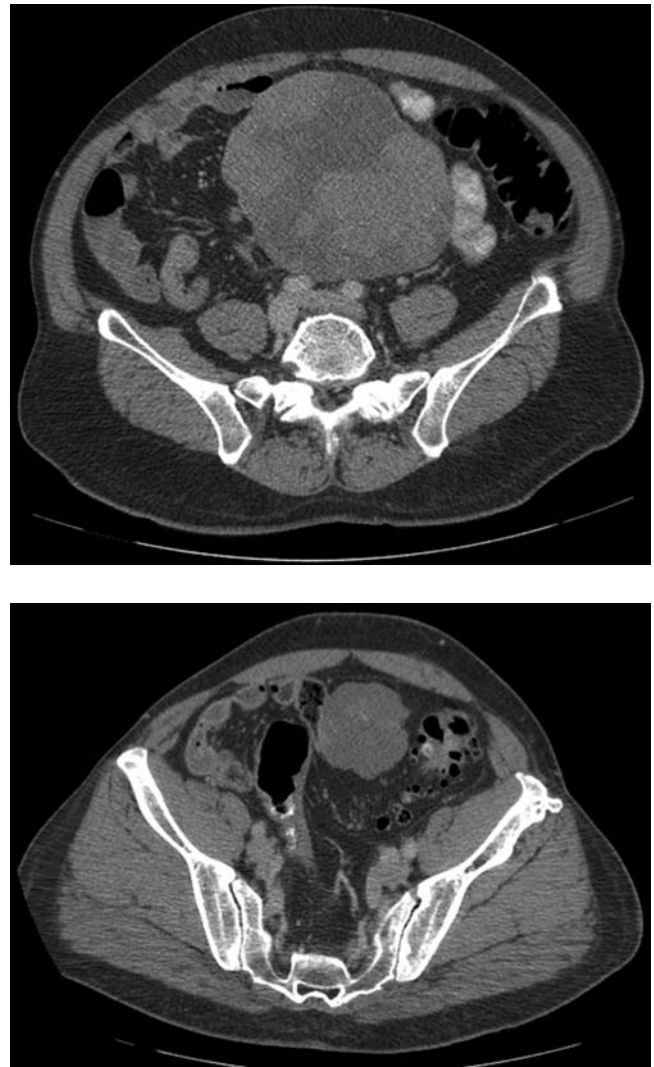

Figure 36-10. A 57-year-old man with a history of a pelvic gastrointestinal stromal tumor involving the small bowel mesentery treated preoperatively with 6 months of imatinib (Gleevec). **A.** Before imatinib. **B.** After imatinib.

determined. It is not possible to compare outcomes for patients treated with kinase inhibitors alone and patients treated with kinase inhibitors plus surgical resection outside the context of randomized trials given the heterogeneity of patients and biases associated with selection of patients for surgical resection.

Postoperative Imatinib

Given the promising results of imatinib therapy for metastatic and locally advanced GIST, the next step was to study the efficacy of imatinib as adjuvant (postoperative) treatment in patients with surgically resectable disease, particularly those at high risk for recurrence because of large tumor size or high mitotic count. The ACOSOG first evaluated the efficacy of 1 year of postoperative imatinib in a single-arm phase II trial with 106 patients with high-risk GIST and compared the results with historical controls. Adjuvant treatment with imatinib for GIST patients was then examined in two key trials. In the ACOSOG randomized, double-blind, phase III Z9001 study,²⁰⁷ treatment with 12 months of imatinib was compared with placebo, following complete resection of a primary GIST >3 cm. Primary and secondary endpoints were recurrence-free survival (RFS) and overall survival (OS), respectively. Results showed a

significant benefit in RFS, but not OS, with 12 months of imatinib. Based on these results, imatinib for the adjuvant treatment of adult patients following resection of KIT-positive GIST was approved by the U.S. Food and Drug Administration in 2008 and by the European Medical Agency (EMA) in 2009.

A more recent study conducted by the Scandinavian Sarcoma Group (SSG) and the Sarcoma Group of the Arbeitsgemeinschaft Internistische Onkologie (AIO; SSGXVIII/AIO trial) compared 12 versus 36 months of adjuvant imatinib 400 mg/d in patients with GIST at high risk of recurrence (defined as a GIST tumor diameter >10 cm, or mitotic count >10 per 50 high-powered fields, or tumor diameter >5 cm and mitotic count >5 per 50 high-power fields, or tumor rupture).²⁰⁸ Results showed that both RFS and OS significantly improved with 36 months of imatinib: the 5-year RFS rates for patients receiving 36 versus 12 months of imatinib were 65.6% versus 47.9%, respectively, and the 5-year OS rates were 92% versus 81.7%, respectively.

The NCCN and the European Society of Medical Oncology now recommend that imatinib be considered for patients at intermediate or high risk of recurrence after resection and that at least 36 months of adjuvant imatinib be considered for patients at high risk of recurrence.²²¹ Further, both the Food and Drug Administration and EMA updated the label, extending the duration of adjuvant therapy to at least 36 months in patients at high risk of recurrence.

Another study, sponsored by the EORTC (EORTC-62024), compared imatinib for 24 months versus no treatment.²⁰⁹ Results will be soon communicated.

Whether longer treatment durations may be of further benefit is still an open question, which will be addressed by future studies. However, paralleling what is commonly done in the metastatic setting, many investigators believe that even adjuvant imatinib should become a chronic therapy. While moving toward more prolonged adjuvant treatment durations, it is all the more essential to identify the appropriate patients to treat to avoid the burden of adverse events or increased financial liability for patients who will not derive therapeutic benefit from imatinib. Risk stratification based on patients' risk of recurrence is a key component to optimizing adjuvant treatment. The most practical stratification scheme to use for making a decision for adjuvant therapy is the modified National Institutes of Health consensus criteria.²²² High-risk GIST patients, whose tumor harbors a sensitive genotype, should be treated by adjuvant imatinib, because they have a poor prognosis. On the contrary, neither low-risk nor intermediate-risk GIST patients need adjuvant therapy, even if their tumor carries a sensitive genotype. In fact, evidence has been provided that the outcome of these patients with intermediate- or low-risk GIST is good. When using other risk stratification schemes, such as the Armed Forces Institute of Pathology table, Memorial Sloan-Kettering Cancer Center nomogram, or the heat map,^{197,223,224} there is a consensus to treat all patients having 30% or higher risk of recurrence, if their tumor carries a sensitive genotype. There is also a consensus not to treat patients having 10% or less risk of recurrence, even if their tumor carries a sensitive genotype. All patients having a risk between 10% and 30% should be evaluated on a case-by-case basis, and advantages/disadvantages of treatment should be made clear and discussed with the patient. Whenever a decision for adjuvant therapy is made, treatment duration of at least 36 months should be considered independently from the risk.

Beside the risk of recurrence, the other important factor to consider is the tumor genotype. In other words, as found in both the metastatic and adjuvant settings, GIST tumors with *KIT* exon 11 and *PDGFRA* non-D842V mutations are sensitive to imatinib. Patients with these mutations are suitable for adjuvant imatinib if the risk determined by stratification tools is significant. Patients with *KIT* exon 9 mutations should also be treated; a higher dose (800 mg/d) may be more appropriate but remains to be studied clinically. Patients with *PDGFRA* D842V–mutated tumors should not be treated with adjuvant imatinib, nor should patients with *KIT* and *PDGFRA* wild-type tumors associated with neurofibromatosis type 1 or the pediatric GIST/Carney-Stratakis syndromes, whatever the risk. Patients with sporadic wild-type GIST could be treated on an individual basis.

Preoperative Imatinib

Patients with marginally resectable GIST or at significant risk for operative morbidity should be considered for preoperative imatinib with close monitoring. Since the optimal duration of preoperative therapy is unknown, imatinib should be continued until maximal response is achieved or until there is evidence of progression.²²⁵ Preoperative imatinib can be stopped immediately before surgery and resumed when oral medications are restarted.

Preoperative imatinib in patients with primary GIST or resectable metastatic GIST has been evaluated in the context of two randomized phase II studies. The Radiation Treatment Oncology Group (RTOG 0132/ACRIN 6665) evaluated the efficacy of preoperative imatinib (600 mg/d) for 8 to 10 weeks before surgery and 24 months after surgery in patients with primary (n = 30) or potentially resectable recurrent or metastatic (n = 22) tumors.²²⁶ Primarily stable disease was noted during imatinib treatment, and the 2-year progression-free survival rates were 83% for primary GIST and 77% for recurrent or metastatic GIST.²²⁷ In another study, 19 patients undergoing surgical resection at a single institution were randomized to preoperative imatinib (600 mg/d) for 3, 5, or 7 days followed by surgical resection and postoperative imatinib for 24 months. The response rate assessed using FDG-PET was 69%, and the median disease-free survival time following treatment with surgery and imatinib was 46 months.²²⁸

Similar results were observed in a prospective series of patients treated at a major institution.²²⁹

All these studies show that neoadjuvant treatment is feasible, but to maximize the benefit of preoperative therapy, the following factors need to be considered. First, the patient should in principle have a favorable mutational status; otherwise, the treatment would be in vane, allowing the tumor to continue growing. Fortunately, the majority of GISTs will respond, but it should not be forgotten that, especially in gastric location, the amount of insensitive mutations in the localized setting is less uncommon than what has been previously reported.²³⁰ However, we do not absolutely need to know the mutational status in advance, but should be aware that mutation is an issue. Alternatively, if mutation status is not determined prior to treatment, we may also check response very early, either by CT, PET, or contrast-enhanced ultrasound. If a radiographic response is detected within a month, then the mutation status is likely favorable, and the treatment could be continued without necessarily pursuing mutation testing. If not, then mutation status should be investigated before continuing the treatment.

Second, the resectability of the tumor and the extent of resection necessary should be considered. Other than presentations of clearly inoperable tumors (which are usually treated with imatinib upfront) or symptomatic tumors requiring urgent intervention (hemorrhage, perforation, etc.), there are few reasons today to perform extended procedures (i.e., multivisceral resections or formal organ resections) without first attempting preoperative therapy. For instance, patients with large GISTs who may require a long midline incision for resection may benefit from neoadjuvant imatinib to downstage the operation, potentially converting an open laparotomy approach to a laparoscopic one. Another typical circumstance in which neoadjuvant therapy may be beneficial is in patients with GISTs arising in the esophagus, gastroesophageal junction, duodenum, or distal rectum. Preoperative treatment may shrink the tumor and allow a more conservative local excision. In general, such patients would normally undergo postoperative adjuvant treatment as well because of the expected recurrence risk. The chance of obtaining a response is high and the benefit for tumor shrinkage obvious, so this approach should always be discussed for patients affected by bulky and/or poorly located disease (esophagus, gastroesophageal junction, duodenum, distal rectum) as well as for those who would be candidates for an adjuvant treatment anyway.

Third, in the studies mentioned earlier, patients underwent surgery after a limited treatment duration (3 months at best). It is now well known that the preoperative treatment may result in sustained tumor shrinkage if given for a longer duration. Surgical resection may then be performed between 6 and 12 months or sooner if treatment effect plateaus. This allows for optimal tumor shrinkage, or at least shrinkage to the point where there is no further benefit to be gained by further neoadjuvant therapy without the risk of developing secondary resistance.

DESMOIDS

Desmoid tumors are not low-grade sarcomas but can be locally aggressive, although they do not metastasize. Approximately half of these tumors arise in the extremities; the remaining lesions are located on the trunk or in the retroperitoneum. Abdominal wall desmoids are associated with pregnancy and are thought to be the result of hormonal influence. Although usually sporadic, desmoids may occur in association with familial adenomatous polyposis, a presentation that is referred to as Gardner's syndrome and is linked to germline mutations in the *APC* gene. Sporadic cases of desmoid fibromatosis are commonly linked to mutations in *CTNGB1*, the gene for β -catenin.

The primary therapy for desmoid tumors has long been considered surgical resection with wide local excision to achieve negative margins. However, local recurrence occurs in up to one third of patients independently of the quality of surgical margins.²³¹⁻²³³ Up to two thirds of the patients operated on with positive margins do not recur. This is why there is growing evidence that the primary approach could be more conservative. Function-sparing operations should be the goal, even if a positive margin is left on a critical structure. Moreover, some authors advocate the possibility to observe patients at presentation, limiting surgery to those who progress or fail medical therapies. It has in fact been reported that by this approach, up to 50% of patients skip surgical resection.^{234,235} Radiation therapy may be effective in patients with unresectable tumors or as adjuvant therapy following surgery for recurrent disease,

although long-term side effects and the risk of radiation-induced sarcoma should always be considered. When used, a dose of 50 to 54 Gy is usually recommended. Systemic treatment is another option, when surgery is not indicated. Hormonal therapies such as tamoxifen have been reported to be beneficial, as have non-steroidal anti-inflammatory drugs, which are known to affect the β -catenin signaling pathways. Chemotherapy is also effective, although usually reserved for patients with tumor-associated symptoms who have not responded to other interventions. Combinations of methotrexate and vinblastine have been shown to have activity, as have single-agent pegylated liposomal doxorubicin²³⁶ and sorafenib.²³⁷ Imatinib has also been studied with unconvincing results.²³⁸⁻²⁴⁰

DERMATOFIBROSARCOMA PROTUBERANS

Dermatofibrosarcoma protuberans is a rare low-grade sarcoma arising in the dermis that rarely metastasizes but is locally aggressive. The overall annual incidence has been estimated at 4.2 cases per million individuals,²⁴¹ and the incidence is higher among blacks than whites (6.5 vs. 3.9 per million per year). Approximately 40% of cases arise on the trunk, and most of the remaining tumors are distributed between the head and neck and the extremities. Dermatofibrosarcoma protuberans presents as a nodular, cutaneous mass that grows slowly and persistently. Satellite lesions may be found in patients with larger tumors. Standard treatment is wide local excision, which generally results in local recurrence rates of less than 10%.²⁴² Although local recurrence rates as high as 30% to 50% have been reported in population-based series, the associated 5-year survival rate is greater than 99%.²⁴¹

Dermatofibrosarcoma protuberans arises from a specific chromosomal translocation involving chromosomes 17 and 22, in which the collagen 1 α 1 gene is fused to the gene for PDGF β -chain (PDGFB).²⁴³ The resultant deregulated expression of PDGFB leads to continuous activation of the PDGFR protein tyrosine kinase, which promotes tumor cell growth. The identification of this chromosomal translocation in more than 90% of cases of dermatofibrosarcoma protuberans has led to the development of targeted therapy. Inhibiting PDGFR with imatinib has been shown to induce clinical and radiologic improvement in patients with unresectable dermatofibrosarcoma protuberans.²⁰ These data have resulted in the approval by the U.S. Food and Drug Administration of imatinib for treatment of patients with locally advanced dermatofibrosarcoma protuberans.

PEDIATRIC SARCOMAS

Soft tissue sarcomas in children are relatively rare, accounting for 7% to 8% of all pediatric cancers and totaling approximately 600 new cases per year.²⁴⁴ Pediatric sarcomas have traditionally been divided into two groups: rhabdomyosarcoma and nonrhabdomyosarcoma soft tissue sarcomas.

Rhabdomyosarcoma

Associated with skeletal muscle, rhabdomyosarcomas are the most common soft tissue tumors among children younger than 15 years and can occur at any site comprised of striated muscle. Patients with these tumors generally present with a painless enlarging mass; about 24% of tumors are located in the genitourinary system, 20% in the extremities, 20% in the head and neck, 16% in the parameningeal region, and 22% in other sites.²⁴⁵

Rhabdomyosarcoma is a small round cell tumor that demonstrates muscle differentiation upon light microscopy and immunohistochemical analysis. Two primary histologic subtypes account for 90% of cases: embryonal (70%) and alveolar (20%). Alveolar rhabdomyosarcoma is associated with cytogenetic translocation [t(2:13)(q35;q14)] in 85% to 90% of cases and [t(1:13)(p36;q14)] in 10% of cases.²⁴⁶ These translocations affect biologic activity at the levels of protein function and gene expression, thereby affecting the control of cell growth, apoptosis, differentiation, and motility and ultimately contributing to tumorigenic behavior.²⁴⁷ Whereas alveolar rhabdomyosarcomas often have translocations, most embryonal rhabdomyosarcomas have an allelic loss at chromosome 11p15.5 that is thought to inactivate a tumor suppressor gene.^{247,248} Both of these distinct molecular subtypes of rhabdomyosarcoma are thought to have similar alterations in downstream targets such as the p53 and Rb pathways.²⁴⁷ Further insight into these genetic alterations may lead to a better understanding of the pathogenesis of rhabdomyosarcoma and provide novel targets for therapeutic approaches.

Extent of disease is the strongest predictor of long-term outcome. Several staging systems for rhabdomyosarcoma are available. The Intergroup Rhabdomyosarcoma Study Group system is based on surgical-pathologic groupings. Multidisciplinary evaluation including pediatric oncologists, surgical subspecialists, and radiation oncologists is critical to plan the best treatment approach to maximize local tumor control while minimizing long-term treatment effects.

Complete surgical resection is the treatment of choice for rhabdomyosarcoma when function and cosmesis can be preserved. Patients who are able to undergo a complete tumor resection with negative (group I) or microscopic surgical margins (group II) are able to undergo less intensive systemic therapy and still have overall survival rates approaching 90%.²⁴⁹ At some anatomic sites, in particular the head and neck and genitourinary system, surgery is often avoided because the associated morbidity would be substantial. Recent findings suggest that chemotherapy alone can adequately control many such tumors. In the second International Society of Paediatric Oncology study of rhabdomyosarcoma (MMT84), the choice of local treatment was based on response to initial chemotherapy such that radical surgery and radiation therapy were avoided in 66% of patients. Among the patients who subsequently developed local relapse, the 5-year overall survival rate after salvage therapy was 46%.²⁴⁹

Unlike other soft tissue sarcomas, rhabdomyosarcomas have a high propensity for lymph node metastasis, with rates up to 20% to 30% for sites such as the extremities, paratesticular nodes, and prostate. Lymph node sampling and, more recently, sentinel lymph node mapping have been used to evaluate regional node status in children with rhabdomyosarcoma.

About 15% to 20% of patients with rhabdomyosarcoma have distant metastasis at presentation, most commonly (40%–50% of cases) to the lungs, followed by bone marrow and bone. However, all patients with rhabdomyosarcoma are assumed to have micrometastatic disease at presentation. Therefore, multiagent chemotherapy is recommended for all patients with rhabdomyosarcoma. Combination regimens including vincristine, dactinomycin, and cyclophosphamide continue to be the basis of effective curative therapy.²⁴⁵ Although various combinations including doxorubicin, ifosfamide, cisplatin, and etoposide have been shown to be active against rhabdomyosarcoma, they have not improved outcomes.^{249,250} Radiation therapy is given to most patients with microscopic residual disease (group II) after resection.

The prognosis for children with rhabdomyosarcomas is related to tumor site, surgical-pathologic grouping, and tumor histology. The 5-year disease-free survival rate for all patients has been reported to be 65%. Five-year disease-free survival rates for patients in groups I, II, III, and IV have been reported to be 84%, 74%, 62%, and 23%, respectively (see Table 36-3).²⁵¹

Nonrhabdomyosarcoma Soft Tissue Sarcomas

Approximately 60% of soft tissue sarcomas in children are non-rhabdomyosarcomas. These include numerous histologic subtypes, which are generally categorized into four groups: (a) fibrosarcoma, (b) Kaposi's sarcoma, (c) other "specified" soft tissue sarcomas (e.g., synovial, angiosarcoma, hemangiopericytoma, leiomyosarcoma, liposarcoma, and extrasosseous Ewing's sarcoma), and (d) "unspecified" soft tissue sarcoma.²⁵² The most common subtypes are synovial sarcoma, MPNST, and fibrosarcoma. No single histology accounts for more than 15% of all cases.

As with adult tumors, the evaluation of the soft tissue mass begins with a history and physical examination followed by imaging, which usually includes MRI. A CT scan of the chest is important for evaluation of metastatic disease. A core needle biopsy is generally required to establish a diagnosis. Surgery remains the primary treatment of nonrhabdomyosarcoma, and local control of large, high-grade tumors is improved with radiation therapy. The prognostic factors for children with nonrhabdomyosarcoma are similar to those for adults, and the role of chemotherapy for high-risk tumors is unclear, as for adults.

RESEARCH PERSPECTIVES

As the molecular alterations associated with various sarcoma subtypes are elucidated, many new potential targets for therapeutic intervention will be identified. A wide variety of DNA alterations have been observed in sarcomas that result in mutated genes encoding proteins ranging from transcription factors to tyrosine kinases to cytokines.²¹⁵ The challenge in identifying therapeutic targets in sarcoma is to identify those that are specifically important to cellular function. The ideal therapeutic target has been described as a single molecule that is critical for pathogenesis, is expressed and active, is involved in a single pathway amenable to blockade (i.e., no alternative bypass pathways exist), and is critical for sarcoma cell survival.²⁴

CONCLUSIONS

Soft tissue sarcomas are a heterogeneous family of rare tumors, accounting for approximately 1% of malignancies in adults. The etiology in the vast majority of patients is sporadic, and the management of such diverse tumors is complex. Diagnosis by light microscopy is inexact, but molecular diagnosis, although still in its infancy, holds great promise. The natural history of soft tissue sarcomas is well established. Approximately two thirds of cases arise in the extremities, and the remaining one third are distributed between the retroperitoneum, trunk, abdomen, and head and neck. The management algorithm for soft tissue sarcomas is

- 6▶ complex and depends on tumor stage, site, and histology.
- 7▶ The most common site of metastasis is the lungs, and metastasis generally occurs within 3 years of diagnosis.

Soft tissue sarcomas have unique molecular profiles that contribute to varying responses to systemic therapy. Doxorubicin-based regimens have been the mainstay of treatment for the past two decades; however, it is now clear that specific histologic

subtypes have increased sensitivity to specific agents. For example, angiosarcomas are more sensitive to paclitaxel, while leiomyosarcoma is sensitive to gemcitabine and docetaxel. Progress in understanding of soft tissue sarcoma biology is crucial for the development of additional therapeutic targets. Drug engineering will enable molecular-based therapies to become increasingly incorporated into clinical trials and, with success, into standard treatment strategies for soft tissue sarcomas in the near future.

REFERENCES

Entries highlighted in bright blue are key references.

- Demetri GD, Benjamin RS, Blanke CD, et al. NCCN Task Force report: management of patients with gastrointestinal stromal tumor (GIST)—update of the NCCN clinical practice guidelines. *J Natl Compr Canc Netw*. 2007;5(Suppl 2):S1-S29; quiz S30.
- Coindre JM, Terrier P, Guillou L, et al. Predictive value of grade for metastasis development in the main histologic types of adult soft tissue sarcomas: a study of 1240 patients from the French Federation of Cancer Centers Sarcoma Group. *Cancer*. 2001;91:1914-1926.
- Gronchi A, Miceli R, Colombo C, et al. Primary extremity soft tissue sarcomas: outcome improvement over time at a single institution. *Ann Oncol*. 2011;22:1675-1681.
- Gronchi A, Pollock R. Surgery in retroperitoneal soft tissue sarcoma: a call for a consensus between Europe and North America. *Ann Surg Oncol*. 2011;18:2107-2110.
- American Cancer Society. Cancer Facts and Figures 2007. Available at: <http://www.cancer.org/research/cancerfactsstatistics/cancerfactsfigures2007/index>.
- Gatta G, Van Der Zwan JM, Casali PG, et al. Rare cancers are not so rare: the rare cancer burden in Europe. *Eur J Cancer*. 2011;47:2493-2511.
- Siegel R, Naishadham D, Jemal A. Cancer statistics, 2012. *CA Cancer J Clin*. 2012;62:10-29.
- Gonin-Laurent N, Hadj-Hamou N, Vogt N, et al. RB1 and TP53 pathways in radiation-induced sarcomas. *Oncogene*. 2007;26:6106-6112.
- Brady MS, Gaynor JJ, Brennan MF. Radiation-associated sarcoma of bone and soft tissue. *Arch Surg*. 1992;127:1379-1385.
- Vorburger SA, Xing Y, Hunt KK, et al. Angiosarcoma of the breast. *Cancer*. 2005;104:2682-2688.
- Riad S, Biau D, Holt GE, et al. The clinical and functional outcome for patients with radiation-induced soft tissue sarcoma. *Cancer*. 2012;118:2682-2692.
- Smith AH, Pearce NE, Fisher DO, et al. Soft tissue sarcoma and exposure to phenoxyherbicides and chlorophenols in New Zealand. *J Natl Cancer Inst*. 1984;73:1111-1117.
- Huang HY, Li CF, Huang WW, et al. A modification of NIH consensus criteria to better distinguish the highly lethal subset of primary localized gastrointestinal stromal tumors: a subdivision of the original high-risk group on the basis of outcome. *Surgery*. 2007;141:748-756.
- Stewart FW. Lymphangiosarcoma in post-mastectomy lymphedema. *Cancer*. 1948;1.
- Stewart NJ, Pritchard DJ, Nascimento AG, et al. Lymphangiosarcoma following mastectomy. *Clin Orthop Relat Res*. 1995;320:135-141.
- Kelly-Hope LA, Thomas BC, Bockarie MJ, et al. Lymphatic filariasis in the Democratic Republic of Congo; micro-stratification overlap mapping (MOM) as a prerequisite for control and surveillance. *Parasit Vectors*. 2011;4:178.
- Pardini M, Bonzano L, Roccatagliata L, et al. Functional magnetic resonance evidence of cortical alterations in a case of reversible congenital lymphedema of the lower limb: a pilot study. *Lymphology*. 2007;40:19-25.
- Schiffman S, Berger A. Stewart-Treves syndrome. *J Am Coll Surg*. 2007;204:328.
- Demicco EG, Maki RG, Lev DC, et al. New therapeutic targets in soft tissue sarcoma. *Adv Anat Pathol*. 2012;19:170-180.
- Wunder JS, Nielsen TO, Maki RG, et al. Opportunities for improving the therapeutic ratio for patients with sarcoma. *Lancet Oncol*. 2007;8:513-524.
- Guillou L, Benhattar J, Gengler C, et al. Translocation-positive low-grade fibromyxoid sarcoma: clinicopathologic and molecular analysis of a series expanding the morphologic spectrum and suggesting potential relationship to sclerosing epithelioid fibrosarcoma: a study from the French Sarcoma Group. *Am J Surg Pathol*. 2007;31:1387-1402.
- Levine EA. Prognostic factors in soft tissue sarcoma. *Semin Surg Oncol*. 1999;17:23-32.
- Sorensen PH, Triche TJ. Gene fusions encoding chimaeric transcription factors in solid tumours. *Semin Cancer Biol*. 1996;7:3-14.
- Borden EC, Baker LH, Bell RS, et al. Soft tissue sarcomas of adults: state of the translational science. *Clin Cancer Res*. 2003;9:1941-1956.
- Oda Y, Tsuneyoshi M. Recent advances in the molecular pathology of soft tissue sarcoma: implications for diagnosis, patient prognosis, and molecular target therapy in the future. *Cancer Sci*. 2009;100:200-208.
- Karnes PS. Neurofibromatosis: a common neurocutaneous disorder. *Mayo Clin Proc*. 1998;73:1071-1076.
- Fong Y, Coit DG, Woodruff JM, et al. Lymph node metastasis from soft tissue sarcoma in adults. Analysis of data from a prospective database of 1772 sarcoma patients. *Ann Surg*. 1993;217:72-77.
- Bennis M, Dalsing M, Sawchuck A, et al. Soft tissue sarcomas may present with deep vein thrombosis. *J Vasc Surg*. 2006;43:788-793.
- Grimer R, Judson I, Peake D, et al. Guidelines for the management of soft tissue sarcomas. *Sarcoma*. 2010;2010:506182.
- Heslin MJ, Smith JK. Imaging of soft tissue sarcomas. *Surg Oncol Clin N Am*. 1999;8:91-107.
- Pearlstone DB, Pisters PW, Bold RJ, et al. Patterns of recurrence in extremity liposarcoma: implications for staging and follow-up. *Cancer*. 1999;85:85-92.
- Roberge D, Hickeyson M, Charest M, et al. Initial McGill experience with fluorodeoxyglucose PET/CT staging of soft-tissue sarcoma. *Curr Oncol*. 2010;17:18-22.
- Tateishi U, Yamaguchi U, Seki K, et al. Bone and soft-tissue sarcoma: preoperative staging with fluorine 18 fluorodeoxyglucose PET/CT and conventional imaging. *Radiology*. 2007;245:839-847.
- Iagaru A, Quon A, McDougall IR, et al. F-18 FDG PET/CT evaluation of osseous and soft tissue sarcomas. *Clin Nucl Med*. 2006;31:754-760.
- Piperkova E, Mikhaeil M, Mousavi A, et al. Impact of PET and CT in PET/CT studies for staging and evaluating treatment response in bone and soft tissue sarcomas. *Clin Nucl Med*. 2009;34:146-150.
- Schuetz SM. Utility of positron emission tomography in sarcomas. *Curr Opin Oncol*. 2006;18:369.
- Schuetz SM, Rubin BP, Vernon C, et al. Use of positron emission tomography in localized extremity soft tissue sarcoma treated with neoadjuvant chemotherapy. *Cancer*. 2004;103:339-348.
- Folpe AL, Lyles RH, Sprouse JT, et al. (F-18) fluorodeoxyglucose positron emission tomography as a predictor of pathologic grade and other prognostic variables in bone and soft tissue sarcoma. *Clin Cancer Res*. 2000;6:1279-1287.
- Eary JF, O'Sullivan F, Powitan Y, et al. Sarcoma tumor FDG uptake measured by PET and patient outcome: a retrospective analysis. *Eur J Nucl Med Mol Imaging*. 2002;29:1149-1154.

40. Benz MR, Czernin J, Allen-Auerbach MS, et al. FDG-PET/CT imaging predicts histopathologic treatment responses after the initial cycle of neoadjuvant chemotherapy in high-grade soft-tissue sarcomas. *Clin Cancer Res.* 2009;15:2856-2863.
41. Kilpatrick SE, Geisinger KR. Soft tissue sarcomas: the usefulness and limitations of fine-needle aspiration biopsy. *Am J Clin Pathol.* 1998;110:50-68.
42. Yang YJ, Damron TA. Comparison of needle core biopsy and fine-needle aspiration for diagnostic accuracy in musculoskeletal lesions. *Arch Pathol Lab Med.* 2004;128:759-764.
43. Clark MA, Fisher C, Judson I, et al. Soft-tissue sarcomas in adults. *N Engl J Med.* 2005;353:701-711.
44. Ayala AG, Ro JY, Fanning CV, et al. Core needle biopsy and fine-needle aspiration in the diagnosis of bone and soft-tissue lesions. *Hematol Oncol Clin North Am.* 1995;9:633-651.
45. Dupuy DE, Rosenberg AE, Punyaratabandhu T, et al. Accuracy of CT-guided needle biopsy of musculoskeletal neoplasms. *AJR Am J Roentgenol.* 1998;171:759-762.
46. Strauss DC, Qureshi YA, Hayes AJ, et al. The role of core needle biopsy in the diagnosis of suspected soft tissue tumours. *J Surg Oncol.* 2010;102:523-529.
47. Skrzynski MC, Biermann JS, Montag A, et al. Diagnostic accuracy and charge-savings of outpatient core needle biopsy compared with open biopsy of musculoskeletal tumors. *J Bone Joint Surg.* 1996;78:644-649.
48. Huvos AG. The importance of the open surgical biopsy in the diagnosis and treatment of bone and soft-tissue tumors. *Hematol Oncol Clin North Am.* 1995;9:541-544.
49. Potter DA, Glenn J, Kinsella T, et al. Patterns of recurrence in patients with high-grade soft-tissue sarcomas. *J Clin Oncol.* 1985;3:353-366.
50. Noria S, Davis A, Kandel R, et al. Residual disease following unplanned excision of a soft-tissue sarcoma of an extremity. *J Bone Joint Surg Am.* 1996;78:650-655.
51. Presant CA, Russell WO, Alexander RW, et al. Soft-tissue and bone sarcoma histopathology peer review: the frequency of disagreement in diagnosis and the need for second pathology opinions. The Southeastern Cancer Study Group experience. *J Clin Oncol.* 1986;4:1658-1661.
52. Pfeifer J, Hill D, O'Sullivan M, et al. Diagnostic gold standard for soft tissue tumours: morphology or molecular genetics? *Histopathology.* 2002;37:485-500.
53. Fletcher CD, Gustafson P, Rydholm A, et al. Clinicopathologic re-evaluation of 100 malignant fibrous histiocytomas: prognostic relevance of subclassification. *J Clin Oncol.* 2001;19:3045-3050.
54. Tschoep K, Kohlmann A, Schlemmer M, et al. Gene expression profiling in sarcomas. *Crit Rev Oncol Hematol.* 2007;63:111-124.
55. Coindre JM, Hostein I, Maire G, et al. Inflammatory malignant fibrous histiocytomas and dedifferentiated liposarcomas: histological review, genomic profile, and MDM2 and CDK4 status favour a single entity. *J Pathol.* 2004;203:822-830.
56. Coindre JM. Grading of soft tissue sarcomas: review and update. *Arch Pathol Lab Med.* 2006;130:1448-1453.
57. DeMatteo RP, Lewis JJ, Leung D, et al. Two hundred gastrointestinal stromal tumors: recurrence patterns and prognostic factors for survival. *Ann Surg.* 2000;231:51-58.
58. Coindre JM, Terrier P, Bui NB, et al. Prognostic factors in adult patients with locally controlled soft tissue sarcoma. A study of 546 patients from the French Federation of Cancer Centers Sarcoma Group. *J Clin Oncol.* 1996;14:869-877.
59. Guillou L, Coindre JM, Bonichon F, et al. Comparative study of the National Cancer Institute and French Federation of Cancer Centers Sarcoma Group grading systems in a population of 410 adult patients with soft tissue sarcoma. *J Clin Oncol.* 1997;15:350-362.
60. Rubin BP, Fletcher CD, Inwards C, et al. Protocol for the examination of specimens from patients with soft tissue tumors of intermediate malignant potential, malignant soft tissue tumors, and benign/locally aggressive and malignant bone tumors. *Arch Pathol Lab Med.* 2006;130:1616-1629.
61. Ramanathan RC, A'Hern R, Fisher C, et al. Modified staging system for extremity soft tissue sarcomas. *Ann Surg Oncol.* 1999;6:57-69.
62. Lahat G, Tuvin D, Wei C, et al. New perspectives for staging and prognosis in soft tissue sarcoma. *Ann Surg Oncol.* 2008;15:2739-2748.
63. Atalay C, Altinok M, Seref B. The impact of lymph node metastases on survival in extremity soft tissue sarcomas. *World J Surg.* 2007;31:1433-1437.
64. Riad S, Griffin AM, Liberman B, et al. Lymph node metastasis in soft tissue sarcoma in an extremity. *Clin Orthop Relat Res.* 2004;426:129-134.
65. Behranwala KA, A'Hern R, Omar AM, et al. Prognosis of lymph node metastasis in soft tissue sarcoma. *Ann Surg Oncol.* 2004;11:714-719.
66. Grobmyer SR, Brennan MF. Predictive variables detailing the recurrence rate of soft tissue sarcomas. *Curr Opin Oncol.* 2003;15:319-326.
67. Gronchi A, Lo Vullo S, Colombo C, et al. Extremity soft tissue sarcoma in a series of patients treated at a single institution: local control directly impacts survival. *Ann Surg.* 2010;251:506.
68. Heslin MJ, Cordon-Cardo C, Lewis JJ, et al. Ki-67 detected by MIB-1 predicts distant metastasis and tumor mortality in primary, high grade extremity soft tissue sarcoma. *Cancer.* 1998;83:490-497.
69. Ch'ng E, Tomita Y, Zhang B, et al. Prognostic significance of CD100 expression in soft tissue sarcoma. *Cancer.* 2007;110:164-172.
70. Kattan MW, Leung DH, Brennan MF. Postoperative nomogram for 12-year sarcoma-specific death. *J Clin Oncol.* 2002;20:791-796.
71. Eilber FC, Kattan MW. Sarcoma nomogram: validation and a model to evaluate impact of therapy. *J Am Coll Surg.* 2007;205:S90-S95.
72. Dalal KM, Kattan MW, Antonescu CR, et al. Subtype specific prognostic nomogram for patients with primary liposarcoma of the retroperitoneum, extremity, or trunk. *Ann Surg.* 2006;244:381-391.
73. Gronchi A, Miceli R, Shurell E, et al. Outcome prediction in primary resected retroperitoneal soft tissue sarcoma: histology-specific overall survival and disease-free survival nomograms built on major sarcoma center datasets. *J Clin Oncol.* 2013;31:1649.
74. Clasby R, Tilling K, Smith M, et al. Variable management of soft tissue sarcoma: regional audit with implications for specialist care. *Br J Surg.* 1997;84:1692-1696.
75. Gutierrez JC, Perez EA, Moffat FL, et al. Should soft tissue sarcomas be treated at high-volume centers? An analysis of 4205 patients. *Ann Surg.* 2007;245:952-958.
76. National Institutes of Health. National Institutes of Health consensus development panel on limb-sparing treatment of adult soft tissue sarcoma and osteosarcomas, Vol. 3, Cancer Treatment Symposium, 1985. Available at: <http://consensus.nih.gov/1984/1984SarcomasOsteosarcomas046html.htm>.
77. McKee MD, Liu DF, Brooks JJ, et al. The prognostic significance of margin width for extremity and trunk sarcoma. *J Surg Oncol.* 2004;85:68-76.
78. Herbert SH, Corn BW, Solin LJ, et al. Limb-preserving treatment for soft tissue sarcomas of the extremities. The significance of surgical margins. *Cancer.* 1993;72:1230-1238.
79. Pisters P, Leung D, Woodruff J, et al. Analysis of prognostic factors in 1,041 patients with localized soft tissue sarcomas of the extremities. *J Clin Oncol.* 1996;14:1679-1689.

80. Alektiar K, Velasco J, Zelefsky M, et al. Adjuvant radiotherapy for margin-positive high-grade soft tissue sarcoma of the extremity. *Int J Radiat Oncol Biol Phys.* 2000;48:1051.
81. Kim BK, Chen YLE, Kirsch DG, et al. An effective preoperative three-dimensional radiotherapy target volume for extremity soft tissue sarcoma and the effect of margin width on local control. *Int J Radiat Oncol Biol Phys.* 2010;77:843-850.
82. McKay A, Motamedi M, Temple W, et al. Vascular reconstruction with the superficial femoral vein following major oncologic resection. *J Surg Oncol.* 2007;96:151-159.
83. Schwarzbach MH, Hormann Y, Hinz U, et al. Results of limb-sparing surgery with vascular replacement for soft tissue sarcoma in the lower extremity. *J Vasc Surg.* 2005;42:88-97.
84. Karakousis CP, Karpaliotis C, Driscoll DL. Major vessel resection during limb-preserving surgery for soft tissue sarcomas. *World J Surg.* 1996;20:345-349; discussion 350.
85. Ghert MA, Davis AM, Griffin AM, et al. The surgical and functional outcome of limb-salvage surgery with vascular reconstruction for soft tissue sarcoma of the extremity. *Ann Surg Oncol.* 2005;12:1102-1110.
86. Brooks A, Gold J, Graham D, et al. Resection of the sciatic, peroneal, or tibial nerves: assessment of functional status. *Ann Surg Oncol.* 2002;9:41-47.
87. Ferguson PC, Griffin AM, O'Sullivan B, et al. Bone invasion in extremity soft-tissue sarcoma: impact on disease outcomes. *Cancer.* 2006;106:2692-2700.
88. Lin PP, Pino ED, Normand AN, et al. Periosteal margin in soft-tissue sarcoma. *Cancer.* 2007;109:598-602.
89. Owens JC, Shiu MH, Smith R, et al. Soft tissue sarcomas of the hand and foot. *Cancer.* 2006;55:2010-2018.
90. Schoenfeld GS, Morris CG, Scarborough MT, et al. Adjuvant radiotherapy in the management of soft tissue sarcoma involving the distal extremities. *Am J Clin Oncol.* 2006;29:62-65.
91. Ferguson PC. Surgical considerations for management of distal extremity soft tissue sarcomas. *Curr Opin Oncol.* 2005;17:366-369.
92. Davidge K, Bell R, Ferguson P, et al. Patient expectations for surgical outcome in extremity soft tissue sarcoma. *J Surg Oncol.* 2009;100:375-381.
93. **Rosenberg SA, Tepper J, Glatstein E, et al. The treatment of soft-tissue sarcomas of the extremities: prospective randomized evaluations of (1) limb-sparing surgery plus radiation therapy compared with amputation and (2) the role of adjuvant chemotherapy. *Ann Surg.* 1982;196:305-315.**
94. Lindberg RD, Martin RG, Romsdahl MM, et al. Conservative surgery and postoperative radiotherapy in 300 adults with soft-tissue sarcomas. *Cancer.* 1981;47:2391-2397.
95. Suit HD, Proppe KH, Mankin HJ, et al. Preoperative radiation therapy for sarcoma of soft tissue. *Cancer.* 1981;47:2269-2274.
96. Leibel SA, Tranbaugh RF, Wara WM, et al. Soft tissue sarcomas of the extremities: survival and patterns of failure with conservative surgery and postoperative irradiation compared to surgery alone. *Cancer.* 1982;50:1076-1083.
97. McBride CM. Sarcomas of the limbs. Results of adjuvant chemotherapy using isolation perfusion. *Arch Surg.* 1974;109:304-308.
98. Hoekstra HJ, Schraffordt Koops H, Molenaar WM, et al. Results of isolated regional perfusion in the treatment of malignant soft tissue tumors of the extremities. *Cancer.* 1987;60:1703-1707.
99. Eggermont AM, Schraffordt Koops H, Klausner JM, et al. Isolated limb perfusion with tumor necrosis factor and melphalan for limb salvage in 186 patients with locally advanced soft tissue extremity sarcomas. The cumulative multicenter European experience. *Ann Surg.* 1996;224:756-764; discussion 764-765.
100. Fraker D, Alexander HR, Ross M. A phase II trial of isolated perfusion with high dose tumor necrosis factor and melphalan for unresectable extremity sarcomas. *Soc Surg Oncol Proc.* Abstract 53, 1999.
101. Lienard D, Ewalenko P, Delmotte JJ, et al. High-dose recombinant tumor necrosis factor alpha in combination with interferon gamma and melphalan in isolation perfusion of the limbs for melanoma and sarcoma. *J Clin Oncol.* 1992;10:52-60.
102. Grunhagen DJ, de Wilt JH, Graveland WJ, et al. Outcome and prognostic factor analysis of 217 consecutive isolated limb perfusions with tumor necrosis factor-alpha and melphalan for limb-threatening soft tissue sarcoma. *Cancer.* 2006;106:1776-1784.
103. **Yang JC, Chang AE, Baker AR, et al. Randomized prospective study of the benefit of adjuvant radiation therapy in the treatment of soft tissue sarcomas of the extremity. *J Clin Oncol.* 1998;16:197-203.**
104. Pisters PW, Harrison LB, Leung DH, et al. Long-term results of a prospective randomized trial of adjuvant brachytherapy in soft tissue sarcoma. *J Clin Oncol.* 1996;14:859-868.
105. Suit HD, Spiro I. Role of radiation in the management of adult patients with sarcoma of soft tissue. *Semin Surg Oncol.* 1994;10:347-356.
106. Barkley HT Jr, Martin RG, Romsdahl MM, et al. Treatment of soft tissue sarcomas by preoperative irradiation and conservative surgical resection. *Int J Radiat Oncol Biol Phys.* 1988;14:693-699.
107. Wilson AN, Davis A, Bell RS, et al. Local control of soft tissue sarcoma of the extremity: the experience of a multidisciplinary sarcoma group with definitive surgery and radiotherapy. *Eur J Cancer.* 1994;30A:746-751.
108. Pisters PW, Harrison LB, Woodruff JM, et al. A prospective randomized trial of adjuvant brachytherapy in the management of low-grade soft tissue sarcomas of the extremity and superficial trunk. *J Clin Oncol.* 1994;12:1150-1155.
109. Geer RJ, Woodruff J, Casper ES, et al. Management of small soft-tissue sarcoma of the extremity in adults. *Arch Surg.* 1992;127:1285-1289.
110. Karakousis CP, Emrich LJ, Rao U, et al. Limb salvage in soft tissue sarcomas with selective combination of modalities. *Eur J Surg Oncol.* 1991;17:71-80.
111. Nielsen OS, Cummings B, O'Sullivan B, et al. Preoperative and postoperative irradiation of soft tissue sarcomas: effect of radiation field size. *Int J Radiat Oncol Biol Phys.* 1991;21:1595-1599.
112. Tseng JF, Ballo MT, Langstein HN, et al. The effect of preoperative radiotherapy and reconstructive surgery on wound complications after resection of extremity soft-tissue sarcomas. *Ann Surg Oncol.* 2006;13:1209-1215.
113. **O'Sullivan B, Davis AM, Turcotte R, et al. Preoperative versus postoperative radiotherapy in soft-tissue sarcoma of the limbs: a randomised trial. *Lancet.* 2002;359:2235-2241.**
114. Davis AM, O'Sullivan B, Turcotte R, et al. Late radiation morbidity following randomization to preoperative versus postoperative radiotherapy in extremity soft tissue sarcoma. *Radiother Oncol.* 2005;75:48-53.
115. Janjan NA, Yasko AW, Reece GP, et al. Comparison of charges related to radiotherapy for soft-tissue sarcomas treated by preoperative external-beam irradiation versus interstitial implantation. *Ann Surg Oncol.* 1994;1:415-422.
116. Griffin AM, Euler CI, Sharpe MB, et al. Radiation planning comparison for superficial tissue avoidance in radiotherapy for soft tissue sarcoma of the lower extremity. *Int J Radiat Oncol Biol Phys.* 2007;67:847-856.
117. Hong L, Alektiar KM, Hunt M, et al. Intensity-modulated radiotherapy for soft tissue sarcoma of the thigh. *Int J Radiat Oncol Biol Phys.* 2004;59:752-759.
118. Alektiar KM, Brennan MF, Singer S. Influence of site on the therapeutic ratio of adjuvant radiotherapy in soft-tissue sarcoma of the extremity. *Int J Radiat Oncol Biol Phys.* 2005;63:202-208.

119. Cannon CP, Ballo MT, Zagars GK, et al. Complications of combined modality treatment of primary lower extremity soft-tissue sarcomas. *Cancer*. 2006;107:2455-2461.
120. Stinson SF, DeLaney TF, Greenberg J, et al. Acute and long-term effects on limb function of combined modality limb sparing therapy for extremity soft tissue sarcoma. *Int J Radiat Oncol Biol Phys*. 1991;21:1493-1499.
121. Kepka L, DeLaney TF, Suit HD, et al. Results of radiation therapy for unresected soft-tissue sarcomas. *Int J Radiat Oncol Biol Phys*. 2005;63:852.
122. Ferrari A, Gronchi A, Casanova M, et al. Synovial sarcoma: a retrospective analysis of 271 patients of all ages treated at a single institution. *Cancer*. 2004;101:627-634.
123. O'Bryan RM, Baker LH, Gottlieb JE, et al. Dose response evaluation of adriamycin in human neoplasia. *Cancer*. 1977;39:1940-1948.
124. Patel SR, Vadhan-Raj S, Papadopolous N, et al. High-dose ifosfamide in bone and soft tissue sarcomas: results of phase II and pilot studies—dose-response and schedule dependence. *J Clin Oncol*. 1997;15:2378-2384.
125. Movva S, Verschraegen C. Systemic management strategies for metastatic soft tissue sarcoma. *Drugs*. 2011;71:2115-2129.
126. Patel SR, Gandhi V, Jenkins J, et al. Phase II clinical investigation of gemcitabine in advanced soft tissue sarcomas and window evaluation of dose rate on gemcitabine triphosphate accumulation. *J Clin Oncol*. 2001;19:3483-3489.
127. Hensley ML, Maki R, Venkatraman E, et al. Gemcitabine and docetaxel in patients with unresectable leiomyosarcoma: results of a phase II trial. *J Clin Oncol*. 2002;20:2824-2831.
128. Dileo P, Morgan JA, Zahrieh D, et al. Gemcitabine and vinorelbine combination chemotherapy for patients with advanced soft tissue sarcomas: results of a phase II trial. *Cancer*. 2007;109:1863-1869.
129. Fata F, O'Reilly E, Ilson D, et al. Paclitaxel in the treatment of patients with angiosarcoma of the scalp or face. *Cancer*. 1999;86:2034-2037.
130. Skubitz KM, Haddad PA. Paclitaxel and pegylated-liposomal doxorubicin are both active in angiosarcoma. *Cancer*. 2005;104:361-366.
131. Demetri GD, van Oosterom AT, Garrett CR, et al. Efficacy and safety of sunitinib in patients with advanced gastrointestinal stromal tumour after failure of imatinib: a randomised controlled trial. *Lancet*. 2006;368:1329-1338.
132. Jung S, Kasper B. Palifosfamide, a bifunctional alkylator for the treatment of sarcomas. *Invest Drugs J*. 2010;13:38.
133. Agulnik M, Okuno S, Von Mehren M, et al. An open-label multicenter phase II study of bevacizumab for the treatment of angiosarcoma. *J Clin Oncol*. 2009;27:10522.
134. Sleijfer S, Ray-Coquard I, Papai Z, et al. Pazopanib, a multikinase angiogenesis inhibitor, in patients with relapsed or refractory advanced soft tissue sarcoma: a phase II study from the European Organisation for Research and Treatment of Cancer-Soft Tissue and Bone Sarcoma Group (EORTC study 62043). *J Clin Oncol*. 2009;27:3126-3132.
135. Ganjoo KN. New developments in targeted therapy for soft tissue sarcoma. *Curr Oncol Rep*. 2010;12:261-265.
136. **Adjuvant chemotherapy for localised resectable soft-tissue sarcoma of adults: meta-analysis of individual data. Sarcoma Meta-Analysis Collaboration. *Lancet*. 1997;350:1647-1654.**
137. Frustaci S, Gherlinzoni F, De Paoli A, et al. Adjuvant chemotherapy for adult soft tissue sarcomas of the extremities and girdles: results of the Italian randomized cooperative trial. *J Clin Oncol*. 2001;19:1238-1247.
138. Frustaci S, De Paoli A, Bidoli E, et al. Ifosfamide in the adjuvant therapy of soft tissue sarcomas. *Oncology*. 2003;65 (Suppl 2):80-84.
139. Cormier JN, Huang X, Xing Y, et al. Cohort analysis of patients with localized, high-risk, extremity soft tissue sarcoma treated at two cancer centers: chemotherapy-associated outcomes. *J Clin Oncol*. 2004;22:4567-4574.
140. Grobmyer SR, Maki RG, Demetri GD, et al. Neo-adjuvant chemotherapy for primary high-grade extremity soft tissue sarcoma. *Ann Oncol*. 2004;15:1667-1672.
141. Woll P, Van Glabbeke M, Hohenberger P, et al. Adjuvant chemotherapy (CT) with doxorubicin and ifosfamide in resected soft tissue sarcoma (STS): interim analysis of a randomised phase III trial. *J Clin Oncol*. 2007;25:10008.
142. O'Connor J, Chacón M, Petraci F, et al. Adjuvant chemotherapy in soft tissue sarcoma (STS): a meta-analysis of published data. ASCO Meeting Abstracts, 2008, Abstract 10526.
143. Pervaiz N, Colterjohn N, Farrokhyar F, et al. A systematic meta-analysis of randomized controlled trials of adjuvant chemotherapy for localized resectable soft-tissue sarcoma. *Cancer*. 2008;113:573-581.
144. Eilber FC, Tap WD, Nelson SD, et al. Advances in chemotherapy for patients with extremity soft tissue sarcoma. *Orthop Clin North Am*. 2006;37:15-22.
145. Gronchi A, Frustaci S, Mercuri M, et al. Short, full-dose adjuvant chemotherapy in high-risk adult soft tissue sarcomas: a randomized clinical trial from the Italian Sarcoma Group and the Spanish Sarcoma Group. *J Clin Oncol*. 2012;30:850-856.
146. Stacchiotti S, Collini P, Messina A, et al. High-grade soft-tissue sarcomas: tumor response assessment—pilot study to assess the correlation between radiologic and pathologic response by using RECIST and Choi Criteria. *Radiology*. 2009;251:447-456.
147. Stacchiotti S, Verderio P, Messina A, et al. Tumor response assessment by modified Choi criteria in localized high-risk soft tissue sarcoma treated with chemotherapy. *Cancer*. 2012;118:5857.
148. Eilber FC, Rosen G, Eckardt J, et al. Treatment-induced pathologic necrosis: a predictor of local recurrence and survival in patients receiving neoadjuvant therapy for high-grade extremity soft tissue sarcomas. *J Clin Oncol*. 2001;19:3203-3209.
149. Eilber FC, Brennan MF, Riedel E, et al. Prognostic factors for survival in patients with locally recurrent extremity soft tissue sarcomas. *Ann Surg Oncol*. 2005;12:228-236.
150. Singer S, Antman K, Corson JM, et al. Long-term salvageability for patients with locally recurrent soft-tissue sarcomas. *Arch Surg*. 1992;127:548-553; discussion 553-554.
151. van Geel AN, Pastorino U, Jauch KW, et al. Surgical treatment of lung metastases: the European Organization for Research and Treatment of Cancer-Soft Tissue and Bone Sarcoma Group study of 255 patients. *Cancer*. 1996;77:675-682.
152. Porter GA, Cantor SB, Walsh GL, et al. Cost-effectiveness of pulmonary resection and systemic chemotherapy in the management of metastatic soft tissue sarcoma: a combined analysis from the University of Texas M. D. Anderson and Memorial Sloan-Kettering Cancer Centers. *J Thorac Cardiovasc Surg*. 2004;127:1366-1372.
153. Whooley BP, Mooney MM, Gibbs JF, et al. Effective follow-up strategies in soft tissue sarcoma. *Semin Surg Oncol*. 1999;17:83-87.
154. Midis GP, Pollock RE, Chen NP, et al. Locally recurrent soft tissue sarcoma of the extremities. *Surgery*. 1998;123:666-671.
155. Karakousis CP, Proimakis C, Rao U, et al. Local recurrence and survival in soft-tissue sarcomas. *Ann Surg Oncol*. 1996;3:255-260.
156. Nori D, Schupak K, Shiu MH, et al. Role of brachytherapy in recurrent extremity sarcoma in patients treated with prior surgery and irradiation. *Int J Radiat Oncol Biol Phys*. 1991;20:1229-1233.
157. Suri RM, Deschamps C, Cassivi SD, et al. Pulmonary resection for metastatic malignant fibrous histiocytoma: an analysis of prognostic factors. *Ann Thorac Surg*. 2005;80:1847-1852.

158. Van Glabbeke M, van Oosterom AT, Oosterhuis JW, et al. Prognostic factors for the outcome of chemotherapy in advanced soft tissue sarcoma: an analysis of 2,185 patients treated with anthracycline-containing first-line regimens—a European Organization for Research and Treatment of Cancer Soft Tissue and Bone Sarcoma Group Study. *J Clin Oncol.* 1999;17:150-157.
159. Zacherl M, Bernhardt GA, Zacherl J, et al. Surgery for liver metastases originating from sarcoma—case series. *Langenbecks Arch Surg.* 2011;396:1083-1091.
160. Jones RL, McCall J, Adam A, et al. Radiofrequency ablation is a feasible therapeutic option in the multi modality management of sarcoma. *Eur J Surg Oncol.* 2010;36:477-482.
161. Maluccio MA, Covey AM, Schubert J, et al. Treatment of metastatic sarcoma to the liver with bland embolization. *Cancer.* 2006;107:1617-1623.
162. Kepka L, Suit HD, Goldberg SI, et al. Results of radiation therapy performed after unplanned surgery (without re-excision) for soft tissue sarcomas. *J Surg Oncol.* 2005;92:39-45.
163. Spillane AJ, Fisher C, Thomas JM. Myxoid liposarcoma—the frequency and the natural history of nonpulmonary soft tissue metastases. *Ann Surg Oncol.* 1999;6:389-394.
164. Estourgie SH, Nielsen GP, Ott MJ. Metastatic patterns of extremity myxoid liposarcoma and their outcome. *J Surg Oncol.* 2002;80:89-93.
165. Lewis JJ, Leung D, Woodruff JM, et al. Retroperitoneal soft-tissue sarcoma: analysis of 500 patients treated and followed at a single institution. *Ann Surg.* 1998;228:355-365.
166. Bonvalot S, Raut CP, Pollock RE, et al. Technical considerations in surgery for retroperitoneal sarcomas: position paper from E-Surge, a Master Class in Sarcoma Surgery, and EORTC-STBSG. *Ann Surg Oncol.* 2012;1-11.
167. Bonvalot S, Miceli R, Berselli M, et al. Aggressive surgery in retroperitoneal soft tissue sarcoma carried out at high-volume centers is safe and is associated with improved local control. *Ann Surg Oncol.* 2010;17:1507-1514.
168. Yeh JJ, Singer S, Brennan MF, et al. Effectiveness of palliative procedures for intra-abdominal sarcomas. *Ann Surg Oncol.* 2005;12:1084-1089.
169. Windham TC, Pisters PW. Retroperitoneal sarcomas. *Cancer Control.* 2005;12:36-43.
170. Tierney JF, Mosseri V, Stewart LA, et al. Adjuvant chemotherapy for soft-tissue sarcoma: review and meta-analysis of the published results of randomised clinical trials. *Br J Cancer.* 1995;72:469-475.
171. Glenn J, Sindelar WF, Kinsella T, et al. Results of multimodality therapy of resectable soft-tissue sarcomas of the retroperitoneum. *Surgery.* 1985;97:316-325.
172. Singer S, Corson JM, Demetri GD, et al. Prognostic factors predictive of survival for truncal and retroperitoneal soft-tissue sarcoma. *Ann Surg.* 1995;221:185-195.
173. Pawlik TM, Ahuja N, Herman JM. The role of radiation in retroperitoneal sarcomas: a surgical perspective. *Curr Opin Oncol.* 2007;19:359-366.
174. Pawlik TM, Pisters PW, Mikula L, et al. Long-term results of two prospective trials of preoperative external beam radiotherapy for localized intermediate- or high-grade retroperitoneal soft tissue sarcoma. *Ann Surg Oncol.* 2006;13:508-517.
175. Tzeng CW, Fiveash JB, Heslin MJ. Radiation therapy for retroperitoneal sarcoma. *Expert Rev Anticancer Ther.* 2006;6:1251-1260.
176. Ballo MT, Zagars GK, Pollock RE, et al. Retroperitoneal soft tissue sarcoma: an analysis of radiation and surgical treatment. *Int J Radiat Oncol Biol Phys.* 2007;67:158-163.
177. Conlon KC, Casper ES, Brennan MF. Primary gastrointestinal sarcomas: analysis of prognostic variables. *Ann Surg Oncol.* 1995;2:26-31.
178. Chou FF, Eng HL, Sheen-Chen SM. Smooth muscle tumors of the gastrointestinal tract: analysis of prognostic factors. *Surgery.* 1996;119:171-177.
179. Horowitz J, Spellman JE Jr, Driscoll DL, et al. An institutional review of sarcomas of the large and small intestine. *J Am Coll Surg.* 1995;180:465-471.
180. Meijer S, Peretz T, Gaynor JJ, et al. Primary colorectal sarcoma. A retrospective review and prognostic factor study of 50 consecutive patients. *Arch Surg.* 1990;125:1163-1168.
181. Kirova YM, Vilcoq JR, Asselain B, et al. Radiation-induced sarcomas after radiotherapy for breast carcinoma: a large-scale single-institution review. *Cancer.* 2005;104:856-863.
182. Chen WH, Cheng SP, Tzen CY, et al. Surgical treatment of phyllodes tumors of the breast: retrospective review of 172 cases. *J Surg Oncol.* 2005;91:185-194.
183. Denschlag D, Masoud I, Stanimir G, et al. Prognostic factors and outcome in women with uterine sarcoma. *Eur J Surg Oncol.* 2007;33:91-95.
184. Reed N, Mangioni C, Malmström H, et al. Phase III randomised study to evaluate the role of adjuvant pelvic radiotherapy in the treatment of uterine sarcomas stages I and II: an European Organisation for Research and Treatment of Cancer Gynaecological Cancer Group Study (protocol 55874). *Eur J Cancer.* 2008;44:808-818.
185. Leunen M, Breugelmans M, De Sutter P, et al. Low-grade endometrial stromal sarcoma treated with the aromatase inhibitor letrozole. *Gynecol Oncol.* 2004;95:769-771.
186. Scribner DR Jr, Walker JL. Low-grade endometrial stromal sarcoma preoperative treatment with Depo-Lupron and Megace. *Gynecol Oncol.* 1998;71:458-460.
187. Grimer R, Judson I, Peake D, et al. Guidelines for the management of soft tissue sarcomas. *Sarcoma.* 2010;2010:506182.
188. Kindblom LG, Remotti HE, Aldenborg F, et al. Gastrointestinal pacemaker cell tumor (GIPACT): gastrointestinal stromal tumors show phenotypic characteristics of the interstitial cells of Cajal. *Am J Pathol.* 1998;152:1259-1269.
189. Hirota S, Isozaki K, Moriyama Y, et al. Gain-of-function mutations of c-kit in human gastrointestinal stromal tumors. *Science.* 1998;279:577-580.
190. Nilsson B, Bummig P, Meis-Kindblom JM, et al. Gastrointestinal stromal tumors: the incidence, prevalence, clinical course, and prognostication in the preimatinib mesylate era—a population-based study in western Sweden. *Cancer.* 2005;103:821-829.
191. Rubio J, Marcos-Gragera R, Ortiz MR, et al. Population-based incidence and survival of gastrointestinal stromal tumours (GIST) in Girona, Spain. *Eur J Cancer.* 2007;43:144-148.
192. Tran T, Davila JA, El-Serag HB. The epidemiology of malignant gastrointestinal stromal tumors: an analysis of 1,458 cases from 1992 to 2000. *Am J Gastroenterol.* 2005;100:162-168.
193. Heinrich MC, Corless CL, Demetri GD, et al. Kinase mutations and imatinib response in patients with metastatic gastrointestinal stromal tumor. *J Clin Oncol.* 2003;21:4342-4349.
194. Debiec-Rychter M, Dumez H, Judson I, et al. Use of c-KIT/PDGFRamutational analysis to predict the clinical response to imatinib in patients with advanced gastrointestinal stromal tumours entered on phase I and II studies of the EORTC Soft Tissue and Bone Sarcoma Group. *Eur J Cancer.* 2004;40:689-695.
195. Heinrich MC, Owzar K, Corless CL, et al. Correlation of kinase genotype and clinical outcome in the North American Intergroup phase III trial of imatinib mesylate for treatment of advanced gastrointestinal stromal tumor: CALGB 150105 Study by Cancer and Leukemia Group B and Southwest Oncology Group. *J Clin Oncol.* 2008;26:5360-5367.
196. Miettinen M, Lasota J. Gastrointestinal stromal tumors: review on morphology, molecular pathology, prognosis, and differential diagnosis. *Arch Pathol Lab Med.* 2006;130:1466-1478.

197. Miettinen M, Lasota J. Gastrointestinal stromal tumors: pathology and prognosis at different sites. *Semin Diagn Pathol.* 2006;70-83.
198. Choi H, Charnsangavej C, Faria SC, et al. Correlation of computed tomography and positron emission tomography in patients with metastatic gastrointestinal stromal tumor treated at a single institution with imatinib mesylate: proposal of new computed tomography response criteria. *J Clin Oncol.* 2007;25:1753-1759.
199. Ng EH, Pollock RE, Munsell MF, et al. Prognostic factors influencing survival in gastrointestinal leiomyosarcomas. Implications for surgical management and staging. *Ann Surg.* 1992;215:68-77.
200. Fletcher CD, Berman JJ, Corless C, et al. Diagnosis of gastrointestinal stromal tumors: a consensus approach. *Hum Pathol.* 2002;33:459-465.
201. van Oosterom AT, Judson I, Verweij J, et al. Safety and efficacy of imatinib (STI571) in metastatic gastrointestinal stromal tumours: a phase I study. *Lancet.* 2001;358:1421-1423.
202. Blanke CD, von Mehren M, Joensuu H, et al. Evaluation of the safety and efficacy of an oral molecularly targeted therapy, STI571, in patients with unresectable metastatic gastrointestinal stromal tumors (GISTs) expressing C-KIT (CD117). *Proc Am Soc Clin Oncol.* 2001;20:1.
203. von Mehren M, Blanke C, Joensuu H, et al. High incidence of durable responses induced by imatinib mesylate (Gleevec) in patients with unresectable and metastatic gastrointestinal stromal tumors. *Proc Am Soc Clin Oncol.* 2002;21:1608.
204. Demetri G, Rankin C, Fletcher C, et al. Phase III dose-randomized study of imatinib mesylate (Gleevec, STI571) for GIST; intergroup S0033 early results. *Proc Am Soc Clin Oncol.* 2002;21:1651.
205. Verweij J, Casali PG, Zalcberg J, et al. Progression-free survival in gastrointestinal stromal tumours with high-dose imatinib: randomised trial. *Lancet.* 2004;364:1127-1134.
206. Blanke CD, Rankin C, Demetri GD, et al. Phase III randomized, intergroup trial assessing imatinib mesylate at two dose levels in patients with unresectable or metastatic gastrointestinal stromal tumors expressing the kit receptor tyrosine kinase: S0033. *J Clin Oncol.* 2008;26:626-632.
207. Zalcberg JR, Verweij J, Casali PG, et al. Outcome of patients with advanced gastro-intestinal stromal tumours crossing over to a daily imatinib dose of 800mg after progression on 400 mg. *Eur J Cancer.* 2005;41:1751-1757.
208. Blay JY, Le Cesne A, Ray-Coquard I, et al. Prospective multicentric randomized phase III study of imatinib in patients with advanced gastrointestinal stromal tumors comparing interruption versus continuation of treatment beyond 1 year: the French Sarcoma Group. *J Clin Oncol.* 2007;25:1107-1113.
209. Benjamin RS, Debiec-Rychter M, Le Cesne A, et al. Gastrointestinal stromal tumors II: medical oncology and tumor response assessment. *Semin Oncol.* 2009;302-311.
210. Maleddu A, Pantaleo MA, Nannini M, et al. Mechanisms of secondary resistance to tyrosine kinase inhibitors in gastrointestinal stromal tumours (review). *Oncol Rep.* 2009;21:1359-1366.
211. Chu D, Lacouture ME, Weiner E, et al. Risk of hand-foot skin reaction with the multitargeted kinase inhibitor sunitinib in patients with renal cell and non-renal cell carcinoma: a meta-analysis. *Clin Genitourin Cancer.* 2009;7:11-19.
212. Zhu X, Stergiopoulos K, Wu S. Risk of hypertension and renal dysfunction with an angiogenesis inhibitor sunitinib: systematic review and meta-analysis. *Acta Oncol.* 2009;48:9-17.
213. Chu TF, Rupnick MA, Kerkela R, et al. Cardiotoxicity associated with the tyrosine kinase inhibitor sunitinib. *Lancet.* 2007;370:2011.
214. Boyar MS, Taub RN. New strategies for treating GIST when imatinib fails. *Cancer Invest.* 2007;25:328-335.
215. Cassier PA, Dufresne A, Fayette J, et al. Emerging drugs for the treatment of soft tissue sarcomas. *Expert Opin Emerg Drugs.* 2007;12:139-153.
216. Andtbacka RH, Ng CS, Scaife CL, et al. Surgical resection of gastrointestinal stromal tumors after treatment with imatinib. *Ann Surg Oncol.* 2007;14:14-24.
217. Desai J, Shankar S, Heinrich MC, et al. Clonal evolution of resistance to imatinib in patients with metastatic gastrointestinal stromal tumors. *Clin Cancer Res.* 2007;13:5398-5405.
218. DeMatteo RP, Maki RG, Singer S, et al. Results of tyrosine kinase inhibitor therapy followed by surgical resection for metastatic gastrointestinal stromal tumor. *Ann Surg.* 2007;245:347-352.
219. Raut CP, Posner M, Desai J, et al. Surgical management of advanced gastrointestinal stromal tumors after treatment with targeted systemic therapy using kinase inhibitors. *J Clin Oncol.* 2006;24:2325-2331.
220. Gronchi A, Fiore M, Miselli F, et al. Surgery of residual disease following molecular-targeted therapy with imatinib mesylate in advanced/metastatic GIST. *Ann Surg.* 2007;245:341-346.
221. The ESMO/European Sarcoma Network Working Group. Gastrointestinal stromal tumors: ESMO clinical recommendations for diagnosis, treatment and follow-up. *Ann Oncol.* 2012;23:49-55.
222. Joensuu H. Risk stratification of patients diagnosed with gastrointestinal stromal tumor. *Hum Pathol.* 2008;39:1411-1419.
223. Gold JS, Gönen M, Gutiérrez A, et al. Development and validation of a prognostic nomogram for recurrence-free survival after complete surgical resection of localised primary gastrointestinal stromal tumour: a retrospective analysis. *Lancet Oncol.* 2009;10:1045-1052.
224. Joensuu H, Vehtari A, Riihimäki J, et al. Risk of recurrence of gastrointestinal stromal tumour after surgery: an analysis of pooled population-based cohorts. *Lancet Oncol.* 2012;13:265.
225. Demetri GD, Antonia S, Benjamin RS, et al. Soft tissue sarcoma. *J Natl Compr Canc Netw.* 2010;8:630-674.
226. van der Zwan SM, DeMatteo RP. Gastrointestinal stromal tumor: 5 years later. *Cancer.* 2005;104:1781-1788.
227. Eisenberg BL, Harris J, Blanke CD, et al. Phase II trial of neoadjuvant/adjuvant imatinib mesylate (IM) for advanced primary and metastatic/recurrent operable gastrointestinal stromal tumor (GIST): early results of RTOG 0132/ACRIN 6665. *J Surg Oncol.* 2008;99:42-47.
228. McAuliffe JC, Hunt KK, Lazar AJF, et al. A randomized, phase II study of preoperative plus postoperative imatinib in GIST: evidence of rapid radiographic response and temporary induction of tumor cell apoptosis. *Ann Surg Oncol.* 2009;16:910-919.
229. Fiore M, Palassini E, Fumagalli E, et al. Preoperative imatinib mesylate for unresectable or locally advanced primary gastrointestinal stromal tumors (GIST). *Eur J Surg Oncol.* 2009;35:739-745.
230. Emile J, Brahimi S, Coindre J, et al. Frequencies of KIT and PDGFRA mutations in the MolecGIST prospective population-based study differ from those of advanced GISTs. *Med Oncol.* 2012;29:1765-1772.
231. Gronchi A, Casali P, Mariani L, et al. Quality of surgery and outcome in extra-abdominal aggressive fibromatosis: a series of patients surgically treated at a single institution. *J Clin Oncol.* 2003;21:1390-1397.
232. Lev D, Kotilingam D, Wei C, et al. Optimizing treatment of desmoid tumors. *J Clin Oncol.* 2007;25:1785-1791.
233. Salas S, Dufresne A, Bui B, et al. Prognostic factors influencing progression-free survival determined from a series of sporadic desmoid tumors: a wait-and-see policy according to tumor presentation. *J Clin Oncol.* 2011;29:3553-3558.

234. Bonvalot S, Eldweny H, Haddad V, et al. Extra-abdominal primary fibromatosis: aggressive management could be avoided in a subgroup of patients. *Eur J Surg Oncol*. 2008;34:462-468.
235. Fiore M, Rimareix F, Mariani L, et al. Desmoid-type fibromatosis: a front-line conservative approach to select patients for surgical treatment. *Ann Surg Oncol*. 2009;16:2587-2593.
236. Constantinidou A, Scurr M, Jones R, et al. Treatment of aggressive fibromatosis with pegylated liposomal doxorubicin: The Royal Marsden Hospital experience. *J Clin Oncol*. (Meeting Abstracts), Abstract 10519, 2009.
237. Gounder MM, Lefkowitz RA, Keohan ML, et al. Activity of sorafenib against desmoid tumor/deep fibromatosis. *Clin Cancer Res*. 2011;17:4082-4090.
238. Dufresne A, Penel N, Salas S, et al. Updated outcome with long term follow-up of imatinib for the treatment of progressive or recurrent aggressive fibromatosis (desmoid tumor): A FNCLCC/French Sarcoma Group phase II trial. *Age*. 2009;40:59.
239. Chugh R, Wathen JK, Patel SR, et al. Efficacy of imatinib in aggressive fibromatosis: results of a phase II multicenter Sarcoma Alliance for Research through Collaboration (SARC) trial. *Clin Cancer Res*. 2010;16:4884-4891.
240. Penel N, Le Cesne A, Bui B, et al. Imatinib for progressive and recurrent aggressive fibromatosis (desmoid tumors): an FNCLCC/French Sarcoma Group phase II trial with a long-term follow-up. *Ann Oncol*. 2011;22:452-457.
241. Criscione VD, Weinstock MA. Descriptive epidemiology of dermatofibrosarcoma protuberans in the United States, 1973 to 2002. *J Am Acad Dermatol*. 2007;56:968-973.
242. Fiore M, Miceli R, Mussi C, et al. Dermatofibrosarcoma protuberans treated at a single institution: a surgical disease with a high cure rate. *J Clin Oncol*. 2005;23:7669-7675.
243. McArthur GA. Molecular targeting of dermatofibrosarcoma protuberans: a new approach to a surgical disease. *J Natl Compr Canc Netw*. 2007;5:557-562.
244. Grovas A, Fremgen A, Rauck A, et al. The National Cancer Data Base report on patterns of childhood cancers in the United States. *Cancer*. 1997;80:2321-2332.
245. Meyer WH, Spunt SL. Soft tissue sarcomas of childhood. *Cancer Treat Rev*. 2004;30:269-280.
246. Barr FG, Chatten J, D'Cruz CM, et al. Molecular assays for chromosomal translocations in the diagnosis of pediatric soft tissue sarcomas. *JAMA*. 1995;273:553-557.
247. Xia SJ, Pressey JG, Barr FG. Molecular pathogenesis of rhabdomyosarcoma. *Cancer Biol Ther*. 2002;1:97-104.
248. Scrabble H, Witte D, Shimada H, et al. Molecular differential pathology of rhabdomyosarcoma. *Genes Chromosomes Cancer*. 1989;1:23-35.
249. Flamant F, Rodary C, Rey A, et al. Treatment of non-metastatic rhabdomyosarcomas in childhood and adolescence. Results of the second study of the International Society of Paediatric Oncology: MMT84. *Eur J Cancer*. 1998;34:1050-1062.
250. Crist WM, Anderson JR, Meza JL, et al. Intergroup rhabdomyosarcoma study-IV: results for patients with nonmetastatic disease. *J Clin Oncol*. 2001;19:3091-3102.
251. Crist WM, Garnsey L, Beltangady MS, et al. Prognosis in children with rhabdomyosarcoma: a report of the intergroup rhabdomyosarcoma studies I and II. Intergroup Rhabdomyosarcoma Committee. *J Clin Oncol*. 1990;8:443-452.
252. Loeb DM, Thornton K, Shokek O. Pediatric soft tissue sarcomas. *Surg Clin North Am*. 2008;88:615-627, vii.

This page intentionally left blank

37 chapter

Inguinal Hernias

Justin P. Wagner, F. Charles Brunicardi, Parviz K. Amid, and David C. Chen

Introduction	1495	Imaging / 1504	
History / 1495		Treatment	1504
Anatomy / 1496		Open Approach / 1505	
Pathophysiology / 1500		Laparoscopic Approach / 1509	
Diagnosis	1502	Prosthesis Considerations / 1513	
History / 1502		Complications	1514
Physical Examination / 1503		Hernia Recurrence / 1514	
		Pain / 1514	
		Cord and Testes Injury / 1515	
		Laparoscopic Complications / 1515	
		Hematomas and Seromas / 1516	
		Outcomes	1516

INTRODUCTION

Inguinal hernia repair is the most commonly performed operation in the United States, owing to a significant lifetime incidence and variety of successful treatment modalities. Approximately 800,000 cases were performed in 2003, not including recurrent or bilateral hernias.¹ Advancements in perioperative anesthesia and operative technique have made this an outpatient ambulatory operation with low recurrence rates and morbidity. Given this success, quality of life and the avoidance of chronic pain have become the most important considerations in hernia repair.

Approximately 75% of abdominal wall hernias occur in the groin. The lifetime risk of inguinal hernia is 27% in men and 3% in women.² Of inguinal hernia repairs, 90% are performed in men and 10% in women. The incidence of inguinal hernias in males has a bimodal distribution, with peaks before the first year of age and after age 40. Abramson demonstrated the age dependence of inguinal hernias in 1978. Those age 25 to 34 years had a lifetime prevalence rate of 15%, whereas those age 75 years and over had a rate of 47% (Table 37-1).³ Approximately 70% of femoral hernia repairs are performed in women; however, inguinal hernias are five times more common than femoral hernias. The most common subtype of groin hernia in men and women is the indirect inguinal hernia.⁴

History

Evidence of surgical repair of inguinal hernias can be traced back to ancient civilizations of Egypt and Greece.⁵ Early management of inguinal hernias often involved a conservative approach with operative management reserved only for complications. Surgery often involved routine excision of the testicle, and wounds were closed with cauterization or left to granulate on their own. Considering these procedures were

performed before the advent of the aseptic technique, it is safe to assume that mortality was quite high. For those that survived the operation, recurrence of the hernia was common.

From the late 1700s to the early 1800s, physicians including Hesselbach, Cooper, Camper, Scarpa, Richter, and Gimbernat identified vital components of the inguinal region, and their contributions are reflected in the current nomenclature. Improved understanding of the anatomy and pathophysiology of inguinal hernias, coupled with the development of aseptic technique, led surgeons such as Marcy, Kocher, and Lucas-Championnière to perform sac dissection, high ligation, and closure of the internal ring. Outcomes improved, but recurrence rates remained high with prolonged follow-up.

Based on a comprehensive understanding of inguinal anatomy, Bassini (1844–1924) transformed inguinal hernia repair into a successful venture with minimal morbidity. The success of the Bassini repair over its predecessors ushered in an era of tissue-based repairs. Modifications of the Bassini repair were manifest in the McVay and Shouldice repairs. All three of these techniques, as well as modern variations such as the Desarda operation, are currently practiced.⁶

In the early 1980s, Lichtenstein popularized the tension-free repair, supplanting tissue-based repairs with the widespread acceptance of prosthetic materials for inguinal floor reconstruction. This technique was superior to previous tissue-based repair in that mesh could restore the strength of the transversalis fascia, thereby avoiding tension in the defect closure. Superior results were reproducible regardless of hernia size and type, and they were achievable among expert and nonexpert hernia surgeons alike.⁷

With the advent of minimally invasive surgery, inguinal hernia repair underwent its most recent transformation. Laparoscopic inguinal hernia repair offers an alternative approach, minimizes postoperative pain, and improves recov-

Key Points

- 1▶ Conservative management of asymptomatic inguinal hernias is acceptable.
- 2▶ A proficient understanding of groin anatomy is essential to successful inguinal hernia treatment.
- 3▶ Elective repair of inguinal hernias can be undertaken using an laparoscopic or open approach.
- 4▶ The use of prosthetic mesh as a reinforcement significantly improves recurrence rates, whether the repair is open or laparoscopic.
- 5▶ Recurrence, pain, and quality of life are important outcome factors.
- 6▶ Laparoscopic inguinal hernia repair results in less pain and faster recovery, yet requires specialized training and equipment.

ery. Since the initial description by Ger, the laparoscopic method has become significantly more sophisticated. Refinements in approach and technique have led to the development of the intraperitoneal onlay mesh, the transabdominal preperitoneal (TAPP) repair, and the totally extraperitoneal (TEP) repair. Furthermore, an array of prosthetic materials has been introduced to minimize recurrence and improve quality of life. Irrespective of the approach, successful surgical treatment of inguinal hernias depends on a sound grasp of inguinal anatomy.

Anatomy

The inguinal canal is an approximately 4- to 6 cm-long cone-shaped region situated in the anterior portion of the pelvic basin (Fig. 37-1). The canal begins on the posterior abdominal wall, where the spermatic cord passes through the deep (internal) inguinal ring, a hiatus in the transversalis fascia. The canal concludes medially at the superficial (external) inguinal ring, the point at which the spermatic cord crosses a defect in the external oblique aponeurosis. The boundaries of the inguinal canal are comprised of the external oblique aponeurosis anteriorly, the internal oblique muscle laterally, the transversalis fascia and transversus abdominis muscle posteriorly, the internal oblique muscle superiorly, and the inguinal (Poupart's) ligament inferiorly. The spermatic cord traverses the inguinal canal, and it contains three arteries, three veins, two nerves, the pampiniform venous plexus, and the vas deferens. It is enveloped in three layers of spermatic fascia.

Additional important structures surrounding the inguinal canal include the iliopubic tract, the lacunar ligament, Cooper's

ligament, and the conjoined tendon (Fig. 37-2). The iliopubic tract is an aponeurotic band that begins at the anterior superior iliac spine and inserts into Cooper's ligament from above. It forms on the deep inferior margin of the transversus abdominis and transversalis fascia. The shelving edge of the inguinal ligament is a structure that connects the iliopubic tract to the inguinal ligament. The iliopubic tract helps form the inferior margin of the internal inguinal ring as it courses medially, where it continues as the anteromedial border of the femoral canal. The lacunar ligament, or ligament of Gimbernat, is the triangular fanning of the inguinal ligament as it joins the pubic tubercle. Cooper's (pectineal) ligament is the lateral portion of the lacunar ligament that is fused to the periosteum of the pubic tubercle. The conjoined tendon is commonly described as the fusion of the inferior fibers of the internal oblique and transversus abdominis aponeurosis at the point where they insert on the pubic tubercle.

Inguinal hernias are generally classified as indirect, direct, and femoral based on the site of herniation relative to surrounding structures. Indirect hernias protrude lateral to the inferior epigastric vessels, through the deep inguinal ring. Direct hernias protrude medial to the inferior epigastric vessels, within Hesselbach's triangle. The borders of the triangle are the inguinal ligament inferiorly, the lateral edge of rectus sheath medially, and the inferior epigastric vessels superolaterally. Femoral hernias protrude through the small and inflexible femoral ring. The borders of the femoral ring include the iliopubic tract and inguinal ligament anteriorly, Cooper's ligament posteriorly, the lacunar ligament medially, and the femoral vein laterally. The Nyhus classification categorizes hernia defects by location, size, and type (Table 37-2).

Table 37-1

Inguinal hernia prevalence by age

AGE (Y)	25-34	35-44	45-54	55-64	65-74	75+
Current prevalence (%)	12	15	20	26	29	34
Lifetime prevalence (%)	15	19	28	34	40	47

Current = repaired hernias excluded; lifetime = repaired hernias included.

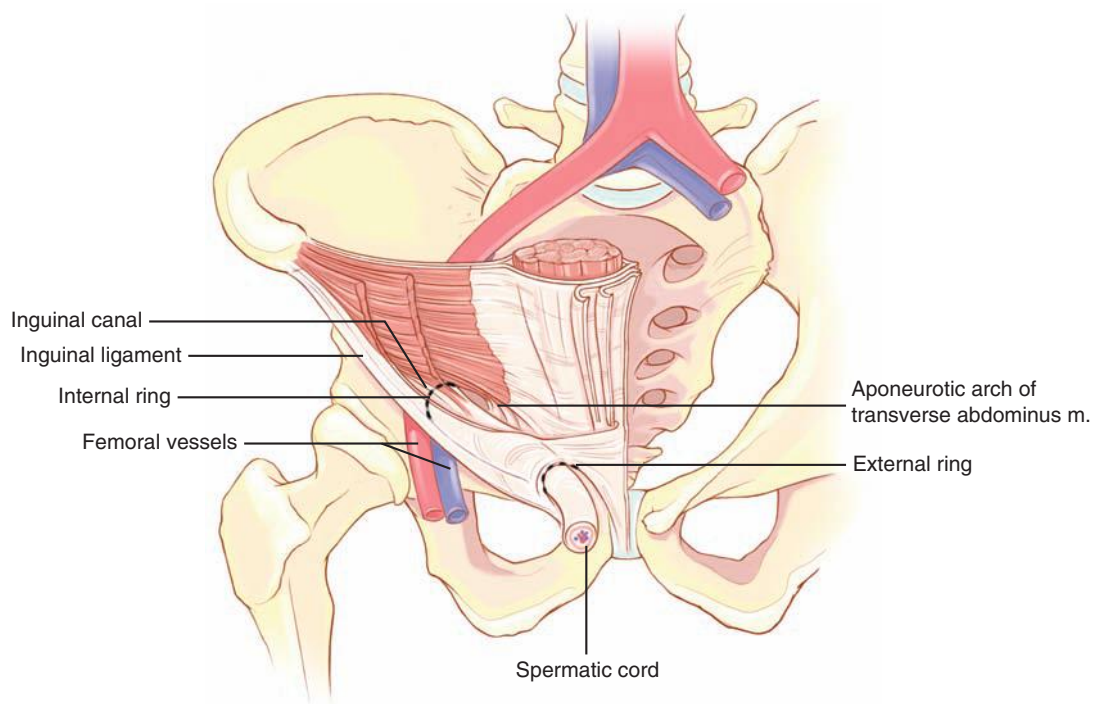


Figure 37-1. Location and orientation of the inguinal canal within the pelvic basin. Boundaries of the canal include: transversus abdominis and transversalis fascia posterior; internal oblique muscle superior; external oblique aponeurosis anterior; inguinal ligament inferior. m. = muscle.

The laparoscopic approach to hernia repair provides a posterior perspective to the peritoneal and preperitoneal spaces (Fig. 37-3). Intraperitoneal points of reference are the five peritoneal folds, bladder, inferior epigastric vessels, and psoas muscle (Fig. 37-4). Two potential spaces exist within the preperitoneum. Between the peritoneum and the posterior lamina of the transversalis fascia is Bogros's (preperitoneal) space. This area contains preperitoneal fat and areolar tissue. The most medial aspect of the preperitoneal space, that which lies superior to the bladder, is known as the space of Retzius. The posterior perspective also allows visualization of the myopectineal orifice of Fruchaud, a relatively weak portion of the abdominal wall that is divided by the inguinal ligament (Fig. 37-5).

The *vascular space* is situated between the posterior and anterior laminae of the transversalis fascia, and it houses the inferior epigastric vessels. The inferior epigastric artery supplies the rectus abdominis. It is derived from the external iliac artery, and it anastomoses with the superior epigastric, a continuation of the internal thoracic artery. The epigastric veins course parallel to the arteries within the rectus sheath, posterior to the rectus muscles. Inspection of the internal inguinal ring will reveal the deep location of the inferior epigastric vessels.

Nerves of interest in the inguinal region are the ilioinguinal, iliohypogastric, genitofemoral, and lateral femoral cutaneous nerves (Figs. 37-6 and 37-7). The ilioinguinal and iliohypogastric nerves arise together from the first lumbar nerve (L1). The

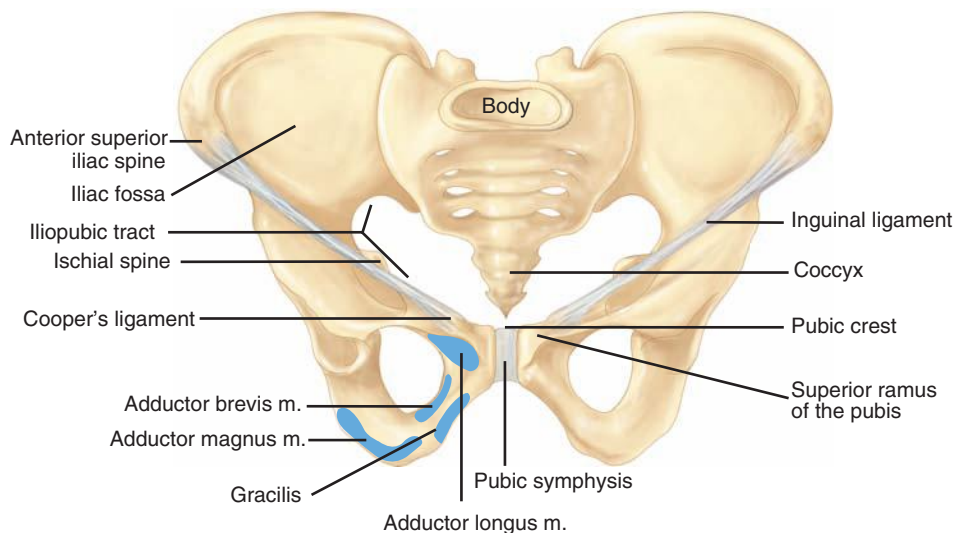


Figure 37-2. Ligaments that contribute to the inguinal canal include the inguinal ligament, Cooper's ligament, and the lacunar ligament. The iliopubic tract originates and inserts in a similar fashion to the inguinal ligament, but in a deeper position. m. = muscle.

Table 37-2

Nyhus classification system

Type I	Indirect hernia; internal abdominal ring normal; typically in infants, children, small adults
Type II	Indirect hernia; internal ring enlarged without impingement on the floor of the inguinal canal; does not extend to the scrotum
Type IIIA	Direct hernia; size is not taken into account
Type IIIB	Indirect hernia that has enlarged enough to encroach upon the posterior inguinal wall; indirect sliding or scrotal hernias are usually placed in this category because they are commonly associated with extension to the direct space; also includes pantaloon hernias
Type IIIC	Femoral hernia
Type IV	Recurrent hernia; modifiers A–D are sometimes added, which correspond to indirect, direct, femoral, and mixed, respectively

ilioinguinal nerve emerges from the lateral border of the psoas major and passes obliquely across the quadratus lumborum. At a point just medial to the anterior superior iliac spine, it pierces the transversus and internal oblique muscles to enter the inguinal canal and exits through the superficial inguinal ring. It supplies somatic sensation to the skin of the upper and medial thigh. In males, it also innervates the base of the penis and upper scrotum. In females, it innervates the mons pubis and labium majus. The iliohypogastric nerve arises from T12–L1. After it pierces the

deep abdominal wall, it courses between the internal oblique and transversus abdominis, supplying both. It then divides into lateral and anterior cutaneous branches. A common variant is for the iliohypogastric and ilioinguinal nerves to exit around the superficial inguinal ring as a single entity. The genitofemoral nerve arises from L1–L2, courses along the retroperitoneum, and emerges on the anterior aspect of the psoas. It then divides into genital and femoral branches. The genital branch enters the inguinal canal lateral to the inferior epigastric vessels, and it courses ventral to the iliac vessels and iliopubic tract. In males, it travels through

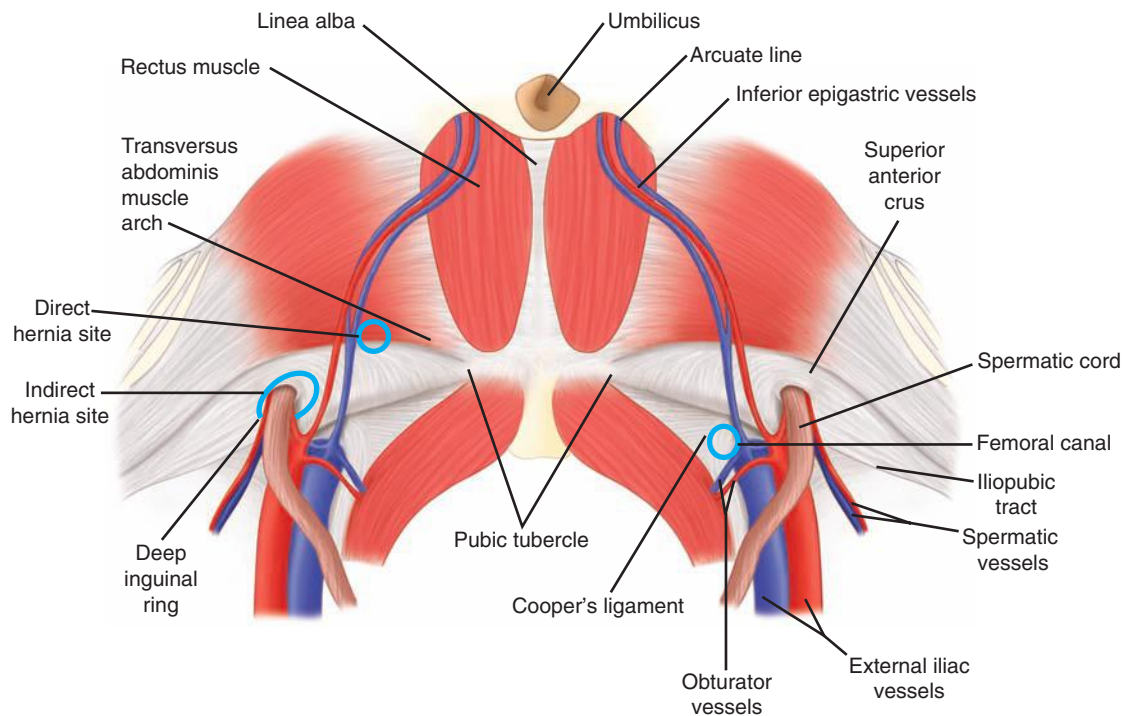


Figure 37-3. Anatomy of the groin region from the posterior perspective.

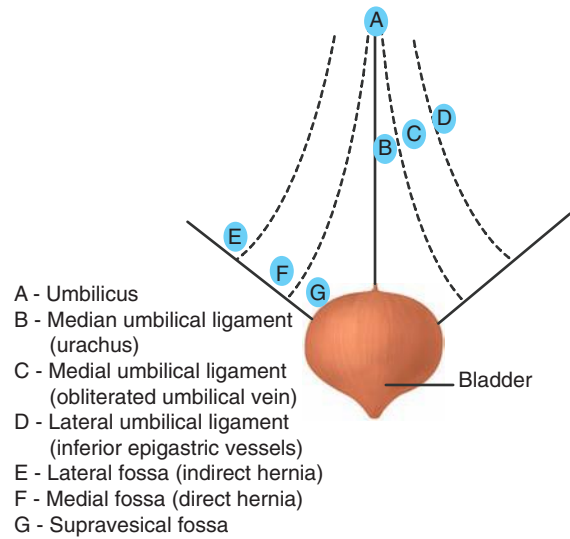


Figure 37-4. Posterior view of intraperitoneal folds and associated fossa: A. Umbilicus. B. Median umbilical ligament. C. Medial umbilical ligament (obliterated umbilical vein). D. Lateral umbilical ligament (inferior epigastric vessels). E. Lateral fossa (indirect hernia). F. Medial fossa (direct hernia). G. Supravesical fossa. (Modified with permission from Rowe JS Jr, Skandalakis JE, Gray SW. Multiple bilateral inguinal hernias. *Am Surg.* 1973;39:269.)

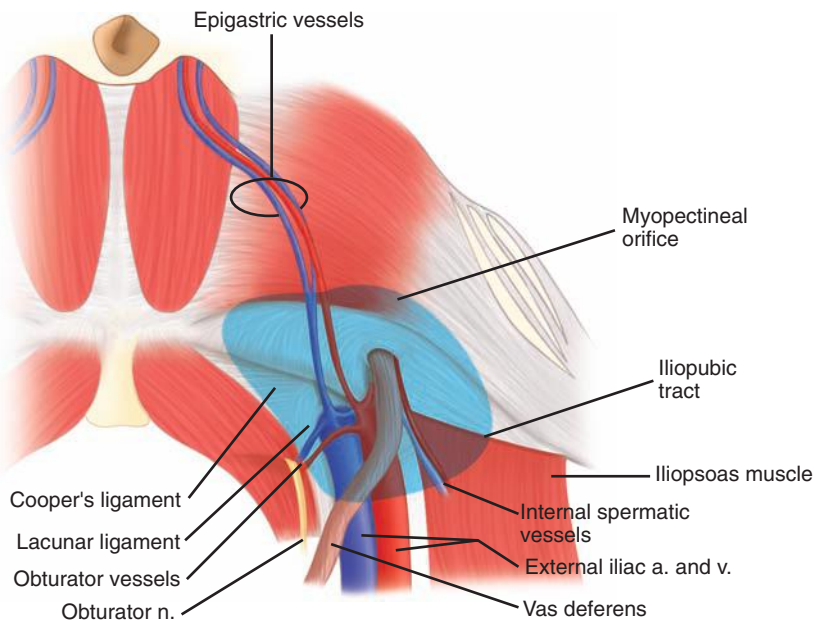


Figure 37-5. Posterior view of the myopectineal orifice of Fruchaud. a. = artery; n. = nerve; v. = vein.

the superficial inguinal ring and supplies the ipsilateral scrotum and cremaster muscle. In females, it supplies the ipsilateral mons pubis and labium majus. The femoral branch courses along the femoral sheath, supplying the skin of the upper anterior thigh. The lateral femoral cutaneous nerve arises from L2–L3, emerges lateral to the psoas muscle at the level of L4, and crosses the iliacus muscle obliquely toward the anterior superior iliac spine. It then passes inferior to the inguinal ligament where it divides to supply the lateral thigh (Fig. 37-8).

The preperitoneal anatomy seen in laparoscopic hernia repair led to characterization of important anatomic areas of

interest, known as the *triangle of doom*, the *triangle of pain*, and the *circle of death* (Fig. 37-9).⁸ The triangle of doom is bordered medially by the vas deferens and laterally by the vessels of the spermatic cord. The contents of the space include the external iliac vessels, deep circumflex iliac vein, femoral nerve, and genital branch of the genitofemoral nerve. The triangle of pain is a region bordered by the iliopubic tract and gonadal vessels, and it encompasses the lateral femoral cutaneous, femoral branch of the genitofemoral, and femoral nerves. The circle of death is a vascular continuation formed by the common iliac, internal iliac, obturator, inferior epigastric, and external iliac vessels.

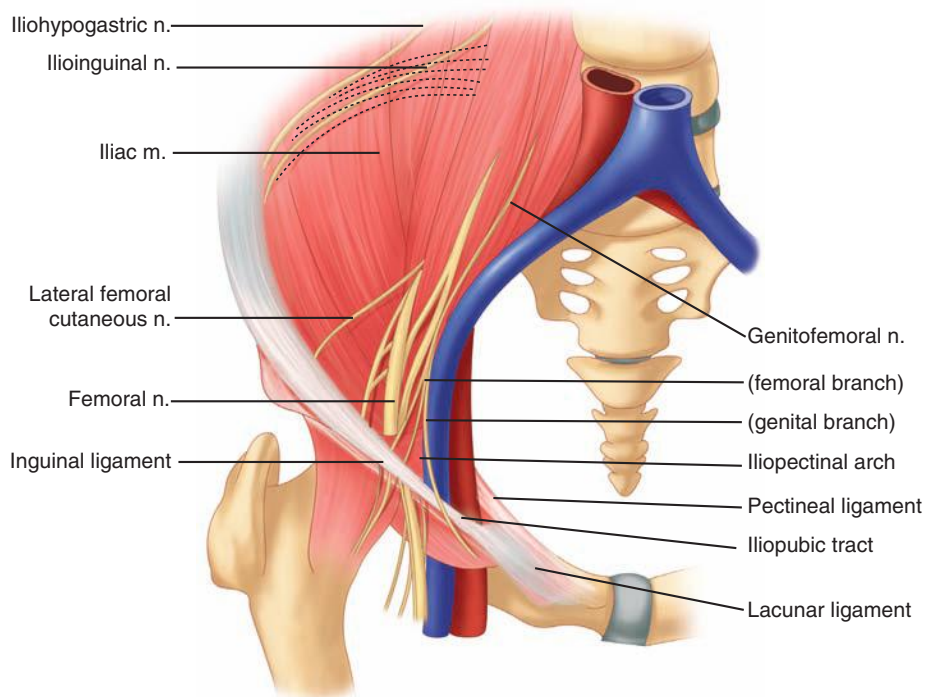


Figure 37-6. Retroperitoneal view of major inguinal nerves and their courses. m. = muscle; n. = nerve.

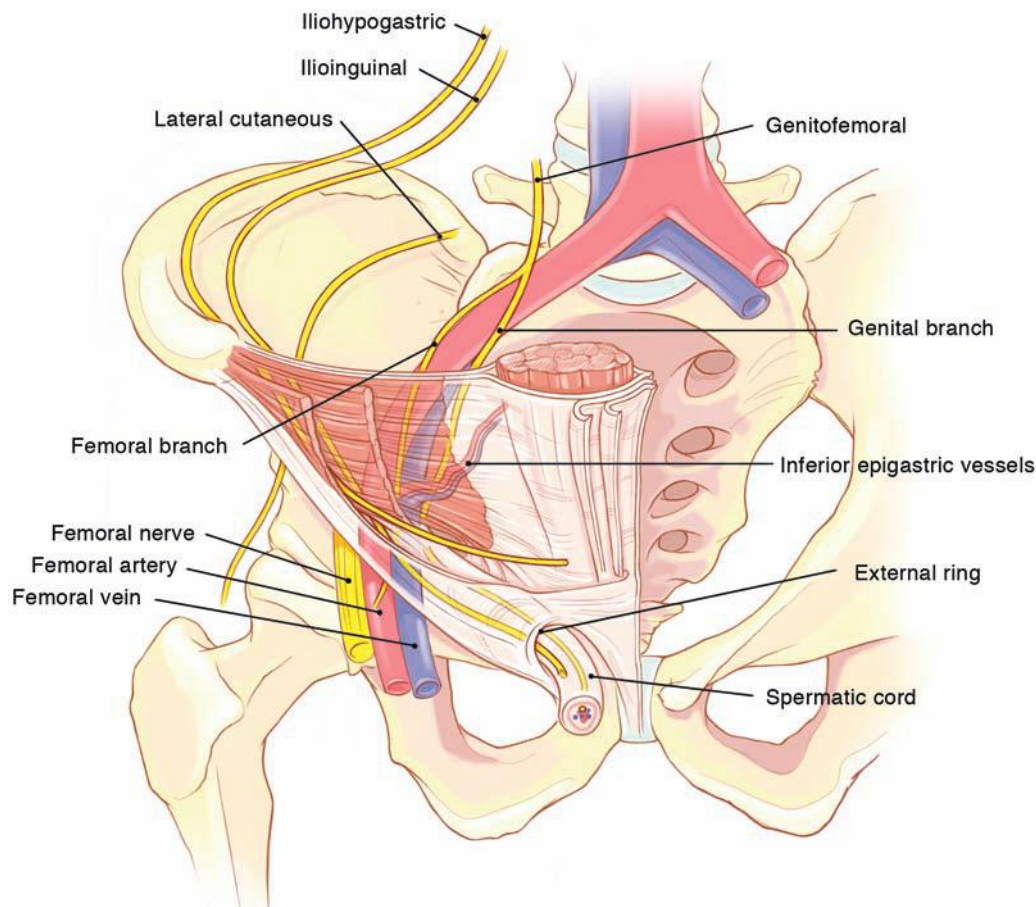


Figure 37-7. Anterior view of the five major nerves of the inguinal region.

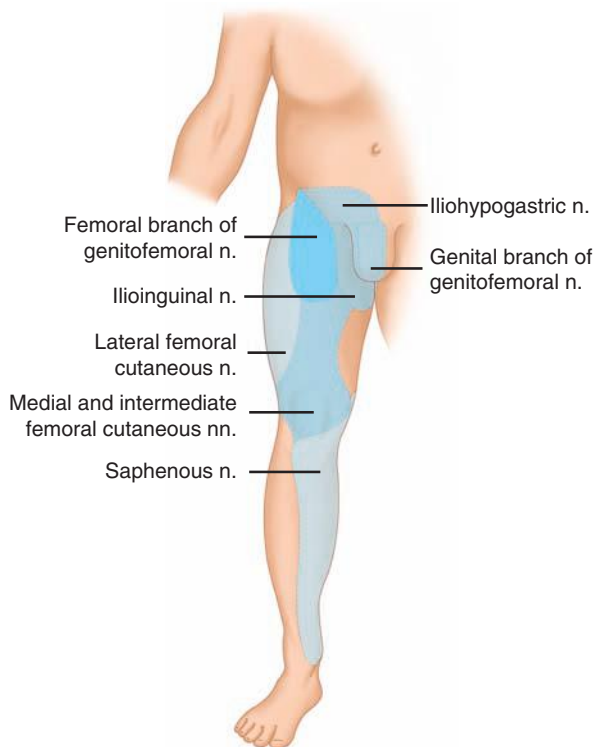


Figure 37-8. Sensory dermatomes of the major nerves in the groin area. n. = nerve.

Pathophysiology

Inguinal hernias may be congenital or acquired. Most adult inguinal hernias are considered acquired defects in the abdominal wall although collagen studies have demonstrated a heritable predisposition. A number of studies have attempted to delineate the precise causes of inguinal hernia formation; however, the best-characterized risk factor is weakness in the abdominal wall musculature (Table 37-3). Congenital hernias, which make up the majority of pediatric hernias, can be considered an impediment of normal development, rather than an acquired weakness. During the normal course of development, the testes descend from the intra-abdominal space into the scrotum in the third trimester. Their descent is preceded by the gubernaculum and a diverticulum of peritoneum, which protrudes through the inguinal canal and becomes the processus vaginalis. Between 36 and 40 weeks of gestation, the processus vaginalis closes and eliminates the peritoneal opening at the internal inguinal ring.⁹ Failure of the peritoneum to close results in a patent processus vaginalis (PPV), hence the high incidence of indirect inguinal hernias in preterm babies. Children with congenital indirect inguinal hernias will present with a PPV; however, a patent processus does not necessarily indicate an inguinal hernia (Fig. 37-10). In a study of nearly 600 adults undergoing general laparoscopy, bilateral inspection revealed that 12% had PPV. None of these patients had clinically significant symptoms of a groin hernia.¹⁰ In a group of 300 patients undergoing unilateral laparoscopic inguinal hernia repair, 12% were found to have a contralateral PPV, which was associated with a fourfold 5-year incidence of inguinal hernia.¹¹

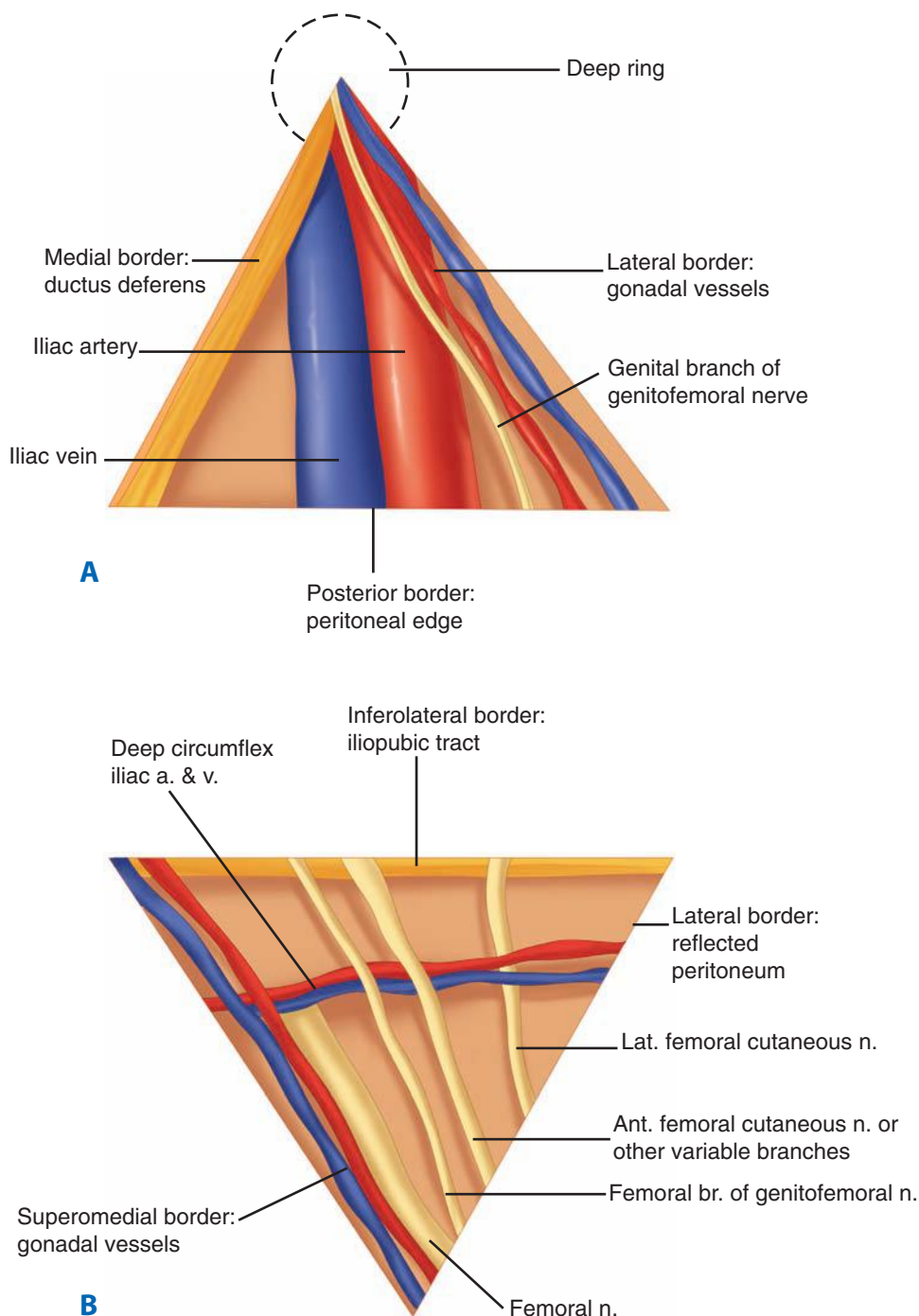


Figure 37-9. Borders and contents of the (A) triangle of doom and (B) triangle of pain. a. = artery; Ant. = anterior; br. = branch; Lat. = lateral; n. = nerve; v. = vein. (Modified with permission from Colborn GL, Skandalakis JE. *Laparoscopic cadaveric anatomy of the inguinal area*. *Probl Gen Surg*. 1995;12:13.)

The presence of a PPV likely predisposes a patient to the development of an inguinal hernia. This likelihood depends on the presence of other risk factors such as inherent tissue weakness, family history, and strenuous activity. Overall, there are limited data regarding the etiology of inguinal hernia development. Several studies have documented strenuous physical activity as a risk factor for acquired inguinal hernia.^{12,13} Repeated physical exertion may increase intra-abdominal pressure; however, whether this process occurs in combination with a PPV or through age-related weakness of abdominal wall musculature is unknown. A case-controlled study of over 1400 male patients with inguinal hernia revealed that a positive family history was

associated with an eightfold lifetime incidence of inguinal hernia. Chronic obstructive pulmonary disease also significantly increases the risk of direct inguinal hernias, as it is accompanied by repeated episodes of high intra-abdominal pressure.¹⁴ Several studies have suggested a protective effect of obesity. In a large, population-based prospective study of American individuals (First National Health and Nutrition Examination Survey), the risk of inguinal hernia development in obese men was only 50% that of normal weight males, whereas the risk in overweight males was 80% that of nonobese men. A possible explanation is the increased difficulty in detecting inguinal hernias in obese individuals.¹⁵

Table 37-3

Presumed causes of groin herniation

Coughing
Chronic obstructive pulmonary disease
Obesity
Straining
Constipation
Prostatism
Pregnancy
Birthweight <1500 g
Family history of a hernia
Valsalva's maneuver
Ascites
Upright position
Congenital connective tissue disorders
Defective collagen synthesis
Previous right lower quadrant incision
Arterial aneurysms
Cigarette smoking
Heavy lifting
Physical exertion

Table 37-4

Connective tissue disorders associated with groin herniation

Osteogenesis imperfecta
Cutis laxa (congenital elastolysis)
Ehlers-Danlos syndrome
Hurler-Hunter syndrome
Marfan's syndrome
Congenital hip dislocation in children
Polycystic kidney disease
α_1 -Antitrypsin deficiency
Williams syndrome
Androgen insensitivity syndrome
Robinow's syndrome
Serpentine fibula syndrome
Alport's syndrome
Tel Hashomer camptodactyly syndrome
Leriche's syndrome
Testicular feminization syndrome
Rokitansky-Mayer-Küster syndrome
Goldenhar's syndrome
Morris syndrome
Gerhardt's syndrome
Menkes' syndrome
Kawasaki disease
Pfannenstiel syndrome
Beckwith-Wiedemann syndrome
Rubinstein-Taybi syndrome
Alopecia-photophobia syndrome

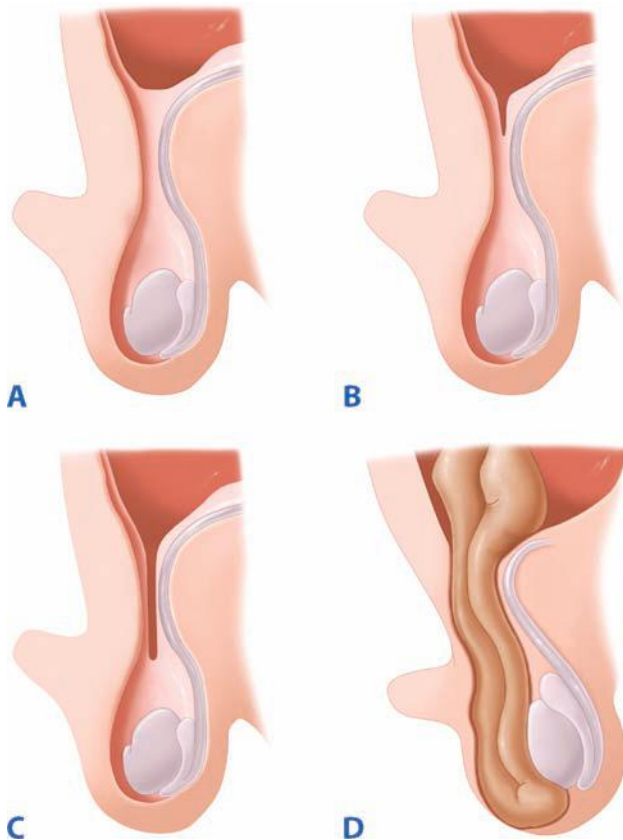


Figure 37-10. Varying degrees of closure of the processus vaginalis (PV). **A.** Closed PV. **B.** Minimally patent PV. **C.** Moderately patent PV. **D.** Scrotal hernia.

Epidemiologic studies have identified risk factors that may predispose to a hernia. Microscopic examination of skin of inguinal hernia patients demonstrated significantly decreased ratios of type I to type III collagen. Type III collagen does not contribute to wound tensile strength as significantly as type I collagen. Additional analyses revealed disaggregated collagen tracts with decreased collagen fiber density in hernia patients' skin.¹⁶ Collagen disorders such as Ehlers-Danlos syndrome are also associated with an increased incidence of hernia formation (Table 37-4). Recent studies have found an association between concentrations of extracellular matrix elements and hernia formation.¹⁷ Although a significant amount of work remains to elucidate the biologic nature of hernias, current evidence suggests they have a multifactorial etiology with both environmental and hereditary influences.

DIAGNOSIS

History

Inguinal hernias present along a spectrum of scenarios. These range from incidental discovery to surgical emergencies such as incarceration and strangulation of the hernia sac contents. Patients who present with a symptomatic groin hernia will

frequently report groin pain. Extrainguinal symptoms such as a change in bowel habits or urinary symptoms are less common. Inguinal hernias may compress adjacent nerves, leading to generalized pressure, localized sharp pain, and referred pain. Pressure or heaviness in the groin is a common complaint, especially at the conclusion of the day or following prolonged activity. Sharp pain tends to indicate an impinged nerve and may not be related to the extent of physical activity performed by the patient. Neurogenic pain may be referred to the scrotum, testicle, or inner thigh. Questions should be directed to elicit and characterize extrainguinal symptoms. A change in bowel habits or urinary symptoms may indicate a sliding hernia consisting of intestinal contents or involvement of the bladder within the hernia sac.

Important considerations of the patient's history include the duration and timing of symptoms. Hernias will often increase in size and content over a protracted time. Much less commonly, a patient will present with a history of acute inguinal herniation following a strenuous activity. It is more likely that an asymptomatic inguinal hernia became evident once the patient experienced symptoms after an acute event. Questions should also be directed to characterize whether the hernia is reducible. Patients will often reduce the hernia by pushing the contents back into the abdomen, thereby providing temporary relief. As the defect size increases and more intra-abdominal contents fill the hernia sac, the hernia may become harder to reduce.

Physical Examination

Physical examination is essential to the diagnosis of inguinal hernia. Asymptomatic hernias are frequently diagnosed incidentally on physical examination or may be brought to the patient's attention as an abnormal bulge. Ideally, the patient should be examined in a standing position to increase intra-abdominal pressure, with the groin and scrotum fully exposed. Inspection is performed first, with the goal of identifying an abnormal bulge along the groin or within the scrotum. If an obvious bulge is not detected, palpation is performed to confirm the presence of the hernia.

Palpation is performed by advancing the index finger through the scrotum toward the external inguinal ring (Fig. 37-11). This allows the inguinal canal to be explored. The patient is then asked to perform Valsalva's maneuver to protrude the hernia contents. These maneuvers will reveal an abnormal bulge and allow the clinician to determine whether the hernia is reducible or not. Examination of the contralateral side affords the clinician the opportunity to compare the presence and extent of herniation between sides. This is especially useful in the case of a small hernia. In addition to inguinal hernia, a number of other diagnoses may be considered in the differential of a groin bulge (Table 37-5).

Certain techniques of the physical examination have classically been used to differentiate between direct and indirect hernias. The inguinal occlusion test entails the examiner blocking the internal inguinal ring with a finger as the patient is instructed to cough. A controlled impulse suggests an indirect hernia, while persistent herniation suggests a direct hernia. Transmission of the cough impulse to the tip of the finger implies an indirect hernia, while an impulse palpated on the dorsum of the finger implies a direct hernia. When results of physical examination are compared against operative findings, there is a probability somewhat higher than chance (i.e., 50%) of correctly diagnosing the type of hernia.^{18,19} Accordingly,

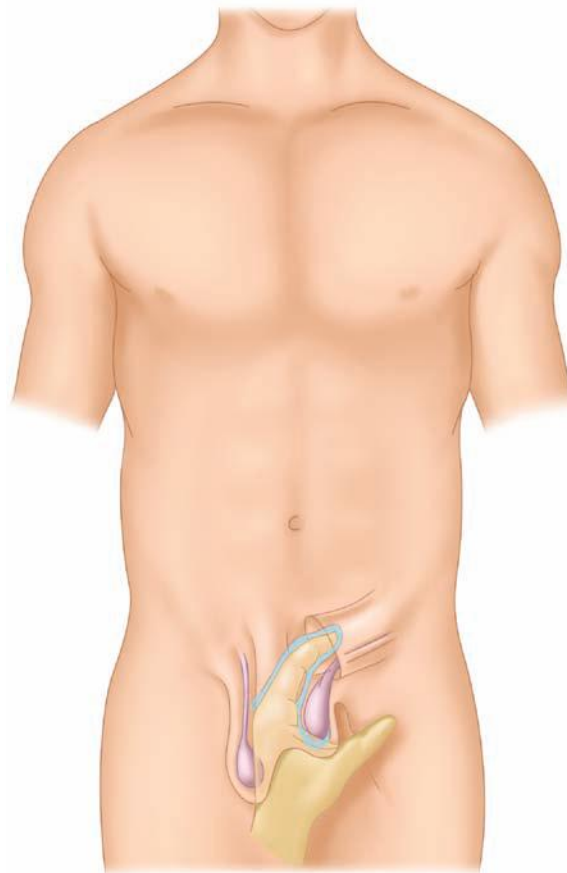


Figure 37-11. Digital examination of the inguinal canal.

Table 37-5

Differential diagnosis of groin hernia

Malignancy
Lymphoma
Retroperitoneal sarcoma
Metastasis
Testicular tumor
Primary testicular
Varicocele
Epididymitis
Testicular torsion
Hydrocele
Ectopic testicle
Undescended testicle
Femoral artery aneurysm or pseudoaneurysm
Lymph node
Sebaceous cyst
Hidradenitis
Cyst of the canal of Nuck (female)
Saphenous varix
Psoas abscess
Hematoma
Ascites

these tests should be used to detect hernias, but not to diagnose hernia types.

External groin anatomy is difficult to assess in obese patients, making the physical diagnosis of inguinal hernia challenging. A further challenge to the physical examination is the identification of a femoral hernia. Femoral hernias should be palpable below the inguinal ligament, lateral to the pubic tubercle. In obese patients, a femoral hernia may be missed or misdiagnosed as a hernia of the inguinal canal. In contrast, a prominent inguinal fat pad in a thin patient, otherwise known as a *femoral pseudohermia*, may prompt an erroneous diagnosis of femoral hernia.

Imaging

In the case of an ambiguous diagnosis, radiologic investigations may be used as an adjunct to history and physical examination. Imaging in obvious cases is unnecessary and costly. The most common radiologic modalities include ultrasonography (US), computed tomography (CT), and magnetic resonance imaging (MRI). Each technique has certain advantages over physical examination alone; however, each modality is associated with potential limitations.

US is the least invasive technique and does not impart any radiation to the patient. Anatomic structures can be more easily identified by the presence of bony landmarks; however, because there are few bones in the inguinal canal, other structures such as the inferior epigastric vessels are used to define groin anatomy. Positive intra-abdominal pressure is used to elicit the herniation of abdominal contents. Movement of these contents through the canal is essential to making the diagnosis with US, and lack of this movement may lead to a false-negative result. A recent meta-analysis demonstrated that US detects inguinal hernia with a sensitivity of 86% and specificity of 77%.²⁰ In thin patients, normal movement of the spermatic cord and posterior abdominal wall against the anterior abdominal wall may lead to false-positive diagnoses of hernia.²¹

CT and MRI provide static images that are able to delineate groin anatomy, to detect groin hernias, and to exclude potentially confounding diagnoses (Fig. 37-12). A meta-analysis determined that standard CT detects inguinal hernia with a

sensitivity of 80% and specificity of 65%. Although direct herniography has a higher sensitivity and specificity than CT, its invasiveness and limited availability restrict its routine use.²⁰ As CT imaging increases in resolution, its sensitivity in detecting inguinal hernia is expected to expand; however, this has yet to be clinically confirmed by surgical correlation.²²

When used to diagnose inguinal hernia, MRI is frequently reserved for cases where physical examination detects a groin bulge, but where US is inconclusive. In a 1999 study of 41 patients with clinical findings of inguinal hernia, laparoscopy revealed that MRI was an effective diagnostic test, with a sensitivity of 95% and specificity of 96%.²³ MRI has become more sophisticated since 1999; however, its high cost and limited access remain obstacles to more routine use.

TREATMENT

Surgical repair is the definitive treatment of inguinal hernias; however, operation is not necessary in a subset of patients. When the patient's medical condition confers an unacceptable level of operative risk, elective surgery should be deferred until the condition resolves, and operations reserved for life-threatening emergencies. Although the natural history of untreated inguinal hernias is poorly defined, the rates of incarceration and strangulation are low in the asymptomatic population. As a result, nonoperative management is an appropriate consideration in minimally symptomatic patients. Prospective studies and meta-analyses have demonstrated no difference in intent-to-treat outcomes, quality of life, or cost-effectiveness between nonoperative management and elective repair among healthy inguinal hernia patients.^{24,25} A 2012 systematic review found that 72% of asymptomatic inguinal hernia patients developed symptoms (mostly pain) and had surgical repair within 7.5 years of diagnosis.²⁶ Nevertheless, the complication rates of immediate and delayed elective tension-free repair are equivalent.^{25,27} A nonoperative strategy is safe for minimally symptomatic inguinal hernia patients, and it does not increase the risk of developing hernia complications.

Nonoperative inguinal hernia treatment targets pain, pressure, and protrusion of abdominal contents in the symptomatic patient population. The recumbent position aids in hernia reduction via the effects of gravity and a relaxed abdominal wall. Trusses externally confine hernias to a reduced state and intermittently relieve symptoms in up to 65% of patients; however, they do not prevent complications, and they may be associated with an increased rate of incarceration.²⁸ The risks of incarceration and strangulation appear to decrease over the first year, likely because gradual enlargement of the abdominal wall defect facilitates spontaneous reduction of hernia contents. The sheer volume of protruding tissue in an inguinal hernia does not necessarily signify severe morbidity.

Femoral and symptomatic inguinal hernias carry higher complication risks, and so surgical repair is performed earlier for these patients. Irrespective of symptoms, one study found the 3-month and 2-year cumulative incidences of strangulation were 2.8% and 4.5%, respectively, for inguinal hernias and 22% and 45%, respectively, for femoral hernias.²⁹ Data from the Swedish Hernia Registry demonstrate that emergent operation is associated with a sevenfold increase in all-cause mortality over that of elective surgery among 107,838 groin hernia repairs.³⁰ For this reason, it is recommended that femoral hernias and symptomatic inguinal hernias be electively repaired, when possible.

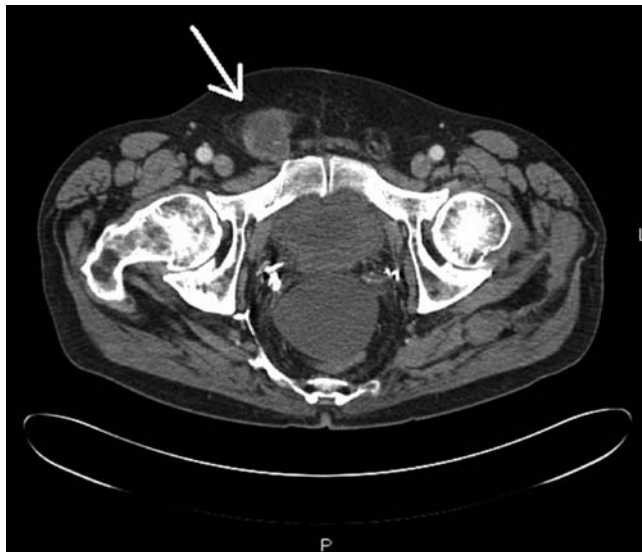


Figure 37-12. Computed tomography scan depicting a large right inguinal hernia (arrow). A smaller left inguinal hernia is also visualized.

The administration of preoperative prophylactic antibiotics in elective inguinal hernia repair remains controversial. A systematic review of 7843 elective open hernia repairs from the Cochrane Database in 2012 revealed an overall decrease in infection rates (odds ratio [OR] 0.64, confidence interval [CI] 0.50–0.82) when prophylactic antibiotics are administered; however, the absolute risk reduction was not sufficient to justify universal recommendations for or against the practice. Overall wound infection rates are higher than those expected for clean operations, and there was a significant reduction in the rate of wound infection among patients undergoing repair with a prosthetic mesh.^{31,32} Although there is no universal guideline regarding the administration of prophylactic antibiotics for open elective hernia repair, it is our experience that meticulous perioperative protocol and surgical technique are more reliable countermeasures to prevent wound infection than antibiotics. Nevertheless, data trends and quality improvement measures have resulted in routine administration of prophylactic perioperative antibiotics in inguinal hernia repairs.

Incarceration occurs when hernia contents fail to reduce; however, a minimally symptomatic, chronically incarcerated hernia may also be treated nonoperatively. Taxis should be attempted for incarcerated hernias without sequelae of strangulation, and the option of surgical repair should be discussed prior to the maneuver. To perform taxis, analgesics and light sedatives are administered, and the patient is placed in the Trendelenburg position. The hernia sac is elongated with both hands, and the contents are compressed in a milking fashion to ease their reduction into the abdomen.

The indication for emergent inguinal hernia repair is impending compromise of intestinal contents. As such, strangulation of hernia contents is a surgical emergency. Clinical signs that indicate strangulation include fever, leukocytosis, and hemodynamic instability. The hernia bulge is usually warm and tender, and the overlying skin may be erythematous or discolored. Symptoms of bowel obstruction in patients with sliding or incarcerated inguinal hernias may also indicate strangulation. Taxis should not be performed when strangulation is suspected, as reduction of potentially gangrenous tissue into the abdomen may result in an intra-abdominal catastrophe. Preoperatively, the patient should receive fluid resuscitation, nasogastric decompression, and prophylactic intravenous antibiotics.

Open Approach

Open inguinal hernia repairs are subdivided into techniques that employ prostheses to create a tension-free repair and those that reconstruct the inguinal floor using native tissue. Tissue repairs are indicated when the use of prosthetic material is contraindicated, (contamination or strangulation).

The option to administer locoregional anesthesia is an advantage of the open approach. Common anesthetic agents include lidocaine or the longer-acting bupivacaine, both with the option of adding epinephrine. In advance of the initial incision, a field block or ilioinguinal nerve block may be employed. A regional block is an option for patients who cannot tolerate general anesthesia, and it exerts a broader effect than local anesthesia alone.

Exposure of the anterior inguinal region is common to the open approaches. An oblique or horizontal incision is performed over the groin (Fig. 37-13). The incision begins two fingerbreadths inferior and medial to the anterior superior iliac spine. It is then extended medially for approximately 6 to 8 cm.

The subcutaneous tissue is dissected using electrocautery. Scarpa's fascia is divided to expose the external oblique aponeurosis. A small incision is made in the external oblique aponeurosis parallel to the direction of the muscle fibers. Metzenbaum scissors are introduced and spread beneath the fibers to separate adhesions to the underlying ilioinguinal nerve. The scissors are then used to incise the aponeurosis superior to the inguinal ligament, splitting the external inguinal ring.

The flaps of the external oblique aponeurosis are elevated with Hemostat clamps. The inferior oblique fibers are dissected bluntly from the overlying external oblique flaps. Dissection of the inferior flap reveals the shelving edge of the inguinal ligament. The iliohypogastric and ilioinguinal nerves are identified and preserved. Effort should be made to avoid removing nerves from their natural bed and disrupting the protective investing fascia. The pubic tubercle is identified and the cord structures are atraumatically dissected off of the pubis, encircled, and elevated with a Penrose drain. The cord is elevated 2 cm over the pubic symphysis in an avascular plane, and cremasteric fibers are preserved to avoid injuring cord structures (Fig. 37-14).

An indirect hernia sac will generally be found on the anterolateral surface of the spermatic cord after division of the cremasteric muscle in the direction of its fibers. The genital nerve is visualized along the inferolateral surface of the cord adjacent to the external spermatic vein. The floor of the inguinal canal is fully assessed for direct hernias. If a hernia is not visualized upon entry into the inguinal canal, the preperitoneal space should be explored for a femoral hernia. In addition to sac identification, the vas deferens and vessels of the spermatic cord must be identified to allow dissection of the sac from the cord. At the leading edge of the sac, the two layers of peritoneum will fold upon themselves and reveal a white edge, which may help in the identification of the sac. The sac can then be grasped with a tissue forceps and bluntly dissected from the cord. The dissection is carried proximally toward the deep inguinal ring.

In cases where the viability of sac contents is in question, the sac should be incised, and hernia contents should be evaluated for signs of ischemia. The defect should be enlarged to augment blood flow to the sac contents. Viable contents may be reduced into the peritoneal cavity, while nonviable contents should be resected, and synthetic prostheses should be avoided in the repair. In elective cases, the sac may be amputated at the internal inguinal ring or inverted into the preperitoneum. Both methods are effective; however, patients undergoing sac excision had significantly increased postoperative pain in a prospective trial.³³ Dissection of a densely adherent sac may result in injury to cord structures and should be avoided; however, sac ligation at the internal inguinal ring is necessary in these cases. A hernia sac that extends into the scrotum may require division within the inguinal canal, as extensive dissection and reduction risks injury to the pampiniform plexus, resulting in testicular atrophy and orchitis.

At this point, the inguinal canal is reconstructed, either with native tissue or with prostheses. The following sections describe the most commonly performed types of tissue-based and prosthetic-based reconstructions.

Tissue Repairs. Tissue-based herniorrhaphy is a suitable alternative when prosthetic materials cannot be used safely. Indications for tissue repairs include operative field contamination, emergency surgery, and when the viability of hernia contents

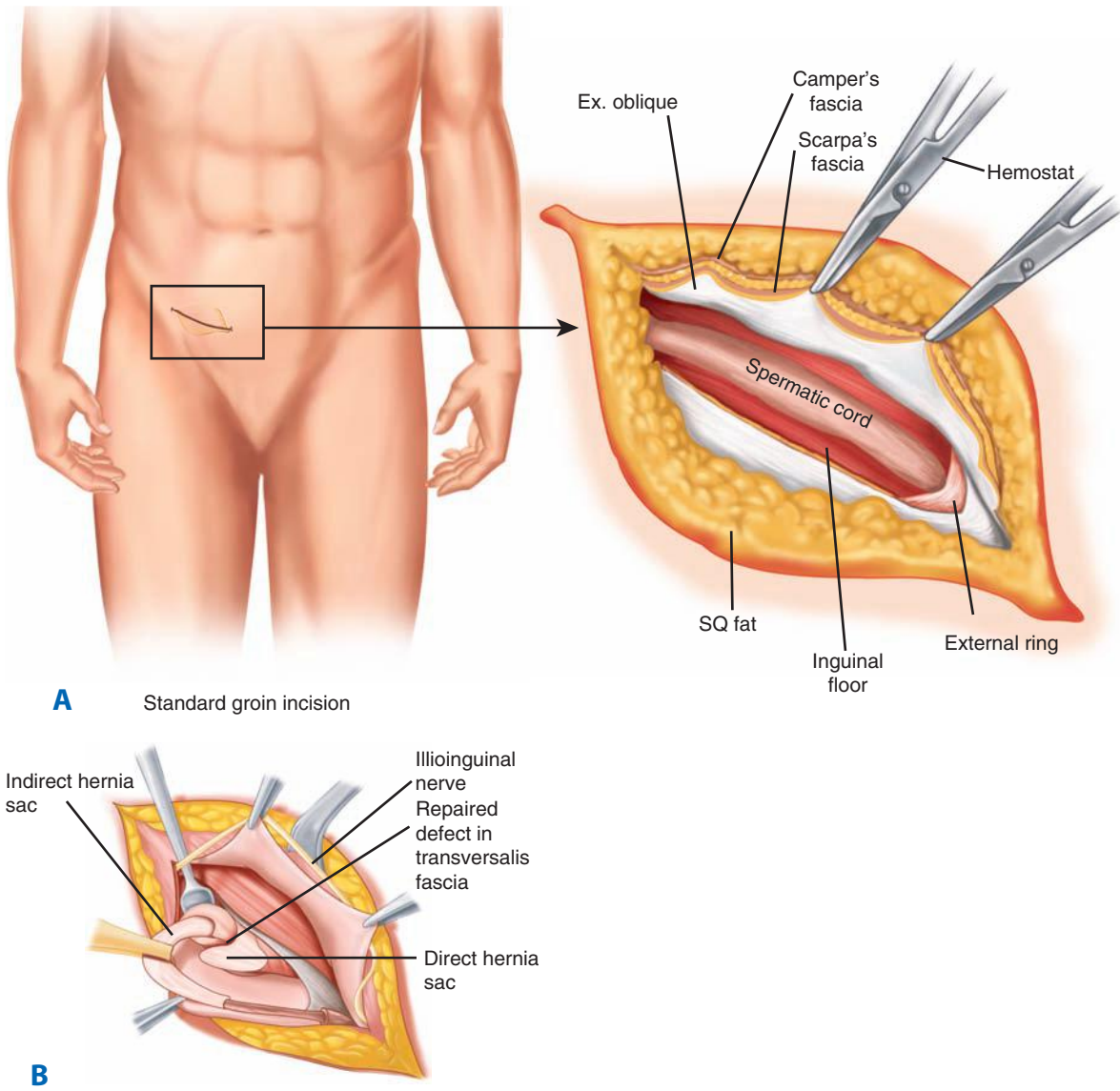


Figure 37-13. **A.** Layers of the abdominal wall in the anterior open approach to hernia repair. **B.** Identification of indirect and direct hernia sacs with retraction of the spermatic cord and ilioinguinal nerve. Ex. = external; SQ = subcutaneous.

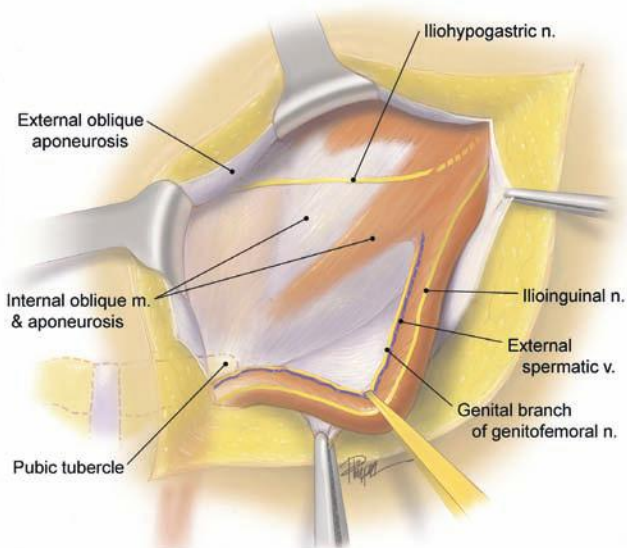


Figure 37-14. Anterior open exposure of the inguinal canal. m. = muscle; n. = nerve; v. = vein.

is uncertain. General surgeons should understand inguinal anatomy and possess the expertise and ability to perform an effective tissue-based repair.

Bassini Repair The Bassini repair was an historic advancement in operative technique. Its current use is limited, as modern techniques reduce recurrence. The original repair includes dissection of the spermatic cord, dissection of the hernia sac with high ligation, and extensive reconstruction of the floor of the inguinal canal (Fig. 37-15). After exposing the inguinal floor, the transversalis fascia is incised from the pubic tubercle to the internal inguinal ring. Preperitoneal fat is bluntly dissected from the upper margin of the posterior side of the transversalis fascia to permit adequate tissue mobilization. A triple-layer repair is then performed. The internal oblique, transversus abdominis, and transversalis fascia are fixed to the shelving edge of the inguinal ligament and pubic periosteum with interrupted sutures. The lateral aspect of the repair reinforces the medial border of the internal inguinal ring.

Shouldice Repair The Shouldice repair recapitulates principles of the Bassini repair, and its distribution of tension over several

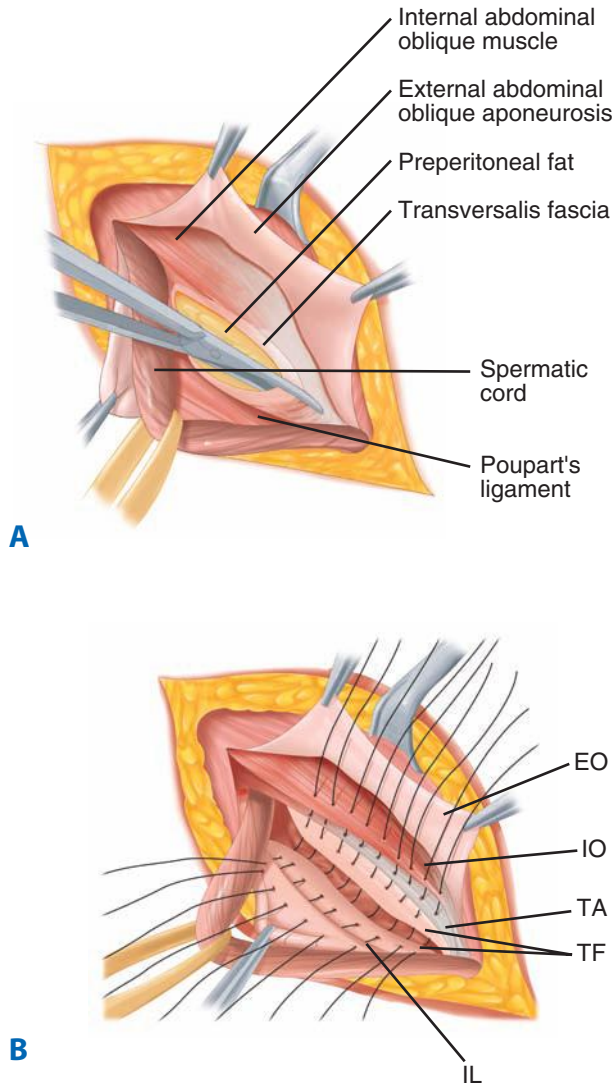


Figure 37-15. Bassini repair. **A.** The transversalis fascia is opened **B.** Reconstruction of the posterior wall by suturing the transversalis fascia (TF), the transversus abdominis muscle (TA), and the internal oblique muscle (IO) medially to the inguinal ligament (IL) laterally. EO = external oblique aponeurosis.

tissue layers results in lower recurrence rates (Fig. 37-16). During dissection of the cord, the genital branch of the genitofemoral nerve is routinely divided, resulting in ipsilateral loss of sensation to the scrotum in men or the mons pubis and labium majus in women. With the posterior inguinal floor exposed, an incision in the transversalis fascia is made between the pubic tubercle and internal ring. Care is taken to avoid injury to preperitoneal structures, which are bluntly dissected to mobilize the upper and lower fascial flaps. At the pubic tubercle, the iliopubic tract is sutured to the lateral edge of the rectus sheath using a synthetic, nonabsorbable, monofilament suture. This continuous suture progresses laterally, approximating the edge of the inferior transversalis flap to the posterior aspect of the superior flap. At the internal inguinal ring, the suture continues back in the medial direction, approximating the edge of the superior transversalis fascia flap to the shelving edge of the inguinal ligament. At the pubic tubercle, this suture is tied to the tail of the original stitch. The next suture begins at the internal inguinal ring, and it continues medially, apposing the aponeuroses of the internal oblique and transversus abdominis to the external oblique aponeurotic fibers. At the pubic

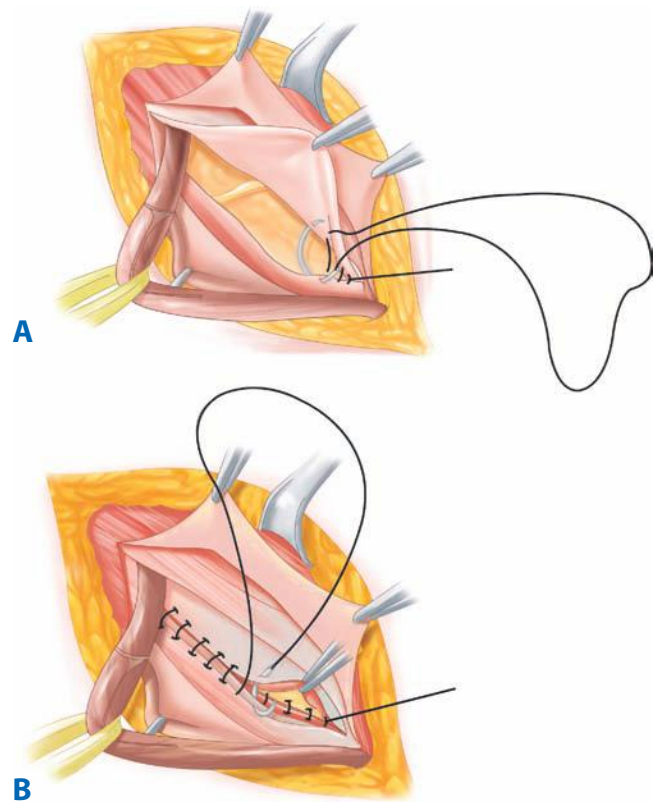


Figure 37-16. Shouldice repair. **A.** The iliopubic tract is sutured to the medial flap of the transversalis fascia and the internal oblique and transverse abdominis muscles. **B.** The second of the four suture lines, reversing toward the pubic tubercle approximating the internal oblique and transversus muscles to the inguinal ligament. Two more suture lines affix the internal oblique and transversus muscles medially.

tubercle, the suture doubles back through the same structures laterally toward the tightened internal ring.

McVay Repair The McVay repair addresses both inguinal and femoral ring defects. This technique is indicated for femoral hernias and in cases where the use of prosthetic material is contraindicated (Fig. 37-17). Once the spermatic cord has been

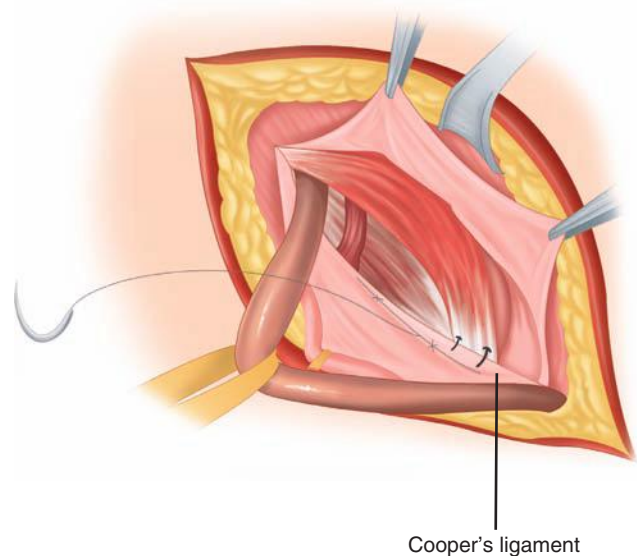


Figure 37-17. McVay Cooper's ligament repair.

isolated, an incision in the transversalis fascia permits entry into the preperitoneal space. The upper flap is mobilized by gentle blunt dissection of underlying tissue. Cooper's ligament is bluntly dissected to expose its surface. A 2- to 4-cm relaxing incision is made in the anterior rectus sheath vertically from the pubic tubercle. This incision is essential to reduce tension on the repair; however, it may result in increased postoperative pain and higher risk of ventral abdominal herniation. Using either interrupted or continuous suture, the superior transversalis flap is then fastened to Cooper's ligament, and the repair is continued laterally along Cooper's ligament to occlude the femoral ring. Lateral to the femoral ring, a transition stitch is placed, affixing the transversalis fascia to the inguinal ligament. The transversalis is then sutured to the inguinal ligament laterally to the internal ring.

Prosthetic Repairs. The popularization of tension-free prosthetic mesh repairs signified a paradigm shift in the surgical concept of inguinal hernia pathophysiology. Mesh-based hernioplasty is the most commonly performed general surgical procedure, owing to the technique's efficacy and improved outcomes. The techniques of the most commonly performed prosthetic repairs are presented in this section.

Lichtenstein Tension-Free Repair The Lichtenstein technique expands the domain of the inguinal canal by reinforcing the inguinal floor with a prosthetic mesh, thereby minimizing tension in the repair (Fig. 37-18). Initial exposure and mobilization of cord structures is identical to other open approaches. The inguinal canal is dissected to expose the shelving edge of the inguinal ligament, the pubic tubercle, and sufficient area for mesh. The mesh is a 7×15 cm rectangle with a rounded medial edge, and it must be large enough to extend 2 to 3 cm superior to Hesselbach's triangle. The lateral portion of the mesh is split such that the superior tail comprises two thirds of its width, and the inferior tail comprises the remaining one third. The medial edge of the mesh is affixed to the anterior rectus sheath such that it overlaps the original pubic tubercle by 1.5 to 2 cm. This refinement to the original Lichtenstein technique minimizes medial recurrence.³⁴

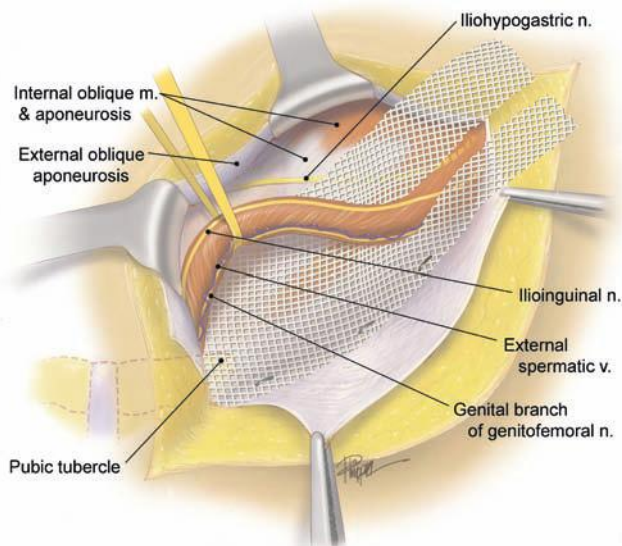


Figure 37-18. Lichtenstein tension-free hernioplasty. m. = muscle; n. = nerve; v. = vein.

For fixation of the inferior margin of the mesh, a permanent, synthetic, monofilament suture is used, taking care to avoid placing sutures directly into the periosteum of the pubic tubercle. Fixation is continued along the shelving edge of the inguinal ligament from medial to lateral, ending at the internal ring. The upper tail of the mesh is then fixed to the internal oblique aponeurosis and the medial edge to the rectus sheath using a synthetic, absorbable suture.

In the case of a femoral hernia, a triangular extension of the inferior aspect of the mesh is sutured to Cooper's ligament medially and to the inguinal ligament laterally. The lateral tails of the mesh are tailored to fit snugly around the cord at the internal ring, but not too tight to strangulate it. The tails are then sutured to the inguinal ligament with an interrupted stitch and placed beneath the external oblique aponeurosis.

Plug and Patch Technique A modification of the Lichtenstein repair, the plug and patch technique was developed by Gilbert and later popularized by Rutkow and Robbins.³⁵ Prior to placing the prosthetic mesh patch over the inguinal floor, a three-dimensional prosthetic plug is placed in the space previously occupied by the hernia sac (Fig. 37-19). In the case of an indirect

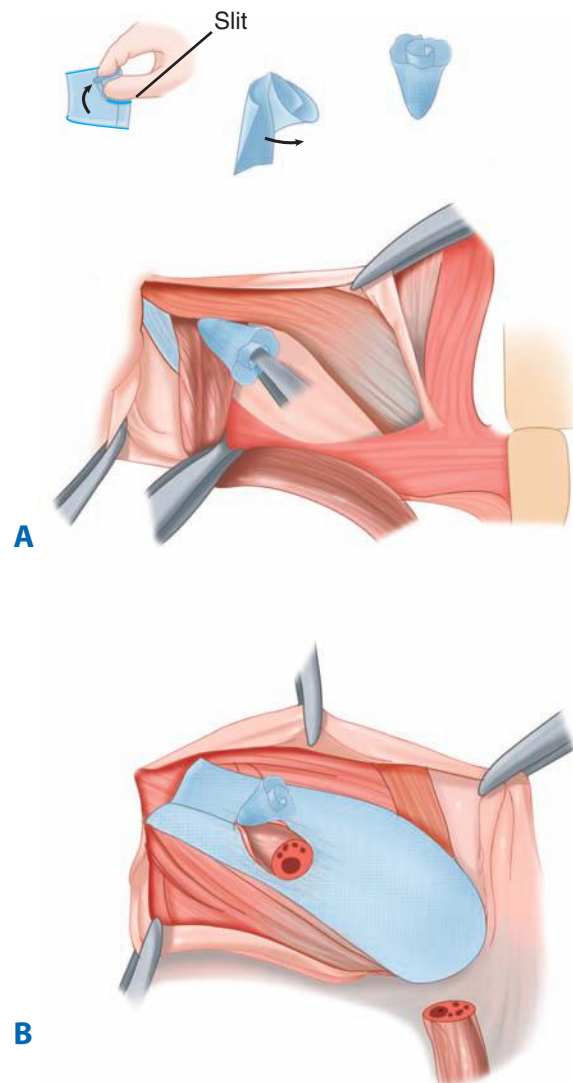


Figure 37-19. Plug and patch repair. **A.** A plug may be created from a flat piece of mesh, or a preformed, commercially available plug is placed in the internal ring. **B.** Final view of the repair following placement of the plug and patch.

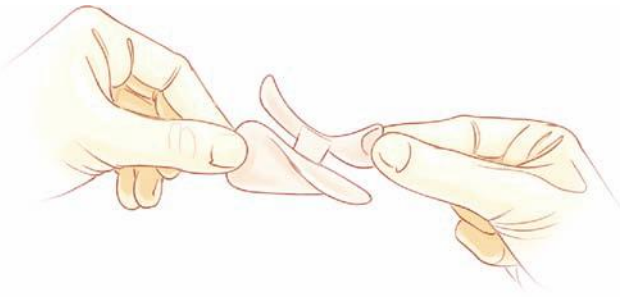


Figure 37-20. The Prolene Hernia System prosthesis.

hernia, the plug is placed alongside the spermatic cord through the internal ring. Prosthetic plugs of various sizes are available, and one of appropriate size is fixed to the margins of the internal ring with interrupted sutures.³⁶ For direct hernias, the sac is reduced, and the plug is sutured to Cooper's ligament, the inguinal ligament, and the internal oblique aponeurosis.

Prolene Hernia System The Prolene Hernia System (PHS) repair provides reinforcement to the anterior and posterior aspects of the abdominal wall. Exposure of the inguinal canal is identical to that of other open approaches. With an indirect hernia, the sac is dissected from the spermatic cord, and the preperitoneal space is bluntly dissected through the internal ring. With a direct hernia, the transversalis fascia is opened at the defect, and the preperitoneal space is bluntly dissected to create space for the mesh. The mesh has an underlay flap and an onlay flap, joined by a short cylindrical connector (Fig. 37-20). The underlay portion of the mesh is then placed through the hernia defect into the preperitoneal space. The advantage of the preperitoneal mesh position is that increased intra-abdominal pressure pushes the mesh into closer apposition to the abdominal wall. The overlay flap reinforces the inguinal floor similar to a tension-free repair. The spermatic cord is placed through a slit in the onlay portion of the mesh. Three to four circumferential interrupted sutures anchor the anterior layer of the mesh to the inguinal canal floor.

Wound Closure. Once the reconstruction of the inguinal canal is complete, the cord contents are returned to their anatomic position. The external oblique aponeurosis is then reapproximated continuously from medial to lateral using an absorbable suture. The external ring should be reconstructed in close apposition to the spermatic cord to avoid the appearance of recurrence on future examination. Scarpa's fascia and skin are appropriately closed.

Giant Prosthetic Reinforcement of the Visceral Sac. In giant prosthetic reinforcement of the visceral sac, also known as the Stoppa repair, a broad prosthetic mesh is placed in the preperitoneal space from an anterior approach. In unilateral repair, an 8- to 10-cm Pfannenstiel or low transverse incision is made above the internal inguinal ring. The lateral aspect of the rectus sheath and the oblique muscles are divided along the length of the incision. The transversalis is incised, and the preperitoneal space is dissected widely (Fig. 37-21). The preperitoneal dissection is carried medially to expose Cooper's ligament and laterally over the iliopubic tract to the anterior superior iliac spine. If bilateral hernias are present, a lower midline incision allows for access and the preperitoneal dissection spans the entire area between both anterior superior iliac spines and both inguinal canals. For direct defects, the transversalis fascia may be sutured

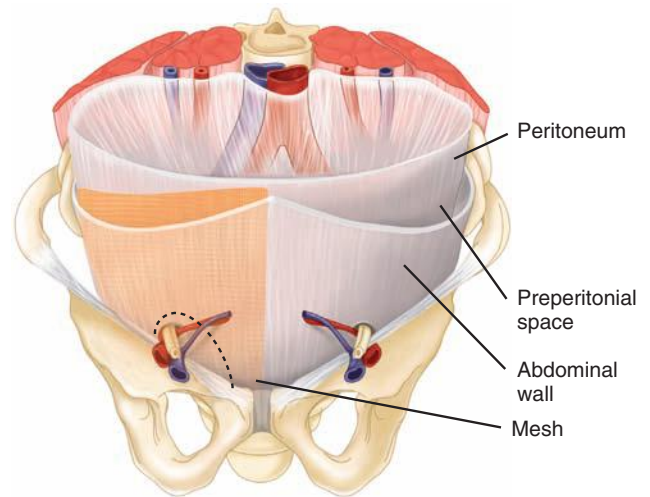


Figure 37-21. Extensive dissection of the preperitoneal space on both sides will accommodate a large prosthesis.

to Cooper's ligament to obliterate the sac's laxity. Indirect hernias require directed dissection from the internal ring. Large or densely adherent indirect hernia sacs are dissected from the cord at the internal ring and ligated, and the peritoneum is closed.

The mesh should be large enough to cover the area from the midline to 1 cm medial to the anterior superior iliac spine and from the umbilicus to the pubic symphysis. The middle portion and lower corners of the mesh are clamped. The mesh is placed flat along the inferior margin of the preperitoneal space (Fig. 37-22). The medial clamp is directed into the space of Retzius, the middle clamp is placed over the pubic ramus and iliac vessels, and the lateral clamp is placed into the iliac fossa cover the spermatic cord. Splitting the mesh to accommodate the cord may predispose to hernia recurrence. Alternatively, the mesh may be fixed with interrupted sutures to the anterior abdominal wall; however, care must be taken to avoid injuring the lateral femoral cutaneous nerve and the inferior epigastric vessels. For bilateral hernias, a single large mesh is placed into the preperitoneal space using up to eight clamps along its inferior edge. The transversalis is reapproximated and the wound is closed.

Laparoscopic Approach

Laparoscopic inguinal hernia repairs reinforce the abdominal wall via a posterior approach. Principal laparoscopic methods include the transabdominal preperitoneal (TAPP) repair, the totally extraperitoneal (TEP) repair, and the less commonly performed intraperitoneal onlay mesh (IPOM) repair.

Although laparoscopic repairs in experienced hands are relatively expedient, they necessitate the administration of general anesthesia and its inherent risks. Any patient with a contraindication to the use of general anesthesia should not undergo laparoscopic hernia repair. Occasionally, general anesthesia induction may result in reduction of an incarcerated or strangulated inguinal hernia. If the surgeon suspects this might have occurred, the abdomen should be explored for nonviable tissue either via laparoscopy or upon conversion to an open laparotomy.

The indications for laparoscopic inguinal hernia repair are similar to those for open repair. Most surgeons would agree that the laparoscopic approach to bilateral or recurrent inguinal hernias is superior to the open approach.³⁷ Concurrent inguinal hernia repair should be considered if a hernia patient

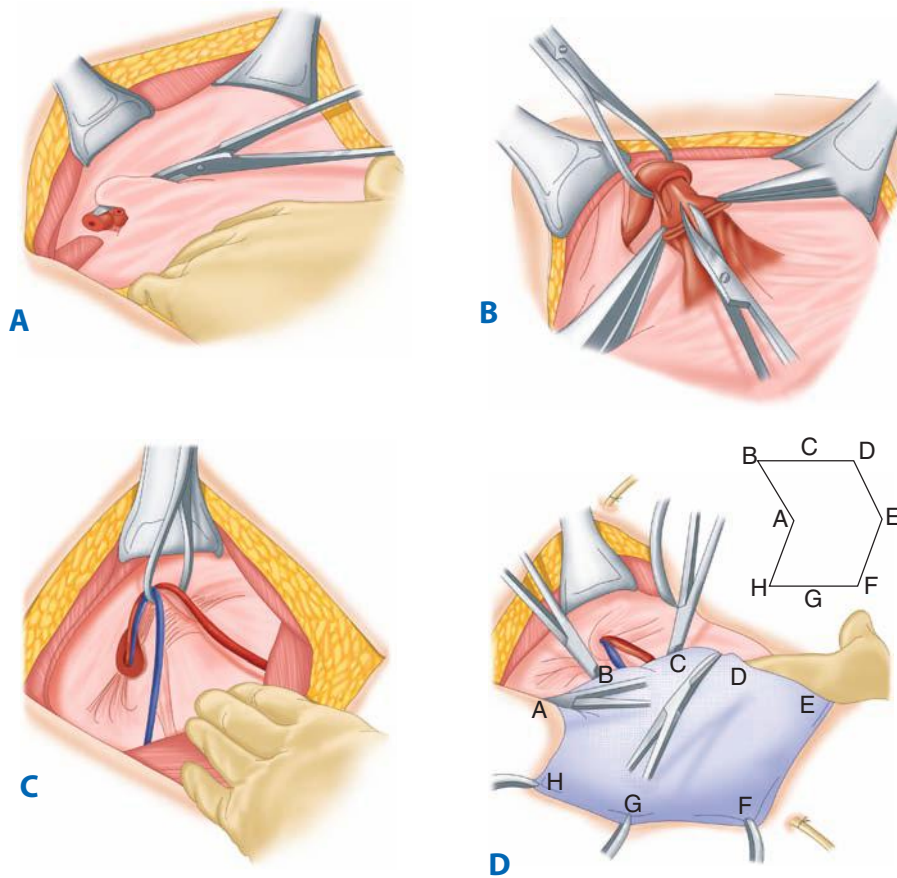


Figure 37-22. Giant prosthetic reinforcement of the visceral sac. **A.** Exposure of the preperitoneal space. **B.** Dissection of the hernia sac from the spermatic cord. **C.** Reduction of the sac and elevation of the cord. **D.** Orientation and placement of the giant mesh.

is scheduled to undergo another clean laparoscopic procedure, such as prostatectomy.^{38,39} International Endohernia Society (IEHS) guidelines offer a Grade A recommendation that TEP and TAPP are preferred alternatives to Lichtenstein repair for recurrent hernias after open anterior repair.⁴⁰ The possibility of bilateral repair should be discussed with all patients undergoing laparoscopic inguinal hernia surgery.

The operating room configuration is identical for TAPP, TEP, and IPOM procedures. The patient is placed in the Trendelenburg position, and video screens are placed at the foot of the bed. The surgeon stands contralateral to the hernia, and the assistant stands opposite the surgeon. The patient's arms are tucked to the sides. Fig. 37-23 demonstrates a typical operating room setup for laparoscopic inguinal hernia repair. The following sections outline the most commonly performed laparoscopic inguinal hernia repair techniques.

Transabdominal Preperitoneal Procedure. The transabdominal approach confers the advantage of an intraperitoneal perspective, which is useful for bilateral hernias, large hernia defects, and scarring from previous lower abdominal surgery. The abdominal cavity is accessed using a dissecting trocar or open Hasson technique. Pneumoperitoneum is instilled to a level of 15 mmHg. Two 5-mm trocars are placed lateral and slightly inferior to the umbilical trocar, avoiding injury to the inferior epigastric vessels (Fig. 37-24). The patient is then placed in the Trendelenburg position, and the pelvis is inspected.

The bladder, median and medial umbilical ligaments, external iliac, and inferior epigastric vessels are visualized. An incision is made in the peritoneum at the medial umbilical

ligament 3 to 4 cm superior to the hernia defect, and it is carried laterally to the anterior superior iliac spine. For bilateral inguinal hernia repair, bilateral peritoneal incisions are advisable, leaving a midline bridge of tissue to avoid injuring a potential patent urachus. The inferior edge of incised peritoneum is retracted, and the preperitoneum is dissected to expose the spermatic cord. If a direct hernia is encountered, the sac is inverted and fixed to Cooper's ligament to prevent development of hematoma or seroma. An indirect hernia sac will usually protrude anterior to the spermatic cord. In this case, the sac is grasped and elevated superiorly from the cord and the space below is developed bluntly to allow for mesh placement. The sac is dissected from its adhesions, and the cord is skeletonized.

The mesh usually measures 10 × 15 cm to completely cover the myopectineal orifice (Fig. 37-25). It is rolled lengthwise and placed through the 12-mm trocar. It is unrolled in the preperitoneal space and secured medially to Cooper's ligament using a spiral tacker. During this fixation, the surgeon palpates the end of the tacker from the abdominal surface to ensure its proper angle and to stabilize the pelvis. The mesh is then pulled taut and fixed lateral to the anterior superior iliac spine. Tacks are placed above the iliopubic tract to avoid injury to the lateral cutaneous nerve of the thigh and the femoral branch of the genitofemoral nerve. The peritoneal edges are reapproximated using tacks or intracorporeal sutures as the mesh is stabilized. The peritoneum should be closed completely to avoid contact between the mesh and the intestine. The abdomen is desufflated and the trocars are removed. The fascial defect of the 12-mm port and the skin incisions are appropriately closed.

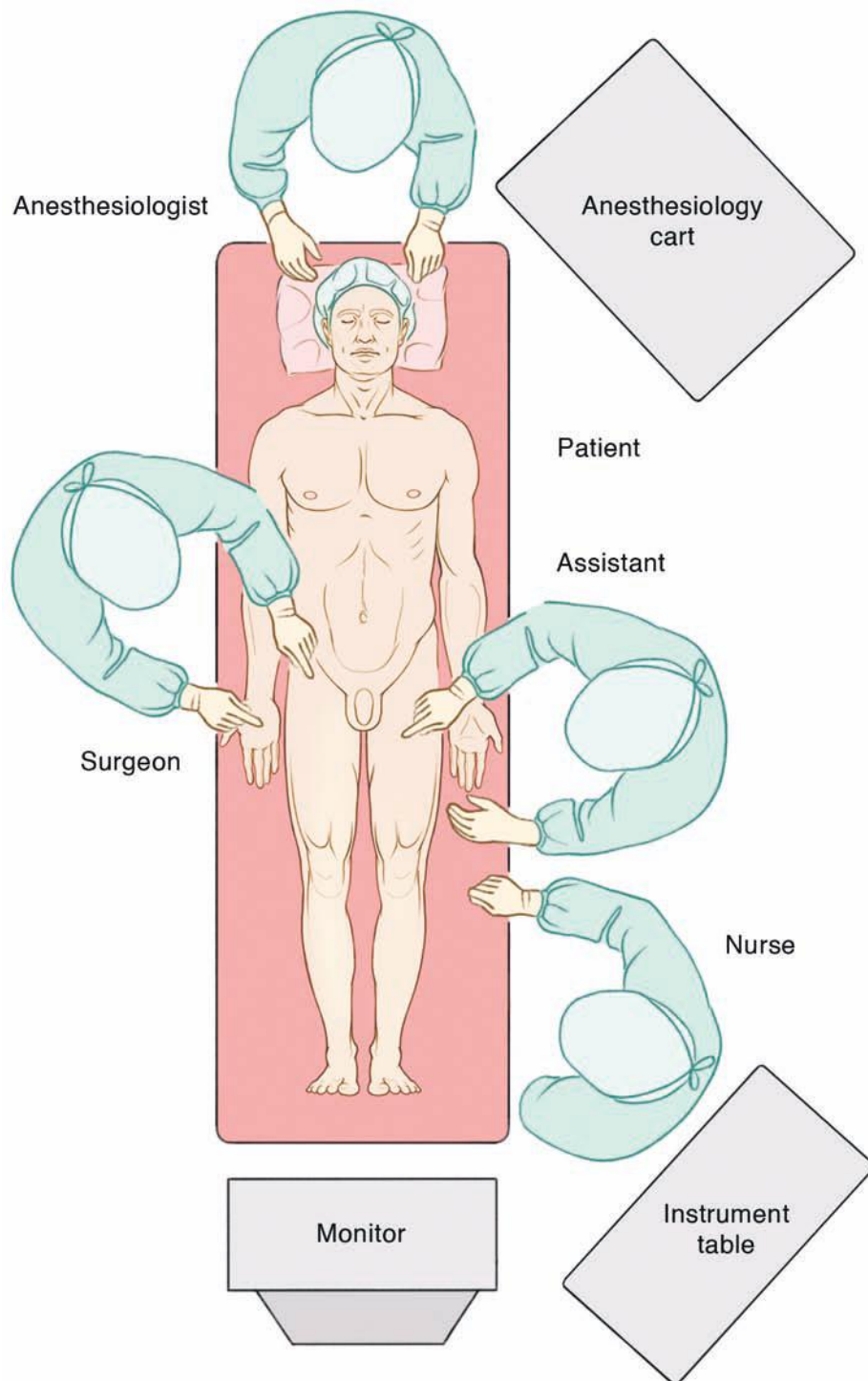


Figure 37-23. Operating room setup for laparoscopic inguinal hernia repair.

Totally Extraperitoneal Procedure. The advantage of the TEP repair is the access to the preperitoneal space without intraperitoneal infiltration. Consequently, this approach minimizes the risk of injury to intra-abdominal organs and port site herniation through an iatrogenic defect in the abdominal wall. As with TAPP, TEP is indicated for repair of bilateral inguinal hernias or for unilateral hernias when scarring makes the anterior approach challenging.

A small horizontal incision is made inferior to the umbilicus. Subcutaneous tissue is dissected to the level of the anterior rectus sheath, which is then incised lateral to the linea alba. The rectus muscle is retracted superolaterally, and a dissect-

ing balloon is advanced through the incision toward the pubic symphysis. Under direct visualization with a 30° laparoscope, the balloon is inflated slowly to bluntly dissect the preperitoneal space (Fig. 37-26). The dissecting balloon is replaced with a 12-mm balloon trocar, and pneumopreperitoneum is achieved by insufflation to 15 mmHg. A 5-mm trocar is placed suprapubically in the midline, and another is placed inferior to the insufflation port (see Fig. 37-24). The patient is placed in the Trendelenburg position, and the operation proceeds in an identical fashion to TAPP. No modifications are necessary to repair bilateral inguinal hernias with the TEP approach.

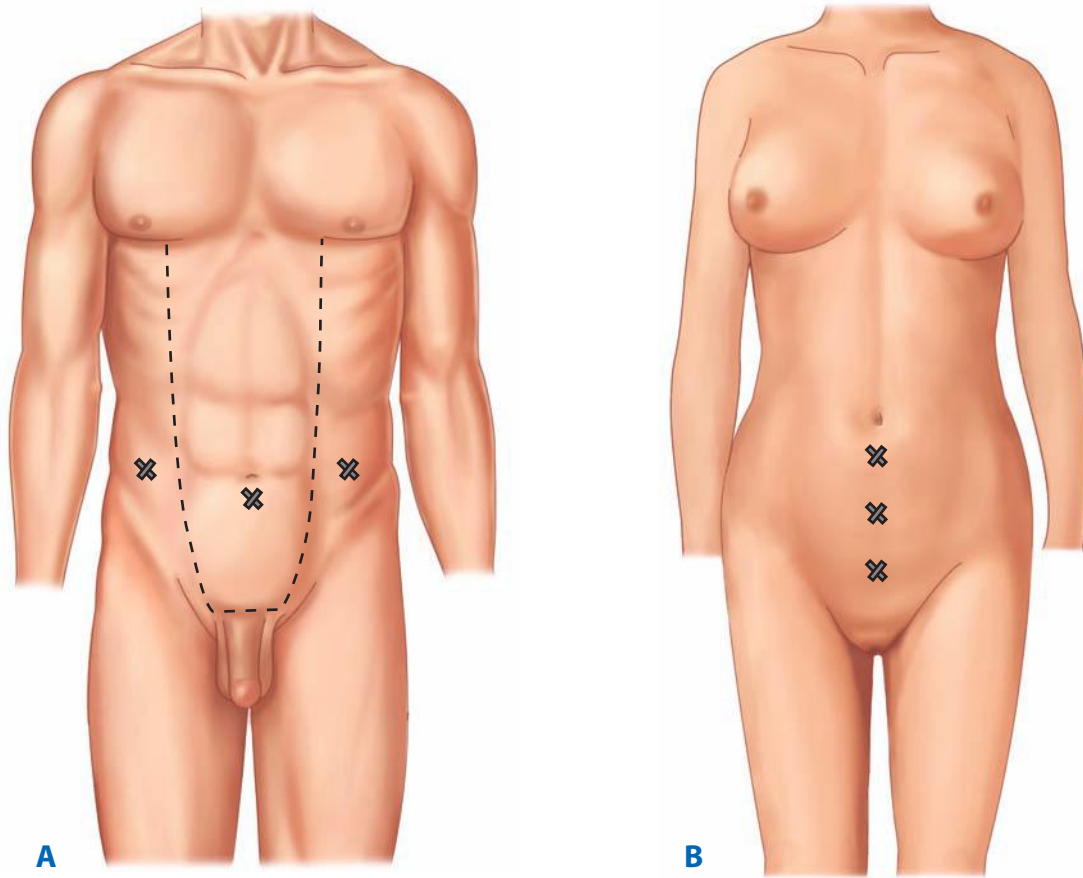


Figure 37-24. Trocar placement for (A) transabdominal preperitoneal repair and (B) totally extraperitoneal repair.

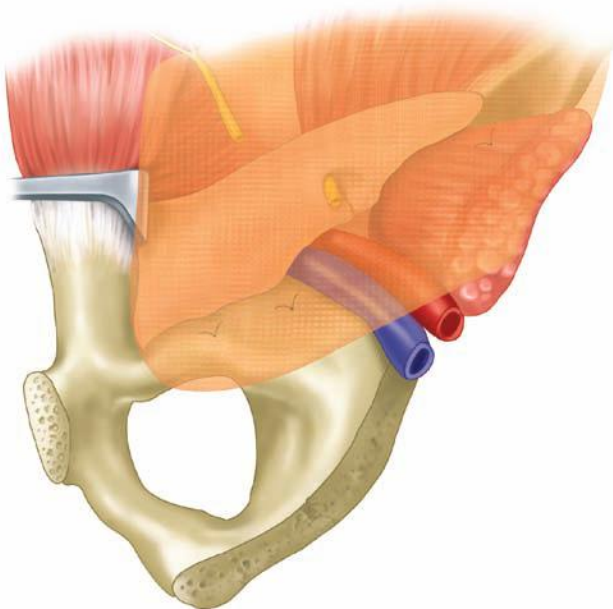


Figure 37-25. View of mesh placement in posterior repairs. A large mesh overlaps the myopectineal orifice.

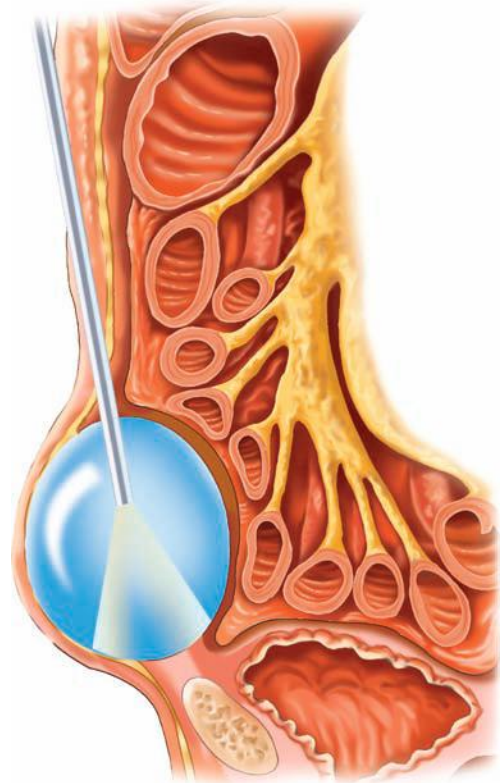


Figure 37-26. Balloon dissection of the preperitoneal space in a totally extraperitoneal inguinal hernia repair.

Any peritoneal rents should be repaired prior to desufflation to prevent mesh from contacting intraperitoneal structures. Following mesh placement, the preperitoneal space is desufflated slowly under direct vision to ensure proper mesh positioning. Trocars are removed, and the anterior rectus sheath is closed with an interrupted suture.

Intraperitoneal Onlay Mesh Procedure. In contrast to TAPP and TEP, the IPOM procedure permits the posterior approach without preperitoneal dissection. It is an attractive procedure in cases where the anterior approach is unfeasible, in recurrent hernias that are refractory to other approaches, or where extensive preperitoneal scarring would make TEP or TAPP challenging. Port placement and inguinal hernia identification are identical to TAPP. Hernia sac contents are reduced; however, the sac itself is not inverted from the preperitoneal space. Instead, mesh is placed directly over the defect and fixed in place with sutures or spiral tacks. Because these anchors are placed through the peritoneum without preperitoneal inspection, the lateral cutaneous nerve of the thigh and the genitofemoral nerve are especially prone to injury. Furthermore, intraperitoneal mesh migration is a documented phenomenon that can lead to postoperative morbidity, recurrence, and reoperation.

Prosthesis Considerations

The success of prosthetic repairs has generated considerable debate about the desirable physical attributes of mesh and their fixation. An ideal mesh should be easy to handle, flexible, strong, immunologically inert, contraction-resistant, infection-resistant, and inexpensive to manufacture.⁴¹ The following section reviews the most common types of mesh and fixatives currently available.

Synthetic Mesh Material. Polypropylene and polyester are the most common synthetic prosthetic materials used in hernia repair. These materials are permanent and hydrophobic, and they promote a local inflammatory response that results in cellular infiltration and scarring with slight contraction in size. Other synthetic mesh materials are under investigation with the goals of minimizing postoperative pain and preventing infection or recurrence. In selecting mesh material, considerations include mesh absorbability, thickness, weight, porosity, and strength.

Variations in the fiber diameter and fiber count of mesh materials categorize them as heavyweight or lightweight in density. Commonly used lightweight mesh materials include β -D-glucan, titanium-coated polypropylene, and polypropylene-polyglactone. These materials have greater elasticity and less theoretical surface area contact with surrounding tissues than their heavyweight counterparts.⁴² Accordingly, they are hypothesized to reduce scarring and chronic pain with equivalent recurrence rates. The use of lightweight mesh in TEP and TAPP repairs is associated with fewer 3-month cumulative mesh-related complications.⁴⁰ A 2012 meta-analysis of 2310 patients undergoing open or laparoscopic hernia repairs found a lower incidence of chronic pain (relative risk [RR] 0.61, CI 0.50–0.74) following use of lightweight mesh versus heavyweight mesh, and no significant difference in rates of recurrence.⁴³ When available, lightweight mesh should be considered for all prosthetic repairs to minimize postoperative chronic pain.

A disadvantage of currently available commercial prostheses is their high cost. In settings where resources are limited, prosthetic repairs are performed using alternative materials. Polypropylene and polyethylene mosquito nets are inexpensive

and ubiquitous in sub-Saharan Africa and India, and they have similar mechanical properties to commercially available hernioplasty meshes. Meta-analysis of 577 hernioplasties performed using sterilized mosquito nets demonstrated similar rates of short-term mesh-related complications (6.1%) and recurrence (0.17%) to those using commercial meshes.⁴⁴ Furthermore, the disability-adjusted life-years (DALYs) prevented by inguinal hernia repair signify a comparable impact to that of vaccination in sub-Saharan Africa.^{45,46} Expensive prostheses are not necessarily needed for hernia surgery, either in resource-limited or in resource-abundant settings, and the anticipated benefits should be evaluated with consideration of increased costs.

Biologic Mesh. Although indications for the use of biologic prostheses have not been absolutely defined, they are commonly reserved for contaminated cases or when domain expansion is necessary in the face of high infection risk. There are numerous biologic materials available with differing properties, but in general, they have lower tensile strength and subsequent higher rates of rupture than synthetic prostheses.⁴⁷ They also have varying degrees of tensile strength and tissue biocompatibility between them. In ventral hernia repairs, xenograft material was associated with a lower rate of recurrence than allograft material.⁴⁸ A review of biologic materials concluded that cross-linked graft materials are more durable and less prone to failure than non-cross-linked grafts.⁴⁹ Nevertheless, their diminished ability to remodel adversely affects rates of infection and incorporation. While new prosthetic materials continue to be developed, no single biologic warrants routine use. These materials will continue to evolve, and they remain an important tool for challenging cases when used judiciously.

Fixation Technique. Independent of prosthesis material, the method of its fixation remains disputed. Suturing, stapling, and tacking prostheses entail tissue perforation, which may cause inflammation, neurovascular injury, and chronic pain development. Conversely, improper prosthesis fixation may result in mesh migration, repair failure, meshoma pain, and hernia recurrence. Mesh may be fixed with fibrin-derived glue, and self-gripping mesh has been developed to minimize trauma to surrounding tissues and to reduce the risk for entrapment neuropathy. For hernias repaired via a strictly preperitoneal approach, prosthesis fixation may not be necessary at all.

Fibrin glue fixation is a successful alternative to tack fixation in hernia repair with a synthetic prosthesis. Recent studies comparing fibrin glue fixation and suture fixation in open hernia repair show superior rates of chronic pain with both Lichtenstein and plug and patch techniques.^{50,51} Meta-analyses of laparoscopic hernia repair determined the incidence of chronic postoperative pain after tacker fixation was significantly higher than after fibrin glue fixation, with one showing an RR of 4.64 (CI 1.9–11.7). Rates of other postoperative complications and recurrence were similar between both fixation methods.^{52,53} Glue fixation is a promising technical refinement; however, its questionable efficacy in larger hernias, long-term outcomes, and cost remain considerations.

In TEP repairs, fixation of mesh may not be compulsory. A prospective randomized trial comparing fixation and no fixation in TEP repairs found a significant increase in new pain and equivalent recurrence rates in the fixation group several months after repair.⁵⁴ A 2012 meta-analysis comparing laparoscopic tacker mesh fixation to no mesh fixation found no statistically significant differences in operative duration, pain, mesh-related

complications, recurrence, or length of stay between the two methods.⁵⁵ Studies of three-dimensional, ergonomically contoured mesh without fixation, as well as self-gripping meshes, have yielded similar results.⁵⁶ In the preperitoneal approach, the re-approximation of surrounding tissues and physiologic intra-abdominal pressure hypothetically prevent mesh migration. Due to higher theoretical risk of mesh migration, repair without fixation is not recommended for anterior or transperitoneal approaches.

COMPLICATIONS

As with other clean operations, the most common complications of inguinal hernia repair include bleeding, seroma, wound infection, urinary retention, ileus, and injury to adjacent structures (Table 37-6). Complications specific to herniorrhaphy and hernioplasty include hernia recurrence, chronic inguinal and pubic pain, and injury to the spermatic cord or testis. The incidence, prevention, and treatment of these complications are discussed in the ensuing section.

Hernia Recurrence

When a patient develops pain, bulging, or a mass at the site of an inguinal hernia repair, clinical entities such as seroma, persistent cord lipoma, and hernia recurrence should be considered. Common medical issues associated with recurrence include malnutrition, immunosuppression, diabetes, steroid use, and smoking. Technical causes of recurrence include improper mesh size, tissue ischemia, infection, and tension in the reconstruction. A focused physical examination should be performed. As with primary hernias, US, CT, or MRI can elucidate ambiguous physical findings. When a recurrent hernia is discovered and warrants re-operation, an approach through a virgin plane facilitates its dissection and exposure. Extensive dissection of the scarred field and mesh may result in injury to cord structures, viscera, large blood vessels, and nerves. After an initial anterior approach, the posterior laparoscopic approach will usually be easier and more effective than another anterior dissection. Conversely, failed preperitoneal repairs should be approached using an open anterior repair.

Pain

Pain after inguinal hernia repair is classified into acute or chronic manifestations of three mechanisms: nociceptive (somatic), neuropathic, and visceral pain. Nociceptive pain is the most common of the three. Because it is usually a result of ligamentous or muscular trauma and inflammation, nociceptive pain is reproduced with abdominal muscle contraction. Treatment consists of rest, nonsteroidal anti-inflammatory drugs (NSAIDs), and reassurance, as it resolves spontaneously in most cases. Neuropathic pain occurs as a result of direct nerve damage or entrapment. It may present early or late, and it manifests as a localized, sharp, burning or tearing sensation. It may respond to pharmacologic therapy and to local steroid or anesthetic injections when indicated. Visceral pain refers to pain conveyed through afferent autonomic pain fibers. It is usually poorly localized and may occur during ejaculation as a result of sympathetic plexus injury.

Chronic postoperative pain remains an important measure of clinical outcome that has been reported in as many as 63% of inguinal hernia repair cases.⁵⁷⁻⁵⁹ Despite the significant anatomic variation in the three inguinal nerves, literature reviews suggest

Table 37-6

Complications of groin hernia repairs

Recurrence
Chronic groin pain
Nociceptive
Somatic
Visceral
Neuropathic
Iliohypogastric
Ilioinguinal
Genitofemoral
Lateral cutaneous
Femoral
Cord and testicular
Hematoma
Ischemic orchitis
Testicular atrophy
Dysejaculation
Division of vas deferens
Hydrocele
Testicular descent
Bladder injury
Wound infection
Seroma
Hematoma
Wound
Scrotal
Retroperitoneal
Osteitis pubis
Prosthetic complications
Contraction
Erosion
Infection
Rejection
Fracture
Laparoscopic
Vascular injury
Intra-abdominal
Retroperitoneal
Abdominal wall
Gas embolism
Visceral injury
Bowel perforation
Bladder perforation
Trocar site complications
Hematoma
Hernia
Wound infection
Keloid
Bowel obstruction
Trocar or peritoneal closure site hernia
Adhesions
Miscellaneous
Diaphragmatic dysfunction
Hypercapnia
General
Urinary
Paralytic ileus
Nausea and vomiting
Aspiration pneumonia
Cardiovascular and respiratory insufficiency

identification of all three nerves is possible in 70% to 90% of cases.⁶⁰ Meticulous nerve identification may prevent injury that results in debilitating chronic postoperative pain syndromes. Notwithstanding, moderate-to-severe pain adversely affects physical activity, social interactions, healthcare utilization, employment, and productivity in 6% to 8% of patients.^{58,59,61-64} Pain in this subset of patients comprises a tremendous individual and societal burden.

Post-herniorrhaphy inguinodynia is a debilitating chronic complication caused by a combination of nociceptive, neuropathic, and visceral elements. Its incidence is independent of the method of hernia repair; however, the original operative technique determines options for intervention and remedial surgery.⁶² Treatment is based on repair technique, subsequent re-operations, pain character, and the presence of recurrence, meshoma, and fixation material. Selective ilioinguinal, iliohypogastric, and genitofemoral neurolysis or neurectomy, removal of mesh and fixation material, and revision of the repair are common options for treatment. Nevertheless, anatomic variation and cross-innervation of the inguinal nerves in the retroperitoneum and inguinal canal make selective neurectomy less reliable.⁶⁵⁻⁶⁹ When inguinodynia is refractory to pharmacologic and interventional measures, triple neurectomy with removal of meshoma is arguably the most effective option for the majority of patients.^{64, 67-74} Refractory inguinodynia with concurrent orchialgia also requires resection of the paravasal nerves.⁷⁴

Other chronic pain syndromes include local nerve entrapment, meralgia paresthetica, and osteitis pubis. At greatest risk of entrapment are the ilioinguinal and iliohypogastric nerves in anterior repairs and the genitofemoral and lateral femoral cutaneous nerves in laparoscopic repairs. Clinical manifestations of nerve entrapment mimic acute neuropathic pain, and they occur with a dermatomal distribution. Injury to the lateral femoral cutaneous nerve results in meralgia paresthetica, a condition characterized by persistent paresthesias of the lateral thigh. Initial treatment of nerve entrapment consists of rest, ice, NSAIDs, physical therapy, and possible local corticosteroid and anesthetic injection. Osteitis pubis is characterized by inflammation of the pubic symphysis and usually presents as medial groin or symphyseal pain that is reproduced by thigh adduction. Avoiding the pubic periosteum when placing sutures and tacks reduces the risk of developing osteitis pubis. CT scan or MRI excludes hernia recurrence, and bone scan is confirmatory for the diagnosis. Initial treatment is identical to that of nerve entrapment; however, if pain remains intractable, orthopedic surgery consultation should be sought for possible bone resection and curettage. Irrespective of treatment, the condition often takes 6 months to resolve.⁷⁵

Cord and Testes Injury

Injury to spermatic cord structures may result in ischemic orchitis or testicular atrophy. Ischemic orchitis is likely caused by injury to the pampiniform plexus and not to the testicular artery. It usually manifests within 1 week of inguinal hernia repair as an enlarged, indurated, and painful testis, and it is almost certainly self-limited. It occurs in <1% of primary hernia repairs; however, this figure is larger for recurrent inguinal hernia repairs.⁷⁶ US will demonstrate testicular blood flow to differentiate between ischemia and necrosis. Emergent orchiectomy is only necessary in the case of necrosis. Injury to the testicular artery also may lead to testicular atrophy, which is manifest over a protracted period. Treatment for ischemic orchitis most frequently

consists of reassurance, NSAIDs, and comfort measures. Intraoperatively, proximal ligation of large hernia sacs to avoid cord manipulation minimizes the risk of injury.

Injury to the vas deferens within the cord may lead to infertility. In open inguinal hernia repairs, isolating the vas deferens along with the cord structures using digital manipulation may cause injury or disruption. In laparoscopic approach, grasping the vas may result in a crush injury. Transections of the vas deferens should be addressed with a urologic consult and early anastomosis, if possible. Historically, surgeons and their patients speculated that synthetic material would increase the risks of mesh rejection, carcinogenesis, and inflammation; however, as mesh became used more frequently, these concerns did not manifest. Nevertheless, one study found prosthetic mesh may exert long-term deleterious effects upon the vas deferens, causing azoospermia.⁷⁷ Similar studies report varied results, though. A recent prospective study from the Swedish Hernia Registry discovered no difference in rates of patient-reported infertility between the general population and patients who underwent either mesh or tissue-based inguinal hernia repair.⁷⁸ Chronic scarring may lead to vas deferens obstruction, resulting in decreased fertility rates and a dysejaculation syndrome. Pain and burning during ejaculation are usually self-limited, and more common causes, such as sexually transmitted diseases, should be excluded.

In females, the round ligament is the analog to the spermatic cord, and it maintains uterine anteversion. Injury to the artery of the round ligament does not result in clinically significant morbidity.

Laparoscopic Complications

In general, the risks of the TEP technique mirror those of open anterior repairs, as the peritoneal space is not violated. Complications of transabdominal laparoscopy include urinary retention, paralytic ileus, visceral injuries, vascular injuries, and less commonly, bowel obstruction, hypercapnia, gas embolism, and pneumothorax. The most common complications of laparoscopic inguinal hernia repair are presented in this section.

Urinary Retention. The most common cause of urinary retention after hernia repair is general anesthesia, which is routine in laparoscopic hernia repairs. Among 880 patients undergoing inguinal hernia repair with local anesthesia only, 0.2% developed urinary retention, whereas the rate of urinary retention was 13% among 200 patients undergoing repair with general or spinal anesthesia.⁷⁹ Other risk factors for postoperative urinary retention include pain, narcotic analgesia, and perioperative bladder distention. Initial treatment of urinary retention requires decompression of the bladder with short-term catheterization. Patients will generally require an overnight admission and trial of normal voiding before discharge. Failure to void normally requires reinsertion of the catheter for up to a week. Chronic requirement of a urinary catheter is rare, although older patients may require prolonged catheterization.

Ileus and Bowel Obstruction. The laparoscopic transabdominal approach is associated with a higher incidence of ileus than other modes of repair. This complication is self-limited; however, it necessitates sustained inpatient observation, intravenous fluid maintenance, and possibly nasogastric decompression. Abdominal imaging may be helpful to confirm the diagnosis and to exclude bowel obstruction. Prolonged absence of bowel function, in conjunction with a suspicious abdominal

series, should raise concern for obstruction. In this case, CT of the abdomen is helpful to distinguish anatomic sites of obstruction, inflammation, and ischemia. In TAPP repairs, obstruction occurs most commonly secondary to herniation of bowel loops through peritoneal defects or large trocar insertion sites; however, the use of smaller trocars and the preponderance of TEP repairs have reduced the frequency of this complication. True obstruction warrants reoperation.

Visceral Injury. Small bowel, colon, and bladder are at risk for injury in laparoscopic hernia repair. The presence of intra-abdominal adhesions from previous surgeries may predispose to visceral injuries. Direct bowel injuries may also result from trocar placement. In reoperative abdominal surgery, open Hasson technique and direct visualization of trocars are recommended to reduce the likelihood of visceral injury. Bowel injury may also occur secondary to electrocautery and instrument trauma outside of the camera field. Missed bowel injuries are associated with increased mortality. If injury to the bowel is suspected, its entire length should be examined, and conversion to open repair may be necessary.

Bladder injuries are less common than visceral injuries, and they are usually associated with perioperative bladder distention or extensive dissection of perivesical adhesions. As with bladder injuries encountered in open surgery, cystotomies must be repaired in several layers with 1 to 2 weeks of Foley catheter decompression. A confirmatory cystogram may be performed before catheter removal to confirm healing of the injury.

Vascular Injury. The most severe vascular injuries usually occur in iliac or femoral vessels, either by misplaced sutures in anterior repairs, or by trocar injury or direct dissection in laparoscopic repairs. In these cases, exsanguination may be swift. Conversion to an open approach may be necessary, and bleeding should be temporarily controlled with mechanical compression until vascular control is obtained.

The most commonly injured vessels in laparoscopic hernia repair include the inferior epigastrics and external ilia. Although apparent upon initial approach, these vessels may be obscured during mesh positioning, and tacks or staples may injure them. Often, due to tamponade effect, injury to the inferior epigastric vessels is not apparent until the adjacent trocar is removed. If injured, the inferior epigastrics may be ligated with a percutaneous suture passer or endoscopic hemoclips.

If the tissue pressure exerted by pneumoperitoneum is greater than an injured vessel's hydrostatic intraluminal pressure, bleeding will not manifest until pneumoperitoneum is released. The presentation of an inferior epigastric vein injury is often delayed because of this effect, and it may result in a significant rectus sheath hematoma. Accordingly, the surgeon should be aware of this intraoperative consideration.

Hematomas and Seromas

Hematomas may present as localized collections or as diffuse bruising over the operative site. Injury to spermatic cord vessels may result in a scrotal hematoma. Although they are self-limited, characteristic dark blue discoloration of the entire scrotum may alarm patients. Intermittent warm and cold compression aids in resolution. Hematomas may also develop in the incision, retroperitoneum, rectus sheath, and peritoneal cavity. The latter three sites are more frequently associated with laparoscopic repair. Bleeding within the peritoneum or preperitoneal space may not be readily apparent on physical examination. For this reason,

close monitoring of subjective complaints, vital signs, urine output, and physical parameters is necessary.

Seromas are loculated fluid collections that most commonly develop within 1 week of synthetic mesh repairs. Large hernia sac remnants may fill with physiologic fluid and mimic seromas. Patients often mistake seromas for early recurrence. Treatment consists of reassurance and warm compression to accelerate resolution. To avoid secondary infection, seromas should not be aspirated unless they cause discomfort or they restrict activity for a prolonged time.

OUTCOMES

The incidence of recurrence is the most-cited measure of postoperative outcome following inguinal hernia repair. In evaluating the various available techniques, other salient signifiers of **5▶** outcome include complication rates, operative duration, hospital stay, and quality of life. The following section summarizes the evidence-based outcomes of the various approaches to inguinal hernia repair.

Among tissue repairs, the Shouldice operation is the most commonly performed technique, and it is most frequently executed at specialized centers. A 2012 meta-analysis from the Cochrane Database demonstrated significantly lower rates of hernia recurrence (OR 0.62, CI 0.45–0.85) in patients undergoing Shouldice operations when compared with other open tissue-based methods.⁸⁰ In experienced hands, the overall recurrence rate for the Shouldice repair is about 1%.⁸¹ Although it is an elegant procedure, its meticulous nature requires significant technical expertise to achieve favorable outcomes, and it is associated with longer operative duration and longer hospital stay. One study found the recurrence rate for Shouldice repairs decreased from 9.4% to 2.5% after surgeons performed the repair six times.⁸² Compared with mesh repairs, the Shouldice technique resulted in significantly higher rates of recurrence (OR 3.65, CI 1.79–7.47); however, it is the most effective tissue-based repair when mesh is unavailable or contraindicated.⁸⁰

Hernia recurrence is drastically reduced as a result of the Lichtenstein tension-free repair.⁸³ Compared with open elective tissue-based repairs, mesh repair is associated with fewer recurrences (OR 0.37, CI 0.26–0.51) and with shorter hospital stay and faster return to usual activities.^{84,85} In a multi-institutional series, 3019 inguinal hernias were repaired using the Lichtenstein technique, with an overall recurrence rate of 0.2%.⁸⁶ Among other tension-free repairs, the Lichtenstein technique remains the most commonly performed procedure worldwide. Meta-analysis demonstrates no significant differences in outcomes between the Lichtenstein and the plug and patch techniques; however, intra-abdominal plug migration and erosion into contiguous structures occurs in approximately 6% of cases.^{84,87,88} The Stoppa technique results in longer operative duration than the Lichtenstein technique. Nevertheless, postoperative acute pain, chronic pain, and recurrence rates are similar between the two methods.⁸⁹ Perhaps the most compelling advantage of the Lichtenstein technique is that nonexpert surgeons rapidly achieve similar outcomes to their expert counterparts. Guidelines issued by the European Hernia Society recommend the Lichtenstein repair for adults with either unilateral or bilateral inguinal hernias as the preferred open technique.⁸⁵

Compared to open approaches, laparoscopic primary inguinal hernia repair produces equivalent recurrence rates and improved recovery time, pain prevention, and return to normal

activities.⁹⁰ In a study of 168 patients randomized to either TEP or Lichtenstein repair, the 5-year recurrence rates were extremely low in both groups.^{91,92} Similarly, a study of 200 male patients randomized to either ambulatory TEP or Lichtenstein repair demonstrated no recurrences in either group after 1 year.⁹³ Because laparoscopic surgery requires specialized instruments and longer operative times, its cost is higher than conventional open repair; however, the potential financial benefit of shorter recovery and decreased pain may offset these costs in the long term.

Perhaps the most salient difference between open and laparoscopic techniques is the number of cases needed to develop technical proficiency. In a randomized controlled trial performed by the Veterans Affairs Cooperative Study, 2-year recurrence rates were 10.1% in patients undergoing laparoscopic repair and 4.9% in those undergoing open repair, and the outcomes of laparoscopic repairs improved after each surgeon performed at least 250 cases.⁹⁴ More recently, Lal and colleagues found that surgeons sustained a decrease from 9% to 2.9% in postoperative recurrences after performing 100 TEP operations.⁹⁵ Other studies also suggest surgeons develop proficiency in these laparoscopic techniques after performing 30 to 100 cases; however, this estimate has decreased precipitously since laparoscopic technique was first introduced.^{94,96,97}

Although controversy persists regarding the utility of TEP vs. TAPP, reviews to date find no significant differences in operative duration, length of stay, time to recovery, or short-term recurrence rate between the two approaches. In TAPP repair, the risk of intra-abdominal injury is higher than in TEP repair. This finding prompted the IEHS to recommend that TAPP should only be attempted by surgeons with sufficient experience.⁴⁰ A Cochrane systematic review found that rates of port-site hernias and visceral injuries were higher for the TAPP technique, whereas TEP may be associated with a higher rate of conversion to an alternative approach; however, neither finding was sufficiently compelling to recommend one technique over the other.⁹⁷

The frequency with which the above inguinal hernia repair techniques are performed reinforces the importance of broad experience. The authors recommend that surgeons become proficient in several techniques to address different manifestations of inguinal hernias. Surgeons should tailor this experience to optimize outcomes for each patient.

REFERENCES

Entries highlighted in bright blue are key references.

1. Rutkow IM. Demographic and socioeconomic aspects of hernia repair in the United States in 2003. *Surg Clin North Am.* 2003;83:1045.
2. Gould J. **Laparoscopic versus open inguinal hernia repair.** *Surg Clin N Am.* 2008;88:1073-1081.
3. Abramson JH, Gofin J, Hopp C, et al. The epidemiology of inguinal hernia. A survey in western Jerusalem. *J Epidemiol Community Health.* 1978;32:59.
4. Rutkow IM. Epidemiologic, economic, and sociologic aspects of hernia surgery in the United States in the 1990s. *Surg Clin North Am.* 1998;78:941.
5. Johnson J, Roth JS, Hazy JW, et al. The history of open inguinal hernia repair. *Curr Surg.* 2004;61:49.
6. Desarda MP. Physiological repair of inguinal hernia: a new technique (study of 860 patients). *Hernia.* 2006;10:143-146.
7. Shulman AG, Amid PK, Lichtenstein IL. A survey of non-expert surgeons using the open tension-free mesh patch repair for primary inguinal hernias. *Int Surg.* 1995;80:35-36.
8. Spaw AT, Ennis BW, Spaw LP. Laparoscopic hernia repair: the anatomic basis. *J Laparoendosc Surg.* 1991;1:269.
9. Miltenburg DM, Nuchtern JG, Jaksic T, et al. Laparoscopic evaluation of the pediatric inguinal hernia—a meta-analysis. *J Pediatr Surg.* 1998;33:874.
10. van Wessem KJ, Simons MP, Plaisier PW, et al. The etiology of indirect inguinal hernias: congenital and/or acquired? *Hernia.* 2003;7:76.
11. van Veen RN, van Wessem KJ, Halm JA, et al. Patent processus vaginalis in the adult as a risk factor for the occurrence of indirect inguinal hernia. *Surg Endosc.* 2007;21:202.
12. Carbonell JF, Sanchez JL, Peris RT, et al. Risk factors associated with inguinal hernias: a case control study. *Eur J Surg.* 1993;159:481.
13. Flich J, Alfonso JL, Delgado F, et al. Inguinal hernia and certain risk factors. *Eur J Epidemiol.* 1992;8:277.
14. Lau H, Fang C, Yuen WK, et al. Risk factors for inguinal hernia in adult males: a case-control study. *Surgery.* 2007;141:262.
15. Ruhl CE, Everhart JE. Risk factors for inguinal hernia among adults in the US population. *Am J Epidemiol.* 2007;165:1154.
16. Klinge U, Binnebosel M, Mertens PR. Are collagens the culprits in the development of incisional and inguinal hernia disease? *Hernia.* 2006;10:472.
17. Franz MG. The biology of hernias and the abdominal wall. *Hernia.* 2006;10:462-471.
18. Ralphs DN, Brain AJ, Grundy DJ, et al. How accurately can direct and indirect inguinal hernias be distinguished? *Br Med J.* 1980;280:1039.
19. Cameron AE. Accuracy of clinical diagnosis of direct and indirect inguinal hernia. *Br J Surg.* 1994;81:250.
20. Robinson A, Light D, Kasim A, et al. A systematic review and meta-analysis of the role of radiology in the diagnosis of occult hernia. *Surg Endosc.* 2013;27:11-18.
21. Jamadar DA, Jacobson JA, Morag Y, et al. Sonography of inguinal region hernias. *AJR Am J Roentgenol.* 2006;187:185.
22. Burkhardt JH, Arshanskiy Y, Munson JL, et al. Diagnosis of inguinal region hernias with axial CT: the lateral crescent sign and other key findings. *Radiographics.* 2011;31:E1-12.
23. van den Berg JC, de Valois JC, Go PM, et al. Detection of groin hernia with physical examination, ultrasound, and MRI compared with laparoscopic findings. *Invest Radiol.* 1999;34:739-743.
24. Fitzgibbons RJ Jr, Giobbie-Hurder A, Gibbs JO, et al. Watchful waiting vs repair of inguinal hernia in minimally symptomatic men: a randomized clinical trial. *JAMA.* 2006;295:285.
25. van den Heuvel, Dwars BJ, Klassen DR, et al. Is surgical repair of an asymptomatic groin hernia appropriate? A review. *Hernia.* 2011;15:251-259.
26. Mizrahi H, Parker MC. **Management of asymptomatic inguinal hernia: a systematic review of the evidence.** *Arch Surg.* 2012;147:277-281.
27. Thompson JS, Gibbs JO, Reda DJ, et al. Does delaying repair of an asymptomatic hernia have a penalty? *Am J Surg.* 2008;195:89-93.
28. Law NW, Trapnell JE. Does a truss benefit a patient with inguinal hernia? *BMJ.* 1992;304:1092.
29. Gallegos NC, Dawson J, Jarvis M, et al. Risk of strangulation in groin hernias. *Br J Surg.* 1991;78:1171.
30. Nilsson H, Stylianidis G, Haapamäki M, et al. **Mortality after groin hernia surgery.** *Ann Surg.* 2007;245:656-660.
31. Sanchez-Manuel FJ, Lozano-Garcia J, Seco-Gil JL. Antibiotic prophylaxis for hernia repair. *Cochrane Database Syst Rev.* 2012;2:CD003769.

32. Yin Y, Song T, Liao B, et al. Antibiotic prophylaxis in patients undergoing open mesh repair of inguinal hernia: a meta-analysis. *Am Surg*. 2012;78:359-365.
33. Delikoukos S, Lavant L, Hlias G, et al. The role of hernia sac ligation in postoperative pain in patients with elective tension-free indirect inguinal hernia repair: a prospective randomized study. *Hernia*. 2007;11:425.
34. Amid PK, Shulman AG, Lichtenstein IL. Critical scrutiny of the open "tension-free" hernioplasty. *Am J Surg*. 1993;165:369-371.
35. Gilbert AI. Sutureless repair of inguinal hernia. *Am J Surg*. 1992;163:331.
36. Millikan KW, Cummings B, Doolas A. The Millikan modified mesh-plug hernioplasty. *Arch Surg*. 2003;138:525, discussion 529.
37. Voyles CR, Hamilton BJ, Johnson WD, et al. Meta-analysis of laparoscopic inguinal hernia trials favors open hernia repair with preperitoneal mesh prosthesis. *Am J Surg*. 2002;184:6.
38. Lee BC, Rodin DM, Shah KK, et al. Laparoscopic inguinal hernia repair during laparoscopic radical prostatectomy. *BJU Int*. 2007;99:637.
39. Antunes AA, Dall'oglio M, Crippa A, et al. Inguinal hernia repair with polypropylene mesh during radical retropubic prostatectomy: an easy and practical approach. *BJU Int*. 2005;96:330.
40. Bittner R, Arregui ME, Bisgaard T, et al. Guidelines for laparoscopic (TAPP) and endoscopic (TEP) treatment of inguinal hernia [International Endohernia Society (IEHS)]. *Surg Endosc*. 2011;25:2773-2843.
41. Earle DB, Romanelli J. Prosthetic materials for hernia: what's new. How to make sense of the multitude of mesh options for inguinal and ventral hernia repairs. *Contemp Surg*. 2007;63:63.
42. Sajid MS, Ladwa N, Kalra L, et al. A meta-analysis examining the use of tacker mesh fixation versus glue mesh fixation in laparoscopic inguinal hernia repair. *Am J Surg*. 2013;206:103-111.
43. Sajid MS, Leaver C, Baig MK, et al. Systematic review and meta-analysis of the use of lightweight versus heavyweight mesh in open inguinal hernia repair. *Br J Surg*. 2012;99:29-37.
44. Sørensen CG, Rosenberg J. The use of sterilized mosquito nets for hernioplasty: a systematic review. *Hernia*. 2012;16:621-625.
45. Jacobs DO. Improving surgical services in developing nations: getting to go. *World J Surg*. 2010;34:2509-2510.
46. Luboga S, Macfarlane SB, von Schreeb J, et al. Increasing access to surgical services in sub-Saharan Africa: priorities for national and international agencies recommended by the Bellagio Essential Surgery Group. *PLoS Med*. 2009;6:1-5.
47. Earle DB, Mark LA. Prosthetic material in inguinal hernia repair: how do I choose? *Surg Clin North Am*. 2008;88:179.
48. Beale EW, Hoxworth RE, Livingston EH, et al. The role of biologic mesh in abdominal wall reconstruction: a systematic review of the current literature. *Am J Surg*. 2012;204:510-517.
49. Smart NJ, Bloor S. Durability of biologic implants for use in hernia repair: a review. *Surg Innov*. 2012;19:221-229.
50. Campanelli G, Cavalli M, Sfeclan CJ, et al. Reducing postoperative pain: the use of Tisseel for mesh fixation in inguinal hernia repair. *Surg Technol Int*. 2012;7:XXII.
51. Fortelny RH, Petter-Puchner AH, Glaser KS, et al. Use of fibrin sealant (Tisseel/Tissucol) in hernia repair: a systematic review. *Surg Endosc*. 2012;26:1803-1812.
52. Kaul A, Hutfless S, Le H, et al. Staple versus fibrin glue fixation in laparoscopic total extraperitoneal repair of inguinal hernia: a systematic review and meta-analysis. *Surg Endosc*. 2012;26:1269-1278.
53. Sajid MS, Ladwa N, Kalra L, et al. A meta-analysis examining the use of tacker mesh fixation versus glue mesh fixation in laparoscopic inguinal hernia repair. *Am J Surg*. 2013;206:103.
54. Taylor C, Layani L, Liew V, et al. Laparoscopic inguinal hernia repair without mesh fixation, early results of a large randomised clinical trial. *Surg Endosc*. 2008;22:757.
55. Sajid MS, Ladwa N, Kalra L, et al. A meta-analysis examining the use of tacker fixation versus no-fixation of mesh in laparoscopic inguinal hernia repair. *Int J Surg*. 2012;10:224-231.
56. Morrison JE Jr, Jacobs VR. Laparoscopic preperitoneal inguinal hernia repair using preformed polyester mesh without fixation: prospective study with 1-year follow-up results in a rural setting. *Surg Laparosc Endosc Percutan Tech*. 2008;18:33.
57. Reinhold WM, Nehls J, Eggert A. Nerve management and chronic pain after open inguinal hernia repair: a prospective two phase study. *Ann Surg*. 2011;254:163-168.
58. Kehlet H. Chronic pain after groin hernia repair. *Br J Surg*. 2008;95:135-136.
59. Aasvang E, Kehlet H. Surgical management of chronic pain after inguinal hernia repair. *Br J Surg*. 2005;92:795-801.
60. Alfieri S, Amid PK, Campanelli G, et al. International guidelines for prevention and management of post-operative chronic pain following inguinal hernia surgery. *Hernia*. 2011;15:239-249.
61. Aasvang EK, Bay-Nielsen M, Kehlet H. Pain and functional impairment 6 years after inguinal herniorrhaphy. *Hernia*. 2006;10:316-321.
62. Bay-Nielsen M, Perkins FM, Kehlet H. Danish Hernia Database. Pain and functional impairment 1 year after inguinal herniorrhaphy: a nationwide questionnaire study. *Ann Surg*. 2001;233:1-7.
63. Callesen T, Bech K, Kehlet H. Prospective study of chronic pain after groin hernia repair. *Br J Surg*. 1999;86:1528-1531.
64. Aasvang EK, Kehlet H. The effect of mesh removal and selective neurectomy on persistent postherniotomy pain. *Ann Surg*. 2009;249:327-334.
65. Rab M, Ebmer J, Dellon AL. Anatomic variability of the ilioinguinal and genitofemoral nerve: implications for the treatment of groin pain. *Plast Reconstr Surg*. 2001;108:1618-1623.
66. Klaassen Z, Marshall E, Tubbs RS, et al. Anatomy of the ilioinguinal and iliohypogastric nerves with observations. Pain Intensity Instruments. *Clin Anat*. 2011;24:454-461.
67. Zacest AC, Magill ST, Anderson VC, et al. Long-term outcome following ilioinguinal neurectomy for chronic pain. *J Neurosurg*. 2010;112:784-789.
68. Loos MJ, Scheltinga MR, Roumen RM. Tailored neurectomy for treatment of postherniorrhaphy inguinal neuralgia. *Surgery*. 2010;147:275-281.
69. Kim DH, Murovic JA, Tiel RL, et al. Surgical management of 33 ilioinguinal and iliohypogastric neuralgias at Louisiana State University Health Sciences Center. *Neurosurgery*. 2005;56:1013; discussion 1013.
70. Starling JR, Harms BA. Ilioinguinal, iliohypogastric, and genitofemoral neuralgia. In: Bendavid R, ed. *Prostheses and Abdominal Wall Hernia*. Austin: RG Landes Co; 1994:351-356.
71. Amid PK. A 1-stage surgical treatment for postherniorrhaphy neuropathic pain: triple neurectomy and proximal end implantation without mobilization of the cord. *Arch Surg*. 2002;137:100-104.
72. Madura JA, Madura JA II, Copper CM, et al. Inguinal neurectomy for inguinal nerve entrapment: an experience with 100 patients. *Am J Surg*. 2005;189:283.
73. Starling JR, Harms BA, Schroeder ME, et al. Diagnosis and treatment of genitofemoral and ilioinguinal entrapment neuralgia. *Surgery*. 1987;102:581-586.
74. Amid PK, Chen DC. Surgical treatment of chronic groin and testicular pain after laparoscopic and open preperitoneal inguinal hernia repair. *J Am Coll Surg*. 2011;213:531-536.
75. LeBlanc KE, LeBlanc KA. Groin pain in athletes. *Hernia*. 2003;7:68.

76. Fong Y, Wantz GE. Prevention of ischemic orchitis during inguinal hernioplasty. *Surg Gynecol Obstet.* 1992; 174:399.
77. Shin D, Lipshultz LI, Goldstein M, et al. Herniorrhaphy with polypropylene mesh causing inguinal vasal obstruction: a preventable cause of obstructive azoospermia. *Ann Surg.* 2005;241:553.
78. Hallén M, Sandblom G, Nordin P, et al. Male infertility after mesh hernia repair: a prospective study. *Surgery.* 2011;149(2): 179-184.
79. Finley RK Jr, Miller SF, Jones LM. Elimination of urinary retention following inguinal herniorrhaphy. *Am Surg.* 1991;57:486; discussion 488.
80. Amato B, Moja L, Panico S, et al. Shouldice technique versus other open techniques for inguinal hernia repair. *Cochrane Database Syst Rev.* 2012;4:CD001543.
81. Glassow F. The Shouldice Hospital technique. *Int Surg.* 1986;71:148.
82. Kingsnorth AN, Britton BJ, Morris PJ. Recurrent inguinal hernia after local anaesthetic repair. *Br J Surg.* 1981;68:273.
83. Lichtenstein IL, Shulman AG, Amid PK. Use of mesh to prevent recurrence of hernias. *Postgrad Med.* 1990;87:155.
84. Scott N, Go PM, Graham P, et al. Open mesh versus non-mesh for groin hernia repair. *Cochrane Database Syst Rev.* 2001;3:CD002197.
85. Simon MP, Aufenacker T, Bay-Nielsen M, et al. European Hernia Society guidelines on the treatment of inguinal hernia in adult patients. *Hernia.* 2009;13:343-403.
86. Schulman A, Amid P, Lichtenstein I. The safety of mesh repair for primary inguinal hernias: results of 3,019 operations from five diverse surgical sources. *Am Surg.* 1992;58:255.
87. Kingsnorth AN, Hyland ME, Porter CA, et al. Prospective double-blind randomized study comparing Perfix[™] plug-and-patch with Lichtenstein patch in inguinal hernia repair: one year quality of life results. *Hernia.* 2000;4:255-258.
88. Li J, Ji Z, Li Y. Comparison of mesh-plug and Lichtenstein for inguinal hernia repair: a meta-analysis of randomized controlled trials. *Hernia.* 2012;16:541-548.
89. Willaert W, De Bacquer D, Rogiers X, et al. Open preperitoneal techniques versus Lichtenstein repair for elective inguinal hernias. *Cochrane Database Syst Rev.* 2012;7:CD008034.
90. McCormack K, Scott NW, Go PM, et al. Laparoscopic techniques versus open techniques for inguinal hernia repair. *Cochrane Database Syst Rev.* 2003;1:CD001785.
91. Andersson B, Hallen M, Leveau P, et al. Laparoscopic extraperitoneal inguinal hernia repair versus open mesh repair: a prospective randomized controlled trial. *Surgery.* 2003;133:464.
92. Hallen M, Bergenfelz A, Westerdahl J. Laparoscopic extraperitoneal inguinal hernia repair versus open mesh repair: long-term follow-up of a randomized controlled trial. *Surgery.* 2008;143:313.
93. Lau H, Patil NG, Yuen WK. Day-case endoscopic totally extraperitoneal inguinal hernioplasty versus open Lichtenstein hernioplasty for unilateral primary inguinal hernia in males: a randomized trial. *Surg Endosc.* 2006;20:76.
94. Neumayer L, Giobbie-Hurder A, Jonasson O, et al. Open mesh versus laparoscopic mesh repair of inguinal hernia. *N Engl J Med.* 2004;350:1819.
95. Lal P, Kajla RK, Chander J, et al. Laparoscopic total extraperitoneal (TEP) inguinal hernia repair: overcoming the learning curve. *Surg Endosc.* 2004;18:642.
96. Katkhouda N, Campos GMR, Mavor E, et al. Laparoscopic extraperitoneal inguinal hernia repair. A safe approach based on the understanding of rectus sheath anatomy. *Surg Endosc.* 1999;13:1243-1246.
97. Wake BL, McCormack K, Fraser C, et al. Transabdominal pre-peritoneal (TAPP) vs totally extraperitoneal (TEP) laparoscopic techniques for inguinal hernia repair. *Cochrane Database Syst Rev.* 2005;1:CD004703.

This page intentionally left blank

38 chapter

Thyroid, Parathyroid, and Adrenal

Geeta Lal and Orlo H. Clark

Thyroid	1521	Solitary Thyroid Nodule / 1537	Adrenal	1574
Historical Background / 1521		Malignant Thyroid Disease / 1540	Historical Background / 1574	
Embryology / 1521		Parathyroid	Embryology / 1574	
Developmental Abnormalities / 1521		Historical Background / 1556	Anatomy / 1575	
Thyroid Anatomy / 1523		Embryology / 1556	Adrenal Physiology / 1575	
Thyroid Histology / 1525		Anatomy and Histology / 1557	Disorders of the Adrenal Cortex / 1578	
Thyroid Physiology / 1525		Parathyroid Physiology	Disorders of the Adrenal Medulla / 1585	
Evaluation of Patients with Thyroid		and Calcium Homeostasis / 1558	The Adrenal Incidentaloma / 1588	
Disease / 1528		Hyperparathyroidism / 1559	Adrenal Insufficiency / 1590	
Benign Thyroid Disorders / 1530		Hypoparathyroidism / 1574	Adrenal Surgery / 1590	

THYROID

Historical Background

Goiters (from the Latin *guttur*, throat), defined as an enlargement of the thyroid, have been recognized since 2700 B.C. even though the thyroid gland was not documented as such until the Renaissance period. In 1619, Hieronymus Fabricius ab Aquapendente recognized that goiters arose from the thyroid gland. The term *thyroid gland* (Greek *thyroeides*, shield-shaped) is, however, attributed to Thomas Wharton in his *Adenographia* (1656). In 1776, the thyroid was classified as a ductless gland by Albrecht von Haller and was thought to have numerous functions ranging from lubrication of the larynx to acting as a reservoir for blood to provide continuous flow to the brain, and to beautifying women's necks. Burnt seaweed was considered to be the most effective treatment for goiters.

The first accounts of thyroid surgery for the treatment of goiters were given by Roger Frugardi in 1170. In response to failure of medical treatment, two setons were inserted at right angles into the goiter and tightened twice daily until the goiter separated. The open wound was treated with caustic powder and left to heal. However, thyroid surgery continued to be hazardous with prohibitive mortality rates (>40%) until the latter half of the nineteenth century, when advances in general anesthesia, antisepsis, and hemostasis enabled surgeons to perform thyroid surgery with significantly reduced mortality and morbidity rates. The most notable thyroid surgeons were Emil Theodor Kocher (1841–1917) and C.A. Theodor Billroth (1829–1894), who performed thousands of operations with increasingly successful results. However, as more patients survived thyroid operations, new problems and issues became apparent. After total thyroidectomy, patients (particularly children) became myxedematous with cretinous features. Myxedema was first effectively treated in 1891 by George Murray using a subcutaneous injection of an extract of sheep's thyroid, and later, Edward Fox demonstrated that oral

therapy was equally effective. In 1909, Kocher was awarded the Nobel Prize for medicine in recognition “for his works on the physiology, pathology, and surgery of the thyroid gland.”

Embryology

The thyroid gland arises as an outpouching of the primitive foregut around the third week of gestation. It originates at the base of the tongue at the foramen cecum. Endoderm cells in the floor of the pharyngeal anlage thicken to form the medial thyroid anlage (Fig. 38-1) that descends in the neck anterior to structures that form the hyoid bone and larynx. During its descent, the anlage remains connected to the foramen cecum via an epithelial-lined tube known as the *thyroglossal duct*. The epithelial cells making up the anlage give rise to the thyroid follicular cells. The paired lateral anlages originate from the fourth branchial pouch and fuse with the median anlage at approximately the fifth week of gestation. The lateral anlages are neuroectodermal in origin (ultimobranchial bodies) and provide the calcitonin producing parafollicular or C cells, which thus come to lie in the superoposterior region of the gland. Thyroid follicles are initially apparent by 8 weeks, and colloid formation begins by the eleventh week of gestation.

Developmental Abnormalities

Thyroglossal Duct Cyst and Sinus. Thyroglossal duct cysts are the most commonly encountered congenital cervical anomalies. During the fifth week of gestation, the thyroglossal duct lumen starts to obliterate, and the duct disappears by the eighth week of gestation. Rarely, the thyroglossal duct may persist in whole or in part. Thyroglossal duct cysts may occur anywhere along the migratory path of the thyroid, although 80% are found in juxtaposition to the hyoid bone. They are usually asymptomatic but occasionally become infected by oral bacteria, prompting the patient to seek medical advice. Thyroglossal duct sinuses result from infection of the cyst secondary to spontaneous or

Key Points

- 1▶ There has been a paradigm shift in the surgical management of Graves' disease with increased use of total or near-total thyroidectomy, rather than subtotal thyroidectomy.
- 2▶ Familial nonmedullary thyroid cancer is increasingly being recognized as a separate entity. Surgeons must be aware of the potential for false-negative fine-needle aspiration biopsy in this setting.
- 3▶ Fine-needle aspiration biopsies are now classified into six groups based on the risk of malignancy associated with each group (Bethesda criteria).
- 4▶ Total thyroidectomy is the surgical treatment of choice for most thyroid cancers, provided complication rates are low.
- 5▶ Due to the limitations of fine-needle aspiration biopsy in the setting of indeterminate thyroid nodules, a number of molecular markers are being evaluated as adjuncts to refine the diagnosis and management of these patients.
- 6▶ Focused mini-incision parathyroidectomy, after appropriate localization, has become the procedure of choice for the treatment of sporadic primary hyperparathyroidism.
- 7▶ Parathyroidectomy has been shown to improve the classic and the so-called *nonspecific symptoms* and metabolic complications of primary hyperparathyroidism.
- 8▶ Normocalcemic hyperparathyroidism is being increasingly recognized; however, there are no definitive guidelines for management.
- 9▶ Very high calcium and parathyroid hormone levels in a patient with primary hyperparathyroidism should alert the surgeon to the presence of a possible parathyroid carcinoma.
- 10▶ Subclinical Cushing's syndrome is characterized by subtle abnormalities in corticosteroid synthesis, and many of its manifestations appear to be treated by adrenalectomy.
- 11▶ Fine-needle aspiration biopsy has a very limited role in the evaluation of adrenal incidentalomas unless the patient has previously had a cancer and should only be performed after appropriate biochemical studies have been performed to rule out pheochromocytoma.
- 12▶ Laparoscopic adrenalectomy has become the procedure of choice for excision of most adrenal lesions, except known or suspected cancers.

surgical drainage of the cyst and are accompanied by minor inflammation of the surrounding skin. Histologically, thyroglossal duct cysts are lined by pseudostratified ciliated columnar epithelium and squamous epithelium, with heterotopic thyroid tissue present in 20% of cases.

The diagnosis usually is established by observing a 1- to 2-cm, smooth, well-defined midline neck mass that moves upward with protrusion of the tongue. Routine thyroid imaging is not necessary, although thyroid scintigraphy and ultrasound

have been performed to document the presence of normal thyroid tissue in the neck. Treatment involves the "Sistrunk operation," which consists of en bloc cystectomy and excision of the central hyoid bone to minimize recurrence. Approximately 1% of thyroglossal duct cysts are found to contain cancer, which is usually papillary (85%). The role of total thyroidectomy in this setting is debated, but is advised in patients with large tumors, particularly if there are additional thyroid nodules and evidence of cyst wall invasion or lymph node metastases.¹ Squamous, Hürthle cell, and anaplastic cancers also have been reported but are rare. Medullary thyroid cancers (MTCs) are, however, not found in thyroglossal duct cysts.

Lingual Thyroid. A lingual thyroid represents a failure of the median thyroid anlage to descend normally and may be the only thyroid tissue present. Intervention becomes necessary for obstructive symptoms such as choking, dysphagia, airway obstruction, or hemorrhage. Many of these patients develop hypothyroidism. Medical treatment options include administration of exogenous thyroid hormone to suppress thyroid-stimulating hormone (TSH) and radioactive iodine (RAI) ablation followed by hormone replacement. Surgical excision is rarely needed but, if required, should be preceded by an evaluation of normal thyroid tissue in the neck to avoid inadvertently rendering the patient hypothyroid.

Ectopic Thyroid. Normal thyroid tissue may be found anywhere in the central neck compartment, including the esophagus, trachea, and anterior mediastinum. Thyroid tissue has been observed adjacent to the aortic arch, in the aortopulmonary window, within the upper pericardium, or in the interventricular septum. Often, "tongues" of thyroid tissue are seen to extend off the inferior poles of the gland and are particularly apparent in large goiters. Thyroid tissue situated lateral to the carotid sheath and jugular vein, previously termed *lateral aberrant*

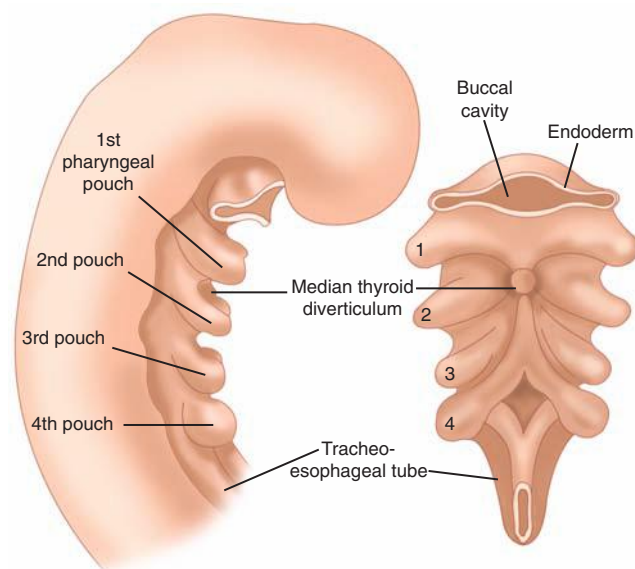


Figure 38-1. Thyroid embryology—early development of the median thyroid anlage as a pharyngeal pouch. (Reproduced with permission from *Embryology and developmental abnormalities*. In: Cady B, Rossi R, eds. *Surgery of the Thyroid and Parathyroid Glands*. Philadelphia: WB Saunders; 1991:6.)

thyroid, almost always represents metastatic thyroid cancer in lymph nodes, and not remnants of the lateral anlage that had failed to fuse with the main thyroid, as previously suggested by Crile. Even if not readily apparent on physical examination or ultrasound imaging, the ipsilateral thyroid lobe contains a focus of papillary thyroid cancer (PTC), which may be microscopic.

Pyramidal Lobe. Normally the thyroglossal duct atrophies, although it may remain as a fibrous band. In about 50% of individuals, the distal end that connects to the thyroid persists as a pyramidal lobe projecting up from the isthmus, lying just to the left or right of the midline. In the normal individual, the pyramidal lobe is not palpable, but in disorders resulting in thyroid hypertrophy (e.g., Graves' disease, diffuse nodular goiter, or lymphocytic thyroiditis), the pyramidal lobe usually is enlarged and palpable.

Thyroid Anatomy

The anatomic relations of the thyroid gland and surrounding structures are depicted in Fig. 38-2. The adult thyroid gland is brown in color and firm in consistency and is located posterior to the strap muscles. The normal thyroid gland weighs

approximately 20 g, but gland weight varies with body weight and iodine intake. The thyroid lobes are located adjacent to the thyroid cartilage and connected in the midline by an isthmus that is located just inferior to the cricoid cartilage. A pyramidal lobe is present in about 50% of patients. The thyroid lobes extend to the midthyroid cartilage superiorly and lie adjacent to the carotid sheaths and sternocleidomastoid muscles laterally. The strap muscles (sternohyoid, sternothyroid, and superior belly of the omohyoid) are located anteriorly and are innervated by the ansa cervicalis (ansa hypoglossi). The thyroid gland is enveloped by a loosely connecting fascia that is formed from the partition of the deep cervical fascia into anterior and posterior divisions. The true capsule of the thyroid is a thin, densely adherent fibrous layer that sends out septa that invaginate into the gland, forming pseudolobules. The thyroid capsule is condensed into the posterior suspensory or Berry's ligament near the cricoid cartilage and upper tracheal rings.

Blood Supply. The superior thyroid arteries arise from the ipsilateral external carotid arteries and divide into anterior and posterior branches at the apices of the thyroid lobes. The inferior

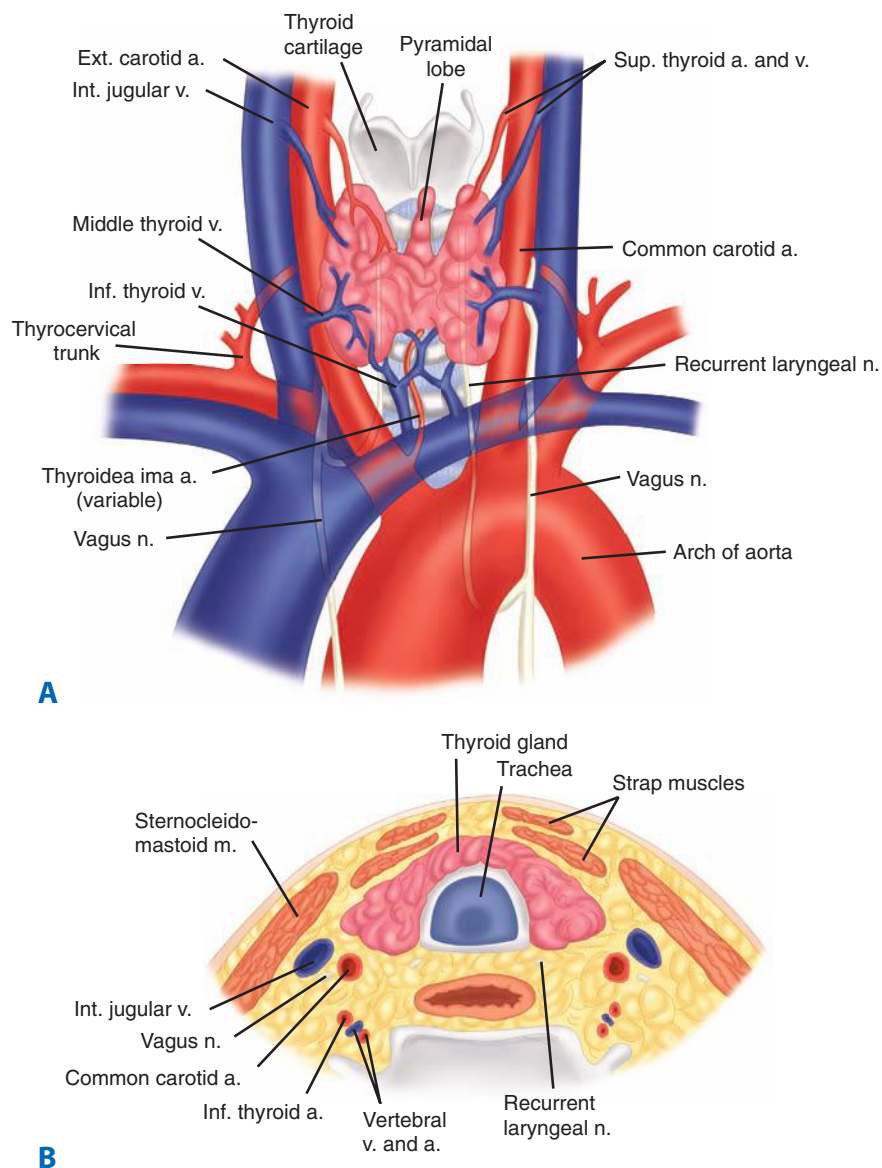


Figure 38-2. Anatomy of the thyroid gland and surrounding structures, viewed anteriorly (A) and in cross-section (B). a. = artery; m. = muscle; n. = nerve; v. = vein.

thyroid arteries arise from the thyrocervical trunk shortly after their origin from the subclavian arteries. The inferior thyroid arteries travel upward in the neck posterior to the carotid sheath to enter the thyroid lobes at their midpoint. A thyroidea ima artery arises directly from the aorta or innominate in 1% to 4% of individuals to enter the isthmus or replace a missing inferior thyroid artery. The inferior thyroid artery crosses the recurrent laryngeal nerve (RLN), necessitating identification of the RLN before the arterial branches can be ligated. The venous drainage of the thyroid gland occurs via multiple small surface veins, which coalesce to form three sets of veins—the superior, middle, and inferior thyroid veins. The superior thyroid veins run with the superior thyroid arteries bilaterally. The middle vein or veins are the least consistent. The superior and middle veins drain directly into the internal jugular veins. The inferior veins often form a plexus, which drains into the brachiocephalic veins.

Nerves. The left RLN arises from the vagus nerve where it crosses the aortic arch, loops around the ligamentum arteriosum, and ascends medially in the neck within the tracheoesophageal groove. The right RLN arises from the vagus at its crossing with the right subclavian artery. The nerve usually passes posterior to the artery before ascending in the neck, its course being more oblique than the left RLN. Along their course in the neck, the RLNs may branch, and pass anterior, posterior, or interdigitate with branches of the inferior thyroid artery (Fig. 38-3). The right RLN may be nonrecurrent in 0.5% to 1% of individuals and often is associated with a vascular anomaly. Nonrecurrent left RLNs are rare but have been reported in patients with situs inversus and a right-sided aortic arch. The RLN may branch in its course in the

neck, and identification of a small nerve should alert the surgeon to this possibility. Identification of the nerves or their branches often necessitates mobilization of the most lateral and posterior extent of the thyroid gland, the tubercle of Zuckerkandl, at the level of the cricoid cartilage. The last segments of the nerves often course below the tubercle and are closely approximated to the ligament of Berry. Branches of the nerve may traverse the ligament in 25% of individuals and are particularly vulnerable to injury at this junction. The RLNs terminate by entering the larynx posterior to the cricothyroid muscle.

The RLNs innervate all the intrinsic muscles of the larynx, except the cricothyroid muscles, which are innervated by the external laryngeal nerves. Injury to one RLN leads to paralysis of the ipsilateral vocal cord, which comes to lie in the paramedian or the abducted position. The paramedian position results in a normal but weak voice, whereas the abducted position leads to a hoarse voice and an ineffective cough. Bilateral RLN injury may lead to airway obstruction, necessitating emergency tracheostomy, or loss of voice. If both cords come to lie in an abducted position, air movement can occur, but the patient has an ineffective cough and is at increased risk of repeated respiratory tract infections from aspiration.

The superior laryngeal nerves also arise from the vagus nerves. After their origin at the base of the skull, these nerves travel along the internal carotid artery and divide into two branches at the level of the hyoid bone. The internal branch of the superior laryngeal nerve is sensory to the supraglottic larynx. Injury to this nerve is rare in thyroid surgery, but its occurrence may result in aspiration. The external branch of the superior laryngeal nerve lies on the inferior pharyngeal constrictor muscle

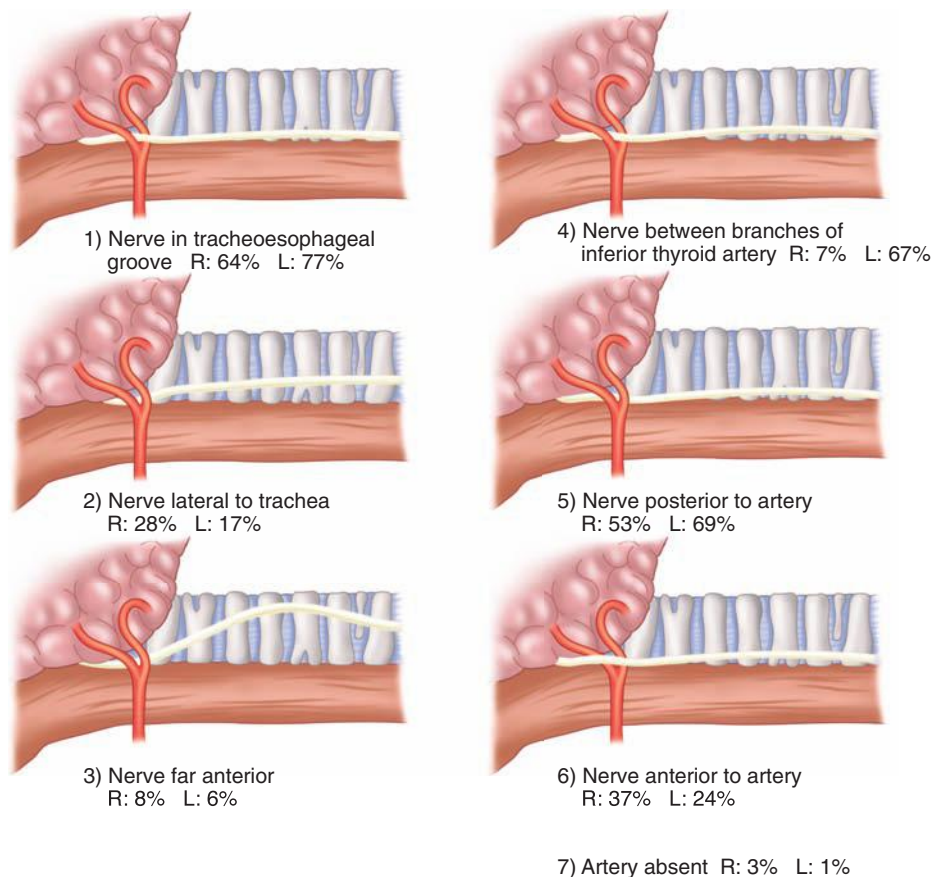


Figure 38-3. Relationship of recurrent laryngeal nerve to the inferior thyroid artery—the superior parathyroid is characteristically dorsal to the plane of the nerve, whereas the inferior gland is ventral to the nerve.

and descends alongside the superior thyroid vessels before innervating the cricothyroid muscle. Cernea and colleagues² proposed a classification system to describe the relationship of this nerve to the superior thyroid vessels (Fig. 38-4). The type 2a variant, in which the nerve crosses below the tip of the thyroid superior pole, occurs in up to 20% of individuals and places the nerve at a greater risk of injury. Therefore, the superior pole vessels should not be ligated en masse, but should be individually divided, low on the thyroid gland and dissected lateral to the cricothyroid muscle. Injury to this nerve leads to inability to tense the ipsilateral vocal cord and hence difficulty “hitting high notes,” difficulty projecting the voice, and voice fatigue during prolonged speech.

Sympathetic innervation of the thyroid gland is provided by fibers from the superior and middle cervical sympathetic ganglia. The fibers enter the gland with the blood vessels and

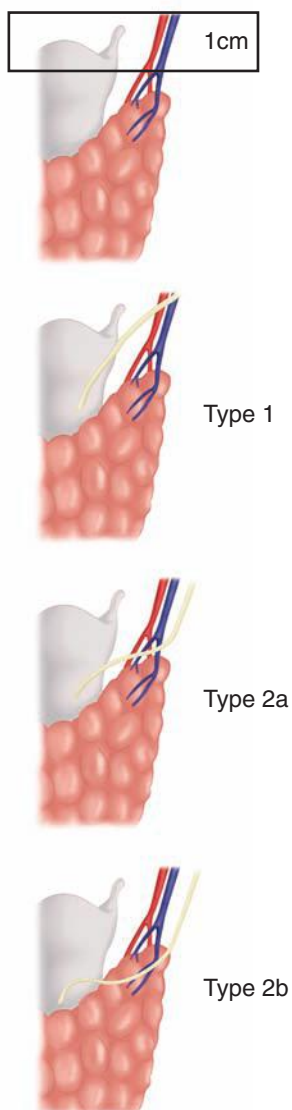


Figure 38-4. Relationship of the external branch of the superior laryngeal nerve and superior thyroid artery originally described by Cernea and colleagues.² In type 1 anatomy, the nerve crosses the artery ≥ 1 cm above the superior aspect of the thyroid lobe. In type 2 anatomy, the nerve crosses the artery < 1 cm above the thyroid pole (2a) or below (2b) it. (Reproduced with permission from Bliss RD et al. *Surgeon's approach to the thyroid gland: Surgical anatomy and the importance of technique*. World J Surg. 2000;24:893. With kind permission of Springer Science + Business Media.)

are vasomotor in action. Parasympathetic fibers are derived from the vagus nerve and reach the gland via branches of the laryngeal nerves.

Parathyroid Glands. The embryology and anatomy of the parathyroid glands are discussed in detail in the Parathyroid Gland section of this chapter. About 85% of individuals have four parathyroid glands that can be found within 1 cm of the junction of the inferior thyroid artery and the RLN. The superior glands are usually located dorsal to the RLN, whereas the inferior glands are usually found ventral to the RLN (Fig. 38-5).

Lymphatic System. The thyroid gland is endowed with an extensive network of lymphatics. Intraglandular lymphatic vessels connect both thyroid lobes through the isthmus and also drain to perithyroidal structures and lymph nodes. Regional lymph nodes include pretracheal, paratracheal, perithyroidal, RLN, superior mediastinal, retropharyngeal, esophageal, and upper, middle, and lower jugular chain nodes. These lymph nodes can be classified into seven levels as depicted in Fig. 38-6. The central compartment includes nodes located in the area between the two carotid sheaths, whereas nodes lateral to the vessels are present in the lateral compartment. Thyroid cancers may metastasize to any of these regions, although metastases to submaxillary nodes (level I) are rare ($< 1\%$). There also can be “skip” metastases to nodes in the lateral ipsilateral neck without central neck nodes.

Thyroid Histology

Microscopically, the thyroid is divided into lobules that contain 20 to 40 follicles (Fig. 38-7). There are about 3×10^6 follicles in the adult male thyroid gland. The follicles are spherical and average 30 μm in diameter. Each follicle is lined by cuboidal epithelial cells and contains a central store of colloid secreted from the epithelial cells under the influence of the pituitary hormone TSH. The second group of thyroid secretory cells is the C cells or parafollicular cells, which contain and secrete the hormone calcitonin. They are found as individual cells or clumped in small groups in the interfollicular stroma and located in the upper poles of the thyroid lobes.

Thyroid Physiology

Iodine Metabolism. The average daily iodine requirement is 0.1 mg, which can be derived from foods such as fish, milk, and eggs or as additives in bread or salt. In the stomach and jejunum, iodine is rapidly converted to iodide and absorbed into the bloodstream, and from there it is distributed uniformly throughout the extracellular space. Iodide is actively transported into the thyroid follicular cells by an adenosine triphosphate (ATP)-dependent process. The thyroid is the storage site of $> 90\%$ of the body's iodine content and accounts for one third of the plasma iodine loss. The remaining plasma iodine is cleared via renal excretion.

Thyroid Hormone Synthesis, Secretion, and Transport.

The synthesis of thyroid hormone consists of several steps (Fig. 38-8). The first, iodide trapping, involves active (ATP-dependent) transport of iodide across the basement membrane of the thyrocyte via an intrinsic membrane protein, the sodium/iodine (Na^+/I^-) symporter. Thyroglobulin (Tg) is a large (660 kDa) glycoprotein, which is present in thyroid follicles and has four tyrosyl residues. The second step in thyroid hormone synthesis involves oxidation of iodide to iodine and iodination of tyrosine residues on Tg, to form monoiodotyrosines (MIT)

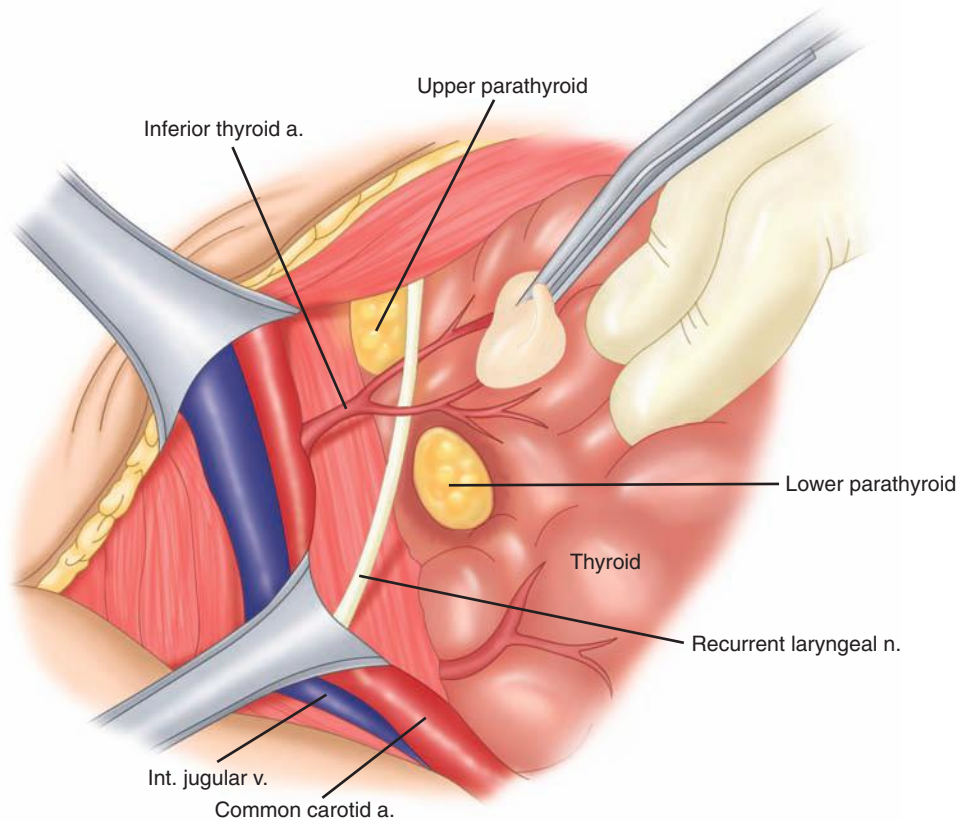


Figure 38-5. Relationship of the parathyroids to the recurrent laryngeal nerve. a. = artery; v. = vein.

and diiodotyrosines (DIT). Both processes are catalyzed by thyroid peroxidase (TPO). A recently identified protein, pendrin, is thought to mediate iodine efflux at the apical membrane. The third step leads to coupling of two DIT molecules to form tetra-iodothyronine or thyroxine (T_4), and one DIT molecule with one MIT molecule to form 3,5,3'-triiodothyronine (T_3) or 3,3',5'-triiodothyronine reverse (rT_3). When stimulated by TSH, thyrocytes form pseudopodia, which encircle portions of cell membrane containing Tg, which in turn, fuse with enzyme-containing lysosomes. In the fourth step, Tg is hydrolyzed to release free iodothyronines (T_3 and T_4) and mono- and diiodotyrosines. The latter are deiodinated in the fifth step to yield iodide, which is reused in the thyrocyte. In the euthyroid state, T_4 is produced and released entirely by the thyroid gland, whereas only 20% of the total T_3 is produced by the thyroid. Most of the T_3 is produced by peripheral deiodination (removal of 5'-iodine from the outer ring) of T_4 in the liver, muscles, kidney, and anterior pituitary, a reaction that is catalyzed by 5'-mono-deiodinase. Some T_4 is converted to rT_3 , the metabolically inactive compound, by deiodination of the inner ring of T_4 . In conditions such as Graves' disease, toxic multinodular goiter, or a stimulated thyroid gland, the proportion of T_3 released from the thyroid may be dramatically elevated. Thyroid hormones are transported in serum bound to carrier proteins such as T_4 -binding globulin, T_4 -binding prealbumin, and albumin. Only a small fraction (0.02%) of thyroid hormone (T_3 and T_4) is free (unbound) and is the physiologically active component. T_3 is the more potent of the two thyroid hormones, although its circulating plasma level is much lower than that of T_4 . T_3 is less tightly bound to protein in the plasma than T_4 , and so it enters tissues more readily. T_3 is three to four times more active

than T_4 per unit weight, with a half-life of about 1 day, compared to approximately 7 days for T_4 .

The secretion of thyroid hormone is controlled by the hypothalamic-pituitary-thyroid axis (Fig. 38-9). The hypothalamus produces a peptide, the thyrotropin-releasing hormone (TRH), which stimulates the pituitary to release TSH or thyrotropin. TRH reaches the pituitary via the portovenous circulation. TSH, a 28-kDa glycopeptide, mediates iodide trapping, secretion, and release of thyroid hormones, in addition to increasing the cellularity and vascularity of the thyroid gland. The TSH receptor (TSH-R) belongs to a family of G-protein-coupled receptors that have seven transmembrane-spanning domains and use cyclic adenosine monophosphate in the signal-transduction pathway. TSH secretion by the anterior pituitary is also regulated via a negative feedback loop by T_4 and T_3 . Because the pituitary has the ability to convert T_4 to T_3 , the latter is thought to be more important in this feedback control. T_3 also inhibits the release of TRH.

The thyroid gland also is capable of autoregulation, which allows it to modify its function independent of TSH. As an adaptation to low iodide intake, the gland preferentially synthesizes T_3 rather than T_4 , thereby increasing the efficiency of secreted hormone. In situations of iodine excess, iodide transport, peroxide generation, and synthesis and secretion of thyroid hormones are inhibited. Excessively large doses of iodide may lead to initial increased organification, followed by suppression, a phenomenon called the *Wolff-Chaikoff effect*. Epinephrine and human chorionic gonadotropin hormones stimulate thyroid hormone production. Thus, elevated thyroid hormone levels are found in pregnancy and gynecologic malignancies such as hydatidiform mole. In contrast, glucocorticoids inhibit thyroid

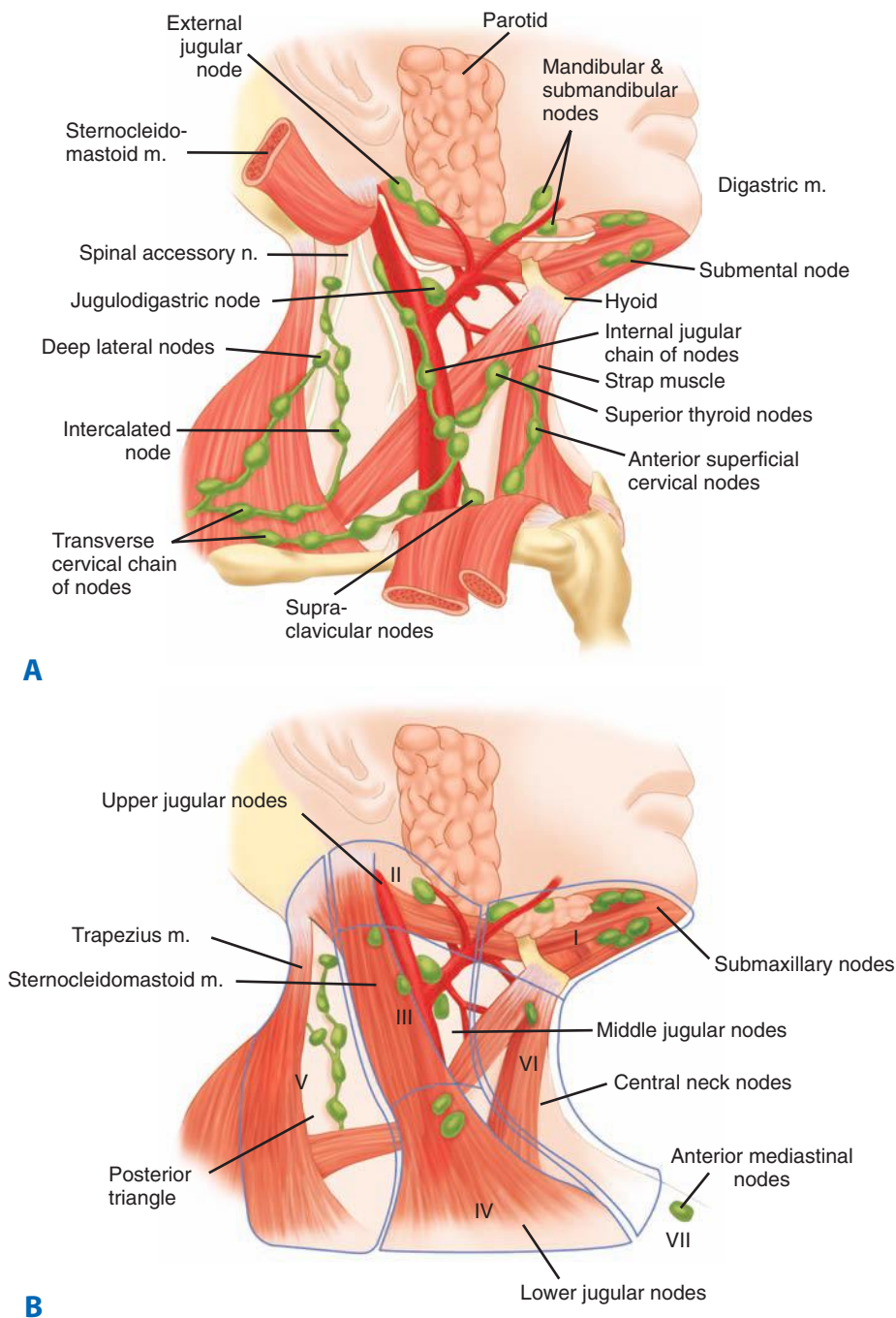


Figure 38-6. A and B. Lymph nodes in the neck can be divided into six regions. Upper mediastinal nodes constitute level VII. m. = muscle; n. = nerve.

hormone production. In severely ill patients, peripheral thyroid hormones may be reduced, without a compensatory increase in TSH levels, giving rise to the euthyroid sick syndrome.

Thyroid Hormone Function. Free thyroid hormone enters the cell membrane by diffusion or by specific carriers and is carried to the nuclear membrane by binding to specific proteins. T_4 is deiodinated to T_3 and enters the nucleus via active transport, where it binds to the thyroid hormone receptor. The T_3 receptor is similar to the nuclear receptors for glucocorticoids, mineralocorticoids, estrogens, vitamin D, and retinoic acid. In humans, two types of T_3 receptor genes (α and β) are located on chromosomes 3 and 17. Thyroid receptor expression depends on peripheral concentrations of thyroid hormones and

is tissue specific—the α form is abundant in the central nervous system, whereas the β form predominates in the liver. Each gene product has a ligand-independent, amino-terminal domain; a ligand-binding, carboxy-terminal domain; and centrally located DNA-binding regions. Binding of thyroid hormone leads to the transcription and translation of specific hormone-responsive genes.

Thyroid hormones affect almost every system in the body. They are important for fetal brain development and skeletal maturation. T_3 increases oxygen consumption, basal metabolic rate, and heat production by stimulation of Na^+/K^+ ATPase in various tissues. It also has positive inotropic and chronotropic effects on the heart by increasing transcription of the Ca^{2+} ATPase in the

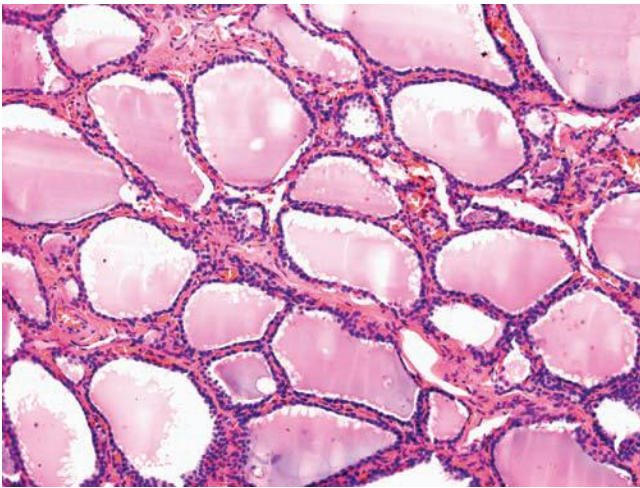


Figure 38-7. Normal thyroid histology—follicular cells surround colloid.

sarcoplasmic reticulum and increasing levels of β -adrenergic receptors and concentration of G proteins. Myocardial α receptors are decreased, and actions of catecholamines are amplified. Thyroid hormones are responsible for maintaining the normal hypoxic and hypercapnic drive in the respiratory center of the brain. They also increase gastrointestinal (GI) motility, leading to diarrhea in hyperthyroidism and constipation in hypothyroidism. Thyroid hormones also increase bone and protein turnover and the speed of muscle contraction and relaxation. They also increase glycogenolysis, hepatic gluconeogenesis, intestinal glucose absorption, and cholesterol synthesis and degradation.

Evaluation of Patients with Thyroid Disease

Tests of Thyroid Function. A multitude of different tests are available to evaluate thyroid function. No single test is sufficient to assess thyroid function in all situations, and the results must be interpreted in the context of the patient's clinical condition.

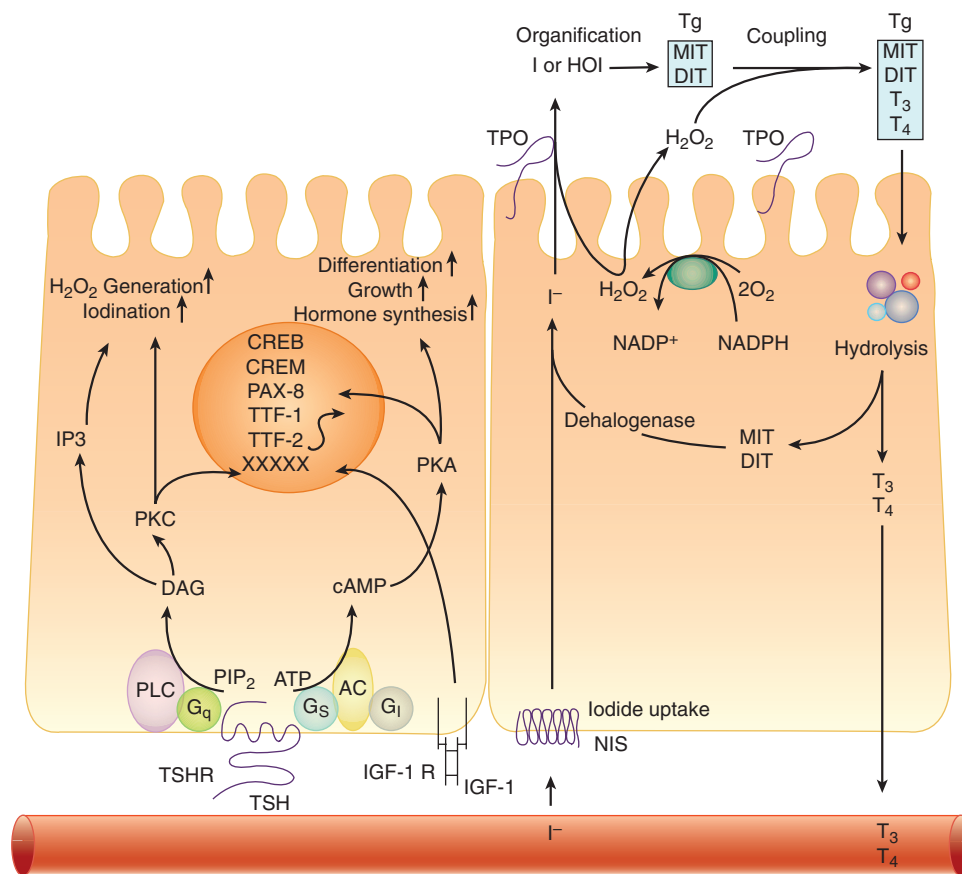


Figure 38-8. Thyroid follicular cell showing the major signaling pathways involved in thyroid cell growth and function and key steps in thyroid hormone synthesis. The basal membrane of the cell in contact with the circulation and its apical surface contact the thyroid follicle. Thyroid hormone synthesis is initiated by the binding of thyroid-stimulating hormone (TSH) to the TSH receptor (TSHR), a G-protein–coupled transmembrane receptor, on the basal membrane. Activation leads to an increase in cyclic adenosine monophosphate (cAMP), phosphorylation of protein kinase A (PKA), and activation of target cytosolic and nuclear proteins. The protein kinase C (PKC) pathway is stimulated at higher doses of TSH. Iodide is actively transported into the cell via the Na/I symporter (NIS) and flows down an electrical gradient to the apical membrane. There, thyroid peroxidase (TPO) oxidizes iodide and iodinated tyrosyl residues on thyroglobulin (Tg) in the presence of peroxide (H_2O_2). Mono- and diiodotyrosyl (MIT, DIT) residues are also coupled to form T_4 and T_3 by TPO. Thyroglobulin carrying T_4 and T_3 is then internalized by pinocytosis and digested in lysosomes. Thyroid hormone is released into the circulation, while MIT and DIT are deiodinated and recycled. ATP = adenosine triphosphate; CREB = cAMP response element binding protein; CREM = cAMP response element modulator; DAG = diacylglycerol; IGF-1 = insulin-like growth factor 1; IP₃ = inositol-3-phosphate; NADP⁺ = nicotinamide adenine dinucleotide phosphate, oxidized form; NADPH = nicotinamide adenine dinucleotide phosphate; PIP₂ = phosphatidylinositol; PLC = phospholipase C; T_3 = 3,5',3-triiodothyronine; T_4 = thyroxine. (Reproduced with permission from Kopp P. *Pendred's syndrome and genetic defects in thyroid hormone synthesis*. Rev Endocr Metab Disord. 2000;1:114. Kluwer Academic Publishers.)

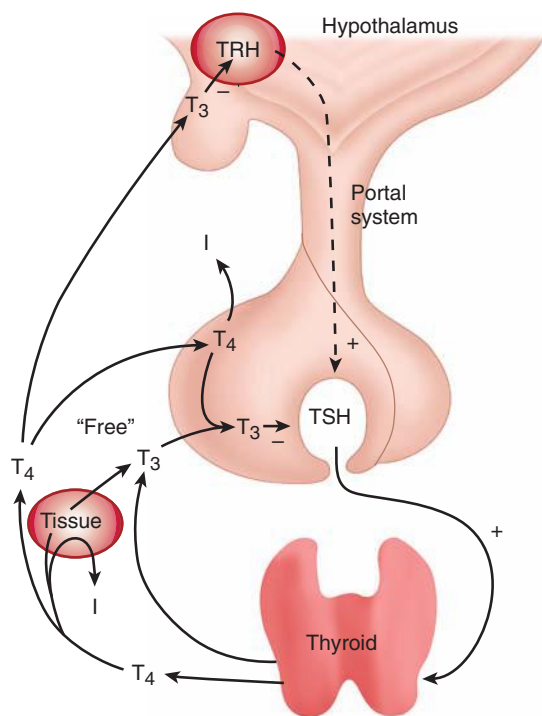


Figure 38-9. Hypothalamic-pituitary-thyroid hormone axis. In both the hypothalamus and pituitary, 3,5',3-triiodothyronine (T_3) is primarily responsible for inhibition of thyrotropin-releasing hormone (TRH) and thyroid-stimulating hormone (TSH) secretion. T_4 = thyroxine. (Reproduced with permission from Greenspan FS. *The thyroid gland*. In: Greenspan FS, Gardner D, eds. *Basic and Clinical Endocrinology*. 6th ed. New York: McGraw-Hill; 2001:217. Copyright © The McGraw-Hill Companies, Inc.)

TSH is the only test necessary in most patients with thyroid nodules that clinically appear to be euthyroid.

Serum Thyroid-Stimulating Hormone (Normal 0.5–5 $\mu\text{U/mL}$)

The tests for serum TSH are based on the following principle: monoclonal TSH antibodies are bound to a solid matrix and bind serum TSH. A second monoclonal antibody binds to a separate epitope on TSH and is labeled with radioisotope, enzyme, or fluorescent tag. Therefore, the amount of serum TSH is proportional to the amount of bound secondary antibody (immunometric assay). Serum TSH levels reflect the ability of the anterior pituitary to detect free T_4 levels. There is an inverse relationship between the free T_4 level and the logarithm of the TSH concentration—small changes in free T_4 lead to a large shift in TSH levels. The ultrasensitive TSH assay has become the most sensitive and specific test for the diagnosis of hyper- and hypothyroidism and for optimizing T_4 therapy.

Total T_4 (Reference Range 55–150 nmol/L) and T_3 (Reference Range 1.5–3.5 nmol/L) Total T_4 and T_3 levels are measured by radioimmunoassay and measure both the free and bound components of the hormones. Total T_4 levels reflect the output from the thyroid gland, whereas T_3 levels in the nonstimulated thyroid gland are more indicative of peripheral thyroid hormone metabolism, and are, therefore, not generally suitable as a general screening test. Total T_4 levels are increased not only in hyperthyroid patients, but also in those with elevated Tg levels secondary to pregnancy, estrogen/progesterone use, or congenital diseases. Similarly, total T_4 levels decrease in hypothyroidism and in patients with decreased Tg levels due to anabolic steroid use and protein-losing disorders like nephrotic syndrome.

Individuals with these latter disorders may be euthyroid if their free T_4 levels are normal. Measurement of total T_3 levels is important in clinically hyperthyroid patients with normal T_4 levels, who may have T_3 thyrotoxicosis. As discussed previously in Thyroid Hormone Synthesis, Secretion, and Transport, total T_3 levels often are increased in early hypothyroidism.

Free T_4 (Reference Range 12–28 pmol/L) and Free T_3 (3–9 pmol/L) These radioimmunoassay-based tests are a sensitive and accurate measurement of biologically active thyroid hormone. Free T_4 estimates are not performed as a routine screening tool in thyroid disease. Use of this test is confined to cases of early hyperthyroidism in which total T_4 levels may be normal but free T_4 levels are raised. In patients with end-organ resistance to T_4 (Refetoff's syndrome), T_4 levels are increased, but TSH levels usually are normal. Free T_3 is most useful in confirming the diagnosis of early hyperthyroidism, in which levels of free T_4 and free T_3 rise before total T_4 and T_3 . Free T_4 levels may also be measured indirectly using the T_3 -resin uptake test. If free T_4 levels are increased, fewer hormone binding sites are available for binding radiolabeled T_3 that has been added to the patient's serum. Therefore, more T_3 binds with an ion-exchange resin, and the T_3 -resin uptake is increased.

Thyrotropin-Releasing Hormone This test is useful to evaluate pituitary TSH secretory function and is performed by administering 500 μg of TRH intravenously and measuring TSH levels after 30 and 60 minutes. In a normal individual, TSH levels should increase at least 6 $\mu\text{IU/mL}$ from the baseline. This test also was previously used to assess patients with borderline hyperthyroidism but has largely been replaced by sensitive TSH assays for this purpose.

Thyroid Antibodies Thyroid antibodies include anti-Tg, antimicrosomal, or anti-TPO and thyroid-stimulating immunoglobulin (TSI). Anti-Tg and anti-TPO antibody levels do not determine thyroid function, but rather indicate the underlying disorder, usually an autoimmune thyroiditis. About 80% of patients with Hashimoto's thyroiditis have elevated thyroid antibody levels; however, levels may also be increased in patients with Graves' disease, multinodular goiter, and occasionally, thyroid neoplasms.

Serum Thyroglobulin Tg is only made by normal or abnormal thyroid tissue. It normally is not released into the circulation in large amounts but increases dramatically in destructive processes of the thyroid gland, such as thyroiditis, or overactive states such as Graves' disease and toxic multinodular goiter. The most important use for serum Tg levels is in monitoring patients with differentiated thyroid cancer for recurrence, particularly after total thyroidectomy and RAI ablation. Elevated anti-Tg antibodies can interfere with the accuracy of serum Tg levels and should always be measured when interpreting Tg levels.

Serum Calcitonin (0–4 pg/mL Basal) This 32-amino-acid polypeptide is secreted by the C cells and functions to lower serum calcium levels, although in humans, it has only minimal physiologic effects. It is also a sensitive marker of MTC.

Thyroid Imaging

Radionuclide Imaging Both iodine-123 (^{123}I) and iodine-131 (^{131}I) are used to image the thyroid gland. The former emits low-dose radiation, has a half-life of 12 to 14 hours, and is used to image lingual thyroids or goiters. In contrast, ^{131}I has a half-life of 8 to 10 days and leads to higher-dose radiation exposure. Therefore, this isotope is used to screen and treat patients with differentiated thyroid cancers for metastatic disease. The images



Figure 38-10. Radioactive iodine scan of the thyroid, with the arrow showing an area of decreased uptake, a cold nodule.

obtained by these studies provide information not only about the size and shape of the gland, but also the distribution of functional activity. Areas that trap less radioactivity than the surrounding gland are termed *cold* (Fig. 38-10), whereas areas that demonstrate increased activity are termed *hot*. The risk of malignancy is higher in “cold” lesions (20%) compared to “hot” or “warm” lesions (<5%). Technetium Tc 99m pertechnetate (^{99m}Tc) is taken up by the thyroid gland and is increasingly being used for thyroid evaluation. This isotope is taken up by the mitochondria, but is not organified. It also has the advantage of having a shorter half-life and minimizes radiation exposure. It is particularly sensitive for nodal metastases. More recently, ^{18}F -fluorodeoxyglucose (FDG) positron emission tomography (PET) combined with computed tomography (CT) is being increasingly used to screen for metastases in patients with

thyroid cancer in whom other imaging studies are negative. PET scans are not routinely used in the evaluation of thyroid nodules; however, they may show clinically occult thyroid lesions. There are several recent reports of rates of malignancy in these lesions ranging from 14% to 63%. These incidentally discovered nodules should be worked up by ultrasound and fine-needle aspiration biopsy (FNAB).

Ultrasound Ultrasound is an excellent noninvasive and portable imaging study of the thyroid gland with the added advantage of no radiation exposure. It is helpful in the evaluation of thyroid nodules, distinguishing solid from cystic ones, and providing information about size and multicentricity. In addition, characteristics such as echotexture, shape, borders and presence of calcifications, and vascularity can provide useful information regarding risk of malignancy. Ultrasound is also especially helpful for assessing cervical lymphadenopathy (Fig. 38-11) and to guide FNAB. An experienced ultrasonographer is necessary for the best results.

Computed Tomography/Magnetic Resonance Imaging Scan CT and magnetic resonance imaging (MRI) studies provide excellent imaging of the thyroid gland and adjacent nodes and are particularly useful in evaluating the extent of large, fixed, or substernal goiters (which cannot be evaluated by ultrasound) and their relationship to the airway and vascular structures. Noncontrast CT scans should be obtained for patients who are likely to require subsequent RAI therapy. If contrast is necessary, therapy needs to be delayed by several months. Combined PET-CT scans are increasingly being used for Tg-positive, RAI-negative tumors.

Benign Thyroid Disorders

Hyperthyroidism. The clinical manifestations of hyperthyroidism result from an excess of circulating thyroid hormone. Hyperthyroidism may arise from a number of conditions that are listed in Table 38-1. It is important to distinguish disorders such as Graves’ disease and toxic nodular goiters that result from increased production of thyroid hormone from those disorders that lead to a release of stored hormone from injury to the thyroid gland (thyroiditis) or from other nonthyroid gland-related conditions. The former disorders lead to an increase in RAI uptake (RAIU), whereas the latter group is characterized by low RAIU. Of these disorders, Graves’ disease, toxic multinodular goiter, and solitary toxic nodule are most relevant to the surgeon.

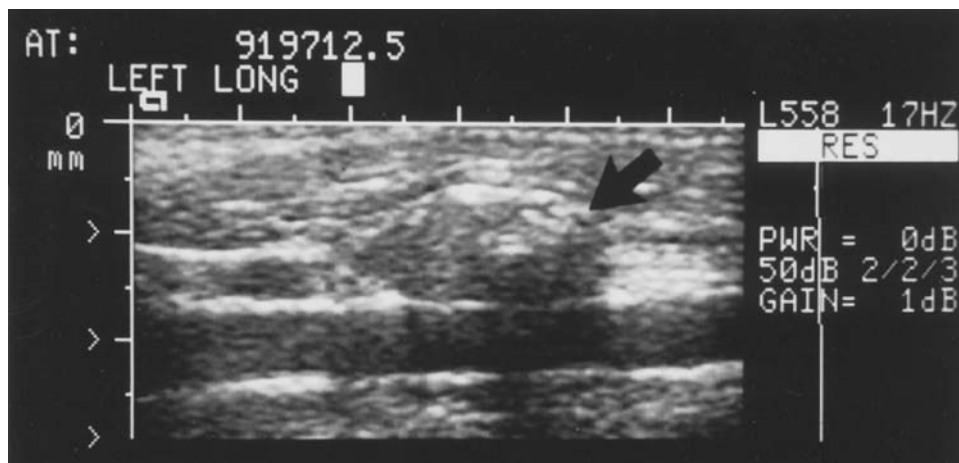


Figure 38-11. Thyroid ultrasound showing a lymph node (arrow) along the carotid artery.

Table 38-1

Differential diagnosis of hyperthyroidism

INCREASED HORMONE SYNTHESIS (INCREASED RAIU)	RELEASE OF PREFORMED HORMONE (DECREASED RAIU)
Graves' disease (diffuse toxic goiter)	Thyroiditis—acute phase of Hashimoto's thyroiditis, subacute thyroiditis
Toxic multinodular goiter	Factitious (iatrogenic)
Toxic adenoma	thyrotoxicosis
Drug induced—amiodarone, iodine	“Hamburger thyrotoxicosis”
Thyroid cancer	
Struma ovarii	
Hydatidiform mole	
TSH-secreting pituitary adenoma	

RAIU = radioactive iodine uptake; TSH = thyroid-stimulating hormone.

Diffuse Toxic Goiter (Graves' Disease) Although originally described by the Welsh physician Caleb Parry in a posthumous article in 1825, this disorder is known as Graves' disease after Robert Graves, an Irish physician who described three patients in 1835. Graves' disease is by far the most common cause of hyperthyroidism in North America, accounting for 60% to 80% of cases. It is an autoimmune disease with a strong familial predisposition, female preponderance (5:1), and peak incidence between the ages of 40 and 60 years. Graves' disease is characterized by thyrotoxicosis, diffuse goiter, and extra-thyroidal conditions including ophthalmopathy, dermopathy (pretibial myxedema), thyroid acropachy, gynecomastia, and other manifestations.

Etiology, Pathogenesis, and Pathology. The exact etiology of the initiation of the autoimmune process in Graves' disease is not known. However, conditions such as the postpartum state, iodine excess, lithium therapy, and bacterial and viral infections have been suggested as possible triggers. Genetic factors also play a role, as haplotyping studies indicate that Graves' disease is associated with certain human leukocyte antigen (HLA) haplotypes, including HLA-B8, HLA-DR3, and HLADQA1*0501 in Caucasian patients, whereas HLA-DRB1*0701 is protective against it. Polymorphisms of the cytotoxic T-lymphocyte antigen 4 (*CTLA-4*) gene also have been associated with Graves' disease development.³ Once initiated, the process causes sensitized T-helper lymphocytes to stimulate B lymphocytes, which produce antibodies directed against the thyroid hormone receptor. TSIs or antibodies that stimulate the TSH-R, as well as TSH-binding inhibiting immunoglobulins or antibodies, have been described. The thyroid-stimulating antibodies stimulate the thyrocytes to grow and synthesize excess thyroid hormone, which is a hallmark of Graves' disease. Graves' disease also is associated with other autoimmune conditions such as type 1 diabetes mellitus, Addison's disease, pernicious anemia, and myasthenia gravis.

Macroscopically, the thyroid gland in patients with Graves' disease is diffusely and smoothly enlarged, with a concomitant increase in vascularity. Microscopically, the gland is hyperplastic, and the epithelium is columnar with minimal colloid present. The nuclei exhibit mitosis, and papillary projections of

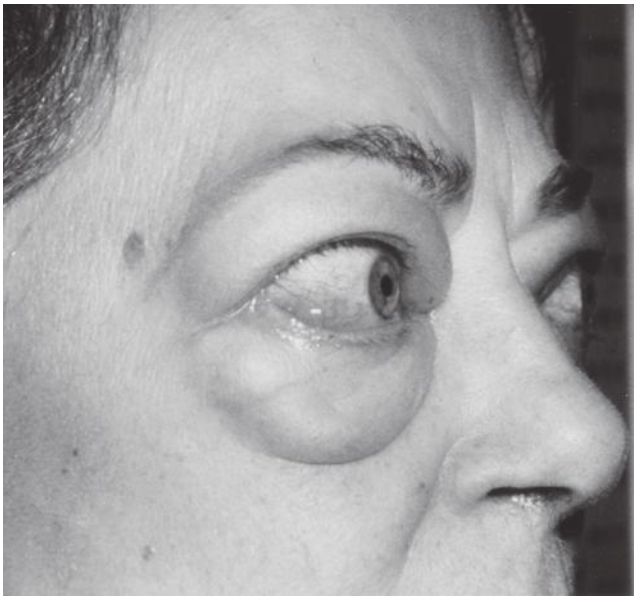hyperplastic epithelium are common. There may be aggregates of lymphoid tissue, and vascularity is markedly increased.

Clinical Features. The clinical manifestations of Graves' disease can be divided into those related to hyperthyroidism and those specific to Graves' disease. Hyperthyroid symptoms include heat intolerance, increased sweating and thirst, and weight loss despite adequate caloric intake. Symptoms of increased adrenergic stimulation include palpitations, nervousness, fatigue, emotional lability, hyperkinesia, and tremors. The most common GI symptoms include increased frequency of bowel movements and diarrhea. Female patients often develop amenorrhea, decreased fertility, and an increased incidence of miscarriages. Children experience rapid growth with early bone maturation, whereas older patients may present with cardiovascular complications such as atrial fibrillation and congestive heart failure.

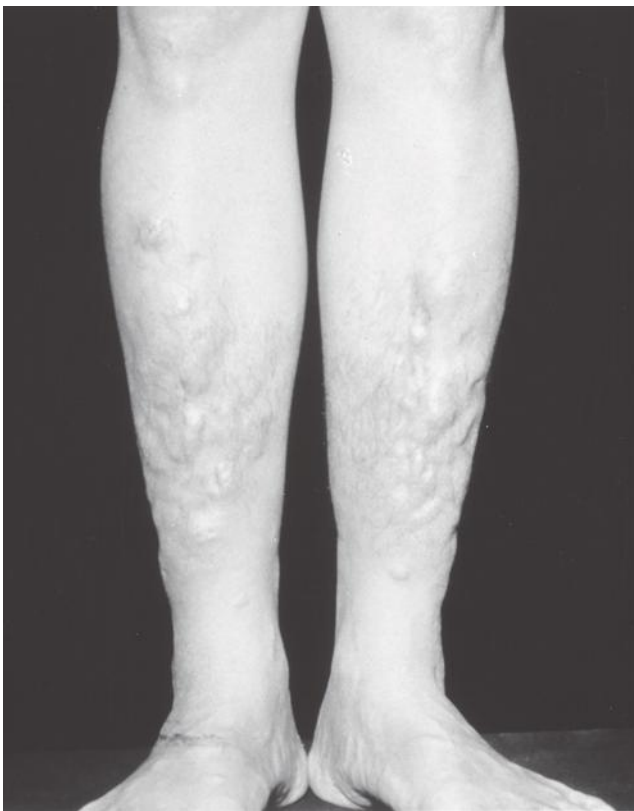On physical examination, weight loss and facial flushing may be evident. The skin is warm and moist, and African American patients often note darkening of their skin. Tachycardia or atrial fibrillation is present, with cutaneous vasodilation leading to a widening of the pulse pressure and a rapid falloff in the transmitted pulse wave (collapsing pulse). A fine tremor, muscle wasting, and proximal muscle group weakness with hyperactive tendon reflexes often are present.

Approximately 50% of patients with Graves' disease also develop clinically evident ophthalmopathy, and dermopathy occurs in 1% to 2% of patients. It is characterized by deposition of glycosaminoglycans, leading to thickened skin in the pretibial region and dorsum of the foot (Fig. 38-12). Eye symptoms include lid lag (von Graefe's sign), spasm of the upper eyelid revealing the sclera above the corneoscleral limbus (Dalrymple's sign), and a prominent stare, due to catecholamine excess. True infiltrative eye disease results in periorbital edema, conjunctival swelling and congestion (chemosis), proptosis, limitation of upward and lateral gaze (from involvement of the inferior and medial rectus muscles, respectively), keratitis, and even blindness due to optic nerve involvement. The etiology of Graves' ophthalmopathy is not completely known; however, orbital fibroblasts and muscles are thought to share a common antigen, the TSH-R. Ophthalmopathy is thought to result from inflammation caused by cytokines released from sensitized killer T lymphocytes and cytotoxic antibodies. Gynecomastia is common in young men. Rare bony involvement leads to subperiosteal bone formation and swelling in the metacarpals (thyroid acropachy). Onycholysis, or separation of fingernails from their beds, is a commonly observed finding. On physical examination, the thyroid usually is diffusely and symmetrically enlarged, as evidenced by an enlarged pyramidal lobe. There may be an overlying bruit or thrill over the thyroid gland and a loud venous hum in the supraclavicular space.

Diagnostic Tests. The diagnosis of hyperthyroidism is made by a suppressed TSH with or without an elevated free T_4 or T_3 level. If eye signs are present, other tests are generally not needed. However, in the absence of eye findings, an ^{123}I uptake and scan should be performed. An elevated uptake, with a diffusely enlarged gland, confirms the diagnosis of Graves' disease and helps to differentiate it from other causes of hyperthyroidism. Technetium scintigraphy (using pertechnetate, which is trapped by the thyroid, but not organified) can also be used to determine etiology. While technetium scans results in low range of normal uptake and high background activity,



A



B

Figure 38-12. A. Graves' ophthalmopathy and (B) pretibial myxedema. This patient demonstrates exophthalmos, proptosis, periorbital swelling, congestion, and edema of the conjunctiva.

total-body radiation exposure is less than that of ^{123}I scans. If free T_4 levels are normal, free T_3 levels should be determined, as they often are elevated in early Graves' disease or toxic nodules (T_3 toxicosis). Anti-Tg and anti-TPO antibodies are elevated in up to 75% of patients but are not specific. Elevated TSH-R or thyroid-stimulating antibodies (TSAb) are diagnostic of Graves' disease and are increased in about 90% of patients. MRI scans of the orbits are useful in evaluating Graves' ophthalmopathy.

Treatment. Graves' disease may be treated by any of three treatment modalities: antithyroid drugs, thyroid ablation with radioactive ^{131}I , and thyroidectomy. The choice of treatment depends on several factors, as discussed in the following sections.

Antithyroid Drugs. Antithyroid medications generally are administered in preparation for RAI ablation or surgery. The drugs commonly used are propylthiouracil (PTU, 100 to 300 mg three times daily) and methimazole (10 to 30 mg three times daily, then once daily). Methimazole has a longer half-life and can be dosed once daily. Both drugs reduce thyroid hormone production by inhibiting the organic binding of iodine and the coupling of iodotyrosines (mediated by TPO). In addition, PTU also inhibits the peripheral conversion of T_4 to T_3 , making it useful for the treatment of thyroid storm. Both drugs can cross the placenta, inhibiting fetal thyroid function, and are excreted in breast milk, although PTU has a lower risk of transplacental transfer. Methimazole also has been associated with congenital aplasia; therefore, PTU is preferred in pregnant and breastfeeding women. Side effects of treatment include reversible granulocytopenia, skin rashes, fever, peripheral neuritis, polyarteritis, vasculitis, hepatitis, and, rarely, agranulocytosis and aplastic anemia. Patients should be monitored for these possible complications and should always be warned to stop PTU or methimazole immediately and seek medical advice should they develop a sore throat or fever. Treatment of agranulocytosis involves admission to the hospital, discontinuation of the drug, and broad-spectrum antibiotic therapy. Surgery should be postponed until the granulocyte count reaches 1000 cells/mm^3 .

The dose of antithyroid medication is titrated as needed in accordance with TSH and T_4 levels. Most patients have improved symptoms in 2 weeks and become euthyroid in about 6 weeks. Some physicians use the block-replace regimen, by adding T_4 (0.05 to 0.10 mg) to prevent hypothyroidism and suppress TSH secretion, because some, but not all, studies suggest that this reduces recurrence rates. The length of therapy is debated. Treatment with antithyroid medications is associated with a high relapse rate when these drugs are discontinued, with 40% to 80% of patients developing recurrent disease after a 1- to 2-year course. Patients with small glands are less likely to recur so that treatment for curative intent is reserved for patients with (a) small, nontoxic goiters less than 40 g; (b) mildly elevated thyroid hormone levels; (c) negative or low or titers of thyroid hormone receptor antibodies; and (d) rapid decrease in gland size with antithyroid medications. The catecholamine response of thyrotoxicosis can be alleviated by administering β -blocking agents. β -Blockade should be considered in all patients with symptomatic thyrotoxicosis and is recommended for elderly patients, those with coexistent cardiac disease, and patients with resting heart rates $>90 \text{ bpm}$. These drugs have the added effect of decreasing the peripheral conversion of T_4 to T_3 . Propranolol is the most commonly prescribed medication in doses of about 20 to 40 mg four times daily. Higher doses are sometimes required due to increased clearance of the medication. Caution should be exercised in patients with asthma. Calcium channel blockers are useful for rate control in patients in whom β -blockers are contraindicated.

Radioactive Iodine Therapy (^{131}I). RAI forms the mainstay of Graves' disease treatment in North America. The major advantages of this treatment are the avoidance of a surgical procedure and its concomitant risks, reduced overall treatment costs, and ease of treatment. Antithyroid drugs are given until the patient

is euthyroid and then discontinued to maximize drug uptake. The ^{131}I dose is calculated after a preliminary scan and usually consists of 8 to 12 mCi administered orally. After standard treatment with RAI, most patients become euthyroid within 2 months. However, only about 50% of patients treated with RAI are euthyroid 6 months after treatment, and the remaining are still hyperthyroid or already hypothyroid.⁴ After 1 year, about 2.5% of patients develop hypothyroidism each year. RAI also has been documented to lead to progression of Graves' ophthalmopathy (33% after RAI compared to 16% after surgery), and ophthalmopathy is more common in smokers. Although there is no evidence of long-term problems with infertility, and overall cancer incidence rates are unchanged, there is a small increased risk of nodular goiter, thyroid cancer,⁵ and hyperparathyroidism (HPT)⁶ in patients who have been treated with RAI. Patients treated with RAI have an unexplained increase in their overall and cardiovascular mortality rates when compared to the general population.

RAI therapy is therefore most often used in older patients with small or moderate-sized goiters, those who have relapsed after medical or surgical therapy, and those in whom antithyroid drugs or surgery are contraindicated. Absolute contraindications to RAI include women who are pregnant (or planning pregnancy within 6 months of treatment) or breastfeeding. Relative contraindications include young patients (i.e., especially children and adolescents), those with thyroid nodules, and those with ophthalmopathy. Lack of access to a high-volume thyroid surgeon is also a consideration. The higher the initial dose of ^{131}I , the earlier the onset and the higher the incidence of hypothyroidism.

Surgical Treatment. In North America, surgery is recommended when RAI is contraindicated as in patients who (a) have confirmed cancer or suspicious thyroid nodules, (b) are young, (c) desire to conceive soon (<6 months) after treatment, (d) have had severe reactions to antithyroid medications, (e) have large goiters (>80 g) causing compressive symptoms, and (f) are reluctant to undergo RAI therapy. Relative indications for thyroidectomy include patients, particularly smokers, with moderate to severe Graves' ophthalmopathy, those desiring rapid control of hyperthyroidism with a chance of being euthyroid, and those demonstrating poor compliance to antithyroid medications. Pregnancy is also a relative contraindication, and surgery should be used only when rapid control is needed and antithyroid medications cannot be used. Surgery is best performed in the second trimester. The goal of thyroidectomy for Graves' disease should be the complete and permanent control of the disease with minimal morbidity. Patients should be rendered euthyroid before operation with antithyroid drugs that should be continued up to the day of surgery. Lugol's iodide solution or saturated potassium iodide generally is administered beginning 7 to 10 days preoperatively (three drops twice daily) to reduce vascularity of the gland and decrease the risk of precipitating thyroid storm. The major action of iodine in this situation is to inhibit release of thyroid hormone. If it is not possible to render the patient euthyroid prior to surgery (if the surgery is urgent or the patient is allergic to antithyroid medications), the patient can be prepared with β -blockade and potassium iodide alone. Steroids can be a useful adjunct in this situation.

The extent of thyroidectomy to be performed used to be determined by the desired outcome (risk of recurrence vs. euthyroidism) and surgeon experience. In patients with coexistent thyroid cancer and those who refused RAI therapy or had severe ophthalmopathy or life-threatening reactions to antithyroid medications (vasculitis, agranulocytosis, or liver failure),

total or near-total thyroidectomy was recommended. Ophthalmopathy has been demonstrated to stabilize or improve in most patients after total thyroidectomy, presumably from removal of the antigenic stimulus. A subtotal thyroidectomy, leaving a 4- to 7-g remnant, was recommended for all remaining patients. During subtotal thyroidectomy, remnant tissue may be left on each side (bilateral subtotal thyroidectomy), or a total lobectomy can be performed on one side with a subtotal thyroidectomy on the other side (Hartley-Dunhill procedure). Results were similar with either procedure,⁷ but the latter procedure was theoretically associated with fewer complications and requires re-entering only one side of the neck should recurrence require reoperation. Most studies, however, show no difference in the rates of complications with either approach, although patients undergoing a total resection had higher rates of temporary hypoparathyroidism. However, patients treated with subtotal thyroidectomy are prone to recurrence, the rates of which are dependent on remnant size. Based on the current evidence, recently published guidelines from the American Thyroid Association (ATA) and the American Association of Clinical Endocrinologists (AAACE) recommend total or near-total thyroidectomy as the procedure of choice for the surgical management of Graves' disease.⁸ Recurrent thyrotoxicosis usually is managed by radioiodine treatment.

Toxic Multinodular Goiter Toxic multinodular goiters usually occur in older individuals, who often have a prior history of a nontoxic multinodular goiter. Over several years, enough thyroid nodules become autonomous to cause hyperthyroidism. The presentation often is insidious in that hyperthyroidism may only become apparent when patients are placed on low doses of thyroid hormone suppression for the goiter. Some patients have T_3 toxicosis, whereas others may present only with atrial fibrillation or congestive heart failure. Hyperthyroidism also can be precipitated by iodide-containing drugs such as contrast media and the antiarrhythmic agent amiodarone (Jod-Basedow hyperthyroidism). Symptoms and signs of hyperthyroidism are similar to Graves' disease, but extrathyroidal manifestations are absent.

Diagnostic Studies. Blood tests are similar to Graves' disease with a suppressed TSH level and elevated free T_4 or T_3 levels. RAI uptake also is increased, showing multiple nodules with increased uptake and suppression of the remaining gland.

Treatment. Hyperthyroidism must be adequately controlled. Both RAI and surgical resection may be used for treatment. When surgery is performed, near-total or total thyroidectomy is recommended to avoid recurrence and the consequent increased complication rates with repeat surgery. Care must be taken in identifying the RLN, which may be found laterally on the thyroid (rather than posterior) or stretched anteriorly over a nodule. RAI therapy is reserved for elderly patients who represent very poor operative risks, provided there is no airway compression from the goiter and thyroid cancer is not a concern. However, because uptake is less than in Graves' disease, larger doses of RAI often are needed to treat the hyperthyroidism. Furthermore, RAI-induced thyroiditis has the potential to cause swelling and acute airway compromise and leaves the goiter intact, with the possibility of recurrent hyperthyroidism.

Toxic Adenoma Hyperthyroidism from a single hyperfunctioning nodule typically occurs in younger patients who note recent growth of a long-standing nodule along with the symptoms of hyperthyroidism. Toxic adenomas are characterized by somatic mutations in the TSH-R gene, although G-protein-stimulating

gene (*gsp*) mutations may occur also.⁹ Most hyperfunctioning or autonomous thyroid nodules have attained a size of at least 3 cm before hyperthyroidism occurs. Physical examination usually reveals a solitary thyroid nodule without palpable thyroid tissue on the contralateral side. RAI scanning shows a “hot” nodule with suppression of the rest of the thyroid gland. These nodules are rarely malignant. Smaller nodules may be managed with antithyroid medications and RAI. Larger nodules can require higher doses, which can lead to hypothyroidism. Surgery (lobectomy and isthmusectomy) is preferred to treat young patients and those with larger nodules. Percutaneous ethanol injection (PEI) has been reported to have reasonable success rates but has not been directly compared with surgery.

Thyroid Storm Thyroid storm is a condition of hyperthyroidism accompanied by fever, central nervous system agitation or depression, and cardiovascular and GI dysfunction, including hepatic failure. The condition may be precipitated by abrupt cessation of antithyroid medications, infection, thyroid or non-thyroid surgery, and trauma in patients with untreated thyrotoxicosis. Occasionally, thyroid storm may result from amiodarone administration or exposure to iodinated contrast agents or following RAI therapy. This condition was previously associated with high mortality rates but can be appropriately managed in an intensive care unit setting. β -Blockers are given to reduce peripheral T_4 to T_3 conversion and decrease the hyperthyroid symptoms. Oxygen supplementation and hemodynamic support should be instituted. Nonaspirin compounds can be used to treat pyrexia, and Lugol’s iodine or sodium ipodate (intravenously) should be administered to decrease iodine uptake and thyroid hormone secretion. PTU therapy blocks the formation of new thyroid hormone and reduces peripheral conversion of T_4 to T_3 . Corticosteroids often are helpful to prevent adrenal exhaustion and block hepatic thyroid hormone conversion.

Hypothyroidism. Deficiency in circulating levels of thyroid hormone leads to hypothyroidism and, in neonates, to cretinism, which is characterized by neurologic impairment and mental retardation. Hypothyroidism also may occur in Pendred’s syndrome (associated with deafness) and Turner’s syndrome. Conditions that cause hypothyroidism are listed in Table 38-2.

Clinical Features Failure of thyroid gland development or function in utero leads to cretinism and characteristic facies similar to those of children with Down syndrome and dwarfism. Failure to thrive and severe mental retardation often are

present. Immediate testing and treatment with thyroid hormone at birth can lessen the neurologic and intellectual deficits. Hypothyroidism developing in childhood or adolescence results in delayed development and may also lead to abdominal distention, umbilical hernia, and rectal prolapse. In adults, symptoms in general are nonspecific, including tiredness, weight gain, cold intolerance, constipation, and menorrhagia. Patients with severe hypothyroidism or myxedema develop characteristic facial features due to the deposition of glycosaminoglycans in the subcutaneous tissues, leading to facial and periorbital puffiness. The skin becomes rough and dry and often develops a yellowish hue from reduced conversion of carotene to vitamin A. Hair becomes dry and brittle, and severe hair loss may occur. There is also a characteristic loss of the outer two thirds of the eyebrows. An enlarged tongue may impair speech, which is already slowed, in keeping with the impairment of mental processes. Patients may also have nonspecific abdominal pain accompanied by distention and constipation. Libido and fertility are impaired in both sexes. Cardiovascular changes in hypothyroidism include bradycardia, cardiomegaly, pericardial effusion, reduced cardiac output, and pulmonary effusions. When hypothyroidism occurs as a result of pituitary failure, other features of hypopituitarism, such as pale, waxy skin; loss of body hair; and atrophic genitalia, may be present.

Laboratory Findings Hypothyroidism is characterized by low circulating levels of T_4 and T_3 . Raised TSH levels are found in primary thyroid failure, whereas secondary hypothyroidism is characterized by low TSH levels that do not increase following TRH stimulation. Thyroid autoantibodies are highest in patients with autoimmune disease (Hashimoto’s thyroiditis, Graves’ disease) and may also be elevated in patients with nodular goiter and thyroid neoplasms. An electrocardiogram demonstrates decreased voltage with flattening or inversion of T waves.

Treatment T_4 is the treatment of choice and is administered in dosages varying from 50 to 200 μg per day, depending on the patient’s size and condition. Starting doses of 100 μg of T_4 daily are well tolerated; however, elderly patients and those with coexisting heart disease and profound hypothyroidism should be started on a considerably lower dose such as 25 to 50 μg daily because of associated hypercholesterolemia and atherosclerosis. The dose can be slowly increased over weeks to months to attain a euthyroid state. A baseline electrocardiogram should always be obtained in patients with severe hypothyroidism before treatment. T_4 dosage is titrated against clinical response

Table 38-2

Causes of hypothyroidism

PRIMARY (INCREASED TSH LEVELS)	SECONDARY (DECREASED TSH LEVELS)	TERTIARY
Hashimoto’s thyroiditis	Pituitary tumor	Hypothalamic insufficiency
RAI therapy for Graves’ disease	Pituitary resection or ablation	Resistance to thyroid hormone
Postthyroidectomy		
Excessive iodine intake		
Subacute thyroiditis		
Medications: antithyroid drugs, lithium		
Rare: iodine deficiency, dyshormogenesis		

RAI = radioactive iodine; TSH = thyroid-stimulating hormone.

and TSH levels, which should return to normal. The management of patients with subclinical hypothyroidism (normal T_4 , slightly raised TSH) is controversial. Some evidence suggests that patients with subclinical hypothyroidism and increased antithyroid antibody levels should be treated, because they will subsequently develop hypothyroidism. Patients who present with myxedema coma may require initial emergency treatment with large doses of IV T_4 (300 to 400 μg), with careful monitoring in an intensive care unit setting.

Thyroiditis. Thyroiditis usually is classified into acute, subacute, and chronic forms, each associated with a distinct clinical presentation and histology.

Acute (Suppurative) Thyroiditis The thyroid gland is inherently resistant to infection due to its extensive blood and lymphatic supply, high iodide content, and fibrous capsule. However, infectious agents can seed it (a) via the hematogenous or lymphatic route, (b) via direct spread from persistent pyriform sinus fistulae or thyroglossal duct cysts, (c) as a result of penetrating trauma to the thyroid gland, or (d) due to immunosuppression. *Streptococcus* and anaerobes account for about 70% of cases; however, other species also have been cultured.¹⁰ Acute suppurative thyroiditis is more common in children and often is preceded by an upper respiratory tract infection or otitis media. It is characterized by severe neck pain radiating to the jaws or ear, fever, chills, odynophagia, and dysphonia. Complications such as systemic sepsis, tracheal or esophageal rupture, jugular vein thrombosis, laryngeal chondritis, and perichondritis or sympathetic trunk paralysis may also occur.

The diagnosis is established by leukocytosis on blood tests and FNAB for Gram's stain, culture, and cytology. CT scans may help to delineate the extent of infection and identify abscesses. A persistent pyriform sinus fistula should always be suspected in children with recurrent acute thyroiditis. The sensitivity of identification of fistulae in the acute setting is lowest for barium esophagography (50%) and best for direct endoscopy (100%), with CT scans being intermediate (80%). Both barium esophagogram and CT scans have improved sensitivity once the acute inflammation has resolved (100% and 83%, respectively), with CT being better at defining the accurate anatomic pathway and its relationship to the thyroid gland.¹¹ Treatment consists of parenteral antibiotics and drainage of abscesses. Thyroidectomy may be needed for persistent abscesses or failure of open drainage. Patients with pyriform sinus fistulae require complete resection of the sinus tract, including the area of the thyroid where the tract terminates, to prevent recurrence. Transnasal flexible fiberoptic laryngoscopy is being increasingly used to identify the internal opening of the pyriform sinus tract and may also allow electrocauterization of the tract, and success rates similar to open surgery have been reported.

Subacute Thyroiditis Subacute thyroiditis can occur in the painful or painless forms. Although the exact etiology is not known, painful thyroiditis is thought to be viral in origin or result from a postviral inflammatory response. Genetic predisposition may also play a role, as manifested by its strong association with the HLA-B35 haplotype. One model of pathogenesis suggests that viral or thyroid antigens, when presented by macrophages in the context of HLA-B35, stimulate cytotoxic T lymphocytes and damage thyroid follicular cells.

Painful thyroiditis most commonly occurs in 30- to 40-year-old women and is characterized by the sudden or gradual onset of neck pain, which may radiate toward the mandible

or ear. History of a preceding upper respiratory tract infection often can be elicited. The gland is enlarged, exquisitely tender, and firm. The disorder classically progresses through four stages. An initial hyperthyroid phase, due to release of thyroid hormone, is followed by a second, euthyroid phase. The third phase, hypothyroidism, occurs in about 20% to 30% of patients and is followed by resolution and return to the euthyroid state in >90% of patients. A few patients develop recurrent disease.

In the early stages of the disease, TSH is decreased, and T_g , T_4 , and T_3 levels are elevated due to the release of preformed thyroid hormone from destroyed follicles. The erythrocyte sedimentation rate is typically >100 mm/h. RAIU also is decreased (<2% at 24 hours), even in euthyroid patients, due to the release of thyroid hormones from destruction of the thyroid parenchyma. Painful thyroiditis is self-limited, and therefore, treatment is primarily symptomatic. Aspirin and other nonsteroidal anti-inflammatory drugs are used for pain relief, but steroids may be indicated in more severe cases. Short-term thyroid replacement may be needed and may shorten the duration of symptoms. Thyroidectomy is reserved for the rare patient who has a prolonged course not responsive to medical measures or for recurrent disease.

Painless thyroiditis is considered to be autoimmune in origin and may occur sporadically or in the postpartum period; the latter typically occurs at about 6 weeks after delivery in women with high TPO antibody titers in early pregnancy. This timing is thought to coincide with a decrease in the normal immune tolerance of pregnancy and consequent rebound elevation of antibody titers.

Painless thyroiditis also is more common in women and usually occurs between 30 and 60 years of age. Physical examination demonstrates a normal sized or minimally enlarged, slightly firm, nontender gland. Laboratory tests and RAIU are similar to those in painful thyroiditis, except for a normal erythrocyte sedimentation rate. The clinical course also parallels painful thyroiditis. Patients with symptoms may require β -blockers and thyroid hormone replacement. Thyroidectomy or RAI ablation is only indicated for the rare patient with recurrent, disabling episodes of thyroiditis.

Chronic Thyroiditis

Lymphocytic (Hashimoto's) Thyroiditis. Lymphocytic thyroiditis was first described by Hashimoto in 1912 as *struma lymphomatosa*—a transformation of thyroid tissue to lymphoid tissue. It is the most common inflammatory disorder of the thyroid and the leading cause of hypothyroidism.

Etiology, Pathogenesis, and Pathology. Hashimoto's thyroiditis is an autoimmune process that is thought to be initiated by the activation of $CD4^+$ T (helper) lymphocytes with specificity for thyroid antigens. Once activated, T cells can recruit cytotoxic $CD8^+$ T cells to the thyroid. Hypothyroidism results not only from the destruction of thyrocytes by cytotoxic T cells but also by autoantibodies, which lead to complement fixation and killing by natural killer cells or block the TSH-R. Antibodies are directed against three main antigens— T_g (60%), TPO (95%), and TSH-R (60%)—and, less commonly, the sodium/iodine symporter (25%). Apoptosis (programmed cell death) also has been implicated in the pathogenesis of Hashimoto's thyroiditis. Chronic thyroiditis also has been associated with increased intake of iodine and administration of medications such as interferon- α , lithium, and amiodarone. Support for an inherited predisposition includes an increased incidence of thyroid

autoantibodies in first-degree relatives of patients with Hashimoto's thyroiditis compared to controls and the occurrence of the autoantibodies and hypothyroidism in patients with specific chromosomal abnormalities such as Turner's syndrome and Down syndrome. Associations with HLA-B8, DR3, and DR5 haplotypes of the major histocompatibility complex also have been described.

On gross examination, the thyroid gland is usually mildly enlarged throughout and has a pale, gray-tan cut surface that is granular, nodular, and firm. On microscopic examination, the gland is diffusely infiltrated by small lymphocytes and plasma cells and occasionally shows well-developed germinal centers. Thyroid follicles are smaller than normal with reduced amounts of colloid and increased interstitial connective tissue. The follicles are lined by Hürthle or Askanazy cells, which are characterized by abundant eosinophilic, granular cytoplasm.

Clinical Presentation. Hashimoto's thyroiditis is also more common in women (male:female ratio 1:10 to 20) between the ages of 30 and 50 years old. The most common presentation is that of a minimally or moderately enlarged firm granular gland discovered on routine physical examination or the awareness of a painless anterior neck mass, although 20% of patients present with hypothyroidism, and 5% present with hyperthyroidism (Hashitoxicosis). In classic goitrous Hashimoto's thyroiditis, physical examination reveals a diffusely enlarged, firm gland, which also is lobulated. An enlarged pyramidal lobe often is palpable.

Diagnostic Studies. When Hashimoto's thyroiditis is suspected clinically, an elevated TSH and the presence of thyroid autoantibodies usually confirm the diagnosis. FNAB with ultrasound guidance is indicated in patients who present with a solitary suspicious nodule or a rapidly enlarging goiter. Thyroid lymphoma is a rare but well-recognized, ominous complication of chronic autoimmune thyroiditis and has a prevalence 80 times higher than expected frequency in this population than in a control population without thyroiditis. Recent studies of clonal similarity indicate that lymphoma may, in fact, evolve from Hashimoto's thyroiditis.¹²

Treatment. Thyroid hormone replacement therapy is indicated in overtly hypothyroid patients, with a goal of maintaining normal TSH levels. The management of patients with subclinical hypothyroidism (normal T_4 and elevated TSH) is controversial. A systematic review of cohort studies showed that in age- and sex-adjusted analyses, subclinical hypothyroidism is associated with a hazard ratio (HR) for coronary heart disease events of 1.89 (95% confidence interval [CI], 1.28 to 2.80; $P < .001$) and coronary heart disease mortality of 1.58 (95% CI, 1.10 to 2.27; $P = .005$) for a TSH level of 10 to 19.9 mIU/L.¹³ The data for TSH levels of 5 to 10 mIU/L were less convincing. An evaluation of the 12 randomized controlled trials in this area only showed a trend toward improvement of some lipid parameters, and none of the included trials evaluated overall mortality or cardiac morbidity. Given the above, levothyroxine is recommended for all patients with TSH levels >10 μ IU/mL and patients with levels of 5 to 10 μ IU/mL in the presence of a goiter or anti-TPO antibodies. Treatment is also advised especially for middle-aged patients with cardiovascular risk factors such as hyperlipidemia or hypertension and in pregnant patients. Surgery may occasionally be indicated for suspicion of malignancy or for goiters causing compressive symptoms or cosmetic deformity.

Riedel's Thyroiditis Riedel's thyroiditis is a rare variant of thyroiditis also known as *Riedel's struma* or *invasive fibrous*

thyroiditis that is characterized by the replacement of all or part of the thyroid parenchyma by fibrous tissue, which also invades into adjacent tissues. The etiology of this disorder is controversial, and it has been reported to occur in patients with other autoimmune diseases. This association, coupled with the presence of lymphoid infiltration and response to steroid therapy, suggests a primary autoimmune etiology. Riedel's thyroiditis also is associated with other focal sclerosing syndromes including mediastinal, retroperitoneal, periorbital, and retro-orbital fibrosis and sclerosing cholangitis, suggesting that it may, in fact, be a primary fibrotic disorder. The disease occurs predominantly in women between the ages of 30 and 60 years old. It typically presents as a painless, hard anterior neck mass, which progresses over weeks to years to produce symptoms of compression, including dysphagia, dyspnea, choking, and hoarseness. Patients may present with symptoms of hypothyroidism and hypoparathyroidism as the gland is replaced by fibrous tissue. Physical examination reveals a hard, "woody" thyroid gland with fixation to surrounding tissues. The diagnosis needs to be confirmed by open thyroid biopsy, because the firm and fibrous nature of the gland renders FNAB inadequate.

Surgery is the mainstay of the treatment. The chief goal of operation is to decompress the trachea by wedge excision of the thyroid isthmus and to make a tissue diagnosis. More extensive resections are not advised due to the infiltrative nature of the fibrotic process that obscures usual landmarks and structures. Hypothyroid patients are treated with thyroid hormone replacement. Some patients who remain symptomatic have been reported to experience dramatic improvement after treatment with corticosteroids and tamoxifen. More recently mycophenolate mofetil has been used to attenuate the inflammatory process and led to dramatic symptom improvements in some patients.¹⁴

Goiter. Any enlargement of the thyroid gland is referred to as a goiter. The causes of nontoxic goiters are listed in Table 38-3. Goiters may be diffuse, uninodular, or multinodular. Most nontoxic goiters are thought to result from TSH stimulation secondary to inadequate thyroid hormone synthesis and other paracrine growth factors.¹⁵ Elevated TSH levels induce diffuse thyroid hyperplasia, followed by focal hyperplasia, resulting in nodules that may or may not concentrate iodine, colloid nodules, or microfollicular nodules. The TSH-dependent nodules progress to become autonomous. Familial goiters resulting from inherited deficiencies in enzymes necessary for thyroid hormone synthesis may be complete or partial. The term *endemic goiter*

Table 38-3

Etiology of nontoxic goiter

CLASSIFICATION	SPECIFIC ETIOLOGY
Endemic	Iodine deficiency, dietary goitrogens (cassava, cabbage)
Medications	Iodide, amiodarone, lithium
Thyroiditis	Subacute, chronic (Hashimoto's)
Familial	Impaired hormone synthesis from enzyme defects
Neoplasm	Adenoma, carcinoma
Resistance to thyroid hormone	—

refers to the occurrence of a goiter in a significant proportion of individuals in a particular geographic region. In the past, dietary iodine deficiency was the most common cause of endemic goiter. This condition has largely disappeared in North America due to routine use of iodized salt and iodination of fertilizers, animal feeds, and preservatives. However, in areas of iodine deficiency, such as Central Asia, South America, and Indonesia, up to 90% of the population have goiters. Other dietary goitrogens that may participate in endemic goiter formation include kelp, cassava, and cabbage. In many sporadic goiters, no obvious cause can be identified.

Clinical Features Most patients with nontoxic goiters are asymptomatic, although patients often complain of a pressure sensation in the neck. As the goiters become very large, compressive symptoms such as dyspnea and dysphagia ensue. Patients also describe having to clear their throats frequently (catarrh). Dysphonia from RLN injury is rare, except when malignancy is present. Obstruction of venous return at the thoracic inlet from a substernal goiter results in a positive Pemberton's sign—facial flushing and dilatation of cervical veins upon raising the arms above the head (Fig. 38-13A). Sudden enlargement of nodules or cysts due to hemorrhage may cause acute pain. Physical examination may reveal a soft, diffusely enlarged gland (simple goiter) or nodules of various size and consistency in case of a multinodular goiter. Deviation or compression of the trachea may be apparent.

Diagnostic Tests Patients usually are euthyroid with normal TSH and low-normal or normal free T_4 levels. If some nodules develop autonomy, patients have suppressed TSH levels or become hyperthyroid. RAI uptake often shows patchy uptake with areas of hot and cold nodules. FNAB is recommended in patients who have a dominant nodule or one that is painful or enlarging, as carcinomas have been reported in 5% to 10% of multinodular goiters. CT scans are helpful to evaluate the extent of retrosternal extension and airway compression (Fig. 38-13B).

Treatment Most euthyroid patients with small, diffuse goiters do not require treatment. Some physicians give patients with large goiters exogenous thyroid hormone to reduce the TSH stimulation of gland growth; this treatment may result in decrease and/or stabilization of goiter size and is most effective for small diffuse goiters. Endemic goiters are treated by iodine administration. Surgical resection is reserved for goiters that (a) continue to increase despite T_4 suppression, (b) cause obstructive symptoms, (c) have substernal extension, (d) have malignancy suspected or proven by FNAB, and (e) are cosmetically unacceptable. Near-total or total thyroidectomy is the treatment of choice, and patients require lifelong T_4 therapy.

Solitary Thyroid Nodule

Solitary thyroid nodules are present in approximately 4% of individuals in the United States, whereas thyroid cancer has a much lower incidence of 40 new cases per 1 million. Therefore, it is of utmost importance to determine which patients with solitary thyroid nodule would benefit from surgery.

History. Details regarding the nodule, such as time of onset, change in size, and associated symptoms such as pain, dysphagia, dyspnea, or choking, should be elicited. Pain is an unusual symptom and, when present, should raise suspicion for intrathyroidal hemorrhage in a benign nodule, thyroiditis, or malignancy. Patients with MTC may complain of a dull, aching sensation. A history of hoarseness is worrisome, as it may be

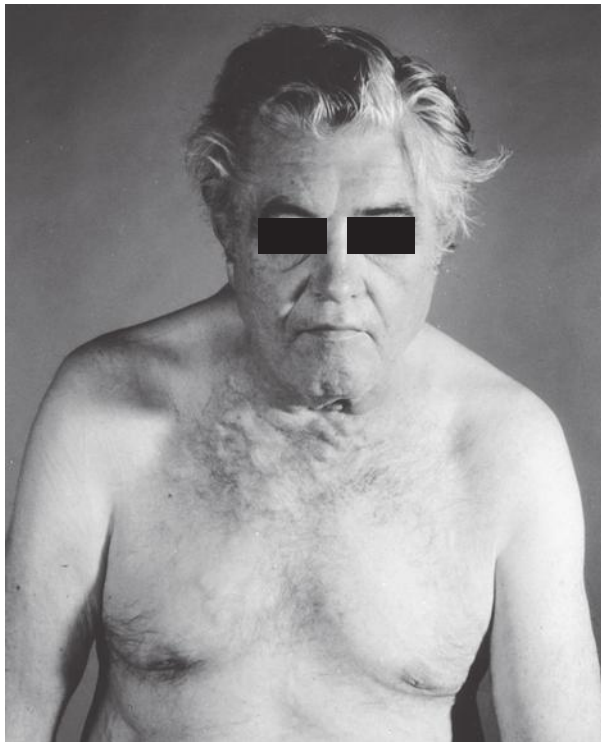
secondary to malignant involvement of the RLNs. Most importantly, patients should be questioned regarding risk factors for malignancy, such as exposure to ionizing radiation and family history of thyroid and other malignancies associated with thyroid cancer.

External-Beam Radiation Low-dose therapeutic radiation has been used to treat conditions such as tinea capitis (6.5 cGy), thymic enlargement (100 to 400 cGy), enlarged tonsils and adenoids (750 cGy), acne vulgaris (200 to 1500 cGy), and other conditions such as hemangioma and scrofula. Radiation (approximately 4000 cGy) is also an integral part of the management of patients with Hodgkin's disease. It is now known that a history of exposure to low-dose ionizing radiation to the thyroid gland places the patient at increased risk for developing thyroid cancer. The risk increases linearly from 6.5 to 2000 cGy, beyond which the incidence declines as the radiation causes destruction of the thyroid tissue. The risk is maximum 20 to 30 years after exposure, but these patients require lifelong monitoring. During the nuclear fallout from Chernobyl in 1986, ^{131}I release was accompanied by a marked increase in the incidence of both benign and malignant thyroid lesions noted within 4 years of exposure, particularly in children.¹⁶ Most thyroid carcinomas following radiation exposure are papillary, and some of these cancers with a solid type of histology and presence of *RET/PTC* translocations appear to be more aggressive. In general, there is a 40% chance that patients presenting with a thyroid nodule and a history of radiation have thyroid cancer. Of those patients who have thyroid cancer, the cancer is located in the dominant nodule in 60% of patients, but in the remaining 40% of patients, the cancer is in another nodule in the thyroid gland.

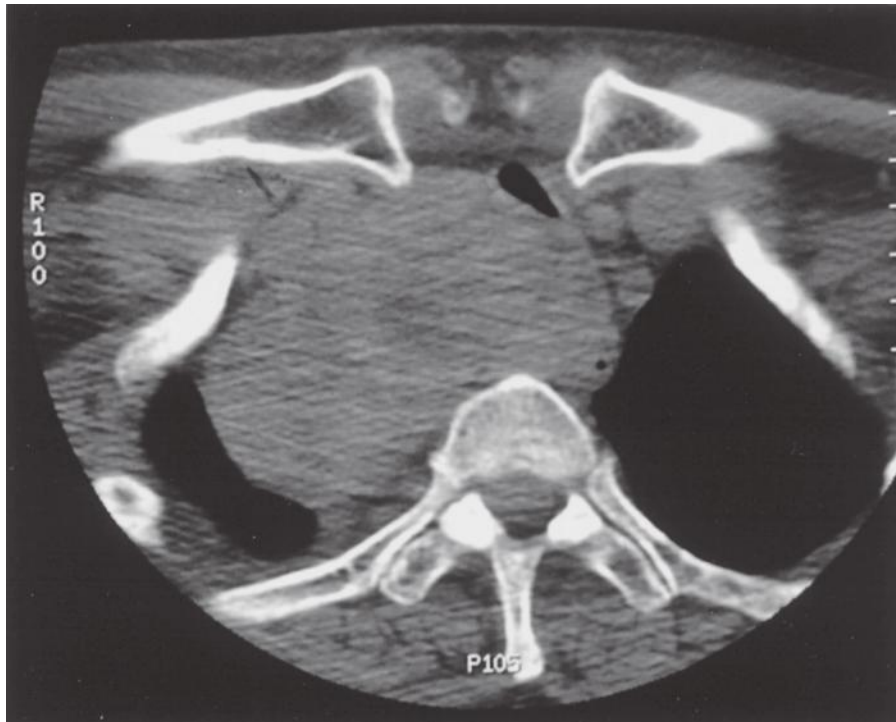
Family History A family history of thyroid cancer is a risk factor for the development of both medullary and nonmedullary thyroid cancer. Familial MTCs occur in isolation or in association with other tumors as part of multiple endocrine neoplasia type 2 (MEN2) syndromes. Nonmedullary thyroid cancers can occur in association with other known familial cancer syndromes such as Cowden's syndrome, Werner's syndrome (adult progeroid syndrome), and familial adenomatous polyposis (Table 38-4). Nonmedullary thyroid cancers can also occur independently of these syndromes as the predominant tumors in the families. The definition of familial nonmedullary thyroid cancer (FNMT) is variable across the literature; however, in most studies, it is defined by the presence of two or more first-degree relatives with follicular cell–derived cancers. FNMT is now recognized as a distinct clinical entity associated with a high incidence of multifocal tumors and benign thyroid nodules.

2► Some studies report that these patients have higher locoregional recurrence rates and consequent shorter disease-free survival. Several candidate loci that predispose to these tumors have been identified, including MNG1 (14q32), thyroid carcinoma with oxphilia (TCO, on 19p13.2), *rPTC/papillary renal neoplasia* (PRN, on 1q21), NMTC (2q21), FTEN (8p23.1-p22), and the telomere-telomerase complex.¹⁷

Physical Examination. The thyroid gland is best palpated from behind the patient and with the neck in mild extension. The cricoid cartilage is an important landmark, as the isthmus is situated just below it. Nodules that are hard, gritty, or fixed to surrounding structures such as the trachea or strap muscles are more likely to be malignant. The cervical chain of lymph nodes should be assessed as well as the nodes in the posterior triangle.



A



B

Figure 38-13. A. Retrosternal extension of a large goiter may result in impeded flow in the superior vena cava, leading to dilated veins over the chest wall. This may become more prominent when patients raise their arms above the head—Pemberton’s sign. B. Computed tomography scan demonstrating retrosternal extension and consequent tracheal deviation and compression from a large goiter.

Diagnostic Investigations. An algorithm for the workup of a solitary thyroid nodule is shown in Fig. 38-14.

Fine-Needle Aspiration Biopsy FNAB has become the single most important test in the evaluation of thyroid masses and can be performed with or without ultrasound guidance.¹⁸ Ultrasound

guidance is recommended for nodules that are difficult to palpate, for cystic or solid-cystic nodules that recur after the initial aspiration, and for multinodular goiters. A 23-gauge needle is inserted into the thyroid mass, and several passes are made while aspirating the syringe. After releasing the suction on the syringe, the needle is withdrawn and the cells are immediately placed on

Table 38-4

Familial cancer syndromes involving nonmedullary thyroid cancer

SYNDROME	GENE	MANIFESTATION	THYROID TUMOR
Cowden's syndrome	<i>PTEN</i>	Intestinal hamartomas, benign and malignant breast tumors	FTC, rarely PTC and Hürthle cell tumors
FAP	<i>APC</i>	Colon polyps and cancer, duodenal neoplasms, desmoids	PTC cribriform growth pattern
Werner's syndrome	<i>WRN</i>	Adult progeroid syndrome	PTC, FTC, anaplastic cancer
Carney complex type 1	<i>PRKAR1α</i>	Cutaneous and cardiac myxomas, breast and adrenal tumors	PTC, FTC
McCune-Albright syndrome	<i>GNAS1</i>	Polyostotic fibrous dysplasia, endocrine abnormalities, café-au-lait spots	PTC clear cell

FAP = familial adenomatous polyposis; FTC = follicular thyroid cancer; PTC = papillary thyroid cancer.

prelabeled dry glass slides; some are immersed in a 70% alcohol solution while others are air dried. A sample of the aspirate is also placed in a 90% alcohol solution for cytospin or cell pellet. The slides are stained by Papanicolaou's or Wright's stains and examined under the microscope. If a bloody aspirate is obtained, the patient should be repositioned in a more upright position and the biopsy repeated with a finer (25- to 30-gauge) needle.

After FNAB, the majority of nodules can be classified into several categories that determine further management. To address the issue of variability in the terminology of fine-needle aspiration (FNA), the National Cancer Institute (NCI) hosted the

3▶ "NCI Thyroid Fine Needle Aspiration State of the Science Conference," which then defined the Bethesda criteria for

thyroid FNA.¹⁹ Accordingly, optimum cytology specimens should have at least six follicles each containing at least 10 to 15 cells from at least two aspirates.

The FNA is classified as "nondiagnostic or unsatisfactory" in 2% to 20% of cases and typically results from a virtually acellular specimen, cyst fluid, or the presence of blood or clotting artifact. The risk of malignancy in this setting ranges from 1% to 4%, and reaspiration under ultrasound guidance is recommended. A "benign" result is obtained in 60% to 70% of thyroid FNAs. The most common lesion in this setting is a follicular nodule (includes adenomatoid nodule, colloid nodule, and follicular adenoma). Other diagnoses include lymphocytic (Hashimoto's) thyroiditis and granulomatous thyroiditis. False-negative results

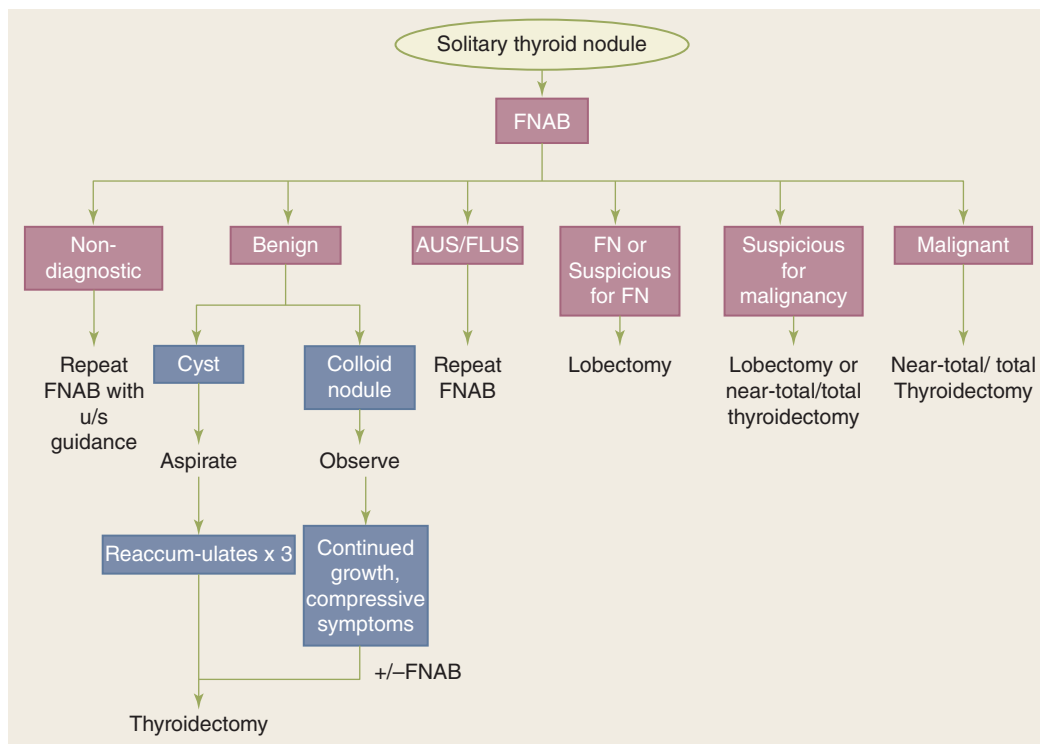


Figure 38-14. Management of a solitary thyroid nodule based on Bethesda criteria. a = except in patients with a history of external radiation exposure or a family history of thyroid cancer; FNAB = fine-needle aspiration biopsy; AUS = atypia of unknown significance; FLUS = follicular lesion of unknown significance; FN = follicular neoplasm.

are reported in up to 3% of cases, and follow-up is recommended. A result of “atypia of unknown significance (AUS) or follicular lesion of unknown significance (FLUS)” is obtained in 3% to 6% of biopsies. The risk of malignancy in this scenario is difficult to determine; however, it is thought to be in the range of 10% to 35% for FLUS and 60% to 75% for AUS. Clinical correlation and a repeat FNA are recommended for AUS lesions (which often results in a more definitive interpretation), although clinical observation or surgery may be appropriate because of worrisome clinical or ultrasound findings. The category of “follicular neoplasm” is intended to identify nodules that might be follicular carcinomas. The term *suspicious for a follicular neoplasm* is preferred by some laboratories for this category because up to 35% of cases turn out not to be neoplasms but hyperplastic proliferations of follicular cells, most commonly those of multinodular goiter. Lobectomy is the preferred treatment for this result, and approximately 15% to 35% of lesions placed in this category prove to be malignant. Hürthle cell neoplasms are also included in this category. Most papillary and other carcinomas can be diagnosed by FNA, but the features are subtle at times, such as in follicular variant of papillary carcinomas. If the diagnosis is uncertain, the lesions are classified as “suspicious for malignancy.” Lobectomy or near-total thyroidectomy is recommended because more than 60% turn out to be malignant. This category also includes lesions suspicious for medullary carcinoma and lymphoma, and ancillary testing such as immunohistochemical analysis and flow cytometry may be helpful. The risk of malignancy in lesions classified as “malignant” by FNA is 97% to 99%, and near-total/total thyroidectomy is recommended.

Laboratory Studies Most patients with thyroid nodules are euthyroid. Determining the blood TSH level is helpful. If a patient with a nodule is found to be hyperthyroid, the risk of malignancy is approximately 1%. Serum Tg levels cannot differentiate benign from malignant thyroid nodules unless the levels are extremely high, in which case metastatic thyroid cancer should be suspected. Tg levels are, however, useful in following patients who have undergone total thyroidectomy for thyroid cancer and also for serial evaluation of patients undergoing nonoperative management of thyroid nodules. Serum calcitonin levels should be obtained in patients with MTC or a family history of MTC or MEN2. There is insufficient evidence to recommend routine calcitonin testing for all nodules. All patients with MTC should be tested for *RET* oncogene mutations and have a 24-hour urine collection with measurement of levels of vanillylmandelic acid (VMA), metanephrine, and catecholamine levels to rule out a coexisting pheochromocytoma. About 10% of patients with familial MTC and MEN2A have *de novo RET* mutations, so that their children are at risk for thyroid cancer.

Imaging Ultrasound is helpful for detecting nonpalpable thyroid nodules, differentiating solid from cystic nodules, and identifying adjacent lymphadenopathy. Ultrasound evaluation can identify features of a nodule that increase the a priori risk of malignancy, such as fine stippled calcification and enlarged regional nodes; however, a tissue diagnosis is strongly recommended before thyroidectomy.²⁰ Ultrasound also provides a noninvasive and inexpensive method of following the size of suspected benign nodules diagnosed by FNAB and for identifying enlarged lymph nodes. Ultrasound elastography is used to evaluate tissue stiffness noninvasively. This technique takes advantage of the fact that malignant nodules tend to be harder than benign nodules and thus deform less compared with the

surrounding normal thyroid parenchyma.²¹ Larger studies are warranted before elastography can be routinely included in the evaluation of thyroid nodules. CT and MRI are unnecessary in the routine evaluation of thyroid tumors except for large, fixed, or substernal lesions. Scanning the thyroid with ¹²³I or ^{99m}Tc is rarely necessary, and thyroid scanning currently is recommended in the assessment of thyroid nodules only in patients who have follicular thyroid nodules on FNAB and a suppressed TSH. PET scanning does not play a major role in the primary evaluation of thyroid nodules.

Management. Malignant tumors are treated by thyroidectomy, as discussed earlier and later in this chapter in Surgical Treatment under Malignant Thyroid Disease. Simple thyroid cysts resolve with aspiration in about 75% of cases, although some require a second or third aspiration. If the cyst persists after three attempts at aspiration, unilateral thyroid lobectomy is recommended. Lobectomy also is recommended for cysts >4 cm in diameter or complex cysts with solid and cystic components, as the latter have a higher incidence of malignancy (15%). When FNAB is used in complex nodules, the solid portion should be sampled. If a colloid nodule is diagnosed by FNAB, patients should still be observed with serial ultrasound and Tg measurements. If the nodule enlarges, repeat FNAB often is indicated. Although controversial, levothyroxine in doses sufficient to maintain a serum TSH level between 0.1 and 1.0 μ U/mL may also be administered. In areas with a high prevalence of iodine deficiency, this can decrease nodule size and potentially prevent the growth of new nodules. In iodine-sufficient populations, the data are less impressive. Randomized controlled trial analyses have shown that less than 25% of benign nodules shrink more than 50% with TSH suppression in iodine-replete populations. Thyroidectomy should be performed if a nodule enlarges on TSH suppression or causes compressive symptoms, or for cosmetic reasons. An exception to this general rule is the patient who has had previous irradiation of the thyroid gland or has a family history of thyroid cancer. In these patients, total or near-total thyroidectomy is recommended because of the high incidence of thyroid cancer and decreased reliability of FNAB in this setting.

Malignant Thyroid Disease

In the United States, thyroid cancer accounts for <1% of all malignancies (2% of women and 0.5% of men) and is the most rapidly increasing cancer in women. Thyroid cancer is responsible for six deaths per million persons annually. Most patients present with a palpable swelling in the neck, which initiates assessment through a combination of history, physical examination, and FNAB.

Molecular Genetics of Thyroid Tumorigenesis. Several oncogenes and tumor suppressor genes are involved in thyroid tumorigenesis,²² as depicted in Table 38-5. The *RET* proto-oncogene (Fig. 38-15) plays a significant role in the pathogenesis of thyroid cancers. It is located on chromosome 10 and encodes a receptor tyrosine kinase, which binds several growth factors such as glial-derived neurotrophic factor and neurturin. The RET protein is expressed in tissues derived from the embryonic nervous and excretory systems. Therefore, *RET* disruption can lead to developmental abnormalities in organs derived from these systems, such as the enteric nervous system (Hirschsprung’s disease) and kidney. Germline mutations in the *RET* proto-oncogene are known to predispose to

Table 38-5

Oncogenes, tumor suppressor genes, and other genetic alterations implicated in thyroid tumorigenesis

GENE	FUNCTION	TUMOR
Oncogenes		
<i>RET</i>	Membrane receptor with tyrosine kinase activity	Sporadic and familial MTC, PTC (RET/PTC rearrangements)
<i>MET</i>	Same	Overexpressed in PTC
<i>TRK1</i>	Same	Activated in some PTC
<i>TSH-R</i>	Linked to heterotrimeric G protein	Hyperfunctioning adenoma
<i>Gsα (gsp)</i>	Signal transduction molecule (GTP binding)	Hyperfunctioning adenoma, follicular adenoma
<i>Ras</i>	Signal transduction protein	Follicular adenoma and carcinoma, PTC
<i>PAX8/PPARγ1</i>	Oncoprotein	Follicular adenoma, follicular carcinoma
<i>B-Raf (BRAF)</i>	Signal transduction	PTC, tall cell and poorly differentiated, anaplastic
<i>CTNNB1 (β-catenin)</i>	Signal transduction	Upregulated in poorly differentiated and anaplastic cancers
Tumor suppressors		
<i>p53</i>	Cell cycle regulator, arrests cells in G ₁ , induces apoptosis	Dedifferentiated PTC, FTC, anaplastic cancers
<i>p16</i>	Cell cycle regulator, inhibits cyclin-dependent kinase	Thyroid cancer cell lines
<i>PTEN</i>	Protein tyrosine phosphatase	Follicular adenoma and carcinoma
Other genetic alterations		
microRNA	Small, noncoding RNA	Specific types upregulated in papillary and some follicular carcinomas

FTC = follicular thyroid cancer; GTP = guanosine triphosphate; MTC = medullary thyroid cancer; PTC = papillary thyroid cancer.

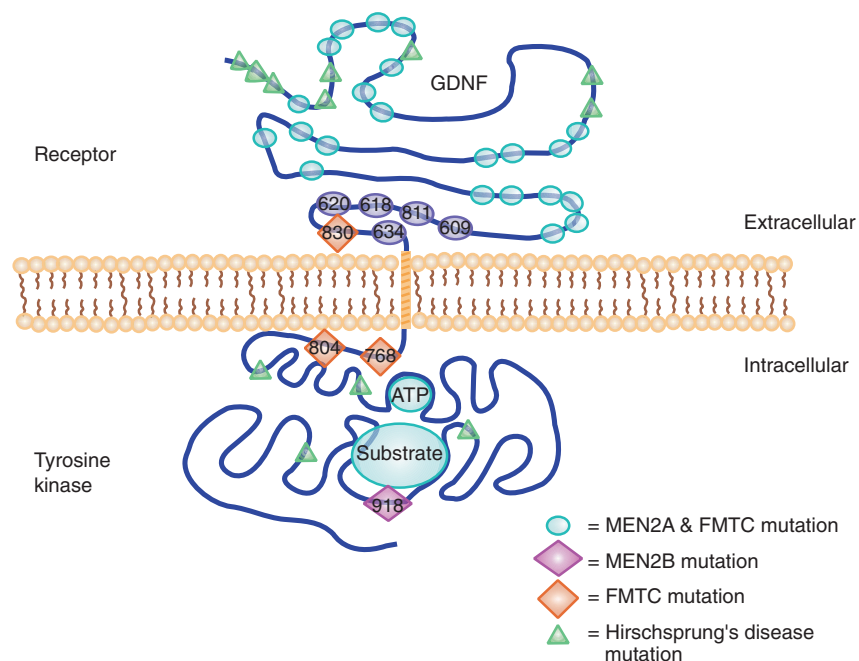


Figure 38-15. Structure of the *RET* tyrosine kinase receptor. Multiple endocrine neoplasia type 2A (MEN2A) and type 2B (MEN2B), familial medullary thyroid cancer (FMTC), and Hirschsprung's disease result from germline mutations in the *RET* proto-oncogene. The extracellular domain binds the ligand glial-derived neurotrophic factor (GDNF) and contains 28 cysteine residues. Mutations in cysteine residues at codons 609, 611, 618, 620, and 634, which are in the juxtamembrane region of the receptor, are associated with MEN2A and FMTC. The ATP-binding site is located intracellularly near the site, which binds the substrate for the tyrosine kinase catalytic domain. Mutations at codon 918 (Met to Thr) alter the substrate binding pocket located in the intracellular region and cause MEN2B. FMTC is associated with mutations at codons 768 and 804. ATP = adenosine triphosphate. (Reproduced with permission from Wells S, Franz C. *Medullary carcinoma of the thyroid*. World J Surg. 2000;24:954. With kind permission of Springer Science + Business Media.)

MEN2A, MEN2B, and familial MTCs, and somatic mutations have been demonstrated in tumors derived from the neural crest, such as MTCs (30%) and pheochromocytomas. The tyrosine kinase domain of *RET* can fuse with other genes by rearrangement. These fusion products also function as oncogenes and have been implicated in the pathogenesis of PTCs. At least 15 *RET/PTC* rearrangements have been described and appear to be early events in tumorigenesis. Young age and radiation exposure seem to be independent risk factors for the development of *RET/PTC* rearrangements. Up to 70% of papillary cancers in children exposed to the radiation fallout from the 1986 Chernobyl disaster carry *RET/PTC* rearrangements, the most common being *RET/PTC1* and *RET/PTC3*. These rearrangements confer constitutive activation of the receptor tyrosine kinases. *RET/PTC3* is associated with a solid type of PTC that appears to present at a higher stage and to be more aggressive. It has now been established that *RET/PTC* signaling involves the mitogen-activated protein kinase (MAPK) pathway via other signaling molecules such as *Ras*, Raf, and MEK. In normal cells, physiologic activation of Raf kinases occurs via direct interaction with guanosine triphosphate (GTP)-bound Ras, a membrane-bound small G protein. Activated Raf, a serine-threonine kinase, in turn phosphorylates MEK, another serine-threonine kinase. This leads to phosphorylation of ERK/MAPK, which phosphorylates regulatory molecules in the nucleus, thereby altering gene expression. Aberrant activation of the MAPK pathway leads to tumorigenesis. Aside from *RET/PTC* alterations, mutations in the *Ras* genes can also activate the MAPK pathway. Mutated *RAS* oncogenes have been identified in up to 20% to 40% of thyroid follicular adenomas and carcinomas, multinodular goiters, and papillary and anaplastic carcinomas. There are three Raf kinases, A-Raf, B-Raf (*BRAF*), and C-Raf. Mutations in *BRAF* also have been implicated in aberrant MAPK pathway activation and tumorigenesis. Of the various identified *BRAF* mutations, T1799A (V600E amino acid substitution) is the most common and occurs frequently in thyroid cancers. Interestingly, *BRAF* mutations occur in papillary and anaplastic tumors (average prevalence of 44% and 22%, respectively),¹⁵ but not in follicular thyroid cancers, suggesting a role in the pathogenesis of these malignancies. Studies also show that *BRAF* mutations are associated with more aggressive clinicopathologic features, including larger tumor size, invasion, and lymphadenopathy, and may have a role as prognostic markers.

The *p53* gene is a tumor suppressor gene encoding a transcriptional regulator, which causes cell cycle arrest allowing repair of damaged DNA, thus helping to maintain genomic integrity. Mutations of *p53* are rare in PTCs but common in undifferentiated thyroid cancers and thyroid cancer cell lines. Other cell cycle regulators and tumor suppressors such as *p15* and *p16* are mutated more commonly in thyroid cancer cell lines than in primary tumors. An oncogene resulting from the fusion of the DNA binding domain of the thyroid-transcription factor *PAX8* gene to the peroxisome proliferator-activated receptor gamma 1 (*PPARγ1*) has been noted to play an important role in the development of follicular neoplasms, including follicular cancers. Thyroid cancer stem cells have also been identified; however, their role in thyroid carcinogenesis remains to be determined.²⁴

Specific Tumor Types

Papillary Carcinoma Papillary carcinoma accounts for 80% of all thyroid malignancies in iodine-sufficient areas and is the

predominant thyroid cancer in children and individuals exposed to external radiation. Papillary carcinoma occurs more often in women, with a 2:1 female-to-male ratio, and the mean age at presentation is 30 to 40 years. Most patients are euthyroid and present with a slow-growing painless mass in the neck. Dysphagia, dyspnea, and dysphonia usually are associated with locally advanced invasive disease. Lymph node metastases are common, especially in children and young adults, and may be the presenting complaint. “Lateral aberrant thyroid” almost always denotes a cervical lymph node that has been invaded by metastatic cancer. Suspicion of thyroid cancer often originates through physical examination of patients and a review of their history. Diagnosis is established by FNAB of the thyroid mass or lymph node. Once thyroid cancer is diagnosed on FNAB, a complete neck ultrasound is strongly recommended to evaluate the contralateral lobe and for lymph node metastases in the central and lateral neck compartments. Distant metastases are uncommon at initial presentation, but may ultimately develop in up to 20% of patients. The most common sites are lungs, followed by bone, liver, and brain.

Pathology. On gross examination, PTCs generally are hard and whitish and remain flat on sectioning with a blade, in contrast to normal tissue or benign nodular lesions that tend to bulge. Macroscopic calcification, necrosis, or cystic change may be apparent. Histologically, papillary carcinomas may exhibit papillary projections (Fig. 38-16A), a mixed pattern of papillary and follicular structures, or a pure follicular pattern (follicular variant). The diagnosis is established by characteristic nuclear cellular features. Cells are cuboidal with pale, abundant cytoplasm, crowded nuclei that may demonstrate “grooving,” and intranuclear cytoplasmic inclusions (leading to the designation of *Orphan Annie* nuclei [Fig. 38-16B]), which allow diagnosis by FNAB. Psammoma bodies, which are microscopic, calcified deposits representing clumps of sloughed cells, also may be present. Mixed papillary-follicular tumors and follicular variants of papillary carcinoma are classified as papillary carcinomas because they behave biologically as papillary carcinomas. Multifocality is common in papillary carcinoma and may be present in up to 85% of cases on microscopic examination. Multifocality is associated with an increased risk of cervical nodal metastases, and these tumors may rarely invade adjacent structures such as the trachea, esophagus, and RLNs. Other variants of papillary carcinoma include tall cell, insular, columnar, diffuse sclerosing, clear cell, trabecular, and poorly differentiated types. These variants account for about 1% of all papillary carcinomas and are generally associated with a worse prognosis.

Minimal or occult/microcarcinoma refers to tumors of 1 cm or less in size with no evidence of local invasiveness through the thyroid capsule or angioinvasion, and that are not associated with lymph node metastases. They are nonpalpable and usually are incidental findings at operative, histologic, or autopsy examination. Studies have demonstrated occult PTC to be present in 2% to 36% of thyroid glands removed at autopsy. These tumors are also being identified more frequently due to the widespread use of ultrasound. These occult tumors are generally associated with a better prognosis than larger tumors, but they may be more aggressive than previously appreciated. About 25% of patients with these tumors have associated occult lymph node metastases.

Prognostic Indicators. In general, patients with PTC have an excellent prognosis with a >95% 10-year survival rate. Several prognostic indicators have been incorporated into various staging

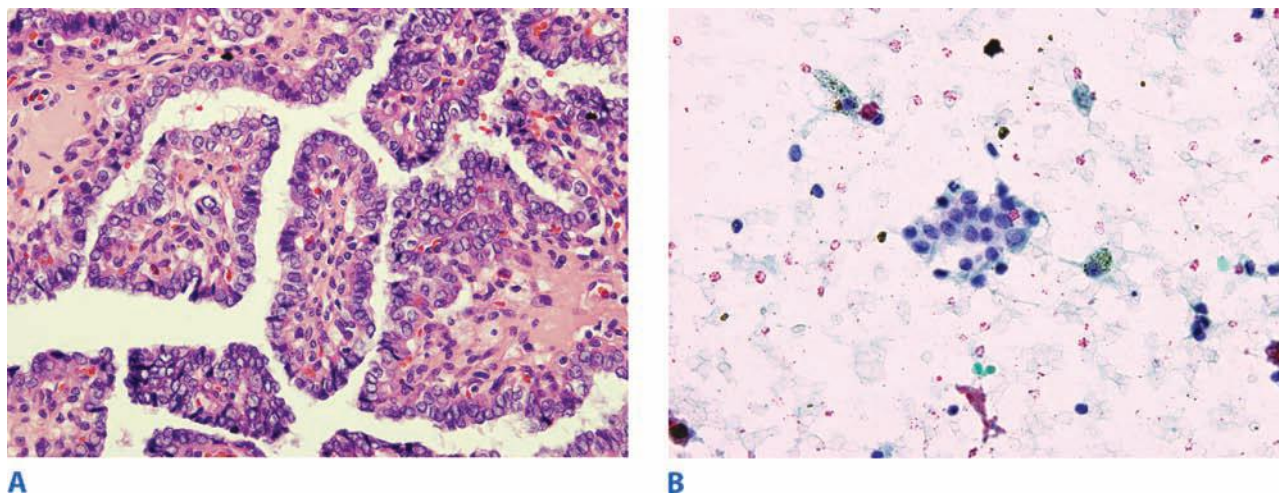


Figure 38-16. A. Histomicrograph of a papillary thyroid cancer (hematoxylin-eosin stain). B. Fine-needle aspiration biopsy specimen from a papillary thyroid cancer showing typical intranuclear cytoplasmic inclusions in the center of the slide.

systems, which enable patients to be stratified into low-risk and high-risk groups. Unfortunately, all of these classification systems rely on data that are not available preoperatively.

In 1987, Hay and colleagues²⁵ at the Mayo Clinic proposed the *AGES* scoring system, which incorporates Age, histologic Grade, Extrathyroidal invasion, and metastases and tumor Size to predict the risk of dying from papillary cancer. Low-risk patients are young, with well-differentiated tumors, no metastases, and small primary lesions, whereas high-risk patients are older, with poorly differentiated tumors, local invasion, distant metastases, and large primary lesions. The *MACIS* scale is a postoperative system modified from the *AGES* scale. This scale incorporates distant Metastases, Age at presentation (<40 or >40 years old), Completeness of original surgical resection, extrathyroidal Invasion, and Size of original lesion (in centimeters) and classifies patients into four risk groups based on their scores. Cady proposed the *AMES* system²⁶ to classify differentiated thyroid tumors into low- and high-risk groups using Age (men <40 years old, women <50 years old), Metastases, Extrathyroidal spread, and Size of tumors (< or >5 cm). Another classification system is the TNM system (Tumor, Nodal status, Metastases; Table 38-6), which used by most medical centers in North America.²⁷ A simplified system by DeGroot and associates²⁸ uses four groups—class I (intrathyroidal), class II (cervical nodal metastases), class III (extrathyroidal invasion), and class IV (distant metastases)—to determine prognosis.

Several molecular and genetic markers such as tumor DNA aneuploidy, decreased cyclic adenosine monophosphate response to TSH, increased epidermal growth factor binding, presence of *N-ras* and *gsp* mutations, overexpression of *c-myc*, and presence of *p53* mutations also have been associated with a worse prognosis. The presence of *BRAF* V600E mutation, as previously mentioned, is associated with aggressive tumor characteristics, including extrathyroidal extension, older age at presentation, and lymph node and distant metastases. This mutation also appears to be an independent predictor of both tumor recurrence (even for early-stage disease) and tumor-related mortality. Some studies propose that *BRAF* mutation status on FNAB can be used to tailor initial management including more extensive initial surgical excision, high-dose postoperative RAI therapy, increased TSH suppression, and closer follow up.²⁹ The correlation of *RET/PTC* rearrangements and *Ras* mutations with prognosis is less clear.

Surgical Treatment. Most authors agree that patients with high-risk tumors (judged by any of the classification systems discussed earlier in Prognostic Indicators) or bilateral tumors should undergo total or near-total thyroidectomy. The optimal surgical strategy in the majority of patients with low-risk (small, unilateral) cancers was controversial for many years, with the focus of the debate centering around outcome data and risks associated with extent of thyroidectomy in this group of patients.

Proponents of total thyroidectomy indicate that it enables the use of RAI to effectively detect and treat residual thyroid tissue or metastatic disease and makes serum Tg level a more sensitive marker of recurrent or persistent disease. It is also known that a significant proportion (33% to 50%) of patients who develop a recurrence die from their disease,³⁰ and even though the data are retrospective, long-term, follow-up studies suggest that recurrence rates are lowered and that survival is improved in patients undergoing near-total or total thyroidectomy^{28, 30-34} (Fig. 38-17). In addition, diminished survival is noted in patients with low-risk disease (mortality rates of 5% at 10 to 20 years), and it is not possible to accurately risk stratify patients preoperatively. More recently, a large study of >50,000 patients with papillary cancer demonstrated that, in multivariate analyses, total thyroidectomy led to a significantly improved recurrence and survival for tumors >1 cm. Furthermore, the authors also showed that patients with tumors 1 to 2 cm in diameter who were treated with lobectomy had a 24% higher risk of recurrence and a 49% higher risk of thyroid cancer mortality.³⁵

4▶ Based on the above, current guidelines for the evidence-based management of thyroid cancers recommend a near-total or total thyroidectomy for primary cancers >1 cm unless there are contraindications to the surgery.³⁶

When PTC is diagnosed by FNAB, the definitive operation can be done without confirming the diagnosis by frozen section during the operation. Patients with a nodule that is suspicious for papillary cancer should be treated by thyroid lobectomy, isthmusectomy, and removal of any pyramidal lobe or adjacent lymph nodes. If intraoperative frozen-section examination of a lymph node or primary tumor confirms carcinoma, completion total or near-total thyroidectomy is performed. If a definitive diagnosis cannot be made or the surgeon is concerned about the viability of the parathyroid glands or the status of the RLN, the operation is terminated. When final histology confirms carcinoma,

Table 38-6

TNM classification of thyroid tumors

PAPILLARY OR FOLLICULAR TUMORS

STAGE	TNM
<45 y	
I	Any T, any N, M0
II	Any T, any N, M1
≥45 y	
I	T1, N0, M0
II	T2, N0, M0
III	T3, N0, M0; T1–3, N1a, M0
IVA	T4a, N0–1a, M0; T1–4a, N1b, M0
IVB	T4b, any N, M0
IVC	Any T, any N, M1

MEDULLARY THYROID CANCER

STAGE	TNM
I	T1, N0, M0
II	T2–3, N0, M0
III	T1–3, N1a, M0
IVA	T4a, N0–1a, M0; T1–4a, N1b, M0
IVB	T4b, any N, M0
IVC	Any T, any N, M1

ANAPLASTIC CANCER

STAGE	TNM
IVA	T4a, Any N, M0
IVB	T4b, Any N, M0
IVC	Any T, Any M, M1

Definitions:

Primary tumor (T)

TX = Primary tumor cannot be assessed

T0 = No evidence of primary tumor

T1 = Tumor ≤2 cm in diameter, limited to thyroid

T2 = Tumor >2 cm but <4 cm in diameter, limited to thyroid

T3 = Tumor >4 cm in diameter, limited to thyroid, or any tumor with minimal extrathyroidal invasion

T4a = Any size tumor extending beyond capsule to invade subcutaneous soft tissue, larynx, trachea, esophagus, or recurrent laryngeal nerve, or intrathyroidal anaplastic cancer

T4b = Tumor invading prevertebral fascia, or encasing carotid artery or mediastinal vessels; or extrathyroidal anaplastic cancer

Regional lymph nodes (N)—include central, lateral cervical, and upper mediastinal nodes

NX = Regional lymph nodes cannot be assessed

N0 = No regional lymph node metastasis

N1 = Regional lymph node metastasis

N1a = Metastases to level VI (pretracheal, paratracheal, and prelaryngeal/Delphian lymph nodes)

N1b = Metastases to unilateral, bilateral, or contralateral cervical or superior mediastinal lymph nodes

Distant metastasis (M)

MX = Distant metastases cannot be assessed

M1 = No distant metastasis

Source: Used with permission of the American Joint Committee on Cancer (AJCC), Chicago, Illinois. The original source for this material is the AJCC Cancer Staging Manual, Seventh Edition (2010) published by Springer Science and Business Media LLC, www.springer.com.

completion thyroidectomy usually is performed. Thyroid lobectomy alone is considered sufficient treatment for small (<1 cm), incidentally discovered, low-risk, unifocal, intrathyroidal papillary carcinomas in the absence of prior head and neck irradiation or radiologically or clinically involved cervical nodal metastases.

During thyroidectomy, enlarged or obviously involved central neck nodes should be removed (therapeutic central-compartment, level VI), along with nodes with known lateral neck metastases. Some investigators recommend routine bilateral central neck dissection due to the high incidence of microscopic metastases and data showing improved rates of recurrence and survival (compared to historic controls). However, these risks need to be balanced with the increased risk of hypoparathyroidism with routine central neck dissection and the fact that some studies do not show any difference in recurrence rates or rates of low or undetectable Tg levels. The 2009 ATA guidelines for thyroid cancer management suggest that prophylactic (ipsilateral or bilateral) dissection may be performed in patients with advanced (T3 or T4) papillary thyroid carcinoma, whereas the procedure is not needed for small (T1 and T2) tumors that are clinically node negative.³⁶ Further prospective studies are needed before definitive recommendations can be made in this regard.

Biopsy-proven lymph node metastases detected clinically or by imaging in the lateral neck in patients with papillary carcinoma are managed with modified radical or functional neck dissection,³⁶ as described later in this chapter in Thyroid Surgery. Dissection of the posterior triangle and suprahyoid dissection usually are not necessary unless there is extensive metastatic disease in levels 2, 3, and 4, but should be performed when appropriate. Prophylactic lateral neck node dissection is not necessary in patients with PTC, because these cancers do not appear to metastasize systemically from lymph nodes, and micrometastases often can be ablated with RAI therapy.

Follicular Carcinoma Follicular carcinomas account for 10% of thyroid cancers and occur more commonly in iodine-deficient areas. The overall incidence of this tumor is declining in the United States, probably due to iodine supplementation and improved histologic classification. Women have a higher incidence of follicular cancer, with a female-to-male ratio of 3:1, and a mean age at presentation of 50 years old. Follicular cancers usually present as solitary thyroid nodules, occasionally with a history of rapid size increase, and long-standing goiter. Pain is uncommon, unless hemorrhage into the nodule has occurred. Unlike papillary cancers, cervical lymphadenopathy is uncommon at initial presentation (about 5%), although distant metastases may be present. In <1% of cases, follicular cancers may be hyperfunctioning, leading patients to present with signs and symptoms of thyrotoxicosis. FNAB is unable to distinguish benign follicular lesions from follicular carcinomas. Therefore, preoperative clinical diagnosis of cancer is difficult unless distant metastases are present. Large follicular tumors (>4 cm) in older men are more likely to be malignant.

Due to the limitations inherent in the FNAB diagnosis, a number of studies have focused on identifying molecular markers to distinguish benign from malignant follicular lesions. **5▶** Many of these genetic changes can be identified using tissue obtained during FNAB. While no single marker has met the ideal characteristics of being simple to use, reproducible, and cost-effective, several studies have explored combinations of markers that appear to be useful in differentiating benign from malignant lesions. Nikiforov and colleagues demonstrated

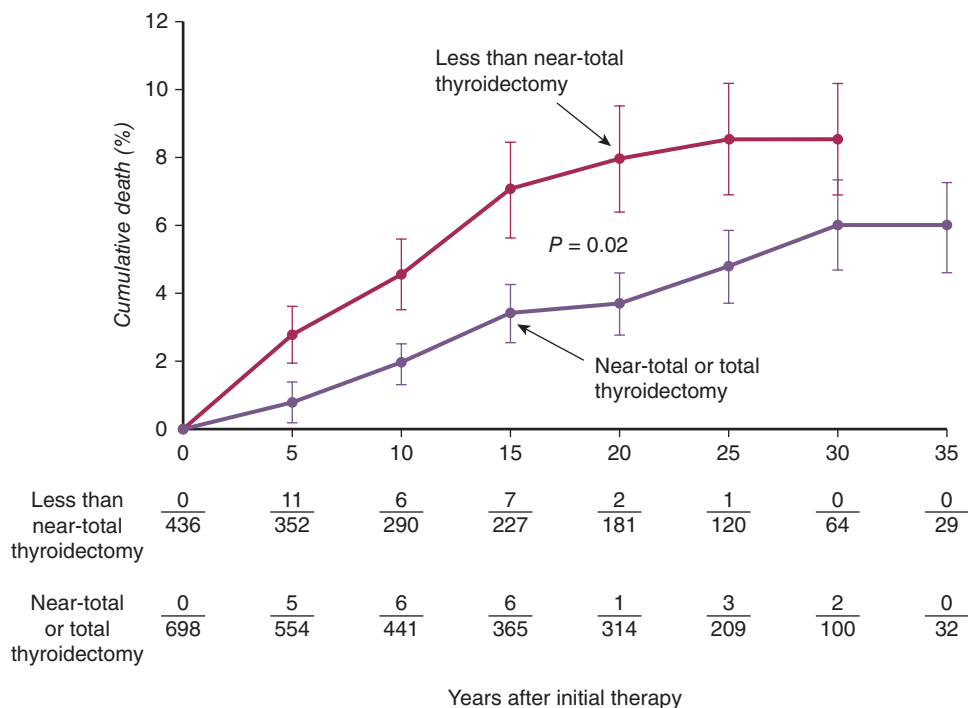


Figure 38-17. Improved survival in patients with papillary or follicular thyroid cancer following total or near-total thyroidectomy compared to those who underwent less than near-total thyroidectomy. (Reproduced with permission from Mazzaferri E, Jhiang S. Long-term impact of initial surgical and medical therapy on papillary and follicular thyroid cancer. *Am J Med.* 1994;97:424. Copyright Elsevier.)

the utility of examining a combination of DNA-based markers including *BRAF*, *RAS*, *RET/PTC*, and *PAX/PPAR γ* abnormalities in the diagnosis of indeterminate nodules. In their study, the presence of any mutation in an FNAB sample was a strong indicator of cancer.^{37,38} Expression arrays also have been used to investigate the role of microRNAs, which are a new class of small, noncoding RNAs that have been implicated in carcinogenesis. The specific microRNAs miR-197 and miR-346 are upregulated in follicular thyroid cancers³⁹ and have the potential to be used as diagnostic markers. Additional studies have also demonstrated the feasibility of studying a panel of microRNAs in a small number of FNA samples. Peripheral blood measurement of TSH-R mRNA levels was able to predict malignancy with a sensitivity of 90% and specificity of 80%; however, its widespread application requires further study.⁴⁰ A recently published prospective, multicenter study validated a novel diagnostic test that measures the expression of 167 genes (Veracyte). The gene expression classifier correctly classified 78 of 85 indeterminate nodules as suspicious with a sensitivity of 92%. Additional studies are needed to assess its utility in the broader clinical setting.⁴¹

Pathology. Follicular carcinomas usually are solitary lesions, and the majority are surrounded by a capsule. Histologically, follicles are present, but the lumen may be devoid of colloid. Architectural patterns depend on the degree of differentiation demonstrated by the tumor. Malignancy is defined by the presence of capsular and vascular invasion (Fig. 38-18). In general, minimally invasive tumors appear grossly encapsulated and have microscopic invasion through the tumor capsule without extension into the parenchyma and/or invasion into small- to medium-sized vessels (venous caliber) in or immediately outside the capsule, but not within the tumor. On the other hand, widely invasive tumors demonstrate evidence of large vessel

invasion and/or broad areas of tumor invasion through the capsule. They may, in fact, be unencapsulated. It is important to note that there is a wide variation of opinion among clinicians and pathologists with respect to the above definitions. Tumor infiltration and invasion, as well as tumor thrombus within the middle thyroid or jugular veins, may be apparent at operation.

Surgical Treatment and Prognosis. Patients diagnosed by FNAB as having a follicular lesion should undergo thyroid lobectomy because at least 80% of these patients will have benign adenomas. Total thyroidectomy is recommended by some surgeons in older patients with follicular lesions >4 cm because of the higher risk of cancer in this setting (50%) and certainly should be performed in patients with atypia on FNA, a family history

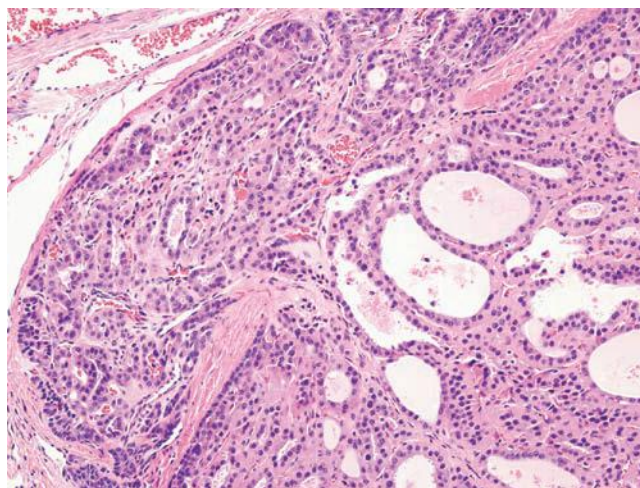


Figure 38-18. Hematoxylin-eosin–stained section from follicular thyroid carcinoma showing capsular invasion.

of thyroid cancer, or a history of radiation exposure. Intraoperative frozen-section examination usually is not helpful, but should be performed when there is evidence of capsular or vascular invasion or when adjacent lymphadenopathy is present. Total thyroidectomy should be performed when thyroid cancer is diagnosed. There is debate among experts about whether patients with minimally invasive follicular cancers should undergo completion thyroidectomy because the prognosis is so good in these patients. A diagnosis of frankly invasive carcinoma or follicular carcinoma with angioinvasion, with or without capsular invasion, necessitates completion of total thyroidectomy primarily so that ^{131}I can be used to detect and ablate metastatic disease. Prophylactic nodal dissection is not needed because nodal involvement is infrequent, but in the unusual patient with nodal metastases, therapeutic neck dissection is recommended. Prophylactic central neck dissection may be considered in patients with large tumors. The cumulative mortality from follicular thyroid cancer is approximately 15% at 10 years and 30% at 20 years. Poor long-term prognosis is predicted by age over 50 years old at presentation, tumor size >4 cm, higher tumor grade, marked vascular invasion, extrathyroidal invasion, and distant metastases at the time of diagnosis.

Hürthle Cell Carcinoma Hürthle cell carcinomas account for approximately 3% of all thyroid malignancies and, under the World Health Organization classification, are considered to be a subtype of follicular thyroid cancer. Hürthle cell cancers also are characterized by vascular or capsular invasion and, therefore, cannot be diagnosed by FNAB. Tumors contain sheets of eosinophilic cells packed with mitochondria, which are derived from the oxyphilic cells of the thyroid gland. Hürthle cell tumors differ from follicular carcinomas in that they are more often multifocal and bilateral (about 30%), usually do not take up RAI (about 5%), are more likely to metastasize to local nodes (25%) and distant sites, and are associated with a higher mortality rate (about 20% at 10 years). Hence, they are considered to be a separate class of tumors by some groups.

Management is similar to that of follicular neoplasms, with lobectomy and isthmusectomy being sufficient surgical treatment for unilateral Hürthle cell adenomas. When Hürthle cell neoplasms are found to be invasive on definitive paraffin-section histology, then total thyroidectomy should be performed. These patients should also undergo routine central neck node removal, similar to patients with MTC, and modified radical neck dissection when lateral neck nodes are palpable or identified by ultrasonography. Although RAI scanning and ablation usually are ineffective, they probably should be considered to ablate any residual normal thyroid tissue and occasionally ablate tumors because there is no other good therapy.

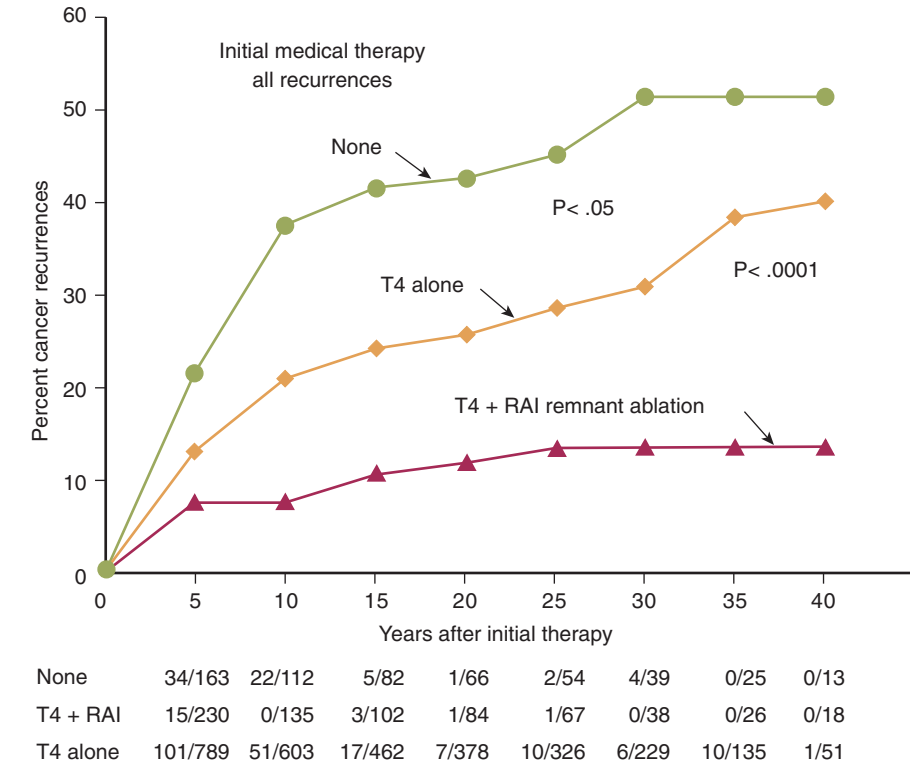
Postoperative Management of Differentiated Thyroid Cancer

Radioiodine Therapy The issue of whether RAI therapy offers any benefit to patients with differentiated thyroid cancer remains controversial in the absence of prospective, randomized controlled trials. Long-term cohort studies by Mazzaferri and associates and DeGroot and colleagues demonstrate that postoperative RAI therapy reduces recurrence (Fig. 38-19) and provides a small improvement in survival, even in low-risk patients.^{28,32} Screening with RAI is more sensitive than chest x-ray or CT scanning for detecting metastases; however, it is less sensitive than Tg measurements for detecting metastatic disease in most differentiated thyroid cancers except Hürthle

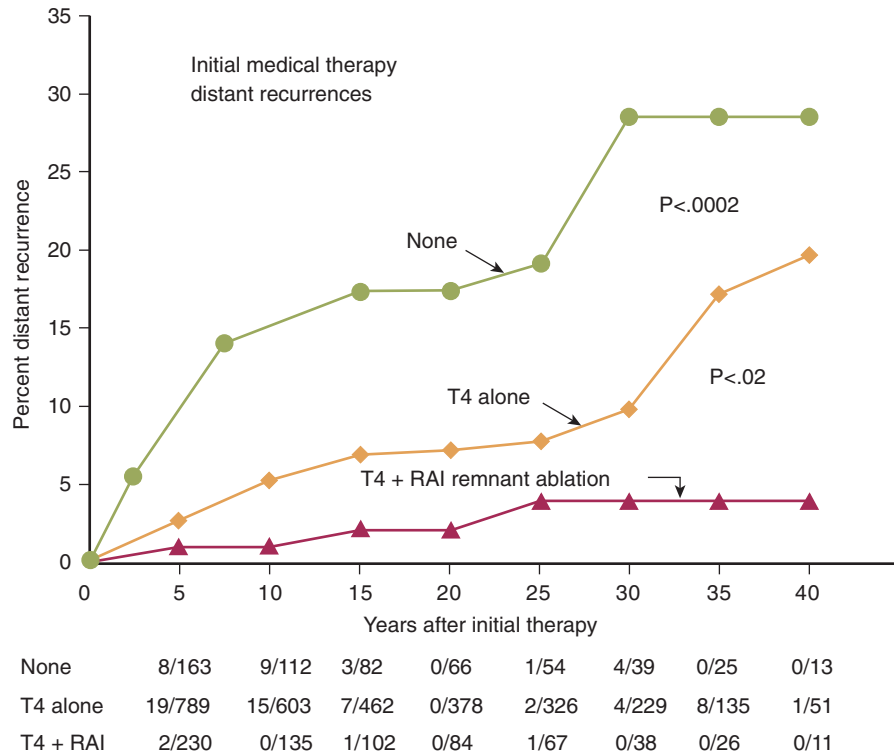
cell tumors. Screening and treatment are facilitated by the removal of all normal thyroid tissue, which effectively competes for iodine uptake. Metastatic differentiated thyroid carcinoma can be detected and treated by ^{131}I in about 75% of patients. Multiple studies show that RAI effectively treats >70% of lung micrometastases that are detected by RAI scan in the presence of a normal chest x-ray, whereas the success rates drop to <10% with pulmonary macrometastases. Early detection therefore appears to be very important to improve prognosis.

Several features place patients at increased risk for local recurrences or metastases. These high-risk features include certain histologic subtypes (such as tall cell, columnar, insular, solid variant and poorly differentiated thyroid cancer), presence of intrathyroidal vascular invasion, or gross or microscopic multifocal disease. However, there are currently inadequate data to determine whether RAI ablation has any benefits based on these features alone, independent of patient age, tumor size, and lymph node status. Thus, the current ATA guidelines strongly recommend RAI after total thyroidectomy only for patients with known distant metastases. In addition, RAI is also indicated for patients with gross extrathyroidal extension of tumor (regardless of size) or tumors >4 cm, even in the absence of other high-risk features. Ablation is also recommended, albeit based on expert opinion, for selected patients with 1- to 4-cm tumors with lymph node metastases or other high-risk features outlined above, when the combination of T and N status, age, and histology predicts an intermediate to high rate of tumor recurrence.³⁶ In contrast, RAI is not indicated for patients with unifocal cancers <1 cm in diameter or patients with multifocal tumors (all <1 cm) without additional high-risk features. *This latter indication is a major change from the 2006 guidelines wherein RAI was recommended for all multifocal tumors.*

Remnant ablation can be performed with either thyroid hormone withdrawal or recombinant TSH (rTSH) stimulation. This is based on randomized studies showing that both techniques are equally effective in preparing patients for ablation, with the latter being associated with an improved quality of life. If hormone withdrawal is used, T_4 therapy should be discontinued for approximately 6 weeks before scanning with ^{131}I . Patients should receive T_3 during this time period to decrease the period of hypothyroidism. T_3 has a shorter half-life than T_4 (1 day vs. 1 week) and needs to be discontinued for 2 weeks to allow TSH levels to rise before treatment. Levels >30 mU/L are considered optimal, based on non-controlled studies. A low-iodine diet also is recommended during this 2-week period. The usual protocol involved administering a screening dose of 1 to 3 mCi and measuring uptake 24 hours later. After a total thyroidectomy, this value should be <1%. A “hot” spot in the neck after initial screening usually represents residual normal tissue in the thyroid bed. Some investigators recommend omitting the scanning dose altogether to minimize thyrocyte “stunning” and subsequent requirement for higher treatment doses. Others recommend scanning only if the size of the remnant cannot be determined by the operative report or ultrasound, or if the results would alter the decision to treat or the dose to be administered. Current guidelines recommend using either ^{123}I or low-activity ^{131}I (1- to 3-mCi dose) and delivering a therapeutic dose within 72 hours. Treatment doses of 30 to 100 mCi are recommended for ablation in low-risk patients as these doses show similar rates of ablation and recurrence rates. A 30-mCi dose is also effective at ablating the remnant with recombinant TSH. In higher risk patients (residual microscopic disease suspected or documented; tall cell, insular, or columnar cell histology), higher doses (100 to



A



B

Figure 38-19. Tumor recurrence at a median of 16.7 years after thyroid surgery. The numerator is the number of patients with recurrence, and the denominator is the number of patients in each time interval. The *P* values are derived from log-rank statistical analysis of 40-year life-table data. Figure shows that all recurrences (A) and distant metastases (B) were reduced in patients who received radioactive iodine (RAI) in addition to thyroxine (T4) therapy. (Reproduced with permission from Mazzaferri E, Kloos R. Current approaches to primary therapy for papillary and follicular thyroid cancer. *J Clin Endocrinol Metab.* 2001;86:1453. Copyright by The Endocrine Society.)

200 mCi) are recommended. If patients have an elevated Tg level, but negative RAI scan, some physicians recommend treating once with 100 mCi of ^{131}I and repeating the imaging 1 to 2 weeks later. Approximately one third of these patients demonstrate uptake on posttreatment imaging, and Tg levels usually decrease in these patients, documenting therapeutic benefit. The maximum dose of radioiodine that can be administered at one time without performing dosimetry is approximately 200 mCi with a cumulative dose of 1000 to 1500 mCi. Up to 500 mCi can be given with proper pretreatment dosimetry. Recent studies also show an increase in the number of second cancers in patients treated with RAI.⁴² The early and delayed complications of RAI therapy are listed in Table 38-7.

External-Beam Radiotherapy and Chemotherapy External-beam radiotherapy is occasionally required to control unresectable, locally invasive or recurrent disease and to treat metastases in support bones to decrease the risk of fractures. It also is of value for the treatment and control of pain from bony metastases when there is minimal or no RAIU. Single-drug and multidrug chemotherapy has been used with little success in disseminated thyroid cancer, and there is no role for routine chemotherapy.³⁶ Doxorubicin (Adriamycin) and paclitaxel (Taxol) are the most frequently used agents. The former acts as a radiation sensitizer and should be considered in patients undergoing external-beam radiation.

Novel Therapies These therapies are directed at the pathways known to be involved in various thyroid cancers.⁴³ Oncogenic kinase inhibitors that inhibit the mutant V600E BRAF kinase

(PLX4032) selectively or both the wild-type and mutant kinase (XL281) have shown promise in the treatment of patients with metastatic papillary cancers. These drugs are associated with GI toxicity (nausea, vomiting, and diarrhea) and an increased risk of cutaneous squamous cell carcinomas. Other kinases targeting the VEGF and RET receptors have also shown promising results. However, the low rate of partial responses, lack of complete response, and ultimate resistance to therapy highlight the need for ongoing research in this area.

Thyroid Hormone T_4 is necessary as replacement therapy in patients after total or near-total thyroidectomy, and also has the additional effect of suppressing TSH and reducing the growth stimulus for any possible residual thyroid cancer cells. TSH suppression reduces tumor recurrence rates. Current guidelines advise maintaining TSH levels <0.1 mU/mL in patients with persistent disease and maintaining TSH in the low normal range (0.3 to 2 mU/mL) in patients who are clinically and biochemically free of disease and at low risk for recurrence. For high-risk patients in the latter group, maintenance of TSH levels of 0.1 to 0.5 mU/mL is advised.³⁶ The risk of tumor recurrence must be balanced with the side effects associated with prolonged TSH suppression, including osteopenia and cardiac problems, particularly in older patients.

Follow-Up of Patients with Differentiated Thyroid Cancer

Thyroglobulin Measurement Tg and anti-Tg antibody levels should be measured initially at 6-month intervals. In low-risk patients, who have low suppressed Tg levels in the first year, serum Tg should be measured after T_4 withdrawal or recombinant TSH stimulation approximately 12 months after ablation. Patients with undetectable stimulated Tg levels can be followed annually with clinical exam and Tg levels on T_4 replacement. A single rTSH-stimulated Tg level of <0.5 ng/mL (with absent antibodies) has a 98% to 99.5% probability of identifying patients completely free of disease on follow-up. A Tg level of >2 ng/mL following rTSH stimulation is highly sensitive in identifying patients with recurrent tumor.³⁶ Tg measurements in FNAB aspirates have also been shown to be useful in the detection of nodal metastatic disease.⁴⁴

Imaging After the first posttreatment scan, low-risk patients with negative TSH-stimulated Tg and cervical ultrasound do not require routine diagnostic whole-body radioiodine scans. However, diagnostic whole-body scans 6 to 12 months after remnant ablation may be of value in the follow-up of patients with high or intermediate risk of persistent disease. It also is recommended that cervical ultrasound be performed to evaluate the thyroid bed and central and lateral cervical nodal compartments at 6 and 12 months after thyroidectomy and then annually for at least 3 to 5 years, depending on the patient's risk for recurrent disease and Tg status. Sonographically suspicious nodes >5 to 8 mm on the smallest diameter measurement should be biopsied for cytology as well as Tg measurement in the aspirate washout. Smaller nodes can be followed and biopsied if there is continued growth.³⁶ FDG-PET and PET-CT scans have been shown to be useful to localize recurrent or persistent thyroid cancer in patients who have Tg-positive, RAI scan-negative disease. FDG-PET can also be useful for the initial staging of patients with poorly differentiated thyroid carcinomas or Hürthle cell tumors, particularly in patients with other evidence of disease on imaging or Tg levels. In addition, they may be used

Table 38-7

Complications of radioactive iodine therapy (^{131}I) and doses at which they are observed

ACUTE	LONG-TERM
Neck pain, swelling, and tenderness	Hematologic
Thyroiditis (if remnant present)	Bone marrow suppression (>500 mCi)
Sialadenitis (50–450 mCi), taste dysfunction	Leukemia (>1000 mCi)
Hemorrhage (brain metastases)	Fertility
Cerebral edema (brain metastases, 200 mCi)	Ovarian/testicular damage, infertility
Vocal cord paralysis	Increased spontaneous abortion rate
Nausea and vomiting (50–450 mCi)	
Bone marrow suppression (200 mCi)	Pulmonary fibrosis
	Chronic sialadenitis, nodules, taste dysfunction
	Increased risk of cancer
	Anaplastic thyroid cancer
	Gastric cancer
	Hepatocellular cancer
	Lung cancer
	Breast cancer (>1000 mCi)
	Bladder cancer
	Hypoparathyroidism

Table 38-8

Clinical and genetic features of medullary thyroid cancer syndromes

SYNDROME	MANIFESTATIONS	RET MUTATIONS
MEN2A	MTC, pheochromocytoma, primary hyperparathyroidism, lichen planus amyloidosis	Exon 10—codons 609, 611, 618, 620
		Exon 11—codon 634 (more commonly associated with pheochromocytoma and primary hyperparathyroidism)
MEN2B	MTC, pheochromocytoma, Marfanoid habitus, mucocutaneous ganglioneuromatosis	Exon 16—codon 918
Familial MTC	MTC	Codons 609, 611, 618, 620, and 634 Codons 768, 790, 791, or 804 (rare)
MEN2A and Hirschsprung's disease	MTC, pheochromocytoma, primary hyperparathyroidism, Hirschsprung's disease	Codons 609, 618, 620

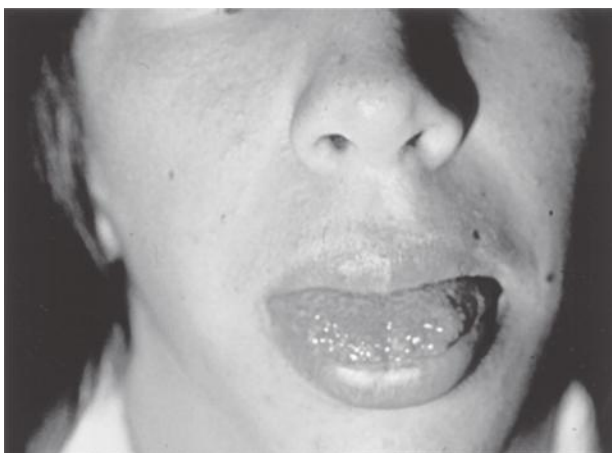
MEN2 = multiple endocrine neoplasia type 2; MTC = medullary thyroid cancer.

as a prognostic tool in patients with metastatic disease and to evaluate the response to treatment in patients with metastatic or locally advanced disease.

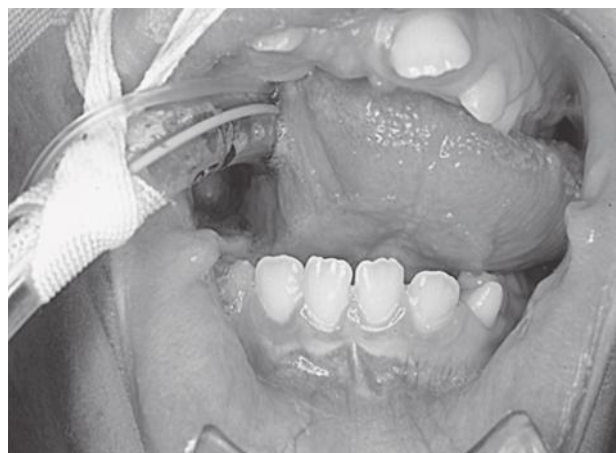
Medullary Carcinoma MTC accounts for about 5% of thyroid malignancies and arises from the parafollicular or C cells of the thyroid, which, in turn, are derived from the ultimobranchial bodies. These cells are concentrated superolaterally in the thyroid lobes, and this is where MTC usually develops. C cells secrete calcitonin, a 32-amino-acid polypeptide that functions to lower serum calcium levels, although its effects in humans are minimal. Most MTCs occur sporadically. However, approximately 25% occur within the spectrum of several inherited syndromes such as familial MTC, MEN2A, and MEN2B. All these variants are known to result secondary to germline mutations in the *RET* proto-oncogene. The syndromes also are characterized by genotype-phenotype correlations, with specific mutations leading to particular clinical manifestations. The salient clinical and genetic features of these syndromes are outlined

in Table 38-8. Some clinical features of MEN2B patients are shown in Fig. 38-20.

Patients with MTC often present with a neck mass that may be associated with palpable cervical lymphadenopathy (15% to 20%). Pain or aching is more common in patients with these tumors, and local invasion may produce symptoms of dysphagia, dyspnea, or dysphonia. Distant blood-borne metastases to the liver, bone (frequently osteoblastic), and lung occur later in the disease. The female-to-male ratio is 1.5:1. Most patients present between 50 and 60 years old, although patients with familial disease present at a younger age. Medullary thyroid tumors secrete not only calcitonin and carcinoembryonic antigen (CEA), but also other peptides such as calcitonin gene-related peptide, histaminadases, prostaglandins E_2 and $F_2\alpha$, and serotonin. Patients with extensive metastatic disease frequently develop diarrhea, which may result from increased intestinal motility and impaired intestinal water and electrolyte flux. About 2% to 4% of patients develop Cushing's syndrome as a result of ectopic production of adrenocorticotrophic hormone (ACTH).



A



B

Figure 38-20. Features of MEN2B: thickened lips (A) and mucosal neuromas (A and B).

Pathology. MTCs typically are unilateral (80%) in patients with sporadic disease and multicentric in familial cases, with bilateral tumors occurring in up to 90% of familial patients. Familial cases also are associated with C-cell hyperplasia, which is considered a premalignant lesion. Microscopically, tumors are composed of sheets of infiltrating neoplastic cells separated by collagen and amyloid. Marked heterogeneity is present; cells may be polygonal or spindle shaped. The presence of amyloid is a diagnostic finding, but immunohistochemistry for calcitonin is more commonly used as a diagnostic tumor marker. These tumors also stain positively for CEA and calcitonin gene-related peptide.

Diagnosis. The diagnosis of MTC is established by history, physical examination, raised serum calcitonin, or CEA levels, and FNAB cytology of the thyroid mass. Attention to family history is important because about 25% of patients with MTC have familial disease. Because it is not possible to distinguish sporadic from familial disease at initial presentation, all new patients with MTC should be screened for *RET* point mutations, pheochromocytoma, and HPT. Screening of patients with familial MTC for *RET* point mutations has largely replaced using provocative testing with pentagastrin or calcium-stimulated calcitonin levels to make the diagnosis. Calcitonin and CEA are used to identify patients with persistent or recurrent MTC. Calcitonin is a more sensitive tumor marker, but CEA is a better predictor of prognosis.

Treatment. The ATA published guidelines for the management of medullary cancers in 2009.⁴⁵ A neck ultrasound is recommended to evaluate the central and lateral neck compartments and the superior mediastinum. Serum calcitonin, CEA, and calcium levels should also be measured, and *RET* proto-oncogene mutation testing should be performed. Pheochromocytomas need to be excluded. If patients are found to have a pheochromocytoma, this must be operated on first. These tumors are generally (>50%) bilateral. Total thyroidectomy is the treatment of choice for patients with MTC because of the high incidence of multicentricity, the more aggressive course, and the fact that ¹³¹I therapy usually is not effective.

Central compartment nodes frequently are involved early in the disease process, so that a bilateral prophylactic central neck node dissection should be routinely performed. In patients with palpable or imaging-detected cervical nodes or calcitonin levels >400 pg/mL, additional imaging to include a neck and chest CT and a triple-phase liver CT or contrast-enhanced MRI is recommended to assess for metastatic disease. In patients with no distant disease, an ipsilateral or bilateral lateral neck dissection (levels IIA, III, IV, and V) is advised. Less aggressive neck surgery should be considered to preserve speech and swallowing while maintaining locoregional control in patients with limited metastatic disease. The role of prophylactic lateral neck dissection is controversial. Some groups favor this procedure if central neck lymph nodes are involved or if the primary tumor is ≥ 1.5 cm.

In the case of locally recurrent or widely metastatic disease, tumor debulking is advised not only to ameliorate symptoms of pain, flushing, and diarrhea, but also to decrease risk of death from recurrent central neck or mediastinal disease. External-beam radiotherapy is controversial but can be considered for patients with resected T4 disease and for patients with unresectable residual or recurrent tumor and symptomatic bony metastases. Liver metastases tend to be multiple and are typically not amenable to resection, percutaneous ethanol ablation,

or radiofrequency ablation. However, chemoembolization may be helpful in this setting. There is no effective chemotherapy regimen.

Various targeted therapies directed against the *RET* kinase have been investigated for the treatment of MTC.⁴³ Many of these also inhibit vascular endothelial growth factor receptor (VEGFR), due to their close structural similarities. Sorafenib, sunitinib, lenvatinib (E7080), and cabozantinib (XL-184) are some such multikinase inhibitors, whereas axitinib and pazopanib act only on VEGFR. Vandetanib inhibits both targets and is also an epidermal growth factor receptor (EGFR) inhibitor, and is the only drug approved by the U.S. Food and Drug Administration for the treatment of advanced and progressive MTC based on data that it prolongs progression-free survival, in addition to reducing secretion of calcitonin and CEA. An anti-CEA monoclonal antibody (labetuzumab) also has shown antitumor response in a small group of patients. Patients with recurrent/metastatic disease should be enrolled in well-designed clinical trials.

In patients who have hypercalcemia and an increased PTH at the time of thyroidectomy, only obviously enlarged parathyroid glands should be removed. The other parathyroid glands should be preserved and marked in patients with normocalcemia, as only about 20% of patients with MEN2A develop HPT. When a normal parathyroid cannot be maintained on a vascular pedicle, it should be removed, biopsied to confirm that it is a parathyroid, and then autotransplanted to the forearm of the nondominant arm, particularly in patients with MEN2A. Re-implantation into the sternocleidomastoid muscle is also acceptable for patients with known MEN2B and familial MTC.

Prophylactic total thyroidectomy is indicated in *RET* mutation carriers once the mutation is confirmed. The ATA stratifies mutation into various risk levels to offer recommendations regarding age at which a prophylactic thyroidectomy should be performed and to predict phenotypes, including pheochromocytomas. In general, in patients with less aggressive mutations, thyroidectomy may be delayed >5 years, especially if there is a normal annual serum calcitonin, neck ultrasound, less aggressive family history, or family preference. Children with mutations at codon 634 are advised to undergo thyroidectomy at <5 years of age, and those with MEN2B-related mutations should undergo the procedure before age 1. Central neck dissection can be avoided in children who are *RET*-positive and calcitonin-negative with a normal ultrasound examination. When the calcitonin is increased or the ultrasound suggests a thyroid cancer, a prophylactic central neck dissection is indicated.

Postoperative Follow-Up and Prognosis. Patients are followed by annual measurements of calcitonin and CEA levels, in addition to history and physical examination. Other modalities used to localize recurrent disease include ultrasound, CT, MRI, and more recently, FDG-PET/CT scans. Prognosis is related to disease stage. The 10-year survival rate is approximately 80% but decreases to 45% in patients with lymph node involvement. Survival also is significantly influenced by disease type. It is best in patients with non-MEN familial MTC, followed by those with MEN2A, and then those with sporadic disease. Prognosis is the worst (survival of 35% at 10 years) in patients with MEN2B. Performing prophylactic surgery in *RET* oncogene mutation carriers not only improves survival rates but also renders most patients calcitonin free.

Anaplastic Carcinoma Anaplastic carcinoma accounts for approximately 1% of all thyroid malignancies in the United

cartilage and inferiorly to the suprasternal notch (Fig. 38-22B). The strap muscles are divided in the midline along the entire length of the mobilized flaps, and the thyroid gland is exposed. On the side to be approached first, the sternohyoid muscles are separated from the underlying sternothyroid muscle by blunt

dissection until the internal jugular vein and ansa cervicalis nerve are identified. The strap muscles rarely need to be divided to gain exposure to the thyroid gland. If this maneuver is necessary, the muscles should be divided high to preserve their innervation by branches of the ansa cervicalis. If there is evidence of direct

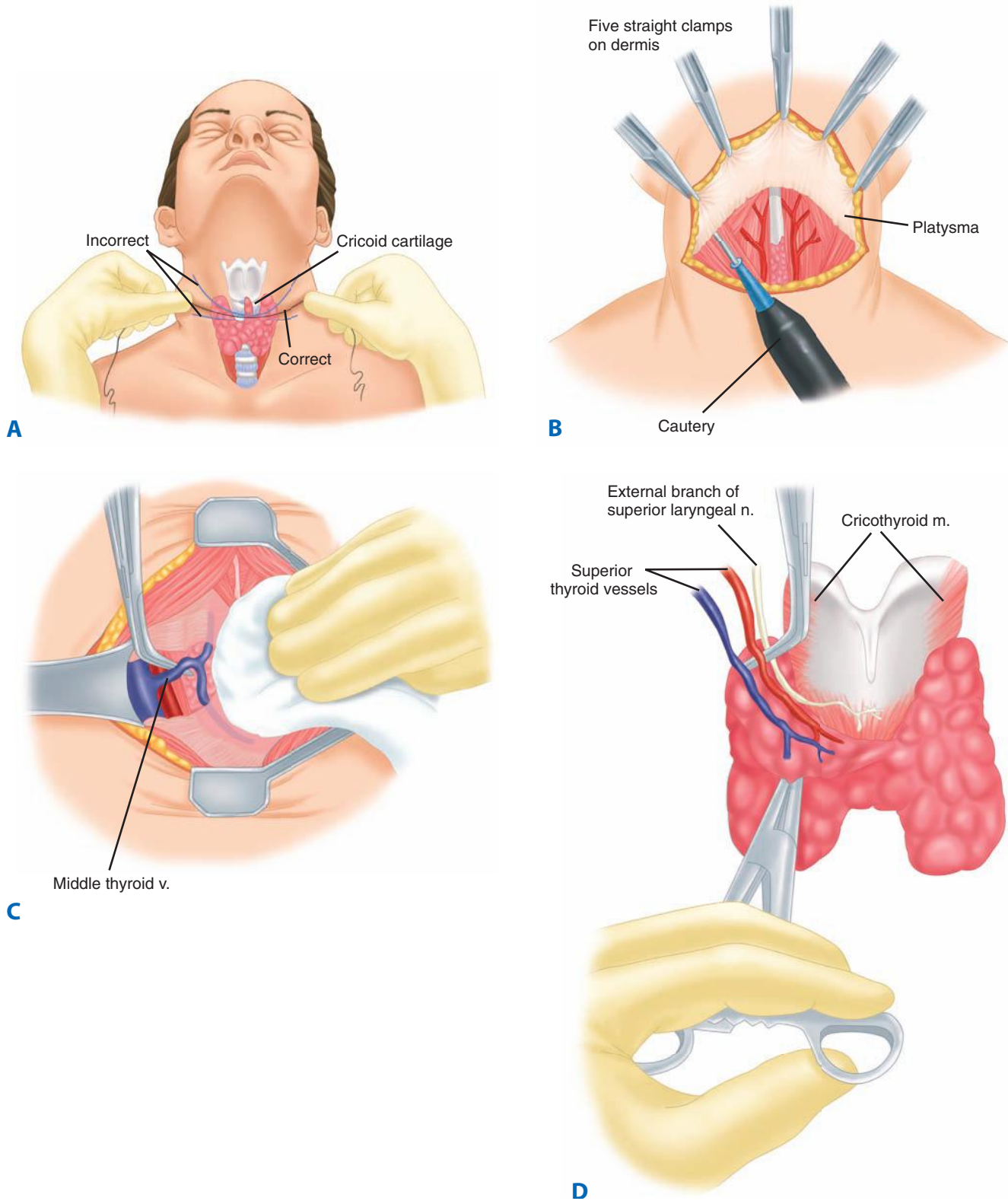


Figure 38-22. Conduct of thyroidectomy. **A.** Correct placement of thyroidectomy incision. **B.** Raising subplatysmal flaps. **C.** Dissection of middle thyroid vein. **D.** Dissection of the superior pole vessels, which should be individually ligated. **E.** Dissection at the ligament of Berry. Note small artery and vein within the ligament and the recurrent laryngeal nerve coursing laterally. **F.** Endoscopic thyroidectomy via axillary incisions. m. = muscle; n. = nerve; v. = vein.

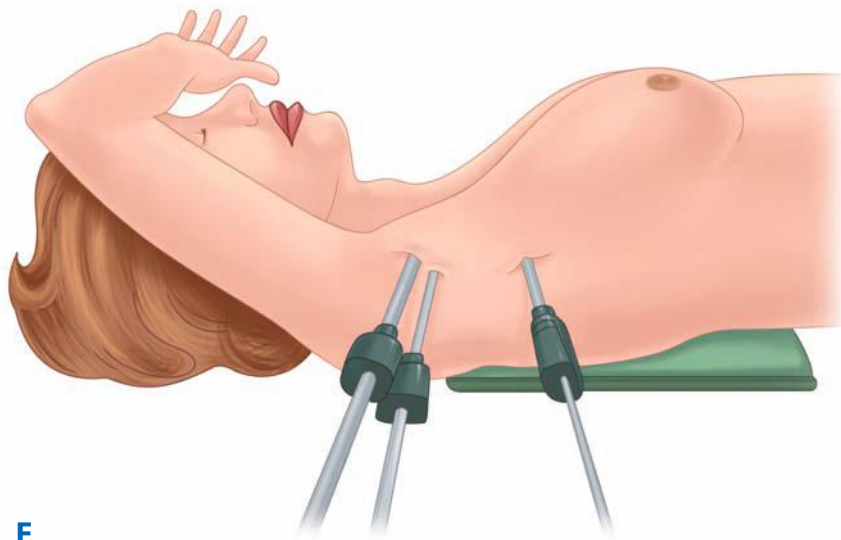
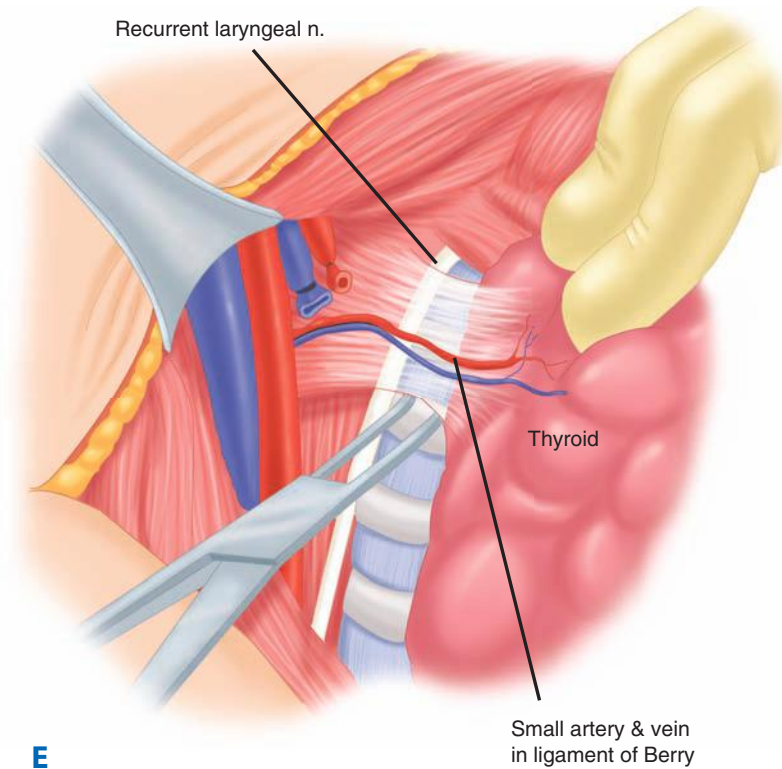


Figure 38-22. (Continued)

tumor invasion into the strap muscles, the portion of involved muscle should be resected en bloc with the thyroid gland. The sternothyroid muscle is then dissected off the underlying thyroid by a combination of sharp and blunt dissection, thus exposing the middle thyroid veins. The thyroid lobe is retracted medially and anteriorly, and the lateral tissues are swept posterolaterally using a peanut sponge. The middle thyroid veins are ligated and divided (Fig. 38-22C). Attention is then turned to the midline where Delphian nodes and the pyramidal lobe are identified. The fascia just cephalad and caudad to the isthmus is divided. The superior thyroid pole is identified by retracting the thyroid first inferiorly and medially, and then the upper pole of the thyroid is mobilized caudally and laterally. The dissection plane is kept

as close to the thyroid as possible, and the superior pole vessels are individually identified, skeletonized, ligated, and divided low on the thyroid gland to avoid injury to the external branch of the superior laryngeal nerve (Fig. 38-22D). Once these vessels are divided, the tissues posterior and lateral to the superior pole can be swept from the gland in a posteromedial direction, to reduce the risk of damaging vessels supplying the upper parathyroid.

The RLNs are then identified. The course of the right RLN is more oblique than the left RLN. The nerves can be most consistently identified at the level of the cricoid cartilage. The parathyroids usually can be identified within 1 cm of the crossing of the inferior thyroid artery and the RLN, although they also may be ectopic in location. The lower pole of the thyroid gland

should be mobilized by gently sweeping all tissues dorsally. The inferior thyroid vessels are dissected, skeletonized, ligated, and divided as close to the surface of the thyroid gland as possible to minimize devascularization of the parathyroids (extracapsular dissection) or injury to the RLN. The RLN is most vulnerable to injury in the vicinity of the ligament of Berry. The nerve often passes through this structure along with small crossing arterial and venous branches (Fig. 38-22E). Any bleeding in this area should be controlled with gentle pressure before carefully identifying the vessel and ligating it. Use of the electrocautery should be avoided in proximity to the RLN. Once the ligament is divided, the thyroid can be separated from the underlying trachea by sharp dissection. The pyramidal lobe, if present, must be dissected in a cephalad direction to above the level of the notch in the thyroid cartilage or higher in continuity with the thyroid gland. If a lobectomy is to be performed, the isthmus is divided flush with the trachea on the contralateral side and suture ligated. The procedure is repeated on the opposite side for a total thyroidectomy.

Parathyroid glands that are located anteriorly on the surface of the thyroid cannot be dissected from the thyroid with a good blood supply or that have been inadvertently removed during the thyroidectomy should be resected, confirmed as parathyroid tissue by frozen section, divided into 1-mm fragments, and reimplanted into individual pockets in the sternocleidomastoid muscle. The sites should be marked with silk sutures and a clip. If a subtotal thyroidectomy is to be performed, once the superior pole vessels are divided and the thyroid lobe mobilized anteriorly, the thyroid lobe is cross-clamped with a Mayo clamp, leaving approximately 4 g of the posterior portion of the thyroid. The thyroid remnant is suture ligated, taking care to avoid injury to the RLN. Routine drain placement rarely is necessary. After adequate hemostasis is obtained, the strap muscles are reapproximated in the midline. The platysma is approximated in a similar fashion. The skin can be closed with subcuticular sutures or clips.

Minimally Invasive Approaches Several approaches to minimally invasive thyroidectomy have been described. Mini-incision procedures use a small, 3-cm incision with no flap creation and minimal dissection to deliver the thyroid into the wound and then perform the pretracheal and paratracheal dissection. Video assistance can be used to improve the visualization via the small incision. Totally endoscopic approaches also have been described, via the supraclavicular, anterior chest, axillary, and breast approach. The axillary, anterior chest, and breast approaches eliminate the skin incision in the neck but are more invasive. The endoscopic approaches can also be performed with the assistance of robotic techniques. More recently, there have been reports of transoral robotic-assisted thyroidectomy in which the thyroid is approached through the oral cavity. These methods are feasible, but clear benefits over the “traditional” open approach via small neck incisions have not been established.⁴⁸

Typically, endoscopic thyroidectomies are performed under general anesthesia. For the axillary approach, a 30-mm skin incision is made in the axilla, and 12-mm and 5-mm trocars are inserted through this incision (Fig. 38-22F). An additional 5-mm trocar is inserted adjacent to the incision. For the anterior chest approach, a 12-mm skin incision is made in the skin of the anterior chest approximately 3 to 5 cm below the border of the ipsilateral clavicle. Two additional 5-mm trocars are inserted by endoscopic guidance below the ipsilateral clavicle, and carbon dioxide (CO₂) is then insufflated up to a pressure of 4 mmHg to facilitate creation of a working space. The anterior border of the sternocleidomastoid muscle is then separated from the sternohyoid muscle to expose

the sternothyroid muscle. The thyroid gland is exposed by splitting the sternothyroid muscle. The lower pole is retracted upward and dissected from the adipose tissue to identify the RLN. As the RLN is exposed, Berry’s ligament is exposed and incised with a 5-mm clip or laparoscopic coagulating shears. The upper pole of the thyroid gland is separated from the cricothyroid muscle, and the external branch of the superior laryngeal nerve can be identified during this maneuver. The upper pole of the thyroid gland then is dissected free.

Surgical Removal of Intrathoracic Goiter A goiter is considered mediastinal if at least 50% of the thyroid tissue is located intrathoracically. Mediastinal goiters can be primary or secondary. Primary mediastinal goiters constitute approximately 1% of all mediastinal goiters and arise from accessory (ectopic) thyroid tissue located in the chest. These goiters are supplied by intrathoracic blood vessels and do not have any connection to thyroid tissue in the neck. The vast majority of mediastinal goiters are, however, secondary mediastinal goiters that arise from downward extension of cervical thyroid tissue along the fascial planes of the neck and derive their blood supply from the superior and inferior thyroid arteries. Virtually all intrathoracic goiters can be removed via a cervical incision. Patients who have (a) invasive thyroid cancers, (b) had previous thyroid operations and may have developed parasitic mediastinal vessels, or (c) primary mediastinal goiters with no thyroid tissue in the neck may require a median sternotomy for removal.⁴⁹ The chest, however, should be prepared in most cases in the event it is necessary to perform a median sternotomy to control mediastinal bleeding or completely remove an unsuspected invasive cancer. The goiter is approached via a neck incision. The superior pole vessels and the middle thyroid veins are identified and ligated first. Early division of the isthmus helps with subsequent mobilization of the substernal goiter from beneath the sternum. Placement of large 1-0 or 2-0 sutures deep into the goiter, when necessary, helps deliver it. For patients in whom thyroid cancer is suspected or demonstrated in an intrathoracic gland, attempts should be made to avoid rupture of the thyroid capsule. When sternotomy is indicated, the sternum usually should be divided to the level of the third intercostal space and then laterally on one side at the space between the third and fourth ribs (Fig. 38-23).

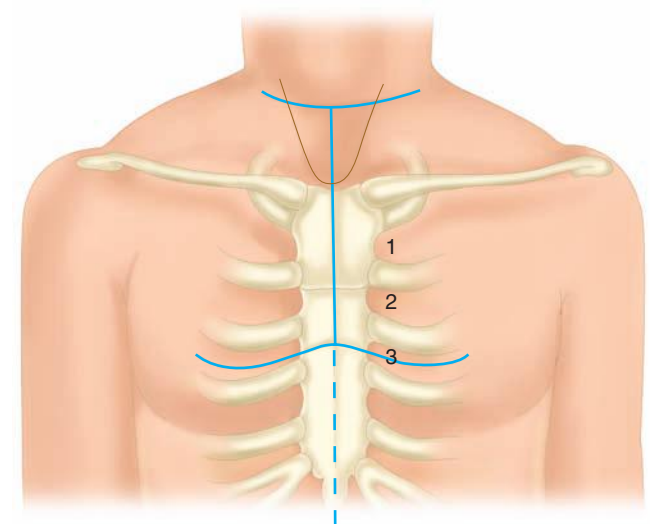


Figure 38-23. Conduct of thyroidectomy. Incisions for a partial sternotomy.

Central and Lateral Neck Dissection for Nodal Metastases

Central compartment (medial to the carotid sheath) lymph nodes frequently are involved in patients with papillary, medullary, and Hürthle cell carcinomas and should be removed at the time of thyroidectomy, preserving the RLNs and parathyroid glands. Central neck dissection is particularly important in patients with medullary and Hürthle cell carcinoma because of the high frequency of microscopic tumor spread and because these tumors cannot be ablated with ^{131}I . An ipsilateral modified radical neck

dissection is indicated in the presence of palpable cervical lymph nodes or prophylactically in some patients with medullary carcinoma.

A modified radical (functional) neck dissection can be performed via the cervical incision used for thyroidectomy, which can be extended laterally (Fig. 38-24A) to the anterior margin of the trapezius muscle. The procedure involves removal of all fibro-fatty tissue along the internal jugular vein (levels II, III, and IV) and the posterior triangle (level V). In contrast to

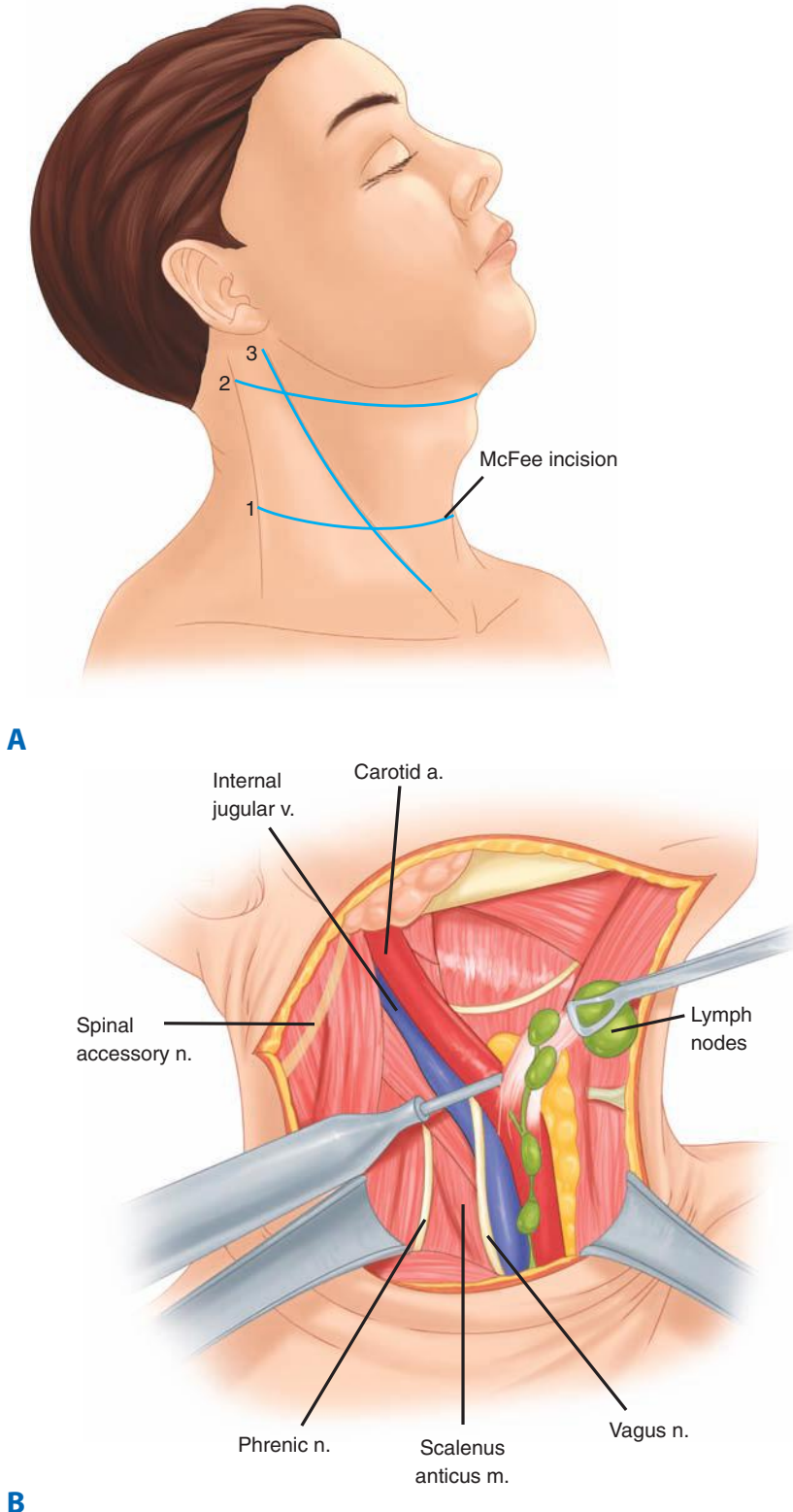


Figure 38-24. Conduct of neck dissection. **A.** Incisions for modified radical neck dissection. **B.** Anatomic relations of structures identified during a modified radical neck dissection. a. = artery; m. = muscle; n. = nerve.

a radical neck dissection, the internal jugular vein, the spinal accessory nerve, the cervical sensory nerves, and the sternocleidomastoid muscle are preserved unless they are adherent to or invaded by tumor. The procedure begins by opening the plane between the strap muscles medially and the sternocleidomastoid muscle laterally. The anterior belly of the omohyoid muscle is retracted laterally, and the dissection is carried posteriorly until the carotid sheath is reached. The internal jugular vein is retracted medially with a vein retractor and the fibro-fatty tissue and lymph nodes are dissected away from it by a combination of sharp and blunt dissection. The lateral dissection is carried along the posterior border of the sternocleidomastoid muscle, removing the tissue from the posterior triangle. The deep dissection plane is the anterior scalenus muscle, the phrenic nerve, the brachial plexus, and the medial scalenus muscle. The phrenic nerve is preserved on the scalenus anterior muscle, as are the cervical sensory nerves in most patients (Fig. 38-24B). Dissection along the spinal accessory nerve superiorly is most important because this is a frequent site of metastatic disease.

Complications of Thyroid Surgery Nerves, parathyroids, and surrounding structures are all at risk of injury during thyroidectomy. Injury to the RLN may occur by severance, ligation, or traction, but should occur in <1% of patients undergoing thyroidectomy by experienced surgeons. The RLN is most vulnerable to injury during the last 2 to 3 cm of its course, but also can be damaged if the surgeon is not alert to the possibility of nerve branches and the presence of a nonrecurrent nerve, particularly on the right side. If the injury is recognized intraoperatively, most surgeons advocate primary reapproximation of the perineurium using nonabsorbable sutures. Approximately 20% of patients are at risk of injury to the external branches of the superior laryngeal nerve, especially if superior pole vessels are ligated en masse. The cervical sympathetic trunk is at risk of injury in invasive thyroid cancers and retroesophageal goiters and may result in Horner's syndrome. Transient hypocalcemia (from surgical injury or inadvertent removal of parathyroid tissue) has been reported in up to 50% of cases, but permanent hypoparathyroidism occurs <2% of the time. Postoperative hypocalcemia is more likely in patients who undergo concomitant thyroidectomy and central and lateral neck dissection and in patients with Graves' disease. Postoperative hematomas or bleeding may also complicate thyroidectomies and rarely necessitate emergency reoperation to evacuate the hematoma. Bilateral vocal cord dysfunction with airway compromises requires immediate reintubation and tracheostomy. Seromas may need aspiration to relieve patient discomfort. Wound cellulitis and infection and injury to surrounding structures, such as the carotid artery, jugular vein, and esophagus, are infrequent.

Nerve Monitoring Intraoperative RLN and external laryngeal nerve monitoring techniques are being increasingly used during thyroid and parathyroid surgery. Both continuous monitoring using endotracheal tube electrodes and intermittent monitoring by periodic stimulation and laryngeal palpation are used. Many published studies have established the feasibility of nerve monitoring; however, none were able to show that the technique equivocally reduces nerve injury (particularly by experienced surgeons and especially when the RLN is routinely visually identified) until recently. In 2009, Barczynski and colleagues⁵⁰ were the first to demonstrate, in their prospective randomized trial with 2000 nerves at risk that neuromonitoring was associated with a statistically significant improvement in transient

RLN injury rates when compared to the practice of visualization of the nerve alone and particularly in patients at higher risk of nerve injury. Of note, there was no difference in permanent RLN injury rates, and a later meta-analysis of all the published studies also failed to show a protective effect of neuromonitoring. Despite this, the technology has become widely adopted. As additional studies have documented that direct RLN stimulation has a low sensitivity of predicting vocal cord paralysis, when compared to vagal stimulation, attempts have been made to identify critical steps in the process. Currently, adequate RLN monitoring includes (a) stimulation of the vagus nerve prior to any dissection in the tracheoesophageal groove; (b) stimulation of the RLN prior to resecting the thyroid; (c) stimulation of the most proximally exposed portion of the RLN after the ligament of Berry has been completely divided; and (d) stimulation of the vagus nerve after complete hemostasis has been achieved on that side of the neck prior to closing or going on to the opposite lobe. Recently, an international group has proposed guidelines for RLN monitoring in thyroid and parathyroid surgery, and pre- and postoperative laryngoscopy is recommended, in addition to vagal stimulation. Not all experts agree with this recommendation.

PARATHYROID

Historical Background

In 1849, the curator of the London Zoological Gardens, Sir Richard Owen, provided the first accurate description of the normal parathyroid gland after autopsy examination of an Indian rhinoceros. However, human parathyroids were not grossly and microscopically described until 1879 by Ivar Sandström, a medical student in Uppsala, Sweden. He suggested that these glands be named the *glandulae parathyroideae*, although their function was not known.

The association of HPT and the bone disease osteitis fibrosa cystica (described by von Recklinghausen) was recognized in 1903. Calcium measurement became possible in 1909, and the association between serum calcium levels and the parathyroid glands was established. The first successful parathyroidectomy was performed in 1925 by Felix Mandl on a 38-year-old man who had severe bone pain secondary to advanced osteitis fibrosa cystica. The patient's condition dramatically improved after the operation, and he lived for another 7 years before dying of recurrent HPT or renal failure. In 1926, the first parathyroid operation was performed at Massachusetts General Hospital. Edward Churchill, assisted by an intern named Oliver Cope, operated on the famous sea captain Charles Martell for severe primary HPT (PHPT). It was not until his seventh operation, which included total thyroidectomy, that an ectopic adenoma was found substernally. Unfortunately, Captain Martell died 6 weeks later, likely due to laryngeal spasm and complications of renal stones and ureteral obstruction. The first successful parathyroidectomy for HPT in the United States was performed on a 56-year-old woman in 1928 by Isaac Y. Olch at the Barnes Hospital in St. Louis, Missouri. At operation, a parathyroid adenoma was found attached to the left lower lobe of the thyroid gland. Postoperatively, the patient developed tetany, requiring lifelong supplemental calcium.

Embryology

In humans, the superior parathyroid glands are derived from the fourth branchial pouch, which also gives rise to the thyroid gland. The third branchial pouches give rise to the inferior parathyroid glands and the thymus (Fig. 38-25). The parathyroids

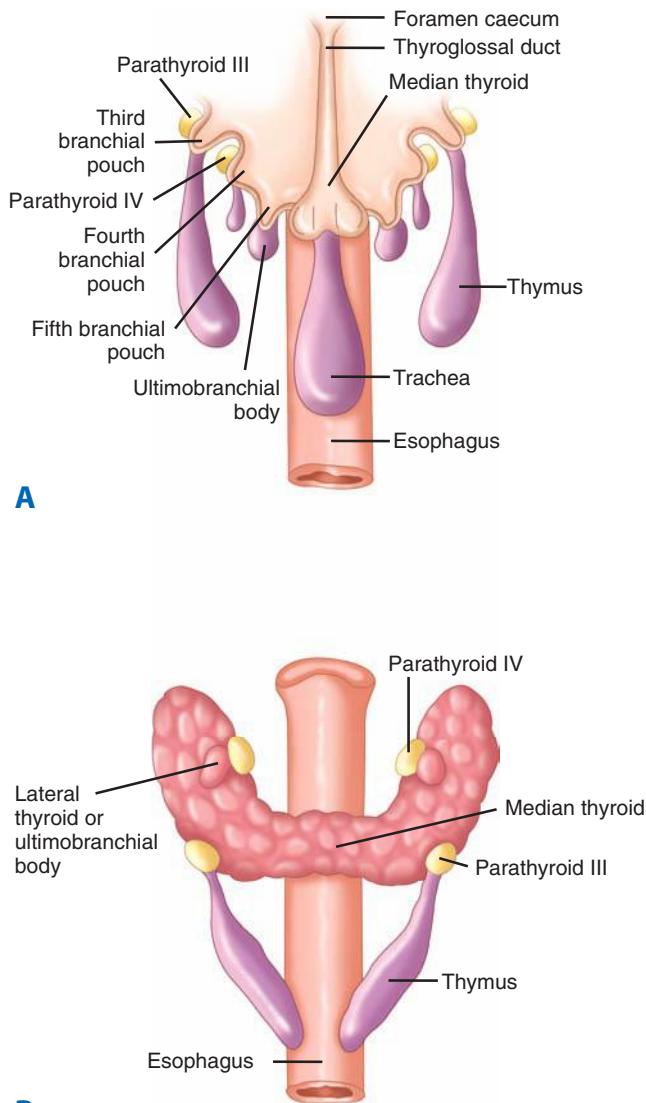


Figure 38-25. Parathyroid embryology. Figure demonstrates a schematic view of the pharynx of an 8- to 10-mm embryo (A) and locations of the thyroid, parathyroid, and thymic tissues in a 13- to 14-mm embryo (B). The lower parathyroids are derived from the third branchial pouch and migrate with the thymus, whereas the upper parathyroids are derived from the fourth branchial pouch and lie in close proximity to the ultimobranchial bodies. (Reproduced with permission from Henry J. *Applied embryology of the thyroid and parathyroid glands*. In: Randolph G, ed. *Surgery of the Thyroid and Parathyroid Glands*. Philadelphia: WB Saunders Company; 2003. Copyright Elsevier.)

remain closely associated with their respective branchial pouch derivatives. The position of normal superior parathyroid glands is more consistent, with 80% of these glands being found near the posterior aspect of the upper and middle thyroid lobes, at the level of the cricoid cartilage.⁵¹ Approximately 1% of normal upper glands may be found in the paraesophageal or retroesophageal space. Enlarged superior glands may descend in the tracheoesophageal groove and come to lie caudal to the inferior glands. Truly ectopic superior parathyroid glands are rare, but may be found in the middle or posterior mediastinum or in the aortopulmonary window.⁵¹ As the embryo matures, the thymus and inferior parathyroids migrate together caudally in the neck. The most common location for inferior glands is within a distance of 1 cm

from a point centered where the inferior thyroid artery and RLN cross. Approximately 15% of inferior glands are found in the thymus. The position of the inferior glands, however, tends to be more variable due to their longer migratory path. Undescended inferior glands may be found near the skull base, angle of the mandible, or superior to the upper parathyroid glands along with an undescended thymus. The frequency of intrathyroidal glands is about 2%.

Anatomy and Histology

Most patients have four parathyroid glands. The superior glands usually are dorsal to the RLN at the level of the cricoid cartilage, whereas the inferior parathyroid glands are located ventral to the nerve. Normal parathyroid glands are gray and semitransparent in newborns but appear golden yellow to light brown in adults. Parathyroid color depends on cellularity, fat content, and vascularity. Moreover, they often are embedded in and sometimes difficult to discern from surrounding fat. Normal parathyroid glands are located in loose tissue or fat and are ovoid. They measure up to 7 mm in size and weigh approximately 40 to 50 mg each. Parathyroid glands usually derive their blood supply from branches of the inferior thyroid artery, although branches from the superior thyroid artery supply at least 20% of upper glands. Branches from the thyroidea ima, and vessels to the trachea, esophagus, larynx, and mediastinum may also be found. The parathyroid glands drain ipsilaterally by the superior, middle, and inferior thyroid veins.

Akerström and colleagues,⁵² in an autopsy series of 503 cadavers, found four parathyroid glands in 84% of cases. Supernumerary glands were present in 13% of patients, most commonly in the thymus. Only 3% of patients had less than four glands. Similar results were obtained in other dissection studies of 428 human subjects by Gilmour who reported a 6.7% incidence of supernumerary glands.⁵³

Histologically, parathyroid glands are composed of chief cells and oxyphil cells arranged in trabeculae, within a stroma composed primarily of adipose cells (Fig. 38-26). The parathyroid glands of infants and children are composed mainly of chief cells, which produce parathyroid hormone (PTH). Acidophilic, mitochondria-rich oxyphil cells are derived from chief cells, can be seen around puberty, and increase in numbers in adulthood. A third group of cells, known as *water-clear cells*, also

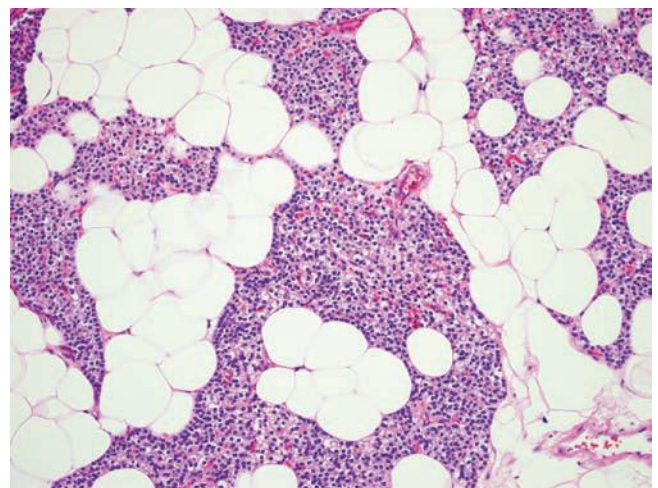


Figure 38-26. Normal parathyroid histology showing chief cells interspersed with adipose cells.

are derived from chief cells, are present in small numbers, and are rich in glycogen. Although most oxyphil and water-clear cells retain the ability to secrete PTH, their functional significance is not known.

Parathyroid Physiology and Calcium Homeostasis

Calcium is the most abundant cation in human beings and has several crucial functions. Extracellular calcium levels are 10,000-fold higher than intracellular levels, and both are tightly controlled. Extracellular calcium is important for excitation-contraction coupling in muscle tissues, synaptic transmission in the nervous system, coagulation, and secretion of other hormones. Intracellular calcium is an important second messenger regulating cell division, motility, membrane trafficking, and secretion. Calcium is absorbed from the small intestine in its inorganic form. Calcium fluxes in the steady state are depicted in Fig. 38-27.

Extracellular calcium (900 mg) accounts for only 1% of the body's calcium stores, the majority of which is sequestered in the skeletal system. Approximately 50% of the serum calcium is in the ionized form, which is the active component. The remainder is bound to albumin (40%) and organic anions such as phosphate and citrate (10%). The total serum calcium levels range from 8.5 to 10.5 mg/dL (2.1 to 2.6 mmol/L), and ionized calcium levels range from 4.4 to 5.2 mg/dL (1.1 to 1.3 mmol/L). Both concentrations are tightly regulated. The total serum calcium level must always be considered in its relationship to plasma protein levels, especially serum albumin. For each gram per deciliter of alteration of serum albumin above or below 4.0 mg/dL, there is a 0.8 mg/dL increase or decrease in protein-bound calcium and, thus, in total serum calcium levels. Total and, particularly, ionized calcium levels are influenced by various hormone systems.

Parathyroid Hormone. The parathyroid cells rely on a G-protein-coupled membrane receptor, designated the calcium-sensing receptor (CASR), to regulate PTH secretion by sensing

extracellular calcium levels⁵⁴ (Fig. 38-28). PTH secretion also is stimulated by low levels of 1,25-dihydroxy vitamin D, catecholamines, and hypomagnesemia. The PTH gene is located on chromosome 11. PTH is synthesized in the parathyroid gland as a precursor hormone preproPTH, which is cleaved first to pro-PTH and then to the final 84-amino-acid PTH. Secreted PTH has a half-life of 2 to 4 minutes. In the liver, PTH is metabolized into the active N-terminal component and the relatively inactive C-terminal fraction. The C-terminal component is excreted by the kidneys and accumulates in chronic renal failure.

PTH functions to regulate calcium levels via its actions on three target organs, the bone, kidney, and gut. PTH increases the resorption of bone by stimulating osteoclasts and promotes the release of calcium and phosphate into the circulation. At the kidney, calcium is primarily absorbed in concert with sodium in the proximal convoluted tubule, but fine adjustments occur more distally. PTH acts to limit calcium excretion at the distal convoluted tubule via an active transport mechanism. PTH also inhibits phosphate reabsorption (at the proximal convoluted tubule) and bicarbonate reabsorption. It also inhibits the Na^+/H^+ antiporter, which results in a mild metabolic acidosis in hyperparathyroid states. PTH and hypophosphatemia also enhance 1-hydroxylation of 25-hydroxyvitamin D, which is responsible for its indirect effect of increasing intestinal calcium absorption.

Calcitonin. Calcitonin is produced by thyroid C cells and functions as an antihypercalcemic hormone by inhibiting osteoclast-mediated bone resorption. Calcitonin production is stimulated by calcium and pentagastrin and also by catecholamines, cholecystokinin, and glucagon. When administered intravenously to experimental animals, it produces hypocalcemia. At the kidney, calcitonin increases phosphate excretion by inhibiting its reabsorption. Calcitonin plays a minimal, if any, role in the regulation of calcium levels in humans. However, it is very useful as a marker of MTC and in treating acute hypercalcemic crisis.

Vitamin D. Vitamin D refers to vitamin D_2 and vitamin D_3 , both of which are produced by photolysis of naturally occurring sterol precursors. Vitamin D_2 is available commercially in pharma-

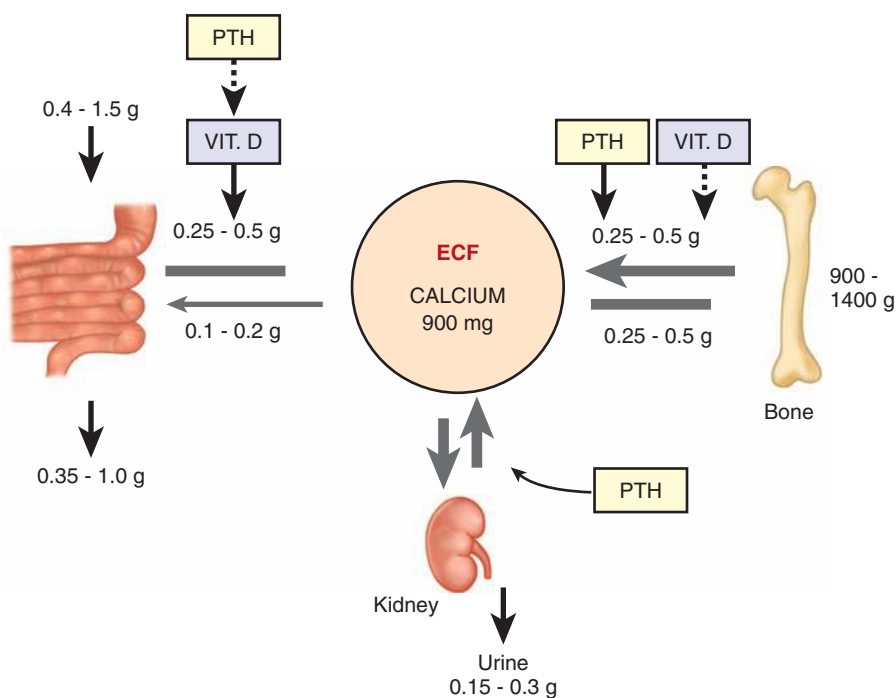


Figure 38-27. Calcium balance and fluxes in a normal human. *Solid arrows* depict a direct effect, whereas *dashed arrows* depict an indirect effect. The thickness of the arrows is representative of the magnitude of the flux. ECF = extracellular fluid; PTH = parathyroid hormone; VIT. = vitamin. (Reproduced with permission from Bruder J, et al. *Mineral metabolism*. In: Felig P, Frohman L, eds. *Endocrinology and Metabolism*. New York: McGraw-Hill Publishers, Inc; 2001:1081. Copyright © The McGraw-Hill Companies, Inc.)

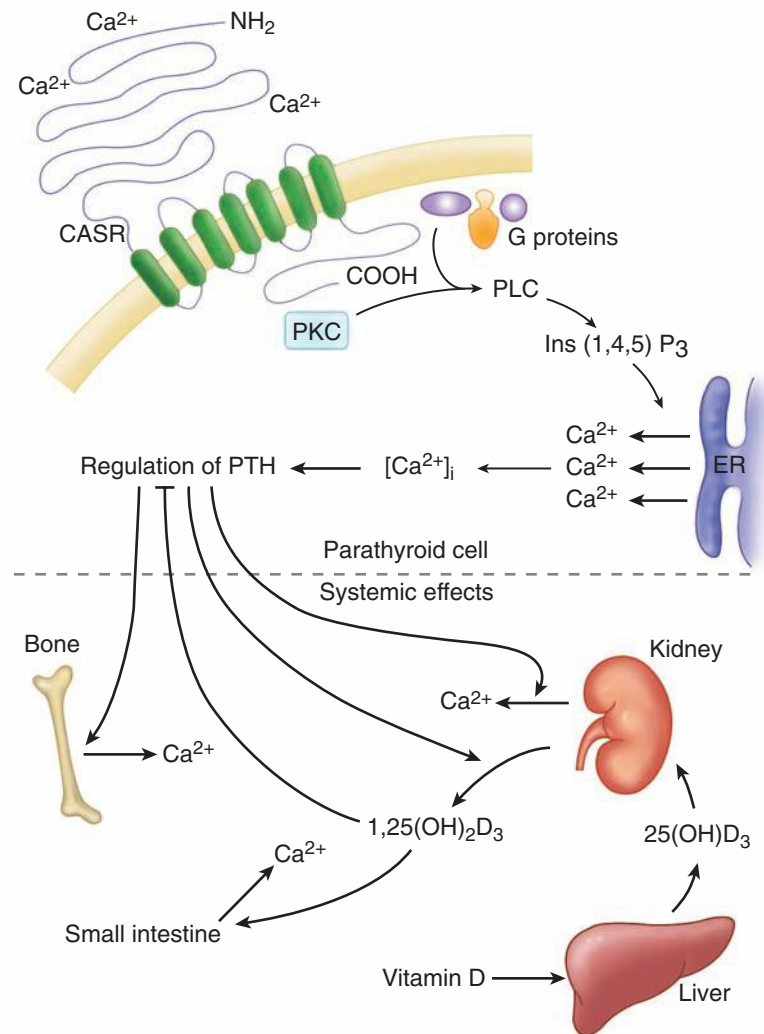


Figure 38-28. Regulation of calcium homeostasis. The calcium-sensing receptor (CASR) is expressed on the surface of the parathyroid cell and senses fluctuations in the concentration of extracellular calcium. Activation of the receptor is thought to increase intracellular calcium levels, which, in turn, inhibit parathyroid hormone (PTH) secretion via posttranslational mechanisms. Increased PTH secretion leads to an increase in serum calcium levels by increasing bone resorption and enhancing renal calcium reabsorption. PTH also stimulates renal 1- α -hydroxylase activity, leading to an increase in 1,25-dihydroxy vitamin D, which also exerts a negative feedback on PTH secretion. PKC = protein kinase C; PLC = phospholipase C. (Reproduced with permission from Carling T. *Molecular pathology of parathyroid tumors*. Trends Endocrinol Metab. 2001;12:54. Copyright Elsevier.)

ceutical preparations, whereas vitamin D₃ is the most important physiologic compound and is produced from 7-dehydrocholesterol, which is found in the skin. Vitamin D is metabolized in the liver to its primary circulating form, 25-hydroxyvitamin D. Further hydroxylation in the kidney results in 1,25-dihydroxy vitamin D, which is the most metabolically active form of vitamin D. Vitamin D stimulates the absorption of calcium and phosphate from the gut and the resorption of calcium from the bone.

Hyperparathyroidism

Hyperfunction of the parathyroid glands may be classified as primary, secondary, or tertiary. PHPT arises from increased PTH production from abnormal parathyroid glands and results from a disturbance of normal feedback control exerted by serum calcium. Elevated PTH levels may also occur as a compensatory response to hypocalcemic states resulting from chronic renal failure or GI malabsorption of calcium. This secondary HPT can be reversed by correction of the underlying problem (e.g., kidney transplantation for chronic renal failure).

However, chronically stimulated glands may occasionally become autonomous, resulting in persistence or recurrence of hypercalcemia after successful renal transplantation, resulting in tertiary HPT.

Primary Hyperparathyroidism. PHPT is a common disorder, affecting 100,000 individuals annually in the United States. PHPT occurs in 0.1% to 0.3% of the general population and is more common in women (1:500) than in men (1:2000). Increased PTH production leads to hypercalcemia via increased GI absorption of calcium, increased production of vitamin D₃, and reduced renal calcium clearance. PHPT is characterized by increased parathyroid cell proliferation and PTH secretion that is independent of calcium levels.

Etiology. The exact cause of PHPT is unknown, although exposure to low-dose therapeutic ionizing radiation and familial predisposition account for some cases. Various diets and intermittent exposure to sunshine may also be related. Other causes include renal leak of calcium and declining renal function with

age as well as alteration in the sensitivity of parathyroid glands to suppression by calcium. The latency period for development of PHPT after radiation exposure is longer than that for the development of thyroid tumors, with most cases occurring 30 to 40 years after exposure. Patients who have been exposed to radiation have similar clinical presentations and calcium levels when compared to patients without a history of radiation exposure. However, the former tend to have higher PTH levels and a higher incidence of concomitant thyroid neoplasms. Lithium therapy has been known to shift the set point for PTH secretion in parathyroid cells, thereby resulting in elevated PTH levels and mild hypercalcemia. Lithium stimulates the growth of abnormal parathyroid glands in vitro and also in susceptible patients in vivo.⁵⁵ PHPT results from the enlargement of a single gland or parathyroid adenoma in approximately 80% of cases, multiple adenomas or hyperplasia in 15% to 20% of patients, and parathyroid carcinoma in 1% of patients. Existence of two enlarged glands or double adenomas is supported by biochemical (calcium and PTH), intraoperative PTH (IOPTH), molecular, and histologic data. This entity is less common in younger patients but accounts for up to 10% of older patients with PHPT. It should be emphasized that when more than one abnormal parathyroid gland is identified preoperatively or intraoperatively, the patient has hyperplasia (all glands abnormal) until proven otherwise.

Genetics Most cases of PHPT are sporadic. However, PHPT also occurs within the spectrum of a number of inherited disorders such as MEN1, MEN2A, isolated familial HPT, and familial HPT with jaw-tumor syndrome. All of these syndromes are inherited in an autosomal dominant fashion. PHPT is the earliest and most common manifestation of MEN1⁵⁶ and develops in 80% to 100% of patients by age 40 years old. These patients also are prone to pancreatic neuroendocrine tumors and pituitary adenomas and, less commonly, to adrenocortical tumors, lipomas, skin angiomas, and carcinoid tumors of the bronchus, thymus, or stomach. About 50% of patients develop gastrinomas, which often are multiple and metastatic at diagnosis. Insulinomas develop in 10% to 15% of cases, whereas many patients have nonfunctional pancreatic endocrine tumors. Prolactinomas occur in 10% to 50% of MEN1 patients and constitute the most common pituitary lesion. MEN1 has been shown to result from germline mutations in the *MEN1* gene, a tumor suppressor gene located on chromosome 11q12-13 that encodes menin, a protein that is postulated to interact with the transcription factors JunD and nuclear factor- κ B in the nucleus, in addition to replication protein A and other proteins.⁵⁷ Most *MEN1* mutations result in a nonfunctional protein and are scattered throughout the translated nine exons of the gene. This makes presymptomatic screening for mutation carriers difficult. *MEN1* mutations also have been found in kindreds initially suspected to represent isolated familial HPT. HPT develops in about 20% of patients with MEN2A and generally is less severe. MEN2A is caused by germline mutations of the *RET* proto-oncogene located on chromosome 10. In contrast to MEN1, genotype-phenotype correlations have been noted in this syndrome in that individuals with mutations at codon 634 are more likely to develop HPT. Patients with the familial HPT with jaw-tumor syndrome have an increased predisposition to parathyroid carcinoma. This syndrome maps to a tumor suppressor locus *HRPT2* (CDC73 or parafibromin) on chromosome 1. Patients belonging to isolated HPT kindreds also appear to demonstrate linkage to *HRPT2*.

Approximately 25% to 40% of sporadic parathyroid adenomas and some hyperplastic parathyroid glands have loss of heterozygosity (LOH) at 11q13, the site of the *MEN1* gene. The parathyroid adenoma 1 oncogene (*PRAD1*), which encodes cyclin D1, a cell cycle control protein, is overexpressed in about 18% of parathyroid adenomas. This was demonstrated to result from a rearrangement on chromosome 11 that places the *PRAD1* gene under the control of the PTH promoter. Other chromosomal regions deleted in parathyroid adenomas and possibly reflecting loss of tumor suppressor genes include 1p, 6q, and 15q, whereas amplified regions suggesting oncogenes have been identified at 16p and 19p. *RET* mutations are rare in sporadic parathyroid tumors. Sporadic parathyroid cancers are characterized by uniform loss of the tumor suppressor gene *RB*, which is involved in cell cycle regulation, and 60% have *HRPT2* (CDC73) mutations. These alterations are rare in benign parathyroid tumors and may have implications for diagnosis. The *p53* tumor suppressor gene is also inactivated in a subset (30%) of parathyroid carcinomas.

Clinical Manifestations Patients with PHPT formerly presented with the “classic” pentad of symptoms (i.e., kidney stones, painful bones, abdominal groans, psychic moans, and fatigue overtones). With the advent and widespread use of automated blood analyzers in the early 1970s, there has been an alteration in the “typical” patient with PHPT. They are more likely to be minimally symptomatic or asymptomatic. Currently, most patients present with weakness, fatigue, polydipsia, polyuria, nocturia, bone and joint pain, constipation, decreased appetite, nausea, heartburn, pruritus, depression, and memory loss. Patients with PHPT also tend to score lower than healthy controls when assessed by general multidimensional health assessment tools such as the Medical Outcomes Study Short-Form Health Survey (SF-36) and other specific questionnaires. Furthermore, these symptoms and signs improve in most, but certainly not all, patients after parathyroidectomy. Truly “asymptomatic” PHPT appears to be rare, occurring in <5% of patients, as determined by prospectively administered questionnaires. Complications of PHPT are described below.

Renal Disease. Approximately 80% of patients with PHPT have some degree of renal dysfunction or symptoms. Kidney stones were previously reported in up to 80% of patients but now occur in about 20% to 25%. The calculi are typically composed of calcium phosphate or oxalate. In contrast, PHPT is found to be the underlying disorder in only 3% of patients presenting with nephrolithiasis. *Nephrocalcinosis*, which refers to renal parenchymal calcification, is found in <5% of patients and is more likely to lead to renal dysfunction. Chronic hypercalcemia also can impair concentrating ability, thereby resulting in polyuria, polydipsia, and nocturia. The incidence of hypertension is variable but has been reported to occur in up to 50% of patients with PHPT. Hypertension appears to be more common in older patients and correlates with the magnitude of renal dysfunction and, in contrast to other symptoms, is least likely to improve after parathyroidectomy.

Bone Disease. Bone disease, including osteopenia, osteoporosis, and osteitis fibrosa cystica, is found in about 15% of patients with PHPT. Increased bone turnover, as found in patients with osteitis fibrosa cystica, can be determined by documenting an elevated blood alkaline phosphatase level. Advanced PHPT with osteitis fibrosa cystica now occurs in <5% of patients. It has pathognomonic radiologic findings, which are best seen

on x-rays of the hands and are characterized by subperiosteal resorption (most apparent on the radial aspect of the middle phalanx of the second and third fingers), bone cysts, and tufting of the distal phalanges (Fig. 38-29). The skull also may be affected and appears mottled with a loss of definition of the inner and outer cortices. Brown or osteoclastic tumors and bone cysts also may be present. Severe bone disease, resulting in bone pain and tenderness and/or pathologic fractures, is rarely observed nowadays. However, reductions of bone mineral density (BMD) with osteopenia and osteoporosis are more common. Patients with normal serum alkaline phosphatase levels almost never have clinically apparent osteitis fibrosa cystica. HPT typically results in a loss of bone mass at sites of cortical bone such as the radius and relative preservation of cancellous bone such as that located at the vertebral bodies. Patients with PHPT, however, also may have osteoporosis of the lumbar spine that improves dramatically following parathyroidectomy. Fractures also occur more frequently in patients with PHPT, and the incidence of fractures also decreases after parathyroidectomy. Bone disease correlates with serum PTH and vitamin D levels.

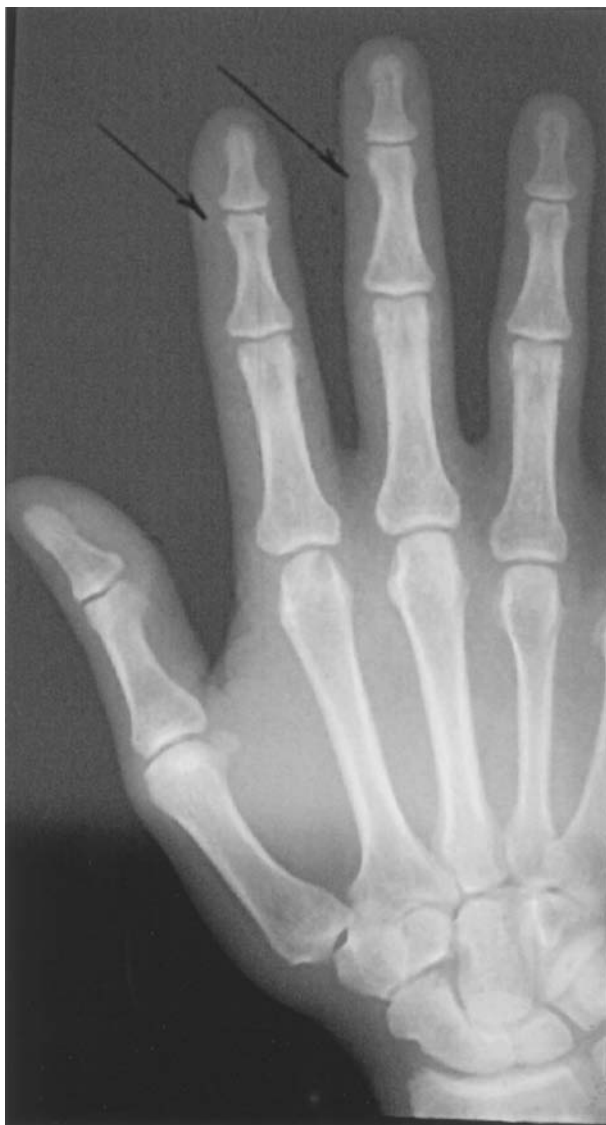

Figure 38-29. X-ray of the hand showing subperiosteal bone resorption most apparent along the radial aspect of the middle phalanx, characteristic of osteitis fibrosa cystica.

Gastrointestinal Complications. PHPT has been associated with peptic ulcer disease. In experimental animals, hypergastrinemia has been shown to result from PTH infusion into blood vessels supplying the stomach, independent of its effects on serum calcium. An increased incidence of pancreatitis also has been reported in patients with PHPT, although this appears to occur only in patients with profound hypercalcemia ($\text{Ca}^{2+} \geq 12.5$ mg/dL). Patients with PHPT also have an increased incidence of cholelithiasis, presumably due to an increase in biliary calcium, which leads to the formation of calcium bilirubinate stones.

Neuropsychiatric Complications. Severe hypercalcemia may lead to various neuropsychiatric manifestations such as florid psychosis, obtundation, or coma. Other findings such as depression, anxiety, and fatigue are more commonly observed in patients with only mild hypercalcemia. The etiology of these symptoms is not known. Studies demonstrate that levels of certain neurotransmitters (monoamine metabolites 5-hydroxyindoleacetic acid and homovanillic acid) are reduced in the cerebrospinal fluid of patients with PHPT when compared to controls. Electroencephalogram abnormalities also occur in patients with primary and secondary HPT and normalize following parathyroidectomy.

Other Features. PHPT also can lead to fatigue and muscle weakness, which is prominent in the proximal muscle groups. Although the exact etiology of this finding is not known, muscle biopsy studies show that weakness results from a neuropathy, rather than a primary myopathic abnormality. Patients with HPT also have an increased incidence of chondrocalcinosis, gout, and pseudogout, with deposition of uric acid and calcium pyrophosphate crystals in the joints. Calcification at ectopic sites such as blood vessels, cardiac valves, and skin also has been reported, as has hypertrophy of the left ventricle independent of the presence of hypertension. There is also evidence for subtle cardiovascular manifestations in mild disease, such as changes in endothelial function, increased vascular stiffness, and perhaps subtle diastolic dysfunction. Several large studies from Europe also suggest that PHPT is associated with increased death rates from cardiovascular disease and cancer even in patients with mild HPT, although this finding was not substantiated in North American studies.

Physical Findings Parathyroid tumors are seldom palpable, except in patients with profound hypercalcemia or parathyroid cancer. A palpable neck mass in a patient with PHPT is more likely to be thyroid in origin or a parathyroid cancer. Patients also may demonstrate evidence of band keratopathy, a deposition of calcium in Bowman's membrane just inside the iris of the eye. This nonspecific condition generally is caused by chronic eye diseases such as uveitis, glaucoma, and trauma but also may occur in the presence of conditions associated with high calcium or phosphate levels. Fibro-osseous jaw tumors, and/or the presence of familial disease in patients with PHPT and jaw tumors, if present, should alert the physician to the possibility of parathyroid carcinoma.

Differential Diagnosis Hypercalcemia may be caused by a multitude of conditions, as listed in Table 38-9. PHPT and malignancy account for >90% of all cases of hypercalcemia. PHPT is more common in the outpatient setting, whereas malignancy is the leading cause of hypercalcemia in hospitalized patients. PHPT can virtually always be distinguished from other diseases causing hypercalcemia by a combination of history, physical examination, and appropriate laboratory investigations.

Table 38-9

Differential diagnosis of hypercalcemia

Hyperparathyroidism
Malignancy—hematologic (multiple myeloma), solid tumors (due to PTHrP)
Endocrine diseases—hyperthyroidism, Addisonian crisis, VIPoma
Granulomatous diseases—sarcoidosis, tuberculosis, berylliosis, histoplasmosis
Milk-alkali syndrome
Drugs—thiazide diuretics, lithium, vitamin A or D intoxication
Familial hypocalciuric hypercalcemia
Paget's disease
Immobilization
PTHrP = parathyroid hormone-related protein; VIP = vasoactive intestinal peptide.

Hypercalcemia associated with malignancy includes three distinct syndromes. Although bone metastases may cause hypercalcemia, patients with solid tumors of the lung, breast, kidney, head and neck, and ovary often have humoral hypercalcemia of malignancy, without any associated bony metastases. In addition, hypercalcemia also may be associated with hematologic malignancies such as multiple myeloma. Humoral hypercalcemia of malignancy is known to be mediated primarily by PTH-related peptide (PTHrP), which also plays a role in the hypercalcemia associated with bone metastases and multiple myeloma.

Thiazide diuretics cause hypercalcemia by decreasing renal clearance of calcium. This corrects in normal patients within days to weeks after discontinuing the diuretic, but patients with PHPT continue to be hypercalcemic. Thiazide diuretics can, therefore, exacerbate underlying PHPT and can be used to unmask PHPT in patients with borderline hypercalcemia. Familial hypocalciuric hypercalcemia (FHH) is a rare autosomal dominant condition with nearly 100% penetrance and results from inherited heterozygous mutations in the CASR gene located on chromosome 3.⁵⁴ Homozygous germline mutations at this locus result in neonatal hypercalcemia, a condition that can rapidly prove fatal. Patients with FHH have lifelong hypercalcemia, which is not corrected by parathyroidectomy. Hypercalcemia also is found in approximately 10% of patients with sarcoidosis secondary to increased 25-hydroxy vitamin D 1-hydroxylase activity in lymphoid tissue and pulmonary macrophages, which is not subject to inhibitory feedback control by serum calcium. Thyroid hormone also has bone-resorption properties, thus causing hypercalcemia in thyrotoxic states, especially in immobilized patients. Hemoconcentration appears to be an important factor in the hypercalcemia associated with adrenal insufficiency and pheochromocytoma, although the latter patients may have associated parathyroid tumors (MEN2A), and some pheochromocytomas are known to secrete PTHrP. Other endocrine lesions such as vasoactive intestinal peptide-secreting tumors may be associated with hypercalcemia due to increased secretion of PTHrP. Milk-alkali syndrome requires the ingestion of large quantities of calcium with an absorbable alkali such as that used in the treatment of peptic ulcer disease with antacids.

Ingestions of large quantities of vitamins D and A are infrequent causes of hypercalcemia, as is immobilization.

Diagnostic Investigations

Biochemical Studies. The presence of an elevated serum calcium and intact PTH or two-site PTH levels, without hypocalciuria, establishes the diagnosis of PHPT with virtual certainty. These sensitive PTH assays use immunoradiometric or immunochemiluminescent techniques and can reliably distinguish PHPT from other causes of hypercalcemia. Furthermore, they do not cross-react with PTHrP (Fig. 38-30). In patients with metastatic cancer and hypercalcemia, intact PTH levels help to determine whether the patient also has concurrent PHPT. Although extremely rare, a patient with hypercalcemia may have a tumor that secretes PTH. FNAB of such a tumor for PTH levels or selective venous catheterization of the veins draining such tumors can help clarify the diagnosis.

Patients with PHPT also typically have decreased serum phosphate (~50%) and elevated 24-hour urinary calcium concentrations (~60%). A mild hyperchloremic metabolic acidosis also is present (80%), thereby leading to an elevated chloride-to-phosphate ratio (>33). Urinary calcium levels need not be measured routinely, except in patients who have not had previously documented normocalcemia or have a family history of hypercalcemia to rule out FHH. In patients with FHH, 24-hour urinary calcium excretion is characteristically low (<100 mg/d). Furthermore, the serum calcium-to-creatinine clearance ratio usually is <0.01 in patients with FHH, whereas it is typically >0.02 in patients with PHPT. Other biochemical features of PHPT are listed in Table 38-10. Elevated levels of alkaline

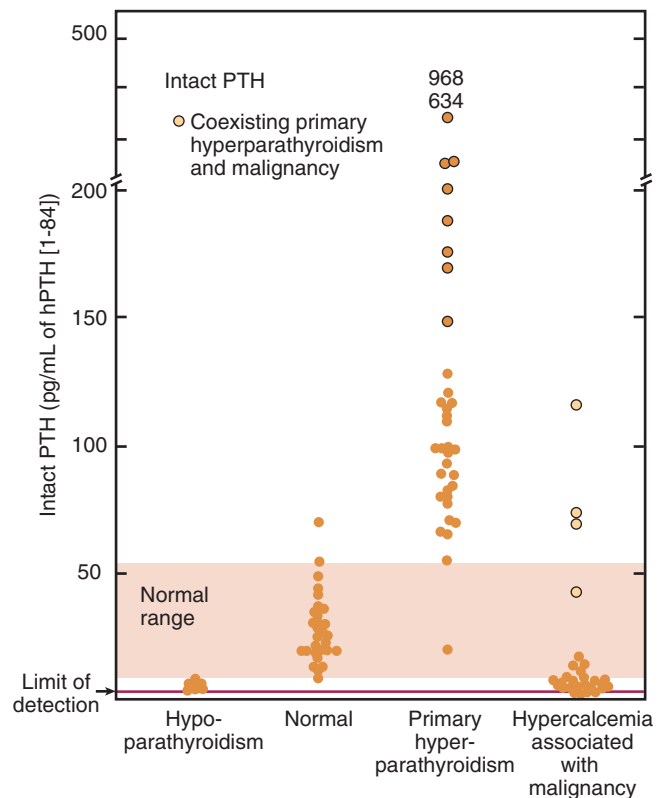


Figure 38-30. Intact parathyroid hormone (PTH) measurement allows differentiation between the various causes of hypercalcemia. (Reproduced with permission from Endres D, et al. *Measurement of parathyroid hormone*. *Endocrinol Metab Clin North Am*. 1989;18:622. Copyright Elsevier.)

Table 38-10

Biochemical features of primary hyperparathyroidism

SERUM TESTS	ALTERATION
Calcium	Increased, except in normocalcemic primary hyperparathyroidism
Intact PTH	Increased or inappropriately high
Chloride	Increased or high normal
Phosphate	Decreased or low normal
Chloride:phosphate ratio	Increased (usually >33)
Magnesium	Unchanged or decreased (in patients with osteitis fibrosa cystica)
Uric acid	Normal or increased
Alkaline phosphatase	Normal or increased (in the presence of high turnover bone disease)
Acid-base status	Mild hyperchloremic metabolic acidosis
Calcium:creatinine clearance ratio	>0.02 (vs. <0.01 in FHH)
1,25-dihydroxy vitamin D	Normal or increased
Urine tests	
24-h urinary calcium	Normal or increased

BFHH = benign familial hypocalciuric hypercalcemia; PTH = parathyroid hormone.

phosphatase may be found in approximately 10% of patients with PHPT and are indicative of high-turnover bone disease. These patients are prone to developing postoperative hypocalcemia due to bone hunger. Serum and urine protein electrophoresis may be necessary to exclude multiple myeloma.

Occasionally, patients present with normocalcemic PHPT due to vitamin D deficiency, a low serum albumin, excessive hydration, a high-phosphate diet, or a low normal blood calcium set point. These patients have increased total PTH levels with or without increased blood ionized calcium levels and must be distinguished from patients with renal leak hypercalciuria who also have increased PTH levels due to excessive calcium loss in the urine. This can be accomplished by administering thiazide diuretics. In patients with idiopathic hypercalciuria, the urinary calcium level falls, and the secondary increase in the blood PTH level also decreases to normal, whereas patients with normocalcemic HPT continue to have elevated urine calcium and blood PTH levels and may, in fact, become hypercalcemic.

Radiologic Tests. In patients with profound hypercalcemia or PHPT associated with vitamin D deficiency, hand and skull x-rays may demonstrate osteitis fibrosa cystica, but this is rare in current clinical practice. BMD studies using dual-energy absorptiometry are being increasingly used to assess the effects of PHPT on bone. Abdominal ultrasound examination is used selectively to document renal stones. Parathyroid localization studies are not used to confirm the diagnosis of PHPT, but rather to aid in identifying the location of the offending gland(s), as discussed later in Preoperative Localization Tests.

Treatment**Indications for Parathyroidectomy and Role of Medical Management.**

Most authorities agree that patients who have developed complications and have “classic” symptoms of PHPT should undergo parathyroidectomy. However, the treatment of patients with asymptomatic PHPT has been the subject of controversy, due, in part, to the fact that there is little agreement on what constitutes an asymptomatic patient.

At the National Institutes of Health consensus conference in 1990, “asymptomatic” PHPT was defined as “the absence of common symptoms and signs of PHPT, including no bone, renal, gastrointestinal, or neuromuscular disorders.” To determine the best course of action for these patients, it is important to consider the natural history of untreated PHPT and the outcomes of treatment options, both medical and surgical.

With respect to the natural history, the panel advocated nonoperative management of these patients with mild PHPT based on observational studies, which suggested relative stability of biochemical parameters over time. However, the consensus panel considered certain patients to be candidates for surgery based on testing or other information indicating end-organ effects or a higher likelihood of disease progression, and this led to the establishment of initial guidelines for parathyroidectomy.⁵⁸ Subsequently, another observational study on the natural history of treated versus untreated HPT was published by Silverberg and colleagues.⁵⁹ In their cohort of 52 patients with asymptomatic HPT followed without surgery, levels of serum and urinary calcium, PTH, alkaline phosphatase, and vitamin D metabolites remained relatively stable over a 10-year period in most patients. Average bone mass also remained relatively stable. However, the study also reported development of a new indication for surgery in 14 (27%) of 52 of their asymptomatic patients and, because approximately 50% of their patients were initially treated surgically, overall, about 75% of patients were underwent parathyroidectomy. Age <50 years was predictive of progression, and patients undergoing parathyroidectomy showed not only normalization of calcium and PTH levels, but also improved BMD at the spine and hip. Based on these and other studies, the guidelines were reassessed at a second workshop on asymptomatic PHPT held at the National Institutes of Health in 2002.⁶⁰

Since that time, additional studies have provided further insights into the natural history of treated and untreated HPT. Three of these were randomized, controlled, prospective studies ranging in duration from 1 to 3.5 years. One was an observational study (a continuation of the Columbia University PHPT Project) but was notable for its long duration of follow-up of 15 years.⁶¹ These studies confirmed the relative stability of various biochemical indices, thus validating the need for guidelines. However, the long-term study suggested that the stability was not indefinite as calcium levels tended to rise in years 13 to 15. In addition, the study also demonstrated that bone density measurements remained stable for 8 to 10 years, but cortical bone density worsened after year 10. More concerning was the fact that 60% of patients lost >10% of their BMD over the 15-year observation period. Furthermore, whether patients met the 2002 guidelines for surgery did not appear to predict the risk of progressive disease, with 40% of patients undergoing follow-up eventually needing surgery. Although there are no randomized trials, registry data also suggest that fracture risk is increased for PHPT up to 10 years prior to diagnosis and treatment.

Medical options for treating PHPT and its complications include antiresorptive treatments such as bisphosphonates,

hormone replacement therapy (HRT), and selective estrogen receptor modulators such as raloxifene.⁶² Bisphosphonates and HRT are reasonable options in patients for whom skeletal protection is needed, as evidence from randomized, placebo-controlled trials indicates that these medications are very effective at decreasing bone turnover and increasing BMD in PHPT, with the effects being comparable to patients undergoing parathyroidectomy. Caution needs to be exercised due to the nonskeletal effects of HRT, and hence, bisphosphonates are preferred. There are no clinical studies regarding the effects of raloxifene on BMD in HPT, and none of these agents affects calcium or PTH levels. More recently, calcimimetics (modifiers of the sensitivity of the CASR) have been used in randomized, multicenter controlled trials and have been shown to decrease both serum calcium and PTH levels in both symptomatic and asymptomatic PHPT patients. Unfortunately, bone density failed to improve in medically treated patients. Although this therapy shows promise, long-term outcome data are lacking, and their routine use is not advocated at this time, except in patients who are very poor operative risks or refuse surgery.

Successful parathyroidectomy results in resolution of osteitis fibrosa cystica and decreased formation of renal stones in symptomatic (classic) patients. In addition, it results in improved BMD (6% to 8% in the first year and up to 12% to 15% at 15 years) and fracture risk (by 50% at hip and upper arm and 30% overall) after adjustment for age, sex, and previous fractures over a 20-year observation period.⁵⁹ There are also data to show that it improves a number of the nonspecific manifestations of PHPT such as fatigue, polydipsia, polyuria and nocturia, bone and joint pain, constipation, nausea, and depression in many patients. This also has been demonstrated using symptom questionnaires and various standardized general quality-of-life assessments such as the SF-36 and a specific parathyroidectomy assessment of symptoms scale.⁶³ The increased death rate in patients with PHPT appears to be reversible by successful parathyroidectomy, at least in some studies. Lastly, parathyroidectomy can be accomplished with >95% success rates with minimal morbidity, even in elderly patients and is the only curative treatment option for PHPT. Previous investigations also have documented that parathyroidectomy is more cost-effective than medical management or follow-up.⁶⁴

Given the above, it is recommended that parathyroidectomy should be offered to virtually all patients except those in whom the operative risks are prohibitive. This is also acknowledged by the panel of the latest workshop, which stated that “even though patients may not meet the guidelines for surgical intervention, it is always a reasonable option in those who do not have medical contraindications.”

Currently, parathyroidectomy is recommended for patients with smaller elevations in serum calcium levels (>1 mg/dL above the upper limit of normal) and if BMD measured at any of three sites (radius, spine, or hip) is greater than 2.5 standard deviations below those of gender- and race-matched, not age-matched, controls (i.e., peak bone density or T score [rather than Z score] <2.5). In addition, patients <50 years of age are advised to undergo parathyroidectomy. The significant changes from the previous guidelines pertain to the fact that (a) hypercalciuria (>400 mg/24 h), in the absence of nephrolithiasis, is no longer considered an indication for parathyroidectomy; and (b) an absolute glomerular filtration rate <60 mL/min, rather than a reduction of creatinine clearance by 30%, is used as a threshold for recommending surgery. These changes are based on (a) data

Table 38-11

Indications for parathyroidectomy in patients with asymptomatic primary HPT (2009 NIH consensus conference guidelines)

- Serum calcium >1 mg/dL above the upper limits of normal
- GFR <60 mL/min
- Substantially decreased bone mineral density at the lumbar spine, hip, or distal radius (>2.5 SD below peak bone mass, T score <-2.5
- Age <50 y
- Long-term medical surveillance not desired or possible

GFR = glomerular filtration rate; HPT = hyperparathyroidism; NIH = National Institutes of Health; SD = standard deviation.

that demonstrate that hypercalciuria per se is not a risk factor for kidney stones, and (b) the most recent epidemiologic data from the U.S. National Health and Nutrition Examination Survey using a numerical cutoff for kidney function that relies on an age invariant standard, similar to densitometric guidelines. Although the guidelines for BMD did not change, it was noted that a patient with a history of fragility fracture(s) should also undergo parathyroidectomy.⁵⁵ The current guidelines are summarized in Table 38-11.

It is important to point out that the neurocognitive and neuropsychological aspects of PHPT remain a topic of controversy with respect to the guidelines for parathyroidectomy. Although there were more studies since the previous iteration of the guidelines, there were concerns that while some lacked adequate controls and were plagued by problems related to the instruments used to quantify these nonspecific symptoms, others showed variability in improvement of neurocognitive symptoms following parathyroidectomy. Similarly, uncertainty is also present concerning the cardiovascular consequences of mild HPT. Therefore, the workshop panel emphasizes that these criteria alone should not be used as guidelines for surgical intervention.

Since there are no definitive criteria to indicate which patients with mild PHPT will develop progressive disease, more clinical studies are required. Patients who do not undergo surgery should undergo routine follow-up as outlined in the recent workshop summary statement, consisting of annual calcium and serum creatinine measurements, and measurements of BMD at three sites every 1 to 2 years.⁶⁵

Preoperative Localization Tests. Localization studies may be classified into noninvasive or invasive modalities. These studies have variable performance characteristics, which, in turn, vary with operator and institutional experience, as outlined in Table 38-12. Localization studies have permitted surgeons to perform more limited operations, some of them under local anesthesia. These “minimally invasive” procedures include unilateral and focused neck exploration, radio-guided parathyroidectomy, and several endoscopic or video-assisted approaches. The use of localization studies has been shown in some studies to be associated with lower morbidity rates (hypoparathyroidism and RLN injury) and decreased operative times, reduced duration of hospital stay, and improved cosmetic outcomes, while maintaining success rates similar to those obtained with traditional bilateral neck explorations. Some studies also show that use of localization studies may be more cost-effective. Overall, it

Table 38-12

Commonly used parathyroid localization studies

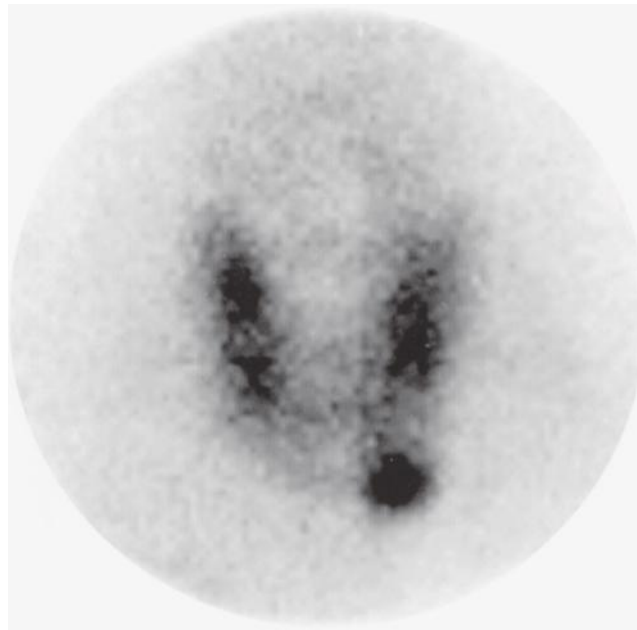
STUDY	ADVANTAGES	DISADVANTAGES
Preoperative, noninvasive		
Sestamibi-technetium-99m scan	Allows planar and SPECT imaging	False-positive tests due to thyroid neoplasms, lymphadenopathy
Ultrasound	Identification of juxta- and intrathyroidal tumors Relatively inexpensive	False-positive results due to thyroid nodules, cysts, lymph nodes, esophageal lesions False-negatives result from substernal, ectopic, and undescended tumors
CT scan	Localization of ectopic (mediastinal) glands	Not useful for juxta- or intrathyroidal glands False-positive results from lymph nodes Relatively high cost Radiation exposure Requires IV contrast Interference from shoulders and metallic clips
MRI scan	Localization of ectopic tumors	Expensive
	No radiation exposure	False-positive results from lymph nodes and thyroid nodules
	No IV contrast	Cannot be used in claustrophobic patients
Four-dimensional CT scan	Structural and functional information	Similar to CT scan
Preoperative, invasive		
FNAB	Can distinguish parathyroid tumor from lymphadenopathy using PTH assay	Experienced cytologist needed
Angiogram	Provides a road map for selective venous sampling	Expensive
	Treatment of mediastinal tumors by embolization	Experienced radiologist needed
		Neurologic complications
Venous sampling	Useful to lateralize tumor in equivocal cases or negative localization studies	Expensive, experienced radiologist needed
Intraoperative		
PTH assay	Immediate confirmation of tumor removal	Expensive
		Increased operative time, decreased accuracy in multiple-gland disease

CT = computed tomography; FNAB = fine-needle aspiration biopsy; IV = intravenous; MRI = magnetic resonance imaging; PTH = parathyroid hormone; SPECT = single-photon emission computed tomography.

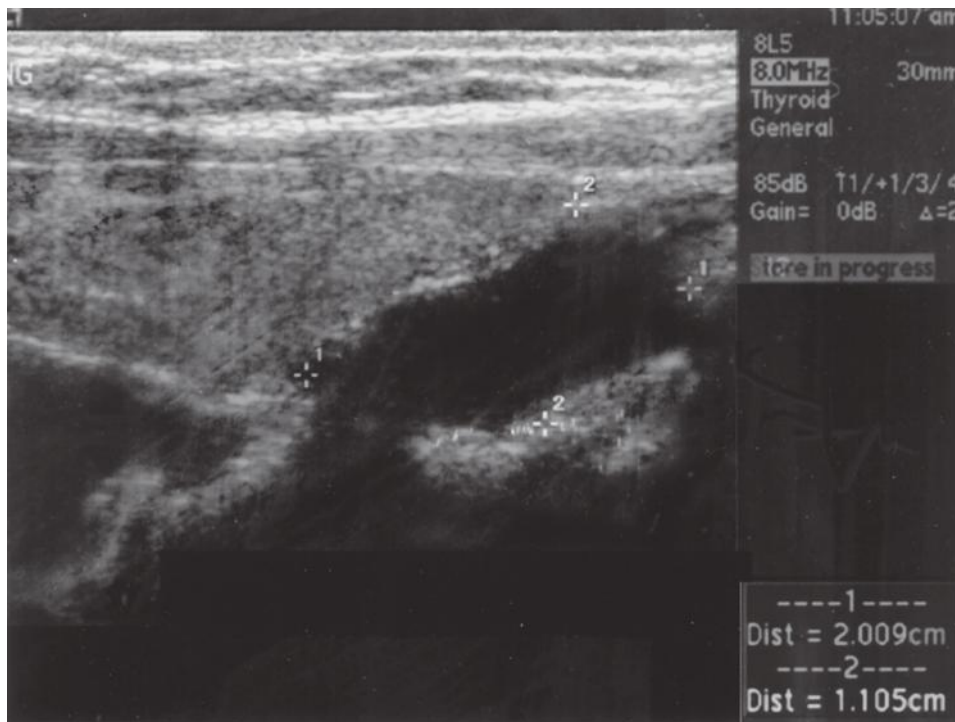
has become routine to localize hyperfunctioning parathyroid glands before parathyroidectomy. It is important to point out that imaging is not a diagnostic approach, and the decision for exploration should be made before any imaging is performed.

^{99m}Tc-labeled sestamibi (Fig. 38-31A) is the most widely used and accurate modality with a sensitivity >80% for detection of parathyroid adenomas. Sestamibi (Cardiolite) initially was introduced for cardiac imaging and is concentrated in mitochondria-rich tissue. It was subsequently noted to be useful for parathyroid localization due to the delayed washout of the radionuclide from hypercellular parathyroid tissue compared to thyroid tissue. Sestamibi scans generally are complemented by neck ultrasound (Fig. 38-31B), which can identify adenomas with >75%

sensitivity in experienced centers and is most useful in identifying intrathyroidal parathyroids. Single-photon emission CT, particularly when used with CT, has been shown to be superior to other nuclear medicine-based imaging. Specifically, single-photon emission CT can indicate whether an adenoma is located in the anterior or posterior mediastinum (aortopulmonary window), thus enabling the surgeon to modify the operative approach accordingly. CT and MRI scans are less sensitive than sestamibi scans, but are helpful in localizing large paraesophageal and mediastinal glands. More recently, four-dimensional CT (4D-CT) has shown utility in parathyroid localization. This technique incorporates the perfusion of contrast in hyperfunctioning parathyroid tissue over time, thus providing functional information in addition to the



A



B

Figure 38-31. A. Sestamibi scan in a patient with primary hyperparathyroidism showing persistent uptake suggesting a left lower hypercellular parathyroid gland. B. Neck ultrasound in a patient with primary hyperparathyroidism showing a left lower parathyroid adenoma.

anatomic information provided by conventional three-dimensional CT imaging. In one study, 4D-CT showed improved sensitivity of 88% compared to that of sestamibi (65%) and ultrasound (57%) for lateralization of the enlarged gland and also showed superiority when localization to the correct quadrant was examined.⁶⁶ A combination of 4D-CT and ultrasound has been reported to have a positive predictive value of 92% for single-gland disease and 75% for multiple-gland disease.

IOPTH was initially introduced in 1993 and is used to determine the adequacy of parathyroid resection (Fig. 38-32).⁶⁷

According to one commonly used criterion, when the PTH falls by 50% or greater 10 minutes after removal of a parathyroid tumor, as compared to the highest preremoval value, the test is considered positive, and the operation is terminated. IOPTH measurements, like localization studies, are less reliable in multiglandular disease. Bilateral internal jugular vein sampling has also been used to lateralize tumors intraoperatively but is less accurate.

Operative Approaches Unilateral parathyroid exploration was first carried out using intraoperative staining of a biopsy from

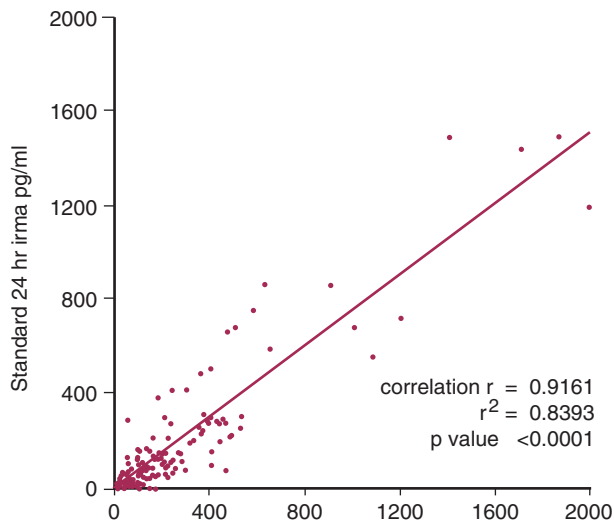


Figure 38-32. Correlation of the 10-minute incubation time quick parathyroid hormone assay with the 24-hour immunoradiometric (irma) parathyroid hormone assay from 138 paired intraoperative samples from 38 patients undergoing parathyroidectomy. (*Reproduced with permission from Irvin G, et al. Clinical usefulness of an intraoperative “quick parathyroid hormone” assay. Surgery. 1993;114:1020. Copyright Elsevier.*)

the normal parathyroid gland with Sudan black dye to rule out a double adenoma. Initially, the choice of side to be explored was random, but the introduction of preoperative localization studies has enabled a more directed approach. In contrast, the focused approach identifies only the enlarged parathyroid gland, and no attempts are made to locate other parathyroid glands. Unilateral neck explorations have several advantages over bilateral neck exploration, including reduced operative times and complications, such as injury to the RLN and hypoparathyroidism. However, most existing studies comparing the two approaches are retrospective and do not analyze the results on an intent-to-treat basis. Another argument against a unilateral exploration is the risk of missing another adenoma on the opposite side of the neck. The incidence of double adenomas has been reported to range from 0% to 10%, with an increased incidence in elderly patients. The risk of missing a second adenoma is higher in populations with a higher incidence of multiple adenomas, such as those with familial HPT, MEN syndromes, and the elderly. Another difficulty inherent with unilateral exploration is the inability to discern whether the combination of an abnormal gland and a normal gland on the initial side constitutes a single adenoma or asymmetric hyperplasia. A recently published update on the 5-year results of a randomized trial comparing unilateral versus bilateral neck exploration did not note any difference in the rates of recurrent or persistent disease in the two groups of patients.⁶⁸ These issues will only be resolved by a large, prospective, multicenter study or improved molecular analytic techniques.

Radio-guided parathyroidectomy takes advantage of the ability of parathyroid tumors to retain ^{99m}Tc-sestamibi. One to 2 mCi of the isotope is injected before surgery, and a hand-held gamma probe is used to guide the identification of the enlarged gland, taking care to ensure the equilibration of radioactivity counts in all quadrants. Reported advantages include easier localization, particularly in reoperative cases, and the ability to perform the procedure under local anesthetic or sedation using smaller incisions. Many studies demonstrated the feasibility of

this technique; however, it is rarely used now, largely because it offers little advantage over preoperative sestamibi scans and is associated with increased operative times. Like preoperative scanning, it also has reduced accuracy in the presence of multiglandular disease.

Endoscopic approaches include both video-assisted and total endoscopic techniques. Total endoscopic parathyroidectomy was first described by Gagner in 1996,⁶⁹ and several other investigators have since reported on this technique. Although port placements are variable, as is the case with endoscopic thyroidectomy, they all involve creation of a working space in the neck using CO₂ insufflation, with the reported advantages being superior cosmesis and excellent visualization. Although feasible, these techniques also have been associated with increased operating times, more personnel, and greater expense, and have, in general, not been useful for patients with multiglandular disease, a large thyroid mass, or previous neck surgery and irradiation. Their greatest use has been in patients with tumors at ectopic sites such as the mediastinum where thoracoscopic parathyroidectomy is an excellent alternative to sternotomy. Robotic approaches using a gasless, transaxillary technique are also being used for parathyroidectomy. Reported advantages include improved three-dimensional magnified visualization, refined ergonomic control, more freedom of motion with multi-articulated instruments, and improved cosmetic result as a result of incision placement in the axilla.⁷⁰

Studies have shown that if both sestamibi scan and neck ultrasound studies independently identify the same, enlarged parathyroid gland, and no other gland, it is indeed the abnormal gland in approximately 95% of cases. These patients with sporadic PHPT are candidates for a focused neck exploration, an approach that is most commonly referred to as *minimally invasive* **7▶** *parathyroidectomy*. A standard bilateral neck exploration is planned if parathyroid localization studies or IOPTH are not available; if the localizing studies fail to identify any abnormal parathyroid gland or identify multiple abnormal glands in patients with a family history of PHPT, MEN1, or MEN2A; or if a concomitant thyroid disorder requires bilateral exploration. In addition, finding a minimally abnormal parathyroid gland on the side indicated by localization studies during focal exploration should prompt a bilateral exploration or at least the identification of a normal parathyroid gland on the same side. In patients with MEN1, HPT should be corrected before treatment of gastrinomas because gastrin levels decline after parathyroidectomy.

Conduct of Parathyroidectomy (Standard Bilateral Exploration) An experienced parathyroid surgeon with a thorough knowledge of parathyroid anatomy and embryology and meticulous technique is crucial for the best surgical results. The procedure usually is performed under general anesthesia. The patient is positioned supine on the operating table with the neck extended. For a bilateral exploration, the neck is explored via a 3- to 4-cm incision just caudal to the cricoid cartilage. The initial dissection and exposure is similar to that used for thyroidectomy. After the strap muscles are separated in the midline, one side of the neck is chosen for exploration. In contrast to a thyroidectomy, the dissection during a parathyroidectomy is maintained lateral to the thyroid, making it easier to identify the parathyroid glands and not disturb their blood supply.

Identification of Parathyroids. A bloodless field is important to allow identification of parathyroid glands. The middle thyroid

veins are ligated and divided, thus enabling medial and anterior retraction of the thyroid lobe, with the aid of a peanut sponge or placement of 2-0 silk sutures into the thyroid. The space between the carotid sheath and thyroid is then opened by gentle sharp and blunt dissection, from the cricoid cartilage superiorly to the thymus inferiorly and the RLN is identified. Approximately 85% of the parathyroid glands are found within 1 cm of the junction of the inferior thyroid artery and RLNs. The upper parathyroid glands usually are superior to this junction and dorsal (posterior) to the nerve, whereas the lower glands are located inferior to the junction and ventral (anterior) to the recurrent nerve. Because parathyroid glands are partly surrounded by fat, any fat lobule at typical parathyroid locations should be explored because the normal or abnormal parathyroid gland may be concealed in the fatty tissue. The thin fascia overlying a “suspicious” fat lobule should be incised using a sharp curved hemostat and scalpel. This maneuver often causes the parathyroid gland to “pop” out. Alternatively, gentle, blunt peanut sponge dissection between the carotid sheath and the thyroid gland often reveals a “float” sign, suggesting the site of the abnormal parathyroid gland. Normal parathyroids are light beige and only slightly darker or brown compared to adjacent fat.

Parathyroid tissue needs to be distinguished from normal or brown fat tissue, thyroid nodules, lymph nodes, and ectopic thymus. Lymph nodes generally are light beige to whitish gray in color, glassy, and multiple in number, whereas thyroid nodules generally are more vascular, firm, dark or reddish brown in color, and have a more variegated appearance. Intraoperatively, a suspicious nodule may be aspirated using a fine needle attached to a syringe containing 1 cc of saline. Very high PTH levels in the aspirate have been shown to be diagnostic in the intraoperative identification of parathyroid glands. Several characteristics such as size (>7 mm), weight, and color are used to distinguish normal from hypercellular parathyroid glands. Hypercellular glands generally are darker, more firm, and more vascular than normocellular glands. No single method is 100% reliable, and therefore, the parathyroid surgeon must rely on experience and, at times, advice from a pathologist to help distinguish normal from hypercellular glands. Although several molecular studies have shown use in distinguishing parathyroid adenomas from hyperplasia, this determination also must be made by the surgeon intraoperatively by documenting the presence of a normal parathyroid gland.

Location of Parathyroid Glands. The majority of lower parathyroid glands are found in proximity to the lower thyroid pole (Fig. 38-33A). If not found at this location, the thyrothymic ligament and thymus should be mobilized. The upper end of the cervical thymus is gently grasped with a right angle clamp, and the distal portion is bluntly dissected from perithymic fat with a peanut sponge. One can then “walk down” the thymus with successive right-angle clamps (Fig. 38-33B). Applying light tension along with a “twisting” motion helps to free the upper thymus. The carotid sheath also should be opened from the bifurcation to the base of the neck if the parathyroid tumor cannot be found. If these maneuvers are unsuccessful, an intrathyroidal gland should be sought by using intraoperative ultrasound, incising the thyroid capsule on its posterolateral surface, or by performing an ipsilateral thyroid lobectomy and “bread- loafing” the thyroid lobe. Preoperative or intraoperative ultrasonography can be useful for identifying intrathyroidal parathyroid glands. Rarely, the third branchial pouch may maldescend and be found high in the neck (undescended parathyrmus), anterior to the carotid

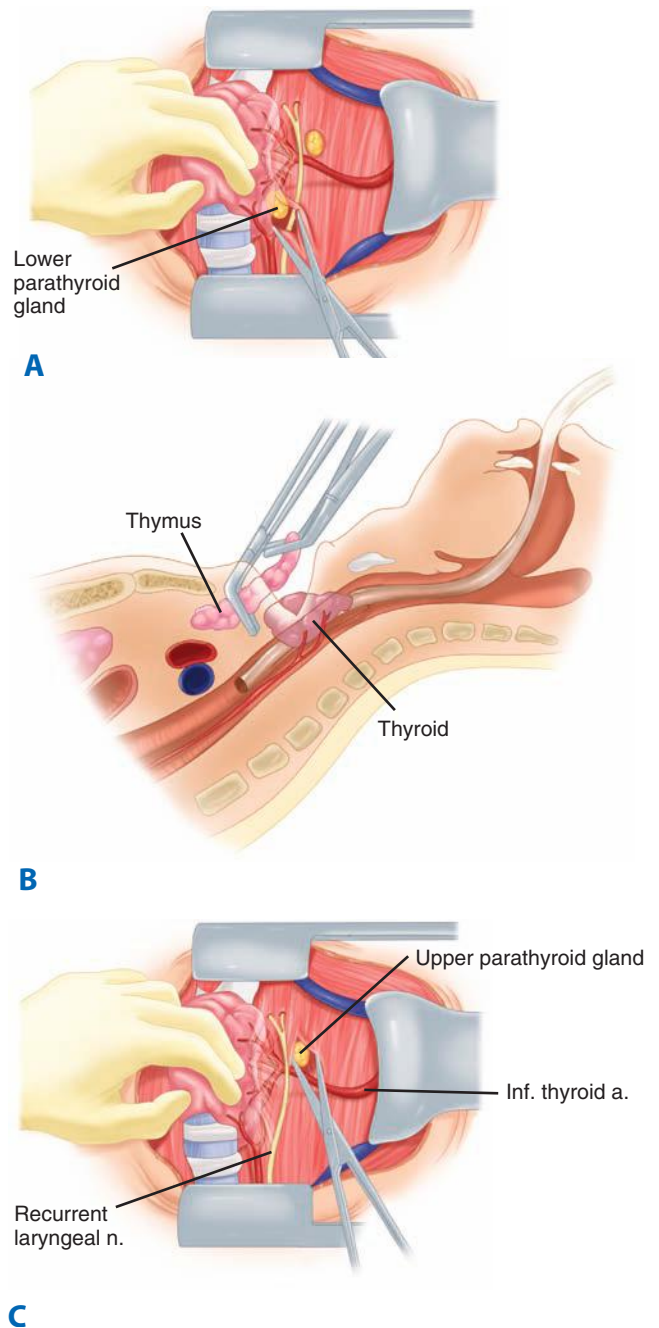


Figure 38-33. Conduct of parathyroidectomy. **A.** Exposure of the lower parathyroid gland near the inferior pole of the thyroid gland and anterior to the recurrent laryngeal nerve. **B.** A thymectomy may be necessary if the lower parathyroid cannot be found in its usual location, or if the patient has familial primary hyperparathyroidism or secondary hyperparathyroidism. **C.** Exposure of the upper parathyroid gland near the insertion of the recurrent laryngeal nerve at the level of the cricothyroid muscle. a. = artery; Inf. = inferior; n. = nerve.

bulb, along with the missing parathyroid gland. Upper parathyroid glands are more consistent in position and usually are found near the junction of the upper and middle thirds of the gland, at the level of the cricoid cartilage (Fig. 38-33C). Ectopic upper glands may be found in carotid sheath, tracheoesophageal groove, retroesophageal, or in the posterior mediastinum. The locations of ectopic upper and lower parathyroid glands are shown in Fig. 38-34. Every attempt must be made to identify

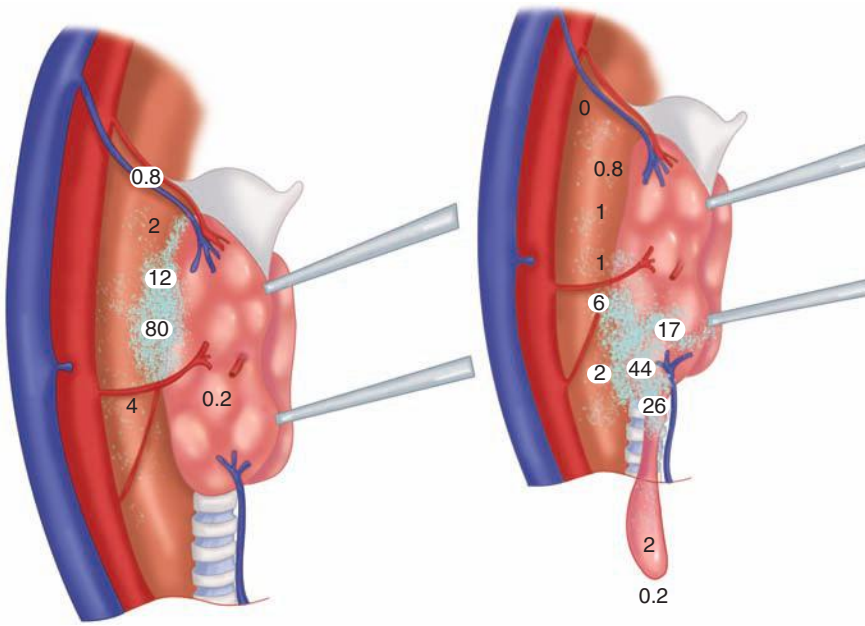


Figure 38-34. Location of ectopic upper and lower parathyroid glands. (Reproduced with permission from Akerström G, et al. *Surgical anatomy of human parathyroid glands*. Surgery. 1984;95:15. Copyright Elsevier.)

all four glands. Treatment depends on the number of abnormal glands.

1. A single adenoma is presumed to be the cause of a patient's PHPT if only one parathyroid tumor is identified and the other parathyroid glands are normal, a situation present in about 80% of patients with PHPT. Adenomas typically have an atrophic rim of normal parathyroid tissue, but this characteristic may be absent. The adenoma is dissected free of surrounding tissue, taking care to stay immediately adjacent to the tumor, without fracturing it. The vascular pedicle is clamped, divided, and ligated. Care should be taken to not rupture the parathyroid gland to decrease the risk of parathyromatosis. If there is any question about the presumed normal glands, one of them should be biopsied and examined by frozen section.
2. If two abnormal and two normal glands are identified, the patient has double adenomas. Triple adenomas are present if three glands are abnormal and one is normal. Multiple adenomas are more common in older patients with an incidence of up to 10% in patients >60 years old. The abnormal glands should be excised, provided the remaining glands are confirmed as such, thus excluding asymmetric hyperplasia after biopsy and frozen section.
3. If all parathyroid glands are enlarged or hypercellular, patients have parathyroid hyperplasia that has been shown to occur in about 15% of patients in various series. These glands are often lobulated, usually lack the rim of normal parathyroid gland seen in adenomas, and may be variable in size. It often is difficult to distinguish multiple adenomas from hyperplasia with variable gland size. Hyperplasia may be of the chief cell (more common), mixed, or clear cell type. Patients with hyperplasia may be treated by subtotal parathyroidectomy or by total parathyroidectomy and autotransplantation, with the choice of procedure being determined by rates of recurrence, postoperative hypocalcemia, and failure rates of autotransplanted tissue. Initial studies demonstrated equivalent cure rates and postoperative hypocalcemia for the two techniques, with the latter having the added advantage of avoiding recurrence in the neck.

However, autotransplanted tissue may fail to function in about 5% of cases.

All four parathyroid glands are identified and carefully mobilized. For patients with hyperplasia, a titanium clip is placed across the most normal gland, leaving a 50-mg remnant and taking care to avoid disturbing the vascular pedicle and that the gland is resected with a sharp scalpel. If possible, it is preferable to subtotally resect an inferior gland, which is more easily accessible in case of recurrence due to its anterior location with respect to the RLN. The resected parathyroid tissue is confirmed by frozen section or PTH assay. If the remnant appears to be viable, the remaining glands are resected. If there is any question as to the viability of the initially subtotally resected gland, another gland is chosen for subtotal resection and the initial remnant is removed. Whenever multiple parathyroids are resected, it is preferable to cryopreserve tissue, so that it may be autotransplanted should the patient become hypoparathyroid. Parathyroid tissue usually is transplanted into the nondominant forearm. A horizontal skin incision is made overlying the brachioradialis muscle a few centimeters below the antecubital fossa. Pockets are made in the belly of the muscle, and one to two pieces of parathyroid tissue measuring 1 mm each are placed into each pocket. A total of 12 to 14 pieces are transplanted. Autotransplanted tissue also has been reported to function when transplanted into fat.

Indications for Sternotomy A sternotomy is usually not recommended at the initial operation, unless the calcium level is >13 mg/dL. Rather, it is preferred to biopsy the normal glands and subsequently close the patient's neck and obtain localizing studies, if they were not obtained previously. Intraoperative PTH assay during the operation from large veins may be helpful. Using highly selective venous catheterization postoperatively also may be needed when noninvasive localization studies are negative, equivocal, or conflicting. Lower parathyroid glands tend to migrate into the anterior mediastinum in the thymus or perithymic fat and usually can be approached via a cervical incision. A sternotomy is needed to deliver these tumors in approximately 5% of cases. Generally, the gland can be approached by

a partial sternotomy to the third intercostal space. The midline sternotomy can be extended to the left or right side as required. Upper glands tend to migrate to the posterior mediastinum in the tracheoesophageal groove. Mediastinal glands also may be found in the aortopulmonary window or pericardium, or attached to the ascending aorta, aortic arch, or its branches.

Special Situations

Normocalcemic Hyperparathyroidism. This disorder is becoming increasingly recognized in clinical practice and is defined by the presence of an elevated PTH level with normal calcium (including ionized calcium) levels. In addition, other secondary

8▶ causes of elevated PTH should be ruled out, namely, vitamin D deficiency, osteomalacia, hypercalciuria (renal leak), and renal insufficiency. Data regarding the natural history of this disorder are limited. In a series of 37 patients, Lowe and colleagues⁷¹ showed that 19% of patients became frankly hypercalcemic within 3 years. In addition, 57% developed osteoporosis, 11% developed fragility fractures, and 14% developed nephrolithiasis. Although the study had some limitations, it led the authors to suggest that normocalcemic HPT may represent a variant of “symptomatic” PHPT and may not be an early form of “asymptomatic” disease. There is still uncertainty about whether normocalcemic HPT carries the same cardiovascular morbidity that is associated with the more severe form of the disease. Limited studies show that parathyroidectomy is more likely to be unsuccessful in these patients. In the absence of strong data, no guidelines are available for this entity.⁶⁵ As such, most clinicians follow a conservative course unless patients have symptoms that can be attributable to HPT.

Parathyroid Carcinoma. Parathyroid cancer accounts for approximately 1% of PHPT cases. It may be suspected preoperatively by the presence of severe symptoms, serum calcium levels >14 mg/dL, significantly elevated PTH levels (five times normal), and a palpable parathyroid gland. Local invasion is quite

9▶ common; approximately 15% of patients have lymph node metastases and 33% have distant metastases at presentation. Intraoperatively, parathyroid cancer is suggested by the presence of a large, gray-white to gray-brown parathyroid tumor that is adherent to or invasive into surrounding tissues like muscle, thyroid, RLN, trachea, or esophagus. Enlarged lymph nodes also may be present. Frozen sections are generally unreliable. Accurate diagnosis necessitates histologic examination. The major diagnostic criteria include vascular or capsular invasion, trabecular or fibrous stroma, and frequent mitoses. It is, however, important to emphasize that these classic findings are not as frequently noted as previously reported, and some may be found in benign adenomas as well.

Treatment of parathyroid cancer consists of neck exploration, with en bloc excision of the tumor and the ipsilateral thyroid lobe, in addition to the removal of contiguous lymph nodes (tracheoesophageal, paratracheal, and upper mediastinal). The recurrent nerve is not sacrificed unless it is directly involved with tumor. Adherent soft tissue structures (strap muscles or other soft tissues) should also be resected. Modified radical neck dissection is recommended in the presence of lateral lymph node metastases. Prophylactic neck dissection is not advised. If the diagnosis is made postoperatively, a decision must be made regarding the adequacy of initial surgery based on a review of operative notes, pathology reports, localization studies, and calcium and PTH levels. If any question exists, histologic review by another experienced pathologist can

be helpful. Additional procedures can include ipsilateral thyroid lobectomy with resection of contiguous structures and lymph nodes if the features are typical or the patient remains hypercalcemic. Patients with equivocal pathologic findings and normocalcemia may be monitored closely. Reoperation is indicated for locally recurrent or metastatic disease to control hypercalcemia. Adjuvant radiation therapy should be considered in patients at high risk of local recurrence such as those with close or positive margins, invasion of surrounding structures, or tumor rupture. Radiation may also be used as primary therapy in unresectable disease or for palliation of bone metastases. Chemotherapy is not very effective. Bisphosphonates have shown some effectiveness in treating hypercalcemia associated with parathyroid carcinoma. Cinacalcet hydrochloride, a calcimimetic, can reduce PTH levels by directly binding to the CASR cells on the parathyroid gland and has been shown to be useful in controlling hypercalcemia in patients with refractory parathyroid carcinoma.⁷² Other promising approaches include anti-parathyroid hormone immunotherapy, octreotide, and the telomerase inhibitor azidothymidine, but additional investigations are needed in this area.

Familial Hyperparathyroidism. PHPT may occur as a component of various inherited syndromes such as MEN1 and MEN2A. Inherited PHPT also can occur as isolated familial HPT (non-MEN) or familial HPT with jaw tumors. The diagnosis of familial HPT is known or suspected in approximately 85% of patients preoperatively. Furthermore, patients with hereditary HPT generally have a higher incidence of multiglandular disease, supernumerary glands, and recurrent or persistent disease. Therefore, these patients warrant a more aggressive approach and are not candidates for various focused surgical approaches.⁶⁶ Although not absolutely necessary, preoperative sestamibi scan and ultrasound can be obtained in patients with inherited HPT to identify potential ectopic glands. A standard bilateral neck exploration is performed, along with a bilateral cervical thymectomy, regardless of the results of localization studies. Both subtotal parathyroidectomy and total parathyroidectomy with autotransplantation are appropriate, and parathyroid tissue also should be cryopreserved. If an adenoma is found in patients with familial HPT, the adenoma and the ipsilateral normal parathyroid glands are resected. The normal-appearing glands on the contralateral side are biopsied and marked, so that only one side of the neck will need to be explored in the event of recurrence. Patients with MEN2A require total thyroidectomy and central neck dissection for prevention/treatment of MTC, a procedure that places the parathyroids at risk. Moreover, HPT is less aggressive in these patients. Hence, only abnormal parathyroid glands need to be resected at neck exploration. The other normal parathyroid glands should be marked with a clip.

Neonatal Hyperparathyroidism. Infants with neonatal HPT present with severe hypercalcemia, lethargy, hypotonia, and mental retardation. This disorder is associated with homozygous mutations in the CASR gene. Urgent total parathyroidectomy (with autotransplantation and cryopreservation) and thymectomy are indicated. Subtotal resection is associated with high recurrence rates.

Parathyromatosis. Parathyromatosis is a rare condition characterized by the finding of multiple nodules of hyperfunctioning parathyroid tissue throughout the neck and mediastinum, usually following a previous parathyroidectomy. The true etiology of parathyromatosis is not known. It is postulated to arise either from overgrowth of congenital parathyroid rests (ontogenous

parathyromatosis) or seeding at surgery from rupture of parathyroid tumors or subtotal resection of hyperplastic glands. Parathyromatosis represents a rare cause of persistent or recurrent HPT⁷³ and can be identified intraoperatively. Aggressive local resection of these deposits can result in normocalcemia but is rarely curative. Some studies suggest that these patients have low-grade carcinoma because of invasion into muscle and other structures distant from the resected parathyroid tumor.

Postoperative Care and Follow-Up Patients who have undergone parathyroidectomy are advised to undergo calcium level checks 2 weeks postoperatively, at 6 months, and then annually. Recurrences are rare (<1%), except in patients with familial HPT. Recurrence rates of 15% at 2 years and 67% at 8 years have been reported for MEN1 patients.

Persistent and Recurrent Hyperparathyroidism. Persistence is defined as hypercalcemia that fails to resolve after parathyroidectomy and is more common than recurrence, which refers to HPT occurring after an intervening period of at least 6 months of biochemically documented normocalcemia.⁷⁴ Recurrent disease is far less common than persistent HPT; however, both occur more frequently in the setting of familial HPT and MEN1, in particular. The most common causes for both these states include ectopic parathyroids, unrecognized hyperplasia, or supernumerary glands. More rare causes include parathyroid carcinoma, missed adenoma in a normal position, incomplete resection of an abnormal gland, parathyromatosis, or an inexperienced surgeon. The most common sites of ectopic parathyroid glands in patients with persistent or recurrent HPT are paraesophageal (28%), mediastinal (26%), intrathyroidic

(24%), intrathyroidal (11%), carotid sheath (9%), and high cervical or undescended (2%) (Fig. 38-35).

Once the diagnosis of persistent or recurrent HPT is suspected, it should be confirmed by the necessary biochemical tests. Other causes of an elevated serum PTH such as renal insufficiency, renal calcium leak, and GI tract abnormalities should be considered. A detailed family history should be performed to screen for familial disease, as this will influence the operative approach. In particular, a 24-hour urine collection should be performed to rule out FHH. In redo-parathyroid surgery, the glands are more likely to be in ectopic locations, and postoperative scarring tends to make the procedure more technically demanding. Cure rates are generally lower (80%–90% compared with 95%–99% for initial operation), and risk of injury to RLNs and permanent hypocalcemia are higher. Therefore, an evaluation of severity of HPT and the patient's anesthetic risk (using the American Society of Anesthesiology classification of physical status or the Goldman cardiac index) is important. There are no published guidelines directly applicable to this group of patients. In general, patients with significant and ongoing problems such as recurrent kidney stones, a markedly elevated calcium level, or ongoing bone loss will need re-exploration. Patients in whom the diagnosis remains in question or those with equivocal or minimal symptoms may be considered for conservative management. Preoperative localization studies are routinely performed. Noninvasive studies such as a sestamibi scan and ultrasound are obtained, supplemented by 4D-CT scans. If these studies are negative, discordant, or equivocal, obtaining an ultrasound-guided aspirate of a suspicious cervical lesion or a highly selective venous catheterization for PTH

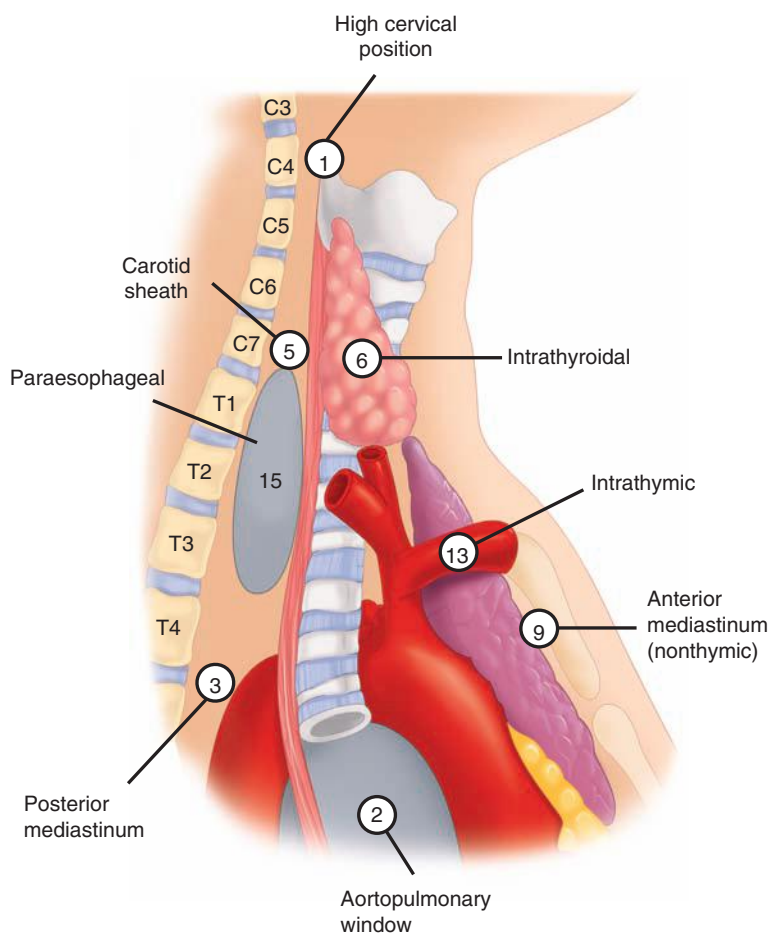


Figure 38-35. Anatomic location of ectopic parathyroid glands. Numbers represent number of glands found in each location, with a total of 54. (Reproduced with permission from Shen W, et al. *Re-operation for persistent or recurrent primary hyperparathyroidism.* Arch Surg. 1996;131:864. Copyright © 1996 American Medical Association. All rights reserved.)

levels (by an experienced angiographer) is recommended. Previous operative notes and pathology reports should be carefully reviewed and reconciled with the information obtained from localization studies before any neck re-exploration. An algorithm for the treatment of patients with recurrent and persistent HPT is shown in Fig. 38-36.

Generally, these patients are approached with a focused exploration. The lateral approach is frequently used and can be achieved via the previous incision. The plane between the sternocleidomastoid and strap muscle is opened and allows for early identification of the RLN. Parathyroid tissue is cryopreserved routinely. Use of adjuncts, such as measuring intraoperative PTH levels, is critical to ensure adequate resection and avoid potentially harmful additional explorations. In case of difficult re-explorations, additional techniques such as bilateral internal jugular vein sampling for PTH, thyroid lobectomy on the side of the missing gland, cervical thymectomy, and ligation of the ipsilateral inferior thyroid artery (after lobectomy, to cause infarction of the missing gland) may be needed. Blind mediastinal exploration is not recommended. In patients who are denied, refuse, or fail exploration, medical options such as cinacalcet may be considered.

Hypercalcemic Crisis. Patients with PHPT may occasionally present acutely with nausea, vomiting, fatigue, muscle weakness, confusion, and a decreased level of consciousness—a complex referred to as *hypercalcemic crisis*. These symptoms result from severe hypercalcemia from uncontrolled PTH secretion, worsened by polyuria, dehydration, and reduced kidney function and may occur with other conditions causing hypercalcemia.

Calcium levels are markedly elevated and may be as high as 16 to 20 mg/dL. Parathyroid tumors tend to be large or multiple and may be palpable. Patients with parathyroid cancer or familial HPT are more likely to present with hypercalcemic crisis.

Treatment consists of therapies to lower serum calcium levels followed by surgery to correct HPT. The mainstay of therapy involves rehydration with a 0.9% saline solution to keep urine output >100 cc/h. Once urine output is established, diuresis with furosemide (which increases renal calcium clearance) is begun. If these methods are unsuccessful, other drugs may be used to lower serum calcium levels as outlined in Table 38-13. Occasionally, in life-threatening cases, hemodialysis may be of benefit.

Secondary Hyperparathyroidism. Secondary HPT commonly occurs in patients with chronic renal failure but also may occur in those with hypocalcemia secondary to inadequate calcium or vitamin D intake or malabsorption. The pathophysiology of HPT in chronic renal failure is complex and appears to be related to hyperphosphatemia (and resultant hypocalcemia), deficiency of 1,25-dihydroxy vitamin D due to loss of renal tissue, low calcium intake, decreased calcium absorption, and abnormal parathyroid cell response to extracellular calcium or vitamin D in vitro and in vivo. Patients generally are hypocalcemic or normocalcemic. Aluminum hydroxide, which often was used as a phosphate binder, has been shown to contribute to the osteomalacia observed in this disease. These patients generally are treated medically with a low-phosphate diet, phosphate binders, adequate intake of calcium and 1, 25-dihydroxy vitamin D, and a high-calcium, low-aluminum dialysis bath. Calcimimetics have been shown to control parathyroid hyperplasia and osteitis fibrosa cystica associated with secondary HPT in animal studies and to decrease plasma PTH and total and ionized calcium levels in humans.

Surgical treatment was traditionally recommended for patients with bone pain, pruritus, and (a) a calcium-phosphate product ≥ 70 , (b) calcium >11 mg/dL with markedly elevated PTH, (c) calciphylaxis, (d) progressive renal osteodystrophy, and (e) soft tissue calcification and tumoral calcinosis, despite maximal medical therapy. Assessment of parathyroid mass is thought to be an important factor for predicting the response to medical management. Therefore, some groups recommend parathyroidectomy if the glands are >1 cm (or >500 mm³) on ultrasound. These glands are apparently more likely to have developed nodular hyperplasia and hence might be refractory to medical management. Following the introduction of calcimimetics, there appears to have been a reduction in parathyroidectomy rates. While parathyroidectomy has been reported to maintain biochemical targets for up to 5 years and improve bone density, fracture risk, calcinosis, hemoglobin levels, and even long-term survival, the effects of calcimimetics on these parameters awaits results of various trials. Studies also show that calcimimetics may be less cost-effective in the long-term. The role of parathyroidectomy in the era of calcimimetics will require long-term studies, specifically prospective studies comparing outcomes of calcimimetics with standard therapy versus parathyroidectomy. In general, parathyroidectomy should be considered if PTH levels remain high despite therapy that includes calcimimetics. Calciphylaxis is a rare, limb- and life-threatening complication of secondary HPT characterized by painful (sometimes throbbing), violaceous, and mottled lesions usually on the extremities, which often become necrotic and progress to nonhealing ulcers, gangrene, sepsis, and death. Skin

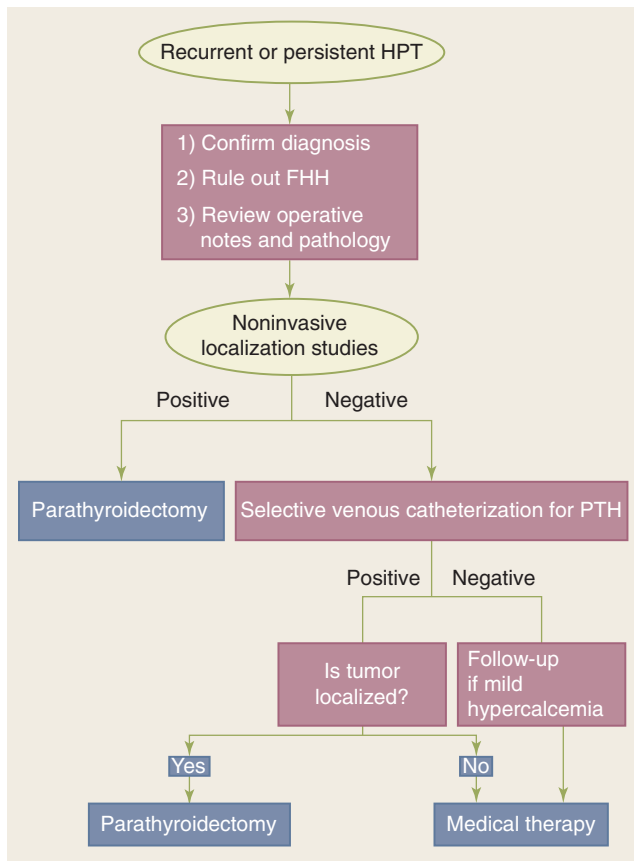


Figure 38-36. Management of recurrent and persistent hyperparathyroidism (HPT). FHH = familial hypocalciuric hypercalcemia; PTH = parathyroid hormone.

Table 38-13

Medications commonly used to treat hypercalcemia

MEDICATION	DOSAGE AND ADMINISTRATION	MECHANISM, ONSET OF ACTION, AND DURATION	SIDE EFFECTS
Bisphosphonates (pamidronate)	60–90 mg IV over 4–24 h	Inhibits osteoclastic bone resorption; rapid onset, 2–3 d	May cause local pain and swelling, low-grade fever, lymphopenia, electrolyte abnormalities
Calcitonin	4 IU/kg SC/IM	Inhibits osteoclast function, augments renal calcium excretion; onset of action in hours; but short lived, therefore not useful as sole therapy	Transient nausea and vomiting, abdominal cramps, flushing, and local skin reaction
Mithramycin (plicamycin)	25 µg/kg/d IV for 3–4 d	Inhibits osteoclasts RNA secretion; rapid onset of action (12 h); peaks at 48–72 h and lasts days to several weeks	May cause renal, hepatic, and hematologic complications, nausea and vomiting
Gallium nitrate	200 mg/m ² BSA/d IV for 5 d	Reduces urinary calcium excretion; onset of action delayed (5–7 d)	Nephrotoxicity, nausea, vomiting, hypotension, anemia, hypophosphatemia
Glucocorticoids	Hydrocortisone 100 mg IV q8h	Delayed onset of action (7–10 d); useful for hematologic malignancies, sarcoidosis, vitamin D intoxication, hyperthyroidism	Hypertension, hyperglycemia

BSA = body surface area; IM = intramuscular; IV = intravenous; SC = subcutaneous.

biopsy can be helpful to make the diagnosis. These are critically ill, high-risk patients, but successful parathyroidectomy sometimes relieves symptoms. Not all patients with calciphylaxis will have high PTH levels, and parathyroidectomy should not be undertaken in the absence of documented hyperparathyroidism.

Patients should undergo routine dialysis the day before surgery to correct electrolyte abnormalities. Localization studies are not necessary but can identify ectopic parathyroid glands. A bilateral neck exploration is indicated. The parathyroid glands in secondary HPT are characterized by asymmetric enlargement and nodular hyperplasia. These patients may be treated by subtotal resection, leaving about 50 mg of the most normal parathyroid gland or total parathyroidectomy and autotransplantation of parathyroid tissue into the brachioradialis muscle of the nondominant forearm, with parathyroid cryopreservation. Upper thymectomy usually is performed because 15% to 20% of patients have one or more parathyroid glands situated in the thymus or perithymic fat. Some groups recommend total parathyroidectomy without autotransplantation because it is associated with a lower rate of recurrence. While it may be preferable in patients with calciphylaxis, this procedure is contraindicated in patients eligible for renal transplant. Since the evidence needed to determine the superiority of one approach over another is lacking, the choice of procedure is influenced by surgeon preference and experience and various patient factors, as indicated earlier.⁷⁵

Tertiary Hyperparathyroidism. Generally, renal transplantation is an excellent method of treating secondary HPT, but some patients develop autonomous parathyroid gland function and tertiary HPT. Tertiary HPT can cause problems similar to

PHPT, such as pathologic fractures, bone pain and worsened bone disease, renal stones, peptic ulcer disease, pancreatitis, and mental status changes. The transplanted kidney is also at risk from tubulointerstitial calcification and volume depletion.⁷⁶ Similar to patients with secondary HPT, many patients with tertiary HPT are being treated with cinacalcet. Although the drug is effective and well-tolerated in these patients, the long-term effects on kidney allograft function are not known, and many of these patients have persistence of their hypercalcemic symptoms. On the other hand, parathyroidectomy has been shown to lead to a more immediate and dramatic reduction in hypercalcemic symptoms. As such, operative intervention is indicated for symptomatic disease or if autonomous PTH secretion persists for >1 year after a successful transplant in patients who are deemed operative candidates. All parathyroid glands should be identified. The traditional surgical management of these patients consisted of subtotal or total parathyroidectomy with autotransplantation and an upper thymectomy. Some authors suggest that these patients derive similar benefit from excision of only obviously enlarged glands, while avoiding the higher risks of hypocalcemia associated with the former approach. Others recommend that all parathyroid glands be identified and subtotal parathyroidectomy be performed as long-term follow-up studies show that limited excisions in these patients are associated with an up to fivefold increased risk of recurrent or persistent disease. Further studies are needed to define the best operative approach for these patients.

Complications of Parathyroid Surgery. Parathyroidectomy can be accomplished successfully in >95% of patients with minimal mortality and morbidity, provided the procedure is

performed by a surgeon experienced in parathyroid surgery. Specific complications include transient and permanent vocal cord palsy and hypoparathyroidism. The latter is more likely to occur in patients who undergo four-gland exploration with biopsies, subtotal resection with an inadequate remnant, or total parathyroidectomy with a failure of autotransplanted tissue. Furthermore, hypocalcemia is more likely to occur in patients with high-turnover bone disease as evidenced by elevated preoperative alkaline phosphatase levels. Vocal cord paralysis and hypoparathyroidism are considered permanent if they persist for >6 months. Fortunately, these complications are rare, occurring in approximately 1% of patients undergoing surgery by experienced parathyroid surgeons.

Patients with symptomatic hypocalcemia or those with calcium levels <8 mg/dL are treated with oral calcium supplementation (up to 1–2 g every 4 hours). 1,25-Dihydroxy vitamin D (calcitriol [Rocaltrol] 0.25–0.5 µg bid) may also be required, particularly in patients with severe hypercalcemia and elevated serum alkaline phosphatase levels preoperatively and with osteitis fibrosa cystica. Intravenous calcium supplementation rarely is needed, except in cases of severe, symptomatic hypocalcemia.

Hypoparathyroidism

Hypocalcemia can be the result of a multitude of conditions, which are listed in Table 38-14. The parathyroid glands may be congenitally absent in DiGeorge syndrome, which also is characterized by lack of thymic development and, therefore, a thymus-dependent lymphoid system. By far, the most common cause of hypoparathyroidism is thyroid surgery, particularly total thyroidectomy with a concomitant central neck dissection. Patients often develop transient hypocalcemia due to ischemia of the parathyroid glands; permanent hypoparathyroidism is rare. Hypoparathyroidism also may occur after parathyroid surgery, which is more likely if patients undergo a subtotal resection or total parathyroidectomy with parathyroid autotransplantation.

Acute hypocalcemia results in decreased ionized calcium and increased neuromuscular excitability. Patients

initially develop circumoral and fingertip numbness and tingling. Mental symptoms include anxiety, confusion, and depression. Physical examination reveals positive Chvostek's sign (contraction of facial muscles elicited by tapping on the facial nerve anterior to the ear) and Trousseau's sign (carpopedal spasm that is elicited by occluding blood flow to the forearm with a blood pressure cuff for 2–3 minutes). Tetany, which is characterized by tonic-clonic seizures, carpopedal spasm, and laryngeal stridor, may prove fatal and should be avoided. Most patients with postoperative hypocalcemia can be treated with oral calcium and vitamin D supplements; IV calcium infusion is rarely required except in patients with postoperative osteitis fibrosa cystica.

ADRENAL

Historical Background

Eustachius provided the first accurate anatomic account of the adrenals in 1563. The anatomic division of the adrenals into the cortex and medulla was described much later, by Cuvier in 1805. Subsequently, Thomas Addison in 1855 described the features of adrenal insufficiency, which still bear his name. DeCreccio provided the first description of congenital adrenal hyperplasia (CAH) occurring in a female pseudohermaphrodite in 1865. Pheochromocytomas were first identified by Frankel in 1885, but were not named as such until 1912 by Pick, who noted the characteristic chromaffin reaction of the tumor cells. Adrenaline was identified as an agent from the adrenal medulla that elevated blood pressure in dogs and was subsequently named epinephrine in 1897. The first successful adrenalectomies for pheochromocytoma were performed by Roux in Switzerland, and Charles Mayo in the United States.

In 1932, Harvey Cushing described 11 patients who had moon facies, truncal obesity, hypertension, and other features of the syndrome that now bears his name. Although several individuals prepared adrenocortical extracts to treat adrenalectomized animals, cortisone was first synthesized by Kendall. Aldosterone was identified in 1952, and the syndrome resulting from excessive secretion of this mineralocorticoid was first described in 1955 by Conn.

Embryology

The adrenal or suprarenal glands are two endocrine organs in one; an outer cortex and an inner medulla, each with distinct embryologic, anatomic, histologic, and secretory features. The cortex originates around the fifth week of gestation from mesodermal tissue near the gonads on the adrenogenital ridge (Fig. 38-37). Therefore, ectopic adrenocortical tissue may be found in the ovaries, spermatic cord, and testes. The cortex differentiates further into a thin, definitive cortex and a thicker, inner fetal cortex. The latter is functional and produces fetal adrenal steroids by the eighth week of gestation, but undergoes involution after birth, resulting in a decrease in adrenal weight during the first three postpartum months. The definitive cortex persists after birth to form the adult cortex over the first 3 years of life. In contrast, the adrenal medulla is ectodermal in origin and arises from the neural crest. At around the same time as cortical development, neural crest cells migrate to the para-aortic and paravertebral areas and toward the medial aspect of the developing cortex to form the medulla. Most extra-adrenal neural tissue regresses but may persist at several sites. The largest of these is located to the left of the aortic bifurcation near the

Table 38-14

Conditions causing hypocalcemia

Hypoparathyroidism
<ul style="list-style-type: none"> • Surgical • Neonatal • Familial • Heavy metal deposition • Magnesium depletion
Resistance to the action of parathyroid hormone
<ul style="list-style-type: none"> • Pseudohypoparathyroidism • Renal failure • Medications—calcitonin, bisphosphonates, mithramycin
Failure of normal 1,25-dihydroxy vitamin D production
Resistance to the action of 1,25-dihydroxy vitamin D
Acute complex formation or deposition of calcium
<ul style="list-style-type: none"> • Acute hyperphosphatemia • Acute pancreatitis • Massive blood transfusion (citrate overload) • “Hungry bones”

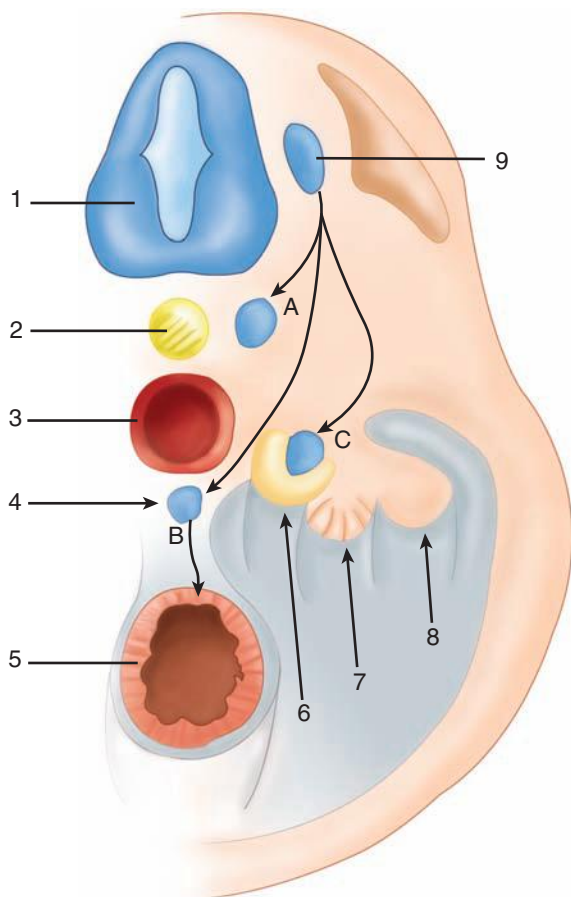


Figure 38-37. Cross-section of the embryo depicting adrenal development: (1) neural tube, (2) chorda, (3) aorta, (4) base of the mesentery, (5) digestive tube, (6) adrenal cortex, (7) undifferentiated gonad, (8) mesonephros, and (9) neural crest. Cells migrate from the neural crest to form the ganglia of the sympathetic trunk (A), sympathetic plexi (B), and the adrenal medulla and paraganglia (C). (Reproduced with permission from Avisse C, et al. *Surgical anatomy and embryology of the adrenal glands*. Surg Clin North Am. 2000;80:414. Copyright Elsevier.)

inferior mesenteric artery origin and is designated as the organ of Zuckerkandl. Adrenal medullary tissue also may be found in neck, urinary bladder, and para-aortic regions. Several factors are involved in adrenal development and include insulin-like growth factor 2; gastric inhibitory peptide; and the dosage-sensitive, sex-reversal adrenal hypoplasia (*DAX1*) gene.

Anatomy

The adrenal glands are paired, retroperitoneal organs located superior and medial to the kidneys at the level of the eleventh ribs. The normal adrenal gland measures $5 \times 3 \times 1$ cm and weighs 4 to 5 g. The right gland is pyramidal shaped and lies in close proximity to the right hemidiaphragm, liver, and inferior vena cava (IVC). The left adrenal is closely associated with the aorta, spleen, and tail of the pancreas. Each gland is supplied by three groups of vessels—the superior adrenal arteries derived from the inferior phrenic artery, the middle adrenal arteries derived from the aorta, and the inferior adrenal arteries derived from the renal artery. Other vessels originating from the intercostal and gonadal vessels may also supply the adrenals. These arteries branch into about 50 arterioles to form a rich plexus beneath the glandular capsule and require careful

dissection, ligation, and division during adrenalectomy. In contrast to the arterial supply, each adrenal usually is drained by a single, major adrenal vein. The right adrenal vein is usually short and drains into the IVC, whereas the left adrenal vein is longer and empties into the left renal vein after joining the inferior phrenic vein. Accessory veins occur in 5% to 10% of patients—on the right, these vessels may drain into the right hepatic vein or the right renal vein; on the left, accessory veins may drain directly into the left renal vein. The anatomic relationships of the adrenals and surrounding structures are depicted in Fig. 38-38.

The adrenal cortex appears yellow due to its high lipid content and accounts for about 80% to 90% of the gland's volume. Histologically, the cortex is divided into three zones—the zona glomerulosa, zona fasciculata, and zona reticularis. The outer area of the zona glomerulosa consists of small cells and is the site of production of the mineralocorticoid hormone, aldosterone. The zona fasciculata is made up of larger cells, which often appear foamy due to multiple lipid inclusions, whereas the zona reticularis cells are smaller. These latter zones are the site of production of glucocorticoids and adrenal androgens. The adrenal medulla constitutes up to 10% to 20% of the gland's volume and is reddish-brown in color. It produces the catecholamine hormones epinephrine and norepinephrine. The cells of the adrenal medulla are arranged in cords and are polyhedral in shape. They often are referred to as chromaffin cells because they stain specifically with chromium salts.

Adrenal Physiology

Cholesterol, derived from the plasma or synthesized in the adrenal, is the common precursor of all steroid hormones derived from the adrenal cortex. Cholesterol initially is cleaved within mitochondria to 5- δ -pregnolone, which in turn is transported to the smooth endoplasmic reticulum where it forms the substrate for various biosynthetic pathways leading to steroidogenesis (Fig. 38-39).

Mineralocorticoids. The major adrenal mineralocorticoid hormones are aldosterone, 11-deoxycorticosterone (DOC), and cortisol. Cortisol has minimal effects on the kidney due to hormone degradation. Aldosterone secretion is regulated primarily by the renin-angiotensin system. Decreased renal blood flow, decreased plasma sodium, and increased sympathetic tone all stimulate the release of renin from juxtaglomerular cells. Renin, in turn, leads to the production of angiotensin I from its precursor angiotensinogen. Angiotensin I is cleaved by pulmonary angiotensin-converting enzyme (ACE) to angiotensin II; the latter is not only a potent vasoconstrictor, but also leads to increased aldosterone synthesis and release. Hyperkalemia is another potent stimulator of aldosterone synthesis, whereas ACTH, pituitary pro-opiomelanocortin, and antidiuretic hormone are weak stimulators.

Aldosterone is secreted at a rate of 50 to 250 $\mu\text{g/d}$ (depending on sodium intake) and circulates in plasma chiefly as a complex with albumin. Small amounts of the hormone bind to corticosteroid-binding globulin, and approximately 30% to 50% of secreted aldosterone circulates in a free form. The hormone has a half-life of only 15 to 20 minutes and is rapidly cleared via the liver and kidney. A small quantity of free aldosterone also is excreted in the urine. Mineralocorticoids cross the cell membrane and bind to cytosolic receptors. The receptor-ligand complex subsequently is transported into the nucleus where it induces the transcription and translation of specific genes.

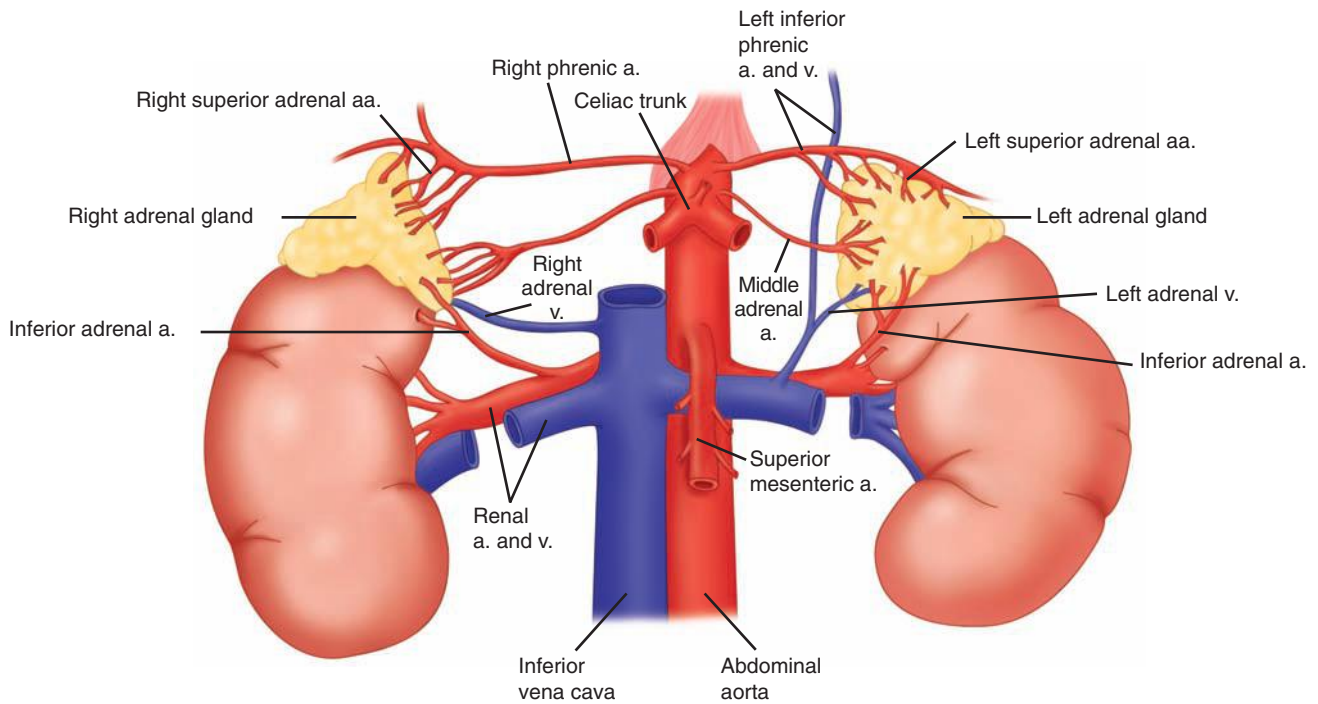


Figure 38-38. Anatomy of the adrenals and surrounding structures. a. = artery; v. = vein.

Aldosterone functions mainly to increase sodium reabsorption and potassium and hydrogen ion excretion at the level of the renal distal convoluted tubule. Less commonly, aldosterone increases sodium absorption in salivary glands and GI mucosal surfaces.

Glucocorticoids. The secretion of cortisol, the major adrenal glucocorticoid, is regulated by ACTH secreted by the anterior pituitary, which, in turn, is under the control of corticotrophin-releasing hormone (CRH) secreted by the hypothalamus. ACTH is a 39-amino-acid protein, which is derived by cleavage from a

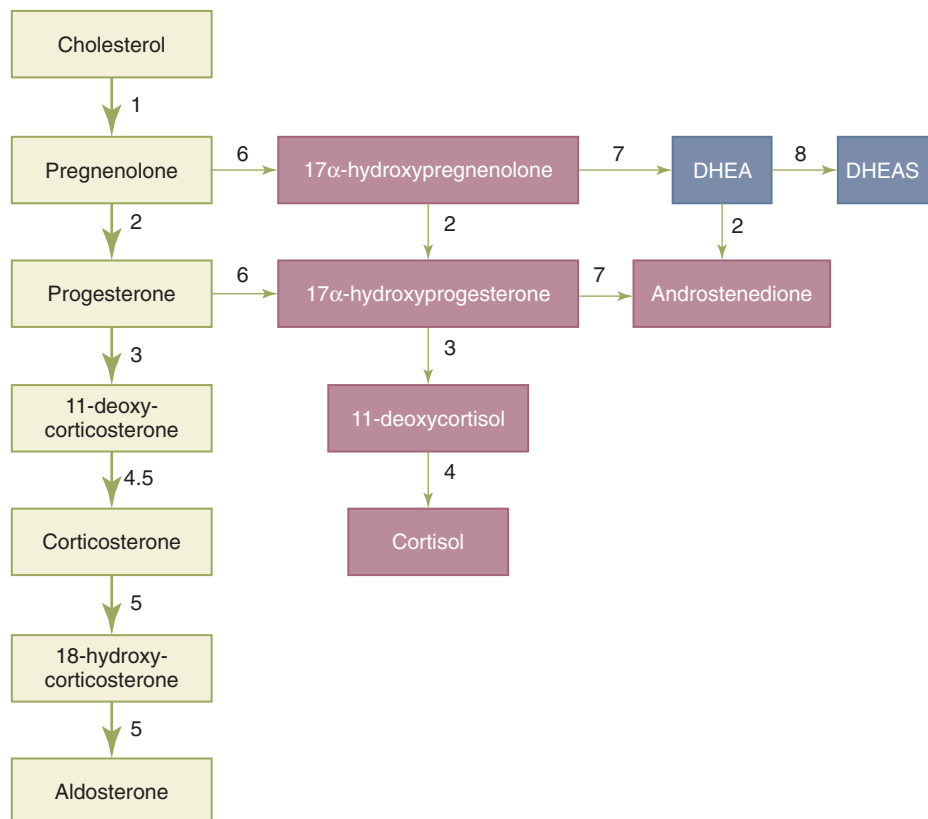


Figure 38-39. Synthesis of adrenal steroids. The enzymes involved are (1) p450scc (cholesterol side chain cleavage), (2) 3 β -hydroxysteroid dehydrogenase, (3) p450c21 (21 β -hydroxylase), (4) p450c11 (11 β -hydroxylase), (5) p450c11AS (aldosterone synthase), (6) p450c17 (17 α -hydroxylase activity), (7) p450c17 (17,20-lyase/desmolase activity), and (8) sulfokinase. DHEAS = dehydroepiandrosterone sulfate.

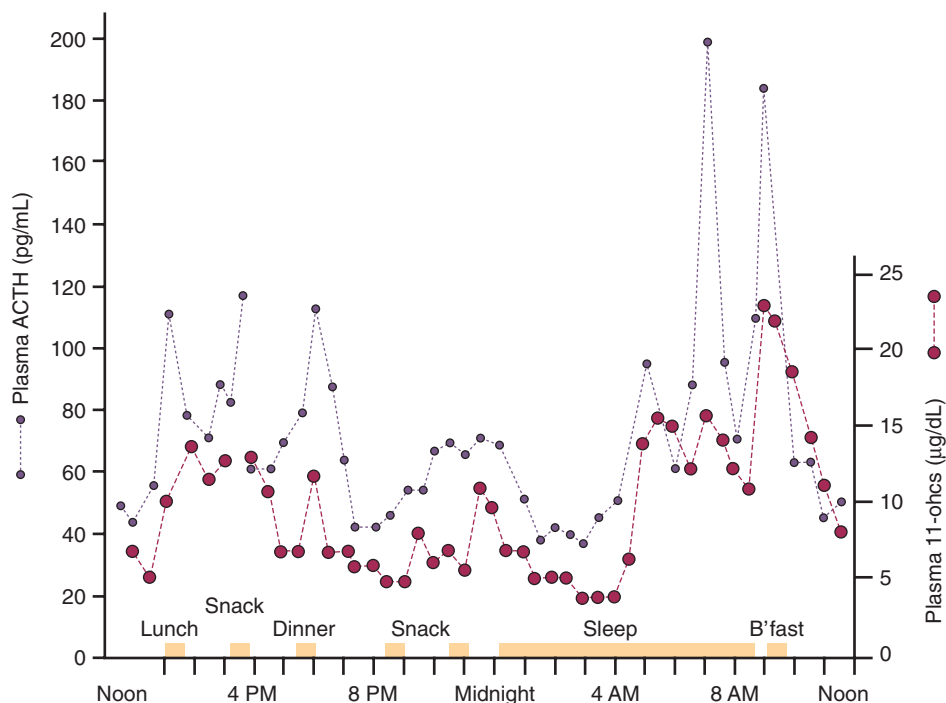


Figure 38-40. Diurnal variation in cortisol levels as determined by half-hourly sampling in a 16-year-old girl. (Reproduced with permission from Krieger DT, et al. *Characterization of the normal temporal pattern of corticosteroid levels.* J Clin Endocrinol Metab. 1971;32:269. Copyright by The Endocrine Society.)

larger precursor, pro-opiomelanocortin. ACTH is further cleaved into α -melanocyte-stimulating hormone and corticotrophin-like intermediate peptide. ACTH not only stimulates the secretion of glucocorticoids, mineralocorticoids, and adrenal androgens, but is also trophic for the adrenal glands. ACTH secretion may be stimulated by pain, stress, hypoxia, hypothermia, trauma, and hypoglycemia. ACTH secretion fluctuates, peaking in the morning and reaching nadir levels in the late afternoon. Thus, there is a diurnal variation in the secretion of cortisol, with peak cortisol excretion also occurring in the early morning and declining during the day to its lowest levels in the evening (Fig. 38-40). Cortisol controls the secretion of both CRH and ACTH via a negative feedback loop. A similar mechanism leads to the inhibition of CRH secretion by ACTH.

Cortisol is transported in plasma bound primarily to corticosteroid-binding globulin (75%) and albumin (15%). Approximately 10% of circulating cortisol is free and is the biologically active component. The plasma half-life of cortisol is 60 to 90 minutes and is determined by the extent of binding and rate of inactivation. Cortisol is converted to di- and tetrahydrocortisol and cortisone metabolites in the liver and the kidney. The majority (95%) of cortisol and cortisone metabolites are conjugated with glucuronic acid in the liver, thus facilitating their renal excretion. A small amount of unmetabolized cortisol is excreted unchanged in the urine.

Glucocorticoid hormones enter the cell and bind cytosolic steroid receptors. The activated receptor-ligand complex is then transported to the nucleus where it stimulates the transcription of specific target genes via a “zinc finger” DNA binding element. Cortisol also binds the mineralocorticoid receptor with an affinity similar to aldosterone. However, the specificity of mineralocorticoid action is maintained by the production of 11β -hydroxysteroid dehydrogenase, an enzyme that inactivates cortisol to cortisone in the kidney. Glucocorticoids have important

functions in intermediary metabolism but also affect connective tissue, bone, immune, cardiovascular, renal, and central nervous systems, as outlined in Table 38-15.

Sex Steroids. Adrenal androgens are produced in the zona fasciculata and reticularis from 17-hydroxypregnenolone in response to ACTH stimulation. They include dehydroepiandrosterone (DHEA) and its sulfated counterpart (DHEAS), androstenedione, and small amounts of testosterone and estrogen. Adrenal androgens are weakly bound to plasma albumin. They exert their major effects by peripheral conversion to the more potent testosterone and dihydrotestosterone but also have weak intrinsic androgen activity. Androgen metabolites are conjugated as glucuronides or sulfates and excreted in the urine. During fetal development, adrenal androgens promote the formation of male genitalia. In normal adult males, the contribution of adrenal androgens is minimal; however, they are responsible for the development of secondary sexual characteristics at puberty. Adrenal androgen excess leads to precocious puberty in boys and virilization, acne, and hirsutism in girls and women.

Catecholamines. Catecholamine hormones (epinephrine, norepinephrine, and dopamine) are produced not only in the central and sympathetic nervous system but also the adrenal medulla. The substrate, tyrosine, is converted to catecholamines via a series of steps shown in Fig. 38-41A. Phenylethanolamine *N*-methyltransferase, which converts norepinephrine to epinephrine, is only present in the adrenal medulla and the organ of Zuckerkandl. Therefore, the primary catecholamine produced may be used to distinguish adrenal medullary tumors from those situated at extra-adrenal sites. Catecholamines are stored in granules in combination with other neuropeptides, ATP, calcium, magnesium, and water-soluble proteins called *chromogranins*. Hormonal secretion is stimulated by various stress stimuli and mediated by the release of acetylcholine at

Table 38-15

Functions of glucocorticoid hormones

FUNCTION/SYSTEM	EFFECTS
Glucose metabolism	Increased hepatic glycogen deposition, gluconeogenesis, decreased muscle glucose uptake and metabolism
Protein metabolism	Decreased muscle protein synthesis, increased catabolism
Fat metabolism	Increased lipolysis in adipose tissue
Connective tissue	Inhibition of fibroblasts, loss of collagen, thinning of skin, striae formation
Skeletal system	Inhibition of bone formation, increased osteoclast activity, potentiate the action of PTH
Immune system	Increases circulation of polymorphonuclear cells; decreases numbers of lymphocytes, monocytes, and eosinophils; reduces migration of inflammatory cells to sites of injury
Cardiovascular system	Increases cardiac output and peripheral vascular tone
Renal system	Sodium retention, hypokalemia, hypertension via mineralocorticoid effect, increased glomerular filtration via glucocorticoid effects
Endocrine system	Inhibits TSH synthesis and release, decreased TBG levels, decreased conversion of T_4 to T_3

PTH = parathyroid hormone; T_3 = 3,5',3-triiodothyronine; T_4 = thyroxine; TBG = thyroxine-binding globulin; TSH = thyroid-stimulating hormone.

the preganglionic nerve terminals. In the circulation, these proteins are bound to albumin and other proteins. Catecholamines are cleared by several mechanisms including reuptake by sympathetic nerve endings, peripheral inactivation by catechol *O*-methyltransferase and monoamine oxidase, and direct excretion by the kidneys. Metabolism of catecholamines takes place primarily in the liver and kidneys and leads to the formation of metabolites such as metanephrines, normetanephrines, and VMA, which may undergo further glucuronidation or sulfation before being excreted in the urine (Fig. 38-41B).

Adrenergic receptors are transmembrane-spanning molecules that are coupled to G proteins. They may be subdivided into α and β subtypes, which are localized in different tissues, have varying affinity to various catecholamines, and mediate distinct biologic effects (Table 38-16). The receptor affinities for α receptors are—epinephrine > norepinephrine

>> isoproterenol; β_1 receptors—*isoproterenol* > epinephrine = norepinephrine; and β_2 receptors—*isoproterenol* > epinephrine >> norepinephrine.

Disorders of the Adrenal Cortex

Hyperaldosteronism. Hyperaldosteronism may be secondary to stimulation of the renin-angiotensin system from renal artery stenosis and to low-flow states such as congestive heart failure and cirrhosis. Hyperaldosteronism resulting from these conditions is reversible by treatment of the underlying cause. Primary hyperaldosteronism results from autonomous aldosterone secretion, which, in turn, leads to suppression of renin secretion. Primary aldosteronism usually occurs in individuals between the ages of 30 to 50 years old and accounts for 1% of hypertension cases. It is associated with hypokalemia; however, more patients with Conn's syndrome are being diagnosed with normal potassium levels. Most cases result from a solitary functioning adrenal adenoma (~70%) and idiopathic bilateral hyperplasia (30%). Adrenocortical carcinoma and glucocorticoid-suppressible hyperaldosteronism are rare, each accounting for <1% of cases. Glucocorticoid-suppressible hyperaldosteronism is an autosomal dominant form of hypertension in which aldosterone secretion is abnormally regulated by ACTH. This condition is caused by recombinations between linked genes encoding closely related isozymes, 11 β -hydroxylase (CYP11B1), and aldosterone synthase (CYP11B2) generating a dysregulated chimeric gene with aldosterone synthase activity.

Symptoms and Signs Patients typically present with hypertension, which is long-standing, moderate to severe, and may be difficult to control despite multiple-drug therapy. Other symptoms include muscle weakness, polydipsia, polyuria, nocturia, headaches, and fatigue. Weakness and fatigue are related to the presence of hypokalemia.

Diagnostic Studies

Laboratory Studies. Hypokalemia is a common finding, and hyperaldosteronism must be suspected in any hypertensive patient who presents with coexisting spontaneous hypokalemia ($K < 3.2$ mmol/L) or hypokalemia (< 3 mmol/L) while on diuretic therapy, despite potassium replacements. However, it is important to note that up to 40% of patients with a confirmed aldosteronoma were normokalemic preoperatively. Once the diagnosis is suspected, further tests are necessary to confirm the diagnosis. Before testing, patients must receive adequate sodium and potassium. Antihypertensive medications should be held, if possible, and spironolactone, β -blockers, ACE inhibitors, and angiotensin II receptor blockers should be avoided. Patients with primary hyperaldosteronism have an elevated plasma aldosterone concentration level with a suppressed plasma renin activity; a plasma aldosterone concentration-to-plasma renin activity ratio of 1:25 to 30 is strongly suggestive of the diagnosis.⁷⁷ False-positive results can occur, particularly in patients with chronic renal failure. Patients with primary hyperaldosteronism also fail to suppress aldosterone levels with sodium loading. This test can be performed by performing a 24-hour urine collection for cortisol, sodium, and aldosterone after 5 days of a high-sodium diet or alternatively giving the patient 2 L of saline while in the supine position, 2 to 3 days after being on a low-sodium diet. Plasma aldosterone level < 5 ng/dL or a 24-hour urine aldosterone < 14 μ g after saline loading essentially rules out primary hyperaldosteronism. Once the biochemical diagnosis is confirmed, further evaluation should be directed at

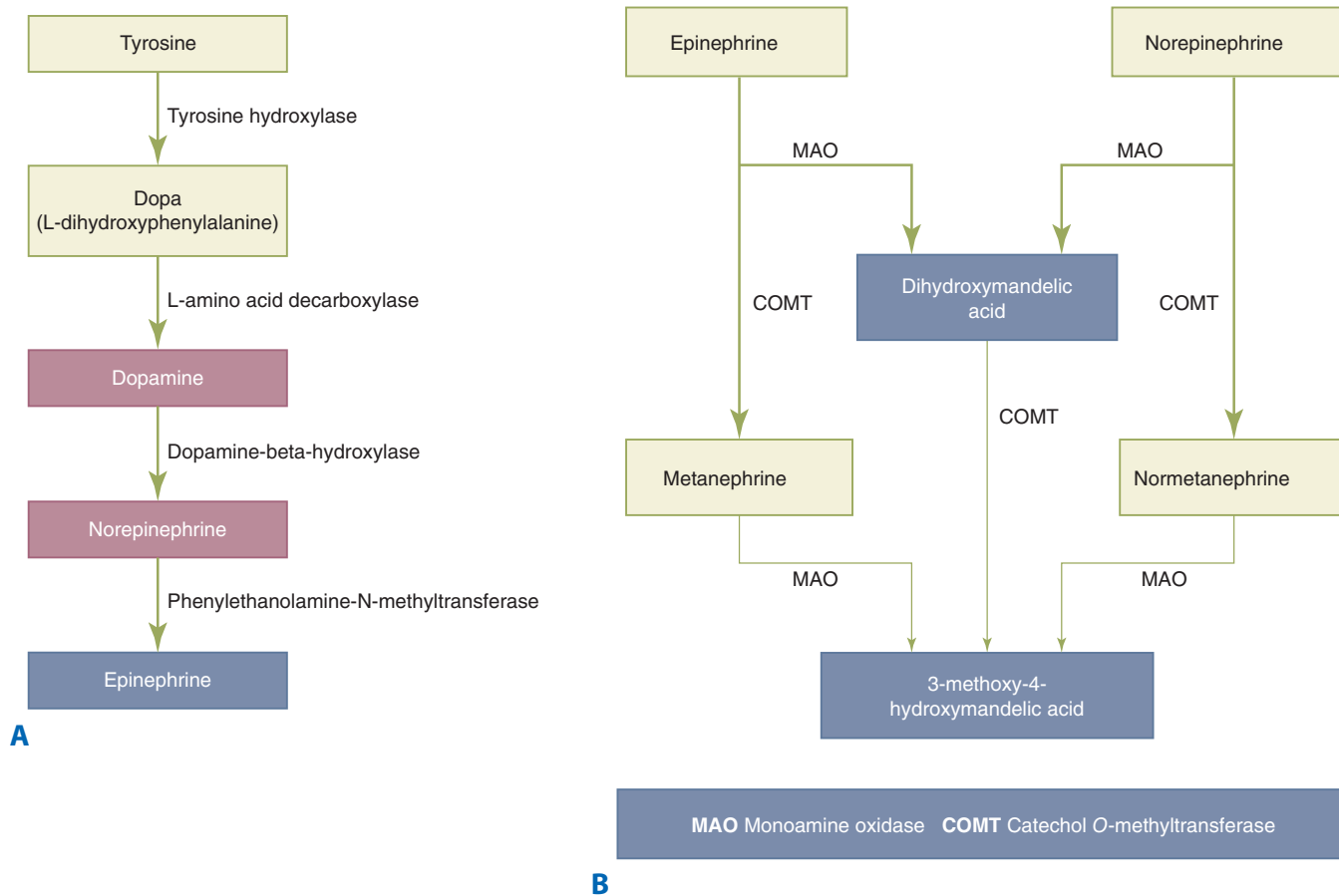


Figure 38-41. **A.** Synthesis of catecholamines. **B.** Metabolism of catecholamine hormones.

Table 38-16

Catecholamine hormone receptors and effects they mediate

RECEPTOR	TISSUE	FUNCTION
α_1	Blood vessels	Contraction
	Gut	Decreased motility, increased sphincter tone
	Pancreas	Decreased insulin and glucagon release
	Liver	Glycogenolysis, gluconeogenesis
	Eyes	Pupil dilation
	Uterus	Contraction
	Skin	Sweating
α_2	Synapse (sympathetic)	Inhibits norepinephrine release
	Platelet	Aggregation
β_1	Heart	Chronotropic, inotropic
	Adipose tissue	Lipolysis
	Gut	Decreased motility, increased sphincter tone
	Pancreas	Increased insulin and glucagon release
β_2	Blood vessels	Vasodilation
	Bronchioles	Dilation
	Uterus	Relaxation

determining which patients have a unilateral aldosteronoma vs. bilateral hyperplasia, because surgery is almost always curative for the former, but usually not the latter. No biochemical studies can make this distinction with 100% sensitivity; thus imaging studies are necessary.

Radiologic Studies. CT scans with 0.5-cm cuts in the adrenal area can localize aldosteronomas with a sensitivity of 90%. A unilateral 0.5- to 2-cm adrenal tumor with a normal-appearing contralateral gland confirms an aldosteronoma in the presence of appropriate biochemical parameters. MRI scans are less sensitive but more specific, particularly if opposed phase chemical shift images are obtained. MRI scans also have increased use in pregnant patients or those unable to tolerate intravenous contrast. If adrenal hyperplasia is suspected, the algorithm depicted in Fig. 38-42 is useful. Selective venous catheterization and adrenal vein sampling for aldosterone have been demonstrated to be 95% sensitive and 90% specific in localizing the aldosteronoma. In this procedure, the adrenal veins are cannulated, and blood samples for aldosterone and cortisol are obtained from both adrenal veins and the vena cava after ACTH administration.⁷⁸ Measurement of cortisol levels is necessary to confirm proper placement of the catheters in the adrenal veins. A greater than fourfold difference in the aldosterone:cortisol ratios between the adrenal veins indicates the presence of a unilateral tumor. Some investigators use this study routinely, but it is invasive,

requires an experienced interventional radiologist, and can lead to adrenal vein rupture in approximately 1% of cases. Therefore, most groups advocate use of this modality selectively in ambiguous cases, when the tumor cannot be localized and in patients with bilateral adrenal enlargement to determine whether there is unilateral or bilateral increased secretion of aldosterone. Scintigraphy with ¹³¹I-6 β -iodomethyl noriodocholesterol (NP-59) also may be used for the same purpose. Like cholesterol, this compound is taken up by the adrenal cortex, but unlike cholesterol, it remains in the gland without undergoing further metabolism. Adrenal adenomas appear as “hot” nodules with suppressed contralateral uptake, whereas hyperplastic glands show bilaterally increased uptake. This test, however, is not widely available.

Treatment Preoperatively, control of hypertension and adequate potassium supplementation (to keep K >3.5 mmol/L) are important. Patients generally are treated with spironolactone (an aldosterone antagonist), amiloride (a potassium-sparing diuretic that blocks sodium channels in the distal nephron), nifedipine (a calcium channel blocker), or captopril (an ACE inhibitor). Unilateral tumors producing aldosterone are best managed by adrenalectomy, either by a laparoscopic approach (preferred) or via a posterior open approach. If a carcinoma is suspected because of the large size of the adrenal lesion or mixed hormone secretion, an anterior transabdominal approach is preferred to permit adequate determination of local invasion and distal metastases. Only 20% to 30% of patients with hyperaldosteronism secondary to bilateral adrenal hyperplasia benefit from surgery, and as described, selective venous catheterization is useful to predict which patients will respond. For the other patients, medical therapy with spironolactone, amiloride, or triamterene is the mainstay of management. Glucocorticoid-suppressible hyperaldosteronism is treated by administering exogenous dexamethasone at doses of 0.5 to 1 mg daily. Treatment with spironolactone may help decrease glucocorticoid requirements in this condition and avoid symptoms of Cushing’s syndrome. Postoperatively, some patients experience transient hypoaldosteronism requiring mineralocorticoids for up to 3 months. Rarely, acute Addison’s disease may occur 2 to 3 days after adrenalectomy. Adrenalectomy is >90% successful in improving hypokalemia and about 70% successful in correcting hypertension. Patients who respond to spironolactone therapy and those with a shorter duration of hypertension with minimal renal damage are more likely to achieve improvement in hypertension, whereas male patients, those >50 years old, and those with multiple adrenal nodules, are least likely to benefit from adrenalectomy.

Cushing’s Syndrome. Cushing described patients with a peculiar fat deposition, amenorrhea, impotence (in men), hirsutism, purple striae, hypertension, diabetes, and other features that constitute the syndrome (Fig. 38-43). He also recognized that several of these patients had basophilic tumors of the pituitary gland and concluded that these tumors produced hormones that caused adrenocortical hyperplasia, thus resulting in the manifestations of the syndrome. Today, the term *Cushing’s syndrome* refers to a complex of symptoms and signs resulting from hypersecretion of cortisol regardless of etiology. In contrast, *Cushing’s disease* refers to a pituitary tumor, usually an adenoma, which leads to bilateral adrenal hyperplasia and hypercortisolism. Cushing’s syndrome (endogenous) is a rare disease, affecting 10 in 1 million individuals. It is more common in adults but may occur in children. Women are more commonly affected (male:female ratio 1:8).

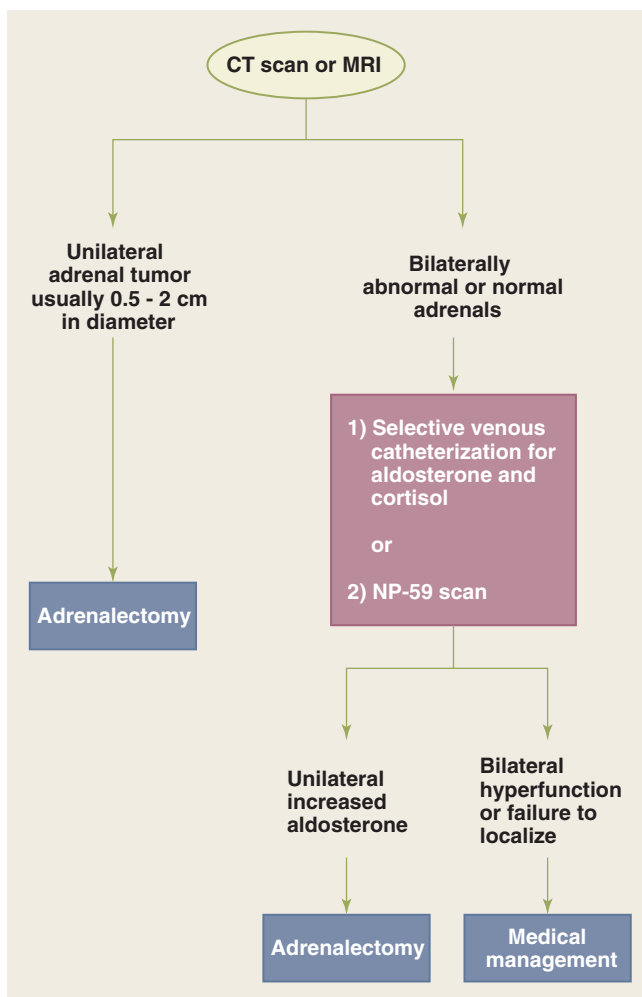


Figure 38-42. Management of an adrenal aldosteronoma. CT = computed tomography; MRI = magnetic resonance imaging.

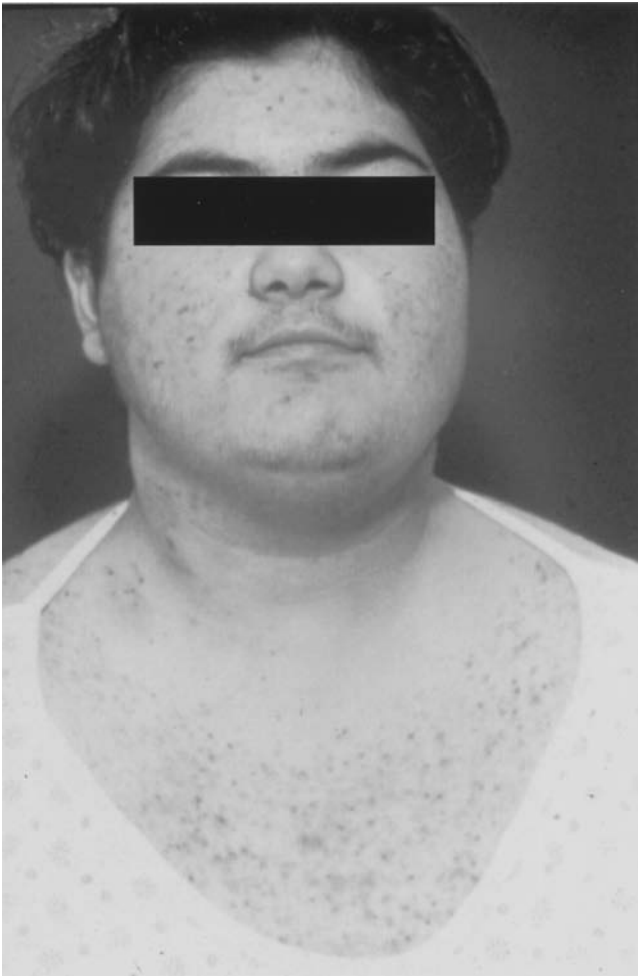

Figure 38-43. Some characteristic features of Cushing's syndrome—moon facies, hirsutism, and acne.

Although most individuals have sporadic disease, Cushing's syndrome may be found in MEN1 families and can result from ACTH-secreting pituitary tumors, primary adrenal neoplasms, or an ectopic ACTH-secreting carcinoid tumor (more common in men) or bronchial adenoma (more common in women).

Cushing's syndrome may be classified as ACTH-dependent or ACTH-independent (Table 38-17). The most common cause of hypercortisolism is exogenous administration of steroids. However, approximately 70% of cases of endogenous Cushing's syndrome are caused by an ACTH-producing pituitary tumor. Primary adrenal sources (adenoma, hyperplasia, and carcinoma) account for about 20% of cases, and ectopic ACTH-secreting tumors account for <10% of cases. CRH also may be secreted ectopically in bronchial carcinoid tumors, pheochromocytomas, and other tumors. These patients are difficult to distinguish from those with ectopic ACTH production, but can be diagnosed by determining CRH levels. Patients with major depression, alcoholism, pregnancy, chronic renal failure, or stress also may have elevated cortisol levels and symptoms of hypercortisolism. However, these manifestations resolve with treatment of the underlying disorder, and these patients are deemed to have pseudo-Cushing's syndrome.

Primary adrenal hyperplasia may be micronodular, macronodular, or massively macronodular. Adrenal hyperplasia resulting from ACTH stimulation usually is macronodular (3-cm nodules). Primary pigmented nodular adrenocortical

Table 38-17

Etiology of Cushing's syndrome

ACTH-dependent (70%)

- Pituitary adenoma or Cushing's disease (~70%)
- Ectopic ACTH production^a (~10%)
- Ectopic CRH production (<1%)

ACTH-independent (20%–30%)

- Adrenal adenoma (10%–15%)
- Adrenal carcinoma (5%–10%)
- Adrenal hyperplasia—pigmented micronodular cortical hyperplasia or gastric inhibitory peptide-sensitive macronodular hyperplasia (5%)

Other

- Pseudo-Cushing's syndrome
- Iatrogenic—exogenous administration of steroids

^aFrom small cell lung tumors, pancreatic islet cell tumors, medullary thyroid cancers, pheochromocytomas, and carcinoid tumors of the lung, thymus, gut, pancreas, and ovary.

ACTH = adrenocorticotropic hormone; CRH = corticotrophin-releasing hormone.

disease is a rare cause of ACTH-independent Cushing's syndrome, which is characterized by the presence of small (<5 mm), black adrenal nodules. Primary pigmented nodular adrenocortical disease may be associated with Carney complex (atrial myxomas, schwannomas, and pigmented nevi) and is thought to be immune related.

Symptoms and Signs The classical features of Cushing's syndrome are listed in Table 38-18. Early diagnosis of this disease requires a thorough knowledge of these manifestations, coupled with a high clinical suspicion. In some patients, symptoms are less pronounced and may be more difficult to recognize, particularly given their diversity and the absence of a single defining symptom or sign. Progressive truncal obesity is the most common symptom, occurring in up to 95% of patients.

Table 38-18

Features of Cushing's syndrome

SYSTEM	MANIFESTATION
General	Weight gain—central obesity, buffalo hump, supraclavicular fat pads
Integumentary	Hirsutism, plethora, purple striae, acne, ecchymosis
Cardiovascular	Hypertension
Musculoskeletal	Generalized weakness, osteopenia
Neuropsychiatric	Emotional lability, psychosis, depression
Metabolic	Diabetes or glucose intolerance, hyperlipidemia
Renal	Polyuria, renal stones
Gonadal	Impotence, decreased libido, menstrual irregularities

This pattern results from the lipogenic action of excessive corticosteroids centrally and catabolic effects peripherally, along with peripheral muscle wasting. Fat deposition also occurs in unusual sites, such as the supraclavicular space and posterior neck region, leading to the so-called buffalo hump. Purple striae are often visible on the protuberant abdomen. Rounding of the face leads to moon facies, and thinning of subcutaneous tissues leads to plethora. There is an increase in fine hair growth on the face, upper back, and arms, although true virilization is more commonly seen with adrenocortical cancers. Endocrine abnormalities include glucose intolerance, amenorrhea, and decreased libido or impotence. In children, Cushing's syndrome is characterized by obesity and stunted growth. Patients with Cushing's disease also may present with headaches, visual field defects, and panhypopituitarism. Hyperpigmentation of the skin, if present, suggests an ectopic ACTH-producing tumor with high levels of circulating ACTH.

Diagnostic Tests The aims of diagnostic tests in the evaluation of patients suspected of having Cushing's syndrome are twofold: to confirm the presence of Cushing's syndrome and to determine its etiology (Fig. 38-44).

Laboratory Studies. Cushing's syndrome is characterized by elevated glucocorticoid levels that are not suppressible by exogenous hormone administration and loss of diurnal variation. This phenomenon is used to screen patients using the overnight low-dose dexamethasone suppression test. In this test, 1 mg of a synthetic glucocorticoid (dexamethasone) is given at 11 p.m. and plasma cortisol levels are measured at 8 a.m. the following morning. Physiologically normal adults suppress cortisol levels to $<3 \mu\text{g/dL}$, whereas most patients with Cushing's syndrome do not. False-negative results may be obtained in patients with mild disease; therefore, some authors consider the test positive only if cortisol levels are suppressed to $<1.8 \mu\text{g/dL}$. False-positive results can occur in up to 3% of patients with chronic renal

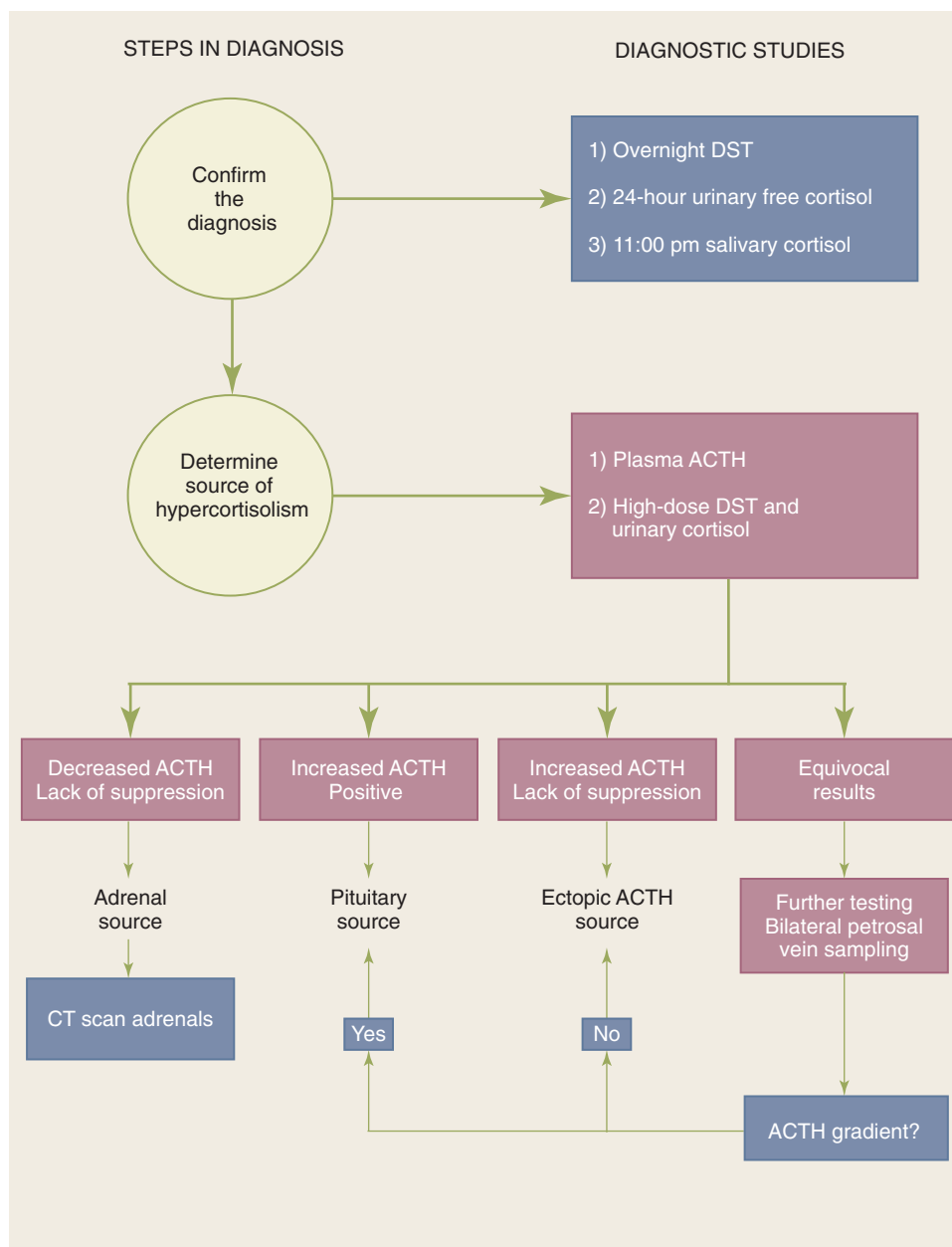


Figure 38-44. Diagnosis of Cushing's syndrome. ACTH = adrenocorticotrophic hormone; CT = computed tomography; DST = dexamethasone suppression test.

failure, depression, or those taking medications such as phenytoin, which enhance dexamethasone metabolism. In patients with a negative test but a high clinical suspicion, the classic low-dose dexamethasone (0.5 mg every 6 hours for eight doses, or 2 mg over 48 hours) suppression test or urinary cortisol measurement should be performed. Measurement of elevated 24-hour urinary cortisol levels is a very sensitive (95%–100%) and specific (98%) modality of diagnosing Cushing's syndrome and is particularly useful for identifying patients with pseudo-Cushing's syndrome. A urinary cortisol-free excretion of less than 100 µg/dL (in most laboratories) rules out hypercortisolism. Recently, salivary cortisol measurements using commercially available kits also have demonstrated superior sensitivity in diagnosing Cushing's syndrome and are being increasingly used. Overall, 24-hour urinary tests for free cortisol and the overnight dexamethasone suppression test at the 5 µg/dL cutoff have the highest specificity for the diagnosis of Cushing's syndrome.⁷⁹

Once a diagnosis of hypercortisolism is established, further testing is aimed at determining whether it is ACTH-dependent or ACTH-independent Cushing's syndrome. This is best accomplished by measurement of plasma ACTH levels (normal 10–100 pg/mL). Elevated ACTH levels are found in patients with adrenal hyperplasia due to Cushing's disease (15–500 pg/mL) and those with CRH-secreting tumors, but the highest levels are found in patients with ectopic sources of ACTH (>1000 pg/mL). In contrast, ACTH levels are characteristically suppressed (<5 pg/mL) in patients with primary cortisol-secreting adrenal tumors. The high-dose dexamethasone suppression test is used to distinguish between the causes of ACTH-dependent Cushing's syndrome (pituitary vs. ectopic). The standard test (2 mg dexamethasone every 6 hours for 2 days) or the overnight test (8 mg) may be used, with 24-hour urine collections for cortisol and 17-hydroxy steroids performed over the second day. Failure to suppress urinary cortisol by 50% confirms the diagnosis of an ectopic ACTH-producing tumor. Patients suspected of having ectopic tumors should also undergo testing for MTC and pheochromocytoma. Bilateral petrosal vein sampling also is helpful for determining whether the patient has Cushing's disease or ectopic Cushing's syndrome.

The CRH test also is helpful in determining the etiology of Cushing's syndrome. Ovine CRH (1 µg/kg) is administered intravenously, followed by serial measurements of ACTH and cortisol at 15-minute intervals for 1 hour. Patients with a primary adrenal hypercortisolism exhibit a blunted response (ACTH peak <10 pg/mL), whereas those with ACTH-dependent Cushing's syndrome demonstrate a higher elevation of ACTH (>30 pg/mL). CRH stimulation also can enhance the usefulness of petrosal vein sampling. Patients with pituitary tumors also have a higher peak ACTH than those with ectopic ACTH-producing tumors.

Radiologic Studies. CT and MRI scans of the abdomen can identify adrenal tumors with 95% sensitivity. They also are helpful in distinguishing adrenal adenomas from carcinomas, as discussed in the subsequent section Adrenocortical Cancer. MRI scans have the added advantage of allowing assessment of vascular anatomy. Adrenal adenomas appear darker than the liver on T2-weighted imaging. Radioscintigraphic imaging of the adrenals using NP-59 also can be used to distinguish adenoma from hyperplasia. Reports suggest that “cold” adrenal nodules are more likely to be cancerous, although this distinction is not absolute. NP-59 scanning is most useful in identifying patients with an adrenal source of hypercortisolism and primary pigmented micronodular hyperplasia.

Thin-section head CT scans are 22% sensitive, and contrast-enhanced brain MRI scans are 33% to 67% sensitive at identifying pituitary tumors. Inferior petrosal sinus sampling for ACTH before and after CRH injection has been helpful in this regard and has a sensitivity approaching 100%. In this study, catheters are placed in both internal jugular veins and a peripheral vein. A ratio of petrosal to peripheral vein ACTH level of >2 in the basal state and >3 after CRH stimulation is diagnostic of a pituitary tumor. In patients suspected of having ectopic ACTH production, CT or MRI scans of the chest and anterior mediastinum are performed first, followed by imaging of the neck, abdomen, and pelvis if the initial studies are negative.

Treatment Laparoscopic adrenalectomy is the treatment of choice for patients with adrenal adenomas. Open adrenalectomy is reserved for large tumors (≥6 cm) or those suspected to be adrenocortical cancers. Bilateral adrenalectomy is curative for primary adrenal hyperplasia.

The treatment of choice in Cushing's disease is transsphenoidal excision of the pituitary adenoma, which is successful in 80% of patients. Pituitary irradiation has been used for patients with persistent or recurrent disease after surgery. However, it is associated with a high rate of panhypopituitarism, and some patients develop visual deficits. This has led to increased use of stereotactic radiosurgery, which uses CT guidance to deliver high doses of radiotherapy to the tumor (photon or gamma knife) and also bilateral laparoscopic adrenalectomy. Patients who fail to respond to either treatment are candidates for pharmacologic therapy with adrenal inhibitors (medical adrenalectomy) such as ketoconazole, metyrapone, or aminoglutethimide.

Patients with ectopic ACTH production are best managed by treating the primary tumor, including recurrences, if possible. Medical or bilateral laparoscopic adrenalectomy has been used to palliate patients with unresectable disease and those whose ectopic ACTH-secreting tumor cannot be localized.

Patients undergoing surgery for a primary adrenal adenoma secreting glucocorticoids require preoperative and postoperative steroids due to suppression of the contralateral adrenal gland. These patients are also at increased predisposition for infectious and thromboembolic complications, the latter due to a hypercoagulable state resulting from an increase in clotting factors including factor VIII and von Willebrand's factor complex, and by impaired fibrinolysis. Duration of steroid therapy is determined by the ACTH stimulation test. Exogenous steroids may be needed for up to 2 years but are needed indefinitely in patients who have undergone bilateral adrenalectomy. This latter group of patients also may require mineralocorticoid replacement therapy. Typical replacement doses include hydrocortisone (10–20 mg every morning and 5–10 mg every evening) and fludrocortisone (0.05–0.1 mg/d every morning).

Adrenocortical Cancer. Adrenal carcinomas are rare neoplasms with a worldwide incidence of two per 1 million. These tumors have a bimodal age distribution, with an increased incidence in children and adults in the fourth and fifth decades of life. The majority are sporadic, but adrenocortical carcinomas also occur in association with germline mutations of *p53* (Li-Fraumeni syndrome) and *MEN1* (multiple endocrine neoplasia type 1) genes. Loci on 11p (Beckwith-Wiedemann syndrome), 2p (Carney complex), and 9q also have been implicated. Somatic *p53* mutations are present in up to 33% of tumors, and LOH at the *p53* locus has been reported in >85% of adrenocortical carcinomas. In addition, Insulin-like growth factor II is overexpressed

in 90% of tumors, and approximately 30% harbor somatic activating mutations in the β -catenin gene.⁸⁰

Symptoms and Signs Approximately 50% of adrenocortical cancers are nonfunctioning.⁸¹ The remaining secrete cortisol (30%), androgens (20%), estrogens (10%), aldosterone (2%), or multiple hormones (35%). Patients with functioning tumors often present with the rapid onset of Cushing's syndrome accompanied by virilizing features. Nonfunctioning tumors more commonly present with an enlarging abdominal mass and abdominal or back pain. Rarely, weight loss, anorexia, and nausea may be present.

Diagnostic Tests Diagnostic evaluation of these patients begins with measurement of serum electrolyte levels to rule out hypokalemia, urinary catecholamines to rule out pheochromocytomas, an overnight 1-mg dexamethasone suppression test, and a 24-hour urine collection for cortisol and 17-ketosteroids to rule out Cushing's syndrome.

CT and MRI scans are useful to image these tumors (Fig. 38-45). The size of the adrenal mass on imaging studies is the single most important criterion to help diagnose malignancy. In the series reported by Copeland, 92% of adrenal cancers were >6 cm in diameter.⁸² The sensitivity, specificity, and likelihood ratio of tumor size in predicting malignancy (based on Surveillance, Epidemiology, and End Results program data) were recently reported as 96%, 51%, and 2 for tumors ≥ 4 cm, and 90%, 78%, and 4.1 for tumors ≥ 6 cm.⁸³ Other CT imaging characteristics suggesting malignancy include tumor heterogeneity, irregular margins, and the presence of hemorrhage and adjacent lymphadenopathy or liver metastases. Moderately bright signal intensity on T2-weighted images (adrenal mass-to-liver ratio 1.2:2.8), significant lesion enhancement, and slow washout after injection of gadolinium contrast also indicate malignancy, as does evidence of local invasion into adjacent structures such as the liver, blood vessels (IVC), and distant metastases. FDG-PET or PET-CT scans may have some utility in distinguishing benign from malignant lesions, as discussed in the section on incidentalomas. Once adrenal cancer is diagnosed, CT scans of the chest and pelvis or FDG-PET or PET-CT scans are performed for staging. The tumor-node-metastasis (TNM) staging

Table 38-19

TNM staging for adrenocortical cancer

STAGE	TNM CLASS
I	T1, N0, M0
II	T2, N0, M0
III	T3, N0, M0
	T1–2, N1, M0
IV	T3–4, N1, M0
	Any T, any N, M1

Primary tumor (T): T1, size ≤ 5 cm without local invasion; T2, size >5 cm without local invasion; T3, any size with local invasion but no involvement of adjacent organs; T4, any size with involvement of adjacent organs.

Nodes (N): N0, no involvement of regional nodes; N1, positive regional lymph nodes.

Metastasis (M): M0, no known distal metastases, M1, distant metastases present.

Source: Used with permission of the American Joint Committee on Cancer (AJCC), Chicago, Illinois. The original source for this material is the AJCC Cancer Staging Manual, Seventh Edition (2010) published by Springer Science and Business Media LLC, www.springer.com.

system for adrenocortical carcinoma is depicted in Table 38-19. Up to 70% of patients present with stage III or IV disease.

Pathology Most adrenocortical cancers are large, weighing between 100 and 1000 g. On gross examination, areas of hemorrhage and necrosis often are evident. Microscopically, cells are hyperchromatic and typically have large nuclei and prominent nucleoli. It is very difficult to distinguish benign adrenal adenomas from carcinomas by histologic examination alone. Capsular or vascular invasion is the most reliable sign of cancer. Weiss and associates studied a combination of nine criteria for their usefulness in distinguishing malignant from benign adrenal tumors: nuclear grade III or IV; mitotic rate greater than 5 per 50 high-power fields; atypical mitoses; clear cells comprising 25% or less of the tumor; a diffuse architecture; microscopic necrosis; and invasion of venous, sinusoidal, and capsular structure. Tumors with four or more of these criteria were likely to metastasize and/or recur.⁸⁴ Rarely, the diagnosis of malignancy of a completely resected adrenal tumor is often only made in retrospect by the finding of metastatic disease many years later. Molecular markers such as Ki67 (indicating proliferative activity) can also be useful in this regard.

Treatment The most important predictor of survival in patients with adrenal cancer is the adequacy of resection. Patients who undergo complete resection have 5-year actuarial survival rates ranging from 32% to 48%, whereas median survival is <1 year in those undergoing incomplete excision. Therefore, adrenocortical carcinomas are treated by excision of the tumor en bloc with any contiguously involved lymph nodes or organs such as the diaphragm, kidney, pancreas, liver, or IVC. This is best accomplished by open adrenalectomy via a generous subcostal incision or a thoracoabdominal incision (on the right side). The incisions should permit wide exposure, minimize chances of capsule rupture and tumor spillage, and allow vascular control of the aorta, IVC, and renal vessels, as needed.

Mitotane or o,p-DDD or 1,1-dichloro-2-(o-chlorophenyl)-2-(p-chlorophenyl) ethane, which is a derivative of the insecticide DDT, has adrenolytic activity and has been used in the

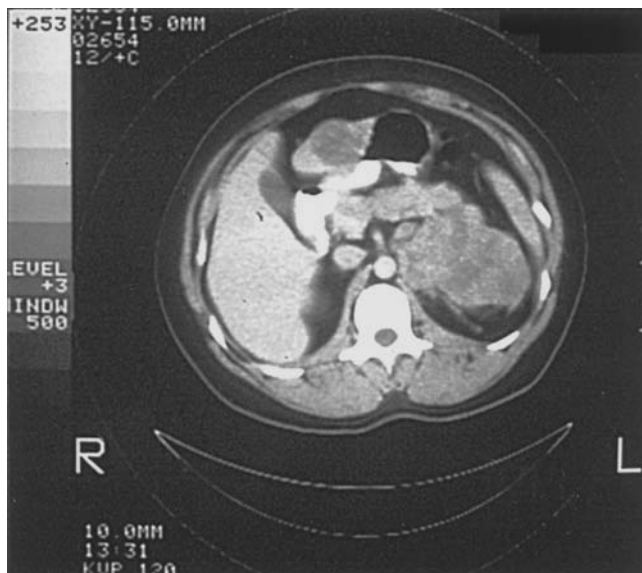

Figure 38-45. Computed tomography scan of the abdomen showing a left adrenocortical cancer with synchronous liver metastasis.

adjuvant setting and for the treatment of unresectable or metastatic disease. However, the therapeutic effectiveness is conflicting, and consistent improvement in survival rates is lacking. Moreover, the drug is associated with significant GI and neurologic side effects, particularly at the effective doses of 2 to 6 g/d. Terzolo and associates retrospectively evaluated the use of mitotane in the adjuvant setting and reported significantly increased recurrence-free survival in the treatment group.⁸⁵ However, the routine use of this medication awaits evaluation in randomized, controlled trials. Determination of blood mitotane levels is helpful to ascertain whether therapeutic and nontoxic levels are present. Adrenocortical tumors commonly metastasize to the liver, lung, and bone.

Surgical debulking is recommended for isolated, recurrent disease and has been demonstrated to prolong survival. Systemic chemotherapeutic agents used in this tumor include etoposide, cisplatin, doxorubicin, and, more recently, paclitaxel, but consistent responses are rare, possibly due to the expression of the multidrug resistance gene (*MDR-1*) in tumor cells. In vitro data indicate that mitotane may be able to reverse this resistance when combined with various chemotherapeutic agents. Results from the First International Randomized Trial in Advanced or Metastatic Adrenocortical Carcinoma Treatment (FIRM-ACT) showed that patients receiving etoposide, doxorubicin, cisplatin, and mitotane had better response rates and progression-free survival rates than patients receiving streptozotocin and mitotane.⁷² There has been recent interest in the use of suramin, a growth factor inhibitor, as therapy for adrenocortical carcinoma; however, this requires further study, particularly because this drug may be associated with significant neurotoxicity. Gossypol, a naturally occurring insecticide (from the cotton plant *Gossypium* species), also appears to inhibit the growth of adrenocortical cancer cell lines and tumors in vivo. However, poor response rates combined with high death rates in limited clinical studies have reduced enthusiasm for this agent. Adrenocortical cancers also are relatively insensitive to conventional external-beam radiation therapy. However, this modality is used in the palliation of bony metastases. Ketoconazole, metyrapone, or aminoglutethimide may also be useful in controlling steroid hypersecretion.

Sex Steroid Excess. Adrenal adenomas or carcinomas that secrete adrenal androgens lead to virilizing syndromes. Although women with virilizing tumors develop hirsutism, amenorrhea, infertility, and other signs of masculinization, such as increased muscle mass, deepened voice, and temporal balding, men with these tumors are more difficult to diagnose and, hence, usually present with disease in advanced stages. Children with virilizing tumors have accelerated growth, premature development of facial and pubic hair, acne, genital enlargement, and deepening of their voice. Feminizing adrenal tumors are less common and occur in men in the third to fifth decades of life. These tumors lead to gynecomastia, impotence, and testicular atrophy. Women with these tumors develop irregular menses or dysfunctional uterine bleeding. Vaginal bleeding may occur in postmenopausal women. Girls with these tumors experience precocious puberty with breast enlargement and early menarche.

Diagnostic Tests Virilizing tumors produce excessive amounts of the androgen precursor, DHEA, which can be measured in plasma or urine as 17-ketosteroids. Patients with feminizing tumors also have elevated urinary 17-ketosteroids in addition to increased estrogen levels. Androgen-producing tumors often

are associated with production of other hormones such as glucocorticoids.

Treatment Virilizing and feminizing tumors are treated by adrenalectomy. Malignancy is difficult to diagnose histologically but is suggested by the presence of local invasion, recurrence, or distal metastases. Adrenolytic drugs such as mitotane, aminoglutethimide, and ketoconazole may be useful in controlling symptoms in patients with metastatic disease.

Congenital Adrenal Hyperplasia. CAH refers to a group of disorders that result from deficiencies or complete absence of enzymes involved in adrenal steroidogenesis. 21-Hydroxylase (CYP21A2) deficiency is the most common enzymatic defect, accounting for >90% of cases of CAH. This deficiency prevents the production of 11-deoxycortisol and 11-DOC from progesterone precursors. Deficiency of glucocorticoids and aldosterone leads to elevated ACTH levels and overproduction of adrenal androgens and corticosteroid precursors such as 17-hydroxyprogesterone and Δ^4 -androstenedione. These compounds are converted to testosterone in the peripheral tissues, thereby leading to virilization. Complete deficiency of 21-hydroxylase presents at birth with virilization, diarrhea, hypovolemia, hyponatremia, hyperkalemia, and hyperpigmentation. Partial enzyme deficiency may present at birth or later with virilizing features. These patients are less prone to the salt wasting that characterizes complete enzyme deficiency. 11 β -Hydroxylase deficiency is the second most common form of CAH and leads to hypertension (from 11-DOC accumulation), virilization, and hyperpigmentation. Other enzyme deficiencies include 3 β -hydroxydehydrogenase and 17-hydroxylase deficiency. Congenital adrenal lipoid hyperplasia is the most severe form of CAH, which is caused by cholesterol desmolase deficiency. It leads to the disruption of all steroid biosynthetic pathways, thus resulting in a fatal salt-wasting syndrome in phenotypic female patients.

Diagnostic Tests The particular enzyme deficiency can be diagnosed by karyotype analysis and measurement of plasma and urinary steroids. The most common enzyme deficiency, absence of 21-hydroxylase, leads to increased plasma 17-hydroxyprogesterone and progesterone levels, because these compounds cannot be converted to 11-deoxycortisol and 11-DOC, respectively. 11 β -Hydroxylase deficiency is the next most common disorder and results in elevated plasma 11-DOC and 11-deoxycortisol. Urinary 17-hydroxyprogesterone, androgens, and 17-ketosteroids also are elevated. The dexamethasone suppression test (2–4 mg divided qid for 7 days) can be used to distinguish adrenal hyperplasia from neoplasia. CT, MRI, and iodocholesterol scans generally are used to localize the tumors.

Treatment Patients with CAH traditionally have been managed medically, with cortisol and mineralocorticoid replacement to suppress the hypothalamic-pituitary-adrenal axis. However, the doses of steroids required often are supraphysiologic and lead to iatrogenic hypercortisolism. More recently, bilateral laparoscopic adrenalectomy has been proposed as an alternative treatment for this disease and has been successfully performed in a limited number of patients for various forms of CAH.

Disorders of the Adrenal Medulla

Pheochromocytomas. Pheochromocytomas are rare tumors with prevalence rates ranging from 0.3% to 0.95% in autopsy series and approximately 1.9% in series using biochemical screening. They can occur at any age, with a peak incidence in the fourth and fifth decades of life, and have no gender predilection.

Extra-adrenal tumors, also called functional paragangliomas, may be found at sites of sympathetic ganglia in the organ of Zuckerkandl, neck, mediastinum, abdomen, and pelvis. Pheochromocytomas often are called the *10 percent tumor* because 10% are bilateral, 10% are malignant, 10% occur in pediatric patients, 10% are extra-adrenal, and 10% are familial.

Pheochromocytomas occur in families with MEN2A and MEN2B in approximately 50% of patients. Both syndromes are inherited in an autosomal dominant fashion and are caused by germline mutations in the *RET* proto-oncogene. Another syndrome with an increased risk of pheochromocytomas is von Hippel-Lindau (VHL) disease, which also is inherited in an autosomal dominant manner. This syndrome also includes retinal angioma, hemangioblastomas of the central nervous system, renal cysts and carcinomas, pancreatic cysts, and epididymal cystadenomas. The incidence of pheochromocytomas in the syndrome is approximately 14%. The gene causing VHL has been mapped to chromosome 3p and is a tumor suppressor gene. Pheochromocytomas also are included within the tumor spectrum of neurofibromatosis type 1 (*NF1* gene) and other neuroectodermal disorders (Sturge-Weber syndrome and tuberous sclerosis), Carney's syndrome (gastric epithelioid leiomyosarcoma, pulmonary chondroma, and extra-adrenal paraganglioma), MEN1 syndrome, and the familial paraganglioma and pheochromocytoma syndrome caused by mutations in the succinyl dehydrogenase family of genes (*SDHB*, *SDHC*, and *SDHD*), which comprise portions of the mitochondrial complex II.⁸⁷ More recently, mutations in *SDHA* and *SDH5* have also been identified. Additional susceptibility loci include *TMEM127* (involved in the mTORC1 signaling pathway) and *MAX* (*myc-associated factor X*).

Symptoms and Signs Headache, palpitations, and diaphoresis constitute the "classic triad" of pheochromocytomas. Symptoms such as anxiety, tremulousness, paresthesias, flushing, chest pain, shortness of breath, abdominal pain, nausea, vomiting, and others are nonspecific and may be episodic in nature. Cardiovascular complications such as myocardial infarction and cerebrovascular accidents may ensue. These symptoms can be incited by a range of stimuli including exercise, micturition, and defecation. The most common clinical sign is hypertension. Pheochromocytomas are one of the few curable causes of hypertension and are found in 0.1% to 0.2% of hypertensive patients. Hypertension related to this tumor may be paroxysmal with intervening normotension, sustained with paroxysms or sustained hypertension alone. Sudden death may occur in patients with undiagnosed tumors who undergo other surgeries or biopsy.

Diagnostic Tests

Biochemical Studies. Pheochromocytomas are diagnosed by testing 24-hour urine samples for catecholamines and their metabolites as well as by determining plasma metanephrine levels. Urinary metanephrines are 98% sensitive and also about 98% specific for pheochromocytomas, whereas VMA measurements are slightly less sensitive and specific. False-positive VMA tests may result from ingestion of caffeine, raw fruits, or medications (α -methyl dopa). Fractionated urinary catecholamines (norepinephrine, epinephrine, and dopamine) also are very sensitive but less specific for pheochromocytomas. Because extra-adrenal sites lack phenylethanolamine *N*-methyltransferase, these tumors secrete norepinephrine, whereas epinephrine is the main hormone secreted from adrenal pheochromocytomas.

Many physiologic and pathologic states can alter the levels of plasma catecholamines. Hence, they often are thought to be less accurate than urinary tests. Both epinephrine and norepinephrine should be measured, as tumors often secrete one or the other hormone. Sensitivities of 85% and specificities of 95% have been reported using cutoff values of 2000 pg/mL for norepinephrine and 200 pg/mL for epinephrine. Clonidine is an agent that suppresses neurogenically mediated catecholamine excess but not secretion from pheochromocytomas. A normal clonidine suppression test is defined by a decrease of basal catecholamine levels to <500 pg/mL within 2 to 3 hours after an oral dose of 0.3 mg of clonidine. Chromogranin A is a monomeric, acidic protein, which is stored in the adrenal medulla and other neuroendocrine tumors and released along with catecholamine hormones. It has been reported to have a sensitivity of 83% and a specificity of 96% and is useful in conjunction with catecholamine measurement for diagnosing pheochromocytomas. Some studies have shown that plasma metanephrines should be the first-line test to identify pheochromocytomas, as the predictive value of a negative test is very high and normal levels exclude pheochromocytoma in patients with preclinical disease or dopamine secreting tumors. Although sensitivities of 96% to 100% have been reported, specificity is lower at 85% to 89% and may be much lower at 77% in elderly patients. Although attractive because of the simplicity of a blood test, measurement of plasma metanephrines is generally reserved for cases for which there is a high index of suspicion.

Radiologic Studies. Radiologic studies are useful to localize tumors and to assess the extent of spread once the diagnosis has been made with biochemical tests. CT scans are 85% to 95% sensitive and 70% to 100% specific for pheochromocytomas (Fig. 38-46A). The scans should be performed without contrast to minimize the risk of precipitating a hypertensive crisis, although some recent studies suggest that intravenous contrast may be used. Images should include the region from the diaphragm to the aortic bifurcation so as to include the organ of Zuckerkandl. CT scans do not provide functional information and cannot definitively diagnose pheochromocytomas. MRI scans are 95% sensitive and almost 100% specific for pheochromocytomas because these tumors have a characteristic appearance on T2-weighted images or after gadolinium. MRI is also the study of choice in pregnant women as there is no risk of radiation exposure. Metaiodobenzylguanidine (MIBG) is taken up and concentrated by vesicles in the adrenal medullary cells because its structure is similar to norepinephrine. Normal adrenal medullary tissue does not take up appreciable MIBG. ¹³¹I-radiolabeled MIBG is, therefore, useful for localizing pheochromocytomas (Fig. 38-46B), especially those in ectopic positions. This test has a reported sensitivity of 77% to 89% and specificity ranging from 88% to 100%.

Treatment The medical management of pheochromocytomas is aimed chiefly at blood pressure control and volume repletion. Irreversible, long-acting α -blockers such as phenoxybenzamine are started 1 to 3 weeks before surgery at doses of 10 mg twice daily, which may be increased to 300 to 400 mg/d with rehydration. Patients should be warned about orthostatic hypotension. β -Blockers such as propranolol at doses of 10 to 40 mg every 6 to 8 hours often need to be added preoperatively in patients who have persistent tachycardia and arrhythmias. β -Blockers should only be instituted after adequate α -blockade and hydration to avoid the effects of unopposed α stimulation (i.e., hypertensive

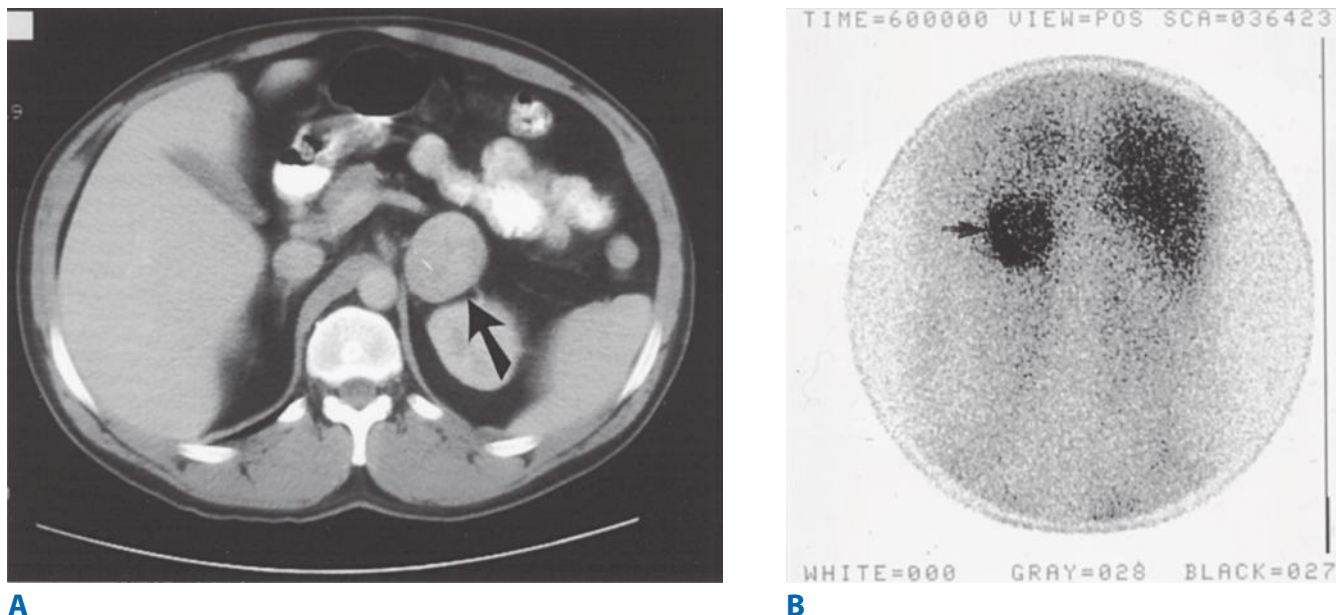


Figure 38-46. A left-sided pheochromocytoma (arrows) imaged by a computed tomography scan of the abdomen (A) and a metaiodobenzylguanidine scan viewed posteriorly (B).

crisis and congestive heart failure) and are typically initiated 3 to 4 days preoperatively. Patients also should be volume repleted preoperatively to avoid postoperative hypotension, which ensues with the loss of vasoconstriction after tumor removal. Other α -blockers such as prazosin, terazosin, and doxazosin, which are selective α_1 -adrenergic blockers, have a better side effect profile and are preferable to phenoxybenzamine when long-term pharmacologic therapy is needed, as in patients with metastatic pheochromocytoma. Nicardipine is the most commonly used calcium channel blocker and inhibits norepinephrine-mediated calcium transport into vascular smooth muscle. When used as the primary mode of treatment, it appears to be just as effective as α - and β -blockade preoperatively. In some patients, catecholamine-synthesis inhibitors such as α -methyl-p-l-tyrosine (metyrosine) may need to be added if standard α - and β -blockade is poorly tolerated or is ineffective in reaching target blood pressure and when moderate intraoperative tumor manipulation is anticipated.

Adrenalectomy is the treatment of choice for patients with pheochromocytoma. The chief goal of surgery is to resect the tumor completely with minimal tumor manipulation or rupture of the tumor capsule. Surgery should be performed with both noninvasive and invasive monitors, including an arterial line and central venous lines. In patients with congestive heart failure or underlying coronary artery disease, Swan-Ganz catheters may be necessary. Stress must be avoided during anesthesia induction, and use of inhaled agents like isoflurane and enflurane are preferred because they have minimal cardiac depressant effects. Fentanyl, ketamine, and morphine should be avoided as they can potentially stimulate catecholamine release from the tumor. The common medications used for intraoperative blood pressure control include nitroprusside, nitroglycerin, phentolamine, and nicardipine. Intraoperative arrhythmias are best managed by short-acting β -blockers such as esmolol. Adrenalectomy usually was performed via an open anterior approach to facilitate detection of bilateral tumors, extra-adrenal lesions, or metastatic lesions. However, most pheochromocytomas <5 cm in diameter can be safely resected laparoscopically. Postoperatively, these patients are prone to hypotension due to loss of adrenergic

stimulation and consequent vasodilatation and therefore need large volume resuscitation.

Hereditary Pheochromocytomas. Inherited pheochromocytomas tend to be multiple and bilateral. Generally, unilateral adrenalectomy is recommended in the absence of obvious lesions in the contralateral adrenal gland because of Addison's disease, requiring lifelong steroid replacement in patients undergoing bilateral adrenalectomy. For patients with tumors in both adrenal glands, cortical-sparing subtotal adrenalectomy may preserve adrenocortical function and avoid the morbidity of bilateral total adrenalectomy. Laparoscopic subtotal adrenalectomy has been shown to provide short-term clinical results comparable to total adrenalectomy, with reduced surgical morbidity.⁸⁸ However, these patients remain at risk for recurrent pheochromocytoma, which has been reported in 20% of patients with VHL disease a median of 40 months after partial adrenalectomy, and in 33% of MEN2 patients followed for 54 to 88 months after surgery. Autotransplantation of adrenocortical tissue after total adrenalectomy may be another option for these patients. However, the transplanted cortical tissue rarely provides full function, and steroid replacement usually is required.

Malignant Pheochromocytomas. Approximately 12% to 29% of pheochromocytomas are malignant, and these tumors are associated with decreased survival. There are no definitive histologic criteria defining malignant pheochromocytomas. In fact, pleomorphism, nuclear atypia, and abundant mitotic figures are seen in benign tumors. Capsular and vascular invasion may be seen in benign lesions as well. Malignancy usually is diagnosed when there is evidence of invasion into surrounding structures or distant metastases. The most common sites for metastatic disease are bone, liver, regional lymph nodes, lung, and peritoneum, although the brain, pleura, skin, and muscles may also occasionally be involved. Some studies also suggest that older patient age and larger tumors are associated with a higher risk of malignancy. Although risk of malignancy increases with size for all pheochromocytomas, size does not seem to reliably predict malignancy in pheochromocytomas with local disease

only.⁸⁹ Given this difficulty defining malignancy clinically (in the absence of metastatic disease), a number of other features such as DNA ploidy, tumor size, and necrosis, neuropeptide Y mRNA expression, and serum neuron-specific enolase expression have been studied. Malignant pheochromocytomas are more likely to express p53 and bcl-2 and have activated telomerase. Recent data suggest that flow cytometry and molecular markers such as expression of Ki-67, tissue inhibitor of metalloproteinase, and COX-2 also have shown some use in determining malignancy. When pheochromocytomas develop in the MEN syndromes, they rarely are malignant. In contrast, patients with germline *SDHB* mutations appear to have a higher propensity for extra-adrenal and malignant tumors. In general, soft tissue lesions are treated with resection if feasible. External-beam radiation can be used for unresectable lesions or symptomatic skeletal metastases. Therapeutic ¹³¹I-MIBG irradiation may be useful in patients with diffuse disease showing ¹²³I-MIBG uptake on a diagnostic scan. If the tumor is positive on somatostatin receptor imaging, long-acting octreotide may be used.

The Adrenal Incidentaloma

Adrenal lesions discovered during imaging performed for unrelated reasons are referred to as *incidentalomas*. This definition excludes tumors discovered on imaging studies performed for evaluating symptoms of hormone hypersecretion or staging patients with known cancer. The incidence of these lesions identified by CT scans ranges from 0.4% to 4.4%.

Differential Diagnosis. The differential diagnosis of adrenal incidentalomas is shown in Table 38-20. Nonfunctional cortical adenomas account for the majority (36%–94%) of adrenal incidentalomas in patients without a history of cancer. In a series of patients from the Mayo Clinic, no nonfunctional lesion progressed to cause clinical or biochemical abnormalities. However, other studies indicate that 5% to 20% of patients with apparently nonfunctioning cortical adenomas have underlying, subtle abnormalities of glucocorticoid secretion, and a rare benign-appearing incidentaloma is a cancer.

By definition, patients with incidentalomas do not have clinically overt Cushing's syndrome, but subclinical Cushing's syndrome is estimated to occur in approximately 8% of patients. This disorder is characterized by subtle features of cortisol excess, such as weight gain, skin atrophy, facial

fullness, diabetes, and hypertension, accompanied by loss of normal diurnal variation in cortisol secretion, autonomous cortisol secretion, and resistance to suppression by dexamethasone. Total cortisol produced and 24-hour urinary cortisol levels may be normal. Examination of the natural history of subclinical Cushing's syndrome indicates that, although most patients remain asymptomatic, some do progress to clinically evident Cushing's syndrome. Furthermore, cases of postoperative adrenal crisis from unrecognized suppression of the contralateral adrenal have been reported, making preoperative identification of this condition imperative, particularly in the era of early discharge following laparoscopic adrenalectomy.

The adrenal is a common site of metastases of lung and breast tumors, melanoma, renal cell cancer, and lymphoma. In patients with a history of nonadrenal cancer and a unilateral adrenal mass, the incidence of metastatic disease has been reported to range from 32% to 73%. Myelolipomas are benign, biochemically nonfunctioning lesions composed of elements of hematopoietic and mature adipose tissue, which are rare causes of adrenal incidentaloma. Other less commonly encountered lesions include adrenal cysts, ganglioneuromas, and hemorrhage.

Diagnostic Investigations. The diagnostic workup of an adrenal incidentaloma is aimed at identifying patients who would benefit from adrenalectomy (i.e., patients with functioning tumors and tumors at increased risk of being malignant). It is not necessary for asymptomatic patients whose imaging studies are consistent with obvious cysts, hemorrhage, myelolipomas, or diffuse metastatic disease to undergo additional investigations. All other patients should be tested for underlying hormonally active tumors using (a) a low-dose (1 mg) overnight dexamethasone suppression test to rule out subclinical Cushing's syndrome and 17-ketosteroids (if sex steroid excess is suspected); (b) a 24-hour urine collection for catecholamines, metanephrines, VMA, or plasma metanephrine to rule out pheochromocytoma; and (c) in hypertensive patients, serum electrolytes, plasma aldosterone, and plasma renin to rule out an aldosteronoma. In patients with a high index of suspicion for subclinical Cushing's (those with hypertension, obesity, or diabetes), three tests (i.e., dexamethasone suppression test, salivary cortisol, and 24-hour urine free cortisol) may be used. Confirmatory tests can be performed based on the results of the initial screening studies.

Determination of the malignant potential of an incidentaloma is more difficult. The risk of malignancy in an adrenal lesion is related to its size. Lesions >6 cm in diameter have an approximate risk of malignancy of about 25%.⁸² However, this size cutoff is not absolute because adrenal carcinomas also have been reported in lesions <6 cm. Carcinomas account for 2% of lesions <4 cm and 6% of lesions 4.1 to 6 cm in size. This has led to increased use of the imaging characteristics of incidentalomas to predict malignancy. Benign adrenal adenomas tend to be homogeneous, well encapsulated, and have smooth and regular margins. They also tend to be hypoattenuating lesions (<10 Hounsfield units) on CT scanning. In contrast, adrenal cancers tend to be hyperattenuating (>18 Hounsfield units) and inhomogeneous, have irregular borders, and may show evidence of local invasion or adjacent lymphadenopathy. On MRI T2-weighted imaging, adenomas demonstrate low signal intensity when compared to the liver (adrenal mass-to-liver ratio <1.4), whereas carcinomas and metastases have moderate intensity (mass-to-liver ratio 1.2:2.8). Pheochromocytomas are extremely bright, with mass-to-liver ratios >3. Unfortunately, the ranges overlap, and signal intensity is not 100% reliable for

Table 38-20

Differential diagnosis of adrenal incidentaloma

FUNCTIONING LESIONS	NONFUNCTIONING LESIONS
Benign	Benign
Aldosteronoma	Cortical adenoma
Cortisol-producing adenoma	Myelolipoma
Sex steroid-producing adenoma	Cyst
Pheochromocytoma	Ganglioneuroma
	Hemorrhage
Malignant	Malignant
Adrenocortical cancer	Metastasis
Malignant pheochromocytoma	Adrenocortical cancer

determining the nature of the lesion. Radionuclide imaging with NP-59 also has been used to distinguish between various adrenal lesions, with some investigators suggesting that uptake of NP-59 was 100% predictive of a benign lesion (adenoma), whereas absence of imaging was 100% predictive of a nonadenomatous lesion. However, the technique has not gained widespread acceptance because patients need to be given cold iodine 1 week before the study to prevent thyroid uptake, imaging needs to be delayed by 5 to 7 days after administration of the contrast, and false-positive and false-negative results occur. FDG-PET or PET-CT scans may have some utility in distinguishing potentially malignant from benign lesions in cases of inconclusive CT densitometry. However, caution must be exercised for false-positive (some adenomas and pheochromocytomas) and false-negative results (small lesions or those with hemorrhage or necrosis).⁹⁰ FNAB cannot be used to distinguish

11▶ adrenal adenomas from carcinomas. This being said, FNAB is useful in the setting of a patient with a history of cancer and a solitary adrenal mass. The positive predictive value of FNAB in this situation has been shown to be almost 100%, although false-negative rates of up to 33% have been reported. Biopsies usually are performed under CT guidance, and appropriate testing to rule out pheochromocytomas should be undertaken before the procedure to avoid precipitating a hypertensive crisis.

Management. An algorithm for the management of patients with incidentalomas is shown in Fig. 38-47. The AACE and American Association of Endocrine Surgeons (AAES) have recently published management guidelines for patients with adrenal incidentalomas.⁹¹ Patients with functional tumors or obviously malignant lesions should undergo adrenalectomy. The optimal management of patients with subclinical Cushing's syndrome is controversial, especially due to the paucity of data from high-quality prospective trials. In general, operative intervention is advised in patients with subclinical Cushing's

syndrome with suppressed plasma ACTH levels and elevated urinary cortisol levels because these patients are at high risk for progression to overt Cushing's syndrome. The adrenal incidentaloma guidelines also recommend adrenalectomy in patients with worsening hypertension, abnormal glucose tolerance, or osteoporosis.

For nonfunctional lesions, the risk of malignancy needs to be balanced with operative morbidity and mortality. The AACE/AAES guidelines recommend that lesions with suspicious features on imaging studies such as heterogeneity, irregular capsule, or adjacent nodes should be treated by adrenalectomy. Nonoperative therapy, with close periodic follow-up, is advised for lesions <4 cm in diameter with benign imaging characteristics, whereas adrenalectomy is recommended for lesions ≥ 4 cm in size due to the increased risk of cancer.

However, several important points must be considered in the management of these patients. First, size criteria for malignancy are not definitive and are derived from a selected series of patients. Second, the actual size of adrenal tumors can be underestimated by at least 1 cm by modalities such as CT and MRI scans, because tumors are larger in a cephalocaudal axis. Third, the natural history of incidentalomas is variable and depends on the underlying diagnosis, age of the study population, and the size of the mass. Older patients are more likely to have nonfunctioning adenomas. Existing data in terms of the long-term behavior of these nonfunctional lesions, although limited, indicate that malignant transformation is uncommon. Furthermore, tumors that increase in size by at least 1 cm over a 2-year follow-up period and those with subtle hormonal abnormalities appear to be more likely to enlarge. Overt hormone overproduction is more likely in tumors >3 cm and those with increased NP-59 uptake. Surgeons are more likely to operate on a 40-year-old patient with a 4-cm lesion, while electing to follow an 80-year-old patient with a similar lesion but multiple concurrent comorbidities. Based on the above considerations,

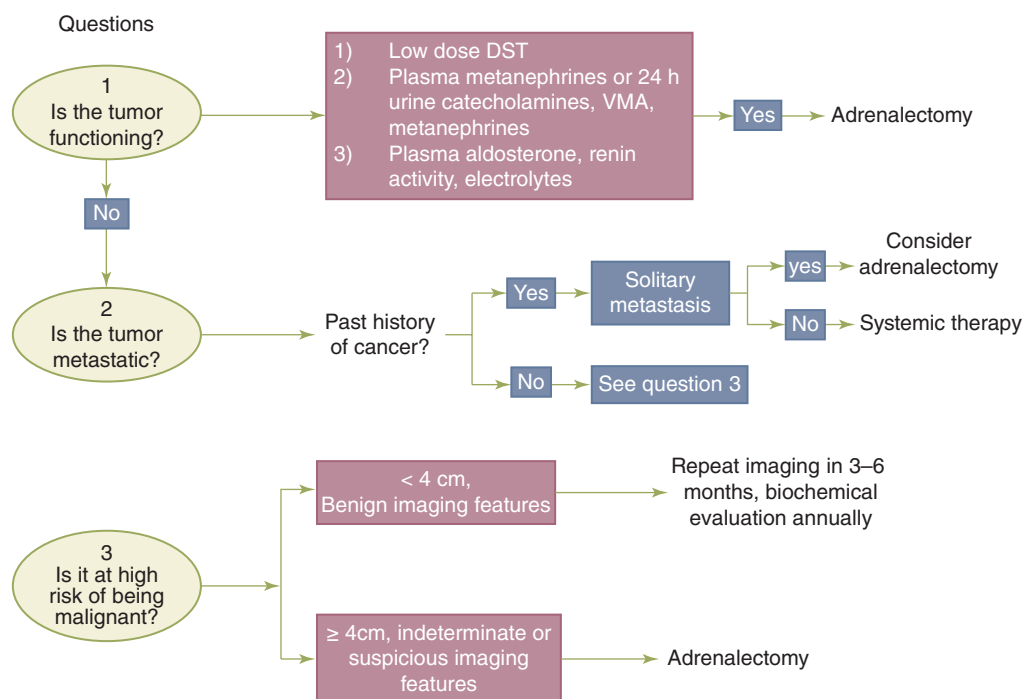


Figure 38-47. Management algorithm for an adrenal incidentaloma. CT = computed tomography; DST = dexamethasone suppression test; VMA = vanillylmandelic acid.

some surgeons use a size threshold for adrenalectomy with a nonfunctioning homogeneous tumor of 3 to 4 cm in young patients with no comorbidities and 5 cm in older patients with significant comorbidity.

Lesions that grow during follow-up also are treated by adrenalectomy. Myelolipomas generally do not warrant adrenalectomy unless there is concern regarding malignancy, which is rare, or bleeding into the lesion, which is more likely in myelolipomas >4 cm in size. These tumors, even when large, can be removed laparoscopically. Resection of solitary adrenal metastases in patients with a history of nonadrenal cancer has been demonstrated to lead to prolonged patient survival. Suspected adrenal metastases also may be resected for diagnosis.

There is no consensus regarding the follow up of patients with adrenal incidentaloma. The AACE/AAES guidelines recommend repeating hormonal screening with a 1-mg dexamethasone suppression test and urinary catecholamines and metabolites yearly for 5 years as the risk of hypersecretion appears to plateau after this time period.⁹¹ It also recommends repeat imaging at 3 to 6 months and then annually for 1 to 2 years. Less frequent imaging is reasonable or small (<2 cm), uniform, hypodense cortical nodules in patients without a history of malignant disease. Adrenalectomy is recommended for lesions that grow ≥ 1 cm or if autonomous hormone secretion develops during follow-up.

Adrenal Insufficiency

Adrenal insufficiency may be primary, resulting from adrenal disease, or secondary, due to a deficiency of ACTH (Table 38-21). The most commonly encountered causes of primary adrenal insufficiency are autoimmune disease, infections, and metastatic deposits. Spontaneous adrenal hemorrhage can occur in patients with fulminant meningococcal septicemia (Waterhouse-Friderichsen syndrome). Bilateral adrenal hemorrhage also can occur secondary to trauma, severe stress, infection, and coagulopathies and, if unrecognized, is lethal. Exogenous glucocorticoid therapy with suppression of the adrenal glands is the most common cause of secondary adrenal insufficiency.

Symptoms and Signs. Acute adrenal insufficiency should be suspected in stressed patients with any of the relevant risk factors. It may mimic sepsis, myocardial infarction, or pulmonary embolus and presents with fever, weakness, confusion, nausea, vomiting, lethargy, abdominal pain, or severe hypotension. Chronic adrenal insufficiency, such as that occurring in patients with metastatic tumors, may be more subtle. Symptoms include fatigue, salt craving, weight loss, nausea, vomiting, and abdominal pain. These patients may appear hyperpigmented from increased secretion of CRH and ACTH, with increased α -melanocyte-stimulating hormone side-products.

Diagnostic Studies. Characteristic laboratory findings include hyponatremia, hyperkalemia, eosinophilia, mild azotemia, and fasting or reactive hypoglycemia. The peripheral blood smear may demonstrate eosinophilia in approximately 20% of patients. Adrenal insufficiency is diagnosed by the ACTH stimulation test. ACTH (250 μ g) is infused intravenously, and cortisol levels are measured at 0, 30, and 60 minutes. Peak cortisol levels <20 μ g/dL suggest adrenal insufficiency. ACTH levels also allow primary insufficiency to be distinguished from secondary causes. High ACTH levels with low plasma cortisol levels are diagnostic of primary adrenal insufficiency.

Table 38-21

Etiology of adrenal insufficiency

PRIMARY	SECONDARY
Autoimmune (autoimmune polyglandular disease type I and II)	Exogenous glucocorticoid therapy
Infectious—TB, fungi, CMV, HIV	Bilateral adrenalectomy
Hemorrhage—spontaneous (Waterhouse-Friderichsen syndrome) and secondary to stress, trauma, infections, coagulopathy, or anticoagulants	Pituitary or hypothalamic tumors
Metastases	Pituitary hemorrhage (postpartum Sheehan's syndrome)
Infiltrative disorders—amyloidosis, hemochromatosis	Transsphenoidal resection of pituitary tumor
Adrenoleukodystrophy	
Congenital adrenal hyperplasia	
Drugs—ketoconazole, metyrapone, aminoglutethimide, mitotane	

CMV = cytomegalovirus; HIV = human immunodeficiency virus; TB = tuberculosis.

Treatment. Treatment must be initiated based on clinical suspicion alone, even before test results are obtained, or the patient is unlikely to survive. Management includes volume resuscitation with at least 2 to 3 L of a 0.9% saline solution or 5% dextrose in saline solution. Blood should be obtained for electrolyte (decreased Na^+ and increased K^+), glucose (low), and cortisol (low) levels; ACTH (increased in primary and decreased in secondary); and quantitative eosinophilic count. Dexamethasone (4 mg) should be administered intravenously. Hydrocortisone (100 mg intravenously every 8 hours) also may be used, but it interferes with testing of cortisol levels. Once the patient has been stabilized, underlying conditions such as infection should be sought, identified, and treated. The ACTH stimulation test should be performed to confirm the diagnosis. Glucocorticoids can then be tapered to maintenance doses (oral hydrocortisone 15–20 mg in the morning and 10 mg in the evening). Mineralocorticoids (fludrocortisone 0.05–0.1 mg daily) may be required once the saline infusions are discontinued.

Adrenal Surgery

Choice of Procedure. Adrenalectomy may be performed via a laparoscopic or open approach. In either approach, the gland may be approached anteriorly, laterally, or posteriorly via the retroperitoneum. The choice of approach depends on the size and nature of the lesion and expertise of the surgeon. Laparoscopic adrenalectomy has rapidly become the standard procedure of choice for the excision of most benign-appearing adrenal lesions <6 cm in diameter. The role of laparoscopic adrenalectomy in the

management of adrenocortical cancers is controversial. The data with respect to local tumor recurrence and intra-abdominal carcinomatosis from laparoscopic adrenalectomy for malignant adrenal tumors that were not appreciated as such, preoperatively or intraoperatively, are conflicting. Although laparoscopic adrenalectomy appears to be feasible and safe for solitary adrenal metastasis⁹² (provided there is no local invasion and the tumor can be resected intact), open adrenalectomy or laparoscopic-assisted open adrenalectomy is the safest option for suspected or known adrenocortical cancers and malignant pheochromocytomas. Technical considerations and surgeon experience, rather than absolute tumor size, usually determine the size threshold for laparoscopic resection. Hand-assisted laparoscopic adrenalectomy may provide a bridge between laparoscopic adrenalectomy and conversion to an open procedure. There have been no randomized trials directly comparing open vs. laparoscopic adrenalectomy. However, studies have shown that laparoscopic adrenalectomy is associated with decreased blood loss, postoperative pain, and narcotic use; reduced length of hospital stay; and faster return to work.

12▶ laparoscopic adrenalectomy is associated with decreased blood loss, postoperative pain, and narcotic use; reduced length of hospital stay; and faster return to work.

Laparoscopic Adrenalectomy. The procedure is performed under general anesthesia. Arterial lines are used routinely, and central lines are necessary for patients in whom massive fluid shifts are anticipated (e.g., those with large, active pheochromocytomas). A nasogastric tube and Foley catheter are recommended. Routine preoperative antibiotics are not needed, except in patients with Cushing's syndrome. The adrenals can be removed laparoscopically via a transabdominal (anterior or lateral) or retroperitoneal (lateral or posterior) approach. The lateral approach is preferred by most laparoscopic surgeons and uses gravity to aid retraction of surrounding organs. Patients, however, need to be repositioned for a bilateral procedure. The anterior transabdominal approach offers the advantage of a conventional view of the abdominal cavity and allows a bilateral adrenalectomy to be performed without the necessity of repositioning the patient. The posterior retroperitoneal approach has also been gaining popularity in recent years, particularly in patients with previous anterior abdominal surgery and peritoneal adhesions. In addition, several centers have successfully utilized robotic approaches for both lateral transabdominal and retroperitoneal laparoscopic adrenal surgery. Single incision laparoscopic adrenalectomy is another option; however, widespread use of these latter approaches awaits analysis of long-term outcomes data and cost analyses.

The lateral transabdominal approach is widely used and described in detail below.

Lateral Transabdominal Approach The patient is placed in the lateral decubitus position, and the operating table is flexed at the waist to open the space between the lower rib cage and the iliac crest (Fig. 38-48). The surgeon and assistant both stand on the same side, facing the front of the patient. Pneumoperitoneum is created using a Veress needle or insufflation via a Hasson port. In general, four 10-mm trocars are placed between the midclavicular line medially and anterior axillary line laterally, one to two fingerbreadths below the costal margin (see Fig. 38-48), although additional ports may be placed, if needed. A 30° laparoscope is inserted through the second or midclavicular port. Most of the dissection is carried out via the two most lateral ports. However, the instruments and ports may be changed to provide optimum exposure, as needed.

For a right adrenalectomy, a fan retractor is inserted through the most medial port to retract the liver. An atraumatic grasper and an L-hook cautery are inserted via the two lateral ports for the dissection. The right triangular ligament is divided and the liver is rotated medially (Fig. 38-49A). Rarely, the hepatic flexure of the colon may need mobilization during a right adrenalectomy. The right kidney is identified visually and by palpation with an atraumatic grasper. The adrenal gland is identified on the superomedial aspect of the kidney. Gerota's fascia is incised with the hook cautery. Dissection of the adrenal is started superomedially and then proceeds inferiorly, dissecting around the adrenal in a clockwise manner. The periadrenal tissues are grasped or moved with a blunt grasper to facilitate circumferential dissection. The right adrenal vein is identified at its junction with the IVC, ligated with clips, and divided using endoscopic scissors. Alternatively, a vascular stapler may be used to divide the vein endoscopically. There may be a second adrenal vein on the right. Generally, two clips are left on the vena cava side. Although early identification of the adrenal vein is helpful to facilitate mobilization and prevent injury, it can be dissected whenever it is safe to do so. Early ligation of the adrenal vein makes it easier to mobilize the gland but may make subsequent dissection more difficult due to venous congestion. The arterial branches to the adrenal gland can be electrocoagulated if small or clipped and divided.

For a left adrenalectomy, the fan retractor is used to retract the spleen. The splenic flexure is mobilized early, and the lateral attachments to the spleen and the tail of the pancreas are

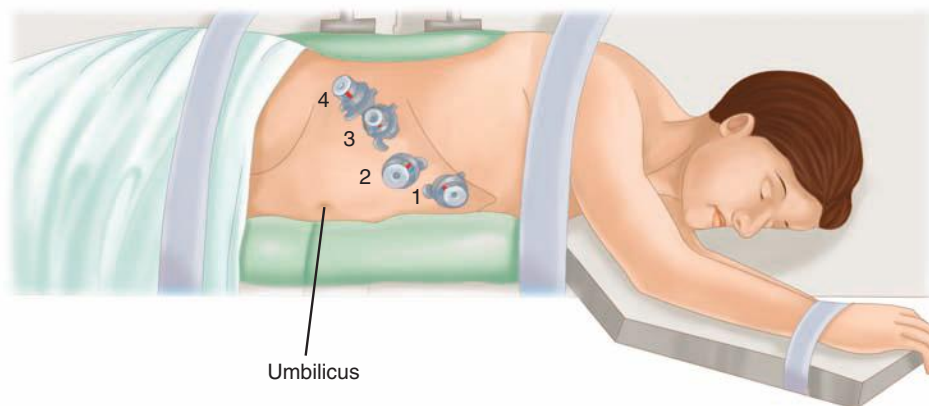


Figure 38-48. Positioning of the patient and placement of trocars for a laparoscopic adrenalectomy. Four trocars are placed from the midclavicular to the anterior axillary line.

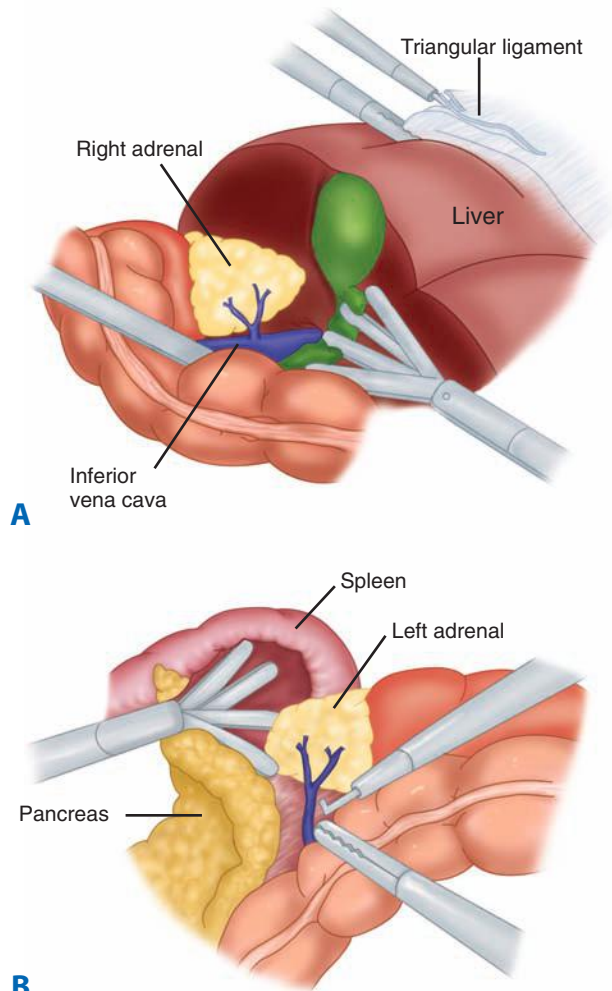


Figure 38-49. Technique of laparoscopic adrenalectomy. Exposure of the right adrenal is facilitated by division of the triangular ligament (**A**) and dissection and reflection of the spleen and tail of the pancreas aids in identifying the left adrenal (**B**).

divided using the electrocautery (Fig. 38-49B). Gravity allows the spleen and the pancreatic tail to fall medially. The remainder of the dissection proceeds similarly to that described for the right adrenal. In addition to the adrenal vein, the inferior phrenic vein, which joins the left adrenal vein medially, also needs to be dissected, doubly clipped, and divided. As with the right adrenal vein, the left-sided veins also can be divided with a vascular stapler. Once the dissection is complete, the area of the adrenal bed can be irrigated and suctioned. A drain is rarely necessary. The gland is placed in a nylon specimen bag, which is brought out via one of the ports after morcellation, if necessary.

Posterior Retroperitoneal Approach The retroperitoneal approach provides a more direct access to the adrenal gland and avoids abdominal adhesions in patients who have had previous abdominal surgery. Furthermore, bilateral adrenalectomy can be performed without repositioning the patient. Intraoperative ultrasound is helpful for identifying the adrenal, but the dissection and exposure are more difficult because the working space is limited. This makes vascular control difficult and also renders it unsuitable for large (>5 cm) lesions. This technique is being increasingly used for small adenomas causing hyperaldosteronism.

The patient is placed in the prone-jackknife position, and the operating table is flexed at the waist to open the space

between the posterior costal margin and the pelvis. Palpation is used to identify the position of the twelfth rib. Percutaneous ultrasound is performed to determine the outline of the underlying kidney and adrenal. When done laparoscopically, the surgeon stands on the side of the adrenal to be removed, and the assistant stands on the opposite side. A 1.5-cm incision is placed 2 cm inferior and parallel to the twelfth rib, laterally at the level of the inferior pole of the kidney. Gerota's space is entered under direct vision using a 12-mm direct viewing trocar with a 0° laparoscope through the muscle layers of the posterior abdominal wall. Alternatively, blunt dissection with the surgeon's finger also can identify the space behind Gerota's fascia. The trocar is then replaced by a dissecting balloon, which is manually inflated using a hand pump under direct vision through the laparoscope. A 12-mm trocar is then reinserted into this space, and CO₂ is insufflated to 12 to 15 mmHg pressure. The 0° laparoscope is replaced by a 45° laparoscope. Two additional 5- or 10-mm trocars are placed, one each on either side of the first port. Laparoscopic ultrasound then is used to help locate the adrenal gland and vessels. The adrenal dissection is begun at the superior pole and then proceeds to the lateral and inferior aspect. The medial dissection usually is performed last, and the vessels are identified and divided as described in the earlier Lateral Transabdominal Approach section.

Open Adrenalectomy. Open adrenalectomy may be performed via four approaches, each with specific advantages and disadvantages. The anterior approach allows examination of the abdominal cavity and resection of bilateral tumors via a single incision. The posterior approach avoids the morbidity of a laparotomy incision, especially in patients with cardiopulmonary disease and those prone to wound complications (Cushing's syndrome) and avoids abdominal adhesions in patients who have undergone previous abdominal surgery. Recovery time is also quicker and hospitalization shorter. However, the retroperitoneal exposure is difficult, particularly in obese patients, and the small working space makes it unsuitable for tumors >6 cm in diameter. The lateral approach is best for obese patients and for large tumors because it provides a bigger working space. The thoracoabdominal approach is most useful for en bloc resection of large (>10 cm), malignant lesions. However, it is associated with significant morbidity and should be used selectively.

Anterior Approach The adrenals may be removed via a midline incision or bilateral subcostal incision (Fig. 38-50). The former allows adequate infraumbilical exposure for examination of extra-adrenal tumors, whereas the latter provides better superior and lateral exposure. For the right side, the hepatic flexure of the colon is mobilized inferiorly, and the triangular ligament is incised to retract the liver medially and superiorly. A generous Kocher maneuver is used to mobilize the duodenum anteriorly and expose the retroperitoneal fat and the IVC (Fig. 38-51A). Gerota's fascia is incised, and the gland is freed of surrounding fibro-fatty tissue and the kidney inferiorly. The lateral and superior surfaces usually are mobilized first. Then, the short, right adrenal vein is dissected, ligated, and divided, taking care not to injure the hepatic veins and IVC. On the left side, the adrenal is located cephalad to the pancreatic tail and just lateral to the aorta. For large tumors, the adrenal is best approached by medial visceral rotation to mobilize the spleen, colon, and pancreas toward the midline (Fig. 38-51B). An alternative approach is to enter the lesser sac by division of the gastrocolic ligament. The pancreas is mobilized superiorly by

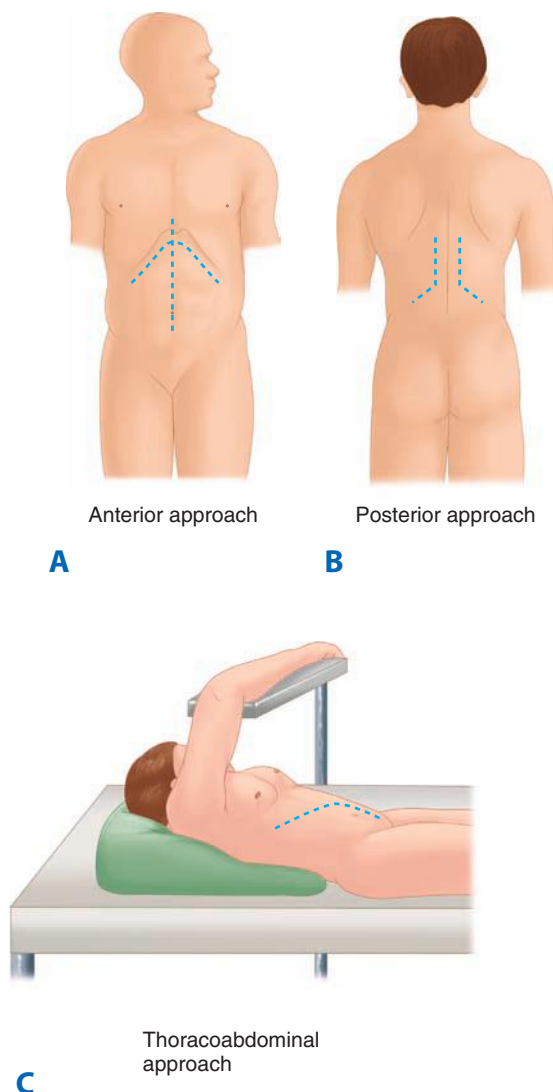


Figure 38-50. Incisions for open adrenalectomy. Anterior approach (A), posterior approach (B), and thoracoabdominal approach (C).

incision of its inferior peritoneal attachments, thus exposing the left kidney and adrenal. The gland is then mobilized as on the right side.

Posterior Approach The patient is placed prone on the operating table, similar to the laparoscopic approach. A hockey stick or curvilinear incision may be used, and extended through the latissimus dorsi and sacrospinous fascia. The twelfth rib generally is excised at its base, and the eleventh rib is retracted superiorly to reveal the pleura and the lateral arcuate ligament of the liver on the right side. The pleura also is mobilized cephalad, and the adrenal and kidney are identified. The superior aspect of the gland is dissected first, and the superior vessels are identified and ligated. This prevents superior retraction of the adrenal gland. The remainder of the gland is then dissected and the adrenal gland and tumor removed. The resulting space generally is filled with perinephric fat and closed in layers. A chest x-ray is obtained postoperatively to rule out a pneumothorax.

Lateral Approach The patient is placed in a lateral position with the table flexed, and an incision is made between the eleventh and twelfth ribs or subcostally. The dissection then is performed as indicated previously in Anterior Approach.

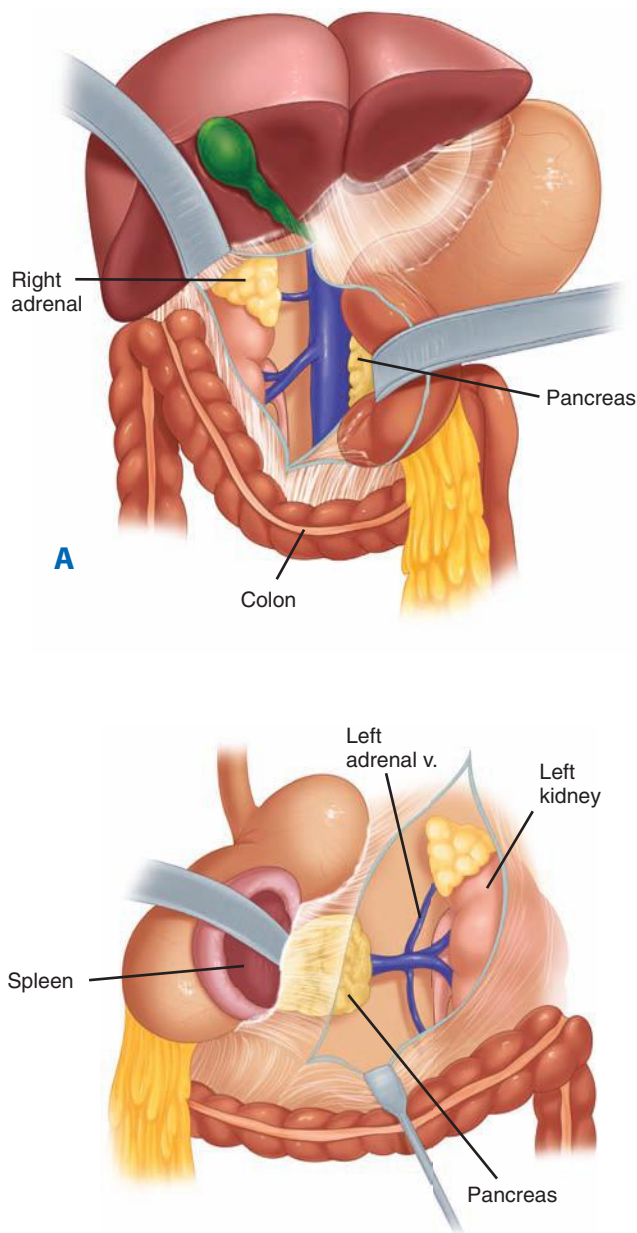


Figure 38-51. Technique of open adrenalectomy. Exposure of the right adrenal is facilitated by a Kocher maneuver to mobilize the duodenum and upward retraction of the liver (A). The left adrenal can be exposed by medial visceral rotation of the spleen and pancreas (B). v. = vein.

Complications of Adrenal Surgery. Patients with Cushing's syndrome are more prone to infectious (incisional and intra-abdominal abscess) and thrombotic complications. Creation of pneumoperitoneum may result in injury to various organs from Veress needle and trocar insertion, subcutaneous emphysema, pneumothorax, and hemodynamic compromise. Excessive retraction and dissection may lead to bleeding from injury to the IVC and renal vessels, or from injury to surrounding organs such as the liver, pancreas, spleen, and stomach. Postoperative hemodynamic instability may be evident in patients with pheochromocytomas, and patients are at risk of adrenal insufficiency after bilateral adrenalectomy and sometimes after unilateral adrenalectomy (unrecognized Cushing's syndrome or, very rarely, Conn's syndrome). Long-term morbidity results mainly

from injury to nerve roots during trocar insertion, which can lead to chronic pain syndromes or muscle weakness, although this is more of an issue in case of open procedures.

Approximately 30% of patients who undergo bilateral adrenalectomy for Cushing's disease are at risk of developing Nelson's syndrome from progressive growth of the pre-existing pituitary tumor. This leads to increased ACTH levels, hyperpigmentation, visual field defects, headaches, and extraocular muscle palsies. Transsphenoidal pituitary resection is the initial mode of therapy, and external-beam radiotherapy is used in patients with residual tumor or extrasellar invasion.

REFERENCES

Entries highlighted in bright blue are key references.

- Plaza CP, Lopez ME, Carrasco CE, Meseguer LM, Perucho Ade L. Management of well-differentiated thyroglossal remnant thyroid carcinoma: time to close the debate? Report of five new cases and proposal of a definitive algorithm for treatment. *Ann Surg Oncol.* 2006;13:745-752.
- Cernea CR, Ferraz AR, Nishio S, Dutra A Jr, Hojaij FC, dos Santos LR. Surgical anatomy of the external branch of the superior laryngeal nerve. *Head Neck.* 1992;14:380-383.
- Si X, Zhang X, Tang W, Luo Y. Association between the CTLA-4 +49A/G polymorphism and Graves' disease: a meta-analysis. *Exp Ther Med.* 2012;4:538-544.
- Hagen F, Chapman EM. Comparison of high and low dosage levels of I-131 in the treatment of thyrotoxicosis. *N Engl J Med.* 1967;277:559.
- Singer RB. Long-term comparative cancer mortality after use of radioiodine in the treatment of hyperthyroidism, a fully reported multicenter study. *J Insur Med.* 2001;33:138.
- Cundiff JG, Portugal L, Sarne DH. Parathyroid adenoma after radioactive iodine therapy for multinodular goiter. *Am J Otolaryngol.* 2001;22:374.
- Muller PE, Bein B, Robens E, et al. Thyroid surgery according to Enderlen-Hotz or Dunhill: a comparison of two surgical methods for the treatment of Graves' disease. *Int Surg* 2001;86:112.
- Bahn RS, Burch HB, Cooper DS, et al. Hyperthyroidism and other causes of thyrotoxicosis: management guidelines of the American Thyroid Association and American Association of Clinical Endocrinologists. *Endocr Pract.* 2011;17:456-520.**
- Krohn K, Paschke R. Somatic mutations in thyroid nodular disease. *Mol Genet Metab.* 2002;75:202.
- Brook I. Microbiology and management of acute suppurative thyroiditis in children. *Int J Pediatr Otorhinolaryngol.* 2003;67:447.
- Masuoka H, Miyauchi A, Tomoda C, et al. Imaging studies in sixty patients with acute suppurative thyroiditis. *Thyroid.* 2011;21:1075-1080.
- Moshynska O, Saxena A. Clonal relationship between Hashimoto's thyroiditis and thyroid lymphoma. *J Clin Pathol.* 2008;61:438-444.
- Rodondi N, den Elzen WP, Bauer DC, et al. Subclinical hypothyroidism and the risk of coronary heart disease and mortality. *JAMA.* 2010;304:1365-1374.
- Levy JM, Hasney CP, Friedlander PL, Kandil E, Occhipinti EA, Kahn MJ. Combined mycophenolate mofetil and prednisone therapy in tamoxifen- and prednisone-resistant Reidel's thyroiditis. *Thyroid.* 2010;20:105-107.
- Knudsen N, Laurberg P, Perrild H, Bulow I, Ovesen L, Jorgensen T. Risk factors for goiter and thyroid nodules. *Thyroid.* 2002;12:879-888.
- Ron E. Thyroid cancer incidence among people living in areas contaminated by radiation from the Chernobyl accident. *Health Phys.* 2007;93:502-511.
- Nose V. Familial thyroid cancer: a review. *Mod Pathol.* 2011;(24 Suppl 2):S19-S33.
- Bajaj Y, De M, Thompson A. Fine needle aspiration cytology in diagnosis and management of thyroid disease. *J Laryngol Otol.* 2006;120:467.
- Cibas ES, Ali SZ, NCI Thyroid FNA State of the Science Conference. The Bethesda System for reporting thyroid cytopathology. *Am J Clin Pathol.* 2009;132:658-665.**
- Nobrega LH, Paiva FJ, Nobrega ML, et al. Predicting malignant involvement in a thyroid nodule: role of ultrasonography. *Endocr Pract.* 2007;13:219.
- Sheth S. Role of ultrasonography in thyroid disease. *Otolaryngol Clin North Am.* 2010;43:239-255, vii.
- Nikiforova MN, Nikiforov YE. Molecular genetics of thyroid cancer: implications for diagnosis, treatment, and prognosis. *Expert Rev Mol Diagn.* 2008;8:83-95.
- Caronia LM, Phay JE, Shah MH. Role of BRAF in thyroid oncogenesis. *Clin Cancer Res.* 2011;17:7511-7517.
- Thomas D, Friedman S, Lin RY. Thyroid stem cells: lessons from normal development and thyroid cancer. *Endocr Relat Cancer.* 2008;15:51-58.
- Hay ID, Grant CS, Taylor WF, McConahey WM. Ipsilateral lobectomy versus bilateral lobar resection in papillary thyroid carcinoma: a retrospective analysis of surgical outcome using a novel prognostic scoring system. *Surgery.* 1987;102:1088-1095.
- Cady B, Rossi R. An expanded view of risk-group definition in differentiated thyroid carcinoma. *Surgery.* 1988;104:947-953.
- American Joint Committee on Cancer. *AJCC Cancer Staging Manual.* 7th ed. New York: Springer-Verlag; 2010.
- DeGroot LJ, Kaplan EL, McCormick M, Straus FH. Natural history, treatment, and course of papillary thyroid carcinoma. *J Clin Endocrinol Metab.* 1990;71:414-424.
- Bhajee F, Nikiforov YE. Molecular analysis of thyroid tumors. *Endocr Pathol.* 2011;22:126-133.
- Cady B, Sedgwick CE, Meissner WA, Wool MS, Salzman FA, Werber J. Risk factor analysis in differentiated thyroid cancer. *Cancer.* 1979;43:810-820.
- Lee JH, Lee ES, Kim YS. Clinicopathologic significance of BRAF V600E mutation in papillary carcinomas of the thyroid: a meta-analysis. *Cancer.* 2007;110:38-46.
- Mazzaferri EL, Jhiang SM. Long-term impact of initial surgical and medical therapy on papillary and follicular thyroid cancer. *Am J Med.* 1994;97:418-428.
- Hay ID, Grant CS, Bergstralh EJ, Thompson GB, van Heerden JA, Goellner JR. Unilateral total lobectomy: is it sufficient surgical treatment for patients with AMES low-risk papillary thyroid carcinoma? *Surgery.* 1998;124:958-964, discussion 64-66.
- Mazzaferri EL, Massoll N. Management of papillary and follicular (differentiated) thyroid cancer: new paradigms using recombinant human thyrotropin. *Endocr Relat Cancer.* 2002;9:227-247.**
- Bilimoria KY, Bentrem DJ, Ko CY, et al. Extent of surgery affects survival for papillary thyroid cancer. *Ann Surg.* 2007;246:375-381, discussion 81-84.**
- American Thyroid Association (ATA) Guidelines Taskforce on Thyroid Nodules and Differentiated Thyroid Cancer, Cooper DS, Doherty GM, et al. Revised American Thyroid Association management guidelines for patients with thyroid nodules and differentiated thyroid cancer. *Thyroid.* 2009;19:1167-1214.**
- Nikiforov YE, Steward DL, Robinson-Smith TM, et al. Molecular testing for mutations in improving the fine-needle aspiration diagnosis of thyroid nodules. *J Clin Endocrinol Metab.* 2009;94:2092-2098.

38. Nikiforov YE, Ohori NP, Hodak SP, et al. Impact of mutational testing on the diagnosis and management of patients with cytologically indeterminate thyroid nodules: a prospective analysis of 1056 FNA samples. *J Clin Endocrinol Metab.* 2011;96:3390-3397.
39. Weber F, Teresi RE, Broelsch CE, Frilling A, Eng C. A limited set of human MicroRNA is deregulated in follicular thyroid carcinoma. *J Clin Endocrinol Metab.* 2006;91:3584-3691.
40. Chia SY, Milas M, Reddy SK, et al. Thyroid-stimulating hormone receptor messenger ribonucleic acid measurement in blood as a marker for circulating thyroid cancer cells and its role in the preoperative diagnosis of thyroid cancer. *J Clin Endocrinol Metab.* 2007;92:468-475.
41. Alexander EK, Kennedy GC, Baloch ZW, et al. Preoperative diagnosis of benign thyroid nodules with indeterminate cytology. *N Engl J Med.* 2012;367:705-715.
42. Iyer NG, Morris LG, Tuttle RM, Shaha AR, Ganly I. Rising incidence of second cancers in patients with low-risk (T1N0) thyroid cancer who receive radioactive iodine therapy. *Cancer.* 2011;117:4439-4446.
43. Sherman SI. Targeted therapies for thyroid tumors. *Mod Pathol.* 2011;(24 Suppl 2):S44-S52.
44. Snozek CL, Chambers EP, Reading CC, et al. Serum thyroglobulin, high-resolution ultrasound, and lymph node thyroglobulin in diagnosis of differentiated thyroid carcinoma nodal metastases. *J Clin Endocrinol Metab.* 2007;92:4278-4281.
45. American Thyroid Association Guidelines Task Force, Kloos RT, Eng C, et al. Medullary thyroid cancer: management guidelines of the American Thyroid Association. *Thyroid.* 2009;19:565-612.
46. Smallridge RC, Ain KB, Asa SL, et al. American Thyroid Association guidelines for management of patients with anaplastic thyroid cancer. *Thyroid.* 2012;22:1104-1139.
47. Sakorafas GH, Kokkoris P, Farley DR. Primary thyroid lymphoma (correction of lymphoma): diagnostic and therapeutic dilemmas. *Surg Oncol.* 2010;19:e124-e129.
48. Linos D. Minimally invasive thyroidectomy: a comprehensive appraisal of existing techniques. *Surgery.* 2011;150:17-24.
49. de Perrot M, Fadel E, Mercier O, et al. Surgical management of mediastinal goiters: when is a sternotomy required? *Thorac Cardiovasc Surg.* 2007;55:39.
50. Barczynski M, Konturek A, Cichon S. Randomized clinical trial of visualization versus neuromonitoring of recurrent laryngeal nerves during thyroidectomy. *Br J Surg.* 2009;96:240-246.
51. Akerstrom G, Malmaeus J, Bergstrom R. Surgical anatomy of human parathyroid glands. *Surgery.* 1984;95:14.
52. Akerstrom G, Malmaeus J, Bergstrom R. Surgical anatomy of human parathyroid glands. *Surgery.* 1984;95:14-21.
53. Gilmour J. The gross anatomy of the parathyroid glands. *J Pathol.* 1938;46:133.
54. Ward BK, Magno AL, Walsh JP, Ratajczak T. The role of the calcium-sensing receptor in human disease. *Clin Biochem.* 2012;45:943-953.
55. Saunders BD, Saunders EF, Gauger PG. Lithium therapy and hyperparathyroidism: an evidence-based assessment. *World J Surg.* 2009;33:2314-2323.
56. Thakker RV, Newey PJ, Walls GV, et al. Clinical practice guidelines for multiple endocrine neoplasia type 1 (MEN1). *J Clin Endocrinol Metab.* 2012;97:2990-3011.
57. Balogh K, Racz K, Patocs A, Hunyady L. Menin and its interacting proteins: elucidation of menin function. *Trends Endocrinol Metab.* 2006;17:357-364.
58. Proceedings of the NIH Consensus Development Conference on diagnosis and management of asymptomatic primary hyperparathyroidism. Bethesda, Maryland, October 29-31, 1990. *J Bone Miner Res.* 1991;(6 Suppl 2):S1-S166.
59. Silverberg SJ, Shane E, Jacobs TP, Siris E, Bilezikian JP. A 10-year prospective study of primary hyperparathyroidism with or without parathyroid surgery. *N Engl J Med.* 1999;341:1249-1255.
60. Bilezikian JP, Potts JT Jr, Fuleihan Gel H, et al. Summary statement from a workshop on asymptomatic primary hyperparathyroidism: a perspective for the 21st century. *J Clin Endocrinol Metab.* 2002;87:5353-5361.
61. Rubin MR, Bilezikian JP, McMahon DJ, et al. The natural history of primary hyperparathyroidism with or without parathyroid surgery after 15 years. *J Clin Endocrinol Metab.* 2008;93:3462-3470.
62. Khan A, Grey A, Shoback D. Medical management of asymptomatic primary hyperparathyroidism: proceedings of the third international workshop. *J Clin Endocrinol Metab.* 2009;94:373-381.
63. Pasiaka JL, Parsons L, Jones J. The long-term benefit of parathyroidectomy in primary hyperparathyroidism: a 10-year prospective surgical outcome study. *Surgery.* 2009;146:1006-1013.
64. Zanooco K, Angelos P, Sturgeon C. Cost-effectiveness analysis of parathyroidectomy for asymptomatic primary hyperparathyroidism. *Surgery.* 2006;140:874-881, discussion 81-82.
65. Bilezikian JP, Khan AA, Potts JT Jr, Third International Workshop on the Management of Asymptomatic Primary Hyperparathyroidism. Guidelines for the management of asymptomatic primary hyperparathyroidism: summary statement from the third international workshop. *J Clin Endocrinol Metab.* 2009;94:335-339.
66. Rodgers SE, Hunter GJ, Hamberg LM, et al. Improved preoperative planning for directed parathyroidectomy with 4-dimensional computed tomography. *Surgery.* 2006;140:932-940, discussion 40-41.
67. Sharma J, Milas M, Berber E, Mazzaglia P, Siperstein A, Weber CJ. Value of intraoperative parathyroid hormone monitoring. *Ann Surg Oncol.* 2008;15:493-498.
68. Westerdahl J, Bergenfelz A. Unilateral versus bilateral neck exploration for primary hyperparathyroidism: five-year follow-up of a randomized controlled trial. *Ann Surg.* 2007;246:976-981.
69. Gagner M. Endoscopic subtotal parathyroidectomy in patients with primary hyperparathyroidism. *Br J Surg.* 1996;83:875.
70. Augustine MM, Bravo PE, Zeiger MA. Surgical treatment of primary hyperparathyroidism. *Endocr Pract.* 2011;17(Suppl 1):75-82.
71. Lowe H, McMahon DJ, Rubin MR, Bilezikian JP, Silverberg SJ. Normocalcemic primary hyperparathyroidism: further characterization of a new clinical phenotype. *J Clin Endocrinol Metab.* 2007;92:3001-3005.
72. Silverberg SJ, Rubin MR, Faiman C, et al. Cinacalcet hydrochloride reduces the serum calcium concentration in inoperable parathyroid carcinoma. *J Clin Endocrinol Metab.* 2007;92:3803-3808.
73. Carpenter JM, Michaelson PG, Lidner TK, Hinni ML. Parathyromatosis. *Ear Nose Throat J.* 2007;86:21.
74. Udelsman R. Approach to the patient with persistent or recurrent primary hyperparathyroidism. *J Clin Endocrinol Metab.* 2011;96:2950-2958.
75. Pitt SC, Sippel RS, Chen H. Secondary and tertiary hyperparathyroidism, state of the art surgical management. *Surg Clin North Am.* 2009;89:1227-1239.
76. Yang RL, Freeman K, Reinke CE, et al. Tertiary hyperparathyroidism in kidney transplant recipients: characteristics of patients selected for different treatment strategies. *Transplantation.* 2012;94:70-76.
77. Schirpenbach C, Reincke M. Primary aldosteronism: Current knowledge and controversies in Conn's syndrome. *Nat Clin Pract Endocrinol Metab.* 2007;3:220.

78. Rossi GP. New concepts in adrenal vein sampling for aldosterone in the diagnosis of primary aldosteronism. *Curr Hypertens Rep.* 2007;9:90.
79. Pecori Giraldi F, Ambrogio AG, De Martin M, Fatti LM, Scacchi M, Cavagnini F. Specificity of first-line tests for the diagnosis of Cushing's syndrome: assessment in a large series. *J Clin Endocrinol Metab.* 2007;92:4123-4129.
80. Bertherat J, Bertagna X. Pathogenesis of adrenocortical cancer. *Best Pract Res Clin Endocrinol Metab.* 2009;23:261-271.
81. Rodgers SE, Evans DB, Lee JE, et al. Adrenocortical carcinoma. *Surg Oncol Clin N Am.* 2006;15:535.
82. Copeland PM. The incidentally discovered adrenal mass. *Ann Surg.* 1984;199:116.
83. Sturgeon C, Shen WT, Clark OH, Duh QY, Kebebew E. Risk assessment in 457 adrenal cortical carcinomas: how much does tumor size predict the likelihood of malignancy? *J Am Coll Surg.* 2006;202:423-430.
84. Aubert S, Wacrenier A, Leroy X, et al. Weiss system revisited: a clinicopathologic and immunohistochemical study of 49 adrenocortical tumors. *Am J Surg Pathol.* 2002;26:1612-1619.
85. Terzolo M, Angeli A, Fassnacht M, et al. Adjuvant mitotane treatment for adrenocortical carcinoma. *N Engl J Med.* 2007;356:2372-2380.
86. Fassnacht M, Terzolo M, Allolio B, et al. Combination chemotherapy in advanced adrenocortical carcinoma. *N Engl J Med.* 2012;366:2189-2197.
87. Fishbein L, Nathanson KL. Pheochromocytoma and paraganglioma: understanding the complexities of the genetic background. *Cancer Genet.* 2012;205:1-11.
88. Sackett WR, Bambach CP. Bilateral subtotal laparoscopic adrenalectomy for phaeochromocytoma. *ANZ J Surg.* 2003;73:664-666.
89. Shen WT, Sturgeon C, Clark OH, et al. Should pheochromocytoma size influence surgical approach? A comparison of 90 malignant and 60 benign pheochromocytomas. *Surgery.* 2004;136:1129.
90. McDermott S, O'Connor OJ, Cronin CG, Blake MA. Radiological evaluation of adrenal incidentalomas: current methods and future prospects. *Best Pract Res Clin Endocrinol Metab.* 2012;26:21-33.
91. Zeiger MA, Thompson GB, Duh QY, et al. American Association of Clinical Endocrinologists and American Association of Endocrine Surgeons Medical guidelines for the management of adrenal incidentalomas. *Endocrine Pract.* 2009;15(Suppl 1):3-20.
92. Strong VE, D'Angelica M, Tang L, et al. Laparoscopic adrenalectomy for isolated adrenal metastasis. *Ann Surg Oncol.* 2007;14:3392.

39 chapter

Pediatric Surgery

David J. Hackam, Tracy Grikscheit, Kasper Wang,
Jeffrey S. Upperman, and Henri R. Ford

Introduction	1597	Gastroesophageal Reflux / 1613	
Pediatric Surgical Themes: Pitfalls and Pearls	1598	Gastrointestinal Tract	1613
General Considerations	1599	An Approach to the Vomiting Infant / 1613	
Fluid and Electrolyte Balance / 1599		Hypertrophic Pyloric Stenosis / 1613	
Acid-Base Equilibrium / 1599		Intestinal Obstruction in the Newborn / 1614	
Blood Volume and Blood Replacement / 1599		Duodenal Obstruction / 1615	
Enteral and Parenteral Nutrition / 1600		Intestinal Atresia / 1615	
Venous Access / 1601		Malrotation and Midgut Volvulus / 1616	
Thermoregulation / 1601		Meconium Ileus / 1617	
Pain Control / 1601		Necrotizing Enterocolitis / 1619	
Neck Masses	1601	Short Bowel Syndrome / 1621	
Lymphadenopathy / 1602		Intussusception / 1622	
Thyroglossal Duct Remnants / 1602		Appendicitis / 1622	
Branchial Cleft Anomalies / 1602		Intestinal Duplications / 1624	
Lymphatic Malformation / 1602		Meckel's Diverticulum / 1624	
Torticollis / 1603		Mesenteric Cysts / 1624	
Respiratory System	1603	Hirschsprung's Disease / 1624	
Congenital Diaphragmatic Hernia (Bochdalek) / 1603		Anorectal Malformations / 1626	
Congenital Lobar Emphysema / 1605		Jaundice	1628
Bronchopulmonary Foregut Malformations / 1606		The Approach to the Jaundiced Infant / 1628	
Bronchiectasis / 1607		Biliary Atresia / 1628	
Foreign Bodies / 1607		Choledochal Cyst / 1630	
Esophagus	1608	Deformities of the Abdominal Wall	1631
Esophageal Atresia and Tracheoesophageal Fistula / 1608		Embryology of the Abdominal Wall / 1631	
Corrosive Injury of the Esophagus / 1612		Umbilical Hernia / 1631	
		Patent Urachus / 1631	
		Omphalocele / 1632	
		Gastroschisis / 1633	
		Prune-Belly Syndrome / 1634	
		Inguinal Hernia / 1634	
		Genitalia	1635
		Undescended Testis / 1635	
		Vaginal Anomalies / 1636	
		Ovarian Cysts and Tumors / 1636	
		Ambiguous Genitalia / 1637	
		Pediatric Malignancy	1638
		Wilms' Tumor / 1638	
		Neuroblastoma / 1639	
		Rhabdomyosarcoma / 1640	
		Teratoma / 1641	
		Liver Tumors / 1641	
		Trauma in Children	1642
		Mechanisms of Injury / 1642	
		Initial Management / 1642	
		Evaluation of Injury / 1643	
		Injuries to the Central Nervous System / 1643	
		Thoracic Injuries / 1643	
		Abdominal Injuries / 1643	
		Fetal Intervention	1644
		Fetal Surgery for Lower Urinary Tract Obstruction / 1645	
		Fetal Surgery for Congenital Diaphragmatic Hernia / 1645	
		Fetal Surgery for Myelomeningocele / 1645	
		The EXIT Procedure / 1645	

INTRODUCTION

In his 1953 classic textbook entitled *The Surgery of Infancy and Childhood*, Dr. Robert E. Gross summarized the essential challenge of pediatric surgery: "Those who daily operate upon adults, even with the greatest of skill, are sometimes appalled – or certainly are not at their best – when called upon to operate upon and care for a tiny patient. Something more than diminutive instruments or scaled-down operative manipulations are necessary to do the job in a suitable manner." To this day, surgical residents and other trainees often approach the pediatric surgical patient with the same mix of fear, trepidation, and anxiety. Importantly, these same trainees typically complete their pediatric surgical rotations with a profound respect for the resilience

of young children to undergo complex operations, and with an appreciation for the precision required from their caregivers, both in the operating room and during the perioperative period. Over the decades, the specialty of pediatric surgery has evolved considerably to encompass not only the care of the smallest patients with surgical disorders, who may require in utero interventions in certain circumstances, but also the care of older infants, children, adolescents, and young adults. Similarly, our understanding of the pathophysiology of the diseases that pediatric surgeons face has evolved to the point that some pediatric surgical diseases are now understood at the level of molecular or cellular signaling pathways. Pediatric surgery provides the opportunity to intervene positively in a wide array of diseases

Key Points

- 1▶ In infants with Bochdalek-type congenital diaphragmatic hernia, the severity of pulmonary hypoplasia and the resultant pulmonary hypertension are key determinants of survival. Barotrauma and hypoxia should be avoided.
- 2▶ During initial management of an infant with esophageal atresia and distal tracheoesophageal fistula, every effort should be made to avoid distending the gastrointestinal tract, especially when using mechanical ventilation. The patient should be evaluated for components of the VACTERL (vertebral, anorectal, cardiac, tracheoesophageal, renal, radial limb) anomalies. Timing and extent of surgery are dictated by the stability of the patient.
- 3▶ Although malrotation with midgut volvulus occurs most commonly within the first few weeks of life, it should always be considered in the differential diagnosis in a child with bilious emesis. Volvulus is a surgical emergency; therefore, in a critically ill child, prompt surgical intervention should not be delayed for any reason.
- 4▶ When evaluating a newborn infant for vomiting, it is critical to distinguish between proximal and distal causes of intestinal obstruction using both prenatal and postnatal history, physical examination, and abdominal radiographs.
- 5▶ Risk factors for necrotizing enterocolitis (NEC) include prematurity, formula feeding, bacterial infection, and intestinal ischemia. Critical to the management of infants with advanced (Bell stage III) or perforated NEC is timely and adequate source control of peritoneal contamination. Early sequelae of NEC include perforation, sepsis, and death. Later sequelae include short bowel syndrome and stricture.
- 6▶ In patients with intestinal obstruction secondary to Hirschsprung's disease, a leveling ostomy or endorectal pull-through should be performed using ganglionated bowel, proximal to the transition zone between ganglionic and aganglionic intestine.
- 7▶ Prognosis of infants with biliary atresia is directly related to age at diagnosis and timing of portoenterostomy. Infants with advanced age at the time of diagnosis or infants who fail to demonstrate evidence of bile drainage after portoenterostomy usually require liver transplantation.
- 8▶ Infants with omphaloceles have greater associated morbidity and mortality than infants with gastroschisis due to a higher incidence of congenital anomalies and pulmonary hypoplasia. Gastroschisis can be associated with intestinal atresia, but not with other congenital anomalies. An intact omphalocele can be repaired electively, whereas gastroschisis requires urgent intervention to protect the exposed intestine.
- 9▶ Prognosis for children with Wilms' tumor is defined by the stage of disease at the time of diagnosis and the histologic type (favorable vs. unfavorable). Preoperative chemotherapy is indicated for bilateral involvement, a solitary kidney, or tumor in the inferior vena cava above the hepatic veins. Gross tumor rupture during surgery automatically changes the stage to 3 (at a minimum).
- 10▶ Injury is the leading cause of death in children older than 1 year of age. Blunt mechanisms account for the majority of pediatric injuries. The central nervous system is the most commonly injured organ system and the leading cause of death in injured children.

and to exert a long-lasting impact on the lives of children and their grateful parents. The scope of diseases encountered in the standard practice of pediatric surgery is immense and includes anomalies of the head and neck, thoracic, gastrointestinal, and genitourinary areas. This chapter is not designed to cover the entire spectrum of diseases a pediatric surgeon is expected to master; rather, it presents a synopsis of a handful of pediatric surgical conditions that a practicing general surgeon is likely to encounter over the course of his or her career.

PEDIATRIC SURGICAL THEMES: PITFALLS AND PEARLS

This chapter focuses on the unique considerations regarding the diagnosis and management of surgical diseases in the pediatric population. Many surgical trainees approach the surgical care of children with some degree of fear and trepidation. As any pediatric caregiver will attest to, the surgical management of infants and children requires delicate, careful, and professional interactions with their parents. The stress that the parents of sick children experience in the hospital setting can, at times, be overwhelming. It is due, in part, to the uncertainty regarding a particular prognosis, the feeling of helplessness that evolves when one is unable to care for one's own child, and in certain cases, the guilt or remorse that one feels for not seeking medical care earlier or for consenting to a particular procedure. Management

of the sick child and his or her family requires not only a certain set of skills, but also a unique knowledge base. This section is included to summarize some important general principles in accomplishing this task.

1. *Children are not little adults, but they are little people.* In practical terms, this often-heard refrain implies that children have unique fluid, electrolyte, and medication needs. Thus, the dosage of medications and the administration of intravenous fluids should be based on their weight. The corollary of this point is that infants and young children are extremely sensitive to perturbations in their normal physiology, and as such may easily experience fluid overload or dehydration.
2. *Sick children whisper before they shout.* Children with surgical diseases can deteriorate very quickly. But before they deteriorate, they often manifest subtle physical findings. These findings—referred to as “whispers”—may include signs such as tachycardia, bradycardia, hypothermia, fever, recurrent emesis, or feeding intolerance. Meticulous attention to these subtle findings may unmask the development of potentially serious, life-threatening physiologic disturbances.
3. *Always listen to the mother and the father.* Surgical diseases in children can be very difficult to diagnose because children are often minimally communicative and information that they communicate may be confusing, conflicting, or both. In all cases, it is wise to listen to the child's parents, who

have closely observed their child and know him or her best. Most importantly, the child's parents know with certainty whether or not the child is sick despite not always knowing the precise diagnosis.

4. *Children suffer pain after surgery.* Timely and adequate pain management must accompany surgical interventions.
5. *Pediatric tissue must be handled delicately and with profound respect.*

GENERAL CONSIDERATIONS

Fluid and Electrolyte Balance

In managing the pediatric surgical patient, an understanding of fluid and electrolyte balance is critical, as the margin between dehydration and fluid overload is rather small. This is particularly true in infants, who have little reserve when ill. Failure to pay meticulous attention to their hydration status can result in significant fluid overload or dehydration. Several surgical diagnoses such as gastroschisis or short-gut syndrome are characterized by a predisposition to fluid loss. Others require judicious restoration of intravascular volume in order to prevent cardiac failure, as is the case in patients with congenital diaphragmatic hernia and associated pulmonary hypertension. The infant's physiologic day is approximately 8 hours in duration. Accordingly, careful assessment of the individual patient's fluid balance, including fluid intake and output for the previous 8 hours, is essential to prevent dehydration or fluid overload. Clinical signs of dehydration include tachycardia, decreased urine output, reduced skin turgor, a depressed fontanelle, absent tears, lethargy, and poor feeding. Fluid overload is often manifested by the onset of new oxygen requirement, respiratory distress, tachypnea, and tachycardia. The physical assessment of the fluid status of each child must include a complete head-to-toe evaluation, with emphasis on determining whether perturbations in normal physiology are present.

At 12 weeks' gestation, the total body water of a fetus is approximately 94 cc/kg. By the time the fetus reaches full term, the total body water has decreased to approximately 80 cc/kg. Total body water drops an additional 5% within the first week of life, and by 1 year of life, total body water approaches adult levels, around 60 to 65 cc/kg. Parallel to the drop in total body water is the reduction in extracellular fluid. These changes are accelerated in the preterm infant who may face additional fluid losses due to coexisting congenital anomalies or surgery. Normal daily maintenance fluids for most children can be estimated using the following formula: 100 mL/kg for the first 10 kg, plus 50 mL/kg for 11 to 20 kg, plus 25 mL/kg for each additional kilogram of body weight thereafter. Because intravenous (IV) fluid orders are written as milliliters per hour, this can be conveniently converted as follows: 4 mL/kg/h up to 10 kg, add 2 mL/kg/h for 11 to 20 kg, and add 1 mL/kg/h for each additional kilogram of body weight thereafter. For example, a 26-kg child has an estimated maintenance fluid requirement of $(10 \times 4) + (10 \times 2) + (6 \times 1) = 66$ mL/h in the absence of massive fluid losses or shock. A newborn infant with gastroschisis will manifest significant evaporative losses from the exposed bowel such that fluid requirements may range from 150 to 180 cc/kg/d. Precise management of a neonate's fluid status requires an understanding of changes in the glomerular filtration rate (GFR) and tubular function of the kidney. The term newborn's GFR is approximately 21 mL/min/1.73 m² compared

to 70 mL/min/1.73 m² in an adult. Within the first 2 weeks of life, GFR increases to approximately 60, and by 2 years of age, it is essentially at adult levels. The capacity to concentrate urine is very limited in preterm and term infants. Compared with an adult who can concentrate urine to 1200 mOsm/kg, infants can concentrate urine at best to 600 mOsm/kg. While infants are capable of secreting antidiuretic hormone (ADH), the aquaporin water channel-mediated osmotic water permeability of the infant's collecting tubules is severely limited compared with that of adults, leading to insensitivity to ADH.

Sodium requirements range from 2 mEq/kg/d in term infants up to 5 mEq/kg/d in critically ill preterm infants as a consequence of salt wasting. Potassium requirements are on the order of 1 to 2 mEq/kg/d. Calcium and magnesium supplementation of IV fluids is essential to prevent laryngospasm, dysrhythmias, and tetany.

Acid-Base Equilibrium

Acute metabolic acidosis usually implies inadequate tissue perfusion and is a serious disorder in children. Potentially life-threatening causes that are specific for the pediatric population must be sought; they include intestinal ischemia from necrotizing enterocolitis (in the neonate), midgut volvulus, or incarcerated hernia. Other causes include chronic bicarbonate loss from the gastrointestinal tract or acid accumulation as in chronic renal failure. Respiratory acidosis implies hypoventilation, the cause of which should be apparent. Treatment of acute metabolic acidosis should be aimed at restoring tissue perfusion by addressing the underlying abnormality first. For severe metabolic acidemia where the serum pH is less than 7.25, sodium bicarbonate should be administered using the following guideline: base deficit \times weight in kilograms \times 0.5 (in newborns). The last factor in the equation should be 0.4 for smaller children and 0.3 for older children. The dose should be diluted to a concentration of 0.5 mEq/mL because full-strength sodium bicarbonate is hyperosmolar. One half of the corrective dose is given, and the serum pH is measured again. During cardiopulmonary resuscitation (CPR), one half of the corrective dose can be given as an IV bolus and the other half given slowly via IV.

Respiratory alkalosis is usually caused by hyperventilation, which is readily correctable. Metabolic alkalosis most commonly implies gastric acid loss, as in the child with pyloric stenosis, or aggressive diuretic therapy. In the child with gastric fluid loss, IV fluids of 5% dextrose, 0.5% normal saline, and 20 mEq KCl/L usually correct the alkalosis.

Blood Volume and Blood Replacement

Criteria for blood transfusion in infants and children remain poorly defined. The decision to transfuse a critically ill pediatric patient may depend on a number of clinical features that include the patient's age, primary diagnosis, the presence of ongoing bleeding, coagulopathy, hypoxia, hemodynamic compromise, lactic acidosis, cyanotic heart disease, and overall severity of illness. A recent survey of transfusion practices among pediatric intensivists showed that the baseline hemoglobin levels that would prompt them to recommend packed red blood cell (PRBC) transfusion ranged from 7 to 13 g/dL. Patients with cyanotic heart disease are often transfused to higher hemoglobin values, although the threshold for transfusion in this population remains to be defined. To decrease the need for transfusion, other strategies have been considered. Studies in both critically ill adults and neonates have shown that administration

of erythropoietin decreases PRBC transfusion requirements. In general terms, there is a trend toward an avoidance of the use of PRBC products whenever possible, as current studies suggest that lower hemoglobin concentrations are well tolerated by many groups of patients, whereas administration of PRBCs may have unintended negative consequences. In addition, there is increasing evidence that PRBC transfusion may have adverse effects on the host immune system, in both children and adults. These effects are poorly understood but may be due to red blood cell (RBC) storage or factors that are particular to the individual RBC donor.

A useful guideline for estimating blood volume for the newborn infant is approximately 80 mL/kg of body weight. When PRBCs are required, the transfusion requirement is usually administered in 10-mL/kg increments, which is roughly equivalent to a 500-mL transfusion for a 70-kg adult. The following formula may be used to determine the volume (mL) of PRBCs to be transfused:

(Target hematocrit – Current hematocrit) × weight (kg) × 80/65
(65 represents the estimated hematocrit of a unit of PRBC)

In the child, coagulation deficiencies rapidly may assume clinical significance after extensive blood transfusion. It is advisable to have fresh frozen plasma and platelets available if more than 30 mL/kg have been transfused. Plasma is given in a dose of 10 to 20 mL/kg, and platelets are given in a dose of 1 unit/5 kg. Each unit of platelets consists of 40 to 60 mL of fluid (plasma plus platelets). Following transfusion of PRBCs to neonates with tenuous fluid balance, a single dose of a diuretic (such as furosemide 1 mg/kg) may help to facilitate excretion of the extra fluid load. Many clinicians prefer to administer fresh products to minimize the deleterious effects of red cell storage.

Enteral and Parenteral Nutrition

The nutritional requirements of the surgical neonate must be met in order for the child to grow and to heal surgical wounds. If inadequate protein and carbohydrate calories are given, the child may not only fail to recover from surgery, but may also exhibit growth failure and impaired development of the central nervous system. In general terms, the adequacy of growth

Table 39-1

Nutritional requirements for the pediatric surgical patient

AGE	CALORIES (kcal/kg/d)	PROTEIN (g/kg/d)
0–6 months	100–120	2
6 months–1 year	100	1.5
1–3 years	100	1.2
4–6 years	90	1
7–10 years	70	1
11–14 years	55	1
15–18 years	45	1

must be assessed frequently, by determining both total body weight and head circumference. Neonates who are particularly predisposed to protein-calorie malnutrition include those with gastroschisis, intestinal atresia, or intestinal insufficiency from other causes, such as necrotizing enterocolitis. The protein and caloric requirements for the surgical neonate are shown in Table 39-1.

Nutrition can be provided via either the enteral or parenteral route. Whenever possible, the enteral route is preferred because it not only promotes the growth and function of the gastrointestinal system, but also ensures that the infant learns how to feed. There are various enteral feeding preparations available; these are outlined in Table 39-2. The choice of formula is based on the individual clinical state of the child. Pediatric surgeons are often faced with situations where oral feeding is not possible. This problem can be seen in the extremely premature infant who has not yet developed feeding skills or in the infant with concomitant craniofacial anomalies that impair sucking, for example. In these instances, enteral feeds can be administered either via a nasojunal or a gastrostomy tube.

When the gastrointestinal tract cannot be used because of mechanical, ischemic, inflammatory, or functional disorders,

Table 39-2

Formulas for pediatric surgical neonates

FORMULA	kcal/mL	PROTEIN (g/mL)	FAT (g/mL)	CARBOHYDRATE (g/mL)
Human milk	0.67	0.011	0.04	0.07
Milk-based formula				
Enfamil 20	0.67	0.015	0.038	0.069
Similac 20	0.67	0.015	0.036	0.072
Soy-based formula				
Prosobee	0.67	0.02	0.036	0.07
Isomil	0.67	0.018	0.037	0.068
Special formula				
Pregestimil	0.67	0.019	0.028	0.091
Alimentum	0.67	0.019	0.038	0.068
Preterm				
Enfamil Premature	0.80	0.024	0.041	0.089

parenteral alimentation must be given. Prolonged parenteral nutrition is delivered via a central venous catheter. Peripheral IV alimentation can be given, using less concentrated but greater volumes of solutions. Long-term parenteral nutrition should include supplemental copper, zinc, and iron to prevent the development of trace metal deficiencies. A major complication of long-term total parenteral nutrition (TPN) is the development of parenteral nutrition-associated cholestasis, which can eventually progress to liver failure. To prevent this major complication, concomitant enteral feedings should be instituted and the gastrointestinal tract should be used as soon as possible. When proximal stomas are in place, gastrointestinal continuity should be restored as soon as possible. Where intestinal insufficiency is associated with dilation of the small intestine, tapering or intestinal lengthening procedures may be beneficial. Other strategies to minimize the development of TPN-related liver disease include meticulous catheter care to avoid infection, which increases cholestatic symptoms, aggressive treatment of any infection, and early cycling of parenteral nutrition in older children who can tolerate not receiving continuous dextrose solution for a limited period. Preliminary evidence suggests the possibility that substituting omega-3 fish oil lipid emulsion in parenteral nutrition for the standard soybean-based emulsions may prevent the development of TPN-related cholestasis and reverse the effects of established liver disease.

Venous Access

Obtaining reliable vascular access in an infant or child is an important task that often becomes the responsibility of the pediatric surgeon. The goal should always be to place the catheter in the least invasive, least risky, and least painful manner, and in a location that is most accessible and allows for use of the catheter without complications for as long as it is needed. In infants, central venous access may be established using a cutdown approach, either in the antecubital fossa, external jugular vein, facial vein, or proximal saphenous vein. If the internal jugular vein is used, care is taken to prevent venous occlusion. In infants over 3 kg and in older children, percutaneous access of the subclavian, internal jugular, or femoral veins is possible in most cases, and central access is achieved using the Seldinger technique. The catheters are tunneled to an exit site separate from the venotomy site. Where available, peripherally inserted central catheter (PICC) lines may be placed, typically via the antecubital fossa. Regardless of whether the catheter is placed by a cutdown approach or percutaneously, a chest x-ray to confirm central location of the catheter tip and to exclude the presence of a pneumothorax or hemothorax is mandatory. When discussing the placement of central venous catheters with parents, it is important to note that the complication rate for central venous lines in children can be high. The incidence of catheter-related sepsis or infection approaches 10% in many series, although recent reports show a lower incidence. Superior or inferior vena caval occlusion is a significant risk after the placement of multiple lines, particularly in the smallest premature patients.

Thermoregulation

Careful regulation of the ambient environment of infants and children is crucial, as these patients are extremely thermolabile. Premature infants are particularly susceptible to changes in environmental temperature. Because they are unable to shiver and lack stores of fat, their potential for thermogenesis is impaired. The innate inability to regulate temperature is compounded by

the administration of anesthetic and paralyzing agents. Since these patients lack adaptive mechanisms to cope with the environment, the environmental temperature must be regulated. Attention to heat conservation during transport of the infant to and from the operating room is essential. Transport systems incorporating heating units are necessary for premature infants. In the operating room, the infant is kept warm by the use of overhead heating lamps, a heating blanket, warming the room as well as inspired gases, and coverage of the extremities and head with occlusive materials. During abdominal surgery, extreme care is taken to avoid wet and cold drapes. All fluids used to irrigate the chest or abdomen must be warmed to body temperature. Laparoscopic approaches for abdominal operations may result in more stable thermoregulation due to decreased heat loss from the smaller wound size. Constant monitoring of the child's temperature is critical in a lengthy procedure, and the surgeon should continuously communicate with the anesthesiologist regarding the temperature of the patient. The development of hypothermia in infants and children can result in cardiac arrhythmias or coagulopathy. These potentially life-threatening complications can be avoided by careful attention to thermoregulation.

Pain Control

All children, including neonates, experience pain. Therefore, careful recognition and management of pediatric pain represents an important component of the perioperative management of all pediatric surgical patients. There is a range of pain management options that can improve the child's well-being, as well as the parents' sense of comfort. The use of a pacifier, which may be dipped in sucrose, has been shown to decrease crying time and neonatal pain scores after minor procedures. For situations where more pain is expected, IV narcotic agents should be used. Morphine and fentanyl have an acceptable safety margin and can be administered judiciously to neonates and children. A randomized clinical trial involving neonates on ventilators showed that the use of a morphine infusion decreased the incidence of intraventricular hemorrhage by 50%. Additional analgesic modalities include the use of topical anesthetic ointment (EMLA cream), regional anesthesia such as caudal blocks for hernias, and epidural or incisional catheter infusions (On-Q™) for large abdominal or thoracic incisions. In surgical neonates who have received large concentrations of narcotics over a prolonged period, transient physical dependence should not only be expected, but anticipated. When narcotics are discontinued, symptoms of narcotic withdrawal may develop, including irritability, restlessness, and episodes of hypertension and tachycardia. Early recognition of these signs is essential, as is timely treatment using naloxone and other agents. In the postoperative period, patient-controlled analgesia is another excellent method of pain control. By ensuring that the pediatric surgical patient has adequate analgesia, the surgeon ensures that the patient receives the most humane and thorough treatment and provides important reassurance to all other members of the healthcare team and to the family that pain control is a very high priority.

NECK MASSES

The management of neck masses in children is determined by their location and the length of time that they have been present. Neck lesions are found either in the midline or lateral compartments. Midline masses include thyroglossal duct remnants, thyroid masses, thymic cysts, or dermoid cysts. Lateral lesions

include branchial cleft remnants, cystic hygromas, vascular malformations, salivary gland tumors, torticollis, and lipoblastoma (a rare benign mesenchymal tumor of embryonal fat occurring in infants and young children). Enlarged lymph nodes and rare malignancies such as rhabdomyosarcoma can occur either in the midline or laterally.

Lymphadenopathy

The most common cause of a neck mass in a child is an enlarged lymph node, which typically can be found laterally or in the midline. The patient is usually referred to the pediatric surgeon for evaluation after the mass has been present for several weeks. A detailed history and physical examination often helps determine the likely etiology of the lymph node and the need for excisional biopsy. Enlarged tender lymph nodes are usually the result of a bacterial infection (*Staphylococcus* or *Streptococcus*). Treatment of the primary cause (e.g., otitis media or pharyngitis) with antibiotics often is all that is necessary. However, when the involved nodes become fluctuant, incision and drainage are indicated. In many North American institutions, there has been an increasing prevalence of methicillin-resistant *Staphylococcus aureus* infection of the skin and soft tissues, leading to increased staphylococcal lymphadenitis in children. More chronic forms of lymphadenitis, including infections with atypical mycobacteria, as well as cat-scratch fever, are diagnosed based on serologic findings or excisional biopsy. The lymphadenopathy associated with infectious mononucleosis can be diagnosed based on serology. When the neck nodes are firm, fixed, and others are also present in the axillae or groin, or the history suggests lymphoma, excisional biopsy is indicated. In these cases, it is essential to obtain a chest radiograph to look for the presence of a mediastinal mass. Significant mediastinal load portends cardiorespiratory collapse due to loss of venous return and compression of the tracheobronchial tree with general anesthesia. Accordingly, such biopsies should be done under local anesthesia.

Thyroglossal Duct Remnants

Pathology and Clinical Manifestations. The thyroid gland buds off the foregut diverticulum at the base of the tongue in the region of the future foramen cecum at 3 weeks of embryonic life. As the fetal neck develops, the thyroid tissue becomes more anterior and caudad until it rests in its normal position. The “descent” of the thyroid is intimately connected with the development of the hyoid bone. Residual thyroid tissue left behind during the migration may persist and subsequently present in the midline of the neck as a thyroglossal duct cyst. The mass is most commonly appreciated in the 2- to 4-year-old child when the baby fat disappears and irregularities in the neck become more readily apparent. Usually the cyst is encountered in the midline at or below the level of the hyoid bone, and moves up and down with swallowing or with protrusion of the tongue. Occasionally it presents as an intrathyroidal mass. Most thyroglossal duct cysts are asymptomatic. If the duct retains its connection with the pharynx, infection may occur, and the resulting abscess will necessitate incision and drainage, occasionally resulting in a salivary fistula. Submental lymphadenopathy and midline dermoid cysts can be confused with a thyroglossal duct cyst. Rarely, midline ectopic thyroid tissue masquerades as a thyroglossal duct cyst and may represent the patient’s only thyroid tissue. Therefore, if there is any question regarding the diagnosis or if the thyroid gland cannot be palpated in its normal anatomic position, it is advisable to obtain a nuclear scan to confirm the

presence of a normal thyroid gland. Although rarely the case in children, in adults the thyroglossal duct may contain thyroid tissue that can undergo malignant degeneration. The presence of malignancy in a thyroglossal cyst should be suspected when the cyst grows rapidly or when the ultrasound demonstrates a complex anechoic pattern or the presence of calcification.

Treatment. If the cyst presents with an abscess, treatment should first consist of drainage and antibiotics. Following resolution of the inflammation, resection of the cyst in continuity with the central portion of the hyoid bone and the tract connecting to the pharynx in addition to ligation at the foramen cecum (the Sistrunk operation) is curative in over 90% of patients. Lesser operations result in unacceptably high recurrence rates, and recurrence is more frequent following infection. According to a recent review, factors predictive of recurrence included more than two infections prior to surgery, age under 2 years, and inadequate initial operation.

Branchial Cleft Anomalies

Paired branchial clefts and arches develop early in the fourth gestational week. The first cleft and the first, second, third, and fourth pouches give rise to adult organs. The embryologic communication between the pharynx and the external surface may persist as a fistula. A fistula is seen most commonly with the second branchial cleft, which normally disappears, and extends from the anterior border of the sternocleidomastoid muscle superiorly, inward through the bifurcation of the carotid artery, and enters the posterolateral pharynx just below the tonsillar fossa. In contrast, a third branchial cleft fistula passes posterior to the carotid bifurcation. The branchial cleft remnants may contain small pieces of cartilage and cysts, but internal fistulas are rare. A second branchial cleft sinus is suspected when clear fluid is noted draining from the external opening of the tract at the anterior border of the lower third of the sternomastoid muscle. Rarely, branchial cleft anomalies occur in association with biliary atresia and congenital cardiac anomalies, an association that is referred to as Goldenhar’s complex.

Treatment. Complete excision of the cyst and sinus tract is necessary for cure. Dissection of the sinus tract is facilitated with passage of a fine lacrimal duct probe through the external opening into the tract and using it as a guide for dissection. Injection of a small amount of methylene blue dye into the tract also may be useful. A series of two or sometimes three small transverse incisions in a “stepladder” fashion is preferred to a long oblique incision in the neck, which is cosmetically undesirable. Branchial cleft cysts can present as abscesses. In these cases, initial treatment includes incision and drainage with a course of antibiotics to cover *Staphylococcus* and *Streptococcus* species, followed by excision of the cyst after the infection resolves.

Lymphatic Malformation

Etiology and Pathology. Lymphatic malformation (previously known as cystic hygroma or lymphangioma) occurs as a result of sequestration or obstruction of developing lymph vessels in approximately 1 in 12,000 births. Although the lesion can occur anywhere, the most common sites are in the posterior triangle of the neck, axilla, groin, and mediastinum. The cysts are lined by endothelium and filled with lymph. Occasionally unilocular cysts occur, but more often, there are multiple cysts “infiltrating” the surrounding structures and

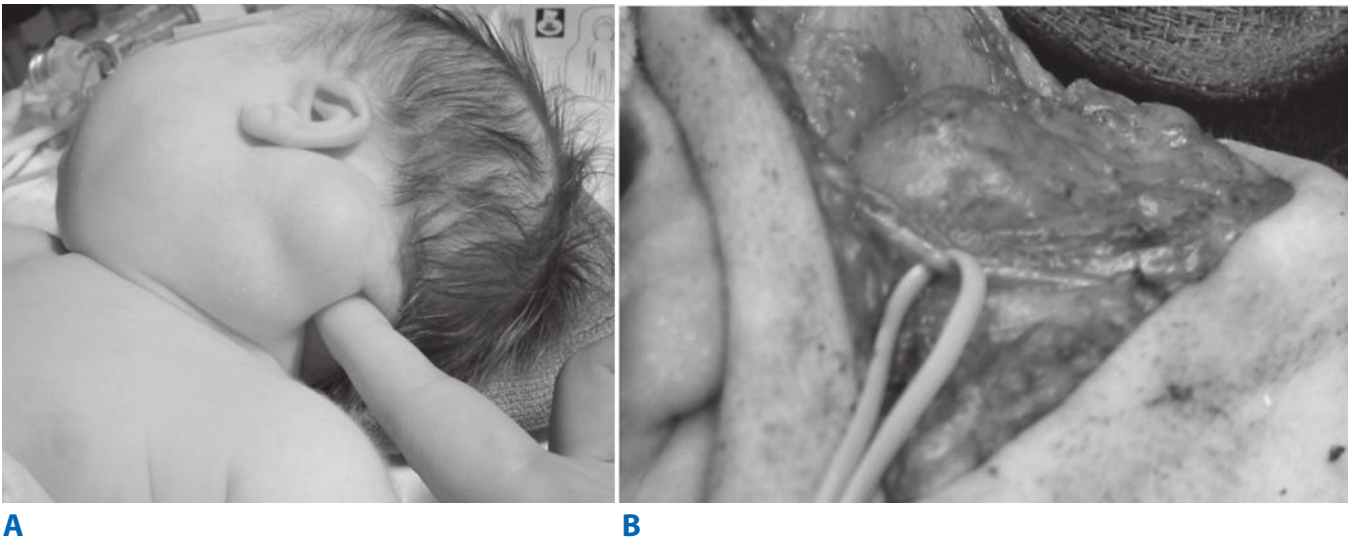

Figure 39-1. **A.** Left cervical lymphatic malformation in a 2-day-old baby. **B.** Intraoperative photograph showing a vessel loop around the spinal accessory nerve.

distorting the local anatomy. A particularly troublesome variant of lymphatic malformation is one that involves the tongue, floor of the mouth, and structures deep in the neck. Adjacent connective tissue may show extensive lymphocytic infiltration. The mass may be apparent at birth or may appear and enlarge rapidly in the early weeks or months of life as lymph accumulates; most present by age 2 years (Fig. 39-1A). Extension of the lesion into the axilla or mediastinum occurs about 10% of the time and can be demonstrated preoperatively by chest x-ray, ultrasound (US), or computed tomography (CT) scan. Occasionally lymphatic malformations contain nests of vascular tissue. These poorly supported vessels may bleed and produce rapid enlargement and discoloration of the mass. Infection within the cysts, usually caused by *Streptococcus* or *Staphylococcus*, may occur. In the neck, this can cause rapid enlargement, which may result in airway compromise. Rarely, it may be necessary to carry out percutaneous aspiration of a cyst to relieve respiratory distress.

The diagnosis of lymphatic malformation by prenatal US, before 30 weeks' gestation, has detected a "hidden mortality" as well as a high incidence of associated anomalies, including abnormal karyotypes and hydrops fetalis. Occasionally, very large lesions can cause obstruction of the fetal airway. Such obstruction can result in the development of polyhydramnios by impairing the ability of the fetus to swallow amniotic fluid. In these circumstances, the airway is usually markedly distorted, which can result in immediate airway obstruction unless the airway is secured at the time of delivery. Orotracheal intubation or emergency tracheostomy while the infant remains attached to the placenta, the so-called EXIT procedure (ex utero intrapartum treatment), may be necessary to secure the airway.

Treatment. The modern management of most lymphatic malformations includes the combination of surgical excision and image-guided sclerotherapy. The initial treatment typically involves surgery in an attempt to safely remove all gross disease without damaging vital structures. Total removal of all gross disease may not be possible because of the extent of the lymphatic malformation and its proximity to, and intimate relationship with, adjacent nerves, muscles, and blood vessels (Fig. 39-1B). Radical ablative surgery is not indicated for this

lesion. A combined sclerotherapy/resectional approach is particularly useful for large lymphatic malformations and those that extend to the base of the tongue or the floor of the mouth. Conservative excision and unroofing of the cysts is advised along with sclerotherapy or repeated partial excision for any residual lymphatic malformation if necessary, preserving all adjacent crucial structures. Postoperative wound drainage is important and is best accomplished by closed-suction technique. Nevertheless, fluid may accumulate beneath the surgically created flaps, requiring multiple needle aspirations.

Torticollis

The presence of a lateral neck mass in infancy in association with rotation of the head toward the opposite side of the mass indicates the presence of congenital torticollis. This lesion results from fibrosis of the sternocleidomastoid muscle. The mass may be palpated in the affected muscle in approximately two thirds of cases. Histologically, the lesion is characterized by the deposition of collagen and fibroblasts around atrophied muscle cells. In the vast majority of cases, physical therapy based on passive stretching of the affected muscle is of benefit. Rarely, surgical transection of the sternocleidomastoid may be indicated.

RESPIRATORY SYSTEM

Congenital Diaphragmatic Hernia (Bochdalek)

Pathology. The septum transversum extends to divide the pleural and coelomic cavities during fetal development. This precursor of the diaphragm normally completes separation of these two cavities at the posterolateral aspects of this mesenchymally derived structure. The most common variant of a congenital diaphragmatic hernia is a posterolateral defect, also known as a Bochdalek hernia. Diaphragmatic defects allow abdominal viscera to fill the chest cavity. The abdominal cavity is small and underdeveloped and remains scaphoid after birth. Both lungs are hypoplastic, with decreased bronchial and pulmonary artery branching. Lung weight, lung volume, and DNA content are also decreased, and these findings are more striking

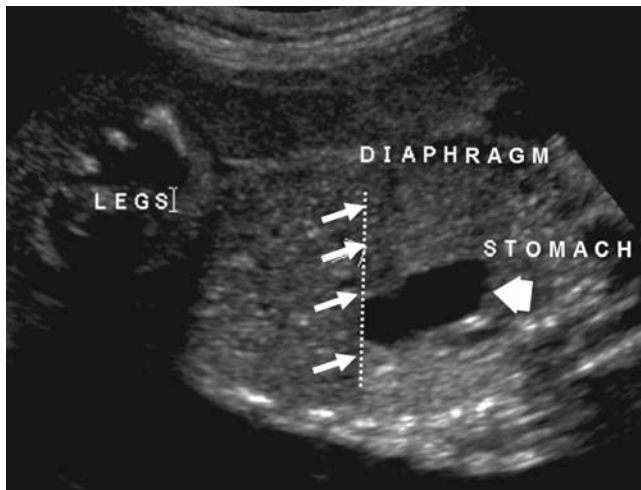


Figure 39-2. Prenatal ultrasound of a fetus with a congenital diaphragmatic hernia. Arrows point to the location of the diaphragm. Arrow head points to the stomach, which is in the thoracic cavity.

on the ipsilateral side. This anomaly is encountered more commonly on the left (80%–90%). Linkage analyses have recently implicated genetic mutations in syndromic variants of congenital diaphragmatic hernias. In many instances, there is a surfactant deficiency, which compounds the degree of respiratory insufficiency. Amniocentesis with karyotype may identify chromosomal defects, especially trisomy 18 and 21. Associated anomalies, once thought to be uncommon, were identified in 65 of 166 patients in one study, predominantly of the heart, followed by abdominal wall defects, chromosomal changes, and other defects. Prenatal ultrasonography is successful in making the diagnosis of congenital diaphragmatic hernia (CDH) as early as 15 weeks' gestation, and early antenatal diagnosis is associated with worse outcomes. US findings include herniated abdominal viscera in the chest, which may also look like a mass or lung anomaly, changes in liver position, and mediastinal shift away from the herniated viscera (Fig. 39-2). Accurate prenatal prediction of outcome for fetuses who have CDH is very difficult. One index of severity for patients with left CDH is the lung-to-head ratio (LHR), which is the product of the length and the width of the right lung at the level of the cardiac atria divided by the head circumference (all measurements in millimeters). An LHR value of less than 1.0 is associated with a very poor prognosis, whereas an LHR greater than 1.4 predicts a more favorable outcome. The utility of the LHR in predicting outcome in patients with CDH has recently been questioned, due to the tremendous interobserver variability in calculating this ratio for a particular patient, as well as the lack of reliable measures to determine postnatal disease severity.

Following delivery, the diagnosis of CDH is made by chest x-ray (Fig. 39-3). The differential diagnosis includes bronchopulmonary foregut malformations, in which the intrathoracic loops of bowel may be confused for lung or foregut pathology. The vast majority of infants with CDH develop immediate respiratory distress, which is due to the combined effects of three factors. First, the air-filled bowel in the chest compresses the mobile mediastinum, which shifts to the opposite side of the chest, compromising air exchange in the contralateral lung. Second, pulmonary hypertension develops. This phenomenon results in persistent fetal circulation, with resultant decreased pulmonary perfusion and impaired gas exchange. Finally, the

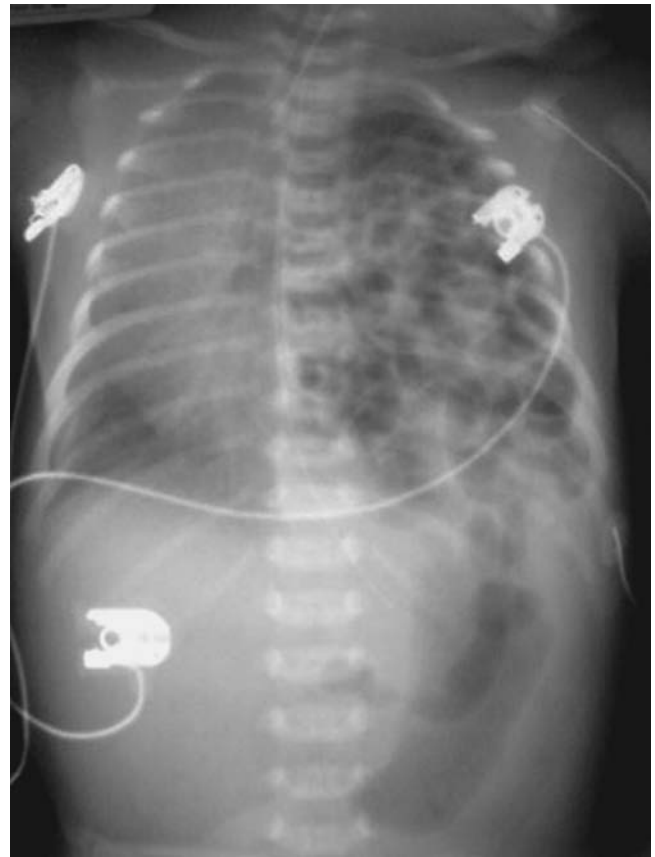


Figure 39-3. Chest x-ray showing a left congenital diaphragmatic hernia.

lung on the affected side is often hypoplastic, such that it is essentially nonfunctional. Varying degrees of pulmonary hypoplasia on the opposite side may compound these effects. The second and third factors are thought to be the most important. Neonates with CDH are usually in respiratory distress requiring ventilation and intensive care, and the overall mortality in most series is around 50%.

Treatment. CDH care has improved considerably through effective use of improved methods of ventilation and timely cannulation for extracorporeal membrane oxygenation (ECMO). Many infants are symptomatic at birth due to hypoxia, hypercarbia, and metabolic acidosis. Prompt cardiorespiratory stabilization is mandatory. It is noteworthy that in some infants, the first 24 to 48 hours after birth are often characterized by a period of relative stability with high levels of PaO₂ and relatively good perfusion. This has been termed the “honeymoon period” and is often followed by progressive cardiorespiratory deterioration. In the past, correction of the hernia was believed to be a surgical emergency, and patients underwent surgery shortly after birth. It is now accepted that the presence of persistent pulmonary hypertension that results in right-to-left shunting across the patent foramen ovale or the ductus arteriosus and the degree of pulmonary hypoplasia are the leading causes of cardiorespiratory insufficiency. Current management therefore is directed toward managing the pulmonary hypertension and minimizing barotrauma while optimizing oxygen delivery. To achieve this goal, infants are placed on mechanical ventilation using relatively low or “gentle” settings that prevent overinflation of the noninvolved lung. Levels of PaCO₂ in the range

of 50 to 60 mmHg or higher are accepted as long as the pH remains ≥ 7.25 . If these objectives cannot be achieved using conventional ventilation, high-frequency oscillatory ventilation (HFOV) may be used to avoid the injurious effects of conventional tidal volume ventilation. Echocardiography will assess the degree of pulmonary hypertension and identify the presence of any coexisting cardiac anomaly. Intensive care unit goals include minimal sedation, meticulous attention to endotracheal tube secretions, and gradual changes to ventilator settings to avoid inducing pulmonary hypertension via hypoxia. To minimize the degree of pulmonary hypertension, inhaled nitric oxide may be administered and, in some patients, improves pulmonary perfusion. Nitric oxide is administered into the ventilation circuit and is used in concentrations up to 40 parts per million. Correction of acidosis using bicarbonate solution may minimize the degree of pulmonary hypertension. As the degree of pulmonary hypertension becomes hemodynamically significant, right-sided heart failure develops and systemic perfusion is impaired. Administration of excess IV fluid will compound the degree of cardiac failure and lead to marked peripheral edema. Inotropic support using epinephrine, dopamine, and milrinone alone or in combination may be useful in optimizing cardiac contractility and maintaining mean arterial pressure.

Infants with CDH who remain severely hypoxic despite maximal ventilatory care may be candidates for treatment of their respiratory failure by ECMO, with access via venovenous (VV) or venoarterial (VA) routes. VV bypass is established with a single cannula through the right internal jugular vein, with blood removed from and infused into the right atrium by separate ports. VA bypass provides additional cardiac support, whereas VV bypass requires a well-functioning heart and relies on the lungs for some oxygenation as well. In VA ECMO, the right atrium is cannulated by means of the internal jugular vein and the aortic arch through the right common carotid artery. As much of the cardiac output is directed through the membrane oxygenator as is necessary to provide oxygenated blood to the infant and remove carbon dioxide. The infant is maintained on bypass until the pulmonary hypertension is resolved and lung function, as measured by compliance and the ability to oxygenate and ventilate, is improved. This is usually seen within 7 to 10 days, but in some infants, it may take up to several weeks to occur. Complications associated with ECMO increase after 14 days and include cannula malposition, bleeding in multiple locations, and infection. The use of ECMO is associated with significant risk. Because patients require systemic anticoagulation, bleeding complications are the most significant. They may occur intracranially or at the site of cannula insertion and can be life threatening. Systemic sepsis is a significant problem and may necessitate decannulation. Criteria for placing infants on ECMO include the presence of normal cardiac anatomy by echocardiography, the absence of fatal chromosome anomalies, and the expectation that the infant would die without ECMO. Traditionally, a threshold of weight greater than 2 kg and gestational age greater than 34 weeks has been applied, although success has been achieved at weights as low as 1.8 kg. Upon decannulation, some centers repair the carotid artery. In instances in which the child is cannulated for a brief period (5 days or less) this may be feasible. A recent study failed to show any benefit from repairing the carotid artery, although this finding remains to be studied further.

A strategy that does not involve the use of ECMO, but instead emphasizes the use of permissive hypercapnia and the

avoidance of barotrauma, may provide equal overall outcome in patients with CDH. This likely reflects the fact that mortality is related to the degree of pulmonary hypoplasia and the presence of congenital anomalies, neither of which are correctable by ECMO.

The timing of diaphragmatic hernia repair is still approached by various routes in major centers, particularly when the infant is on ECMO. In patients who are not on ECMO, repair should be performed once the hemodynamic status has been optimized. In neonates who are on ECMO, some surgeons perform early repair on bypass; others wait until the infant's lungs are improved and the pulmonary hypertension has subsided, repair the diaphragm, and discontinue bypass within hours of surgery. Still others repair the diaphragm only after the infant is off bypass. Operative repair of the diaphragmatic hernia may be accomplished by either an abdominal or transthoracic approach and can be performed either via open or minimally invasive techniques. Through a subcostal incision, the abdominal viscera are withdrawn from the chest, exposing the defect in the diaphragm. Care must be taken when reducing the spleen and liver, as bleeding from these structures can be fatal. The anterior margin is often apparent, while the posterior muscular rim is attenuated. If the infant is heparinized on bypass, minimal dissection of the muscular margins is performed. Electrocautery is used liberally to minimize postoperative bleeding. Most infants who require ECMO support prior to hernia repair have large defects, often lacking the medial and posterior margins. About three fourths of infants repaired on bypass require prosthetic material to patch the defect, suturing it to the diaphragmatic remnant or around ribs or costal cartilages for the large defects. If there is adequate muscle for closure, a single layer of nonabsorbable horizontal mattress sutures, pledgeted or not, closes the defect. Just before the repair is complete, a chest tube may be positioned in the thoracic cavity but is not mandatory. Patients repaired on ECMO are at risk for developing a hemothorax, which can significantly impair ventilation. Anatomic closure of the abdominal wall may be impossible after reduction of the viscera. Occasionally a prosthetic patch or acellular material may be sutured to the fascia to facilitate closure. The patch can be removed at a later time, and the ventral hernia can be closed at that time or subsequently. In patients who are deemed to be candidates for a minimally invasive approach (stable patients, >2 kg, no pulmonary hypertension), a thoracoscopic repair may be safely performed, although concerns have been raised about possible effects of the longer operative time for thoracoscopic repair and higher recurrence rates. If the diaphragm has been repaired on ECMO, weaning and decannulation are accomplished as soon as possible. All infants are ventilated postoperatively to maintain preductal arterial oxygenation of 80 to 100 Torr. Very slow weaning from the ventilator is necessary to avoid recurrent pulmonary hypertension.

Congenital Lobar Emphysema

Congenital lobar emphysema (CLE) is a condition manifested during the first few months of life as a progressive hyperexpansion of one or more lobes of the lung. It can be life-threatening in the newborn period if extensive lung tissue is involved, but in the older infant and in cases in which the lesion is less severely distended, it causes less respiratory distress. Air entering during inspiration is trapped in the lobe; on expiration, the lobe cannot deflate and progressively overexpands, causing atelectasis of the adjacent lobe or lobes. This hyperexpansion eventually

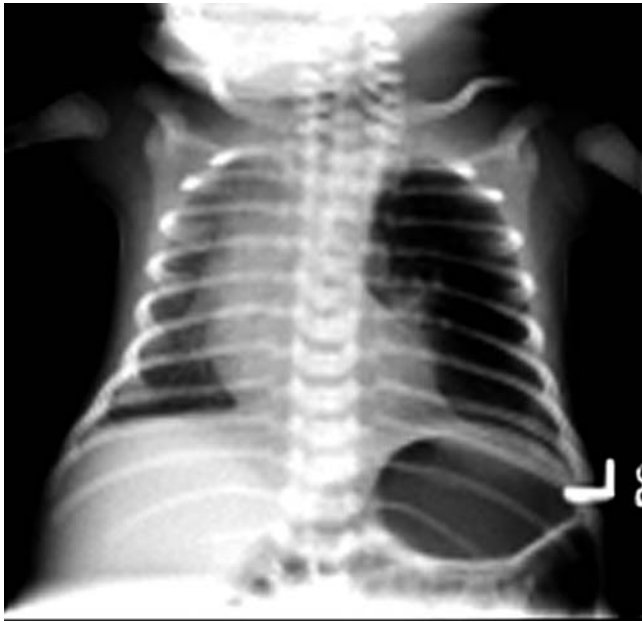


Figure 39-4. Congenital lobar emphysema of the left upper lobe in a 2-week-old boy. Mediastinal shift is present.

shifts the mediastinum to the opposite side and compromises the other lung. CLE usually occurs in the upper lobes of the lung (left greater than right), followed next in frequency by the right middle lobe, but it also can occur in the lower lobes. It is caused by intrinsic bronchial obstruction from poor bronchial cartilage development or extrinsic compression. Approximately 14% of children with this condition have cardiac defects, with an enlarged left atrium or a major vessel causing compression of the ipsilateral bronchus.

Symptoms range from mild respiratory distress to full-fledged respiratory failure with tachypnea, dyspnea, cough, and late cyanosis. These symptoms may be stationary, or they may progress rapidly or result in recurrent pneumonia. Occasionally, infants with CLE present with failure to thrive, which likely reflects the increased work associated with the overexpanded lung. A hyperexpanded hemithorax on the ipsilateral side is pathognomonic for CLE. Diagnosis is typically confirmed by chest x-ray, which shows a hyperlucent affected lobe with adjacent lobar compression and atelectasis. The mediastinum may be shifted as a consequence of mass effect to the contralateral side causing compression and atelectasis of the contralateral lung (Fig. 39-4). Although chest radiograph is usually sufficient, it is sometimes important to obtain a CT scan of the chest to clearly establish the diagnosis of CLE. This should be done only in the stable patient. Unless foreign body or mucus plugging is suspected as a cause of hyperinflation, bronchoscopy is not advisable because it can lead to more air trapping and cause life-threatening respiratory distress in a stable infant. Treatment is resection of the affected lobe, which can be safely performed using either an open or thoracoscopic approach. Unless symptoms necessitate earlier surgery, resection can usually be performed after the infant is several months of age. The prognosis is excellent.

Bronchopulmonary Foregut Malformations

Bronchopulmonary foregut malformations include foregut duplication cysts, congenital pulmonary airway malformations, and pulmonary sequestrations as discussed below.

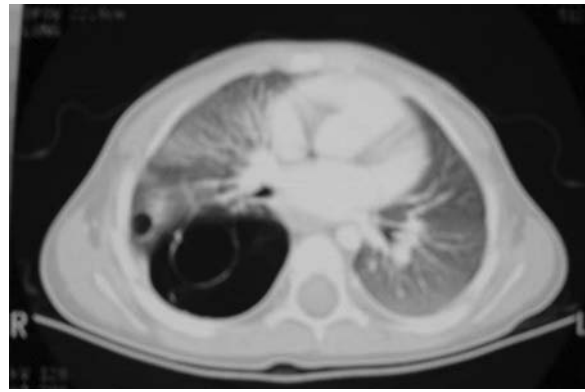


Figure 39-5. Computed tomography scan of the chest showing a congenital pulmonary airway malformation involving the left lower lobe.

Congenital Pulmonary Airway Malformations. Previously denoted as congenital cystic adenomatoid malformation (CCAM), congenital pulmonary airway malformation (CPAM) exhibits cystic proliferation of the terminal airway, producing cysts lined by mucus-producing respiratory epithelium, and elastic tissue in the cyst walls without cartilage formation. There may be a single cyst with a wall of connective tissue containing smooth muscle. Cysts may be large and multiple (type I), smaller and more numerous (type II), or resemble fetal lung without macroscopic cysts (type III). CPAMs frequently occur in the left lower lobe. However, this lesion can occur in any location and may occur in more than one lobe on more than one side, although this is rare. Clinical symptoms range from none to severe respiratory failure at birth. Over time, these malformations can be subject to repeated infections and produce fever and cough in older infants and children. The diagnosis is usually confirmed by CT for surgical planning and characteristic features that might delineate other bronchopulmonary foregut malformations (Fig. 39-5). Prenatal US may suggest the diagnosis. Resection is curative and may need to be performed urgently in the infant with severe respiratory distress. Long term, there is a risk of malignant degeneration in unresected CPAMs, but this risk occurs over decades and has not been fully defined. As a result, resection of the affected lobe is usually performed (Fig. 39-6).

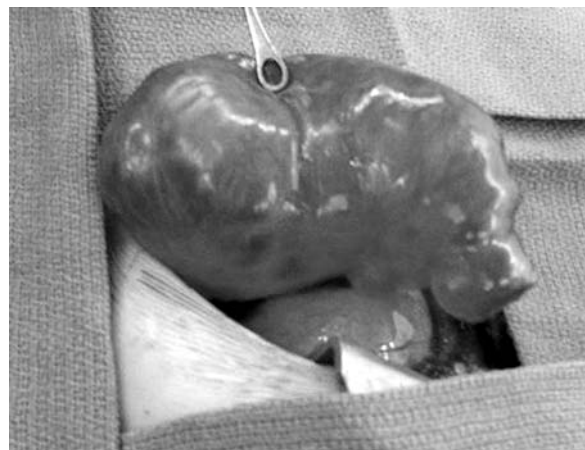

Figure 39-6. Intraoperative photograph showing left lower lobe congenital pulmonary airway malformation seen in Fig. 39-5.

Pulmonary Sequestration. Pulmonary sequestration is uncommon and consists of a mass of lung tissue, usually in the left lower chest, occurring without the usual connections to the pulmonary artery or tracheobronchial tree, yet with a systemic blood supply from the aorta. There are two kinds of sequestration. Extralobar sequestration is usually a small area of nonaerated lung separated from the main lung mass, with a systemic blood supply, located immediately above the left diaphragm. It is commonly found in cases of CDH. Intralobar sequestration more commonly occurs within the parenchyma of the left lower lobe but can occur on the right. There is no major connection to the tracheobronchial tree, but a secondary connection may be established, perhaps through infection or via adjacent intrapulmonary shunts. The blood supply frequently originates from the aorta below the diaphragm; multiple vessels may be present (Fig. 39-7). Venous drainage of both types can be systemic or pulmonary. The cause of sequestration is unknown but most probably involves an abnormal budding of the developing lung that picks up a systemic blood supply and never becomes connected with the bronchus or pulmonary vessels. Sequestrations may, in some cases, exhibit mixed pathology with components consistent with CPAMs. Extralobar sequestration is asymptomatic and is usually discovered incidentally on chest x-ray. If the diagnosis can be confirmed (e.g., by CT scan), resection is not necessary. Diagnosis of intralobar sequestration may be made prenatally and confirmed on postnatal CT scan. Alternatively, the diagnosis of intralobar sequestration may be established after repeated infections manifested by cough, fever, and consolidation in the posterior basal segment of the left lower lobe. Increasingly the diagnosis is being made in the early months of life by US, and color Doppler often can be helpful in delineating the systemic arterial supply. Removal of the entire left lower lobe is usually necessary since the diagnosis often is made late after multiple infections. Occasionally segmental resection of the sequestered part of the lung can be performed using an open or, ideally, a thoracoscopic approach. If an open approach is used, it is important to open the chest through a low intercostal space (sixth or seventh) to gain access to the vascular attachments to the aorta. These attachments may insert into the aorta below the diaphragm; in these cases division of the vessels as they traverse the thoracic cavity is essential. Prognosis is generally excellent. However, failure to obtain adequate control of these vessels may result in their retraction into the abdomen and result in uncontrollable hemorrhage. It is also possible to

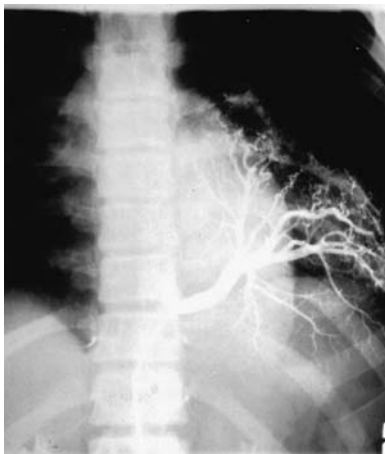

Figure 39-7. Arteriogram showing large systemic artery supply to intralobar sequestration of the left lower lobe.

perform a combined thoracoscopic and open approach, wherein the vessels are clipped and divided thoracoscopically and then the lesion is safely removed through a limited thoracotomy.

Bronchogenic Cyst. Bronchogenic cysts are duplication cysts originating from the airway, regardless of the identity of the epithelial lining. They can occur anywhere along the respiratory tract and can present at any age, although typically they present after accumulation of intraluminal contents, and not within the newborn period. Histologically, they are hamartomatous and usually consist of a single cyst lined with an epithelium; the mesenchyme contains cartilage and smooth muscle. They are probably embryonic rests of foregut origin that have been pinched off from the main portion of the developing tracheobronchial tree and are closely associated in causation with other foregut duplication cysts such as those arising from the esophagus. Bronchogenic cysts may be seen on prenatal US but are discovered most often incidentally on postnatal chest x-ray. Although they may be completely asymptomatic, bronchogenic cysts may produce symptoms, usually compressive in nature, depending on the anatomic location and size, which increase over time if there is no egress of accumulating luminal contents. In the paratracheal region of the neck, they can produce airway compression and respiratory distress. In the lung parenchyma, they may become infected and present with fever and cough. In addition they may cause obstruction of the bronchial lumen with distal atelectasis and infection, or they may cause mediastinal compression. Rarely, rupture of the cyst can occur. Chest x-ray usually shows a dense mass, and CT scan or magnetic resonance imaging (MRI) delineates the precise anatomic location of the lesion. Treatment consists of resection of the cyst, which may need to be undertaken in emergency circumstances for airway or cardiac compression. Resection can be performed either as an open procedure or, more commonly, using a thoracoscopic approach. If resection of a common wall will result in injury to the airway, resection of the inner epithelial cyst lining after marsupialization is acceptable.

Bronchiectasis

Bronchiectasis is an abnormal and irreversible dilatation of the bronchi and bronchioles associated with chronic suppurative disease of the airways. Usually patients have an underlying congenital pulmonary anomaly, cystic fibrosis, or immunologic deficiency. Bronchiectasis can also result from chronic infection secondary to a neglected bronchial foreign body. The symptoms include a chronic cough, often productive of purulent secretions, recurrent pulmonary infection, and hemoptysis. The diagnosis is suggested by a chest x-ray that shows increased bronchovascular markings in the affected lobe. Chest CT delineates bronchiectasis with excellent resolution. The preferred treatment for bronchiectasis is medical, consisting of antibiotics, postural drainage, and bronchodilator therapy, since many children with the disease show signs of airflow obstruction and bronchial hyperresponsiveness. Lobectomy or segmental resection is indicated for localized disease that has not responded appropriately to medical therapy. In severe cases, lung transplantation may be required to replace the terminally damaged, septic lung.

Foreign Bodies

The inherent curiosity of children and their innate propensity to place new objects into their mouths to fully explore them place them at great risk for aspiration. Aspirated objects can be found either in the airway or in the esophagus; in both cases, the results can be life-threatening.

Airway Ingestion. Aspiration of foreign bodies most commonly occurs in the toddler age group. Peanuts are the most common object that is aspirated, although other materials (popcorn, for instance) may also be involved. A solid foreign body often will cause air trapping, with hyperlucency of the affected lobe or lung seen especially on expiration. Oil from the peanut is very irritating and may cause pneumonia. Delay in diagnosis can lead to atelectasis and infection. The most common anatomic location for a foreign body is the right main stem bronchus or the right lower lobe. The child usually will cough or choke while eating but may then become asymptomatic. Total respiratory obstruction with tracheal foreign body may occur; however, respiratory distress is usually mild if present at all. A unilateral wheeze is often heard on auscultation. This wheeze often leads to an inappropriate diagnosis of “asthma” and may delay the correct diagnosis for some time. Chest x-ray will show a radiopaque foreign body, but in the case of nuts, seeds, or plastic toy parts, the only clue may be hyperexpansion of the affected lobe on an expiratory film or fluoroscopy. Bronchoscopy confirms the diagnosis and allows removal of the foreign body. It can be a very simple procedure, or it may be extremely difficult, especially with a smooth foreign body that cannot be grasped easily or one that has been retained for some time. The rigid bronchoscope should be used in all cases, and utilization of the optical forceps facilitates grasping the inhaled object. Epinephrine may be injected into the mucosa when the object has been present for a long period of time, which minimizes bleeding. Bronchiectasis may be seen as an extremely late phenomenon after repeated infections of the poorly aerated lung and may require partial or total resection of the affected lobe. The differential diagnosis of a bronchial foreign body includes an intraluminal tumor (i.e., carcinoid, hemangioma, or neurofibroma).

Foreign Bodies and Esophageal Injury. The most common foreign body in the esophagus is a coin, followed by small toy parts. Toddlers are most commonly affected. The coin is retained in the esophagus at one of three locations: the cricopharynx, the area of the aortic arch, or the gastroesophageal junction—all areas of normal anatomic narrowing. Symptoms are variable depending on the anatomic position of the foreign body and the degree of obstruction. There is often a relatively asymptomatic period after ingestion. The initial symptoms are gastrointestinal and include dysphagia, drooling, and dehydration. The longer the foreign body remains in the esophagus with oral secretions

unable to transit the esophagus, the greater the incidence of respiratory symptoms including cough, stridor, and wheezing. These findings may be interpreted as signs of upper respiratory infections. Objects that are present for a long period, particularly in children who have underlying neurologic impairment, may manifest as chronic dysphagia. The chest x-ray is diagnostic in the case of a coin. A contrast swallow, or preferably an esophagoscopy, may be required for nonradiopaque foreign bodies. Coins lodged within the upper esophagus for less than 24 hours may be removed using Magill forceps during direct laryngoscopy. For all other situations, the treatment is by esophagoscopy, rigid or flexible, and removal of the foreign body. In the case of sharp foreign bodies such as open safety pins, extreme care is required on extraction to avoid injury to the esophagus. Rarely, esophagotomy is required for removal, particularly of sharp objects. Diligent follow-up is required after removal of foreign bodies, especially batteries, which can cause strictures, and sharp objects, which can injure the underlying esophagus. In the case of a retained battery, this case should be handled as a surgical emergency, as the negative pole of the battery directly damages the surrounding tissue, and tracheoesophageal fistula, aortic exsanguination, and mediastinitis have all been described after local tissue necrosis at the site where the battery has lodged.

ESOPHAGUS

Esophageal Atresia and Tracheoesophageal Fistula

Esophageal atresia (EA) with tracheoesophageal fistula (TEF) is one of the most gratifying pediatric surgical conditions to treat. In the not-so-distant past, nearly all infants born with EA and TEF died. In 1939, Ladd and Leven performed the first successful repair by ligating the fistula, placing a gastrostomy, and reconstructing the esophagus at a later time. Subsequently, Dr. Cameron Haight in Ann Arbor, Michigan, performed the first successful primary anastomosis for EA, which remains the current approach for treatment of this condition. Despite the fact that there are several common varieties of this anomaly and the underlying cause remains obscure, a careful approach consisting of meticulous perioperative care and attention to the technical detail of the operation can result in an excellent prognosis in most cases.

Anatomic Varieties. The five major varieties of EA and TEF are shown in Fig. 39-8. The most commonly seen variety is EA

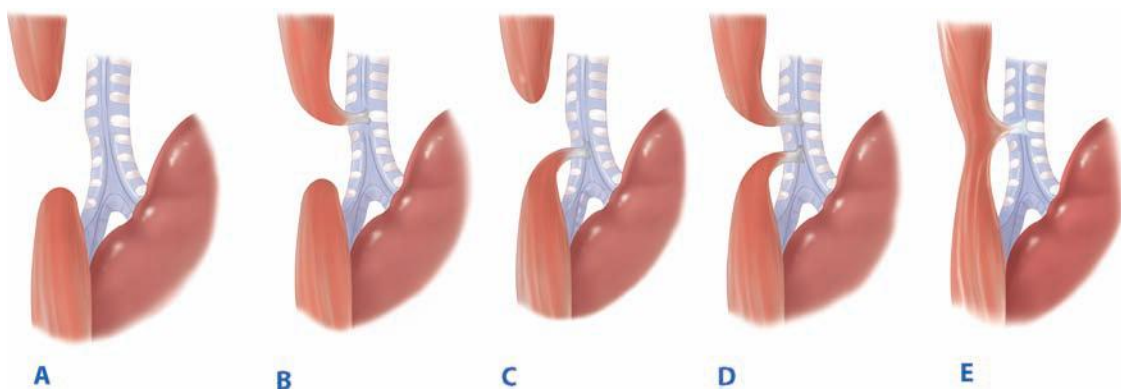


Figure 39-8. The five varieties of esophageal atresia and tracheoesophageal fistula. **A.** Isolated esophageal atresia. **B.** Esophageal atresia with tracheoesophageal fistula between proximal segment of esophagus and trachea. **C.** Esophageal atresia with tracheoesophageal fistula between distal esophagus and trachea. **D.** Esophageal atresia with fistula between both proximal and distal ends of esophagus and trachea. **E.** Tracheoesophageal fistula without esophageal atresia (H-type fistula).

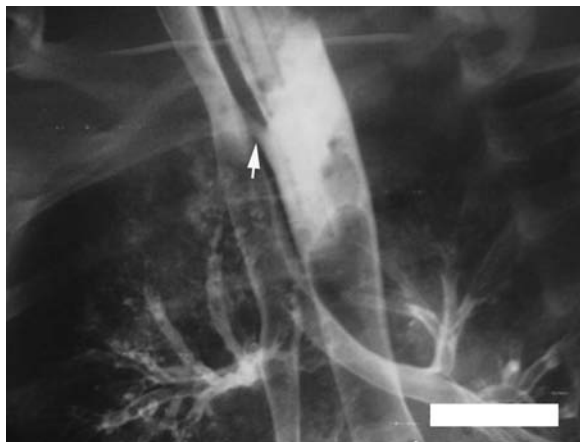


Figure 39-9. Barium esophagram showing H-type tracheoesophageal fistula (arrow).

with distal TEF (type C), which occurs in approximately 85% of the cases in most series. The next most frequent type is pure EA (type A), occurring in 8% to 10% of patients, followed by TEF without EA (type E). This occurs in 8% of cases and is also referred to as an H-type fistula, based on the anatomic similarity to that letter (Fig. 39-9). EA with fistula between both proximal and distal ends of the esophagus and trachea (type D) is seen in approximately 2% of cases, and type B, EA with TEF between proximal esophagus and trachea, is seen in approximately 1% of all cases.

Etiology and Pathologic Presentation. The esophagus and trachea share a common embryologic origin. At approximately 4 weeks' gestation, a diverticulum forms off the anterior aspect of the proximal foregut in the region of the primitive pharynx. This diverticulum extends caudally with progressive formation of the laryngotracheal groove, thus creating a separate trachea and esophagus. Successful development of these structures is the consequence of extremely intricate interplay of growth and transcription factors necessary for rostral-caudal and anterior-posterior specification. The variations in clinically observed EA and TEF that must result in failure of successful formation of these structures are depicted in Fig. 39-8. Although definitive genetic mutations have been difficult to identify in isolated EA-TEF, mutations in *N-myc*, *Sox2*, and *CHD7* have been characterized in syndromic EA-TEF with associated anomalies.

Other congenital anomalies commonly occur in association with EA-TEF. For instance, VACTERL syndrome is associated with vertebral anomalies (absent vertebrae or hemivertebrae) and anorectal anomalies (imperforate anus), cardiac defects, tracheoesophageal fistula, renal anomalies (renal agenesis, renal anomalies), and radial limb hyperplasia. In nearly 20% of the infants born with EA, some variant of congenital heart disease occurs.

Clinical Presentation of Infants with Esophageal Atresia and Tracheoesophageal Fistula.

The anatomic variant of infants with EA-TEF predicts the clinical presentation. When the esophagus ends either as a blind pouch or as a fistula into the trachea (as in types A, B, C, or D), infants present with excessive drooling, followed by choking or coughing immediately after feeding is initiated as a result of aspiration through the fistula tract. As the neonate coughs and cries, air is transmitted through the fistula into the stomach, resulting in abdominal distention. As the abdomen distends, it

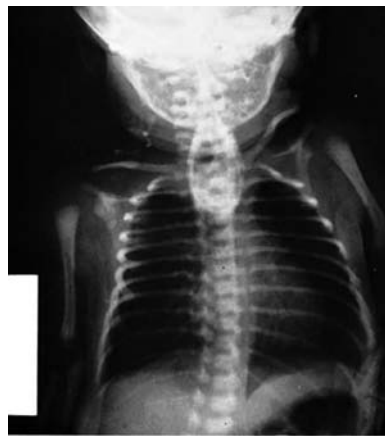

Figure 39-10. Type C esophageal atresia with tracheoesophageal fistula. Note the catheter that is coiled in the upper pouch and the presence of gas below the diaphragm, which confirms the presence of the tracheoesophageal fistula.

becomes increasingly more difficult for the infant to breathe. This leads to further atelectasis and respiratory compromise. In patients with type C and D varieties, the regurgitated gastric juice passes through the fistula where it collects in the trachea and lungs and leads to a chemical pneumonitis, which further exacerbates the pulmonary difficulties. In many instances, the diagnosis is actually made by the nursing staff who attempt to feed the baby and notice the accumulation of oral secretions.

The diagnosis of EA is confirmed by the inability to pass an orogastric tube into the stomach (Fig. 39-10). The dilated upper pouch may be occasionally seen on a plain chest radiograph. If a soft feeding tube is used, the tube will coil in the upper pouch, which provides further diagnostic certainty. An important alternative diagnosis that must be considered when an orogastric tube does not enter the stomach is that of an esophageal perforation. This problem can occur in infants after traumatic insertion of a nasogastric or orogastric tube. In this instance, the perforation classically occurs at the level of the piriform sinus, and a false passage is created, which prevents the tube from entering the stomach. Whenever there is any diagnostic uncertainty, a contrast study will confirm the diagnosis of EA and occasionally document the TEF. The presence of a TEF can be demonstrated clinically by finding air in the gastrointestinal tract. This can be proven at the bedside by percussion of the abdomen and confirmed by obtaining a plain abdominal radiograph. Occasionally, a diagnosis of EA-TEF can be suspected prenatally on US evaluation. Typical features include failure to visualize the stomach and the presence of polyhydramnios. These findings reflect the absence of efficient swallowing by the fetus.

In a child with EA, it is important to identify whether coexisting anomalies are present. These include cardiac defects in 38%, skeletal defects in 19%, neurologic defects in 15%, renal defects in 15%, anorectal defects in 8%, and other abnormalities in 13%. Examination of the heart and great vessels with echocardiography is important to exclude cardiac defects, as these are often the most important predictors of survival in these infants. The echocardiogram also demonstrates whether the aortic arch is left sided or right sided, which may influence the approach to surgical repair. Vertebral anomalies are assessed by plain radiography, and a spinal US is obtained if any are detected. A patent anus should be confirmed clinically. The kidneys in

a newborn may be assessed clinically by palpation. An US of the abdomen will demonstrate the presence of renal anomalies, which should be suspected in the child who fails to make urine. The presence of extremity anomalies is suspected when there are missing digits and confirmed by plain radiographs of the hands, feet, forearms, and legs. Rib anomalies may also be present. These may include the presence of a thirteenth rib.

Initial Management. The initial treatment of infants with EA-TEF includes attention to the respiratory status, decompression of the upper pouch, and appropriate timing of surgery. Because the major determinant of poor survival is the presence of other severe anomalies, a search for other defects including congenital cardiac disease is undertaken in a timely fashion. The initial strategy after the diagnosis is confirmed is to place the neonate in an infant warmer with the head elevated at least 30°. A sump catheter is placed in the upper pouch on continuous suction. Both of these strategies are designed to minimize the degree of aspiration from the esophageal pouch. When saliva accumulates in the upper pouch and is aspirated into the lungs, coughing, bronchospasm, and desaturation episodes can occur, which may be minimized by ensuring the patency of the sump catheter. IV antibiotic therapy is initiated, and warmed electrolyte solution is administered. Where possible, the right upper extremity is avoided as a site to start an IV line, as this location may interfere with positioning of the patient during the surgical repair.

The timing of repair is influenced by the stability of the patient. Definitive repair of the EA-TEF is rarely a surgical emergency. If the child is hemodynamically stable and is oxygenating well, definitive repair may be performed within 1 to 2 days after birth. This allows for a careful determination of the presence of coexisting anomalies and for selection of an experienced anesthetic team.

Management of Esophageal Atresia and Tracheoesophageal Fistula in the Preterm Infant.

The ventilated, premature neonate with EA-TEF and associated hyaline membrane disease represents a patient who may develop severe, progressive, cardiopulmonary dysfunction. The TEF can worsen the fragile pulmonary status as a result of recurrent aspiration through the fistula and increased abdominal distention, which impairs lung expansion. Moreover, the elevated airway pressure that is required to ventilate these patients can worsen the clinical course by forcing air through the fistula into the stomach, thereby exacerbating the degree of abdominal distention

and compromising lung expansion. In this situation, the first priority is to minimize the degree of positive pressure needed to adequately ventilate the child. This can be accomplished using HFOV. If the gastric distention becomes severe, a gastrostomy tube should be placed. This procedure can be performed at the bedside under local anesthetic, if necessary. The dilated, air-filled stomach can easily be accessed through an incision in the left upper quadrant of the abdomen. Once the gastrostomy tube is placed and the abdominal pressure is relieved, the pulmonary status can paradoxically worsen. This is because the ventilated gas may pass preferentially through the fistula, which is the path of least resistance, and bypass the lungs, thereby worsening the hypoxemia. To correct this problem, the gastrostomy tube may be placed under water seal, elevated, or intermittently clamped. If these maneuvers are to no avail, ligation of the fistula may be required. This procedure can be performed in the neonatal intensive care unit if the infant is too unstable to be transported to the operating room. These

interventions allow for the infant's underlying hyaline membrane disease to improve, for the pulmonary secretions to clear, and for the infant to reach a period of stability so that definitive repair can be performed.

Primary Surgical Correction. In a stable infant, definitive repair is achieved through performance of a primary esophago-esophagostomy. There are two approaches to this operation: open thoracotomy or thoracoscopy. In the open approach, the infant is brought to the operating room, intubated, and placed in the lateral decubitus position with the right side up in preparation for right posterolateral thoracotomy. If a right-sided arch was determined previously by echocardiography, consideration is given to performing the repair through the left chest, although most surgeons believe that the repair can be performed safely from the right side as well. Bronchoscopy may be performed to exclude the presence of additional, upper pouch fistulae in cases of EA (i.e., differentiation of type B, C, and D variants) and to identify a laryngotracheoesophageal cleft.

The operative technique for primary repair is as follows (Fig. 39-11). A retropleural approach is generally used, as this technique prevents widespread contamination of the thorax if a postoperative anastomotic leak occurs. The sequence of steps is as follows: (a) mobilization of the pleura to expose the structures in the posterior mediastinum; (b) division of the fistula and closure of the tracheal opening; (c) mobilization of the upper esophagus sufficiently to permit an anastomosis without tension and to determine whether a fistula is present between the upper esophagus and the trachea (forward pressure by the anesthesia staff on the sump drain in the pouch can greatly facilitate dissection at this stage of the operation; care must be taken when dissecting posteriorly to avoid violation of the lumen of the trachea and esophagus); (d) mobilization of the distal esophagus (this needs to be performed judiciously to avoid devascularization, since the blood supply to the distal esophagus is segmental from the aorta; most of the esophageal length is obtained from mobilizing the upper pouch, since the blood supply travels via the submucosa from above); (e) performing a primary esophago-esophageal anastomosis (most surgeons perform this procedure in a single layer using 5-0 sutures; if there is excess tension, the muscle of the upper pouch can be circumferentially incised without compromising blood supply to increase its length; many surgeons place a transanastomotic feeding tube in order to institute feeds in the early postoperative period); and (f) placement of a retropleural drain and closure of the incision in layers.

When a minimally invasive approach is selected, the patient is prepared for right-sided, transthoracic thoracoscopic repair. The same steps as described earlier for the open repair are undertaken, and the magnification and superb optics that are provided by the thoracoscopic approach provide for superb visualization. Identification of the fistula is performed as a first step; this can be readily ligated and divided between thoracoscopically placed sutures. The anastomosis is performed in a single layer. The thoracoscopically performed TEF repair requires clear and ongoing communication between the operating surgeons and the anesthesiologist; visualization can be significantly reduced with sudden changes in lung inflation, potentially leading to the need to convert to an open repair. Although clear guidelines for patient selection for a thoracoscopic repair as opposed to an open repair remain lacking, reasonable selection criteria include patients over 2.5 kg who are hemodynamically stable and without comorbidities.

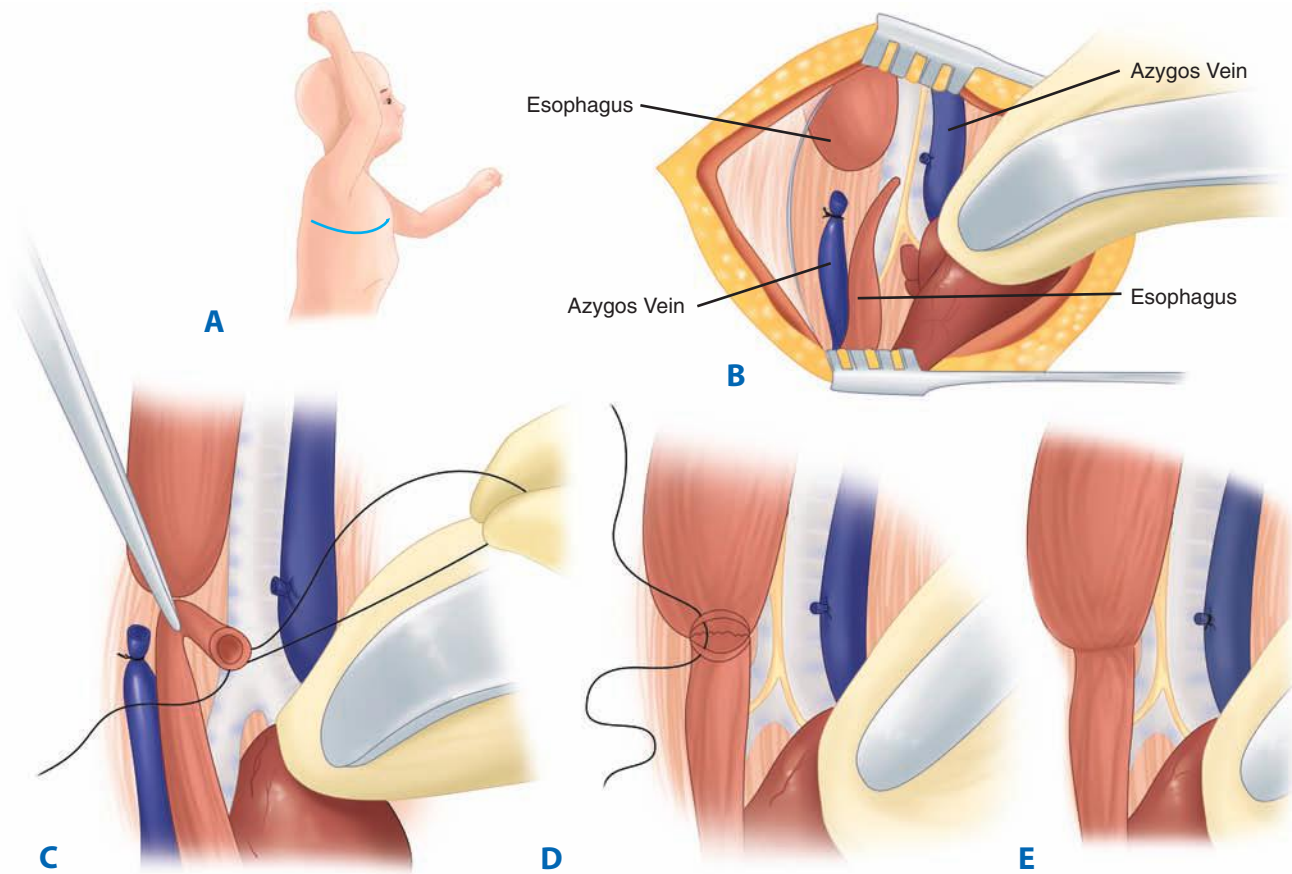


Figure 39-11. Primary repair of type C tracheoesophageal fistula. **A.** Right thoracotomy incision. **B.** Azygos vein transected, proximal and distal esophagus demonstrated, and fistula identified. **C.** Tracheoesophageal fistula transected and defect in trachea closed. **D.** End-to-end anastomosis between proximal and distal esophagus (posterior row). **E.** Completed anastomosis.

Postoperative Course. The postoperative management strategy of patients with EA-TEF is influenced to a great degree by the preference of the individual surgeon and the institutional culture. Many surgeons prefer not to leave the infants intubated postoperatively, to avoid the effects of positive pressure on the site of tracheal closure. However, early extubation may not be possible in babies with preoperative lung disease either from prematurity or pneumonia or when there is any vocal cord edema. When a transtomotic tube is placed, feeds are begun slowly in the postoperative period. Some surgeons institute parenteral nutrition for several days, using a central line. The retropleural drain is assessed daily for the presence of saliva, indicating an anastomotic leak. Many surgeons obtain a contrast swallow 1 week after repair to assess the caliber of the anastomosis and to determine whether a leak is present. If there is no leak, feedings are started. The principal benefit of the thoracoscopic approach is that postoperative pain is significantly reduced, as is the requirement for postoperative narcotic analgesia.

Complications of Surgery. Anastomotic leak occurs in 10% to 15% of patients and may be seen either in the immediate postoperative period or after several days. Early leakage (i.e., within the first 24 to 48 hours) is manifested by a new pleural effusion, pneumothorax, and sepsis, and requires immediate exploration. In these circumstances, the anastomosis may be completely disrupted, possibly due to excessive tension. Revision of the anastomosis may be possible. If not, cervical esophagostomy and gastrostomy placement are required, with a subsequent

procedure to re-establish esophageal continuity. Anastomotic leakage that is detected after several days usually heals without intervention, particularly if a retropleural approach is used. Under these circumstances, broad-spectrum antibiotics, pulmonary toilet, and optimization of nutrition are important. After approximately a week or so, a repeat esophagram should be performed, at which time the leakage may have resolved.

Strictures are not infrequent (10%–20%), particularly if a leak has occurred. A stricture may become apparent at any time, from the early postoperative period to months or years later. It may present as choking, gagging, or failure to thrive, but often becomes clinically apparent with the transition to eating solid food. A contrast swallow or esophagoscopy is confirmatory, and simple dilatation is usually corrective. Occasionally, repeated dilatations are required. These may be performed in a retrograde fashion, during which a silk suture is placed into the oropharynx and delivered from the esophagus through a gastrostomy tube. Tucker dilators are then tied to the suture and passed in a retrograde fashion from the gastrostomy tube and delivered out of the oropharynx. Increasing sizes are used, and the silk is replaced at the end of the procedure where it is taped to the side of the face at one end and to the gastrostomy tube at the other. Alternatively, image-guided balloon dilatation over a guide wire may be performed, using intraoperative contrast radiography to determine the precise location of the stricture and to assess the immediate response to the dilation.

“Recurrent” TEF may represent a missed upper pouch fistula or a true recurrence. This may occur after an anastomotic disruption, during which the recurrent fistula may heal spontaneously. Otherwise, reoperation may be required. Recently, the use of fibrin glue has been successful in treating recurrent fistulas, although long-term follow-up is lacking.

Gastroesophageal reflux commonly occurs after repair of EA-TEF, potentially due to alterations in esophageal motility and the anatomy of the gastroesophageal junction. The clinical manifestations of such reflux are similar to those seen in other infants with primary gastroesophageal reflux disease. A loose antireflux procedure, such as a Nissen fundoplication, is used to prevent further reflux, but the child may have feeding problems after antireflux surgery as a result of the intrinsic dysmotility of the distal esophagus. The fundoplication may be safely performed laparoscopically in experienced hands, although care should be taken to ensure that the wrap is not excessively tight.

Special Circumstances. Patients with type E TEFs (also called H-type) most commonly present beyond the newborn period. Presenting symptoms include recurrent chest infections, bronchospasm, and failure to thrive. The diagnosis is suspected using barium esophagography and confirmed by endoscopic visualization of the fistula. Surgical correction is generally possible through a cervical approach with concurrent placement of a balloon catheter across the fistula and requires mobilization and division of the fistula. Outcome is usually excellent.

Patients with duodenal atresia and EA-TEF may require urgent treatment due to the presence of a closed obstruction of the stomach and proximal duodenum. In stable patients, treatment consists of repair of the esophageal anomaly and correction of the duodenal atresia if the infant is stable during surgery. If not, a staged approach should be used consisting of ligation of the fistula and placement of a gastrostomy tube. Definitive repair can then be performed at a later point in time.

Primary EA (type A) represents a challenging problem, particularly if the upper and lower ends are too far apart for an anastomosis to be created. Under these circumstances, treatment strategies include placement of a gastrostomy tube and performing serial bougienage to increase the length of the upper pouch. This occasionally allows for primary anastomosis to be performed. Occasionally, when the two ends cannot be brought safely together, esophageal replacement is required using a gastric pull-up, reverse gastric tube, or colon interposition (see below).

Outcome. Various classification systems have been used to predict survival in patients with EA-TEF and to stratify treatment. A system devised by Waterston in 1962 was used to stratify neonates based on birth weight, the presence of pneumonia, and the identification of other congenital anomalies. In response to advances in neonatal care, the surgeons from the Montreal Children’s Hospital proposed a new classification system. In the Montreal experience, only two characteristics independently affected survival: preoperative ventilator dependence and associated major anomalies. Pulmonary disease as defined by ventilator dependence appeared to be more accurate than pneumonia. When the two systems were compared, the Montreal system more accurately identified children at highest risk. Spitz and colleagues analyzed risk factors in infants who died with EA-TEF. Two criteria were found to be important predictors of outcome: birth weight less than 1500 g and the presence of major congenital cardiac disease. A new classification for predicting

outcome in EA was therefore proposed: group I: birth weight ≥ 1500 g, without major cardiac disease, survival 97% (283 of 293); group II: birth weight < 1500 g, or major cardiac disease, survival 59% (41 of 70); and group III: birth weight < 1500 g, and major cardiac disease, survival 22% (2 of 9).

In general, surgical correction of EA-TEF leads to a satisfactory outcome with nearly normal esophageal function in most patients. Overall survival rates of greater than 90% have been achieved in patients classified as stable in all the various staging systems. Unstable infants have an increased mortality (40% to 60% survival) because of potentially fatal associated cardiac and chromosomal anomalies or prematurity. However, the use of a staged procedure also has increased survival in even these high-risk infants.

Corrosive Injury of the Esophagus

Injury to the esophagus after ingestion of corrosive substances most commonly occurs in the toddler age group. Both strong alkali and strong acids produce injury by liquefaction or coagulation necrosis, and since all corrosive agents are extremely hygroscopic, the caustic substance will cling to the esophageal epithelium. Subsequent strictures occur at the anatomic narrowed areas of the esophagus, cricopharyngeus, midesophagus, and gastroesophageal junction. A child who has swallowed an injurious substance may be symptom free but usually will be drooling and unable to swallow saliva. The injury may be restricted to the oropharynx and esophagus or may extend to include the stomach. There is no effective immediate antidote. Diagnosis is by careful physical examination of the mouth and endoscopy with a flexible or a rigid esophagoscope. It is important to endoscope only to the first level of the burn in order to avoid perforation. Early barium swallow may delineate the extent of the mucosal injury. It is important to realize that the esophagus may be burned without evidence of injury to the mouth. Although previously used routinely, steroids have not been shown to alter stricture development or modify the extent of injury. Therefore, they are no longer part of the management of caustic injuries. Antibiotics are administered during the acute period.

The extent of injury is graded endoscopically as either mild, moderate, or severe (grade I, II, or III). Circumferential esophageal injuries with necrosis have an extremely high likelihood of stricture formation. These patients should undergo placement of a gastrostomy tube once clinically stable. A string should be inserted through the esophagus either immediately or during repeat esophagoscopy several weeks later. When established strictures are present (usually 3–4 weeks), dilatation is performed. Retrograde dilatations are safest, using graduated dilators brought through the gastrostomy and advanced into the esophagus via the transesophageal string. For less severe injuries, dilatation may be attempted in antegrade fashion by either graded bougies or balloons. Management of esophageal perforation during dilation should include antibiotics, irrigation, and closed drainage of the thoracic cavity to prevent systemic sepsis. When recognition is delayed or if the patient is systemically ill, esophageal diversion may be required with staged reconstruction at a later time.

Although the native esophagus can be preserved in most cases, severe stricture formation that does not respond to dilation is best managed by esophageal replacement. The most commonly used options for esophageal substitution are the colon (right colon or transverse/left colon) and the stomach (gastric

tube or gastric pull-up). Pedicled or free grafts of the jejunum are less commonly used. The right colon is based on a pedicle of the middle colic artery, and the left colon on a pedicle of the middle colic or left colic artery. Gastric tubes are fashioned from the greater curvature of the stomach based on the pedicle of the left gastroepiploic artery. When the entire stomach is used, as in gastric pull-up, the blood supply is provided by the right gastric artery. The neoesophagus may traverse: (a) sub-sternally; (b) through a transthoracic route; or (c) through the posterior mediastinum to reach the neck. A feeding jejunostomy is placed at the time of surgery, and tube feedings are instituted once the postoperative ileus has resolved. In a recent review of patients treated by gastric pull-up, long-term outcome was very good. Complications included esophagogastric anastomotic leak ($n = 15$, 36%), which uniformly resolved without intervention, and stricture formation ($n = 20$, 49%), which responded to a course of dilation. Long-term follow-up has shown that all methods of esophageal substitution can support normal growth and development, and the children enjoy reasonably normal eating habits. Because of the potential for late complications such as ulceration and stricture, follow-up into adulthood is mandatory, but complications appear to diminish with time.

Gastroesophageal Reflux

Gastroesophageal reflux (GER) occurs to some degree in all children and refers to the passage of gastric contents into the esophagus. By contrast, gastroesophageal reflux disease (GERD) describes the situation where reflux is symptomatic. Typical symptoms include failure to thrive, bleeding, stricture formation, reactive airway disease, aspiration pneumonia, and apnea. Failure to thrive and pulmonary problems are particularly common in infants with GERD, whereas strictures and esophagitis are more common in older children and adolescents. GERD is particularly problematic in neurologically impaired children.

Clinical Manifestations. Because all infants experience occasional episodes of GER to some degree, care must be taken before a child is labeled as having pathologic reflux. A history of repeated episodes of vomiting that interferes with growth and development or the presence of apparent life-threatening events is required for the diagnosis of GERD. In older children, esophageal bleeding, stricture formation, severe heartburn, or the development of Barrett's esophagus unequivocally connotes pathologic reflux or GERD. In neurologically impaired children, vomiting due to GER must be distinguished from chronic retching.

The workup of patients suspected of having GERD includes documentation of the episodes of reflux and evaluation of the anatomy. A barium swallow should be performed as an initial test. This will determine whether there is obstruction of the stomach or duodenum (due to duodenal webs or pyloric stenosis) and will determine whether malrotation is present. The frequency and severity of reflux should be assessed using a 24-hour pH probe study. Although this test is poorly tolerated, it provides the most accurate determination that GERD is present. Esophageal endoscopy with biopsies may identify the presence of esophagitis and is useful to determine the length of intra-abdominal esophagus and the presence of Barrett's esophagus. Some surgeons obtain a radioisotope "milk scan" to evaluate gastric emptying, although there is little evidence to show that this test changes management when a diagnosis of GERD has been confirmed using the above modalities.

Treatment. Most patients with GERD are treated initially by conservative means. In the infant, propping and thickening the formula with rice cereal are generally recommended. Some authors prefer a prone, head-up position. In the infant unresponsive to position and formula changes and the older child with severe GERD, medical therapy is based on gastric acid reduction with an H_2 -blocking agent and/or a proton pump inhibitor. Medical therapy is successful in most neurologically normal infants and younger children, many of whom will outgrow their need for medications. In certain patients, however, medical treatment does not provide symptomatic relief, and surgery is therefore indicated. The least invasive surgical option includes the placement of a nasojejunal or gastrojejunal feeding tube. Because the stomach is bypassed, food contents do not enter the esophagus, and symptoms are often improved. However, as a long-term remedy, this therapy is associated with several problems. The tubes often become dislodged, acid reflux still occurs, and bolus feeding is generally not possible. Fundoplication provides definitive treatment for GER and is highly effective in most circumstances. The fundus may be wrapped around the distal esophagus either 360° (i.e., Nissen) or to lesser degrees (i.e., Thal or Toupet). At present, the standard approach in most children is to perform these procedures laparoscopically whenever possible. In children with feeding difficulties and in infants under 1 year of age, a gastrostomy tube should be placed at the time of surgery. Early postoperative complications include pneumonia and atelectasis, often due to inadequate pulmonary toilet and pain control with abdominal splinting. Late postoperative complications include wrap breakdown with recurrent reflux, which may require repeat fundoplication, and dysphagia due to a wrap performed too tightly, which generally responds to dilation. These complications are more common in children with neurologic impairment. The keys to successful surgical management of patients with GERD include careful patient selection and meticulous operative technique.

GASTROINTESTINAL TRACT

An Approach to the Vomiting Infant

The majority of infants vomit. Because infant vomiting is so common, it is important to differentiate between normal vomiting, which occurs in almost all babies, to some degree, and abnormal vomiting, which may be indicative of a potentially serious underlying disorder. To determine the seriousness of a particular infant's bouts of emesis, one needs to characterize what the vomit looks like and how sick the baby is. Vomit that looks like feeds and comes up immediately after a feeding is almost always *gastroesophageal reflux*. This may or may not be of concern, as described earlier. Vomiting that occurs a short while after feeding or vomiting that projects out of the baby's mouth may be indicative of *pyloric stenosis*. By contrast, **vomit that has any green color in it is always worrisome**. This may be reflective of intestinal *volvulus*, an underlying infection, or some other cause of intestinal obstruction. A more detailed description of the management of these conditions is provided in the following sections.

Hypertrophic Pyloric Stenosis

Clinical Presentation. Infants with hypertrophic pyloric stenosis (HPS) typically present with nonbilious vomiting that becomes increasingly projectile over the course of several days to weeks due to progressive thickening of the pylorus muscle.

HPS occurs in approximately 1 in 300 live births and commonly in infants between 3 and 6 weeks of age. Male-to-female ratio is nearly 5:1.

Eventually, as the pyloric muscle thickening progresses, the infant develops a complete gastric outlet obstruction and is no longer able to tolerate any feeds. Over time, the infant becomes increasingly hungry, unsuccessfully feeds repeatedly, and becomes increasingly dehydrated. Wet diapers become less frequent, and there may even be a perception of less passage of flatus. HPS may be associated with jaundice due to an indirect hyperbilirubinemia, although the nature of this relationship is unclear.

The cause of HPS has not been determined. Studies have shown that HPS is found in several generations of the same family, suggesting a familial link. Administration of erythromycin in early infancy has been linked to the subsequent development of HPS, although the cause is unclear. Infant positioning in the prone position was implicated as a cause of HPS particularly when, in Denmark and Sweden, a drop in both cases of sudden infant death syndrome (SIDS) and HPS were reported. More recently, a similar drop in both SIDS and HPS was noted in Germany, although the distribution of case rate declines were different across regions in Germany, suggesting that the etiology of HPS is not likely simply due to positioning.

Infants with HPS develop a hypochloremic, hypokalemic metabolic alkalosis. The urine pH level is high initially, but eventually drops because hydrogen ions are preferentially exchanged for sodium ions in the distal tubule of the kidney as the hypochloremia becomes severe (paradoxical aciduria). The diagnosis of pyloric stenosis usually can be made on physical examination by palpation of the typical “olive” in the right upper quadrant and the presence of visible gastric waves on the abdomen. When the olive cannot be palpated, US can diagnose the condition accurately in 95% of patients. Criteria for US diagnosis include a channel length of over 16 mm and pyloric thickness over 4 mm.

Treatment. Given frequent fluid and electrolyte abnormalities at time of presentation, pyloric stenosis is never a surgical emergency. Fluid resuscitation with correction of electrolyte abnormalities and metabolic alkalosis is essential prior to induction of general anesthesia for operation. For most infants, fluid containing 5% dextrose and 0.45% saline with added potassium of 2 to 4 mEq/kg over 24 hours at a rate of approximately 150 to 175 mL/kg per 24 hours will correct the underlying deficit. It is important to ensure that the child has an adequate urine output (>2 cc/kg/h) as further evidence that rehydration has occurred. After resuscitation, a Fredet-Ramstedt pyloromyotomy is performed (Fig. 39-12). It may be performed using an open or laparoscopic approach. The open pyloromyotomy is performed through either an umbilical or a right upper quadrant transverse abdominal incision. The former route is cosmetically more appealing, although the transverse incision provides easier access to the antrum and pylorus. In recent years, the laparoscopic approach has gained great popularity. Two randomized trials have demonstrated that both the open and laparoscopic approaches may be performed safely with equal incidence of postoperative complications, although the cosmetic result is clearly superior with the laparoscopic approach. Whether done through an open or laparoscopic approach, surgical treatment of pyloric stenosis involves splitting the pyloric muscle while leaving the underlying submucosa intact. The incision extends from

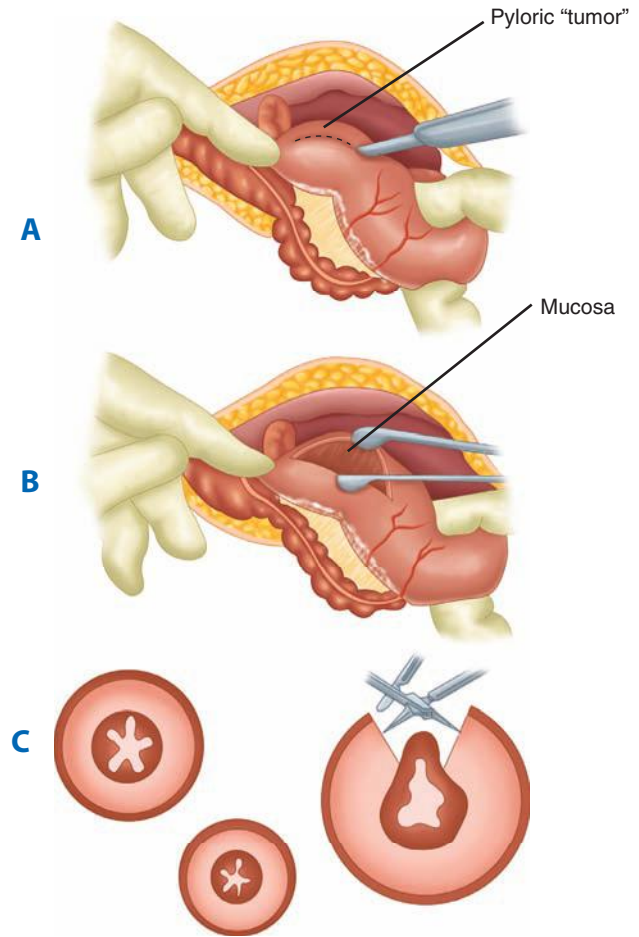


Figure 39-12. Fredet-Ramstedt pyloromyotomy. **A.** Pylorus delivered into wound and seromuscular layer incised. **B.** Seromuscular layer separated down to submucosal base to permit herniation of mucosa through pyloric incision. **C.** Cross-section demonstrating hypertrophied pylorus, depth of incision, and spreading of muscle to permit mucosa to herniate through incision.

just proximal to the pyloric vein of Mayo to the gastric antrum; it typically measures between 1 and 2 cm in length. Postoperatively, IV fluids are continued for several hours, after which Pedialyte is offered, followed by formula or breast milk, which is gradually increased to 60 cc every 3 hours. Most infants can be discharged home within 24–48 hours following surgery. Recently, several authors have shown that ad lib feeds are safely tolerated by the neonate and result in a shorter hospital stay.

The complications of pyloromyotomy include perforation of the mucosa (1%–3%), bleeding, wound infection, and recurrent symptoms due to inadequate myotomy. When perforation occurs, the mucosa is repaired with a stitch that is placed to tack the mucosa down and reapproximate the serosa in the region of the tear. A nasogastric tube is left in place for 24 hours. The outcome is generally very good.

Intestinal Obstruction in the Newborn

The cardinal symptom of intestinal obstruction in the newborn

▶ is bilious emesis. Prompt recognition and treatment of neonatal intestinal obstruction can truly be life saving.

The incidence of neonatal intestinal obstruction is 1 in 2000 live births. The approach to intestinal obstruction in the newborn infant is critical for timely and appropriate intervention. When a neonate develops bilious vomiting, one must

consider a surgical etiology. Indeed, the majority of newborns with bilious emesis have a surgical condition. In evaluating a potential intestinal obstruction, it is helpful to determine whether the intestinal obstruction is either proximal or distal to the ligament of Treitz. One must conduct a detailed prenatal and immediate postnatal history and a thorough physical examination. In all cases of intestinal obstruction, it is vital to obtain abdominal films in the supine and upright (or lateral decubitus) views to assess the presence of air-fluid levels or free air as well as how far downstream air has managed to travel. Importantly, one should recognize that it is difficult to determine whether a loop of bowel is part of either the small or large intestine, as neonatal bowel lacks clear features, such as haustra or plica circulares, normally present in older children or adults. As such, contrast imaging may be necessary for diagnosis in some instances.

Proximal intestinal obstructions typically present with bilious emesis and minimal abdominal distention. The normal neonate should have a rounded, soft abdomen; in contrast, a neonate with a proximal intestinal obstruction typically exhibits a flat or scaphoid abdomen. On a series of upright and supine abdominal radiographs, one may see a paucity or absence of bowel gas, which normally should be present throughout the gastrointestinal tract within 24 hours. Of utmost importance is the exclusion of a malrotation with midgut volvulus from all other intestinal obstructions as this is a surgical emergency.

Distal obstructions typically presents with bilious emesis and abdominal distention. Passage of black-green meconium should have occurred within the first 24 to 38 hours. Of great importance, one should determine whether or not there is tenderness or discoloration of the abdomen, visible or palpable loops of intestine, and presence or absence of a mass, and whether or not the anus is patent and in the appropriate location. Abdominal radiographs may demonstrate calcifications, which may indicate complicated meconium ileus; pneumatosis and/or pneumoperitoneum may indicate necrotizing enterocolitis. A contrast enema may show whether there is a microcolon indicative of jejunoileal atresia or meconium ileus. If a microcolon is not present, then the diagnoses of Hirschsprung's disease, small left colon syndrome, or meconium plug syndrome should be considered.

Duodenal Obstruction

Whenever the diagnosis of duodenal obstruction is entertained, malrotation and midgut volvulus must be excluded. This topic is covered in further detail later in this chapter. Other causes of duodenal obstruction include duodenal atresia, duodenal web, stenosis, annular pancreas, or duodenal duplication cyst. Duodenal obstruction is easily diagnosed on prenatal US, which demonstrates the fluid-filled stomach and proximal duodenum as two discrete cystic structures in the upper abdomen. Associated polyhydramnios is common and presents in the third trimester. In 85% of infants with duodenal obstruction, the entry of the bile duct is proximal to the level of obstruction, such that vomiting is bilious. Abdominal distention is typically not present because of the proximal level of obstruction. In infants with obstruction proximal to the bile duct entry, the vomiting is nonbilious. The classic finding on abdominal radiography is the "double bubble" sign, which represents the dilated stomach and duodenum (Fig. 39-13). In association with the appropriate clinical picture, this finding is sufficient to confirm the diagnosis of duodenal obstruction. However, if there is any uncertainty,

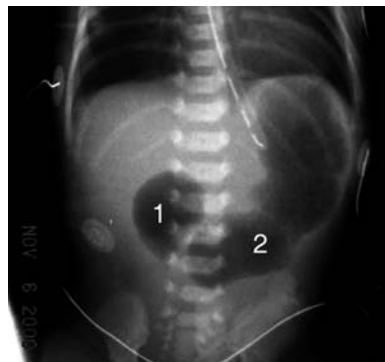

Figure 39-13. Abdominal x-ray showing "double bubble" sign in a newborn infant with duodenal atresia. The two "bubbles" are numbered.

particularly when a partial obstruction is suspected, a contrast upper gastrointestinal series is diagnostic.

Treatment. An orogastric tube is inserted to decompress the stomach and duodenum, and the infant is given IV fluids to maintain adequate urine output. If the infant appears ill or if abdominal tenderness is present, a diagnosis of malrotation and midgut volvulus should be considered, and surgery should not be delayed. Typically, the abdomen is soft, and the infant is very stable. Under these circumstances, the infant should be evaluated thoroughly for other associated anomalies. Approximately one third of newborns with duodenal atresia have associated Down syndrome (trisomy 21). These patients should be evaluated for associated cardiac anomalies. Once the workup is complete and the infant is stable, he or she is taken to the operating room, and the abdomen is entered through a transverse right upper quadrant supraumbilical incision under general endotracheal anesthesia. Associated anomalies should be searched for at the time of the operation. These include malrotation, anterior portal vein, a second distal web, and biliary atresia. The surgical treatment of choice for duodenal obstruction due to duodenal stenosis or atresia or annular pancreas is a duodeno-duodenostomy. This procedure can be most easily performed using a proximal transverse-to-distal longitudinal (diamond-shaped) anastomosis. In cases where the duodenum is extremely dilated, the lumen may be tapered using a linear stapler with a large Foley catheter (24 F or greater) in the duodenal lumen. It is important to emphasize that an annular pancreas is never divided but rather is bypassed to avoid injury to the pancreatic ducts. Treatment of duodenal web includes vertical duodenotomy, excision of the web, oversewing of the mucosa, and closing the duodenotomy horizontally. Gastrostomy tube placement is not routinely performed. Recently reported survival rates exceed 90%. Late complications from repair of duodenal atresia occur in approximately 12% to 15% of patients and include megaduodenum, intestinal motility disorders, and GER.

Intestinal Atresia

Obstruction due to intestinal atresia can occur at any point along the intestinal tract. Intestinal atresias were previously thought to be the result of in utero mesenteric vascular accidents leading to segmental loss of the intestinal lumen, although, more likely they are due to developmental defects in normal intestinal organogenesis due to disruption of various signaling pathways such as fibroblast growth factor, bone morphogenic protein, and β -catenin pathways. The incidence of intestinal atresia has been

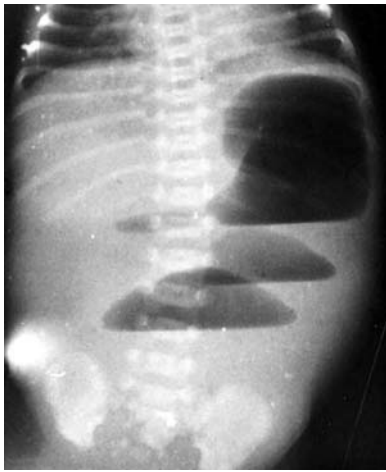


Figure 39-14. Intestinal obstruction in the newborn showing several loops of distended bowel with air-fluid levels. This child has jejunal atresia.

estimated to be between 1 in 2000 and 1 in 5000 live births, with equal representation of the sexes. Infants with jejunal or ileal atresia present with bilious vomiting and progressive abdominal distention. The more distal the obstruction, the more distended the abdomen becomes, and the greater is the number of obstructed loops on upright abdominal films (Fig. 39-14).

In cases where the diagnosis of complete intestinal obstruction is ascertained by the clinical picture and the presence of staggered air-fluid levels on plain abdominal films, the child can be brought to the operating room after appropriate resuscitation. In these circumstances, there is little extra information to be gained by performing a barium enema. By contrast, when there is diagnostic uncertainty or when distal intestinal obstruction is apparent, a barium enema is useful to establish whether a microcolon is present and to diagnose the presence of meconium plugs, small left colon syndrome, Hirschsprung's disease, or meconium ileus. Judicious use of barium enema is therefore required in order to safely manage neonatal intestinal obstruction, based on an understanding of the expected level of obstruction.

Surgical correction of the small intestinal atresia should be performed urgently. At laparotomy, one of several types of atresia will be encountered. In type 1, there is a mucosal atresia with intact muscularis. In type 2, the atretic ends are connected by a fibrous band. In type 3A, the two ends of the atresia are separated by a V-shaped defect in the mesentery. Type 3B is an "apple peel" deformity or "Christmas tree" deformity in which the bowel distal to the atresia receives its blood supply in a retrograde fashion from the ileocolic or right colic artery (Fig. 39-15). In type 4 atresia, there are multiple atresias with a "string of sausage" or "string of beads" appearance. Disparity in lumen size between the proximal distended bowel and the small diameter of collapsed bowel distal to the atresia has led to a number of innovative techniques of anastomosis. However, under most circumstances, an anastomosis can be performed using the end-to-back technique in which the distal, compressed loop is "fish-mouthed" along its antimesenteric border. The proximal distended loop can be tapered as described earlier. Because the distended proximal bowel rarely has normal motility, the extremely dilated portion should be resected prior to performing the anastomosis.

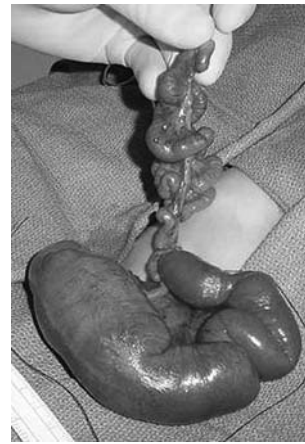

Figure 39-15. Operative photograph of newborn with "Christmas tree" type of ileal atresia.

Occasionally the infant with intestinal atresia will develop ischemia or necrosis of the proximal segment secondary to volvulus of the dilated, bulbous, blind-ending proximal bowel. Under these conditions, an end ileostomy and mucus fistula should be created, and the anastomosis should be deferred to another time after the infant stabilizes.

Malrotation and Midgut Volvulus

Embryology. During the sixth week of fetal development, the midgut grows too rapidly to be accommodated in the abdominal cavity and therefore herniates into the umbilical cord. Between the tenth and twelfth weeks, the midgut returns to the abdominal cavity, undergoing a 270° counterclockwise rotation around the superior mesenteric artery. Because the duodenum also rotates caudal to the artery, it acquires a C-loop that traces this path. The cecum rotates cephalad to the artery, which determines the location of the transverse and ascending colon. Subsequently, the duodenum becomes fixed retroperitoneally in its third portion and at the ligament of Treitz, while the cecum becomes fixed to the lateral abdominal wall by peritoneal bands. The takeoff of the branches of the superior mesenteric artery elongates and becomes fixed along a line extending from its emergence from the aorta to the cecum in the right lower quadrant. Genetic mutations likely disrupt the signaling critical for normal intestinal rotation. For instance, mutations in the gene *BCL6* resulting in absence of left-sided expression of its transcript lead to reversed cardiac orientation, defective ocular development, and malrotation. The essential role of the dorsal gut mesentery in mediating normal intestinal rotation and the role of the forkhead box transcription factor *Foxf1* in formation of the dorsal mesentery in mice are consistent with the noted association of intestinal malrotation with alveolar capillary dysplasia, caused by mutations in *FOXF1*. If rotation is incomplete, the cecum remains in the epigastrium, but the bands fixing the duodenum to the retroperitoneum and cecum continue to form. This results in (Ladd's) bands extending from the cecum to the lateral abdominal wall and crossing the duodenum, which creates the potential for obstruction. The mesenteric takeoff remains confined to the epigastrium, resulting in a narrow pedicle suspending all the branches of the superior mesenteric artery and the entire midgut. A volvulus may therefore occur around the mesentery. This twist not only obstructs the proximal jejunum, but also cuts off the blood

supply to the midgut. Intestinal obstruction and complete infarction of the midgut occur unless the problem is promptly corrected surgically.

Presentation and Management. Midgut volvulus can occur at any age, although it is seen most often in the first few weeks of life. Bilious vomiting is usually the first sign of volvulus, and all infants with bilious vomiting must be evaluated rapidly to ensure that they do not have intestinal malrotation with volvulus. The child with irritability and bilious emesis should raise particular suspicions for this diagnosis. If left untreated, vascular compromise of the midgut initially causes bloody stools, but eventually results in circulatory collapse. Additional clues to the presence of advanced ischemia of the intestine include erythema and edema of the abdominal wall, which progresses to shock and death. It must be re-emphasized that the index of suspicion for this condition must be high, since abdominal signs are minimal in the early stages. Abdominal films show a paucity of gas throughout the intestine with a few scattered air-fluid levels (Fig. 39-16). When these findings are present, the patient should undergo immediate fluid resuscitation to ensure adequate perfusion and urine output followed by prompt exploratory laparotomy. In cases where the child is stable, laparoscopy may be considered.

Often the patient will not appear ill, and the plain films may suggest partial duodenal obstruction. Under these conditions, the patient may have malrotation without volvulus. This is best diagnosed by an upper gastrointestinal series that shows incomplete rotation with the duodenojejunal junction displaced to the right. The duodenum may show a corkscrew effect diagnosing volvulus or complete duodenal obstruction, with the small bowel loops entirely in the right side of the abdomen. Barium enema may show a displaced cecum, but this sign is unreliable, especially in the small infant in whom

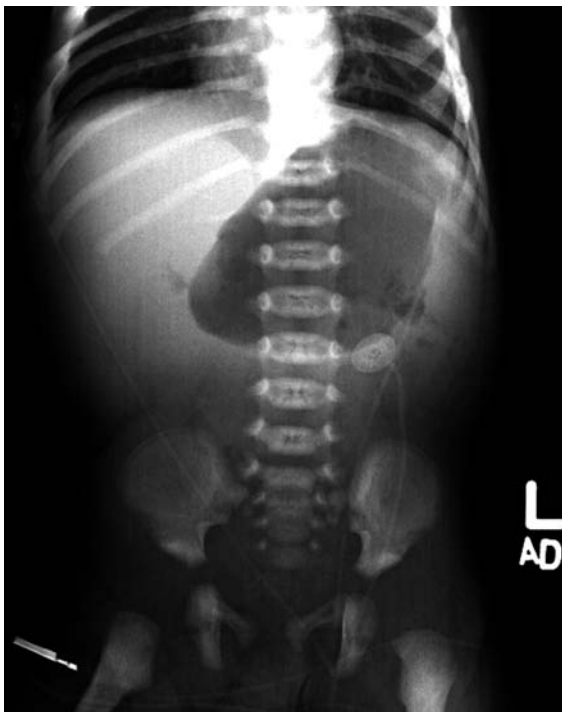

Figure 39-16. Abdominal x-ray of a 10-day-old infant with bilious emesis. Note the dilated proximal bowel and the paucity of distal bowel gas, characteristic of a volvulus.

the cecum is normally in a somewhat higher position than in the older child.

When volvulus is suspected, early surgical intervention is mandatory if the ischemic process is to be avoided or reversed. Volvulus occurs clockwise and is therefore untwisted counterclockwise. This can be remembered using the memory aid “turn back the hands of time.” Subsequently, a Ladd procedure is performed. This operation does not correct the malrotation, but does broaden the narrow mesenteric pedicle to prevent volvulus from recurring. This procedure is performed as follows (Fig. 39-17). The bands between the cecum and the abdominal wall and between the duodenum and terminal ileum are divided sharply to splay out the superior mesenteric artery and its branches. This maneuver brings the straightened duodenum into the right lower quadrant and the cecum into the left lower quadrant. The appendix is removed to avoid diagnostic errors in later life. No attempt is made to suture the cecum or duodenum in place. With advanced ischemia, reduction of the volvulus without the Ladd procedure is accomplished, and a “second look” 24 to 36 hours later often will show some vascular recovery. A plastic transparent silo may be placed to facilitate constant evaluation of the intestine and to plan for the timing of re-exploration. Frankly necrotic bowel can then be resected conservatively. With early diagnosis and correction the prognosis is excellent. However, diagnostic delay can lead to mortality or to short-gut syndrome requiring intestinal transplantation.

A subset of patients with malrotation will demonstrate chronic obstructive symptoms. These symptoms may result from Ladd’s bands across the duodenum or, occasionally, from intermittent volvulus. Symptoms include intermittent abdominal pain and intermittent vomiting, which may occasionally be bilious. Infants with malrotation may demonstrate failure to thrive, and they may be diagnosed initially as having GERD. Surgical correction using the Ladd procedure, as described earlier, can prevent volvulus from occurring and improve symptoms in many instances.

Meconium Ileus

Pathogenesis and Clinical Presentation. Infants with cystic fibrosis have characteristic pancreatic enzyme deficiencies and abnormal chloride secretion in the intestine that result in the production of viscous, water-poor meconium. This phenotype is explained by the presence of mutations in the *CFTR* gene. Meconium ileus occurs when this thick, highly viscous meconium becomes impacted in the ileum and leads to high-grade intestinal obstruction. Recently, additional mutations were recently identified in genes encoding multiple apical plasma membrane proteins of infants with meconium ileus. Meconium ileus can be either uncomplicated, in which there is no intestinal perforation, or complicated, in which prenatal perforation of the intestine has occurred or vascular compromise of the distended ileum develops. Antenatal US may reveal the presence of intra-abdominal or scrotal calcifications or distended bowel loops. These infants present shortly after birth with progressive abdominal distention and failure to pass meconium with intermittent bilious emesis. Abdominal radiographs show dilated loops of intestine. Because the enteric contents are so viscous, air-fluid levels do not form, even when obstruction is complete. Small bubbles of gas become entrapped in the inspissated meconium in the distal ileum, where they produce a characteristic “ground glass” appearance.

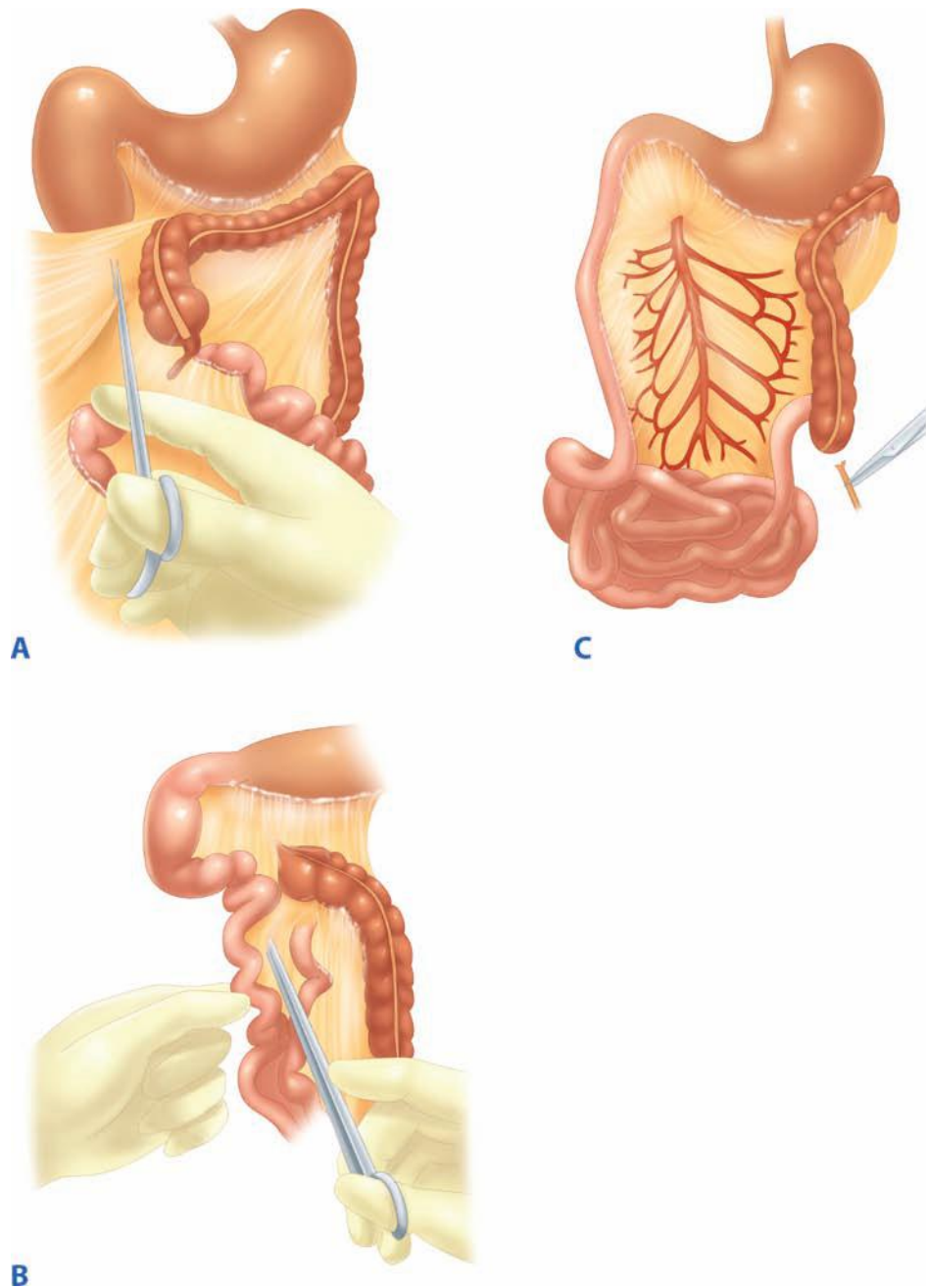


Figure 39-17. Ladd procedure for malrotation. **A.** Lysis of cecal and duodenal bands. **B.** Broadening the mesentery. **C.** Appendectomy.

The diagnosis of meconium ileus is confirmed by a contrast enema, which typically demonstrates a microcolon. In patients with uncomplicated meconium ileus, the terminal ileum is filled with pellets of meconium. In patients with complicated meconium ileus, intraperitoneal calcifications form, producing an eggshell pattern on plain abdominal x-ray.

Management. The treatment strategy depends on whether the patient has complicated or uncomplicated meconium ileus. Patients with uncomplicated meconium ileus can be treated nonoperatively. Either dilute water-soluble contrast or *N*-acetylcysteine (Mucomyst[®]) is infused transanally via catheter under fluoroscopic control into the dilated portion of the ileum. Because these agents act by absorbing fluid from the bowel wall into the intestinal lumen, infants undergoing treatment are at risk of fluid and electrolyte abnormalities,

so appropriate resuscitation of the infant during this maneuver is extremely important. The enema may be repeated at 12-hour intervals over several days until all the meconium is evacuated. Inability to reflux the contrast into the dilated portion of the ileum signifies the presence of an associated atresia or complicated meconium ileus, and thus warrants exploratory laparotomy. If surgical intervention is required because of failure of contrast enemas to relieve obstruction, operative irrigation with dilute contrast agent, *N*-acetylcysteine, or saline through a purse-string suture may be successful. Alternatively, resection of the distended terminal ileum is performed, and the meconium pellets are flushed from the distal small bowel. At this point, an end ileostomy may be created. The distal bowel may be brought up as a mucus fistula or sewn to the side of the ileum as a Bishop-Koop anastomosis.

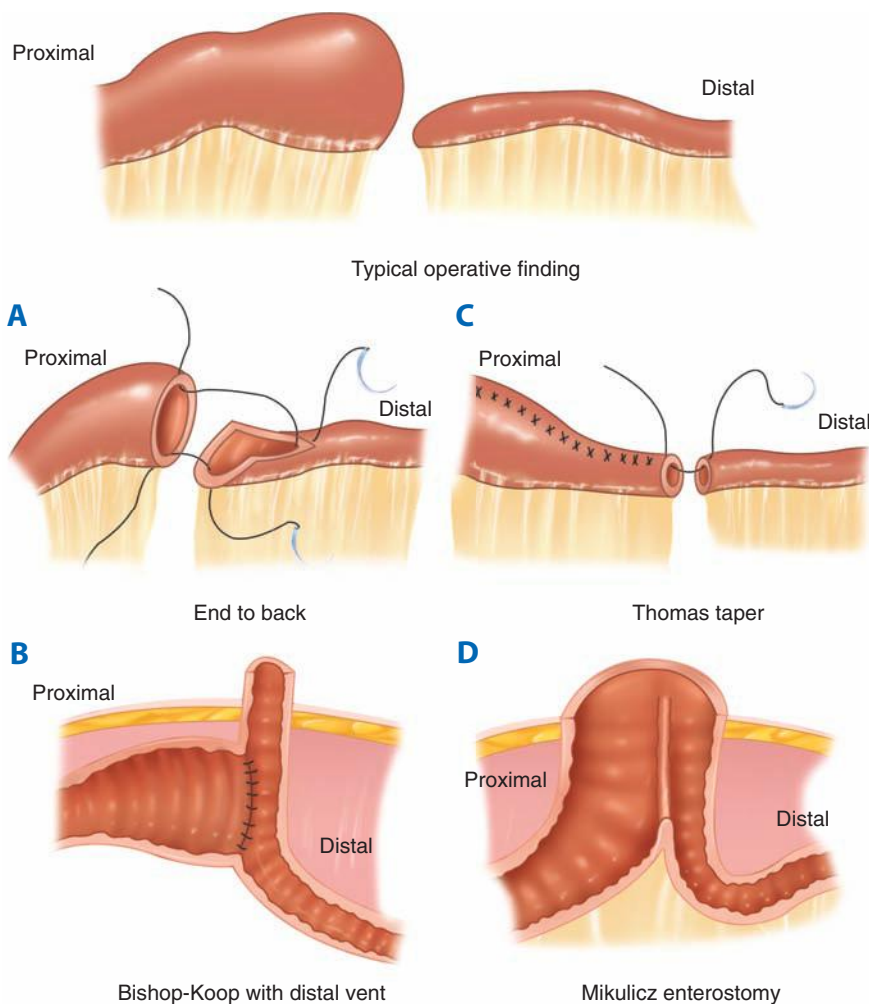


Figure 39-18. Techniques of intestinal anastomosis for infants with small bowel obstruction. **A.** End to back: distal limb has been incised, creating “fish mouth” to enlarge the lumen. **B.** Bishop-Koop: proximal distended limb joined to side of distal small bowel, which is vented by “chimney” to the abdominal wall. **C.** Tapering: portion of antimesenteric wall of proximal bowel excised, with longitudinal closure to minimize disparity in the limbs. **D.** Mikulicz double-barreled enterostomy is constructed by suturing the two limbs together and then exteriorizing the double stoma. The common wall can be crushed with a special clamp to create a large stoma. The stoma can be closed in an extraperitoneal manner.

An end-to-end anastomosis may also be considered in the appropriate setting (Fig. 39-18).

Necrotizing Enterocolitis

Clinical Features. Necrotizing enterocolitis (NEC) is the most frequent and lethal gastrointestinal disorder affecting the intestine of the stressed, preterm neonate. Over 25,000 cases of NEC are reported annually. The overall mortality ranges between 10% and 50%. Advances in neonatal care such as surfactant therapy and improved methods of mechanical ventilation have resulted in increasing numbers of low birth weight infants surviving neonatal hyaline membrane disease. An increasing proportion of survivors of neonatal respiratory distress syndrome will therefore be at risk for developing NEC. Consequently, it is estimated that NEC soon will surpass respiratory distress syndrome as the principal cause of death in the preterm infant.

Multiple risk factors have been associated with the development of NEC. These include prematurity, initiation of enteral feeding, bacterial infection, intestinal ischemia resulting from birth asphyxia, umbilical artery cannulation, persistence of a

patent ductus arteriosus, cyanotic heart disease, and maternal cocaine abuse. Nonetheless, the mechanisms by which these complex interacting etiologies lead to the development of the disease remain undefined. The only consistent epidemiologic precursors for NEC are prematurity and enteral alimentation, representing the commonly encountered clinical situation of a stressed infant who is fed enterally. Of note, there is some debate regarding the type and strategy of enteral alimentation in the pathogenesis of NEC. A prospective randomized study showed no increase in the incidence of NEC despite an aggressive feeding strategy.

The indigenous intestinal microbial flora has been postulated to play a central role in the pathogenesis of NEC. Bacterial colonization may be a prerequisite for the development of this disease because oral prophylaxis with vancomycin or gentamicin reduced the incidence of NEC. The importance of bacteria in the pathogenesis of NEC is further supported by the finding that NEC occurs in episodic waves that can be abrogated by infection control measures and the fact that NEC usually develops at least 10 days postnatally, when the gastrointestinal tract is colonized by coliforms. More recently, outbreaks of NEC have

been reported in infants fed formula contaminated with *Cronobacter sakazakii*. Common bacterial isolates from the blood, peritoneal fluid, and stool of infants with advanced NEC include *Escherichia coli*, *Enterobacter*, *Klebsiella*, and occasionally, coagulase-negative *Staphylococcus* species.

NEC may involve single or multiple segments of the intestine, most commonly the terminal ileum, followed by the colon. The gross findings in NEC include bowel distention with patchy areas of thinning, pneumatosis, gangrene, or frank perforation. The microscopic features include the appearance of a “bland infarct” characterized by full-thickness necrosis.

Clinical Manifestations. Infants with NEC present with a spectrum of disease. In general, the infants are premature and may have sustained one or more episodes of stress, such as birth asphyxia, or they may have congenital cardiac disease. The clinical picture of NEC has been characterized by Bell and colleagues as progressing from a period of mild illness to that of severe, life-threatening sepsis. Although not all infants progress through the various “Bell stages,” this classification scheme provides a useful format to describe the clinical picture associated with the development of NEC. In the earliest stage (Bell stage I), infants present with feeding intolerance. This is suggested by vomiting or by the presence of a large residual volume from a previous feeding in the stomach at the time of the next feeding. Following appropriate treatment, which consists of bowel rest and IV antibiotics, many of these infants will not progress to more advanced stages of NEC. These infants are colloquially described as suffering from a “NEC scare” and represent a population of neonates who are at risk of developing more severe NEC if a more prolonged period of stress supervenes.

Infants with Bell stage II have established NEC that is not immediately life threatening. Clinical findings include abdominal distention and tenderness, bilious nasogastric aspirate, and bloody stools. These findings indicate the development of intestinal ileus and mucosal ischemia, respectively. Abdominal examination may reveal a palpable mass indicating the presence of an inflamed loop of bowel, diffuse abdominal tenderness, cellulitis, and edema of the anterior abdominal wall. The infant may appear systemically ill, with decreased urine output, hypotension, tachycardia, and noncardiac pulmonary edema. Hematologic evaluation reveals either leukocytosis or leukopenia, an increase in the number of bands, and thrombocytopenia. An increase in the blood urea nitrogen and plasma creatinine levels may be found, which signifies the development of renal dysfunction. The diagnosis of NEC may be confirmed by abdominal radiography. The pathognomonic radiographic finding in NEC is pneumatosis intestinalis, which represents invasion of the ischemic mucosa by gas-producing microbes (Fig. 39-19). Other findings include the presence of ileus or portal venous gas. The latter is a transient finding that indicates the presence of severe NEC with intestinal necrosis. A fixed loop of bowel may be seen on serial abdominal radiographs, which suggests the possibility that a diseased loop of bowel, potentially with a localized perforation, is present. Although these infants are at risk of progressing to more severe disease, with timely and appropriate treatment, they often recover.

Infants with Bell stage III have the most advanced form of NEC. Abdominal radiographs often demonstrate the presence of pneumoperitoneum, indicating that intestinal perforation has occurred. These patients may develop a fulminant course with

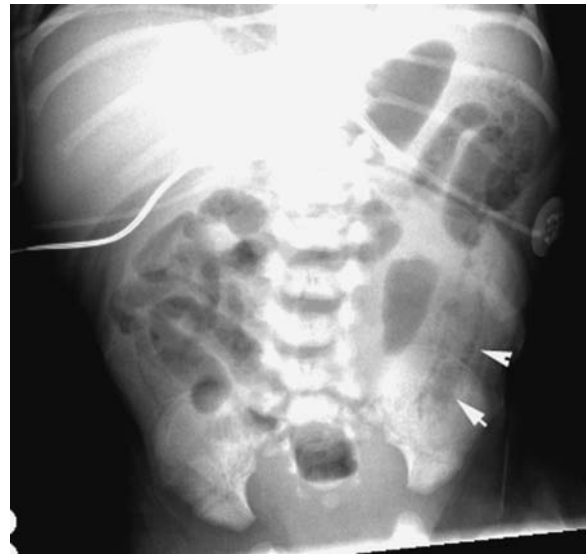

Figure 39-19. Abdominal radiograph of infant with necrotizing enterocolitis. Arrows point to area of pneumatosis intestinalis.

progressive peritonitis, acidosis, sepsis, disseminated intravascular coagulopathy, and death.

Pathogenesis of Necrotizing Enterocolitis. Several theories have been proposed to explain the development of NEC. To more precisely understand the mechanisms that contribute to the pathogenesis of NEC, several groups have focused on understanding the potential clues that may be revealed by studying patients who have progressed from Bell stage I to Bell stage III disease. In general terms, the development of diffuse pneumatosis intestinalis, which is associated with the development of stage II NEC, is thought to be due to the presence of gas within the wall of the intestine from enteric bacteria, suggesting the causative role of bacteria in the pathogenesis of NEC. Furthermore, the development of pneumoperitoneum indicates disease progression with severe disruption of the intestinal barrier (intestinal perforation). Finally, systemic sepsis with diffuse multisystem organ dysfunction suggests the role for circulating proinflammatory cytokines in the pathogenesis of NEC. It has also been demonstrated that the premature intestine responds in an exaggerated fashion to bacterial products, rendering the host susceptible to barrier dysfunction and the development of NEC. As was recently summarized by the 2006 National Institute of Child Health and Development (NICHD) workshop on NEC research, “NEC can be thought to arise from an uncontrolled exuberant inflammatory response to bacterial colonization that characterizes the intestine of premature infants.”

Treatment. In all infants suspected of having NEC, feedings are discontinued, a nasogastric tube is placed, and broad-spectrum parenteral antibiotics are given. The infant is resuscitated, and inotropes are administered to maintain perfusion as needed. Intubation and mechanical ventilation may be required to maintain oxygenation. TPN is started. Subsequent treatment may be influenced by the particular stage of NEC that is present. Patients with Bell stage I are closely monitored and generally remain NPO (nothing by mouth) and on IV antibiotics for 5 to 7 days, prior to reinitiating enteral nutrition. If the infant fully recovers, feedings may be reinitiated.

Patients with Bell stage II disease merit close observation. Serial physical examinations are performed looking for the

development of diffuse peritonitis, a fixed mass, progressive abdominal wall cellulitis, or systemic sepsis. Serial abdominal radiographs are obtained at regular intervals to look for the presence of pneumoperitoneum or a fixed loop of bowel. If infants fail to improve after several days of treatment or if abdominal radiographs show a fixed intestinal loop, consideration should be given to exploratory laparotomy. Paracentesis may be performed, and if the Gram stain demonstrates multiple organisms and leukocytes, perforation of the bowel should be suspected, and patients should undergo laparotomy.

In the most severe form of NEC (Bell stage III), patients have definite intestinal perforation or have not responded to nonoperative therapy. Two schools of thought direct further management. One group favors exploratory laparotomy. At laparotomy, frankly gangrenous or perforated bowel is resected, and the intestinal ends are brought out as stomas. When there is massive intestinal involvement, marginally viable bowel is retained, and a “second look” procedure is carried out after the infant stabilizes (24–48 hours). Patients with extensive necrosis at the second look may be managed by placing a proximal diverting stoma, resecting bowel that is definitely not viable, and leaving questionably viable bowel behind, distal to the diverted segment. When the intestine is viable except for a localized perforation without diffuse peritonitis and if the infant’s clinical condition permits, intestinal anastomosis may be performed. In cases where the diseased, perforated segment cannot be safely resected, drainage catheters may be left in the region of the diseased bowel, and the infant is allowed to stabilize.

An alternative approach to the management of infants with perforated NEC involves drainage of the peritoneal cavity. This may be performed under local anesthesia at the bedside and can be an effective means of stabilizing the desperately ill infant by relieving increased intra-abdominal pressure and allowing ventilation. When successful, this method also allows for drainage of perforated bowel by establishing a controlled fistula. Approximately one third of infants treated with drainage alone survive without requiring additional operations. Infants who do not respond to peritoneal drainage alone after 48 to 72 hours should undergo laparotomy. This procedure allows for the resection of frankly necrotic bowel diversion of the fecal stream and facilitates more effective drainage. It is noteworthy that a recent randomized controlled trial demonstrated that outcomes were similar in infants with NEC who were treated either with primary peritoneal drainage or laparotomy.

Necrotizing Enterocolitis in Older Infants. Although NEC is typically a disease that affects preterm infants, several independent groups have reported a tendency for early onset of NEC in term and near-term infants. In these patients, the pattern of disease was found to be different from that found in premature infants. Specifically, NEC in older infants typically is localized to the end of the small intestine and beginning of the colon, suggestive of an ischemic pathophysiology. There are four pertinent associations that are observed in term infants who develop NEC: congenital heart disease, in utero growth restriction, polycythemia, and perinatal hypoxic-ischemic events. As with NEC in preterm infants, NEC in older patients is also associated with formula consumption and is very rare in exclusively breast-fed infants. Patients with NEC at full term typically present with bloody stools and may be characterized by rapid onset of symptoms and a fulminant course. Thus, although it is true that NEC is typically a disease of premature babies, in the appropriate setting, NEC can develop at any age.

Spontaneous Intestinal Perforation Versus Necrotizing Enterocolitis. In addition to NEC, preterm infants with intestinal pathology may develop spontaneous intestinal perforation (SIP). SIP is a distinct clinical entity from NEC and is essentially a perforation in the terminal ileum. The histopathology of SIP is different from NEC. Specifically, the mucosa is intact and not necrotic, there is no sign of ischemia, and the submucosa is thinned at the site of perforation. In contrast to NEC, pneumatosis intestinalis is absent in SIP. Moreover, the demographics of NEC and SIP are slightly different, in that patients with SIP tend to be slightly more premature, smaller, and more likely to have been on inotropic support. However, both NEC and SIP occur with similar frequency in low birth weight infants. The outcome of patients in the two groups is slightly different. Because patients with SIP have isolated disease without necrosis or systemic inflammation, they tend to have a better outcome. In short, the diagnosis of SIP versus NEC has important prognostic significance. The treatment strategies, however, are essentially the same.

Outcome. Survival in patients with NEC is dependent on the stage of disease, the extent of prematurity, and the presence of associated comorbidities. Survival by stage has recently been shown to be approximately 85%, 65%, and 35% for stages I, II, and III, respectively. Strictures develop in 20% of medically or surgically treated patients, and a contrast enema is mandatory before re-establishing intestinal continuity. If all other factors are favorable, the ileostomy is closed when the child is between 2 and 2.5 kg. At the time of stoma closure, the entire intestine should be examined to search for strictures. Patients who develop massive intestinal necrosis are at risk of developing short bowel syndrome, particularly when the total length of the viable intestinal segment is less than 40 cm. These patients require TPN to provide adequate calories for growth and development and may develop parenteral nutrition–associated cholestasis and hepatic fibrosis. In a significant number of these patients, transplantation of the liver and small bowel may be required.

Short Bowel Syndrome

Short bowel syndrome (SBS) is an expensive, morbid condition with an increasing incidence. Various congenital and perinatal acquired conditions such as gastroschisis, malrotation, atresia, and NEC may lead to SBS. NEC is the most common gastrointestinal emergency in neonates and primarily occurs in premature infants. As rates of prematurity are increasing, so are the numbers of children with SBS. Medical and surgical treatment options carry high dollar and human costs and morbidities including multiple infections and hospitalizations for vascular access, liver failure in conjunction with parenteral nutrition-associated cholestasis, and death. Small bowel transplant has a reported 5-year graft survival of 48%, but is attended by rejection, the morbidity of major surgery, and a lifelong need for antirejection medication. A report on 989 grafts in 923 patients by the Intestine Transplant Registry reveals improving outcomes, but 1-year graft and patient survival rates are 65% and 77%, respectively. If successful in the human, engineered intestine from autologous cells could avoid the problems of transplantation: donor supply and immunosuppression. Because engineered small and large intestine, esophagus, stomach, and specific portions of the gastrointestinal tract such as the gastroesophageal junction form by the same process, other intestinal deficiencies may possibly be addressed.

Intussusception

Intussusception is the leading cause of intestinal obstruction in the young child. It refers to the condition whereby a segment of intestine becomes drawn into the lumen of the more proximal bowel. The process usually begins in the region of the terminal ileum and extends distally into the ascending, transverse, or descending colon. Rarely, an intussusception may prolapse through the rectum.

The cause of intussusception is not clear, although one hypothesis suggests that hypertrophy of the Peyer's patches in the terminal ileum from an antecedent viral infection acts as a lead point. Peristaltic action of the intestine then causes the bowel distal to the lead point to invaginate into itself. Idiopathic intussusception occurs in children between the ages of approximately 6 and 24 months of age. Beyond this age group, one should consider the possibility that a pathologic lead point may be present. These include polyps, malignant tumors such as lymphoma, enteric duplication cysts, or Meckel's diverticulum. Such intussusceptions are rarely reduced by air or contrast enema, and thus the lead point is identified when operative reduction of the intussusception is performed.

Clinical Manifestations. Since intussusception is frequently preceded by a gastrointestinal viral illness, the onset may not be easily determined. Typically, the infant develops paroxysms of crampy abdominal pain and intermittent vomiting. Between attacks, the infant may act normally, but as symptoms progress, increasing lethargy develops. Bloody mucus ("currant jelly" stool) may be passed per rectum. Ultimately, if reduction is not accomplished, gangrene of the intussusceptum occurs, and perforation may ensue. On physical examination, an elongated mass is detected in the right upper quadrant or epigastrium with an absence of bowel in the right lower quadrant (Dance's sign). The mass may be seen on plain abdominal x-ray but is more easily demonstrated on air or contrast enema.

Treatment. Patients with intussusception should be assessed for the presence of peritonitis and for the severity of systemic illness. Following resuscitation and administration of IV antibiotics, the child is assessed for suitability to proceed with radiographic versus surgical reduction. In the absence of peritonitis, the child should undergo radiographic reduction. If peritonitis is present or if the child appears systemically ill, urgent laparotomy is indicated.

In the stable patient, the air enema is diagnostic and may also be curative, and it is the preferred method of diagnosis and treatment of intussusception. Air is introduced with a manometer, and the pressure that is administered is carefully monitored. Under most instances, this should not exceed 120 mmHg. Successful reduction is marked by free reflux of air into multiple loops of small bowel and symptomatic improvement as the infant suddenly becomes pain free. Unless both of these signs are observed, it cannot be assumed that the intussusception is reduced. If reduction is unsuccessful and the infant remains stable, the infant should be brought back to the radiology suite for a repeat attempt at reduction after a few hours. This strategy has improved the success rate of nonoperative reduction in many centers. In addition, hydrostatic reduction with barium may be useful if pneumatic reduction is unsuccessful. The overall success rate of radiographic reduction varies based on the experience of the center and is typically between 60% and 90%.

If nonoperative reduction is successful, the infant may be given oral fluids after a period of observation. Failure to reduce

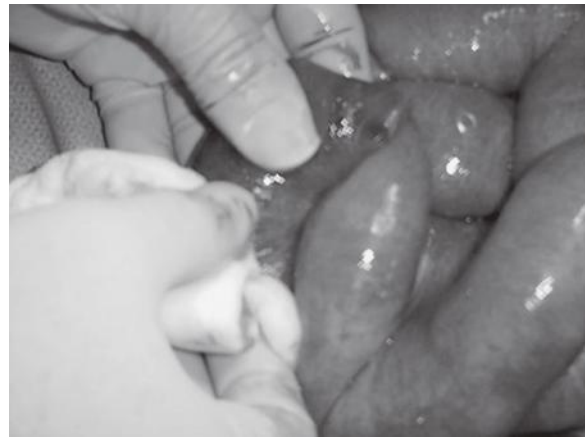

Figure 39-20. Open reduction of intussusception showing how the bowel is milked backward to relieve the obstruction.

the intussusception mandates surgery. Two approaches are used. In an open procedure, exploration is carried out through a right lower quadrant incision, delivering the intussuscepted mass into the wound. Reduction usually can be accomplished by gentle distal pressure, where the intussusceptum is gently milked out of the intussusciens (Fig. 39-20). Care should be taken not to pull the bowel out, as this can cause damage to the bowel wall. The blood supply to the appendix is often compromised, and appendectomy is performed. If the bowel is frankly gangrenous, resection and primary anastomosis are performed. In experienced hands, laparoscopic reduction may be performed, even in very young infants. This is performed using a 5-mm laparoscope placed in the umbilicus and two additional 5-mm ports in the left and right lower quadrants. The bowel is inspected, and if it appears to be viable, reduction is performed by milking the bowel or using gentle traction, although this approach is normally discouraged during manual reduction. Atraumatic bowel graspers allow the bowel to be handled without injuring it.

IV fluids are continued until the postoperative ileus subsides. Patients are started on clear liquids, and their diet is advanced as tolerated. Of note, recurrent intussusception occurs in 5% to 10% of patients, independent of whether the bowel is reduced radiographically or surgically. Patients present with recurrent symptoms in the immediate postoperative period. Treatment involves repeat air enema, which is successful in most cases. In patients who experience three or more episodes of intussusception, the presence of a pathologic lead point should be suspected and carefully evaluated using contrast studies. After the third episode of intussusception, many pediatric surgeons will perform an exploratory laparotomy to reduce the bowel and to resect a pathologic lead point if identified.

Appendicitis

Presentation. Correct diagnosis of appendicitis in children can be one of the most humbling and challenging tasks facing the pediatric surgeon. The classical presentation is known to all students and practitioners of surgery: generalized abdominal pain that localizes to the right lower quadrant followed by nausea, vomiting, fever, and localized peritoneal irritation in the region of McBurney's point. When children present in this manner, there should be little diagnostic delay. The child should be made NPO, administered IV fluids and broad-spectrum antibiotics, and brought to the operating room for an appendectomy.

However, children often do not present in this manner. The coexistence of nonspecific viral syndromes and the inability of young children to describe the location and quality of their pain often result in diagnostic delay. As a result, children with appendicitis often present with perforation, particularly those who are under 5 years of age. Perforation increases the length of hospital stay and makes the overall course of the illness significantly more complex.

Diagnosis of Appendicitis in Children. Controversy exists regarding the role of radiographic studies in the diagnosis of acute appendicitis. Because children have less periappendiceal fat than adults, CT is less reliable in making the diagnosis. In addition, radiation exposure resulting from the CT scan may have potentially long-term adverse effects. Likewise, US is neither sufficiently sensitive nor specific to accurately make the diagnosis of appendicitis, although it is very useful for excluding ovarian causes of abdominal pain. Therefore, the diagnosis of appendicitis remains largely clinical, and each clinician should develop his or her own threshold to operate or to observe the patient. A reasonable practice guideline is as follows: When the diagnosis is clinically apparent, appendectomy should obviously be performed with minimal delay. Localized right lower quadrant tenderness associated with low-grade fever and leukocytosis in boys should prompt surgical exploration. In girls, ovarian or uterine pathology must also be considered. When there is diagnostic uncertainty, the child may be observed, rehydrated, and reassessed. In girls of menstruating age, US may be performed to exclude ovarian pathology (cysts, torsion, or tumor). If all studies are negative, yet the pain persists, and the abdominal findings remain equivocal, diagnostic laparoscopy may be employed to determine the etiology of the abdominal pain. The appendix should be removed even if it appears to be normal, unless another pathologic cause of the abdominal pain is definitively identified and the appendectomy would substantially increase morbidity.

Surgical Treatment of Appendicitis. The definitive treatment for acute appendicitis is appendectomy. Prior to surgery, it is important that patients receive adequate IV fluids in order to correct dehydration that commonly develops as a result of fever and vomiting in patients with appendicitis. Patients should also be started on antibiotics (such as a second-generation cephalosporin). Most surgeons will perform a laparoscopic appendectomy, which may have some advantage over removing the appendix through a single larger incision. During the laparoscopic appendectomy, a small incision is made at the umbilicus, and two additional incisions are made in the lower abdomen. The appendix is typically delivered through the umbilicus, and all incisions are then closed with dissolvable sutures. If the appendix is not ruptured, the patient may start drinking liquids shortly after waking up from the operation and may be advanced to a solid diet the next day. In general, the same steps are taken when appendectomy is performed through an open approach. The most common complication after appendectomy is a surgical site infection. Other risks, including bleeding or damage to other structures inside the abdomen, are extremely rare. Recovery from surgery is dependent on the individual patient. Most children are back to school approximately 1 week after surgery and usually are allowed to return to full physical activity after 2 to 3 weeks. During the recovery period, over-the-counter pain medication may be required. Older patients tend to require a longer time for full recovery.

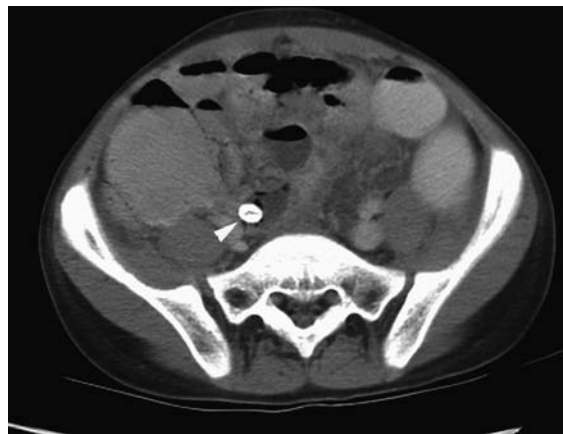

Figure 39-21. Computed tomography scan of the abdomen showing the presence of a ruptured appendix with pelvic fluid and a fecalith (arrow).

Management of the Child with Perforated Appendicitis. The signs and symptoms of perforated appendicitis can closely mimic those of gastroenteritis and include abdominal pain, vomiting, and diarrhea. Alternatively, the child may present with symptoms of intestinal obstruction. An abdominal mass may be present in the lower abdomen. When the symptoms have been present for more than 4 or 5 days and an abscess is suspected, it is reasonable to obtain a CT of the abdomen and pelvis with IV, oral, and rectal contrast to visualize the appendix and the presence of an associated abscess, phlegmon, or fecalith (Fig. 39-21).

An individualized approach is necessary for the child who presents with perforated appendicitis. When there is evidence of generalized peritonitis, intestinal obstruction, or systemic toxicity, the child should undergo appendectomy. This should be delayed only for as long as is required to ensure adequate fluid resuscitation and administration of broad-spectrum antibiotics. The operation can be performed through an open or laparoscopic approach. One distinct advantage of the laparoscopic approach is that it provides excellent visualization of the pelvis and all four quadrants of the abdomen. At the time of surgery, adhesions are gently lysed, abscess cavities are drained, and the appendix is removed. Drains are seldom used, and the skin incisions can be closed primarily. If a fecalith is identified outside the appendix on CT, every effort should be made to retrieve it and to remove it along with the appendix, if at all possible. Often, the child in whom symptoms have been present for more than 4 or 5 days will present with an abscess without evidence of generalized peritonitis. Under these circumstances, it is appropriate to perform image-guided percutaneous drainage of the abscess followed by broad-spectrum antibiotic therapy. The inflammation will generally subside within several days, and the appendix can be safely removed as an outpatient 6 to 8 weeks later. If the child's symptoms do not improve or if the abscess is not amenable to percutaneous drainage, then laparoscopic or open appendectomy and abscess drainage is required. Patients who present with a phlegmon in the region of a perforated appendix may be managed in a similar manner. In general, children who are younger than 4 or 5 years of age do not respond as well to initial nonoperative approach because their bodies do not localize or isolate the inflammatory process. Thus, these patients are more likely to require early surgical intervention. Patients who have had symptoms of appendicitis for no more

than 4 days should probably undergo “early” appendectomy, since the inflammatory response is not as excessive during that initial period and the procedure can be performed safely.

Other Causes of Abdominal Pain That Mimic Appendicitis in Children. As mentioned earlier, appendicitis can be one of the most difficult diagnoses to establish in children with abdominal pain, in part because of the large number of diseases that present in a similar fashion. Patients with urinary tract infection can present very similar to those with appendicitis. However, patients with urinary tract infection are less likely to present with vomiting and are likely to also experience difficulty with urination, characterized by pressure, burning, and frequency. Constipation may be commonly confused with appendicitis in its earliest stages. However, patients with constipation rarely have fever and will not have abnormalities in their blood work. Ovarian torsion can mimic appendicitis, given the severe abdominal pain that accompanies this condition. However, patients with ovarian torsion are generally asymptomatic until the acute onset of severe pain. By contrast, patients with appendicitis generally experience gradual onset of pain associated with nausea and vomiting. Finally, children and young adults are always at risk for the development of gastroenteritis. However, unlike appendicitis, patients with gastroenteritis generally present with persistent vomiting and occasionally diarrhea, which precedes the onset of the abdominal pain.

Intestinal Duplications

Duplications represent mucosa-lined structures that are in continuity with the gastrointestinal tract. Although they can occur at any level in the gastrointestinal tract, duplications are found most commonly in the ileum within the leaves of the mesentery. Duplications may be long and tubular, but usually, they are cystic masses. In all cases, they share a common wall with the intestine. Symptoms associated with enteric duplication cysts include recurrent abdominal pain, emesis from intestinal obstruction, or hematochezia. Such bleeding typically results from ulceration in the duplication or in the adjacent intestine if the duplication contains ectopic gastric mucosa. On examination, a palpable mass is often identified. Children may also develop intestinal obstruction. Torsion may produce gangrene and perforation.

The ability to make a preoperative diagnosis of enteric duplication cyst usually depends on the presentation. CT, US, and technetium pertechnetate scanning can be very helpful. Occasionally, a duplication can be seen on small bowel follow-through or barium enema. In the case of short duplications, resection of the cyst and adjacent intestine with end-to-end anastomosis can be performed. If resection of long duplications would compromise intestinal length, multiple enterotomies and mucosal stripping in the duplicated segment will allow the walls to collapse and become adherent. An alternative method is to divide the common wall using the GIA stapler, forming a common lumen. Patients with duplications who undergo complete excision without compromise of the length of remaining intestine have an excellent prognosis.

Meckel’s Diverticulum

A Meckel’s diverticulum is a remnant of a portion of the embryonic omphalomesenteric (vitelline) duct. It is located on the antimesenteric border of the ileum, usually within 2 ft of the ileocecal valve (Fig. 39-22). It may be found incidentally at surgery or may present with inflammation masquerading as

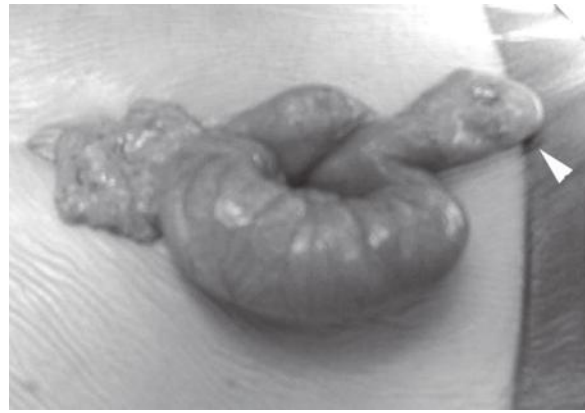

Figure 39-22. Operative photograph showing the presence of a Meckel’s diverticulum (*arrow*).

appendicitis. Perforation of a Meckel’s diverticulum may occur if the outpouching becomes impacted with food, leading to distention and necrosis. Occasionally, bands of tissue extend from the Meckel’s diverticulum to the anterior abdominal wall, and these may represent lead points around which internal hernias may develop. This is an important cause of intestinal obstruction in the older child who has a scarless abdomen. Similar to duplications, ectopic gastric mucosa may produce ileal ulcerations that bleed and lead to the passage of maroon-colored stools. Pancreatic mucosa may also be present. Diagnosis may be made by technetium pertechnetate scans when the patient presents with bleeding. Treatment is surgical. If the base is narrow and there is no mass present in the lumen of the diverticulum, a wedge resection of the diverticulum with transverse closure of the ileum can be performed. A linear stapler is especially useful in this circumstance. When a mass of ectopic tissue is palpable, if the base is wide, or when there is inflammation, it is preferable to perform a resection of the involved bowel and end-to-end ileoileostomy.

Mesenteric Cysts

Mesenteric cysts are similar to duplications in their location within the mesentery. However, they do not contain any mucosa or muscular wall. Chylous cysts may result from congenital lymphatic obstruction. Mesenteric cysts can cause intestinal obstruction or may present as an abdominal mass. The diagnosis may be made by abdominal US or CT. Treatment involves surgical excision. This may require resection of the adjacent intestine, particularly for extensive, multicystic lesions. In cases where complete excision is not possible due to the close proximity to vital structures, partial excision or marsupialization should be performed.

Hirschsprung’s Disease

Pathogenesis. In his classic textbook entitled *Pediatric Surgery*, Dr. Orvar Swenson, who is eponymously associated with one of the classic surgical treatments for Hirschsprung’s disease, described this condition as follows: “Congenital megacolon is caused by a malformation in the pelvic parasympathetic system which results in the absence of ganglion cells in Auerbach’s plexus of a segment of distal colon. Not only is there an absence of ganglion cells, but the nerve fibers are large and excessive in number, indicating that the anomaly may be more extensive than the absence of ganglion cells.” This narrative

of Hirschsprung's disease is as accurate today as it was more than 50 years ago and summarizes the essential pathologic features of this disease: absence of ganglion cells in Auerbach's plexus and hypertrophy of associated nerve trunks. The cause of Hirschsprung's disease remains incompletely understood, although current thinking suggests that the disease results from a defect in the migration of neural crest cells, which are the embryonic precursors of the intestinal ganglion cell. Under normal conditions, the neural crest cells migrate into the intestine from cephalad to caudad. The process is completed by the twelfth week of gestation, but the migration from midtransverse colon to anus takes 4 weeks. During this latter period, the fetus is most vulnerable to defects in migration of neural crest cells. This may explain why most cases of aganglionosis involve the rectum and rectosigmoid. The length of the aganglionic segment of bowel is therefore determined by the most distal region that the migrating neural crest cells reach. In rare instances, total colonic aganglionosis may occur.

Recent studies have shed light on the molecular basis for Hirschsprung's disease. Patients with Hirschsprung's disease have an increased frequency of mutations in several genes, including *GDNF*, its receptor *Ret*, or its coreceptor *Gfra-1*. Moreover, mutations in these genes also lead to aganglionic megacolon in mice, which provides the opportunity to study the function of the encoded proteins. Initial investigations indicate that GDNF promotes the survival, proliferation, and migration of mixed populations of neural crest cells in culture. Other studies have revealed that GDNF is expressed in the gut in advance of migrating neural crest cells and is chemoattractive for neural crest cells in culture. These findings raise the possibility that mutations in the *GDNF* or *Ret* genes could lead to impaired neural crest migration in utero and the development of Hirschsprung's disease.

Clinical Presentation. The incidence of sporadic Hirschsprung's disease is 1 in 5000 live births. There are reports of increased frequency of Hirschsprung's disease in multiple generations of the same family. Occasionally such families have mutations in the genes described earlier, including the *Ret* gene. Because the aganglionic colon does not permit normal peristalsis to occur, the presentation of children with Hirschsprung's disease is characterized by a functional distal intestinal obstruction. In the newborn period, the most common symptoms are abdominal distention, failure to pass meconium, and bilious emesis. Any infant who does not pass meconium beyond 48 hours of life must be investigated for the presence of Hirschsprung's disease. Occasionally, infants present with a dramatic complication of Hirschsprung's disease called enterocolitis. This pattern of presentation is characterized by abdominal distention and tenderness and is associated with manifestations of systemic toxicity that include fever, failure to thrive, and lethargy. Infants are often dehydrated and demonstrate a leukocytosis or increase in circulating band forms on hematologic evaluation. On rectal examination, forceful expulsion of foul-smelling liquid feces is typically observed and represents the accumulation of stool under pressure in an obstructed distal colon. Treatment includes rehydration, systemic antibiotics, nasogastric decompression, and rectal irrigations while the diagnosis of Hirschsprung's disease is being confirmed. In children who do not respond to nonoperative management, a decompressive stoma is required. It is important to ensure that this stoma is placed in ganglion-containing bowel, which must be confirmed by frozen section at the time of stoma creation.

In approximately 20% of cases, the diagnosis of Hirschsprung's disease is made beyond the newborn period. These children have severe constipation, which has usually been treated with laxatives and enemas. Abdominal distention and failure to thrive may also be present at diagnosis.

Diagnosis. The definitive diagnosis of Hirschsprung's disease is made by rectal biopsy. Samples of mucosa and submucosa are obtained at 1, 2, and 3 cm from the dentate line. This can be performed at the bedside in the neonatal period without anesthesia, as samples are taken in bowel that does not have somatic innervation and is thus not painful to the child. In older children, the procedure should be performed using IV sedation. The histopathology of Hirschsprung's disease is the absence of ganglion cells in the myenteric plexuses, increased acetylcholinesterase staining, and the presence of hypertrophied nerve bundles.

It is important to obtain a barium enema in children in whom the diagnosis of Hirschsprung's disease is suspected. This test may demonstrate the location of the transition zone between the dilated ganglionic colon and the distal constricted aganglionic rectal segment. Our practice is to obtain this test before instituting rectal irrigations if possible, so that the difference in size between the proximal and distal bowel is preserved. Although the barium enema can only suggest, but not reliably establish, the diagnosis of Hirschsprung's disease, it is very useful in excluding other causes of distal intestinal obstruction. These include small left colon syndrome (as occurs in infants of diabetic mothers), colonic atresia, meconium plug syndrome, or the unused colon observed in infants after the administration of magnesium or tocolytic agents. The barium enema in total colonic aganglionosis may show a markedly shortened colon. Some surgeons have found the use of rectal manometry helpful, particularly in older children, although it is relatively inaccurate.

Treatment. The diagnosis of Hirschsprung's disease requires surgery in all cases. The classic surgical approach consisted of a multiple-stage procedure. This included a colostomy in the newborn period, followed by a definitive pull-through operation after the child was over 10 kg. There are three viable options for the definitive pull-through procedure that are currently used. Although individual surgeons may advocate one procedure over another, studies have demonstrated that the outcome after each type of operation is similar. For each of the operations that is performed, the principles of treatment include confirming the location in the bowel where the transition zone between ganglionic and aganglionic bowel exists, resecting the aganglionic segment of bowel, and performing an anastomosis of ganglionated bowel to either the anus or a cuff of rectal mucosa (Fig. 39-23).

It is now well established that a primary pull-through procedure can be performed safely, even in the newborn period. This approach follows the same treatment principles as a staged procedure and saves the patient from an additional surgical procedure. Many surgeons perform the intra-abdominal dissection using the laparoscope. This approach is especially useful in the newborn period, as this provides excellent visualization of the pelvis. In children with significant colonic distention, it is important to allow for a period of decompression using a rectal tube if a single-staged pull-through is to be performed. In older children with very distended, hypertrophied colon, it may be prudent to perform a colostomy to allow the bowel to decompress, prior to performing a pull-through procedure. However,

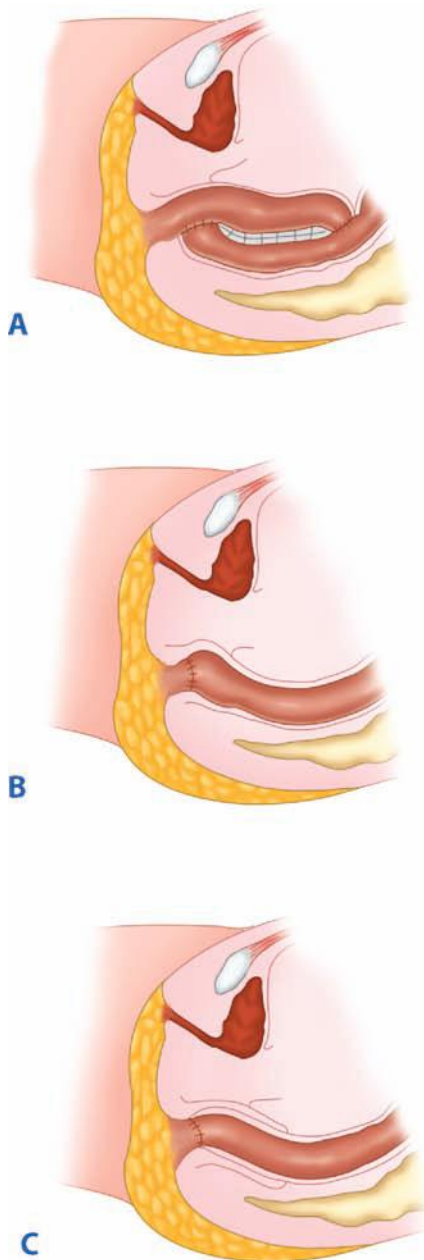


Figure 39-23. The three operations for surgical correction of Hirschsprung's disease. **A.** The Duhamel procedure leaves the rectum in place and brings ganglionic bowel into the retrorectal space. **B.** The Swenson procedure is a resection with end-to-end anastomosis performed by exteriorizing bowel ends through the anus. **C.** The Soave operation is performed by endorectal dissection and removal of mucosa from the aganglionic distal segment and bringing the ganglionic bowel down to the anus within the seromuscular tunnel.

it should be emphasized that there is no upper age limit for performing a primary pull-through.

Of the three pull-through procedures performed for Hirschsprung's disease, the first is the original Swenson procedure. In this operation, the aganglionic rectum is dissected in the pelvis and removed down to the anus. The ganglionic colon is then anastomosed to the anus via a perineal approach. In the Duhamel procedure, dissection outside the rectum is confined to the retrorectal space, and the ganglionic colon is anastomosed posteriorly just above the anus. The anterior wall of the ganglionic colon and the posterior wall of the aganglionic rectum are

anastomosed using a stapler. Although both of these procedures are extremely effective, they are limited by the possibility of damage to the parasympathetic nerves that are adjacent to the rectum. To circumvent this potential problem, the Soave procedure involves dissection entirely within the rectum. The rectal mucosa is stripped from the muscular sleeve, and the ganglionic colon is brought through this sleeve and anastomosed to the anus. This operation may be performed completely from below. In all cases, it is critical that the level at which ganglionated bowel exists be determined. Most surgeons believe that the anastomosis should be performed at least 5 cm from the point at which ganglion cells are found. This avoids performing a pull-through in the transition zone, which is associated with a high incidence of complications due to inadequate emptying of the pull-through segment. Up to one third of patients who undergo a transition zone pull-through will require a reoperation.

The main complications of all of the procedures include postoperative enterocolitis, constipation, and anastomotic stricture. As mentioned, long-term results with the three procedures are comparable and generally excellent in experienced hands. These three procedures also can be adapted for total colonic aganglionosis in which the ileum is used for the pull-through segment.

Anorectal Malformations

Anatomic Description. Anorectal malformations describe a spectrum of congenital anomalies that include imperforate anus and persistent cloaca. Anorectal malformations occur in approximately 1 in 5000 live births and affect males and females almost equally. The embryologic basis includes failure of descent of the urorectal septum. The level to which this septum descends determines the type of anomaly that is present, which subsequently influences the surgical approach.

In patients with imperforate anus, the rectum fails to descend through the external sphincter complex. Instead, the rectal pouch ends "blindly" in the pelvis, above or below the levator ani muscle. In most cases, the blind rectal pouch communicates more distally with the genitourinary system or with the perineum through a fistulous tract. Traditionally, anatomic description of imperforate anus has been characterized as either "high" or "low" depending on whether the rectum ends above the levator ani muscle complex or partially descends through this muscle (Fig. 39-24). Based on this classification system, in male patients with high imperforate anus, the rectum usually

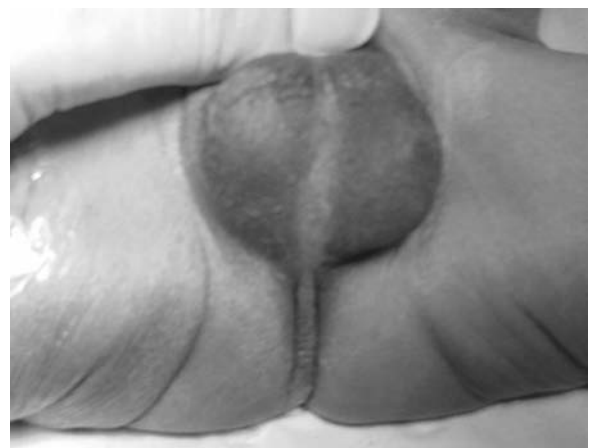

Figure 39-24. Low imperforate anus in a male. Note the well-developed buttocks. The perineal fistula was found at the midline raphe.

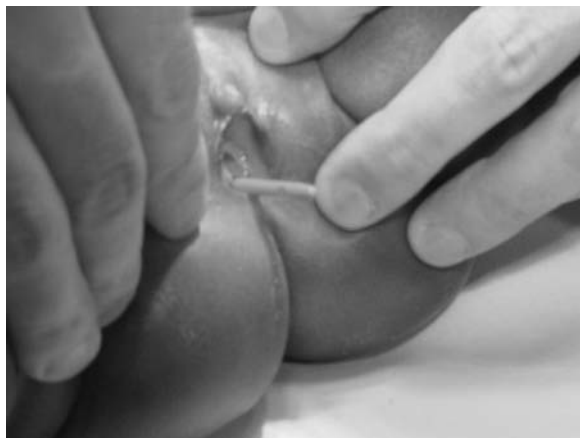

Figure 39-25. Imperforate anus in a female. A catheter has been placed into the fistula, which is in the vestibule of the vagina.

ends as a fistula into the membranous urethra. In females, high imperforate anus often occurs in the context of a persistent cloaca. In both males and females, low lesions are associated with a fistula to the perineum. In males, the fistula connects with the median raphe of the scrotum or penis. In females, the fistula may end within the vestibule of the vagina, which is located immediately outside the hymen or at the perineum.

Because this classification system is somewhat arbitrary, Peña proposed a classification system that specifically and unambiguously describes the location of the fistulous opening. In males, the fistula may communicate with: (a) the perineum (cutaneous perineal fistula); (b) the lowest portion of the posterior urethra (rectourethral bulbar fistula); (c) the upper portion of the posterior urethra (rectourethral prostatic fistula); or (d) the bladder neck (rectovesicular fistula). In females, the fistula may open to the perineum between the female genitalia and the center of the sphincter (cutaneous perineal fistula) or into the vestibule of the vagina (vestibular fistula) (Fig. 39-25). In both sexes, the rectum may end in a completely blind fashion (imperforate anus without fistula). In rare cases, patients may have a normal anal canal, yet there may be total atresia or severe stenosis of the rectum.

The most frequent defect in males is imperforate anus with rectourethral fistula, followed by rectoperineal fistula then rectovesical or rectobladder neck fistula. In females, the most frequent defect is the rectovestibular fistula, followed by the cutaneous perineal fistula. The third most common defect in females is the persistent cloaca. This lesion represents a wide spectrum of malformations in which the rectum, vagina, and urinary tract meet and fuse into a single common channel. On physical examination, a single perineal orifice is observed and is located at the place where the urethra normally opens. Typically, the external genitalia are hypoplastic.

Associated Malformations. Approximately 60% of patients have an associated malformation. The most common is a urinary tract defect, which occurs in approximately 50% of patients. Skeletal defects are also seen, and the sacrum is most commonly involved. Spinal cord anomalies, especially tethered cord, are common, particularly in children with high lesions. Gastrointestinal anomalies occur, most commonly EA. Cardiac anomalies may be noted, and occasionally patients present with a constellation of defects as part of the VACTERLL syndrome (described earlier).

Management of Patients with Imperforate Anus. Patients with imperforate anus are usually stable, and the diagnosis is readily apparent. Despite the obstruction, the abdomen is initially not distended, and there is rarely any urgency to intervene. The principles of management center around diagnosing the type of defect that is present (high vs. low) and evaluating the presence of associated anomalies. It may take up to 24 hours before the presence of a fistula on the skin is noted, and thus it is important to observe the neonate for some period before definitive surgery is undertaken. All patients should therefore have an orogastric tube placed and be monitored for the appearance of meconium in or around the perineum or in the urine. Investigation for associated defects should include an US of the abdomen to assess for the presence of urinary tract anomaly. Other tests should include an echocardiogram and spinal radiographs. A US of the spine should be performed to look for the presence of a tethered cord. To further classify the location of the fistula as either “high” vs. “low,” a lateral abdominal radiograph can be obtained with a radiopaque marker on the perineum. By placing the infant in the inverted position, the distance between the most distal extent of air in the rectum and the perineal surface can be measured. This study is imprecise, however, and may add little to the overall management of these patients.

The surgical management of infants with imperforate anus is determined by the anatomic defect. In general, when a low lesion is present, only a perineal operation is required without a colostomy. Infants with a high lesion require a colostomy in the newborn period, followed by a pull-through procedure at approximately 2 months of age. When a persistent cloaca is present, the urinary tract needs to be carefully evaluated at the time of colostomy formation to ensure that normal emptying can occur and to determine whether the bladder needs to be drained by means of a vesicostomy. If there is any doubt about the type of lesion, it is safer to perform a colostomy rather than jeopardize the infant’s long-term chances for continence by an injudicious perineal operation.

The type of pull-through procedure favored by most pediatric surgeons today is the posterior sagittal anorectoplasty (PSARP) procedure, as described by Peña and DeVries. This involves placing the patient in the prone jackknife position, dividing the levator ani and external sphincter complex in the midline posteriorly, dividing the communication between the gastrointestinal tract and the urinary tract, and bringing down the rectum after sufficient length is achieved. The muscles are then reconstructed and sutured to the rectum. The outcome of 1192 patients who had undergone this procedure has been reviewed by Peña and Hong. Seventy-five percent of patients were found to have voluntary bowel movements, and nearly 40% were considered totally continent. As a rule, patients with high lesions demonstrate an increased incidence of incontinence, whereas those with low lesions are more likely to be constipated. Management of patients with high imperforate anus can be greatly facilitated using a laparoscopic-assisted approach, in which the patient is operated on in the supine position, and the rectum is mobilized down to the fistulous connection to the bladder neck. This fistulous connection is then divided, and the rectum is completely mobilized down to below the peritoneal reflection. The operation then proceeds at the perineum, and the location of the muscle complex is determined using the nerve stimulator. A Veress needle is then advanced through the skin at the indicated site, with the laparoscope providing guidance to the exact intrapelvic orientation. Dilators are then placed over

the Veress needle, the rectum is pulled through this peritoneal opening, and an anoplasty is performed.

JAUNDICE

The Approach to the Jaundiced Infant

Jaundice is present during the first week of life in 60% of term infants and 80% of preterm infants. There is usually accumulation of unconjugated bilirubin, but there may also be deposition of direct bilirubin. During fetal life, the placenta is the principal route of elimination of unconjugated bilirubin. In the newborn infant, bilirubin is conjugated through the activity of *glucoronyl transferase*. In the conjugated form, bilirubin is water soluble, which results in its excretion into the biliary system and then into the gastrointestinal tract. Newborns have a relatively high level of circulating hemoglobin and relative immaturity of the conjugating machinery. This results in a transient accumulation of bilirubin in the tissues, which is manifested as jaundice. Physiologic jaundice is evident by the second or third day of life and usually resolves within approximately 5 to 7 days. By definition, jaundice that persists beyond 2 weeks is considered pathologic.

Pathologic jaundice may be due to biliary obstruction, increased hemoglobin load, or liver dysfunction. The workup of the jaundiced infant therefore should include a search for the following possibilities: (a) obstructive disorders, including biliary atresia, choledochal cyst, and inspissated bile syndrome; (b) hematologic disorders, including ABO incompatibility, Rh incompatibility, and spherocytosis; (c) metabolic disorders, including α_1 -antitrypsin deficiency, galactosemia, and pyruvate kinase deficiency; and (d) congenital infection, including syphilis and rubella.

Biliary Atresia

Pathogenesis. Biliary atresia is a rare disease associated with significant morbidity and mortality. This disease is characterized by a fibroproliferative obliteration of the biliary tree, which progresses toward hepatic fibrosis, cirrhosis, and end-stage liver failure. The incidence of this disease is approximately 1 in 8000 to 1 in 18,000. The etiology of biliary atresia is likely multifactorial. In the classic textbook *Abdominal Surgery of Infancy and Childhood*, Ladd and Gross described the cause of biliary atresia as an “arrest of development during the solid stage of bile duct formation.” Previously proposed theories on the etiology of biliary atresia have focused on defects in hepatogenesis, prenatal vasculogenesis, immune dysregulation, infectious agents, and exposure to toxins. More recently, genetic mutations in the *cfc1* gene, implicated in left-right axis determinations, were identified in patients with biliary atresia-splenic malformation syndrome. Additionally, the detection of a higher incidence of maternal microchimerism in the livers of males with biliary atresia has led to the suggestion that consequent expression of maternal antigens may lead to an autoimmune process leading to inflammation and obliteration of the biliary tree. Recent animal studies strongly implicate perinatal exposure to reovirus or rotavirus. Such viral exposure may lead to periportal inflammation mediated by interferon- γ and other cytokines.

Clinical Presentation. Infants with biliary atresia present with jaundice at birth or shortly thereafter. The diagnosis of biliary atresia is frequently not entertained by pediatricians in part because physiologic jaundice of the newborn is so common and

biliary atresia is so uncommon. As such, it is not unusual for there to be a delay in diagnosis. However, infants with biliary atresia characteristically have acholic, pale gray-appearing stools, secondary to obstructed bile flow. With further passage of time, these infants manifest progressive failure to thrive, and if untreated, they develop stigmata of liver failure and portal hypertension, particularly splenomegaly and esophageal varices.

The obliterative process of biliary atresia involves the common duct, cystic duct, one or both hepatic ducts, and the gallbladder, in a variety of combinations. The histopathology of patients with biliary atresia includes inflammatory changes within the parenchyma of the liver, as well as fibrous deposition at the portal plates that is observed on trichrome staining of frozen tissue sections. In certain cases, bile duct proliferation may be seen, a relatively nonspecific marker of liver injury. Approximately 25% of patients with biliary atresia have coincidental malformations, often associated with polysplenia and which may include intestinal malrotation, preduodenal portal vein, and intrahepatic vena cava.

Diagnosis. In general, the diagnosis of biliary atresia is made using a combination of studies, as no single test is sufficiently sensitive or specific. Fractionation of the serum bilirubin is performed to determine if the associated hyperbilirubinemia is conjugated or unconjugated. Workup commonly includes the analysis of TORCH infection titers as well as viral hepatitis. Typically, US is performed to assess the presence of other causes of biliary tract obstruction including choledochal cyst. The absence of a gallbladder is highly suggestive of the diagnosis of biliary atresia. However, the presence of a gallbladder does not exclude the diagnosis of biliary atresia because in approximately 10% of biliary atresia patients, the distal biliary tract is patent and a gallbladder may be visualized, even though the proximal ducts are atretic. It is important to note that the intrahepatic bile ducts are never dilated in patients with biliary atresia. In many centers, a nuclear medicine scan using technetium-99m iminodiacetic acid, performed after pretreatment of the patient with phenobarbital, has proven to be an accurate and reliable study. If radionuclide appears in the intestine, there is patency of the biliary tree and the diagnosis of biliary atresia is excluded. If radionuclide is concentrated by the liver but not excreted despite treatment with phenobarbital and the metabolic screen, particularly α_1 -antitrypsin determination, is normal, the presumptive diagnosis is biliary atresia. A percutaneous liver biopsy might potentially distinguish between biliary atresia and other sources of jaundice such as neonatal hepatitis. When these tests point to or cannot exclude the diagnosis of biliary atresia, surgical exploration is warranted. At surgery, a cholangiogram may be performed if possible, using the gallbladder as a point of access. This may be performed using a laparoscope. The cholangiogram demonstrates the anatomy of the biliary tree, determines whether extrahepatic bile duct atresia is present, and evaluates whether there is distal bile flow into the duodenum. The cholangiogram may demonstrate hypoplasia of the extrahepatic biliary system. This condition is associated with hepatic parenchymal disorders that cause severe intrahepatic cholestasis, including α_1 -antitrypsin deficiency and biliary hypoplasia (Alagille’s syndrome). Alternatively, a cursory assessment of the extrahepatic biliary tree may clearly delineate the atresia.

Inspissated Bile Syndrome. This term is applied to patients with normal biliary tracts who have persistent obstructive jaundice. Increased viscosity of bile and obstruction of the canaliculi

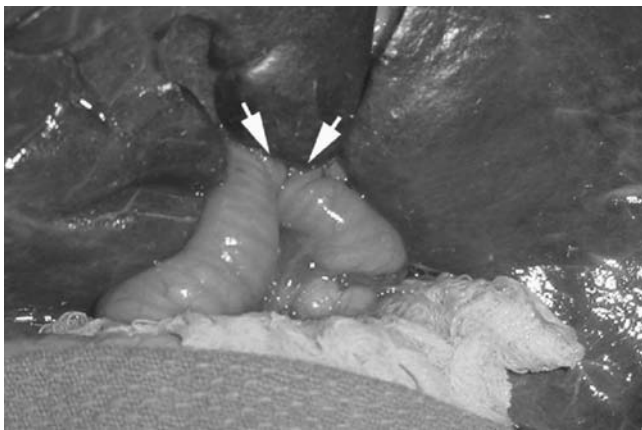

Figure 39-26. Operative photograph showing Kasai portoenterostomy. Arrows denote site of the anastomosis. Note the engorged liver.

are implicated as causes. The condition has been seen in infants receiving parenteral nutrition, but it is also encountered in conditions associated with hemolysis or in cystic fibrosis. In some instances, no etiologic factors can be defined. *Neonatal hepatitis* may present in a similar fashion to biliary atresia. This disease is characterized by persistent jaundice due to acquired biliary inflammation without obliteration of the bile ducts. There may be a viral etiology, and the disease is usually self-limited. In this case, cholangiography is both diagnostic and therapeutic.

Treatment. If the diagnosis of biliary atresia is confirmed intraoperatively, then surgical treatment is undertaken at the same setting. Currently, first-line therapy consists of creation of a hepatoportoenterostomy, as described by Kasai. The purpose of this procedure is to promote bile flow into the intestine. The procedure is based on Kasai's observation that the fibrous tissue at the porta hepatis invests microscopically patent biliary ductules that, in turn, communicate with the intrahepatic ductal system (Fig. 39-26). Transecting this fibrous tissue at the portal plate, invariably encountered cephalad to the bifurcating portal vein, opens these channels and establishes bile flow into a surgically constructed intestinal conduit, usually a Roux-en-Y limb of jejunum (Fig. 39-27). Some authors believe that an intussuscepted antireflux valve is useful in preventing retrograde bile reflux, although the data suggest that it does not impact outcome. A liver biopsy is performed at the time of surgery to determine the degree of hepatic fibrosis that is present. The diameter of bile ducts at the portal plate is predictive of likelihood of long-term success of biliary drainage through the portoenterostomy. Numerous studies also suggest that the likelihood of surgical success is inversely related to the age at the time of portoenterostomy. Infants treated prior to 60 days of

life are more likely to achieve successful and long-term biliary drainage than older infants. Although the outlook is less favorable for patients after the twelfth week, it is reasonable to proceed with surgery even beyond this time point, as the alternative is certain liver failure. It is noteworthy that a significant number of patients have had favorable outcomes after undergoing portoenterostomy despite advanced age at time of diagnosis.

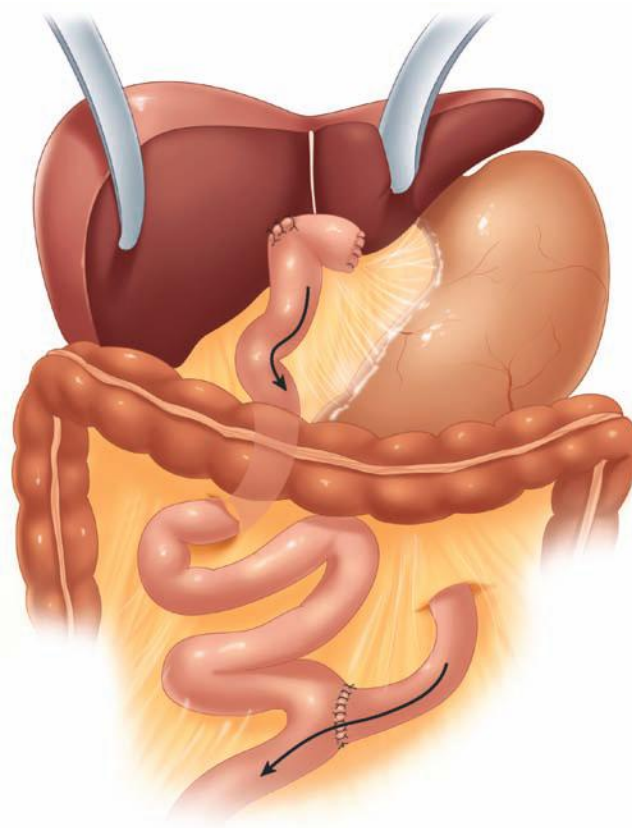


Figure 39-27. Schematic illustration of the Kasai portoenterostomy for biliary atresia. An isolated limb of jejunum is brought to the porta hepatis and anastomosed to the transected ducts at the liver plate.

factors that predict failure of the procedure include bridging liver fibrosis at the time of surgery and postoperative cholangitic episodes. A review of the data of the Japanese Biliary Atresia Registry (JBAR), which includes the results of 1381 patients, showed that the 10-year survival rate was 53% without transplantation and 66.7% with transplantation. A common postoperative complication is cholangitis. There is no effective strategy to completely eliminate this complication, and the effectiveness of long-term prophylactic antibiotics has not been fully resolved. The Childhood Liver Research and Education Network (ChiLDREN, formerly the Biliary Atresia Research Consortium) is an active consortium of 15 children's hospitals in the United States, funded by the National Institutes of Health (NIH), which studies rare cholestatic liver diseases of infants and children (<http://childrennetwork.org/>). The primary disease of research interest is biliary atresia, as four of the seven active studies are dedicated to biliary atresia. Two of these four biliary atresia studies are therapeutic trials. Currently, enrollment for an NIH-funded, randomized, double-blind, placebo-controlled trial designed to determine if adjuvant steroids improves outcome of infants undergoing Kasai portoenterostomy has been completed. Treatment arms will be unblinded, and outcomes of patients in this trial in terms of successful biliary drainage and survival with patients' native livers will be determined. Additionally, ChiLDREN is about to embark on a phase I trial looking at the safety and efficacy of adjuvant IV immunoglobulin (IVIg) given to infants with biliary atresia following Kasai portoenterostomy.

From this consortium, Superina and colleagues recently reported on the prospectively collected clinical, surgical, and outcomes data on 244 patients with biliary atresia. Notably, over 80% of infants manifested Ohi type III variant (atresia of the porta hepatis) compared with 10% with Ohi type I (atresia of the common bile duct) or 7% with Ohi type II (atresia of the hepatic duct). Outcomes analysis revealed a significantly greater survival with one's native liver for infants with type I compared with those with type II or III. Moreover, infants with Ohi distal subtype a (patent common bile duct) had significantly improved survival compared to those with Ohi distal subtypes b, c, or d (nonpatent common bile duct). Improved survival with the child's native liver was also observed in this study in patients less than 75 days old at time of Kasai portoenterostomy, no ascites at exploration, nonnodular liver, and low fibrosis score. Importantly, clearance of jaundice as defined by achieving a total bilirubin of less than 2 mg/dL within 3 months after portoenterostomy was highly predictive of survival with the native liver. The effect of hospital volume was not the focus of this publication. However, Davenport and colleagues recently reported on their experience in the United Kingdom where surgical care of infants with biliary atresia has been centralized to three hospitals. The authors report successful clearance of jaundice in 55% of patients, which is considerably better than clearance rates reported from the United States, France, or Switzerland and comparable to clearance rates reported from Taiwan where there is centralization of care.

Improved survival with one's native liver following Kasai portoenterostomy has previously been noted by numerous authors, as in the ChiLDREN consortium. Tseng and colleagues reported on improved rates of early diagnosis of biliary atresia (<60 days of age) following implementation of a national screening program for infant stool color in Taiwan. Given that early diagnosis of biliary atresia is associated with greater success of bile drainage, the authors reasonably speculate that higher rates of early diagnosis of biliary atresia nationally will translate into improved outcomes following the Kasai procedure.

Previous authors have published merits of revising the portoenterostomy in select patients if drainage of bile stops. Recently, Bondoc and colleagues reported on their experience with revision of portoenterostomies. Specifically, the authors reported on 183 patients who underwent Kasai portoenterostomy for biliary atresia, of whom 24 underwent revision for recurrence of nondrainage after successful bypass. Of the patients who underwent revision for nondrainage, 75% ultimately again achieved drainage after the second procedure, of whom nearly 50% survived long term with their native livers. The authors conclude that in selected patients in whom bile flow was established following the Kasai procedure and who then lost that flow, revision of the portoenterostomy is a reasonable treatment option with good success.

Choledochal Cyst

Classification. The term *choledochal cyst* refers to a spectrum of congenital biliary tract disorders that were previously grouped under the name *idiopathic dilation of the common bile duct*. After the classification system proposed by Alonso-Lej, five types of choledochal cyst are described. Type I cyst is characterized by fusiform dilatation of the bile duct. This is the most common type and is found in 80% to 90% of cases. A type II choledochal cyst appears as an isolated diverticulum protruding from the wall of the common bile duct. The cyst may be joined

to the common bile duct by a narrow stalk. Type III choledochal cysts arise from the intraduodenal portion of the common bile duct and are also known as choledochoceles. Type IVA cysts consist of multiple dilatations of the intrahepatic and extrahepatic bile ducts. Type IVB choledochal cysts are multiple dilatations involving only the extrahepatic bile ducts. Type V (Caroli's disease) consists of multiple dilatations limited to the intrahepatic bile ducts.

Choledochal cyst is most appropriately considered the predominant feature in a constellation of pathologic abnormalities that can occur within the pancreato-biliary system. Frequently associated with choledochal cyst is an anomalous junction of the pancreatic and common bile ducts. The etiology of choledochal cyst is controversial. Babbit proposed an abnormal pancreatic and biliary duct junction, with the formation of a "common channel" into which pancreatic enzymes are secreted. This process results in weakening of the bile duct wall by gradual enzymatic destruction, leading to dilatation, inflammation, and finally cyst formation. Not all patients with choledochal cyst demonstrate an anatomic common channel, which raises questions regarding the accuracy of this model.

Clinical Presentation. Choledochal cyst is more common in females than in males (4:1). Typically these present in children beyond the toddler age group. The classic symptom triad consists of abdominal pain, mass, and jaundice. However, this complex is actually encountered in fewer than half of the patients. The more usual presentation is that of episodic abdominal pain, often recurring over the course of months or years and generally associated with only minimal jaundice that may escape detection. If left undiagnosed, patients may develop cholangitis or pancreatitis. Cholangitis may lead to the development of cirrhosis and portal hypertension. Choledochal cyst can present in the newborn period, where the symptoms are very similar to those of biliary atresia. Often neonates will have an abdominal mass at presentation.

Diagnosis. Choledochal cyst is frequently diagnosed in the fetus at a screening prenatal US. In the older child or adolescent, abdominal ultrasonography may reveal a cystic structure arising from the biliary tree. CT will confirm the diagnosis. These studies will demonstrate the dimensions of the cyst and define its relationship to the vascular structures in the porta hepatis, as well as the intrahepatic ductal configuration. Endoscopic retrograde cholangiopancreatography (ERCP) is reserved for patients in whom confusion remains after evaluation by less invasive imaging modalities. Magnetic resonance cholangiopancreatography may provide a more detailed depiction of the anatomy of the cyst and its relationship to the bifurcation of the hepatic ducts and into the pancreas.

Treatment. The cyst wall is composed of fibrous tissue and is devoid of mucosal lining. As a result, the treatment of choledochal cyst is surgical excision followed by biliary-enteric reconstruction. There is no role for internal drainage by cystoenterostomy, which leaves the cyst wall intact and leads to the inevitable development of cholangitis. Rarely, choledochal cyst can lead to the development of a biliary tract malignancy. This provides a further rationale for complete cyst excision.

Resection of the cyst requires circumferential dissection. The posterior plane between the cyst and portal vein must be carefully dissected to accomplish removal. The pancreatic duct, which may enter the distal cyst, is vulnerable to injury during distal cyst excision but can be avoided by avoiding

entry into the pancreatic parenchyma. In cases where the degree of pericyclic inflammation is dense, it may be unsafe to attempt complete cyst removal. In this instance, it is reasonable to dissect within the posterior wall of the cyst, which allows the inner lining of the back wall to be dissected free from the outer layer that directly overlies the portal vascular structures. The lateral and anterior cyst, as well as the internal aspect of the back wall, is removed, yet the outer posterior wall remains behind. Cyst excision is accomplished, and the proximal bile duct is anastomosed to the intestinal tract typically via a Roux-en Y jejunal limb. More recently, laparoscopic-assisted resections of choledochal cysts have been described. In these cases, the end-to-side jejunojejunostomy is performed extracorporeally, but the remainder of the procedure is completed using minimally invasive techniques.

The prognosis for children who have undergone complete excision of choledochal cyst is excellent. Complications include anastomotic stricture, cholangitis, and intrahepatic stone formation. These complications may develop a long time after surgery has been completed.

DEFORMITIES OF THE ABDOMINAL WALL

Embryology of the Abdominal Wall

The abdominal wall is formed by four separate embryologic folds: cephalic, caudal, right, and left lateral folds. Each of these is composed of somatic and splanchnic layers and develops toward the anterior center portion of the coelomic cavity, joining to form a large umbilical ring that surrounds the two umbilical arteries, the vein, and the yolk sac or omphalomesenteric duct. These structures are covered by an outer layer of amnion, and the entire unit composes the umbilical cord. Between the fifth and tenth weeks of fetal development, the intestinal tract undergoes rapid growth outside the abdominal cavity within the proximal portion of the umbilical cord. As development is completed, the intestine gradually returns to the abdominal cavity. Contraction of the umbilical ring completes the process of abdominal wall formation.

Failure of the cephalic fold to close results in sternal defects such as congenital absence of the sternum. Failure of the caudal fold to close results in exstrophy of the bladder and, in more extreme cases, exstrophy of the cloaca. Interruption of central migration of the lateral folds results in omphalocele. Gastroschisis, originally thought to be a variant of omphalocele, possibly results from a fetal accident in the form of intrauterine rupture of a hernia of the umbilical cord, although other hypotheses have been advanced.

Umbilical Hernia

Failure of the umbilical ring to close results in a central defect in the linea alba. The resulting umbilical hernia is covered by normal umbilical skin and subcutaneous tissue, but the fascial defect allows protrusion of abdominal contents. Hernias less than a centimeter in size at the time of birth usually will close spontaneously by 4 to 5 years of life and, in most cases, should not undergo early repair. Sometimes the hernia is large enough that the protrusion is disfiguring and disturbing to both the child and the family. In such circumstances, early repair may be advisable (Fig. 39-28).

Umbilical hernias are generally asymptomatic protrusions of the abdominal wall. They are generally noted by parents or physicians shortly after birth. All families of patients with

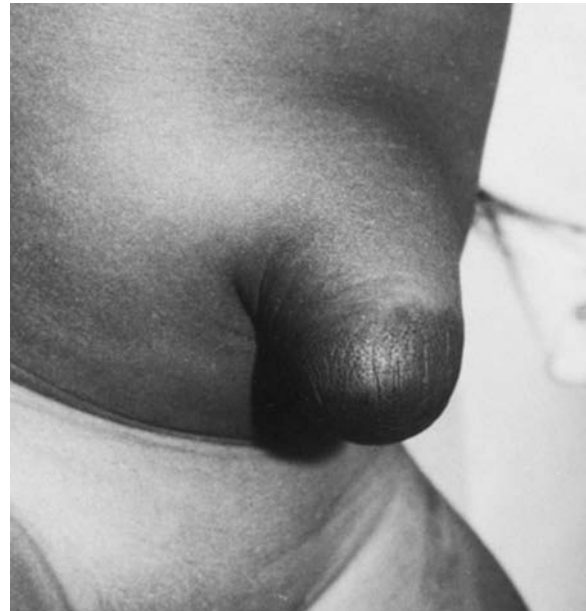

Figure 39-28. Umbilical hernia in a 1-year-old female.

umbilical hernia should be counseled about signs of incarceration, which is rare in umbilical hernias and more common in smaller (≤ 1 cm) than larger defects. Incarceration presents with abdominal pain, bilious emesis, and a tender, hard mass protruding from the umbilicus. This constellation of symptoms mandates immediate exploration and repair of the hernia to avoid strangulation. More commonly, the child is asymptomatic and treatment is governed by the size of the defect, the age of the patient, and the concerns that the child and family have regarding the cosmetic appearance of the abdomen. When the defect is small and spontaneous closure is likely, most surgeons will delay surgical correction until 5 years of age. If closure does not occur by this time or a younger child has a very large or symptomatic hernia, it is reasonable to proceed to repair.

Repair of uncomplicated umbilical hernia is performed under general anesthesia as an outpatient procedure. A small curving incision that fits into the skin crease of the umbilicus is made, and the sac is dissected free from the overlying skin. The fascial defect is repaired with permanent or long-lasting absorbable, interrupted sutures that are placed in a transverse plane. The skin is closed using subcuticular sutures. The postoperative recovery is typically uneventful, and recurrence is rare, but more common in children with elevated intra-abdominal pressures such as those with a ventriculoperitoneal shunt.

Patent Urachus

During the development of the coelomic cavity, there is free communication between the urinary bladder and the abdominal wall through the urachus, which exits adjacent to the omphalomesenteric duct. Persistence of this tract results in a communication between the bladder and the umbilicus. The first sign of a patent urachus is moisture or urine flow from the umbilicus. Recurrent urinary tract infections can result. The urachus may be partially obliterated, with a remnant beneath the umbilicus in the extraperitoneal position as an isolated cyst that may be identified by US. A urachal cyst usually presents as an inflammatory mass inferior to the umbilicus. Initial treatment is drainage of the infected cyst followed by cyst excision as a separate procedure once the inflammation has resolved.

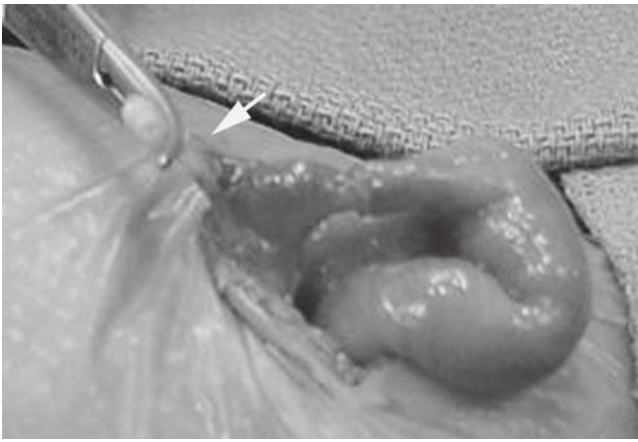


Figure 39-29. Patent vitelline duct. Note the communication between the umbilicus and the small bowel at the site of a Meckel's diverticulum.

In the child with a persistently draining umbilicus, a diagnosis of patent urachus should be considered. The differential diagnosis includes an umbilical granuloma, which generally responds to local application of silver nitrate. The diagnosis of patent urachus is confirmed by umbilical exploration. The urachal tract is excised and the bladder is closed with an absorbable suture. A patent vitelline duct may also present with umbilical drainage. In this circumstance, there is a communication with the small intestine, often at the site of a Meckel's diverticulum. Treatment includes umbilical exploration with resection of the duct remnant (Fig. 39-29).

Omphalocele

Presentation. Omphalocele refers to a congenital defect of the abdominal wall in which the bowel and solid viscera are covered by peritoneum and amniotic membrane (Fig. 39-30). The umbilical cord inserts into the sac. Omphalocele can vary

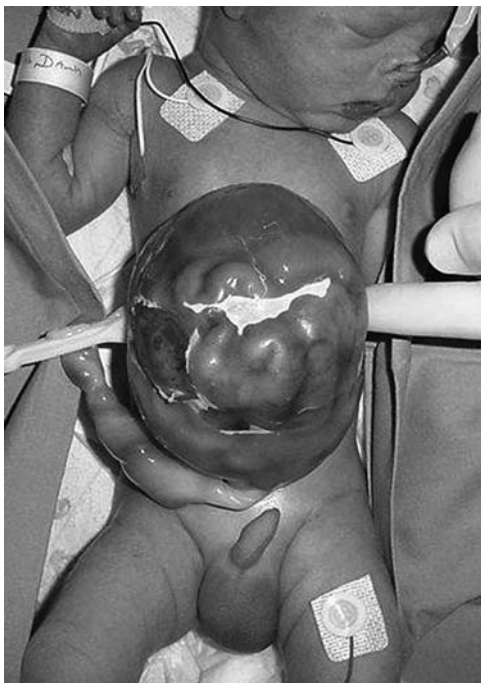

Figure 39-30. Giant omphalocele in a newborn male.

from a small defect with intestinal contents to giant omphalocele in which the abdominal wall defect measures 4 cm or more in diameter and contains liver. The overall incidence is approximately 1 in 5000 live births, with 1 in 10,000 that are giant omphaloceles. Omphalocele occurs in association with special syndromes such as exstrophy of the cloaca (vesicointestinal fissure), the Beckwith-Wiedemann constellation of anomalies (macroglossia, macrosomia, hypoglycemia, and visceromegaly and omphalocele), and Cantrell's pentalogy (lower thoracic wall malformations [cleft sternum], ectopia cordis, epigastric omphalocele, anterior midline diaphragmatic hernia, and cardiac anomalies). There is a 60% to 70% incidence of associated anomalies, especially cardiac (20%–40% of cases) and chromosomal abnormalities. Chromosomal anomalies are more common in children with smaller defects. Omphalocele is associated with prematurity (10%–50% of cases) and intrauterine growth restriction (20% of cases).

Treatment. Immediate treatment of an infant with omphalocele consists of attending to the vital signs and maintaining the body temperature. A blood glucose should be evaluated because of the association with Beckwith-Wiedemann. The omphalocele should be covered to reduce fluid loss, but moist dressings may result in heat loss and are not indicated. No pressure should be placed on the omphalocele sac in an effort to reduce its contents, as this maneuver may increase the risk of rupture of the sac or may interfere with abdominal venous return. Prophylactic broad-spectrum antibiotics should be administered in case of rupture. The subsequent treatment and outcome are determined by the size of the omphalocele. In general terms, small to medium-sized defects have a significantly better prognosis than extremely large defects in which the liver is present. In these cases, not only is the management of the abdominal wall defect a significant challenge, but these patients often have concomitant pulmonary insufficiency that can lead to significant morbidity and mortality. If possible and if the pulmonary status will permit it, a primary repair of the omphalocele should be undertaken. This involves resection of the omphalocele membrane and closure of the fascia. A layer of prosthetic material may be required to achieve closure. In infants with a giant omphalocele, the defect cannot be closed primarily because there is not adequate intraperitoneal domain to reduce the viscera (see Fig. 39-30). Some infants may have associated congenital anomalies that complicate surgical repair, and because cardiac anomalies are common, an echocardiogram should be obtained prior to any procedure. If repair is contraindicated, a nonoperative approach can be used. The omphalocele sac can be treated with topical treatments. Various authors describe success with iodine-containing solutions, silver sulfadiazine, or saline, and some surgeons rotate these solutions because of the impact of iodine on the thyroid and the difficulty of cleaning off all of the silver sulfadiazine and its association with leukopenia. It typically takes 2 to 3 months before re-epithelialization occurs. In the past, mercury compounds were used, but they have been discontinued because of associated systemic toxicity. After epithelialization has occurred, attempts should be made to achieve closure of the anterior abdominal wall, but they may be delayed by associated pulmonary insufficiency. Such procedures typically require complex measures to achieve skin closure, including the use of biosynthetic materials or component separation. In cases of giant omphalocele, prolonged hospitalization is typical.

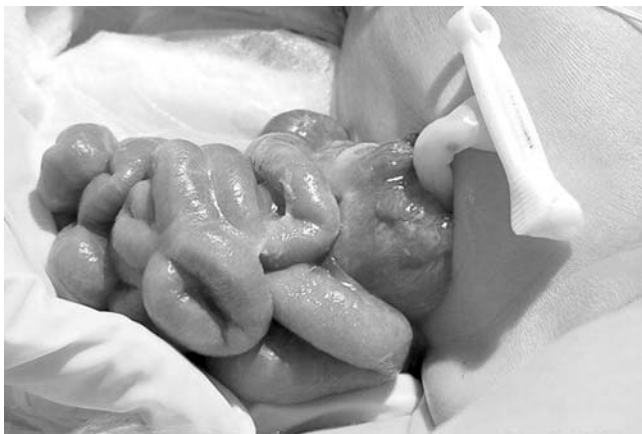

Figure 39-31. Gastroschisis in a newborn. Note the location of the umbilical cord and the edematous, thickened bowel.

Gastroschisis

Presentation. Gastroschisis represents a congenital anomaly characterized by a defect in the anterior abdominal wall through which the intestinal contents freely protrude. Unlike omphalocele, there is no overlying sac and the size of the defect is usually <4 cm. The abdominal wall defect is located at the junction of the umbilicus and normal skin and is almost always to the right of the umbilicus (Fig. 39-31). The umbilicus becomes partly detached, allowing free communication with the abdominal cavity. The appearance of the bowel provides some information with respect to the in utero timing of the defect. The intestine may be normal in appearance, suggesting that the rupture occurred relatively late during the pregnancy. More commonly, however, the intestine is thick, edematous, discolored, and covered with exudate, implying a more longstanding process. Progression to full enteral feeding is usually delayed, with diminished motility that may be related to these changes.

Unlike infants born with omphalocele, associated anomalies are not usually seen with gastroschisis except for a 10% rate of intestinal atresia. This defect can readily be diagnosed on prenatal US (Fig. 39-32). There is no advantage to performing a cesarean section instead of a vaginal delivery. In a decade-long retrospective review, early delivery did not affect the thickness of bowel peel, yet patients delivered

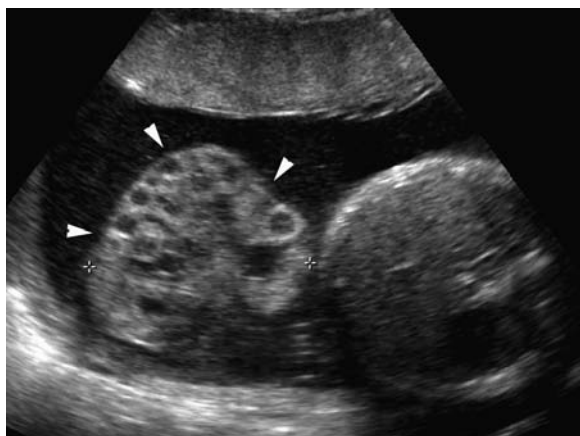

Figure 39-32. Prenatal ultrasound of a 30-week gestation fetus with a gastroschisis. Arrows point to the bowel outside within the amniotic fluid.

before 36 weeks had significantly longer length of stay in the hospital and time to enteral feeds. Based on these findings, fetal well-being should be the primary determinant of the timing of delivery for gastroschisis.

Treatment. All infants born with gastroschisis require urgent surgical treatment. Of equal importance, these infants require vigorous fluid resuscitation in the range of 150 to 180 cc/kg/d to replace significant evaporative fluid losses. In many instances, the intestine can be returned to the abdominal cavity, and a primary surgical closure of the abdominal wall is performed. Some surgeons believe that they can facilitate primary closure with mechanical stretching of the abdominal wall, thorough orogastric suctioning with foregut decompression, rectal irrigation, and evacuation of meconium. Care must be taken to prevent markedly increased abdominal pressure during the reduction, which will lead to compression of the inferior vena cava, respiratory embarrassment, and abdominal compartment syndrome. To avoid this complication, it is helpful to monitor the bladder or airway pressures during reduction. In infants whose intestine has become thickened and edematous, it may be impossible to reduce the bowel into the peritoneal cavity in the immediate postnatal period. Under such circumstances, a plastic spring-loaded silo can be placed onto the bowel and secured beneath the fascia or a sutured silastic silo constructed. The silo covers the bowel and allows for graduated reduction on a daily basis as the edema in the bowel wall decreases (Fig. 39-33). It is important to ensure that the silo-fascia junction does not become a constricting point or “funnel” in which case the intestine will be injured upon return to the peritoneum. In this case, the fascial opening must be enlarged. Surgical closure can usually be accomplished within approximately 1 to 2 weeks. A prosthetic piece of material may be required to bring the edges of the fascia together. If an atresia is noted at the time of closure,

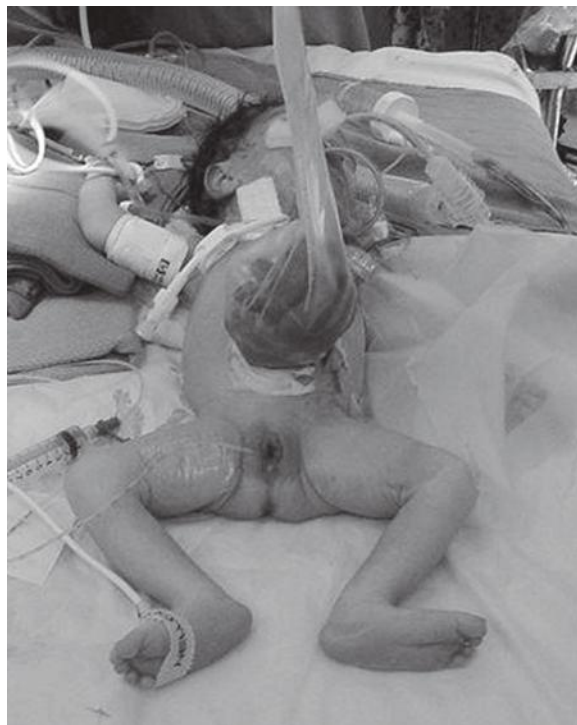

Figure 39-33. Use of a silo in a patient with gastroschisis to allow the bowel wall edema to resolve to facilitate subsequent closure of the abdominal wall.

it is prudent to reduce the bowel at the first operation, then to return after several weeks once the edema has resolved to correct the atresia. Intestinal function does not typically return for several weeks in patients with gastroschisis. This is especially true if the bowel is thickened and edematous. As a result, these patients will require central line placement and institution of TPN in order to grow. Feeding advancement should be slow and typically requires weeks to arrive at full enteral nutrition.

Prune-Belly Syndrome

Clinical Presentation. Prune-belly syndrome refers to a disorder that is characterized by extremely lax lower abdominal musculature, dilated urinary tract including the bladder, and bilateral undescended testes (Fig. 39-34). The term prune-belly syndrome appropriately describes the wrinkled appearance of the anterior abdominal wall that characterizes these patients. Prune-belly syndrome is also known as Eagle-Barrett syndrome and the triad syndrome, because of the three major manifestations. The incidence is significantly higher in males. Patients manifest a variety of comorbidities. The most significant is pulmonary hypoplasia, which is not survivable in the most severe cases. Skeletal abnormalities include dislocation or dysplasia of the hip and pectus excavatum.

The major genitourinary manifestation in prune-belly syndrome is ureteral dilation. The ureters are typically long and tortuous and become more dilated distally. Ureteric obstruction is rarely present, and the dilation may be caused by decreased smooth muscle and increased collagen in the ureters. Approximately 80% of these patients will have some degree of vesicoureteral reflux, which can predispose to urinary tract infection. Despite the marked dilatation of the urinary tract, most children with prune-belly syndrome have adequate renal parenchyma for growth and development. Factors associated with the development of long-term renal failure include the presence of abnormal kidneys on US or renal scan and persistent pyelonephritis.

Treatment. Despite the ureteric dilation, there is currently no role for ureteric surgery unless an area of obstruction develops. The testes are invariably intra-abdominal, and bilateral orchiopexy can be performed in conjunction with abdominal wall reconstruction at 6 to 12 months of age. Despite orchiopexy, fertility in a boy with prune-belly syndrome is unlikely as spermatogenesis over time is insufficient. Deficiencies in the production

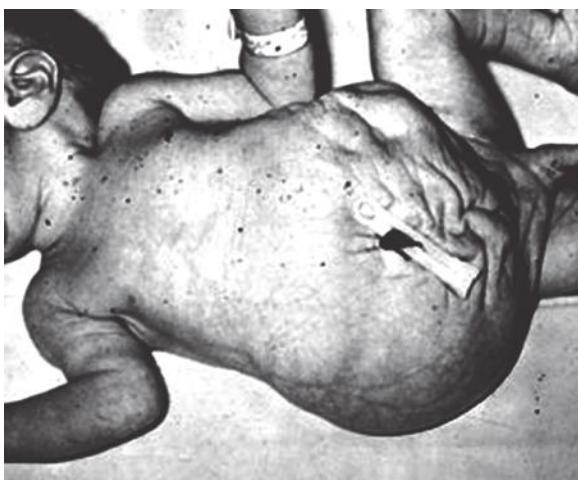

Figure 39-34. Eagle-Barrett (prune-belly) syndrome. Notice the lax, flaccid abdomen.

of prostatic fluid and a predisposition to retrograde ejaculation contribute to infertility. Abdominal wall repair is accomplished through an abdominoplasty, which typically requires a transverse incision in the lower abdomen extending into the flanks.

Inguinal Hernia

An understanding of the management of pediatric inguinal hernias is a central component of modern pediatric surgical practice. Inguinal hernia repair represents one of the most common operations performed in children. The presence of an inguinal hernia in a child is an indication for surgical repair. The operation is termed a herniorrhaphy because it involves closing off the patent processus vaginalis. This is to be contrasted with the hernioplasty that is performed in adults, which requires a reconstruction of the inguinal floor.

Embryology. In order to understand how to diagnose and treat inguinal hernias in children, it is critical to understand their embryologic origin. It is very useful to describe these events to the parents, who often are under the misconception that the hernia was somehow caused by their inability to console their crying child or by the child's high activity level. Inguinal hernia results from a failure of closure of the processus vaginalis, a finger-like projection of the peritoneum that accompanies the testicle as it descends into the scrotum. Closure of the processus vaginalis normally occurs a few months prior to birth. This explains the high incidence of inguinal hernias in premature infants. When the processus vaginalis remains completely patent, a communication persists between the peritoneal cavity and the groin, resulting in a hernia. Partial closure can result in entrapped fluid, which is known as a hydrocele. A communicating hydrocele refers to a hydrocele that is in communication with the peritoneal cavity and can therefore be thought of as a hernia. Using the classification system that is typically applied to adult hernias, all congenital hernias in children are by definition indirect inguinal hernias. Children also present with direct inguinal and femoral hernias, although these are much less common.

Clinical Manifestation. Inguinal hernias occur more commonly in males than females (10:1) and are more common on the right side than the left. Infants are at high risk for incarceration of an inguinal hernia because of the narrow inguinal ring. Patients most commonly present with a groin bulge that is noticed by the parents as they change the diaper (Fig. 39-35). Older children may notice the bulge themselves. On examination, the cord on the affected side will be thicker, and pressure

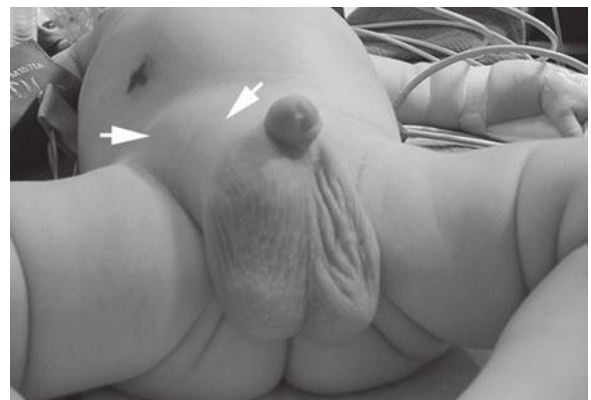

Figure 39-35. Right inguinal hernia in a 4-month-old male. The arrows point to the bulge in the right groin.

on the lower abdomen usually will display the hernia on the affected side. The presence of an incarcerated hernia is manifested by a firm bulge that does not spontaneously resolve and may be associated with fussiness and irritability in the child. The infant who has a strangulated inguinal hernia will manifest an edematous, tender bulge in the groin, occasionally with overlying skin changes. The child will eventually develop intestinal obstruction, peritonitis, and systemic toxicity.

Usually an incarcerated hernia can be reduced. Occasionally this may require light sedation. Gentle pressure is applied on the sac from below in the direction of the internal inguinal ring. Following reduction of the incarcerated hernia, the child may be admitted for observation, and herniorrhaphy is performed within the next 24 hours to prevent recurrent incarceration. Alternatively, the child may be scheduled for surgery at the next available time slot. If the hernia cannot be reduced or if evidence of strangulation is present, emergency operation is necessary. This may require a laparotomy and bowel resection.

When the diagnosis of inguinal hernia is made in an otherwise normal child, operative repair should be planned. Spontaneous resolution does not occur, and therefore, a non-operative approach cannot ever be justified. An inguinal hernia in a female infant or child frequently contains an ovary rather than intestine. Although the gonad usually can be reduced into the abdomen by gentle pressure, it often prolapses in and out until surgical repair is carried out. In some patients, the ovary and fallopian tube constitute one wall of the hernia sac (sliding hernia), and in these patients, the ovary can be reduced effectively only at the time of operation. If the ovary is irreducible, prompt hernia repair is indicated to prevent ovarian torsion or strangulation.

When a hydrocele is diagnosed in infancy and there is no evidence of a hernia, observation is proper therapy until the child is older than 12 months. If the hydrocele has not disappeared by 12 months, invariably there is a patent processus vaginalis, and operative hydrocelectomy with excision of the processus vaginalis is indicated. When the first signs of a hydrocele are seen after 12 months of age, the patient should undergo elective hydrocelectomy, which in a child is always performed through a groin incision. Aspiration of hydroceles is discouraged, since almost all without a patent processus vaginalis will resorb spontaneously, and those with a communication to the peritoneum will recur and require operative repair eventually. Transillumination as a method to distinguish between hydrocele and hernia is nonspecific. A noncommunicating hydrocele is better identified by palpation of a nonreducible oval structure that appears to have a blunt end below the external ring, indicating an isolated fluid collection without a patent connection to the peritoneum.

Surgical Repair. The repair of a pediatric inguinal hernia can be extremely challenging, particularly in the premature child with incarceration. A small incision is made in a skin crease in the groin directly over the internal inguinal ring. Scarpa's fascia is seen and divided. The external oblique muscle is dissected free from overlying tissue, and the location of the external ring is confirmed. The external oblique aponeurosis is then opened along the direction of the external oblique fibers over the inguinal canal. The undersurface of the external oblique is then cleared from surrounding tissue. The cremasteric fibers are separated from the cord structures and hernia sac, and these are then elevated into the wound. Care is taken not to grasp the vas deferens. The hernia sac is then dissected up to the internal ring

and doubly suture ligated. The distal part of the hernia sac is opened widely to drain any hydrocele fluid. When the hernia is very large and the patient very small, tightening of the internal inguinal ring or even formal repair of the inguinal floor may be necessary, although the vast majority of children do not require any treatment beyond high ligation of the hernia sac.

Controversy exists regarding the role for exploration of an asymptomatic opposite side in a child with an inguinal hernia. Several reports indicate that frequency of a patent processus vaginalis on the side opposite the obvious hernia is approximately 30%, although this figure decreases with increasing age of the child. Management options include never exploring the opposite side or exploring only under certain conditions such as in premature infants or in patients in whom incarceration is present. The opposite side may readily be explored laparoscopically. To do so, a blunt 3-mm trocar is placed into the hernia sac of the affected side. The abdominal cavity is insufflated, and the 2.7-mm 70° camera is placed through the trocar such that the opposite side is visualized. The status of the processus vaginalis on the opposite side can be visualized. However, the presence of a patent processus vaginalis by laparoscopy does not always imply the presence of a hernia.

Several authors have now reported a completely laparoscopic approach in the management of inguinal hernias in children. This technique requires insufflation through the umbilicus and the placement of an extraperitoneal suture to ligate the hernia sac. Proponents of this procedure emphasize the fact that no groin incision is used and there is a decreased chance of injuring cord structures. The long-term results of this technique remain to be established.

Inguinal hernias in children recur in less than 1% of patients, and recurrences usually result from missed hernia sacs at the first procedure, a direct hernia, or a missed femoral hernia. All children should have local anesthetic administered either by caudal injection or by direct injection into the wound. Spinal anesthesia in the preterm infant decreases the risk of postoperative apnea when compared with general anesthesia.

GENITALIA

Undescended Testis

Embryology. The term undescended testicle (cryptorchidism) refers to the interruption of the normal descent of the testis into the scrotum. The testicle may reside in the retroperineum, in the internal inguinal ring, in the inguinal canal, or even at the external ring. The testicle begins as a thickening on the urogenital ridge in the fifth to sixth week of embryologic life. In the seventh and eighth months, the testicle descends along the inguinal canal into the upper scrotum, and with its progress, the processus vaginalis is formed and pulled along with the migrating testicle. At birth, approximately 95% of infants have the testicle normally positioned in the scrotum.

A distinction should be made between an undescended testicle and an ectopic testicle. An ectopic testis, by definition, is one that has passed through the external ring in the normal pathway and then has come to rest in an abnormal location overlying either the rectus abdominis or external oblique muscle, or the soft tissue of the medial thigh, or behind the scrotum in the perineum. A congenitally absent testicle results from failure of normal development or an intrauterine accident leading to loss of blood supply to the developing testicle.

Clinical Presentation. The incidence of undescended testes is approximately 30% in preterm infants and 1% to 3% in term infants. For diagnosis, the child should be examined in the supine position, where visual inspection may reveal a hypoplastic or poorly rugated scrotum. Usually a unilateral undescended testicle can be palpated in the inguinal canal or in the upper scrotum. Occasionally, the testicle will be difficult or impossible to palpate, indicating either an abdominal testicle or congenital absence of the gonad. If the testicle is not palpable in the supine position, the child should be examined with his legs crossed while seated. This maneuver diminishes the cremasteric reflex and facilitates identification of the location of the testicle. If there is uncertainty regarding location of a testis, repeated evaluations over time may be helpful.

It is now established that cryptorchid testes demonstrate an increased predisposition to malignant degeneration. In addition, fertility is decreased when the testicle is not in the scrotum. For these reasons, surgical placement of the testicle in the scrotum (orchidopexy) is indicated. It should be emphasized that this procedure does improve the fertility potential, although it is never normal. Similarly, the testicle is still at risk of malignant change, although its location in the scrotum facilitates potentially earlier detection of a testicular malignancy. Other reasons to consider orchidopexy include the risk of trauma to the testicle located at the pubic tubercle and increased incidence of torsion, as well as the psychological impact of an empty scrotum in a developing male. The reason for malignant degeneration is not established, but the evidence points to an inherent abnormality of the testicle that predisposes it to incomplete descent and malignancy rather than malignancy as a result of an abnormal environment.

Treatment. Males with bilateral undescended testicles are often infertile. When the testicle is not within the scrotum, it is subjected to a higher temperature, resulting in decreased spermatogenesis. Mengel and coworkers studied 515 undescended testicles by histology and demonstrated a decreasing presence of spermatogonia after 2 years of age. Despite orchidopexy, the incidence of infertility is approximately two times higher in men with unilateral orchidopexy compared to men with normal testicular descent. Consequently, it is now recommended that the undescended testicle be surgically repositioned by 1 year of age.

The use of chorionic gonadotropin occasionally may be effective in patients with bilateral undescended testes, suggesting that these patients are more apt to have a hormone insufficiency than children with unilateral undescended testicle. The combination of micro-penis and bilateral undescended testes is an indication for hormonal evaluation and testosterone replacement if indicated. If there is no testicular descent after a month of endocrine therapy, operative correction should be undertaken. A child with unilateral cryptorchidism should have surgical correction of the problem. The operation is typically performed through a combined groin and scrotal incision. The cord vessels are fully mobilized, and the testicle is placed in a dartos pouch within the scrotum. An inguinal hernia often accompanies a cryptorchid testis. This should be repaired at the time of orchidopexy.

Patients with a nonpalpable testicle present a challenge in management. The current approach involves laparoscopy to identify the location of the testicle. If the spermatic cord is found to traverse the internal ring or the testis is found at the ring and can be delivered into the scrotum, a groin incision is made and an orchidopexy is performed. If an abdominal testis is identified

that is too far to reach the scrotum, a two-stage Fowler-Stephens approach is used. In the first stage, the testicular vessels can be clipped via laparotomy or laparoscopically. This promotes neovasculation along the vas deferens. Several months later, the second stage is performed during which the testis is mobilized intra-abdominally along with a swath of peritoneum with collateralized blood supply along the vas. This may be done laparoscopically as well. Preservation of the gubernacular attachments with its collaterals to the testicle may confer improved testicular survival following orchidopexy in over 90% of cases. It is, nonetheless, preferable to preserve the testicular vessels whenever possible and complete mobilization of the testicle with its vessels intact. Some surgeons advocate aggressive mobilization of testicular vessels up to the renal hilum if the intra-abdominal testis is within 1 or 2 cm of the internal ring. Other surgeons feel that the staged approach to orchidopexy is superior. To date, no large-scale trial has been performed to answer this question. In either case, meticulous mobilization of the intra-abdominal testis is critical for its survival and successful pexy.

Vaginal Anomalies

Surgical diseases of the vagina in children are either congenital or acquired. Congenital anomalies include a spectrum of diseases that range from simple defects (imperforate hymen) to more complex forms of vaginal atresia, including distal, proximal, and, most severe, complete. These defects are produced by abnormal development of müllerian ducts and/or urogenital sinus. The diagnosis is made most often by physical examination. Secretions into the obstructed vagina produce hydrocolpos, which may present as a large, painful abdominal mass. The anatomy may be defined using US. Pelvic MRI provides the most thorough and accurate assessment of the pelvic structures. Treatment is dependent on the extent of the defect. For an imperforate hymen, division of the hymen is curative. More complex forms of vaginal atresia require mobilization of the vaginal remnants and creation of an anastomosis at the perineum. Laparoscopy can be extremely useful in mobilizing the vagina, in draining hydrocolpos, and in evaluating the internal genitalia. Complete vaginal atresia requires the construction of skin flaps or the creation of a neovagina using a segment of colon.

The most common acquired disorder of the vagina is the straddle injury. This often occurs as young girls fall on blunt objects, which cause a direct injury to the perineum. Typical manifestations include vaginal bleeding and inability to void. Unless the injury is extremely superficial, patients should be examined in the operating room where the lighting is optimal and sedation can be administered. Vaginal lacerations are repaired using absorbable sutures, and the proximity to the urethra should be carefully assessed. Prior to hospital discharge, it is important that girls are able to void spontaneously. In all cases of vaginal trauma, it is essential that the patient be assessed for the presence of sexual abuse. In these cases, early contact with the sexual abuse service is necessary, so that the appropriate microbiologic and photographic evidence can be obtained.

Ovarian Cysts and Tumors

Pathologic Classification. Ovarian cysts and tumors may be classified as nonneoplastic or neoplastic. Nonneoplastic lesions include cysts (simple, follicular, inclusion, paraovarian, or corpus luteum), endometriosis, and inflammatory lesions. Neoplastic lesions are classified based on the three primordia

that contribute to the ovary: mesenchymal components of the urogenital ridge, germinal epithelium overlying the urogenital ridge, and germ cells migrating from the yolk sac. The most common variety is germ cell tumors. Germ cell tumors are classified based on the degree of differentiation and the cellular components involved. The least differentiated tumors are the dysgerminomas, which share features similar to the seminoma in males. Although these are malignant tumors, they are extremely sensitive to radiation and chemotherapy. The most common lesions are the teratomas, which may be mature, immature, or malignant. The degree of differentiation of the neural elements of the tumor determines the degree of immaturity. The sex cord stromal tumors arise from the mesenchymal components of the urogenital ridge. These include the granulosa-theca cell tumors and the Sertoli-Leydig cell tumors. These tumors often produce hormones that result in precocious puberty or hirsutism, respectively. Although rare, epithelial tumors do occur in children. These include serous and mucinous cystadenomas.

Clinical Presentation. Children with ovarian lesions usually present with abdominal pain. Other signs and symptoms include a palpable abdominal mass, evidence of urinary obstruction, symptoms of bowel obstruction, and endocrine imbalance. The surgical approach depends on the appearance of the mass at operation (i.e., whether it is benign-appearing or is suspicious for malignancy). In the case of a simple ovarian cyst, surgery depends on the size of the cyst and the degree of symptoms it causes. In general, large cysts (over 4–5 cm in size) should be resected, as they are unlikely to resolve, may be at risk of torsion, and may mask an underlying malignancy. Resection may be performed laparoscopically; ovarian tissue should be spared in all cases.

Surgical Management. For ovarian lesions that appear malignant, it is important to obtain tumor markers including α -fetoprotein (teratomas), lactate dehydrogenase (dysgerminoma), β -human chorionic gonadotropin (choriocarcinoma), and CA-125 (epithelial tumors). Although the diagnostic sensitivity of these markers is not always reliable, they provide material for postoperative follow-up and indicate the response to therapy. When a malignancy is suspected, the patient should undergo a formal cancer operation. This procedure is performed through either a midline incision or a Pfannenstiel approach. Ascites and peritoneal washings should be collected for cytologic study. The liver and diaphragm are inspected carefully for metastatic disease. An omentectomy is performed if there is any evidence of tumor present. Pelvic and para-aortic lymph nodes are biopsied, and the primary tumor is resected completely. Finally, the contralateral ovary is carefully inspected, and if a lesion is seen, it should be biopsied. Dysgerminomas and epithelial tumors may be bilateral in up to 15% of cases. It is occasionally possible to preserve the ipsilateral fallopian tube. More radical procedures are not indicated.

Ovarian Cysts in the Newborn. An increasing number of ovarian cysts are being detected by prenatal US. In the past, surgical excision was recommended for all cysts greater than 5 cm in diameter because of the perceived risk of ovarian torsion. More recently, it has become apparent from serial US examinations that many of these lesions will resolve spontaneously. Therefore, asymptomatic, simple cysts may be observed, and surgery can be performed only when they fail to decrease in size or become symptomatic. Typically, resolution occurs by approximately 6 months of age. A laparoscopic approach is

preferable in these cases. By contrast, complex cysts of any size require surgical intervention at presentation.

Ambiguous Genitalia

Embryology. Normal sexual differentiation occurs in the sixth fetal week. In every fetus, wolffian (male) and müllerian (female) ducts are present until the onset of sexual differentiation. Normal sexual differentiation is directed by the sex-determining region of the Y chromosome (SRY). This is located on the distal end of the short arm of the Y chromosome. SRY provides a genetic switch that initiates gonadal differentiation in the mammalian urogenital ridge. Secretion of müllerian-inhibiting substance (MIS) by the Sertoli cells of the seminiferous tubules results in regression of the müllerian duct, the anlage of the uterus, fallopian tubes, and the upper vagina. Therefore, the result of MIS secretion is a phenotypic male. In the absence of SRY in the Y chromosome, MIS is not produced, and the müllerian duct derivatives are preserved. Thus, the female phenotype prevails.

In order for the male phenotype to develop, the embryo must have a Y chromosome, the SRY must be normal without point mutations or deletions, testosterone and MIS must be produced by the differentiated gonad, and the tissues must respond to these hormones. Any disruption of the orderly steps in sexual differentiation may result in disorders of sex development (DSDs), formerly known as intersex syndromes. DSDs are now classified as: (a) ovotesticular DSD or 46,XX testicular DSD (formerly referred to as true hermaphrodite), (b) 46,XY DSD (male pseudohermaphrodite), (c) 46,XX DSD (female pseudohermaphrodite), and (d) mixed gonadal dysgenesis (usually underdeveloped or imperfectly formed gonads).

Ovotesticular DSD or 46,XX Testicular DSD. This represents the rarest form of ambiguous genitalia. Patients have both normal male and female gonads, with an ovary on one side and a testis on the other. Occasionally, an ovotestis is present on one or both sides. The majority of these patients have a 46,XX karyotype. Both the testis and the testicular portion of the ovotestis should be removed.

46,XY DSD. This condition occurs in infants with an XY karyotype but deficient masculinization of the external genitalia. Bilateral testes are present, but the duct structures differentiate partly as phenotypic females. Causes include inadequate testosterone production due to biosynthetic error, inability to convert testosterone to dihydrotestosterone due to 5- α -reductase deficiency, or deficiencies in androgen receptors. The latter disorder is termed testicular feminization syndrome. Occasionally, the diagnosis in these children is made during routine inguinal herniorrhaphy in a phenotypic female at which time testes are found. The testes should be resected due to the risk of malignant degeneration, although this should be performed only after a full discussion with the family has occurred.

46,XX DSD. The most common cause of this disorder is congenital adrenal hyperplasia. These children have a 46,XX karyotype but have been exposed to excessive androgens in utero. Common enzyme deficiencies include 21-hydroxylase, 11-hydroxylase, and 3- β -hydroxysteroid dehydrogenase. These deficiencies result in overproduction of intermediary steroid hormones, which results in masculinization of the external genitalia of the XX fetus. These patients are unable to synthesize cortisol. In 90% of cases, deficiency of 21-hydroxylase causes adrenocorticotrophic hormone (ACTH) to stimulate the secretion

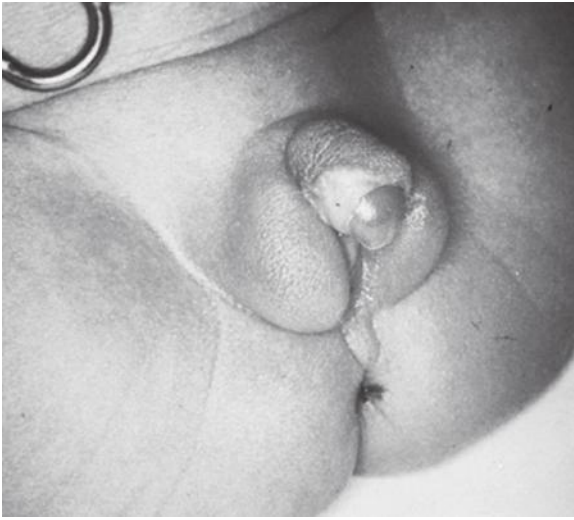

Figure 39-36. Ambiguous genitalia manifest as enlarged clitoris and labioscrotal folds in a baby with the adrenogenital syndrome.

of excessive quantities of adrenal androgen, which masculinizes the developing female (Fig. 39-36). These infants are prone to salt loss and require cortisol replacement. Those with mineralocorticoid deficiency also require fludrocortisone replacement.

Mixed Gonadal Dysgenesis. This syndrome is associated with dysgenetic gonads and retained müllerian structures. The typical karyotype is mosaic, usually 45,XO/46,XY. There is a high incidence of malignant tumors in the dysgenetic gonads, most commonly gonadoblastoma. Therefore, they should be removed.

Management. In the differential diagnosis of patients with intersex anomalies, the following diagnostic steps are necessary: (a) evaluation of the genetic background and family history; (b) assessment of the anatomic structures by physical examination, US, and/or chromosome studies; (c) determination of biochemical factors in serum and urine to evaluate the presence of an enzyme defect; and (d) laparoscopy for gonadal biopsy. Treatment should include correction of electrolyte and volume losses in cases of congenital adrenal hyperplasia and replacement of hormone deficiency. Surgical assignment of gender should never be determined at the first operation. Although historically female gender had been assigned, there is abundant and convincing evidence that raising a genotypic male as a female has devastating consequences, not only anatomically but also psychosocially. This is particularly relevant given the role of pre- and postnatal hormones on gender imprinting and identity. In general terms, surgical reconstruction should be performed after a full genetic workup and with the involvement of pediatric endocrinologists, pediatric plastic surgeons, and ethicists with expertise in gender issues. Discussion with the family also plays an important role. This approach will serve to reduce the anxiety associated with these disorders and will help to ensure the normal physical and emotional development of these patients.

PEDIATRIC MALIGNANCY

Cancer is the second leading cause of death in children after trauma and accounts for approximately 11% of all pediatric deaths in the United States. Several features distinguish pediatric from adult cancers, including the presence of tumors that

are predominantly seen in children, such as neuroblastoma and germ cell tumors, and the favorable response to chemotherapy observed for many pediatric solid malignancies, even in the presence of metastases.

Wilms' Tumor

Clinical Presentation. Wilms' tumor is the most common primary malignant tumor of the kidney in children. There are approximately 500 new cases annually in the United States, and most are diagnosed between 1 and 5 years with the peak incidence at age 3. Advances in the care of patients with Wilms' tumor have resulted in an overall cure rate of roughly 90%, even in the presence of metastatic spread. The tumor usually develops in otherwise healthy children as an asymptomatic mass in the flank or upper abdomen. Frequently, the mass is discovered by a parent while bathing or dressing the child. Other symptoms include hypertension, hematuria, obstipation, and weight loss. Occasionally the mass is discovered following blunt abdominal trauma.

Genetics of Wilms' Tumor. Wilms' tumor can arise from both germline and somatic mutations and can occur in the presence or absence of a family history. Nearly 97% of Wilms' tumors are sporadic, in that they occur in the absence of a heritable or congenital cause or risk factor. When a heritable risk factor is identified, the affected children often present at an earlier age and are frequently bilateral. Most of these tumors are associated with germline mutations. It is well established that there is a genetic predisposition to Wilms' tumor in the WAGR syndrome, which consists of Wilms' tumor, aniridia, genitourinary abnormalities, and mental retardation. In addition, there is an increased incidence of Wilms' tumor in certain overgrowth conditions, particularly Beckwith-Wiedemann syndrome and hemihypertrophy. The WAGR syndrome has been shown to result from the deletion of one copy each of the Wilms' tumor gene, *WT1*, and the adjacent aniridia gene, *PAX6*, on chromosome 11p13. Beckwith-Wiedemann syndrome is an overgrowth syndrome that is characterized by visceromegaly, macroglossia, and hyperinsulinemic hypoglycemia. It arises from mutations at the 11p15.5 locus. There is evidence to suggest that analysis of the methylation status of several genes in the 11p15 locus could predict the individual risk of developing Wilms' tumor. Importantly, most patients with Wilms' tumor do not have mutations at these genetic loci.

Surgical Treatment. Before operation, all patients suspected of having Wilms' tumor should undergo abdominal and chest CT. These studies characterize the mass, identify the presence of metastases, and provide information on the opposite kidney (Fig. 39-37). CT scanning also indicates the presence of nephrogenic rests, which are precursor lesions to Wilms' tumor. An abdominal US should be performed to evaluate the presence of renal vein or vena caval extension.

The management of patients with Wilms' tumor has been carefully analyzed within the context of large studies involving thousands of patients. These studies have been coordinated by the National Wilms' Tumor Study Group (NWTSG) in North America and the International Society of Paediatric Oncology (SIOP), mainly involving European countries. Significant differences in the approach to patients with Wilms' tumor have been highlighted by these studies. NWTSG supports a strategy of surgery followed by chemotherapy in most instances, whereas the SIOP approach is to shrink the tumor using preoperative chemotherapy. There are instances where preoperative chemotherapy is supported by both

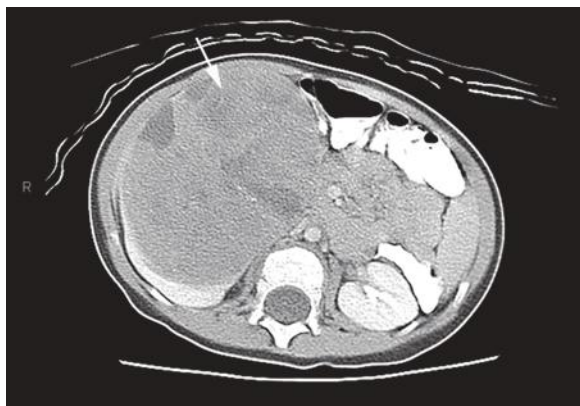

Figure 39-37. Wilms' tumor of the right kidney (*arrow*) in a 3-year-old girl.

groups, including the presence of bilateral involvement or inferior vena cava involvement that extends above the hepatic veins and involvement of a solitary kidney by Wilms' tumor. The NWTSG proponents argue that preoperative therapy in other instances results in a loss of important staging information, and therefore places patients at higher risk for recurrence; alternatively, it may lead to overly aggressive treatment in some cases and greater morbidity. However, the overall survival rates are not different between the NWTSG and SIOP approaches.

The goal of surgery is complete removal of the tumor. It is crucial to avoid tumor rupture or injury to contiguous organs. A sampling of regional lymph nodes should be included, and all suspicious nodes should be sampled. Typically a transverse abdominal incision is made, and a transperitoneal approach is used. The opposite side is carefully inspected to ensure that there is no disease present. Although historically this involved the complete mobilization of the contralateral kidney, current evidence indicates that preoperative high-resolution CT scanning is of sufficient accuracy for the detection of clinically significant lesions if they are present. Provided only unilateral disease is present, a radical nephroureterectomy is then performed with control of the renal pedicle as an initial step. If there is spread above the hepatic veins, an intrathoracic approach may be required. If bilateral disease is encountered, both lesions are biopsied, and chemotherapy is administered followed by a nephron-sparing procedure.

Chemotherapy. Following nephroureterectomy for Wilms' tumor, the need for chemotherapy and/or radiation therapy is determined by the histology of the tumor and the clinical stage of the patient (Table 39-3). Essentially, patients who have disease confined to one kidney that is completely excised surgically receive a short course of chemotherapy and can expect a 97% 4-year survival, with tumor relapse rare after that time. Patients with more advanced disease or with unfavorable histology receive more intensive chemotherapy and radiation. Even in stage IV, cure rates of 80% are achieved. The survival rates are worse in the small percentage of patients considered to have unfavorable histology.

Neuroblastoma

Clinical Presentation. Neuroblastoma is the third most common pediatric malignancy and accounts for approximately 10% of all childhood cancers. The vast majority of patients have advanced disease at the time of presentation, and unlike

Table 39-3

Staging of Wilms' tumor

Stage I: Tumor limited to the kidney and completely excised.

Stage II: Tumor that extends beyond the kidney but is completely excised. No residual tumor is apparent at or beyond the margins of excision. The tumor was biopsied, or there was local spillage of tumor confined to the flank.

Stage III: Residual tumor confined to the abdomen. Lymph nodes in the renal hilus, the periaortic chains, or beyond contain tumor. Diffuse peritoneal contamination by the tumor, such as by spillage of tumor beyond the flank before or during surgery or by tumor growth that has penetrated through the peritoneal surface. Implants are found on the peritoneal surfaces. Tumor extends beyond the surgical margins either microscopically or grossly. Tumor is not completely resectable because of local infiltration into vital structures.

Stage IV: Hematogenous metastases

Stage V: Bilateral renal involvement

Source: D'Angio GJ, Breslow N, Beckwith JB, et al. Treatment of Wilms' tumor. Results of the Third National Wilms' Tumor Study. *Cancer*. 1989;64:349-360.

Wilms' tumor, in which cure is expected in the vast majority of patients, the overall survival of patients with neuroblastoma is significantly lower. Over 80% of cases present before the age of 4 years, and the peak incidence is 2 years of age. Neuroblastomas arise from the neural crest cells and show different levels of differentiation. The tumor originates most frequently in the adrenal glands, posterior mediastinum, neck, or pelvis but can arise in any sympathetic ganglion. The clinical presentation depends on the site of the primary and the presence of metastases.

Two thirds of these tumors are first noted as an asymptomatic abdominal mass. The tumor may cross the midline, and a majority of patients will already show signs of metastatic disease. Occasionally, children may experience pain from the tumor mass or from bony metastases. Proptosis and periorbital ecchymosis may occur due to the presence of retrobulbar metastasis. Because they originate in paraspinal ganglia, neuroblastomas may invade through neural foramina and compress the spinal cord, causing muscle weakness or sensory changes. Rarely, children may have severe watery diarrhea due to the secretion of vasoactive intestinal peptide by the tumor or have paraneoplastic neurologic findings including cerebellar ataxia or opsoclonus/myoclonus.

Diagnostic Evaluation. Since these tumors derive from the sympathetic nervous system, catecholamines and their metabolites will be produced at increased levels. These include elevated levels of serum catecholamines (dopamine, norepinephrine) or urine catecholamine metabolites (vanillylmandelic acid [VMA] or homovanillic acid [HVA]). Measurement of VMA and HVA in serum and urine aids in the diagnosis and in monitoring adequacy of future treatment and recurrence. The minimum criterion for a diagnosis of neuroblastoma is based on one of the following: (a) an unequivocal pathologic diagnosis made from tumor tissue by light microscopy (with or without immunohistology, electron

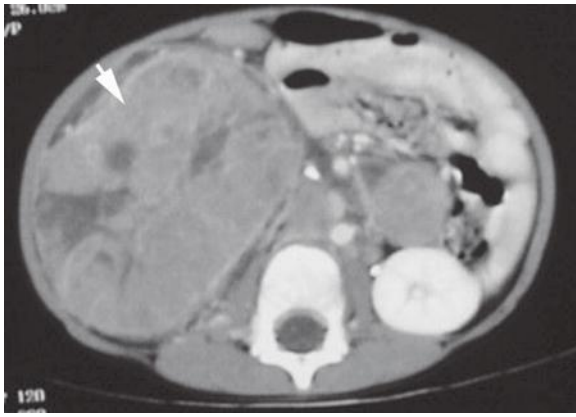


Figure 39-38. Abdominal neuroblastoma arising from the right retroperitoneum (arrow).

microscopy, or increased levels of serum catecholamines or urinary catecholamine metabolites); or (b) the combination of bone marrow aspirate or biopsy containing unequivocal tumor cells and increased levels of serum catecholamines or urinary catecholamine metabolites as described earlier.

The patient should be evaluated by abdominal CT, which may show displacement and occasionally obstruction of the ureter of an intact kidney (Fig. 39-38). Prior to the institution of therapy, a complete staging workup should be performed. This includes radiograph of the chest, bone marrow biopsy, and radionuclide scans to search for metastases. Any abnormality on chest x-ray should be followed up with CT of the chest.

Prognostic Indicators. A number of biologic variables have been studied in children with neuroblastoma. An open biopsy is required in order to provide tissue for this analysis. Hyperdiploid tumor DNA is associated with a favorable prognosis, and *N-myc* amplification is associated with a poor prognosis regardless of patient age. The Shimada classification describes tumors as either favorable or unfavorable histology based on the degree of differentiation, the mitosis-karyorrhexis index, and the presence or absence of schwannian stroma. In general, children of any age with localized neuroblastoma and infants younger than 1 year of age with advanced disease and favorable disease characteristics have a high likelihood of disease-free survival. By contrast, older children with advanced-stage disease have a significantly decreased chance for cure despite intensive therapy. For example, aggressive multiagent chemotherapy has resulted in a 2-year survival rate of approximately 20% in older children with stage IV disease. Neuroblastoma in the adolescent has a worse long-term prognosis regardless of stage or site and, in many cases, a more prolonged course.

Surgery. The goal of surgery is complete resection. However, this is often not possible at initial presentation due to the extensive locoregional spread of the tumor at the time of presentation. Under these circumstances, a biopsy is performed and preoperative chemotherapy is provided based on the stage of the tumor. After neoadjuvant treatment has been administered, surgical resection is performed. The principal goal of surgery is to obtain at least 95% resection, without compromising major structures. Abdominal tumors are approached through a transverse incision. Thoracic tumors may be approached through a posterolateral thoracotomy or through a thoracoscopic approach. These may have an intraspinal component. In all cases of intrathoracic neuroblastoma, particularly those at the thoracic inlet, it is

important to be aware of the possibility of a Horner's syndrome (anhidrosis, ptosis, meiosis) developing. This typically resolves, although it may take many months to do so.

Neuroblastoma in Infants. Spontaneous regression of neuroblastoma has been well described in infants, especially in those with stage IVS disease. Regression generally occurs only in tumors with a near triploid number of chromosomes that also lack *N-myc* amplification and loss of chromosome 1p. Recent studies indicate that infants with asymptomatic, small, low-stage neuroblastoma detected by screening may have tumors that spontaneously regress. These patients may be observed safely without surgical intervention or tissue diagnosis.

Rhabdomyosarcoma

Rhabdomyosarcoma is a primitive soft tissue tumor that arises from mesenchymal tissues. The most common sites of origin include the head and neck (36%), extremities (19%), genitourinary tract (21%), and trunk (9%), although the tumor can arise virtually anywhere. The clinical presentation of the tumor depends on the site of origin. The diagnosis is confirmed with incisional or excisional biopsy after evaluation by MRI, CT scans of the affected area and the chest, and bone marrow biopsy. The tumor grows locally into surrounding structures and metastasizes widely to lung, regional lymph nodes, liver, brain, and bone marrow. The staging system for rhabdomyosarcoma is based on the TNM system, as established by the Soft Tissue Sarcoma Committee of the Children's Oncology Group. It is shown in Table 39-4. Surgery is an important component of the staging strategy and involves biopsy of the lesion and evaluation of lymphatics. Primary resection should be undertaken when complete excision can be performed without causing disability. If this is not possible, the lesion is biopsied, and intensive chemotherapy is administered. It is important to plan the biopsy so that it does not interfere with subsequent resection. After the tumor has decreased in size, resection of gross residual disease should be performed. Radiation therapy is effective in achieving local control when microscopic or gross residual disease exists

Table 39-4

Staging of rhabdomyosarcoma

Stage 1: Localized disease involving the orbit or head and neck (excluding parameningeal sites), genitourinary region (excluding bladder/prostate sites), or biliary tract (favorable sites).

Stage 2: Localized disease of any other primary site not included in the stage 1 category (unfavorable sites). Primary tumors must be ≤ 5 cm in diameter, and there must be no clinical regional lymph node involvement by tumor.

Stage 3: Localized disease of any other primary site. These patients differ from stage 2 patients by having primary tumors greater than 5 cm and/or regional node involvement.

Stage 4: Metastatic disease at diagnosis.

Sources: Lawrence W Jr, Gehan EA, Hays DM, et al. Prognostic significance of staging factors of the UICC staging system in childhood rhabdomyosarcoma: a report from the Intergroup Rhabdomyosarcoma Study (IRS-II). *J Clin Oncol.* 1987;5:46-54.

Lawrence W Jr, Anderson JR, Gehan EA, et al. Pretreatment TNM staging of childhood rhabdomyosarcoma: a report of the Intergroup Rhabdomyosarcoma Study Group. Children's Cancer Study Group. Pediatric Oncology Group. *Cancer.* 1997;80:1165-1170.

following initial treatment. Patients with completely resected tumors of embryonal histology do well without radiation therapy, but radiation therapy benefits patients with group I tumors with alveolar or undifferentiated histology.

Prognosis. The prognosis for rhabdomyosarcoma is related to the site of origin, resectability, presence of metastases, number of metastatic sites, and histopathology. Primary sites with more favorable prognoses include the orbit and nonparameningeal head and neck, paratestis and vagina (nonbladder, nonprostate genitourinary), and biliary tract. Patients with tumors less than 5 cm in size have improved survival compared to children with larger tumors, whereas children with metastatic disease at diagnosis have the poorest prognosis. Tumor histology influences prognosis. The embryonal variant is favorable, whereas the alveolar subtype has an unfavorable prognosis.

Teratoma

Teratomas are tumors composed of tissue from all three embryonic germ layers. They may be benign or malignant, may arise in any part of the body, and are usually found in midline structures. Thoracic teratomas usually present as an anterior mediastinal mass. Ovarian teratomas present as an abdominal mass often with symptoms of torsion, bleeding, or rupture. Retroperitoneal teratomas may present as a flank or abdominal mass.

Mature teratomas usually contain well-differentiated tissues and are benign, whereas immature teratomas contain varying degrees of immature neuroepithelium or blastemal tissues. Immature teratomas can be graded from 1 to 3 based on the amount of immature neuroglial tissue present. Tumors of higher grade are more likely to have foci of yolk sac tumor. Malignant germ cell tumors usually contain frankly neoplastic tissues of germ cell origin (i.e., yolk sac carcinoma, embryonal carcinoma, germinoma, or choriocarcinoma). Yolk sac carcinomas produce α -fetoprotein (AFP), whereas choriocarcinomas produce β -human chorionic gonadotropin (BHCG), resulting in elevation of these substances in the serum, which can serve as tumor markers. In addition, germinomas can also produce elevation of serum BHCG but not to the levels associated with choriocarcinoma.

Sacroccygeal Teratoma. Sacroccygeal teratoma usually presents as a large mass extending from the sacrum in the newborn period. Diagnosis may be established by prenatal US. In fetuses with evidence of hydrops and a large sacroccygeal teratoma, prognosis is poor; thus, prenatal intervention has been advocated in such patients. The mass may be as small as a few centimeters in diameter or as massive as the size of the infant (Fig. 39-39). The tumor has been classified based on the location and degree of intrapelvic extension. Lesions that grow predominantly into the presacral space often present later in childhood. The differential diagnosis consists of neural tumors, lipoma, and myelomeningocele.

Most tumors are identified at birth and are benign. Malignant yolk sac tumor histology occurs in a minority of these tumors. Complete resection of the tumor as early as possible is essential. The rectum and genital structures are often distorted by the tumor but usually can be preserved in the course of resection. Perioperative complications of hypothermia and hemorrhage can occur with massive tumors and may prove lethal. This is of particular concern in small, preterm infants with large tumors. The cure rate is excellent if the tumor is excised completely. The majority of patients who develop recurrent disease are salvageable with subsequent platinum-based chemotherapy.

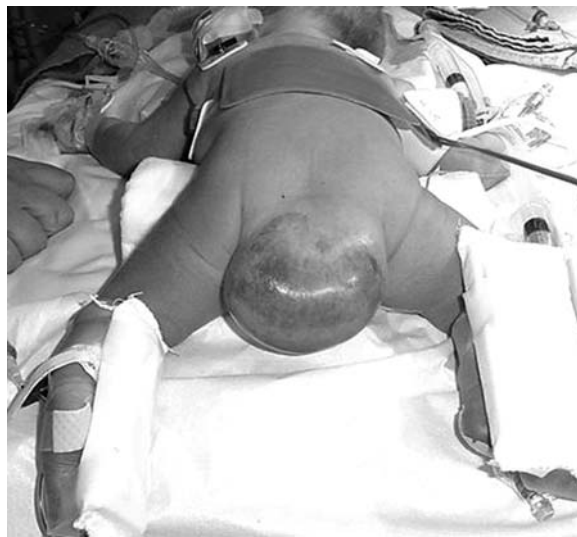

Figure 39-39. Sacroccygeal teratoma in a 2-day-old boy.

Liver Tumors

More than two thirds of all liver tumors in children are malignant. There are two major histologic subgroups: hepatoblastoma and hepatocellular carcinoma. The age of onset of liver cancer in children is related to the histology of the tumor. Hepatoblastoma is the most common malignancy of the liver in children, with most of these tumors diagnosed before 4 years of age. Hepatocellular carcinoma is the next most common, with a peak age incidence between 10 and 15 years. Malignant mesenchymomas and sarcomas are much less common but constitute the remainder of the malignancies. The finding of a liver mass does not necessarily imply that a malignancy is present. Nearly 50% of all masses are benign, and hemangiomas are the most common lesion.

Most children with a liver tumor present with an abdominal mass that is usually painless, which the parents note while changing the child's clothes or while bathing the child. The patients are rarely jaundiced but may complain of anorexia and weight loss. Most liver function tests are normal. AFP levels are increased in 90% of children with hepatoblastomas but much less commonly in other liver malignancies. Radiographic evaluation of these children should include an abdominal CT scan to identify the lesion and to determine the degree of local invasiveness (Fig. 39-40). For malignant-appearing lesions, a

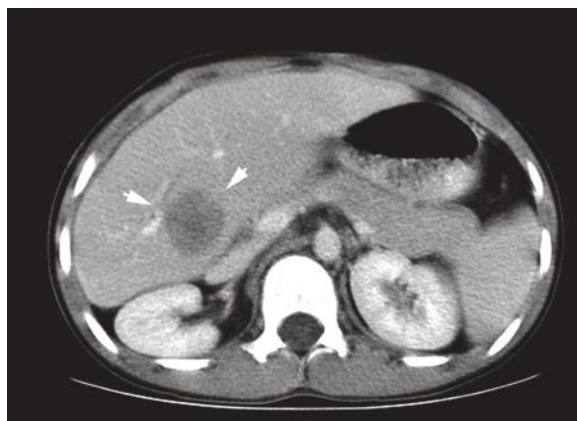

Figure 39-40. Computed tomography of the abdomen showing a hepatocellular carcinoma in a 12-year-old boy.

Table 39-5

Staging of pediatric liver cancer**Stage I:** No metastases, tumor completely resected**Stage II:** No metastases, tumor grossly resected with microscopic residual disease (i.e., positive margins); or tumor rupture, or tumor spill at the time of surgery**Stage III:** No distant metastases, tumor unresectable or resected with gross residual tumor, or positive lymph nodes**Stage IV:** Distant metastases regardless of the extent of liver involvement

Source: Douglass E, Ortega J, Feusner J, et al. Hepatocellular carcinoma (HCA) in children and adolescents: results from the Pediatric Intergroup Hepatoma Study (CCG 8881/POG 8945). *Proc Am Soc Clin Oncol*. 1994;13:A-1439.

biopsy should be performed unless the lesion can be completely resected easily. Hepatoblastoma is most often unifocal, whereas hepatocellular carcinoma is often extensively invasive or multicentric. If a hepatoblastoma is completely removed, the majority of patients survive, but only a minority of patients have lesions amenable to complete resection at diagnosis.

A staging system based on postsurgical extent of tumor and surgical resectability is shown in Table 39-5. The overall survival rate for children with hepatoblastoma is 70%, but is only 25% for hepatocellular carcinoma. Children diagnosed with stage I and II hepatoblastoma have a cure rate of greater than 90% compared to 60% for stage III and approximately 20% for stage IV. In children diagnosed with hepatocellular carcinoma, those with stage I disease have a good outcome, whereas stages III and IV are usually fatal. The fibrolamellar variant of hepatocellular carcinoma may have a better prognosis.

Surgery. The abdominal CT scan usually will determine the resectability of the lesion, although occasionally this can only be determined at the time of exploration. Complete surgical resection of the tumor is the primary goal and is essential for cure. For tumors that are unresectable, preoperative chemotherapy should be administered to reduce the size of the tumor and improve the possibility for complete removal. Chemotherapy is more successful for hepatoblastoma than for hepatocellular carcinoma. Areas of locally invasive disease, such as the diaphragm, should be resected at the time of surgery. For unresectable tumors, liver transplantation may be offered in select patients. The fibrolamellar variant of hepatocellular carcinoma may have a better outcome with liver transplantation than other hepatocellular carcinomas.

TRAUMA IN CHILDREN

Injury is the leading cause of death among children older than 1 year. In fact, trauma accounts for almost half of all pediatric deaths, more than cancer, congenital anomalies, pneumonia, heart disease, homicide, and meningitis combined. Motor vehicle collisions are the leading cause of death in people age 1 to 19 years, followed by homicide or suicide (predominantly with firearms) and drowning. Unintentional injuries account for 65% of all injury-related deaths in children younger than 19 years. Each year, approximately 20,000 children and teenagers die as a result of injury in the United States. For every child who dies from an injury, it is calculated that 40 others are hospitalized and 1120 are treated in emergency departments. An estimated

50,000 children acquire permanent disabilities each year, most of which are the result of head injuries. Thus, the problem of pediatric trauma continues to be one of the major threats to the health and well-being of children.

Specific considerations apply to trauma in children that influence management and outcome. These relate to the mechanisms of injury, the anatomic variations in children compared to adults, and the physiologic responses.

Mechanisms of Injury

Most pediatric trauma is blunt. Penetrating injuries are seen in the setting of gun violence, falls onto sharp objects, or penetration by glass after falling through windows. Age and gender significantly influence the patterns of injury. Male children between 14 and 18 years of age are exposed to contact sports and gun violence and, in some jurisdictions, drive motor vehicles. As a result, they have a different pattern of injury than younger children, characterized by higher injury severity scores. In the infant and toddler age group, falls are a common cause of severe injury. Injuries in the home are extremely common. These include falls, near-drownings, caustic ingestion, and nonaccidental injuries.

Initial Management

The goals of managing the pediatric trauma patient are similar to those of adults and follow advanced trauma life support guidelines as established by the American College of Surgeons Committee on Trauma. Airway control is the first priority. In a child, respiratory arrest can proceed quickly to cardiac arrest. It is important to be aware of the anatomic differences between the airway of the child and the adult. The child has a large head, shorter neck, smaller and anterior larynx, floppy epiglottis, short trachea, and large tongue. The size of the endotracheal tube can be estimated by the formula $(\text{age} + 16)/4$. It is important to use uncuffed endotracheal tubes in children younger than 8 years in order to minimize tracheal trauma. After evaluation of the airway, breathing is assessed. It is important to consider that gastric distention from aerophagia can severely compromise respirations. A nasogastric tube should therefore be placed early during the resuscitation if there is no head injury suspected, or an orogastric tube should be placed in cases of head injury. Pneumothorax or hemothorax should be treated promptly. When evaluating the circulation, it is important to recognize that tachycardia is usually the earliest measurable response to hypovolemia. Other signs of impending hypovolemic shock in children include changes in mentation, delayed capillary refill, skin pallor, and hypothermia. IV access should be rapidly obtained once the patient arrives in the trauma bay. The first approach should be to use the antecubital fossa. If this is not possible, a cut-down into the saphenous at the groin can be performed quickly and safely. Intraosseous cannulation can provide temporary access in children up to 6 years old until IV access is established. Percutaneous neck lines should generally be avoided. Blood is drawn for cross-match and evaluation of liver enzymes, lipase, amylase, and hematologic profile after the IV lines are placed.

In patients who show signs of volume depletion, a 20 mL/kg bolus of saline or lactated Ringer's should be promptly given. If the patient does not respond to two boluses, blood should be transfused (10 mL/kg). The source of bleeding should be established. Common sites include the chest, abdomen, pelvis, extremity fractures, or large scalp wounds. These should be carefully sought. Care is taken to avoid hypothermia by infusing warmed fluids and using external warming devices.

Evaluation of Injury

All patients should receive an x-ray of the cervical spine, chest, and abdomen with pelvis. All extremities that are suspicious for fracture should also be evaluated by x-ray. Plain cervical spine films are preferable to performing routine neck CT scans in the child, as x-rays provide sufficient anatomic detail. But if a head CT is obtained, it may be reasonable to obtain images down to C2 since odontoid views in small children are difficult to obtain. In most children, it is possible to diagnose clinically significant cervical spine injuries using this approach while minimizing the degree of radiation exposure. Screening blood work that includes aspartate aminotransferase, alanine aminotransferase, and amylase/lipase is useful for the evaluation of liver and pancreatic injuries. Significant elevation in these tests requires further evaluation by CT scanning. The child with significant abdominal tenderness and a mechanism of injury that could cause intra-abdominal injury should undergo abdominal CT scanning using IV and oral contrast in all cases. There is a limited role for diagnostic peritoneal lavage (DPL) in children as a screening test. Although focused abdominal US (FAST exam) is extremely useful in the evaluation of adult abdominal trauma, it is not widely accepted in the management of pediatric blunt abdominal trauma. In part this relates to the widespread use of nonoperative treatment for most solid-organ injuries. Thus a positive abdominal US scan would not alter this approach in a hemodynamically stable patient. However, FAST exam can be very useful in the child who needs to go emergently to the operating room for management of significant intracranial hemorrhage, to ensure that there is no intraabdominal source of bleeding.

Injuries to the Central Nervous System

The central nervous system (CNS) is the most commonly injured organ system and is the leading cause of death among injured children. In the toddler age group, nonaccidental trauma is the most common cause of serious head injury. Findings suggestive of abuse include the presence of retinal hemorrhage on fundoscopic evaluation, intracranial hemorrhage without evidence of external trauma (indicative of a shaking injury), and fractures at different stages of healing on skeletal survey. In older children, CNS injury occurs most commonly after falls and bicycle and motor vehicle collisions. The initial head CT can often underestimate the extent of injury in children. Criteria for head CT include any loss of consciousness or amnesia to the trauma or inability to assess the CNS status as in the intubated

patient. Patients with mild, isolated head injury (Glasgow Coma Scale [GCS] 14–15) and negative CT scans can be discharged if their neurologic status is normal after 6 hours of observation. Young children and those in whom there is multisystem involvement should be admitted to the hospital for observation. Any change in the neurologic status warrants neurosurgical evaluation and repeat CT scanning. In patients with severe head injury (GCS ≤ 8), urgent neurosurgical consultation is required. These patients are evaluated for intracranial pressure monitoring and for the need to undergo craniotomy.

Thoracic Injuries

The pediatric thorax is pliable due to incomplete calcification of the ribs and cartilages. As a result, blunt chest injury commonly results in pulmonary contusion, although rib fractures are infrequent. Diagnosis is made by chest radiograph and may be associated with severe hypoxia requiring mechanical ventilation. Pulmonary contusion usually resolves with careful ventilator management and judicious volume resuscitation. Children who have sustained massive blunt thoracic injury may develop traumatic asphyxia. This is characterized by cervical and facial petechial hemorrhages or cyanosis associated with vascular engorgement and subconjunctival hemorrhage. Management includes ventilation and treatment of coexisting CNS or abdominal injuries. Penetrating thoracic injuries may result in damage to the lung or in major disruption of the bronchi or great vessels.

Abdominal Injuries

In children, the small rib cage and minimal muscular coverage of the abdomen can result in significant injury after seemingly minor trauma. The liver and spleen in particular are relatively unprotected and are often injured after direct abdominal trauma. Duodenal injuries are usually the result of blunt trauma, which may arise from child abuse or injury from a bicycle handlebar. Duodenal hematomas usually resolve without surgery. Small intestinal injury usually occurs in the jejunum in the area of fixation by the ligament of Treitz. These injuries are usually caused by rapid deceleration in the setting of a lap belt. There may be a hematoma on the anterior abdominal wall caused by a lap belt, the so-called “seat belt sign” (Fig. 39-41A). This should alert the caregiver to the possibility of an underlying small bowel injury (Fig. 39-41B), as well as to a potential lumbar spine injury (Chance fracture).

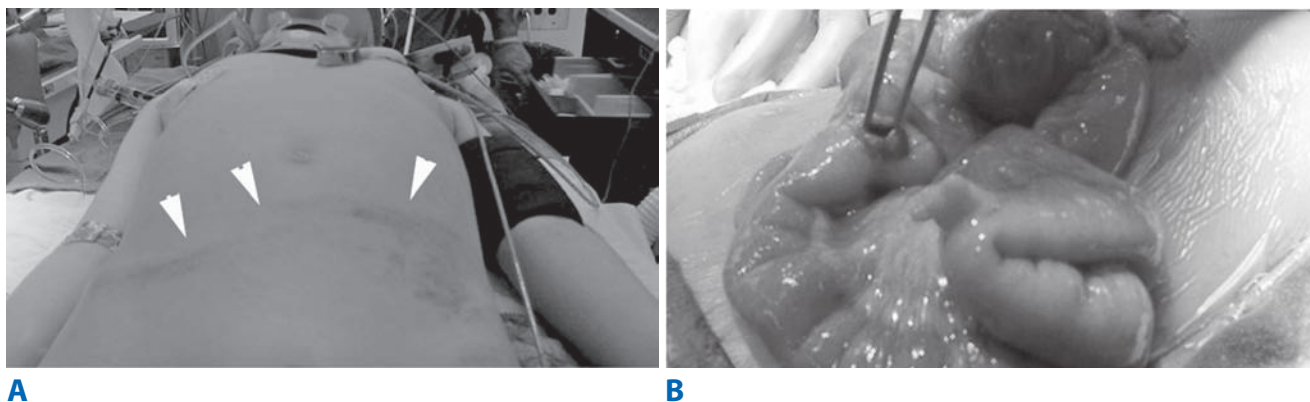


Figure 39-41. Abdominal computed tomography of patient who sustained a lap belt injury. **A.** Bruising is noted across the abdomen from the lap belt. **B.** At laparotomy, a perforation of the small bowel is identified.

Table 39-6

Grading of splenic injuries

Grade I: Subcapsular hematoma, <10% surface area capsular tear, <1 cm in depth

Grade II: Subcapsular hematoma, nonexpanding, 10%–50% surface area; intraparenchymal hematoma, nonexpanding, <2 cm in diameter; capsular tear, active bleeding, 1–3 cm, does not involve trabecular vessel

Grade III: Subcapsular hematoma, >50% surface area or expanding; intraparenchymal hematoma, >2 cm or expanding; laceration >3 cm in depth or involving trabecular vessels

Grade IV: Ruptured intraparenchymal hematoma with active bleeding; laceration involving segmental or hilar vessels producing major devascularization (>25% of spleen)

Grade V: Shattered spleen; hilar vascular injury which devascularizes spleen

The spleen is injured relatively commonly after blunt abdominal trauma in children. The extent of injury to the spleen is graded (Table 39-6), and the management is governed by the injury grade. Current treatment involves a nonoperative approach in most cases, even for grade IV injuries, assuming the patient is hemodynamically stable. This approach avoids surgery in most cases. All patients should be placed in a monitored unit, and type-specific blood should be available for transfusion. When nonoperative management is successful, as it is in most cases, an extended period of bed rest is prescribed. This optimizes the chance for healing and minimizes the likelihood of reinjury. A typical guideline is to keep the children on extremely restricted activity for 2 weeks longer than the grade of spleen injury (i.e., a child with a grade IV spleen injury receives 6 weeks of restricted activity). In children who have an ongoing fluid requirement or when a blood transfusion is required, exploration should not be delayed. At surgery, the spleen can often be salvaged. If a splenectomy is performed, prophylactic antibiotics and immunizations should be administered to protect against overwhelming postsplenectomy sepsis. The liver is also commonly injured after blunt abdominal trauma. A grading system is used to characterize hepatic injuries (Table 39-7), and nonoperative management is usually successful (Fig. 39-42). Recent studies have shown that associated injuries are more significant

Table 39-7

Liver injury grading system

Grade I: Capsular tear <1 cm in depth

Grade II: Capsular tear 1–3 cm in depth, <10 cm length

Grade III: Capsular tear >3 cm in depth

Grade IV: Parenchymal disruption 25%–75% of hepatic lobe or 1–3 Couinaud's segments

Grade V: Parenchymal disruption >75% of hepatic lobe or >3 Couinaud's segments within a single lobe, injury to retrohepatic vena cava

Source: Reproduced with permission from Moore EE, Cogbill TH, Malangoni MA, et al. Organ injury scaling. *Surg Clin North Am.* 1995;75:293-303. Copyright Elsevier.

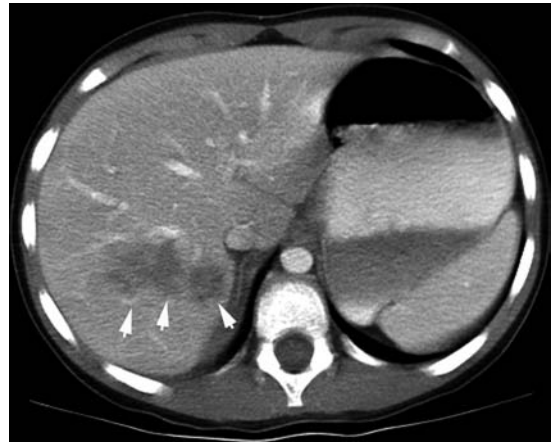

Figure 39-42. Abdominal computed tomography in a child demonstrating a grade III liver laceration (arrows).

predictors of outcome in children with liver injuries than the actual injury grade. Criteria for surgery are similar to those for splenic injury and primarily involve hemodynamic instability. The intraoperative considerations in the management of massive hepatic injury are similar in children and adults. Renal contusions may occur after significant blunt abdominal trauma. Nonoperative management is usually successful, unless patients are unstable due to active renal bleeding. It is important to confirm the presence of a normal contralateral kidney at the time of surgery.

FETAL INTERVENTION

One of the most exciting developments in the field of pediatric surgery has been the emergence of fetal therapy. In general terms, performance of a fetal intervention may be justified in the setting where a defect is present that would cause devastating consequences to the infant if left uncorrected. For the vast majority of congenital anomalies, postnatal surgery is the preferred modality. However, in specific circumstances, fetal surgery may offer the best possibility for a successful outcome. The decision to perform a fetal intervention requires careful patient selection, as well as a multidisciplinary center that is dedicated to the surgical care of the fetus and the mother. Patient selection is dependent in part on highly accurate prenatal imaging that includes US and MRI. Significant risks may be associated with the performance of a fetal surgical procedure, to both the mother and the fetus. From the maternal viewpoint, open fetal surgery may lead to uterine bleeding due to the uterine relaxation required during the procedure. The long-term effects on subsequent pregnancies remain to be established. For the fetus, in utero surgery carries the risk of premature labor and amniotic fluid leak. As a result, these procedures are performed only when the expected benefit of fetal intervention outweighs the risk to the fetus of standard postnatal care. Currently, open fetal intervention may be efficacious in certain instances of large congenital lung lesions with hydrops, large teratomas with hydrops, twin-twin transfusion syndrome, certain cases of congenital lower urinary tract obstruction, and *myelomeningocele*. This list of potential diagnoses that may benefit from a fetal intervention is significantly shorter than that of a decade ago, due in part to improvements in outcome of several diseases that are managed in the postnatal period, as well as the recognition of the relative lack of benefit of fetal surgery for many conditions.

Fetal Surgery for Lower Urinary Tract Obstruction

Lower urinary tract obstruction refers to a group of diseases characterized by obstruction of the distal urinary system. Common causes include the presence of posterior urethral valves and urethral atresia, as well as other anomalies of the urethra and bladder. The pathologic effects of lower urinary tract obstruction lie in the resultant massive bladder distention that occurs, which can lead to reflux hydronephrosis. This may result in oligohydramnios and cause limb contractures, facial anomalies (Potter sequence), and pulmonary hypoplasia. Carefully selected patients with lower urinary tract obstruction may benefit from vesicoamniotic shunting. By relieving the obstruction and improving renal function, fetal growth and lung development may be preserved.

Fetal Surgery for Congenital Diaphragmatic Hernia

Given the high mortality associated with the most severe cases of CDH, tremendous efforts have been undertaken to determine whether fetal intervention could improve the outcome of this disease. In 1990, Harrison and colleagues reported the first open fetal repair for CDH. The high morbidity of the open technique led to the development of fetal tracheal occlusion as a therapeutic approach. This was based on the observation that tracheal occlusion could lead to increased lung growth and reduction of the intrathoracic viscera in animal models. Tracheal occlusion can be achieved in utero by placement of clips that are removed at the time of delivery. Despite initial enthusiasm for this approach, a recent randomized trial that compared fetal tracheal occlusion with standard postnatal care for left-sided CDH showed no improvement in survival for patients treated with tracheal occlusion.

Fetal Surgery for Myelomeningocele

Myelomeningocele refers to a spectrum of anomalies in which portions of the spinal cord are uncovered by the spinal column. This leaves the neural tissue exposed to the injurious effects of the amniotic fluid, as well as to trauma from contact with the uterine wall. Nerve damage ensues, resulting in varying degrees of lower extremity paralysis as well as bowel and bladder dysfunction. Initial observations indicated that the extent of injury progressed throughout the pregnancy, which provided the rationale for fetal intervention. The current in utero approach for the fetus with myelomeningocele has focused on obtaining coverage of the exposed spinal cord. The efficacy of in utero treatment vs. postnatal repair was recently compared in a large multicenter trial and showed that prenatal surgery for myelomeningocele reduced the need for shunting and improved motor outcomes at 30 months but was associated with maternal and fetal risks. The results of this study have paved the way for the acceptance of in utero repair of myelomeningocele in certain centers with the experience and expertise to perform this procedure safely.

The EXIT Procedure

The EXIT procedure is an abbreviation for *ex utero intrapartum treatment*. It is used in circumstances where airway obstruction is predicted at the time of delivery, due to the presence of a large neck mass, such as a cystic hygroma or teratoma (Fig. 39-43), or congenital tracheal stenosis. The success of the procedure is dependent on the maintenance of utero-placental perfusion for

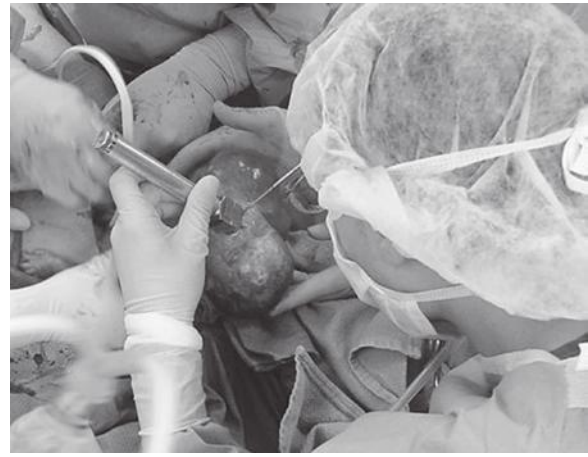

Figure 39-43. The EXIT procedure (ex utero intrapartum treatment) in a 34-week gestation age baby with a large cervical teratoma. Intubation is being performed while the fetus is on placental support.

a sufficient duration to secure the airway. To achieve this, deep uterine relaxation is obtained during a cesarean section under general anesthesia. Uterine perfusion with warmed saline also promotes relaxation and blood flow to the placenta. On average, between 20 and 30 minutes of placental perfusion can be achieved. The fetal airway is secured either by placement of an orotracheal tube or performance of a tracheostomy. Once the airway is secured, the cord is cut and a definitive procedure may be performed to relieve the obstruction in the postnatal period. In general terms, cystic neck masses such as lymphangiomas have a more favorable response to an EXIT procedure as compared to solid tumors, such as teratomas, particularly in premature infants.

BIBLIOGRAPHY

Entries highlighted in bright blue are key references.

- Adzick NS, Thom EA, Spong CY, et al. A randomized trial of prenatal versus postnatal repair of myelomeningocele. *N Engl J Med.* 2011;364:993.
- Ahuja AT, King AD, King W, et al. Thyroglossal duct cysts: sonographic appearances in adults. *AJNR Am J Neuroradiol.* 1999;20:579.
- American Academy of Pediatrics Section on Orthopaedics. Management of pediatric trauma. *Pediatrics.* 2008;121:849-854.
- Andersen B, Kallehave F, Anderson H. Antibiotics versus placebo for prevention of postoperative infection after appendectomy. *Cochrane Database Syst Rev.* 2005;2:CD001439.
- Anderson KD, Rouse TM, Randolph J. A controlled trial of corticosteroids in children with corrosive injury of the esophagus. *N Engl J Med.* 1990;323:637.
- Azarow K, Messineo A, Pearl R, et al. Congenital diaphragmatic hernia—a tale of two cities: the Toronto experience. *J Pediatr Surg.* 1997;32:395.
- Ballance WA, Dahms BB, Shenker N, Kliegman RM. Pathology of neonatal necrotizing enterocolitis: a ten-year experience. *J Pediatr.* 1990;117:S6.
- Barraco RD, Cheng JD, Bromberg WJ, et al. Child passenger safety: an evidence-based review. *J Trauma.* 2010;69:1588-1990.
- Barthel ER, Pierce JR, Goodhue CJ, Burke RV, Ford HR, Upperman JS. Can a pediatric trauma center improve the response to a mass casualty incident? *J Trauma Acute Care Surg.* 2012;73:885-889.

- Bell MJ, Ternberg JL, Feigin RD, et al. Neonatal necrotizing enterocolitis. Therapeutic decisions based upon clinical staging. *Ann Surg.* 1978;187:1.
- Billmire D, Vinocur C, Rescorla F, et al. Malignant mediastinal germ cell tumors: an intergroup study. *J Pediatr Surg.* 2001;36:18.
- Bohn D. Congenital diaphragmatic hernia. *Am J Respir Crit Care Med.* 2002;166:911.
- Boloker J, Bateman DA, Wung JT, et al. Congenital diaphragmatic hernia in 120 infants treated consecutively with permissive hypercapnea/spontaneous respiration/elective repair. *J Pediatr Surg.* 2002;37:357.
- Bouchard S, Johnson MP, Flake A, et al. The EXIT procedure: experience and outcome in 31 cases. *J Pediatr Surg.* 2002;37:418.
- Branstetter BF, Weissman JL, Kennedy T, et al. The CT appearance of thyroglossal duct carcinoma. *AJNR Am J Neuroradiol.* 2000;21:1547.
- Bratton S, Annich G. Packed red blood cell transfusions for critically ill pediatric patients: when and for what conditions? *J Pediatr.* 2003;142:95.
- Breneman JC, Lyden E, Pappo A, et al. Prognostic Factors and clinical outcomes in children and adolescents with metastatic rhabdomyosarcoma—a report from the Intergroup Rhabdomyosarcoma Study IV. *J Clin Oncol.* 2003;21:78.
- Brown RL. Epidemiology of injury and the impact of health disparities. *Curr Opin Pediatr.* 2010;22:321-325.
- Bruner JP, Tulipan N, Paschall R, et al. Fetal surgery for myelomeningocele and the incidence of shunt-dependent hydrocephalus. *JAMA.* 1999;282:1819.
- Callaghan WM, MacDorman MF, Rasmussen SA, Qin C, Lackritz EM. The contribution of preterm birth to infant mortality rates in the United States. *Pediatrics.* 2006;118:1566.
- Cassady G, Crouse DT, Kirklind JW, et al. A randomized, controlled trial of very early prophylactic ligation of the ductus arteriosus in babies who weighed 1000 g or less at birth. *N Engl J Med.* 1989;320:1511.
- Chertin B, De Caluwé D, Gajaharan M, et al. Is contralateral exploration necessary in girls with unilateral inguinal hernia? *J Pediatr Surg.* 2003;38:756.
- Choi RS, Vacanti JP. Preliminary studies of tissue-engineered intestine using isolated epithelial organoid units on tubular synthetic biodegradable scaffolds. *Transplant Proc.* 1997;29:848.
- Cikrit D, Mastandrea J, West KW, Schreiner RL, Grosfeld JL. Necrotizing enterocolitis: factors affecting mortality in 101 surgical cases. *Surgery.* 1984;96:648.
- Cohen J, Schanen NC. Branchial cleft anomaly, congenital heart disease, and biliary atresia: Goldenhar complex or Lambert syndrome? *Genet Couns.* 2000;11:153.
- Cohn SL, London WB, Huang D, et al. MYCN expression is not prognostic of adverse outcome in advanced-stage neuroblastoma with nonamplified MYCN. *J Clin Oncol.* 2000;18:3604.
- Collins SR, Griffin MR, Arbogast PG, et al. The rising prevalence of gastroschisis and omphalocele in Tennessee. *J Pediatr Surg.* 2007;42:1221.
- Cook RC, Blinman TA. Nutritional support of the pediatric trauma patient. *Semin Pediatr Surg.* 2010;19:242-251.
- Coppes MJ, Haber DA, Grundy P. Genetic events in the development of Wilms' tumor. *N Engl J Med.* 1994;331:586.
- Cotterill SJ, Pearson ADJ, Pritchard J, et al. Clinical prognostic factors in 1277 patients with neuroblastoma: results of The European Neuroblastoma Study Group 'Survey' 1982-1992. *Eur J Cancer.* 2000;36:901.
- Crystal P, Hertzanu Y, Farber B, et al. Sonographically guided hydrostatic reduction of intussusception in children. *J Clin Ultrasound.* 2002;30:343.
- Darnell CM, Thompson J, Stromberg D, Roy L, Sheeran P. Effect of low-dose naloxone infusion on fentanyl requirements in critically ill children. *Pediatrics.* 2008;121:e1363-e1371.
- Davit-Spraul A, Baussan C, Hermeziu B, et al. CFC1 gene involvement in biliary atresia with polysplenia syndrome. *J Pediatr Gastroenterol Nutr.* 2008;46:111-112.
- DeRusso PA, Ye W, Shepherd R, et al. Growth failure and outcomes in infants with biliary atresia: a report from the Biliary Atresia Research Consortium. *Hepatology.* 2007;46:1632-1638.
- Doné E, Gucciardo L, Van Mieghem T, et al. Prenatal diagnosis, prediction of outcome and in utero therapy of isolated congenital diaphragmatic hernia. *Prenat Diagn.* 2008;28:581-591.
- Dunn J, Fonkalsrud E, Atkinson J. Simplifying the Waterston's stratification of infants with tracheoesophageal fistula. *Am Surg.* 1999;65:908.
- Ein SH, Njere I, Ein A. Six thousand three hundred sixty-one pediatric inguinal hernias: a 35-year review. *J Pediatr Surg.* 2006;41:980-986.
- Evans GS, Flint N, Somers AS, Eyden B, Potten CS. The development of a method for the preparation of rat intestinal epithelial cell primary cultures. *J Cell Sci.* 1992;101(Pt 1):219.
- Ferrari A, Bisogno G, Casanova M, et al. Paratesticular rhabdomyosarcoma: report from the Italian and German Cooperative Group. *J Clin Oncol.* 2002;20:449.
- Fisher JC, Jefferson RA, Arkovitz MS, Stolar CJ. Redefining outcomes in right congenital diaphragmatic hernia. *J Pediatr Surg.* 2008;43:373-379.
- Freedman AL, Johnson MP, Smith C, et al. Long-term outcome in children after antenatal intervention for obstructive uropathies. *Lancet.* 1999;354:374.
- Gajewski JL, Johnson VV, Sandler SG, Sayegh A, Klumpp TR. A review of transfusion practice before, during, and after hematopoietic progenitor cell transplantation. *Blood.* 2008;112:3036.
- Geisler DP, Jegathesan S, Parmley M, et al. Laparoscopic exploration for the clinically undetected hernia in infancy and childhood. *Am J Surg.* 2001;182:693.
- Geneviève D, de Pontual L, Amiel J, Sarnacki S, Lyonnet S. An overview of isolated and syndromic oesophageal atresia. *Clin Genet.* 2007;71:392-399.
- Georgeson K. Results of laparoscopic antireflux procedures in neurologically normal infants and children. *Semin Laparosc Surg.* 2002;9:172.
- Georgeson K. Laparoscopic-assisted pull-through for Hirschsprung's disease. *Semin Pediatr Surg.* 2002;11:205.
- Georgoula C, Gardiner M. Pyloric stenosis 100 years after Ramstedt. *Arch Dis Child.* 2012;97:741-745.
- Gollin GA, Abarbanell AA, Baerg J, et al. Peritoneal drainage as definitive management of intestinal perforation in extremely low-birth-weight infants. *J Pediatr Surg.* 2003;38:1814.
- Gorsler C, Schier F. Laparoscopic herniorrhaphy in children. *Surg Endosc.* 2003;17:571.
- Grant D, Abu-Elmagd K, Reyes J, et al. 2003 report of the intestine transplant registry: a new era has dawned. *Ann Surg.* 2005;241:607.
- Grikscheit TC, Ochoa ER, Ramsanahie A, et al. Tissue-engineered large intestine resembles native colon with appropriate in vitro physiology and architecture. *Ann Surg.* 2003;238:35.
- Grikscheit TC, Siddique A, Ochoa ER, et al. Tissue-engineered small intestine improves recovery after massive small bowel resection. *Ann Surg.* 2004;240:748.
- Gura KM, Lee S, Valim C, et al. Safety and efficacy of a fish-oil-based fat emulsion in the treatment of parenteral nutrition-associated liver disease. *Pediatrics.* 2008;121:e678-e686.
- Guthrie S, Gordon P, Thomas V, et al. Necrotizing enterocolitis among neonates in the United States. *J Perinatol.* 2003;23:278.
- Hackam DJ, Filler R, Pearl R. Enterocolitis after the surgical treatment of Hirschsprung's disease: risk factors and financial impact. *J Pediatr Surg.* 1998;33:830.

- Hackam DJ, Potoka D, Meza M, et al. Utility of radiographic hepatic injury grade in predicting outcome for children after blunt abdominal trauma. *J Pediatr Surg.* 2002;37:386.
- Hackam DJ, Reblock K, Barksdale E, et al. The influence of Down's syndrome on the management and outcome of children with Hirschsprung's disease. *J Pediatr Surg.* 2003;38:946.
- Hackam DJ, Superina R, Pearl R, et al. Single-stage repair of Hirschsprung's disease: a comparison of 109 patients over 5 years. *J Pediatr Surg.* 1997;32:1028.
- Hammer CE, Groner JJ, Caniano DA, Hayes JR, Kenney BD. Blunt intraabdominal arterial injury in pediatric trauma patients: injury distribution and markers of outcome. *J Pediatr Surg.* 2008;43:916-923.
- Harrison MR. Fetal surgery: trials, tribulations, and turf. *J Pediatr Surg.* 2003;38:275.
- Harrison MR, Keller RL, Hawgood S, et al. A randomized trial of fetal endoscopic tracheal occlusion for severe fetal congenital diaphragmatic hernia. *N Engl J Med.* 2003;349:1916.
- Harrison MR, Sydorak RM, Farrell J, et al. Fetoscopic temporary tracheal occlusion for congenital diaphragmatic hernia: prelude to a randomized, controlled trial. *J Pediatr Surg.* 2003;38:1012.
- Heath JK. Transcriptional networks and signaling pathways that govern vertebrate intestinal development. *Curr Top Dev Biol.* 2010;90:159-192.
- Hedrick H, Flake A, Crombleholme T, et al. History of fetal diagnosis and therapy: Children's Hospital of Philadelphia experience. *Fetal Diagn Ther.* 2003;18:65.
- Hilton EN, Manson FD, Urquhart JE, et al. Left-sided embryonic expression of the BCL-6 corepressor, BCOR, is required for vertebrate laterality determination. *Hum Mol Genet.* 2007;16:1773-1782.
- Hirschl RB, Philip WF, Glick L, et al. A prospective, randomized pilot trial of perfluorocarbon-induced lung growth in newborns with congenital diaphragmatic hernia. *J Pediatr Surg.* 2003;38:283.
- Huh JW, Raghupathi R. New concepts in treatment of pediatric traumatic brain injury. *Anesthesiol Clin.* 2009;27:213-240.
- Hutchings L, Willett K. Cervical spine clearance in pediatric trauma: a review of current literature. *J Trauma.* 2009;67:687-691.
- Johnigan RH, Pereira KD, Poole MD. Community-acquired methicillin-resistant *Staphylococcus aureus* in children and adolescents: changing trends. *Arch Otolaryngol Head Neck Surg.* 2003;129:1049-1052.
- Johnson MP, Sutton LN, Rintoul N, et al. Fetal myelomeningocele repair: short-term clinical outcomes. *Am J Obstet Gynecol.* 2003;189:482.
- Kalapurakal J, Li S, Breslow N, et al. Influence of radiation therapy delay on abdominal tumor recurrence in patients with favorable histology Wilms' tumor treated on NWTS-3 and NWTS-4: a report from the National Wilms' Tumor Study Group. *Int J Radiat Oncol Biol Phys.* 2003;57:495.
- Kamata S, Ishikawa S, Usui N, et al. Prenatal diagnosis of abdominal wall defects and their prognosis. *J Pediatr Surg.* 1996;31:267.
- Kantarci S, Al-Gazali L, Hill RS, et al. Mutations in LRP2, which encodes the multiligand receptor megalin, cause Donnai-Barrow and facio-oculo-acoustico-renal syndromes. *Nat Genet.* 2007;39:957-959.
- Katzenstein HM, Krailo MD, Malogolowkin M, et al. Hepatocellular carcinoma in children and adolescents: results from the Pediatric Oncology Group and the Children's Cancer Group Intergroup Study. *J Clin Oncol.* 2002;20:2789.
- Kim HB, Fauza D, Garza J, Oh JT, Nurko S, Jaksic T. Serial transverse enteroplasty (STEP): a novel bowel lengthening procedure. *J Pediatr Surg.* 2003;38:425.
- Kim HB, Lee PW, Garza J, et al. Serial transverse enteroplasty for short bowel syndrome: a case report. *J Pediatr Surg.* 2003;38:881.
- Kliegman RM. Models of the pathogenesis of necrotizing enterocolitis. *J Pediatr.* 1990;117:S2.
- Kliegman RM, Fanaroff AA. Necrotizing enterocolitis. *N Engl J Med.* 1984;310:1093.
- Konkin D, O'hali W, Webber E, et al. Outcomes in esophageal atresia and tracheoesophageal fistula. *J Pediatr Surg.* 2003;38:1726.
- Kosloske AM. Operative techniques for the treatment of neonatal necrotizing enterocolitis. *Surg Gynecol Obstet.* 1979;149:740.
- Kosloske AM. Indications for operation in necrotizing enterocolitis revisited. *J Pediatr Surg.* 1994;29:663.
- Kosloske AM, Lilly JR. Paracentesis and lavage for diagnosis of intestinal gangrene in neonatal necrotizing enterocolitis. *J Pediatr Surg.* 1978;13:315.
- Langer J, Durrant A, de la Torre L, et al. One-stage transanal Soave pullthrough for Hirschsprung disease: a multicenter experience with 141 children. *Ann Surg.* 2003;238:569.
- Levitt MA, Ferraraccio D, Arbesman M, et al. Variability of inguinal hernia surgical technique: a survey of North American pediatric surgeons. *J Pediatr Surg.* 2002;37:745.
- Lille ST, Rand RP, Tapper D, Gruss JS. The surgical management of giant cervicofacial lymphatic malformations. *J Pediatr Surg.* 1996;31:1648-1650.
- Limmer J, Gortner L, Kelsch G, Schutze F, Berger D. Diagnosis and treatment of necrotizing enterocolitis. A retrospective evaluation of abdominal paracentesis and continuous postoperative lavage. *Acta Paediatr Suppl.* 1994;396:65.
- Lintula H, Kokki H, Vanamo K. Single-blind randomized clinical trial of laparoscopic versus open appendectomy in children. *Br J Surg.* 2001;88:510.
- Lipshutz G, Albanese C, Feldstein V, et al. Prospective analysis of lung-to-head ratio predicts survival for patients with prenatally diagnosed congenital diaphragmatic hernia. *J Pediatr Surg.* 1997;32:1634.
- Little D, Rescorla F, Grosfeld J, et al. Long-term analysis of children with esophageal atresia and tracheoesophageal fistula. *J Pediatr Surg.* 2003;38:852.
- Loeb DM, Thornton K, Shokek O. Pediatric soft tissue sarcomas. *Surg Clin North Am.* 2008;88:615-627.
- Luig M, Lui K. Epidemiology of necrotizing enterocolitis—Part I: changing regional trends in extremely preterm infants over 14 years. *J Paediatr Child Health.* 2005;41:169.
- Lynch L, O'Donoghue D, Dean J, O'Sullivan J, O'Farrelly C, Golden-Mason L. Detection and characterization of hemopoietic stem cells in the adult human small intestine. *J Immunol.* 2006;176:5199.
- Mallick IH, Yang W, Winslet MC, Seifalian AM. Ischemia-reperfusion injury of the intestine and protective strategies against injury. *Dig Dis Sci.* 2004;49:1359.
- Marianowski R, Ait Amer JL, Morisseau-Durand MP, et al. Risk factors for thyroglossal duct remnants after Sistrunk procedure in a pediatric population. *Int J Pediatr Otorhinolaryngol.* 2003;67:19.
- Maris JM, Weiss MJ, Guo C, et al. Loss of heterozygosity at 1p36 independently predicts for disease progression but not decreased overall survival probability in neuroblastoma patients: a Children's Cancer Group Study. *J Clin Oncol.* 2000;18:1888.
- Martinez-Tallo E, Claire N, Bancalari E. Necrotizing enterocolitis in full-term or near-term infants: risk factors. *Biol Neonate.* 1997;71:292.
- Meyers RL, Book LS, O'Gorman M, et al. High-dose steroids, ursodeoxycholic acid, and chronic intravenous antibiotics improve bile flow after Kasai procedure in infants with biliary atresia. *J Pediatr Surg.* 2003;38:406.
- Miyano T, Yamataka A, Kato Y, et al. Hepaticoenterostomy after excision of choledochal cyst in children: a 30-year experience with 180 cases. *J Pediatr Surg.* 1996;31:1417.

- Molik KA, West KW, Rescorla F, et al. Portal venous air: the poor prognosis persists. *J Pediatr Surg*. 2001;36:1143.
- Moss R, Dimmitt R, Henry M, et al. A meta-analysis of peritoneal drainage versus laparotomy for perforated necrotizing enterocolitis. *J Pediatr Surg*. 2001;36:1210.
- Moss RL, Das JB, Raffensperger JG. Necrotizing enterocolitis and total parenteral nutrition-associated cholestasis. *Nutrition*. 1996;12:340.
- Moyer V, Moya F, Tibboel F, et al. Late versus early surgical correction for congenital diaphragmatic hernia in newborn infants. *Cochrane Database Syst Rev*. 2002;CD001695.
- Nadler E, Stanford A, Zhang X, et al. Intestinal cytokine gene expression in infants with acute necrotizing enterocolitis: interleukin-11 mRNA expression inversely correlates with extent of disease. *J Pediatr Surg*. 2001;36:1122.
- Neville HL, Andrassy RJ, Lally K, et al. Lymphatic mapping with sentinel node biopsy in pediatric patients. *J Pediatr Surg*. 2000;35:961.
- Nio M, Ohi R, Miyano T, et al. Five- and 10-year survival rates after surgery for biliary atresia: a report from the Japanese Biliary Atresia Registry. *J Pediatr Surg*. 2003;38:997.
- O'Donovan DJ, Baetiong A, Adams K, et al. Necrotizing enterocolitis and gastrointestinal complications after indomethacin therapy and surgical ligation in premature infants with patent ductus arteriosus. *J Perinatol*. 2003;23:286.
- Olutoye OO, Coleman BG, Hubbard A, et al. Prenatal diagnosis and management of congenital lobar emphysema. *J Pediatr Surg*. 2000;35:792.
- Ortega JA, Douglass EC, Feusner J, et al. Randomized comparison of cisplatin/vincristine/fluorouracil and cisplatin/continuous infusion doxorubicin for treatment of pediatric hepatoblastoma: a report from the Children's Cancer Group and the Pediatric Oncology Group. *J Clin Oncol*. 2000;18:2665.
- Pandya S, Heiss K. Pyloric stenosis in pediatric surgery: an evidence-based review. *Surg Clin North Am*. 2012;92:527-539, vii-vii.
- Panesar J, Higgins K, Daya H, et al. Nontuberculous mycobacterial cervical adenitis: a ten-year retrospective review. *Laryngoscope*. 2003;113:149.
- Pedersen A, Petersen O, Wara P, et al. Randomized clinical trial of laparoscopic versus open appendectomy. *Br J Surg*. 2001;88:200.
- Pena A, Guardino K, Tovilla J, et al. Bowel management for fecal incontinence in patients with anorectal malformations. *J Pediatr Surg*. 1998;33:133.**
- Poenaru D, Laberge J, Neilson IR, et al. A new prognostic classification for esophageal atresia. *Surgery*. 1993;113:426.
- Potoka D, Schall L, Ford H. Improved functional outcome for severely injured children treated at pediatric trauma centers. *J Trauma*. 2001;51:824.
- Potoka DA, Schall LC, Ford H. Risk factors for splenectomy in children with blunt splenic trauma. *J Pediatr Surg*. 2002;37:294.
- Powers CJ, Levitt MA, Tantoco J, et al. The respiratory advantage of laparoscopic Nissen fundoplication. *J Pediatr Surg*. 2003;38:886.
- Pritchard-Jones K. Controversies and advances in the management of Wilms' tumour. *Arch Dis Child*. 2002;87:241.
- Puapong D, Kahng D, Ko A, et al. Ad libitum feeding: safely improving the cost-effectiveness of pyloromyotomy. *J Pediatr Surg*. 2002;37:1667.
- Quinton AE, Smolencic JS. Congenital lobar emphysema—the disappearing chest mass: antenatal ultrasound appearance. *Ultrasound Obstet Gynecol*. 2001;17:169.
- Reyes J, Bueno J, Kocoshis S, et al. Current status of intestinal transplantation in children. *J Pediatr Surg*. 1998;33:243.
- Rosen NG, Hong AR, Soffer S, et al. Rectovaginal fistula: a common diagnostic error with significant consequences in girls with anorectal malformations. *J Pediatr Surg*. 2002;37:961.
- Rothenberg S. Laparoscopic Nissen procedure in children. *Semin Laparosc Surg*. 2002;9:146.
- Rothenberg SS. Thoracoscopic pulmonary surgery. *Semin Pediatr Surg*. 2007;16:231-237.
- Samuel M, McCarthy L, Boddy S. Efficacy and safety of OK-432 sclerotherapy for giant cystic hygroma in a newborn. *Fetal Diagn Ther*. 2000;15:93.
- Sandler A, Ein S, Connolly B, et al. Unsuccessful air-enema reduction of intussusception: is a second attempt worthwhile? *Pediatr Surg Int*. 1999;15:214.
- Sarioglu A, McGahren ED, Rodgers BM. Effects of carotid artery repair following neonatal extracorporeal membrane oxygenation. *Pediatr Surg Int*. 2000;16:15-18.
- Schier F, Montupet P, Esposito C. Laparoscopic inguinal herniorrhaphy in children: a three-center experience with 933 repairs. *J Pediatr Surg*. 2002;37:395.
- Schonfeld D, Lee LK. Blunt abdominal trauma in children. *Curr Opin Pediatr*. 2012;24:314-318.
- Section on Hematology/Oncology. Guidelines for the pediatric cancer center and role of such centers in diagnosis and treatment. *Pediatrics*. 1997;99:139.
- Shamberger R, Guthrie K, Ritchey M, et al. Surgery-related factors and local recurrence of Wilms tumor in National Wilms Tumor Study 4. *Ann Surg*. 1999;229:292.
- Shimada H, Ambros I, Dehner L, et al. The International Neuroblastoma Pathology Classification (the Shimada system). *Cancer*. 1999;86:364.**
- Shivakumar P, Campbell KM, Sabla GE, et al. Obstruction of extrahepatic bile ducts by lymphocytes is regulated by IFN-gamma in experimental biliary atresia. *J Clin Invest*. 2004;114:322-329.
- Simons SHP, van Dijk M, van Lingen R, et al. Routine morphine infusion in preterm newborns who received ventilatory support: a randomized controlled trial. *JAMA*. 2003;290:2419.
- Soffer SZ, Rosen NG, Hong AR, et al. Cloacal exstrophy: a unified management plan. *J Pediatr Surg*. 2000;35:932.
- Spitz L, Kiely E, Morecroft J, et al. Oesophageal atresia: at-risk groups for the 1990s. *J Pediatr Surg*. 1994;29:723.**
- Strauss RA, Balu R, Kuller J, et al. Gastroschisis: the effect of labor and ruptured membranes on neonatal outcome. *Am J Obstet Gynecol*. 2003;189:1672.
- Sun L, Rommens JM, Corvol H, et al. Multiple apical plasma membrane constituents are associated with susceptibility to meconium ileus in individuals with cystic fibrosis. *Nat Genet*. 2012;44:562-569.
- Suzuki N, Tsuchida Y, Takahashi A, et al. Prenatally diagnosed cystic lymphangioma in infants. *J Pediatr Surg*. 1998;33:1599.
- Teich S, Barton D, Ginn-Pease M, et al. Prognostic classification for esophageal atresia and tracheoesophageal fistula: Waterston versus Montreal. *J Pediatr Surg*. 1997;32:1075.
- Teitelbaum D, Coran A. Reoperative surgery for Hirschsprung's disease. *Semin Pediatr Surg*. 2003;12:124.
- Thibeault DW, Olsen SL, Truog W, et al. Pre-ECMO predictors of nonsurvival in congenital diaphragmatic hernia. *J Perinatol*. 2002;22:682.**
- Tolia V, Wureth A, Thomas R. Gastroesophageal reflux disease: review of presenting symptoms, evaluation, management, and outcome in infants. *Dig Dis Sci*. 2003;48:1723.
- Tsao K, St Peter SD, Sharp SW, et al. Current application of thoracoscopy in children. *J Laparoendosc Adv Surg Tech A*. 2008;18:131-135.
- Tulipan N, Sutton L, Bruner J, et al. The effect of intrauterine myelomeningocele repair on the incidence of shunt-dependent hydrocephalus. *Pediatr Neurosurg*. 2003;38:27.
- Vargas JV, Vlassov D, Colman D, Brioschi ML. A thermodynamic model to predict the thermal response of living beings during pneumoperitoneum procedures. *J Med Eng Technol*. 2005;29:75-81.

- Variations in incidence of necrotizing enterocolitis in Canadian neonatal intensive care units. *J Pediatr Gastroenterol Nutr.* 2004;39:366.
- Wang KS, Shaul DB. Two-stage laparoscopic orchidopexy with gubernacular preservation: preliminary report of a new approach to the intraabdominal testis. *J Pediatr Endosurg Innovative Tech.* 2004;8:252-255.
- Wenzler D, Bloom D, Park J. What is the rate of spontaneous testicular descent in infants with cryptorchidism? *J Urol.* 2004;171:849.
- Wildhaber B, Coran A, Drongowski R, et al. The Kasai portoenterostomy for biliary atresia: a review of a 27-year experience with 81 patients. *J Pediatr Surg.* 2003;38:1480.
- Wood JH, Partrick DA, Johnston RB Jr. The inflammatory response to injury in children. *Curr Opin Pediatr.* 2010;22:315-320.
- Yang EY, Allmendinger N, Johnson SM, Chen C, Wilson JM, Fishman SJ. Neonatal thoracoscopic repair of congenital diaphragmatic hernia: selection criteria for successful outcome. *J Pediatr Surg.* 2005;40:1369-1375.

This page intentionally left blank

40 chapter

Urology

Karim Chamie, Jeffrey La Rochelle,
Brian Shuch, and Arie S. Belldegrun

Anatomy	1651	Urethra / 1660	Lower Urinary Tract	
Kidney and Adrenal / 1651		Testes / 1660	Obstruction	1665
Ureter / 1652		Penis / 1661	Benign Prostatic Hyperplasia / 1665	
Bladder and Prostate / 1652		Emergencies	Urethral Stricture / 1665	
Penis / 1652		1661	Upper Urinary Tract	
Scrotum and Testes / 1653		Acute Urinary Retention / 1661	Obstruction	1665
Urologic Malignancies	1653	Testicular Torsion / 1662	Urolithiasis / 1666	
Bladder Cancer / 1653		Fournier's Gangrene / 1663	Retroperitoneal Fibrosis / 1666	
Testicular Cancer / 1654		Priapism / 1663	Pediatric Urology	1667
Kidney Cancer / 1655		Paraphimosis / 1664	Ureteropelvic Junction	
Prostate Cancer / 1657		Empysematous Pyelonephritis / 1664	Obstruction / 1667	
Trauma	1658	Infections	Vesicoureteral Reflux / 1667	
Kidney / 1658		Cystitis / 1664	Ureterocele / 1667	
Ureter / 1659		Pyelonephritis / 1664	Posterior Urethral Valve / 1667	
Bladder / 1660		Prostatitis / 1664		
		Epididymo-orchitis / 1665		

ANATOMY

The anatomic structures that fall under the purview of genitourinary surgery are the adrenals, kidneys, ureters, bladder, prostate, seminal vesicles, urethra, vas deferens, penis, and testes. Some of these structures are situated outside the peritoneum, but urologic surgery frequently involves intraperitoneal approaches to the kidney, bladder, and retroperitoneal lymph nodes. Furthermore, urologists must be familiar with the techniques of intestinal surgery for the purposes of urinary diversion and bladder augmentation.

Kidney and Adrenal

The kidneys are paired retroperitoneal organs that are invested in a fibro-fatty layer: fascia of Zuckerkandl posteriorly and Gerota's fascia anteriorly. Posterolaterally, the kidneys are bordered by the quadratus lumborum and posteromedially by the psoas muscle. Anteriorly, they are confined by the posterior layer of the peritoneum. On the left, the spleen lies superolaterally, separated from the kidney and Gerota's fascia by the peritoneum. On the right, the liver is situated superiorly and anteriorly and also is separated by the peritoneum. The second portion of the duodenum is in close proximity to the right renal vessels, and during right renal surgery, it must be reflected anteromedially (Kocherized) to achieve vascular control. The renal arteries, in the typical configuration, are single vessels extending from the aorta that branch into several segmental arteries before entering the renal sinus. The right renal artery passes posterior to the vena cava and is significantly longer than the left renal artery. Occasionally, the kidney is supplied by a second renal artery, an accessory renal artery, typically to the lower pole. Within

the kidney, there is essentially no anastomotic arterial flow, so the kidneys are prone to infarction when branch vessels are interrupted. The renal veins, which course anteriorly to the renal arteries, drain directly into the vena cava. The left renal vein passes anterior to the aorta and is much longer than the right renal vein. This explains why most surgeons prefer to take the left kidney for living donor transplantation. The left vein is in continuity with the left gonadal vein, the left inferior adrenal vein, and a lumbar vein. These veins provide adequate drainage for the left kidney in the event that drainage to the vena cava is interrupted. The right renal vein has no such collateral venous drainage.

The collecting system of the kidney is composed of several major and minor calyces that coalesce into the renal pelvis. The renal pelvis can have either a mainly intrarenal or extrarenal position. The renal pelvis tapers into the ureteropelvic junction (UPJ) where it joins with the ureter.

The adrenal glands lie superomedially to the kidneys within Gerota's fascia. There is a layer of Gerota's fascia between the adrenal and the kidney. However, in the presence of a tumor or inflammatory process, the adrenal can become very adherent to the kidney, and separation can be difficult. The arterial supply of the adrenals derives from the inferior phrenic, aorta, and small branches from the renal arteries. The venous drainage on the left is mainly through the inferior phrenic vein and through the left renal vein via the inferior adrenal vein. On the right, the adrenal is drained by a very short (<1 cm) vein to the vena cava. It can be avulsed by moderate traction and can be the source of troublesome bleeding.

Key Points

- 1▶ In the surgical treatment of invasive bladder cancer, a thorough lymph node dissection is essential.
- 2▶ Patients with testicular cancer without radiographic evidence of metastasis often harbor microscopic occult deposits of disease and require either adjuvant treatment or very close surveillance.
- 3▶ Partial nephrectomy is the mainstay of treatment for small renal masses, whereas radical nephrectomy provides a survival benefit in the setting of metastatic disease.
- 4▶ The vast majority of renal trauma can be treated conservatively, with early surgical intervention reserved for persistent bleeding, renal vascular, or ureteral injuries.
- 5▶ Distal ureteral injuries should only be treated with uretero-neocystostomy (bladder reimplantation) because of the high failure rate of distal uretero-ureterostomies.
- 6▶ Extraperitoneal bladder ruptures can be treated conservatively, but intraperitoneal ruptures typically require surgical repair.
- 7▶ Nearly all episodes of acute urinary retention can be treated with conservative measures such as decreasing narcotic usage and increasing ambulation.
- 8▶ Testicular torsion is an emergency where successful testicular salvage is inversely related to the delay in repair, so cases with a high degree of clinical suspicion should not wait for a radiologic diagnosis.
- 9▶ Fournier's gangrene is a potentially lethal condition that requires aggressive débridement and close follow-up due to the frequent need for repeat débridement.
- 10▶ Most small ureteral calculi will pass spontaneously or with the use of medical expulsive therapy, but larger stones (>6 mm) are better treated with ureteral stenting or lithotripsy.

Ureter

The ureters are muscular structures that course anterior to the psoas muscles from the renal pelvis to the bladder. The blood supply of the proximal ureter derives from the aorta and renal artery and comes mainly from the medial direction. However, once it crosses the iliac vessels at the pelvic brim near where the iliac vessels bifurcate, it derives its blood supply laterally from branches from the iliac arteries. The blood supply has implications for managing ureteral injuries. Mobilizing the distal ureter for anastomosis requires releasing its lateral attachments, which results in ischemia, so for this reason, distal ureteral injuries are typically managed by anastomosing the proximal ureter to the bladder.

The ureters course along the pelvic sidewall and pass under the uterine arteries in women, making them vulnerable to injury during hysterectomy, especially in the context of pelvic bleeding. They enter the bladder at the lateral aspect of the base. They course through the bladder musculature at an oblique angle and open into the bladder at the ureteral orifices that are relatively close to the bladder outlet.

Bladder and Prostate

The urinary bladder is situated in the retropubic space in an extraperitoneal position. A portion of the bladder dome is adjacent to the peritoneum, so ruptures at this point can result in intraperitoneal urine leakage. The anatomic relations of the bladder are dependent on the degree of filling. A very distended bladder can project above the umbilicus. At physiologic volumes (200–400 mL), the bladder projects modestly into the abdomen. The sigmoid colon lies superolaterally and may become adherent or fistulize to the bladder secondary to diverticulitis. The rectum lies posterior to the bladder in males, whereas the vagina and uterus are posterior in females.

In males, the prostate is in continuity with the bladder neck, and the urethra courses through it. The prostate has a significant component of smooth muscle and can provide urinary continence even in the absence of the external striated sphincter. The puboprostatic ligaments connect the prostate to the pubic

symphysis, and pelvic fractures often result in proximal urethral injuries due to the traction that these ligaments provide. Between the prostate and the rectum lies Denonvilliers' fascia, which is the main anatomic barrier that prevents prostate cancer from regularly penetrating into the rectum. Just beyond the apex of the prostate is the external (voluntary) sphincter, which is part of the genitourinary diaphragm.

Penis

The penis is composed of three main bodies, along with fascia, neurovascular structures, and skin. The corpora cavernosum are the paired, cylinder-like structures that are the main erectile bodies of the penis. Proximally, they lie along the medial aspects of the inferior pubic rami in the perineum. Distally, they fuse along their medial aspects and form the pendulous penis. The corpora cavernosum consist of a tough outer layer called the *tunica albuginea* and spongy, sinusoidal tissue inside that fills with blood to result in erection. The two corpora cavernosum have numerous vascular interconnections, so they function as one compartment. The cavernosal arteries, which are branches of the penile artery, course through the center of the corporal sinusoidal tissue. The sinusoidal tissue is innervated by the cavernosal nerves, which are autonomic nerves that originate in the hypogastric plexus and play a critical role in erection. Before entering the penis, the cavernosal nerves travel immediately adjacent to the prostate, which explains why they often are damaged at radical prostatectomy. Injury or excess traction of these nerves may cause erectile dysfunction. On the underside of the penis lies the corpus spongiosum, which surrounds the urethra. The spongiosum does not have the same tunical layers as the corpora cavernosum, so it does not exhibit the same firmness during erection. The tip of the penis, called the glans, is in continuity with the corpus spongiosum. This highlights the point that when men develop priapism—persistent erection for greater than 4 hours unrelated to sexual stimulation—the two corpora cavernosum remain rigid while the glans (derived from the corpora spongiosum) can be soft.

Surrounding all three bodies of the penis are the outer dartos fascia and the inner Buck's fascia. The dorsal nerves of the penis, which provide sensation to the penile skin, derive from the pudendal nerves and, along with the dorsal penile arteries, travel along the dorsum of the penis within Buck's fascia. The neurovascular bundle of the penis must be avoided during surgical exploration of the penis for injuries or reconstruction, as injury may result in permanent erectile and/or ejaculatory dysfunction.

Scrotum and Testes

The scrotum is a capacious structure that contains the testes and epididymes. Because of its dependent position, significant edema can develop when a patient is fluid overloaded. Additionally, since the scrotum is capacious, any significant bleeding will result in the accumulation of large hematomas—even as large as a basketball. Beneath the skin, from superficial to deep, are the dartos, external spermatic, cremasteric, and internal spermatic fascias. These layers are not always distinct. Beneath the internal fascia are the parietal and visceral layers of the tunica vaginalis, between which hydroceles form. The visceral layer of the tunica vaginalis is adherent to the testis. The noncompliant outer testis layer is the tunica albuginea. Inside the tunica are the seminiferous tubules. The blood supply enters the testis at the superior pole by way of the spermatic cord. In addition to the vas deferens, the cord carries three separate sources of arterial blood flow—the testicular artery that arises from the aorta below the renal artery, the cremasteric artery, and the deferential artery. Interruption of one of the arteries during vasectomy or inguinal surgery will not result in ischemia to the testis. Some children are born with an undescended abdominal testicle. Often, it is difficult to derive enough length to place the testicles in the scrotum. In these instances, the testicular artery is ligated as a first-stage operation, and the testicle is then delivered into the scrotum as a second-stage procedure (i.e., Fowler-Stephens orchiopexy). Most of these testicles remain viable as a result of collaterals. However, if a patient has undergone a prior Fowler-Stephens procedure, any manipulation of the collaterals during inguinal surgery may compromise the testicle. Venous drainage parallels the arterial inflow except that the left gonadal vein drains into the renal vein rather than the vena cava. Dilation of spermatic veins is called a *varicocele* and may be palpable when a patient is standing or with Valsalva. They do not need to be treated unless they cause discomfort, are discovered on infertility workup, or are found in children.

UROLOGIC MALIGNANCIES

Bladder Cancer

The most common form of bladder cancer in the United States is urothelial carcinoma. Tobacco use is the most frequent risk factor, followed by occupational exposure to various carcinogenic materials such as automobile exhaust or industrial solvents. However, many patients develop bladder cancer without any identifiable risks.¹ Other forms of bladder cancer, such as adenocarcinoma and squamous cell carcinoma, occur in distinct patient populations. Patients with chronic irritation from catheters, bladder stones, or schistosomiasis infection are at risk for the squamous cell variant, whereas those with urachal remnants or bladder exstrophy have an increased risk of adenocarcinoma. However, the aforementioned variant histology should not be confused with urothelial carcinoma with variant transformation.

Bladder cancer can be categorized into invasive and non-invasive types. Management of urothelial carcinoma varies greatly, depending on the depth of invasion. A complete transurethral resection of the bladder tumor, which allows for staging of the tumor, is the first step. The tumor should be completely removed, if possible, along with a sampling of the muscular bladder wall underlying the tumor. An exam under anesthesia should be performed for all patients with newly diagnosed bladder tumors. The exam under anesthesia can help determine clinical staging and whether there is fixation of the bladder to adjacent structures. Radiologic imaging of most bladder tumors is of limited benefit in determining the presence, grade, or size/stage of a bladder tumor. However, in the presence of a known bladder tumor, unilateral or bilateral hydronephrosis is an ominous sign of locally advanced disease (at least muscle-invasive bladder cancer).² Computed tomography (CT) scans do provide valuable information regarding metastatic involvement of pelvic lymph nodes, liver, or lung. Historically, 25% of patients with preoperative CT scans demonstrating no evidence of lymphatic spread will actually have lymph node involvement during radical cystectomy and pelvic lymphadenectomy. The utility of a positron emission tomography (PET)-CT scan has emerged as an important imaging modality to minimize this rate to 5% to 10%. For patients who have disease invading into bladder muscle (T2), immediate (within 3 months of diagnosis) cystectomy with extended lymph node dissection offers the best chance of survival. Additionally, surgeons should send lymph node specimens in separate packets and not en bloc in an effort to increase nodal yield. Current long-term cure for those presenting with clinically localized disease has not significantly changed over the last two decades.³ The addition of neoadjuvant or adjuvant chemotherapy in those without discernible metastatic spread is gaining increasing acceptance and does provide a survival benefit.⁴ Patients with limited lymph node involvement may be cured with surgery alone, but those with extensive lymph node involvement have a dismal prognosis.

Patients have multiple reconstructive options, including continent and noncontinent urinary diversions. The orthotopic neobladder has emerged as a popular urinary diversion for patients without urethral involvement. This diversion type involves the detubularization of a segment of bowel, typically distal ileum, which is then refashioned into a pouch that is anastomosed to the proximal urethra (neobladder) or to the skin (continent cutaneous diversion). Detubularization decreases intrapouch filling pressure, which improves urinary storage capacity. In the case of a neobladder, the external sphincter is still intact, and voiding is achieved through sphincteric relaxation and a Valsalva maneuver. In the case of the continent cutaneous diversion, patients attain continence by utilizing a bowel segment (appendix or tapered small bowel) that has a high length-to-lumen ratio. The most common diversion is noncontinent, the ileal conduit, whereby a segment of distal ileum is isolated with one end brought out through the abdominal wall as a urostomy. Ileal conduits are preferred for renal insufficiency because urine is not “stored” and therefore has less time in contact with the absorptive surface of the ileal segment. Conduits are also used when the bladder is unresectable, but urinary diversion is necessary due to intractable bleeding, severe voiding pain, and hydronephrosis. Each segment of bowel that is used offers its own advantages and inherent complications.

Patients with non-muscle-invasive bladder cancer (confined to the bladder mucosa or submucosa) can be managed

with transurethral resection alone and adjuvant intravesical (instilled into the bladder) chemotherapy/immunotherapy. The use of these intravesical agents is critical since patients with non-muscle-invasive bladder cancer are at risk for tumor recurrence and progression. Tumor grade is extremely important in assessing the risk of disease progression. Those patients with high-grade disease or recurrent tumors can be treated with intravesical agents such as bacille Calmette-Guérin or mitomycin C. These agents decrease risk of progression and recurrence, by induction of an effective immunologic antitumor response in the case of bacille Calmette-Guérin and through direct cytotoxicity for mitomycin C. Those patients at high risk of progression who fail conservative therapy should be offered cystectomy. Because upper tract recurrence is fairly common (up to 17% of patients with carcinoma in situ), surveillance must be performed with retrograde pyelograms or CT urograms.

Surgical Approaches and Complications. The typical surgical approach for cystectomy is a lower midline incision from just above the umbilicus to the pubic symphysis. This allows adequate exposure of the pelvic contents, iliac vessels, and lower abdominal cavity. The peritoneum between the median umbilical ligaments (urachal remnant) also is taken with the specimen. In men, the prostate is removed with the bladder. In women, the uterus, ovaries (in postmenopausal women), and anterior wall of the vagina are removed with the bladder. The vagina may be spared, depending on the location and extent of the tumor, but significantly more operative bleeding results. Robotic approaches for cystectomy are increasingly used, but the urinary diversion is still usually performed through an open incision. The benefits of the robotic portion are decreased blood loss during the pelvic dissection (due to pneumoperitoneum) and the shortening of the time that the abdomen is open. However, recent evidence (randomized controlled trials of open versus robot-assisted radical cystectomy) did not demonstrate any difference in oncologic efficacy or complication rates.

Complications of bladder cancer surgery involve bladder perforation during transurethral resection of the bladder tumor, which requires catheter drainage for several days if small (common) or open repair if large and intraperitoneal (rare). Cystectomy and urinary diversion may result in prolonged ileus, bowel obstruction, intestinal anastomotic leak, urine leak, or rectal injury. A urine leak from the ureteroileal anastomoses is a common cause of ileus, intra-abdominal urinoma, abscess formation, and wound dehiscence. Deep venous thrombosis is common after cystectomy⁵ due to the advanced age of most patients, proximity of the iliac veins to the resection and lymph node dissection, and the presence of malignancy. Pulmonary embolism is one of the leading causes of death in the perioperative period after radical cystectomy. The utility of subcutaneous heparin in the perioperative period can minimize the risk of venous thromboembolism.

Testicular Cancer

Testicular cancer is the most common solid malignancy in men age 15 to 35 years.⁶ Most men are diagnosed with an asymptomatic enlarging mass (Fig. 40-1). A major risk for the development of testicular cancer is cryptorchidism. Although the debate continues over whether early surgical intervention to bring an undescended testis into the scrotum alters the future risk of cancer, it is generally accepted that doing so allows much easier monitoring for the development of a testicular mass.

Most neoplasms arise from the germ cells, although non-germ cell tumors arise from Leydig's or Sertoli's cells. The non-germ cell tumors are rare and generally follow a more benign course. Germ

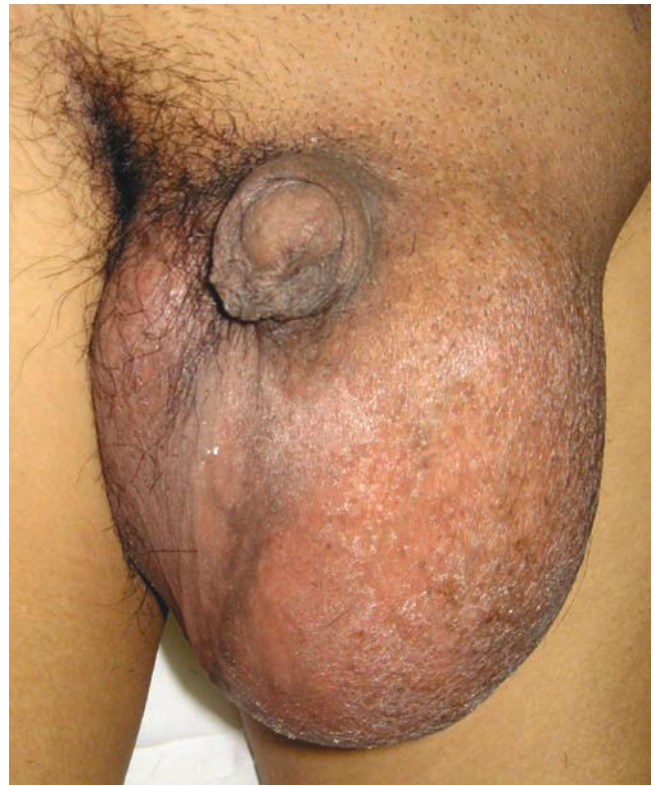


Figure 40-1. Testicular cancer. Patients often present with advanced disease despite scrotal enlargement for several months.

cell cancers are categorically divided into seminomatous and non-seminomatous forms that follow different treatment algorithms.

Since the vast majority of solid testicular masses are cancerous, any observed mass on physical examination and/or documented on ultrasound is malignant until proven otherwise. Initial studies must include tumor markers, including α -fetoprotein, β -human chorionic gonadotropin, and lactate dehydrogenase. Elevated tumor markers are found almost exclusively in nonseminomatous germ cell tumors, although up to 10% of patients with localized seminomas and 25% with metastatic seminomas will have a modest rise in β -human chorionic gonadotropin. Chest and abdominal imaging must be performed to evaluate for evidence of metastasis. The most common site of spread is the retroperitoneal lymph nodes extending from the common iliac vessels to the renal vessels, and abdominal imaging should be performed in all patients. There is no role for percutaneous biopsy of testicular masses due to (a) the risk of seeding the scrotal wall; (b) changing the natural retroperitoneal lymphatic drainage of the testicle (because the testes have a remarkably predictable pattern of lymphatic drainage); and (c) the propensity of a testicular mass being cancerous. In cases where metastatic disease to the testicle is suspected, an open testicular biopsy by delivery of the testicle through the inguinal canal is recommended. Lymphoma (especially among the elderly) may involve one or both testes. Often, evidence of lymphoma usually is present elsewhere in the body, although relapses may be isolated to the testes.

Even in the absence of enlarged lymph nodes on CT imaging (stage I), occult micrometastatic disease is often present (30% of the time), so adjuvant surgery, radiation, or chemotherapy is offered. However, active surveillance protocols **2**▶ have been gaining traction for both seminoma and non-seminomatous tumors. Retroperitoneal lymph node dissection

(RPLND) is potentially curative in the setting of limited lymph node involvement and has been the preferred adjuvant treatment of those with stage I nonseminomatous disease. Alternatively, patients with stage I nonseminomatous tumors can also choose to receive two cycles of chemotherapy. Pure seminoma is exquisitely radiosensitive, and stage I, IIa, and IIb disease can be treated with external-beam radiation to the retroperitoneal nodes. However, a single dose of carboplatin for stage I seminoma was found to be just as effective as radiation therapy. Both forms of germ cell tumors, in the setting of disseminated disease or large bulky lymph nodes, are best treated with four cycles of chemotherapy. However, teratoma frequently is a component of retroperitoneal lymph node metastasis, and it is not responsive to chemotherapy or radiation and can demonstrate aggressive malignant degeneration. Postchemotherapy RPLND for residual masses can be challenging. Large bulky metastases may encase the great vessels, and vascular graft placement after resection occasionally is required.

Surgical Approach and Complications. For orchiectomy, an inguinal incision is made over the external ring and carried laterally over the internal ring. It is important to not violate the scrotal skin during orchiectomy, for fear (mostly theoretical) of altering the lymphatic drainage of the testis. For RPLND, a midline incision usually is made from the xiphoid process to the umbilicus for most patients with stage I disease. If it is in a setting of a postchemotherapy residual mass, the incision is extended down to the pubic symphysis. The use of robotic-assisted RPLND is rarely used for stage I nonseminomatous disease, although with increasing demand for minimally invasive surgery, one would anticipate that it will be the happy compromise for those who wish to avoid a major incision but are not interested in active surveillance or systemic chemotherapy.

Complications of testicular cancer surgery include scrotal hematoma formation, which can be prevented by meticulous hemostasis. Complications after RPLND include bowel obstruction; excessive bleeding, particularly from retrocaval lumbar veins; and chylous ascites. Patients who undergo a full, bilateral RPLND often suffer from ejaculatory dysfunction due to the interruption of the descending postganglionic sympathetic nerve fibers that are involved in seminal emission. For this reason, right and left templates have been developed that limit bilateral dissection (especially below the inferior mesenteric artery) and preserve some of these nerves with a low risk of leaving residual microscopic cancer.⁷

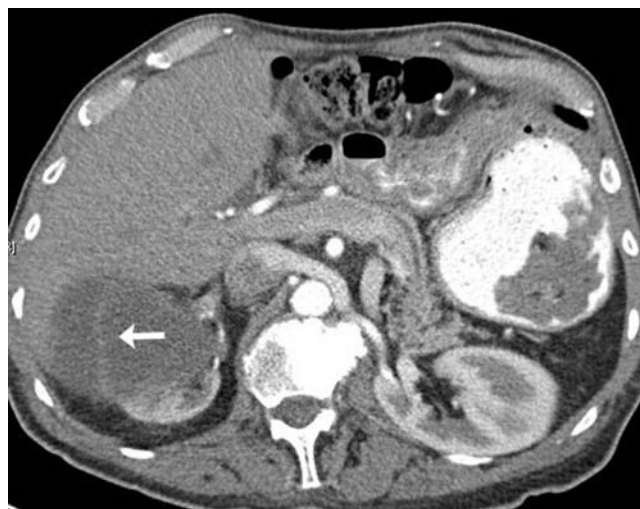

Figure 40-2. Complex renal cyst. A right kidney with a Bosniak type 3 renal cyst. Note the enhancing septum (arrow). This cyst was removed and found to be a high-grade papillary renal cell carcinoma.

Kidney Cancer

Renal cell carcinoma (RCC) is a malignancy of the renal epithelium that can arise from any component of the nephron (Fig. 40-2). In 2012, there were over 64,000 new cases in the United States, with over 13,000 deaths.⁸ With the widespread use of imaging for many medical complaints, a stage migration has led to an increased incidence of small renal masses.⁹ Surprisingly, this has not led to lower mortality rates. Various histologic subtypes include clear cell, papillary (types I and II), chromophobe, collecting duct, and unclassified forms. Collecting duct and unclassified forms have dismal prognoses and do not routinely respond to systemic therapy. Benign lesions, common in the setting of a small renal mass, include oncocytomas and angiomyolipomas. Renal tumors are usually solid, but they also can be cystic. Simple cysts are very common and are not malignant, but more complex cysts may be malignant. The Bosniak classification system, based on septations, calcifications, and enhancement, is used to assess the likelihood of malignancy (Table 40-1).¹⁰

Most cases of RCC are sporadic, but many hereditary forms have been described. These syndromes frequently involve

Table 40-1.

Bosniak renal cyst computed tomography classification

CATEGORY	DESCRIPTION	RISK OF MALIGNANCY/MANAGEMENT
I	Thin-walled cyst with water density with no septations or calcifications.	0%/nonsurgical
II	Thin-walled cyst with few hairline septa that may contain fine or very limited thick calcifications. Also includes homogeneously hyperdense cysts <3 cm.	0%/nonsurgical
II F (follow)	Multiple hairline or slightly thickened septa without measurable enhancement. May contain nodular calcification. Also includes hyperdense cysts >3 cm.	~5%/should be followed for progression
III	Irregular or smooth thickened walls or septa with measurable enhancement.	~50%/surgical
IV	Same as III, but with enhancing solid components.	~100%/surgical

Source: Adapted with permission from Israel GM, Bosniak MA. An update of the Bosniak renal cyst classification system. *Urology*. 2005;66:484. Copyright Elsevier.

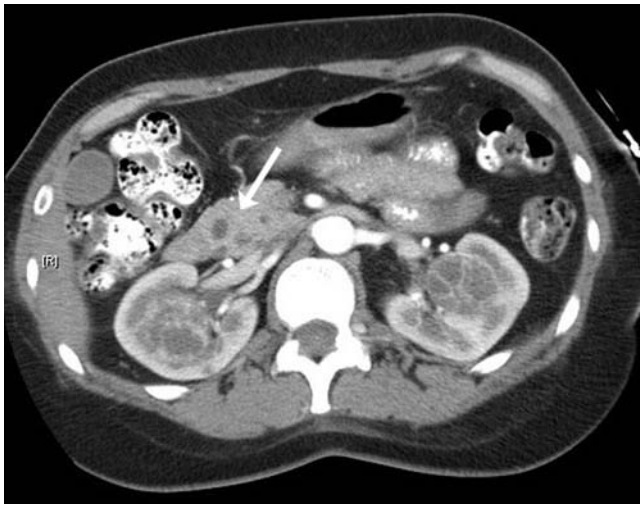


Figure 40-3. von Hippel-Lindau disease. A computed tomography image of a patient with von Hippel-Lindau disease and bilateral kidney tumors that are predominantly intrarenal. Note the numerous cysts in the head of the pancreas (*arrow*).

a germline mutation in a tumor suppressor gene. von Hippel-Lindau disease is associated with multiple tumors including clear cell RCC (Fig. 40-3). The involved gene, *vhl*, also frequently is mutated or hypermethylated in sporadic RCC.¹¹ Other rare forms include Birt-Hogg-Dubé syndrome, where patients get oncocytomas or chromophobe tumors. Patients with hereditary papillary RCC and hereditary leiomyomatosis develop papillary RCC.

The most common sites of metastasis are the retroperitoneal lymph nodes and lungs, but liver, bone, and brain also are common sites of spread. Up to 20% to 30% of patients may present with metastatic disease, in which case, surgical debulking can improve survival, as shown in randomized controlled trials.^{12,13} Patients with all but the smallest renal masses should undergo testing for the presence of metastatic disease including chest CT, bone scan, and liver function tests.

Patients with localized disease may be cured with either partial or radical nephrectomy (Fig. 40-4). The oncologic efficacy of partial nephrectomy (nephron sparing) appears to be similar to that of radical nephrectomy. However, patients

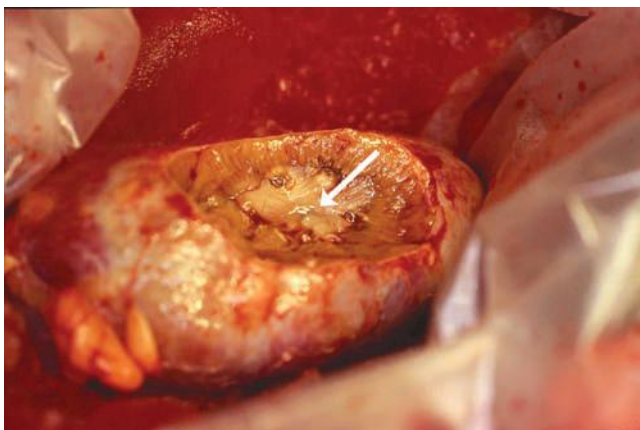

Figure 40-4. Partial nephrectomy. A kidney after partial resection for a small renal mass. Note the visible collecting system in the base of the defect (*arrow*).

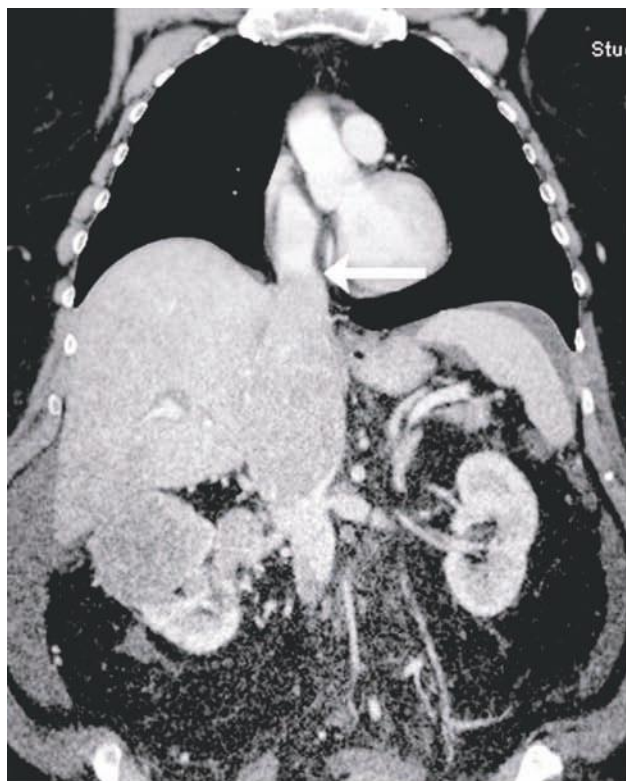
with larger tumors or with a more central tumor location may be at increased risk for surgical complications. Nephron-sparing surgery should be considered in all patients, if feasible, as those patients undergoing a radical nephrectomy are at risk for future chronic kidney disease.¹⁴ The lack of harm from nephrectomy due to malignancy has been extrapolated from the fact that kidney donors do not routinely develop renal insufficiency. However, kidney donors are a highly selected group, and patients with renal tumors are typically older and have more comorbidities. Additionally, the risk of contralateral RCC is 2% to 3% in most series,¹⁵ and a partial nephrectomy may prevent the future need for dialysis in case of a contralateral kidney tumor. While we should all strive to

3▶ preserve as many nephrons as possible, we do not have level 1 evidence that supports the use of partial nephrectomy over radical nephrectomy for patients with small renal masses.

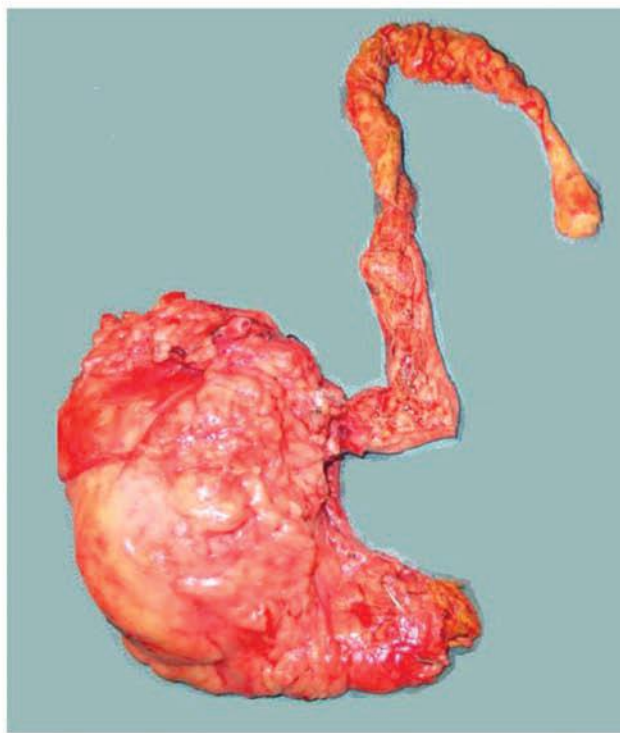
Minimally invasive techniques for renal surgery have greatly changed the field of kidney cancer. Laparoscopic and robot-assisted laparoscopic renal surgery allows for more rapid convalescence and decreased narcotic requirements. While laparoscopic partial nephrectomy is challenging and is performed only in experienced hands due to its associated high rate of complications, the advent of robot-assisted surgery has changed the landscape. Surgeons are now capable of performing intracorporeal suturing with much greater ease. Ablative techniques such as cryoablation and radiofrequency ablation are also popular choices, especially among those who are poor surgical candidates. However, long-term results from these techniques are currently lacking due to their recent development. Active surveillance is another viable alternative for small renal masses, especially in patients with multiple comorbidities or advanced age. Most small renal masses are low grade with a slow growth rate, and patients very rarely progress to metastatic disease after limited follow-up of 2 to 3 years.¹⁶

Up to 10% of RCC invades the lumen of the renal vein or vena cava. The degree of venous extension directly impacts the surgical approach. Patients with thrombus below the level of the liver can be managed with cross-clamping above and below the thrombus and extraction from a cavotomy at the insertion of the renal vein (Fig. 40-5A). Usually, the thrombus is not adherent to the vessel wall. However, cross-clamping the vena cava above the hepatic veins can drastically reduce cardiac preload, and therefore, bypass techniques often are necessary. For thrombus above the hepatic veins, a multidisciplinary approach with either venovenous or cardiopulmonary bypass is necessary. In cases of invasion of the wall of the vena cava or atrium, deep hypothermic circulatory arrest may be used to give a completely bloodless field. Tumor thrombus embolization to the pulmonary artery is a rare but known complication during these cases and is associated with a high mortality rate (Fig. 40-5B). For cases of extensive tumor thrombus, intraoperative transesophageal echocardiography should be considered for monitoring and assessment of possible thrombus embolization. If a thrombus embolization occurs, a sternotomy/cardiopulmonary bypass with extraction of the thrombus may be life saving.

Patients undergoing resection of localized renal masses are at substantial risk of future recurrence. Many predictive features have been recognized, but the most widely accepted prognostic findings are tumor stage, grade, and size, each of which exerts an independent effect on recurrence. Isolated solitary recurrences,



A



B

Figure 40-5. Inferior vena cava thrombus. **A.** A multidetector computed tomography image displaying a tumor thrombus extending above the diaphragm (*arrow*) arising from a right renal mass. **B.** An en bloc removal of a different right renal mass with a tumor thrombus that extended to the pulmonary artery. This patient is alive 6 years after surgery.

either local or distant, can be resected with long-term disease-free rates approaching 50%.¹⁷

Surgical Approach and Complications. Nephrectomy, either partial or radical, can be performed through a number of surgical approaches. Flank incisions over the eleventh or twelfth ribs from the anterior axillary line to the lateral border of the rectus muscle provide access to the kidney without entering the peritoneum. However, entry into the pleura is not uncommon. If small, the pleurotomy usually can be closed without need for a chest tube. The anterior subcostal approach also is used for nephrectomy. There is no risk for pleural entry, but this incision is transperitoneal, so ileus is somewhat more likely. Laparoscopic nephrectomy is now common, and robot-assisted laparoscopic partial nephrectomy is gaining significant traction in the management of small renal masses. For large tumors, particularly on the right side where the liver makes exposure of the tumor more difficult, a thoracoabdominal approach is very helpful. In these cases, the flank incision is made over the tenth rib and carried further posterior and anterior than a typical flank incision. The chest and abdominal cavities are intentionally entered for maximum exposure, and the diaphragm is partially divided in a circumferential fashion, which allows cephalad retraction of the liver. A chest tube is used postoperatively. The adrenal gland is no longer routinely removed unless the tumor is adherent to it. The benefit of lymph node dissection when the nodes are not clinically involved is uncertain.

Complications of radical nephrectomy include bleeding, pneumothorax, splenic injury, liver injury, and pancreatic tail injury. Partial nephrectomy has the added risks of delayed

bleeding and urine leak. Ileus is not common when the peritoneal cavity is not entered.

Prostate Cancer

Prostate cancer is the most common nonskin malignancy in men, with an incidence of approximately 200,000 per year. Yearly screening consisting of digital rectal exam and serum prostate-specific antigen (PSA) testing has been a topic of much debate. The U.S. Preventive Services Task Force has advised against the routine use of prostate cancer screening. The American Urological Association has advised for screening for men 55 to 69 years of age. Patients of African American descent or those with a family history of prostate cancer should be considered for screening at an earlier age (as early as 40). Men with abnormal digital rectal exams or PSA elevation have an indication for prostate biopsy to determine the presence of the disease. With the advent of PSA screening, prostate cancer has experienced a stage migration, with most cases now discovered locally confined within the prostate. The majority of patients with prostate cancer will not die of the disease by 10 to 15 years, whether it is treated at diagnosis or not. However, those undergoing initial treatment have improved cancer-specific survival.¹⁸

Prostate cancer is graded according to the Gleason scoring system.¹⁹ A primary and secondary score are assigned based on the most common and second most common histologic patterns. Grades range from 1 for the most differentiated to 5 for the least. The grades are added to give the Gleason score. In current practice, scores below 6 are almost never assigned. Gleason score, preoperative PSA level, and digital rectal exam are used

to estimate the likelihood of whether the cancer is localized, locally advanced, or metastatic. Prostate cancer with a high Gleason score (8 to 10) or a high PSA level (>20) is much more likely to have spread, often at a micrometastatic level. After definitive treatment, an increasing PSA is indicative of recurrent cancer.

The most common site of spread of prostate cancer is the pelvic lymph nodes and bone. For patients with high-risk disease based on clinical stage, grade on biopsy, and PSA level, staging includes bone scan and CT imaging to evaluate for bony metastases or pelvic lymphadenopathy. Multiple treatment options are available for men with localized disease, including radical prostatectomy (retropubic, perineal, or robotic-assisted laparoscopic approaches), brachytherapy, and external-beam radiation therapy. For low-risk disease, the efficacy of each treatment modality is thought to be similar. For low-risk disease, radical prostatectomy (open or robotic) can be performed with unilateral or bilateral cavernosal nerve sparing to limit postoperative erectile dysfunction (ED). For high-risk disease, either non-nerve-sparing surgery or external-beam radiation therapy plus androgen deprivation may be performed. The associated morbidity of each treatment differs, and it is important to discuss the side effects with patients. Irritative voiding and bowel symptoms are common after radiation therapy, with ED being a late side effect. Radical prostatectomy is associated with early incontinence and ED (depending on nerve sparing). Incontinence improves significantly with time, with <1% of men in experienced hands suffering severe long-term problems with urinary control. Likewise, ED improves with time. The large majority of younger men (<55 years of age) regain erectile function, often with the aid of oral medications, if both cavernosal nerves are spared.²⁰ Older men or those with no nerves or one nerve spared have lower rates of erectile function.

Active surveillance has emerged as a safe and viable option for men with anticipated survival of <10 years, low Gleason score (6), early-stage disease (cT1c), and small-volume disease as determined by biopsy. Patients should be monitored closely with digital rectal exam, PSA testing, and repeat biopsy at 1 to 2 years to assess the possible progression of disease. Once prostate cancer has spread, it is no longer curable. Medications that lower serum testosterone or that block the androgen receptor are able to control the disease, often for years, but the cancer inevitably becomes resistant to this treatment. Nevertheless, patients with noncurable prostate cancer can live many years, and a large number die of causes other than prostate cancer.

Surgical Approach and Complications. The approach for an open radical retropubic prostatectomy uses a lower midline incision from the pubic symphysis to approximately 5 cm below the umbilicus. The peritoneum is not entered. Lymph nodes are removed between the external iliac vein and obturator vessels bilaterally, although this may be omitted in cases where the probability of involvement is very low. Some regularly perform a wider dissection that may improve staging, although any therapeutic benefit is uncertain. The cavernosal nerves lay immediately posterolateral to the prostatic capsule. They may be spared if the cancer is not likely to penetrate the capsule on that side, which is a function of preoperative parameters such as biopsy results, PSA, and clinical examination. Robot-assisted laparoscopic radical prostatectomy has superseded laparoscopic prostatectomy due to the learning curve and increased agility that facilitates intracorporeal suturing. Benefits over open

radical retropubic prostatectomy include lower blood loss and faster convalescence. Some claim faster return of continence and lower ED rates, but these findings have not yet been widely demonstrated.

Complications of prostatectomy depend on approach. Retropubic approaches may result in urine leaks, lymphocele, and very rarely, rectal or ureteral injury. Robotic prostatectomy uses a transperitoneal approach that can occasionally result in ileus, particularly in cases of a urine leak from the vesicourethral anastomosis. All approaches carry a small risk of urinary incontinence and a more substantial risk of ED.

TRAUMA

Kidney

Renal injuries are more common during blunt trauma, accounting for 90% of injuries to the kidney. Any patient with a major deceleration injury, shock, or gross hematuria should undergo radiographic imaging of the kidneys. All patients with penetrating injuries to the flank or abdomen must undergo imaging unless unstable and requiring immediate exploration.

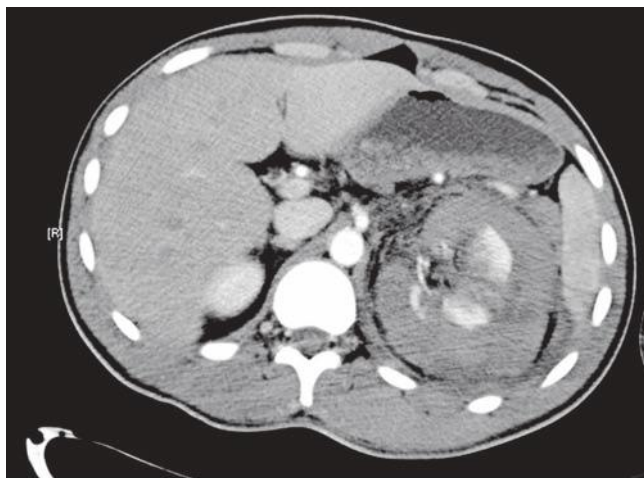
Renal injuries are classified by extent of damage (Table 40-2). Blunt traumatic injuries usually can be managed conservatively, while penetrating renal injuries usually require exploration. Urinary extravasation alone does not require exploration, but reimaging is necessary and, if persistent leakage is

Table 40-2.

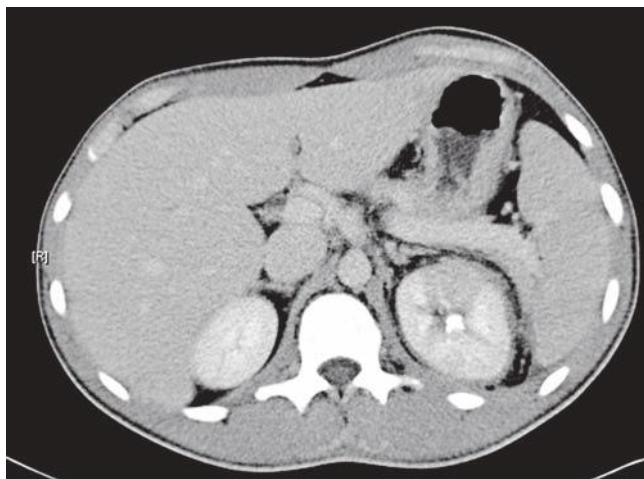
American Association for the Surgery of Trauma renal injury scale

GRADE	INJURY TYPE	DESCRIPTION
1	Contusion	Microscopic or gross hematuria with normal imaging
	Hematoma	Subcapsular, nonexpanding without parenchymal laceration
2	Hematoma	Nonexpanding perirenal hematoma confined to renal retroperitoneum
		<1 cm in depth without urinary extravasation
3	Laceration	>1 cm in depth without collecting system rupture or urinary extravasation
4	Laceration	Parenchymal laceration through cortex, medulla, and collecting system
4	Vascular	Main renal artery or vein injury with contained hemorrhage
5	Laceration	Completely shattered kidney
5	Laceration	Avulsion of renal hilum leading to devascularized kidney

Source: Adapted with permission from Moore EE, Cogbill TH, Malanconi MA, et al. Organ injury scaling. *Surg Clin North Am.* 1995;75:293. Copyright Elsevier.



A



B

Figure 40-6. Blunt renal trauma after a bicycle accident. **A.** A computed tomography image of a left kidney with several deep lacerations into the collecting system and a large perirenal hematoma. Delayed images showed urinary extravasation. This patient was managed nonoperatively. **B.** Computed tomography image at 45 days showing significant improvement in the appearance of the kidney.

present, a stent or nephrostomy tube is indicated. All grade V vascular injuries should be considered for immediate exploration, as a delay of several hours greatly decreases the risk of renal salvage. High-grade renal injuries are associated with significant bleeding, but patients who are stable and without a pulsatile or expanding hematoma can be observed. Even in expert hands, the risk of renal loss at surgery is significant and must be considered before opening the retroperitoneum. Additionally, most grade IV injuries can be managed nonoperatively (Fig. 40-6).²¹ Patients typically are placed on restricted activity until hematuria resolves. Table 40-3 lists indications for assessing surgical intervention in renal trauma patients.

If immediate operative exploration for other injuries is required, renal injury staging can be performed while in the operating room. If concern exists over renal injury or the presence of a retroperitoneal hematoma, a single-shot, 10-minute delayed intravenous pyelogram (IVP) (2 mL/kg contrast) is useful at assessing the presence of two functional kidneys and

Table 40-3.

Indications for surgical intervention for renal trauma

Absolute indications

1. Persistent, life-threatening hemorrhage from probable renal injury
2. Renal pedicle avulsion (grade 5 injury)
3. Expanding, pulsatile, or uncontained retroperitoneal hematoma

Relative indications

1. Large laceration of the renal pelvis or avulsion of the ureteropelvic junction
2. Coexisting bowel or pancreatic injuries
3. Persistent urinary leakage, postinjury urinoma, or perinephric abscess with failed percutaneous or endoscopic management
4. Abnormal intraoperative one-shot intravenous urogram
5. Devitalized parenchymal segment with associated urine leak
6. Complete renal artery thrombosis of both kidneys or of a solitary kidney when renal perfusion appears preserved
7. Renal vascular injuries after failed angiographic management
8. Renovascular hypertension

Source: Reproduced with permission of Wiley-Blackwell. From Santucci RA, Wessells H, Bartsch G, et al. Evaluation and management of renal injuries: consensus statement of the renal trauma subcommittee. *BJU Int.* 2004;93:937.

extent of injury. If the IVP is abnormal or the hematoma is pulsatile, renal exploration should be performed.

Renal exploration should begin once the renal hilum is controlled. Although rarely necessary, temporary control of the renal hilum may decrease the need for nephrectomy when a significant injury is found on exploration. Complete exposure is necessary to evaluate the extent of injury. All nonviable tissue should be débrided and segmental and intralobar arteries ligated with 4-0 chromic or polydioxanone sutures. If the collecting system is injured, it should be repaired at this time. A stent and percutaneous drain should be considered to prevent urinoma formation. A partial vascular injury to the renal vein or artery can be repaired with 5-0 or 6-0 Prolene sutures. A complete injury may require débridement, and if an end-to-end anastomosis cannot be performed, a vascular graft may be required.

Ureter

The retroperitoneal location of the ureter protects it from external trauma, and blunt injury is rare but can occur with rapid deceleration injuries. Penetrating trauma may occur, but a high index of clinical suspicion is required to make the appropriate diagnosis. Any penetrating trauma involving the retroperitoneum should undergo evaluation with intraoperative inspection, IVP, or CT urogram. A retrograde pyelogram is the most sensitive test for ureteral injury, and a stent can be placed if a partial transection is observed. The ureter also is frequently injured intraoperatively, most commonly from open and laparoscopic surgical procedures including hysterectomy, low anterior colonic resections, or aortic surgery. Endoscopic procedures such as ureteroscopy also can lead to ureteral injury such as perforation and avulsion.

Surgical repair depends on location and extent of injury. A briefly misplaced suture may be removed usually without consequence. Partial injuries can be primarily repaired, although all devitalized tissue must be débrided to avoid delayed tissue breakdown and urinoma formation. Ureteral stents should be placed in this situation to facilitate healing without stricture. Lower ureteral injuries (below the iliac vessels) are best treated with ureteral reimplantation, as the blood supply can be tenuous, and strictures are more common with a distal uretero-ureterostomy. Midureteral level injuries can be treated with a uretero-ureterostomy if a spatulated, tension-free repair can be achieved. For longer defects, the bladder can be mobilized and brought up to the psoas muscle (psoas hitch). For additional length, a tubularized flap of bladder (Boari flap) can be created and anastomosed to the remaining ureter. Renal mobilization with nephropexy by anchoring to the psoas muscle can provide additional length. Autotransplantation, transuretero-ureterostomy, and ileal ureter are rarely needed in the acute setting.

Bladder

Bladder injury can occur from penetrating and blunt trauma. The diagnosis should be entertained for any lower abdominal or pelvic trauma. Intraperitoneal ruptures are less common than retroperitoneal injuries but may be seen in the setting of a full bladder before injury. Bladder injuries often are associated with pelvic fractures and may frequently occur in conjunction with urethral injuries. Nearly all patients present with gross hematuria, although occasionally microscopic hematuria is present. A delayed presentation can be associated with intoxication, but it also may occur as a result of iatrogenic injury. These patients often have electrolyte abnormalities such as metabolic derangements, azotemia, and leukocytosis from urine absorption. Patients clinically present with fevers or a prolonged ileus.

Radiographic evaluation begins with either a fluoroscopic or CT cystogram. It is vital to avoid underfilling, as it may lead to a false-negative study. A preset amount can be instilled based on age calculations, which is typically approximately 300 to 400 mL in adults. The bladder can be filled under gravity by raising the Foley catheter to 15 cm above the pubic ramus. The contrast material should be allowed to fill to the natural capacity of the bladder. It is important to have a postdrainage film to assess for persistent contrast, which may indicate a rupture.

Extraperitoneal bladder injuries can typically be managed with catheter drainage for 7 to 10 days. If intraoperative exploration is to occur for other injuries, repair can be performed at that time. For patients with pelvic injuries that require placement of metal hardware, repair of the bladder rupture should be performed concurrently. Intraperitoneal bladder injuries should be explored immediately and repaired. However, in cases of a missed intraperitoneal injury, patients often do well with catheter drainage only. For large ruptures after repair, a suprapubic tube is recommended, but a large urethral catheter is sufficient for smaller injuries. All injuries, especially those managed nonoperatively, should be followed up by a cystogram to document healing before catheter removal.

Urethra

Urethral injuries can be divided by anterior (penile and bulbar urethra) and posterior (membranous and prostatic) location. Any patient with blunt pelvic trauma, blood present at the urethral meatus, hematuria, inability to void, or perineal hematoma should

be considered to have a urethral injury until proven otherwise. Urethral injuries should be anticipated with pubic ramus fractures and occur in 10% of unilateral ramus and 20% of bilateral rami injuries.²²

Staging is performed by retrograde urethrography. This study can be easily performed in the trauma suite with the patient in an oblique position and a 12F catheter placed in the urethral meatus. With the penis placed on traction, 30 mL of contrast is instilled while an x-ray is obtained during filling. The addition of fluoroscopy is a valuable addition to the procedure but can be omitted if not available. A partial or complete disruption can be diagnosed based on extravasation or filling of the proximal urethra. Catheter placement can be attempted in patients with partial urethral injuries. Those with complete disruptions should have placement of a suprapubic tube.

Anterior injuries often are related to blunt straddle injuries and penetrating trauma. Blunt anterior urethral injury can be managed in multiple ways, and only small series are available in the literature to compare methods. Immediate surgical repair is not recommended in the acute setting with the exception of low-velocity penetrating injuries. If the patient is stable with minimal hematoma formation, repair should be considered. In the setting of a 1- to 2-cm defect, the urethra can be débrided, spatulated, and anastomosed in an end-to-end, watertight fashion. Large defects should have treatment deferred, as grafts or flaps may be required for repair and the success may diminish with infections. For most cases, catheter drainage is recommended. Many advocate avoiding placement of a urethral catheter, as it may convert a partial tear to a complete dissection. However, a single gentle passage performed by a urologist is safe. For a complete disruption, the placement of a suprapubic tube is recommended; however, a stricture at the site of injury may ensue.

Posterior urethral injuries usually result from pelvic crush injuries and shearing forces causing a prostatomembranous disruption. The patient's other injuries dictate urologic management. Initial open surgical exploration of the urethral injury should be avoided due to altered anatomy, risk of bleeding, and high likelihood of incontinence and ED from injury of adjacent nerves. Patients can be managed with suprapubic tube and delayed repair or with delayed primary realignment. Primary endoscopic realignment, when possible, leads to decreased rates of strictures without increasing adverse outcomes.^{23,24}

Urethral strictures can be caused by trauma or inflammatory conditions. They should be staged with either a retrograde urethrography or voiding cystourethrogram (VCUG). Patients with short defects may be amenable to dilatation or cystoscopic urethrotomy. Depending on location, length, and severity, open repairs may be required. Long defects may require grafting to avoid significant penile shortening. Young patients should be considered for open surgical management to definitely repair the stricture due to the tendency of strictures to recur when treated with simple dilation.

Testes

Testicular injury most commonly occurs with blunt injuries when the testicle is forcibly compressed against the thigh or pubic bone with enough force to rupture the tunica albuginea. For patients with scrotal trauma, ultrasound is the preferred modality for staging the extent of injury. Ultrasound can evaluate the testicular blood flow, the presence of testicular

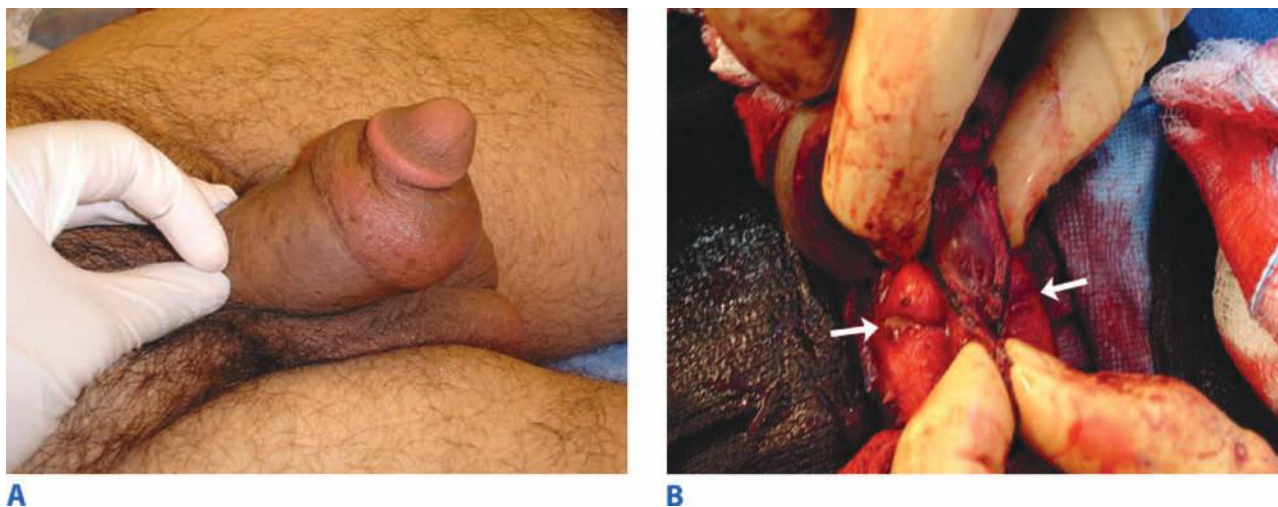


Figure 40-7. Penile fracture. **A.** A patient with a penile fracture that was suspected based on history and examination. Note the lack of skin discoloration that is often present. **B.** Intraoperative finding of bilateral corporal body ruptures (*arrows*) along the ventral penile surface. The urethra, which is between the surgeon's fingers, surprisingly escaped injury.

contusions, intratesticular hematomas, hematoceles, or a disrupted tunica albuginea. The presence of a hematocele should increase suspicion for testicular rupture because ultrasound may not detect the tunical defect in this setting.²⁵

The goal of surgery is to salvage as much parenchyma as possible and to avoid delayed complications such as ischemic atrophy or abscess formation. A large hematocele, if not evacuated, could lead to ischemic atrophy, and drainage should be considered. A ruptured tunica albuginea can be repaired primarily, and nonviable parenchyma may need to be débrided. For penetrating trauma, immediate exploration is recommended for accurate staging and repair. Frequently, these injuries result in major devascularization and nonviable tissue (especially gunshot wounds). Although salvage may be possible, an orchiectomy usually is required.

Penis

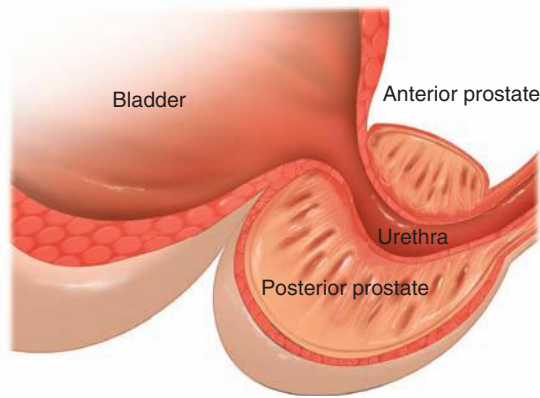
Penile fractures are injuries that involve a traumatic rupture of the tunica albuginea, usually occurring during sexual intercourse—usually with the female partner on top. The engorged penile corporal bodies can rupture if sufficient force is generated against the partner's pubic symphysis or perineum (Fig. 40-7). Men may notice an immediate audible “pop” and experience rapid penile detumescence. Immediate swelling develops. If Buck's fascia is disrupted, swelling and ecchymosis can be noted throughout the perineum (“butterfly sign”). At presentation, a classic “eggplant” appearance of the penis is often, although not always, seen. Exploration by a circumcising (de-gloving) incision and repair of the defect offers the best chance at avoiding permanent ED and penile deformity while also minimizing the risk of infection.²⁶ A retrograde urethrogram should be performed to rule out urethral injury at the time of surgery. Alternatively, the urethra can be manually occluded intraoperatively at the penoscrotal junction and a dilute methylene blue solution injected under pressure into the urethral meatus with a catheter-tip syringe. Leakage should be visualized if there is a urethral disruption. If present, the urethra should be repaired, taking care not to significantly narrow the lumen. A Foley catheter is left in place for several days after surgery. Any penetrating injury to the penis must undergo exploration to repair any injuries to the corporal bodies or the urethra.

EMERGENCIES

Acute Urinary Retention

Acute urinary retention (AUR) can happen in men or women and results from a variety of causes, although it most commonly occurs in men with benign prostatic hyperplasia (BPH). Other chronic causes of poor bladder emptying, such as diabetic neuropathy, urethral stricture, multiple sclerosis, or Parkinson's disease, can result in episodes of complete urinary retention, often when the bladder becomes overdistended. This frequently occurs in the hospital setting when patients have limited mobility and are receiving medications that decrease bladder contractility, including opiates or anticholinergics. Constipation, **7▶** a common side effect of those medications, can itself worsen urinary retention. Significant hematuria can result in the formation of blood clots, which may block the urethra and cause retention.

Although some patients receiving large doses of narcotics or those with chronically decompensated bladders may not experience discomfort, most patients with AUR have significant pain. If the urinary retention has lasted several days (often accompanied by overflow incontinence), patients may develop acute renal failure. Treatment should include placement of a urethral catheter as quickly as possible. However, BPH or urethral strictures often make the placement of a catheter difficult. For men with BPH, a coude (French for *curved*) catheter is helpful in negotiating past the angulation in the prostatic urethra (Fig. 40-8A). The curved portion (which is angled in line with the balloon port) is maintained at the 12 o'clock position as it is passed through the urethra (Fig. 40-8B). A common mistake is to use a smaller catheter to bypass the enlarged prostate. However, a larger (18F to 20F) catheter is less flexible and is more likely to push into the bladder rather than curl in the prostatic urethra. Smaller catheters are useful for bypassing a urethral stricture. A urethral stricture should be suspected when the catheter meets resistance closer to the meatus, as many strictures occur in the distal urethra, which is narrower than the proximal portion. Using a 12F or 14F catheter often will allow the passage of the catheter into the bladder. If catheter placement is not successful, a urologic consultation should be requested. The urologist can either choose to (a) use a cystoscope, guidewire,



A



B

Figure 40-8. Coude catheter. **A.** A schematic drawing of a lateral view of the prostatic urethra showing the upward angulation at the bladder neck, which a coude catheter is helpful in negotiating. **B.** The tip of a coude catheter. Note the curved tip, which should always point to 12 o'clock when inserted.

and urethral dilators to dilate the stricture and place a Counsel-tip catheter via Seldinger technique; or (b) place a suprapubic tube approximately two fingerbreadths above the pubic symphysis. With regard to the suprapubic tube, aspiration with a finder needle should be used first to localize the bladder and avoid intra-abdominal contents, although bowel injury is unlikely with a distended bladder filling the pelvis. If hematuria is the cause of retention, continuous bladder irrigation often is necessary to prevent clot formation. This is done through a large three-way catheter that has an additional port for fluid inflow. Fluid is infused by gravity only because the use of higher pressure may result in bladder rupture if outflow is occluded.

A urinalysis should be checked because a poorly emptying bladder is prone to infection. Renal function also should be assessed for those in AUR by checking the creatinine level. An elevated creatinine level suggests that AUR has resulted in renal dysfunction, and these patients are at risk for postobstructive diuresis. These patients must be closely watched for excessive urine output, often caused by an osmotic diuresis due to retained nitrogenous waste products or a temporary renal concentrating defect. Fluid and electrolytes must be replaced if the urine output exceeds 200 mL/h, especially if hemodynamic instability or electrolyte

imbalances are seen. Fluid replacement typically is 0.5 mL of 0.45 normal saline for every 1 mL of urine output above 200 mL in 1 hour, although sodium and potassium supplementation requirements depend on the electrolyte status of the patient.

Once the bladder is adequately drained, the cause of AUR should be addressed. For men with suspected BPH, an α -blocker such as tamsulosin should be started. Although finasteride and dutasteride (5 α -reductase inhibitors) have been shown to reduce the incidence of urinary retention by 50%, they require a few months to take effect and, hence, will not provide significant benefit in the short term. Narcotics should be tapered as tolerated, and constipation should be treated. Acute spinal cord compression, which is accompanied by saddle paresthesias, is a neurologic emergency that requires neurosurgical or orthopedic consultation. In most cases, except severe neurologic injuries, patients will be able to resume voiding, and the catheter can be removed after 1 to 2 days. Postvoid residuals should be checked with a portable ultrasound device (bladder scanner) or by "straight" catheterization to determine the residual amount of urine left after the patient tries to empty his or her bladder. In patients with severe liver dysfunction, the bladder scanner may inadvertently misinterpret ascites for urine. The inability to void or the presence of a postvoid residual over 200 mL is concerning for development of another episode of AUR. Patients may be given the option of an indwelling catheter for another few days with a subsequent voiding trial, or learning to clean intermittent catheterization (CIC), whereby, after predetermined intervals (4–6 hours) or after voiding attempts, the patient passes a catheter into the bladder and empties it. This is the preferred method, because it reduces the likelihood of infections from indwelling catheters and may improve bladder functionality. However, most patients are resistant to this approach.

Testicular Torsion

The differential diagnosis of acute scrotal pain includes testicular torsion. This usually occurs in neonates or adolescent males but may be observed in other age groups. The blood supply to the testicle is compromised due to twisting of the spermatic cord within the tunica vaginalis, resulting in ischemia to the epididymis and the testis. In newborns, an extravaginal torsion also can occur with twisting of the tunica vaginalis and spermatic cord together. Risk factors for torsion include undescended testis, testicular tumor, and a "bell-clapper" deformity—poor gubernacular fixation of the testicles to the scrotal wall.

Clinical history is vital for diagnosis. Patients describe a sudden onset of pain at a distinct point in time, with subsequent swelling. Physical examination may demonstrate a swollen, asymmetric scrotum with a tender, high-riding testicle. Children normally have a brisk cremasteric reflex that usually is lost in the setting of torsion. The diagnosis is made by clinical history and examination, but can be supported by a Doppler ultrasound, which typically shows decreased intratesticular blood flow relative to the contralateral testis. If an ultrasound is not promptly available, timely surgical exploration should ensue if there is reasonable suspicion of torsion. However, besides ruling out other pathologies, an ultrasound can rule out an associated testicular neoplasm that would necessitate tumor serum marker evaluation and an inguinal, rather than a scrotal, incision.

Immediate surgical exploration can salvage an ischemic testis. More than 80% of testes can be salvaged if surgery is performed within 6 hours; this rate decreases to <20% as time lapses beyond 12 hours.²⁷ At the time of surgery, the

8▶ contralateral testes also must be explored and fixed to the dartos fascia due to the possibility that the same anatomic defect allowing torsion exists on the contralateral side. Midline (along the median raphe) or bilateral transverse scrotal incisions are made. Once the testis is detorsed, it should be assessed for viability after being given time for normal blood flow to resume. One can assess for blood flow by intraoperative Doppler or by incising the tunica vaginalis and examining for blood. The testes are fixed to the dartos fascia with a small, nonabsorbable suture on their medial, lateral, and dependent aspects, taking care to ensure that the spermatic cord is not twisted before doing so. An orchiectomy should be performed to avoid later risk of abscess formation only if the testis is clearly necrotic because overall testicular function may be improved with testicular preservation in cases of moderately delayed (15 hours) presentation.²⁸

Fournier's Gangrene

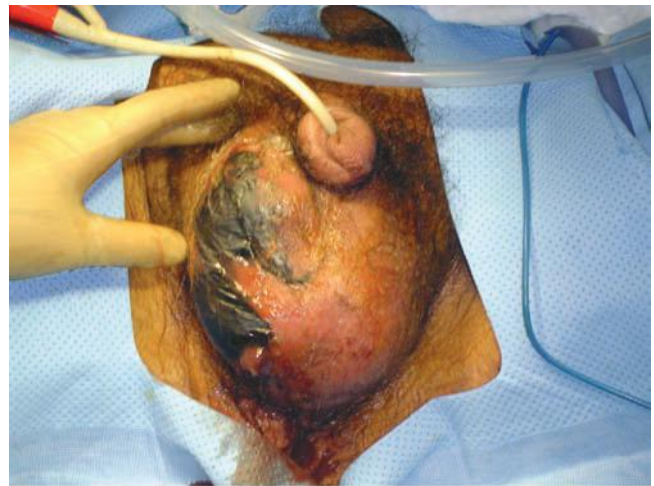Fournier's gangrene is a necrotizing fasciitis of the male genitalia and perineum that can be rapidly progressing and fatal if not treated promptly (Fig. 40-9A). The mortality rate has been reported to be as high as 30% to 40%.²⁹ Risk factors for Fournier's gangrene include urethral strictures, perirectal abscesses, poor perineal hygiene, diabetes, cancer, human immunodeficiency virus (HIV), and other immunocompromised states.³⁰ The infection spreads along the dartos, Scarpa's, and Colles' fascias. Clinical signs include fevers, perineal and scrotal pain, and associated indurated tissue. Cellulitis, eschars, necrosis, flaking skin, and crepitus may all be observed. The diagnosis is largely made on clinical suspicion, and significantly less often made on laboratory or radiographic findings. Classically, the patient describes pain out of proportion to the physical findings.

Prompt débridement of nonviable tissue and broad-spectrum antibiotics are necessary to prevent further spread (Fig. 40-9B). If there is damage to the external anal sphincter, patients may require a colostomy.³⁰ Because the testes have a

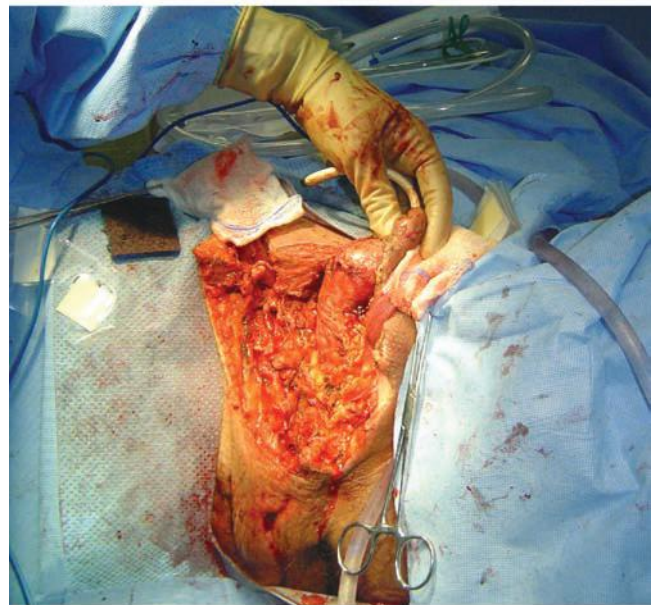
9▶ separate blood supply, they are usually not threatened and do not need to be removed. They may be tucked subcutaneously into the thigh ("thigh pouch") to ease postoperative management. Patients frequently require return trips to the operating room for further débridement. Tight glucose control and adequate nutrition are necessary to facilitate wound healing. The large tissue defect should be initially treated with frequent dressing changes. Reconstructive strategies involving skin grafting are needed when large tissue defects result from extensive tissue damage.

Priapism

Priapism is a persistent erection for greater than 4 hours unrelated to sexual stimulation. Priapism is divided into two types, based on the underlying pathophysiology. The most common type—low-flow/ischemic priapism—is a medical emergency. On examination, the penis is very tender, and both cavernosal bodies will be rigid while the glans will be flaccid. Decreased venous outflow with persistent inflow results in increased intracorporeal pressure and tumescence, which is the normal process of erection. Diminished arterial inflow due to elevated intrapenile pressure usually is brief under normal circumstances. Priapism is essentially a compartment syndrome.³⁰ With prolonged erection (priapism), the sustained decrease in arterial inflow ultimately causes tissue hypoxia, acidosis, and edema and results in long-term fibrosis and impotence, and sometimes frank necrosis. Risk factors include sickle cell disease or trait, malignancy,



A



B

Figure 40-9. Fournier's gangrene. **A.** Necrotic scrotal skin from Fournier's gangrene. **B.** Débridement of gangrenous tissue. Note the extensive débridement, which is commonly required. The right testicle required removal in this case (the left is wrapped in gauze), but typically the testes are not involved with the necrotic process.

medications, cocaine abuse, certain antidepressants, and total parenteral nutrition.³²⁻³⁴ If a cause is not identified, a hematologic workup is necessary to rule out malignancy or blood dyscrasias.

The management of priapism is rapid detumescence with the goal of preservation of future erectile function. The ability to achieve normal erections is directly related to length of the episode of priapism.³⁰ Low-flow priapism can be confirmed with a penile blood gas of the cavernosal bodies demonstrating hypoxic, acidotic blood. Initial management can include oral agents such as pseudoephedrine or baclofen, but more aggressive measures usually are necessary to achieve rapid detumescence. Insertion of a large-gauge needle (18-gauge) into the lateral aspect of one corporal body allows thorough aspiration and irrigation of both corporal bodies because of widely communicating channels. Injection of phenylephrine (up to 200 mg in 20 mL normal saline) into the corporal bodies may be required. For those with sickle cell disease, hydration and

oxygen administration should be performed first, because these are sometimes successful in this group.³⁵

A surgical shunt is sometimes necessary to resolve the episode. Distal shunts should be performed first, because they can be done quickly in the emergency room with a True-Cut needle (Winter shunt). If this fails, an operative distal shunt can be performed (Al-Ghorab). Proximal shunts such as Grayhack (corporal-saphenous vein) or Quackel (proximal cavernosum-spongiosum) shunts may be required in refractory cases.

The other form, high-flow/traumatic priapism, is rare and is related to penile or perineal trauma resulting in a cavernous artery–corporal body fistula. This form is not painful because it is not related to ischemia and can be managed conservatively. Many cases will resolve with time; those that do not can undergo selective arterial embolization.³⁶

Paraphimosis

Foreskin emergencies occur in uncircumcised men. Paraphimosis is a common problem that represents a true medical emergency. When foreskin is retracted for prolonged periods, constriction of the glans penis may ensue. This is particularly likely in hospitalized patients who are confined to bed or who have altered mentation. Edema often forms in the genitals of supine patients due to the dependent position of that area. Patients with diminished consciousness will not be aware of the penile pain from paraphimosis, which may delay recognition of the problem until too late. Delay can be catastrophic as penile necrosis may occur due to ischemia.³⁷ Penile blocks, pain medication, and sedation are sometimes necessary before manual reduction. It is useful to apply firm pressure to the edematous distal penis for several minutes. Although painful, this reduction in penile edema can be the key to success. With the fingers pulling the constricting band distally, the thumbs can push the glans penis back into normal location. If the foreskin cannot be manually reduced, surgical intervention is required.

Emphysematous Pyelonephritis

Emphysematous pyelonephritis is a life-threatening infection that results from complicated pyelonephritis by gas-producing organisms. It is an acute necrotizing infection of the kidney that occurs predominantly in diabetic patients.³⁸ Patients frequently present with sepsis and ketoacidosis. *Escherichia coli* appears to be the most frequent organism responsible for this infection.³⁹

Patients require supportive care, intravenous (IV) antibiotics, and relief of any urinary tract obstruction. Emphysematous pyelonephritis can be subdivided based on extent of infection. Those with gas confined to the parenchyma frequently can be managed conservatively with placement of a nephrostomy tube to allow drainage of purulent material. Patients with extensive involvement of the perirenal tissue may not respond to conservative management, and strong consideration should be given to expeditious nephrectomy, particularly if the patient is displaying signs of sepsis.⁴⁰

INFECTIONS

Cystitis

Cystitis is an infection in the bladder with common symptoms of dysuria, urinary frequency, and urgency. Urinary culture (10^5 colony-forming units) is necessary to make a definitive diagnosis, although lower thresholds are meaningful if clinical suspicion is high. Urinalysis can assist with the diagnosis, as leukocyte esterase is a marker of inflammation, and nitrites are

formed from bacterial reduction of nitrates. Risk factors include female gender, urinary instrumentation, urinary obstruction, diabetes, and neurologic bladder dysfunction.

An uncomplicated episode of cystitis requires a 3-day course of antibiotics. Those with complicated cystitis require 7 days of antibiotics and possible imaging studies. Asymptomatic bacteriuria does not necessarily need to be treated except if found in a pregnant woman, before a planned urinary tract surgery, or with associated urinary tract obstruction. Patients undergoing nonurologic surgery also should be considered for treatment, especially in surgery involving cardiac valves or orthopedic hardware.

Pyelonephritis

Pyelonephritis is a bacterial infection of the kidney that usually manifests itself by fevers and flank tenderness. It is frequently attributed to ascending bacteria along the path of the ureters and is rarely due to hematogenous bacterial spread. Patients typically present with flank pain and fevers. However, very young or elderly patients may not demonstrate these symptoms but rather irritability, poor appetite, or altered mental status. Urinary tract imaging is not required unless urinary obstruction or stones are suspected or the patient is not responding to antibiotics. Patients who are not septic and can tolerate fluids can be discharged home on a 2-week course of oral antibiotics. Otherwise, they should be hospitalized for IV antibiotics. Fevers from pyelonephritis may take 24 to 48 hours to subside in the setting of effective antibiotic therapy. Pyelonephritis can result in renal scarring that is accelerated in the setting of urinary obstruction. Emphysematous pyelonephritis can be a life-threatening condition with a mortality of up to 30% (see Emphysematous Pyelonephritis in the Emergencies section).

Occasionally, pyelonephritis can develop into an abscess that can be located within the renal parenchyma (renal abscess) or between the capsule and Gerota's fascia (perinephric abscess). Any patient who is not properly responding to antibiotic therapy after 72 hours should undergo CT imaging to rule out an abscess or obstruction. Treatment consists of broad-spectrum IV antibiotics and percutaneous drainage.

Prostatitis

Acute prostatitis is a bacterial infection in the prostate gland, most commonly by urinary pathogens. Patients present with fevers, dysuria, and perineal or back discomfort. A digital rectal examination may indicate an indurated and tender gland. However, a brisk digital rectal examination should be avoided, as it is extremely uncomfortable for patients and is thought to cause bacteremia. Patients require a 4- to 6-week course of antibiotic therapy, typically a quinolone. Those who continue to have no improvement after 48 hours should be considered for imaging to rule out a prostatic abscess. If present, large abscesses can be managed with transurethral unroofing or percutaneous drainage.

Chronic prostatitis presents with continued lower urinary tract symptoms and pelvic pain. Chronic prostatitis may be bacterial or nonbacterial, which can be distinguished by culturing pre- and postprostatic massage urine. The bacterial form is a frequent cause of recurrent urinary tract infections in men and can be treated with a prolonged course of antibiotics. Chronic nonbacterial prostatitis does not respond to antibiotics or most other medications. Biofeedback, physical therapy, and other non–prostate-specific treatments may be effective in the treatment of this challenging clinical entity.⁴¹

Epididymo-orchitis

Epididymo-orchitis is typically the result of bacterial infection originating in the urinary tract. However, most men will not show evidence of urinary tract infection. Symptoms consist of unilateral painful swelling of the epididymis and/or testis, often with fever. The scrotum may be erythematous on the side of involvement. The white blood cell (WBC) count often is elevated. The onset is fairly rapid, but not as sudden as torsion. An ultrasound may provide supporting evidence such as increased blood flow to the epididymis. A reactive hydrocele may be present. Intratesticular infection can result in ischemic orchitis, and reduced testicular blood flow can be seen on ultrasound. Although the clinical history of gradual onset may point to an infectious etiology, scrotal exploration is necessary when blood flow is reduced to rule out torsion unless other signs such as pyuria, elevated WBC count, or fevers are present.

Treatment is with oral antibiotics if the patient is not markedly febrile and is otherwise stable. Hospitalization and parenteral antibiotics are required if the patient has high fevers or significantly elevated WBC or is hemodynamic unstable, as sepsis from epididymo-orchitis is possible. Intratesticular abscesses may form and usually result in orchiectomy. The tunica albuginea of the testis is not compliant, so elevated pressures from intratesticular inflammation can result in ischemic necrosis of the parenchyma.

LOWER URINARY TRACT OBSTRUCTION

Benign Prostatic Hyperplasia

BPH is a clinical diagnosis describing urinary symptoms attributable to obstruction by the prostate, although some patients with BPH have minimally enlarged glands, and some with large prostates have no symptoms. The symptoms of BPH are urinary frequency, urgency, hesitancy, slow stream, and/or nocturia. These symptoms are not specific and may be caused by infection, urethral strictures, or neurologic dysfunction from diabetes, Parkinson's disease, multiple sclerosis, stroke, or spinal cord injury. Besides voiding symptoms, consequences of BPH include gross hematuria, infections due to incomplete emptying, bladder calculi, and urinary retention. Over time, incomplete emptying may lead to chronic bladder overdistension that can result in a defunctionalized bladder.

Medical treatment of BPH is usually the first step. α -Blockers act on α receptors in the smooth muscle of the prostate and decrease its tone. 5α -Reductase inhibitors, which block the conversion of testosterone to the more potent Z , shrink

the prostate over several months. Both are used either singly or in combination as medical therapy for BPH. If medications are ineffective at alleviating urinary symptoms or other consequences of BPH, surgical intervention is indicated. Transurethral resection of the prostate is the mainstay of endoscopic surgical BPH treatment. It is extremely effective at improving flow and decreasing residual urine. Complications are rare but include incontinence and excessive fluid absorption of the hypotonic irrigating solution used during resection, resulting in the transurethral resection syndrome. It is due to hyponatremia and fluid overload, and although rare, can result in death. Mental status changes and pulmonary edema are managed by diuresis and sodium supplementation with hypertonic saline in severe cases. Because of these rare, but potentially dangerous side effects, laser or electrovaporization of the prostate has grown popular. It is associated with very limited fluid absorption, and saline can be used because there is no monopolar electrocautery. There also is less bleeding. Urinary outcomes appear to be similar to transurethral resection of the prostate.⁴² When the prostate is very enlarged (>100 g), endoscopic management is less effective and open surgical procedures can be used. Suprapubic (simple) prostatectomy involves enucleation of the majority of the prostate, but the capsule is left so there is minimal effect on continence and erectile function.

Urethral Stricture

The voiding symptoms of urethral stricture are very similar to BPH. Strictures may result from scarring due to infectious urethritis, prior instrumentation, trauma, or cancer. Urethral carcinoma is very rare, particularly in males, so most strictures are due to benign causes. Diagnosis is by retrograde urethrogram or cystoscopy. They may be treated with dilation or transurethral incision, but they have a tendency to recur after treatment. Open surgical excision is preferred for long or recalcitrant strictures, and long-term success rates are excellent.⁴³

UPPER URINARY TRACT OBSTRUCTION

The hallmark of partial or complete upper urinary tract obstruction is hydronephrosis (HN), with the ureteral dilation extending to the level of the obstruction (Fig. 40-10). HN may be seen on CT imaging or ultrasound, and it may range from very mild to severe, with associated parenchymal thinning in chronic cases. In the acute setting, the degree of HN does not necessarily correlate with the degree of obstruction, as it may take time for severe HN to develop. The obstruction may be intrinsic, as with calculi or ureteral tumors, or due to extrinsic

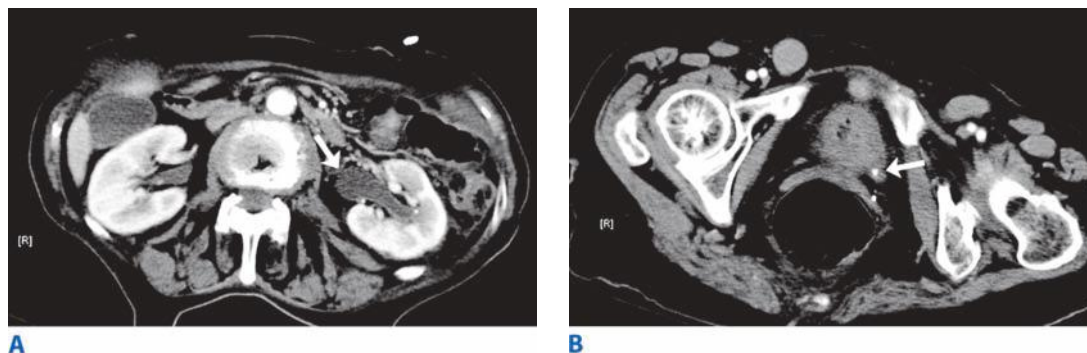


Figure 40-10. Hydronephrosis and ureteral calculus. **A.** Left hydronephrosis from distal obstruction (*arrow*). **B.** A 4-mm calculus at the ureterovesical junction (*arrow*).

compression due to varied causes, such as an intra-abdominal tumor, iliac aneurysm, or gravid uterus. Serum creatinine may be elevated, but the contralateral kidney will compensate so serum chemistries may not indicate renal impairment. Normal renal function makes intervention less urgent, but even partial obstruction may result in permanent loss of function on the affected side if not alleviated within several weeks.⁴⁴ Complete occlusion can cause permanent dysfunction within 2 weeks.⁴⁵

Treatment of ureteral obstruction is by endoscopic placement of a ureteral stent, which is a temporary plastic tube with curls on each end to prevent migration. Stents allow flow both through the lumen and around it. When chronic stenting is required, it must be changed every 3 months to prevent severe encrustation with urinary sediments. Stents commonly become colonized with bacteria, but symptomatic infections are less common.⁴⁶ Once a stent is in place, mild residual HN often will persist due to ureteral aperistalsis and urinary reflux, but unless severe, it does not represent residual obstruction.

When stent placement is unsuccessful or fails to provide adequate drainage due to severe extrinsic compression, a percutaneous nephrostomy (PCN) should be placed. This is the preferred approach when a patient is unstable because it requires less anesthesia and provides more rapid and reliable decompression of the renal collecting system.

Urolithiasis

Urolithiasis, or urinary calculus disease, may affect up to 10% of the population over the course of a lifetime.⁴⁷ Calculi are crystalline aggregates of one or more components, most commonly calcium oxalate. They also may contain calcium phosphate, magnesium ammonium phosphate (struvite), uric acid, or cystine. Calcium- and struvite-containing stones often are visible on plain radiographs, but CT scans will demonstrate all calculi except those composed of crystalline-excreted indinavir, an antiretroviral medication.⁴⁸ For this reason, noncontrast CT scans have become the study of choice to evaluate for urolithiasis.

Several underlying causes exist for the formation of urinary calculi. Hypercalciuria due to hyperparathyroidism, sarcoidosis, “renal leaks,” or idiopathic overabsorption can lead to calcium-containing stones. Patients often will develop calculi after gastric bypass, which has been attributed to increased oxalate excretion in the urine.⁴⁹ After bypass, dietary calcium is bound by unabsorbed dietary fats (saponification), preventing it from binding dietary oxalate, thereby making oxalate more available for intestinal absorption. Patients with gout are at risk for uric acid stones due to increased urinary uric acid and decreased urine pH, which diminishes uric acid solubility.

Urinary calculi may occur anywhere in the urinary tract. They usually are asymptomatic in the renal pelvis or bladder, but they are a very common cause of symptomatic ureteral obstruction. The obstruction may be partial or complete. Smaller stones (up to 6 mm) may cause severe symptoms, such as flank pain and

10 ▶ nausea, but typically pass without intervention beyond supportive care.⁵⁰ α -Blockers, which relax the distal ureter, may be given to reduce renal colic.⁵¹ Calculi ≥ 7 mm are more likely to become impacted or to have a prolonged passage through the ureter. For this reason, intervention at the time of presentation is preferred for larger stones (except in cases where the calculus is in the very distal ureter) due to the likelihood of repeat emergency room visits for severe symptoms.

Several methods for treating urinary calculi are available, depending on location. Obstructing stones often are temporized with stent placement, which allows proximal collecting system decompression. When urinary infection coexists with an obstructing stone, a stent can be placed, but a PCN is preferable if the patient demonstrates any instability. Definitive treatment of renal or ureteral calculi (lithotripsy) is through ureteroscopy, percutaneous nephrostolithotomy (PCNL), or extracorporeal shock wave lithotripsy (ESWL). Ureteroscopy is performed with a flexible or semirigid device that is passed to the level of the calculus. Under direct visualization, a laser fiber is passed through the scope, and energy is delivered to fragment the calculus. Fragments are extracted, although they usually will pass spontaneously. PCNL is performed through a percutaneous tract into the kidney, where a larger scope and various energy sources (laser, ultrasound) are used to fragment and aspirate large renal calculi. This approach is well suited to staghorn calculi. ESWL is completely noninvasive and uses a device that delivers convergent shockwave energy to the calculus under fluoroscopic guidance. However, the lower efficacy rate of ESWL, when compared with ureteroscopy or PCNL, highlights the point that despite ESWL being less invasive, patients will often undergo multiple procedures to be rendered stone free.

Complications of lithotripsy are specific to the technique used. Ureteroscopy may occasionally lead to strictures due to scarring from trauma to the ureter. If performed in the setting of infection, endoscopic irrigation can force bacteria into the renal parenchyma and result in sepsis. PCNL can cause significant bleeding, and if the tract used to access the kidney traverses the lower aspect of the pleura, large amounts of irrigating fluid can result in a significant hydrothorax. ESWL can occasionally cause renal hematomas, and splenic rupture has been seen after the treatment of a left-sided stone.^{52,53}

Patients with recurrent stones will benefit from examination of stone composition and 24-hour urine metabolic workup to determine the underlying etiology. Better hydration is useful for all etiologies. Additionally, most patients will benefit from alkalization of the urine (e.g., potassium citrate). Patients with calcium-containing stones do not benefit from a reduction in dietary calcium unless they have absorptive hypercalciuria, which most do not. In fact, patients with higher dietary calcium have, on average, fewer episodes of urolithiasis.⁵⁴

Retroperitoneal Fibrosis

Retroperitoneal fibrosis is a process resulting in encasement of the ureters, along with the great vessels, in a dense fibrotic mass. Many patients present in acute renal failure, and imaging demonstrates medially displaced ureters with a homogeneous, plaque-like mass in the retroperitoneum. The cause may occasionally be a neoplastic process such as histiocytosis or lymphoma—which must be ruled out—but most are idiopathic.⁵⁵ Many medications such as the ergot derivative methysergide, methyl dopa, and β -blockers have been implicated as precipitating factors for the inflammatory process.⁵⁶

Bilateral ureteral stent or PCN placement provides temporary relief of the obstruction. Corticosteroids may be given to reverse the inflammatory process, but surgical ureterolysis still usually is required to free the ureters from retroperitoneal encasement. They are brought into the peritoneum and wrapped in omentum to prevent re-entrapment.

Ureteropelvic Junction Obstruction

UPJ obstruction is the most common cause of hydronephrosis found on prenatal ultrasound. UPJ obstruction also is commonly observed in children and young adults. Intrinsic and extrinsic causes of UPJ obstruction exist and can be determined by presentation. Intrinsic UPJ obstruction occurs in neonates due to an adynamic or stenotic segment of proximal ureter. This impairs flow of urine into the ureter, particularly during times of high flow, and causes dilatation of the collecting system. Over time, elevated renal pelvic pressures and recurrent infections can injure renal parenchyma. Abnormal lower pole (i.e., accessory) renal arteries may be a secondary cause of UPJ obstruction by kinking the proximal ureter. Nuclear scans (mercaptoacetyltri-glycine or ^{99m}Tc diethylene-triamine-penta-acetic acid) have replaced the IVP as the diagnostic modality of choice. Delayed clearance of contrast or radiotracer implies obstruction. Invasive pressure-flow examinations (Whitaker test) rarely are performed.

Not every case of UPJ obstruction requires operative intervention. Many children with hydronephrosis due to an apparent UPJ obstruction are not highly obstructed and will improve with time. However, patients with infections or impaired renal function require repair to improve drainage. Open dismembered pyeloplasty is considered the gold standard approach, especially in infants. In older children or adults, laparoscopic or robotic approaches for pyeloplasty can expedite convalescence and diminish postoperative pain. An endoscopic approach, endopyelotomy, is also an option in older children and adults. However, it is not as effective as a dismembered pyeloplasty. Surgery involves ureteroscopy and a full-thickness lateral incision into the affected ureteral segment with a laser or knife taking care not to injure the renal hilar vessels (or accessory vessels in cases of a crossing vessel).

Vesicoureteral Reflux

Vesicoureteral reflux (VUR) is the second most common cause of hydronephrosis after UPJ obstruction. Up to two thirds of infants presenting with urinary tract infections have VUR.⁵⁷ VUR is significantly more common among white children (10 times as common) than black children. Although VUR is more prevalent in male newborns, among children older than 1 year of age, girls are five to six times more likely to have VUR than boys. The incidence of VUR decreases with advancing age. Primary reflux is a congenital anomaly caused by insufficient intramural tunneling of the distal ureter, although bladder outlet obstruction may cause unilateral or bilateral secondary reflux when the ureters are anatomically normal. The primary danger of VUR is reflux of infected urine that results in recurrent episodes of pyelonephritis, which can cause scarring and cumulative renal damage.

Neonates with hydronephrosis detected on prenatal ultrasound or infants/children experiencing a urinary tract infection should be evaluated for VUR with a voiding cystourethrogram (VCUG). VUR is graded according to the International Classification System. Spontaneous resolution of VUR, which is the norm, is a function of the grade of VUR.⁵⁸ The large majority of low-grade (1–2) reflux cases will spontaneously resolve, whereas 30% to 50% of grade 3 and 4 reflux cases and 9% of grade 5 reflux cases will resolve.^{58,59} The initial management of VUR is controversial, particularly for moderate degrees.

Surgical repair with ureteral reimplantation is effective, but may be overtreatment for those destined to resolve spontaneously. However, conservative management, consisting of antibiotic prophylaxis, may result in breakthrough infections with resistant organisms. Submucosal injection of bulking agents at the ureteral orifice (Deflux[™]) is being used with increasing frequency. Although patients with high-grade VUR still undergo ureteral reimplantation, those with low-grade VUR are increasingly more likely to undergo submucosal injection of bulking agents instead of being managed conservatively. It is a minimally invasive technique that may, in some patients, obviate the need for long-term suppressive antibiotics. Submucosal bulking is not effective in every case, and patients with severe reflux will likely need reimplantation.

Ureterocele

A ureterocele is a cystic dilation of the terminal ureter thought to result from a persistent membrane between the ureteral bud and the urogenital sinus. Most patients will have associated genitourinary anomalies such as duplicated collecting systems or an ectopic ureteral location. Patients frequently present during childhood and can present in multiple ways depending on size and degree of obstruction. Patients may have hydronephrosis and pyelonephritis. A large, prolapsing ureterocele can cause bladder outlet obstruction, and rarely, a large ureterocele can present as an intralabial mass in a newborn child. Diagnosis can be confirmed with cystoscopy, VCUG, or IVP.

Patients with a functioning renal moiety can undergo endoscopic incision of the ureterocele; however, VUR is common postoperatively. A ureterocele in a nonfunctioning duplicated system may require a heminephrectomy to avoid infections.

Posterior Urethral Valve

Posterior urethral valves can be a particularly damaging cause of bilateral hydronephrosis in a newborn boy. The “valves,” which are tissue folds located in the prostatic urethra, cause bladder outlet obstruction. Diagnosis is established with a VCUG, which may show poor bladder emptying and a dilated posterior urethra. A Foley catheter should be placed in the bladder to decompress the urinary system in the hopes of facilitating recovery of renal function. Treatment involves cystoscopic ablation or resection of the valve. Even after ablation of the valves and elimination of the urethral obstruction, patients with posterior urethral valves are at significant risk of renal failure, depending on the degree of prenatal obstruction.⁶⁰ Bladders frequently suffer damage and become partially defunctionalized from prolonged prenatal obstruction, and normal voiding patterns often are not established. The most serious outcome of posterior urethral valves is pulmonary hypoplasia due to intra-uterine oligohydramnios, and efforts have been made prenatally to transplacentally decompress the urinary bladder and prevent this dreaded development.

REFERENCES

Entries highlighted in bright blue are key references.

1. Wynder EL, Goldsmith R. The epidemiology of bladder cancer: a second look. *Cancer*. 1977;40:1246.
2. Canter D, Guzzo TJ, Resnick MJ, et al. Hydronephrosis is an independent predictor of poor clinical outcome in patients treated for muscle-invasive transitional cell carcinoma with radical cystectomy. *Urology*. 2008;72:379.

3. Stein JP, Cai J, Groshen S, et al. Risk factors for patients with pelvic lymph node metastases following radical cystectomy with en bloc pelvic lymphadenectomy: concept of lymph node density. *J Urol.* 2003;170:35.
4. Grossman HB, Natale RB, Tangen CM, et al. Neoadjuvant chemotherapy plus cystectomy compared with cystectomy alone for locally advanced bladder cancer. *N Engl J Med.* 2003;349:859.
5. Lawrance WT, Rumohr JA, Chang SS, et al. Contemporary open radical cystectomy: analysis of perioperative outcomes. *J Urol.* 2008;179:1313.
6. Bosl GJ, Motzer RJ. Testicular germ-cell cancer. *N Engl J Med.* 1997;337:242.
7. Donohue JP, Thornhill JA, Foster RS, et al. Retroperitoneal lymphadenectomy for clinical stage A testis cancer (1965 to 1989): modifications of technique and impact on ejaculation. *J Urol.* 1993;149:237.
8. Siegel R, Naishadham D, Jemal A. Cancer statistics, 2012. *CA Cancer J Clin.* 2012;62:10-29.
9. Hollingsworth JM, Miller DC, Daignault S, et al. Rising incidence of small renal masses: a need to reassess treatment effect. *J Natl Cancer Inst.* 2006;98:1331.
10. Israel GM, Bosniak MA. Follow-up CT of moderately complex cystic lesions of the kidney (Bosniak category IIF). *AJR Am J Roentgenol.* 2003;181:627.
11. Linehan WM, Walther MM, Zbar B. The genetic basis of cancer of the kidney. *J Urol.* 2003;170:2163.
12. Flanigan RC, Salmon SE, Blumenstein BA, et al. Nephrectomy followed by interferon alfa-2b compared with interferon alfa-2b alone for metastatic renal cell cancer. *N Engl J Med.* 2001;345:1655.
13. Mickisch GHJ, Garin A, van Poppel H, et al. Radical nephrectomy plus interferon-alfa-based immunotherapy compared with interferon alfa alone in metastatic renal cell carcinoma: a randomized trial. *Lancet.* 2001;358:966.
14. Huang WC, Levey AS, Serio AM, et al. Chronic kidney disease after nephrectomy in patients with renal cortical tumors: a retrospective cohort study. *Lancet Oncol.* 2006;7:735.
15. Rabbani F, Herr HW, Almahmeed T, et al. Temporal change in risk of metachronous contralateral renal cell carcinoma: influence of tumor characteristics and demographic factors. *J Clin Oncol.* 2002;20:2370.
16. Bosniak MA, Birnbaum BA, Krinsky GA, et al. Small renal parenchymal neoplasms: further observations on growth. *Radiology.* 1995;197:589.
17. Kavolius JP, Mastorakos DP, Pavlovich C, et al. Resection of metastatic renal cell carcinoma. *J Clin Oncol.* 1998;16:2261.
18. Bill-Axelsson A, Holmberg L, Filen F, et al. Radical prostatectomy versus watchful waiting in localized prostate cancer: the Scandinavian Prostate Cancer Group-4 Randomized Trial. *J Natl Cancer Inst.* 2008;100:1144.
19. Gleason DF, Mellinger GT, Veterans Administration Cooperative Research Group. Prediction of prognosis for prostatic adenocarcinoma by combined histologic grading and clinical staging. *J Urol.* 1974;111:58.
20. Walsh PC, Marschke P, Ricker D, et al. Patient-reported urinary continence and sexual function after anatomic radical prostatectomy. *Urology.* 2000;55:58.
21. Buckley JC, McAninch JW. Selective management of isolated and nonisolated grade IV renal injuries. *J Urol.* 2006;176:2498.
22. Koraitim MM. Pelvic fracture urethral injuries: the unresolved controversy. *J Urol.* 1999;161:1433.
23. Moudouni SM, Patard JJ, Manunta A, et al. Early endoscopic realignment of post-traumatic posterior urethral disruption. *Urology.* 2001;57:628.
24. Mouraviev V, Coburn M, Santucci R. The treatment of posterior urethral disruption associated with pelvic fractures: comparative experience of early realignment versus delayed urethroplasty. *J Urol.* 2005;173:873.
25. Corrales JG, Corbel L, Cipolla B, et al. Accuracy of ultrasound diagnosis after blunt testicular trauma. *J Urol.* 1993;150:1834.
26. Sawh SL, O'Leary MP, Ferreira MD, et al. Fractured penis: a review. *Int J Impot Res.* 2008;20:366.
27. Donohue RE, Utley WLF. Torsion of the spermatic cord. *J Urol.* 1978;40:33.
28. Taskinen S, Taskinen M, Rintala R. Testicular torsion: orchietomy or orchiopexy? *J Pediatr Urol.* 2008;4:210.
29. Tahmaz L, Eredemir F, Kibar Y, et al. Fournier's gangrene: report of 33 cases and a review of the literature. *Int J Urol.* 2006;13:960.
30. Pryor J, Akkus E, Alter G, et al. Priapism. *J Sex Med.* 2004;1:116.
31. Verit A, Verit FF. Fournier's gangrene: the development of a classical pathology. *BJU Int.* 2007;100:1218.
32. Ekstrom B, Olsson AM. Priapism in patients treated with total parenteral nutrition. *Br J Urol.* 1987;59:170.
33. Dent LA, Brown WC, Murney JD. Citalopram-induced priapism. *Pharmacotherapy.* 2002;22:538.
34. Pecknold JC, Langer SF. Priapism: trazodone versus nefazodone. *J Clin Psychiatry.* 1996;57:547.
35. Miller ST, Rao SO, Dunn EK, et al. Priapism in children with sickle cell disease. *J Urol.* 1995;154:844.
36. Hellstrom WJ, Derosa A, Lang E. The use of transcatheter superselective embolization to treat high flow priapism (arteriocavernosal fistula) caused by straddle injury. *J Urol.* 2007;178:1059.
37. Williams JC, Morrison PM, Richardson JR. Paraphimosis in elderly men. *Am J Emerg Med.* 1995;13:351.
38. Huang JJ, Tseng CC. Emphysematous pyelonephritis: clinicoradiological classification, management, prognosis, and pathogenesis. *Arch Int Med.* 2000;160:797.
39. Aswathaman K, Gopalakrishnan G, Gnanaraj L, et al. Emphysematous pyelonephritis: outcome of conservative management. *Urology.* 2008;71:1007.
40. Abdul-Halim H, Kehinde EO, Abdeen S, et al. Severe emphysematous pyelonephritis in diabetic patients: diagnosis and aspects of surgical management. *Urol Int.* 2005;75:123.
41. Capodice JL, Bemis DL, Buttyan R, et al. Complementary and alternative medicine for chronic prostatitis/chronic pelvic pain syndrome. *Evid Based Complement Alternat Med.* 2005;2:495.
42. Spaliviero M, Araki M, Wong C. Short-term outcomes of Greenlight HPS laser photoselective vaporization prostatectomy (PVP) for benign prostatic hyperplasia (BPH). *J Endourol.* 2008;22:2341.
43. Andrich DE, Mundy AR. What is the best technique for urethroplasty? *Eur Urol.* 2008;54:1031.
44. Leahy AL, Ryan PC, McEntree GM. Renal injury and recovery in partial ureteric obstruction. *J Urol.* 1989;142:199.
45. Vaughan ED, Gillenwater JY. Recovery following complete chronic unilateral ureteral occlusion: functional, radiographic, and pathologic alterations. *J Urol.* 1971;106:27.
46. Paick SH, Park HK, Oh SJ, et al. Characteristics of bacterial colonization and urinary tract infection after indwelling of double-J ureteral stent. *Urology.* 2003;62:214.
47. Johnson CM, Wilson DM, O'Fallon WM, et al. Renal stone epidemiology: a 25-year study in Rochester, Minnesota. *Kidney Int.* 1979;16:624.
48. Daudon M, Estepa L, Kebede M, et al. Urinary calculi and crystalluria in HIV+ patients treated with indinavir sulfate. *Presse Med.* 1997;26:1612.
49. Cryer PE, Garber AJ, Hoffsten P, et al. Renal failure after small intestinal bypass for obesity. *Arch Intern Med.* 1975;135:1610.

50. Ueno A, Kawamura T, Ogawa A, et al. Relation of spontaneous passage of ureteral calculi to size. *Urology*. 1977;10:544.
51. Sayed MA, Abolysor A, Abdalla MA, et al. Efficacy of tamsulosin in medical expulsive therapy for distal ureteral calculi. *Scand J Urol Nephrol*. 2008;42:59.
52. Rashid P, Steele D, Hunt J. Splenic rupture after extracorporeal shock wave lithotripsy. *J Urol*. 1996;156:1756.
53. Marcuzzi D, Gray R, Wesley-James T. Symptomatic splenic rupture following extracorporeal shock wave lithotripsy. *J Urol*. 1991;145:547.
54. Curhan GC, Willett WC, Rimm EB, et al. A prospective study of dietary calcium and other nutrients and the risk of symptomatic kidney stones. *N Engl J Med*. 1993;328:833.
55. Koep L, Zuidema GD. The clinical significance of retroperitoneal fibrosis. *Surgery*. 1977;81:250.
56. Srinivas V, Dow D. Retroperitoneal fibrosis. *Can J Surg*. 1984;27:111.
57. Smellie JM, Normand IC. Clinical features and significance of urinary tract infection in children. *Arch Dis Child*. 1968;43:468.
58. Duckett JW. Vesicoureteral reflux: a "conservative" analysis. *Am J Kidney Dis*. 1983;3:139.
59. Arant BS. Medical management of mild and moderate vesicoureteral reflux: Follow up studies of infants and young children. A preliminary report of the Southwest Nephrology Group. *J Urol*. 1992;148:1683.
60. Kousidis G, Thomas DF, Morgan H, et al. The long-term outcome of prenatally detected posterior urethral valves: a 10 to 23-year follow-up. *BJU Int*. 2008;102:1020.

This page intentionally left blank

41 chapter

Gynecology

Chad Hamilton, Michael Stany, W. Thomas Gregory,
and Elise C. Kohn

Pathophysiology and Mechanisms of Disease 1671

Anatomy 1671

Structure and Support of the Pelvis
and Genitalia / 1671

Vasculature and Nerves
of the Pelvis / 1672

Vulva / 1673

Vagina / 1674

Fibrovascular Ligaments and Avascular
Tissue Planes / 1674

Uterus / 1675

Cervix / 1675

Fallopian Tubes / 1675

Ovaries / 1675

Evaluation and Diagnosis 1675

Elements of a Gynecologic History / 1675

The Gynecologic Examination / 1675

Common Screening and Testing / 1676

Common Office Procedures
for Diagnosis / 1677

Benign Gynecologic Conditions 1678

Vulvar Lesions / 1678

Vaginal Lesions / 1680

Cervical Lesions / 1681

Uterine Corpus / 1682

Benign Ovarian and Fallopian Tube
Lesions / 1689

Other Pelvic Pathology / 1689

Pregnancy-Related Surgical Conditions 1691

Conditions and Procedures Performed
Before Viability / 1691

Conditions and Procedures Performed
After Viability / 1692

Pelvic Floor Dysfunction 1694

Evaluation / 1694

Surgery for Pelvic Organ Prolapse / 1694

Surgery for Stress Urinary
Incontinence / 1695

Gynecologic Cancer 1696

Vulvar Cancer / 1696

Vaginal Cancer / 1697

Cervical Cancer / 1697

Uterine Cancer / 1698

Ovarian, Tubal, and Primary
Peritoneal Cancer / 1701

Minimally Invasive Gynecologic Surgery 1704

Hysteroscopy / 1704

Laparoscopy / 1704

Complications Related to Gynecologic
Surgery / 1704

Robotic Surgery / 1705

PATHOPHYSIOLOGY AND MECHANISMS OF DISEASE

The female reproductive tract is a unique component of the body with a multitude of tightly regulated functions. Many of the activities normally ongoing, such as angiogenesis and physiologic invasion, are necessary in order for the reproductive organs to fulfill their purpose and are usurped in disease. Immune surveillance is modified by multiple mechanisms under investigation and regulated in a different fashion, in order to allow implantation, placentation, and development of the fetus. How this potential disruption of normal immune barriers is involved in pathologic events is incompletely understood.

The pelvis is a very complex area, with a multitude of spatially and temporally varied functions. It is a site where pathologies ranging from mechanical events, such as ovarian torsion or ruptured ectopic pregnancy, to infection, such as pelvic inflammatory disease, to mass effects, including leiomyomata and malignancy, can present with similar and even overlapping symptoms and signs. An acute abdomen presentation in a woman of child-bearing potential can range from pregnancy-related catastrophes to appendicitis.

The ongoing rupture, healing, angiogenesis, and regrowth of the ovarian capsule and endometrium during the menstrual cycle uses the same series of biological and biochemical events that are also active in pathologic events such as endometriosis and endometriomas, mature teratomas, dysgerminomas, and progression to malignancy. Genetic abnormalities, both germline and somatic, that may

cause competence and/or promote disease are now being uncovered, especially in the progression to malignancy, in pharmacogenomics, and in surgical risks such as bleeding and clotting. Incorporation of genetic and genomic information in disease diagnosis and assessment is a wave for the near future and may alter how we diagnose and follow disease, in whom we increase our diligence in searching for disease, and ultimately how we use the drug and other therapeutic armamentarium available to the treating physician.

These points will be incorporated with surgical approaches into discussions of anatomy, diagnostic workup, infection, surgical and medical aspects of the obstetric patient, pelvic floor dysfunction, and neoplasms.

ANATOMY

Clinical gynecologic anatomy centers on the pelvis (from Latin meaning *basin*). Aptly named, the bowl-shaped pelvis houses the confluence and intersection of multiple organ systems. Understanding those structural and functional relationships is essential for the surgeon and allows an appreciation for the interplay of sexual function and reproduction and a context for understanding gynecologic pathology.

Structure and Support of the Pelvis and Genitalia

The bony pelvis is comprised by the *sacrum* posteriorly and the *ischium*, *ilium*, and *pubis* bones anteromedially. It supports the upper body and transmits the stresses of weight bearing to the

Key Points

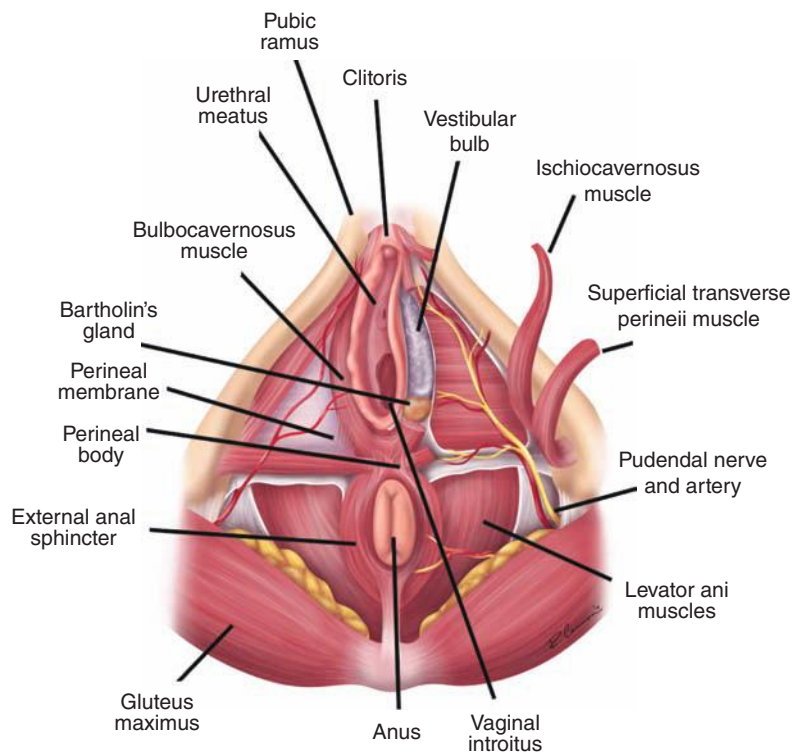
- 1▶ Gynecologic causes of acute abdomen include pelvic inflammatory disease, tubo-ovarian abscess, ovarian torsion, ruptured ectopic pregnancy, and septic abortion. Pregnancy must be ruled out early in assessment of reproductive-age patients presenting with abdominal or pelvic pain.
- 2▶ The general gynecology exam must incorporate the whole physical examination in order to adequately diagnosis and treat gynecologic disorders.
- 3▶ Benign gynecologic pathologies that are encountered at the time of surgery include endometriosis, endometriomas, fibroids, and ovarian cysts.
- 4▶ It is critical that abnormal lesions of the vulva, vagina, and cervix are biopsied for diagnosis before any treatment is planned; postmenopausal bleeding should always be investigated to rule out malignancy.
- 5▶ Early-stage cervical cancer is managed surgically, whereas chemoradiation is preferred for stage IB2 and above.
- 6▶ Pregnancy confers important changes to both the cardiovascular system and the coagulation cascade. Trauma in pregnancy must be managed with these changes in mind.
- 7▶ Pelvic floor dysfunction (pelvic organ prolapse, urinary and fecal incontinence) is common; 11% of women will undergo a reconstructive surgical procedure at some point in their lives.
- 8▶ Radical hysterectomy has unique risks of ureteral fistula and bowel dysfunction.
- 9▶ Risk-reducing salpingo-oophorectomy (RRSO) should be considered in women with *BRCA1* or *BRCA2* mutations; RRSO and complete hysterectomy should be considered in women with Lynch syndrome.
- 10▶ Optimal debulking for epithelial ovarian cancer is a critical element in patient response and survival. The preferred primary therapy for optimally debulked advanced-stage ovarian epithelial ovarian cancer is intraperitoneal chemotherapy.

lower limbs in addition to providing anchors for the supporting tissues of the pelvic floor.¹ The opening of the pelvis is spanned by the muscles of the pelvic diaphragm (Fig. 41-1). The muscles of the pelvic sidewall include the *iliacus*, the *psaos*, and the *obturator internus* muscle (Fig. 41-2). These muscles contract tonically and include, from anterior to posterior, bilaterally, the *pubococcygeus*, *puborectalis*, *iliococcygeus*, and *coccygeus* muscles. The first two of these muscles contribute fibers to the fibromuscular perineal body. The *urogenital hiatus* is bordered laterally by the pubococcygeus muscles and anteriorly by the *symphysis pubis*. It is through

this muscular defect that the urethra and vagina pass, and it is the focal point for the study of disorders of pelvic support such as cystocele, rectocele, and uterine prolapse.

Vasculature and Nerves of the Pelvis

The rich blood supply to the pelvis arises largely from the *internal iliac* arteries except for the *middle sacral* artery originating at the aortic bifurcation and the ovarian arteries originating from the abdominal aorta. The internal iliac, or hypogastric, arteries divide into anterior and posterior branches. The latter supply lumbar and gluteal branches. From the anterior division of



1672 **Figure 41-1.** Deeper muscles of the pelvic floor.

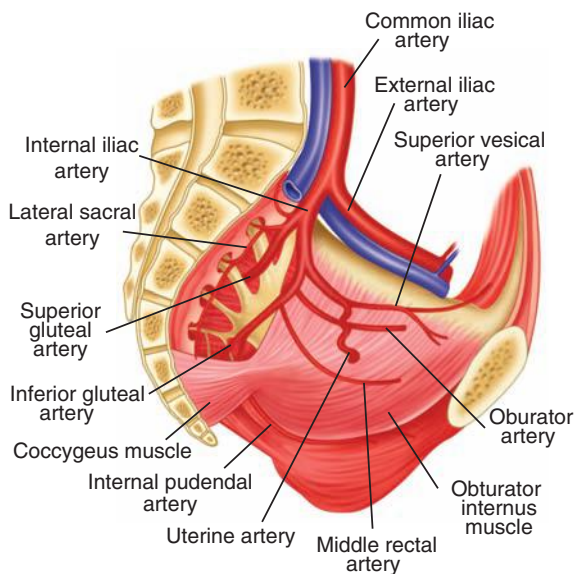


Figure 41-2. The muscles and vasculature of the pelvis.

the hypogastric arteries arise the *obturator, uterine, pudendal, middle rectal, inferior gluteal, and superior and middle vesical* arteries (see Fig. 41-2).

The major nerves found in the pelvis are the *sciatic, obturator, and femoral* nerves. Sympathetic fibers course along the major arteries, and parasympathetics form the superior and inferior *pelvic plexus* (Fig. 41-3). The *pudendal* nerve arises from S2-S4 and travels laterally, exiting the greater sciatic foramen, hooking around the ischial spine and *sacrospinous ligament*, and returning via the greater sciatic foramen. It travels through Alcock's canal and becomes the sensory and motor nerve of the perineum (see Figs. 41-1 and 41-3). The motor neurons serve the tonically contracting urethral and anal sphincter, and direct branches from the

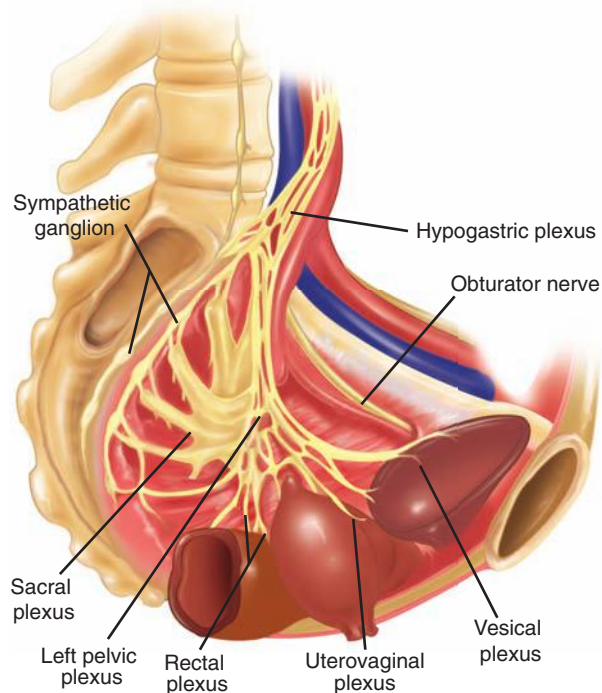


Figure 41-3. The nerve supply of the female pelvis.

S2-S4 nerves serve the *levator ani* muscles. During childbirth and other excessive straining, this tethered nerve (along with the levator ani muscles) is subject to stretch injury and at least partially responsible for many female pelvic floor disorders.

Vulva

The *labia majora* form the cutaneous boundaries of the lateral vulva and represent the female homologue of the male scrotum (Fig. 41-4). The labia majora are fatty folds covered by hair-bearing

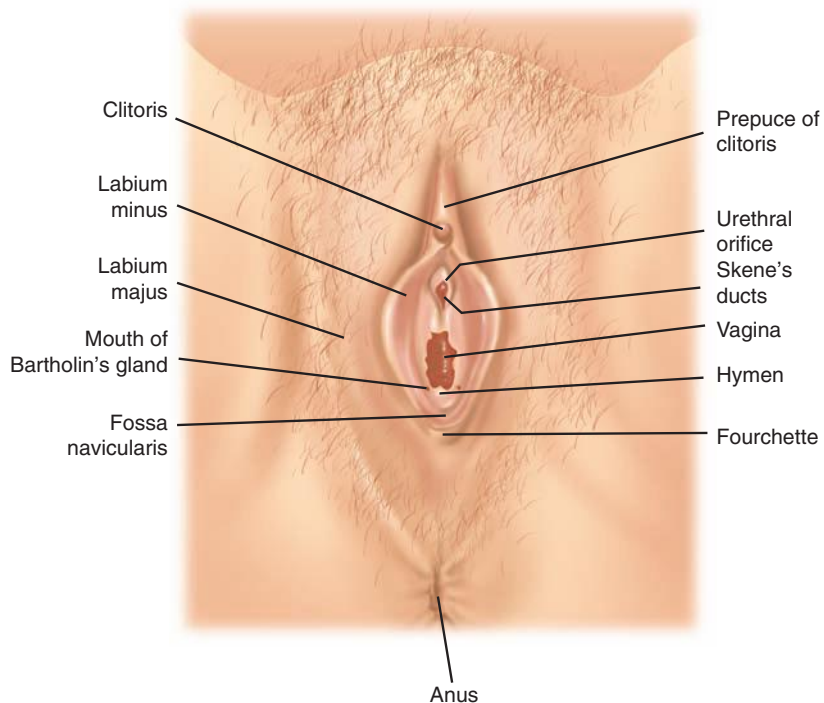


Figure 41-4. External genitalia. (Reproduced with permission from Rock J, Jones HW. *TeLinde's Operative Gynecology*. 9th ed. Philadelphia, PA: Lippincott Williams & Wilkins; 2003, Fig. 5-1, p. 70.)

skin in the adult. They fuse anteriorly over the anterior prominence of the *symphysis pubis*, the *mons pubis*. The deeper portions of the adipose layers are called Colles' fascia and insert onto the inferior margin of the perineal membrane, limiting spread of superficial hematomas inferiorly. Adjacent and medial to the labia majora are the *labia minora*, smaller folds of connective tissue covered laterally by non-hair-bearing skin and medially by vaginal mucosa. The anterior fusion of the labia minora forms the *prepuce and frenulum of the clitoris*; posteriorly, the labia minora fuse to create the *fossa navicularis* and *posterior fourchette*. The term *vestibule* refers to the area medial to the labia minora bounded by the *fossa navicularis* and the clitoris. Both the urethra and the vagina open into the vestibule. Skene's glands lie lateral and inferior to the urethral meatus. Cysts, abscesses, and neoplasms may arise in these glands.

Erectile tissues and associated muscles are in the space between the perineal membrane and the vulvar subcutaneous tissues (see Fig. 41-1). The clitoris is formed by two crura and is suspended from the pubis. Overlying the crura are *ischio-cavernosus* muscles, which run along the inferior surfaces of the *ischiopubic rami*. Extending medially from the inferior end of the ischiocavernosus muscles are the *superficial transverse perinei* muscles. These terminate in the midline in the perineal body, caudal and deep to the posterior fourchette. *Vestibular bulbs* lie just deep to the vestibule and are covered laterally by *bulbocavernosus* muscles. These originate from the perineal body and insert into the body of the clitoris. At the inferior end of the vestibular bulbs are Bartholin's glands, which connect to the vestibular skin by ducts.

Vagina

The vagina is an elastic fibromuscular tube opening from the vestibule running superiorly and posteriorly, passing through the *perineal membrane*. The lower third is invested by the superficial and deep perineal muscles; it incorporates the urethra in its anterior wall and has a rich blood supply from the vaginal branches of the *external and internal pudendal* arteries. The upper two thirds of the vagina are not invested by muscles. This portion lies in opposition to the bladder base anteriorly and the rectum and posterior pelvic cul-de-sac superiorly. The cervix opens into the posterior vaginal wall bulging into the vaginal lumen.

Fibrovascular Ligaments and Avascular Tissue Planes

Figure 41-5 is a view of the internal genitalia as one would approach the pelvis from a midline abdominal incision. The central uterus and uterine cervix are supported by the pelvic floor muscles. They are suspended by the lateral fibrous cardinal, or *Mackenrodt's ligament*, and the *uterosacral ligaments*, which insert into the *paracervical fascia* medially and into the muscular sidewalls of the pelvis laterally. Posteriorly, the uterosacral ligaments provide support for the vagina and cervix as they course from the sacrum lateral to the rectum and insert into the paracervical fascia. Emanating from the *uterine cornu* and traveling through the inguinal canal are the *round ligaments*, eventually attaching to the subcutaneous tissue of the mons pubis. The peritoneum enfolding the *adnexa* (tube, round ligament, and ovary) is referred to as the *broad ligament*, which separates the pelvic cavity into an anterior and posterior component.

The peritoneal recesses in the pelvis anterior and posterior to the uterus are referred to as the *anterior* and *posterior*

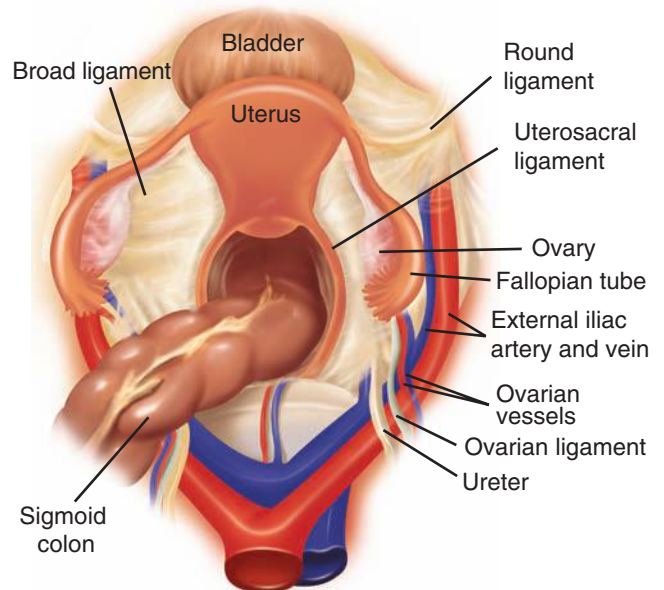


Figure 41-5. Internal pelvic anatomy, from above.

cul-de-sacs. The latter is also called the *pouch* or *cul-de-sac of Douglas*. On transverse section, several avascular, and therefore important, surgical planes can be identified (Fig. 41-6). These include the lateral paravesical and pararectal spaces and, from anterior to posterior, the retropubic or prevesical space of Retzius and the vesicovaginal, rectovaginal, and retrorectal or presacral spaces.

These avascular tissue planes are often preserved and provide safe surgical access when the intraperitoneal pelvic anatomy is distorted by tumor, endometriosis, adhesions, or infection. As an example, the ureter is at significant risk of iatrogenic injury in the context of such pathology. Using the avascular retroperitoneal planes, the ureter can be traced into the pelvis as it crosses the distal common iliac arteries laterally into the pararectal space and then courses inferior to the ovarian arteries and veins until crossing under the uterine arteries into the paravesical space just lateral to the cervix. After traveling to the cervix, the ureters course downward and medially over the anterior surface of the vagina before entering the base of the bladder in the vesicovaginal space.

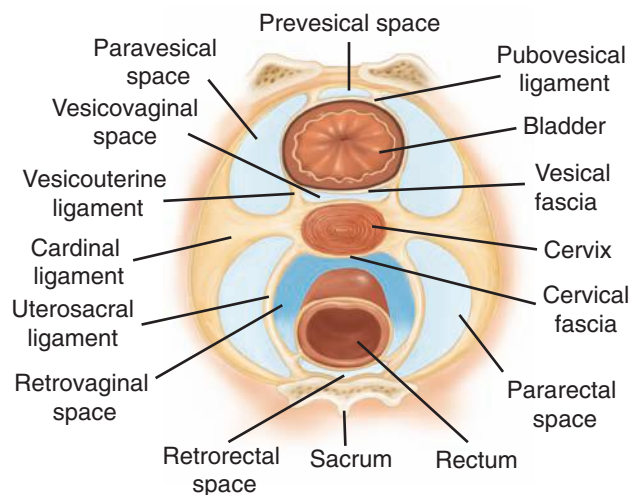


Figure 41-6. The avascular spaces of the female pelvis.

Uterus

The typically pear-shaped uterus consists of a fundus, cornua, body, and cervix. It lies between the bladder anteriorly and the rectosigmoid posteriorly. The *endometrium* lines the cavity and has a superficial functional layer that is shed with menstruation and a basal layer from which the new functional layer is formed. Sustained estrogenic stimulation can lead to hyperplastic changes or carcinoma. Adenomyosis is a condition in which benign endometrial glands infiltrate into the muscle or myometrium of the uterus. The *myometrium* is composed of smooth muscle, and the contraction of myometrium is a factor in menstrual pain and is essential in childbirth. The myometrium can develop benign smooth muscle neoplasms known as leiomyoma or fibroids.

Cervix

The cervix connects the uterus and vagina and projects into the upper vagina. The vagina forms an arched ring around the cervix described as the *vaginal fornices*—lateral, anterior, and posterior. The cervix is about 2.5 cm long with a fusiform endocervical canal lined by columnar epithelium lying between an *internal and external os*, or opening. The vaginal surface of the cervix is covered with stratified squamous epithelium, similar to that lining the vagina. The squamocolumnar junction, also referred to as the *transformation zone*, migrates at different stages of life and is influenced by estrogenic stimulation. The transformation zone develops as the columnar epithelium is replaced by squamous metaplasia. This transformation zone is vulnerable to human papillomavirus (HPV) infection and resultant dysplastic changes. These changes can be detected by microscopic assessment of a cervical cytologic (or Pap) smear. If the duct of a cervical gland becomes occluded, the gland distends to form a retention cyst or Nabothian follicle.

Fallopian Tubes

The bilateral fallopian tubes arise from the upper lateral *cornua* of the uterus and course posterolaterally within the upper border of the broad ligament. The tubes can be divided into four parts. The *interstitial* part forms a passage through the myometrium. The *isthmus* is the narrow portion extending out about 3 cm from the myometrium. The *ampulla* is thin-walled and tortuous with its lateral end free of the broad ligament. The *infundibulum* is the distal end fringed by a ring of delicate fronds or *fimbriae*. The fallopian tubes receive the ovum after ovulation. Peristalsis carries the ovum to the ampulla where fertilization occurs. The zygote transits the tube over the course of 3 to 4 days to the uterus. Abnormal implantation in the fallopian tube is the most common site of ectopic pregnancies. The tubes may also be infected by ascending organisms, resulting in tubo-ovarian abscesses.

Ovaries

The ovaries are attached to the uterine cornu by the *proper ovarian ligaments*, or the *utero-ovarian ligaments*. The ovaries are suspended from the lateral pelvis by their vascular pedicles, the *infundibulopelvic (IP) ligaments* or *ovarian arteries*. The IP ligaments are paired branches from the abdominal aorta arising just below the renal arteries. They merge with the peritoneum over the psoas major muscle and pass over the pelvic brim and the external iliac vessels. The ovarian veins ascend at first with the ovarian arteries, and then track more laterally. The right ovarian vein ascends to drain directly into the inferior

vena cava, whereas the left vein drains into the left renal vein. Lymphatic drainage follows the arteries to the para-aortic lymph nodes. The ovaries are covered by a single layer of cells that is continuous with the mesothelium of the peritoneum. Beneath this is a fibrous stroma within which are embedded germ cells. At ovulation, an ovarian follicle ruptures through the ovarian epithelium.

EVALUATION AND DIAGNOSIS

Elements of a Gynecologic History

A complete history is a seminal part of any assessment (Table 41-1). Many gynecologic diseases can present with broad constitutional symptoms, occur secondary to other conditions, or be related to medications. A full history should include particular attention to family history; organ system history, including breast, gastrointestinal, and urinary tract symptoms; and a careful medication, anesthesia, and surgical history. The key elements of a focused gynecologic history include the following:

- Date of last menstrual period, if premenopausal
- History of contraceptive and postmenopausal hormone use
- Obstetrical history
- Age at menarche and menopause (method of menopause, e.g., drug, surgical)
- Menstrual bleeding pattern
- History of pelvic assessments, including cervical smear results
- History of pelvic infections, including HPV, and human immunodeficiency virus (HIV) status
- Sexual history (number of lifetime partners)
- Prior gynecologic surgery(s)

The Gynecologic Examination

For many women, their gynecologist is their primary care physician. When that is the case, it is necessary that a full medical and surgical history be taken and that, in addition to the pelvic examination, the minimum additional examination should include assessment of the thyroid, breasts, and cardiopulmonary system. The pelvic examination starts with a full abdominal examination. Inguinal node evaluation is performed before placing the patient's legs in the dorsal lithotomy position (in stirrups). A flexible, focused light source is essential, and vaginal instruments including speculums of variable sizes and shapes including pediatric sizes (Graves and Pederson) are required to assure that the patient's anatomy can be fully and comfortably viewed.

The external genitalia are inspected, noting the distribution of pubic hair, the skin color and contour, the Bartholin and Skene's glands, and perianal area. Abnormalities are documented, and a map with measurements of abnormalities is drawn. A warmed lubricated speculum is inserted into the vagina and gently opened to identify the cervix if present, or the vaginal apex if not. If there is a concern that a malignancy is present, careful digital assessment of a vaginal mass and location may be addressed prior to speculum placement in order to avoid abrading a vascular lesion and inducing hemorrhage. The speculum would then be inserted just short of the length to the mass in order to view that area directly before advancing. An uncomplicated speculum exam includes examination of the vaginal sidewalls; assessment of secretions, including culture if necessary; and collection of the cervical cytologic specimen if indicated (see later section, Common Screening and Testing).

Table 41-1

Key elements of the gynecologic history

ISSUE	ELEMENTS TO EXPLORE	ASSOCIATED ISSUES
Menstrual history	Age at menarche, menopause. Bleeding pattern, postmenopausal bleeding, spotting between periods Any medications (warfarin, heparin, aspirin, herbals, others) or personal or family history that might lead to prolonged bleeding times	Identifies abnormal patterns related to endocrine, structural, infectious, and oncologic etiologies
Obstetrical history	Number of pregnancies, dates, type of deliveries, pregnancy loss, abortion, complications	Identifies potential surgical complications due to previous cesarean sections
Infectious diseases	Sexually transmitted diseases (STDs) and treatment and/or testing for these	Also need to explore history of other gastrointestinal diseases that may mimic STD (Crohn's, diverticulitis)
Contraceptive history	Present contraception if appropriate, prior use, type and duration	Concurrent pregnancy with procedure or complications of contraceptives
Cytologic screening	Frequency, results (normal, prior abnormal Pap), any prior surgery or diagnoses, human papillomavirus testing history	Prolonged intervals increase risk of cervical cancer Relationship to anal, vaginal, vulvar cancers
Prior gynecologic surgery	Type (laparoscopy, vaginal, abdominal); diagnosis (endometriosis?, ovarian cysts?, tubo-ovarian abscess?); actual pathology if possible	Assess present history against this background (for example, granulosa cell pathology; is it now recurrent?)
Pain history	Site, location, relationship (with urination, with menses, with intercourse at initiation or deep penetration, with bowel movements), referral	Assesses relationship to other organ systems and potential involvement of these with process Common examples presenting as pelvic pain, ureteral stone, endometriosis with bowel involvement, etc.

A bimanual examination is performed by placing two fingers in the vaginal canal; one finger may be used if patient has significant vaginal atrophy or has had prior radiation with stenosis (Fig. 41-7). Carefully and sequentially assess the size and shape of the uterus by moving it against the abdominal hand, and assess the adnexa by carefully sweeping the abdominal hand down the side of the uterus. The rectovaginal examination, consisting of one finger in the vagina and one in the rectal vault, is used to further examine and characterize the location, shape, fixation, size, and complexity of the uterus, adnexa, cervix, and anterior and posterior cul-de-sacs. The rectovaginal exam also allows examination of the uterosacral ligaments from the back of the uterus sweeping laterally to the rectal finger and the sacrum, and a stool sample for occult blood can be obtained during this exam.

It is critical that presurgical assessments include a full general examination. This is particularly important with potential oncologic diagnoses or infectious issues, in order to assure that the proposed surgery is both safe and appropriate. Complications such as sites of metastatic cancer or infection, associated bleeding and/or clotting issues and history, and drug exposure, allergies, and current medications must be addressed.

Common Screening and Testing

Cervical Preinvasive and Invasive Disease Screening.

The most recent cervical cytology guidelines by the U.S. Preventative Services Task Force has increased the intervals for

most women given the known natural history of HPV-related cervical dysplasia progression to cancer.² The very high negative predictive value of the HPV test allows for this change. The current recommendations call for cervical smear screening every 3 years in women age 21 to 65 years. If an HPV test

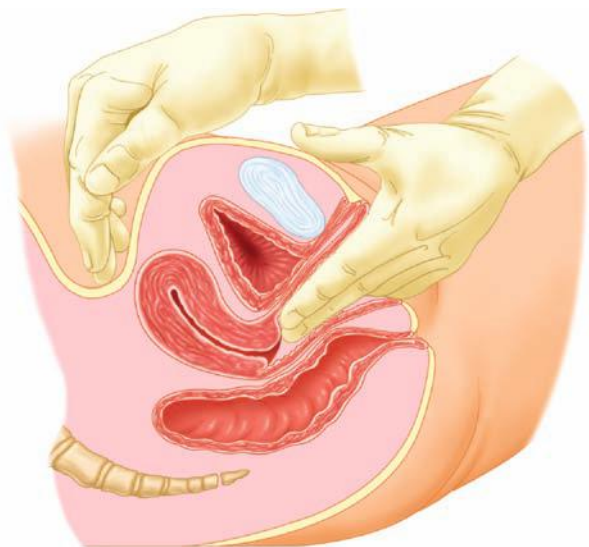


Figure 41-7. Bimanual abdominovaginal palpation of the uterus.

Table 41-2

Features of common causes of vaginitis

	BACTERIAL VAGINOSIS	VULVOVAGINAL CANDIDIASIS	TRICHOMONIASIS
Pathogen	Anaerobic organisms	<i>Candida albicans</i>	<i>Trichomonas vaginalis</i>
% of vaginitis	40	30	20
pH	>4.5	<4.5	>4.5
Signs and symptoms	Malodorous, adherent discharge	White discharge, vulvar erythema, pruritus, dyspareunia	Malodorous purulent discharge, vulvovaginal erythema, dyspareunia
Wet mount	Clue cells	Pseudohyphae or budding yeasts in 40% of cases	Motile trichomonads
KOH mount		Pseudohyphae or budding yeasts in 70% of cases	
Amine test	+	–	–
Treatment	Metronidazole 500 mg bid × 7 d or 2 g single dose, metronidazole or clindamycin vaginal cream	Oral fluconazole 150 mg single dose, vaginal antifungal preparations	Metronidazole 2 g single dose and treatment of partner

+ = positive; – = negative; bid = twice a day; KOH = potassium hydroxide.

performed at the same time also is negative, a Pap and HPV test combination does not need to be repeated in women age 30 to 65 for 5 years. HPV testing should not be performed as a screening test in women under age 30 due to the high prevalence of HPV, as well as the high likelihood of resolution of infection. Women with a history of cervical dysplasia or cancer need more frequent screening based on their diagnosis.

Microscopy of Vaginal Discharge. During a speculum exam, a cotton-tipped applicator is used to collect the vaginal discharge; it is smeared on a slide with several drops of 0.9% normal saline to create a saline wet mount. A cover slide is placed and the slide is evaluated microscopically for the presence of mobile trichomonads (*Trichomonas vaginalis*) or clue cells (epithelial cells studded with bacteria, seen in bacterial vaginosis; Table 41-2). A potassium hydroxide (KOH) wet mount is the slide application of the collected vaginal discharge with 10% KOH; this destroys cellular elements. The test is positive for vaginal candidiasis when pseudohyphae are seen (Table 41-2).

Chlamydia/Gonorrhea Testing. Nucleic acid amplification testing (NAAT) has emerged as the diagnostic test of choice for *Neisseria gonorrhoeae* and *Chlamydia trachomatis*. A vaginal swab, endocervical swab, and/or urine sample can be used for this test. The test can be completed within hours and has been found to be more sensitive than cultures.

β-Human Chorionic Gonadotropin (β-hCG) Testing. Qualitative urinary pregnancy tests for β-hCG are standard prior to any surgery in a woman of reproductive age and potential, regardless of contraception history. In addition, serum quantitative β-hCG testing is appropriate for evaluation of suspected ectopic pregnancy, gestational trophoblastic disease, or ovarian mass in a young woman. In the case of ectopic pregnancy, serial levels are required when a pregnancy cannot be identified in the uterine cavity. As a general rule, 85% of viable intrauterine pregnancies will have at least a 66% rise in the β-hCG level over 48 hours.

Common Office Procedures for Diagnosis

Vulvar/Vaginal Biopsy. Any abnormal vulvar or vaginal lesion including skin color changes, raised lesions, or ulcerations should be biopsied. Local infiltration with local anesthetic is followed by a 3- to 5-mm punch biopsy appropriate to the lesion. The specimen is elevated with Adson forceps and cut from its base with scissors. The vaginal biopsy can sometimes be difficult to perform because of the angle of the lesion. After injection with local anesthetic, traction of the area with Allis forceps and direct resection of the lesion with scissors or cervical biopsy instrument (Schubert, Kevorkian, etc.) can achieve an adequate biopsy.

Colposcopy and Cervical Biopsy. In cases of an abnormal Pap smear cytology, a colposcopy is performed for a histologic evaluation. A colposcope is used to achieve 2× to 15× magnification of the cervix. Once the cervix is visualized, cervical mucus, if present, is removed, and then 3% acetic acid is applied to the cervix for 1 minute. This application dehydrates cells and causes dysplastic cells with dense nuclei to appear white. The entire squamocolumnar junction is visualized during an adequate colposcopy. This area is seen as the transition from the smooth-appearing squamous ectocervix to the pink endocervical tissue. Acetowhite areas or areas with punctuation, mosaicism, or atypical blood vessels seen during colposcopy may represent dysplasia or cancer and should be biopsied.

Endometrial Biopsy. Endometrial sampling should be performed before planned hysterectomy if there is a history of bleeding between periods, heavy and/or frequent menstrual periods, or postmenopausal bleeding. A patient with the potential for pregnancy should have a pregnancy test before the procedure. An endometrial pipelle is inserted after cervical cleaning, and the depth of the uterine cavity is noted. The endometrial specimen is obtained by pulling on the plunger within the pipelle, creating a small amount of suction. The pipelle is rotated and pulled back from the fundus to the lower uterine segment within

the cavity to access all sides.³ Additional passes may be needed in order to acquire an adequate amount of tissue.

Evaluation for Fistula. When a patient presents with copious vaginal discharge, the provider must be concerned about a fistula with the urinary or gastrointestinal tract. A simple office procedure can be performed when there is a concern for a vesicovaginal fistula. A vaginal tampon is placed, followed by instillation of sterile blue dye through a transurethral catheter into the bladder; a positive test is blue staining of the tampon. If the test is negative, one can evaluate for a ureterovaginal fistula. The patient is given phenazopyridine, which changes the color of urine to orange. If a tampon placed in the vagina stains orange, the test is positive. Alternatively, the patient can be given an intravenous injection of indigo carmine.

Rectal fistula must be considered when a patient reports stool evacuation per vagina. It can be identified in a similar fashion using a large Foley catheter placed in the distal rectum through which dye may be injected or with the use of an oral charcoal slurry and timed examination. Common areas for fistulae are at the vaginal apex, at the site of a surgical incision, or around the site of a prior episiotomy or perineal repair after a vaginal delivery.

BENIGN GYNECOLOGIC CONDITIONS

Vulvar Lesions

Many women suffer with undiagnosed symptoms of vulvar disease. Patients presenting with chronic vulvar symptoms should be carefully interviewed, examined, and a vulvar biopsy obtained whenever the diagnosis is in question, the patient is not responding to treatment, or premalignant or malignant disease is suspected. Vulvar conditions such as contact dermatitis, atrophic vulvovaginitis, lichen sclerosis, lichen planus, lichen chronicus simplex, Paget's disease, Bowen's disease, and invasive vulvar cancer are not uncommon. Systemic diseases like psoriasis, eczema, Crohn's disease, Behçet's disease, vitiligo, and seborrheic dermatitis may also involve the vulvar skin.

Vulvar Contact Dermatitis. This dermatitis is a common cause of acute or chronic vulvar pruritus and can be irritant or allergic.⁴ Irritant dermatitis usually results from overzealous hygiene habits, such as the use of harsh soaps and frequent douching. It is also common in patients with urinary or fecal incontinence, especially the elderly and the disabled. Allergic vulvar dermatitis is caused by a variety of allergens, such as fragrances and topical antibiotics. The mainstay of treatment is to identify and discontinue the offending agent or practice or providing a skin barrier in the case of incontinence.

Leukoplakias. There are three types of leukoplakia, a flat white abnormality. Lichen sclerosis is the most common cause of leukoplakia.⁴ It affects women 30 to 40 years of age. Classically, it results in a figure-of-eight pattern of white epithelium around the anus and vulva resulting in variable scarring and itching and, less commonly, pain. Diagnosis is confirmed with biopsy, and treatment consists of topical steroids. Lichen planus is a cause of leukoplakia with an onset in the fifth and sixth decades of life. Lichen planus, in contrast to lichen sclerosis, which is limited to the vulva and perianal skin, can involve the vagina and oral mucosa, and erosions occur in the majority of patients, leading to a variable degree of scarring. Patients usually have a history of dysuria and dyspareunia and complain

of a burning vulvar pain. Histology is not specific, and biopsy is recommended. Treatment is with steroid ointments. Systemic steroids are indicated for severe and/or unresponsive cases. Lichen simplex chronicus is the third cause of leukoplakia but is distinguished from the other lichen diseases by epidermal thickening, absence of scarring, and a severe intolerable itch.⁴ Intense scratching is not uncommon and contributes to the severity of the symptoms and predisposes the cracked skin to infections. Treatment consists of cessation of the scratching, which sometimes requires sedation; elimination of any allergen or irritant; suppression of inflammation with potent steroid ointments; and treatment of any coexisting infections.

Bartholin's Cyst or Abscess. Bartholin's glands, great vestibular glands, are located at the vaginal orifice at the four and eight o'clock positions; they are rarely palpable in normal patients. They are lined with cuboidal epithelium and secrete mucoid material to keep the vulva moist. Their ducts are lined with transitional epithelium, and their obstruction secondary to inflammation may lead to the development of a Bartholin's cyst or abscess. Bartholin's cysts range in size from 1 to 3 cm and are detected on exam or are recognized by the patient. They occasionally result in discomfort and dyspareunia and require treatment. Cysts and ducts can become infected and form abscesses. Infections are often polymicrobial; however, sexually transmitted *N. gonorrhoeae* and *C. trachomatis* are sometimes implicated. Treatment consists of incision and drainage and placement of a Word catheter, a small catheter with a balloon tip, for 2 to 3 weeks to allow for formation and epithelialization of a new duct. Appropriate antibiotic therapy should be instituted. Recurrent cysts or abscesses are usually marsupialized, but on occasion necessitate excision of the whole gland. Marsupialization is done by incising the cyst or abscess wall and securing its lining to the skin edges with interrupted sutures.⁵ Cysts or abscesses that fail to resolve after drainage and those occurring in patients over age 40 should be biopsied to exclude malignancy.

Molluscum Contagiosum. Molluscum contagiosum presents with dome-shaped papules and is caused by the poxvirus. The papules are usually 2 to 5 mm in diameter and classically have a central umbilication. They are spread by direct skin contact and present on the vulva, as well as abdomen, trunk, arms, and thighs. Lesions typically clear in several months but can be treated with cryotherapy, curettage, or cantharidin, a topical blistering agent.

Genital Ulcer Syndromes. The frequency of the infectious etiologies of genital ulcers varies by geographic location. The most common causes of sexually transmitted genital ulcers in young adults in the United States are, in descending order of prevalence, herpes simplex virus (HSV), syphilis, and chancroid.⁶ Others infectious causes of genital ulcers include lymphogranuloma venereum and granuloma inguinale. Non-infectious etiologies include Behçet's disease, neoplasms, and trauma. Table 41-3 outlines a rational approach to their evaluation and diagnosis.

Vulvar Condyloma. Condylomata acuminata (anogenital warts) are viral infections caused by HPV.⁷ Genital infection with HPV is the most common sexually transmitted infection in the United States today. HPV types 6 and 11 are the most common low-risk types and are implicated in 90% of cases of genital warts.⁸ High-risk types can be found in association

Table 41-3

Clinical features of genital ulcers syndromes

	HERPES	SYPHILIS	CHANCROID	LYMPHOGRANULOMA VENEREUM	GRANULOMA INGUINALE (DONOVANOSIS)
Pathogen	Herpes simplex virus (HSV) type II and less commonly HSV type I	<i>Treponema palladium</i>	<i>Haemophilus ducreyi</i>	<i>Chlamydia trachomatis</i> L1-L3	<i>Calymmatobacterium granulomatis</i>
Incubation period	2–7 days	2–4 weeks (1–12 weeks)	1–14 days	3 days–6 weeks	1–4 weeks (up to 6 months)
Primary lesion	Vesicle	Papule	Papule or pustule	Papule, pustule, or vesicle	Papule
Number of lesions	Multiple, may coalesce	Usually one	Usually multiple, may coalesce	Usually one	Variable
Diameter (mm)	1–2	5–15	2–20	2–10	Variable
Edges	Erythematous	Sharply demarcated, elevated, round, or oval	Undermined, ragged, irregular	Elevated, round, or oval	Elevated, irregular
Depth	Superficial	Superficial or deep	Excavated	Superficial or deep	Elevated
Base	Serous, erythematous	Smooth, nonpurulent	Purulent	Variable	Red and rough (“beefy”)
Induration	None	Firm	Soft	Occasionally firm	Firm
Pain	Common	Unusual	Usually very tender	Variable	Uncommon
Lymphadenopathy	Firm, tender, often bilateral	Firm, nontender, bilateral	Tender, may suppurate, usually unilateral	Tender, may suppurate, loculated, usually unilateral	Pseudo-adenopathy
Treatment	Acyclovir (ACV) 400 mg PO tid for 7–10 days for primary infection and 400 mg PO tid for 5 days for episodic management	Primary, secondary, and early latent (<1 year): penicillin G (PCN-G) benzathine 2.4 million U IM × 1 Late latent (>1 year) and latent of unknown duration: PCN-G benzathine 2.4 million U IM every week × 3	Azithromycin 1 g PO or ceftriaxone 250 mg IM × 1 <i>or</i> ciprofloxacin 500 mg PO bid for 3 days Erythromycin base 500 mg PO tid for 7 days	Doxycycline 100 mg PO bid for 21 days <i>or</i> erythromycin base 500 mg PO qid for 21 days	Doxycycline 100 mg PO bid for 3 weeks until all lesions have healed
Suppression	ACV 400 mg PO bid for those with frequent outbreaks				

bid = twice a day; IM = intramuscular; PO = oral; qid = four times a day; tid = twice a day.

Data from Stenchever M, Droegemueller W, Herbst A, et al. *Comprehensive Gynecology*. 4th ed. St. Louis: Mosby; 2001.

with invasive cancers. Genital warts are skin-colored or pink and range from smooth flattened papules to verrucous papilliform lesions. Lesions may be single or multiple and extensive. Diagnosis should be confirmed with biopsy because verrucous vulvar cancers can be mistaken for condylomata.⁹ Treatment modalities range from patient-applied ointments to physician-applied agents and office procedures. If small, self-administered topical imiquimod 5% cream or trichloroacetic acid for in-office applications may be tried. Extensive lesions may require surgical modalities that include cryotherapy, laser ablation, cauterization, and surgical excision.

Paget's Disease of the Vulva. Paget's disease of the vulva is an intraepithelial disease of unknown etiology that affects mostly white postmenopausal women in their sixth decade of life. It causes chronic vulvar itching and is sometimes associated with an underlying invasive vulvar adenocarcinoma or invasive cancers of the breast, cervix, or gastrointestinal tract. Grossly, the lesion is variable but usually confluent, raised, erythematous to violet, and waxy in appearance. Biopsy is required for diagnosis; the disease is intraepithelial and characterized by Paget's cells with large pale cytoplasm. Treatment is assessment for other potential concurrent adenocarcinomas, and then surgical removal by wide local resection of the involved area with a 2-cm margin. Free margins are difficult to obtain because the disease usually extends beyond the clinically visible area.^{10,11} Intraoperative frozen section of the margins can be done; however, Paget's vulvar lesions have a high likelihood of recurrence even after securing negative resection margins.

Vulvar Intraepithelial Neoplasia (VIN). VIN is similar to its cervical intraepithelial neoplasia (CIN) counterpart and is graded on the degree of epithelial involvement as mild (VIN I), moderate (VIN II), severe (VIN III), or vulvar carcinoma in situ (Bowen's disease).¹² Risk factors include HPV infection, prior VIN, HIV infection, immunosuppression, smoking, vulvar dermatoses such as lichen sclerosis, CIN, and cervical cancer. VIN can be unifocal or multifocal. Unifocal lesions commonly affect postmenopausal women and lack a clear association with HPV, while multifocal disease mostly affects younger reproductive-age females and has a strong association with HPV infection. Fifty percent of patients are asymptomatic, with vulvar pruritus being the most common complaint in those with symptoms. Lesions may be vague or raised and velvety with sharply demarcated borders. Diagnosis is made with a vulvar skin biopsy, and multiple biopsies are sometimes necessary. Colposcopy with application of 5% acetic acid and identification of the acetowhite lesions of VIN is a valuable diagnostic tool for subtle lesions and will help guide the biopsy. Evaluation of the perianal and anal area is important as the disease may involve these areas, particularly in immunocompromised and/or nicotine-addicted women. Once invasive disease is ruled out, treatment usually involves wide surgical excision; however, the initial treatment approach may include 5% imiquimod cream, CO₂ laser ablation, or cavitation ultrasonic surgical aspiration, and depends on the number of lesions and their severity. When laser ablation is used, a 1-mm depth in hair-free areas is usually sufficient, whereas hairy lesions require ablation to a 3-mm depth because the hair follicles' roots can reach a depth of 2.5 mm. Unfortunately, VIN tends to recur in up to 30% of cases, and high-grade lesions (VIN III, carcinoma in situ) progress to invasive disease in approximately 10% of patients if left untreated.¹³

Vaginal Lesions

Vaginitis (see Table 41-2). Vulvovaginal symptoms are extremely common, accounting for over 10 million office visits per year in the United States. The causes of vaginal complaints are commonly infectious in origin, but they include a number of noninfectious causes, such as chemicals or irritants, hormone deficiency, foreign bodies, systemic diseases, and malignancy. Symptoms are commonly nonspecific and include abnormal vaginal discharge, pruritus, irritation, burning, odor, dyspareunia, bleeding, and ulcers. A purulent discharge from the cervix should always raise suspicion of these infections even in the absence of pelvic pain or other signs.

Normal vaginal discharge is white or transparent, thick, and mostly odorless. It increases during pregnancy, with use of estrogen-progestin contraceptives, or at mid-cycle around the time of ovulation. Complaints of foul odor and abnormal vaginal discharge should be investigated. Candidiasis, bacterial vaginosis, and trichomoniasis account for 90% of vaginitis cases. The initial workup includes pelvic examination, vaginal pH testing, microscopy, vaginal cultures if microscopy is normal, and gonorrhea/chlamydia NAAT (see earlier section, Common Screening and Testing).¹⁴ The pH of normal vaginal secretions is 3.8 to 4.4, which is hostile to growth of pathogens. A pH greater than or equal to 4.9 is indicative of a bacterial or protozoal infection. Treatment of vaginal infection before anticipated surgery is appropriate, particularly for bacterial vaginosis, which may be associated with a higher risk for vaginal cuff infections (Fig. 41-8).

Bacterial Vaginosis (BV). BV accounts for 50% of vaginal infections. It results from reduction in concentration of the normally dominant lactobacilli and increase in concentration of anaerobic organisms like *Gardnerella vaginalis*, *Mycoplasma hominis*, *Bacteroides* species, and others.¹⁵ Diagnosis is made by microscopic demonstration of clue cells. The discharge typically produces a fishy odor upon addition of KOH (amine or Whiff test). Initial treatment is usually a 7-day course of metronidazole.

Vulvovaginal Candidiasis (VVC). VVC is the most common cause of vulvar pruritus. It is generally caused by *Candida albicans* and occasionally by other *Candida* species. It is common in pregnant women, diabetics, patients taking antibiotics, and immunocompromised hosts. Initial treatment is usually with topical antifungals, although single-dose oral antifungal treatments are also common.

Trichomonas vaginalis. Trichomoniasis is a sexually transmitted infection of a flagellated protozoan and can present with malodorous, purulent discharge. It is typically diagnosed with visualization of the trichomonads during saline wet mount microscopy. Initial treatment is usually a 7-day course of metronidazole.

Gartner's Duct Cyst. A Gartner's duct cyst is a remnant of the Wolffian tract; it is typically found on the lateral vaginal walls. Patients can be asymptomatic or present with complaints of dyspareunia or difficulty inserting a tampon. If symptomatic, these cysts may be surgically excised or marsupialized. If surgery is planned, a preoperative magnetic resonance imaging (MRI) scan should be obtained to determine the extent of the cyst.

Vaginal Condyloma. The etiology and treatment of vaginal condyloma is similar to vulvar condyloma (see earlier section, Vulvar Condyloma).

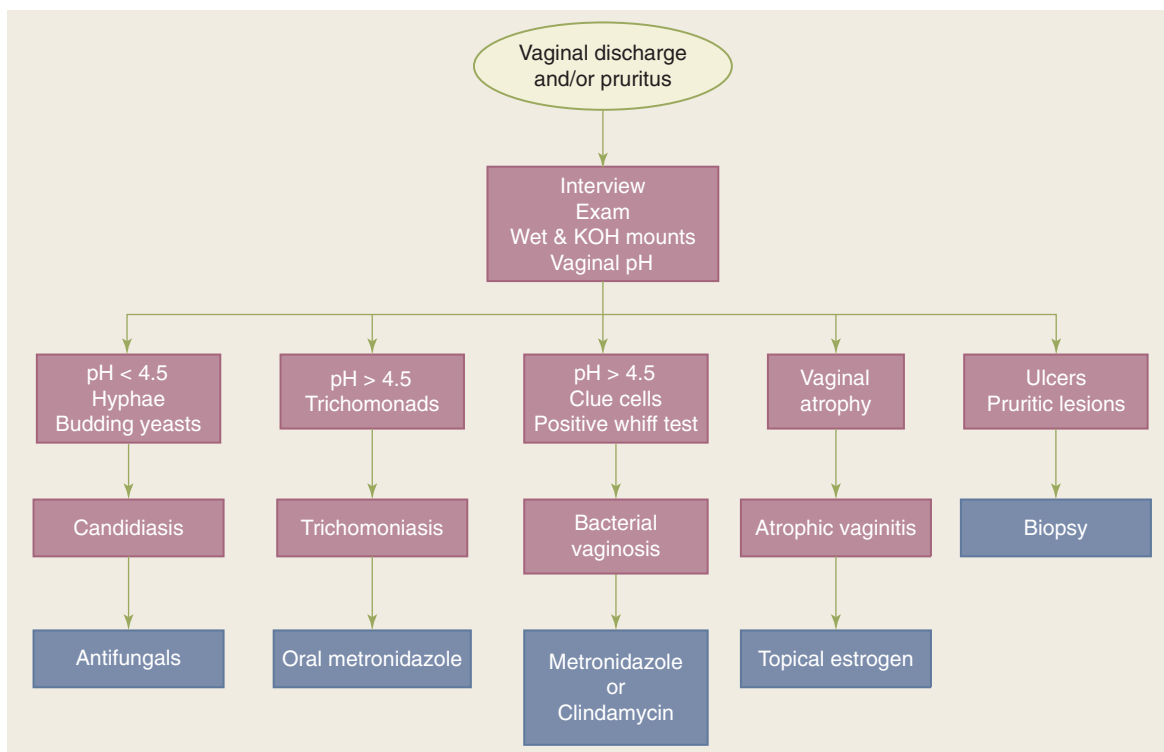


Figure 41-8. Treatment algorithm for vulvovaginitis.

Vaginal Intraepithelial Neoplasia. Vaginal intraepithelial neoplasia, or VaIN, is similar to VIN and is classified based on the degree of epithelial involvement as mild (I), moderate (II), severe (III), or carcinoma in situ.¹² Sixty-five percent to 80% of VaIN or vaginal cancers are associated with HPV infection. The majority of lesions are located in the upper one third of the vagina. Lesions are usually asymptomatic and found incidentally on cytologic screening. Diagnosis is made via guided biopsy of acetowhite lesions at the time of colposcopy. Lesions may appear flat or raised and white with sharply demarcated borders and may show vascular changes. The presence of aberrant vessels with marked branching is suggestive of invasive disease. VaIN is treated with laser ablation, surgical excision, or topical 5-fluorouracil therapy.

Cervical Lesions

Benign Cervical Lesions. Benign lesions of the cervix include endocervical polyps, Nabothian cysts (clear, fluid-filled cysts with smooth surfaces), trauma (such as delivery-related cervical tear or prior cervical surgery), malformation of the cervix, and cervical condyloma. For endocervical polyps, exploration of the base of the polyp with a cotton swab tip to identify that it is cervical and not uterine and to identify the stalk characteristics can help identify the appropriate surgical approach. Small polyps with identifiable base can be removed by grasping the polyp with ring forceps and slowly rotating it until separated from its base. Use of loop electro-excisional procedure (LEEP) is appropriate for larger lesions. Laser or other ablative procedures are appropriate for condyloma proven by biopsy.

Cervical Intraepithelial Neoplasia (CIN). High-grade cervical dysplasia (CIN II or III) has a high chance of persistent HPV infection with risk of transformation to malignancy; thus an excisional procedure is usually indicated. This

serves a therapeutic purpose by removal of dysplastic cells and a diagnostic purpose for histologic review to rule out concomitant early-stage cervical cancer. Either a LEEP or cold knife conization (CKC) may be used for surgical excision of the squamocolumnar junction (SCJ) and outer endocervical canal. Risks of both procedures include bleeding, postprocedure infection, cervical stenosis, and risk of preterm delivery with subsequent pregnancies. A looped wire attachment for a standard monopolar electro-surgical unit is used to perform a LEEP excision. Loops range in a variety of shapes and sizes to accommodate different sizes of cervix. Optimally, one pass of the loop should excise the entire SCJ. Hemostasis of the remaining cervix is achieved with the ball electrode and ferrous sulfate paste (Monsel's solution).

Different from a LEEP, a cervical CKC does not use energy to excise the specimen. The advantage of this procedure is that the margin status is not obscured by cauterized artifact. This is important in cases of adenocarcinoma in situ and micro-invasive squamous cell carcinoma, where margin status dictates the type of and indication for future therapy. During a CKC, a #11 blade is used to circumferentially excise the conical biopsy. Hemostasis is achieved with the ball electrode, Monsel's solution, or suture.

HPV Vaccine. Two HPV vaccines have been developed and approved by the U.S. Food and Drug Administration (FDA).¹⁶ Gardasil is a quadrivalent vaccine that targets HPV genotypes 16 and 18, which cause approximately 70% of cervical cancers and about 50% of precancerous lesions (CIN II/III) worldwide, and HPV genotypes 6 and 11, which cause 90% of genital warts. Cervarix is a bivalent vaccine that targets HPV genotypes 16 and 18. In contrast to natural infection, the vaccine is highly immunogenic, activating both humoral and cellular immune responses. Vaccination generates high concentrations of neutralizing antibodies to HPV L1 protein, the antigen in both

vaccines. It is thought that vaccination may provide protection against HPV infection through neutralization of virus by serum immunoglobulin that diffuses from capillaries to the genital mucosal epithelium.¹⁷

Several randomized clinical trials¹⁸⁻²⁰ involving approximately 35,000 young women have shown that both Gardasil and Cervarix prevent nearly 100% of the HPV subtype-specific precancerous cervical cell changes for up to 4 years after vaccination among women who were not infected at the time of vaccination; vaccination occurred before sexual debut. These major clinical trials have used prevention of CIN II/III and carcinoma in situ as the efficacy endpoints. Vaccination has not yet been shown to protect women who are already infected with HPV-16 or HPV-18 at the time of vaccination.

Current FDA approval applies to use in women who are between 9 and 26 years of age for the prevention of the following: cervical, vulvar, and vaginal cancer caused by HPV-16 or -18, genital warts caused by HPV-6 or -11, and lesions caused by HPV-6, -11, -16, or -18 (CIN I, II, and III; cervical carcinoma in situ; VIN; or VaIN II/III). The Advisory Committee on Immunization Practices (ACIP) recommends routine vaccination for females 11 to 12 years of age, maybe starting at age 9; catch-up vaccination is recommended for females 13 to 26 years of age who did not get all three doses when they were younger. Studies to evaluate the efficacy of the vaccine in healthy women 26 years of age and older with no prior exposure to HPV is ongoing, and additional information on the length of protection is forthcoming. In 2009, the FDA approved the quadrivalent vaccine for use to prevent genital warts in men and boys, and in 2011, the ACIP recommended that all males 11 to 12 years of age be vaccinated, stating that this may reduce some of the HPV-related burden suffered by women.

Immunocompromised women may receive the quadrivalent vaccine. Although the safety and immunogenicity of HPV vaccination in this population are not well established, the vaccine could be beneficial in these women since they are at increased risk for HPV-related cancers. Vaccination is not recommended for pregnant women, although neither vaccine has been shown to be causally associated with adverse outcomes in pregnant women or their fetuses. If pregnant women are vaccinated inadvertently, completion of the series should be delayed until after the pregnancy.

Cervical cancer screening continues to play an important role in detection and treatment of CIN II/III and prevention of cervical cancer in these high-risk patients. Cervical cancer screening continues to be of great importance since HPV immunization will not prevent approximately 25% to 30% of cervical cancers in HPV-naïve women and does not protect against the development of cancer in women already infected with carcinogenic HPV types.

Uterine Corpus

The average age of menarche, or first menstrual period, in the United States is 12 years and 5 months. Duration of normal menstruation is between 2 and 7 days, with a flow of less than 80 mL, cycling every 21 to 35 days.²¹ Nonpregnant patients, who present with heavy bleeding and are 35 years of age and older or have risk factors for endometrial cancer, must be ruled out for malignancy as the first step in their management (see earlier section, Endometrial Biopsy).

Abnormal Uterine Bleeding (AUB). Abnormal uterine bleeding is described based on the bleeding pattern. Menorrhagia is

prolonged (>7 days) or excessive (>80 mL daily) menstrual cycles occurring at regular intervals, and metrorrhagia is bleeding between menstrual periods. Menometrorrhagia is the occurrence of both. Intermenstrual bleeding, also known as spotting, is bleeding of variable amounts occurring between regular menstrual cycles. Poly-, oligo-, and amenorrhea are menstrual cycles of less than 21 days, longer than 35 days, or the absence of uterine bleeding for 6 months or a period equivalent to three missed cycles, respectively. Because there are many causes of AUB, they are divided into two categories: structural causes and nonstructural causes.²² Structural causes include polyps, adenomyosis, leiomyomata, and malignancy. Nonstructural causes can include coagulopathy, ovulatory dysfunction, endometrial effects, and iatrogenic causes.

Endometrial Polyps. Endometrial polyps are localized hyperplastic growth of endometrial glands and stroma around a vascular core forming sessile or pedunculated projections from the surface of the endometrium.²³ Endometrial polyps are rarely neoplastic (<1%) and may be single or multiple. Many are asymptomatic; however, they are responsible for about 25% of cases of abnormal uterine bleeding, usually metrorrhagia. Polyps are common in patients on tamoxifen therapy and in peri- and postmenopausal women. Up to 2.5% of patients with a polyp may harbor foci of endometrial carcinoma.²⁴ Diagnosis can be made with saline-infused hysterosonography, hysterosalpingogram, or direct visualization at the time of hysteroscopy. Definitive treatment, in the absence of malignancy, involves resection with an operative hysteroscope or by sharp curettage.

Adenomyosis. Adenomyosis refers to ectopic endometrial glands and stroma situated within the myometrium. When diffuse, it results in globular uterine enlargement secondary to hyperplasia and hypertrophy of the surrounding myometrium. Adenomyosis is very common, tends to occur in parous women, and is frequently an incidental finding at the time of surgery. Diagnosis is suspected in a parous woman with menorrhagia, dysmenorrhea, and diffuse globular uterine enlargement. MRI may reveal islands within the myometrium with increased signal intensity.²⁵ Hysterectomy is the only treatment, providing material for definitive pathologic diagnosis.

Uterine Leiomyomas. Leiomyomas, also known colloquially as fibroids, are the most common female pelvic tumor and occur in response to growth of the uterine smooth muscle cells (myometrium). They are common in the reproductive years, and by age 50, at least 60% of white and up to 80% of black women are or have been affected. Leiomyomas are described according to their anatomic location (Fig. 41-9) as intramural, subserosal, submucosal, pedunculated, cervical, and rarely ectopic.²¹ Most are asymptomatic; however, abnormal uterine bleeding caused by leiomyomas is the most common indication for hysterectomy in the United States. Other manifestations include pain, pregnancy complications, and infertility. Pain generally results from degenerating myomas that outgrew their blood supply or from compression of other pelvic organs such as the bowel, bladder, and ureters. High levels of pregnancy hormones frequently cause significant enlargement of pre-existing myomas, which may lead to significant distortion of the uterine cavity resulting in recurrent miscarriages, fetal malpresentations, intrauterine growth restriction, obstruction of the birth canal and the subsequent need for cesarean delivery, abortion, preterm labor, and pain from degeneration.

Bleeding is usually heavy and irregular (menometrorrhagia) and can be severe at times, requiring hospitalization. Examination

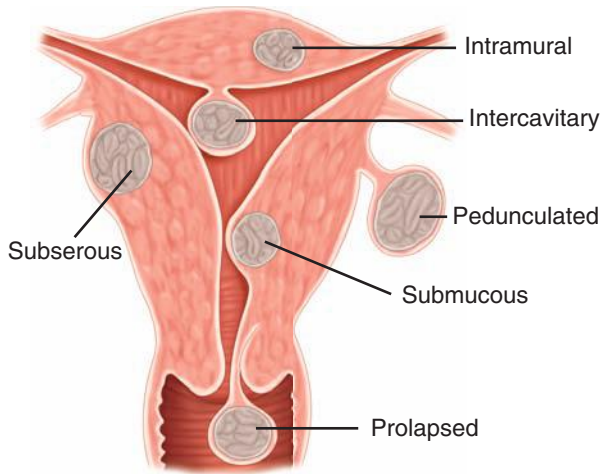


Figure 41-9. Types of uterine myomas.

reveals an enlarged irregular uterus and, in severe cases, a large solid pelvic mass extending to the upper abdomen. Diagnosis is usually made by transvaginal ultrasonography. Other diagnostic modalities, including MRI, computed tomography (CT), and hysterosalpingogram or saline-infused hysterosalpingography, are especially useful in the cases of submucosal and intrauterine myomas. Most are benign; malignant degeneration occurs in less than 1% of cases and is usually encountered in the menopausal years. Management options of leiomyomas are tailored to the individual patient depending on her age and desire for fertility and the size, location, and symptoms of the myomas. Conservative management options include oral contraceptive pills, medroxyprogesterone acetate, gonadotropin-releasing hormone (GnRH) agonists, uterine artery embolization, and myomectomy.²⁶⁻²⁸ Uterine artery embolization is contraindicated in patients planning future pregnancy and frequently results in acute degeneration of myomas requiring hospitalization for pain control. Myomectomy is indicated in patients with infertility and those who wish to preserve their reproductive capacity. Hysterectomy is the only curative therapy. Treatment with GnRH agonists for 3 months prior to surgery is recommended in anemic patients and may allow them time to normalize their hematocrit, avoiding transfusions; GnRH also decreases blood loss at hysterectomy and shrinks the myomas by an average of 30%. The latter may make the preferred vaginal surgical approach more feasible.

Endometrial Hyperplasia. Endometrial hyperplasia is caused by chronic unopposed hyperestrogenic state (relative absence of progesterone) and is characterized by proliferation of endometrial glands resulting in increased gland-to-stroma ratio. It can be asymptomatic or, more commonly, result in abnormal vaginal bleeding. Hyperplasia can be either simple or complex, based on the architecture of the glands. Of greater importance is the presence or absence of nuclear atypia, described by the World Health Organization (WHO) classification.²⁹ Untreated endometrial hyperplasia progresses to malignancy in 1%, 3%, 8%, and 29% of cases of simple, complex, simple with atypia, and complex hyperplasia with atypia, respectively.³⁰ Simple and complex hyperplasias can be treated with progestins, and women should have repeat endometrial sampling in 3 to 6 months. Atypical hyperplasia is considered a premalignant condition and is treated ideally with simple hysterectomy. When a patient has a preoperative diagnosis of complex atypical

hyperplasia, the likelihood of a concomitant endometrial cancer at hysterectomy is 38% to 60%.³¹ If preservation of fertility is desired or surgery contraindicated, treatment with high-dose progestins such as megestrol acetate 40 to 160 mg/d usually reverses these lesions. Close follow-up and repeated sampling are necessary.

Procedures Performed for Structural Causes of Abnormal Uterine Bleeding

Dilation and Curettage. The patient is placed on the operating table in a lithotomy position, and the vagina and cervix are prepared as for any vaginal operation. The cervix is grasped on the anterior lip with a tenaculum. Some traction on the cervix is necessary to straighten the cervical canal and the uterine cavity. A uterine sound is inserted into the uterine cavity, and the depth of the uterus is noted. The cervical canal is then systematically dilated beginning with a small cervical dilator. Most operations can be performed after the cervix is dilated to accommodate a number 8 or 9 Hegar dilator or its equivalent. Dilatation is accomplished by firm, constant pressure with a dilator directed in the axis of the uterus (Fig. 41-10). After the cervix is dilated to admit the curette, the endocervical canal should be curetted and the sample submitted separately from the endometrial curettings. The endometrial cavity is then systemically scraped with a uterine curette. Uterine perforation is the major complication of dilatation and curettage, diagnosed when the operator finds no resistance to a dilator or curette. Laparoscopy to identify any damage to vessels or bowel may be required. Curettage of the postabortal uterus must be approached carefully because the uterus is extremely soft and perforation can occur with very little warning. Using the largest curette available or suction curettage is a safer choice than a small curette, which tends to cause perforation with less pressure.

Hysteroscopy. Hysteroscopy, like laparoscopy, has gained widespread support for use both for diagnosis and treatment of intrauterine pathology and for ablation of the endometrium as an alternative to hysterectomy for the treatment of abnormal uterine bleeding. Scopes can have an objective lens that is offset from the long axis from 0° to 30°. The diagnostic hysteroscope usually has an external diameter of 5 mm. Some diagnostic sheaths allow passage of flexible instruments for biopsy and cutting. An operative hysteroscope is wider and usually has an integral unipolar or bipolar resecting loop identical to a urologic resectoscope. The loop can be replaced with a roller ball for endometrial ablation.

Several types of distention media exist and vary by electrolyte composition and osmolarity. High-viscosity (e.g., dextran 70), low-viscosity/electrolyte-poor (e.g., glycine and sorbitol), and low-viscosity/electrolyte-containing (e.g., normal saline and lactated Ringer's solution) medias are commonly used for distension of the uterus during hysteroscopy.³² The use and safety profiles of these medias vary, however. Dextran 70 allows excellent visibility, but the manufacturer recommends that no more than 250 mL be absorbed because of the concern for pulmonary edema. Anaphylactic reactions and coagulopathy are rare complications that have been described.³³ Glycine and sorbitol allow the use of monopolar cautery during operative hysteroscopy. Large volume deficits have been associated with secondary hyponatremic hypervolemia due to their metabolism to free water after intravasation.³³ When fluid deficits reach 1000 to 1500 mL, the procedure should be terminated, and the patient's serum electrolytes assessed. Patients who have excessive intravasation experience

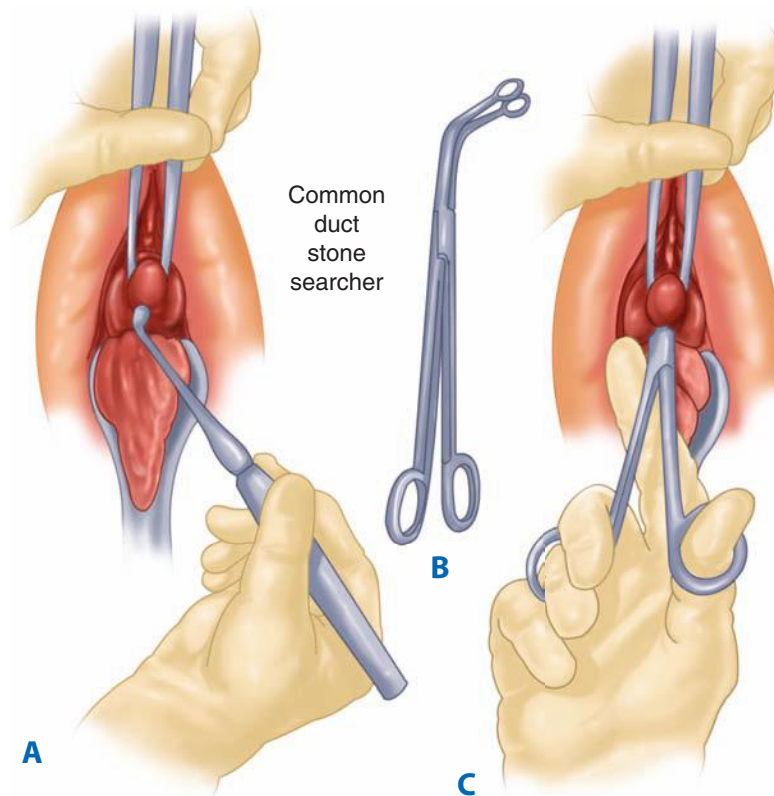


Figure 41-10. A through C. Dilatation and curettage of the uterus.

headache, nausea, vomiting, and agitation.³⁴ This manifestation can progress to pulmonary and cerebral edema. These patients require close monitoring and diuretic administration.

Unlike glycine and sorbitol, normal saline and lactated Ringer's solution have physiologic osmolarity and contain sodium. Although excessive intravasation does not lead to hyponatremia, it can lead to volume overload. Media deficits of greater than 2500 mL should prompt conclusion of the procedure and assessment of electrolytes.³⁵ Fluid-management systems are available to monitor the amount of distension media lost during hysteroscopy. Media intravasation can be lessened by using the minimum intrauterine pressure needed to perform the hysteroscopy and by minimizing operating time. The physician must be aware that certain procedures such as endometrial ablation and resection of myomas open vascular channels and place the patient at increased risk for fluid overload.³³

Diagnostic Hysteroscopy. Following dilation of the cervix, a diagnostic hysteroscope is placed and the uterine cavity distended with the media of choice. Inspection of the cavity includes identifying the uterine fundus, cornua, and any other anomalies to include polyps, leiomyomas, or uterine septum.

Hysteroscopic Polypectomy or Myomectomy. If an intrauterine polyp is discovered, the base of the polyp is incised with hysteroscopic scissors, and the polyp is grasped with grasping forceps. The hysteroscope, sleeve, and polyp are removed simultaneously, because most polyps will not fit through the operating channel. Extremely large polyps may have to be removed piecemeal. Any residual base of the polyp may be removed with biopsy forceps. Pedunculated or submucosal leiomyoma can be removed safely hysteroscopically. Because myoma tissue is relatively dense, a power cutting instrument is required.

The most common method is use of electro-surgery. A monopolar device may be used with an electrolyte-poor distention medium. Only bipolar devices may be used with normal saline or lactated Ringer's solution. Both pedunculated and submucosal fibroids are shaved into small pieces with the hysteroscopic resectoscope. Stalk resection should only be done to release a pedunculated fibroid if it is 10 mm or less in size; larger fibroids are difficult to remove in one piece without excessive cervical dilatation. Morcellation is much easier when the stalk is still attached for stability. Hysteroscopes with a morcellation attachment have been recently developed.³⁶

Endometrial Ablation. A common treatment for abnormal uterine bleeding in the absence of endometrial hyperplasia is ablation of the endometrium. Historically, this was performed with an operative hysteroscope using an electro-surgical "roller ball," where the endometrium was destroyed down to the myometrium in a systematic fashion. Currently, hysteroscopic endometrial ablation has been widely supplanted by various devices, including heated free fluid, cryotherapy, thermal balloon, microwave, and radiofrequency electricity. Most ablation techniques result in amenorrhea in approximately half the patients and decreased menstruation in another third of the patients over the first year of therapy.³⁷

Myomectomy. Myomectomy (Fig. 41-11) is the removal of fibroids, and it can be treatment for abnormal uterine bleeding, bulk symptoms, or infertility. Hemostasis during myomectomy can be aided medically by direct injection of dilute vasopressin at the site of the intended uterine incision (10 U in 50 mL). It can be aided further through the placement of a Penrose drain around the base of the uterus, pulled through small perforations in the broad ligament lateral to the uterine blood supply on either

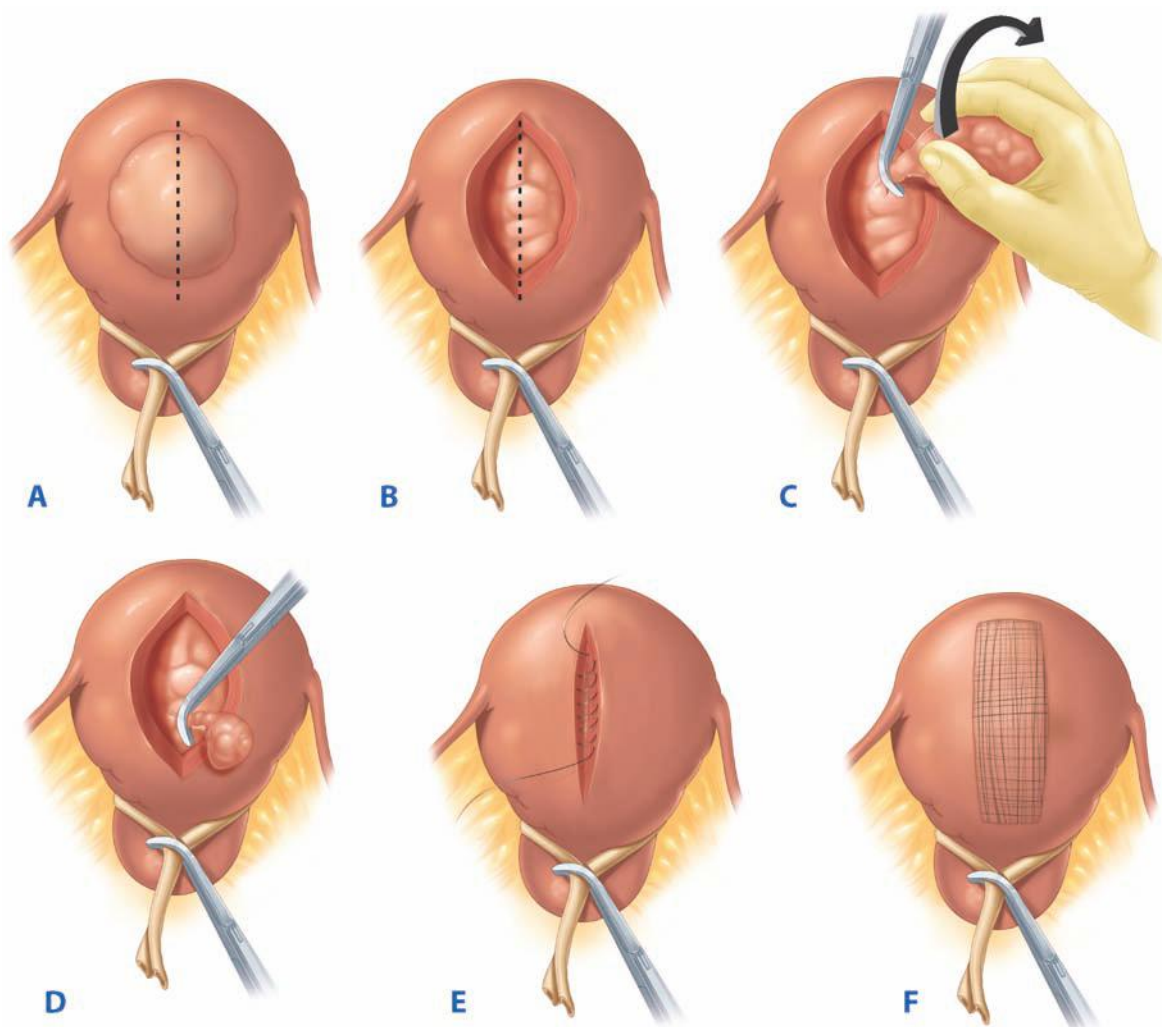


Figure 41-11. Myomectomy. **A.** Hemostatic “tourniquet” in place before myomectomy. **B.** Uterine incision for myomectomy. **C.** Removal of myoma. **D.** Several myomas may be removed through a single incision. **E.** The uterine wound is closed with an absorbable suture. **F.** The uterine wound covered with mesh to retard adhesions.

side and clamped to form a tourniquet for uterine blood flow. An incision is then made through the uterine serosa into the myoma. The pseudocapsule surrounding the tumor is identified and the tumor is bluntly dissected out with scissors, or bluntly if open. Vessels to the myoma are desiccated with the electro-surgical unit. Several myomas may be removed through a single incision, depending on size. The uterine wounds are closed with absorbable sutures to obliterate the dead space and provide hemostasis. The uterine serosa is closed with a 3-0 absorbable suture, placed subserosally if possible. Because myomectomies are associated with considerable postoperative adhesion formation, barrier techniques are used to decrease adhesion formation.

During a laparoscopic myomectomy, hemostasis is assisted by intrauterine injection of dilute vasopressin (10 U in 50 mL) at the site of incision, similar to an open procedure. This is usually performed percutaneously with a spinal needle. Pedunculated leiomyomas can be excised at the base using scissors or a power instrument. Intramural leiomyomas require deep dissection into the uterine tissue, which must be closed subsequently with laparoscopic suturing techniques. Removing the specimen often requires morcellation, and power morcellators have been developed that significantly expedite this technique. Adhesion barriers are placed laparoscopically.

Total Abdominal Hysterectomy (Fig. 41-12). After the abdomen is entered, the upper abdomen is examined for evidence of extrapelvic disease, and a suitable retractor is placed in the abdominal incision. The uterus is grasped at either cornu with clamps and pulled up into the incision. The round ligament is identified and divided. The peritoneal incision is extended from the round ligament to just past the ovarian hilum, lateral to the infundibulopelvic ligament, if the ovaries are to be removed. The retroperitoneal space is bluntly opened, the ureter identified on the medial leaf of the broad ligament, and the infundibulopelvic ligament isolated, clamped, cut, and suture-ligated; a similar procedure is carried out on the opposite side. If the ovaries are to be left in situ, the ureter is identified and an opening below the utero-ovarian ligament and fallopian tube created. The fallopian tube and utero-ovarian ligament are clamped, cut, and ligated. The bladder is mobilized by sharply dissecting it free of the anterior surface of the uterus and cervix. Clamps are placed on the uterine vessels at the cervicouterine junction, and they are cut and suture-ligated. The cardinal ligaments are then serially clamped, cut, and ligated. Following division of the remaining cardinal ligaments, the uterus is elevated and the vagina clamped. The cervix is amputated from the vagina with scissors or a knife. Sutures are placed at each lateral angle of the

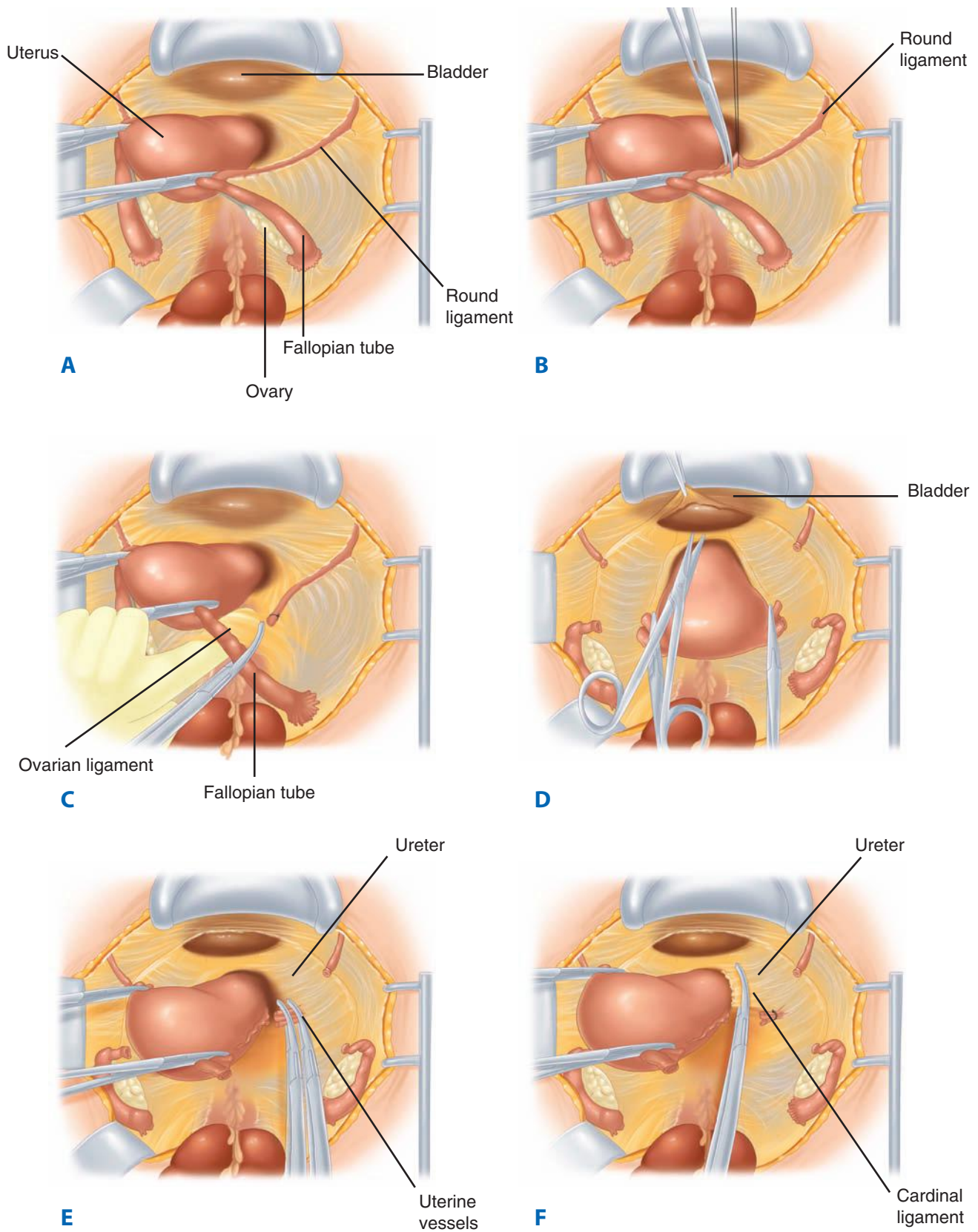


Figure 41-12. Hysterectomy. **A.** The uterus grasped at the cornua. **B.** The round ligament is cut. **C.** The ovarian ligament and fallopian tube are isolated. **D.** The bladder is mobilized. **E.** The uterine vessels are clamped. **F.** The cardinal ligaments are clamped. **G.** The vagina is entered. **H.** The cardinal ligaments are sutured to the vagina. **I.** The vagina is “closed open.”

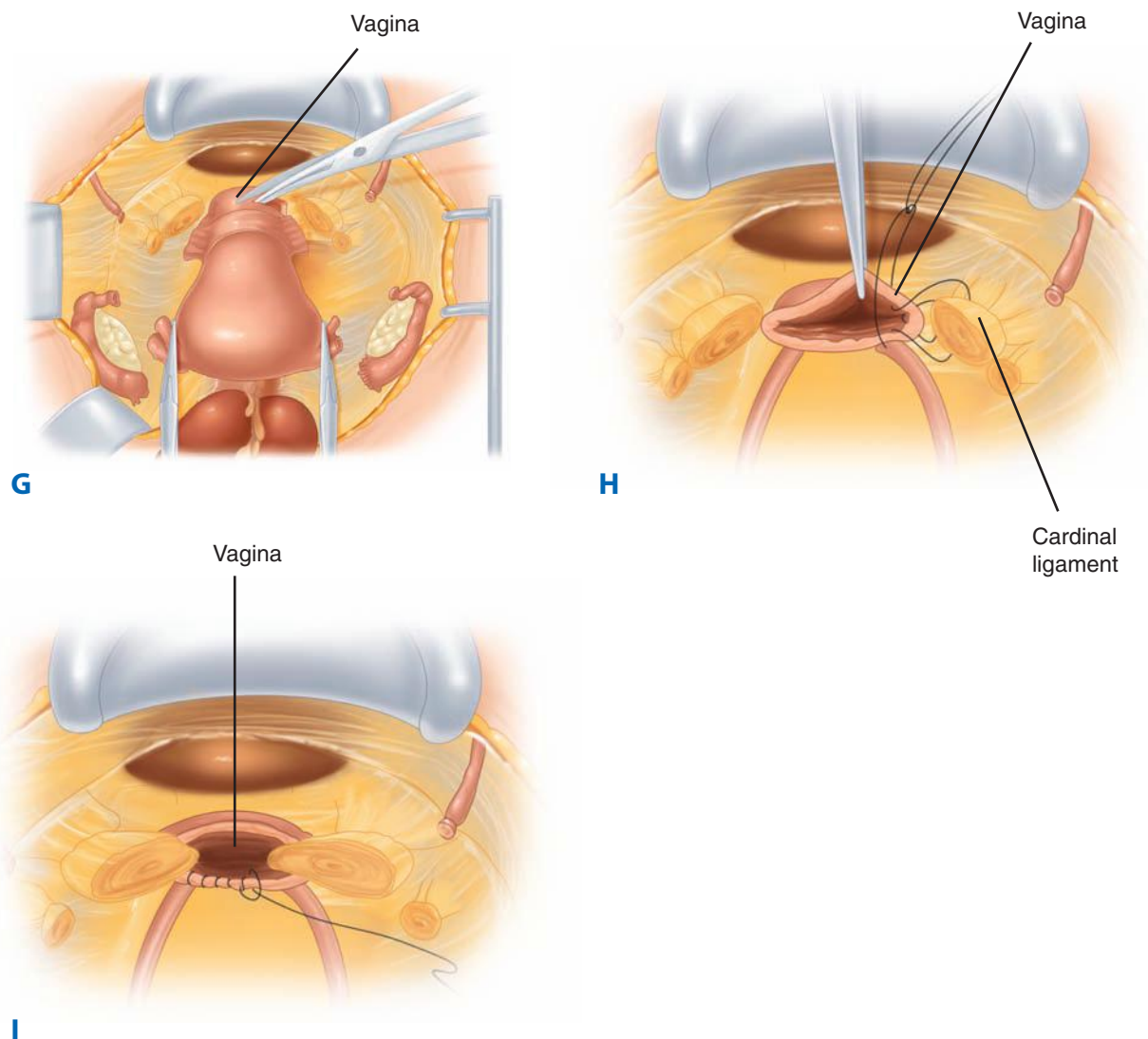


Figure 41-12. (Continued)

vagina, and the remainder of the vagina is closed with a running absorbable suture. Pelvic reoperation is not necessary.

Transvaginal Hysterectomy (Fig. 41-13). Vaginal hysterectomy is the preferred approach in patients in whom the uterus descends and the pubic arch allows enough space for a vaginal operation. A bladder catheter can be placed before the procedure, and the patient is placed in a lithotomy position. A weighted vaginal speculum is placed in the vagina, and the cervix is grasped with a tenaculum and pulled in the axis of the vagina. Injection of the cervix and paracervical tissue with analgesic with epinephrine may be helpful in defining planes and decreasing obscuring bleeding. A circumferential incision may be made with a scalpel or scissors. The posterior cul-de-sac is identified and entered with scissors. A long weighted speculum is then placed through this opening into the peritoneal cavity. Metzenbaum scissors are used to dissect anteriorly on the cervix down to the pubocervical-vesical fascia, reflecting the bladder off the lower uterine segment. When the peritoneum of the anterior cul-de-sac is identified, it is entered with the scissors, and a retractor is placed in the defect. The uterosacral ligaments are identified, doubly clamped, cut, and ligated. Serial clamps are placed on the parametrial structures above the uterosacral ligament; these pedicles are cut and ligated. At the cornu of the uterus, the

round ligament, and utero-ovarian ligament of the ovary are doubly clamped and cut. The procedure is carried out usually concurrently on the opposite side, and the uterus is removed. The pelvis is inspected for hemostasis; all bleeding must be meticulously controlled at this point.

The pelvic peritoneum is closed with a running purse-string suture incorporating the uterosacral and ovarian pedicles, those that were held. This exteriorizes those areas that might tend to bleed. The sutures attached to the ovarian pedicles are cut. The vagina may be closed with interrupted mattress stitches, incorporating the uterosacral ligaments into the corner of the vagina with each lateral stitch. On occasion, the uterus, which is initially too large to remove vaginally, may be reduced in size by morcellation (Fig. 41-14). After the uterine vessels have been clamped and ligated, serial wedges are taken from the central portion of the uterus in order to reduce the uterine mass. This procedure will allow the vaginal delivery of even very large uterine leiomyomas.

Laparoscopic Hysterectomy. Laparoscopy has been used to augment vaginal hysterectomy to avoid laparotomy in patients with known pelvic adhesions, with endometriosis, or in whom the uterus is enlarged by leiomyoma. Although multiple variations in technique exist, there are three basic laparoscopic

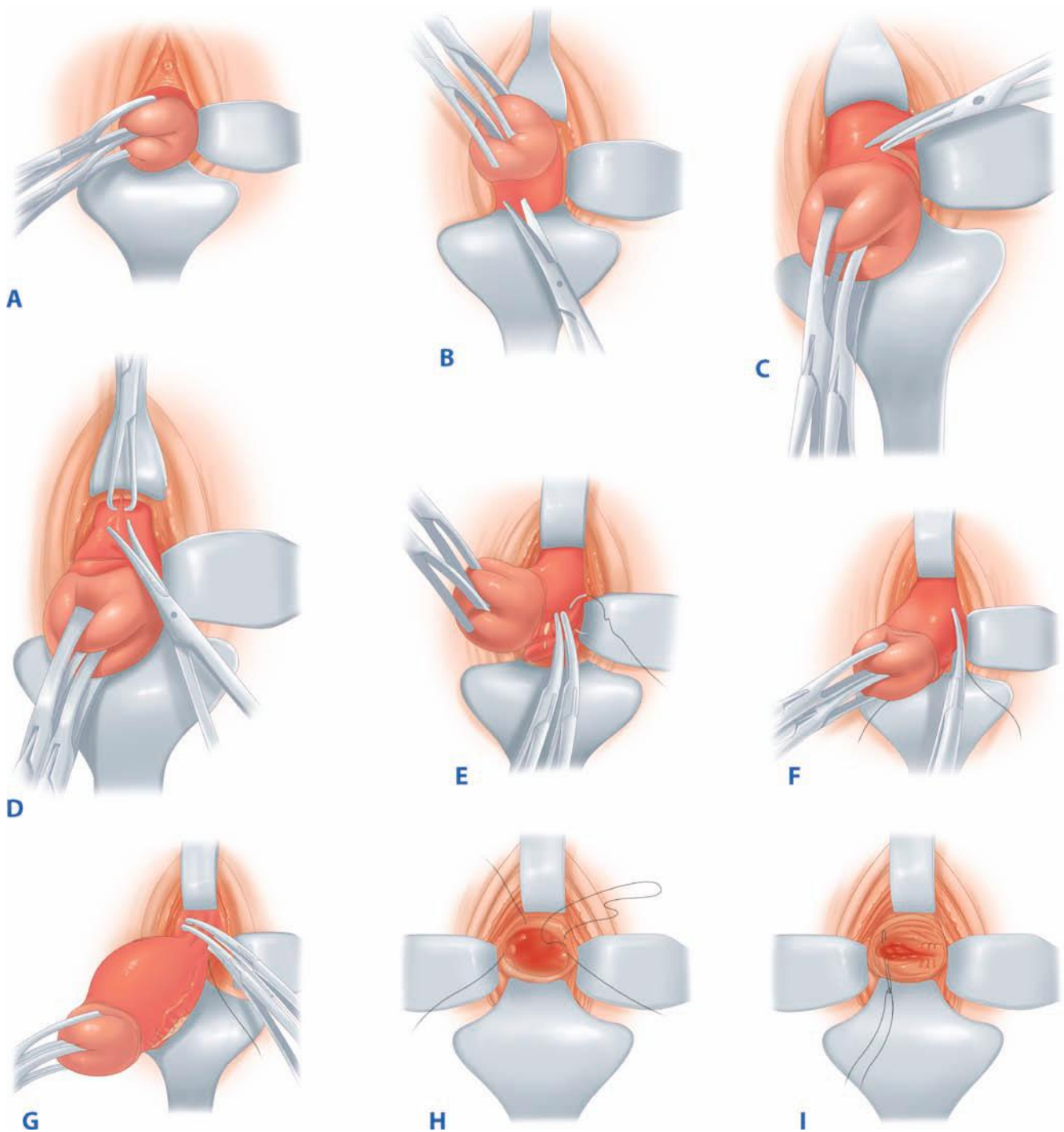


Figure 41-13. Vaginal hysterectomy. **A.** Traction is placed on the uterus. **B.** The posterior cul-de-sac is entered. **C.** The vaginal mucosa is circumcised. **D.** The anterior cul-de-sac is entered. **E.** The uterosacral ligaments are clamped. **F.** The uterosacral ligaments are tied. **G.** The fallopian tube, round ligament, and ovarian ligament are ligated. **H.** The peritoneum is closed. **I.** The vaginal mucosa is closed.

approaches for hysterectomy: laparoscopic-assisted vaginal hysterectomy (LAVH), total laparoscopic hysterectomy (TLH), and laparoscopic supracervical hysterectomy (LSH). The technically simplest is the LAVH. A multiple-port approach is used to survey the peritoneal cavity, and any pelvic adhesions are lysed. The round ligaments are then occluded and divided, and the uterovesical peritoneum and peritoneum lateral to the ovarian ligament are incised. The course of the ureter and any adhesions or implants, such as endometriosis that might place the ureter in the way of the surgical dissection, are carefully dissected. Next, the proximal uterine blood supply is dissected for identification

and then occluded with a laparoscopic energy device. When the ovaries are removed, the infundibulopelvic ligaments containing the ovarian vessels are divided. If the ovaries are conserved, the utero-ovarian ligament and blood vessels are divided and occluded. In many cases, the posterior cul-de-sac is also incised laparoscopically and the uterosacral ligaments separated with an energy device. The amount of dissection that is done prior to the vaginal portion depends on individual patient characteristics and may include as little as ovarian and adhesion management to full dissection including bladder dissection, with only the last vaginal incision done by the vaginal approach. During a

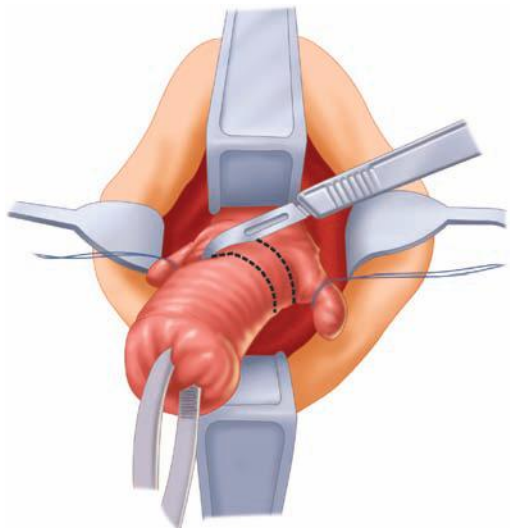


Figure 41-14. Uterine morcellation through the vagina.

TLH, the vaginal incision is performed laparoscopically, and the vaginal incision may be closed with laparoscopic suturing. This procedure is used for the indications listed earlier and also when lack of uterine descent makes the vaginal approach impossible.

During an LSH, the uterine vessels are divided after the bladder is dissected from the anterior uterus. The ascending branches of the uterine arteries are occluded, and the entire uterine fundus is amputated from the cervix. The endocervix is either cauterized or cored out. The fundus is then morcellated and removed through a 12-mm abdominal port or through a special transcervical morcellator. The end result is an intact cervix, with no surgical dissection performed below the uterine artery. This approach avoids both a large abdominal incision and a vaginal incision. According to its advocates, this approach minimizes operating time, recovery time, and risk of both infection and ureteral injury. LSH has yet to be widely applied, in part out of concern for the subsequent risk of developing cancer in the residual cervical stump. In addition, women may develop bleeding from the remaining lower uterine segment that can be bothersome, even if preventive measures had been taken.

Benign Ovarian and Fallopian Tube Lesions

The most common ovarian benign findings include functional follicular cysts, endometriomas (due to ovarian endometriosis), and serous cystadenomas or cystadenofibromas. These can present with varying degrees of pelvic pain, or sometimes be completely asymptomatic. Ultrasound is the best initial imaging modality for evaluating ovarian abnormalities.

Ovarian Cystectomy. When a cystic lesion persists or causes pelvic pain, surgical intervention is usually justified. Performing a cystectomy with ovarian preservation is recommended in women who desire future fertility. Whether the cystectomy is performed laparoscopically or by laparotomy, the procedure is initiated with inspection of the peritoneal cavity, peritoneum, diaphragm, liver, and pelvis. In the absence of signs of malignancy, pelvic washings are obtained and the ovarian capsule is incised superficially sharply or with the electro-surgical unit. The cyst is shelled out carefully through the incision. During laparoscopy, it is placed in a bag, intact if possible, and the bag opening is brought through a 10-mm port. If a cyst should rupture before removal, contents are aspirated thoroughly, and

the cyst wall is removed and sent for pathologic evaluation. The peritoneal cavity is copiously rinsed with Ringer's lactate solution. This is especially important when a dermoid cyst is ruptured, because the sebaceous material can cause a chemical peritonitis unless all the visible oily substance is carefully removed. A cyst may need to be drained to facilitate removal, but only after bag edges are firmly out of the abdomen assuring no leakage within the abdomen. Hemostasis of the ovary is achieved with bipolar electrocoagulation, but the ovary is usually not closed. If there are solid growths within the cyst, it should be sent for frozen section to verify the absence of the malignancy. If malignancy is detected, immediate definitive surgery is recommended.

Removal of Adnexa. Indications for removal of adnexa include persistent ovarian cyst, pelvic pain, concern for malignancy, and risk reduction surgery in women with genetic predisposition for ovarian or endometrial cancers (*BRCA1/2* mutation carrier, Lynch syndrome). In general, the peritoneum lateral to the infundibulopelvic (IP) ligament is incised in a parallel fashion to allow retroperitoneal dissection and identification of the ureter. Once this has been accomplished, the IP ligament is ligated with suture or an energy source (ultrasonic or bipolar). The remaining posterior leaf of the broad ligament is incised toward the uterus in a direction parallel to the utero-ovarian ligament, to avoid ureteral injury. The fallopian tube and utero-ovarian ligaments are then ligated with either suture or an energy source. If performed laparoscopically, the specimen or specimens are removed in a bag as described earlier.

Tubal Sterilization. As in diagnostic laparoscopy, a one- or two-port technique can be used. Fallopian tubes are occluded in the mid-isthmic section, approximately 3 cm from the cornua, using clips, elastic bands, or bipolar electrosurgery. With electrosurgery, approximately 2 cm of tube should be desiccated. Pregnancy rates after any of these techniques have been reported in the range of 3 per 1000 women.

Other Pelvic Pathology

Chronic Pelvic Pain. Chronic pelvic pain is defined as pain below the umbilicus that has lasted at least 6 months or causes functional disability, requiring treatment. While there can be gastrointestinal and urologic causes of chronic pelvic pain, gynecologic causes are frequently identified. Often, a surgical evaluation is needed for diagnosis and/or intervention. The most common gynecologic causes of chronic pelvic pain include endometriosis, adenomyosis, uterine leiomyomas, and adhesive disease.

Endometriosis. Endometriosis is the finding of ectopic endometrial glands and stroma outside the uterus. It affects 10% of the general population and is an incidental finding at the time of laparoscopy in more than 20% of asymptomatic women. It is especially prevalent in patients suffering from chronic pelvic pain (80%) and infertility (20%–50%).²¹ The pathophysiology of endometriosis is poorly understood; etiologic theories explaining dissemination of endometrial glands include retrograde menstruation, lymphatic and vascular spread of endometrial glands, and coelomic metaplasia. Endometriosis commonly involves the ovaries, pelvic peritoneal surfaces, and uterosacral ligaments. Other possible sites include the rectovaginal septum, sigmoid colon, intraperitoneal organs, retroperitoneal space, ureters, incisional scars, umbilicus, and even the thoracic cavity. Involvement of the fallopian tubes may lead to scarring,

blockage, and subsequent infertility. Ovarian involvement varies from superficial implants to large complex ovarian masses called endometriomas or “chocolate cysts.” Endometriomas are found in approximately one third of women with endometriosis and are often bilateral.

While endometriosis can be totally asymptomatic, more commonly, women are symptomatic, and complaints vary from mild dyspareunia and cyclic dysmenorrhea to debilitating chronic pelvic pain with acute exacerbations at the time of menses. Less common manifestations include painful defecation, hematochezia, and hematuria if there is bowel and/or bladder involvement. Pelvic examination in symptomatic patients typically demonstrates generalized pelvic tenderness and nodularity of the uterosacral ligaments, and at times, a pelvic mass may be appreciated if an endometrioma is present. The severity of symptoms does not correlate with the degree of clinical disease present. Endometriosis can also cause increases in serum cancer antigen 125 (CA-125). Definitive diagnosis usually requires laparoscopy and visualization of the pathognomonic endometriotic implants. These appear as blue, brown, black, white, or yellow lesions that can be raised and at times puckered, giving them a “gunpowder” appearance. Biopsy is not routinely done but should be obtained if the diagnosis is in doubt.

Treatment is guided by severity of the symptoms and whether preservation of fertility is desired and varies from expectant, to medical, to surgical.^{38,39} Expectant management is appropriate in asymptomatic patients. Those with mild symptoms can be managed with oral contraceptive pills and/or nonsteroidal anti-inflammatory analgesia; moderate symptoms are treated with medroxyprogesterone acetate. Severe symptoms are treated with GnRH agonists to induce medical pseudo-menopause.

Surgical management for endometriosis varies depending on the age and fertility desires of the patient. A diagnostic laparoscopy with biopsies may be indicated to confirm the diagnosis of endometriosis. If endometriosis is suspected, an operative laparoscopy with ablation of endometriotic implants usually decreases the severity of pelvic pain. Ablation of endometriotic implants can be performed with CO₂ laser or electrocautery and/or resection of deep endometriotic implants.³⁸ Endometriomas can cause pain and, if found, should be treated by ovarian cystectomy. Complete resection of the cyst wall is required because recurrence of the endometrioma is common after partial removal. Conservative surgical therapy in endometriosis patients with patent fallopian tubes results in pregnancy in about 50% of cases. Unfortunately, endometriosis is a chronic disease and conservative therapy, medical or surgical, provides only temporary relief, with the majority of patients relapsing with 1 to 2 years. Patients with severe debilitating symptoms who do not desire future fertility and have not responded to conservative management can undergo extirpative surgery to remove the uterus, ovaries, and fallopian tubes; this intervention is curative and should be considered.

Pelvic Adhesive Disease. Pelvic adhesions usually are related to previous surgery, endometriosis, or infection, the latter of which can be either genital (i.e., pelvic inflammatory disease) or extra-genital (e.g., ruptured appendix) in origin. Adhesions can be lysed mechanically with scissors if not vascular, harmonic scissors, or any of the power techniques as discussed elsewhere in this text. Postoperatively, adhesion barrier methods have been shown to decrease adhesion formation in both animal and human studies but have not been demonstrated to improve outcome in terms of either subsequent pregnancies or pain relief.

Pelvic Inflammatory Disease. Pelvic inflammatory disease (PID) is an infection of the upper female genital tract involving the uterus, fallopian tubes, and ovaries resulting in endometritis, salpingitis, and oophoritis. It often involves contiguous pelvic organs, resulting in peritonitis, tubo-ovarian abscesses, and occasionally perihepatitis (Fitz-Hugh-Curtis syndrome). Long-term sequelae can include infertility, chronic pelvic pain, and increased risk of ectopic pregnancy.^{40,41} PID is mostly a sexually transmitted ascending infection caused by *N. gonorrhoeae* and/or *C. trachomatis*, but numerous other organisms have been implicated, including normal vaginal flora. Screening for concomitant HIV infection is strongly recommended. Less commonly, PID may result from extension of other pelvic and abdominal infections, such as appendicitis and diverticulitis, or may be precipitated by a medical procedure, such as hysterosalpingography, endometrial biopsy, or dilation and curettage.

Differential diagnosis includes appendicitis, cholecystitis, inflammatory bowel disease, pyelonephritis, nephrolithiasis, ectopic pregnancy, and ovarian torsion.^{40,41} The Centers for Disease Control and Prevention recommend treatment of suspected PID in patients with pelvic or lower abdominal pain who also exhibit cervical motion tenderness, uterine tenderness, or adnexal tenderness (Table 41-4). Transvaginal ultrasound may

Table 41-4

CDC recommended treatment of PID (2010)⁴²

ORAL REGIMENS

Ceftriaxone 250 mg IM in a single dose *plus* doxycycline 100 mg PO bid for 14 days

with or without metronidazole 500 mg PO bid for 14 days
OR

Cefoxitin 2 g IM in a single dose and probenecid 1 g PO administered concurrently in a single dose *plus* doxycycline 100 mg PO bid for 14 days *with or without* metronidazole 500 mg PO bid for 14 days

OR

Other parenteral third-generation cephalosporin (e.g., ceftizoxime or cefotaxime) *plus* doxycycline 100 mg PO bid for 14 days *with or without* metronidazole 500 mg PO bid for 14 days

PARENTERAL REGIMENS

Recommended Regimen A

Cefotetan 2 g IV every 12 hours *or* cefoxitin 2 g IV every 6 hours *plus* doxycycline 100 mg PO or IV every 12 hours

Recommended Regimen B

Clindamycin 900 mg IV every 8 hours *plus* gentamicin loading dose IV or IM (2 mg/kg of body weight), followed by a maintenance dose (1.5 mg/kg) every 8 hours; single daily dosing may be substituted

Alternative Parenteral Regimen

Ampicillin/sulbactam 3 g IV every 6 hours *plus* doxycycline 100 mg PO or IV every 12 hours

bid = twice a day; CDC = Centers for Disease Control and Prevention; IM = intramuscular; IV = intravenous; PID = pelvic inflammatory disease; PO = oral.

reveal thickened fluid-filled tubes with or without free pelvic fluid. Laparoscopic findings include swollen erythematous tubes with exudates. Criteria for hospitalization and intravenous antibiotic treatment include the following⁴²: surgical emergencies (e.g., appendicitis), infection during pregnancy, failure to respond to or inability to follow or tolerate outpatient oral medication regimens, severe illness with nausea and vomiting or high fever, and tubo-ovarian abscess.

First-line treatment for tubo-ovarian abscess includes broad-spectrum antibiotics and, sometimes, percutaneous drainage. Surgical intervention becomes necessary if medical therapy fails or if the abscess ruptures. Rupture is a surgical emergency with a high mortality rate if not recognized and managed promptly. In addition to management of the septic shock state, hysterectomy and bilateral salpingo-oophorectomy is the procedure of choice; however, conservative surgery must be considered in young patients desiring future fertility. The abdomen should be explored for metastatic abscesses, and special attention must be paid to bowel, bladder, and ureteral safety due to the friability of the infected tissue and the adhesions commonly encountered at the time of surgery. Placement of an intraperitoneal drain and mass closure of the peritoneum, muscle, and fascia with delayed-absorbable or permanent sutures is advised. Closure of the skin and subcutaneous layer should be avoided in patients with frank pus, and delayed primary closure or closure by secondary intention is recommended because of the high rate of wound infections. Conservative surgery, when feasible, may be attempted by laparoscopy and may involve unilateral salpingo-oophorectomy or drainage of the abscess and liberal irrigation of the abdomen and pelvis.

PREGNANCY-RELATED SURGICAL CONDITIONS

Many pregnant women will undergo invasive diagnostic procedures for prenatal diagnosis, and in the United States, nearly one third of all births are cesarean deliveries.⁴³ About 1 in 500 **6▶** pregnant women will require surgery for nonobstetrical issues.^{44,45} Diagnostic challenges and physiologic changes due to pregnancy, as well as the unique anesthesia risks and potential risks to the pregnancy, should be kept in mind whether the primary surgeon is an obstetrician gynecologist or a general surgeon (Table 41-5).⁴⁵

Trauma in the obstetric patient requires stabilization of the mother while considering the fetal compartment.^{45,46} Trauma-related hypovolemia may be compounded by pregnancy-induced decreases in systemic vascular resistance and, when supine, the weight of the gravid uterus on the vena cava. When feasible, a left lateral tilt should be instituted to improve venous return to the right heart. Later in pregnancy, the small bowel is displaced into the upper abdomen, making it vulnerable to complex injury from penetrating upper abdominal trauma. Although the small bowel is displaced from the pelvis, the dramatic increase in pelvic blood flow can lead to rapid blood loss due to penetrating pelvic trauma, fractures, or avulsion of pelvic vessels. Gastric motility is decreased, increasing the risk of aspiration. Peritoneal signs may be attenuated by the stretching of the abdominal wall. Several coagulation factors are also increased in pregnancy, increasing the likelihood for thromboembolic events, but also giving the unsuspecting surgeon false security when low-normal levels are observed during resuscitative efforts. Although treating the maternal compartment is the

Table 41-5

Physiologic changes due to pregnancy⁴⁵

Cardiovascular changes

- Increased cardiac output
- Increased blood volume
- Increased heart rate
- Decreased blood pressure
- Decreased systemic vascular resistance
- Decreased venous return from lower extremities

Respiratory changes

- Increased minute ventilation
- Decreased functional residual capacity

Gastrointestinal changes

- Decreased gastric motility
- Delayed gastric emptying

Coagulation changes

- Increased clotting factors (II, VII, VIII, IX, X)
- Increased fibrinogen
- Increased risk for venous thromboembolism

Renal changes

- Increased renal plasma flow and glomerular filtration rate
- Ureteral dilation

Source: Reproduced with permission from Gabbe et al.⁴⁵ Copyright Elsevier.

primary concern, it should also be recognized that the fetus will be impacted significantly by maternal hypotension, as blood may be shunted away from the uterus. Only the third-trimester fetus has any ability to autoregulate in the context of decreased uterine blood flow and oxygen delivery.

Conditions and Procedures Performed Before Viability

Amniocentesis/Chorionic Villus Sampling. Amniocentesis is a procedure in which amniotic fluid is aspirated from the uterine cavity, typically under ultrasound guidance with a 20- to 22-gauge needle. Common indications include prenatal genetic testing, assessment of fetal lung maturity, and evaluation for intrauterine infection. Chorionic villus sampling (CVS) is performed for prenatal genetic testing. During the procedure, placental villi are obtained through transcervical or transabdominal access to the placenta. CVS is typically performed after 9 completed weeks of gestation, while genetic amniocentesis is offered between 15 and 20 weeks. Pregnancy loss attributable to genetic amniocentesis is 1 in 300 to 500. The rate is slightly higher after CVS due in large part to the higher background spontaneous pregnancy loss between 9 and 16 weeks of gestation.⁴⁷

Pregnancy Terminations. Although legal nonsurgical options are now available for early pregnancy termination, the safest and most commonly performed termination procedure is a cervical dilation and suction curettage. The uterine cervix is grasped with a tenaculum and then mechanically dilated with tapered rods occasionally using adjunctive prostaglandins, and an appropriately sized vacuum cannula is inserted into the uterus and rotated on its axis to remove the products of conception. Additional forceps can be used as needed and will be necessary in later

second-trimester dilation and extractions. The most common complications are infection, hemorrhage due to uterine atony, cervical lacerations, uterine perforations, and inadvertent bowel injury from the vacuum cannula or forceps.

Cerclage. Cervical insufficiency is defined as painless cervical dilation leading to recurrent second-trimester pregnancy loss, or shortened cervical length as determined by transvaginal ultrasound, or advanced cervical change before 24 weeks gestation in a woman with either prior preterm birth/loss or significant risk factors for insufficiency. A cervical cerclage refers to a procedure in which suture or synthetic tape is used to circumferentially reinforce the cervix to improve pregnancy outcome in at-risk patients.⁴⁸ Shirodkar and McDonald techniques have been described^{49,50}; both involve transvaginally placing a non-absorbable suture at the uterocervical junction to lengthen and close the cervix. A laparotomy can access the abdominal portion of the lower uterine segment for an abdominal cerclage for a patient with a severely shortened or absent cervix.

Ectopic Pregnancies. Extrauterine pregnancies are most commonly located along the fallopian tubes and on the ovary. Rarely, implantation can occur primarily on other abdominal organs or surfaces. A high index of suspicion and early diagnosis, typically using sensitive β -hCG assays and ultrasound, are the key to minimizing maternal morbidity and mortality. Early ectopic pregnancies can be managed medically with methotrexate, whereas advanced ectopic pregnancies and unstable women are managed by laparoscopy or laparotomy. Linear salpingostomy along the antimesenteric border and removal of the products of conception is a reasonable option. The tube should be removed (salpingectomy) if the oviduct has already ruptured and a large hemoperitoneum already exists.⁵¹

Conditions and Procedures Performed After Viability

Fetal Surgery. The Management of Myelomeningocele (MOMs) trial tested the safety and efficacy of fetal surgery for myelomeningocele between 2003 and 2010. During this procedure, surgeons expose the gravid uterus via low transverse or vertical incision and position the fetus manually within the uterus under ultrasound guidance with the myelomeningocele sac centered at the proposed hysterotomy site. The uterus is entered sharply between two full-thickness stay sutures, and the hysterotomy is extended 6 to 8 cm with a uterine stapling device. The myelomeningocele is closed in standard fashion under magnification. Early outcomes data revealed that fetal surgery reduced the risk of death or need for shunt placement during the first year of life and also improved mental development and motor function at 30 months of age. These outcomes in the fetal surgery arm were despite higher preterm delivery rates, and the trial was stopped early because of efficacy.⁵²

Obstetric Lacerations and Repair. The mean biparietal diameter of a term infant approaches 10 cm. The measured hiatus of the nulliparous vaginal introitus is approximately 2 cm. As a result, at the time of vaginal delivery, perineal lacerations and, with decreasing frequency, episiotomies are quite common. These lacerations involve, in varying degrees, the vaginal mucosa, the muscular elements inserting onto the perineal body, the levator ani, and in 4% to 5% of vaginal deliveries, the anal sphincter or anorectal mucosa.

Episiotomies and Perineal Laceration. First-degree tears involve only the perineal skin and may or may not need to be reapproximated. Second-degree tears involve the perineal body and can generally be repaired with some variation using a single continuous, nonlocking suture technique, typically a 2-0 or 3-0 synthetic delayed absorbable suture. The apex of the vaginal epithelial is approximated first including epithelium and underlying tissue to build up the rectovaginal septum. Upon reaching the hymenal ring, the perineal body and bulbocavernosus muscle are reapproximated, and a transition stitch is placed from the vaginal mucosa, which was repaired along a horizontal plane, to the deep perineal layer, which lies in a vertically oriented plane. A running closure is then completed incorporating the deep perineal tissues from the introitus to the extent of the perineal defect. At this point, the perineal skin is closed from inferior to superior in a subcuticular fashion and tied just inside the introitus.

Third-degree lacerations extend through the perineal body and involve the external anal sphincter, whereas fourth-degree lacerations involve the internal anal sphincter and rectal mucosa. When present, third- and fourth-degree lacerations should be repaired first before proceeding with the second-degree repair. This is accomplished by first closing the anal mucosa and then identifying and closing the internal anal sphincter in a second layer. The external anal sphincter is then identified, and the muscular cylinder is reconstructed by suturing the severed ends together using either an end-to-end or overlapping technique. Although these are typically straightforward layered closures, knowledge of the anatomy is important. Incomplete reconstruction, particularly of third- or fourth-degree lacerations, can contribute to future pelvic floor disorders, as well as the development of fistulae or incontinence.

Cervical and Vaginal Lacerations. Significant lacerations to the cervix or vagina may also occur during childbirth, particularly with instrumented deliveries or macrosomic infants. These lacerations may present as persistent bleeding, not readily recognized due to their location, and often in association with a firmly contracted uterus. Vaginal lacerations may be repaired primarily but should only be closed after deeper tissues are inspected to ensure no active bleeding. Cervical lacerations can be repaired in a running, locking fashion, ensuring that the apex of the laceration is incorporated in the closure. If the apex is challenging to reach, the closure can be started more distally using the suture to apply traction so that the apex may be closed.

Puerperal Hematoma. Trauma during childbirth can occasionally result in significant hematoma formation with or without a visible laceration. These hematomas may hide significant blood loss and most commonly occur in the vulva, paravaginal, and pelvic retroperitoneum. Typical presentation is pain and mass effect. Small hematomas can be managed conservatively with close observation and patient monitoring. Although there are no evidence-based size criteria, an unstable patient or expanding hematomas should prompt surgical intervention. After the hematoma is incised and drained, diffuse venous oozing is usually encountered rather than a single bleeding vessel. Hemostasis can be achieved using electrosurgery or fine absorbable suture, although caution must be used due to the proximity of bowel, bladder, and ureters to some hematomas. Pressure on the vulva or packing the vagina, rather than the hematoma cavity, may prevent further bleeding.

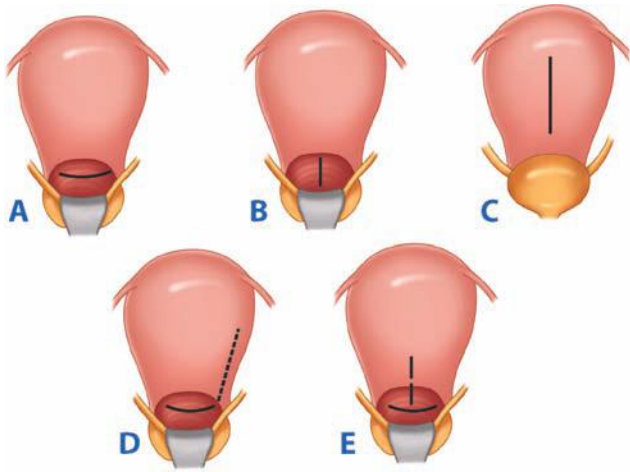


Figure 41-15. Uterine incisions for cesarean delivery. **A.** Low transverse incision. **B.** Low vertical incision. **C.** Classical incision. **D.** J incision. **E.** T incision. (Reproduced from Gabbe S, Niebyl J, Simpson J. *Obstetrics: Normal and Problem Pregnancies*. 5th ed. Philadelphia: Churchill Livingstone; 2007, Fig. 19-3. Copyright Elsevier.)

Cesarean Deliveries. Typical indications for cesarean delivery include nonreassuring fetal status, breech or other malpresentations, triplet and higher order gestations, cephalopelvic disproportion, failure to progress, placenta previa, and active genital herpes. Previous low transverse cesarean delivery is not a contraindication to subsequent vaginal birth after cesarean; however, much of the increase in cesarean delivery in the past decade is attributable to planned repeat cesareans. Cesarean deliveries typically are performed via a lower anterior (caudal) uterine transverse incision because there is decreased blood loss, and the uterine rupture rate with future pregnancies is about 0.5% (Fig. 41-15). A prior classical cesarean delivery is an absolute indication for a planned repeat cesarean delivery because of a high rate of uterine rupture during labor, unlike with the lower anterior uterine transverse incision. Abdominal access is obtained by a Pfannenstiel or Maylard incision. Once the abdomen is entered, a vesicouterine reflection is created if a low transverse uterine incision is planned. The uterine incision is then made and extended laterally, avoiding the uterine vessels. After amniotomy, the baby is delivered, and the uterus closed. Approximately 1000 mL of blood is typically lost during a cesarean delivery. Along with rapid closure of the uterine incision, uterotonics, such as intravenous oxytocin, are administered. A classical, vertical, uterine incision is made in certain very early viable gestations or in the case of certain transverse lies. Infection, excessive blood loss due to uterine atony, and urinary tract and bowel injuries are potential complications at the time of cesarean delivery. The risk of those injuries, as well as abnormal placentation (placenta accreta, increta, and percreta), rises with each subsequent cesarean delivery. Bleeding can only be controlled in some instances by performing a cesarean hysterectomy.

Postpartum Hemorrhage. Postpartum hemorrhage is an obstetrical emergency that can follow either vaginal or cesarean delivery. Hemorrhage is usually caused by uterine atony, trauma to the genital tract, or rarely, coagulation disorders. Management consists of mitigating potential obstetric causes while simultaneously acting to avert or treat hypovolemic shock.

In the absence of atony, the genital tract should be thoroughly evaluated for trauma. Atony is the most common cause of postpartum hemorrhage. It is typically treated with fundal massage and uterotonics such as oxytocin, methylergonovine, carboprost tromethamine, and misoprostol. When aggressive medical management fails, surgical management may be necessary and life-saving.⁵³

Uterine Curettage. Retained products of conception may result in uterine atony. It may be possible to remove retained products via manual extraction or with ring forceps. Bedside ultrasound may be helpful in localization. When clinical suspicion is high, uterine curettage is indicated. A blunt, large curette, the banjo curette, is introduced, and removal of retained tissue typically results in contraction of the myometrium and cessation of bleeding.

Procedures Short of Hysterectomy. As bleeding from postpartum hemorrhage becomes increasingly acute, interventions short of hysterectomy should be carried out expeditiously while supporting the hemodynamic status of the patient and preparing for possible definitive surgery. A number of techniques for packing and tamponade of the uterus have been described, including a balloon device reported by Bakri and colleagues.⁵⁴ These are typically left in place for 24 to 36 hours and appear to be safe and often effective conservative measures short of laparotomy and hysterectomy. The B-Lynch compression suture may control bleeding of atony at the time of cesarean section. A suture is placed through the hysterotomy, around the fundus of the uterus anterior to posterior, and then through the posterior lower uterine segment, to the contralateral side. At this point, the steps are reversed, with the suture brought around the fundus posterior to anterior, through the contralateral side of the hysterotomy, and then tied in the midline to compress the uterus. Additional procedures described include the O'Leary uterine artery ligation and the hypogastric artery ligation. "O'Leary stitches" are a series of sutures placed around the branches of the uterine artery and through the myometrium, resulting in compression of the vessels against the uterus. Hypogastric artery ligation entails the isolation of the internal iliac artery at its bifurcation with the external iliac artery. The hypogastric artery is ligated at least 3 cm distal to the bifurcation to avoid compromising the posterior division.

Hysterectomy. A cesarean or postpartum (absent a prior cesarean delivery) hysterectomy involves the same steps as in a nonpregnant patient, but is distinctly different due to the engorged vessels and the pliability of the tissues. If a cesarean section has been performed, occasionally the incision can be used for traction to keep the vessels and tissues attenuated. Vascular pedicles should be secured with clamps, but not ligated until both uterine arteries have been secured, to fully control bleeding. Lack of typical anatomic landmarks requires careful identification of the ureters and the dilated cervix visually or by palpation, to separate them from the bladder and vagina (Fig. 41-16). This procedure is often done for life-threatening hemorrhage; thus, appropriate blood products, including packed red blood cells, fresh frozen plasma, platelets, and fibrinogen, should be on call and are usually required. Fibrinogen is typically elevated in a pregnant woman, such that a low-normal fibrinogen level can be a cause for alarm, and further fibrinogen may be required before consumptive coagulopathy reverses. A massive transfusion protocol is often helpful.

Gestational Trophoblastic Disease. Gestational trophoblastic disease (GTD) is characterized by abnormal trophoblastic proliferations most commonly related to a pregnancy event.

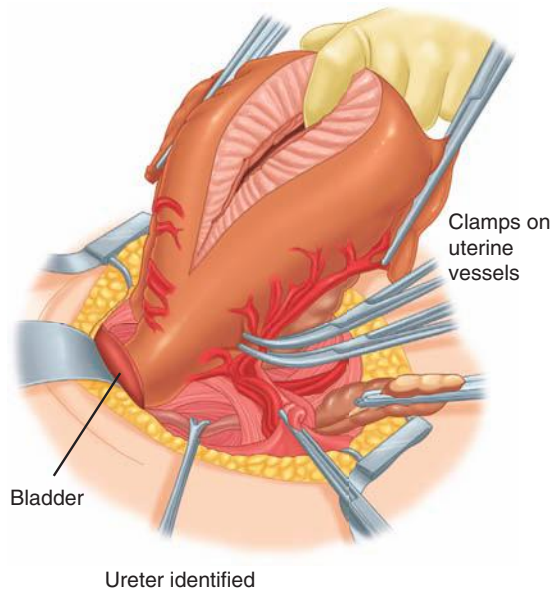


Figure 41-16. Demonstration of location of distal ureter and bladder and their relationship to uterine vessels. (Reproduced from *Nichols DH. Gynecologic and Obstetric Surgery, Vol. 1, 1993, Fig. 68-5, p. 1130. Copyright Elsevier.*)

Histologic types include hydatidiform moles, invasive moles, choriocarcinoma, and placental site trophoblastic tumors. It is an important gynecologic entity to consider when uterine size is significantly greater than expected for date in pregnancy, when bleeding occurs in pregnancy, or with abnormal bleeding after pregnancy loss, abortion, or full-term delivery. Diagnosis is usually made by ultrasound and measurement of serum β -hCG, followed by pathologic examination of curettage specimens. There are two subtypes of hydatidiform moles. Complete moles contain no fetal tissue and have a diploid karyotype. Partial moles contain fetal tissue and have triploid karyotypes. The chromosome pattern suggests paternal origin. These can be associated with theca lutein ovarian cysts often greater than 6 cm in diameter that are fragile; they should generally be followed without surgical intervention as they resolve with removal or treatment of the GTD. Metastatic GTD can present on the cervix, vagina, liver, or lung, and should not be managed surgically. Chemotherapy is primary therapy, and the incidence of bleeding complications is significant.

Primary surgery for diagnosis and initial therapy is a suction dilatation and curettage. Oxytocin is started either prior to anesthesia or immediately as the cervix is being dilated. The largest suction catheter possible (12 mm preferred) is gently inserted through the cervix and suction turned on, to allow the tissue to be removed and the uterus to rapidly decrease with less blood loss. Following this, a careful sharp curettage of the uterus is done acknowledging the increased risk for perforation. β -hCG is then followed weekly until normal for 3 weeks, then monthly for at least 6 months. Any increase in β -hCG should trigger further evaluation and consideration of chemotherapy.^{55,56}

PELVIC FLOOR DYSFUNCTION

Pelvic floor disorders can be categorized, from a urogynecologic perspective, into three main topics: female urinary incontinence and voiding dysfunction, pelvic organ prolapse, and disorders of defecation.⁵⁷ Approximately 11% of

women will undergo surgery for incontinence or prolapse.⁵⁸ The normal functions of support, storage, and evacuation can be altered by derangements in neuromuscular function both centrally and peripherally and through acquired changes in connective tissue. Reconstructive surgeons aim to repair or compensate for many of these losses.

Evaluation

Diagnostic evaluations, in addition to the history and examinations described earlier, can aid in the diagnosis of many pelvic floor disorders. Cystoscopy, multichannel urodynamics, and/or fluoroscopic evaluation of the urinary tract can be obtained for patients with urinary incontinence or voiding dysfunction.⁵⁹ Defecography, anal manometry, and endorectal ultrasound may be useful for diagnosis of defecatory dysfunction. A standardized examination called the pelvic organ prolapse quantification (POP-Q)⁵⁹ helps to clarify which vaginal compartment, and therefore which specific structure, has lost its anatomic integrity in women with uterovaginal prolapse. Finally, dynamic MRI and pelvic floor electromyography have demonstrated growing utility for all three disorders.

Surgery for Pelvic Organ Prolapse

Many factors are important in determining which reconstructive operation is optimal for a given patient with pelvic organ prolapse. Surgical decisions are often based on case series and expert opinions that may not have universal applicability. However, the few reports with the highest level of evidence suggest that failure rates for prolapse reconstruction may be twice as high using the vaginal approach when compared with the abdominal route.^{60,61}

Colporrhaphy. Anterior colporrhaphy, also known as an “anterior repair,” is performed for a symptomatic cystocele. The procedure begins with incision of the anterior vaginal epithelium in a midline sagittal direction. The epithelium is dissected away from the underlying vaginal muscularis. The vaginal muscularis is plicated with interrupted delayed absorbable stitches, after which the epithelium is trimmed and reapproximated. The vaginal canal is therefore shortened and narrowed proportionate to the amount of removed epithelium. Posterior colporrhaphy is performed for a symptomatic rectocele. This procedure is performed in a similar manner, often including the distal pubococcygeus muscles in the plication. Recently, in attempts to decrease surgical failures alluded to earlier, many surgeons have opted to use grafts and meshes to augment these vaginally performed procedures. Unfortunately the apparent number of postoperative complications, including mesh erosion, pelvic pain and dyspareunia, prompted the FDA to publish a warning encouraging a much more limited use of vaginal mesh for prolapse repair until greater surveillance and more rigorous studies could be completed.⁶²

Sacrospinous and Uterosacral Ligament Fixations. Both the sacrospinous ligament fixation (SSLF) and uterosacral ligament fixation (USLF) procedures are vaginal procedures that suspend the apex of the vagina using native tissue for treatment of apical prolapse. The sacrospinous ligament is found embedded in and continuous with the coccygeus muscle, which extends from the ischial spine to the lateral surface of the sacrum. The procedure begins with entry into the rectovaginal space, usually by incising the posterior vaginal wall at its attachment to the perineal body. The space is developed to the level of the vaginal apex, and the rectal pillar is penetrated to gain access to the pararectal space. A long-ligature carrier is used to

place sutures medial to the ischial spine, through the substance of the ligament-muscle complex. Structures at risk in this procedure include the pudendal neurovascular bundle, the inferior gluteal neurovascular bundle, lumbosacral plexus, and sciatic nerve. After the stitches are placed, the free ends are sewn to the undersurface of the vaginal cuff. The sacrospinous stitches are tied to firmly approximate the vagina to the ligament without suture bridging.

When using the uterosacral ligaments for repair of prolapse, it is important to recall that these structures are not “ligaments” in the true sense of the word, but rather condensations of smooth muscle, collagen, and elastin. Several support sutures are placed from the lateral-most portion of the vaginal cuff to the distal-most part of the ligament, and from the medial vaginal cuff to the proximal ligament. Intraoperative evaluation of the lower urinary tract is important to confirm the absence of ureteral compromise.

Colpocleisis. Colpocleisis is reserved for patients who are elderly, who do not wish to retain coital ability, and for whom there is good reason not to perform a more extensive reconstructive operation. A colpocleisis removes of part or all of the vaginal epithelium, obliterating the vaginal vault and leaving the external genitalia unchanged. The procedure can be performed with or without a hysterectomy. Successive purse-string sutures through the vaginal muscularis are used to reduce the prolapsed organs to above the level of the levator plate.

Sacrocolpopexy. The best procedure for patient with prolapse of the vaginal apex is an abdominal sacrocolpopexy. In these patients, the natural apical support structure, the cardinal-uterosacral ligament complex, is often damaged and attenuated. The abdominal placement, as opposed to vaginal placement, of graft material to compensate for defective vaginal support structures is well described.⁶³ Apical support defects rarely exist in isolation, and the sacrocolpopexy may be modified to include the anterior and posterior vaginal walls as well as the perineal body in the suspension. Sacrocolpopexies can be performed via laparotomy as well as via laparoscopy. Like rectopexies and low anterior resections, deep pelvic access is needed. Significant suturing at varied angles is required. The advent of the DaVinci robotic laparoscopic system has made visualization and adequate placement of the mesh and sutures easier to perform when using the minimally invasive approach.

During a sacrocolpopexy, a rigid stent (usually an EEA sizer) is placed into the vagina to facilitate its dissection from the overlying bladder and rectum and to allow the graft material to be spread evenly over its surface. A strip of synthetic mesh is fixed to the anterior and posterior vaginal walls. The peritoneum overlying the presacral area is opened, extending to the posterior cul-de-sac. The sigmoid colon is retracted medially, and the anterior surface of the sacrum is skeletonized. Two to four permanent sutures are placed through the anterior longitudinal ligament in the midline, starting at the S2 level and proceeding distally. The sutures are passed through the graft at an appropriate location to support the vaginal vault without tension. The peritoneum is then closed with an absorbable running suture. The most dangerous potential complication of sacrocolpopexy is sacral hemorrhage.

Surgery for Stress Urinary Incontinence

Stress incontinence is believed to be caused by lack of urethrovaginal support (urethral hypermobility) or intrinsic sphincter

deficiency (ISD). ISD is a term applied to a subset of stress-incontinent patients who have particularly severe symptoms, including urine leakage with minimal exertion. This condition is often recognized clinically as the low pressure or “drainpipe” urethra. The urethral sphincter mechanism in these patients is severely damaged, limiting coaptation of the urethra. Standard surgical procedures used to correct stress incontinence share a common feature: partial urethral obstruction that achieves urethral closure under stress.

Burch Procedure. The most quoted description of this procedure is that of Tanagho in 1976.⁶⁴ The space of Retzius is approached extraperitoneally, from an abdominal approach, allowing the bladder to be mobilized from the surrounding adipose tissue and lateral pelvis. Overlying fat and blood vessels in the area of the vesical neck are cleared away. Two pairs of large-caliber nonabsorbable sutures, although the original description advocated delayed absorbable sutures, are placed through the periurethral vaginal wall, one pair at the midurethra and one at the urethrovesical junction. Each stitch is then anchored to the ipsilateral Cooper’s (iliopectineal) ligament. The sutures are tied with the operator’s nondominant hand placed vaginally to give preferential support to the urethrovesical junction relative to the anterior vaginal wall without overcorrection. Long-term outcome studies up to 10 years have shown that the Burch procedure yields cure rates of 80% to 85%.

Tensionless Sling. The tension-free vaginal tape (TVT) is a modified sling that uses a strip of polypropylene mesh. Unlike traditional sling procedures, the mesh is positioned at the midurethra, not the urethrovesical junction, and is not sutured or otherwise fixed into place. Advantages of TVT include the ability to perform the procedure under local anesthesia on an outpatient basis. Small subepithelial tunnels are made bilaterally to the descending pubic rami through an anterior vaginal wall incision. A specialized conical metal needle coupled to a handle is used to drive one end of the sling through the perineal membrane, space of Retzius, and through one of two small suprapubic stab incisions. The tape is set in place without any tension after bringing up the other end of the tape through the other side. Recently, multiple modifications have been made to carry the tape through the bilateral medial portions of the obturator space. Risks of the procedure include visceral injury from blind introduction of the needle, bleeding, and nerve and muscle injury in the obturator space. Additionally, voiding dysfunction and delayed erosion of mesh into the bladder or urethra have been seen.

Urethral Bulking Injections. A transurethral or periurethral injection of bulking agents is indicated for patients with intrinsic sphincter deficiency. Several synthetic injectable agents (e.g., polydimethylsiloxane, calcium hydroxylapatite) are now used because glutaraldehyde cross-linked (GAX) bovine dermal collagen is no longer commercially available.⁶⁵ Anesthesia is easily obtained by using intraurethral 2% lidocaine jelly and/or transvaginal injection of the periurethral tissues with 5 mL of 1% lidocaine. The material is injected underneath the urethral mucosa at the bladder neck and proximal urethra at multiple positions, until mucosal bulk has improved. Patients must demonstrate a negative reaction to a collagen skin test prior to injection. The long-term cure rate is 20% to 30%, with an additional 50% to 60% of patients demonstrating improvement.⁵⁷ Repeat injections are frequently necessary because of migration and dissolution of the collagen material.

Vulvar Cancer

Vulvar cancer is the fourth most common gynecologic cancer. The mean age at diagnosis is 65, although this has trended down over the last several decades.⁶⁶ Evidence supports an HPV-dependent pathway of carcinogenesis with risks factors similar to VIN in the majority of cases. A second pathway independent of HPV is associated with chronic inflammation and vulvar dystrophy.⁶⁷ Patients usually present with a vulvar ulcer or mass. Pruritus is a common complaint, and vulvar bleeding or enlarged inguinal lymph nodes are signs of advanced disease. Careful evaluation of the patient is necessary to rule out concurrent lesions of the vagina and cervix. Biopsy is required and should be sufficient to allow evaluation of the extent of stromal invasion. Vulvar carcinomas are squamous in 90% of cases. Other less common histologies include melanoma (5%), basal cell carcinoma (2%), and soft tissue sarcomas (1%–2%).

Spread of vulvar carcinoma is by direct local extension and via lymphatic microembolization. Hematogenous spread is uncommon except for vulvar melanoma. Lymphatic spread seems to follow a stepwise, predictable pattern traveling from superficial, above the cribriform fascia, to deep inguinofemoral nodes and ultimately to the pelvic and external iliac nodal basins (Fig. 41-17).^{68,69} The node of Cloquet is an important sentinel node situated in the route of spread to the pelvic lymph nodes.

Staging and primary surgical treatment are typically performed as a single procedure and tailored to the individual patient (Table 41-6). Surgical staging accounts for the most important prognostic factors including tumor size, depth of invasion, inguinofemoral node status, and distant spread. The most conservative procedure should be performed in view of the high morbidity of aggressive surgical management. This typically involves radical resection of the vulvar tumor targeting a 1- to 2-cm margin around the lesion, and carried to the deep perineal fascia of the urogenital diaphragm with an ipsilateral or bilateral inguinofemoral lymphadenectomy (Fig. 41-18). For tumors ≤ 2 cm in size with ≤ 1 mm invasion (International Federation of Gynecology and Obstetrics [FIGO] stage IA), lymphadenectomy may be safely omitted, and wide local or radical local excision is adequate. Patients with stage IB tumors have deeper invasion but negative nodes and therefore carry an excellent prognosis. Stage II includes patients with local extension and

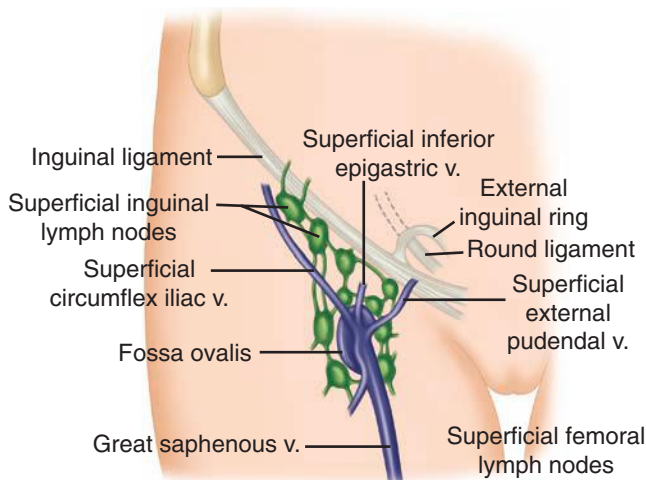


Figure 41-17. Lymphatic drainage of the vulva delineated by Stanley Way.

Table 41-6

2009 International Federation of Gynecology and Obstetrics staging of vulvar carcinoma⁷⁸

IA	Tumor confined to the vulva or perineum, ≤ 2 cm in size with stromal invasion ≤ 1 mm, negative nodes
IB	Tumor confined to the vulva or perineum, >2 cm in size or with stromal invasion >1 mm, negative nodes
II	Tumor of any size with adjacent spread (1/3 lower urethra, 1/3 lower vagina, anus), negative nodes
IIIA	Tumor of any size with positive inguinofemoral lymph nodes
(i)	1 lymph node metastasis ≥ 5 mm
(ii)	1–2 lymph node metastasis(es) of <5 mm
IIIB	(i) 2 or more lymph nodes metastases ≥ 5 mm
(ii)	3 or more lymph nodes metastases <5 mm
IIIC	Positive node(s) with extracapsular spread
IVA	(i) Tumor invades other regional structures (2/3 upper urethra, 2/3 upper vagina), bladder mucosa, rectal mucosa, or fixed to pelvic bone
(ii)	Fixed or ulcerated inguinofemoral lymph nodes
IVB	Any distant metastasis including pelvic lymph nodes

negative nodes, and therefore, these patients have a prognosis similar to other node-negative patients.

Stage III disease includes patients with lymph node metastases, and stage IV disease is either locally advanced or distant metastasis. Treatment options for stage III and IV disease include: (a) chemoradiation followed by limited resection if needed; (b) radical vulvectomy; and (c) radical vulvectomy coupled with pelvic exenteration. External-beam radiotherapy combined with radiosensitizing chemotherapy of cisplatin and 5-fluorouracil is emerging as the preferred initial management

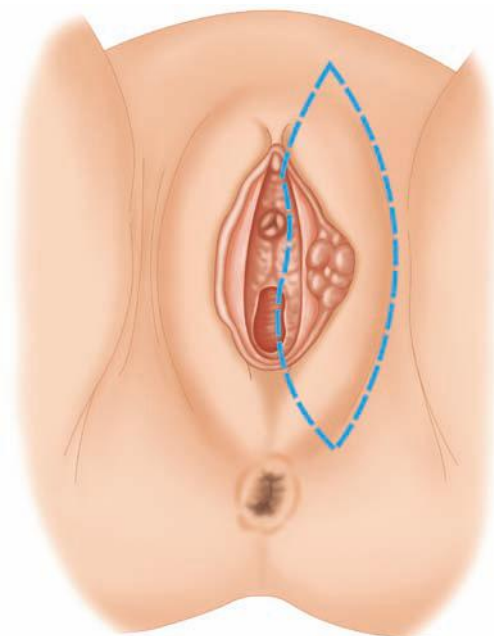


Figure 41-18. Extent of modified radical hemivulvectomy for stages I and II squamous cancer of the vulva.

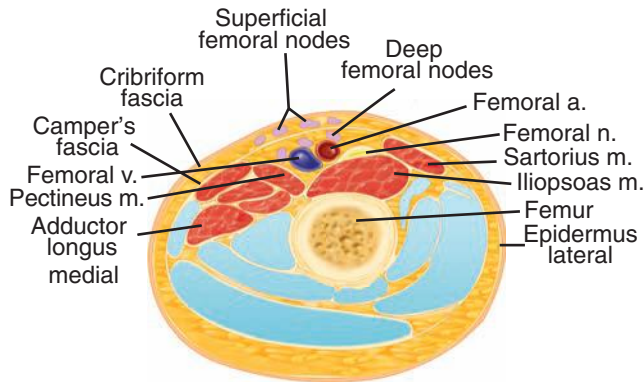


Figure 41-19. Superficial inguinal lymphadenectomy. a. = artery; m. = muscle; n. = nerve.

of advanced disease followed by limited surgical resection of residual disease.⁷⁰⁻⁷² Reconstruction of the vulva and groin, if needed, can be accomplished using grafts and rotational or myocutaneous flaps depending on the size and type of defect.

Inguinofemoral lymphadenectomy is indicated beyond clinical stage IA. Unilateral lymphadenectomy is recommended for lateralized lesions, and bilateral lymphadenectomy is recommended for central lesions that cross the midline or those involving the periclitoral area (Figs. 41-19 and 41-20). The role of vulvar sentinel lymph node biopsy is under investigation by the Gynecologic Oncology Group (GOG) and is in use by a growing number of gynecologic oncologists. Preliminary data are encouraging and may allow patients with negative sentinel nodes to avoid complete groin dissection and its attendant morbidity such as lower extremity lymphedema.

Nodal failure in the groin and pelvis is difficult to treat successfully, and attention to primary management of these areas is key. Postoperative adjuvant inguinal and pelvic radiotherapy is indicated when inguinal lymph nodes are positive and is superior to pelvic lymphadenectomy, which has been largely abandoned. It is also indicated when the vulvectomy margins are positive or close positive for disease and further surgical management is not anatomically feasible.

Vaginal Cancer

Vaginal carcinoma is a rare gynecologic malignancy and accounts for about 3% of cancers affecting the female reproductive

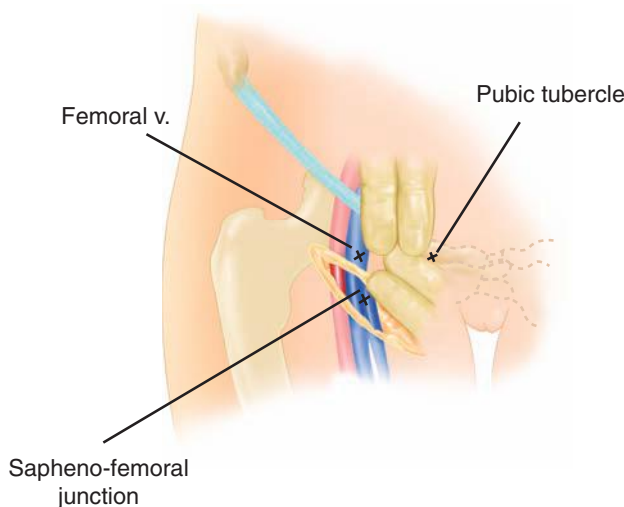


Figure 41-20. Incision recommended for superficial inguinal lymphadenectomy. v. = vein.

Table 41-7

International Federation of Gynecology and Obstetrics staging of vaginal carcinoma

0	Carcinoma in situ; intraepithelial neoplasia grade 3
I	Tumor limited to the vaginal wall
II	Tumor has involved the subvaginal tissue but has not extended to the pelvic wall
III	Tumor extends to the pelvic wall
IV	Tumor has extended beyond the true pelvis or has involved the mucosa of the bladder or rectum
IVA	Tumor invades bladder and/or rectal mucosa and/or direct extension beyond the true pelvis
IVB	Distant metastasis

system.⁶⁶ Squamous cell carcinomas account for 85% to 90% of cases; more than two thirds of vaginal cancers are diagnosed in women 60 years of age or older. Risk factors are similar to other HPV-related cervical and vulvar cancers. Rare clear cell carcinoma of the vagina is associated with in utero exposure to diethylstilbestrol (DES), which is now largely of historical interest due to aging of the exposed cohort.⁷³ Patients with vaginal cancer usually present with postmenopausal and/or postcoital bleeding and may also complain of vaginal discharge, vaginal mass, dysuria, hematuria, rectal bleeding, or pelvic pain, which may be indicative of advanced disease. Diagnosis is made via biopsy of suspicious lesions, which may require colposcopic guidance.⁶⁷

Vaginal cancer is staged clinically by pelvic exam, chest x-ray, cystoscopy, and proctoscopy (Table 41-7).⁷⁴ Vaginal cancer spreads by local extension to adjacent pelvic structures, by lymphatic embolization to regional lymph nodes, and less commonly via the hematogenous route. Lymphatic drainage is complex, but in general, lesions in the upper vagina drain to the pelvic lymph nodes, while lesions involving the lower third drain to the inguinofemoral lymph nodes.

Stage I disease, involving the upper vagina, may be treated surgically or with intracavitary radiation therapy.^{68,69,75} Surgery consists of a radical hysterectomy, upper vaginectomy, and bilateral pelvic lymphadenectomy. Stage I disease in the mid to lower vagina is usually treated with radiation and concurrent chemotherapy. External-beam pelvic radiation is the mainstay of treatment for stage II to IV disease and may be followed by intracavitary and/or interstitial brachytherapy. Prognosis for treated early-stage disease is excellent, with 5-year survival rates greater than 90%. Advanced-stage disease, however, carries a poor prognosis, with 5-year survival rates of only 15% to 40%.

Cervical Cancer

General Principles. There are over 12,000 new cases of cervical cancer and over 4000 cervical cancer deaths annually in the United States. It is a major killer worldwide, causing 275,000 deaths annually.⁷⁶ Risk factors for cervical squamous cell carcinoma and adenocarcinoma, the two most common histologies, are largely related to acquisition of and immune response to carcinogenic subtypes of the HPV virus. The presence of inherited genetic variations that increase the likelihood of developing cervical cancer when exposed to oncogenic subtypes of HPV is under active investigation. Cervical screening is correlated with

Table 41-8

2009 International Federation of Gynecology and Obstetrics cervical cancer staging and management options⁷⁸

STAGE	DESCRIPTION	OPTIONS FOR MANAGEMENT
0	Carcinoma in situ	Adenocarcinoma in situ: hysterectomy, although some may be followed for preservation if all margins negative on cone Squamous in situ: local excision with LEEP or cone or laser ablation
I	Confined to the cervix A1: Confined to the cervix, diagnosed only by microscopy with invasion of ≤ 3 mm in depth and lateral spread ≤ 7 mm A2: Confined to the cervix, diagnosed with microscopy with invasion of >3 mm and <5 mm with lateral spread ≤ 7 mm B1: Clinically visible lesion or greater than A2, ≤ 4 cm in greatest dimension B2: Clinically visible lesion, >4 cm in greatest dimension	A1 and some A2: fertility preservation through large cone followed by close monitoring, followed by hysterectomy B1 and B2: radical hysterectomy or chemoradiation; radical trachelectomy with uterine preservation for childbearing is under investigation for highly selected patients
II	A1: Involvement of the upper two thirds of the vagina, without parametrial invasion, ≤ 4 cm in greatest dimension A2: >4 cm in greatest dimension B: Parametrial involvement	For some IIA, radical hysterectomy may be considered IIA and IIB: chemoradiation is preferred
III	A: Involvement of the lower third of the vagina B: Involvement of a parametria to the sidewall or obstruction of one or both ureters on imaging	Chemoradiation
IV	A: Local involvement of the bladder or rectum B: Distant metastases	A: Chemoradiation B: Chemotherapy with palliative radiation as indicated

LEEP = loop electro-excisional procedure.

early identification and treatment of preinvasive disease.⁷⁷ Cervical cancer is most commonly identified in women with long intervals between screening or with no prior screening.

Early cervical cancer is usually asymptomatic, although irregular or postcoital bleeding may be present, particularly in more advanced disease. The diagnosis of cervical cancer is made by cervical biopsy, either of a gross lesion or a colposcopically identified lesion. Cervical cancer is staged clinically.⁷⁸ Staging and management options are outlined in Table 41-8.

Procedures for Cervical Cancer Treatment

Radical Hysterectomy. This procedure may be performed via laparotomy or, increasingly, via a minimally invasive (laparoscopic or robotic) approach.⁷⁹ The key elements are dissection of the pelvic and paraortic nodes and the dissection of the parametrium from the pelvic sidewall to allow en bloc removal with the uterus. The principle steps of an open procedure are demonstrated in Fig. 41-21. In contrast to a typical simple hysterectomy, the radical hysterectomy involves dissection much closer to the bowel, bladder, ureters, and great vessels, resulting in a higher complication rate to these organs. Additionally, disruption of the nerves supplying the bladder and the rectum, which traverse the cardinal and uterosacral ligaments, may result in temporary or long-term bladder and bowel dysfunction. Radical hysterectomies allow for the maintenance of the ovaries since the incidence of metastases to this area is very low, providing a clear advantage of surgery over radiation therapy in the younger patient.

Radical Trachelectomy. Interest in fertility preservation with stage IA1 and IA2 and stage IB1 lesions has led to the development of methods of radical trachelectomy with uterine preservation. This procedure depends on an adequate blood supply to the uterus from the ovarian anastomoses, as the cervical portion is removed. The lower uterine segment is closed with a cerclage and attached directly to the vaginal cuff. The rates of recurrence, pregnancy outcomes, and the best surgical candidates for this surgery are still under study.⁸⁰

Pelvic Exenteration for Recurrent Disease (Fig. 41-22). Cervical cancer recurrences after primary surgical management are treated with radiation. Surgery may be a consideration in selected patients with recurrent cervical cancer who have received maximal radiation therapy. If the recurrence is locally confined with no evidence of spread or metastatic disease, then pelvic exenteration may be considered. Attempted exenteration procedures are aborted intraoperatively if metastatic disease is found. Exenteration is tailored to the disease size and location and may be suprapubic or extend below the levator ani muscle and require vulvar resection. Reconstruction of the pelvis may require a continent urinary pouch (if radiation enteritis is limited) or ileal conduit and colostomy, as well as rebuilding of the pelvic floor and vagina with grafts or myocutaneous flaps.

Uterine Cancer

Endometrial Cancer. Endometrial cancer is the most common gynecologic malignancy and fourth most common cancer in

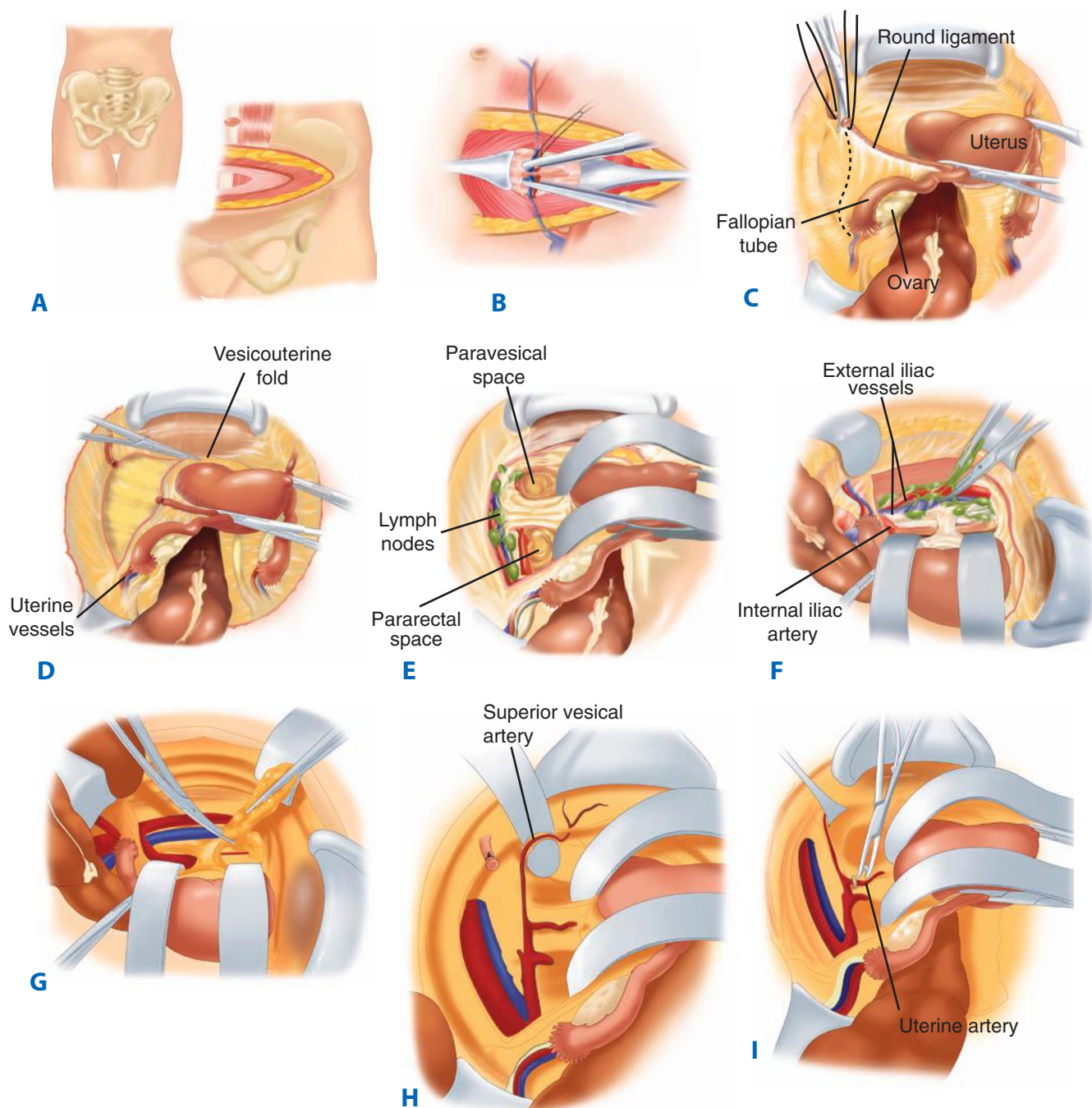


Figure 41-21. Radical hysterectomy. **A.** Exposure of the inferior epigastric vessels before transection of the rectus muscles. **B.** Ligation of the inferior epigastric vessels before transection of the rectus muscles. **C.** Ligation and division of the round ligaments opens the pelvic retroperitoneum. **D.** First peritoneal incision lateral to the ovarian vessels and across the vesicouterine fold. **E.** Narrow malleable retractors (Indiana retractors) are placed into the paravesical and pararectal spaces to provide excellent access to the lateral pelvic sidewall and pelvic lymph nodes. **F.** Pelvic lymphadenectomy (external and internal iliac vessels). **G.** Pelvic lymphadenectomy (obturator fossa). **H.** Development of the uterine and superior vesical arteries. **I.** The uterine artery has been clipped and divided near its origin. **J.** The proper ovarian ligament and proximal fallopian tube are clamped and divided if the ovary is to be preserved. **K.** The ureters have been detached from the posterior peritoneum of the broad ligament and are retracted laterally. The rectovaginal space is developed using blunt finger dissection. **L.** Transection of the uterosacral ligaments. **M.** Clamps are placed on the lateral vagina, taking care to remove 3 to 4 cm of the upper vagina.

women.⁶⁶ It is most common in menopausal women in the fifth decade of life; up to 15% to 25% of cases occur prior to menopause, and 1% to 5% occur before age 40. Risk factors for the most common type of endometrial cancer include increased exposure to estrogen without adequate opposition by progesterone, either endogenous (obesity, chronic anovulation) or exogenous (hormone replacement). Additional risk factors

include diabetes, Lynch II syndrome (hereditary nonpolyposis colorectal cancer), and prolonged use of tamoxifen. Tamoxifen is a mixed agonist/antagonist ligand for the estrogen receptor. It is an agonistic in the uterus and an antagonistic to the breast and ovary. Protective factors for endometrial cancer include smoking and use of combination oral contraceptive pills. Adenocarcinomas are the most prevalent histologic type.

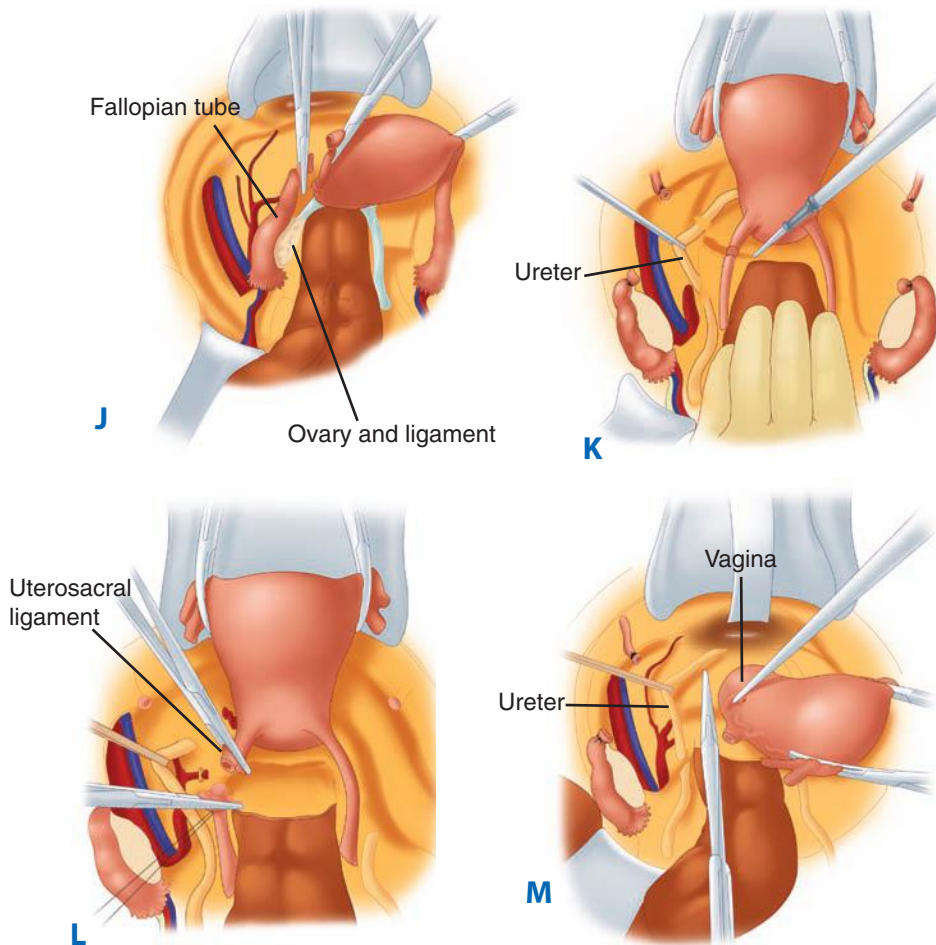


Figure 41-21. (Continued)

Endometrial adenocarcinomas are divided into type I and type II, although there is a trend to return to histology as a divider. Type I tumors are estrogen-dependent endometrioid histology and have a relatively favorable prognosis. Type II endometrial cancers are estrogen-independent, aggressive, and characterized by nonendometrioid, serous, or clear cell histology.⁸¹ Postmenopausal bleeding is the most common presentation of type I disease and often permits early-stage diagnosis,

resulting in a favorable prognosis. Abnormal bleeding should prompt endometrial evaluation and sampling, which is usually done with an office endometrial biopsy, although at times, it requires operative curettage or diagnostic hysteroscopy. Transvaginal ultrasonography (TVUS) often reveals a thickened endometrial stripe. An endometrial stripe measuring 5 mm or more in a postmenopausal patient raises concern and should be followed by endometrial sampling; patients with stripe of 4 mm

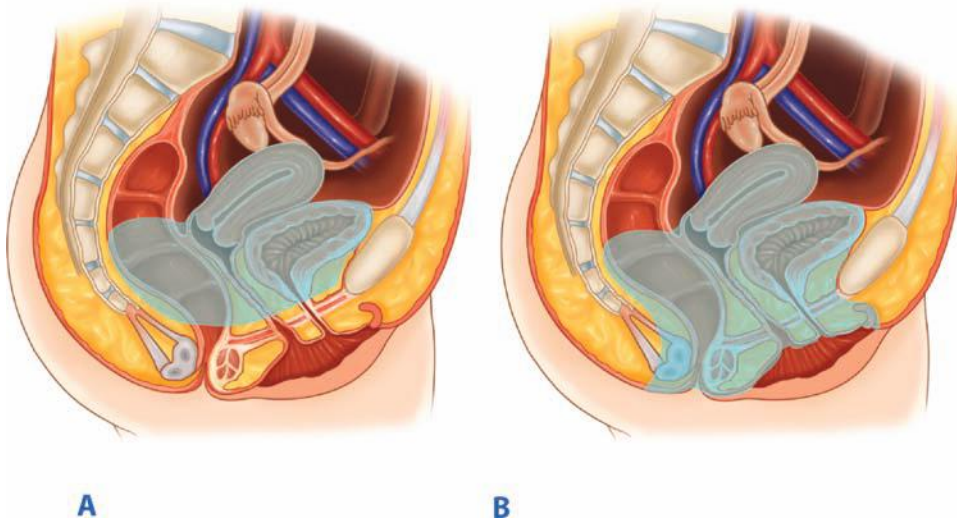


Figure 41-22. Pelvic exenteration may be limited to the supralelevator space (A) or can extend below the levator ani muscle (shaded area) (B).

Table 41-9

2009 International Federation of Gynecology and Obstetrics staging of carcinoma of the uterine corpus⁷⁸

IA	Tumor confined to the uterus, no or <½ myometrial invasion
IB	Tumor confined to the uterus, >½ myometrial invasion
II	Cervical stromal invasion, but not beyond uterus
IIIA	Tumor invades serosa or adnexa
IIIB	Vaginal and/or parametrial involvement
IIIC1	Pelvic node involvement
IIIC2	Para-aortic involvement
IVA	Tumor invasion bladder and/or bowel mucosa
IVB	Distant metastases including abdominal metastases and/or inguinal lymph nodes

or less rarely have occult malignancy, and TVUS may thus be used to triage patients before invasive endometrial sampling. Uterine cancer is surgically staged and is graded based on the degree of histologic differentiation of the glandular components (Table 41-9).⁷⁸ Grade is an important prognostic factor, independent of stage.

Treatment is surgical and most commonly involves hysterectomy, bilateral salpingo-oophorectomy, peritoneal cytology, pelvic and para-aortic lymphadenectomy, and resection of any gross disease.^{68,69,75} Evidence supports equivalent oncologic outcomes with minimally invasive approaches.⁸² The utility of lymphadenectomy is an area of great controversy. The need for postoperative adjuvant radiation or chemotherapy is individualized based on the histology, stage, and risk factors such as age, lymphovascular space invasion, and histology. Early-stage patients are typically cured with surgery alone, whereas patients with high- or intermediate-risk factors, as defined by collaborative trials groups, commonly receive intracavitary brachytherapy to decrease local recurrence.^{83,84} Patients with advanced disease and adverse histologies commonly receive platinum-based chemotherapy with or without radiation.

Lynch Syndrome. Lynch syndrome, a cancer family syndrome, also known as hereditary nonpolyposis colorectal cancer (HNPCC), is an autosomal dominant inherited predisposition to develop colorectal carcinoma and extracolonic cancers, predominantly including tumors of the uterus and ovaries, with rare but defined inclusion of breast cancer.⁸⁵ Genes involved in HNPCC are those required for proper single-strand DNA repair via the mismatch repair pathway; most commonly involved are *MLH1*, *MSH2*, and *MSH6*. The risk of colorectal carcinoma is as high as 75% by age 75. Affected female patients have a 40% and 10% lifetime risk of developing uterine and ovarian cancers, respectively. Surveillance has not been proven to identify early-stage disease in these patients, although it is recommended and should include annual cervical cytology, mammography, transvaginal ultrasonography, CA-125 measurements, and an endometrial biopsy. Risk reduction salpingo-oophorectomy with hysterectomy is now being recommended for women who have completed childbearing, ideally 5 to 10 years earlier than the first case of endometrial or ovarian cancer in the family.

Uterine Sarcomas. Uterine sarcomas arise from the uterine muscle and connective tissue elements and are typically aggressive tumors with a poorer prognosis compared to the

more common endometrial carcinomas. The most common histopathologic types are endometrial stromal sarcomas, undifferentiated endometrial sarcomas, and leiomyosarcomas. Risk factors are challenging to assess but may include African American race, pelvic radiation, and tamoxifen exposure. Patients typically present with bleeding or mass effects, although some are discovered incidentally at the time of hysterectomy for other indications. Leiomyosarcoma is the most common uterine sarcoma, and hysterectomy with salpingo-oophorectomy is the treatment of choice. Lymph node metastases are rare in sarcomas in general, and in uterine sarcomas in the absence of palpable nodes or extrauterine disease. There are limited data to support cytoreduction when extrauterine disease is present. Benefits of adjuvant therapy are unknown. Advanced disease is typically treated with systemic chemotherapy.⁸⁶

Ovarian, Tubal, and Primary Peritoneal Cancer

Epithelial Ovarian, Tubal, and Primary Peritoneal Cancer.

There were an estimated 22,280 new cases and 15,500 deaths due to ovarian cancers in 2012, yielding a fractional death rate of 70% and making ovarian cancer the most deadly of all women's cancers.⁶⁶ One in 60 to 70 women in the United States will develop ovarian cancer during her lifetime, with a median age at diagnosis of 63 years. Symptoms for either benign or malignant ovarian tumors are nonspecific but frequent. Goff and colleagues, in a 2007 publication, described symptoms of bloating, pelvic or abdominal pain, difficulty eating or feeling full quickly, and urinary symptoms of urgency or frequency,⁸⁷ which form the basis of an ovarian cancer symptom index (Table 41-10), the use of which is endorsed by the Ovarian Cancer National Alliance, the Gynecologic Cancer Foundation, the Society of Gynecologic Oncologists, and the American Cancer Society. These symptoms, when newly developed and persistent or when representing a distinct change from a personal norm, should prompt an evaluation specifically targeted for identification of gynecologic malignancy.

High-grade, particularly serous epithelial cancers of the ovary, fallopian tube, and peritoneum are clinically similar and often combined under the rubric of epithelial ovarian cancer (EOC) in clinical practice, as well as in research and clinical trials. Risk factors for development of EOC include events that appear to increase the number of lifetime ovulations (e.g., early menarche, late menopause, nulliparity), whereas events that decrease the number of ovulations decrease risk (e.g., pregnancy, breastfeeding, oral contraceptives). Additionally, a history of tubal ligation or hysterectomy also decreases EOC risk. Family history of breast cancer and/or EOC is one of the strongest factors for lifetime risk of having breast cancer or EOC. Approximately 85% of ovarian cancer is sporadic; of the remaining 10% of cases, 75% of hereditary ovarian cancer has been attributed to mutations in the *BRCA1* and *BRCA2* genes, 7% to HNPCC, and the remainder to familial cancer of undefined genetic origin.⁸⁸ The lifetime risk of ovarian cancer in *BRCA1* mutation carriers has been estimated at 40% to 60%, and it is 15% to 45% in *BRCA2* carriers. The only confirmed prevention is risk-reducing salpingo-oophorectomy (RRSO).^{89,90} The lifetime risk of ovarian or tubal malignancy is reduced to approximately 5% with RRSO, with the resultant cancer presenting as a primary peritoneal cancer.

Physical examination of patients with EOC may reveal evidence of metastatic disease, whereas a pelvic mass may be

Table 41-10

Ovarian cancer symptom index (2007) and ACOG guidelines for patient referral to gynecologic oncology^{87, 104}

OVARIAN CANCER SYMPTOM INDEX	ACOG GUIDELINES FOR REFERRAL OF PREMENOPAUSAL WOMEN WITH MASS SUSPICIOUS FOR OVARIAN CANCER	ACOG GUIDELINES FOR REFERRAL OF POSTMENOPAUSAL WOMEN WITH MASS SUSPICIOUS FOR OVARIAN CANCER
<i>Development of, change in, and/or persistence in:</i>	<i>1 or more of:</i>	<i>1 or more of:</i>
Bloating	CA-125 >200 U/mL	Elevated CA-125
Pelvic or abdominal pain	Ascites	Ascites
Difficulty eating or feeling full quickly	Evidence of abdominal or distant metastasis	Nodular or fixed pelvic mass
Urinary symptoms of urgency or frequency	Family hx of 1 or more first-degree relatives with ovarian or breast cancer	Evidence of abdominal or distant metastasis
		Family hx of 1 or more first-degree relatives with ovarian or breast cancer

ACOG = American Congress of Obstetricians and Gynecologists; hx = history.

appreciated on exam. Ultrasound is particularly useful in the evaluation of a pelvic mass, whereas CT scan may detect evidence of metastatic disease. In the presence of a radiographically complex mass, CA-125 may provide further evidence for or against a possible ovarian malignancy. Concerning physical or radiographic exam findings should prompt referral to a gynecologic oncologist (see Table 41-10), as studies demonstrate inferior patient outcomes for women who have had primary surgery by nongynecologic oncologists.

The objectives of surgery in EOC are threefold. The first is to make the histologic diagnosis. The second is to assess the extent of disease through complete surgical staging (Tables 41-11 and 41-12). The third objective is (complete when feasible) surgical cytoreduction or debulking. An optimal cytoreduction is defined as no gross residual lesion greater than 1 cm, although

outcomes are improved with complete resection of all gross disease. The extent of disease upon entering the abdomen and the residual disease upon completion of the debulking surgery are independent prognostic variables for patient outcome. When EOC is identified on frozen section and disease is grossly limited to the pelvis, complete staging with node dissection will upstage nearly one third of patients.⁹¹ Decisions about the benefits and risks of radical debulking for individual presentations and diverse pathology depend on the age and medical stability of the patient, as well as the pathologic type of the cancer. Conservative, fertility-sparing surgery can be considered for likely stage I, grade 1 EOC. In a patient who is medically compromised or in whom complete primary cytoreduction is unlikely, neoadjuvant chemotherapy followed by interval debulking may be more appropriate and is supported by a recent randomized controlled trial.⁹² Patients usually receive three cycles of platinum-based chemotherapy prior to debulking, and then three additional cycles after surgery.

Early-stage EOC has an excellent outcome. Low-grade, stage IA and IB disease can be cured in up to 90% to 95% of cases by a complete surgical procedure. The prevailing position in the United States is that such patients do not benefit from

Table 41-11

Risk and protective factors for epithelial ovarian and fallopian tube cancers

PROTECTIVE FACTORS	RISKS
Oral contraceptive use, especially >5 years	Primary and secondary infertility
Tubal ligation	Nulliparity
Lactation	<i>BRCA1/2</i> mutation and HNPCC syndrome
Pregnancy	Family history without genetic risk
Oophorectomy, salpingectomy	Endometriosis
	Personal history of breast cancer or first-degree relative with breast cancer
	? Hormone replacement therapy

HNPCC = hereditary nonpolyposis colorectal cancer.

Table 41-12

Components of comprehensive surgical staging and debulking of epithelial ovarian cancer

Vertical abdominal incision adequate to visualize the diaphragms
Evacuation of ascites
Peritoneal washings of each pelvic gutter and diaphragm
En bloc hysterectomy and bilateral salpingo-oophorectomy
Supracolic omentectomy
Retroperitoneal and pelvic lymph node dissection
Examination of the entire bowel
Random biopsies of apparently uninvolved areas of peritoneum, pericolic gutters, diaphragm

chemotherapy.⁹³ The standard of care for women with stages IC and II and all women with grade 3 or clear cell histology is adjuvant chemotherapy with three to six cycles of cisplatin or carboplatin in combination with paclitaxel or docetaxel.⁹⁴

Since GOG-111⁹⁵ was published in 1996, and through much of the subsequent decade, standard-of-care adjuvant therapy of advanced-stage EOC has been intravenous (IV) platinum and taxane. More recent trials have sustained that chemotherapy backbone but prompt an individualized, more nuanced approach. In 2006, the National Cancer Institute issued a Clinical Alert indicating that inclusion of intraperitoneal chemotherapy administration in adjuvant therapy should be considered first line for women with optimally cytoreduced (defined as no residual lesions >1 cm in diameter) EOC. This was the result of completion and analysis of three independent randomized clinical trials showing a significant survival advantage for intraperitoneal therapy.^{96,97} It is unclear whether it is the site of drug administration and/or the doses and dose density used that contributed to the improved outcomes. The intraperitoneal port is usually a 9.6-French venous catheter, with the port placed over the right or left costal margin. The catheter is tunneled caudad with insertion through the fascia in the lower abdomen and the tip in the pelvis.

Patients who have suboptimally debulked advanced-stage disease and/or who are not candidates for intraperitoneal therapy should receive IV adjuvant chemotherapy. Interest has increased in both dose-dense IV chemotherapy dosing as well as incorporation of biologic agents. The Japanese Gynecologic Oncology Group phase III trial of carboplatin and weekly, dose-dense paclitaxel demonstrated significant improvement in both progression-free and overall survival⁹⁸; the U.S. study of this regimen is now maturing. Addition of the angiogenesis inhibitor, bevacizumab, to the standard carboplatin-paclitaxel backbone and its continuance in maintenance therapy provided a modest increase in progression-free survival without an overall survival advantage. Patients with bulky disease after primary surgery appeared to derive the greatest benefit in post-hoc analysis.^{99,100}

Secondary cytoreduction upon recurrence can be considered (Table 41-13). Patients who have had a disease-free period of at least 12 months, following an initial complete clinical

response to surgery and initial chemotherapy, who have no evidence of carcinomatosis on imaging, and who have disease that can be completely resected are considered optimal candidates. A randomized controlled trial is ongoing to validate that current state of treatment. Debulking surgery done after subsequent relapses or in women with early recurrence has not been shown to result in an outcome benefit. Finally, surgery is used to palliate disease complications. The most common cause of palliative surgery is bypass of bowel obstruction.

Chemotherapy is the mainstay of therapy for recurrent EOC. Treatment approaches are based on platinum sensitivity¹⁰¹ (Table 41-14). Referral to an oncologist with specific expertise in chemotherapeutic treatment of ovarian cancer and access to clinical trials is important. In determining secondary and subsequent therapy, consideration of prior therapies, sites of disease, organs at risk from cancer, organs sustaining injury from prior therapy, and quality of life desires of the patient should be taken into consideration.

Ovarian Germ Cell Tumors. Ovarian germ cell tumors occur most commonly in women under age 30. Malignant forms often grow and disseminate rapidly and are symptomatic. The rapid growth may be accompanied by torsion producing an acute abdomen and need for emergent intervention. Because they are derived from primordial germ cells, many produce characteristic tumor markers. The most common benign germ cell neoplasm is the mature cystic teratoma; approximately 1% of teratomas contain a secondary malignancy arising from one of the components, most commonly squamous cell cancer. Immature teratomas comprise a significant proportion of malignant germ cell tumors and may be associated with elevated lactate dehydrogenase (LDH) or α -fetoprotein (AFP). Excluding teratomas, the most common malignant germ cell tumor is dysgerminoma, made up of pure undifferentiated germ cells. Bilaterality occurs in up to 15% of patients; lactate dehydrogenase is commonly elevated, and elevated β -hCG may occur. Staging, including removal of the involved ovary, biopsy of any suspicious areas, node dissection, and omentectomy, should be done initially but does not require hysterectomy or removal of the second ovary if fertility preservation is of concern and no extension of disease is observed. Evidence of extraovarian spread, such

Table 41-13

Guidelines for secondary debulking of epithelial ovarian cancer

TIME FROM COMPLETION OF PRIMARY THERAPY	DEFINITION	INTERVENTION
Progression on therapy	Platinum-refractory	No value of secondary debulking unless remediating complication such as bowel obstruction Nonplatinum-based chemotherapy Platinum with gemcitabine (class I) Nonplatinum-based chemotherapy
Progression within 6 months of completion of primary therapy	Platinum-resistant	No value of secondary debulking unless remediating complication such as bowel obstruction Nonplatinum-based chemotherapy Platinum with gemcitabine (class I) Nonplatinum-based chemotherapy
Progression 6 months after completion of primary therapy	Platinum-sensitive	Consider secondary debulking if greater than 12-month interval Consider platinum +/- taxane +/- bevacizumab, +/- pegylated liposomal doxorubicin, +/- gemcitabine (class I) Nonplatinum-based chemotherapy

Table 41-14

Definitions of platinum resistance and guidelines for treatment of recurrent disease

PLATINUM SENSITIVITY	DEFINITION	INTERVENTION
Refractory	Progression while receiving a platinum	Nonplatinum-based chemotherapy Platinum with gemcitabine
Resistant	Progression within 6 months of completing treatment	Nonplatinum-based chemotherapy Platinum with gemcitabine
Sensitive	Progression after 6 months of completing treatment	Consider secondary debulking if >12 months since treatment Consider platinum ± taxane Nonplatinum-based chemotherapy

as nodal metastases, requires adjuvant chemotherapy. The cure rate remains high, near 90% with metastatic disease; recurrent disease is more difficult to eradicate.¹⁰²

Less common are malignant germ cell tumors, including endodermal sinus or yolk sac tumors, embryonal carcinomas, mixed germ cell neoplasms, polyembryomas, and choriocarcinomas. Endodermal sinus tumors may have elevated AFP levels in the blood, whereas embryonal and mixed germ cell tumors may have elevated β -hCG, LDH, or AFP. Tumor markers are useful to follow during definitive therapy. Early spread of these tumors occurs, and other than completely resected stage I, grade I immature teratoma, all others require adjuvant therapy with a platinum-containing regimen.¹⁰³

Ovarian Sex Cord-Stromal Tumors. Although rare, sex cord-stromal cell tumors are derived from cells that support and surround the oocyte and can present with symptoms referable to endocrine activity of the tumor. These include granulosa cell tumors (female differentiated), fibroma-thecomas, and Sertoli-Leydig cell tumors (male differentiated). Granulosa cell tumors are the most common in this group and are a low-grade malignancy with less than 3% bilaterality. They are treated with conservative surgery, similar to germ cell tumors in young women.¹⁰³ Hysterectomy and bilateral salpingo-oophorectomy are recommended for women who have completed childbearing. Nodal staging can be safely omitted in the absence of grossly involved nodes, and fertility preservation is possible in disease limited to one ovary, the most common presentation. Debulking surgery is recommended for more extensive disease. These tumors and the thecomas in the same class often stimulate estrogen production and can be found in association with endometrial hyperplasia and cancer (5%). Granulosa cell tumors can recur over a prolonged period given their low rate of proliferation and tendency for local or intraperitoneal recurrence. Inhibin has been shown to be elaborated by these tumors and often is followed to identify recurrence of the disease. The Sertoli-Leydig cell tumors can present with virilization as a primary symptom. Evaluation of the ovary when this symptom is found is always of value.

MINIMALLY INVASIVE GYNECOLOGIC SURGERY

Hysteroscopy

See earlier section, Hysteroscopy, under Procedures Performed for Structural Causes of Abnormal Uterine Bleeding.

Laparoscopy

The standard method for gynecologic laparoscopy follows the same methods as all minimally invasive surgery. In general, a camera port is placed near the umbilicus. Sometimes it must be placed more cephalad if the patient has a larger fibroid uterus. Two additional ports are placed laterally, usually just superior and medial to the anterior superior iliac spines (ASIS). Sometimes one additional suprapubic port is placed for extra traction or instrumentation as described elsewhere in this text.

Complications Related to Gynecologic Surgery

Abdominal Wall Vessels. The vessel at greatest risk of injury during the lateral trocar placement is the inferior epigastric artery. The superficial epigastric vessels and the superficial circumflex iliac vessels can be injured as well (Fig. 41-23). The primary methods to avoid vessel injury are knowledge of the vessels at risk and their visualization prior to trocar placement, when possible. The superficial vessels often can be seen and avoided by transillumination of the abdominal wall with the laparoscope. In contrast, the larger inferior epigastric vessels cannot be seen by transillumination because of their deeper location; these vessels often can be seen laparoscopically and avoided as they course along the peritoneum between the lateral umbilical fold of the bladder and the insertion of the round

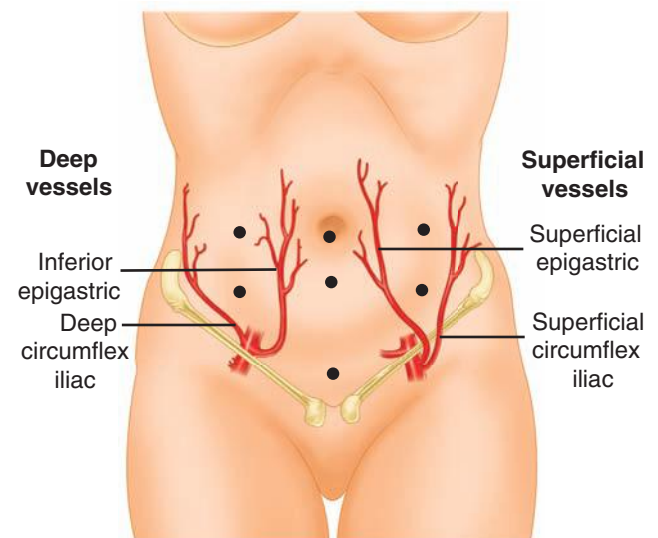


Figure 41-23. Location of anterior abdominal wall blood vessels.

ligament into the inguinal canal. Anatomic variation and anastomoses between vessels make it impossible to know the exact location of all the abdominal wall vessels. For this reason, other strategies also should be used to avoid vessel injury, including the use of trocars with conical tips rather than pyramid tips and the use of the smallest trocars possible lateral to the midline.

Intestinal Injury. Another potentially serious complication of laparoscopic surgery is injury to either small or large intestines. An unrecognized bowel injury may occur at the time of trocar insertion, especially if the patient has had previous abdominal procedures that often result in bowel adhesions to the anterior abdominal wall peritoneum. An open technique for placement of the first port is advocated to minimize the risk of bowel injury in patients who have undergone previous laparotomy. Some bowel injuries may not be seen during surgery because of the limited field of view. These injuries usually manifest 1 to 3 days after surgery, well after the patient has been released following these primarily outpatient procedures, and any patient concerns in this time period should be addressed seriously and rapidly.

Urologic Injuries. Bladder injury is an uncommon laparoscopic injury, occurring as a result of retroperitoneal perforation during lower trocar placement or during sharp dissection of the bladder from the lower uterine segment during hysterectomy. The latter of these two situations is usually recognized intraoperatively; the first sign of the former may be postoperative hematuria or lower-port incisional drainage. Once diagnosed, large defects require layered closure, whereas smaller defects usually close spontaneously within days or weeks with the aid of transurethral catheter drainage. Ureteral injury may occur as a result of any procedure that requires dissection or ligation of sidewall vessels, such as removal of adnexa, because the ureter is adjacent to the pelvic peritoneum in the area of the ovarian fossa (see Fig. 41-5). This complication also has been reported after fulguration of endometriosis on the pelvic sidewall. Another common cause of ureteral injury is hysterectomy, because the ureter is often located less than 2 cm from the cervix. This type of injury appears to be increased during laparoscopic hysterectomy, compared to abdominal or vaginal approaches. Ureteral injuries, including complete ligation, partial resection, or thermal injuries, usually will manifest within hours to days of surgery. Complete obstruction most often manifests as flank pain, whereas the first sign of partial or complete transection may be symptoms of intra-abdominal irritation caused by urine leakage. Transperitoneal thermal injuries resulting from fulguration of endometriosis may be similar to those after transection, but the appearance of symptoms may be delayed several days until tissue necrosis occurs.

Robotic Surgery

Over the last decade, there has been increased use of robotics for gynecologic surgery. With the DaVinci robotic system, the surgeon sits at a console and visualizes the operative field with three-dimensional optics. The laparoscopic instruments are “wristed” and move as the surgeon’s hands/fingers move the actuators at the console. Robotic surgery uses a camera port, two to three robotic ports, and an accessory port. More meticulous dissection, improved visualization, and ability to operate with lower intra-abdominal pressures make the robotic platform advantageous, especially in obese patients. Longer set-up time and increased cost, however, are distinct disadvantages. The use of robotic surgery has been described for virtually every gynecologic procedure that has been performed abdominally or laparoscopically.

REFERENCES

1. Anson B. *Atlas of Human Anatomy*. Philadelphia: WB Saunders, 1950.
2. Screening for Cervical Cancer. Available at: <http://www.uspreventiveservicestaskforce.org/uspstf11/cervcancer/cervcancers.htm>. Accessed March 2012.
3. Mutch DG, Powell MA, Allsworth JE, Taylor NP, Brooks RA. How accurate is Pipelle sampling: a study by Huang et al. *Am J Obstet Gynecol*. 2007;196:280-281.
4. Margesson LJ. Vulvar disease pearls. *Dermatol Clin*. 2006;24:145-155.
5. Downs MC, Randall HW Jr. The ambulatory surgical management of Bartholin duct cysts. *J Emerg Med*. 1989;7:623-626.
6. Workowski KA, Berman SM. Sexually transmitted diseases treatment guidelines, 2006. *MMWR Recomm Rep*. 2006;55(RR-11):1-94.
7. Stanley M. Chapter 17: Genital human papillomavirus infections—current and prospective therapies. *J Natl Cancer Inst Monogr*. 2003;31:117-124.
8. Habel LA, Van Den Eeden SK, Sherman KJ, McKnight B, Stergachis A, Daling JR. Risk factors for incident and recurrent condylomata acuminata among women. A population-based study. *Sex Transm Dis*. 1998;25:285-292.
9. Brodell LA, Mercurio MG, Brodell RT. The diagnosis and treatment of human papillomavirus-mediated genital lesions. *Cutis*. 2007;79(4 Suppl):5-10.
10. Fanning J, Lambert HC, Hale TM, Morris PC, Schuerch C. Paget’s disease of the vulva: prevalence of associated vulvar adenocarcinoma, invasive Paget’s disease, and recurrence after surgical excision. *Am J Obstet Gynecol*. 1999;180(1 Pt 1):24-27.
11. Tebes S, Cardosi R, Hoffman M. Paget’s disease of the vulva. *Am J Obstet Gynecol*. 2002;187(2):281-283, discussion 83-84.
12. Cardosi RJ, Bomalaski JJ, Hoffman MS. Diagnosis and management of vulvar and vaginal intraepithelial neoplasia. *Obstet Gynecol Clin North Am*. 2001;28:685-702.
13. Modesitt SC, Waters AB, Walton L, Fowler WC Jr, Van Le L. Vulvar intraepithelial neoplasia III: occult cancer and the impact of margin status on recurrence. *Obstet Gynecol*. 1998;92:962-966.
14. Anderson MR, Klink K, Cohns A. Evaluation of vaginal complaints. *JAMA*. 2004;291:1368-1379.
15. Eschenbach DA, Davick PR, Williams BL, et al. Prevalence of hydrogen peroxide-producing *Lactobacillus* species in normal women and women with bacterial vaginosis. *J Clin Microbiol*. 1989;27:251-256.
16. Food and Drug Administration. Product approval information: human papillomavirus quadrivalent (types 6, 11, 16, 18) vaccine, recombinant. Silver Spring, MD: Food and Drug Administration.
17. Kahn JA. HPV vaccination for the prevention of cervical intraepithelial neoplasia. *N Engl J Med*. 2009;361:271-278.
18. Paavonen J, Naud P, Salmeron J, et al. Efficacy of human papillomavirus (HPV)-16/18 AS04-adjuvanted vaccine against cervical infection and precancer caused by oncogenic HPV types (PATRICIA): final analysis of a double-blind, randomised study in young women. *Lancet*. 2009;374:301-314.
19. Quadrivalent vaccine against human papillomavirus to prevent high-grade cervical lesions. *N Engl J Med*. 2007;356:1915-1927.
20. Garland SM, Hernandez-Avila M, Wheeler CM, et al. Quadrivalent vaccine against human papillomavirus to prevent anogenital diseases. *N Engl J Med*. 2007;356:1928-1943.
21. Stenchever M, Droegemueller W, Herbst A, Mishell D. *Comprehensive Gynecology*. St Louis: Mosby; 2001.

22. Munro MG, Critchley HO, Broder MS, Fraser IS. FIGO classification system (PALM-COEN) for causes of abnormal uterine bleeding in nonpregnant women of reproductive age. *Int J Gynaecol Obstet.* 2011;113:3-13.
23. Van Bogaert LJ. Clinicopathologic findings in endometrial polyps. *Obstet Gynecol.* 1988;71:771-773.
24. Costa-Paiva L, Godoy CE Jr, Antunes A Jr, Caseiro JD, Arthuso M, Pinto-Neto AM. Risk of malignancy in endometrial polyps in premenopausal and postmenopausal women according to clinicopathologic characteristics. *Menopause.* 2011;18:1278-1282.
25. Byun JY, Kim SE, Choi BG, Ko GY, Jung SE, Choi KH. Diffuse and focal adenomyosis: MR imaging findings. *Radiographics.* 1999;19 Spec No:S161-S170.
26. Filicori M, Hall DA, Loughlin JS, Rivier J, Vale W, Crowley WF Jr. A conservative approach to the management of uterine leiomyoma: pituitary desensitization by a luteinizing hormone-releasing hormone analogue. *Am J Obstet Gynecol.* 1983;147:726-727.
27. Matsuo H, Maruo T. GnRH analogues in the management of uterine leiomyoma. *Nippon Rinsho.* 2006;64(Suppl 4):75-79.
28. Szabo E, Nagy E, Morvay Z, Palko A, Csernay L. Uterine artery embolization for the conservative management of leiomyoma. *Orv Hetil.* 2001;142:675-680.
29. Mutter GL. Diagnosis of premalignant endometrial disease. *J Clin Pathol.* 2002;55:326-331.
30. Kurman RJ, Kaminski PF, Norris HJ. The behavior of endometrial hyperplasia. A long-term study of "untreated" hyperplasia in 170 patients. *Cancer.* 1985;56:403-412.
31. Miller C, Bidus MA, Pulcini JP, Maxwell GL, Cosin JA, Rose GS. The ability of endometrial biopsies with atypical complex hyperplasia to guide surgical management. *Am J Obstet Gynecol.* 2008;199:69.e1-e4.
32. Stany MP, Farley JH. Complications of gynecologic surgery. *Surg Clin North Am.* 2008;88:343-359, vii.
33. Cooper JM, Brady RM. Intraoperative and early postoperative complications of operative hysteroscopy. *Obstet Gynecol Clin North Am.* 2000;27:347-366.
34. Witz CA, Silverberg KM, Burns WN, Schenken RS, Olive DL. Complications associated with the absorption of hysteroscopic fluid media. *Fertil Steril.* 1993;60:745-756.
35. ACOG technology assessment in obstetrics and gynecology, number 4, August 2005: hysteroscopy. *Obstet Gynecol.* 2005;106:439-442.
36. van Dongen H, Emanuel MH, Wolterbeek R, Trimbos JB, Jansen FW. Hysteroscopic morcellator for removal of intrauterine polyps and myomas: a randomized controlled pilot study among residents in training. *J Minim Invasive Gynecol.* 2008;15:466-471.
37. ACOG Practice Bulletin. Clinical management guidelines for obstetrician-gynecologists. Number 81, May 2007. *Obstet Gynecol.* 2007;109:1233-1248.
38. Boing C, Kimmig R. Surgical management of endometriosis—an overview. *Gynakol Geburtshilfliche Rundsch.* 2007;47:124-131.
39. Petta CA, Matos AM, Bahamondes L, Faundes D. Current practice in the management of symptoms of endometriosis: a survey of Brazilian gynecologists. *Rev Assoc Med Bras.* 2007;53:525-529.
40. Bernstein R, Kennedy WR, Waldron J. Acute pelvic inflammatory disease: a clinical follow-up. *Int J Fertil.* 1987;32:229-232.
41. Chow JM, Yonekura ML, Richwald GA, Greenland S, Sweet RL, Schachter J. The association between *Chlamydia trachomatis* and ectopic pregnancy. A matched-pair, case-control study. *JAMA.* 1990;263:3164-3167.
42. Workowski KA, Berman S. Sexually transmitted diseases treatment guidelines, 2010. *MMWR Recomm Rep.* 2010;59(RR-12):1-110.
43. Menacker FHB. Recent trends in cesarean delivery in the United States. NCHS data brief. Hyattsville: National Center for Health Statistics; 2010.
44. Dietrich CS III, Hill CC, Hueman M. Surgical diseases presenting in pregnancy. *Surg Clin North Am.* 2008;88:403-419, vii-viii.
45. Gabbe S, Niebyl J, Simpson J. *Obstetrics: Normal and Problem Pregnancies.* 6th ed. Philadelphia: Saunders; 2012.
46. Brown HL. Trauma in pregnancy. *Obstet Gynecol.* 2009;114:147-160.
47. ACOG Practice Bulletin No. 88, December 2007. Invasive prenatal testing for aneuploidy. *Obstet Gynecol.* 2007;110:1459-1467.
48. Owen J, Mancuso M. Cervical cerclage for the prevention of preterm birth. *Obstet Gynecol Clin North Am.* 2012;39:25-33.
49. McDonald IA. Suture of the cervix for inevitable miscarriage. *J Obstet Gynaecol Br Emp.* 1957;64:346-350.
50. Shirodkar V. New method of operative treatment for habitual abortions in the second trimester of pregnancy. *Antiseptic.* 1955;52:299.
51. Stock L, Milad M. Surgical management of ectopic pregnancy. *Clin Obstet Gynecol.* 2012;55:448-454.
52. Adzick NS, Thom EA, Spong CY, et al. A randomized trial of prenatal versus postnatal repair of myelomeningocele. *N Engl J Med.* 2011;364:993-1004.
53. Porreco RP, Stettler RW. Surgical remedies for postpartum hemorrhage. *Clin Obstet Gynecol.* 2010;53:182-195.
54. Bakri YN, Amri A, Abdul Jabbar F. Tamponade-balloon for obstetrical bleeding. *Int J Gynaecol Obstet.* 2001;74:139-142.
55. Lurain JR. Gestational trophoblastic disease I: epidemiology, pathology, clinical presentation, and diagnosis of gestational trophoblastic disease, and management of hydatidiform mole. *Am J Obstet Gynecol.* 2010;203:531-539.
56. Lurain JR. Gestational trophoblastic disease II: classification and management of gestational trophoblastic neoplasia. *Am J Obstet Gynecol.* 2011;204:11-18.
57. Walters M, Karram M. *Urogynecology and Reconstructive Pelvic Surgery.* Philadelphia: Mosby; 2007.
58. Olsen AL, Smith VJ, Bergstrom JO, Colling JC, Clark AL. Epidemiology of surgically managed pelvic organ prolapse and urinary incontinence. *Obstet Gynecol.* 1997;89:501-506.
59. Bump RC, Mattiasson A, Bo K, et al. The standardization of terminology of female pelvic organ prolapse and pelvic floor dysfunction. *Am J Obstet Gynecol.* 1996;175:10-17.
60. Benson JT, Lucente V, McClellan E. Vaginal versus abdominal reconstructive surgery for the treatment of pelvic support defects: a prospective randomized study with long-term outcome evaluation. *Am J Obstet Gynecol.* 1996;175:1418-1421, discussion 21-22.
61. Maher CF, Qatawneh AM, Dwyer PL, Carey MP, Cornish A, Schluter PJ. Abdominal sacral colpopexy or vaginal sacrospinous colpopexy for vaginal vault prolapse: a prospective randomized study. *Am J Obstet Gynecol.* 2004;190:20-26.
62. Food and Drug Administration. Urogynecologic Surgical mesh: update on the safety and effectiveness of transvaginal placement for pelvic organ prolapse. Available at: <http://www.fda.gov/downloads/medicaldevices/safety/alertsandnotices/ucm262760.pdf>. Accessed December 27, 2012.
63. Nygaard IE, McCreery R, Brubaker L, et al. Abdominal sacrocolpopexy: a comprehensive review. *Obstet Gynecol.* 2004;104:805-823.
64. Tanagho EA. Colpocystourethropexy: the way we do it. *J Urol.* 1976;116(December):751-753.
65. Reynolds WS, Dmochowski RR. Urethral bulking: a urology perspective. *Urol Clin North Am.* 2012;39:279-287.
66. Siegel R, Naishadham D, Jemal A. Cancer statistics, 2012. *CA Cancer J Clin.* 2012;62:10-29.
67. Carter JS, Downs LS Jr. Vulvar and vaginal cancer. *Obstet Gynecol Clin North Am.* 2012;39:213-231.

68. Berek J, Hacker N. *Practical Gynecologic Oncology*. 5th ed. Philadelphia: Lippincott Williams & Wilkins; 2010.
69. Disaia PCW. *Clinical Gynecologic Oncology*. 8th ed. Philadelphia: Saunders; 2012.
70. Montana GS, Thomas GM, Moore DH, et al. Preoperative chemo-radiation for carcinoma of the vulva with N2/N3 nodes: a gynecologic oncology group study. *Int J Radiat Oncol Biol Phys*. 2000;48:1007-1013.
71. Moore DH, Thomas GM, Montana GS, Saxer A, Gallup DG, Olt G. Preoperative chemoradiation for advanced vulvar cancer: a phase II study of the Gynecologic Oncology Group. *Int J Radiat Oncol Biol Phys*. 1998;42:79-85.
72. Shylasree TS, Bryant A, Howells RE. Chemoradiation for advanced primary vulval cancer. *Cochrane Database Syst Rev*. 2011;4:CD003752.
73. Goodman A, Schorge J, Greene MF. The long-term effects of in utero exposures—the DES story. *N Engl J Med*. 2011;364:2083-2084.
74. Beller U, Benedet JL, Creasman WT, et al. Carcinoma of the vagina. FIGO 6th Annual Report on the Results of Treatment in Gynecological Cancer. *Int J Gynaecol Obstet*. 2006;95(Suppl 1):S29-S42.
75. Barakat RMM, Randall M: *Principles and Practice of Gynecologic Oncology*. 5th ed. Philadelphia: Lippincott Williams & Wilkins; 2009.
76. Jemal A, Bray F, Center MM, Ferlay J, Ward E, Forman D. Global cancer statistics. *CA Cancer J Clin*. 2011;61:69-90.
77. Wright TC Jr, Massad LS, Dunton CJ, Spitzer M, Wilkinson EJ, Solomon D. 2006 consensus guidelines for the management of women with cervical intraepithelial neoplasia or adenocarcinoma in situ. *J Low Genit Tract Dis*. 2007;11:223-239.
78. Pecorelli S. Revised FIGO staging for carcinoma of the vulva, cervix, and endometrium. *Int J Gynaecol Obstet*. 2009;105:103-104.
79. Pikaart DP, Holloway RW, Ahmad S, et al. Clinical-pathologic and morbidity analyses of types 2 and 3 abdominal radical hysterectomy for cervical cancer. *Gynecol Oncol*. 2007;107:205-210.
80. Kim CH, Abu-Rustum NR, Chi DS, et al. Reproductive outcomes of patients undergoing radical trachelectomy for early-stage cervical cancer. *Gynecol Oncol*. 2012;125:585-588.
81. Leslie KK, Thiel KW, Goodheart MJ, De Geest K, Jia Y, Yang S. Endometrial cancer. *Obstet Gynecol Clin North Am*. 2012;39:255-268.
82. Walker JL, Piedmonte MR, Spirtos NM, et al. Recurrence and survival after random assignment to laparoscopy versus laparotomy for comprehensive surgical staging of uterine cancer: Gynecologic Oncology Group LAP2 Study. *J Clin Oncol*. 2012;30:695-700.
83. Creutzberg CL, Nout RA, Lybeert ML, et al. Fifteen-year radiotherapy outcomes of the randomized PORTEC-1 trial for endometrial carcinoma. *Int J Radiat Oncol Biol Phys*. 2011;81:e631-e638.
84. Keys HM, Roberts JA, Brunetto VL, et al. A phase III trial of surgery with or without adjunctive external pelvic radiation therapy in intermediate risk endometrial adenocarcinoma: a Gynecologic Oncology Group study. *Gynecol Oncol*. 2004;92:744-751.
85. Aarnio M, Mecklin JP, Aaltonen LA, Nystrom-Lahti M, Jarvinen HJ. Life-time risk of different cancers in hereditary non-polyposis colorectal cancer (HNPCC) syndrome. *Int J Cancer*. 1995;64:430-433.
86. Reichardt P. The treatment of uterine sarcomas. *Ann Oncol*. 2012;23(Suppl 10):x151-x157.
87. Goff BA, Mandel LS, Drescher CW, et al. Development of an ovarian cancer symptom index: possibilities for earlier detection. *Cancer*. 2007;109:221-227.
88. Lu KH. Hereditary gynecologic cancers: differential diagnosis, surveillance, management and surgical prophylaxis. *Fam Cancer*. 2008;7:53-58.
89. Kauff ND, Satagopan JM, Robson ME, et al. Risk-reducing salpingo-oophorectomy in women with a BRCA1 or BRCA2 mutation. *N Engl J Med*. 2002;346:1609-1615.
90. American Congress of Obstetricians and Gynecologists. Elective and risk-reducing salpingo-oophorectomy. *ACOG Practice Bulletin*. 2008;89:1-12.
91. Young RC, Decker DG, Wharton JT, et al. Staging laparotomy in early ovarian cancer. *JAMA*. 1983;250:3072-3076.
92. Vergote I, Trope CG, Amant F, et al. Neoadjuvant chemotherapy or primary surgery in stage IIIC or IV ovarian cancer. *N Engl J Med*. 2010;363:943-953.
93. Young RC, Walton LA, Ellenberg SS, et al. Adjuvant therapy in stage I and stage II epithelial ovarian cancer. *N Engl J Med*. 1990;322:1021-1027.
94. Bell J, Brady MF, Young RC, et al. Randomized phase III trial of three versus six cycles of adjuvant carboplatin and paclitaxel in early stage epithelial ovarian carcinoma: a Gynecologic Oncology Group study. *Gynecol Oncol*. 2006;102:432-439.
95. McGuire WP, Hoskins WJ, Brady MF, et al. Cyclophosphamide and cisplatin compared with paclitaxel and cisplatin in patients with stage III and stage IV ovarian cancer (see comments). *N Engl J Med*. 1996;334:1-6.
96. Armstrong DK, Bundy BN, Wenzel L, et al. Intraperitoneal cisplatin and paclitaxel in ovarian cancer. *N Engl J Med*. 2006;354:34-43.
97. Walker JL, Armstrong DK, Huang HQ, et al. Intraperitoneal catheter outcomes in a phase III trial of intravenous versus intraperitoneal chemotherapy in optimal stage III ovarian and primary peritoneal cancer: a Gynecologic Oncology Group Study. *Gynecol Oncol*. 2006;100:27-32.
98. Katsumata N, Yasuda M, Takahashi F, et al. Dose-dense paclitaxel once a week in combination with carboplatin every 3 weeks for advanced ovarian cancer: a phase 3, open-label, randomised controlled trial. *Lancet*. 2009;374:1331-1338.
99. Burger RA, Brady MF, Bookman MA, et al. Incorporation of bevacizumab in the primary treatment of ovarian cancer. *N Engl J Med*. 2011;365:2473-2483.
100. Perren TJ, Swart AM, Pfisterer J, et al. A phase 3 trial of bevacizumab in ovarian cancer. *N Engl J Med*. 2011;365:2484-2496.
101. Markman M, Reichman B, Hakes T, Jones W. Responses to second-line cisplatin-based intraperitoneal therapy in ovarian cancer: influence of a prior response to intravenous cisplatin. *J Clin Oncol*. 1991;9:1801-1805.
102. Parkinson CA, Hatcher HM, Ajithkumar TV. Management of malignant ovarian germ cell tumors. *Obstet Gynecol Surv*. 2011;66:507-514.
103. Gershenson DM. Treatment of ovarian cancer in young women. *Clin Obstet Gynecol*. 2012;55:65-74.
104. Dearnik AC, Aletti GD, McGree ME, Weaver AL, Sommerfield MK, Cliby WA. How relevant are ACOG and SGO guidelines for referral of adnexal mass? *Obstet Gynecol*. 2007;110:841-848.

This page intentionally left blank

42 chapter

Neurosurgery

Casey H. Halpern and
M. Sean Grady

Overview	1709	Intracranial Tumors / 1732	Infection	1745
Neuroanatomy	1709	Metastatic Tumors / 1732	Cranial / 1745	
Neurologic Examination	1711	Glial Tumors / 1733	Spine / 1745	
Diagnostic Studies / 1712		Neural Tumors and Mixed Tumors / 1734	Functional Neurosurgery	1746
Neurologic and Neurosurgical Emergencies	1713	Neural Crest Tumors / 1735	Epilepsy Surgery / 1746	
Raised Intracranial Pressure / 1713		Miscellaneous Tumors / 1735	Deep Brain Stimulation / 1747	
Brain Stem Compression / 1714		Embryologic Tumors / 1736	Trigeminal Neuralgia / 1748	
Stroke / 1714		Spinal Tumors / 1737	Stereotactic Radiosurgery	1749
Seizure / 1715		Intradural Extramedullary Tumors / 1738	Arteriovenous Malformations / 1749	
Trauma	1715	Spine: Basic Concepts	Vestibular Schwannomas / 1749	
Head Trauma / 1715		Stability / 1739	Intracranial Metastases / 1749	
Spine Trauma / 1721		Neural Compression / 1739	Congenital and Developmental Anomalies	1749
Peripheral Nerve Trauma / 1726		Patterns of Disease / 1740	Dysraphism / 1749	
Cerebrovascular Disease	1727	Spine Fusion Surgery / 1743	Spina Bifida Occulta / 1749	
Ischemic Diseases / 1727		Spinal Instrumentation / 1743	Spina Bifida with Myelomeningocele / 1750	
Thrombotic Disease / 1728		Arthrodesis / 1743	Encephalocele / 1750	
Embolic Disease / 1728		Peripheral Nerve	Craniosynostosis / 1750	
Hemorrhagic Diseases / 1728		Peripheral Nerve Tumors / 1744	Hydrocephalus / 1750	
Tumors of the Central Nervous System	1732	Entrapment Neuropathies / 1744	Chiari I Malformation / 1751	
		Autoimmune and Inflammatory Disorders / 1744		

OVERVIEW

Neurologic surgery provides the operative and nonoperative management (i.e., prevention, diagnosis, evaluation, treatment, critical care, and rehabilitation) of disorders of the central, peripheral, and autonomic nervous systems (ANSs). Such disorders include those of the brain, meninges, skull and skull base, and their blood supply, including surgical and endovascular treatment of disorders of the intracranial and extracranial vasculature supplying the brain and spinal cord; disorders of the pituitary gland; disorders of the spinal cord, meninges, and vertebral column, including those that may require treatment by fusion, instrumentation, or endovascular techniques; and disorders of the cranial and spinal nerves throughout their distribution.

An accurate history is the first step toward neurologic diagnosis. A history of trauma or of neurologic symptoms is of obvious interest, but general constitutional symptoms are also important. Neurologic disease may have systemic effects, while diseases of other systems may affect neurologic function. The patient's general medical ability to withstand the physiologic stress of anesthesia and surgery should be understood. A detailed history from the patient and/or family, along with a reliable physical examination, will clarify these issues.

NEUROANATOMY

An understanding of neuroanatomy is the foundation of comprehensive neurologic examination and diagnosis. Salient features will be considered, from cephalad to caudad. The cerebral hemispheres (or telencephalon) consist of the cerebral cortex, underlying white matter, the basal ganglia, hippocampus, and amygdala. The cerebral cortex is the most recently evolved part of the nervous system. Its functions are mapped to discrete anatomic areas. The frontal areas are involved in executive function, decision making, and restraint of emotions. The motor strip, or precentral gyrus, is the most posterior component of the frontal lobes, and is arranged along a homunculus with the head inferior and lateral to the lower extremities superiorly and medially. The motor speech area (Broca's area) lies in the left posterior inferior frontal lobe in almost all right-handed people and in up to 90% of left-handed people. The parietal lobe lies between the central sulcus anteriorly and the occipital lobe posteriorly. The postcentral gyrus is the sensory strip, also arranged along a homunculus. The rest of the parietal lobe is involved with awareness of one's body in space and relative to the immediate environment, body orientation, and spatial relationships. The occipital lobes are most posterior. The visual cortex is arrayed along the apposing medial surfaces of the occipital lobes. The left occipital lobe

Key Points

- 1▶ Neurologic surgery specializes in primarily surgical management of central, peripheral, and autonomic nervous system disorders.
- 2▶ Although clinical examination is paramount, neurosurgical diagnosis and treatment are aided largely by a variety of modalities, such as MRI and intracranial pressure monitoring.
- 3▶ The common treatment goals for traumatic brain and spinal injury are aimed at preventing secondary insults of hypoxia and hypotension.
- 4▶ Aneurysmal subarachnoid hemorrhage remains one of the most morbid and intensive neurosurgical diseases. Endovascular therapy is a growing technology that allows for safer securing of ruptured aneurysms.
- 5▶ Brain tumors can arise from primary or metastatic tissues. Treatment typically involves resection, followed by radiation and/or chemotherapy, depending on the type and grade of tumor.
- 6▶ Spinal instrumentation is used for surgical stabilization of many types of spinal instability, including traumatic, infectious, oncologic, and degenerative.
- 7▶ Infection of the nervous system is a serious and prevalent medical problem. Operative management is indicated for most conditions in which there is symptomatic compression of neural structures.
- 8▶ Functional neurosurgery via device implantation is a rapidly evolving discipline that has already become the standard of care in treating medically refractory Parkinson's disease and essential tremor. A wider variety of deep brain stimulation targets will treat additional neuropsychiatric diseases.
- 9▶ Stereotactic radiosurgery is a powerful treatment option for intracranial disease, whether it is primary or adjunct. Gamma knife surgery can be used to treat tumors, vascular malformations, and cranial neuralgias.

receives and integrates data from the left half of each retina. A left occipital lesion would therefore result in an inability to see objects right of center. The temporal lobes lie below the sylvian fissures. The hippocampus, amygdala, and lower optic radiations (Meyer's loops) are important components of the temporal lobe and are involved in memory, emotion, and vision, respectively. The receptive speech area (Wernicke's area) typically is found in the area of the left posterior superior temporal lobe and inferior parietal lobe. The basal ganglia include the caudate, putamen, globus pallidus, subthalamic nucleus, substantia nigra, and nucleus accumbens. These structures are involved in the selection, activation and termination of movement, and facilitate learning of appropriate context-dependent motor behaviors.

Lying deep to the cerebral hemispheres is the diencephalon, which includes the thalamus and hypothalamus. The thalamus is a key processor and relay circuit for most motor and sensory information traveling to or from cortex. The hypothalamus regulates homeostasis via the autonomic and neuroendocrine systems.

The brain stem consists of the midbrain (mesencephalon), pons (metencephalon), and medulla (myelencephalon). Longitudinal fibers run through the brain stem, carrying motor and sensory information between the cerebral hemispheres and spinal cord. The corticospinal tract is the major motor tract, while the medial lemniscus and spinothalamic tracts are the major sensory tracts. The nuclei of cranial nerves III through XII are also located within the brain stem. These nerves relay the motor, sensory, and special sense functions of the eye, face, mouth, and throat.

The cerebellum arises from the dorsal aspect of the brain stem. It integrates somatosensory, vestibular, and motor information for coordination and timing of movement. Midline, or vermal, lesions lead to truncal ataxia. Lateral, or hemispheric, lesions lead to tremor and dyscoordination in the extremities.

The ventricular system is the cerebrospinal fluid (CSF)-containing contiguous space inside the brain, continuous with the subarachnoid space outside the brain. The paired lateral ventricles consist of temporal, occipital, and frontal horns, as well as the main body. CSF travels from each lateral ventricle through the foramina of Monroe to the third ventricle, located between the left and right thalami. CSF then drains through the cerebral aqueduct to the fourth ventricle within the brain

stem. The foramen of Magendie (midline) and paired foramina of Luschka (lateral) drain to the subarachnoid space. The approximate CSF volume in an average adult is 150 mL, and the choroid plexus produces approximately 500 mL of CSF per day.

The spinal cord starts at the bottom of the medulla and extends caudally through the spinal canal to the first lumbar vertebra, approximately. Motor tracts (efferent pathways) continue from the brain stem down via the lateral and anterior corticospinal tracts to anterior horn cells, and then exit via ventral nerve roots. Sensory information (afferent pathways) enters via dorsal nerve roots, travels cranially via the dorsal columns (proprioception and fine touch) or spinothalamic tract (pain and temperature), and into the brain stem. Paired nerves exit the spinal cord at each level. There are 31 pairs: 8 cervical, 12 thoracic, 5 lumbar, 5 sacral, and 1 coccygeal.

The dorsal and ventral nerve roots at each level fuse to form mixed motor-sensory spinal nerves and spread through the body to provide innervation to muscles and sensory organs. The C5–T1 spinal nerves intersect in the brachial plexus and divide to form the main nerve branches to the arm, including the median, ulnar, and radial nerves. The L2–S4 spinal nerves intersect in the lumbosacral plexus, and divide to form the main nerve branches to the leg, including the femoral and sciatic nerves.

The principal motor tract of the spinal cord is the corticospinal tract. It is a two-neuron path, including an upper motor neuron and a lower motor neuron. The upper motor neuron cell body is located within the motor strip of the cerebral cortex. The axon travels through the internal capsule to the brain stem, decussates at the brain stem–spinal cord junction, and travels down the contralateral corticospinal tract to the lower motor neuron in the anterior horn at the appropriate level. The lower motor neuron axon then travels via peripheral nerves to its target muscle. Damage to upper motor neurons typically results in hyperreflexia and mild atrophy. Damage to lower motor neurons results in flaccidity and significant atrophy.

The two major sensory tracts are three-neuron pathways. Fine touch and proprioceptive signals enter the spinal cord via the dorsal root ganglia and then ascend ipsilaterally via the dorsal columns. Then they synapse and decussate in the lower medulla, travel up the contralateral medial lemniscus to make a second synapse in the thalamus, and then finally ascend to the sensory cortex. Pain and temperature fibers first synapse in the dorsal horn of the spinal cord

at their entry level, decussate, and then travel up the contralateral spinothalamic tracts to the thalamus. The second synapse occurs in the thalamus, and the output axons ascend to the sensory cortex.

The aforementioned motor and sensory tracts together constitute the somatic nervous system. In addition to this system, the ANS is the other constituent of the nervous system. The ANS carries messages for homeostasis and visceral regulation from the central nervous system (CNS) to target structures such as arteries, veins, the heart, sweat glands, and the digestive tract.¹ CNS control of the ANS arises particularly from the hypothalamus and the nucleus of the tractus solitarius. The ANS is divided into the sympathetic, parasympathetic, and enteric systems. The sympathetic system drives the “fight or flight” response, using epinephrine to increase heart rate, blood pressure, blood glucose, and temperature, as well as to dilate the pupils. It arises from the thoracolumbar spinal segments. The parasympathetic system promotes the “rest and digest” state, and uses acetylcholine to maintain basal metabolic function under nonstressful conditions. Parasympathetic fibers arise from cranial nerves III, VII, IX, and X, and from the second to fourth sacral segments. The enteric nervous system controls the complex synchronization of the digestive tract, especially the pancreas, gallbladder, and small and large bowels. It can run autonomously but is regulated by the sympathetic and parasympathetic systems.

NEUROLOGIC EXAMINATION

The neurologic examination is divided into several components, and generally is done from head to toe. First, one must assess mental status. A patient may be awake, lethargic (will follow commands and answer questions, but then returns to sleep), stuporous (difficult to arouse), or comatose (no

Table 42-1

Motor scoring system

GRADE	DESCRIPTION
0	No muscle contraction
1	Visible muscle contraction without movement across the joint
2	Movement in the horizontal plane, unable to overcome gravity
3	Movement against gravity
4	Movement against some resistance
5	Normal strength

purposeful response to voice or pain). Cranial nerves may be thoroughly tested in the awake patient, but pupil reactivity, eye movement, facial symmetry, and gag are the most relevant measures when mental status is impaired. Motor testing is based on maximal effort of major muscle groups in those able to follow commands, while assessing for amplitude and symmetry of movement to deep central pain may be all that is possible for stuporous patients. Table 42-1 details scoring for motor assessment tests. Characteristic motor reactions to pain in patients with depressed mental status include withdrawal from stimulus, localization to stimulus, flexor (decorticate) posturing, extensor (decerebrate) posturing, or no reaction (in order of worsening pathology). Figure 42-1 diagrams the clinical patterns of posturing. This forms the basis of determining the Glasgow Coma Scale (GCS) motor

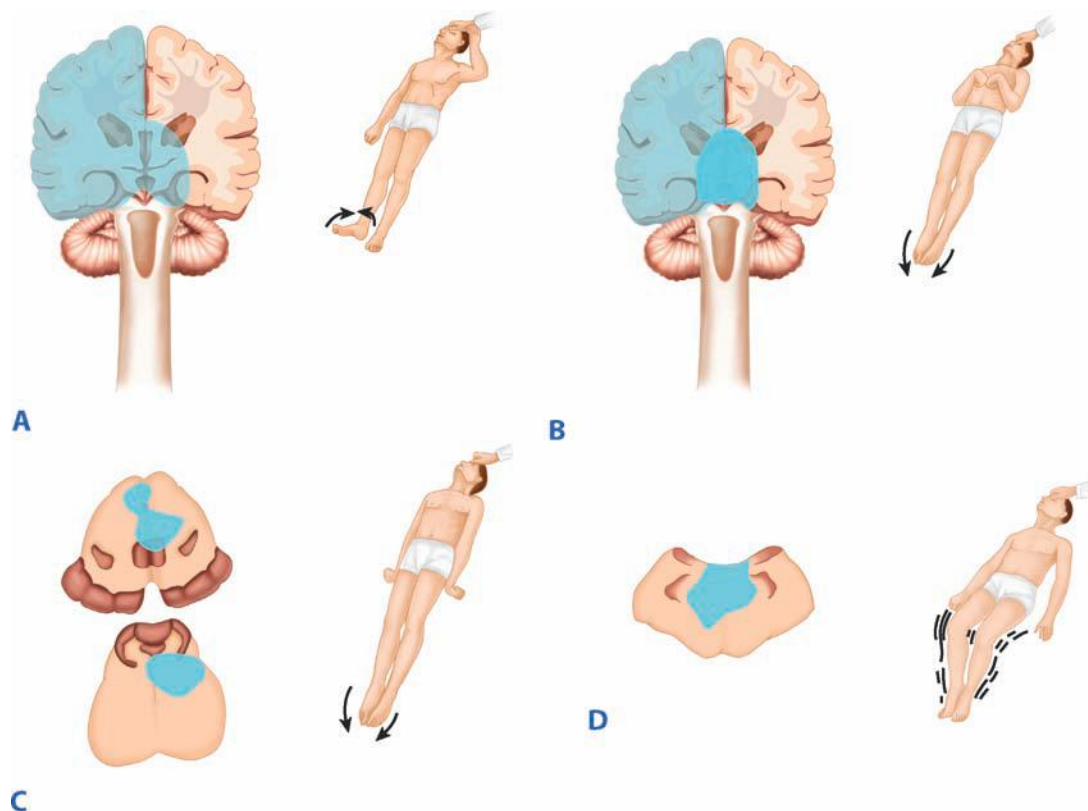


Figure 42-1. Patterns of motor responses associated with various lesions. **A.** Left hemispheric lesion with right hemiplegia and left localization. **B.** Deep cerebral/thalamic lesion with bilateral flexor posturing. **C.** Midbrain or pontine lesion with bilateral extensor posturing. **D.** Medullary lesion with general flaccidity. (Adapted with permission from Rengachary SS: *Impaired consciousness*, in Rengachary SS, Ellenbogen RG [eds]: *Principles of Neurosurgery*, 2nd ed. Edinburgh; New York: Elsevier Mosby, 2005. Copyright Elsevier.)

Table 42-2

The Glasgow Coma Scale score^a

MOTOR RESPONSE		VERBAL RESPONSE		EYE-OPENING RESPONSE	
Obeys commands	6	Oriented	5	Opens spontaneously	4
Localizes to pain	5	Confused	4	Opens to speech	3
Withdraws from pain	4	Inappropriate words	3	Opens to pain	2
Flexor posturing	3	Unintelligible sounds	2	No eye opening	1
Extensor posturing	2	No sounds	1		
No movement	1				

^aAdd the three scores to obtain the Glasgow Coma Scale (GCS) score, which can range from 3 to 15. Add “T” after the GCS if intubated and no verbal score is possible. For these patients, the GCS can range from 3T to 10T.

score, as detailed in Table 42-2. Light touch, proprioception, temperature, and pain testing may be useful in awake patients but is often impossible without good cooperation. It is critical to document sensory patterns in spinal cord injury (SCI) patients. Muscle stretch reflexes should be examined. Often comparing left to right or upper extremity to lower extremity reflexes for symmetry is the most useful for localizing a lesion. Check for ankle-jerk clonus or up-going toes (Babinski’s test). Presence of either is pathologic and signifies upper motor neuron disease.

Diagnostic Studies

Plain Films. Plain X-rays of the skull may demonstrate fractures, osteolytic or osteoblastic lesions, or pneumocephaly (air in the head). The use of skull plain films has decreased given the rapid availability and significantly increased detail of head computed tomography (CT) scans. Plain films of the cervical, thoracic, and lumbar spine are used to assess for evidence of bony trauma or soft tissue swelling suggesting fracture. Spinal deformities and osteolytic or osteoblastic pathologic processes also will be apparent. The shoulder girdle usually poses problems in visualizing the cervicothoracic junction clearly.

Computed Tomography. The noncontrast CT scan of the head is an extremely useful diagnostic tool in the setting of new focal neurologic deficit, decreased mental status, or trauma. It is rapid and almost universally available in hospitals in the United States. Its sensitivity allows for the detection of acute hemorrhage. A contrast-enhanced CT scan will help show neoplastic or infectious processes. In the current era, contrast CT generally is used for those patients who cannot undergo magnetic resonance imaging (MRI) scanning due to pacemakers or metal in the orbits. Fine-slice CT scanning of the spine is helpful for defining bony anatomy and pathology, and is usually done after an abnormality is seen on plain films, or because plain films are inadequate (especially to visualize C7 and T1 vertebrae). Finally, high-speed multislice scanners, combined with timed-bolus contrast injections, allow CT angiography. A thin-slice axial scan is obtained during the passage of contrast through the cerebral arteries and reconstructed in three dimensions to assess for vascular lesions. CT angiography does not reliably detect lesions, such as cerebral aneurysms <3 mm across, but can provide detailed morphologic data of larger lesions. Newer, multislice scanner technology is approaching the resolution of conventional angiography.

Magnetic Resonance Imaging. MRI provides excellent imaging of soft tissue structures in the head and spine. It is a complex and evolving science. Several of the most clinically useful MRI sequences are worth describing. T1 sequences made before and after gadolinium administration are useful for detecting neoplastic and infectious processes. T2 sequences facilitate assessment of lesion-associated edema in the brain and neural compression in the spine by the presence or absence of bright T2 CSF signals. Diffusion-weighted images can detect ischemic stroke earlier than CT. Fine-slice time-of-flight axial images can be reformatted in three dimensions to build MRI angiograms and MRI venograms. MRI angiograms can detect stenosis of the cervical carotid arteries or intracranial aneurysms >3 mm in diameter. MRI venograms can assess the dural venous sinuses for patency or thrombosis.

Angiography. Transarterial catheter-based angiography remains the gold standard for evaluation of vascular pathology of the brain and spine. The current state of the art is biplanar imaging to reduce dye load and facilitate interventional procedures. Digital subtraction technologies minimize bony interference in the resultant images. Bilateral carotid arteries and bilateral vertebral arteries may be injected and followed through arterial, capillary, and venous phases for a complete cerebral angiogram.

Electromyography and Nerve Conduction Studies. Electromyography and nerve conduction studies (EMG/NCS) are useful for assessing the function of peripheral nerves. EMG records muscle activity in response to a proximal stimulation of the motor nerve. NCS record the velocity and amplitude of the nerve action potential. EMG/NCS typically is performed approximately 3 to 4 weeks after an acute injury, as nerves distal to the injury continue to transmit electrical impulses normally until degeneration of the distal nerve progresses.

Invasive Monitoring. The most reliable monitor, *always*, is an alert patient with a reliable neurologic examination. If a reliable neurologic examination is not possible due to the presence of brain injury, sedatives, or paralytics, or if there is active and unstable intracranial pathology, invasive monitoring is required. There are several methods of monitoring intracranial physiology. The three described below are bedside intensive care unit (ICU) procedures that allow for continuous monitoring. All three procedures involve making a small hole in the skull with a hand-held drill. They generally are placed in the right frontal

region to minimize the neurologic impact of possible complications such as hemorrhage.

External Ventricular Drain. An external ventricular drain is also known as a *ventriculostomy*. A perforated plastic catheter is inserted into the frontal horn of the lateral ventricle. An uninterrupted fluid column through a rigid tube allows transduction of intracranial pressure (ICP). CSF also can be drained to reduce ICP or sampled for laboratory studies.

Intraparenchymal Fiber-Optic Pressure Transducer. An intraparenchymal fiber-optic pressure transducer is commonly referred to as a *bolt*. A threaded post locks securely into the hole made in the skull, and holds the fiber-optic catheter in place. A bolt allows ICP monitoring only, but it is smaller and less invasive than a ventriculostomy, and may be associated with fewer complications, although the data do not clearly support this.

Brain Tissue Oxygen Sensors. The brain tissue oxygen sensor is a recent development that has already demonstrated a mortality benefit in traumatic brain injury patients.² This sensor is part of a bolt, which is screwed into the skull in the same manner as the bolt described previously, however, is engineered to hold a pressure sensor, oxygen sensor, and brain temperature sensor. The oxygen sensor catheter has an electrochemical oxygen–tension sensitive membrane. Patients with severe brain injury due to trauma or aneurysmal hemorrhage may benefit from placement of these three sensors in addition to a ventriculostomy to drain CSF for control of ICP. Such monitoring requires two twist-drill holes, which may be placed on adjacent or opposite sides of the head.

NEUROLOGIC AND NEUROSURGICAL EMERGENCIES

Raised Intracranial Pressure

ICP normally varies between 4 and 14 mmHg. Sustained ICP levels above 20 mmHg can injure the brain. The Monro-Kellie doctrine states that the cranial vault is a rigid structure, and therefore, the total volume of the contents determines ICP. The three normal contents of the cranial vault are brain tissue, blood, and CSF. The brain's contents can expand due to swelling from traumatic brain injury (TBI), stroke, or reactive edema. Blood volume can increase by extravasation to form a hematoma, or by reactive vasodilation in a hypoventilating, hypercarbic patient. CSF volume increases in the setting of hydrocephalus. Figure 42-2 demonstrates the classic CT findings of hydrocephalus. The addition of a lesion, such as a tumor or abscess, also will increase ICP. The pressure-volume curve depicted in Fig. 42-3 demonstrates a compensated region with a small $\Delta P/\Delta V$, and an uncompensated region with large $\Delta P/\Delta V$. In the compensated region, increased volume is offset by decreased volume of CSF and blood.

Increased ICP can injure the brain in several ways. Focal mass lesions cause shift and herniation. Temporal lesions push the uncus medially and compress the midbrain. This phenomenon is known as *uncal herniation*. The posterior cerebral artery (PCA) passes between the uncus and midbrain and may be occluded, leading to an occipital infarct. Masses higher up in the hemisphere can push the cingulate gyrus under the falx cerebri. This process is known as *subfalcine herniation*. The anterior cerebral artery (ACA) branches run along the

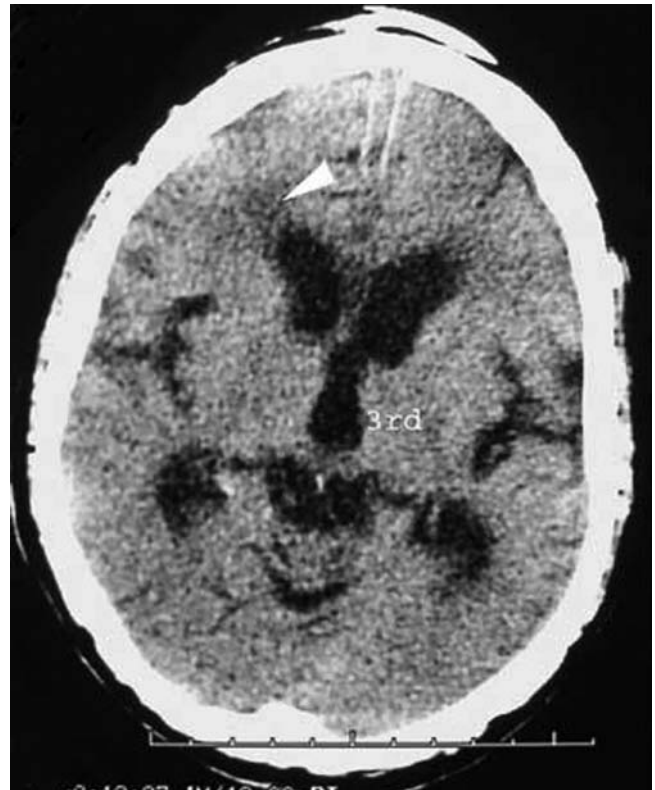

Figure 42-2. Head computed tomography scan demonstrating hydrocephalus. The third ventricle (*3rd*) is widened and rounded, the anterior horns of the lateral ventricles are plump, and pressure-driven flow of cerebrospinal fluid into brain parenchyma adjacent to the ventricles is seen (*arrowhead*). This is known as *transeptal flow of cerebrospinal fluid*.

medial surface of the cingulate gyrus and may be occluded in this case, leading to medial frontal and parietal infarcts. Diffuse increases in pressure in the cerebral hemispheres can lead to central, or transtentorial, herniation. Increased pressure in the posterior fossa can lead to upward central herniation or downward tonsillar herniation through the foramen magnum. Uncal, transtentorial, and tonsillar herniation can cause direct damage to the brain stem. Figure 42-4 diagrams patterns of herniation.

Patients with increased ICP, or intracranial hypertension, often will present with headache, nausea, vomiting, and progressive mental status decline. Cushing's triad is the classic presentation of intracranial hypertension, bradycardia, and irregular respirations. Focal neurologic deficits such as hemiparesis may be present if there is a focal mass lesion causing the problem. Patients with these symptoms should undergo an immediate head CT and rapid neurosurgical evaluation.

Initial management of intracranial hypertension includes airway protection and adequate ventilation. A bolus of mannitol up to 1 g/kg causes free water diuresis, increased serum osmolality, and extraction of water from the brain. The effect is delayed by about 20 minutes and has a transient benefit. Driving serum osmolality above 300 mOsm/L is of indeterminate benefit and can have deleterious cardiovascular side effects, such as hypovolemia that leads to hypotension and decreased brain perfusion. A ventriculostomy and/or craniectomy may be needed for definitive decompression.

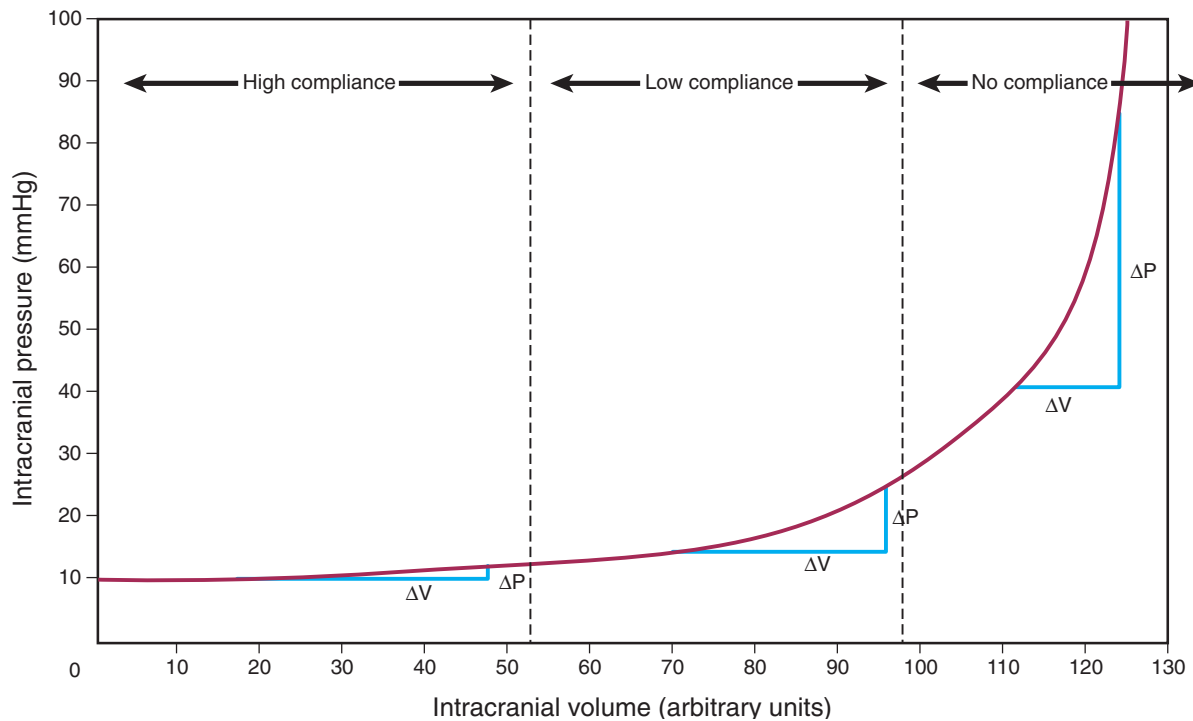


Figure 42-3. Pressure-volume curve demonstrating the effect of changing the volume of intracranial contents on intracranial pressure. Note the compensated zone, with little change of pressure with change of volume, and the uncompensated zone, with significant change of pressure with change of volume. (Adapted with permission from Morton R, Ellenbogen RG: *Intracranial consciousness*, in Ellenbogen RG et al (eds): *Principles of Neurosurgery*, 3rd ed. Philadelphia: Elsevier Saunders, 2012, p 313. Copyright Elsevier.)

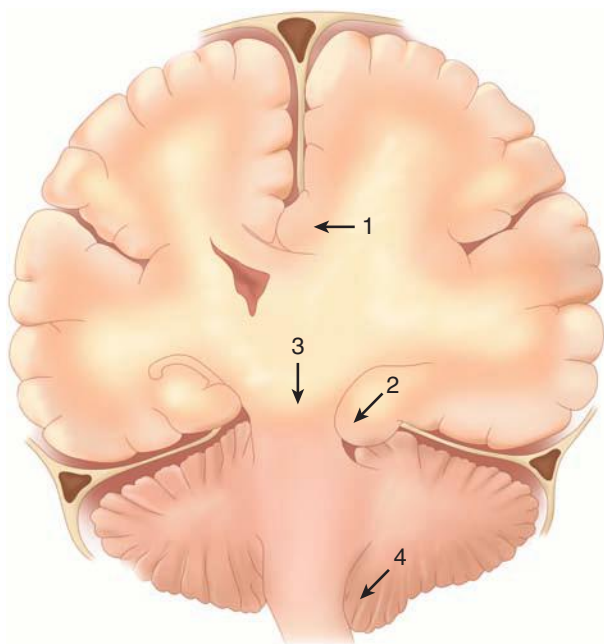


Figure 42-4. Schematic drawing of brain herniation patterns. 1. Subfalcine herniation. The cingulate gyrus shifts across midline under the falx cerebri. 2. Uncal herniation. The uncus (medial temporal lobe gyrus) shifts medially and compresses the midbrain and cerebral peduncle. 3. Central transtentorial herniation. The diencephalon and midbrain shift caudally through the tentorial incisura. 4. Tonsillar herniation. The cerebellar tonsil shifts caudally through the foramen magnum. (Reproduced with permission from Cohen DS, Quest DO: *Increased intracranial pressure, brain herniation and their control*, in Wilkins RH, Rengachary SS [eds]: *Neurosurgery*, 2nd ed. New York: McGraw Hill, 1996, p 349.)

It is critical to note that lethargic or obtunded patients often have decreased respiratory drive. This causes the partial pressure of arterial carbon dioxide (P_{aCO_2}) to increase, resulting in cerebral vasodilation and worsening of intracranial hypertension. This cycle causes a characteristic “crashing patient,” who rapidly loses airway protection, becomes apneic, and herniates. Emergent intubation and ventilation to reduce P_{aCO_2} to roughly 35 mmHg can reverse this process.

Brain Stem Compression

The posterior fossa (brain stem and cerebellum) requires special consideration because the volume of the posterior fossa within the cranial vault is small. Posterior fossa lesions such as tumors, hemorrhage or stroke can cause mass effect that can rapidly kill the patient in two ways. Occlusion of the fourth ventricle can lead to acute obstructive hydrocephalus, raised ICP, herniation, and eventually death. This mass effect can also lead directly to brain stem compression (Fig. 42-5). Symptoms of brain stem compression include hypertension, agitation, and progressive obtundation, followed rapidly by brain death. A patient exhibiting any of these symptoms needs an emergent neurosurgical evaluation for possible ventriculostomy or suboccipital craniectomy (removal of the bone covering the cerebellum). This situation is especially critical, as expeditious decompression can lead to significant functional recovery.

Stroke

Patients presenting with acute focal neurologic deficits at a clearly defined time of onset (i.e., when the patient was last seen in a normal state of health) must be evaluated as rapidly as possible. An emergent head CT scan should be done.

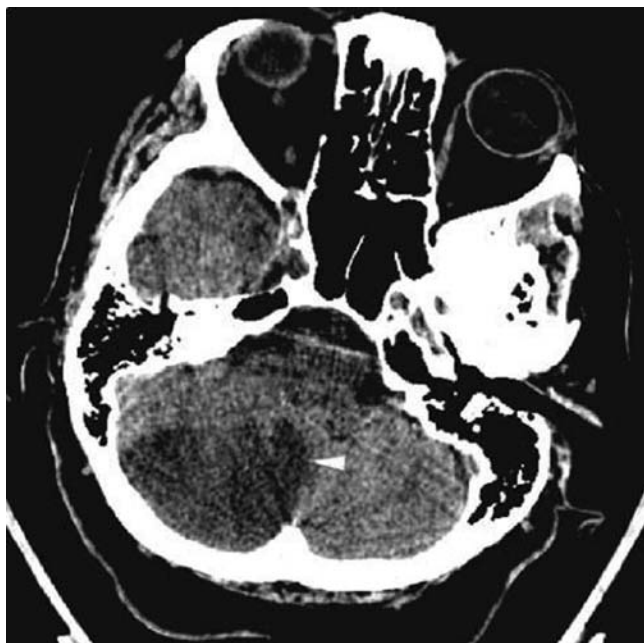

Figure 42-5. Maturing cerebellar stroke seen as a hypodense area in the right cerebellar hemisphere (*arrowhead*) on head computed tomography in a patient with rapidly progressing obtundation 2 days after the initial onset of symptoms. Swelling of the infarcted tissue causes posterior fossa mass effect. The fourth ventricle is obliterated and not visible, and the brain stem is being compressed.

The study is often normal, because CT changes from ischemic stroke may take up to 24 hours to appear (Fig. 42-6). A patient with a clinical diagnosis of acute stroke <3 hours old, without hemorrhage on CT, may be a candidate for thrombolytic therapy with tissue plasminogen activator (tPA). An emergent MRI is helpful but not always diagnostically necessary.

Seizure

A seizure is defined as an uncontrolled synchronous organization of neuronal electrical activity. A new-onset seizure often signifies an irritative mass lesion in the brain, particularly in adults, in whom tumors commonly present with seizure. Patients with traumatic intracranial hemorrhage are at risk for seizure. In addition to airway and ventilatory problems, a seizing patient is also at risk for neural excitotoxicity if the activity is prolonged, such as in *status epilepticus*. Any patient with a new-onset seizure should have imaging of the brain after the seizure is controlled and the patient is resuscitated.

TRAUMA

Trauma is the leading cause of death in children and young adults; however, the incidence of death and disability from trauma has been slowly decreasing. This decline is partly attributable to increased awareness of safety devices such as seat belts and motorist helmets. Nonetheless, trauma remains a major cause of morbidity and mortality, and it can affect every major organ system in the body. The three main areas of neurosurgical focus are: traumatic brain injury (TBI), spinal cord injury (SCI), and peripheral nerve injury.

Head Trauma

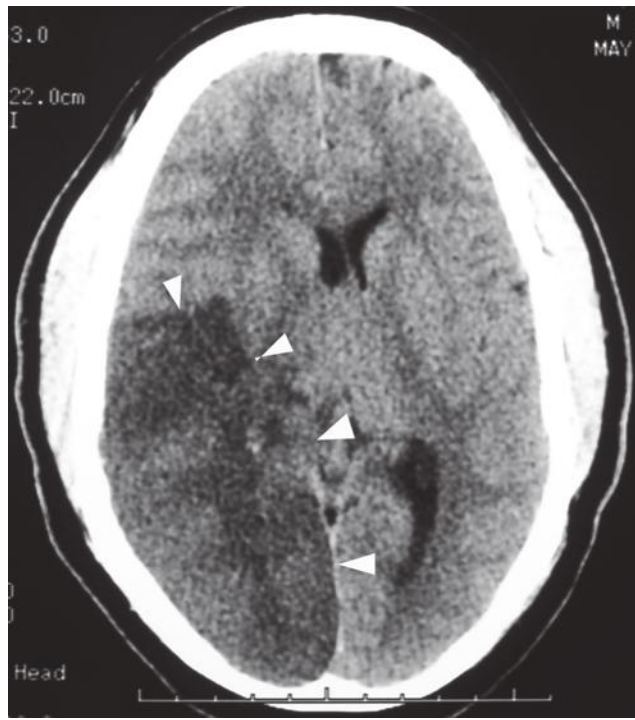Glasgow Coma Scale Score. The initial assessment of the trauma patient includes the primary survey, resuscitation, secondary survey, and definitive care. Neurosurgical evaluation begins during the primary survey with the determination of the GCS score (usually referred to simply as the *GCS*) for the patient. The GCS is determined by adding the scores of the best responses of the patient in each of three categories. The motor score ranges from 1 to 6, verbal from 1 to 5, and eyes from 1 to 4. The GCS therefore ranges from 3 to 15, as detailed in Table 42-2. Tracheal intubation or severe facial or eye swelling can impede verbal and eye responses. In these circumstances, the patient is given the score of 1 with a modifier, such as verbal “1T” where T = tube.

Scalp Injury. Blunt or penetrating trauma to the head can cause injury to the densely vascularized scalp, and significant blood loss can result. Direct pressure initially controls the bleeding, allowing close inspection of the injury. If a simple laceration is found, it should be copiously irrigated and closed primarily. If the laceration is short, a single-layer, percutaneous suture closure will suffice. If the laceration is long or has multiple arms, the patient may need debridement and closure in the operating room, with its superior lighting and wider selection of instruments and suture materials. Careful reapproximation of the galea will provide a more secure closure and better hemostasis. Blunt trauma also can cause crush injury with subsequent tissue necrosis. These wounds require debridement and consideration of advancement flaps to cover the defect.

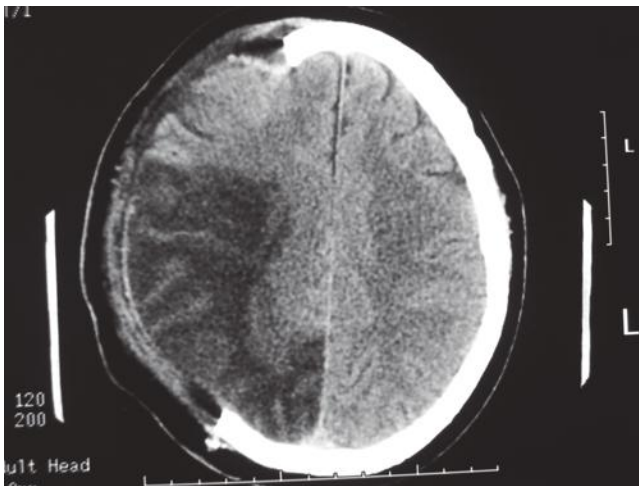
Skull Fractures. The usual classification system for bony fractures may be applied to the skull. The fracture may be characterized by skull X-rays or head CT.³ A closed fracture is covered by intact skin. An open, or compound, fracture is associated with disrupted overlying skin. The fracture lines may be single (linear); multiple and radiating from a point (stellate); or multiple, creating fragments of bone (comminuted). Closed skull fractures do not normally require specific treatment. Open fractures require repair of the scalp and operative debridement. Indications for craniotomy include depression greater than the cranial thickness, intracranial hematoma, and frontal sinus involvement.⁴ Skull fractures generally indicate that a significant amount of force was transmitted to the head and should increase the suspicion for intracranial injury. Fractures that cross meningeal arteries can cause rupture of the underlying vessels and subsequent epidural hematoma (EDH) formation.

Depressed skull fractures may result from a focal injury of significant force. The inner and outer cortices of the skull are disrupted, and a fragment of bone is pressed in toward the brain in relation to adjacent intact skull. The fragment may overlap the edge of intact bone, or may plunge completely below the level of adjacent normal skull. The inner cortex of the bone fragments often has multiple sharp edges that can lacerate dura, brain, and vessels. Craniotomy is required to elevate the fracture, repair dural disruption, and obtain hemostasis in these cases (Fig. 42-7). However, fractures overlying dural venous sinuses require restraint. Surgical exploration can lead to life-threatening hemorrhage from the lacerated sinus.

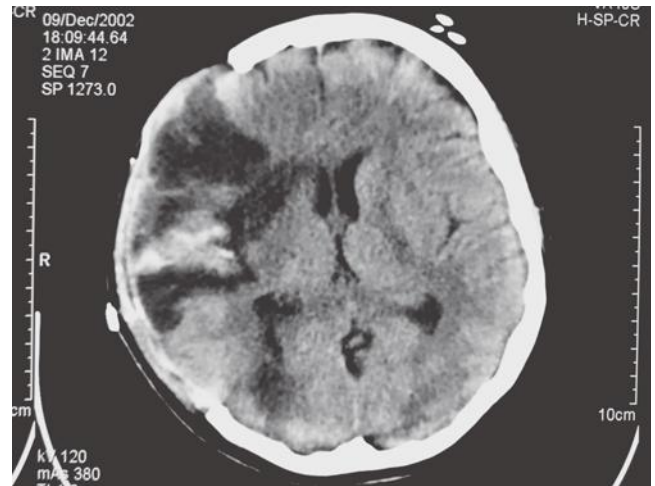Fractures of the skull base are common in head-injured patients, and they indicate significant impact. They are generally apparent on routine head CT, but should be evaluated with



A



B



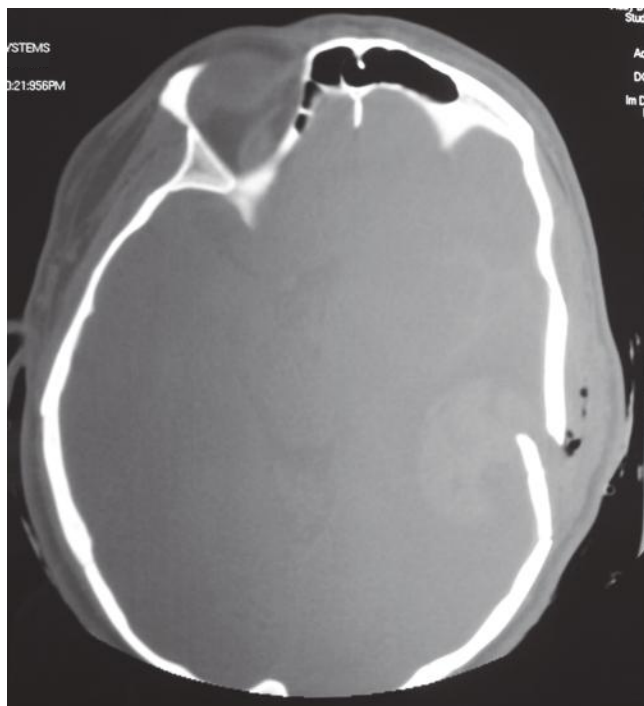
C

Figure 42-6. **A.** Head computed tomography scan of a patient with a 4-day-old stroke that occluded the right middle cerebral and posterior cerebral arteries. The infarcted tissue is the hypodense (*dark*) area indicated by the *arrowheads*. The patient presented with left-sided weakness and left visual field loss, but then became less responsive, prompting this head computed tomography. Note the right-to-left midline shift. **B.** Same patient status post decompressive right hemicraniectomy. Note the free expansion of swollen brain outside the normal confines of the skull. **C.** Patient with a right middle cerebral artery ischemic stroke with areas of hemorrhagic conversion, seen as hyperdense (*bright*) areas within the infarcted tissue. This patient also required hemicraniectomy for severe mass effect. Note the lack of midline shift postoperatively.

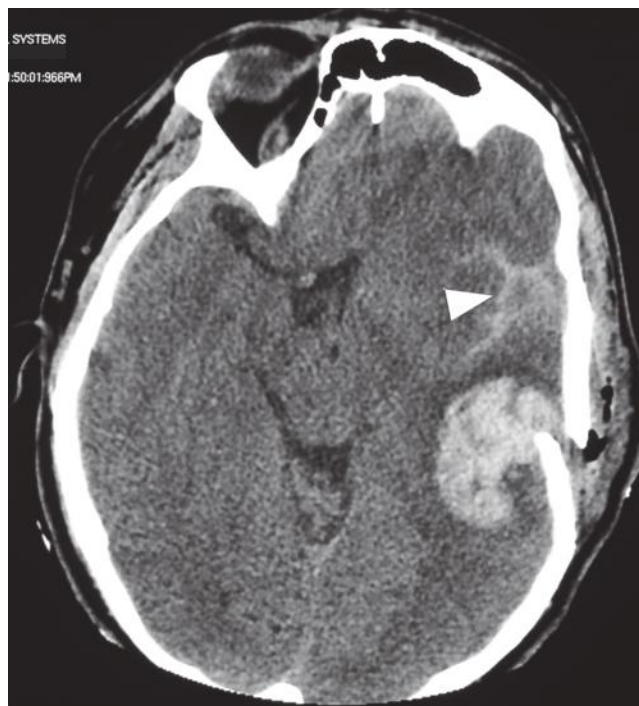
dedicated fine-slice coronal-section CT scan to document and delineate the extent of the fracture and involved structures. If asymptomatic, they require no treatment. Skull base fractures requiring intervention include those with an associated cranial nerve deficit or CSF leak. A fracture of the temporal bone, for instance, can damage the facial or vestibulocochlear nerve, resulting in vertigo, ipsilateral deafness, or facial paralysis. A communication may be formed between the subarachnoid space and the middle ear, allowing CSF drainage into the pharynx via the eustachian tube or from the ear (otorrhea). Extravasation

of blood results in ecchymosis behind the ear, known as *Battle's sign*. A fracture of the anterior skull base can result in anosmia (loss of smell from damage to the olfactory nerve), CSF drainage from the nose (rhinorrhea), or periorbital ecchymoses, known as *raccoon eyes*.

Copious clear drainage from the nose or ear makes the diagnosis of CSF leakage obvious. Often, however, the drainage may be discolored with blood or small in volume if some drains into the throat. The halo test can help differentiate. Allow a drop of the fluid to fall on an absorbent surface such as



A



B

Figure 42-7. A. Bone-window axial head computed tomography (CT) of a patient who presented aphasic after being struck with the bottom of a beer bottle. CT demonstrates a depressed skull fracture in the left posterior temporoparietal area. B. Brain-window axial head CT demonstrating intraparenchymal hematoma caused by laceration of cortical vessels by the edge of the fractured bone. Arrowhead indicates traumatic subarachnoid hemorrhage in the sylvian fissure.

a facial tissue. If blood is mixed with CSF, the drop will form a double ring, with a darker center spot containing blood components surrounded by a light halo of CSF. If this test is indeterminate, the fluid can be sent for beta-2 transferrin testing, a carbohydrate-free isoform of transferrin exclusively found in the CSF.

Many CSF leaks will heal with elevation of the head of the bed for several days. A lumbar drain can augment this method. A lumbar drain is a catheter placed in the lumbar CSF cistern to decompress the cranial vault and allow the defect to heal by eliminating normal hydrostatic pressure. There is no proven efficacy of antibiotic coverage for preventing meningitis in patients with CSF leaks.

Traumatic cranial neuropathies generally can be managed conservatively, with documentation of the extent of impairment and signs of recovery. Patients with traumatic facial nerve palsies may benefit from a course of steroids, although their benefit is unproven. Patients with facial nerve palsy of abrupt onset, who do not respond to steroids within 48 to 72 hours, may be considered for surgical decompression of the petrous portion of the facial nerve. Patients also may present with delayed-onset facial nerve palsy. Again, steroids are used and surgery can be considered, with mixed results.

Closed Head Injury. Closed head injury (CHI) is the most common type of TBI and a significant cause of morbidity and mortality in the United States. There are two important factors that affect the outcome of CHI in general. The initial impact causes the *primary injury*, defined as the immediate injury to neurons from transmission of the force of impact. The long, delicate axons of the neurons can shear as they undergo differential acceleration or deceleration along their projecting

pathways. Prevention strategies, such as wearing helmets, remain the best means to decrease disability from primary injury. Subsequent neuronal damage due to the sequelae of trauma is referred to as *secondary injury*. Hypoxia, hypotension, hydrocephalus, intracranial hypertension, thrombosis, and intracranial hemorrhage may all be mechanisms of secondary injury. One focus of basic research in TBI, critical care medicine, and neurosurgical intervention is to decrease the effects of secondary injury.

The Brain Trauma Foundation's most recent summary of management recommendations for TBI patients was published in 2007 and is endorsed by the American Association of Neurological Surgeons, Congress of Neurological Surgeons, and the World Health Organization. The guidelines standardize the care of these patients with the hope of improving outcomes. Some of the common patterns of CHI, including concussion, contusion, and diffuse axonal injury, are discussed in Types of Closed Head Injury.⁵

Initial Assessment The initial evaluation of a trauma patient remains the same whether or not the primary surveyor suspects head injury. The first three elements of the ABCDs of resuscitation—*airway*, *breathing*, and *circulation*—must be assessed and stabilized. Hypoxia and hypotension are known to worsen outcome in TBI (due to secondary injury), making cardiopulmonary stabilization critical. Patients who cannot follow commands require intubation for airway protection and ventilatory control. The fourth element, assessment of “D,” for *disability*, is undertaken next. Motor activity, speech, and eye opening can be assessed in a few seconds and a GCS score assigned.

The following is an example of how a primary surveyor may efficiently assess disability and GCS: Approach the patient

and enter his or her field of view. Observe whether the patient is visually attentive. Clearly command: "Tell me your name." Then ask the patient to lift up two fingers on each side sequentially, and wiggle the toes. A visually or verbally unresponsive patient should be assessed for response to peripheral stimuli such as nail-bed pressure, or deep central painful stimulation, such as a firm, twisting pinch of the sensitive supraclavicular skin. Watch for eye opening and movement of the extremities, whether purposeful or reflexive. Assess the verbal response. The motor, verbal, and eye-opening scores may be correctly assigned using this rapid examination. An initial assessment of the probability of significant head injury can be made, assuming that pharmacologic and toxic elements have not obscured the examination. The surveyor must also take note of any external signs of head injury, including bleeding from the scalp, nose, or ear, or deformation of the skull or face.

Medical Management Several medical steps may be taken to minimize secondary injury and the systemic consequences of head injury. Patients with a documented CHI and evidence of intracranial hemorrhage or a depressed skull fracture should receive a 17-mg/kg phenytoin loading dose, followed by 1 week of therapeutic maintenance phenytoin, typically 300 to 400 mg/d. Phenytoin prophylaxis has been shown to decrease the incidence of early posttraumatic seizures.⁶ There is no evidence to support long-term use of prophylactic antiepileptic agents. Blood glucose levels should be closely monitored by free blood sugar checks and controlled with sliding scale insulin. Fevers also should be evaluated and controlled with antipyretics, as well as source-directed therapy when possible. Hyperglycemia and hyperthermia are toxic to injured neurons and contribute to secondary injury. Head-injured patients have an increased prevalence of peptic ulceration and GI bleeding. Peptic ulcers occurring in patients with head injury or high ICP are referred to as Cushing's ulcers. Ulcer prophylaxis should be used. Compression stockings or athrombic pumps should be used when the patient cannot be mobilized rapidly for prophylaxis of deep venous thrombosis.

Classification TBI can be classified as mild, moderate, or severe. For patients with a history of head trauma, classification is as follows: severe head injury if the GCS score is 3 to 8, moderate head injury if the GCS score is 9 to 12, and mild head injury if the GCS score is 13 to 15. Many patients present to emergency rooms and trauma bays with a history of TBI. A triage system must be used to maximize resource utilization while minimizing the chance of missing occult or progressing injuries.

TBI patients who are asymptomatic, who have only headache, dizziness, or scalp lacerations, and who did not lose consciousness, have a low risk for intracranial injury and may be discharged home without a head CT scan.^{7,8} Head-injured patients who are discharged should be sent home with reliable family or friends who can observe the patient for the first postinjury day. Printed discharge instructions, which describe monitoring for confusion, persistent nausea, weakness, or speech difficulty, should be provided to the caretaker. The patient should return to the emergency department for evaluation of such symptoms.

Patients with a history of altered consciousness, amnesia, progressive headache, skull or facial fracture, vomiting, or seizure have a moderate risk for intracranial injury and should undergo a prompt head CT. If the CT is normal, and the neurologic examination has returned to baseline (excluding amnesia

of the event), then the patient can be discharged to the care of a responsible adult, again with printed criteria for returning to the emergency room. Otherwise the patient must be admitted for a 24-hour observation period.

Patients with depressed consciousness, focal neurologic deficits, penetrating injury, depressed skull fracture, or changing neurologic examination have a high risk for intracranial injury. These patients should undergo immediate head CT and admission for observation or intervention as needed.

Types of Closed Head Injury

Concussion A concussion is defined as temporary neuronal dysfunction following nonpenetrating head trauma. The head CT is normal, and deficits resolve over minutes to hours. Definitions vary; some require transient loss of consciousness, while others include patients with any alteration of mental status. Memory difficulties, especially amnesia of the event, are very common. Concussions may be graded. One method is the Colorado grading system.⁹ Head trauma patients with confusion only are grade 1, patients with amnesia are grade 2, and patients who lose consciousness are grade 3. Studies have shown that the brain remains in a hypermetabolic state for up to a week after injury. The brain is also much more susceptible to injury from even minor head trauma in the first 1 to 2 weeks after concussion. This is known as second-impact syndrome, and patients should be informed that, even after mild head injury, they might experience memory difficulties or persistent headaches.

Contusion A contusion is a bruise of the brain, and occurs when the force from trauma is sufficient to cause breakdown of small vessels and extravasation of blood into the brain. The contused areas appear bright on CT scan, as seen in Fig. 42-8. The frontal,

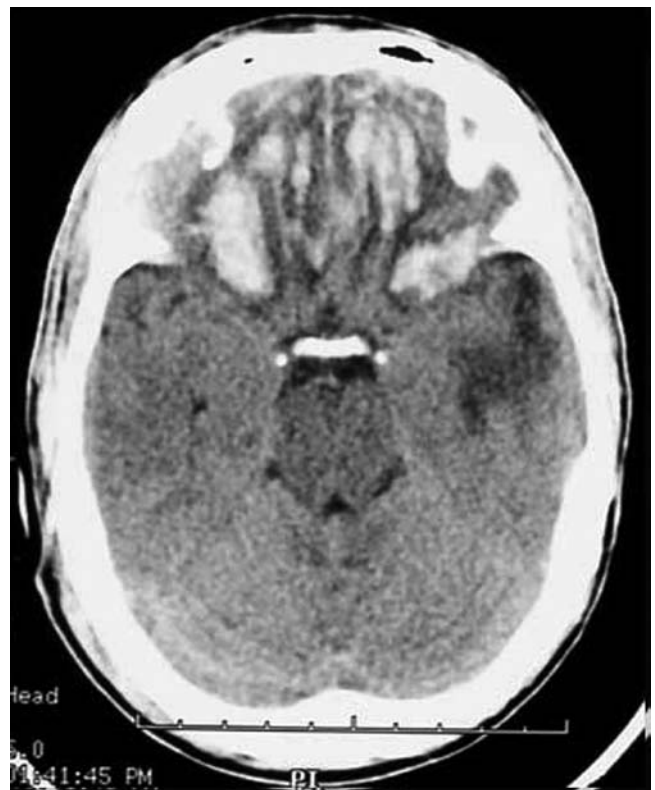

Figure 42-8. Severe bilateral contusions in the basal aspect of the frontal lobes, caused by the brain moving over the rough, irregular skull base during sudden cranial acceleration.

occipital, and temporal poles are most often involved. The brain sustains injury as it collides with rough, bony surfaces. Contusions themselves rarely cause significant mass effect as they represent small amounts of blood in injured parenchyma rather than coherent blood clots. Edema may develop around a contusion, causing mass effect. Contusions may enlarge or progress to frank hematoma, particularly during the first 24 hours. Contusions also may occur in brain tissue opposite the site of impact. This is known as a *contre-coup injury*. These contusions result from deceleration of the brain against the skull.

Diffuse Axonal Injury Diffuse axonal injury is caused by damage to axons throughout the brain, due to rotational acceleration and then deceleration. Axons may be completely disrupted and then retract, forming axon balls. Small hemorrhages can be seen in more severe cases, especially on MRI. Hemorrhage is classically seen in the corpus callosum and the dorsolateral midbrain.

Penetrating Injury These injuries are complex and must be evaluated individually. The two main subtypes are missile (e.g., due to bullets or fragmentation devices) and nonmissile (e.g., due to knives or ice picks). Some general principles apply. If available, skull X-rays and CT scans are useful in assessing the nature of the injury. Cerebral angiography must be considered if the object passes near a major artery or dural venous sinus. Operative exploration is necessary to remove any object extending out of the cranium, as well as for debridement, irrigation, hemostasis, and definitive closure. Small objects contained within brain parenchyma are often left in place to avoid iatrogenic secondary brain injury. Antibiotics are given to decrease the chances of meningitis or abscess formation. High-velocity missile injuries (from high-powered hunting rifles or military weapons) are especially deadly, because the associated shock wave causes cavitory tissue destruction of an area that is much larger than the projectile itself. Projectiles that penetrate both hemispheres or traverse the ventricles are almost universally fatal.

Traumatic Intracranial Hematomas. The various traumatic intracranial hematomas contribute to death and disability secondary to head injury. Hematomas can expand rapidly and cause brain shift and subsequent herniation. Emergent neurosurgical evaluation and intervention often are necessary.

Epidural Hematoma EDH is the accumulation of blood between the skull and the dura. EDH usually results from arterial disruption, especially of the middle meningeal artery. The dura is adherent to bone, and some pressure is required to dissect between the two. EDH has a classic, three-stage clinical presentation that is probably seen in only 20% of cases. The patient is initially unconscious from the concussive aspect of the head trauma. The patient then awakens and has a “lucid interval,” while the hematoma subclinically expands. As the volume of the hematoma grows, the decompensated region of the pressure-volume curve is reached, ICP increases, and the patient rapidly becomes lethargic and herniates. Uncal herniation from an EDH classically causes ipsilateral third nerve palsy and contralateral hemiparesis.

On head CT the blood clot is bright, biconvex in shape (lentiform), and has a well-defined border that usually respects cranial suture lines. An EDH is typically found over the convexities but may rarely occur in the posterior fossa as well.

Open craniectomy for evacuation of the congealed clot and hemostasis generally is indicated for EDH. Patients who meet all of the following criteria may be managed conservatively: clot volume <30 cm³, maximum thickness <1.5 cm, and

GCS score >8.¹⁰ Prognosis after successful evacuation is better for EDH than subdural hematoma (SDH). EDHs are associated with lower-energy trauma with less resultant primary brain injury. Good outcomes may be seen in 85% to 90% of patients, with rapid CT scan and intervention.¹¹

Acute Subdural Hematoma An acute SDH is the result of an accumulation of blood between the arachnoid membrane and the dura. Acute SDH usually results from venous bleeding, typically from tearing of a bridging vein running from the cerebral cortex to the dural sinuses. The bridging veins are subject to stretching and tearing during acceleration/deceleration of the head, because the brain shifts in relation to the dura, which firmly adheres to the skull. Elderly and alcoholic patients are at higher risk for acute SDH formation after head trauma due to brain atrophy.

On head CT scan, the clot is bright or mixed-density, crescent-shaped (lunate), may have a less distinct border, and does not cross the midline due to the presence of the falx. Most SDHs occur over the cerebral hemispheres, but they may also occur between the hemispheres or layer over the tentorium.

Open craniotomy for evacuation of acute SDH is indicated for any of the following: thickness >1 cm, midline shift >5 mm, or GCS drop by two or more points from the time of injury to hospitalization. Nonoperatively managed hematomas may stabilize and eventually reabsorb, or evolve into chronic SDHs.¹² This management requires frequent neurologic examinations until the clot stabilizes based on serial head CT scans.

The prognosis for functional recovery is significantly worse for acute SDH than EDH because it is associated with greater primary injury to brain parenchyma from high-energy impacts. Prompt recognition and intervention minimizes secondary injury. The elderly patients with low admission GCS, or high postoperative ICP do poorly, with as few as 5% attaining functional recovery.¹³

Chronic Subdural Hematoma Chronic SDH is a collection of blood breakdown products that is at least 2 to 3 weeks old. Acute hematomas are bright white (hyperdense) on CT scan for approximately 3 days, after which they fade to isodensity with brain, and then to hypodensity after 2 to 3 weeks. A true chronic SDH will be nearly as dark as CSF on CT. Traces of white are often seen due to small, recurrent hemorrhages into the collection. These small bleeds may expand the collection enough to make it symptomatic. This phenomenon is referred to as an *acute-on-chronic SDH*. Figure 42-9 demonstrates the CT appearance of an acute-on-chronic SDH. Vascularized membranes form within the hematoma as it matures. These membranes may be the source of acute hemorrhage.

Chronic SDHs often occur in patients without a clear history of head trauma, as they may arise from minor head injury. Alcoholics, the elderly, and patients on anticoagulation are at higher risk for developing chronic SDH. Patients may present with headache, seizure, confusion, contralateral hemiparesis, or coma.

A chronic SDH >1 cm or any symptomatic SDH should be surgically drained. Unlike acute SDH, which consists of a thick, congealed clot, chronic SDH typically consists of a viscous fluid with the texture and dark brown color reminiscent of motor oil. A simple burr hole can effectively drain most chronic SDHs. However, the optimal treatment of chronic SDH remains controversial.¹⁴ Most authorities agree that burr hole drainage should be attempted first to obviate the risks of formal craniotomy. A single burr hole placed over the dependent edge of the

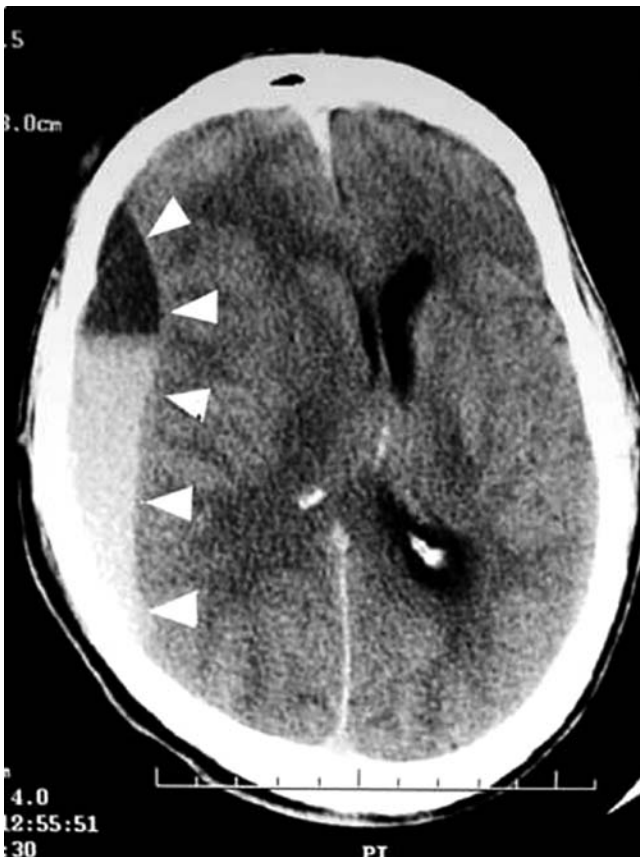

Figure 42-9. Head computed tomography scan of an elderly patient with progressing left hemiplegia and lethargy, demonstrating an acute-on-chronic subdural hematoma. History revealed that the patient sustained a fall 4 weeks before presentation. *Arrowheads* outline the hematoma. The acute component is slightly denser and is seen as the hyperdense area in the dependent portion.

collection can be made, and the space copiously irrigated until the fluid is clear. A second, more anterior burr hole can then be placed if the collection does not drain satisfactorily due to containment by membranes. The procedure is converted to open craniotomy if the SDH is too congealed for irrigation drainage, the complex of membranes prevents effective drainage, or persistent hemorrhage occurs that cannot be reached with bipolar cautery through the burr hole. The required surgical prepping and draping are always performed to allow simple conversion to craniotomy, and the scalp incision and burr holes are placed to allow easy incorporation into larger skin flaps.

There are various strategies to prevent reaccumulation of blood. Subdural or subgaleal drains may be left in place for 1 to 2 days. Mild hydration and bedrest with the head of the bed flat may encourage brain expansion. High levels of inspired oxygen may help draw nitrogen out of the cavity. Regardless of the strategy used, follow-up head CT scans are required postoperatively and approximately 1 month later to document resolution.

Intraparenchymal Hemorrhage Isolated hematomas within the brain parenchyma are most often associated with hypertensive hemorrhage or arteriovenous malformations (AVMs). Bleeding may occur in a contused area of brain. Mass effect from developing hematomas may present as a delayed neurologic deficit. Delayed traumatic intracerebral hemorrhage is most likely to occur within the first 24 hours. Patients with contusion on the initial head CT scan should be reimaged 24 hours

after the trauma to document stable pathology. Indications for craniotomy include: any clot volume $>50\text{ cm}^3$ or a clot volume $>20\text{ cm}^3$ with referable neurologic deterioration (GCS 6–8) and associated midline shift $>5\text{ mm}$ or basal cistern compression.¹⁵

Vascular Injury. Trauma to the head or neck may cause damage to the carotid or vertebrobasilar systems. Generally, *dissection* refers to violation of the vessel wall intima. Blood at arterial pressures can then open a plane between the intima and media, within the media, or between the media and adventitia. The newly created space within the vessel wall is referred to as the *false lumen*. Tissue or organs supplied by dissected vessels may subsequently be injured in several ways. Expansion of the hematoma within the vessel wall can lead to narrowing of the true vessel lumen and reduction or cessation of distal blood flow. Slow-flowing or stagnant blood within the false lumen exposed to thrombogenic vessel wall elements may thrombose. Pieces of thrombus may then detach and cause distal embolic arterial occlusion. Also, the remaining partial-thickness vessel wall may rupture, damaging adjacent structures.

Traumatic dissection may occur in the carotid artery (anterior circulation) or the vertebral or basilar arteries (posterior circulation). Dissections may be extradural or intradural. Intradural dissection can present with subarachnoid hemorrhage (SAH). Traditional angiography remains the basis of diagnosis and characterization of arterial dissection. Angiographic abnormalities include stenosis of the true lumen, or “string-sign,” visible intimal flaps, and the appearance of contrast in the false lumen. Four-vessel cerebral angiography should be performed when suspicion of dissection exists.

Historically, patients with documented arterial dissection have been anticoagulated with heparin and then warfarin to prevent thromboembolic stroke. Trauma patients often have concomitant absolute or relative contraindications to anticoagulation, complicating management. Antiplatelet therapy is often implemented in lieu of full anticoagulation, however, there is no randomized clinical trial comparing the two therapies.¹⁶ Consider surgical or interventional techniques for persisting embolic disease and for vertebral dissections presenting with SAH. Surgical options include vessel ligation and bypass grafting. Interventional radiology techniques include stenting and vessel occlusion. Occlusion techniques require sufficient collateral circulation to perfuse the vascular territory previously supplied by the occluded vessel.

Carotid Dissection Carotid dissection may result from neck extension combined with lateral bending to the opposite side, or trauma from an incorrectly placed shoulder belt tightening across the neck in a motor vehicle accident. Extension or bending stretches the carotid over the bony transverse processes of the cervical vertebrae, while seat belt injuries cause direct trauma. Symptoms of cervical carotid dissection include contralateral neurologic deficit from brain ischemia, headache, and ipsilateral Horner’s syndrome from disruption of the sympathetic tracts ascending from the stellate ganglion on the surface of the carotid artery. The patient may complain of a bruit.

Traumatic vessel wall injury to the portion of the carotid artery running through the cavernous sinus may result in a carotid-cavernous fistula (CCF). This creates a high-pressure, high-flow pathophysiologic blood flow pattern. CCFs classically present with pulsatile proptosis (the globe pulses outward with arterial pulsation), retro-orbital pain, and decreased visual acuity or loss of normal eye movement (due to damage to cranial nerves

III, IV, and VI as they pass through the cavernous sinus). Symptomatic CCFs should be treated to preserve eye function. Fistulae may be closed by balloon occlusion using interventional neuro-radiology techniques. Fistulae with wide necks are difficult to treat and may require total occlusion of the parent carotid artery.

Vertebrobasilar Dissection Vertebrobasilar dissection may result from sudden rotation or flexion/extension of the neck, chiropractic manipulation, or a direct blow to the neck. Common symptoms are neck pain, headache, and brain stem stroke or SAH. The risks and benefits of aspirin therapy are unclear when a vertebral dissection extends intracranially. The theoretically increased friability of the vessel wall may increase the risk of SAH when coupled with an antiplatelet agent. Consultation of a stroke neurologist is recommended in this situation.

Brain Death. Brain death occurs when there is an absence of signs of brain stem function or motor response to deep central pain in the absence of pharmacologic or systemic medical conditions that could impair brain function.

Clinical Examination A neurologist, neurosurgeon, or intensivist generally performs the clinical brain death examination. Two examinations consistent with brain death 12 hours apart, or one examination consistent with brain death followed by a consistent confirmatory study generally is sufficient to declare brain death (see below). Hospital regulations and local laws regarding documentation should be followed closely.

Establish the absence of complicating conditions before beginning the examination. The patient must be normotensive, eutermic, and oxygenating well. The patient may not be under the effects of any sedating or paralytic drugs.

Documentation of no brain stem function requires the following: nonreactive pupils; lack of corneal blink, oculocephalic (doll's eyes), oculovestibular (cold calorics) reflexes; and loss of drive to breathe (apnea test). The apnea test demonstrates no spontaneous breathing even when $Paco_2$ is allowed to rise above 60 mmHg.

Deep central painful stimuli are provided by bilateral forceful twisting pinch of the supraclavicular skin and pressure to the medial canthal notch. Pathologic responses such as flexor or extensor posturing are *not* compatible with brain death. Spinal reflexes to peripheral pain, such as triple flexion of the lower extremities, are compatible with brain death.

Confirmatory Studies Confirmatory studies are performed after a documented clinical examination consistent with brain death. A study consistent with brain death may obviate the need to wait 12 hours for a second examination. This is especially important when the patient is a potential organ donor, as brain-dead patients often have progressive hemodynamic instability. Lack of cerebral blood flow consistent with brain death may be documented by cerebral angiography or technetium radio-nuclide study. A "to-and-fro" pattern on transcranial Doppler ultrasonography indicates no net forward flow through the cerebral vasculature, consistent with brain death. An electroencephalogram (EEG) documenting electrical silence has been used, but generally is not favored because there is often significant artifact which impairs interpretation.

Spine Trauma

The spine is a complex biomechanical structure. The spine provides structural support for the body as the principal component of the axial skeleton, while protecting the spinal cord and nerve roots. Trauma may fracture bones or cause ligamentous

disruption. Often, bone and ligament damage occur together. Damage to these elements reduces the strength of the spine and may cause instability, which compromises both supportive and protective functions. Spine trauma may occur with or without neurologic injury.

Neurologic injury from spine trauma is classified as either incomplete or complete. If there is some residual motor or sensory neurologic function below the level of the lesion, as assessed by clinical examination, the injury is defined as incomplete.¹⁷ A patient with complete neurologic dysfunction persisting 24 hours after injury has a very low probability of return of function in the involved area.

Neurologic injury from spine trauma may occur immediately or in delayed fashion. Immediate neurologic injury may be due to direct damage to the spinal cord or nerve roots from penetrating injuries, especially from stab wounds or gunshots. Blunt trauma may transfer sufficient force to the spine to cause acute disruption of bone and ligament, leading to subluxation, which is a shift of one vertebral element in relation to the adjacent level. Subluxation decreases the size of the spinal canal and neural foramina and causes compression of the cord or roots. Such neural impingement can also result from retropulsion of bone fragments into the canal during a fracture. Transection, crush injury, and cord compression impairing perfusion are mechanisms leading to SCI. Delayed neurologic injury may occur during transportation, examination of an improperly immobilized patient, or during a hypotensive episode.

The Mechanics of Spine Trauma. Trauma causes a wide variety of injury patterns in the spine due to its biomechanical complexity. A mechanistic approach facilitates an understanding of the patterns of injury, as there are only a few types of forces that can be applied to the spine. Although these forces are discussed individually, they often occur in combination. Several of the most common injury patterns are then presented to illustrate the clinical results of these forces applied at pathologically high levels.

Flexion/Extension Bending the head and body forward into a fetal position flexes the spine. Flexion loads the spine anteriorly (the vertebral bodies) and distracts the spine posteriorly (the spinous process and interspinous ligaments). High flexion forces occur during front-end motor vehicle collisions, and backward falls when the head strikes first. Arching the neck and back extends the spine. Extension loads the spine posteriorly and distracts the spine anteriorly. High extension forces occur during rear-end motor vehicle collisions (especially if there is no headrest), frontward falls when the head strikes first, or diving into shallow water.

Compression/Distraction Force applied along the spinal axis (axial loading) compresses the spine. Compression loads the spine anteriorly and posteriorly. High compression forces occur when a falling object strikes the head or shoulders, or when landing on the feet, buttocks, or head after a fall from height. A pulling force in line with the spinal axis distracts the spine. Distraction unloads the spine anteriorly and posteriorly. Distraction forces occur during a hanging, when the chin or occiput strikes an object first during a fall, or when a passenger submarines under a loose seat belt during a front-end motor vehicle collision.

Rotation Force applied tangential to the spinal axis rotates the spine. Rotation depends on the range of motion of intervertebral facet joints. High rotational forces occur during off-center impacts to the body or head or during glancing automobile accidents.

Patterns of Injury. Certain patterns of injury resulting from combinations of the previously mentioned forces occur commonly and should be recognized during plain film imaging of the spine. Always completely evaluate the spine. A patient with a spine injury at one level has a significant risk for additional injuries at other levels.

Cervical The cervical spine is more mobile than the thoracolumbar spine. Stability comes primarily from the multiple ligamentous connections of adjacent vertebral levels. Disruption of the cervical ligaments can lead to instability in the absence of fracture. The mass of the head transmits significant forces to the cervical spine during abrupt acceleration or deceleration, increasing risk for injury.

Jefferson Fracture A Jefferson fracture is a bursting fracture of the ring of C1 (the atlas) due to compression forces. There are usually two or more fractures through the ring of C1. The open-mouth odontoid view may show lateral dislocation of the lateral masses of C1. The rule of Spence states that 7 mm or greater combined dislocation indicates disruption of the transverse ligament. The transverse ligament stabilizes C1 with respect to C2. Jefferson fractures dislocated <7 mm usually are treated with a rigid collar, while those dislocated 7 mm or greater usually are treated with a halo vest. Surgical intervention is not indicated.

Odontoid Fractures The odontoid process, or dens, is the large ellipse of bone arising anteriorly from C2 (the axis) and projecting up through the ring of C1 (the atlas). Several strong ligaments connect the dens to C1 and to the base of the skull. Odontoid fractures usually result from flexion forces. Odontoid fractures are classified as type I, II, or III. A type I fracture involves the tip only. A type II fracture passes through the base of the odontoid process. A type III fracture passes through the body of C2. Types II and III are considered unstable and should be externally immobilized or fused surgically. Surgery often is undertaken for widely displaced fractures (poor chance of fusing) and for those that fail external immobilization. Type I fractures usually fuse with external immobilization only.

Hangman's Fracture Traditionally considered a hyperextension/distraction injury from placement of the noose under the angle of the jaw, hangman's fractures also may occur with hyperextension/compression, as with diving accidents, or hyperflexion. The injury is defined by bilateral C2 pars interarticularis fractures. The pars interarticularis is the bone between superior and inferior facet joints. Thus, the posterior bony connection between C1 and C3 is lost. Hangman's fractures heal well with external immobilization. Surgery is indicated if there is spinal cord compression or after failure of external immobilization.

Jumped Facets—Hyperflexion Injury The facet joints of the cervical spine slope forward. In a hyperflexion injury, the superior facet can “jump” over the inferior facet of the level above if the joint capsule is torn. Hyperflexion/rotation can cause a unilateral jumped facet, whereas hyperflexion/distraction leads to bilateral jumped facets. Patients with unilateral injury usually are neurologically intact. Those with bilateral injury, however, typically suffer from spinal cord damage, since the anteroposterior diameter of the spinal canal is compromised by bilateral injury, leading to spinal cord compression (Fig. 42-10).

Thoracolumbar The thoracic spine is stabilized significantly by the rib cage. The lumbar spine has comparatively large vertebrae. Thus, the thoracolumbar spine has a higher threshold for injury than the cervical spine. A three-column model is useful for categorizing thoracolumbar injuries.¹⁸ The anterior longitudinal ligament and the anterior half of the vertebral body constitute the anterior column. The posterior half of the vertebral body and the posterior longitudinal ligament constitute the middle column. The pedicles, facet joints, laminae, spinous processes, and interspinous ligaments constitute the posterior column.

Compression Fracture Compression fracture is a compression/flexion injury causing failure of the anterior column only. It is stable and not associated with neurologic deficit, although the patient may still have significant pain (Fig. 42-11).

Burst Fracture Burst fracture is a pure axial compression injury causing failure of the anterior and middle columns. It is unstable, and perhaps half of patients have neurologic deficit due to compression of the cord or cauda equina from bone fragments retropulsed into the spinal canal.

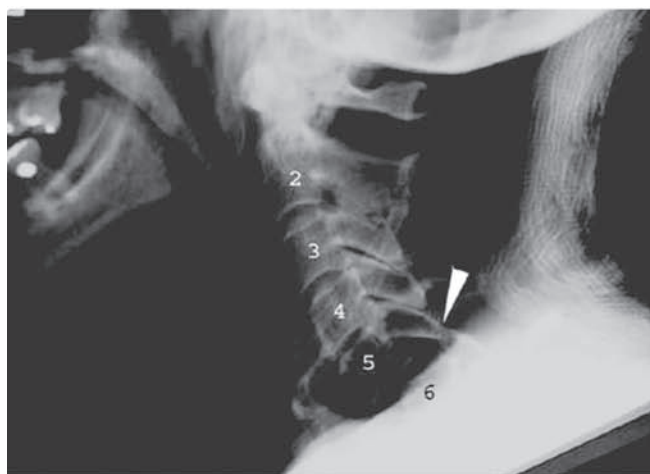Chance Fracture Chance fracture is a flexion-distraction injury causing failure of the middle and posterior columns, sometimes with anterior wedging. Typical injury is from a lap seat-belt hyperflexion with associated abdominal injury. It often is unstable and associated with neurologic deficit.

Fracture-Dislocation Fracture-dislocation is failure of the anterior, middle, and posterior columns caused by flexion/distraction, shear, or compression forces. Neurologic deficit can result from retropulsion of middle column bone fragments into the spinal canal, or from subluxation causing decreased canal diameter (Fig. 42-12).

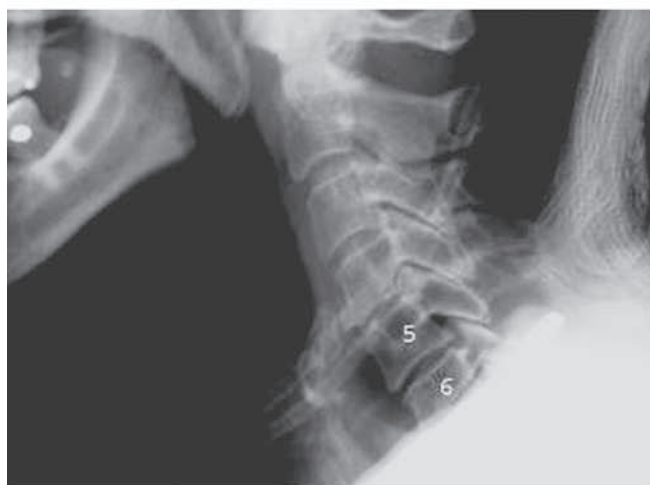Initial Assessment and Management. The possibility of a spine injury must be considered in all trauma patients. A patient with no symptoms referable to neurologic injury, a normal neurologic examination, no neck or back pain, and a known mechanism of injury unlikely to cause spine injury is at minimal risk for significant injury to the spine. Victims of moderate or severe trauma, especially those with injuries to other organ systems, usually fail to meet these criteria or cannot be assessed adequately. The latter often is due to impaired sensorium or significant pain. Because of the potentially catastrophic consequences of missing occult spine instability in a neurologically intact patient, a high level of clinical suspicion should govern patient care until completion of clinical and radiographic evaluation.

The trauma patient should be kept on a hard flat board with straps and pads used for immobilization. A hard cervical collar is kept in place. These steps minimize forces transferred through the spine, and therefore decrease the chance of causing dislocation, subluxation, or neural compression during transport to the trauma bay. The patient is then moved from the board to a flat stretcher. The primary survey and resuscitation are completed. Physical examination and initial X-rays follow.

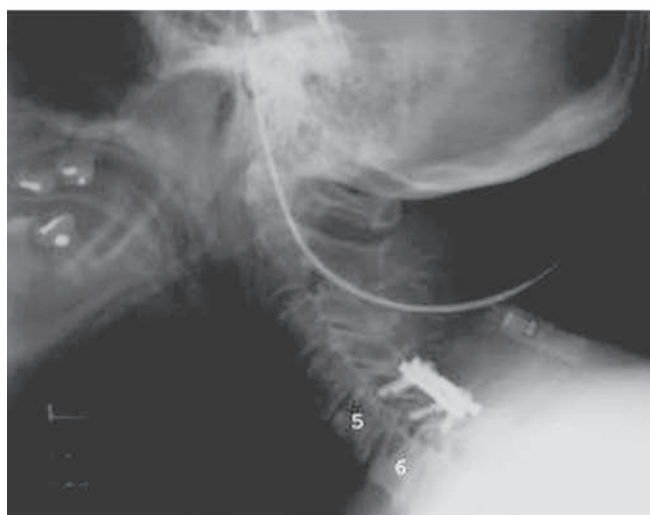For the examination, approach the patient as described in the section on Neurologic Examination earlier in this chapter. Evaluation for spine or SCI is easier and more informative in awake patients. If the patient is awake, ask if he or she recalls details of the nature of the trauma, and if there



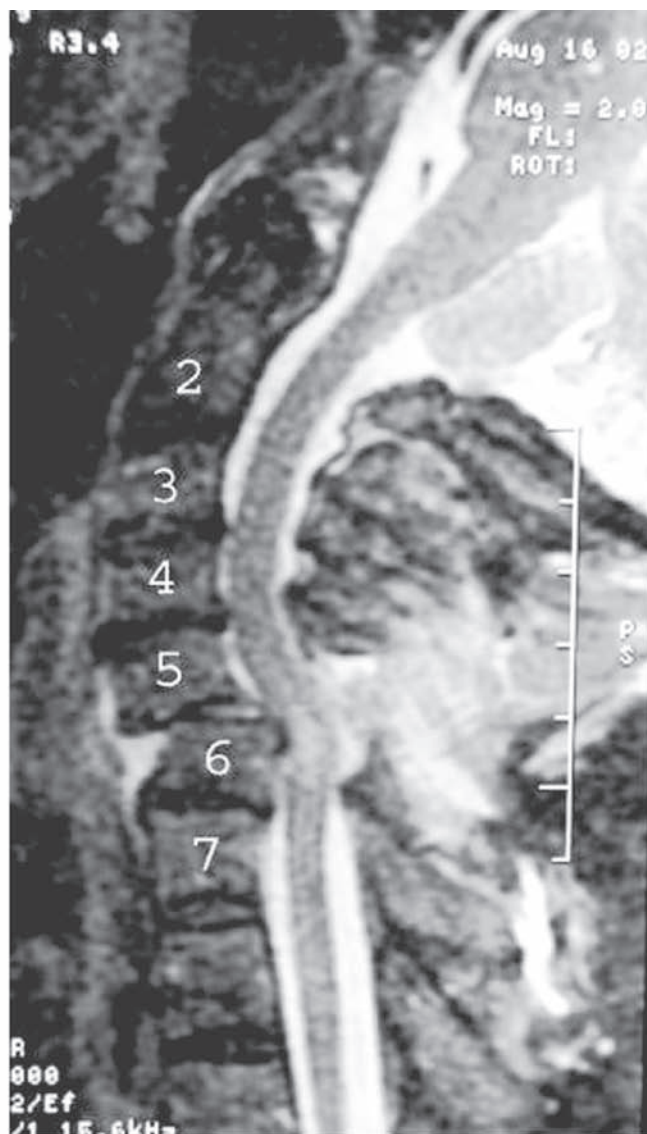
A



C



D

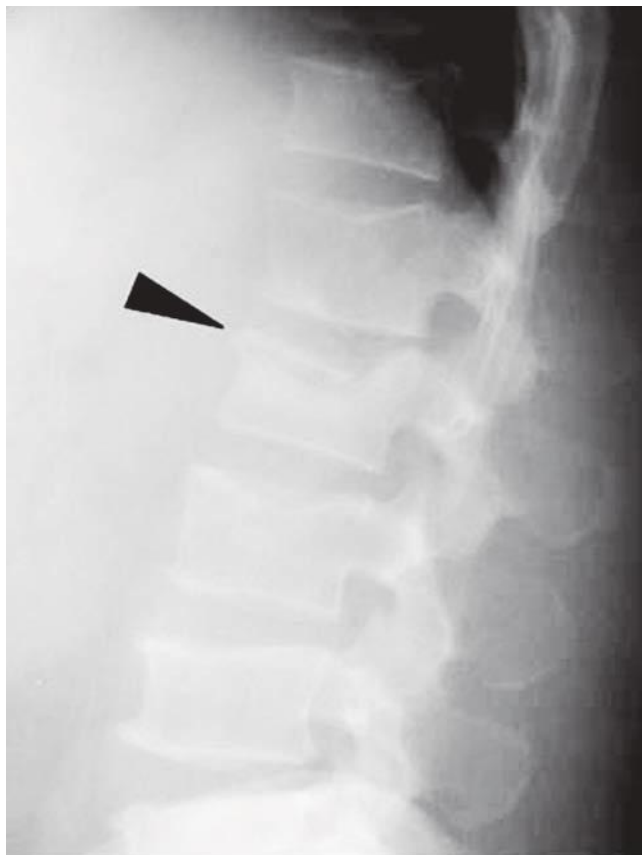

B

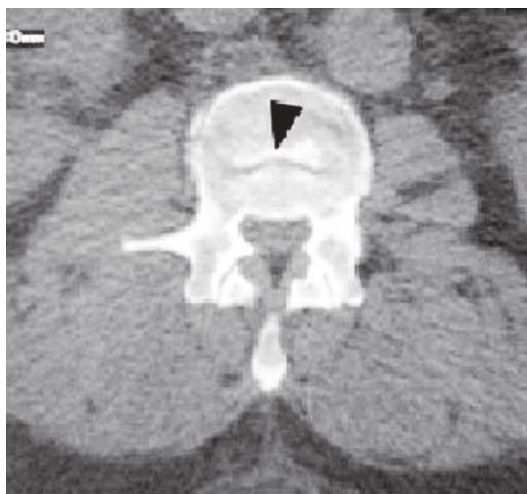
Figure 42-10. A. Lateral cervical spine X-ray of an elderly woman who struck her head during a backward fall. *Arrowhead* points to jumped facets at C5–C6. Note the anterior displacement of the C5 body with respect to the C6 body. B. Sagittal T2-weighted magnetic resonance imaging of the same patient, revealing compromise of the spinal canal and compression of the cord. Note the bright signal within the cord at the level of compression, indicating spinal cord injury. C. Lateral cervical spine X-ray of same patient after application of cervical traction and manual reduction. Note restoration of normal alignment. D. Lateral cervical spine X-ray after posterior cervical fusion to restabilize the C5–C6 segment of the spine.

was loss of consciousness, numbness, or inability to move any or all limbs. Assess motor function by response to commands or pain, as appropriate. Assess pinprick, light touch, and joint position, if possible. Determining the anatomically lowest level of intact sensation can pinpoint the level of the

lesion along the spine. Testing sensation in an ascending fashion will allow the patient to better discern the true stimulus as opposed to determine when it is extinguished. Document muscle stretch reflexes, lower sacral reflexes (i.e., anal wink and bulbocavernosus), and rectal tone.



A



B

Figure 42-11. A. Lateral lumbar spine X-ray showing a compression fracture of L2. *Arrowhead* points to anterior wedge deformity. Note the posterior wall of the vertebral body has retained normal height and alignment. B. Axial computed tomography scan through the same fracture. *Arrowhead* demonstrates a transverse discontinuity in the superior endplate of the L2 body.

American Spinal Injury Association Classification The American Spinal Injury Association provides a method of classifying patients with spine injuries. The classification indicates completeness and level of the injury and the associated deficit. A form similar to that shown in Fig. 42-13 should be available in the trauma bay and completed for any spine injury patient. The

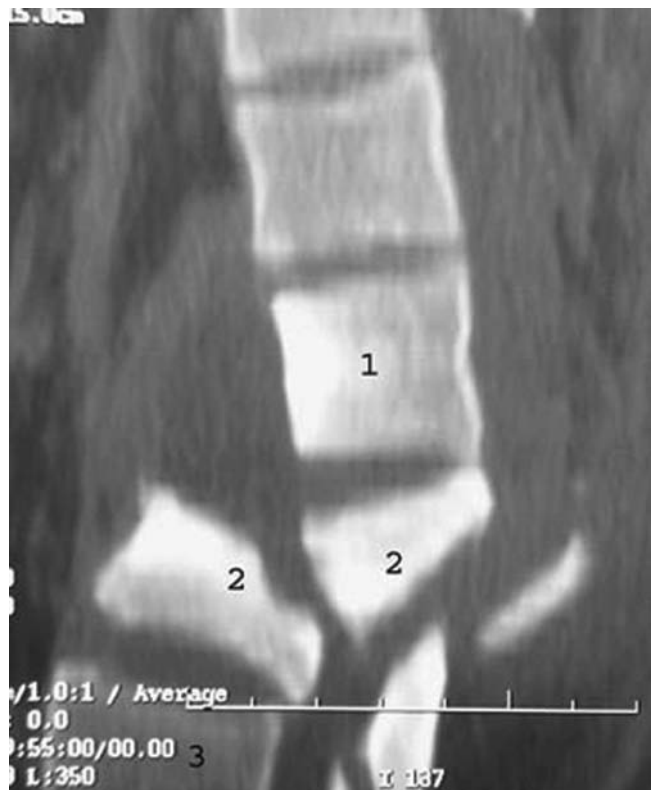


Figure 42-12. Sagittal reconstruction of an axial fine-slice computed tomography scan through the lumbar spine demonstrating a severe fracture-dislocation through the body of L2.

association also has worked to develop recommendations and guidelines to standardize the care of SCI patients in an effort to improve the quality of care.

Neurologic Syndromes. Penetrating, compressive, or ischemic cord injury can lead to several characteristic presentations based on the anatomy of injury. The neurologic deficits may be deduced from the anatomy of the long sensory and motor tracts and understanding of their decussations (Fig. 42-14). Four patterns are discussed. First, injury to the entire cord at a given level results in anatomic or functional cord transection with total loss of motor and sensory function below the level of the lesion. The typical mechanism is severe traumatic vertebral subluxation reducing spinal canal diameter and crushing the cord. Second, injury to half the cord at a given level results in Brown-Séquard syndrome, with loss of motor control and proprioception ipsilaterally and loss of nociception and thermoception contralaterally. The typical mechanism is a stab or gunshot wound. Third, injury to the interior gray matter of the cord in the cervical spine results in a central cord syndrome, with upper extremity worse than lower extremity weakness and various degrees of numbness. The typical mechanism is transient compression of the cervical cord by the ligamentum flavum buckling during traumatic neck hyperextension. This syndrome occurs in patients with preexisting cervical stenosis. Fourth, injury to the ventral half of the cord results in the anterior cord syndrome, with paralysis and loss of nociception and thermoception bilaterally. The typical mechanism is an acute disc herniation or ischemia from anterior spinal artery occlusion.

Studies. Anteroposterior and lateral plain films provide a rapid survey of the bony spine. Plain films detect fractures

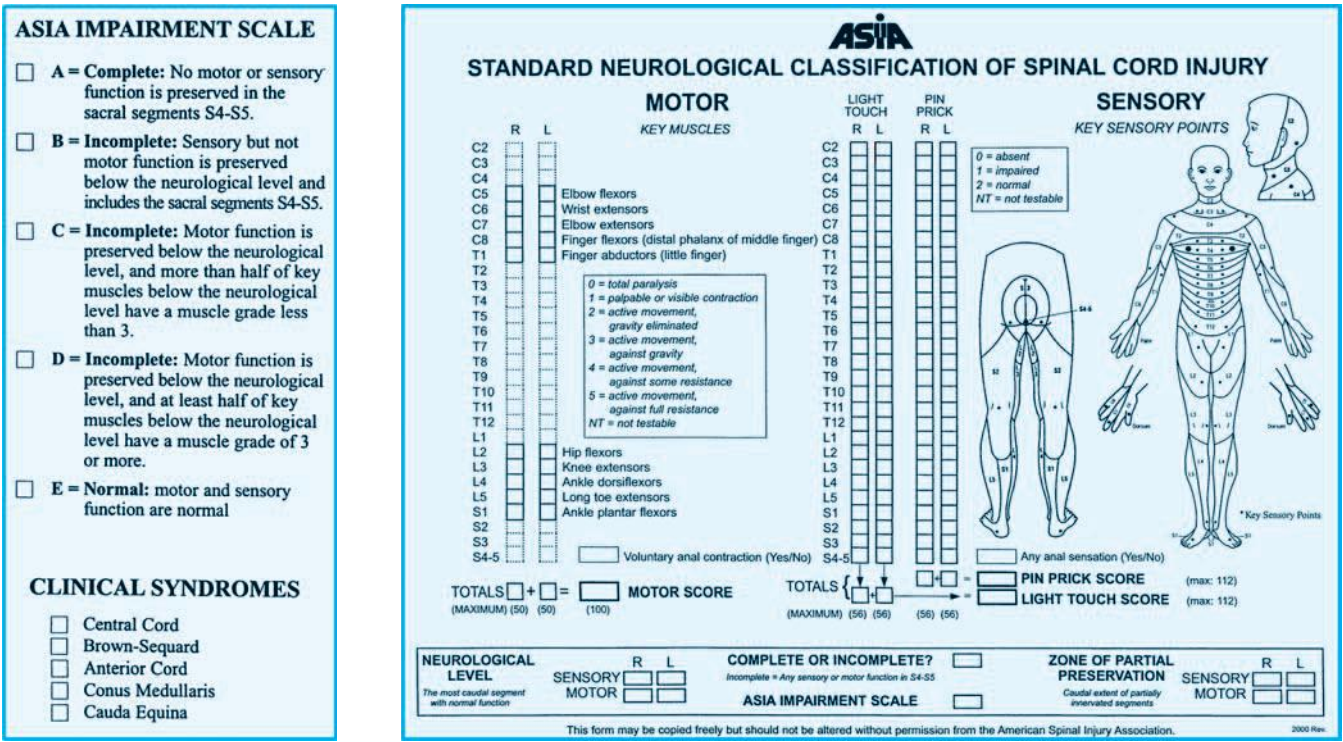


Figure 42-13. The American Spinal Injury Association system for categorizing spinal cord injury patients according to level and degree of neurologic deficit.

and dislocations well. Adequate visualization of the lower cervical and upper thoracic spine often is impossible because of the shoulder girdle. Complete plain film imaging of the cervical spine includes an open-mouth view to assess the odontoid process and the lateral masses of C1. Fine-slice CT scan with sagittal and coronal reconstructions provides good detail of bony anatomy and is good for characterizing fractures seen on plain films, as well as visualizing C7-T1 when not well seen on plain films. MRI provides the best soft tissue imaging. Canal compromise from subluxation, acute disc herniations, or ligamentous disruption is clearly

seen. MRI also may detect EDHs or damage to the spinal cord itself, including contusions or areas of ischemia.

Definitive Management

Spinal-Dose Steroids The National Acute Spinal Cord Injury studies (NASCIS I and II) provide the basis for the common practice of administering high-dose steroids to patients with acute SCI. A 30-mg/kg IV bolus of methylprednisolone is given over 15 minutes, followed by a 5.4-mg/kg per hour infusion begun 45 minutes later. The infusion is continued for 23 hours if the bolus is given within 3 hours of injury, or for 47 hours if

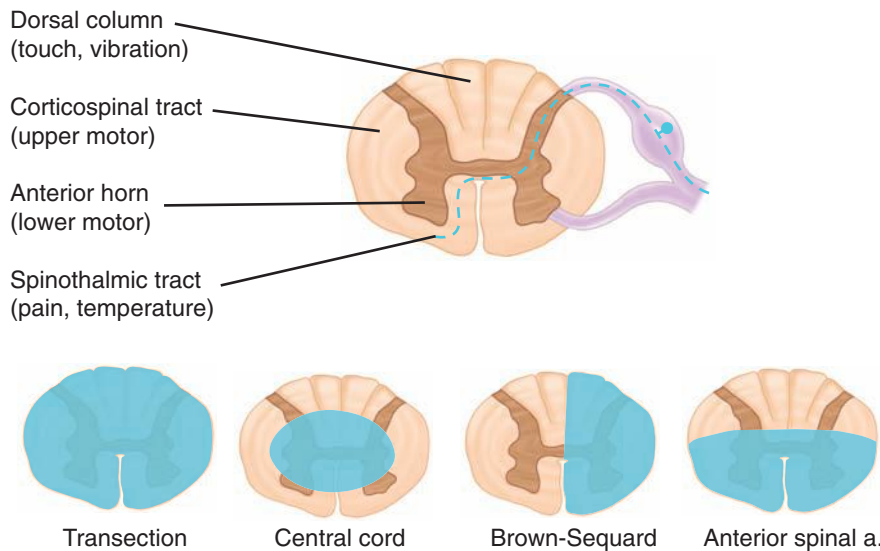


Figure 42-14. Spinal cord injury patterns. a. = artery. (Adapted with permission from Hoff J, Boland M: Neurosurgery, in Schwartz SI, et al (eds): Principles of Surgery, 7th ed., New York: McGraw-Hill, 1999, p 1837. Copyright © The McGraw-Hill Companies, Inc.)

the bolus is given within 8 hours of injury. The papers indicate greater motor and sensory recovery at 6 weeks, 6 months, and 1 year after acute SCI in patients who received methylprednisolone.^{19,20} However, the NASCIS trial data have been extensively criticized, as many argue that the selection criteria and study design were flawed, making the results ambiguous. Patients who receive such a large corticosteroid dose have increased rates of medical and ICU complications, such as pneumonias, which have a deleterious effect on outcome. Thus, clear consensus on the use of spinal-dose steroids does not exist.²¹ A decision to use or not use spinal-dose steroids may be dictated by local or regional practice patterns, especially given the legal liability issues surrounding SCI. Patients with gunshot or nerve root (cauda equina) injuries, or those who are pregnant, <14 years old, or on chronic steroids were excluded from the NASCIS studies and should not receive spinal-dose steroids. In addition to steroids, hypothermia for SCI has also received attention. There is even less evidence supporting the use of this treatment, and thus, it is not currently recommended.²²

Orthotic Devices Rigid external orthotic devices can stabilize the spine by decreasing range of motion and minimizing stress transmitted through the spine. Commonly used rigid cervical orthoses include Philadelphia and Miami-J collars. Cervical collars are inadequate for C1, C2, or cervicothoracic instability. Cervicothoracic orthoses brace the upper thorax and the neck, improving stabilization over the cervicothoracic region. Minerva braces improve high cervical stabilization by bracing from the upper thorax to the chin and occiput. Halo-vest assemblies provide the most external cervical stabilization. Four pins are driven into the skull to lock the halo ring in position. Four posts arising from a tight-fitting rigid plastic vest immobilize the halo ring. Lumbar stabilization may be provided by thoracolumbosacral orthoses. A variety of companies manufacture lines of spinal orthotics. A physician familiar with the technique should fit a halo-vest. Assistance from a trained orthotics technician improves fitting and adjustment of the other devices.

Surgery Neurosurgical intervention has two goals. First is the decompression of the spinal cord or nerve roots in patients with incomplete neurologic deficits. These patients should be decompressed expeditiously, especially if there is evidence of neurologic deterioration over time. Second is the stabilization of injuries judged too unstable to heal with external immobilization only. Spine trauma patients with complete neurologic deficit, without any signs of recovery, or those without any neurologic deficits who have bony or ligamentous injury requiring open fixation, may be medically stabilized before undergoing surgery. Surgical stabilization may be indicated for some injuries that would eventually heal with conservative treatment. It also can allow early mobilization, aggressive nursing care, and physical therapy. Solid surgical stabilization may also allow a patient to be managed with a rigid cervical collar who would otherwise require halo-vest immobilization.

Continued Care. Regional SCI centers with nurses, respiratory therapists, pulmonologists, physical therapists, physiatrists, and neurosurgeons specifically trained in caring for these patients may improve outcomes. Frequently encountered ICU issues include hypotension and aspiration pneumonia. Chronically, prevention and treatment of deep venous thrombosis, autonomic hyperreflexia, and decubitus ulcer formation are important. Many patients with cervical or high thoracic cord injuries require prolonged ventilatory support until the chest

wall becomes stiff enough to provide resistance for diaphragmatic breathing. Patients with high cervical cord injuries (C4 or above) will often require permanent ventilatory support. Patients should be transferred to SCI rehabilitation centers after stabilization of medical and surgical issues.

Peripheral Nerve Trauma

The peripheral nervous system extends throughout the body and is subject to injury from a wide variety of trauma. Peripheral nerves transmit motor and sensory information from the CNS to the body. An individual nerve may have pure motor, pure sensory, or mixed motor and sensory functions. The key information-carrying structure of the nerve is the axon. The axon transmits information from the neuronal cell body and may measure from <1 mm to >1 m in length. Axons that travel a significant distance are often covered with myelin, which is a lipid-rich, electrically insulating sheath formed by Schwann cells. Myelinated axons transmit signals much more rapidly than unmyelinated axons because the voltage shifts and currents that define action potentials effectively jump from gap to gap over the insulated lengths of the axon.

Axons, whether myelinated or unmyelinated, travel through a collagenous connective tissue known as *endoneurium*. Groups of axons and their endoneurium form bundles known as *fascicles*. Fascicles run through a tubular collagenous tissue known as *perineurium*. Groups of fascicles are suspended in mesoneurium. Fascicles and their mesoneurium run through another tubular collagenous tissue known as *epineurium*. The epineurium and its contents form the nerve.

There are four major mechanisms of injury to peripheral nerves. Nerves may be lacerated, stretched, compressed, or contused. Knives, passing bullets, or jagged bone fractures may lacerate nerves. Adjacent expanding hematomas or dislocated fractures may stretch nerves. Expanding hematomas, external orthoses such as casts or braces, or blunt trauma over a superficial nerve may compress or crush nerves. Shock waves from high-velocity bullets may contuse nerves. These mechanisms of injury cause damage to the various anatomic components of the nerve. The patterns of damage are categorized in Types of Injury section.

Certain nerve segments are particularly vulnerable to injury. The following four characteristics make a nerve segment more vulnerable: proximity to a joint, superficial course, passage through a confined space, and being fixed in position.

Types of Injury. The traditional classification system for peripheral nerve injury is the Seddon classification. Seddon described three injury patterns as defined in the Neurapraxia, Axonotmesis, and Neurotmesis sections. The Seddon classification provides a simple, anatomically based approach to peripheral nerve injury.²³

Neurapraxia Neurapraxia is defined as the temporary failure of nerve function without physical axonal disruption. Axon degeneration does not occur. Return of normal axonal function occurs over hours to months, often in the 2- to 4-week range.

Axonotmesis Axonotmesis is the disruption of axons and myelin. The surrounding connective tissues, including endoneurium, are intact. The axons degenerate proximally and distally from the area of injury. Distal degeneration is known as *Wallerian degeneration*. Axon regeneration within the connective tissue pathways can occur, leading to restoration of function. Axons regenerate at a rate of 1 mm per day. Significant functional recovery may occur for up to 18 months. Scarring at the site of injury from connective tissue reaction can form a neuroma and interfere with regeneration.

Neurotmesis Neurotmesis is the disruption of axons and endoneurial tubes. Peripheral collagenous components, such as the epineurium, may or may not be intact. Proximal and distal axonal degeneration occurs. The likelihood of effective axonal regeneration across the site of injury depends on the extent of neuroma formation and on the degree of persisting anatomic alignment of the connective tissue structures. For instance, an injury may damage axons, myelin, and endoneurium, but leave perineurium intact. In this case, the fascicle sheath is intact, and appropriate axonal regeneration is more likely to occur than if the sheath is interrupted.

Management of Peripheral Nerve Injury. The sensory and motor deficits should be accurately documented. Deficits are usually immediate. Progressive deficit suggests a process such as an expanding hematoma and may warrant early surgical exploration. Clean, sharp injuries may also benefit from early exploration and reanastomosis. Most other peripheral nerve injuries should be observed. EMG/NCS studies should be done 3- to weeks postinjury if deficits persist. Axon segments distal to the site of injury will conduct action potentials normally until Wallerian degeneration occurs, rendering EMG/NCS before 3 weeks uninformative. Continued observation is indicated if function improves. Surgical exploration of the nerve may be undertaken if no functional improvement occurs over 3 months. If intraoperative electrical testing reveals conduction across the injury, continue observation. In the absence of conduction, the injured segment should be resected and end-to-end primary anastomosis attempted. However, anastomoses under tension will not heal. A nerve graft may be needed to bridge the gap between the proximal and distal nerve ends. The sural nerve often is harvested, as it carries only sensory fibers and leaves a minor deficit when resected. The connective tissue structures of the nerve graft may provide a pathway for effective axonal regrowth across the injury.

Patterns of Injury

Brachial Plexus The brachial plexus may be injured in a variety of ways. Parturition or a motorcycle accident can lead to plexus injury due to dislocation of the glenohumeral joint. Attempting to arrest a fall with one's hands can lead to a stretch injury of the plexus due to abrupt movement of the shoulder girdle. An apical lung (Pancoast) tumor can cause compression injury to the plexus. There are many patterns of neurologic deficits possible with injury to the various components of the brachial plexus, and understanding them all would require extensive neuroanatomic discussion. Two well-known eponymous syndromes are Erb's palsy and Klumpke's palsy. Injury high in the plexus to the C5 and C6 roots resulting from glenohumeral dislocation causes Erb's palsy with the characteristic "bellhop's tip" position. The arm hangs at the side, internally rotated. Hand movements are not affected. Injury low in the plexus, to the C8 and T1 roots, resulting from stretch or compression injury, causes Klumpke's palsy with the characteristic "claw hand" deformity. There is weakness of the intrinsic hand muscles, similar to that seen with ulnar nerve injury.

Radial Nerve The radial nerve courses through the axilla, then laterally and posteriorly in the spiral groove of the humerus. Improper crutch use can cause damage to the axillary portion. The section of the nerve traversing the spiral groove can be damaged by humerus fractures or pressure from improper positioning during sleep. This classically occurs when the patient is intoxicated and is called "Saturday night palsy." The key finding is wrist drop (i.e., weakness of hand and finger extensors). Axillary (proximal) injury causes triceps weakness in addition to wrist drop.

Common Peroneal Neuropathy The common peroneal nerve forms the lateral half of the sciatic nerve (the medial half being the tibial nerve). It receives contributions from L4, L5, S1, and S2. It emerges as a separate nerve in the popliteal fossa and laterally wraps around the fibular neck, after which it splits to form the deep and superficial peroneal nerves. The superficial, fixed location at the fibular neck makes the common peroneal nerve susceptible to compression. The classic cause of traumatic peroneal neuropathy is crush injury from a car bumper striking the lateral aspect of the leg at the knee. Symptoms of common peroneal neuropathy include foot drop (weakness of the tibialis anterior), eversion weakness, and numbness over the anterolateral surface of the lower leg and dorsum of the foot. In contrast, a foot drop due to L5 radiculopathy spares eversion because the S1 fibers are intact. Surgical exploration of a common peroneal crush lesion is typically a low yield endeavor. Rare cases may be due to compressive fibers or adhesions that may be lysed, with the possibility of return of function.

CEREBROVASCULAR DISEASE

Cerebrovascular disease is the most frequent cause of new, rapid-onset, nontraumatic neurologic deficit. It is far more common than seizures or tumors. Vascular structures are subject to a variety of chronic pathologic processes that compromise vessel wall integrity. Diabetes, high cholesterol, high blood pressure, and smoking are risk factors for vascular disease. These conditions can lead to vascular damage by such mechanisms as atheroma deposition causing luminal stenosis, endothelial damage promoting thrombogenesis, and weakening of the vessel wall resulting in aneurysm formation or dissection. These processes may coexist. For instance, a vessel containing an atheromatous plaque will have a decreased luminal diameter. The plaque also may have compromised endothelium, providing the opportunity for thrombus formation, which can lead to acute total occlusion of the remaining lumen. Aneurysms and dissection often occur in atheromatous vessels. Specific patterns of disease relevant to the cerebrovascular system include atheromatous and thrombotic carotid occlusion, brain ischemia from proximal embolic disease, vessel wall rupture leading to hemorrhage, and rupture of abnormal, thin-walled structures, specifically aneurysms and AVMs.

Ischemic Diseases

Ischemic stroke accounts for approximately 85% of acute cerebrovascular events. Symptoms of acute ischemic stroke vary based on the functions of the neural tissues supplied by the occluded vessel, and the presence or absence of collateral circulation. The circle of Willis provides extensive collateral circulation, as it connects the right and left carotid arteries to each other and each to the vertebrobasilar system. Patients with complete occlusion of the carotid artery proximal to the circle of Willis may be asymptomatic if the blood flow patterns can shift and provide sufficient circulation to the ipsilateral cerebral hemisphere from the contralateral carotid and the basilar artery. However, the anatomy of the circle of Willis is highly variable. Patients may have a hypoplastic or missing communicating artery with resultant bilateral ACA supply by one carotid; or the PCA may be supplied by the carotid artery rather than the basilar. Similarly, one vertebral artery is often dominant and the other is hypoplastic. These variations may make disease in a particular vessel more neurologically devastating than in a

patient with full collateral circulation. Occlusion distal to the circle of Willis generally results in a stroke in the territory supplied by that particular artery.

Neurologic deficit from occlusive disease may be temporary or permanent. A patient with sudden-onset focal neurologic deficit that resolves within 24 hours has had a transient ischemic attack. A patient with permanent deficit has had a completed stroke.

Thrombotic Disease

The most common area of neurologically significant vessel thrombosis is the carotid artery in the neck. Disease occurs at the carotid bifurcation. Thrombosis of a carotid artery chronically narrowed by atheroma can lead to acute carotid occlusion. As discussed previously, this can be asymptomatic. The more common concern is thromboembolus. Intracranial arterial occlusion by local thrombus formation may occur, but it is rare compared to embolic occlusion.

Management. Complete occlusion of the carotid artery without referable neurologic deficit requires no treatment. A patient with new neurologic deficit and an angiographically confirmed complete carotid occlusion contralateral to the symptoms should be considered for emergent carotid endarterectomy.²⁴ Surgery should be performed within 2 hours of symptom onset. This time restriction significantly reduces the number of candidates. Surgery should not be performed on obtunded or comatose patients. This time restriction significantly reduces the number of candidates.

Embolic Disease

Emboli causing strokes may originate from a number of sources, including: the left atrium, during atrial fibrillation, a hypokinetic left ventricular wall segment, valvular vegetations, an atheromatous aortic arch, stenotic/atheromatous carotid bifurcations, or from the systemic venous system in the presence of a right-to-left shunt, such as a patent foramen ovale. The majority of emboli enter the anterior (carotid) circulation rather than the posterior (vertebrobasilar) circulation. Characteristic clinical syndromes result from embolic occlusion of the various vessels.

Common Types of Strokes

Anterior Cerebral Artery Stroke The ACA supplies the medial frontal and parietal lobes, including the motor strip, as it courses into the interhemispheric fissure. ACA stroke results in contralateral leg weakness.

Middle Cerebral Artery Stroke The MCA supplies the lateral frontal and parietal lobes and the temporal lobe. MCA stroke results in contralateral face and arm weakness. Dominant-hemisphere MCA stroke causes language deficits. Proximal MCA occlusion with ischemia and swelling in the entire MCA territory can lead to significant intracranial mass effect and midline shift (see Fig. 42-6).

Posterior Cerebral Artery Stroke The PCA supplies the occipital lobe. PCA stroke results in a contralateral homonymous hemianopsia (see Fig. 42-6).

Posterior Inferior Cerebellar Artery Stroke The PICA supplies the lateral medulla and the inferior half of the cerebellar hemispheres. PICA stroke results in nausea, vomiting, nystagmus, dysphagia, ipsilateral Horner's syndrome, and ipsilateral limb ataxia. The constellation of symptoms resulting from PICA occlusion is referred to as the *lateral medullary* or *Wallenberg's syndrome*.

Management. Ischemic stroke management has two goals: reopen the occluded vessel and maintain blood flow to ischemic "penumbra" tissues bordering the vascular territory. Reopening the vessel may be attempted with recombinant tPA.²⁵ tPA administration within 3 hours of the onset of neurologic deficit improves outcome at 3 months. In the setting of suspected ischemic stroke, a head CT must be performed immediately to differentiate ischemic from hemorrhagic stroke. Intracranial hemorrhage, major surgery within the previous 2 weeks, GI or genitourinary hemorrhage in the previous 3 weeks, platelet count less than 100,000/ μ L, and systolic blood pressure >185 mmHg are among the contraindications to tPA therapy.

Patients not eligible for tPA require hemodynamic optimization and neurologic monitoring. Admit such patients to the ICU stroke service for blood pressure management and frequent neurologic checks. Permissive hypertension allows for maximal cerebral perfusion. Systolic blood pressure >180 mmHg may require treatment, but the optimal mean arterial pressure goal is between 100 to 140 mmHg. Give normal saline solution without glucose (which could injure neurons in the penumbra), and aim for normovolemia. A stroke patient who worsens clinically should undergo repeat head CT to evaluate for hemorrhage or increasing mass effect from swelling, which typically peaks 3 to 5 days after the stroke. Significant swelling from an MCA or cerebellar strokes may cause herniation and brain stem injury. A decompressive hemicraniectomy or suboccipital craniectomy can be a life-saving intervention for these select stroke patients.

Hemorrhagic Diseases

Intracranial hemorrhage from abnormal or diseased vascular structures accounts for approximately 15% of acute cerebrovascular events. Hypertension and amyloid angiopathy account for most intraparenchymal hemorrhages, although AVMs, aneurysms, venous thrombosis, tumors, hemorrhagic conversion of ischemic infarct, and fungal infections also may be the cause. The term *intracranial hemorrhage* frequently is used to mean intraparenchymal hemorrhage and will be used here. Intracranial hemorrhage causes local neuronal injury and dysfunction and also may cause global dysfunction due to mass effect if sufficiently large. AVM or aneurysm rupture results in SAH because the major cerebral and cortical blood vessels travel in the subarachnoid space, between the pia and the arachnoid membrane. SAH can cause immediate concussive-like neuronal dysfunction by exposure of the brain to intra-arterial pressure pulsations during the hemorrhage; it can cause delayed ischemia from cerebral arterial vasospasm. Patients presenting with intracranial hemorrhages that do not follow typical patterns should undergo angiography or MRI to evaluate for possible underlying lesions, such as AVM or tumor.

Hemorrhagic stroke typically occurs within the basal ganglia or cerebellum. The patient is usually hypertensive on admission and has a history of poorly controlled hypertension. Such patients are more likely to present with lethargy or obtundation, compared to those who suffer an ischemic stroke. Depressed mental status results from brain shift and herniation secondary to mass effect from the hematoma in deep structures. Ischemic stroke does not cause mass effect acutely; and therefore, patients are more likely to present with normal consciousness and a focal neurologic deficit. Hemorrhagic strokes tend to present with a relatively gradual decline in neurologic function as the hematoma expands, rather than the immediately maximal symptoms caused by ischemic stroke. Table 42-3 provides a

Table 42-3

Anatomic distribution of intracranial hemorrhages and correlated symptoms

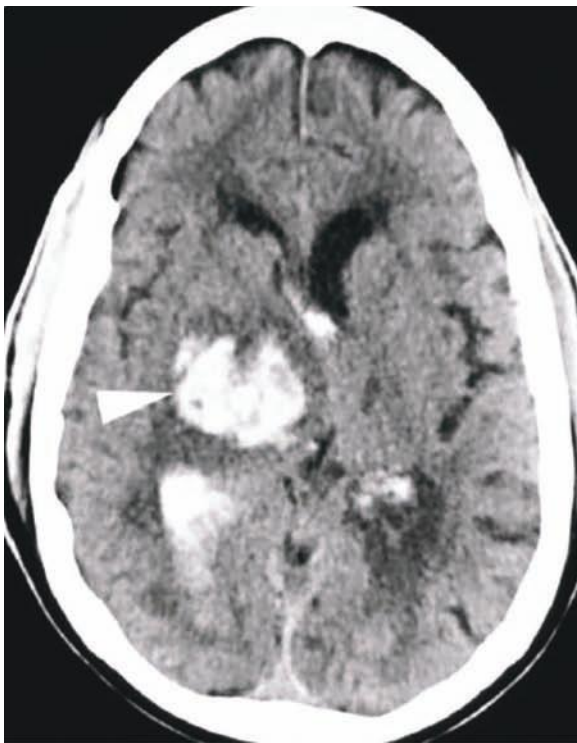
% OF INTRACRANIAL HEMORRHAGES	LOCATION	CLASSIC SYMPTOMS
50	Basal ganglia (putamen, globus pallidus), internal capsule	Contralateral hemiparesis
15	Thalamus	Contralateral hemisensory loss
10–20	Cerebral white matter (lobar)	Depends on location (weakness, numbness, partial loss of visual field)
10–15	Pons	Hemiparesis; may be devastating
10	Cerebellum	Lethargy or coma due to brain stem compression and/or hydrocephalus
1–6	Brain stem (excluding pons)	Often devastating

listing of relative incidences of intracranial hemorrhage by anatomic distribution

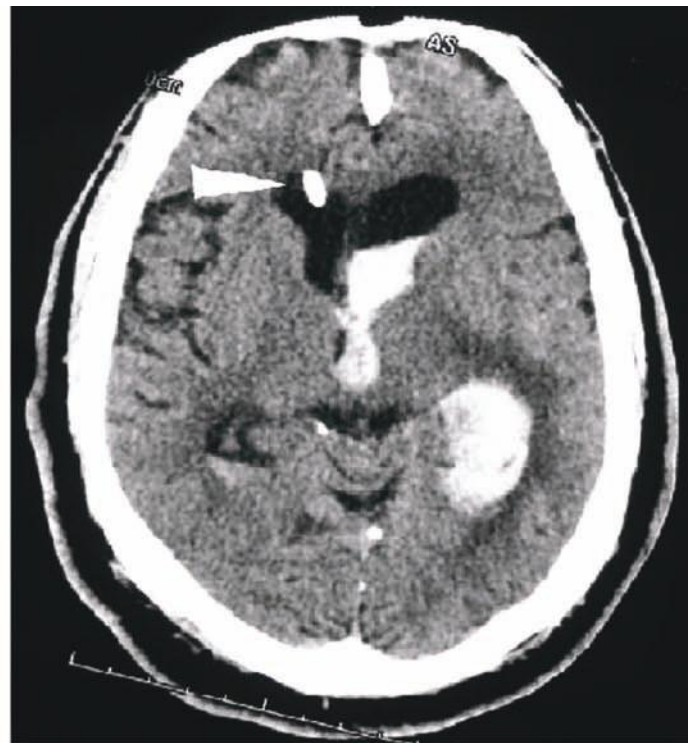
Hypertension. Hypertension increases the relative risk of intracranial hemorrhage by approximately fourfold, likely due to chronic degenerative vasculopathy. Hypertensive hemorrhages often present in the basal ganglia, thalamus, or pons, and result from breakage of small perforating arteries that branch off of much larger parent vessels (Fig. 42-15).

Most hypertensive hemorrhages should be medically managed. The hematoma often contains intact, salvageable axons because the blood dissects through and along neural tracts, and

surgical clot evacuation destroys these axons. Factors potentially favoring surgery include: superficial clot location, young age, nondominant hemisphere, rapid deterioration, and significant mass effect. However, the most comprehensive randomized clinical trials to date did not show an overall improved outcome in surgically evacuated intracranial hemorrhage, except for the subgroup of patients with clot <1 cm from the cortical surface.²⁶ Medical management includes moderate blood pressure control, normalizing platelet and clotting function, phenytoin, and electrolyte management. Intubate patients who cannot clearly follow commands to prevent aspiration and hypercarbia. Follow and



A



B

Figure 42-15. A. Head computed tomography scan of a patient with left-sided weakness and progressive lethargy reveals a right basal ganglia hemorrhage (*arrowhead*). The blood clot is bright white. Hypodensity around the clot represents cerebral edema. There is blood within the ventricular system. B. Another patient with intraventricular extension of a basal ganglia hemorrhage. The patient developed right-sided weakness and then lethargy. Head computed tomography indicated hydrocephalus. A ventriculostomy was placed for cerebrospinal fluid drainage (*arrowhead* indicates cross-sectional view of the catheter entering the anterior horn of the right lateral ventricle).

document the neurologic examination and communicate with the family regarding appropriateness for rehabilitation vs withdrawal of care.

Amyloid Angiopathy. The presence of pathologic amyloid deposition in the media of small cortical vessels compromises vessel integrity and tends to cause more superficial (lobar) hemorrhages than hypertensive intracranial hemorrhage. Amyloid laden vessels may hemorrhage multiple times. The superficial location of amyloid hemorrhages may make surgical evacuation less morbid compared to typical deep hypertensive hemorrhages. Nonetheless, medical management and family counseling should be approached similarly to patients with hypertensive hemorrhages.

Cerebral Aneurysm. An aneurysm is a focal dilatation of the vessel wall and is most often a balloon-like outpouching, but may also be fusiform. Aneurysms usually occur at branch points of major vessels (e.g., internal carotid artery bifurcation), or at the origin of smaller vessels (e.g., posterior communicating artery or ophthalmic artery). Approximately 85% of aneurysms arise from the anterior circulation (carotid) and 15% from the posterior circulation (vertebrobasilar). Table 42-4 shows the percentage distribution of cerebral aneurysms by location. Aneurysms are thin walled and at risk for rupture. The major cerebral vessels, and therefore aneurysms, lie in the subarachnoid space. Rupture results in SAH. The aneurysmal tear may be small and seal quickly, or it may not. SAH may consist of a thin layer of blood in the CSF spaces, or thick layers of blood around the brain and extending into brain parenchyma, resulting in a clot with mass effect. Because the meningeal linings of the brain are sensitive, SAH usually results in a sudden, severe “thunderclap” headache. A patient will classically describe “the worst headache of my life.” Presenting neurologic symptoms may range from mild headache to coma to sudden death. The Hunt-Hess grading system categorizes patients clinically (Table 42-5).

Patients with symptoms suspicious for SAH should have a head CT immediately. Acute SAH appears as a bright signal in the fissures and CSF cisterns around the base of the brain, as shown in Fig. 42-16. CT is rapid, noninvasive, and approximately 95% sensitive. In patients with suspicious symptoms but negative head CT, a lumbar puncture (LP) should be

Table 42-4

Prevalence of cerebral aneurysm by location

PREVALENCE	ANEURYSM LOCATION (VERNACULAR NAME)
Anterior circulation 85%	30% Anterior communicating artery (A-Comm)
	25% Posterior communicating artery (P-Comm)
	20% Middle cerebral artery bifurcation
	10% Other
Posterior circulation 15%	10% Basilar artery, most frequently at the basilar tip
	5% Vertebral artery, usually at the posterior inferior cerebellar artery

Table 42-5

The Hunt-Hess clinical grading system for subarachnoid hemorrhage

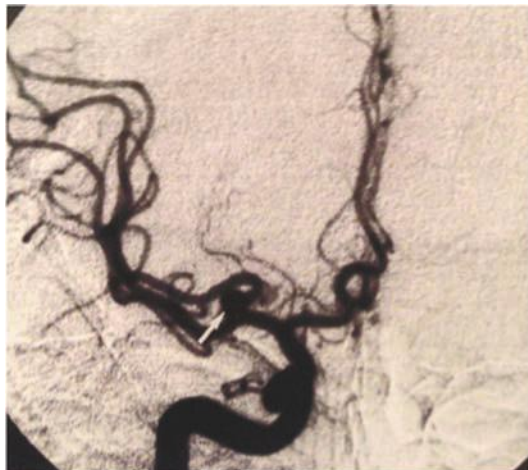
HUNT-HESS GRADE	CLINICAL PRESENTATION
0	Asymptomatic; unruptured aneurysm
1	Awake; asymptomatic or mild headache; mild nuchal rigidity
2	Awake; moderate to severe headache, cranial nerve palsy (e.g., cranial nerve III or IV), nuchal rigidity
3	Lethargic; mild focal neurologic deficit (e.g., pronator drift)
4	Stuporous; significant neurologic deficit (e.g., hemiplegia)
5	Comatose; posturing

performed. An LP with xanthochromia and high red blood cell counts (usually 100,000/mL), which do not decrease between tubes 1 and 4, is consistent with SAH. Negative CT and LP essentially rules out SAH. Patients diagnosed with SAH

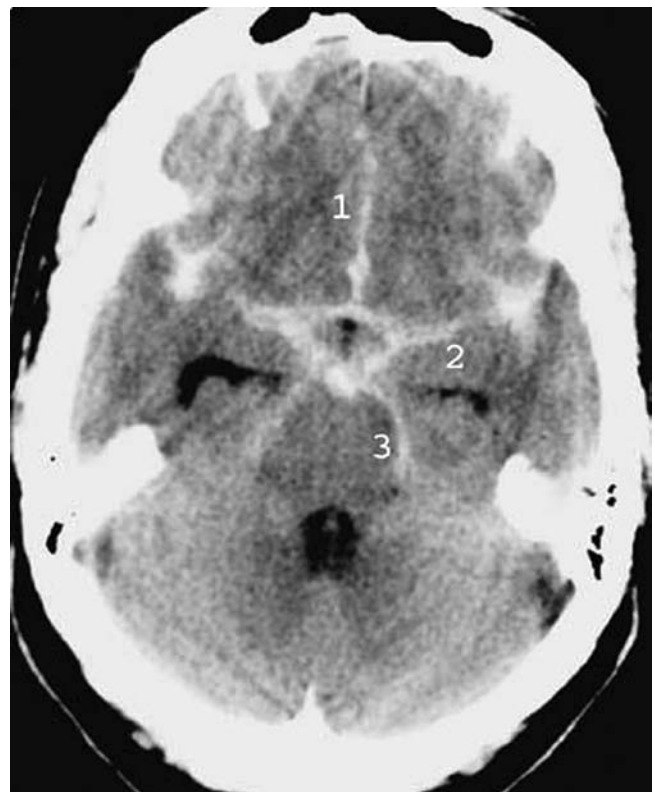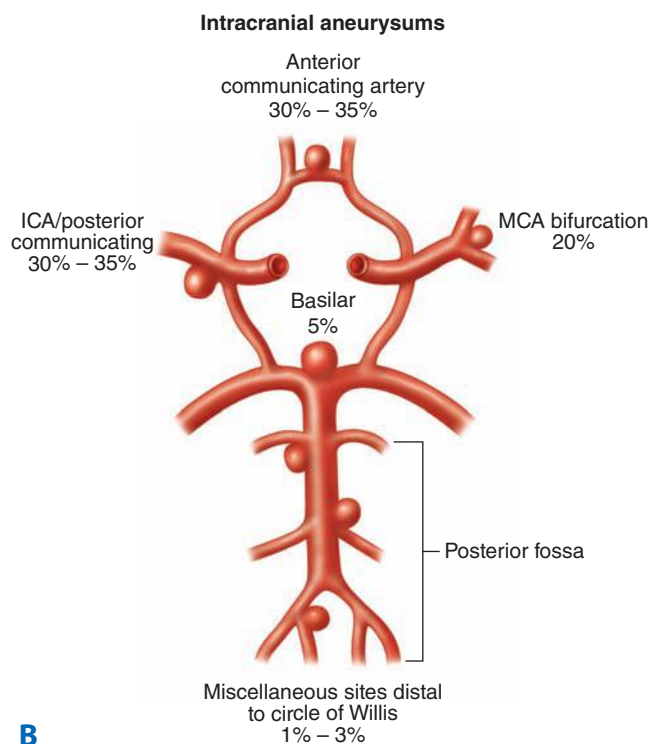


Figure 42-16. Head computed tomography scan of a patient who experienced a sudden, severe headache. Subarachnoid hemorrhage is visible as hyperdense signal in the interhemispheric fissure (1), bilateral sylvian fissures (2 shows the left fissure), and in the ambient cisterns around the midbrain (3). This gives the classic five-pointed-star appearance of a subarachnoid hemorrhage. Visible temporal tips of the lateral ventricles indicate hydrocephalus.

require four-vessel cerebral angiography within 24 hours to assess for aneurysm or other vascular malformation. Catheter angiography remains the gold standard for assessing the patient's cerebral vasculature, relevant anomalies, and presence, location, and morphology of the cerebral aneurysms. Figure 42-17A demonstrates the typical anteroposterior digital subtraction angiographic view of a cerebral aneurysm. Figure 42-17B shows the anatomy of the circle of Willis in a simplified graphic representation to assist in visualizing the locations of various cerebral aneurysms.



A



B

Figure 42-17. A. Anteroposterior view after injection of contrast dye in the right internal carotid artery demonstrates an aneurysm of the middle cerebral artery bifurcation. B. Figure depicting the anatomy of the circle of Willis and the common sites for aneurysms. ICA = internal cerebral artery; MCA = middle cerebral artery. (Reproduced with permission from Osborn AG: *Handbook of Neuro-radiology: Brain and Skull, 1st ed. St. Louis: Mosby-Year Book, Inc., 1991, p 81. Copyright Elsevier.*)

SAH patients should be admitted to the neurologic ICU. Hunt-Hess grade 4 and 5 patients require intubation and hemodynamic monitoring and stabilization. The current standard of care for ruptured aneurysms requires early aneurysmal occlusion. There are two options for occlusion. The patient may undergo craniotomy with microsurgical dissection and placement of a titanium clip across the aneurysm neck to exclude the aneurysm from the circulation and reconstitute the lumen of the parent vessel. The second option is to “coil” the aneurysm via an endovascular approach. The patient is taken to the interventional neuroradiology suite for placement of looped titanium coils inside the aneurysm dome. The coils support thrombosis and prevent blood flow into the aneurysm. Factors favoring craniotomy and clipping include young age, good medical condition, and broad aneurysm necks. Factors favoring coiling include age, medical comorbidities, and narrow aneurysm necks. Due to coil migration or compaction over time, surgical clipping is believed to result in a more definitive cure. The decision to clip or coil is complex and should be fully explored. The International Subarachnoid Aneurysm Trial researchers suggested that endovascular occlusion resulted in better outcomes for certain types of cerebral aneurysms, although this trial was marred by poor selection and randomization techniques, and the validity of its conclusions have been questioned.²⁷ Long-term outcomes may be better in younger patients with clipped aneurysms.²⁸ Debate also continues regarding optimal care for unruptured intracranial aneurysms.²⁹

SAH patients often require 1 to 3 weeks of ICU care after aneurysm occlusion for medical complications that accompany neurologic injury. In addition to routine ICU concerns, SAH patients are also at risk for cerebral vasospasm. In vasospasm, cerebral arteries constrict pathologically and can cause ischemia or stroke from 4 to 21 days after SAH. Current vasospasm prophylaxis includes maintenance of optimal perfusion with hypertension and mild hypervolemia, as well as administration of nimodipine, a calcium channel blocker that may decrease the incidence and degree of spasm. Neurointerventional options for treating symptomatic vasospasm include intra-arterial papaverine or nicardipine, and balloon angioplasty for larger caliber vessels.

Aneurysmal SAH has an approximate mortality rate of 50% in the first month. Approximately one-third of survivors return to pre-SAH function, and the remaining two thirds have mild to severe disability. Most require rehabilitation after hospitalization.

Arteriovenous Malformations. AVMs are abnormal, dilated arteries and veins without an intervening capillary bed. The nidus of the AVM contains a tangled mass of vessels but no neural tissue. AVMs may be asymptomatic or present with SAH, intraparenchymal hemorrhage, or seizures. Small AVMs present with hemorrhage more often than large AVMs, which tend to present with seizures. Headache, bruit, or focal neurologic deficits are less common symptoms. AVMs hemorrhage at an average rate of 2% to 4% a year. Figure 42-18 demonstrates the angiographic appearance of an AVM in arterial and venous phases.

There are several management differences for intracranial hemorrhage due to AVM vs. aneurysm. Definitive therapy for the AVM usually is delayed 3 to 4 weeks to allow the brain to recover from acute injury. There is less risk of devastating early rebleeding from AVMs, and vasospasm is much less common. Three therapeutic modalities for AVMs are currently in common use: microsurgical excision, interventional radiology or endovascular embolization, and stereotactic radiosurgery

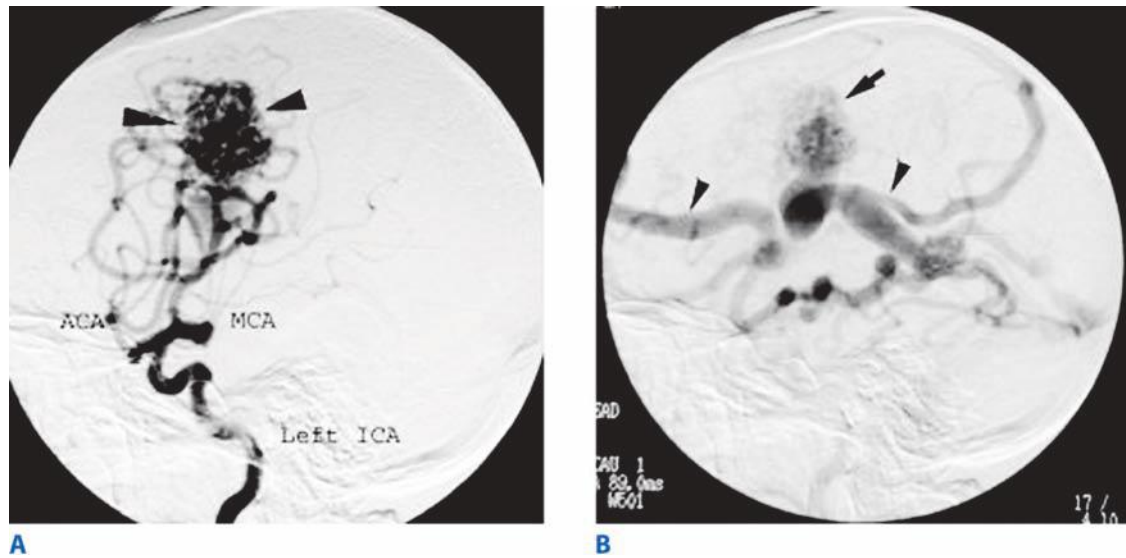


Figure 42-18. **A.** Lateral view after injection of contrast dye in the left internal carotid artery demonstrates a 3 × 4 cm left frontal arteriovenous malformation indicated by *arrowheads*. This image was taken 1.06 seconds after dye injection, and is referred to as an *arterial phase image*. **B.** Same view taken 4.10 seconds after dye injection, providing a *venous phase image*. The *arrow* points to the arteriovenous malformation nidus. The *arrowheads* indicate two pathologically enlarged draining veins. ACA = anterior cerebral artery; ICA = internal carotid artery; MCA = middle cerebral artery.

(SRS). AVMs that are large, near eloquent cortex, or that drain to deep venous structures are considered high grade and more difficult to surgically resect without causing a significant neurologic deficit. Radiosurgery can treat these lesions, although it is limited to lesions <3 cm in diameter and has a 2-year lag time (i.e., the AVM may bleed in the interval). Embolization reduces flow through the AVM. It is usually considered adjunctive therapy, but it may serve as the sole treatment for deep, inaccessible lesions.

TUMORS OF THE CENTRAL NERVOUS SYSTEM

A wide variety of tumors affect the brain and spine. Primary benign and malignant tumors arise from the various elements of the CNS, including neurons, glia, and meninges. Tumors metastasize to the CNS from many primary sources. Presentation varies widely depending on relevant neuroanatomy. **5▶** Prognosis depends on histology and anatomy. Modern brain tumor centers use team approaches to CNS tumors, as patients may require a combination of surgery, radiation therapy, chemotherapy, SRS, and research protocol enrollment. Tumors affecting the peripheral nervous system are discussed in the Peripheral Nerve section.

Intracranial Tumors

Intracranial tumors can cause brain injury from mass effect, dysfunction or destruction of adjacent neural structures, swelling, or abnormal electrical activity (seizures). Supratentorial tumors commonly present with focal neurologic deficit, such as contralateral limb weakness, visual field deficit, headache, or seizure. Infratentorial tumors often cause increased ICP due to hydrocephalus from compression of the fourth ventricle, leading to headache, nausea, vomiting, or diplopia. Cerebellar hemisphere or brain stem dysfunction can result in ataxia, nystagmus, or cranial nerve palsies. Infratentorial tumors rarely cause seizures.

All patients with symptoms concerning for brain tumor should undergo MRI with and without gadolinium. Initial man-

agement of a patient with a symptomatic brain tumor generally includes dexamethasone for reduction of vasogenic edema and phenytoin if the patient has seized. Patients with significant weakness, lethargy, or hydrocephalus should be admitted for observation until definitive care is administered.

Metastatic Tumors

Prolonged cancer patient survival and improved CNS imaging have increased the likelihood of diagnosing cerebral metastases. The sources of most cerebral metastases are (in decreasing frequency): lung, breast, kidney, GI tract, and melanoma. Lung and breast cancers account for more than half of cerebral metastases. Metastatic cells usually travel to the brain hematogenously and frequently seed the gray-white junction. Other common locations are the cerebellum and the meninges. Meningeal involvement may result in carcinomatous meningitis, also known as *leptomeningeal carcinomatosis*. MRI pre- and postcontrast administration is the study of choice for evaluation. Figure 42-19 demonstrates bilateral cerebellar metastases. These lesions are typically well circumscribed, round, and multiple. Such findings should prompt a metastatic work-up, including CT scan of the chest, abdomen, and pelvis, and a bone scan.

Management largely depends upon the primary tumor, overall tumor burden, patient's medical condition, and location and number of metastases. The beliefs of the patient and family regarding aggressive care must be considered. Craniotomy plus whole-brain radiation therapy (WBRT) or stereotactic radiosurgery (SRS) to the tumor bed has been shown to benefit patients with a single surgically accessible metastatic lesion, compared to radiation therapy alone. Median survival increased from 15 to 40 weeks in one randomized trial.³⁰ Postoperative radiotherapy may not increase overall survival but it does significantly reduce original lesion recurrence.³¹ Studies do not support craniotomy unless all detectable metastases can be resected. Recent data suggest that SRS (e.g., gamma knife) may be applied to multiple metastases in one session with improved outcome.³²

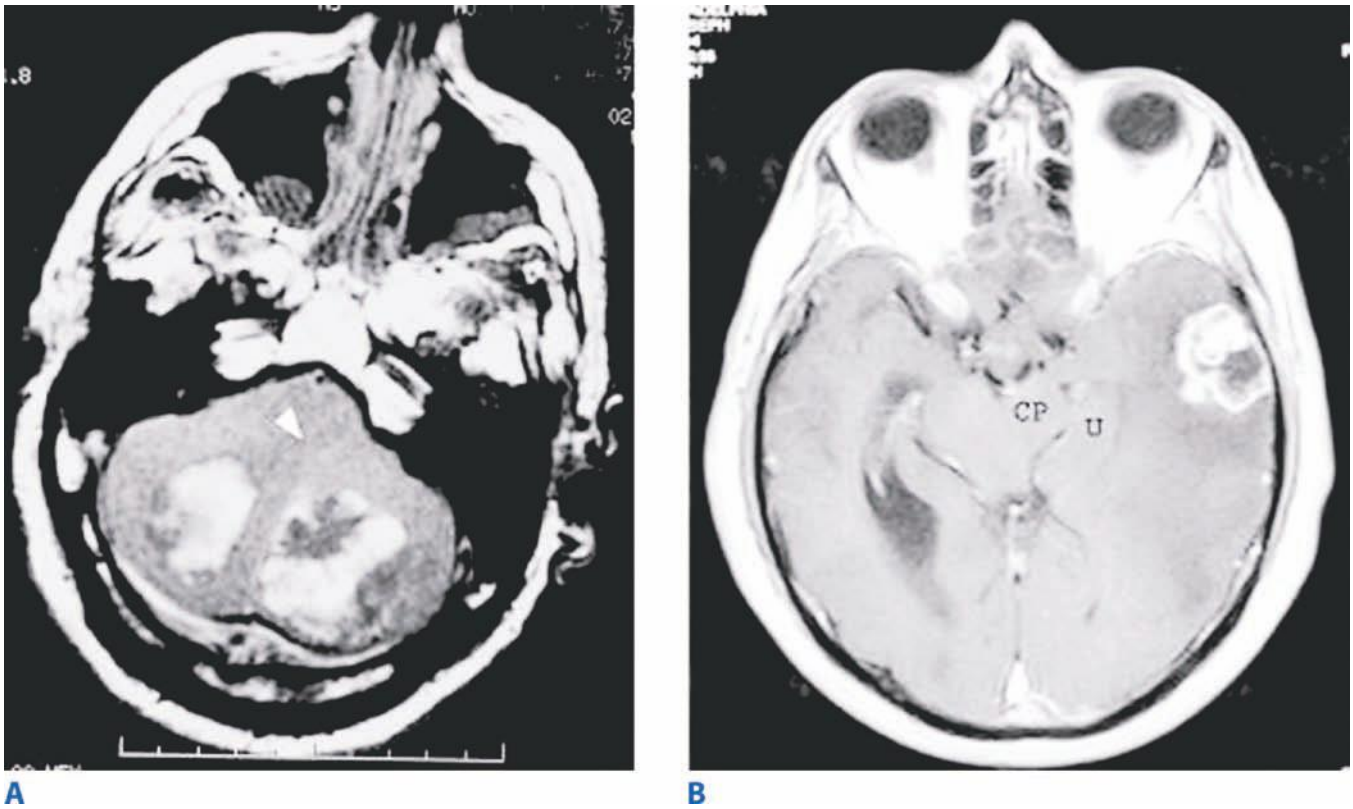


Figure 42-19. **A.** Precontrast T1-weighted axial magnetic resonance imaging demonstrating bilateral hemorrhagic cerebellar metastases. Patient presented with ataxia and then lethargy progressing to deep coma. This patient has total effacement of the fourth ventricle and severe brain stem compression. The fourth ventricle cerebrospinal fluid space should be at the tip of the *arrowhead*. Patient recovered to normal mental status after emergent posterior fossa craniotomy. **B.** Postcontrast T1-weighted axial magnetic resonance imaging demonstrating a ring-enhancing lesion in the lateral left temporal lobe with moderate edema. The uncus (*U*) is compressing the left cerebral peduncle (*CP*) and displacing the brain stem to the right.

Glial Tumors

Glial cells provide the anatomic and physiologic support for neurons and their processes in the brain. The several types of glial cells give rise to distinct primary CNS neoplasms.

Astrocytoma. Astrocytoma is the most common primary CNS neoplasm. The term *glioma* often is used to refer to astrocytomas specifically, excluding other glial tumors. Astrocytomas are graded from I to IV. Grades I and II are referred to as low-grade astrocytoma, grade III as anaplastic astrocytoma, and grade IV as glioblastoma multiforme (GBM). Prognosis varies significantly between grades I/II, III, and IV, but not between I and II. Median survival is 8 years after diagnosis with a low-grade tumor, 2 to 3 years with an anaplastic astrocytoma, and roughly 1 year with a GBM. GBMs account for almost two-thirds of all astrocytomas, anaplastic astrocytomas account for two-thirds of the rest, and low-grade astrocytomas the remainder. Figure 42-20 demonstrates the typical appearance of a GBM.

The great majority of astrocytomas infiltrate adjacent brain. Juvenile pilocytic astrocytomas and pleomorphic xanthoastrocytomas are exceptions. These tumors are circumscribed, low grade, and associated with a good prognosis. Histologic features associated with higher grade include hypercellularity, nuclear atypia, and endovascular hyperplasia. Necrosis is present only with GBMs; it is required for the diagnosis.

Gross total resection should be attempted for suspected astrocytomas. Motor cortex, language centers, deep or midline

structures, or brain stem location may make this impossible without unacceptable, devastating neurologic deficit. Such lesions may be limited to stereotactic needle biopsy specimen. Gross total resection followed by radiation therapy improves survival for all grades, although radiation therapy may be delayed until recurrence in low-grade tumors. Chemotherapy such as temozolomide is of limited efficacy and typically is reserved for GBM. There are various ongoing research studies for GBM adjuvant therapy; these should be discussed with the patient and family. Other options include Iotrex-containing balloons for conformal radiation brachytherapy (Glia-Site), placed in the resection cavity at the time of surgery for recurrence. Adjuvant therapy remains marginally effective; survival has changed little over the last several decades.

Oligodendroglioma. Oligodendroglioma accounts for approximately 10% of gliomas. They often present with seizures. Calcifications and hemorrhage on CT or MRI suggest the diagnosis. Oligodendrogliomas are also graded from I to IV; grade portends prognosis. Prognosis is better overall than for astrocytomas. Median survival ranges from 2 to 7 years for highest and lowest grade tumors, respectively. Aggressive resection improves survival. Many oligodendrogliomas will respond to procarbazine, lomustine (CCNU), vincristine (PCV) chemotherapy. A particular chromosomal deletion, 1p19q, has been associated with robust response to the chemotherapeutic agent temozolomide. Radiation has not been clearly shown to prolong survival.

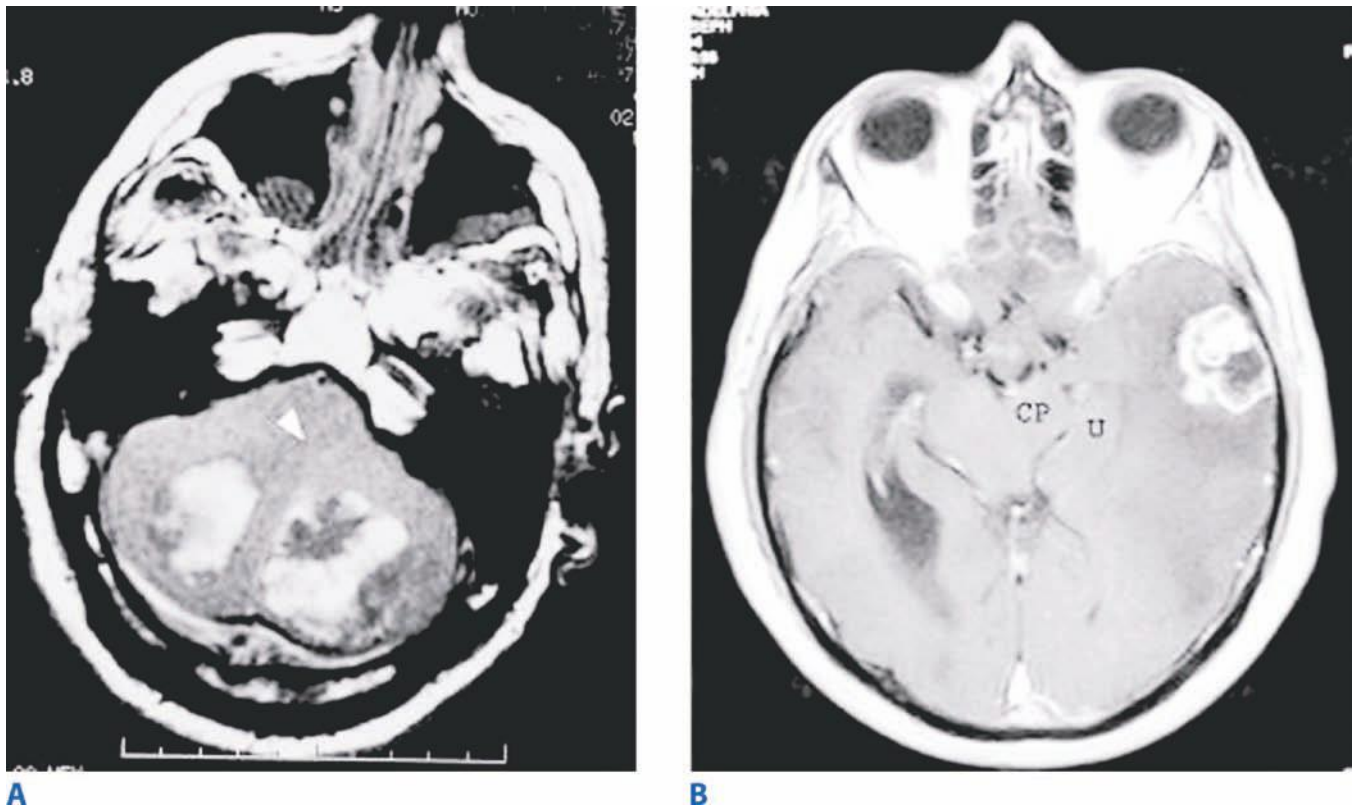


Figure 42-20. A. Postcontrast T1-weighted axial magnetic resonance imaging demonstrating a ring-enhancing lesion in the anteromedial right temporal lobe with central necrosis (dark area) consistent with glioblastoma multiforme. B. T2-weighted axial magnetic resonance imaging with extensive bright signal signifying peritumoral edema seen with glioblastoma multiformes.

Ependymoma. The lining of the ventricular system consists of cuboidal/columnar ependymal cells from which ependymomas may arise. Although most pediatric ependymomas are supratentorial, two-thirds of adult ependymomas are infratentorial. Supratentorial ependymomas arise from the lateral or third ventricles. The infratentorial tumors arise from the floor of the fourth ventricle (i.e., off the posterior brain stem). The most common symptoms are headache, nausea, vomiting, or vertigo, secondary to increased ICP from obstruction of CSF flow through the fourth ventricle. The tumors may grow out the foramina of Luschka to form a cerebellopontine angle mass. They may also spread through the CSF to form “drop mets” in the spinal canal. The two main histologic subtypes are papillary and anaplastic, the latter characterized by increased mitotic activity and areas of necrosis. Gross total resection often is impossible because the tumor arises from the brain stem. The goal of surgery is to achieve maximal resection without injuring the very delicate brain stem. Suboccipital craniotomy and midline separation of the cerebellar hemispheres allows access to tumors in the fourth ventricle. Postoperative radiation therapy significantly improves survival. Patients with CSF spread documented by LP or contrast MRI should also have whole-spine radiation plus focused doses to visualized metastases.

Choroid Plexus Papilloma. The choroid plexus is composed of many small vascular tufts covered with cuboidal epithelium. It represents part of the interface between blood and brain. The choroid cells create CSF from blood and release it into the ventricular system. Choroid plexus papillomas and

choroid plexus carcinomas (rare, mostly pediatric) may arise from these cells. Papillomas usually occur in infants (typically supratentorial in the lateral ventricle) but also occur in adults (usually infratentorial in the fourth ventricle). Papillomas are well circumscribed and vividly enhance due to extensive vasculature. Like ependymomas, adult choroid plexus papillomas usually present with symptoms of increased ICP. Treatment is surgical excision. Total surgical excision is curative; recurrent papillomas should be re-resected. Radiation or chemotherapy are not indicated for papillomas. Radiation is adjunctive to aggressive surgery for carcinomas, but the results are generally poor.

Neural Tumors and Mixed Tumors

Neural and mixed tumors are a diverse group that includes tumors variously containing normal or abnormal neurons and/or normal or abnormal glial cells. Primitive neuroectodermal tumors arise from bipotential cells, capable of differentiating into neurons or glial cells.

Medulloblastoma. Primitive neuroectodermal tumor is the most common type of medulloblastoma. Most occur in the first decade of life, but there is a second peak around age 30. Medulloblastoma is the most common malignant pediatric brain tumor. They are usually midline. Most occur in the cerebellum and present with symptoms of increased ICP. Histologic characteristics include densely packed small round cells with large nuclei and scant cytoplasm. They are generally not encapsulated, frequently disseminate within the CNS, and should undergo surgical resection followed by radiation therapy and chemotherapy.

Ganglioglioma. Ganglioglioma is a mixed tumor in which both neurons and glial cells are neoplastic. They occur in the first three decades of life, often in the medial temporal lobe, as circumscribed masses that may contain cysts or calcium and may enhance. The presenting symptom is usually a seizure, due to the medial temporal location. Patients have a good prognosis after complete surgical resection.

Neural Crest Tumors

Multipotent neural crest cells develop into a variety of disparate cell types, including smooth muscle cells, sympathetic and parasympathetic neurons, melanocytes, Schwann cells, and arachnoid cap cells. They migrate in early development from the primitive neural tube throughout the body.

Miscellaneous Tumors

Meningioma. Meningiomas are derived from arachnoid cap cells of the arachnoidea mater. They appear to arise from the dura mater grossly and on MRI and are commonly referred to as *dural-based tumors*. The most common intracranial locations are along the falx (Fig. 42-21), the convexities (i.e., over the cerebral hemispheres), and the sphenoid wing. Less common locations include the foramen magnum, olfactory groove, and inside the lateral ventricle. Most are slow growing, encapsulated, benign tumors. Aggressive atypical or malignant meningiomas may invade adjacent bone or cerebral cortex. Previous

cranial irradiation increases the incidence of meningiomas. Approximately 10% of patients with a meningioma have multiple meningiomas. Total resection is curative, although involvement with small perforating arteries or cranial nerves may make total resection of skull base tumors impossible without significant neurologic deficit. Small, asymptomatic meningiomas can be followed until symptomatic or until significant growth is documented on serial imaging studies. Atypical and malignant meningiomas may require postoperative radiation. Patients may develop recurrences from the surgical bed or distant de novo tumors.

Vestibular Schwannoma (Acoustic Neuroma). Vestibular schwannomas predominantly arise from the superior half of the vestibular portion of the vestibulocochlear nerve (cranial nerve VIII) (Fig. 42-22). Commonly, patients present with progressive hearing loss, tinnitus, or balance difficulty. Large tumors may cause brain stem compression and obstructive hydrocephalus. Bilateral acoustic neuromas are pathognomonic for neurofibromatosis type 2 (NF2), a syndrome resulting from mutation of chromosome 22. NF2 patients have an increased incidence of spinal and cranial meningiomas and gliomas.

Vestibular schwannomas may be treated with microsurgical resection or SRS (gamma knife or linear accelerator technology). The main complication with treatment is damage to the facial nerve (cranial nerve VII), which runs through the internal auditory canal with the vestibulocochlear nerve. Risk of facial nerve dysfunction increases with increasing tumor diameter.

Pituitary Adenoma. Pituitary adenomas arise from the anterior pituitary gland (adenohypophysis). Tumors <1 cm diameter are considered microadenomas; larger tumors are macroadenomas. Pituitary tumors may be functional (i.e., secrete endocrinologically active compounds at pathologic levels) or nonfunctional (i.e., secrete nothing or inactive compounds). Functional tumors are often diagnosed when quite small, due to endocrine dysfunction. The most common endocrine syndromes are Cushing's disease, due to adrenocorticotrophic hormone secretion, Forbes-Albright syndrome, due to prolactin secretion, and acromegaly, due to growth hormone secretion. Nonfunctional tumors are typically diagnosed as larger lesions causing mass effects such as visual field deficits due to compression of the optic chiasm or panhypopituitarism due to compression of the gland. Figure 42-23 demonstrates a large pituitary adenoma. Hemorrhage into a pituitary tumor causes abrupt symptoms of headache, visual disturbance, decreased mental status, and endocrine dysfunction. This is known as *pituitary apoplexy*.

Symptomatic pituitary tumors should be decompressed surgically to eliminate mass effect and/or to attempt an endocrine cure. However, prolactin-secreting tumors (prolactinomas) usually shrink with dopaminergic therapy alone, namely bromocriptine, which inhibits production and secretion of prolactin. Consider surgery for prolactinomas with persistent mass effect or endocrinologic dysfunction in spite of adequate dopamine agonist therapy. Most pituitary tumors are approached through the nose via the transsphenoidal approach, and minimally invasive, endoscopic surgical techniques are being used increasingly.

Hemangioblastoma. Hemangioblastomas occur almost exclusively in the posterior fossa, with about 20% occurring in patients with von Hippel-Lindau (VHL) disease, a multisystem neoplastic disorder. Other tumors associated with VHL are renal cell

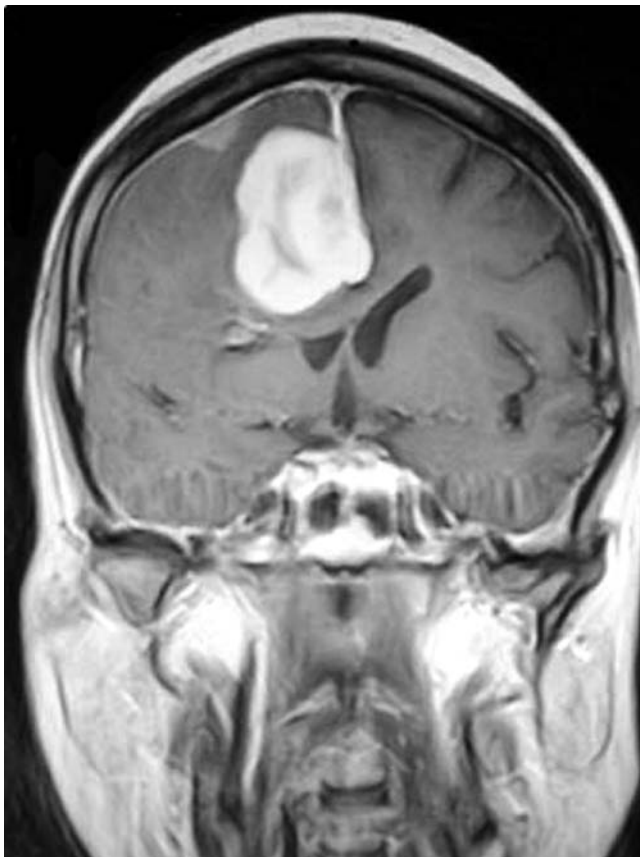
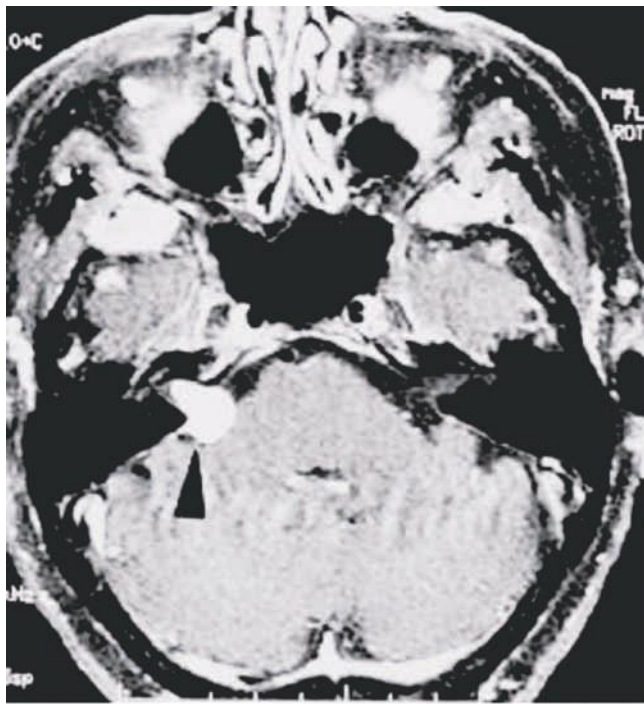
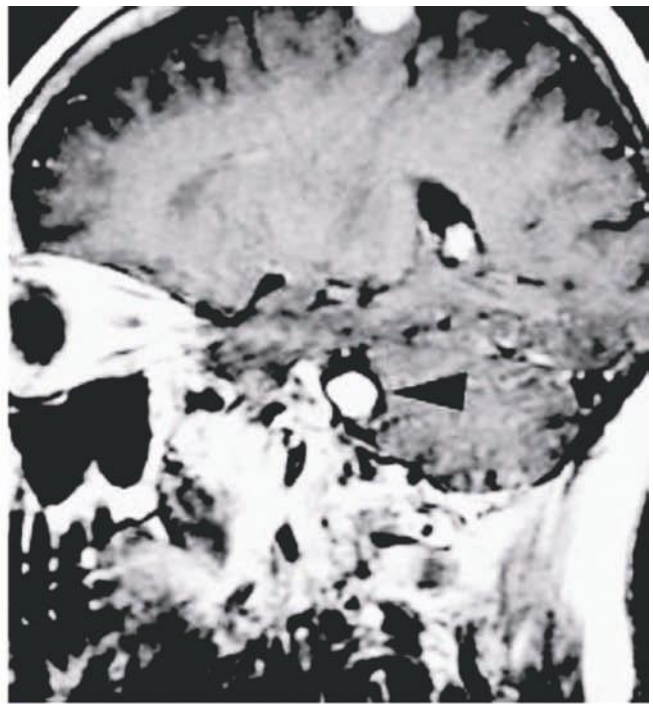


Figure 42-21. Postcontrast T1-weighted coronal magnetic resonance imaging demonstrating a brightly enhancing lesion arising from the falx cerebri with moderate edema and mass effect on the right lateral ventricle. This is a falcine meningioma. Note also the small separate meningioma arising from the dura over the cerebral convexity.



A



B

Figure 42-22. A. Postcontrast T1-weighted axial magnetic resonance imaging demonstrating a brightly enhancing mass on the right vestibular nerve with an enhancing tail going into the internal auditory canal (*arrowhead*). Pathology demonstrated vestibular schwannoma. B. Postcontrast T1-weighted sagittal magnetic resonance imaging of the same lesion, indicated by the *arrowhead*. Note small incidental meningioma at the top of the scan.

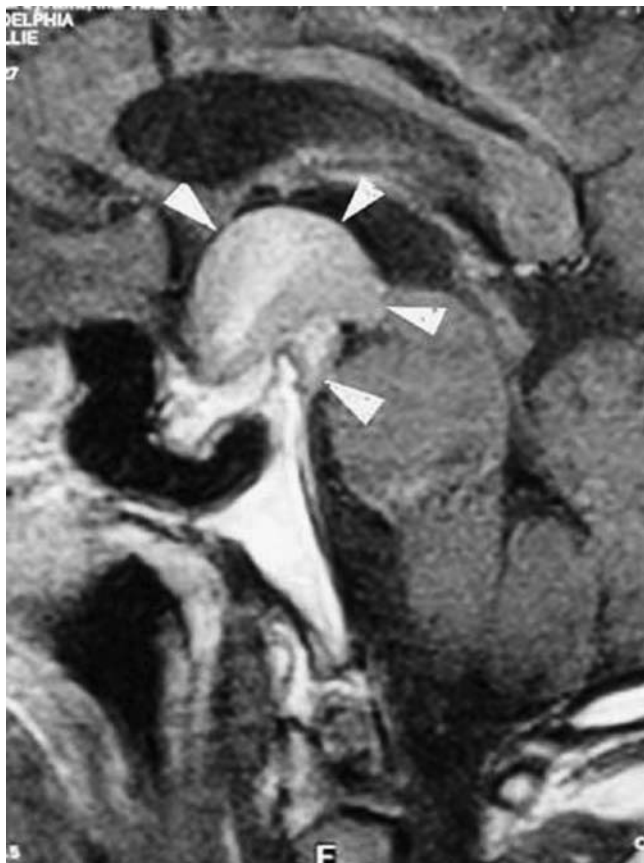

Figure 42-23. Postcontrast T1-weighted sagittal magnetic resonance imaging demonstrating a large sellar/suprasellar lesion (*arrowheads*) involving the third ventricle superiorly and abutting the midbrain and pons posteriorly. The patient presented with progressive visual field and acuity loss. Pathology and lab work revealed a nonfunctioning pituitary adenoma.

carcinoma, pheochromocytoma, and retinal angiomas. Many appear as cystic tumors with an enhancing tumor on the cyst wall known as the *mural nodule*. Surgical resection is curative for sporadic (non-VHL associated) tumors. Pathology reveals abundant thin-walled vascular channels; internal debulking may be bloody. En bloc resection of the mural nodule alone, leaving the cyst wall, is sufficient.

Lymphoma. CNS lymphoma may arise either primarily in the CNS or secondarily from systemic disease. Recent rising incidence may be due to growing transplant and AIDS populations. Presenting symptoms include mental status changes, headache due to increased ICP, and cranial nerve palsy due to lymphomatous meningitis (analogous to carcinomatous meningitis). Often, lymphoma appears hyperdense on CT due to dense cellularity, and most lesions typically enhance with contrast. Surgical excision is not indicated. A stereotactic needle biopsy specimen usually confirms the diagnosis. Subsequent treatment includes steroids, whole-brain radiation, and chemotherapy. Intrathecal methotrexate is an option.

Embryologic Tumors

Embryologic tumors result from embryonal remnants that fail to involute completely or differentiate properly during development.

Craniopharyngioma. Craniopharyngiomas are benign cystic lesions that occur most frequently in children. There is a second peak of incidence around 50 years of age. Calcification occurs in all pediatric and roughly half of adult craniopharyngiomas. Symptoms result from compression of adjacent structures, especially the optic chiasm. Pituitary or hypothalamic dysfunction or hydrocephalus may develop. Treatment is primarily surgical. Excision is somewhat easier in children, as the tumor is often soft and easily suctioned. Adult tumors are often firm and adherent to adjacent vital structures. Visual loss, pituitary endocrine

hypofunction, diabetes insipidus, and cognitive impairment from basal frontal injury are common complications.

Epidermoid. Epidermoid tumors are cystic lesions with stratified squamous epithelial walls from trapped ectodermal cell rests that grow slowly and linearly by desquamation into the cyst cavity. The cysts contain keratin, cholesterol, and cellular debris (Fig. 42-24). They occur most frequently in the cerebellopontine angle and may cause symptoms due to brain stem compression. Recurrent bouts of aseptic meningitis may occur due to release of irritative cyst contents into the subarachnoid space (Mollaret's meningitis). Treatment is surgical drainage and removal of the cyst wall. Intraoperative spillage of cyst contents may lead to severe chemical meningitis and must be avoided by containment and aspiration.

Dermoid. Dermoids are less common than epidermoid tumors. They contain hair follicles and sebaceous glands in addition to a squamous epithelium. Dermoids may be found anywhere along the craniospinal axis. They are more commonly midline structures and are associated with more anomalies than epidermoids. They may be associated with trauma, as from a lumbar puncture that drags skin structures into the spine. Bacterial meningitis may occur when dermoids are associated with a dermal sinus tract. Treatment of symptomatic lesions is surgical resection, again with care to control cyst contents.

Teratoma. Teratomas are germ cell tumors that arise in the midline, often in the pineal region (the area behind the third ventricle, above the midbrain and cerebellum). They contain elements from all three embryonal layers: ectoderm, meso-

derm, and endoderm. Teratomas may contain skin, cartilage, GI glands, and teeth. Teratomas with more primitive features are more malignant, while those with more differentiated tissues are more benign. Surgical excision may be attempted. However, the prognosis for malignant teratomas is very poor.

Spinal Tumors

A wide variety of tumors affect the spine. Approximately 20% of CNS tumors occur in the spine. Unlike cranial tumors, the majority of spinal tumors are histologically benign. Understanding two major spinal concepts—stability and neural compression—facilitates an understanding of the effects of spinal tumors. Destruction of bones or ligaments can cause spinal instability, leading to deformities such as kyphosis, subluxation, or possible subsequent neural compression. Tumor growth in the spinal canal or neural foramina can cause direct compression of the spinal cord or nerve roots and cause pain and loss of function. Classically, the pain is worse at night. Anatomic categorization provides the most logical approach to these tumors. Certain tumors present in characteristic locations. An understanding of the anatomy leads to an understanding of the clinical presentation and possible therapeutic options.

Extradural Tumors. Extradural tumors account for approximately 55% of spinal tumors. This category includes tumors arising within the bony vertebral structures and from within the epidural space. Destruction of the bone can lead to instability and fractures, causing pain and/or deformity. Epidural expansion can lead to spinal cord or nerve root compression with myelopathy, radiculopathy, or a combination thereof.

Metastatic Tumors Metastatic tumors are the most common extradural tumors. Spinal metastases most commonly occur in the thoracic and lumbar vertebral bodies because the greatest volume of red bone marrow is found in these regions. The most common primary sources of spine metastasis are lymphoma, lung, breast, and prostate. Other sources include renal, colon, thyroid, sarcoma, and melanoma. Most spinal metastases create osteolytic lesions. Osteoblastic, sclerotic lesions suggest prostate cancer in men and breast cancer in women.

Patients with progressive neurologic dysfunction due to a metastatic lesion should undergo urgent surgery followed by radiation therapy.³³ Patients with debilitating pain may undergo radiation therapy with close observation for neurologic deterioration. Preoperative neurologic function correlates with postoperative function. Patients may lose function over hours. These patients should be given high-dose IV dexamethasone, taken immediately to MRI, and then to the OR or radiation therapy suite. Indications for surgery include failure of radiation therapy, spinal instability, recurrence after radiation therapy, and the need for diagnosis in cases of unknown primary tumors. Most cases with significant bone involvement require both decompression and fusion. Bony fusion usually takes 2 to 3 months. Prognosis governs operative decisions. Surgery is unlikely to improve quality of life for patients with a life expectancy of 3 months or less, but it is likely to improve quality of life for patients with life expectancy of 6 months or more. Benefit for patients with 3- to 6-months life expectancy is unclear and requires frank discussion with the patient and family. Patients who are unlikely to tolerate general anesthesia, are already completely paralyzed, or who have very radiosensitive tumors such as multiple myeloma and lymphoma, should not generally undergo surgery.

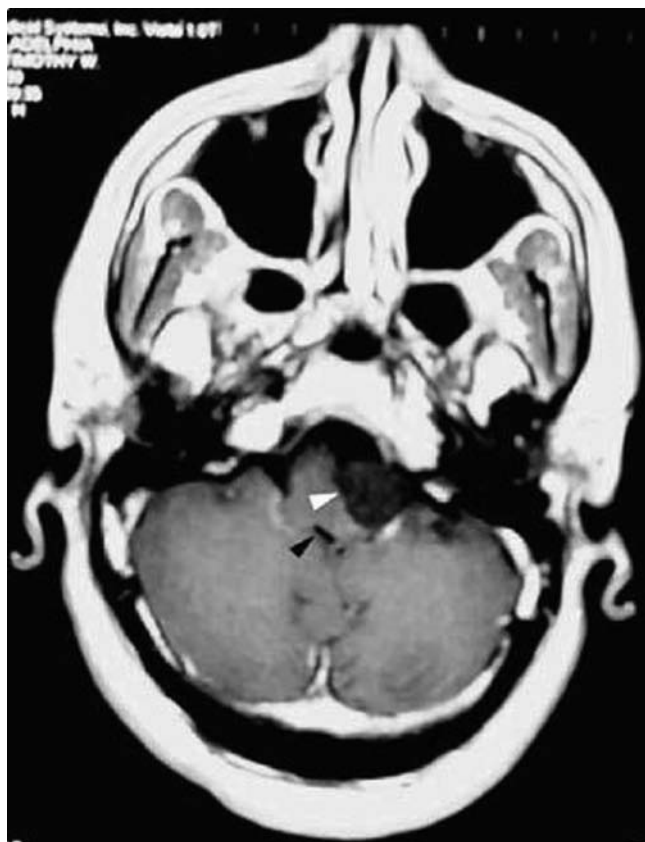

Figure 42-24. Postcontrast T1-weighted axial magnetic resonance imaging demonstrating a nonenhancing mass in the left cerebellopontine angle with brain stem compression. *White arrowhead* indicates interface of tumor and brain stem. *Black arrowhead* indicates deformed fourth ventricle. Pathology revealed epidermoid tumor.

Primary Tumors Hemangiomas are benign tumors found in 10% of people at autopsy. They occur in the vertebral bodies of the thoracolumbar spine and are frequently asymptomatic. They are often vascular and may hemorrhage, causing pain or neurologic deficit. Large hemangiomas can destabilize the spine and predispose to fracture. Osteoblastic lesions include osteoid osteoma and osteoblastoma. The latter tends to be larger and more destructive. Aneurysmal bone cysts are nonneoplastic, expansile, lytic lesions containing thin-walled blood cavities that usually occur in the lamina or spinous processes of the cervicothoracic spine. They may cause pain or sufficiently weaken the bone to cause a fracture. Cancers arising primarily in the bony spine include Ewing's sarcoma, osteosarcoma, chondrosarcoma, and plasmacytoma.

Intradural Extramedullary Tumors

Intradural extramedullary tumors constitute approximately 40% of spinal tumors and arise from the meninges or nerve root elements. They may compress the spinal cord, causing myelopathy, or the nerve roots, causing radiculopathy. The most common intradural extramedullary tumors are typically benign, slow growing, and well circumscribed. Rare benign epidural masses include arachnoid cysts, dermoids, and epidermoids. Rare malignant epidural tumors include metastases and high-grade gliomas, or "drop" metastases from posterior fossa gliomas.

Meningioma Meningiomas arise from the arachnoidea mater. They appear to be dural based and enhance on MRI. An enhancing "dural tail" may be seen. They occur most commonly in the thoracic spine (Fig. 42-25) but also arise in the cervical and lumbar regions. Some spinal meningiomas grow into the epidural space. Growth causes cord compression and progressive myelopathy with hyperreflexia, spasticity, and gait difficulties. Surgical excision is the treatment of choice. The surgeon often finds a clean margin between the tumor, dura, and spinal cord, allowing en bloc resection without damage to the cord.

Schwannoma Schwannomas are derived from peripheral nerve sheath Schwann cells. They are benign, encapsulated tumors that rarely undergo malignant degeneration. While two-thirds are entirely intradural, one-sixth are entirely extradural, and one-sixth have a classic "dumbbell" shape from intradural and extradural components. Symptoms result from radiculopathy, often presenting as pain or myelopathy. Symptomatic lesions should be surgically resected. The parent nerve root usually can be preserved. Patients with multiple schwannomas likely have NF2. In these patients, a careful neurologic examination is needed to determine which lesions are symptomatic and require resection.

Neurofibroma In contrast to schwannomas, neurofibromas tend to appear more fusiform and to grow within the parent nerve, rather than forming an encapsulated mass branching off the nerve. Neurofibromas are benign but not encapsulated. They present similarly to schwannomas, and the two may be difficult to differentiate on imaging. Salvage of the parent nerve is more challenging with neurofibromas. To improve the likelihood of total resection, thoracic and high cervical nerve roots may be sacrificed with minimal deficit. Patients with multiple neurofibromas likely have NF1, also known as *von Recklinghausen's neurofibromatosis*. Resection for symptomatic lesions should be offered.

Intramedullary Tumors. Intramedullary tumors constitute approximately 5% of spinal tumors. They arise from within the parenchyma of the spinal cord. Common presenting symptoms

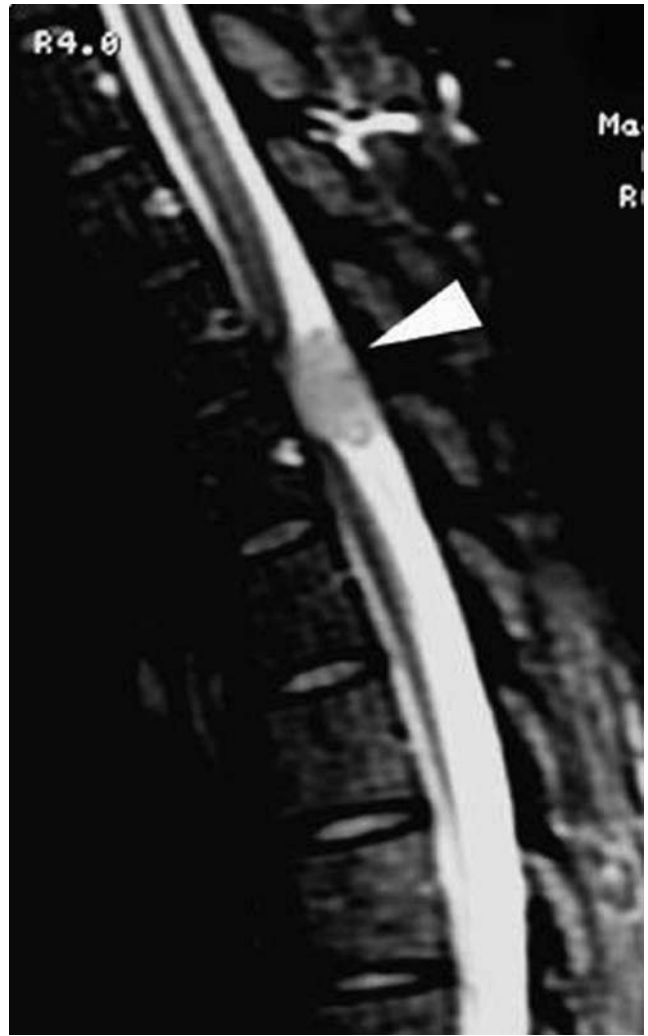

Figure 42-25. T2-weighted sagittal magnetic resonance imaging of the midthoracic spine demonstrating a well-encapsulated tumor arising from the dura posteriorly and compressing the spinal cord. Arrowhead points to dorsal location of the mass. The patient presented with worsening gait and lower extremity spasticity. Pathology demonstrated meningioma.

are local dysesthesia, burning pain, radicular pain, sensory loss, weakness, or sphincter dysfunction. Patients with such symptoms should undergo MRI of the entire spine with and without enhancement.

Ependymoma Ependymomas are the most common intramedullary tumors in adults. There are several histologic variants. The myxopapillary type occurs in the conus medullaris or the filum terminale in the lumbar region and has the best prognosis after resection. The cellular type occurs more frequently in the cervical cord. Many spinal ependymomas have cystic areas and may contain hemorrhage. Surgical removal can improve function. A distinct tumor margin often exists, allowing safer excision. Postoperative radiation therapy after subtotal resection may prolong disease control.

Astrocytoma Astrocytomas are the most common intramedullary tumors in children, although they also occur in adults. They may occur at all levels, although more often in the cervical cord. The tumor may interfere with the CSF-containing central canal of the spinal cord, leading to a dilated central canal, referred to as *syringomyelia* (*syrinx*). Spinal astrocytomas are usually

low grade, but complete excision is rarely possible due to the nonencapsulated, infiltrative nature of the tumor. As a result, patients with astrocytomas fare worse overall than patients with ependymomas.

Other Tumors. Other types of rare tumors include high-grade astrocytomas, dermoids, epidermoids, teratomas, hemangiomas, hemangioblastomas, and metastases. Patients usually present with pain. Prognosis generally depends on preoperative function and the histologic characteristics of the lesion.

SPINE: BASIC CONCEPTS

The spine is a complex structure and is subject to an extensive array of pathologic processes, including degeneration, inflammation, infection, neoplasia, and trauma. Discussions of spine trauma, tumor, and infection are addressed separately in this chapter in the Infection—Spine, Spinal Tumors, and Spine Trauma sections. General concepts, common patterns of disease, and basic operative interventions are presented here.

The spine consists of a series of stacked vertebrae, intervening discs, and longitudinal ligaments. The vertebrae consist of the vertebral body anteriorly and the pedicles, articular facets, laminae, and spinous processes posteriorly. The intervertebral discs have two components. The tough, fibrous ring that runs around the outer diameter of the two adjacent vertebral bodies is known as the *annulus fibrosus*. The spongy material inside the ring of the annulus is known as the *nucleus pulposus*. The annulus and the nucleus provide a cushion between adjacent vertebral bodies, absorb forces transmitted to the spine, and allow some movement between the vertebral bodies. The ligaments stabilize the spine by limiting the motion of adjacent vertebrae.

Stability and neural compression are the two concepts critical to understanding the mechanics and pathologic processes affecting the spine.

Stability

The spinal column is the principal structural component of the axial spine, and it must bear significant loads. The vertebrae increase in size from the top to the bottom of the spine, correlating with the increased total loads that the more caudal elements must bear. The cervical spine is the most mobile. Cervical stability depends greatly on the integrity of the ligaments that run from level to level. The thoracic spine is the least mobile, due to the stabilizing effect of the rib cage. The lumbar spine has relatively massive vertebrae, supports heavy loads, and has intermediate mobility. The sacral spine is fused together and has no intrinsic mobility. The load borne by the lumbar spine is transmitted to the sacrum, and then the pelvis through the sacroiliac joints. The coccyx is the most inferior segment of the spine and has no significant contribution to load bearing or mobility.

A stable spine is one that can bear normally experienced forces resulting from body mass, movement, and muscle contraction, while maintaining normal structure and alignment. An unstable spine will shift or sublux under these forces. The determinants of spinal stability vary throughout the cervical, thoracic, and lumbar portions. In elementary form, stability depends on the structural integrity of the hard, bony elements of the vertebral column, as well as the tensile integrity and security of the supporting ligamentous attachments. Plain X-rays and CT scans are sensitive for detecting bony defects such as fractures or subluxation, while MRI better detects disruptions of the soft tissues, including ligaments and intervertebral discs. Specific

patterns of abnormalities seen on imaging studies may suggest or diagnose spinal instability.

A common form of nontraumatic spinal instability is lumbar spondylolisthesis, which is typically a forward slippage of a lumbar vertebra relative to the lower vertebra on which it rests. This results from congenital or degenerative disruption of the pars interarticularis, the critical bridge of bone that spans adjacent facet joints. In the setting of a pars defect, there is no solid bony connection between the adjacent vertebrae. The spine is unstable and anterior listhesis (slippage) may result. Patients typically present with severe low back pain that is exacerbated with movement and load bearing (mechanical low back pain). Radiculopathy in this setting indicates neuroforaminal compression. Figure 42-26 demonstrates an L4 and L5 spondylolisthesis.

Neural Compression

Besides providing a stable, central element of the body's support structure, the spine also protects the spinal cord and nerve roots as they pass through the neural foramina to form the peripheral nervous system. In a healthy spine, the spinal cord and nerve roots are suspended in CSF, free of mechanical compression. Pathologic processes that can lead to CSF space impingement and neural compression include: hypertrophic degenerative changes in the intervertebral discs and facet joints, expansion of epidural masses such as tumors or abscesses, and subluxation (i.e., slippage) of adjacent vertebral bodies. Subluxation may be due to trauma that exceeds the spine's load-bearing capabilities and leads to structural failure, or chronic structural degradation by degenerative disease, infection, or tumor. Subluxation

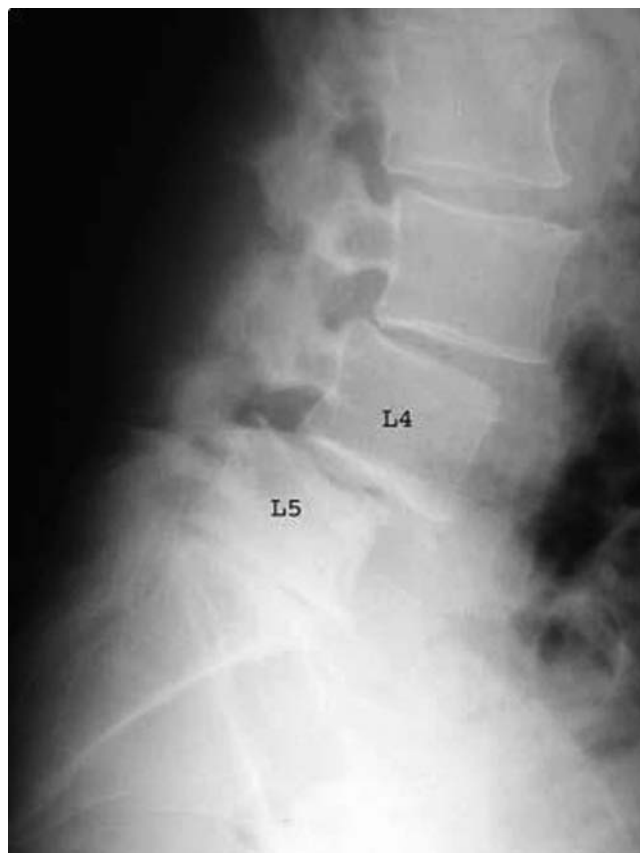


Figure 42-26. Lateral lumbar spine X-ray demonstrates a 25% anterior slippage of L4 on L5 due to a defect in the L4 pars interarticularis. This is called *spondylolisthesis*.

reduces the cross-sectional area of the central canal and the neural foramina (see Fig. 42-10B). Reduced central canal area can lead to myelopathy. Reduced neural foraminal area can lead to radiculopathy.

Myelopathy. Compression of the spinal cord can cause disturbance of function known as *myelopathy*. This dysfunction may be secondary to the direct effects of compression, cord ischemia due to reduced perfusion, or pathologic changes due to repeated cord trauma. These mechanisms lead to demyelination of the corticospinal tracts, which are long descending motor tracts. Corticospinal tract damage leads to upper motor neuron signs and symptoms, including hyperreflexia, spasticity, and weakness. These mechanisms also cause damage to the dorsal columns, which carry ascending proprioception, vibration, and two-point discrimination information. Loss of proprioception makes fine motor tasks and ambulation difficult.

Radiculopathy. Compression of the nerve roots causes disturbance of root function, known as *radiculopathy*. Characteristic features of radiculopathy include lower motor neuron signs and symptoms (hyporeflexia, atrophy, and weakness) and sensory disturbances such as numbness or tingling sensations (paresthesias), burning sensations (dysesthesias), and shooting (radicular) pain. Myelopathy and radiculopathy often present together in diseases that involve the central canal and the neural foramina. This combination can lead to lower motor neuron dysfunction at the level of disease, and upper motor neuron dysfunction below that level.

Patterns of Disease

Cervical Radiculopathy. The cervical nerve roots exit the central canal above the pedicle of the same-numbered vertebra and at the level of the higher adjacent intervertebral disc. For example, the C6 nerve root passes above the C6 pedicle at the level of the C5–C6 discs. The cervical nerve roots may be compressed acutely by disc herniation, or chronically by hypertrophic degenerative changes of the discs, facets, and ligaments. Table 42-6 summarizes the effects of various disc herniations. Most patients with acute disc herniations will improve without surgery. NSAIDs or cervical traction may help alleviate symptoms. Patients whose symptoms do not resolve or who have significant weakness should undergo decompressive surgery. The two main options for nerve root decompression are anterior cervical discectomy and fusion (ACDF) and posterior cervical foraminotomy (keyhole foraminotomy). ACDF allows more direct access to and removal of the pathology (anterior to the nerve root). However, the procedure requires fusion because discectomy causes a collapse of the interbody space and instability will likely occur. Figure 42-27 demonstrates a

C6–C7 ACDF with the typical interposed graft and plating system. Keyhole foraminotomy allows for decompression without requiring fusion, but it is less effective for removing centrally located canal pathology.

Cervical Spondylotic Myelopathy. The term *spondylosis* refers to diffuse degenerative and hypertrophic changes of the discs, intervertebral joints, and ligaments, which collectively result in spinal stenosis. Spinal cord dysfunction (myelopathy) due to cord compression from cervical spinal degenerative disease is therefore referred to as *cervical spondylotic myelopathy* (CSM). Classically CSM presents with spasticity and hyperreflexia due to corticospinal tract dysfunction, upper extremity weakness and atrophy from degeneration of the motor neurons in the anterior horns of the spinal gray matter, and loss of lower extremity proprioception due to dorsal column injury. Figure 42-28 demonstrates typical findings. Some patients complain of difficulty buttoning shirts, using utensils, and ambulating. Spondylosis is usually diffuse, so the usual treatment for CSM is multilevel (usually C3–C7) cervical laminectomy, although patients with disease localized over one to three levels may be candidates for anterior decompression and fusion. Figure 42-29 demonstrates the postoperative appearance of a vertebral corpectomy and fusion for CSM. Thorough cervical laminectomy decompresses the cord posteriorly. Patients often have slow recovery due to the extensive chronic changes in the cervical cord and may benefit from rehabilitation programs. The other disease that classically presents with combined upper and lower motor neuron symptoms is amyotrophic lateral sclerosis (ALS). Care must be taken to avoid offering cervical laminectomy to a patient with undiagnosed ALS. Two findings help differentiate CSM from ALS: cranial nerve dysfunction such as dysphagia (not typically caused by cervical spine disease) and sensory disturbance (not found in ALS).

Thoracic Disc Herniation. Thoracic disc herniation accounts for <1% of herniated discs. A patient may present with radicular pain or sensorimotor changes in the lower extremities due to cord compression. A posterior approach via midline incision and laminectomy should be avoided because of the high incidence of cord injury from manipulation and retraction. Anterior approaches via thoracotomy minimize risk to the cord and allow excellent access to the disc. The radicular arteries running from the aorta to the thoracic cord should be spared, when possible, to avoid ischemia. Alternatively, a posterolateral approach is possible via resection of the rib head and facet joint. Finally, a transpedicular approach may be attempted for lateral disc herniations.³⁴

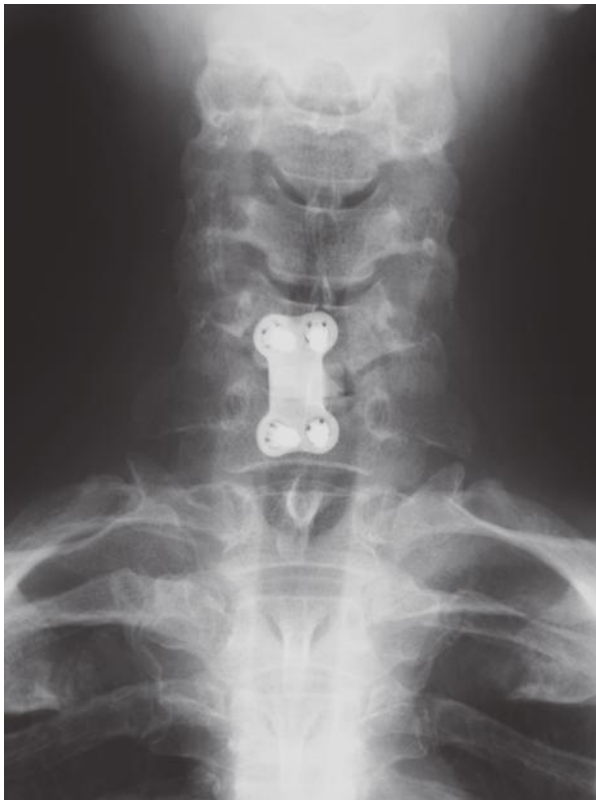Lumbar Radiculopathy. Lumbar nerve roots exit the thecal sac, pass over the higher adjacent disc space, and exit the canal under the pedicle of the same-numbered vertebra. Therefore,

Table 42-6

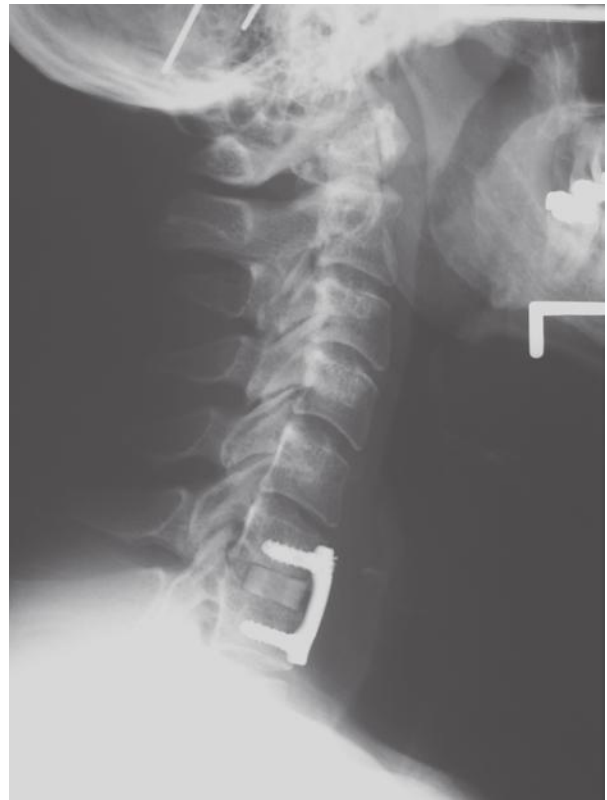Cervical disc herniations and symptoms by level

LEVEL	FREQUENCY (%)	ROOT INJURED	REFLEX	WEAKNESS	NUMBNESS
C4–C5	2	C5	—	Deltoid	Shoulder
C5–C6	19	C6	Biceps	Biceps brachii	Thumb
C6–C7	69	C7	Triceps	Wrist extensors (wrist drop)	Second and third digits
C7–T1	10	C8	—	Hand intrinsic	Fourth and fifth digits

Source: Adapted with permission from Greenberg MS. *Handbook of Neurosurgery*, 7th ed. New York: Thieme, 2010. Table 18–18, p 461.



A



B

Figure 42-27. A. Anteroposterior cervical spine X-ray showing the position of an anterior cervical plate used for stabilization after C6–C7 discectomy. Patient presented with right triceps weakness and dysesthesias in the right fifth digit. Magnetic resonance imaging revealed a right paracentral C6–C7 herniated disc compressing the exiting C7 nerve root. B. Lateral cervical spine X-ray of the same patient clearly demonstrates the position of the plate and screws. The allograft bone spacer placed in the drilled-out disc space is also apparent.

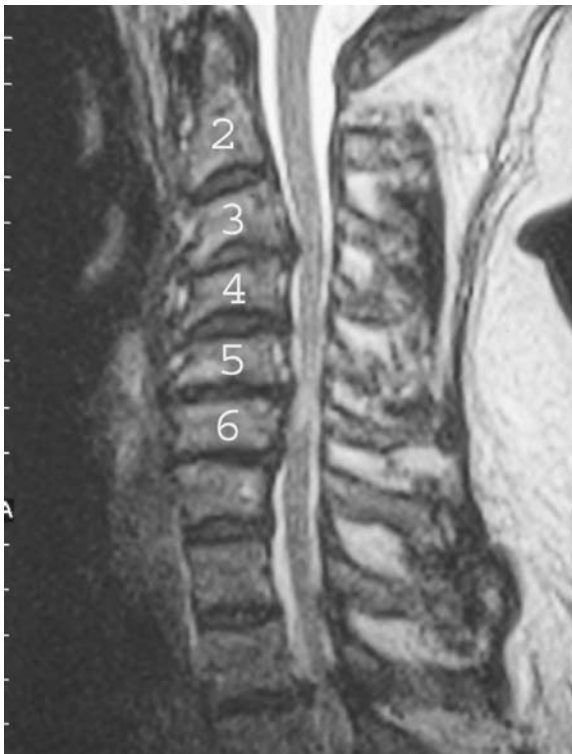

Figure 42-28. T2-weighted sagittal magnetic resonance imaging of the cervical spine showing multilevel degenerative changes causing spinal stenosis that is worst at C5–C6. Note the bright signal within the cord at that level, consistent with myelopathy.

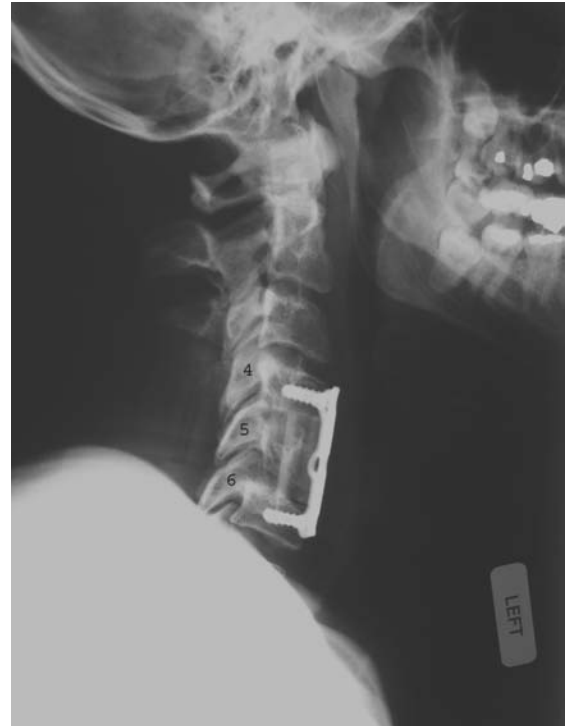

Figure 42-29. Lateral cervical spine X-ray status post C5 corpectomy for cervical spondylotic myelopathy. This involves removal of the C4–C5 disc, C5 vertebral body, and C5–C6 disc, decompressing at two levels. A bone strut is visible bridging C4 to C6. The plate and screws stabilize the segments.

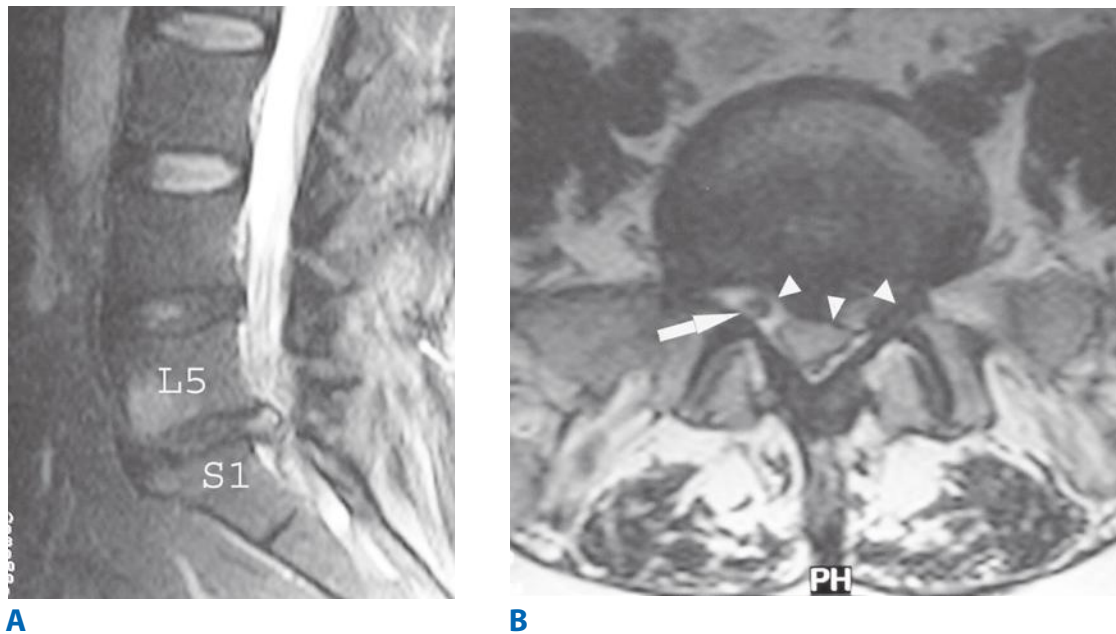

Figure 42-30. **A.** T2-weighted sagittal magnetic resonance imaging shows an L5–S1 disc herniation causing significant canal compromise and displacement of nerve roots. **B.** T2-weighted axial magnetic resonance imaging of the same patient shows the large left paracentral disc herniation at L5–S1. *Arrowheads* delineate the extent of the herniation. The *arrow* indicates the right S1 nerve root passing through free of compression. The left S1 nerve root is under severe compression and is not seen.

the L5 nerve root passes over the L4–L5 disc space and exits under the L5 pedicle (Fig. 42-30). Lumbar discs may herniate with or without a history of trauma or straining. Normally they cause lancinating (radicular) pain down the leg (Table 42-7). Most acute herniated lumbar discs improve symptomatically without surgery. Surgery is indicated for symptoms persisting more than 6 to 8 weeks, progressive motor deficit (e.g., foot drop), or for patients with incapacitating pain not manageable with analgesics.

Discectomy is performed using a midline incision, partial removal of the overlying laminae (hemilaminectomy or laminotomy), identification of the thecal sac and nerve root, and extraction of disc fragments. Free-floating disc fragments may be found. Often, however, the herniated disc material is still contained within the annulus, requiring incision of the posterior longitudinal ligament and curettage of the disc space. After lumbar discectomy, approximately two-thirds of patients will have complete relief of pain, and up to 85% will have significant improvement.

Neurogenic Claudication. Neurogenic claudication is characterized by low back and leg pain that occurs while walking and is relieved by stopping, leaning forward, or sitting. It is normally caused by degenerative lumbar stenosis causing

compression of the cauda equina. Neurogenic claudication must be distinguished from vascular claudication, which tends to resolve quickly with cessation of walking. There is typically no need to change position, and the pain follows a stocking distribution rather than a dermatomal distribution. Pallor and coldness of the feet, and normal neurologic examination are also typical, though diabetic patients may present a challenge with microvascular neuropathy. Patients with neurogenic claudication have a slowly progressive course and may be surgical candidates when their pain interferes with their lifestyle. The usual surgery is an L3 to L5 lumbar laminectomy to decompress the nerve roots.

Cauda Equina Syndrome. Cauda equina syndrome is due to compression of the cauda equina and may result from massive disc herniation, EDH, epidural abscess, tumor, or subluxation from trauma. Patients with cauda equina compression often present with urinary retention, saddle anesthesia, or progressing leg weakness. Saddle anesthesia is numbness in the perineum, genitals, buttocks, and upper inner thighs. Patients with suspected cauda equina syndrome should undergo immediate MRI of the lumbar spine to evaluate for a surgical lesion. Mass lesions should be removed urgently via laminectomy to preserve sphincter function and ambulation.

Table 42-7

Lumbar disc herniations and symptoms by level

LEVEL	FREQUENCY (%)	ROOT INJURED	REFLEX	WEAKNESS	NUMBNESS
L3–L4	5	L4	Patellar	Quadriceps	Anterior thigh
L4–L5	45	L5	—	Tibialis anterior (foot drop)	Great toe
L5–S1	50	S1	Achilles	Gastrocnemius	Lateral foot

Source: Adapted with permission from Greenberg MS. *Handbook of Neurosurgery*, 7th ed. New York: Thieme, 2010. Table 18–13, p 445.

Spine Fusion Surgery

Fusion surgery is often required for patients with spinal instability resulting from disease, surgical intervention, or both. Fusion procedures lock adjacent vertebrae together. Fusion occurs when the body forms a solid mass of bone incorporating the adjacent vertebrae, eliminating normal intervertebral movement. Stabilization and immobilization promote bony fusion. Internal instrumentation and external orthoses are often used to stabilize and immobilize the fused spinal segments.

Spinal Instrumentation

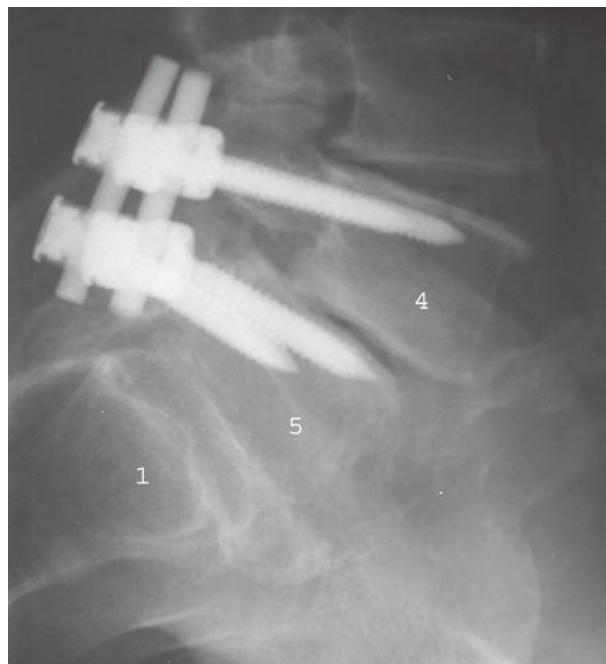
Internal fixation devices for spinal segmental immobilization have been developed for all levels of the spine. Most

6▶ spinal instrumentation constructs have two elements. The first element is a device that solidly attaches to the vertebral bodies. Options include wires wrapped around laminae or spinous processes, hooks placed under the lamina or around the pedicles, or screws placed in the pedicles or the vertebral bodies. The second element is a device that traverses vertebral segments. Options include rods and plates that lock directly to the wires, hooks, or screws at each vertebral level. Spinal instrumentation devices are available for anterior and posterior fusion in the cervical, thoracic, and lumbar regions. Most modern spinal instrumentation devices are made of titanium to minimize problems with future MRI scanning (Fig. 42-31). All spinal instrumentation constructs will eventually fail by loosening or breaking if bony fusion does not occur.

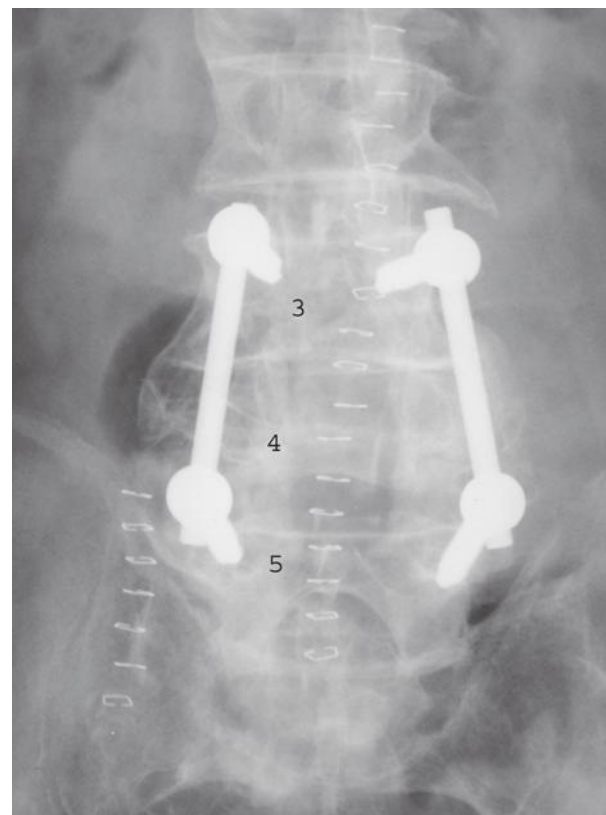
Arthrodesis

Arthrodesis refers to the obliteration of motion or instability by incorporating the relevant components into a solid mass of bone. Arthrodesis must occur in any fused segment to have long-term stability. Failure of arthrodesis results in failed fusion, often in the form of a fibrous nonunion. The rates of successful fusion are higher in the cervical spine than the lumbar spine. Arthrodesis requires ingrowth of new bone formed by the patient's osteoblasts across the unstable defect. Inserting graft material, such as autograft or allograft, into the defect provides a bridge for osteoblasts and promotes fusion. The term *autograft* refers to the patient's own bone, often harvested from the iliac crest. Iliac crest bone graft is a source of both cortical and cancellous bone. Cortical bone provides structural support, while cancellous bone provides a matrix for bony ingrowth. The term *allograft* refers to sterilized bone from human tissue banks. Allografts also may be cortical, cancellous, or both. Allograft lacks the array of osteoinductive endogenous compounds intrinsic to autograft, although supplemental products such as demineralized bone matrix paste can be added to encourage new bone formation. Other techniques for increasing the rates of successful fusion are being developed, including the integration of osteoinductive bone morphogenetic proteins, known as *BMPs*, into the fusion constructs.

Dynamic stabilization refers to the creation of spinal stability without achieving a bony fusion. The concept applies to both cervical and lumbar motion segments. Artificial lumbar and cervical disc replacement therapies are recent developments in degenerative spine disease that address this concept. However, their use is limited to very select cases. Another motion preservation technique that may hold promise is segmental "soft" stabilization.³⁵ In



A



B

Figure 42-31. A. Lateral lumbar spine X-ray showing pedicle screws and connecting rods used to stabilize L4 with respect to L5. This instrumentation was placed as part of a fusion operation to stabilize progressive L4–L5 spondylolisthesis with intractable low back pain. B. Anteroposterior lumbar spine X-ray showing L3 to L5 instrumentation with pedicle screws and connecting rods. The patient had previously sustained an L4 burst fracture. Note the significant loss of height of the L4 body compared to adjacent levels. The small row of staples to the right delineates the incision over the iliac crest used to harvest cancellous bone as a nonstructural osteoinductive autograft fusion designed to induce formation of a solid bone bridge from L3 to L5 (arthrodesis).

cases of degenerative spondylolisthesis, such systems in the lumbar spine allow for decompressive laminectomy without increasing slippage. In theory, adjacent level facets and discs are spared the stresses of a neighboring bony fusion moment arm.

PERIPHERAL NERVE

Common pathologic processes that compromise function of the peripheral nervous system include mechanical compression, ischemia, inflammation, and neoplasia.

Peripheral Nerve Tumors

Most peripheral nerve tumors are benign and grow slowly. Significant pain increases the likelihood that the patient has a malignant tumor. Treatment for peripheral nerve tumors is surgical resection to establish diagnosis and evaluate for signs of malignancy. These tumors have various degrees of involvement with the parent nerve. Some can be resected with minimal or no damage to the nerve. Tumors that grow within the nerve often contain functioning fascicles. Total excision of these tumors requires sacrifice of the parent nerve. The choice of subtotal resection, nerve preservation, and observation, vs. total resection with nerve sacrifice depends on tumor histology and the function of the parent nerve.

Schwannoma. Schwannomas are the most common peripheral nerve tumors, also referred to as *neurilemomas* or *neurinomas*. Most occur in the third decade of life. These benign tumors arise from Schwann cells, which form myelin in peripheral nerves. The most characteristic presentation is a mass lesion with point tenderness and shooting pains on direct palpation. Spontaneous or continuous pain suggests malignancy. Schwannomas tend to grow slowly and eccentrically on parent nerves. The eccentric location and discrete encapsulated nature of these tumors often allow total resection without significant damage to the parent nerve. Subtotal resection and observation is reasonable for schwannomas entwined in important nerves, as the incidence of malignant transformation is extremely low.

Neurofibroma. Neurofibromas arise within the nerve and tend to be fusiform masses, unlike schwannomas, which tend to grow out of the nerve. Neurofibromas often present as a mass that is tender to palpation. They usually lack the shooting pains characteristic of schwannomas. Neurofibromas are often difficult to resect completely without sacrifice of the parent nerve. Neurofibromas have a higher incidence of malignant transformation; therefore, patients with known residual tumors require close observation. Patients with NF1 often have multiple neurofibromas. These patients should be offered resection for symptomatic tumors. Risk of malignant degeneration is up to 10%. Malignant neurofibromas have the histologic characteristics of sarcoma.

Malignant Nerve Sheath Tumors. Malignant nerve sheath tumors include solitary sarcomas, degenerated neurofibromas, and neuroepitheliomas. Patients with malignant peripheral nerve tumors typically complain of constant pain, rather than pain only on palpation, and are more likely to have motor and sensory deficits in the distribution of the parent nerve. Treatment for these tumors is radical excision. This often requires sacrifice of the parent nerve. Invasion of nearby soft tissues may

occur and necessitate wide resection or amputation in an attempt to prevent systemic metastasis.

Entrapment Neuropathies

Entrapment neuropathy presents as neurologic dysfunction in nerves passing through a pathologically small, fixed space. Nerve dysfunction may result directly from chronic, repetitive pressure on the nerve, or from ischemic damage due to impaired perfusion.³⁶ Entrapment causing dysfunction of nerve signaling may be associated with numbness, paresthesias, weakness, or muscle atrophy. The two most common sites of entrapment neuropathy are the ulnar nerve at the medial aspect of the elbow and the median nerve at the wrist. Usually EMG/NCS demonstrate slowing across the entrapped segment of nerve. Mechanical peripheral nerve disorders resulting from trauma (brachial plexus disruption, radial nerve damage from humerus fractures, and common peroneal nerve crush injuries) are discussed in the section on Trauma.

Ulnar Neuropathy. The ulnar nerve has contributions from the C7, C8, and T1 nerve roots, arises from the medial cord of the brachial plexus, and supplies most of the intrinsic hand muscles (interossei and third and fourth lumbricals), and sensation to the fourth and fifth digits. It passes posteriorly to the medial epicondyle at the elbow in the condylar groove. This segment is superficial and subject to external compression and repetitive minor impacts. Patients with ulnar entrapment at the elbow present with numbness and tingling in the medial palm, as well as the fourth and fifth digits. Motor deficits include weakness and wasting of the intrinsic hand muscles. Treatment for symptomatic ulnar entrapment neuropathy is surgical exploration and incision of the fibrous aponeurotic arch that overlies the nerve. A 6-cm curvilinear incision centered between the medial epicondyle and the olecranon allows exploration of up to 10 cm of nerve and lysis of compressive tissues.

Carpal Tunnel Syndrome. The median nerve has contributions from the C5 to T1 nerve roots, arises from the medial and lateral cords of the brachial plexus, and supplies the muscles of wrist and finger flexion and sensation to the palmar aspect of the first, second, and third digits. The median nerve passes through the carpal tunnel in the wrist, lying superficial to the four deep and four superficial flexor tendons. The transverse carpal ligament is a tough, fibrous band that forms the roof of the carpal tunnel. The ligament attaches to the pisiform and hamate medially and the trapezium and scaphoid laterally. Patients complain of numbness and tingling in the supplied digits, clumsiness, and worsening with sleep or repetitive wrist movement. Patients may notice wasting of the thenar eminence. Treatment for symptomatic carpal tunnel syndrome unresponsive to splinting, analgesics, and rest is surgical division of the flexor retinaculum. This often provides prompt relief of pain symptoms and slow recovery of numbness and strength.

Autoimmune and Inflammatory Disorders

These are not surgical diseases, but they merit brief mention as they are included in the differential diagnosis for new-onset weakness. Their characteristic presentations help distinguish them from weakness due to structural lesions.

Guillain-Barré Syndrome. Guillain-Barré syndrome is an acute inflammatory demyelinating polyradiculopathy often occurring after viral infection, surgery, inoculations, or

mycoplasma infections. Patients classically present with weakness ascending from the legs to the body, arms, and even cranial nerves. Symptoms usually progress over 2 to 4 weeks and then resolve. Care is supportive. Respiratory weakness may require ventilatory support.

Myasthenia Gravis. Myasthenia gravis is an autoimmune process in which antibodies form to the acetylcholine receptors of muscles, leading to fluctuating weakness. Most patients have either thymic hyperplasia or thymoma. The most common symptoms are diplopia, ptosis, dysarthria, and dysphagia. More severe cases have limb or respiratory involvement. Weakness worsens with repetitive movement. Treatment is with acetylcholinesterase inhibitors and possible thymectomy.

Eaton-Lambert Syndrome. Eaton-Lambert syndrome is an autoimmune process with antibodies to the presynaptic calcium channels. This is a paraneoplastic syndrome most commonly associated with oat cell carcinoma. Patients have weakness of proximal limb muscles that improves with repetitive movement. This diagnosis must prompt oncologic evaluation.

INFECTION

CNS infections of interest to neurosurgeons include those that cause focal neurologic deficit due to mass effect, require surgical aspiration or drainage because antibiotic therapy alone is insufficient, cause mechanical instability of the spine, or occur after neurosurgical procedures.

Cranial

Osteomyelitis. The skull is highly vascular and resistant to infections. Osteomyelitis of the skull may develop by contiguous spread from pyogenic sinus disease or from contamination by penetrating trauma. *Staphylococcus aureus* and *S. epidermidis* are the most frequent causative organisms. Patients usually present with redness, swelling, and pain. Contrast head CT aids diagnosis and shows the extent of involved bone, along with associated abscesses or empyema. Osteomyelitis treatment entails surgical debridement of involved bone followed by 2 to 4 months of antibiotics. Craniotomy wound infections are a special concern because performing a craniotomy creates a devascularized free bone flap susceptible to infection and not penetrated by antibiotics. These wounds must be débrided and the bone flaps removed and discarded. Subsequent care involves appropriate antibiotic therapy, observation for signs of recurrent infection off antibiotics, and return to the OR for titanium or methylmethacrylate cranioplasty 6 to 12 months later.

Subdural Empyema. Subdural empyema is a rapidly progressive pyogenic infection. The subdural space lacks significant barriers to the spread of the infection, such as compartmentalization or septations. Subdural empyemas usually occur over the cerebral convexities. Potential infectious sources include sinus disease, penetrating trauma, and otitis. Streptococci and staphylococci are the most frequent sources. Presenting symptoms include fever, headache, neck stiffness, seizures, or focal neurologic deficit. Neurologic deficit results from inflammation of cortical blood vessels, leading to thrombosis and stroke. The most common deficit is contralateral hemiparesis. Patients with suggestive symptoms should undergo rapid contrast CT scan. LP frequently fails to yield the offending organism and risks

herniation due to mass effect. Typical treatment is wide hemi-craniectomy, dural opening, and lavage. The pus may be thick or septated, making burr hole drainage or small craniotomy insufficient. Patients then require 1 to 2 months of antibiotics. Subdural empyema has 10% to 20% mortality risk and common chronic sequelae, including development of a seizure disorder and residual hemiparesis. However, many patients do make a good recovery.

Brain Abscess. Brain abscess is encapsulated infection within the brain parenchyma. It may spread hematogenously in patients with endocarditis or intracardiac or intrapulmonary right-to-left shunts, by migration from the sinuses or ear, or via direct seeding by penetrating trauma. Disorganized cerebritis often precedes formation of the organized, walled-off abscess. Patients may present with nonspecific symptoms such as headache, nausea, or lethargy, or with focal neurologic deficit such as hemiparesis. Alternatively, patients may present in extremis if the abscess ruptures into the ventricular system. Abscesses appear as well-demarcated, ring-enhancing, thin-walled lesions on CT scan and MRI, and often have associated edema and mass effect. Patients require antibiotic therapy after needle aspiration or surgical evacuation. Antibiotic therapy without surgical evacuation may be considered for patients with small, multiple, or critically located abscesses. Abscesses that are large, cause mass effect, decreased mental status, or that fail to decrease in size after 1 week of antibiotics, should be evacuated. Nonsurgical management still requires aspiration or biopsy specimen for organism culture and sensitivities. Blood and CSF cultures rarely give definitive diagnosis. Removal of an encapsulated abscess significantly shortens the length of antibiotic therapy required to eliminate all organisms. Common chronic sequelae after successful treatment include seizures or focal neurologic deficit.

Spine

Pyogenic Vertebral Osteomyelitis. Pyogenic vertebral osteomyelitis is a destructive bacterial infection of the vertebrae, usually of the vertebral body. Vertebral osteomyelitis frequently results from hematogenous spread of distant disease, but may occur as an extension of adjacent disease, such as psoas abscess or perinephric abscess. *S. aureus* and *Enterobacter* spp. are the most frequent etiologic organisms. Patients usually present with fever and back pain. Diabetics, IV drug abusers, and dialysis patients have increased incidence of vertebral osteomyelitis. Epidural extension may lead to compression of the spinal cord or nerve roots with resultant neurologic deficit. Osteomyelitis presents a lytic picture on imaging and must be distinguished from neoplastic disease. Adjacent intervertebral disc involvement occurs frequently with pyogenic osteomyelitis, but rarely with neoplasia. Plain films and CT help assess the extent of bony destruction or deformity such as kyphosis. MRI shows adjacent soft tissue or epidural disease. Most cases can be treated successfully with antibiotics alone, although the organism must be isolated to steer antibiotic choice. Blood cultures may be positive. Surgical intervention may be required for debridement when antibiotics alone fail, or for stabilization and fusion in the setting of instability and deformity.

Tuberculous Vertebral Osteomyelitis. Tuberculous vertebral osteomyelitis, also known as *Pott's disease*, occurs most commonly in underdeveloped countries and in the immunocompromised.

Several features differentiate tuberculous osteomyelitis from bacterial osteomyelitis. The infection is indolent and symptoms often progress slowly over months. Tuberculosis rarely involves the intervertebral disc. The involved bodies may have sclerotic rather than lytic changes. Multiple nonadjacent vertebrae may be involved. The upper lumbar and lower thoracic vertebrae are most commonly affected. Diagnosis requires documentation of acid-fast bacilli. Treatment involves long-term antimycobacterial drugs. Patients with spinal instability or neural compression from epidural inflammatory tissue should undergo debridement and fusion as needed.

Discitis. Primary infection of the intervertebral disc space, or discitis, is most commonly secondary to postoperative infections. Spontaneous discitis occurs more commonly in children. *S. aureus* and *S. epidermidis* account for most cases. The primary symptom is back pain. Other signs and symptoms include radicular pain, fevers, paraspinal muscle spasm, and localized tenderness to palpation. Many cases will resolve without antibiotics, which generally are given for positive blood or biopsy specimen cultures or persistent constitutional symptoms. Most patients will have spontaneous fusion across the involved disc and do not need debridement or fusion.

Epidural Abscess. Epidural abscesses may arise from or spread to the adjacent bone or disc, so distinguishing between vertebral osteomyelitis or discitis and a spinal epidural abscess may be difficult. The most common presenting signs and symptoms are back pain, fever, and tenderness to palpation of the spine. The most significant risk of epidural abscess is weakness progressing to paralysis due to spinal cord or nerve root damage. Cord and root damage may be due to direct compression or to inflammatory thrombosis resulting in venous infarction. *S. aureus* and *Streptococcus* spp. are the most common organisms. Methicillin-resistant *S. aureus* now constitutes a significant proportion of these infections, as high as 40%.³⁷ The source may be hematogenous spread, local extension, or operative contamination. MRI best demonstrates the epidural space and degree of neural compromise. Patients with spinal epidural abscess and neurologic compromise should undergo surgical debridement for decompression and diagnosis, followed by culture-directed antibiotic therapy. Relative contraindications to surgery include prohibitive comorbidities or total lack of neurologic function below the involved level. Patients with no neurologic deficits and an identified organism may be treated with antibiotics alone and very close observation. However, this management strategy remains somewhat controversial because these patients can undergo rapid and irreversible neurologic decline. Most epidural abscesses can be accessed via laminectomy without fusion. Collections predominantly anterior to the cervical or thoracic cord may require anterior approach and fusion.

FUNCTIONAL NEUROSURGERY

Epilepsy Surgery

Seizures result from uncontrolled neuronal electrical activity. Seizures may result from irritative lesions in the brain, such as tumors or hematomas, or from physiologic or structural abnormalities. Seizures may involve a part of the brain (focal) or the entire brain (generalized). Focal seizures may be associated with normal consciousness (simple) or decreased consciousness (complex). All generalized seizures cause loss of consciousness. Focal seizures may secondarily generalize. Patients with

multiple unprovoked seizures over time are considered to have epilepsy. The type of epilepsy depends on such factors as type of seizures, electroencephalographic (EEG) findings, associated syndromes, and identifiable etiologies. All patients with unexplained seizures (i.e., no obvious cause such as head trauma or alcohol withdrawal) require thorough neurologic evaluation, including imaging to evaluate for a mass lesion. Antiepileptic drugs (AEDs) form the first line of therapy for epilepsy, initially as monotherapy, then as combination therapy. Epilepsy patients who have failed satisfactory trials of several AED combination regimens may be candidates for surgical intervention. Lack of seizure control or patient intolerance of the medications may constitute failure. Epilepsy surgery can decrease the frequency of seizures by resection of the electrical source of the seizures, or decrease the severity of seizures by disconnecting white matter tracts through which the abnormal electrical activity spreads. Four types of epilepsy surgery are discussed in sections that follow. Epilepsy surgery appears to be extremely underused, given the relatively low risk of the procedures, and the crippling social and economic effects of uncontrolled or partially controlled epilepsy.³⁸ Patients with symptoms, imaging abnormalities, and EEG analysis compatible with a specific seizure focus are most likely to have good results from epilepsy surgery.

Anterior Temporal Lobectomy. Medial temporal lobe structural abnormalities can lead to complex partial seizures (CPS). Many patients with CPS have poor seizure control on medications. Patients with CPS may have significant reduction in seizure frequency or cessation of seizures after resection of the anterior temporal lobe. The amygdala and the head of the hippocampus are removed as part of the lobectomy. Resection may be taken back approximately 4.5 cm from the temporal tip in the language-dominant hemisphere, and 6 cm from the temporal tip in the language nondominant hemisphere, with low risk of significant neurologic deficits.³⁹ The two main risks of anterior temporal lobectomy are memory impairment and visual loss. Removal of the hippocampus in a patient with an atrophied or nonfunctional contralateral hippocampus causes a global memory deficit. Interruption of the optic radiations, which carry visual signals from the contralateral superior visual quadrants of both eyes, causes a contralateral superior quadrantanopia, known as a *pie in the sky* field cut.

Corpus Callosotomy. Patients with generalized seizures, atonic seizures associated with drop attacks, or absence seizures, who are found to have bilaterally coordinated pathologic cortical discharges on EEG and who fail AED therapy, may be candidates for corpus callosotomy. The corpus callosum is a large white matter tract that connects the cerebral hemispheres. Loss of consciousness requires simultaneous seizure activity in both hemispheres. Focal or partial seizures may spread via the corpus callosum to the contralateral hemisphere, causing generalization and loss of consciousness. Division of the corpus callosum can interrupt this spread. Patients may have decreased numbers of seizures and/or fewer episodes of lost consciousness. Usually only the anterior half or two-thirds of the corpus callosum is divided, as more extensive division increases the risk of disconnection syndrome. Patients with disconnection syndrome are unable to match objects in the opposite visual hemifields, to identify objects held in one hand with the other hemifield, and to write with the left hand or name objects held in the left hand (in left hemisphere-dominant patients).

Hemispherectomy. Children with intractable epilepsy, structural anomalies in one hemisphere, and contralateral hemiplegia, may have improved seizure control after resection of the hemisphere (anatomic hemispherectomy) or disruption of all connections to the hemisphere (functional hemispherectomy). Functional hemispherectomy often is preferred over anatomic hemispherectomy because of the high incidence of complications such as hematoma formation and ventriculoperitoneal shunt dependence associated with the latter.

Vagus Nerve Stimulation. Neuromodulatory treatments like vagus nerve stimulation (VNS), approved by the FDA in 1997, are less invasive and offer some titratability in addition to reversibility unlike the resective surgical options previously described. Since first reported in 1985, VNS has proven to be efficacious in certain patient populations for several disorders such as treatment-resistant major depressive disorder, bipolar disorder, and epilepsy. In VNS, a pulse generator is placed under the skin in the chest and is connected to the vagus nerve by an electrical lead. Chronic, intermittent VNS has been proven to be an effective option for patients suffering from medically refractory seizures who are not candidates for surgical resection. Although only a small minority of patients will be entirely seizure-free, three blinded, randomized-controlled trials have examined VNS, and demonstrated significant clinical improvement compared to sham.⁴⁰⁻⁴² Generally VNS is well-tolerated and safe, as device implantation is associated with a low rate of perioperative complications. Additionally, the majority of side effects are stimulation-dependent and thus, reversible. For the most part, VNS is limited in its application because it can only exert its effects by altering neural activity via the vagus nerve. Procedures with brain region-specificity are being investigated.

Deep Brain Stimulation

The following summary of deep brain stimulation (DBS) will include a review of the current U.S. Food and Drug Administration (FDA)-approved indications, as well the expanding applications of this therapy, currently being investigated preclinically and in clinical trials. While the mechanism of action of DBS continues to elude our understanding, it is well-established that administering electrical stimulation to a nucleus in the brain known to be involved in a given disease can disrupt the pathologic signals emanating to or from this brain region. A fine electrical lead is placed in a deep brain nucleus and connected to pulse generators placed in the chest in a manner similar to cardiac pacemakers. Connector wires travel from the generators in the subcutaneous space up the neck and in the subgaleal space in the head, to connect the pulse generators to the electrical leads. Proper lead placement is accomplished with stereotactic guidance. A frame is rigidly fixed to the patient's head, and an MRI is obtained with the frame in place. Calculation of the coordinates of the millimeter-sized deep brain nuclei is performed in relation to the three-dimensional space defined by the fixed frame, allowing for accurate targeting of the nucleus (Fig. 42-32). Postoperatively, the pulse generators can be interrogated and adjusted with hand-held, transcutaneous, noninvasive devices as needed for symptom control.

Essential Tremor. Essential tremor is the most common movement disorder in the western world and is characterized by action tremor (4–8 Hz rhythmic oscillations) of the hands, forearms, head, and voice. Essential tremor often starts in the third or fourth decade of life, and increases in frequency and

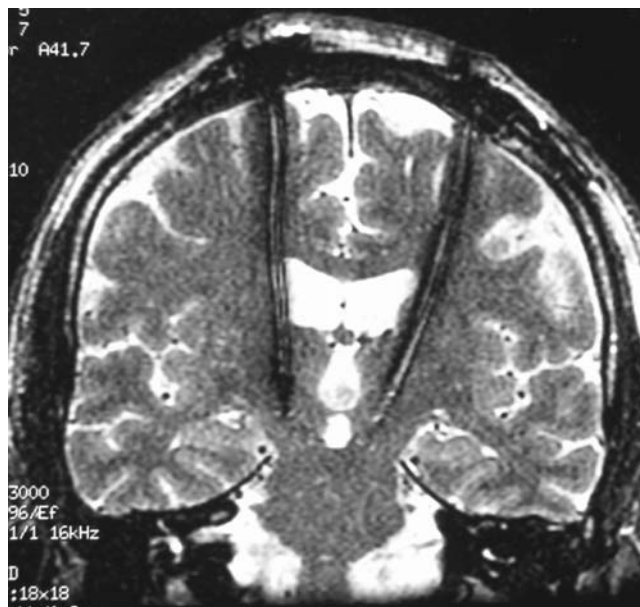

Figure 42-32. Fast spin echo coronal magnetic resonance imaging demonstrating position of deep brain stimulator leads in the subthalamic nuclei bilaterally. The electrodes appear thick and wavy due to magnetic susceptibility artifact.

amplitude with age. Beta blockers can decrease symptoms, but patients with poor medical control and significant functional impairment significantly benefit from placement of a deep brain stimulator in the contralateral ventralis intermediate nucleus of the thalamus. In properly selected patients, DBS of this region of the thalamus appears to provide robust and durable symptom control.^{43,44}

Parkinson's Disease. Parkinson's disease is a progressive disorder characterized by rigidity, bradykinesia, and resting tremor, due to loss of dopamine-secreting neurons in the substantia nigra. Dopaminergic agents such as levodopa/carbidopa and anticholinergic agents such as amantadine and selegiline form the basis of medical therapy. Patients with poor medical control or significant drug side effects may benefit significantly from placement of bilateral deep brain stimulators in the subthalamic nuclei. Although the globus pallidus interna has also been a widely targeted area, the subthalamic nuclei is now the most accepted target in deep brain stimulation for Parkinson's disease.⁴⁵ Deep brain stimulation provides durable symptom relief with good postoperative neuropsychologic function in properly selected patients.⁴⁶

Recently, a large randomized controlled trial compared bilateral DBS ($n=121$) to best medical therapy in advanced Parkinson's disease ($n=134$).⁴⁷ The DBS group did significantly better in both motor function and quality of life. While adverse events were 3.8 times more likely in the DBS group, 99% of these events had resolved by 6 months. There was a 0.8% risk of death due to the procedure, and there was no difference in risk of adverse events when comparing older (≥ 70 years) to younger patients (< 70 years). Thus, the benefits of DBS over medical therapy are clear, especially when considering quality of life measures.

Another recent randomized controlled trial focused on defining the optimal targets for DBS in Parkinson's disease.⁴⁸ While the subthalamic nucleus (STN) and the globus pallidus interna (GPi) have been successfully targeted in the past, a direct comparison of the two was lacking. In this study, 299 subjects

were randomized to receive either bilateral STN or GPi stimulators and were evaluated for 2 years. The primary outcome was motor function, as assessed by part III of the Unified Parkinson's Disease Rating Scale (UPDRS). The study found no significant difference in motor improvement between target sites. However, a significant difference was found in a secondary outcome measuring depression. On the Beck Depression Inventory, the pallidal stimulation group improved slightly compared with the STN group, which actually worsened slightly. Nevertheless, the actual incidence of depressive episodes requiring prolonged or new hospitalization was 2.6% and 0.7% in GPi and STN, respectively, which was not significantly different. On the other hand, the STN group was found to require less adjunctive dopaminergic pharmacotherapy than the GPi group. In terms of overall severe adverse events, there was no difference between groups. The investigators concluded that both target sites are effective and that nonmotor factors such as psychiatric symptoms may be a consideration in DBS target selection.

Dystonia. The FDA humanitarian device exemption has been made for DBS for dystonia, but is limited to patients ≥ 7 years of age with primary dystonia, including generalized and/or segmental dystonia, hemidystonia, or cervical dystonia (torticollis). Dystonia is characterized by sustained muscle contractions that cause repetitive movements and involuntary postures. Cognitive function is typically spared, and pharmacological therapy is frequently inadequate. The positive impact of DBS on Parkinson's and essential tremor has led neurologists and neurosurgeons to direct their attention to DBS for treatment of idiopathic focal and generalized dystonia.

Although the pathophysiology of idiopathic dystonia is unclear, positron-emission tomography studies have shown disturbed glucose metabolism in the GPi, suggesting secondary pathologic activation of the motor cortex. Indeed, the GPi is currently considered the most efficacious target for dystonia, and controlled trials indicate approximately a 50% improvement in motor function and disability.⁴⁹ Since many patients undergoing surgery for dystonia are children and young adults, DBS is an attractive surgical option because it can be titrated, revised and reversed according to individual needs and growth patterns.

Obsessive-Compulsive Disorder. The safety and efficacy of DBS, as well as its titratability and reversibility, that have been demonstrated for the treatment of movement disorders in the 1990s and 2000s has spawned an increasing interest and awareness of the capabilities of nonlesional surgical treatments for diseases of the brain. An obvious outgrowth of DBS for movement disorders has been the treatment of medically refractory psychiatric disorders. Despite the dark history of frontal leucotomy procedures that dominated the early 20th century, nonlesional DBS for psychiatric disorders are now considered potential treatment strategies.

Functional neuroimaging has implicated certain brain regions in the pathogenesis of a variety of psychiatric disorders. The FDA has approved a humanitarian device exemption for DBS targeting the ventral capsule/ventral striatum for severe obsessive-compulsive disorder (OCD). Recent case reports and pilot studies have reported remission in patients suffering from refractory OCD following DBS. A pilot study using a blinded, staggered-onset design found that four (66.7%) of six patients met a stringent criterion as "responders" ($\geq 35\%$ improvement), according to the Yale-Brown Obsessive Compulsive Scale after 12 months of stimulation.⁵⁰ In this study, patients did not improve during the sham phase. Adverse events were generally

mild and modifiable with setting changes, and stimulation interruption led to rapid yet reversible development of depressive symptoms in two cases. Thus, DBS has promise as a therapy of last resort for carefully selected cases of severe OCD.

Expanding Indications of Deep Brain Stimulation. There are multiple disorders, both psychiatric and neurologic, that have exhibited significant promise as potential indications for DBS in large-scale trials. Recently, there have been reports of significant improvements in refractory depression with DBS. Lozano and colleagues performed an open label study with extended follow-up on 20 patients targeting an area within the subcallosal cingulate gyrus (SCG) with bilateral DBS.⁵¹ At the last follow-up visit in this study (range: 3–6 years), the average response rate was 64%, according to the Hamilton Rating Scale for Depression. Of note, impairment in social functioning was improved, and no significant adverse events were reported. Because two patients died by suicide during depressive relapses, it remains unclear if DBS can only improve quality of life or significantly suppress relapses and extend life-span in this extremely delicate patient population. Of note, as seen in OCD, the ventral capsule/ventral striatum has also been targeted for depression, as well as the nucleus accumbens directly, which lies within the ventral striatum. Studies of DBS in this region report an approximate 40% to 60% response rate, and results from a recent, multicenter randomized controlled trial are pending.⁵²

DBS as a potential therapy for epilepsy targeting the anterior nucleus of the thalamus has been investigated in a multicenter, double-blind, randomized trial (SANTE).⁵³ In this trial, the group receiving DBS showed a 29% greater reduction in seizure frequency in relation to the sham group in the last month of the blinded phase. Complex partial and the "most severe" seizures were significantly reduced in the DBS-on group. After the blinded phase of the trial was complete, 54% of patients had a seizure reduction of at least 50%. Fourteen patients were seizure-free for at least 6 months; eight were seizure-free for at least one year, four for at least two years, and one patient for more than four years. Because of the modest benefit during the blinded phase of this trial, FDA-approval has yet to be granted to DBS for epilepsy targeting the thalamus in the United States, though approval has been given in Europe and Canada.

The region-specific, neuromodulatory capabilities of DBS have inspired the open label use of this technique in many other neurologic and psychiatric disorders, including but not limited to Tourette syndrome, Huntington's disease, and Alzheimer disease. Preclinical studies of both substance abuse and obesity have also shown promise.^{54,55} The opportunity to model reward-seeking behaviors associated with these disorders in animals provides the ability to not only test safety, but also study mechanisms and inform the design of future clinical trials.

Trigeminal Neuralgia

Trigeminal neuralgia, also known as *tic douloureux*, is characterized by repetitive, unilateral, sharp, and lancinating pains in the distribution of, typically, the second, but sometimes third, branch of cranial nerve V, the trigeminal nerve. The patient may describe a "trigger point," an area on the face that elicits the pain when touched. A current leading etiologic hypothesis for trigeminal neuralgia is irritation and pulsatile compression of the root entry zone of the nerve by an artery in the posterior fossa, usually a loop of the superior cerebellar artery. The pain is excruciating and can be debilitating. Medical therapy, including carbamazepine and amitriptyline, may

reduce the frequency of events. Options for medically refractory cases include percutaneous injection of glycerol into the path of the nerve, peripheral transection of the nerve branches, SRS, and microvascular decompression (MVD).

MVD involves performing a small posterior fossa craniotomy on the side of the symptoms, retraction of the cerebellar hemisphere, and exploration of cranial nerve V. If an artery is found near the nerve, the vessel is freed of any adhesions and nonabsorbable material is placed between the nerve root and the artery. MVD remains the first definitive management option because SRS is associated with a substantial incidence of facial numbness.^{56,57}

STEREOTACTIC RADIOSURGERY

The term *stereotactic radiosurgery* (SRS) refers to techniques that allow delivery of high-dose radiation that conforms to the shape of the target and has rapid isodose fall-off, minimizing damage to adjacent neural structures. The two most common devices used for conformal SRS for intracranial lesions are the LINAC (linear accelerator) and the gamma knife. LINAC delivers a focused beam of X-ray radiation from a port that arcs part way around the patient's head. Linear accelerators are commonly used to provide fractionated radiation for lesions outside the CNS. They are found in most radiation oncology departments. After upgrades to the software and collimators, SRS can be performed with these existing units. The gamma knife delivers 201 focused beams of gamma radiation from cobalt sources through a specially designed colander-like helmet. Gamma knife units are used only for intracranial disease and cost up to \$5 million; thus, they are most appropriate in high patient-volume centers. There is ongoing debate in the literature regarding the two technologies.^{58–60} Both continue to evolve, allowing more precise and complex isodose conformation to complex lesions. Most lesions can be treated equally well with either technology. Lesions abutting the medulla or the spinal cord should not be treated with SRS, because these structures do not tolerate the radiation dose delivered to structures within millimeters of the target. Also, medullary or spinal cord compression can result from swelling of the lesion after the radiosurgery dose, resulting in devastating neurologic deficit.

Proton beam is an evolving SRS technology that may play a specialized role in treatment of lesions where posttarget exiting radiation limits photon-based therapies.⁶¹ For example, the physical properties of protons cause destruction upon entry and exit from tissue, which can be particularly harmful to skull-base or clival lesions such as chordoma, in which the exiting pathway travels through the brain stem. Proton beam therapy uses accelerated protons, which dissipate energy upon impact and do not cause additional exiting damage. Currently, there are very few centers using this technology.

CyberKnife is another radiosurgery system that has neurosurgical application. It is a frameless, robotic, LINAC-based system that allows for targeting of spinal neoplasms with higher resolution than conventional external beam radiotherapy.⁶² Using imaging tracking in real time, the CyberKnife is able to adjust to breathing artifact and patient movement. The application of this technology is rapidly growing.

Arteriovenous Malformations

SRS has been found to be an effective stand-alone therapy for AVMs up to 3 cm in diameter. SRS is best for lesions that are difficult to access surgically due to high likelihood of postoperative neurologic deficit. However, SRS is not effective

for lesions >3 cm. Effective obliteration and elimination of the risk of hemorrhage takes 2 to 3 years. Overall, there is an approximately 2% annual incidence of AVM hemorrhage,⁶³ although one study found a 50% decrease in hemorrhage rate during the latency period before angiographic obliteration.⁶⁴ Nonetheless, surgical excision remains the preferred therapeutic modality, while SRS is reserved for cases deemed very high-risk for surgery due to location or patient factors.⁶⁵ Some patients with large AVMs who undergo surgery will have unresectable residual lesions. In these patients, SRS may be used as an effective adjunctive therapy in these patients.

Vestibular Schwannomas

SRS has been introduced as a therapeutic alternative to microsurgical resection for vestibular schwannomas up to 2.5 cm in maximum diameter. SRS provides high rates of tumor growth arrest and possible reduction in size with low rates of facial nerve palsy. Patients with functional ipsilateral preprocedure hearing may be more likely to retain functional hearing postprocedure than with microsurgery. The limitations of SRS include inability to treat tumors >2.5 cm, the possibility of radiation-induced malignant transformation of these benign tumors, and lack of long-term follow-up. SRS centers are accumulating experience with these tumors and accumulating data on long-term results.^{66,67} The indications for microsurgery and SRS will continue to evolve. Either approach should be undertaken at a high-volume center, as studies show the patient outcomes improve with increased surgeon experience.⁶⁸

Intracranial Metastases

Patients with solitary or multiple intracranial metastases may be treated primarily with SRS.⁶⁹ Patients have improved survival after SRS compared to no treatment or WBRT, and similar survival to patients undergoing total surgical resection. Patients with lesions >3 cm in diameter or evidence of ICH should undergo surgical decompression rather than SRS. Some studies show improved survival with up to seven intracranial masses. Patients with multiple intracranial masses have almost zero long-term survival, and most will die of their intracranial disease. Patients with intracranial metastases live 3 to 6 months on average with medical care and WBRT. This can be extended to 9 to 16 months with SRS or surgery, depending on tumor type, age, and patient condition.⁷⁰

CONGENITAL AND DEVELOPMENTAL ANOMALIES

Dysraphism

Dysraphism describes defects of fusion of the neural tube involving the neural tube itself, or overlying bone or skin. Dysraphism may occur in the spine or head. Neural tube defects are among the most common congenital abnormalities. Prenatal vitamins, especially folic acid, reduce the incidence of neural tube defects.

Spina Bifida Occulta

Spina bifida occulta is congenital absence of posterior vertebral elements. The spinous process is always missing, the laminae may be missing to various degrees, but the underlying neural tissues are not involved. Spina bifida occulta is found in 25% of the general population, and is asymptomatic unless associated with other developmental abnormalities.

Spina Bifida with Myelomeningocele

Spina bifida with myelomeningocele describes the congenital absence of posterior vertebral elements with protrusion of the meninges through the defect, with underlying neural structural abnormalities. Common findings include weakness and atrophy of the lower extremities, gait disturbance, urinary incontinence, constipation, and deformities of the foot. Myelomeningoceles arising from the high lumbar cord usually cause total paralysis and incontinence, while those arising from the sacral cord may have only clawing of the foot and partial urinary function loss. Myelomeningocele patients often have hydrocephalus and a Chiari II malformation, an abnormal downward herniation of the cerebellum and brain stem through the foramen magnum. Patients with abnormal protrusion of meninges through the bony defect without abnormalities of the underlying neural tissue have a meningocele. Most of these patients are neurologically normal.

Encephalocele

Herniation of brain encased in meninges through the skull that forms an intracranial mass is referred to as *encephalocele*. Herniation of meninges without brain tissue is referred to as a *meningocele*. Most occur over the convexity of the skull. More rarely, the tissue protrudes through the skull base into the sinuses. Treatment involves excision of the herniated tissue and closure of the defect. Most patients with encephaloceles and meningoceles have impaired cognitive development. Patients with greater amounts of herniated neural tissue tend to have more severe cognitive deficits.

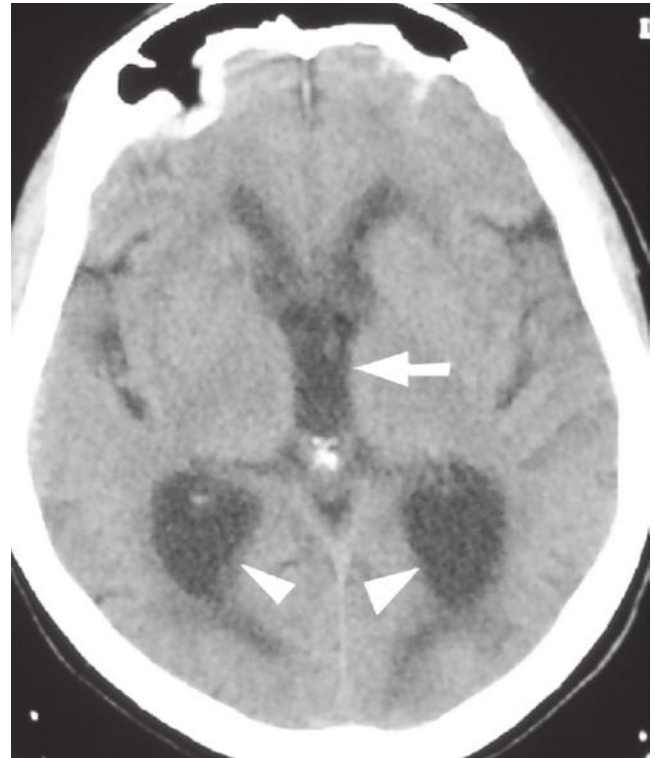Craniosynostosis

Craniosynostosis is the abnormal early fusion of a cranial suture line with resultant restriction of skull growth in the affected area and compensatory bulging at the other sutures. Skull growth occurs at the cranial sutures for the first 2 years of life, at the end of which the skull has achieved >90% of its eventual adult size. Fusion of the sagittal suture, or sagittal synostosis, results in a boat-shaped head, known as *scaphocephaly*. Unilateral coronal synostosis results in ipsilateral forehead flattening and outward deviation of the orbit, known as *plagiocephaly*. The contralateral normal forehead appears to bulge by comparison. Bilateral coronal synostosis results in a broad, flattened forehead, known as *brachycephaly*, and is often associated with maxillary hypoplasia and proptosis. Unilateral or bilateral lambdoid synostosis results in flattening of the occiput. Occipital flattening can result from abnormal suture fusion (synostosis), or from physical remodeling of the skull caused by always placing the baby in the supine position for sleep (known as *positional plagiocephaly*). Placing the baby in the prone position or tilted onto the contralateral side may restore near-normal skull shape in most cases of lambdoid synostosis, avoiding surgery. Treatment for synostoses in general is surgical, involving resection of the fused suture, or more complex reconstructive techniques for severe or refractory cases.

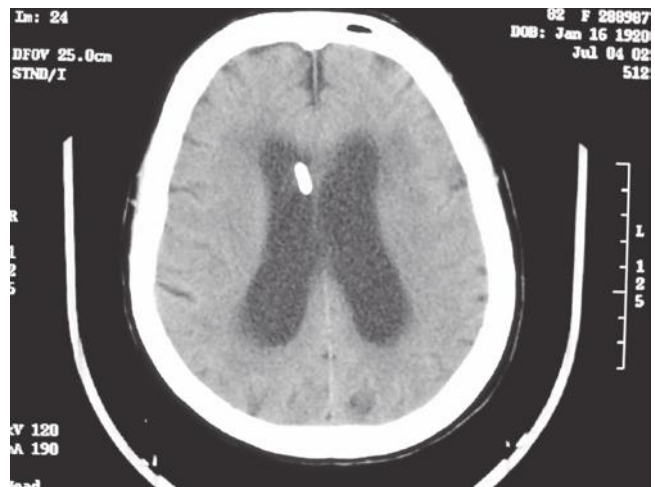Hydrocephalus

Excess CSF in the brain that results in enlarged ventricles is known as *hydrocephalus*. CSF flows from the ventricles to the subarachnoid space and is then absorbed into the venous blood through the arachnoid granulations. Hydrocephalus may be classified as communicating or obstructive (outlined in the next two sections), and congenital or acquired. Congenital lesions

associated with or causing hydrocephalus include stenosis of the cerebral aqueduct, Chiari malformation, myelomeningocele, and intrauterine infection. Acquired hydrocephalus may result from occlusion of arachnoid granulations by meningitis, germinal matrix hemorrhage, or SAH. CSF pathways may be occluded by adjacent tumors (Fig. 42-33).



A



B

Figure 42-33. **A.** Axial head computed tomography scan revealing dilated ventricular system. Note dilated atria of the lateral ventricles (*arrowheads*) and rounded third ventricle (*arrow*). The large size of the ventricles and lack of transependymal flow indicate a chronic process (contrast to Fig. 42-2). The patient had normal-pressure hydrocephalus and had improved ambulation after placement of a ventriculoperitoneal shunt. **B.** Higher cut from same scan showing ventricular catheter in place in the frontal horn of the right lateral ventricle.

Communicating Hydrocephalus. Obstruction at the level of the arachnoid granulations constitutes communicating hydrocephalus. This usually causes dilation of the lateral, third, and fourth ventricles equally. The most common causes in adults are meningitis and SAH. Hydrocephalus may be transient after SAH, with re-establishment of normal CSF absorption after the protein content of the CSF returns to normal and the granulations reopen.

Obstructive Hydrocephalus. Obstruction of CSF pathways is known as *obstructive hydrocephalus*. Ventricles proximal to the obstruction dilate, while those distal to the obstruction remain normal in size. Typical patterns include dilation of the lateral ventricles due to a colloid cyst occluding the foramen of Monro, dilation of the lateral and third ventricles due to a tectal (midbrain) glioma or pineal region tumor occluding the cerebral aqueduct, or dilation of the lateral and third ventricles with obliteration of the fourth ventricle by an intraventricular tumor of the fourth ventricle. Obstructive hydrocephalus may present precipitously and require urgent shunting to prevent herniation.

Chiari I Malformation

Chiari I malformation is the caudal displacement of the cerebellar tonsils below the foramen magnum. It may be seen as an incidental finding on MRI scans in asymptomatic patients. Symptomatic patients usually present with headache, neck pain, or symptoms of myelopathy, including numbness or weakness in the extremities. A syrinx may be associated, but the brain stem and lower cranial nerves are normal in Chiari I malformations. Chiari II malformations are more severe and involve caudal displacement of the lower brain stem and stretching of the lower cranial nerves. Symptomatic patients may be treated with suboccipital craniectomy to remove the posterior arch of the foramen magnum, along with removal of the posterior ring of C1. Removal of these bony structures relieves the compression of the cerebellar tonsils and cervicomedullary junction, and may allow re-establishment of normal CSF flow patterns. Figure 42-34 demonstrates typical MRI appearance of a Chiari I malformation.

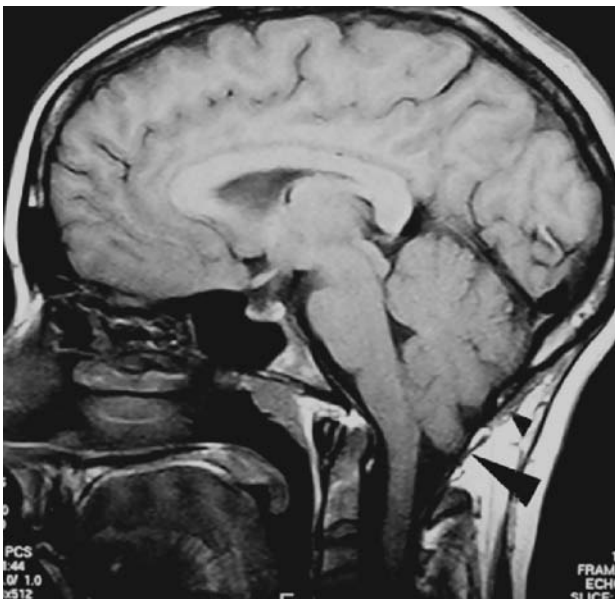


Figure 42-34. T1-weighted sagittal magnetic resonance imaging of a patient with a Chiari I malformation. The *large arrowhead* points to the cerebellar tonsils. The *small arrowhead* points to the posterior arch of the foramen magnum.

REFERENCES

Entries highlighted in bright blue are key references.

- Kandel E, Schwartz J, Jessell T. *Principles of Neural Science*, 4th ed. New York: McGraw-Hill Professional;2000.
- Stiefel MF, Spiotta A, Gracias VH, et al. Reduced mortality rate in patients with severe traumatic brain injury treated with brain tissue oxygen monitoring. *J Neurosurg*. 2005;103:805-811.
- Masters SJ, McClean PM, Arcarese JS, et al. Skull x-ray examinations after head trauma. Recommendations by a multidisciplinary panel and validation study. *N Engl J Med*. 1987;316:84-91.
- Bullock MR, Chesnut R, Ghajar J, et al. Surgical management of depressed cranial fractures. *Neurosurgery*. 2006;58:S56-S60.
- Brain Trauma Foundation, American Association of Neurological Surgeons, Congress of Neurological Surgeons. Guidelines for the management of severe traumatic brain injury. *J Neurotrauma*. 2007;24:S91-S95.**
- Temkin NR, Dikmen SS, Wilensky AJ, et al. A randomized, double-blind study of phenytoin for the prevention of post-traumatic seizures. *N Engl J Med*. 1990;323:497-502.
- Ingebrigtsen T, Romner B. Routine early CT-scan is cost saving after minor head injury. *Acta Neurologica Scandinavica*. 1996;93:207-210.
- Stein SC, Ross SE: The value of computed tomographic scans in patients with low-risk head injuries. *Neurosurgery*. 1990;26:638-640.
- Kelly JP, Nichols JS, Filley CM, et al. Concussion in sports. Guidelines for the prevention of catastrophic outcome. *JAMA*. 1991;266:2867-2869.
- Bullock MR, Chesnut R, Ghajar J, et al. Surgical management of acute epidural hematomas. *Neurosurgery*. 2006;58:S7-S15.
- Jones NR, Molloy CJ, Kloeden CN, et al. Extradural haematoma: trends in outcome over 35 years. *Br J Neurosurg*. 1993;7:465-471.
- Bullock MR, Chesnut R, Ghajar J, et al. Surgical management of acute subdural hematomas. *Neurosurgery*. 2006;58:S16-S24.
- Howard MA III, Gross AS, Dacey RG Jr, et al. Acute subdural hematomas: an age-dependent clinical entity (see comment). *J Neurosurg*. 1989;71:858-863.
- Hamilton MG, Frizzell JB, Tranmer BI. Chronic subdural hematoma: the role for craniotomy reevaluated. *Neurosurgery*. 1993;33:67-72.
- Bullock MR, Chesnut R, Ghajar J, et al. Surgical management of traumatic parenchymal lesions. *Neurosurgery*. 2006;58:S25-S46.
- Lyrer P, Engelter S. Antithrombotic drugs for carotid artery dissection. *Stroke*. 2004;35:613-614.
- Maynard FM Jr, Bracken MB, Creasey G, et al. International standards for neurological and functional classification of spinal cord injury. American Spinal Injury Association. *Spinal Cord*. 1997;35:266.
- Denis F: The three column spine and its significance in the classification of acute thoracolumbar spinal injuries. *Spine* 1983;8:817-831.**
- Bracken MB, Shepard MJ, Collins WF, et al. A randomized, controlled trial of methylprednisolone or naloxone in the treatment of acute spinal-cord injury. Results of the second national acute spinal cord injury study (see comment). *N Engl J Med*. 1990;322:1405-1411.
- Bracken MB, Shepard MJ, Collins WF Jr, et al. Methylprednisolone or naloxone treatment after acute spinal cord injury: 1-year follow-up data. Results of the second national acute spinal cord injury study (see comment). *J Neurosurg*. 1992;76:23-31.

21. Hugenholtz H, Cass DE, Dvorak MF, et al. High-dose methylprednisolone for acute closed spinal cord injury—only a treatment option. *Can J Neurol Sci.* 2002;29:227-235.
22. Resnick DK, Kaiser MG, Fehlings M, et al: *Hypothermia and Human Spinal Cord Injury: Position Statement and Evidence Based Recommendations from the AANS/CNS Joint Section on Disorders of the Spine and the AANS/CNS Joint Section on Trauma.* Washington: AANS/CNS Joint Section of Disorders of the Spine and Peripheral Nerves; 2007.
23. Seddon HJ. Three types of nerve injury. *Brain.* 1943;66:237.
24. North American Symptomatic Carotid Endarterectomy Trial Collaborators. Beneficial effect of carotid endarterectomy in symptomatic patients with high-grade carotid stenosis. (see comment). *N Engl J Med.* 1991;325: 443-445.
25. The National Institute of Neurological Disorders and Stroke rt-PA Stroke Study Group. Tissue plasminogen activator for acute ischemic stroke. (see comment). *N Engl J Med.* 1995; 333:1581-1588.
26. Mendelow AD, Gregson BA, Fernandes HM, et al. Early surgery versus initial conservative treatment in patients with spontaneous supratentorial intracerebral haematomas in the International Surgical Trial in Intracerebral Haemorrhage (STICH): A randomised trial. *Lancet.* 2005; 365:387-397.
27. Molyneux A, Kerr R, Stratton I, et al. International subarachnoid aneurysm trial (ISAT) of neurosurgical clipping versus endovascular coiling in 2143 patients with ruptured intracranial aneurysms: a randomised trial (see comment) (reprint in *J Stroke Cerebrovasc Dis* 11:304, 2002). *Lancet.* 2002;360:1267-1274.
28. Mitchell P, Kerr R, Mendelow AD, et al. Could late rebleeding overturn the superiority of cranial aneurysm coil embolization over clip ligation seen in the international subarachnoid aneurysm trial? *J Neurosurg.* 2008;108:437.
29. Raftopoulos C, Goffette P, Vaz G, et al. Surgical clipping may lead to better results than coil embolization: results from a series of 101 consecutive unruptured intracranial aneurysms. *Neurosurgery.* 2003;52:1280, discussion 1287.
30. Patchell RA, Tibbs PA, Walsh JW, et al. A randomized trial of surgery in the treatment of single metastases to the brain. *N Engl J Med.* 1990;322:494-500.
31. Patchell RA, Tibbs PA, Regine WF, et al. Postoperative radiotherapy in the treatment of single metastases to the brain: a randomized trial. *JAMA.* 1998;280:1485-1489.
32. Aoyama H, Shirato H, Tago M, et al: Stereotactic radiosurgery plus whole-brain radiation therapy vs stereotactic radiosurgery alone for treatment of brain metastases: A randomized controlled trial. *JAMA.* 2006;295:2483-2491.
33. Patchell RA, Tibbs PA, Regine WF, et al. Direct decompressive surgical resection in the treatment of spinal cord compression caused by metastatic cancer: a randomised trial. *Lancet.* 2005;366:643-648.
34. Le Roux PD, Haglund MM, Harris AB. Thoracic disc disease: experience with the transpedicular approach in twenty consecutive patients. *Neurosurgery.* 1993;33:58-66.
35. Mulholland RC, Sengupta DK. Rationale, principles, and experimental evaluation of the concept of soft stabilization. *Eur Spine J.* 2002;11:S198-S205.
36. Dawson D, Hallett M, Wilbourn A. *Entrapment Neuropathy*, 3rd ed. Baltimore: Lippincott Raven;1999.
37. Darouiche RO. Spinal epidural abscess. *N Engl J Med.* 2006;355:2012-2020.
38. Benbadis SR, Heriaud L, Tatum WO, et al. Epilepsy surgery, delays and referral patterns—are all your epilepsy patients controlled? *Seizure.* 2003;12:167-170.
39. Rausch R, Kraemer S, Pietras CJ, et al. Early and late cognitive changes following temporal lobe surgery for epilepsy (see comment). *Neurology.* 2003;60:951-959.
40. Ben-Menachem E, Manon-Espaillet R, Ristanovic R, et al. Vagus nerve stimulation for treatment of partial seizures. A controlled study of effect on seizures. First International Vagus Nerve Stimulation Study Group. *Epilepsia.* 1994;35:616-626.
41. Handforth A, DeGiorgio CM, Schachter SC, et al. Vagus nerve stimulation therapy for partial-onset seizures: a randomized active-control trial. *Neurology.* 1998;51:48-55.
42. Amar AP, Heck CN, Levy ML, et al: An institutional experience with cervical vagus nerve trunk stimulation for medically refractory epilepsy: rationale, technique, and outcome. *Neurosurgery.* 1998;1265-1276.
43. Fields JA, Troster AI, Woods SP, et al: Neuropsychological and quality of life outcomes 12 months after unilateral thalamic stimulation for essential tremor. *J Neurol Neurosurg Psychiatry.* 2003;74:305.
44. Rehnrota S, Johnels B, Widner H, et al: Long-term efficacy of thalamic deep brain stimulation for tremor: Double-blind assessments. *Mov Disord.* 2003;18:163.
45. Kleiner-Fisman G, Herzog J, Fisman DN, et al: Subthalamic nucleus deep brain stimulation: Summary and meta-analysis of outcomes. *Mov Disord.* 2006;21:S290.
46. Perozzo P, Rizzone M, Bergamasco B, et al: Deep brain stimulation of the subthalamic nucleus in Parkinson's disease: Comparison of pre- and postoperative neuropsychological evaluation. *J Neurol Sci.* 2001;192:9.
47. Weaver FM, Follett K, Stern M, et al. Bilateral deep brain stimulation vs. best medical therapy for patients with advanced Parkinson disease: a randomized controlled trial. *JAMA.* 2009;301:63-73.
48. Follett KA, Weaver FM, Stern M, et al. Pallidal versus subthalamic deep-brain stimulation for Parkinson's disease. *N Engl J Med.* 2010;362(22): 2077-2091.
49. Vidailhet M, Vercueil L, Houeto JL, et al. Bilateral deep-brain stimulation of the globus pallidus in primary generalized dystonia. *N Engl J Med.* 2005;352(5): 459-467.
50. Goodman WK, Foote KD, Greenberg BD, et al. Deep brain stimulation for intractable obsessive compulsive disorder: pilot study using a blinded, staggered-onset design. *Biol Psychiatry.* 2010;67:535-542.
51. Lozano AM, Giacobbe P, Hamani C, et al. A multicenter pilot study of subcallosal cingulate area deep brain stimulation for treatment-resistant depression. *J Neurosurg* 2012;116:315-322.
52. Bewernick BH, Kayser S, Sturm V, et al. Long-term effects of nucleus accumbens deep brain stimulation in treatment-resistant depression: evidence for sustained efficacy. *Neuropsychopharmacology* 2012;37:1975-1985.
53. Fisher R, Salanova V, Witt T, et al. Electrical stimulation of the anterior nucleus of thalamus for treatment of refractory epilepsy. *Epilepsia.* 2010;51:899-908.
54. Vassoler FM, Schmidt HD, Gerard ME, et al. Deep brain stimulation of the nucleus accumbens shell attenuates cocaine priming-induced reinstatement of drug seeking in rats. *J Neurosci.* 2008;28:8735-8739.
55. Halpern CH, Tekriwal A, Santollo J, et al. Amelioration of binge eating by nucleus accumbens shell deep brain stimulation in mice involves D2 receptor modulation. *J Neurosci*, in press.
56. Barker FG II, Jannetta PJ, Bissonette DJ, et al. The long-term outcome of microvascular decompression for trigeminal neuralgia. *N Engl J Med.* 1996;334:1077-1083.
57. Kondo A. Microvascular decompression surgery for trigeminal neuralgia. *Stereotact Funct Neurosurg.* 2001;77:187-189.
58. Bova FJ, Goetsch SJ. Modern linac stereotactic radiosurgery systems have rendered the gamma knife obsolete. *Medical Physics.* 2001;28:1839-1841.
59. Konigsmairer H, de Pauli-Ferch B, et al. The costs of radiosurgical treatment: comparison between gamma knife and linear accelerator. *Acta Neurochirurgica.* 1998;140:1110-1111.

60. Suh JH, Barnett GH, Miller DW, et al. Successful conversion from a linear accelerator-based program to a gamma knife radiosurgery program: The Cleveland Clinic experience. *Stereot Funct Neurosurg.* 1999;72:159-167.
61. Chen CC, Chapman P, Petit J, et al. Proton radiosurgery in neurosurgery. *Neurosurg Focus.* 2007;23:E5.
62. Gerszten PC, Ozhasoglu C, Burton SA, et al. CyberKnife frameless stereotactic radiosurgery for spinal lesions: clinical experience in 125 cases. *Neurosurgery.* 2004;55:89-98, discussion 98-99.
63. Karlsson B, Lax I, Soderman M. Risk for hemorrhage during the 2-year latency period following gamma knife radiosurgery for arteriovenous malformations. *Int J Radiat Oncol Biol Phys.* 2001;49:1045-1051.
64. Maruyama K, Kawahara N, Shin M, et al. The risk of hemorrhage after radiosurgery for cerebral arteriovenous malformations. *N Engl J Med.* 2005;352:146-153.
65. Pan DH, Guo WY, Chung WY, et al. Gamma knife radiosurgery as a single treatment modality for large cerebral arteriovenous malformations. *J Neurosurg.* 2000;93:113-119.
66. Regis J, Pellet W, Delsanti C, et al. Functional outcome after gamma knife surgery or microsurgery for vestibular schwannomas. *J Neurosurg.* 2002;97:1091-1100.
67. Shin M, Ueki K, Kurita H, et al. Malignant transformation of a vestibular schwannoma after gamma knife radiosurgery. *Lancet.* 2002;360:309-310.
68. Elsmore AJ, Mendoza ND. The operative learning curve for vestibular schwannoma excision via the retrosigmoid approach. *Br J Neurosurg.* 2002;16:448-455.
69. Gerosa M, Nicolato A, Foroni R, et al. Gamma knife radiosurgery for brain metastases: a primary therapeutic option. *J Neurosurg.* 2002;97:515-524.
70. Pollock BE, Brown PD, Foote RL, et al. Properly selected patients with multiple brain metastases may benefit from aggressive treatment of their intracranial disease. *J Neurooncol.* 2003;61:73-80.

This page intentionally left blank

43 chapter

Orthopedic Surgery

Bert J. Thomas, Freddie H. Fu, Bart Muller,
Dharmesh Vyas, Matt Niesen, Jonathan Pribaz,
and Klaus Draenert

Introduction	1756	Collateral Ligaments / 1768	Orthopedic Pathology and Oncology	1778
Orthopedic Trauma	1756	Cruciate Ligaments / 1768	Diagnosis of Malignant Bone Tumors / 1778	
Introduction / 1756		Posterolateral Corner / 1769	Osteosarcoma	1779
Open Fractures / 1757		Hip	Parosteal Osteosarcoma / 1779	
Compartment Syndrome / 1757		Femoroacetabular Impingement / 1769	Periosteal Osteosarcoma / 1779	
Treatment of Fractures and Dislocations	1757	Spine	Paget's Sarcoma / 1779	
Clavicle Fractures / 1757		Spinal Trauma / 1770	Radiation-Induced Sarcoma / 1779	
Scapula Fractures / 1759		Occipital Cervical Dislocation / 1770	Ewing's Sarcoma	1779
Shoulder Dislocations / 1759		Fractures of C1 (Jefferson Fracture) / 1770	Cartilage Forming Tumors	1780
Proximal Humerus Fractures / 1759		Fractures of C2 (Odontoid Fracture) / 1770	Chondrosarcomas / 1780	
Humeral Shaft Fractures / 1759		Hangman's Fractures of C2 / 1770	Fibrous Lesions of Bone	1780
Distal Humerus Fractures / 1759		Compression Fracture of the Cervical Spine / 1770	Desmoplastic Fibroma / 1780	
Elbow Dislocations / 1759		Burst Fractures of the Cervical Spine / 1770	Malignant Fibrous Histiocytoma of Bone / 1780	
Radial Head Fractures / 1759		Unilateral and Bilateral Facet Dislocation / 1770	Malignant Vascular Tumors / 1780	
Olecranon Fractures / 1760		Clay-Shoveler's Injury / 1770	Hemangiopericytoma / 1780	
Forearm Fractures / 1760		Fractures of the Thoracic and Lumbar Spine	Angiosarcoma of Bone / 1780	
Pelvic Fractures / 1760		Thoracic Lumbar Spine Injury / 1770	Miscellaneous Tumors	1780
Acetabular Fractures / 1760		Compression Fracture / 1770	Giant Cell Tumor of Bone / 1780	
Hip Dislocations / 1760		Burst Fracture / 1771	Ossifying Fibroma and Adamantinoma / 1781	
Hip Fractures / 1760		Seatbelt Injuries (Flexion Distraction Injuries) / 1771	Primary Lymphoma of Bone / 1781	
Femoral Shaft Fractures / 1762		Fracture Dislocations of the Spine / 1771	Chordoma / 1781	
Distal Femur Fractures / 1762		Disc Herniation / 1771	Multiple Myeloma / 1781	
Knee Dislocations / 1762		Spinal Stenosis / 1771	Metastatic Bone Tumors	1781
Patella/Extensor Mechanism Injuries / 1762		Back Pain and Degenerative Disc Disease / 1771	Pediatric Orthopedics	1781
Tibial Plateau Fractures / 1762		Scoliosis / 1771	Birth Injuries	1781
Tibial Shaft Fractures / 1764		Idiopathic Scoliosis / 1772	Brachial Plexus Palsy / 1781	
Tibial Plafond (Pilon) Fractures / 1764		Neuromuscular Scoliosis / 1772	Cerebral Palsy / 1782	
Ankle Dislocations / 1764		Joint Reconstruction	Skeletal Growth / 1782	
Ankle Fractures / 1764		Introduction to Arthritis / 1772	Pediatric Fractures / 1782	
Calcaneal Fractures / 1764		Conservative Management and Prevention of Arthritis / 1772	Classification of Growth Plate Injuries / 1782	
Talus Fractures / 1764		Examination of the Patient / 1772	Diaphyseal Injuries in a Pediatric Patient / 1782	
Foot Fractures / 1765		Injections / 1772	Fractures of the Pediatric Hip / 1782	
Introduction	1765	Surgical Management of Arthritis / 1772	Fractures of the Femoral Shaft / 1782	
Sports Medicine / 1765		Computer Navigation and Joint Arthroplasty / 1776	Pediatric Ankle Fractures / 1783	
Shoulder	1765	Fixation Options in Joint Arthroplasty / 1776	Pediatric Elbow Fractures / 1783	
Rotator Cuff / 1765			Developmental Disease	1783
Shoulder Instability / 1765			Developmental Dysplasia of the Hip / 1783	
Superior Labrum and Biceps Tendon / 1766			Treatment of DDH / 1783	
Impingement Syndromes / 1766				
The Acromioclavicular Joint / 1766				
Knee	1767			
Menisci / 1767				

Key Point

- 1▶ The main principle of internal fixation for fracture care (most commonly intramedullary nails or plate and screw fixation) is to create a stable construct that will allow the fracture to heal in proper alignment.
- 2▶ Often, in open fractures, definitive treatment of the fracture is delayed until the wound is sufficiently cleaned and healthy soft tissue is available to cover the fracture.
- 3▶ When compartment syndrome is suspected, emergent fasciotomy must be performed in which the overlying tight fascia is released through long incisions. These must be done as soon as possible because the damage to muscles and nerves will result in irreversible necrosis and contractures causing severe loss of function.
- 4▶ Fractures of the scapula often result from significant trauma and can be associated with injuries to the head, lungs, ribs, and spine.
- 5▶ The shoulder is one of the most commonly dislocated joints and most dislocations are anterior. Posterior dislocations are associated with seizures or electric shock.
- 6▶ Humeral shaft fractures occur from direct trauma to the arm or from a fall on an outstretched arm, especially in elderly patients. The radial nerve spirals around the humeral shaft and is at risk for injury, therefore a careful neurovascular exam is important.
- 7▶ Hemorrhage from pelvic trauma can be life threatening. An important first line treatment in the emergency room is the application of a pelvic binder or sheet that is wrapped tightly around the pelvis to control bleeding.
- 8▶ In spinal injury spinal stability must be assessed, and the patient immobilized until his spine is cleared. CT scan is more reliable in assessing spine injury than plain radiographs.
- 9▶ Spinal cord injuries should be triaged to trauma centers since trauma center care is associated with reduced paralysis.
- 10▶ According to the CDC and the National Health Interview Survey approximately 50 million adults (22% of the US population) have been diagnosed with some form of arthritis. This number is projected to grow to an astounding 67 million adults by 2030 (or 25% of the U.S. population).
- 11▶ Weight loss of as little as 11 pounds has been shown to decrease the risk of developing knee osteoarthritis in women by 50%. Similarly, patients who engage in regular physical activity have been found to have lower incidence of arthritis.
- 12▶ Smaller incisions come with the disadvantage of decreased visualization intra-operatively and associated risks of component malposition, intraoperative fracture and nerve or vascular injury. The only documented benefit of minimally invasive techniques appears to be improved cosmesis.

INTRODUCTION

Orthopedic surgery is a specialty with which every physician should be familiar. Anyone who cares for patients in an outpatient or emergency room setting will find that the majority of presenting complaints involve the musculoskeletal system. A basic understanding of musculoskeletal anatomy is assumed, and understanding the principles of care for musculoskeletal trauma is essential.

For physicians, the field of orthopedics offers an array of subspecialties with such diversity that it seems that “there is something for everyone.” Trauma specialists have the satisfaction of physically putting complex fractures back together. Sports medicine offers remarkably rapid recovery in athletes who have suffered fibrocartilage tears with ever improving arthroscopic techniques and instrumentation. Spine surgeons see remarkable results from their minimally invasive microscopic techniques, while also managing massive deformities with new instrumentation and open surgery. Joint reconstruction is one of our most exciting subspecialties, working with orthopedic bioengineers to develop improved designs, biomaterials, and minimally invasive surgical approaches to return function faster for patients crippled by arthritis and injury. Musculoskeletal oncology offers the intellectual challenge of arriving at appropriate differential diagnoses as well as the technical challenge of limb salvage and major reconstructive surgery. Pediatric orthopedics is an especially challenging and rewarding

subspecialty because of the remarkable ability of children to heal even severe injuries rapidly and completely. The incredible array of congenital and developmental disorders makes pediatrics a uniquely intellectually challenging field as well. The authors hope that our readers will share our enthusiasm for orthopedic surgery and all of its subspecialties: trauma, sports, spine, joint replacement, musculoskeletal oncology, and pediatric orthopedics.

ORTHOPEDIC TRAUMA

Introduction

Musculoskeletal injuries resulting from trauma include fractures of bones, damage to joints, and injuries to soft tissues. Long bone fractures can be described as transverse, oblique, spiral, segmental, or comminuted (Fig. 43-1). The goals of treating musculoskeletal injuries are to restore the normal anatomy, immobilize injured extremities for both pain relief and to allow for healing, and to repair or reconstruct these injuries to restore function.

Fractures frequently result from high energy trauma as well as from falls onto an extremity (Fig. 43-2). The majority of fractures can heal well with immobilization, which stabilizes the fracture while new bone forms at the fracture site. Methods of immobilization can vary and depend on the fracture being treated. The most common tool used in orthopedics to

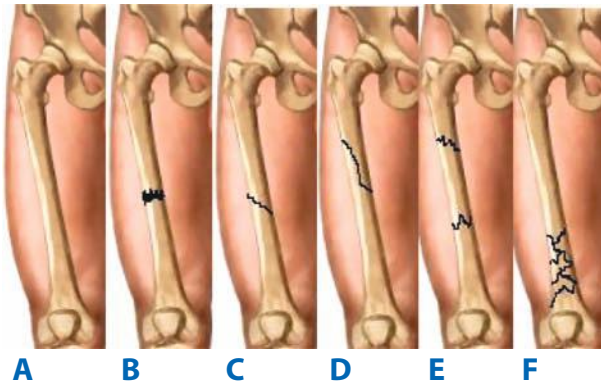


Figure 43-1. Types of fractures **A.** normal femur, **B.** transverse, **C.** oblique, **D.** spiral, **E.** segmental, **F.** comminuted.

treat fractures is immobilization with a splint or cast, and their proper application is important to successfully treat the injury without causing additional problems. A successful splint contains adequate padding on the underlying skin, and particularly over bony prominences, to prevent pressure or burns that can be caused by plaster. Splints, which are not circumferential, are preferred for acute injuries because they allow room for swelling which inevitably occurs after a fracture.

Fractures that are displaced or angulated require closed reduction to properly realign the bone. This is done using analgesia, local or general anesthesia, and often muscle relaxation. Reduction is performed with axial traction and reversal of the mechanism of injury in order to restore length, rotation, and angulation. A splint is then applied and can be gently molded to help hold the reduction in place. It is important to obtain X-rays after a close reduction to verify acceptable alignment of the fracture, and to perform a neurovascular exam to ensure the splint is not too tight.

For certain fractures, splint or cast immobilization alone is not enough and in these instances internal fixation is used.

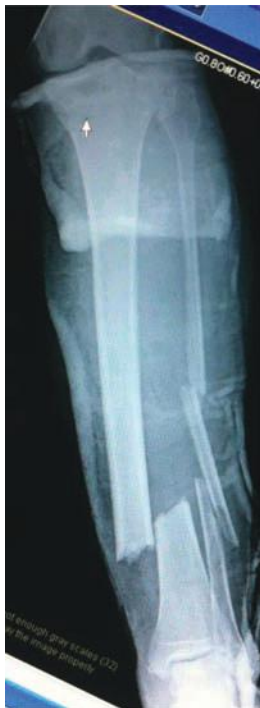

Figure 43-2. Transverse tibia fracture and segmental fibula fracture.

The main principle of orthopedic implants for fracture care is to create a stable construct that will allow the fracture to heal in

1▶ proper alignment. Screws can be placed across a fracture to create compression at the fracture site, which promotes healing. Plates can be placed on the cortex of bones and held with screws, which creates a long area of fixation to stabilize the fracture. Intramedullary rods are commonly used for long bone fractures, such as the femur and tibia (Fig. 43-3A). Prior to their placement, the marrow in the canal is usually removed with a reamer. The rod is then inserted into the canal. Screws can then be placed across the cortices of the bone through holes in the rod proximal and distal to the fracture to create a locked construct that further stabilizes the rod (Fig. 43-3B). In situations where patients are severely injured and cannot safely undergo surgery, or when the soft tissues are too swollen or injured to allow for surgical incisions to be safely made, an external fixation device can be used to temporarily immobilize the fracture. External fixators involve pins placed in bone proximal and distal to the fracture through healthy tissues that are connected by strong rods on the outside extremity, creating a stable construct.

Open Fractures

An open fracture occurs when the bone breaks through the skin. These typically result from high energy injuries and are often associated with significant damage to the surrounding soft tissues and contamination of the wound (Fig. 43-4A). These injuries require immediate irrigation and debridement in the operating room and treatment with antibiotics to prevent wound infections and osteomyelitis (Fig. 43-4B). They can also cause **2▶** injuries to surrounding vessels and nerves, which must be addressed as well. Often, definitive treatment of the fracture is delayed until the wound is sufficiently cleaned and healthy soft tissue is available to cover the fracture.

Compartment Syndrome

Compartment syndrome is an orthopedic emergency caused by significant swelling within a compartment of an injured extremity that jeopardizes blood flow to the limb. Increased pressure within the compartment compromises perfusion to muscles and can cause ischemia or necrosis. Patients complain of pain and numbness, and passive stretch of muscles within the compartment causes severe pain. While the diagnosis is based on clinical exam, pressures can be measured with needles placed into the compartment, which is necessary in unconscious patients who will not show these exam findings. When compartment syndrome is suspected, emergent fasciotomy must be performed in which the overlying tight **3▶** fascia is released through long incisions. These must be done as soon as possible because the damage to muscles and nerves will result in irreversible necrosis and contractures causing severe loss of function.

TREATMENT OF FRACTURES AND DISLOCATIONS

Clavicle Fractures

Fractures of the clavicle are one of the most common fractures in orthopedics. They typically occur following a fall onto the shoulder and the majority of clavicle fractures occur in the middle third of the clavicle. Since the bone is subcutaneous, the fracture is often evident on inspection. Most clavicle fractures can be treated nonoperatively with a sling, range of motion

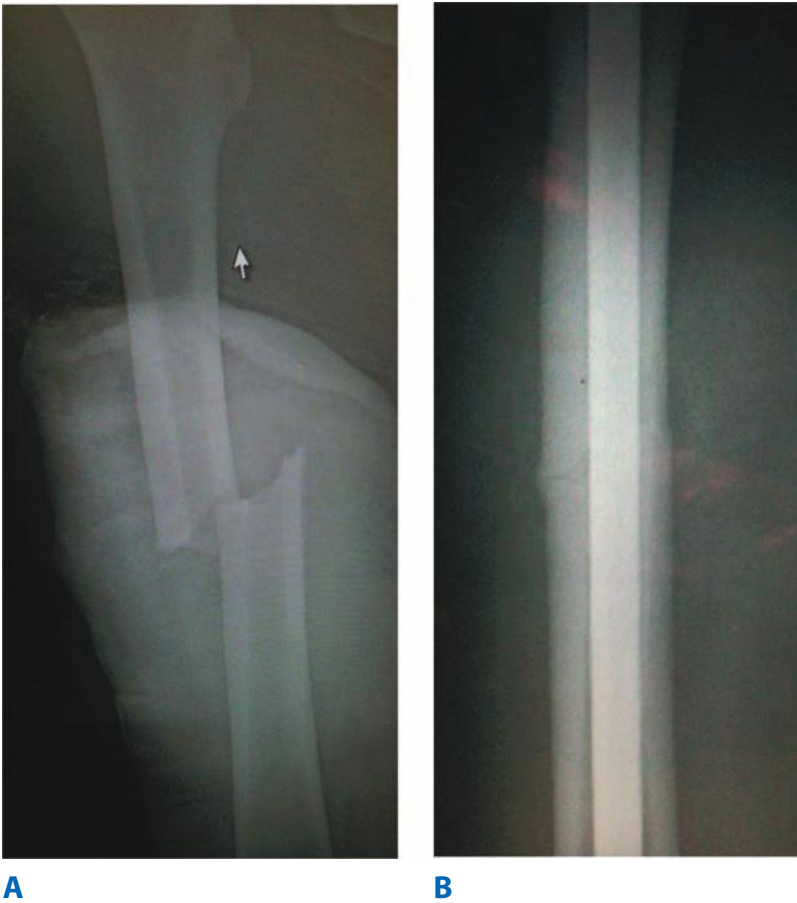


Figure 43-3. A. Transverse femur fracture. B. Intramedullary rod stabilizes femur fracture.

exercises, and gradual return to normal activities. Fractures that are significantly displaced and shortened, or that penetrate the skin, are treated with open reduction internal fixation, typically with plate and screw fixation.

Distal clavicle fractures are less common and may occur along with coracoclavicular ligament ruptures. These injuries can be more troublesome and are at risk for nonunion if the bone

ends are not in contact. If there is displacement of the fracture, surgical management is often recommended.

Acromioclavicular (AC) joint injuries occur from either a fall directly onto the shoulder or onto an outstretched hand and can result in tears of the acromioclavicular and coracoclavicular ligaments. A step-off, or separation, of the AC joint may be apparent on radiographs. The majority of

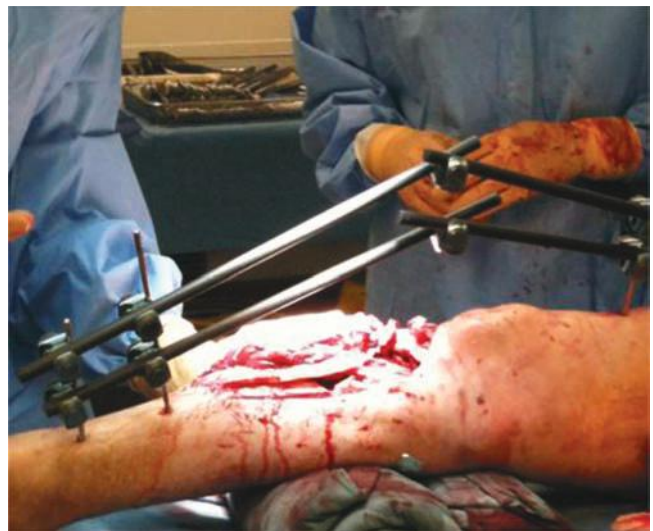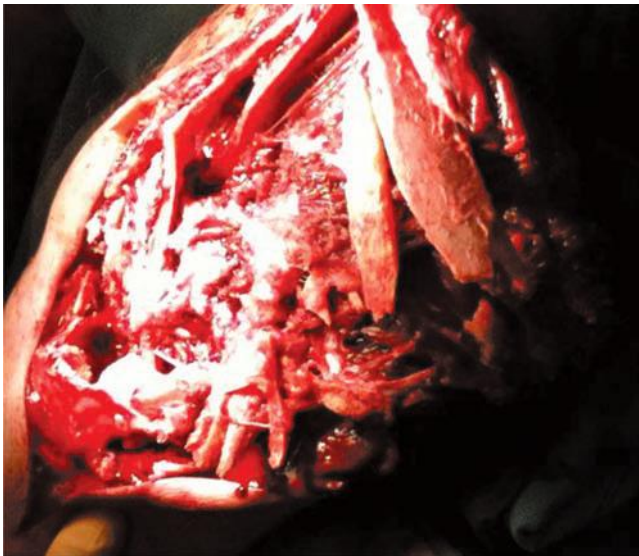


Figure 43-4. A. Open grade 3 comminuted tibia-fibula fracture (motorcycle injury). B. External fixator temporarily stabilizes grade 3 open tibia fracture.

these injuries can be treated with a sling and gentle range of motion. Injuries resulting in severe displacement of the clavicle may require open reduction and surgical repair.

The sternoclavicular (SC) joint is the only articulation between the upper extremity and the axial skeleton, and injuries to this joint are rare. Anterior dislocations occur more frequently and closed reduction can be attempted, followed by sling immobilization. Posterior SC joint dislocations can be dangerous, resulting in pulmonary or neurovascular compromise, and closed reduction under general anesthesia is recommended with a vascular surgeon present in case of vascular injury.

Scapula Fractures

Fractures of the scapula often result from significant trauma and can be associated with injuries to the head, lungs, ribs, and spine.

4► Most scapula fractures are treated nonoperatively with the exception of fractures to the glenoid. As with most intra-articular fractures, displacement of the articular surface of the glenoid is an indication for open reduction and internal fixation.

Shoulder Dislocations

The shoulder is one of the most commonly dislocated joints and most dislocations are anterior. They are often associated with injuries to the labrum (Bankart lesion), impression fractures of the humeral head (Hill-Sachs lesion), and rotator cuff tears. Posterior dislocations are associated with seizures or electric

5► shock. Adequate radiographs are required to diagnose a shoulder dislocation, with the axillary view being the most critical. If proper X-rays are not performed then dislocations can be missed and can result in significant debilitation of the shoulder. Dislocation of the shoulders can be managed with closed reduction followed by a short period of sling immobilization.

Proximal Humerus Fractures

Proximal humerus fractures occur most frequently in elderly patients following a fall onto the shoulder, though they can also occur following high-energy trauma. They have historically been classified by the number of fracture fragments using the Neer classification, which divides the proximal humerus into 4 parts: the humeral head, greater and lesser tuberosities, and the humeral shaft. Treatment is determined by the displacement of the fracture fragments, the amount of angulation of the fracture, and the amount of comminution (which means multiple fracture fragments). If there is suspicion of an intra-articular fracture, a computerized tomography (CT) scan is often indicated. The majority of proximal humerus fractures is minimally displaced and can be treated with sling immobilization, followed by early shoulder motion and pendulum exercises. Displaced fractures and fractures involving the humeral head are at increased risk for osteonecrosis and therefore surgery is often recommended. If there is adequate bone stock and the fracture can be successfully reduced, open reduction internal fixation with plate and screw fixation is the treatment of choice. Older patients with osteoporotic bone and comminuted fractures are typically treated with a prosthetic replacement of the humeral head, or a hemiarthroplasty.

Humeral Shaft Fractures

Humeral shaft fractures occur from direct trauma to the arm or from a fall on an outstretched arm, especially in elderly patients. The radial nerve spirals around the humeral shaft and

6► is at risk for injury, therefore a careful neurovascular exam is important. Most radial nerve injuries are neuropraxias,

or stretching of the nerve, and function typically returns in 3 to 4 months. The majority of humeral shaft fractures can heal with nonsurgical management if they are within an acceptable degree of angulation. They are treated with a coaptation splint or functional bracing, which consists of a plastic clamshell brace with Velcro straps. Close follow-up with serial radiographs is important to verify healing of the fracture, and gentle motion exercises are begun within 1 to 2 weeks. Fractures with significant angulation are most commonly treated with open reduction and plate fixation, with care to protect the radial nerve as it often lies close to the fracture site. Intramedullary nailing can also be performed, though it carries the risk of shoulder pain from the nail insertion.

Distal Humerus Fractures

Fractures of the distal humerus result from falls onto the elbow or onto an outstretched arm. Supracondylar fractures are most common, occurring above the elbow joint and do not involve the articular surface. Those minimally displaced can be treated with a posterior long arm splint, with the elbow typically flexed to 90 degrees. Fractures involving the articular surface are treated with plate fixation, and depending on the fracture pattern may require 2 plates, one placed medially and one posterolaterally. As with other intra-articular fractures, the goals of treatment are anatomic reduction of the joint surface with stable fixation, restoration of the anatomic alignment of the joint, and early range of motion. Severely comminuted fractures, especially in the elderly, may be treated with a total elbow replacement, which involves replacing the joint surfaces of the distal humerus, proximal ulna, and radial head with prosthetic components. Fractures about the elbow are notorious for developing stiffness and therefore early motion of the elbow is paramount to a successful outcome. Range of motion should be started as soon as the patient can tolerate therapy.

Elbow Dislocations

Dislocations of the elbow are common and typically occur posteriorly after a fall on an outstretched hand. A dislocation results in injury to the joint capsule and rupture of the lateral collateral ligament, though the medial collateral ligament can also be involved. They may even be associated with a fracture of the radial head, coronoid, or the epicondyles of the humerus. Simple elbow dislocations should be urgently reduced with the patient under sedation and treated briefly in a posterior long arm splint. Stiffness of the elbow is a common complication following elbow dislocations and therefore short-term immobilization (about 7–10 days) and early range of motion is recommended.

Dislocations associated with fractures may be treated surgically if there is any instability of the elbow joint. A severe injury, known as the “*Terrible Triad*,” includes an elbow dislocation, a radial head fracture, and a coronoid fracture. These are unstable injuries and require repair of the torn lateral collateral ligament (LCL), fixation or replacement of the radial head, and possible fixation of the coronoid depending on the size of the fracture fragment.

Radial Head Fractures

Most fractures of the radial head can be treated nonoperatively, simply with a sling for 1 to 2 days followed by motion exercises. However, if there is a displaced fracture or if the fracture blocks pronation or supination of the forearm, then surgery is recommended. If the fracture can be well reduced, it is fixed with 1 or 2 screws. If the radial head is fractured into multiple pieces, the treatment of choice is a radial head replacement with a

metallic implant. Excision of the radial head can also be performed, but this is reserved for elderly patients with limited demands and may contribute to elbow instability or wrist symptoms over time.

Olecranon Fractures

Olecranon fractures occur following a fall directly onto a flexed elbow. Nondisplaced fractures are treated with a splint in 45 to 90 degrees of flexion for a short time followed by range of motion exercises to prevent stiffness. Because the triceps inserts on the olecranon, the pull of the muscle often displaces the fracture, causing a loss of the ability to actively extend the elbow, and therefore should be fixed surgically. Simple transverse fractures can be fixed with a tension band construct, which consists of cerclage wiring passed through the ulna and wrapped in a figure-of-8 fashion around 2 pins placed proximally into the olecranon, creating a compressive force across the fracture to promote healing. Comminuted fractures are treated with plate and screw fixation. Because of the subcutaneous location of the olecranon, this hardware can be irritating to the patient and may need to be removed after the fracture has healed.

Forearm Fractures

Forearm fractures are common injuries that result from high energy trauma or from falls onto an outstretched arm. Both bone forearm fractures often require surgery with plate and screw fixation. The radius has a bow and rotates around the straight ulna for proper pronation and supination of the forearm, and therefore this anatomic relationship needs to be restored to maintain function. An isolated fracture of the ulna shaft, or a “nightstick fracture,” occurs from a direct blow to the side of the forearm. These can usually be treated in a cast, though fractures that are angulated or displaced can be treated with open reduction and plate fixation. A Monteggia fracture is an ulna shaft fracture along with a radial head dislocation. The radial head dislocation may be missed without radiographs of the elbow and therefore a fracture of the ulna should raise suspicion of this injury. These injuries require surgery to fix the ulna fracture with plate and screw fixation and to reduce radial head. A Galeazzi fracture is a radial shaft fracture with disruption of the distal radioulnar joint (DRUJ) at the wrist. After the radius is fixed with plate and screw fixation, the DRUJ is assessed for stability and may need wires placed across the joint temporarily.

Pelvic Fractures

Pelvic fractures are indicative of high energy trauma and are associated with head, chest, abdominal, and urogenital injuries. Hemorrhage from pelvic trauma can be life threatening and patients can present with hemodynamic instability, requiring significant fluid resuscitation and blood transfusions. The bleeding that occurs is often due to injury to the venous plexus in the posterior pelvis, though it can also be due to a large vessel injury such as a gluteal artery. Immediate resuscitation is critical and these patients may require surgical exploration or interventional radiology embolization to stop the bleeding. An important first-line treatment in the emergency room is the application of a pelvic binder or sheet that is wrapped tightly around the pelvis to help control bleeding. An external fixator may also be placed in the operating room. Other associated injuries are bladder and urethral injuries that manifest with bleeding from the urethral meatus or blood in the catheter and need to be assessed with a retrograde urethrogram.

The pelvis is a ring structure made up of the sacrum and the two innominate bones that are held together by

strong ligaments. Because it is a ring, displacement can only occur if the ring is disrupted in two places. This may occur either from fractures of the bones or tears of the ligaments. There are three main fracture patterns that occur from trauma to the pelvis. An anteroposterior force to the pelvis causes an “open book” injury pattern in which the pelvis springs open, hinged on the intact posterior ligaments with widening of the pubic symphysis. A lateral compression pattern results from a crush injury that causes fractures to the ileum, sacrum, and pubic rami. Vertical shear injuries are very unstable since they result from disruption of the strong posterior pelvic ligaments and are associated with significant blood loss and visceral injuries. Fractures of the sacrum may be difficult to see on x-ray and therefore CT scans are often needed to visualize the fracture pattern. The sacral nerves pass through foramen in the sacrum and therefore fractures that are close to this foramen can result in nerve injuries.

Treatment of pelvic fractures depends on the fracture pattern. Stable, minimally displaced fractures can be treated nonoperatively with protected weight bearing. Open book injuries in which the pubic symphysis is widened and the posterior pelvic ligaments are also injured need to be fixed surgically, which is typically performed with screws placed percutaneously through the ileum into sacrum to stabilize the pelvis posteriorly and a plate and screws over the pubic symphysis to stabilize it anteriorly. Displaced sacral fractures and iliac wing fractures are treated with screws or plates, while pubic rami fractures can usually be managed nonoperatively. While most pelvic fractures are caused by high energy trauma, elderly patients with osteoporotic bone can also suffer pelvic fractures after a fall, usually fracturing the pubic rami. Since these are stable injuries, they can be managed nonoperatively with protected weight bearing.

Acetabular Fractures

The acetabulum forms the socket of the hip joint, and fractures occur when the femoral head is driven into it in the setting of high energy trauma. CT scans are important to visualize the fracture pattern. These fractures often require surgery in order to restore a congruent, stable acetabulum, because incongruity of the hip can lead to early degenerative changes and osteoarthritis. These are best treated in the hands of experienced orthopedic trauma surgeons.

Hip Dislocations

Hip dislocations almost always result from high energy trauma and most commonly occur posteriorly. They can cause injury to the sciatic nerve, which runs directly posterior to the hip joint, and may be associated with a fracture of the acetabulum or femoral head. Hip dislocations need to be emergently reduced because of the risk of osteonecrosis of the femoral head when reduction is delayed. They can usually be reduced in the emergency room with adequate sedation and muscle relaxation, but sometimes patients need general anesthesia to aid in the reduction. If this is unsuccessful, or if a fracture fragment gets trapped inside the joint, then an open reduction is performed. Hip dislocations that are associated with a femoral head fracture are at increased risk for osteonecrosis of the femoral head and post-traumatic osteoarthritis.

Hip Fractures

Hip fractures are an extremely common injury seen in orthopedics and are associated with significant morbidity and mortality. They most often occur in elderly patients after ground level falls, are much more common in women than men, and

occur more commonly in patients with osteoporosis. Patients who suffer hip fractures are at increased risk for many complications, including deep vein thrombosis, pulmonary embolism, pneumonia, deconditioning, pressure sores, and even death, as the mortality rate in the first year following a hip fracture is around 25%. One of the most important reasons for performing surgery is to prevent these complications, and getting patients out of bed and walking as soon as possible diminishes their risk. Therefore, surgery is almost always the treatment of choice for hip fractures, and the type of surgery performed is determined by the anatomic location of the fracture and the fracture pattern. Surgery should be performed as soon as possible, typically within 24 to 48 hours; however, since many of these patients suffer other comorbidities, they must be properly medically optimized before surgery. The goals of surgery are to minimize pain, restore hip function, and allow early mobilization, the importance of which cannot be overemphasized. The functional outcome for patients following a hip fracture is largely based on their level of mobility and independence before their injury. Many patients become less independent, may require assistive devices to help them walk, and some may require a long-term nursing or rehabilitation facility.

Femoral Neck Fractures Femoral neck fractures occur with the capsule of the hip joint. The blood supply to the femoral neck and head comes from branches of the medial and lateral femoral circumflex arteries, which run along the femoral neck, and therefore fractures in this area put the vascular supply at risk and can lead to osteonecrosis. Femoral neck fractures that are nondisplaced have a low risk of disruption of blood flow and therefore can be treated with in situ internal fixation.

Three cancellous screws are placed through a small incision over the lateral proximal femur, directed up through the femoral neck and into the femoral head. Patients can usually begin protected weight bearing immediately after surgery. Displaced femoral neck fractures will likely disrupt the blood supply and therefore need to be treated with a prosthetic replacement. Most commonly a hemiarthroplasty is performed in which the femoral neck and head are replaced with a metal stem into the femoral canal and a metal head (Fig. 43-5A). Patients who have severe osteoarthritis of the hip joint and had significant arthritic hip pain before their fracture may receive a total hip replacement, in which the acetabulum is also replaced with a prosthesis, typically a plastic cup inside a metal shell (Fig. 43-5B). Patients can begin weight bearing immediately after surgery.

Intertrochanteric Hip Fractures. Intertrochanteric hip fractures occur between the greater and lesser trochanters of the proximal femur. Because the blood supply to this area is abundant, osteonecrosis is uncommon and therefore these fractures can be fixed with internal fixation. Displaced fractures need to be realigned, and this involves placing the patient on a fracture table where traction and rotation can be applied to the affected leg to reduce the fracture. There are two devices that can be used. A sliding hip screw includes a large screw placed from the lateral cortex of the proximal femur across the fracture and into the femoral neck and head, followed by a side plate along with lateral cortex of the femur, which is then fixed to the shaft with screws. A cephalomedullary nail includes a nail placed down the medullary canal from the piriformis fossa and a large screw that engages the nail as it is passed from the lateral cortex up into the neck and head. Both devices form stable constructs (though the

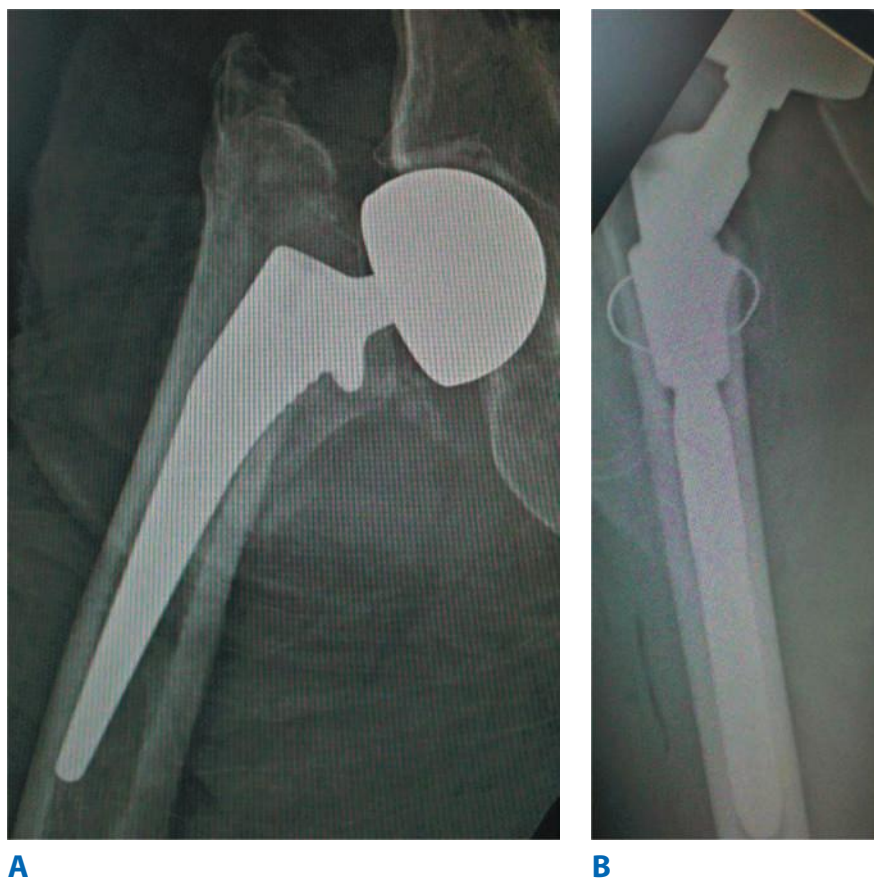


Figure 43-5. **A.** Failed hip hemiarthroplasty (periprosthetic fracture). **B.** Periprosthetic fracture repaired with modular femoral component.

cephalomedullary nail is preferred for certain fracture patterns) and allow protected weight bearing postoperatively.

Subtrochanteric Hip Fractures. Subtrochanteric hip fractures occur in the proximal femoral shaft just distal to the lesser trochanter in an area of high biomechanical stresses. While they can occur in elderly patients after a fall, they are also seen in high energy trauma. Because of the forces of muscles attached to the fractured segments, they tend to be significantly displaced and it can be difficult to reduce these fractures. They are most often treated with a long cephalomedullary nail that includes a screw distally to lock the nail in place and prevent rotation of the femur. Fractures that cannot be reduced closed on a fracture table or that are severely comminuted require open reduction followed by a cephalomedullary nail or by a plate and screws that is placed over the lateral cortex of the femoral shaft. In most cases, protected weight bearing can begin soon after surgery.

Femoral Shaft Fractures

Fractures of the femoral shaft are caused by high energy trauma and may be associated with other severe injuries. Long bone fractures, such as femoral shaft fractures, put these patients are risk for complications such as thromboembolic events and acute respiratory distress syndrome (ARDS), and therefore it is important to fix these quickly, typically within 24 hours. They are most commonly fixed with an intramedullary nail that can be placed antegrade (from the piriformis fossa or greater trochanter down the canal) or retrograde (through an incision into the knee joint and up the canal), with screws placed through proximal and distal holes to lock the nail in place, creating a stable fixation to allow weight bearing. Trauma patients who are hemodynamically unstable or who have other life-threatening injuries are treated temporarily with an external fixator until they can safely undergo surgery.

Distal Femur Fractures

Distal femur fractures are the result of a fall from a height or from high-energy trauma. They can also occur in elderly patients with osteoporotic bone after a fall onto the knee. While nondisplaced fractures in the elderly may be treated nonoperatively with a hinged knee brace and motion exercises, most require surgery. These fractures can involve the articular surface of the knee joint, so anatomic reduction of the joint surface is crucial. They are fixed with plates and screws placed over the medial or lateral cortex, depending on the fracture pattern, and early knee range of motion is encouraged to prevent stiffness. These intra-articular fractures require the patient to be nonweight bearing until the fracture shows signs of healing.

Knee Dislocations

Dislocation of the knee is a rare but devastating injury that can be limb-threatening. When the knee dislocates, the anterior cruciate ligament (ACL) and posterior cruciate ligament (PCL) are torn, and various degrees of injury occur to the LCL, medial collateral ligament (MCL), posterolateral corner, joint capsule, and menisci. The danger however is due to the close proximity of the popliteal artery that runs directly behind the knee, which may kink or suffer a tear of the intimal wall when the knee dislocates. A neurovascular exam is extremely important, followed by immediate reduction of the knee and repeat exam of the pulses. If there is evidence of diminished or absent pulses, an angiogram must be performed, and vascular surgery may need to perform emergent vascular repair. With regard to the

ligamentous injuries, an MRI will identify what structures have been torn. Because a dislocation causes so much damage to the knee, multiligamentous reconstruction is recommended in order to stabilize the knee joint. Stiffness and instability of the knee are common complications after this injury.

Patella/Extensor Mechanism Injuries

The extensor mechanism is comprised of the quadriceps tendon, the patella, and the patella ligament and functions to extend the knee. Injuries can result after a fall directly onto the knee or from forcible contraction of the quadriceps. It is important to examine the knee for the ability to actively extend the knee, since quadriceps tendon ruptures, patella fractures, or patella ligament ruptures can result in a loss of active knee extension, requiring surgery. Nondisplaced patella fractures can be treated nonoperatively with a cast or knee immobilizer, holding the knee in full extension, and weight bearing is permitted. Displaced or comminuted fractures require surgery with either tension band wiring or screws. Acute osteochondral fractures can be managed with internal fixation (Fig. 43-6A and B). Quadriceps tendon and patella ligament ruptures with loss of active knee extension are treated with suture repair. After surgery, the knee is held in extension and knee flexion is slowly increased over several weeks using a hinged knee brace.

Patella dislocations are common injuries that occur when the femur is forcibly internally rotated on an externally rotated tibia while the foot is planted on the ground. They typically dislocate laterally and often relocate spontaneously. Patients present with a significant knee effusion and on physical exam may elicit a positive apprehension test, in which a lateral force to the patella elicits pain and the sensation of an impending dislocation. Dislocated patellas can be reduced by extending the knee and manual reduction, and are treated with temporary knee immobilization. There is a high risk for recurrent dislocations, which may require surgical intervention. Osteochondral injuries to the trochlear groove and patella may be managed with the Draenert technique of autologous osteochondral transplant (Fig. 43-7A and B).

Tibial Plateau Fractures

The tibial plateau is comprised of the articular surfaces and underlying cancellous bone of the medial and lateral plateaus of the proximal tibia. Fractures of the plateau result from axial loads sustained in falls from a height or high energy trauma, and are often associated with injuries to the menisci and cartilage of the knee. Fractures can involve the medial, lateral, or both plateaus with significant comminution, angulation, and depression, creating a challenging injury to fix. A CT scan is important to visualize the intra-articular involvement of the fracture. Minimally displaced fractures may be treated nonoperatively with strict nonweight bearing until the fracture heals. Fractures associated with displaced articular fragments require surgery in order to restore the smooth contour of the articular surface. They are treated with plates and screws placed medially, laterally, or both. Since there is often a depression of the cancellous bone, bone graft or bone substitutes may be needed to buttress the articular surface and restore the anatomic alignment of the tibia. Patients are kept strictly nonweight bearing for several weeks until the fracture begins to heal, though early range of motion is encouraged. Repair of ligament or meniscus injuries may also be indicated at the time of surgery. Knee stiffness and osteoarthritis are common complications of these injuries.

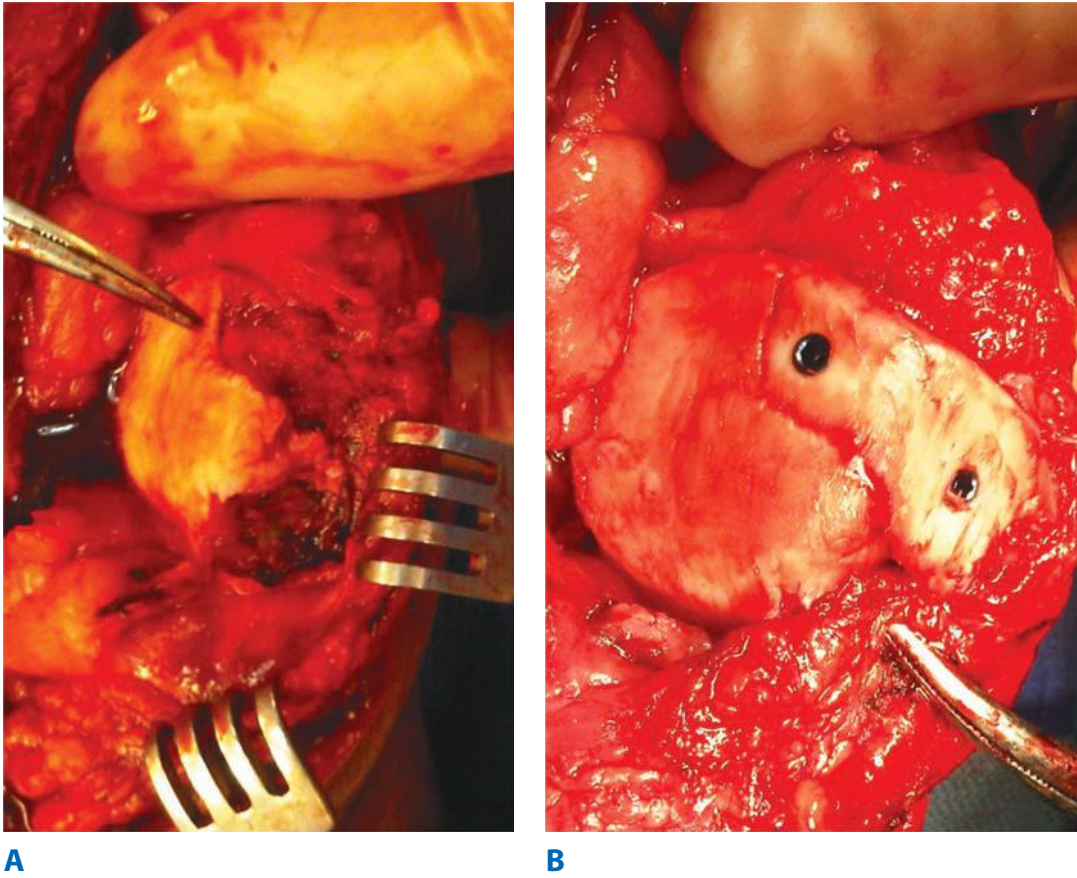


Figure 43-6. **A.** Osteochondral Patella Fracture. **B.** Internal fixation of osteochondralpatellar fracture.

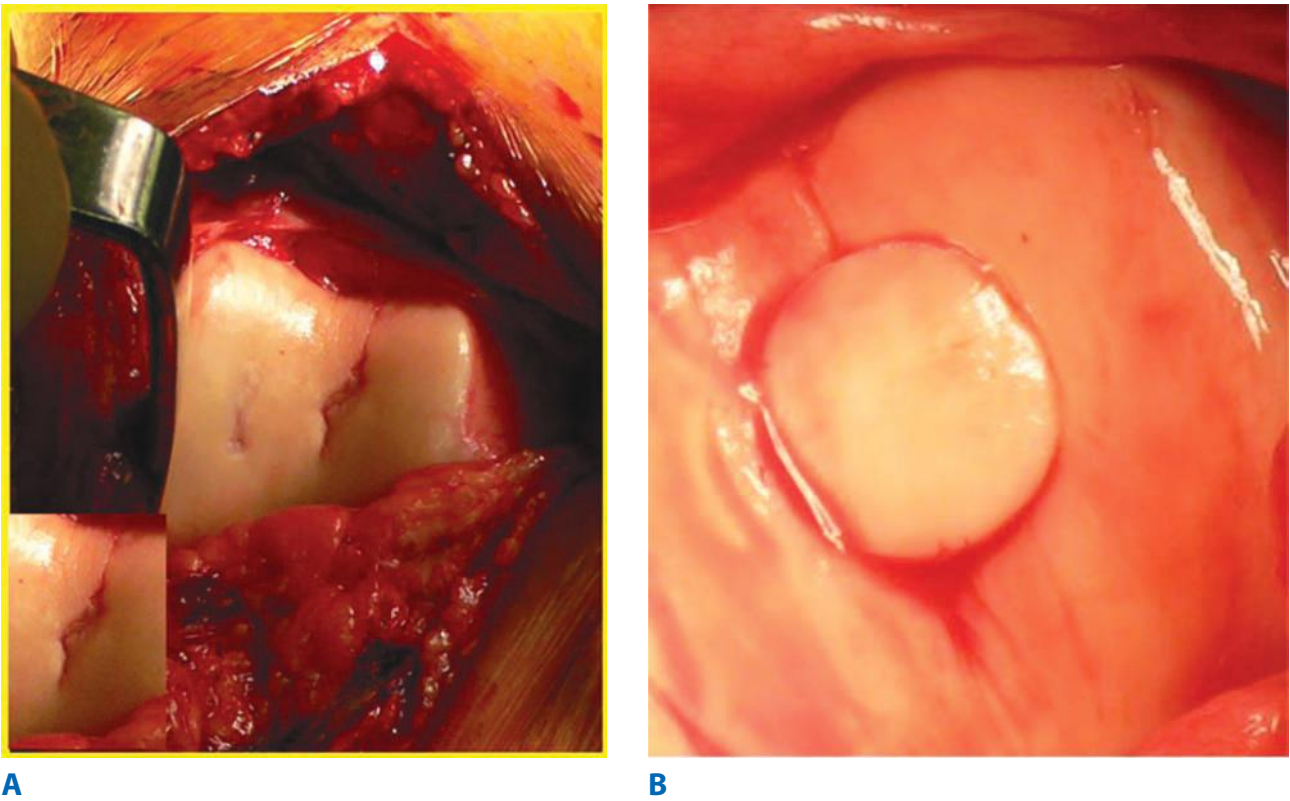


Figure 43-7. **A.** Knee traumatic articular lesion (trochlear groove). **B.** Lesion repaired with Draenert technique (autologous osteochondral transplant).

Tibial Shaft Fractures

Tibial shaft fractures are the most common long bone fractures and they occur following high energy trauma, direct blows, and severe twisting injuries. Trauma and direct blows to the tibia result in transverse or comminuted fracture patterns, while torsional injuries cause spiral fractures. Fractures with minimal angulation can be treated with reduction and casting, followed by transition to a functional brace and slow return to weight bearing, and may need to be immobilized for several months since these fractures can be slow to heal. Most tibial shaft fractures, especially comminuted and angulated fractures, are treated with an intramedullary nail placed down the tibial canal, with interlocking screws placed proximally and distally, and weight bearing can begin soon after surgery. Plate and screw fixation can also be used, however since the tibia is subcutaneous, hardware placed along the shaft can increase the risk of wound breakdown, and therefore intramedullary nailing is the preferred treatment. Fibula shaft fractures often occur along with tibial shaft fractures, though they usually heal well without surgery.

Tibial Plafond (Pilon) Fractures

The tibial plafond is the distal tibial articular surface of the ankle joint. Pilon fractures are typically high energy injuries from axial compression or a shear force. These injuries can cause significant soft tissue injury, severely comminuted intra-articular fragments, and wound healing problems, making these fractures very difficult to treat. Due to the soft tissue injury, these fractures are initially treated with external fixation until the swelling subsides, which may take several days to weeks. The goals of surgery are to restore the articular surface, fix the fibula in order to maintain and establish anatomic length, bone graft any cancellous bone defects, and stabilize the distal tibia with plate and screw fixation. Patients are kept nonweight bearing for many weeks until the fracture heals. Despite best efforts, patients may suffer from ankle pain and stiffness, arthritis, wound healing problems, infection, nonunion, and some patients eventually need ankle fusion in the future.

Ankle Dislocations

The ankle joint is a complex hinge joint comprised of the distal tibial plafond, medial malleolus, and lateral malleolus and their articulation with the talus. Several ligaments also contribute to the stability of the ankle joint, including the deltoid ligament medially, the syndesmotic ligaments between the tibia and fibula, and the anterior talofibular, posterior talofibular, and calcaneofibular ligaments laterally. Dislocations of the ankle joint result from a severe twisting injury and often occur with fractures. At times, dislocations can place significant pressure on the overlying skin and can cause neurovascular compromise, therefore prompt reduction is extremely important followed by splinting.

Ankle Fractures

Ankle fractures are very common and result from a twisting injury to the ankle. The patterns of ankle fractures depend on the direction of force and the position of the foot and ankle at the time of injury. The goals of treating ankle fractures are to restore the anatomy of the ankle joint and to restore the length and rotation of the fibula. Initial treatment includes closed reduction and placement of a well-padded splint in order to protect the skin. Swelling can be a significant problem so elevation of the foot is encouraged. If surgery is to be performed, it is usually delayed 1 to 2 weeks until the swelling decreases to limit the risk of wound healing problems.

Lateral Malleolus Fractures Isolated fractures of the lateral malleolus require anatomic reduction of the fracture in order to restore normal ankle joint congruity. The talus can sublux laterally following lateral malleolus fractures, and even 1 millimeter of talar shift decreases the surface contact between the talus and the tibia by 40%, increasing the risk of developing arthritis. Closed reduction and casting can be successful, however if the fracture cannot be adequately reduced, then open reduction internal fixation of the fibula is done with plate and screw fixation.

Medial Malleolar Fractures An isolated fracture of the medial malleolus is usually an avulsion-type injury. Minimally displaced fractures can be treated with a cast or walking boot, while displaced fractures are fixed with screws placed up through the tip of the malleolus.

Bimalleolar Fractures Fractures to both the medial and lateral malleoli often require surgery. These injuries are more unstable and the talus will often sublux or completely dislocate laterally. They are treated by reducing and fixing both malleoli during surgery. Occasionally, the posterior articular surface of the distal tibia, or posterior malleolus, can be fractured as well, resulting in a trimalleolar ankle fracture. Often it is a small fragment and does not need to be fixed, however if it involves >25% of the articular surface it should be fixed with screws placed either anteriorly or posteriorly.

Syndesmosis injuries The syndesmosis is comprised of several ligaments between the distal tibia and fibula that provide stability to the ankle joint by resisting axial, rotational, and translational forces. The syndesmosis can be disrupted at the time of ankle fractures and requires special attention. Widening of the space between the distal tibia and fibula after fixing the fractures is indicative of a syndesmosis injury and it is treated with 1 or 2 screws placed laterally from the fibula into the tibia, parallel to the ankle joint. Patients are kept non-weight bearing for several weeks. The screws are often removed after 12 weeks, though they can be left in place and are typically asymptomatic.

Calcaneal Fractures

Calcaneal fractures occur following a fall from a height and are often associated with other injuries, including lumbar spine fractures. These injuries are often intra-articular and can result in collapse of weight-bearing posterior facet of the calcaneus. CT scans are useful to better visualize the fracture pattern. Most fractures can be treated nonoperatively in a well-padded splint and patients are kept nonweight bearing for up to 12 weeks. Displaced intraarticular fractures can be treated surgically once the swelling subsides with lag screws or with a thin plate and screw fixation. Despite adequate treatment, calcaneal fractures can be debilitating injuries, leading to significant heel pain and arthritis.

Talus Fractures

Fractures of the talus commonly result from forced dorsiflexion of the ankle, causing the talar neck to impact on the anterior distal tibia. The blood supply to the talus can be jeopardized after a fracture and may lead to osteonecrosis, which is an unfortunately common complication following talus fractures. Nondisplaced fractures are treated with a cast and have a 15% risk of osteonecrosis, while displaced fractures are often treated surgically with screw fixation. There is a high risk of osteonecrosis, ranging from 30% to 100%, and a high risk of arthritis.

Foot Fractures

The tarsal bones, including the navicular, the cuboid, and the three cuneiform bones, link the hind foot to the metatarsals and provide mechanical stability to the arch of the foot. Isolated fractures to these bones are rare and are often treated nonoperatively with a cast or boot. The Lisfranc ligament, which connects the 2nd metatarsal head to the medial cuneiform, is an important stabilizer of the midfoot. Lisfranc injuries can be seen following torsional forces to the foot or from crush injuries. These injuries often require surgery since anatomic reduction is extremely important for a successful outcome. Metatarsal fractures similarly result from twisting or crush injuries and most can be treated nonoperatively with a hard-soled shoe and weight bearing as tolerated. The base of the 5th metatarsal, however, warrants close attention. Fractures at the metaphyseal-diaphyseal junction of the proximal 5th metatarsal (Jones fractures) can jeopardize blood flow and are at risk for nonunion. Therefore, Jones fractures need close follow-up to assess for healing and may need screw fixation. Injuries to the metatarsal-phalangeal joints and phalangeal fractures can be treated symptomatically or with buddy taping with weight bearing as tolerated in a hard-soled shoe.

INTRODUCTION

Sports Medicine

Sports medicine deals with the prevention and treatment of injuries related to sports and exercise. These injuries encompass various areas in the musculoskeletal system. In recent years, sports-related injuries have increased and the sports medicine field has been expanding. The growth in sports and sports-related injuries has likely to do with: a) that athletes participate in sport-specific training year round (and in multiple sports) rather than just seasonal training, b) that there has been an increase in “weekend warriors,” c) that patients have become more aware of physical fitness, are better educated, and have higher performance expectations, and d) that more people undertake recreational activities.

The orthopedic subspecialty of sports medicine treats a broad spectrum of patients, ranging from children who have just started participating in their first sports to the specialized care of professional athletes. Medical treatment of athletes, recreational or professional, can be complex as short- and long-term outcomes are influenced by the higher demand that athletes put on their bodies. Additionally, the orthopedic sports medicine specialist does not only treat the patient’s injuries, but also has to consider the return to activity in a later stadium. “Getting back in the game” is sometimes subject to pressure from third parties (e.g., team members, coaches, parents, fans), which makes treatment and the rehabilitation a challenging process.

Surgical intervention for ligament and cartilage injuries in sports medicine patients is usually done using arthroscopic techniques. The most frequently injured joints are the shoulder, hip and knee. Therefore, treatment of common injuries in these joints will be the scope of this paragraph.

SHOULDER

Rotator Cuff

Rotator cuff injuries are among the most common reasons to visit an orthopedic sports specialist. Often, these injuries are associated with either forceful or repeated overhead or pulling movements. The rotator cuff provides shoulder movement and

glenohumeral joint stability and injuries typically lead to pain, weakness and restricted movement of the arm. Over recent years, the treatment of the rotator cuff injuries has considerably improved with regard to indication for surgery, surgical techniques and rehabilitation protocols. With the introduction of arthroscopy, shoulder surgery has become less invasive with all advantages associated. Currently, it has been established that arthroscopic techniques are equal or superior to open techniques for most indications. Controversies surrounding rotator cuff repair remain and include, but are not limited to, use of acromioplasty, enhancement of healing with orthobiologics (Fig. 43-8), single- vs. double-row fixation and the treatment of massive or large tears. Rehabilitation after surgery plays an important role to restore strength, motion and function and to enable the patient to return to sports. Typically, rehabilitation is made up of three consecutive stages: immobilization, passive exercise, and active exercise. Immobilization and passive exercise usually start in the first 4 to 6 weeks after surgery. Immobilization can be established by using a sling and passive exercise should be initiated by the therapist. The therapist moves the arm in different positions to improve range of motion (ROM) while providing support. After 4 to 6 weeks, active exercises can be gradually introduced. At 8 to 12 weeks, muscle strength and improvement of arm control are increased by starting a strengthening exercise program.

Shoulder Instability

The most common etiology for shoulder instability is related to trauma, especially shoulder dislocation. After a shoulder has dislocated, it becomes vulnerable to repeat episodes of instability and may develop to being a chronic problem. Most of the shoulder’s stability is provided by the rotator cuff and shoulder capsule. The most common dislocation is in the anterior-inferior direction, although posterior dislocations do occur. Typically, patients with an anterior dislocation present with pain and an internally rotated shoulder. Younger patients are more susceptible to suffer from repeat dislocations than older patients.⁶⁻⁸ The position of the humeral head with respect to the glenoid and other bony pathology can be identified with radiographs. Views from different angles should be obtained to thoroughly evaluate; an anterior-posterior (AP) view, along with glenoid (axillary) view, and a “Y” view of the shoulder are recommended in assessing this injury. Since most of the shoulder’s stability is provided by soft tissue, usually this is also injured. Following successful reduction magnetic resonance imaging (MRI) should be obtained to identify underlying causes and concomitant injuries.

Relocation of the shoulder is generally accomplished with the patient in supine position and the arm under gentle traction and slight abduction. Some sedation is helpful as it relaxes the patient’s musculature and relieves the pain. Whether or not to immobilize a first-time-dislocated shoulder or not, remains controversial, as well as the position of immobilization or the early surgical repair of capsulolabral structures. Prolonged immobilization is not recommended since this will often lead to substantial stiffness in the shoulder and does not appreciably decrease the redislocation rate. A small minority of patients with atraumatic multidirectional instability can generally be treated with shoulder rehabilitation. Unfortunately, many patients experience recurrent dislocations, in which case surgical stabilization of the shoulder should be considered. Many open stabilizing procedures have been described and, depending on etiology,

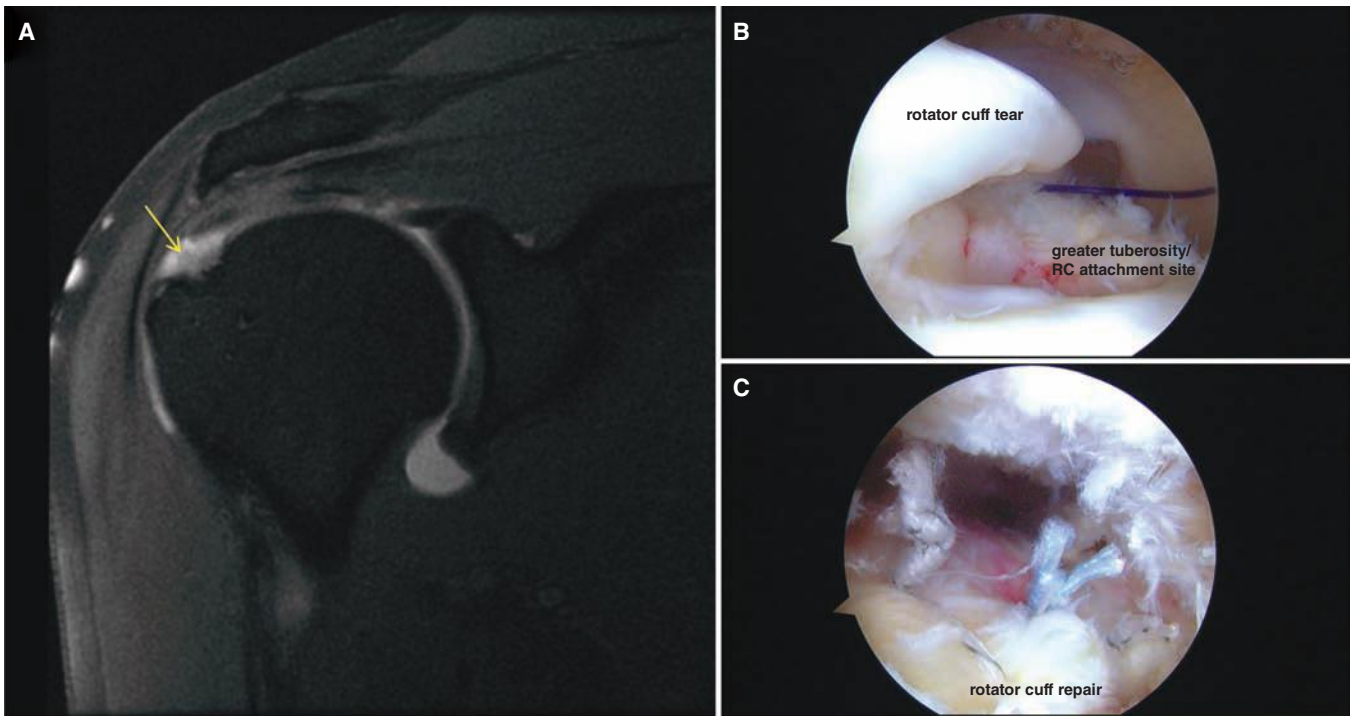


Figure 43-8. Imaging and treatment of rotator cuff tears. **A.** MRI coronal T2 image showing a full-thickness and moderately retracted tear (arrow) of the supraspinatus tendon. **B.** Arthroscopic image showing the supraspinatus tendon tear as viewed from a posterior portal during the surgery. **C.** Arthroscopic image showing completion of repair of the supraspinatus tendon tear using suture anchors imbedded in the greater tuberosity of the humerus and attached sutures that capture and reduce the torn tendon to its native insertion site.

many are still being applied such as the open Bankart repair, Latarjet procedure, remplissage and humeral head restoration. However, arthroscopic soft-tissue restoration has been the front-line treatment for recurrent instability. After surgery, the shoulder is temporarily immobilized with a sling. When the sling is removed, exercises to rehabilitate the ligaments, improve ROM and prevent from scarring, will be started. Strengthening exercises will gradually be added to the rehabilitation plan.

Superior Labrum and Biceps Tendon

The labrum helps to deepen the socket and stabilizes the glenohumeral joint. Additionally, it serves as an attachment point for many of the shoulder ligaments, as well one of the biceps tendons. A superior labrum anterior and posterior lesion may occur in the superior part of the labrum, usually anterior and posterior to the attachment of the biceps tendon, with occasional involvement of the biceps tendon in certain cases. Injuries to the superior labrum can be caused by trauma or by repetitive shoulder motion. Radiographs are generally obtained to evaluate for concomitant injuries or osteoarthritic changes. The labrum itself, and other soft tissue, is better visualized with MRI with addition of a gadolinium arthrogram adding sensitivity for labral injury detection (Fig. 43-9).

Conservative and operative treatments have had mixed results depending on the patient's age, activity level, type of tear and presence of concomitant injuries. If symptoms do not improve with adequate physical therapy and/or nonsteroidal anti-inflammatory drugs (NSAIDs), surgical intervention is usually indicated. Some SLAP injuries involve the biceps tendon, which may require either tenotomy or tenodesis.^{10,11}

After surgical labrum repair, the shoulder needs to be immobilized to protect the repair and allow for healing.

Usually a sling is used for 4 weeks after surgery. Then a physical therapy program will gradually start improving ROM and prevent from scar formation and stiffness to develop. As healing progresses, exercises to strengthen the shoulder muscles and the rotator cuff will gradually be added to the program around 4 to 6 weeks after surgery. Return to early interval throwing can generally be allowed around 3 to 4 months after surgery.

Impingement Syndromes

After minor trauma or repetitive injury, patients may experience pain and discomfort which can be due to irritation of the tissues in the subacromial space. In many cases these shoulder impingement syndromes are caused by simple bursitis or tendonitis of the long head of the biceps or supraspinatus tendon.⁵ Occasionally, impingement syndromes can progress to tears of the supraspinatus tendon, which can be confirmed by MRI or ultrasound.

The goal of treatment is to reduce pain and restore function. Initial treatment is generally nonsurgical and based on rest, NSAIDs, and physical therapy. If pain is not relieved, an injection of a local anesthetic and a cortisone preparation may be helpful.

If conservative treatment does not relieve pain, surgery is recommended, with the goal to excise the bursa and create more subacromial space. Generally, surgery is performed arthroscopically and encompasses bursectomy and subacromial decompression via acromioplasty. If the rotator cuff (supraspinatus tendon) is also injured, arthroscopic repair is usually indicated to restore function, sometimes is accompanied by a bony resection of the inferior portion of the acromion.

The Acromioclavicular Joint

The acromioclavicular joint is a gliding synovial joint and not very mobile. The joint is stabilized by three ligaments: the superior acromioclavicular ligament, the inferior acromioclavicular

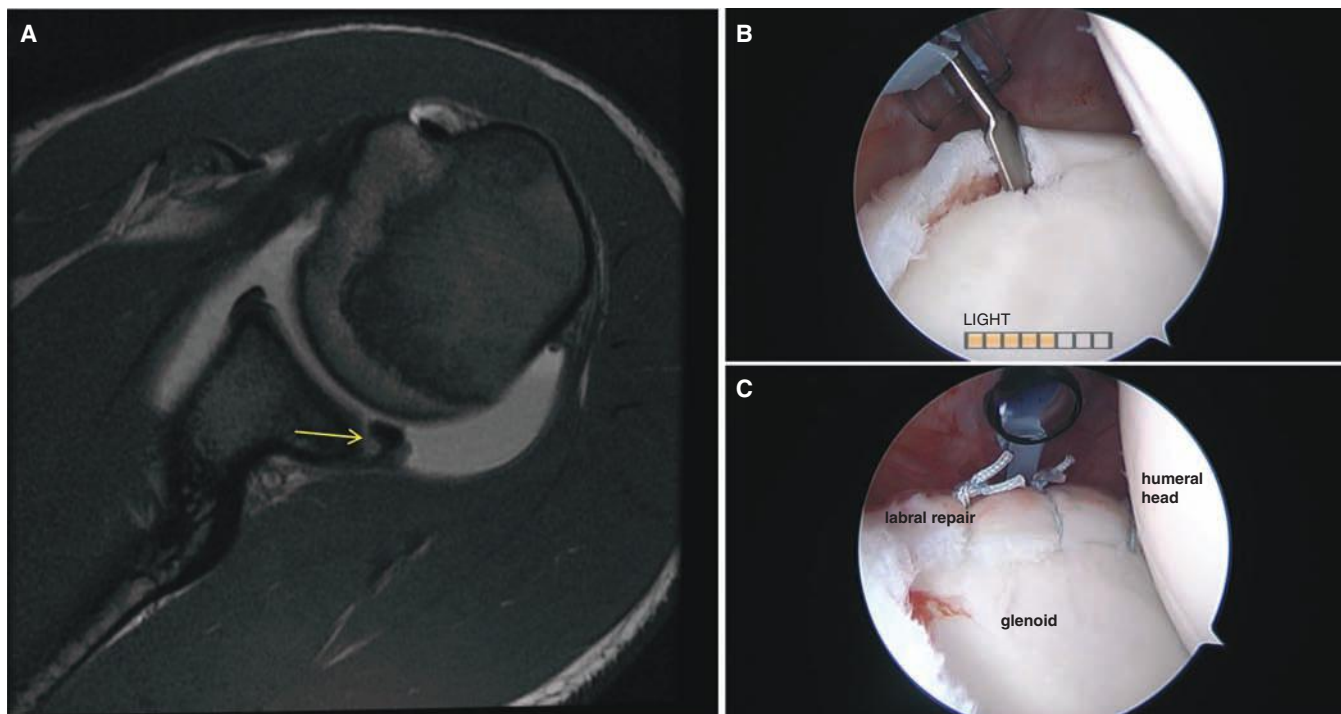


Figure 43-9. Imaging and treatment of a shoulder glenoid labrum tear. **A.** MRI axial T1 image showing a tear of the posterior superior labrum (arrow). **B.** Arthroscopic image with the patient in the lateral decubitus position showing detachment of the torn labrum away from the glenoid. **C.** Arthroscopic image demonstrating repair of the labrum to its attachment site using anchors in the glenoid and sutures that fixes the labrum to the glenoid.

ligament, and the coracoclavicular ligament. Injuries to these ligaments are commonly sustained playing contact sports such as football and ice hockey and may cause displacement of the joint. An acromioclavicular sprain is referred to as a shoulder separation and type I and II are usually treated symptomatically. Controversy exists however regarding early or delayed surgical reconstruction for type III tears. Frank tearing of the coracoclavicular ligaments, associated with significant displacement, is oftentimes reconstructed surgically.

KNEE

The knee is the largest joint in the human body and is a pivotal hinge joint, which allows flexion and extension as well as a medial and lateral rotation. The knee bears tremendous axial loads as well as torsional and shear forces, making it vulnerable to both acute injury and the development of osteoarthritis. In sports, the major stabilizing structures such as the ACL and the medial collateral ligament (MCL) are frequently injured. Other frequent knee injuries are to the menisci, posterolateral corner, the posterior cruciate ligament (PCL) or patellofemoral.

Menisci

The menisci are crescent-shaped pieces of fibrocartilage shaped that provide joint stability, shock absorption, load distribution, and proprioception. Sudden meniscal tears often happen during sports, usually during contact or while squatting and twisting the knee. Typical symptoms associated with meniscus injury are pain, stiffness and swelling, catching or locking of the knee, buckling or “giving way” and impaired ROM. Radiographs are typically obtained to assess possible concomitant injuries, the

presence of (early) osteoarthritis, and leg alignment. However, since menisci do not show on radiographs, an MRI is obtained to assess the status of the menisci and the soft tissue surrounding the knee joint (Fig. 43-10). Small tears on the outer edge of the meniscus may not cause symptoms and—provided the knee is stable—nonsurgical treatment may be sufficient.

The most commonly performed surgical procedure for meniscus tears is partial (subtotal) meniscectomy. However, it has become increasingly clear over recent years that preservation of the load-distributing function of the meniscus is important in preventing from development of early osteoarthritis. Research into the use of orthobiologics (e.g. microfracture of the notch, fibrin clot) for meniscal repairs has expanded the indications for repair over (subtotal) meniscectomy.¹⁵⁻¹⁹ Tears have been reported in virtually all portions of the meniscus, with radial and longitudinal tears being the most common. Tears of the root of the meniscus are less common, but are increasingly being recognized as devastating injuries that cause serious alterations of knee contact forces. Surgical techniques are developing to repair the root to restore its function.^{20,21} Meniscus transplantation may be an option for young patients with a largely deficient meniscus.²²

The paradigm of treatment of torn menisci is shifting thanks to the development of superior surgical techniques, use of orthobiologics and promising first results with root repair and meniscus transplantations. Physicians must be further educated on the significance of meniscal preservation when there is potential for healing.

Directly after surgery, the knee is immobilized with a brace and weight bearing is protected to allow the meniscus to heal. When healing is complete, ROM and strength will need

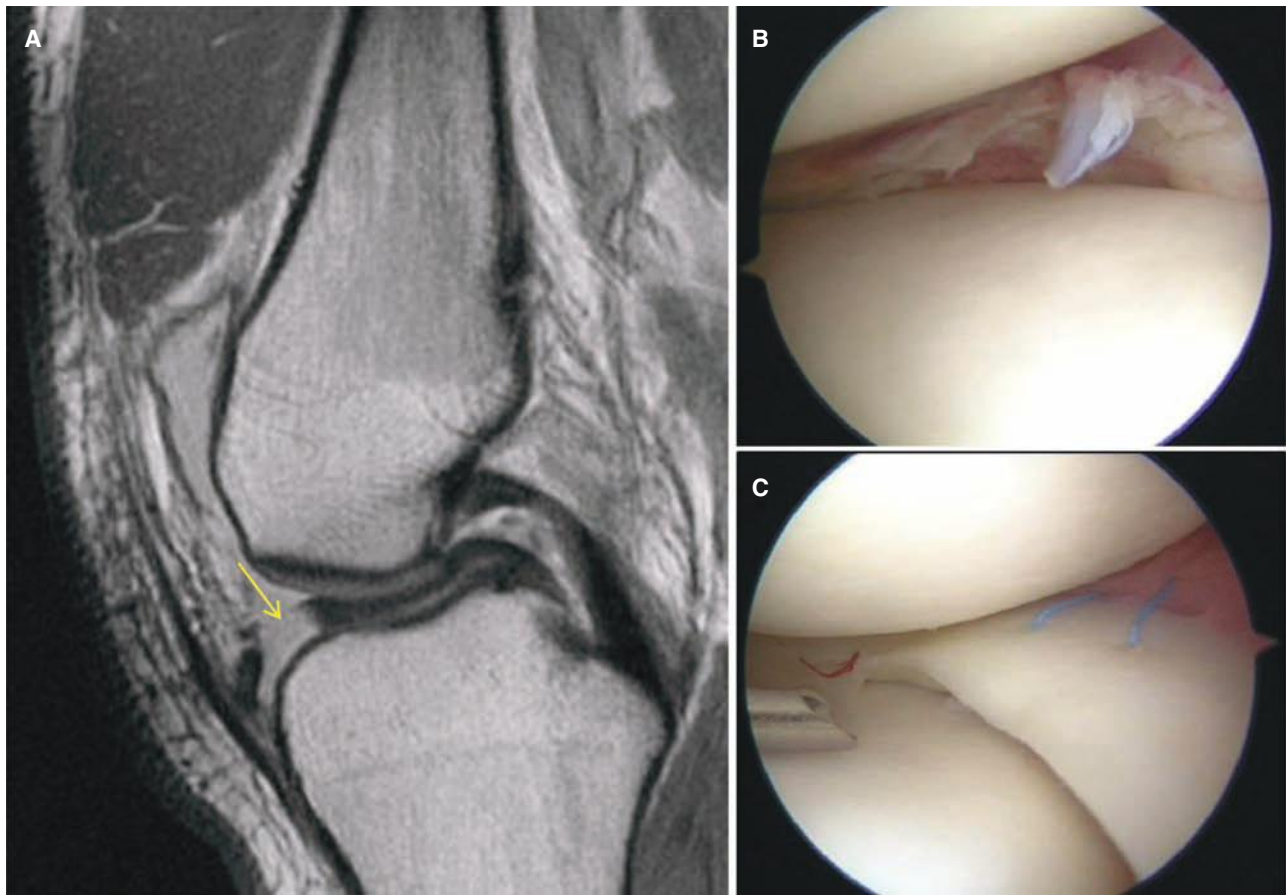


Figure 43-10. Imaging and treatment of a knee lateral and meniscus tear. **A.** MRI sagittal T2 image of the knee showing a displaced bucket-handle lateral meniscus tear (arrow). **B.** Arthroscopic image showing the remnant rim of the lateral meniscus prior to reduction and fixation of the torn bucket-handle fragment. **C.** Arthroscopic image after the torn segment is reduced and fixed to the remaining meniscus and the lateral capsule using suture.

to be regained. Physical therapy is an integral component of healing and return to play, which usually is allowed between 4 to 6 months after surgery.

Collateral Ligaments

The MCL is the most frequently injured knee ligament, which usually occurs after excessive valgus stress of the knee. Oftentimes, this is associated with (medial) meniscus injury and sometimes with an ACL. The combination of MCL, medial meniscus, and ACL injury is also known as the “unhappy triad” and occurs most commonly in contact sports.

The MCL has good healing potential and grade I and II injuries usually improve with bracing and activity modification. Grade III injuries may also improve with conservative treatment and often these injuries are treated non-operatively initially. The majority of MCL injuries occur in the mid-substance or at the femoral insertion side. There is a small subset of tibial sided grade III tears though, that is associated with worse clinical outcome and surgical repair is more often advocated. Reconstruction is rare, since surgical repair is usually effective in restoring the MCL. Lateral collateral ligament (LCL) injuries are much less common than MCL ligament injuries, but similarly most often managed conservatively.

With return of ROM and normal gait pattern, patients are functionally progressed towards return to sports. A functional brace during sports is advised.

Cruciate Ligaments

The cruciate ligaments are situated centrally within the intercondylar notch of the knee. The biomechanical function of both the ACL and the PCL is complex and three-dimensional, but to simplify: both play an important role in providing antero-posterior and rotational stability of the knee.

ACL tears are a common sports injury, especially in sudden cutting and stopping sports (e.g. soccer, basketball) or contact sports (e.g. football). A torn ACL will result in altered knee biomechanics and kinematics and thus potentially lead to the early development of degenerative changes in the knee joint. Since a torn ACL will not heal without surgery, surgical ACL reconstruction is generally treatment of choice in patients who are young and active. Patients with a more sedentary lifestyle and who experience no persisting or disabling instability in daily life, may be effectively treated with conservative management (i.e., bracing and physical therapy).

A patient with an ACL tear typically presents with pain and swelling, instability, loss of ROM, joint line tenderness (with associated meniscus injury), and discomfort while walking. Radiographs are obtained to evaluate joint condition and possible associated osseous injuries. To visualize the ACL and other soft tissue in the knee however, an MRI should be obtained. Although an MRI is not required to make the diagnosis, the information it provides is invaluable with regard to objectifying anatomic characteristics by taking measurements,

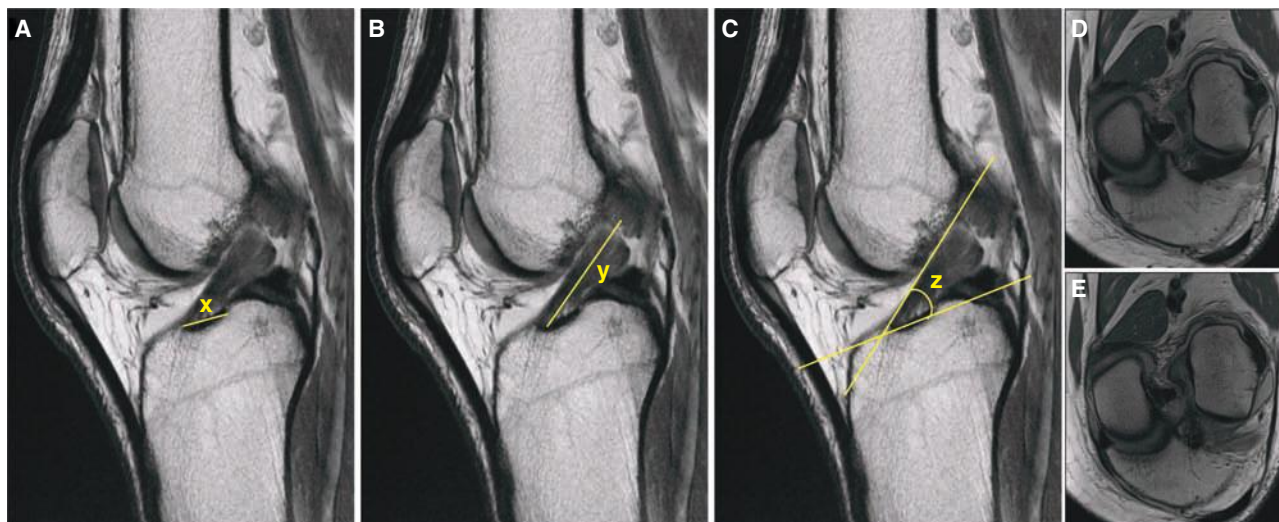


Figure 43-11. MR imaging of a torn ACL. (A-C) Proton density sagittal cuts; showing anteroposterior tibial insertion site length measurement “x”, intra-articular ligament length measurement “y” and ACL inclination angle measurement “z”. Oblique (in the same plane as the ACL runs) coronal cuts showing a complete ACL tear with separate images of a PL bundle tear (D) and an AM bundle tear (E).

assessing concomitant injuries and presurgical planning in general (Fig. 43-11).

Reconstruction is performed with use of a tendon-graft that will replace the native ACL. Commonly used graft sources are the patellar tendon, the hamstrings and the quadriceps tendon. These tendons can be harvested from the same knee (i.e., autografts), during the same procedure. Alternatively a donor graft (i.e., allograft) can be used. Both have their own subset of pros and cons, with the most important pro being absence of donor-site morbidity for allograft and better healing potential for autograft.

Injuries of the PCL are less common than other knee ligament injuries. Frequently seen causes are a bent knee hitting a dashboard in a car accident or falling on a knee that is bent during running. A rupture of the PCL is usually better tolerated than ACL rupture, since many tears (i.e., grade I and II) have the potential to heal on their own and do not result in much knee stability problems. Most Grade I and II injuries are treated nonoperatively. Combined PCL/PLC and PCL/MCL and Grade III PCL injuries however, do present a challenge with regard to management decision-making. Chronic PCL-deficient (Grade III) knees have an increased incidence of osteoarthritis, particularly in the patellofemoral and medial knee compartments. Indication for surgery is influenced by age, activity level, and presence of concomitant injuries. Different surgical techniques have been proposed; the most common are the “inlay” technique and the transtibial technique.

The goal of cruciate ligament (both ACL and PCL) reconstruction is to restore native knee kinematics, to provide the patient with the best potential for a successful outcome and to prevent from the development of long-term complications, such as osteoarthritis.

Posterolateral Corner

Critical structures of the posterolateral corner (PLC) are the LCL, popliteus tendon and popliteofibular ligament. These structures each contribute to the static and dynamic stability of the knee and are commonly injured concomitant with other ligamentous injury, mostly together with the torn ACL.³⁸ The importance of closely evaluating the PLC after knee injury is demonstrated by the fact that a deficient PLC causes altered

knee biomechanics and subsequently increases stress on surrounding stabilizing structures. As such, it has been shown that a deficient PLC is a primary cause of cruciate ligament reconstruction failure.

Acute high-grade injuries of the PLC with obvious deficient structures require surgical intervention. Since primary repair becomes increasingly difficult as time between injury and surgery increases, a cut-off of 2 to 3 weeks is usual to either repair or reconstruct the deficient structures. With more chronic PLC injuries, reconstruction is recommended to restore knee stability.

HIP

Femoroacetabular Impingement

Femoroacetabular impingement (FAI) is a pathologic condition that refers to impingement of the anterior femoral head-neck junction against the anterosuperior labrum. This is frequently caused by abnormal bony offset at the femoral head-neck junction, abnormal acetabular anteversion or excessive anterolateral acetabular bony rim coverage (Pincer lesion), and combined CAM-Pincer lesions. Recognition of FAI can be clinically and radiologically difficult. However, familiarity with this disorder is essential, as FAI can lead to labral tears, cartilage delamination, and if untreated, osteoarthritis.

Commonly, patients present with anterior groin pain exacerbated by activities involving hip flexion or pain over the greater trochanter as well as grinding or popping. Patients report pain with flexion and internal rotation and after prolonged sitting. On examination, there is a decrease in internal rotation that appears out of proportion to the loss of the other ranges of motion and there is limited flexion. The impingement test, elicited by 90 degrees of flexion, adduction and internal rotation of the hip, is almost always positive.

The imaging findings of FAI can be seen on plain radiographs, CT scan, MRI, and MRA. Some of the abnormalities seen include abnormal lateral femoral head/neck offset seen as a lateral femoral neck bump, os acetabulae, synovial herniation pits, acetabular over-coverage, hyaline cartilage abnormalities, and labral tears.

Treatment of FAI has traditionally been surgical and has come from open surgical treatment with open acetabuloplasty, and later open procedures through a transtrochanteric approach and combined open-arthroscopy assisted techniques to full arthroscopic approaches. Hip arthroscopy is becoming increasingly popular and being more frequently applied for this indication. This popularity is largely the result of studies reporting on improvement of functional outcome measures with follow-up up to 10 years, with low complication rates in several large study populations.

SPINE

Spinal Trauma

In spinal injury spinal stability must be assessed, and the patient immobilized until his spine is cleared. CT scan is more reliable in assessing spine injury than plain radiographs. When neurologic deficits are present a decompressive procedure may be indicated. In spinal cord compression, prompt decompression should be performed. Animal models of spinal cord injury suggest that prompt decompression can lead to objective improvement of recovery. Spinal cord injuries should be triaged to trauma centers since trauma center care is associated with reduced paralysis.

Occipital Cervical Dislocation

Motor vehicle accidents can cause dislocation of the occiput on the condyles of the atlas (C1). Most patients with this injury suffer cervical cord injury, and do not survive. Traction on the spine is contraindicated. Treatment consists of stabilization and fusion in situ using a screw plate from the mid cervical spine to the occiput.

Fractures of C1 (Jefferson Fracture)

Fracture of the C1 ring was described by Jefferson in 1920. The thin anterior and posterior rings of the C1 vertebra fracture with axial loads. C1 fracture causes the lateral masses of C1 to spread, which is visible on a through-the-mouth AP X-Ray image of the cervical spine. This injury is rarely associated with neurologic injury. Bracing with a cervicothoracic orthosis or a halo ring and vest is the recommended treatment for a Jefferson fracture.

Fractures of C2 (Odontoid Fracture)

Half of normal cervical rotation occurs at the atlanto-axial joint. The odontoid (Dens) is a small bony process which arises from the body of C2, and articulates with the body of C1 (the Atlas). Odontoid fractures are most often type I fractures (an avulsion fracture off the tip of the dens). Type I fractures occur when there is tension applied to the alar ligaments (which span from the tip of the odontoid to the skull bypassing the C1 vertebra). Type I fractures are stable and managed nonoperatively.

A type II fracture, at the base of the odontoid, results from lateral loading forces. Operative stabilization is the preferred treatment since immobilization in a halo vest results in non-union rates ranging from 20% to 80%. Transfixing the odontoid fracture with a screw maintains rotational movement. Posterior fusion of C1 on C2 with sublaminar wiring resulting in decreased range of motion is another option.

Type III fractures extend into the body of C2, below the origin of the odontoid process. Type III fractures are generally treated with halo brace. (Anderson and D'Alonzo)

Hangman's Fractures of C2

Hangman's fractures result from sudden extension forces on the neck and occur between the superior and inferior facets (pars interarticularis) of C2. Treatment is simple immobilization in a halo vest. Higher energy injuries causing severe extension forces can dislocate the C2-3 facet complex and damage the C2-3 disc. Such fractures can compromise the spinal canal, and death can occur from compromise of respiration. Significantly displaced Hangman's fractures are managed by internal fixation and bone grafting between C2 and C3.

Compression Fracture of the Cervical Spine

In C3 to C7 an axial load can cause fracture of the endplate while preserving the posterior cortex of the vertebral body. These fractures generally heal well, and are treated nonoperatively with analgesics and a cervical brace.

Burst Fractures of the Cervical Spine

Diving accidents are the classic cause of *Burst fractures* of the cervical spine. The axial load when an unrestrained passenger in an automobile accident strikes the windshield the posterior cortex of the vertebral body fractures leading to displacement of bony fragments into the canal injuring the spinal cord. Burst fractures are treated surgically by anterior debridement of the fracture and reconstruction using a bone graft strut stabilized with a plate and screws.

Unilateral and Bilateral Facet Dislocation

Another injury associated with motor vehicle accidents is facet dislocation. A restrained passenger can suffer forced flexion with distraction resulting in dislocation of the facets. The diagnosis can be made on lateral radiographs. Treatment consists of axial traction with cranial tongs, graduated application of weight, and periodic X-Rays. The patient is kept awake for safety concerns. When reduction is attained, patients are taken to surgery for posterior fusion with interspinous process wiring or a screw plate.

Clay-Shoveler's Injury

Clay-Shoveler's injury can result from a motor vehicle accident or from shoveling soil or clay. The injury (of C6, C7, T1, and T2) is the result of avulsion fracture of the spinous process by the paraspinal muscle forces. The fracture is treated nonoperatively with analgesics and a soft collar.

FRACTURES OF THE THORACIC AND LUMBAR SPINE

Thoracic Lumbar Spine Injury

The ribs stabilize fractures of the thoracic spine, making these fractures more stable than similar fractures of the lumbar spine. Neurologic injuries are more common in the thoracic and proximal lumbar spine because of the presence of the spinal cord, which ends at the L2 level.

Compression Fracture

Compression fractures result from osteoporosis and abnormal bone density as well as trauma. Compression fractures involve a fracture of the superior or inferior endplate without associated posterior cortex fracture. Thoracolumbar compression fractures are treated nonoperatively with braces and analgesics.

Burst Fracture

Burst fractures are caused by falls and high energy automobile accidents. One or both endplates and the anterior cortex of the vertebrae with an associated fracture of the posterior cortex. The posterior cortex fracture differentiates the burst fracture from a compression fracture and results in retropulsion of bone into the canal, which can cause nerve injury. A vertical lamina fracture may contain an invaginated segment of the dura mater with accompanying nerve roots, and posterior surgery can result in dural tear or nerve injury.

If nerve injury is noted, treatment is an anterior exposure and removal of the fractured anterior elements (corpectomy) and a strut graft is placed. A laterally placed plate and screws add stability to the construct.

Seatbelt Injuries (Flexion Distraction Injuries)

A seatbelt injury occurs when there is acute forward flexion of the trunk and anterior (i.e. seatbelt) restraint. The pelvis and upper torso move forward, and failure of the spine under tension begins with the posterior elements. Tearing of the dorsal fascia, the interspinous ligament, dislocation of the facets, and tearing of the discs occurs. The bone of the spinous process, the lamina, the pedicles, and the vertebral body fail in tension (“Chance Fracture”).

In flexion distraction injuries through soft tissue, posterior internal fixation and bone graft is recommended. “Chance fractures” are treated with bracing.

Fracture Dislocations of the Spine

Fracture dislocations of the spine displace the bony elements by translation or rotation resulting in canal narrowing and nerve injury.

Reduction of the displaced bones is the best way to improve the canal dimensions.

Patients with fracture dislocations of the spine and partial nerve function can recover. Fracture dislocations are treated operatively with surgical stabilization.

Disc Herniation

Disc herniation, most common between ages of 20 and 50, can occur in the cervical, thoracic, or the lumbar spine, and consists of a tear of the annulus allowing the nucleus pulposus material to extrude through the annulus and enter the canal, pressing on the exiting nerve or the ‘traversing’ nerve roots. In the cervical spine, spinal cord compression can occur.

Symptoms of most disc herniations resolve within eight weeks as the nerve root accommodates and inflammation recedes. The bulk of the extruded nucleus pulposus resorbs over time. When symptoms persist beyond six to eight weeks, excision of the involved disc and decompression of the nerve roots may be indicated.

In cervical disc herniation an anterior approach to the spine is performed with dissection through a transverse incision on the neck. Dissection is carried between the trachea and the carotid sheath. The disc is then removed. The disc space may be bone grafted to fuse the vertebrae. A locking screw low profile titanium plate is then attached to the vertebrae.

Posterior decompression and laminectomy exposes the posterior elements of the spine. A portion of the lamina is removed to allow access to the canal to correct foraminal impingement or to remove lateral disc herniations. While the posterior approach

does not require fusion with plates and screws, central disc herniation cannot be managed through a posterior approach since the spinal cord cannot be safely retracted.

For lumbar disc herniation a midline incision is used and laminectomy allows visualization of the lateral recess. Retraction of the dura allows visualization of the traversing nerve roots as well as of the disc fragment.

Spinal Stenosis

A loss of hydration of the discs causes loss of disc height and bulging of annular tissue and the ligamentum flavum which effectively narrows the canal (spinal stenosis). Osteophyte formation on the facet joints can also cause nerve impingement. Cervical stenosis can cause myelopathic symptoms (hyperreflexia, ataxia, balance problems, weakness, and pain).

Lumbar stenosis causes neurogenic claudication (progressive pain, weakness, and numbness in the legs). The claudication symptoms result from standing and walking which increases lumbar lordosis. The symptoms resolve with sitting and bending forward (decreasing lumbar lordosis).

Spinal stenosis is treated with epidural steroid injections and physical therapy. Resistant cases may require surgical decompression and stabilization with plates and screws.

Spinal stenosis usually occurs in patients over 50 years of age. With degenerative spondylolisthesis or scoliosis fusion procedures with instrumentation may be required to prevent progression of the deformity.

Back Pain and Degenerative Disc Disease

Back pain occurs in the majority of adults but is usually self-limited resolving in one to two weeks. Chronic unremitting back pain suggests the possibility of infection, malignancy, or metastatic disease.

While radiographs are one option in the management of disabling low back pain, they are ineffective at ruling out malignancy, and radiographic findings correlate poorly with symptoms. Patients with severe degenerative symptoms may have no pain, while others with mild degenerative findings complain of severe pain. The potential for secondary gain and psychiatric problems and the unpredictable results of spine fusion add to the difficulty of diagnosis and choosing a treatment plan.

Intervertebral disc replacement prostheses are now used to treat degenerative disc disease. The potential for loosening, creation of wear debris, and bone loss complicating revision surgery are concerns, as are the proximity of the device to the spinal canal and the great vessels.

Scoliosis

Scoliosis is a lateral curvature of the spine. Lateral bending of the spine is always accompanied by rotational deformity (coupling).

In order to measure the severity of scoliosis lines are drawn along the endplates of the vertebral bodies at either end of the curve and the angle formed when these lines intersect is magnitude of the curve.

Scoliotic curves are classified as congenital, degenerative, metabolic (mucopolysaccharidoses), neurogenic (cerebral palsy), and myogenic curves (muscular dystrophy). Idiopathic scoliosis is the most common form, and represents a spectrum of genetic disease.

Adults with scoliosis may present with axial pain and imbalance in posture. Treatment for scoliosis may include medications, therapy, and activity modification. In severe cases with objective deformity surgical correction of the deformity may be indicated.

Idiopathic Scoliosis

The majority of idiopathic scoliosis curves become apparent during adolescence and progress during skeletal growth. Initial management consists of observation. Rapidly progressing curves are treated with braces. Brace treatment is recommended for curves between 20 and 40 degrees. For patients with large curves, surgical intervention may be needed using rods with grafting and fusion.

Neuromuscular Scoliosis

Neurologic conditions such as polio and cerebral palsy can lead to ‘uncompensated’ scoliosis curves where the patient is unable to lean with his upper body to restore balance. Scoliosis correction surgery may be needed to facilitate sitting balance, and to avoid skin breakdown caused by pelvic obliquity.

JOINT RECONSTRUCTION

Introduction to Arthritis

Arthritis refers to a large number of medical conditions, including osteoarthritis, rheumatoid arthritis, septic arthritis, and post-traumatic arthritis. Each has the potential to lead to loss of articular cartilage lining the joints. According to the CDC and the National Health Interview Survey approximately 50 million adults (22% of the U.S. population) have been diagnosed with some form of arthritis. This number is projected to grow to an astounding 67 million adults by 2030 (or 25% of the U.S. population).

The number of individuals suffering from arthritic conditions will continue to rise as the ‘baby boomer’ generation enters old age and with the rise in obesity in the U.S. population, as age and obesity are two major factors in the onset of arthritis.

Conservative Management and Prevention of Arthritis

Conservative measures to treat arthritis include weight loss, activity modification, rest, bracing, physical therapy, pain management, and assistive devices such as canes or walkers. Conservative measures have the potential to decrease symptoms and improve function and quality of life. These measures can successfully manage a patient’s condition and avoid a surgical procedure. Osteoarthritis symptoms tend to be intermittent in nature or associated with high impact activities. Initially treat all patients with conservative measures and avoid surgery if possible.

Conservative measures can also play a role in the prevention of arthritis. Weight loss of as little as 11 pounds has been shown to decrease the risk of developing knee osteoarthritis in women by 50%. Similarly, patients who engage in regular physical activity have been found to have lower incidence of arthritis.

Arthritis causes pain, loss of range of motion, decreased ability to perform work duties or participate in social functions, and decreased quality of life. Despite conservative therapy, frequently more invasive treatments are needed to effectively manage the patient’s symptoms.

Examination of the Patient

A thorough history and physical examination (H&P) is indicated for all orthopedic patients. Patient history should include location, quality, severity, timing, and radiation of pain along with any referred pain, associated signs and symptoms, modifying

factors, prior treatments, including both conservative and surgical treatments. Other details within the H&P are equally important for diagnostic purposes and to successfully develop a treatment plan. If you listen carefully to your patient, they will often tell you their diagnosis. Location of “hip pain” can narrow a differential diagnosis. Patients with activity related groin pain often are found to have hip arthritis, whereas patients with peri-trochanteric pain (lateral hip pain) may be suffering from trochanteric bursitis. The importance of listening and focusing on the patient’s description of location and type of pain cannot be overemphasized.

Physical examination should begin by observing the patient’s gait, both with and without assistive devices if possible. This demonstrates how significantly the patient is affected functionally and the effect of the patient’s pain. Typical gait patterns include a “Trendelenburg gait” where abductor weakness may lead to a poor outcome following total hip arthroplasty. Other aspects of the exam include assessment for leg length discrepancy, joint contractures, skin changes, assessment for prior surgical incisions to evaluate for prior treatments or to plan future surgical approaches, neurovascular examination, strength and range of motion. These details document functional status and help to formulate a differential diagnosis. Patients with ‘hip pain’ may have lumbar spinal stenosis, radiculopathy, or vascular disease that may be playing a large role in their presentation. Once an appropriate physical examination is complete, weight-bearing radiographs are needed. Advanced imaging, including CT and MRI are rarely indicated in initial work up of patients. Once a diagnosis is made, specific treatment directed towards the patient’s condition can be initiated. The goals of treatment are to improve pain, preserve motion and to maximize patient function, independence, and quality of life.

Injections

Joint injections are commonly performed into the knee and shoulder. Common injections into the knee include corticosteroids and Hyaluronic-acid gels. Corticosteroid injections can decrease inflammation within the joint. These injections are usually administered in combination with a local anesthetic, such as Lidocaine, in order to provide more immediate relief for both diagnostic and therapeutic purposes. If the patient has immediate relief of their pain symptoms with injection of the joint, this localizes the source of the patient’s pain to the joint and may assist with diagnosis. At the same time any benefit received is therapeutic for the patient. Hyaluronic acid injections have become popular and are commonly referred to as “*viscosupplementation*.” The exact mechanism of these injections is not known, however patients may benefit from these injections by increasing the viscosity of the synovial fluid. The injections do not lead to articular cartilage repair. There is a risk of joint infection, cartilage injury from the needle, hemarthrosis, and failure to receive benefit. A theoretical risk of altered glucose metabolism in diabetics also exists with corticosteroid injections.

Surgical Management of Arthritis

The most commonly performed procedure for arthritis of a major joint is arthroplasty, or joint replacement. Joint replacements, including hip and knee arthroplasty are considered two of the most successful procedures performed in all of surgery. However, other nonarthroplasty options exist. These are typically performed for specific diagnoses under specific indications.

Osteotomy. Osteotomy is cutting the bone to change the position of the fragments in order to improve length, rotation, alignment, or angulation. Osteotomy can be performed for both congenital and acquired deformities that are thought to be contributing to the patient's pain or development or progression of disease. Pelvic and femoral osteotomy can be utilized in treatment of developmental dysplasia of the hip. With this procedure the position of the acetabulum can be altered in order to provide more appropriate coverage of the femoral head, which is usually deficient anteriorly and laterally. Femoral osteotomies can also be performed to correct anteversion and varus/valgus deformity of the femoral neck. Osteotomies are performed to obtain more normal alignment and coverage of the femoral head within the acetabulum to prevent or delay future disease.

An osteotomy commonly used in the knee is a proximal tibia osteotomy. An adult patient who presents with isolated medial compartment knee arthritis and associated varus deformity would be an ideal candidate for valgus (high tibial) osteotomy. An osteotomy that realigns the knee into slight valgus has the potential to off-load the medial compartment, slow disease progression and prevent or delay the need for more invasive procedures (unicompartmental or total knee arthroplasties).

Arthrodesis. Arthrodesis is a treatment option for severe arthritis where the overlying articular cartilage is removed and the two opposing bones are allowed to heal together. After successful arthrodesis no motion is possible through the joint and the source of pain is removed. Arthrodesis of large joints, such as the knee, shoulder or hip, are typically explored as an option in the face of infection, in elderly, low demand patients or in young and active patients who are considered too young for a joint replacement (concern for component wear and need for early revision). Arthrodesis can also serve as a "last resort" procedure in orthopedics, when joint preserving treatments fail, fracture, infection, etc. Arthrodesis requires removal of overlying articular cartilage from bone and frequently the use of autograft or allograft bone and the use of hardware for internal fixation or temporary external fixation.

Joint Arthroplasty/Joint Replacement. Joint arthroplasty is considered the final option for patients suffering from pain associated with arthritis in the joint. The surfaces of the bones are replaced after removing the damaged articular cartilage. The amount of bone and the determination of how to make the bone cuts is made based on pre-operative radiographs and templating, cutting guides, computer navigation, and anatomic measurements. The cut bony surfaces are covered with new components, usually made of metal, ceramic, or polyethylene. These new components are sized to appropriately match the patient, based on templating pre-operative radiographs, intra-operative measurements, and examination for stability, leg length, alignment, and range of motion.

If all compartments or surfaces of the joint are replaced, the arthroplasty is referred to as a total joint arthroplasty. In comparison, if only one surface or compartment of the joint is replaced, it is referred to as hemiarthroplasty (hip, shoulder) or unicompartmental arthroplasty (knee). Total hip and knee arthroplasties are considered the most successful of all surgical procedures performed in terms of patient outcome and improvement in pain.

Hip Arthroplasty

Background Hip arthroplasty is utilized for end stage arthritis in the hip that has failed a reasonable trial of non-operative measures (Fig. 43-12). Conventional hip arthroplasty commonly refers to *total hip arthroplasty* where both the femoral

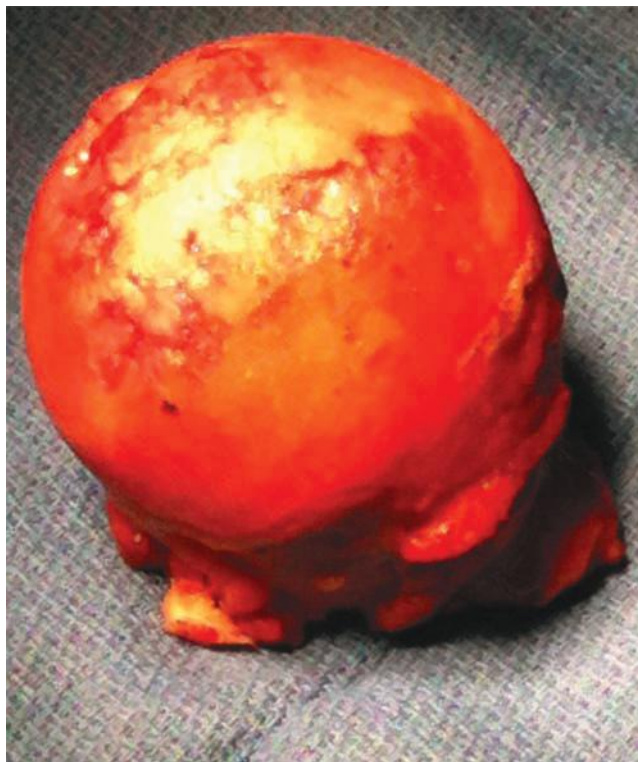


Figure 43-12. Osteoarthritis femoral head. Note erosion of weight-bearing cartilage and peripheral osteophytes.

head and neck are replaced. Hip resurfacing is a form of hip arthroplasty, used in younger patients with end stage arthritis. Resurfacing of the femoral head is performed with a metal cap (without performing a femoral neck cut and placing a stemmed femoral component) and the acetabular surface is replaced with a metal cup. Resurfacing functionally achieves the same result as a total hip arthroplasty, however it preserves femoral bone for later conversion to total hip arthroplasty if necessary. Finally, hemiarthroplasty describes the replacement of the femoral head and neck with a stemmed femoral component in isolation. The acetabulum is not addressed surgically.

History of Hip Arthroplasty The history of hip arthroplasty (hip replacement) may be broken down into a "Pre-Charnley" era and a "Post-Charnley" era, referring to the significant contributions of Sir John Charnley to the evolution of hip arthroplasty. Prior to Charnley's contributions, hip arthroplasty consisted of a variety of procedures with highly variable results. Early attempts at relieving hip pain were made with interpositional arthroplasty, where tissue layers, plastic, or metal were placed between the worn articular surfaces. Fracture of the interposed material or loosening of components often led to failure.

Later attempts introduced stemmed components to improve fixation. One of the earliest femoral components was designed by Austin-Moorem. This prosthesis replaced the femoral head and neck with a metal component secured into the femoral shaft with a stem extending down the diaphysis. This prosthesis was utilized in hemiarthroplasty for many years and served as a step in the development of total hip arthroplasty with the later addition of the acetabular component.

Surgical Approaches to the Hip A variety of approaches to the hip joint have been utilized in joint arthroplasty, including anterior approach (Smith Petersen), anterolateral approach

(Watson-Jones), lateral approach (Hardinge), and posterior approach (Kocher Langenbach). Each approach contains a unique set of advantages and disadvantages. Below, a comparison of the anterior and posterior approaches is made.

Anterior approach (Smith Petersen)—This approach utilizes the internervous plane between the femoral nerve and superior gluteal nerve. Superficially, the plane between the sartorius (femoral nerve) and tensor fasciae lata (superior gluteal nerve) is dissected, while deep, the plane between the rectus femoris (femoral nerve) and gluteus minimus (superior gluteal nerve) is dissected. The anterior approach to the hip is a “muscle sparing approach” and theoretically leads to less muscle damage and functional loss. Measuring serum CK values, the level of CK found with a posterior approach is nearly 2 times the value found in comparison to that seen with an anterior approach to the hip. Other advantages to this approach include low dislocation rates, decreased postoperative restrictions, and excellent acetabular exposure. Downsides include difficult preparation and placement of the femoral component and lack of a true extensile approach.

Posterior approach (Kocher Langenbach)—In comparison to the anterior approach, the posterior approach is a muscle splitting approach. In addition, there is no true internervous plane. After incising the skin and subcutaneous fat, the fascia lata is incised along with the gluteus maximus in line with the skin incision. The short external rotators are exposed and dissected, including the piriformis, superior and inferior gemelli, obturator internus and externus, and quadratus femoris. This allows internal rotation of the hip along with flexion and adduction to dislocate the femoral head for exposure. The posterior approach has an increased risk of post-operative dislocation, however this is minimized if soft tissue repair is performed. Postoperatively patients are required to follow strict hip precautions to minimize risk of dislocations; avoiding placing the hip in excessive flexion, adduction, and internal rotation (“The Heisman pose”). The posterior approach is extensile and provides excellent exposure of both the femur and acetabulum for complex and revision cases.

Minimally invasive total hip arthroplasty has been advocated in recent years. Theoretical benefits include improved cosmesis, decreased soft tissue damage, and decreased blood loss, quicker postoperative recovery and a shorter hospital stay. However, smaller incisions come with the disadvantage of decreased visualization intra-operatively and associated risks of component malposition, intraoperative fracture, and nerve or vascular injury. In fact, the only documented benefit of minimally invasive techniques appears to be improved cosmesis.

A greater trochanteric osteotomy can be performed in order to mobilize the abductors. This can improve exposure to the acetabulum and femur and can be useful particularly in revision cases.

Bearing Surfaces in Hip Arthroplasty The most common combination of bearing surfaces used in total hip arthroplasty is a metal femoral head (generally cobalt chrome), articulating with a polyethylene liner. Ceramic and metal are alternative bearing surfaces commonly utilized in total hip arthroplasty, either used in combination with a polyethylene acetabular liner (ceramic on poly or metal on poly) or in metal on metal and ceramic on

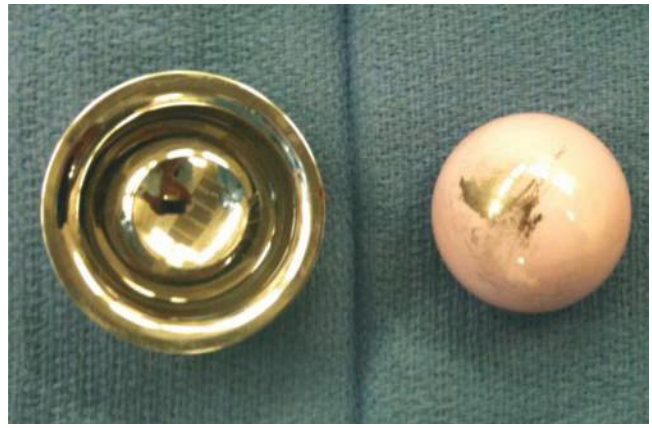


Figure 43-13. Failed ceramic on metal hip arthroplasty components. Note the metallic staining on the ceramic femoral head.

ceramic articulations. Metal on metal and ceramic on ceramic articulations have the advantage of lower friction and decreased wear rates in comparison to metal on polyethylene articulations. Metal on metal articulation is utilized commonly in hip resurfacing, however its use in total hip arthroplasty is controversial. Metal on metal articulation has many advantages, including lower wear rates and decreased associated osteolysis. The surgeon also has the ability to use a larger femoral head, thus achieving a greater femoral head to neck ratio and providing the patient a greater arc of motion prior to impingement and subsequent dislocation. Metal on metal (MOM) articulations have been associated with production of metal ions, pseudotumors, hypersensitivity reactions, and early failure when used in total hip arthroplasty (Fig. 43-13). Metal ions pose a theoretic risk of causing problems with pregnancy or a theoretic risk of cancer. Studies have failed to demonstrate a statistical increase in cancer in patients who have MOM articulations in comparison to metal on poly articulations. Ceramic on ceramic articulations have the lowest wear rate and friction of all current bearing combinations. However, ceramic has poor mechanical properties and can lead to component fracture due to its comparatively brittle nature.

Alignment of Hip Arthroplasty Components Proper alignment of hip arthroplasty components is vital to a successful procedure and patient outcome. Surgeons aim for appropriate alignment of components to restore a functional and stable range of motion. This is accomplished with combined anteversion of the femoral and acetabular components, appropriate abduction of the acetabulum and focus on staying true to Sir John Charnley’s principles: establishing a low friction articulation, medializing the acetabular component and center of rotation and restoring abductor length and tension with restoration of appropriate length and femoral offset. Inappropriate placement of components can lead to early failure, accelerated component wear, dislocation, need for revision surgery and poor patient outcome and satisfaction.

Knee Arthroplasty

Background Knee Arthroplasty is indicated for end stage arthritis within the knee that has failed to respond to a reasonable trial of non-operative and conservative measures. (Figs. 43-14 and 43-15) Knee arthroplasty commonly refers to total knee arthroplasty where the distal femur, tibia, and patella are resurfaced after any remaining articular cartilage and a layer of subchondral bone are resected. A unicompartmental knee arthroplasty

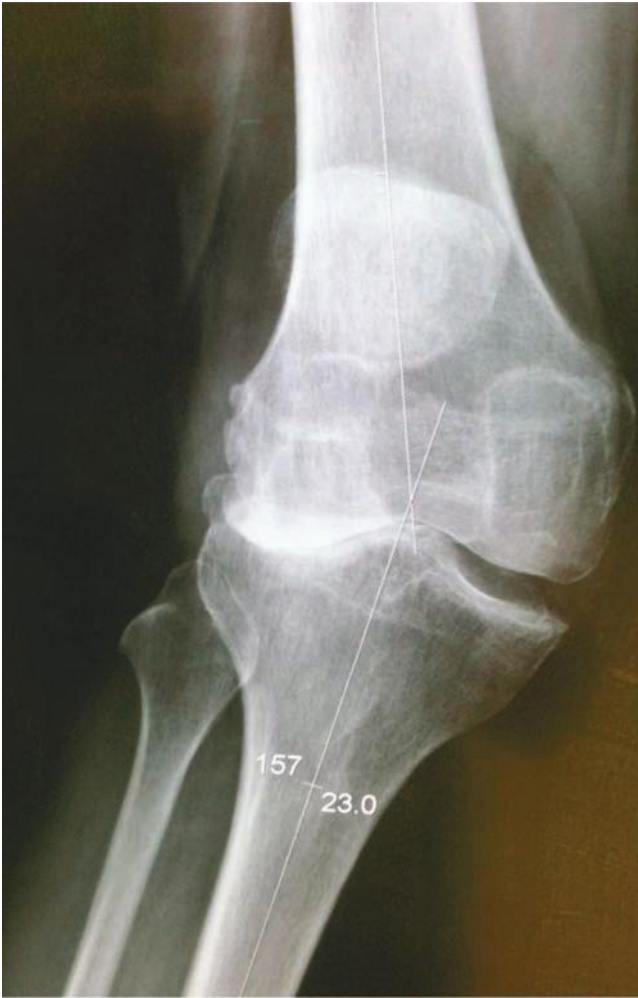

Figure 43-14. Valgus deformity. Osteoarthritis of lateral compartment right knee.

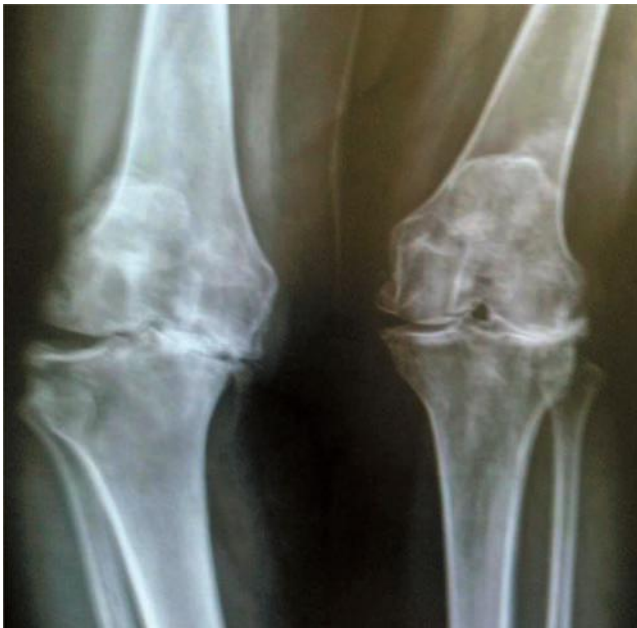

Figure 43-15. Osteoarthritis of both knees. Note varus alignment of right knee, and valgus alignment of left knee (“windswept deformity”).

consists of replacing one compartment of the knee, most commonly the medial compartment, for unicompartmental disease. Similarly, isolated replacement of the patellofemoral joint can be performed for end stage patellofemoral arthritis

Surgical Approach to the Knee Total knee arthroplasty is generally accomplished through a medial parapatellar approach. This approach utilizes a longitudinal skin incision, usually midline over the patella, extending on average from 5 cm proximal to the patella to the tibial tubercle distally. Dissection is carried down to the capsule where a medial parapatellar arthrotomy is performed to gain access to the joint. This approach provides excellent exposure to all three compartments of the knee after patellar dislocation. On occasion, a lateral parapatellar arthrotomy is warranted and this can be performed safely. In the event that the patella does not dislocate, the arthrotomy can be extended proximally through the quadriceps. This has no effect on patient outcome.

Once the joint surfaces are adequately exposed, remaining articular cartilage and a thin layer of underlying bone are removed prior to placement of prosthetic components. Bone cuts are made based on pre-operative templating, cutting guides, computer navigation, and anatomic measurements (Figs. 43-16 and 43-17).

Bearing Surfaces in Knee Arthroplasty The femoral component consists of a metal prosthetic cap designed and sized to fit the normal shape of the femoral condyles. The tibia is cut perpendicular to the anatomic and mechanical axis and a flat, stemmed, metal tray is placed, which most often articulates with a polyethylene liner. The patella is resurfaced with a polyethylene component. Options exist for a mobile bearing



Figure 43-16. Standard total knee instruments.

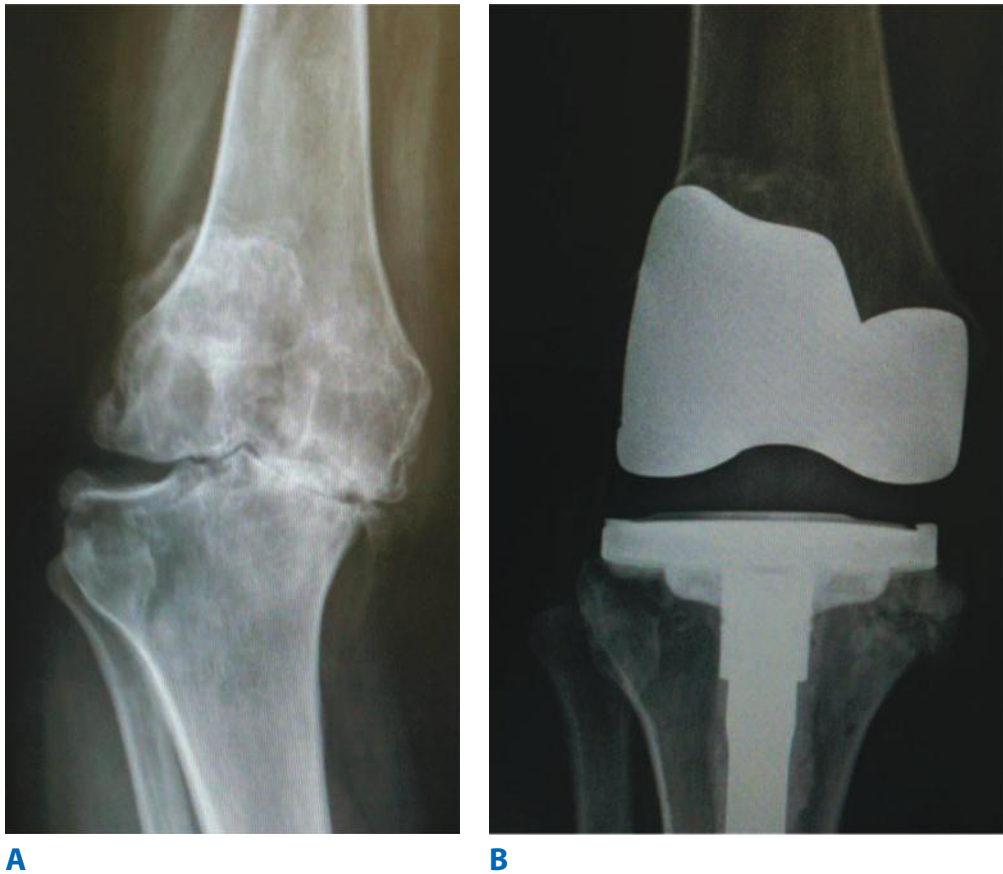


Figure 43-17. A. Varus knee with osteoarthritis. B. Right total knee replacement.

knee arthroplasty. With this design the polyethylene component is not fixed rigidly to the metal tibial tray and has the ability to more highly conform to the femoral component through the range of motion arc with designed ability for motion in its articulation with the tibial tray. Although excellent results have been published, this design has not been proven to lead to improved outcome or decreased component wear.

Two types of primary total knee arthroplasty systems exist, including cruciate retaining and posterior stabilized systems. As the name implies, with cruciate retaining systems, the posterior cruciate ligament (PCL) is retained in hopes of preserving more normal knee kinematics and femoral rollback with flexion, while in posterior stabilized systems the ligament is sacrificed and the components are designed to accommodate for the loss. These two systems have equivalent results in knee arthroplasty.

Alignment and Balancing in Knee Arthroplasty Appropriate alignment of the components and balancing of the flexion and extension gaps are essential for a successful result in knee arthroplasty. Inappropriate component position can lead to early wear and failure, knee instability, pain, and post-operative stiffness with poor range of motion. The surgeon must perform appropriate soft tissue balancing and bone cuts to accomplish this and subsequently must place the appropriate sized components, usually replacing the exact amount of bone and cartilage that was removed to create the articulation, and restore stability. The knee must be stable to varus and valgus stress at all points through the range of motion arc and still be able to attain a full range of motion arc from full extension to deep flexion.

Computer Navigation and Joint Arthroplasty

Computer navigated joint arthroplasty has the theoretical benefit of more accurate and consistent placement of arthroplasty components through intraoperative feedback to the surgeon regarding component position, planned bone cuts and alignment (Fig. 43-18). In theory this would lead to improved patient outcomes (Fig. 43-19A and B). Negatives include increased costs of the technology and prolonged operative times. Use of computer navigation in total joint arthroplasty has been shown to provide statistically significant improvement in accuracy of component placement. Use of computer navigation will likely increase in the future as technology continues to improve.

Fixation Options in Joint Arthroplasty

Components in hip and knee arthroplasty can be secured into position with cement or biologic fixation. The cement most commonly used is polymethylmethacrylate (PMMA). PMMA serves as a grout between the component and the bone surface. Components secured without cement are grit blasted or porous coated to allow bony ongrowth or ingrowth, respectively. Hydroxyapatite can also be utilized on the implant surfaces to promote bone ingrowth or ongrowth through osteoconductive properties. A majority of hip joint arthroplasty components are now secured without cement where initial fixation of components is accomplished through press fit techniques. In knee arthroplasty, cement utilization is generally preferred. In hip replacement patients where biologic fixation would be unreliable such as an elderly, osteoporotic patient, or patients with prior radiation, cement may be a better option. With revision total hip arthroplasty, cement fixation

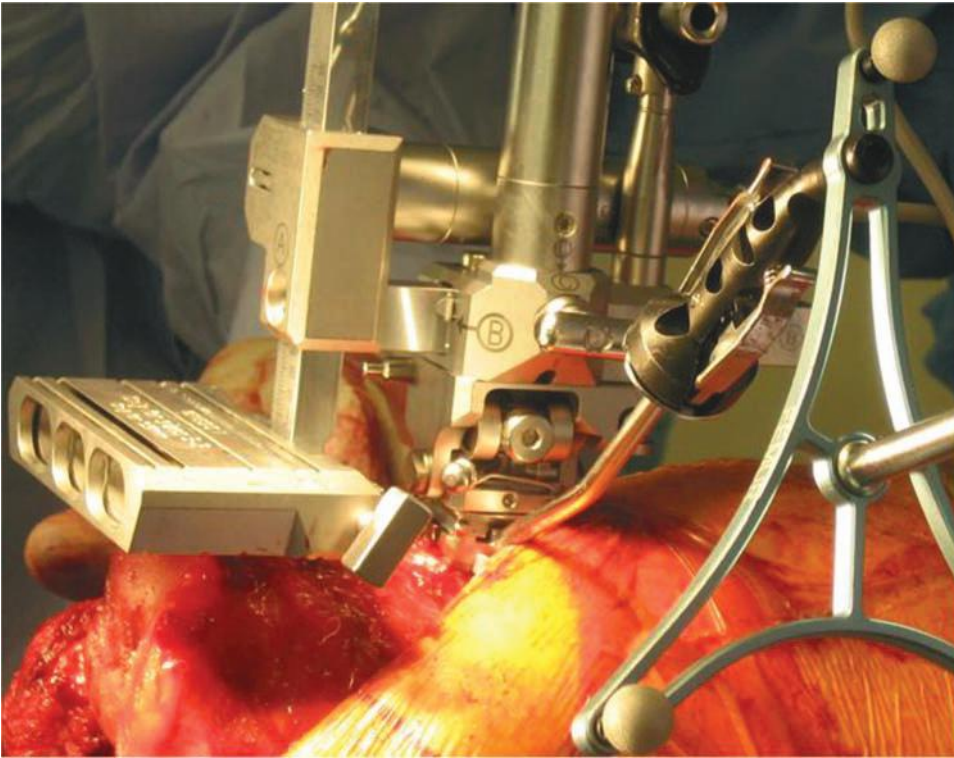
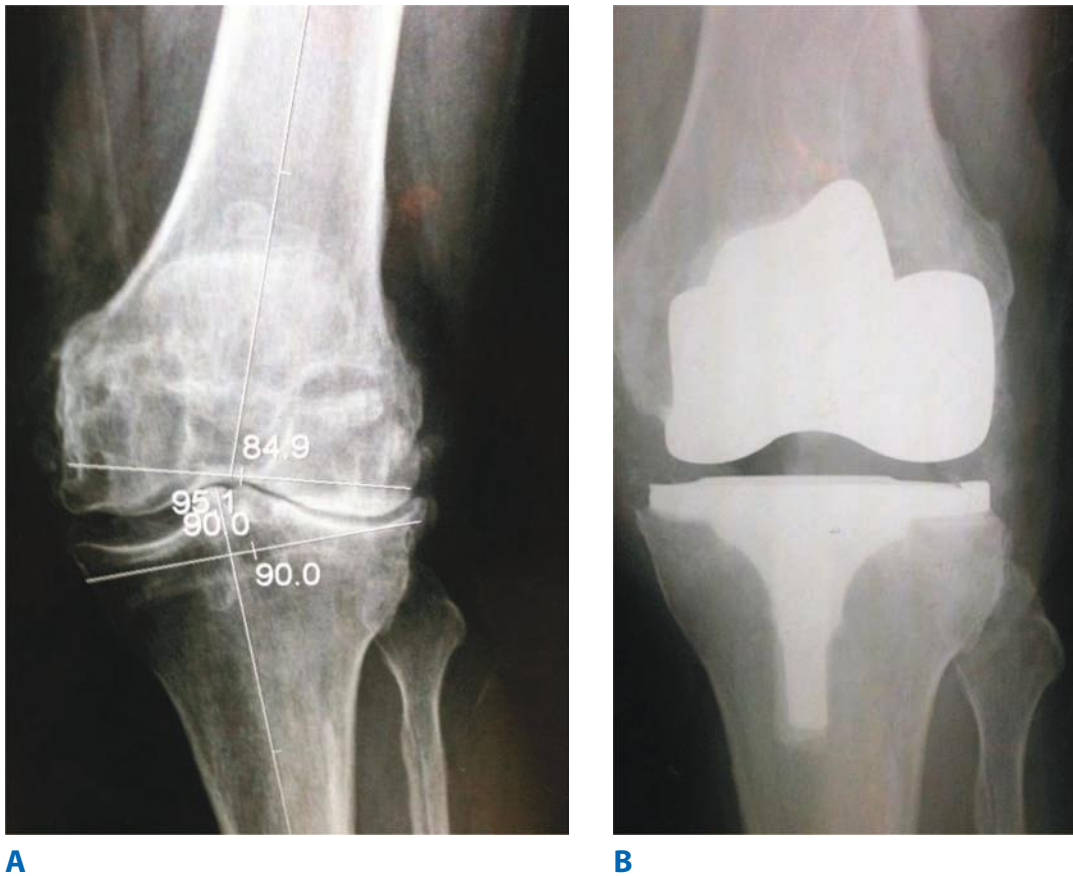


Figure 43-18 Computer assisted robotic targeting arm for total knee replacement.

of components has been shown to lead to earlier mechanical failure.

Osteolysis and Aseptic loosening. Osteolysis is a term used to describe abnormal resorption of bone. Osteolysis can be caused by underlying infection, metastatic disease, or in

the case of joint replacement, the production of wear debris. Even with appropriately positioned components, some wear of the bearing surfaces is expected. However, the wear rates and the size and amount of wear debris with the different bearing surfaces can be quite different. The wear rate of ceramic



A

B

Figure 43-19. **A.** Valgus knee with osteoarthritis. **B.** Robotic assisted total knee.

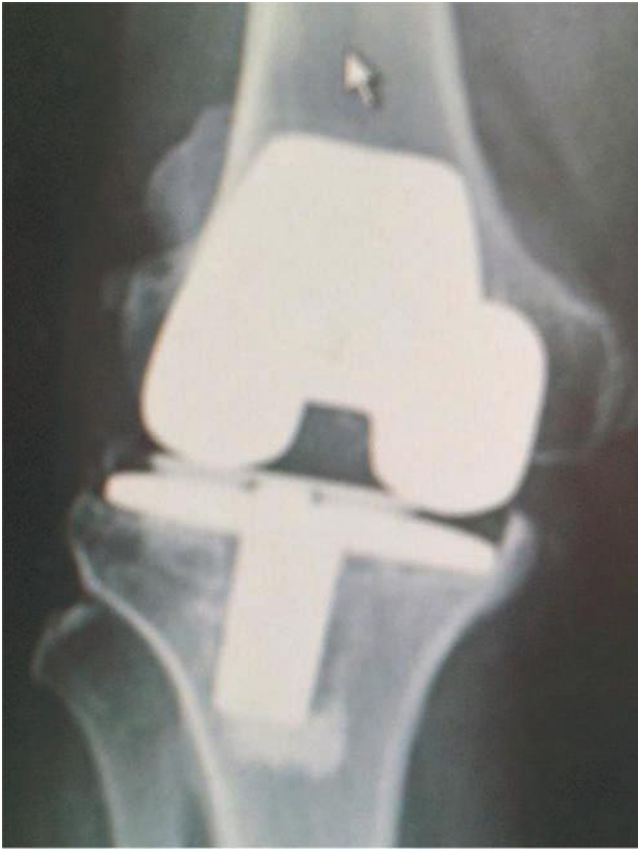

Figure 43-20 Failed total knee replacement. Note subsided, loose, tibial component.

on ceramic articulations is the lowest of all bearing surfaces, however there is increased risk of component fracture and postoperative “squeaking.” In metal on polyethylene articulations, wear debris is produced and polyethylene particles are phagocytized by local macrophages. “Activated” macrophages lead to an osteolytic process and bone resorption. Particulate methylmethacrylate cement debris can also play a role in osteolysis. Improperly positioned components or patient related factors such as high impact activities can lead to a high wear rate. A substantial osteolytic response may occur and lead to component micromotion and aseptic loosening. Patients who present to clinic with pain following joint arthroplasty and an increasing zone of osteolysis in the periprosthetic region frequently need revision surgery (Fig. 43-20) Alternative bearing surfaces continue to be explored in hopes of decreasing or completely preventing wear of components and associated osteolysis and aseptic loosening.

Complications in Joint Arthroplasty. The risk of any complication following joint arthroplasty procedures falls in the range of 5% to 10%. Risks shared by hip and knee arthroplasties include infection, intra-operative or post-operative fracture, vascular injury with need of intra-operative or post-operative blood transfusion, nerve injury or nerve palsy (most commonly involving the deep peroneal nerve and loss of ankle dorsiflexion), periprosthetic fracture, stress shielding, component fracture or wear, and medical complications, including venous thromboembolic disease (DVT and PE), myocardial infarction, or cerebrovascular accident. Complications unique to total hip arthroplasty include dislocation, leg length discrepancy, iliopsoas impingement, or tendonitis.

Dislocation Following Hip Arthroplasty. Dislocation can result from malpositioned components (inadequate combined anteversion of the femoral neck and acetabulum, excessive ab- or adduction of the acetabular component), non-compliant patients, those with cognitive or neuromuscular disorders, inadequate soft tissue repair or excessive soft tissue loss from surgeries or revision surgery, fracture, improper restoration of length, and/or offset. Historically, there has been significant debate as to the role of the surgical approach and incidence of hip dislocation following hip arthroplasty. However, comparable dislocation rates have been found with anterolateral (0.70%), lateral (0.43%), and posterior with soft tissue repair (1.01%) approaches. Dislocation is often the result of poor patient compliance with post-operative restrictions, neuromuscular or cognitive conditions, or excessive soft tissue loss. History, physical examination and appropriate radiographs are vital to proper treatment of dislocation. Closed reduction can usually be performed with conscious sedation and gentle traction or manipulation. Rarely, open reduction may be necessary. Patients with multiple dislocations should be assessed for improperly positioned components. Patients with recurrent dislocations and improperly positioned components may need revision of the component. Patients with recurrent dislocations and properly positioned components should be considered for conversion to hemiarthroplasty or to a constrained total hip arthroplasty which provides improved stability.

ORTHOPEDIC PATHOLOGY AND ONCOLOGY

Diagnosis of Malignant Bone Tumors

History. Diagnosis of musculoskeletal tumors begins with a thorough patient history. A history of unremitting pain, unrelated to activity, or pain that interferes with sleep, suggests malignancy. Patient age can help in establishing a differential. Round blue cell lesions are most likely neuroblastoma in a five-year old, Ewing’s sarcoma in a 10-year old, lymphoma in a 20-year old, and myeloma in a 60-year old. Gender also adds information, for instance, giant cell tumor is more common in females, osteosarcoma in males. Multiple bone involvement may suggest fibrous dysplasia, enchondromas (Ollier disease, Maffucci’s syndrome), or osteochondromas (multiple hereditary exostoses).

Laboratory Test. Laboratory tests determine the level of cellular turnover (lactate dehydrogenase [LDH]) or of bone destruction (calcium, alkaline phosphatase). Elevated Prostate-specific antigen (PSA) suggests prostate cancer.

Imaging. Radiographic studies are critical to the diagnosis of bony tumors. Radiographs can help assess the aggressiveness of the tumor. Four questions should be addressed when assessing radiographs: (a) Where is the tumor—in which bone (Table 43-1) and in which part of the bone (Table 43-2)? (b) What is the tumor doing to the bone (clinical behavior)? (c) What is the bone doing to the tumor (biologic response)? (d) What is the matrix pattern? Matrix is the acellular interstitial substance produced by tumor cells. Particular attention should be paid to the junction between the tumor and the host bone since this margin can also indicate the aggressiveness of the tumor. Ewing’s sarcoma has a characteristic ‘onion skin’ periosteal reaction pattern. This reaction pattern also occurs in other tumors and infections.

Table 43-1

Common locations of bone tumors

FEMUR	
Distal posterior	Parosteal osteosarcoma
Distal anterior	Periosteal osteosarcoma, periosteal chondroma or chondrosarcoma, myositis ossificans
TIBIA	
Adamantinoma, chondromyxoid, Fibroma	
HANDS AND FEET	
Enchondroma, exostosis	
Calcaneus	Unicameral bone cyst, lipoma, chondroblastoma, osteosarcoma
SPINE	
Anterior	Metastatic, myeloma, Paget disease, vascular malformation, Giant Cell Tumor
Posterior	Osteoid osteoma, osteoblastoma; Aneurysmal Bone Cyst
PELVIS	
Metastatic, myeloma, chondrosarcoma, giant cell tumor, aneurysmal bone cyst, Paget disease, Ewing's Sarcoma	
SACRUM	
Chordoma (midline), chondrosarcoma, giant cell tumor, aneurysmal bone cyst, lymphoma	
RIBS	
Metastatic, myeloma, fibrous dysplasia, chondrosarcoma	

OSTEOSARCOMA

The most common primary malignant bone tumor is osteosarcoma (Fig. 43-21). Osteosarcomas are classified as osteoblastic, chondroblastic, fibroblastic, telangiectatic, round cell, and MFH-like, according to the predominant cell type. Most osteosarcomas present in patients between 10 and 20 years of age. Secondary osteosarcomas occur in older patients in abnormal bone affected by Paget's disease or radiation.

Table 43-2

Tumor location in bone

Epiphysis

Chondroblastoma, clear cell chondrosarcoma, GCT, infection, dysplasia epiphysealis hemimelica (DEH)

Metaphysis

Most common site of involvement

Diaphysis

FEGNOMASHIC: F-Fibrous dysplasia, EG-Eosinophilic Granuloma, N- NonOssifying Fibroma, O-Osteoid osteoma, M- Myeloma, A-Adamantinoma, S-Simple Bone Cyst, H-Histiocytosis, I-Infection

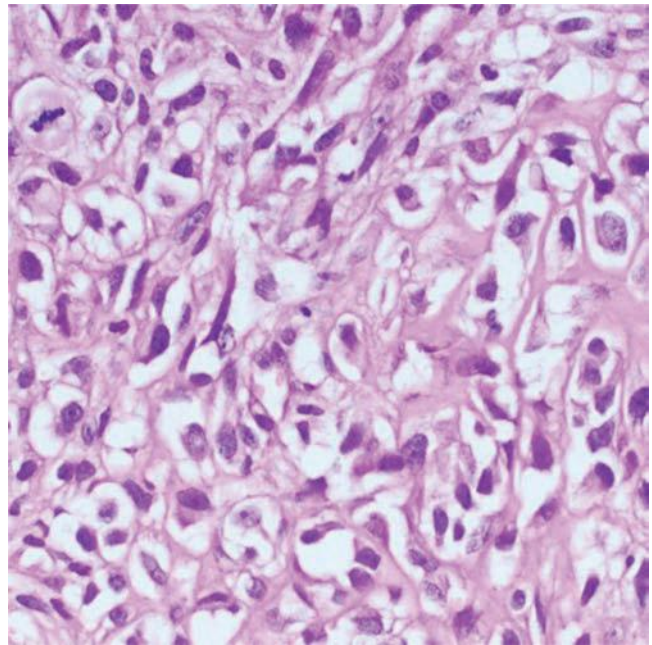


Figure 43-21. Osteosarcoma.

Parosteal Osteosarcoma

Parosteal osteosarcomas occur in women ages 20 to 50, “pasted on” the surface of the posterior distal femoral metaphysis. The preferred treatment is wide surgical excision.

Periosteal Osteosarcoma

Periosteal osteosarcoma occurs on the anterior surface of the distal femur or proximal tibia. The lesion appears chondroblastic on histology. Radiographs show scalloping of the underlying cortex with a ‘sunburst’ periosteal reaction. Treatment is wide surgical excision.

Paget's Sarcoma

Paget's sarcoma is a rare complication of Paget's disease. In Paget's disease with multiple bone involvement, osteogenic sarcoma, fibrosarcoma, chondrosarcoma, and MFH have occurred, most often in the pelvis, but also in the humerus, femur, spine, and skull. Imaging may demonstrate osteolytic areas, and loss of normal fatty marrow and multifocal lesions. Treatment of Paget's sarcoma is surgical excision, but the prognosis is poor.

Radiation-Induced Sarcoma

The three criteria for diagnosis sarcoma of radiation induced sarcoma are: (a) histology different from the original lesion, (b) sarcoma develops in the irradiated field, and (c) 3 to 5 year latent period between radiation and sarcoma development. Radiation for carcinoma of the breast and cervix can result in osteosarcoma, chondrosarcoma, fibrosarcoma, or MFH. Treatment is a combination of chemotherapy and surgery.

EWING'S SARCOMA

Ewing's sarcoma is the second most common primary bone tumor in patients under 30. The typical presentation is a tumor in the diaphysis of the femur in a young white male.

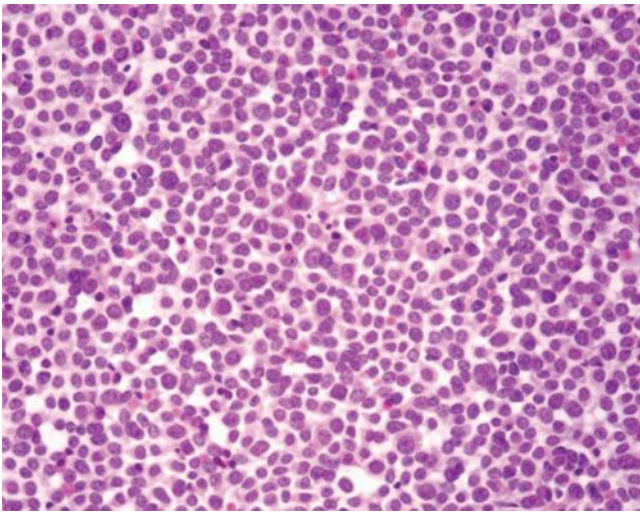


Figure 43-22. Ewing's sarcoma.

An “onion skin” periosteal reaction may be seen on radiographs. A large soft-tissue extension from the primary bone tumor may be seen and histology reveals a small round blue cell tumor (Fig. 43-22). Diagnosis is confirmed with bone marrow biopsy specimen. Bone scan can identify multiple lesions. Treatment is chemotherapy and surgery or radiation therapy for spine or pelvic lesions.

CARTILAGE FORMING TUMORS

Chondrosarcomas

Chondrosarcomas typically occur in male patients over 40 years of age, and are the third most common primary bone malignancies. Primary chondrosarcomas can form clear cell, mesenchymal, or dedifferentiated neoplastic cartilage. Secondary chondrosarcomas may also develop in pre-existing lesions such as exostoses or enchondromas. Pelvis, shoulder, and ribs are frequent locations. Chondroid or “popcorn” calcifications are typical on radiographs. Clear cell chondrosarcoma and mesenchymal chondrosarcoma occur in younger patients (second to fifth decades of life). Clear cell chondrosarcomas are low-grade lesions that often affect the epiphyses.

The treatment of chondrosarcoma is surgical excision, since cells are not chemosensitive or radiosensitive. For high-grade lesions, wide or radical resection is recommended. Pelvic and scapular chondrosarcomas have a high recurrence rate and adjuvant chemotherapy does not improve survival rates.

FIBROUS LESIONS OF BONE

Desmoplastic Fibroma

Desmoplastic fibroma is a rare tumor occurring in the mandible, femur, pelvis, radius, or tibia in young adults. Radiographs show a metadiaphyseal “soap bubble” appearance and endosteal scalloping. Histology resembles desmoid tumors or fibromatosis. Recommended treatment is wide excision.

Malignant Fibrous Histiocytoma of Bone

MFH occurs in the metadiaphysis of long bones after conditions like nonossifying fibromas and bone infarcts. Radiographs typically show destructive lesions with soft-tissue extension.

Histology resembles osteosarcoma with fibroblasts, histiocytes and giant cells, but no neoplastic osteoid formation. Treatment is wide surgical excision.

Malignant Vascular Tumors

Hemangioendothelioma. Hemangioendothelioma is a malignant neoplasm arising from vascular endothelium in long bones. Radiographs show a metadiaphyseal lytic lesion with a “soap bubble” appearance. Histology reveals eosinophilic cells in a basophilic stroma. Lesions may be multifocal. Treatment consists of curettage for low-grade lesions and wide excision for high-grade lesions.

Hemangiopericytoma

Hemangiopericytoma is usually a solitary lesion occurring in the soft tissues or the axial skeleton and proximal long bones in middle-aged or elderly males. Histology reveals branching “staghorn” vascular spaces. The tumor cells resemble cells normally seen adjacent to capillaries. Treatment is wide excision.

Angiosarcoma of Bone

Angiosarcoma is a soft tissue malignancy usually seen in elderly males. Histology reveals vascular channels with anaplasia. Treatment is wide excision, or if inaccessible surgically, radiation.

MISCELLANEOUS TUMORS

Giant Cell Tumor of Bone

Giant cell tumor occurs in the knee, distal radius, proximal humerus, and pelvis in women 20 to 40 years of age. Presenting complaints include pain and pathologic fracture. Imaging reveals eccentric, epimetaphyseal lytic lesions eroding the subchondral bone. Histology reveals multinucleate giant cells and mononuclear stromal cells (Fig. 43-23). These tumors can occasionally metastasize to the chest. Primary malignant giant cell tumor has a poor prognosis. Treatment of giant cell tumors is with curettage and high-speed burr. Recurrence rates are high with simple curettage, and the use of cryosurgery, phenol, or polymethylmethacrylate bone cement may help decrease recurrence rates. After pathologic fractures, wide excision may

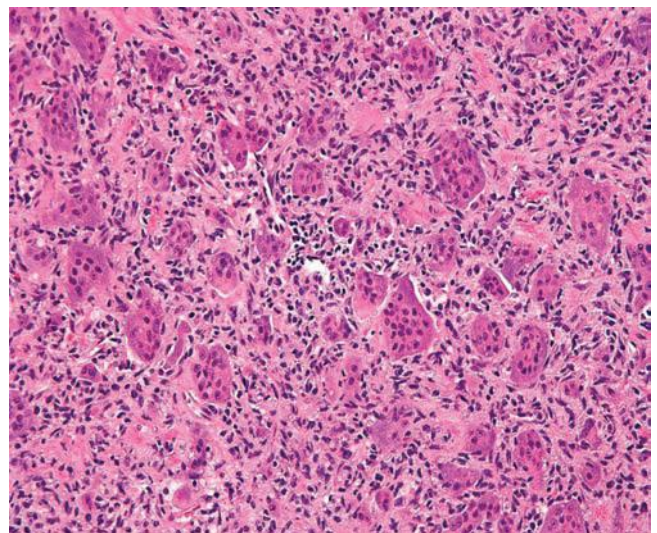


Figure 43-23. Giant cell tumor.

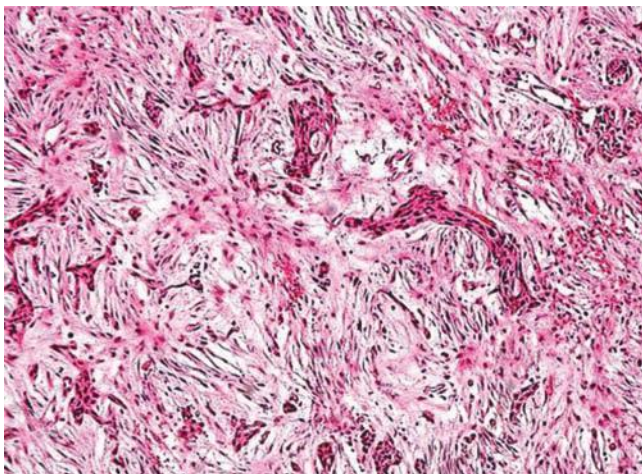


Figure 43-24. Adamantinoma.

be required. In tumors that are inaccessible surgically, radiation may be indicated.

Ossifying Fibroma and Adamantinoma

Ossifying fibroma occurs in the anterior cortex of the tibial diaphysis of young males. Radiographs have a soap bubble appearance. Patients may present with pain but often the diagnosis is incidental on radiographs. Histology resembles fibrous dysplasia, but with osteoblastic rimming. Ossifying fibroma may be a precursor to adamantinoma.

Adamantinomas are low grade malignancies capable of metastasis seen in the tibia. Histology reveals a tubular, basoid, squamoid, or spindled pattern (Fig. 43-24). While ossifying fibroma is benign, careful monitoring is needed because they may be a precursor of adamantinoma. The treatment of adamantinoma is with wide surgical excision.

Primary Lymphoma of Bone

Primary lymphoma accounts for about 5% of all neoplasms of bone. Long bone involvement is more frequent than spine. Lymphoma of bone typically occurs in males in their forties. Histology reveals large B cell lymphomas. Treatment is a combination of chemotherapy and radiation. Surgery may be required for stabilization of pathologic fractures.

Chordoma

Chordoma arises from notochordal rests in the sacrum. These tumors are found in middle-aged to older men and presents with bladder and bowel symptoms. An MRI shows a destructive lesion with a large soft-tissue mass. Histology shows epithelioid cells arranged in cords with vacuolated physaliferous cells. Treatment is surgical excision and muscle flaps and a mesh for reconstruction. Urinary diversion and colostomy may be needed for loss of bladder and bowel control.

Multiple Myeloma

Myeloma, the most common primary bone malignancy, is a proliferative disorder of B cells, with plasma cells, evidence of monoclonal M protein in the serum and/or urine, and hypercalcemia, renal insufficiency, anemia, or bone disease. A solitary myeloma lesion in bone is known as a *plasmacytoma* (Fig. 43-25). Presenting symptoms in myeloma range from bone pain and osteopenia, to focal lytic lesions with pathologic fractures and hypercalcemia. Myeloma protein 1-alpha stimulates

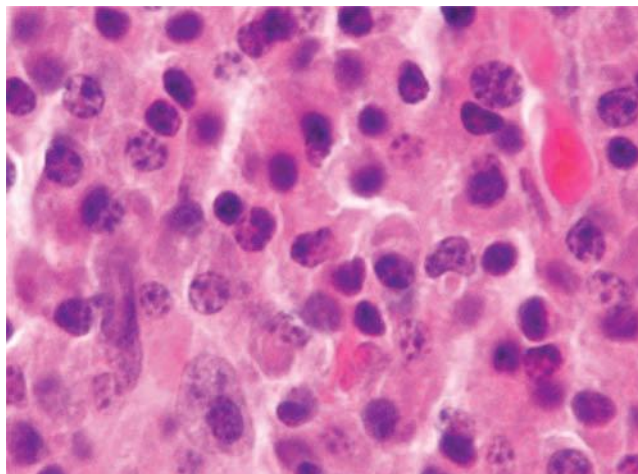


Figure 43-25. Plasmacytoma.

osteoclast formation. Osteoclast activating factors increase receptor activator of nuclear factor κ B ligand (RANKL) in the bone marrow. RANKL induces osteoclast differentiation and activation. Myeloma cells inhibit osteoblast differentiation and activity. Serum and urine electrophoresis detect the M protein. Work up also includes complete blood cell count, erythrocyte sedimentation rate, calcium levels, renal function assessment, and β -2-microglobulin levels, and a skeletal survey. Bone scans may show a false-negative result in more than two-thirds of patients and a dual energy X-ray absorptiometry scan. Plasmacytoma is usually treated with radiation to the lesion. Myeloma is treated with chemotherapy, stem cell transplantation, and radiation therapy. Many patients with myeloma develop a vertebral compression fracture. Kyphoplasty can be useful in providing pain relief. The risks of cement extravasation and related complications are lower with kyphoplasty than with vertebroplasty. If there is instability or if there is neural compression, surgical stabilization may be required.

METASTATIC BONE TUMORS

Metastatic bone tumors are more common than primary bone tumors. Metastatic tumors affect the lung, liver, and bone. Cancers that commonly metastasize to bone are breast, prostate, lung, thyroid, and kidney. In patients older than 40 years of age, metastases and myeloma are the most common lesions in bone. The most common site of involvement is the axial skeleton and proximal ends of long bones. Bronchogenic and renal cell carcinomas can metastasize distal to the knee and elbow. Malignant cells are able to detach from one location and set up a focus at a distant site. Work up of a patient with suspected metastatic disease to bone should include CT of chest, abdomen, and pelvis, mammography, tumor markers, serum, and urine electrophoresis, and bone scans.

PEDIATRIC ORTHOPEDICS

BIRTH INJURIES

Brachial Plexus Palsy

Injury of the brachial plexus during delivery occurs in two births in every 1000. Large birth weight, forceps delivery, breech presentation, and prolonged labor are risk factors. Brachial plexus

injury usually represents a stretch injury on the nerve roots. Management is therapy and passive exercise to preserve motion in the shoulder while awaiting return of neurologic and motor function. Surgical repair of injured nerve roots and trunks may be required in severe cases.

Cerebral Palsy

Cerebral palsy results from an injury to the brain which may be associated with mental impairment. Cerebral palsy is classified as spastic, athetotic, ataxic, and may present with spasticity, hemiplegia, diplegia, or scoliosis. The typical cerebral palsy patient is hyperreflexic with increased muscle tone and spasm. Treatment includes tendon lengthening procedures, release of contractures, and tendon transfers to maintain motion and function.

Hip dislocation or subluxation results from unbalanced muscle forces in many cerebral palsy patients. Treatment consists of abductor tendon releases. When soft tissue releases are unsuccessful, tendon balancing procedures may be combined with open reduction of a hip joint and acetabular reconstruction and osteotomy of the proximal femur. Knee contractures are treated with hamstring lengthening.

Foot and ankle deformities are treated even in nonambulatory patients to facilitate shoe wear. The most common foot deformity in cerebral palsy is an equinovalgus foot caused by heel cord contracture and peroneal spasm. Tendon balancing is usually necessary and bony reconstruction may also be needed in severe cases.

Skeletal Growth

Injury, inflammatory disease, and developmental disorders in actively growing bones requires special attention to preserving the growth plates. The pediatric skeleton is incompletely ossified making diagnosis of an injury difficult, since significant portions of the skeleton are invisible on radiographs. The epiphysis, generally containing an articular surface, is found at the ends of the long bone. The physis or growth plate is found beneath the epiphysis. The physis has six specific zones: the *reserve zone*, the *zone of differentiation*, the *zone of proliferation*, the *zone of maturation*, the *hypertrophic zone*, and finally, the *zone of calcification*.

Injury or insult to the growth plate can lead to premature growth arrest or angular deformity of the limb. Surrounding the metaphyseal and diaphyseal bone, is the periosteum. This metabolically active layer of tissue synthesizes new bone onto the diaphyseal and metaphyseal bone and provides circumferential growth of the bones.

Ossification centers in the epiphysis and appear in a predictable order, and can help determine “bone age.”

Pediatric Fractures

In a pediatric patient, the epiphyseal growth plate is unossified and at risk of fracture. Reduction and stabilization of epiphyseal fractures is critical to minimize permanent growth disturbances and deformity.

Classification of Growth Plate Injuries

Salter and Harris described a useful classification for epiphyseal fractures. A Salter-Harris Type I injury is a simple transverse fracture through the physis. A Salter-Harris Type II fracture contains a component of fracture through the growth plate in continuity with a fracture of the metaphysis. Salter-Harris Type III fracture occurs through the physis and exits through the growth plate. While a Salter-Harris Type IV fracture line extends

through the physis from the metaphysis into the epiphysis. A Salter-Harris Type V fracture crushes the physis itself.

Treatment of growth plate fracture requires anatomic reduction of the fragments. Internal fixation avoids placing hardware across the growth plate to minimize the chance of premature growth plate closure.

Diaphyseal Injuries in a Pediatric Patient

Long bones diaphyseal fractures are generally treated closed. Pediatric patients are capable of extensive remodeling so that an angular deformity within the plane of an adjacent joint is often completely remodeled by the growth of the child. When internal fixation of a diaphyseal fracture is required, the physis is avoided.

Fractures of the Pediatric Hip

Pediatric patients with hip fractures may be treated with a spica cast. The spica cast includes the abdomen, lower back, pelvis, and lower limb, and derives its name from the resemblance of the plaster wrap over the hip to wheat (“spica”).

Fractures of the Femoral Shaft

Femoral shaft fractures in a child younger than six years old may be managed with a spica cast. Femur fractures in patients older than six years of age can be managed by internal fixation with a flexible intramedullary nail. Children 14 years of age are treated with an adult style intramedullary reamed nail. Extra-articular fractures of the distal femur or proximal tibia are managed in a long leg cast.

Pediatric Ankle Fractures

Salter-Harris I and II fractures are managed with casting. Salter-Harris III or IV fractures are managed by closed reduction and internal fixation with percutaneous pins or screws. Smooth pins are used, and the physis is avoided unless necessary for stability.

The Tillaux (Salter-Harris Type II) fracture involves a fracture through the lateral epiphysis and the lateral physis. In these patients the growth plate is in the process of closing and open reduction and internal fixation is needed. The “triplane” fracture (Salter-Harris Type IV) is managed by closed reduction with percutaneous pinning.

Pediatric Elbow Fractures

Management of pediatric elbow fractures is complex. A fracture of the distal humeral epiphysis can be misdiagnosed as a dislocation of the elbow. Familiarity with the timing of the ossification centers’ appearance aids in diagnosis. Treatment is closed reduction and percutaneous pinning.

Injury to the brachial artery, the radial, ulnar, and medial nerves are possible. Neurovascular exam is required before, during, and after treatment. Close follow-up for maintenance of reduction and neurovascular status is needed.

DEVELOPMENTAL DISEASE

Developmental Dysplasia of the Hip

Developmental dysplasia of the hip (DDH) is seen in firstborn females with a positive family history, and breech birth.

Untreated hip dislocations can lead to a dysplastic acetabulum. Newborns are examined for hip instability within the first 72 hours. Ortolani’s test consists of gentle elevation and abduction of the femur causing a palpable click in the relocation of a dislocated hip. Barlow’s test is gentle adduction and depression of the femur which causes a palpable click as a hip slips into a dislocated position. Infants with a dislocated or dislocatable hip

will have apparent length discrepancies of the femur when hip is positioned in 90 degrees. Since the bones are not yet ossified, X-ray images of the acetabulum and femoral head are not reliable for diagnosis. Ultrasound can often demonstrate a dislocated or dislocatable hip. Early treatment with abduction and flexion in a Pavlik harness can result in a normal hip joint.

Treatment of DDH

In a child with a dislocatable hip, a Pavlik harness can maintain the hips in flexion and abduction. Avoid severe abduction to avoid avascular necrosis of the head. For mild to moderate dysplasia, 6 to 12 weeks in a Pavlik harness is sufficient. In severe disease, adductor tenotomy may be needed.

If treatment is delayed, open reduction may be necessary. Through an anterior approach the pulvinar can be removed and the femoral head located. Adductor tenotomy and femoral shortening may be indicated. Osteonecrosis of the femoral head can result from open reduction resulting in pain and decreased motion. Some patients with severe DDH may require pelvic osteotomy creating an acetabular shelf, or a varus osteotomy of the proximal femur, or a combination of the two.

Legg-Calvé-Perthes Disease

Osteonecrosis of the proximal femoral epiphysis can cause flattening of the femoral head called Legg-Calvé Perthes disease. The typical patient is a 7-year-old male who presents with groin or knee pain, decreased hip motion, and a limp. Treatment includes traction, physical therapy, abduction exercises, and crutches. Femoral and pelvic osteotomies may be needed in extreme cases.

Slipped Capital Femoral Epiphysis

Children ages 10 to 16 years old can develop displacement of the epiphysis on the femoral neck with no history of injury. Slipped capital femoral epiphysis (SCFE) is associated with African American heritage, obesity, and is more common in boys than in girls. One-quarter of cases are bilateral. Patients generally present with groin and anterior thigh or even knee pain and decreased motion. In pediatric patients with knee pain, assess the ipsilateral hip as well.

Treatment for slipped capital femoral epiphysis patients is percutaneous screw fixation through the femoral neck to engage the epiphysis. Reduction of the slipped epiphysis is not recommended because of an increased risk of avascular necrosis. One screw is adequate to prevent further slip.

Lower Extremity Rotational Abnormalities

Intoeing can result from femoral anteversion, tibial torsion, and metatarsus adductus. Remember that a mild degree of intoeing is normal in young children 3 to 5 years of age.

Excessive internal rotation of the femur will usually correct by age 8. Severe rotation with functional impairment that does not correct by age 10 or 11 may require rotational femoral osteotomy.

Bilateral intoeing gait in one- and two-year-old children can result from tibial torsion which generally will completely resolve without treatment.

Metatarsus adductus in infants will also resolve spontaneously in most cases.

Congenital Talipes Equinovarus

Club foot is a common problem associated with contractures of the medial tendons of the foot, a tight Achilles tendon, and contractures of the ankle, hindfoot, and midfoot. Talipes equinovarus can be corrected by sequential corrective casting

of the foot. A successful program of casting may be complete in one to five months. In patients with severe disease or who initiate treatment after nine months of age, surgical release of contracted soft tissues may be necessary.

Osgood-Schlatter Disease

Osgood-Schlatter disease is a common problem most often seen in athletically active adolescents. This disorder is characterized by ossification in the distal patellar tendon at the point of its tibial insertion. This disorder is thought to result from mechanical stress on the tendinous insertion. Radiographs show calcified ossicles within the tendon at its insertion. The disease presents with severe local pain and tenderness in the area of the tibial tubercle.

Treatment for the disease is activity restriction. If the symptoms are improved, athletic participation can be resumed. Symptoms regress after skeletal maturity or the discontinuance of active athletic participation.

BIBLIOGRAPHY

Entries highlighted in bright blue are key references.

Trauma

- Bone LB, Johnson KD, Weigelt J, et al. Early vs. delayed stabilization of femoral fractures. A prospective randomized study. *J Bone Joint Surg.* 1989;71:336-340.
- Bottlang M, Krieg JC, Mohr M, Simpson TS, Madey SM. Emergent management of pelvic ring fractures with use of circumferential compression. *J Bone Joint Surg Am.* 2002;84-A Suppl 2:43-47.**
- Burgess AR, Eastridge BJ, Young JWR, et al. Pelvic ring disruptions: Effective classification system and treatment protocols. *J Trauma.* 1990;30:848.
- Chandler RWW. Principles of internal fixation. In: Buchholz RW, Heckman JD, eds. *Rockwood and Green's Fractures in Adults*, 5th ed. Philadelphia: Lippincott Williams & Wilkins; 2001.
- De Ugarte DA, Morizono K, Elbarbary A, et al. Comparison of multi-lineage cells from human adipose and bone marrow. *Cells, Tissue, and Organs.* 2003;174:101-109.
- Dragoo JL, Samimi B, Zhu M, et al. Tissue-engineered cartilage and bone using stem cells from human infrapatellar fat pads. *JBJS.* 2003; 85-B:740-747.
- Holstein A, Lewis GB. Fractures of the humerus with radial-nerve paralysis. *J Bone Joint Surg Am.* 1963;45:1382-1388.
- Lauge-Hansen N. Fractures of the ankle. II. Combined experimental-surgical and experimental-roentgenologic investigations. *Arch Surg.* 1950;60:957-985.
- Letourmel E. Acetabulum fractures: classification and management. *ClinOrthop.* 1980;151:81-106.
- Lin J. Treatment of humeral shaft fractures with humeral locked nail and comparison with plate fixation. *J Trauma.* 1998 May;44(5):859-864.
- Moran CG, Wenn RT, Sikand M, Taylor AM. Early mortality after hip fracture: is delay before surgery important? *J Bone Joint Surg Am.* 2005;87:483-489.**
- Moro JK, Werier J, MacDermid JC, Patterson SD, King GJ. Arthroplasty with a metal radial head for unreconstructible fractures of the radial head. *J Bone Joint Surg Am.* 2001;83-A(8): 1201-1211.
- Nicoll EA. Fractures of the tibial shaft: a survey of 705 cases. *J Bone Joint Surg Br.* 1964;46:373-387.
- Nork SE, Cannada LK. Hip dislocations and femoral head and neck fractures. In: Baumgaertner MR, Tornetta P III, eds. *Orthopaedic Knowledge Update: Trauma 3. Rosemont: American Academy of Orthopaedic Surgeons; 2005:365-376.*
- Ring D, Jupiter JB, Zilberfarb J. Posterior dislocation of the elbow with fractures of the radial head and coronoid. *J Bone Joint Surg Am.* 2002;84:547-551.

- Ring D, Quintero J, Jupiter JB. Open reduction and internal fixation of fractures of the radial head. *J Bone Joint Surg Am.* 2002;84-A(10):1811-1815.
- Roberts CS, Pape HC, Jones AL. Damage control orthopaedics: Evolving concepts in the treatment of patients who have sustained orthopaedic trauma. *Instr Course Lect.* 2005;54:447-462.
- Ross G, McDevitt ER, Chronister R, Ove PN. Treatment of simple elbow dislocation using immediate motion protocol. *AJSM.* 1999;27:308-311.
- Sarmiento A, Kinman PB, Galvin EG, et al. Functional bracing of fractures of the shaft of the humerus. *J Bone Joint Surg Am.* 1977;59:596-601.
- Schatzker J, McBroom R, Bruce DD. The tibial plateau fracture: The Toronto experience 1968-1975. *ClinOrthop.* 1979;138:94-104.
- Schemitsch EH, Richards RR. The effect of malunion on functional outcome after plate fixation of fractures of both bones of the forearm in adults. *J Bone Joint Surg Am.* 1992;74(7):1068-1078.
- Shin SSS. Circulatory and vascular changes in the hip following traumatic hip dislocation. *ClinOrthop.* 1979;140:255-261.
- Tile MM. Acute pelvic fracture II. Principles of management. *J Am AcadOrthop.* 1996;4:152-161.
- Tile MM. Acute pelvic fracture: I. Causation and classification. *J Am AcadOrthop.* 1996;4:143-151.
- Yagishita K, Thomas BJ. Use of allograft for large Hill-Sachs lesion associated with anterior glenohumeral dislocation. A case report. *Injury.* 2002;33:791-794.
- Sports**
- Allaire R, Muriuki M, Gilbertson L, Harner CD. Biomechanical consequences of a tear of the posterior root of the medial meniscus. Similar to total meniscectomy. *J Bone Joint Surg Am.* 2008;90(9):1922-1931.
- Araujo P, Van Eck CF, Torabi M, Fu FH. How to optimize the use of MRI in anatomic ACL reconstruction. *Knee Surg Sports TraumatolArthrosc.* 2013;21(7):1495-1501.
- Arnoczky SP, Warren RF, Spivak JM. Meniscal repair using an exogenous fibrin clot. An experimental study in dogs. *J Bone Joint Surg Am.* 1988;70(8):1209-1217.
- Brophy RH, Marx RG. The treatment of traumatic anterior instability of the shoulder: nonoperative and surgical treatment. *Arthroscopy.* 2009;25:298-304.
- Ceccarelli E, Bondi R, Alvitì F, Garofalo R, Miulli F, Padua R. Treatment of acute grade III acromioclavicular dislocation: a lack of evidence. *J OrthopTraumatol.* 2008;9(2):105-108.
- Clarke MT, Arora A, Villar RN. Hip arthroscopy: complications in 1054 cases. Clinical orthopaedics and related research. 84-88.
- Frank C, Amiel D, Akeson WH. Healing of the medial collateral ligament of the knee. A morphological and biochemical assessment in rabbits. *Acta Orthop Scand.* 1983;54(6):917-923.
- Frank C, Woo SL, Amiel D, Harwood F, Gomez M, Akeson W. Medial collateral ligament healing. A multidisciplinary assessment in rabbits. *Am J Sports Med.* 1983;11(6):379-89.
- Frost A, Zafar MS, Maffulli N. Tenotomy versus tenodesis in the management of pathologic lesions of the tendon of the long head of the biceps brachii. *Am J Sports Med.* 2009;37(4):828-833.
- Gartsman GM. Arthroscopic management of rotator cuff disease. *J Am AcadOrthop Surg.* 1998;6(4):259-266.
- Goldberg BA, Scarlat MM, Harryman DT. Management of the stiff shoulder. *J Orthop Sci.* 1999;4(6):462-471.
- Harner CD, Mauro CS, Lesniak BP, Romanowski JR. Biomechanical consequences of a tear of the posterior root of the medial meniscus. *J Bone Joint Surg Am.* 2009;91 Suppl 2:257-270.
- Hovelius L. The natural history of primary anterior dislocation of the shoulder in the young. *J Orthop Sci.* 1999;4(4):307-317.
- Ishida K, Kuroda R, Miwa M, et al. The regenerative effects of platelet-rich plasma on meniscal cells in vitro and its in vivo application with biodegradable gelatin hydrogel. *Tissue Eng.* 2007;13(5):1103-1112.
- Jakobsen BW, Johannsen HV, Suder P, Søjbjerg JO. Primary repair versus conservative treatment of first-time traumatic anterior dislocation of the shoulder: a randomized study with 10-year follow-up. *Arthroscopy.* 2007;23:118-123.
- Kim S, Bosque J, Meehan JP, Jamali A, Marder R. Increase in outpatient knee arthroscopy in the United States: a comparison of National Surveys of Ambulatory Surgery, 1996 and 2006. *J Bone Joint Surg Am.* 2011;93(11):994-1000.
- McAndrews PT, Arnoczky SP. Meniscal repair enhancement techniques. *Clin Sports Med.* 1996;15(3):499-510.
- Mohtadi NG, Hollinshead RM, Sasyniuk TM, Fletcher JA, Chan DS, Li FX. A randomized clinical trial comparing open to arthroscopic acromioplasty with mini-open rotator cuff repair for full-thickness rotator cuff tears: disease-specific quality of life outcome at an average 2-year follow-up. *Am J Sports Med.* 2012;40(10):2103-2111.
- Morse K, Davis AD, Afra R, Kaye EK, Schepsis A, Voloshin I. Arthroscopic versus mini-open rotator cuff repair: a comprehensive review and meta-analysis. *Am J Sports Med.* 2008;36:1824-1828.
- Nho SJ, Shindle MK, Sherman SL, Freedman KB, Lyman S, MacGillivray JD. Systematic review of arthroscopic rotator cuff repair and mini-open rotator cuff repair. *J Bone Joint Surg Am.* 2007;89:127-136.
- Pallis M, Svoboda SJ, Cameron KL, Owens BD. Survival comparison of allograft and autograft anterior cruciate ligament reconstruction at the United States Military Academy. *Am J Sports Med.* 2012;40(6):1242-1246.
- Rodeo SA. Arthroscopic meniscal repair with use of the outside-in technique. Instructional course lectures. 2000;49:195-206.
- Sekiya JK, West RV, Groff YJ, Irrgang JJ, Fu FH, Harner CD. Clinical outcomes following isolated lateral meniscal allograft transplantation. *Arthroscopy.* 2008;22:771-780.
- Silliman JF, Hawkins RJ. Classification and physical diagnosis of instability of the shoulder. *Clin Orthop Relat Res.* 1993;291:7-19.
- Simovitch R, Sanders B, Ozbaydar M, Lavery K, Warner JJP. Acromioclavicular joint injuries: diagnosis and management. *J Am AcadOrthop Surg.* 2009; 17(4):207-219.
- Tashman S, Kolowich P, Collon D, Anderson K, Anderst W. Dynamic function of the ACL-reconstructed knee during running. *Clin Orthop Relat Res.* 2007; 454:66-73.
- Tumia NS, Johnstone AJ. Platelet derived growth factor-AB enhances knee meniscal cell activity in vitro. *Knee.* 2009;16(1):73-76.
- Verma NN, Dunn W, Adler RS, et al. All-arthroscopic versus mini-open rotator cuff repair: a retrospective review with minimum 2-year follow-up. *Arthroscopy.* 2006;22:587-594.
- Wolf RS, Zheng N, Weichel D. Long head biceps tenotomy versus tenodesis: a cadaveric biomechanical analysis. *Arthroscopy.* 2005; 21:182-185.
- Li H, Tao H, Cho S, Chen S, Yao Z, Chen S. Difference in graft maturity of the reconstructed anterior cruciate ligament 2 years postoperatively: a comparison between autografts and allografts in young men using clinical and 3.0-T magnetic resonance imaging evaluation. *Am J Sports Med.* 2012;40(7):1519-1526.
- Baer GS, Harner CD. Clinical outcomes of allograft versus autograft in anterior cruciate ligament reconstruction. *Clin Sports Med.* 2007;26(4):661-681.
- Carey JL, Dunn WR, Dahm DL, Zeger SL, Spindler KP. A systematic review of anterior cruciate ligament reconstruction with autograft compared with allograft. *J Bone Joint Surg Am.* 2009;91(9):2242-2250.

- Samuelsson K, Andersson D, Karlsson J. Treatment of anterior cruciate ligament injuries with special reference to graft type and surgical technique: an assessment of randomized controlled trials. *Arthroscopy*. 2009;25:1139-1174.
- Van Eck CF, Lesniak BP, Schreiber VM, Fu FH. Anatomic single- and double-bundle anterior cruciate ligament reconstruction flowchart. *Arthroscopy*. 2010;26:258-268.
- Skyhar MJ, Warren RF, Ortiz GJ, Schwartz E, Otis JC. The effects of sectioning of the posterior cruciate ligament and the posterolateral complex on the articular contact pressures within the knee. *J Bone Joint Surg Am*. 1993;75(5):694-699.
- Harner CD, Vogrin TM, Höher J, Ma CB, Woo SL. Biomechanical analysis of a posterior cruciate ligament reconstruction. Deficiency of the posterolateral structures as a cause of graft failure. *Am J Sports Med*. 2000;28(1):32-39.
- MacGillivray JD, Stein BES, Park M, Allen AA, Wickiewicz TL, Warren RF. Comparison of tibial inlay versus transtibial techniques for isolated posterior cruciate ligament reconstruction: minimum 2-year follow-up. *Arthroscopy*. 2006;22:320-328.
- Seon JK, Song EK. Reconstruction of isolated posterior cruciate ligament injuries: a clinical comparison of the transtibial and tibial inlay techniques. *Arthroscopy*. 2006; 22:27-32.
- Ranawat A, Baker CL, Henry S, Harner CD. Posterolateral corner injury of the knee: evaluation and management. *J Am Acad Orthop Surg*. 2008;16(9):506-518.
- LaPrade RF, Resig S, Wentorf F, Lewis JL. The effects of grade III posterolateral knee complex injuries on anterior cruciate ligament graft force. A biomechanical analysis. *Am J Sports Med*. 1999;27(4):469-475.
- Swenson TM, Harner CD. Knee ligament and meniscal injuries. Current concepts. *Orthop Clin North Am*. 1995;26(3):529-546.
- Ganz R, Parvizi J, Beck M, Leunig M, Nötzli H, Siebenrock KA. Femoroacetabular impingement: a cause for osteoarthritis of the hip. *Clin Orthop Relat Res*. 2003;417:112-120.
- Byers PD, Contepomi CA, Farkas TA. A post mortem study of the hip joint. Including the prevalence of the features of the right side. *Ann Rheum Dis*. 1970;29(1):15-31.
- Leunig M, Beck M, Woo A, Dora C, Kerboull M, Ganz R. Acetabular rim degeneration: a constant finding in the aged hip. *Clin Orthop Relat Res*. 2003;413:201-207.
- Seldes RM, Tan V, Hunt J, Katz M, Winiarsky R, Fitzgerald RH. Anatomy, histologic features, and vascularity of the adult acetabular labrum. *Clin Orthop Relat Res*. 2001;382:232-40.
- Byrd JWT, Jones KS. Arthroscopic femoroplasty in the management of cam-type femoroacetabular impingement. *Clin Orthop Relat Res*. 2009;467:739-746.
- Byrd JWT, Jones KS. Prospective analysis of hip arthroscopy with 10-year followup. *Clin Orthop Relat Res*. 2010;468:741-746.
- Ilizaliturri VM, Orozco-Rodriguez L, Acosta-Rodríguez E, Camacho-Galindo J. Arthroscopic treatment of cam-type femoroacetabular impingement: preliminary report at 2 years minimum follow-up. *J Arthroplasty*. 2008;23:226-234.
- Larson CM, Giveans MR. Arthroscopic management of femoroacetabular impingement: early outcomes measures. *Arthroscopy*. 2008; 24:540-546.
- Philippon MJ, Briggs KK, Yen YM, Kuppersmith DA. Outcomes following hip arthroscopy for femoroacetabular impingement with associated chondrolabral dysfunction: minimum two-year follow-up. *J Bone Joint Surg Br*. 2009;91:16-23.
- Sampson TG. Complications of hip arthroscopy. *Clinics in sports medicine*. 2001;20:831-835.
- injury: A prospective comparison.** *J Trauma*. 2009; 66(6):1605-1609.
- Bellarbarba C, Mirza SK, West GA, et al. Diagnosis and treatment of craniocervical dislocation in a series of 17 consecutive survivors during an 8-year period. *J Neurosurg Spine*. 2006;4(6):429-440.
- Ben Galim PJ, Sibai T, Hipp JA, et al. Internal Decapitation: Survival After Head to Neck Dissociation Injuries. *Spine*. 2008; 33:16
- Dimar JR, Glassman SD, Raque GH, Zhang YP, Shields CB. The influence of spinal canal narrowing and timing of decompression on neurologic recovery after spinal cord contusion in a rat model. *Spine*. 1999;24:1623-1633.
- Fehlings MG, Sekhon LH, Tator C. The role and timing of decompression in acute spinal cord injury. *Spine*. 2001;26:s101-s110.
- Fehlings MG, Tator CH: An evidence-based review of decompressive surgery in acute spinal cord injury: Rationale, indications, and timing based on experimental and clinical studies. *J Neurosurg Spine*. 1999;91:1-11.
- Macias CA, Rosengart MR, Puyana JC, et al: The effects of trauma center care, admission volume, and surgical volume on paralysis after traumatic spinal cord injury.** *Ann Surg*. 2009;249(1):10-17.
- Shields CB, Zhang YP, Shields LB, Han Y, Burke DA, Mayer NW. The therapeutic window for spinal cord decompression in a rat spinal cord injury model. *J Neurosurg Spine*. 2005;3:302-307.

Joint Reconstruction

- Alazzawi S, Bardakos NV, Hadfield SG, Butt U, Beer ZH, Field RE. Patient-reported complications after elective joint replacement surgery: are they correct? *Bone Joint Surg Br*. 2012;94(8):1120-1125. doi: 10.1302/0301-620X.94B8.29040.
- Am J Prev Med 2006;30(5):385-393. [Data Source: 2002 NHIS]
- Arch Intern Med 2001;161(19):2309-2316. [Data Source: FAST Trial]
- Arthritis Care Res 2011;63(6):788-99. [Data Source: 2005, 2007, 2009 BRFSS]
- Arthritis Rheum 1998;41(8):1343-1355. [Data source: Framingham Osteoarthritis Study]
- Arthritis Rheum 2004;50(9, suppl):5641. [Data Source: 2002 NHIS]
- Arthritis Rheum 2008;59(9):1207-1213. abstract [Data Source: 1999-2003 Johnston County Osteoarthritis Project data]
- Bergin PF, Doppelt JD, Kephart CJ, et al. Comparison of minimally invasive direct anterior vs. posterior total hip arthroplasty. *JBJS Am*. 2011; 93(15):1392-1398.
- Cheng YJ, Hootman JM, Murphy LB, Langmaid GA, Helmick CG. Prevalence of doctor-diagnosed arthritis and arthritis-attributable activity limitation—United States, 2007-2009. *MMWR*. 2010;59(39):1261-1265.
- Davis CM III, Berry DJ, Harmsen WS. Cemented revision of failed uncemented femoral components of total hip arthroplasty. *J Bone Joint Surg Am*. 2003;85-A(7):1264-1269.
- Haaker RG, Tiedjen K, Ottersbach A, Rubenthaler F, Stockheim M, Stiehl JB. Comparison of conventional versus computer-navigated acetabular component insertion. *J Arthroplasty*. 2007;22(2):151-159.
- Hootman JM, Helmick CG. Projections of U.S. prevalence of arthritis and associated activity limitations. *Arthritis Rheum*. 2006;54(1):266-229.
- Johnston RC, Brand RA, Crowninshield RD. Reconstruction of the hip. A mathematical approach to determine optimum geometric relationships. *J Bone Joint Surg Am*. 1979;61:639-652.
- Kim YH, Park JW, Kim JS. Computer-Navigated Versus Conventional Total Knee Arthroplasty: A Prospective Randomized Trial. *J Bone Joint Surg Am*. 2012; 94(22):2017-24.
- Kwon MS, Kuskowski M, Mulhall KJ, Macaulay W, Brown TE, Saleh KJ. Does surgical approach affect total hip arthroplasty dislocation rates? *Clin Orthop Relat Res*. 2006;447:34-38.

Spine

Bailitz J, Starr F, Beecroft M, et al: CT should replace three-view radiographs as the initial screening test in patients at high, moderate, and low risk for blunt cervical spine

- Pospischill M, Kranzl A, Attwenger B, Knahr K. Minimally invasive compared with traditional transgluteal approach for total hip arthroplasty: a comparative gait analysis. *J Bone Joint Surg Am.* 2010 Feb;92(2):328-337.
- Soong M, Rubash HE, Macaulay W. Dislocation after total hip arthroplasty. *Am Acad Orthop Surg.* 2004 ;12: 314-321.
- Vail, T, Callaghan, J. Minimal incision total hip arthroplasty. *J Am Acad Orthop Surg.* 2007;15:707-715.

Orthopedic Oncology

- Giuffrida AY, Burgueno JE, Koniaris LG, Gutierrez JC, Duncan R, Scully SP. Chondrosarcoma in the United States (1973 to 2003): an analysis of 2890 cases from the SEER database. *J Bone Joint Surg Am.* 2009;91(5): 1063-1072.
- Jawad MU, Cheung MC, Min ES, Schneiderbauer MM, Koniaris LG, Scully SP. Ewing's sarcoma demonstrates racial disparities in incidence-related and sex-related differences in outcome: an analysis of 1631 cases from the SEER database, 1973-2005. *Cancer.* 2009;115(15): 3526-3536.
- Mirabello L, Troisi RJ, Savage SA. Osteosarcoma incidence and survival rates from 1973 to 2004: data from the surveillance, epidemiology, and end results program. *Cancer.* 2009;115(7):1531-1543.
- Rougraff BT. Evaluation of the patient with carcinoma of unknown origin metastatic to bone. *Clin Orthop Relat Res.* 2003; (415, Suppl):S105-S109.
- Spychalski JN, Thomas BJ. Treatment and Rehabilitation of Pathologic Fractures, State of the Art Reviews: Physical Medicine and Rehabilitation. 1995;9(1):77-92.
- Visuri T, Pukkala E, Paavolainen P, Pulkkinen P, Riska EB. Cancer risk after metal on metal and polyethylene on metal total hip arthroplasty. *Clin Orthop Relat Res.* 1996 Aug;(329 Suppl): S280-S289.

Pediatric Orthopedics

- Crawford AH, Mehlman CT, Slovek RW. The fate of untreated developmental dislocation of the hip: Longterm follow-up of eleven patients. *J Pediatr Orthop.* 1999;19(5):641-644.
- Jessel RH, Zurakowski D, Zilkens C, Burstein D, Gray ML, Kim YJ. Radiographic and patient factors associated with pre-radiographic osteoarthritis in hip dysplasia. *J Bone Joint Surg Am.* 2009;91(5):1120-1129.
- Mahan ST, Katz JN, Kim YJ. To screen or not to screen? A decision analysis of the utility of screening for developmental dysplasia of the hip. *J Bone Joint Surg Am.* 2009;91(7):1705-1719.
- Murray AW, Wilson NI. Changing incidence of slipped capital femoral epiphysis: a relationship with obesity? *J Bone Joint Surg Br.* 2008;90(1):92-94.
- Palocaren T, Holmes L, Rogers K, Kumar SJ. Outcome of in situ pinning in patients with unstable slipped capital femoral epiphysis: Assessment of risk factors associated with avascular necrosis. *J Pediatr Orthop.* 2010;30(1):31-36.
- Parsch K, Weller S, Parsch D. Open reduction and smooth Kirschner wire fixation for unstable slipped capital femoral epiphysis. *J Pediatr Orthop.* 2009;29(1):1-8.
- Stevenson DA, Mineau G, Kerber RA, Viskochil DH, Schaefer C, Roach JW. Familial predisposition to developmental dysplasia of the hip. *J Pediatr Orthop.* 2009;29(5):463-466.
- Tokmakova KP, Stanton RP, Mason DE. Factors influencing the development of osteonecrosis in patients treated for slipped capital femoral epiphysis. *J Bone Joint Surg Am.* 2003; 85(5):798.
- Trousdale RT. Acetabular osteotomy: indications and results. *Clin Orthop Relat Res.* 2004;429:182-187.

44 chapter

Surgery of the Hand and Wrist

Scott D. Lifchez and J. Alex Kelamis

Introduction	1787	Complications	1801	Malignant Soft Tissue Tumors—Cutaneous / 1817
Anatomy of the Hand and Wrist	1787	Nonunion / 1801		Malignant Soft Tissue Tumors—Noncutaneous / 1818
Bones / 1787		Stiffness / 1805		Benign Bone Tumors / 1818
Muscles Affecting the Hand and Wrist / 1788		Neuroma / 1805		Malignant Bone Tumors / 1819
Tendons and Pulleys / 1791		Regional Pain Syndromes / 1805		Secondary Metastatic Tumors / 1820
Vascular / 1791		Nerve Compression	1805	Burns
Nerve / 1792		Carpal Tunnel Syndrome / 1805		Acute Management / 1820
Hand Examination	1793	Cubital Tunnel Syndrome / 1806		Surgical Management / 1821
Emergency Room/Inpatient Consultation / 1793		Other Sites of Nerve Compression / 1806		Reconstruction / 1821
Hand Imaging	1794	Degenerative Joint Disease	1806	Special Considerations / 1822
Plain X-Rays / 1794		Small Joints (Metacarpophalangeal and Interphalangeal) / 1807		Vascular Disease
Computed Tomography / 1794		Wrist / 1807		Progressive Thrombotic Disease / 1822
Ultrasonography / 1794		Rheumatoid Arthritis / 1808		Systemic Vasculopathy / 1822
Magnetic Resonance Imaging / 1794		Dupuytren's Contracture	1808	Vasospastic Disorders / 1823
Angiography / 1794		Infections	1809	Congenital Differences
Trauma	1795	Cellulitis / 1809		Failure of Formation / 1823
Local Anesthesia / 1795		Abscess / 1809		Failure of Differentiation / 1823
Fractures and Dislocations / 1796		Collar-Button Abscess / 1810		Duplication / 1823
Tendons / 1798		Osteomyelitis / 1810		Overgrowth / 1823
Nerve Injuries / 1798		Pyogenic Arthritis / 1811		Undergrowth / 1823
Vascular Injuries / 1799		Necrotizing Infections / 1811		Constriction Band Syndrome / 1823
Special Considerations	1800	Infectious Flexor Tenosynovitis / 1811		Generalized Skeletal Anomalies and Syndromes / 1824
Amputations and Replantation / 1800		Felon / 1813		Reconstructive Transplantation of the Upper Extremity
Fingertip Injuries / 1800		Paronychia / 1813		1824
High-Pressure Injection Injuries / 1801		Tumors	1814	
Compartment Syndromes / 1801		Benign Soft Tissue Tumors / 1815		

INTRODUCTION

The highly mobile, functional, and strong hand is a major distinguishing point between humans and the nonhuman primates. The hand is an essential participant for activities of daily living, vocation, and recreational activities. The hand is even adaptable enough to read for the blind and speak for the mute. The underlying goal of all aspects of hand surgery is to maximize mobility, sensibility, stability, and strength while minimizing pain. These goals are then maximized to the extent possible given the patient's particular pathology. Hand surgery is a regional specialty. Hand surgeons integrate components of neurologic, orthopedic, plastic, and vascular surgery in the care of patients with disorders of the upper extremities.

ANATOMY OF THE HAND AND WRIST

In order to understand any disorder of the hand, one must understand the anatomy of the underlying structures. Examination of the hand is based on demonstrating the function or lack thereof of each of these structures.

Bones

The hand is highly mobile in space to allow maximum flexibility in function. As such, a number of directions particular to the hand are necessary in order to properly describe position, motion, and so on.¹ Palmar (or volar) refers to the anterior surface of the hand in the anatomic position; dorsal refers to the posterior surface in the anatomic position. The hand can

Key Points

- 1▶ Surgery of the hand is a regional specialty, integrating components of neurologic, orthopedic, plastic, and vascular surgery.
- 2▶ Understanding hand anatomy is the key to proper diagnosis of injury, infection, and degenerative disease of the hand.
- 3▶ After evaluation and/or treatment, patients should be splinted to protect the injured digits and keep the collateral ligaments of the injured joints on tension (metacarpophalangeal joints flexed, interphalangeal joints extended).
- 4▶ Healing of an injured or diseased structure in the hand is not the endpoint of treatment; the goal of any intervention must be

to obtain structure healing, relief of pain, and maximization of function.

- 5▶ If a patient managed conservatively for cellulitis does not improve within 24 to 48 hours of appropriate intravenous antibiotics, abscess must be suspected.
- 6▶ Clinical examination, particularly noting the area of greatest tenderness and/or inflammation, is the most useful diagnostic tool for hand infections.

rotate at the wrist level; rotation to bring the palm down is called pronation, rotation to bring the palm up is called supination. Because the hand can rotate in space, the terms medial and lateral are avoided. Radial and ulnar are used instead as these terms do not vary with respect to the rotational position of the hand. Abduction and adduction, when used on the hand, refer to movement of the digits away from and toward the middle finger, respectively (Fig. 44-1).

The hand is comprised of 19 bones arranged in five rays.² A *ray* is defined as a digit (finger or thumb) from the metacarpal base to the tip of the digit (Fig. 44-2A). The rays are numbered 1 to 5, beginning with the thumb. By convention, however, they are referred to by name: thumb, index, middle, ring, and small. There are five metacarpals, comprising the visible palm of the hand. Each digit has a proximal and a distal phalanx, but only the fingers have a middle phalanx as well. The metacarpophalangeal (MP) joint typically allows 90° of flexion with a small amount of hyperextension. In addition, the fingers can actively abduct (move away from the middle finger) and adduct (move toward the middle finger). The thumb, in contrast, moves principally in the flexion-extension arc at the MP joint. Although there can be laxity in the radial and ulnar direction, the thumb cannot actively move in these directions at the MP level. The proximal interphalangeal joint (PIP) is the critical joint for finger mobility. Normal motion is 0 to 95° (full extension to flexion). The distal interphalangeal joint (DIP) also moves only in a flexion-extension plane from 0 to 90° on average. The thumb interphalangeal joint (IP) also moves only in a flexion-extension plane. Its normal motion is highly variable between individuals, but averages 0 to 80°.

Each of the MP and IP joints has a radial and ulnar collateral ligament to support it. The IP joint collateral ligaments are on tension with the joint fully extended. For the fingers, the MP joint collateral ligaments are on tension with the joint bent 90°. Collateral ligaments have a tendency to contract when not placed on tension; this becomes relevant when splinting the hand (see later Trauma section on splinting).

The wrist consists of eight carpal bones divided into two rows (Fig. 44-2B).² The proximal row consists of the scaphoid, lunate, and triquetrum. The lunate is the principle axis of motion of the hand onto the forearm. It bears approximately 35% of the load of the wrist onto the forearm. The scaphoid is shaped like the keel of a boat and bears 55% of the load of the hand onto the forearm, but also serves as the principle link between the proximal and distal rows, allowing for motion while

maintaining stability. Both the scaphoid and the lunate articulate with the radius. The triquetrum resides ulnar to the lunate. It does not interact with the ulna proximally; rather, it interacts with a cartilage suspended between the ulnar styloid and the distal radius called with triangular fibrocartilage complex (TFCC) (Fig. 44-2B). The remaining 10% of load of the hand onto the forearm is transmitted through the TFCC.³

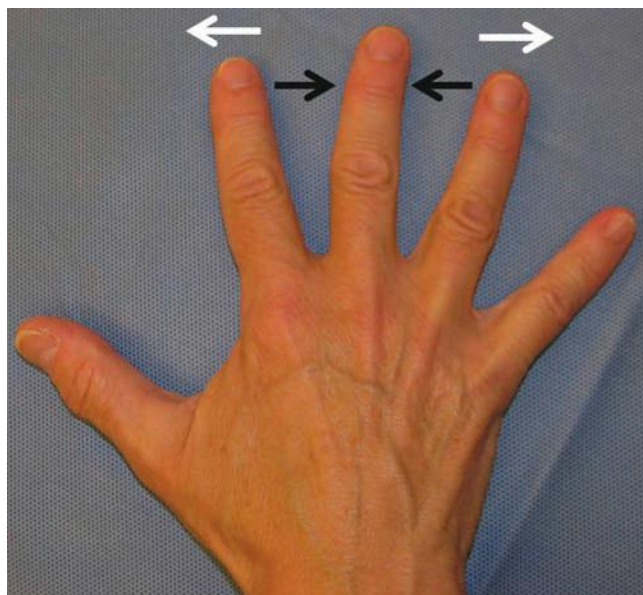
The distal row consists of four bones. The trapezium resides between the scaphoid and the thumb metacarpal. Distally, it has a saddle-shaped surface, which interacts with a reciprocally saddle-shaped base of the thumb metacarpal to allow for high mobility of the thumb carpometacarpal (CMC) joint in radial-ulnar and palmar-dorsal directions and opposition (Fig. 44-1B). The trapezoid rests between the scaphoid and the index finger metacarpal. The capitate, the largest carpal bone and first to ossify in a child, lies between the lunate and the middle finger metacarpal, but also interacts with the scaphoid on its proximal radial surface. The index and middle finger CMC joints are highly stable and have minimal mobility. The hamate is the ulnar-most bone in the distal row, sitting between the triquetrum proximally and the ring and small finger metacarpals distally. The ring and small finger CMC joints are mobile, principally in the flexion-extension direction.

The pisiform is a carpal bone only by geography. It is a sesamoid bone within the FCU tendon (see below). It does not bear load and can be excised, when necessary, without consequence.

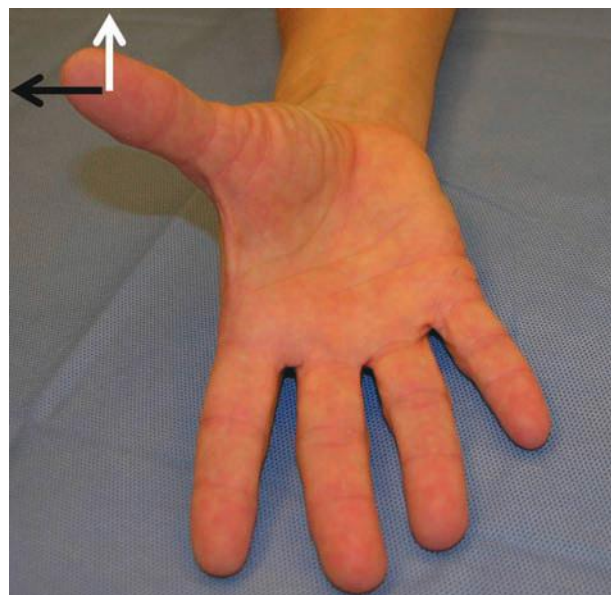
Muscles Affecting the Hand and Wrist

The wrist is moved by multiple tendons that originate from the forearm and elbow. The digits of the hand are moved by both intrinsic (originating within the hand) and extrinsic (originating in the forearm) muscles. All of these muscles are innervated by the median, radial, or ulnar nerves (or their branches) (Fig. 44-3).

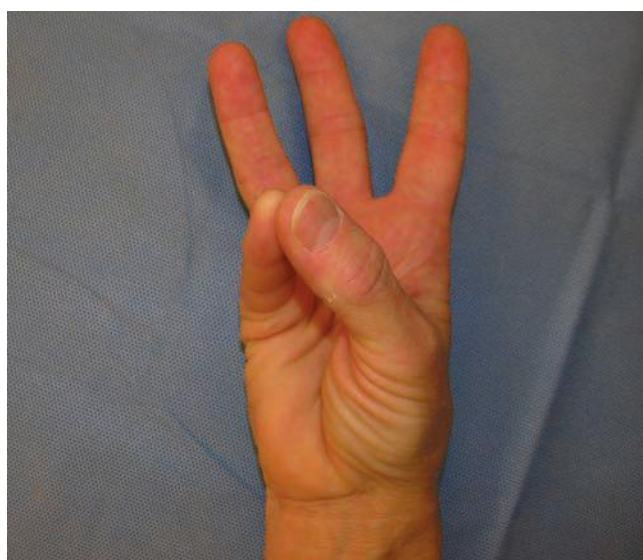Three muscles flex the wrist, all of which originate from the medial epicondyle of the humerus. The flexor carpi radialis (FCR, median nerve) inserts on the volar base of the index finger metacarpal. The flexor carpi ulnaris (FCU, ulnar nerve) also originates from the proximal ulna and inserts on the volar base of the small finger metacarpal. The palmaris longus (PL) tendon does not insert on a bone; it inserts on the palmar fascia, located deep to the skin in the central proximal palm, and is absent in up to 15% of patients. The FCR also deviates the wrist radially, whereas the FCU deviates the wrist ulnarly.



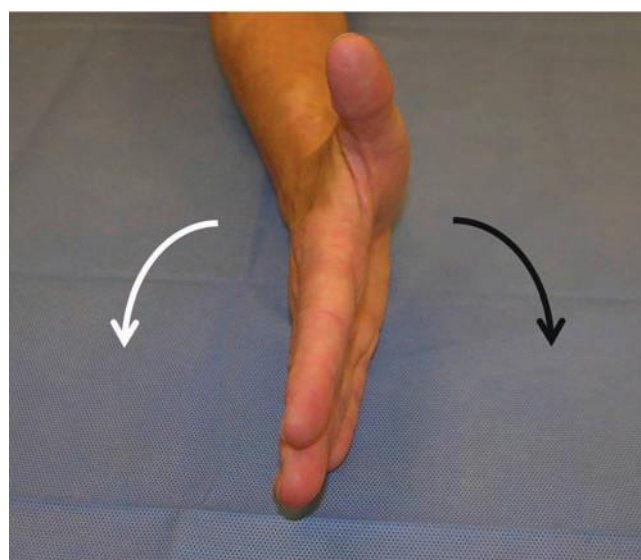
A



B



C



D

Figure 44-1. Directions of finger, hand, and wrist motion. **A.** Finger abduction (*white arrows*) and adduction (*black arrows*). **B.** Thumb radial (*black arrow*) and palmar (*white arrow*) abduction. **C.** Thumb and small finger opposition. **D.** Hand/wrist pronation (*black arrow*) and supination (*white arrow*).

All three wrist extensors are innervated by the radial nerve or its branches. The extensor carpi radialis longus (ECRL) originates from the distal shaft of the humerus and inserts on the dorsal base of the index finger metacarpal. The extensor carpi radialis brevis (ECRB) originates from the lateral epicondyle of the humerus and inserts on the dorsal base of the middle finger metacarpal. The extensor carpi ulnaris (ECU) also originates from the lateral epicondyle of the humerus and inserts on the dorsal base of the small finger metacarpal. The ECRL deviates the wrist radially, whereas the ECU deviates the wrist ulnarly.

The long flexors of the fingers all originate from the medial epicondyle of the humerus. The flexor digitorum superficialis (FDS) inserts on the base of the middle phalanx of each finger and primarily flexes the PIP joint. The flexor digitorum profundus (FDP) inserts on the base of the distal phalanx and

primarily flexes the DIP joint. The flexor pollicis longus (FPL) originates more distally, from the ulna, radius, and interosseous membrane between them in the forearm. It inserts on the base of the distal phalanx of the thumb and primarily flexes the IP joint. All of these tendons can also flex the more proximal joint(s) in their respective rays. All of these muscles are innervated by the median nerve (or its branches) except the FDP to the ring and small fingers, which are innervated by the ulnar nerve.

The extrinsic extensors of the fingers and thumb are all innervated by the posterior interosseous nerve (PIN, branch of the radial nerve). The extensor digitorum communis (EDC) originates from the lateral epicondyle of the humerus and extends the MP joints of the fingers. Unlike most tendons that attach directly into a bone, the EDC tendons do not insert on the dorsal base of the proximal phalanx, but rather into a soft tissue sling called the

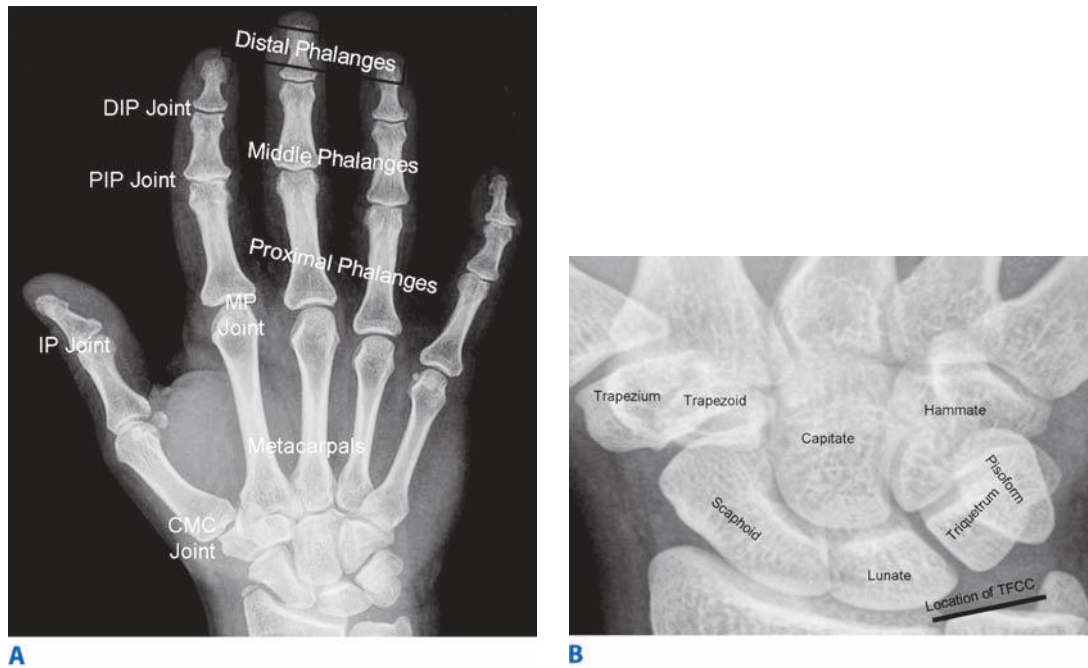

Figure 44-2. Bony architecture of the hand and wrist. **A.** Bones of the hand and digits. All rays have metacarpophalangeal (MP) joints. The fingers have proximal and distal interphalangeal joints (PIP and DIP), but the thumb has a single interphalangeal (IP) joint. **B.** Bones of the wrist. The proximal row consists of the scaphoid, lunate, and capitate. The distal row bones articulate with the metacarpals: the trapezium with the thumb, the trapezoid with the index, the capitate with the middle, and the hamate with the ring and small. The pisiform bone is a sesamoid within the flexor carpi ulnaris tendon. It overlaps the triquetrum and hamate but does not contribute to a carpal row. CMC = carpometacarpal; TFCC = triangular fibrocartilage complex.

sagittal hood, which surrounds the proximal phalanx base and pulls up on the volar surface in a hammock-like manner. More distally in the dorsal forearm, the extensor indices proprius (EIP) and extensor digiti quinti (EDQ) originate from the ulna, radius, and posterior interosseous membrane and insert on the sagittal hood of the index and small fingers, respectively.

The thumb has three separate extrinsic extensors. All of these originate from the dorsal ulna in the mid-forearm and are innervated by the PIN. The abductor pollicis longus (APL) inserts on the radial base of the thumb metacarpal to produce some extension, but mostly abduction. The extensor pollicis brevis (EPB) inserts on the base of the thumb proximal phalanx.

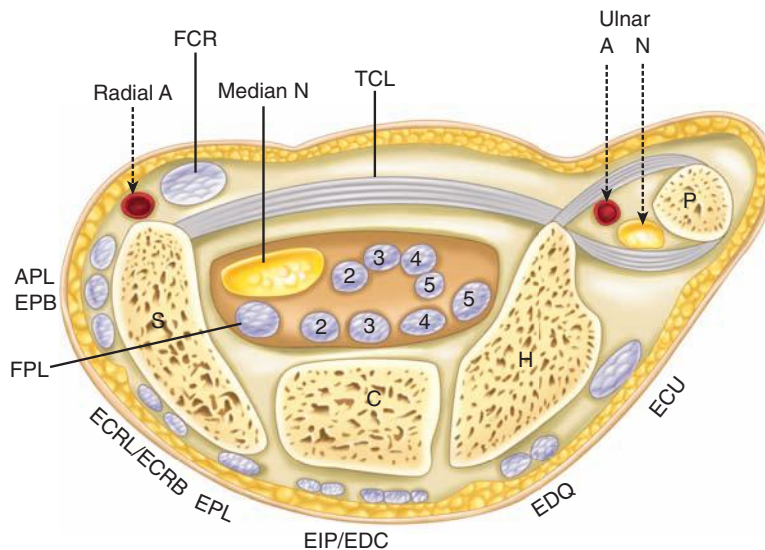


Figure 44-3. Cross-section of the wrist at the midcarpal level. The relative geography of the neurologic and tendinous structures can be seen. The transverse carpal ligament (TCL) is the roof of the carpal tunnel, passing volar to the median nerve and long flexor tendons. The TCL is also the floor of the ulnar tunnel, or Guyon's canal, passing dorsal to the ulnar artery and nerve. The wrist and digital extensor tendons are also seen, distal to their compartments on the distal radius and ulna. Bones: C = capitate; H = hamate; P = pisiform; S = scaphoid. Tendons (flexor digitorum superficialis is volar to flexor digitorum profundus within the carpal tunnel): 2 = index finger; 3 = middle finger; 4 = ring finger; 5 = small finger. A = artery; APL = abductor pollicis longus; ECRB = extensor carpi radialis brevis; ECRL = extensor carpi radialis longus; ECU = extensor carpi ulnaris; EDC = extensor digitorum communis; EDQ = extensor digiti quinti; EIP = extensor indices proprius; EPB = extensor pollicis brevis; EPL = extensor pollicis longus; FCR = flexor carpi radialis; FPL = flexor pollicis longus; N = nerve.

The extensor pollicis longus (EPL) inserts on the base of the thumb distal phalanx.

The intrinsic muscles of the hand are what allow humans fine, subtle movements of the hand. Microsurgery, typing, and even video gaming would be difficult, if not impossible, without them.

The thenar muscles originate from the volar radial surface of the scaphoid and trapezium and the flexor retinaculum. The abductor pollicis brevis (APB) inserts on the radial base of the thumb proximal phalanx and abducts the thumb in a radial and volar direction. The opponens pollicis (OP) inserts on the radial distal aspect of the thumb metacarpal and draws the thumb across the palm toward the small finger. The flexor pollicis brevis (FPB) inserts on the base of the thumb proximal phalanx and flexes the thumb MP joint. The APB, OP, and superficial head of the FPB are all innervated by the thenar motor branch of the median nerve.

The lumbrical muscles are unique in the body in that they originate from a tendon. Each finger's lumbrical originates from the FDP tendon in the palm. The lumbrical tendon passes along the radial aspect of the digit to flex the MP and extend the IP joints. The index and middle lumbricals are median nerve innervated, and the ring and small finger lumbricals are ulnar nerve innervated.

The hypothenar muscles originate from the pisiform, hamate, and flexor retinaculum and insert on the ulnar base of the small finger proximal phalanx. The abductor digiti quinti (ADQ) abducts the small finger. The opponens digiti quinti (ODQ) brings the small finger across the palm in reciprocal motion to the OP. The flexor digiti quinti (FDQ) flexes the small finger metacarpal. All of these muscles are innervated by the ulnar nerve.

The interosseous muscles occupy the space between the metacarpal bones. Their tendons insert on the bases of the proximal phalanges. All act to flex the MP joints and extend the IP joints. The three palmar interosseous muscles adduct the fingers. The four dorsal interosseous muscles abduct the fingers. The adductor pollicis originates from the middle finger metacarpal and inserts on the ulnar base of the thumb proximal phalanx. It acts to adduct the thumb. All of these muscles, as well as the deep head of the FPB, are innervated by the ulnar nerve.

Tendons and Pulleys

Multiple pulleys pass over or surround the extrinsic tendons en route to or within the hand. Their purpose is to maintain tendon position near the bone, allowing maximal translation of tendon excursion into joint motion.

The most well known of the wrist-level pulleys is the flexor retinaculum, also known as the transverse carpal ligament. It attaches to the scaphoid tubercle and trapezium radially and the hook of the hamate bone and pisiform ulnarly. Deep to this ligament, between the scaphoid (radially) and the hamate (ulnarly), pass the FDS, FDP, and FPL tendons as well as the median nerve. This area is also known as the carpal tunnel (see Fig. 44-3).

On the dorsum of the wrist, the extensor retinaculum is divided into six compartments. Beginning on the radial aspect of the radius, the first compartment contains the APL and EPB tendons. The second holds the ECRL and ECRB tendons. The EPL passes through the third compartment. The fourth compartment contains the EIP and EDC tendons, the fifth the EDQ, and the sixth the ECU. The sixth compartment is located on the

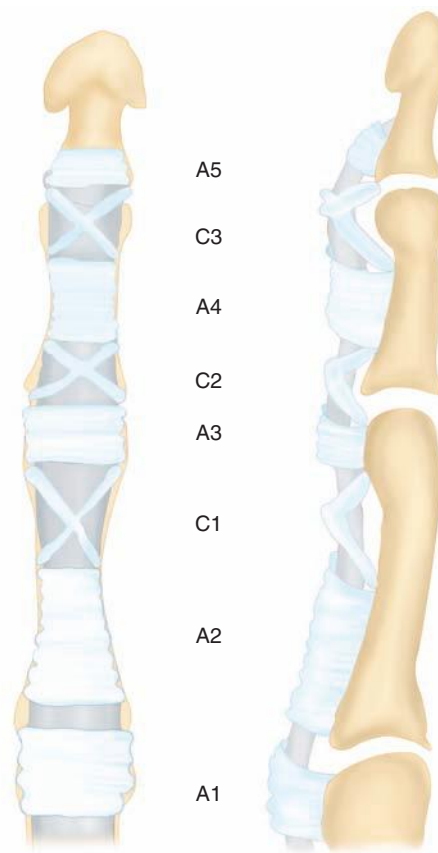


Figure 44-4. Drawing of anteroposterior and lateral view of the pulley system.

ulnar aspect of the distal ulna. Although the compartments end at the radiocarpal/ulnocarpal joints, the relative geography of the tendons is preserved over the carpal bones (see Fig. 44-3).

In the hand, the pulleys maintain the long flexor tendons in close apposition to the fingers and thumb. There are no extensor pulleys within the hand. Each finger has five annular and three cruciate pulleys (Fig. 44-4). The second and fourth (A2 and A4) pulleys are the critical structures to prevent bowstringing of the finger.⁴ The remaining pulleys can be divided as needed for surgical exposure or to relieve a stricture area.

Vascular

Two major arteries serve the hand. The radial artery travels under the brachioradialis muscle in the forearm. At the junction of the middle and distal thirds of the forearm, the artery becomes superficial and palpable, passing just radial to the FCR tendon. At the wrist level, the artery splits into two branches. The smaller, superficial branch passes volarly into the palm to contribute to the superficial palmar arch. The larger branch passes dorsally over the scaphoid bone, under the EPL and EPB tendons (known as the anatomic snuffbox) and back volarly between the proximal thumb and index finger metacarpals to form the superficial palmar arch.

The ulnar artery travels deep to the FCU muscle in the forearm. When the FCU becomes tendinous, the ulnar artery resides deep and slightly radial to it. At the wrist, the artery travels between the hamate and pisiform bones superficial to the transverse carpal ligament (known as Guyon's canal) into the palm. The larger, superficial branch forms the superficial palmar arch. The deeper branch contributes to the deep palmar

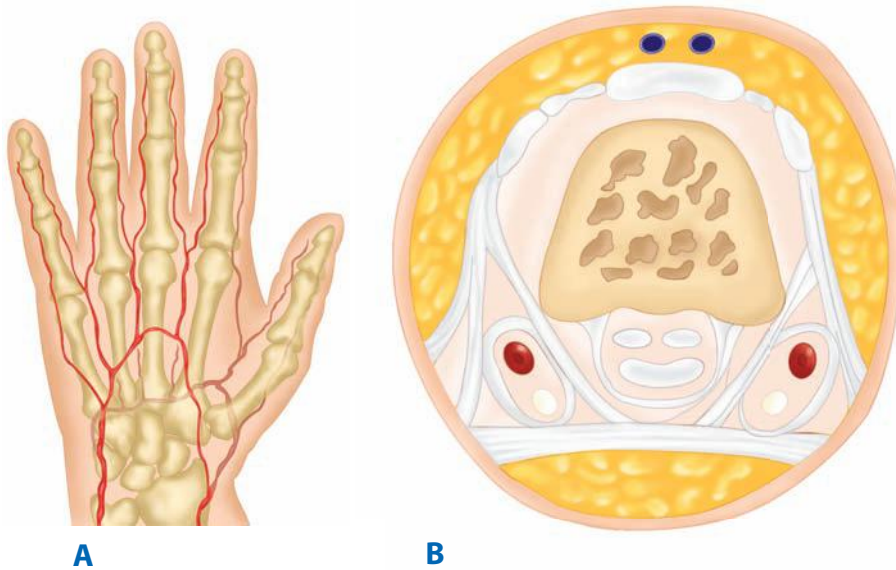


Figure 44-5. Arteries of the hand and finger. **A.** Relative position of the superficial and deep palmar arches to the bony structures and each other; note the radial artery passes dorsal to the thumb metacarpal base, through the first web space, and anterior to the index metacarpal base as it forms the deep arch. **B.** The neurovascular bundles lay volar to the midaxis of the digit with the artery dorsal to the nerve; Grayson's ligament (volar) and Cleland's ligament (dorsal) connect the bone to the skin surrounding the bundle.

arch (Fig. 44-5A). In 97% of patients, at least one of the deep or superficial palmar arches is intact, allowing for the entire hand to survive on the radial or ulnar artery.⁵

Each digit receives a radial and ulnar digital artery. For the thumb, the radial digital artery may come from the deep palmar arch or the main body of the radial artery. The larger ulnar digital artery comes off the deep arch as either a discrete unit, the princeps pollicis artery, or less frequently as the first common digital artery, which then splits into the radial digital artery to the index finger and the ulnar digital artery to the thumb. The second, third, and fourth digital arteries typically branch off the superficial palmar arch and pass over the similarly named interosseous spaces respectively, ultimately dividing into two proper digital arteries each. The ulnar digital artery of the small finger comes off as a separate branch from the superficial arch. Within the finger, the proper digital arteries travel lateral to the bones and tendons, just palmar to the midaxis of the digit, but dorsal to the proper digital nerves (Fig. 44-5B).

Nerve

Three principal nerves serve the forearm, wrist, and hand: the median, radial, and ulnar nerves. The most critical of these from a sensory standpoint is the median nerve. The median nerve begins as a terminal branch of the medial and lateral cords of the brachial plexus. It receives fibers from C5–T1. The palmar cutaneous branch of the median nerve separates from the main body of the nerve 6 cm proximal to the volar wrist crease and serves the proximal, radial-sided palm. The main body of the median nerve splits into several branches after the carpal tunnel: a radial digital branch to the thumb, an ulnar digital nerve to the thumb, and a radial digital nerve to the index finger (sometimes beginning as a single first common digital nerve); the second common digital nerve that branches into the ulnar digital nerve to the index finger and the radial digital nerve to the middle finger; and a third common digital nerve that branches into the ulnar digital nerve to the middle finger and a radial digital nerve to the ring finger. The digital nerves provide volar-sided sensation from the metacarpal head level to the tip of the digit. They also, through their dorsal branches, provide dorsal-sided sensation to

the digits from the midportion of the middle phalanx distally via dorsal branches. The thenar motor branch of the median nerve most commonly passes through the carpal tunnel and then travels in a recurrent fashion back to the thenar muscles. Less commonly, the nerve passes through or proximal to the transverse carpal ligament en route to its muscles.

In the forearm, the median nerve gives motor branches to all of the flexor muscles except the FCU, and the ring and small finger portions of the FDP. Distal median motor fibers (with the exception of those to the thenar muscles) are carried through a large branch called the anterior interosseous nerve.

The ulnar nerve is a terminal branch of the medial cord of the brachial plexus. It receives innervation from C8 and T1 roots. The FCU and FDP (ring/small) receive motor fibers from the ulnar nerve. In the distal forearm, 5 cm above the head of the ulna, the nerve gives off a dorsal sensory branch. Once in the hand, the nerve splits into the motor branch and sensory branches. The motor branch curves radially at the hook of the hamate bone to innervate the intrinsic muscles, as described earlier. The sensory branches become the ulnar digital nerve to the small finger and the fourth common digital nerve, which splits into the ulnar digital nerve to the ring finger and the radial digital nerve to the small finger. The sensory nerves provide distal dorsal sensation similar to the median nerve branches.

The radial nerve is the larger of two terminal branches of the posterior cord of the brachial plexus. It receives fibers from C5–T1 nerve roots. It innervates all of the extensor muscles of the forearm and wrist through the PIN branch except for the ECRL, which is innervated by the main body of the radial nerve in the distal upper arm. There is no ulnar nerve contribution to extension of the wrist, thumb, or finger MP joints. As noted earlier, the ulnar innervated intrinsic hand muscles are the principle extensors of the finger IP joints, although the long finger extensors (EDC, EIP, EDQ) make a secondary contribution to this function.

In the proximal dorsal forearm, the superficial radial nerve (SRN) is the other terminal branch of the radial nerve. It travels deep to the brachioradialis muscle until 6 cm proximal to the radial styloid, where it becomes superficial. The SRN provides sensation to the dorsal hand and the radial three and a half digits up to the

level of the mid-middle phalanx (where the dorsal branches of the proper digital nerves take over, as described earlier). The dorsal branch of the ulnar nerve provides sensation to the ulnar one and a half digits and dorsal hand in complement to the SRN.

HAND EXAMINATION

Emergency Room/Inpatient Consultation

A common scenario in which the hand surgeon will be introduced to the patient is in trauma or other acute situations. The patient is evaluated by inspection, palpation, and provocative testing.

On inspection, one should first note the position of the hand. The resting hand has a normal cascade of the fingers, with the small finger flexed most and the index finger least (Fig. 44-6). Disturbance of this suggests a tendon or skeletal problem. Also note any gross deformities or wounds and what deeper structures, if any, are visible in such wounds. Observe

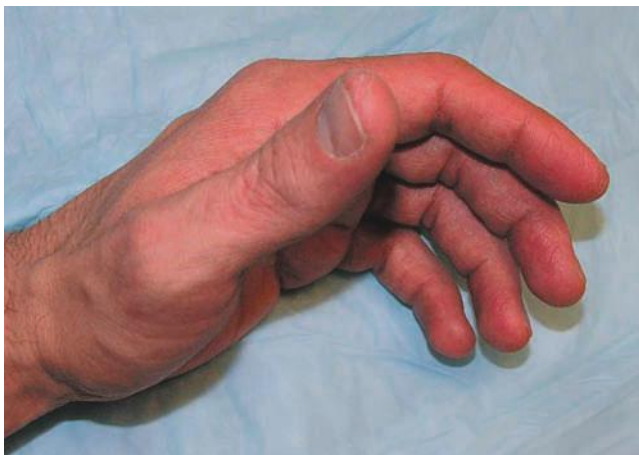
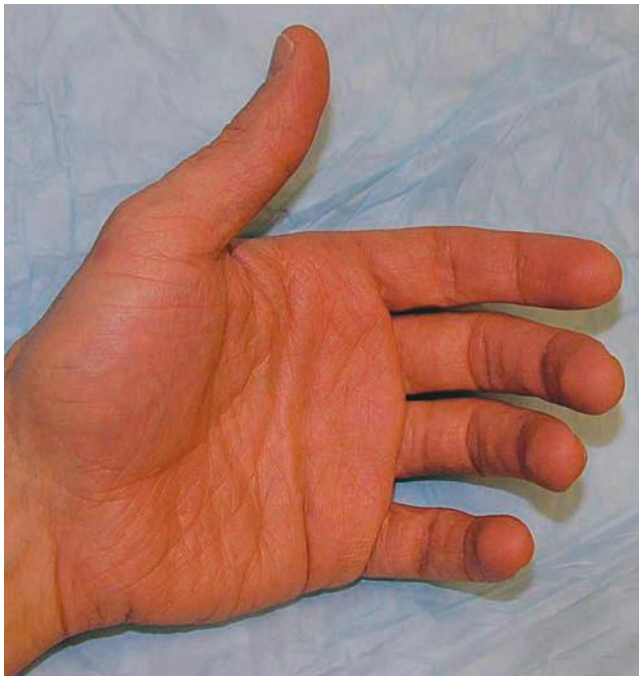
Figure 44-6. In the normal resting hand, the fingers assume a slightly flexed posture from the index finger (least) to the small finger (most).

for abnormal coloration of a portion or all of the hand (this can be confounded by ambient temperature or other injuries), edema, and/or clubbing of the fingertips.

Palpation typically begins with the radial and ulnar artery pulses at the wrist level. Pencil Doppler examination can supplement this and evaluate distal vessels. A pulsatile signal is normally detectable by pencil Doppler in the pad of the finger at the center of the whorl of creases. Discrepancies between digits should be noted. If all other tests are inconclusive, pricking the involved digit with a 25-gauge needle should produce bright red capillary bleeding. If an attached digit demonstrates inadequate or absent blood flow (warm ischemia), the urgency of completing the evaluation and initiating treatment markedly increases.

Sensation must be evaluated prior to any administration of local anesthetic. At a minimum, light and sharp touch sensation should be documented for the radial and ulnar aspects of the tip of each digit. Beware of writing “sensation intact” at the conclusion of this evaluation. Rather, one should document what was tested (e.g., “light and sharp touch sensation present and symmetric to the tips of all digits of the injured hand”). In the setting of a sharp injury, sensory deficit implies a lacerated structure until proven otherwise. Once sensation has been evaluated and documented, the injured hand can be anesthetized for patient comfort during the remainder of the examination (see below).

Ability to flex and extend the wrist and digital joints is typically examined next. At the wrist level, the FCR and FCU tendons should be palpable during flexion. The wrist extensors are not as readily palpated due to the extensor retinaculum. Ability to flex the DIP joint (FDP) is tested by blocking the finger at the middle phalanx level. To test the FDS to each finger, hold the remaining three fingers in slight hyperextension and ask the patient to flex the involved digit (Fig. 44-7). This maneuver makes use of the fact that the FDP tendons share a common muscle belly. Placing the remaining fingers in extension prevents the FDP from firing, and allows the FDS, which

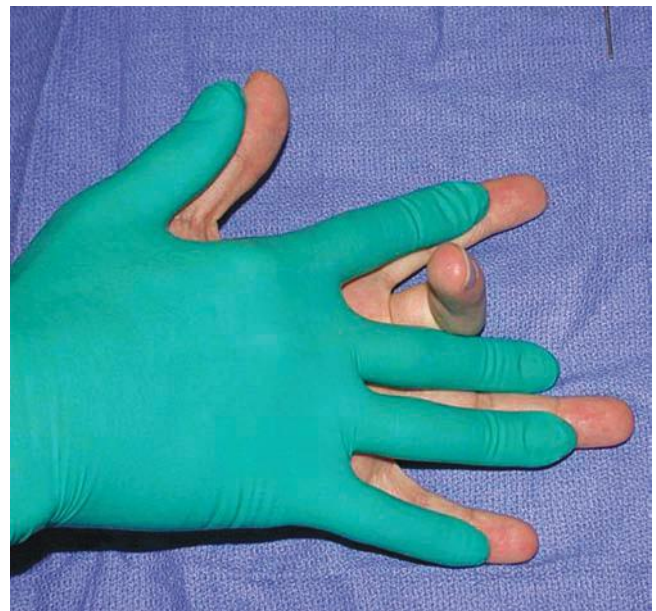

Figure 44-7. The examiner holds the untested fingers in full extension, preventing contracture of the flexor digitorum profundus. In this position, the patient is asked to flex the finger, and only the flexor digitorum superficialis will be able to fire.

has a separate muscle belly for each tendon, to fire. Strength in grip, finger abduction, and thumb opposition is tested and compared to the uninjured side. Range of motion for the wrist, MP, and IP joints should be noted and compared to the opposite side.

If there is suspicion for closed space infection, the hand should be evaluated for erythema, swelling, fluctuance, and localized tenderness. The dorsum of the hand does not have fascial septae; thus dorsal infections can spread more widely than palmar ones. The epitrochlear and axillary nodes should be palpated for enlargement and tenderness. Findings for specific infectious processes will be discussed in the Infections section.

Additional exam maneuvers and findings, such as those for office consultations, will be discussed with each disease process covered later in this chapter.

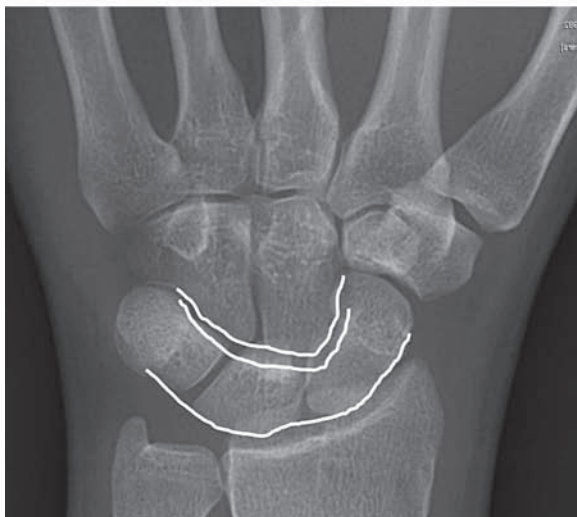HAND IMAGING

Plain X-Rays

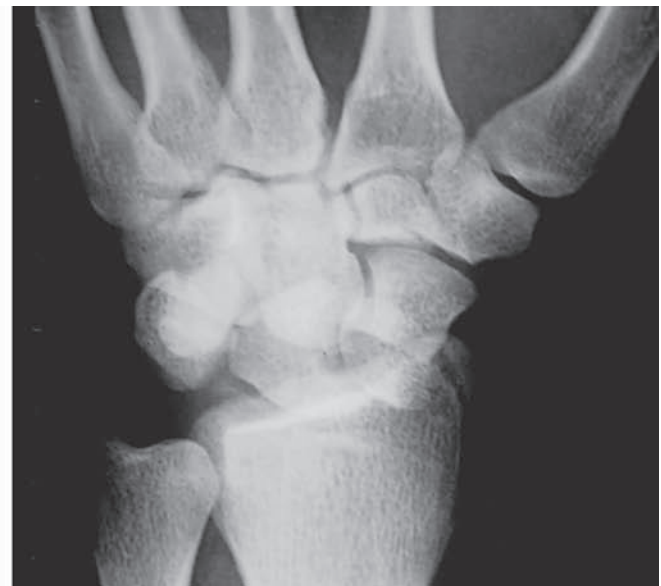Almost every hand evaluation should include plain X-rays of the injured or affected part. A standard, anteroposterior, lateral, and oblique view of the hand or wrist (as appropriate) is rapid, inexpensive, and usually provides sufficient information about the bony structures to achieve a diagnosis in conjunction with the symptoms and findings.⁶

Lucencies within the bone should be noted. Most commonly, these represent fractures, but they can on occasion represent neoplastic or degenerative processes. Great care should be taken to evaluate the entire X-ray, typically beginning away from the area of the patient's complaint. Additional injuries can be missed, which might affect the treatment plan selected and eventual outcome.

Congruency of adjacent joints should also be noted. The MP and IP joints of the fingers should all be in the same plain on any given view. Incongruency of the joint(s) of one finger implies fracture with rotation. At the wrist level, the proximal and distal edge of the proximal row and proximal edge of the distal row should be smooth arcs,⁷ known as Gilula's arcs (Fig. 44-8A). Disruption of these implies ligamentous injury or possibly dislocation (Fig. 44-8B).



A



B

Figure 44-8. Gilula's arcs are seen shown in this normal patient (A) and in a patient with a scaphoid fracture and perilunate dislocation (B).

Computed Tomography

Computed tomography (CT) scanning of the hand and wrist can provide additional bony information when plain X-rays are insufficient. Comminuted fractures of the distal radius can be better visualized for number and orientation of fragments. Scaphoid fractures can be evaluated for displacement and comminution preoperatively as well as for the presence of bony bridging postoperatively (Fig. 44-9). CT scans are also useful for CMC fractures of the hand where overlap on a plain X-ray lateral view may make diagnosis difficult.

Unlike the trunk and more proximal extremities, CT scans with contrast are less useful to demonstrate abscess cavities due to the small area of these spaces.

Ultrasonography

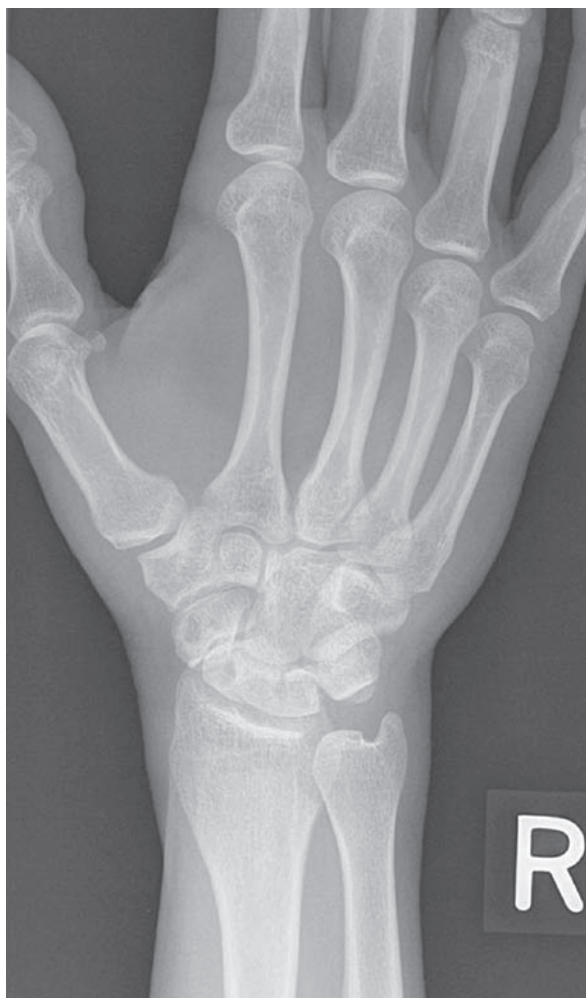Ultrasonography has the advantages of being able to demonstrate soft tissue structures and being available on nights and weekends. Unfortunately, it is also highly operator dependent. In the middle of the night when magnetic resonance imaging (MRI) is not available, ultrasound may be able to demonstrate a large deep infection in the hand but is rarely more useful than a thorough clinical examination.

Magnetic Resonance Imaging

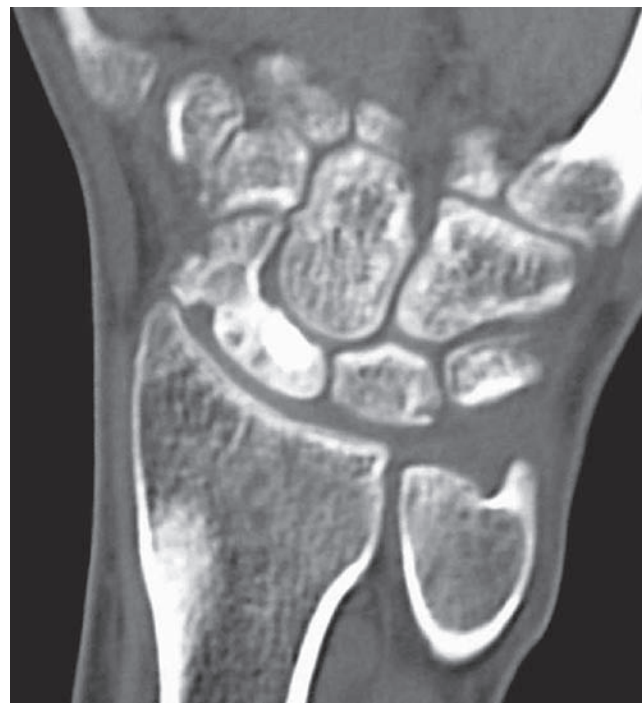MRI provides the best noninvasive visualization of the soft tissue structures. With contrast, MRI can demonstrate an occult abscess. Unfortunately, it is often not available on an urgent basis for hand issues when this information is often needed. MRI can also demonstrate soft tissue injuries such as cartilage or ligament tears or tendonitis (usually by demonstrating edema in the area in question). It can demonstrate occult fractures that are not sufficiently displaced to be seen on X-ray or CT (again, by demonstrating edema). MRI can also demonstrate vascular disturbance of a bone, as in a patient with avascular necrosis of the scaphoid (Fig. 44-10).

Angiography

Angiography of the upper extremity is rarely used. In many centers, MRI and CT angiography provide sufficient resolution of the vascular structures to make traditional angiography unnecessary.



A



B

Figure 44-9. A. Preoperative images demonstrate a nonunion of a scaphoid fracture sustained 4 years earlier. Postoperatively, cross-sectional imaging with a computed tomography scan in the coronal plan demonstrates bone crossing the previous fracture line. This can be difficult to discern on plain X-rays due to overlap of bone fragments.

Also, primary vascular disease of the upper extremity is relatively uncommon. In the trauma setting, vascular disturbance usually mandates exploration and direct visualization of the structures in question, and angiography is thus obviated.

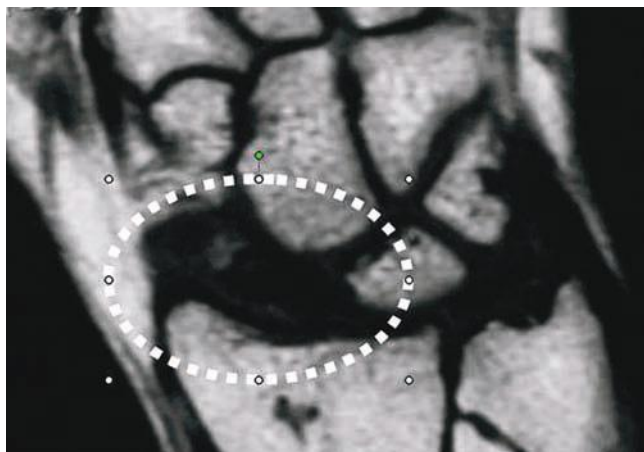


Figure 44-10. T1-weighted magnetic resonance imaging shows perfused bone as white. In this patient, there is the absence of whiteness where the scaphoid should be (dashed circle), consistent with avascular necrosis.

For a patient with vascular disease of the upper extremity, angiography of the upper extremity is usually performed through a femoral access much like with the leg. An arterial catheter can be used to deliver thrombolytic drugs to treat a thrombotic process.

TRAUMA

The upper extremity-injured patient may have additional injuries to other parts of the body. All injured patients should receive an appropriate trauma survey to look for additional injuries.

The patient with upper extremity trauma is evaluated as described in the Hand Examination section. Sensory examination should be performed early. Once sensory status has been documented, administration of local anesthesia can provide comfort to the patient during the remainder of the evaluation and subsequent treatment. Patients should receive tetanus toxoid for penetrating injuries if more than 5 years have passed since the last vaccination.

Local Anesthesia

Anesthetic blockade can be administered at the wrist level, digital level, or with local infiltration as needed. Keep in mind that all local anesthetics are less effective in areas of inflammation.

The agents most commonly used are lidocaine and bupivacaine. Lidocaine has the advantage of rapid onset, whereas bupivacaine has the advantage of long duration (average 6–8 hours).⁸ Although bupivacaine can produce irreversible heart block in high doses, this is rarely an issue with the amounts typically used in the hand. For pediatric patients, the tolerated dose is 2.5 mg/kg. This can be easily remembered by noting that when using 0.25% bupivacaine, 1 mL/kg is acceptable dosing.

A commonly held axiom is that epinephrine is unacceptable to be used in the hand. Several recent large series have dispelled this myth.⁹ Epinephrine should not be used in the fingertip and not in concentrations higher than 1:100,000 (i.e., what is present in commercially available local anesthetic with epinephrine). Beyond that, its use is acceptable and may be useful in an emergency room (ER) where tourniquet control may not be available. Also, because most ER procedures are done under pure local anesthesia, many patients will not tolerate the discomfort of the tourniquet beyond 30 minutes.¹⁰ Epinephrine will provide hemostasis and also prolong the effect of the local anesthetic.

Simple lacerations, particularly on the dorsum of the hand, can be anesthetized with local infiltration. This is performed in the standard fashion.

Blocking of the digital nerves at the metacarpal head level is useful for volar injuries distal to this point and for dorsal injuries beyond the midpoint of the middle phalanx (via dorsal branches of the proper digital nerves). Fingertip injuries are particularly well anesthetized by this technique. A digit can be anesthetized via a flexor sheath approach or via the dorsal web space (Fig. 44-11A,B).

Blocking one or more nerves as they cross the wrist can provide several advantages: anesthesia for multiple injured digits, avoiding areas of inflammation where the local anesthetic agent may be less effective, and avoiding injection where the volume of fluid injected may make treatment harder (such as fracture reduction). Four major nerves cross the wrist: the median nerve, SRN, ulnar nerve, and dorsal sensory branch of the ulnar nerve (Fig. 44-11C–E). When blocking the median and ulnar nerves, beware of intraneural injection, which can cause irreversible neural scarring. If the patient complains of severe paresthesias with injection or high resistance is encountered, the needle should be repositioned.

Fractures and Dislocations

For dislocations and displaced fractures, a visible deformity is often present. Nondisplaced fractures may not show a gross deformity but will have edema and tenderness to palpation at the fracture site. A fracture is described by its displacement, rotation, and angulation. A fracture is also described in terms of comminution and the number and complexity of fracture fragments. Displacement is described as a percentage of the diameter of the bone; rotation is described in degrees of supination or pronation with respect to the rest of the hand; angulation is described in degrees. To avoid confusion, it is useful to describe which direction the angle of the fracture points. All injuries should be evaluated for nearby wounds (open) that may introduce bacteria into the fracture site or joint space.

Once the initial force on the fracture ceases, the tendons passing beyond the fracture site provide the principal deforming force. Their force is directed proximally and,

to a lesser extent, volarly. Based on this, the stability of a fracture can be determined by the orientation of the fracture with respect to the shaft of the bone. Transverse fractures are typically stable. Oblique fractures typically shorten. Spiral fractures typically rotate as they shorten and thus require surgical treatment.

Fractures of the tuft of the distal phalanx are common. Catching of a finger in a closing door is a common causative mechanism. These fractures are often nondisplaced and do not require treatment beyond protection of the distal phalanx from additional trauma while the fracture heals.

Displaced transverse fractures of the phalanges can usually be reduced with distraction. The distal part is pulled away from the main body of the hand and then pushed in the direction of the proximal shaft of the finger, and then distraction is released. Postreduction X-rays should routinely be performed to document satisfactory reduction. Oblique and spiral fractures usually are unstable after reduction. The involved digit(s) should be splinted until appropriate surgical intervention can be performed.

Articular fractures of the IP and MP joints are worrisome because they may compromise motion. Chip fractures must be evaluated for instability of the collateral ligaments. If the joint is stable, the patient should initially be splinted for comfort. Motion therapy should be instituted early (ideally within the first week) to prevent stiffness. For larger fractures, the patient should be splinted until surgical treatment can be performed. In surgery, the fracture is typically internally fixated to allow for early motion, again with the goal of preventing stiffness.¹¹

Dislocations of the PIP joints produce traction on the neurovascular structures but usually do not lacerate them. In general, the patient should not be sent home with a joint that remains dislocated. Most commonly, the distal part is dorsal to the proximal shaft and sits in a hyperextended position. For this patient, the examiner gently applies pressure to the base of the distal part until it passes beyond the head of the proximal phalanx. Once there, the relocated PIP joint is gently flexed, confirming the joint is in fact reduced. The joint is splinted in slight flexion to prevent redislocation. On occasion, the head of the proximal phalanx may pass between the two slips of the FDS tendon. For these patients, the joint may not be reducible in a closed fashion.

Angulated fractures of the small finger metacarpal neck (“boxer’s fracture”) are another common injury seen in the ER. Typical history is that the patient struck another individual or rigid object with a hook punch. These are often stable after reduction using the Jahss maneuver (Fig. 44-12).

Fractures of the thumb metacarpal base are often unstable. The Bennett fracture displaces the volar-ulnar base of the bone. The remainder of the articular surface and the shaft typically dislocate dorsoradially and shorten. The thumb often appears grossly shortened, and the proximal shaft of the metacarpal may reside at the level of the trapezium or even the scaphoid on X-ray. In a Rolando fracture, a second fracture line occurs between the remaining articular surface and the shaft. These fractures nearly always require open reduction and internal fixation.

Most nondisplaced fractures do not require surgical treatment. The scaphoid bone of the wrist is a notable exception to this rule. Due to peculiarities in its vascular supply, particularly vulnerable at its proximal end, nondisplaced scaphoid fractures

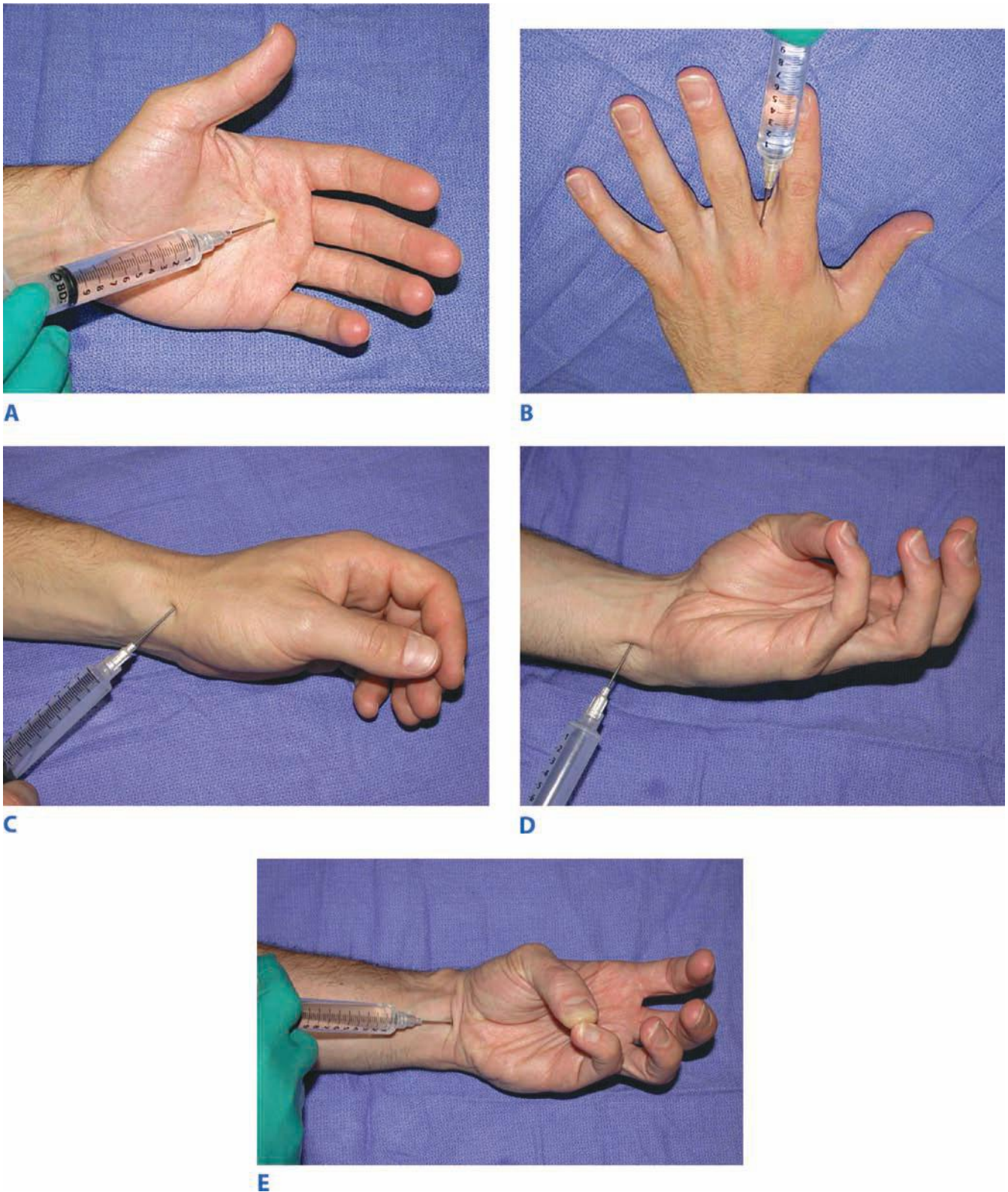


Figure 44-11. Local anesthesia can be administered at the digital or the wrist level. **A.** A single injection into the flexor tendon sheath at the metacarpal head level provides complete anesthesia for the digit. **B.** Alternatively, one can inject from a dorsal approach into the web space on either side. **C.** The superficial radial nerve is blocked by infiltrating subcutaneously over the distal radius from the radial artery pulse to the distal radioulnar joint. The dorsal sensory branch of the ulnar nerve is blocked in similar fashion over the distal ulna. **D.** To block the ulnar nerve, insert the needle parallel to the plane of the palm and deep to the flexor carpi ulnaris tendon; aspirate to confirm the needle is not in the adjacent ulnar artery. **E.** To block the median nerve, insert the needle just ulnar to the palmaris longus tendon into the carpal tunnel. One should feel two points of resistance: one when piercing the skin, the second when piercing the antebrachial fascia.

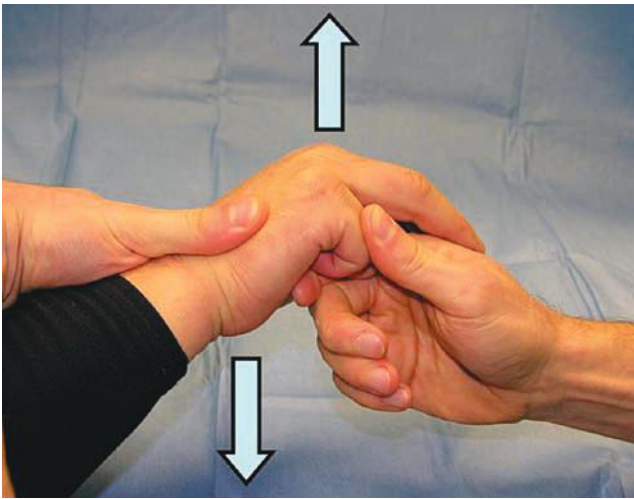


Figure 44-12. The Jahss maneuver. The surgeon fully flexes the patient's small finger into the palm and secures it in his distal hand. The proximal hand controls the wrist and places the thumb on the patient's fracture apex (the most prominent dorsal point). The examiner distracts the fracture, pushes dorsally with the distal hand (*up arrow*), and resists dorsal motion with the proximal hand (*down arrow*).

can fail to unite in up to 20% of patients even with appropriate immobilization. Recent developments in hardware and surgical technique have allowed stabilization of the fracture with minimal surgical exposure. One prospective randomized series of scaphoid wrist fractures demonstrated shortening of time to union by up to 6 weeks in the surgically treated group, but no difference in rate of union.¹² Surgery may be useful in the younger, more active patient who would benefit from an earlier return to full activity.

Ligament injuries of the wrist can be difficult to recognize. Patients often present late and may not be able to localize their pain. In severe cases, the ligaments of the wrist can rupture to the point of dislocation of the capitate off the lunate or even the lunate off the radius. Mayfield and colleagues classified the progression of this injury into four groups.¹³ In the most severe group, the lunate dislocates off the radius into the carpal tunnel. In some circumstances, the scapholunate ligament rupturing. Attention to the congruency or disruption of Gilula's arcs will help the examiner to recognize this injury. For patients with type 4 (most severe) and some with type 3 injury, the examiner should also evaluate for sensory disturbance in the median nerve distribution because this may indicate acute carpal tunnel syndrome and necessitate more urgent intervention. Although the Mayfield pattern of injury is most common, force can also transmit along alternate paths through the carpus.¹⁴

After reduction of fractures and dislocations (as well as after surgical repair of these and many other injuries), the hand must be splinted in a protected position. For the fingers, MP joints should be splinted 90°, and the IP joints at 0° (called the *intrinsic plus position*). The wrist is generally splinted at 20° extension because this puts the hand in a more functional position. This keeps the collateral ligaments on tension and helps prevent secondary contracture. In general, one of three splints should be used for the ER patient (Fig. 44-13). The ulnar gutter splint uses plaster around the ulnar

border of the hand. It is generally appropriate for small finger injuries only. Dorsal plaster splints can be used for injuries of any of the fingers. Plaster is more readily contoured to the dorsal surface of the hand than the volar surface, particularly in the setting of trauma-associated edema. For thumb injuries, the thumb spica splint is used to keep the thumb radially and palmarly abducted from the hand.

Tendons

Injuries to the flexor and extensor tendons compromise the mobility and strength of the digits. On inspection, injury is normally suspected by loss of the normal cascade of the fingers. The patient should be examined as described earlier to evaluate for which tendon motion is deficient. If the patient is unable to cooperate, extension of the wrist will produce passive flexion of the fingers and also demonstrate a deficit. This is referred to as the tenodesis maneuver.

Flexor tendon injuries are described based on zones (Fig. 44-14). Up until 40 years ago, zone 2 injuries were always reconstructed and never repaired primarily due to concern that the bulk of repair within the flexor sheath would prevent tendon glide. The work of Dr. Kleinert and colleagues at the University of Louisville changed this "axiom" and established the principle of primary repair and early controlled mobilization postoperatively.¹⁵ Flexor tendon injuries should always be repaired in the operating room. Although they do not need to be repaired on the day of injury, the closer to the day of injury they are repaired, the easier it will be to retrieve the retracted proximal end in surgery. The laceration should be washed out and closed at the skin level only using permanent sutures. The hand should be splinted as described earlier; one notable difference is that the wrist should be splinted at slight flexion (about 20°) to help decrease the retracting force on the proximal cut tendon end.

Extensor tendons do not pass through a sheath in the fingers. As such, bulkiness of repair is less of a concern. With proper supervision/experience and equipment, primary extensor tendon repair can be performed in the ER.

Very distal extensor injuries near the insertion on the dorsal base of the distal phalanx may not have sufficient distal tendon to hold a suture. Closed injuries, called mallet fingers, can be treated with extension splinting of the DIP joint for 6 continuous weeks. For patients with open injuries, a dermatotenodesis suture is performed. A 2-0 or 3-0 suture is passed through the distal skin, tendon remnant, and proximal tendon as a mattress suture. Using a suture of a different color than the skin closing sutures will help prevent removing the dermatotenodesis suture(s) too soon. The DIP joint is splinted in extension.

More proximal injuries are typically repaired with a 3-0 braided permanent suture. Horizontal mattress or figure-of-eight sutures should be used, two per tendon if possible. Great care should be used to ensure matching the appropriate proximal and distal tendon ends. The patient is splinted with IP joints in extension and the wrist in extension per usual. MP joints should be splinted in 45° flexion, sometimes less. Although this position is not ideal for MP collateral ligaments, it is important for taking tension off of the tendon repairs.

Nerve Injuries

In the setting of a sharp injury, a sensory deficit implies a nerve laceration until proven otherwise. For blunt injuries, even displaced fractures and dislocations, nerves are often contused but not lacerated and are managed expectantly. Nerve repairs require

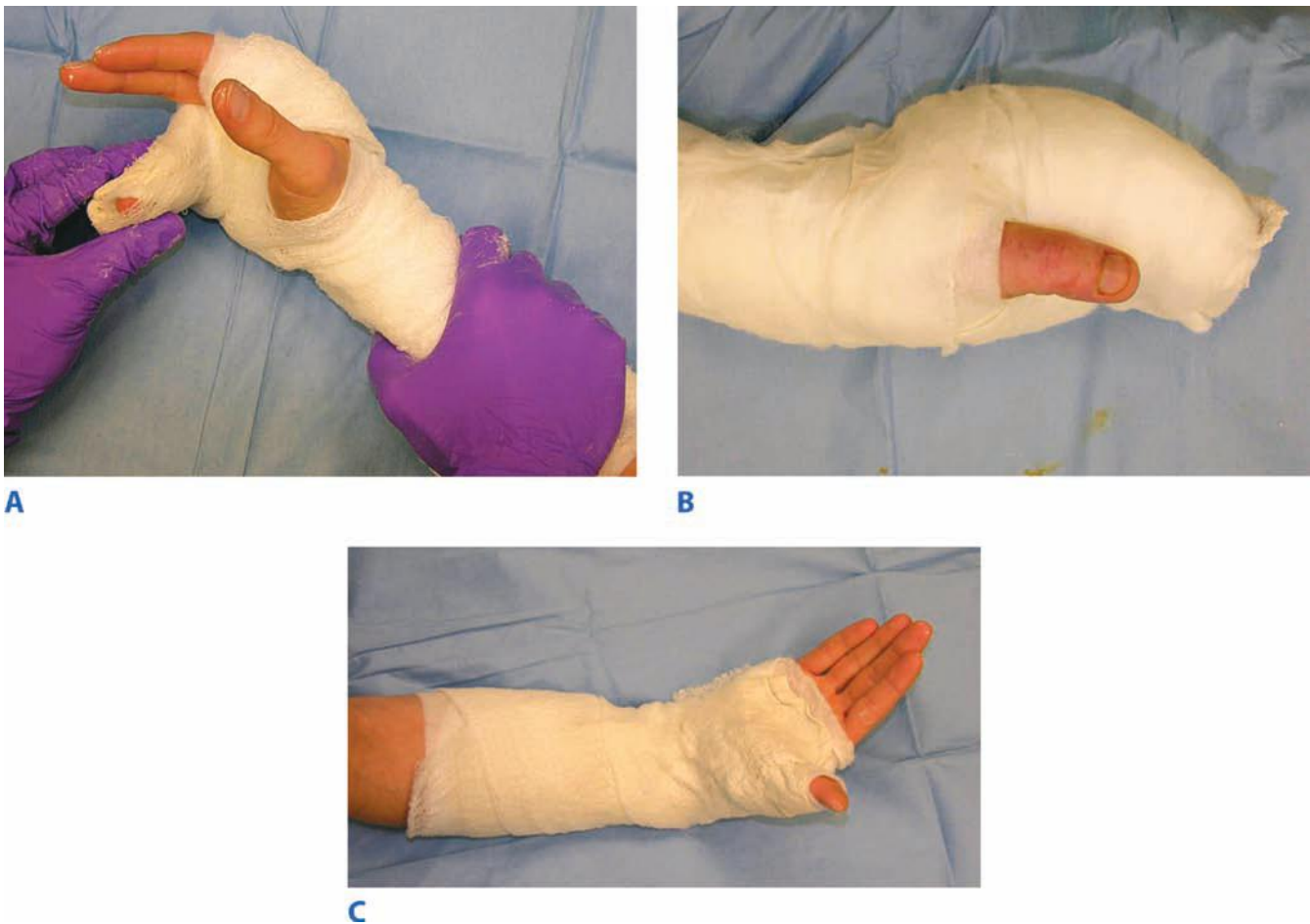

Figure 44-13. Commons splints used for hand injuries/surgeries. **A.** Ulnar gutter splint. The ring and small fingers are included. The surgeon pushes on the dorsum of the fingers with the distal hand to produce interphalangeal (IP) joint extension and metacarpophalangeal (MP) joint flexion to 90° , while the proximal hand controls wrist position. **B.** Dorsal four-finger splint. As with the ulnar gutter splint, finger MP joints are flexed to 90° with IP joints kept fully extended. **C.** Thumb spica splint. One easy method to fabricate is to place one slab of plaster radially over the wrist and thumb with a second square of plaster over the thenar eminence, which joins the first. In this patient, the IP joint was not included. For injuries at, or distal to, the MP joint, the IP should be included in the splint.

appropriate microsurgical equipment and suture; they should not be performed in the ER. As with tendons, nerve injuries do not require immediate exploration. However, earlier exploration will allow for easier identification of structures and less scar tissue to be present. The nerve must be resected back to healthy nerve fascicle prior to repair. Delay between injury and repair can thus make a difference between the ability to repair a nerve primarily or the need to use a graft. The injured hand should be splinted with MPs at 90° and IPs at 0° , as described earlier.

Vascular Injuries

Vascular injuries have the potential to be limb or digit threatening. A partial laceration of an artery at the wrist level can potentially cause exsanguinating hemorrhage. Consultations for these injuries must be evaluated urgently.

Initial treatment for an actively bleeding wound should be direct local pressure for no less than 10 continuous minutes. If this is unsuccessful, an upper extremity tourniquet inflated to 100 mmHg above the systolic pressure should be used. One should keep this tourniquet time to less than 2 hours to avoid tissue necrosis. Once bleeding is controlled well enough to evaluate the wound, it may be cautiously explored to evaluate

for bleeding points. One must be very cautious if attempting to ligate these to ensure that adjacent structures such as nerves are not included in the ligation.

The hand must be evaluated for adequacy of perfusion to the hand as a whole as well as the individual digits. Capillary refill, turgor, Doppler signal, and bleeding to pinprick all provide useful information regarding vascular status. The finger or hand with vascular compromise requires urgent operative exploration. Unlike the complete amputation, in which the amputated part can be cold preserved (see below), devascularization without amputation produces warm ischemia, which is tolerated only for a matter of hours.

For the noncritical vascular injury, two treatment options exist. Simple ligation will control hemorrhage. At least one of the palmar arterial arches is intact in 97% of patients,⁵ so this will usually not compromise hand perfusion. Each digit also has two arterial inflows and can survive on one (see Amputations and Replantation section below). In the academic hospital setting, however, consideration should be given to repairing all vascular injuries. Instructing a resident in vascular repair in the noncritical setting will produce a more skilled and prepared resident for when a critical vascular injury does arise.

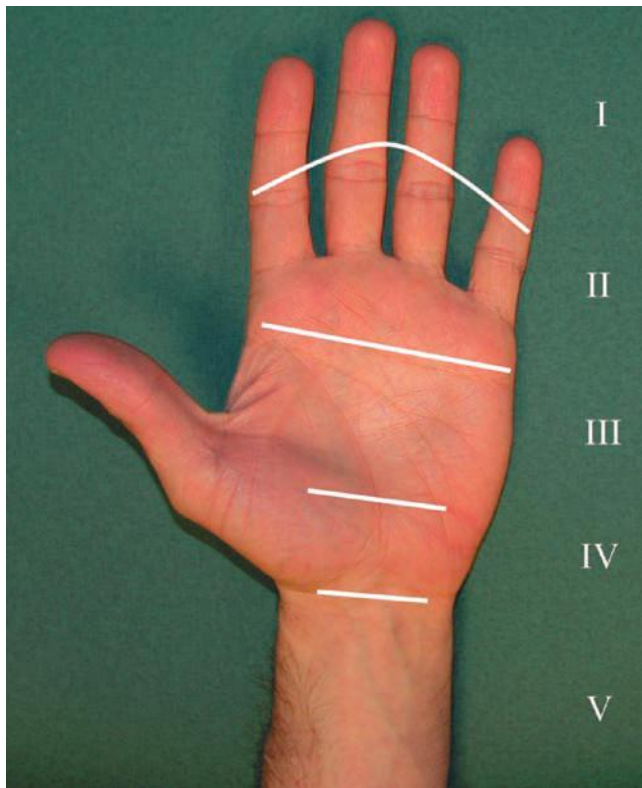


Figure 44-14. The zones of flexor tendon injury. *I.* Flexor digitorum superficialis insertion to the flexor digitorum profundus insertion. *II.* Start of the A1 pulley to the flexor digitorum superficialis insertion. *III.* End of the carpal tunnel to the start of the A1 pulley. *IV.* Within the carpal tunnel. *V.* Proximal to the carpal tunnel.

SPECIAL CONSIDERATIONS

Amputations and Replantation

After replantation was first reported,¹⁶ replantation was attempted for nearly all amputations. Over the ensuing decades, more stringent guidelines have been established regarding what should be replanted. Indications for replantation include amputations of the thumb, multiple digit amputations, and amputations in children. Relative contraindications to replantation include crush injuries, injuries to a single digit distal to the PIP joint, and patients who are unable to tolerate a long surgical procedure. As with all guidelines, one should evaluate the particular needs of the injured patient.

In preparation for replantation, the amputated part and proximal stump should be appropriately treated. The amputated part should be wrapped in moistened gauze and placed in a sealed plastic bag. This bag should then be placed in an ice water bath. Do not use dry ice, and do not allow the part to contact ice directly; frostbite can occur in the amputated part, which will decrease its chance of survival after replantation. Bleeding should be controlled in the proximal stump by as minimal a means necessary, and the stump should be dressed with a nonadherent gauze and bulky dressing.

For digital amputations deemed unsalvageable, revision amputation can be performed in the ER if appropriate equipment is available. Bony prominences should be smoothed off with a rongeur and/or rasp. Great care must be taken to identify the digital nerves and resect them back as far proximally in the wound as possible; this helps decrease the chance of painful

neuroma in the skin closure. Skin may be closed with permanent or absorbable sutures; absorbable sutures will spare the patient the discomfort of suture removal several weeks later. For more proximal unsalvageable amputations, revision should be performed in the operating room to maximize vascular and neural control.

Prostheses can be made for amputated parts. The more proximal the amputation, the more important to function the prosthesis is likely to be. Although finger-level prostheses are generally considered cosmetic, patients with multiple finger amputations proximal to the DIP have demonstrable functional benefit from their prosthesis as well.¹⁷

Fingertip Injuries

Fingertip injuries are among the most common pathologies seen in an ER. The usual history is that a door closed on the finger (commonly the middle, due to its increased length) or something heavy fell on the finger.

Initial evaluation should include: wound(s) including the nail bed, perfusion, sensation, and presence and severity of fractures. For the common scenario, complex lacerations with minimally displaced fracture(s) and no loss of perfusion, the wound is cleansed, sutured, and splinted in the ER. To properly assess the nail bed, the nail plate (hard part of the nail) should be removed. A Freer periosteal elevator is well suited for this purpose. Lacerations are repaired with 6-0 fast gut suture. Great care must be taken when suturing because excessive traction with the needle can further lacerate the tissue. After repair, the nail folds are splinted with the patient's own nail plate (if available) or with aluminum foil from the suture pack. This is done to prevent scarring from the nail folds down to the nail bed that would further compromise healing of the nail.

In some situations, tissue may have been avulsed in the injury and be unavailable for repair. Choice of treatment options depends on the amount and location of tissue loss (Fig. 44-15).

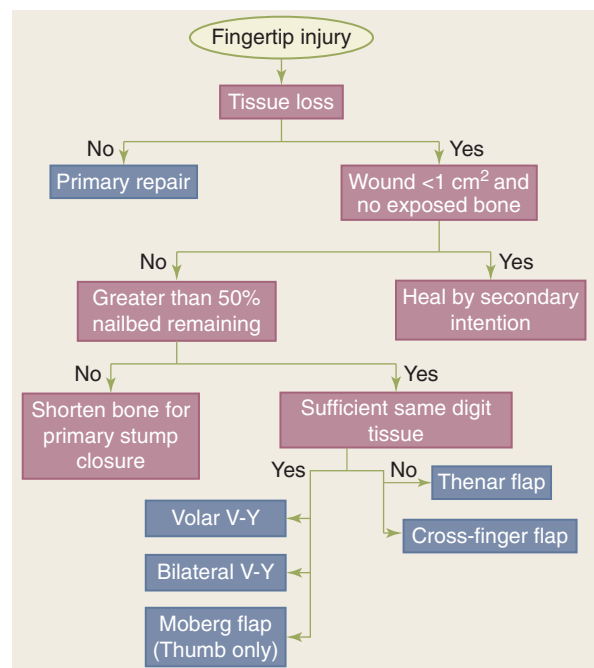


Figure 44-15. Treatment algorithm for management of fingertip injuries. See text for description of flaps.

For wounds less than 1 cm² with no exposed bone, secondary intention will produce excellent functional and aesthetic results. For larger wounds or wounds with bone exposed, one must decide if the finger is worth preserving at the current length or if shortening to allow for primary closure is a better solution. A useful guideline is the amount of fingernail still present; if greater than 50% is present, local or regional flap coverage may be a good solution.

If sufficient local tissue is present, homodigital flaps can be considered. A wide range of antegrade and retrograde homodigital flaps can be mobilized to cover the defect. Some carry sensation or can receive nerve coaptation to recover sensation over time.¹⁸ For the thumb only, the entire volar skin including both neurovascular bundles can be raised and advanced distally up to 1.5 cm.¹⁹ The thumb receives separate vascularity to its dorsal skin from the radial artery. This flap is not appropriate for the fingers. Patients retain full sensibility in the advanced skin and can be mobilized within days of surgery (Fig. 44-16A–C).

For wounds too large to cover with homodigital tissue, regional flaps can be considered. The skin from the distal radial thenar eminence can be raised as a random pattern flap (Fig. 44-16D–F). The finger is maintained in flexion for 14 to 21 days until division of the flap pedicle and inset of the flap. Some authors have reported prolonged stiffness in patients over 30 years old, but careful flap design helps minimize this complication.²⁰ Alternatively, the skin from the dorsum of the middle phalanx of an adjacent digit can be raised as a flap to cover the volar P3 (Fig. 44-16G–I). The flap is inset at 14 to 21 days. Long-term studies have shown this flap develops sensation over time.²¹

Patients with fingertip injuries must be assessed for the possibility of salvage of the injured digit(s) taken within the context of the patient's recovery needs and goals. The surgeon then matches the available options to the particular patient needs.

High-Pressure Injection Injuries

High-pressure devices are commonly used for cleaning and applications of liquids such as lubricants and paint. Most commonly, the inexperienced worker accidentally discharges the device into his nondominant hand at the base of the digit. Severity of injury depends on the amount and type of liquid injected; hydrophobic compounds cause greater damage.

These injuries are typically quite innocuous to inspection. They are, however, digit-threatening emergencies. The patient should be informed of the severity of the injury, and exploration is ideally performed within 6 hours of injury. Up to 50% of such injuries result in loss of the digit, but early recognition and treatment are associated with increased chance of digit survival.²² Early frank discussion with the patient and initiation of appropriate treatment produce the best results and medicolegal protection.

Compartment Syndromes

Compartment syndromes can occur in the forearm and/or the hand. As in other locations, these are potentially limb-threatening issues. Principle symptoms are pain in the affected compartments, tense swelling, tenderness to palpation over the compartment, and pain with passive stretch of the muscles of the compartment.²³ Pulse changes are a late finding; normal pulses do not rule out compartment syndrome.

There are three compartments in the forearm and four groups of compartments in the hand. The volar forearm is one

compartment. On the dorsum of the forearm, there is the dorsal compartment as well as the mobile wad compartment, beginning proximally over the lateral epicondyle. In the hand, the thenar and hypothenar eminences each represent a compartment. The seven interosseous muscles each behave as a separate compartment.

Compartment syndrome can be caused by intrinsic and extrinsic causes. Intrinsic causes include edema and hematoma due to fracture. Extrinsic causes include splints and dressings that are circumferentially too tight and intravenous infiltrations. Infiltrations with hyperosmolar fluids such as x-ray contrast are particularly dangerous, because additional water will be drawn in to neutralize the hyperosmolarity.

Measurement of compartment pressures can be a useful adjunct to assessment of the patient. The Stryker pressure measurement device or similar device is kept in many operating rooms for this purpose. The needle is inserted into the compartment in question, a gentle flush with 0.1 to 0.2 cc of saline clears the measurement chamber, and a reading is obtained. Studies have disagreed about whether the criterion is a measured pressure (30–45 mmHg, depending on the series) or within a certain amount of the diastolic blood pressure.²⁴

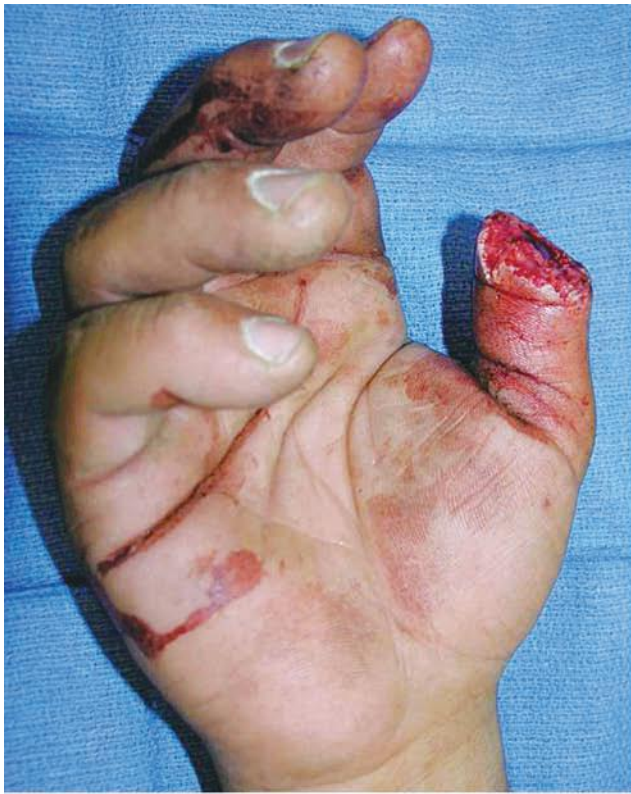Compartment releases are performed in the operating room under tourniquet control. Release of the volar forearm compartment includes release of the carpal tunnel. As the incision travels distally, it should pass ulnar and then curve back radially just before the carpal tunnel. This avoids a linear incision across a flexion crease and also decreases the chance of injury to the palmar cutaneous branch of the median nerve. One dorsal forearm incision can release the dorsal compartment and the mobile wad. In the hand, the thenar and hypothenar compartments are released each with a single incision. The interosseous compartments are released with incisions over the index and ring metacarpal shafts. Dissection then continues radial and ulnar to each of these bones and provides release of all the muscle compartments. Any dead muscle is debrided. Incisions are left open and covered with a nonadherent dressing. The wounds are reexplored in 2 to 3 days to assess for muscle viability. Often the incisions can be closed primarily, but a skin graft may be needed for the forearm.

If the examiner feels the patient does not have a compartment syndrome, elevation and serial examination are mandatory. When in doubt, it is safer to release an early compartment syndrome than wait to release and risk muscle necrosis. Progression of compartment syndrome can lead to Volkmann's ischemic contracture with muscle loss and scarring that may compress nerves and other critical structures. Medicolegally, it is far easier to defend releasing an early compartment syndrome than delaying treatment until the process has progressed to necrosis and/or deeper scarring.

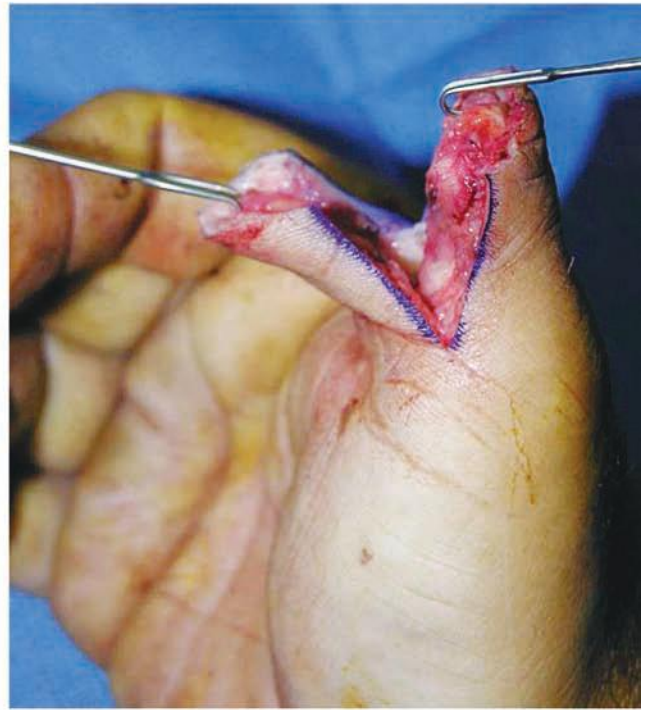COMPLICATIONS

Nonunion

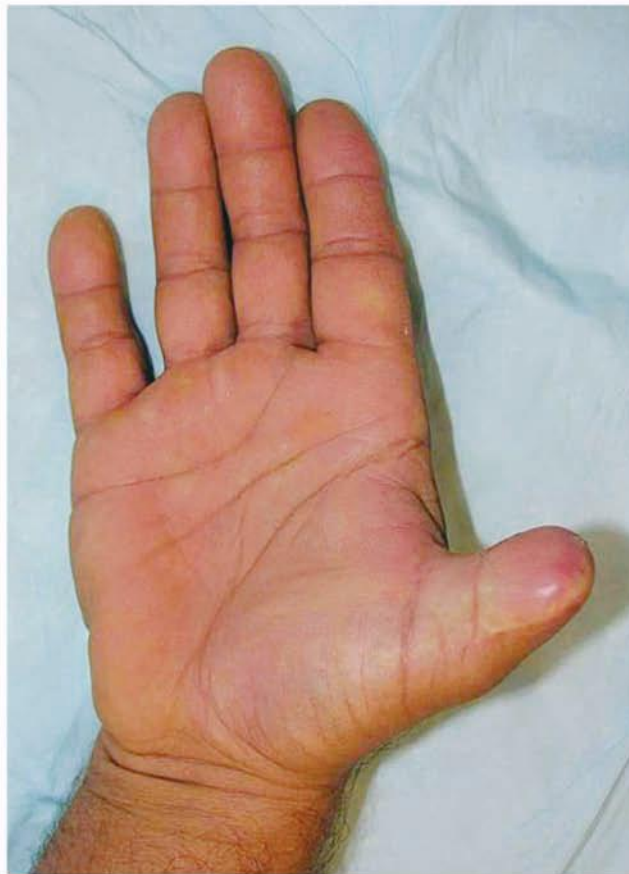Any fractured bone has the risk of failing to heal. Fortunately, in the fingers and hand, this is a rare problem. Tuft injuries, where soft tissue interposes between the fracture fragments, have relatively higher risk of this problem. The nonunited tuft can be treated with débridement and bone grafting or revision amputation depending on the needs and goals of the patient. Phalangeal and metacarpal nonunions are also quite rare. They can similarly be treated with débridement of the nonunion, grafting,



A

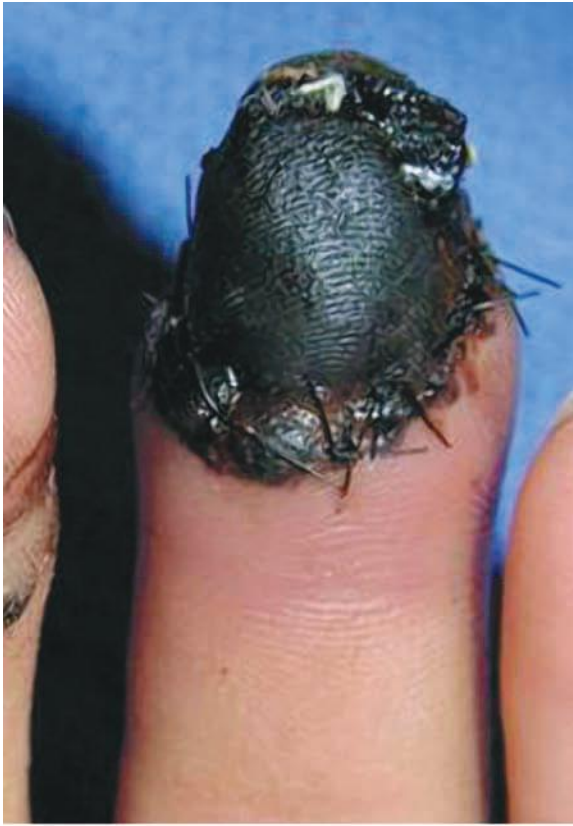

B

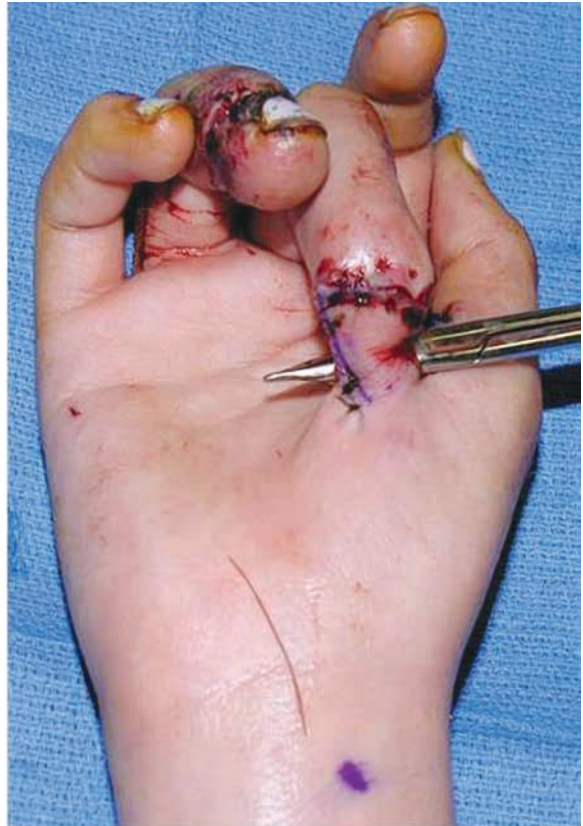


C

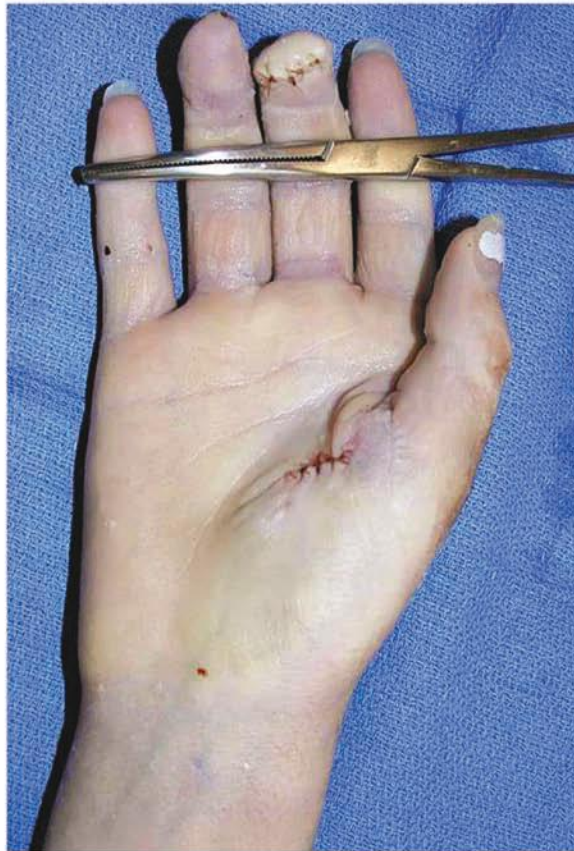Figure 44-16. Local flaps for digital tip coverage. **A–C.** For thumb injuries, Moberg described elevation of the entire volar skin with both neurovascular bundles for distal advancement. Sensation to the advanced skin is maintained. **D–F.** An 8-year-old girl underwent fingertip replantation that did not survive. A thenar flap was transferred to cover the defect. Some authors advise against its use in patients over 30 years old. **G–I.** In this 45-year-old man, the entire skin of P3 of the long finger was avulsed and unrecoverable. A cross-finger flap was transferred and provides excellent, durable coverage. The border of the flap and surrounding skin is still apparent 4.5 months after surgery.



D

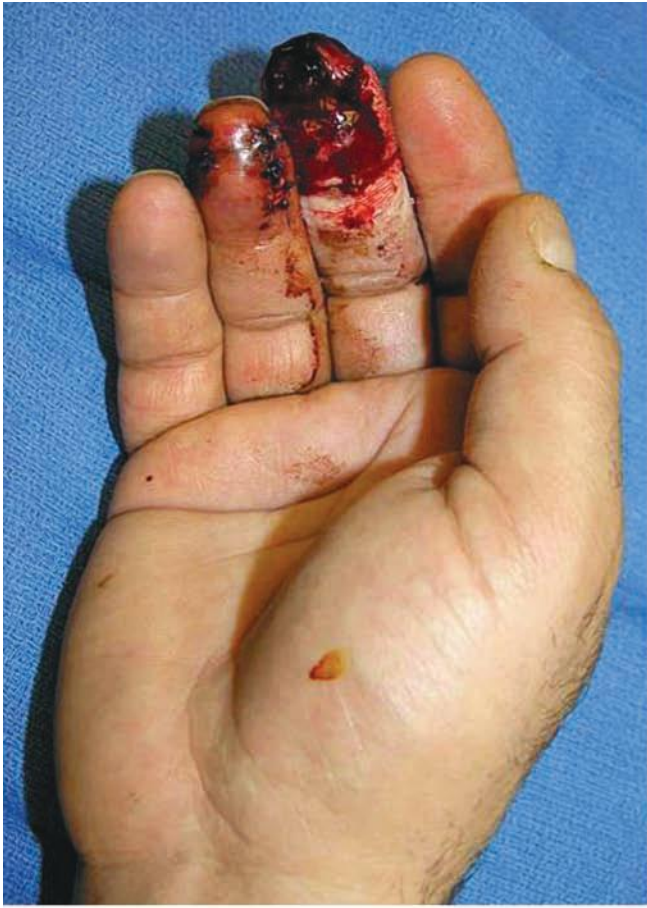

E

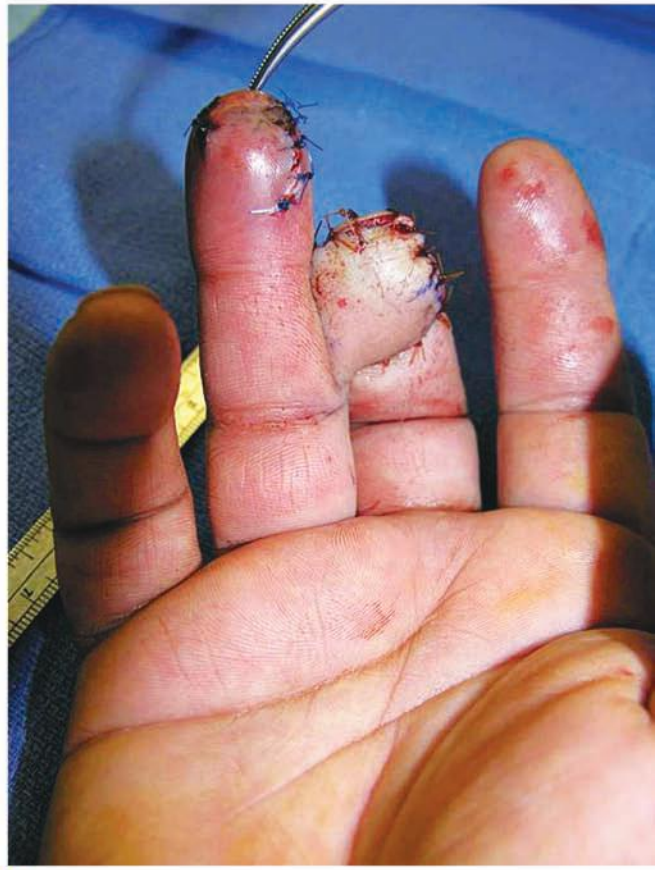

F

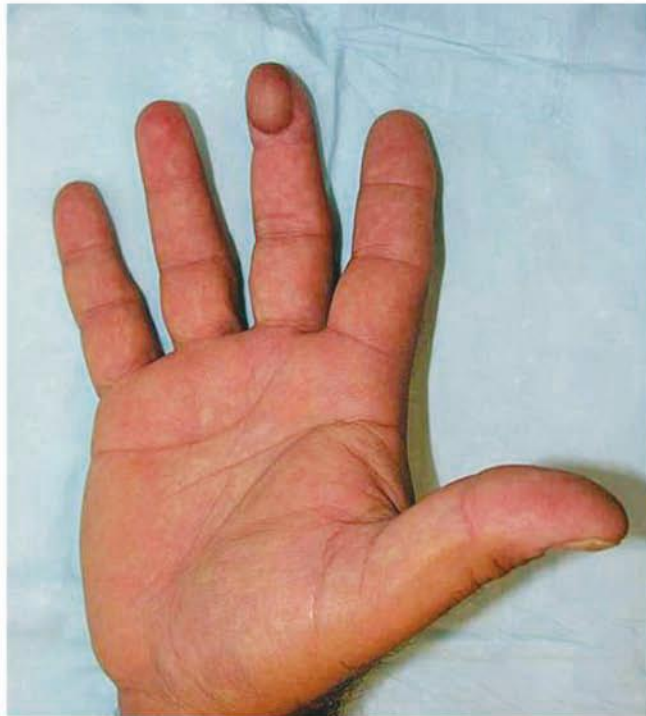Figure 44-16 (Continued)



G



H



I

Figure 44-16 (Continued)

and rigid fixation.²⁵ More proximally, the scaphoid bone of the wrist has a significant risk of nonunion even if nondisplaced (see Fig. 44-9A). Any patient suspected of a scaphoid injury, namely those with tenderness at the anatomic snuffbox, should be placed in a thumb spica splint and reevaluated within 2 weeks even if initial X-rays show no fracture. Scaphoid nonunions can be quite challenging to repair,²⁶ and immobilization at the time of injury in a thumb spica splint is essentially always warranted.

Stiffness

The desired outcome of any hand injury is a painless, mobile, functional hand. Multiple factors can contribute to decreased mobility, including complex injuries of soft tissue and bone, noncompliance of the patient with postoperative therapy, and inappropriate splinting. The surgeon performing the initial evaluation can greatly impact this last factor. The goal of splinting is to keep the collateral ligaments on tension (MPs at 90°, IP joints straight). For severe cases of stiffness, mobilization surgeries such as tenolysis and capsulotomies²⁷ can be performed, but these rarely produce normal range of motion. Prevention of joint contractures with appropriate splinting and early, protected mobilization is the best option to maximize mobility at the end of healing. Healing of an injured or diseased structure in the hand is not the endpoint of treatment; the goal of any intervention must be to obtain structure healing, relief of pain, and maximization of function.



Neuroma

Any lacerated nerve will form a neuroma. A neuroma consists of a ball of scar and axon sprouts at the end of the injured nerve.²⁸ In unfavorable circumstances, this neuroma can become painful. The SRN is particularly notorious for this problem. By providing proximal axon sprouts a target, nerve repair is an excellent preventive technique. In some circumstances, such as injuries requiring amputation, this is not possible. As mentioned earlier, the surgeon should resect the nerve stump as far proximally in the wound as possible to avoid the nerve stump healing in the cutaneous scar to minimize this risk.

For the patient who develops a painful neuroma, nonsurgical treatments are initiated first. The neuroma can be identified by the presence of a Tinel's sign. Therapy techniques of desensitization, ultrasound, and electrical stimulation have all proven useful. Corticosteroid injection to the neuroma has also proven useful in some hands.

When these techniques fail, surgery is contemplated. The neuroma can be resected, but a new one will form to replace it. The nerve ending can be buried in muscle or even bone to prevent the neuroma from residing in a superficial location where it may be impacted frequently.

Regional Pain Syndromes

Injuries to the upper extremity can occasionally result in the patient experiencing pain beyond the area of initial injury. Reflex sympathetic dystrophy and sympathetic mediated pain are two terms that have been used in the past to describe this phenomenon. Both are inaccurate, as the sympathetic nervous system is not always involved. Current terminology for this condition is complex regional pain syndrome (CRPS). Type I occurs in the absence of a documented nerve injury; type II occurs in the presence of one.²⁹

CRPSs manifest as pain beyond the area of initial injuries. There is often associated edema and changes in hair and/or sweat distribution. Comparison to the unaffected side

is useful to better appreciate these findings. There are currently no imaging studies that can be considered diagnostic for CRPS.³⁰

For the patient in whom the diagnosis of CRPS is not clear, no definitive diagnostic study exists. Patients suspected of CRPS should be referred for aggressive hand therapy. Brief trials of oral corticosteroids have been successful in some series. Referral to a pain management specialist including a trial of stellate ganglion blocks is also frequently employed.

NERVE COMPRESSION

Nerves conduct signals along their axonal membranes toward their end organs. Sensory axons carry signals from distal to proximal; motor axons from proximal to distal. Myelin from Schwann cells allows faster conduction of signals. Signals jump from the start of one Schwann cell to the end of the cell (a location called a gap junction) and only require the slower membrane depolarization in these locations.

Nerve compression creates a mechanical disturbance of the nerve.³¹ In early disease, the conduction signal is slowed across the area of compression. When compression occurs to a sufficient degree for a sufficient time, individual axons may die. On a nerve conduction study, this manifests as a decrease in amplitude. Muscles receiving motor axons may show electrical disturbance on electromyogram (EMG) when sufficiently deprived of their axonal input.

Compression of sensory nerves typically produces a combination of numbness, paresthesias (pins and needles), and pain. Knowledge of the anatomic distribution of the peripheral nerves can aid in diagnosis. Sensory disturbance outside an area of distribution of a particular nerve (e.g., volar and dorsal radial-sided hand numbness for median nerve) makes compression of that nerve less likely. Diseases that cause systemic neuropathy (e.g., diabetes) can make diagnosis more difficult.

Nerve compression can theoretically occur anywhere along a peripheral nerve's course. The most common sites of nerve compression in the upper extremity are the median nerve at the carpal tunnel, ulnar nerve at the cubital tunnel, and ulnar nerve at Guyon's canal. Other, less common locations of nerve compression are described as well. In addition, a nerve can become compressed in scar due to a previous trauma.

Carpal Tunnel Syndrome

The most common location of upper extremity nerve compression is the median nerve at the carpal tunnel, called carpal tunnel syndrome (CTS). The carpal tunnel is bordered by the scaphoid bone radially, the lunate and capitate bones dorsally, and the hook of the hamate bone ulnarly (see Fig. 44-3). The transverse carpal ligament, also called the flexor retinaculum, is its superficial border. The FPL, four FDS, and four FDP tendons pass through the carpal tunnel along with the median nerve. Of these 10 structures, the median nerve is relatively superficial and radial to the other nine.

An estimated 53 per 10,000 working adults have evidence of CTS. The National Institute for Occupational Safety and Health website asserts, "There is strong evidence of a positive association between exposure to a combination of risk factors (e.g., force and repetition, force and posture) and CTS."³² There is disagreement among hand surgeons regarding whether occurrence of CTS in a patient who does repetitive activities at work represents a work-related injury.

Initial evaluation of the patient consists of symptom inventory: location and character of the symptoms, sleep disturbance due to symptoms, history of dropping objects, and difficulty manipulating small objects such as buttons, coins, or jewelry clasps.

Physical examination should begin with inspection. Look for evidence of wasting of the thenar muscles. Tinel's sign should be tested over the median nerve from the volar wrist flexion crease to the proximal palm, although this test has significant interexaminer variability.³³ Applying pressure over the carpal tunnel while flexing the wrist has been shown in one series to have the highest sensitivity when compared to Phalen's and Tinel's signs.³⁴ Strength of the thumb in opposition should also be tested.

Early treatment of CTS consists of conservative management. The patient is given a splint to keep the wrist at 20° extension worn at nighttime. Many patients can have years of symptom relief with this management. As a treatment and diagnostic modality, corticosteroid injection of the carpal tunnel is often employed. Mixing local anesthetic into the solution provides the benefit of early symptom relief (corticosteroids often take 3–7 days to provide noticeable benefit), and report of postinjection anesthesia in the median nerve distribution confirms the injection went into the correct location. Multiple authors have shown a strong correlation to relief of symptoms with corticosteroid injection and good response to carpal tunnel release.³⁵

When lesser measures fail or are no longer effective, carpal tunnel release is indicated. Open carpal tunnel release is a time-tested procedure with documented long-term relief of symptoms. A direct incision is made over the carpal tunnel, typically in line with where the ring finger pad touches the proximal palm in flexion. Skin is divided followed by palmar fascia. The carpal tunnel contents are visualized as they exit the carpal tunnel. The transverse carpal ligament is divided with the median nerve visualized and protected at all times. Improvement in symptoms is typically noted by the first postoperative visit, although symptom relief may be incomplete for patients with long-standing disease or systemic nerve-affecting diseases such as diabetes.

Endoscopic techniques have been devised to address CTS. All involve avoidance of incising the skin directly over the carpal tunnel. In experienced hands, endoscopic carpal tunnel release provides the same relief of CTS with less intense and shorter lasting postoperative pain. After 3 months, however, the results are equivalent to open release.³⁶ In inexperienced hands, there may be a higher risk of injury to the median nerve with the endoscopic techniques; this procedure is not for the occasional carpal tunnel surgeon.

Cubital Tunnel Syndrome

The second most common location of upper extremity nerve compression is the ulnar nerve where it passes behind the elbow at the cubital tunnel. The cubital tunnel retinaculum passes between the medial epicondyle of the humerus and the olecranon process of the ulna. It stabilizes the ulnar nerve in this location during elbow motion. Over time, or sometimes after trauma, the ulnar nerve can become less stabilized in this area. Motion of the elbow then produces trauma to the nerve as it impacts the retinaculum and medial epicondyle.

Cubital tunnel syndrome may produce sensory and motor symptoms.³⁷ The small finger and ulnar half of the ring fingers

may have numbness, paresthesias, and/or pain. The ulnar nerve also innervates the dorsal surface of the small finger and ulnar side of the ring finger, so numbness in these areas can be explained by cubital tunnel syndrome. The patient may also report weakness in grip due to effects on the FDP tendons to the ring and small fingers and the intrinsic hand muscles. Patients with advanced disease may complain of inability to fully extend the ring and small finger IP joints.

Physical examination for cubital tunnel syndrome begins with inspection. Look for wasting in the hypothenar eminence and the interdigital web spaces. When the hand rests flat on the table, the small finger may rest in abduction with respect to the other fingers; this is called Wartenberg's sign. Tinel's sign is often present at the cubital tunnel. Elbow flexion test will often be positive. Grip strength and finger abduction strength should be compared to the unaffected side. Froment's sign can be tested by placing a sheet of paper between the thumb and index finger and instructing the patient to hold on to the paper while the examiner pulls it away without flexing the finger or thumb (this tests the strength of the adductor pollicis and first dorsal interosseous muscles). If the patient must flex the index finger and/or thumb (FDP-index and FPL, both median nerve supplied) to maintain traction on the paper, this is a positive response.

Early treatment of cubital tunnel syndrome begins with avoiding maximal flexion of the elbow. Splints are often used for this purpose. Corticosteroid injection is rarely done for this condition; unlike in the carpal tunnel, there is very little space within the tunnel outside of the nerve. Injection in this area runs a risk of intraneural injection, which can cause permanent scarring of the nerve and dysfunction.

When conservative management fails, surgery has been contemplated. Treatment options include releasing the cubital tunnel retinaculum with or without transposing the nerve anterior to the elbow. While some authors advocate anterior transposition into the flexor-pronator muscle group with the goal of maximizing nerve recovery,³⁷ recent studies have demonstrated equivalent results between transposition and in situ release of the nerve even in advanced cases.³⁸ For this reason, the simpler in situ release, either open or endoscopic, is preferred by many surgeons.

Other Sites of Nerve Compression

All nerves crossing the forearm have areas described where compression can occur.³⁷ The median nerve can be compressed as it passes under the pronator teres. The ulnar nerve can be compressed as it passes through Guyon's canal. The radial nerve, or its posterior interosseous branch, can be compressed as it passes through the radial tunnel (distal to the elbow where the nerve divides and passes under the arch of the supinator muscle). The SRN can be compressed distally in the forearm as it emerges from under the brachioradialis tendon, called Wartenberg's syndrome. As mentioned previously, any nerve can become compressed in scar at the site of a previous trauma.

DEGENERATIVE JOINT DISEASE

As with other joints in the body, the joints of the hand and wrist can develop degenerative changes. Symptoms typically begin in the fifth decade of life. Symptoms consist of joint pain and stiffness and often are exacerbated with changes in the weather. Any of the joints can become involved. As the articular cartilage wears out, pain typically increases and range of motion

decreases. The patient should always be asked to what degree symptoms are impeding activities.

Physical findings are documented in serial fashion from the initial visit and subsequent visits. Pain with axial loading of the joint may be present. Decreased range of motion may be a late finding. Instability of the collateral ligaments of the joint is uncommon in the absence of inflammatory arthritis.

Plain X-rays are typically sufficient to demonstrate arthritis. Initially, the affected joint has a narrower radiolucent space between the bones. As joint degeneration progresses, the joint space further collapses. Bone spurs, loose bodies, and cystic changes in the bone adjacent to the joint all may become apparent. X-ray findings do not always correlate with patient symptoms. Patients with advanced x-ray findings may have minimal symptoms, and vice versa. Treatment is initiated and progressed based on the patient's symptoms regardless of imaging findings.

Initial management begins with rest of the painful joint. Splints are often useful, but may significantly impair the patient in activities and thus are frequently used at nighttime only. Oral nonsteroidal anti-inflammatory medications such as ibuprofen and naproxen are also useful. Patients on anticoagulants and antiplatelet medications may not be able to take these, and some patients simply do not tolerate the gastric irritation side effect even if they take the medication with food.

For patients with localized disease affecting only one or a few joints, corticosteroid injection may be contemplated. Needle insertion can be difficult since these joint spaces are quite narrow even before degenerative disease sets in. Also, many corticosteroid injections are suspensions, not solutions; injected corticosteroid will remain in the joint space and can be seen as a white paste if surgery is performed on a joint that has been previously injected.

Small Joints (Metacarpophalangeal and Interphalangeal)

When conservative measures fail, two principal surgical options exist: arthrodesis and arthroplasty. The surgeon and patient must decide together as to whether conservative measures have failed. Surgery for arthritis, whether arthrodesis or arthroplasty, is performed for the purpose of relieving pain. Arthrodesis, fusion of a joint, provides excellent relief of pain and is durable over time. However, it comes at the price of total loss of motion.

Silicone implant arthroplasty has been available for over 40 years.³⁹ Rather than a true replacement of the joint, the silicone implant acts as a spacer between the two bones adjacent to the joint. This allows for motion without bony contact that would produce pain. Long-term studies have shown that all implants fracture over time, but usually continue to preserve motion and pain relief.⁴⁰

In the past 15 years, resurfacing implant arthroplasties have become available for the small joints of the hand. Multiple different materials have been used to fabricate such implants. These are designed to behave as a true joint resurfacing (as knee and hip arthroplasty implants are) and have shown promising outcomes in short- and intermediate-term studies.⁴⁰ Neither the silicone nor the resurfacing arthroplasties preserve (or restore) full motion of the MP or PIP joints.

Wrist

The CMC joint of the thumb, also called the basilar joint, is another common location of arthritis pain. Pain in this joint particularly disturbs function because the CMC joint is essential for

opposition and cylindrical grasp. Patients will typically complain of pain with opening a tight jar or doorknob and strong pinch activities such as knitting. Conservative management is used first, as described earlier. Prefabricated, removable thumb spica splinting can provide excellent relief of symptoms for many patients.

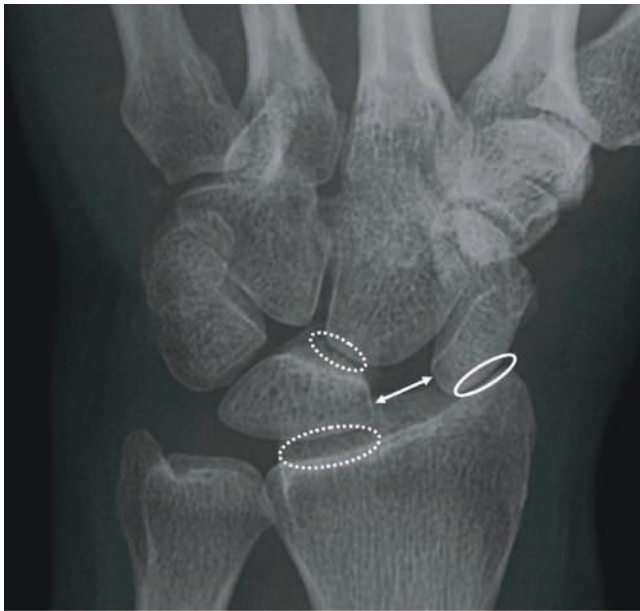Multiple surgical options exist for thumb CMC arthritis. Many resurfacing implants have been used in the past; often they have shown good short- and intermediate-term results and poor long-term results. Resection of the arthritic trapezium provides excellent relief of pain; however, most authors feel that stabilization of the thumb metacarpal base is necessary to prevent shortening and instability.⁴¹ Recently, one author demonstrated excellent long-term results from resection of the trapezium without permanent stabilization of the metacarpal base.⁴² For both of these operations, the thumb base may not be sufficiently stable to withstand heavy labor. For these patients, fusion of the thumb CMC in mild opposition provides excellent pain relief and durability. The patient must be warned preoperatively that he will not be able to lay his hand flat after the surgery. This loss of motion can be problematic when the patient attempts to tuck in clothing or reach into a narrow space.

Degenerative change of the radiocarpal and midcarpal joints is often a consequence of scapholunate ligament injury. Often the initial injury goes untreated, with the patient believing it is merely a "sprain"; the patient is first diagnosed with the initial injury when he presents years later with degenerative changes.

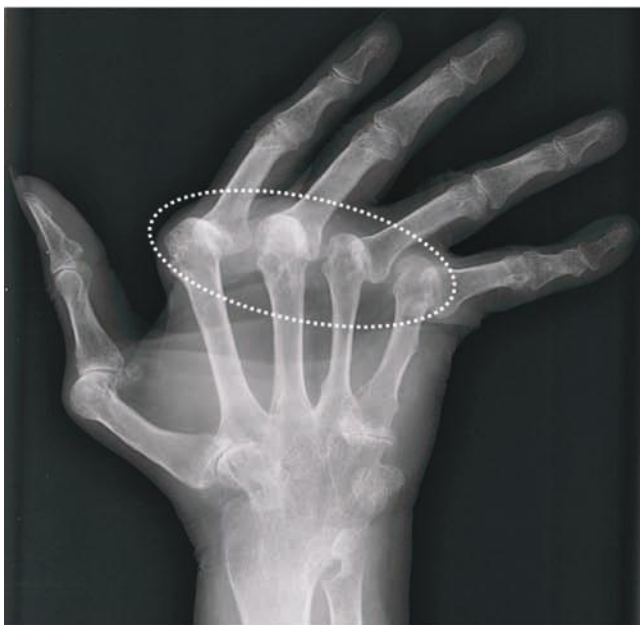Degenerative wrist changes associated with the scapholunate ligament follow a predictable pattern over many years, called *scapholunate advanced collapse* or *SLAC wrist*.⁴³ Because of this slow progression (Fig. 44-17A), patients can usually be treated with a motion-sparing procedure. If there is truly no arthritic change present, the scapholunate ligament can be reconstructed.

If arthritis is limited to the radiocarpal joint, two motion-sparing options are available. The proximal carpal row (scaphoid, lunate, and triquetrum) can be removed (proximal row carpectomy [PRC]). The lunate facet of the radius then articulates with the base of the capitate, whose articular surface is similar in shape to that of the base of the lunate. Most series show maintenance of about 66% of wrist motion and 66% of hand strength or more, as compared to the opposite side.⁴⁴ Alternatively, the scaphoid can be excised, and four-bone fusion (lunate, capitate, hamate, and triquetrum) can be performed. This maintains the full length of the wrist and the lunate in the lunate facet of the radius. Some series have shown better strength but less mobility with this technique, others have shown equivalent results to the PRC.⁴⁵ The four-bone fusion does appear to be more durable for younger patients and/or those who perform heavy labor.

If the patient presents with pancarpal arthritis or motion-sparing measures have failed to alleviate pain, total wrist fusion is the final surgical option. The distal radius is fused, through the proximal and distal carpal rows to the third metacarpal, typically with a dorsal plate and screws. Multiple long-term studies have shown excellent pain relief and durability; this comes at the cost of total loss of wrist motion. This is surprisingly well tolerated in most patients, especially if the other hand/wrist is unaffected. The only activity of daily living that cannot be done with a fused wrist is personal toileting.



A



B

Figure 44-17. Arthritis of the hand and wrist. **A.** This patient injured her scapholunate ligament years prior to presentation. The scapholunate interval is widened (*double arrow*), and the radioscaphoid joint is degenerated (*solid oval*), but the radiolunate and lunocapitate joint spaces are well preserved (*dashed ovals*). **B.** This patient has had rheumatoid arthritis for decades. The classic volar subluxation of the metacarpophalangeal joints of the fingers (*dashed oval*) and radial deviation of the fingers are apparent.

Rheumatoid Arthritis

Rheumatoid arthritis (RA) is an inflammatory arthritis that can affect any joint in the body. Inflamed synovium causes articular cartilage breakdown with pain and decreased range of motion. The goals of hand surgery for the RA patient are relief of pain, improvement of function, slowing progression of disease, and improvement in appearance.⁴⁶ In addition, swelling of the joint due to the inflammation can cause laxity and even failure of the collateral ligaments supporting the joints. Recent advances in

the medical care of RA have made the need for surgical care of these patients far less common than in previous decades.

MP joints of the fingers are commonly affected. The base of the proximal phalanx progressively subluxates and eventually dislocates volarly with respect to the metacarpal head. The collateral ligaments, particularly on the radial side, stretch out and cause the ulnar deviation of the fingers characteristic of the rheumatoid hand. In more advanced cases, the joint may not be salvageable (Fig. 44-17B). For these patients, implant arthroplasty is the mainstay of surgical treatment. Silicone implants have been used for over 40 years with good results.⁴⁷ The silicone implant acts as a spacer between proximal and distal bone, rather than as a true resurfacing arthroplasty. The radial collateral ligament must be repaired to appropriate length to correct the preoperative ulnar deviation of the MP joint. Extensor tendon centralization is then performed, as needed, at the end of the procedure.

For MP joint and PIP joint disease, fusion is an option. However, since RA usually affects multiple joints, fusion is typically avoided due to impaired function of adjacent joints, which would leave a severe motion deficit to the finger.

Failure of the support ligaments of the distal radioulnar joint (DRUJ) leads to the *caput ulnae* posture of the wrist with the ulnar head prominent dorsally. As this dorsal prominence becomes more advanced, the ulna head, denuded of its cartilage to act as a buffer, erodes into the overlying extensor tendons. Extensor tenosynovitis, followed ultimately by tendon rupture, begins ulnarly and proceeds radially. Rupture of the ECU tendon may go unnoticed due to the intact ECRL and ECRB tendons to extend the wrist. EDQ rupture may go unnoticed if a sufficiently robust EDC tendon to the small finger exists. Once the fourth compartment (EDC) tendons begin to fail, the motion deficit is unable to be ignored by the patient.

Surgical solutions must address the tendon ruptures as well as the DRUJ synovitis and instability and ulna head breakdown that led to them.⁴⁶ Excision of the ulna head removes the bony prominence. The DRUJ synovitis must also be resected. Alternatively, the DRUJ can be fused and the ulna neck resected to create a pseudoarthrosis to allow for rotation. For both procedures, the remaining distal ulna must be stabilized. Multiple techniques have been described using portions of FCU, ECU, wrist capsule, and combinations thereof.

The ruptured extensor tendons are typically degenerated over a significant length. Primary repair is almost never possible, and the frequent occurrence of multiple tendon ruptures makes repair with graft less desirable due to the need for multiple graft donors.

Strict compliance with postoperative therapy is essential to maximizing the surgical result. Due to the chronic inflammation associated with RA, tendon and ligament repairs will be slower to achieve maximal tensile strength. Prolonged nighttime splinting, usually for months, helps prevent recurrence of extensor lag. Finally, the disease may progress over time. Reconstructions that were initially adequate may stretch out or fail over time. Medical management is the key to slowing disease progression and maximizing the durability of any surgical reconstruction.

DUPUYTREN'S CONTRACTURE

In 1614, a Swiss surgeon named Felix Plater first described contracture of multiple fingers due to palpable, cord-like structures on the volar surface of the hand and fingers. The disease state he described would ultimately come to be known as Dupuytren's

contracture. Dupuytren's name came to be associated with the disease after he performed an open fasciotomy of a contracted cord before a class of medical students in 1831.⁴⁸

The palmar fascia consists of collagen bundles in the palm and fingers. These are primarily longitudinally oriented and reside as a layer between the overlying skin and the underlying tendons and neurovascular structures. There are also connections from this layer to the deep structures below and the skin above. Much is known about the progression of these structures from their normal state (called bands) to their contracted state (called cords), but little is known on how or why this process begins.

Increased collagen deposition leads to a palpable nodule in the palm. Over time, there is increased deposition distally into the fingers. This collagen becomes organized and linearly oriented. These collagen bundles, with the aid of myofibroblasts, contract down to form the cords, which are the hallmark of the symptomatic patient. Detail of the molecular and cell biology of Dupuytren's disease is beyond the scope of this chapter but is available in multiple hand surgery texts.⁴⁹

Most nonoperative management techniques will not delay the progression of disease. Corticosteroid injections may soften nodules and decrease the discomfort associated with them but are ineffective against cords. Splinting has similarly been shown not to retard disease progression.

Disruption of the cord with a needle is an effective means of releasing contractures, particularly at the MP joint level. Long-term studies have demonstrated more rapid recovery from needle fasciotomy, as the procedure is called, but more durable results with fasciectomy.⁵⁰ Injectable clostridial collagenase was approved by the U.S. Food and Drug Administration in 2009 and shows good early results.⁵¹

For patients with advanced disease including contractures of the digits that limit function, surgery is the mainstay of therapy. Although rate of progression should weigh heavily in the decision of whether or not to perform surgery, general guidelines are MP contractures $\geq 30^\circ$ and/or PIP contractures $\geq 20^\circ$.⁵²

Surgery consists of an open approach through the skin down to the involved cords. Skin is elevated off of the underlying cords. Great care must be taken to preserve as much of the subdermal vascular plexus with the elevated skin flaps to minimize postoperative skin necrosis. All nerves, tendons, and blood vessels in the operative field should be identified. Once this is done, the involved cord is resected while keeping the critical deeper structures under direct vision. Skin is then closed, with local flap transpositions as needed, to allow for full extension of the fingers that have been released (Fig. 44-18).

Alternative cord resection techniques include removal of the skin over the contracture (dermatofasciectomy). This requires a skin graft to the wound and should only be done if skin cannot be separated from the cords and local tissue cannot be rearranged with local flaps to provide closure of the wound.

Complications of surgical treatment of Dupuytren's disease occur in as many as 24% of cases.⁵³ Problems include digital nerve laceration, digital artery laceration, buttonholing of the skin, hematoma, swelling, and pain, including some patients with CRPS (see earlier section on CRPS). Digital nerve injury can be quite devastating, producing annoying numbness at best or a painful neuroma in worse situations.

Hand therapy is typically instituted within a week of surgery to begin mobilization of the fingers and edema control. The therapist can also identify any early wound problems because

he or she will see the patient more frequently than the surgeon. Extension hand splinting is maintained for 4 to 6 weeks, with nighttime splinting continued for an additional 6 to 8 weeks. After this point, the patient is serially followed for evidence of recurrence or extension of disease.

INFECTIONS

Trauma is the most common cause of hand infections. Other predisposing factors include diabetes, neuropathies, and immunocompromised patients. Proper treatment consists of incision and drainage of any collections followed by débridement, obtaining wound cultures, antibiotic therapy, elevation, and immobilization. *Staphylococcus* and *Streptococcus* are the offending pathogens in about 90% of hand infections. Infections caused by intravenous drug use or human bites and those associated with diabetes will often be polymicrobial, including gram-positive and gram-negative species. Heavily contaminated injuries require anaerobic coverage. Although α -hemolytic *Streptococcus* and *Staphylococcus aureus* are the most commonly encountered pathogens in human bites, *Eikenella corrodens* is isolated in up to one-third of cases and should be considered when choosing antimicrobial therapy. Ziehl-Neelsen staining and cultures at 28°C to 32°C in Lowenstein-Jensen medium must be performed if there is a suspicion for atypical mycobacteria.⁵⁴

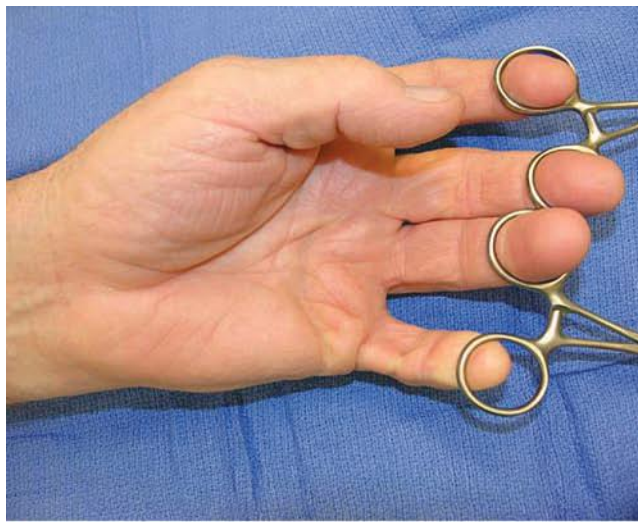
Cellulitis

Cellulitis is characterized by a nonpurulent diffuse spreading of inflammation characterized by erythema, warmth, pain, swelling, and induration. Skin breakdown is a frequent cause, but often no inciting factor is identified. Group A β -hemolytic *Streptococcus* is the most common offending pathogen and causes a more diffuse spread of infection. *S. aureus* is the second most common offending pathogen and will cause a more localized cellulitis. The diagnosis of cellulitis is clinical. Septic arthritis, osteomyelitis, an abscess, a deep-space infection, and necrotizing fasciitis are severe infectious processes that may initially mimic cellulitis. These must be ruled out appropriately before initiating treatment, and serial exams should be conducted to ensure proper diagnosis. Treatment of cellulitis consists of elevation, splint immobilization, and antibiotics that cover both *Streptococcus* and *Staphylococcus*.

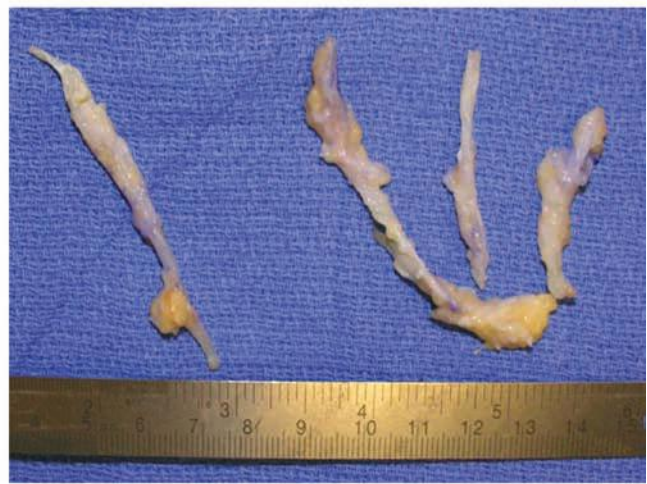5▶ Intravenous antibiotics are usually initiated for patients with severe comorbidities and those who fail to improve on oral antibiotics after 24 to 48 hours. Failure to improve after 24 hours indicates a need to search for an underlying abscess or other infectious cause.⁵⁴

Abscess

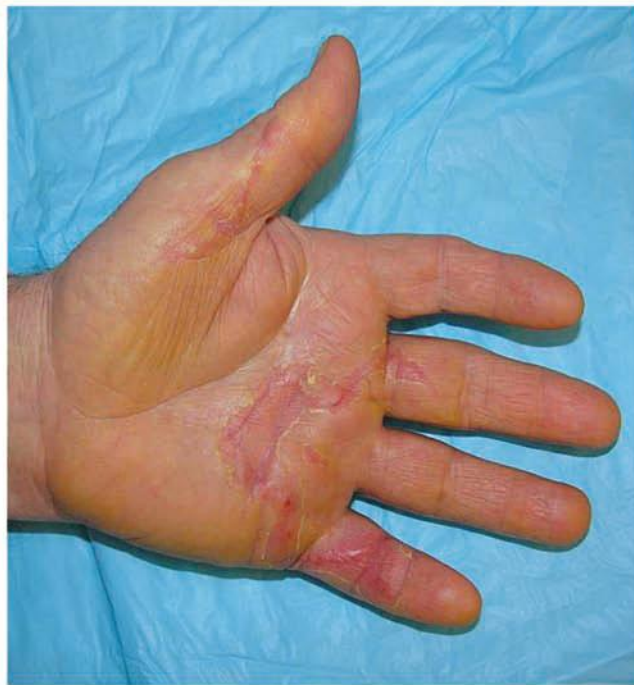An abscess will present much like cellulitis, but they are two clinically separate entities. The defining difference is an area of fluctuance. Skin-puncturing trauma is the most common cause. *S. aureus* is the most common pathogen, followed by *Streptococcus*. Treatment consists of incision and drainage with appropriate débridement, wound cultures, wound packing, elevation, immobilization, and antibiotics. The packing should be removed in 12 to 24 hours or sooner if there is clinical concern, and warm soapy water soaks with fresh packing should be initiated. Most should be allowed to heal secondarily. Delayed primary closure should only be performed after repeat washouts for larger wounds where complete infection has been achieved.



A



B



C

Figure 44-18. Dupuytren's disease. **A.** This patient has cords affecting the thumb, middle, ring, and small fingers. **B.** The resected specimens are shown. **C.** Postoperatively, the patient went on to heal all his incisions and, with the aid of weeks of hand therapy, recover full motion.

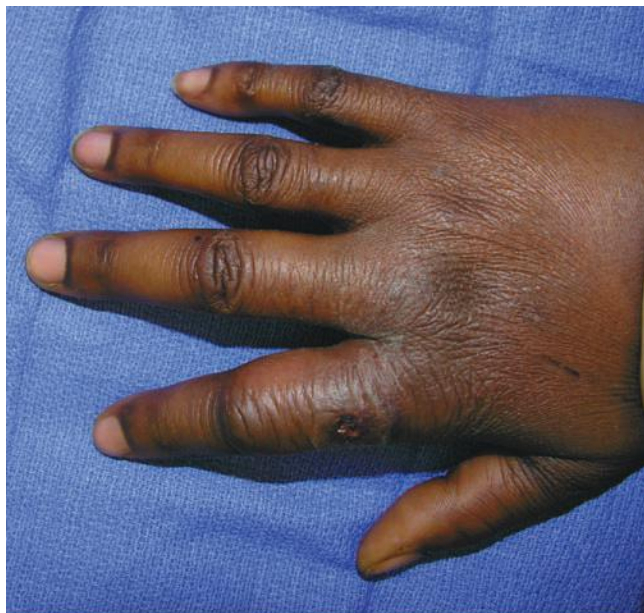
Collar-Button Abscess

This is a subfascial infection of a web space and is usually caused by skin trauma that becomes infected; it often occurs in laborers. The adherence of the palmar web space skin to the palmar fascia prevents lateral spread, so the infection courses dorsally, resulting in both palmar web space tenderness and dorsal web space swelling and tenderness. The adjacent fingers will be held in abduction with pain on adduction (Fig. 44-19). Incision and drainage, often using separate volar and dorsal incisions, is mandatory, and follows the same treatment as for any abscess or deep-space infection.

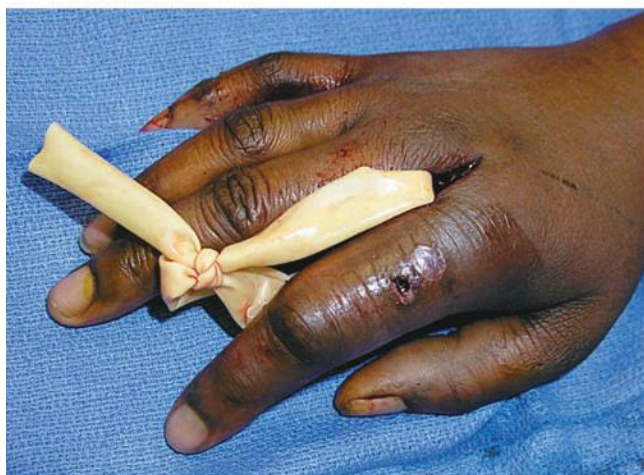Osteomyelitis

Osteomyelitis in the hand usually occurs due to an open fracture with significant soft tissue injury. The presence of infected hardware, peripheral vascular disease, diabetes, and alcohol or drug

abuse are also predisposing factors. Presentation includes persistent or recurrent swelling with pain, erythema, and possible drainage. It will take 2 to 3 weeks for periosteal reaction and osteopenia to be detected on radiographs. Bone scans and MRI are useful modalities to aid in diagnosis. Erythrocyte sedimentation rate (ESR) and C-reactive protein (CRP) have low specificity but are useful for monitoring the progress of treatment, with CRP being more reliable. Treatment consists of antibiotics alone in the early stage as long as there is favorable response. All necrotic bone and soft tissue, if present, must be débrided. Initial intravenous antibiotic therapy should cover *S. aureus*, the most common pathogen, and should then be adjusted according to bone cultures. Antibiotic therapy is continued for 4 to 6 weeks once the patient clinically improves and there is no further need for débridement. For osteomyelitis in the setting of an acute fracture with internal fixation in place, the hardware should



A



B

Figure 44-19. **A.** The fingers surrounding the involved (second) web space rest in greater abduction than the other fingers. **B.** Dorsal and volar drainage incisions are made, separated by a bridge of intact web skin; a Penrose drain prevents the skin from closing too early.

be left in place as long as it is stable and the fracture has not yet healed. If the hardware is unstable, it must be replaced. An external fixation device may be useful in this setting. If osteomyelitis occurs in a healed fracture, all hardware and necrotic bone and soft tissue must be removed.⁵⁵

Pyogenic Arthritis

Infection of a joint will progress quickly to severe cartilage and bony destruction if not addressed quickly. Direct trauma and local spread of an infection are the most common causes. Hematogenous spread occurs most commonly in patients who are immunocompromised. *S. aureus* is the most common pathogen, followed by *Streptococcus* species. *Neisseria gonorrhoeae* is the most common cause of atraumatic septic arthritis in an adult less than 30 years of age. Presentation includes exacerbation of pain with any joint movement, severe pain on axial load, swelling,

erythema, and tenderness. Radiographs may show a foreign body or fracture, with widened joint space early in the process and decreased joint space late in the process due to destruction. Joint aspiration with cell count, Gram stain, and culture is used to secure the diagnosis. Treatment of nongonococcal septic arthritis includes open arthrotomy, irrigation, débridement, and packing the joint or leaving a drain in place. Intravenous antibiotics are continued until there is clinical improvement, followed by 2 to 4 weeks of additional oral or intravenous antibiotics. Gonococcal septic arthritis is usually treated nonoperatively. Intravenous ceftriaxone is first-line therapy. Joint aspiration may be used to obtain cultures and decrease joint pressure.⁵⁶

Necrotizing Infections

Necrotizing soft tissue infections occur when the immune system is unable to contain an infection, leading to extensive spread with death of all involved tissues. This is different from an abscess, which forms when a functioning immune system is able to “wall off” the infectious focus. Necrotizing infections can result in loss of limb or life, even with prompt medical care.

Bacteria spread along the fascial layer, resulting in the death of soft tissues, which is in part due to the extensive blood vessel thrombosis that occurs. An inciting event is not always identified. Immunocompromised patients and those who abuse drugs or alcohol are at greater risk, with intravenous drug users having the highest increased risk. The infection can be mono- or polymicrobial, with group A β -hemolytic *Streptococcus* being the most common pathogen, followed by α -hemolytic *Streptococcus*, *S. aureus*, and anaerobes. Prompt clinical diagnosis and treatment are the most important factors for salvaging limbs and saving life. Patients will present with pain out of proportion with findings. Appearance of skin may range from normal to erythematous or maroon with edema, induration, and blistering. Crepitus may occur if a gas-forming organism is involved. “Dirty dishwasher fluid” may be encountered as a scant grayish fluid, but often there is little to no discharge. There may be no appreciable leukocytosis. The infection can progress rapidly and can lead to septic shock and disseminated intravascular coagulation. Radiographs may reveal gas formation, but they must not delay emergent débridement once the diagnosis is suspected. Intravenous antibiotics should be started immediately to cover gram-positive, gram-negative, and anaerobic bacteria. Patients will require multiple débridements, and the spread of infection is normally wider than expected based on initial assessment.⁵⁴

Necrotizing myositis, or myonecrosis, is usually caused by *Clostridium perfringens* due to heavily contaminated wounds. Unlike necrotizing fasciitis, muscle is universally involved and found to be necrotic. Treatment includes emergent débridement of all necrotic tissue along with empirical intravenous antibiotics.

Wet gangrene is most common in diabetics with renal failure and an arteriovenous shunt. It is usually polymicrobial. Patients will present with a necrotic digit that is purulent and very malodorous, with rapidly evolving pain, swelling, skin discoloration, and systemic collapse. Emergent treatment is the same as for other necrotizing infections, and amputation of the involved digit or extremity must often be performed.

Infectious Flexor Tenosynovitis

Flexor tenosynovitis (FTS) is a severe pathophysiologic state causing disruption of normal flexor tendon function in the hand. A variety of etiologies are responsible for this process. Most acute cases of FTS are due to purulent infection. FTS also can

occur secondary to chronic inflammation as a result of diabetes, RA, crystalline deposition, overuse syndromes, amyloidosis, psoriatic arthritis, systemic lupus erythematosus, and sarcoidosis.

The primary mechanism of infectious FTS usually is penetrating trauma. Most infections are caused by skin flora, including both *Staphylococcus* and *Streptococcus* species. Bacteria involved vary by etiology of the infection: bite wounds (*Pasteurella multocida*—cat, *E. corrodens*—human); diabetic patients (*Bacteroides*, *Fusobacterium*, *Haemophilus* species, gram-negative organisms); hematogenous spread (*Mycobacterium tuberculosis*, *N. gonorrhoeae*); or water-related punctures (*Vibrio vulnificus*, *Mycobacterium marinum*). Infection in any of the fingers may spread proximally into the wrist, carpal tunnel, and forearm, also known as Parona's space.⁵⁷

Suppurative FTS has the ability to rapidly destroy a finger's functional capacity and is considered a surgical emergency. Suppurative FTS results from bacteria multiplying in the closed space of the flexor tendon sheath and culture-rich synovial fluid medium causing migration of inflammatory cells and subsequent swelling. The inflammatory reaction within the closed tendon sheath quickly erodes the paratenon, leading to adhesions and scarring, as well as increase in pressures within the tendon sheath that may lead to ischemia. The ultimate consequences are tendon necrosis, disruption of the tendon sheath, and digital contracture.

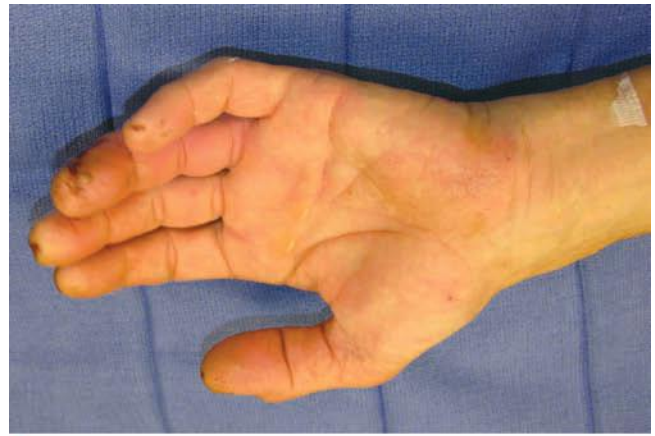
Patients with infectious FTS present with pain, redness, and fever (Fig. 44-20). Physical examination reveals Kanavel's "cardinal" signs of flexor tendon sheath infection: finger held in slight flexion, fusiform swelling, tenderness along the flexor tendon sheath, and pain over the flexor sheath with passive extension of the digit.⁵⁸ Kanavel's signs may be absent in patients who are immunocompromised, have early manifestations of infection, have recently received antibiotics, or have a chronic, indolent infection.

If a patient presents with suspected infectious FTS, empiric intravenous antibiotics should be initiated. Prompt medical therapy in early cases may prevent the need for surgical drainage. For healthy individuals, empiric antibiotic therapy should cover *Staphylococcus* and *Streptococcus*. For immunocompromised patients (including diabetics) or infections associated with bite wounds, empiric treatment should include coverage of gram-negative organisms as well.

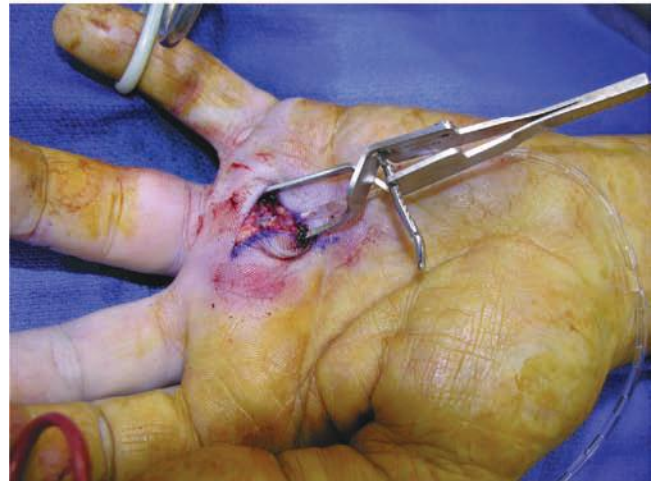Adjuncts to antibiotics include splint immobilization (intrinsic plus position preferred) and elevation until infection is under control. Hand rehabilitation (i.e., range-of-motion exercises and edema control) should be initiated once pain and inflammation are under control.

If medical treatment alone is attempted, then initial inpatient observation is indicated. Surgical intervention is necessary if no obvious improvement has occurred within 12 to 24 hours.

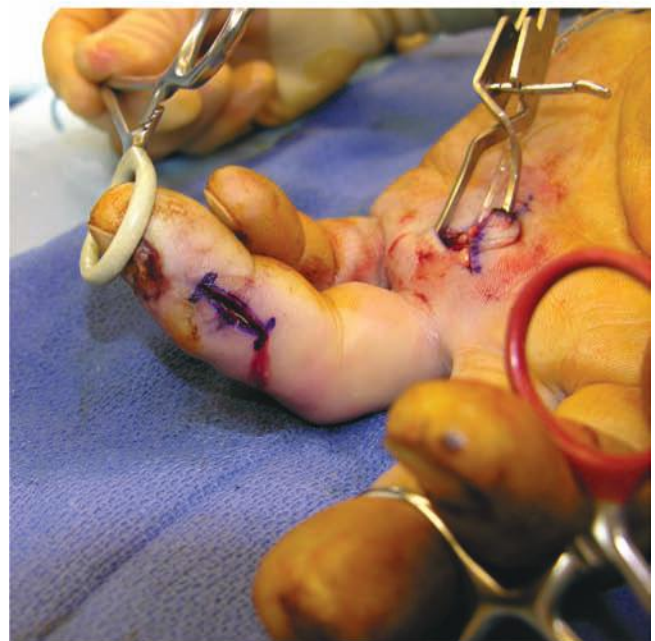Several surgical approaches can be used to drain infectious FTS. The method used is based on the extent of the infection. Michon developed a classification scheme that can be useful in guiding surgical treatment (Table 44-1).⁵⁹ Figure 44-20B & C demonstrates drainage of a stage II FTS. A Brunner incision allows better initial exposure but may yield difficulties with tendon coverage if skin necrosis occurs. A 16-gauge catheter or 5-French pediatric feeding tube then is inserted into the tendon sheath through the proximal incision. The sheath is copiously irrigated with normal saline. Avoid excessive fluid extravasation into the soft tissue, because the resulting increase in tissue pressure can lead to necrosis of the digit. The catheter is removed after irrigation. The incisions



A



B



C

Figure 44-20. Suppurative flexor tenosynovitis of the ring finger. **A.** The finger demonstrates fusiform swelling and flexed posture. **B.** Proximal exposure for drainage. **C.** Distal drainage incision.

Table 44-1

Michon's stages of suppurative flexor tenosynovitis and appropriate treatment

STAGE	FINDINGS	TREATMENT
I	Increased fluid in sheath, mainly a serous exudate	Catheter irrigation
II	Purulent fluid, granulomatous synovium	Minimal invasive drainage ± indwelling catheter irrigation
III	Necrosis of the tendon, pulleys, or tendon sheath	Extensive open débridement and possible amputation

are left open. Some surgeons prefer a continuous irrigation technique for a period of 24 to 48 hours. The catheter is sewn in place, and a small drain is placed at the distal incision site. Continuous or intermittent irrigation every 2 to 4 hours with sterile saline can then be performed through the indwelling catheter.

After surgery, an intrinsic plus splint is applied, the hand is elevated, and the appropriate empiric antibiotic coverage is instituted while awaiting culture results. The hand is reexamined the following day. Whirlpool therapy and range of motion are begun. Drains are removed before discharge from the hospital. The wounds are left open to heal by secondary intention. In severe cases, repeat irrigation and operative débridement may be required.

Antibiotic therapy is guided by culture results as well as clinical improvement. Once there is no further need for débridement, a 7- to 14-day course of oral antibiotics is generally prescribed. Consultation with an infectious disease specialist should be considered early in order to maximize efficiency and efficacy of therapy.

Felon

A felon is a subcutaneous abscess of the fingertip and is most commonly caused by penetrating trauma. *S. aureus* is the most common pathogen. The fingertip contains multiple septa connecting the distal phalanx to the skin. These septa are poorly compliant, and presence of an abscess will increase pressure and lead to severe pain and tissue death. Patients will experience erythema, swelling, and tenderness of the volar digital pad. Oral antibiotics may resolve the infection if diagnosed very early, but incision and drainage is indicated when fluctuance is identified. A digital block should be performed, followed by a longitudinal incision over the point of maximal fluctuance (Fig. 44-21). Transverse and lateral incisions should be avoided, and the incision should never extend across the distal phalangeal joint crease. Deep incision should not be performed as this may cause seeding of bacteria into the flexor tendon sheath. The wound is irrigated and packed, with warm soapy water soaks and packing changes initiated within 24 hours and performed two to three times daily until secondarily healed. Antibiotic coverage should cover for *Staphylococcus* and *Streptococcus* species.⁶⁰

Paronychia

Paronychia is an infection beneath the nail fold. The nail plate can be viewed as an invagination into the dorsal skin extending down to the distal phalanx periosteum. Predisposing factors include anything that causes nail trauma, such as manicures,

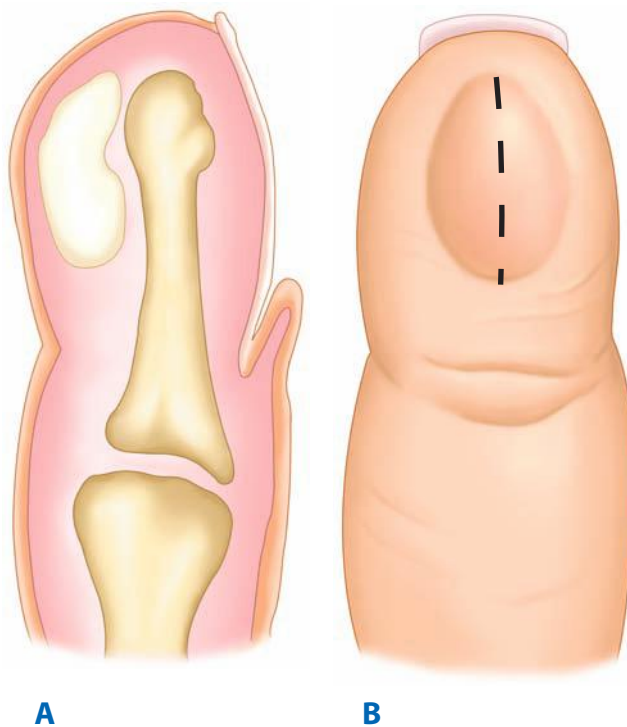


Figure 44-21. Felon. **A.** Lateral view of the digit showing fluctuance between the skin of the pad and the underlying distal phalanx bone. **B.** The authors prefer to drain felons with a longitudinal incision (dashed line) directly over the area of maximal fluctuance.

artificial nails, or nail biting. The infection may spread around the nail plate from one side to the other, or it may extend into the pulp and result in a felon. An acute paronychia is usually caused by *S. aureus* or *Streptococcal* species. Patients report pain, erythema, swelling, and possibly purulent drainage involving the periungual tissue. Treatment consists of warm water soaks and oral antibiotics if diagnosed early. If purulence or fluctuance is present, then a freer elevator or 18-gauge needle can be passed along the involved nail fold to decompress the collection (Fig. 44-22). If the infection involves the eponychial

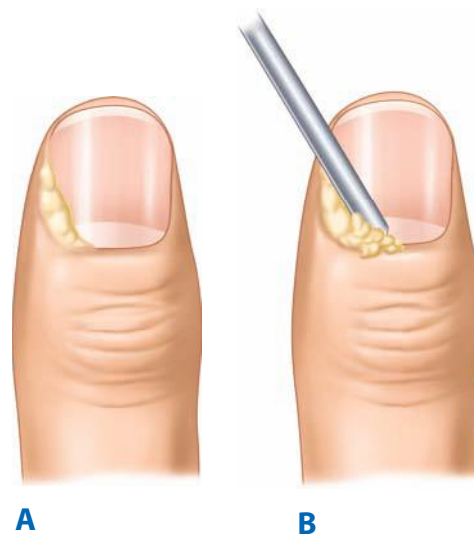

Figure 44-22. Paronychia. **A.** Fluctuance in the nail fold is the hallmark of this infection. **B.** The authors prefer to drain a paronychia using the bevel of an 18-gauge needle inserted between the nail fold and the nail plate at the location of maximal fluctuance.

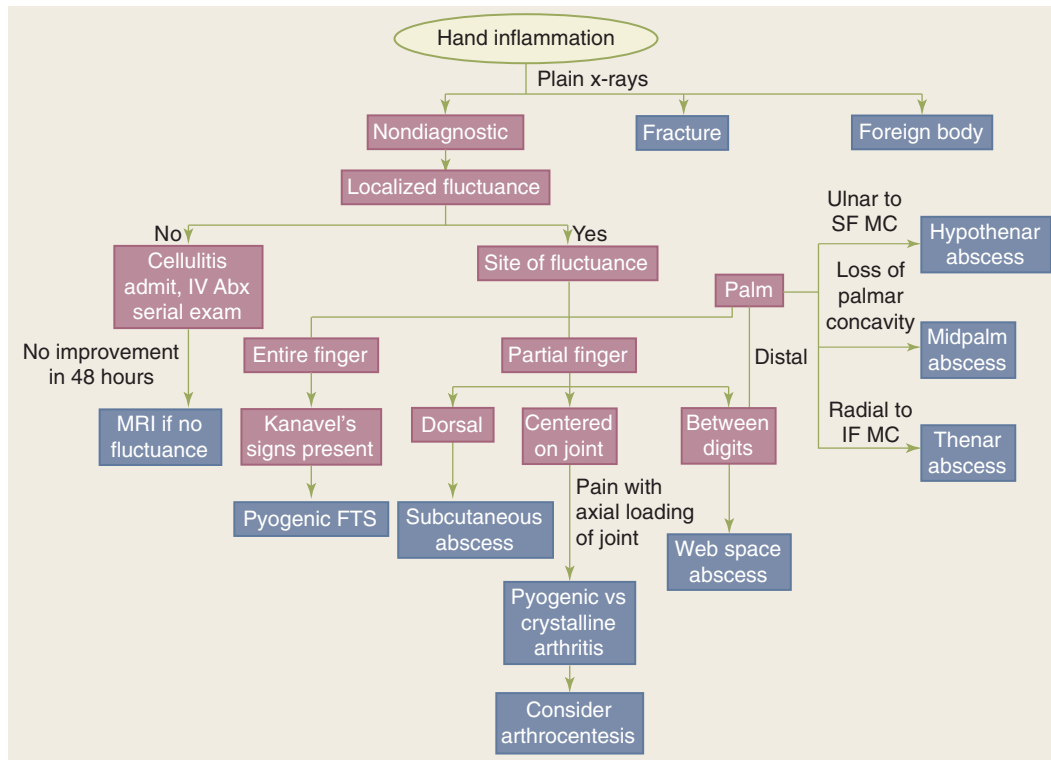


Figure 44-23. Diagnostic algorithm. Diagnostic workup for a patient with hand inflammation to evaluate for infection. See text for details about particular infectious diagnoses. Abx = antibiotics; FTS = flexor tenosynovitis; IF MC = index finger metacarpal; MRI = magnetic resonance imaging; SF MC = small finger metacarpal.

fold, a small proximally based flap of eponychium is created by using a scalpel, followed by irrigation and packing. The nail plate must be removed if the infection extends beneath the nail plate. Packing is kept in place for 24 to 48 hours, followed by warm water soaks and local wound care. Usually, the wound cannot be repacked once the dressing is removed.⁶⁰

A chronic paronychia is most commonly caused by *Candida* species and is most often found in patients who perform jobs involving the submersion of their hands in water or other moist environments. These develop into thickened nails with callus-like formation along the nail folds and may occasionally become red and inflamed. They do not respond to antibiotic treatment, and nail plate removal with marsupialization of the skin proximal to the eponychial fold will allow the wound to heal secondarily. The environmental factors leading to the chronic paronychia must also be corrected in order for treatment to be successful.

All hand infections other than cellulitis will require surgical management. Clinical examination, particularly noting the area of greatest tenderness and/or inflammation, is the single most useful diagnostic tool to localize any purulence requiring drainage. Specific recommendations for differentiating among the possible locations of hand infection are included in the diagnostic algorithm shown in Fig. 44-23.

TUMORS

Tumors of the hand and upper extremity can be classified as benign soft tissue tumors; malignant soft tissue tumors (subclassified into cutaneous and noncutaneous malignancies); benign bony tumors; malignant bony tumors; and secondary metastatic

tumors. Initial investigation for any mass starts with a complete history and physical exam. Hand and/or wrist X-rays should be obtained in every patient presenting with a mass unless clearly not indicated (e.g., a superficial skin lesion with no aggressive/malignant features). The workup proceeds in an orderly fashion until a diagnosis is obtained. Once a benign diagnosis is secured (by strong clinical suspicion in an experienced hand surgeon, radiographic evidence, or tissue biopsy), further workup is not needed; this may occur at any point in the workup of a mass.

Most hand masses are benign and can be readily diagnosed without advanced imaging or tissue biopsy. When necessary, additional workup may include baseline laboratory studies, CT and/or MRI of the involved region, and a bone scan or positron emission tomography (PET) scan. Staging of a malignant tumor may occur before biopsy if a malignancy is strongly suspected, or it may occur after formal biopsy. Staging includes a chest X-ray and CT with intravenous contrast of the chest, abdomen, and pelvis to detect possible metastasis. Biopsy of the mass is always the last step of a workup and should occur only after all other available information has been gathered. Any mass that is over 5 cm in size, is rapidly increasing in size (as judged by an experienced surgeon or oncologist), is symptomatic or painful, or has an aggressive clinical or radiographic appearance warrants workup and biopsy to rule out malignancy.

CT scans are useful for detecting bony tumor extension across planes and identifying tumors of small bones, such as the carpal bones. MRI is useful for evaluating soft tissue tumor involvement (e.g., which muscle compartments are involved) as well as intramedullary lesions. Most soft tissue tumors will appear dark on T1-weighted images and bright on T2-weighted images. Hematomas, hemangiomas, lipomas, liposarcomas,

and adipose tissue will appear bright on T1-weighted images and dark on T2-weighted images. Scintigraphy uses methylene diphosphonate attached to technetium-99m. This complex will attach to hydroxyapatite. Immediate uptake is seen in areas of increased vascularity, such as infection, trauma, and neoplasia. Increased uptake 2 to 3 hours later is seen in “pooled” areas where new bone formation has occurred. This modality is useful for detecting areas of tumor invasion or metastases not otherwise seen on prior CT, MRI, or radiographs.

Biopsy is reserved for masses that cannot be diagnosed as benign based on prior clinical and radiographic exams. Needle biopsy is not reliable for primary diagnosis, but it can be useful for recurrent or metastatic disease. Open excisional (if mass is <5 cm in size) or incisional (if mass is >5 cm in size) biopsy is the most common biopsy method. Proper surgical oncologic technique is strictly adhered to in order to prevent tumor spread into uninvolved tissues or compartments. This includes making all incisions longitudinally using sharp dissection and meticulous hemostasis; carrying the incision directly down to the tumor with no development of tissue planes (i.e., making a straight-line path from skin to tumor); incising through the fewest number of muscle compartments; and avoiding critical neurovascular structures. The CT or MRI images will help determine the best surgical approach for biopsy or resection in order to avoid uninvolved compartments and critical structures.⁶¹

Benign Soft Tissue Tumors

Ganglion Cyst. This is the most common soft tissue tumor of the hand and wrist, comprising 50% to 70% of all soft tissue tumors in this region. They can occur at any age but are most common in the second to fourth decades with a slight predilection toward females. Patients may report a slow-growing soft mass that may fluctuate in size and can sometimes be associated with mild pain. Compressive neuropathies may be seen if they occur in Guyon’s canal or the carpal tunnel, but are uncommon. There are no reports of malignant degeneration.⁶² History and physical exam are usually sufficient to establish a diagnosis. Occurrence by location is as follows: 60% to 70% occur on the dorsal wrist between the third and fourth extensor compartments and are connected by a stalk to the scapholunate ligament (Fig. 44-24); 18% to 20% occur on the volar wrist; and 10% to 12% occur in the digits as volar retinacular or flexor tendon sheath cysts. The cyst transilluminates. There is always a stalk that communicates with the underlying joint or tendon sheath. The cyst wall is composed of compressed collagen fibers with no epithelial or synovial cells present. Clear viscous mucin fills the cyst and is composed of glucosamine, albumin, globulin, and hyaluronic acid. The etiology is unclear. The most accepted theory currently is Angelides’ who proposed that repeated stress of a joint, ligament, or tendon sheath causes an increase of mucin-producing cells and subsequent mucin production. The increased mucin production dissects superficially and coalesces into a cyst. The successful treatment of dorsal ganglion cysts by excising only the stalk supports this theory.⁶³

Treatment consists of observation if asymptomatic. If symptoms exist or the patient desires removal for cosmetic appearance, aspiration of the cyst may be performed with a successful cure rate ranging from 15% to 89%. The benefit of injected steroids is inconclusive. Aspiration of a volar wrist ganglion cyst can be dangerous due to the potential of injuring neurovascular structures. Open excision and arthroscopic excision of the cyst stalk are surgical options for cysts that are not

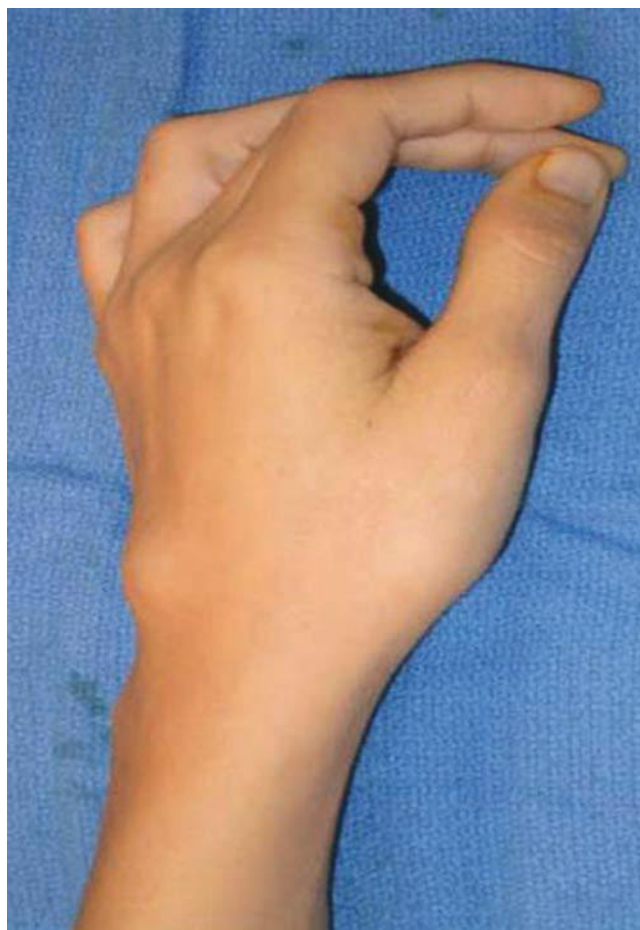

Figure 44-24. Dorsal wrist ganglion cyst. These typically occur between the third and fourth dorsal extensor compartments and have a stalk connecting the base of the cyst to the scapholunate ligament.

amendable to aspiration. Recurrence rate after surgical excision ranges from 4% to 40%.⁶²

Mucous Cyst. A mucous cyst is a ganglion cyst of the DIP joint. They occur most commonly in the fifth to seventh decades, and the underlying cause is associated osteoarthritis of the DIP joint. They are slow growing and usually occur on one side of the terminal extensor tendon between the DIP joint and the eponychium. The earliest clinical sign is often longitudinal grooving of the involved nail plate followed by a small enlarging mass and then attenuation of overlying skin. X-rays will show signs of osteoarthritis within the DIP joint. Heberden nodes (osteophytes within the DIP joint) are often seen on X-ray.

Possible treatment includes observation, aspiration, or excision. If the cyst is not draining and the overlying skin is intact, the patient may be offered reassurance. A draining cyst poses risk of DIP joint infection due to the tract communicating with the DIP joint and should be excised. If the cyst is symptomatic, painful, or the patient desires removal for cosmetic purposes, excision should be performed. Any osteophytes in the DIP joint must be removed to reduce recurrence. Aspiration is an option for treatment, but this poses the risk of DIP joint infection through seeding of bacteria into the joint or by the development of a draining sinus tract. It is generally not performed.

Giant Cell Tumor of the Tendon Sheath. Also known as a fibrohistocytoma, fibrous xanthoma, localized nodular

synovitis, or pigmented villonodular synovitis, this is the second most common soft tissue mass of the hand and wrist. It is a benign lesion with no clear pathogenesis. The tumor is a growth of polyclonal cells with no risk of metastases. Despite the similarity in name, it is not histopathologically related to giant cell tumor of the bone.⁶⁴

Giant cell tumor of the tendon sheath occurs as a firm slow-growing painless mass over months to years and will often feel bumpy or nodular, which is a distinguishing characteristic helpful for diagnosis. It has a predilection for occurring in close proximity to joints along flexor surfaces of the wrist, hands, and digits (especially the PIP joints of the radial digits) and occurs most commonly between the second and fifth decades (Fig. 44-25A). These tumors do not transilluminate. Direct extension into joints and ligaments can make complete excision difficult. Gross appearance of the tumor will show a well-circumscribed nodular firm mass with a deep brown color due to the large amount of hemosiderin content, which is easily detected on histologic staining (Fig. 44-25B). Multinucleated giant cells and hemosiderin-laden macrophages are characteristic.⁶⁴

This tumor is not visible on radiographs. Approximately 20% will show extrinsic cortical erosion on X-ray. This is a risk factor for recurrence, and removal of the cortical shell should be considered. MRI is useful for delineating involvement with tendons, ligaments, and joints.

The standard treatment is marginal excision. These tumors will often grow next to or around neurovascular bundles, and an Allen's test should always be performed preoperatively to

confirm adequate blood supply by both ulnar and radial arteries as well as dual blood supply to an involved digit via the ulnar and radial proper digital arteries. It is important to completely excise the stalk because this will greatly reduce tumor recurrence even in the setting of residual tumor. If tumor is suspected to have extended into the joint, the joint must be opened and all tumor removed. Despite this being a benign lesion, local recurrence is approximately 30% (range, 5%–50%). Some variants can mimic more aggressive processes, and malignancy must be considered if aggressive features are identified, such as direct bony invasion.⁶⁴

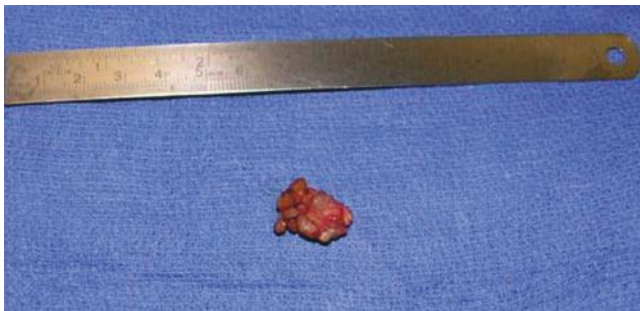Lipoma. Lipomas of the hand and wrist may occur in multiple anatomic locations, including subcutaneous tissues; intramuscularly (especially thenar or hypothenar muscles); deep spaces; carpal tunnel or Guyon's canal; and rarely bone or nerve. They typically present as a painless, slow-growing, soft, and mobile mass over a period of months to years. Painful findings suggest close approximation to a neurovascular structure or, less commonly, a malignant lesion such as liposarcoma. Lipomas do not transilluminate. They resemble mature fat histologically. X-rays typically reveal no abnormality. MRI is the most helpful imaging modality to evaluate a lipoma and will show a bright T1 lesion and dark T2 lesion.⁶⁵

Asymptomatic lesions with no aggressive findings may be observed. Marginal excision is recommended for symptomatic, painful, or enlarging lipomas or those that cause dysfunction. MRI is recommended for deep lipomas to evaluate proximity or involvement of critical structures, followed by marginal excision if MRI findings are consistent with a lipoma. If MRI findings are not consistent with a lipoma, incisional biopsy is warranted. Recurrence after marginal excision is rare. Malignant degeneration to liposarcoma is exceedingly rare but has been reported.

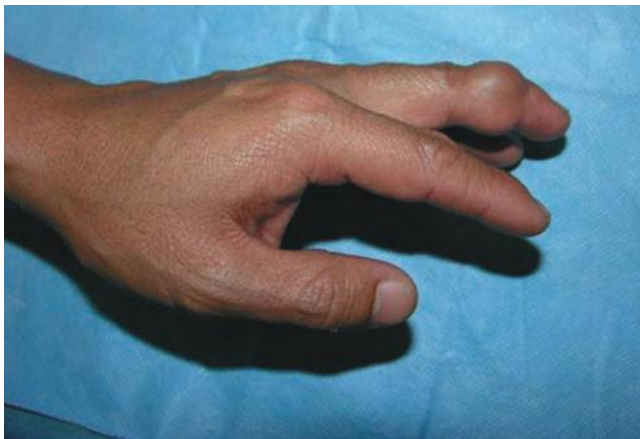Schwannoma. A schwannoma, also known as a neurilemmoma, is a type of benign peripheral nerve sheath tumor. It is the most common benign peripheral nerve sheath tumor of the upper extremity.⁶⁶ The majority occur as single solitary masses. Patients with neurofibromatosis type 1 (NF1) or 2 (NF2) may develop multiple schwannomas involving large peripheral nerve trunks or bilateral acoustic schwannomas, respectively. These tumors arise from the Schwann cell and occur most often in the middle decades of life. They grow as painless, slow-growing, firm, round, well-encapsulated masses with a predilection toward flexor surfaces of the forearm and palm (given their presence of large nerves). Schwannomas grow from the peripheral nerve sheath and are usually connected by a pedicled stalk. The tumor is well demarcated and can be readily separated from the nerve fascicles (Fig. 44-26). Unlike neurofibromas, they do not grow within the nerve. Paresthesias or other neurologic findings may occur, but they are usually absent, as is the Tinel's sign. Findings such as pain, paresthesias, or numbness should raise concern for a tumor causing a compressive neuropathy or a tumor that is malignant.⁶⁶

Histologic exam reveals Antoni type A palisades of spindle cells with large oval nuclei with interlacing fascicles. Less cellular regions appear as Antoni type B areas. Mutations of the schwannomin gene on chromosome 22 are found in 50% of sporadic cases and 100% of acoustic schwannomas in patients with NF2.⁶⁷

Surgical treatment is reserved for symptomatic tumors and those that require biopsy to rule out a malignant process. An MRI should be obtained prior to surgery to confirm that the



A



B

Figure 44-25. Giant cell tumor of tendon sheath. **A.** The mass produces lobulated enlargement of the external finger. **B.** The excised giant cell tumor has a multilobulated, tan-brown appearance.

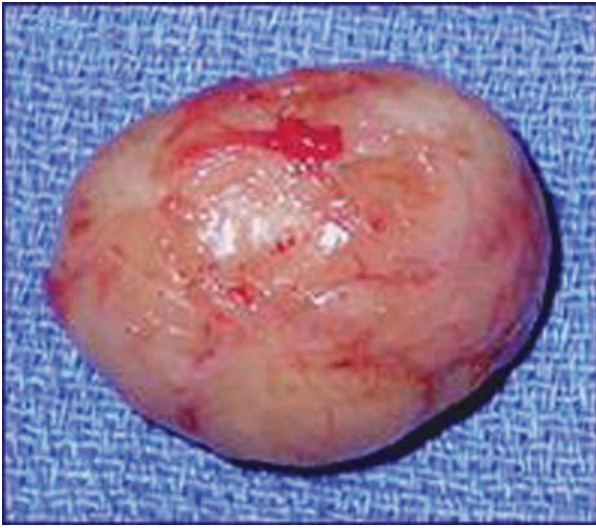

Figure 44-26. Schwannomas grow as a firm, round, well-encapsulated mass within the epineurium of a peripheral nerve. Schwannomas are able to be separated from the nerve fascicles relatively easily because they do not infiltrate between them (unlike neurofibromas).

tumor is not located within the nerve (i.e., a neurofibroma) and that it is consistent with a schwannoma. Operative treatment involves excisional biopsy. If the tumor is adherent to adjacent soft tissue or not encapsulated, incisional biopsy is performed and excision is delayed pending pathology results. Malignant degeneration is exceedingly rare.⁶⁶

Malignant Soft Tissue Tumors—Cutaneous

Squamous Cell Carcinoma. Squamous cell carcinoma (SCC) is the most common primary malignant tumor of the hand, accounting for 75% to 90% of all malignancies of the hand. Eleven percent of all cutaneous SCC occurs in the hand.⁶⁸ It is the most common malignancy of the nail bed. Risk factors include sun exposure, radiation exposure, chronic ulcers, immunosuppression, xeroderma pigmentosa, and actinic keratosis. Marjolin's ulcers represent malignant degeneration of old burn or traumatic wounds into an SCC and are a more aggressive type. Transplant patients on immunosuppression have a four-fold increased risk and patients with xeroderma pigmentosa have a 1000-fold increased risk of developing an SCC. They often develop as small, firm nodules or plaques with indistinct margins and surface irregularities ranging from smooth to verruciform or ulcerated (Fig. 44-27). They are locally invasive, with 2% to 5% lymph node involvement. Metastasis rates of up to 20% have been reported in radiation or burn wounds. Standard treatment is excision with 0.5- to 1.0-cm margins. Other treatment options include curettage and electrodesiccation, cryotherapy, and radiotherapy.⁶⁸

Basal Cell Carcinoma. Basal cell carcinoma (BCC) is the second most common primary malignancy of the hand, accounting for 3% to 12%; 2% to 3% of all BCCs occur on the hand. Risk factors are similar for SCC and include chronic sun exposure, light complexion, immunosuppression, inorganic arsenic exposure, and Gorlin's syndrome. Presentation includes a small, well-defined nodule with a translucent, pearly border and

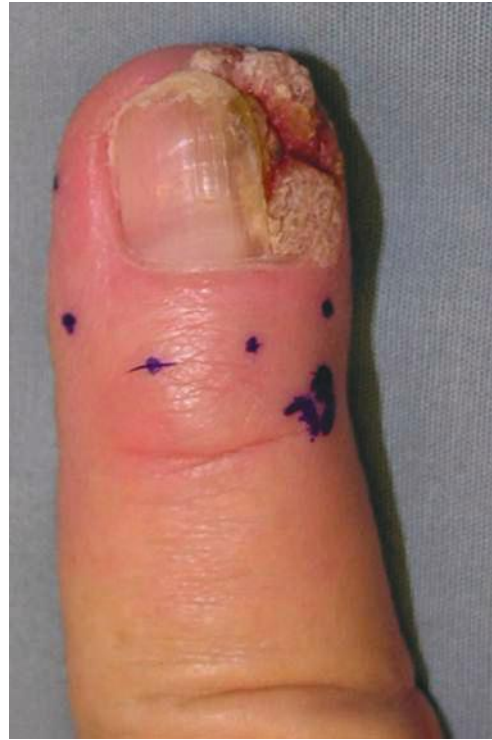

Figure 44-27. Squamous cell carcinoma involving the nail fold and nail bed. Note the wart-like and ulcerated appearance.

overlying telangiectasias (Fig. 44-28). Metastasis is very rare. Standard treatment is excision with 5-mm margins. Other treatment options include curettage and electrodesiccation, cryotherapy, and radiotherapy.⁶⁸

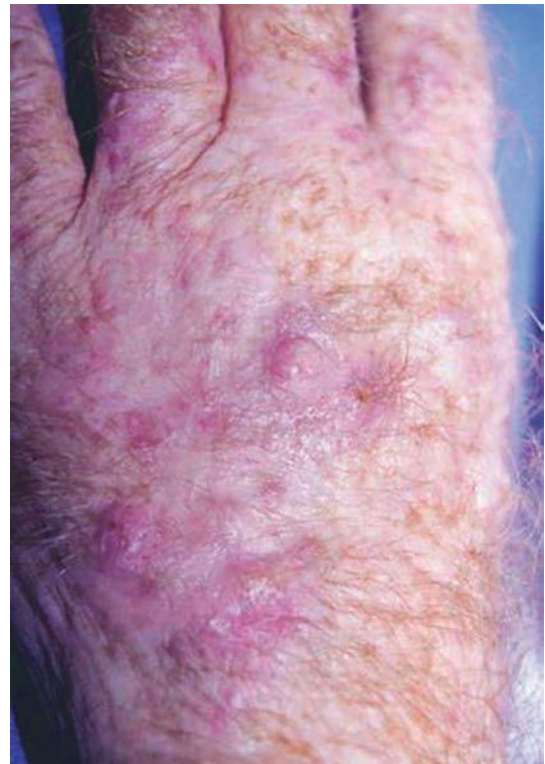

Figure 44-28. Basal cell carcinoma of the dorsal hand with surrounding telangiectasia.

Melanoma. Melanoma accounts for approximately 3% of all primary malignant hand tumors.⁶⁹ Risk factors include sun exposure (especially blistering sunburns as a child), dysplastic nevi, light complexion, family history of melanoma, and congenital nevi. Pigmented lesions with irregular borders, color changes, increase in growth, or change in shape are suggestive of melanoma. Breslow thickness is the most important factor in predicting survival for a primary melanoma. Surgical treatment includes excision with 1-cm margins for lesions up to 1 mm in thickness and 2-cm margins for lesions over 1 mm in thickness. Sentinel lymph node biopsy is done for lesions over 1 mm in thickness or for any lesion that is ulcerated and over 0.76 mm in thickness.⁷⁰ Any clinically palpable lymph node requires a formal lymph node dissection of the involved basin, as do sentinel lymph nodes positive for melanoma. Lymph node dissection has not been shown to offer any survival benefit, but the information gained from sentinel lymph node biopsy (or lymph node dissection) does offer valuable staging information that is important for prognosis. Subungual melanomas are treated with DIP amputation, with 5-year survival reported at 66%.⁷¹

Malignant Soft Tissue Tumors—Noncutaneous

Primary soft tissue sarcomas of the upper extremity are very rare, and most hand surgeons will only see several throughout their entire career. Only 14% of all soft tissue sarcomas occur in the entire upper extremity. Statistical inference is limited due to the rare occurrence of these tumors, but mortality rate is very high despite the aggressive treatments. Fewer than 5% of soft tissue sarcomas of the upper extremity will develop lymph node metastasis. Cutaneous malignancies must be considered in the differential diagnosis for any patient with palpable lymph nodes in the setting of any upper extremity mass. Any lesion of the upper extremity that is over 5 cm in diameter, rapidly enlarges, or is painful should be considered malignant until proven otherwise.⁷²

Treatment for soft tissue sarcomas can range from palliative debulking to attempted curative resection. Many muscles of the upper extremity and their compartments cross joints (e.g., forearm flexors). Any malignancy within a compartment mandates complete resection of that compartment, and therefore, amputations must often be performed at levels much more proximal than the level of the actual tumor. Many soft tissue sarcomas are not responsive to radiation or chemotherapy, and use of these adjuvant treatments must be decided upon after discussion with medical and radiation oncologists in a multidisciplinary team. Several studies have shown higher mortality rates in patients who undergo initial tumor biopsy of sarcomas at institutions from which they do not ultimately receive treatment. These studies recommend biopsy be performed at the institution at which definitive treatment will be provided.⁷³ Institutions best suited for such treatment should have pathologists familiar with soft tissue sarcomas, medical and radiation oncologists, surgical oncologists, and a multidisciplinary tumor board.

An in-depth review of each type of soft tissue sarcoma is beyond the scope of this chapter. *Epithelioid sarcoma* is the most common primary soft tissue sarcoma of the upper extremity and usually presents as a benign-like slow-growing mass during the third or fourth decades. It has a propensity for the forearm, palm, and digits. Spread to lymph nodes has been reported. It typically spreads along fascial planes.⁷⁴ *Synovial sarcoma* is argued by some to be the most common primary soft tissue sarcoma of the *hand and wrist*, but the paucity of

case reports is inconclusive. It is a high-grade malignancy that is painless and slow-growing and usually occurs adjacent to, but not involving, joints. It is most common in the second to fifth decades of life. Tumor size (>5 cm) is positively correlated with mortality. Other sarcomas include malignant fibrous histiocytoma, liposarcoma, fibrosarcoma, dermatofibrosarcoma protuberans, and malignant peripheral nerve sheath tumors, and more information can be found in further selected reading.⁷⁵ The majority of metastases to the hand involve secondary bone tumors and are discussed later in the section Secondary Metastatic Tumors.

Benign Bone Tumors

Primary benign bone tumors of the hand and wrist make up a total of 7% of all primary benign bone tumors in the body. Benign tumors of cartilage origin comprise 79% of all primary benign bone tumors of the hand and wrist.⁷⁶

Enchondroma. This is the most common primary benign bone tumor of the hand and wrist and is of cartilage origin. Up to 90% of all bone tumors in the hand and wrist are enchondromas, with 35% to 54% of all enchondromas occurring in the hand and wrist. They are often found incidentally on X-rays taken for other reasons (e.g., hand trauma). They are usually solitary and favor the diaphysis of small tubular bones and are most common in the second and third decades of life. The most common location is in the proximal phalanges, followed by the metacarpals and then middle phalanges. Enchondroma has never been reported in the trapezoid. Presentation is usually asymptomatic, but pain may occur if there is a pathologic fracture or impending fracture. The etiology is believed to be from a fragment of cartilage from the central physis. Histology shows well-differentiated hyaline cartilage with lamellar bone and calcification.⁷⁶

Two variants of enchondroma include Ollier's disease (multiple enchondromatosis) and Maffucci's syndrome (multiple enchondromatosis associated with multiple soft tissue hemangiomas). Malignant transformation is very rare in the solitary form, but there is a 25% incidence by age 40 in Ollier's patients and a 100% life-time incidence in Maffucci's patients. When malignant transformation does occur, it is almost uniformly a chondrosarcoma with pain and rapid growth.⁷⁷

Diagnosis is usually made based on history, physical exam, and X-rays. There is a well-defined, multilobulated central lucency in the metaphysis or diaphysis that can expand causing cortical thinning or, sometimes, thickening (Fig. 44-29A). Further imaging is seldom needed, but a CT would be the study of choice.

Observation is indicated for asymptomatic enchondromas with no risk of impending fracture, followed by annual X-rays for 2 years. If a pathologic fracture is found, it is treated with immobilization until fracture union and then surgically treated. If there is any uncertainty as to whether it is an enchondroma, incisional biopsy is indicated and definitive treatment is postponed pending final pathology. Symptomatic lesions and those with impending fracture are treated surgically. Surgical treatment consists of an open incisional biopsy and confirmation by frozen section that it is well-differentiated hyaline cartilage. Curettage and high-speed burring are used to ablate the tumor. Intraoperative fluoroscopy is used to confirm complete ablation (Fig. 44-29B). The defect is then packed with bone graft or bone substitute. Recurrence ranges from 2% to 15%. X-rays should be obtained serially after surgery.⁷⁶

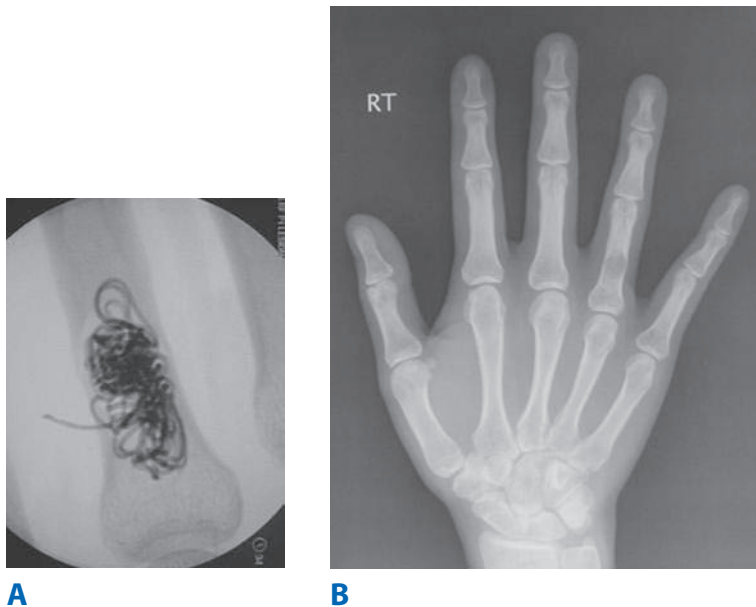


Figure 44-29. Enchondroma. **A.** X-ray of the phalanx demonstrates a well-defined central lucency. Surrounding cortex may thin or thicken. Thinning of the cortex contributes to risk of pathologic fracture. **B.** Intraoperative fluoroscopy after curettage of the tumor. A radiopaque ribbon is used to occupy the defect to help ensure that there is no tumor (similarly radiolucent to the defect after curettage) left behind prior to bone grafting.

Periosteal Chondroma. Periosteal chondromas are benign bone tumors of cartilage origin that arise most commonly within or adjacent to periosteum at the metaphyseal-diaphyseal junction in phalanges. They occur usually in the second or third decade as solitary lesions with pain, swelling, deformity, and possible pathologic fracture. X-rays reveal a subperiosteal lytic, unilobular lesion with erosion into adjacent cortex. There is often a rim of sclerosis. Histologically, they appear as aggressive cartilage with atypia, and it can be difficult to differentiate these from chondrosarcomas.⁷⁶

Diagnosis involves X-rays with incisional biopsy to confirm the benign diagnosis and avoid unnecessary amputation. Treatment includes en-bloc resection of periosteum and corticocancellous bone. Recurrence is less than 4%.

Osteoid Osteoma. This is a tumor of bone origin. Approximately 5% to 15% of all osteoid osteomas occur in the hand and wrist and are most often found in the proximal phalanx or carpus. They usually occur in the second or third decade and present with a deep, dull ache that is classically worse at night and relieved by nonsteroidal anti-inflammatory drugs (NSAIDs). X-rays reveal a central lucency that is usually less than 1 cm in diameter surrounded by reactive sclerosis. Bone scan or CT is helpful to secure the diagnosis.⁷⁸

Treatment consists of NSAID therapy only, and resolution occurs at an average of 33 months. If the patient does not wish to undergo prolonged discomfort with conservative therapy, curettage or percutaneous ablation of the nucleus may be performed.⁷⁸

Giant Cell Tumor of Bone. Giant cell tumors of bone make up only 5% of all benign bone tumors in the body, and only 12% of these occur in the hand or wrist. Although its name is similar to that of “giant cell tumor of tendon sheath,” they are two separate tumors and do not share the same clinical or histopathologic characteristics. Approximately 2% occur in the hand and 10% occur in the distal radius; those within the distal radius are more aggressive. They usually occur in the fourth decade with pain and swelling and possibly pathologic fracture.⁷⁹

Giant cell tumor of the bone is unique in that it is benign on histology but does have metastatic potential and can cause

death. It should be considered a low-grade malignancy.⁷⁹ Workup includes a CT of the chest and total-body scintigraphy to evaluate for metastases and multifocal lesions and MRI to evaluate the extent of local tissue involvement. Treatment consists of amputation of involved phalanges or metacarpals and wide excision of entire carpal rows. Local and systemic surveillance must be done for at least 10 years because metastasis has been reported to occur as late as 10 years postoperatively.⁷⁹

Malignant Bone Tumors

Malignant primary and secondary bone tumors of the hand, like soft tissue malignancies, are exceedingly rare. An in-depth review is beyond the scope of this chapter. The same principles for soft tissue sarcomas of the upper extremity apply here with regard to evaluation, biopsy, and treatment.

Chondrosarcoma comprises 41% of all primary malignant bone tumors of the hand and wrist but only 1.5% of all chondrosarcomas overall. It is most likely to occur from malignant degeneration from a preexisting lesion, with enchondromatosis and osteochondromatosis being the most common. It usually presents as a slow-growing, painless mass in the fourth to sixth decades and can be difficult to differentiate from its benign counterparts. X-ray reveals endosteal erosion, cortical expansion, cortical destruction, and calcification. Metastasis has never been reported for chondrosarcomas of the hand. Chondrosarcomas are not responsive to chemotherapy or radiation.⁸⁰

Osteosarcoma of the hand is exceedingly rare; only 0.18% of osteosarcomas occur in the hand. It usually presents as a painful swelling with pathologic fracture in the fifth to eighth decades of life. Radiation exposure is believed to be a possible risk factor. X-ray findings vary widely, with 90% of tumors occurring at a metaphyseal location. Findings include an osteoblastic or osteolytic lesion, cortical breakthrough with soft tissue extension, a “sunburst” pattern radially, or periosteal elevation (Codman’s triangle). The presence or absence of metastasis is the most important prognostic factor, with a 5-year survival of 70% in the absence of metastases and a 5-year survival of 10% if present. Preoperative chemotherapy is usually given, but radiation therapy plays no role.⁸¹

Secondary Metastatic Tumors

Metastases to the hand or wrist are rare, with only 0.1% of skeletal metastases occurring in the hand. The majority of metastases to the hand are bone lesions, but soft tissue metastases have been reported. The most common primary site is the lung (40%), followed by the kidney (13%) and the breast (11%). Approximately 16% will have no known diagnosis of cancer.⁸² The most common sites are the distal phalanges, followed by the proximal and middle phalanges, metacarpals, and carpus. Patients will present with pain, swelling, and erythema. Differential diagnosis includes felon, gout, osteomyelitis, trauma, RA, or skin cancer. Treatment of a hand or wrist metastatic lesion must not interfere with treatment of the primary cancer. Treatment is usually palliative (simple excision or amputation). The average life expectancy for these patients is less than 6 months.⁸²

BURNS

The palm of the hand makes up only 1% of total body surface area. A burn involving the entire hand and digits is unlikely to cause life-threatening injury or shock, but seemingly small burns to the hand may cause severe permanent loss of function if not treated appropriately. Burns to the hand can cause serious short- and long-term disability. All burns to the hand are considered severe injuries that warrant transfer to a dedicated burn center for specialized treatment. This management will include a multidisciplinary team consisting of hand surgeons, burn surgeons, burn-specialized nurses, occupational therapists, case managers, and social workers.

First-degree burns involve damage to the epidermis only and present with erythema, no blistering, and full sensation with blanching of skin. These will heal without scarring. Second-degree burns are classified as superficial or deep. Superficial second-degree burns involve damage to the papillary dermis; all skin appendages are preserved, and therefore, these readily reepithelialize with minimal to no scarring. Superficial second-degree burns are sensate and present with pain, erythema, blistering, and blanching of skin. Topical dressings are the mainstay of treatment. Deep second-degree burns involve damage to the reticular dermis with damage to skin appendages, as well as the dermal plexus blood vessels and nerves. These have decreased sensation and no cap refill and appear pale or white. Blistering may be present. Damage to the skin appendages and blood supply in the dermal plexus precludes spontaneous healing without scar. Excision with skin grafting is needed. Third-degree burns involve full-thickness damage through the dermis and are insensate with no blistering. They appear dry, leathery, and even charred.

Acute Management

Advanced Trauma Life Support guidelines should be followed. After primary survey, circulation to the hand should be assessed. Palpation and Doppler ultrasound should be used to evaluate blood flow within the radial and ulnar arteries, the palmar arches, and digital blood flow at the radial and ulnar aspect of each volar digital pad. A sensorimotor exam should be performed. Objective evidence of inadequate perfusion (i.e., deteriorating clinical exam with changes in or loss of pulse or Doppler signal) indicates the need for escharotomy, especially in the setting of circumferential burns. Escharotomy may be performed at bedside with scalpel or electrocautery under local anesthesia or intravenous sedation. The depth

of the escharotomy incision should extend into the dermis but not into subcutaneous tissues. In the forearm, axially oriented midradial and midulnar incisions are made for the entire extent of the burn. Escharotomy should proceed as distally as necessary into the wrist and hand to restore perfusion. Digital escharotomies are made via a midaxial (the middle of the longitudinal axis on sagittal view) incision over the radial aspects of the thumb and small finger and the ulnar aspects of the index, middle, and ring fingers.⁸³ These locations for digital escharotomies avoid painful scars on the heavy-contact surfaces of each respective digit. After primary survey, vascular, and sensorimotor exams are complete, careful documentation should be made of all burns. This is best done with a Lund and Browder chart and includes location, surface area, and initial depth of burn.

The burns should be dressed as soon as examination is complete. Gauze moistened with normal saline is a good initial dressing because it is easy, readily available, and will not leave ointment or cream on the wounds, which can hinder frequent examinations in the initial period. It is critical that no dressing is wrapped in a circumferential manner around any body part. Edema and swelling can lead to extremity ischemia if a circumferential dressing is in place. It is important to maintain body temperature above 37°C, especially in burn patients who have lost thermoregulatory function of the skin and now have moist dressings in place. The hands should be elevated above heart level to decrease edema formation, which can hinder motion and lead to late scar contracture. The hand should be splinted in the intrinsic plus position with the MPs flexed to 90° (placing MP collateral ligaments under tension), the IPs in straight extension (prevents volar plate adhesion), and the wrist in approximately 15° of extension.⁸⁴ If the burn involves the thenar eminence, thumb, or first web space, the thumb should be splinted in full abduction (to open up the first web space). Any other web space that is burned should have the adjacent fingers splinted in abduction. This will help prevent web space contracture. In rare cases, Kirschner wires or heavy steel wires/pins are needed to keep a joint in proper position. These are placed percutaneously through the involved joint and serve as a temporary joint stabilizer.

After the primary and secondary surveys are complete, the wound should be evaluated again. Devitalized tissue should be débrided. Wounds should be cleansed twice daily, typically with normal saline. Second-degree superficial burns may be dressed with Xeroform gauze and Bacitracin. Silver sulfadiazine cream is another option for any second- or third-degree wound. It covers gram-positive and gram-negative microbes, but it does not penetrate eschar. It should be applied at least one-sixteenth of an inch thick. Sulfamylon can be used in conjunction with silver sulfadiazine or alone. It deeply penetrates eschar and tissues and has good gram-positive coverage.

After débridement of necrotic skin, grafting will eventually be necessary. Allograft (human cadaver skin) is an expensive but useful temporary dressing for second- and third-degree burns. It can remain in place for up to 14 days before the body will reject it. It typically is left in place for 7 days. Allograft stimulates a wound to begin healing and can also serve as a way of “testing” a wound that needs skin grafting. If the allograft is adherent and there is evidence of temporary ingrowth, this suggests that the wound is ready to receive a skin graft.

Occupational hand therapy has played a major role in preserving hand function following burn injuries. Reestablishment

of hand function is pivotal for burn patients and is directly dependent on their ability or effort to participate with an occupational therapist. Early work with an occupational therapist can minimize the need for later reconstruction.⁸⁴ Hand therapy should be initiated as soon as possible. Hand therapists are also able to make customized molded splints that facilitate frequent dressing changes.

Surgical Management

Any burn wound will eventually heal with proper wound care. However, this may involve unacceptable scarring, deformity, contractures, pain, and unstable wounds that are prone to breakdown. The goal is to restore preinjury function as much as possible with a wound that is durable, supple, nonpainful, and allows the patient to return to society as an active member. Local wound care is the ideal treatment for wounds that can heal completely within 14 days while not sacrificing function. Purely cosmetic concerns are addressed after complete scar maturation (~12 months). In other cases, surgical excision and skin grafting are necessary. Skin grafting should be done as soon as it becomes obvious that a wound will not be healed completely by postburn day 14. It should also be considered for wounds that are likely to cause contractures, especially along the joints and web spaces.⁸⁴

Considerable controversy surrounds the need, timing, and method of grafting burns. Careful consideration must be given to the patient's overall status, their preinjury state, and the type of work and recreational activities they enjoyed in order to have a better understanding of which issues should be addressed.⁸⁵ Tangential excision of the wounds should be performed under tourniquet to minimize blood loss and is carried down to viable tissue. Avoid excising through fascia (epimysium) overlying muscles or exposing tendons, bone, joint capsules, or neurovascular structures. Tissues capable of receiving a skin graft include well-vascularized fat, muscle, perineurium, paratenon, perichondrium, and periosteum. Exposure of deep structures without an adequately graftable bed mandates further coverage before skin grafting can occur (discussed later in Reconstruction section).

Once there is an adequate bed, grafting is the next step. If there is any doubt as to whether the wound bed can support a skin graft, a temporary dressing should be placed and the patient reexamined frequently for signs of granulation tissue and wound bed viability. Skin grafts to the dorsum of the hand are typically split-thickness sheet grafts (not meshed). There are no functional differences between a sheet graft and a meshed graft, but sheet grafts have a much better final appearance. Skin grafts to the palmar aspects of the hand should be full-thickness in order to provide the dermal durability needed for daily functions.⁸⁴ Skin grafts are secured with staples, sutures, fibrin glue, or even skin glue. It is important to bolster every skin graft. This prevents shearing loss and also keeps the skin graft in contact with the wound bed, preventing fluid collections that can lead to graft loss. A bolster may consist of a tie-over bolster and a splint or a negative-pressure dressing. The hand should be splinted in intrinsic plus for 7 days after skin grafting. Once the graft is adherent, hand therapy should begin, consisting of active and passive range-of-motion exercises and modalities.

Reconstruction

Reconstruction of burn wounds can begin as early as the acute setting and continue into the subacute and late stages. Burns

may initially be superficial but later convert to deep burns (especially with grease, oil, and alkali burns) due to infection, tissue desiccation, or continued trauma, or they may be deep from the outset of injury. Débridement or excision of burns may result in exposure of viable muscle, bone, tendon, cartilage, joints, and neurovascular structures, as well as loss of fascial layers that are required for overlying soft tissue to glide during movement. Simply skin grafting these exposed structures will result in unstable wounds that are prone to chronic breakdown. Soft tissue contractures will develop as the skin grafts adhere to the structures, effectively anchoring them in static position. This is especially true for tendons, where gliding capability is paramount for function. Flap coverage is required in these situations. The reversed radial forearm flap is a local flap and is often the first choice for flap coverage of the hand. If the zone of injury or size of defect precludes its use, other skin and fat flaps, including the free lateral arm, free anterolateral thigh, or even free parascapular flaps, may be useful, provided the patient can tolerate a free tissue transfer (see Chapter 45) operation (Fig. 44-30). The digits may also be buried subcutaneously in the lower abdominal skin or groin crease. Vascular ingrowth from the digits into the abdominal or groin skin occurs over 2 to 3 weeks, allowing division of the flap(s) and achieving full-thickness coverage of the wounds.^{84,85}

An acellular dermal regenerative substitute (e.g., Integra) may be used for wounds that have exposed structures and require more durability than is offered by a skin graft⁸⁶ such as full-thickness loss overlying the extensor tendons of the wrist and hand. Dermal substitute is a good option for wounds that are not extensive enough to warrant a flap and for patients who are poor candidates for an extensive surgery. Integra is composed of acellular cross-linked bovine tendon collagen and glycosaminoglycan with an overlying silicone sheet. It is applied much like a skin graft. After incorporation in 14 to 21 days, it is capable of accepting a skin graft (after removing the silicone sheet). Conceptually, it works by replacing the lost dermis and adds durability to a wound bed. It may be reapplied multiple times to the same area if thicker neodermis is desired. Although cultured autologous keratinocytes have been used, they are expensive, time-consuming, and do not provide prompt or durable coverage. They are not widely used.

Web space contractures are the most common deformity resulting after hand burns. They may occur late despite the best

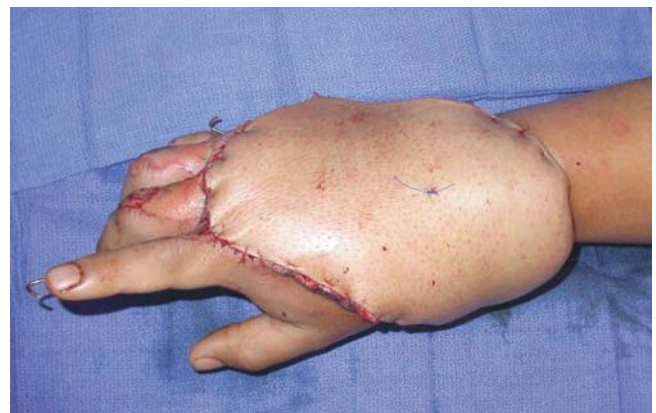
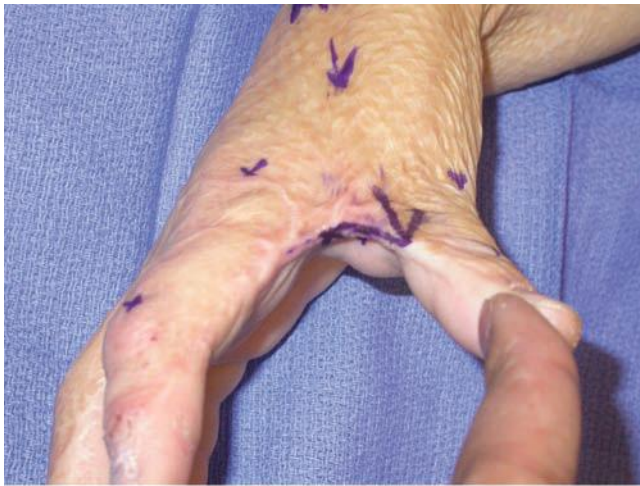
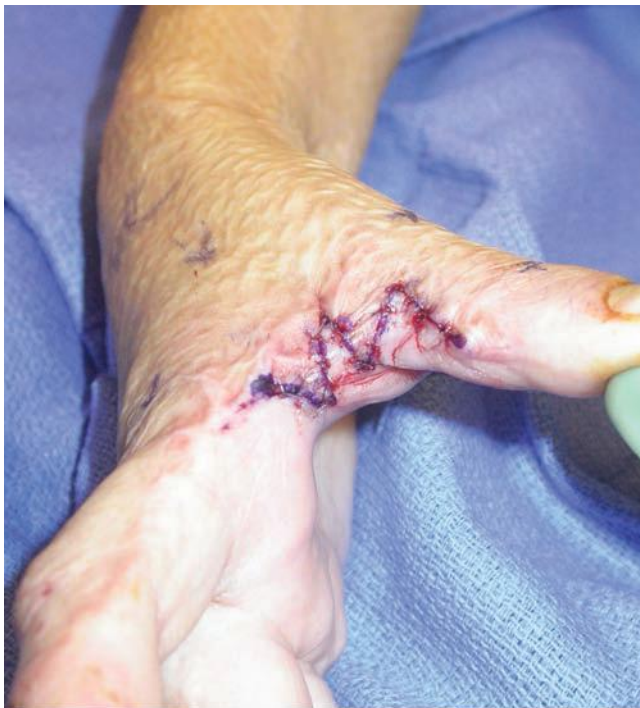Figure 44-30. Free anterolateral thigh flap reconstruction of a large dorsal hand wound. Once wound coverage is stable, this flap will need to be surgically revised to achieve proper contour.



A



B

Figure 44-31. Z-plasty release of web space contracture. **A.** First web space burn contracture. **B.** Immediate postoperative result.

efforts. In the normal web space, the leading edge of the volar aspect of the web is distal to the dorsal aspect. This is reversed in web space contractures and limits digit abduction. Local modified Z-plasty (double-opposing Z-plasty) is the preferred treatment (Fig. 44-31).

Special Considerations

Chemical burns pose a risk to healthcare providers and should be considered hazardous material. They must also be removed from the patient or continued burn injury will occur. A complete discussion of all chemicals causing burns is beyond the scope of this chapter. Hydrofluoric acid produces a slow onset of severe pain and continues to penetrate deeper structures. It avidly binds tissue and circulating calcium and can lead to hypocalcemia and cardiac arrest. The wound should be irrigated

copiously with water followed by topical application of an aqueous mixture of calcium gluconate. Calcium gluconate may also be infiltrated intradermally throughout the wound. Effectiveness of treatment is assessed by relief of pain. Intra-arterial injection of calcium gluconate into the artery supplying blood flow is another alternative if the other measures fail.⁸⁷ Alkaline and acid burns require copious irrigation with water, with alkali burns often requiring hours of irrigation. Phenol burns should be irrigated with water and treated topically with polyethylene glycol. Phosphorus burns leave phosphorus particles within the wound. A 0.5% copper sulfate solution is applied to stain the particles black, followed by débridement.^{84,85}

VASCULAR DISEASE

Vascular disease encompasses a broad spectrum of disorders leading to compromised perfusion to the hand and digits and may potentially cause ischemia and necrosis. Chronic vascular disorders tend to develop slowly and are typically seen in older patients. This includes progressive thrombosis, aneurysms, systemic vasculopathy, and vasospastic disorders. Disorders unique or common to the hand are discussed in the following sections.

Progressive Thrombotic Disease

Hypothenar hammer syndrome involves occlusion of the ulnar artery at the wrist and is the most common occlusive vascular disorder of the upper extremity. The etiology is believed to be chronic trauma to the ulnar artery as it exits Guyon's canal. The classic example is a construction worker who frequently uses heavy equipment, such as jackhammers, that cause prolonged vibration and repetitive impact on the ulnar aspect of the palm. This causes periadventitial arterial damage that results in scarring and eventual compression, as well as medial and intimal damage.⁸⁸ The artery then becomes weakened and prone to aneurysm and/or thrombosis. If a thrombus forms, it may embolize, producing digital ischemia. Symptoms may be chronic or acute and include pain, numbness and tingling, weakness of grip, discoloration of the fingers, and even gangrene or ulcers of the fingertips.

If acute in onset, proximal occlusions may be extracted with a balloon catheter or, sometimes, under direct vision via an arteriotomy. Very distal embolism may require infusion of thrombolytics to dissolve clots and allow reperfusion. Large-vessel acute embolism and reperfusion may result in edema and compartment syndrome, requiring fasciotomy. A high index of suspicion must be maintained.

For the more common scenario of chronic, progressive occlusion, the involved segment of ulnar artery should be resected. There is disagreement in the literature regarding whether simple ligation and excision is sufficient for patients with sufficient distal flow or if all patients should undergo vascular reconstruction.⁸⁹ The authors' personal preference is to reconstruct all patients.

Systemic Vasculopathy

Buerger's disease (thromboangiitis obliterans) is an inflammatory occlusive disease affecting small and medium-sized arteries and veins. It is strongly influenced by smoking and will often resolve upon smoking cessation. Typical onset is before 50 years of age. Migratory phlebitis occurs distal to the elbow, resulting in ischemia, ulceration, and necrosis of the digits. It can continue to cause more proximal ischemia and ultimately lead to loss of the hands. Treatment must start with smoking

cessation. Failure to stop smoking will make any surgical intervention unsuccessful. Arteriography is useful to determine arterial flow and whether bypass is possible. If direct bypass is not possible, alternatives include arterialization of the venous system by connecting the dorsal venous network to the brachial artery or possible free microvascular omental transfer beneath the dorsal forearm or hand for indirect revascularization.⁹⁰

Vasospastic Disorders

Raynaud's syndrome results from excessive sympathetic nervous system stimulation. Perfusion is diminished and fingers often become cyanotic. Although the onset of the symptoms is benign, chronic episodes can result in atrophic changes and painful ulceration or gangrene of the digits. Raynaud's disease occurs without another associated disease. This disease predominately affects young women and is often bilateral. The vascular system is structurally intact without any obstructions. There is no ulceration, gangrene, or digit loss. In contrast, Raynaud's phenomenon is associated with an underlying connective tissue disorder, such as scleroderma. Arterial stenosis is present due to disease changes in blood vessels as a result of the specific medical disorder.⁹⁰

Scleroderma is an autoimmune connective tissue disorder resulting in fibrosis and abnormal collagen deposition in tissue. Many organs can be affected, with the skin most commonly and noticeably involved. In this disease, blood vessels are injured by intimal fibrosis leading to microvascular disease. The vessels become subject to Raynaud's phenomenon, and patients develop painful, ulcerated, and sometimes necrotic digits.^{91,92}

Sympathectomy can provide pain relief and healing of ulcers for patients with scleroderma and Raynaud's phenomenon. In this procedure, adventitia is stripped from the radial artery, ulnar artery, superficial palmar arch, and digital arteries in various combinations based on the affected digits being treated. The decrease in sympathetic tone allows for vasodilation and increased blood flow. If the patient notes significant distal pain relief and/or previously ischemic tissue improves in color after a test administration of local anesthetic, sympathectomy may provide the same results in a long-term fashion.^{91,92}

CONGENITAL DIFFERENCES

Congenital differences in a newborn can be particularly disabling as the child learns to interact with the environment by using the hands. The degree of anomaly can range from minor, such as a digital disproportion, to severe, such as total absence of a forearm bone. In recent years, increasing knowledge of the molecular basis of embryonic limb development has significantly enhanced the understanding of congenital differences. Congenital hand differences have an incidence of 1:1500 births. The two most common differences encountered are syndactyly and polydactyly.⁹³

There are numerous classification systems for hand differences. The Swanson classification, adopted by the American Society for Surgery of the Hand, delineates seven groups organized based on anatomic parts affected by types of embryonic failures.⁹⁴

Failure of Formation

The failure of the formation of parts is a group of congenital differences that forms as a result of a transverse or longitudinal arrest of development. Conditions in this group include radial club hand, a deformity that involves some or all of the tissues

on the radial side of the forearm and hand, and ulnar club hand, which involves underdevelopment or absence of the ulnar-sided bones.

Failure of Differentiation

The failure of the differentiation of parts comprises conditions where the tissues of the hand fail to separate during embryogenesis. Syndactyly, in which two or more fingers are fused together, is the most common congenital hand deformity and occurs in seven out of every 10,000 live births. There is a familial tendency to develop this deformity. This deformity often involves both hands, and males are more often affected than females. Syndactyly is classified as either simple (soft tissue only) or complex (bone and/or cartilage also involved), and complete (full length of the digits) or incomplete (less than the full length).

Surgical release of syndactyly requires the use of local flaps to create a floor for the interdigital web space and to partially surface the adjacent sides of the separated digits (Fig. 44-32). Residual defects along the sides of the separated fingers are covered with full-thickness skin grafts. Surgery usually is performed at 6 to 12 months of age.

Duplication

Duplication of digits is also known as polydactyly. Radial polydactyly is usually manifests as thumb duplication. Wassel described a classification system for thumb duplications based on the level of bifurcation.⁹⁵ When two thumbs are present in the same hand, they are rarely both normal in size, alignment, and mobility. In the most common form of thumb duplication, a single broad metacarpal supports two proximal phalanges, each of which supports a distal phalanx. Optimal reconstruction requires merging of elements of both component digits. Usually the ulnar thumb is maintained. If the duplication occurs at the MP joint, the radial collateral ligament is preserved with the metacarpal and attached to the proximal phalanx of the retained ulnar thumb. Surgery is usually performed at 6 to 12 months of age. Ulnar-sided polydactyly may often be treated by simple excision of the extra digit.

Overgrowth

Overgrowth of digits also is known as macrodactyly, which causes an abnormally large digit. In this situation, the hand and the forearm also may be involved. In this rare condition, all parts of a digit are affected; however, in most cases, only one digit is involved, and it is usually the index finger. This condition is more commonly seen in males. Surgical treatment of this condition is complex, and the outcomes may be less than desirable. Sometimes, amputation of the enlarged digit provides the best functional result.

Undergrowth

Underdeveloped fingers or thumbs are associated with many congenital hand deformities. Surgical treatment is not always required to correct these deformities. Underdeveloped fingers may include the following: small digits (brachydactyly), missing muscles, underdeveloped or missing bones, or absence of a digit.

Constriction Band Syndrome

Constriction band syndrome is a set of congenital differences that occurs when a tissue band forms around the digit(s) or arm in utero, impairing blood flow and growth. This condition may

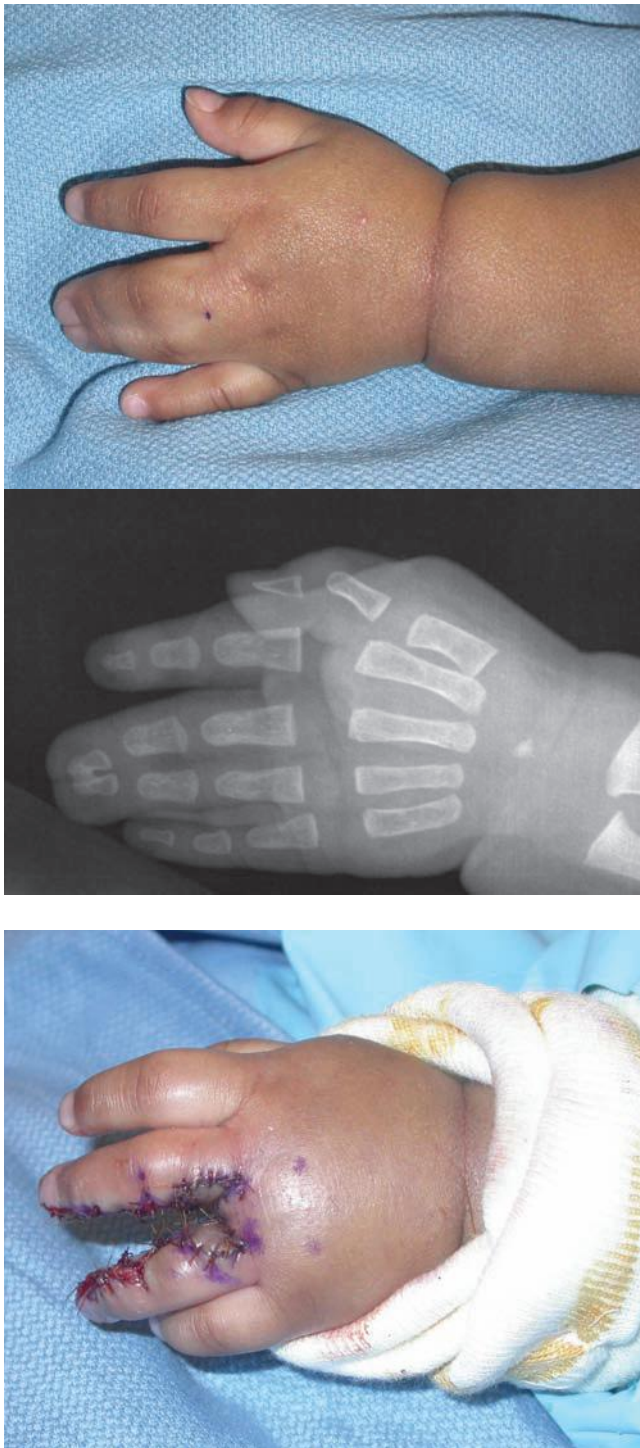

Figure 44-32. Syndactyly. Hand of a 1-year-old patient with complex syndactyly between the long and ring fingers. Complex syndactyly refers to fingers joined by bone or cartilaginous union, usually in a side-to-side fashion at the distal phalanges. The syndactyly is divided with interdigitating full-thickness flaps, a dorsal trapezoidal-shaped flap to resurface the floor of the web space, and full-thickness skin grafts. Note the skin grafts on the ulnar and radial sides of the new web space.

be associated with other problems such as clubfoot, cleft lip, cleft palate, or other craniofacial anomalies. The cause of the ring constrictions is unknown. Some theories suggest that folds or bands in the amniotic membrane may be responsible for this condition.

Generalized Skeletal Anomalies and Syndromes

This is a rare and complex group of unclassified problems.

RECONSTRUCTIVE TRANSPLANTATION OF THE UPPER EXTREMITY

Hand transplantation was first performed in humans in the late 1990s both in Louisville, Kentucky, and Lyon, France.⁹⁶ The treating surgeons were able to successfully remove an upper extremity from a brain-dead donor, attach it to an upper extremity amputee, and have the tissue survive. In the subsequent 15 years, many additional centers have achieved technical success with upper extremity transplantation as well.

The technical considerations of hand transplantation have proven to be only the beginning of challenges in bringing this treatment option to the general public. Replantation of an amputated limb was first reported by Malt in 1962.⁹⁷ In a limb replantation, there is a zone of injury, and cold preservation of the amputated part does not begin immediately. In a limb transplant, the harvest can be done as proximally as necessary to ensure that only healthy tissue is present on both sides of the repair and to obviate the need for limb shortening, and cold preservation of the amputated part can begin immediately after harvest.

A major concern regarding the use of limb transplantation is the immunosuppression medications required to prevent rejection of the transplanted limb. Unlike organ transplantation, which provides a critical organ without which the recipient could not survive or would require chronic mechanical support (e.g., hemodialysis), the absence of one or even multiple limbs does not represent an immediate threat to a patient's survival. Multiple studies have documented the nephrotoxic and other side effects of tacrolimus (FK 506), the principle antirejection agent used in transplant immunomodulation protocols.^{98,99}

Due to these concerns, much research has been directed at minimizing the amount of antirejection medication as well as promoting tolerance or even chimerism. Donor bone marrow transplantation to the limb transplant recipient has been shown to be beneficial toward this purpose and is part of the limb transplant protocol in some centers.¹⁰⁰ Recent research with donor bone marrow infusions has shown that lower levels of immunosuppressive drugs may be possible, as well as fewer immunosuppressive agents.¹⁰⁰ Further research is needed in order to determine the efficacy and utility of donor bone marrow transfusions and how they impact transplant recipients in the short and long term.

The final challenge in consideration of a patient for limb transplantation is selection of an appropriate candidate. There are multiple patient factors that need to be considered to determine if a patient is an appropriate candidate for hand transplantation. These include medical concerns, such as immunologic issues (both antibodies and the presence of occult neoplasms or indolent viruses such as cytomegalovirus), hematologic issues including coagulopathies, and anatomic issues such as quality of skin envelope and amputation level of the bone and neuromuscular structures. Psychological and social factors must also be considered related to the recipient's ability to comply with postoperative medication and therapy protocols as well as to cope with a continuous visible presence of a limb originating from another person.¹⁰¹

The promise of upper limb transplantation as a reconstructive technique remains high. Both civilian and military amputees

stand to receive a marked functional benefit from this treatment. With the number of transplants performed worldwide approaching 100 as well as decades of animal research, understanding of how best to use this technique from functional, patient safety, and cost-effectiveness standpoints continues to grow.

REFERENCES

Entries highlighted in bright blue are key references.

- American Society for Surgery of the Hand. *The Hand: Examination and Diagnosis*. 3rd ed. New York: Churchill Livingstone; 1990:5-13.
- Moore KL. The upper limb. In: Moore KL, ed. *Clinically Oriented Anatomy*. 3rd ed. Baltimore: Williams & Wilkins; 1992:501-635.
- Schuind F, Cooney WP, Linscheid RL, An KN, Chao EY. Force and pressure transmission through the normal wrist. A theoretical two-dimensional study in the posteroanterior plane. *J Biomech*. 1995;28:587-601.
- Gordon JA, Stone L, Gordon L. Surface markers for locating the pulleys and flexor tendon anatomy in the palm and fingers with reference to minimally invasive incisions. *J Hand Surg Am*. 2012;37:913-918.
- Dumanian GA, Segalman K, Buehner JW, Koontz CL, Hendrickson MF, Wilgis EF. Analysis of digital pulse-volume recordings with radial and ulnar artery compression. *Plast Reconstr Surg*. 1998;102:1993-1998.
- Green DP. General principles. In: Green DP, Hotchkiss RN, Pedersen WC, Wolfe SW, eds. *Green's Operative Hand Surgery*. 5th ed. Philadelphia: Churchill Livingstone; 2005:3-24.
- Gilula LA. Carpal injuries: analytic approach and case exercises. *AJR Am J Roentgenol*. 1979;133:503-517.
- Cousins MJ, Mather LE. Clinical pharmacology of local anaesthetics. *Anaesth Intensive Care*. 1980;8:257-277.
- Lalonde D, Bell M, Benoit P, Sparkes G, Denkler K, Chang P. **A multicenter prospective study of 3110 consecutive cases of elective epinephrine use in the fingers and hand: the Dalhousie Project clinical phase.** *J Hand Surg Am*. 2005;30:1061-1067.
- Yousif NJ, Grunert BK, Forte RA, Matloub HS, Sanger JR. A comparison of upper arm and forearm tourniquet tolerance. *J Hand Surg Br*. 1993;18:639-641.
- Hastings H II, Carroll C IV. Treatment of closed articular fractures of the metacarpophalangeal and interphalangeal joints. *Hand Clin*. 1988;4:203-227.
- Bond CD, Shin AY, McBride MT, Dao KD. Percutaneous screw fixation or cast immobilization for nondisplaced scaphoid fractures. *J Bone Joint Surg Am*. 2001;83A:483-488.
- Mayfield JK, Johnson RP, Kilcoyne RF. The ligaments of the wrist and their functional significance. *Anat Rec*. 1976;186:417-428.
- Apostolides JG, Lifchez SD, Christy MR. Complex and rare fracture patterns in perilunate dislocations. *Hand (NY)*. 2011;6:287-294.
- Kleinert HE, Kutz JE, Atasoy E, Stormo A. **Primary repair of flexor tendons.** *Orthop Clin North Am*. 1973;4:865-876.
- Komatsu S, Tamai S. Successful replantation of a completely cut-off thumb: case report. *Plast Reconstr Surg*. 1968;42:374-377.
- Lifchez SD, Marchant-Hanson J, Matloub HS, Sanger JR, Dzwierzynski WW, Nguyen HH. Functional improvement with digital prosthesis use after multiple digit amputations. *J Hand Surg Am*. 2005;30:790-794.
- Bickel KD, Dosanjh A. Fingertip reconstruction. *J Hand Surg Am*. 2008;33:1417-1419.
- Moberg E. The treatment of mutilating injuries of the upper limb. *Surg Clin North Am*. 1964;44:1107-1113.
- Melone CP Jr, Beasley RW, Carstens JH Jr. The thenar flap: an analysis of its use in 150 cases. *J Hand Surg Am*. 1982;7:291-297.
- Johnson RK, Iverson RE. Cross-finger pedicle flaps in the hand. *J Bone Joint Surg Am*. 1971;53:913-919.
- Bekler H, Gokce A, Beyzadeoglu T, Parmaksizoglu F. The surgical treatment and outcomes of high-pressure injection injuries of the hand. *J Hand Surg Eur Vol*. 2007;32:394-399.
- Kalyani BS, Fisher BE, Roberts CS, Giannoudis PV. Compartment syndromes of the forearm: a systematic review. *J Hand Surg Am*. 2011;36:535-543.
- Gulgonen A. Compartment syndrome. In: Green DP, Hotchkiss RN, Pedersen WC, Wolfe SW. *Green's Operative Hand Surgery*. 5th ed. Philadelphia: Churchill Livingstone; 2005:1985-2013.
- Wray RC Jr, Glunk R. Treatment of delayed union, nonunion, and malunion of the phalanges of the hand. *Ann Plast Surg*. 1989;22:14-18.
- Munk B, Larsen CF. Bone grafting the scaphoid nonunion: a systematic review of 147 publications including 5246 cases of scaphoid nonunion. *Acta Orthop Scand*. 2004;75:618-629.
- Curtis RM. Capsulectomy of the interphalangeal joints of the fingers. *J Bone Joint Surg Am*. 1954;36-A:1219-1232.
- Nath RK, Mackinnon SE. Management of neuromas of the hand. *Hand Clin*. 1996;12:745-756.
- Stanton-Hicks M, Jänig W, Hassenbusch S, Haddox JD, Boas R, Wilson P. Reflex sympathetic dystrophy: changing concepts and taxonomy. *Pain*. 1997;63:127-133.
- Schürmann M, Zaspel J, Löhr P, et al. Imaging in early post-traumatic complex regional pain syndrome: a comparison of diagnostic methods. *Clin J Pain*. 2007;23:449-457.
- Mackinnon SE. Pathophysiology of nerve compression. *Hand Clin*. 2002;18:231-241.
- National Institute for Occupational Safety and Health. Hand/wrist musculoskeletal disorders (carpal tunnel syndrome, hand/wrist tendinitis, and hand/arm vibration syndrome): evidence for work-relatedness. NIOSH Publication No. 97-141. Available at: <http://www.cdc.gov/niosh/docs/97-141/pdfs/97-141e.pdf>. Accessed December 4, 2013.
- Lifchez SD, Means KR Jr, Dunn RE, Williams EH, Dellon AL. Intra- and inter-examiner variability in performing Tinel's test. *J Hand Surg Am*. 2010;35:212-216.
- Williams TM, Mackinnon SE, Novak CB, McCabe S, Kelly L. Verification of the pressure provocative test in carpal tunnel syndrome. *Ann Plast Surg*. 1992;29:8-11.
- O'Gradaigh D, Merry P. Corticosteroid injection for the treatment of carpal tunnel syndrome. *Ann Rheum Dis*. 2000;59:918-919.
- Trumble TE, Diao E, Abrams RA, Gilbert-Anderson MM. Single-portal endoscopic carpal tunnel release compared with open release: a prospective, randomized trial. *J Bone Joint Surg Am*. 2002;84-A:1107-1115.
- Mackinnon SE, Novak CB. **Compression neuropathies.** In: Green DP, Hotchkiss RN, Pedersen WC, Wolfe SW, eds. *Green's Operative Hand Surgery*. 5th ed. Philadelphia: Churchill Livingstone; 2005:999-1045.
- Goldfarb CA, Sutter MM, Martens EJ, Manske PR. Incidence of re-operation and subjective outcome following in situ decompression of the ulnar nerve at the cubital tunnel. *J Hand Surg Eur Vol*. 2009;34:379-383.
- Swanson AB. Implant resection arthroplasty of the proximal interphalangeal joint. *Orthop Clin North Am*. 1973;4:1007-1029.
- Branam BR, Tuttle HG, Stern PJ, Levin L. Resurfacing arthroplasty versus silicone arthroplasty for proximal interphalangeal joint osteoarthritis. *J Hand Surg Am*. 2007;32:775-788.
- Burton RI Pellegrini VD Jr. Surgical management of basal joint arthritis of the thumb. Part II. Ligament reconstruction with

- tendon interposition arthroplasty. *J Hand Surg Am.* 1986;11:324-332.
42. Gray KV, Meals RA. Hematoma and distraction arthroplasty for thumb basal joint osteoarthritis: minimum 6.5 year follow-up evaluation. *J Hand Surg Am.* 2007;32:23-29.
 43. Watson HK, Ballet FL. The SLAC wrist: scapholunate advanced collapse pattern of degenerative arthritis. *J Hand Surg Am.* 1984;93:358-365.
 44. Stern PJ, Agabegi SS, Kiefhaber TR, Didonna ML. Proximal row carpectomy. *J Bone Joint Surg Am.* 2005;87(Suppl 1):166-174.
 45. Goldfarb CA, Stern PJ, Kiefhaber TR. Palmar midcarpal instability: the results of treatment with 4-corner arthrodesis. *J Hand Surg Am.* 2004;29:258-263.
 46. Feldon P, Terrono AL, Nalebuff EA, Millender LH. Rheumatoid arthritis and other connective tissue disorders. In: Green DP, Hotchkiss RN, Pedersen WC, Wolfe SW. *Green's Operative Hand Surgery.* 5th ed. Philadelphia: Churchill Livingstone; 2005:2049-2136.
 47. Swanson AB. Finger joint replacement by silicone rubber implants and the concept of implant fixation by encapsulation. *Ann Rheum Dis.* 1969;28(Suppl):47-55.
 48. Elliot D, Ragowansi R. Dupuytren's disease secondary to acute injury, infection or operation distal to the elbow in the ipsilateral upper limb—a historical review. *J Hand Surg Br.* 2005;30:148-156.
 49. McGrouther DA. Dupuytren's contracture. In: Green DP, Hotchkiss RN, Pedersen WC, Wolfe SW. *Green's Operative Hand Surgery.* 5th ed. Philadelphia: Churchill Livingstone; 2005:159-185.
 50. van Rijssen AL, ter Linden H, Werker PM. Five-year results of a randomized clinical trial on treatment in Dupuytren's disease: percutaneous needle fasciotomy versus limited fasciectomy. *Plast Reconstr Surg.* 2012;129:469-477.
 51. Hurst LC, Badalamente MA, Hentz VR, et al. Injectable collagenase clostridium histolyticum for Dupuytren's contracture. *N Engl J Med.* 2009;361:968-979.
 52. Saar JD, Grothaus PC. Dupuytren's disease: an overview. *Plast Reconstr Surg.* 2000;106:125-134.
 53. Crean SM, Gerber RA, Le Graverand MP, Boyd DM, Cappelleri JC. The efficacy and safety of fasciectomy and fasciotomy for Dupuytren's contracture in European patients: a structured review of published studies. *J Hand Surg Eur Vol.* 2011;36:396-407.
 54. Abrams RA, Botte MJ. Hand infections: treatment recommendations for specific types. *J Am Acad Orthop Surg.* 1996;4:219-230.
 55. Honda H, McDonald JR. Current recommendations in the management of osteomyelitis of the hand and wrist. *J Hand Surg Am.* 2009;34A:1135-1136.
 56. Murray PM. Septic arthritis of the hand and wrist. *Hand Clin.* 1998;14:579-587.
 57. Boles SD, Schmidt CC. Pyogenic flexor tenosynovitis. *Hand Clin.* 1998;14:567-578.
 58. Kanavel AB. The treatment of acute suppurative tenosynovitis—discussion of technique. In: *Infections of the Hand; A Guide to the Surgical Treatment of Acute and Chronic Suppurative Processes in the Fingers, Hand, and Forearm.* 5th ed. Philadelphia: Lea and Febiger; 1925:985.
 59. Michon J. Phlegmon of the tendon sheaths. *Ann Chir.* 1974;28:277-280.
 60. Hausman MR, Lisser SP. Hand infections. *Orthop Clin North Am.* 1992;23:171-185.
 61. Athanasian E. Bone and soft tissue tumors. In: Green DP, Hotchkiss RN, Pederson WC, Wolfe SW, eds. *Green's Operative Hand Surgery.* 5th ed. Philadelphia: Elsevier; 2005:2211-2264.
 62. Angelides AC. Ganglions of the hand and wrist. In: Green DP, Hotchkiss RN, Pederson WC, eds. *Operative Hand Surgery.* vol. 2, 4th ed. New York: Churchill Livingstone; 1999:2171-2183.
 63. Rizzo M, Berger RA, Steinmann SP, et al. Arthroscopic resection in the management of dorsal wrist ganglions: results with a minimum 2-year follow-up period. *J Hand Surg Am.* 2004;29:59-62.
 64. Glowacki KA, Weiss APC. Giant cell tumors of tendon sheath. *Hand Clin.* 1995;II:245-253.
 65. Calandruccio JH, Jobe MT. Tumors and tumorous conditions of the hand. In: Canale ST, Campbell WC, eds. *Campbell's Operative Orthopaedics.* 9th ed. St. Louis: Mosby; 1998:3703-3733.
 66. Phalen GS. Neurilemmomas of the forearm and hand. *Clin Orthop.* 1976;114:219-222.
 67. Lekanne Deprez RH, Bianchi AB, Groen NA, et al. Frequent NF2 gene transcript mutations in sporadic meningiomas and vestibular schwannomas. *Am J Hum Genet.* 1994;54:1022-1029.
 68. TerKonda SP, Perdakis G. Non-melanotic skin tumors of the upper extremity. *Hand Clin.* 2004;20:293-301.
 69. Glat PM, Shapiro RL, Roses DF, et al. Management considerations for melanonychia striata and melanoma of the hand. *Hand Clin.* 1995;11:183-189.
 70. Balch CM, Soong SJ, Smith T, et al. Long-term results of a prospective surgical trial comparing 2 cm vs. 4 cm excision margins for 740 patients with 1-4 mm melanomas. *Ann Surg Oncol.* 2001;8:101-108.
 71. Heaton KM, El-Naggar A, Ensign LG, et al. Surgical management and prognostic factors in patients with subungual melanoma. *Ann Surg.* 1994;219:197-204.
 72. Mahajan A. The contemporary role of the use of radiation therapy in the management of sarcoma. *Surg Oncol Clin N Am.* 2000;9:503-524.
 73. Mankin HJ, Mankin CJ, Simon MA. The hazards of the biopsy, revisited. Members of the Musculoskeletal Tumor Society. *J Bone Joint Surg Am.* 1996;78:656-663.
 74. Athanasian EA. Bone and soft tissue tumors. In: Green DP, Hotchkiss RN, Pederson WC, eds. *Green's Operative Hand Surgery.* 4th ed. New York: Churchill Livingstone; 1999:2223-2253.
 75. Murray PM. Soft tissue sarcomas of the upper extremity. *Hand Clin.* 2004;20:325-333.
 76. Unni KK, Dahlin DC. *Dahlin's Bone Tumors: General Aspects and Data on 11,087 Cases.* 5th ed. Philadelphia: Lippincott-Raven; 1996.
 77. Schwartz HS, Zimmerman NB, Simon MA, et al. The malignant potential of enchondromatosis. *J Bone Joint Surg Am.* 1987;69:269-274.
 78. Marcuzzi A, Acciaro AL, Landi A. Osteoid osteoma of the hand and wrist. *J Hand Surg Br.* 2002;27:440-443.
 79. Maloney WJ, Vaughan LM, Jones HH, et al. Benign metastasizing giant-cell tumor of bone. Report of three cases and review of the literature. *Clin Orthop.* 1989;243:208-215.
 80. Ogose A, Unni KK, Swee RG, et al. Chondrosarcoma of small bones of the hands and feet. *Cancer.* 1997;80:50-59.
 81. Okada K, Wold LE, Beabout JW, et al. Osteosarcoma of the hand: a clinicopathologic study of 12 cases. *Cancer.* 1993;72:719-725.
 82. Amadio PC, Lombardi RM. Metastatic tumors of the hand. *J Hand Surg Am.* 1987;12:311-316.
 83. Sheridan RL. Acute hand burns in children: management and long-term outcome based on a 10-year experience with 698 injured hands. *Ann Surg.* 1999;229:558-564.
 84. Robson MC, Smith DJ. Burned hand. In: Jurkiewicz MJ, ed. *Plastic Surgery: Principles and Practices.* St. Louis: C.V. Mosby Co; 1990.

85. Herndon DN, ed. *Total Burn Care*. 2nd ed. London: WB Saunders; 2002.
86. Haslik W, Kamolz LP, Nathschläger G, et al. First experiences with the collagen-elastin matrix Matriderm as a dermal substitute in severe burn injuries of the hand. *Burns*. 2007;33:364-368.
87. Hatzifotis M, Williams A, Muller M, et al. Hydrofluoric acid burns. *Burns*. 2004;30:156-159.
88. Conn J Jr, Bergan JJ, Bell JL. Hypothenar hammer syndrome: posttraumatic digital ischemia. *Surgery*. 1970;68:1122-1128.
89. Lifchez SD, Higgins JP. Long-term results of surgical treatment for hypothenar hammer syndrome. *Plast Reconstr Surg*. 2009;124:210-216.
90. McClinton MA, Wilgis EFS. Ischemic conditions of the hand. In: Mathes SJ, Hentz VR, eds. *Plastic Surgery*. Philadelphia: WB Saunders; 2006:791-822.
91. Ruch DS, Holden M, Smith BP, et al. Periarterial sympathectomy in scleroderma patients: intermediate-term follow-up. *J Hand Surg Am*. 2002;27:258-264.
92. Jones NF. **Acute and chronic ischemia of the hand: pathophysiology, treatment, and prognosis.** *J Hand Surg*. 1991;16A:1074-1083.
93. Giele H, Giele C, Bower C, et al. The incidence and epidemiology of congenital upper limb anomalies: a total population study. *J Hand Surg Am*. 2001;26:628-634.
94. Swanson AB. **A classification for congenital limb malformations.** *J Hand Surg Am*. 1976;1:8-22.
95. Wassel HD. The results of surgery for polydactyly of the thumb. A review. *Clin Orthop Relat Res*. 1969; 64:175-193.
96. Lee WP, Mathes DW. Hand transplantation: pertinent data and future outlook. *J Hand Surg Am*. 1999;24:906-913.
97. Malt RA, McKhann CF. Replantation of severed arms. *JAMA*. 1964;189:716.
98. Starzl TE, Fung J, Jordan M, et al. Kidney transplantation under FK 506. *JAMA*. 1990;264:63-67.
99. Gorantla VS, Brandacher G, Schneeberger S, et al. Favoring the risk-benefit balance for upper extremity transplantation: the Pittsburgh Protocol. *Hand Clin*. 2011;27:511-520.
100. Schneeberger S, Gorantla VS, Brandacher G, et al. Upper-extremity transplantation using a cell-based protocol to minimize immunosuppression. *Ann Surg*. 2013;257:345-351.
101. Shores JT. Recipient screening and selection: who is the right candidate for hand transplantation. *Hand Clin*. 2011;27:539-543.

This page intentionally left blank

45 chapter

Plastic and Reconstructive Surgery

Joseph E. Losee, Michael L. Gimbel, J. Peter Rubin,
Christopher G. Wallace, and Fu-Chan Wei

Historical Background	1829	Reconstructive Surgery	1852	Pressure Sore Treatment / 1880	
General Principles	1829	Facial Reconstruction after Fracture / 1852		Reconstructive Transplant Surgery / 1881	
Skin Incisions / 1829		Ear Reconstruction / 1855		Aesthetic Surgery	1882
Wound Healing / 1830		Nasal Reconstruction / 1856		Assessment of Facial Aesthetics / 1882	
Skin Grafts and Skin Substitutes / 1832		Lip Reconstruction / 1856		Blepharoplasty and Browlift / 1882	
Flaps / 1833		Eyelid Reconstruction / 1858		Facelift / 1883	
Free Tissue Transfer / 1838		Skull and Scalp Reconstruction / 1860		Rhinoplasty / 1883	
Tissue Expansion / 1840		Head and Neck Reconstruction / 1860		Suction Lipectomy / 1883	
Pediatric Plastic Surgery	1840	Facial Reanimation / 1865		Autologous Fat Grafting / 1885	
Cleft Lip and Palate / 1840		Breast Reconstruction / 1866		Excisional Body Contouring / 1886	
Craniofacial Anomalies / 1844		Trunk and Abdominal Reconstruction / 1872		Reduction Mammoplasty / 1887	
Vascular Anomalies / 1849		Extremity Reconstruction / 1876		Mastopexy / 1889	
Congenital Melanocytic Nevi / 1852				Augmentation Mammoplasty / 1890	
				Gynecomastia / 1891	

HISTORICAL BACKGROUND

The field of plastic surgery focuses on the restoration of form and function to those who have congenital and acquired deformities. Plastic surgery routinely addresses novel problems and challenges; therefore, the plastic surgeon must have an expert knowledge of anatomy and surgical technique to address new challenges.

The word *plastic* is derived from the Greek *plastikos*, meaning “to mold.” Although the term *plastic surgery* can be found in several medical writings from the eighteenth and nineteenth centuries, it was John Staige Davis who established the name of the specialty with the 1919 publication *Plastic Surgery—Its Principles and Practice*.

One of the earliest accounts of reconstructive surgery can be found in the *Sushruta Samhita*, an early text from the sixth or seventh century B.C. by the practitioner Sushruta. In this writing, the reconstruction of an amputated nose with a pedicled forehead flap and the reconstruction of the ear with cheek flaps were described. In addition, in the first century A.D., the Roman physicians Aulus Cornelius Celsus and Paulus Aegineta described operations for facial reconstruction.

The first textbook of plastic surgery is believed to be Gaspara Tagliacozzi’s 1597 publication *De Curtorum Chirurgia per Insitionem*. This text describes the reconstruction of the nose with a pedicled arm flap. The nineteenth century saw advances in reconstructive surgery, including Giuseppe Baronio’s successful grafting of sheepskin. The techniques for perfecting human skin grafting followed later in the nineteenth century.

Great advances in plastic surgery occurred as a result of the first and second world wars. Out of the fields of dental surgery, otolaryngology, ophthalmology, and general surgery, the discipline of plastic surgery was established. The founders of the field include Sir Harold Gillies, an otolaryngologist who established a center for the treatment of maxillofacial injuries in England; V. H. Kazanjian, a dental surgeon from Boston, who established a center in France for the treatment of facial injuries incurred in World War II; and Vilray P. Blair, from St. Louis, who established centers for the treatment of soft tissue and maxillofacial reconstruction for the U.S. Army. With the onset of World War II, centers of excellence for hand reconstruction appeared as well.

In the last 50 years, advances in plastic surgery have included the transplantation of both autologous and allogeneic tissue, tissue expansion, regional muscle and myocutaneous flap transfers, distant transfer of free flaps using microsurgery, replantation of traumatically amputated extremities and digits, and the emergence of craniofacial surgery. The future of plastic surgery will likely see further advances in the realms of regenerative medicine, fetal surgery, and reconstructive transplantation.

GENERAL PRINCIPLES

Skin Incisions

Human skin exists in a state of tension created by internal and external factors. Externally, skin and underlying subcutaneous tissue are acted on by gravity and clothing. Internally, skin is subjected to forces generated by underlying muscles, joint

Key Points

- 1▶ Plastic surgery is the field of surgery that addresses congenital and acquired defects, striving to return form and function.
- 2▶ Plastic surgery has been a field of innovation. The future of the specialty likely includes advancements in the areas of regenerative medicine, fetal surgery, and reconstructive transplantation with composite tissue allotransplants.
- 3▶ Children diagnosed with cleft and craniofacial anomalies benefit from interdisciplinary care at a specialized center focusing on team care. Long-term follow-up during growth and development is critical for optimal outcomes.
- 4▶ Reconstructive surgery attempts to restore form and function through techniques that include skin grafting, use of muscle flaps, bone grafting, tissue expansion, free tissue transfer with microsurgery, and replantation.
- 5▶ Aesthetic surgery is surgery performed to reshape the normal structure of the body to improve the patient's appearance and self-esteem. Patients undergoing aesthetic surgery present a unique challenge. The most important outcome parameter is patient satisfaction, and therefore, a thorough understanding of the patient's motivations, goals, and expectations is critical.

extension and flexion, and tethering of fibrous tissues from zones of adherence. As a result, when skin is incised linearly, it gapes to variable degrees. When a circular skin excision is performed, the skin defect assumes an elliptical configuration paralleling the lines of greatest tension. Carl Langer, an anatomist from Vienna, first fully described these tension lines in the mid-1800s based on his studies of fresh cadavers.¹ A. F. Borges described another set of skin lines that, different from Langer's lines, reflect the vectors of relaxed skin tension.² Although the term *Langer's lines* often is used interchangeably with the term *relaxed skin tension lines*, the former lines describe skin tension vectors observed in the stretched integument of cadavers exhibiting rigor mortis, whereas the latter lines lay perpendicular to and more accurately reflect the action of underlying muscle² (Fig. 45-1). Relaxed skin tension lines may be exploited to create incisions that minimize anatomic distortion and improve cosmesis. In areas of anatomic mobility, such as the neck or over joints, incisions are oriented less for aesthetic reasons and more with the goal of avoiding scar contractures and subsequent functional compromise. In general, incisions are placed perpendicular to the action of the joint.

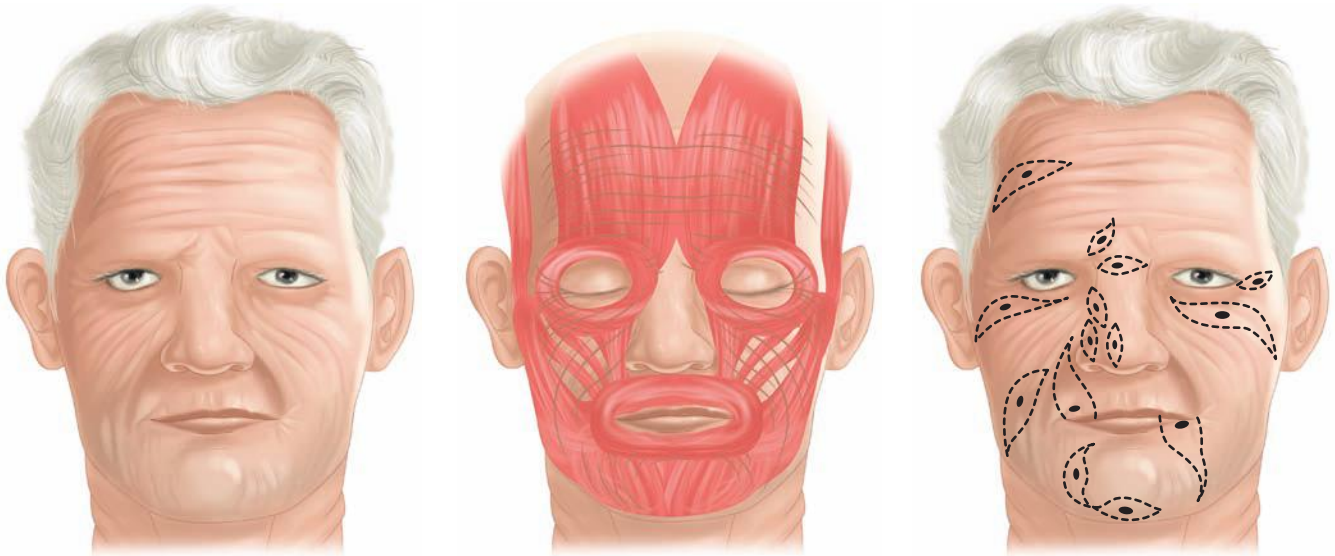There are situations, however, in which the direction of the incision has been preestablished, as in acute lacerations, burns,

or old contracted and distorting scars. In these circumstances, the principles of proper incision placement can be combined with simple surgical techniques to reorient the scar and lessen the deformity. The Z-plasty technique uses the transposition of random skin flaps both to break up a linear scar and to release a scar contracture through lengthening (Fig. 45-2; Table 45-1). W-plasty is the technique of scar excision and reconstruction in zigzag fashion to camouflage the resulting scar.

Wound Healing

The fundamentals of plastic surgery are based on wound healing physiology. Wound repair consists of an exquisitely regulated symphony of molecular and cellular instruments that act in concert to restore the local tissue environment to prewound conditions. Metabolic imbalances in the wound milieu drive this orchestration and continue to direct it until healing resolves the disturbance. Although a detailed review of wound physiology is presented elsewhere in this text, it is useful to emphasize several points.

Tissue injury disrupts the tissue microenvironment and sets into motion a cascade of events that combine to reestablish the environmental status quo. Disrupted blood vessels fill the wound space with red blood cells and plasma. Injured cells



1830 **Figure 45-1.** Relaxed skin tension lines. (Reprinted with permission from *Wilhelmi et al.*¹)

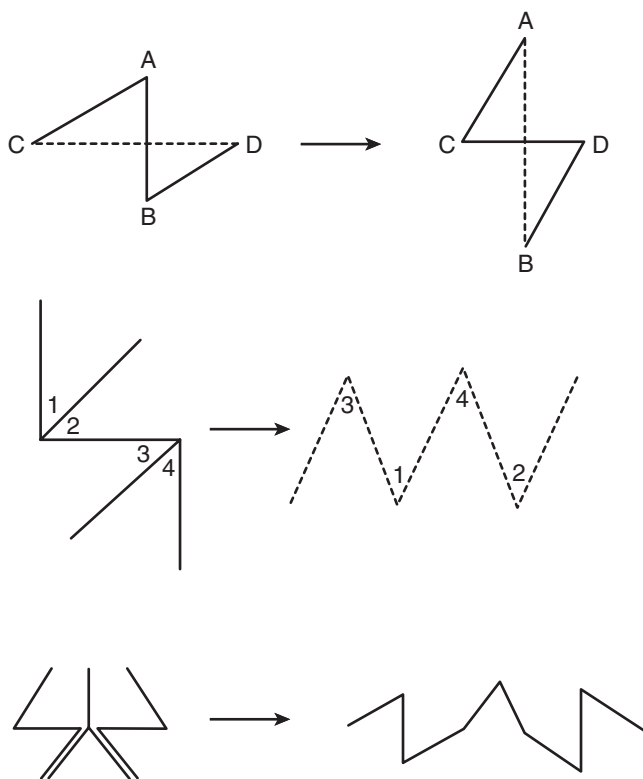


Figure 45-2. Schematic of the Z-plasty technique. *Top:* Simple Z-plasty. *Middle:* Four-flap Z-plasty. *Bottom:* Five-flap Z-plasty. (Modified with permission from Hudson DA: *Some thoughts on choosing a Z-plasty: The Z made simple.* *Plast Reconstr Surg.* 2000;106:665.)

release factor III (thromboplastin), which accelerates the clotting cascade. Clotting factors in the plasma are activated, and the coagulation cascade forms thrombin and eventually fibrin. Simultaneously, the complement system activates and produces chemoattractive complement protein fragments. Platelets, activated by thrombin and exposed collagen, release a number of growth factors and cytokines. Traumatized vessels contract in response to both direct physical stimulation and prostaglandins released by platelets. Intact local microvasculature vasodilates and leaks plasma in response to inflammatory mediators such as

histamine, kinins, and serotonin. These early events, and others, establish inflammation and, finally, homeostasis.³

Platelet activation initiates the first major escalation in the inflammatory response. Within minutes, platelets release signaling molecules from their α -granules to attract macrophages, polymorphonuclear cells (PMNs), fibroblasts, and vascular endothelial cells. Within a few hours of injury, PMNs and macrophages invade the wound and remove tissue debris, coagulation proteins, and bacteria. Although both PMNs and macrophages begin to marginate early, PMNs dominate during the first few days. PMNs also constitute the primary defense against invading organisms that have breached the epithelial barrier. PMNs and macrophages, in concert with the complement system, form the basis of “natural” or “nonspecific” immunity. If there is no infection or foreign material, the neutrophil population diminishes by the second day, whereas macrophages continue to amass.³

Macrophages become the major population by the third day after injury. These cells then dominate the wound region for days to weeks. Macrophages are the “masterminds” behind the finely tuned array of repair events that characterizes the proliferative phase of healing. Like neutrophils, activated macrophages continue the task of wound débridement. They are a rich source of degradative enzymes that process the extracellular matrix to make room for remodeling. Tightly coordinated release of the many growth factors, colony-stimulating factors, interleukins, interferons, and cytokines gives the macrophage the ability to regulate migration, proliferation, and specific protein synthesis of multiple cell lines. Macrophages lead the procession of new tissue into the wound dead space. Immature, replicating fibroblasts follow the macrophages. Mature fibroblasts then advance into the wound and are, in turn, followed by newly forming capillary buds, the last cells in the procession.³

Thus, injury perturbs the microenvironment and leads to the autoamplifying inflammatory phase. As a result of these processes, three changes occur in the wound: the environment becomes hypoxic, acidotic, and hyperlactated. One biochemical pathway by which this low redox potential state can signal cells to take biologic action is the adenosine diphosphoribose (ADPR) system. Recent evidence has shown that alterations of the polyADPR system affect regulation of collagen and vascular endothelial growth factor (VEGF) transcription.³ Consequently, the metabolic state that is so deranged in the wound microenvironment is intimately linked to altered cellular function and leads to reparative cell phenotypes.

After inflammation has begun, fibroblasts are attracted by many stimuli and then proliferate and migrate into the site of injury. Fibroblasts are the major producers of collagen in the repair response. Substances that increase collagen deposition and maturation include lactate, oxygen, and growth factors. Lack of these agents as well as steroid treatments decrease collagen in wounds.

Macrophages also usher along angiogenesis, largely through the release of VEGF. VEGF production is upregulated by the same wound metabolic environment that stimulates collagen production. As neovascularization takes place, many of the conditions that signaled the start of the inflammatory and proliferative phases are resolved, and the wound healing response recedes.

Epidermal cells are attracted to the healing wound by the same cytokines that attract other wound cells. Epithelialization proceeds best in a moist environment with high oxygen tension.³

Table 45-1

Tissue lengthening with Z-plasty

TYPE OF Z-PLASTY	INCREASE IN LENGTH OF CENTRAL LIMB (%)
Simple 45°	50
Simple 60°	75
Simple 90°	100
Four-flap with 60° angles	150
Double-opposing	75
Five-flap	125

Source: Modified with permission from Hudson DA. *Some thoughts on choosing a Z-plasty: the Z made simple.* *Plast Reconstr Surg.* 2000;106:665.

Table 45-2

Preoperative management

- Assess and optimize cardiopulmonary function; correct hypertension.
- Treat vasoconstriction: attend to blood volume, thermoregulatory vasoconstriction, pain, and anxiety.
- Assess recent nutrition and provide treatment as appropriate.
- Treat existing infection.
- Assess wound risk using the SENIC index.
- Start administration of vitamin A in patients taking glucocorticoids.
- Maintain tight blood glucose control.

SENIC = Study on the Efficacy of Nosocomial Infection Control.

Source: Modified with permission from Hunt TK, Hopf HW. Wound healing and wound infection: what surgeons and anesthesiologists can do. *Surg Clin North Am.* 1997;77:587. Copyright Elsevier.

Preoperative, intraoperative, and postoperative interventions may be taken by the surgeon to minimize infection and optimize wound healing (Tables 45-2–45-4). These measures all draw on what we understand of the physiologic wound healing process.

Skin Grafts and Skin Substitutes

Skin is comprised of 5% epidermis and 95% dermis. The dermis contains sebaceous glands, whereas sweat glands and hair follicles are located in the subcutaneous tissue. The dermal thickness and concentration of skin appendages vary widely from one location to another on the body. The skin vasculature is superficial to the superficial fascial system and parallels the skin surface. The cutaneous vessels branch at right angles to penetrate subcutaneous tissue and arborize in the dermis, finally forming capillary tufts between dermal papillae.⁴

Skin grafting techniques date back >3000 years to India, where forms of the technique were used to resurface nasal defects in thieves who were punished for their crimes with nose amputation. Modern skin grafting methods include split-thickness grafts, full-thickness grafts, and composite tissue

Table 45-3

Intraoperative management

- Administer appropriate prophylactic antibiotics at start of procedure. Keep antibiotic levels high during long operations.
- Keep patient warm.
- Maintain gentle surgical technique with minimal use of ties and cautery.
- Keep wounds moist.
- Perform irrigation in cases of contamination.
- Elevate tissue oxygen tension by increasing the level of inspired oxygen.
- Delay closure of heavily contaminated wounds.
- Use appropriate sutures (and skin tapes).
- Use appropriate dressings.

Source: Modified with permission from Hunt TK, Hopf HW. Wound healing and wound infection: what surgeons and anesthesiologists can do. *Surg Clin North Am.* 1997;77:587. Copyright Elsevier.

Table 45-4

Postoperative management

- Keep patient warm.
- Provide analgesia to keep patient comfortable, if not pain free.
- Keep up with third-space losses. Remember that fever increases fluid losses.
- Assess perfusion and react to abnormalities.
- Avoid diuresis until pain is gone and patient is warm.
- Assess losses (including thermal losses) if wound is open.
- Assess need for parenteral/enteral nutrition and respond.
- Continue to control hypertension and hyperglycemia.

Source: Modified with permission from Hunt TK, Hopf HW. Wound healing and wound infection: what surgeons and anesthesiologists can do. *Surg Clin North Am.* 1997;77:587. Copyright Elsevier.

grafts (Table 45-5). Each technique has advantages and disadvantages. Selection of a particular technique depends on the requirements of the defect to be reconstructed, the quality of the recipient bed, and the availability of donor site tissue.

Split-Thickness Grafts. Split-thickness skin grafting represents the simplest method of superficial reconstruction in plastic surgery. Many of the characteristics of a split-thickness graft are determined by the amount of dermis present. Less dermis translates into less primary contraction (the degree to which a graft shrinks in surface area after harvesting and before grafting), more secondary contraction (the degree to which a graft shrinks during healing), and better chance of graft survival. Thin split grafts have low primary contraction, high secondary contraction, and high reliability of graft take, often even in imperfect recipient beds. Thin grafts, however, tend to heal with abnormal pigmentation and poor durability compared with thick split grafts and full-thickness grafts. Thick split grafts have more primary contraction, less secondary contraction, and may take less hardily. Split grafts may be meshed to expand the surface area that can be covered. This technique is particularly useful when a large area must be resurfaced, as in major burns.

Table 45-5

Classification of skin grafts

TYPE	DESCRIPTION	THICKNESS (IN)
Split thickness	Thin (Thiersch-Ollier)	0.006–0.012
	Intermediate (Blair-Brown)	0.012–0.018
	Thick (Padgett)	0.018–0.024
Full thickness	Entire dermis (Wolfe-Krause)	Variable
Composite tissue	Full-thickness skin with additional tissue (subcutaneous fat, cartilage, muscle)	Variable

Source: Modified with permission from Andreassi A, Bilenchi R, Biagioli M, et al. Classification and pathophysiology of skin grafts. *Clin Dermatol.* 2005;23:332. Copyright Elsevier.

Meshed grafts usually also have enhanced reliability of engraftment, because the fenestrations allow for egress of wound fluid and excellent contour matching of the wound bed by the graft. The fenestrations in meshed grafts reepithelialize by secondary intention from the surrounding graft skin. The major drawbacks of meshed grafts are poor cosmetic appearance and high secondary contraction. Meshing ratios used usually range from 1:1.5 to 1:6, with higher ratios associated with magnified drawbacks.

Full-Thickness Grafts. By definition, full-thickness skin grafts include the epidermis and the complete layer of dermis. The subcutaneous tissue is carefully removed from the deep surface of the dermis to maximize the potential for engraftment. Full-thickness grafts are associated with the least secondary contraction upon healing, the best cosmetic appearance, and the highest durability. As a result, they are frequently used in reconstructing superficial wounds of the face and the hands. These grafts require pristine, well-vascularized recipient beds without bacterial colonization, previous irradiation, or atrophic wound tissue.

Graft Take. Skin graft take occurs in three phases: imbibition, inosculation, and revascularization. Plasmatic imbibition refers to the first 24 to 48 hours after skin grafting, during which time a thin film of fibrin and plasma separates the graft from the underlying wound bed. It remains controversial whether this film provides nutrients and oxygen to the graft or merely a moist environment to maintain the ischemic cells temporarily until a vascular supply is reestablished. After 48 hours, a fine vascular network begins to form within the fibrin layer. These new capillary buds interface with the deep surface of the dermis and allow for transfer of some nutrients and oxygen. This phase, called *inosculation*, transitions into revascularization, the process by which new blood vessels either directly invade the graft or anastomose to open dermal vascular channels and restore the pink hue of skin. These phases are generally complete by 4 to 5 days after graft placement. During these initial few days, the graft is most susceptible to interference in engraftment caused by infection, mechanical shear forces, and hematoma or seroma.⁴

Composite Grafts. Composite tissue grafts are donor tissue containing more than just epidermis and dermis. They commonly include subcutaneous fat, cartilage and perichondrium, and muscle. Although less common than skin grafts, grafts of this type are particularly useful in select cases of nasal reconstruction. Excision of the thick skin of the nasal lobule may create too deep a defect to reconstruct with a full-thickness skin graft. The ear lobe composite graft provides thicker coverage with good color match and a fairly inconspicuous donor site (Fig. 45-3). Similarly, the root of the helix of the ear may be used to reconstruct the alar rim, providing skin coverage, cartilaginous support, and internal lining in a single technique.

Flaps

A flap is a vascularized block of tissue that is mobilized from its donor site and transferred to another location, adjacent or remote, for reconstructive purposes. The difference between a graft and a flap is that a graft brings no vascular pedicle and derives its blood flow from recipient site revascularization, whereas a flap arrives with its blood supply intact.

Random Pattern Flaps. Random pattern flaps have a blood supply based on tiny blood vessels in the dermal-subdermal

plexus, as opposed to the discrete, well-described vessels of axial pattern flaps (Fig. 45-4).⁵ Random flaps are typically used to reconstruct relatively small, full-thickness defects that are not amenable to skin grafting. Unlike axial pattern flaps, random flaps are limited by their geometry. The generally accepted reliable length-to-width ratio for a random flap is 3:1. Exceptions to this rule abound, however. There are many different types of random cutaneous flaps that differ in geometry and mobility. A *transposition flap* is rotated about a pivot point into an adjacent defect (Fig. 45-5). A *Z-plasty* is a type of transposition flap in which two flaps are rotated, each into the donor site of the other, to achieve central limb lengthening (see Fig. 45-2). Another common transposition flap is the *rhomboid (Limberg) flap* (Fig. 45-6). *Rotational flaps* are similar to transposition flaps but differ in that they are semicircular (Fig. 45-7). *Advancement flaps* slide forward or backward along the flap's long axis. Two common variants include the rectangular advancement flap and the V-Y advancement flap (Fig. 45-8). Like transposition flaps, *interpolation flaps* rotate about a pivot point. Unlike transposition flaps, they are inset into defects near, but not adjacent, to the donor site. An example of an interpolation flap is the thenar flap for fingertip reconstruction (Fig. 45-9).

Fasciocutaneous and Myocutaneous Flaps. The *composition* of a flap describes its tissue components. For example, a cutaneous flap contains skin accompanied by a variable amount of subcutaneous fat. A fasciocutaneous flap contains skin and fascia, whereas an adipofascial flap contains subcutaneous fat and fascia without overlying skin. A muscle flap contains muscle only, whereas a myocutaneous flap also contains the overlying skin and intervening tissues. An osseous flap contains vascularized bone only, whereas an osteomyocutaneous flap contains, in addition, muscle, skin, and subcutaneous tissues.

The *contiguity* of a flap describes its position related to its source. Local flaps are transferred from a position adjacent to the defect. Regional flaps are from the same anatomic region of the body as the defect (e.g., the lower extremity region or the head and neck region). Distant flaps are transferred from a different anatomic region to the defect. They may remain attached to the source anatomic region (*pedicled flaps*) or may be transferred as *free flaps* by microsurgery. These are completely detached from the body, and their blood supply is reinstated by microvascular anastomoses to recipient vessels close to the defect.

The term *pedicle* was originally used to describe a bridge of tissue that remained between a flap and its source, similar to how a peninsula remains attached to its mainland. However, as knowledge of flap blood supply and (micro)vascular anatomy has improved over the years, the term pedicle has increasingly become reserved for describing the blood vessels that nourish the flap. Thus its current use is, in essence, *vascular pedicle* in shortened form. As a refinement, it is possible to dissect the pedicle free of its surrounding tissues (termed *skeletonization*) to allow any tortuosity of the supplying blood vessels to be released in order to maximize their reach toward a given defect. This is usually performed in a retrograde direction starting from where the pedicle enters the flap tissues. Similarly, it is possible to detach the desired skin paddle circumferentially from all unneeded surrounding tissues in order to maximize the freedom with which the flap can be inset to reconstruct the defect. Hence, a *pedicled island* flap has had its cutaneous component circumferentially incised while preserving its vascular pedicle. Therefore, a free flap and a pedicled island flap differ only in

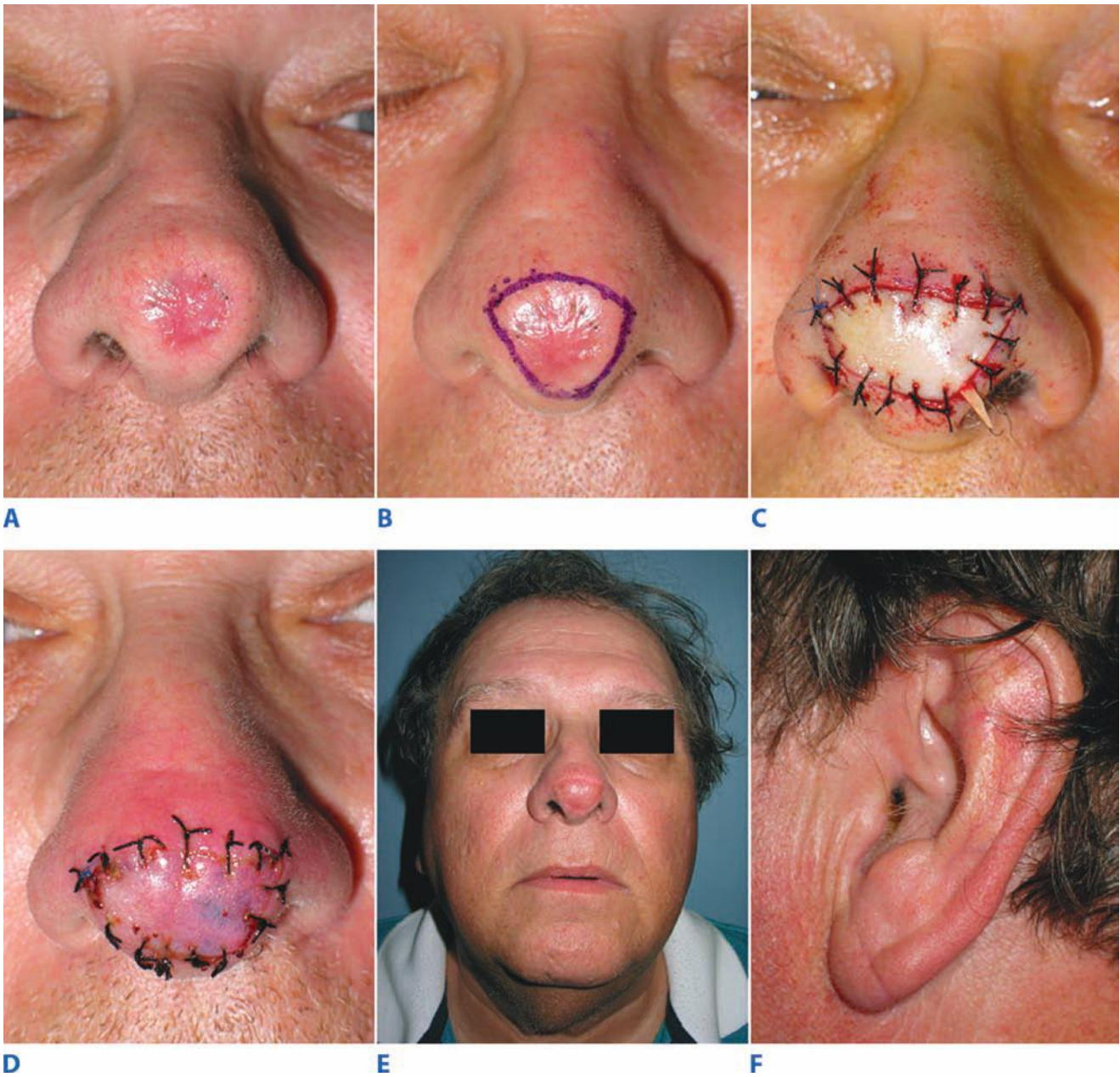

Figure 45-3. Composite graft reconstruction of nasal lobule. **A.** Scarred lobule from previous lesion excision. **B.** Scar excision markings. **C.** Insetting of composite ear lobe skin and subcutaneous fat graft. **D.** Postoperative day 3; note the pink hue of revascularization. **E.** Appearance at 5 weeks postoperatively. **F.** Donor site at 5 weeks postoperatively.

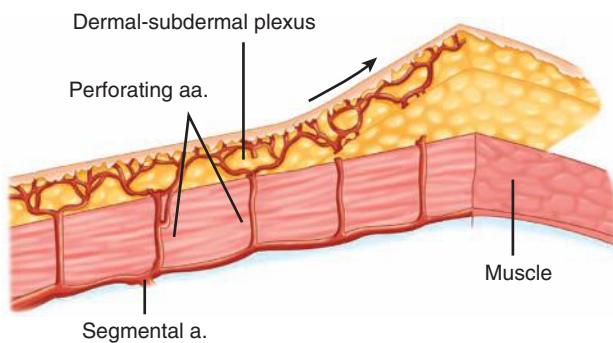


Figure 45-4. Random pattern flap architecture. a. = artery. (Reproduced with permission from Aston *et al.*⁵)

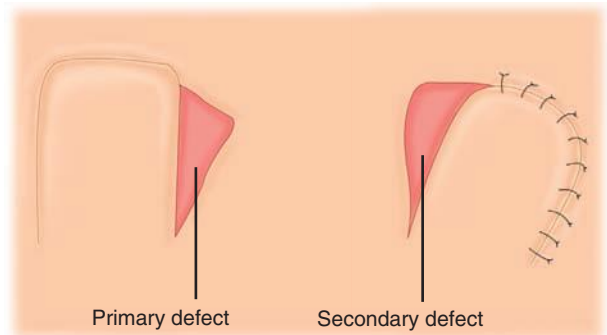


Figure 45-5. Random pattern transposition flap.

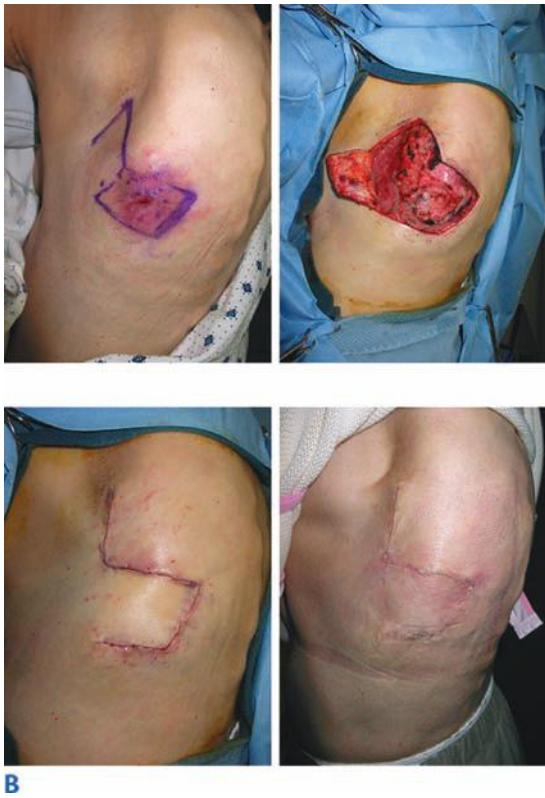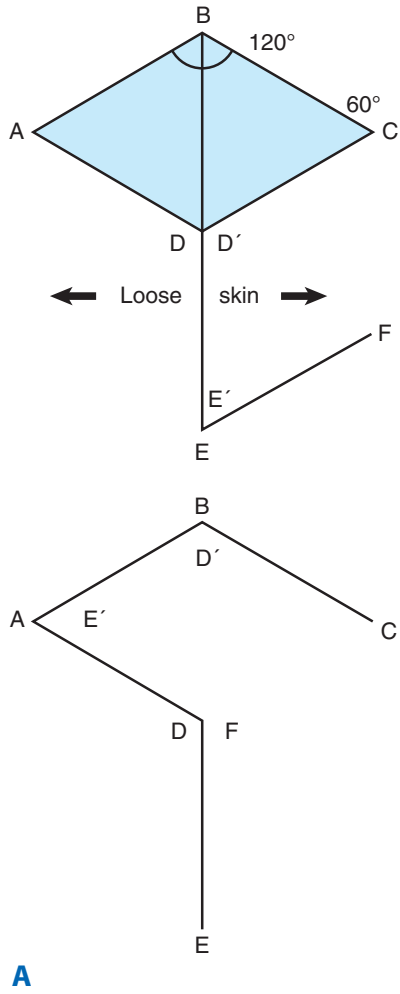


Figure 45-6. A and B. Random pattern transposition flap, the rhomboid flap. (Photographs reproduced with permission from M. Gimbel.)

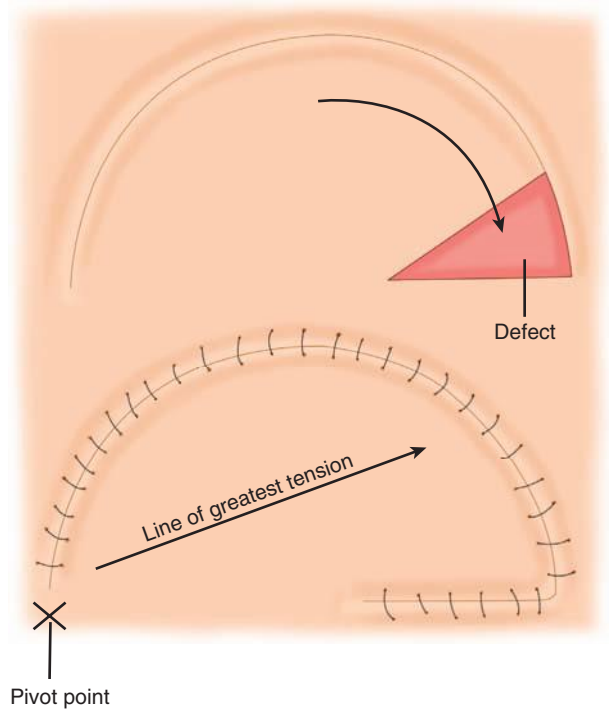


Figure 45-7. Random pattern rotational flap. (Reproduced with permission from Aston et al.⁵)

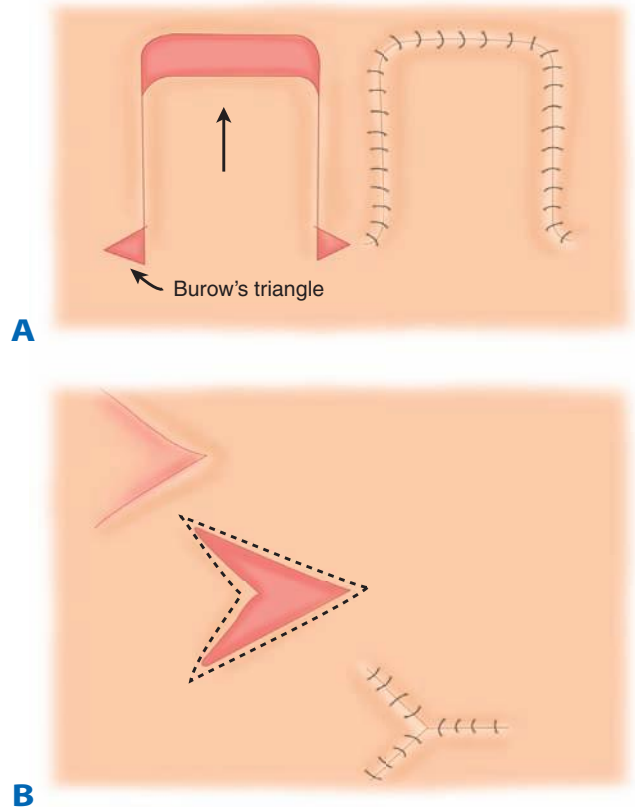


Figure 45-8. Random pattern advancement flap. A. Rectangular advancement flap with Burow's triangle excision. B. V-Y advancement flap. (Reproduced with permission from Aston et al.⁵)

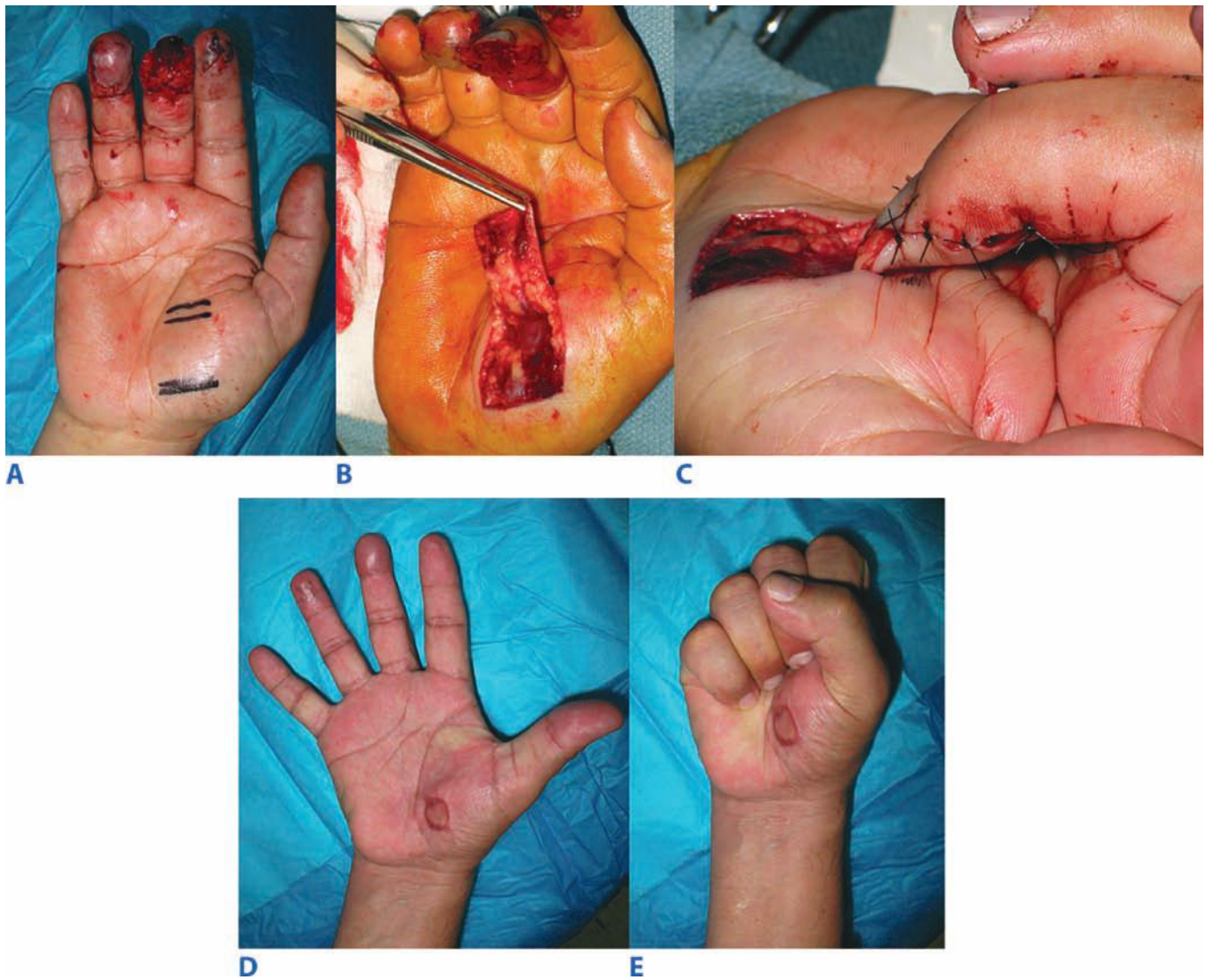


Figure 45-9. Random pattern interpolation flap—the thenar flap. **A.** Middle fingertip injury with exposed bone and tendon. **B.** Elevation of distally based random pattern thenar flap. **C.** Insetting. **D** and **E.** Function and form at 3 months, after skin grafting of donor site. (Photographs reproduced with permission from M. Gimbel.)

that the former requires transection of the vascular pedicle for anastomosis to alternative recipient vessels, whereas the pedicle of the latter remains in continuity.

Such flaps that are supplied by an anatomically defined configuration of vessels are described as having an *axial pattern* blood supply and can be transferred as local, regional, or distant, and pedicled, island pedicled, or free flaps.⁶ Arising from the aorta are arteries that supply the internal viscera and other deep vessels that divide to form the main arterial supplies to the trunk, head, and extremities. They ultimately feed interconnecting vessels that supply the vascular plexuses of the fascia, subcutaneous tissue, and skin. These interconnecting vessels reach the skin via either fasciocutaneous (also called *septocutaneous*) vessels that traverse fascial septae between muscles, musculocutaneous perforators that penetrate muscle bellies, or direct cutaneous vessels that traverse neither muscle bellies nor fascial septae.⁷ Axial pattern flaps, incorporating suprafascial tissues, are supplied by these fasciocutaneous (septocutaneous), musculocutaneous, or direct cutaneous arteries. The internal viscera are also a source of axial pattern flaps, such as the jejunum

flap and omentum flap. The circulation of bone- and muscle-containing flaps also is mainly axial in pattern. It also is possible to design local flaps, such as V-Y advancements and rhomboid flaps, as axial pattern flaps. In contrast to axial pattern flaps, random pattern flaps are only commonly transferred as local flaps by virtue of their lack of a defined vascular pedicle and cannot be transferred as island pedicled or free flaps. Axial pattern flaps may possess some areas with random pattern circulation, usually located at the flap periphery.

The volume of tissue reliably vascularized by the pedicle of an axial pattern flap defines its limits. In other words, the portion of a flap that extends beyond the capabilities of its vascular pedicle to perfuse it reliably will ordinarily undergo necrosis of that portion. This can be clarified conceptually. The arterial tree can be described in terms of its *angiosomes*.⁸ An angiosome is a block of tissue that is reliably supplied by a given artery. Neighboring angiosomes overlap, just as the dermatomes of neighboring nerves overlap. An anatomic angiosome is defined by the limits of an artery's ramifications, where it forms anastomoses with a neighboring anatomic angiosome. The vessels that pass

between these anatomic angiosomes are called *choke vessels*. In life, these may open or close in response to physiologic changes to increase or decrease, respectively, an artery's *dynamic angiosome* momentarily. Accordingly, at any given time point, the dynamic angiosome of an artery may be approximated by the volume of tissue stained by an intravascular administration of fluorescein into that artery (indicating the reach of blood flow from that artery into tissues). The *potential angiosome* of an artery is the volume of tissue that can be included in a flap that has undergone *conditioning* (see below). Both the dynamic and potential angiosomes extend beyond the anatomic angiosome of an artery. Although the angiosomal concept provides some guidance to the size and volume limits of a flap harvest, there remains no quantifiable method to predict safe flap harvest limits exactly.

Conditioning refers to any procedure that increases the reliability of a flap by enlarging the angiosome of the pedicle artery from its dynamic toward its potential angiosome. Invoking the *delay phenomenon*, for example, has improved the survival of flaps that otherwise would more frequently be complicated by unpredictable partial necrosis, such as the pedicled transverse rectus abdominis myocutaneous (TRAM) flap. The procedure can be particularly useful in patients at higher risk, such as those who are obese, smoke, or have received radiotherapy. One method of delay for the pedicled TRAM flap is to divide a major portion of its blood supply, the deep inferior epigastric artery on both sides, approximately 2 weeks before transfer. In response, blood from the anatomic angiosome of the superior epigastric artery appears to flow into that of the interrupted deep inferior epigastric artery via intervening choke vessels. As a result, the flap becomes conditioned to rely on the superior epigastric artery. The TRAM flap can then be transferred based on the superior epigastric artery with less risk of its distal portions becoming ischemic and possibly necrotic. Several theories have been proposed to explain the delay phenomenon, including metabolic compensatory responses to relative ischemia and dilatation of choke vessels; however, its mechanisms remain incompletely understood.⁹

Further subclassifications of flap circulation have been introduced for muscular and fasciocutaneous flaps.¹⁰ Individual muscles have been classified by Mathes and Nahai into five types (I–V) according to their blood supply (Table 45-6). This classification is also applied to the respective myocutaneous flaps. Fasciocutaneous flaps also have been classified by these authors into types A, B, and C (Table 45-7). The inclusion of muscle in a flap may serve to increase flap bulk (so as to obliterate dead space) or to provide a functioning component with the harvest of its motor nerve for coaptation to a recipient motor nerve. The purported advantages of muscle-containing flaps over fasciocutaneous flaps for use in previously infected tissue beds or for fracture healing have been debated.

With progressive advancements in flap transfer techniques and in understanding of microvascular flap anatomy, plastic surgeons have steadily increased the number and variety of available flaps, thereby improving the results of flap reconstructions. In addition, this knowledge has reduced the morbidity associated with flap harvest. Perhaps the most important advancement in flap surgery within recent decades has been the introduction of the perforator flap.¹¹ Perforator flaps evolved from the observation that the muscle component of myocutaneous flaps served as a carrier of blood vessels to the overlying fasciocutaneous tissues. Prior to this, it had been deemed mandatory to include the

Table 45-6

Mathes-Nahai classification of muscular flaps

CLASSIFICATION	VASCULAR SUPPLY	EXAMPLE
Type I	One vascular pedicle	Gastrocnemius
Type II	Dominant and minor pedicles (the flap cannot survive based only on the minor pedicles)	Gracilis
Type III	Two dominant pedicles	Rectus abdominis
Type IV	Segmental pedicles	Sartorius
Type V	One dominant pedicle with secondary segmental pedicles (the flap can survive based only on the secondary pedicles)	Pectoralis major

muscle for reliable harvest of fasciocutaneous tissues supplied by musculocutaneous perforators, even if it was not necessary to include that muscle for the reconstruction. This unfortunately caused an unnecessary muscular deficit at the donor site, and for this reason, fasciocutaneous flaps that were supplied by musculocutaneous perforators instead of septocutaneous vessels were sometimes abandoned. The introduction of intramuscular retrograde dissection techniques, however, allowed the skeletonization of a musculocutaneous perforator from its encasement within a muscle belly, which spared that muscle from flap harvest and preserved its donor site function.^{7,11} Further refinement of this concept gave rise to the harvest of cutaneous flaps based on any vessel that penetrated the fascia, which preserved the muscle (when the vessel was a musculocutaneous perforator) as well as the fascia (by suprafascial dissection). Within the last decade, free-style flap harvest has also been introduced.¹² With a handheld Doppler ultrasound probe, the surgeon is able to identify an arterial supply to almost any area of skin with the desired reconstructive characteristics and trace that pedicle in retrograde fashion along whatever direction it takes, preserving donor site fascia and muscle as necessary. Although the exact definition of what a perforator flap is remains contentious, its advantages

Table 45-7

Nahai-Mathes classification of fasciocutaneous flaps

CLASSIFICATION	VASCULAR SUPPLY	EXAMPLE
Type A	Direct cutaneous vessel that penetrates the fascia	Temporoparietal fascial flap
Type B	Septocutaneous vessel that penetrates the fascia	Radial artery forearm flap
Type C	Musculocutaneous vessel that penetrates the fascia	Transverse rectus abdominis myocutaneous flap

remain clear: reduced donor site morbidity, reduced flap bulk, and increased flexibility in choosing desired flap components for reconstruction. The circulation of perforator flaps is axial in pattern; consequently, they can be transferred as pedicled island flaps or by microvascular free tissue transfer.

Free Tissue Transfer

A free tissue transfer, often referred to as a *free flap* procedure, is an autogenous transplantation of vascularized tissues. Any axial pattern flap with pedicle vessels of a suitable diameter can be transferred as a free flap. This involves three main steps: (a) complete detachment of the flap, with devascularization, from the donor site; (b) revascularization of the flap with anastomoses to blood vessels in the recipient site; and (c) an intervening period of flap ischemia. Flap circulation must be restored within a tolerable ischemia time.

Given the small diameter of most flap pedicle vessels (usually between 0.8 and 4.0 mm), these anastomoses are usually performed using an operative microscope that provides dedicated illumination and between 6× and 40× magnification. Any surgery performed with the aid of an operative microscope is termed *microsurgery*; such anastomoses are therefore termed *microvascular anastomoses*. High-magnification surgical loupes are usually used for flap harvest, especially for dissecting the flap pedicle, because they allow greater operator freedom. Aside from microvascular anastomosis, microsurgical techniques include microneural coaptation, microlymphatic anastomosis, and microtubular anastomosis.

The first successful free tissue transfer in humans was of a jejunal free flap for cervical esophagus reconstruction in 1957; however, the surgeons did not use microsurgery for the anastomoses. The first *microvascular* free tissue transfers in humans were carried out during the late 1960s and early 1970s. Free flaps were initially considered to be a last-resort option to reconstruct the most complex defects. However, as a result of improved microsurgical techniques and microinstrumentation, as well as proper patient and free flap selection and effective postoperative monitoring methods, the success rates have increased to exceed 95%.¹³ Today, free tissue transfer is often the first-choice treatment for many defects and is no longer considered the last-ditch effort. It is now ubiquitously used in appropriate patients by reconstructive plastic surgeons worldwide.

The predetermining factor in free flap failure is occlusion of its blood supply due to thrombosis. As enumerated by Virchow's triad, any factors that alter normal laminar blood flow, cause endothelial damage, or change the constitution of blood (producing hypercoagulability) increase the risk of

thrombosis (Table 45-8).¹⁴ Avoidance of this complication, therefore, begins with a thorough patient evaluation for the presence of acquired or inherited thrombophilic tendencies. The patient's hemodynamic status influences that of the free flap and should be optimized. The effect of tobacco smoking on free flap success has been debated, with some larger retrospective studies reporting no difference in thromboembolic complications; however, smoking is well known to affect wound healing.^{13,15} Smoking and the use of potentially vasoconstrictive agents, such as caffeine, should be avoided for several weeks before and after a free flap procedure. The restoration of normal laminar blood flow and avoidance of endothelial damage are addressed principally by careful flap inseting and meticulous microvascular surgical technique.

Planning a free flap goes beyond a simple calculation of matching flap and defect dimensions and tissue characteristics. The surgeon must, in addition, consider several important technicalities: what flap pedicle length and size are required (affected by flap choice); which recipient vessels to use; how to orient anastomoses (end to end or end to side), deal with mismatched donor and recipient vessel dimensions, overcome unhealthy donor and/or recipient vessels (e.g., traumatic dissection, scarred surgical field due to previous operation or radiotherapy), inset flap tissues (to maximize functional and cosmetic results without detriment to flap circulation), route the pedicle (to restore normal blood flow without pedicle kinking, twisting, or compression), position the patient (especially if the flap is to be inset over mobile soft tissue or joints), and place postoperative dressings (so as to produce no compression of the flap or pedicle); and what donor site morbidity will likely result (there is a risk-benefit decision between defect severity and flap choice).¹⁶ In addition, the surgeon must have a suitable backup plan to overcome intraoperative troubles; for example, insufficient pedicle length can be addressed with an interpositional vein graft adjoining the donor and recipient vessels, and iatrogenic vessel injury or severely aberrant anatomy may necessitate use of a backup flap or backup recipient vessels.¹³

A clear understanding of the blood supply to the free flap and its tissue components is a prerequisite to harvesting a viable free flap. Pedicle vessels must be identified and protected and handled minimally and atraumatically to avoid thrombogenic factors (see Table 45-8). Meticulous technique also reduces the risk of vasospasm, but the latter can be ameliorated by topical lidocaine or papaverine should it occur. Critical vessels connecting flap components must also be recognized and preserved. Under microscope magnification, the donor and recipient

Table 45-8

Thrombogenic factors that can affect free flap pedicles and anastomoses

ALTERED LAMINAR BLOOD FLOW	ENDOTHELIAL DAMAGE	HYPERCOAGULABILITY
Tension or intimal malalignment at the anastomosis site; twisting, kinking, compression, or vasospasm of pedicle vessels	Iatrogenic damage (e.g., back-walled anastomotic suture, poor vessel handling, too many sutures)	Acquired thrombophilic tendency (e.g., pregnancy, paraneoplastic Trousseau's syndrome, antiphospholipid antibody syndromes)
Intraluminal structures (e.g., atherosclerotic plaque, venous valves, back-walled anastomotic suture)	Previous vessel damage (e.g., atherosclerosis, trauma)	Hereditary thrombophilias (e.g., activated protein C resistance, protein C/protein S deficiency, hyperhomocysteinemia)

vessels should be dissected back to health. The presence of, for example, venous valves, atherosclerotic plaques, intimal trauma, and intraluminal prolapse of adventitial tissue at or adjacent to the anastomosis site increases the risk of thrombosis. The vessel ends should be cleared of periadventitial tissues for 3 to 5 mm with sharp dissection under the microscope. Periadventitial dissection should be limited to this extent, so as to avoid potential devascularization of the vessel wall by removal of the vasa vasorum and prevent the subsequent delayed development of a perianastomotic pseudoaneurysm. Adventitiectomy also helps relieve vasospasm by increasing compliance of the vessel wall and by inducing a local sympathectomy effect. The vessel ends usually are stabilized with a double approximating microvascular clamp for anastomosis. Interrupted sutures or, less commonly, continuous sutures can accomplish the anastomosis. The microneedle typically has a three-eighths circle curvature and is between 30 and 150 μm in size. Its monofilament microsuture is usually between 9-0 and 11-0 caliber. The dimensions of the vessels to be anastomosed define the choice of microneedle and microsuture. Less commonly, suture alternatives such as fibrin adhesives or laser welding (these remain largely experimental) and mechanical anastomotic devices (e.g., venous couplers) may be used. Triangulating or bisecting suturing techniques can help to achieve an even placement of sutures. Normally, each suture should include the full thickness of both vessel walls, none should catch the opposite vessel wall (which causes disastrous luminal occlusion and intimal trauma), and the size of each bite should approximate the vessel wall thickness. The configuration of the anastomosis can be either end-to-end (Fig. 45-10), if the distal circulation can be adequately preserved, or end-to-side (Fig. 45-11), if the distal circulation must be preserved, as in the case of an extremity supplied by one dominant vessel. An end-to-side orientation may also be useful to overcome dramatically mismatched donor-recipient vessel dimensions. Whatever the method chosen, microanatomic differences between the vessels should be respected so as to achieve accurately approximated

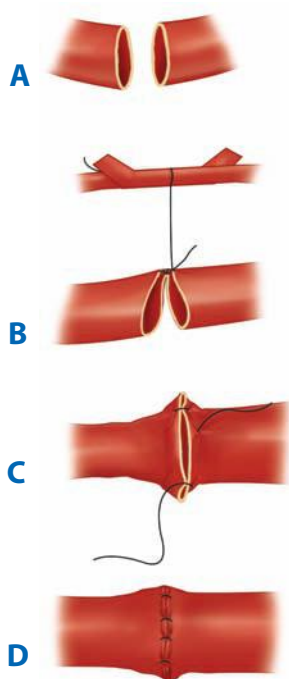


Figure 45-10. A through D. End-to-end anastomosis.

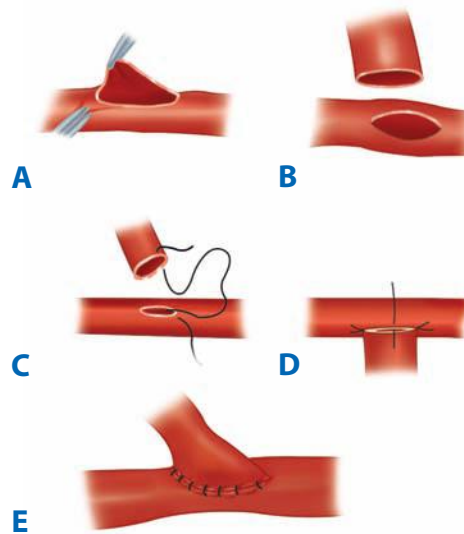


Figure 45-11. A through E. End-to-side anastomosis.

intimal surfaces in a tension-free anastomosis, devoid of redundancy that might promote kinking.¹³

The clinical monitoring of a free flap should start during flap harvest, especially before its pedicle is divided. A free flap that is struggling to maintain normal perfusion characteristics during harvest most likely has insufficient circulation, which may be due to arterial or venous compromise or a combination of both (Table 45-9). Flap compromise may be due to reversible factors such as pedicle kinking, tensioning, or twisting; patient hemodynamic compromise; or an overly large flap harvest for the chosen pedicle vessels. If poor flap perfusion continues despite the absence or correction of all these factors, an inherent flap problem or a critical vascular injury to the flap or its pedicle must be considered, and it may not be safe to continue its harvest. This is one example of a situation in which a backup plan may require execution.

Clinical flap monitoring continues after successful restoration of arterial inflow and venous outflow. The mainstay of postoperative free flap monitoring is clinical assessment (see Table 45-9), although supplementary instrument monitoring

Table 45-9

Clinical signs of arterial and venous compromise in a free flap^a

CLINICAL SIGN	ARTERIAL COMPROMISE	VENOUS COMPROMISE
Color	Becoming paler	Increasingly reddish or purplish
Temperature	Becoming cooler	Becoming warmer
Tissue turgor	Reducing	Increasing
Capillary refill time	Becoming slower	Becoming faster
Pinprick bleeding	Increasingly sluggish	Quickening (and darkening)

^aNote that venous and arterial compromise may coexist, and one may lead to the other.

also can be helpful. Doppler ultrasound assessment of arterial and venous signals is useful for monitoring buried or concealed flaps. If flap perfusion was healthy before division of its donor site pedicle, then poor perfusion after anastomoses is likely due to either a technical error or insufficient systemic hemodynamics. The latter usually is correctable by ensuring that the patient and the patient's environment are suitably warm and by initiating intravenous colloid challenge or, if indicated, blood transfusion. Numerous potential technical errors, which have been described in the earlier paragraphs on planning and anastomosis technique, may occur. Routine postoperative patient monitoring includes measurement of total fluid inputs, urinary catheter output (which should be >1 mL/kg per hour), core temperature, and arterial blood pressure (systolic pressure should be >100 mmHg), as well as pulse oximetry. The patient and free flap are best monitored in an intensive care setting by experienced staff until both are stable enough for routine ward assessments.¹⁷

Occlusion of the anastomosis most commonly arises from intraluminal thrombosis or from external compression of the pedicle, such as from surrounding tissues, fluid accumulation (e.g., hematoma and tissue edema), or overly tight dressings or skin sutures. Because there is a threshold of ischemia beyond which a flap will sustain irreversible tissue and/or microcirculatory damage, it is important that the early signs of flap circulatory compromise be recognized as quickly as possible and the underlying problem diagnosed and corrected promptly if flap health is to be restored successfully.¹⁷ Different tissues tolerate differing durations of ischemia in correlation with their tissue-specific basal metabolic rate. Although cooling free flaps (to reduce basal metabolic rate) has a variably protective effect in experimental settings, it appears that this practice contributes little to improving free flap success in the clinical setting as long as warm ischemia times are kept to <4 hours for most tissues; exceptions include bowel flaps, which are more susceptible to ischemia.¹³

Given that the predisposing factor for free flap failure is thrombus formation, it is understandable that plastic surgeons have looked to anticoagulant therapies in an effort to improve success rates. Although such drugs, including the dextrans, aspirin, heparins, and also some fibrinolytics, appear beneficial in experimental settings, large clinical trials have failed to show any conclusive associations between their use and either free flap success or failure rates.¹⁸ It seems intuitive to use these drugs for failing free flaps as an adjunctive measure alongside operative reexploration and surgical intervention. The surgeon must be aware of their contraindications and recognize that their side effects, apart from bleeding, are occasionally serious. Venous congestion may be addressed by surgical measures as well as by application of medicinal *Hirudo medicinalis* leeches (with concomitant *Aeromonas hydrophila* prophylaxis) or by chemical "leeching" (topical heparin combined with dermal punctures).

Unfortunately, the "no-reflow" phenomenon is occasionally witnessed and leads to irreversible flap failure. This describes a situation in which no venous return drains into the pedicle vein of the flap, even though adequate arterial inflow passes the arterial anastomoses and is seen to enter the flap tissues. The no-reflow phenomenon sometimes follows an extended ischemic insult and appears to be a self-perpetuating cycle of endothelial cellular swelling, inflammatory vasoconstriction, impaired microcirculatory flow, stasis, microcirculatory thromboses, progressive ischemia, and flap failure.¹³

Despite these potential problems, free flap success rates exceed 95% in experienced hands. There is no doubt that increasing microsurgical experience is critical to improving free flap success rates. The laboratory setting is an excellent environment in which to progress beyond the early portion of one's learning curve through supervised microsurgical training and execution of microvascular anastomoses and microvascular free flap procedures in small animals.

Tissue Expansion

Although skin grafts and local flaps are very useful in reconstructing many superficial defects, they are not without their drawbacks. Both leave donor site defects with cosmetic and/or functional sequelae. Grafts are limited in color match and durability, whereas local flaps may supply insufficient tissue and produce contour irregularities. The advent of tissue expansion has created the potential to increase the amount of local, well-matched tissue that can be advanced or transposed as a flap while decreasing donor site morbidity.

The most common method of skin expansion involves the placement of an inflatable silicon elastomer balloon with an integrated or remote port beneath the skin and subcutaneous tissue followed by serial inflation with saline. After completion of expansion, usually over weeks to months, the expander is removed and the redundant overlying skin may be advanced into an adjacent defect. Expanders are available in a multitude of shapes and sizes that can be tailored to the reconstruction. In breast reconstruction, the tissue expander is replaced with a permanent implant instead of using the tissue as a flap to re-create the volume of the breast mound. Histologically, expanded skin demonstrates thickened dermis with enhanced vasculature and diminished subcutaneous fat. Studies have shown that the skin expansion is due not merely to stretch or creep but also to actual generation of new tissue.¹⁹

The technique of tissue expansion comes with its share of potential complications, including infection, hematoma, seroma, expander extrusion, implant failure, skin necrosis, pain, and neurapraxia. Furthermore, an inflated expander is a very visible, albeit temporary, deformity that may cause patients much distress.

Despite these imperfections, tissue expansion has become a major treatment modality in the management of giant congenital nevi, secondary reconstruction of extensive burn scars, scalp reconstruction, and breast reconstruction. The technique has permitted the plastic surgeon to perform reconstructions with tissue of similar color, texture, and thickness with minimal donor site morbidity.

PEDIATRIC PLASTIC SURGERY

Cleft Lip and Palate

Orofacial clefting is the most common congenital anomaly and is known to occur in 1 in 500 live white births.²⁰ The incidence is lower in African Americans and higher in Native Americans and Asians. Clefting of the lip and/or palate is felt to occur around the eighth week of embryogenesis, either by failure of fusion of the medial nasal process and the maxillary prominence or by failure of mesodermal migration and penetration between the epithelial bilayer of the face. The cause of orofacial clefting is felt to be multifactorial. Factors that likely increase the incidence of clefting include increased parental age, drug use and infections during pregnancy, smoking during pregnancy, and

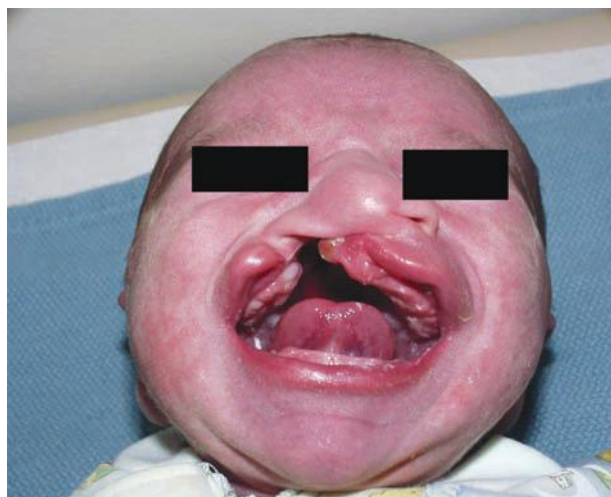a family history of orofacial clefting. The increased chance of clefting when there is an affected parent is approximately 4%.

The *primary palate* is defined as all tissue anterior to the incisive foramen, including the anterior hard palate (premaxilla), alveolus, lip, and nose. The secondary palate includes everything posterior to the incisive foramen, including the majority of the hard palate and the soft palate (velum). Clefting can involve the lip and nose, with or without a palatal cleft. Clefts of the lip and/or palate are first classified as unilateral or bilateral and then as complete or incomplete (Fig. 45-12). Complete clefts of the lip affect the entire lip and extend up into the nose. Incomplete clefts affect only a portion of the lip and contain a bridge of tissue connecting the central and lateral lip elements, referred to as *Simonart's band*.

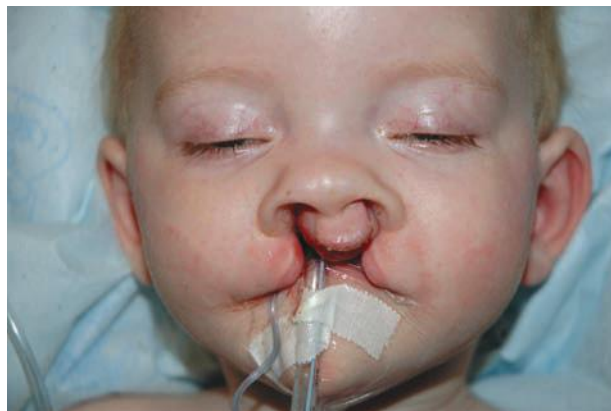Treatment Protocol. Considerable controversy remains over the details of the timing, technique, and protocol for treating children with orofacial clefting. The treatment protocol described in this chapter is accepted at many large cleft centers around the United States. All infants born with cleft-craniofacial anomalies benefit from care by a specialized team dedicated to the treatment of congenital anomalies. Today, this is widely accepted as the standard of care. Often, patients are seen prenatally after a diagnosis is made using sophisticated antenatal ultrasonography. The prenatal consultation has proven to be beneficial to parents, serving to dispel fears and uncertainties, and assuring them that treatment exists. After the infant's birth, a team evaluation occurs, and input is obtained from the surgeon, speech and language pathologist, social worker, craniofacial orthodontist, geneticist, otorhinolaryngologist, and pediatrician. For infants born with orofacial clefting, initial concerns relate to successful feeding and breathing. Infants with palatal clefts cannot generate negative pressure when suckling and therefore need milk dispensed into their mouths from a specialized nurser when they make suckling motions.

Once adequate nutrition and a safe airway are ensured, attention is turned to the cleft anomaly. Attempts to lessen the deformity and set the stage for the surgical repair of the lip and nose begin with a process known as *presurgical infant orthopedics (PSIO)*, which includes procedures such as nasoalveolar molding (NAM) (Fig. 45-13). NAM repositions the neonatal alveolar segments, brings the lip elements into close approximation, stretches the deficient nasal components, and turns wide complete clefts into the morphology of narrow "incomplete" clefts. After PSIO with NAM, the definitive single-stage cleft lip and nose repair is performed at 3 to 6 months of age. With this initial operation, the lip deformity is repaired and a primary nasoplasty reconstructs the cleft lip nasal deformity. If the family does not have access to PSIO or have the resources for this time-intensive therapy, a cleft lip adhesion can be performed as an initial stage in the repair. The preliminary cleft lip adhesion unites the upper lip and nasal sill, truly converting complete clefts into incomplete clefts. A cleft lip adhesion is performed in the first or second month of life, and the definitive cleft lip and nose repair follows at 4 to 6 months. After the definitive cleft lip and nose repair, the cleft palate is repaired in a single stage at 9 to 12 months of age.

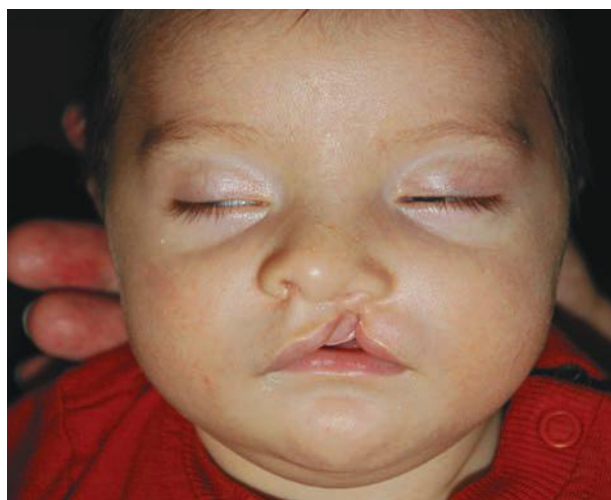Unilateral Cleft Lip. The unilateral cleft lip is classically associated with a cleft lip nasal deformity. The cleft lip nasal deformity includes lateral, inferior, and posterior displacement of the alar cartilage. This results from the deficient and clefted underlying skeleton as well as the unopposed pull of the clefted orbicularis



A



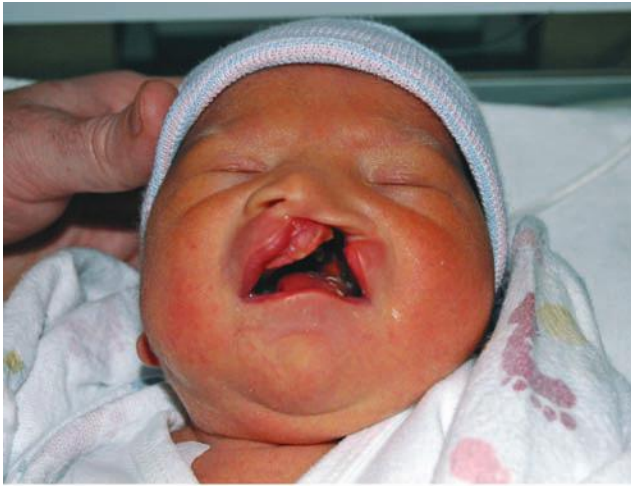B



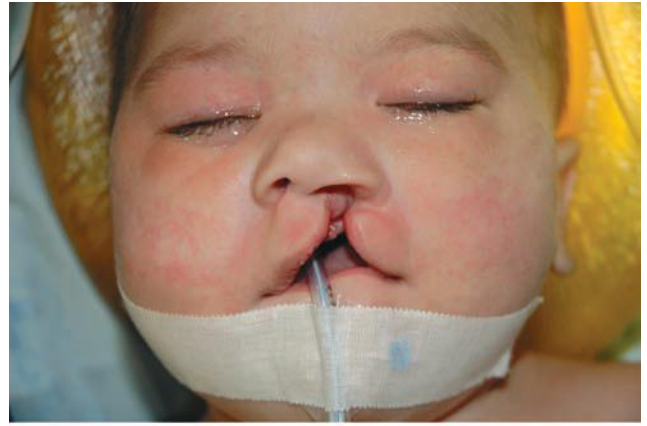C

Figure 45-12. A. Unilateral cleft lip and palate. B. Bilateral cleft lip and palate. C. Incomplete unilateral cleft lip.

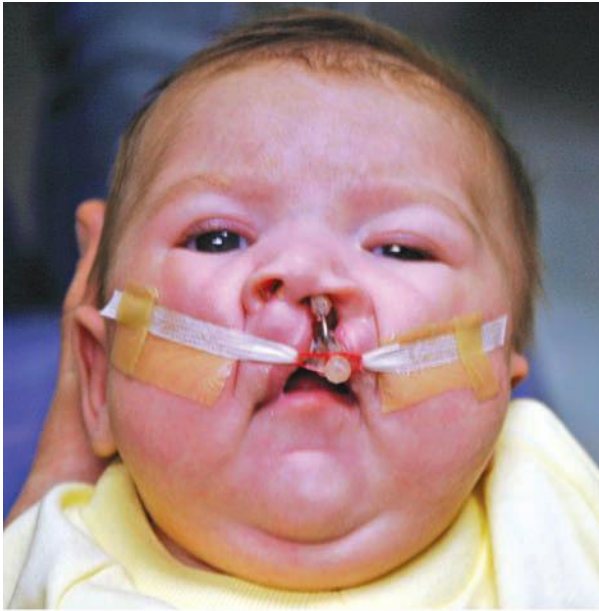oris muscle abnormally inserted on the alar base (Fig. 45-14A). The maxillary minor segment (the smaller alveolar/maxillary segment on the clefted side) is collapsed medially. The process of unilateral cleft lip repair can be thought of as "philtral subunit reconstruction." The goal of the operation is to level Cupid's bow and reconstruct the central philtrum of the lip, ideally placing the incision and subsequent scar as close to the normal philtral



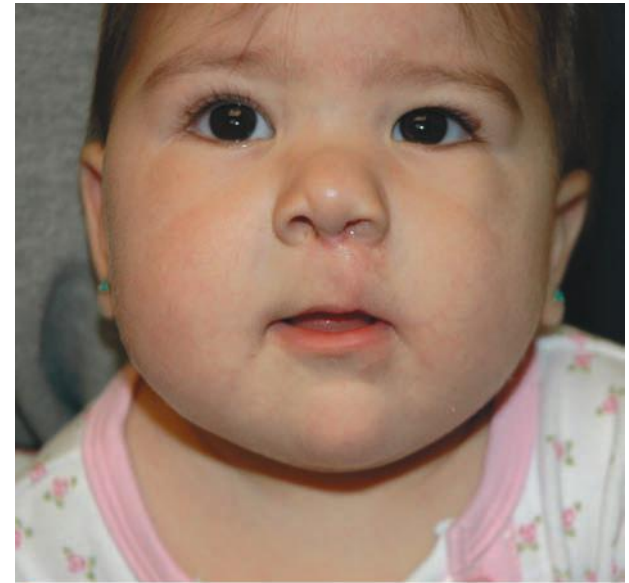A



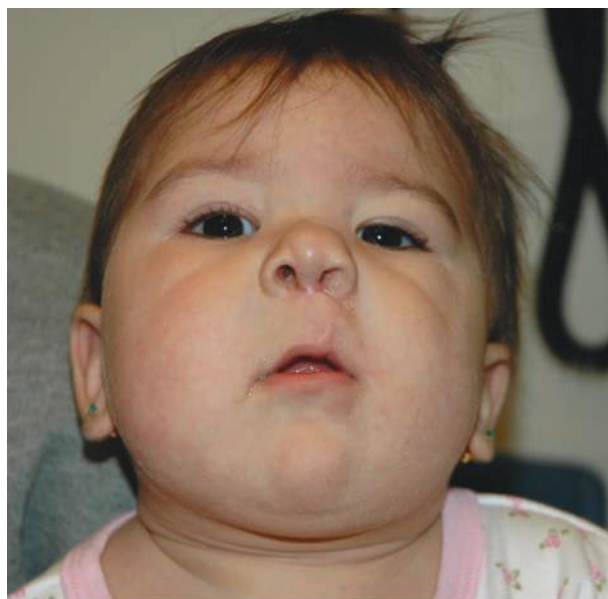
C



B

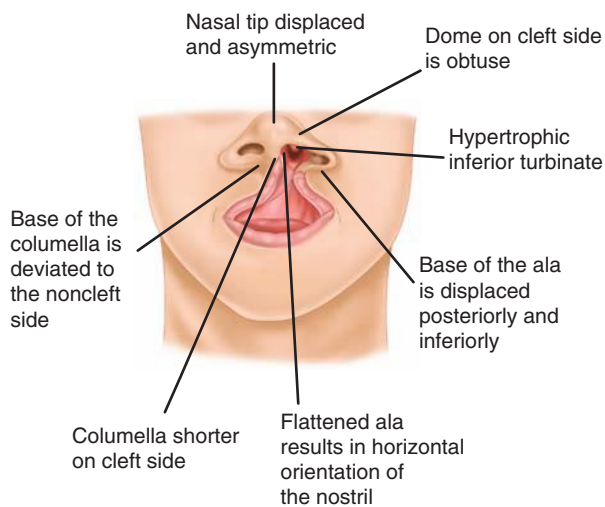


D

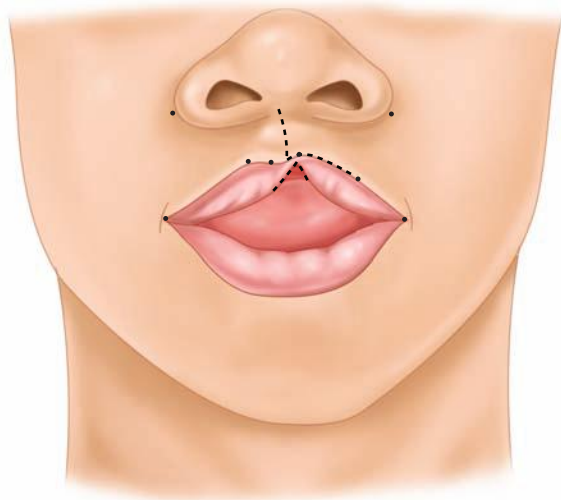


E

Figure 45-13. A. Complete left-sided cleft lip, nose, and palate. B. Nasoalveolar molding. C. After nasoalveolar molding, preoperative appearance before cleft lip and nose repair. D. Frontal view after cleft lip and nose repair. E. Worm's-eye view after cleft lip and nose repair.



A



B

Figure 45-14. A. Unilateral cleft lip and nose deformity. B. The rotation-advancement repair.

column as possible. The surgical repair is performed under general anesthesia, and local anesthesia containing epinephrine is used. Many different techniques of cleft lip and nose repair have been proposed; however, most of the commonly used procedures are variations of a “rotation-advancement” procedure.²¹ The rotation-advancement procedure, as championed by Millard (Fig. 45-14B), rotates the philtral subunit of the central lip downward to level Cupid’s bow as the lateral lip element is advanced into the defect created by the downward rotation of the philtrum. Some surgeons choose to perform primary closure of the alveolar cleft at the time of primary lip and nose repair, called a *gingivoperiosteoplasty*. If the alveolar cleft is to be repaired, the gingivoperiosteoplasty is performed by raising mucoperiosteal flaps within the alveolar cleft margin and reapproximating them across the alveolar cleft defect. This creates a bony tunnel closed with periosteal flaps and facilitates the generation of bone in the alveolar defect. It is accepted today that some form of primary nasoplasty should be performed at the time of primary definitive lip repair. Techniques to release and reposition the nasal tip cartilages, as well as the ala, are performed with variations of tip rhinoplasties using suture methods. Some surgeons choose to use postoperative internal and/or external splints to maintain the nasal correction achieved at surgery during the healing process.

Bilateral Cleft Lip. In the complete bilateral cleft lip and nose deformity, the central lip element, called the *prolabium*, is entirely separate from the rest of the upper lip. The prolabium is displaced on top of the central alveolar segment, called the *premaxilla*, containing the unerupted four central incisors. Often, the premaxilla and prolabium are outwardly displaced. This is referred to as a *flyaway premaxilla*. For the child with a complete bilateral cleft lip and nose, PSIO is a very important step in preparing the child for definitive lip and nose surgery by retracting the premaxilla into the maxillary arch, repositioning the lip segments, and stretching the rudimentary columella. Bilateral cleft lip and nose repairs often are versions of straight-line repairs, with the Mulliken technique being the more commonly performed (Fig. 45-15). In the bilateral cleft lip deformity, the new philtrum is made from the prolabium and is united to the lateral lip elements on top of the repaired orbicularis oris muscle.²²

Cleft Palate. During the eighth to twelfth weeks of gestation, the mandible becomes more prognathic, the tongue drops from beneath the clefted lateral palatine processes, and the palatal

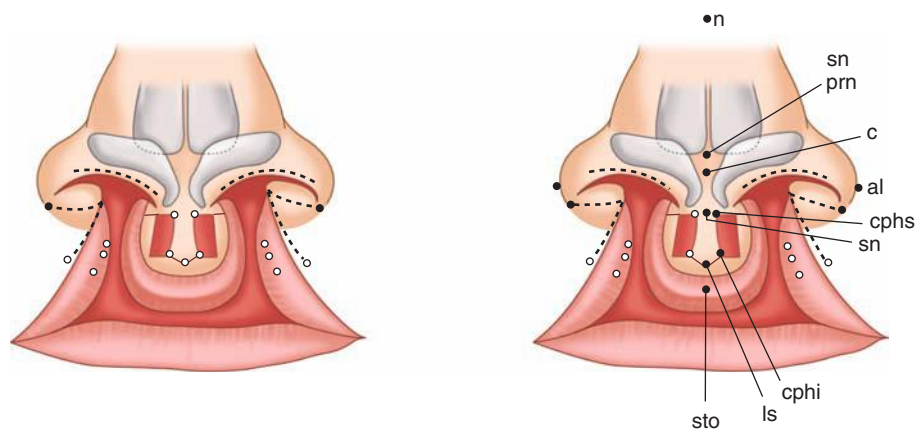


Figure 45-15. Mulliken bilateral cleft lip and nose repair. al = ala nasi; c = highest point of columella nasi; cphi = crista philtri inferior; cphi = crista philtri superior; ls = labiale superius; n = nasion; prn = pronasale; sn = subnasale; sto = stomion.

shelves migrate upward into a more horizontal position and fusion occurs. A cleft palate results from the failure of fusion of the two palatal processes. As with labial clefting, isolated clefts of the palate are multifactorial in etiology, and isolated clefts of the palate are more likely to be associated with other anomalies. Between 8% and 10% of isolated clefts of the palate are associated with the 22q deletion of velocardiofacial syndrome.²³

The main goal of cleft palate surgery is to help the patient attain normal speech, which results from velopharyngeal competence. During speech, the soft palate, or velum, is moved posteriorly and superiorly, primarily by the levator palatini muscle sling that suspends the velum from the skull base. Velopharyngeal competence is obtained during attempted speech when the velum approximates the posterior pharyngeal wall, preventing air and liquid from regurgitating into the nasal cavity. Velopharyngeal competence allows intraoral pressure to be built up for speech sounds. A cleft palate precludes this from occurring and results in velopharyngeal incompetence (VPI). Because it is impossible for the oral and nasal cavities to be partitioned in the patient with a cleft palate, it is also difficult for the patient to develop negative intraoral pressure for an effective suck. Therefore, specialized nursers are used to dispense liquid into the infant's mouth during the suckling motions. Children with clefts of the palate have an increased incidence of otitis media; this may be related to the abnormality of the velar musculature and ineffective function of the eustachian tube. The increased incidence of otitis media can result in hearing loss if not treated appropriately. In addition, VPI and nasal air escape during speech results in hypernasal speech.

As with the repair of cleft lip and nose, the timing, technique, and protocols for cleft palate repair are controversial. Most agree that palate repair should be performed before the development of speech. The cleft palate usually is repaired when the infant is between 6 and 18 months of age. Cleft palate repair also is performed under general anesthesia, with the head slightly hyperextended and a retractor, such as the Dingman mouth gag, placed intraorally to retract the tongue and endotracheal tube. An epinephrine solution is injected into the palate. Techniques of hard palate closure include the use of unipedicled hard palate mucoperiosteal flaps as in the Wardill-Veau-Kilner repair or bipedicled hard palate mucoperiosteal flaps as in the von Langenbeck repair. Both the unipedicled and bipedicled hard palate palatoplasty techniques rely on the greater palatine neurovascular pedicle. Soft palate or velar closure techniques are divided into straight-line and Z-plasty procedures. With either a straight-line or Z-plasty velar repair, the levator palatini muscle should be independently repaired; this is called an *intravelar veloplasty*. The clefted levator is identified coursing sagittally in an anterior-posterior direction, abnormally inserted onto the posterior edge of the hard palate. In intravelar veloplasty, it is released from the posterior edge of the hard palate in the midline and dissected free from abnormal attachments to the aponeurosis of the tensor veli palatini muscle and superior constrictor laterally. After its complete release, the levator palatini muscle is united in the midline, with reconstruction of the levator muscle sling that suspends the velum from the skull base and aids in velopharyngeal competence.

The authors prefer the double opposing Z-plasty technique of soft palate or velar reconstruction known as the *Furlow palatoplasty*.²⁴ The procedure uses four triangular flaps, two oral and two nasal, with the posteriorly based flaps containing the released levator muscles. The Z-plasty lengthens the soft palate, prevents longitudinal scarring from a straight-line repair, and

produces a secondary pharyngoplasty effect by narrowing the velopharyngeal port (Fig. 45-16).

Complications of palatoplasty include wound healing problems resulting in a breakdown of the suture line and the development of a fistula. The literature reports fistula rates ranging from approximately 1% to 20%. Treatment of palatal fistulae is particularly challenging, because the recurrence rates have been noted to approach 96%. The second most common complication of palatoplasty is the incomplete correction of speech and the development of postoperative VPI. The literature reports postoperative VPI rates ranging from 10% to 40%. Some of the best rates of velopharyngeal competence have been reported with the Furlow double opposing Z-plasty palatoplasty. Postoperative VPI is treated with pharyngoplasty—either a posterior pharyngeal flap pharyngoplasty or a sphincter pharyngoplasty. A posterior pharyngeal flap is a static flap formed from the posterior pharyngeal wall including mucosa and a portion of the superior constrictor muscle. The midline superiorly based pharyngeal flap is inset into the posterior free edge of the soft palate, permanently attaching it to the posterior pharyngeal wall. The sphincter pharyngoplasty has been reported to involve creation of a dynamic sphincter made with the bilateral posterior tonsillar pillars containing the palatopharyngeus muscle. The superiorly based tonsillar pillars are elevated from the lateral pharynx and inset into a horizontal incision on the posterior pharyngeal wall at the level of the adenoid pad.

Craniofacial Anomalies

History, Overview, and Classification System. Craniofacial surgery is the subspecialty of plastic surgery dealing with hard and soft tissue deformities of the craniofacial skeleton, treating the congenital, developmental, and acquired defects of the cranial and/or facial skeleton. Craniofacial surgery addresses the functional and equally important appearance-related issues surrounding these deformities. Attempting to separate the functional impairment from the appearance-related issues is arbitrary, because it can be argued that the most important function of a face is to look like a face.²⁵ Numerous studies have established the importance of facial form and the significant emotional impact that facial deformities have on a person's life and sense of self.

The field of craniofacial surgery finds its origins in the aftermath of the world wars and the need to treat massive facial injuries. In 1967, Dr. Paul Tessier, now recognized as the father of craniofacial surgery, first publicly presented his concepts of using wide exposure and a transcranial route to treating craniofacial deformities with large segmental movements of bone. An American disciple of Dr. Tessier, Dr. Linton Whitaker of the Children's Hospital of Philadelphia, working with the Committee on Nomenclature and Classification of Craniofacial Anomalies of the American Cleft Palate-Craniofacial Association, presented a simple and practical classification system for craniofacial anomalies (Table 45-10).

It is the standard of care today that an interdisciplinary team of experts with specialized knowledge and training in treating children with craniofacial anomalies care for children who have such anomalies. The preoperative workup and evaluation must be thorough and should include imaging (computed tomography [CT], magnetic resonance imaging [MRI], and cephalography), photography, blood work, anesthesia consultation, and other components as the condition dictates. Craniofacial procedures are often long, complicated surgeries of significant magnitude, with an attendant risk of blood loss, serious morbidity, and even mortality. Significant blood loss is a realistic possibility, and

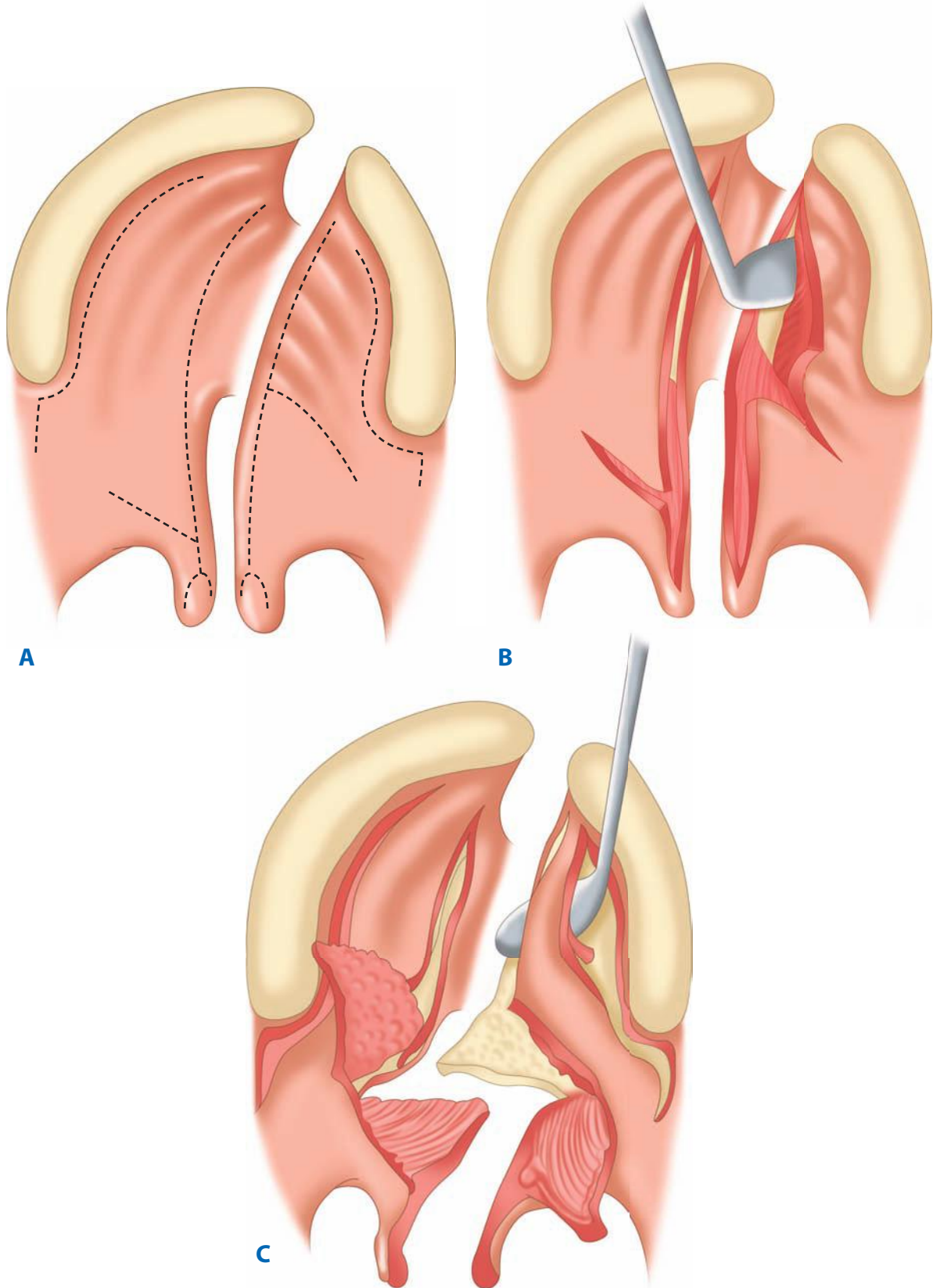


Figure 45-16. A. Markings for the Furlow double opposing Z-plasty palatoplasty. B. Raising the oral flaps in a Furlow palatoplasty. C. The complete dissection of a Furlow palatoplasty.

Table 45-10

Classification of craniofacial anomalies

- I. Clefts
 - a. Centric
 - b. Acentric
- II. Synostoses
 - a. Symmetric
 - b. Asymmetric
- III. Atrophy, hypoplasia
- IV. Neoplasia, hypertrophy, hyperplasia
- V. Unclassified

preparation for blood conservation and transfusion must be made. The routine surgical approach to the craniofacial skeleton can be via a coronal incision, and after a bifrontal craniotomy, the orbital and facial skeleton can be addressed. Bone grafts for reconstruction can be split calvarial grafts or, alternatively, grafts from the ribs or iliac crest. Rigid fixation is obtained with bioresorbable plates, screws, and sutures. Despite the magnitude of the procedures, significant morbidity (e.g., blindness, brain injury, significant infection, cerebrospinal fluid leak, intracranial hematoma) or mortality is rare.

Craniofacial Clefts. The rare craniofacial clefts have been subclassified by Tessier (Fig. 45-17). The Tessier classification

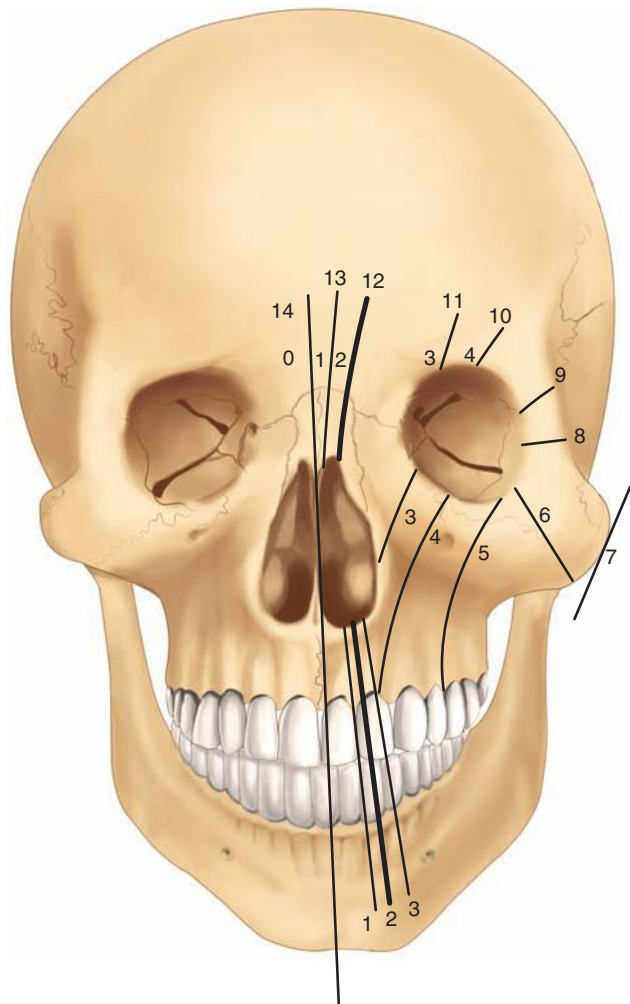
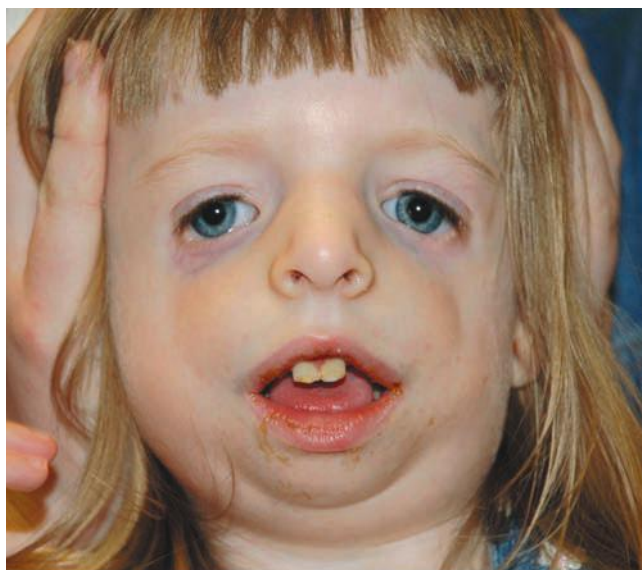


Figure 45-17. Tessier's classification of craniofacial clefts.

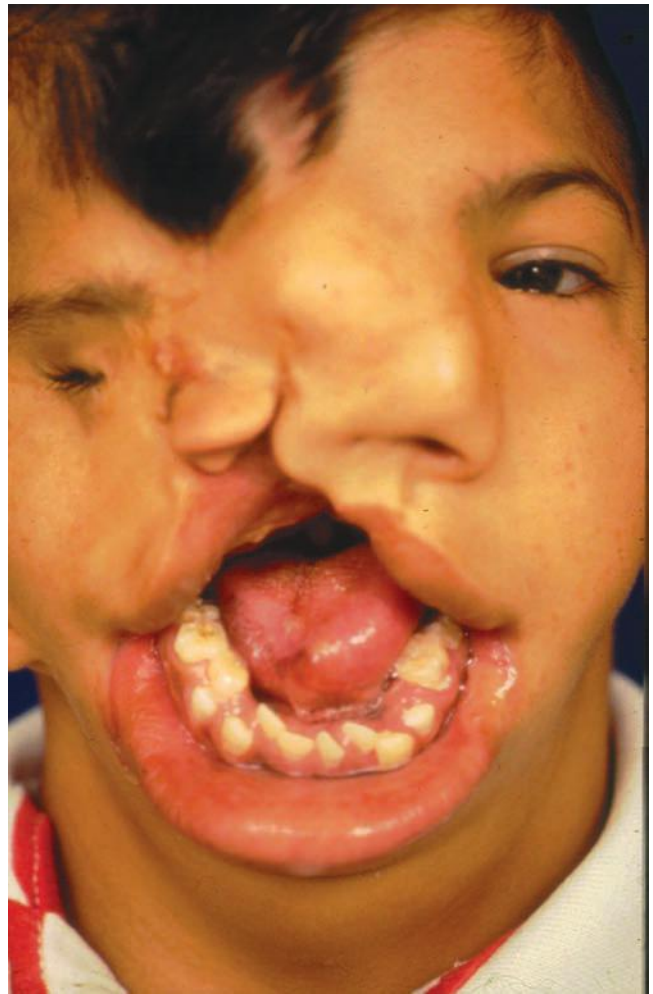

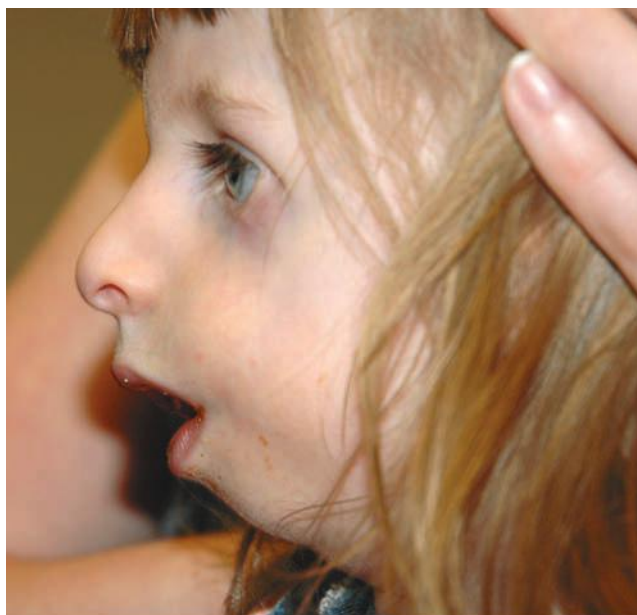Figure 45-18. Craniofacial cleft. (Reproduced with permission from Losee J, Kirschner R, eds. *Comprehensive Cleft Care*. 1st ed. New York: McGraw-Hill Professional; 2008, Chap. 27, Fig. 3. Copyright © The McGraw-Hill Companies, Inc.)

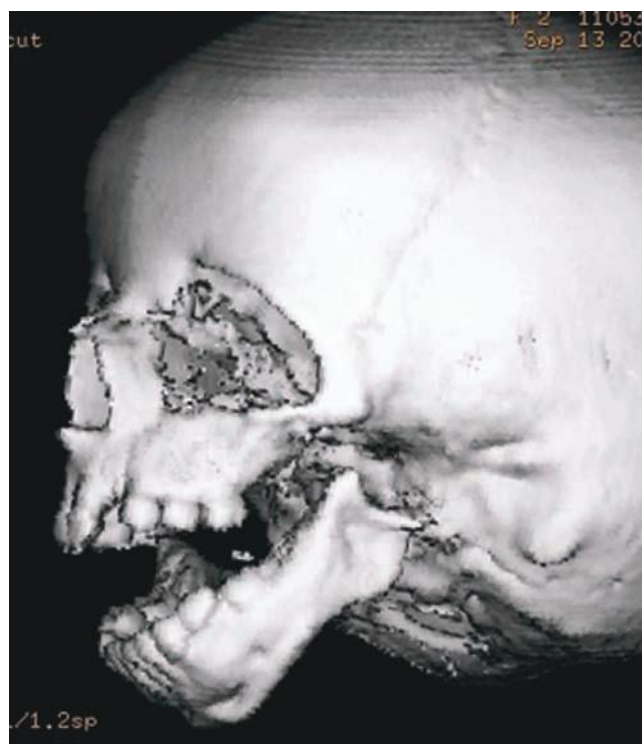of craniofacial clefts considers the orbit as the center around which the clefts radiate as the spokes of a wheel, numbered from 0 to 14. The facial clefts (0 to 7) and their cranial extensions (8 to 14) are often associated and total 14 (Fig. 45-18). Treacher Collins syndrome (Fig. 45-19), also known as *mandibulofacial dysostosis*, is a type of craniofacial clefting disorder representing bilateral 6-7-8 clefts. This autosomal dominant disorder with variable penetrance has the following manifestations: hypoplasia of the zygomas, asymmetry and hypoplasia of the mandible, ear anomalies, and colobomas of the lower eyelids. Craniofacial microsomia, also known as *hemifacial microsomia*, can be classified as a form of clefting as well (Fig. 45-20). Manifestations of this anomaly usually involve the hard and soft tissue of one half of the craniofacial skeleton. Deformities range in severity from complete absence of an affected facial component (globe, mandible, ear) to mild asymmetries. Ear deformities range from complete absence of the ear to only preauricular skin tags. Similarly, the eye deformities range from complete absence of the globe to various anomalies including epibulbar dermoids. Hypoplasia of the temporal skull, maxilla and zygoma, and orbit are seen in varying degree and affect the underlying skeleton as well as the overlying soft tissues. The classical deformity of hemifacial microsomia affects the mandible. Hypoplasia of the hemimandible, as well as the maxilla, results in dental malocclusions (Fig. 45-20C). Mandibular hypoplasia may range from



A



B



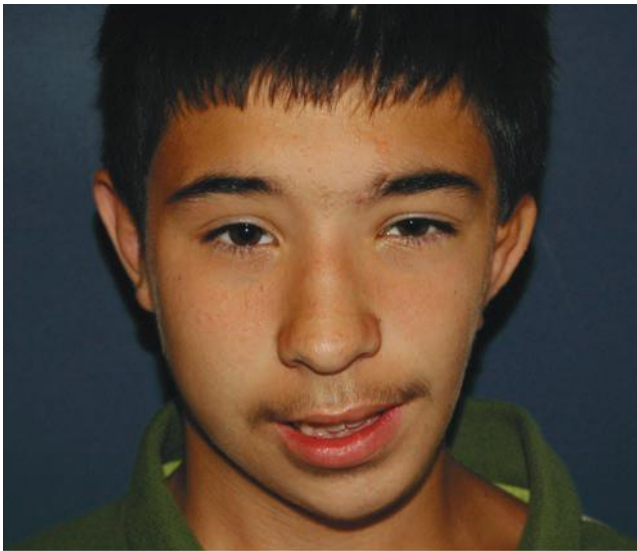C

Figure 45-19. Child with Treacher Collins syndrome. **A.** Frontal view. **B.** Lateral view. **C.** Three-dimensional computed tomographic scan of the craniofacial skeleton.

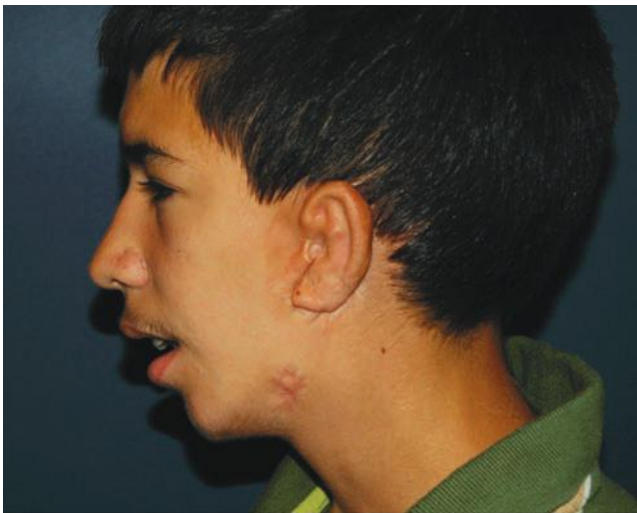minor underdevelopment of otherwise normal components to complete absence of the condyle, ramus, and proximal body.

Treatment of hemifacial microsomia includes management of the airway and attention to other functional conditions. Treatment of the mandibular deformity includes distraction osteogenesis during growth and orthognathic procedures at skeletal maturity. Ear deformities are reconstructed with techniques using costal cartilage and local soft tissue. Soft tissue

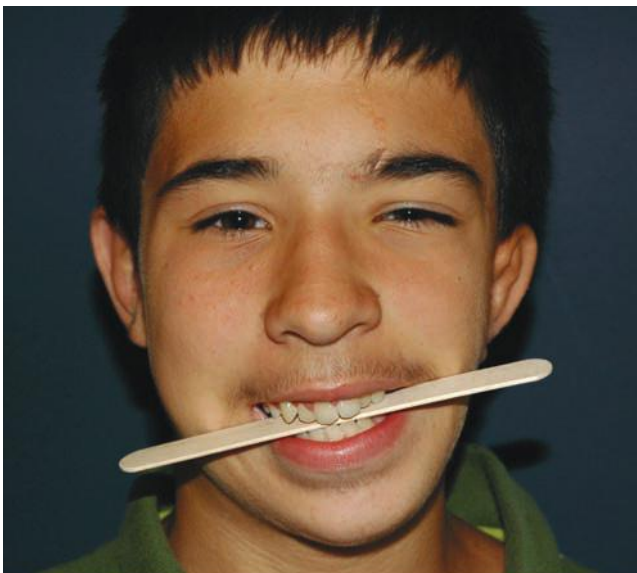deficiencies of the hemiface can be treated with fat injections, dermal-fat grafts, or free tissue transfer. Orbital hypertelorism is yet another type of midline craniofacial (0-14) clefting. *Orbital hypertelorism* is defined as a lateralization of the entire orbit, increasing the intraorbital distance and resulting from midline conditions such as encephaloceles, frontonasal dysplasia, and syndromic craniosynostosis. The treatment of severe orbital hypertelorism includes a transcranial approach to four-wall



A



B



C

Figure 45-20. Child with left-sided craniofacial/hemifacial microsomia. **A.** Frontal view. **B.** Lateral view. **C.** Bite plane.

orbital box osteotomies, resection or treatment of the abnormal midline process, mobilization, medialization of the orbital complexes, and nasal reconstruction with a cantilever nasal bone graft.

Craniosynostosis. The craniosynostoses are a group of disorders that result from the abnormal obliteration or premature fusion of the cranial sutures. The craniosynostoses can be subdivided into simple or single-suture craniosynostoses, and complex, syndromic, or multiple-suture craniosynostoses. The cranial sutures allow for the normal growth of the skull, and therefore, the classic presentation of craniosynostosis is an abnormal head shape. The resultant abnormal head shapes are secondary to an inhibition of skull growth at right angles to the fused suture and a compensatory overexpansion of the skull perpendicular to the fused suture into areas with open sutures. These abnormal head shapes provide a basis for the classification of craniosynostoses. In addition to appearance-related deformities resulting from craniosynostosis, important functional aspects include the potential for intracranial hypertension, which may result from brain growth restricted by an unyielding skull. The chances of intracranial hypertension increase with the number of sutures affected. Blindness and mental deficiencies secondary to an increase in intracranial pressure can likely be prevented by the surgical expansion of the cranium to release the fused suture, correct the abnormal head shape, and remodel the skull. The standard procedure used today in the correction of these synostotic deformities is fronto-orbital advancement. Fronto-orbital advancement, performed using a transcranial approach, includes a frontal craniotomy and orbital repositioning. The complex or multisutural synostoses are often syndromic, resulting from gain-of-function mutations of the fibroblast growth factor receptors (*FGFR1*, *FGFR2*, *FGFR3*). These syndromes of craniosynostosis include Apert's, Crouzon's, Pfeiffer's, and Saethre-Chotzen syndromes. The syndromic craniosynostoses not only include bicoronal synostosis but also involve the midface, with resulting exorbitism and midface hypoplasia. Multilevel airway anomalies, obstructive sleep apnea, corneal exposure, intracranial hypertension, feeding difficulties, and severe malocclusion are some of the associated anomalies found in children with syndromic craniosynostoses. In addition to fronto-orbital advancement, facial osteotomies (i.e., Le Fort III craniofacial disjunction) are required to treat the orbital, midfacial, and occlusal deformities.

Atrophy and Hypoplasia. The categories of craniofacial atrophy and hypoplasia encompass many conditions such as Pierre Robin sequence and Romberg's progressive hemifacial atrophy. Pierre Robin sequence is characterized by three pathognomonic findings: microretrognathia, glossoptosis, and respiratory distress. Pierre Robin sequence may or may not be associated with a palatal cleft. It is thought by some to occur secondary to a fixed and flexed fetal head position that inhibits mandibular growth and results in micrognathia. The micrognathia prevents the natural caudal migration of the tongue from between the clefted palatal shelves, and the resulting deformity as described earlier. The functional consequences include intermittent respiratory obstruction and obstructive sleep apnea that may affect feeding, growth, and safety of the airway. Treatment of a child mildly affected with Pierre Robin sequence may include simply positioning the child prone until the child "grows out" of the condition. However, if the child is severely affected and unable to feed adequately or has an unsafe airway, surgical intervention

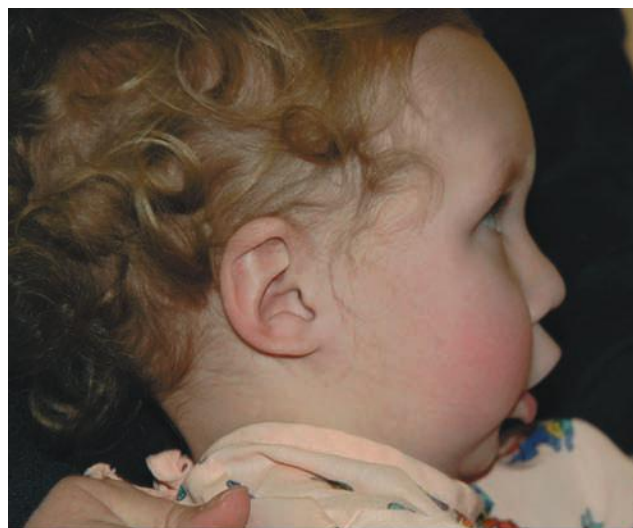is required. For decades, tracheotomy was the initial and definitive treatment of choice; however, today many initially attempt a tongue-lip adhesion, treating the glossoptosis and alleviating respiratory obstruction by suturing the tongue tip to the lower lip. The tongue-lip adhesion is taken down at the time of palatoplasty. Should the tongue-lip adhesion not adequately correct the obstruction, then neonatal mandibular distraction can be used to correct the underlying microretrognathia and relieve the obstructive symptoms (Fig. 45-21). Another syndrome of atrophy and hypoplasia is Romberg's progressive hemifacial atrophy, also known as *Parry-Romberg syndrome* (Fig. 45-22). Romberg's disease is a disorder of unknown etiology, beginning in childhood or adolescence, in which hemifacial atrophy of the skin, subcutaneous fat, muscle, bone, and cartilage progresses for a variable period of time before spontaneously ceasing or "burning out" 2 to 10 years after beginning. Most believe treatment should be delayed until at least 1 year after the process of atrophy has ceased. Some hematologists and oncologists have treated the early presentation of Romberg's disease with chemotherapy. After the cessation of atrophy, reconstruction of the craniofacial skeleton and soft tissues may begin with bone and/or cartilage grafts, alloplastic implants, dermal-fat grafts, fat grafting, and possibly free tissue transfers.

Hyperplasia, Hypertrophy, and Neoplasia. The categories of craniofacial hyperplasia, hypertrophy, and neoplasia encompass a wide variety of conditions affecting the craniofacial skeleton. These include vascular anomalies (discussed later in this chapter), neurofibromatosis, hemifacial hypertrophy, and bony conditions such as osteomas and fibrous dysplasia. Fibrous dysplasia can be monostotic, affecting a single location, or polyostotic, affecting more than a single location in the skeleton; it may be associated with skin pigmentation abnormalities and endocrine involvement, and be termed *polyostotic* or *McCune-Albright syndrome*. Treatment of fibrous dysplasia of the craniofacial skeleton includes block resection and reconstruction with bone grafts. If extensive involvement exists and block resection is not possible or feasible, partial resection and contouring of the affected bone is possible, as long as there is the understanding that long-term outcomes and the behavior of the disease are unpredictable.

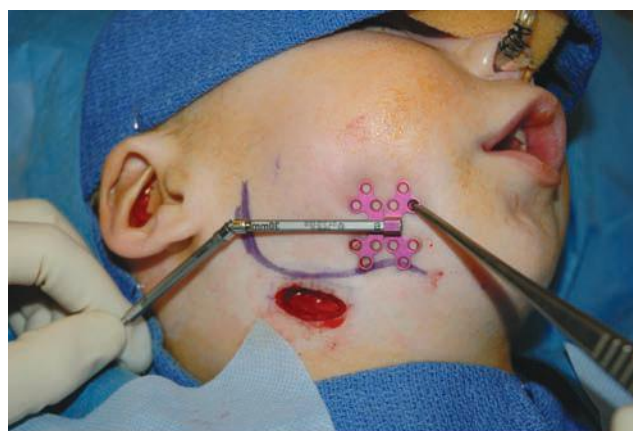Vascular Anomalies

Vascular anomalies are vascular birthmarks that all appear similar: flat or raised, in various shades of red and purple.²⁶ For centuries, they have been named by similarly colored food and drink (i.e., strawberry hemangioma, port-wine stain). Today these vascular birthmarks have been biologically classified as either *hemangiomas* or *vascular malformations*. The Greek suffix *-oma* means "swelling" or "tumor" and today connotes a lesion characterized by hyperplasia. Hemangiomas are congenital vascular anomalies that undergo a phase of rapid growth followed by slow regression, based on endothelial cell kinetics. Malformations are abnormal vascular channels lined with quiescent endothelium, usually are seen at birth, never regress, and have the potential to expand. The differential diagnosis of vascular anomalies is routinely made by a detailed accurate history and clinical examination. For deep lesions, radiographic studies may help determine the diagnosis. Biopsy is used if the diagnosis is uncertain or there is concern over the potential of malignancy.

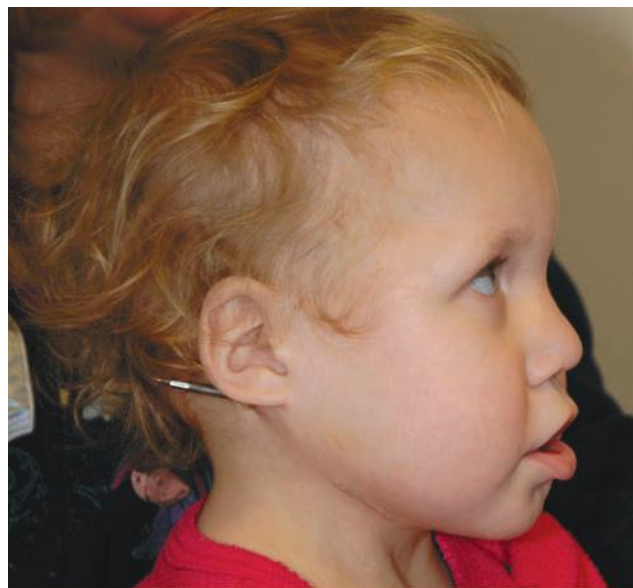Hemangiomas. The infantile hemangioma is the most common birthmark, affecting 10% to 12% of whites, with a 3:1 to 5:1 predilection for females and an increased incidence in



A



B



C

Figure 45-21. A. Lateral view of a child with Pierre Robin sequence and mandibular microretrognathia. B. Intraoperative photo of a submandibular incision and planning for the placement of a buried mandibular distractor. C. Lateral view of the child after mandibular distraction with slight overcorrection of retrognathia. The distractor is still in place as evident from the activating rod seen exiting the skin retroauricularly.

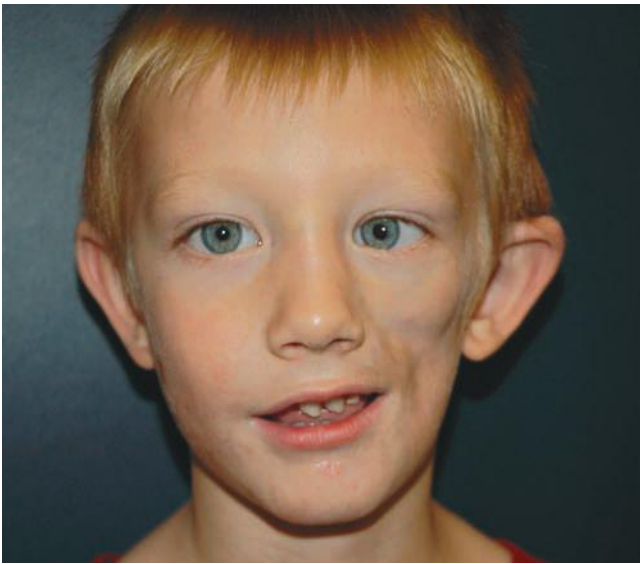

Figure 45-22. Frontal view of a child with left-sided Romberg's progressive hemifacial atrophy.

preterm infants (23%) (Fig. 45-23). Hemangiomas are solitary in 80% of cases and multiple in 20%. In children with multiple (more than three) cutaneous hemangiomas, abdominal ultrasound is suggested to rule out hemangiomatosis with visceral involvement. Hemangiomas do not cause bleeding disorders; however, more invasive lesions such as kaposiform hemangioendothelioma can result in Kasabach-Merritt syndrome, characterized by platelet trapping and disordered bleeding.

Hemangiomas are usually first noted around 2 weeks of life as a flat pink spot, often confused with a superficial scratch.

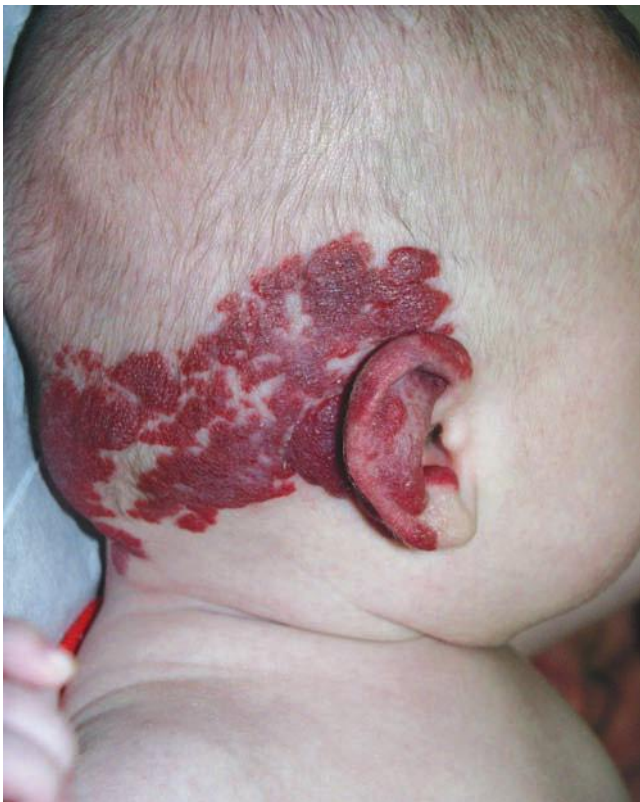

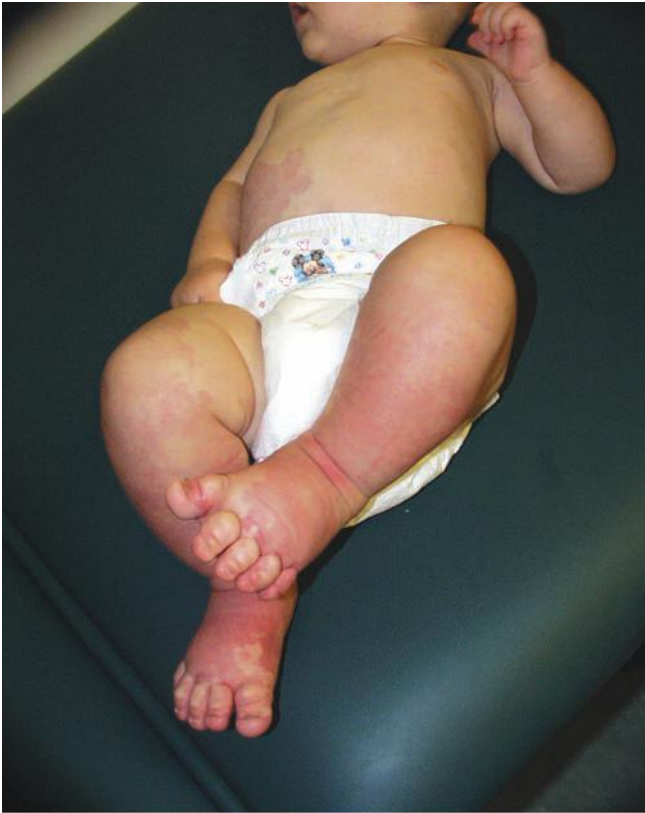Figure 45-23. Hemangioma of the ear and retroauricular region.

Around the second month of life, they enter the *proliferating phase* in which rapid growth is seen caused by plump, rapidly dividing endothelial cells. If the hemangioma is superficial, the skin becomes crimson and raised; if the lesion is deep, a dark blue or purple color is noted with less superficial swelling. Hemangioma growth frequently peaks before the first year, and then the lesions enter the *involuting phase* in which growth is commiserate with the child. The involuting phase is characterized by diminishing endothelial activity and luminal enlargement. The lesion begins to “gray,” losing its intense reddish color and taking on a purple-gray shade with overlying “crepe paper” skin. The involution phase continues until 5 to 10 years of age. Regression of the lesion is then complete. The *involved phase* begins in 50% of children by 5 years of age and in 70% by 7 years. If there was cutaneous ulceration during the proliferative phase, a cutaneous scar may persist, along with the yellow-gray crepe paper–like skin with fibro-fatty deposition. In 50% of children, near-normal skin is restored.

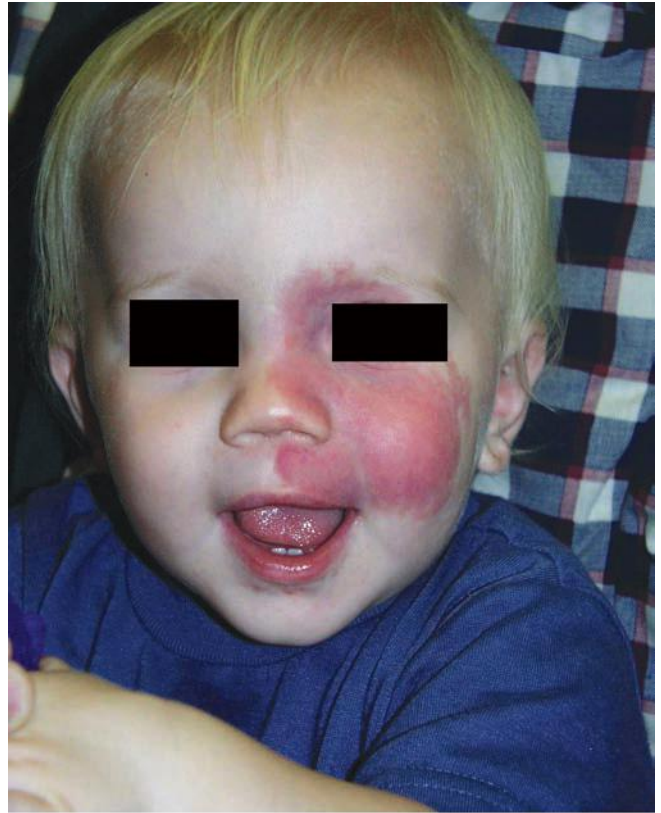The treatment of hemangiomas is largely observational, with reassurance of parents that regression and involution will occur. Cutaneous ulceration secondary to a proliferating hemangioma occurs in 5% of cases and more frequently with lip or urogenital lesions. Local wound care, topical application of lidocaine for pain, and laser cauterization may be beneficial treatment modalities. Problematic or endangering hemangiomas (i.e., periocular lesions threatening amblyopia, airway lesions, facially disfiguring lesions) occur in 10% of cases. The first-line treatment for problematic hemangiomas is systemic corticosteroid therapy, which is particularly effective (85% response rate). Second-line therapies include interferon and vincristine, each with its own attendant effectiveness and morbidity. Laser therapy has been claimed by some to be effective in the treatment of early hemangiomas; however, there has been no conclusive proof that laser therapy either diminishes lesion bulk or induces involution. Laser therapy has been effective in lightening affected skin. Surgery for hemangiomas in the proliferating phase is largely limited to treatment of problematic lesions (i.e., eyelid lesions threatening amblyopia). Hemangioma surgery usually is reserved for the treatment of secondary deformities and residual fibro-fatty depositions, among other indications.

Vascular Malformations. Vascular malformations are subclassified by vessel type, such as lymphatic, capillary, venous, or arterial, and by rheologic characteristics, such as slow flow and fast flow. Slow-flow lesions include capillary malformations (CMs) and telangiectasias, lymphatic malformations (LMs), and venous malformations (VMs). Fast-flow lesions include arterial malformations (AMs) and arteriovenous malformations (AVMs). In addition, there are combined malformations. One such combined lesion occurs in Klippel-Trénaunay syndrome in which CMs, LMs, and VMs are found and may be associated with soft tissue and skeletal hypertrophy in one or more of the limbs (Fig. 45-24A).

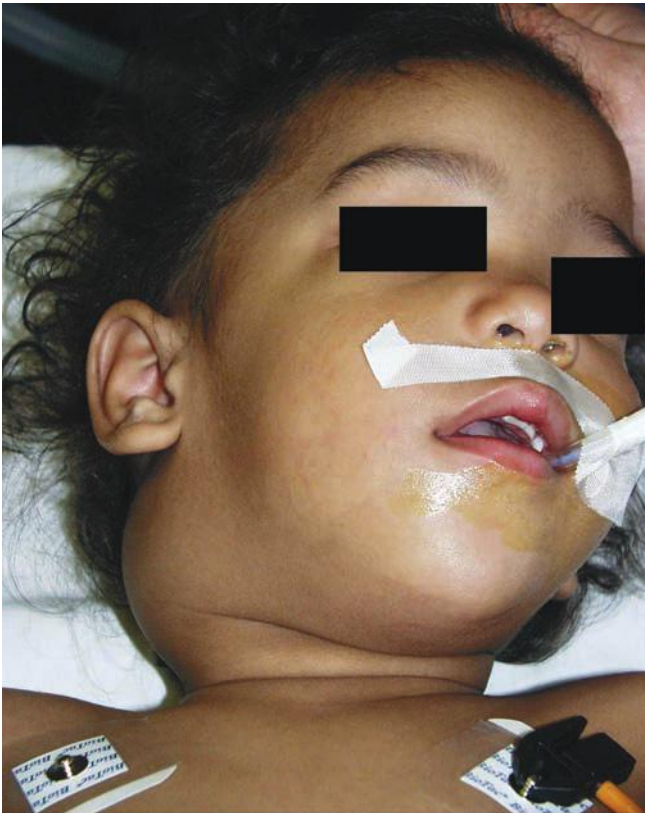CMs are pink-red macular vascular stains that are present at birth and persist throughout life. These lesions tend to become more verrucous and darker throughout life. CMs are effectively treated with a pulsed-dye laser, and the results often are better with treatment in infancy and young childhood. Laser therapy often is repetitive and prolonged. CMs of the head and neck, historically called *port-wine stains*, may be associated with Sturge-Weber syndrome, which includes vascular involvement of the leptomeninges and ocular pathology (Fig. 45-24B).



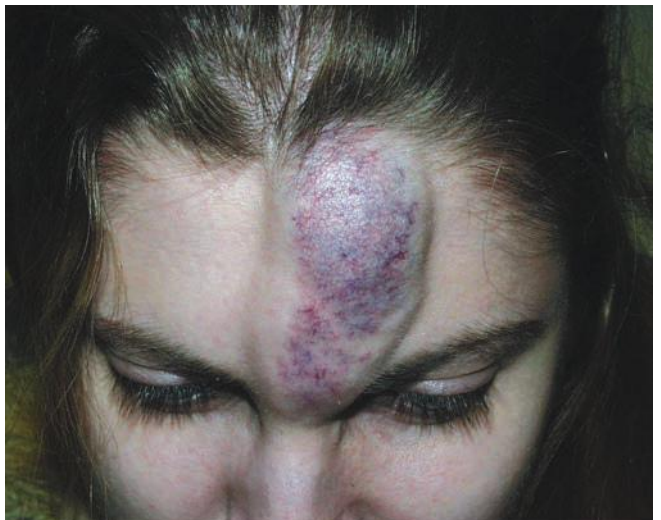A



B



C



D

Figure 45-24. A. Klippel-Trénaunay syndrome, with combined vascular anomaly (capillary malformation, lymphatic malformation, venous malformation) of the leg. B. Sturge-Weber syndrome, with V1 and V2 capillary malformation of the left face. C. Lymphatic malformation of the neck, previously referred to as *cystic hygroma*. D. Venous malformation of the forehead.

LMs are anomalous lymphatic channels that never regress and have the potential to affect underlying muscle and bone, causing significant swelling and bony overgrowth. They have historically been called *lymphangiomas* or *cystic hygromas* (Fig. 45-24C). LMs can be classified as microcystic, macrocystic, or both. LMs expand or contract with the flow of lymph, infection, or intralesional hemorrhage. Superficial LMs that affect the skin often produce cutaneous vesicles that may coalesce and weep lymph fluid. Sclerotherapy remains a major treatment modality for LMs, and lesions that are macrocystic can be aspirated before sclerotherapy. Although surgery rarely removes the entire lesion, surgical resection is the only possibility for cure. These resections often are challenging, lengthy, and associated with significant blood loss, and the potential exists for regeneration of lymph channels and recurrence of the LMs postoperatively.

VMs are frequently bluish, soft, and compressible, and swell when dependent (Fig. 45-24D). VMs grow with the child, expand slowly, and may enlarge during puberty. Patients often complain about stiffness and pain with thrombosis. VMs can affect the skin, muscle, and bone. MRI is the modality of choice for imaging these lesions. Preoperative sclerosis followed by surgical extirpation is the treatment of choice for VMs that cause functional or appearance-related disability. VMs have the tendency to recanalize and re-expand. Use of elastic support stocking and low-dose aspirin therapy are important adjunctive treatment modalities for VMs involving the legs.

Pure AMs are rare and more commonly present as AVMs. AVMs appear as red violaceous skin with a palpable mass beneath. Local warmth, bruit, and thrill are frequently present. AVMs have the likely consequences of ischemic changes, ulceration, intractable pain, and intermittent bleeding. The natural history of AVMs has been described as consisting of four stages: quiescence, expansion, destruction, and decompensation. Usually, treatment for AVM is initiated when signs and symptoms of ischemic pain, ulceration, bleeding, or hemodynamic instability (stages 3 and 4) are evident. Surgical treatment includes arterial embolization to temporarily occlude the nidus 24 to 72 hours before surgical extirpation. The nidus and overlying affected skin must be widely excised, and reconstruction can be performed afterward.

Congenital Melanocytic Nevi

Congenital melanocytic nevi (CMNs) contain nevus cells and are usually present at birth. Lesions are frequently light to dark brown and round or oval, and vary greatly in size, pattern, and anatomic location. The most common location of CMNs is the trunk, followed by the extremities and head and neck. Frequently, larger lesions are associated with multiple smaller satellite lesions. Over time, these lesions may become less (or sometimes more) pigmented and develop hypertrichosis and a variegated texture, including nodularity. Small CMNs are <1.5 cm in diameter, and large ones are >10 cm. Giant CMNs usually are >20 cm in their greatest dimension in adulthood, and this correlates with a 9-cm scalp lesion or a 6-cm trunk lesion in an infant. All CMNs should be monitored for worrisome changes that indicate the need for biopsy, including ulceration, uneven pigmentation, change in shape, and nodularity. There is controversy over the actual incidence of malignant transformation of CMNs; however, most experts believe that melanoma may arise directly from a CMN. No convincing study to date has proven that excision of a CMN reduces

the rate of malignant transformation to melanoma; however, many clinicians feel that excision serves at least to debulk the lesion. The reported lifetime risk for melanoma arising in small or large CMNs is between 0% and 5%; the risk for giant CMNs is estimated to be between 5% and 10%.²⁷ In addition to being at risk for melanoma, patients with large or giant CMNs are at risk for neurocutaneous melanocytosis (leptomeningeal melanosis), and this condition includes collections of melanocytes in the leptomeninges. Neurocutaneous melanocytosis carries a lifetime nonreducible risk of central nervous system melanoma and other morbidity and mortality from seizures, hydrocephalus, and other central nervous system conditions. MRI screening for infants born with large or giant CMNs is recommended to make the diagnosis of neurocutaneous melanocytosis.

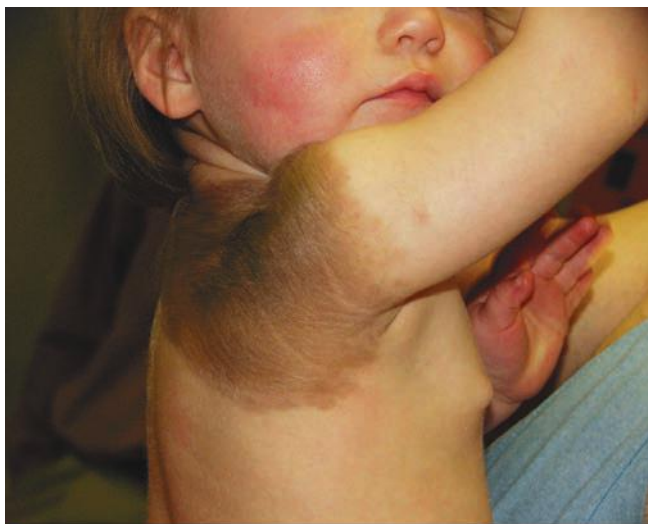Many different treatments have been advocated for the child with CMN; however, the overwhelming goals are to remove (or at least reduce) the risk of malignant transformation, preserve function, and improve cosmesis. Dermabrasion, chemical peels, and laser therapy have been reported to improve the appearance; however, none of these modalities completely removes nevus cells. To address malignant potential, only complete excision is a possible solution, and this is difficult, because nevus cells may extend beyond the skin and into the deep subcutaneous tissue and even the underlying muscle. The surgical options include direct excision and primary closure, serial excision, excision and skin grafting, and staged tissue expansion with subsequent lesion excision and flap reconstruction (Fig. 45-25). Treatment options have particular indications with respect to the location of the nevus. Scalp lesions are best treated with tissue expansion. Full-thickness skin grafting is best used for ear and eyelid reconstruction. Tissue expansion is associated with increased morbidity in lower extremity reconstruction, and therefore excision and grafting, even with previously expanded full-thickness skin grafts, is often the treatment of choice. In summary, CMNs often are treated surgically to decrease the risk of malignant degeneration to melanoma as well as to correct the significant appearance-related deformity.

4► RECONSTRUCTIVE SURGERY

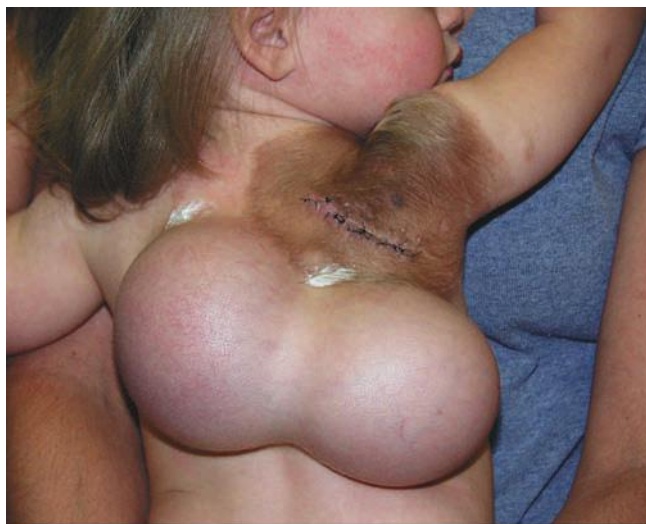Facial Reconstruction after Fracture

General Principles. As technologic advances raise the level of energy involved in modern systems of transportation, recreation, and weaponry, so follow increases in the degree of maxillofacial destruction related to misadventures with this technology. The first phase of care for the patient with maxillofacial trauma is activation of the advanced trauma life support protocol. Concomitant injuries beyond the face are the rule rather than the exception. The most common life-threatening considerations in the facial trauma patient are airway maintenance, control of bleeding, identification and treatment of aspiration, and identification of other injuries. Once the patient's condition has been stabilized and life-threatening injuries treated, attention is directed to diagnosis and management of craniofacial injuries.

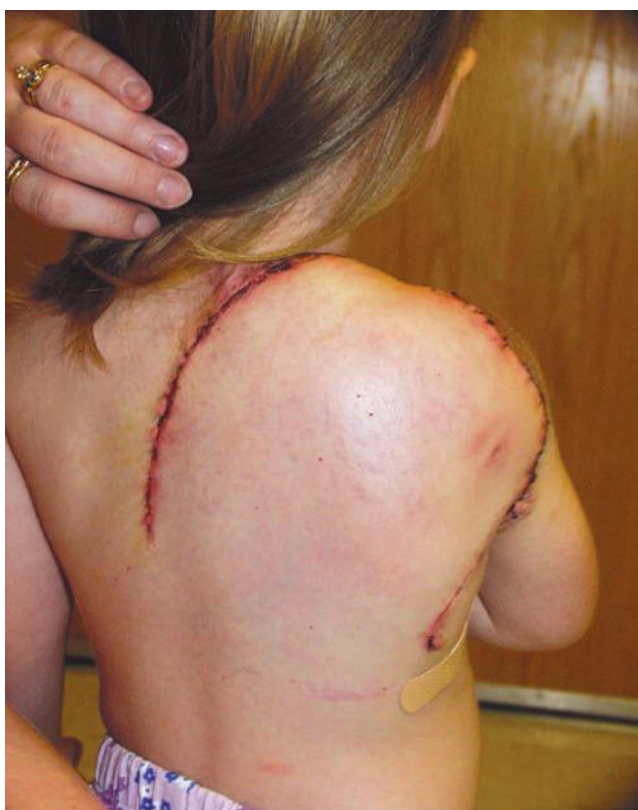Physical examination of the face with attention to lacerations, bony step-offs, instability, tenderness, ecchymosis, facial asymmetry, and deformity guides the examiner to underlying hard tissue injuries. Traditional specialized radiography has largely been replaced by widely available high-resolution CT. Coronal, sagittal, and three-dimensional reconstructions of images further elucidate complex injuries.



A



B



C

Figure 45-25. A. Congenital melanocytic nevus (CMN) of the posterior shoulder. B. Treatment of CMN of the posterior shoulder with tissue expansion. C. Appearance of the posterior shoulder after removal of tissue expanders, excision of the CMN, and flap coverage.

Mandible Fractures. Mandibular fractures are common injuries that may lead to permanent disability if not diagnosed and properly treated. The mandibular angle, ramus, coronoid process, and condyle are points of attachment for the muscles of mastication, including the masseter, temporalis, lateral pterygoid, and medial pterygoid muscles (Fig. 45-26). Fractures are frequently multiple, and disturbances in dental occlusion reflect the forces of the many muscles of mastication on the fracture segments. Dental occlusion is perhaps the most important basic relationship to understand about fracture of the midface and mandible. The Angle classification system describes the relationship of the maxillary teeth to the mandibular teeth.

Class I is normal occlusion, with the mesial buccal cusp of the first maxillary molar fitting into the intercuspal groove of the mandibular first molar. Class II malocclusion is characterized by anterior (mesial) positioning, and class III malocclusion is posterior (distal) positioning of the maxillary teeth with respect to the mandibular teeth (Fig. 45-27).

Nonsurgical treatment may be used in situations in which there is minimal displacement, preservation of the pretraumatic occlusive relationship, and normal range of motion. The goals of surgical treatment include restoration of pretraumatic dental occlusion, reduction and stable fixation of the fracture, and repair of soft tissue. Operative repair involves seating of the

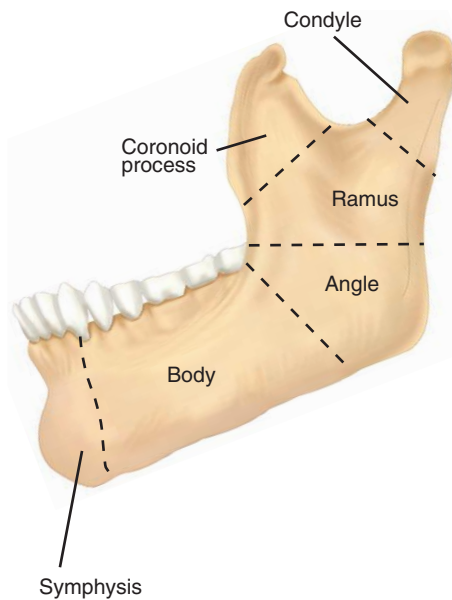


Figure 45-26. Mandibular anatomy. (Reproduced with permission from Thornton J, Hollier L. *Facial fractures II: lower third*. Selected Readings Plast Surg. 2002;9:1.)

condyles within the glenoid fossa, achievement of maxillary-mandibular fixation with arch bars or intermaxillary screws to establish proper dental occlusion, and intraoral, extraoral, or combination surgical exposure of fracture lines. The mandibular plating approach follows one of two schools of thought: rigid fixation as espoused by the Association for Osteosynthesis/Association for the Study of Internal Fixation (AO/ASIF) and less rigid but functionally stable fixation (Champy technique). Regardless of the stabilization approach, one of the

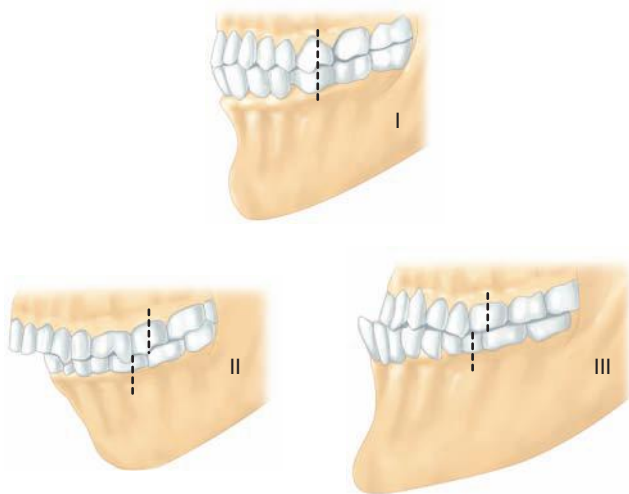


Figure 45-27. Angle classification. Class I: The mesial buccal cusp of the maxillary first molar fits into the intercusp groove of the mandibular first molar. Class II: The mesial buccal cusp of the maxillary first molar is mesial to the intercusp groove of the mandibular first molar. Class III: The mesial buccal cusp of the maxillary first molar is distal to the intercusp groove of the mandibular first molar. (Reproduced with permission from Thornton J, Hollier L. *Facial fractures II: lower third*. Selected Readings Plast Surg. 2002;9:1.)

postoperative objectives is release from maxillary-mandibular fixation and resumption of range of motion as soon as possible to minimize the risk of ankylosis. Other potential complications include infection, nonunion, malunion, malocclusion, facial nerve branch injury, infra-alveolar or mental nerve injury, and dental fractures.

Orbital Fractures. Treatment of all but the simplest orbital injuries should include evaluation by an eye specialist to assess visual acuity and rule out globe injury. Orbital fractures may involve the orbital roof, floor, or lateral or medial walls. The most common orbital fracture is the orbital floor blow-out fracture caused by direct pressure to the globe and sudden increase in intraorbital pressure. Because the medial floor and inferior medial wall are made of the thinnest bone, fractures occur most frequently at these locations. These injuries may be treated expectantly if they are sufficiently small and without complication. However, larger blow-out fractures and those associated with enophthalmos (increased intraorbital volume), entrapment of inferior orbital tissues, or diplopia lasting >2 weeks generally require surgical treatment.²⁸ There are many approaches to the orbital floor, including the transconjunctival, subciliary, and lower blepharoplasty incisions. All provide access to the orbital floor and allow for repair with a multitude of different autogenous and synthetic materials. Late complications include persistent diplopia, enophthalmos, ectropion, and entropion.

Lateral and inferior orbital rim fractures also are not uncommon and are often associated with the zygomaticomaxillary complex fracture pattern, as discussed later.

Special mention should be made of two uncommon complications after orbital fracture. Superior orbital fissure syndrome results from compression of structures contained in the superior orbital fissure in the posterior orbit. These include cranial nerves III, IV, and VI, and the first sensory division of cranial nerve V. Compression of these structures leads to symptoms of eyelid ptosis, globe proptosis, paralysis of the extraocular muscles, and anesthesia in the cranial nerve VI distribution. If the optic nerve (cranial nerve II) is also involved, symptoms include blindness and the syndrome is dubbed *orbital apex syndrome*. Both of these syndromes are medical emergencies, and steroid therapy and surgical decompression are considered.

Zygoma and Zygomaticomaxillary Complex Fractures. The zygoma forms the lateral and inferior borders of the orbit. It articulates with the sphenoid bone in the lateral orbit, the maxilla medially and inferiorly, the frontal bone superiorly, and the temporal bone laterally (Fig. 45-28). Zygoma fractures may involve the arch alone or many of its bony relationships. Isolated arch fractures manifest as a flattened, wide face with associated edema and ecchymosis. Nondisplaced fractures may be treated nonsurgically, whereas displaced and comminuted arch fractures may be reduced and stabilized indirectly (Gilles approach) or, for more complicated fractures, directly through a coronal incision.

The zygomaticomaxillary complex (ZMC) fracture involves disruption of the zygomatic arch, the inferior orbital rim buttress, the zygomaticomaxillary buttress, the lateral orbital wall, and the zygomaticofrontal buttress. The fracture segment tends to rotate laterally and inferiorly, creating an expanded orbital volume, limited mandibular excursion, an inferior cant to the palpebral fissure, and a flattened malar eminence. ZMC fractures are almost always accompanied by numbness in the infraorbital nerve distribution and subconjunctival hematoma.

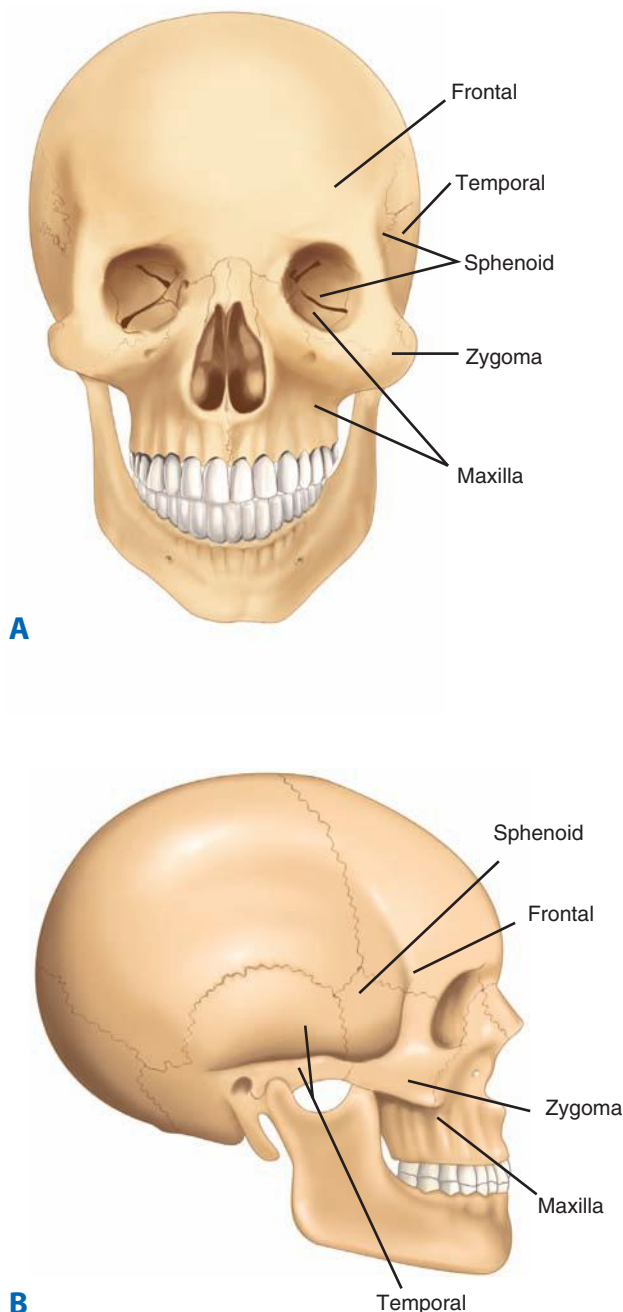


Figure 45-28. Facial bone anatomy. (Reproduced with permission from Hollier and Thornton.²⁸)

Displaced fractures are treated by exposure through multiple incisions to gain access to all of the buttresses requiring fixation. These include the upper eyelid incision (zygomaticofrontal buttress and lateral orbital wall), the subtarsal or transconjunctival incision (orbital floor and infraorbital rim), and the maxillary gingivobuccal sulcus incision (zygomaticomaxillary buttress). Again, significantly complex zygomatic fractures require wide exposure through a coronal approach.⁵

Naso-Orbital-Ethmoid Fractures. Naso-orbital-ethmoid (NOE) fractures are often part of a constellation of panfacial fractures and intracranial injuries. Anatomically, the fracture pattern involves the medial orbits, nasal bones, nasal processes of the frontal bone, and frontal processes of the maxilla. These injuries result in severe functional deficit and cosmetic

deformity from collapse of the nose, ethmoids, and medial orbits; displacement of medial canthal ligament fixation; and nasolacrimal apparatus disruption. Telecanthus is produced by splaying apart of the nasomaxillary buttresses to which the medial canthal ligaments are attached. Treatment typically involves plating or wiring all bone fragments meticulously, potentially with primary bone grafting, to restore their normal configuration. Key to the successful repair of an NOE fracture is the careful re-establishment of the nasomaxillary buttress and restoration of the pretrauma fixation points of the medial canthal ligaments. If comminution is severe, this may be achievable using transnasal wiring of the ligaments.

Frontal Sinus Fractures. The region of the frontal sinus is a relatively weak structural point in the upper face. For this reason, it is a common location for fracture in facial trauma. The paired sinuses each have an anterior bony table that determines the contour of the forehead and a posterior table that separates the sinus from the dura. Each sinus drains through the medial floor into its frontonasal duct, which empties into the middle meatus within the nose. Treatment of a frontal sinus fracture depends on the fracture characteristics (Fig. 45-29).

Nasal Fractures. The nose is the most common facial fracture site due to its prominent location, and such fracture can involve the cartilaginous nasal septum, the nasal bones, or both. It is important to perform an intranasal examination to determine whether a septal hematoma is present. If present, a septal hematoma must be incised, drained, and packed to prevent pressure necrosis of the nasal septum and long-term midvault collapse. Closed reduction of nasal fractures may be performed under local or general anesthesia. Unfortunately, many, if not most, show some deformity upon final healing, requiring rhinoplasty if airway obstruction is present or if improved appearance is desired.

Panfacial Fractures. Fractures of multiple bones in various locations fall into the category of panfacial fracture. These may involve frontal and maxillary sinus fractures, NOE fractures, orbital and ZMC fractures, palatal fractures, and complex mandible fractures. The difficulty in the repair of these injuries lies not in the technical aspects of fixation but in the reestablishment of normal relationships between facial features in the absence of all pretraumatic reference points. Without proper correction of bony fragment relationships, facial width is exaggerated and facial projection is lost. The key point in approaching the patient with a panfacial fracture is first to reduce and repair the zygomatic arches and frontal bar to establish the frame and width of the face. The nasomaxillary and zygomaticomaxillary buttresses may then be repaired within this correct frame. Next, the maxilla may be reduced to this framework, followed by palatal fixation if needed. Finally, now that the midface relationships have been corrected, maxillary-mandibular fixation can be applied with the mandible in correct occlusion followed by plating of any mandibular fractures.²⁹

Ear Reconstruction

Acquired defects of the auricle have many causes, and many different choices for reconstruction are available. Reconstructive approach often is determined by the size and location of the defect. Small helical lesions may be simply excised as a wedge and closed primarily. Larger defects of the upper and middle thirds of the ear may use antihelical and conchal cartilage reduction patterns to reduce the circumference of the helix to allow

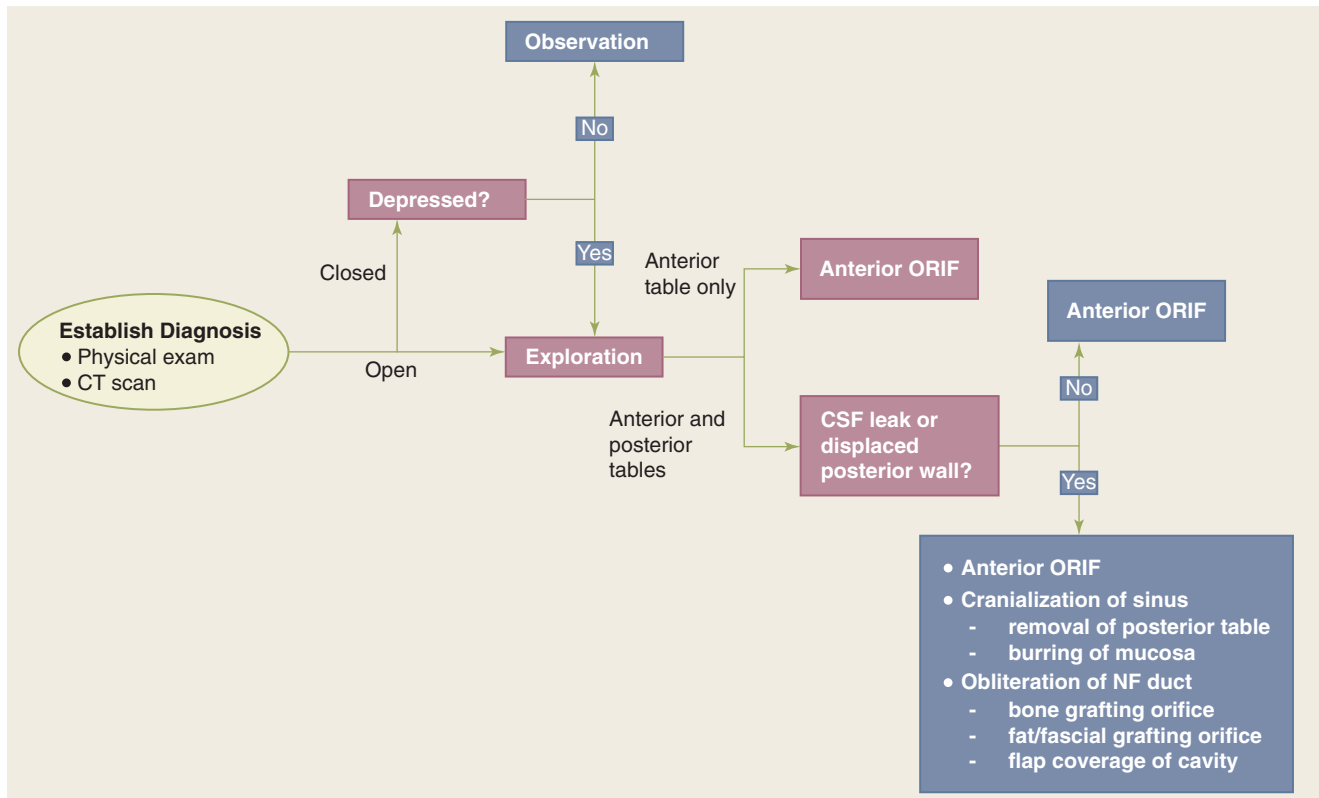


Figure 45-29. Algorithm for the treatment of frontal sinus fracture. CSF = cerebrospinal fluid; CT = computed tomography; NF = nasofrontal; ORIF = open reduction, internal fixation.

primary closure. When helical defects are too large for this solution, local flaps may be used to close or re-create the missing tissue. Postauricular flaps created in staged procedures may be manipulated to create a skin tube mimicking the furled helix and bridging the gap of a defect. Alternatively, use of an Antia-Buch chondrocutaneous advancement flap combined with cartilaginous reduction allows for closure of defects³⁰ (Fig. 45-30). Even larger defects of the upper and middle thirds of the ear may be reconstructed with large local skin flaps combined with contralateral cartilage grafts or contralateral composite grafts. Although ear lobe defects are relatively simple to close primarily, lower third auricular defects that involve more than just the lobe are complex and require cartilaginous support, often combined with local skin flaps.

Nasal Reconstruction

Reconstruction of the nose requires appreciation of the nine aesthetic subunits that are defined by normal anatomic contours and lighting patterns (Fig. 45-31). In general, if a defect involves $\geq 50\%$ of a subunit, the remainder of the subunit should be excised and included in the reconstruction. The nose can be thought of as being composed of three layers: skin cover, structural support, and mucosal lining. When a defect or anticipated defect is evaluated, it is useful to consider what layers of tissue will be missing so that a reconstruction can be devised that replaces each layer. Healing by secondary intention is successfully used in concavities such as the alar groove. Split- or full-thickness skin grafts may be used for superficial defects of the nasal dorsum or sidewall. Composite grafts may be used for the nasal tip or alar rim (see Fig. 45-3). Local random pattern flaps are useful in closing small defects of the dorsum and tip and may be combined with cartilage grafts if structural

support is needed. Axial pattern flaps are commonly used for larger defects. These flaps have the advantage of being able to cover and revascularize underlying cartilage grafts and enjoy a close color match to surrounding skin. Workhorse flaps used in nasal reconstruction include the nasolabial flap and the paramedian forehead flap (Fig. 45-32). Even larger defects may require scalping flaps or free radial forearm flaps. Split calvarial cantilever bone grafts may provide the nasal dorsum support. Lining is generally achieved with scar tissue turnover flaps, mucoperichondrial flaps from within the nasal vestibule, or skin grafting of the underside of transposed flaps.

Lip Reconstruction

The lips are important for articulate speech, eating, maintenance of oral competence, facial expression, and aesthetic harmony of the lower face. Three layers of tissue form the upper and lower lips: skin, muscle, and mucosa. Blood supply is through the facial artery and its branches to the lip, the superior and inferior labial arteries. Lip defects can arise from trauma, burns, neoplasms, congenital lesions, clefts, or infection. As with almost all types of reconstruction, choice of technique is heavily dependent on defect size, location, and deficient structures. The goals of lip reconstruction are restoration of the competent oral sphincter with vermilion apposition, preservation of sensation, and avoidance of microstomia, all while preserving a near-normal static and dynamic appearance. In the upper and lower lip, vermilion-only defects can be corrected with advancement of the labial mucosa, often called a *lip shave*. In defects of less than one-third the horizontal length, enough redundancy is present to allow primary closure. More complex decisions must be made for defects that are between one-third and two-thirds of the total lip length.

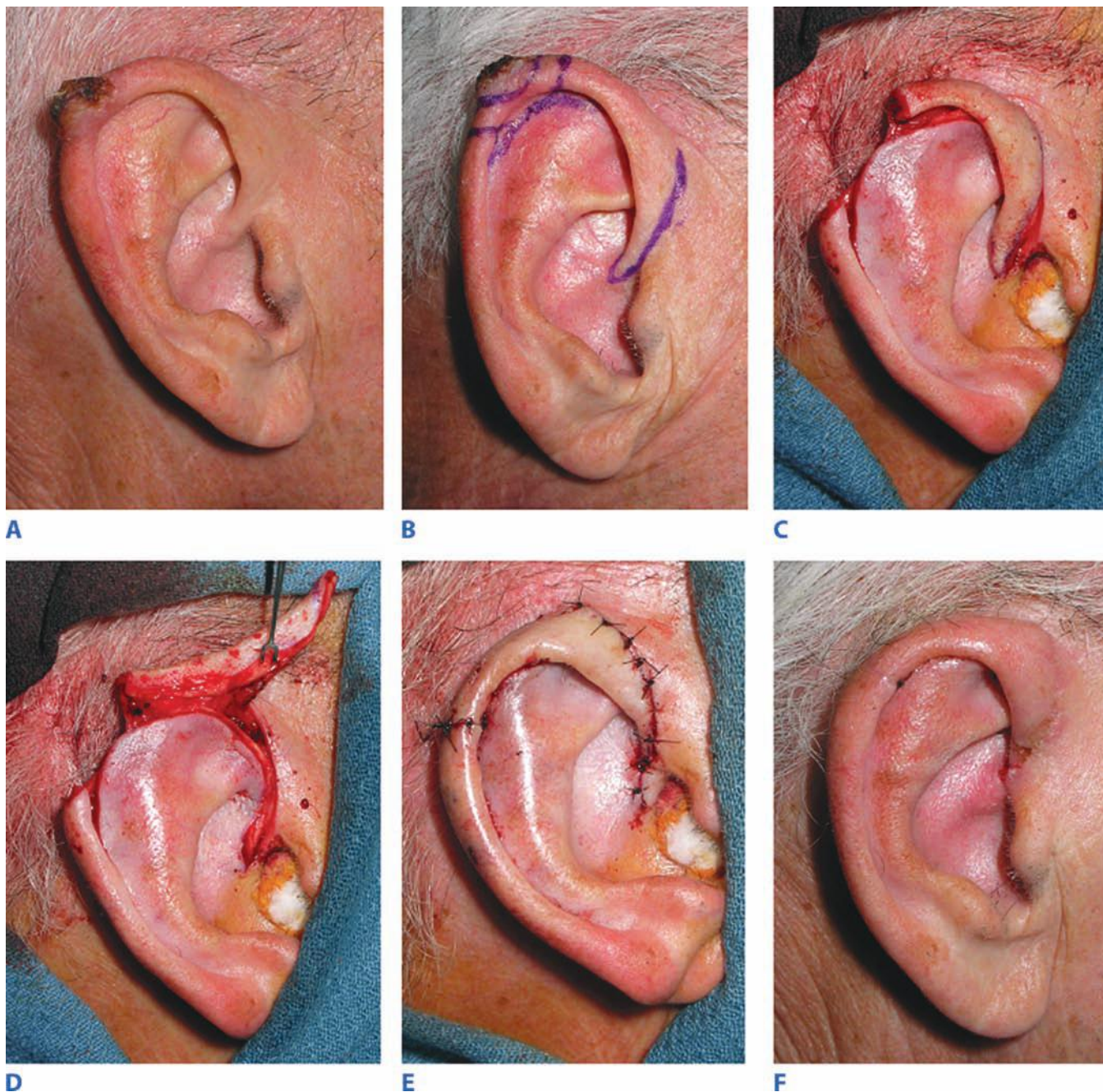


Figure 45-30. Modified Antia-Buch ear reconstruction. **A.** Superior helix lesion. **B.** Excision pattern and reconstruction markings. **C.** Defect, flap elevation, and cartilage reduction. **D.** V-Y advancement of the flap. **E.** Flap inseting. **F.** Appearance at 1 month after surgery. (Photographs reproduced with permission from M. Gimbel.)

The two categories of lip flap technique are transoral cross-lip flaps and circumoral advancements flaps. Cross-lip flaps include the Abbé flap and the Estlander flap. The Abbé flap was originally designed to reconstruct central upper lip (tubercle) defects with lower lip full-thickness tissue vascularized by one of the labial arteries (Fig. 45-33). The technique requires a second-stage procedure for division of the pedicle. The Estlander flap is similar in principle but is based laterally at the oral commissure and is used to reconstruct lateral upper or lower lip lesions. Both the Estlander and Abbé flaps are denervated, but sensation and perhaps even motor function return over months.³¹ The Karapandzic technique is an advancement-rotation flap technique designed for central lower lip defects.

Although good function, sensation, and mobility are preserved, a side effect is reduction in the size of the oral aperture. The Webster-Bernard technique uses cheek tissue advancement flaps to replace defects with full-thickness or partial-thickness cheek incisions extended laterally from the commissure (Fig. 45-34). When performed bilaterally, both the Karapandzic and the Webster-Bernard methods can be used to reconstruct a complete upper or lower lip.

In addition, microvascular free tissue transfer reconstruction may be necessary in cases where there is no remaining lip. The radial forearm free flap is the most commonly used for this purpose, usually transferred with the palmaris longus tendon for lip support.

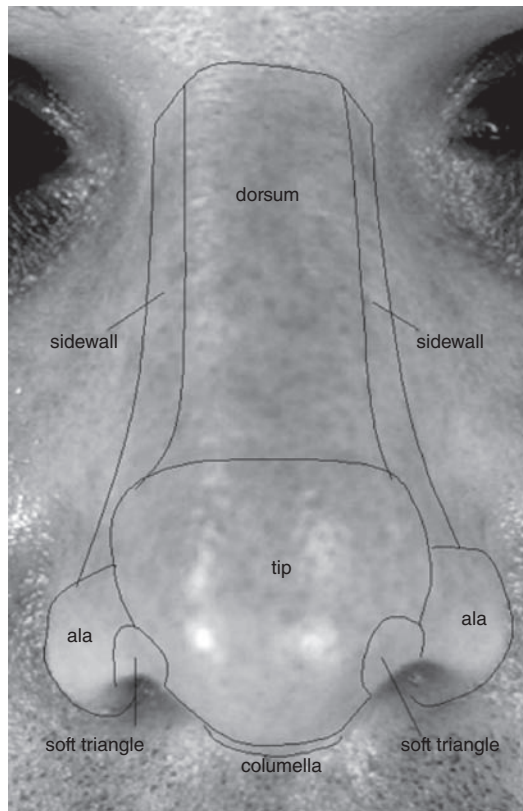


Figure 45-31. Nasal aesthetic subunits. (Photograph reproduced with permission from M. Gimbel.)

Eyelid Reconstruction

The eyelids protect the eye from exposure and are another crucial aesthetic structure of the face. They consist of an anterior lamella (skin and orbicularis oculi muscle) and a posterior lamella (tarsus and conjunctiva). The eyelid blood supply is robust, and ischemia is rarely a concern in reconstruction.

Upper Eyelid. Defects comprising <25% of the upper eyelid can generally be closed primarily in pentagonal approximating fashion (Fig. 45-35). For defects involving 25% to 50% of the upper eyelid, lateral canthotomy (release of the lateral canthal tendon) and cantholysis (release of the superior limb of the lateral palpebral tendon) can be performed to allow advancement and are often combined with use of a lateral semicircular flap (Fig. 45-36). Defects larger than 50% of the upper eyelid may be reconstructed with a Cutler-Beard full-thickness advancement flap or a modified Hughes tarsoconjunctival advancement flap (Fig. 45-37).

Lower Eyelid. Lower eyelid reconstruction considerations parallel those for the upper eyelid. In addition, special attention must be given to the prevention of scleral visibility and ectropion, which can arise from excessive vertical tension due to either technique or scarring. Similar reconstructive methods may be used, including direct closure, semicircular flaps and canthal release, and advancement flaps. Grafts may also be used if the defect is partial thickness. Full-thickness contralateral upper eyelid skin grafts are suitable for replacing the anterior lamella. The posterior lamella requires sturdy, nonkeratinized graft tissue, such as cartilage (tarsal, ear, or

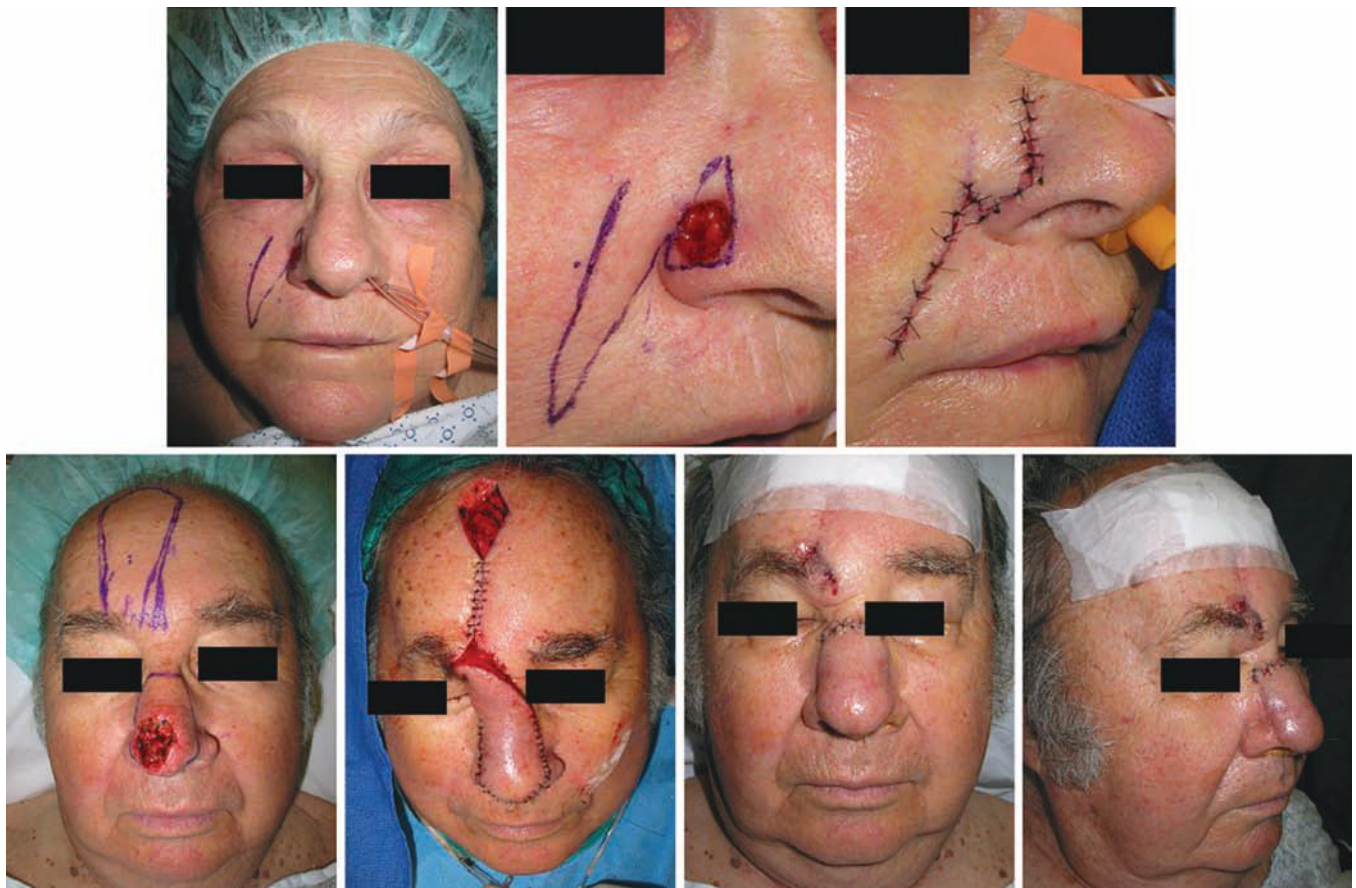

Figure 45-32. Nasal reconstruction with axial pattern flaps. *Top row:* Nasolabial flap reconstruction of an alar defect. *Bottom row:* Paramedian forehead flap reconstruction of the nasal lobule. (Photographs reproduced with permission from M. Gimbel.)

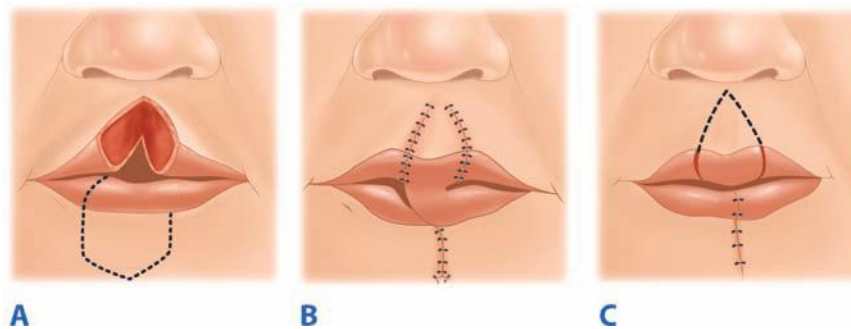


Figure 45-33. Abbé flap upper lip reconstruction. **A.** Defect and flap design. **B.** Rotation of the flap and primary closure of the donor site. **C.** Division of the pedicle (after 2 to 3 weeks) and final inseting.

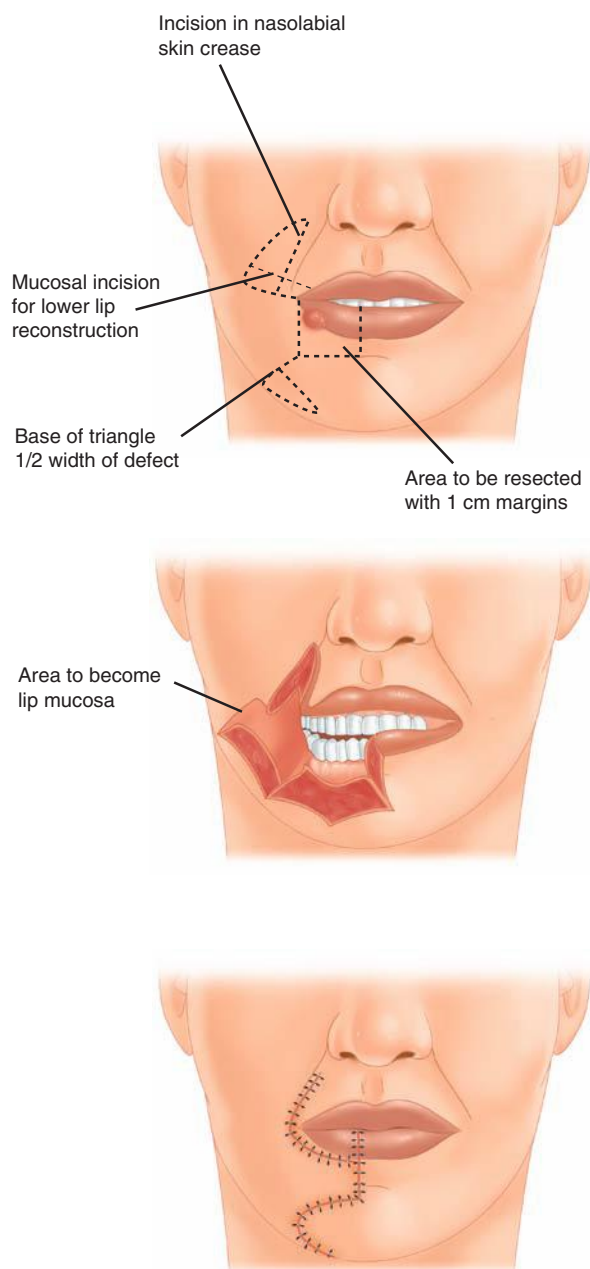


Figure 45-34. Webster-Bernard lip reconstruction technique. (Reproduced with permission from Closmann JJ, Pogrel A, Schmidt BL. Reconstruction of perioral defects following resection for oral squamous cell carcinoma. *J Oral Maxillofac Surg.* 2006;64:367. Copyright Elsevier.)

nasal septal) or hard palate mucosal grafts, to allow globe apposition.³²

Ptosis. In the normal eyelid, the orbicularis oculi muscle, Müller's muscle, and levator palpebrae muscle act in concert to open and close the palpebral aperture and to maintain the level of the upper eyelid with respect to the pupil. Eyelid ptosis is created by derangement of this cooperative action. Ptosis may be congenital or acquired. Congenital ptosis is caused by lid anomalies, ophthalmoplegia, and synkinesis, whereas acquired ptosis can be neurogenic, myogenic, or traumatic in nature. Horner's syndrome is a form of neurogenic ptosis caused by interrupted sympathetic innervation that leads to ptosis, miosis, and anhidrosis. A thorough evaluation of the ptotic patient includes a general eye and visual acuity examination, attention to signs of exposure or irritation, measurement of marginal-reflex distance, observation of the height of the supratarsal fold, and assessment of levator function. Severity of ptosis and degree of levator dysfunction are critical in deciding the appropriate corrective procedure (Table 45-11). Mild ptosis may be addressed with the Fasanella-Servat procedure, which involves excision of the superior tarsal edge, conjunctiva, and levator aponeurosis, and mullerectomy. Other corrections of mild ptosis usually involve variations on this procedure. Moderate ptosis with fair to good levator function may be treated with some form of a levator aponeurosis shortening procedure. Severe ptosis with poor levator

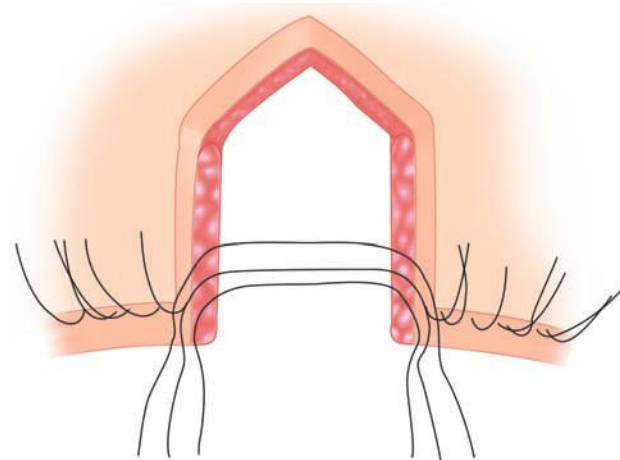


Figure 45-35. Upper eyelid defect of <25%. Primary closure. (Reproduced with permission from Pham RT. Reconstruction of the upper eyelid. *Otolaryngol Clin North Am.* 2005;38:1023. Copyright Elsevier.)

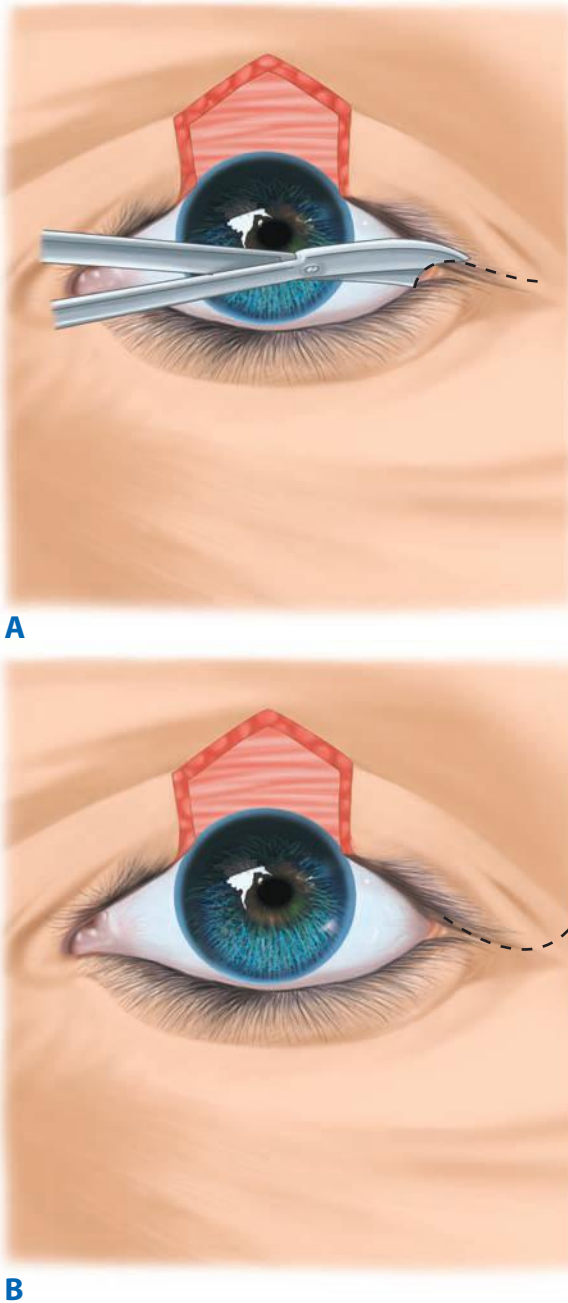


Figure 45-36. Upper eyelid defect of 25% to 50%. **A.** Lateral canthotomy. **B.** Semicircular flap. (Reproduced with permission from Pham RT. *Reconstruction of the upper eyelid*. *Otolaryngol Clin North Am.* 2005;38:1023. Copyright Elsevier.)

function requires use of an alternate eyelid motor. The frontalis muscle fascial sling technique, which uses strips of fascial grafts sutured to the frontalis muscle, is one such solution.

Skull and Scalp Reconstruction

Scalp Reconstruction. The scalp is formed of five layers: Skin, subCutaneous tissue, galea Aponeurotica, Loose areolar tissue, and Pericranium (SCALP). The scalp is well vascularized bilaterally by branches of the external carotid artery, including the superficial temporal arteries, the occipital arteries, and the posterior auricular arteries. In addition, the bilateral supraorbital and supratrochlear arteries contribute to the

forehead and anterior scalp blood supply. These vessels run in the subcutaneous tissue layer, just superficial to the galea. Because of this rich blood supply, scalp lacerations can lead to dramatic blood loss, an event that usually can be curtailed by a simple running/locking suture closure.

Partial-thickness scalp loss due to trauma usually occurs at the level of the loose areolar tissue plane and is treated initially with débridement of devitalized tissue. If a partial-thickness defect is small enough, primary closure or skin graft can be used. Although the cosmetic result is often less than desirable, all layers of the scalp will accept a skin graft, including the calvaria if it is burred down to its diploë. Because the scalp is relatively inelastic, scoring of the galeal layer often facilitates closure of full-thickness defects, but care must be taken to avoid lacerating the blood vessels just superficial to the galea. Larger areas of loss (4–8 cm) may be covered with large scalp flaps, as classically described by Orticochea.³³ Grafting of defects or donor sites leaves a visible area of alopecia. Tissue expansion has been very successful in replacing scarred or grafted regions with hair-bearing skin. Defects larger than 8 to 10 cm are best treated with microsurgical free tissue transfer. Total or subtotal scalp avulsions are rare injuries that usually occur when a person's long hair becomes caught in rotating machinery. These potentially devastating injuries are ideally treated by scalp replantation, because the avulsed segment usually has preserved vessels (Fig. 45-38).

Calvarial Reconstruction. Autogenous bone remains the material of choice for reconstruction of skull defects. Its advantages include resistance to infection and ability to heal with strength. All autogenous bone sources have the disadvantage of donor site morbidity. Bone grafts can be harvested from a normal area of the calvaria, of which the outer table may be used as a graft for defects of limited size. Care must be taken during harvest to avoid compromise of the inner table. Rib bone may also be used, either as a split-rib graft or as a microsurgical free osseous flap. Unfortunately, use of ribs to reconstruct the skull may give an unappealing “washboard” appearance to the scalp. Another disadvantage of bone grafts, although not flaps, is graft resorption over time.

Alternative materials to autogenous bone exist for calvarial reconstruction, including methyl methacrylate, titanium, and hydroxyapatite (with or without bone morphogenic protein). Although they have the advantage of no donor site, these plastics and metals are associated with a higher risk of infection necessitating removal. Various formulations of calcium phosphate hydroxyapatites are being actively studied as bone replacement materials.

Head and Neck Reconstruction

The head and neck region has a compact arrangement of critical and complex structures encasing the essential routes to the gastrointestinal and respiratory systems. The tissues of the face, mouth, and cavities serve as a primary communication interface with the external environment through facial and verbal expression. Therefore, cancer resections with adequate safety margins can be severely and multiply debilitating. The management of head and neck cancer patients demands an integrated multidisciplinary team approach that includes the skills of ablative and reconstructive surgeons, medical and radiation oncologists, pathologists, nutritionists, and functional and psychological rehabilitation specialists.

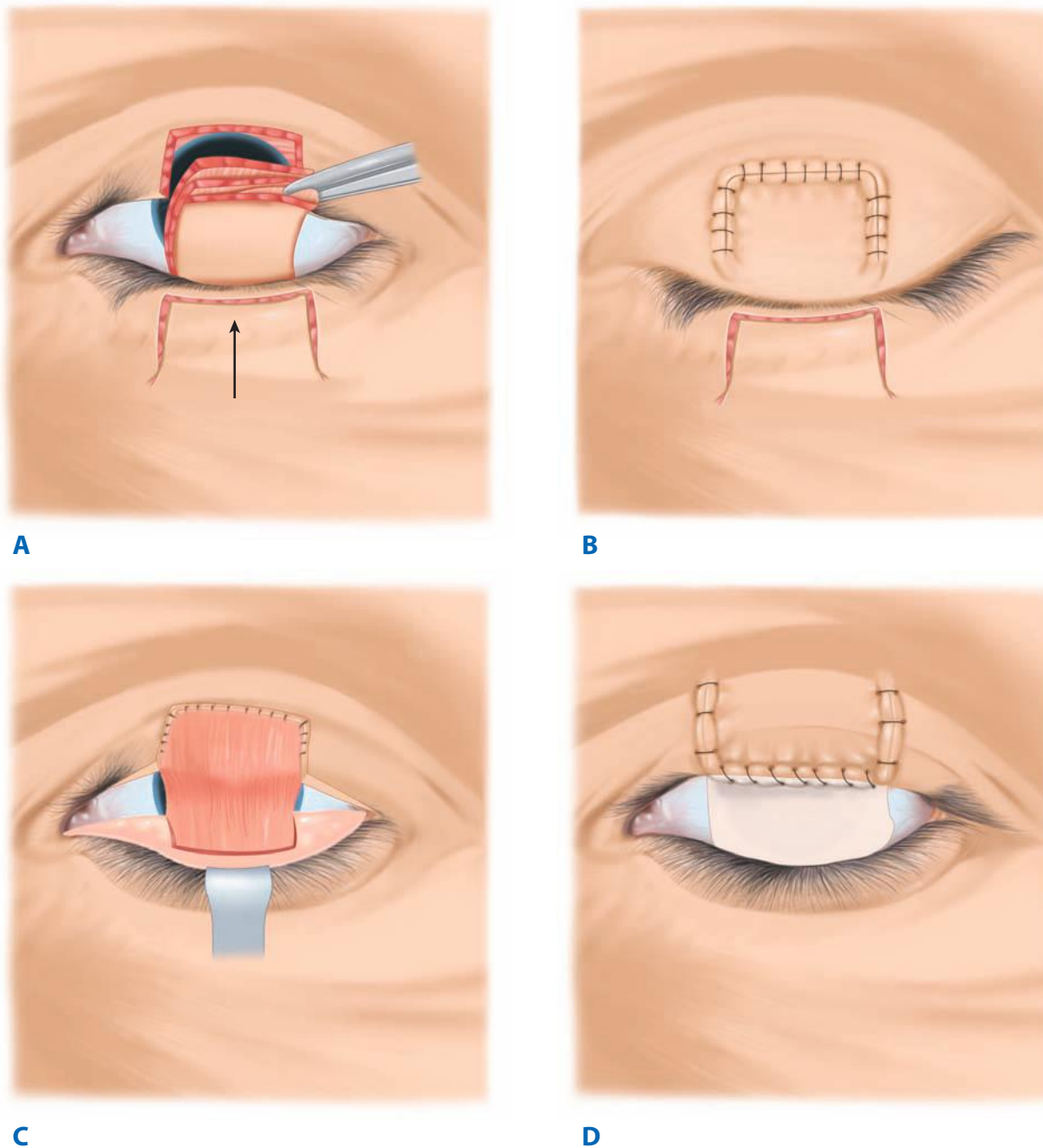


Figure 45-37. Upper eyelid defect of >50%. **A** and **B**. Cutler-Beard full-thickness lower eyelid advancement flap. **C** and **D**. Hughes lower eyelid tarsoconjunctival advancement flap. (Reproduced with permission from Pham RT. *Reconstruction of the upper eyelid*. Otolaryngol Clin North Am. 2005;38:1023. Copyright Elsevier.)

Table 45-11

Eyelid ptosis classification

Classification of ptosis severity	
Mild	1–2 mm
Moderate	3 mm
Severe	4+ mm
Classification of levator function	
Excellent	12–15 mm
Good	8–12 mm
Fair	5–7 mm
Poor	2–4 mm

Tumor-Ablative Surgery. The freedom available to the ablative surgeon to completely excise a tumor is limited, at least partly, by the capability of the reconstructive surgeon to restore anatomic continuity and achieve successful wound healing. A neck dissection to remove cervical lymphatics and nodes may be performed for prophylactic or curative intent, for more accurate prognostication by operative staging, and/or for solidification of plans for adjunctive treatments. It is important to be familiar with the tumor-node-metastasis (TNM) classification and staging of head and neck cancers. The N and M parameters are fairly constant for most head and neck cancers, whereas the T parameter varies according to tumor location.

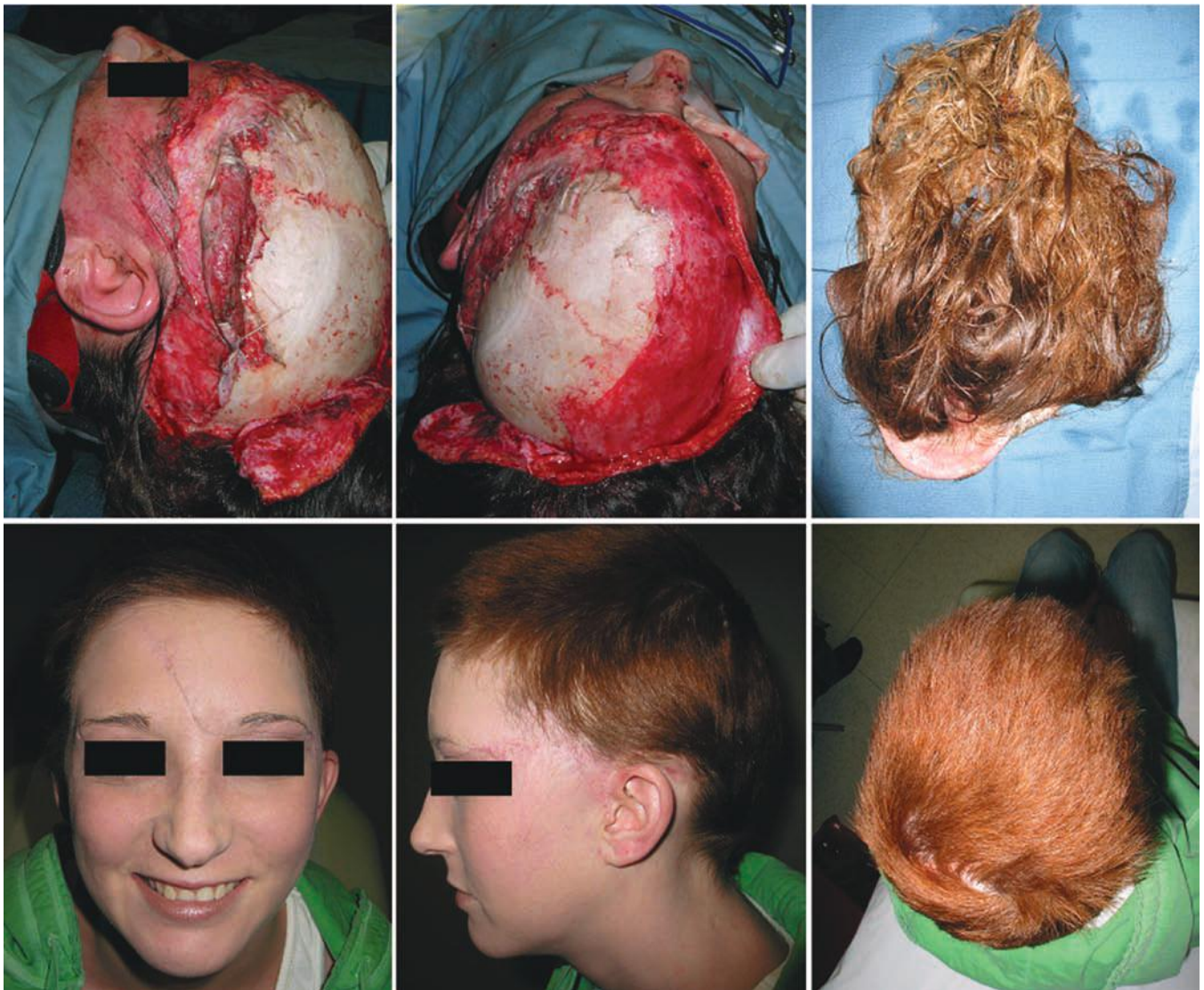

Figure 45-38. Twenty-five-year-old woman with 70% scalp avulsion after a pedestrian-automobile accident. *Top row:* Defect and specimen intraoperatively. *Bottom row:* Appearance 9 weeks after microsurgical scalp replantation. (Photographs reproduced with permission from M. Gimbel.)

Principles of Reconstruction. The reconstructive surgeon aims to restore lost anatomic components adequately. Residual deficits, seemingly inconsequential, may progress to psychological morbidity, societal malacceptance, and social withdrawal. Uncomplicated and timely wound healing is important to allow adjuvant therapies when indicated and smooth discharge to home and occupation.

Each defect can be addressed by a number of methods, but the technique must be decided for each individual patient. Although a more complex reconstruction might offer improved outcomes, it may bring an increased risk of complications. Some patients may therefore benefit from use of a simpler method with more acceptable anesthetic and operative risk rather than a gold-standard reconstruction. Such an approach may be appropriate, for example, for an elderly patient with an advanced T4 cancer and short life expectancy. Reconstruction is impossible for some functional losses, such as the enucleation of an eye, but replacement by a reasonably aesthetic prosthesis may be achievable.³⁴

Reconstructive Options by Region. Before the 1970s, autogenous tissue reconstructions were largely restricted to local or regional pedicled flaps, including the trapezius, pectoralis, and deltopectoral workhorse flaps. With microvascular free tissue transplantation, defects that were previously deemed nearly impossible to reconstruct can now be addressed in a single operation. Consequently, head and neck cancers that were historically unresectable have become more operable.

Intraoral Structures The reconstructive choice for floor of mouth, tongue, and other intraoral defects is dictated by the dimension of the defect, the volume of tissue lost, and residual tongue mobility. The tongue and adjacent mucosal surfaces heal exceptionally well, so small defects may be treated by primary closure or even left to heal spontaneously. Smaller defects, less than one-fourth glossectomy, may be treated with a skin graft or perhaps primary closure if tongue mobility is preserved. Larger defects, more than one-third glossectomy, call for reconstruction by free tissue transfer, commonly a free radial forearm or anterolateral thigh flap for smaller- or larger-volume defects,

respectively. Total glossectomy defects are a major challenge, and no ideal method exists to restore tongue motor functions. The primary goal is to protect the airway from aspiration. Swallowing and articulation are often suboptimal after total glossectomy reconstructions. Options include bulkier myocutaneous free flaps harvested from the anterolateral thigh, the back (latissimus dorsi), or the abdomen (rectus abdominis), or pedicled regional flaps (e.g., latissimus dorsi).³⁵

The reconstructive choice for other intraoral soft tissue defects should also take into consideration the specific characteristics of the defect, such as its thickness and dimensions, and involvement of the oral commissure, facial skin, and/or neck. Buccal defects, for example, may be adequately treated with a radial forearm free flap or a thin anterolateral thigh flap. Thicker defects may be more appropriately reconstructed with a fasciocutaneous anterolateral thigh free flap. Those that extend through the full thickness of the cheek to involve the external facial skin may be reconstructed with a cutaneous or myocutaneous anterolateral thigh free flap that has been folded to address the internal mucosal, external skin, and intervening soft tissue defects simultaneously.³⁶ When the contour of the neck is expected to be sunken and asymmetric after a neck dissection, it is possible to improve symmetry by inseting part of the flap into the neck. This maneuver also obliterates dead space and helps protect the adjacent major neurovascular structures.

Mandible and Midface Mandibular defects may arise from the ablation of tumors involving the bone itself or from the need to satisfy clearance margins for adjacent soft tissue tumors. Segmental mandibular defects can be classified as isolated bone defects, compound defects (bone and oral lining *or* skin), composite defects (bone, oral lining, *and* skin), or extensive composite defects (bone, oral lining, skin, and soft tissues).³⁷ The primary goals of mandibular reconstruction are to restore bony continuity, masticatory (with accurate dental occlusion) and speech functions, and facial contour, and to maintain tongue mobility. Occasionally, a small segmental mandibular defect may be amenable to reconstruction with a nonvascularized bone graft, but these are poorly suited to the forces of mastication and are prone to resorption and failure amid radiotherapy or infection.

The best option for most segmental mandibular defects is the fibula bone free flap with an adjoined skin island supplied by reliable septocutaneous vessels (occasionally musculocutaneous perforators) from the peroneal artery and vein; this is termed a *fibula osteoseptocutaneous free flap*.³⁸ Its many desirable characteristics include (a) the ability to withstand multiple osteotomies (as long as the periosteal blood supply is protected) so that the bone can be folded to re-create the contour of any mandibular region, (b) an unmatched supply of sturdy bone length (22–26 cm in the adult) sufficient to reconstruct even angle-to-angle defects, (c) a bicorticocancellous structure that can tolerate the forces of mastication as well as the incorporation of osseointegrated dental implants, (d) acceptable donor site morbidity when the flap is appropriately harvested, and (e) a donor site location that allows a two-team approach for simultaneous tumor ablation and flap harvest.^{39,40} Reasonable alternatives include vascularized bone flaps from the iliac crest, radius, or ribs. Extensive composite mandibular defects may demand more than one free flap (such as one anterolateral thigh free flap with one fibula osteoseptocutaneous free flap) to reconstruct the

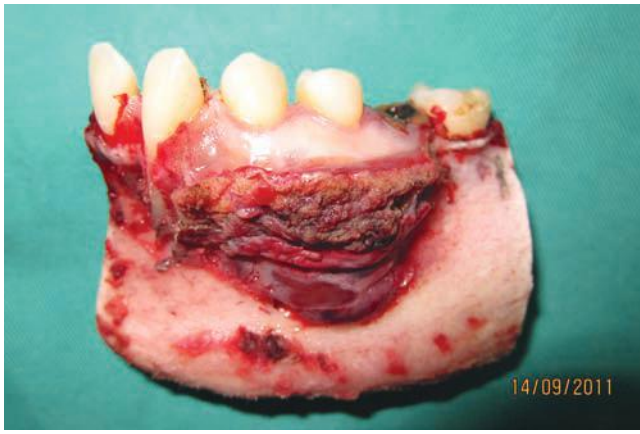
entire anatomy in one operation.⁴¹ Later, dental rehabilitation can be achieved with conventional dentures if alveolar ridge height and soft tissue quality allow. However, for select patients, osseointegrated dental implants offer a far superior alternative. These can be secured into the neomandible, either at the time of reconstruction (primarily; Fig. 45-39) or more commonly at a later stage (secondarily), and ultimately will support a dental prosthesis that can closely match the native dentition for excellent aesthetic and masticatory outcomes.⁴²

Similar principles are also applicable to other bony defects in the head and neck region, including maxillary and other midfacial defects, although non-load-bearing, facial, bone-only defects may be more amenable to nonvascularized bone grafting such as from the calvarium. The goals of midface reconstruction include the restoration of facial contour and projection, achievement of accurately occlusive maxillary dentition, provision of appropriate infraocular support, and sealed separation of adjacent nasal and oral cavities.

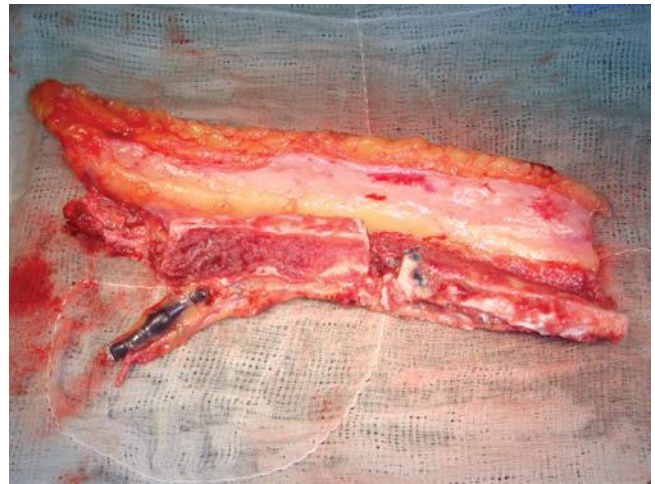Esophagus and Hypopharynx The goals of reconstruction for esophageal and hypopharyngeal defects, which may be circumferential or partial, are to maintain luminal patency, restore speech and swallowing, and avoid strictures, fistulas, and gastrointestinal anastomotic leaks. Reconstructive options for partial defects include primary closure, if luminal narrowing is insignificant, and skin (or dermal) grafts for partial-lining defects. A regional muscle flap may be useful for patching small full-thickness defects, but larger defects call for free tissue transfer of a jejunal flap or a tubed fasciocutaneous flap.⁴³ The jejunal flap involves the harvest of a proximal segment based on its mesenteric blood supply and inset into the neck in the isoperistaltic direction. Disadvantages of the jejunal flap include halitosis, slow swallowing transit times, and a “wet” voice. Tubed fasciocutaneous free flap options, including the anterolateral thigh and radial forearm flaps, are also popular; however, they may have a greater risk of stricturing than the free jejunal flap. Nevertheless, proponents of such flaps favor the resultant vocal qualities and faster transit times.

Recipient Vessels in the Head and Neck for Free Flaps Commonly used recipient arteries for free tissue transfer in the head and neck include the ipsilateral superior thyroid, lingual, facial, superficial temporal, and transverse cervical arteries. End-to-side anastomosis with the carotid artery is associated with potentially lethal carotid blow-out injury. Anastomoses with contralateral vessels are useful when ipsilateral vessels are not available, such as in patients with recurrent cancer who have undergone previous free flap procedures or irradiation.³⁶ Vein grafts can be avoided by using carefully planned flaps that offer longer pedicles (such as the anterolateral thigh of fibula osteoseptocutaneous free flaps) but may occasionally be necessary. For venous drainage, tributaries of the superficial and deep jugular systems are convenient. Finally, protection of the major vessels and nerves of the neck is possible after neck dissection by overlaying residual free flap tissues. This also aids in improving the contour and symmetry of the neck for aesthetic purposes and obliterates any dead space.

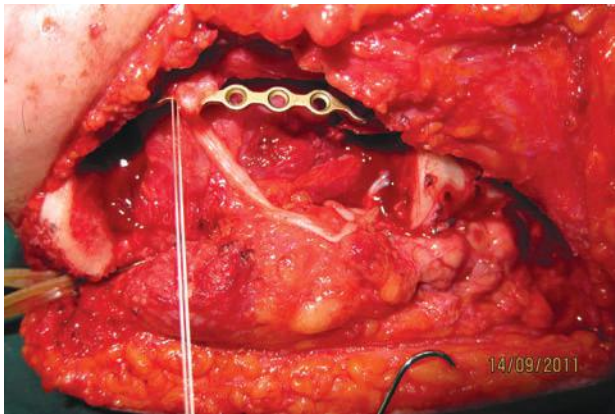
Complications Apart from the general complications that may be encountered with any major operation, there are several specific potential complications of head and neck ablative and reconstructive surgery. Specific intraoperative complications include air embolus, pneumothorax, and injuries to important



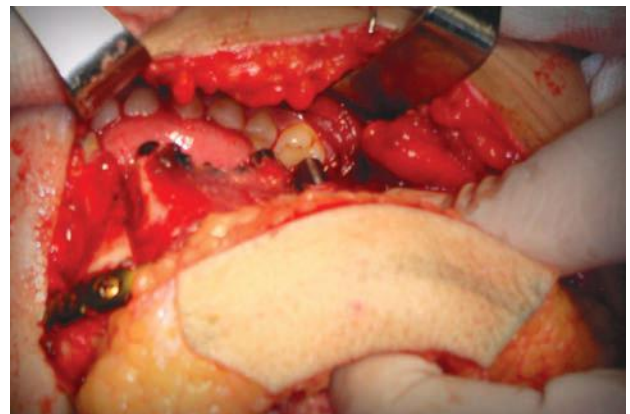
A



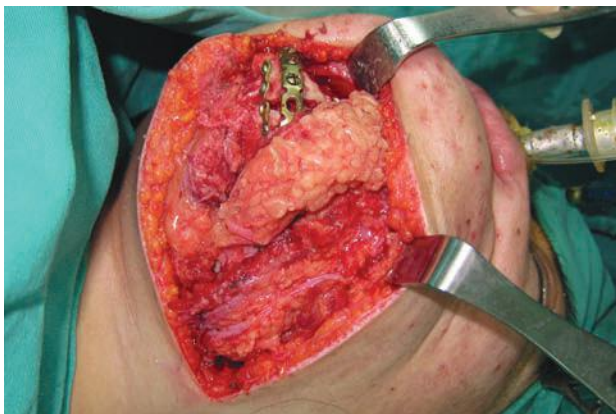
B



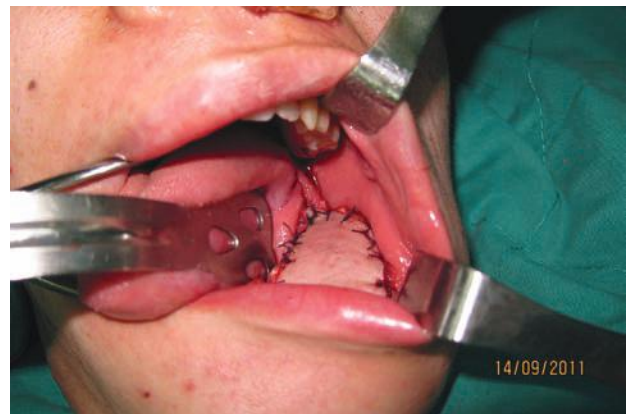C



D

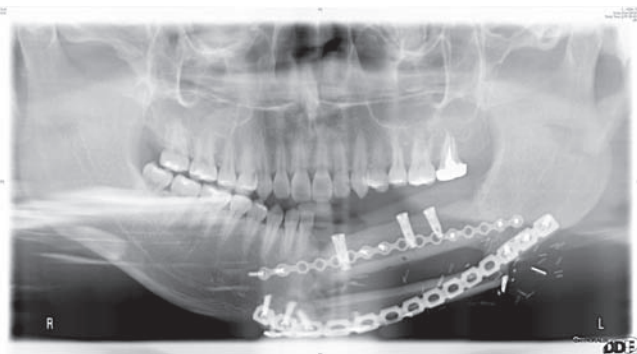

E

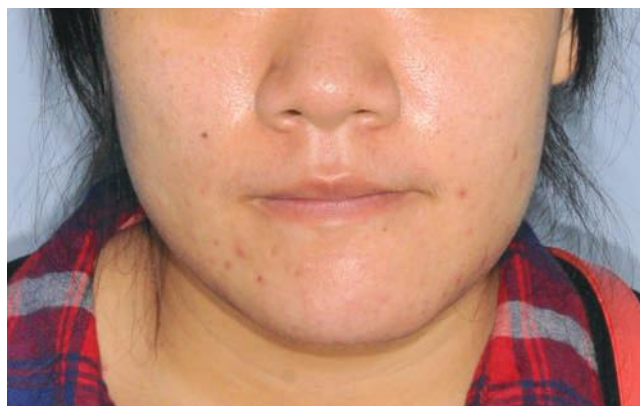

F

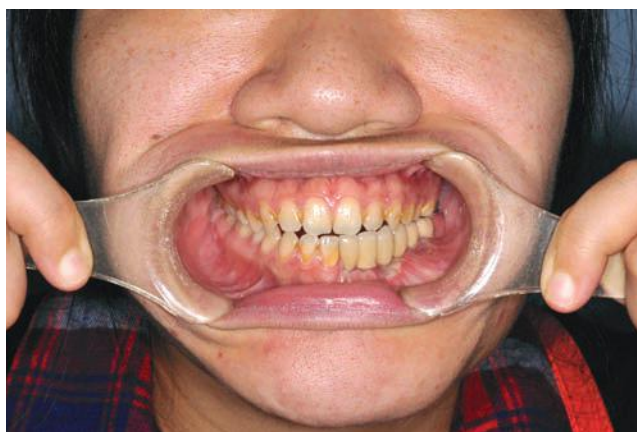Figure 45-39. Free double-barreled fibula osteoseptocutaneous flap with primary osseointegrated dental implants used to reconstruct a compound segmental mandibular defect from ameloblastoma resection. **A.** Left parasymphseal segmental mandibulectomy with contiguous dentition and oral lining. **B.** The osteotomized fibula osteoseptocutaneous free flap ready to be double-barreled; note that a segment of bone between the two struts (barrels) has been discarded to allow safe folding of the construct without compression or kinking of the intervening periosteal blood supply. **C.** Segmental reconstruction of the resected inferior alveolar nerve with a cutaneous nerve graft from the fibula donor site to restore mentolabial sensation; note the extent of the segmental mandibular defect. **D.** Three osseointegrated dental fixtures have been loaded into the upper barrel of the fibula; abutments are fitted to the fixtures to allow accurate occlusal matching with the corresponding maxillary dentition before finalizing fibula fixation. **E.** The de-epithelialized portion of the skin paddle was used to cover the reconstruction plate as well as to contour the soft tissue profile of the neomandibular margin. **F.** The skin paddle has been inset to reconstruct the oral lining; note that the fibula osteoseptocutaneous flap is best raised with a skin paddle even when there is no cutaneous defect so that it can provide a sentinel flap monitor of the underlying bone as well as facilitate wound closure. At this point, the dental fixtures are sealed with cover plates under the flap skin paddle but will later be fitted with final abutments and a dental prosthesis. **G.** Panorex radiograph: By 5 months postoperatively, the fibula had consolidated with the native mandible. **H** and **I.** At 10 months, the patient has an aesthetic neomandibular margin as well as functional and accurate occlusion after finalization with a dental prosthesis. (Photographs reproduced with permission from F. Wei.)



G



H



I

Figure 45-39. (Continued)

vessels, lymphatics, or cranial nerves. Specific perioperative complications include carotid artery blow-out, flap necrosis, infections, saliva or chyle leakage, airway problems, and acute psychiatric disturbances. Examples of later complications are prolonged pain syndromes, fistulas, scar contractures, and problems associated with radiotherapy such as flap shrinkage (potentially with metalwork exposure) and osteoradionecrosis.

Facial Reanimation

Facial nerve paralysis is a debilitating and emotionally depressing condition that presents many functional and aesthetic problems. Loss of mimetic muscle activity leads to poor articulation and drooling from oral incompetence, exposure keratopathy from dysfunctional lacrimation and paralytic ectropion, and impaired socialization from facial disfigurement and difficulty expressing emotion. Facial nerve dysfunction has a number of possible causes, including oncologic resection, temporal bone or skull base surgery, trauma, congenital conditions (Möbius' syndrome), and idiopathic origin. The main considerations in treatment are management of forehead and brow symmetry, eyelid closure, oral competence and symmetry, and smile dynamics. The long-term goals include normal static appearance, symmetry with movement, and restoration of voluntary muscular control. Although the best results usually require multistaged, complex surgeries, the elderly patient is better

served by a single-stage procedure that provides immediate improvement.

Neural Techniques. Traumatic injuries to the facial nerve without segmental nerve loss are best treated with primary end-to-end neurorrhaphy of the facial nerve stumps. The success of this repair depends on accurate approximation of nerve ends and achievement of a tension-free epineural repair with fine sutures. In segmental facial nerve loss due to trauma or oncologic resection, interpositional nerve grafts lead to the most successful reconstruction and may approach the results of primary repair. Grafting ideally is performed at the time of the injury rather than in delayed fashion. Donor nerves include the cervical plexus, great auricular nerve, and sural nerve. Timing of reanimation after nerve repair depends on distance of the repair from the motor end plates. Axonal regeneration proceeds at approximately 1 mm/d, whereas motor end plates deteriorate at approximately 1% per week and are gone by 2 to 3 years. In general, facial tone returns approximately 6 months after repair and voluntary motion a few months later.⁴⁴ Problems associated with facial nerve repair and grafting are weakness, mass movement (synkinesia), and dyskinesia. If the proximal facial nerve stump is available but the distal stumps are not, the cervical plexus can be harvested and proximally anastomosed to the facial nerve stump and distally implanted into the mimetic muscles to allow neurotization and partial restoration of function.

Nerve transfer techniques borrow other local cranial nerves to innervate the distal facial nerve stump if grafting cannot be done. This requires the availability of distal facial nerve or nerve branch stumps. Typically used donor nerves include the ipsilateral hypoglossal nerve, spinal accessory nerve, and cross-face sural nerve graft from a contralateral facial nerve branch (redundant buccal or zygomatic branch). Disadvantages of this technique include those of nerve repair or grafting plus loss of donor nerve function and facial hypertonia. Transfer of the complete hypoglossal nerve creates ipsilateral tongue paralysis and hemitongue atrophy with mild to moderate intraoral dysfunction.⁴⁴

Muscle Transposition Techniques. All of the aforementioned neural techniques rely on the presence of a functional distal neuromuscular unit. When the distal neuromuscular unit is deficient, as in congenital facial paralysis or in situations in which reconstruction is not undertaken until 2 to 3 years after the original insult, muscle transposition is considered. Muscle transposition techniques require intense muscular retraining to achieve the intended dynamics. A classic muscle dynamic facial sling uses the temporalis muscle, innervated by the trigeminal nerve and perfused by the deep temporal branch of the internal maxillary artery. The muscle is released along with its aponeurosis from the temporal fusion line, reflected inferomedially, and attached to the modiolus at the oral commissure, the nasolabial fold, and potentially the orbicularis oculi. Disadvantages include lack of spontaneous movement, temporomandibular joint dysfunction, and soft tissue fullness over the zygomatic arch. Other transferable muscle units include the masseter muscle and the anterior belly of the digastric muscle.⁴⁴

Innervated Free Tissue Transfer. Microsurgical free innervated muscle transfer may be considered in the same situations as local muscle transfers but is especially appropriate when concomitant soft tissue augmentation is needed. Muscles described for this purpose include the gracilis, latissimus dorsi, serratus anterior, and pectoralis minor muscles. The procedure may be performed in a single stage if the proximal facial nerve stump is available for anastomosis or if a long enough donor muscle nerve is present to reach the contralateral facial nerve branches. Often, however, it is a staged procedure beginning with establishment of a local neural source via cross-facial nerve grafting. The extent of axonal regeneration through the graft is monitored using Tinell's test. After sufficient axonal progression, approximately 6 to 12 months, the free muscle transfer is performed via vascular anastomoses to the superficial temporal or facial vessels, recipient and donor nerve coaptation, and fixation of the muscle to the zygoma superolaterally and to the nasolabial fold, upper lip orbicularis, and lower lip orbicularis inferomedially. Disadvantages of free muscle transfer include donor site morbidity, lengthy surgical times, and the need for specialized microsurgical skills.

Ancillary Procedures. One of the most important goals of treatment for facial paralysis is rehabilitation of the periocular region. This objective may be simply achieved with implantation of gold or platinum upper eyelid weights, which allows gravity to assist with lid closure. Static fascial slings are used to improve symmetry when comorbid conditions preclude more extensive and staged surgeries. Sling materials include tensor fasciae latae, Gore-Tex, and human acellular dermal allograft. Nonsurgical techniques play a significant role in improving facial symmetry, both as a primary intervention and an adjunct to surgery. Contralateral mimetic muscle hypertonicity is

tempered with botulinum toxin injections. Finally, soft tissue rejuvenative techniques such as cervicofacial rhytidectomy, blepharoplasty, browlift, and midface lift can improve the soft tissue effects of facial nerve paralysis (Fig. 45-40).

Breast Reconstruction

Breast cancer is the most common malignancy and the second leading cause of cancer-related death among women in the United States. One in eight women will develop breast cancer sometime during their life. Breast reconstruction began as a means to reduce chest wall complications and deformities from mastectomy. Reconstruction has now been shown to benefit women in terms of psychological well-being and quality of life.⁴⁵ The goal of breast reconstruction is to re-create form and symmetry while avoiding delay in adjuvant cancer treatment. A number of studies have shown that breast reconstruction, both immediate and delayed, does not impede standard oncologic treatment, does not delay detection of recurrent cancer, and does not change the overall mortality associated with the disease.⁴⁶⁻⁴⁸

Preoperative counseling of the breast cancer patient regarding reconstruction options should include discussion of the timing and type of reconstruction, alternatives to surgical reconstruction, and realistic expectations. The plastic surgeon and surgical oncologist must maintain close communication to achieve optimal results.

Timing of Reconstruction. *Immediate reconstruction* is defined as initiation of the breast reconstructive process at the time of the ablative surgery. This is usually done in patients with early-stage disease for whom there is low expectation of postoperative radiation therapy. Immediate reconstruction takes advantage of the preserved, supple skin envelope made possible by the skin-sparing mastectomy approach. In general, this allows a more aesthetically pleasing and symmetric reconstruction. It is also psychologically advantageous to the patient to avoid living with the mastectomy deformity, as in delayed reconstruction. Furthermore, the cost to the medical system is less with immediate reconstruction because fewer operations are required than for staged procedures. Disadvantages include the potential delay of adjuvant therapy due to surgical site complication, partial necrosis of mastectomy skin flaps, and the possibility that unanticipated postoperative radiation therapy is required. Breast reconstructions by all techniques are adversely affected by radiation therapy, and many surgeons feel reconstruction should be delayed until at least 6 months after treatment.

Delayed breast reconstruction is initiated at least 3 to 6 months after mastectomy. This approach avoids mastectomy flap unreliability and radiation therapy unpredictability. However, the patient is subjected to an additional operative procedure, and overall cosmetic result is often worse (especially with autologous tissue reconstruction).

Partial Breast Reconstruction. Over the last decade, many women have chosen breast conservation therapy (BCT) consisting of segmental mastectomy with sentinel lymph node biopsy and/or axillary lymph node dissection combined with postoperative whole-breast irradiation. Although this less invasive cancer treatment is quite beneficial to many women, significant breast deformity can result from the tissue removal and radiation-induced changes, especially in women with small breasts. *Oncoplastic surgery* refers to the set of techniques developed to lessen breast deformity from partial mastectomy, both

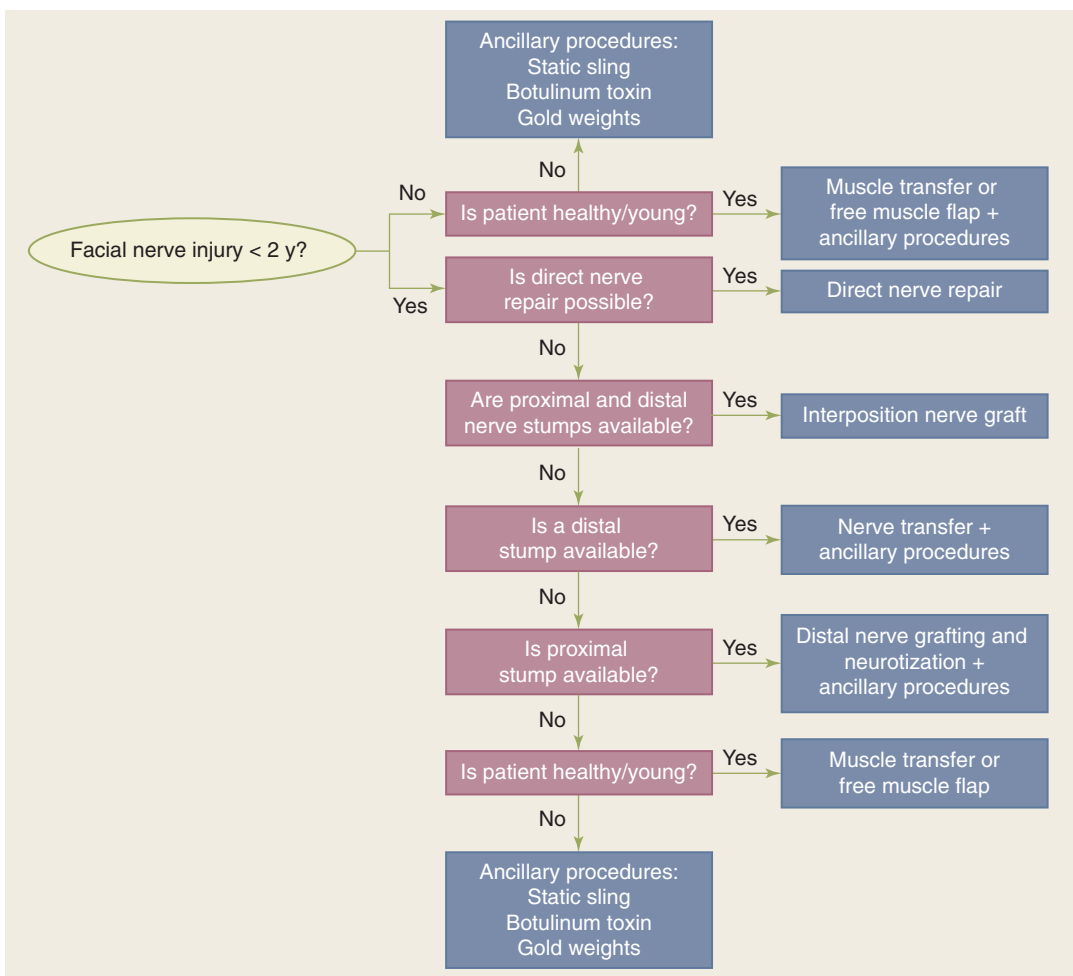


Figure 45-40. Facial reanimation treatment algorithm.

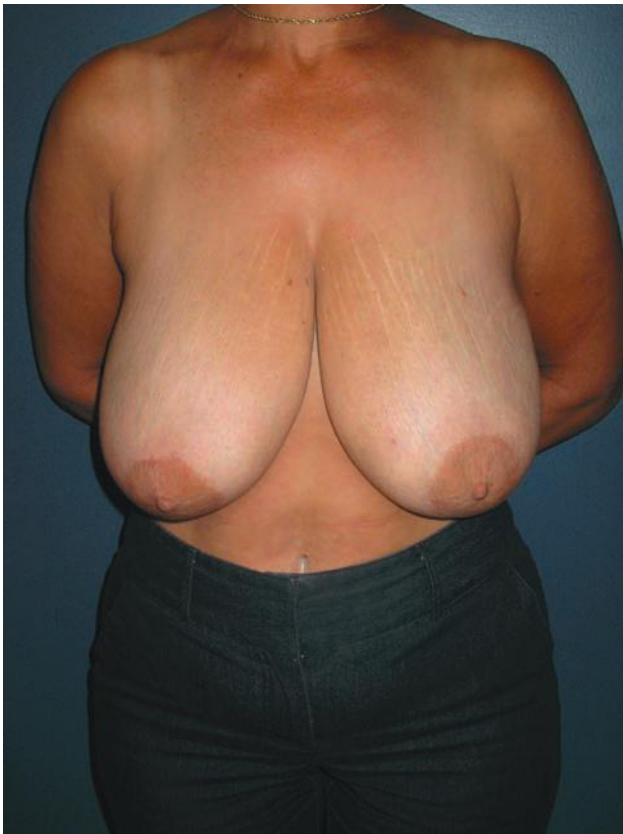in the delayed and the immediate settings. One of the most common methods of minimizing defect visibility in large-breasted women is to rearrange the breast parenchyma at the time of tumor extirpation using reduction mammoplasty techniques. Dermatoglandular pedicles supporting the nipple-areolar complex can be designed in any number of orientations to avoid the defect location. This procedure, combined with traditional contralateral breast reduction, can result in excellent cosmetic outcomes, often better than the preoperative appearance (Fig. 45-41). The lateral thoracodorsal flap, based on the lateral intercostal perforators at the inframammary fold, is particularly useful in correcting lateral breast defects⁴⁹

One drawback of these oncoplastic techniques when performed at the time of segmental mastectomy is the chance that, if the specimen margins are not clear, the reconstruction must be taken down to allow for reexcision. The oncologic implications of reusing the flap in this setting are unclear. Another shortcoming is the potential for fat necrosis, especially distally, in these nonaxial pattern flaps.

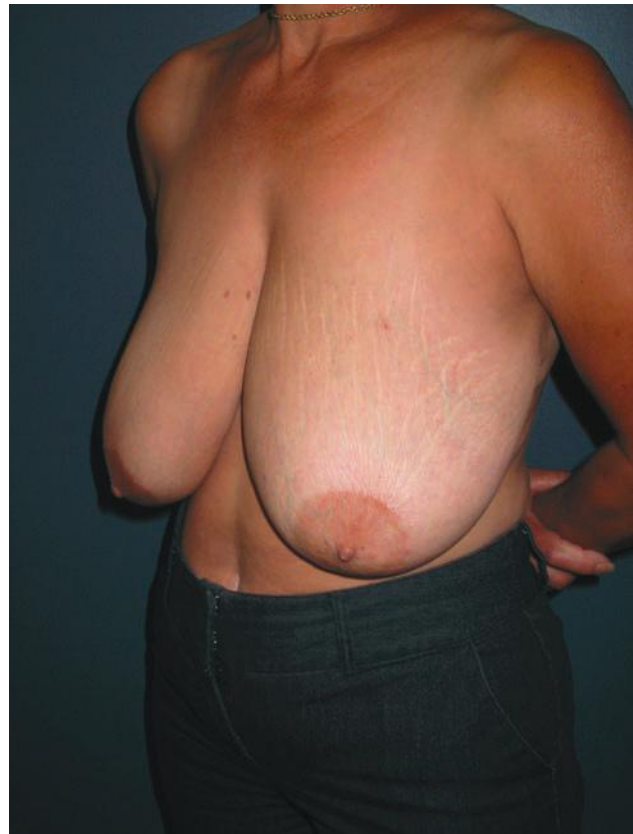Implant-Based Reconstruction. By necessity or patient choice, many women undergo mastectomy for local control of breast cancer. In fact, recently in response to the increased recognition of multifocal disease and experience with poor aesthetic results after BCT in small-breasted patients, some women have chosen mastectomy despite being candidates for BCT.

The simplest method of reconstructing the breast is placement of an implant into the mastectomy defect. Occasionally an implant may be placed at the time of mastectomy as a one-stage mound reconstruction. Usually, however, the first stage involves placement of a silicone shell tissue expander under the chest wall musculature (pectoralis major, serratus anterior, superior rectus sheath), followed by expansion of the skin and pocket regularly over the following few months. The patient then returns to the operating room for removal of the expander and placement of a saline or silicone breast implant (Figs. 45-42 and 45-43). After exhaustive investigation, silicone implants have been proven as safe and effective as saline implants in breast augmentation and reconstruction. After another few months, the nipple is reconstructed.

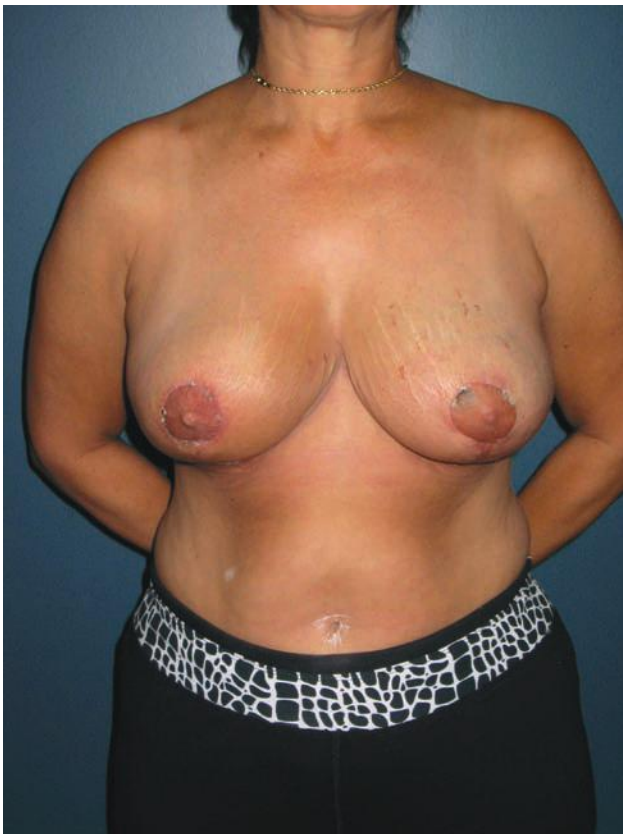The advantages of the tissue expander/implant-based reconstruction are absence of donor site morbidity, short operative times, and short recovery periods. The disadvantages include the need for more reconstructive stages and longer cumulative time to completion of reconstruction. Implant breast reconstructions tend to lack the natural breast feel and ptotic appearance. This is particularly noticeable in unilateral reconstructions. Some of these disadvantages have been mitigated by the advent of nipple-sparing mastectomy and immediate, acellular dermal matrix-assisted implant reconstruction (Fig. 45-44). Complications related to prosthetic-based breast reconstruction include infection, malposition, hematoma, seroma, and rupture



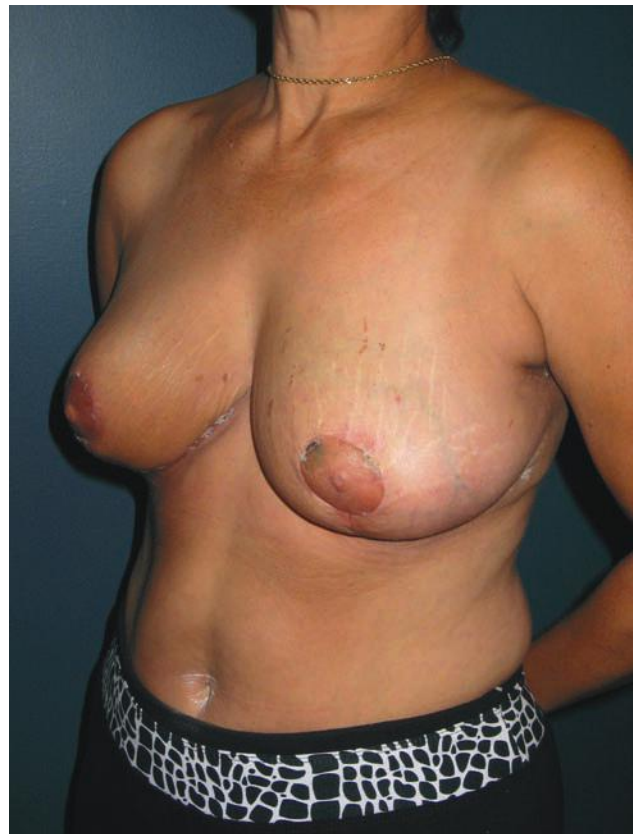
A



B



C



D

Figure 45-41. Preoperative (*top row*) and 3-week postoperative (*bottom row*) photos of a 52-year-old patient with cancer at the 6 o'clock position of the left breast. Oncoplastic superomedial pedicle reduction on the left breast was performed simultaneously with a left segmental mastectomy of the lesion and a contralateral symmetrization reduction. (*Photographs reproduced with permission from M. Gimbel.*)

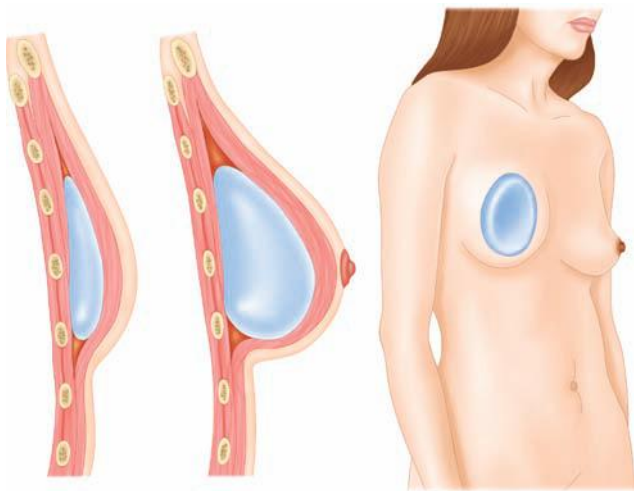


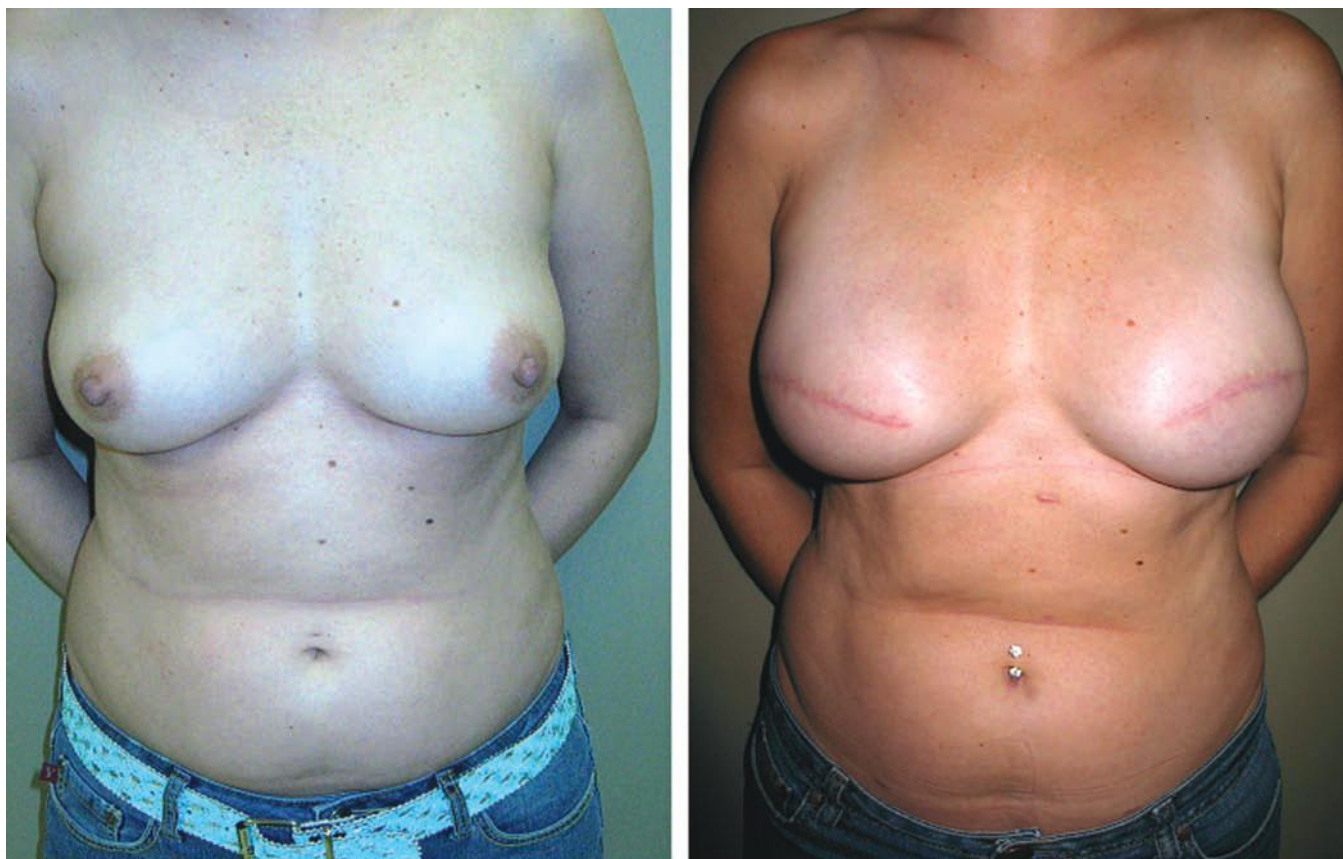
Figure 45-42. Tissue expansion and implant-based breast reconstruction. (Illustrations reproduced with permission from M. Gimbel.)

and deflation. Long term, the most common problem requiring reoperation is the formation of dense scarring around the implant (capsular contracture) causing firmness, visible deformity, and even discomfort. In addition, implants are medical devices that undergo mechanical wear, ultimately leading to leakage and deflation. All in all, the chance that a woman will need additional unanticipated surgery on her reconstructed breast within 5 years of prosthetic-based reconstruction is approximately 35%.⁵⁰

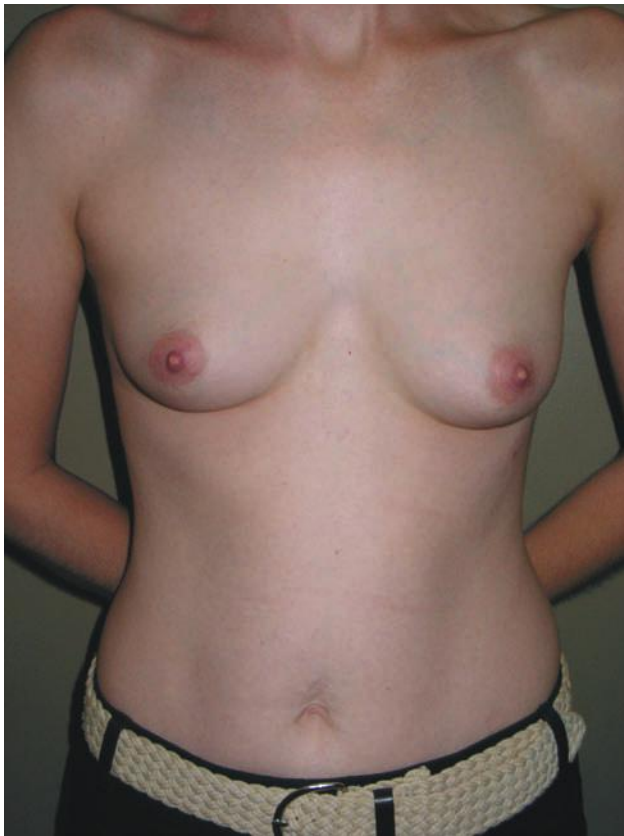The cosmetic results worsen and the rate of complications increases when implants are placed in an irradiated chest wall, regardless of whether the radiation therapy occurs before or after reconstruction.

Total Autologous Tissue Reconstruction. An entirely different way to reconstruct the breast avoids the placement of implants in favor of using only the patient's own redundant tissue. Indications for total autologous breast reconstruction are many and varied, including patient preference, previous or anticipated chest wall radiation treatment, a ptotic contralateral breast, and previous failed implant reconstruction. Contraindications are lack of a suitable donor site due to scarring or minimal adiposity, morbid obesity, and serious comorbidities that preclude a longer surgery and recovery period.

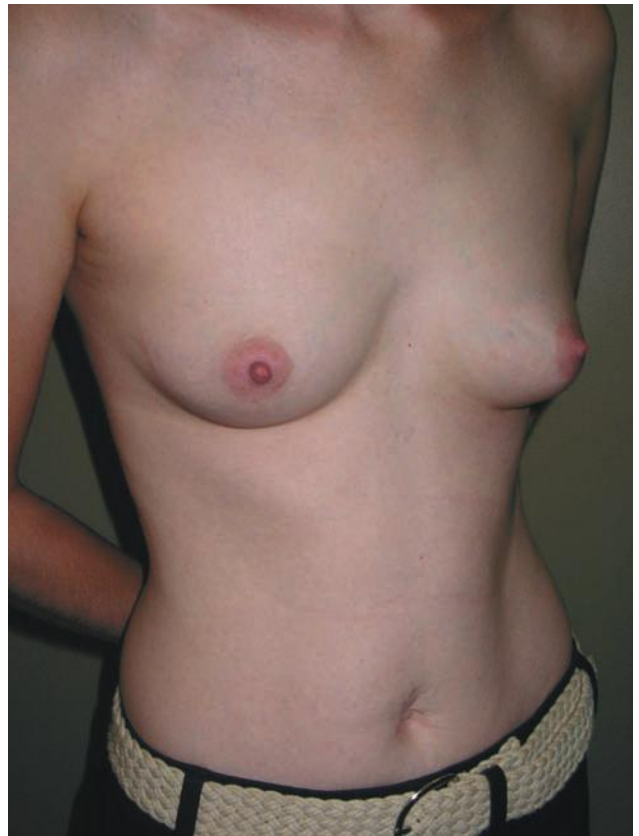
The most commonly used donor site is the abdomen. Most women in the breast cancer patient population have redundant skin and fat in the lower abdomen that may be transferred to the chest wall and fashioned into a breast mound. Many techniques have been developed to transfer this tissue, both as pedicled myocutaneous flaps and as free flaps. The workhorse abdominal flap for breast reconstruction is the pedicled transverse rectus abdominis myocutaneous (TRAM) flap. This flap is based on the superior epigastric vessels that run on the undersurface of the rectus abdominis muscle. A transversely oriented skin paddle with underlying fat is isolated based on its perforating vessels that course through the rectus muscle to join the main superior epigastric pedicle. The flap, along with the rectus muscle and blood supply, is tunneled under the anterior chest wall and



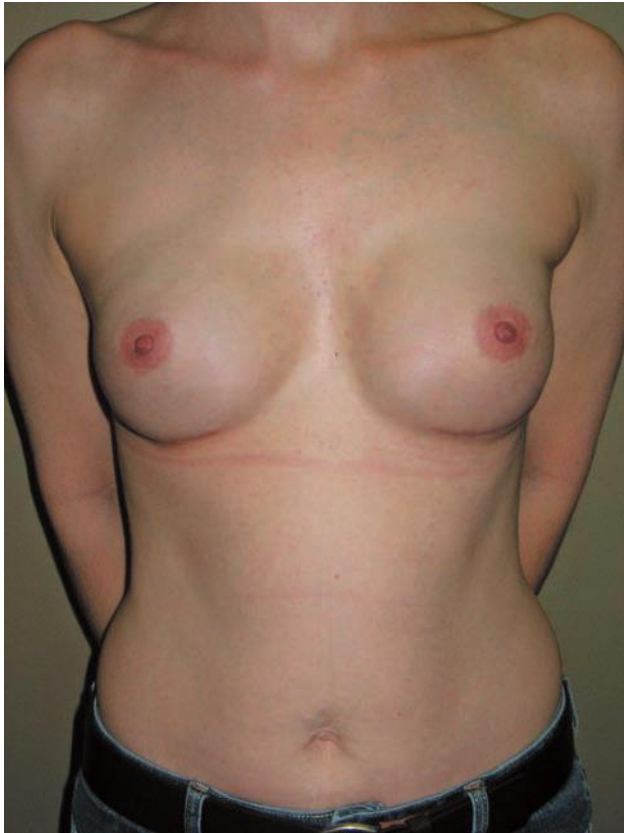A **B**
Figure 45-43. Bilateral tissue expander/implant-based breast reconstruction. Appearance preoperatively (A) and 2 months after saline implant exchange (B). (Photographs reproduced with permission from M. Gimbel.)



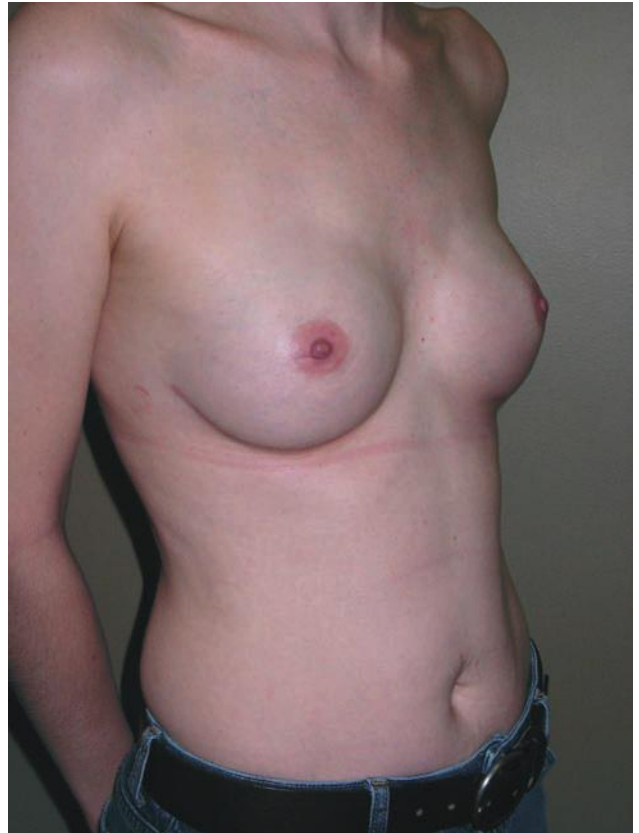
A



B



C



D

Figure 45-44. Immediate single-stage implant-based breast reconstruction after bilateral prophylactic nipple-sparing mastectomy (NSM). **A.** Preoperative photo. **B.** Postoperative photo after bilateral NSM and immediate acellular dermal matrix-assisted silicone gel implant reconstruction. (Photographs reproduced with permission from M. Gimbel.)

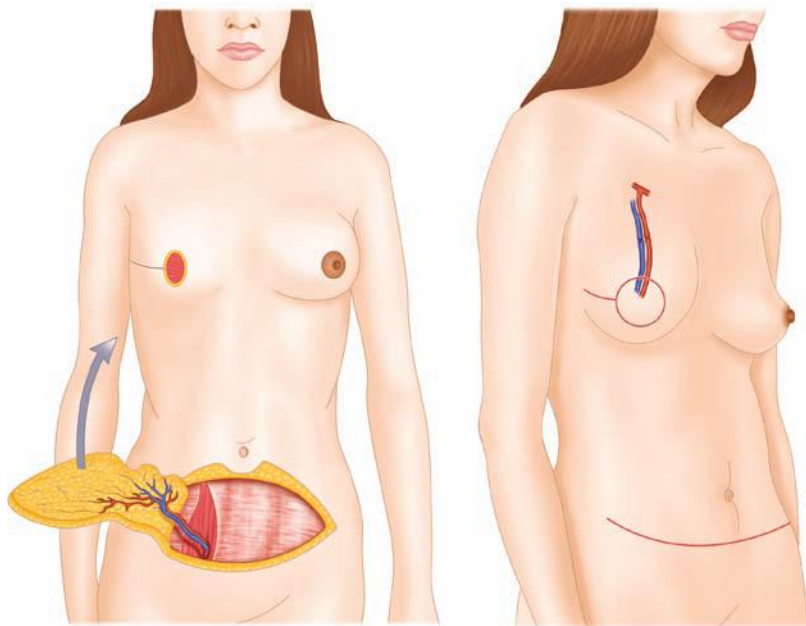


Figure 45-45. Deep inferior epigastric perforator flap breast reconstruction. (Illustrations reproduced with permission from M. Gimbel.)

delivered into the mastectomy defect, where it is then shaped into a breast mound. The donor site is closed in a manner similar to an abdominoplasty. The advantages of this and all total autologous reconstruction techniques are creation of a breast that looks and feels natural, that changes volume along with the patient's weight (and the contralateral natural breast), and that avoids the potential complications of breast implants. In addition, patients are often pleased to have the incidental benefit of an abdominoplasty. The pedicled TRAM flap procedure is also relatively quick for a total autologous reconstruction. Downsides include the potential for partial or complete flap failure, fat necrosis, fullness in the upper abdomen from the tunneled pedicle, abdominal wall bulge or hernia, and abdominal wall weakness.

The free TRAM flap was introduced to improve on the sometimes limited volume of tissue that can be carried by the relatively indirect blood supply of the pedicled TRAM's superior epigastric vessels. The free TRAM flap is similar to the pedicled TRAM flap but is based on the deep inferior epigastric vessels, which are the dominant blood supply to the lower abdomen. The flap is harvested as a free flap, and the deep inferior epigastric artery and vein are anastomosed to recipient vessels in the chest, usually the internal mammary or the thoracodorsal vessels. A refinement to this method is the muscle-sparing free TRAM flap procedure, in which less fascia and rectus abdominis muscle is harvested with the flap to minimize donor site morbidity. The ultimate muscle-sparing free TRAM flap is the deep inferior epigastric perforator flap (Fig. 45-45). In this case, the fascia is opened but no muscle is included with the flap, and the perforating vessels of the deep inferior epigastric system are dissected between the muscle fibers to join the main pedicle. When patients are carefully selected, muscle-sparing techniques decrease abdominal wall morbidity and increase useful pedicle length for microsurgery without significantly compromising flap perfusion⁵¹ (Fig. 45-46A,B). Finally, in some patients, the lower abdominal tissue may be transferred to the breast as a free flap without violating the abdominal wall fascia at all. The superficial inferior epigastric artery is often capable of supporting enough abdominal

tissue volume to reconstruct the breast. Because this artery and its accompanying vein do not traverse the anterior rectus sheath, the flap can be harvested with no more abdominal wall morbidity than an abdominoplasty. Unfortunately, this artery is frequently absent or too diminutive in size to be used in the majority of patients. Despite the many advantages of microsurgical total autologous breast reconstruction, it is associated with longer operative times than pedicled TRAM procedures, requires expertise in microsurgery, and has the potential for complete flap failure due to microvascular thrombosis.

Implant and Autologous Tissue Reconstruction. The pedicled latissimus dorsi myocutaneous flap procedure is a straightforward, reliable method used for breast reconstruction. It is often reserved for reconstructing breasts when other methods have previously failed. The latissimus flap is relegated to second-choice status because it carries the major disadvantage of autologous tissue reconstruction (donor site morbidity) as well as all of the potential complications associated with breast implants. That aside, the latissimus flap/implant–based reconstruction can produce excellent cosmetic results with relatively low donor site morbidity (Fig. 45-47). The latissimus dorsi muscle with overlying skin paddle is elevated based on its thoracodorsal vessel pedicle, tunneled through the axilla, and delivered into the mastectomy site. After partial inset, either a tissue expander or permanent implant is usually placed behind the muscle to give adequate volume to the reconstruction (Fig. 45-48). Drawbacks specific to this method include contour irregularity of the back, high rate of donor site seroma, and shoulder weakness (uncommon).

Accessory Procedures. After creation of the breast mound, refinements and accessory procedures are performed after approximately 3 months. These may include breast mound revision, scar revisions, fat grafting, and nipple-areola complex reconstruction. Scores of methods have been described for reconstructing the nipple. These include local flap techniques (e.g., star flap, skate flap, C-V flap), grafting techniques (contralateral nipple/areola sharing, groin skin, labia skin), and tattooing.

Radiation-Related Considerations. With some notable exceptions, most surgeons advocate avoidance of implant-based breast reconstruction in chest walls that have previously received radiation or are likely to receive radiation due to the relatively high rate of complications and disappointing results. Delayed total autologous reconstructions bring healthy nonirradiated tissue to replace the damaged fibrotic tissue and are the preferred mode of breast reconstruction in this setting. Similarly, latissimus dorsi/implant reconstructions replace much of the irradiated skin, which probably explains to some degree why, in the face of previous irradiation, implants fair better with an overlying latissimus flap than without.

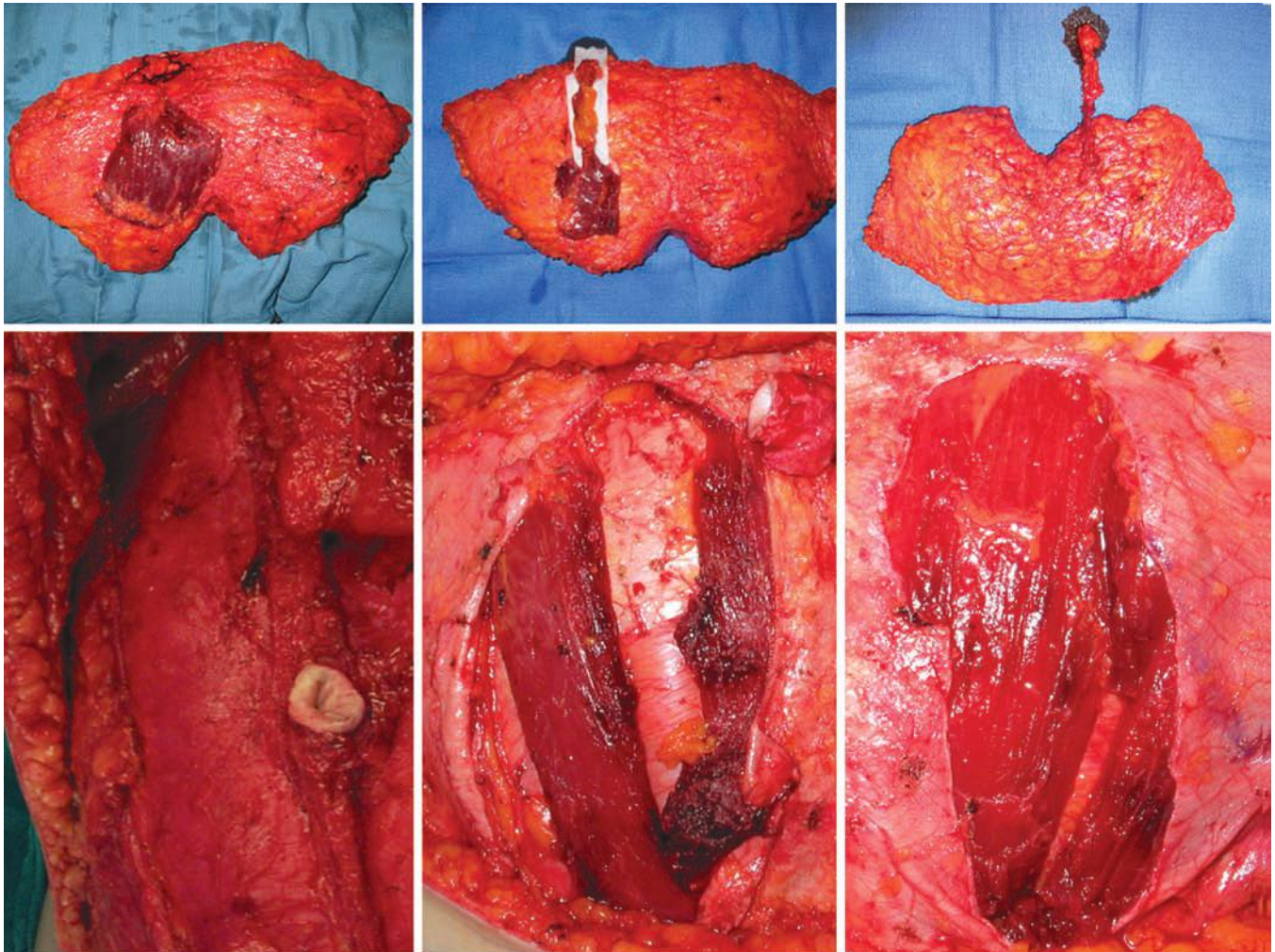
The question of whether total autologous reconstructions should be done before or after anticipated radiation therapy is still controversial. Those in favor of delaying the reconstruction argue that an irradiated flap will exhibit shrinkage and fibrosis that subtracts from the overall aesthetic result. Those in favor of performing immediate reconstruction in this setting feel that, because immediate reconstructions have inherently better aesthetics, the imperfect result due to irradiation it is still comparable to the result of delayed reconstruction without the additional

operation. To date, no prospective study has been performed comparing the two approaches.

Trunk and Abdominal Reconstruction

In the trunk, as in most areas of the body, choice of reconstructive method is determined by the location and size of the defect and the properties of the deficient tissue. A distinction is made between partial-thickness and full-thickness defects in deciding between grafts, flaps, synthetic materials, or a combination of techniques. Unlike the head and the lower leg, the trunk harbors a relative wealth of regional transposable axial pattern flaps that allow sturdy reconstruction, only rarely requiring distant free tissue transfer. Indeed, the trunk serves as the body's arsenal, providing its most robust flaps to rebuild its largest defects.

Thoracic Wall. The chest wall is a rigid framework designed to resist both the negative pressure associated with respiration and the positive pressure from coughing and from transmitted intra-abdominal forces. Furthermore, it protects the heart, lungs, and great vessels from external trauma. Reconstructions of chest wall defects must emulate these functions.



A
Figure 45-46. **A.** Left upper and lower panels: Free transverse rectus abdominis myocutaneous (FTRAM) flap and its donor site defect. Middle upper and lower panels: Muscle-sparing FTRAM flap and its donor site defect. Right upper and lower panels: Deep inferior epigastric perforator flap and its donor site defect. **B.** Preoperative and postoperative photos of a 43-year-old woman with a left muscle-sparing FTRAM breast reconstruction and right symmetrization reduction mammoplasty. (Photographs reproduced with permission from M. Gimbel.)

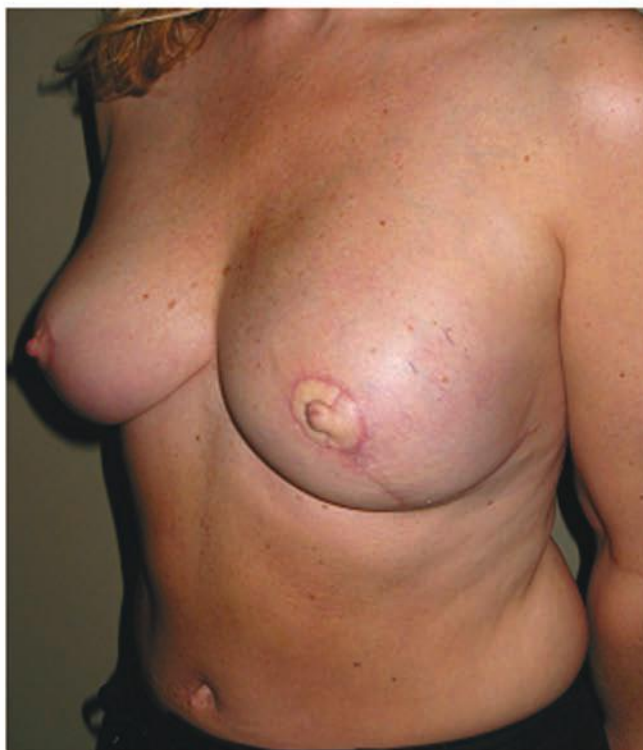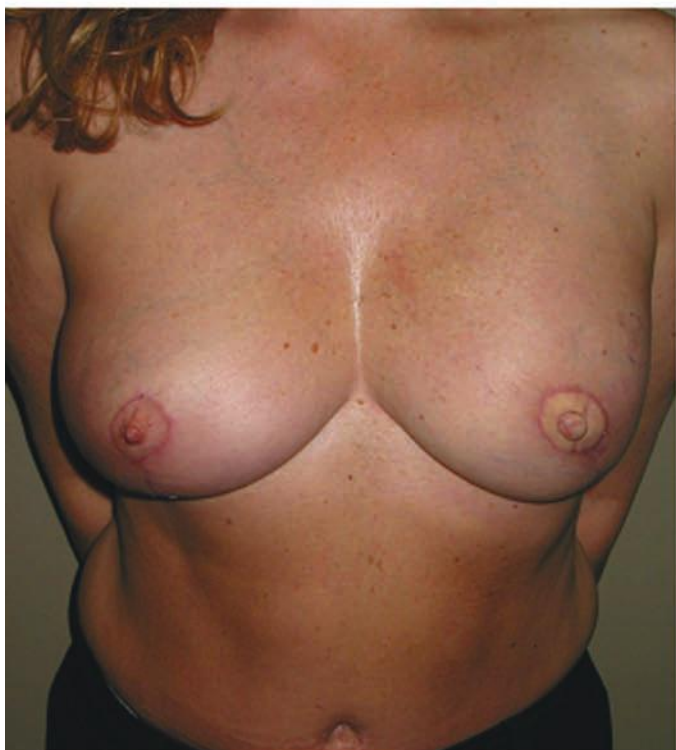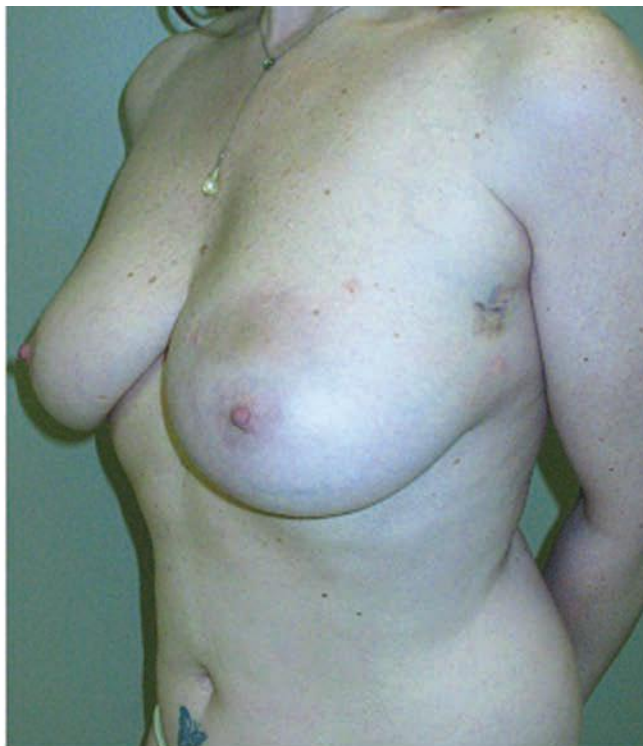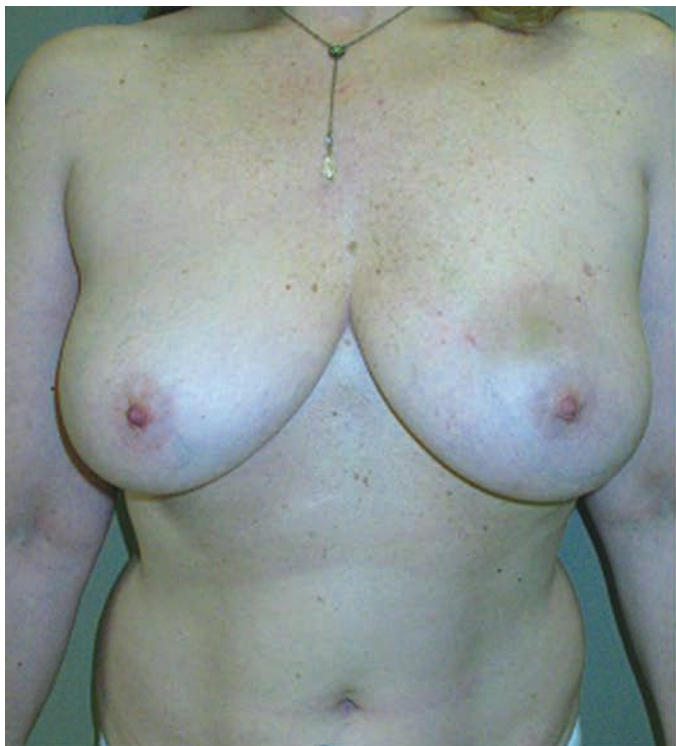**B**

Figure 45-46. (Continued)

The pectoralis major muscle is the workhorse pedicled flap for coverage of the sternum, upper chest, and neck. It is a Mathes and Nahai type V flap with one dominant pedicle (pectoral branch of the thoracoacromial artery) and several secondary segmental pedicles (intercostal perforators and the pectoral branch of the lateral thoracic artery).⁵² The muscle may be advanced or transposed on its dominant pedicle or used as a

turnover flap based on its internal mammary perforators. Both methods are useful in covering the sternum after dehiscence or infection. Before the turnover flap is elevated, previous operative notes should be reviewed carefully to determine whether the internal mammary artery is still a viable perfusion source; the artery, especially the left, is frequently used for heart revascularization. The muscle may also be used for obliteration of

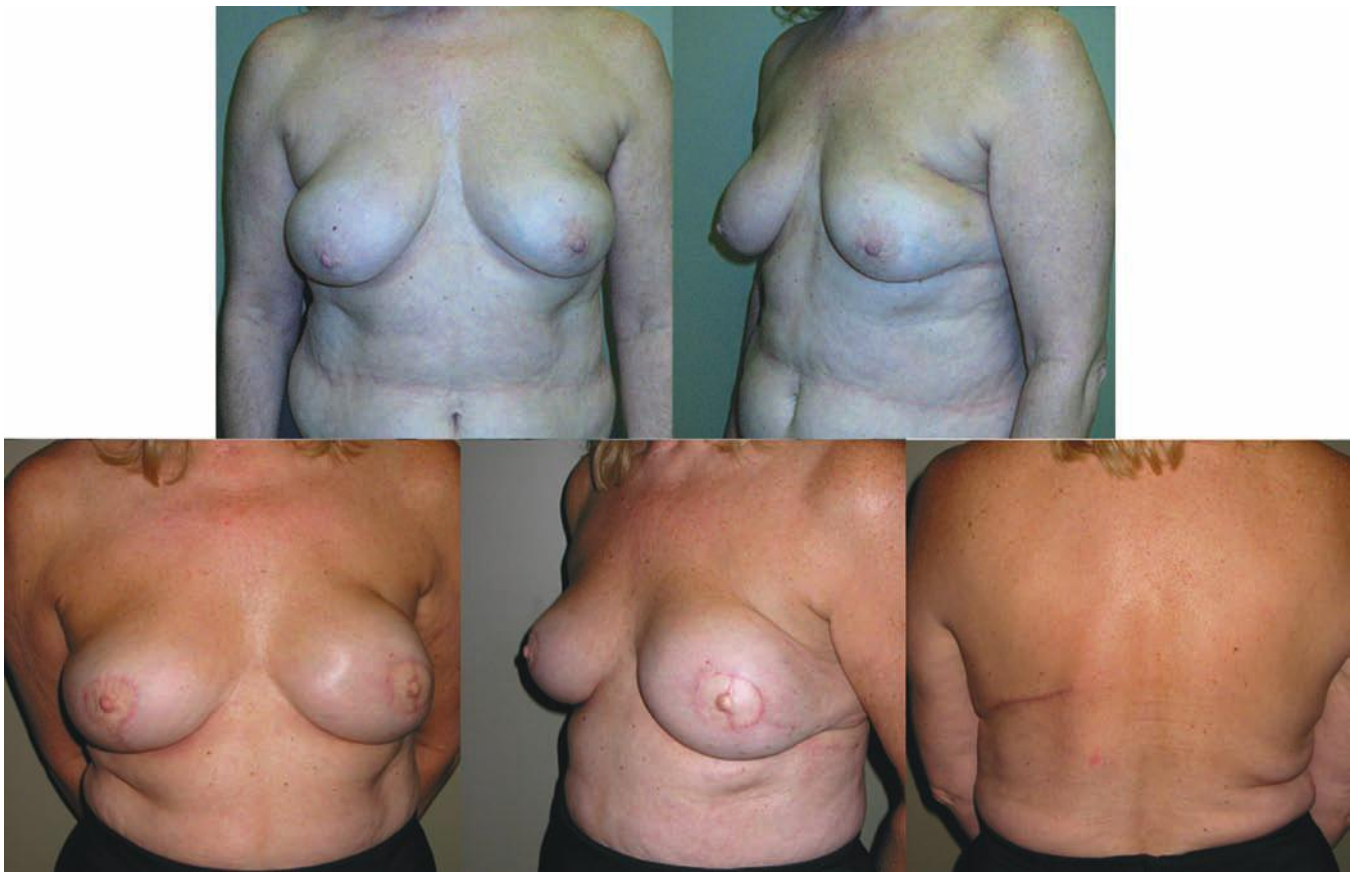


Figure 45-47. Preoperative and postoperative photos of a 58-year-old woman with a left latissimus dorsi flap/silicone implant breast reconstruction and right symmetrization mastopexy. (Photographs reproduced with permission from M. Gimbel.)

intrathoracic dead space infections and as a myocutaneous flap for head and neck reconstruction. Although it is a reliable flap, the loss of the pectoralis major muscle results in upper extremity weakness and cosmetic deformity from loss of the anterior axillary fold.⁵³

The rectus abdominis muscle is a type III axial pattern flap that can be based on the superior epigastric vessels or the deep

inferior epigastric vessels.⁵¹ When elevated as a myocutaneous flap it can be designed with a transverse (TRAM) or vertical rectus abdominis myocutaneous skin paddle. Although the vertical rectus abdominis muscle flap has better vascularized skin due to its multiple longitudinally oriented perforators, the TRAM flap provides a larger area of donor skin that can be primarily closed with an easily concealable scar. The rectus abdominis muscle is frequently used for lower sternum reconstruction when the pectoralis muscle is insufficient. It can also be used in pedicle or free flap configuration for repair of large chest wall defects from cancer resection (Fig. 45-49).

The latissimus dorsi myocutaneous flap is probably the most widely used flap in nonsternal chest wall reconstructions due to its broad size, location, reliability, and pedicle length. The flap is based on the thoracodorsal vessels arising from the subscapular system. Its secondary blood supply comes from the posterior intercostal and lumbar vessels.⁵² The arc of rotation of this flap can extend to most areas on the ipsilateral torso as well as to the abdomen, head and neck, and upper arm. The serratus anterior muscle can be included on the same vascular pedicle to further increase its surface area. Use of this donor site is relatively well tolerated, but shoulder weakness can be significant. The major drawbacks of the latissimus flap are its conspicuous scar and the high risk of seroma.⁵³

The trapezius muscle flap, based on the transverse cervical vessels, is generally used as a pedicled flap to cover the upper midback, base of neck, and shoulder. The superior portion of the muscle along with the acromial attachment and spinal accessory nerve are preserved to maintain shoulder elevation function.

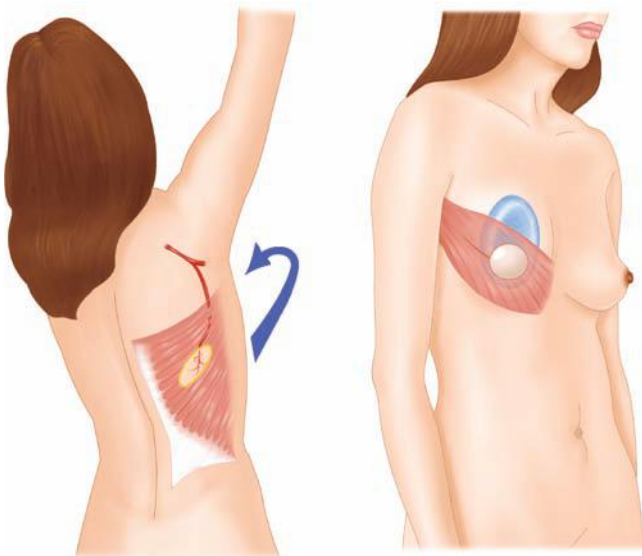


Figure 45-48. Latissimus dorsi flap/implant–based breast reconstruction. (Illustrations reproduced with permission from M. Gimbel.)

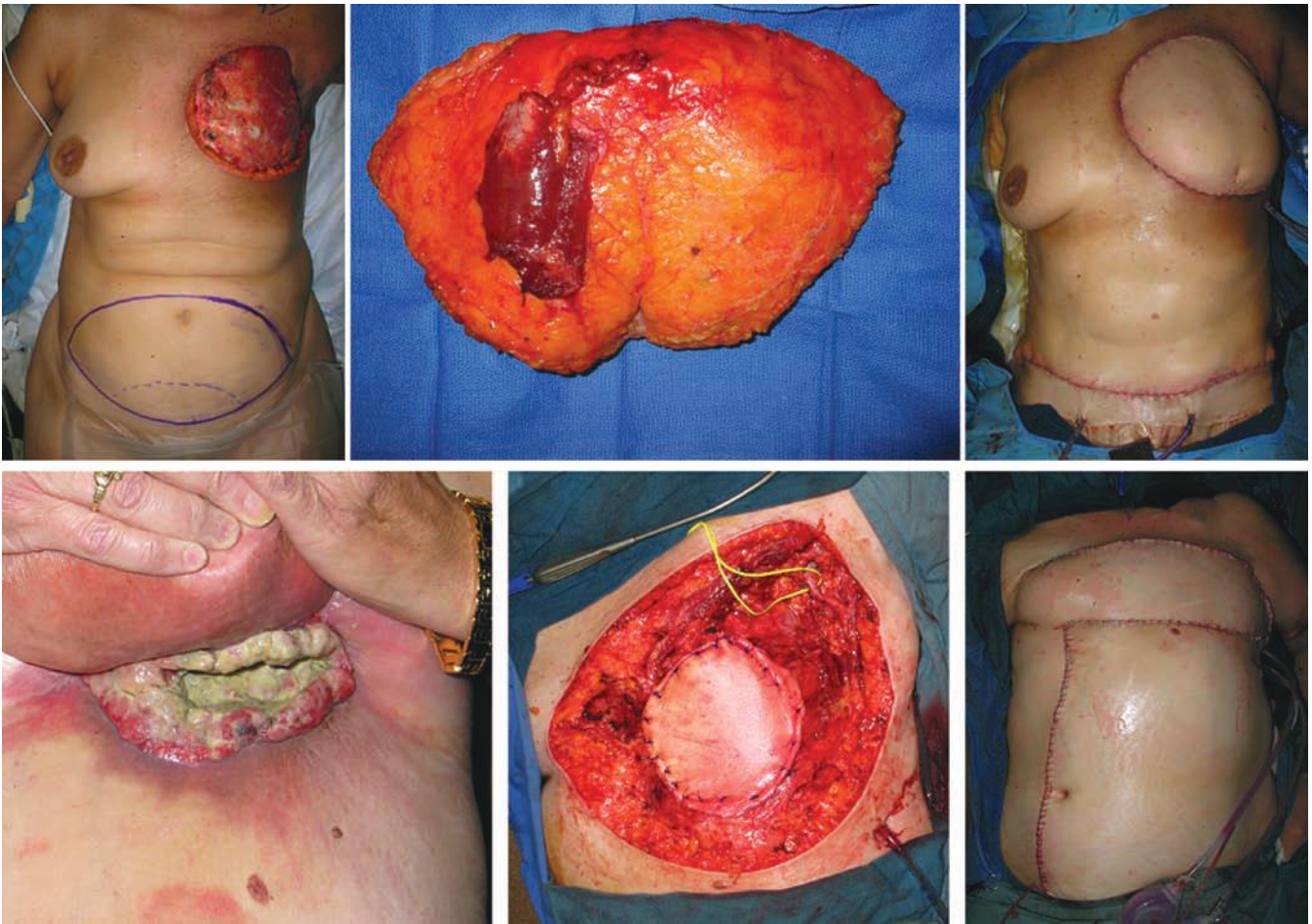


Figure 45-49. *Top row:* Free transverse rectus abdominis muscle reconstruction of a large partial-thickness chest wall defect. *Bottom row:* Full-thickness chest wall defect reconstructed in two layers with human acellular dermal allograft and overlying pedicled vertical rectus abdominis muscle flap. (Photographs reproduced with permission from M. Gimbel.)

Other useful flaps of the thoracic region include the scapular/parascapular fasciocutaneous flap, the external oblique flap, the medially or laterally based thoracoepigastric skin flaps, and the omental flap.

When a full-thickness defect of the chest wall involves more than two adjacent ribs, the inherent rigidity of soft tissue flaps may provide insufficient chest wall integrity. Although cadaveric bone and autologous bone grafts have been used in the past to lend structural support, the availability of well-tolerated synthetic and biologic materials has become more common. These materials include polypropylene (Prolene), polyethylene (Marlex), and polytetrafluoroethylene (Gore-Tex) meshes, methyl methacrylate, and acellular dermal allograft. Even if these avascular foreign bodies must be removed due to chronic infection, often a thick fibrous layer of tissue will have formed that can maintain chest wall stability.⁵³

Abdominal Wall. The abdominal wall also protects the internal vital organs from trauma, but with layers of strong torso-supporting muscles and fascia rather than with osseous structures. The goals of reconstruction are restoration of structural integrity, prevention of visceral eventration, and provision of dynamic muscular support. Defects in the abdominal wall may arise from trauma, oncologic resection, congenital deformities, and infection. By far the most common reason for abdominal wall deficiency, however, is incisional fascial dehiscence

and herniation after laparotomy. When a reconstruction plan is being formulated, careful physical examination and review of the medical history will help prevent selection of an otherwise sound strategy that, because of previous incisions and trauma, is destined for failure.

Partial Defects of the Abdominal Wall. Large defects of the abdominal skin and subcutaneous tissue are usually easily controlled with skin grafts, local advancement flaps, or tissue expansion. Myofascial defects are more difficult to manage. The abdominal wall fascia requires a minimal-tension closure to avoid dehiscence, recurrent incisional hernia formation, or abdominal compartment syndrome.⁵⁴ Prosthetic meshes are frequently used to replace the fascia in clean wounds and in operations that create myofascial defects. When the area of fascial deficiency is contaminated, as in infected mesh reconstructions, enterocutaneous fistulas, or viscus perforations, prosthetic mesh is avoided because of the risk of infection. A delayed reconstruction can be prefaced by inseting a resorbable polyglactin (Vicryl) mesh that will eventually granulate to allow skin grafting. The ensuing hernia is repaired later with prosthetics under cleaner conditions. The separation-of-components procedure has enjoyed much success in closing large midline defects without resorting to mesh. This procedure involves advancement of bilateral myofascial flaps consisting of the anterior rectus fascia/rectus abdominis/internal oblique/transversus abdominis muscle complex.

Mobility of this myofascial unit is created by release of the external oblique muscle at the semilunate line. Midline defects measuring up to 10 cm superiorly, 18 cm centrally, and 8 cm inferiorly can be closed using separation of components.⁵⁵ This technique is less effective in closing lateral defects, for which regional muscle and fascial flaps are usually better suited (rectus abdominis flap, internal oblique flap, external oblique flap).⁵⁴

Full-thickness abdominal defects and large myofascial defects require large robust pedicled flaps or free flaps for closure. The tensor fasciae latae pedicled flap, based on the ascending branch of the lateral circumflex femoral vessels, is useful in reconstructing the lower two-thirds of the abdomen. Bilateral flaps can be used for very large defects, although the skin-grafted donor site is unsightly. The rectus femoris flap and the vastus lateralis flap can be used for smaller lower abdominal defects. The “mutton-chop” flap, which is an extended rectus femoris flap with fascia lata included distally, has been used successfully in closing massive defects.^{56,57} Large defects of the upper abdominal wall may be repaired with pedicled extended latissimus dorsi flaps with attached pregluteal fascia. Very large full-thickness defects, especially superiorly, are best treated with free tissue transfer of large myofascial units such as the latissimus dorsi or the tensor fasciae latae. These can also be innervated flaps to reestablish contractile force and strength in the abdominal wall.

Extremity Reconstruction

Posttraumatic Reconstruction. With the beginnings of modern orthopedic and plastic surgery, improvements in the understanding of anesthesia, trauma resuscitation, infection, and the availability of early antibiotics, the requirement to amputate almost all open (compound) lower extremity fractures as a life-saving procedure gradually decreased while attempts at limb salvage became more realistic. The introduction and maturation of microsurgical techniques witnessed increasing successes in distal extremity replantations and free flap reconstructions. Soft tissue reconstruction thus advanced alongside evolving techniques of bone fixation, joint reconstruction, general vascular surgery, and acute multitrauma management. Current lower extremity reconstruction incorporates the use of vascularized bone, bone distraction techniques, composite tissue flaps, and functioning muscle transfers tailored to the given defect.⁵⁸ The future may behold the use of cadaveric vascularized composite allografts or even tissue-engineered vascularized composite tissue constructs.

Common causes of high-energy lower extremity trauma include road traffic accidents, falls from a height, direct blows, sports injuries, and gunshots. Understanding the anatomy of the lower limb compartments, nerve and vascular supplies, muscle functions, skeletal structure, and mechanics is essential for accurate bony and soft tissue restoration for function and appearance. Several limb-salvage scoring systems have been suggested to aid in the decision regarding whether to amputate or attempt limb salvage, but their routine use remains controversial; nevertheless, they can provide guidance during this life-altering decision process.⁵⁹ Compound fractures are often classified according to the system devised by Gustilo and colleagues (Table 45-12).⁶⁰

In addition to following standard multiple trauma evaluation and resuscitation guidelines, the multidisciplinary team must assess the injured limb for neurovascular status, soft tissue defects and degloving, configuration of fractures, and

Table 45-12

Gustilo and Anderson classification of compound fractures

CLASSIFICATION	DESCRIPTION
Grade I	Wound <1 cm; minimal contamination, comminution, and soft tissue damage
Grade II	Wound >1 cm; moderate soft tissue damage and minimal periosteal stripping
Grade IIIa	Substantial contamination and severe soft tissue damage but adequate fracture coverage; usually due to high-energy trauma
Grade IIIb	Substantial contamination, periosteal stripping, severe soft tissue damage, and inadequate fracture coverage; usually due to high-energy trauma
Grade IIIc	Any open fracture with an associated arterial injury requiring repair

presence of compartment syndrome. Neurovascular status and evidence for compartment syndrome require frequent reassessment, particularly following interventions such as fracture reduction, splintage, and surgery. Bony stabilization may be critical to controlling fracture hemorrhage. Doppler ultrasound examination may help assess vascular integrity. Angiography is a lengthier procedure that provides more detailed information, but the team must be cognizant that delay to revascularization increases the risk of massive reperfusion injury and multiple organ failure.⁶¹ Compartment syndrome must be released with urgent fasciotomies when present. Its most critical early feature is increasingly severe pain especially on passive stretch of the compartment's musculature; pulselessness, pallor, paresthesia, and paralysis are late signs. Compartment pressure monitors are useful in patients who are unconscious or have proximal nerve blocks in place. Antitetanus vaccine and antibiotics should be provided as soon as possible according to contemporary guidelines.⁶² An evaluation of the patient as a whole allows treatment to be planned within the context of comorbidities, socioeconomic considerations, and rehabilitative potential. The loss of plantar sensation historically favored below-knee amputation, but this is no longer an absolute recommendation.⁶¹

With the availability of microvascular free tissue transplantation, radical débridement (i.e., wound excision) can be adequate even for the largest wound. Early one-stage wound coverage and bony reconstruction is generally advocated and should be performed jointly by extremity trauma orthopedic and plastic surgical teams whenever possible.^{61,62} It is reasonable for reconstruction to be deferred briefly if there remain tissues of questionable viability so that these can be reassessed and débrided as required. Placement of a temporary negative pressure dressing between débridements helps reduce bacterial ingress and the inflammatory response. If débridement produces an irregular dead space that cannot be completely obliterated, or if tissues remain questionable even after a second look, the resultant cavity may be filled with antibiotic-impregnated beads or available vascularized soft tissues to act as a spacer

until definitive reconstruction is possible. This applies also to segmental bone losses within a soft tissue envelope of doubtful viability. In these situations, soft tissue coverage preferably is still achieved early; bony reconstruction can be completed at a later date, when both the bone and soft tissue envelope are stable and healthy. It remains debated whether fasciocutaneous or muscular flaps are superior for treating compound fractures. Dead space is critical to obliterate, and this is more readily achieved using muscle. Fasciocutaneous flaps may be superior for coverage of metaphyseal fractures, particularly around the ankle. Reviewed experimental data in animals suggest that diaphyseal tibial fractures with periosteal stripping are better covered by muscle instead of fasciocutaneous flaps.⁶³ Perforator-based chimeric flaps, such as the anterolateral thigh flap with a chimeric portion of vastus lateralis, can be designed to incorporate the best features of both tissue types for the given defect.

Once meticulous débridement is complete, the order of surgical repair is fracture stabilization followed by vascular repair and reconstruction of a stable soft tissue envelope. The choice of method for soft tissue coverage is determined by the location and extent of the injury (Table 45-13). Coverage for weight-bearing areas should be durable, stable (nonshearing), and sensate. Properly fitted footwear provides essential protection against pressure-related complications. Split-thickness skin grafts are reasonable for coverage of exposed healthy muscle or soft tissue. Local flaps may be used to cover smaller defects. Island pedicled perforator-based flaps are more versatile in design and inset, preserve viable muscles by excluding them from flap harvest, and can be a useful option when there is no significant degloving injury (Fig. 45-50). Using retrograde pedicle dissection, they can be harvested in freestyle fashion both to avoid the zone of injury and to suit the defect requirements.⁶⁴ Free tissue transplantation is preferred for larger or more complex defects, particularly in the middle and lower thirds of the leg where there are less soft tissues available for reconstruction. Free flaps need not be limited to providing only soft tissue coverage; incorporation of vascularized bone, such as of fibula or iliac crest, can aid in fracture management.⁶⁵ Chimeric flap configurations can improve flap inset into composite defects. Flow-through designs, such as the anterolateral thigh flow-through free flap, can be used to bridge segmental vascular defects to revascularize the distal extremity.⁶⁶ Muscular flaps can be motor innervated to restore lost muscle functions at the recipient site.⁶⁷ Other techniques such as bone distraction and tissue expansion may be indicated in select circumstances. Traditional cross-leg flaps are almost never used now; they cause complete immobilization and increase the risk of deep vein thrombosis and contracture formation.

Osteomyelitis often complicates inadequately débrided compound leg fractures. Delayed coverage also appears to increase the risk of this dreaded complication. Generous irrigation, débridement, removal of dead bone (even in a segment), expedient antibiotic therapy, and healthy soft tissue coverage are important in both acute compound fracture and established posttraumatic osteomyelitis. Large segmental bone losses can be addressed with microvascular free transplantation of osseous flaps or distraction lengthening.^{61,68}

When limb salvage either is not possible or is not in the best interests of the patient, attention is directed to providing soft tissue stump coverage suitable for weight bearing and allowing ambulation with a properly fitted prosthesis. Ideally, local tissues

Table 45-13

Some lower extremity reconstructive options for soft tissue coverage after fracture

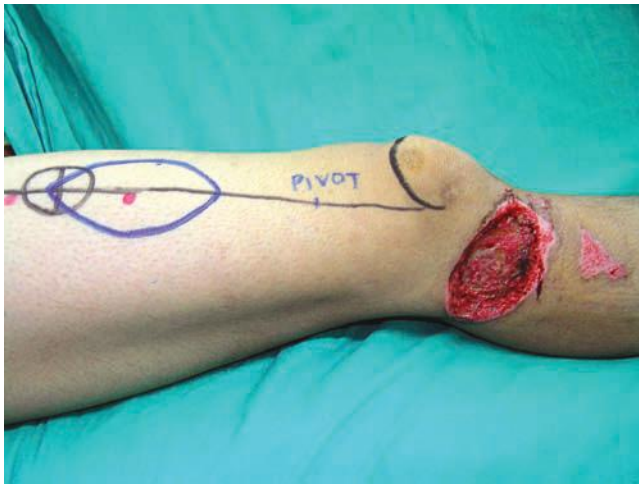
AREA OF DEFECT	RECONSTRUCTIVE OPTIONS
Femur	Sartorius muscle/MC flap (anterior defects) TFL muscle/MC flap (posterior defects) Vastus lateralis/medialis muscle/MC (mid to lower thigh defects) ALT/AMT and posterior thigh fasciocutaneous flap Free osseous flaps (e.g., double-barreled fibula osteoseptocutaneous flap) useful for segmental femur defects
Knee and proximal third of tibia	Gastrocnemius muscle (medial or lateral head, or both) with SSG Island pedicled fasciocutaneous flaps (e.g., distally based anterolateral thigh flap; medial sural artery perforator flap) Free tissue transfer for larger defects
Middle third of tibia	Soleus muscle with SSG Gastrocnemius head(s) with SSG Tibialis anterior muscle “open-book flap” (preserves function) Island pedicled fasciocutaneous flaps (e.g., posterior tibial and peroneal perforator flaps) Free tissue transfer for larger defects
Distal third of tibia	Free tissue transfer usually the first choice Reverse flow sural neurovascular flap Island pedicled fasciocutaneous flaps (e.g., posterior tibial and peroneal perforator flaps) Local muscle flaps for smaller defects

ALT = anterolateral thigh; AMT = anteromedial thigh; MC = myocutaneous; SSG = split-thickness skin graft; TFL = tensor fasciae latae.

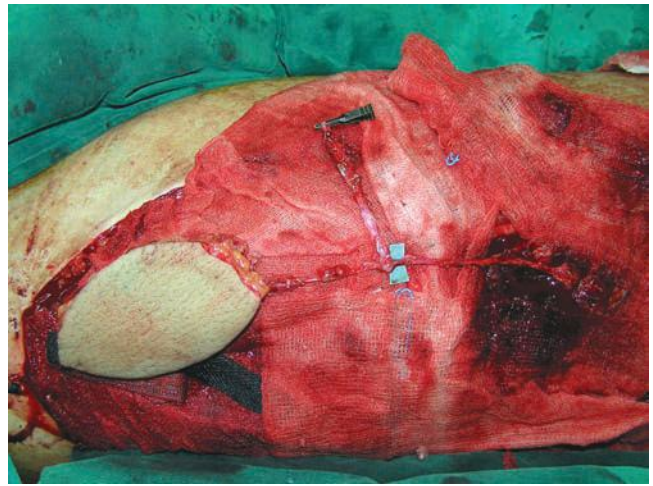
are used; however, when they are unavailable or inadequate, the amputated part can be a useful source of skin grafts or tissues for microvascular free transfers to the stump, which preserves length and avoids a more proximal amputation.

Reconstruction after Oncologic Resection. The refinements in surgical ablation techniques, in adjuvant radiation therapy and chemotherapy, and in limb reconstruction methods have opened the possibility for curative limb-sparing treatments instead of amputation. Extensive soft tissue and segmental long bone defects from radical tumor resection and radiation-compromised wound healing can often be reconstructed now by liberal importation of fresh tissues through microvascular free tissue transplantation tailored to the defect.

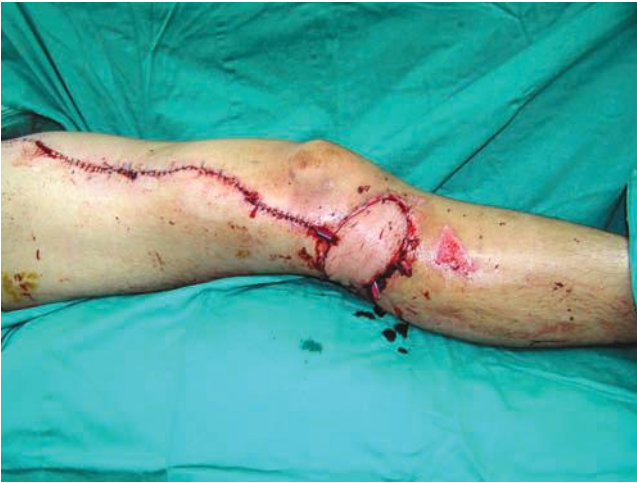Diabetic Ulceration. The pathophysiology of primary diabetic lower limb complications has three main components: peripheral neuropathy (motor, sensory, and autonomic), peripheral vascular disease, and immunodeficiency. Altered foot



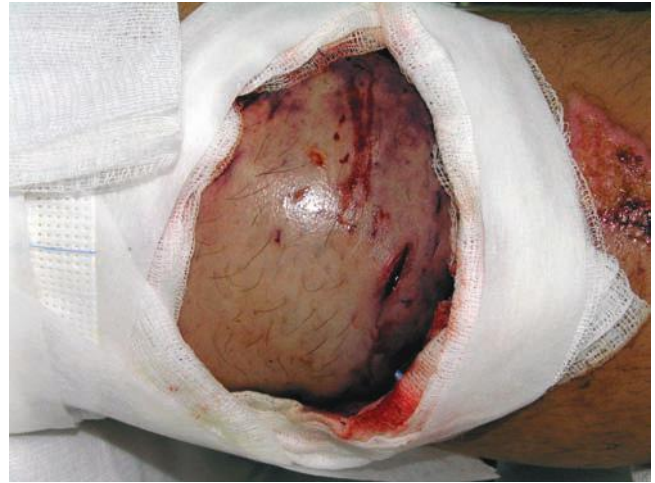A



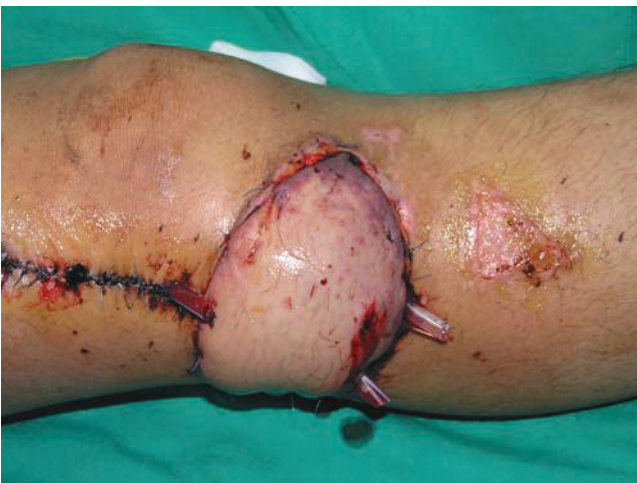B



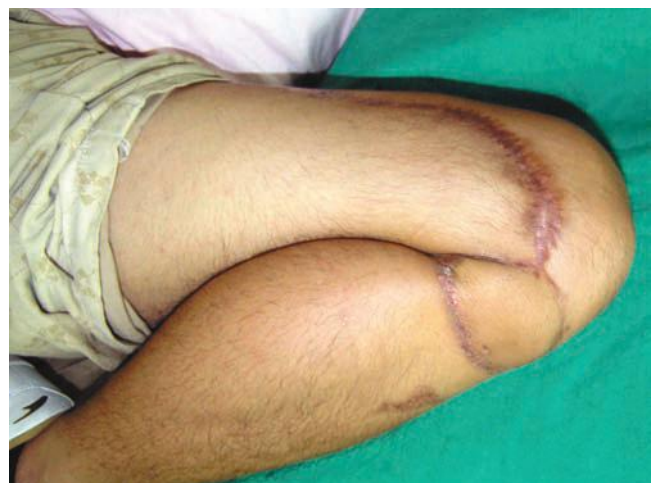C



D



E



F

Figure 45-50. Perforator-based island pedicled anterolateral thigh flap for soft tissue coverage of the upper third lateral leg. **A.** Soft tissue defect with exposed tibial metaphysis after débridement. Note the arterial handheld Doppler signal (red dot) around which the flap has been designed. The flap has been reverse-planned and the pivot point determined along the axis of the descending branch of the lateral circumflex femoral artery (black line). **B.** The flap has been harvested and its pedicle skeletonized to maximize freedom of flap motion; note the additional backup vein in case venous supercharge might be required. **C.** Satisfactory flap perfusion following inset. **D.** Flap perfusion became compromised postoperatively but (**E**) improved with bedside maneuvers; if improvement did not occur, backup venous supercharge would have been available. **F.** The regional fasciocutaneous flap has provided durable, color- and texture-matched soft tissues for reconstruction around the knee; importantly, the pliability of the flap tissues has allowed for a full range of knee movement to be maintained. (Photographs reproduced with permission from L. Lin.)

biomechanics and gait caused by painless collapse of ligamentous support, foot joints, and foot arches change weight-bearing patterns. Blunted pain allows cutaneous fissuring and ulceration to progress. Multiflora infections are established amid local immunodeficiency and microvasculopathy. Frank neuroarthropathic Charcot's foot deformities may ultimately result. Cutaneous ulcerations may chronically deteriorate relatively painlessly, involving deeper tissues, including bone. Persistent soft tissue infection and osteomyelitis, worsened by peripheral vascular compromise and immunodeficiency, traditionally ends in gangrene and amputation. More than 60% of nontraumatic lower extremity amputations occur in diabetics.⁶⁹ Indeed, the age-adjusted lower extremity amputation rate in diabetics (5.5 per 1000 diabetics) was approximately 28 times that of people without diabetes (0.2 per 1000 people).⁶⁹ Improved patient education and medical management, timelier detection of diabetic foot problems and referral for treatment, and the use of more refined techniques for wound management play important roles in improving the chances of limb preservation.⁷⁰

Diabetic patients with lower limb disease often have significant multisystemic comorbidities that must be optimized for surgery; strict perioperative control of blood glucose levels is mandatory. Clinical examination must include documentation of sensory deficits, vascular insufficiencies, and evidence of osteomyelitis. Plain radiographs, MRI, nuclear bone scans, and angiography or duplex imaging may be indicated. A patient with significant vascular disease may be a candidate for lower extremity endovascular revascularization or open bypass.⁷¹ Nerve conduction studies may diagnose surgically reversible neuropathies at compressive sites and aid in decisions about whether to perform sensory nerve transfers to restore plantar sensibility.⁷⁰ Antibiotic and fungal therapies should be guided by tissue culture results.

Plastic surgical management starts with thorough débridement of devitalized or infected tissues, purulent cavities, and osteomyelitic bone. Methods of wound closure are dictated by the extent and location of the postdébridement defect (Table 45-14). Vacuum-assisted closure may be appropriate for superficial defects. Skin grafts should be used cautiously and not in weight-bearing areas. Local and regional flaps can be used after careful evaluation of their vascularity given concurrent peripheral vascular disease and possible recent distal vascular bypass procedures. Microvascular free tissue transfers are appropriate when defects are large or when local flaps are not available. Combination lower extremity bypass and free flap coverage has proved beneficial for the treatment of the diabetic foot in terms of healing and reduction of disease progression.⁷² Orthopedic surgeons should be consulted to improve foot biomechanics and address bony prominences to reduce the risk of recurrent ulceration. Proper footwear (including orthotic devices and off-loading shoe inserts), hygiene, and toenail and skin care are essential.⁷⁰

Lymphedema. The lymphatic system provides a high-volume transport mechanism, clearing proteins and lipids from the interstitial space to the systemic vasculature by means of differential pressure gradients. Factors that contribute to circulatory lymphatic flow include segmental lymphangion contractility, skeletal muscle activity, and one-way valves that prevent back-flow.^{73,74} The lymphatics course throughout the body alongside the venous system, into which they eventually drain via the

Table 45-14

Some reconstructive options for the diabetic foot

AREA OF DEFECT	RECONSTRUCTIVE OPTIONS
Forefoot	V-Y advancement Toe island flap Single toe amputation Lisfranc's amputation
Midfoot	V-Y advancement Toe island flap Medial plantar artery flap Free tissue transfer Transmetatarsal amputation
Hindfoot	Lateral calcaneal artery flap Reversed sural artery flap Medial plantar artery flap ± flexor digitorum brevis Abductor hallucis muscle flap Abductor digiti minimi muscle flap Free tissue transfer Syme's amputation
Foot dorsum	Supramalleolar flap Reversed sural artery flap Thinner free flaps (e.g., temporoparietal fascia, radial forearm, groin, thinned anterolateral thigh flaps)

major thoracic and cervical ducts. With lymphatic obstruction, abnormal connections form between the superficial and deep lymphatics and between the lymphatic and venous systems. Lymphatic stagnation, hypertension, and valvular incompetence contribute to edema, inflammatory fibrovascular proliferation, and collagen deposition, causing firm, nonpitting swelling with peau d'orange cutaneous changes. Lymphoscintigraphy reveals the lymphatic anatomy and quantifies lymphatic flow. MRI provides anatomic information regarding lymphatic trunks, nodes, and obstructive lesions. It is essential to rule out neoplastic lymphatic invasion, especially after oncologic ablation, as a cause of secondary lymphedema. Lymphangiosarcoma is a rare cause of lymphedema that is deadly if diagnosed late.⁷⁵

Primary lymphatic obstruction may arise from congenital malformations of the lymphatic system such as lymphatic hypoplasia, functional insufficiency, or absence of lymphatic valves. Identified genetic causes include the autosomal dominant Milroy's disease. Lymphedema praecox accounts for >90% of cases of primary lymphedema, generally appears during puberty but sometimes as late as the third decade, and occurs more commonly in females. It is usually unilateral and limited to the foot and calf. Lymphedema tarda appears after the age of 35 years and is relatively rare. Secondary (acquired) lymphedema is much more common, with filariasis being the leading cause worldwide.⁷⁶ In Western countries, secondary lymphedema is more commonly the result of neoplasms and their surgical treatments and radiotherapy.⁷⁶

The mainstays of management for lower extremity lymphedema are patient education and nonsurgical measures, including one or more of the following: use of external compressive garments and devices, limb elevation, administration of antibiotics for episodes of cellulitis, and specialized complex physical therapy.^{77,78}

Until recently, the efficacy of available surgical options was generally poor, so they were reserved for cases in which aggressive nonsurgical measures had failed. The classic Charles procedure involved radical excision of lymphedematous suprafascial tissues with skin grafting for coverage; cosmetic outcomes were often disastrous, and functional problems arose due to high rates of contracture, wound breakdown, and ulcerations. This method was later modified into multiple staged excisions of subcutaneous tissues. Other techniques include liposuction and bridging procedures.⁷⁸ Microsurgical lymphatic-lymphatic, lymphatic-venous, lymphatic-venous-lymphatic, and lymph node-venous anastomoses were all tried historically, with some techniques showing efficacy early on but long-term results showing high variability.⁷⁹ Recently, however, with an increased understanding of its pathophysiology and improved preoperative investigations, objective staging of lymphedema severity has become more accurate and allowed microsurgeons to tailor treatments for properly selected patients.^{80,81} These factors, alongside improvements in microsurgical techniques, instrumentation, and long-term postoperative care, have provided better surgical results and a resurgence in interest in microsurgical treatment for lymphedema.⁷⁶ Nonsurgical techniques can be, and usually are, combined with any of the surgical methods.

Pressure Sore Treatment

A *pressure ulcer* is defined as tissue injury, usually over a bony prominence, due to pressure or a combination of pressure and shear forces. These wounds occur in patients debilitated by age, illness, immobilization from orthopedic injuries, or spinal cord injury. Prevention of pressure ulcers first requires identification of susceptible patients. Once such patients are identified, measures to prevent development of ulceration include frequent position changes (by both the patient and caretakers), use of pressure reduction equipment (low air loss mattresses and seat cushions, heel protectors), nutritional optimization, hygienic control of incontinence, and medical and/or surgical treatment of muscle spasm and joint contracture. Once an ulcer has developed, these same factors must be carefully evaluated and deficiencies corrected before embarking on a complex reconstructive treatment plan. Successful reconstruction also requires a medically stable, cooperative, motivated patient with adequate social support.

Pressure ulcers are described by their stage, based on depth of tissue injury (Table 45-15).⁸² Stage I and II ulcers are treated

conservatively with dressing changes and basic pressure ulcer prevention strategies as already discussed. Patients with stage III or IV ulcers should be evaluated for surgery. The wound is examined for soft tissue infection or abscess, osteomyelitis, and involvement of deeper structures or spaces (e.g., joint space, urethra, spinal canal) to determine the urgency and specific requirements of the problem. Blood laboratory work and imaging studies are performed to help establish whether soft tissue or bone infection is present. Radiographs are usually adequate to rule out osteomyelitis; CT and MRI are helpful when plain films are equivocal. Wet gangrenous tissue and abscesses should be surgically débrided without delay to prevent or treat sepsis. In patients who do not meet the strict reconstruction criteria, débridement to healthy tissue without subsequent reconstruction may be the optimal treatment. If bone is present at the wound base, it should be débrided only to bleeding bone and left with a smooth contour. Complete ischiectomy should not be performed for ischial decubitus ulcers, because removal of one ischium only transfers subsequent pressure trauma to the contralateral ischium or the perineum. If osteomyelitis is present, which is best proven by culture of specimens obtained by intraoperative bone biopsy, long-term antibiotic therapy guided by microorganism sensitivity is indicated. A special note should be made regarding surgical treatment of spinal cord injury patients with T5 or higher injuries. In these patients, manipulation of a pressure ulcer and even simple urinary retention can trigger autonomic hyperreflexia. This dangerous condition is characterized by critically high blood pressure elevation and sympathetic discharge. Effective management is immediate recognition and reversal of trigger factors along with prompt administration of pharmacologic agents to prevent complications such as intracranial and retinal hemorrhage, seizure, cardiac irregularities, and death.

Direct closure of a pressure ulcer is rarely performed because it usually creates tension in the healing tissues already stressed by nonphysiologic external pressure, predisposing the closure to breakdown. Skin grafting is useful for shallow ulcers with well-vascularized beds that are not subjected to high mechanical shear. Unfortunately, these requirements remove most pressure ulcers from skin graft candidacy. The mainstay of deep pressure ulcer reconstruction is coverage with well-vascularized local flaps. There is debate over whether myocutaneous flaps are better than fasciocutaneous flaps for resurfacing regions prone to excess pressure and shear. Although myocutaneous flaps have excellent bulk and blood supply, muscle has low tolerance for ischemic injury. From an anatomic viewpoint, there is no pressure point on the human body where bone is padded by muscle. On the other hand, although fasciocutaneous flaps provide reasonable bulk and are teleologically appropriate, some argue that subcutaneous fat and fascia have low resistance to pressure and shear forces and have less robust perfusion than muscle.⁸³

The anatomic location of the pressure ulcer naturally has a profound impact on flap choice. Regardless of the wound site, however, the flap design should be very large, more than needed for closure, so that if the ulcer recurs the flap can be readvanced. In addition, care should be taken to place suture lines, the weakest part of the reconstruction, away from pressure points. Over the last few decades, patterns have developed in the selection of particular flaps for particular pressure sores. Sacral decubiti are well treated with gluteus maximus myocutaneous flaps (Fig. 45-51). In ambulatory patients, either the superior or the inferior gluteus muscle is spared to preserve hip extension function. The downside of using the gluteal muscle is the relatively

Table 45-15

National pressure ulcer advisory panel staging system

CLASSIFICATION	DESCRIPTION
Stage I	Intact skin with nonblanchable redness
Stage II	Partial-thickness loss of dermis; may present as blister
Stage III	Full-thickness loss of dermis with visible subcutaneous fat (no deeper structures exposed)
Stage IV	Full-thickness loss of dermis with exposed bone, tendon, or muscle
Unstageable	Full-thickness loss of dermis with ulcer base obscured by eschar

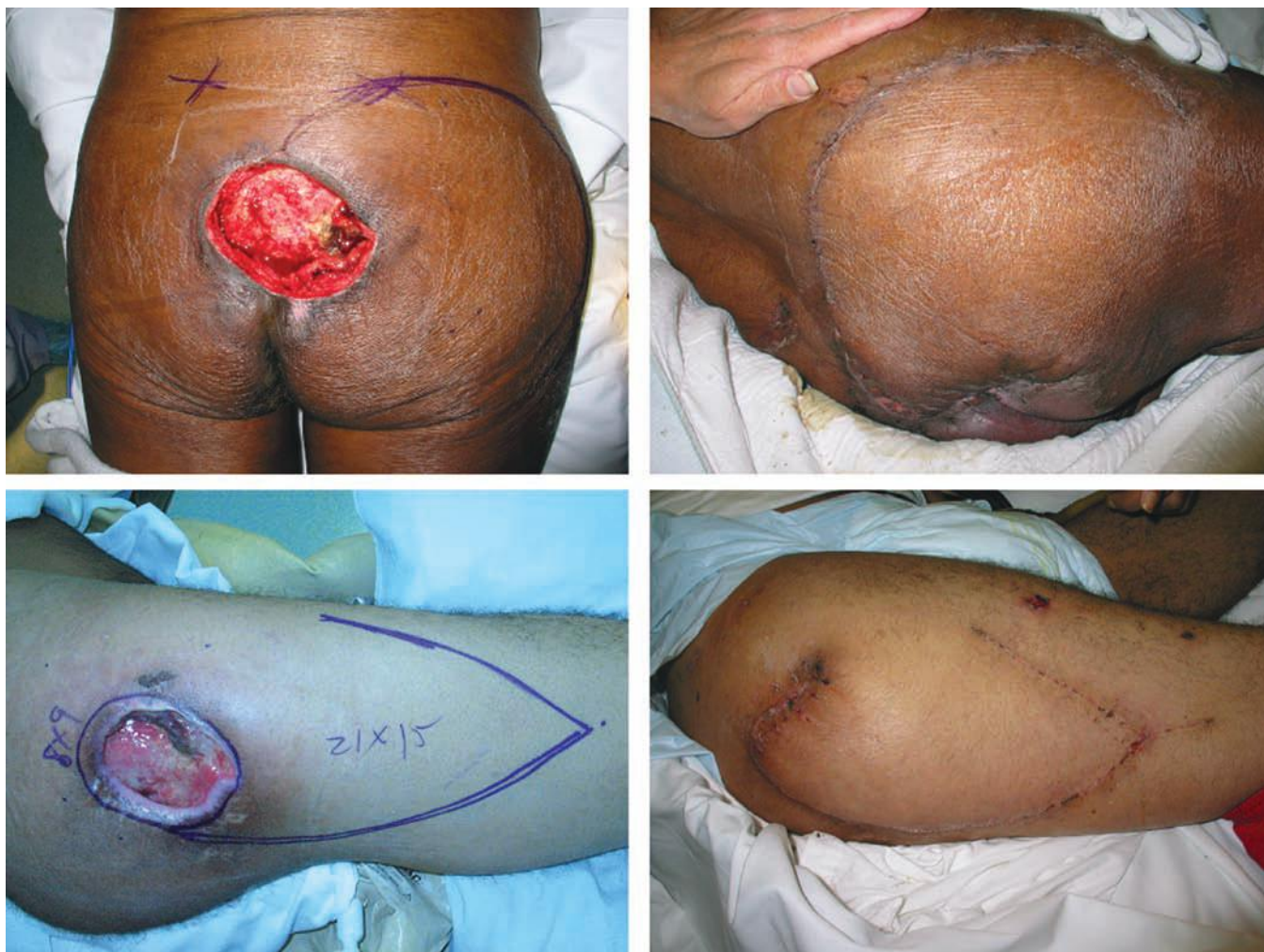

Figure 45-51. Flap reconstruction of pressure ulcers. *Top row:* Preoperative and 1-month postoperative photos of a stage IV sacral decubitus ulcer treated with a myocutaneous gluteus maximus flap. *Bottom row:* Preoperative and 1-month postoperative photos of a stage IV trochanteric ulcer treated with a myocutaneous V-Y tensor fasciae latae flap. (Photographs reproduced with permission from M. Gimbel.)

bloody dissection. A common alternative is the gluteal fasciocutaneous advancement or rotational flap. Ischial pressure sores are generally due to sitting in a wheelchair with improper cushioning or insufficient position changes. A good first-choice flap for ischial wound reconstruction is the hamstring V-Y myocutaneous flap. The gluteus maximus flap may also be transposed inferiorly to cover this wound. A fasciocutaneous alternative is the posterior thigh flap, based on the continuation of the inferior gluteal artery. Trochanteric ulcers develop from prolonged positioning in the lateral decubitus position or from poorly fitting seat or wheelchair equipment. The tensor fasciae latae myocutaneous flap is an expendable muscle unit in ambulatory patients that has a reliable blood supply. It can be advanced superiorly or transposed on its long arc of rotation (see Fig. 45-51). Good second-choice flaps are the rectus femoris muscle flap and the vastus lateralis myocutaneous flap. When pressure sores are neglected, they can become confluent, forming large areas of deep tissue destruction. This dire situation may require hip disarticulation and use of the upper leg soft tissue as a total thigh flap for coverage.

The postoperative care after flap reconstruction of pressure ulcers is as important for success as the surgery itself. The authors recommend transfer of the patient from the operating room table onto an air-fluidized bed, where the patient will remain for the next 7 to 10 days in the hospital. Meticulous instructions must be

given to the nursing staff and therapists regarding the positioning and rolling of the patient to prevent stressing the suture lines during these maneuvers. Nutrition and muscle spasm control are carefully maintained. The posthospitalization care plan, which should have been arranged preoperatively, is confirmed to avoid lapses in proper care. Patients with ischial sores are advised to abstain from sitting for 6 weeks to allow for sufficient healing. Care of the pressure ulcer patient is a labor-intensive process that requires attention to detail by the surgeon, nurses, therapists, caseworkers, and family. Unfortunately, small gaps in care inevitably lead to large gaps in the debilitated patient's integument.

Reconstructive Transplant Surgery

Composite tissue allotransplantation (CTA), such as hand and face transplantation, has become a clinical reality and offers enormous potential for many reconstructive problems, including amputation of extremities. However, as with solid organ transplantation, there remains the issue of allograft rejection. In contrast to visceral organ transplantation, which involves homogeneous tissues, CTA may involve a combination of skin, subcutaneous tissue, nerve, blood vessels, muscle, tendon, and bone, and thus carry the antigenicities of all these tissue types. The basic principles of immunosuppression for solid organ

transplantation have been applied to CTA and include therapy with a variety of combinations of T-cell-depleting agents, monoclonal antibodies, calcineurin inhibitors, antimetabolites, and rapamycin. The complications associated with immunosuppression are well known, including opportunistic infections, metabolic disturbances, and malignancies. Patients selected to undergo CTA, specifically hand transplantation, are young and healthy and therefore more resistant to immunosuppressive side effects than typically less robust solid organ recipients.

As with any surgical procedure, the benefits, success rate, and complications must be understood. Unlike solid organ transplantation, CTA is not a lifesaving procedure. There remains much debate over the risks associated with lifelong administration of potentially dangerous immunosuppressive agents to patients who have no life-threatening illness. The ultimate goal in CTA research is immune tolerance in which the recipient of the allograft remains fully immunocompetent yet does not mount an immunologic response to the transplanted allograft. Accomplishment of this goal would allow the decrease or possible elimination of immunosuppressive medications. If immune tolerance is achieved, CTA clinical applications will broaden dramatically as they become the next frontier in reconstructive surgery⁸⁴ (Fig. 45-52).

AESTHETIC SURGERY

The American Medical Association defines *cosmetic surgery* as “surgery performed to reshape normal structures of the body

5► to improve the patient’s appearance and self-esteem.” *Reconstructive surgery* is performed on structures of the body that are abnormal due to congenital defects, developmental abnormalities, trauma, infection, tumors, or disease. It is generally performed to improve function but may also be done to approximate a normal appearance.⁸⁵ In practical terms, there are both reconstructive and cosmetic elements to almost every plastic surgery case, and the definition of “normal” structure is sometimes unclear. Nevertheless, there are patients for whom it is a priority to make surgical changes to their bodies in the clear absence of a functional deformity. Aesthetic surgery patients present a unique challenge to the plastic surgeon, because the most important outcome parameter is not truly appearance, but patient satisfaction. Optimally, a good cosmetic outcome will be associated with a high level of patient satisfaction. For this to be the case, the plastic surgeon must do a careful analysis of the patient’s motivations for wanting surgery, along with the patient’s goals and expectations. The surgeon must make a reasonable assessment that the improvements that can be achieved through surgery will meet the patient’s expectations. The surgeon must appropriately counsel the patient about the magnitude of the recovery process, the exact location of scars, and potential complications. If complications do occur, the surgeon must manage these in a manner that preserves a positive doctor-patient relationship.

Assessment of Facial Aesthetics

A thorough evaluation of the patient who presents for facial aesthetic surgery should start with elicitation of the patient’s chief complaint, and the examination should be focused on that region. Physical examination of the entire face should note skin quality as well as the presence of redundant skin on the neck, jowls, and eyelids. Depth of the nasolabial folds and the presence of “marionette” lines on the chin should be noted.

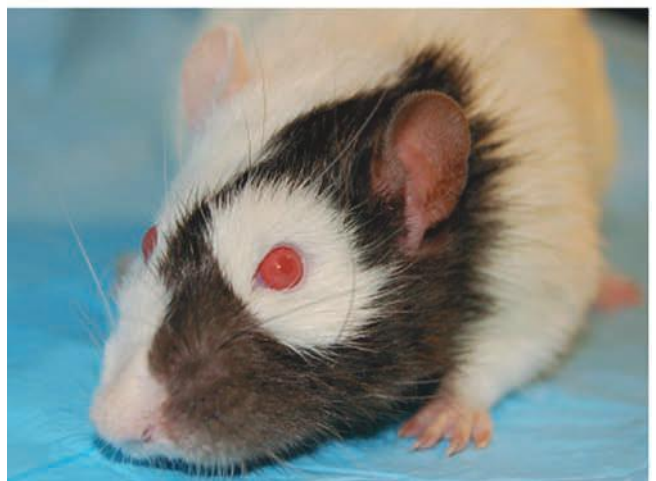
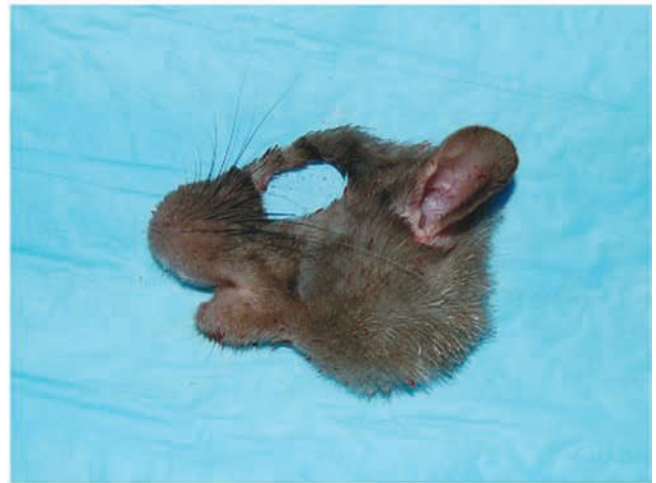
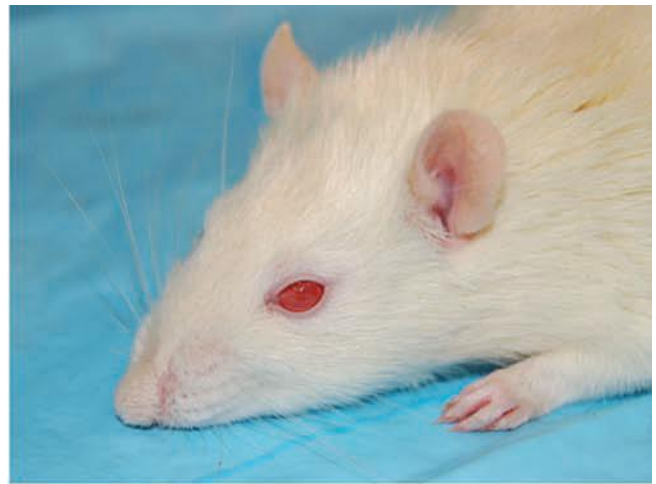Figure 45-52. Hemifacial composite tissue allotransplantation in a rat model. (Photographs reproduced with permission from K. McLean.)

Brow position should be evaluated, along with the distance from brow to hairline. Bulging fat in the lower eyelid region and the presence of a “tear trough” deformity, or deep fold at the lid-cheek junction, should be evaluated. Facial fat atrophy and descent, a hallmark of facial aging, should be noted.

Blepharoplasty and Browlift

Excess skin and adipose deposits of the upper eyelid are approached through an incision based on the supratarsal crease.

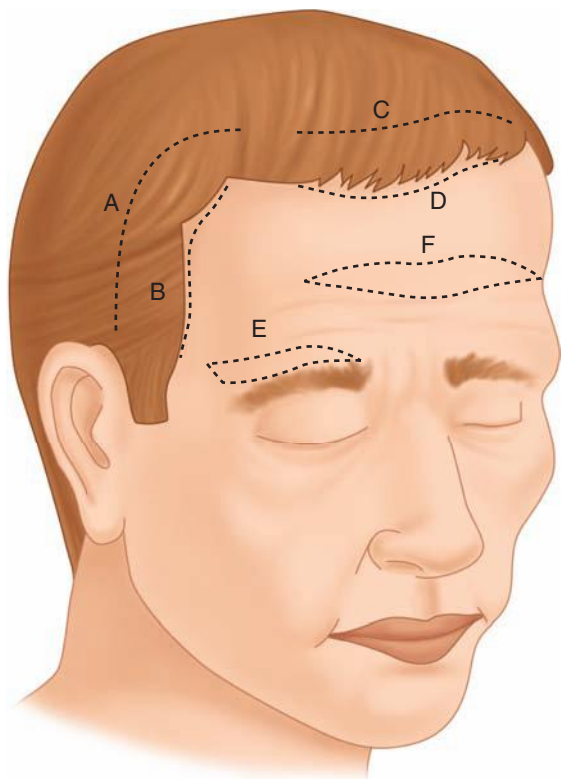


Figure 45-53. Incisions for browlift. *A*, Temporal scalp incision; *B*, temporal hairline incision; *C*, midline scalp incision; *D*, mid-hairline incision; *E*, direct eyebrow incision; *F*, direct forehead incision.

Careful attention to marking will avoid the complication of overresection. A strip of orbicularis muscle is often excised to accentuate the supratarsal fold. Fat deep to the orbital septum is resected selectively. In the lower lid, excess skin is removed through a subciliary incision. Lower eyelid fat may be either excised or repositioned. Complications can include hematoma, lower lid retraction, and injury to ocular muscles. If a hematoma forms in the retro-orbital region, a true surgical emergency exists. Permanent vision loss can occur if it is not immediately decompressed. Brow ptosis, judged relative to the superior orbital rim, can be corrected through a number of incisions (Fig. 45-53).⁸⁶

Facelift

Correction of jowls, nasolabial folds, and redundant neck skin can be accomplished with a facelift procedure that both removes skin and tightens the superficial musculoaponeurotic system (SMAS) layer. The SMAS lies deep to the subcutaneous tissue and contains the muscles of facial expression. The facial nerves are in a plane just deep to the SMAS. The SMAS can be simply plicated or a portion of it excised and closed. A sub-SMAS dissection technique can help to elevate and develop this layer in separate fashion, with care being taken to avoid injury to the underlying facial nerves. The incisions for most facelift techniques are preauricular with extension into the temporal hairline superiorly and into the retroauricular region posteriorly and inferiorly (Figs. 45-54 and 45-55). The platysmal layer is continuous with the SMAS layer and can be plicated through a small neck incision to eliminate the appearance of vertical bands along the muscle edge. The most common facelift complication is hematoma, which may require operative drainage to prevent skin flap necrosis. Injury to facial nerves, most often temporal

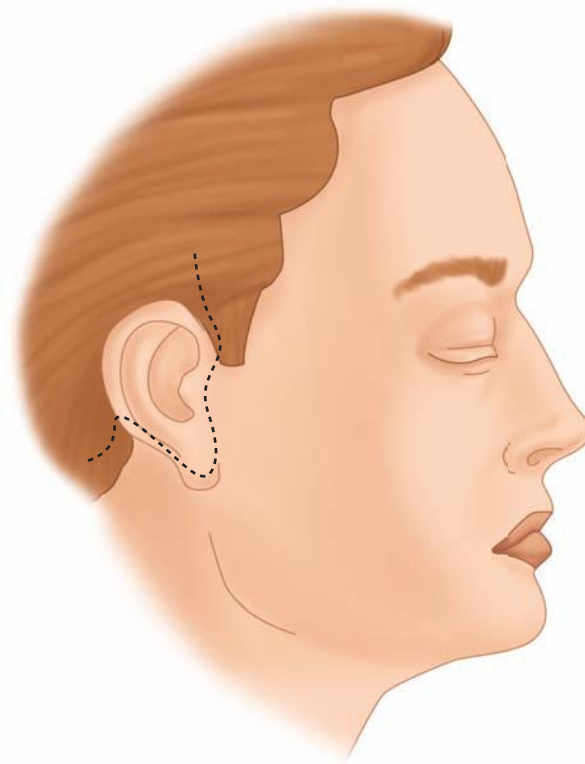


Figure 45-54. Incisions for cervicofacial rhytidectomy.

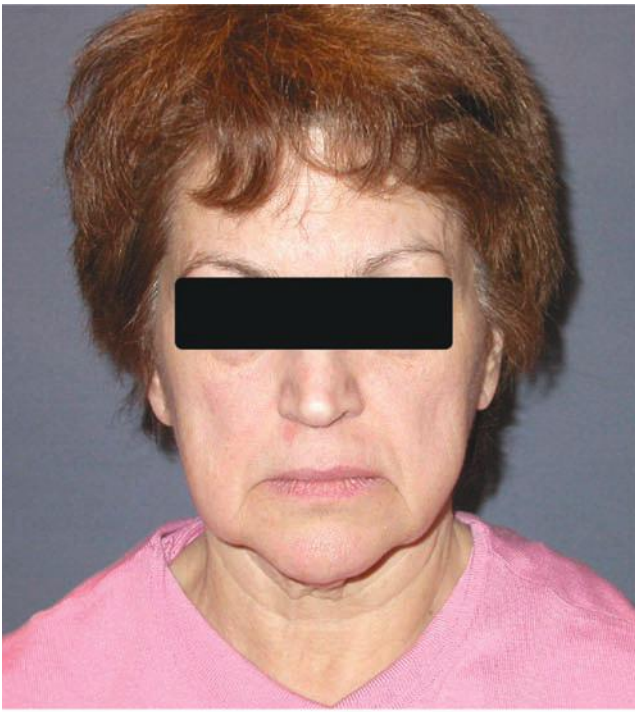branch and marginal mandibular branch, is seen in approximately 1% of cases.⁸⁷

Rhinoplasty

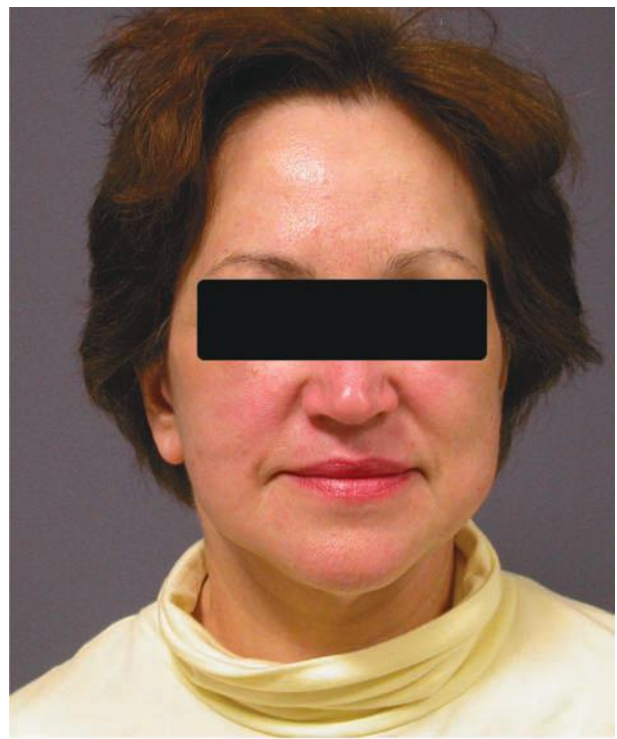The key to understanding rhinoplasty is appreciating the complex nasal anatomy (Fig. 45-56) and the way in which altering this framework will impact the appearance of the nose. Evaluation of the rhinoplasty patient not only should include the aesthetic complaints, but also should consider the function of the nasal airways. Nasal airway obstruction can occur from several structural problems. A deviated septum can severely impede airflow, as can problems with the internal nasal valve. Obstruction at the internal nasal valve, which is the junction of the upper lateral cartilage and septum, can be identified by applying lateral traction on the cheek skin to open the valve and observing whether airflow improves (Cottle sign). Airway obstruction can be addressed surgically at the time of rhinoplasty. Aesthetic deformities of the dorsum of the nose are treated by a combination of osteotomies, which serve to reposition the nasal bones, and rasping of the bone. Aesthetic deformities of the tip of the nose are treated by reducing the width of the lower lateral cartilages and/or sewing the cartilages together to reduce tip width. Small tips can be augmented with cartilage grafts harvested from septum or auricle (Fig. 45-57). Complications of rhinoplasty include induction of new nasal airway obstruction and a variety of aesthetic deformities.⁸⁸

Suction Lipectomy

Liposuction involves the removal of adipose tissue through minimal incisions using a hollow suction cannula. Although the scarring is quite innocuous, a key principle of liposuction is that fat is being removed without skin tightening. Therefore, one relies on the patient's inherent skin elasticity to provide retraction over the treated adipose depot. Assessment of skin tone is



A



B

Figure 45-55. Facelift. **A.** Preoperative appearance. **B.** Postoperative appearance.

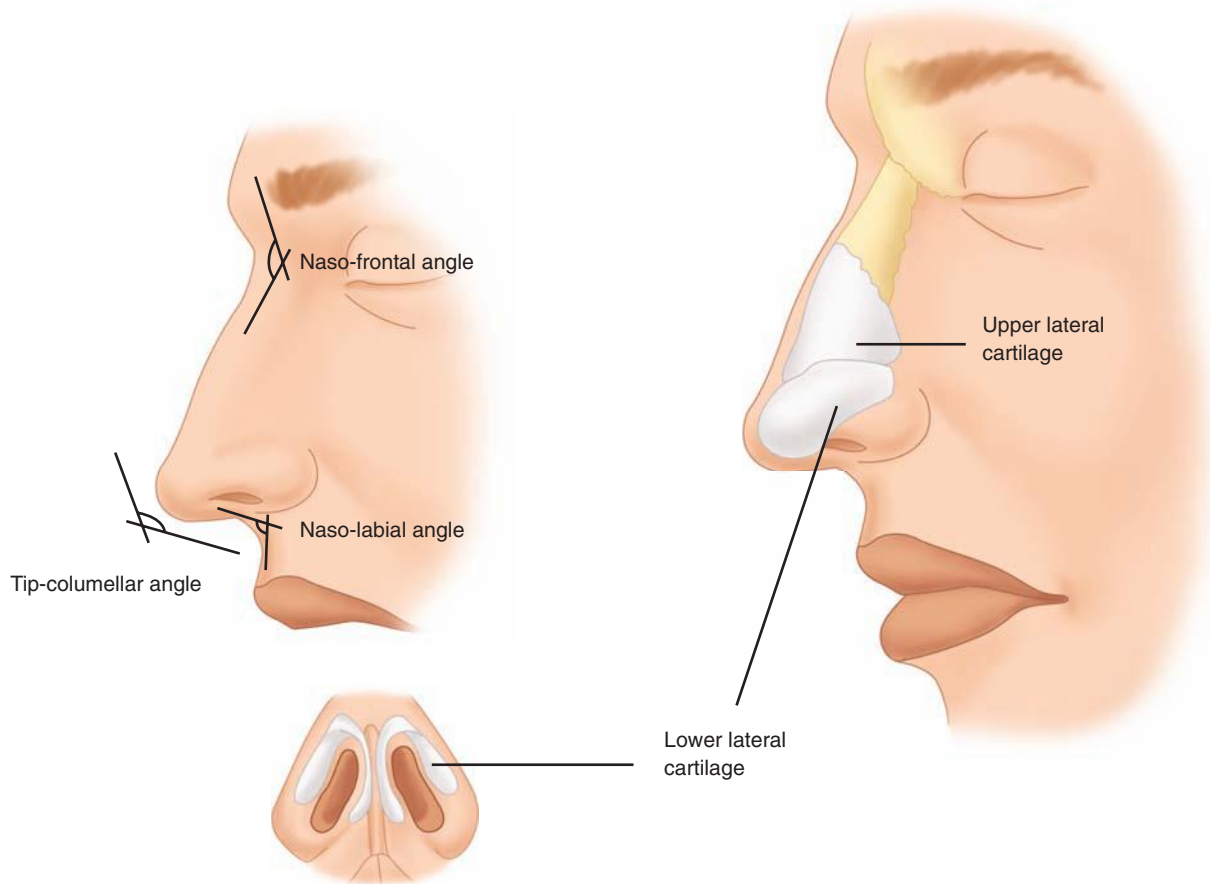
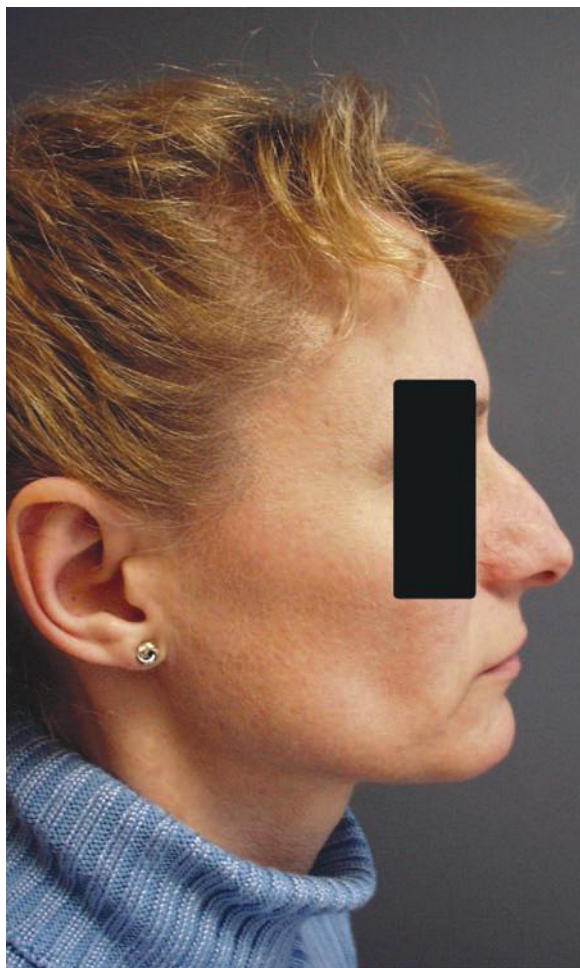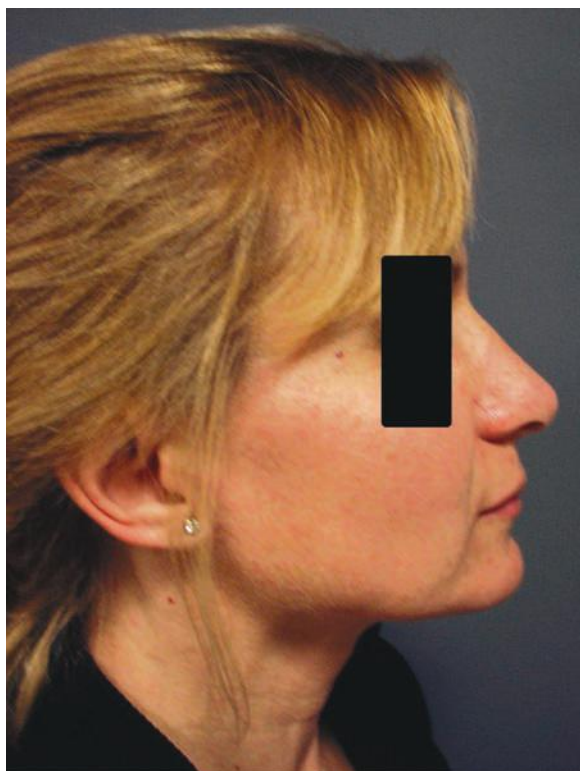


Figure 45-56. Rhinoplasty anatomy.



A



B

Figure 45-57. Rhinoplasty. **A.** Preoperative appearance. **B.** Postoperative appearance.

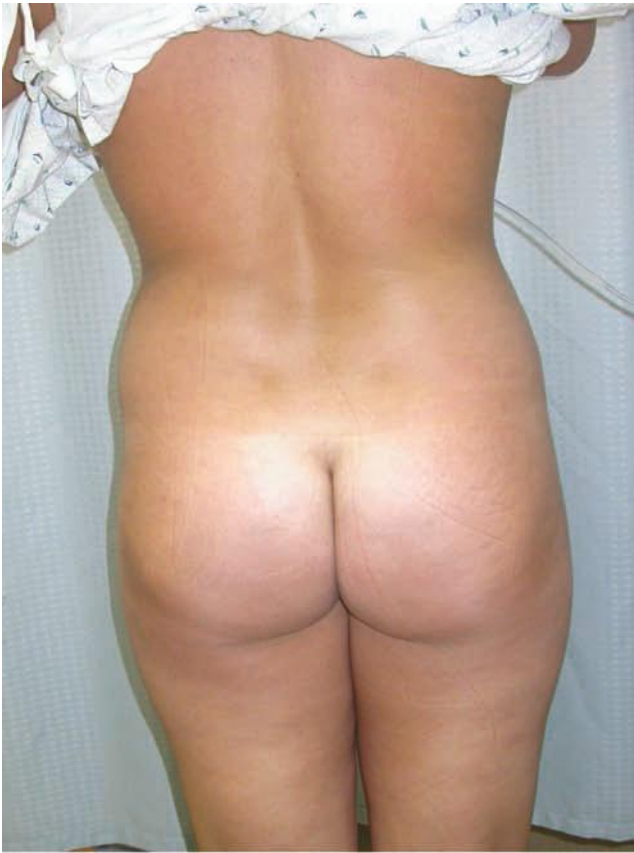a vital part of the patient evaluation. If there is skin laxity in the area to be treated, it may worsen after liposuction. Importantly, liposuction should be used as a tool for contouring prominent adipose depots and is not considered a weight loss treatment. The best candidates for liposuction are individuals who are close to their goal weight and have focal adipose deposits that are resistant to diet and exercise (Fig. 45-58). The suction cannula removes fat by avulsing small parcels of adipose tissue into small holes at the cannula tip. With standard suction lipectomy, fat is removed only when the cannula is actively moved through the tissue planes. Minimal tissue effects are seen when the cannula is stationary. In general, larger-diameter cannulas remove adipose tissue at a faster rate but carry a higher risk of causing contour irregularities such as grooving and uneven removal of fat. Newer liposuction technology uses an ultrasonic probe to emulsify the fat via cavitation before suction. Advocates of ultrasonic liposuction report that the technique provides a more even and uniform removal of adipose tissue. Recognizing that no one technique is best for all patients and all anatomic regions, many surgeons use ultrasonic energy selectively.

A major advance in the field of liposuction was the development of tumescent local anesthesia. This method involves the infiltration of very dilute lidocaine and epinephrine (lidocaine 0.05% and epinephrine 1:1,000,000) in large volumes throughout the subcutaneous tissues. Tumescent volumes may range from one to three times the anticipated aspirate volume. The dilute lidocaine provides sufficient anesthesia to allow the liposuction to be performed without additional agents, although many surgeons prefer to use sedation or even general anesthetic when large volumes of fat are to be removed. When general anesthesia is used, the lidocaine dose may be reduced or even eliminated. With tumescent anesthesia, the absorption of the dilute lidocaine from the subcutaneous tissue is very slow, with peak plasma concentrations occurring approximately 10 hours after the procedure.⁸⁹ Therefore, the standard lidocaine dosing limit of 7 mg/kg may be safely exceeded. Current recommendations suggest a limit of 35 mg/kg of lidocaine with tumescent anesthesia.⁹⁰ A very important component of the tumescent anesthetic solution is the dilute epinephrine, which limits blood loss during the procedure.

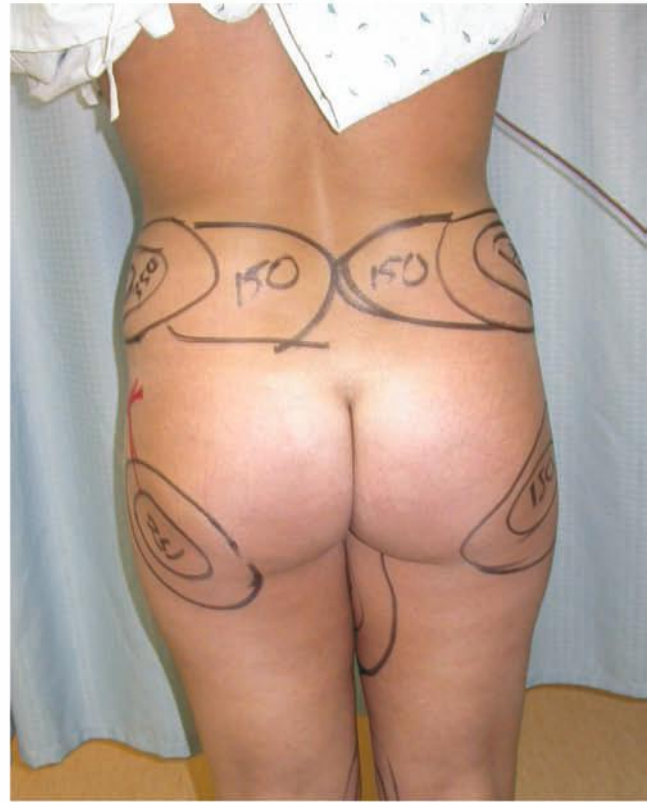
Safety issues are paramount for liposuction because of potential fluid shifts postoperatively and hypothermia. If ≥ 5000 mL of aspirate is to be removed, the procedure should be performed in an accredited acute care hospital facility. After the procedure, vital signs and urinary output should be monitored overnight in an appropriate facility by qualified and competent staff who are familiar with perioperative care of the liposuction patient.⁹⁰

Autologous Fat Grafting

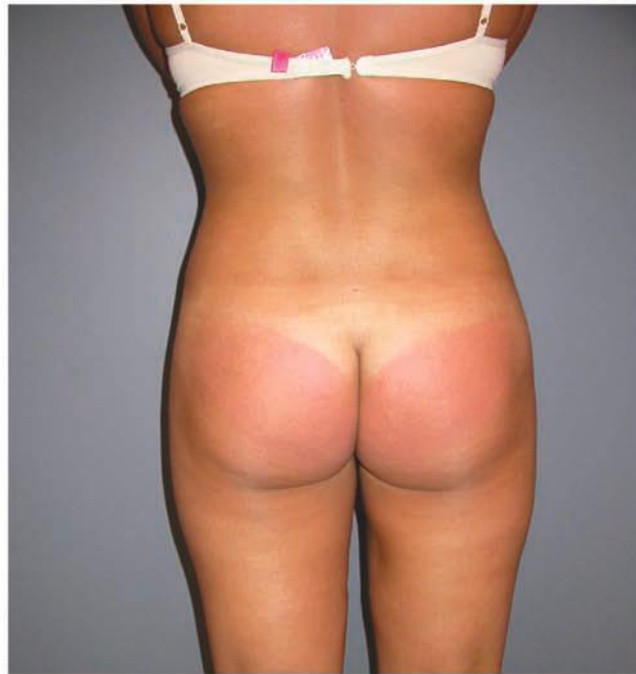The concept of reinjecting fat tissue harvested by liposuction has been put into practice for decades. Key to the technique is a processing step in which the sterilely collected fat is separated from the aqueous (primarily tumescent fluid) and free lipid fractions. This can be done by centrifugation or filtering. The adipose grafts are then injected into the tissues using specially designed blunt-tipped cannulas. Small aliquots of graft material are injected with each cannula pass, and the fat is interposed within the vascularized tissues of the recipient bed in small channels. Autologous fat grafting has been used primarily for facial aesthetic augmentation of the midface, but has been gaining popularity for breast aesthetic applications, buttock augmentation, and breast reconstruction.



A



B



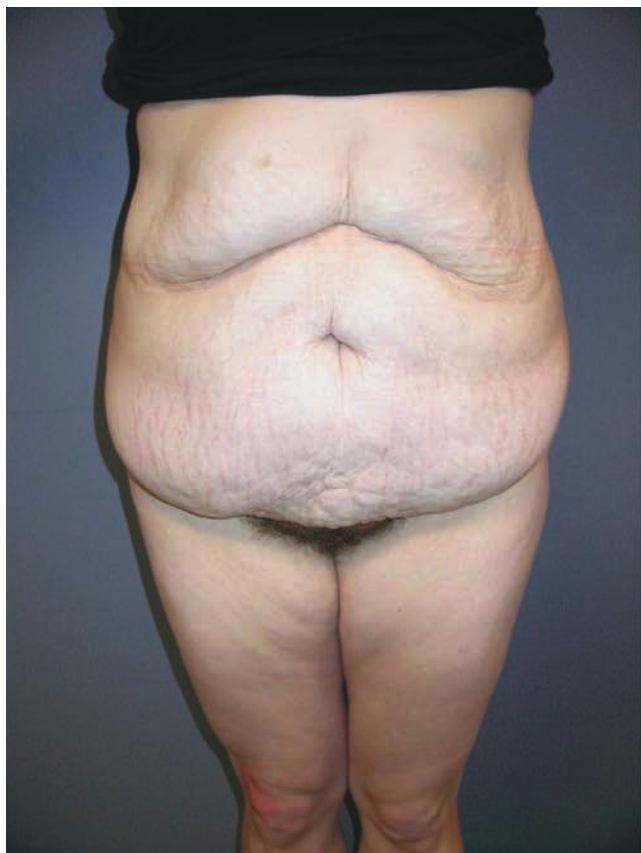C

Figure 45-58. A and B. Preoperative photos of a 22-year-old woman with focal adipose deposits on the trunk and extremities. C. Patient 3 months after surgery.

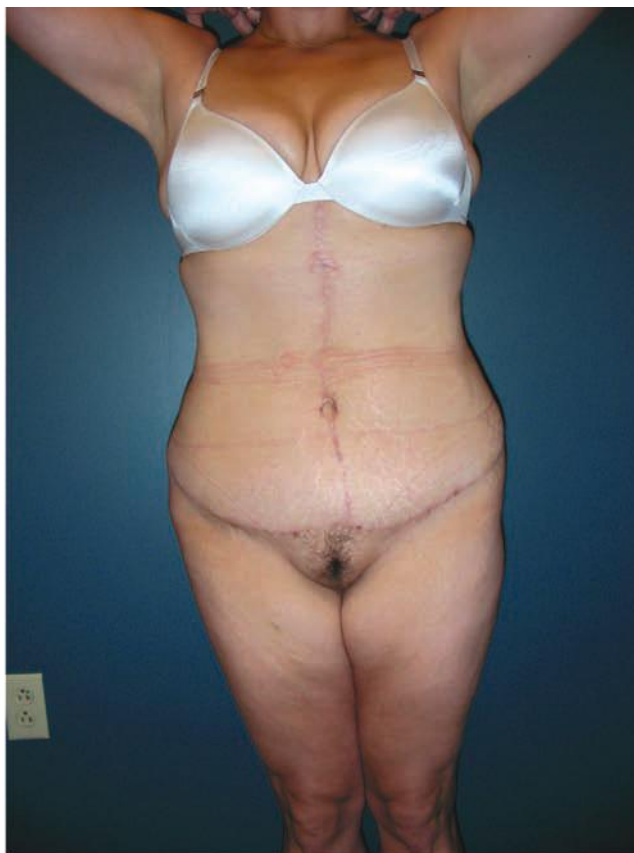Excisional Body Contouring

When significant skin laxity is present, improvement in contour can be achieved only through skin excision. Therefore, all body-contouring surgery represents a trade of excess skin for scar, and this must be emphasized during patient consultation.

The patient willing to accept scars in exchange for improved contour is likely to be satisfied with the procedures. With the increased number of bariatric surgery procedures over the past decade, body-contouring surgery has become very popular and is emerging as a new subspecialty of plastic surgery.



A Figure 45-59. **A.** Preoperative photo of 35-year-old woman after gastric bypass and massive weight loss. **B.** Patient 12 months after a fleur-de-lis abdominoplasty.



Abdominoplasty/Panniculectomy. Abdominoplasty/panniculectomy is the most common body-contouring procedure and can range from a limited-incision skin removal in the lower abdomen to a major skin excision with transposition of the umbilicus and placcation of the rectus muscles to further enhance contour.⁹¹ Some patients may benefit from a concurrent vertical incision to remove skin in two vectors (Fig. 45-59). Possible complications include skin necrosis, persistent paresthesias of the abdominal wall, seroma, and wound separation. Necrosis of the umbilicus may complicate preservation of that structure if the stalk is excessively long or an umbilical hernia is repaired. Adding a vertical resection increases the incidence of skin necrosis, especially at the confluence of scars in the lower abdomen.

Brachioplasty (Arm Lift). Brachioplasty, or arm lift, leaves a visible longitudinal scar on the upper arm. Therefore, it is reserved for patients with excessive skin in that region. The patient willing to accept the scar can be happy with the results. Complications include distal seroma and wound separation. Paresthesias in the upper arm and forearm may occur secondary to injury of sensory nerves passing through the resection area, although this rarely affects function. Scar contracture in the axilla may limit shoulder excursion in rare cases and require revision.

Thigh and Buttock Lift. Treatment of loose skin on the thighs and buttocks involves a spectrum of operations customized to the individual patient. The outer thighs can be lifted at the same time that an abdominoplasty is performed with one continuous

scar along the belt line. The same scar can be continued all the way around the back to lift the buttocks as well. This combination of abdominoplasty, thigh lift, and buttock lift is commonly referred to as a *circumferential lower body lift*. The inner thighs can be contoured by lifting the skin and placing the incisions along the groin crease. Firmly anchoring the deep thigh fascia to Colles' fascia is essential to help prevent spreading of the labia. In cases of severe excess skin on the inner thighs, a long vertical incision is necessary. Complications of thigh and buttock lift include seroma, wound separation, skin necrosis, and change in the shape of the genital region (with possible sexual dysfunction). Blood loss during the procedure may necessitate transfusion.

Reduction Mammoplasty

Breast reduction is performed to treat symptoms of macromastia, most commonly consisting of the triad of upper back pain, bra strap grooving, and rashes under the fold of the breasts. Although this procedure has reconstructive indications, the aesthetic outcome is of considerable importance. Fundamental to the success of the procedure is the establishment of symmetric and proper nipple position. Nipple ptosis is graded by the nipple position relative to the inframammary fold (IMF). Grade 1 ptosis describes a nipple ≤ 1 cm below the IMF. Grade 2 ptosis describes a nipple 1 to 3 cm below the IMF. Grade 3 ptosis describes a nipple position >3 cm below the IMF. *Pseudoptosis* or *bottoming out* is a term used to describe the descent of the breast tissue below the nipple and is a potential long-term complication of breast reduction. In addition to classification of

nipple ptosis, a thorough preoperative evaluation also includes measurement of the distance from sternal notch to nipple bilaterally, as well as measurement of the distance from nipple to IMF. The base width of the breast should also be considered. Many patients are found to have significant baseline asymmetries in these measurements. Preoperative breast cancer screening consistent with current American Cancer Society guidelines should be performed for all patients undergoing elective breast reshaping surgery. The planned new nipple position should be symmetrical

at the IMF along the breast meridian. There are many technical variations of the breast reduction procedure, but nearly all of them have common elements of reshaping the skin envelope in three dimensions and moving the nipple to a new location on a vascularized tissue pedicle. The pedicle is de-epithelialized to preserve the subdermal vascular plexus. Fig. 45-60 shows the classic "keyhole" Wise pattern reduction technique. The skin resection is designed to create a conical shape, and the nipple is transposed on an inferiorly based pedicle.⁹² This results in an inverted T-shaped

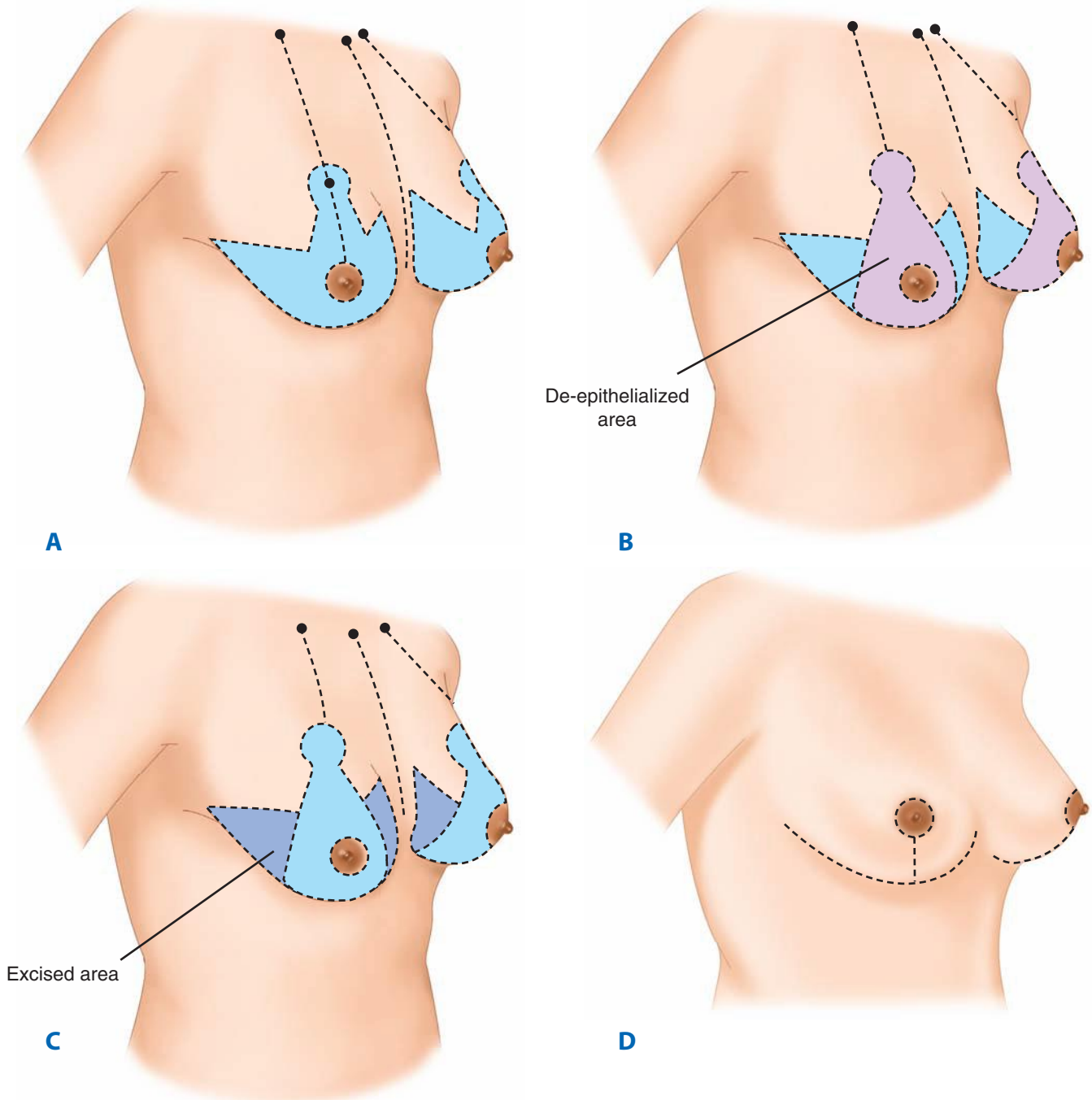
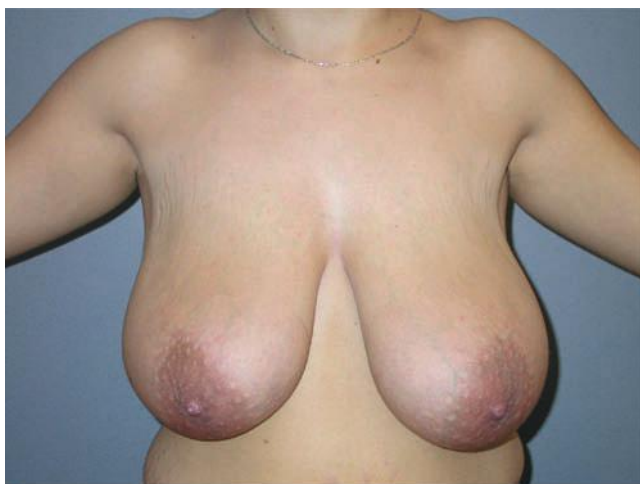
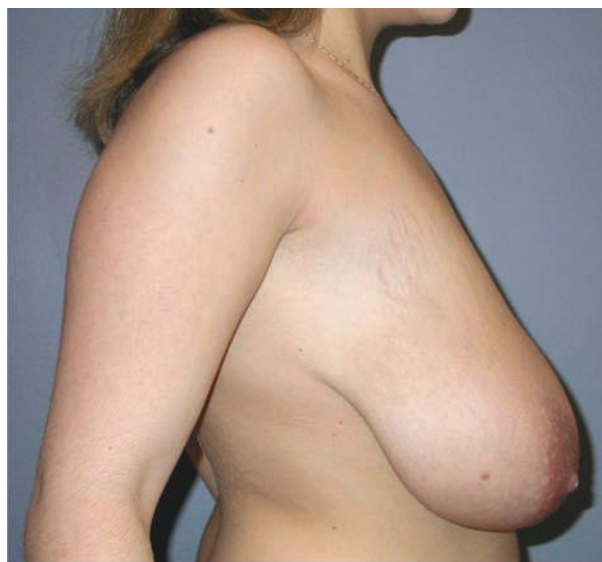
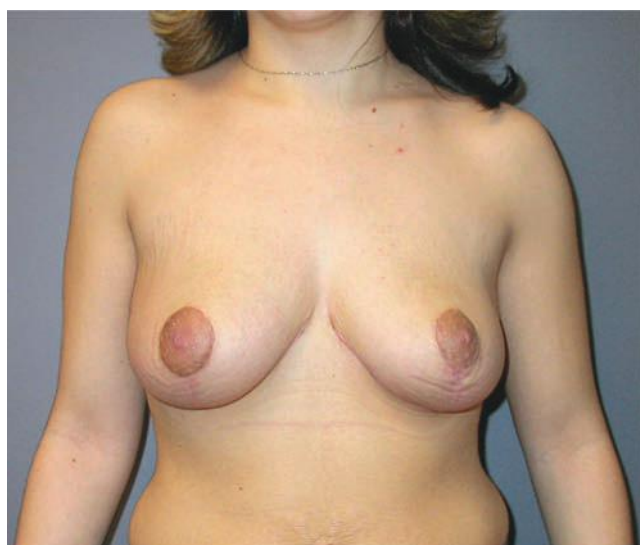Figure 45-60. Inferior pedicle reduction mammoplasty. **A.** Markings for Wise pattern reduction. **B.** Purple area is region to be de-epithelialized. **C.** Dark blue region is area to be resected. A segment of the inferior pedicle is de-epithelialized. The inferior pedicle is dissected straight down to the chest wall, with maintenance of an 8- to 10-cm pedicle width. Lateral and medial segments are resected. After this is accomplished, the superior flap is dissected to the clavicle. Breast subcutaneous tissue and parenchyma are resected from the superior pole. The vertical limbs are brought together and to the meridian of the inframammary fold. The nipple is then set in its new superior position. **D.** T-shaped incision on final closure.



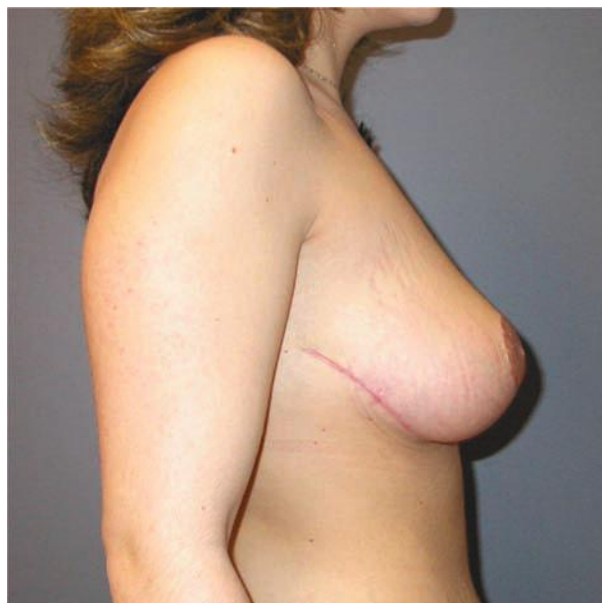A



B



C



D

Figure 45-61. A and B. Preoperative photos of a 25-year-old woman with symptoms of upper back pain, bra strap grooving, and rashes under the folds of her breasts treated with a Wise pattern inferior pedicle reduction. C and D. Patient 6 months after surgery.

scar. Fig. 45-61 shows a patient treated using this technique. All breast reduction techniques keep the scars on the lower half of the breast so they are covered by clothing. Techniques have been designed to minimize scar length and even eliminate the horizontal component in the IMF. Fig. 45-62 depicts a vertical scar skin resection pattern with the nipple preserved on a superior pedicle.^{93,94} For excessively large breasts, the required pedicle length may be too long to provide adequate blood supply to the nipple. In such cases, the nipple is removed and replaced onto a viable tissue bed as a full-thickness skin graft. Complications of breast reduction include decreased nipple sensation, nipple loss (rare), skin necrosis, hematoma, and fat necrosis. This last complication can result in a firm mass of scar within the breast that may need careful evaluation and follow-up to distinguish it from a neoplastic mass. Long-term

complications include inability to breastfeed and pseudoptosis, as mentioned earlier.

Mastopexy

In contradistinction to breast reduction, in which patients are treated for symptoms related to heavy breasts, mastopexy is a three-dimensional reshaping of the breast performed with no or minimal volume removal. The principles are the same, however. The skin envelope is contoured, and the nipple location is optimized. Because the degree of ptosis may be less severe than in breast reduction cases, the patterns of skin resection can vary widely. Minimal patterns may involve excision of just a crescent of skin from above the areola or a periareolar (“donut”) resection. The Wise keyhole pattern can be used for larger skin excisions.

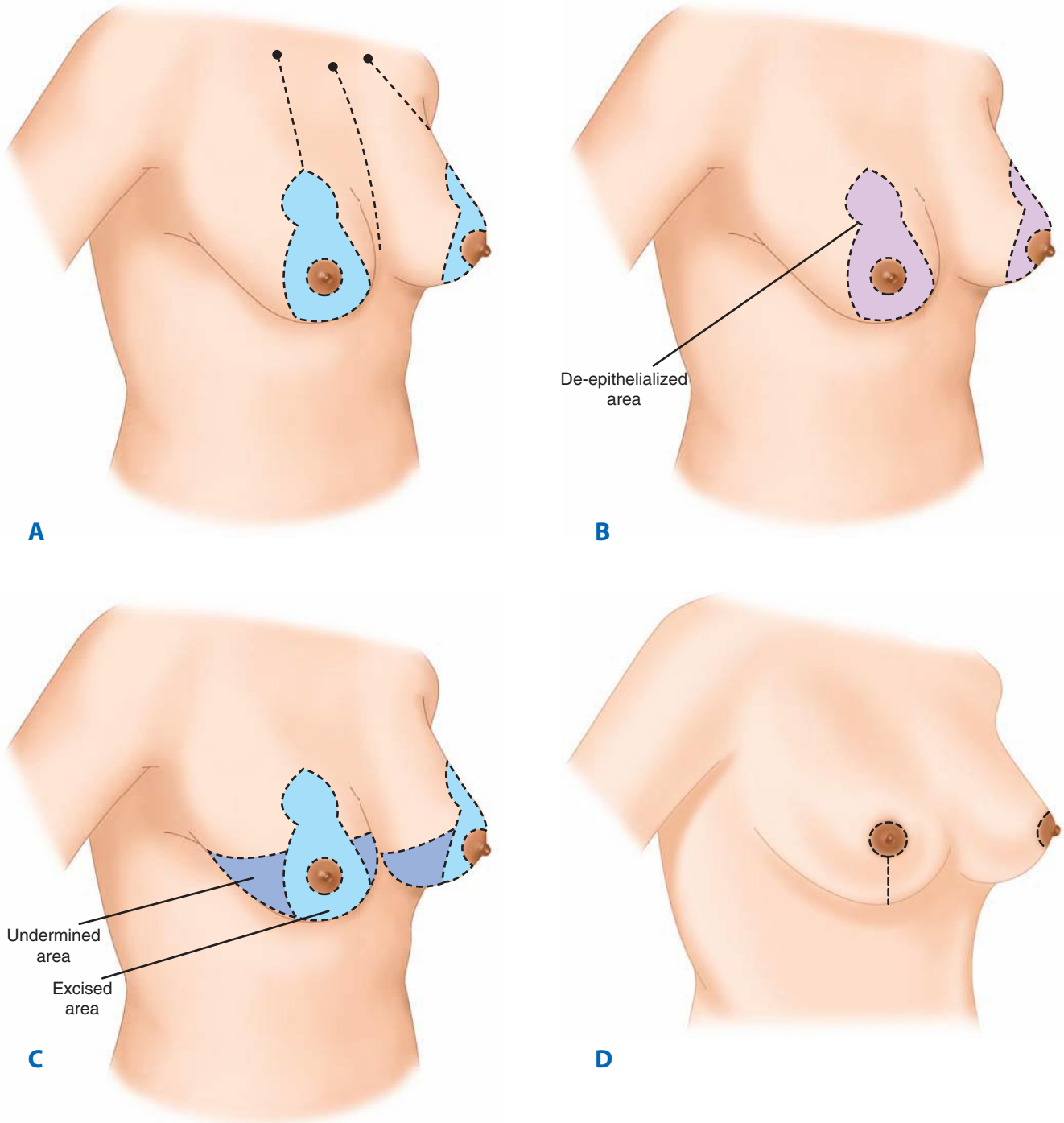


Figure 45-62. Vertical reduction mammoplasty, Lejour technique. **A.** Markings for vertical reduction. **B.** Purple area is region to be de-epithelialized. **C.** Dark blue region represents inferior pole to be resected. The shaded regions are the lateral and medial segments that are to be undermined; these areas can also be liposuctioned. The superior pedicle is de-epithelialized and dissected to the chest wall. The tissue and parenchyma from the inferior pole are resected. The pillars from the lateral and medial segments are sewn together. The nipple is transposed on its pedicle to its new position. **D.** Closure of the vertical mammoplasty. There is bunching up of skin and tissue along the vertical limb that will resolve over time; in addition, the new inframammary fold will declare itself superior to the original one.

Augmentation Mammoplasty

Although the use of prosthetic implants can successfully increase breast size, the surgeon must fully understand both the risks of the biomaterials and the way in which a specific implant of given shape and size can be surgically integrated into the existing breast mound to achieve the desired result.⁹⁵ To address the latter point, the surgeon must first consider

the possible surgical approaches for implant placement. The three commonly used incisions for placement of cosmetic breast implants are inframammary, periareolar, and axillary (Fig. 45-63).⁹⁶ A transumbilical breast augmentation technique has been advocated by some surgeons more recently, but critics of this approach point out that there is poor control over the dissection of the implant pocket and that direct access to the

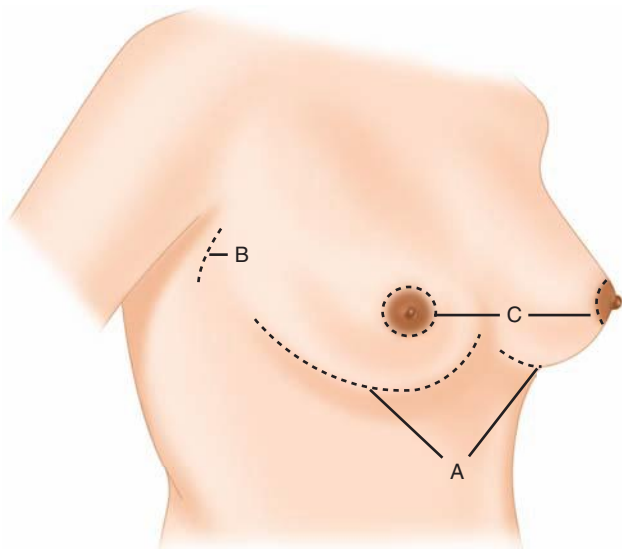


Figure 45-63. Incisions for augmentation mammoplasty. A, Inframammary; B, axillary; C, periareolar.

tissues of the breast is inadequate to control bleeding vessels. In addition, only saline implants can be used with transumbilical breast augmentation because the prefilled silicone implants are too large to pass through the incision and narrow tunnel. The implants may be placed in a subglandular or subpectoral position (Fig. 45-64). Many surgeons prefer the subpectoral placement because it provides greater soft tissue coverage in the upper pole of the breast and can hide contour irregularities related to the implant. This soft tissue coverage is especially important with saline implants, because visible rippling can occur. The next issue to consider is existing nipple position. If a patient has mild ptosis, the sheer volume of the implant may raise the nipple to an acceptable level. For more severe ptosis, a concurrent mastopexy is necessary. Some surgeons advocate performing the mastopexy as a second stage after the implant has settled into position.

Potential complications related to the implant itself are numerous, and the patient must be fully informed of these possibilities before undergoing surgery. One important point is that there is a high likelihood that the patient will require a second

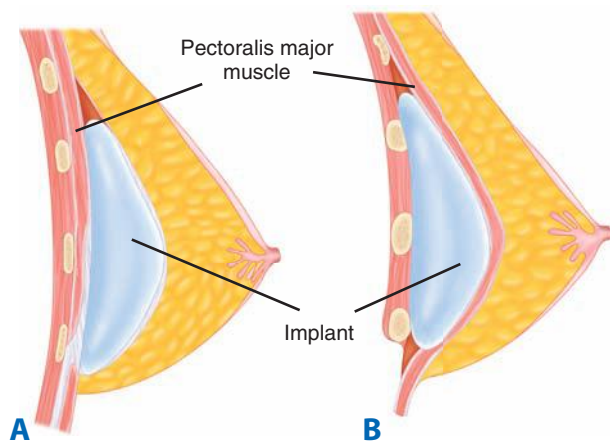


Figure 45-64. Placement of breast implant. A, Subglandular. B, Subpectoral.

operation to address an implant problem. The implant complications are essentially all local. Although there was concern in the past that implants might be associated with systemic connective tissue disorders, large epidemiologic studies have not supported such a link. The fears over implant safety were so strong that the Food and Drug Administration (FDA) declared a moratorium on the use of silicone gel implants in 1992. At that time, saline-filled implants were still allowed for general cosmetic use. Data were compiled on silicone gel implants, and these devices were approved by the FDA for general use in 2006.⁹⁷ A potential implant complication is rupture of the device. For saline implants, this results in rapid deflation. For silicone gel implants, the rupture may not be obvious and can be confirmed by MRI. Another complication is capsular contracture, which results in a tight envelope of scar that can distort the shape of the implant and cause pain in severe cases. A complication more common to saline devices is the appearance of rippling in the upper pole of the device. Implant malposition can also distort the breast shape and require reoperation. Safety data printed on the official FDA-approved package insert from one of the device manufacturers show the incidence of reoperation to be 29.9% over 7 years in a study of 901 women undergoing primary breast augmentation with saline-filled implants (postapproval study). The rate of severe capsular contracture (grade 3 or 4 on a 4-point scale) was 15.7%, and the rate of implant rupture was 9.8%.⁹⁸ For silicone gel-filled implants, the reoperation rate was observed to be 23.5% over 4 years in a study of 455 women undergoing primary breast augmentation. The rate of severe capsular contracture (grade 3 or 4 on a 4-point scale) was 13.2%, and the rate of implant rupture (evaluated by MRI) was 2.7%. The three most common reasons for operation, in order, were capsular contracture (28.9%), implant malposition (15.6%), and ptosis (14.1%). For secondary augmentation, complication rates were much higher, with the reoperation rate over 4 years rising to 35.2%. The rate of capsular contracture was 17.0%, and the rate of implant rupture was 4.0%.⁹⁹

Another concern regarding breast implants is the issue of whether adequate mammography can be performed after augmentation. Displacement techniques can be used by the mammographer to view the breast tissue. Although patients are advised that implants may affect mammography, a study surveying women who did and did not undergo breast augmentation found no statistical difference in survival or detection of carcinoma between the two cohorts.¹⁰⁰

Gynecomastia

Male breast excess or gynecomastia can be caused by a host of medical diseases and pharmacologic agents. Medical conditions associated with gynecomastia include liver dysfunction, endocrine abnormalities, Klinefelter's syndrome, renal disease, testicular tumors, adrenal or pituitary adenomas, secreting lung carcinomas, and male breast cancer. Causative pharmacologic agents include marijuana, digoxin, spironolactone, cimetidine, theophylline, diazepam, and reserpine. Although these numerous causes must be considered, a majority of patients present with either idiopathic enlargement of the breast parenchyma (more common in teenagers) or simple skin ptosis and excess adipose deposits on the chest wall (considered pseudogynecomastia; more common in adult males). To obtain a flat chest, both liposuction and/or skin excision techniques can be used.¹⁰¹

Entries highlighted in bright blue are key references.

1. Wilhelmi BJ, Blackwell SJ, Phillips LG. Langer's lines: to use or not to use. *Plast Reconstr Surg.* 1999;104:208-214.
2. Borges AF. *Elective Incisions and Scar Revision*, vol. 1. Boston: Little, Brown; 1973:2.
3. Gimbel ML, Hunt TK. Wound healing and hyperbaric oxygen. In: Kindwall EP, Whelan HT, eds. *Hyperbaric Medicine Practice*. 2nd ed. Flagstaff: Best Publishing Company; 1999:169.
4. Kelton PL. Skin grafts and skin substitutes. *Selected Readings Plast Surg.* 1999;9:1.
5. Aston JS, Beasley RW, Thorne CHM, eds. *Grabb and Smith's Plastic Surgery*. 5th ed. Philadelphia: Lippincott-Raven Publishers; 1997.
6. McGregor IA, Morgan G. Axial and random pattern flaps. *Br J Plast Surg.* 1973;26:202-213.
7. Wei FC, Jain V, Suominen S, et al. Confusion among perforator flaps: what is a true perforator flap? *Br J Plast Surg.* 2001;107:874-876.
8. Taylor GI, Palmer JH. The vascular territories (angiosomes) of the body: experimental study and clinical applications. *Br J Plast Surg.* 1987;40:113-141.
9. Ghali S, Butler PE, Tepper OM, et al. Vascular delay revisited. *Plast Reconstr Surg.* 2007;119:1735-1744.
10. Mathes SJ, Nahai F. *Reconstructive Surgery: Principles, Anatomy, and Technique*. Vol. 1. New York: Churchill Livingstone; 1997.
11. Koshima I, Soeda S. Inferior epigastric artery skin flaps without rectus abdominis muscle. *Br J Plast Surg.* 1989;42:645-648.
12. Wei FC, Mardini S. Free-style free flaps. *Plast Reconstr Surg.* 2004;114:910-916.
13. Wei FC, Suominen S. Principles and techniques of microvascular surgery. In: Mathes SJ, ed. *Plastic Surgery*. 2nd ed. Philadelphia: Elsevier; 2006:507.
14. Widmaier EP, Raff H, Strang KT. Cardiovascular physiology. In: *Vander, Sherman, and Luciano's Human Physiology—The Mechanisms of Body Function*. 9th ed. New York: McGraw-Hill; 2004:375.
15. Chang DW, Reece GP, Wang B, et al. Effect of smoking on complications in patients undergoing free TRAM flap breast reconstruction. *Plast Reconstr Surg.* 2000;105:2374-2380.
16. Lutz BS, Wei FC. Microsurgical workhorse flaps in head and neck reconstruction. *Clin Plast Surg.* 2005;32:421-430.
17. Chen KT, Mardini S, Chuang DC, et al. Timing of presentation of the first signs of vascular compromise dictates the salvage outcome of free flap transfers. *Plast Reconstr Surg.* 2007;120:187-195.
18. Kroll SS, Miller MJ, Reece GP, et al. Anticoagulants and hematomas in free flap surgery. *Plast Reconstr Surg.* 1995;96:643-647.
19. Kayser MR. Surgical flaps. *Selected Readings Plast Surg.* 1999;9:1.
20. Centers for Disease Control and Prevention. Improved national prevalence estimates for 18 selected major birth defects—United States, 1999–2001. *MMWR Morb Mortal Wkly Rep* 2006;54:1301-1305.
21. Salyer KE, Marchac A, Chang MS, et al. Unilateral cleft lip/nose repair. In: Losee JE, Kirschner RE, eds. *Comprehensive Cleft Care*. New York: McGraw-Hill Professional; 2008.
22. Mulliken JB. Mulliken bilateral cleft nasolabial repair. In: Losee JE, Kirschner RE, eds. *Comprehensive Cleft Care*. New York: McGraw-Hill Professional; 2008.
23. McDonald-McGinn D, Zackai EH. 22q11.2 deletion syndrome. In: Losee JE, Kirschner RE, eds. *Comprehensive Cleft Care*. New York: McGraw-Hill Professional; 2008.
24. LaRossa D, Kirschner RE. Modified Furlow cleft palate repair. In: Losee JE, Kirschner RE, eds. *Comprehensive Cleft Care*. New York: McGraw-Hill Professional; 2008.
25. Whitaker LA, Barlett SP. Craniofacial anomalies. In: Jurkiewicz MJ, Krizek TJ, Mathes SJ, et al, eds. *Plastic Surgery: Principles and Practice*. Vol. 1. St. Louis: Mosby; 1990:99.
26. Mulliken JB. Vascular anomalies. In: Thorne CH, ed. *Grabb and Smith's Plastic Surgery*. Part III. Philadelphia: Lippincott Williams & Wilkins; 2007:191.
27. Jenson J, Gosain A. Congenital melanocytic nevi. In: Thorne CH, ed. *Grabb and Smith's Plastic Surgery*. Part II. Philadelphia: Lippincott Williams & Wilkins; 2007:120.
28. Hollier L, Thornton J. Facial fracture I: upper two-thirds. *Selected Readings Plast Surg.* 2002;9:1.
29. Gruss JS, Bubak PJ, Egbert MA. Craniofacial fractures: an algorithm to optimize results. *Clin Plastic Surg.* 1992;19:195-206.
30. Antia NH, Buch MS. Chondrocutaneous advancement flap for the marginal defect of the ear. *Plast Reconstr Surg.* 1967;39:472-477.
31. Anvar BA, Evans BC, Evans GR. Lip reconstruction. *Plast Reconstr Surg.* 2007;120:57e-64e.
32. Chandler DB, Gausas RE. Lower eyelid reconstruction. *Otolaryngol Clin North Am* 2005;38:1033-1042.
33. Orticochea M. New three-flap reconstruction technique. *Br J Plast Surg.* 1971;24:184-188.
34. Tanner PB, Mobley SR. External auricular and facial prosthetics: a collaborative effort of the reconstructive surgeon and anaplastologist. *Facial Plast Surg Clin North Am* 2006;14:137-145.
35. Yu P, Robb GL. Reconstruction for total and near-total glossectomy defects. *Clin Plast Surg.* 2005;32:411-419.
36. Wei FC, Jain V, Celik N, et al. Have we found an ideal soft-tissue flap? An experience with 672 anterolateral thigh flaps. *Plast Reconstr Surg.* 2002;109:2219-2226.
37. Daniel R. Mandibular reconstruction with vascularized iliac crest: a 10-year experience (discussion). *Plast Reconstr Surg.* 1988;82:792-803.
38. Wei FC, Chen HC, Chuang CC, et al. Fibular osteoseptocutaneous flap: anatomic study and clinical application. *Plast Reconstr Surg.* 1986;78:191-200.
39. Wei FC, Santamaria E, Chang YM, et al. Mandibular reconstruction with fibular osteoseptocutaneous free flap and simultaneous placement of osseointegrated dental implants. *J Craniofac Surg.* 1997;8:512-521.
40. Wei FC, Seah CS, Tsai YC, et al. Fibula osteoseptocutaneous flap for reconstruction of composite mandibular defects. *Plast Reconstr Surg.* 1994;93:294-304.
41. Wei FC, Yazar S, Lin CH, et al. Double free flaps in head and neck reconstruction. *Clin Plast Surg.* 2005;32:303-308.
42. Wallace CG, Chang YM, Tsai CY, Wei FC. Harnessing the potential of the free fibula osteoseptocutaneous flap in mandible reconstruction. *Plast Reconstr Surg.* 2010;125:305-314.
43. Archibald S, Young JE, Thoma A. Pharyngo-cervical esophageal reconstruction. *Clin Plast Surg.* 2005;32:339-346.
44. Tate JR, Tollefson TT. Advances in facial reanimation (review). *Curr Opin Otolaryngol Head Neck Surg.* 2006;14:242-248.
45. Wilkins EG, Cederna PS, Lowery JC, et al. Prospective analysis of psychosocial outcomes in breast reconstruction: one-year postoperative results from the Michigan Breast Reconstruction Outcome Study. *Plast Reconstr Surg.* 2000;106:1014-1025.
46. Alderman AK, Wilkins EG, Kim HM, et al. Complications in postmastectomy breast reconstruction: two-year results of the Michigan Breast Reconstruction Outcome Study. *Plast Reconstr Surg.* 2002;109:2265-2274.
47. Wilson CR, Brown IM, Weiller-Mithoff E, et al. Immediate breast reconstruction does not lead to a delay in the delivery of adjuvant chemotherapy. *Eur J Surg Oncol.* 2004;30:624-627.

48. Newman LA, Kuerer HM, Hunt KK, et al. Presentation, treatment, and outcome of local recurrence after skin-sparing mastectomy and immediate breast reconstruction. *Ann Surg Oncol*. 1998;5:620-626.
49. Munhoz AM, Montag E, Arruda EG, et al. The role of the lateral thoracodorsal fasciocutaneous flap in immediate conservative breast surgery reconstruction. *Plast Reconstr Surg*. 2006;117:1699-1710.
50. Handel N, Cordray T, Gutierrez J, et al. A long-term study of outcomes, complications, and patient satisfaction with breast implants. *Plast Reconstr Surg*. 2006;117:757-767, discussion 768.
51. Nahabedian MY, Manson PN. Contour abnormalities of the abdomen after transverse rectus abdominis muscle flap breast reconstruction: a multifactorial analysis. *Plast Reconstr Surg*. 2002;109:81-87.
52. Mathes SJ, Nahai F. *Reconstructive Surgery: Principles, Anatomy, and Technique*. New York: Churchill Livingstone; 1997.
53. Skoracki RJ, Chang DW. Reconstruction of the chest wall and thorax. *J Surg Oncol*. 2006;94:455-465.
54. Rohrich RJ, Lowe JB, Hackney FL, et al. An algorithm for abdominal wall reconstruction. *Plast Reconstr Surg*. 2000;105:202-216.
55. Shestak KC, Edington HJ, Johnson RR. The separation of anatomic components technique for the reconstruction of massive midline abdominal wall defects: anatomy, surgical technique, applications, and limitations revisited. *Plast Reconstr Surg*. 2000;105:731-738.
56. Brown DM, Sicard GA, Flye MW, et al. Closure of complex abdominal wall defects with bilateral rectus femoris flaps with fascial extensions. *Surgery*. 1993;114:112-116.
57. Dibbell DG, Mixer RC, Dibbell DG Sr. Abdominal wall reconstruction (the "mutton chop" flap). *Plast Reconstr Surg*. 1991;87:60-65.
58. Wu CW, Wallace CG, Wei FC. Lower extremity reconstruction following trauma and tumors. In: Sieninow M, Eisenman-Klein M, eds. *Plastic & Reconstructive Surgery*. New York: Springer; 2010:631-644.
59. Bosse MJ, MacKenzie EJ, Kellam JF, et al. An analysis of outcomes of reconstruction or amputation after leg-threatening injuries. *N Engl J Med*. 2002;347:1924-1931.
60. Gustilo RB, Merkow RL, Templeman D. The management of open fractures. *J Bone Joint Surg Am*. 1990;72:299-304.
61. British Association of Plastic, Reconstructive and Aesthetic Surgeons and British Association of Orthopaedic Surgeons. *Standards for the Management of Open Fractures of the Lower Limb*. London: Royal Society of Medicine Press; 2009.
62. Crowley DJ, Kanakaris NK, Giannoudis PV. Débridement and wound closure of open fractures: the impact of the time factor on infection rates. *Injury*. 2007;38:879-889.
63. Chan JK, Harry L, Williams G, Nanchahal J. Soft-tissue reconstruction of open fractures of the lower limb: muscle versus fasciocutaneous flaps. *Plast Reconstr Surg*. 2012;130:284e-295e.
64. Gir P, Cheng A, Oni G, Mojallal A, Saint-Cyr M. Pedicled-perforator (propeller) flaps in lower extremity defects: a systematic review. *J Reconstr Microsurg*. 2012;28:595-602.
65. Yazar S, Lin CH, Wei FC. One-stage reconstruction of composite bone and soft-tissue defects in traumatic lower extremities. *Plast Reconstr Surg*. 2004;114:1457-1466.
66. Tseng WS, Chen HC, Hung J, et al. "Flow-through" type free flap for revascularization and simultaneous coverage of a nearly complete amputation of the foot: case report and literature review. *J Trauma*. 2000;48:773-776.
67. Lin CH, Wei FC, Lin YT, et al. Lateral circumflex femoral artery system: warehouse for functional composite free-tissue reconstruction of the lower leg. *J Trauma*. 2006;60:1032-1036.
68. Patzakis MJ, Zalavras CG. Chronic posttraumatic osteomyelitis and infected nonunion of the tibia: current management concepts. *J Am Acad Orthop Surg*. 2005;13:417-427.
69. Centers for Disease Control and Prevention. *2007 National Diabetes Fact Sheet*. Atlanta: U.S. Department of Health and Human Services, Centers for Disease Control and Prevention; 2008.
70. Colen LB, Uroskie T. Foot reconstruction. In: Mathes SJ, ed. *Plastic Surgery*. 2nd ed. Philadelphia: Elsevier; 2006:1403.
71. Hinchliffe RJ, Andros G, Apelqvist J, et al. A systematic review of the effectiveness of revascularization of the ulcerated foot in patients with diabetes and peripheral arterial disease. *Diabetes Metab Res Rev*. 2012;28(Suppl 1):179-217.
72. Fitzgerald O'Connor EJ, Vesely M, Holt PJ, et al. A systematic review of free tissue transfer in the management of non-traumatic lower extremity wounds in patients with diabetes. *Eur J Vasc Endovasc Surg*. 2011;41:391-399.
73. Szuba A, Rockson SG. Lymphedema: anatomy, physiology, and pathogenesis. *Vasc Med*. 1997;2:321-326.
74. Szuba A, Rockson SG. Lymphedema: classification, diagnosis, and therapy. *Vasc Med*. 1998;3:145-156.
75. Chung KC, Kim HJ, Jeffers LL. Lymphangiosarcoma (Stewart-Treves syndrome) in postmastectomy patients. *J Hand Surg Am*. 2000;25:1163-1168.
76. Warren AG, Brorson H, Borud LJ, et al. Lymphedema: a comprehensive review. *Ann Plast Surg*. 2007;59:464-472.
77. Beahm EK, Walton RL, Lohman RF. Vascular insufficiency of the lower extremity: lymphatic, venous, and arterial. In: Mathes SJ, ed. *Plastic Surgery*. 2nd ed. Philadelphia: Elsevier; 2006:1455.
78. Brorson H, Svensson H, Norrgren K, et al. Liposuction reduces arm lymphedema without significantly altering the already impaired lymph transport. *Lymphology*. 1998;31:156-172.
79. O'Brien BM, Mellow CG, Khazanchi RK, et al. Long-term results after microlymphaticovenous anastomoses for the treatment of obstructive lymphedema. *Plast Reconstr Surg*. 1990;85:562-572.
80. Salgado CJ, Mardini S, Spanio S, Tang WR, Sassu P, Chen HC. Radical reduction of lymphedema with preservation of perforators. *Ann Plast Surg*. 2007;59:173-179.
81. Demirtas Y, Ozturk N, Yapici O, et al. Comparison of primary and secondary lower extremity lymphedema treated with supermicrosurgical lymphaticovenous anastomosis and lymphaticovenous implantation. *J Reconstr Microsurg*. 2010;25:137-143.
82. Black J, Baharestani MM, Cuddigan J, et al. National Pressure Ulcer Advisory Panel's updated pressure ulcer staging system. *Adv Skin Wound Care*. 2007;20:269-274.
83. Sorensen JL, Jorgensen BJ, Gottrup F. Surgical treatment of pressure ulcers. *Am J Surg*. 2004;188:42S.
84. Hettiaratchy S, Randolph MA, Petit F, et al. Composite tissue allotransplantation—a new era in plastic surgery? *Br J Plast Surg*. 2004;57:381-391.
85. American Medical Association. *H-475.992 Definitions of "Cosmetic" and "Reconstructive" Surgery*. Chicago: American Medical Association; 2002.
86. Paul MD. The evolution of the brow lift in aesthetic plastic surgery. *Plast Reconstr Surg*. 2001;108:1409-1424.
87. Thorne CM, Aston SG. Aesthetic surgery of the aging face. In: Aston SG, Beasley RW, Thorne CH, eds. *Grabb and Smith's Plastic Surgery*. 5th ed. Philadelphia: Lippincott-Raven Publishers; 1997:633.
88. Sheen JH. *Aesthetic Rhinoplasty*. St. Louis: Mosby; 1987.
89. Rubin JP, Bierman C, Rosow CE, et al. The tumescent technique for local anesthesia: the effect of high tissue pressure and dilute epinephrine on absorption of lidocaine. *Plast Reconstr Surg*. 1999;103:990-996.

90. Iverson RE, Lynch DJ. Practice advisory on liposuction. *Plast Reconstr Surg* 2004;113:1478-1490.
91. Ramirez OM. Abdominoplasty and abdominal wall rehabilitation: a comprehensive approach. *Plast Reconstr Surg*. 2000;105:425-435.
92. Courtiss EH, Goldwyn RM. Reduction mammoplasty by the inferior pedicle technique. *Plast Reconstr Surg*. 1977;59:500-507.
93. Lassus C. A 30-year experience with vertical mammoplasty. *Plast Reconstr Surg* 1996;97:373-380.
94. Lejour M. Vertical mammoplasty without inframammary scar and with breast liposuction. *Perspect Plast Surg*. 1990;4:369-379.
95. Tebbetts JB. A system for breast implant selection based on patient tissue characteristics and implant—soft tissue dynamics. *Plast Reconstr Surg*. 2002;109:1396-1409.
96. Hidalgo DA. Breast augmentation: choosing the optimal incision, implant, and pocket plane. *Plast Reconstr Surg*. 2000;105:2202-2216.
97. U.S. Food and Drug Administration. Breast implants home page, 2006. Available at: <http://www.fda.gov/cdrh/breastimplants/index.html>. Accessed January 15, 2008.
98. Allergan saline-filled breast implants (package insert). Santa Barbara: Allergan; 2007.
99. Allergan silicone-filled breast implants (package insert). Santa Barbara: Allergan; 2007.
100. Miglioretti DL, Rutter CM, Geller BM, et al. Effect of breast augmentation on the accuracy of mammography and cancer characteristics. *JAMA*. 2004;291:442-450.
101. Braunstein GD. Gynecomastia. *N Engl J Med*. 1993;328:490-495.

46 chapter

Anesthesia for the Surgical Patient

Robert S. Dorian

True Collaboration	1895	Anesthetic Agents	1899	Recovery from Anesthesia	1915
Brief History of Anesthesia	1895	General Anesthesia / 1899		Reversal of Neuromuscular Blockade / 1915	
Modern Beginnings / 1895		Local Anesthetics / 1902		The Postanesthesia Care Unit / 1915	
Ether Day / 1895		Regional Anesthesia: Peripheral vs. Central / 1903		Postoperative Nausea and Vomiting / 1915	
The First Anesthesiologists / 1896		Anesthesia Management	1904	Pain: The Fifth Vital Sign / 1915	
Cocaine: The First Local Anesthetic / 1896		Preoperative Evaluation and Preparation / 1904		Multimodal Analgesia	1916
The Twentieth Century / 1897		Risk Assessment / 1905		The Transversus Abdominis Plane Block	1916
Anesthesiology Today—The Perioperative Physician / 1897		Intraoperative Management	1909	Malignant Hyperthermia	1918
Basic Pharmacology	1897	Induction of Anesthesia / 1909		Future Direction of Anesthesia	1918
Pharmacokinetics / 1897		Management of the Airway / 1910			
Pharmacodynamics / 1898		Fluid Therapy / 1911			
Potency, Efficacy, Lethal Dose, and Therapeutic Index / 1898		Transfusion of Red Blood Cells / 1914			

TRUE COLLABORATION

The discipline of anesthesia embodies control of three great concerns of humankind: consciousness, pain, and movement. The field of anesthesiology combines the administration of anesthesia with the perioperative management of the patient's concerns, pain management, and critical illness. The fields of surgery and anesthesiology are truly collaborative and continue to evolve together, enabling the care of sicker patients and rapid recovery from outpatient and minimally invasive procedures.

BRIEF HISTORY OF ANESTHESIA

The discovery of anesthesia is one of the seminal American contributions to the world. Along with infection control and blood transfusion, anesthesia has enabled surgery to occupy its fundamental place in medicine. Before the advent of modern anesthesia in the 1840s, many substances and methods were tried in the search for pain relief and better operating conditions. Opium, alcohol, exposure to cold, compression of peripheral nerves, constriction of the carotid arteries to produce unconsciousness, and hypnosis (mesmerism) all proved less than satisfactory and dictated rapid and crude surgical procedures. Patients had to be restrained by several attendants, and only the most stoic could tolerate the screams heard in the operating theater. Charles Darwin, who witnessed two such operations, "rushed away before they were completed. Nor did I ever attend again, for hardly any inducement would have been strong enough to make me do so; this being long before the blessed days of chloroform. The two cases fairly haunted me for many a long year."¹

Modern Beginnings

Although Humphrey Davy (1778–1829) suggested using nitrous oxide for the relief of pain in surgical procedures in 1800, this was not pursued until 1844 by dentist Horace Wells (1815–1848). Wells astutely observed that a man who was injured after inhaling nitrous oxide during an exhibition of the "laughing gas" displayed no awareness of pain. After experimenting on himself, Wells attempted to demonstrate the analgesic effects of nitrous oxide for a dental procedure at Harvard Medical School in 1845. The public demonstration was a failure because nitrous oxide has analgesic properties, but does not suffice as the sole anesthetic agent in every patient. Wells never recovered from his humiliating experience and eventually committed suicide. However, he does hold a place in history as the first person to recognize and use the only anesthetic from the 1800s that is still in use today—nitrous oxide.

In 1842, Crawford Long (1815–1878), a physician in rural Georgia, used diethyl ether to induce surgical anesthesia for the removal of two small neck tumors. Diethyl ether had been known for over 800 years but was not used for analgesic purposes. It became an inexpensive and popular recreational drug in the mid-nineteenth century and was used by American medical students at "ether frolics." Although Long did experiments to verify the analgesic effects of ether, he did not publish his work until 1848, in the *Southern Medical Journal*, too late to be the unquestioned discoverer of anesthesia.²

Ether Day

William Morton (1819–1868) was a dentist and partner of Horace Wells. After taking a course in anesthesia from Wells, Morton left the partnership in Hartford, Connecticut, and established himself in Boston. He continued his interest in anesthesia,

Key Points

- 1▶ The incremental interchange of ideas across the specialties of anesthesia and surgery demonstrates the collaborative nature of science in general and medicine in particular. Many surgeons contributed to the growth in anesthesia; more comprehensive anesthesia, in turn, allowed more complex surgery to develop.
- 2▶ The role of the anesthesiologist has expanded to become the perioperative physician. The anesthesiologist evaluates the patient preoperatively, provides the anesthetic, and is involved in postoperative pain relief.
- 3▶ New and improved airway and intubation devices, such as the laryngeal mask airway and the video laryngoscope, along with

the American Society of Anesthesiologists' airway management algorithm, have led to improved management and control of routine and difficult airways.

- 4▶ The specialties of critical care medicine and pain medicine have grown out of the expanded field of anesthesiology. The postanesthesia care unit gave rise to the intensive care unit; the treatment of acute and chronic pain syndromes by anesthesiologists contributed to the growth of pain medicine as a specialty.
- 5▶ The study of proteomics will lead to anesthetics tailored to individuals, maximizing effects and reducing side effects of various anesthetic drugs.

but with diethyl ether replacing nitrous oxide. Ether proved a good choice, as it supports respiration and the cardiovascular system at analgesic levels and is potent enough to administer in room air without hypoxia. He practiced the administration of ether on a dog and then used it when extracting teeth from patients in his office. On October 16, 1846, Morton gave the first public demonstration of ether as an anesthetic for Johns Collins Warren, distinguished surgeon and a founder of Massachusetts General Hospital. In attendance in the surgical amphitheater were several surgeons, medical students, and a newspaper reporter. After anesthesia was induced using a makeshift inhaler, Warren successfully removed a vascular mass from the patient's neck with no ill effects. Warren was an originator of the *Boston Medical and Surgical Journal* (now *The New England Journal of Medicine*), and by November 1846, the demonstration was published in an article by Henry J. Bigelow.³ The stature of Warren and Bigelow lent considerable credence to the advent of surgical anesthesia; as news spread rapidly, surgeons around the world were quick to adopt this "American invention." Massachusetts General Hospital has restored and preserved the original amphitheater where the demonstration took place, now called the *Ether Dome*. It is designated as a Registered National Historic Landmark commemorating the first public demonstration, rather than discovery, of the use of ether as an anesthetic.

The First Anesthesiologists

John Snow (1813–1858) made science out of the art of anesthesia. He was a respected London physician who applied a scholarly, scientific method to investigate the clinical properties and pharmacology of ether, chloroform, and other anesthetic agents. Snow was an astute observer and published a detailed account of the five degrees of etherization in 1847. He vastly improved the apparatus for administering ether and mastered the clinical techniques of anesthetizing patients. As the leading anesthetist of his day, he gave anesthetics to the royal family, including chloroform during labor to Queen Victoria for the birth of Prince Leopold. The Queen's endorsement of "that blessed chloroform" removed the moral and social stigma against relieving pain during childbirth and brought anesthesia into public awareness. Chloroform, popularized in England by James Simpson (1811–1870), had a narrow therapeutic index and placed great clinical demands on the anesthetist. Ether, with its ability to maintain the cardiovascular and respiratory systems, remained in common use in the United States and often was administered by house staff, medical students,

or nurses. Snow encouraged the administration of anesthesia by a physician and felt that a physician dedicated specifically to that purpose was appropriate and necessary. Snow and other exceptional British physicians specializing in anesthesia (Joseph Clover [1825–1882] and Sir Frederick Hewitt [1857–1916]) created a standard of excellence in the latter half of the nineteenth century. This atmosphere of professionalism led to the formation of anesthesia societies and the publication of papers in the prestigious *British Medical Journal* and *The Lancet* in England years before such organizations existed in America.⁴

Cocaine: The First Local Anesthetic

The ancient Incas chewed coca leaves as a stimulant and may have been aware of its local anesthetic properties, allegedly facilitating trephination of the skull by chewing a clump of coca leaves and dripping the resultant saliva into the wound. The active alkaloid of the coca leaf was synthesized in 1860 and called *cocaine* by German chemist Albert Niemann, who noted that it "benumbs the nerves of the tongue, depriving it of feeling."⁵ Sigmund Freud (1856–1939) of Vienna received a supply of cocaine from Merck, studied its properties, and wrote the famous monograph "Über Coca" in 1884. Freud was primarily interested in the stimulant and euphoric effects of cocaine and attempted to use it to treat morphine addiction. Freud and Karl Koller (1857–1944), an ophthalmologic intern, began to perform physiologic experiments with cocaine, measuring its effects on muscle strength. Although they both noted that the drug caused numbness of the tongue when swallowed, it was Koller who first instilled it into his own cornea; report of its use as a local anesthetic galvanized the medical world. Soon after, young American surgeons William Halsted (1852–1922) and Richard Hall described intradermal injection of cocaine and were the first to use it for regional blocks of the facial nerves, brachial plexus, and internal pudendal and posterior tibial nerves.⁶ Halsted later became the first professor of surgery and chief surgeon at Johns Hopkins University, where he remained for more than 30 years. One of the founding fathers of modern surgery, he pioneered radical mastectomy with lymphadenectomy and the use of rubber gloves. While experimenting on themselves, Halsted and other early researchers became addicted to cocaine.⁷ Its toxic effects were the stimulus to find other local anesthetics—procaine was synthesized in 1905 and lidocaine in 1943.

The New York neurologist Leonard Corning (1855–1923) observed the regional blocks of Halsted and Hall, analytically studied local anesthesia effects on dogs, applied his knowledge

to humans, and published the first textbook on local anesthesia in 1886. After experimenting on the spinal nerves of a dog, he intradurally injected a solution of cocaine into a patient, called it *spinal anesthesia*, and commented that it might be useful in surgery. His suggestion went unheeded for more than 10 years, until August Bier (1861–1949), a prominent German surgeon, gave the first deliberate spinal anesthetic.⁸ This incremental interchange of ideas and advances across the Atlantic and across the specialties of anesthesia and surgery demonstrates the collaborative nature of science in general and medicine in particular. The development of surgery and anesthesia exemplifies the dichotomy of two fledgling specialties that are mutually dependent, yet increasingly autonomous.

The Twentieth Century

Developments in anesthesia on both sides of the Atlantic progressed rapidly in the twentieth century. The convergence of technologies that produced the hollow needle and syringe, coupled with the synthesis of barbiturates, gave rise to intravenous (IV) anesthesia in the early 1900s. Barbitol, followed by hexobarbital and thiopental in 1934, produced rapid and more pleasant induction of anesthesia than the inhaled gases. The concept of “balanced anesthesia” began in 1925, when John Lundy (1894–1973) proposed the use of thiopentone for induction, followed by inhaled agents for maintenance of anesthesia. Lundy directed the department of anesthesiology at the Mayo Clinic for 28 years. He established the first recovery room and blood bank, authored the first textbook on modern anesthesia, and helped found the American Board of Anesthesiology.

Nitrous oxide, diethyl ether, and chloroform, all discovered fortuitously by observation, remained the dominant inhalation agents until the accidental discovery of cyclopropane’s anesthetic properties in 1923. Although rapid acting and pleasant smelling, cyclopropane was limited by its flammability and cardiac irritability. Because it was known that fluorination would reduce or eliminate flammability of chemical compounds, British chemist Charles Suckling set out to synthesize an anesthetic that was stable, potent, volatile, and not flammable. He successfully produced halothane in 1953. Introduced into clinical practice in 1956 after extensive testing in Manchester, England, and paired with an accurate calibrated vaporizer, halothane quickly became the most widely used fluorinated anesthetic. Enflurane and isoflurane, synthesized in the United States by Ross Tyrell, were introduced into clinical practice in 1972 and 1981, respectively. The newest agents, desflurane and sevoflurane, were introduced into clinical practice in the early 1990s. They possess a low solubility and are characterized by rapid onset and recovery, making them particularly well suited to outpatient surgery.

The motto of the American Society of Anesthesiologists (ASA) is “Vigilance,” and to that end, there has been continued progress in objective mechanical measurement of patient well-being. The early anesthesiologists used clinical signs such as patient color, depth of respiration, and pulse rate to monitor depth of anesthesia and patient homeostasis. Harvey Cushing, who eventually became Moseley Professor of Surgery at the Peter Bent Brigham Hospital, began the first anesthesia records or “ether charts” in 1895 while a medical student. They recorded pulse, respiratory rates, pupillary diameter, and the amounts of ether and other drugs administered. He later introduced the use of the portable sphygmomanometer of Riva-Rocci to measure blood pressure and the precordial stethoscope to monitor breath

and heart sounds. Monitoring has since progressed to its current state with incremental developments in electrocardiography, pulse oximetry, and mass spectrometry, all mandatory for the safe administration of any anesthetic.

The control of the patient’s airway and respiration as the purview of the anesthesiologist evolved with techniques of endotracheal intubation as pioneered by Sir Ivan Magill (1888–1986) and the invention of the cuffed endotracheal tube by Arthur Guedel (1883–1965). This later merged with the invention of mechanical ventilation and its introduction to the operating room as the embodiment of today’s anesthesia machine. It was this expertise at control of respiration that paved the way for the most revolutionary modern development in anesthesia—the use of muscle relaxants. Curare, a nondepolarizing muscle relaxant, was popularized by Harold Griffith of Montreal. His report of the successful use of curare was a galvanizing event that revolutionized the practice of anesthesia, as the relaxation of abdominal muscles could be controlled to facilitate surgery.⁹ The depolarizing relaxant succinylcholine was introduced in 1949, and research has continued to provide the newer nondepolarizing drugs mivacurium, pancuronium, rocuronium, atracurium, and cisatracurium.

Anesthesiology Today—The Perioperative Physician

The specialty of anesthesia is no longer limited to the operating room. It is natural that anesthesiology, born out of the quest to relieve pain, gave rise to the field of acute and chronic pain medicine. The anesthesiologist consulting on the acute pain service may recommend oral, intramuscular, or IV analgesia with a variety of agents, or patient-controlled analgesia. Postsurgical patients also may be treated with nerve blocks: regional (e.g., brachial plexus, popliteal, and femoral) or neuraxial (epidural or intrathecal). The discipline of chronic pain addresses patients who suffer for months or years with cancer or other debilitating diseases. Treatment modalities escalate from orally administered drugs, to diagnostic and therapeutic nerve blocks, to more invasive measures like dorsal column nerve stimulators and radiofrequency or cryosurgical nerve ablation.

Daily management of the airway, fluids and transfusions, ventilation, drug delivery, monitoring, and caring for the sickest patients in the postanesthesia care unit prepared anesthesiologists to become major contributors to the development of critical care medicine. Of the 28 founding members of the Society of Critical Medicine, 10 were anesthesiologists.¹⁰

The American Board of Anesthesiology became an independent board in 1941 and, since then, has granted board certification to more than 25,000 diplomates. Certificates in Anesthesia Pain Management and Anesthesia Critical Care Medicine are granted to those completing additional postgraduate training. The ASA has more than 35,000 members, and its official journal, *Anesthesiology*, has a monthly circulation of 40,000 worldwide.

BASIC PHARMACOLOGY

Pharmacokinetics

Pharmacokinetics or the *time dependency* of a drug describes the relationship between the dose of a drug and its plasma or tissue concentration. It is what the body does to the drug. It relates to absorption, distribution, metabolism, and elimination. The route of administration, metabolism, protein binding, and

tissue distribution all affect the pharmacokinetics of a particular drug.

Administration, Distribution, Metabolism, and Elimination.

Administration of a drug affects its pharmacokinetics, as there will be different rates of drug entry into the circulation. For example, the oral and IV routes are subject to first-pass effect of the portal circulation; this can be bypassed with the nasal or sublingual route. Other routes of drug administration include transdermal, intramuscular, subcutaneous, or inhalation.

Distribution is the delivery of a drug from the systemic circulation to the tissues. Once a drug has entered the systemic circulation, the rate at which it will enter the tissues depends on several factors:

- Molecular size of the drug, capillary permeability, polarity, and lipid solubility. Small molecules will pass more freely and quickly across cell membranes than large ones, but capillary permeability is variable and results in different diffusion rates. Renal glomerular capillaries are permeable to almost all non-protein-bound drugs; capillaries in the brain are fused (i.e., they have tight junctions) and are relatively impermeable to all but the tiniest molecules (the blood-brain barrier). Un-ionized molecules pass more easily across cell membranes than charged molecules; diffusibility also increases with increasing lipid solubility.
- Plasma protein and tissue binding. Many drugs bind to circulating proteins like albumin, glycoproteins, and globulins. Disease, age, and the presence of other drugs will affect the amount of protein binding; drug distribution is affected because only the unbound free portion of the drug can pass across the cell membrane. Drugs also bind reversibly to body tissues; if they bind with high affinity, they are said to be sequestered in that tissue (e.g., heavy metals are sequestered in bone).¹¹
- The fluid volume in which a drug distributes is termed the *volume of distribution* (V_d). This mathematically derived value gives a rough estimation of the overall physical distribution of a drug in the body. A general rule for volume distribution is that the greater the V_d , the greater the diffusibility of the drug. Because drugs have variable ionization rates and bind differently to plasma proteins and tissues, the V_d is not a good predictor of the actual concentration of the drug after administration. Determining the apparent V_d (dose/concentration) is an attempt to more accurately ascertain the drug dose administered and its final concentration.

Metabolism is the permanent breakdown of original compounds into smaller metabolites. Drug *elimination* varies widely; some drugs are excreted unchanged by the body, some decompose via plasma enzymes, and some are degraded by organ-based enzymes in the liver. Many drugs rely on multiple pathways for elimination (i.e., metabolized by liver enzymes and then excreted by the kidney).

When a drug is given orally, it reaches the liver via the portal circulation and is partially metabolized before reaching the systemic circulation. This is why an oral dose of a drug often must be much higher than an equally effective IV dose. Some drugs (e.g., nitroglycerine) are hydrolyzed presystemically in the gut wall and must be administered sublingually to achieve an effective concentration.

It is important to remember that the response to drugs varies widely. The disposition of drugs is affected by age; weight;

sex; pregnancy; disease states; and the concomitant use of alcohol, tobacco, and other licit and illicit drugs. Genetic polymorphism, or variations in genes that cause differing drug effects, is another explanation of varying drug response. This will be discussed later in the Future Direction of Anesthesia section on proteomics. This as yet unpredictable response to drugs underscores the importance of the most important monitor in the operating room—the anesthesiologist, who continuously assesses the patient's vital signs and adjusts the doses of anesthetic agents to match the surgical stimulus.

Pharmacodynamics

Pharmacodynamics, or how the plasma concentration of a drug translates into its effect on the body, depends on biologic variability, receptor physiology, and clinical evaluations of the actual drug. It is what the drug does to the body. An *agonist* is a drug that causes a response. A *full agonist* produces the full tissue response, and a *partial agonist* provokes less than the maximum response induced by a full agonist. An antagonist is a drug that does not provoke a response itself, but blocks agonist-mediated responses. An *additive effect* means that a second drug acts with the first drug and will produce an effect that is equal to the algebraic summation of both drugs. A *synergistic effect* means that two drugs interact to produce an effect that is greater than expected from the two drugs' algebraic summation.¹²

Hyporeactivity means a larger than expected dose is required to produce a response, and this effect is termed *tolerance*, *desensitization*, or *tachyphylaxis*. Tolerance usually results from chronic drug exposure, either through enzyme induction (e.g., alcohol) or depletion of neurotransmitters (e.g., cocaine).

Potency, Efficacy, Lethal Dose, and Therapeutic Index

The *potency* of a drug is the dose required to produce a given effect, such as pain relief or a change in heart rate. The average sensitivity to a particular drug can be expressed through the calculation of the effective dose; ED_{50} would have the desired effect in 50% of the general population. The *efficacy* of any therapeutic agent is its power to produce a desired effect. Two drugs may have the same efficacy but different potencies. The difference in potency of the two drugs is described by the ratio $ED_{50}b/ED_{50}a$, where *a* is the less potent drug. If the $ED_{50}b$ equals 4 and the $ED_{50}a$ equals 0.4, then drug *a* is 10 times as potent as drug *b*. For example, 10 mg of morphine produces analgesia equal to that of 1 mg of hydromorphone. They are equally effective, but hydromorphone is 10 times as potent as morphine.

Dose-response curves show the relationship between the dose of a drug administered (or the resulting plasma concentration) and the pharmacologic effect of the drug. The pharmacologic effect might be secretion of a hormone, a change in heart rate, or contraction of a muscle. Between 20% and 80% of the maximum effect, the logarithm of the dose and its response has a linear relationship. The term *dose* only applies to the amount administered and not the actual concentration. If the concentration of an antagonist is increased (in the presence of a fixed concentration of agonist), the dose-response curve will be shifted to the right, and a higher agonist concentration will be required to achieve the desired effect. A basic dose-response curve is shown in Fig. 46-1.

The *lethal dose* (LD_{50}) of a drug produces death in 50% of animals to which it is given. The ratio of the lethal dose and

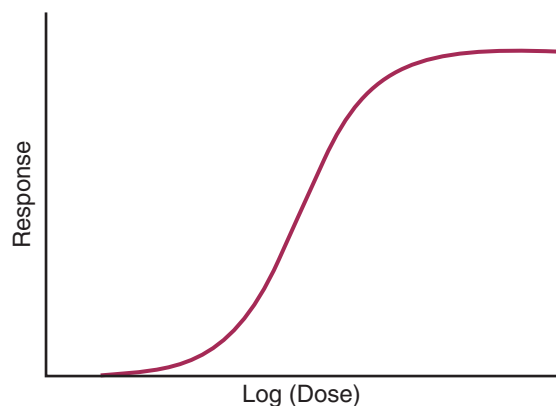


Figure 46-1. Basic dose-response curve.

effective dose, LD_{50}/ED_{50} , is the *therapeutic index*. A drug with a high therapeutic index is safer than a drug with a low or narrow therapeutic index.

ANESTHETIC AGENTS

Anesthesia can be *local*, *regional*, or *general* (Table 46-1). Local anesthesia is accomplished using a local anesthetic drug that can be injected intradermally and is used for the removal of small lesions or to repair traumatic injuries. Local anesthesia is the most frequent anesthetic administered by surgeons and may be accompanied by IV sedation to improve patient comfort.

General Anesthesia

General anesthesia describes a triad of three major and separate effects: unconsciousness (and amnesia), analgesia, and muscle relaxation (see Table 46-1). IV drugs usually produce a single,

Table 46-1

Anesthetic agents, their actions, and their clinical uses

EFFECT	MONITOR	IV DRUGS	POTENT GASES	WEAK GAS	LOCAL ANESTHETICS ^c	
Unconscious (amnesia) (anxiolysis)	EEG and/or clinical signs	Benzodiazepines Midazolam Lorazepam Diazepam Barbiturates Etomidate Ketamine ^a	Sevoflurane Desflurane Isoflurane Enflurane Halothane	Nitrous oxide ^b		
Analgesia	Heart rate Blood pressure Respiratory rate	Opioids Fentanyl Morphine Hydromorphone Nonopioid Ketamine ^a Parecoxib Dexmedetomidine Acetaminophen IV Ketorolac	Sevoflurane Desflurane Isoflurane Enflurane Halothane	Nitrous oxide ^b	Amides	Esters
					Lidocaine Bupivacaine Ropivacaine Prilocaine Mepivacaine	Cocaine Procaine Chlorprocaine Tetracaine Benzocaine
Muscle relaxation (paralysis)	Nerve stimulator	Depolarizer Succinylcholine Nondepolarizers Pancuronium Vecuronium Rocuronium Atracurium	Sevoflurane Desflurane Isoflurane Enflurane Halothane		Peripheral nerve blocks (brachial plexus, femoral, etc.) Central nerve blocks (spinal, epidural)	

EEG = electroencephalogram; IV = intravenous.

^aNote that the IV agents are quite specific in their effects, except for ketamine, which has both amnestic and analgesic qualities.

^bThe potent inhalational anesthetics contribute to all three components of anesthesia, but nitrous oxide has weak amnestic and analgesic properties and provides no muscle relaxation at all.

^cThe local anesthetics produce excellent analgesia and muscle relaxation but contribute nothing to amnesia or anxiolysis; these anesthetics must be supplemented with an IV sedative.

discrete effect, while most inhaled anesthetics produce elements of all three. General anesthesia is achieved with a combination of IV and inhaled drugs, each used to its maximum benefit. The science and art of anesthesia are dynamic processes. As the amount of stimulus to the patient changes during surgery, the patient's vital signs are used as a guide and the quantity of drugs is adjusted, maintaining an equilibrium between stimulus and dose. General anesthesia is what patients commonly think of when they are to be “put under” and can be a cause of considerable preoperative anxiety.¹³

Intravenous Agents

Unconsciousness and Amnesia The IV agents that produce unconsciousness and amnesia are frequently used for the induction of general anesthesia. They include barbiturates, benzodiazepines, propofol, etomidate, and ketamine. Except for ketamine, the following agents have no analgesic properties and do not cause paralysis or muscle relaxation.

Barbiturates The most common barbiturates are thiopental, thiamylal, and methohexital. The mechanism of action is at the γ -aminobutyric acid (GABA) receptor, where they inhibit excitatory synaptic transmission. They produce a rapid, smooth induction within 60 seconds, and wear off in about 5 minutes. In higher doses and in patients with intravascular depletion, they cause hypotension and myocardial depression. The barbiturates are anticonvulsants and protect the brain during neurosurgery by reducing cerebral metabolism.

Propofol Propofol is an alkylated phenol that inhibits synaptic transmission through its effects at the GABA receptor. With a short duration, rapid recovery, and low incidence of nausea and vomiting, it has emerged as the agent of choice for ambulatory and minor general surgery. Additionally, propofol has bronchodilatory properties that make its use attractive in asthmatic patients and smokers. Propofol may cause hypotension and should be used cautiously in patients with suspected hypovolemia and/or coronary artery disease (CAD), the latter of which may not tolerate a sudden drop in blood pressure. It can be used as a continuous infusion for sedation in the intensive care unit setting. Propofol is an irritant and frequently causes pain on injection.

Benzodiazepines The most important uses of the benzodiazepines are for reduction of anxiety and to produce amnesia. Frequently used IV benzodiazepines are diazepam, lorazepam, and midazolam. They all inhibit synaptic transmission at the GABA receptor but have differing durations of action. The benzodiazepines can produce peripheral vasodilatation and hypotension but have minimal effects on respiration when used alone. They must be used with caution when given with opioids; a synergistic reaction causing respiratory depression is common. The benzodiazepines are excellent anticonvulsants and only rarely cause allergic reactions.

Etomidate Etomidate is an imidazole derivative used for IV induction. Its rapid and almost complete hydrolysis to inactive metabolites results in rapid awakening. Like the above IV agents, etomidate acts on the GABA receptor. It has little effect on cardiac output and heart rate, and induction doses usually produce less reduction in blood pressure than that seen with thiopental or propofol. Etomidate is associated with pain on injection and more nausea and vomiting than thiopental or propofol.

Ketamine Ketamine differs from the above IV agents in that it produces analgesia as well as amnesia. Its principal action is on

the *N*-methyl-D-aspartate receptor; it has no action on the GABA receptor. It is a dissociative anesthetic, producing a cataleptic gaze with nystagmus. Patients may associate this with delirium and hallucinations while regaining consciousness. The addition of benzodiazepines has been shown to prevent these side effects. Ketamine can increase heart rate and blood pressure, which may cause myocardial ischemia in patients with CAD. Ketamine is useful in acutely hypovolemic patients to maintain blood pressure via sympathetic stimulation but is a direct myocardial depressant in patients who are catecholamine depleted. Ketamine is a bronchodilator, making it useful for asthmatic patients, and rarely is associated with allergic reactions.

Analgesia. The IV analgesics most frequently used in anesthesia today have little effect on consciousness, amnesia, or muscle relaxation. The most important class is the *opioids*, so called because they were first isolated from opium, with morphine, codeine, meperidine, hydromorphone, and the fentanyl family being the most common. The most important *nonopioid* analgesics are ketamine (discussed earlier in the Ketamine section) and ketorolac, an IV nonsteroidal anti-inflammatory drug (NSAID).

Opioid Analgesics The commonly used opioids—morphine, codeine, oxycodone, meperidine, and the fentanyl-based compounds—act centrally on μ -receptors in the brain and spinal cord. The main side effects of opioids are euphoria, sedation, constipation, and respiratory depression, which also are mediated by the same μ -receptors in a dose-dependent fashion. Although opioids have differing potencies required for effective analgesia, *equianalgesic doses of opioids result in equal degrees of respiratory depression*. Thus, there is no completely safe opioid analgesic. The synthetic opioid fentanyl and its analogues sufentanil, alfentanil, and remifentanil are commonly used in the operating room. They differ pharmacokinetically in their lipid solubility, tissue binding, and elimination profiles and thus have differing potencies and durations of action. Remifentanil is remarkable in that it undergoes rapid hydrolysis that is unaffected by sex, age, weight, or renal or hepatic function, even after prolonged infusion. Recovery is within minutes, but there is little residual postoperative analgesia.

Naloxone and the longer-acting naltrexone are pure opioid *antagonists*. They can be used to reverse the side effects of opioid overdose (e.g., respiratory depression), but the analgesic effects of the opioid also will be reversed.

Nonopioid Analgesics *Ketamine*, an *N*-methyl-D-aspartate receptor antagonist, is a potent analgesic, but is one of the few IV agents that also causes significant sedation and amnesia. Unlike the μ -receptor agonists, ketamine supports respiration. It can be used in combination with opioids, but the dysphoric effects must be masked with the simultaneous use of sedatives, usually a benzodiazepine like midazolam.

Ketorolac is a parenteral NSAID that produces analgesia by reducing prostaglandin formation via inhibition of the enzyme cyclooxygenase (COX). Intraoperative use of ketorolac reduces postoperative need for opioids. Two forms of COX have been identified: COX-1 is responsible for the synthesis of several prostaglandins as well as prostacyclin, which protects gastric mucosa, and thromboxane, which supports platelet function. COX-2 is induced by inflammatory reactions to produce more prostaglandins. Ketorolac (as well as many oral NSAIDs, aspirin, and indomethacin) inhibits both COX-1 and COX-2, which causes the major side effects of gastric bleeding, platelet dysfunction, and hepatic and renal damage.

Parecoxib is a parenteral, predominantly COX-2 NSAID that presumably produces analgesia and reduces inflammation without causing gastrointestinal bleeding or platelet dysfunction.

Dexmedetomidine is an IV α_2 -adrenergic agonist, administered as a continuous infusion, and has sedative and analgesic properties. It is useful for sedation in an intensive care unit setting and as an adjunct to general anesthesia. Side effects are hypotension and bradycardia.

IV *acetaminophen* is an analgesic drug and antipyretic of moderate potency; its site of action is in the central nervous system (CNS), not peripherally. It does not have anti-inflammatory properties and is not considered an NSAID.¹⁴ When used as part of postoperative analgesic therapy, it will reduce the amount of opioids required, reducing side effects (e.g., constipation, sedation, respiratory depression).

Neuromuscular Blocking Agents. Neuromuscular blocking agents have no amnestic, hypnotic, or analgesic properties; patients must be properly anesthetized *before* and *in addition* to the administration of these agents. A paralyzed but unsedated patient will be aware, conscious, and in pain, yet be unable to communicate their predicament. Inappropriate administration of a neuromuscular blocking agent to an awake patient is one of the most traumatic experiences imaginable. Neuromuscular blockade is not a substitute for adequate anesthesia, but is rather an adjunct to the anesthetic. Depth of neuromuscular blockade is best monitored with a nerve stimulator to ensure patient immobility intraoperatively and to confirm a lack of residual paralysis postoperatively.¹⁵

Unlike the local anesthetics, which affect the ability of nerves to conduct impulses, the neuromuscular blockers have no effect on either nerves or muscles, but act primarily on the *neuromuscular junction*.

There is one commonly used *depolarizing* neuromuscular blocker—succinylcholine. This agent binds to acetylcholine receptors on the postjunctional membrane in the neuromuscular junction and causes depolarization of muscle fibers.

Although the rapid onset (<60 seconds) and rapid offset (5–8 minutes) make succinylcholine ideal for management of the airway in certain situations, total body muscle fasciculations can cause postoperative aches and pains, an elevation in serum potassium levels, and an increase in intraocular and intragastric pressure. Its use in patients with burns or traumatic tissue injuries may result in a high enough rise in serum potassium levels to produce arrhythmias and cardiac arrest. Unlike other neuromuscular blocking agents, the effects of succinylcholine cannot be reversed. Succinylcholine is rapidly hydrolyzed by plasma cholinesterase, also referred to as *pseudocholinesterase*.

There are many reasons for a patient to have low pseudocholinesterase levels, such as liver disease, concomitant use of other drugs, pregnancy, and cancer. These factors are usually not clinically problematic, delaying return of motor function only by several minutes. Some patients have a genetic disorder manifesting as atypical plasma cholinesterase; the atypical enzyme has less-than-normal activity, and/or the patient has extremely low levels of the enzyme. The incidence of the homozygous form is approximately 1 in 3000; the effects of a single dose of succinylcholine may last several hours instead of several minutes. Treatment is to keep the patient sedated and unaware he or she is paralyzed, continue mechanical ventilation, test the return of motor function with a peripheral nerve stimulator, and extubate the patient only after he or she has fully regained motor strength. Two separate blood tests must be drawn: *pseudocholinesterase level* to determine the amount of enzyme present, and *dibucaine number*, which indicates the quality of the enzyme. Patients with laboratory-confirmed abnormal pseudocholinesterase levels and/or dibucaine numbers should be counseled to avoid succinylcholine as well as mivacurium, which is also hydrolyzed by pseudocholinesterase. First-degree family members should also be tested. Succinylcholine is the only IV triggering agent of malignant hyperthermia (discussed later in the Malignant Hyperthermia section).

There are several competitive *nondepolarizing* agents available for clinical use. The longest acting is *pancuronium*, which is excreted almost completely unchanged by the kidney. Intermediate-duration neuromuscular blockers include *vecuronium* and *rocuronium*, which are metabolized by both the kidneys and liver, and *atracurium* and *cisatracurium*, which undergo breakdown in plasma known as *Hofmann elimination*. The agent with shortest duration is *mivacurium*, the only nondepolarizer that is metabolized by plasma cholinesterase, and like succinylcholine, is subject to the same prolonged blockade in patients with plasma cholinesterase deficiency. All nondepolarizers reversibly bind to the postsynaptic terminal in the neuromuscular junction and prevent acetylcholine from depolarizing the muscle. Muscle blockade occurs without fasciculation and without the subsequent side effects seen with succinylcholine. The most commonly used agents of this type and their advantages and disadvantages are listed in Table 46-2.

The reversal of neuromuscular blockade is not a true reversal of the drug (as with protamine reversal of heparin) but a reversal of the effect of the neuromuscular blockade. Neuromuscular blocking reversal agents, usually neostigmine, edrophonium, or pyridostigmine, increase acetylcholine levels by inhibiting acetylcholinesterase, the enzyme that breaks

Table 46-2

Advantages and disadvantages to common nondepolarizing neuromuscular blocking agents

AGENT	DURATION (H)	ADVANTAGES	DISADVANTAGES
Pancuronium	>1	No histamine release	Tachycardia; slow onset; long duration
Vecuronium	<1	No cardiovascular effects	Intermediate onset
Rocuronium	<1	Fast onset; no cardiovascular effects	—
Mivacurium	<1	Fast onset; short duration & histamine release	—

Source: Adapted with permission from Rutter TW, Tremper KK. Anesthesiology and pain management. In: Mulholland MW et al, eds. *Greenfield's Surgery: Scientific Principles and Practice*. 4th ed. Philadelphia: Lippincott Williams & Wilkins; 2006:271.

down acetylcholine. The subsequently increased circulating levels of acetylcholine prevail in the competition for the post-synaptic receptor, and motor function returns. Use of the peripheral nerve stimulator is required to follow depth and reversal of motor blockade, but it is essential to correlate data from the nerve stimulator with clinical signs that indicate return of motor function, including tidal volume, vital capacity, hand grip, and 5-second sustained head lift.

Inhalational Agents. Unlike the IV agents, the inhalational agents provide all three characteristics of general anesthesia: unconsciousness, analgesia, and muscle relaxation. However, it would be impractical to use an inhalation-only technique in larger surgical procedures, because the doses required would cause unacceptable side effects, so IV adjuncts such as opioid analgesics and neuromuscular blockers are added to optimize the anesthetic. All inhaled anesthetics display a dose-dependent reduction in mean arterial blood pressure except for nitrous oxide, which maintains or slightly raises the blood pressure. Nitrous oxide, although not potent enough to use alone, provides partial anesthesia and allows a second agent to be used in smaller doses, reducing side effects.

Minimum alveolar concentration (MAC) is a measure of anesthetic potency. It is the ED₅₀ of an inhaled agent (i.e., the dose required to block a response to a painful stimulus in 50% of subjects). The higher the MAC, the less potent an agent is. The potency and speed of induction of inhaled agents correlate with their lipid solubility, and this is known as the *Meyer-Overton rule*. Nitrous oxide has a low solubility and is a weak anesthetic agent, but has the most rapid onset and offset. The “potent” gases (e.g., desflurane, sevoflurane, enflurane, and halothane) are more soluble in blood than nitrous oxide and can be given in lower concentrations, but have longer induction and emergence characteristics.

Sevoflurane and desflurane are the two most recently introduced inhalational agents in common use. Because of their relatively lower tissue and blood solubility, induction and recovery are more rapid than with isoflurane or enflurane.

All of the potent inhalational agents (e.g., halothane, isoflurane, enflurane, sevoflurane, and desflurane), as well as the

depolarizing agent succinylcholine, are triggering agents for malignant hyperthermia. Table 46-3 lists the advantages and disadvantages of each agent.

Local Anesthetics

Local anesthetics are divided into two groups based on their chemical structure: the amides and the esters. In general, the amides are metabolized in the liver, and the esters are metabolized by plasma cholinesterases, which yield metabolites with slightly higher allergic potential than the amides (Table 46-4).

Amides. Lidocaine, bupivacaine, mepivacaine, prilocaine, and ropivacaine have in common an amide linkage between a benzene ring and a hydrocarbon chain that, in turn, is attached to a tertiary amine. The benzene ring confers lipid solubility for penetration of nerve membranes, and the tertiary amine attached to the hydrocarbon chain makes these local anesthetics water soluble. Lidocaine has a more rapid onset and is shorter acting than bupivacaine; however, both are widely used for tissue infiltration, regional nerve blocks, and spinal and epidural anesthesia. Ropivacaine is the most recently introduced local anesthetic. It is clinically similar to bupivacaine in that it has a slow onset and a long duration, but is less cardiotoxic. All amides are 95% metabolized in the liver, with 5% excreted unchanged by the kidneys.

Esters. Cocaine, procaine, chlorprocaine, tetracaine, and benzocaine have an ester linkage in place of the amide linkage mentioned earlier in the Amides section. Unique among local anesthetics, cocaine occurs in nature, was the first used clinically, produces vasoconstriction (making it useful for topical application, e.g., for intranasal surgery), releases norepinephrine from nerve terminals resulting in hypertension, and is highly addictive. Cocaine is a Schedule II drug. Procaine, synthesized in 1905 as a nontoxic substitute for cocaine, has a short duration and is used for infiltration. Tetracaine has a long duration and is useful as a spinal anesthetic for lengthy operations. Benzocaine is for topical use only. The esters are hydrolyzed in the blood by pseudocholinesterase. Some of the metabolites have a greater allergic potential than the metabolites of the amide anesthetics, but true allergies to local anesthetics are rare.

Table 46-3

Advantages and disadvantages of common inhalational agents

AGENT	MAC (%)	ADVANTAGES	DISADVANTAGES
Nitrous oxide	105	Analgesia; minimal cardiac and respiratory depression	Sympathetic stimulation; expansion of closed air space
Halothane	0.75	Effective in low concentrations; minimal airway irritability; inexpensive	Cardiac depression and arrhythmia hepatic necrosis; slow elimination
Enflurane	1.68	Muscle relaxation No effect on cardiac rate or rhythm	Strong smell; seizures
Isoflurane	1.15	Muscle relaxation; no effect on cardiac rate or rhythm	Strong smell
Desflurane	6	Rapid induction and emergence	Coughing; high cost
Sevoflurane	1.71	Rapid induction and emergence; pleasant smell; ideal for mask induction	High cost; metabolized by liver

MAC = minimum alveolar concentration.

Source: Adapted with permission from Rutter TW, Tremper KK. Anesthesiology and pain management. In: Mulholland MW et al, eds. *Greenfield's Surgery: Scientific Principles and Practice*. 4th ed. Philadelphia: Lippincott Williams & Wilkins; 2006:270.

Table 46-4

Biologic properties of commonly used local anesthetics

AGENT	EQUIANESTHETIC CONCENTRATION (%)	APPROXIMATE ANESTHETIC DURATION (MIN)	SITE OF METABOLISM
Esters			
Procaine	2	50	Plasma
Chloroprocaine	2	45	Plasma
Tetracaine	0.25	175	Plasma
Amides			
Prilocaine	1	100	Liver/lung
Lidocaine	1	100	Liver
Mepivacaine	1	100	Liver
Bupivacaine	0.25	175	Liver
Ropivacaine	0.3	150	Liver
Etidocaine	0.25	200	Liver

Source: Reproduced with permission from Mather LE, Tucker GT. Properties, absorption, and disposition of local anesthetic agents. In: Cousins MJ, Bridenbaugh PO, eds. *Cousins and Bridenbaugh's Neural Blockade in Clinical Anesthesia and Pain Medicine*. 4th ed. Philadelphia: Lippincott Williams & Wilkins; 2009:49.

The common characteristic of all local anesthetics is a reversible block of the transmission of neural impulses when placed on or near a nerve membrane. Local anesthetics block nerve conduction by stabilizing sodium channels in their closed state, preventing action potentials from propagating along the nerve. The individual local anesthetic agents have different recovery times based on lipid solubility and tissue binding, but return of neural function is spontaneous as the drug is metabolized or removed from the nerve by the vascular system.

Toxicity of local anesthetics results from absorption into the bloodstream or from inadvertent direct intravascular injection. Toxicity manifests first in the more sensitive CNS and then the cardiovascular system.

Central Nervous System Toxicity. As plasma concentration of local anesthetic rises, symptoms progress from restlessness to complaints of tinnitus. Slurred speech, seizures, and unconsciousness follow. Cessation of the seizure via administration of a benzodiazepine or thiopental and maintenance of the airway are the immediate treatment. If the seizure persists, the trachea must be intubated with a cuffed endotracheal tube to guard against pulmonary aspiration of stomach contents.

Cardiovascular System Toxicity. With increasingly elevated plasma levels of local anesthetics, progression to hypotension, increased P-R intervals, bradycardia, and cardiac arrest may occur. Bupivacaine is more cardiotoxic than other local anesthetics. It has a direct effect on ventricular muscle, and because it is more lipid soluble than lidocaine, it binds tightly to sodium channels (it is called the *fast-in, slow-out local anesthetic*). Patients who have received an inadvertent intravascular injection of bupivacaine have experienced profound hypotension, ventricular tachycardia and fibrillation, and complete atrioventricular heart block that is extremely refractory to treatment. The toxic dose of lidocaine is approximately 5 mg/kg; that of bupivacaine is approximately 3 mg/kg.

Calculation of the toxic dose before injection is imperative. It is helpful to remember that for any drug or solution,

1% = 10 mg/mL. For a 50-kg person, the toxic dose of bupivacaine would be approximately 3 mg/kg, or $3 \times 50 = 150$ mg. A 0.5% solution of bupivacaine is 5 mg/mL, so $150 \text{ mL} / 5 \text{ mg/mL} = 30$ mL as the upper limit for infiltration. For lidocaine in the same patient, the calculation is $50 \text{ kg} \times 5 \text{ mg/mL} = 250$ mg toxic dose. If a 1% solution is used, the allowed amount would be $250 \text{ mg} / 10 \text{ mg/mL} = 25$ mL.

Additives to Local Anesthetics. Epinephrine has one physiologic and several clinical effects when added to local anesthetics. Epinephrine is a vasoconstrictor, and by reducing local bleeding, molecules of the local anesthetic remain in proximity to the nerve for a longer time period. Onset of the nerve block is faster, the quality of the block is improved, the duration is longer, and less local anesthetic will be absorbed into the bloodstream, thereby reducing toxicity. Although epinephrine 1:200,000 (5 g/mL) added to a local anesthetic for infiltration will greatly lengthen the time of analgesia, epinephrine-containing solutions should not be injected into body parts with end-arteries, such as toes or fingers, as vasoconstriction may lead to ischemia or loss of a digit. When added to the local anesthetic, sodium bicarbonate will raise the pH, favoring the nonionized uncharged form of the molecule. This speeds the onset of the block, especially in local anesthetics that are mixed with epinephrine. The pH of such solutions is around 4.5; therefore, the addition of sodium bicarbonate results in a relatively large increase in pH.¹⁶

Regional Anesthesia: Peripheral vs. Central

Peripheral Nerve Blocks. Local anesthetic can be injected *peripherally*, near a large nerve or plexus, to provide anesthesia to a larger region of the body. Examples include the brachial plexus for surgery of the arm or hand, blockade of the femoral and sciatic nerves for surgery of the lower extremity, ankle block for surgery of the foot or toes, intercostal block for analgesia of the thorax postoperatively, or blockade of the cervical plexus, which is ideal for carotid endarterectomy. Risks of peripheral regional nerve blocks are dependent on their location.

For example, nerve blocks injected into the neck risk puncture of the carotid or vertebral arteries, intercostal nerves are in close proximity to the vascular bundle and have a high rate of absorption of local anesthetic, and nerve blocks of the thorax run the risk of causing pneumothorax. All peripheral nerve blocks may be supplemented intraoperatively with IV sedation and/or analgesics.

Central Nerve Blocks: Spinal and Epidural. Local anesthetic injected *centrally* near the spinal cord—spinal or epidural anesthesia—provides anesthesia for the lower half of the body. This is especially useful for genitourinary, gynecologic, inguinal hernia, or lower extremity procedures. Spinal and epidural anesthesia block the spinal nerves as they exit the spinal cord. Spinal nerves are mixed nerves; they contain motor, sensory, and sympathetic components. The subsequent block will cause sensory anesthesia, loss of motor function, and blockade of the sympathetic nerves from the level of the anesthetic distally to the lower extremities. Subsequent vasodilation of the vasculature from sympathetic block may result in hypotension, which is treatable with IV fluids and/or pressors.

Spinal Anesthesia Local anesthetic is injected directly into the dural sac surrounding the spinal cord. The level of injection is usually below L1 to L2, where the spinal cord ends in most adults. Because the local anesthetic is injected directly into the cerebrospinal fluid surrounding the spinal cord, only a small dose is needed, the onset of anesthesia is rapid, and the blockade is thorough. Lidocaine, bupivacaine, and tetracaine are commonly used agents of differing durations; the block wears off naturally via drug uptake by the cerebrospinal fluid, bloodstream, or diffusion into fat. Epinephrine as an additive to the local anesthetic will significantly prolong the blockade.

Possible complications include hypotension, especially if the patient is not adequately prehydrated; high spinal block requires immediate airway management; and postdural puncture headache sometimes occurs. Spinal headache is related to the diameter and configuration of the spinal needle and can be reduced to approximately 1% with the use of a small 25- or 27-gauge needle.

Cauda equina syndrome is injury to the nerves emanating distal to the spinal cord resulting in bowel and bladder dysfunction and lower extremity sensory and motor loss. It has mainly been seen in cases in which indwelling spinal microcatheters and high (5%) concentrations of lidocaine were used. Indwelling spinal catheters are no longer used.

Epidural Anesthesia Epidural anesthesia could also be called *extradural anesthesia*, because local anesthetics are injected into the epidural space surrounding the dural sac of the spinal cord. Much greater volumes of anesthetic are required than with spinal anesthesia, and the onset of the block is longer—10 to 15 minutes. As in spinal anesthesia, local anesthetic bathes the

spinal nerves as they exit the dura; the patient achieves analgesia from the sensory block, muscle relaxation from blockade of the motor nerves, and hypotension from blockade of the sympathetic nerves as they exit the spinal cord. Note that regional anesthesia, whether peripheral or central, provides only two of the three major components of anesthesia—analgesia and muscle relaxation. Anxiolysis, amnesia, or sedation must be attained by supplemental IV administration of other drugs (e.g., the benzodiazepines or propofol infusion).

Complications are similar to those of spinal anesthesia. Inadvertent injection of local anesthetic into a dural tear will result in a high block, manifesting as unconsciousness, severe hypotension, and respiratory paralysis requiring immediate aggressive hemodynamic management and control of the airway. Indwelling catheters are often placed through introducers into the epidural space, allowing an intermittent or continuous technique, as opposed to the single-shot method of spinal anesthesia. By necessity, the epidural-introducing needles are of a much larger diameter (17- or 18-gauge) than spinal needles, and accidental dural puncture more often results in a severe headache that may last up to 10 days if left untreated.

ANESTHESIA MANAGEMENT

Preoperative Evaluation and Preparation

The ASA has adopted basic standards for the evaluation of patients before surgery. These standards require the anesthesiologist to determine the medical status of the patient by developing a plan of anesthetic care and to discuss this plan with the patient and/or legal guardian.

The preoperative visit results in a summary of all pertinent findings, including a detailed medical history, current drug therapy, complete physical examination, and laboratory and specific testing results. Based on these findings, the anesthesiologist may find that the patient is not in optimal medical condition to undergo elective surgery. These findings and opinions are then discussed with the patient's primary physician, and the surgery may be delayed or cancelled until the patient's medical condition is further tested and optimized.

The detailed medical history obtained at the preoperative visit should include the patient's previous exposure and experience with anesthesia, as well as any family history of problems with anesthesia. History of atopy (medication, foods, or environmental) is an important aspect of this evaluation in that it may predispose patients to form antibodies against antigens that may be represented by agents administered during the perioperative period. A careful review of major organ systems and their function also should be performed.

The physical examination is targeted primarily at the CNS, cardiovascular system, lungs, and upper airway. Specific areas to investigate are shown in Table 46-5.

Table 46-5

Preoperative physical examination

CENTRAL NERVOUS SYSTEM	CARDIOVASCULAR SYSTEM	RESPIRATORY SYSTEM	ORAL AIRWAY
Consciousness; neurocognition; peripheral sensory	Blood pressure; standing and sitting, bilateral; peripheral pulses; heart auscultation; heart rate; murmur; rhythm	Auscultation of lungs; wheezes; rales	Cervical spine mobility; visualize uvula; artificial teeth; thyromental distance

Concurrent medications must be fully explored, and adverse interactions with agents administered during the perioperative period need to be considered. However, concurrent medications that produce desired effects (i.e., β -blockade, anti-hypertensive, and antiasthma medications) can and should be continued throughout the perioperative period; patients should be counseled to continue these medications up to and including the morning of surgery. Careful documentation will allow the anesthesiologist to make informed decisions about the perioperative selection of drugs and therapy as well as monitoring techniques.

Preoperative laboratory data and specific testing for elective surgery should be patient and situation specific. Examples include serum potassium for a patient on diuretics, glucose in a diabetic patient, or hemoglobin concentration in any surgery with a high risk of blood loss. Coagulation tests are not necessary if the patient is not receiving anticoagulants or has no signs or symptoms of abnormal clotting. Otherwise healthy patients usually do not need preoperative laboratory testing, and tests performed within the previous 6 months are usually sufficient.¹⁷ Other tests that should be generated by history and physical examination include chest radiograph if there is evidence of chest disease and pulmonary function tests in patients who are morbidly obese, severe asthmatics, or patients undergoing pulmonary resection surgery. An electrocardiogram should be performed in all symptomatic patients and in asymptomatic men age 45 years or older and asymptomatic women age 50 years or older. Urine pregnancy testing should be performed on the day of surgery in all women of childbearing age.

Risk Assessment

An integral part of the preoperative visit is for the anesthesiologist to assess patient risk. Risk assessment encompasses two major questions: (a) Is the patient in optimal medical condition for surgery? and (b) Are the anticipated benefits of surgery greater than the surgical and anesthetic risks associated with the procedure?

Research into quantifying preoperative factors that correlate with the development of postoperative morbidity and mortality has recently gained great interest. Originally designed as a simple classification of a patient's physical status immediately before surgery, the ASA physical status scale is one of the few prospective scales that correlate with the risk of anesthesia and surgery (Table 46-6).

Criticism of the ASA scale is primarily due to its exclusion of age and difficulty of intubation (discussed later in

Table 46-7

American Society of Anesthesiologists physical status and mortality

SCORE	MORTALITY (%)
P1	0.1
P2	0.2
P3	1.8
P4	7.8
P5	9.4

Source: Reproduced with permission from Aitkenhead AR, Rowbotham D, Smith G, eds. *Textbook of Anesthesia*. 4th ed. New York: Churchill Livingstone; 2001:288. Copyright Elsevier.

this chapter). Cullen and associates examined 1095 patients undergoing total hip replacement, prostatectomy, or cholecystectomy, and found that both age and ASA scale accurately predict postoperative morbidity and mortality¹⁸ (Table 46-7). The ASA scale remains useful and should be applied to all patients during the preoperative visit.

Evaluation of the Airway. The airway examination is an effort to identify those patients in whom management of the airway and conventional endotracheal intubation may be difficult. It is vitally important to recognize such patients before administering medications that induce apnea.

Mallampati Classification. The amount of the posterior pharynx one can visualize preoperatively is important and correlates with the difficulty of intubation. A large tongue (relative to the size of the mouth) that also interferes with visualization of the larynx on laryngoscopy will obscure visualization of the pharynx. The Mallampati classification (Fig. 46-2, Table 46-8) is based on the structures visualized with maximal mouth opening and tongue protrusion in the sitting position.

Other predictors of difficult intubation include obesity, immobility of the neck, interincisor distance <4 cm in an adult, a large overbite, or the inability to shift the lower incisors in front of the upper incisors. The thyromental distance (i.e., the distance from the thyroid cartilage to the mentum [tip of the chin]) should be >6.5 to 7 cm.

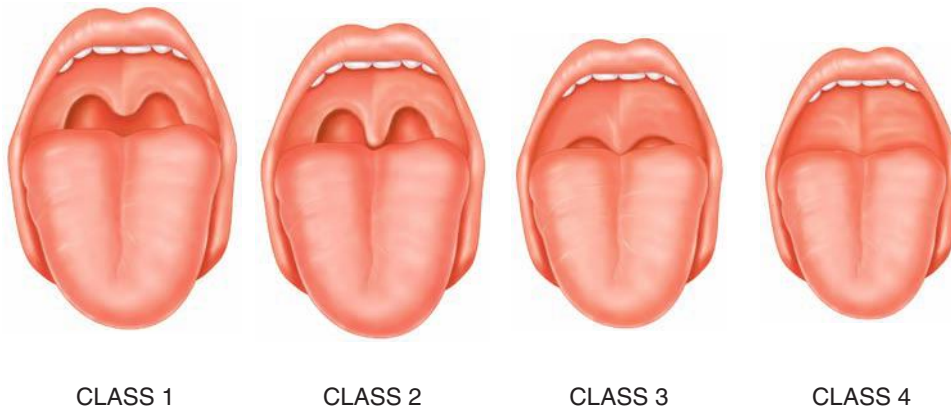
Consideration of Patients with Comorbidities. A thorough knowledge of the pathophysiology of concurrent medical conditions regardless of the reason for surgery is essential for optimal perioperative care. Optimal anesthesia extends beyond pharmacology and technical procedures. Specifically, ischemic heart disease, renal dysfunction, pulmonary disease, metabolic and endocrine disorders, CNS diseases, and diseases of the liver and biliary tract can have major impact on the management of anesthesia.

Ischemic Heart Disease. Ischemic heart disease is the result of the heart demanding more oxygen (O_2) than its supply can provide. A supply problem may be due to many factors, including hypoxia, anemia, hypotension and coronary artery atherosclerosis, thrombosis, or spasm. Additionally, the problem may be an increase in myocardial O_2 demand (tachycardia). In the vast majority of cases, the most responsible lesion is a reduction in the luminal area of coronary arteries due to atherosclerosis.

Table 46-6

American Society of Anesthesiologists physical status classification system

P1	A normal healthy patient
P2	A patient with mild systemic disease
P3	A patient with severe systemic disease
P4	A patient with severe systemic disease that is a constant threat to life
P5	A moribund patient who is not expected to survive without the operation
P6	A declared brain-dead patient whose organs are being removed for donor purposes



MALLAMPATI CLASSIFICATION

- CLASS 1: Soft palate, fauces, uvula, pillars
 CLASS 2: Soft palate, fauces, portion of uvula
 CLASS 3: Soft palate, base of uvula
 CLASS 4: Hard palate only

Figure 46-2. The Mallampati classification.

An estimated 14 million people in the United States have ischemic heart disease. Of these, as many as 4 million have few or no symptoms and are unaware that they are at risk for angina pectoris, myocardial infarction, or sudden death.

An important goal of the preoperative visit is for the anesthesiologist to ascertain the patient's severity, progression, and functional limitations induced by ischemic heart disease. Furthermore, this visit can elucidate the possibility of previously undiagnosed ischemic heart disease. A thorough investigation of risk factors for ischemic heart disease is essential during the preoperative visit. The risk of perioperative death due to myocardial infarction in patients without ischemic heart disease is approximately 1%.¹⁹ In contrast, the risk in patients with known or suspected ischemic heart disease is approximately 3%,¹⁹ and in patients undergoing surgery for peripheral vascular disease, the combined risk of death due to cardiac causes is 29%.²⁰

Major Risk Factors for Coronary Artery Disease. The risk of *hypercholesterolemia* is proportional to the increased serum level of low-density lipoprotein cholesterol. Reduction achieved via decreased dietary fat or pharmacotherapy reduces risk.

Hyperlipidemia may be familial and thus may account for the fact that a strong family history of premature CAD is a significant risk factor. High-density lipoprotein cholesterol is protective.

Although definitely a risk factor, hypertension alone probably does not cause plaques. Rather, it may act synergistically with hypercholesterolemia by first causing mechanical wall stress and damage.

Smoking causes endothelial damage, and therefore promotes plaque thrombosis. Cessation greatly reduces the risk of CAD.

Diabetes mellitus is a strong independent risk factor. A hypothesis is that glycosylation products cause release of growth factors that stimulate smooth muscle proliferation.

Other Risk Factors. *Hyperhomocysteinemia* is becoming an established independent risk factor, but is still under evaluation. Reduction of levels by folate therapy may be beneficial.

Advanced age, male sex, obesity, and a sedentary lifestyle can also put a person at risk for developing ischemic heart disease.²¹

Drugs used for the medical management of patients with ischemic heart disease should be continued throughout the perioperative period. Withdrawal of an antihypertensive drug or suspension of β -blockade can induce unwanted increases in sympathetic nervous system activity.¹² Induction of anesthesia in patients with ischemic heart disease can be safely accomplished with a number of IV drugs. As many as 45% of patients have been shown to have myocardial ischemia during the stress of tracheal intubation, and direct laryngoscopy should be used for the shortest time possible to minimize the magnitude of stimulation.²²

The intraoperative anesthetic technique should allow for the prompt control of hemodynamic variables; the maintenance of the balance between myocardial O₂ delivery and myocardial O₂ demand is probably the single most important factor in managing patients with ischemic heart disease. In this regard, muscle relaxants with minimal to no effects on heart rate and blood pressure, such as vecuronium and rocuronium, are attractive choices for neuromuscular blockade. Additionally, controlled myocardial depression using a volatile anesthetic in patients with a normal left ventricular ejection fraction may help to minimize the stimulation of the sympathetic nervous system and subsequent increases in myocardial O₂ requirements. In patients with impaired left ventricular function, continued myocardial depression with volatile anesthetics may not be tolerated; the addition of short-acting opioids such as fentanyl is beneficial. In cardiac surgical patients, it is not uncommon for high-dose opioids to be used as the predominant anesthetic.

Pulmonary Disease. Chronic pulmonary disease has developed into a worldwide public health problem. Chronic obstructive

Table 46-8

Mallampati classification

- Class I: soft palate, fauces, uvula, pillars
 Class II: soft palate, fauces, portion of uvula
 Class III: soft palate, base of uvula
 Class IV: hard palate only

pulmonary disease (COPD), distinguished from asthma, which is characterized by reversible airway smooth muscle constriction, is a progressive disease that leads to the destruction of the lung parenchyma.

Infection, noxious particles, and gases can exacerbate COPD. Historically, certain lung function parameters (i.e., significantly abnormal spirometry or arterial blood gas analysis) were once considered contraindications for anesthesia. However, anesthetic techniques have improved, and it has been shown that patients with severe lung disease can safely undergo anesthesia.²³ Zollinger and Pasch found no specific parameters of lung function that were predictive of postoperative lung complications. The highest predictive parameter found was upper abdominal surgery and thoracic surgery.²⁴

General anesthesia can be performed safely in patients with pulmonary disease.²⁵ Inhaled anesthetics are often used due to their bronchodilating properties.²⁶ Some authors have advocated pretreatment with salbutamol, a long-acting β -agonist, which may prevent bronchoconstriction during anesthetic induction.^{27,28}

Regional and local anesthesia have the benefit of avoiding tracheal irritation and stimulating bronchospasm. However, patients with COPD may become hypoxic while lying strictly supine, and sensory levels of anesthetic above T10 are associated with the impairment of respiratory muscle activity necessary for patients with COPD to maintain adequate ventilation.¹²

Intraoperatively, mechanical ventilation using a slow breathing rate (at eight breaths per minute) should be used to allow for passive exhalation in the presence of increased airway resistance. This slow breathing, facilitated by high inspiratory flow rate, may allow for improved maintenance of normal partial pressure of arterial oxygen (PaO_2) and partial pressure of arterial carbon dioxide (CO_2) levels. Patients should also be well hydrated during the procedure with adequate crystalloid/colloid volume therapy, which may allow for less viscous pulmonary secretions following surgery.

Renal Disease. Five percent of the adult population may have pre-existing renal disease that could contribute to perioperative morbidity.²⁹ In addition, the risk of acute renal failure is increased by certain events or patient characteristics independent of pre-existing renal disease, such as hypovolemia and obstructive vascular disease. Ischemic tubular damage (i.e., acute tubular necrosis) is the most likely cause of acute renal failure in the perioperative period, reflecting events that cause an imbalance of O_2 supply to O_2 demand in the medullary ascending tubular cells.

Virtually all anesthetic drugs and techniques are associated with decreases in renal blood flow, the glomerular filtration rate, and urine output, reflecting multiple mechanisms such as decreased cardiac output, altered autonomic nervous system activity, neuroendocrine changes, and positive pressure ventilation. Renal blood flow (15%–25% of the cardiac output) far exceeds renal O_2 needs, but ensures optimal clearance of wastes and drugs. Prehydration and the depth of anesthesia may influence the renal response to anesthesia.

Management of anesthesia in patients with chronic renal disease requires attention to intraoperative fluid management and tight control of ventilation, as respiratory alkalosis will shift the oxyhemoglobin dissociation curve, and respiratory acidosis could raise serum potassium to dangerous levels. Because of

decreased excretion by the kidney, doses of opioids and neuromuscular blocking agents must be attenuated.

Hepatobiliary Disease. Management of anesthesia for the patient with liver disease requires an understanding of the many physiologic functions of the liver: synthesis of albumin and coagulation factors, metabolism of drugs, glucose homeostasis, and the production of bilirubin. Data from the 1970s suggested that approximately 1 in every 700 adult patients who are scheduled for elective surgical procedures has unknown liver disease or is in the prodromal phase of viral hepatitis. Severe hepatic necrosis following surgery and anesthesia is most often due to decreased hepatic O_2 delivery rather than the anesthetic.

Regional anesthesia may be useful in patients with advanced liver disease, assuming coagulation status is acceptable. When general anesthesia is selected, administration of modest doses of volatile anesthetics with or without nitrous oxide or fentanyl often is recommended. Selection of nondepolarizing muscle relaxants should consider clearance mechanisms for these drugs. For example, patients with hepatic cirrhosis may be hypersensitive to mivacurium because of the lowered plasma cholinesterase activity. Perfusion to the liver is maintained by administering fluids (guided by filling pressures) and maintaining adequate systemic pressure and cardiac output.

The coexisting presence of liver disease may influence the selection of volatile anesthetics. Halothane is the anesthetic most studied regarding possible hepatotoxicity. Halothane hepatitis occurs rarely (approximately 1:25,000 patients) and may have an immune-mediated mechanism stimulated by repeated exposures to halothane.³⁰ Halothane, enflurane, isoflurane, and desflurane all yield a reactive oxidative trifluoroacetyl halide and may be cross-reactive, but the magnitude of metabolism of the volatile anesthetics is a probable factor in the ability to cause hepatitis.³¹ Halothane is metabolized 20%, enflurane 2%, isoflurane 0.2%, and desflurane 0.02%; desflurane probably has the least potential for liver injury. Sevoflurane does not yield any trifluoroacetylated metabolites and is unlikely to cause hepatitis. An estimated 15 to 20 million adults in the United States have biliary tract disease. Treatment of gallbladder disease by open or laparoscopic cholecystectomy is most often performed with general anesthesia supplemented with muscle relaxants. Complete biliary tract obstruction could interfere with the clearance of some muscle relaxants dependent on liver metabolism, such as vecuronium and pancuronium. Anesthetic considerations for laparoscopic cholecystectomy are similar to those for other laparoscopic procedures. Insufflation of the abdominal cavity with CO_2 results in increased intra-abdominal pressure that may interfere with the ease of ventilation and venous return. During laparoscopic cholecystectomy, placement of the patient in the reverse Trendelenburg position favors movement of abdominal contents away from the operative site and may improve ventilation. However, this position may further interfere with venous return and reduce cardiac output, emphasizing the need to maintain intravascular fluid volume. Mechanical ventilation of the lungs is recommended to ensure adequate ventilation in the presence of increased intra-abdominal pressure and to offset the effects of systemic absorption of CO_2 used during insufflation of the abdominal cavity. High intra-abdominal pressure may increase the risk of passive reflux of gastric contents. Tracheal intubation with a cuffed tube is advised to minimize the risk of pulmonary aspiration.

Metabolic and Endocrine Disease. Metabolic and endocrine disorders encompass a wide range of diseases. These diseases may be the primary reason for surgery or can exist in patients requiring surgery for other unrelated disorders. Preoperative evaluation of endocrine function consists of relevant medical history, glucose or protein in the urine, vital signs, history of fluctuations in body weight, survey of sexual function, and concomitant medications. The three metabolic and endocrine conditions that are most prevalent in patients undergoing surgery are diabetes mellitus, hypothyroidism, and obesity. The prevalence of all three conditions, either alone or in combination, in the general population has been steadily rising throughout the world for the past 20 to 30 years.^{12,32} The aging population and changes in the diagnostic criteria for diabetes mellitus are sure to continue this trend.^{12,33}

Patients with diabetes are at an increased risk for perioperative myocardial ischemia, stroke, renal dysfunction or failure, and increased mortality.³⁴ Increased wound infections and impairment of wound healing also are associated with the pre-existence of diabetes in patients undergoing surgery.³⁵

The stress response to surgery is associated with hyperglycemia in nondiabetic patients due to increased secretion of catabolic hormones and a combination of reduced insulin secretion and increased insulin resistance.^{36,37} Improved glycemic control in diabetic patients undergoing major surgery has been shown to improve perioperative morbidity and mortality; avoidance of hypoglycemia and hyperglycemic events is the standard of care in these patients.^{33, 38-40}

Anesthetic techniques in the diabetic patient can modulate the secretion of catabolic hormones.⁴¹ However, regional anesthesia may carry greater risks to the diabetic patient with autonomic neuropathy, and the hypotension associated with regional anesthesia may be deleterious to the diabetic patient with coexisting CAD.³³ There is no evidence that regional anesthesia or general anesthesia, either alone or in combination, offers any benefit to the diabetic surgical patient in terms of morbidity or mortality.³³

Hypothyroidism is a deficiency in the secretion of the thyroid hormones, thyroxine and 3,5',3-triiodothyronine, by the thyroid gland. More than 5 million Americans have this common medical condition, and as many as 10% of women may have some degree of thyroid hormone deficiency. Controlled clinical trials have not shown an increase in risk when patients with mild to moderate hypothyroidism undergo surgery.⁴² Nevertheless, close monitoring of these patients for adverse effects of anesthesia, including delayed gastric emptying, adrenal insufficiency, and hypovolemia, is warranted.⁴³

The prevalence of significant obesity continues to rise both in developed and developing countries and is associated with an increased incidence of a wide spectrum of medical and surgical pathologies⁴⁴ (Table 46-9). In the United States, one-third of people have a body weight more than 20% above their ideal weight.⁴⁵ Body mass index (BMI) is calculated by dividing the weight in kilograms by the square of the height in meters. In the United States, the prevalence of a BMI >25 kg/m² is 59.4% for men, 50.7% for women, and 54.9% for adults overall. Patients with a BMI >28 kg/m² have increased perioperative morbidity over the general population.

Anesthetic management of the obese patient is problematic, and tasks such as establishing IV access, applying monitoring equipment, managing the airway, and transporting the patient are more difficult. Ventilation may be a particular

Table 46-9

Disease conditions associated with obesity

CATEGORY	EXAMPLES
Cardiovascular disease	Sudden death, cardiomyopathy, hypertension, coronary artery disease, peripheral vascular disease
Respiratory disease	Restrictive lung disease, sleep apnea
Endocrine disease	Diabetes mellitus, hypothyroidism
GI disease	Hernia, gallstones
Malignancy	Breast, prostate, colorectal cancer
Musculoskeletal	Osteoarthritis, back pain

Source: Reproduced with permission from Adams JP, Murphy PG. Obesity in anaesthesia and intensive care. *Br J Anaesth.* 2000;85:91. By permission of Oxford University Press.

problem because of obstructive sleep apnea or because obesity itself imposes a restrictive ventilatory state with decreased expiratory reserve and vital capacity.¹² Induction of anesthesia is particularly challenging in the obese patient, as there is increased risk of pulmonary aspiration, and the increased mass of soft tissue about the head and neck makes establishing and maintaining a patent airway difficult.

The impact of obesity on the pharmacokinetics of anesthetic drugs is variable. For example, blood volume is often increased in obese patients, which can decrease predicted concentrations of drugs, but adipose tissue has low blood flow, which could elevate blood concentrations of these agents. It is prudent to calculate the first dose of anesthetic based on ideal body weight and to base subsequent dosages on the patient's responsiveness.^{12,46}

Central Nervous System Disease. Diseases of the CNS present unique situations for the anesthesiologist and require an understanding of the relationship between intracranial pressure (ICP), cerebral blood flow (CBF), and cerebral metabolic rate of O₂ consumption (CMRO₂). Preoperative assessment of ICP is difficult, as symptoms of headache, nausea, and vomiting are nonspecific, and signs of retinal changes do not occur acutely. A midline shift on computed tomography scanning or magnetic resonance imaging may indicate an expanding lesion in the brain.

Provision of anesthesia for intracranial procedures must balance hemodynamic factors such as fluid volume, mean arterial pressure, ICP, and CBF. For intracranial tumors, the mass effect of the tumor makes control of ICP and CBF critical. In intracranial aneurysm surgery, the goal of the anesthetic is to prevent sudden increases in systemic blood pressure that could rupture the aneurysm, especially during the stress of laryngoscopy and endotracheal intubation. The relationship between mean arterial pressure, ICP, and CBF is affected by pharmacologic agents. Inhalational agents in high concentrations (>0.6 MAC) cause dilation of the cerebral vasculature, decreasing cerebral vascular resistance. CBF is therefore increased in a dose-dependent fashion, despite decreases in CMRO₂.¹²

Propofol decreases CBF, ICP, and $CMRO_2$.⁴⁷ Propofol may also decrease systemic blood pressure, resulting in a decrease in cerebral perfusion pressure; however, propofol does not alter the autoregulation of CBF.⁴⁸ Etomidate is a potent cerebral vasoconstrictor that reduces CBF and ICP and should be used with caution in patients with epilepsy due to its excitatory effects seen on electroencephalograms.⁴⁹

Opioids decrease CBF and may also decrease ICP under certain conditions. However, Sperry and associates have reported increases in ICP with the administration of fentanyl in head trauma patients.⁵⁰ Additionally, opioids have a depressant effect on consciousness and ventilation that may increase ICP if accompanied by an increase in partial pressure of arterial CO_2 ; opioids should be used with caution in head trauma patients.

Regardless of the drugs or technique selected, maintenance of stable hemodynamics is optimal. Recovery from anesthesia should be smooth, avoiding pain, coughing, and straining, all of which can increase blood pressure and ICP and cause bleeding at the surgical site.

Fluid therapy can increase cerebral edema and ICP when administered in large quantities, resulting in hypervolemia. Euvolemia should be the goal in head trauma patients, whereas hypervolemia may be beneficial for patients with intracranial aneurysms to reduce vasospasm.

INTRAOPERATIVE MANAGEMENT

Induction of Anesthesia

During induction of anesthesia, the patient becomes unconscious and rapidly apneic, myocardial function is usually depressed, and vascular tone abruptly changes. The induction of general anesthesia is the most critical component of practicing anesthesia, as the majority of catastrophic anesthetic complications occur during this phase. There are several different techniques used for the induction of general anesthesia, each with significant advantages and disadvantages (Fig. 46-3). Each patient

must be carefully evaluated during the preoperative period to ensure that the most efficacious and safe technique is used.

IV induction, used primarily in adults, is smooth and is associated with a high level of patient satisfaction. The addition of opioids will blunt the response of laryngoscopy and intubation to avoid hypertension and tachycardia.

In a patient with a full stomach, the standard induction technique may result in vomiting and pulmonary aspiration of stomach contents. The goal of *rapid sequence induction* is to achieve secure protection of the airway with a cuffed endotracheal tube while preventing vomiting and aspiration.

Rapid sequence induction is performed as follows:

- Proceed only after evaluation of the airway predicts an uncomplicated intubation.
- Preoxygenate the patient.
- Rapidly introduce an IV induction agent (e.g., propofol).
- An assistant to the anesthesiologist presses firmly down on the cricoid cartilage to block any gastric contents from being regurgitated into the trachea, a muscle relaxant is injected, and the trachea is quickly intubated.
- The assistant is instructed not to release pressure on the cricoid cartilage until the cuff of the endotracheal tube is inflated and the position of the tube is confirmed.

Patients undergoing *inhalation induction* progress through three stages: (a) awake, (b) excitement, and (c) surgical level of anesthesia. Adult patients are not good candidates for this type of induction, as the smell of the inhalation agent is unpleasant and the excitement stage can last for several minutes, which may cause hypertension, tachycardia, laryngospasm, vomiting, and aspiration. Children, however, progress through stage 2 quickly and are highly motivated for inhalation induction as an alternative to the IV route. The benefit of postinduction IV cannulation is the avoidance of many presurgical anxieties, and inhalation induction is the most common technique for pediatric surgery.

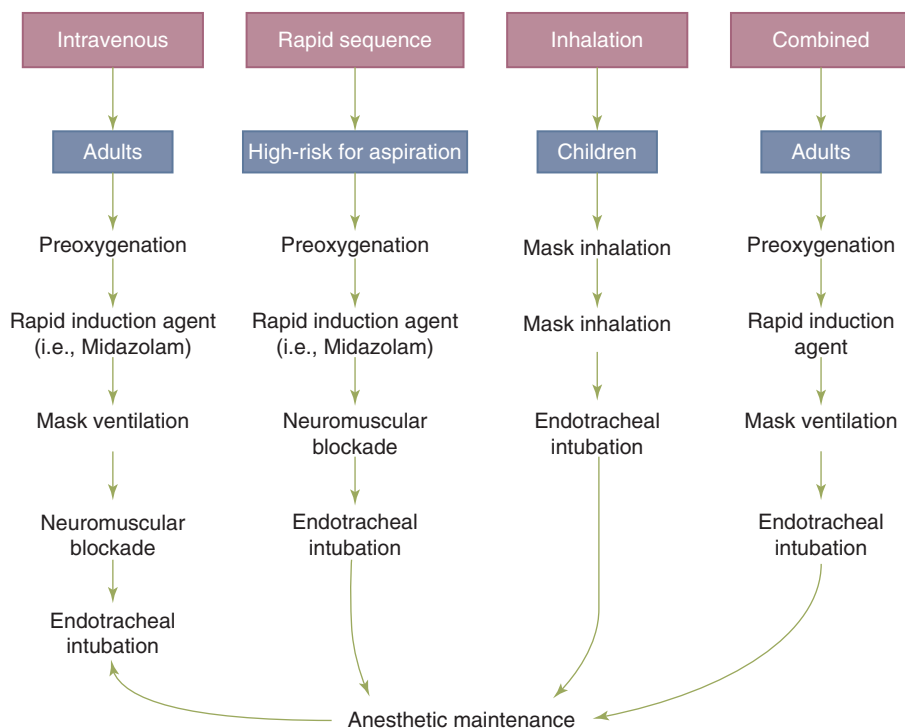


Figure 46-3. Techniques for the induction of general anesthesia.

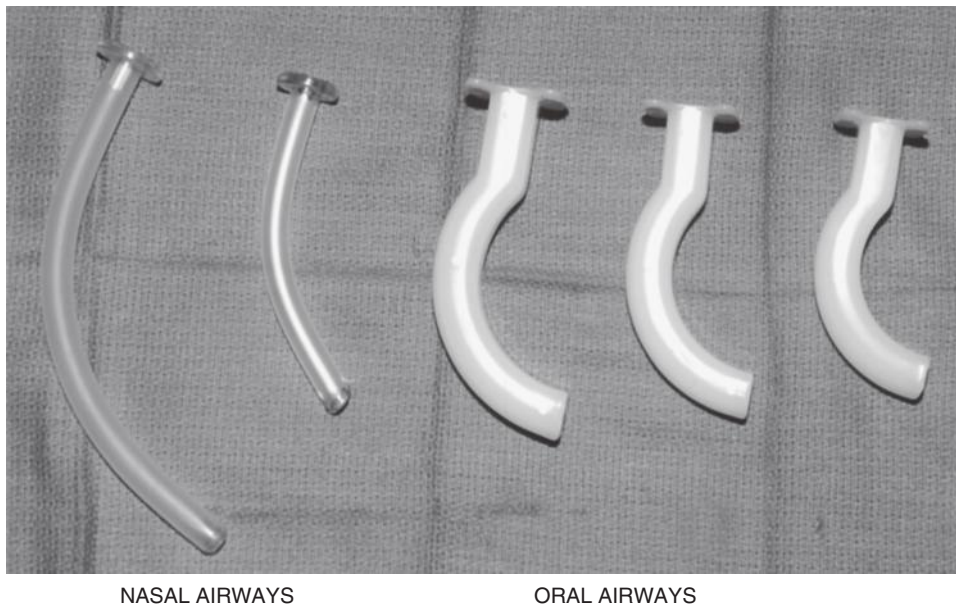


Figure 46-4. From left to right: two nasal airways and three oral airways.

Management of the Airway

After induction of anesthesia, the airway may be managed in several ways, including by face mask, with a laryngeal mask airway (LMA), or, most definitively, by endotracheal intubation with a cuffed endotracheal tube. Nasal and oral airways can help establish a patent airway in a patient being ventilated with a mask by creating an air passage behind the tongue (Fig. 46-4).

3▶ The LMA is a cuffed oral airway that sits in the oropharynx. It is passed blindly, and the cuff is inflated to push the soft tissues away from the laryngeal inlet. Because it does not pass through the vocal cords, it does not fully protect against aspiration. It should not be used in patients with a full stomach (Fig. 46-5; lower left). The accurate placement of an endotracheal tube requires skill and proper equipment and conditions. Usually, the patient is unconscious and immobile (including paralysis of the muscles of respiration). Intubation is typically performed under direct visualization by looking through the mouth with a laryngoscope directly at the vocal cords (direct laryngoscopy) and watching the endotracheal tube pass through the cords into the trachea. To obtain a direct line of sight, the patient is placed in the sniffing position. The neck is flexed at the lower cervical spine and extended at the atlanto-occipital joint. This flexion and extension are amplified during laryngoscopy. Laryngoscope handles contain batteries and can be fitted with curved (Macintosh) or straight (Miller) blades (see Fig. 46-5, top row).

Some patients have physical characteristics or a history suggesting difficulty in placing an endotracheal tube. A short neck, limited neck mobility, small interincisor distance, short thyromental distance, and Mallampati class IV may all represent a challenge to endotracheal intubation. Several devices have been developed to assist in management of the difficult airway. The Bullard rigid fiberoptic laryngoscope is a self-contained device that can be passed through a mouth with a narrow opening (Fig. 46-6). The head and neck also can be kept in a neutral position, as a direct line of sight needed with a standard laryngoscope is not necessary. Another new intubating device is the Glidescope, which allows visualization of the vocal cords on a screen (Fig. 46-7)

The intubating laryngeal mask airway (ILMA) is an advanced form of LMA designed to maintain a patent airway as

well as facilitate tracheal intubation with an endotracheal tube. The ILMA can be placed in anticipated or unexpectedly difficult airways as an airway rescue device and as a guide for intubating the trachea. An endotracheal tube can be passed blindly through the ILMA into the larynx, or the ILMA can be used as a conduit for a flexible fiberoptic scope (Fig. 46-8).

The flexible fiberoptic intubation scope is the gold standard for difficult intubation. It is indicated in difficult or compromised airways where neck extension is not desirable or in cases with risk of dental damage. The scope is constructed of fiberoptic bundles and cables encased in a sheath. The cables

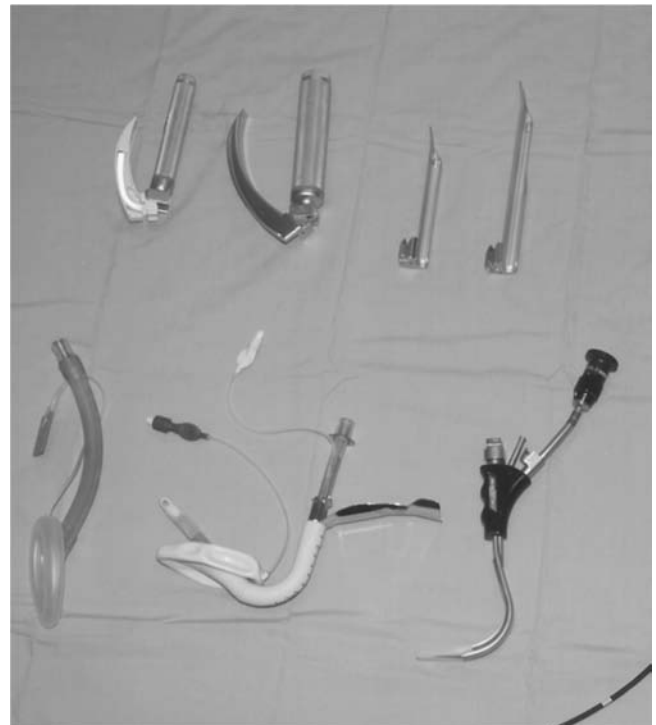

Figure 46-5. (Top) Laryngoscopes with curved straight blades. (Bottom) Laryngomask airway, intubating laryngomask airway, and Bullard rigid fiberoptic laryngoscope.

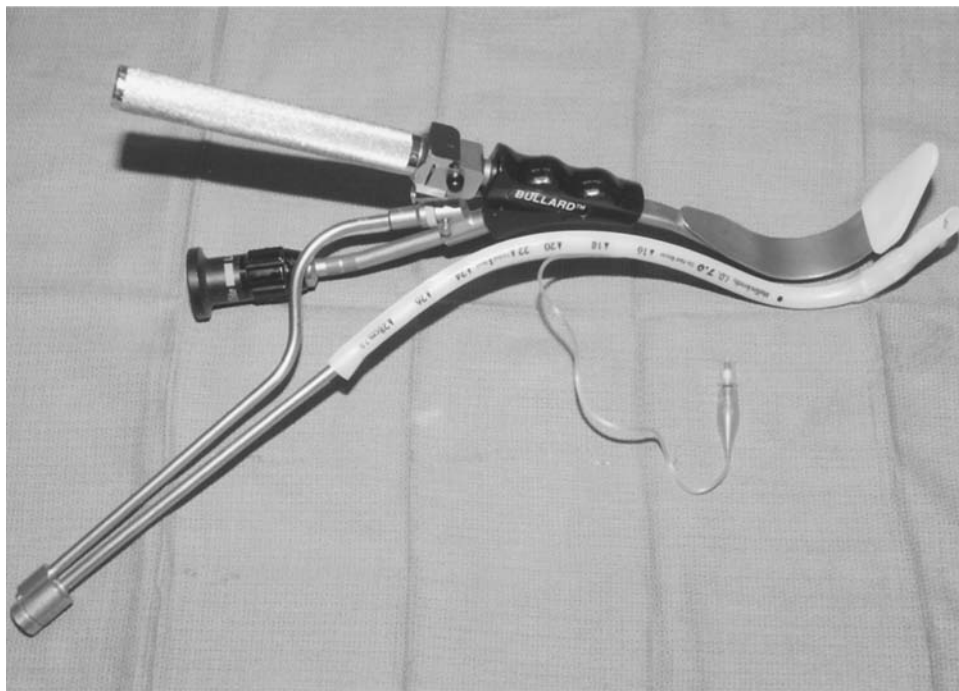


Figure 46-6. The Bullard rigid fiberoptic laryngoscope with endotracheal tube.

permit manipulation of the tip of the scope by adjustments made at the operating end of the device. There is a port for suction and/or insufflation of O_2 . The scope gives excellent visualization of the airway with minimal hemodynamic stress when used properly. It can be used nasally or orally in an awake, spontaneously ventilating patient whose airway has been treated with topical anesthetic. It requires skill for proper use, is expensive, and requires careful maintenance (Fig. 46-9).

The ASA has developed algorithms for management of the difficult airway (Figs. 46-10 and 46-11).⁵¹

Fluid Therapy

Numerous preparations of IV fluid are available for the replacement of perioperative fluid losses in patients undergoing surgery. Different fluid preparations may influence clinical parameters (e.g., platelet function) and may also affect postoperative outcome.

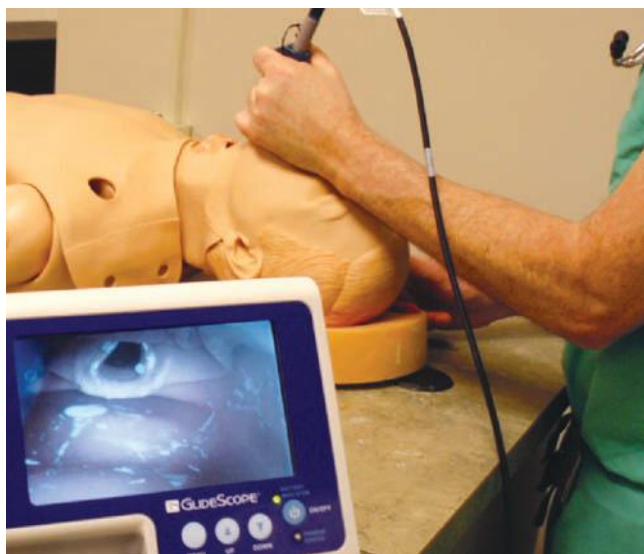

Figure 46-7. Video laryngoscope showing view of vocal cords.

Traditionally, IV fluids have been classified according to whether they are crystalloid or colloid in nature. Crystalloid fluids comprise electrolyte solutions with or without a bicarbonate precursor such as acetate or lactate. The colloids contain a complex sugar or protein suspended in an electrolyte solution. A further distinction between IV fluid types may be based on the nature of the solution. Normal saline-based (0.9% sodium chloride) preparations (crystalloid or colloid) contain no electrolytes other than sodium and chloride. In contrast, balanced salt-based fluids such as lactated Ringer's solution contain other electrolytes, with or without a bicarbonate precursor.

Several types of colloids are available, but three are most commonly used—hydroxyethyl starch (HES), gelatin, and albumin. The HES preparations differ from one another according to their concentration, molecular weight, and extent of hydroxy-ethylation or substitution, with resultant varying physicochemical properties. HES solutions most often are described according to their weight-averaged mean molecular weight in kilodaltons (kDa): high molecular weight (450 kDa), middle molecular weight (200 kDa, 270 kDa), and low molecular weight (130 kDa, 70 kDa). HES 450 kDa solutions are available in a normal saline solution (HES 450/NS) and in a lactated, balanced salt solution (HES 450/BS). Although all of these colloids are used in Europe, gelatins are not available in the United States, and the only HES preparations approved by the U.S. Food and Drug Administration are the 6% high molecular weight (450 kDa) formulations.

The administration of a large volume of any type of IV fluid will cause dilution of platelets and coagulation factors and may lead to coagulopathy (i.e., dilutional coagulopathy). In addition, fluids can have a direct impact on blood clotting through effects on circulating components of the coagulation cascade or by altering platelet function.

Recent evidence suggests that the nature of the solution itself may influence coagulation and bleeding. HES 450/NS may be associated with more bleeding than other fluids. HES 450 in a balanced salt solution appears to be equivalent to 5% albumin

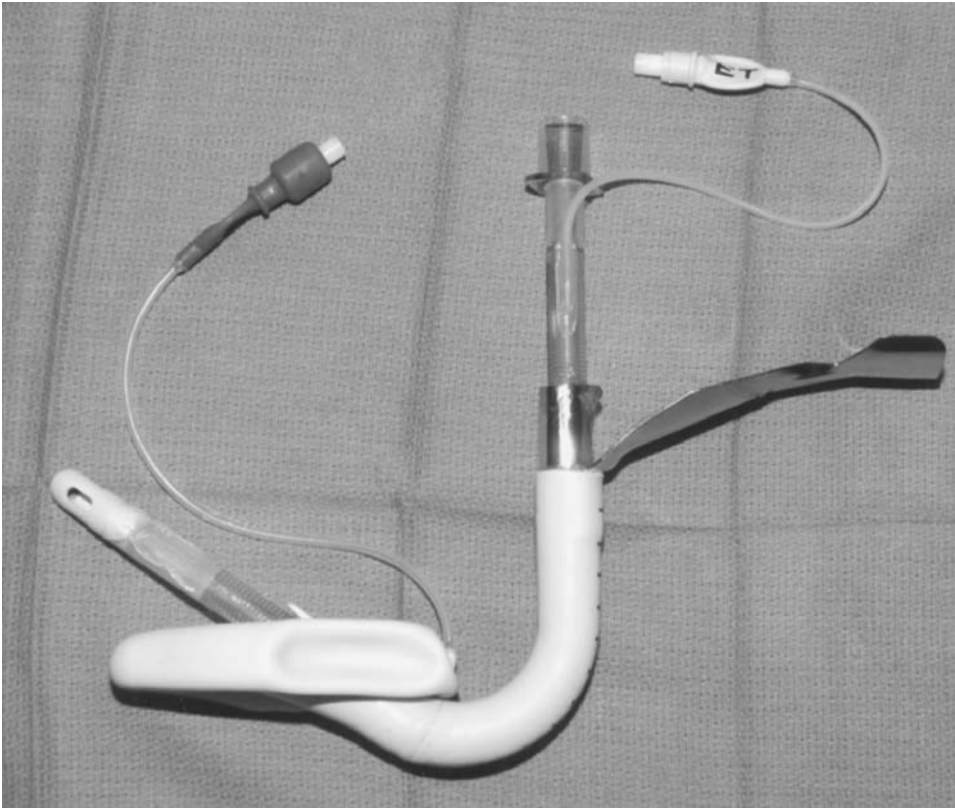


Figure 46-8. Intubating laryngeal mask airway with endotracheal tube.

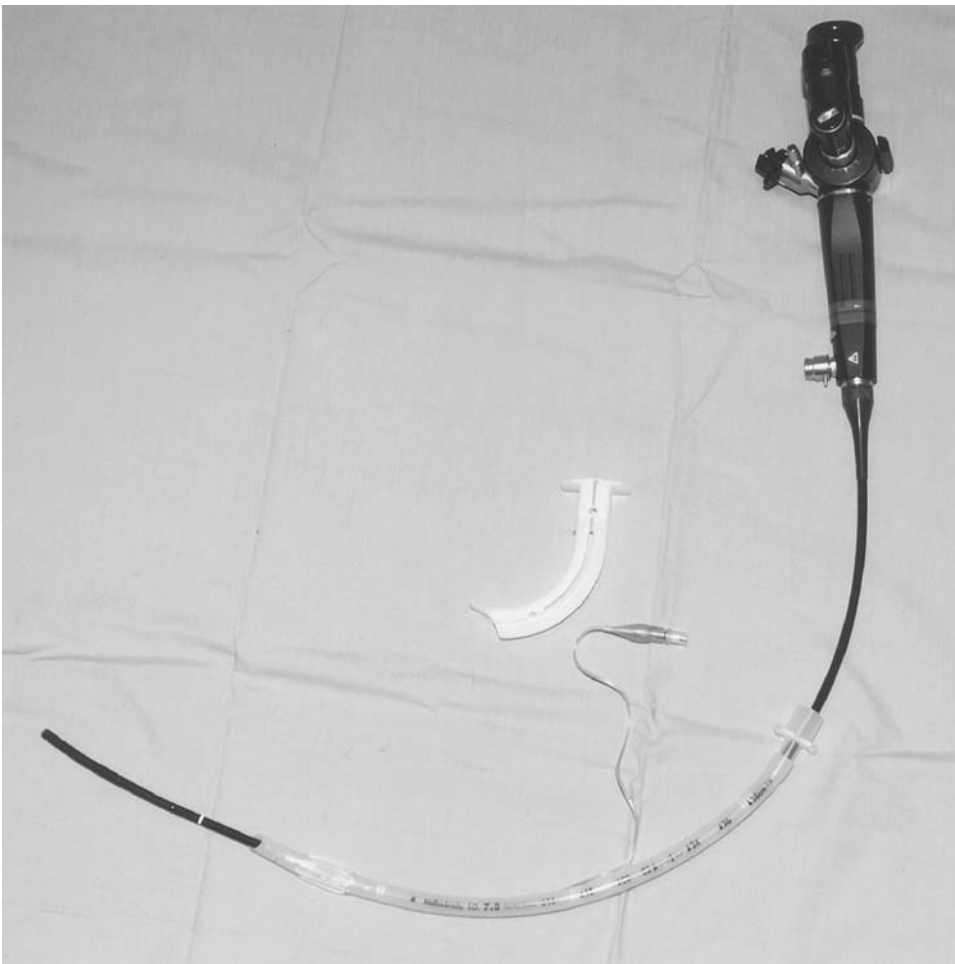

Figure 46-9. Flexible fiberoptic intubation scope with endotracheal tube.

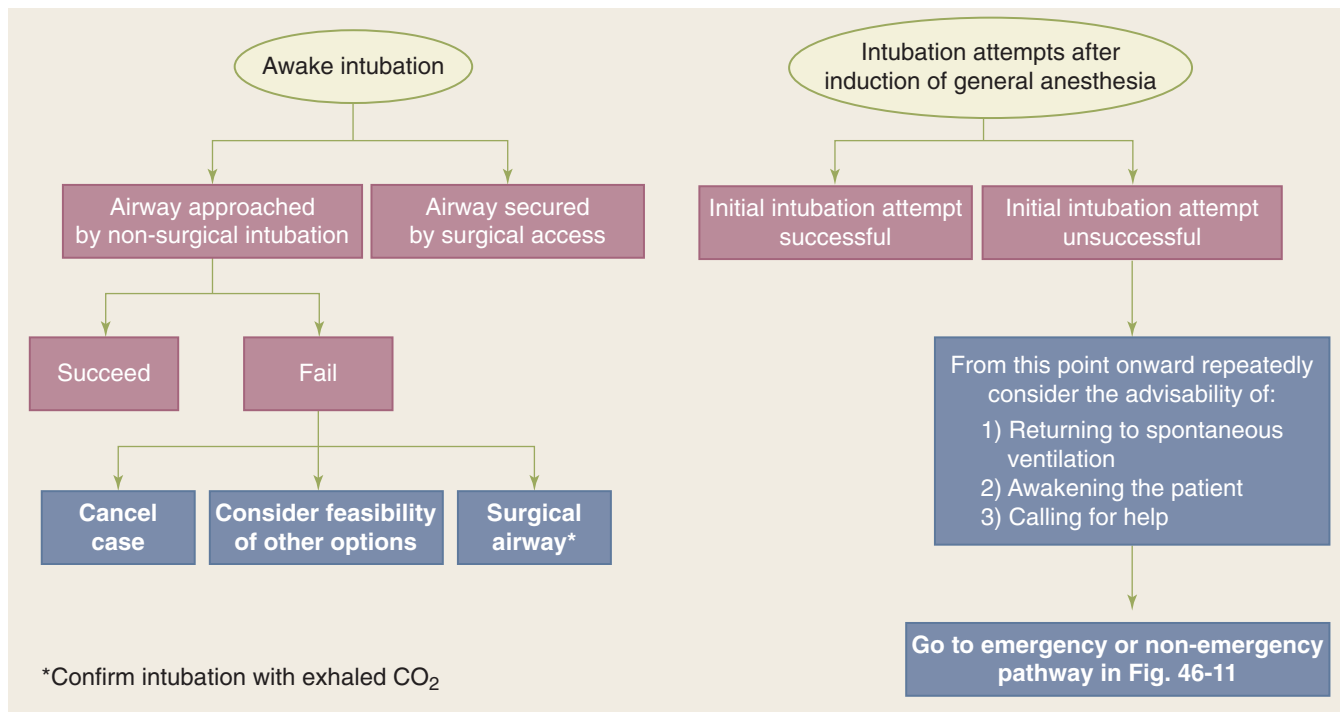


Figure 46-10. American Society of Anesthesiologists airway management algorithm, Part I. CO₂ = carbon dioxide. (Reproduced with permission from *Practice guidelines for management of the difficult airway: An updated report by the American Society of Anesthesiologists Task Force on Management of the Difficult Airway*. *Anesthesiology*. 2003;98:1269.)

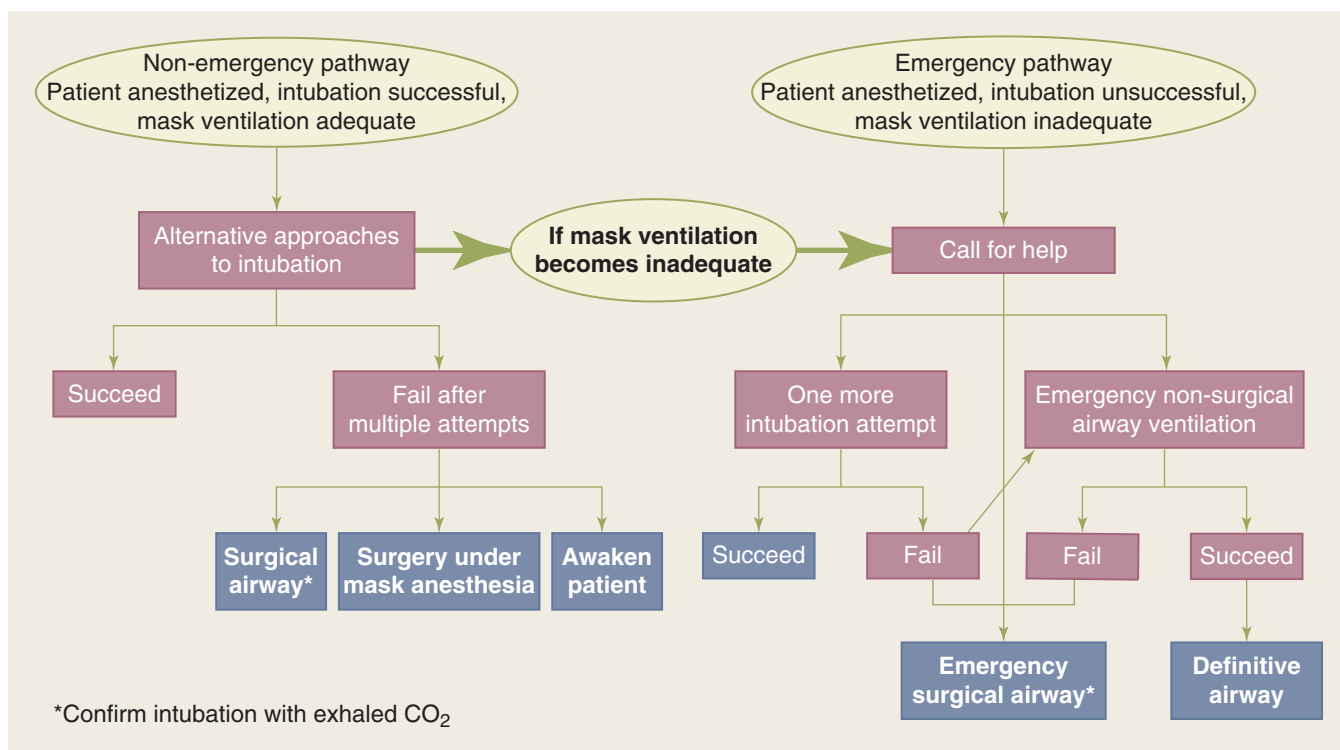


Figure 46-11. American Society of Anesthesiologists airway management algorithm, Part II. CO₂ = carbon dioxide. (Reproduced with permission from *Practice guidelines for management of the difficult airway: An updated report by the American Society of Anesthesiologists Task Force on Management of the Difficult Airway*. *Anesthesiology*. 2003;98:1269.)

with respect to bleeding outcomes.⁵²⁻⁵⁴ Waters and colleagues reported that patients undergoing abdominal aortic aneurysm repair who received lactated Ringer's solution received smaller volumes of platelets and had less blood product exposure than those treated with normal saline.⁵⁵

It is possible that certain fluids may induce hypercoagulability that may be reflected not only by less bleeding, but also by an increased incidence of postoperative thrombotic complications (e.g., deep vein thrombosis and cerebrovascular accident). There are laboratory data⁵⁶ to suggest that IV fluid administration may induce a hypercoagulable state, but the clinical significance of this remains unclear. The type of fluid administered intraoperatively to a patient can have a significant impact on renal function. The administration of HES/NS or normal saline to critically ill patients or elderly patients undergoing major surgery was associated with the development of renal dysfunction.⁵⁷⁻⁵⁹

The administration of adequate IV fluids during the perioperative period results in a lower incidence of nausea, vomiting, and antiemetic use after minor or day case surgery.⁶⁰ In major noncardiac surgical patients, the administration of HES 450 (in a balanced salt or normal saline solution, or a combination of balanced crystalloid and colloid) has been associated with less postoperative nausea, vomiting, and antiemetic use and earlier return of postoperative bowel function, as reflected by first consumption of solid food, than the administration of 5% albumin, lactated Ringer's solution, or normal saline alone.⁶¹ Studies of patients undergoing ambulatory surgery have shown that perioperative IV fluid administration decreases the incidence of dizziness, drowsiness, thirst, and headache.⁶² In a randomized crossover study of healthy volunteers, subjective deterioration in mental status (lassitude and difficulty in abstract thinking) was reported only by individuals who received 0.9% sodium chloride and not by those who received lactated Ringer's solution.⁶³ The possible effect of different IV fluid preparations on CNS function has not yet been fully explored.

The relative impact of crystalloids and/or colloids on pulmonary function has been the subject of long-standing debate. No difference in postoperative pulmonary function was seen in cardiac surgery patients, orthopedic patients, or urologic surgery patients treated intraoperatively with different colloids.^{57,64,65} In a number of studies in major surgical patients that compared crystalloid (lactated Ringer's solution) with colloid (HES 130/NS, HES 450/NS, 5% albumin/BS),⁶⁶⁻⁶⁸ no difference was seen in the incidence or duration of mechanical ventilation or other indices of respiratory function. These findings suggest that the intraoperative administration of crystalloids does not have a detrimental effect on pulmonary function compared with the administration of colloids.

Transfusion of Red Blood Cells

ABO Blood Groups. There are four different ABO groups, which are determined by whether or not an individual's red blood cells (RBCs) carry the A antigen, the B antigen, both A and B antigens, or neither. From early in childhood, normal healthy individuals make antibodies against A or B antigens that are not expressed on their own cells. People who are group A have anti-B antibodies in their plasma, people who are group B have anti-A antibodies, people who are group O have anti-A and anti-B antibodies, and people who are group AB have neither of these antibodies. These naturally occurring antibodies are mainly immunoglobulin M that attack and rapidly destroy

RBCs. Anti-A antibodies attack RBCs of group A (or AB), and anti-B antibodies attack RBCs of group B (or AB).

ABO-Incompatible Red Cell Transfusion. If RBCs of the wrong group are transfused, in particular if group A RBCs are infused into a recipient who is group O, the recipient's anti-A antibodies bind to the transfused cells. This activates the complement pathways, which damages the red cell membranes and lyses the RBCs. Hemoglobin released from the damaged RBCs is toxic to the kidneys, while the fragments of ruptured cell membranes activate the blood-clotting pathways. The patient suffers acute renal failure and disseminated intravascular coagulation.

Basics of Red Blood Cell Compatibility. Ensuring that the right blood group is transfused is imperative. It is essential to ensure that no ABO-incompatible RBC transfusion is ever given. This avoidable accident is likely to kill or harm the patient. Procedures in which compatibility is determined by establishing both transfusion recipient and donor blood ABO types via crossmatch analysis have evolved over years of clinical and laboratory experience to minimize the risk of this disastrous error. These procedures will continue to evolve as improved computerized systems are introduced to help staff avoid errors in blood administration.

Rhesus D Antigen and Antibody In a white population, about 15% will lack the Rhesus D (Rh D) antigen and are termed Rh D negative. Antibodies to Rh D antigen occur only in individuals who are Rh D negative and as a consequence of transfusion or pregnancy. Even small amounts of Rh D–positive cells entering the circulation of an Rh D–negative person can stimulate the production of antibodies to Rh D, usually immunoglobulin G.

Physiologic Response and Tolerance of Anemia. O₂ is carried in blood in two distinct forms: bound to hemoglobin (Hb) within the RBC and dissolved in the plasma. The actual oxygen content of arterial blood (Ca_{O₂}) is determined by the concentration of Hb in the blood, the arterial oxygen saturation of Hb (Sa_{O₂}), the O₂-binding capacity of Hb, the Pa_{O₂}, and the O₂ solubility of plasma. These variables are interrelated and can be expressed in the following equation:

$$\text{Ca}_{\text{O}_2} = (\text{Hb} \times \text{Sa}_{\text{O}_2} \times \text{Hb O}_2 \text{ binding capacity}) + (\text{Pa}_{\text{O}_2} \times \text{plasma O}_2 \text{ solubility}).$$

Adult Hb consists of four protein chains, each carrying one heme group. One mole of Hb is able to bind to a maximum of 4 moles of O₂. O₂-binding capacity per gram of Hb is 1.39 g/mL. The relationship between Pa_{O₂} and Hb O₂ saturation is shown in Fig. 46-12. The steep part of this curve (partial pressure of oxygen [Po₂] 20–40 mmHg) facilitates O₂ release from Hb. Tissue Po₂ values of different organs are also shown in Fig. 46-12 and lie on this steep part of the curve, facilitating O₂ release from Hb.

Hemodilution and Critical Hematocrit. The intentional dilution of blood volume often is referred to as acute normovolemic hemodilution (ANH) anemia. ANH is a technique in which whole blood is removed from a patient, while the circulating blood volume is maintained with acellular fluid. Blood is collected via central lines with simultaneous infusion of crystalloid or colloid solutions. Collected blood is reinfused after major blood loss has ceased, or sooner, if indicated. Blood units are reinfused in the reverse order of collection. Under conditions of ANH, the increased plasma compartment becomes an important source of O₂, which is delivered to the tissues.

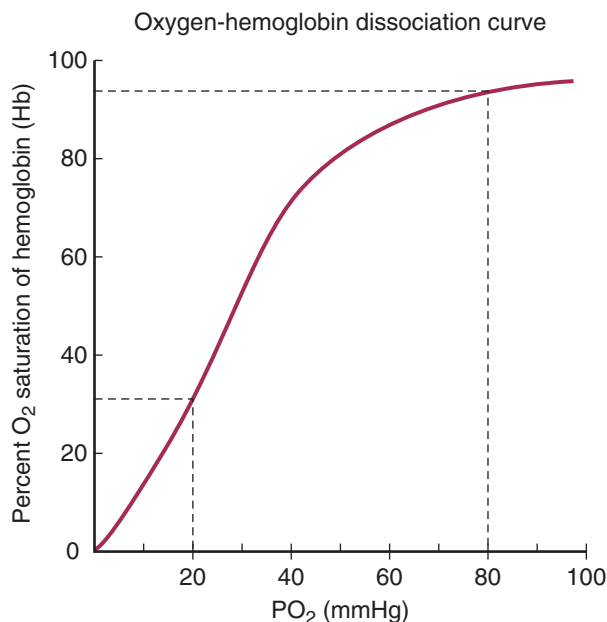


Figure 46-12. Oxygen hemoglobin dissociation curve. O₂ = oxygen; PO₂ = partial pressure of oxygen.

Oxygenation is maintained by increased cardiac output and increased O₂ extraction by the tissues, and when these compensatory mechanisms fail to match the O₂ needs of the tissues, the “critical hematocrit” is said to have been reached. The critical hematocrit has been a source of debate for many years. A theoretical model was developed that describes the relation between hematocrit, myocardial O₂ demand, and the required coronary blood flow during progressive hemodilution.⁶⁹ Using this model, the determinants of critical hematocrit and the limits of ANH can be calculated based on the limits of coronary reserve. Because the critical hematocrit varies with O₂ consumption and degree of CAD, a fixed critical hematocrit as a transfusion trigger is not appropriate in most patients. Rather, the indication for blood transfusions must individually take into account the specific circumstances of the patient, such as expected blood loss and required O₂ transport capacity reserves, hemodynamic stability, CAD, and systemic O₂ consumption.

RECOVERY FROM ANESTHESIA

Reversal of Neuromuscular Blockade

The elimination of neuromuscular blocking agents from the body and subsequent resumption of neuromuscular transmission takes a considerable amount of time, even with drugs such as vecuronium that have relatively short half-lives. Additionally, it is time consuming to wait for complete spontaneous recovery at the end of a surgical procedure. Therefore, it has become routine to antagonize the neuromuscular block pharmacologically with the use of reversal agents. Reversal agents raise the concentration of the neurotransmitter acetylcholine to a higher level than that of the neuromuscular blocking agent. This is accomplished by the use of anticholinesterase agents, which reduce the breakdown of acetylcholine. The most commonly used agents are neostigmine, pyridostigmine, and edrophonium.

The common side effects of these three anticholinesterase agents are bradycardia, bronchial and intestinal smooth muscle contractions, and excessive secretions from salivary and bronchial glands. These effects are primarily mediated by effects on muscarinic receptors, which are effectively blocked by the concomitant use of antimuscarinic drugs such as atropine or glycopyrrolate. To ensure adequate ventilation postoperatively, it is important that the neuromuscular blocking agents are fully reversed, as assessed by monitoring twitch strength with a nerve stimulator and clinically correlating this with signs such as grip strength or 5-second head lift.

The Postanesthesia Care Unit

It is of primary importance that all patients awakening from anesthesia are followed in a recovery room, as approximately 10% of all anesthetic accidents occur in the recovery period. As more serious surgeries are performed on older and sicker patients, the number of patients requiring postoperative ventilation and medications to support their circulation increases with age. The new trend for postoperative pain control with continuous epidural administration of local anesthetics and narcotics demands close observation, because respiratory depression can occur. In most hospitals, the number of intensive care beds is too small to accommodate the increasing number of these patients. What originally began as the recovery room now must function as an intensive care unit setting for short stays. The name “recovery room” has been changed to postanesthetic care unit (PACU). A variety of physiologic disorders that can affect different organ systems need to be diagnosed and treated in the PACU during emergence from anesthesia and surgery. Postoperative nausea and vomiting (PONV), airway support, and hypotension requiring pharmacologic support have been observed to be the most frequent complications in the PACU.⁷⁰ Abnormal bleeding, hypertension, dysrhythmia, myocardial infarction, and altered mental status are not uncommon.⁷⁰

Postoperative Nausea and Vomiting

PONV typically occurs in 20% to 30% of surgical cases,⁷¹ with considerable variation in frequency reported between studies (range, 8%–92%).⁷² PONV is generally considered a transient, unpleasant event carrying little long-term morbidity; however, aspiration of emesis, gastric bleeding, and wound hematomas may occur with protracted or vigorous retching or vomiting. Troublesome PONV can prolong recovery room stay and hospitalization and is one of the most common causes of hospital admission following ambulatory surgery. Published evidence suggests that prophylactic administration of antiemetics is not cost-effective in the surgical setting.⁷³ Recent consensus guidelines using data from systematic reviews, randomized trials and studies, and logistic regression models have been published (Fig. 46-13).⁷³

Agents usually administered for PONV are the serotonin receptor antagonists (e.g., ondansetron, dolasetron, granisetron, and tropisetron). The safety and efficacy of the compounds, when given at the end of surgery, are virtually identical.^{73,74} Metoclopramide (not a true antiemetic), when used in the standard dose of 10 mg, is ineffective for PONV.⁷⁵ Although some studies have shown higher doses (20 mg) to have some effect on PONV, most evidence suggests that the serotonin receptor antagonists are the most efficacious choice.

Pain: The Fifth Vital Sign

Analgesic research methodology has been enhanced since the 1960s through the use of graduated and visual analog scales,

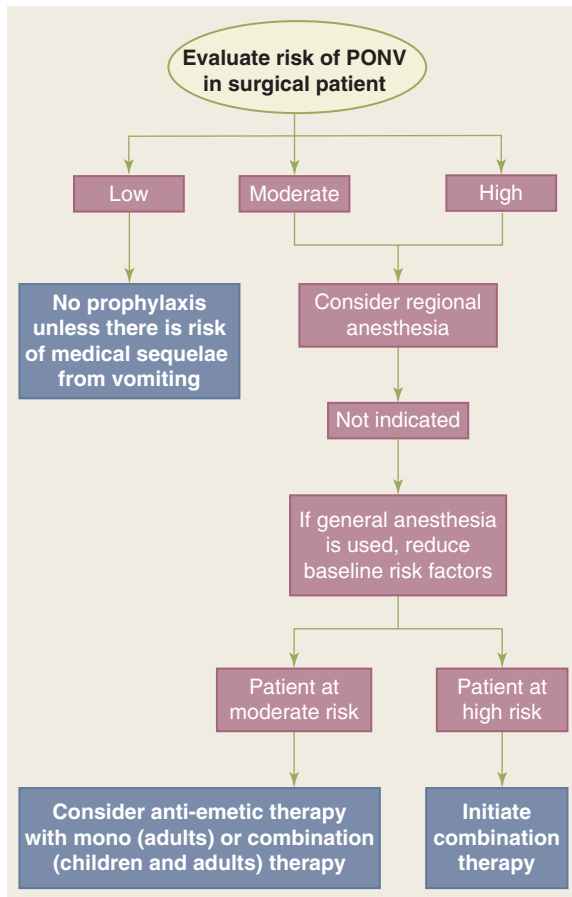


Figure 46-13. Algorithm for the management of postoperative nausea and vomiting (PONV). (Reproduced with permission from Gan TJ, Meyer T, Apfel CC, et al: *Consensus guidelines for managing postoperative nausea and vomiting*. *Anesth Analg*. 2003;97:62.)

tools that permit the standardization of pain scores. One frequently used graduated scale is a four-point measure of pain intensity (0 = no pain, 1 = mild pain, 2 = moderate pain, and 3 = severe pain) and a five-point measure of relief (0 = no relief, 1 = a little relief, 2 = some relief, 3 = a lot of relief, and 4 = complete relief).

Acute postoperative pain and its treatment (or prophylaxis) are significant challenges for the healthcare professional. Despite the recent development of new nonnarcotic analgesics and a better understanding of the side effects associated with pain medication of all types, acute postoperative pain remains a significant concern for patients and represents an extremely negative experience for patients undergoing surgery. Many patients experience pain in the postoperative period despite the use of potent techniques such as patient-controlled analgesia, epidural analgesia, and regional anesthesia. The culture of acceptance of postoperative pain is changing. The American Pain Society has advocated the assessment of pain as the fifth vital sign, along with temperature, pulse, blood pressure, and respiratory rate. The four vital signs provide a quick snapshot of a patient's general condition, but pain management advocates claim the picture is not complete without including pain as the fifth vital sign.

This approach may improve the efficacy of pain treatment. Many departments of anesthesiology support an active pain

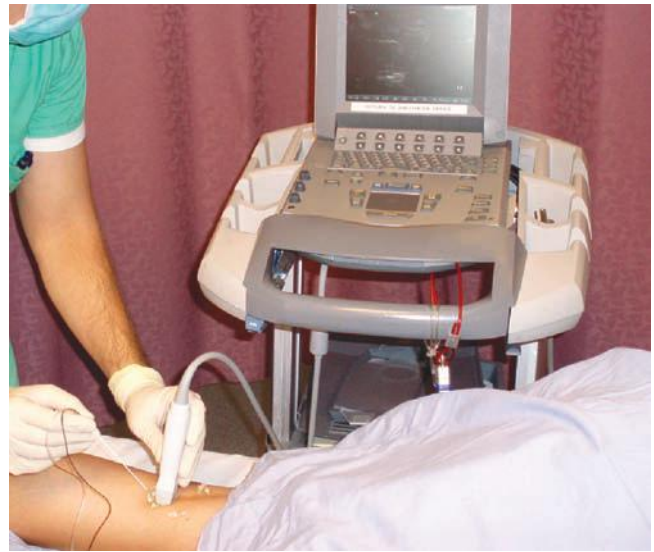

Figure 46-14. Use of ultrasound to identify the popliteal nerve for analgesia of the ankle.

service and provide consultation for postoperative pain relief, including the administration of nerve blocks.

MULTIMODAL ANALGESIA

Opioids, long the staple of postoperative pain management, reduce pain by acting on the μ -receptor. Analgesia is accompanied by unwanted side effects also promulgated by the μ -receptor (e.g., sedation, nausea and vomiting, constipation, respiratory depression). Reducing opioid use and those side effects by the addition of nonopioid analgesics is called multimodal analgesia.⁷⁶ Aniline derivatives (IV acetaminophen),⁷⁷ NSAIDs like celecoxib⁷⁸ and ketorolac,⁷⁹ steroids (dexamethasone),⁸⁰ and anticonvulsants (gabapentin and pregabalin)^{81,82} have all been used as opioid-sparing methods to attenuate postoperative pain. The best mixture of drugs is yet to be found; continued work is necessary to find the idea combination.⁸³

Regional analgesia, (i.e., nerve blocks) is an effective method for reducing postoperative pain while minimizing opioid consumption. Nerve blocks can be of the upper or lower extremities, truncal, epidural, or paravertebral (Fig. 46-14).

THE TRANSVERSUS ABDOMINIS PLANE BLOCK

The transversus abdominal plane (TAP) block is truncal regional analgesia that results in analgesia to the anterior abdominal wall and has rapidly gained popularity. Pain secondary to any transgression of the abdominal wall can be attenuated by a TAP block, including laparoscopic procedures⁸⁴; vertical or Pfannenstiel incisions; inguinal,⁸⁵ incisional, or umbilical hernia repair; hysterectomy; cholecystectomy; and appendectomy (Figs. 46-15–46-18).⁸⁶⁻⁸⁸

Somatic nerves supplying the abdominal wall travel in the plane between the internal oblique muscle and the transversus abdominis muscle (Fig. 46-19). Injection of local anesthetic into this plane under ultrasound guidance results in pain relief for 8 to 12 hours (Figs. 46-20–46-22).

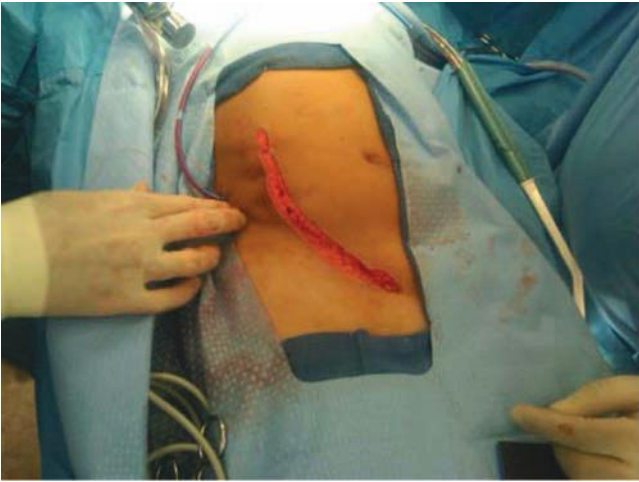

Figure 46-15. Kidney transplant recipient incisions.

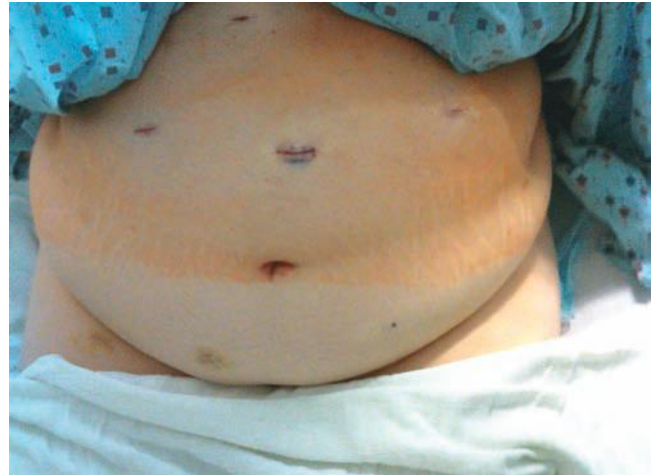

Figure 46-17. Laparoscopy incisions.

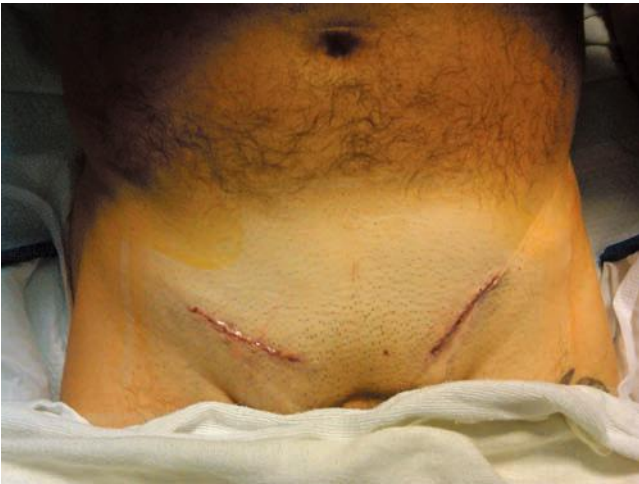

Figure 46-16. Inguinal hernia incisions.

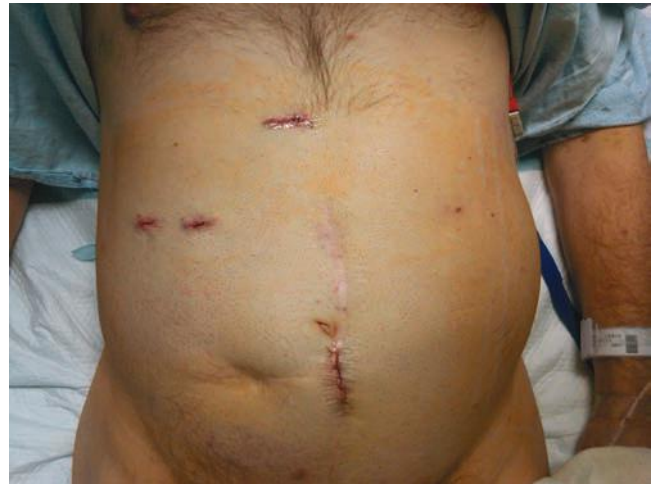

Figure 46-18. Pain from these incisions is reduced by transversus abdominal plane block.

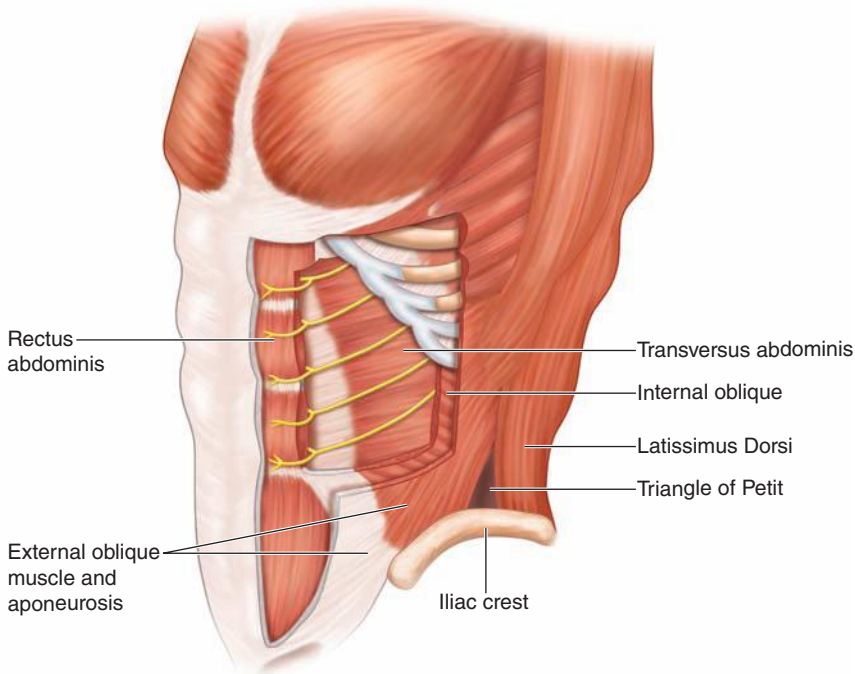


Figure 46-19. Sensory nerves travel to the anterior abdominal wall in the plane between the internal oblique and transversus abdominis muscles. (Reproduced with permission from *Ultrasound for Regional Anesthesia* website, www.usra.ca.)

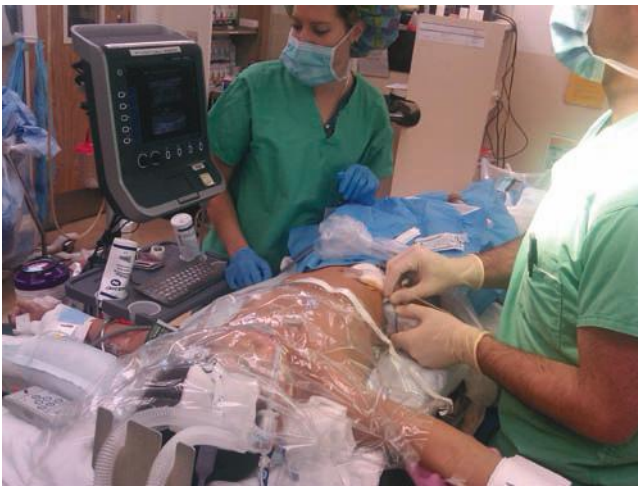

Figure 46-20. The use of ultrasound to perform a transversus abdominis plane block.

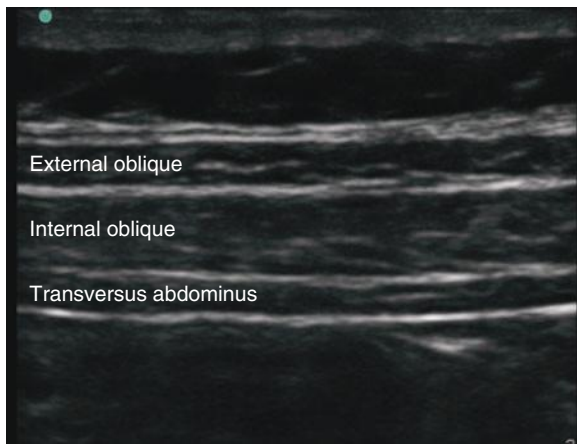


Figure 46-21. Ultrasound view of external oblique, internal oblique, and transversus abdominis muscles.

MALIGNANT HYPERTHERMIA

Malignant hyperthermia (MH) is a hereditary, life-threatening, hypermetabolic acute disorder, developing during or after receiving general anesthesia.⁸⁹ The clinical incidence of MH is about 1:12,000 in children and 1:40,000 in adults. A genetic predisposition and one or more triggering agents are necessary to evoke MH. Triggering agents include all volatile anesthetics (e.g., halothane, enflurane, isoflurane, sevoflurane, and desflurane) and the depolarizing muscle relaxant succinylcholine. Volatile anesthetics and/or succinylcholine cause a rise in the myoplasmic calcium concentration in susceptible patients, resulting in persistent muscle contraction.

MH is an autosomal dominant disorder associated with several gene loci, predominantly the ryanodine receptor gene *RYR1*. MH can be diagnosed with the caffeine-contraction halothane test (which requires muscle biopsy). Genetic testing is helpful after the fact; there is no simple reliable blood screening test yet available.

The classic MH crisis entails a hypermetabolic state, tachycardia, and the elevation of end-tidal CO₂ in the face of constant minute ventilation. Respiratory and metabolic acidosis and muscle rigidity follow, as well as rhabdomyolysis,

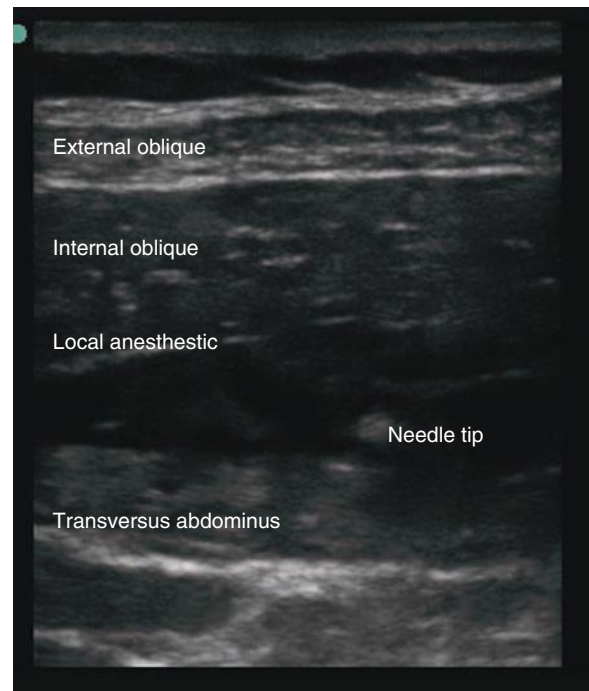


Figure 46-22. Ultrasound image of local anesthetic above the transversus abdominis.

arrhythmias, hyperkalemia, and sudden cardiac arrest. A rise in temperature is often a late sign of MH. Treatment must be aggressive and begin as soon as a case of MH is suspected:

- Call for help.
- Stop all volatile anesthetics and give 100% O₂.
- Hyperventilate the patient up to three times the calculated minute volume.
- Give bicarbonate to treat acidosis if dantrolene is ineffective.
- Treat hyperkalemia with insulin, glucose, and calcium.
- Avoid calcium channel blockers
- Begin infusion of dantrolene sodium, 2.5 mg/kg IV. Repeat as necessary, titrating to clinical signs of MH. Repeat dantrolene at 1 mg/kg every 6 to 8 hours at least twice, and monitor the patient in an intensive care unit setting for 24 hours or more for possible recrudescence.
- Call the MH hotline to report the case and get advice: 1-888-274-7899.

FUTURE DIRECTION OF ANESTHESIA

The general mantra of “gene therapy is the future of medicine” must be more specifically related to how those genes create, shape, and regulate proteins. The study of how proteins manifest their activity and/or concentration is called proteomics (from proteome—a fusion of “protein” and “genome”).

As the technology advances to biologically identify individual proteins, studies of individual levels of proteomes will allow the study of disease processes on the molecular level, directly aiding diagnosis and therapeutics.⁹⁰

Specifically to the field of anesthesiology, the technology of proteomics will be used to elucidate the actual mechanism of action of our anesthetic drugs and how these drugs have differing effects on different individuals. There will be a day when a

buccal swab in the preoperative clinic will become routine, with the results telling us which opioids carry the fewest side effects for that particular patient, for example, or which antiemetics are most effective, or which postoperative analgesics to use—a tailored anesthetic.

Recent studies in mice have examined the $\alpha 5$ subunit of the GABA receptor, which appears to regulate memory. The human genome is polymorphic for the $\alpha 5$ gene; because each variant may manifest in different amounts of memory/amenia, proteomics may someday lead to tests that determine the propensity of a particular patient to experience awareness and allow us to tailor the anesthetic even further.⁹¹

Genetic testing for cytochrome P450 deficiencies is now commercially available.⁹² As the number of enzymes able to be tested increases, we will be able to choose the most appropriate match between drug and patient.

REFERENCES

Entries highlighted in bright blue are key references.

- Darwin F, Darwin C. *The Autobiography of Charles Darwin*. Kallista, Victoria, Australia: Totem Books; 2003:12.
- Calverly RK. Anesthesia as a specialty: past, present, and future. In: Barash PG, Cullen BF, Stoelting RK, eds. *Clinical Anesthesia*. Philadelphia: Lippincott-Raven; 1996:6.
- Bigelow HJ. Insensibility during surgical operations produced by inhalation. *Boston Med Surgical J*. 1846;35:356.
- Vandam LD. History of anesthetic practice. In: Miller RD, ed. *Anesthesia*. Philadelphia: Churchill Livingstone; 2000:7.
- Meade RH. *An Introduction to the History of General Surgery*. Philadelphia: WB Saunders Co; 1968:78.
- Rushman GB, Davies NJH, Atkinson RS. *A Short History of Anaesthesia*. Oxford: Butterworth-Heinemann; 1998:140.
- Hall RJ. Hydrochlorate of cocaine. *NY Med J*. 1884;40:643.
- Rushman GB, Davies NJH, Atkinson RS. *A Short History of Anaesthesia*. Oxford: Butterworth-Heinemann; 1998:145.
- Griffith HR, Johnson GE. The use of curare in general anesthesia. *Anesthesiology*. 1942;3:418.
- Stoelting RK, Miller RD. *Basics of Anesthesia*. Philadelphia: Churchill-Livingstone; 2000:436.
- Hull CJ. Principles of pharmacokinetics. In: Hemmings H, Hopkins PM, eds. *Foundations of Anesthesia*. London: Mosby; 2000:77.
- Stoelting RD, Dierdorf SF. *Stoelting's Anesthesia and Co-Existing Disease*. 5th ed. Philadelphia: Saunders; 2008.
- Royston D, Cox F. Anaesthesia: the patient's point of view. *Lancet*. 2003;362:1648-1658.
- Chandrasekharan NV, Dai H, Roos KL, et al. COX-3, a cyclooxygenase-1 variant inhibited by acetaminophen and other analgesic/antipyretic drugs: cloning, structure, and expression. *Proc Natl Acad Sci USA*. 2002;99:13926-13931.
- Savarese JJ, Caldwell JE, Lien CA, et al. Pharmacology of muscle relaxants and their antagonists. In: Miller RD, ed. *Anesthesia*. Philadelphia: Churchill Livingstone; 2000:414.
- Butterworth JF IV. Local anesthetics and regional anesthesia. In: Hemmings H, Hopkins PM, eds. *Foundations of Anesthesia*. London: Mosby; 2000:298.
- Kaplan EB, Sheiner LB, Boeckmann AJ, et al. The usefulness of preoperative laboratory screening. *JAMA*. 1985;253:3576-3581.
- Cullen DJ, Apolone G, Greenfield S, et al. ASA physical status and age predict morbidity after three surgical procedures. *Ann Surg*. 1994;220:3-9.
- Mangano DT, Goldman L. Preoperative assessment of patients with known or suspected coronary disease. *N Engl J Med*. 1995;333:1750-1756.
- Wong T, Detsky AS. Preoperative cardiac risk assessment for patients having peripheral vascular surgery. *Ann Intern Med*. 1992;116:743-753.
- Lee TH, Marcantonio ER, Mangione CM, et al. Derivation and prospective validation of a simple index for prediction of cardiac risk of major noncardiac surgery. *Circulation*. 1999;100:1043-1049.
- Kleinman B, Henkin RE, Glisson SN, et al. Qualitative evaluation of coronary flow during anesthetic induction using thallium-201 perfusion scans. *Anesthesiology*. 1986;64:157-164.
- Smetana GW. Preoperative pulmonary evaluation. *N Engl J Med*. 1999;340:937-944.
- Zollinger AH, C Pasch T. Preoperative pulmonary evaluation: facts and myths. *Curr Opin Anesthesiol*. 2002;14:59-63.
- Warner DO, Warner MA, Offord KP, et al. Airway obstruction and perioperative complications in smokers undergoing abdominal surgery. *Anesthesiology*. 1999;90:372-379.
- Mutlu GM, Factor P, Schwartz DE, et al. Severe status asthmaticus: management with permissive hypercapnia and inhalation anesthesia. *Crit Care Med*. 2002;30:477-480.
- Scalfaro P, Sly PD, Sims C, et al. Salbutamol prevents the increase of respiratory resistance caused by tracheal intubation during sevoflurane anesthesia in asthmatic children. *Anesth Analg*. 2001;93:898-902.
- Groeben H, Schlicht M, Stieglitz S, et al. Both local anesthetics and salbutamol pretreatment affect reflex bronchoconstriction in volunteers with asthma undergoing awake fiberoptic intubation. *Anesthesiology*. 2002;97:1445-1450.
- Byrick RJ, Rose DK. Pathophysiology and prevention of acute renal failure: the role of the anesthetist. *Can J Anaesth*. 1990;37:457-467.
- Elliott RH, Strunin L. Hepatotoxicity of volatile anaesthetics. *Br J Anaesth*. 1993;70:339-348.
- Njoku D, Laster MJ, Gong DH, et al. Biotransformation of halothane, enflurane, isoflurane, and desflurane trifluoroacetylated liver proteins: association between protein acylation and hepatic injury. *Anesth Analg*. 1997;84:173-178.
- Eldridge AJ, Sear JW. Peri-operative management of diabetic patients. Any changes for the better since 1985? *Anaesthesia*. 1996;51:45-51.
- McAnulty GR, Robertshaw HJ, Hall GM. Anaesthetic management of patients with diabetes mellitus. *Br J Anaesth*. 2000;85:80-90.
- Risum O, Abdelnoor M, Svennevig JL, et al. Diabetes mellitus and morbidity and mortality risks after coronary artery bypass surgery. *Scand J Thorac Cardiovasc Surg*. 1996;30:71-75.
- Zacharias A, Habib RH. Factors predisposing to median sternotomy complications. Deep vs. superficial infection. *Chest*. 1996;110:1173-1178.
- Halter JB, Pflug AE. Effects of anesthesia and surgical stress on insulin secretion in man. *Metabolism*. 1980;29:1124-1127.
- Thorell A, Nygren J, Hirshman MF, et al. Surgery-induced insulin resistance in human patients: Relation to glucose transport and utilization. *Am J Physiol*. 1999;276:E754-E761.
- Das UN. Is insulin an endogenous cardioprotector? *Crit Care*. 2002;6:389-393.
- Das UN. Insulin and inflammation: further evidence and discussion. *Nutrition*. 2002;18:526-527.
- Das UN. Insulin and the critically ill. *Crit Care*. 2002;6:262-263.
- Hall GM. The anaesthetic modification of the endocrine and metabolic response to surgery. *Ann R Coll Surg Engl*. 1985;67:25-29.
- Weinberg AD, Brennan MD, Gorman CA, et al. Outcome of anesthesia and surgery in hypothyroid patients. *Arch Intern Med*. 1983;143:893-897.

43. Murkin JM. Anesthesia and hypothyroidism: a review of thyroxine physiology, pharmacology, and anesthetic implications. *Anesth Analg*. 1982;61:371-383.
44. Adams JP, Murphy PG. Obesity in anaesthesia and intensive care. *Br J Anaesth*. 2000;85:91-108.
45. Rosenbaum M, Leibel RL, Hirsch J. Obesity. *N Engl J Med*. 1997;337:396-407.
46. Bouillon T, Shafer SL. Does size matter? *Anesthesiology*. 1998;89:557-560.
47. Pinaud M, Lelausque JN, Chetanneau A, et al. Effects of propofol on cerebral hemodynamics and metabolism in patients with brain trauma. *Anesthesiology*. 1990;73:404-409.
48. Strebel S, Kaufmann M, Guardiola PM, et al. Cerebral vasomotor responsiveness to carbon dioxide is preserved during propofol and midazolam anesthesia in humans. *Anesth Analg*. 1994;78:884-888.
49. Reddy RV, Moorthy SS, Dierdorf SF, et al. Excitatory effects and electroencephalographic correlation of etomidate, thiopental, methohexital, and propofol. *Anesth Analg*. 1993;77:1008-1011.
50. Sperry RJ, Bailey PL, Reichman MV, et al. Fentanyl and sufentanil increase intracranial pressure in head trauma patients. *Anesthesiology*. 1992;77:416-420.
51. American Society of Anesthesiologists Task Force on Management of the Difficult Airway. Practice guidelines for management of the difficult airway: an updated report by the American Society of Anesthesiologists Task Force on Management of the Difficult Airway. *Anesthesiology*. 2003;98:1269-1277.
52. Bennett-Guerrero EFR, Mets B, Manspeizer HE, et al. Impact of normal saline based versus balanced salt intravenous fluid replacement on clinical outcomes: a randomized blinded trial. *Anesth Analg*. 2001;95:A147.
53. Gan T. Randomized comparison of coagulation profile when Hextend or 5% albumin is used for intraoperative fluid resuscitation. *Anesth Analg*. 2001;95:A193.
54. Petroni KG, Brimingham S. Hextend is a safe alternative to 5% albumin for patients undergoing elective cardiac surgery. *Anesth Analg*. 2001;95:A198.
55. Waters JH, Gottlieb A, Schoenwald P, et al. Normal saline versus lactated Ringer's solution for intraoperative fluid management in patients undergoing abdominal aortic aneurysm repair: an outcome study. *Anesth Analg*. 2001;93:817-822.
56. Gan TJ, Bennett-Guerrero E, Phillips-Bute B, et al. Hextend, a physiologically balanced plasma expander for large volume use in major surgery: a randomized phase III clinical trial. Hextend Study Group. *Anesth Analg*. 1999;88:992-998.
57. Gallandat Huet RC, Siemons AW, Baus D, et al. A novel hydroxyethyl starch (Voluven) for effective perioperative plasma volume substitution in cardiac surgery. *Can J Anaesth*. 2000;47:1207-1215.
58. Cittanova ML, Leblanc I, Legendre C, et al. Effect of hydroxyethylstarch in brain-dead kidney donors on renal function in kidney-transplant recipients. *Lancet*. 1996;348:1620-1622.
59. Schortgen F, Lacherade JC, Bruneel F, et al. Effects of hydroxyethylstarch and gelatin on renal function in severe sepsis: a multicentre randomised study. *Lancet*. 2001;357:911-916.
60. Elhakim M, el-Sebaie S, Kaschef N, et al. Intravenous fluid and postoperative nausea and vomiting after day-case termination of pregnancy. *Acta Anaesthesiol Scand*. 1998;42:216-219.
61. Gan TJ, Soppitt A, Maroof M, et al. Goal-directed intraoperative fluid administration reduces length of hospital stay after major surgery. *Anesthesiology*. 2002;97:820-826.
62. Yogendran S, Asokumar B, Cheng DC, et al. A prospective randomized double-blinded study of the effect of intravenous fluid therapy on adverse outcomes on outpatient surgery. *Anesth Analg*. 1995;80:682-686.
63. Williams EL, Hildebrand KL, McCormick SA, et al. The effect of intravenous lactated Ringer's solution versus 0.9% sodium chloride solution on serum osmolality in human volunteers. *Anesth Analg*. 1999;88:999-1003.
64. Vogt NH, Bothner U, Lerch G, et al. Large-dose administration of 6% hydroxyethyl starch 200/0.5 total hip arthroplasty: plasma homeostasis, hemostasis, and renal function compared to use of 5% human albumin. *Anesth Analg*. 1996;83:262-268.
65. Vogt N, Bothner U, Brinkmann A, et al. Peri-operative tolerance to large-dose 6% HES 200/0.5 in major urological procedures compared with 5% human albumin. *Anaesthesia*. 1999;54:121-127.
66. Lang K, Boldt J, Suttner S, et al. Colloids versus crystalloids and tissue oxygen tension in patients undergoing major abdominal surgery. *Anesth Analg*. 2001;93:405-409.
67. Marik PE, Iglesias J, Maini B. Gastric intramucosal pH changes after volume replacement with hydroxyethyl starch or crystalloid in patients undergoing elective abdominal aortic aneurysm repair. *J Crit Care*. 1997;12:51-55.
68. Virgilio RW, Rice CL, Smith DE, et al. Crystalloid vs. colloid resuscitation: is one better? A randomized clinical study. *Surgery*. 1979;85:129-139.
69. Hoeft A, Wietasch JK, Sonntag H, et al. Theoretical limits of "permissive anemia." *Zentralbl Chir*. 1995;120:604-613.
70. Hines R, Barash PG, Watrous G, et al. Complications occurring in the postanesthesia care unit: a survey. *Anesth Analg*. 1992;74:503-509.
71. Watcha MF, White PF. Postoperative nausea and vomiting. Its etiology, treatment, and prevention. *Anesthesiology*. 1992;77:162-184.
72. Camu F, Lauwers MH, Verbessem D. Incidence and aetiology of postoperative nausea and vomiting. *Eur J Anaesthesiol*. 1992;9:25-31.
73. Gan TJ, Meyer T, Apfel CC, et al. Consensus guidelines for managing postoperative nausea and vomiting. *Anesth Analg*. 2003;97:62-71.
74. Sun R, Klein KW, White PF. The effect of timing of ondansetron administration in outpatients undergoing otolaryngologic surgery. *Anesth Analg*. 1997;84:331-336.
75. Henzi I, Walder B, Tramer MR. Metoclopramide in the prevention of postoperative nausea and vomiting: a quantitative systematic review of randomized, placebo-controlled studies. *Br J Anaesth*. 1999;83:761-771.
76. Kehlet H, Dahl JB. The value of "multimodal" or "balanced analgesia" in postoperative pain treatment. *Anesth Analg*. 1993;77:1048-1056.
77. Gorocs TS, Lambert M, Rinne T, Krekler M, Modell S. Efficacy and tolerability of ready-to-use intravenous paracetamol solution as monotherapy or as an adjunct analgesic therapy for postoperative pain in patients undergoing elective ambulatory surgery: open, prospective study. *Int J Clin Pract*. 2009;63:112-120.
78. Sun T, Sacan O, Whit PF, et al. Perioperative vs. postoperative celecoxib on patient outcome after major plastic surgery procedures. *Anesth Analg*. 2008;106:950-958.
79. De Oliveira GS, Agarwal D, Benzon HT. Perioperative single dose ketorolac to prevent postoperative pain: a meta-analysis of randomized trials. *Anesth Analg*. 2012;114:424-433.
80. Coloma M, Duffy LL, White PF, Kendall Tongier W, Huber PJ Jr. Dexamethasone facilitates discharge after outpatient anorectal surgery. *Anesth Analg*. 2001;92:85-88.
81. Clarke H, Pereira S, Kennedy D, et al. Gabapentin decreases morphine consumption and improves functional recovery following total knee arthroplasty. *Pain Res Manage*. 2009;14:217-222.
82. Agarwal A, Gautam S, Gupta D, et al. Evaluation of a single preoperative dose of pregabalin for attenuation of postoperative

- pain after laparoscopic cholecystectomy. *Br J Anaesth*. 2008;101:700-704.
83. Buvanendran A, Kroin JS. Multimodal analgesia for controlling acute postoperative pain. *Curr Opin Anaesthesiol*. 2009;22:588-593.
84. Chetwood A, Agrawal S, Hrouda D, Doyle P. Laparoscopic assisted transversus abdominal plane block: a novel insertion technique during laparoscopic nephrectomy. *Anaesthesia*. 2011;66:317-318.
85. Heil JW, Ilfeld BM, Loland VJ, Sandhu NS, Mariano ER. Ultrasound-guided transversus abdominis plane catheters and ambulatory perineural infusions for outpatient inguinal hernia repair. *Reg Anesth Pain Med*. 2010;35:556-558.
86. McDonnell JG, Laffey JG. Transversus abdominis plane block. *Anesthes Analg*. 2007;105:883.
87. Bharti N, Kumar P, Bala I, Gupta V. The efficacy of a novel approach to transversus abdominis plane block for postoperative analgesia after colorectal surgery. *Anesthes Analg*. 2011;112:1504-1508.
88. Mukhtar K, Khattak I. Transversus abdominis plane blocks for renal transplant recipients. *Br J Anaesth*. 2010;104:663-664.
89. Rosenberg H, Davis M, James D, Pollock N, Stowell K. Malignant hyperthermia. *Orphanet J Rare Dis*. 2007;2:21
90. Atkins JH, Johansson JS. Technologies to shape the future: proteomics applications in anesthesiology and critical care medicine. *Anesth Analg*. 2006;102:1207-1216.
91. Orser BA, Mazer CD, Baker AJ. Awareness during anesthesia. *CMAJ*. 2008;178:185-188.
92. Tennant F. Interpretations and actions following cytochrome P450 testing. *Practical Pain Manage*. 2013;47-50.

This page intentionally left blank

47 chapter

Surgical Considerations in the Elderly

Rosemarie E. Hardin and Michael E. Zenilman

General Considerations	1923	Cancer / 1931	Endovascular Surgery / 1936	
Physiology of Aging	1924	Breast Cancer / 1932	Thyroid Surgery	1936
Surgery in the Elderly	1924	Colorectal Cancer / 1933	Parathyroid Surgery	1937
Preoperative Assessment	1926	Lung Cancer / 1933	Palliative Surgery	1938
Specific Considerations	1929	Trauma / 1934	The Role of the Surgeon in Geriatric Patients Is Not Limited to the OR	1938
Cardiovascular / 1929		Minimally Invasive Surgery	1935	
Valve Replacement / 1930		Laparoscopy / 1935		

GENERAL CONSIDERATIONS

As our population ages, a dramatic increase is anticipated in the number of geriatric patients that will require various surgical interventions. The U.S. Census Bureau estimates that the number of people age 65 years and older will double between 2010 and 2050.¹ By 2030, people 65 years of age or older will account for 20% of the overall population. Furthermore, half of all Americans currently alive can expect to reach the ninth decade of life.² Geriatric patients represent a unique surgical challenge due to the complexity of comorbid conditions coupled with the physiologic changes that occur with aging. As a result of these considerations, and in response to research and specialized care protocols which are tailored for its age range, geriatric surgery has emerged as a subspecialty of surgery much as pediatric surgery developed decades ago.

Physiologic age is of greater importance in perioperative management of elderly surgical patients than chronologic age because it takes into account the burden of comorbid disease. It is, therefore, an accurate predictor of postoperative morbidity and mortality. The hallmark of physiologic aging or “senescence” is decreased functional reserve of critical organ systems, resulting in the decreased ability of these systems to respond to a challenge, with surgical stress being a prime example. The age of 70 years is typically accepted as the start of senescence because age-related organ dysfunction and the development of comorbid conditions sharply increases between ages 70 and 75 years.³ This criterion for senescence is in contrast to clinical studies published just 50 years ago that categorized elderly patients as those over the age of 55 years. With improved technologies and expanded criteria for surgical interventions in extremely aged patients, increased awareness of the special needs of this population is required to ensure a comprehensive preoperative assessment, delivery of optimal surgical care, and minimization of postoperative complications. It is also critical that a multidisciplinary approach be developed, which involves the patient and their home caregivers, geriatric physicians, surgeons, and, at times, specialists in intensive care.

It is estimated that, by the year 2030, there will be 70 million people >65 years old in the United States, a stark increase over the 35 million in 2000.⁴ This ever growing elderly population will increasingly require surgical care, and patients >65 years old already account for approximately 60% of the general surgeon’s workload.⁵ Patients >65 years old account for approximately 50% of all emergent operations and 75% of operative mortality.⁴ These statistics challenge a surgeon to have an in-depth understanding of the careful perioperative evaluation required in elderly patients and the tailoring of surgical interventions based on the unique changes in physiologic reserve and comorbid conditions that make elderly patients more susceptible to postoperative complications.

The goal of this chapter is to highlight salient management strategies for aged surgical patients to achieve optimal care and reduce postoperative complications. Particular problems in the elderly population which impact on surgical care include the potential delay in surgical treatment due to a missed or delayed diagnosis secondary to an atypical presentation of disease, and the postponement of needed elective surgery because of the misconception that an elderly patient will suffer a poor outcome as a result of advanced age alone. For example, elective inguinal and umbilical hernia repairs are often postponed due to age bias; this can lead to potentially devastating consequences of bowel ischemia, gangrene, and perforation, to which elderly patients respond poorly. As a result, emergency hernia repairs are among the most common procedures performed in older patients; approximately 40% of hernia repairs are performed for incarceration or bowel obstruction in patients >65 years old.⁵ Emergency repair of hernias is associated with an increased morbidity rate of approximately 50% and a mortality rate ranging between 8% to 14%; a significant increase from the 2% mortality rate following elective repair in age-matched patients.⁵

Another significant consideration with the geriatric population is the need to balance optimal health care delivery with rising health care costs. The goal of surgical therapy in the elderly is to provide needed interventions which result in maximum benefit to the patient without compromising quality of life or

Key Points

- 1▶ Frailty, dementia, and geriatric syndromes have recently been identified as major factors in the development of postoperative complications in the elderly.
- 2▶ Emergency surgery in the elderly carries a mortality rate that is 3 to 4 times that seen after elective surgery.
- 3▶ Impaired cardiac function is responsible for more than half of the postoperative deaths in elderly patients, so careful attention must be paid to intravascular volume status in the perioperative period.
- 4▶ In elderly patients with acute appendicitis or acute cholecystitis, one-third lack fever, one-third lack an elevated white blood cell count, and one-third lack physical findings of peritonitis.
- 5▶ Physiologic age, not chronologic age, is the consequence of diminished functional reserve due to comorbid conditions, and is the major predictor of perioperative morbidity and mortality in the elderly.
- 6▶ Laparoscopic approaches to surgical management, including the use of exploratory laparoscopy to rule out surgical disease, are associated with fewer complications and more rapid recovery in the elderly.
- 7▶ New tools exist to help assess perioperative risk in geriatric patients, in addition to medical comorbidities. They include identification of geriatric syndromes, frailty indicators.

unwanted adverse outcomes. For example, screening for breast or colorectal cancer should be performed if the patient has a reasonable expectation of quality and quantity of life. An extensive and/or invasive workup should not be performed if the patient would not tolerate the anticipated therapeutic intervention.

Finally, a fifth of elderly patients die in ICU settings and half of them require mechanical ventilation and a quarter undergo cardiopulmonary resuscitation in the days before their death.⁶ Although Medicare expenditures in the last year of life are approximately five times higher than in nonterminal years, the actual quality of care at the end of life is often poor due to debilitating and persistent symptoms. Even more worrisome is the fact that some patients receive treatments which are inconsistent with their preferences for end of life measures. An additional component of geriatric surgery is therefore the provision of compassionate care that is more focused on symptomatic relief than on cure in patients who are near the end of life.

PHYSIOLOGY OF AGING

Elderly surgical patients are a heterogeneous cohort with various degrees of functional impairments and comorbid burdens. The “young old patient” may lead an active lifestyle with few, if any, comorbid conditions. But even for this seemingly healthy individual, it is crucial to remember that there are inherent physiologic changes that occur with aging and which affect every organ system. These physiologic changes may become more apparent and clinically consequential with the stress of major illness and operative interventions.

An important criterion in the geriatric surgery patient is the frailty score. Frailty is a syndrome associated with advanced age that results from decreased physiologic reserve and which makes patients less resistant to major stressors such as invasive surgical procedures. Frail patients are prone to poorer outcomes, due to falls, disability, impaired ability to perform activities of daily living (ADLs), prolonged hospitalizations and an increase in mortality.¹ Frail patients are more likely to require discharge to skilled nursing facilities postoperatively. Prior to surgery, frail patients and their family members should be aware of this possibility. Therefore, the frailty score is a more accurate representation of the patient’s physiologic age.

Chronologic age is rarely an accurate predictor of morbidity and mortality from surgical interventions. It is, however,

an accurate marker for declining physiologic reserve and the likelihood of the presence of comorbid conditions. These place elderly patients at higher risk because of impaired cardiac, pulmonary, renal, and neurological reserves, which increase the morbidity and mortality risk of surgical interventions. Physiologic age, in addition to comorbid conditions, more accurately predicts surgical outcomes in the elderly than chronologic age. The physiologic changes of aging are summarized in Table 47-1.

The terms “frailty,” “disability” and “comorbidity” have mistakenly been used interchangeably. These terms have very different connotations for the geriatric patient. Disability is defined as dependence on assistance with ADLs, and contributes to the risk of frailty. Comorbidity is defined as the presence of two or more existing diseases, and is quantified by the Charlson comorbidity index.⁷ Geriatric assessment markers for frailty and disability include cognition, albumin level, history of falls, hematocrit level, and dependence on assistance with ADLs. These objective measures have been shown to predict six month postoperative mortality or the need for long term institutionalized care after surgery.⁷ (Table 47-2)

SURGERY IN THE ELDERLY

It is critical in the assessment of any elderly patient to maintain a high index of suspicion for surgical pathology. Elderly patients often present with atypical symptoms and/or a misleadingly benign-appearing abdominal examination that may mask an intra-abdominal catastrophe. The effects of age-related impairments in immune function can be compounded by co-existent medical problems and altered mentation as a result of dementia, drugs, infection, or dehydration.

Acute appendicitis and acute cholecystitis are classic examples of common acute surgical pathologies in which elderly patients have a delay in diagnosis or misdiagnosis. This often leads to higher rates of perforation and complications that adversely affect morbidity and mortality.⁸ Biliary tract disease, including acute cholecystitis, is the most common indication for surgical intervention in the elderly. This is likely related to age-related changes within the biliary system, such as increased lithogenicity of bile and an increased prevalence of cholelithiasis. Delayed diagnosis due to atypical or misleading symptoms may lead to complications such as ascending cholangitis, gallbladder perforation, or gallstone ileus.

Table 47-1

Physiologic limitations of aging, their clinical consequences, and “best practices” in the elderly surgical patient.

AGE-RELATED CHANGES	CLINICAL CONSEQUENCES	BEST PRACTICES
Body Composition		
<ul style="list-style-type: none"> • Significantly decreased muscle mass, accounting for much of decreased lean tissue mass • Increased fat mass 	<ul style="list-style-type: none"> • Erosion of muscle mass during acute illness may result in strength rapidly falling below important clinical thresholds (e.g., impaired coughing, decreased mobility, increased risk of venous thrombosis) • Altered volumes of drug distribution 	<ul style="list-style-type: none"> • Maintain physical function through effective pain relief, avoiding tubes, drains, and other “restraints,” early mobilization, and assistance with mobilization. • Minimize fasting, provide early nutritional supplementation or support (both protein-calorie and micronutrient). • Adjust drug dosages for volume of distribution.
Respiratory		
<ul style="list-style-type: none"> • Decreased vital capacity • Increased closing volume • Decreased airway sensitivity and clearance • Decreased partial pressure of oxygen 	<ul style="list-style-type: none"> • Less effective cough • Predisposition to aspiration • Increased closure of small airways during tidal respiration, especially postoperatively and when supine, leading to increased atelectasis and shunting • Predisposition to hypoxemia 	<ul style="list-style-type: none"> • Provide early mobilization, assumption of upright rather than supine position. • Ensure effective pain relief to allow mobilization, deep breathing. • Provide routine supplemental oxygen in the immediate postoperative period, and then, as needed. • Minimize use of nasogastric tubes.
Cardiovascular		
<ul style="list-style-type: none"> • Decreased maximal heart rate, cardiac output, ejection fraction • Reliance on increased end-diastolic volume to increase cardiac output • Slowed ventricular filling, increased reliance on atrial contribution • Decreased baroreceptor sensitivity • Thermoregulation • Diminished sensitivity to ambient temperature and less efficient mechanisms of heat conservation, production, and dissipation • Febrile responses to infection may be blunted in frail or malnourished elderly and those at extreme old age. 	<ul style="list-style-type: none"> • Greater reliance on ventricular filling and increases in stroke volume (rather than ejection fraction) to achieve increases in cardiac output • Intolerant of hypovolemia • Intolerant of tachycardia, dysrhythmias, including atrial fibrillation • Predisposition to hypothermia (e.g., decline in body temperature during surgery is more marked unless preventive measures are taken) • If there is hypothermia, shivering may result, associated with marked increases in oxygen consumption and cardiopulmonary demands. • Fever may be absent despite serious infection, especially in frail elderly. 	<ul style="list-style-type: none"> • Use vigorous fluid resuscitation to achieve optimal ventricular filling. • Nonvasoconstricting inotropes and afterload reduction may be more effective, if pharmacologic support is required. • Use active measures to maintain normothermia during surgical procedures and to rewarm after trauma: warmed IV fluids, humidified gases, warm air. • Maintaining intraoperative normothermia reduces wound infections, adverse cardiac events, and length of hospital stay. • Be aware of hypothermia in trauma resuscitation.

(Continued)

Table 47-1

Physiologic limitations of aging, their clinical consequences, and “best practices” in the elderly surgical patient. (continued)

Renal function, fluid-electrolyte homeostasis

<ul style="list-style-type: none"> • Decreased sensitivity to fluid, electrolyte perturbations • Decreased efficiency of solute, water conservation, and excretion • Decreased renal mass, renal blood flow, and glomerular filtration rate • Increased renal glucose threshold 	<ul style="list-style-type: none"> • Predisposition to hypovolemia • Predisposition to electrolyte disorders, (e.g., hyponatremia) • Predisposition to hyperglycemia • Predisposition to hyperosmolar states 	<ul style="list-style-type: none"> • Pay meticulous attention to fluid and electrolyte management. • Recognize that a “normal” serum creatinine value reflects decreased creatinine clearance because muscle mass (i.e., creatinine production) is decreased concurrently. • Select drugs carefully: Avoid those that may be nephrotoxic (e.g., aminoglycosides) or adversely affect renal blood flow (e.g., NSAIDs). • Adjust drug dosages as appropriate for altered pharmacokinetics.
---	--	--

Source: Reproduced with permission from Watters JM: Surgery in the elderly. *Can J Surg* 45:106, 2002. © 2002 Canadian Medical Association.

Elderly patients with acute peritonitis may not present with typical symptoms of acute abdominal pain, fever, or leukocytosis, due to a depressed immune response. In older patients presenting with acute appendicitis, the initial diagnosis is correct in less than half of the patients.⁸ A careful assessment and high index of suspicion are crucial to achieve timely operative intervention.

PREOPERATIVE ASSESSMENT

Surgical risk increases with advancing age as a consequence of physiologic decline and the development of comorbid conditions that make the elderly surgical patient more susceptible to postoperative complications. Geriatric patients may have masked vulnerabilities due to their unique physiologic state that requires a more detailed preoperative assessment. Comorbid illness serves as the basis for the American Society of Anesthesiologists' (ASA) physical status classification. This is a valuable tool for identifying elderly patients who are at high risk for postoperative complications because it is based on organ system dysfunction and severity of functional impairment. It helps to identify subgroups of patients in whom appropriate measures should be taken to reduce the risk of adverse outcomes.

Table 47-2

Frailty, disability, and comorbidities measures which are significant preoperative predictors of outcomes in the geriatric patient.⁷

MARKER	MEASURE
Frailty	Cognition (Mini-Cog test ≤ 3) Falls ≥ 1 in last six months Albumin ≤ 3.3 gm/dL Hematocrit $\leq 35\%$
Disability	DependanceDependence on ≥ 1 activity of daily living
Comorbidity	Charlson index ≥ 3

2► Importantly, it also quantifies the risks of morbidity and mortality for emergency surgery. A careful assessment of potential problems in the perioperative period combined with implementation of preventative measures can significantly reduce complications associated with general anesthesia in the elderly patient.⁹ A useful algorithm for the preoperative assessment of an elderly surgical patient is provided in Fig. 47-1.

Cardiac complications are the leading cause of perioperative complications and death in surgical patients of all age groups, but particularly among the elderly. This is because patients often have co-existing cardiac dysfunction, combined with normal physiologic decline and poor functional reserve. The combined effect of depletion of intravascular volume, age-related impairment of response to catecholamines, and increased myocardial relaxation time adversely affects the cardiac function of an elderly patient under stress in the perioperative period.¹⁰ Aging has been demonstrated to cause a decrease in cardiac output by approximately 1% per year. Older individuals fail to augment heart rate to the same extent as younger individuals. More importantly, the ability to increase cardiac output with aging is dependent on ventricular dilatation, which is determined by preload.¹¹ Therefore careful attention must be paid to volume status in the perioperative period. Dehydration or poor resuscitation may occur in elderly surgical patients for a variety of reasons, and both are poorly tolerated. Over one half of all postoperative deaths in elderly patients and 11% of postoperative complications are a result of impaired cardiac function under physiologic stress. Incomplete emptying of the ventricle at end systole and subsequent reduction in ejection fraction is characteristic of the aging heart.¹⁰ Reduced distensibility, in addition to acute stressors, leads to impaired coronary perfusion and cardiac ischemia.

3► As a result, the physiologic stress of general anesthesia and surgical interventions can unmask the limited cardiac reserve of the elderly patient. Poor reserve may become evident with increased myocardial oxygen demand resulting from tachycardia or loss of vascular tone from the vasodilatory effects of many general anesthetic agents. An important predictor of surgical

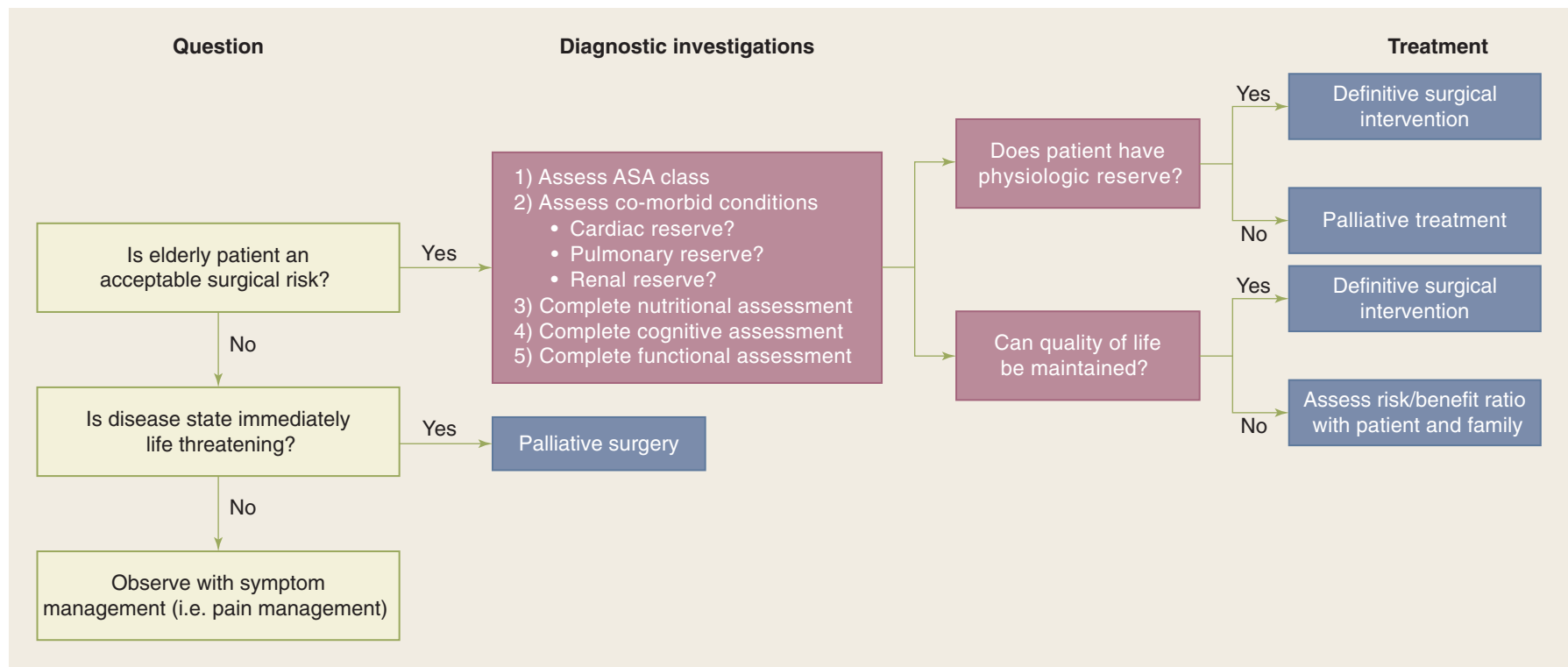


Figure 47-1. Useful preoperative algorithm to determine elderly patient's suitability for definitive surgical intervention balancing therapeutic goals, physiologic reserve, and quality of life with palliative treatment and surgery as viable options. ASA = American Society of Anesthesiologists.

outcomes and cardiac complications in the elderly is congestive heart failure (CHF). CHF is present in approximately 10% of patients older than 65 years and is the leading cause of postoperative morbidity and mortality.¹² This prevalence will likely increase as percutaneous interventions and medical therapy prolongs survival from myocardial ischemia and acute myocardial infarction. Therefore, identifying correctable and uncorrectable cardiovascular disease is critical before elective surgical interventions.

Pulmonary complications are a major source of morbidity and mortality in elderly surgical patients. The age-related changes that occur in the respiratory system limits the maximal breathing capacity by age 70 to 50% of the capacity present at age 30.¹² In addition, there is a decline in the forced expiratory volume in 1 second (FEV1) with advancing age. It is estimated that humans lose 35 mL of their FEV1 per year over the age of 35 years old. There is a slow decline between ages 35 and 65 years old followed by a much more progressive decline at approximately 75 years of age.¹³ Pulmonary complications account for up to 50% of postoperative complications and 20% of preventable deaths.¹⁴ Risk factors for pulmonary complications include a positive smoking history, presence of shortness of breath, or clinical evidence of chronic obstructive pulmonary disease. All elderly patients undergoing major surgical interventions should have a baseline chest radiograph. Screening spirometry can be performed to determine forced vital capacity and FEV1. A baseline arterial blood gas measurement also will help to identify hypoxemia and hypercapnia, both of which may increase postoperative complications. If abnormalities are found, perioperative use of bronchodilators and incentive spirometry may be invaluable. When possible, regional anesthetic techniques may provide excellent analgesia while helping to reduce the postoperative pulmonary complications associated with general anesthesia and endotracheal intubation.

Renal complications are also increased in elderly surgical patients in the perioperative period. Renal size and volume decrease with age, accompanied by intrarenal vascular changes. There is a decrease in the number of glomeruli and nephron mass, resulting in decreased filtration area. Serum creatinine concentration is an insensitive indicator of renal function in the elderly, however.¹⁰ The physiologic age-related changes in renal function increase susceptibility to renal ischemia as well as to nephrotoxic agents. Age-related changes in renal function result from progressive glomerulosclerosis and reduction in renal mass resulting in decreased creatinine clearance and glomerular filtration rate. This is worsened by a decline in cardiac output with increasing age and subsequent decrease in renal blood flow. It has been shown that patients with impaired glomerular filtration rate are more susceptible to volume changes that occur in the perioperative period. Furthermore, decreased drug elimination can potentiate the effects of nephrotoxic drugs and prolong the sedative effects of anesthetics and narcotic used for postoperative pain management.¹² Acute renal failure is proven to dramatically increase morbidity and mortality in elderly patients. The mortality risk of perioperative renal failure in all patients is approximately 50% and may be even higher in elderly patients. Therefore, careful management of fluid and electrolyte status is prudent to avoid imbalances and limit exposure to nephrotoxic diagnostic studies and medications in the perioperative period. Patients >70 years old may be susceptible to the nephrotoxic effects of certain anesthetic agents, and thus should be protected by hydration and diuresis, as long as they can tolerate the fluid load.¹⁰ Prompt recognition of renal compromise, marked by an elevation of blood

urea nitrogen or creatinine levels or oliguria, requires aggressive correction of underlying causes. Furthermore, electrolyte imbalances can lead to potentially devastating cardiac conduction abnormalities and arrhythmias.¹² Although not routinely advocated in younger patients, elderly patients should have routine electrolyte panels and urinalysis before all surgical interventions to identify potential renal dysfunction.¹⁵ Underlying causes of abnormalities found on screening should be corrected before surgery and may necessitate intravascular volume repletion to ensure adequate renal perfusion perioperatively.

A *functional evaluation* which includes an assessment of the cognitive level of functioning is an important part of the preoperative evaluation of elderly surgical candidates. This ensures that operative intervention will not significantly impair the quality of life of an elderly surgical candidate. The ability to withstand the stress of surgical interventions is dependent on functional reserve and the ability to build an appropriate response to peri-operative stress.¹⁰ The ability to perform ADLs such as feeding, dressing, bathing, and toileting have been correlated with postoperative morbidity and mortality (Table 47-2). Preoperative functional assessment can be measured by hand grip strength, timed “up and go,” and functional reach tests⁷. All of these tests independently predicted better recovery and shorter time to recover ADLs after major surgery. In addition, these tests provide an accurate assessment of a patient’s muscle mass, nutritional status, coordination, gait speed, balance, and mobility.⁵ Proper functional assessment will accurately predict rehabilitation needs, estimate biologic reserve, and indicate an enhanced risk of complications.¹⁰

The functional status of an elderly patient is directly and inversely correlated to pulmonary and cardiac complications that may ensue following surgical interventions. For example, functional impairment often leads to immobility, which can lead to increased risk of postoperative atelectasis, pneumonia, deep vein thrombosis (DVT), and pulmonary embolism. Furthermore, proper functional assessment has been shown to improve diagnostic and therapeutic outcomes as well as to lead to identification of previously undiagnosed conditions that may be treatable preoperatively or managed peri-operatively.¹⁰

Cognitive function often is overlooked in the preoperative assessment of patients, because patients are not typically formally evaluated before surgical intervention (i.e., mini-mental state examination). However, knowledge of baseline cognitive function provides invaluable information because subtle changes in cognition often herald postoperative complications, such as underlying infection. Cognitive impairment, including delirium and confusion commonly occur in the elderly patient during the early postoperative period and can result in increased morbidity, delayed functional recovery, and prolonged hospitalizations. The etiology of this postoperative cognitive dysfunction may be multifactorial. Advanced age, history of alcohol abuse, baseline cognitive disturbance, hypoxia, and hypotension have all been shown to be contributing factors.¹⁶ It is crucial that careful attention be paid to adequate postoperative analgesia to improve recovery while avoiding compromise of cognitive function. Methods such as “Beer’s Criteria” are useful tools to assess whether a particular drug is appropriate for the aged patient. Finally, dementia is a known predictor of poor long-term survival.

A *formal nutritional assessment* is invaluable in the perioperative assessment of elderly patients. Poor nutritional status in elderly patients is common and results from the interplay between physiologic, psychosocial, and economic changes that accompany the aging process. Elderly patients may have poor nutritional

status because of either poor intake due to the underlying illness or pre-existing comorbid conditions. In the outpatient setting, it is estimated that 9% to 15% of persons >65 years old are malnourished. This increases to 12% to 50% and 25% to 60% in the acute inpatient hospital setting and chronic institutional settings, respectively.¹⁷ The cycle of frailty that occurs with chronic undernutrition or malnutrition can lead to progressive functional decline, loss of muscle mass, and decreased oxygen consumption and metabolic rate in this population.¹⁷ Therefore, adequate assessment of nutritional status of these patients preoperatively and the prompt institution of nutritional support is of utmost importance. This is an integral component of the preoperative assessment, considering that nutritional status is a proven independent predictor of surgical outcomes. Deterioration of a patient's nutritional state in the perioperative period contributes to adverse outcomes. Poor nutrition can lead to increased nosocomial infections, multiorgan system dysfunction, poor wound healing, and impaired functional recovery. Therefore, nutritional assessment and support, if necessary, not only give patients additional reserve to minimize postoperative complications, but aid in appropriate wound healing, functional recovery, and rehabilitation.

Protein energy malnutrition (PEM) also can result from maintaining compromised surgical patients nil per os (NPO). PEM may occur quickly in the elderly, malnourished surgical patient in a hypermetabolic state induced by stress of illness and surgery. The physiologic consequences of PEM are multiple and include anorexia, hepatic dysfunction, decreased mucosal proliferation, and sarcopenia.¹⁷ A good marker of PEM is hypoalbuminemia, also shown to be an extremely accurate predictor of surgical outcomes. The incidence of postoperative complications is increased in patients with serum albumin levels <3.5 g/L.¹⁷ Current recommendations indicate that if patients demonstrate compromise of nutritional status as defined by >10% weight loss and serum albumin level <2.5 g/dL, they should be considered for a minimum of 7 to 10 days of nutritional repletion prior to surgery.¹⁰

The significant impact of nutritional status on surgical outcomes and functional recovery in the elderly population after surgical intervention underscores the importance of an accurate preoperative nutritional assessment. In busy surgical practices, the question arises as to whether this can be done in a simple, reproducible, and cost-effective manner while obtaining vital information. There are several methods of assessing nutritional status, including anthropomorphic measures (i.e., body mass index), biochemical laboratory values (i.e., transferrin, albumin, and prealbumin), and clinical assessments.¹⁷

The Mini Nutritional Assessment (MNA) is an established, validated nutritional assessment tool which can be useful for the preoperative assessment of the elderly surgical candidate. The MNA consists of a screening portion assessing the patient's current body mass index, food intake and weight loss, mobility, and presence of stressors, depression, or dementia, all of which can exacerbate undernutrition or malnutrition in the elderly patient. The goal is to identify patients at risk for malnutrition, and who need further evaluation involving a more complete psychosocial assessment and determination of mode of feedings. This tool helps to identify undernutrition and malnutrition in older individuals, >65 years old, and helps to direct timely interventions which result in improved functional recovery.

The combined effects of poor nutrition, decreased cognition, and immune impairments due to nutritional or pharmacologic factors create a treacherous circumstance for elderly

patients with poorly defined symptoms or who present with more advanced disease. In acute abdominal conditions, such as acute appendicitis and acute cholecystitis, one third of elderly patients will lack an elevated white blood cell count, one third will lack fever, and one third will lack physical findings of localized peritonitis. These deficits contribute to a three-
4► fold higher rate of perforated appendicitis and of gangrene of the gallbladder in elderly patients compared to young patients. An "unimpressive" physical exam in an elderly patient with acute onset of abdominal symptoms should never be taken as a sign of the absence of surgical disease.

The value of the multifaceted geriatric preoperative assessment led to the formation of an expert geriatric surgery panel by the American College of Surgeons National Surgical Quality Improvement Program (ACS NSQIP) and the American Geriatric Society (AGS). The panel formulated best practice guidelines for surgery in the elderly that have been adopted as standards for training programs (see Fig. 47-2). This checklist may prove to be a useful tool in the preoperative identification of issues that may play an important role in the outcome of a surgical procedure. This not only highlights the importance of the factors described previously but also provides a tool that physicians can utilize in the nonurgent setting to institute preventative or corrective measures to help the geriatric patient maintain their quality of life. (Table 47-3)

Checklist for the Optimal Preoperative Assessment of the Geriatric Surgical Patient

In addition to conducting a complete history and physical examination of the patient, the following assessments are strongly recommended:

- Assess the patient's cognitive ability and capacity to understand the anticipated surgery.
- Screen the patient for depression.
- Identify the patient's risk factors for developing postoperative delirium.
- Screen for alcohol and other substance abuse/dependence.
- Perform a preoperative cardiac evaluation according to the American College of Cardiology/American Heart Association algorithm for patients undergoing noncardiac surgery.
- Identify the patient's risk factors for postoperative pulmonary complications and implement appropriate strategies for prevention.
- Document functional status and history of falls.
- Determine baseline frailty score.
- Assess patient's nutritional status and consider preoperative interventions if the patient is at severe nutritional risk.
- Take an accurate and detailed medication history and consider appropriate perioperative adjustments. Monitor for polypharmacy.
- Determine the patient's treatment goals and expectations in the context of the possible treatment outcomes.
- Determine patient's family and social support system.
- Order appropriate preoperative diagnostic tests focused on elderly patients.

Figure 47-2. Checklist of questions to be used during assessment of geriatric patient. This novel tool takes into consideration issues unique to geriatric patients, including frailty, cognition, and support systems. (From Chow WB et al¹ with permission from Elsevier. © 2012 American College of Surgeons.)

Table 47-3

Goals for ethical decision making in elderly surgical patient.

1. Acknowledge medical futility; physicians are not required to provide life-sustaining treatment that is deemed medically futile.
2. Clarify patients' wishes regarding life-sustaining therapies in accordance with Patient Self-Determination Act (i.e., advance directives, living wills, do not intubate/resuscitate orders).
3. Respect patient autonomy: right to accept and refuse treatment despite consequences of decision.
 - Ensure mental competency before establishing autonomy.
 - May appoint surrogate decision maker in case of incapacitation.

SPECIFIC CONSIDERATIONS

Cardiovascular

It is estimated that approximately 40% of the projected 25 million octogenarians comprising the U.S. population by the year 2025 will suffer cardiovascular symptoms, many of whom will require cardiovascular surgical treatment.¹⁸ With advances in cardiopulmonary bypass technique, myocardial protection, and improved perioperative care, coronary artery bypass grafting (CABG) and valve replacement operations can be safely performed in elderly patients. Senile calcific aortic stenosis is common within this population, and referral for aortic valve replacement is increasing, encompassing many patients who are >75 years old. Interestingly, despite some degree of age bias in the referral of patients for major cardiac surgery, advanced age alone is not a predictor of poorer outcomes or increased mortality compared to younger patients. It has been demonstrated that emergency operations, preoperative New York Heart Association (NYHA) functional class 3 or greater, and chronic renal failure were the main predictors of increased operative mortality, but not patient age, per se.¹⁸ In one study, preoperative renal dysfunction, cerebrovascular disease, valve surgery, and catastrophic state were independent predictors of increased mortality in elderly patients.¹⁹ Elderly patients with nondialysis-dependent renal dysfunction had a 60% chance of death during a 5-year follow-up period compared to 25% in elderly patients without a history of renal dysfunction. Similarly, the presence of cerebrovascular disease resulted in a two-fold increase in mortality among elderly patients.¹⁹ Even patients who were 80 years of age or more did not have any significant increase in surgical risk and within this population, the 4-year actuarial survival was 70.5% with an event-free survival of approximately 60.6%.¹⁹

There has been an increase in definitive operative intervention to elderly patients requiring CABG. Although older patients have higher morbidity and mortality rates after cardiac surgery than do younger patients, these rates are decreasing. The Society of Thoracic Surgeons reports that perioperative mortality rates range from 1.6% in patients 51 to 60 years of age to 7.7% in those 81 to 90 years of age.²⁰ This decline in morbidity and mortality rates likely reflects better preoperative assessment and patient selection. Furthermore, this decline has occurred despite the advancing age of cardiac patients at time of referral, advanced disease, and greater comorbid disease burden. Elderly patients are more likely to have significant triple-vessel disease accom-

panied by poor ejection fraction, left ventricular hypertrophy, significant valvular disease, and previous history of myocardial infarction than are younger patients.²⁰ Elderly patients also are more likely to be classified as NYHA functional class 3 or higher and are more likely to present on an emergent basis, in part because of reluctance to provide elective surgical intervention because of presumptive poorer outcome. Despite the increased risk of morbidity and mortality compared to younger patients, elderly patients, including those >80 years old, can undergo CABG with acceptable mortality risk. The overall mortality rate is approximately 7% to 12% for elderly patients, including those in whom CABG is performed under emergency conditions. The mortality rate decreases to approximately 2.8% when CABG is performed electively with careful preoperative evaluation.²¹

Valve Replacement

There also is an increasing percentage of the geriatric population who present with symptomatic valvular disease requiring intervention. The most common valvular abnormality present in elderly patients is calcific aortic stenosis, which can lead to angina and syncope.²² The operative mortality from aortic valve replacement is estimated to be between 3% and 10%, with an average of approximately 7.7%.²⁰ If aortic stenosis is allowed to progress without operative intervention, CHF will ensue. The average survival of these patients is approximately 1.5 to 2 years. If a patient is a candidate for operative intervention, age should not be a deterrent, especially considering the potential to increase life expectancy. It has been recommended that the carefully selected, minimally symptomatic octogenarian with aortic stenosis should be considered a low-risk patient and be expected to experience an uneventful operative course and expedient recovery. More importantly, if elective procedures are delayed until symptoms or left ventricular dysfunction develop, patients may suffer from unnecessary increased operative risk and mortality.¹⁸ Early intervention results in a demonstrable improvement in quality of life in these patients, with many improving their NYHA functional classification.

Elderly patients require surgery for mitral valve disease when ischemic regurgitation is present. Surgery for mitral valve disease carries a higher morbidity and mortality risk than for aortic intervention, with an estimated mortality rate as high as 20%.²⁰ Left ventricular function usually is compromised in patients requiring intervention, leading to a poorer outcome in these patients. The surgical outcome for mitral valve procedures depends on the extent of the disease, age of the patient, presence of pulmonary hypertension, and extent of coronary artery disease. The presence of comorbid conditions combined with the emergent nature of surgery in a large percentage of elderly patients further worsens the outcome. Therefore, a decision regarding management of mitral valve disease should be individualized to each patient with the previously mentioned factors considered. Another concern regarding elderly patients who require surgery for valve disease is the additional requirement for coronary revascularization. This increases the morbidity and mortality from surgical intervention. An elderly patient with many comorbid conditions in need of a combined procedure should only have critically stenosed vessels bypassed.²² Therefore, advanced age is not a contraindication to performing combined procedures; however, a higher mortality rate should be expected. Neurologic complications from valve surgery are particularly common in elderly patients. It has been estimated that approximately 30% of patients >70 years old who undergo valve procedures develop either transient or permanent

neurologic dysfunction.²² This often is a result of embolism from debris dislodged from the valve during the procedure or from a formed thrombus in the right atrium.

An important consideration in valve replacement procedures in elderly patients is the type of prosthesis to be used. Elderly patients are at increased risk from bleeding-associated anticoagulation complications. This is especially significant in patients who have experienced falls and minor trauma that have resulted in intracranial hemorrhage. To avoid the lifelong requirement for anticoagulants, bioprosthetic valves should be used in place of mechanical valves whenever possible.²² Although the bioprosthetic valves are not as durable as mechanical valves, studies demonstrate excellent structural integrity 10 years postprocedure, making it an appropriate choice in an elderly patient.

Cancer

The incidence of most cancers is age dependent, and the expanding aged population is rapidly increasing the number of elderly patients who require multimodal therapy for various oncologic diseases, including lung, breast, pancreas, esophagus, stomach, and colorectal malignancies. Approximately 50% of cancer diagnoses are currently made in patients aged 70 years or older.¹⁰ It is predicted that the increase in the elderly population will account for up to a 50% increase in the number of patients undergoing oncologic procedures by the year 2020. The increased life expectancy of the geriatric patient coupled with the increasing incidence of cancer with advancing age will lead to an increased prevalence of

malignant disease requiring surgical intervention. This is an area of great interest given that randomized clinical trials to determine the outcomes of elderly patients undergoing curative resections, as well as neoadjuvant and adjuvant therapy, are lacking. In addition, elderly patients are rarely included in clinical trials; therefore, treatment decisions are often based on individual surgeon experience and non-geriatric data, and may be flawed by inherent biases regarding the outcome of complete oncologic resections in elderly patients. Surgeons may also be reluctant to expose older patients to the toxic effects of chemotherapy and radiation without proven efficacy in this geriatric population. This highlights the need for research targeting the specific needs of elderly patients with malignancy to aid in the development of specific treatment guidelines for various cancers within this age cohort.

Currently, the geriatric population is undertreated for malignant diseases and does not receive curative resections or adjuvant therapies afforded to same-stage younger patients.¹¹ Potential reasons include poorer functional status compared to younger patients, patient and family preference, age bias, life expectancy, and concerns regarding quality of life after major operative interventions.²³ Surgeons will be challenged to decide whether major surgery is justified in elderly patients, especially those with limited life expectancy. Effectiveness of oncologic surgery in elderly patients depends on whether a cure can be achieved safely without compromise to functional status or quality of life. Postoperative life expectancy should be improved by surgery, or, at the very least, not diminished. A useful treatment algorithm is provided in Fig. 47-3. A study undertaken

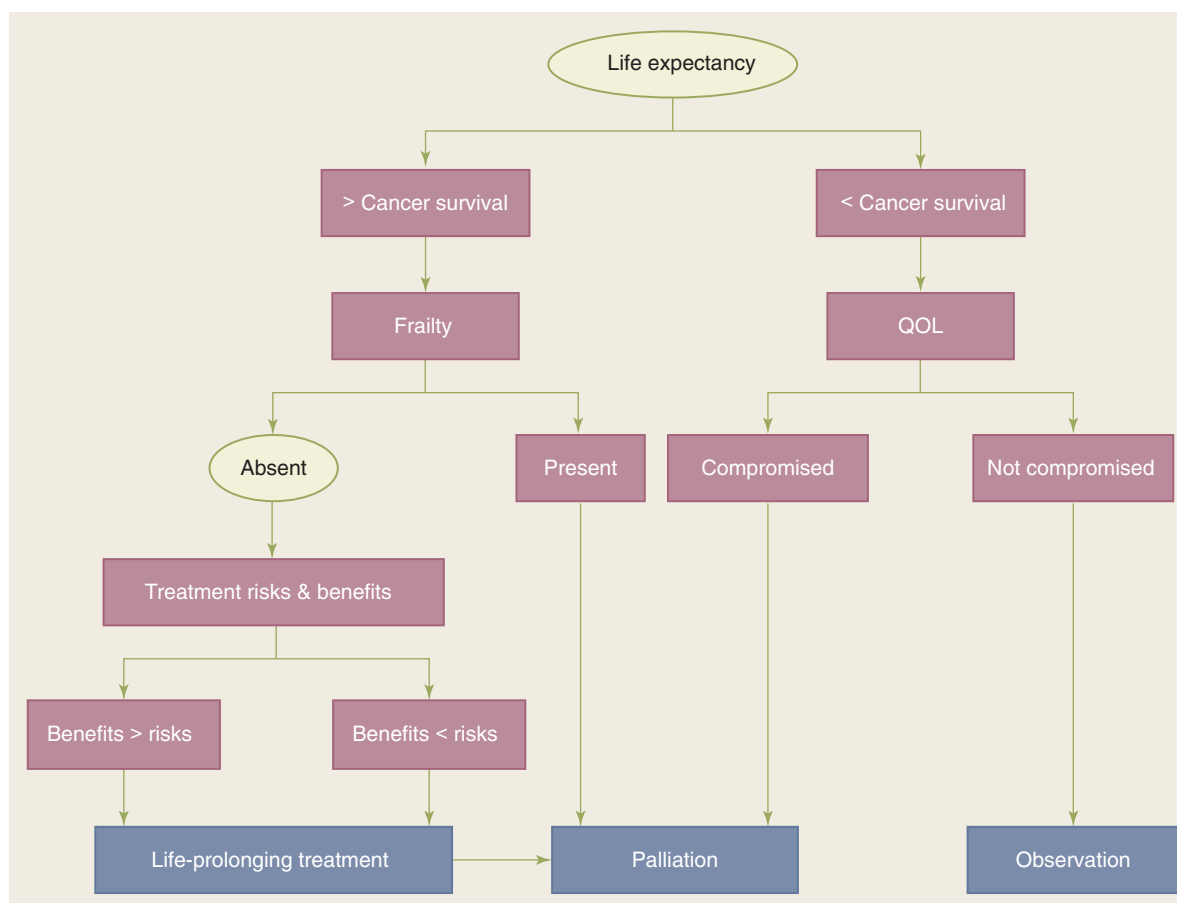


Figure 47-3. A useful treatment algorithm to illustrate the effectiveness of oncologic surgery depends on the balance between achieving cure and maintaining functional quality of life (QOL). (Reproduced with permission from Balducci L, Beghe C. *Cancer Control. Journal of the Moffitt Cancer Center.* 1999; 6:466.)

using the Surveillance, Epidemiology and End Results database assessing cancer-directed surgery (CDS) for localized disease for solid malignancies found that the rates of CDS declined with increasing age for all cancers, especially noted for the aged elderly >70 years old. In addition, CDS was less likely to occur with patients found to have lung, esophagus, stomach, liver, or pancreatic cancer. A careful assessment of the general and cancer-related condition of the patient is crucial to planning the best surgical intervention and postoperative adjuvant therapy.

Formulating a comprehensive, multimodal treatment plan for an elderly patient with a malignancy amenable to surgical intervention is based on careful consideration of the patient's expected life span, specifically if the life span is expected to exceed survival from the malignancy. Additionally, considerations include the patient's ability to tolerate the surgery and any complications that may ensue, as well as the likelihood that the patient would suffer a complication from the cancer which would adversely impact quality of life.²⁴ An ongoing international study that is titled "Preoperative Assessment of Cancer in the Elderly (PACE)" is designed to evaluate a scoring system that aids in assessing the oncogeriatric patient for surgical intervention. The PACE study incorporates several validated instruments that assess the functional and physiologic status of patients, including the Mini Mental State Examination, capacity to perform ADLs, Geriatric Depression Scale, and the ASA classification among other useful instruments. Interestingly, the PACE assessment also includes The Physiological and Operative Severity Score which has been shown to predict morbidity and postoperative mortality in general surgery and in patients with lung and colorectal malignancy. This score includes the age of the patient and gives consideration to operative factors, including the type of surgical procedure used, the presence and extent of malignancy, and the timing of the operation (i.e., planned elective procedure or an emergency intervention).¹⁰ Palliative interventions are a part of the therapeutic armamentarium; however, a surgeon must weigh these variables carefully to determine which surgical intervention (i.e., palliative vs. curative) is appropriate.

Breast Cancer

It is projected that there will be a 72% increase in the number of elderly women diagnosed with breast cancer in the United States by 2025. Furthermore, 50% of breast cancers occur after the age of 65 years old and 25% after the age of 75 years old.²⁵ The estimated risk for development of new breast cancer is one in 14 women aged 60 to 79 years old compared to one in 24 in women aged 40 to 59 years old.²⁵ Mortality rates following breast cancer surgery in elderly women is <1%, and therefore, surgical interventions remain the cornerstone of therapy for breast cancer in elderly women. However, as expected, the presence of comorbid conditions affects clinical outcomes in elderly patients with breast cancer. A recent study demonstrated the presence of comorbid conditions in patients with breast cancer rose to as high as 55% in patients >80 years of age, with cardiovascular disease, diabetes, and previous cancer being most common.²⁶ As expected, the resulting 5-year survival rate was lower in patients with two or more comorbid conditions.

A recent study on risk factors for breast cancer in patients >75 years of age showed similarity to younger women and included obesity, nulliparity, family history, and advanced age at menopause.²⁷ Interestingly, although breast cancer presentation in elderly patients may be diagnosed at more advanced stages, both clinical and pathologic data demonstrate less aggressive disease

in elderly women with more favorable biologic characteristics. Elderly breast cancer patients are more likely to have estrogen-positive tumors and increasing endocrine responsiveness.²⁷ Despite these relative advantages, a large number of elderly women are not offered conventional therapies for breast cancer. Moreover, elderly patients who are offered breast conservation surgery for breast cancer are less likely to have axillary dissection, postoperative radiation, and chemotherapy. This will undoubtedly influence surgical outcomes in elderly patients with breast cancer considering that local recurrence rates after conservative surgery without radiotherapy are reported as high as 47%. Advancing age has been demonstrated to be an independent predictor of nonconcordance with treatment guidelines for definitive surgical therapy and adjuvant chemotherapy, as well as hormonal therapy. One study demonstrated that the odds of receiving a recommendation for chemotherapy decreased by 22% for each year of advancing patient age.²³ The nonsurgical management of breast cancer in elderly patients is falling out of favor because there is currently no rationale for denying surgical therapy for elderly breast cancer patients. Surgery and hormonal therapy were the best options for overall survival, breast cancer-specific survival, and disease-free survival. A Cochrane Review concluded that treatment with tamoxifen alone is not an acceptable option because of higher local progression of disease; 81% compared to 38% with surgical intervention. Furthermore, the response rate only lasts for approximately 18 to 24 months.²³ The final conclusion is that surgery remains the standard of care for elderly patients with breast cancer. Alternative therapies should be reserved for patients who have multiple comorbid conditions leading to poor candidacy for operative intervention, those who are frail, or those who refuse surgery.

A timely study comparing the mortality after breast-conserving surgery (BCS) alone, BCS plus radiation therapy, mastectomy, and the receipt of adjuvant tamoxifen in elderly breast cancer patients confirmed that less than standard treatment for these patients resulted in increased mortality. Elderly women receiving BCS without radiotherapy have more than twice the rate of breast cancer mortality compared to women undergoing mastectomy. In addition, in older women with estrogen receptor and progesterone receptor positive tumors receiving tamoxifen, the rate of breast cancer death increased substantially with the decreasing duration of tamoxifen use.²⁸ The standard of treatment for elderly patients with breast cancer should be the same as younger patients; BCS plus radiotherapy when indicated. If patients decline postoperative radiotherapy or are medically unfit for radiotherapy, mastectomy should be performed. Furthermore, elderly patients with tumor size <2 to 3 cm and no clinical evidence of axillary involvement should be offered sentinel node biopsy.²⁹

One of the most interesting controversies surrounding breast cancer in elderly women is the appropriate age limits of screening. A retrospective study demonstrated a decline in cancer-related mortality among women who underwent regular screening mammography up to 75 years of age.²⁷ Women who underwent at least two mammographic examinations between the ages of 70 and 79 years experienced a two-and-one-half-fold reduction in breast cancer mortality compared to elderly women who did not undergo screening.²³ The screening benefits depend on life expectancy. In women with multiple comorbidities, the decision to perform screening should be based on estimated life expectancy. People with <5 years of life expectancy are unlikely to benefit from screening. The American Geriatric Society recommends that screening should be individualized rather than set by age-specific guidelines. The current recommendation is that

no upper age limit for screening be set as long as the estimated life expectancy is 4 or more years.

Colorectal Cancer

The incidence of colorectal cancer (CRC) increases with advancing age, similar to most other malignant conditions. Approximately 90% of cases of CRC are diagnosed in patients >55 years old.³³ Of concern is the increased postoperative morbidity and mortality following extensive surgical resections in elderly patients, with a significant increase in patients >70 years old. In fact, in-hospital mortality for patients >85 years old undergoing surgery for colorectal malignancy is estimated to be nine-fold greater than for younger patients.³⁰ Furthermore, elderly patients often have decreased cancer-specific survival compared to younger patients. It has been proven that the 5-year cancer-specific survival for CRC is similar among the age cohorts. Therefore, age is not an independent factor accounting for the decreased survival among elderly patients. It is rather a consequence of comorbid conditions and impaired physical capacity necessary for recovery from perioperative physiological stress.³⁰ This leads to bias regarding poorer outcomes in elderly patients. For this reason, many elderly patients are receiving suboptimal cancer therapy and limited resections resulting in decreased survival rates and poorer outcomes. With the ever aging population, this must be addressed and clinical modifications implemented to improve outcomes of elderly patients undergoing surgical interventions for colorectal malignancies. Elderly patients should have continued, aggressive screening for colorectal malignancy and strict adherence to accepted surgical and adjuvant treatment guidelines.

One of the most important aspects to delivering appropriate care to elderly patients with CRC is to consider the patient's wishes as well as expectations from the surgical intervention. In this respect, functional outcomes and quality of life take precedence in treating elderly patients, especially the aged elderly. Of patients >75 years old who underwent elective surgery, few demonstrated protracted decline in ADLs and most experienced significant improvement in quality of life.³¹ Approximately 10% of elderly patients >80 years old have protracted postoperative disability. Estimation of physical ability and surgical stress is useful for predicting decline in ADLs and postoperative disability. It has been shown that, in patients <80 years of age, a complete resection for cure is most important, whereas in patients >80 years old, avoidance of a stoma becomes paramount. These are important considerations for the geriatric surgeon.³⁰

A prospective study was recently undertaken to specifically evaluate the epidemiology and risk of surgical intervention for CRC in elderly patients. A large cohort of 47,455 patients was divided based on age <75 years old and >75 years old.³⁰ It was determined that a significant portion of elderly CRC patients are female, with multiple comorbidities leading to advanced ASA levels of 3 and above. The study determined that elderly patients underwent surgical interventions less often than younger patients (81% vs. 88%, respectively, $P < .001$), more frequently required urgent or emergency operations, and were more likely to have operative procedures in which the primary cancer was not resected. Obstructive tumors are significantly more common in patients >70 years old, and elderly patients are still presenting far too commonly with surgical emergencies resulting from obstruction and perforation in up to 40% of the cases.¹¹ In addition, elderly patients had higher postoperative mortality than younger patients (10.6% vs. 3.8%, respectively). Right colectomies, Hartmann's procedures with colostomy,

transanal endoscopic microsurgery, and transanal resection of tumors were more common in elderly patients, whereas formal resections, including low anterior and abdominoperineal resections, were more common in younger patients.³⁰ Elderly patients are less likely to undergo CDS; with each half a decade increase in age >70 years old, the odds of receiving cancer-directed surgery were reduced by 44%. Interestingly, many of these patients presented with lesions of lower-stage Duke's cancer classification. However, this was not secondary to earlier presentations as one might assume, but rather secondary to understaging from surgical treatment. Accurate staging may not be possible with local resections, limiting the number of lymph nodes available for proper staging.³² Elderly patients also are less likely to undergo preoperative irradiation and neoadjuvant chemotherapy, reducing the likelihood of curative resection.³⁰

Liver resection for CRC liver metastases in properly selected elderly patients 70 years of age or greater is feasible with older patients having similar operative survival to younger patients. Palliative surgery remains a viable option for elderly patients with disseminated CRC and should be aimed at the reduction of symptoms such as pain, obstruction, or hemorrhage. Bowel obstruction can be relieved with intestinal bypass or a diverting colostomy. The most common site of disseminated disease is the liver, and uncontrolled liver metastases are responsible for pain, abdominal distention, jaundice, and inferior vena caval obstruction. Elderly patients with metastatic disease who are not candidates for curative resection may be considered for ablation of the lesions by local destruction, cryotherapy, or radiofrequency ablation. More traditional means such as chemotherapy, which can be administered via the hepatic artery or radiation, also may be used.³³

Similar to breast cancer, an upper age limit for CRC has not been clearly established. Screening for CRC may not lead to an observed survival benefit until 5 years or longer after screening had occurred. This would limit the benefit of screening in aged populations with limited life expectancy. An interesting way of looking at this controversy is from a recent study that determined that the number of screening colonoscopies needed to prevent one CRC-related death (the number necessary for survival or NNS) increased as with increasing age and comorbidities. For example, in healthy men and women aged 75 to 79 years old, the NNS was 50. The corresponding NNS in patients 90 years and older was 279 in women and 482 in men.³⁴ Consideration for continued screening in very elderly patients should take into account age and predicted life expectancy, comorbid burden, expected duration of the protective effect of screening, risk for cancer, results of previous screening colonoscopies, and patient preference.³⁴

Lung Cancer

Lung cancer is the leading cause of cancer-related deaths in the United States for patients >70 years old. National Cancer Institute statistics show that the peak incidence of lung cancer is between 75 and 79 years of age. Elderly lung cancer patients also have a higher mortality rate, and therefore, the peak mortality rate is between ages 75 and 84 years.³⁵ Non-small cell lung cancer accounts for roughly 80% of all lung cancer cases, and >50% of these patients are >65 years of age. Interestingly, approximately 30% of these patients are 70 years or older at diagnosis.³⁶ Lung cancer is highly prevalent among elderly patients, so much so that a 2-cm, asymptomatic, solitary pulmonary nodule in a 70-year-old male smoker has a >70% chance of being an occult lung cancer. Squamous cell carcinomas are more common among elderly patients than among younger

patients, and these tumors are associated with a higher incidence of local disease, tend to have lower recurrence rates, and have longer survival times than nonsquamous cancers.³⁵ In cases of resectable primary lung cancer, surgery remains the treatment of choice independent of age.¹¹

The estimated life expectancy of untreated lung cancer is approximately 9 months. This can increase to as high as 18 months with palliative chemotherapy and radiation. However, the life expectancy of an elderly patient who has undergone a successful operative resection is estimated to be as high as 31 months, making this the preferred option when feasible.¹³ However, despite this and the fact that more elderly patients present with stage I disease, elderly patients are offered curative surgery less frequently than younger counterparts. The same holds true for chemotherapy and radiation.

Advanced age is an independent risk factor for death after thoracotomy, with significantly increased mortality after age 65. These reasons are multifactorial partly due to the physiologic debilitation that occurs with division of the intrathoracic muscles that aid in respiratory function and the loss of lung volume after resections.¹³ One study demonstrated that patients 70 years of age or older who underwent thoracotomy for lung cancer had an operative mortality rate of 14%, which is directly related to the extent of the pulmonary resection. In one of the largest prospective, multi-institutional trials conducted, The Lung Cancer Study Group, increasing age led to a significant increase in 30-day mortality for patients undergoing thoracotomy and lung resection.¹³ They found overall mortality to be approximately 3.5% in patients <65 years old, which rose to 7.3% for patients 70 years or older and as high as 8.1% for octogenarians. However, with improved surgical options, including minimally invasive video-assisted thoracic surgery (VATS) in the past decade, the mortality rate has ranged from 3% to 5% in carefully selected patients.² In a recent study conducted to determine if VATS resulted in lower morbidity in the elderly population in comparison to open, rib-spreading thoracotomy, the overall morbidity for minimally invasive surgery was 28%; this increased to 45% with traditional open procedures.³⁶ Furthermore, elderly patients undergoing VATS tended to have less severe complications compared to patients undergoing thoracotomy.³⁶ Limited resections (segmentectomies) may be a consideration in elderly patients with limited life expectancy or poor cardiac and pulmonary reserve who may not tolerate a more extensive procedure. Some studies have shown that limited resections may provide a comparable survival rate to lobectomies in elderly patients as long as the resection includes all foci of tumors and provides a microscopically free margin. The most striking finding was that any survival difference between treatment modalities disappeared after 71 years of age. Interestingly, even smaller resections such as VATS and wedge resection may be a viable oncologic option in an elderly patient with resectable disease but limited life expectancy.¹³ This is limited to very small tumors <7 mm in diameter and not yet proven to be clinically efficacious. Of particular interest is that VATS procedures may result in lower rates of postoperative confusion in elderly patients and this may be secondary to the decreased physiologic stress of minimally invasive procedures, faster recovery rates, and decreased narcotic requirement for pain control.¹³ Careful preoperative selection and optimization combined with aggressive postoperative care and rehabilitation make surgical intervention for resectable disease feasible in aged populations.

Trauma

Patients >65 years of age currently account for approximately 23% of total hospital trauma admissions—many of which are multisystem and life threatening.³⁷ Geriatric trauma will continue to challenge surgeons in understanding the physical and physiologic impact of various mechanisms of injury, the need for careful assessment of comorbid conditions with particular attention to medication regimens, the rehabilitative capacity of an elderly trauma patient, and the knowledge of specific interventions that help to minimize morbidity and mortality in this population following traumatic injury.

The current geriatric population has fewer disabilities and is considerably more active than previous generations, which predisposes them to traumatic injuries. The most common type of trauma is blunt injury resulting from falls and motor vehicle collisions or pedestrian accidents. Falls currently account for 20% of severe injuries in elderly patients. Many underlying chronic and acute diseases common to elderly patients place them at increased risk for falls. These diseases include postural hypotension, leading to syncopal “drop attacks”; dysrhythmias from sick sinus syndrome; autonomic dysfunction; polypharmacy with improper dosage of antihypertensive and oral hypoglycemic agents resulting in hypotension; and hypoglycemia, respectively.³⁸

Elderly patients also can fall victim to penetrating trauma, especially in elderly patients who may have underlying depression and suicidal ideations or are victims of elder abuse. It is estimated that approximately 40% of all trauma patients by 2050 will be >65 years old.³⁹ With the expanding elderly population, this will be an increasing source of morbidity and mortality; the risk of death after major trauma with multi-system and life-threatening injuries rises steeply after age 45 years old and doubles by age 75 years old. In contrast to what is observed for abdominal and thoracic surgery, even after controlling for injury severity and pre-existing medical conditions, patients aged 65 years and older sustaining traumatic injury were 4.6 times more likely to die than younger patients.³⁹ Of note, there are several interesting aspects of care of the acutely injured elderly patient that must be kept in mind. First, physiologic reserve can be challenged by trauma. For example, previously unknown disease such as cardiac impairment may be acutely unmasked. Secondly, medications common to elderly patients, such as beta blockers and anticoagulation, cannot only inhibit the physiologic response to stress but may even worsen injury. Finally, elderly patients with impaired functional status posttrauma are more likely to lose their ability to function independently without the support of a nursing home.

Elderly patients are particularly susceptible to trauma due to changes that occur with aging, specifically, gait instability, decreased hearing and visual acuity, presence of confusion or dementia, underlying comorbid conditions, and poor to tolerate the physiologic stress of traumatic injuries. Pre-existing medical conditions increase the risk of death after trauma significantly (up to three-fold).³⁷ This is worsened when combined with an elderly patient’s decreased functional reserve for handling physiologic abnormalities accompanying major trauma, such as hypotension and hypoxia. It is important to consider a trauma patient’s age, as patients aged 65 to 80 years old have a 6.6% overall mortality rate after traumatic injury, which rises to 10% in patients 80 years or older.⁴²

Despite the increased risk of morbidity and mortality after traumatic injury, it is interesting to note that there is currently an undertriaging of elderly patients to level I trauma centers despite high injury severity scores.³⁹ In one study, elderly patients >65 years old were five times more likely to be

undertriaged to nondesignated trauma hospitals than younger counterparts.³⁹ However, a reduction in morbidity and mortality and posttraumatic complications as well as faster rehabilitation can result from better triaging practices. In one particular study involving acutely injured octogenarians with injury severity scores between 21 and 45, in-hospital survival was as high as 56% in trauma centers, and this dramatically decreased to 8% in those treated at nontrauma hospitals.³⁹

It is important to determine the medication regimen of elderly trauma patients. Medications such as beta blockers, calcium channel blockers, diuretics, and afterload reduction agents may impair critical augmentation of myocardial function in trauma patients, especially if they are hypovolemic. Approximately 20% of the elderly population with coronary artery disease and 10% of those with hypertension are currently on beta blocker therapy.³⁹ Therefore, tachycardia, one of the most valued signs of continued hypovolemia from either ongoing blood volume loss or underresuscitation, is lost in the elderly patient on beta blocker therapy. This makes interpretation of hemodynamic parameters in elderly patients inaccurate and, at times, misleading, which could lead to delays in appropriate interventions and resuscitation. However, it is important to keep in mind that, to date, evidence supporting early hemodynamic monitoring in elderly patients is lacking.

The other medication class that can be detrimental to an elderly, acutely injured patient is anticoagulation, ranging from aspirin and clopidogrel (Plavix) to warfarin, which may, at times, be supratherapeutic. Massive intracranial hemorrhages resulting from minor falls from standing in elderly patients are demonstrated in Fig. 47-4. Warfarin therapy may be used

in patients with atrial fibrillation, DVT, and prosthetic heart valves. The mortality rate of elderly patients on warfarin with a traumatic intracranial hemorrhage was 48% compared with 10% in an age-matched cohort not on anticoagulation therapy; it is unknown for the newer factor Xa inhibitors.³⁹ One of the most important caveats to treating elderly patients on anticoagulation with blunt head injury is the potential for significant, life-threatening intracranial hemorrhage despite initial normal head (computed tomography) CT scans. In one study, >70% of patients with minor mechanisms and negative CT scan, admitted for observation subsequently, clinically deteriorated within 12 hours of admission with a Glasgow Coma Scale of <10 and were subsequently found to have significant intracranial hemorrhages.³⁹ Therefore, prompt reversal of anticoagulation, particularly if supratherapeutic, is warranted to reduce morbidity and mortality following blunt head injury. In addition to increased risk of mortality in elderly patients sustaining blunt head trauma, a significant portion fail to resume functional independence after traumatic injury. It is estimated that approximately 20% to 25% of elderly trauma patients require discharge to a skilled nursing facility for long-term care and rehabilitation.³⁷ Poor functional outcome has been attributed to several factors among which are age >75 years old, presence of shock on admission, severe head injury, and development of infectious complications.

MINIMALLY INVASIVE SURGERY

Laparoscopy

Open abdominal procedures may require more intensive postoperative care, longer hospital stays, and an increased need for postoperative rehabilitation and possible institutionalization for elderly patients with limited reserve. However, the increasing experience with laparoscopic techniques, combined with minimized pain, decreased length of hospital stay, and low morbidity and mortality rates, has led to the increased use of minimal access procedures among elderly patients. It has expanded from cholecystectomies to more complex procedures, including colon resections, gastrectomies, and cardiac surgery.

Minimally invasive laparoscopic surgery reduces common postoperative complications such as atelectasis, gastrointestinal ileus, and wound infections. In elderly surgical patients, these complications easily progress to pneumonia, DVT, and metabolic and electrolyte disturbances.⁴⁰ Decreased postoperative pain from smaller incisions leads to faster return to a preoperative level of functioning, including early ambulation, which decreases complications from prolonged bed rest, such as DVT and pneumonia from compromised pulmonary mechanics. The latter is especially important for elderly patients because deconditioning occurs with long hospital stays, which depresses their ability to return to preoperative functional status. Laparoscopic surgery also provides the added benefit of reduction of the inflammatory, hormonal, and metabolic stress induced by major open surgical operations. The net result is that patients who undergo laparoscopic procedures may do better; in colon

6 ► surgery it has been shown to increase the chance that the patient returns home over an interim rehabilitation center.

However, these benefits must be balanced against the potential adverse effects of carbon dioxide (CO₂) insufflation and hemodynamic alterations induced by pneumoperitoneum and increased intra-abdominal pressure with concomitant decrease in venous return.⁴¹ Therefore, decisions to perform minimal access procedures in the elderly must be individualized to the patient

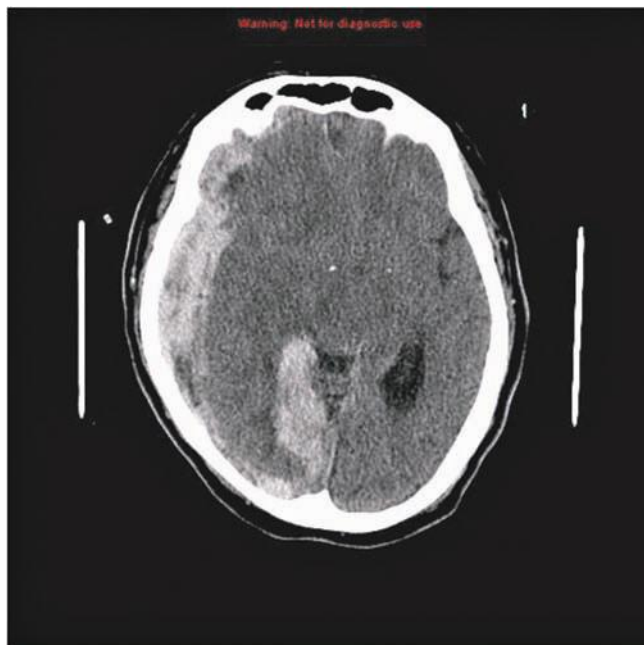


Figure 47-4. Massive intracranial hemorrhage resulting from seemingly minor trauma. An 86-year-old patient fell from a standing position and presented to the emergency room with six hours of injury with a Glasgow Coma Scale of 5 and a blood pressure of 167/55. She was on aspirin and clopidogrel therapy for ischemic heart disease, along with 14 other medications for congestive heart failure, diabetes, and hypertension. She expired from her intracranial wounds. (Photo used with permission of Dany Westerband, MD, Suburban Hospital, Bethesda, MD).

with careful consideration of the impact of comorbid conditions and the potential for poor cardiopulmonary reserves. This helps to provide the optimal circumstance for intervention resulting in improved surgical outcomes.

It is important to consider using a reduced intra-abdominal insufflation pressure during a laparoscopic procedure in an elderly patient. Pressures up to 20 mmHg are associated with increased filling pressures and cardiac output. However, further increased elevations result in decreased central venous pressures and cardiac output, which can be life threatening in a patient with preexisting cardiac dysfunction and poor functional reserve.

Studies have demonstrated that both advanced age >70 years old and an ASA classification of 3 or 4 are associated with higher conversion rates for laparoscopic cholecystectomy to open cholecystectomy.⁴² These additional challenges, however, are not a contraindication to attempting the less invasive approach because conversion to an open procedure does not adversely impact the overall morbidity and mortality of the patient.

A particularly useful application of minimally invasive techniques is to rule out a surgical abdomen in an elderly patient presenting with acute abdominal pain. Vague, poorly localized pain, further obscured by several underlying confounding comorbid conditions, as is the case with ischemic colitis and mesenteric ischemia, may subject an elderly patient with poor reserve to the risk of general anesthesia and a negative exploratory laparotomy (Fig. 47-5). Analysis of several studies directed at the application of laparoscopic techniques for the patient with acute abdominal pain demonstrated that approximately 41% had pathology necessitating open laparotomy, 10% had pathology amendable to laparoscopic intervention (i.e., acute cholecystitis), and 48% had nonsurgical disease that was subsequently managed nonoperatively, avoiding a negative exploration.⁴² Therefore, laparoscopic evaluation of abdominal pain in the critically ill elderly patient may prove to be a valuable tool.

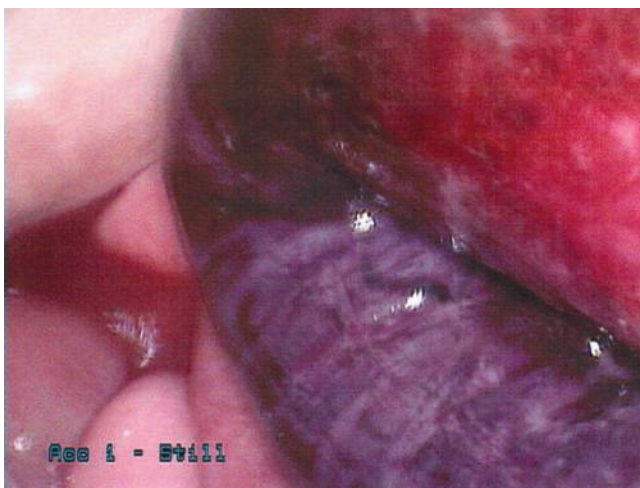

Figure 47-5. Diagnostic laparoscopy in an 80-year-old patient with abdominal pain, elevated white blood cell count and signs of bowel obstruction and sepsis. Comorbidities included severe aortic stenosis. Findings included a localized segment of bowel which was necrotic, associated with an adhesive band. The rest of the small intestine and colon were inspected, all of which were viable. A local resection was performed, and the patient recovered quickly.

Endovascular Surgery

Abdominal aortic aneurysm (AAA) is a disease that primarily affects the elderly male patient. With increasing use of screening abdominal CT scans and ultrasounds for evaluation of various abdominal complaints, AAAs are being identified with greater frequency, most of which are diagnosed in elderly patients, given the increased prevalence of AAA with increasing age. In fact, the percentage of AAA rises from about 1% at age 55 to 60 years to approximately 10% in patients 80 years of age or older.⁴³ Elderly patients, and octogenarians in particular, were deemed poor operative candidates for the traditional open repair given the frequent presence of comorbid conditions and limited cardiopulmonary reserve to tolerate a major operation or the many hours of required operative time and general anesthesia. Elderly patients had an increased perioperative morbidity and mortality following open aortic surgery in comparison to younger cohorts. However, the introduction of endovascular techniques for repair of AAA has shifted the risk-benefit ratio for operative intervention, allowing greater life expectancy for the elective repair of this potentially life-threatening condition with the benefits of minimally invasive techniques as previously described.

Studies have demonstrated that endovascular aortic repair (EVAR) is feasible and efficacious in elderly patients, including those previously considered unfit for open repair. EVAR is a minimally invasive technique in which a prosthetic graft is introduced into the aortic lumen via the common femoral artery to exclude the aortic aneurysm sac. EVAR significantly reduces operative and anesthesia times, blood loss, intensive care needs, length of stays, and major postoperative morbidity associated with open AAA repair. The most common complication following EVAR in elderly patients is renal impairment. Typically, patients are discharged 1 to 2 days following surgery and the graft is deployed via small bilateral groin incisions, obviating the need for a major laparotomy incision. Figure 47-6 demonstrates the endovascular repair of AAA and right iliac artery aneurysm via bilateral groin access in an 82-year-old man who was discharged from the hospital on postoperative Day 2. This procedure also can be done using epidural anesthesia for high-risk candidates who may tolerate general anesthesia poorly. Endovascular repair has even been described under local anesthesia in patients at extreme high risk of rupture and death or after rupture and hemodynamic instability, precluding the ability to tolerate general anesthesia.⁴⁴

Careful consideration of the life expectancy and the risk of rupture dictate the necessity for intervention. EVAR remains a viable option in elderly patients. Nonoperative management is justified in frail elderly patients with multiple comorbidities and reduced life expectancy whose operative risks outweigh the risk of rupture and in those who are unlikely to survive long enough to benefit from the repair.

THYROID SURGERY

The prevalence of thyroid disease increases with advancing age. The etiologies, risk factors, and presentations of thyroid disease are similar across all ages, and therefore, are not discussed in detail. Of note, however, is that elderly patients more often present with cardiac manifestations of hyperthyroidism, such as atrial fibrillation, than do their younger counterparts. A common finding requiring evaluation in elderly patients is

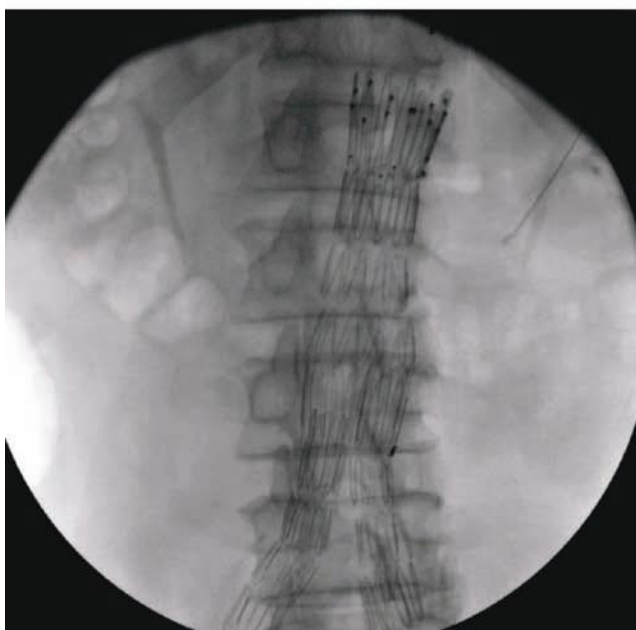
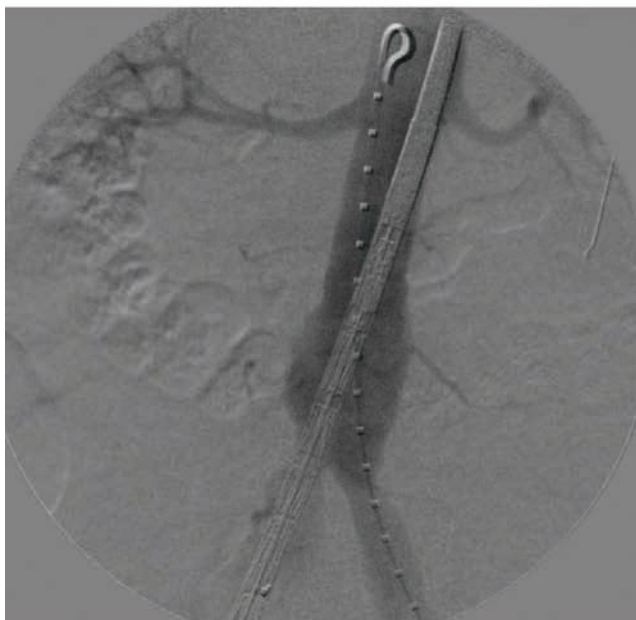
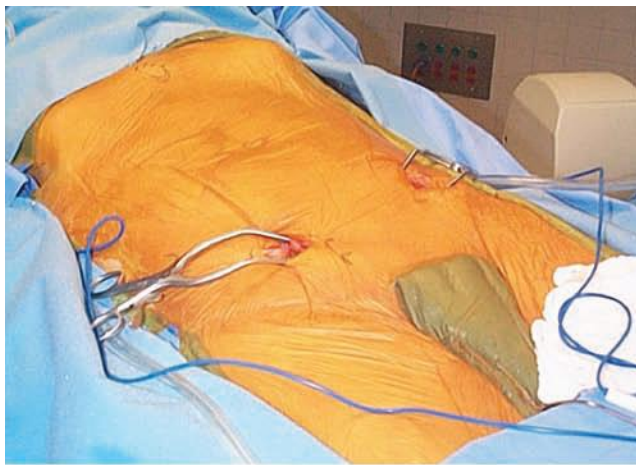
Figure 47-6. Endovascular repair of abdominal aortic aneurysms (AAAs) is gaining favor for suitable elderly patients to prevent rupture. Through minimal groin incisions, this 82-year-old patient underwent repair of an AAA and right iliac artery aneurysm and was discharged on postoperative day 2.

the presence of a thyroid nodule, usually detected by physical examination. These nodules usually are single and four times more common in women, making them a particular concern for postmenopausal elderly women. Papillary carcinoma in elderly patients tends to be sporadic with a bell-shaped distribution of age at presentation, occurring primarily in patients aged 30 to 59 years old. The incidence of papillary carcinoma decreases in patients >60 years of age.⁴⁵ However, patients >60 years of age have increased risk of local recurrence and for the development of distant metastases. Metastatic disease may be more common in this population secondary to delayed referral for surgical intervention because of the misconception that the surgeon will be unwilling to operate on an elderly patient with thyroid disease. Age is also a prognostic indicator for patients with follicular carcinoma. There is a 2.2 times increased risk of mortality from follicular carcinoma per 20 years of increasing age.⁴⁶ Therefore, prognosis for elderly patients with differentiated thyroid carcinomas is worse compared to younger counterparts. The higher prevalence of vascular invasion and extracapsular extension among older patients is, in part, responsible for the poorer prognosis in geriatric patients. Advancing age leads to increased mortality risk for patients with thyroid cancer and is demonstrated by the AMES (*age, metastases, extent of primary tumor, and size of tumor*) classification system developed by the Lahey Clinic.

PARATHYROID SURGERY

Approximately 2% of the geriatric population, including 3% of women 75 years of age or older, will develop primary hyperparathyroidism.⁴⁷ Geriatric patients are usually referred to surgery only when advanced disease is present because of concerns regarding the risks of surgery, but low rates of morbidity and negligible mortality combined with high cure rates of approximately 95% to 98% make parathyroidectomy safe and effective. Convincing evidence of the benefit of surgery is the usual marked symptomatic improvement, which greatly improves the quality of life for most patients. The National Institutes of Health Consensus Development Statement recommends curative therapy after diagnosis of primary hyperthyroidism is established in a patient regardless of age. Specific indications for operative intervention regardless of age include a 30% decrease in creatinine clearance, 24-hour urinary calcium excretion >400 mg, and decreased bone density.⁴⁸

Elderly patients are especially prone to developing mental manifestations of hyperparathyroidism that may be severe enough to produce a dementia-like state. There often is a significant improvement in mental status after parathyroidectomy. Another specific symptom of hyperparathyroidism that may easily be mistaken for osteoporosis and can be present in postmenopausal, elderly women is orthopedic disease; specifically back pain, and possibly, the occurrence of vertebral fractures. This pain can be of moderate intensity, leading to impaired mobility and severely affecting the quality of life of elderly patients. The decreased bone density observed in elderly patients with hyperparathyroidism tends to improve during the first 2 years after successful parathyroid surgery.

Limited parathyroidectomies with minimal dissection in geriatric patients are an effective alternative. This is a viable option in patients with multiple comorbid conditions in whom the increased risk of surgical intervention or general anesthesia remains a concern. One study demonstrated that preoperative

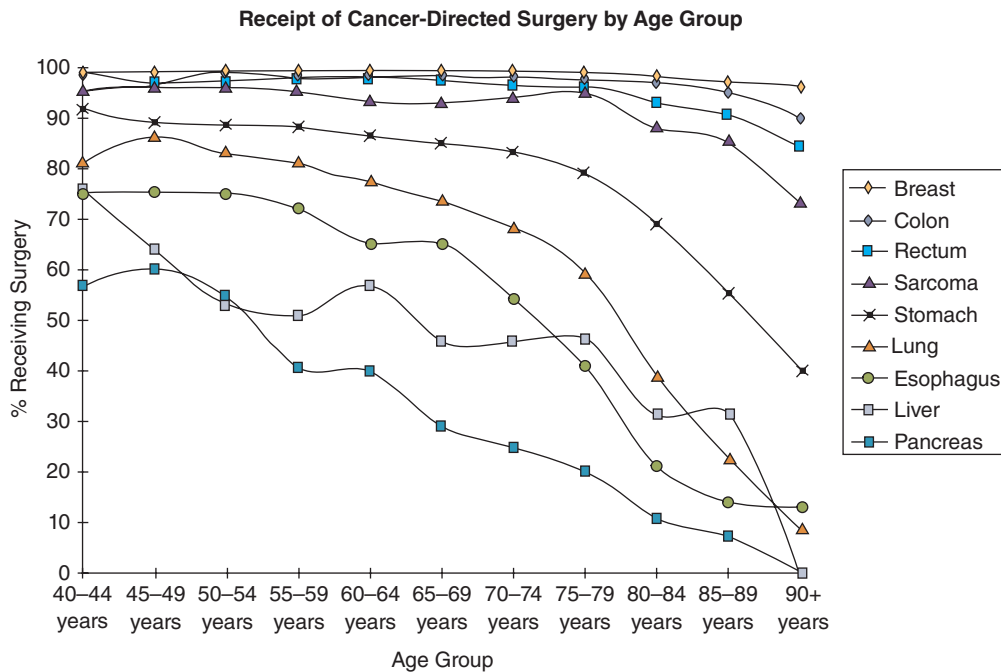


Figure 47-7. Decreased referrals of patients to oncologic surgery based on age. This graph includes potentially resectable lesions. The authors found that only 10% of patients over the age of 70 who had liver or pancreatic cancers were referred for cancer-directed surgery. (Reproduced with permission from O’Connell JB, Maggard MA, Ko CY. Cancer-directed surgery for localized disease: decreased use in the elderly. *Ann Surg Oncol.* 2004;11:962. With kind permission from Springer Science + Business Media.)

localization of the hyperfunctioning gland with the aid of ^{99m}Tc -sestamibi nuclear scanning, as well as intraoperative parathyroid hormone (PTH) assays to rapidly confirm that all hypersecreting glands have been removed, allows limited parathyroidectomy to be performed with accuracy in elderly patients.⁴⁷ This procedure is described as “limited” because bilateral neck dissection for identification and biopsy of the remaining glands to determine if they are hypersecreting becomes unnecessary. The half-life of intact PTH is approximately 3 to 4 minutes. Therefore, a drop in the intraoperative PTH level at approximately 10 minutes after resection of the suspect hypersecreting gland suggests a 98% probability that the patient will return to normocalcemic levels postoperatively.⁴⁷

PALLIATIVE SURGERY

Palliative surgery is defined as surgical intervention targeted to alleviate a patient’s symptoms, thus improving the patient’s quality of life despite minimal impact on the patient’s survival.⁵⁴ With an increasing number of aging surgical patients who often present with advanced disease, surgeons must be familiar with the concept of palliation to control disease. This concept focuses on providing the maximal benefit to the patient using the least-invasive intervention. Ultimately, this leads to symptom relief and preservation of the quality of life in terminal disease states. The uses of palliative surgery can range from extensive debulking operations aimed at aiding in the effectiveness of chemotherapy and radiation, to less complex operations to alleviate symptoms such as intractable vomiting, severe pain, cachexia, and anorexia that are common to terminal disease states. The success of palliative surgery is a careful balance between achieving symptom relief while ensuring that the development of new symptoms from the palliative intervention itself does not occur.

THE ROLE OF THE SURGEON IN GERIATRIC PATIENTS IS NOT LIMITED TO THE OR

The need for surgical input in helping elderly patients make decisions has never been more important. Inherent biases to age exist, such that patients who can be cured or palliated by surgical procedures are in many cases not being helped. For example, O’Connell demonstrated a decrease in referrals to surgery in aged patients with potentially curable oncologic illnesses, including those of breast, gastrointestinal, and lung (Fig. 47-7).⁵⁰ Only a surgeon with knowledge of the current best practice approach for the aged patient can help a patient—and his or her referring physicians—understand the real risks and potential benefits of an intervention, be it curative or palliative.

The challenge for us is to improve perioperative care of the elderly surgical patient using new tools for careful patient selection, accurately assess risk factors to reduce postoperative morbidity and mortality, and deliver quality surgical interventions without compromising functional vitality.

REFERENCES

Entries highlighted in bright blue are key references.

1. Chow WB, Rosenthal RA, Merkow RP, Ko CY, Esnaola NF; American College of Surgeons National Surgical Quality Improvement Program; American Geriatrics Society. Optimal preoperative assessment of the geriatric surgical patient: a best practices guideline from the American College of Surgeons National Surgical Quality Improvement Program and the American Geriatrics Society. *J Am Coll Surg.* 2012 Oct;215(4):453-466, doi: 10.1016/j.jamcollsurg.2012.06.017. Epub 2012 Aug 21.
2. Jaklitsch MT, Bueno R, Swanson SJ, et al. New surgical options for elderly lung cancer patients. *Chest.* 1999;116:480S-485.
3. Asmis TR, Ding K, Seymour L et al. Age and comorbidity as independent factors in the treatment of non-small cell

- lung cancer: a review of National Cancer Institute of Canada Clinical Trials Group Trials. *J Clin Oncol*. 2008;26:54-59.
4. Richardson J, Cocanour C, Kern J, et al. Perioperative risk assessment in the elderly and high risk patients. *J Am Coll Surg*. 2004;199:133-146.
 5. Williams SL, Jones PB, Pofahl WE. Preoperative management of the older patient—A surgeon's perspective: part 1. *Clin Geriatr*. 2006;14:24.
 6. Kwok AC, Semel ME, Lipsitz SR, et al. The intensity and variation of surgical care at the end of life: a retrospective cohort study. *Lancet*. 2011;378:1408-1413.
 7. Robinson TN, Eiseman B, Wallace JI, et al. Redefining geriatric preoperative assessment using frailty, disability and co-morbidity. *Ann Surg*. 2009;250:449-455.
 8. Zenilman ME. Surgery in the elderly. *Curr Probl Surg*. 1998;35:99-179.
 9. Hazen SE, Larsen PD, Martin JL. General anesthesia and elderly surgical patients. *AORN J*. 1997; 65:819.
 10. Pasetto LM, Lise M, Monfardini S. Preoperative assessment of elderly cancer patients. *Crit Rev Oncol Hematol*. 2007; 64:10.
 11. Ramesh HS, Pope D, Gennari R, et al. Optimising surgical management of elderly cancer patients. *World J Surg Oncol*. 2005; 3:17.
 12. Lorán DB, Zwischenberger JB, et al. Thoracic surgery in the elderly. *J Amer Coll Surg*. 2004;199:773, 2004.
 13. Jaklitsch MT, Pappas-Estocin A, Bueno R. Thoracoscopic surgery in elderly lung cancer patients. *Crit Rev Oncol Hematol*. 2004;49:154-171.
 14. Ergina PL, Gold SL, Meakins JL. Preoperative care of the elderly surgical patient. *World J Surg*. 1993;17:192-198.
 15. Beck LH. Perioperative renal, fluid, and electrolyte management. *Clin Geriatr Med*. 1990;6:557-569.
 16. Chen X, Xhao M, White PF, et al. The recovery of cognitive function after general anesthesia in elderly patients: a comparison of desflurane and sevoflurane. *Anesth Analg*. 93:1489-1494.
 17. Rosenthal RA. Nutritional concerns in the older surgical patient. *J Am Coll Surg*. 2004;199:785-791.
 18. Cerillo AG, Kodami AA, Solinas M, et al. Aortic valve surgery in the elderly patient: a retrospective review. *Interact Cardiovasc Thorac Surg*. 2007;6:308-313.
 19. Srinivasan AK, Oo AY, Grayson AD, et al. Mid-term survival after cardiac surgery in elderly patients: Analysis of predictors for increased mortality. *Interact Cardiovasc Thorac Surg*. 2004;3:289-293.
 20. Davis EA, Gardner TJ, Gillinov AM, et al. Valvular disease in the elderly: influence on surgical results. *Ann Thorac Surg*. 1993;55:333-337.
 21. Richmond TS, Kaunder D, Strumpf N, et al. Characteristics and outcomes of serious traumatic injury in older adults. *J Am Geriatr Soc*. 2002;50:215-222.
 22. Aziz S, Grover FL. Cardiovascular surgery in the elderly. *Cardiol Clin*. 1999;17:213-231.
 23. Giordano SH, Hortobagyi GN, Kau SC, et al. Breast cancer treatment guidelines in older women. *J Clin Oncol*. 2005;23: 783-791.
 24. Hoekstra HJ. Cancer surgery in the elderly. *Eur J Cancer*. 37:S235-S244.
 25. Dellapasqua S, Colleoni M, Castiglione M, et al. New criteria for selecting elderly patients for breast cancer adjuvant treatment studies. *Oncologist*. 2007;12:952-959.
 26. Scalliet P, Kirkove C. Breast cancer in elderly women: can radiotherapy be omitted? *Eur J Cancer*. 2007;43:2264.
 27. Gennari R. Breast cancer in elderly women. Optimizing the treatment. *Breast Cancer Res Treat*. 2008;110:199-209.
 28. Yood MU, Owusu C, Buist DSM, et al. Mortality impact of less than standard treatment in older breast cancer patients. *J Amer Coll Surg*. 2008;206:66-75.
 29. Wildiers H, Kunkler I, Biganzoli L, et al. Management of breast cancer in elderly individuals: recommendations of the International Society of Geriatric Oncology. *Lancet Oncol*. 2007;8:1101-1115.
 30. Tan E, Tilney H, Thompson M, et al. The United Kingdom National Bowel Cancer Project: Epidemiology and surgical risk in the elderly. *Eur J Cancer*. 2007;43:2285-2294.
 31. Amemiya T, Oda K, Ando M, et al. Activities of daily living and quality of life of elderly patients after elective surgery for gastric and colorectal cancers. *Ann Surg*. 2007;246:222-228.
 32. Chang GJ, Skibber JM, Feig BW. Are we undertreating rectal cancer in the elderly? *Ann Surg*. 2007;246:215-221.
 33. McCahill LE, Krouse RS, Chu DZ, et al. Decision making in palliative surgery. *J Am Coll Surg*. 2002; 195:411-422.
 34. Kahi CJ, Azzouz F, Juliar BE, Imperiale TF. Survival of elderly persons undergoing colonoscopy: implications for colorectal cancer screening and surveillance. *Gastrointest Endosc*. 2007;66:544-550.
 35. Mery CM, Pappas AN, Bueno R, et al. Similar long-term survival of elderly patients with non-small cell lung cancer treated with lobectomy or wedge resection within the surveillance, epidemiology, and end results database. *Chest*. 2005;28:237-245.
 36. Cattaneo SM, Park BJ, Wilton AS, et al. Use of video-assisted thoracic surgery for lobectomy in the elderly results in fewer complications. *Ann Thoracic Surg*. 2008;85:231-235.
 37. Richmond TS, Kaunder D, et al. Characteristics and outcomes of serious traumatic injuries in older adults. *J Am Geriatr Soc*. 2002;50:215-222.
 38. Rubenstein LZ, Josephson KR. The epidemiology of falls and syncope. *Clin Geriatr Med*. 2002;18:141-158.
 39. Chang TT, Schecter WP. Injury in the elderly and end-of-life decisions. *Surg Clin North Am*. 2007;87:229-245.
 40. Stewart BT, Stitz RW, Lumley JW. Laparoscopically assisted colorectal surgery in the elderly. *Br J Surg*. 1999;86:938-941.
 41. Ballista-Lopez C, Cid JA, Poves I, et al. Laparoscopic surgery in the elderly patient. *Surg Endosc*. 2003;17:333.
 42. Rosenthal RA, Zenilman ME, Katlic MR (eds). *Principles and Practice of Geriatric Surgery*. 2nd ed. New York: Springer-Verlag; 2011.
 43. Biebl M, Lau LL, Hakaim AG, et al. Midterm outcomes of endovascular abdominal aortic aneurysm repair in octogenarians: a single institution's experience. *J Vasc Surg*. 2004;40:435-442.
 44. Morales JP, Irani FG, Junes KG, et al. Endovascular repair of a ruptured aortic aneurysm under local anesthesia. *Brit J Radiol*. 2005;78:62-64.
 45. McConahey WM, Hay ID, Wodner LB, et al. Papillary thyroid cancer treated at the Mayo Clinic, 1946 through 1970: initial manifestations, pathologic findings, therapy, and outcome. *Mayo Clin Proc*. 1986;61:978-996.
 46. Mueller-Gaertner H, Brzac HT, Rehpenning W. Prognostic indices for tumor relapse and tumor mortality in follicular thyroid carcinoma. *Cancer*. 1991;67:1903-1911.
 47. Irvin GL, Carneiro DM. "Limited" parathyroidectomy in geriatric patients. *Ann Surg*. 2001;233:612-616.
 48. Sheldon DG, Lee FT, Neil NJ, Ryan JA Jr. Surgical treatment of hyperparathyroidism improves health related quality of life. *Arch Surg*. 2002;137:1022-1026.
 49. O'Connell JB, Maggard MA, Ko CY. Cancer-directed surgery for localized disease: decreased use in the elderly. *Ann Surg Oncol*. 2004;11(11):962-969.
 50. Sullivan DJ, Hansen-Flaschen J. Termination of life support after major trauma. *Surg Clin North Am*. 2000;80:1055-1066.
 51. Hinshaw DB, Carnahan JM, Johnson DL. Depression, anxiety, and asthenia in advanced illness. *J Am Coll Surg*. 2002;195:271-277.
 52. Dunn GP, Milch RA, Mosenthal AC, et al. Palliative care by the surgeon: how to do it. *J Am Coll Surg*. 2002;194:509-537.
 53. Conner SR. *Hospice: Practice, Pitfalls, and Promise*. Washington: Taylor and Francis; 1988.
 54. Sheehan DC, Forman WB. *Hospice and Palliative Care Concepts and Practice*. Boston: Jones and Bartlett; 1996.
 55. Breen CM, Abernethy AP, Abbott KM, et al. Conflict associated with decisions to limit life-sustaining treatment in intensive care units. *J Gen Intern Med*. 16:283-289.

This page intentionally left blank

48 chapter

Ethics, Palliative Care, and Care at the End of Life

Daniel E. Hall, Peter Angelos, Geoffrey P. Dunn, Daniel B. Hinshaw, and Timothy M. Pawlik

Why Ethics Matter	1941	General Principles of Palliative Care / 1946	Pronouncing Death / 1949
Definitions and Overview	1941	Concepts of Suffering, Pain, Health, and Healing / 1947	Professional Ethics: Conflict of Interest, Research, and Clinical Ethics
Specific Issues in Surgical Ethics	1942	Effective Communication and Negotiating the Goals of Care / 1947	1949
Informed Consent / 1942		Care at the End of Life	Conflict of Interest / 1949
The Boundaries of Autonomy: Advanced Directives and Powers of Attorney / 1944		1948	Research Ethics / 1952
Withdrawing and Withholding Life-Sustaining Therapies / 1945		The Syndrome of Imminent Demise / 1948	Special Concerns in Surgical Research / 1952
Palliative Care	1946	Common Symptoms at the End of Life and Their Management / 1948	Surgical Innovation and Surgical Research / 1952
			Clinical Ethics: Disclosure of Errors / 1952

Dedicated to the advancement of surgery along its scientific and moral side.

June 10, 1926, dedication on the Murphy Auditorium, the first home of the American College of Surgeons

WHY ETHICS MATTER

Ethical concerns involve not only the interests of patients, but also the interests of surgeons and society. Surgeons choose among the options available to them because they have particular opinions regarding what would be good (or bad) for their patients. Aristotle described practical wisdom (Greek: *phronesis*) as the capacity to choose the best option from among several imperfect alternatives (Fig. 48-1).¹ Frequently, surgeons are confronted with clinical or interpersonal situations in which there is incomplete information, uncertain outcomes, and/or complex personal and familial relationships. The capacity to choose wisely in such circumstances is the challenge of surgical practice.

DEFINITIONS AND OVERVIEW

Biomedical ethics is the system of analysis and deliberation dedicated to guiding surgeons toward the “good” in the practice of surgery. One of the most influential ethical “systems” in the field of biomedical ethics is the principlist approach as articulated by Beauchamp and Childress.² In this approach to ethical issues, moral dilemmas are deliberated by using four guiding principles: autonomy, beneficence, nonmaleficence, and justice.²

The principle of autonomy respects the capacity of individuals to choose their own destiny, and it implies a right for individuals to make those choices. It also implies an obligation for physicians to permit patients to make autonomous choices about their medical care. Beneficence requires that proposed actions aim

at and achieve something good whereas nonmaleficence aims at avoiding concrete harm: *primum non nocere*[®]. Justice requires fairness where both the benefits and burdens of a particular action are distributed equitably.

The history of medical ethics has its origins in antiquity. The Hippocratic Oath along with other professional codes has guided the actions of physicians for thousands of years. However, the growing technical powers of modern medicine raise new questions that were inconceivable in previous generations. Life support, dialysis, and modern drugs, as well as organ and cellular transplantation, have engendered new moral and ethical questions. As such, the ethical challenges faced by the surgeon have become more complex and require greater attention.

The case-based paradigm for bioethics is used when the clinical team encounters a situation in which two or more values or principles come into apparent conflict. The first step is to clarify the relevant principles (e.g., autonomy, beneficence, nonmaleficence, and justice) and values at stake (e.g., self-determination, quality of life, etc.). After identifying the principles and values that are affecting the situation, a proposed course of action is considered given the circumstances.

Much of the discourse in bioethics adopts this “principlist” approach in which the relevant principles are identified, weighed and balanced, and then applied to formulate a course of action. This approach to bioethics is a powerful technique for thinking through moral problems because the four principles help identify what is at stake in any proposed course of action. However, the principles themselves do not resolve ethical dilemmas. Working together, patients and surgeons must use wise judgment to choose the best course of action for the specific case.

Choosing wisely requires the virtue of practical wisdom first described by Aristotle (Fig. 48-1). Along with the other cardinal virtues of courage, justice and temperance, practical wisdom is a central component of virtue ethics which complement principlist

*“First do no harm.”

Key Points

- 1▶ The physician should document that the patient or surrogate has the capacity to make a medical decision.
- 2▶ The physician discloses to the patient details regarding the diagnosis and treatment options sufficient for the patient to make an informed consent.
- 3▶ Living wills are written to anticipate treatment options and choices in the event that a patient is rendered incompetent by a terminal illness.
- 4▶ The durable power of attorney for healthcare identifies surrogate decision makers and invests them with the authority to make healthcare decisions on the patient's behalf in the event that they are unable to speak for themselves.
- 5▶ Surgeons should encourage their patients to clearly identify their surrogates early in the course of treatment.
- 6▶ Earlier referral and wider use of palliative and hospice care may help more patients achieve their goals at the end of life.
- 7▶ Seven requirements for the ethical conduct of clinical trials have been articulated: value, scientific validity, fair subject selection, favorable risk-benefit ratio, independent review, informed consent, and respect for enrolled subjects.
- 8▶ Disclosure of error is consistent with recent ethical advances in medicine toward more openness with patients and the involvement of patients in their care.

ethics by guiding choices toward the best options for treatment. Practical wisdom cannot be learned from books and is developed only through experience. The apprenticeship model of surgical residency fosters the development of practical wisdom through experience. More than teaching merely technical mastery, surgical residency is also moral training. In fact, the sociologist Charles Bosk argues that the “postgraduate training of surgeons is above all things an ethical training.”³




Figure 48-1. Bust of Aristotle. Marble, Roman copy after a Greek bronze original by Lysippos from 330 B.C. [From http://en.wikipedia.org/wiki/File:Aristotle_Altemps_Inv8575.jpg: Ludovisi Collection, Accession number Inv. 8575, Palazzo Altemps, Location Ground Floor, Branch of the National Roman Museum. Photographer/source Jastrow (2006) from Wikipedia (accessed April 8, 2014).]

SPECIFIC ISSUES IN SURGICAL ETHICS

Informed Consent

Although a relatively recent development, the doctrine of informed consent is one of the most widely established tenets of modern biomedical ethics. During the nineteenth and early twentieth centuries, most physicians practiced a form of benign paternalism whereby patients were rarely involved in the decision-making process regarding their medical care, relying instead on the beneficence of the physician. Consensus among the wider public eventually changed such that surgeons are now expected to have an open discussion about diagnosis and treatment with the patient to obtain informed consent. In the United States, the legal doctrine of *simple* consent dates from the 1914 decision in *Schloendorff vs. The Society of New York Hospital* regarding a case in which a surgeon removed a diseased uterus after the patient had consented to an examination under anesthesia, but with the express stipulation that no operative excision should be performed. The physician argued that his decision was justified by the beneficent obligation to avoid the risks of a second anesthetic. However, Justice Benjamin Cardozo stated:

*Every human being of adult years and sound mind has a right to determine what shall be done with his body; and a surgeon who performs an operation without his patient's consent commits an assault, for which he is liable in damages . . . except in cases of emergency, where the patient is unconscious, and where it is necessary to operate before consent can be obtained.*⁴

Having established that patients have the right to determine what happens to their bodies, it took some time for the modern concept of *informed* consent to emerge from the initial doctrine of *simple* consent. The initial approach appealed to a *professional practice standard* whereby physicians were obligated to disclose to patients the kind of information that experienced surgeons customarily disclosed.⁵ However, this disclosure was not always adequate for patient needs. In the 1972 landmark case, *Canterbury vs. Spence*, the court rejected the professional practice standard in favor of the *reasonable person standard* whereby physicians are obliged to disclose to patients all information regarding diagnosis, treatment options, and risks that a “reasonable patient” would want to know in a similar situation. Rather than relying on the practices or consensus of the medical community, the reasonable person standard empowers

the public (reasonable persons) to determine how much information should be disclosed by physicians to ensure that consent is truly informed. The court did recognize, however, that there are practical limits on the amount of information that can be communicated or assimilated.⁵ Subsequent litigation has revolved around what reasonable people expect to be disclosed in the consent process to include the nature and frequency of potential complications, the prognostic life expectancy,⁶ and the surgeon-specific success rates.⁴ Despite the litigious environment of medical practice, it is difficult to prosecute a case of inadequate informed consent so long as the clinician has made a concerted and documented effort to involve the patient in the decision-making process.

Adequate informed consent entails at least four basic elements: (a) the physician documents that the patient or surrogate has the capacity to make a medical decision; (b) **1▶** the surgeon discloses to the patient details regarding the diagnosis and treatment options sufficiently for the patient to make an informed choice; (c) **2▶** the patient demonstrates understanding of the disclosed information before (d) authorizing freely a specific treatment plan without undue influence (Fig. 48-2). These goals are aimed at respecting each patient's prerogative for autonomous self-determination. To accomplish these goals, the surgeon needs to engage in a discussion about the causes and nature of the patient's disease, the risks and benefits of available treatment options, as well as details regarding what patients can expect after an operative intervention.⁷⁻¹⁴

Informed consent can be challenging in certain clinical settings. For example, obtaining consent for emergency surgery, where decisions are often made with incomplete information,

can be difficult. Emergency consent requires the surgeon to consider if and how possible interventions might save a patient's life, and if successful, what kind of disability might be anticipated. Surgical emergencies are one of the few instances where the limits of patient autonomy are freely acknowledged, and surgeons are empowered by law and ethics to act promptly in the best interests of their patients according to the surgeon's judgment. Most applicable medical laws require physicians to provide the standard of care to incapacitated patients, even if it entails invasive procedures without the explicit consent of the patient or surrogate. If at all possible, surgeons should seek the permission of their patients to provide treatment, but when emergency medical conditions render patients unable to grant that permission, and when delay is likely to have grave consequences, surgeons are legally and ethically justified in providing whatever surgical treatment the surgeon judges necessary to preserve life and restore health.⁴ This justification is based on the social consensus that most people would want their lives and health protected in this way, and this consensus is manifest in the medical profession's general orientation to preserve life. It may be that subsequent care may be withdrawn or withheld when the clinical prognosis is clearer, but in the context of initial resuscitation of injured patients, incomplete information makes clear judgments about the patient's ultimate prognosis or outcome impossible.

The process of consent can also be challenging in the pediatric population. For many reasons, children and adolescents cannot participate in the process of giving informed consent in the same way as adults. Depending on their age, children may lack the cognitive and emotional maturity to participate fully

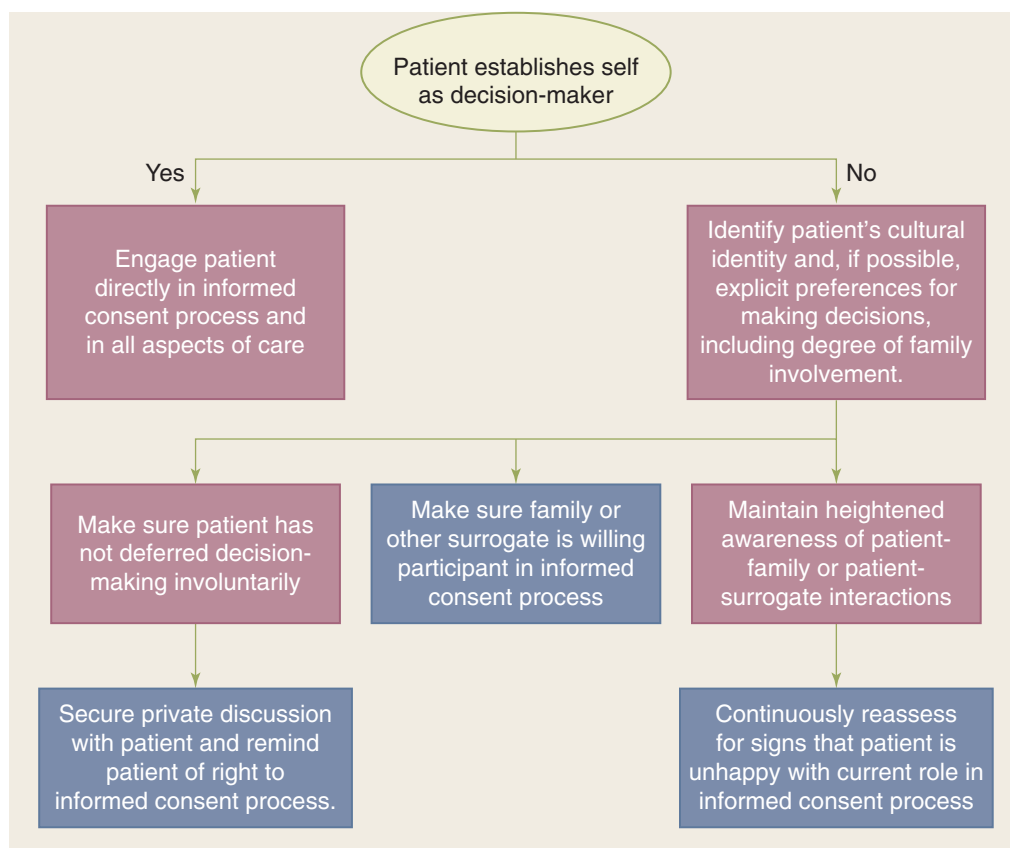


Figure 48-2. Algorithm for navigating the process of informed consent. (From Childers R, Lipsett A, Pawlik T. *Informed consent and the surgeon*. *J Am Coll Surg*. E-pub Jan. 21, 2009. Copyright 2009, with permission from Elsevier.)

in the process. In addition, depending on the child's age, their specific circumstances, as well as the local jurisdiction, children may not have legal standing to fully participate on their own independent of their parents. The use of parents or guardians as surrogate decision makers only partially addresses the ethical responsibility of the surgeon to involve the child in the informed consent process. The surgeon should strive to augment the role of the decision makers by involving the child in the process. Specifically, children should receive age-appropriate information about their clinical situation and therapeutic options so that the surgeon can solicit the child's "assent" for treatment. In this manner, while the parents or surrogate decision makers formally give the informed consent, the child remains an integral part of the process.

Certain religious practices can present difficulties in treating minor children in need of life-saving blood transfusions; however, case law has made clear the precedent that parents, regardless of their held beliefs, may not place their minor children at mortal risk. In such a circumstance, the physician should seek counsel from the hospital medicolegal team, as well as from the institutional ethics team. Legal precedent has, in general, established that the hospital or physician can proceed with providing all necessary care for the child.

Obtaining "consent" for organ donation deserves specific mention.¹⁵ Historically, discussion of organ donation with families of potential donors was performed by transplant professionals, who were introduced to families by intensivists after brain death had been confirmed and the family had been informed of the fact of death. In other instances, consent might be obtained by intensivists caring for the donor, as they were assumed to know the patient's family and could facilitate the process. However, issues of moral "neutrality" as part of end-of-life care in the intensive care unit have caused a shift in how obtaining "consent" for organ donation is handled. Responsibility for obtaining consent from the donor family is now vested in trained "designated requestors" (or "organ procurement coordinators")¹⁶ or by "independent" intensivists who do not have a therapeutic clinical relationship with the potential donor.¹⁷ In this way, the donor family can be allowed to make the decision regarding donation in a "neutral" environment without erosion of the therapeutic relationship with the treating physician.

The process of informed consent also can be limited by the capacity of patients to assimilate information in the context of their illness. For example, despite the best efforts of surgeons, evidence suggests that patients rarely retain much of what is disclosed in the consent conversation, and they may not remember discussing details of the procedure that become relevant when postoperative complications arise.¹⁸ It is important to recognize that the doctrine of informed consent places the most emphasis on the principle of autonomy precisely in those clinical situations when, because of their severe illness or impending death, patients are often divested of their autonomy.

The Boundaries of Autonomy: Advanced Directives and Powers of Attorney

Severe illness and impending death can often render patients incapable of exercising their autonomy regarding medical decisions. One approach to these difficult situations is to make decisions in the "best interests" of patients, but because such decisions require value judgments about which thoughtful people frequently disagree, ethicists, lawyers, and legislators have sought a more reliable solution. Advanced directives of

various forms have been developed to carry forward into the future the autonomous choices of competent adults regarding health care decisions. Furthermore, the courts often accept "informal" advanced directives in the form of sworn testimony about statements the patient made at some time previous to their illness. When a formal document expressing the patient's advanced directives fails to exist, surgeons should consider the comments patients and families make when asked about their wishes in the setting of debilitating illness.

Living wills are written to anticipate treatment options and choices in the event that a patient is incapacitated by a terminal illness. In the living will, the patient indicates which treatments she wishes to permit or prohibit in the setting of terminal illness. The possible treatments addressed often include mechanical ventilation, cardiopulmonary resuscitation, artificial nutrition, dialysis, antibiotics, or transfusion of blood products. Unfortunately, living wills are often too vague to offer concrete guidance in complex clinical situations, and the language ("terminal illness," "artificial nutrition") can be interpreted in many ways. Furthermore, by limiting the directive only to "terminal" conditions, it does not provide guidance for common clinical scenarios like advanced dementia, delirium, or persistent vegetative states where the patient is unable to make decisions, but is not "terminally" ill. Perhaps even more problematic is the evidence that demonstrates that healthy patients cannot reliably predict their preferences when they are actually sick. This phenomenon is called "affective forecasting" and applies to many situations. For example, the general public estimates the health-related quality of life (HRQoL) score of patients on dialysis at 0.39, although dialysis patients themselves rate their HRQoL at 0.56.¹⁹ Similarly, patients with colostomies rated their HRQoL at 0.92, compared to a score of 0.80 given by the general public for patients with colostomies.¹⁹ For these and other reasons, living wills are often unable to provide the extent of assistance they promise.²⁰

An alternative to living wills is the durable power of attorney for health care in which patients identify surrogate decision makers and invest them with the authority to make health care decisions on their behalf in the event that they are unable to speak for themselves. Proponents of this approach hope that the surrogate will be able to make decisions that reflect the choices that the patients themselves would make if they were able. Unfortunately, several studies demonstrate that surrogates are not much better than chance at predicting the choices patients make when the patient is able to state a preference. For example, a recent meta-analysis found that surrogates predicted patients' treatment preferences with only 68% accuracy.²¹ These data reveal a flaw in the guiding principle of surrogate decision making: Surrogates do not necessarily have privileged insight into the autonomous preferences of patients. However, the durable power of attorney at least allows patients to choose the person who will eventually make prudential decisions on their behalf and in their best interests; therefore, respecting the judgment of the surrogate is a way of respecting the self-determination of the incapacitated patient.²²

There is continuing enthusiasm for a wider use of advanced directives. In fact, the 1991 Patient Self Determination Act requires all U.S. health care facilities to (a) inform patients of their rights to have advanced directives, and (b) to document those advanced directives in the chart at the time any patient is admitted to the health care facility.⁴ However, only a minority of patients in U.S. hospitals have advanced directives despite

concerted efforts to teach the public of their benefits. For example, the ambitious SUPPORT trial used specially trained nurses to promote communication between physicians, patients, and their surrogates to improve the care and decision making of critically ill patients. Despite this concerted effort, the intervention demonstrated “no significant change in the timing of do not resuscitate (DNR) orders, in physician-patient agreement about DNR orders, in the number of undesirable days (patients experiences), in the prevalence of pain, or in the resources consumed.”²³

Some of the reluctance around physician-patient agreement about DNR orders may reflect patient and family anxiety that DNR orders equate to “do not treat.” Patients and families should be assured, when appropriate, that declarations of DNR/do not intubate will not necessarily result in a change in ongoing routine clinical care. The issue of temporarily rescinding DNR/do not intubate orders around the time of an operative procedure may also need to be addressed with the family.

Patients should be encouraged to clearly identify their surrogates, both formally and informally, early in the course of treatment, and before any major elective operation. Often, **5▶** around the time of surgery or at the end of life, there are limits to patient autonomy in medical decision making. Seeking an advanced directive or surrogate decision maker requires time that is not always available when the clinical situation deteriorates. As such, these issues should be clarified as early as possible in the patient-physician relationship.

Withdrawing and Withholding Life-Sustaining Therapies

The implementation of various forms of life support technology raise a number of legal and ethical concerns about when it is permissible to withdraw or withhold available therapeutic technology. There is general consensus among ethicists that there are no philosophic differences between withdrawing (stopping) or withholding (not starting) treatments that are no longer beneficial.²⁴ However, the right to refuse, withdraw, and withhold beneficial treatments was not established before the landmark case of Karen Ann Quinlan. In 1975, Quinlan lapsed into a persistent vegetative state requiring ventilator support. After several months without clinical improvement, Quinlan’s parents asked the hospital to withdraw ventilator support. The hospital refused, fearing prosecution for euthanasia. The case was appealed to the New Jersey Supreme Court where the justices ruled that it was permissible to withdraw ventilator support.²⁵ This case established a now commonly recognized right to withdraw “extraordinary” life-saving technology if it is no longer desired by the patient or the patient’s surrogate.

The difference between “ordinary” and “extraordinary” care, and whether there is an ethical difference in withholding or withdrawing “ordinary” vs. “extraordinary” care, has been an area of much contention. The 1983 Nancy Cruzan case highlighted this issue. In this case, Cruzan had suffered severe injuries in an automobile crash that rendered her in a persistent vegetative state. Cruzan’s family asked that her tube feeds be withheld, but the hospital refused. The case was appealed to the U.S. Supreme Court, which ruled that the tube feeding could be withheld if her parents demonstrated “clear and convincing evidence” that the incapacitated patient would have rejected the treatment.²⁶ In this ruling, the court essentially ruled that there was no legal distinction between “ordinary” vs. “extraordinary” life-sustaining therapies.²⁷ In allowing the feeding tube to be

removed, the court accepted the principle that a competent person (even through a surrogate decision maker) has the right to decline treatment under the Fourteenth Amendment of the U.S. Constitution. The court noted, however, that there has to be clear and convincing evidence of the patient’s wishes (principle of autonomy) and that the burdens of the medical intervention should outweigh its benefits (consistent with the principles of beneficence and nonmaleficence).

In deliberating the issue of withdrawing vs. withholding life-sustaining therapies, the principle of “double effect” is often mentioned. According to the principle of “double effect,” a treatment (e.g., opioid administration in the terminally ill) that is intended to help and not harm the patient (i.e., relieve pain) is ethically acceptable even if an unintended consequence (side effect) of its administration is to shorten the life of the patient (e.g., by respiratory depression). Under the principle of double effect, a physician may withhold or withdraw a life-sustaining therapy if the surgeon’s *intent* is to relieve suffering, not to hasten death. The classic formulation of double effect has four elements (Fig. 48-3).

Withholding or withdrawing of life-sustaining therapy is ethically justified under the principle of double effect if the physician’s intent is to relieve suffering, not to kill the patient. Thus, in managing the distress of the dying, there is a fundamental ethical difference between titrating medications rapidly to achieve relief of distress and administering a very large bolus with the intent of causing apnea. It is important to note, however, that although the use of opioids for pain relief in advanced illness is frequently cited as the classic example of the double effect rule, opioids can be used safely without significant risk. In fact, if administered appropriately, in the vast majority of instances the

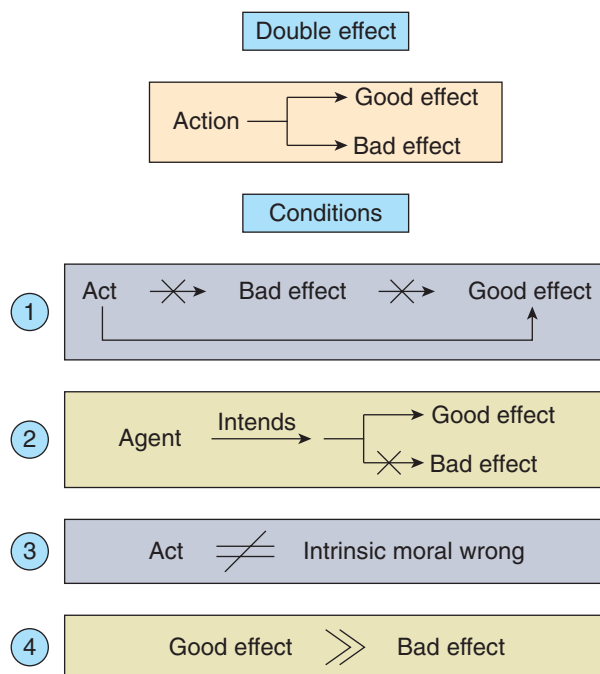


Figure 48-3. The four elements of the double effect principle: a) The good effect is produced directly by the action and not by the bad effect. b) The person must intend only the good effect, even though the bad effect may be foreseen. c) The act itself must not be intrinsically wrong, or needs to be at least neutral. d) The good effect is sufficiently desirable to compensate for allowing the bad effect.

rule of double effect need not be invoked when administering opioids for symptom relief in advanced illness.²⁸

In accepting the ethical equivalence of withholding and withdrawing of life-sustaining therapy, surgeons can make difficult treatment decisions in the face of prognostic uncertainty.²⁴ In light of this, some important principles to consider when considering withdrawal of life-sustaining therapy include: (a) Any and all treatments can be withdrawn. If circumstances justify withdrawal of one therapy (e.g., IV pressors, antibiotics), they may also justify withdrawal of others; (b) Be aware of the symbolic value of continuing some therapies (e.g., nutrition, hydration) even though their role in palliation is questionable; (c) Before withdrawing life-sustaining therapy, ask the patient and family if a spiritual advisor (e.g., pastor, imam, rabbi, or priest) should be called; and (d) Consider requesting an ethics consult.

Although the clinical setting may seem limited, a range of options usually exists with respect to withdrawing or withholding treatment, allowing for an incremental approach, for example (a) continuing the current regimen without adding new interventions or tests; (b) continuing the current regimen but withdrawing elements when they are no longer beneficial; and (c) withdrawing and withholding all treatments that are not targeted to relieve symptoms and maximize patient comfort.²⁹

The surgeon might consider discussing the clinical situation with the patient or proxy decision maker, identify the various therapeutic options, and delineate the reasons why withholding or withdrawing life-sustaining therapy would be in the patient's best interest. If the patient (or designated proxy decision maker) does not agree with withholding or withdrawing life-sustaining therapy, the surgeon should consider or recommend a second medical opinion. If the second opinion corroborates that life-sustaining therapy should be withheld or withdrawn but the patient/family continues to disagree, the surgeon should consider assistance from institutional resources such as the ethics committee and hospital administration. Although the surgeon is not ethically obligated to provide treatment that he or she believes is futile, the surgeon is responsible for continued care of the patient, which may involve transferring the patient to a surgeon who is willing to provide the requested intervention.²⁴

PALLIATIVE CARE

General Principles of Palliative Care

Palliative care is a coordinated, interdisciplinary effort that aims to relieve suffering and improve quality of life for patients and their families in the context of serious illness.³⁴ It is offered simultaneously with all other appropriate medical treatment, and its indication is not limited to situations associated with a poor prognosis for survival. Palliative care strives to achieve more than symptom control, but it should not be confused with noncurative treatment.

The World Health Organization defines palliative care as “an approach that improves the quality of life of patients and their families facing the problems associated with life-threatening illness, through the prevention and relief of suffering by means of early identification and impeccable assessment and treatment of pain and other problems, physical, psychosocial, and spiritual.”²⁹ Palliative care is both a philosophy of care and an organized, highly structured system for delivering care.

Palliative care includes the entire spectrum of intervention for the relief of symptoms and the promotion of quality of life.

No specific therapy, including surgical intervention, is excluded from consideration. Therefore, surgeons have valuable contributions to make to palliative care. In fact, the term *palliative care* was coined in 1975 by Canadian surgeon, Balfour Mount. Furthermore, *surgical palliative care* can be defined as the treatment of suffering and the promotion of quality of life for seriously or terminally ill patients under the care of surgeons.³¹ The standard of palliative treatment lies in the agreement between patient and physician that the expected outcome is relief from distressing symptoms, lessening of pain, and improvement of quality of life. The decision to intervene is based on the treatment's ability to meet the stated goals, rather than its impact on the underlying disease.

The fundamental elements of palliative care consist of pain and nonpain symptom management, communication among patients, their families, and care providers, and continuity of care across health systems and through the trajectory of illness. Additional features of system-based palliative care are team-based planning that includes patient and family; close attention to spiritual matters; and psychosocial support for patients, their families, and care providers, including bereavement support.

Indications for palliative care consultation in surgical practice include: (a) patients with conditions that are progressive and life-limiting, especially if characterized by burdensome symptoms, functional decline, and progressive cognitive deficits; (b) assistance in clarification or reorientation of patient/family goals of care; (c) assistance in resolution of ethical dilemmas; (d) situations in which a patient/surrogate declines further invasive or curative treatments with stated preference for comfort measures only; (e) patients who are expected to die imminently or shortly after hospital discharge; and (f) provision of bereavement support for patient care staff, particularly after loss of a colleague under care³¹ (Table 48-1). Although all patients, regardless of prognosis, may benefit from the services of a palliative care physician, hospice care is a specific form of palliative care intended for patients who have an estimated prognosis of 6 months or less to live. Hospice care is covered under Medicare Part A, and benefits may be continued beyond the original 6 months of estimated survival if physicians certify that life expectancy remains limited to 6 months or less.

▶ Although most Americans indicate a preference to die at home, nearly 75% die in an institutional setting. Earlier referral and wider use of the hospice benefit may help more patients achieve their goal of dying at home.

Table 48-1

Indications for palliative care consultation

Patients with conditions that are progressive and life-limiting, especially if characterized by burdensome symptoms, functional decline, and progressive cognitive deficits
Assistance in clarification or reorientation of patient/family goals of care
Assistance in resolution of ethical dilemmas
Situations in which patient/surrogate declines further invasive or curative treatments with stated preference for comfort measures only
Patients who are expected to die imminently or shortly after hospital discharge
Provision of bereavement support for patient care staff, particularly after loss of a colleague under care

Concepts of Suffering, Pain, Health, and Healing

Palliative care addresses specifically the individual patient's experience of suffering due to illness. Indeed, the philosophical origins of palliative care began with attention to suffering and the existential questions suffering engenders. More than mere technologic evolution in the management of symptoms, the early proponents of palliative care sought a revolution in the moral foundations of medicine that challenged the assumptions that so often seemed to result in futile invasive intervention, and identified many of the problems that were subsequently taken up by medical ethicists. This reorientation of the goals of medical care from a focus on disease and its management to the patient's experience of illness focuses attention on the purpose of medicine and the meaning of health and healing.

Over the past half century, several concepts and theories about the nature of pain, suffering, and health have been proposed in service of the evolving conceptual framework of palliative care. For example, while considering the differences between disease-oriented and illness-oriented approaches to the care of seriously ill patients, psychiatrist Arthur Kleinman wrote, "There is a moral core to healing in all societies. [Healing] is the central purpose of medicine . . . the purpose of medicine is both control of disease processes and care for the illness experience. Nowhere is this clearer than in the relationship of the chronically ill to their medical system: For them, the control of disease is by definition limited; care for the life problems created by the disorder is the chief issue."³⁴

The relief of pain has been the clinical foundation for hospice and palliative care. It has been defined by the International Association for the Study of Pain as "An unpleasant sensory and emotional experience associated with actual or potential tissue damage, or described in terms of such damage."³⁵ For purposes of interdisciplinary palliative care, Saunders's concept of "Total Pain"³¹ is a more useful definition and is frequently used as the basis for palliative assessments. Total Pain is the sum total of four principal domains of pain: physical, psychologic, social or socioeconomic, and spiritual. Each of these contributes to, but is not synonymous with, suffering.

Effective Communication and Negotiating the Goals of Care

Changing the goals of care from cure to palliation near the end of life is both emotionally and clinically challenging, and it depends on a clear prognosis and effective communication. Unfortunately, prognostication can be notoriously difficult and inaccurate in advanced illness, and Christakis has argued that, to a large degree, physicians have abdicated their traditional responsibility to provide clear prognosis regarding incurable disease and approaching death.³⁷ However, there are validated tools for prognosis in critical illness (APACHE, MODS, etc.), and with most advanced diseases, functional status is the most powerful predictor of survival. For example, patients with advanced metastatic cancer who are resting/sleeping for 50% or more of normal waking hours and require some assistance with activities of daily living (ADL) have a projected survival of weeks, and patients who are essentially bedfast and dependent for ADL have a projected survival of days to a week or two at best. Table 48-2 shows a simple prognostic tool to aid clinicians in recognizing patients nearing the end of life.

Alternatively, the Karnofsky Performance Scale is a scale of functional status ranging from 100 (high level of function) to

Table 48-2

Simple prognostication tool in advanced illness (especially cancer)

FUNCTIONAL LEVEL	PERFORMANCE STATUS (ECOG)	PROGNOSIS
Able to perform all basic ADLs independently and some IADLs	2	Months
Resting/sleeping up to 50% or more of waking hours and requiring some assistance with basic ADLs	3	Weeks to a few months
Dependent for basic ADLs and bed-to-chair existence	4	Days to a few weeks at most

These observations apply to patients with advanced, progressive, incurable illnesses (e.g., metastatic cancer refractory to treatment). Basic ADL = activities of daily living (e.g., transferring, toileting, bathing, dressing, and feeding oneself); IADL = instrumental activities of daily living (e.g., more complex activities such as meal preparation, performing household chores, balancing a checkbook, shopping, etc.); ECOG = Eastern Cooperative Oncology Group functional (performance) status.

0 (death). It is commonly used in palliative care to roughly assess patient anticipated needs as well as prognosis. The Palliative Performance Scale³⁸ is a validated³⁹ expansion of the Karnofsky Performance Scale that includes five palliative-focused domains, including ambulation, activity level, self-care, intake, and level of consciousness, in addition to evidence of disease. The Missoula-Vitas Quality of Life Index is a 25-question scale specifically for palliative care and hospice patients that scores symptoms, function, interpersonal relationships, well-being, and spirituality. Updates and Spanish versions are available.³⁶

Regardless of the prognostic tool used, the prognosis should be conveyed to the patient and family. If done well, communication and negotiation with patients and families about advanced terminal illnesses can potentially avoid great psychologic harm and help make a difficult transition easier. To communicate effectively and compassionately, it is helpful to pursue an organized process similar to the structured history and physical central to the evaluation of any patient. One such structured approach to delivering unfavorable news proposes six steps that can be easily learned by clinicians: (a) getting started by selection of the appropriate setting, introductions, and seating; (b) determining what the patient or family knows; (c) determining what the patient or family wants to know; (d) giving the information; (e) expressing empathy; and (f) establishing expectations, planning, and aftercare (Table 48-3).⁴⁰ Success with this approach to breaking bad news is critically dependent upon the clinician's ability to empathically respond to the patient's (and family's) reaction to the news.⁴¹ The empathic response does not require the surgeon to share the same emotions of the patient, but it does require the surgeon to identify the patient's emotion and accurately reflect that awareness back to the patient. Patient assessment in these conversations should give the highest priority to identifying and responding to the most immediate source of distress. Relieving a pressing symptom is prerequisite for a more thorough search for other potential sources of

Table 48-3

Communicating unfavorable news: Important principles

- Setting: Find a quiet, private place to meet. Sit down close to the patient.
- Listen: Clarify the patient's and/or the family's understanding of the situation.
- "Warning shot": Prepare patient and family and obtain their permission to communicate bad news (e.g., "I'm afraid I have bad news.>").
- Silence: Pause after giving bad news. Allow patient/family to absorb/react to the news.
- Encourage: Convey hope that is realistic and appropriate to the circumstances (e.g., patient will not be abandoned; symptoms will be controlled).

suffering, and the assessment process, itself, can be therapeutic if conducted in a respectful and gentle manner.

CARE AT THE END OF LIFE

The process of dying and the care of a patient at the time of death is a distinct clinical entity that demands specific skills from physicians. The issues specific to dying and the available tools for compassionate care at the end of life are addressed in this section.

The Syndrome of Imminent Demise^{29,42}

In a patient who has progressed to the terminal stage of an advanced illness (e.g., cancer), a number of signs provide evidence of imminent death. As terminally ill patients progress toward death, they become increasingly bedbound, requiring assistance for all basic ADL. There is a steady decrease in desire and requests for food and fluids. More distressing to the dying patient is a progressively dry mouth that may be confused by the treating team as thirst. It is often exacerbated by anticholinergic medications, mouth breathing, and supplemental oxygen (O₂) administered without humidification.

With progressive debility, fatigue, and weight loss, it is common for terminally ill patients to experience increasing difficulty swallowing. This may result in aspiration episodes and an inability to swallow tablets, requiring alternative routes for medication administration (e.g., IV, SC, PR, sublingual, buccal, or transdermal). In addition to the increased risk of aspiration, patients near death develop great difficulty clearing oropharyngeal and upper airway secretions, leading to noisy breathing or the so-called "death rattle." As death approaches, the respiratory pattern may change to increasingly frequent periods of apnea often following a Cheyne-Stokes pattern of rapid, progressively longer breaths leading up to an apneic period. As circulatory instability develops near death, patients may exhibit cool and mottled extremities. Periods of confusion are often accompanied by decreasing urine output and episodes of fecal and urinary incontinence.

A number of cognitive changes occur as death approaches. Patients who are in the last days of life may demonstrate some signs of confusion or delirium. Agitated delirium is a prominent feature of a difficult death. Other cognitive changes that may be seen include a decreased interest in social interactions, increased somnolence, reduced attention span, disorientation to time (often with altered sleep-wake cycles), and an altered

dream life, including vivid "waking dreams" or visual hallucinations. Reduced hearing and visual acuity may be an issue for some patients; however, patients who appear comatose may still be aware of their surroundings. Severely cachectic patients may lose the ability to keep their eyes closed during sleep because of loss of the retro-orbital fat pad.

Common Symptoms at the End of Life and Their Management^{29,42,43}

The three most common, major symptoms that threaten the comfort of dying patients in their last days are respiratory distress, pain, and cognitive failure. General principles that are applicable to symptom management in the last days of life include: (a) anticipating symptoms before they develop; (b) minimizing technologic interventions (usually manage symptoms with medications); and (c) planning alternative routes for medications in case the oral route fails. It may be possible to cautiously reduce the dose of opioids and other medications as renal clearance decreases near the end of life, but it is important to remember that increased somnolence and decreasing respirations are prominent features of the dying process independent of medication side effects. Sudden cessation of opioid analgesics near the end of life could precipitate withdrawal symptoms, and therefore, medications should not be stopped for increasing somnolence or slowed respirations.

The principles of pharmacotherapy for pain and non-pain symptoms in the palliative care setting are outlined in Table 48-4. The World Health Organization,³⁰ the United States Agency for Health Care Policy and Research,⁴⁴ the Academy of Hospice and Palliative Medicine,⁴⁵ and many other agencies have endorsed a "step ladder" approach to cancer pain management that can predictably result in satisfactory pain control in most patients (Table 48-5). More refractory pain problems require additional expertise, and occasionally, more invasive approaches (Tables 48-6 and 48-7).

The primary treatment of dyspnea (air hunger) in the dying is opioids, which should be cautiously titrated to increase comfort and reduce tachypnea to a range of 15 to 20 breaths/min. Air movement across the face generated by a fan can sometimes be quite helpful. If this is not effective, empirical use of supplemental O₂ by nasal cannula (2–3 L/min) may bring some subjective relief, independent of observable changes in pulse oximetry. Supplemental O₂ should be humidified to avoid exacerbation of dry mouth. Typical starting doses of an immediate release opioid for breathlessness should be one-half to two-thirds of a starting dose of the same agent for cancer pain. For patients already on opioids for pain, a 25% to 50% increment in the dose of the current immediate release agent for breakthrough pain often will be effective in relieving breathlessness in addition to breakthrough pain.

The availability and variety of drugs should not prevent consideration of nonpharmacologic therapy. Massage therapy, music therapy, art therapy, guided imagery, hypnosis, physical therapy, pet therapy, and others play a constructive role not only for the relief of symptoms, but for promoting a sense of hope through improving function, aesthetic pleasure, and social connectedness. Talents and capacities neglected during the treatment and progression of disease can be recovered even in the most advanced stages of illness.

Pain is often less of a problem in the last days of life because the reduced activity level is associated with lower incident pain. This, combined with lower renal clearance of opioids,

Table 48-4

Principles of pharmacotherapy in palliative care

- Believe patient report of symptoms.
- Modify pathologic process when possible and appropriate.
- In terminally ill, avoid medications not directly linked to symptom control.
- Use a multidisciplinary approach.
- Consider nonpharmacologic approaches whenever possible.
- Engage participation of clinical pharmacist in treatment plan.
- Select drugs that can multitask (i.e., use haloperidol for agitated delirium and nausea).
- For pain, use adjuvant medications when possible (see Table 48-7).
- When using opioids, spare when possible (adjuvant medication, local or regional anesthetics, surgical interventions, etc.).
- Avoid fixed combination drugs.
- Avoid excessive cost.
- Select agents with minimum side effects.
- Anticipate and prophylax against side effects.
- For the elderly, the hypoproteinemic, theazotemic: “Start low and go slow.”
- Oral route whenever possible and practical.
- No IM injections.
- Scheduled dosing, not prn, for persistent symptoms.
- Stepwise approach. (See the World Health Organization Analgesic Ladder for pain. See Table 48-5.)
- Reassess continuously and titrate to effect.
- Use equianalgesic doses when changing opioids (see Table 48-5).
- Assess patient/family’s comprehension of management plan.

may result in greater potency of the prescribed agents. Severe pain crises are fortunately rare, but when they are inadequately addressed, can cause great and lasting distress (complicated grief) for loved ones who witness the final hours or days of agony. Such situations may require continuous administration of parenteral opioids. As death approaches and patients become less verbal, it is important to assess pain frequently, including the use of close observation for nonverbal signs of distress (e.g., grimacing, increased respiratory rate). Adequate dosing of opioid analgesics may require alternate route(s) of administration as patients become more somnolent or develop swallowing

Table 48-5

The World Health Organization three-step ladder for control of cancer pain³⁰

- Step 1: mild pain (visual analogue scale, 1–3)
Nonopioid ± adjuvant medication
- Step 2: moderate pain (visual analogue scale, 4–6)
Opioid for mild to moderate pain and nonopioid ± an adjuvant
- Step 3: severe pain (visual analogue scale, 7–10)
Opioid for moderate to severe pain ± nonopioid ± an adjuvant

difficulties. Opioids should not be stopped abruptly, even if the patient becomes nonresponsive because sudden withdrawal can cause severe distress.^{46,47}

Cognitive failure at the end of life is manifested in most patients by increasing somnolence and delirium. Gradually increasing somnolence can be accompanied by periods of disorientation and mild confusion, and it may respond to the reassuring presence of loved ones and caregivers with minimal need for medications. A more distressing form of delirium also can develop, manifested by increasing agitation that may require the use of neuroleptic medications. Increasing amounts of opioids and/or benzodiazepines may exacerbate the delirium (especially in the elderly).

Pronouncing Death⁴⁸

If the body is hypothermic or has been hypothermic, such as a drowning victim pulled from the water in the winter, the physician should not declare death until warming attempts have been made. In the hospital, hospice, or home setting, the declaration of death becomes part of the medical or legal record of the event. There are a number of physical signs of death a physician should look for in confirming the patient’s demise: complete lack of responsiveness to verbal or tactile stimuli, absence of heart beat and respirations, fixed pupils, skin color change to a waxy hue as blood settles, gradual poikilothermia, and sphincter relaxation with loss of urine and feces. For deaths in the home with patients who have been enrolled in hospice, the hospice nurse on call should be contacted immediately. In some states, deaths at home may require a brief police investigation and report. For deaths in the hospital, the family must be notified (in person, if possible). A coroner or medical examiner may need to be contacted under specific circumstances (e.g., deaths in the operating room), but most deaths do not require their services. However, the pronouncing physician will need to complete a death certificate according to local regulations. Survivors may also be approached, if appropriate, regarding potential autopsy and organ donation. Finally, it is important to accommodate religious rituals that may be important to the dying patient or the family. *Bereavement* is the experience of loss by death of a person to whom one is attached. *Mourning* is the process of adapting to such a loss in the thoughts, feelings, and behaviors that one experiences after the loss.⁴⁹ Although grief and mourning are accentuated in the immediate period around death, it is important to note that patients and families may begin the process of bereavement well before the time of death as patients and families grieve incremental losses of independence, vitality, and control. In addition to the surviving loved ones, it is important to acknowledge that caregivers also experience grief for the loss of their patients.^{50,51}

PROFESSIONAL ETHICS: CONFLICT OF INTEREST, RESEARCH, AND CLINICAL ETHICS**Conflict of Interest**

Conflicts of interest for surgeons can arise in many situations in which the potential benefits or gains to be realized by the surgeon are, or are perceived to be, in conflict with the responsibility to put the patient’s interests before the surgeon’s own. Conflicts of interest for the surgeon can involve actual or perceived situations in which the individual stands to gain monetarily by his or her role as a physician or investigator. In the academic community, monetary gain may not be the primary factor. Instead,

Table 48-6

Analgesics for persistent pain

DRUG	INITIAL DOSING (ADULT, >60 kg)	COMMENTS
Mild persistent pain, visual analogue scale (VAS) 1–3 Acetaminophen (Tylenol)	325–650 mg PO qid Maximum = 3200 mg/24 h	Use <2400 mg if other potentially hepatotoxic drugs taken. Acetaminophen contained in concurrent nonprescription medications can easily exceed maximum daily allowable dose.
Aspirin	600–1500 mg PO qid	Gastric bleeding, platelet dysfunction
Choline magnesium trisalicylate (Trilisate)	750–1500 mg PO bid	Useful for avoiding platelet dysfunction
Ibuprofen (Advil, Motrin)	200–400 mg PO qid Maximum = 3200 mg/24 h	Gastropathy, nephropathy, decreased platelet aggregation
Naproxen (Naprosyn)	250 mg PO bid Maximum = 1300 mg/24 h	Available as a transcutaneous gel
Moderate persistent pain, VAS 4–6 Hydrocodone (Vicodin, Lortab)	5–7.5 mg PO q4h	Most prescribed drug in the United States Acetaminophen in compounded drug limits use to moderate pain.
Oxycodone	5 mg PO q4h	Sold as single agent or compounded with aspirin or acetaminophen. Slow release form available (Oxycontin)
Severe persistent pain, VAS 7–10 Morphine	10 mg PO q2–4h 2–4 mg IV, SC q1–2h	Standard drug for comparison to alternative opioids. Avoid or caution when giving to the elderly, patients with diminished glomerular filtration rate, or liver disease. Slow release PO form available (MS Contin).
Hydromorphone	1–3 mg PO, PR q4h 1 mg IV, SC q1–2h	Suppository form available Oral dose forms limited to 4 mg maximum
Fentanyl, transdermal	12 µg/h patch q72h	Not for acute pain management. Do not use on opioid-naïve patients. Absorption unpredictable in cachectic patients.
Methadone	Consultation with pain management, clinical pharmacists, or palliative care/hospice services skilled in methadone use is recommended for those inexperienced in prescribing methadone.	Not a first-line agent, although very effective, especially for pain with a neuropathic component Very inexpensive Can be given PO, IV, SC, PR, sublingually, and vaginally Its long half-life makes dosing more difficult than alternative opioids and close monitoring is required when initiating Numerous medications, alcohol, and cigarette smoking can alter its serum levels Physicians who write methadone prescriptions for pain should specify this indication. Methadone use for drug withdrawal treatment requires special licensure.

Risk factors for NSAID-induced nephropathy include: advanced age, decreased glomerular filtration rate, congestive heart failure, hypovolemia, pressors, hepatic dysfunction, concomitant nephrotoxic agents. Dose reduction and hydration reduce risk.

Opioids compounded with aspirin or acetaminophen are limited to treatment of moderate persistent pain because of dose-limiting toxicities of acetaminophen and aspirin.

Slow-release preparations of morphine and oxycodone may be given rectally.

Timed-release tablets or patches should never be crushed or cut.

Opioid analgesics are the agents of choice for severe cancer-related pain. Sedation is a common side effect when initiating opioid therapy. Tolerance to this usually develops within a few days. If sedation persists beyond a few days, a stimulant (methylphenidate 2.5–5 mg PO bid) can be given.

Initiate bowel stimulant prophylaxis for constipation when prescribing opioids unless contraindicated.

Adjuvant or coanalgesic agents are drugs that enhance analgesic efficacy of opioids, treat concurrent symptoms that exacerbate pain, or provide independent analgesia for specific types of pain (e.g., a tricyclic antidepressant for treatment of neuropathic pain). Coanalgesics can be initiated for persistent pain at any visual analogue scale level. Gabapentin is commonly used as an initial agent for neuropathic pain.

No place for meperidine (Demerol), propoxyphene (Darvon, Darvocet, or mixed agonist-antagonist agents [Stadol, Talwin]) in management of persistent pain. Always consider alternative approaches (axial analgesia, operative approaches, etc.) when managing severe persistent pain.

Note: These are not recommendations for specific patients. The inter- and intraindividual variability to opioids requires individualizing dosing and titration to effect.

Source: Adapted with permission from Dunn GP: Surgical palliative care, in Cameron JL (ed): *Current Surgical Therapy*, 9th ed. Philadelphia: Elsevier, 2008. Copyright Elsevier.

Table 48-7

Examples of adjuvant medications for treatment of neuropathic, visceral, and bone pain^a

DRUG CLASS	INITIAL DOSING (ADULT, >60 kg)	COMMENTS
<p>Tricyclic antidepressants</p> <p>Best for continuous burning or tingling pain and allodynia</p> <p>Efficacy for pain not due to antidepressant effect</p> <p>Dose generally less than that required for antidepressant effect</p> <p>Dose titrated up every few days until effect. Pain may respond to alternative antidepressants if no response to initial agent.</p>	<p>Amitriptyline 10–25 mg PO qhs</p> <p>Nortriptyline 10–25 mg PO qd</p> <p>Doxepin 10–25 mg PO qhs</p> <p>Imipramine 10–25 mg PO qd</p>	<p>Sedating properties may be useful for relief of other concurrent symptoms. Side effects may precede benefit.</p> <p>Avoid in the elderly due to anticholinergic side effects.</p> <p>Less anticholinergic effect</p>
<p>Anticonvulsants</p> <p>For shooting, stabbing pain</p>	<p>Gabapentin 100–300 mg PO qd. Titrate up rapidly as needed. Max: 1800 mg qd</p> <p>Carbamazepine 200 mg PO q12h</p> <p>Valproic acid 250 mg PO tid</p>	<p>Commonly used first-line agent. Generally well tolerated. Does not require blood level monitoring.</p> <p>Effective. Well studied. Requires blood monitoring.</p>
<p>Local anesthetics</p> <p>Systemic use requires monitoring.</p> <p>Nebulized local anesthetics (lidocaine, bupivacaine) can be used for severe, refractory cough.</p>	<p>Lidocaine transdermal patch 5%. Apply to painful areas. Max: 3 simultaneous patches over 12 h (each patch contains 700 mg lidocaine).</p> <p>Lidocaine/prilocaine topical. Apply to painful areas.</p>	<p>Systemic toxicity can result from applying more than recommended number per unit time and in patients with liver failure. Effective for postherpetic neuralgia.</p>
Miscellaneous	<p>Bisphosphonates (pamidronate, zoledronic acid)</p> <p>Calcitonin nasal spray</p> <p>Dexamethasone</p> <p>Radionuclides (Sr-89)</p> <p>Octreotide</p>	<p>For bone pain and reduced incidence of skeletal complications secondary to malignancy—best results in myeloma and breast cancer. Contraindicated in renal failure.</p> <p>Refractory bone pain</p> <p>For bone pain, acute nerve compression, visceral pain secondary to tumor infiltration or luminal obstruction by reducing inflammatory component of tumor</p> <p>For malignant bone pain secondary to osteoclastic activity. 4–6 wk delay in benefit. Requires adequate bone marrow reserve. For prognosis of more than 3 mo.</p> <p>Reduces GI secretions that contribute to visceral pain</p>

^aRecommendations are based on experience of practitioners of hospice and palliative medicine and in some instances do not reflect current clinical trials. Source: Adapted, with permission from Dunn GP: Surgical palliative care, in Cameron JL (ed): *Current Surgical Therapy*, 9th ed. Philadelphia: Elsevier, 2008. Copyright Elsevier.

motivators such as power, tenure, or authorship on a publication may serve as potential sources of conflict of interest. For example, the accrual of subjects in research studies or patients in surgical series may ensure surgeons better authorship or more financial gains. The dual-role of the surgeon-scientist therefore needs to be considered because the duty as surgeon can conflict with the role of scientist or clinical researcher.

Research Ethics

Over the last three decades in the United States, the ethical requirements for the conduct of human subject research have been formalized and widely accepted. Although detailed informed consent is a necessary condition for the conduct of ethically good human subject research, other factors also determine whether research is designed and conducted ethically. Emanuel and colleagues⁵² described seven requirements for all clinical research studies to be ethically sound: (a) value—**7▶** enhancement(s) of health or knowledge must be derived from the research; (b) scientific validity—the research must be methodologically rigorous; (c) fair subject selection—scientific objectives, not vulnerability or privilege, and the potential for and distribution of risks and benefits, should determine communities selected as study sites and the inclusion criteria for individual subjects; (d) favorable risk-benefit ratio—within the context of standard clinical practice and the research protocol, risks must be minimized, potential benefits enhanced, and the potential benefits to individuals and knowledge gained for society must outweigh the risks; (e) independent review—unaffiliated individuals must review the research and approve, amend, or terminate it; (f) informed consent—individuals should be informed about the research and provide their voluntary consent; and (g) respect for enrolled subjects—subjects should have their privacy protected, the opportunity to withdraw, and their well-being monitored.⁵²

Special Concerns in Surgical Research

A significant issue for clinical surgical research is that it is often analyzed in a retrospective manner and not commonly undertaken in a prospective double-blind, randomized fashion. For a randomized trial to be undertaken, the researchers should be in a state of equipoise—that is, there must be a state of genuine uncertainty on the part of the clinical investigator or the expert medical community regarding the comparative therapeutic merits of each arm in a trial.⁵³ To randomize subjects to receive two different treatments, a researcher must believe that the existing data are not sufficient to conclude that one treatment strategy is better than another. In designing surgical trials, surgeons usually have biases that one treatment is better than another and often have difficulty maintaining the state of equipoise. As such, it is frequently difficult to demonstrate that a randomized trial is necessary or feasible, and treatment options that question the validity of clinical tenets are difficult to accept. Meakins has suggested that a slightly different hierarchy of evidence applies to evidence-based surgery.⁵⁴

A second major issue for surgical trials is whether it is ethically acceptable to have a placebo-controlled surgical trial. Some commentators have argued that sham surgery is always wrong because, unlike a placebo medication that is harmless, every surgical procedure carries some risk.⁵⁵ Others have argued that sham operations are essential to the design of a valid randomized clinical trial because, without a sham operation, it is

not possible to know if the surgical intervention is the cause of improvement in patient symptoms or whether the improvement is due to the effect of having surgery.^{56,57} Most surgeons readily agree that designing an appropriately low-risk sham surgical procedure would create problems for the surgeon-patient relationship in that the surgeon would need to keep the sham a secret.⁵⁸ In this sense, a sham surgical arm of a trial is very different from a placebo medication in that there cannot be blinding of the surgeon as to which procedure was undertaken. As a result, to have a sham surgery arm in a clinical trial, the interactions between the surgeon and the subject must be limited and the surgeon performing the procedure should not be the researcher who follows the subject during the trial. Despite difficulties with designing a surgical trial in which the surgeon could ethically perform a sham operation, there are specific circumstances that allow for placebo operations to be conducted, so long as certain criteria are met and are analyzed on a case by case basis.^{59,60}

Surgical Innovation and Surgical Research

An important issue is whether surgical innovation should be treated as research or as standard of care. Many of the advances in surgical technique and surgical technology have resulted from the innovations that individual surgeons have discovered or created during the course of challenging operations. As every patient is different and the surgeon is always trying to determine the best way to complete an operation, innovations have developed that have often moved the field of surgery forward.⁶¹ In the Korean and Vietnam wars, the military guidelines for the treatment of vascular injuries recommended ligation and amputation rather than interposition grafting of vascular injuries. Individual surgeons chose to ignore those guidelines and subsequently demonstrated the value of reconstructive techniques that ultimately became the standard of care. It is debated whether modifications in an accepted surgical technique based on the circumstances of an individual patient and the skill and judgment of an individual surgeon should require the same type of prior approval that enrollment in a clinical trial would warrant.⁶² However, if a surgeon decides to use a new technique on several occasions and to study the outcomes, Institutional Review Board approval and all other ethical requirements for research are necessary. These situations require strict oversight as well as explicit consent by the patient.⁶³ In particular, when developing new and innovative techniques, the surgeon should work in close consultation with his or her senior colleagues, including the chairperson of the department. Frequently, more senior individuals can provide sage ethical advice regarding what constitutes minor innovative changes in a technique vs. true novel research.

Compared to the formalized process for new drug approval by the Food and Drug Administration, the process for a surgeon developing an innovative operation is relatively unregulated and unsupervised.

Clinical Ethics: Disclosure of Errors

Disclosure of error—either in medical or research matters—is important, but often difficult (see Chap. 12). Errors of judgment, errors in technique, and system errors are responsible for most errors that result in complications and deaths. Hospitals are evaluated based on the number of complications and deaths that occur in surgical patients, and surgeons traditionally review their complications and deaths in a formal exercise known as

the *mortality and morbidity conference*, or *M&M*. The exercise places importance on the attending surgeon's responsibility for errors made, whether he or she made them themselves, and the value of the exercise is related to the effect of "peer pressure"—the entire department knows about the case—on reducing repeated occurrences of such an error. Although a time-honored ritual in surgery, the *M&M* conference is nonetheless a poor method for analyzing causes of error and for developing methods to prevent them. Moreover, the proceedings of the *M&M* conference are protected from disclosure by the privilege of "peer review," and the details are rarely shared with patients or those outside the department.

A report from the United States Institute of Medicine titled "To Err Is Human" highlighted the large number of medical errors that occur and encouraged efforts to prevent patient harm.⁶⁴ Medical errors are generally considered to be "preventable adverse medical events."⁶⁵ Given that medical errors clearly occur with some frequency, the question becomes what and how should patients be told of medical errors and what is the surgeon's ethical responsibility for this disclosure.⁶⁶

Disclosure of error is consistent with the ethical tenets of openness with patients and the involvement of patients in their care. In contrast, failing to disclose errors to patients undermines public trust in medicine and potentially compromises the treatment of the consequences of errors. In addition, failure to self-disclose medical errors can be construed as a breach of professional ethics, as it is a failure to act solely for the patient's best interests. Patients require information regarding medical errors so that additional harm can be avoided. In addition, information regarding a medical error may be needed so that patients can make independent and well-informed decisions about future aspects of their care. The principles of autonomy and justice dictate that surgeons need to respect individuals by being fair in providing accurate information about all aspects of their care—even the medical errors.

Disclosing one's own errors is therefore part of the ethical standard of honesty and putting the patient's interests above one's own. Disclosing the errors of others is more complicated and may require careful consideration and consultation. Surgeons sometimes discover that a prior operation has included an apparent error; an injured bile duct or a stenotic anastomosis may lead to the condition for which the surgeon is now treating the patient. Declaring a finding as an "error" may be inaccurate, however, and a non-judgmental assessment of the situation is usually advisable. When clear evidence of a mistake is at hand, the surgeon's responsibility is defined by his or her obligation to act as the patient's agent.

REFERENCES

Entries highlighted in bright blue are key references.

1. Aristotle. *Nicomachean Ethics*, Book VI. In Ackrill J, ed. *A New Aristotle Reader*. Princeton, NJ: Princeton University Press; 1987, p 416.
2. **Beauchamp TL, Childress JF. *Principles of Biomedical Ethics*, 3rd ed. New York: Oxford University Press; 1989.**
3. Bosk, C. *Forgive and Remember*, 2nd ed. Chicago, University of Chicago Press, 2003 (1979).
4. McCullough LB, Jones JW, Brody BA, (eds): *Surgical Ethics*. New York: Oxford University Press, 1998.
5. **Faden RR, Beauchamp TL. *A History and Theory of Informed Consent*. New York: Oxford University Press; 1986.**
6. Bernat JL, Peterson LM. Patient-centered informed consent in surgical practice. *Arch Surg*. 2006;141:86-92.
7. Schneider CE. *The Practice of Autonomy: Patients, Doctors, and Medical Decisions*. New York: Oxford University Press; 1998.
8. Robb A, Etchells E, Cusimano MD, et al. A randomized trial of teaching bioethics to surgical residents. *Am J Surg*. 2005;189:453-457.
9. Steinemann S, Furoy D, Yost F, et al. Marriage of professional and technical tasks: a strategy to improve obtaining informed consent. *Am J Surg*. 2006;191:696-700.
10. Guadagnoli E, Soumerai SB, Gurwitz JH, et al: Improving discussion of surgical treatment options for patients with breast cancer: local medical opinion leaders versus audit and performance feedback. *Breast Cancer Res Treat*. 2000;61:171-2000.
11. Braddock CH III, Edwards KA, Hasenberg NM, et al. Informed decision making in outpatient practice: time to get back to basics. *JAMA*. 1999;282:2313-2320.
12. Leeper-Majors K, Veale JR, Westbrook TS, et al. The effect of standardized patient feedback in teaching surgical residents informed consent: results of a pilot study. *Curr Surg*. 2003;60:615-622.
13. Courtney MJ. Information about surgery: what does the public want to know? *ANZ J Surg*. 2001;71:24-26.
14. Newton-Howes PA, Dobbs B, Frizelle F. Informed consent: what do patients want to know? *N Z Med J*. 1998;111:340-342.
15. Streat S. Clinical review: moral assumptions and the process of organ donation in the intensive care unit. *Crit Care*. 2004;8:382-388.
16. Williams MA, Lipsett PA, Rushton CH, et al. The physician's role in discussing organ donation with families. *Crit Care Med*. 2003;31:1568-1573.
17. Pearson IY, Zurynski Y. A survey of personal and professional attitudes of intensivists to organ donation and transplantation. *Anaesth Intensive Care*. 1995;23:68-74.
18. Sulmasy DP, Lehmann LS, Levine DM, et al. Patients' perceptions of the quality of informed consent for common medical procedures. *J Clin Ethics*. 1994;5:189-194.
19. Ubel PA, Loewenstein G, Jepson C. Whose quality of life? A commentary exploring discrepancies between health state evaluations of patients and the general public. *Qual Life Res*. 2003;12:599-607.
20. Schneider CE. After autonomy. *Wake Forest Law Review*. 2006;41:411.
21. Shalowitz, DI, Garrett-Mayer, E, et al. The accuracy of surrogate decision makers: A systematic review. *Archives of Internal Medicine*. 2006;166(5): 493-497.
22. Sulmasy DP, Hughes MT, Thompson RE, et al. How would terminally ill patients have others make decisions for them in the event of decisional incapacity? A longitudinal study. *J Am Geriatr Soc*. 2007;55:1981-1988.
23. SUPPORT Principle Investigators. A controlled trial to improve care for seriously ill hospitalized patients. The study to understand prognoses and preferences for outcomes and risks of treatments (SUPPORT). The SUPPORT Principal Investigators. *JAMA*. 1995;274:1591-1598.
24. Pawlik TM. Withholding and withdrawing life-sustaining treatment: a surgeon's perspective. *J Am Coll Surg*. 2006;202:990-994.
25. In re *Quinlan*. 355 A2d 647 (NJ). Vol 429 US 922(1976).
26. *Cruzan vs. Director, Missouri Dept of Health*, 497(1990).
27. Annas GJ. Nancy Cruzan and the right to die. *N Engl J Med*. 1990;323:670-673.
28. Sykes N, Thorns A. The use of opioids and sedatives at the end of life. *Lancet Oncol*. 2003;4:312-318.
29. Nelson KA, Walsh D, Behrens C, et al. The dying cancer patient. *Semin Oncol*. 2000;27:84.
30. WHO. Definition of Palliative Care, 2008, World Health Organization. Available at: www.who.int/cancer/palliative/definition/en/print.html [accessed March 25, 2009].
31. **Dunn G. Surgical palliative care. In: Mosby, ed. *Current Surgical Therapy*, 9th ed. Philadelphia: Elsevier; 2008.**

32. Saunders C. The challenge of terminal care. In: Symington T, Carter R, eds. *Scientific Foundations of Oncology*. London: Heineman; 1976, p 673.
33. Nuland S. *How We Die: Reflections on Life's Final Chapter*. New York: Alfred A. Knopf; 1994.
34. Kleinman A. *The Illness Narratives. Suffering, Healing & the Human Condition*. New York: Basic Books; 1988.
35. International Association for the Study of Pain, Subcommittee on Taxonomy. Part II. Pain Terms: a current list with definitions and notes on usage. *Pain*. 1979;6:249.
36. Byock IR, Merriman MP. Measuring quality of life for patients with terminal illness: The Missoula-VITAS quality of life index. *Palliat Med*. 1998;12:231-244.
37. Christakis NA, Lamont EB. Extent and determinants of error in doctors' prognoses in terminally ill patients: prospective cohort study. *BMJ*. 2000;320:469-472.
38. Anderson F, Downing GM, Hill J, et al. Palliative performance scale (PPS): a new tool. *J Palliat Care*. 1996;12:5-11.
39. Morita T, Tsunoda J, Inoue S, et al. Validity of the palliative performance scale from a survival perspective. *J Pain Symptom Manage*. 1999;18:2-3.
40. Buckman R. *How to Break Bad News. A Guide for Health Care Professionals*. Baltimore: Johns Hopkins University Press; 1992.
41. Kubler-Ross E. *On Death and Dying*. London: Routledge; 1973.
42. Twycross R, Lichter I. The terminal phase. In: Doyle D, Hanks G, MacDonald N, eds. *Oxford Textbook of Palliative Medicine*. New York: Oxford University Press; 1998, p 977.
43. Hinshaw DB. **Spiritual issues in surgical palliative care.** *Surg Clin North Am*. 2005;85:257-272.
44. Jacox A, Carr D, Payne R, et al. **Management of cancer pain. AHCPR Publication No. 94-052: Clinical Practice Guideline No. 9.** Rockville: US Department of Health and Human Services, Public Health Service; 1994.
45. Storey P, Knight C. *UNIPAC Three: Assessment and Treatment of Pain in the Terminally Ill*, 2nd ed. New York: Mary Ann Liebert, Inc; 2003.
46. Rubenfeld GD, Crawford SW. Principles and practice of withdrawing life-sustaining treatment in the ICU. In: Curtis JR, Rubenfeld GD, eds. *Managing Death in the Intensive Care Unit*. New York: Oxford University Press; 2001.
47. Rousseau P. Existential distress and palliative sedation. *Anesth Analg*. 2005;101:611-612.
48. The EPEC-O Project, Educating Physicians in End-of-Life Care-Oncology: *Module 6: Last Hours of Living*. Bethesda: National Cancer Institute; 2007.
49. Worden J. *Bereavement Care*. Philadelphia: Lippincott Williams and Wilkins; 2002.
50. Bishop JP, Rosemann PW, Schmidt FW. Fides ancilla medicinae: on the ersatz liturgy of death in biopsychosociospiritual medicine. *The Heythrop Journal*. 2008;49:20.
51. Schroeder-Sheker T. *Transitus: A Blessed Death in the Modern World*. Mt. Angel: St. Dunstan's Press; 2001.
52. Emmanuel EJ, Wendler D, Grady C: What makes clinical research ethical? *JAMA* 2000;283:2701-2711.
53. Freedman B. Equipoise and the ethics of clinical research. *N Engl J Med*. 1987;317:141-145.
54. Meakins J. Innovation in surgery. The rules of evidence. *Am J Surg*. 2002;183:399-405.
55. Lefering R, Neugebauer E. Problems of randomized controlled trials in surgery. Paper presented at: Nonrandomized Comparative Clinical Studies 1997, Heidelberg.
56. Flum DR. Interpreting surgical trials with subjective outcomes: avoiding UnSPORTsmanlike conduct. *JAMA*. 2006;296:2483-2485.
57. Moseley JB, O'Malley K, Petersen NJ, et al. A controlled trial of arthroscopic surgery for osteoarthritis of the knee. *N Engl J Med*. 2002;347:81. Summary for patients in: *J Fam Pract*. 2002;51:813.
58. Angelos PA. Sham surgery in research: a surgeon's view. *Am J Bioeth*. 2003;3:65-66.
59. Miller FG. Sham surgery: an ethical analysis. *Sci Eng Ethics*. 2004;10:157-166.
60. Angelos P. Sham surgery in clinical trials. *JAMA*. 2007;297:1545-1546, author reply 1546.
61. Riskin DJ, Longaker MT, Gertner M, et al. Innovation in surgery: a historical perspective. *Ann Surg*. 2006;244:686-693.
62. Biffel WL, Spain DA, Reitsma AM, et al. Responsible development and application of surgical innovations: A position statement of the Society of University Surgeons (draft statement of 2/19/08).
63. McKneally MF, Daar AS. Introducing new technologies: protecting subjects of surgical innovation and research. *World J Surg*. 2003;27:930-934.
64. Kohn LT, Corrigan JM, Donaldson MS. *To Err Is Human: Building a Safer Health System*. Washington: National Academy Press; 2000.
65. Brennan TA, Leape LL, Laird NM, et al. Incidence of adverse events and negligence in hospitalized patients. Results of the Harvard Medical Practice Study I. *N Engl J Med*. 1991;324:370-376.
66. Hebert PC, Levin AV, Robertson G. Bioethics for clinicians: 23. Disclosure of medical error. *CMAJ*. 2001;164:509-513.

49 chapter

Global Surgery

Raymond R. Price and Catherine R. deVries

Introduction	1955	Initiatives for Outreach and Engagement / 1963	Academic Partnerships / 1977
Defining Global Surgery	1956	International Organizations / 1963	Ethics / 1977
Global Surgery Ecosystem / 1956		Global Surgery and Public Health / 1968	Innovation in Global Surgery / 1978
Burden of Surgical Disease / 1957		Cancer Initiatives / 1970	The Future for Global Surgery 1978
Human Resources / 1960		Advanced Surgical Care for Resource-Poor Areas / 1976	
Strategies for Development	1963		

INTRODUCTION

Modern surgery can save lives, help expand economies, and offer hope to individuals and communities. Prior to the acceptance and availability of aseptic technique to prevent or decrease infections, and improved anesthesia for controlling pain, surgery as a specialty was held in very low esteem. Over the last 100 years, surgery has developed into an elite discipline that not only provides opportunities for curing certain diseases, but fulfills a special role in preventing and mitigating disability.

Yet, surgery is currently unavailable to most people worldwide. The vast majority—90%—of the world's population receives only 10% of the surgical care delivered. Said another way, 90% of the world's surgical resources are consumed by the most privileged 10% of the world's population. More than 2 billion people lack access to even basic surgical care.¹ Very few surgical procedures occur in countries spending less than US \$100/ person on health care per year compared to countries spending greater than U.S. \$1000/ person (Fig. 49-1).²

Examples of disparities abound. In many countries, including the wealthiest, deep pockets of poverty coexist within cities replete with material resources. Tertiary level hospitals operate within eyesight of slums whose inhabitants have no access to even basic care. Most of the people without access—people in rural areas and in countries with poor infrastructure—are the very people most at risk for death or disability due to lack of surgical care. Often the poor accept and endure many painful and potentially correctable fatal conditions as a fact of life.³⁻⁶ Care for trauma and obstetrical emergencies are considered basic surgical needs but are absent in many rural regions. Other chronic conditions—often equally debilitating—progress to death or serious disability due to lack of available, safe surgery and anesthesia.

Many factors contribute to the disparity in access to surgical care. Poverty, a primary risk factor for all types of diseases, is a major obstacle hindering access to surgery. Healthcare professionals, including surgeons, migrate from areas of need due to a lack of infrastructure (hospitals, roadways, and stable electrical sources), limited supplies and equipment, lack of human

resources, few opportunities for professional development, and concerns for personal safety. Finally, the lack of information about the burden of surgical disease and surgery's impact on communities has led to misconceptions of policy makers that quality surgical care is cost prohibitive and too complex to be seriously considered a viable conduit for improving global health.^{7,8}

1▶ Disparities in care and outcomes are multidimensional, and no simple solution exists to improve access to appropriate and affordable surgical care. Yet, five major forces are reshaping priorities and strategies leading the charge for the globalization of surgical care:

1. *The epidemiologic transition of diseases* from primarily infectious to more chronic conditions;
2. *The mobile nature of the world's populations* allows more convenient travel opportunities for people to move freely between more isolated areas of the world leading to a more integrated global community;
3. *Ubiquitous information access* exponentially enabling universal participation in understanding and designing innovative opportunities for high-quality surgical care;
4. *A revolution for equity and human rights* where the world's poor are demanding benefits to surgical care similar to those found in developed countries;
5. *Recognition of the cost-effectiveness of surgical care*, and its potential to build economies, demonstrating the potential value of, including surgery in global health strategies.^{9,10}

The potential benefits of surgical care for economic productivity are astounding. Considering that the annual economic loss from road traffic injuries alone exceeds U.S. \$500 billion globally, a panel of expert economists at the Copenhagen Consensus of 2012, including four Nobel prize laureates, understandably prioritized strengthening surgical capacity as the eighth most cost-effective investment for addressing the world's current most pressing problems.^{8,11} Good health, which fosters productive economies and political stability, must include access to the full spectrum of health care, including surgical care to

Key Points

- 1▶ There are five major forces reshaping priorities and strategies for the globalization of surgical care:
 - a. The epidemiologic transition of diseases
 - b. The mobile nature of the world's populations
 - c. Ubiquitous information access
 - d. A revolution for equity and human rights
 - e. Recognition of the cost-effectiveness of surgical care
- 2▶ Understanding and addressing the necessary communication, energy and transportation technologies along with the underlying cultural context represent the foundation critical to implementing sustainable infrastructure necessary for appropriate surgical care.
- 3▶ The key components of the global surgery ecosystem include technology, education, community, healthcare, business, and multidisciplinary engagement between a variety of disciplines.
- 4▶ There has been a significant shift from communicable, maternal, neonatal, and nutritional causes to noncommunicable causes, many of which require surgical care.
- 5▶ Patients and their communities in low-middle income countries (LMICs) bear a much greater share of the burden of cancer than high-income countries.

- 6▶ Globally, trauma has become a leading cause of death and disability; 90% of trauma deaths occur in LMICs.
- 7▶ The burden of disease is greatest in areas where human resources—physicians, nurses, pharmacists, and other healthcare workers—are the least.
- 8▶ Surgery is gaining an increasingly recognized role for improving public health.
- 9▶ Surgery has a role in prevention as well as treatment.
- 10▶ The cost-effectiveness of various aspects of surgical care has allowed surgical initiatives to be included when prioritizing public health initiatives.
- 11▶ Developing advanced surgical capabilities in resource-poor countries has the potential to decrease overall cost and actually develop the infrastructure necessary to entice physicians and other healthcare workers to remain in their own countries.
- 12▶ Academic involvement in global surgery provides training for the next generation of surgical leaders.
- 13▶ Surgical innovations that consider cost as well as quality and design for challenging energy environments will foster equity in surgical care for LMICs.

“advance the quality of life for billions of citizens around the world.”⁸

This chapter examines the need for expanding surgical care globally, explores some of the seemingly insurmountable challenges, and presents potential guiding concepts along

with examples of successful strategies for sustainable surgical development.

DEFINING GLOBAL SURGERY

Global Surgery Ecosystem

To understand how surgery fits into healthcare systems and to understand its unique needs, it is helpful to consider global surgery as an ecosystem. The emerging field of global surgery considers surgical care to be a fundamental component of global health. As a system with both local and international scope, global surgery encompasses not just the medical and technical aspects of surgical care but also the societal and environmental context in which surgery is performed. Surgery as an ecosystem considers the diverse but interrelated systems that must be functional for quality surgical care to be delivered. Only part of these systems falls within the traditional training of surgeons. Yet, modern surgical care requires these systems to work in a coordinated fashion to support three priorities critical for expanding surgery globally—accessibility, affordability, and innovation (Fig. 49-2). Global surgery is a way to consider a “systems-based practice” beyond a single hospital or community for the benefit of people worldwide. Many of the interrelated components of this surgical ecosystem originate outside the hospital.

- 2▶ Disparities in surgical care have geographical, socioeconomic, and cultural components. Most people who live in major cities in northern and western hemisphere countries take for granted a functioning energy grid. The development of energy beyond major cities has enabled many wealthier communities to imagine, and indeed, to expect healthcare to be available at all times and to be affordable. Yet, a lack of reliable energy sources is a major limiting factor. Communication and transportation technologies, for example, the mobile phone and air and ground travel, have dramatically progressed

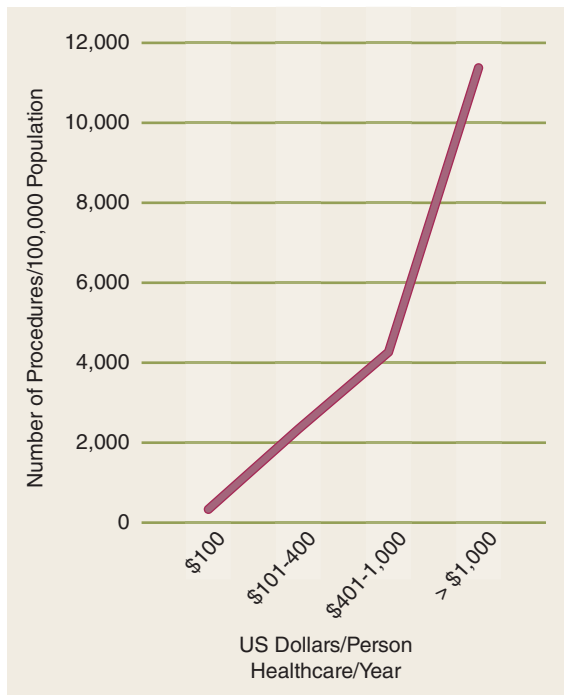


Figure 49-1. Worldwide distribution of surgical procedures. (Data from Weiser TG, Regenbogen SE, Thompson KD, et al. An estimation of the global volume of surgery: a modeling strategy based on available data. *Lancet*. 2008;372(9633):139-144. Illustration reproduced with permission from Intermountain Healthcare.)

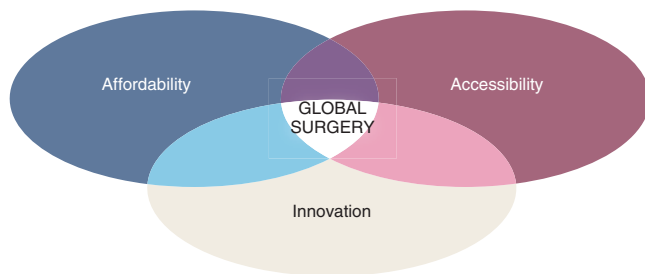


Figure 49-2. Global surgery priorities. (Reproduced with permission from University of Utah Center for Global Surgery and Intermountain Healthcare.)

in high- and middle-income countries but are still rudimentary in poor countries. Many of the current disparities in health care, particularly surgical care, are due to the lack of penetration of these technologies. Understanding and addressing the necessary communication, energy and transportation deficits as well as the underlying cultural nuances are necessary to support the sustainable development of surgical care (Fig. 49-3).

Electricity is necessary for all modern surgery. Anesthesia monitoring, OR lighting, cautery, suction, and patient warming devices all require sources of electricity that are stable, without huge electrical surges. Only in the last 50 years or so could stable electricity be expected in most wealthy cities. However, in rural areas of even wealthy countries, electricity remains unpredictable (Fig. 49-4).

In poorer countries, the cost and availability of electricity is frequently the limiting factor for more advanced diagnostic and therapeutic technology—from laboratories that require refrigeration to radiology in all of its various branches. Modern design for surgical devices has, for the most part, not taken into account the wide range of energy environments where surgery is practiced. Fragile instruments and monitors that cannot survive the rigors of the real working environment limit the types of surgery that can be provided.

Components of the Global Surgery Ecosystem. Improvements in energy, transportation, and communication are critical to support the growth of six key components of surgical care (Fig. 49-5).⁹ While building capacity within each component is important, it is the interaction between the components that creates a functioning, sustainable system.

When surgeons think of surgery, they usually think in terms of science and hands-on technical expertise. However, global



Figure 49-3. Foundation for creating surgical infrastructure. (Reproduced with permission from Catherine R. deVries, M.D., University of Utah, and Intermountain Healthcare.)

surgery requires a broader understanding of systems in other disciplines. Surgeons must work collaboratively with engineers and business leaders to develop technology that can function in lower resource environments. These innovations can provide a source of economic growth for the community, which in turn supports better health care.

No sustainable surgical system in the modern age can function without specialists in bioengineering, sterile process, supply chain, hospital safety and waste management. These often unappreciated colleagues make possible the daily practice of surgery. Similarly, specialists in anesthesia, nursing, and the diagnostic specialties of radiology, pathology, and laboratory services are fundamental to a fully functional surgical service.

Burden of Surgical Disease

Epidemiologic Transition of Disease. The population on Earth currently stands at more than 7 billion. While the rate of growth has slowed in recent years, projections estimate that the population will continue to grow to 9 billion by 2050.¹² When thinking about global surgery, it is helpful to step back from the individual and consider families, communities, and nations. Each entity has its unique cultural and economic history and geographic advantages or disadvantages. Each has its own system for addressing surgical care but operates within a larger ecosystem, including energy availability, telecommunications and social networks, an interdependent global economy, and local material resources.

Population characteristics are changing rapidly. According to United Nations estimates, the human population of the entire world is aging, even in low-income countries, and by 2050, 2 billion people will be over the age of 60. Currently, Asia is home to 55% of the world's population over the age of 60.¹³ Until recently, infectious diseases dominated public health strategy. Now with major scourges like polio isolated to relatively small regions of the world and HIV and malaria decreasing in their relative impact worldwide, chronic diseases and their complications, as well as the effects of aging, are gaining dominance in health care needs. Many of these chronic diseases are best approached by surgery.

The lack of metrics and paucity of data identifying the unmet burden of surgical need in many countries have been obstacles facing global surgery initiatives. The 2010 Global Burden of Disease Study was the first worldwide comprehensive burden of disease evaluation since the initial 1990 epidemiologic study. Using the disability-adjusted life years (DALY), a metric initially proposed for the 1990 study that captures both premature mortality and the prevalence and severity of illnesses, disease burdens were calculated for 291 causes in 21 regions of the world (including 187 countries) for 1990, 2005, and 2010 to enable identification of significant trends over time.¹⁴ While the global DALYs remained stable from 1990 to 2010, the study identified a significant shift from communicable, maternal, neonatal, and nutritional causes to noncommunicable causes (Fig. 49-6).¹⁵

In the 2006 *Disease Control Priorities 2nd edition*, the global burden of premature death and disability from surgically treatable conditions was estimated at 11% of the total global burden of disease.¹⁰ Recently, country-wide population surveys using the Surgeons OverSeas Assessment of Surgical Need (SOSAS) methodology identified a large unmet burden of surgical disease. In Sierra Leone, 25% of deaths of household members during the previous year might have been averted

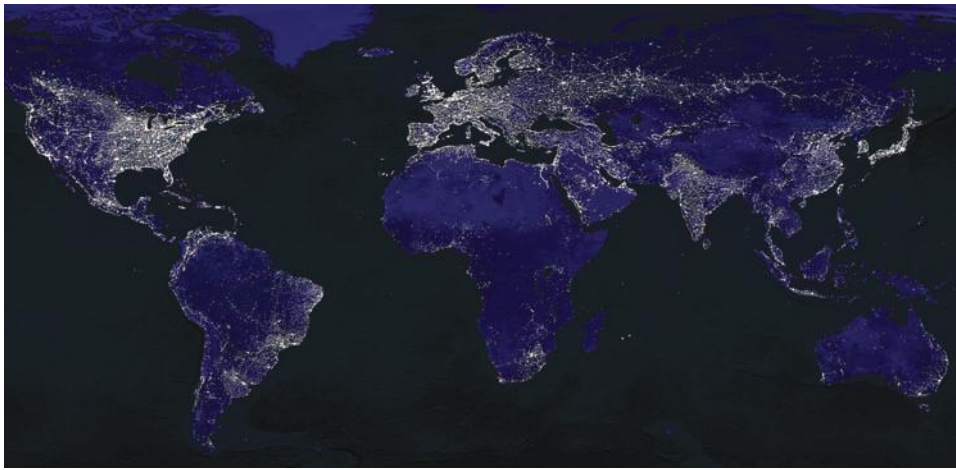

Figure 49-4. Map of world electrification. (NASA, Visible Earth, <http://visibleearth.nasa.gov/view.php?id=79765>)

by timely surgical care; 25% of respondents also reported a current condition needing surgical attention.¹⁶ In Rwanda, in 2011, the SOSAS survey found 41.2% of the population had at least one operative condition during their life time; 6.4% of the population was found to have a current surgically treatable condition.¹⁷ Using the percentage of the population currently needing surgical care from Rwanda and Sierra Leone combined with the 2012 population in Sub-Saharan Africa of almost 900 million, there are between 56 million and 218 million people just in Sub-Saharan Africa needing surgical attention today! Untreated acute and chronic surgical conditions represent a significant unmet burden of disease that have major impact on the economies of these nations.¹⁸

Cancer. Patients and their communities in low- and middle-income countries (LMICs) bear a much greater share of the burden of cancer than high-income countries. The dramatic increase in the proportion of reported cancer cases in LMICs is a result of population growth, aging populations, and the decreased mortality from infectious diseases. In 1970, only 15% of newly reported cancer cases worldwide were from the developing world; by 2008, this proportion rose dramatically

to 58% and is expected to grow to 70% by 2030.¹⁹ Previously thought to be a disease almost exclusive to high-income countries, nearly two-thirds of the 7.6 million cancer deaths worldwide occur in LMICs. Mortality from cancer correlates inversely with a country's economy for certain treatable cancers, including breast, testicular, and cervical cancer—LMICs have higher case fatality rates than high-income countries (Fig. 49-7).^{19,20}

For example, breast cancer case fatality rates illustrate the great disparity in outcomes between regions. Case fatality rates in East Africa reach an unacceptable 59% compared to 19% in the United States.²⁰ In LMICs, patients have very limited access to screening. They present for care with much later stages of cancer. In Haiti, after the great earthquake, in 2010, and after the initial onslaught of orthopedic injuries, many aid organizations found themselves faced with the unmet underlying burden of disease, including late stage breast cancer and other tumors (Fig. 49-8).

Trauma. Trauma has become a leading cause of death and disability around the world; 90% of trauma deaths occur in LMICs.²¹ Approximately 32% more people die

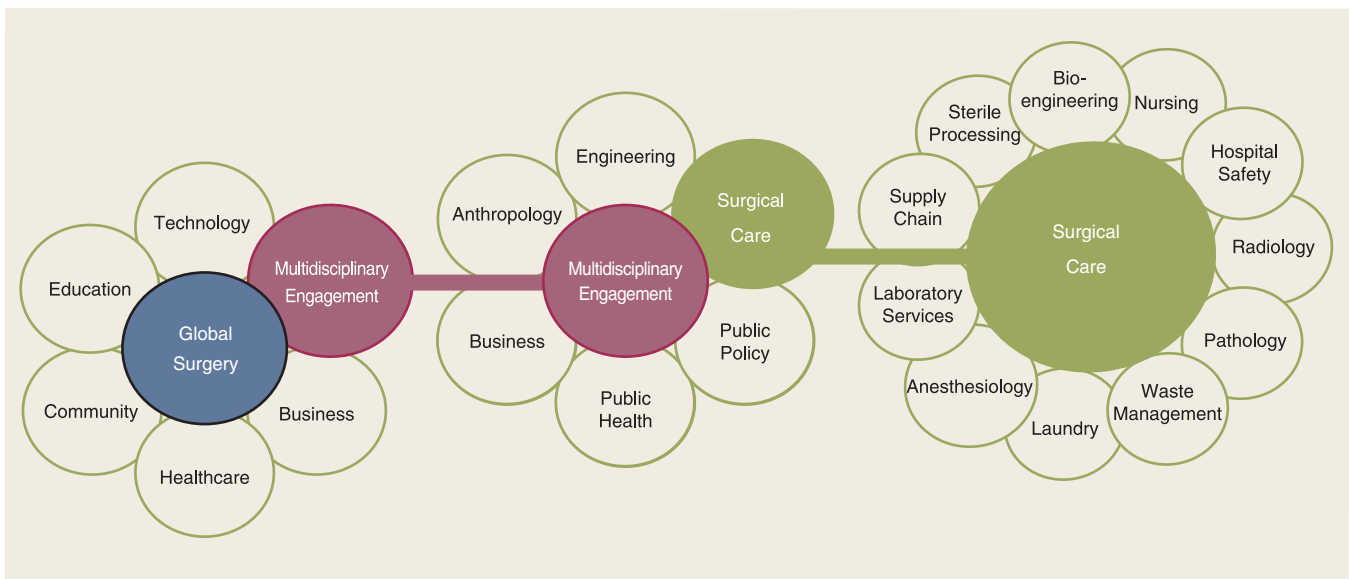


Figure 49-5. Key components of the global surgery ecosystem. (Reproduced with permission from Intermountain Healthcare.)

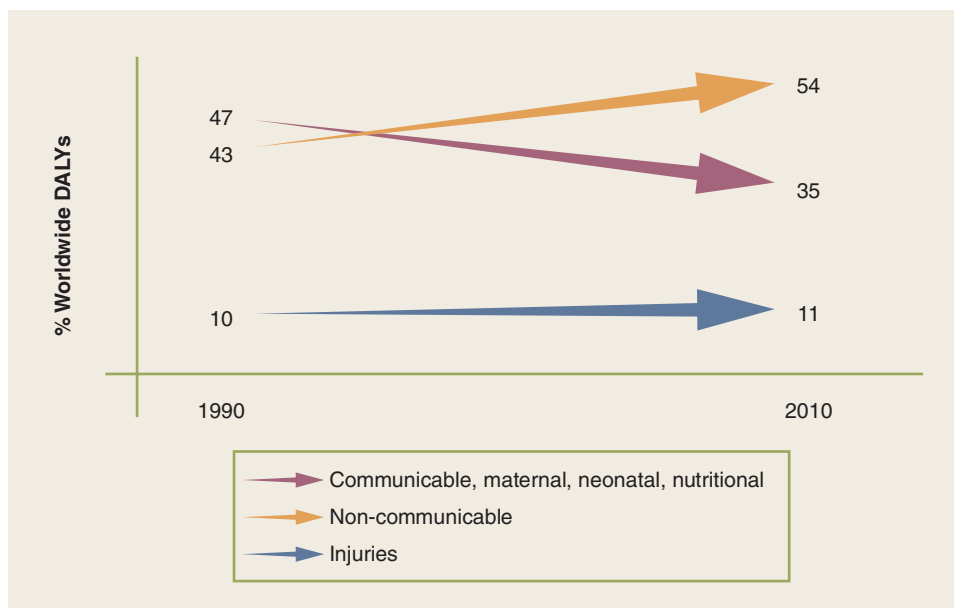


Figure 49-6. Shift in disease burden 1990–2010. (Data from Murray CJ, Vos T, Lozano R, et al. Disability-adjusted life years (DALYs) for 291 diseases and injuries in 21 regions, 1990–2010: a systematic analysis for the Global Burden of Disease Study 2010. *Lancet*. 2012;380(9859):2197–2223. Illustration reproduced with permission from Intermountain Healthcare.)

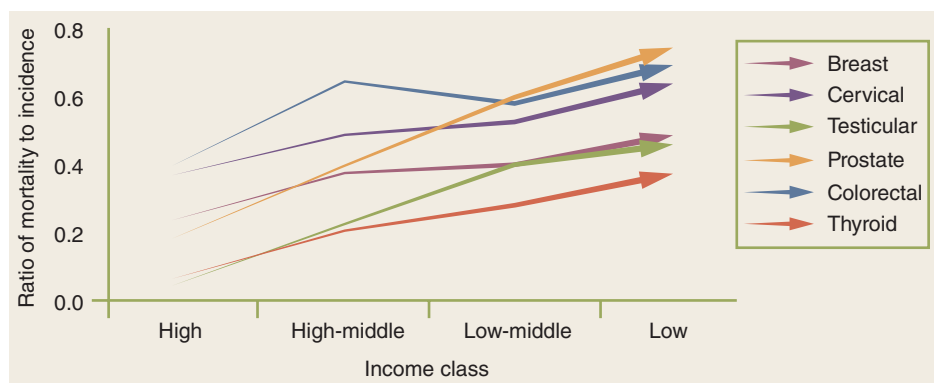


Figure 49-7. Ratio of mortality to incidence by solid tumor type and country income (2008). (Data from Farmer P, Frenk J, Knaul FM, et al. Expansion of cancer care and control in countries of low and middle income: a call to action. *Lancet*. 2010;376(9747):1186–1193. Illustration reproduced with permission from Intermountain Healthcare.)

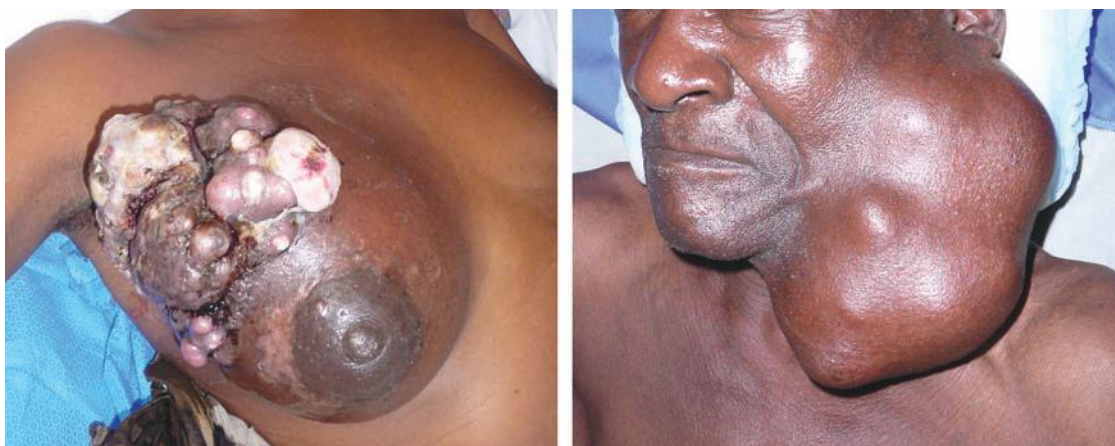

Figure 49-8. Underlying unmet cancer burden in Haiti (2010). (Photos reproduced with permission from R. Dirk Noyes, MD; layout reproduced with permission from Intermountain Healthcare.)

Injuries and Violence: the Scale of the Problem

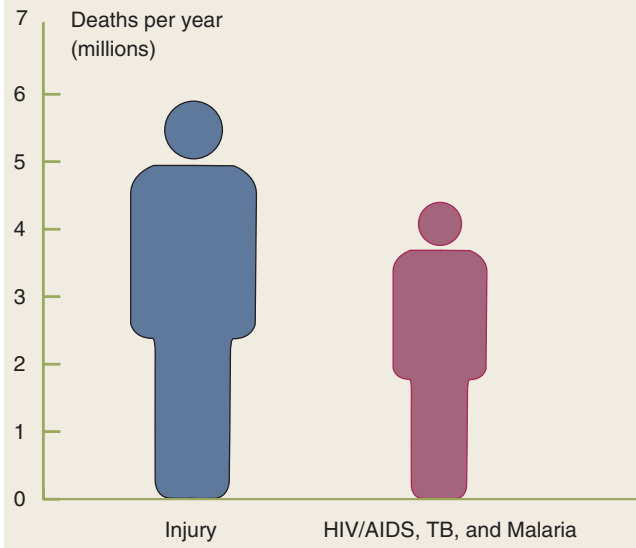


Figure 49-9. Injuries and violence: the scale of the problem. (*Injuries and violence: the facts*. Geneva, World Health Organization, 2010, http://www.who.int/violence_injury_prevention/key_facts/VIP_key_fact_1.pdf)

as a result from injuries than from malaria, tuberculosis, and HIV/AIDS combined representing 10% of the world's deaths (Fig. 49-9).^{22,23} In the United States, a patient presenting with an injury in a rural community has a higher mortality than those from an urban setting.²⁴ This disparity is much more pronounced in economically disadvantaged societies where seriously injured patients from road traffic accidents are twice as likely to die compared to similarly injured patients in a high-income setting (Fig. 49-10).^{22,25} Additionally, death is much more likely to occur in the pre-hospital settings for injured patients from low-income countries. The lack of integrated communication and

emergency transportation systems contribute to the pre-hospital risk, while the lack of infrastructure, supplies, and personnel contribute to in-hospital mortality.

Burns. Almost 11 million people worldwide sought medical or surgical care related to burns in 2004. However, the vast majority of burned people never present for medical care. Burns represent a significant cause of death as well as disability globally.²⁶ The vast majority of deaths from fires (95%) occur in LMICs. Burns result in nearly 200,000 deaths each year from fires while other forms of burns, including scalds and electrical burns, represent another significant source of death and disability. Women and children in LMICs are most likely to be burned in domestic kitchens; men are more likely to be burned in the workplace. The economic and social impact from long hospitalizations and from the resulting disfigurement provides a significant negative stigma causing ostracism and rejection.

Of all the forms of trauma worldwide, burns are the only type that predominantly afflicts women and children. Southeast Asia accounts for 27% of the burn-related deaths worldwide; 70% of people dying from burns in the region are women.²⁷ Cooking on wood, charcoal, or low kerosene stoves also puts children at risk, particularly from scalding (Fig. 49-11). Small children in the WHO African region have triple the number of burn deaths as children worldwide. Contrast this with the United States, where more burns and burn deaths affect men.

People living in rural areas suffer disproportionately because there are fewer facilities capable of managing the acute and chronic aspects of burn management and because the population is generally poorer. Surgical grafting and management of contractures is often best done in specialized burn centers, but these are rare in LMICs. Telemedicine has been shown to be effective in managing burns and preventing complications.²⁸

Human Resources

▶ The greatest burden of disease occurs in areas where human resources—physicians, nurses, pharmacists, and other healthcare workers—are scarce (Fig. 49-12).²⁹ The proportion of physicians is low both in high population areas and in areas

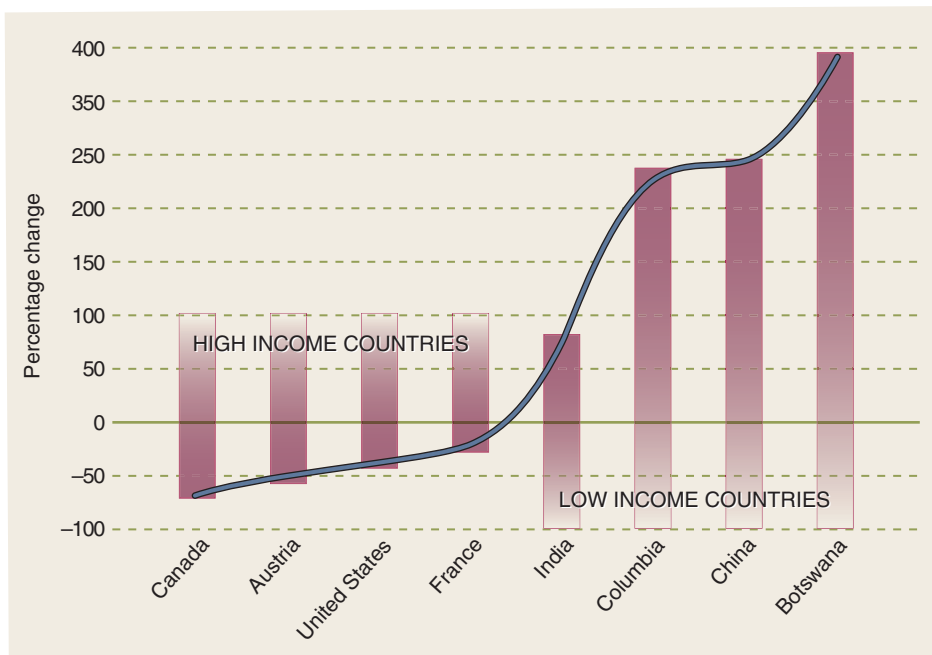


Figure 49-10. Change in traffic fatality risk (deaths/10,000 persons), 1975-1998). (Data from Kopits E, Cropper M. *Traffic fatalities and economic growth*. *Accid Anal Prev*. 2005;37(1):169-178. Illustration reproduced with permission from Intermountain Healthcare.)



Figure 49-11. Domestic kitchen: risk factor for burns in women and children in LMICs. (Reproduced with permission from James H. Kenney, Jr.)

where the population is growing most rapidly (Fig. 49-13).^{30,31} Fully trained surgeons and anesthesiologists comprise only a small proportion of the total number of the Human Resources in Health (HRH). In the Eastern Mediterranean, Southeast Asia, and Africa, HRH per 1000 people falls below the WHO minimum threshold (Fig. 49-14).²⁹ Many countries in Africa—for example Tanzania and Ethiopia—have only 0.6 surgeons per 100,000 population while the United States and Canada have 51 and 26 surgeons per 100,000 population, respectively.³² To provide the same concentration of surgeons in East Africa that currently exists in Canada would require training an estimated additional 42,000 surgeons.³³

Primary care physicians, nurses, midwives, or advanced care practitioners (ACPs) provide much of the basic surgical and anesthetic care in LMICs. Where regulations allow, “task shifting,” or training ACPs to deliver surgery and anesthesia services previously allowed only under the purview of fully trained specialists, can provide expanded access to care.³⁴⁻³⁶ Non-M.D. practitioners, variously known as *assistant medical officers (AMOs)* or “*tecnicos de cirurgia*” in Mozambique, often have extensive operative experience, including obstetrical care and are the primary providers of surgical care in a region.³⁷⁻³⁸ Task shifting to ACPs also occurs in the United States and other countries where they fill a need otherwise unmet by specialists

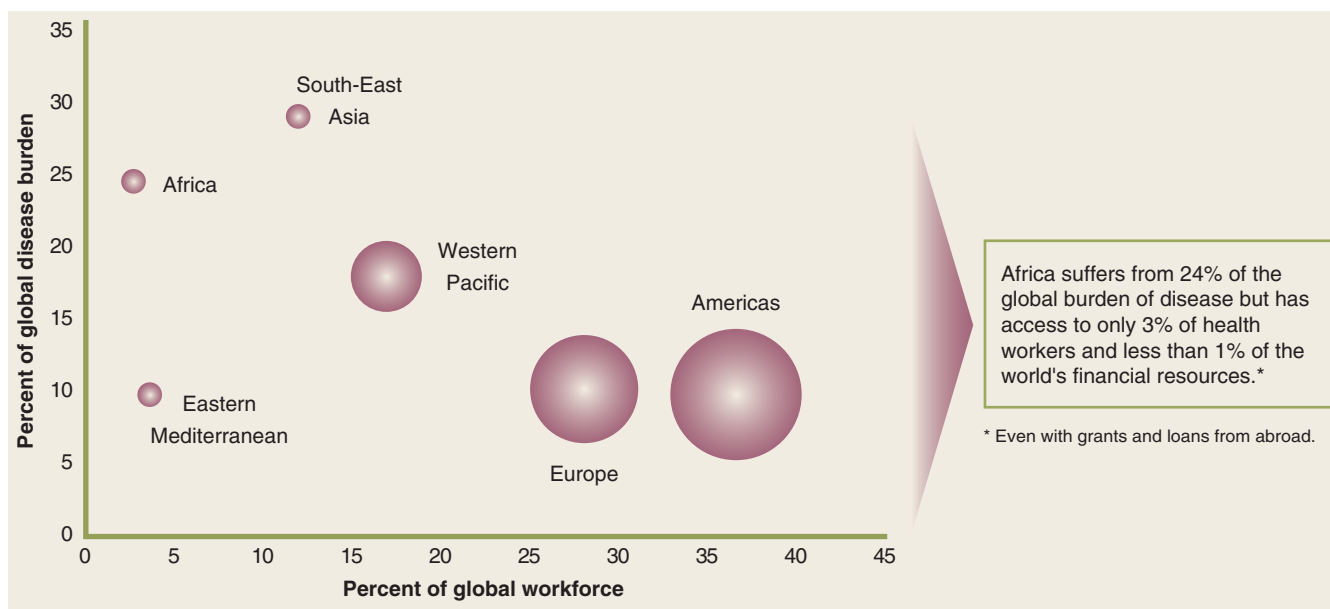


Figure 49-12. Distribution of healthcare workers by burden of disease in WHO regions. (Redrawn from Fig 5.1, *The Business of Health in Africa* (29) by permission. Reproduced with permission from Intermountain Healthcare.)

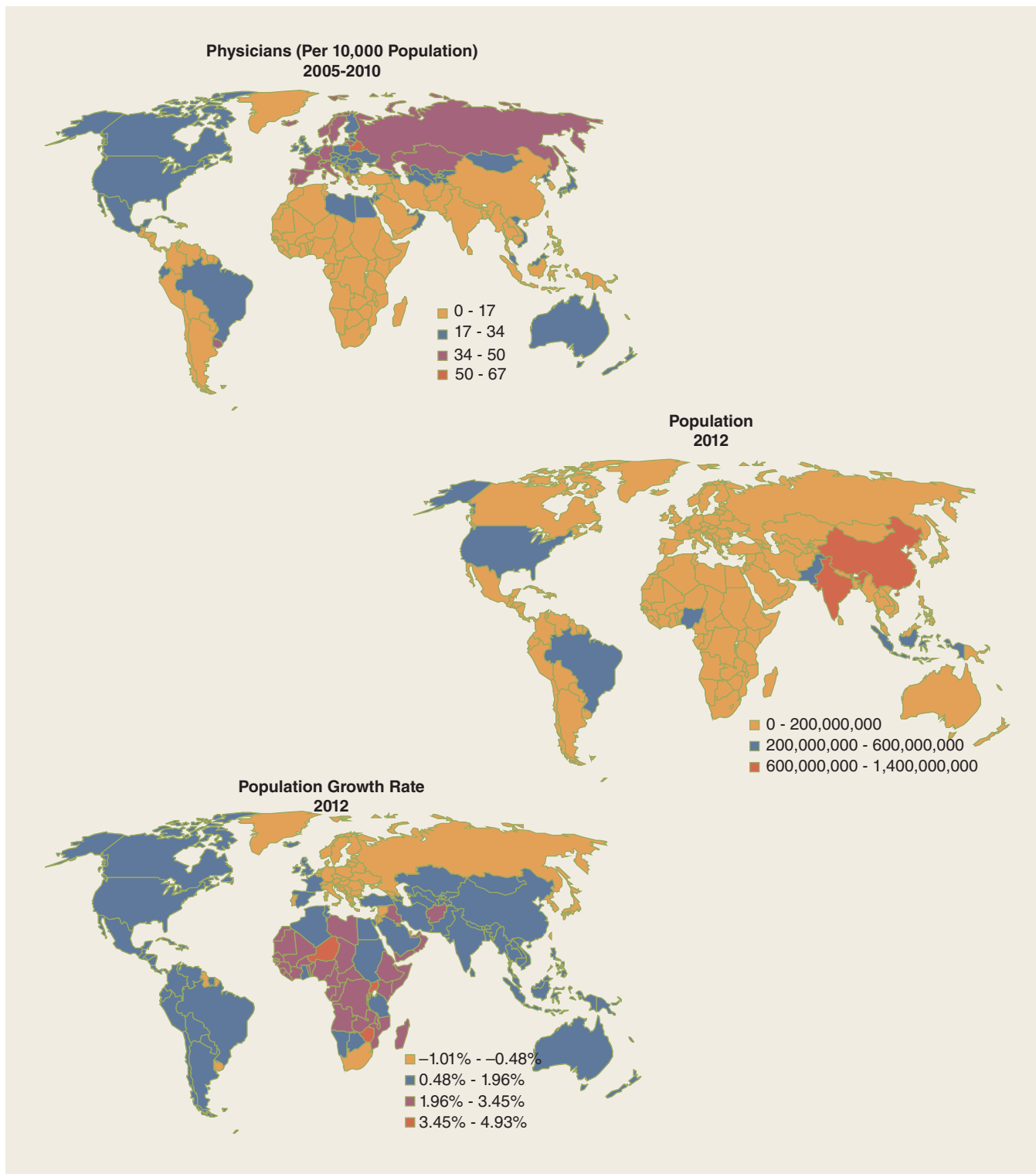


Figure 49-13. Number of physicians, world populations, and world population growth rates. (Figure Created from Data: Number of physicians per 10,000 population, 2005-2010, WHO, World Health Statistics 2012, available at: http://www.who.int/gho/publications/world_health_statistics/2012/en/index.html. See also, WHO, Global Health Observatory, available at: <http://www.who.int/gho/database/en/>; Population 2012, Sources: CIA, The World Factbook, available at: <https://www.cia.gov/library/publications/the-world-factbook/>.)

even in major tertiary care centers.³⁹ However, concerns about the quality of care, lack of adequate supervision, and the effect on prestige and professional development for specialists and ACPs, continue to be topics for debate.⁴⁰

Migration of practitioners to economically and culturally favorable locales is universal and not restricted to low-resource countries.⁴¹ However, the net impact on poor countries

is greater. In a 2004 study, more than 23% of U.S. physicians received their medical training from other countries; of these 64% were from low-income countries.⁴² Investments in training greater numbers of doctors in these countries, including surgical specialists, have been only partially successful in meeting the demand in poor countries. Until economic conditions improve or opportunities for professional development increase,

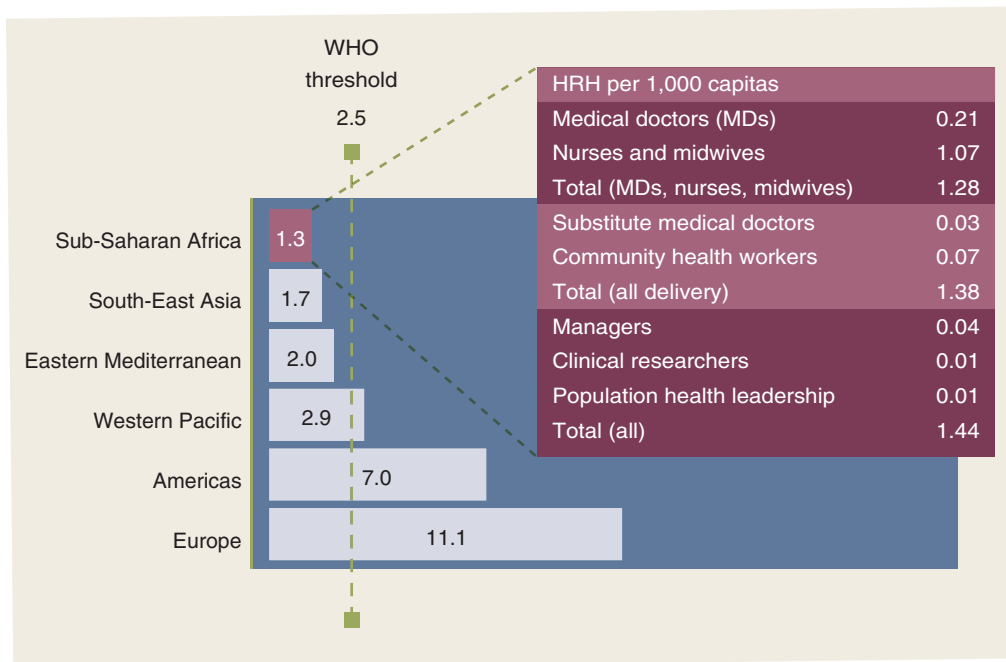


Figure 49-14. Human resources for health (HRH) by WHO region, 2006. (Redrawn from Fig 5.2, *The Business of Health in Africa* (29) by permission. Reproduced with permission from Intermountain Healthcare.)

and incentives enticing migration of health care workers to high-income countries abate, it is unlikely that the most skilled practitioners will remain in resource-poor areas beyond their immediate obligations.⁴³⁻⁴⁷

STRATEGIES FOR DEVELOPMENT

Initiatives for Outreach and Engagement

Many models for outreach and engagement have had a positive impact on the accessibility of surgery. Organizations participating in outreach are guided by a wide range of motivations and resources (Fig. 49-15). Some organizations are purely humanitarian and service oriented; others are primarily educational. Some even use the promise of healthcare to advance political, religious, or personal agendas.

Responding to the challenges of disparities, new generations of students, faculty, philanthropists, private industry leaders and policy makers have demonstrated a growing passion to address global surgery as part of global health. Prior to 1984 only 0.32% of physicians and 0.12% of nurses were involved in international health (either paid or volunteer).⁴⁸ Recently, interest in global health has exploded among medical students in the United States. A 2009 survey indicated that 25% of U.S. medical students have traveled to LMICs for clinical and research electives. At some medical schools the number has risen to over 50%.^{49,50} In 2004, 40% of medical students in the United Kingdom spent their 6 to 12 week elective rotation in developing countries.⁵¹ A structured questionnaire was administered anonymously to all American College of Surgeons resident members. Approximately 94% of the respondents were general surgery residents, and 92% were interested in an international elective with many planning to volunteer in the future.⁵²

Many patients have benefited from the multitude of service-oriented volunteer “missions” providing much needed surgical care that would otherwise have been unavailable. While

volunteerism and medical missions are laudable activities, they are not a sustainable solution to long-term manpower shortages for health.⁵³ Comprehensive initiatives are also necessary to engage local healthcare professionals and organizations, governments, and academic institutions to build capacity at home.⁵⁴

International Organizations

United Nations (UN). Committed to maintaining international peace, developing friendly relations between nations, and promoting better standards of living (conquering hunger, disease, and illiteracy) and human rights, representatives from 51 nations in 1945 signed the United Nations Charter at the United Nations Conference on International Organization held in San Francisco, California.⁵⁵ There are now 193 member states.⁵⁶ The UN promotes a social justice agenda advocating for worldwide health, engagement of philanthropies and civil society in global health initiatives, and supports the Millennium Development Goals (MDGs).

Millennium Development Goals (MDGs). Leaders from 189 countries gathered at the UN headquarters in September 2000 and agreed on eight specific “Millennium Development Goals” (Table 49-1).⁵⁷ Some have argued that strengthening basic surgical care at district level hospitals is critical to reaching MDGs 4, 5, and 6 (reducing child and maternal mortality and halting and reversing the spread of AIDS).^{6,58} In poor countries, the enormous shortfalls in infrastructure, and human and material resources severely limits the capabilities to provide access to life-saving and life-changing services such as timely Cesarean-section, control of peri-partum hemorrhage, appropriate care for pediatric trauma, and treatment for a multitude of congenital diseases.^{3,59-64} While the evolution of public policy has been slow to accept surgical care as integral to poverty reduction and public healthcare, surgeons are actively campaigning for and joining the process of negotiating for inclusion of surgical care development into the new post-2015 to 2030 MDGs.⁶⁵

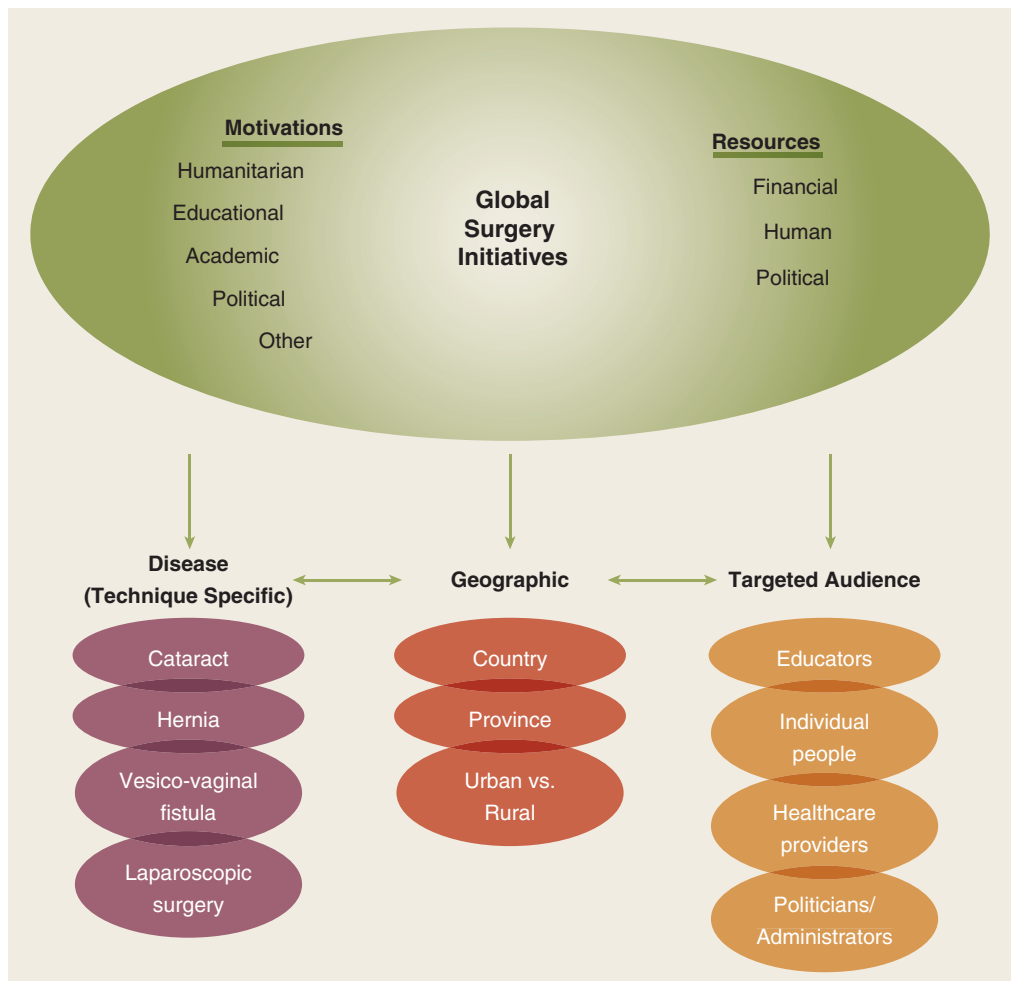


Figure 49-15. Global surgery initiatives. (Illustration reproduced with permission from Intermountain Healthcare.)

World Health Organization (WHO). The initial UN Conference in 1945 voted to establish a new international health organization. The Constitution of the World Health Organization (WHO) was approved and ratified in 1948.⁵⁵ The first World Assembly in 1948 established malaria, tuberculosis, venereal diseases, maternal and child health, sanitary engineering, and nutrition as WHO priorities. One of the WHO's greatest public health stories is the worldwide eradication of smallpox that began with the USSR proposal for the WHO-led program in 1958 culminating in the last identified case in Somalia in 1977.

Table 49-1

Millennium development goals 2000–2015

1. Reduce by half the number of people who suffer from hunger and whose income is < \$ 1/ day
2. Provide universal primary education
3. Promote gender equality
4. Reduce mortality rate for children < 5 years by two-thirds
5. Reduce maternal mortality rate by three quarters
6. Halt and reverse the spread of AIDS, malaria, tuberculosis, and other major diseases
7. Improve the environment
8. Strengthen the global partnership for development.

Data adapted from Millennium Development Goals. <http://www.undp.org/content/undp/en/home/mdgoverview/>

While the disease burden from communicable diseases has abated in large part from these successful international cooperative interventions, little has been done to address the growing global burden of surgical disease. Despite the laudable 1978 Declaration of Alma Alta that expressed the need for urgent action for the world community to protect and promote the health for all people, the declaration did so by crowning primary health care as the key to achieving the goal of health for all—which was then accepted by the member countries in the World Health Organization.⁶⁶ Although the Alma-Ata slogan “Health for all by 2000” did not materialize, it did galvanize efforts for global partnerships for healthcare improvements and poverty reduction.

The Violence and Injury Prevention Program (VIP) and the Global Initiative for Emergency and Essentials Surgical Care (GIEESC) are two programs related to surgery within the WHO that began before 2008. But, as a response to a growing recognition of the significant unmet surgical need, in 2008, the WHO for the first time included basic surgery as a component for community primary health care (Fig. 49-16).⁶⁷

The Global Initiative for Emergency and Essential Surgical Care (GIEESC). The Clinical Procedures (CPR) team in the WHO Department of Essential Health Technologies (EHT) convened a multidisciplinary group of experts from various surgical disciplines, professionals and civic leaders from national and international organizations, and representative from various WHO departments in December 2005 in Geneva, Switzerland, to formally organize the GIEESC.⁶⁸ GIEESC's main aim was

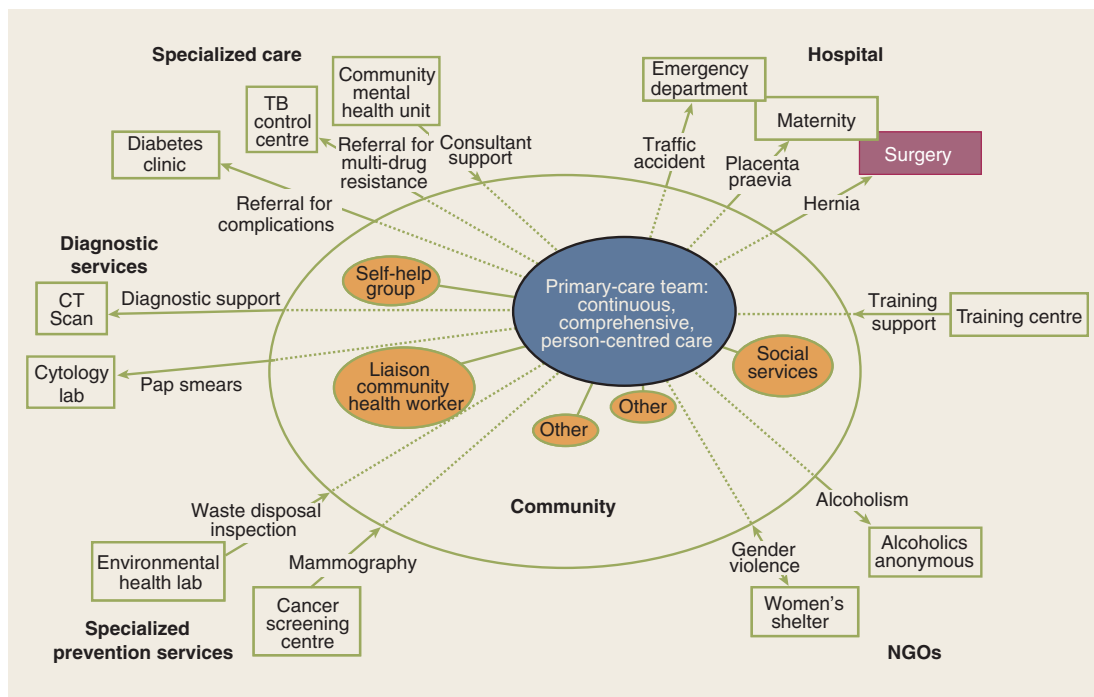


Figure 49-16. Emergency and essential surgery: an integral component of primary care. (*The World Health Report 2008, Primary Health Care Report, Now More Than Ever*, p. 55, Figure 3.5. <http://www.who.int/whr/2008/en/>)

to assist member states with capacity strengthening in the safe and appropriate use of emergency and essential surgical care (procedures, equipment) at resource-limited healthcare facilities through training and education programs. The training program was built around the WHO “Integrated Management of Emergency and Essential Surgical Care (IMEESC)” tool kit.⁶⁹ The tool kit included best practice protocols, guidelines on policies, training curriculum, emergency equipment, teaching slides, and

monitoring and evaluation instructions. Additionally, low-cost editions of the manual *Surgical Care at the District Hospital* have been made available in local languages. A Mongolian edition facilitated early expansion of GIEESC throughout the country. Mongolia has improved basic infrastructure, human resources and capabilities; and the use of the tool kit system has led to its incorporation into the countrywide healthcare plan.⁷⁰ (**Box:** Mongolia GIEESC)

Mongolia GIEESC

The WHO situational analysis tool developed in 2007 to assess the availability of emergency and essential surgical care (EESC) at individual health facilities has been utilized in 35 different countries documenting the limited infrastructure, human resources, procedures, equipment and supplies available for even basic EESC.⁶⁹ For example, there were no trained surgeons or anesthetists at 44 first referral hospitals in Mongolia.³ Only 66% of the facilities had electricity and 45% had running water (Fig. 49-17).

Most facilities lacked any policy for EESC, disaster preparedness, basic equipment to provide EESC, or any access to training for EESC. Adopting a health systems strengthening approach to rectify these glaring deficiencies, Mongolia implemented a nationwide EESC program involving 14 of the 21 provinces (Aimags) from 2004 to 2010 (Fig. 49-18).⁷⁰ In six years, dramatic improvements in short-term process measures were identified using the WHO Monitoring and Process form: 57.1% increase in availability of emergency rooms; 59.1% increase in the supply of emergency tool kits; and a 73.6% increase in the recording of emergency cases (Figs. 49-19 and 49-20).⁷⁰ More important, countrywide morbidity and mortality dropped significantly (Fig. 49-21).⁷¹



Figure 49-17. First Level (Soum) Hospital. (Photos reproduced with permission from Raymond R. Price MD. Layout reproduced with permission from Intermountain Healthcare.)

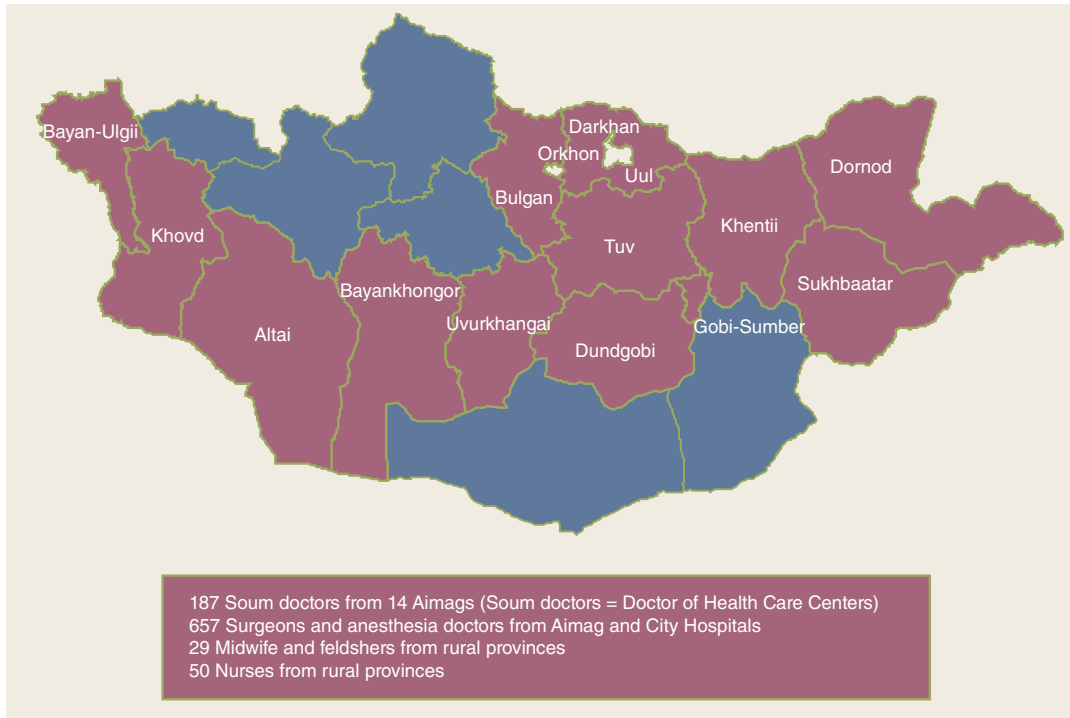


Figure 49-18. EESC Project: Mongolia 2004–2010. (Henry JA, Orgoi S, Govind S, Price RR, Lundeg G, Kehrer B. Strengthening Surgical Services at the Soum (First-referral) Hospital: The WHO Emergency and Essential Surgical Care (EESC) Program in Mongolia. World J Surg. 2012;36(10):2367, Fig. 2, With kind permission from Springer Science and Business Media.)

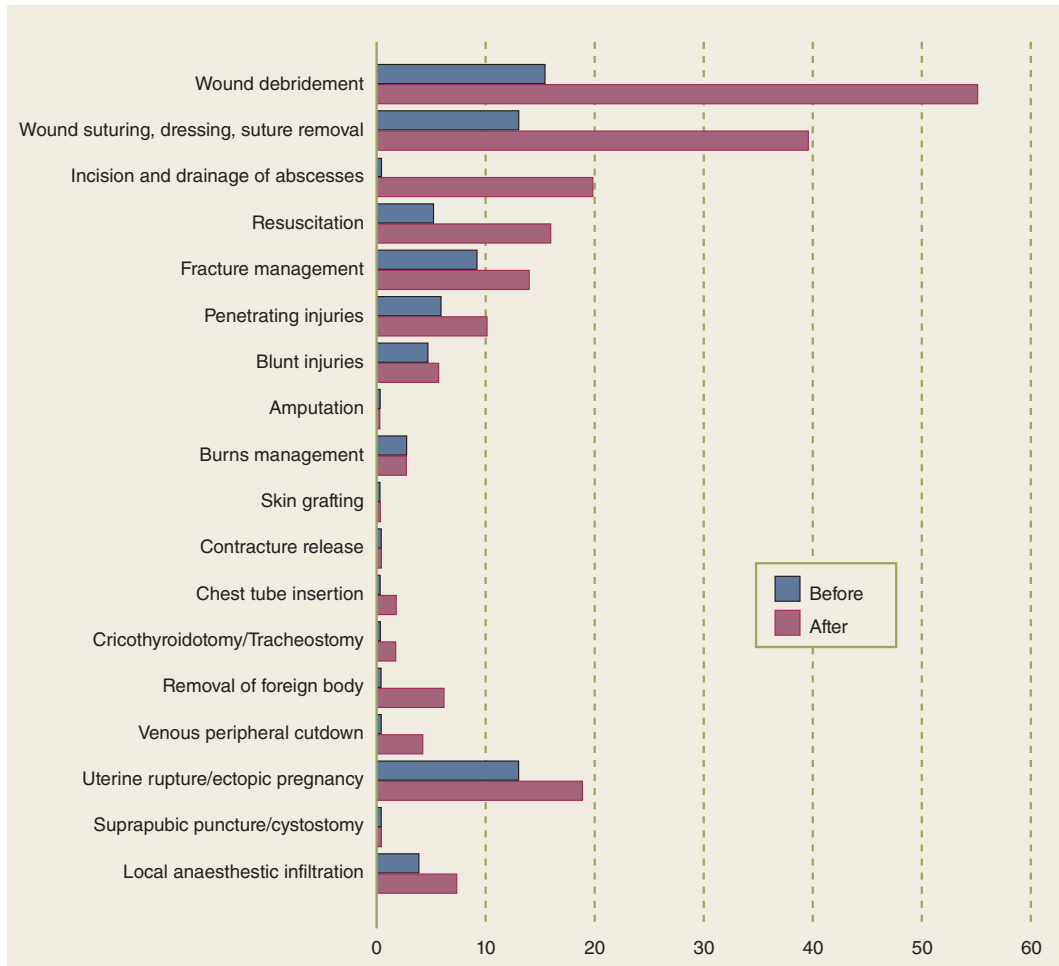


Figure 49-19. Surgical procedures performed 1-2 years Post-training (13 soum hospitals evaluated). (Henry JA, Orgoi S, Govind S, Price RR, Lundeg G, Kehrer B. Strengthening Surgical Services at the Soum (First-referral) Hospital: The WHO Emergency and Essential Surgical Care (EESC) Program in Mongolia. World J Surg. 2012;36(10):2367, Fig. 6, With kind permission from Springer Science and Business Media.)

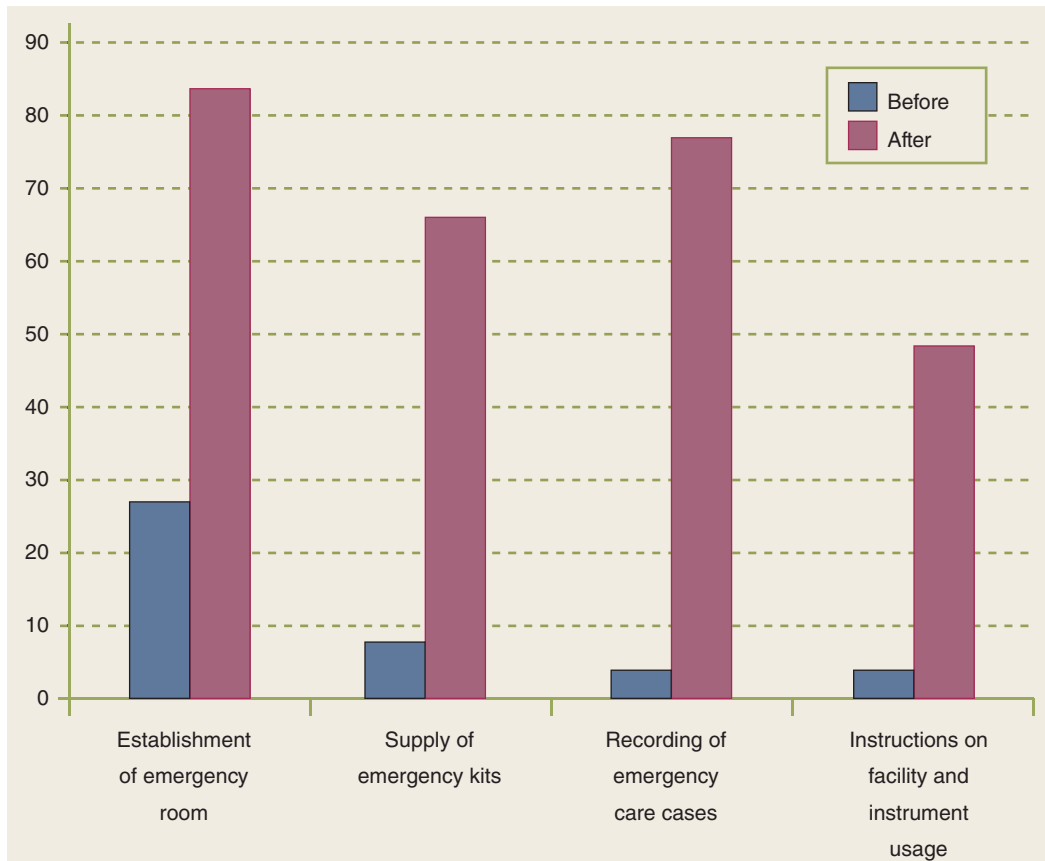


Figure 49-20. Pilot Soum hospitals' evaluation 2 years post-training. (Henry JA, Orgoi S, Govind S, Price RR, Lundeg G, Kehrer B. *Strengthening Surgical Services at the Soum (First-referral) Hospital: The WHO Emergency and Essential Surgical Care (EESC) Program in Mongolia.* World J Surg. 2012;36(10):2367, Fig. 5, With kind permission from Springer Science and Business Media.)

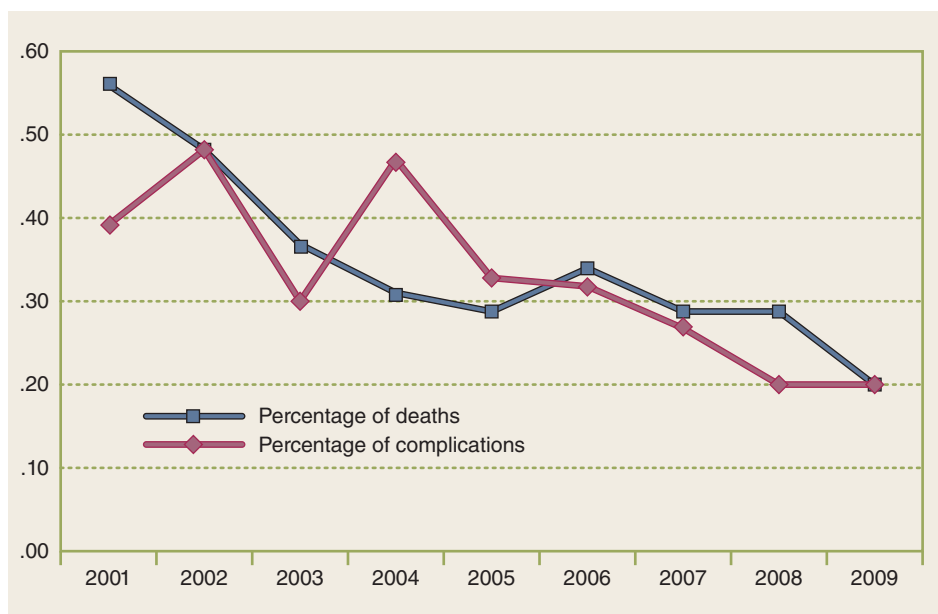


Figure 49-21. Surgical morbidity and mortality: Mongolia 2001–2009. (Adapted from *Indicators of Surgical Operation (Mongolia 2001–2009)*. 2010 [cited 2011 November 2]; Available from: www.doh.gov.mn. Illustration reproduced with permission from Intermountain Health-care.)

Violence and Injury Prevention (VIP). The Violence and Injury Prevention (VIP) program promotes numerous activities to assist countries to prevent and mitigate the consequences of violence and injury.⁷² While injury prevention is paramount, VIP provides guidance for strengthening trauma systems in countries of all economic levels to improve emergency care and rehabilitation. VIP also encourages development of systematic data collection and analysis to better guide appropriate interventions. Prevention programs include the WHO Helmet initiative while the Essential Trauma Care Project (ESTC) creates standards for the care of injured patients and promotes systematic capacity building.

WHO Safe Surgery Saves Lives Initiative. Surgeons have always sought ways to prevent peri-operative complications. Aseptic technique, one of the greatest forms of prevention in surgical care, requires vigilant reinforcement to prevent serious wound infections. In resource-limited areas inadequate pre-, intra-, and post-operative monitoring, lack of critical medications, and poor documentation can be severely lacking placing patients at increased risk for serious complications. The WHO Safe Surgery Saves Lives Initiative is a worldwide attempt to prevent peri-operative complications.⁷³

Deaths from surgery occur at 0.4% to 0.8% globally; however, they may exceed 5% to 10% in developing countries. There are about 1 million deaths and 7 million disabling complications related to surgery worldwide, 50% of which are estimated to be preventable. The WHO Safe Surgery Saves Lives initiative targets preventable surgical injuries.⁷³ The initiative identified 10 basic and essential objectives that can help prevent peri-operative injuries (Table 49-2).⁷⁴ A three-stage simple checklist (initiated as the patient entered the operating room, just before the procedure, and just prior to the patient leaving the room) implemented in 8 countries from high-, middle-, and

low-income countries found a 50% reduction in the failure to meet basic safety standards resulting in a 50% decrease in mortality (Fig. 49-22).⁷⁵

Global Surgery and Public Health

8▶ Surgical care is increasingly recognized as an integral component of public health. Traditional public health teaching portrays surgery as the antithesis of public health: treating the individual instead of the community, reactionary instead of preventative, and too expensive especially for countries with developing economies. Yet in reality, surgery and public health priorities overlap in many areas (Fig. 49-23). For example, providing *access* to obstetrical care or birth attendants for every delivery could *prevent* the majority of vesico-vaginal fistulas and markedly decrease the most common cause of maternal death—hemorrhage—for entire communities.

Even after Learmonth presented his landmark lecture in 1949 “The Contributions of Surgery to Preventive Medicine” at the University of London’s Health Clark Lecture series, surgery has been neglected as a component of public health.^{7,76} The World Bank, in the 2006 *Disease Priorities, 2nd edition*, included its first chapter on surgery. An entire volume dedicated to surgical care is planned for the 3rd edition. There are three significant developments helping to accelerate the integration of surgery and public health:

1. Improved understanding of the burden of surgical disease and its significant component of the overall burden of global disease;
2. Recognition that surgery has a primary, secondary, and tertiary preventative role; and
3. Documentation that surgical care can be cost-effective for community-based healthcare.

Assigning Disease Priorities. Global surgery interventions can be prioritized to identify those conditions in which clinicians and public health professionals should collaborate most closely—targeting those diseases that impose the largest burden on a society and have a highly successful surgical outcome (Table 49-3).^{69,77} Levels defining public health burden, success, and feasibility have not been precisely defined. However, four broad, high-priority areas where surgery has an important role for public health interventions include: trauma care; obstetrical emergencies; acute-surgical emergencies; and nonacute surgical conditions that significantly affect the quality of life (Table 49-4).¹⁰

Trauma Care. The Essential Trauma Care Project (EsTC) begun in 2001 is a collaboration effort between the International Association for Trauma Surgery and Intensive Care, an integrated society within the International Society of Surgery-Societe-Internationale Chirurgie (ISS-SIC) and the World Health Organization (WHO), specifically the Violence and Injury Prevention unit. The project culminated in a document that identified 11 core Essential Trauma Care services (identified as the “rights of the injured patient”) that should be available at all levels of healthcare facilities (Table 49-5).⁷⁸ In addition, the document delineated 260 human and physical resources that should be available based on the type of facility (Table 49-6).

The EsTC recommendations provide a cost-effective framework for LMICs to improve their trauma care. These recommendations have been used as a planning guide and as an advocacy statement. To catalyze strengthening trauma and

Table 49-2

Ten basic and essential objectives for safe surgery (WHO*)

1. Operate on the correct patient at the correct site
2. Use method known to prevent harm from anesthetic administration, while protecting the patient from pain
3. Recognize and effectively prepare for life-threatening loss of airway or respiratory function
4. Recognize and effectively prepare for risk of high blood loss
5. Avoid inducing any allergic or adverse drug reaction known to be a significant risk for the patient
6. Consistently use method known to minimize risk of surgical site infection
7. Prevent inadvertent retention of instruments or sponges in surgical wounds
8. Secure and accurately identify all surgical specimens
9. Effectively communicate and exchange critical patient information for the safe conduct of the operation
10. Establish routine surveillance of surgical capacity, volume, and results

*WHO: World Health Organization.

Data from WHO Guidelines for Safe Surgery 2009 http://whqlibdoc.who.int/publications/2009/9789241598552_eng.pdf.

Surgical Safety Checklist		
Before induction of anaesthesia	Before skin incision	Before patient leaves operating room
(with at least nurse and anaesthetist)	(with nurse, anaesthetist and surgeon)	(with nurse, anaesthetist and surgeon)
<p>Has the patient confirmed his/her identity, site, procedure, and consent?</p> <input type="checkbox"/> Yes	<p><input type="checkbox"/> Confirm all team members have introduced themselves by name and role.</p> <p><input type="checkbox"/> Confirm the patient's name, procedure, and where the incision will be made.</p>	<p>Nurse Verbally Confirms:</p> <input type="checkbox"/> The name of the procedure <input type="checkbox"/> Completion of instrument, sponge and needle counts <input type="checkbox"/> Specimen labeling (read specimen labels aloud, including patient name) <input type="checkbox"/> Whether there are any equipment problems to be addressed
<p>Is the site marked?</p> <input type="checkbox"/> Yes <input type="checkbox"/> Not applicable	<p>Has antibiotic prophylaxis been given within the last 60 minutes?</p> <input type="checkbox"/> Yes <input type="checkbox"/> Not applicable	<p>To Surgeon, Anaesthetist and Nurse:</p> <input type="checkbox"/> What are the key concerns for recovery and management of this patient?
<p>Is the anaesthesia machine and medication check complete?</p> <input type="checkbox"/> Yes	<p>Anticipated Critical Events</p> <p>To Surgeon:</p> <input type="checkbox"/> What are the critical or non-routine steps? <input type="checkbox"/> How long will the case take? <input type="checkbox"/> What is the anticipated blood loss? <p>To Anaesthetist:</p> <input type="checkbox"/> Are there any patient-specific concerns? <p>To Nursing Team:</p> <input type="checkbox"/> Has sterility (including indicator results) been confirmed? <input type="checkbox"/> Are there equipment issues or any concerns?	
<p>Is the pulse oximeter on the patient and functioning?</p> <input type="checkbox"/> Yes	<p>Is essential imaging displayed?</p> <input type="checkbox"/> Yes <input type="checkbox"/> Not applicable	
<p>Does the patient have a:</p> <p>Known allergy?</p> <input type="checkbox"/> No <input type="checkbox"/> Yes <p>Difficult airway or aspiration risk?</p> <input type="checkbox"/> No <input type="checkbox"/> Yes, and equipment/assistance available <p>Risk of >500ml blood loss (7ml/kg in children)?</p> <input type="checkbox"/> No <input type="checkbox"/> Yes, and two IVs/central access and fluids planned		
<p>This checklist is not intended to be comprehensive. Additions and modifications to fit local practice are encouraged.</p> <p>Based on the WHO Surgical Safety Checklist http://whqlibdoc.who.int/publications/2009/9789241598590_eng_Checklist.pdf © World Health Organization 2009 All rights reserved</p>		

Figure 49-22. Surgical safety checklist. (WHO surgical safety checklist. 2009, http://whqlibdoc.who.int/publications/2009/9789241598590_eng_Checklist.pdf. © World Health Organization 2009 All rights reserved.)

emergency care in low-and middle-income countries, in 2007, the World Health Assembly (WHA) adopted a resolution on Emergency Care Systems (Resolution WHA 60.22).^{79,80} This first-ever WHA resolution dedicated specifically to trauma care highlights the importance accorded by world governments in caring for their injured.

Obstetrical and Other Acute Surgical Emergencies. Reduction of maternal deaths and long term disability are high priorities for the international community.⁸¹ Despite the 47% reduction in maternal deaths from 1990 to 2010, many women—mostly

in LMICs—still die daily from preventable causes related to pregnancy and childbirth.⁸² The global maternal mortality ratio (the number of maternal deaths per 100,000 live births) declined by only 3.1% per year which is significantly less than the 5.5% reduction necessary to achieve MDG 5—to decrease maternal mortality by 75% by 2015.⁸² For every maternal death, 30 women are incapacitated by chronic problems that reduce their quality of life and ability to care for their families. High priority surgical procedures to improve maternal health include Cesarean-section, hysterectomy for postpartum bleeding and uterine rupture, management of ectopic pregnancy, and dilatation and curettage.⁷⁷

About 90% of other acute surgical emergencies could be addressed by developing the capability to care for the 10 most common acute surgical conditions in any local region. While a few types of disease processes vary by geographical location, there are many that are universal, including appendicitis, strangulated hernia, small bowel obstruction, perforated peptic ulcer, fractures, lacerations, and wounds.

Nonacute Surgical Conditions. Even common nonacute conditions can have significant impact on the quality of life. Hernias can prevent otherwise healthy individuals from working, especially in societies where the economy relies heavily on manual labor. Cleft lip and cleft palate deformities interfere with the ability to speak or eat properly and predispose affected individuals to chronic ear infections leading to hearing loss. Many live in isolation because social ostracism prevents them from attending school, marrying, or holding jobs.⁸³ Plastic surgeons who pioneered global outreach for reconstructive procedures for

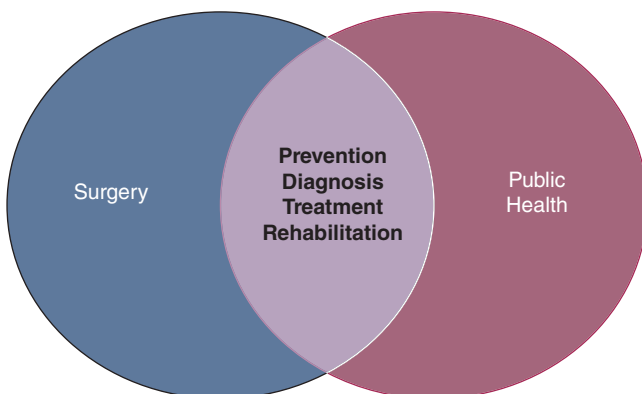


Figure 49-23. Overlapping priorities of surgery and public health. (Illustration reproduced with permission from Intermountain Healthcare.)

Table 49-3

Prioritization of surgical conditions

PRIORITY*	PUBLIC HEALTH BURDEN	SURGICAL PROCEDURE SUCCESSFUL	COST-EFFECTIVE AND FEASIBLE TO PROMOTE GLOBALLY
1	High	Highly	Highly
2	Moderate	Moderately	Moderately
3	Low	Neither highly or moderately	Low

*Priority one implies that all three conditions must be met. The priority should be shifted to 2 or 3 if any of the conditions are moderate or low.

Data adapted from: Mock C, et al. Developing priorities for addressing surgical conditions globally: furthering the link between surgery and public health policy. *World J Surg.* 2010;34(3): 381–385.

cleft lip and palate opened the door for subsequent outreach by other specialties, including ophthalmology, orthopedics, general surgery, urology, and dentistry.⁸⁴⁻⁸⁶

The most common form of blindness is caused by cataracts. Cataracts decrease the quality of life and the socioeconomic status for both the blind person and his family. The fact that 90% of blind people no longer work, places extra burdens on the family members who care for them.⁸⁷ The Himalayan Cataract Project (HCP) is a highly successful initiative focusing on cataracts in Asia and Africa. HCP priorities and measurable outcomes illustrates how combining key public health concepts with a comprehensive approach to surgical care creates a model for curing disease, building economies, and delivering hope in resource-poor areas.⁹ (**Box:** The Himalayan Cataract Project: A Sustainable Public Health Approach for Curing Blindness)

Cancer Initiatives

Surgery for cancer in public health plays a role not only for curative surgery, but also for early diagnosis, prevention, and

palliation.^{19,91-93} Solid tumors, in their early stages, presents insidiously as a nonacute surgical problem. Due to cancer's recent recognition as a leading cause of death, cancer has been identified as a health priority in LMICs. Most solid tumors are incurable without surgery and at a minimum require surgical excision of the primary lesion.⁹¹

It is often not appreciated that surgeons provide a significant amount of primary care and are the principle providers involved in endoscopic screening and treatment of gastrointestinal tumors in LMICs. In countries without specialized services, low-cost and effective treatment options combining early prevention and treatment with off-patent drug use have led to coverage of cancer treatment in several middle-income countries' national health insurance plans.¹⁹ Cancer care provides significant opportunity for including surgery in community-wide public health programs as a high priority according to the prioritization model; cancer has a high public health burden, is treated with highly successful procedures, and can be cost-effective and feasible globally. In 2009, a coalition of leaders in cancer care and public health organized the Global Task Force on Expanded Access to Cancer Care and Control in Developing Countries (GTFCCC)⁹⁴ GTFCCC's mission is to expand access

Table 49-4

The role of surgery for public health strategies

Trauma care	Prevention of death and chronic disability by the provision of timely, expert, and complete surgical care
Obstetrical emergencies	Timely surgical intervention in obstructed labor, in pre- and post-partum hemorrhage, and other obstetrical complications
Acute surgical emergencies	Provision of competent surgery to treat a wide range of emergency abdominal and nonabdominal conditions
Nonacute surgical conditions	Surgical care for several elective conditions that have a significant effect on the quality of life such as cataract, otitis media, clubfoot, and hernias

Data adapted from Debas, HT, et al, *Surgery, in Disease Control Priorities in Developing Countries*. 2nd ed. Jamison DT, Breman JG, Measham AR et al (eds.) New York: Oxford University Press for The World Bank, 2006, p. 1245–59.

Table 49-5

Essential trauma care services

1. Obstructed airway appropriately maintained
2. Impaired breathing supported
3. Pneumothorax and hemothorax promptly diagnosed and treated
4. Bleeding promptly stopped (internal or external)
5. Shock recognized and treated appropriately (I.V. fluids)
6. Timely decompression of space occupying lesions to prevent secondary brain injury
7. Abdominal injuries diagnosed and promptly repaired (intestinal injuries and others)
8. Disabling extremity injuries corrected
9. Potentially unstable spine injuries identified and managed (early immobilization)
10. Minimize consequences of injuries by appropriate rehabilitative services
11. Medication to provide above services and relieve pain readily available

Data adapted from Mock C, Joshipura M, Goosen J, Maier R. Overview of the Essential Trauma Care Project. *World J Surg.* 2006;30(6): 919–929.

Table 49-6

Airway management recommendations for physical and human resources based on type of facility (sample from EsTC*)

KNOWLEDGE AND SKILLS	FACILITY LEVEL			
	BASIC	GENERAL PRACTITIONER	SPECIALIST	TERTIARY
Assessment of airway compromise	E	E	E	E
Manual maneuvers (chin lift, jaw thrust)	E	E	E	E
Insertion of oral or nasal airway	D	E	E	E
Endotracheal Intubation	D	D	E	E
Equipment and supplies				
Oral or nasal airway	D	E	E	E
Laryngoscope	D	D	E	E
Endotracheal tube	D	D	E	E
Capnography	I	D	D	D

E: essential; D: desirable; I: irrelevant (not usually to be considered at the level in question).

*EsTC: Essential Trauma Care.

Data adapted from Mock C, Lormand JD, Goosen J, Joshipura M, Peden M. *Guidelines for essential trauma care*, 2004, Geneva: World Health Organization, p. 21.

The Himalayan Cataract Project (HCP): A Sustainable Public Health Approach for Curing Blindness

According to the WHO criteria, 180 million people worldwide are visually disabled. Of that population, 45 million are classified as bilaterally blind; 90% live in the developing world where poor water quality, lack of sanitation, malnutrition, and inadequate services cause a higher incidence of eye disease.⁸⁷ The most common cause of avoidable blindness in LMICs is cataract (50%). Nepal has one of the highest incidences of cataracts due to increased exposure to ultraviolet sunlight encountered at its higher elevations; 70% of curable blindness in Nepal is due to cataracts.⁸⁸

In 1995, Sanduk Ruit joined forces with Geoffrey Tabin to establish the Himalayan Cataract Project (HCP). In the early 1990's, difficult geography and lack of transportation, the cost of the intraocular lens, and lack of trained ophthalmologists, assistants, and nurses limited access to cataract surgery for the poor.

HCP developed and defined six priorities each with an associated public health principle and outcome measurements that provided the basis for assessing success and for implementing change (Fig. 49-24). HCP's care model targeted the entire population of blind people with cataracts regardless of the ability to pay. Since most of the potential patients lived in remote areas, HCP found it imperative to take cataract surgery to the local communities. The Tilganga Institute of Ophthalmology (TIO) in Katmandu, Nepal, has served as a base from which over 100 doctors and 100 ophthalmic assistants and nurses have been trained.⁸⁹ Through the TIO and its outreach programs, over 2,573,000 people have been screened and more than 172,000 eye surgeries have been performed since 1994 (Fig. 49-25).⁸⁹

The TIO developed an ophthalmology residency training program implementing standards set forth by the American Academy of Ophthalmology. In addition to the formal residency program for ophthalmologists, HCP established training programs for community eye care workers in a three-year Ophthalmic Assistant Training Program.

Ruit developed an innovative suture-less technique for cataract surgery yielding equivalent results to those in developed countries but also reproducible in resource-constrained areas. By redesigning the intraocular lens and mass producing it locally in Nepal for U.S. \$4.00, Ruit and Tabin provided a low cost alternative to the higher-priced lens produced in developed countries. A local business—the Fred Hollows Intraocular Lens Factory—mass produces the lenses and helps support the local economy by introducing a new sustainable business locally.⁹⁰

HCP also designed a socially acceptable method for cost-recovery that involves a sliding scale for payment: 45% of patients pay U.S. \$120.00; 20% pay a smaller amount based on their economic situation; and 35% receive cataract surgery for free.

HCP Priorities	Public Health Principles	Implementation
Humanitarian	Accessible	Entire Population Care at Local Level
High Quality	Appropriate	Care Comparable to Western Standards Disease with High Incidence/Prevalence
Innovation	Disruptive Technology	Designed \$4 lens Local Business
Direct Impact	Sustainable Growth	Skills Transfer Building Infrastructure
Affordability	Affordable	Delivery Model \$20 Cost/Cataract
Replication	Sustainability	Meet Needs of Current Population Culturally and Economically Acceptable

Figure 49-24. Himalayan cataract project priorities, public health principles, and outcome measurements. (Redrawn from *Himalayan Cataract Project and Tilganga Eye Center*, (Cureblindness.org) (82-84) by permission. Illustration reproduced with permission from Intermountain Healthcare.)

to cancer prevention, detection, and care in LMICs. Successful partnerships have already been entered into Haiti, Rwanda, Mexico, Malawi, and Jordan.

The Preventive Role of Surgery. Surgery plays a significant role at all levels of prevention of disease (Table 49-7). Trying to disassociate treatment from prevention presents challenges. Treatments can also be a form of prevention. For example, one of the root causes for the development of a vesico-vaginal fistula is lack of access to appropriate peri-partum care. Expediently performing a Cesarean-section (a form of secondary prevention) for obstructed labor primarily prevents the

development of vesico-vaginal fistulas (primarily preventing the development of a different disease).

The surgeon's role for disease prevention in the developing world is in its infancy of realization. Diseases commonly present in very late stages in LMICs and in disadvantaged populations in developed countries. Many morbid conditions could have been cured while localized in their earlier stages and likely eradicated by a local surgical procedure. Early recognition and treatment of surgically correctable diseases is a critical preventative role for surgery. Many surgical procedures are not only a form of tertiary prevention, but are also forms of primary prevention (Table 49-8).⁹¹

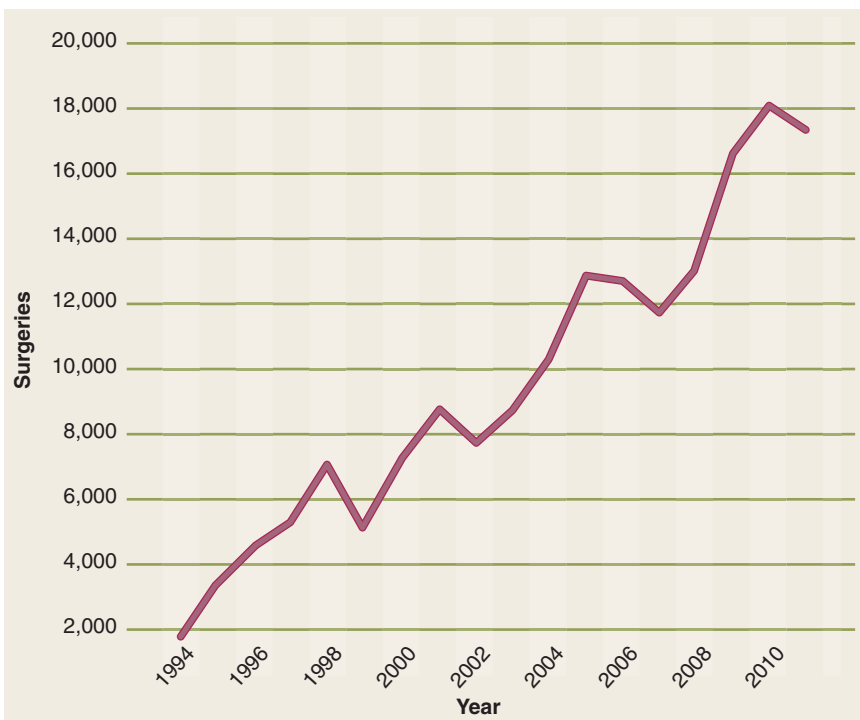


Figure 49-25. Eye surgeries Tilganga eye center and outreach. (Redrawn from *Himalayan Cataract Project and Tilganga Eye Center*, (Cureblindness.org) (82-84) by permission. Illustration reproduced with permission from Intermountain Healthcare.)

Table 49-7

Prevention strategies

PREVENTION STRATEGY	TARGET	GOAL
1. Primary	Root causes of disease	Eliminate or reduce risk of developing illness
2. Secondary	Illness or disease at earliest stages	Limit progression of disease
3. Tertiary	Disease at later stages	Cure or limit the effect of existing disease

Data adapted from deVries, C. and R.R. Price. *Global Surgery and Public Health: A New Paradigm*. 1st ed, 2012, Sudbury, MA: Jones & Bartlett Learning, LLC, p. 43-45.

Cost-effectiveness of Surgical Care. Funders in healthcare look for measurable return on their investments. While comparison of outcomes and objective measures would be ideal, reality demonstrates that healthcare budgets more commonly are dictated by politics rather than actual need. Nevertheless, in a world of limited resources and tightening budgets for healthcare, cost-effective analysis of various options for intervention are critical for policy makers. Comparing various options that have different outcomes is an approach called cost-utility analysis (CUA). Surgical interventions can be evaluated by specific diseases or conditions, or by systems or services required to support the delivery of surgical care. In 1990, the World Bank defined the Disability Adjusted Life Year (DALY) as the sum of Years of Life Lost (YLL) due to premature mortality in the population and the Years Lost due to Disability (YLD) for people living with the health condition or its consequences. (DALY = YLL + YLD). Evaluating the cost per DALY averted is one approach for comparing the cost-utility between medical and surgical interventions. Recent surgical cost/DALY studies

10► identifying the cost-effectiveness of various types of

Table 49-8

The role of surgery for primary prevention of cancer

TERTIARY SURGICAL PROCEDURE	PRIMARY CANCER PREVENTED
Breast lumpectomy for ductal carcinoma in situ	Breast
Colonoscopic polypectomy	Colon
Colposcopy and excision	Cervical
Resection of actinic keratosis	Skin
Resection of leukoplakia and erythroplakia	Oral

Data adapted from Riviello R, Meara JG, Rogers SO. Commentary: Cancer Care and Control - the role of surgery. *Global Surgery and Anesthesia*. 2010. Retrieved February 20, 2013, from <http://www.ghdonline.org/surgery/discussion/cancer-care-and-control-the-role-of-surgery/>

surgical care have allowed surgical initiatives to be considered when prioritizing public health initiatives.

The World Bank arbitrarily defined U.S. \$100/DALY averted per day in low-income countries as highly cost-effective. Compared to other public health initiatives, developing basic and emergency surgical care at the district level hospital is as cost-effective as or more so than typical public health programs such as retroviral treatments for HIV/AIDS or immunization for measles (Table 49-9).⁹⁵⁻⁹⁹

Using the WHO's cost-effectiveness standards, investing in emergency obstetrical systems, including timely Caesarean delivery can also be considered "highly cost-effective" for 48 of 49 countries in which there are currently inadequate numbers of Cesarean deliveries^{100,101}. The median cost per DALY averted by Cesarean-section was \$304. In addition, the cost-benefit ratio in 46 of 49 countries was >1, suggesting that investment in Caesarean delivery is a viable economic proposition.

Table 49-9

Cost effectiveness of public health measures

PUBLIC HEALTH INTERVENTION	COST-EFFECTIVENESS (U.S. \$/DALY* AVERTED)
Rapid impact package for neglected tropical diseases	2-9 ^a
Measles vaccination	5 ^a
Basic surgical services district hospital	11-33 ^a
Antiviral therapy for HIV	300-500 ^a
Lichtenstein hernia repair with mosquito net mesh Western Ghana	12 ^b
Lichtenstein hernia repair with polypropylene or mosquito net Ecuador	78 ^c
Emergency systems for Caesarean delivery	304 ^d
Cataract surgery	57 ^e

*DALY: Disability Adjusted Life Year

a. Ozgediz D, Riviello R. The "other" neglected diseases in global public health: surgical conditions in sub-Saharan Africa. *PLoS Med*. 2008; 5(6):e121; **b.** Shillcutt SD, Clarke MG, Kingsnorth AN. Cost-effectiveness of groin hernia surgery in the Western Region of Ghana. *Arch Surg*. 2010;145(10):954-961; **c.** Shillcutt SD, et al. Cost-effectiveness of inguinal hernia surgery in northwestern Ecuador. *World J Surg*. 2013;37(1):32-41; **d.** Alkire BC, et al. Obstructed labor and caesarean delivery: the cost and benefit of surgical intervention. *PLoS One*. 2012;7(4): e34595; **e.** Baltussen R, Sylla M, Mariotti SP. Cost-effectiveness analysis of cataract surgery: a global and regional analysis. *Bull WHO*. 2004;82:338-345.)

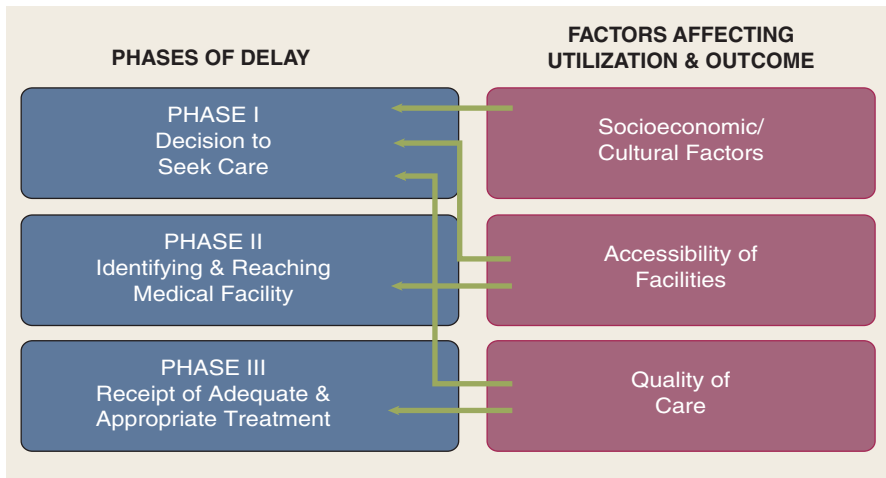


Figure 49-26. Factors affecting utilization and outcome of surgical care. (Adapted from UNFPA United Nations Population Fund (UNFPA); *Providing emergency obstetric and newborn care to all in need*. [cited 2013 February 27]; Available from: <http://www.unfpa.org/public/mothers/pid/4385>. Illustration reproduced with permission from Inter-mountain Healthcare.)

Inguinal hernia repair is one of the most common operations performed worldwide. Tension-free inguinal hernia repairs performed with mosquito netting or polypropylene mesh was cost-effective in Western Ecuador and Western Ghana (\$78.18/DALY and \$12.88/DALY averted, respectively).^{96,102} Using mosquito netting in India was 3700 times cheaper than using traditional polypropylene mesh.¹⁰³

Factors Affecting Utilization and Outcome for Surgical Care. There are three major factors that severely limit utilization of surgical services:

1. socioeconomic and cultural
2. accessibility of facilities and
3. quality of care (Fig. 49-26)¹⁰⁴

The decision to seek timely care is affected by the costs associated with time off from work and inability to support the family during the absence, transportation and lodging, and the surgical services themselves. Cultural and religious traditions may define acceptability of various treatment options. For example, many people in Mongolia refuse to have surgery on Tuesdays as this is viewed as a “bad luck” day. Understanding local customs and cultural concerns can improve utilization of surgical services.

Austere environments, difficult terrain, and long distances from health care facilities significantly delay or prevent access to surgical care. Triage and transfer guidelines along with telemedicine have the potential to mitigate the limitations of geography. However, without adequately trained care providers and support staff, the risk for poor outcomes is increased.

Recognizing these three important factors for increasing utilization and outcomes, Mongolia initiated a public health approach for the management of gallbladder disease incorporating minimally invasive surgery. (**Box:** The Public Health Approach to Management of Gallbladder Disease in Mongolia)

The Public Health Approach to Management of Gallbladder Disease in Mongolia

Mongolia, the most sparsely populated country in the world, covers a large geographic area nestled between China and Siberia.¹⁰⁵ The austere environment with extremes of weather, dry deserts, and high mountains present significant obstacles for road building limiting transportation for patients

in the vast rural areas (Fig. 49-27). Significant deficiencies in infrastructure, supplies, equipment, and human resources at primary healthcare facilities exist: sporadic electricity, no fully qualified surgeons or anesthesiologists, and less than half the facilities with running water.³In 2006, Healthcare expenditures reached only U.S. \$23.2 per capita.^{106,107}

The second most common cause of inpatient morbidity in Mongolia has transitioned to gastrointestinal diseases with liver disease, appendicitis, and gallbladder disease the top three causes.¹⁰⁸ While laparoscopic cholecystectomy was introduced in Mongolia in 1994, by 2005 only 2% of gallbladders were removed laparoscopically, and then, only in the capital city.¹⁰⁹ A cohort study in 2005 comparing open with laparoscopic cholecystectomy by Dr. Sergelen, the chief of surgery at the Health Sciences University of Mongolia (HSUM), found the wound infection rate to be significantly lower, hospital stays shorter, and hospital expenditures 50% less with laparoscopy compared to open cholecystectomy.¹¹⁰ Dr. Sergelen formulated a plan to expand access to laparoscopic surgery throughout Mongolia. This plan targeted the three main areas affecting utilization and outcome.

- a) **Quality of Care** Develop a laparoscopic training didactic and practical course to train surgical teams.
- b) **Accessibility of Quality Care** Begin training surgical teams in the capital city, but then expand them to four carefully selected regional diagnostic treatment and referral centers (RDTRCs) in all four quadrants of the country.
- c) **Quality of Care** Improve the surgical infrastructure for each facility.
- d) **Socioeconomic/Cultural Factors** Educate the public on the increased benefits of laparoscopic surgery so they would initiate lobbying efforts demanding the government increase funding for these services.
- e) **Socioeconomic/Cultural Factors** Educate government leaders about the need and benefit of laparoscopic cholecystectomy for the Mongolian people.
- f) **Quality of Care** Expand the surgical residency to include laparoscopic training.
- g) **Accessibility and Quality** Invite industry to offer cost-affordable supplies and replacement parts to sustain the laparoscopic equipment in Mongolia.



Figure 49-27. Rural Ger. (Photo reproduced with permission from Michelle K. Price.)

Laparoscopic cholecystectomy has been expanded within the capital city and established in the initial 4 key Regional Diagnostic and Treatment Referral Centers (RDTRCs) and an additional fifth regional hospital creating countrywide access to high-quality modern surgery for a regionally prevalent disease through a multinational partnership directed by the chief of surgery at HSUM (Fig. 49-28).^{105,111}

As people began to see their neighbors return to functional ability faster with the laparoscopic approach, the Mongolian people developed increased trust in their healthcare

providers and the quality of care they could receive. This led to not only an increase in laparoscopic cholecystectomy but an increase in open cholecystectomy and many other procedures (Fig. 49-29).¹⁰⁵

The Mongolian surgical residency has been expanded to incorporate laparoscopic training. The MOH has committed to increase funding for laparoscopic cholecystectomy and change existing laws making it easier for hospitals to purchase their needed supplies.

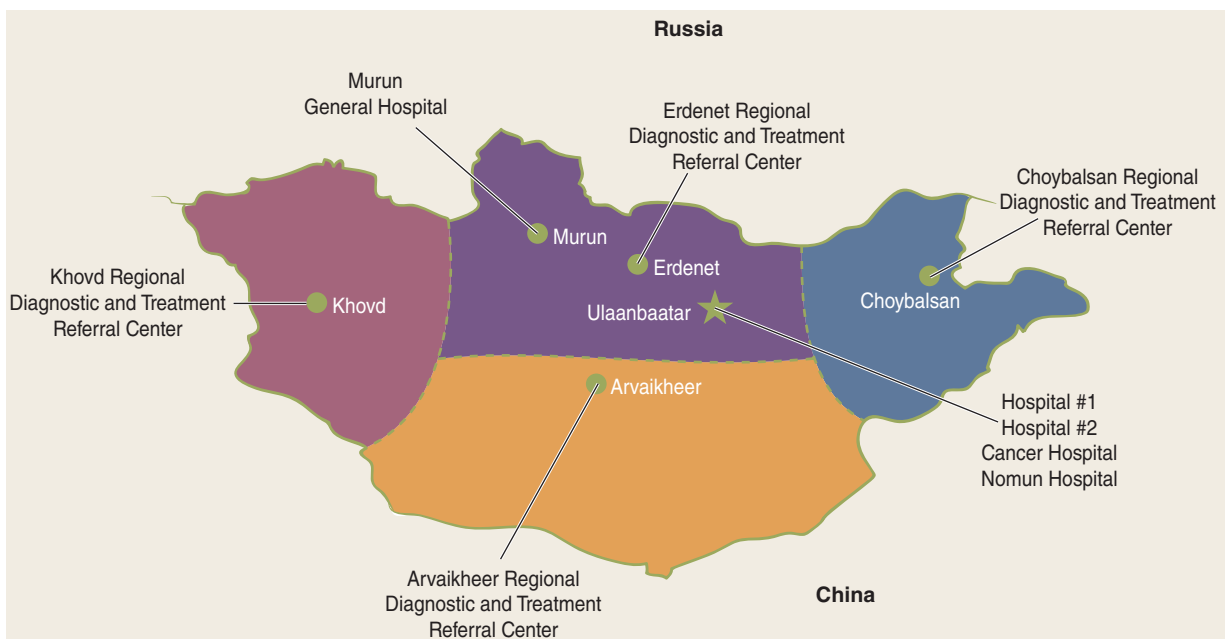

Figure 49-28. Regional diagnostic treatment and referral centers of Mongolia (RDTRCs). (Illustration reproduced with permission from Intermountain Healthcare.)

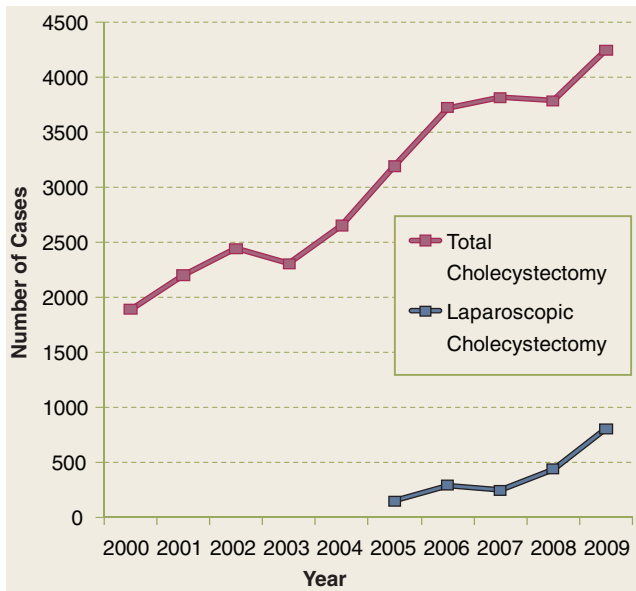


Figure 49-29. Cholecystectomy trends in Mongolia. (Adapted from: Unursaikhan C. (2010). Information of biliary track surgery in Mongolia. Health Sciences University of Mongolia, unpublished data. Illustration reproduced with permission from Intermountain Healthcare.)

Advanced Surgical Care for Resource-Poor Areas

Limited financial, physical, and human resources, political and social conflicts, and austere environments cause many to believe that advanced surgical care is inappropriate in resource poor countries.^{77,112-114} Misconception of the needs and abilities

11▶ of people in LMICs cause some policy makers to discount the desire of people worldwide for advanced surgical care.¹⁰⁵ Developing these capabilities in resource-poor countries has the potential to decrease overall cost and actually develop the infrastructure necessary to entice physicians and other healthcare workers to remain in their own countries. Establishing advanced surgical care requires expertise and services that symbiotically support and improve general medical care. Therefore, many developing countries are actively building capacity and capability to provide the full spectrum of modern surgical care locally.¹¹⁵

As economies improve and the benefits of laparoscopic surgery for resource-poor areas become better delineated, patients and doctors, surgical societies, ministries of health, and industries are demanding the benefits of minimally invasive surgery for patients and communities.^{111,116-122} The economic impact of laparoscopy may be even greater in LMICs than in developed countries.¹²³ Worldwide surgeons have identified laparoscopic training as one of their greatest needs. In a recent survey, developing laparoscopic and endoscopic skills were identified as the most important skills desired by surgeons from the West Africa College of Surgeons (WACS) (Fig. 49-30).¹²⁴

Transplantation is another area of great interest to people in poor countries partly because of the high prevalence of kidney failure and because chronic dialysis facilities are limited. Hepatoma and liver failure are very common in countries with a strong prevalence of hepatitis B and C. Transplantation has become the treatment of choice for end-stage kidney disease in developed countries as it dramatically improves the quality of life and increases survival rates compared to medical management.¹²⁵ Yet, transplantation eludes most of the developing world. Initial attempts to transport critically ill patients from LMICs to developed countries for kidney transplantation were

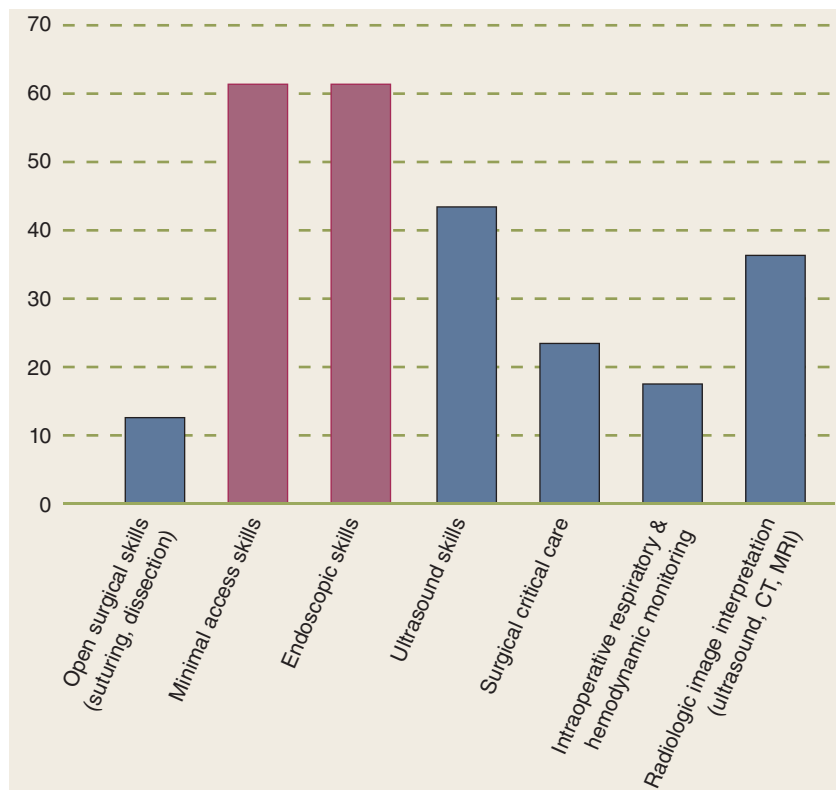


Figure 49-30. West African College of Surgeons: most desired skills. (Adapted from Trigen Survey WACS: Akporiaye L. (2010). Trigen Survey: West African College of Surgeon. Port-Harcourt: Unpublished data. Illustration reproduced with permission from Intermountain Healthcare.)

cost-prohibitive.¹²⁶ With the alarming increase in the rate at which young people have been presenting with kidney disease in developing countries, the increased utilization placed on the few dialysis machines has been overwhelming.¹²⁷ Dialysis units which previously were utilized three times a week, now operate 24 hours a day, 7 days a week, and cannot begin to provide the needed services to the multitudes needing treatment. Even programs to develop peritoneal dialysis cannot fully ease the demand.

The majority of kidney transplants in developing countries are from living related donation. Laparoscopic living related donation has the potential to increase the voluntary donor pool as patients have less postoperative pain, return to work and activities quicker, and have much better cosmesis than open surgery.¹²⁸ Adapting to the limited resources, surgeons have described various cost-saving techniques to facilitate the laparoscopic approach in resource poor areas such as using endoclips instead of staplers for vascular control, modifications to the surgical approach, and suprapubic extraction of the kidney rather than endocatch removal.¹²⁸⁻¹³⁰

Academic Partnerships

Academic institutions have historically pioneered discovery in disease causation and treatment. As globalization expands, academic surgical programs are beginning to respond by broadening their vision for an interdisciplinary and collaborative approach to research, education, development, and advocacy.¹³¹⁻¹³²

12▶ Academic involvement in global surgery provides training for the next generation of surgical leaders. Leaders for the 21st century will need to know how to provide outstanding cost-effective clinical care for all environments. With a more global view, the significant advances in scientific knowledge and clinical practice realized through basic and clinical research will potentially provide solutions for access to surgical care for all patients worldwide. Partnering academic programs with NGOs provides another opportunity for collaboration. (**Box:** Academic Global Surgery Partnerships)

Ethics

The ethics involved in working outside one's own home country are complex. While a practitioner's scope of practice is usually constrained by regulation in America and Europe, in many countries the limits of what one can do are neither regulated nor enforced. Guidelines for what should be done—where, and under what circumstances are beyond the expertise of some ministries of health. Some problems are so episodic that they are not anticipated, and few guidelines exist. For example, in natural disasters and emergencies, should any willing provider from any country be granted permission to provide care? Should specific disaster-related training be encouraged or required?^{134,135} In the

research, and mentoring throughout the length of their surgical residency at BWH. During the research years, GHE residents engage in collaborative field-based programs and research that link and support many of BWH global surgery activities. Projects to date include: Understanding Trauma Epidemiology in Rwanda, Understanding Surgical Epidemiology of Burera District, Cost-Effectiveness analysis of the Team Heart global cardiac surgery program, and Breast cancer epidemiology of Rwanda.^{133*} —Robert Riviello MD

B. Rwanda Human Resources for Health (HRH) Program

“The Rwanda HRH program is an ambitious 7-year long, U.S. federally funded, collaborative program of the Rwanda Ministry of Health (MOH) and 13 U.S. academic medical centers and universities. HRH seeks to greatly expand and improve Rwanda's health care workforce by strengthening national training programs of specialized physicians, nurses, oral health providers, and hospital managers by recruiting U.S. faculty educators to join the National University of Rwanda (NUR) training faculty. In year one of the program (August 2012–July 2103), BWH contributed the largest number of physician educators to the program, recruiting 40% of the U.S. HRH physician faculty, including 6 surgeons. These surgeons have worked closely with their Rwandan faculty counterparts to restructure and organize the NUR surgery residency program, including development of curriculum, organizing didactic and clinical teaching, and greatly strengthening resident supervision and mentorship¹³³.” —Robert Riviello MD

C. Coordinating Non-Governmental Organizations (NGO) and Academic Organizations: IVUmed

Nonprofit organizations (NGO) have filled a niche in establishing surgical care in countries where training centers and healthcare systems are historically non-existent or understaffed. More recently, professional organizations have developed a focus on specific diseases or patient groups and have become a resource for education and training in poor countries.

For more than 20 years, the IVUmed NGO has focused on urological education and hands-on training in Africa, Asia, and Latin America. IVUmed evolved from a need identified by plastic surgeons that had seen many children with hypospadias and other urological anomalies such as exstrophy, when providing care for children with cleft lip and palate. Adult surgeons were not trained in the delicate reconstruction of pediatric genitourinary anomalies, and pediatric surgeons were not trained in endoscopic or reconstructive urological surgery. The program has expanded to support training in all aspects of urological care, including adult reconstruction, oncology, and endoscopic management of stones and prostatic disease.

As a nonprofit organization, IVUmed is a partnership between surgeons, anesthesiologists and nurses, academic medical centers, urological professional associations, industry and the public with urologic surgery training in more than 20 countries. It also provides North American trainees scholarships to travel to low-resource countries to learn and to share knowledge gained in their own programs. Many former scholars become mentors for other residents when they complete their training. The sites with the longest collaborations have developed their own educational programs in general urology or subspecialty areas and are now providing advanced training and care locally (Fig. 49-31).

Academic Global Surgery Partnerships

A. Global Health Equity Residency

“In 2012, Brigham and Women's Hospital (BWH) Center for Surgery and Public Health (CSPH) launched the Global Health Equity in Surgery (GHE-S) residency program. Related to its sister program in Internal Medicine at BWH, the GHE-S program seeks to create future leaders in academic global surgery through structured education, field work,

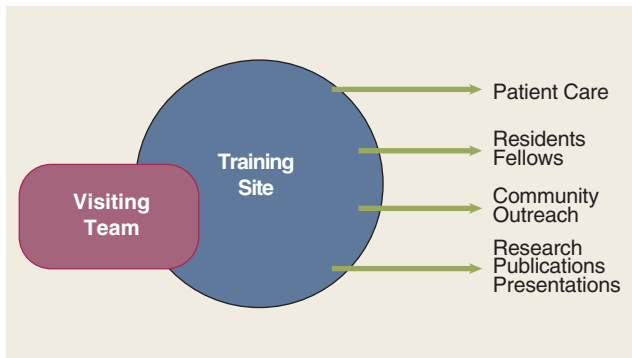


Figure 49-31. Training outcomes from NGO/academic partnership. (Reproduced with permission from *IVUmed and Intermountain Healthcare*.)

non-acute setting, should practitioners not licensed or credentialed in their home environments be allowed to perform volunteer surgery in other countries? What entity should oversee the flow of volunteer practitioners? Can a standard set of guidelines meet the needs of most countries? Currently, there is little cross national agreement between state entities, like ministries of health and independent organizations and individuals. While many countries require at least temporary licensure, some do not. In many cases enforcement is inconsistent.

With respect to research, the poor historically have not received benefit from research performed on them. In international studies, even local collaborators have been left out of study design and publication.¹³⁶ As Internet communications have improved, these lapses no longer are tolerated.¹³⁷ Informed consent for surgical procedures, given in the appropriate language and respectful of local customs, are becoming more the norm. Few hospitals outside academic medical centers have institutional review boards (IRBs) to oversee the implementation and review of clinical research. In recent years, peer reviewed journals have become more mindful of attribution of credit, and authors are strongly encouraged to design and report studies with local input at all levels.

With regard to transplantation, many countries have laws against cadaveric transplants because of the very real concern for illegal marketing of organs. Even living-donor transplantation has seen effects of coercion in some regions and for some populations such as prisoners. Nevertheless, the need and popular desire for transplantation is accelerating acquisition of skills and technology to make transplantation available worldwide.¹³⁸

Finally, what is considered ethical in one country or one community might be considered highly unethical in another. Consent for surgery may in one setting rest with the patient, but in another, with the community or family. And values about privacy vary markedly from region to region. Health information in many cultures is considered to be a community concern and not the personal property of an individual patient.

Innovation in Global Surgery

The pressing need for surgical care at all levels and the shortage of fully trained surgeons, anesthesiologists and support personnel, equipment and supplies means that opportunities abound for innovation. Innovations in education, including simulation, can potentially shorten the time necessary for learning technical skills. Gaming technology can potentially teach algorithms for decision making and

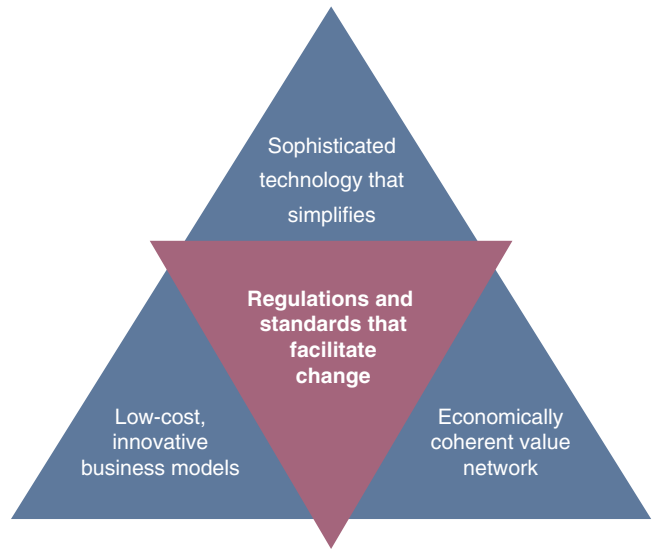


Figure 49-32. Elements of disruptive innovation. (Redrawn with permission from Christensen CM, Grossman JH, Hwang J. *The Innovator's Prescription*. New York: McGraw-Hill, 2009. Copyright © The McGraw-Hill Companies, Inc. Illustration reproduced with permission from *Intermountain Healthcare*.)

interpretation of X-rays and ultrasounds. Telemedicine/telehealth has the potential to transform education through combinations of clinical case-based learning and massively open online courses (MOOC). The potential for education innovation in surgery beyond the apprenticeship system championed by Halsted in 1904 is vast.

Innovation that radically changes the way we do things, that changes a paradigm of a service or system is called “disruptive”; it abruptly changes an older and more expensive system in favor of a less expensive, more widely available technology or process. The ability for disruptive innovations to transform products and services into affordable realities requires three main factors (Fig. 49-32).¹³⁹

Regulations and standards that vary between countries and locales can facilitate or impede disruptive change. While disruptions often are not qualitatively superior to the status quo, they make the process both less expensive and more accessible, and through multiple iterations, ultimately improve quality as they cycle through the transformative process.

De-centralizing education, laboratory testing, and medical records have been made possible through Free and Open Source Software, apps, and devices such as smart phones, tablets, and laptop computers. Monitoring devices, laparoscopic instruments, and imaging devices designed for low resource environments have the potential to not only improve accessibility in poor countries, but also to radically reduce surgical costs in wealthy ones.

THE FUTURE FOR GLOBAL SURGERY

Surgeons of the future will need to educate themselves in areas that have not historically been taught in surgical curricula. Beyond the business of surgical practice, there is a complex ecosystem that supports surgical care. Surgeons must become more aware of the complexities of cost in order to be able to shape the

environment in which they work. They must understand better what patients are seeking from the surgical experience rather than focusing primarily on a narrow view of what surgery might have to offer. Surgeons must engage in policy development and advocate for affordable and accessible surgical care without sacrificing quality. Thoughtful technology design can focus on improving quality and on decreasing cost, both in poor and wealthy countries. As our colleagues in public health and the World Bank, Paul Farmer and Jim Kim have challenged us, “We need our surgical colleagues to speak fluently about rebuilding infrastructure, training, personnel, and delivering high-quality care to the very poorest.”⁷⁷

REFERENCES

Entries highlighted in bright blue are key references.

1. Funk VA, Thomas-Oates JE, Kielland SL, Bates PA, Olafson RW. Global operating theatre distribution and pulse oximetry supply: an estimation from reported data. *Lancet*. 2010;376(9746):1055-1061.
2. Weiser TG, Regenbogen SE, Thompson KD, et al. **An estimation of the global volume of surgery: a modelling strategy based on available data.** *Lancet*. 2008;372(9633):139-144.
3. Chang L, Lacy BE, Spiegel BM. Quantifying surgical and anesthetic availability at primary health facilities in Mongolia. *World J Surg*. 2011;35(2):272-279.
4. Contini S, Taqdeer A, Cherian M, et al. Emergency and essential surgical services in Afghanistan: still a missing challenge. *World J Surg*. 2010;34(3):473-479.
5. Choo S, Perry H, Hesse AA, et al. Assessment of capacity for surgery, obstetrics and anaesthesia in 17 Ghanaian hospitals using a WHO assessment tool. *Trop Med Int Health*. 2010;15(9):1109-1115.
6. Kushner AL, Cherian MN, Noel L, Spiegel DA, Groth S, Etienne C. Addressing the Millennium Development Goals from a surgical perspective: essential surgery and anaesthesia in 8 low- and middle-income countries. *Arch Surg*. 2010;145(2):154-159.
7. Farmer PE, Kim JY. Surgery and global health: a view from beyond the OR. *World J Surg*. 2008; 32(4):533-536.
8. Casey KM, Putting the “global” back in global health. *Arch Surg*. 2012; 147(5):404-407.
9. deVries C, Price RR. **Global Surgery and Public Health: A New Paradigm.** 1st ed. Sudbury Jones and Bartlett Learning, LLC; 2012:300.
10. Debas HT. **Surgery.** In: Jamison DT, ed. *Disease Control Priorities in Developing Countries*. 2006;1245-1259.
11. *Copenhagen Consensus: Nobel Laureates: More should be spent on hunger, health: Top economists identify the smartest investments for policy-makers and philanthropists.* 2012; Available at: www.copenhagenconsensus.com.
12. *Global population to pass 10 billion by 2100, UN projections indicate.* UN News Centre 2011 [cited 2013 February 20]; Available from: <http://www.un.org/apps/news/story.asp?NewsID=38253#UST1tDfheSp>.
13. *Population ageing and development: Ten years after Madrid,* in *Population Facts*, U. Nations, Editor 2012, United Nations, Department of Economic and Social Affairs, Population Division. p. 4.
14. Salomon JA, Vos T, Hogan DR. Common values in assessing health outcomes from disease and injury: disability weights measurement study for the Global Burden of Disease Study 2010. *Lancet*. 2012;380(9859):2129-2143.
15. Murray CJ, Vos T, Lozano R, et al. **Disability-adjusted life years (DALYs) for 291 diseases and injuries in 21 regions, 1990-2010: a systematic analysis for the Global Burden of Disease Study 2010.** *Lancet*. 2012;380(9859):2197-2223.
16. Groen RS, Samai M, Stewart KA, et al. Untreated surgical conditions in Sierra Leone: a cluster randomised, cross-sectional, countrywide survey. *Lancet*. 2012;380(9847):1082-1087.
17. Petroze RT, Groen RS, Niyonkuru F, et al. Estimating operative disease prevalence in a low-income country: results of a nationwide population survey in Rwanda. *Surgery*. 2012.
18. Duda RB, Hill AG. Surgery in Developing Countries: should surgery have a role in population-based health care? *American College of Surgeons Bulletin*. 2007;92(5):12-18, 35.
19. Farmer P, Frenk J, Knaul FM, et al. Expansion of cancer care and control in countries of low and middle income: a call to action. *Lancet*. 2010;376(9747):1186-1193.
20. Mody GN, Nduaguba A, Ntiringanya F, Rivello R. Characteristics and presentation of patients with breast cancer in Rwanda. *Am J Surg*. 2013;205:409-413.
21. Mock C, Joshipura M, Goosen J, Maier R. Overview of the Essential Trauma Care Project. *World J Surg*. 2006;30:919-929.
22. Mock C. Strengthening care for the injured globally. *J Trauma*. 2011;70(6):1307-1316.
23. *Injury and Violence: the Facts.* 2004 [cited 2013 January 30]; Available from: http://www.who.int/violence_injury_prevention/key_facts/VIP_key_fact_1.pdf.
24. Foley TM, et al. *Rural Trauma Team Development Course, 3d edition.* 2nd ed, ed. A.C.o. Surgeons 2011, Chicago: American College of Surgeons.
25. Kopits E, Cropper M. Traffic fatalities and economic growth. *Accid Anal Prev*. 2005;37: 169-178.
26. *Burns: World Health Organization Fact Sheet.* 2012 [cited 2013 February 23]; Available from: <http://www.who.int/mediacentre/factsheets/fs365/en/index.html>.
27. CM., et al. *A WHO plan for burn prevention and care,* W.H. Organization, Editor 2008, World Health Organization: Geneva.
28. Saffle JR, et al. Telemedicine evaluation of acute burns is accurate and cost-effective. *J Trauma*. 2009;67(2):358-365.
29. *The Business of Health in Africa: Partnering with the Private Sector to Improve People's Lives,* W.B.G. International Finance Corporation, Editor 2008, International Finance Corporation, World Bank Group: Washington DC. pp. 1-136.
30. *CIA World Fact Book.* 2013 [cited 2013 February 23]; Available from: <https://www.cia.gov/library/publications/the-world-factbook/>
31. *World Health Statistics 2012.* Global Health Observatory 2012 [cited 2013 February 23]; Available from: http://www.who.int/gho/publications/world_health_statistics/2012/en/.
32. Merson MH, Black RE, Mills AJ. *International Public Health: Disease, Programs, Systems, and Policies.* Frederick; Aspen Publishers:2001.
33. Taylor RH, Hollaar G. Review of a Canadian forum on international surgery: the Bethune Round Table. *Can J Surg*. 2005;48(6):479-484.
34. Chu K, et al. Surgical task shifting in Sub-Saharan Africa. *PLoS Med*. 2009;6: e1000078.
35. Sheldon GF, Ricketts TC, Charles A, King J, Fraher EP, Meyer A. The global health workforce shortage: role of surgeons and other providers. *Adv Surg*. 2008;42:63-85.
36. Mkandawire N, Ngulube C, Lavy C. Orthopaedic clinical officer program in Malawi: a model for providing orthopaedic care. *Clinical Orthopaedics and Related Research*. 2008;466(10):2385-2391.
37. Pereira C, Cumbi A, Malalane R, et al. Meeting the need for emergency obstetric care in Mozambique: work performance and histories of medical doctors and assistant medical officers trained for surgery. *BJOG*. 2007;114(12):1530-1553.

38. Kruk ME, Pereira C, Vaz F, Bergström S, Galea S. Economic evaluation of surgically trained assistant medical officers in performing major obstetric surgery in Mozambique. *BJOG*. 2007;114(10):1253-1260.
39. Sherwood KL, Price RR, White TW, Stevens MH, Van Boerum DH. A role in trauma care for advanced practice clinicians. *JAAPA*. 2009;22(6):33-36, 41.
40. Ozgediz D, Kijjambu S, Galukande M, et al. Africa's neglected surgical workforce crisis. *Lancet*. 2008;371:627-628.
41. Mullan, F. The metrics of the physician brain drain. *N Engl J Med*. 2005;353(17):1810-1818.
42. Hagopian A, Thompson MJ, Fordyce M, Johnson KE, Hart LG. The migration of physicians from sub-Saharan Africa to the United States of America: measures of the African brain drain. *Hum Resour Health*. 2004;2(1):17.
43. Hagander LE, Hughes CD, Nash K, et al. Surgeon migration between developing countries and the United States: train, retain, and gain from brain drain. *World J Surg*. 2013;37(1):14-23.
44. Mills EJ, Schabas WA, Volmink J, et al. Should active recruitment of health workers from sub-saharan africa be viewed as a crime? *Lancet*. 2008;371:685-688.
45. McCoy D, Bennett S, Witter S, et al. Salaries and incomes of health workers in sub-Saharan Africa. *Lancet*. 2008;371(9613):675-681.
46. Riviello R, Ozgediz D. International medical graduates and the global surgical workforce: the perspective from the other side. *J Am Coll Surg*. 2008;207(1):143-144.
47. Chambostl, *Health workers for all and all for health workers. The Kampala declaration and agenda for global action., in The First Global Forum on Human Resources for Health*, G.H.W. Alliance, Editor 2008, The First Global Forum on Human Resources for Health: Kampala, Uganda. p. 2.
48. Baker TD, Weisman C, Piwoz E. U.S. physicians in international health. Report of a current survey. *JAMA*. 1984;251(4):502-504.
49. Busnaina I. *Medical School Admissions Doctor*. 2012 [cited 2013 January 12]; Available from: <http://www.usnews.com/education/blogs/medical-school-admissions-doctor/2012/04/09/medical-students-should-consider-overseas-clinical-experience>.
50. Provenzano AM, Graber LK, Elansary M, Khoshnood K, Rastegar A, Barry M. Short-term global health research projects by U.S. medical students: ethical challenges for partnerships. *Am J Trop Med Hyg*. 2010;83(2):211-214.
51. Banerjee, A. Medical electives: a chance for international health. *J R Soc Med*. 2010; 103(1):6-8.
52. Powell AC, Casey K, Liewehr DJ, Hayanga A, James TA, Cherr GS. Results of a national survey of surgical resident interest in international experience, electives, and volunteerism. *J Am Coll Surg*. 2009;208(2):304-312.
53. Kingham TP, Price RR, Casey KM, Rogers SO, Kushner AI. Beyond volunteerism: augmenting surgical care in resource-limited settings. *Bull Am Col Sur*. 2011;96(7).
54. Gosselin RA, Gyamfi YA, Contini S. Challenges of meeting surgical needs in the developing world. *World J Surg*. 2011;35(2):258-261.
55. *History of the United Nations*. 2013 [cited 2013 January 16]; Available from: <http://www.un.org/eboutun/history/>.
56. *UN at a Glance*. 2013 [cited 2013 January 16]; Available from: <http://www.un.org/en/aboutun/index.shtml>.
57. Hulme, D, ed. *The Millennium Development Goals (MDGs): A Short History of the World's Biggest Promise*. ed. B.W.P. Institute 2009, Brooks World Poverty Institute: Manchester. 55.
58. *The Millennium Development Goals Report 2012*, U. Nations, Editor 2012, United Nations: New York City. 72.
59. Liu L, Johnson HL, Cousens S, Perin J, et al. Global, regional, and national causes of child mortality: an updated systematic analysis for 2010 with time trends since 2000. *Lancet*. 2012;79(9832):2151-2161.
60. Henry JA, Windapo O, Kushner AL, Groen RS, Nwomeh BC. A survey of surgical capacity in rural southern Nigeria: opportunities for change. *World J Surg*. 2012;36(12):2811-2818.
61. Abdullah F, Choo S, Hesse AA, et al. Assessment of surgical and obstetrical care at 10 district hospitals in Ghana using on-site interviews. *J Surg Res*. 2010.
62. Mock C, Abantanga F, Goosen J, Joshipura M, Juillard C. Strengthening care of injured children globally. *Bull World Health Organ*. 2009;87(5):382-389.
63. Kingham TP, Kamara TB, Cherian MN. Quantifying surgical capacity in Sierra Leone: a guide for improving surgical care. *Arch Surg*. 2009;144(2): 122-127; discussion 128.
64. Mock C, Nguyen S, Quansah R, Arreola-Risa C, Viradia R, Joshipura M. Evaluation of trauma care capabilities in four countries using the WHO-IATSIC guidelines for essential trauma care. *World J Surg*. 2006;30(6):946-956.
65. Maru, DS, R, et al. *Global surgical care in 2030: metrics and strategies for expansion in access and quality*. 2012.
66. *Alma Ata Declaration*. 2012 October 31, 2012 [cited 2013 January 17]; Available from: http://en.wikipedia.org/wiki/Alma_Atta_Declaration.
67. *The World Health Report: Primary Health Care: Now more than ever*, W.H. Organization, Editor 2008, World Health Organization: Geneva. p. 148.
68. WHO, *Report: WHO meeting towards a global initiative for emergency and essential surgical care (GIEESC)*, 2005, World Health Organization: Geneva. p. 30.
69. Spiegel DA, Abdullah F, Price RR, Gosselin RA, Bickler SW. World health organization global initiative for emergency and essential surgical care: 2011 and beyond. *World J Surg*. 2012;1462-1469.
70. Henry JA, Orgoi S, Govind S, Price RR, Lundeg G, Kehrer B. Strengthening surgical services at the Soum (First-referral) hospital: the WHO emergency and essential surgical care (EESC) program in Mongolia. *World J Surg*. 2012;36(10):2359-2370.
71. *Indicators of Surgical Operation (Mongolia 2001-2009)*. 2010 [cited 2011 November 2]; Available from: www.doh.gov.mn.
72. *World Health Organization, Violence and Injury Prevention (VIP)*. [cited 2013 February 28]; Available from: http://www.who.int/violence_injury_prevention/violence/en/.
73. Haynes AB, Weiser TG, Berry WR, et al. A surgical safety checklist to reduce morbidity and mortality in a global population. *N Engl J Med*. 2009;360(5):491-499.
74. *WHO guidelines for safe surgery 2009: Safe surgery saves lives*. ed. W.H. Organization 2009, World Health Organization: Geneva. 133.
75. *WHO surgical safety checklist*. 2009 [cited 2013 February 4]; Available from: http://whqlibdoc.who.int/publications/2009/9789241598590_eng_Checklist.pdf
76. Learmonth, J. *The Contributions of Surgery to Preventive Medicine*. London: Oxford University Press, Geoffrey Cumberlege, Publisher to the University;1951:55.
77. Mock C, Cherian M, Juillard C, et al. Developing priorities for addressing surgical conditions globally: furthering the link between surgery and public health policy. *World J Surg*. 2010;34(3):381-385.
78. Mock C, Lormand JD, Goosen J, Joshipura M, Peden M, *Guidelines for essential trauma care*. Geneva: World Health Organization; 2004:106.
79. *Health systems: emergency-care systems (Sixtieth World Health Assembly: WHA 60.22)*, W.H. Assembly, Editor 2007, World Health Assembly: New York. p. 3.
80. Mock C. WHA resolution on trauma and emergency care services. *Inj Prev*. 2007;13(4):285-286.

81. Khan KS, Wojdyla D, Say L, Gülmezoglu AM, Van Look PF. WHO analysis of causes of maternal death: a systematic review. *Lancet*. 2006;367(9516):1066-1074.
82. *Maternal Mortality Fact Sheet*. 2013 [cited 2013 February 9]; Available from: <http://www.who.int/mediacentre/factsheets/fs348/en/index.html>.
83. Corlew DS. Perspectives on plastic surgery and global health. *Ann Plast Surg*. 2009;62(5):473-477.
84. *Smile Train*. 2013 [cited 2013 February 15]; Available from: <http://www.smiletrain.org/>.
85. *Operation Smile*. 2013 [cited 2013 February 15]; Available from: <http://www.operationssmile.org/>.
86. *ReSurge International*. 2013 [cited 2013 February 15]; Available from: <http://resurge.org/home/home.cfm>.
87. *World Blindness Overview*. 2013 [cited 2013 February 15]; Available from: <http://www.cureblindness.org/world-blindness/>.
88. *Nepal*. 2013 [cited 2013 February 15]; Available from: <http://www.cureblindness.org/where/himalayas/nepal/>.
89. *Tilganga Eye Centre*. 2013 [cited 2013 February 15]; Available from: <http://www.cureblindness.org/what/infrastructure/specialty-hospitals/tilganga/>.
90. *HCP's Eye Care Model*. 2013 [cited 2013 February 15]; Available from: <http://www.cureblindness.org/what/hcp-eye-care-model/>.
91. Riviello R, Meara JG, Rogers SO. *Commentary: Cancer Care and Control - the role of surgery*. *Global Surgery and Anesthesia 2010* [cited 2013 February 20]; Available from: <http://www.ghdonline.org/surgery/discussion/cancer-care-and-control-the-role-of-surgery/>.
92. Kushner, A. Malawi Esophageal Cancer Palliative Care Program. In: Kingham P, ed. *Quarterly Newsletter, Society of International Humanitarian Surgeons*. New York; Society of International Humanitarian Surgeons:2009.
93. Agarwal G, Ramakant P, Forgach ER, et al. Breast cancer care in developing countries. *World J Surg*. 2009;33(10):2069-2076.
94. *Global Task Force on Expanded Access to Cancer Care and Control in Developing Countries*: 2013 [cited 2013 February 24]; Available from: "http://gtfcc.harvard.edu/icb/icb.do?keyword=k69586&tabgroupid=icb.tabgroup132925.
95. Ozgediz D, Riviello R. The "other" neglected diseases in global public health: surgical conditions in sub-Saharan Africa. *PLoS Med*. 2008;5(6):e121.
96. Shillcutt SD, Clarke MG, Kingsnorth AN. Cost-effectiveness of groin hernia surgery in the Western Region of Ghana. *Arch Surg*. 2010;145(10):954-961.
97. Gosselin RA, Heitto M. Cost-effectiveness of a district trauma hospital in Battambang, Cambodia. *World J Surg*. 2008;32(11):2450-2453.
98. Gosselin RA, Thind A, Bellardinelli A. Cost/DALY averted in a small hospital in Sierra Leone: what is the relative contribution of different services? *World J Surg*. 2006;30(4):505-511.
99. McCord C, Chowdhury Q. **A cost effective small hospital in Bangladesh: what it can mean for emergency obstetric care.** *Int J Gynaecol Obstet*. 2003;81(1): 83-92.
100. Alkire BC, Vincent JR, Burns CT, Metzler IS, Farmer PE, Meara JG. Obstructed labor and caesarean delivery: the cost and benefit of surgical intervention. *PLoS One*. 2012;7(4):e34595.
101. Murray CJ. Quantifying the burden of disease: the technical basis for disability-adjusted life years. *Bull World Health Organ*. 1994;72:429-445.
102. Shillcutt SD, Sanders DL, Teresa Butrón-Vila M, Kingsnorth AN. Cost-effectiveness of inguinal hernia surgery in north-western Ecuador. *World J Surg*. 2013;37(1):32-41.
103. Tongaonkar RR, et al. Preliminary multicentric trial of cheap indigenous mosquito-net cloth for tension-free hernia repair. *Indian Journal of Surgery*. 2003;65(1):89-95.
104. *United Nations Population Fund (UNFPA); Providing emergency obstetric and newborn care to all in need*. [cited 2013 February 27]; Available from: <http://www.unfpa.org/public/mothers/pid/4385>.
105. **Price R, Sergelen O, Unursaikhan C. Improving surgical care in Mongolia: a model for sustainable development.** *World J Surg*. 2012;37:1492-1499.
106. Guntsentsoodol B, Nachin B, Dashzeveg T. Surgery in Mongolia. *Arch Surg*.2006;141(12):1254-1257.
107. WHO. *World Health Statistics 2011*. 2011 [cited 2011 Nov 27, 2011]; Available from: http://en.wikipedia.org/wiki/List_of_countries_by_total_health_expenditure_%28PPP%29_per-capita.
108. *Health Indicators 2006*, N.C.f.H.D. Health Statistics Department, Editor 2007, National Center for Health Development: Ulaanbataar p. 93.
109. Rusher AH. Outreach surgery. Surgical technology arrives in Mongolia. *Bulletin of the American College of Surgeons*. 1999;84(3):21-25.
110. Sergelen O. *Development of Laparoscopic Surgery in Mongolia*. 2006 [cited 2010 March 13]; Available from: http://www.gfmer.ch/Medical_education_En/PGC_RH_2006/Reviews/pdf/Orgoi_laparoscopy_2006.pdf.
111. Straub CM, Price RR, Matthews D, Handrahan DL, Sergelen D. Expanding laparoscopic cholecystectomy to rural Mongolia. *World J Surg*. 2011;35(4):751-759.
112. Manning RG, Azziz AQ. Should laparoscopic cholecystectomy be practiced in the developing world? The experience of the first training program in Afghanistan. *Ann Surg*. 2009;249(5):794-798.
113. Contini S, Taqdeer A, Gosselin RA. Should laparoscopic cholecystectomy be practiced in the developing World? The experience of the first training program in Afghanistan. *Ann Surg*. 2010;251(3):574; author reply 575.
114. Alfa-Wali M, Antoniou A. Should laparoscopic cholecystectomy be practiced in the developing world? *Ann Surg*. 2010;251(2):387; author reply 387-388.
115. Castadot RG, Magarick RH, Sheppard L, Burkman RT. **A review of ten years' experience with surgical equipment in international health programs.** *Int J Gynaecol Obstet*. 1986;24(1):53-60.
116. Udwadia TE. **Navigating laparoscopic surgery into the next decade in developing countries—a personal perspective.** *Langenbecks Arch Surg*. 2007;392(1):99-104.
117. Udwadia TE. One world, one people, one surgery. *Surg Endosc*. 2001;15(4):37-343.
118. Vargas G, Price RR, Sergelen O, Lkhagvabayar B, Batcholuun P, Enkhamagalan T. A successful model for laparoscopic training in Mongolia. *Int Surg*. 2012;97(4):363-371.
119. Clegg-Lampsey JN, Amponsah G. Laparoscopic cholecystectomy at the Korle Bu Teaching Hospital, Accra, Ghana: an initial report. *West Afr J Med*. 2010; 29(2):113-116.
120. Baigrie RJ, Stupart D. Introduction of laparoscopic colorectal cancer surgery in developing nations. *Br J Surg*. 2010;97(5):625-627.
121. Udwadia TE. Low-cost laparoscopic cholecystectomy. *Br J Surg*. 2002; 89:1602-1607). *Br J Surg*. 2003;90(6):761.
122. Piukala S. Laparoscopic cholecystectomy: complications and experiences in Tonga. *Pac Health Dialog*. 2006;13(2):107-110.
123. Udwadia TE, Udwadia RT, Menon K. et al. Laparoscopic surgery in the developing world. An overview of the Indian scene. *Int Surg*. 1995;80(4):371-375.
124. Akporiaye L. *Trigen Survey: West African College of Surgeon*, in *Unpublished data 2010*, Trigen, Lagos, Nigeria, Unpublished data.
125. Al-Bazzaz PH. Kidney transplantation in Erbil, Iraq: a single-center experience. *Saudi J Kidney Dis Transpl*. 2010;21(2):359-362.

126. Basinda SL, Maro EE, McLarty DG, Young AE, Wing AJ. Ten Tanzanian transplants: problems and perspectives. *Postgrad Med J*. 1988; 64(756):778-782.
127. *Korle-Bu to begin kidney transplant in last quarter*. 2012 [cited 2013 January 23]; Available from: <http://www.ghanaweb.com/GhanaHomePage/NewsArchive/artikel.php?ID=238839>.
128. Kumar A, Dubey D, Gogoi S, Arvind NK. Laparoscopy-assisted live donor nephrectomy: a modified cost-effective approach for developing countries. *J Endourol*. 2002;16(3):155-159.
129. Kumar A, Chaudhary H, Srivastava A, Raghavendran M. Laparoscopic live-donor nephrectomy: modifications for developing nations. *BJU Int*. 2004, 93(9):1291-1295.
130. Simforoosh N, Basiri A, Tabibi A, Shakhssalim N. Laparoscopic donor nephrectomy—an Iranian model for developing countries: a cost-effective no-rush approach. *Exp Clin Transplant*. 2004;2(2):249-253.
131. Mitchell KB, Tarpley MJ, Tarpley JL, Casey KM. Elective global surgery rotations for residents: a call for cooperation and consortium. *World J Surg*. 2011;35(12):2617-2264.
132. *American College of Surgeons: Operation Giving Back: Residents*. 2013 [cited 2013 February 24]; Available from: <http://www.operationgivingback.facs.org/content2271.html>.
133. Riviello R. *Academic Global Surgery Partnerships*, R.R. Price, Editor 2013: Salt Lake City. p. 1.
134. Sztajnkrzyer MD, Madsen BE, Alejandro Báez A. Unstable ethical plateaus and disaster triage. *Emerg Med Clin North Am*. 2006;24(3):749-768.
135. Ramsey KM, Weijer CR. Ethics of surgical training in developing countries. *World J Surg*. 2007;31(11):2067-2069; discussion 2070-2071.
136. Zumla A, Costello A. Ethics of healthcare research in developing countries. *J R Soc Med*. 2002;95(6): 275-276.
137. Kushner AL, Kyamanywa P, Adisa CA, et al. Editorial policy on co-authorship of articles from low- and middle-income countries. *World J Surg*, 2011;35:2367-2368.
138. Cameron JS, Hoffenberg R. The ethics of organ transplantation reconsidered: paid organ donation and the use of executed prisoners as donors. *Kidney Int*. 1999;55(2):724-732.
139. Christensen CM, Grossman JH, Hwang J, *The Innovator's Prescription 2009*, New York McGraw-Hill. 441.

Index

Note: Page numbers followed by *t* indicate tables; those followed by *f* indicate figures.

- A**
- A-A index in vascular trauma, 182
- Abatacept, 328
- Abbe-Estlander flap in lip reconstruction, 582
- Abbé flap in lip reconstruction, 1857, 1859*f*
- Abdominal aortic aneurysms, 850–859
- anatomy in, 851–852, 851*f*
 - clinical manifestations in, 851
 - computed tomography angiography in, 832*f*, 852*f*
 - diagnostic evaluation in, 852, 852*f*
 - in elderly, 1936, 1937*f*
 - endovascular repair with stent graft, 850, 853–857, 854*f*
 - advantages and risks of, 855–856
 - compared to open repair, 857–858
 - complications in, 855–856, 859
 - cost analysis of, 858
 - devices available for, 855, 857–858
 - in elderly, 1936, 1937*f*
 - endoleaks in, 855–856, 858–859, 858*f*, 859*t*
 - endotension phenomenon in, 859
 - indications for, 855, 855*t*
 - secondary interventions in, 859
 - Seldinger technique, 856
 - surveillance after, 857
 - technical considerations in, 856–857, 856*f*
- etiology and pathogenesis in, 787–788
- with iliac artery aneurysm, 855, 856
- mortality rate in, 850, 851
- natural history of, 850–851, 851*t*
- physical examination in, 829
- risk of rupture in, 850, 851*t*
- surgical repair of, 852–853, 853*f*, 854*f*
- advantages and risks of, 852–853
 - annual number of, 375, 375*t*
 - compared to endovascular repair, 857–858
 - quality and safety in, 375
- Abdominal compartment syndrome, 217–218, 218*f*–219*f*. *See also* Compartment syndromes, abdominal
- Abdominal infections, 149–150, 256
- abscess in, 150, 391
 - adhesions in, 263
 - antibiotics in, 142
 - postoperative, 146, 391
 - in transplantation procedures, 329
 - of liver, 329, 351
 - of pancreas, 329
- Abdominal pain
- in appendicitis, 1243
 - in colorectal disorders, 1183
 - differential diagnosis in, 1246–1248
 - in HIV infection and AIDS, 1248
 - in elderly, 1936
 - in mesenteric ischemia, 860, 861, 1167
 - in peptic ulcer disease, 1059
- Abdominal trauma, 179–181, 203–212
- blunt, 181
 - algorithm on evaluation of, 181*f*
 - emergent exploration in, 188–189 - in children, 222–223, 1643–1644
 - of colon, 209–210, 1234
 - compartment syndrome in, 217–218, 218*f*–219*f*. *See also* Compartment syndromes, abdominal
 - damage control surgery in, 195, 196*f*
 - diagnostic peritoneal lavage and aspiration in, 180–181, 180*f*, 181*t*
 - in pregnancy, 218, 221 - emergent exploration in, 188–191, 189*f*–191*f*
 - of gallbladder, 204, 1331–1332
 - of genitourinary tract, 211–212
 - grading of injuries in, 181, 183*t*, 1644, 1644*t*
 - hemorrhage in, 181, 182*f*, 189–191
 - of liver, 203–206, 1644, 1644*t*
 - of pancreas, 207–209, 1341
 - penetrating, 179–181
 - algorithm on evaluation of, 180*f*
 - emergent exploration in, 189 - in pregnancy, 221
 - of rectum, 209–210
 - in seat belt injuries, 223, 1643–1644, 1643*f*
 - of small intestine, 207, 1643, 1643*f*
 - of spleen, 206–207, 1644
 - of stomach, 207
 - vascular injuries in, 181, 182*f*, 210–211, 214–215
 - of liver, 203–204
- Abdominal wall, 1449–1462, 1631–1635
- acquired disorders of, 1453–1456
 - anatomy of, 1449–1450, 1450*f*, 1451*f*, 1452*f*
 - blood supply of, 1449–1450, 1452*f*
 - and vascular injuries in laparoscopy, 1704–1705, 1704*f* - congenital disorders of, 1453, 1631–1635
 - desmoid tumors, 1454
 - embryonic development of, 1453, 1631
 - gastroschisis of, 1633–1634
 - hernias of, 1454–1456. *See also* Hernia, abdominal
 - incisions in, 1451–1453, 1452*f*
 - hernia of, 1454–1455, 1455 - innervation of, 1450, 1452*f*
 - muscular layers of, 1449, 1451*f*, 1496, 1499*f*
 - omphalocele of, 1632
 - in patent urachus, 1631–1632
 - physiology of, 1450–1451
 - in prune-belly syndrome, 1634
 - reconstructive surgery of, 1875–1876
 - flaps in, 1875–1876
 - prosthetic mesh in, 1875 - in rectus abdominis diastasis, 1453, 1453*f*
- Abdominoperineal resection, 1189
- Abdominoplasty, 1887
- after bariatric surgery and weight loss, 1129, 1130*f*, 1887*f*
- Abductor muscles of hand, anatomy of, 1791
- Ablative carbon dioxide laser, in burn, 235
- ABO blood groups, 96, 1914
- Abortion, induced, 1691–1692
- Abrasions in head and neck injuries, 575
- Abscess
- abdominal, 150, 391
 - anorectal, 1227–1229
 - in Crohn's disease, 1200 - of Bartholin's glands, 1678
 - of brain, 1745
 - of breast, 506
 - subareolar, 511, 511*t*
 - treatment in, 511 - cryptoglandular, 1227–1228
 - epidural, 1746
 - of hand, 1809
 - of kidney, 1664
 - of liver, 150, 1284–1285, 1284*f*, 1285
 - amebic, 1285
 - pyogenic, 387 - of lung, 650–651, 650*t*, 652*f*, 653*t*
 - of pancreas, 150–151, 1375*t*
 - pelvic, in diverticulitis, 1202*f*
 - perinephric, 1664
 - psoas, in Crohn's disease, 1198
 - retroperitoneal, 1460, 1461*f*
 - of spleen, splenectomy in, 1430*t*, 1436
 - tubo-ovarian, 1691
- Absorption
- in gallbladder, 1313
 - in large intestine, 1179
 - in small intestine, 1140–1143
- Abuse
- of children, 222, 1636
 - of elderly, 1934
- Accommodation response
- of rectum, in defecation, 1180
 - of stomach, 1047
- Accreditation Council for Graduate Medical Education, in surgery leadership, 3, 4*t*, 9
- Acetabulum, fractures of, 1760
- Acetaminophen, 1901
- hepatotoxicity of, 1276, 1277
 - liver transplantation in, 347, 1277, 1277*t*

- Acetaminophen (*Cont.*):
 liver metabolism of, 1270
 overdose of, 1270, 1276
 in persistent pain, 1949*t*
- Acetylcholine, 19, 19*f*, 35*f*
 in gastric acid secretion, 1041, 1043, 1044*f*
 in pepsinogen secretion, 1044
- N*-Acetylcysteine in acetaminophen overdose, 1276
- Achalasia, 990–992, 991*f*, 992*f*
 bird's beak appearance in, 991, 992*f*
 botulinum toxin injection in, 998, 1000, 1003
 esophageal myotomy in, 991*f*
 Heller technique, 997–999
 laparoscopic, 1000
 open, 1000
 peroral, 434*f*
 outcome assessment in, 1000–1003
 pneumatic dilation in, 1000, 1003
 perforation of esophagus in, 1019, 1019*f*, 1020*f*
 vigorous, 992, 997, 1000
- Achlorhydria in VIPoma, 1392
- Acid-base balance, 73–76
 buffering systems in, 73
 in children, 1599
 homeostasis, 73
 in shock, 130–131
 hemorrhagic, 120, 121*f*
- Acidemia, metabolic, in children, 1599
- Acidosis
 metabolic, 73–75, 74*t*, 75*t*
 in children, 1599
 etiologies of, 74, 75*t*
 lactic acid, 74
 in renal failure, 81
 in shock, 115
 in trauma, 217
 and bloody vicious cycle, 185, 193, 194*f*
 respiratory, 75
 acute, 74*t*
 in children, 1599
 chronic, 74*t*
 etiologies of, 75, 75*t*
- Acid secretion, gastric, 1041–1044
 analysis of output in, 963, 1051
 basal output in, 963, 1044, 1051
 gastrin as stimulant of, 1041, 1043, 1044*f*, 1045
 in gastrinoma, 1073
 in *Helicobacter pylori* infections, 1054
 maximal output in, 1044, 1051
 parietal cells in, 1041–1043, 1043*f*
 in peptic ulcer disease, 1055–1057, 1057*f*
 physiology of, 1041–1044, 1043*f*, 1044*f*
 in response to food ingestion, 1043, 1043–1044
 in short bowel syndrome, 1171
 somatostatin in regulation of, 1043, 1045
 in Zollinger-Ellison syndrome, 1073
- Acid substances
 ingestion of, 1021
 by children, 1612
 skin injuries from, 479–480
 burns in, 1822
- Acinar cells of pancreas, 1347, 1347*f*, 1348, 1353–1354, 1354*f*
- Acrochordons, 486
- Acrodermatitis enteropathica, 249
- Acromegaly, colorectal cancer risk in, 1204
- Acromioclavicular joint injuries, 1758
- Actinomycosis, 484, 651
- Activators, 449
- Active transport, 1140
- Acute coagulopathy of trauma (ACOT), 184
- Acute lung injury, 385
- Acyl-coenzyme A, 47, 47*f*, 48*f*, 49*f*
- Adalimumab, in Crohn's disease, 1197
- Adamantinoma, ossifying, 1781, 1781*f*
- Additive effect of drugs, 1898
- Adductor pollicis muscle, 1791
- Adenitis, acute mesenteric, differential diagnosis of, 1246
- Adenocarcinoma
 of anus, 1218
 of appendix, 1258
 colorectal, 1203–1216
 diagnosis, 628*f*
 differentiated from mesothelioma, 688, 688*t*
 endometrial, 1699–1700
 of esophagus
 in Barrett's esophagus, 969, 970*f*, 979, 1003
 chemoradiation in, 1005, 1014*t*
 epidemiology of, 1003
 in gastroesophageal reflux disease, 967, 969, 979
 selection of treatment approach in, 1007
 of lung, 614–615, 615*t*, 623
 colloid, 615
 in situ, 615
 invasive, 615, 616*f*
 lepidic, 615
 minimally invasive, 615
 of pancreas, 1395
 ampullary, 1408
 of small intestine, 1159, 1160, 1161, 1161*t*
 of stomach, 1074–1084
 of vagina, 1697
- Adenocarcinoma in situ (AIS), 615
- Adenoid cystic carcinoma, 599–600
 of breast, 556
 of lung, 617
 of trachea, 610
- Adenoidectomy of trachea, 571
- Adenoiditis, 570
- Adenoids and tonsils, 570
 hypertrophy of, 570, 571
- Adenolipoma of breast, 509
- Adenoma
 of breast, 509
 colorectal, carcinoma development in, 1205–1206
 of liver, 1290–1291, 1290*f*
 of pancreas, periampullary, 1408
 of parathyroid, 672, 1556
 hyperparathyroidism in, 1560, 1565, 1567–1568, 1569
 parathyroidectomy in, 1567–1568, 1569
 of pituitary
 Cushing's disease in, 1583, 1735
 parathyroidectomy in, 1735, 1736*f*
 prolactin-secreting, 554, 1735
 of small intestine, 1159, 1159*f*, 1160
 treatment in, 1161
 of thyroid, hyperthyroidism in, 1533–1534
- Adenomatoid malformation, congenital cystic, 1606, 1606*f*
- Adenomatous hyperplasia of lungs, atypical, 614
- Adenomyomatosis of gallbladder, 1320
- Adenomyosis of uterus, 1682
- Adenosine diphosphoribose, in wound healing, 1831
- Adenosine monophosphate, cyclic, 43*f*, 50
 in fatty acid oxidation, 47, 47*f*
- Adenosine triphosphate, and cellular metabolism in shock, 114–115
- Adenosis, sclerosing, of breast, 508, 509, 510–511
- Adenotonsillitis, 570, 571
- Adhesions
 pelvic, laparoscopy in, 1689
 peritoneal, 263, 263*f*
 postoperative, intestinal obstruction in, 386, 1146, 1150
 prevention of, 1151
- Adipose cells
 in obesity, 1101
 of parathyroid gland, 1557, 1557*f*
- Adjuvant! Online, 535
- Adnexa, removal of, 1689
- Adolescents
 breast hypertrophy in, 507
 gynecomastia in, 505
 informed consent for, 1943
 obesity in, 1125–1126
 and bariatric surgery, 1125–1126
- Adoptive transfer in cancer immunotherapy, 311
- Adrenal artery anatomy, 1575, 1576*f*
- Adrenalectomy, 1590–1594
 in adrenocortical carcinoma, 1584, 1591
 in breast cancer, 553
 complications of, 1593–1594
 in Cushing's syndrome, 1583, 1591
 complications of, 1593–1594
 historical aspects of, 1574
 in hyperaldosteronism, 1580
 in incidentaloma, 1589–1590
 laparoscopic, 1591–1592, 1591*f*, 1592*f*
 hand-assisted, 1591
 lateral transabdominal approach, 1591–1592
 posterior retroperitoneal approach, 1592
 open procedure, 1592–1593, 1593*f*
 anterior approach, 1592–1593
 lateral approach, 1593
 posterior approach, 1593
 in pheochromocytoma, 1587, 1591
 in sex steroid excess, 1585
- Adrenal gland, 1574–1594
 adenoma of
 adrenalectomy in, 1583
 differentiated from carcinoma, 1583, 1584
 hyperaldosteronism in, 1578, 1580
 nonfunctioning, 1588, 1588*t*
 sex steroid excess in, 1585
 adrenalectomy of, 1590–1594. *See also* Adrenalectomy
 anatomy of, 1575, 1576*f*, 1651
 cancer of, 1583–1585
 adrenalectomy in, 1584, 1591
 diagnosis of, 1584, 1584*f*
 differentiated from adenoma, 1583, 1584
 hyperaldosteronism in, 1578, 1580
 sex steroid excess in, 1585
 staging of, 1584, 1584*t*

- symptoms and sign in, 1584
 treatment in, 1584–1585
 cortical insufficiency of, 21, 1590
 etiologies of, 1590, 1590*t*
 postoperative, 392
 Cushing's syndrome of, 1580–1583
 ectopic tissue, 1574
 embryonic development of, 1574–1575
 historical studies of, 1574
 hormones released by, 1575–1578
 aldosterone, 22–23, 1575–1576
 catecholamines, 22, 1577–1578, 1579*f*, 1579*t*
 glucocorticoids, 1576–1577, 1578*t*
 mineralocorticoids, 1575–1576
 sex steroids, 1577, 1585
 in shock response, 113
 hyperaldosteronism of, 1578–1579
 hyperplasia of
 adrenalectomy in, 1583
 congenital, 1574, 1585
 ambiguous genitalia in, 1637–1638, 1638*f*
 Cushing's syndrome in, 1581
 hyperaldosteronism in, 1578, 1580
 incidentalomas of, 1588–1590
 diagnosis of, 1588–1589
 differential diagnosis in, 1588, 1588*t*
 treatment of, 1589–1590, 1589*f*
 pheochromocytoma of, 1585–1588
 physiology of, 1575–1578
 Adrenal vein anatomy, 1575, 1576*f*
 β -Adrenergic antagonists
 in aortic dissection, 812–813
 in elderly, 1935
 Adrenergic receptors, 1578, 1579*t*
 Adrenocorticotrophic hormone, 20
 in adrenocortical insufficiency, 1590
 in Cushing's syndrome, 1580, 1581–1582, 1581*t*, 1583
 deficiency of, 1590
 elevated levels in lung cancer, 626–627
 in glucocorticoid production, 20*f*, 1576–1577
 pituitary tumor secreting, 1580
 in response to stress and injury, 20
 in shock, 113
 stimulation test in adrenocortical insufficiency, 1590
 Adrenogenital syndrome, 1638*f*
 Advance directives, 1944
 Advanced Trauma Life Support, 161
 Advancement flaps, 1833, 1837
 endorectal
 in fistula in ano, 1231
 in rectovaginal fistula, 1231, 1232*f*
 Adverse events, 367*t*
 risk management in, 380
 Surgical Care Improvement Project on, 374, 374*t*
 Aerodigestive tract, upper
 cancer of, 578–600
 anatomy in, 578, 579*f*
 second primary tumors in, 580
 staging of, 580, 581*t*
 papillomavirus infections of, 579
 recurrent, 572
 Aesthetic surgery, 1882–1891
 Affiliative leadership, 9
 Afterload, cardiac, 114, 402
 in shock, 114, 125
 Agency for Healthcare Research and Quality on patient safety indicators, 373, 373*t*
 Age-related changes, 221, 221*t*, 1923, 1924, 1925*t*–1926*t*
 in breasts, 500, 504, 504*f*
 and benign breast disorders, 507–508, 507*t*
 in colorectal cancer risk, 1203
 in inguinal hernia prevalence, 1500
 in nutritional requirements, 1600*t*
 in wound healing, 252–253
 AGES scoring system in papillary carcinoma of thyroid, 1543
 Agonist drugs, 1898
 Air embolism, 171, 172*f*
 in central venous catheterization, 381
 Airway management
 in anesthesia, 1909*f*, 1910–1911, 1910*f*, 1911*f*, 1912*f*
 algorithms on, 1913*f*
 in bariatric surgery, 1106
 preoperative evaluation for, 1905, 1906*f*, 1906*t*
 in burns, 227, 230
 ex utero intrapartum therapy (EXIT) procedure in, 1645, 1645*f*
 in hemoptysis, 662
 recommendations for healthcare workers, 1971*t*
 in trauma, 161–163
 in children, 222, 1642
 of head, 1717
 Airway pressures, 409–410
 peak, 409–410
 plateau, 409–410
 Alagille's syndrome, 1628
 Alanine transaminase serum levels in liver disorders, 1270, 1271–1272
 Albumin, 1911
 in chyle, 686*t*
 liver synthesis of, 1271
 in resuscitative fluids, 76*t*, 77
 serum levels of
 and calcium serum levels, 1558
 in cirrhosis, Child-Turcotte-Pugh score on, 1280*t*
 Albuterol in hyperkalemia, 78
 Alcohol use and alcoholism
 breast cancer risk in, 511
 esophageal cancer in, 1003
 head and neck tumors in, 578, 579, 586
 liver disorders in, 1271
 transplantation of liver in, 346
 pancreatitis in
 acute, 1352
 chronic, 1362–1365, 1363*f*, 1368, 1368*f*
 cessation of alcohol use in, 1379
 pseudocyst in, 1376*f*
 survival in, 1374, 1375*f*
 Aldosterone, 22–23, 1575–1576, 1576*f*
 elevated levels of, 1578–1579
 Aldosteronoma, 1578
 Alemtuzumab, 325, 325*t*
 Alfentanil, 1900
 Alginate acid in gastroesophageal reflux disease, 971
 Alkaline agents
 ingestion of, 1021
 in children, 1612
 skin injuries from, 479–480, 480*f*
 Alkaline phosphatase, 1271
 to antibiotics, 1270
 in diagnostic peritoneal lavage in abdominal trauma, 181*t*
 Alkaloids, plant, in chemotherapy, 307, 308*t*
 Alkalosis
 metabolic, 75, 75*t*
 in children, 1599
 etiologies of, 75, 75*t*
 respiratory, 75, 75*t*
 in children, 1599
 ALK gene in familial neuroblastoma, 288*t*
 Alkylating agents in chemotherapy, 307, 308*t*
 Allelic loss, 287
 Allergic reactions
 to antibiotics, 146
 aspergillosis in, 655
 fungal sinusitis in, 569
 in transfusions, 100–101, 102*t*
 Allografts
 in burns, 1820
 composite tissue, 1881–1882, 1882*f*
 heart valve, 750
 in spinal arthrodesis, 1743
 Altmeier procedure in rectal prolapse, 1219
 Alteplase
 in arterial vasospasm, 215*t*
 in venous thromboembolism, 924
 Alvarado Scale on appendicitis diagnosis, 1245, 1245*t*
 Alveolar mucosa tumors of oral cavity, 585
 mandibulotomy in, 585, 586*f*
 Alveolar spaces, pulmonary, 612
 Amastia, 500
 Amaurosis fugax in cerebral ischemia, 839
 Ambiguous genitalia, 1637–1638, 1638*f*
 Amebic infections
 anorectal, 1233
 liver abscess in, 1285
 Amenorrhea, 1682
 American Association for the Surgery of Trauma grading scale for solid organ injuries, 181, 183*t*
 American Burn Association, 227
 American Cancer Society cancer screening guidelines, 297, 298*t*–299*t*, 299, 513
 American Joint Committee on Cancer cancer staging system, 300
 in breast cancer, 531, 531*t*–532*t*
 in colorectal cancer, 1211*t*
 in esophageal cancer, 1005, 1006*t*
 in head and neck tumors, 580, 581*t*
 in lung cancer, 634*t*
 in melanoma, 488
 in soft tissue sarcomas, 1470–1471
 in stomach cancer, 1079
 American Society of Anesthesiologists airway management algorithms, 1911, 1913*f*
 classification of surgical risk, 1905, 1905*t*, 1926
 American Society of Clinical Oncology guidelines, 301
 American Spinal Injury Association classification of spine injuries, 1724, 1725*f*
 AMES classification of papillary thyroid carcinoma, 1543
 Amikacin, 144*t*
 Amine precursor uptake and decarboxylation cells, 1390
 Amino acids
 in enteral nutrition, 53–54
 metabolism of, 53–54
 in injury, 50
 in parenteral nutrition, 58
 in wound healing, 254–255
 Aminoacyl-tRNA synthetases, 447

- ε-Aminocaproic acid, 92
 in cardiopulmonary bypass, 95
 Aminoglycosides, 144*t*
 5-Aminosalicylic acid in Crohn's disease, 1156
 Amitriptyline in pain, 1950*t*
 Ammonia absorption in colon, 1179
 Amnesia in general anesthesia, 1900
 Amniocentesis, 1691
 Amoxicillin in peptic ulcer disease, 1061*t*
 Amphibole asbestos fibers, 688
 Amphotericin B, 141*t*, 658
 in aspergillosis, 655–656
 in blastomycosis, 661
 in candidal infections, 658
 in coccidioidomycosis, 661
 Ampicillin-sulbactam, 143*t*, 257*t*
 in pelvic inflammatory disease, 1690*t*
 AMPLE history in trauma, 173
 Amputation
 surgical
 in femoropopliteal occlusive disease, 898
 in soft tissue sarcoma, 1473, 1474
 in trauma, 1877
 traumatic, in hand injuries, 1800, 1802*f*–1804*f*
 replantation in, 1800
 Amrinone, in cardiogenic shock, 127
 Amsterdam criteria on hereditary nonpolyposis colorectal cancer, 292, 292*t*
 Amyand, Claudius, 1241
 Amylase
 in carbohydrate digestion, 1141, 1142*f*
 in diagnostic peritoneal lavage in abdominal trauma, 181*t*
 pancreatic secretion of, 1347, 1348*t*
 serum levels in acute pancreatitis, 1355–1356, 1357
 Amylin, 1349*t*, 1350
 Amyloidosis
 intracranial hemorrhage in, 1730
 splenectomy in, 1430*t*, 1438
 Amyotrophic lateral sclerosis, differential diagnosis in, 1740
 Anaerobic bacterial infections, 140, 140*t*
 antibiotic therapy in, 143*t*–145*t*
 Anal canal
 abdominoperineal resection of, 1189
 anatomy of, 1176, 1177–1178, 1177*f*, 1178*f*
 lymphatic, 1178–1179, 1217, 1217*f*
 nerve supply in, 1179
 vascular, 1178, 1179*f*
 anesthesia in surgery of, 1194
 clinical evaluation of disorders, 1180–1185
 Crohn's disease of, 1200, 1200*f*
 endoscopy of, 1180–1181
 fissures in, 1225–1227, 1226*f*
 hemorrhoids of, 1222–1225
 positioning of patient for surgery of, 1194
 preoperative preparations for surgery of, 1194–1195
 trauma of, 1235
 tumors of, 1217–1218
 ultrasonography of, endoanal, 1181, 1185, 1185*f*
 Analgesia, 1900–1901
 in children and infants, 1601
 nonopioid, 1900–1901
 opioid, 1900
 in pancreatitis, chronic, 1379
 in persistent pain, 1949*t*
 postoperative, 1916, 1916*f*
 Anal gland infections, 1227–1228
 Anal sphincters, 1178, 1185*f*
 artificial, 1235
 division in anal fissure, 1225, 1226*f*
 in fecal continence, 1180, 1185, 1185*f*, 1235
 innervation of, 1179
 trauma of, 1235
 sphincteroplasty in, 1235, 1235*f*
 ultrasonography of, endoanal, 1185
 Anaphylaxis in antibiotic therapy, 146–147
 Anaplastic carcinoma of thyroid, 1550–1551, 1551*f*
 Anastomosis
 in aortic coarctation repair, 705
 biliary enteric, 1327, 1329*f*
 in colorectal surgery, 1189–1191, 1190*f*, 1191*f*
 end-to-end, 1190, 1190*f*, 1191*f*
 end-to-side, 1190, 1190*f*
 hand-sutured technique, 1190–1191, 1190*f*
 ileal pouch anal anastomosis in, 1188, 1189*f*, 1194
 in familial adenomatous polyposis, 1207
 in ulcerative colitis, 1198
 side-to-end, 1190
 side-to-side, 1190, 1190*f*
 stapled technique, 1190*f*, 1191, 1191*f*
 in esophagus caustic injury, 1023*f*
 in free tissue transfer, 1838, 1839*f*
 end-to-end, 1839, 1839*f*
 end-to-side, 1839, 1839*f*
 microvascular, 1838
 occlusion of, 1838, 1839
 in liver transplantation, 348–349
 in lung transplantation, 357, 357*f*
 in pancreaticoduodenectomy, 1403–1407
 Roux-en-Y. *See* Roux-en-Y anastomosis
 Anastrozole, 552–553
 Androgens, adrenal, 1577
 excess of, 1585
 Androstenedione, 1577
 Anemia, 1914
 hemolytic, 1272
 in hiatal hernia, 981
 postoperative, in gastric surgery, 1094
 transfusions in, 98
 wound healing in, 253
 Anesthesia, 1895–1919
 agents used in, 1899–1904, 1899*t*
 in anorectal procedures, 1194
 in bariatric surgery, 1106–1107
 in colon surgery, 1194
 future trends in, 1917–1919
 general, 1899–1902
 induction of, 1909, 1909*f*
 rapid sequence, 1909
 inhalational agents in, 1902, 1902*t*
 intravenous agents in, 1900–1901
 neuromuscular blocking agents in, 1901–1902, 1901*t*
 in hand and wrist injuries, 1795–1796, 1797*f*
 historical aspects of, 1895–1897
 in inguinal hernia repair, 1505, 1515
 intraoperative management of, 1909–1915
 airway management in, 1910–1911
 fluid therapy in, 1911, 1914
 transfusions in, 1914–1915
 local, 1902–1903, 1903*t*
 additives in, 1903
 cardiovascular disorders in, 1903
 central nervous system disorders in, 1903
 malignant hyperthermia in, 393, 1916–1917
 in minimally invasive surgery, 419
 pharmacology of, 1897–1899
 preoperative evaluation and preparation for, 1904–1905
 risk assessment in, 1905–1909
 recovery from, 1915–1916
 regional, 1903–1904
 epidural, 1903*t*, 1904
 peripheral nerve blocks in, 1903–1904
 spinal, 1897, 1904
 Aneurysms
 of aorta. *See* Aorta, aneurysms of
 in Behçet's syndrome, 903
 of carotid artery, 848, 849*f*
 in fibromuscular dysplasia, 847, 848
 cerebral, 1728–1732
 locations of, 1730, 1730*t*
 subarachnoid hemorrhage in, 1730–1731, 1730*f*, 1730*t*, 1731*f*
 of coronary arteries in Kawasaki syndrome, 902
 of iliac artery, with abdominal aortic aneurysm, 855, 856
 of left ventricle, postinfarction, 766–768, 767*f*
 of splenic artery, 1438
 splenectomy in, 1430*t*, 1438
 Angina pectoris, 735–736
 in aortic stenosis, 758
 chronic, 742
 in coronary artery disease, 742
 indications for bypass surgery in, 742
 results of bypass surgery in, 745
 disability assessment in, 737, 737*t*
 risk of noncardiac surgery in, 738
 Angioembolization, 203
 Angiogenesis
 in tumors, 283–284
 in breast cancer, 535
 in wound healing, 243*t*, 244, 1831
 Angiography, 832–833, 918
 in aortic aneurysm, thoracic, 791
 bronchial, in hemoptysis, 663
 in carotid artery occlusive disease, 840–841, 841*f*
 in colorectal disorders, 1181
 complications of, 382–383
 computed tomography technique. *See* Computed tomography angiography
 coronary preoperative, 834
 digital subtraction technique, 833, 833*f*
 in carotid artery occlusive disease, 840–841
 in renal artery stenosis, 869
 in gastrinoma, 1073
 in lower extremity arterial occlusive disease, 882
 magnetic resonance technique, 882. *See also* Magnetic resonance angiography
 in mesenteric ischemia, 862
 nephropathy from contrast agents in, 383
 in neurologic examination, 1712
 in portal hypertension, 1280

- in renal artery fibromuscular dysplasia, 867, 867f
of spleen, 1429
in subarachnoid hemorrhage, 1731, 1731f
in Takayasu's arteritis, 901, 901t
of upper extremity, 1794–1795
in venous thromboembolism, 921
- Angiopathy, amyloid, 1730
- Angioplasty
in aortoiliac occlusive disease, 879–880, 881
balloons used in, 835–836, 836f
in carotid artery occlusive disease, 842–843, 845–847
 compared to endarterectomy, 842–843
 embolic protection devices in, 845–846, 846t
 in fibromuscular dysplasia, 904
 technique in, 845–846, 846f
coronary
 in cardiogenic shock, 128
 compared to bypass surgery, 742–743, 743t
 prior to other surgeries, 834
in lower extremity arterial occlusive disease, 892–894, 893f
 compared to surgical treatment, 899
 complications of, 896–897
 cryoplasty technique, 892, 893f, 897
 subintimal technique, 892, 894, 896–897
in mesenteric artery occlusive disease, 864, 865
percutaneous transluminal, 879–880, 892–894
in renal artery occlusive disease, 870–871
- Angiopoietins in angiogenesis, 284
- Angiosarcoma, 493, 776, 1468, 1470, 1476, 1481, 1780
of breast, 556
- Angiosomes, 1837–1838
- Angiotensin, 1575
and renin activity. *See* Renin-angiotensin system
- Angle classification of dental occlusion in mandibular fractures, 1853, 1854f
- Anidulafungin, 141t, 658
- Animal bites, 478, 479f
- Animal models in genetic research, 463–467
 gene knockout in, 464–466, 465f
 transgenic mice in, 463–464, 463f
- Anion gap in metabolic acidosis, 74, 75t
- Ankle
 dislocations of, 1764
 fractures of, 1764
 in children, 1783
 syndesmosis of, 1764
- Ankle-brachial index, 829
in aortoiliac occlusive disease, 872
 calculation of, 829, 830f
 in lower extremity arterial occlusive disease, 882
- Ankyrin, 1429
- Annuloplasty
 of mitral valve, 756, 756f
 of tricuspid valve, 763
- Annulus fibrosus, 1739, 1771
- Anorectoplasty in imperforate anus, 1627–1628
- Anorexia, in appendicitis, 1243
- Anoscopy, 1180
- Antacids in gastroesophageal reflux disease, 971
- Antagonist drugs, 1898
- Anterior cord syndrome, 1724, 1725f
- Anterior partial fundoplication, 976, 978–979
- Anthrax, 136
 as biologic warfare agent, 156–157
- Antia-Buch ear reconstruction technique, 1856, 1857f
- Antibiotics, 142, 143t–145t, 146–147
 allergic reactions to, 146
 antitumor, 307, 308t
 in appendicitis, 1248, 1251
 in children, 1623
 in asplenia, 1445
 in bronchiectasis, 653–654
 in cholecystitis, acute, 1321
 in Crohn's disease, 1156, 1196
 in cystitis, 1664
 duration of therapy with, 142, 146
 empiric therapy with, 142
 in epididymo-orchitis, 1665
 historical development of, 136–137
 in inflammatory bowel disease, 1156, 1196
 in liver abscess, 1284
 in lung abscess, 651
 in lymphedema, 936
 in mastitis, 506
 misuse of, 147
 in otitis media, 566
 ototoxicity of, 384
 for pancreatitis, acute, 1359
 in pelvic inflammatory disease, 1690t
 in peritonitis, 150
 in pneumonia, 385
 in portal hypertension and variceal bleeding, 1282–1283
 in postsplenectomy infections, 1445
 prophylactic use of, 142, 146t
 in bowel preparation, 1194
 in surgery, 255–256, 257t
 in trauma, 185–187
 in prostatitis, 1664
 pseudomembranous colitis associated with, 1222
 selection of, 142
 in sepsis, 154, 155t
 and shock, 124–125
 in sinusitis, 567, 568
 in soft tissue infections, 151, 152
 in surgical drains, 389, 390
 in surgical site infections, 142, 255–256, 257t–258t, 389
 in urinary tract infections, 390
 in wound infections, 265
- Antibodies
 anticardiolipin, in antiphospholipid syndrome, 93
 antineutrophil cytoplasmic, in Crohn's disease, 1155
 depleting, 325
 monoclonal, 325, 328–329
 nondepleting, 325
 polyclonal, 325
 thyroid, 1529
- Anticardiolipin antibodies in antiphospholipid syndrome, 93
- Anticholinesterase agents in reversal of neuromuscular blockade, 1915
- Anticoagulation therapy, 94–95
 in elderly, 1931, 1935
 in free tissue transfer, 1840
- heparin in. *See* Heparin therapy
in lower extremity arterial occlusive disease, 887
perioperative management in, 94–95
 in bariatric surgery, 1105
 in emergency operations, 94
 in valve replacement, 761, 1931
 in venous thromboembolism, 921–923
warfarin in. *See* Warfarin therapy
- Anticonvulsant drugs
 in pain, 1950t
 in seizures, 1746
- Antidepressants, tricyclic, in pain, 1950t
- Antidiuretic hormone secretion inappropriate, 80
 hyponatremia in, 69, 80
 in lung cancer, 626
- Antiepileptic drugs
 in pain, 1950t
 in seizures, 1746
- Antifungal agents, 140, 141t
 in blastomycosis, 661
 in candidal infections, 658
 in coccidioidomycosis, 661
 in histoplasmosis, 659
 in pulmonary infections, 661
- Antigen-presenting cells, 324
- Antihypertensive therapy in aortic dissection, 812, 819
- Anti-inflammatory drugs, nonsteroidal
 peptic ulcer disease from, 1053, 1054, 1057–1058
 hospitalization rates in, 1058t
 medical treatment in, 1061
 perforation in, 1068
 risk factors in, 1058, 1059t
- Anti-inflammatory response
 cholinergic pathways in, 19
 counterregulatory syndrome (CARS), 14f
- Antimetabolites in chemotherapy, 307, 308t
- Antineutrophil cytoplasmic antibody in Crohn's disease, 1155
- Antiphospholipid syndrome, 93–94
 α_2 -Antiplasmin, 88
- Antireflux surgery, 973–980
 in Barrett's esophagus, 969, 972
 indications for, 972
 outcome of, 979, 979t
 reoperation of, 979–980
 Belsey repair in, 973f
 in children, 1613
 in esophageal motility disorders, 995, 995f
 and Heller myotomy, 997–999, 1000, 1001f
 outcome assessment in, 1001, 1002t
 failure of, 1002t
 in gastroesophageal reflux, 965–967
 in hiatal hernia, 983
 indications for, 972
 Nissen fundoplication in, 974–975. *See also* Nissen fundoplication
 outcome in, 977–978
 preoperative evaluation in, 972–973
 principles of, 973–974, 973f
 reoperation in failure of, 979–980
 in respiratory disorders, 971
 Toupet fundoplication in, 975–976
- Antithrombin globulin in chyle, 686t
- Antithrombin III, 88
- Antithrombotics
 in cerebrovascular injuries, 199, 199f
 in venous thromboembolism, 921–923

- Antithymocyte globulin, 325
 Antithyroid drugs in Graves' disease, 1532
 Antrectomy in peptic ulcer disease, 1062*t*, 1063, 1071*f*
 Antroduodenal motility testing, 1053
 Anus
 abdominoperineal resection of, 1189
 anatomy of, 1177–1178
 Crohn's disease of, 1200, 1200*f*
 embryonic development of, 1175–1176
 fissures in, 1225–1227, 1226*f*
 fistula of, 1229–1231, 1229*f*, 1230*f*
 imperforate, 1626–1628, 1626*f*, 1627*f*
 anomalies associated with, 1627
 classification of, 1627
 resection in total proctocolectomy, 1188
 tumors of, 275*t*, 1217–1218
 Aorta, 785–820
 abdominal
 aneurysms of, 850–859. *See also*
 Abdominal aortic aneurysms
 atherosclerosis of, 872–881
 anatomy of, 785, 786*f*
 aneurysms of
 abdominal, 850–859. *See also*
 Abdominal aortic aneurysms
 in aortic arch, 795–796, 798*f*
 hybrid repair of, 804, 803*f*,
 805*f*–806*f*
 in aortic root, 758
 with aortic valve insufficiency, 758–761,
 789, 793
 ascending
 anatomy of, 785
 dissection of, 813–815, 814*f*, 819
 atherosclerosis of, 872–881
 aneurysm in, 787, 850
 balloon pump in, 768
 in cardiogenic shock, 127
 coarctation of, 705–706
 compared to dissection, 807
 descending, dissection of, 815–816, 820
 dissection of, 806–816
 acute, 808
 endovascular repair in, 815–816
 open repair in, 816
 with aortic valve insufficiency, 760,
 809, 813
 ascending, 813–815, 814*f*, 819
 blood pressure control in, 812, 815
 chronic, 808, 815
 endovascular repair in, 816
 open repair in, 816, 817*f*–818*f*
 clinical history of, 809
 clinical manifestations in, 809–810,
 811*t*
 compared to aneurysm, 807
 complications in, 809–810, 811*t*
 descending, 815–816, 820
 diagnostic evaluation of, 810–812,
 812*f*
 endovascular treatment in, 815–816
 fenestration technique, 815
 outcome in, 820
 indications for surgery in, 815
 initial assessment and management
 in, 812–813
 location of, 807, 809*f*
 malperfusion syndrome in, 807, 810,
 811
 endovascular treatment in, 815
 iliofemoral, 815
 indications for surgery in, 815
 open repair in, 816
 management algorithm on, 810*f*
 nonoperative management of, 815,
 820
 open repair in, 816, 820
 outcomes in, 819, 820
 pathology and classification of,
 806–809, 807*f*, 808*f*
 proximal extension of, 807
 retrograde, 807
 risk factors for, 809
 subacute, 808
 thoracic aortic aneurysm in, 787
 true and false lumen in, 806
 variants of, 808–809
 distal
 anatomy of, 785
 aneurysm repair in, 799–804,
 819–820
 in double-outlet right ventricle, 721–722
 fusiform, 785, 795
 intimal tear of, 807
 in Marfan's syndrome, 902
 Takayasu's arteritis of, 901, 901*t*
 in transposition of great arteries,
 720–721
 intramural hematoma of, 807*f*; 808–809
 in Marfan's syndrome, 248, 787, 789
 dissection of, 813, 815
 mega, 785
 outcome of surgery in, 816–820
 proximal
 anatomy of, 785
 aneurysm repair in, 793–799, 795*t*,
 817, 818–819
 pseudoaneurysms of, 785, 788
 saccular, 785, 789, 795
 Takayasu's arteritis of, 788
 thoracic, 785–806. *See also* Thoracic
 aortic aneurysms
 anatomy of, 785, 786*f*
 aneurysms of, 785–806. *See also*
 Thoracic aortic aneurysms
 medial degeneration of, 787
 thoracoabdominal, 799–801, 800*f*,
 803–804
 hybrid repair technique in, 804
 open repair in, 819–820
 outcome of surgery in, 819–820
 trauma of, 177–178, 200–201, 200*f*
 chest radiography in, 177, 178*f*, 178*t*
 computed tomography in, 177, 179*f*
 damage control surgery in, 193
 emergent abdominal exploration in,
 189–190, 190*f*
 endovascular stenting in, 201
 interposition graft repair in, 201, 210
 ulcer of, penetrating, 808, 809
 endovascular treatment of, 816
 Aortic arch
 aneurysms in, 795–797, 798*f*
 hybrid repair of, 803*f*, 804, 805*f*–806*f*
 in hypoplastic left-heart syndrome,
 716–719
 interrupted, 729, 729*f*
 anatomic types of, 729, 729*f*
 surgical repair of, 729
 Aortic root
 aneurysm of, 758
 replacement in thoracic aortic aneurysm
 repair, 793–795, 794*f*
 Aortic stenosis
 congenital, 698–702
 anatomy and classification of,
 698–699
 diagnosis of, 699
 disorders associated with, 698–699
 in hypoplastic left-heart syndrome,
 716
 pathophysiology in, 699
 subvalvular, 698, 699*f*, 702
 supravalvular, 698, 699*f*, 702
 treatment of, 699–702, 700*f*
 Konno procedure in, 702, 703*f*
 pulmonary valve transposition in,
 701–702, 701*f*–702*f*
 Ross procedure in, 701–702, 702
 valvular, 698, 699, 699*f*, 716. *See also*
 Aortic valve disorders, stenosis
 Aortic valve disorders, 756–762, 757*f*,
 759*t*
 atresia in hypoplastic left-heart
 syndrome, 716
 bicuspid valve, 756, 758
 thoracic aortic aneurysm in, 788
 in hypoplastic left-heart syndrome,
 716–719
 insufficiency and regurgitation, 758–761
 in aortic dissection, 760, 809, 813
 indications for surgery in, 747, 761
 repair procedure in, 761–762
 in thoracic aortic aneurysm, 789, 793
 minimally invasive surgery in, 761
 with mitral valve disease, 763
 myxomatous degeneration, 758
 prosthetic replacement in, 749, 761–762
 in congenital stenosis, 701–702,
 701*f*–702*f*
 in elderly, 761, 1930
 indications for, 761
 minimally invasive technique, 761
 operative technique in, 757*f*,
 761–762, 761*f*
 postoperative care in, 761
 pulmonary valve autograft in, 751,
 762
 results in, 761
 Ross procedure in, 751, 762
 transcatheter aortic valve, 762
 repair procedures in, 761–762
 valve-sparing root replacement, 761
 in rheumatic heart disease, 756
 stenosis, 747, 756–758
 calcific, 756–757, 757*f*
 in elderly, 1930
 congenital, 698, 699, 699*f*
 in hypoplastic left-heart syndrome,
 716
 degenerative or senile, 756–757
 indications for surgery in, 758
 with tricuspid valve disease, 763
 trileaflet, 756
 Aortitis, 788
 in syphilis, 788
 Aortobifemoral bypass in aortoiliac
 occlusive disease, 876–877,
 876*f*; 880–881
 Aortoiliac occlusive disease, 872–881
 classification of, 873–875, 874*f*
 Trans-Atlantic Inter-Society
 Consensus
 system in, 875, 875*f*; 875*t*
 collateral pathways in, 873, 873*f*
 diagnostic evaluation in, 872
 differential diagnosis in, 872–873
 endovascular therapy in, 875, 879–881
 compared to surgical treatment,
 880–881
 complications of, 880
 surgical reconstruction in, 876–878
 aortobifemoral bypass in, 876–877,
 876*f*; 880–881

- axillofemoral bypass in, 877
 compared to endovascular therapy, 880–881
 complications of, 878–879, 878*t*
 endarterectomy in, 877
 femorofemoral bypass in, 877
 iliofemoral bypass in, 877, 877*f*
 obturator bypass in, 878
 thoracofemoral bypass in, 878
 type I, 873–874, 874*f*
 type II, 874, 874*f*
 type III, 874, 874*f*, 875*f*
- Aortoplasty in coarctation of aorta, 705
- Aortopulmonary window region
 congenital disorder, 711–712, 711*f*, 712*f*
 classification of, 711*f*
 two-patch repair technique in, 711–712, 712*f*
 lung cancer metastasis to, 671, 673*f*
- Aortorenal bypass in renal artery occlusive disease, 869
- APACHE II score in acute pancreatitis, 1357
- APC gene
 in colorectal cancer, 1183, 1204
 in familial adenomatous polyposis, 288*t*, 291, 1206–1207
- Apligraf in venous ulcer treatment, 932–933, 933*f*
- Apnea in sleep, obstructive, 572
 in obesity, 1105, 1128
 bariatric surgery affecting, 1111, 1112*t*, 1128
 respiratory disturbance index in, 572
- Apocrine carcinoma of breast, 556
- Apocrine glands, 475
- Apoeccrine glands, 475
- Apoplexy, pituitary, 1735
- Apoptosis, 37*f*, 450, 451*f*
 activation of, 450
 in breast cancer, indicators of, 535
 in cancer cells, 281–283
 differentiated from necrosis, 281
 pathways in, 281–282, 450, 451*f*
- Apoptosome, 281
- Appendectomy, 1251–1256
 in children, 1623
 compared to antibiotics in appendicitis, 1251
 historical aspects of, 136, 1241
 incidence of, 1243
 incidental, 1257
 financial issues in, 1257
 indications for, 1257
 incomplete, 1257
 and inflammatory bowel disease, 1242–1243
 interval, 1251, 1252*t*
 laparoscopic, 1252–1256, 1253*f*, 1254*f*
 in children, 1623
 compared to open procedure, 1253–1254, 1255*t*
 in pregnancy, 436
 open, 1251–1252
 compared to laparoscopic procedure, 1253–1254, 1255*t*
 in pregnancy, 436
 in tumors of appendix, 1258, 1259
 urgent versus emergent, 1250, 1250*t*
- Appendicitis, 1243–1251
 acute, 1243–1251
 in children, 1622–1624
 Alvarado Scale on, 1245, 1245*t*
 antibiotics in, 1248, 1251
 in children, 1623
 bacteriology of, 1243
 in children. *See* Children and infants, appendicitis in
 clinical scoring systems, 1245
 complicated, 1250–1251
 diagnostic laparoscopy in, 1254
 differential diagnosis in, 1246–1248
 in children, 1246, 1624
 in HIV infection and AIDS, 1248
 in elderly, 1246, 1256, 1924, 1929
 etiology and pathogenesis in, 1243
 historical treatment of, 136, 1241
 in HIV infection and AIDS, 1248
 imaging studies in, 1245–1246
 in children, 1623, 1623*f*
 incidence of, 1243
 and incidental appendectomy, 1257
 initial management of, 1248–1251, 1249*t*
 interval appendectomy following nonoperative management, 1251
 operative versus nonoperative, 1248, 1251
 laboratory findings in, 1244–1245
 laparoscopic single-incision appendectomy, 1254
 natural orifice transluminal endoscopic surgery in, 1254, 1256
 perforation and rupture in, 1243, 1250–1251
 age-related differences in, 1246–1248
 in children, 1246, 1256, 1623–1624, 1623*f*
 in HIV infection and AIDS, 1248
 in pregnancy, 1248, 1256–1257
 signs and symptoms in, 1243–1244, 1244*t*
 in children, 1622–1623
 stump, 1257
 uncomplicated, 1248–1250
 Valentino's, 1252
- Appendicitis Inflammatory Response Score, 1245, 1245*t*
- Appendix vermiform, 1241–1259
 anatomy and function of, 1242–1243
 appendectomy of. *See* Appendectomy
 appendicitis of, 1243–1251. *See also* Appendicitis
 critical view, 1253, 1254*f*
 embryonic development of, 1241–1242
 operative interventions, 1251–1256
 perforation and rupture in appendicitis, 1250–1251
 age-related differences in, 1246–1248
 in children, 1244, 1251, 1256, 1623–1624, 1623*f*
 in HIV infection and AIDS, 1248
 in pregnancy, 1248, 1256–1257
 retrocecal, 1244
 tumors of, 1257–1259
- Appetite, ghrelin regulation of, 1045
- Apple peel deformity in intestinal atresia, 1616
- Aprotinin, in cardiopulmonary bypass, 95
- Aquaporins, 1140–1141
- Arachidonic acid, 31–32, 31*f*, 43*f*
 released from platelet membranes, 85
- Arantius' ligament, 1265
- Arcuate ligament syndrome, median, 861, 862*f*, 866
 surgical repair in, 864
- Arcuate line of Douglas, 1449, 1451*f*
- Areola, anatomy of, 501
- Argatroban in venous thromboembolism, 922–923
- Arginine, 54
 in wound healing, 254–255, 255*f*
 Arginine vasopressin, 113. *See also* Antidiuretic hormone secretion
- Argon beam coagulation, 428
- Aristotle, 1941, 1942*f*
- Arm lift procedure, 1887
- Aromatase inhibitors in breast cancer, 552–553
- Arrhythmias, 770–772
 atrial fibrillation. *See* Atrial fibrillation
 in central venous catheterization, 381
 Cox-Maze IV procedure, 771–772, 771*f*
 defibrillators in, implantable, 770
 in Ebstein's anomaly, 719
 electrocardiography in, 401
 pacemaker implantation in, 770
 postoperative, 386, 393
 in tetralogy of Fallot, 725–726
 signs and symptoms in, 736
 in trauma, 171
- Arterial disorders, 827–906
 angiography in, 832–833
 ankle-brachial index in, 829, 830*f*
 aortic aneurysms
 abdominal, 850–859
 thoracic, 785–806
 aortoiliac occlusive disease, 872–881
 arteritis. *See* Arteritis
 in Behçet's syndrome, 903
 in Buerger's disease, 906
 of carotid artery, 837–850
 in Ehlers-Danlos syndrome, 901–902
 endovascular therapy in, 834–837
 in fibromuscular dysplasia, 904–905
 general approach to, 828–834
 history of patient in, 828–829, 828*t*
 in Kawasaki syndrome, 902
 lower extremity occlusive disease, 881–900
 in malformations, 1850, 1852
 in Marfan's syndrome, 902
 of mesenteric artery, 859–866
 pain in, 828
 on ambulation, 828
 at rest, 828
 physical examination in, 829
 of popliteal artery, 905–906
 in pseudoxanthoma elasticum, 902
 in Raynaud's syndrome, 904
 of renal artery, 866–872
 segmental limb blood pressure in, 829–830
 in thromboangiitis obliterans, 906
 ultrasonography in, 830
- Arteriography, 1051
- Arteriovenous malformations, 574, 1850, 1852
 intracranial hemorrhage in, 1731, 1732*f*
 stereotactic radiosurgery in, 1749
- Arteritis
 classification of, 903, 903*t*
 giant cell, 788, 901
 inflammatory, 902–903
 in polyarteritis nodosa, 903
 radiation-induced, 903–904
 Takayasu's, 788, 901, 901*t*
- Arthritis
 conservative management and prevention of, 1772
 of hand and wrist, 1806–1808, 1808*f*
 septic, 1811
 in inflammatory bowel disease, 1196
 introduction of, 1772
 rheumatoid

- Arthritis, rheumatoid (*Cont.*):
 aortitis in, 788
 of hand and wrist, 1808, 1808*f*
 septic
 of hand and wrist, 1811
 surgical treatment of, 1772–1776, 1773*f*,
 1774*f*, 1775
- Arthrodesis, 1772
 of hand and wrist joints, 1807
 spinal, 1743–1744
- Arthroplasty, 1773–1778
 complications of, 1777–1778
 osteolysis in, 1777–1778
 wear debris in, 1777–1778
 computer navigation and, 1776, 1777*f*
 fixation options in, 1776–1778
 of hand and wrist, 1807, 1808
 of hip, 1773–1774, 1773*f*
 of knee, 1774–1776, 1775*f*–1776*f*,
 1777*f*, 1778*f*
- Arthroscopy, in meniscus tears, 1768*f*
- Asbestos exposure, 293
 amphibole fiber type in, 687
 interaction with smoking, 293, 619
 mesothelioma in, 687
 serpentine fiber type in, 687
- Ascariasis, 1286, 1324
- ASCERT Study, 743
- Aschoff-Rokitansky sinuses, 1319
- Ascites
 abdominal hernia in, 1279, 1455
 chylous, 1169–1170
 etiologies of, 1169
 in cirrhosis, 1279
 Child-Turcotte-Pugh score on,
 1280*t*
 liver transplantation in, 347
 pancreatic, 1378, 1378*f*
 in portal hypertension, 1281
 postoperative, 387
 transjugular intrahepatic portosystemic
 shunt in, 347
- Aspartate transaminase serum levels in
 liver disorders, 1270, 1271–1272
- Aspergilloma, pulmonary, 655–656, 657*f*
- Aspergillus* infections
 pulmonary, 655–658, 657*f*
 invasive, 658
 sinusitis in, 569–570, 570
- Aspiration
 of foreign body by children, 1608
 of gastric contents in gastroesophageal
 reflux, respiratory disorders in,
 970–971
- Aspiration procedure, peritoneal, in
 abdominal trauma, 180–181,
 180*f*
- Aspirin
 in carotid artery occlusive disease,
 841, 846
 peptic ulcer disease from, 1057–1058,
 1059*t*
 perforation in, 1068
 risk factors for, 1058, 1059*t*
 in persistent pain, 1949*t*
 platelet dysfunction from, 91–92
- Asthma
 in gastroesophageal reflux, 969, 971
 in obesity, 1105, 1128–1129
- Astrocytoma
 intracranial, 1733
 spinal, 1738–1739
- Asymptomatic Carotid Atherosclerosis
 Study, 842
- Atelectasis, postoperative, 384, 1444
- Atherectomy in lower extremity arterial
 occlusive disease, 895–896
 complications of, 897
 devices used in, 895
 laser technique, 896
- Atherosclerosis
 angiography in, 832–833
 aortic aneurysm in
 abdominal, 850
 thoracic, 787
 aortoiliac, 872–881
 of carotid artery, 837–847
 of coronary arteries, 741–747.
See also Coronary arteries,
 atherosclerosis of
 general approach to patient in, 828–834
 of hand, 1822–1823
 lower limb ischemia in, 882
 atherectomy in, 895–896
 mesenteric ischemia in, 859, 860, 1167
 surgical repair in, 864
 preoperative evaluation in, 742, 793,
 833–834, 1905
 renal artery occlusion in, 866, 866*f*
 surgical repair in, 870
 risk factors for, 741–742
- Athletic injuries. *See* Sports injuries
- Atlantoaxial instability in Down syndrome
 adenotonsillectomy precautions
 in, 571
- Atlas, cervical
 in atlantoaxial instability, 571
 Jefferson fracture of, 1722, 1770
 in occipital dislocation, 1770
- ATM gene, 288*t*
- Atracurium, 1901
- Atresia
 of aortic valve in hypoplastic left-heart
 syndrome, 716
 biliary, 1628–1630. *See also* Biliary
 tract, atresia of
 of esophagus, 1608–1612. *See also*
 Esophagus/atresia of
 intestinal, 1615–1616, 1616*f*
 of duodenum, 1612, 1615–1616,
 1616*f*
 of jejunum, 1616*f*
 of mitral valve in hypoplastic left-heart
 syndrome, 716
 of tricuspid valve, 712–716
- Atrial fibrillation, 771–772
 in mitral insufficiency, 752
 in mitral stenosis, 752
 peripheral artery embolism in, 885
 signs and symptoms in, 736
- Atrial natriuretic peptides, 43
- Atrioventricular canal defects, 726*f*,
 727–729
 classification of, 727–729, 728*f*
 complete, 727, 728*f*, 729
 operative repair of, 729
 partial, 727, 728*f*
- Atrium
 arrhythmias of
 fibrillation. *See* Atrial fibrillation
 lesion sets, 772
 postoperative, 386
 in cor triatriatum, 710, 711*f*
 myxomas of, 775–776, 775*f*
 septal defect of, 695–698
 anatomy of, 695–696, 696*f*
 in cor triatriatum, 710, 711
 diagnosis of, 697
 in Ebstein's anomaly, 719
 embryology of, 695
 pathophysiology in, 696–697
 percutaneous closure in, 698
 results of treatment in, 698
 in tricuspid atresia, 712
- Atrophy
 craniofacial, 1848–1849, 1849*f*, 1850*f*
 gastritis in, 1077, 1077*f*
 intestinal, in parenteral nutrition, 59
- Atypical ductal hyperplasia (ADH), 510
- Auditory canal tumors, 594
- Auerbach's myenteric plexus, 1039
 in Hirschsprung's disease, 1625
- Augmentation mammoplasty, 1890–1891,
 1891*f*
- Authoritative leadership, 9
- Autografts
 in aortic valve replacement, 751, 762
 in spinal arthrodesis, 1743
- Autoimmune disorders
 Graves' disease in, 1531
 hemolytic anemia in, 1430*t*, 1431–1432
 pancreatitis in, 1365*t*, 1366
 of peripheral nerves, 1744–1745
- Autonomic nervous system, 1711
 hormones regulated by, 20*t*
 parasympathetic. *See* Parasympathetic
 nervous system
 in shock response, 112
 sympathetic. *See* Sympathetic nervous
 system
- Autonomy principle, 1941
 in informed consent, 1944
 in withdrawing or withholding of life-
 sustaining therapies, 1945
- Autophagy in cancer cells, 283
- Autotransplantation, 322
 of islet cells in chronic pancreatitis,
 1390
- Axillary artery
 in axillofemoral bypass, 877
 palpation of, 829
- Axillary lymph nodes
 anatomy of, 502–503, 502*f*
 in breast cancer, 547–548, 554
 dissection after chemotherapy,
 551–552
 dissection in mastectomy, 548–549,
 548*f*
 early invasive, 539–541
 in elderly, 1932
 historical aspects of surgery in, 498
 natural history in, 518, 519*f*
 and sentinel node dissection, 545, 547
 staging of, 531, 531*t*–532*t*
 in unknown primary cancer, 554
- Axillary vein
 anatomy of, 916
 thrombosis of, 928–929
- Axillofemoral bypass in aortoiliac
 occlusive disease, 877
- Axis, cervical
 in atlantoaxial instability, 571
 fractures of, 1722, 1770
- Axitinib, 310*t*
- Axon injury, 251, 1726
 diffuse, 1719
- Axonotmesis, 251, 1726
- Azathioprine
 in Crohn's disease, 1156, 1196
 in immunosuppression, 323, 325*t*, 326,
 327*t*
 side effects of, 326, 326*t*
 in ulcerative colitis, 1196
- Azithromycin, 145*t*
- Aztreonam, 144*t*

- B**
- B cells**
 in small intestine immune function, 1144
 in transplant rejection, 324
- Bacille Calmette-Guérin** in bladder cancer, 1654
- Bacillus anthracis**, 136
 as biologic warfare agent, 156–157
- Back pain**, 625
- Bacteria**
 in cutaneous microflora, 137, 141
 in intestinal microflora, 137, 1179
 in necrotizing enterocolitis, 1619–1620
 translocation of, 151
 transcription in, 447
- Bacterial colonization**, 258, 389
- Bacterial contamination**, 258
 in surgery, 141, 146, 147*t*, 148*t*, 256
 in transfusions, 100, 102*t*
- Bacterial infections**, 139–140, 140*t*
 anorectal, 1232–1233
 aortic aneurysm in, 788
 appendicitis in, 1243–1251
 common organisms in, 1243
 of breast, 506
 in central venous catheterization, 381
 compared to contamination and colonization, 258
 cystitis in, 1664
 empyema in, 683–684
 epididymo-orchitis in, 1665
 liver abscess in, 150, 1284
 of lungs, 650–658
 abscess in, 650–651
 peritonitis in, 149–150
 pharyngitis in, 570
 prostatitis in, 1664
 pyelonephritis in, 1664
 sinusitis in, 568
 of skin and subcutaneous tissues, 477, 483–484
 of surgical site, 142, 256, 257*t*–258*t*, 1257
 in transplant recipients, 329
 vulvovaginitis in, 1677*t*, 1680, 1681*f*
- Balloon dilatation**, 430–431
 in aortic coarctation, 705
- Balloon expulsion test**, 1182
- Balloon pump**, intra-aortic, 768
 in cardiogenic shock, 127
- Balloon valvotomy** in congenital aortic stenosis, 700–701
- Balloon valvuloplasty** in mitral stenosis, 753
- Banding of stomach**, 1108–1112. *See also* Gastric banding
- Banting**, Frederick, 4, 1349
- Barbiturates** in general anesthesia, 1900
- Bariatric surgery**, 1099–1131
 in adolescents, 1125–1126
 anemia risk in, 1094
 anesthesia in, 1106–1107
 biliopancreatic diversion and duodenal switch in, 1103, 1107, 1119–1121
 in centers of excellence, 1099, 1107
 complications in, in sleeve gastrectomy, 1124
 contraindications to, 1104, 1104*t*
 in biliopancreatic diversion and duodenal switch, 1120
 in gastric bypass, 1115
 in diabetes mellitus, 1112*t*, 1127
 gastric banding in, 1111, 1128
 gastric bypass in, 1116, 1127
 in elderly, 1125–1126
 in fatty liver, 1106, 1129
 gastric banding in, 1108–1112. *See also* Gastric banding
 gastric bypass in, Roux-en-Y, 1103, 1112–1119. *See also* Gastric bypass surgery, Roux-en-Y
 in gastroesophageal reflux disease, 1105, 1116, 1128
 ghrelin levels after, 1045, 1046*f*
 in hyperlipidemia, 1112*t*, 1116, 1128
 in hypertension, 1111, 1112*t*, 1116, 1128
 indications for, 1104, 1104*t*, 1107
 laparoscopic, 1103
 biliopancreatic diversion and duodenal switch in, 1120, 1121
 compared to open procedures, 1107, 1118, 1118*t*
 conversion to open procedure, 1107*t*
 gastric banding in, 1108–1112
 gastric bypass in, 1112–1118
 hand-assisted, 1107
 sleeve gastrectomy in, 1121–1125
 malabsorptive, 1102, 1103*t*, 1107, 1119–1121
 combined with restrictive mechanisms, 1102, 1103*t*
 in metabolic syndrome, 1127–1128
 open
 biliopancreatic diversion and duodenal switch in, 1119–1121
 compared to laparoscopic procedures, 1107, 1118, 1118*t*
 conversion of laparoscopic procedure to, 1107*t*
 gastric bypass in, 1118–1119
 outcomes in, 1112*t*
 in biliopancreatic diversion and duodenal switch, 1120–1121
 in gastric banding, 1111–1112
 in gastric bypass, 1116–1118, 1117*t*, 1118*t*, 1119
 in sleeve gastrectomy, 1124
 overview of, 1102–1104
 patient education in, 1106
 patient selection for, 1105
 in biliopancreatic diversion and duodenal switch, 1120
 in gastric banding, 1110
 in gastric bypass, 1115, 1118
 in sleeve gastrectomy, 1121–1125
 plastic surgery after, 1129, 1130*f*, 1887*f*
 postoperative care and follow-up in, 1107–1108
 in biliopancreatic diversion and duodenal switch, 1120
 in gastric banding, 1110–1111, 1111*f*
 in gastric bypass, 1115–1116, 1118–1119
 in sleeve gastrectomy, 1123–1124
 pregnancy after, 1126
 preoperative assessment and preparation, 1105–1106
 in biliopancreatic diversion and duodenal switch, 1120
 in gastric banding, 1110
 in gastric bypass, 1115, 1118
 in sleeve gastrectomy, 1121–1125
 recent trends in, 1099–1100, 1104*f*
 restrictive, 1102, 1103*t*
 combined with malabsorptive mechanisms, 1102, 1103*t*
 historical development of, 1103
 revolution in, 1103–1104
 in sleep apnea, 1105, 1111, 1112*t*, 1128
 sleeve gastrectomy in, 1103, 1104, 1121–1125
- Barium studies**
 in colorectal cancer screening, 1208*t*, 1209
 colorectal injury in, 1234
 of eosinophilic esophagitis, 986
 of esophagus, 950–951, 953*f*, 963
 in antireflux surgery, 973
 in diverticula, 994*f*
 in leiomyoma, 1017, 1017*f*
 in sarcoma, 1015, 1016*f*
 in gastric disorders, 1051, 1052*f*
 in hiatal hernia, 950–951, 953*f*, 982
 in Hirschsprung's disease, 1625
 in large intestine disorders, 1181
 in ulcerative colitis, 1197
- Baroreceptors**, 68, 69
 in shock response, 112
- Barotrauma**, 410
- Barrett**, Norman, 969
- Barrett's esophagus**, 967, 969, 979
 adenocarcinoma in, 969, 970*f*, 972, 1003
 risk for, 1003
 surgical treatment of, 1008
 antireflux surgery in
 indications for, 972
 outcome of, 979, 979*t*
 reoperation of, 979–980
 surveillance for, 969
 columnar-lined esophagus in, 950, 969, 1003
 drug therapy in, 971
 in duodenal reflux, 967–968
 endoscopy in, 950, 951*f*
 intestinal metaplasia in, 950, 969
 structurally defective sphincter in, 967*t*
 surveillance for, 979
- Bartholin's glands**, 1674
 cyst and abscess of, 1678
- Basal cell carcinoma**, 486–487
 of anus, 1218
 of hand, 1817, 1817*f*
 Moh's microsurgery in, 486
 types of, 486
- Basal cell nevus syndrome**, 486
- Base deficit**
 in shock, 130–131
 hemorrhagic, 120, 121*f*
 in trauma, 217
- Basilar artery injuries**, 1720, 1721
- Basilic vein anatomy**, 917
- Basiliximab**, 325, 325*t*
- Bassini repair** in inguinal hernia, 1495, 1506, 1507*f*
- Battle's sign**, 174
 in skull fractures, 1716
- Baux score** in burns, 230
- Bax death signal protein** in breast cancer, 535
- Bcl-2 proteins**, 282
 in breast cancer, 535
- Bcr-Abl**, and imatinib therapy in chronic myeloid leukemia, 455, 455*f*
- Beck's triad**, 128, 167
- Beckwith-Wiedemann syndrome**, 1638
- Beclin gene**, in autophagy, 283
- Bed rest** in lymphedema, 936
- Beer's law**, 409
- Beger procedure** in chronic pancreatitis, 1385–1386, 1387, 1387*f*
- Behavioral modification** in obesity, 1102

- Behçet's syndrome, 903
 Belatacept, 325*t*, 326*t*, 328
 Bell's palsy, 567
 Bell stages in necrotizing enterocolitis, 1620
 Belsey fundoplication, 973*f*
 lower esophageal sphincter myotomy with, 999
 Beneficence principle, 1941
 in withdrawing or withholding of life-sustaining therapies, 1945
 Bennett fracture, 1796
 Bentall procedure in thoracic aortic aneurysm repair, 795, 797*f*
 Bentiromide test in chronic pancreatitis, 1374
 Benzocaine in local anesthesia, 1899*t*, 1902
 Benzodiazepines in general anesthesia, 1900
 Bereavement, 1951
 Bernard-Soulier syndrome, 89
 Berne procedure in chronic pancreatitis, 1387, 1389*f*
 Best, Charles, 1349
 Beta blockers
 in aortic dissection, 812–813
 in elderly, 1935
 Betel nut quid, head and neck tumors associated with, 579
 Bevacizumab, 310*t*
 in breast cancer, 535
 in ovarian and fallopian tube cancer, 1703
 Bezoars, 1089, 1089*f*
 Bicarbonate
 in gastrointestinal secretions, 69*t*
 in parenteral nutrition, 76*t*
 therapy with
 in hyperkalemia, 78, 78*t*
 in metabolic acidosis, 74
 Bier, August, 1897
 Bifunctional RNAi technology, 467–468
 Bigelow, Henry J., 1896
 Bile, 1312–1313
 composition of, 69*t*, 1270, 1312–1313, 1318*f*
 formation of, 1270, 1312–1313
 functions of, 1270
 gallbladder storage and regulation of, 1313
 leak in cholecystectomy complications, 1333, 1333*f*
 reflux of, gastritis in, 1093–1094
 Bile acids, 1270, 1312
 in fat metabolism, 1143
 in gastroesophageal reflux, 967–968, 968*f*
 Bile ducts
 anatomy of, 1268, 1310–1311, 1311*f*
 anomalies in, 1312
 carcinoma of, 1291–1293, 1335–1338, 1336*f*. *See also* Cholangiocarcinoma
 cholangiography of. *See* Cholangiography
 common
 anatomy of, 1310–1311
 choledocholithiasis in, 1322, 1325–1327. *See also* Choledocholithiasis
 cysts of, 1330, 1330*f*; 1630–1631
 idiopathic dilatation of, 1630
 laparoscopic exploration of, 1325–1327, 1328*f*
 outlet stenosis of, 1331
 hamartoma of, 1291
 radionuclide scans of, 1315
 strictures of, 1331, 1332*f*
 trauma of, 1332–1334
 in cholecystectomy, 1331, 1332–1333, 1332*f*, 1333*f*
 ultrasonography of, 1314
 Bile salts, 1270, 1312
 Biliary ascites, in liver trauma, 205
 Biliary tract, 1309–1338
 acute pancreatitis in disorders of, 1352
 anatomy of, 1309–1311
 anesthesia in disorders of, 1907
 atresia of, 1628–1630
 clinical presentation in, 1628
 diagnosis of, 1628
 etiology of, 1628
 liver transplantation in, 349, 1629
 pathogenesis in, 1628
 portoenterostomy in, 1629–1630, 1629*f*
 treatment of, 1629–1630, 1629*f*
 Caroli's disease of, 1289
 cholangiocarcinoma of, 1291–1293, 1335–1338. *See also* Cholangiocarcinoma
 cholangitis of, 1331. *See also* Cholangitis
 cystadenoma of, 1288
 cysts of, 1330, 1630–1631
 classification of, 1330, 1330*f*; 1630
 clinical presentation in, 1630
 diagnosis of, 1630
 etiology of, 1630
 treatment of, 1630–1631
 diagnostic studies of, 1313–1316
 gallbladder in. *See* Gallbladder
 gallstones in, 1316–1327. *See also* Gallstones
 hamartoma of, 1291
 Oddi sphincter in. *See* Oddi sphincter
 physiology of, 1312–1313
 postoperative disorders of, 387
 in liver transplantation, 351
 in pancreatic cancer, 1399–1400, 1400*f*
 stent placement in
 in cholangiocarcinoma, 1337
 in chronic pancreatitis, 1380, 1381*f*
 in pancreatic cancer, 1406
 strictures of bile ducts in, 1331, 1332*f*
 trauma of, 1331–1334
 in cholecystectomy, 1331, 1332–1333, 1332*f*, 1333*f*
 Biliopancreatic diversion procedure, 1103
 configuration in, 1119*f*; 1120
 with duodenal switch, 1103, 1107, 1119–1121
 laparoscopic, 1120, 1121
 operative technique in, 1120
 outcomes in, 1112*t*, 1120–1121
 patient selection and preparation in, 1120
 postoperative care and follow-up in, 1120
 historical aspects of, 1103, 1119
 Bilirubin
 conjugated or direct, 1271, 1272
 in diagnostic peritoneal lavage in abdominal trauma, 181*t*
 esophageal exposure to, in gastroesophageal reflux, 968, 968*f*
 metabolism in liver, 1270, 1271–1272
 serum levels of, 1271–1272
 in liver disorders, 1270, 1271–1272, 1280*t*
 postoperative, 387
 unconjugated or indirect, 1271, 1272
 Bilirubin diglucuronide, 1313
 Billroth, C. A. Theodor, 1521
 Billroth techniques, 207
 in gastroduodenostomy, in peptic ulcer disease, 1063, 1067*f*
 in gastrojejunostomy
 in bile reflux gastritis, 1093
 in peptic ulcer disease, 1063, 1067*f*
 in stomach cancer, 1081
 Biloma in liver trauma, 205, 205*f*
 Bioengineering of blood vessels in coronary artery disease, 747
 Bioimpedance, 407
 Biologic warfare agents, 156–157
 Biomarkers of tumors, 301–304
 in breast cancer, 303, 531–536, 536*t*
 predictive, 534
 prognostic, 534
 surrogate endpoint, 534
 in colorectal cancer, 301, 302–303, 1182–1183
 in fallopian tube cancer, 1702
 in mediastinal tumors, 672
 in ovarian cancer, 1702
 Biomolecular therapy in coronary artery disease, 747
 Biopsy, 299–300
 in breast cancer, 529, 531
 excisional technique with needle localization, 544–545, 544*f*; 545*f*; 546*f*
 incisions in, 544, 544*f*; 545*f*
 mammography in, 544–545, 546*f*
 nonpalpable lesions, 529
 palpable lesions, 529, 531
 of sentinel lymph nodes, 305–306, 545–547
 of cervix uteri, 1677
 in chest wall tumors, 665–666
 complications of, 383
 core-needle, 300
 in breast cancer, 529, 531
 in chest wall tumors, 666
 in soft tissue sarcomas, 1469
 endometrial, 1677–1678
 excisional, 300
 in breast cancer, 544–545, 544*f*; 545*f*; 546*f*
 in chest wall tumors, 666
 in soft tissue sarcomas, 1470
 fine-needle aspiration, 300
 in breast cancer, 529, 531
 in chest wall tumors, 666
 in soft tissue sarcomas, 1469
 in thyroid nodule, solitary, 1538–1540, 1540
 in hand tumors, 1815
 incisional, in soft tissue sarcomas, 1469–1470
 of liver
 in cirrhosis, 1279
 in incidental mass, 1288
 of lung, 630
 in lymph node assessment, 631, 632*t*
 in mediastinal tumors, 672–673
 in melanoma, 488, 489, 489*f*; 489*f*–490*f*
 in neck mass, 595
 open, 300
 rectal, in Hirschsprung's disease, 1625
 of sentinel lymph nodes

- in breast cancer, 305–306, 545–547
 - in melanoma, 489, 489f–490f
 - in vulvar cancer, 1697
- in soft tissue sarcomas, 1469–1470
- in stomach cancer, 1080
- of thyroid, in solitary nodule, 1538–1540, 1540
- of vagina, 1677
- of vulva, 1677
- Bird's beak appearance in achalasia, 991, 992f
- Birth injuries, 1782–1783
 - maternal, perineal lacerations in, 1692
 - neonatal, brachial plexus palsy in, 1782
- Bishop-Koop anastomosis, 1618, 1619f
- Bismuth-Corlette classification of bile duct carcinoma, 1335–1336, 1335f, 1336–1337
- Bismuth subsalicylate in peptic ulcer disease, 1061t
- Bispectral index in electroencephalography, 411
- Bisphosphonates
 - in bone pain, 1950t
 - in hypercalcemia, 1573t
 - in hyperparathyroidism, 1563–1564
- Bisulfite sequencing, 462
- Bite wounds, 478–479
 - of hand, 1812
 - in human bites, 1812
 - risk for infections in, 478–479, 479f
- Bivalirudin in venous thromboembolism, 922
- Black pigment gallstones, 1318
- Bladder
 - anatomy of, 1652
 - cancer of, 1653–1654
 - cystectomy in, 1654
 - epidemiology of, 275t, 276t, 277f, 278t, 618f
 - urinary diversion procedures in, 1653, 1654
 - fetal surgery for anomalies of, 1645
 - fistula of
 - with colon in diverticulitis, 1203
 - with vagina, 1678
 - infections of, 1664–1665
 - Candida albicans*, 390
 - pressure measurement, 411
 - in abdominal compartment syndrome, 217, 217t, 411
 - trauma of, 211–212, 1660
 - extraperitoneal, 212, 1660
 - in inguinal hernia repair, 1515
 - intraperitoneal, 212, 1660
 - in laparoscopy, 1515, 1705
- Blalock-Taussig shunts in tricuspid atresia, 713
- Blastomyces dermatitidis, 329
- Blastomycosis, 661
- Blatchford score in peptic ulcer disease, 1059, 1060t
- Bleeding time test, 103
- Bleomycin in esophageal cancer, 1013t
- Blepharoplasty, 1882–1883
- Blindness, transient monocular, in cerebral ischemia, 839
- Blood
 - banked whole, 96
 - fresh whole, 96, 184
 - oxygen-carrying capacity of, 97–98
 - transfusion of. *See* Transfusions
- Blood-borne infections, 156
 - occupational exposures to, 156
 - universal precautions in, 156
- Blood gas analysis, 409
- Blood groups, ABO, 96, 1914
- Blood pressure, 400–401
 - ankle-brachial index of, 829, 830f
 - in aortic dissection, 812, 815
 - in burns, 230
 - diastolic, 400
 - in hemorrhagic shock, 119, 120f, 122
 - in hypertension. *See* Hypertension
 - in hypotension. *See* Hypotension
 - invasive monitoring of, 401
 - complications in, 401
 - resonance frequency and damping in, 401
 - in kidney transplantation, 339
 - noninvasive measurement of, 400–401
 - segmental limb, in arterial disease, 829–830
 - systolic, 400
 - in trauma
 - of head, 197
 - initial evaluation and management of, 165
 - monitoring of, 216–217
 - persistent hypotension in, 171–173
- Blood volume in children, 1599–1600
- Bloody vicious cycle in trauma, 185, 193, 194f
- Bloom syndrome, 288t
- Blowout fractures, orbital, 577, 577f
- Blunt trauma, 173–174
 - in children, 1643
 - of heart, 127, 171
- BMPRIA* in juvenile polyposis coli, 288t
- Boari flap in ureteral trauma, 212, 1660
- Bochdalek's hernia, 1603–1605
- Body contouring, excisional, 1886–1887, 1887f
- Body lift procedure, circumferential, 1887
- Body mass index
 - in obesity, 1100–1101, 1100t, 1102, 1908
 - bariatric surgery affecting, 1116, 1125
 - in medical management, 1102
 - in single-incision laproscopic surgery, 434
- Boerhaave's syndrome, 1018
- Bombesin, 1045
- Bone marrow
 - micrometastasis in, 304
 - splenectomy in disorders of, 1435–1436
- Bone morphogenetic proteins, 251
- Bones
 - angiosarcoma of, 1780
 - cysts of aneurysmal, 1738
 - fibrous lesions of, 1780
 - fractures of, 1757–1765. *See also* Fractures
 - grafts in spinal arthrodesis, 1743
 - growth of, 1782
 - growth plate injuries of, 1782
 - of hand and wrist, 1787–1788, 1790f
 - healing of, 249–251
 - in hyperparathyroidism, 1556, 1560–1561, 1561f, 1563
 - malignant fibrous histiocytoma of, 1780
 - metabolic disorders in gastric surgery, 1094–1095
 - mineral density in hyperparathyroidism, 1561, 1563
 - ossification centers in, 1782
 - osteoporosis of. *See* Osteoporosis
 - Paget's sarcoma of, 1779
 - remodeling fractures of, 250
 - tumors of
 - in chest wall, 666, 667
 - in eosinophilic granuloma, 666
 - epidemiology of, 275t
 - giant cell, 1780–1781, 1780f
 - metastatic, 454, 1782
 - in lung cancer, 627
 - in osteochondroma, 666
 - in sarcomas of chest wall, 667
- Bookwalter retractor, 1453, 1453f
- Borst's elephant trunk technique in aortic aneurysm repair, 795, 798f, 799f
- Bortezomib, in immunosuppression, 325t
- Bosniak classification of renal cysts, 1655, 1655t
- Bosutinib, 310t
- Botulinum toxin in achalasia, 998, 1000, 1003
- Bovine aortic arch, 788
- Bowel preparation, preoperative, 1194–1195
 - antibiotics in, 1194
 - mechanical, 1194–1195
- Bowen's disease, 487, 1217–1218, 1680
- Boxer's fracture, 1796
- Boyd perforator veins, 916
- Brachial artery
 - atherosclerosis of, 1822–1823
 - injuries of, 215
 - palpation of, 829
 - puncture for endovascular therapy
 - access, 834–835, 835f
- Brachial plexus injuries, 215, 1727
 - in birth, 1782
- Brachioplasty, 1887
- Brachycephaly, 1750
- Brachydactyly, 1823
- Brachytherapy, 313
 - in soft tissue sarcoma of extremity, 1474
- Bradycardia in trauma, 170
- Bradykinin, 33, 88
- Brain
 - abscess of, 1745
 - afferent signals to, in inflammatory response, 18–23, 19f
 - deep stimulation of, 1747–1748, 1747f
 - herniation of
 - central or transtentorial, 1713, 1714f
 - in encephalocele, 1750
 - in intracranial pressure increase, 1713–1714, 1714f
 - subfalcine, 1713, 1714f
 - uncal, 1713, 1714f
 - oxygen consumption rate in anesthesia, 1908–1909
 - oxygen tension in tissue, 412
 - sensors monitoring, 1713
 - traumatic injury of, 195, 1717–1720
 - in children, 222, 1643
 - contre-coup, 1719
 - contusion in, 1718–1719, 1718f
 - diffuse axonal, 1719
 - intracranial pressure increase in, 411
 - intraparenchymal hemorrhage in, 1720
 - monitoring in, 411, 412
 - tumors of, 1732–1737
 - epidemiology of, 275t, 276t, 278t, 618f
 - metastatic, 1732, 1733f
 - stereotactic radiosurgery in, 1749
- Brain death, 1721
 - diagnosis of, 330, 1721
 - organ donation process in, 330–331
 - multiple organ procurement in, 331, 331f

- Brain stem
 anatomy of, 1714, 1715f
 compression of, 1714, 1715f
- Branchial cleft, 1602
 cyst of, 598, 598f
 fistula of, 1602
- Braun enteroenterostomy in bile reflux
 gastritis, 1093–1094
- BRCA1 and BRCA2, 514–517
 in breast cancer, 514–517, 514t
 in breast-ovarian syndrome, 288t, 291
 in ovarian cancer, 515, 1701
 risk management in, 516–517, 1701
 testing for mutations in, 515–516
- BRCAPRO model on breast cancer risk,
 512
- Breast, 497–557
 aberrations of normal development and
 involution (ANDI), 507–508,
 507t
 abscess of, 506
 subareolar, 511, 511t
 treatment in, 511
 accessory, 500
 age-related changes in, 500, 504, 504f
 and benign breast disorders, 507–508,
 507t
 anatomy of, 500–503, 500f
 benign disorders and diseases of,
 507–511
 classification of, 507, 509t
 nonproliferative, 508–509
 pathology in, 508–509
 proliferative, 509–510
 blood supply of, 501–502, 502f
 calcium deposits in, 509
 cancer of, 511–557. *See also* Breast
 cancer
 cysts of, 508, 510, 528f
 development of, 499–500, 503–504
 disorders in, 507–508, 507t
 embryonic, 499–500
 hormones affecting, 500, 503–504,
 503f
 ductal ectasia of, 508, 509
 fibroadenomas of, 507, 508f, 509
 treatment of, 510
 fibrocystic disease of, 509
 in gynecomastia, 505–506. *See also*
 Gynecomastia
 hyperplasia of, 507, 508f, 508t
 cancer risk in, 508, 508t, 509–510
 pathology in, 509–510
 inactive and active, 501
 infectious and inflammatory disorders
 of, 506–507
 innervation of, 502
 lobular involution of, 508
 lymphatics of, 502–503, 502f
 levels of, 503
 and mammary milk line, 500, 500f
 mastitis of. *See* Mastitis
 nipple discharge from, 554
 nodularity of, 508
 Paget's disease of, 506, 521
 phyllodes tumors of, 555, 555f
 physical examination of, 523, 523f
 physiology of, 503–506
 plastic and reconstructive surgery of,
 1866–1872. *See also* Breast
 plastic and reconstructive
 surgery
 in pregnancy and lactation, 500, 501,
 501f, 504–505, 504f
 epithelial hyperplasia of, 508
 radial scars of, 509, 511
 sarcoma of, 556, 1481
 sclerosing adenosis of, 508, 509,
 510–511
- Breast cancer, 511–557
 adenoid cystic, 556
 advanced local-regional, 541–543
 angiogenesis in, 535
 as therapy target, 535
 antiestrogen therapy in, 552
 anti-*HER-2/Neu* antibody therapy in,
 535, 553–554
 apocrine, 556
 axillary lymph nodes in. *See* Axillary
 lymph nodes, in breast cancer
 biomarkers in, 303, 531–536, 536t
 biopsy in, 529, 531
 excisional, with needle localization,
 544–545, 544f, 545f, 546f
 incisions in, 544, 544f, 545f
 mammography in, 544–545, 546f
 of sentinel lymph nodes, 305–306,
 545–547
 breast conservation surgery in, 547. *See*
also Breast conservation surgery
 chemoprevention of, 315, 513–514,
 552
 chemotherapy in, 307, 550–552. *See*
also Chemotherapy, in breast
 cancer
 circulating tumor cells in, 303
 conserving surgery, 499
 diagnosis of, 522–531
 ductography in, 526–527, 527f
 magnetic resonance imaging in, 527,
 529
 mammography in, 523–526,
 524f–526f
 physical examination in, 523, 523f
 ultrasonography in, 527, 528f, 529f,
 530f
- ductal carcinoma. *See* Ductal carcinoma
 of breast
 early invasive, treatment of, 537–541
 in elderly, 1932–1933
 endocrine therapy in, 308–309, 552
 ablative, 553
 neoadjuvant, 552
 epidemiology of, 274, 276, 278t,
 517–519, 618f
 compared to other cancers, 275t, 276t,
 277f
 incidence rates in, 275t, 276t, 277f,
 279f, 517
 international variations in, 517
 mortality rates in, 275t, 276t,
 517–518, 518f, 519f
 survival rates in, 517–518, 519f
 estrogen and progesterone receptor
 status, 534, 535–536
 fatality rates, 1958
 genetic factors in. *See* Genetic factors,
 in breast cancer
 grave signs of, 498
 histopathology of, 519–522
 historical development of therapy in,
 497–499
 immunotherapy in, 454
 inflammatory, 555–556, 556f
 differentiated from noninflammatory
 cancer, 556, 556t
 in situ (stage 0)
 histopathology in, 519–520
 treatment of, 537–538
 invasive, 520–522
 risk for, in ductal carcinoma in situ,
 520, 521f
 lobular carcinoma. *See* Lobular
 carcinoma of breast
 local-regional recurrence of, 543–544
 lymphatic mapping in, 305, 305f,
 545–546
 in male, 554–555
 mammary lymph nodes in, internal, 543
 mastectomy in, 497–499, 548–549.
See also Mastectomy in breast
 cancer
 medullary carcinoma, 521
 metastasis of, 285, 543
 ablative endocrine therapy in, 553
 to axillary lymph nodes. *See* Axillary
 lymph nodes, in breast cancer
 bone marrow micrometastasis in, 304
 distant (stage IV), 518–519, 543
 to mammary lymph nodes, 543
 natural history in, 518–519, 519f
 staging of, 531, 531t–532t
 trastuzumab therapy in, 553–554
 mucinous carcinoma, 520–521
 multicentricity in, 519, 520t
 multifocality in, 519
 natural history of, 518–519
 in axillary lymph node metastasis,
 518, 519f
 in distant metastasis, 518–519
 in primary cancer, 518
 nipple discharge in, 554
 oncoplastic surgery in, 547, 1866–1867,
 1868f, 1869f
 Oncotype DX assay in, 301–302
 papillary carcinoma, 522
 in pregnancy, 554
 prognosis in, 544
 radiation therapy in, 550. *See also*
 Radiation therapy, in breast
 cancer
 radium treatment, 499
 rare types of, 556–557
 reconstructive surgery in, 549–550,
 1866–1872
 recurrence risk in, 301–302, 301f
 risk factors for, 511–517
 assessment of, 296, 297t, 511–512,
 512t
 Claus model on, 512
 in elderly, 1932
 Gail model on, 296, 512, 512t
 management of, 512–514, 516–517
 risk-reducing surgery, 514
 screening for, 298t, 299
 in elderly, 1932–1933
 magnetic resonance imaging in, 516
 mammography in, 513, 523–526
 sentinel lymph node surgery in,
 305–306, 545–547
 and breast conservation surgery, 547
 and chemotherapy, 551–552
 specimen processing in, 546
 squamous cell, 556
 staging of, 531, 531t–532t, 533t
 and prognosis, 544
 and treatment options, 536–544
 tubular carcinoma, 522
- Breast Cancer Prevention Trial, 513–514
- Breast conservation surgery, 547
 in advanced local-regional breast cancer,
 543
 in ductal carcinoma in situ, 539
 in early invasive breast cancer, 539
 in elderly, 1932

- local-regional recurrence of breast cancer in, 543
- oncoplastic techniques in, 547, 1866–1867, 1868*f*, 1869*f*
- in pregnancy, 554
- and radiation therapy, 550
- reconstructive surgery after, 1866–1867, 1868*f*
- sentinel lymph node dissection in, 547
- Breast plastic and reconstructive surgery, 1866–1872
- accessory procedures in, 1871
- augmentation mammoplasty in, 1890–1891, 1891*f*
- autologous tissue reconstruction in, 1872*f*–1873*f*
- with implant, 1871, 1874*f*
- total, 1869–1871
- in cancer, 549–550, 1866–1872
- epigastric perforator flap in, 1871, 1871*f*
- in gynecomastia, 1891
- implants in, 1867–1869, 1869*f*, 1870*f*
- with autologous tissue reconstruction, 1871, 1874*f*
- latissimus dorsi myocutaneous flap in, 550, 1871, 1874*f*
- in mastectomy for breast cancer, 549–550
- mastopexy in, 1889
- nipple reconstruction in, 1871
- radiation therapy affecting, 1872
- reduction mammoplasty in, 1887–1889, 1888*f*, 1889*f*, 1890*f*
- Wise pattern reduction technique in, 1888–1889, 1888*f*, 1889*f*
- timing of, 1866
- tissue expansion for, 1840, 1867–1869, 1869*f*, 1870*f*
- transverse rectus abdominis myocutaneous flap in, 1869–1871
- free, 1871, 1872*f*–1873*f*
- pedicle, 1869–1871
- Briefings, preoperative, 370, 370*t*
- BRIP1* in breast cancer, 288*t*
- Broad ligament of uterus, anatomy of, 1674, 1674*f*
- Bronchial arteries, 661
- hemoptysis in bleeding from, 663
- Bronchial gland tumors, 617
- Bronchiectasis, 651–654, 653*f*
- in children, 1607
- diagnosis of, 653
- etiologies of, 651–653
- hemoptysis in, 653
- management of, 653–654
- types of, 653
- Bronchioles, 612
- Bronchiolitis obliterans, 664, 664*f*
- Bronchogenic cysts, 679, 1018, 1607
- Bronchopleural fistula, drainage in, 681*f*
- Bronchoscopy, 651
- complications of, 382
- in hemoptysis, 662–663
- in lung cancer, 629–630
- in tracheal neoplasms, 610
- Brooke ileostomy, 1188, 1192, 1192*f*
- functional results in, 1194
- Browlift, 1882–1883, 1883*f*
- Brown pigment gallstones, 1318–1319
- Brown-Séquard syndrome, 176, 1724, 1725*f*
- BUB1B* gene, 288*t*
- Buccal mucosa tumors, 586
- reconstructive surgery in, 586, 1863
- Budd-Chiari syndrome, 1283–1284
- Buerger's disease, 906, 1822–1823
- Buffering systems in acid-base balance, 73
- Bulbocavernosus muscles, 1674
- Bullard rigid fiberoptic laryngoscope, 1910, 1910*f*, 1911*f*
- Bupivacaine, 1899*t*, 1902, 1903*t*
- cardiotoxicity of, 1903
- in hand and wrist injuries, 1796
- in wound care, 264
- Burch procedure in stress urinary incontinence, 1695
- Burns, 227–236, 1820–1822
- acute management in, 1820–1821
- from caustic substances, 479–480, 1021, 1021*t*
- chemical, 229, 479–480, 1822
- classification of, 228–229
- compartment syndromes in, 233–234
- complications in, 233
- Curling ulcer in, 1058
- death due to, 1960
- depth of, 229–230
- electrical, 228–229
- of esophagus, 1021, 1021*t*
- excision and grafting in, 234, 1820, 1821
- fluid therapy in, 228, 230–231
- future research on, 236
- of hand, 1820–1822
- reconstructive surgery in, 1821–1822, 1821*f*, 1822*f*
- vacuum-assisted closure devices in, 1822*f*
- hypermetabolic response in, 232, 233
- hyperthermic, 480
- inhalation injuries in, 231–232
- initial evaluation in, 227–228
- nutrition in, 232–233
- prevention of, 235
- prognosis in, 230
- radiation, 235–236
- referral to specialized burn center in, 227, 228*t*
- rehabilitation in, 235
- rule of nines on, 228, 229*f*
- skin substitutes in, 234
- surgical management in, 1821
- topical agents for wound care in, 232
- total body surface area involved in, 227, 229*f*, 230
- and caloric requirements, 232–233
- transfusions in, 231
- ventilatory support in, 232
- zone of hyperemia in, 230
- Burrow's triangle, 1835*f*
- Burst fractures, 1722
- of cervical spine, 1770
- of thoracic and lumbar spine, 1771
- Buschke-Lowenstein tumor, 1218
- Butterfly sign in penile trauma, 1661
- Buttock lift procedure, 1887
- Bypass
- aortobifemoral, in aortoiliac occlusive disease, 876–877, 876*f*; 880–881
- aortorenal, in renal artery occlusive disease, 869
- axillofemoral, in aortoiliac occlusive disease, 877
- biliary-enteric, in pancreatic cancer, 1399, 1400*f*
- cardiopulmonary, 740–741. *See also* Cardiopulmonary bypass
- coronary, 742–747. *See also* Coronary arteries, bypass surgery
- femorofemoral, in aortoiliac occlusive disease, 877
- femoropopliteal, 897–898
- compared to endovascular therapy, 899–900
- endobypass with stent graft, 895
- with saphenous vein graft, 898, 899
- stenosis of, 897–898
- gastric Roux-en-Y. *See* Gastric bypass surgery, Roux-en-Y
- hepatorenal, in renal artery occlusive disease, 869–870
- ileocolic, in obesity, 1103
- iliofemoral, in aortoiliac occlusive disease, 877, 877*f*
- intestinal, in Crohn's disease, 1157
- jejunoileal, in obesity, 1103, 1107
- mesenteric artery, 864
- obturator, in aortoiliac occlusive disease, 878
- splenorenal, in renal artery occlusive disease, 869–870
- thoracofemoral, in aortoiliac occlusive disease, 878
- venoarterial, in congenital diaphragmatic hernia, 1605
- venovenous
- in congenital diaphragmatic hernia, 1605
- in liver transplantation, 348
- in liver trauma, 204, 204*f*
- Bystander effect in radiation exposure, 295
- C**
- Cabozantinib, 310*t*
- Cabrol technique in thoracic aortic aneurysm repair, 795
- Cadherins, 283, 292
- in gastric cancer, 292
- Cajal interstitial cells, 1047, 1481
- Calcaneus, fractures of, 1764
- Calcification
- of breast, 509
- of pulmonary nodule, solitary, 622
- Calcimimetics in hyperparathyroidism, 1564
- Calciphylaxis, 1572
- Calcitonin, 1558
- secretion of, 1525
- serum levels of, 1529
- in medullary thyroid cancer, 1550
- therapy with
- in bone pain, 1950*t*
- in hypercalcemia, 1573*t*
- Calcitonin gene-related peptide, 1346
- Calcium
- absorption of, 1143, 1559
- gastric surgery affecting, 1094
- extracellular, 1558
- in intracellular signaling pathways, 119
- in parenteral nutrition, 76*t*
- released from endoplasmic reticulum, 35*f*
- serum levels of, 72, 78
- in cancer patients, 81, 82
- in hypercalcemia, 72, 72*t*. *See also* Hypercalcemia
- in hyperparathyroidism, 1560–1563, 1563*t*
- hypocalcemia, 72. *See also* Hypocalcemia, 72*t*
- parathyroid gland affecting, 1556, 1558–1559, 1558*f*, 1559*f*
- supplemental, in children and infants, 1599

- Calcium (*Cont.*):
 urine levels of
 in familial hypocalciuric hypercalcemia, 1562
 in hyperparathyroidism, 1562, 1563*t*
- Calcium channel blockers in aortic dissection, 813
- Calcium chloride
 in hyperkalemia, 78
 in hypermagnesemia, 78
- Calcium gluconate in hyperkalemia, 78, 78*t*
- Calculi
 gallstones. *See* Gallstones
 urinary, 1666
 in hyperparathyroidism, 1560, 1666
- Callus formation in fracture healing, 250
- Caloric requirements, 44*t*
 age-related differences in, 1600*t*
 in burns, 232–233
 in enteral nutrition, 53, 54
 for children, 1600*t*
 estimation of, 51, 52*t*
 in burns, 232–233
 and overfeeding in overestimation of, 52
 in fasting, 46
 hypocaloric feeding, 53
 in injury, 46, 46*f*
 in obesity
 and bariatric surgery, 1106
 in medical management, 1102
 in parenteral nutrition, 56
 sources of, 44*t*
- Calorimetry, indirect, 51
- Calvarial reconstruction, 1860
- Cambridge classification of pancreatitis, 1369*t*, 1374*t*
- Camera systems
 in endoscopy, 424–427, 427*f*
 in robotic surgery, 430
- Canadian Cardiovascular Society anginal classification, 737, 737*t*
- Cancer, 273–316. *See also* Tumors
- Cancer antigens, 454
 CA 15-3, 303
 CA 19-9, 303
 in pancreatic cancer, 1397, 1407
 CA 27-29, 303
 CA 125 in ovarian and fallopian tube cancer, 1702
 in melanoma, 311
- Candidal infections
 of bladder, 390
 pharyngitis in, 571
 pulmonary, 658
 vulvovaginitis in, 1677*t*, 1680, 1681*f*
- Cantlie's line, 1265
- Capacitive coupling, 427–428, 428*f*
- Capillary malformations, 574, 1850, 1852*f*
- Capillary perfusion in shock, 114
- Capitate
 anatomy of, 1788, 1790*f*
 dislocation of, 1798
- Capnometry, 410
- Capsule endoscopy, 1180–1181
 in Crohn's disease, 1154, 1155*f*
 in obscure gastrointestinal hemorrhage, 1168
- Captopril in renal scanning in renal artery stenosis, 867
- Caput medusa, 1279
- Carbamazepine in pain, 1950*t*
- Carbapenems, 144*t*
- Carbohydrates
 dietary sources of, 1141
 in enteral nutrition solutions for children, 1600*t*
 metabolism of, 48–50, 49*f*
 in injury, 48–50, 49*f*
 in liver, 1269
 in small intestine, 48, 1141, 1142*f*
- Carbon dioxide
 arterial partial pressure, 410
 in intracranial pressure increase, 1714
 concentration in shock, 131
 diffusion in lungs, in lung cancer
 prediction of postoperative values, 636, 636*f*
 preoperative assessment of, 636, 638*f*
 in end-tidal exhaled gas, 410, 411
 partial rebreathing approach to cardiac output measurement, 408
 permissive hypercapnia in congenital diaphragmatic hernia, 1605
 in pneumoperitoneum for laparoscopy, 417, 417*f*
 tissue capnometry, 410
- Carbonic acid, 4
- Carbon monoxide poisoning in burns, 228
- Carboplatin
 in lung cancer, 644*t*
 in ovarian or tubal cancer, 1703, 1703*t*
- Carbuncles, 483
- Carcinoembryonic antigen, 302–303
 in colorectal cancer, 1182–1183
 in medullary thyroid cancer, 1550
- Carcinogenesis. *See* Tumorigenesis
- Carcinogens
 chemical, 293, 294*t*
 physical, 293, 295
 viral, 295–296, 295*t*, 296*t*
- Carcinoid tumors
 of appendix, 1258
 colorectal, 1216
 of liver, 1294
 of lung, 617
 of small intestine, 1160, 1161–1162, 1161*t*
 of stomach, 1085–1086
- Carcinoma
 adrenal, 1583–1585
 adrenalectomy in, 1584, 1591
 diagnosis of, 1584, 1584*f*
 differentiated from adenoma, 1583, 1584
 hyperaldosteronism in, 1578, 1580
 sex steroid excess in, 1585
 staging of, 1584, 1584*t*
 symptoms and sign in, 1584
 treatment of, 1584–1585
 anal and perianal, 1218
 basal cell. *See* Basal cell carcinoma
 of bile ducts, 1335–1338, 1336*f*
 of bladder, 1653–1654
 of breast, 519–522
 ductal. *See* Ductal carcinoma of breast
 inflammatory, 555–556, 556*f*, 556*t*
 lobular. *See* Lobular carcinoma of breast
 rare types of, 556–557
 colorectal, 1203–1216
 endometrial, 1699–1700, 1701*t*
 of esophagus, 1003–1014
 of gallbladder, 1334–1335
 of hand, 1817, 1817*f*
 hepatocellular. *See* Hepatocellular carcinoma
 of lung, 623–645
 adenoid cystic, 617
 large cell, 617
 mucoepidermoid, 617
 neuroendocrine, 617
 non-small cell, 614–617
 small cell. *See* Small cell carcinoma of lung
 squamous cell, 616–617
 of pancreas, 1394
 of parathyroid, hyperparathyroidism in, 1560, 1570
 renal cell, 288*t*, 1655–1657
 of skin, 487, 487*f*, 492
 squamous cell. *See* Squamous cell carcinoma
 thymic, 676
 of thyroid, 1540–1556, 1937
 anaplastic, 1550–1551
 in elderly, 1937
 follicular, 1544–1546
 Hürthle cell, 1546
 medullary, 1549–1550
 papillary, 1542–1544, 1937
 of trachea, 610
 of vagina, 1697
 of vulva, 1696–1697
- Carcinoma in situ
 of breast
 ductal. *See* Ductal carcinoma of breast, in situ
 lobular, 519–520, 537–538
 of lungs, 613–614, 615
- Carcinomatosis, leptomeningeal, 1732
- Carcinosarcoma of esophagus, 1015, 1017
- Cardiac death, organ donation in, 331–332
- Cardiac evaluation in burn, 231
- Cardiac output, 399, 402–409, 739
 in Doppler ultrasonography, 407
 Fick calculation method, 403, 739
 in impedance cardiography, 407
 in partial carbon dioxide rebreathing, 408
 preload affecting, 408–409
 in pulse contour analysis, 408
 in shock, 113, 114, 131
 cardiogenic, 127
 septic, 124
 thermodilution technique for
 measurement of, 403–404
 in transesophageal echocardiography, 408
- Cardiogenic shock. *See* Shock, cardiogenic
- Cardiography, impedance, 407
- Cardiomyopathy
 ischemic
 coronary bypass grafting in, 765
 in mitral regurgitation, 765–766
 peripheral artery embolism in, 885
 restrictive, 773
- Cardiomyotomy, laparoscopic, 1000, 1001*f*–1002*f*
- Cardioplegia, for myocardial protection in cardiopulmonary bypass, 741
- Cardiopulmonary bypass, 740–741
 in aortic aneurysm repair, thoracic, 797, 798*f*, 799*f*
 in aortic valvotomy for congenital stenosis, 700, 700*f*
 in aortal septal defect, 697
 in atrioventricular canal defect repair, 727
 bleeding disorders in, 95
 historical development of, 740
 myocardial protection in, 741
 systemic response to, 741

- technique in, 740
 in tetralogy of Fallot repair, 724
 in truncus arteriosus repair, 707
 in ventricular septal defect repair, 726
- Cardiovascular disorders**
 acquired, 735–776
 arterial, 827–906
 congenital, 695–729
 in elderly, 1925*t*, 1929–1930
 endovascular surgery in, 1936
 surgical risk in, 1926, 1928
 of kidney transplantation, 335
 in local anesthesia, 1903
 in obesity, 1128, 1908*t*
 physical examination in, 737
 in postoperative complications, 374, 375*t*, 386
 preoperative assessment of, 1905–1906
 in bariatric surgery, 1105
 in elderly, 1926, 1928
 in esophageal cancer, 1007
 in noncardiac surgery, 737–738
 in thoracic aortic aneurysm repair, 793
 venous, 915–936
- Cardioverter-defibrillator, implantable, 770**
- Carditis in gastroesophageal reflux, 967**
- Carney complex, 1539*t*, 1581**
- Carnitine, 47, 48*f*, 49*f***
- Caroli's disease, 1289, 1630**
- Carotid artery, 837–850**
 aneurysms of, 848, 849*f*
 in fibromuscular dysplasia, 847, 848
 arteritis of, radiation-induced, 903–904
 dissection of, 848, 848*f*
 traumatic, 850, 1720–1721
 elongation and kinking of, 847, 847*f*
 endarterectomy of, 842–845. *See also*
 Endarterectomy, carotid
 fibromuscular dysplasia of, 847–848, 848*f*, 904
 injuries of, 198, 850, 1720–1721
 carotid-cavernous fistula in, 1720
 operative approach for exposure in, 187*f*, 188
 transposition procedure for repair in, 192, 193*f*
 metastasis involving, 597
 occlusive disease of, 837–847, 1728
 angioplasty and stenting in, 842–843, 845–847
 approved stents in, 845, 847*t*
 complications of, 846–847
 contraindications to, 845, 846*t*
 embolic protection devices in, 845–846, 846*t*
 technique in, 845–846, 846*f*
 asymptomatic, 842
 atheroembolism in, 838, 838*f*
 diagnostic evaluation in, 839–841
 endarterectomy in, 842–845
 epidemiology and etiology of, 837–838
 grading of stenosis in, 840, 840*t*
 physical examination in, 829
 signs symptoms in, 828, 839
 stroke risk in, 841–842
 transient ischemic attacks in, 838, 839, 841
 treatment in, 841–847
 palpation of, 829
 thrombosis of, 1728
- Carotid body tumors, 849–850, 849*f***
- Carpal bones**
 anatomy of, 1788, 1790*f*
 in degenerative wrist changes, 1807, 1808*f*
 Carpal ligament, transverse, 1790*f*, 1791
- Carpal tunnel**
 anatomy of, 1790*f*, 1791
 median nerve compression in, 1744, 1805–1806
- Carpentier classification of mitral regurgitation, 765–766**
- Carpometacarpal joint**
 anatomy of, 1788, 1790*f*
 arthritis of, 1807
- Cartilage**
 healing of injuries, 251
 tumors forming, 1780
- CA. *See* Cancer antigens**
- Caspases in apoptosis, 37*f*, 281, 282**
- Caspofungin, 141*t*, 658**
- Cataract and global surgery, 1970, 1973*f***
- Catecholamines, 22, 50, 1577–1578, 1579*f*, 1579*t***
 in fight or flight response, 109
 serum levels in neuroblastoma, 1639
 in shock response, 113
 as therapy in cardiogenic shock, 127
 urine levels of
 in neuroblastoma, 1639
 in pheochromocytoma, 1586
- Cathepsin B, 1354**
- Catheterization**
 arterial, complications of, 381
 cardiac, 739, 740*f*
 in aortic aneurysm, 791
 in aortic insufficiency, 761
 in aortic stenosis, 758
 in atrial septal defect, 697
 in pericarditis, chronic constrictive, 773–774
 in total anomalous pulmonary venous connection, 708
 central venous
 in children, 1601
 compared to pulmonary artery catheterization, 405–406, 405*t*
 complications of, 380–381
 oxygen saturation measurements in, 404–405
 directed thrombolysis, 924
 in endovascular therapy
 access for, 834, 835*f*
 with angioplasty balloon, 835–836, 836*f*
 guidewires for, 835
 introducer sheaths for, 835, 835*f*
 types of catheters in, 835
 for fluid therapy in trauma, 165–166, 165*f*
 infections related to, 381
 in burns, 233
 in parenteral nutrition, 58–59
 postoperative, 152–154
 urinary, 390
 pulmonary artery, 402–403
 in burns, 230
 rupture of pulmonary artery in, 381
 in trauma, 216–217
 urinary
 in acute urine retention, 1661–1662, 1662*f*
 complications of, 390
 for renal monitoring, 410–411
 in trauma, 173
- Cauda equina syndrome, 1742, 1904**
- Caudate lobe of liver, 1267**
- Cautic and corrosive substances**
 burns from, 479–480, 1021, 1021*t*
 ingestion of, 942, 1020–1023
 by children, 1020, 1608, 1612–1613
 grades of injury in, 1021, 1021*t*, 1612
 locations of injury in, 1021, 1021*t*
 management algorithm on, 1022*f*
 skin injuries from, 479–480
- Cautery, 95**
- Cavopulmonary anastomosis in tricuspid atresia, 713–715, 714*f***
- C cells of thyroid, 1525, 1549, 1558**
- CD14, 37*f***
- CD18, 41*t***
- CD20, in rituximab therapy, 328**
- CD25, monoclonal antibodies against, 325**
- CD29, 41*t***
- CD31, 535**
- CD52, in alemtuzumab therapy, 325**
- CD95, 36**
 in apoptosis, 37*f*
- CD117, in gastrointestinal stromal tumors, 1481**
- CDH1 in hereditary diffuse gastric cancer, 288*t*, 292**
- CDK (cyclin-dependent kinases), 450**
 CDK4, 288*t*, 292
 inhibitors of, 288*t*, 450
- Cecum, 1220**
 anatomy of, 1176
 Crohn's disease of, 1198–1199
 diverticula of, 1203
 ileocolic resection of, 1187
 volvulus of, 1219
- Cefazolin, 257*t*–258*t***
- Cefepime, 144*t***
- Cefotaxime, 143*t***
- Cefotetan, 143*t***
 in pelvic inflammatory disease, 1690*t*
- Cefoxitin, 143*t*, 257*t***
 in pelvic inflammatory disease, 1690*t*
- Ceftaroline, 144*t***
- Ceftazidime, 144*t***
- Ceftriaxone, 144*t***
 in pelvic inflammatory disease, 1690*t*
 in portal hypertension and variceal bleeding, 1282
- Cefuroxime, 144*t*, 257*t***
- Celecoxib in peptic ulcer disease, 1058*t***
- Celiac artery, 860**
 compression syndrome, 861, 862*f*, 864
- Celiac plexus neurolysis in chronic pancreatitis, 1380**
- Cells**
 apoptosis of, 450. *See also* Apoptosis
 cancer
 apoptosis alterations in, 281–283
 autophagy in, 283
 cell cycle of
 in chemotherapy, 307
 circulating, 303–304
 dysregulation in, 279
 metastasis of, 277–278, 454, 454*f*
 proliferation and transformation of, 454*f*
 in radiation therapy, 313
 culture of, 462–463, 462*f*
 cycle of, 450, 450*f*
 in cancer, 279
 and chemotherapy, 307
 in radiation therapy, 313
 phases in, 279, 281*f*, 450, 450*f*
 hypoperfusion in shock, 115
 response to injury, 34–36
 apoptosis in, 37*f*
 inflammatory response in, 38–40
 signaling pathways in, 34–36

- Cells (*Cont.*):
 signaling pathways of, 34–36, 118–119.
See also Signal transduction pathways
 transfection of, 462*f*, 463
- CellSearch, 303
- Cellulitis, 151, 483
 of hand, 1809
 in lymphedema, 934, 935, 936
- Centers for Medicare and Medicaid Services (CMS), 1099
- Central cord syndrome, 176, 1724, 1725*f*
- Central nervous system, 1711
 anesthesia affecting, 1903
 anesthesia in disorders of, 1908–1909
 brain in. *See* Brain
 congenital and developmental anomalies of, 1749–1751
 infections of, 1745–1746
 in inflammatory response, 18–23, 19*f*
 spinal cord in. *See* Spinal cord
 tumors of, 1732–1739
- Central venous catheterization
 in children, 1601
 compared to pulmonary artery catheterization, 405–406, 405*t*
 complications of, 380–381
 oxygen saturation measurements in, 404–405
- Cephalexin, 143*t*
- Cephalic vein
 anatomy of, 916
 thrombosis of, 928, 928*f*
- Cephazolin, 143*t*
- Cerclage, cervical, 1692
- Cerebellar artery, posterior inferior, stroke in occlusion of, 1728
- Cerebellar tumors, metastatic, 1732, 1733*f*
- Cerebral arteries
 aneurysms of, 1728–1732
 stroke in occlusion of, 1716*f*, 1728
- Cerebral palsy, 1782
 scoliosis in, 1782
- Cerebral perfusion
 in anesthesia, 1909
 in aortic aneurysm repair, 797, 798*f*, 799*f*
 in aortic dissection repair, 813
 pressure of, 411
 in head trauma, 195
- Cerebral salt wasting, 81
- Cerebrospinal fluid, 1710
 in hydrocephalus, 1750–1751
 leak in skull fractures, 1716–1717
- Cerebrovascular disorders, 1727–1732
 acute, 1715
 completed stroke, 839
 hemorrhagic, 837, 1728–1732. *See also* Hemorrhage, intracranial
 ischemic, 838, 1727–1728. *See also* Ischemia, cerebral
 postoperative, 384
 stroke in evolution, 839
 in trauma, 1720
 assessment of, 175, 175*f*
 in blunt injuries, 198–198, 199*f*
 Denver grading scale of, 198*f*
- Cervical fascia of neck, deep, 598–599
- Cervical lymph nodes
 in head and neck tumors, 595–597, 596*f*, 597*f*
 anatomy and levels of, 595, 595*f*
 modified radical neck dissection in, 596
 radical neck dissection in, 596
 selective neck dissection in, 596
 lateral, 596, 596*f*
 posterolateral, 596, 597*f*
 supraomohyoid, 596, 596*f*
 skip metastasis in, 595, 596
 in parathyroid carcinoma, 1570
 pediatric disorders of, 1602
 in thyroid cancer, 1555, 1555*f*
- Cervical spine
 intervertebral disc herniation in, 1740, 1740*t*, 1741*f*, 1771
 level and symptoms in, 1740*t*
 surgical treatment of, 1771
 spondylosis of, 1740, 1741*f*
 stability of, 1739
 and atlantoaxial instability in Down syndrome, 571
 stenosis of, 1771
 trauma of, 197–198, 1722
 in children, 1643
 clay shoveler's injury in, 1770
 dislocations in, 1770
 evaluation in, 175–177
 facet dislocation in, 1722, 1723*f*
 fractures in, 1722
 immobilization and protection in, 162, 1722
 orthotic devices in, 1726
- Cervix uteri
 anatomy of, 1675
 benign lesions of, 1681
 biopsy of, 1677
 cancer of, 1697–1698
 epidemiology of, 275*t*, 278*t*
 pelvic exenteration in, 1698, 1700*f*
 radical hysterectomy in, 1686*f*–1687*f*, 1698, 1699*f*–1700*f*
 screening for, 298*t*, 1676–1677
 staging of, 1697, 1698*t*
 trachelectomy in, 1698
 cerclage technique, 1692
 condylomata of, 1678–1679
 papillomavirus infections of, 1676–1677
 polyps of, 1681–1682
- Cesarean delivery, 1693, 1693*f*
 incisions in, 1693, 1693*f*
 indications for, 1693
- Cetuximab, 310*t*
- CFTR in chronic pancreatitis, 1361–1362, 1366
- Chagas' disease, megacolon in, 1221
- Chamberlain procedure in lung cancer, 674
- Champy technique in mandibular fractures, 1854
- Chance fractures, 1722
- Chancroid, 1232, 1678, 1679*t*
- Charcot's triad in cholangitis, 1323
- Charles procedure in lymphedema, 1880
- Chemicals
 burns from, 229, 479–480, 1822
 carcinogenic, 293, 294*t*
 soft tissue sarcoma associated with, 1466
- Chemodectomas, 678, 849
- Chemoembolization in hepatocellular carcinoma, 1295–1296
- Chemokines, 40–41
- Chemoprevention of cancer, 315
 of breast, tamoxifen in, 513–514, 552
- Chemoreceptors in shock response, 112
- Chemotherapy, 306–308, 455
 adjuvant, 307, 455
 in adrenocortical carcinoma, 1585
 agents used in, 306–308, 308*t*
 administration of, 308
 combination of, 307–308, 455
 resistance to, 312–313, 313*t*
 toxicity of, 308
- in anal and perianal tumors, 1218
 in bladder cancer, 1654
 in breast cancer, 550–552
 adjuvant, 550–552, 551*t*
 advanced local-regional, 544
 in distant metastasis, 543
 early invasive, 537–541
 in elderly, 1932
 neoadjuvant, 550–552
 in pregnancy, 554
 and trastuzumab therapy, 553–554
 in cholangiocarcinoma, 1292, 1337
 in colorectal cancer, 1212, 1215
 in elderly, 1933
 in endometrial cancer, 1701
 in esophageal cancer, 1004, 1008, 1012–1014, 1013*t*, 1014*t*
 salvage esophagectomy after, 1011
 extravasation injuries in, 480
 in fallopian tube cancer, 1703, 1703*t*
 in histiocarcinoma, malignant fibrous, 668*t*
 in laryngeal cancer, 591–592
 in liposarcoma, 668*t*
 in liver tumors, 1296
 in children, 1642
 hepatic artery pump chemoperfusion of, 1296
- in lung cancer
 early-stage, 643
 in elderly, 1934
 locoregional advanced, 644*t*
 preoperative, 644*t*
 survival rates in, 644*t*
- in melanoma, 491
 in mesothelioma, 688
 in nasopharyngeal cancer, 594
 in neuroectodermal tumors, primitive, 668*t*
- in ovarian cancer
 interval debulking in, 1703
 intraperitoneal therapy in, 1703, 1703*t*
- in pancreatic cancer, 1400, 1407
 in paranasal sinus tumors, 593
 postoperative, 307
 preoperative, 307
 principles of, 307
 with radiation therapy, 314
 response to, 307
- in rhabdomyosarcoma
 of chest wall, 667, 668*t*, 669
 in children, 1486, 1640
- in sarcoma
 of bone, 667, 668*t*
 of chest wall, 667, 668*t*, 669
 in children, 1486, 1640
 Ewing's, 667, 668*t*
 of extremity, 1475–1476
 isolated regional perfusion technique in, 1473–1474
 in multimodality therapy, 1475–1476
 with radiation therapy, 1474
 metastatic, 1478–1479
 response to, 667, 668*t*
 retroperitoneal, 1480
- in stomach cancer, 1083
 in thymoma, 676
 in thyroid cancer, 1548
 anaplastic, 1551
 in lymphoma, 1551

- in vaginal cancer, 1697
- in vulvar cancer, 1696
- in Wilms' tumor, 1639
- wound healing in, 253
- Chest pain
 - in cardiac disorders, 735, 742, 965
 - differential diagnosis in, 965
 - noncardiac causes of, 736, 965, 993
 - in esophageal motility disorders, 992, 993
 - in gastroesophageal reflux disease, 965
- Chest trauma, 177–179, 200–203
 - blunt, 177, 203
 - heart injury in, 127, 171, 202
 - cardiac tamponade in, 166–167
 - in children, 222, 1643
 - damage control surgery in, 194–195
 - in elderly, 222
 - flail chest in, 164, 165f, 203
 - heart injuries in, 201–202
 - blunt, 127, 171, 202
 - penetrating, 201–202, 201f
 - hemothorax in, 166, 166f, 177, 177f, 200
 - indications for operative treatment in, 200–203, 200t
 - operative approaches and exposure in, 188, 189f
 - penetrating, 178–179
 - heart injuries in, 201–202, 201f
 - pneumothorax in, 164, 165f, 177, 200
 - respiratory disorders in, 202
 - vascular injuries in, 203
 - of aorta, 177, 178f, 178t, 179f, 200–201, 200f, 201f
 - hematoma in, 177, 178f
 - of innominate artery, 200, 200f
- Chest tubes
 - complications of, 382
 - in empyema, 685
 - in lung abscess, 651
 - in pleural effusions, 681f
 - in pneumothorax, 164, 164f, 649
- Chest wall, 664–670
 - reconstructive surgery of, 1872–1875, 1875f
 - flaps in, 670, 670f, 1873–1874, 1875f
 - prosthetic materials in, 670, 670f, 1875
 - in tumors, 670, 670f
- trauma of, 203
- tumors of, 664–669
 - benign, 666
 - biopsy in, 665–666
 - in bone, 666, 667
 - clinical approach to, 664–665, 665f
 - laboratory tests in, 665
 - malignant, 665, 666–669
 - radiography in, 665
 - reconstructive surgery in, 669–670, 670f
 - in soft tissue, 666–669, 668t
- Chiari malformations, 1751, 1751f
- Chief cells
 - of parathyroid gland, 1557, 1557f
 - of stomach, 1040, 1041f, 1042f, 1042t
 - pepsinogen secretion of, 1041, 1044
- Children and infants, 1597–1645
 - abdominal wall deformities in, 1631–1635
 - abused, 222, 1636
 - acid-base balance in, 1599
 - ambiguous genitalia in, 1637–1638
 - anorectal malformations in, 1626–1628, 1626f, 1627f
 - aortic coarctation in, 705, 706
 - appendicitis in, 1244, 1246, 1251, 1622–1624
 - clinical presentation of, 1622–1623
 - differential diagnosis in, 1246, 1624
 - imaging studies in, 1623, 1623f
 - perforation and rupture in, 1244, 1251, 1256, 1623–1624, 1623f
 - astrocytoma in, 1738–1739
 - blood volume in, 1599–1600
 - bone growth in, 1782
 - brachial plexus palsy in, 1782
 - branchial cleft anomalies in, 1602
 - bronchiectasis in, 1607
 - bronchogenic cysts in, 1607
 - burns in, 228, 233
 - fluid therapy in, 230
 - skin grafts in, 234
 - caustic and corrosive substances
 - ingested by, 1020, 1608, 1612–1613
 - cerebral palsy in, 1782
 - cervical lymphadenopathy in, 1602
 - choledochal cysts in, 1630–1631
 - chondroma in, 666
 - cleft lip and palate in, 1840–1844
 - craniofacial anomalies in, 1844–1849
 - atrophy and hypoplasia in, 1848–1849, 1849f, 1850f
 - classification of, 1844, 1846f, 1846t
 - clefts in, 1846–1847, 1846f, 1846f–1848f
 - craniosynostosis in, 1848
 - hyperplasia and hypertrophy in, 1849
 - craniohypopharyngioma in, 1736–1737
 - Cushing's syndrome in, 1582
 - diaphragmatic hernia in, congenital, 1603–1605, 1604f
 - emphysema in, congenital lobar, 1605–1606, 1606f
 - eosinophilic granulomas in, 666
 - ependymoma in, 1734
 - esophageal atresia and
 - tracheoesophageal fistula in, 1608–1612
 - esophageal injury from corrosive
 - substance ingestion in, 1612–1613
 - fluid and electrolyte balance in, 1599
 - foreign bodies in, 1607–1608
 - fractures in, 1782–1783
 - growth plate injuries in, 1782
 - ganglioneuroblastoma in, 678
 - gastroesophageal reflux in, 1613
 - in esophageal atresia and
 - tracheoesophageal fistula, 1612
 - gastroschisis in, 1633–1634
 - general principles of surgery in, 1599–1601
 - hand and wrist injuries in, 1796
 - heart disorders in, congenital, 695–729
 - hemangiomas in, 574, 1849–1850, 1850f
 - Hirschsprung's disease in, 1624–1626, 1626f
 - historical aspects of surgery in, 1597–1598
 - hyperparathyroidism in, 1570
 - hypothyroidism in, 1534
 - informed consent for, 1943
 - inguinal hernia in, 1500, 1502f, 1634–1635
 - clinical manifestations of, 1634–1635, 1634f
 - embryology of, 1634
 - incarcerated, 1635
 - laparoscopic repair of, 1635
 - intestinal atresia in, 1615–1616
 - intestinal duplications in, 1624
 - intestinal malrotation in, 1616–1617
 - intestinal obstruction in, 1614–1615
 - intestinal transplantation in, 352
 - in short bowel syndrome, 1621
 - intussusception in, 1170, 1622, 1622f
 - jaundice in, 1628–1631
 - laparoscopy in, 435–436
 - Legg-Calvé-Perthes disease in, 1783
 - liver transplantation in, 349
 - in biliary atresia, 1629
 - split-liver procedure, 349
 - liver tumors in, 1641–1642
 - lymphatic malformations in, 1602–1603, 1603f
 - Meckel's diverticulum in, 1624, 1624f
 - meconium ileus in, 1617–1619
 - mediastinal tumors in, 671, 673t
 - melanocytic nevi in, congenital, 1852
 - mesenteric cysts in, 1624
 - neck mass in, 595, 1601–1603
 - necrotizing enterocolitis in, 1619–1621
 - neuroblastoma in, 678, 1639–1640
 - nutrition in, 1600–1601, 1600t
 - enteral, 1600–1601, 1600t
 - parenteral, 1601
 - obesity in, 1101, 1125
 - omphalocele in, 1632
 - orthopedic surgery in, 1782–1783
 - ovarian cysts and tumors in, 1636–1637
 - pain control in, 1601
 - parathyroid gland in, 1557
 - Pavlik harness in developmental hip
 - dysplasia, 1783
 - pharyngitis in, streptococcal, 571
 - plastic and reconstructive surgery in, 1840–1852
 - postoperative complications in, 393
 - prune-belly syndrome in, 1634, 1634f
 - pulmonary airway malformation in,
 - congenital, 1606, 1606f
 - pulmonary sequestration in, 1607, 1607f
 - pyloric stenosis in, hypertrophic, 1613–1614, 1614f
 - retinoblastoma in, 287
 - rhabdomyosarcoma in, 1485–1486, 1640–1641
 - sarcoma in, 1465, 1485–1486, 1640–1641
 - short bowel syndrome in, 1621
 - surgical themes in, 1598–1599
 - teratoma in, 1641
 - testicular torsion in, 1662
 - thermoregulation in, 1601
 - thrombocytopenic purpura in,
 - idiopathic, 1433–1434
 - thyroglossal duct cysts in, 1602
 - tonsillectomy in, 571
 - torticollis in, congenital, 1603
 - transfusions in, 1599–1600
 - trauma in, 222–223, 1642–1644
 - abdominal, 188, 1643–1644
 - in abuse, 222, 1636
 - age-appropriate equipment in
 - treatment of, 222
 - of central nervous system, 1643
 - and fluid therapy, 168–171
 - of head, 222, 1643
 - initial management in, 1642
 - mechanisms of injury in, 1642
 - thoracic, 1643
 - vaginal, 1636
 - undescended testis in, 1635–1636

- Children and infants (*Cont.*):
 ureterocele in, 1667
 ureteropelvic junction obstruction in, 1667
 urethral valves in, posterior, 1667
 vaginal anomalies in, 1636
 vascular anomalies in, 1849–1852
 venous access in, 1601
 vesicoureteral reflux in, 1667
 vocal cord paralysis in, 574
 volvulus of midgut in, 1616–1617, 1617f
 vomiting of, differential diagnosis in, 1613
 Wilms' tumor in, 1638–1639
- Child-Turcotte-Pugh score in cirrhosis, 1280, 1280t
- Chimeras, 465–466
- CHK2*, 288t
- Chlamydia trachomatis* infections,
 lymphogranuloma venereum in, 1678, 1679t
- Chloride
 absorption in large intestine, 1179
 in gastrointestinal secretions, 69t
 in parenteral nutrition, 76, 76t
 serum levels in hyperparathyroidism, 1562, 1563t
- Chloroform, historical use of, 1895
- Chloroprocaine in local anesthesia, 1899t, 1902, 1903t
- Choke vessels, 1837
- Cholangiocarcinoma, 1291–1293, 1292f, 1335–1338
 Bismuth-Corlette classification of, 1335–1336, 1335f, 1336–1337
 and cholangitis, 1292, 1331, 1335, 1336
 clinical manifestations and diagnosis in, 1292, 1336
 computed tomography in, 1315f, 1336
 etiologies of, 1335
 hilar, 1292
 incidence of, 1335
 in inflammatory bowel disease, 1196
 liver transplantation in, 347
 pathology in, 1292, 1335–1336
 percutaneous transhepatic
 cholangiography in, 1316f, 1336, 1337f
 peripheral or intrahepatic, 1292
 prognosis in, 1293, 1337–1338
 recurrent, 1338
 risk factors for, 1335
 stent placement in, 1337
 treatment of, 1292, 1336–1337, 1337f
- Cholangiography
 in choledocholithiasis, 1321–1322
 endoscopic retrograde, 1315, 1317f
 intraoperative, 1325, 1327f
 of liver, 1274
 percutaneous transhepatic, 1315, 1316f
 in cholangiocarcinoma, 1316f, 1336, 1337f
- Cholangiohepatitis, 1324
- Cholangiojejunostomy in
 cholangiocarcinoma, 1336
- Cholangiopancreatography
 endoscopic retrograde, 1315–1316
 in chronic pancreatitis, 1370–1371, 1371f, 1374, 1374t
 in gallstone pancreatitis, 1358–1359
 pancreatitis after, 1352, 1358–1359
 small intestine perforation in, 1169
 magnetic resonance, 1315, 1317f
 in chronic pancreatitis, 1370, 1370f
- Cholangitis, 1322–1323
 and cholangiocarcinoma, 1292, 1331, 1335, 1336
 in gallstone disease, 1322–1323
 primary sclerosing, 1331
 in inflammatory bowel disease, 1196, 1331
 liver transplantation in, 346, 1331
 recurrent pyogenic, 1324
 secondary sclerosing, 1331
- Cholecystectomy
 in acalculous cholecystitis, 1330
 in carcinoma of gallbladder, 1335
 in choledocholithiasis, 1322
 retained or recurrent stones in, 1322, 1323f
 complications of, 387
 bile duct trauma in, 1331, 1332–1333, 1332f, 1333f
 bile leak in, 1333, 1333f
 in gallstones, 1324–1325. *See also*
 Gallstones, cholecystectomy in
 laparoscopic, 1325
 in acute cholecystitis, 1321
 anesthesia in, 1907
 bile duct strictures after, 1331, 1332f
 bile duct trauma in, 1331, 1332–1333, 1332f
 in chronic cholecystitis, 1320
 in elderly, 436–437, 1936
 in gallstones, 1320, 1321, 1324, 1325, 1326f
 in pregnancy, 436, 1320
 technique in, 1325, 1326f
 in natural orifice transluminal
 endoscopic surgery, 433f
 in single-incision laparoscopic surgery, 435, 435f
 trends in Mongolia, 1974–1975, 1976f
- Cholecystitis
 acute, 1320–1321
 acalculous, 1320, 1327, 1330
 clinical manifestations in, 1320
 diagnosis of, 1320–1321, 1321f
 in elderly, 1924, 1929
 in gallstones, 1320–1321
 pathogenesis in, 1320
 radionuclide scans in, 1315, 1320–1321
 treatment of, 1321
 chronic, 1319–1320
 clinical presentation in, 1319, 1319f
 diagnosis of, 1319–1320
 in gallstones, 1319–1320
 management of, 1320
- Cholecystography, oral, 1314
- Cholecystokinin, 1145, 1146t, 1313, 1348
 effects on gallbladder and sphincter of Oddi, 1313, 1314f
 in gastric motility and emptying, 1049, 1049f
- Cholecystostomy in gallstones, 1322, 1324, 1324f
- Choledochoduodenostomy, 1327, 1329f
- Choledochojejunostomy, 1327, 1329f
- Choledocholithiasis, 1321–1322
 drainage procedures in, 1327, 1329f
 endoscopic sphincterotomy in, 1322, 1322f
 laparoscopic exploration in, 1325–1327, 1328f
 retained or recurrent stones in, 1322, 1323f
 transduodenal sphincterotomy in, 1327
 ultrasonography in, 1321
- Choledochotomy in choledocholithiasis, 1325, 1328f
- Cholelithiasis. *See also* Gallstones
 carcinoma risk in, 1334
 Cholescintigraphy, 963
- Cholestasis, 387, 1271, 1314
- Cholesteatoma, 567
- Cholesterol
 in bile, 1313, 1318, 1318f
 in chyle, 686t
 in gallstones, 1317, 1318, 1318f
 serum levels in coronary artery disease, 742, 1906
 steroid synthesis from, 20f, 1575, 1576f
- Cholesterolemia, 1320
- Choline magnesium trisalicylate in
 persistent pain, 1949t
- Cholinergic anti-inflammatory pathways, 19
- Chondrocytes, 251
- Chondroitin sulfate, 245
- Chondroma, 1781
 of chest wall, 666
 periosteal, 1819
- Chondrosarcoma, 1780, 1819
 chemotherapy in, 1475
 of chest wall, 666, 667, 669f
- Chordoma, retrorectal, 1217
- Choriocarcinoma, 1641
 ovarian, 1637
- Chorionic villus sampling, 1691
- Choroid plexus
 anatomy of, 1710
 papilloma of, 1734
- Christmas factor (factor IX), 88, 99t, 103
- Christmas tree deformity in intestinal
 atresia, 1616, 1616f
- Chromatin immunoprecipitation (ChIP)
 sequencing, 462
- Chromogranins, 1577
- Chronic obstructive pulmonary disease
 anesthesia in, 1906–1907
 lung transplantation in, 663–664
 lung volume reduction surgery in, 663
- Chvostek's sign, 72, 73, 1574
- Chyle, 685, 1169–1170
 composition of, 685, 686t
- Chylomicrons, 1169–1170
- Chylothorax, 685–687
 etiologies of, 685, 686t
 management of, 686–687, 687f
 pathophysiology in, 685–686
- Chymotrypsin, 1347, 1348t
- Chymotrypsinogen, 1347, 1348t
- Cineradiography of esophagus, 955, 961, 961f
 in motility disorders, 987–988
- Ciprofloxacin, 144t, 257t
- Circulation
 collateral
 in aortoiliac occlusive disease, 873, 873f
 in mesenteric artery occlusion, 860, 860f
 enterohepatic, 1270, 1312
 extracorporeal, 740–741. *See also*
 Cardiopulmonary bypass
 homeostasis in, 114
 left dominant, 739
 mechanical support of, 768–770
 microvascular, 114
 right dominant, 739
 in trauma, initial evaluation and
 management of, 164–167
 in children, 1643

- Circulatory arrest
 in aortic aneurysm repair, 797, 801
 perfusion strategies in, 797, 798f, 799f
 in aortic dissection repair, 813
- Cirrhosis, 1277–1280
 Child-Turcotte-Pugh score in, 1280, 1280t
 clinical manifestations of, 1279, 1280t
 compensated, 1279
 decompensated, 1279
 end-stage liver disease in, 1277, 1280
 etiology of, 1278–1279, 1278t
 hepatic reserve in, 1279–1280
 hepatocellular carcinoma in, 1279, 1291
 histology of, 1278f
 laboratory findings in, 1279
 liver biopsy in, 1279
 liver transplantation in, 346, 347, 1277, 1283
 macronodular, 1278
 micronodular, 1278
 minimally invasive surgery in, 437
 morphologic classification of, 1277–1278
 portal hypertension in, 1280, 1282
 postoperative complications in, 387
 preoperative assessment of surgical risk in, 1279–1280
 variceal bleeding in, 1281
- Cisratrium, 1901
- Cisplatin
 in esophageal cancer, 1012, 1013t
 in lung cancer, 644t
 in ovarian cancer, 1703, 1703t
 in pancreatic cancer, 1407
- Clarithromycin, 145t
 in peptic ulcer disease, 1061t
- Claudication
 neurogenic, 1742
 differential diagnosis in, 1742
 in spinal stenosis, 1771
 vascular intermittent, 828, 882
 differential diagnosis in, 882, 884t
 nonatherosclerotic causes of, 882, 885t
- Claus model on breast cancer risk, 512
- Clavicle fractures, 203, 1757–1759
- Clay shoveler's injury, 1770
- CLDN2, 1362
- Cleaning agents
 ingestion of, 1021
 skin injuries from, 479
- Clear-cell sarcoma, 1467, 1470
- Cleft
 craniofacial, 1846–1847, 1846f, 1846f–1848f
 of lip and palate, 1840–1844, 1969–1970
 bilateral, 1841, 1841f, 1843, 1843f
 Mulliken technique in, 1843, 1843f
 complete, 1841, 1842f
 Furlow palatoplasty in, 1844, 1845f
 incomplete, 1841, 1841f
 nasoalveolar molding technique in, 1841, 1841f
 presurgical infant orthopedics in, 1841, 1843
 treatment protocol in, 1841
 unilateral, 1841–1843, 1841f, 1843f
 incomplete, 1841, 1841f
 rotation-advancement procedure in, 1843, 1843f
- Clindamycin, 145t, 257t
 in human bites, 479
 in pelvic inflammatory disease, 1690t
- Clitoris, anatomy of, 1674
- Cloaca, persistent, 1176, 1627
- Cloning, 444, 456–457
- Clonorchis, 1335
- Clopidogrel
 in carotid artery occlusive disease, 841, 842, 845, 846
 platelet dysfunction from, 91–92
- Clostridium difficile* infections
 in appendicitis, 1243
 pseudomembranous colitis in, 1222
- Clotting factors. *See* Factors, clotting
- Clover, Joseph, 1896
- Club hand, radial, 1823
- Coaching style leadership, 9
- Coagulation
 clotting factors in. *See* Factors, clotting disorders of, 88–89, 123f
 in anticoagulation therapy, 94–95
 in antiphospholipid syndrome, 93–94
 in congenital deficiency of clotting factors, 88–89
 in fluid therapy, 1914
 in liver disease, 92–93, 92t, 348
 mortality risk in, 123
 in trauma, 93, 94f, 185, 193, 194f
 disseminated intravascular, 92, 104, 389
 extrinsic pathway in, 87, 87f
 final common pathway in, 87, 87f
 intrinsic pathway in, 87, 87f
 kinetics, 104
 laboratory tests of, 87, 102–104
 preoperative, 102–104
 thromboelastography in, 103, 103f
- Coagulation devices, bipolar, 428, 428f
- Coarctation of aorta, 705–706
- Cobalamin deficiency, 1044
 in gastric surgery, 1094
 in malabsorption, 1143
- Cobblestone appearance
 in Crohn's disease, 1195
 in gastroesophageal reflux disease, 950, 951f
- Cocaine, as anesthetic, 1896–1897, 1899t, 1902
- Cocarcinogens, 293
- Coccidioides immitis, 330
- Coccidioidomycosis, pulmonary, 659, 661
- Coccygeus muscle, 1672
- Cockett perforator veins, 259, 915–916
- Codeine, 1900
- Codon, 447
- Coercive leadership, 9
- Cognitive function
 in dying patients, 1951
 in elderly, preoperative assessment of, 1928–1929
 in neurologic examination, 1711
 postoperative changes in, 383, 383t
- Cold exposure, frostbite injury in, 480–481
- Cold preservation of organs for transplantation, 331
- Colectomy, 1185–1188
 anastomosis in, 1189–1191, 1190f, 1191f
 ileorectal, 1198, 1207
 anterior, 1188–1189, 1193–1194
 bowel preparation for, 1194
 in colorectal cancer, 1185, 1186f, 1212
 laparoscopic, 1216
 in emergency, 1185–1187
 in familial adenomatous polyposis, 1207
 functional results in, 1193–1194
 in Hartmann's procedure, 1189
- left, 1187
 extended, 1187
 minimally invasive technique, 1187
 in colorectal cancer, 1216
 mucus fistula in, 1189, 1193
 positioning of patient in, 1194
 right, 1187
 extended, 1187
 segmental, in Crohn's disease, 1199–1200
 sigmoid, 1187–1188
 in diverticulitis, 1202, 1203
 subtotal, 1188
 total, 1188
 transverse, 1187
 types of, 1187–1188, 1188f
 in ulcerative colitis, 1198
- Colic arteries, anatomy of, 1176
- Colic, biliary, in gallstone disease, 1317, 1319–1320
- Colipase, 1348
- Colitis
 cystica profunda, 1219
 diversion, 1179
 fulminant, 1195, 1197, 1198, 1199
 indeterminate, 1195, 1201
 epidemiology of, 1195
 treatment of, 1201
 infectious, 1222
 ischemic, 1221–1222
 in aortic aneurysm repair, 853
 diagnosis of, 1222
 signs and symptoms in, 1222
 treatment of, 1222
 pseudomembranous, 1222
 ulcerative, 1195, 1197–1198
 diagnosis of, 1197
 differentiated from Crohn's disease, 1154, 1195
 elective surgery in, 1198
 emergent surgery in, 1198
 epidemiology of, 1195
 etiology of, 1195
 indications for surgery in, 1197
 nonoperative management of, 1196–1197
 pathology and differential diagnosis in, 1195–1196
- Collagen, 475
 in Ehlers-Danlos syndrome, 246, 787, 902
 injection in stress urinary incontinence, 1695
 synthesis of, 244–245, 244f
 in gastrointestinal tract, 249, 250f, 250t
 types of, 244, 475
 in inguinal hernia, 1502
 in wound healing, 242f, 243f, 244–245
 in cartilage, 251
 corticosteroid therapy affecting, 253
 in gastrointestinal tract, 249, 250f
 in hypertrophic scars and keloids, 261, 262
 nutrition affecting, 254, 254f
 in tendons, 251
- Collagenase, 249, 250t
- Collagenolysis, 245
 in gastrointestinal tract, 249, 250f
- Collar button abscess, 1810, 1811f
- Collateral circulation
 in aortoiliac occlusive disease, 873, 873f
 in mesenteric artery occlusion, 860, 860f
- Collateral ligaments of knee injuries, 1768–1769

- Collett and Edwards classification of truncus arteriosus, 706, 706*f*
- Collis gastroplasty, 977, 977*f*
in hiatal hernia, 983
in scleroderma of esophagus, 985
- Colloid carcinoma, 520–521
- Colloid solutions, 76, 1911, 1914
in burns, 230
- Colography, computed tomographic, in colorectal cancer, 1209
- Colon, 1175–1236
anatomy of, 1176–1179
landmarks in, 1176
lymphatic, 1177
nerve supply in, 1177
vascular, 1176–1177, 1177*f*
anesthesia in surgery of, 1194
cancer of. *See* Colorectal cancer
carcinoid tumors of, 1216
clinical evaluation of disorders, 1180–1185
colitis of. *See* Colitis
composition of secretions, 69*t*
diverticular disease of, 1201–1203
embryonic development of, 1175–1176
endoscopy of, 1180–1181. *See also* Colonoscopy
as esophageal substitute, 1024–1025
in composite with stomach and jejunum, 1025
in vagal sparing esophagectomy, 1025–1026
fistula with pancreas in chronic pancreatitis, 1378
gastrointestinal stromal tumors of, 1216
inflammatory bowel disease of, 1195–1201
leiomyoma and leiomyosarcoma of, 1216
lipoma of, 1216
lymphoma of, 1216
microflora in, 1179
motility of, 1180
multidisciplinary approach to disorders of, 1195
preoperative preparations for surgery of, 1194–1195
pseudo-obstruction of, 1221
resection of, 1185–1189. *See also* Colectomy
sarcoma of, 1481
trauma of, 209–210, 209*f*; 1234–1235
blunt, 1234
colostomy in, 209–210, 1234*t*
damage control surgery in, 195
iatrogenic, 1234–1235
penetrating, 1233–1234
suture repair and anastomosis in, 209
volvulus of, 1219–1220
sigmoid, 1219–1220, 1221*f*
transverse, 1220
- Colonization, bacterial, 258, 389
- Colonography, computed tomographic, 1181
in colorectal cancer, 1209
- Colonoscopy, 1180
perforation in, 1234–1235
in screening for colorectal cancer, 1208*t*, 1209
in elderly, 1933
virtual, in colorectal cancer screening, 1208*t*, 1209
- Colony-forming units, 137
- Colony-stimulating factors, granulocyte-macrophage, 28*t*, 30–31, 248*t*
- Colorectal cancer, 1203–1216
clinical presentation in, 1209
diagnostic algorithm on, 1214*f*
differential diagnosis in, 1246
drug resistance in, 313
in elderly, 1933
epidemiology of, 274, 276, 1203–1204
compared to other cancers, 275*t*, 276*t*, 277*f*, 278*t*, 618*f*
familial, 1206–1207, 1210*t*
fecal occult blood testing in, 1182, 1183, 1208–1209
field defect in, 1212
follow-up and surveillance in, 1215
genetic factors in, 1183, 1204–1207
in heterozygosity loss, 1205
in replication errors, 1205
hereditary nonpolyposis, 289*t*, 291–292, 1183, 1207
Amsterdam criteria on, 292, 292*t*
endometrial cancer associated with, 1701
genetic factors in, 1207
screening guidelines in, 1210*t*
in inflammatory bowel disease
risk for, 1197, 1199, 1204
screening for, 1210*t*
locally advanced, 1214–1215
metastasis of, 1209–1211, 1213, 1215
to liver, 1210, 1213, 1293–1294, 1295
in elderly, 1933
hepatectomy in, 1301
to lymph nodes, 1212, 1215
staging of, 1210, 1211*t*
natural history and routes of spread in, 1209
pathogenesis of, 1204–1205
in polyps, 1205–1206
preoperative evaluation in, 1211–1212
recurrent, 1212, 1215–1216
resection procedures in, 1185, 1186*f*, 1212–1215
in colon carcinoma, 1212
in elderly, 1933
minimally invasive, 1216
in rectal carcinoma, 1213
risk factors for, 1203–1204
screening for, 298*t*, 299, 1208–1209
advantages and disadvantages in, 1208*t*
in elderly, 1933
guidelines on, 1209, 1210*t*
second primary tumors in, 1212, 1215
sentinel lymph nodes in, 1177
staging of, 1209–1212, 1211*t*
and treatment options, 1212–1215
survival rates in, 1210–1211, 1211*t*
total mesorectal excision in, 305, 1213
treatment of, 1212–1215
in colonic carcinoma, 1212–1215
in rectal carcinoma, 1213–1215
in recurrence, 1215–1216
tumorigenesis in, 278, 280*f*
tumor markers in, 301, 302–303, 1182–1183
ultrasonography in, endorectal, 1211–1212, 1211*f*
- Colostomy, 1193, 1193*f*
in colorectal trauma, 209–210, 211*f*, 1234*t*
complications of, 1193
diversion colitis in, 1179
end, 1193, 1193*f*
Hartmann's procedure in, 1189, 1193
- loop, 1193
mucus fistula created in, 1189, 1193
- Colostrum, 501
- Colpocleisis, 1695
- Colporrhaphy, 1694
anterior, 1694
posterior, 1694
- Colposcopy, 1677
- Colposuspension, retropubic, in stress urinary incontinence, 1695
- Coma
hepatic, 1276
myxedema, in hypothyroidism, 1535
- Commissurotomy, mitral, 753
operative technique in, 755
- Communication
as core competency, 4*t*
in culture of safety, 368–369
implementation of, 372
risk management in, 380
in handoffs of patient care, 369
sign outs in, 371–372
on medical errors, 380, 1952
in operating room, 368, 369, 370–371
safety checklist on, 370, 371*f*
in surgical counts, 378
in wrong-site surgery, 378
in palliative care, 1946–1947, 1947*t*
in postoperative debriefings, 370–371
in preoperative briefings, 370, 370*t*, 372*f*
in teleconsultation and telementoring, 437
- Comorbidity, 1924, 1926*t*
- Compartment syndromes
abdominal, 217–218, 218*f*–219*f*
bladder pressure in, 217, 217*t*, 411
in burns, 233, 234
closure technique in, 218, 218*f*–219*f*, 220*f*
complications in, 218, 220*f*
decompression in, 217, 389
grades of, 217*t*
multiple organ impact of, 217, 218*f*
postoperative, 389
in burns, 233
in fractures, 1757
of lower extremity
fasciotomy in, 215, 216*f*, 888
in ischemia treatment complications, 888–889, 889*f*, 889*t*
in trauma, 215
postoperative, 388, 389
thoracic, in burns, 233, 234
of upper extremity, 1801
- Complement system, 33
in microbial invasion response, 138
in shock response, 118
- Complex regional pain syndrome in upper extremity trauma, 1805
- Compliance with therapy, in compression therapy for venous insufficiency, 931
- Complications, postoperative, 380–393.
See also Postoperative period
- Comprehensive unit-based safety program (CUSP), 372–373
- Compression injury
of cauda equina, 1742
of peripheral nerves
in hand and wrist, 1744, 1805–1806
in orbital fractures, 1854
of popliteal artery, 905*t*
of spinal cord, 1739–1740
of spine, 1721
fractures in, 1722, 1724*f*; 1770

- Compression therapy
 in hypertrophic scars, 263
 in lymphedema, 935–936
 in thromboembolism prevention, 186
 in varicose veins, 929
 in venous insufficiency, 259–260, 931–933, 931*f*, 932*f*
 compliance with, 931
 and ulcerations, 259–260, 931–933
- Computed tomography
 in abdominal trauma, 180, 181, 183*f*
 of abdominal wall tumors, 1454
 in adrenal carcinoma, 1584, 1584*f*
 in aortic aneurysm
 abdominal, 832*f*, 852, 852*f*
 in endoleaks, 858–859, 858*f*
 in postoperative surveillance, 857
 thoracic, 790–791
 in aortic dissection, 811–812, 812*f*, 815
 in aortoiliac occlusive disease, 874*f*
 in appendicitis, 1246
 in children, 1623, 1623*f*
 in biliary disorders, 1315, 1315*f*
 in carotid artery occlusive disease, 840, 841*f*
 in cerebrovascular disorders, 1714–1715, 1716*f*
 in cervical spine trauma, 175
 in chest wall tumors, 665, 667*f*
 of coronary arteries, 739–740
 in esophageal cancer, 1004–1005, 1008
 in gallbladder cancer, 1334, 1334*f*
 in goiter, 1538*f*
 of hand and wrist, 1794
 in hand tumors, 1815
 in head trauma, 175, 175*f*, 1718
 in children, 1643
 in skull fractures, 1715–1716, 1717*f*
 in inguinal hernia, 1504, 1504*f*
 in large intestine disorders, 1181
 virtual colonoscopy in, 1181, 1208*t*, 1209
 of liver, 1273–1274, 1274*f*
 in benign lesions, 1289, 1290, 1290*f*
 in hepatocellular carcinoma, 1291, 1292*f*
 in incidental mass, 1288
 in pyogenic abscess, 1284, 1284*f*
 in lower extremity arterial occlusive disease, 882, 883*f*
 of lungs, 622*f*
 in cancer assessment, 629, 631, 633
 screening for, 619–621
 in solitary nodule, 621–622
 in mediastinal tumors, 671–672
 in mesenteric ischemia, 862, 862*f*
 in minimally invasive surgery, 416
 in neurologic examination, 1712
 in pancreatic cancer, 1397–1398, 1398*f*
 in pancreatitis
 acute, 1355, 1355*f*, 1358, 1358*f*
 chronic, 1369–1370, 1370*f*
 of parathyroid gland, in preoperative localization studies, 1565–1566, 1565*t*
 in pheochromocytoma, 1586, 1587*f*
 in sinusitis, 567, 568–569, 568*f*
 in small intestine obstruction, 1147–1149, 1148*f*, 1149*f*
 in soft tissue sarcomas
 in initial assessment, 1468, 1468*f*
 retroperitoneal, 1479, 1479*f*
 in surveillance for recurrence, 1477–1478
 in spine trauma, 1725
 of spleen, 1428
 of stomach, 1051, 1052*f*
 in cancer, 1080
 of thyroid, 1530
 virtual colonoscopy in, 1181, 1208*t*, 1209
- Computed tomography angiography, 830, 832, 832*f*
 in abdominal aortic aneurysm, 832*f*, 852*f*
 in aortoiliac occlusive disease, 874*f*
 in carotid artery occlusive disease, 840, 841*f*
 coronary, 739–740
 in lower extremity arterial occlusive disease, 882, 883*f*
 in mesenteric ischemia, 862*f*
- Computer enhanced surgery, 415, 430
- Concussion in head trauma, 1718
- Conditioning of flaps, 1837
- Condyloma acuminata, 485, 1232, 1233, 1678, 1680
 cervical, 1678–1679
 giant, 1218
- Conflict resolution technique, 7
- Conflicts of interest, ethical issues in, 1951
- Congenital disorders
 of abdominal wall, 1453, 1453*f*, 1631–1635
 adenomatoid malformation in, cystic, 1606, 1606*f*
 adrenal hyperplasia in, 1574, 1585, 1637–1638, 1638*f*
 ambiguous genitalia in, 1637–1638, 1638*f*
 aortic stenosis in, 698–702
 in hypoplastic left-heart syndrome, 716
 of branchial cleft, 1602
 of breast, 500
 of central nervous system, 1749–1751
 cleft lip and palate in, 1840–1844
 clotting factor deficiencies in, 88–89
 diaphragmatic hernia in, 1603–1605
 emphysema in, lobar, 1605–1606, 1606*f*
 esophageal cysts in, 1018
 of hand, 1823–1824
 of heart, 695–729
 hepatic cysts in, 1288
 inguinal hernia in, 1500, 1502*f*, 1634–1635
 of large intestine, 1179
 lymphedema in, 934
 Meckel's diverticulum in, 1163–1165
 nevi in, 485
 giant, 485
 melanocytic, 1852, 1853*f*
 pulmonary airway malformation in, 1606, 1606*f*
 small intestine obstruction in, 1146
 talipes equinovarus in, 1783
 torticollis in, 1603
 of vagina, 1636
- Conjoined tendon, anatomy of, 1496
- Connective tissue disorders, 246–249
 in Ehlers-Danlos syndrome, 246, 787, 901
 inguinal hernia in, 1502, 1502*t*
 in Marfan's syndrome, 248, 787, 902
 in pseudoxanthoma elasticum, 902
- Conn's syndrome, 1578
- Consent, informed, 1941–1944
 autonomy principle in, 1944
 for children and adolescents, 1943
 elements of, 1942, 1943*f*
 legal issues in, 1941–1942, 1943
 professional practice standard, 1942
 reasonable person standard, 1942
 in research, 1951
 surgical emergency and, 1942–1943
- Constipation, 1183–1184
- Constriction band syndrome, 1823–1824
- Consultations, in teleconsultation and telerenting, 437
- Contact dermatitis of vulva, 1678
- Contamination, bacterial, 102*t*, 258
 in surgery, 141, 146, 147*t*, 148*t*, 256
 in transfusions, 100
- Continence
 fecal, 1180
 disorders of, 1185. *See also*
 Incontinence, fecal
 urinary, disorders of, 1695. *See also*
 Incontinence, urinary
- Contractility, cardiac, 114, 402
 ejection fracture as measure of, 403*t*
 isovolumic pressure line in, 402
 in shock, 125, 127
- Contraction of wounds, 246
- Contractures
 in burns, 1821, 1822*f*
 Dupuytren's, 1808–1809, 1810*f*
 postoperative, 388
- Contrast agents, renal toxicity of, 383, 791
- Contusion
 cardiac, 202
 cerebral, 1718–1719, 1718*f*
 pancreatic, 207
 pulmonary
 in children, 1643
 in elderly, 222
 renal, 1658*t*
 in children, 1644
- Cooper's ligament
 anatomy of, 1496, 1497*f*, 1498*f*
 in McVay repair of inguinal hernia, 1507*f*, 1508
- Corditis of vocal cord, polypoid, 573
- Core competencies for leadership in surgery, 3–8
- Cori cycle, 45, 45*f*
- Corkscrew deformity of esophagus, 992, 992*f*
- Corneal abrasions in surgery, 383
- Corning, Leonard, 1896–1897
- Corona radiata sign in solitary pulmonary nodule, 622, 622*f*
- Coronary arteries
 aneurysm in Kawasaki syndrome, 902
 angiography of
 in atherosclerosis, 739, 740*f*
 computed tomography technique, 739–740
 preoperative, 834
 angioplasty of, percutaneous transluminal
 in cardiogenic shock, 128
 compared to bypass surgery, 742–743, 743*t*
 prior to other surgeries, 834
 atherosclerosis of, 741–747
 angina pectoris in, 742
 indications for bypass surgery in, 742
 results of bypass surgery in, 745
 angiography in, 739, 740*f*
 biomolecular therapy and tissue engineering in, 747
 bypass grafting in, 742–747
 clinical manifestations in, 742

- Coronary arteries, atherosclerosis of
(*Cont.*):
in elderly, 1930
etiology and pathogenesis in, 741
historical aspects of, 741
laser revascularization in,
transmyocardial, 747
preoperative assessment of, 742,
833–834
in anesthesia management, 1906
in aortic aneurysm repair, 793
in noncardiac surgery, 738
risk factors for, 741–742, 1906
bypass surgery, 742–747
anastomotic devices in, 749
compared to percutaneous
interventions, 742–743, 743*t*
in elderly, 1930
endoscopic, 746
historical development of, 741
indications for, 742
in ischemic cardiomyopathy, 765
mammary artery graft in, 741,
743–744, 745*f*, 746
median sternotomy incision in,
745, 745*f*
minimally invasive direct technique,
746
off-pump technique, 745–746, 746*f*
operative techniques in, 743–747,
745*f*
prior to other surgeries, 834
results of, 745, 746
saphenous vein graft in, 741, 744
occlusion of
in aortic dissection, 809
in atherosclerosis, 741–747
in transposition of great arteries,
720–721
in truncus arteriosus, 706
Coronary ligament of liver, 1265
Corpus callosum in seizures, 1746
Corrigan's pulse in aortic insufficiency,
760
Corrosive substances. *See* Caustic and
corrosive substances
Corticospinal tract, anatomy of, 1710
Corticosteroid therapy
in adrenocortical insufficiency, 1590
in carpal tunnel syndrome, 1806
in Crohn's disease, 1156, 1196
in hypercalcemia, 1573*t*
in immunosuppression, 325–326, 325*t*,
327*t*
adverse effects of, 326, 326*t*
in inflammatory bowel disease, 1156,
1196
intra-articular, 1772
intralesional, in hypertrophic scars and
keloids, 262
postoperative, 392
in Cushing's syndrome, 1583
in septic shock, 126, 154, 155*t*
in spinal cord injury, 197–198,
1725–1726
stress dose in, 392
in thrombocytopenic purpura,
idiopathic, 1433
wound healing in, 253
Corticotrophin-releasing hormone, 1576
in Cushing's syndrome diagnosis, 1583
Cortisol, 1575, 1576*f*, 1577
functions of, 1577
serum levels of, 1575
in adrenocortical insufficiency, 1590
in Cushing's syndrome, 1583
diurnal variation in, 1575, 1577*f*
in shock response, 113
Cor triatriatum, 710–711, 711*f*
Cosmetic surgery, 1882–1891
Cost-utility analysis (CUA), 1973
Cottle sign, 1883
Coude catheter in acute urinary retention,
1661, 1662*f*
Couinaud, Claude, 1265
Counterregulatory anti-inflammatory
response syndrome (CARS), 14*f*
Counts, surgical, in prevention of retained
surgical items, 378
Cowden disease, 289*t*, 292, 1206, 1539*t*
breast cancer risk in, 517
diagnostic criteria on, 292
thyroid cancer in, 1537
COX-2 in stomach cancer, 1075, 1077*f*
Cox-Maze IV procedure, 771–772, 771*f*
Craniofacial disorders
in children, 1844–1849
atrophy and hypoplasia in, 1848–
1849, 1849*f*, 1850*f*
classification of, 1844, 1846*f*, 1846*t*
clefts in, 1846–1847, 1846*f*,
1846*f*–1848*f*
craniosynostosis in, 1750, 1848
hyperplasia and hypertrophy in, 1849
in Le Fort fractures, 577
Cranioopharyngioma, 1736–1737
Craniosynostosis, 1750, 1848
Crawford classification of
thoracoabdominal aortic
aneurysm, 801, 801*f*
C-reactive protein, in acute pancreatitis,
1357
Creatinine
clearance ratio to calcium, in
hyperparathyroidism, 1562,
1563*t*
serum levels in kidney transplantation,
339
Cremaster muscle, 1499
CREST syndrome, 993
Cretinism, 1534
Crick, Francis H. C., 443, 444, 445*t*
Cricohyoidoepiglottomy in laryngeal
cancer, 591
Cricopharyngeal muscle
anatomy of, 943–944, 943*f*
motility disorders of, 987–988
myotomy of, 989
Cricopharyngotomy, endoscopic, 989–990,
990*f*
Cricothyroidotomy in trauma, 163, 163*f*
in children, 222
Crigler-Najjar syndrome, 1272
Criminal nerve of Grassi, 1039
Crisis
hypercalcemic, 1572
splenic sequestration, 1432
Critical illness
growth hormone resistance in, 23
hyperglycemia and insulin resistance
in, 23
Crocidolite asbestos fibers, 688
Crohn's disease, 1153–1157, 1195
acute inflammatory, 1198
anal and perianal, 1200, 1200*f*
in appendectomy, 1243
capsule endoscopy in, 1154, 1155*f*
chronic fibrotic, 1198
cobblestone appearance in, 1195
diagnosis of, 1154–1155, 1155*f*, 1198
differential diagnosis of, 1154,
1195–1196, 1252
epidemiology of, 1153, 1195
etiology of, 1195
fat wrapping of intestines in, 1154,
1154*f*
genetic factors in, 1153
ileocolic, 1198–1199
intestinal obstruction in, 1146, 1150,
1156
pathology and differential diagnosis in,
1195–1196
rectovaginal fistula in, 1200, 1231
recurrent, 1157, 1200
signs and symptoms in, 1154
extraintestinal, 1154, 1155*t*, 1196
treatment of, 1155–1157, 1198
drug therapy in, 1155–1156,
1196–1197, 1200
surgical, 1156–1157, 1156*t*, 1157*f*,
1198
Cronkite-Canada syndrome, 1206
Cruciate ligaments, injuries of, 1768–1769,
1769*f*
Cruevilhier-Baumgarten murmur, 1279
Cruzan, Nancy, 1945
Cryoplasty, in lower extremity arterial
occlusive disease, 892, 893*f*, 897
Cryoprecipitate in massive transfusions,
101*t*
Cryopreserved grafts in femoropopliteal by
pass, 899
Cryosurgery in liver tumors, 1295
Cryptococcosis, 658
Cryptoglandular abscess, 1227–1228
Cryptorchidism, 1635–1636
risk for testicular cancer in, 1636, 1654
two-stage repair in, 1636
Crypts of small intestine, 1138
Crystalloid solutions, 98, 1911, 1914
in hemorrhagic shock, 122
in trauma, 216
CTLA-4 in cancer immunotherapy, 312
Cubital tunnel syndrome, 1806
Cuboid bone fracture, 1765
Cullen's sign, 1356
Cultured epithelial autografts (CEAs),
266–267
Culture, organizational
communication in, 368–369
safety issues in, 368
assessment of, 368
in high reliability organizations,
365–366
in operating room, 368
teamwork in, 368–369
Cultures, cell, 462–463, 462*f*
Cuneiform bone fracture, 1765
Curling ulcer in burns, 1058
Curreri formula on caloric requirements in
burns, 233
Cushing, Harvey, 1574, 1897
Cushing's disease, 1580
in pituitary adenoma, 1583, 1735
treatment of, 1583, 1594
Cushing's syndrome, 1580–1583
adrenalectomy in, 1583, 1590
complications of, 1593–1594
in adrenal incidentaloma, 1588
adrenocorticotrophic hormone in, 1580,
1581–1582, 1581*t*, 1583
clinical features in, 1580, 1581–1582,
1581*f*, 1581*t*
diagnosis of, 1582–1583, 1582*f*
historical aspects of, 1574

- in lung cancer, 626–627
 - obesity in, 1582
 - treatment of, 1583
 - Cushing's triad in intracranial pressure crease, 1713
 - Cushing's ulcer, 1058, 1718
 - Cutler-Beard advancement flap in eyelid reconstruction, 1858, 1861f
 - Cyanide, and burn, 228
 - Cyclin, 450
 - Cyclin-dependent kinases (CDK), 450
 - CDK4, 288t, 292
 - inhibitors of, 450
 - Cyclooxygenase, 31f, 32, 85
 - Cyclophosphamide
 - in lung cancer, 644t
 - in ovarian cancer, 1703t
 - Cyclosporine, 323, 325t, 327t, 328
 - adverse effects of, 326t, 328
 - in inflammatory bowel disease, 1196–1197
 - in liver transplantation, 346
 - in lung transplantation, 355
 - metabolism of, 328
 - Cystadenocarcinoma of pancreas
 - mucinous, 1410–1413
 - serous, 1409–1410
 - Cystadenoma
 - biliary, 1288
 - of pancreas, 1409–1410
 - mucinous, 1410–1413
 - serous, 1409–1410, 1410f
 - Cystectomy in bladder cancer, 1654
 - robotic approach in, 1654
 - Cystectomy, ovarian, 1689
 - Cystic artery anatomy, 1309–1310
 - anomalies in, 1312, 1312f
 - Cystic duct anatomy, 1310, 1311f
 - Cystic fibrosis
 - lung transplantation in, 663–664
 - meconium ileus in, 1618
 - Cystic hygroma, 598, 1602–1603, 1852, 1852f
 - treatment of, 598
 - ex utero intrapartum therapy (EXIT) procedure in, 1645
 - Cystitis, 1664
 - Cystogastrostomy in pancreatic pseudocyst, 1377, 1377f
 - Cystosarcoma phyllodes, 555, 555f, 1481
 - Cystourethrogram, voiding, 1660
 - Cysts
 - of Bartholin's glands, 1678
 - biliary, 1330, 1630–1631. *See also* Biliary tract, cysts of
 - bone, aneurysmal, 1738
 - branchial cleft, 598, 598f, 1602–1603
 - of breast, 508, 510, 528f
 - bronchogenic, 679, 1018, 1607
 - dermoid, 486, 1217, 1737
 - enteric, 679, 1018
 - epidermal, 486
 - epidermoid, retrorectal, 1217
 - of esophagus, 679, 1017, 1018
 - foregut duplication, 1607
 - ganglion, of hand and wrist, 1815, 1815f
 - of liver, 1288–1289. *See also* Liver, cysts of
 - mediastinal, 673t, 679
 - mesenteric, 1459–1460, 1460f, 1624
 - mucous, of hand and wrist, 1815
 - omental, 1457
 - ovarian. *See* Ovaries, cysts of
 - of pancreas, 1410–1413, 1410f
 - pericardial, 679
 - of popliteal artery adventitia, 905
 - in pulmonary airway malformation, 1606, 1606f
 - renal, 1655, 1655f, 1655t
 - Bosniak classification of, 1655, 1655t
 - of spleen, 1437f
 - in parasitic infections, 1430t, 1436–1437
 - splenectomy in, 1430t, 1436–1437
 - thymic, 679
 - thyroglossal duct, 598, 1521–1522, 1602
 - of thyroid, 1540
 - trichilemmal, 486
 - of vocal cord, 573, 573f
 - Cytokine receptor, 34
 - Cytokines, 26–30, 27t–28t
 - anti-inflammatory, 26–30, 116–118, 118t
 - in microbial invasion response, 138
 - proinflammatory, 26–30, 116–118, 118t
 - in shock, 114, 116–118
 - in wound healing, 243, 244
 - Cytology
 - cervical, 1677
 - peritoneal, in stomach cancer, 1080–1081
 - Cytomegalovirus infections in transplant recipients, 329
 - Cytotoxic T-lymphocyte antigen 4 in cancer immunotherapy, 312
- D**
- D cells of stomach, 1040
 - in regulation of gastric acid secretion, 1043, 1044f
 - somatostatin secretion of, 1040, 1044, 1045, 1146t
 - in *Helicobacter pylori* infections, 1054
 - D-dimers, 88
 - in aortic dissection, 811
 - Dabigatran, 94
 - Dacron graft, 4
 - Dalrymple's sign in Graves' disease, 1531
 - Damage-associated molecular pattern molecules (DAMPs), 14–17
 - in shock, 110, 115, 116t, 117f, 123
 - Damage control resuscitation strategy, 98, 100
 - in hemorrhagic shock, 122
 - Damage control surgery, 192–195, 194f–196f
 - in liver trauma, 194, 194f, 204
 - Damus-Kaye-Stansel anastomosis
 - in hypoplastic left-heart syndrome, 716
 - in Taussig-Bing syndrome, 723
 - DaNang lung, 110
 - Dance's sign in intussusception, 1622
 - Dantrolene sodium in malignant hyperthermia, 1917
 - Daptomycin, 145t
 - Darwin, Charles, 1895
 - Dasatinib, 310t
 - Da Vinci robotic system, 415, 417, 427, 430
 - Davy, Humphrey, 1895
 - DCC in colorectal cancer, 1205
 - Death
 - brain death, 1721
 - diagnosis of, 330, 1721
 - organ donation process in, 330–331, 331f
 - cardiac death, organ donation in, 331–332
 - declaration of, 1951
 - Death domains, 36, 37f
 - Death-inducing signaling complex (DISC), 282
 - DeBakey classification of aortic dissection, 808, 809f
 - DeBakey, Michael E, 4
 - Decubitus ulcers, 260–261. *See also* Pressure ulcers
 - Deep brain stimulation, 1747–1748, 1747f
 - expanding indications of, 1748
 - Defecation, 1180
 - accommodation response in, 1180
 - evacuation studies of, 1182
 - incontinence in. *See* Incontinence, fecal neurophysiologic testing in, 1182
 - obstructed, 1183–1184
 - sampling reflex in, 1180
 - Defecography, 1182
 - Defibrillators, implantable, 770
 - Degenerative disorders
 - of hand and wrist joints, 1806–1808
 - of spine
 - scoliosis in, 1771
 - of thoracic aorta, medial
 - cystic, 787
 - nonspecific, 787
 - wallerian, 251
 - Dehydration in children, 1599
 - Dehydroepiandrosterone, 1577
 - Delivery, 1693
 - brachial plexus palsy from injuries in, 1782
 - cesarean, 1693, 1693f
 - ex utero intrapartum therapy (EXIT) procedure in, 1645, 1645f
 - perineal lacerations in, 1692
 - Delorme procedure in rectal prolapse, 1219
 - Deltopectoral fasciocutaneous flap in head and neck reconstructive surgery, 601
 - Democratic leadership, 9
 - Dendrocytes, 475–476
 - Denonvilliers' fascia, 1177
 - Dense granule deficiency, 89
 - Dental occlusion in mandibular reconstruction, 1853, 1854f, 1863
 - Dentate line, 1177
 - 11-Deoxycorticosterone, 1575, 1576f
 - Deratan sulfate, 245
 - Dermatitis
 - perianal, 1231–1232
 - of vulva, 1678
 - Dermatofibromas, 486
 - Dermatofibrosarcoma protuberans, 492–493, 1470, 1485
 - Dermis
 - anatomy and histology of, 475–476
 - dermatofibrosarcoma protuberans of, 492–493, 1470, 1485
 - fibers of, 475
 - replacement products, 482
 - Dermoid tumors
 - of central nervous system, 1737
 - cutaneous, 486
 - retrorectal, 1217
 - Desflurane, 1902, 1902t, 1907
 - malignant hyperthermia from, 1917
 - Desmoid tumors, 1485
 - of abdominal wall, 1454
 - of chest wall, 666
 - common locations of, 1485
 - disorders associated with, 666
 - in familial adenomatous polyposis, 1207
 - genetic factors in, 1485

- Desmoplastic fibroma, 1780
- Desmopressin acetate
in cardiopulmonary bypass, 95
in von Willebrand's disease, 89
- Dexamethasone
in adrenocortical insufficiency, 1590
in bone pain, 1950*t*
suppression test in Cushing's syndrome, 1582–1583
- Dexmedetomidine, 1901
- Dextran in resuscitative fluids, 76*t*, 77
- Dextrose
in parenteral nutrition solutions, 58, 76
in postoperative fluid therapy, 80
in preoperative fluid therapy, 79
- Diabetes insipidus, 81
central, 81
drug-induced, 81
nephrogenic, 81
- Diabetes mellitus
anesthesia management in, 1908
bariatric surgery in, 1112*t*, 1127
adjustable gastric banding in, 1111, 1128
Roux-en-Y gastric bypass in, 1116, 1127
coronary artery disease in, 742, 1906
diagnosis of, 1349
foot reconstruction in, 1877, 1879, 1879*t*
gastroparesis in, 1087
in glucagonoma, 1393
laboratory findings in, 1350*t*
pancreas transplantation in, 340
islet cell, 344–345
pancreatic cancer in, 1394
pancreatogenic, 1372–1373
parenteral nutrition in, 59
type II, 1373
insulin signaling pathway in, 452
type III, in chronic pancreatitis, 1373
ulcers in, 260, 267
reconstructive surgery in, 1877, 1879
wound healing problems in, 253, 260, 267
- Diaphragmatic hernia
congenital, 1603–1605
chest radiography in, 1604, 1604*f*
fetal surgery in, 1645
honeymoon period in, 1604
lung-to-head ratio in, 1604
prenatal ultrasonography in, 1604, 1604*f*
giant paraesophageal, 980–984
- Diaphragm, trauma of, 202–203
- Diaphysis, fractures of, 1782
- Diarrhea, 1184–1185
chronic, 1184–1185
postgastrectomy, 1093
in pseudomembranous colitis, 1222
in VIPoma, 1392
- Diastasis recti, 1453, 1453*f*
- Dibucaine number, 1901
- Diencephalon, 1710
- Diethylstilbestrol exposure, vaginal cancer associated with, 1697
- Diet. *See* Nutrition
- Dieulafoy's lesion, 1089
- DiGeorge's syndrome, 706, 1574
- Digestion
bile functions in, 1270
in small intestine, 1140–1143
- Digital subtraction angiography, 833, 833*f*
in carotid artery occlusive disease, 840–841
in renal artery stenosis, 869
- Dilatation and curettage procedure
in gestational trophoblastic disease, 1694
for termination of pregnancy, 1692
uterine bleeding, 1683, 1684*f*
- Diphtheria, pharyngitis in, 571
- Disability, 1924, 1926*t*
- Disability Adjusted Life Year (DALY), 1957, 1973, 1974
- Disability assessment
in heart disease, 737, 737*t*
in trauma, 168
- Discitis, 1746
- Discrimination in obesity, 1101
- Discs, intervertebral. *See* Intervertebral discs
- Disease burden and global surgery, 1957–1960, 1959*f*
- Dislocations
of ankle, 1764
of elbow, 1759
in hand, 1796–1798
of hip, 1760
after arthroplasty, 1778
in cerebral palsy, 1782
of knee, 1762
of patella, 1762
perilunate, 1794*f*
of shoulder, 1759
of spinal facets, cervical, 1722, 1723*f*, 1770
- Dissection, aortic, 806–816. *See also* Aorta, dissection of
- Distribution of drugs
factors affecting, 1898
volume of, 1898
- Diuretic drugs, hypercalcemia from, 1562
- Diverticulectomy
in esophageal diverticula, 993–994, 995, 997
Zenker's, 989, 990*f*
in small intestine diverticula, 1165, 1167
- Diverticulitis, 1201–1203
complicated, 1202–1203
differential diagnosis in, 1201, 1203, 1246
Hinchey staging system in, 1202
in Meckel's diverticula, 1163–1165, 1246
differential diagnosis in, 1252
pelvic abscess in, 1202*f*
uncomplicated, 1201–1202
- Diverticulopexy in Zenker's diverticulum, 989, 990*f*
- Diverticulosis, 1201, 1201*f*
- Diverticulotomy, and endoscopic cricopharyngotomy in Zenker's diverticulum, 988–989, 990*f*
- Diverticulum
of esophagus, 987*f*, 988–989, 993–994, 994*f*
diverticulectomy in, 989, 990*f*, 993–994, 995, 997
diverticulopexy in, 989, 990*f*
endoscopic cricopharyngotomy and diverticulotomy in, 988–989, 990*f*
endoscopic evaluation of, 950
epiphrenic, 994, 995, 997, 998*f*
fistula in, 1023
with hiatal hernia, 994
with motility disorders of esophagus, 993
pulsion, 994
traction, 994, 994*f*
of large intestine, 1201–1203
false, 1201
giant colonic, 1203
hemorrhage in, 1201, 1203
right-sided, 1203
- Meckel's. *See* Meckel's diverticulum
- of small intestine, 1163–1167
acquired, 1165–1167
duodenal, 1165, 1166, 1166*f*
false, 1165
hemorrhage in, 1164, 1167
jejunoileal, 1165, 1166, 1166*f*
juxtapapillary, 1165
Meckel's, 1163–1165
periampullary, 1165, 1166
peri-Vaterian, 1165
of stomach, 1089, 1089*f*
- DNA, 35, 444*f*
analysis of, 457–462
microarray technology in, 459–460, 461*f*
polymerase chain reaction technique in, 458, 459*f*
Southern blot hybridization in, 457–458, 457*f*
cloning of, 444, 456–457
double-helical structure of, 444, 445*f*
double-strand breaks in, 293
and hereditary, 444–446
loss of heterozygosity, colorectal cancer in, 1205
microsatellite instability, 292
colorectal cancer in, 1205
mismatch repair, 292
in hereditary nonpolyposis colon cancer, 1207
next-generation sequencing, 460, 462
radiation damage of, 313
recombinant technology, 444, 456–457, 457*f*
in transfusion products, 97
replication of, 443, 446, 446*f*
errors in, and colorectal cancer, 1205
transfection with, 463, 463*f*, 467
in transgenic mice, 463–464, 463*f*
- DNA tumor viruses, 295
- Dobutamine
in cardiogenic shock, 127
in sepsis, 125
in stress echocardiography, 738
- Docetaxel, 1703*t*
in lung cancer, 644*t*
in ovarian or tubal cancer, 1703
- Docosahexaenoic acid, 32
- Dog bites, 478, 479*f*
- Domperidone in delayed gastric emptying, 1050*t*
- Donabedian model on quality measurement, 366–367, 367*f*
- Donors
in blood transfusion, 1914
in organ transplantation, 330–332
consent issues in, 1943–1944
deceased, 330–332
brain death diagnosis in, 330
in cardiac death, 331–332
multiple organ procurement from, 331, 331*f*
organ preservation methods in, 331
of kidney, 322, 331, 334
operative technique in, 333*f*
living, 332
non-heart-beating, 331–332
of pancreas, 331, 343–344

- Donovanosis, 1678, 1679*t*
 Dopamine, 1577–1578, 1579*f*
 in cardiogenic shock, 127
 in neurogenic shock, 130
 Doppler ultrasonography, 407, 830
 in brain death, 1721
 cardiac output in, 407
 in carotid artery occlusive disease, 839
 flow time corrected parameter in, 407
 of liver, 1272
 in portal hypertension, 1280
 transcranial, 411–412
 Dor fundoplication and esophageal myotomy, 999, 1001, 1001*f*
 Dormancy phenomenon in tumors, 285
 Dorsalis pedis artery palpation, 829
 Dose of drugs
 equianalgesic, 1900
 lethal, 1898–1899
 and response curves, 1898, 1899*f*
 Double effect principle, 1945, 1945*f*
 Double-outlet right ventricle, 721–722
 ventricular septal defect in, 722–723, 723*f*
 doubly committed, 722, 723, 723*f*
 noncommitted, 722–723, 723*f*
 subaortic, 722, 723, 723*f*
 Douglas pouch, 1674
 Down syndrome
 atlantoaxial instability in, and adenotonsillectomy precautions, 571
 duodenal atresia in, 1615
 Doxepin in pain, 1950*t*
 Doxorubicin
 in skin injury, 480
 in soft tissue sarcoma of extremity, 1475–1476
 Doxycycline, 145*t*, 257*t*
 in pelvic inflammatory disease, 1690*t*
 Drainage techniques, 389–340, 390*f*
 antibiotic therapy in, 390
 choledochal, 1327, 1329*f*
 indications for, 389–340
 in pancreatitis, chronic, 1383–1384, 1384*f*, 1385*f*
 in pleural effusions, 681–682, 681*f*
 DREAM trial, 857
 Dressings, 265–266
 absorbable materials in, 266
 absorbent, 265
 alginate, 266
 in burns, 232, 234, 1820
 and skin grafts, 234
 for compression therapy in venous insufficiency, 931, 931*f*, 932
 desired characteristics of, 266*t*
 historical development of, 241
 hydrocolloid and hydrogel, 265–266
 hydrophilic and hydrophobic, 265
 medicated, 266
 nonadherent, 265
 occlusive and semioclusive, 265
 primary, 265
 secondary, 265
 Drug-eluting stents, 432, 836
 Drug-induced disorders
 in elderly, 1935
 gynecomastia in, 506
 hepatotoxicity of acetaminophen, 1276
 liver transplantation in, 347, 1277, 1277*t*
 hypercalcemia in, 71, 1562
 hyperkalemia in, 71
 hyperparathyroidism in, 1560
 hypokalemia, 71
 hyponatremia in, 69
 liver failure in, from acetaminophen, 1276
 ototoxicity of aminoglycoside antibiotics, 384
 pancreatitis in, 1353
 peptic ulcer disease in, 1053, 1054, 1057–1058, 1058*t*, 1059*t*
 hospitalization rates in, 1058*t*
 medical treatment in, 1061
 perforation in, 1068
 thrombocytopenia from heparin, 90–91, 95, 389, 922
 in burns, 233
 toxic epidermal necrolysis in, 477, 477*f*
 Drug resistance in tumors, 312–313
 Drugs
 additive effects of, 1898
 agonist, 1898
 antagonist, 1898
 distribution of, 1898
 dose of
 equianalgesic, 1900
 lethal, 1898–1899
 and response curve, 1898, 1899*f*
 efficacy of, 1898
 hyporeactivity, 1898
 metabolism of, 1898
 liver functions in, 1270
 pharmacodynamics of, 1898
 pharmacokinetics of, 1897–1898
 potency of, 1898
 resistance to
 in bacterial infections, 143*t*–145*t*
 in chemotherapy, 312–313, 313*t*
 plasmids encoding markers, 457
 in sepsis, 155
 in tuberculosis, 654, 655
 synergistic effects of, 1898
 therapeutic index on, 1899
 tolerance to, 1898
 Drummond marginal artery, 1177
 Dubin-Johnson syndrome, 1272
 Ductal carcinoma of breast
 in situ
 growth patterns in, 520
 histopathology in, 520, 520*t*, 521*f*
 in male, 555
 pathology in, 510
 radiation therapy in, 537, 550
 risk for invasive cancer in, 520, 521*f*
 tamoxifen therapy in, 552
 treatment of, 537–538
 invasive, 520–521, 522*f*
 Ductography in breast cancer diagnosis, 526–527, 527*f*
 Ductus arteriosus patency, 702–705
 anatomy in, 702–703
 and aortic stenosis, 698, 699
 clinical manifestations and diagnosis of, 703–704
 incidence of, 703
 and interrupted aortic arch, 729
 natural history in, 703
 persistent, 703
 prolonged, 703
 treatment in, 704, 704*f*
 catheter-based, 704
 outcomes of, 704–705
 surgical closure, 704, 704*f*
 in tricuspid atresia, 712
 Duhamel procedure in Hirschsprung's disease, 1626, 1626*f*
 Dumping syndrome, 1049, 1090–1092
 early reaction in, 1091
 late reaction in, 1091
 medical therapy in, 1091
 surgical management of, 1091–1092
 Duodenal switch, biliopancreatic diversion with, 1119–1121
 configuration in, 1119*f*, 1120
 Duodenojejunostomy, Roux-en-Y, in duodenal injuries, 207, 208*f*
 Duodenum
 access for enteral nutrition, 55, 55*t*
 anatomy of, 1138
 atresia of, 1612, 1615–1616, 1616*f*
 compression from superior mesenteric artery, 1147
 diverticula of, 1165, 1166*f*; 1167
 embryonic development of, 1139, 1140*f*
 fistula in trauma, 209
 neoplasms of, 1159*f*, 1160
 treatment in, 1161
 obstruction of
 double bubble sign in, 1615, 1615*f*
 in neonates, 1615, 1615*f*
 in pancreatic cancer, 1399
 peptic ulcer disease of, 1053–1073
 perforation of, 1169
 reflux of secretions, 967–968, 968*f*
 trauma of, 207–209, 208*f*
 in children, 1643
 damage control surgery in, 195
 emergent abdominal exploration in, 191
 pyloric exclusion procedure in, 209, 209*f*
 Roux-en-Y duodenojejunostomy in, 207, 208*f*
 Duplex ultrasonography, 830, 918
 in carotid artery occlusive disease, 839, 840*t*
 grading of stenosis in, 840, 840*t*
 in lymphedema, 935
 in mesenteric ischemia, 862
 in renal artery stenosis, 867–868, 868*t*
 in venous insufficiency, 930, 931*f*
 in venous thromboembolism, 920, 920*f*
 Duplications, intestinal, 1624
 Dupuytren's contracture, 1808–1809, 1810*f*
 Durable power of attorney for health care, 1944
 Duval procedure in chronic pancreatitis, 1383, 1384*f*
 Dysgerminoma, ovarian, 1637, 1703
 Dysostosis, mandibulofacial, 1846, 1847*f*
 Dysoxia, 115
 Dyspepsia, 1050
 Dysphagia, 625
 barium studies in, 953
 in cancer of esophagus, 1004
 functional grades of, 1008, 1008*t*
 preoperative nutritional status in, 1008
 esophagoscopy in, 953
 in gastroesophageal reflux disease, 965
 and hiatal hernia, 981
 indications for surgery in, 972
 outcome of surgery in, 977, 979, 980
 postoperative recurrence of, 980
 in hiatal hernia, 981
 postoperative, 983
 in hypertensive lower esophageal sphincter, 993
 in motility disorders of esophagus, 986
 long esophageal myotomy in, 995–997

- Dysphagia (*Cont.*):
 in sarcoma of esophagus, 1014
 in Schatzki's ring, 984
- Dysplasia
 of colon
 high-grade, 1209, 1212
 in ulcerative colitis, 1197
 fibromuscular, 904–905
 of carotid artery, 847–848, 848*f*, 904
 of renal artery, 866, 867*f*, 904
 endovascular therapy in, 871
 fibrous, of chest wall, 666
 of hip, in children
 Pavlik harness in, 1783
 of lungs, squamous, 613–614
 of stomach, adenocarcinoma
 development in, 1078
- Dysplastic nevus syndrome, 488
- Dyspnea
 in cardiac disorders, 735, 736
 in aortic valve insufficiency, 760
 in aortic valve stenosis, 758
 in dying patients, 1948
- Dysraphism, 1749
- Dystonia, deep brain stimulation in, 1748
- E**
- Eagle-Barrett syndrome, 1634, 1634*f*
- Early Breast Cancer Trialists'
 Collaborative Group (EBCTCG),
 499
- Ears
 infections of, 565–567
 common organisms causing, 565, 566
 myringotomy and tube placement in,
 566*f*, 567
 otitis in. *See* Otitis
 postoperative, 383–384
 postoperative complications of,
 383–384
 reconstructive surgery of, 1855–1856,
 1857*f*
 tumors of, 594–595
- Eaton-Lambert syndrome, 1745
- Ebstein's anomaly, 719–720
 one-and-a-half ventricle repair in, 720
 Starnes procedure in, 720
- Eccrine glands, 475
- Echinocandins, 658
- Echinococcosis, hydatid disease in,
 1285–1286
- Echocardiography, 738–739
 in aortic aneurysm, thoracic, 790
 in aortic dissection, 811–812
 in aortic stenosis, 699, 758
 in aortic valve insufficiency, 760–761
 in atrial septal defect, 697
 dobutamine stress technique, 738
 in double-outlet right ventricle, 722
 in mitral stenosis, 752
 speckle-tracking, 738–739
 in total anomalous pulmonary venous
 connection, 708
 transesophageal, 738, 811
 cardiac output in, 408
 transthoracic, 738
 in tricuspid valve disorders, 763
 in truncus arteriosus, 707
 in valvular heart disease, 749*t*
- Eck fistula, in portal hypertension and
 gastroesophageal varices, 1282,
 1283
- Ectasia, ductal, of breast, 508, 509
- Ectopic conditions
 of adrenal gland, 1574
 of endometrial glands, 679, 1557, 1568,
 1569*f*
 in adenomyosis, 1682
 in endometriosis, 1689–1690
 of parathyroid gland, persistent
 hyperparathyroidism in, 1571,
 1571*f*
 in pregnancy, 1692
 differential diagnosis in, 1248
 testing for, 1677
 of testis, 1635
 of thyroid gland, 679, 1522–1523
- Ecuzimab, 325*t*, 329
- Edema
 in burns, 1820
 cerebral, in liver failure, 347
 of leg, in chronic venous insufficiency,
 916*f*, 917
 lymphedema, 934–936. *See also*
 Lymphedema
 pulmonary
 in mitral stenosis, 751
 postexpansion, 682
 of vocal cord, 573
- Edrophonium reversal of neuromuscular
 blockade, 1915
- Education of patients, in bariatric surgery,
 1105–1106
- Efficacy of drugs, 1898
- Effort thrombosis, 928
- Effusions, pleural, 680
 access and drainage in, 680–682, 681*f*
 diagnostic work-up in, 680–682
 differential diagnosis in, 682, 683*t*
 etiologies of, 680, 681*t*
 exudative, 681, 681*t*, 682, 683*t*
 in lung cancer, 632–633
 malignant, 682, 684*t*
 transudative, 681, 681*t*, 682, 683*t*
 treatment algorithm on, 682, 684*f*
- Ehlers-Danlos syndrome, 246, 248*t*, 787,
 901–902
 aortic aneurysms in, 787
 clinical features in, 246, 248*t*
 inheritance of, 248*t*, 901–902
 types of, 248*t*, 787, 902
- Eicosanoids, 31–33, 32*t*
- Eicosapentaenoic acid, 32
- Eisenmenger's syndrome, 727
- Ejection fraction, 403*t*
- Elastase, 1348, 1348*t*
- Elastography, ultrasonography, 1273
- Elbow
 dislocations of, 1759
 fractures of
 in children, 1783
 ulnar nerve compression at, 1744,
 1806
- Elderly, 1923–1938
 abuse of, 1934
 appendicitis in, 1246, 1256, 1924, 1929
 bariatric surgery in, 1127
 body composition in, 1925*t*
 cancer in, 1931–1934
 of breast, 1932–1933
 colorectal, 1933
 effectiveness of oncologic surgery in,
 1931*f*, 1938*f*
 of esophagus, 1007
 of lung, 1933–1934
 palliative care in, 1938
 of pancreas, 1393
 of thyroid, 1937
 cardiovascular disorders in, 1925*t*,
 1929–1930
 and endovascular surgery, 1936,
 1937*f*
 and surgical risk, 1926, 1928
 cerebrovascular disorders in, 1930–1931
 cholecystitis in, 1924, 1929
 cognitive function in, 1928–1929
 drug-induced disorders in, 1935
 falls in, 1934
 functional status of, 1928
 hemorrhagic shock in, 119–120
 kidney function in
 age-related changes in, 1926*t*, 1928
 and surgical risk, 1928
 minimally invasive surgery in, 436–437,
 1935–1936
 nutritional status of, 1929
 osteoporosis in, 1937
 pain in, abdominal, 1936
 palliative care of, 1938
 parathyroid gland in, 1937–1938
 physiologic effects of aging in, 221,
 221*t*, 1923, 1924, 1925*t*–1926*t*
 postoperative complications in, 386, 393
 preoperative assessment in, 1926–1929,
 1930*f*
 algorithm on, 1927*f*
 in cancer, 1931–1932
 preoperative predictors of outcomes,
 1924, 1926*t*
 respiratory disorders in, 1925*t*
 and surgical risk, 1928
 surgical risk assessment in, 1926
 thyroid disorders in, 1936–1937
 trauma in, 1934–1935
 of head, 221–222, 1935, 1935*f*
 intracranial hemorrhage in, 1935,
 1935*f*
 umbilical hernia in, 1923
 valve replacement in, 1930–1931
 aortic, 761, 1930
 wound healing in, 252–253
- Electrical burns, 228–229
- Electricity in global surgery, 1957
- Electrocardiography, 401–402, 738
 in aortic dissection, 810–812
 in aortic insufficiency, 760
 in aortic stenosis, 699, 758
 in atrial fibrillation, 886
 in atrial septal defect, 697
 continuous monitoring in, 401
 12-lead, 401
 in mitral stenosis, 752
- Electrocautery, 95
- Electroencephalography, 411
 bispectral index in, 411
 in brain death, 1721
 continuous monitoring in, 411
- Electrogastrography, 1053
- Electrohydraulic lithotriptors, 429
- Electrolarynx, for speech rehabilitation
 after laryngectomy, 592
- Electrolytes, 65–82
 calcium, 72, 78
 in children, 1599
 magnesium, 73, 78
 normal exchange of, 67
 in parenteral solutions, 76, 76*t*
 phosphorus, 73, 78
 potassium, 70–71, 77
 in preoperative fluid therapy, 79
 sodium, 68, 77
- Electromyography, 1712
 in peripheral nerve trauma, 1727
 of puborectalis muscle, 1182
- Electrosurgery, 427–428

- bipolar, 427, 428f
 capacitive coupling in, 427–428, 428f
 monopolar, 427, 428
- Elephant trunk procedure in aortic aneurysm repair, 818
 Borst's technique, 795, 798f, 799f
 completion of, 804
 frozen, 813
 reversed technique, 802, 802f
- Elliptocytosis, hereditary, splenectomy in, 1430t, 1431
- Elongation factors, 447
- Embolectomy
 in limb ischemia
 endovascular technique, 887
 surgical technique, 887–888
 pulmonary, 925
- Embolic protection devices in carotid angioplasty and stenting, 845–846, 846t
- Embolism
 air, 171, 172f
 in central venous catheterization, 381
 in aortic aneurysm, 789
 in carotid angioplasty and stenting, 845–846, 846t
 cerebral, 1728
 gas, in laparoscopy, 418
 limb ischemia in, 881, 885–886
 clinical manifestations in, 887
 endovascular therapy in, 887
 surgical treatment in, 887–888
 mesenteric artery, 860, 861f, 863–864, 1167
 surgical repair in, 864
 pulmonary, 924–925, 925f, 927
 in burns, 233
 computed tomography of, 926f
 diagnosis of, 385–386
 epidemiology of, 918
 in kidney transplantation, 339
 in laparoscopy, 418
 pleural effusions in, 680, 681t, 682, 683t
 prevention and treatment of, 386
 in trauma, 186
- Embolization
 in hemoptysis, 663
 in liver tumors
 chemoembolization in, 1295–1296
 radioembolization in, 1296
 of portal vein, prior to liver resection, 1300–1301
 of splenic artery, 1429, 1438
- Embryonic development
 of abdominal wall, 1453, 1631
 of adrenal gland, 1574–1575, 1575f
 of aortic coarctation, 705
 of aortopulmonary window, 711
 of appendix vermiform, 1241–1242
 of atrial septum, 695
 of breast, 499–500
 of gastrointestinal tract, 1175, 1616–1617
 midgut in, 1175, 1179, 1616–1617
 small intestine in, 1139–1140, 1140f
 of inguinal hernia, 1500, 1634
 of Meckel's diverticulum, 1139, 1164, 1453
 of mesentery, 1457, 1458f
 of omentum, 1457
 of pancreas, 1344, 1344f
 of parathyroid gland, 1556–1557, 1557f
 sexual differentiation in, 1637
 of spleen, 1424
- of testis, 1635
 of thyroid, 1521, 1522f, 1602
 abnormalities in, 1521–1523
 of total anomalous pulmonary venous connection, 707–708, 708f
 of truncus arteriosus, 706
 tumors from remnants in, 1736–1737
- Emesis, in burn, 236
- Emphysema
 congenital lobar, 1605–1606, 1606f
 lung volume reduction surgery in, 663
- Emptying studies, gastric, 963
 liquid, 1049–1050, 1050f
 solid, 1050
- Empyema, 682–685
 etiologies of, 682–683, 685t
 of gallbladder, 1320
 management of, 685
 pathophysiology in, 682–685
 postoperative, 390–391, 682–683
 subdural, 1745
 in trauma, 202, 682–683
- Encephalocele, 1750
- Encephalopathy, hepatic, 1276
 in cirrhosis, Child-Turcotte-Pugh score on, 1280t
 extracorporeal liver support in, 1277
 liver transplantation in, 347
- Enchondromas, 1778
 of hand and wrist, 1818
- Enchondromatosis, multiple, 1778
- End-of-life care, 1947–1951
 advance directives and living wills on, 1944
 in cognitive failure, 1951
 declaration of death in, 1951
 in dyspnea, 1948
 pain management in, 1946, 1948, 1950
 adjuvant medications in, 1950t
 in persistent pain, 1949t
 step ladder approach to, 1948, 1948t
 prognostic tools in, 1946–1947, 1947t
 signs of imminent death in, 1947–1948
 syndrome of imminent demise in, 1947–1948
 withdrawing or withholding life-sustaining therapies in, 1944–1945
- Enderectomy
 aortoiliac, 877
 carotid, 842–845
 compared to angioplasty and stenting, 842–843
 compared to medical therapy, 841–842
 complications in, 384, 843, 845
 high-risk, 842, 842t
 surgical technique in, 843–845, 843f, 844f, 845f
 in femoropopliteal occlusive disease, 897
 in mesenteric occlusive disease, 864
 in renal artery occlusive disease, 869
- Endocarditis
 in aortic valve replacement, 761
 in ductus arteriosus patency, 703, 704
 peripheral artery embolism in, 885
- Endocrine cells of stomach, 1041, 1042f, 1042t
- Endocrine system. *See also specific glands*
 anesthesia in disorders of, 1908
 ectopic glands of, 679
 pancreas in, 1348–1351
 neoplasms of, 1390–1391
 small intestine functions in, 1145, 1146t
- Endodermal sinus tumors, 1704
- Endogastrotomy, percutaneous, complications of, 382
- Endoleaks
 in abdominal aortic aneurysm repair, 855–856, 858–859, 858f, 859t
 detection of, 858–859
 types of, 858–859, 858f, 859t
 in thoracic aortic aneurysm repair, 806, 806t
- Endoluminal surgery, 428, 430–432, 431t
 energy sources for, 427–429
- Endometrial cancer screening, 298t
- Endometriomas, 1690
- Endometriosis, 1689–1690
 ovarian, 1636, 1689–1690
- Endometrium
 ablation procedure in abnormal bleeding, 1684
 anatomy of, 1675
 biopsy of, 1677–1678, 1684
 cancer of, 1698–1701, 1701t
 staging in, 1701, 1701t
 hyperplasia of, 1683
 polyps of, 1682
 sarcoma of, 1481, 1701
- Endoneurium, 1726
- Endoscopic retrograde cholangiopancreatography (ERCP), 203, 387
- Endoscopy
 of anal canal, 1180
 capsule, 1180–1181
 in Crohn's disease, 1154, 1155f
 in obscure gastrointestinal hemorrhage, 1168
 of colon, 1180–1181. *See also* Colonoscopy
 complications of, 382
 coronary artery bypass surgery in, 746
 energy sources in, 427–429, 428f
 of esophagus, 950
 in hiatal hernia, 950, 981, 982f
 mucosal resection in, 1008, 1009
 in gastrointestinal hemorrhage, 1168
 in gastrointestinal sarcomas, 1480
 in hiatal hernia, 950, 981, 982f
 historical aspects of, 416
 in inguinal hernia repair complications, 1515–1516
 natural orifice transluminal endoscopic surgery. *See* Natural orifice transluminal endoscopic surgery
 in pancreatitis, chronic, 1380–1383, 1381f
 parathyroidectomy in, 1567
 in portal hypertension and variceal bleeding, 1282
 in sinusitis, 568, 568f
 and nasal polyps, 568, 568f
 small intestine perforation in, 1169
 of stomach, 1050t
 in cancer
 gastrectomy in, 1083–184
 ultrasonography in, 1051, 1080
 indications for, 1050–1051
 ultrasonography in, 1051, 1080
 surgical access to, 423
 thyroidectomy in, 1553f, 1554
 transanal microsurgery scope, 434, 434f
 ultrasonography in
 in biliary disorders, 1316
 in esophageal cancer, 1005, 1008
 in gastric disorders, 1051, 1080
 in cancer, 1051, 1080
 in pancreatitis, 1369, 1370f, 1374
 video systems in, 424–427, 427f

- Endotension in aortic aneurysm repair, 859
 Endothelial cells in wound healing, 244
 Endothelins, 42–43, 43f
 Endothelium, 40–43
 and neutrophil interactions, 40, 42f, 118
 Endothelium-derived relaxing factor, 41
 Endotracheal intubation
 in anesthesia, 1910–1911
 preoperative airway evaluation for, 1905, 1906f, 1906t
 in hemoptysis, 662, 663
 injury of trachea in, 605, 607–608, 608f
 in trauma, 162
 in children, 222, 164z
 Endovascular therapy, 430–432, 834–837
 angioplasty balloons in, 835–836, 836f
 in aortic aneurysm
 abdominal, 850, 853–857, 854f
 thoracic, 792–793, 797, 804
 complications of, 805–806
 endoleaks in, 806, 806t
 outcome in, 819
 in aortic dissection, 815–816
 fenestration technique in, 815
 outcome in, 820
 in aortoiliac occlusive disease, 875, 879–881
 compared to surgical treatment, 880–881
 complications of, 880
 in carotid artery occlusive disease, 842, 845–847
 catheters in, 835
 guidewires in, 835
 hemostatic sheaths in, 835, 835f
 in lower extremity arterial occlusive disease, 882
 acute, 887
 chronic, 891–892
 advantages and disadvantages of, 892t
 infrapopliteal, 891, 892t, 894
 stent grafts in, 895
 stent placement in, 895, 900
 technical considerations in, 891–892
 compared to surgical treatment, 899–900
 complications of, 896–897
 in mesenteric ischemia, 864–865
 clinical results of, 865–866
 compared to open surgical repair, 866
 complications of, 865
 techniques in, 865
 needles and vascular access in, 834–835, 835f
 in renal artery occlusive disease, 870–872
 clinical results of, 871–872, 872t
 complications of, 870
 indications for, 869
 techniques in, 870
 stent grafts in, 836–837, 838f. *See also* Stent grafts
 stent placement in, 836, 837f. *See also* Stent placement
 Enflurane, 1902, 1902t, 1907
 malignant hyperthermia from, 1917
Entamoeba histolytica infections
 anorectal, 1233
 liver abscess in, 1285
 Enteral nutrition, 52–56. *See also* Nutrition, enteral
 Enteric nervous system, 1145, 1711
 Enteritis
 radiation, 1162–1163
 acute, 1162, 1163
 chronic, 1162, 1163
 diagnosis of, 1162–1163, 1163f
 outcomes in, 1163
 treatment and prevention of, 1163
 Enterochromaffin-like cells of stomach, 1040, 1043
 carcinoid tumors of, 1085–1086
 Enteroclysis
 in Meckel's diverticulum, 1164
 in radiation enteritis, 1163
 in small intestine neoplasms, 1161
 Enterococcal infections, antibiotic therapy
 in, 143t–145t
 resistance to, 143t–145t
 Enterocolitis
 in Hirschsprung's disease, 1625
 necrotizing, 1619–1621
 Bell stages in, 1620
 clinical manifestations in, 1620
 intestinal perforation in, 1620, 1621
 compared to spontaneous perforation, 1621
 in older infants, 1621
 pathogenesis in, 1620
 pneumatosis intestinalis in, 1620, 1620f
 risk factors for, 1619
 short bowel syndrome in, 1621
 treatment of, 1620–1621
 neutropenic, 1236
 Enterocytes, 1139
 Enteroendocrine cells of small intestine, 1139
 Enteroenterostomy in laparoscopic Roux-en-Y gastric bypass, 1114f, 1116
 Enteroplasty, serial transverse, in short bowel syndrome, 1172, 1172f
 Enteroscopy in gastrointestinal hemorrhage, 1168
 push technique, 1168
 Sonde technique, 1168
 wireless capsule technique, 1168
 Enterostomal therapy nurse, 1192
 Entrapment syndromes. *See also* Compression injury
 of peripheral nerves, 1744
 in hand and wrist, 1744, 1805–1806
 of popliteal artery, 905–906, 905t
 Environmental factors in colorectal cancer risk, 1204
 Enzyme-linked immunosorbent spot (ELISPOT) analysis, 468
 Enzymes, pancreatic, 1348–1349, 1348t
 in acute pancreatitis, 1353–1354, 1355
 in chronic pancreatitis, administration of, 1379–1380, 1380t
 Eosinophilic esophagitis, 986–987, 986f
 Eosinophils, functions of, 39
 Ependymoma
 intracranial, 1734
 spinal, 1738
 Epidemiologic transition of disease in global surgery, 1957–1958
 Epidermal appendages, 475
 Epidermal growth factor, 247t
 Epidermal growth factor receptors, 281, 288t
 in breast cancer, 534–535
 in lung cancer, 627
 Epidermis, 486
 anatomy and histology of, 473
 Epidermodysplasia verruciformis, 485
 Epidermoid tumors
 anal and perianal, 1218
 of breast, 556
 of central nervous system, 1737, 1737f
 Epidermolysis bullosa, 248–249
 squamous cell carcinoma in, 487
 Epididymo-orchitis, 1665
 Epidural anesthesia, 1904
 Epigastric arteries, 1450, 1452f
 inferior, 1497, 1516
 injury in laparoscopy, 1704–1705, 1704f
 in inguinal hernia repair, 1516
 rectus sheath hematoma in hemorrhage from, 1455
 Epigastric perforator flap in breast reconstruction, 1871, 1871f
 Epigastric veins, 1497
 Epiglottis, anatomy of, 580, 589
 Epilepsy
 drug therapy in, 1746
 surgical treatment in, 1746–1747
 Epinephrine, 22, 1577–1578, 1579f
 in pheochromocytoma, 1586
 in shock response, 115
 therapy with
 in cardiogenic shock, 127
 in hand and wrist injuries, 1796
 in local anesthesia, 1903
 in wound care, 264
 Epineurium, 1726
 Epiphysis, 1782
 slipped capital femoral, 1783
 Epiploic foramen, 1265, 1265f
 Epirubicin in soft tissue sarcoma of extremity, 1476
 Epistaxis, postoperative, 384
 Epithelial cells of stomach, 1039–1040, 1041f, 1042t
 surface, 1039–1040, 1044–1045
 restitution of, 1045
 Epithelialization in wound healing, 245–246, 245f, 1831
 Epithelial-mesenchymal transition (EMT), in tumor invasion, 285
 Epithelial tumors of ovary, 1637
 Epithelioid cells, 660f
 Epithelioid sarcoma, 1818
 Epsilon cells, pancreas, 1350
 Epstein-Barr virus infections
 pharyngitis in, 571
 in transplant recipients, 329
 and posttransplant lymphoproliferative disorder, 329
 tumors associated with
 of nasopharynx, 593
 and posttransplant lymphoproliferative disorder, 295t
 of stomach, 1075
 Equinovagis foot deformity in cerebral palsy, 1782
c-erbB-2, 281
 Erb's palsy, 1727
 Erection of penis, 1652
 in priapism, 1663–1664
 prostatectomy affecting, 1658
 Erlotinib, 310t
 Errors, medical
 in communication issues, 368–369
 disclosure of, 380, 1952
 high-profile, 368
 Institute of Medicine report on, 366, 1952

- legal issues in, 380, 380t
 in wrong-site surgery, 378–379
 and near misses, 367t
 retained surgical items in, 377–378, 377t
 risk management in, 380
 in surgical specimen labeling, 371, 371f
 systems change in, 367
 types of, 367t
 wrong-site surgery in, 378
- Ertapenem, 144t
- Erythema nodosum in inflammatory bowel disease, 1196
- Erythrocytes. *See* Red blood cells
- Erythromycin, 145t
 in delayed gastric emptying, 1050t
 in preoperative bowel preparation, 1194
- Erythroplasia of Queyrat, 487
- ESCAPE trial, 406
- Escharotomy in burns, 234, 1820
- Escherichia coli*
 antibiotics for infections of, 143t–145t
 in DNA recombinant technology, 457, 457f
- Esmolol in aortic injuries, 201
- Esophageal speech after laryngectomy, 592
- Esophagectomy
 in cancer of esophagus, 1009
 in cervical portion, 589
 Ivor Lewis en bloc technique, 1011
 salvage procedure, 1011
 transhiatal approach, 1009–1012, 1011–1012
 minimally invasive, 1010–1011, 1010f
 open, 1010
 transthoracic approach, 1011–1012
 minimally invasive three-field, 1010–1011
 minimally invasive two-field, 1010–1011
 open three-field, 1011
 in caustic injury of esophagus, 1022
- Ivor-Lewis
 in cancer of esophagus, 1011
 complications of, 386
 reconstructive surgery after, 1024–1025
 thoracic duct injury and chylothorax in, 685, 686f
 vagal sparing, colon interposition in, 1025–1026
- Esophagitis in gastroesophageal reflux, 967, 967t, 968, 969
 antireflux surgery in, 972
 endoscopy in, 950, 951f
- Esophagoesophagostomy, in esophageal atresia and tracheoesophageal fistula, 1610
- Esophagogastroduodenoscopy, indications for, 1050–1051, 1050t
- Esophagogastrojejunostomy in peptic ulcer disease, 1071f
- Esophagoscopy, 950
 in hiatal hernia, 950, 982, 982f
 mucosal resection in, 1008, 1009
- Esophagus, 941–1026
 achalasia of, 990–992, 991f, 992f.
 See also Achalasia
 anatomy of, 941–947, 942f, 943f
 abdominal, 944
 lymphatic, 946–947, 946f
 muscles in, 944–945
 nerves in, 946, 946f
 normal areas of narrowing in, 942, 943f
 thoracic, 944, 944f
 vascular, 945–946, 945f, 946f
 atresia of, 1608–1612
 anatomic varieties of, 1608–1609, 1608f
 clinical presentation in, 1609–1610, 1609f
 coexisting anomalies in, 1609
 complications of surgery in, 1611–1612
 etiology and pathologic presentation in, 1609
 initial management of, 1610
 outcome in, 1612
 postoperative management in, 1611
 in preterm infant, 1610
 primary surgical correction of, 1610
 Barrett's. *See* Barrett's esophagus
 benign tumors of, 1017–1018
 burns of, in caustic ingestion, 1020, 1021t
 cancer of, 1003–1014
 algorithm on management of, 1014, 1015f
 in Barrett's esophagus, 969, 970f, 972, 979, 1003
 in cervical portion, 588, 1005, 1007f
 clinical manifestations in, 1003–1004
 endoscopic mucosal resection in, 1007, 1008, 1009
 epidemiology of, 275t, 276t, 278t, 618f, 1003, 1004f
 esophagectomy in, 1009. *See also* Esophagectomy, in cancer of esophagus
 in gastroesophageal reflux disease, 967, 969, 979
 general approach to, 1005
 locations of, 1005, 1007f
 palliative treatment in, 1005, 1007f
 preoperative evaluation in, 1007
 risk factors for, 1003
 staging of, 1004–1005, 1006t
 treatment decisions based on, 1005
 surgical treatment of, 1009
 factors affecting decision for, 1005, 1007f
 caustic and corrosive injury of, 942, 1020–1023
 in children, 1020, 1608, 1612–1613
 grades of, 1021, 1021t, 1612
 management algorithm on, 1022f
 in caustic injury, 1020–1023
 columnar-lined, in Barrett's esophagus, 950, 969, 1003
 complications in surgery of, 386
 corkscrew deformity of, 992, 992f
 cysts of, 679, 1017, 1018
 congenital, 1018
 diverticulum of. *See* Diverticulum, of esophagus
 evaluation of, 950–964
 duodenogastric function tests in, 963–964
 functional, 953–964
 structural, 950–953
 fistula of, 1023–1024
 with trachea, 609, 1608–1612. *See also* Tracheoesophageal fistula
 foreign body in, 942
 in children, 1607–1608
 in gastroesophageal reflux disease, 964–980
 hiatal hernia of, 980–984
 leiomyoma of, 1017–1018, 1017f
- Mallory-Weiss tears of, 1020
- manometry of. *See* Manometry, esophageal
- motility of
 barium studies of, 950–951, 953f
 disorders of, 986–995
 end-stage, 1003
 of esophageal body and lower esophageal sphincter, 990–994
 long esophageal myotomy in, 995–997, 995f, 996f–997f
 nonspecific, 993
 pharyngoesophageal, 986–990
 primary, 990–993, 990t, 991t
 in scleroderma, 984–985, 985f
 secondary, 990t, 993
 manometry in assessment of, 953–955, 990
 radionuclide scans of, 955
 in swallowing mechanism, 947–949
 video- and cineradiography of, 955, 961, 961f
- nutcracker, 992–993
- perforation of, 1018–1020
 diagnosis of, 1018, 1019f
 management in, 1018–1020, 1019f, 1020f
- pH monitoring of, 949, 955, 962f
 composite score in, 962, 962t
 equipment used in, 963–964, 964f
 with gastric pH monitoring, 963, 964f
 in gastroesophageal reflux, 961–963, 964, 964f, 967, 968f
 and respiratory disorders, 969–972, 971
 in hiatal hernia, 983
 normal values in, 962, 962t
 sensitivity and specificity of, 963–964
- physiology of, 947–949
- pseudodiverticulosis of, 992
- reconstructive surgery of, 1024–1026, 1863
 in caustic and corrosive injury, 1020–1023, 1022f, 1023f, 1612–1613
 composite of colon, jejunum, and stomach in, 1025
 in end-stage motor disorders, 1003
 jejunal flap in, 1863
 in partial esophageal resection, 1024, 1024f
 in total esophagectomy, 1024–1025
- resection of. *See* Esophagectomy
- sarcoma of, 1014–1017, 1016f
 polypoid, 1015
- Schatzki's ring of, 984, 984f
- scleroderma of, 984–985, 985f, 993
- spasm of, diffuse and segmental, 992, 992f, 993f
- sphincter muscles of, 944
 in achalasia, 992
 in gastroesophageal reflux, 949, 965–967, 966f, 972
 and antireflux surgery, 973, 973f
 and hiatal hernia, 966–967
 permanently defective, 966
 Heller myotomy of, 997–999, 999f
 hypertensive, 993
 manometry of, 953–955, 965
 motility disorders of, 990–994
 pressure regulation, 949
 in scleroderma, 985
 in swallowing mechanism, 947–949

- Esophagus (*Cont.*):
 strictures of
 in caustic ingestion, 1021, 1022, 1611
 stent placement in, 1022, 1022*f*
 in gastroesophageal reflux, 967–969,
 967*t*
 indications for antireflux surgery
 in, 972
 outcome of surgery in, 979
 structural abnormalities of, 950–953
 trauma of, 178, 200, 202
 from caustic and corrosive
 substances, 942, 1020–1023,
 1608, 1612–1613
 fistula in, 1023
 from foreign bodies, 1018, 1608
 perforation in, 1018, 1019
 varices of, 1283. *See also* Varices,
 gastroesophageal
- Essential Trauma Care project (ESTC), 1968
- Estlander flap in lip reconstruction, 1857
- Estrogen
 and breast cancer risk, 511
 antiestrogen therapy in, 552–553
 in breast development and function, 500,
 503, 505
- Estrogen receptor status in breast cancer,
 534, 535–536
 and endocrine therapy, 552
- Ethanol, percutaneous injection in
 hepatocellular carcinoma, 1295
- Ether, historical use of, 1895–1896
- Ethical issues, 1941–1952
 in advance directives and living wills,
 1944
 in conflicts of interest, 1951
 definitions of terminology related to,
 1941
 in disclosure of errors, 1952
 in informed consent, 1941–1944
 in palliative care, 1946–1947
 in power of attorney for health care,
 1944
 in research, 1951–1952
 in withdrawing and withholding life
 sustaining therapies, 1944–1945
- Ethmoid sinus
 in naso-orbital-ethmoid fractures, 1855
 tumors of, 593
- Etomidate, 1900, 1909
- Etoposide in lung cancer, 644*t*
- Eukaryotes, transcription in, 447
- European Carotid Surgery Trial, 841, 842
- European Organization for Research and
 Treatment of Cancer (EORTC)
 protocol, 537, 1476–1477, 1484
- Evacuation studies, rectal, 1182
- EVAR-1 trial, 857
- Everolimus, 310*t*
- Evoked potentials, somatosensory and
 brain stem, 411
- Ewing's sarcoma, 665, 667, 1465
 chemotherapy in, 667, 668*t*
 genetic factors in, 1467
- Excimer laser atherectomy, 896
- Excisional biopsy, 300
 in breast cancer, 544–545, 544*f*, 545*f*,
 546*f*
 in chest wall tumors, 666
 in soft tissue sarcomas, 1470
- Excisional body contouring, 1886–1887,
 1887*f*
- Exenteration, pelvic
 in cervical cancer recurrence, 1698,
 1700*f*
 in rectal cancer recurrence, 1213
- Exercise in obesity
 and bariatric surgery, 1108
 in medical management, 1102
- Exercise testing
 preoperative, 637*t*
 in cardiac risk assessment, 738, 739
 in lung cancer, 637
 radionuclide scans in, 739
- Exocrine pancreas, 1348–1349
 neoplasms of, 1393–1412, 1410*t*
- Exons, 446
- Extensor muscles of hand, 1789–1791
- Extensor retinaculum, 1791
- Extracellular fluids
 composition of, 65, 66
 osmolality of, 67
 third-space or nonfunctional losses of,
 79
 volume deficit in, 67
- Extracorporeal membrane oxygenation
 in burns, 232
 in congenital diaphragmatic hernia,
 1604–1605
- Extracorporeal perfusion, 740–741. *See also*
 Cardiopulmonary bypass
- Extracorporeal shock wave lithotripsy,
 429, 1666
 in pancreatic duct stones, 1380–1383,
 1382*f*
- Extradural anesthesia, 1904
- Extravasation injuries, 480, 481*f*
- Extremities
 lower. *See* Lower extremity
 reconstructive surgery of, 1876–1880
 in diabetic ulceration, 1877, 1879
 in lymphedema, 1879–1880
 in trauma, 1876–1877
 in tumors, 1877
 trauma of
 fractures in, 214–215, 1876–1877,
 1876*t*
 in elderly, 1935*f*
 reconstructive surgery in,
 1876–1877
 in tumors, 185*t*
 vascular injuries in, 182–183, 184*f*,
 185*t*, 214–215
 tumors of
 in osteosarcoma, 1779
 reconstructive surgery in, 1877
 in soft tissue sarcomas, 1472–1479
 upper. *See* Upper extremity
- Ex utero intrapartum therapy (EXIT)
 procedure, 1645, 1645*f*
- Eye
 cancer of, 275*t*
 inflammatory bowel disease involving,
 1196
 postoperative complications of, 383–384
- Eyelid
 lacerations of, 575, 575*f*
 plastic and reconstructive surgery of,
 1858–1860
 blepharoplasty in, 1882–1883
 Cutler-Beard advancement flap in,
 1858, 1861*f*
 Hughes advancement flap in, 1858,
 1861*f*
 of lower eyelid, 1858–1859
 in ptosis, 1859–1860, 1861*t*
 of upper eyelid, 1858, 1859*f*, 1860*f*,
 1861*f*
 ptosis of, 1859–1860, 1861*t*
 classification of, 1861*t*
- F**
- Face
 anatomy of bones in, 1854*f*
 buttresses supporting midface, 577, 577*f*
 plastic and reconstructive surgery of,
 1882–1883
 browlift in, 1882–1883, 1883*f*
 in cleft lip and palate, 1840–1844
 composite tissues in, 1834*f*,
 1881–1882, 1882*f*
 facelift in, 1883, 1883*f*, 1884*f*
 in fractures, 1852–1855, 1853*f*, 1854*f*,
 1855*f*
 reanimation in, 1865–1866
 skin tension lines in, 1830*f*
 trauma of, 197, 197*f*, 576
 fractures in, 197, 197*f*, 576–578,
 576*f*–578*f*
 panfacial, 1855
 reconstructive surgery in,
 1852–1855, 1853*f*, 1854*f*, 1855*f*
- Facelift, 1883, 1883*f*, 1884*f*
- Facet dislocation in cervical spinal trauma,
 1722, 1723*f*, 1770
- Facial nerve
 paralysis of, 1865–1866, 1867*f*
 ancillary procedures in, 1866
 idiopathic, 567
 innervated free tissue transfer in,
 1865–1866
 muscle transposition techniques in,
 1866
 nerve transfer techniques in, 1866
 neurorrhaphy in, 1865
 in otitis media complications, 567
 in skull fractures, 1717
 in temporal bone fractures, 578
 treatment algorithm on, 1867*f*
 in viral infections, 567
 trauma of, 567, 576
 in temporal bone fractures, 576, 578
- Factor I, 87, 99*t*. *See also* Fibrinogen
- Factor II, 86, 87, 99*t*. *See also* Prothrombin
- Factor V, 86, 87, 88, 99*t*
 deficiency of, 89, 99*t*
 laboratory tests of, 103
 Leiden mutation, 88
 venous thromboembolism in, 918
- Factor VII, 86, 87, 88, 99*t*
 administration of, 89
 deficiency of, 89, 99*t*
- Factor VIII, 86, 87, 88, 99*t*
 deficiency of, 88, 89, 99*t*
 inhibitors of, 89
 laboratory tests of, 103
- Factor IX, 86, 87, 88, 99*t*
 administration of, 89
 deficiency of, 88, 99*t*
 laboratory tests of, 103
- Factor X, 86, 87, 88, 99*t*
 deficiency of, 89, 99*t*
 laboratory tests of, 103
- Factor XI, 86, 87, 99*t*
 deficiency of, 89, 99*t*
- Factor XII, 86, 87, 99*t*
 deficiency of, 99*t*
 laboratory tests of, 103
- Factor XIII, 88, 89, 99*t*
 deficiency of, 89, 99*t*
- Factors, clotting, 86*f*, 87, 87*f*
 deficiency of
 congenital, 88–89
 replacement in, 99*t*
 laboratory tests of, 102–104
 liver disease affecting, 92*t*, 93

- liver synthesis of, 1271
 vitamin K–dependent, 92*t*, 93, 94, 103
- Falciform ligament, 1264, 1264*f*; 1265
- Fallopian tubes
 anatomy of, 1675
 benign neoplasms of, 1689
 cancer of, 1701–1703
 biomarkers in, 1702
 chemotherapy in, 1703, 1703*t*
 recurrent, 1703–1704, 1704*t*
 risk factors for, 1702, 1702*t*
 risk-reducing salpingo-oophorectomy in, 1701
 endometriosis of, 1689, 1689–1690
 intraepithelial neoplasia of, 1689
 laparoscopic occlusion for sterilization, 1689
 trauma of, 212
 in tubo-ovarian abscess, 1691
- FalLOT, Etienne Louis, 724
- FalLOT tetralogy, 724–726
 anatomy in, 724–726, 724*f*
 classic presentation in, 724
 operative repair in, 724–725, 725*f*
- Falls
 in children, 222
 in elderly, 1934
 in pregnancy, 218
- FANG™ (furin-knockdown and GMCSF-augmented), 468
- Fas-associated death domain, 36, 37*f*
- Fascial planes of neck, deep, 598–599
- Fasciitis
 necrotizing, 151, 153*f*; 256, 483
 postoperative, 391
- Fasciocutaneous flaps, 1833, 1836–1838, 1837*t*
 in head and neck reconstructive surgery, 601
- Fasciotomy in compartment syndrome, 215, 216*f*; 888
- Fasting, metabolism in, 44–46, 44*t*
 in extended starvation, 45, 45*f*
 in short-term fast, 44*f*
- Fat
 in chyle, 686*t*
 in enteral nutrition solutions for children, 1600*t*
 malabsorption in chronic pancreatitis, 1371*f*; 1372
 metabolism of
 in fasting, 44*f*; 44*t*, 45*f*
 in injury, 46, 46*f*
 in small intestine, 1142–1143, 1143*f*
 in parenteral nutrition, 58
 in stool, in chronic pancreatitis, 1374
- Fatigue
 in cardiac disorders, 736
 in hyperparathyroidism, 1561
- Fatty acids, 32–33
 deficiency in parenteral nutrition, 58
 in enteral nutrition, 54
 metabolism of
 in fasting, 46
 in injury, 46–47, 47*f*
 oxidation in, 47, 48*f*; 49*f*
 in small intestine, 1142–1143, 1143*f*
 short-chain, 1179
- Fatty liver
 in inflammatory bowel disease, 1196
 in obesity, 1129
 bariatric surgery in, 1106, 1129
- FEC-75, 553
- Feces. *See* Stool
- Felon, 1813, 1813*f*
- Felty's syndrome, 1438
 splenectomy in, 1430*t*, 1438
- Femoral artery
 in aortoiliac occlusive disease
 and aortobifemoral bypass, 876–877
 and axillofemoral bypass, 877
 and femorofemoral bypass, 877
 and iliofemoral bypass, 877, 877*f*
 and thoracofemoral bypass, 878
 injuries of, 215
 occlusive disease of, 828
 angioplasty in, 892–894, 893*f*; 899
 bypass grafting in, 897–898, 899, 900
 chronic, 889, 891*f*
 computed tomography angiography in, 832*f*; 891*f*
 endarterectomy in, 897
 stent graft in, 895
 stent placement in, 895, 900
 complications of, 897, 897*f*
 symptoms in, 889–890
 pulse palpation, 829
 in limb ischemia, 887
 puncture for endovascular therapy
 access, 834, 835*f*
 antegrade technique, 834, 835*f*
 in aortic aneurysm repair, 856, 856*f*
 in mesenteric artery occlusive disease, 865
 in renal artery occlusive disease, 870
 retrograde technique, 834
- Femoral canal, 1496
- Femoral hernia, 1504
 in children, 1634
 classification of, 1496
 diagnosis of, 1504
 McVay repair in, 1507–1508
- Femoral lymph nodes in vulvar cancer
 anatomy of, 1696, 1696*f*
 staging of involvement, 1696
- Femoral nerve, lateral cutaneous
 anatomy of, 1498*f*; 1499
 injury in inguinal hernia repair, 1515
- Femoral pseudohermia, 1504
- Femoral vein
 anatomy of, 215
 thromboembolism in, 920*f*; 924
- Femorofemoral bypass in aortoiliac occlusive disease, 877
- Femoropopliteal occlusive disease
 atherectomy in, 895–896
 classification of, 883, 885*t*, 886*f*
 endovascular therapy in, 891–892
 angioplasty in, 892–894, 893*f*, 896–897, 899
 compared to surgical treatment, 899–900
 complications of, 896–897
 stent graft in, 895, 897
 stent placement in, 895, 897, 897*f*; 900
 surgical treatment of, 897–898
 amputation in, 898
 bypass grafting in, 897–898, 899, 900
 compared to endovascular therapy, 899–900
 complications of, 898
 endarterectomy in, 897
 symptoms in, 889–890
- Femur
 fractures of, 1758*f*
 in children, 1782
 distal, 1762
 hemorrhage in, 173
 intertrochanteric, 1761–1762
 in neck, 1761
 reconstructive surgery in, 1877*t*, 1878*f*
 in shaft, 1762
 subtrochanteric, 1762
 vascular injury in, 186*f*
 osteosarcoma of, 1779
 rotational abnormalities of, 1783
 slipped capital epiphysis of, 1783
- Fentanyl for pain control, 1900
 in children and infants, 1601
 in persistent pain, 1949*t*
- Ferguson hemorrhoidectomy, 1223
- Fernel, Jean, 1241
- Fertility issues
 alpha-Fetoprotein, 302–303
 in cryptorchidism, 1636
 in obesity, 1126
 in hepatocellular carcinoma, 1279
- Fetus
 death of, in trauma, 218, 221
 diagnosis of disorders in, 1691
 fluid and electrolyte balance in, 1599
 interventions for disorders in, 1644–1645
 ex utero intrapartum therapy (EXIT) procedure in, 1645, 1645*f*
 monitoring of
 in laparoscopy, 436
 in trauma, 220–221
 prenatal ultrasonography of
 in diaphragmatic hernia, 1604, 1604*f*
 in gastroschisis, 1633, 1633*f*
 in ovarian cysts, 1637
 wound healing in, 251–252
- Fever
 in liver trauma, 205
 puerperal, 135, 241
 in transfusion reactions, 100, 102*t*
- Fiber in enteral formulas, 53
- Fiberoptic pressure transducer,
 intraparenchymal, in intracranial pressure monitoring, 1713
- Fibrillation
 atrial, 736, 771–772. *See also* Atrial fibrillation
 ventricular, 736
- Fibrillin, 245
 abnormalities in Marfan's syndrome, 248, 787, 902
- Fibrin
 dissolution of, 88, 88*f*; 263
 formation of, 87
 in peritoneal adhesions, 263, 263*f*
 in topical hemostatic agents, 96
- Fibrin glue in fistula, 1231
- Fibrinogen, 87, 99*t*
 in chyle, 686*t*
 deficiency of, 92, 99*t*
 laboratory tests of, 103
 radioactive uptake in venous thromboembolism, 921
- Fibrinolysis, 86*f*; 88, 88*f*; 184, 263
 pathologic, 92
- Fibrinopeptides A and B, 87
- Fibroadenomas of breast, 507, 508*f*; 509
 treatment in, 510
- Fibroblast growth factor, 246, 247*t*
- Fibroblasts, 475
 fetal, 252
 in hypertrophic scars and keloids, 261–262
 and skin substitutes, 267
 in wound healing, 242*f*; 243*f*; 244, 259
- Fibrocystic disease of breast, 509

- Fibroelastomas of heart, 776
 Fibroelastosis, endocardial, 699
 Fibroids, uterine, 1682–1683, 1683f
 Fibroma
 desmoplastic, 1780
 of heart, 776
 ossifying, 1781
 Fibromuscular dysplasia, 904–905. *See also* Dysplasia, fibromuscular
 Fibronectin in wound healing, 245
 in hypertrophic scars and keloids, 261–262
 Fibroplasia, 253
 Fibrosarcoma, 669
 chemotherapy in, 1475
 Fibrosis
 cystic
 lung transplantation in, 663–664
 meconium ileus in, 1618
 hepatic, in cirrhosis, 1277
 pancreatic
 asymptomatic, 1365t, 1367
 in chronic pancreatitis, 1367–1368, 1367f, 1368f
 periductal, 508
 pulmonary idiopathic, lung
 transplantation in, 663–664
 retroperitoneal, 1460–1462
 urinary obstruction in, 1666
 Fibrous tumors of pleura, 688, 690
 Fibula
 fractures of, 1757f, 1764
 osteocutaneous flaps from
 in femoral fracture, 1878f
 in mandibular reconstruction, 601, 1863, 1864f–1865f
 Fick equation, 404, 408
 Fick method of cardiac output
 measurement, 403, 739
 Field defect in colorectal cancer, 1212
 Field effect in cancer, 278
 Fight or flight response, 109
 Financial issues
 in endovascular repair of aortic
 aneurysm, 858
 in incidental appendectomy, 1257
 in minimally invasive surgery, 437
 Finney pyloroplasty
 in Crohn's disease, 1157, 1157f
 in peptic ulcer disease, 1063, 1065f
 Fisher, Bernard, 499
 Fish-eye lesion in intraductal papillary
 mucinous neoplasms of
 pancreas, 1411f, 1412
 Fissures, anal, 1225–1227, 1226f
 Fistulas, 149f
 anal, 1229–1231, 1229f, 1230f
 in Crohn's disease, 1200, 1200f
 aortoenteric, in aortoiliac reconstruction, 879
 biliary, in liver trauma, 205
 of bladder
 with colon in diverticulitis, 1203
 with vagina, 1678
 branchial cleft, 1602
 bronchopleural
 drainage in, 681f
 carotid-cavernous, 1720
 esophageal, 1023–1024
 with trachea, 609, 1608–1612
 extrasphincteric, 1230
 gastrointestinal, 386
 intersphincteric, 1230
 intestinal, 1157–1159
 in Crohn's disease, 1198
 in diverticulitis, 1203
 spontaneous closure of, 1158, 1158t
 in trauma, 209
 treatment of, 1158
 mammary duct, 508
 mucus, in colorectal resection, 1189, 1193
 pancreatic
 in chronic pancreatitis, 1378
 postoperative, in
 pancreaticoduodenectomy, 1403–1407
 in trauma, 209
 periductal, 511
 rectal, 1678
 with vagina, 1231
 in Crohn's disease, 1200, 1231
 endorectal advancement flap in, 1231, 1232f
 suprasphincteric, 1230
 tracheal, 608–609
 tracheoesophageal, 609, 1608–1612
 tracheoinnominate artery, 608–609, 609f
 in tracheostomy complications, 382, 382f, 608–609
 transsphincteric, 1230
 ureteral, 1678
 of vagina
 with bladder, 1678
 with colon in diverticulitis, 1203
 with rectum, 1231
 in Crohn's disease, 1200, 1231
 endorectal advancement flap in, 1231, 1232f
 vitelline duct, 1453
 Fistulogram in intestinal fistulas, 1158
 Fitz-Hugh-Curtis syndrome, 1690
 Fitz, Reginald, 1241
 FK506, 325t, 326t, 327t, 328
 Flail chest, 164, 165f, 203
 Flaps, 1833–1840
 advancement, 1833, 1835f
 endorectal
 in anal fistula, 1231
 in rectovaginal fistula, 1231, 1232f
 axial pattern, 1836
 free transfer of, 1838
 in nasal reconstruction, 1856, 1859f
 bipedicle, 1833
 Burow's triangle in, 1835f
 circulation in, 1836
 in free tissue transfer, 1838–1840
 Mathes-Nahai classification of, 1837, 1837t
 monitoring of, 1839–1840, 1839t
 conditioning of, 1837
 cutaneous, 1833, 1836–1838, 1837
 fasciocutaneous, 1833, 1836–1838
 vascular supply of, 1836, 1837t
 free, 1833, 1838–1840
 anastomosis in, 1838, 1839f
 occlusion of, 1838, 1839
 fibula osteocutaneous
 in femoral fracture, 1878f
 in mandibular reconstruction, 601, 1863, 1864f–1865f
 in head and neck reconstruction, 601–602, 601f, 1863
 monitoring of circulation in, 1839–1840, 1839t
 no-reflow phenomenon in, 1840
 thrombosis affecting, 1838, 1838t, 1839
 in hand reconstruction
 in burns, 1821–1822, 1821f
 in fingertip injuries, 1801, 1802f–1804f, 1833, 1836f
 interpolation flaps in, 1833, 1836f
 in head and neck reconstruction, 600–601, 601f
 mandibular, 601, 1863, 1864f–1865f
 interpolation, 1833, 1836f
 local, 1836
 in head and neck reconstruction, 600
 muscular, 1836
 blood supply of, 1837
 myocutaneous, 1833, 1836–1838, 1837
 in breast reconstruction, 549, 550, 1869–1871, 1872f–1873f
 in chest wall reconstruction, 670, 670f, 1874, 1875f
 in head and neck reconstruction, 601
 in pressure ulcers, 1880–1881, 1881f
 perforator, 1837–1838
 in breast reconstruction, 1871, 1871f
 random pattern, 1833, 1834f, 1835f, 1836f
 regional, 1836
 in head and neck reconstruction, 600
 rhomboid, 1833, 1835f
 rotational, 1833, 1835f
 tissue expansion for, 1840
 transposition, 1833, 1835f
 Fleischer's syndrome, 500
 Flexion injuries of spine, 1721, 1722, 1771
 Flexor muscles of hand, 1791
 examination of, 1793–1794, 1793f
 Flexor retinaculum, 1791
 Fluconazole, 141t, 658
 Fludrocortisone
 in adrenocortical insufficiency, 1590
 in Cushing's syndrome, 1583
 in septic shock, 126
 Fluids, 65–76
 absorption of
 in large intestine, 1179
 in small intestine, 1140–1141, 1140f
 in children, 1599
 classification of body fluids, 67–68
 compartments, 65
 composition of
 of body fluids, 65–66, 67f
 changes in, 68, 70–73
 in therapy, 76, 76t
 extracellular, 65, 66
 interstitial, 65, 66f, 67f
 intracellular, 65, 66f, 67f
 normal exchange of, 67
 osmolality of, 67
 pH of, 73–76
 therapy with, 76–80
 in acute pancreatitis, 1357–1358
 in burns, 228, 230–231
 composition of solutions in, 76, 76t
 in hemorrhagic shock, 122
 in hypernatremia, 77
 intraoperative, 79, 1911, 1914
 in kidney transplantation, 339
 for maintenance, 78
 postoperative, 78–80
 preoperative, 78–80
 in sepsis, 154, 155t
 and shock, 125
 in trauma, 218
 in initial management, 165–166, 165f, 168–171
 intraosseous infusions of, 165–166, 165f
 response to, 171

- saphenous vein access for, 165–166, 165f
 in total body water, 65–66
 volume of body fluids, 68–69, 68t
- Fluids and Catheters Treatment Trial (FACTT), 406
- Fluorodeoxyglucose positron emission tomography, 1275
- Fluoroquinolones, 144t
- 5-Fluorouracil
 in esophageal cancer, 1012, 1013t
 in pancreatic cancer, 1407
- Fluorouracil, in basal cell carcinoma, 487
- Folate deficiency in gastric surgery, 1094
- Follicle-stimulating hormone, 504
- Follicular carcinoma of thyroid, 1544–1546, 1544t, 1545f
- Folliculitis, 483, 483
- Fondaparinux in venous thromboembolism, 921, 922, 927
- Fontaine classification of peripheral arterial disease, 883, 885t
- Fontan procedures
 in hypoplastic left-heart syndrome, 718
 in tricuspid atresia, 713–715, 714f
- Food. *See also* Nutrition
 gastric acid secretion in response to, 1043–1044, 1044f
 and gastric cancer risk, 1074
- Foot
 diabetic ulcers of, 260, 1877, 1879, 1879t
 equinovagis deformity in cerebral palsy, 1782
 metatarsal fractures in, 1765
 metatarsal-phalangeal joint in fractures of, 1765
 tarsal fractures of, 1765
 trash foot or gangrene of, in aortoiliac occlusive disease, 874, 874f
- Foramen ovale
 embryonic development of, 695
 patent, 698
- Forced expiratory volume in lung cancer prediction of postoperative value, 636–637
 preoperative assessment of, 636, 638f
- Forearm
 compartment syndrome of, 1801
 fractures of, 1760
- Foregut
 duplication cyst of, 1607
 embryonic development of, 1175
- Foreign bodies
 carcinogenesis in, 293
 in children, 1607–1608
 rectal, 1235
 in retained surgical items, 377–378, 377t
 counting protocol for prevention of, 378
 risk factors for, 377, 377t
 in stomach, 1089–1090
- Formulas in enteral nutrition, 53–55
- c-fos*, 281
- Fossa navicularis, 1674
- Fothergill's sign in rectus sheath hematoma, 1454
- Fourchette, posterior, 1674
- Fournier's gangrene, 484, 1663, 1663f
- Fractures, 1757–1765
 of ankle, 1764
 in children, 1783
 Bennett, 1796
 of calcaneus, 1764
 in children, 1782–1783
 growth plate injuries in, 1782
 of clavicle, 203, 1757–1759
 compartment syndrome in, 1757
 of elbow
 in children, 1783
 in extremity trauma, 214–215, 1876–1877, 1876t
 in elderly, 1935f
 soft tissue coverage in, 1877, 1877t, 1878f
 facial, 197, 197f, 576–578, 576f–578f
 panfacial, 1855
 reconstructive surgery in, 1852–1855, 1853f, 1854f, 1855f
 of femur. *See* Femur, fractures of
 of forearm, 1760
 Gustilo and Anderson classification of, 1875–1876, 1876t
 in hand, 1796–1798
 Jahss maneuver in, 1796, 1798f
 nonunion of, 1801, 1805
 types of, 1798f
 hangman's, 1722, 1770
 healing process in, 249–251
 growth factors in, 251
 stages in, 250
 of hip, 1760–1762
 in children, 1782
 of humerus, 1759
 internal fixation techniques in, 1763f
 Jefferson, 1722, 1770
 of knee, 1767–1769
 malleolar, 1764
 metatarsal, 1765
 of metatarsal-phalangeal joint, 1765
 nose, 197
 open, 1757, 1758f
 of orbit, 197, 1854
 blowout, 577, 577f, 1854
 in naso-orbital-ethmoid fractures, 1855
 of patella, 1762
 pelvic. *See* Pelvic fractures
 of radius, 1759–1760
 of ribs, 202–203
 in children, 1643
 in elderly, 222
 hemorrhage in, 173, 203
 Rolando, 1796
 of scapula, 1759
 of shoulder, 1759
 of skull, 1715–1717, 1717f
 of spine, 1722, 1724f, 1770
 cervical, 1722
 of talus, 1764
 of tarsal bones, 1765
 of temporal bone, 578, 578f
 of tibia, 1762, 1764
 hemorrhage in, 173
 reconstructive surgery in, 1877t
 types of, 1757f
 of ulna, 1760
 Frailty, 1924, 1926t
Francisella tularensis as biologic warfare agent, 157
 Frank-Starling curve, 114
 Fredet-Ramstedt pyloromyotomy in hypertrophic pyloric stenosis, 1614, 1614f
 Free tissue transfer, 1838–1840
 anastomosis in, 1838, 1839f
 end-to-end, 1839, 1839f
 end-to-side, 1839, 1839f
 occlusion of, 1838, 1839
 in facial nerve paralysis, 1865–1866
 fibula osteocutaneous
 in femoral fracture, 1878f
 in mandibular reconstruction, 601, 1863, 1864f–1865f
 in head and neck reconstruction, 601, 601f, 1863
 of mandible, 601, 1863, 1864f–1865f
 monitoring of circulation in, 1839–1840, 1839t
 no-reflow phenomenon in, 1840
 thrombosis affecting, 1838, 1838t, 1839
- French Federation of Cancer Centers soft tissue sarcoma classification system, 1470
- Freud, Sigmund, 1896
- Frey procedure in chronic pancreatitis, 1386, 1387, 1388f, 1390
- Froment's sign, 1806
- Frontal sinus fractures, 1855, 1856f
- Frostbite, 480–481
- Fruchaud myopectineal orifice, 1497, 1498f
- Fructose, 48, 1141, 1142f
 transport of, 1141, 1142f
- Frugardi, Roger, 1521
- Fundoplication procedures, 973–980
 anterior partial, 976, 978–979
 in children, 1613
 in esophageal motility disorders, 995, 995f
 and Heller myotomy, 997–999, 1000, 1001f
 outcome assessment in, 1001, 1002t, 1003
 in hiatal hernia, 983
 Nissen technique, 974–975. *See also* Nissen fundoplication
 outcome in, 977–978
 in scleroderma of esophagus, 984–985
 Toupet technique, 975–976
 esophageal myotomy with, 999, 1000, 1001f
- Fungal ball
 pulmonary, 655, 657f
 sinus, 569–570, 570f
- Fungal infections, 140, 140t, 141t
 of bladder, 390
 of breast, 506
 drug therapy in, 140, 141t
 pharyngitis in, 571
 pulmonary, 655–658
 sinusitis in, 569–570, 570f
 in transplant recipients, 329
- Furlow palatoplasty in cleft palate, 1844, 1845f
- Furuncles, 483
- Fusion surgery, spinal, 1743, 1743f
- G**
- G cells of stomach, 1041
 gastrin secretion of, 1041, 1045
 in regulation of gastric acid secretion, 1044f
- Gabapentin in pain, 1950t
- Gail model on breast cancer risk, 296–297, 512, 512t
- Gait trendelenburg, 1772
- Galactose, 48, 1141, 1142f
 transport of, 1141, 1142f
- Galanin, 1346, 1350
- Galen of Pergamum, 241, 497
- Gallbladder
 absorption in, 1313
 adenomyomatosis of, 1320

- Gallbladder (*Cont.*):
 anatomy of, 1309–1310, 1310f
 anomalies in, 1312
 anesthesia in disorders of, 1907
 in biliary atresia, 1628
 cancer of, 1293, 1334–1335
 clinical manifestations and diagnosis of, 1334–1335
 epidemiology of, 275t
 etiology of, 1334
 incidence of, 1334
 pathology in, 1334, 1334f
 prognosis in, 1335
 recurrent, 1335
 treatment of, 1335
 cholecystectomy of. *See* Cholecystectomy
 cholecystitis of. *See* Cholecystitis
 cholecystokinin affecting, 1313, 1314f
 computed tomography of, 1315
 disease in Mongolia, 1974
 emphysematous, 1320
 empyema of, 1320
 functions of, 1313
 hydrops of, 1319
 lymphatics, 1309–1310
 magnetic resonance imaging of, 1315
 motor activity of, 1313
 neurohormonal regulation of, 1313
 porcelain, 1317–1318
 carcinoma risk in, 1334
 radionuclide scans of, 1315
 secretions of, 1313
 sludge in, 1319–1320
 strawberry, 1320
 trauma of, 204, 1331–1332
 ultrasonography of, 1314, 1314f, 1320, 1321f
- Gallium nitrate in hypercalcemia, 1573t
- Gallstones, 1316–1327
 carcinoma of gallbladder in, 1334
 cholangiography in
 endoscopic retrograde, 1315, 1317f
 intraoperative, 1325, 1327f
 cholangitis in, 1322–1323
 cholecystectomy in, 1324–1325
 in acute cholecystitis, 1321
 and bariatric surgery in obesity, 1105
 in chronic cholecystitis, 1320
 complications of, 1324
 contraindications to, 1324
 laparoscopic, 1320, 1321, 1324, 1325, 1326f
 open procedure, 1320, 1321, 1324, 1325
 in pancreatitis, 1358–1359
 cholecystitis in, 1319–1321
 acute, 1320–1321
 chronic, 1319–1320
 cholecystography in, oral, 1314
 cholecystostomy in, 1321, 1324f
 choledocholithiasis in, 1321–1322
 cholesterol stones, 1317, 1318, 1318f
 epidemiology of, 1316–1317
 formation of, 1318–1319
 natural history in, 1317–1318
 in obesity, 1105
 pain in, 1319
 common sites of, 1319, 1319f
 pancreatitis in, 1324, 1351–1352
 Ranson criteria on, 1356t
 treatment of, 1358–1359
 pigment stones, 1317, 1318–1319
 black, 1318
 brown, 1318–1319
 postoperative, in gastric surgery, 1094
 in pregnancy, 1320
 ultrasonography in, 1314, 1314f, 1319–1320, 1321f
- Gammopathies, monoclonal, platelet dysfunction in, 92
- Ganglioglioma, 1735
- Ganglion cell tumors, mediastinal, 677t, 678
- Ganglion cysts of hand and wrist, 1815, 1815f
- Ganglioneuroblastoma, mediastinal, 678
- Ganglioneuroma, mediastinal, 678
- Gangrene, 149f, 151
 of foot, in aortoiliac occlusive disease, 874, 874f
 Fournier's, 484, 1663, 1663f
- Gardner's syndrome, 666, 1207, 1485
- Gas, intestinal, 1179
- Gases, arterial blood, 409
- Gastrectomy
 in biliopancreatic diversion procedure, 1120
 complications of, 1090–1094
 anemia in, 1094
 bile reflux gastritis in, 1093–1094
 bone disease in, 1094–1095
 diarrhea in, 1093
 dumping syndrome in, 1090–1092
 gallstones in, 1094
 gastric stasis in, 1093
 Roux syndrome in, 1094
 weight loss in, 1094
 ghrelin levels after, 1045, 1045f, 1046f
 in peptic ulcer disease, 1063, 1071f
 cancer in gastric remnant in, 1078
 sleeve, in obesity, 1103, 1104, 1121–1125
 complications in, 1124
 outcomes in, 1124
 patient selection and preparation in, 1121–1125
 postoperative care and follow-up in, 1123–1124
 technique in, 1121f, 1122–1123, 1122f, 1123f
 in stomach cancer, 1081–1082, 1081f, 1082f
 endoscopic procedure, 1083–1084
 reconstruction after, 1081, 1082f
 survival rates in, 1082, 1082t
- Gastric acid secretion. *See* Acid secretion, gastric
- Gastric arteries, anatomy of, 1037, 1038f
- Gastric banding
 adjustable, 1103, 1107, 1108–1112
 band adjustments in, 1111, 1111f
 with cholecystectomy for gallstones, 1105
 complications in, 1112
 diabetes mellitus resolution in, 1111, 1128
 in gastroesophageal reflux disease, 1128
 outcomes in, 1111–1112, 1112t
 patient selection and preparation in, 1110
 postoperative care and follow-up in, 1110–1111, 1111f
 pregnancy after, 1126
 technique in, 1108–1110, 1108f, 1109f, 1110f
 fixed, 1103
- Gastric bypass surgery, Roux-en-Y, 1112–1119
 in adolescents, 1125–1126
 annual number performed, 1104f, 1112
 configuration in, 1113, 1113f
 in fatty liver, 1129
 in gastroesophageal reflux disease, 1128
 historical development of, 1103
 laparoscopic, 1103, 1107, 1112–1118
 antecolic approach, 1114
 with cholecystectomy for gallstones, 1106
 compared to open procedure, 1118, 1118t
 complications in, 1116–1118, 1117t, 1118t
 creation of gastric pouch in, 1114, 1114f
 enteroenterostomy in, 1114f, 1116
 gastrojejunostomy in, 1115, 1115f
 stenosis of, 1118
 hematemesis in, 1118
 leaks in, 1118
 length of Roux limb in, 1114
 outcomes in, 1116–1118, 1117t, 1118t
 patient selection and preparation in, 1115
 port placement in, 1113–1114, 1113f
 postoperative care and follow-up in, 1115–1116
 retrocolic approach, 1114
 small intestine obstruction after, 1116f, 1117
 technique in, 1113–1115, 1113f, 1114f–1116f
 in metabolic syndrome, 1128
 open, 1107, 1118–1119
 with cholecystectomy for gallstones, 1105
 compared to laparoscopic procedure, 1118, 1118t
 complications in, 1118t, 1119
 outcomes in, 1118t, 1119
 patient selection and preparation in, 1118
 postoperative care and follow-up in, 1118–1119
 technique in, 1118
 outcomes in, 1112t
 in diabetes mellitus, 1116, 1127
 in laparoscopic procedure, 1116–1118, 1117t, 1118t
 pregnancy after, 1126
 small intestine intussusception in, 1170
- Gastric veins, anatomy of, 1037
- Gastrin
 elevated serum levels of. *See* Hypergastrinemia
 G cell secretion of, 1041, 1045
 in stimulation of gastric acid secretion, 1041, 1043, 1044f, 1045
- Gastrinoma, 1391–1392, 1392f
 diagnosis of, 1072–1073, 1073f, 1392
 familial, 1071
 locations of, 1071, 1073, 1073f, 1391f, 1392
 metastasis of, 1392
 sporadic or nonfamilial, 1073
 treatment of, 1392
 Zollinger-Ellison syndrome in, 1071–1073, 1391–1392
- Gastrin-releasing peptide, 1045
- Gastritis, 1073–1074
 atrophic, 1077, 1077f
 in bile reflux, 1093–1094
 etiologies of, 1073–1074

- in *Helicobacter pylori* infections, 1054, 1076f
- in stress, 1073–1074
- Gastrocolic ligament, 1457
- Gastrooduodenal artery
 - anatomy of, 1344–1345
 - pseudoaneurysm of, 1376f
- Gastrooduodenostomy in peptic ulcer disease, 1063, 1067f
 - cancer of gastric remnant in, 1078
- Gastroenteritis, acute, differential diagnosis in, 1246
- Gastroenterostomy, cancer of gastric remnant in, 1078
- Gastroepiploic artery, anatomy of, 1037, 1038f
- Gastroepiploic vein, anatomy of, 1037
- Gastroesophageal flap valve, endoscopic appearance of, 950, 952f–953f
- Gastroesophageal junction, anatomy of, 1035
- Gastroesophageal reflux, 964–980
 - adenocarcinoma in, 967, 969, 970f, 979
 - antireflux surgery in, 965–967, 973–980. *See also* Antireflux surgery
 - Barrett's esophagus in, 967, 967t, 969, 1003
 - antireflux surgery in, 969, 972
 - outcome of, 979, 979t
 - reoperation of, 979–980
 - drug therapy in, 971
 - endoscopy in, 950, 951f
 - bile acid concentration in, 967–968, 968f
 - bilirubin exposure in, 968, 968f
 - in children, 1613
 - in esophageal atresia and tracheoesophageal fistula, 1612
 - cobblestone appearance in, 950, 951f
 - complications of, 967–972, 967t
 - endoscopy in, 950, 951f
 - diaphragmatic repair, 983
 - duodenal origin of, 967–968, 968f
 - endoscopy in, 950, 951f
 - eosinophilic esophagitis in, 986–987, 986f
 - esophageal impedance in evaluation of, 955
 - esophageal rupture in, 1018
 - esophagitis in, 967, 967t, 968, 969
 - endoscopy in, 950, 951f
 - and hiatal hernia, 966–967, 966f
 - antireflux surgery in, 983
 - clinical manifestations in, 981–982
 - pathophysiology in, 982
 - indications for surgery in, 972
 - lower esophageal sphincter function in, 949, 965–966, 966f
 - and indications for surgery, 972
 - medical therapy in, 971
 - in obesity
 - bariatric surgery affecting, 1116, 1128
 - preoperative evaluation of, 1105
 - pathophysiology in, 964–965
 - in hiatal hernia, 982
 - pH monitoring in, 961–963, 967, 968f
 - gastric and esophageal, 964, 964f
 - in respiratory disorders, 971
 - physiologic, 949–950
 - preoperative evaluation in, 972–973
 - principles of surgical therapy in, 973–974
 - radiographic detection of, 963
 - respiratory disorders in, 969–972
 - antireflux surgery in, 971
 - in aspiration of gastric contents, 970–971
 - pH monitoring in, 971
 - reflex mechanisms in, 970–971
 - and Schatzki's ring, 984
 - and scleroderma of esophagus, 985
 - selection of procedure in, 974
 - stepwise approach to therapy in, 971–972
 - symptoms in, 964, 965t
 - in hiatal hernia, 981–982
 - preoperative evaluation of, 972–973
- Gastrohepatic ligament, 1037, 1265, 1265f, 1457
- Gastrointestinal stromal tumors, 1481–1485
 - colorectal, 1216
 - genetic factors in, 1482
 - localized, 1482
 - locally advanced, 1482–1483
 - metastatic, 1482–1483
 - multidisciplinary approach to, 1483, 1483f
 - prognostic factors in, 1482
 - of small intestine, 1159, 1160, 1161f, 1161t
 - outcome in, 1162
 - treatment in, 1162
 - of stomach, 1074, 1084–1085, 1086f
- Gastrointestinal tract
 - bacteria in, 137, 1179
 - in necrotizing enterocolitis, 1619–1620
 - translocation of, 151
 - diverticulum of. *See* Diverticulum
 - embryonic development of, 1175–1176, 1616–1617
 - midgut in, 1175, 1179, 1616–1617
 - small intestine in, 1139–1140, 1140f
 - endogenous microflora of, 137
 - enterocolitis of, necrotizing, 1619–1621
 - gastrointestinal disorders in
 - in inguinal hernia repair, 1516
 - healing of wounds in, 249, 250f, 250t
 - in anastomosis, 249
 - compared to skin healing, 250t
 - hemorrhage from. *See* Hemorrhage, gastrointestinal
 - Hirschsprung's disease of, 1624–1626, 1626f
 - in hyperparathyroidism, 1561
 - intestinal duplications in, 1624
 - intestinal perforation of
 - in necrotizing enterocolitis, 1620, 1621
 - spontaneous, 1621
 - intestinal transplantation procedure, 352–354, 353f–354f
 - living donor in, 332
 - in short bowel syndrome, 1172
 - intussusception of. *See* Intussusception
 - large intestine in, 1175–1236. *See also* Large intestine
 - malrotation of, 1616–1617
 - multivisceral transplantation, 352–354
 - obstruction of, 1146–1151
 - double bubble sign in, 1615, 1615f
 - in inguinal hernia, 1505
 - in Meckel's diverticulum, 1163f, 1164
 - in neonates, 1614–1615
 - in pancreatic cancer, 1399
 - postoperative, 386
 - in bariatric surgery, 1116f, 1117
 - in inguinal hernia repair, 1515–1516
 - pediatric disorders of, 1613–1628
 - peritoneal adhesions affecting, 263
 - postoperative disorders of, 386–387
 - in bariatric surgery, 1116, 1116f
 - ileus, 1151–1153
 - in inguinal hernia repair, 1515–1516
 - nausea and vomiting, 1914, 1915, 1916f
 - small intestine obstruction, 1149–1150
 - sarcomas of, 1480–1481
 - short bowel syndrome of, 1621
 - small intestine in, 1137–1174. *See also* Small intestine
 - stomach in, 1035–1095. *See also* Stomach
 - stromal tumors of, 1480–1481. *See also* Gastrointestinal stromal tumors
 - trauma of, 207, 209–210
 - damage control surgery in, 195
 - emergent abdominal exploration in, 191
 - in inguinal hernia repair, 1515–1516
 - in laparoscopy, 1705
 - wound healing in, 249, 250f, 250t
 - volvulus of. *See* Volvulus
- Gastrojejunostomy
 - in bile reflux gastritis, 1093–1094
 - in Crohn's disease, 1157
 - dumping syndrome in, 1092
 - in laparoscopic Roux-en-Y gastric bypass, 1115, 1115f
 - stenosis of, 1118
 - in peptic ulcer disease, 1062, 1063f
 - Billroth technique, 1063, 1067f
 - Roux-en-Y technique, 1063, 1068f
 - Roux syndrome in, 1094
 - in stomach cancer, 1081
 - volvulus of. *See* Volvulus
- Gastroparesis, 1087
 - in diabetes mellitus, 1087
 - etiologies of, 1087t
 - postoperative, 1093
- Gastropathy, hypertrophic, 1088, 1088f
- Gastroplasty
 - Collis
 - in hiatal hernia, 983
 - in scleroderma of esophagus, 985
 - vertical banded, 1103, 1108
- Gastroschisis, 1453, 1631, 1633–1634, 1633f
 - anomalies associated with, 1633
 - clinical presentation of, 1633, 1633f
 - fluid requirements in, 1599, 1633
 - prenatal ultrasonography in, 1633, 1633f
 - treatment of, 1633–1634, 1633f
 - silos device in, 1633, 1633f
- Gastrosplenic ligament, 1425, 1425f, 1457
- Gastrostomy, 1090
 - open technique, 56, 1090
 - percutaneous endoscopic, 55–56, 1090, 1091f
 - complications of, 56
 - indications for, 55
 - Janeway technique, 1090, 1092f
 - with jejunostomy, 56
 - placement of, 55–56
 - Stamm technique, 1090, 1090f
 - Witzel technique, 1090
- Gateway technology, 457
- Gatifloxacin, 257t
- Gaucher's disease, splenectomy in, 1430t, 1437–1438
- GDNF* in Hirschsprung's disease, 1624–1625
- Gefitinib, 310t

- Gelatin, 1911
in topical hemostatic agents, 96
- Gelofusine in resuscitative fluids, 76*t*, 77
- Gemcitabine
in pancreatic cancer, 1400, 1407
in soft tissue sarcoma of extremity, 1476
- Gene array, 460
- Gene chips, 460, 461*f*
- Gene knockout in mice, 464–466, 465*f*
- Genes
analysis of
animal models in, 463–467
DNA microarray technology in, 459–460, 461*f*
expression and regulation of, 446–449
in breast cancer, 536
in cancer initiation, 278–279, 280*f*
in metastasis, 285
in shock, 115, 119
in human genome, 449
manipulation of, 463–468
metastasis-suppressor, 287
mismatch repair, 292
oncogenes, 278, 279–281, 287
tumor suppressor, 278, 280*f*
in hereditary cancer syndromes, 287–291
- GeneSearch Breast Lymph Node Assay, 541
- Gene therapy, 1917–1919
in cancer, 311*f*, 312, 455–456
of pancreas, 1408
vector systems in, 312, 455
in coronary artery disease, 747
in situ, 455
in wound healing, 267–268
- Genetic code, 447, 448*t*
- Genetic factors
in aortic aneurysms, thoracic, 787, 792
in biliary atresia, 1628
in breast cancer, 512
expression of, 536
health insurance concerns in, 516
in hereditary syndromes, 288*t*, 291, 514–517, 514*t*
as predictive markers, 301–302
prophylactic mastectomy in, 513, 514
risk assessment in, 296
in cancer, 287–291
and gene therapy, 311*f*, 312, 455–456
Knudson's two-hit hypothesis on, 287, 287*f*
somatic mutations in, 286, 286*f*
surgical prevention in, 315
and targeted therapy, 309, 310*t*
in colorectal cancer, 1183, 1204–1207
CpG island methylation, 1205
in heterozygosity loss, 1205
in replication errors, 1205
in Crohn's disease, 1153
in dermatofibrosarcoma protuberans, 1485
in Ehlers-Danlos syndrome, 248*t*, 902
in gastrointestinal stromal tumors, 1482
in Graves' disease, 1531
in head and neck tumors, 580
in Hirschsprung's disease, 1625
in hyperparathyroidism, 1560
in kidney cancer, 1656
manipulation of, 463–468
in Marfan's syndrome, 248, 902
in neuroblastoma, 1640
in neuroectodermal tumors, primitive, 669
in ovarian cancer, 288*t*, 291, 515, 1701
risk management in, 516–517, 1701
in pancreatic cancer, 1395
in therapy, 1408
in pancreatitis, 1352, 1360–1362
in pheochromocytoma, 1586, 1587
in polycystic liver disease, 1288
in polyposis, familial adenomatous, 288*t*, 291, 1183, 1206–1207
in pseudoxanthoma elasticum, 902
in rhabdomyosarcoma, 1486
in small intestine neoplasms, 1159
in soft tissue sarcoma, 1467–1468
in stomach cancer, 1075–1076, 1077*t*, 1078
in thyroid cancer, 1539*t*, 1540, 1541*f*, 1541*t*, 1542
follicular, 1545
medullary, 1549*t*, 1550
papillary, 1543
of thyroid, in solitary nodule, 1537
in venous thromboembolism, 918–919
in Wilms' tumor, 1638
- Genetic instability, 446
- Genetic testing for *BRCA* mutations, 515–516
- Gengraf and Neoral, 328
- Genitalia, ambiguous, 1637–1638
- Genitofemoral nerve, anatomy of, 1498–1499, 1498*f*, 1499*f*
- Genome, 448
human, 449
- Genomics, 444*f*, 449
functional, 449
in personalized medicine, 468
- Genotoxins, 293
- Genotype
in gene knockout mice, 466
and phenotype correlations, 291
in transgenic mice, 464
- Gentamicin, 144*t*, 257*t*
in pelvic inflammatory disease, 1690*t*
- Geriatric patients. *See* Elderly
- Germ cell tumors, 1641
of central nervous system, 1737
mediastinal, 678–679
biomarkers in, 672
incidence of, 673*t*
signs and symptoms in, 674*t*
ovarian, 1637, 1703–1704
testicular, 1654–1655
- Germ theory of Pasteur, 135
- Gestational trophoblastic disease, 1693–1694
- Ghon complex, 654
- Ghrelin, 22, 1045, 1047, 1348
in appetite regulation, 1045, 1350
functions of, 1349*t*, 1350
serum levels of, 1045
in bariatric surgery, 1045, 1046*f*
in gastrectomy, 1045, 1045*f*, 1046*f*
- Giant cell arteritis, 788, 901
- Giant cell tumors
of bone, 1780–1781, 1780*f*, 1816*f*, 1819
of tendon sheath in hand, 1815–1816, 1816*f*
- Giardia lamblia* infections, anorectal, 1233
- Gibbs-Donnan equilibrium equation, 66
- Gigantomastia, 507
- Gilbert syndrome, 1272
- Gilula's arc, 1794, 1794*f*, 1798
- Gimbernat ligament, 1496
- Gingiva, tumors of, 585
- Gingivoperiosteoplasty, 1843
- Glanzmann thrombasthenia, 89
- Glasgow Coma Scale, 168, 170*t*, 1711, 1712*t*
in head trauma, 195, 1712*t*, 1715, 1717, 1718
in children, 1643
in initial assessment, 1717, 1718
- Gleason scoring of prostate cancer, 1657–1658
- Gleevec, in myeloid leukemia, chronic, 455, 455*f*
- Glenn shunts
in hypoplastic left-heart syndrome, 718*f*
in tricuspid atresia, 713–715, 714*f*
- Glial tumors, 1733–1734, 1734*f*
- Glide scope, 1910, 1912*f*
- Glioblastoma multiforme, 1733, 1734*f*
- Glisson's capsule, 1264
- Global surgery
academic training in, 1977, 1978*f*
assigning disease priorities, 1968, 1970*t*
benefits for economic productivity, 1955
burden of disease, 1957–1960, 1959*f*
burns and, 1960
cancer and, 1958, 1970–1976, 1973*t*
definitions of terminology related to, 1956–1963
ecosystem of, 1956–1957
components of, 1957, 1958*f*
electricity in, 1957
emergency care, 1969
ethics, 1977–1978
future trends in, 1978–1979
healthcare workers for, 1960–1963, 1961*f*, 1962*f*, 1963*f*, 1971*t*
innovation in, 1978, 1978*f*
international organizations in, 1963–1966
introduction of, 1955–1979
millennium development goals, 1963, 1964*t*
outreach and engagement initiatives, 1963, 1964*f*
priorities of, 1956, 1957*f*
and public health, 1968–1970, 1969*f*, 1970*t*
safety checklist, 1969*f*
strategies for, 1963–1978
trauma and, 1958–1960, 1968–1969, 1970*t*
violence and injury prevention program, 1963, 1965
and world health organization, 1964, 1968
worldwide distribution of, 1956*f*
- Glomerular filtration rate in children, 1599
- Glossectomy in tongue cancer, 584, 587
reconstructive surgery after, 1862–1863
- Glottis
anatomy of, 579, 589, 589*f*
tumors of, 590, 591
laryngeal preservation techniques in treatment of, 591
laryngectomy in, 590*f*
- Glucagon, 1348
deficiency in chronic pancreatitis, 1373
functions of, 1349*t*
secretion of, 1350
serum levels in glucagonoma, 1393
Glucagon-like peptide 2 (GLP-2), 1145, 1146*t*
- Glucagonoma, 1393
- Glucocorticoid receptor, 19*f*, 20–21
- Glucocorticoids, 1576–1577, 1578*t*
functions of, 1577, 1578*t*
synthesis of, 20*f*

- Gluconeogenesis
 in injury, 46*f*
 in starvation, 45–46, 45*f*
- Glucose, 1141, 1142*f*
 administration of, 48
 excessive, 48–49
 in hyperkalemia, 78, 78*t*
 in parenteral nutrition, 59
 blood levels of
 in anesthesia management, 1908
 in burns, 233
 in critical illness, 22
 in hyperglycemia. *See* Hyperglycemia
 in hyponatremia, 69
 in injury, 49, 1718
 liver functions affecting, 1269
 in pancreas transplantation, 340
 in parenteral nutrition, 58
 postoperative, 392
 in septic shock, 125
 intolerance in parenteral nutrition, 59
 metabolism of
 in fasting, 44
 in injury, 48–50, 49*f*
 and osmolality of body fluids, 67
 tolerance tests, 1349
 transport and signaling, 50, 50*t*, 1141, 1142*f*
 urine levels in parenteral nutrition, 58
- Glucose-dependent insulinotropic polypeptide, 1349
- Glucose-6-phosphate, 48, 49*f*
- Glucose-6-phosphate dehydrogenase deficiency, splenectomy in, 1430*t*, 1431
- Glucose transporters (GLUTs), 50, 50*t*, 1141, 1142*f*
- Glucuronyl transferase, 1628
- Glutamic-oxaloacetic transaminase, 1271
- Glutamic-pyruvic transaminase, 1271
- Glutamine, 53–54, 1142
- γ -Glutamyltranspeptidase serum levels in liver disorders, 1270, 1271
- Gluteus maximus myocutaneous flap in pressure ulcers, 1880–1881, 1881*f*
- Glycerol as fuel, 47
- Glycogen
 in liver, 44, 44*t*, 45*f*
 in muscle, 44, 50
- Glycogen in, 44*t*, 45*f*
- Glycogenolysis, 45
- Glycopeptides, 144*t*
- Glycoprotein ligand-1, 40
- Glycosaminoglycans, 245
- Goblet cells
 in small intestine, 1139
 in tracheobronchial tree, 612
- Goiter
 historical aspects of, 1521
 intrathoracic, 1554
 sternotomy in, 1554, 1554*f*
 mediastinal, 1554
 nontoxic, 1536–1537, 1536*t*, 1538*f*
 toxic
 diffuse, 1531–1533
 multinodular, 1533
- Goldenhar's complex, 1602
- Gonadal dysgenesis, mixed, 1638
- Gonadotropin, chorionic
 in cryptorchidism, 1636
 in gestational trophoblastic disease, 1694
 in pregnancy test, 1677
- Gonadotropin-releasing hormone, 504
- Gonadotropin-releasing hormone agonists
 in endometriosis, 1690
 in leiomyoma of uterus, 1690
- Gonorrhea, proctitis in, 1232
- Goodsall's rule on fistula in ano, 1229, 1229*f*
- GPC3* gene in Simpson-Golabi-Behmel syndrome, 288*t*
- G-protein, 35*f*, 452
- Graafian follicle rupture, 1246
- Gracilis muscle transposition in anal sphincter injury, 1235
- Grafts
 bone, in spinal arthrodesis, 1743
 composite tissue, 1833, 1881–1882
 skin, 264–265, 266, 1832–1833. *See also* Skin grafts
 vascular, 192, 200, 210, 211
 in aortic aneurysm, 853, 853*f*, 854*f*
 in aortoiliac occlusive disease, 876–877, 878
 in femoropopliteal occlusive disease, 898
 in renal artery occlusive disease, 869–870
 stent grafts in. *See* Stent grafts
- Gram-negative bacteria, 140, 140*t*
- Gram-positive bacteria, 140, 140*t*
- Gram's stain, 139–140
- Granular cell tumors, 486
- Granulocyte-macrophage colony-stimulating factor, 28*t*, 30–31, 247*t*
- Granuloma
 eosinophilic, of chest wall, 666
 inguinale, 1232, 1678, 1679*t*
 laryngeal, 572–573, 572*f*
 mediastinal, 674*t*
 pulmonary, 622
 in histoplasmosis, 659, 660*f*
 in tuberculosis, 654
- Granulomatous disease, chronic, 258
- Granulosa cell tumors, 1637, 1704
- Grassi criminal nerve, 1039
- Graves' disease, 1531–1533
 clinical features in, 1531, 1532*f*
 diagnostic tests in, 1529, 1531–1532
 treatment of, 1532–1533
- Great Ormond Street Score in Ebstein's anomaly, 719
- Greenfield filter in pulmonary embolism, 386
- Grey Turner's sign, 1356
- Grief and mourning, 1951
- Griffith, Harold, 1897
- Gross, Robert E., 1597
- Ground substance, 475
- Growth factors in wound healing, 246, 247*t*, 259
 in bone injuries, 251
 fetal, 252
 in hypertrophic scars and keloids, 262
 in nerve injuries, 251
 therapeutic use of, 267
- Growth hormone, 21–22
- Growth hormone-releasing hormone, 21
- Growth plate of bones, injuries of, 1782
- Guanosine monophosphate, cyclic, 41, 43*f*
- Guedel, Arthur, 1897
- Guidewires in endovascular therapy, 835
- Guillain-Barré syndrome, 1745–1746
- Gunshot wounds, 174
 abdominal, 180
 in pregnancy, 221
 of chest, 178–179, 202
- hemorrhage and persistent hypotension in, 172
- Gustilo and Anderson classification of fractures, 1876, 1876*t*
- Gut-associated lymphoid tissue, 1143, 1144*f*
- Gut hormones, 1145
- Gynecologic disorders, 1671–1705
 anatomy in, 1671–1675
 diagnosis of, 1675–1678
 biopsy in, 1677–1678
 history-taking in, 1675, 1676*t*
 in fistulae, 1678
 hysterectomy in, 1684
 hysteroscopy in, 1683–1684
 in infections
 pelvic inflammatory disease in, 1690–1691
 screening for, 1676–1677
 ulcer syndromes in, 1678, 1679*t*
 myomectomy in, 1684
 in neoplasms, 1696–1704
 in obesity, 1126
 pathophysiology and disease mechanisms in, 1671
 in pelvic organ prolapse, 1694–1695
 physical examination in, 1675–1676, 1676*f*
 bimanual, 1676, 1676*f*
 with speculum, 1675
 in ulcer syndromes, 1678, 1679*t*
 urinary incontinence in, 1695
- Gynecomastia, 505–506
 breast cancer risk in, 555
 clinical classification of, 505
 pathophysiology of, 505, 505*t*
 refeeding, 505
 surgical treatment in, 1891
- H**
- Haemophilus ducreyi* infections, chancroid in, 1678, 1679*t*
- Hageman factor (factor XII), 86, 87, 99*t*, 103
- Hair follicles, 474
- Hairy cell leukemia, splenectomy in, 1430*t*, 1434
- Hall, Richard, 1896
- Halothane, 1902, 1902*t*
 hepatotoxicity of, 1907
 malignant hyperthermia from, 1917
- Halstead's concept of surgical mentor, 10
- Halsted radical mastectomy, 498–499, 547
- Halsted theory on lymphadenectomy in cancer, 305
- Halsted, William, 498, 1896
- Hamartoma
 of bile duct, 1291
 of breast, 509
- Hamburg procedure in chronic pancreatitis, 1386, 1389*f*
- Hand, 1787–1825
 anatomy of, 1787–1793, 1790*f*
 bite wounds of, 1812
 bones in, 1787–1788, 1790*f*
 fractures of, 1796–1798
 burns of, 1820–1822, 1822*f*
 reconstructive surgery in, 1821–1822, 1821*f*, 1822*f*
 congenital anomalies of, 1823–1824
 degenerative joint disorders of, 1806–1808
 Dupuytren's contracture of, 1808–1809
 examination of, 1793–1794, 1793*f*

- Hand (*Cont.*):
 fractures in, 1796–1798
 Jahss maneuver in, 1796, 1798*f*
 nonunion of, 1801, 1805
 types of, 1798*f*
 imaging of, 1794–1795
 infections of, 1794, 1809–1814
 diagnostic algorithm on, 1814*f*
 joint space, 1810
 necrotizing, 1811
 osteomyelitis in, 1810–1811
 palmar space, 1810
 web space, 1810, 1811*f*
 mallet finger in, 1798
 motions of, 1788, 1789*f*, 1793–1794
 stiffness in, 1805
 muscles in, 1788–1791
 nerves in, 1792–1793
 compression of, 1805–1806
 injuries of, 1798–1799, 1805
 neuroma in, 1805
 reconstructive surgery of
 in burns, 1821–1822, 1821*f*, 1822*f*
 in fingertip injuries, 1801,
 1802*f*–1804*f*, 1833, 1836*f*
 interpolation flaps in, 1833, 1836*f*
 tendons in, 1791
 examination of, 1793
 inflammation of, 1811–1813, 1812*f*,
 1813*f*
 injuries of, 1798
 tenodesis maneuver in, 1798
 zones in, 1798, 1800*f*
 and pulley system, 1791, 1791*f*
 tenosynovitis of flexor, 1811–1813,
 1812*f*, 1813*f*
 trauma of, 1795–1799
 amputation and replantation in, 1800,
 1802*f*–1804*f*
 in bites, 1812
 in burns, 1820–1822
 of fingertips, 1800–1801, 1800*f*,
 1802*f*–1804*f*
 interpolation flaps in, 1833, 1836*f*
 in high pressure injection injuries,
 1801
 local anesthesia in, 1795–1796,
 1797*f*
 reconstructive surgery in, 1801,
 1802*f*–1804*f*
 splints in, 1796, 1799*f*, 1805
 stiffness and limited mobility in,
 1805
 tumors of, 1814–1820, 1815*f*, 1816*f*
 biopsy in, 1815
 diagnosis of, 1815–1816
 melanoma, 488, 1818
 vascular supply of, 1791–1792, 1792*f*
 disorders in, 1822–1823
 injuries of, 1799, 1821–1822
- Hand-assisted laparoscopy, 1187
 access for, 423, 424*f*
 splenectomy in, 1441, 1443
- Handoff communication, 369
 sign outs in, 371–372
- Hand washing for infection control, 135
- Hangman's fracture, 1722, 1770
- Harris-Benedict equation, 51, 232–233
- Hartley-Dunhill procedure in
 hyperthyroidism, 1533
- Hartmann's procedure, 210, 1189, 1193
- Hashimoto's thyroiditis, 1529, 1535–1536
- Hasson technique in laparoscopy, 422
- Headache in subarachnoid hemorrhage,
 1730
- Head and neck disorders, 565–602
 in adenotonsillar hyperplasia,
 obstructive, 571
 benign, 565–575
 in children, 1840–1852
 of ears, 565–567, 594–595, 1855–1856
 in hemorrhage. *See* Hemorrhage,
 intracranial
 of larynx, 572–574, 589–591
 of lips, 579, 580, 582, 1856
 long-term management and
 rehabilitation in, 602
 of nose and paranasal sinuses, 567–570,
 592–593, 1855, 1856
 of pharynx, 570–571
 plastic and reconstructive surgery in.
 See Head and neck plastic and
 reconstructive surgery
 tracheostomy in, 602
 in trauma, 195–197, 575–578,
 1715–1721. *See also* Head trauma
 in tumors, 578–600, 1862–1863
 anatomy and histopathology in, 578,
 579*f*
 carcinogenesis in, 580
 epidemiology of, 578
 etiology of, 578
 follow-up care in, 602
 genetic factors in, 580
 intracranial, 1732–1737
 lymph node metastasis in, 595–597,
 595*f*, 596*f*, 597*f*
 second primary tumors in, 580
 staging of, 580, 581*t*
 of unknown primary site, 592
 of upper aerodigestive tract, 580–592
 in vascular lesions, 574–575
- Head and neck plastic and reconstructive
 surgery, 600–602, 1860–1865
 aesthetic, 1882–1883
 blepharoplasty and browlift in,
 1882–1883
 browlift in, 1882–1883, 1883*f*
 in children, 1840–1852
 in cleft lip and palate, 1840–1844
 complications in, 1863, 1865
 composite tissues in, 1834*f*, 1881–1882,
 1882*f*
 of ears, 1855–1856
 of eyelids, 1858–1860, 1882–1883
 facelift in, 1883, 1883*f*, 1884*f*
 in facial fractures, 1852–1855, 1853*f*,
 1854*f*, 1856*f*
 free flaps in, 601–602, 601*f*, 1863
 in mandibular reconstruction, 601,
 1863, 1864*f*–1865*f*
 of lips, 580, 582, 582*f*, 583*f*, 1856
 local flaps in, 600
 nasal, 1856, 1883
 reanimation in, 1865–1866
 regional flaps in, 600
 rhinoplasty in, 1883
 skin tension lines in, 1830*f*
 skull and scalp reconstruction in, 1860
 in tumors, 580, 583*f*, 600–602, 1861
 of buccal mucosa, 586, 1863
 in floor of mouth, 584–585, 585*f*,
 1862
 free tissue transfer in, 601–602, 601*f*
 of larynx, 591, 591*f*
 of lip, 582, 582*f*, 1856
 of temporal bone, 594–595
 of tongue, 583, 583*f*, 587, 1862
- Head trauma, 195–197, 575–578,
 1715–1721
- brain death in, 1721
 in children, 222, 1643
 classification of, 1718
 closed injury in, 1717–1719
 concussion in, 1718
 contusion in, 1718–1719, 1718*f*
 diffuse axonal injury in, 1719
 in elderly, 221–222, 1935, 1935*f*
 epidural hematoma in, 175*f*, 1719
 burr hole placement for
 decompression in, 195, 197*f*
 evaluation of, 174–175, 175*f*
 in initial assessment, 1717–1718
 facial fractures in, 197, 197*f*, 576–578,
 576*f*–578*f*
 panfacial, 1855
 reconstructive surgery in, 1852–1855,
 1853*f*, 1854*f*, 1856*f*
 Glasgow Coma Scale in, 195, 1712*t*,
 1715, 1717, 1718
 in children, 1643
 in initial assessment, 1717, 1718
 hemorrhage in, 195, 197, 1720
 in scalp injuries, 166, 173, 1715
 intracranial, 195–197
 intracranial pressure increase in, 195,
 197, 411
 lacerations in, 575–576, 575*f*–576*f*
 of scalp, 166, 173, 1715
 maxillofacial, 197, 197*f*
 medical management of, 1718
 neurologic monitoring in, 411, 412
 penetrating, 175, 1719
 scalp injury in, 1715, 1860, 1862*f*
 hemorrhage in, 166, 173, 1715
 seizures in, 1718
 skull fractures in, 1715–1717
 soft tissue injuries in, 575–576
 subdural hematoma in, 1719–1720
 vascular injuries in, 1720
 wound closure in, 575–576, 575*f*–576*f*
- Healing process, 241–268
 in bones, 249–251
 in burns, 234, 1820
 in cartilage, 251
 cellular events in, 1831
 in connective tissue diseases, 246–249
 delayed, 252, 252*f*
 epithelialization in, 245–246, 245*f*, 1831
 excessive, 261–263
 factors affecting, 252–259, 253*t*
 fetal, 251–252
 in fractures, 249–251
 in gastrointestinal tract, 249
 growth factors in, 246, 267
 historical aspects of, 241
 impaired, 252, 252*f*
 incisional hernia in disorders of, 1455
 inflammatory response in, 242–244,
 242*f*, 243*f*, 1831
 fetal, 251
 matrix synthesis in, 242*f*, 243*t*, 244–245
 maturation and remodeling in, 242*f*, 245
 in nerves, 251
 phases in, 241–246, 242*f*, 1831
 in plastic and reconstructive surgery,
 1830–1832
 postoperative, 1832, 1832*t*
 preoperative and intraoperative
 management in, 1832, 1832*t*
 by primary intention, 252, 252*f*
 proliferation in, 242*f*, 243*f*, 244
 by secondary intention, 246, 252, 252*f*
 in tendons, 251
 by tertiary intention, 252, 252*f*

- Healthcare workers for global surgery, 1960–1963, 1961*f*, 1962*f*, 1963*f*, 1971*t*
- Health insurance concerns in hereditary breast cancer risk, 516
- Health Insurance Portability and Accountability Act (HIPAA), 516
- Health-related quality of life, 1944
- Heart
- acquired disorders of, 735–776
 - in aortic coarctation, 705–706
 - in aortic stenosis, 698–702
 - in aortopulmonary window, 711–712
 - arrhythmias of, 770–772. *See also* Arrhythmias
 - assessment of disorders, 735–740
 - on disability, 737, 737*t*
 - in noncardiac surgery, 737–738
 - atrial septal defect of, 695–698
 - atrioventricular canal defects of, 727–729
 - cardiomyopathy of. *See* Cardiomyopathy
 - catheterization. *See* Catheterization, cardiac
 - congenital disorders of, 695–729
 - in coronary artery disease, 741–747
 - in cor triatriatum, 710–711
 - double-outlet right ventricle of, 721–722
 - in ductus arteriosus patency, 702–705
 - in Ebstein's anomaly, 719–720
 - hypoplastic left-heart syndrome of, 716–719
 - in interrupted aortic arch, 729
 - mechanical circulatory support in disorders of, 768–770
 - myocardial disorders of. *See* Myocardium
 - neoplasms of, 774–776
 - metastatic, 776
 - myxomas, 775–776, 775*f*
 - pericardial disorders of, 772–774
 - physical examination in, 737
 - signs and symptoms in disorders of, 735
 - in Taussig-Bing syndrome, 723–724
 - in tetralogy of Fallot, 724–726
 - in total anomalous pulmonary venous connections, 707–710
 - total artificial, 770
 - transplantation of, 354–358
 - complications in, 356
 - evaluation of, 355
 - historical aspects of, 323, 354
 - in hypoplastic left-heart syndrome, 718
 - indications of, 355
 - with lung transplantation, 354–358, 664
 - organ preservation methods and time in, 331
 - postoperative care in, 356
 - surgical procedure in, 355–356
 - ventricular assist devices as bridge to, 769–770, 770
 - in transposition of great arteries, 720–721
 - trauma of, 201–202
 - blunt, 127, 171, 202
 - penetrating, 200*f*, 201–202, 201*f*
 - in truncus arteriosus, 706–707
 - valvular disorders of, 712–716, 747–751. *See also* Valvular heart disease
 - ventricular septal defect of, 726–727
- Heartburn in gastroesophageal reflux disease, 964–965, 965*t*, 969
- and hiatal hernia, 981
- outcome of surgery in, 977, 980
- postoperative recurrence of, 980
- Heart failure, 764–770
- in aortic stenosis, 758
 - in coronary artery disease, 742
 - epidemiology of, 764–765
 - etiology of, 765
 - mechanical circulatory support in, 768–770
 - in mitral insufficiency, 753
 - in obesity, 1128
 - pathophysiology in, 765
 - pleural effusions in, 680, 681*t*, 683*t*
 - pulmonary artery catheterization in, 406
 - signs and symptoms in, 736
 - total artificial heart in, 770
 - in tricuspid atresia, 713
 - ventricular assist devices in, 768
 - in ventricular septal defect, 727
- Heart Rhythm Society, 771
- Heart sounds
- in atrial septal defect, 697
 - in mitral stenosis, 752
- Heat applications for local hemostasis, 95
- Heat shock proteins, 19*f*, 20, 282
- Heineke-Mikulicz pyloroplasty
- in Crohn's disease, 1157, 1157*f*
 - in peptic ulcer disease, 1063, 1064*f*
- Heinz bodies, 1426
- Helicobacter pylori* infections
- gastric cancer in, 293, 1076*f*
 - risk for, 1074–1075
 - gastric lymphoma in, 1054, 1084
 - peptic ulcer disease in, 1051, 1054–1055, 1076*f*
 - diagnosis of, 1059, 1059*t*, 1061
 - pathophysiology in, 1054–1055, 1054*f*, 1055*f*, 1056*f*, 1057*f*
 - treatment of, 1059*t*, 1061, 1061*t*, 1062*t*
 - testing for, 1051, 1053*f*
 - fecal antigen test in, 1051
 - in peptic ulcer disease, 1059
 - urea breath test in, 1051, 1053*f*
- Heller, Ernst, 1000
- Heller myotomy, 997–999, 999*f*
- laparoscopic, 1000, 1001*f*–1002*f*
 - modified, 1000
 - outcome assessment in, 1003
- Hemangioblastoma, 1735–1736
- mural nodule in, 1736
- Hemangioendothelioma, 1780
- Hemangiomas, 485
- capillary, 575
 - in children, 574, 1849–1850, 1850*f*
 - of head and neck, 574–575, 1849–1850, 1850*f*
 - of liver, 1289–1290, 1290*f*
 - spinal extradural, 1737
- Hemangiopericytoma, 1780
- Hematemesis, postoperative, in
- laparoscopic Roux-en-Y gastric bypass, 1118
- Hematocele in testicular trauma, 1661
- Hematochezia, 1183
- Hematocrit, critical, 1914–1915
- Hematologic disorders, postoperative, 389–390
- Hematoma
- aortic intramural, 807*f*, 808–809
 - auricular, 576
 - in chest trauma, 177, 178*f*
 - duodenal, 207
 - epidural, 175*f*, 1719
 - burr hole placement for decompression in, 195, 197*f*
 - in skull fracture, 1715
 - in inguinal hernia repair, 1516
 - rectus sheath, 1453–1454, 1454*f*
 - in renal trauma, 1658*t*
 - subdural, 174, 1719–1720
 - acute, 1719
 - chronic, 1719–1720, 1720*f*
- Hematopoiesis, spleen functions in, 1428
- Hemihepatectomy
- left, 1299–1300
 - right, 1298–1299
- Hemispherectomy in epilepsy, 1747
- Hemobilia in liver trauma, 205
- Hemodilution, acute normovolemic, 1914–1915
- Hemodynamic monitoring, 399–412
- of arterial blood pressure, 400–401
 - of cardiac output and related parameters, 399, 402–409
 - normal range of values in, 404*t*
 - pulmonary artery catheterization for, 403, 403*t*
 - in valvular heart disease, 748*t*
- Hemoglobin, 97–98
- in anemia, 98, 1432
 - and oxygen dissociation curve, 1914, 1914*f*
 - oxygen saturation, 1914
 - arterial, 410
 - tissue, 409
 - polymerized human, 98
 - sickle cell, 1432
 - splenectomy in disorders of, 1432
 - in thalassemia, 1432
 - in trauma resuscitation, optimal level of, 216
- Hemolysis in transfusion reactions, 101, 102*t*
- Hemolytic anemia, 1272
- autoimmune
 - splenectomy in, 1430*t*, 1431–1432
 - warm-antibody, 1430*t*, 1431–1432
 - splenectomy in, 1430*t*, 1431–1432
 - outcome of, 1444
- Hemolytic uremic syndrome, 91
- Hemoperitoneum, massive, 166
- Hemophilia, 88–89
- Hemoptysis
- in aspergillosis, 657
 - in bronchiectasis, 653
 - in coccidioidomycosis, 661
 - in lung abscess, 651
 - massive, 661–663
 - anatomy in, 661
 - etiologies of, 661, 662*t*
 - treatment of, 661–663, 662*t*, 663*t*
 - urgent surgery in, 663, 663*t*
 - in tuberculosis, 655
- Hemorrhage
- in abdominal trauma, 181, 182*f*, 189–191
 - blood pressure in, 122
 - and mortality risk in, 120, 120*f*
 - in persistent hypotension, 171–172, 173
 - bloody vicious cycle in, 185, 193, 194*f*
 - in chest trauma, 201, 203
 - compensatory mechanisms in, 119
 - damage control surgery in, 193, 194*f*
 - excessive perioperative, 104

- Hemorrhage (*Cont.*):
 gastrointestinal, 386–387, 387*t*,
 1167–1168, 1183
 angiography in, 1181
 common causes of, 386–387, 387*t*
 in diverticula, 1201, 1203
 acquired, 1166
 Meckel's, 1164
 in gastric varices, 1088
 initial evaluation and management
 of, 1183
 in Mallory-Weiss tear, 1020, 1090
 massive, 1087–1088
 obscure, 1167–1168, 1169*f*
 occult, 1167, 1182, 1183
 in colorectal cancer, 1208–1209
 overt, 1167–1168
 in peptic ulcer disease, 1059–1061,
 1064–1068
 risk stratification in, 1059, 1060*t*
 treatment algorithms on, 1069*f*,
 1070*f*
 perioperative, 386–387
 from small intestine, 1167–1168
 treatment algorithms on, 1069*f*, 1070*f*,
 1169*f*, 1184*f*
 in head trauma, 195, 197, 1720
 in scalp injuries, 166, 173, 1715
 hemoptysis in, massive, 661–663
 hemostasis in, 95
 mechanical procedures for, 95
 thermal agents for, 95
 topical agents for, 96
 hemothorax in, 166, 166*f*
 identification of blood loss source in,
 120, 122, 172
 initial evaluation and management of,
 164–167
 intracranial, 1728–1732
 in amyloid angiopathy, 1730
 in arteriovenous malformations, 1731,
 1733*f*
 in cerebral aneurysms, 1728–1732
 in elderly, 1935, 1935*f*
 in head trauma, 195, 197
 in hypertension, 1729–1730
 in limb ischemia treatment
 complications, 888
 locations and symptoms in, 1729*t*
 subarachnoid, 1730–1731. *See also*
 Subarachnoid hemorrhage
 intraparenchymal, in head trauma,
 1720
 in kidney transplantation, 339
 in liver transplantation, 351
 neuroendocrine response to, 112
 in pancreaticoduodenectomy, 1407
 in pelvic fractures, 173, 181, 212–214
 in portal hypertension, liver
 transplantation in, 347
 postpartum, 1693
 resuscitation in, 121–123, 166
 damage control strategy in, 98, 100
 historical development of, 110
 in trauma, 166
 in scalp injury, 166, 173, 1715
 shock in, 110, 119–123. *See also* Shock,
 hypovolemic/hemorrhagic
 in transfusion reactions, 104
 transfusions in, 184
 indications for, 97–98
 in trauma, 184
 uterine, 1682
 endometrial ablation in, 1684
 in leiomyomas, 1682–1683
 vascular repair techniques in, 191–192,
 192*f*–193*f*
 volume of blood loss in, 98, 119, 120*t*,
 171, 173
 Hemorrhoidal venous plexus, 1178
 Hemorrhoidectomy, 1223–1224
 closed submucosal, 1223–1224, 1225*f*
 complications in, 1224–1225
 stapled, 1224
 Hemorrhoids, 1222–1225
 in Crohn's disease, 1200
 Doppler-guided artery ligation, 1224
 external, 1223
 thrombosed, excision of, 1223
 internal, 1223
 grades of, 1223
 postpartum, 1223
 treatment of, 1223–1224
 rubber band ligation in, 1223, 1224*f*
 Hemostasis, 85–104
 biology of, 85–88, 86*f*
 clotting factors in, 86*f*, 87, 87*f*. *See also*
 Factors, clotting
 disorders of, 88–96
 acquired, 90–96
 in congenital factor deficiencies,
 88–89
 fibrinolysis in, 86*f*, 88, 88*f*
 laboratory tests of, 87, 102–104
 preoperative, 102–104
 local, 95
 in liver trauma, 204
 mechanical procedures in, 95
 thermal agents in, 95
 topical agents in, 96
 platelet function in, 85–86, 86*f*, 87*f*
 congenital disorders of, 89–90
 qualitative disorders of, 90*t*, 91
 quantitative disorders of, 90–91, 90*t*
 preoperative evaluation of, 102–104
 primary, 85
 thromboelastography in, 103, 103*f*
 vasoconstriction in, 85, 86*f*
 in wound healing, 242–244, 243*f*
 Hemostatic sheaths in endovascular
 therapy, 835, 835*f*
 Hemothorax, 200
 caked, 177, 177*f*
 in children, 222
 massive, 166, 166*f*
 postoperative, 384
 Henderson-Hasselbalch equation, 131
 Heparin therapy, 94–95
 in aortic aneurysm repair, 852, 856
 in aortic trauma, 201
 in burns, 233
 in cardiopulmonary bypass, 740
 in carotid endarterectomy, 844
 in cerebrovascular trauma, 199
 coagulation tests in, 103
 complications of, 922
 emergency operations in, 95
 in lower extremity arterial occlusive
 disease, 892
 low molecular weight heparin in, 922
 in mesenteric ischemia, 865
 in splenectomy, 1439
 thrombocytopenia in, 90–91, 95, 233,
 389, 922
 unfractionated heparin in, 921–922
 in venous thromboembolism, 921–922,
 925
 duration of, 923*t*
 in prevention, 186, 927
 Hepatectomy, 1296–1301
 in cancer of liver, 1294–1295
 in colorectal cancer metastasis, 1301
 recurrent, 1301
 devices and procedures in, 1296–1297,
 1297*t*
 historical aspects of, 1264
 ischemic preconditioning in, 1300
 laparoscopic, 1301–1302
 left, 1299–1300, 1299*f*
 in living donor kidney transplantation,
 332, 333*f*
 nomenclature on, 1296, 1297*f*, 1297*t*
 portal vein embolization prior to,
 1300–1301
 Pringle maneuver in, 1300
 right, 1298–1299, 1298*f*
 steps in, 1297–1300
 two-stage, 1301
 Hepatic artery
 anatomy of, 1266–1267, 1266*f*, 1345
 common variations in, 1266–1267,
 1266*f*, 1312, 1345
 as route for chemoembolization in
 hepatocellular carcinoma, 1296
 thrombosis in liver transplantation, 351
 Hepatic duct anatomy, 1268, 1269*f*, 1310
 common variations in, 1268, 1269*f*,
 1312
 Hepaticojejunostomy, 1327, 1329*f*
 in cholangiocarcinoma, 1337
 Hepatic veins
 anatomy of, 1267–1268, 1268*f*
 Budd-Chiari syndrome in obstruction of,
 1283–1284
 pressure measurement in, 1280–1281
 thrombosis of, 1283, 1284
 Hepatitis
 anesthesia management in, 1907
 in kidney transplant recipients, 335
 neonatal, 1629
 Hepatitis A, 1286
 liver transplantation in, 347
 Hepatitis B, 156, 1286
 liver transplantation in, 347
 tumors associated with, 295, 295*t*
 vaccination, 156
 Hepatitis C, 156, 1286
 in kidney transplant recipients, 335
 tumors associated with, 295, 295*t*
 Hepatitis E, liver transplantation in, 347
 Hepatoblastoma in children, 1641–1642
 Hepatocellular carcinoma, 295, 295*t*, 1291,
 1292*f*, 1294–1296
 chemoembolization in, 1295–1296
 in children, 1641–1642, 1641*f*, 1642*t*
 staging of, 1642, 1642*t*
 treatment of, 1642
 in cirrhosis, 1279, 1291
 ethanol ablation in, 1295
 hepatectomy in, 1294–1295
 recurrent, 1301
 liver transplantation in, 347, 1291, 1295,
 1642
 Milan criteria on, 347, 1291
 positron emission tomography for,
 1275
 radiofrequency ablation in, 1295
 risk factors for, 1291
 treatment algorithm on, 1291, 1293*f*
 tumor markers in, 302–303
 Hepatocyte growth factor, 283
 Hepatoduodenal ligament, 1265, 1265*f*,
 1457
 Hepatogastric ligament, 1037, 1265,
 1265*f*, 1457

- Hepatopulmonary syndrome, liver transplantation in, 348
- Hepatorenal bypass in renal artery occlusive disease, 869–870
- Hepatorenal syndrome, liver transplantation in, 347
- Hepatotoxicity of acetaminophen, 1276
liver transplantation in, 347, 1277, 1277t
- Hereditary, 444–446
- Hermansky-Pudlak syndrome, 90
- Hermaphroditism, true, 1637
- HER2/neu*, 281
in breast cancer, 454, 534–535, 535–536
as therapy target, 309, 310t, 535, 553–554
signaling pathways, 281, 282f
- Hernia
abdominal, 1454–1456
epigastric, 1455
incarcerated, 1455
incisional, 1454–1455, 1455
inguinal, 1634–1635
in liver disease and ascites, 1279, 1455
spigelian, 1455
strangulated, 1455
umbilical, 1455, 1631, 1631f
in elderly, 1923
ventral, 1454–1455
diaphragmatic. *See* Diaphragmatic hernia
femoral. *See* Femoral hernia
hiatal. *See* Hiatal hernia
inguinal. *See* Inguinal hernia
Littre's, 1164
Meckel's diverticula in, 1164
mesocolic, 1458, 1458f
parastomal, 1193
small bowel obstruction in, 1146
- Herniation
of brain, 1713–1714, 1714f. *See also* Brain, herniation of
of intervertebral discs, 1771
cervical, 1740, 1740t, 1741f, 1771
lumbar, 1742, 1742f, 1742t, 1771
thoracic, 1740, 1771
- Herniorrhaphy in inguinal hernia, 1504–1517
anesthesia in, 1505
in children, 1634, 1635
laparoscopic, 1635
complications of, 1514–1516
endoscopic procedures, 1509–1513
open procedures, 1504–1509
postoperative pain in, 1514–1515
- Herpes simplex virus infections
anorectal, 1233
facial nerve paralysis in, 567
genital, 1678, 1679t
in transplant recipients, 329
- Hetastarch in resuscitative fluids, 76t, 77
- Hewitt, Frederick, 1896
- Hextend in resuscitative fluids, 76t, 77
- Hiatal hernia, 980–984
clinical manifestations in, 981–982
diagnosis of, 982
barium studies in, 950–951, 953f, 982
endoscopy in, 950, 981, 982f
diaphragmatic repair, 983
and esophageal diverticula, 994
esophageal rupture in, 1018
etiology of, 980–981
and gastroesophageal reflux, 966–967, 966f
antireflux surgery in, 983
pathophysiology in, 982
symptoms in, 981–982
giant paraesophageal, 980–984
incidence of, 980–981
indications for surgery in, 982–983
intrathoracic stomach in, 980, 981f, 982
laparoscopic repair in, 983
pathophysiology in, 982
postoperative recurrence of, 983
results of surgery in, 984
and Schatzki's ring, 984, 984f
and scleroderma of esophagus, 985
sliding, 980f, 981, 981f, 982
surgical approach in, 982–983
types of, 980, 980f–981f
- Hidradenitis suppurativa, 476, 506, 1233
- High mobility group box 1 (HMGB1), 28t, 38
- High-pressure injection injuries of hand, 1801
- Hinchey staging system in diverticulitis, 1202
- Hindgut, embryonic development of, 1175–1176, 1179
- Hip
arthroplasty of, 1773–1774, 1773f, 1774f
alignment of components, 1774
bearing surfaces in, 1774
history of, 1773
surgical approach, 1773–1774
dislocations of, 1760
in cerebral palsy, 1782
failed hemiarthroplasty, 1761f
fractures of, 1760–1762
in acetabulum, 1760
in children, 1782
intertrochanteric, 1761–1762
subtrochanteric, 1762
pain, patient examination in, 1772
- Hirschsprung's disease, 1624–1626, 1626f
clinical presentation of, 1625
congenital megacolon in, 1220–1221, 1624
diagnosis of, 1625
genetic factors in, 1625
pathogenesis of, 1624–1625
treatment of, 1625–1626, 1626f
ultrashort-segment, 1221
- Hirudin in venous thromboembolism, 922
- Histamine, 34
gastric cells secreting, 1040
receptor subtypes, 34
in stimulation of gastric acid secretion, 1041, 1043, 1044f
- Histamine₂ blockers
in peptic ulcer disease, 1061
- Histiocytes, 660f, 666, 668
- Histiocytoma, malignant fibrous, 1465, 1470, 1780
of chest wall, 667, 668, 668t
- Histiocytosis, Langerhans cell, 666
- Histoplasma capsulatum, 330
- Histoplasmosis, 658–659, 660f
- Historical aspects
of adrenal disorders, 1574
of anesthesia, 1895–1897
of appendicitis, 136, 1241
of bariatric surgery, 1103
of breast cancer therapy, 497–499
of cardiopulmonary bypass, 740
of coronary artery disease, 741
of gastric surgery, 1035, 1036t
of genetics and molecular biology, 443, 445t
of inguinal hernia treatment, 1495–1496
of liver surgery, 1263–1264
of minimally invasive surgery, 415–417
of parathyroid gland, 1556
of pediatric surgery, 1597–1598
of plastic and reconstructive surgery, 1829, 1832
craniofacial, 1844
free tissue transfer in, 1838
of shock, 109–110
of solitary thyroid nodule, 1537
of spleen studies, 1423–1424
of surgical infections, 135–137
of thyroid surgery, 1521
of transplantation, 322–323, 323t
of kidney, 322–323, 334
of liver, 323, 345–346
of pancreas, 323, 340
of wound healing, 241
- History-taking
in anesthesia management, 1904
in arterial disease, 828, 828t
in cardiac disorders, 737
in gynecologic disorders, 1675, 1676t
in inguinal hernia, 1502–1503
in large intestine disorders, 1180
in trauma, 173
- HIV infection and AIDS, 156
appendicitis in, 1248
coccioidomycosis in, 661
gastrointestinal disorders in, 1235–1236
postexposure prophylaxis in, 156
skin manifestations in, 485
transfusion-associated, 388, 388t
tuberculosis in, 654
tumors associated with, 295t
Kaposi's sarcoma, 485
lymphoma, 1736
- HLA antigens, 334, 336, 901
in Behçet's syndrome, 903
functions of, 324
in giant cell arteritis, 901
in Graves' disease, 1531
in transplantation procedures, 324
- HMGB1 (high mobility group box 1), 28t, 38
- Hodgkin's lymphoma
of breast, 557
mediastinal, 678
splenectomy in, 1430t, 1434
stages of, 1434
types of, 1434
- Hofmann elimination, 1901
- Hollenhorst plaque, 839
- Homeostasis, 109
circulatory, 114
- Homocysteine serum levels in ischemic heart disease, 1906
- Homograft heart valves, 750–751
- Hormones
adrenal, 22–23, 1575–1578
and breast cancer risk, 511, 513, 534, 535–536
in breast development and function, 500, 503–504, 503f, 505
in cancer therapy, 308–309
gastric, 1045–1047
gut, 1145
in hypothalamic-pituitary-adrenal axis, 19–21, 20t
pancreatic, 1348–1351, 1349t
parathyroid. *See* Parathyroid hormone
in postmenopausal therapy, 513
in shock response, 113–114
in stress response, 19–23, 112
of thyroid, 1525–1528

- Horner's syndrome, 623
 Hospice care
 in head and neck tumors, 602
 pain management in, 1946
 Host defense mechanisms, 137–138
 skin in, 137
 small intestine in, 1144
 spleen in, 1426
 Houston valves of rectum, 1177
 HRAS gene in Costello syndrome, 288t
 HRPT2 in hyperparathyroidism, 288t, 1560
 Hughes advancement flap in eyelid reconstruction, 1858, 1861f
 Human bite wounds, 479
 Humerus
 fractures of, 1759
 distal, 1759
 proximal, 1759
 in shaft, 1759
 osteosarcoma of, 1779
 Hunter, John, 241
 Hunt-Hess grading system for subarachnoid hemorrhage, 1730, 1730t
 Hurewitz, Mike, 376, 377t
 Hürthle cell carcinoma of thyroid, 1546
 Hyaluronic acid
 in fetal wound healing, 252
 joint injections of, 1772
 Hydatid disease, 1285–1286
 Hydrocele, 1634, 1635
 communicating, 1634
 Hydrocephalus, 1713, 1713f, 1750–1751, 1750f
 communicating, 1751
 obstructive, 1751
 Hydrochloric acid secretion, gastric.
 See Acid secretion, gastric
 Hydrocodone in persistent pain, 1949t
 Hydrocortisone
 in adrenocortical insufficiency, 1590
 in Cushing's syndrome, 1583
 in hypercalcemia, 1573t
 in septic shock, 126, 154, 155t
 Hydrofluoric acid, skin injuries from, 480
 Hydrofluoride, skin injury, 479
 Hydromorphone in persistent pain, 1949t
 Hydronephrosis, 1665–1666, 1665f
 in bladder cancer, 1653
 in children, 1667
 in posterior urethral valves, 1667
 in ureteropelvic junction obstruction, 1667
 in vesicoureteral reflux, 1667
 Hydrops of gallbladder, 1319
 Hydroxyecosatetraenoic acids, 31f, 32, 32t
 Hydroxyethyl starch solutions, 77, 1911, 1914
 21-Hydroxylase deficiency, 1585, 1637
 5-Hydroxytryptamine, 33–34
 Hygroma, cystic, 598, 1852, 1852f
 treatment of, 598
 ex utero intrapartum therapy (EXIT) procedure in, 1645
 Hymen imperforate, in children, 1636
 Hyperaldosteronism, 1578–1579
 Hyperamylasemia in acute pancreatitis, 1356
 Hyperbaric oxygen therapy in soft tissue infections, 152
 Hyperbilirubinemia, 1271–1272
 postoperative, 387
 Hypercalcemia, 71
 differential diagnosis in, 1561–1562, 1562f, 1563t
 drug-induced, 71
 etiologies of, 72
 familial hypocalciuric, 1562
 in hyperparathyroidism, 72, 1560–1563
 crisis in, 1572
 disorders associated with, 1561
 pancreatitis in, 1353, 1365
 persistent and recurrent, 1571
 of malignancy, 82, 1561–1562
 in lung cancer, 626
 signs and symptoms in, 72, 72t
 treatment of, 78, 1572, 1573t
 Hypercapnia, permissive, in congenital diaphragmatic hernia, 1605
 Hypercholesterolemia, coronary artery disease in, 1906
 Hypercoagulopathy, in kidney transplant recipients, 336
 Hypercortisolism, Cushing's syndrome in, 1580, 1581
 Hyperemia zone in burns, 230
 Hypergastrinemia, 1045
 algorithm on diagnosis and management of, 1072f
 chronic, 1045
 differential diagnosis in, 1071–1072
 in *Helicobacter pylori* infections, 1055
 in Zollinger-Ellison syndrome, 1071–1073
 Hyperglycemia
 in burns, 233
 in critical illness, 23
 in head trauma, 1718
 hyponatremia in, 69
 in parenteral nutrition, 59
 in septic shock, 125
 Hyperhomocysteinemia, ischemic heart disease in, 1906
 Hyperkalemia, 71
 in cancer, 81
 drug-induced, 71
 etiology of, 71, 71f
 signs and symptoms in, 71, 72t
 treatment of, 77–78, 78t
 Hyperkeratosis in lymphedema, 934, 934f
 Hyperlipidemia
 coronary artery disease in, 742, 1906
 in obesity
 bariatric surgery affecting, 1112t, 1116, 1128
 ileocolic bypass in, 1103
 pancreatitis in, 1352–1353, 1365
 Hypermagnesemia, 73
 etiologies of, 73
 signs and symptoms in, 72t, 73
 treatment of, 78
 Hypermnatremia, 69–70, 70f
 in cancer, 81
 etiologies of, 69
 hypervolemic, 69
 hypovolemic, 69, 77
 postoperative, 392
 signs and symptoms in, 69, 71f
 treatment of, 77
 Hyperparathyroidism, 1559–1574
 in adenoma of parathyroid, 1560
 bone disease in, 1556, 1560–1561, 1561f, 1563
 in carcinoma of parathyroid, 1560, 1570
 in elderly, 1937
 familial, 1560, 1570
 gastrointestinal disorders in, 1561
 hypercalcemia in, 72, 1560–1563, 1571
 crisis in, 1572
 disorders associated with, 1561
 pancreatitis in, 1353, 1365
 neonatal, 1570
 neuropsychiatric disorders in, 1561
 normocalcemic, 1570
 parathyroidectomy in, 1563–1574, 1567f
 operative procedure in, 1566–1569, 1568f
 preoperative localization tests in, 1564–1566, 1565t
 in secondary hyperparathyroidism, 1572–1573
 in tertiary hyperparathyroidism, 1573
 persistent and recurrent, 1571–1572, 1572f
 primary, 1559–1571
 clinical manifestations in, 1560–1561
 diagnostic studies in, 1562–1563
 differential diagnosis in, 1561–1562
 etiology of, 1559–1560
 genetic factors in, 1560
 treatment of, 1563–1574
 renal disease in, 1560
 secondary, 1559, 1572–1573
 tertiary, 1559, 1573
 urinary calculi in, 1560, 1666
 Hyperphosphatemia, 73
 in cancer, 81, 82
 treatment of, 78
 Hyperplasia
 of adrenal gland. *See* Adrenal gland, hyperplasia of
 of breast, 507, 508f, 508t
 atypical ductal, 510
 cancer risk in, 508, 508t, 509–510
 pathology in, 509–510
 craniofacial, 1849
 endometrial, 1683
 of liver, focal nodular, 1290f, 1291
 of lungs, 614, 617
 of prostate, benign, 1662, 1665
 of thymus, 674–675
 Hypersensitivity reactions. *See* Allergic reactions
 Hypersplenism, 1427
 differentiated from splenomegaly, 1427
 in Gaucher's disease, 1437–1438
 Hypertelorism, orbital, 1847
 Hypertension
 aortic dissection in, 812, 815
 coronary artery disease in, 742
 in elderly, 1935
 in hyperaldosteronism, 1578, 1580
 intra-abdominal, 217, 218f, 389
 intracranial, 411, 1713–1714
 brain herniation in, 1713–1714, 1714f
 in head trauma, 195, 197, 411
 pressure-volume curve in, 1713, 1714f
 intracranial hemorrhage in, 1729–1730
 in obesity, bariatric surgery affecting, 1111, 1112t, 1116, 1128
 in pheochromocytoma, 1586
 portal, 1280–1281. *See also* Portal hypertension
 postoperative, 386
 in aortic coarctation, 705
 intra-abdominal, 389
 pulmonary
 in congenital diaphragmatic hernia, 1604, 1605
 liver transplantation in, 348
 lung transplantation in, 664
 renovascular, 865, 867
 diagnosis of, 867

- endovascular therapy in, 871–872, 871f
 - surgical treatment in, 870
 - Hyperthermia
 - in aortic dissection repair, 813
 - malignant, 393, 1916–1917
 - skin injuries in, 480
 - Hyperthyroidism, 1530–1534
 - differential diagnosis in, 1531t
 - in elderly, 1937
 - in goiter, 1531–1533
 - in Graves' disease, 1531–1533
 - Jod-Basedow, 1533
 - postoperative, 392
 - radioactive iodine uptake in, 1530, 1531t
 - thyroid function tests in, 1529
 - in thyroid storm, 1534
 - in toxic adenoma, 1533–1534
 - Hypertonic formulas in burns, 230
 - Hypertriglyceridemia, chronic pancreatitis in, 1365
 - Hypertrophy
 - adenotonsillar, 570, 571
 - of breast in adolescents, 507
 - craniofacial, 1849
 - left ventricular, 757–758
 - Hypervolemia, 68t
 - hyponatremia in, 69
 - postoperative, 80
 - signs and symptoms in, 68t, 80
 - Hypocalcemia, 72, 78
 - in cancer, 81
 - etiologies of, 72, 1574, 1574t
 - hyperparathyroidism in, secondary, 1572
 - in hypoparathyroidism, 1574, 1574t
 - postoperative, 384
 - in parathyroidectomy, 1574
 - in thyroidectomy, 1556
 - signs and symptoms in, 72, 72t
 - treatment of, 78, 78t
 - Hypocalciuric hypercalcemia, familial, 1562
 - Hypodermis, 476
 - Hypofibrinogenemia, acquired, 92
 - Hypogastric nerve plexus, 1179
 - Hypokalemia, 71
 - in cancer, 81
 - drug-induced, 71
 - etiologies of, 71, 71f
 - in hyperaldosteronism, 1578, 1580
 - and hypomagnesemia, 71
 - signs and symptoms in, 71, 72t
 - treatment of, 78, 78t
 - in VIPoma, 1392
 - Hypomagnesemia, 73
 - in cancer, 81
 - etiologies of, 73
 - and hypokalemia, 71
 - signs and symptoms in, 72t, 73
 - treatment of, 78, 78t
 - Hyponatremia, 69, 70f
 - in cancer, 81, 626
 - dilutional, 69
 - drug-induced, 69
 - etiologies of, 69
 - in inappropriate antidiuretic hormone secretion, 69, 80
 - postoperative, 392
 - signs and symptoms in, 69, 71f, 77
 - treatment of, 77
 - Hypoparathyroidism, 1574
 - hypocalcemia in, 1574, 1574t
 - postoperative
 - in parathyroidectomy, 1574
 - in thyroidectomy, 1574
 - Hypoperfusion, wound healing in, 253
 - Hypopharyngeal cancer, 588f, 589
 - anatomy in, 580, 588, 588f
 - metastasis in, 588f, 589
 - reconstructive surgery in, 1863
 - Hypophosphatemia, 73
 - in cancer, 81, 82
 - treatment of, 78, 78t
 - Hypophysectomy in breast cancer, 553
 - Hypoplasia
 - craniofacial, 1848–1849, 1849f, 1850f
 - of left heart, 716–719, 717f, 718f
 - of right ventricle in tricuspid atresia, 712
 - Hypotension
 - in hemorrhage, 119, 120f, 122, 171–172, 173
 - in neurogenic shock, 130
 - in trauma, 171–173
 - of head, 195
 - initial evaluation and management of, 163
 - persistence of, 168–169, 171–173
 - Hypothalamic-pituitary-adrenal (HPA) axis, 19–21
 - Hypothalamus
 - anatomy of, 1710
 - hormones regulated by, 20t, 1526, 1529f
 - Hypothar hammer syndrome, 1822
 - Hypothenar muscles, 1791
 - Hypothermia
 - in aortic aneurysm repair, 797, 801, 818
 - in hemorrhagic shock, 123, 187
 - in organ preservation for transplantation, 332, 334
 - postoperative, 393
 - skin injuries in, 480–481
 - in trauma, 187
 - in bloody vicious cycle, 185, 193, 194f
 - Hypothyroidism, 1534–1535
 - anesthesia management in, 1908
 - clinical features in, 1534
 - diagnostic tests in, 1529, 1534
 - etiologies of, 1534t
 - postoperative, 392–393
 - treatment of, 1534–1535
 - Hypoventilation
 - in obesity, 1105, 1106
 - respiratory acidosis in, 75, 75t
 - Hypovolemia, 67, 68t
 - hyponatremia in, 69, 77
 - postoperative, 80
 - in kidney transplantation, 339
 - preoperative fluid therapy in, 79
 - shock in. *See* Shock, hypovolemic/hemorrhagic
 - signs and symptoms in, 68t, 80
 - in trauma, 168
 - in children, 1642
 - response to fluid therapy in, 170
 - Hypoxia
 - in head trauma, 195
 - wound healing in, 253
 - Hysterectomy, 1683–1684, 1684
 - abdominal procedure, 1685, 1686f–1687f, 1687
 - in endometrial cancer, 1698
 - laparoscopic, 1687–1689
 - in leiomyomas of uterus, 1683
 - peripartum, 1693, 1694f
 - radical, in cervical cancer, 1686f–1687f, 1698, 1699f–1700f
 - vaginal procedure, 1684
 - Hysteroscopy, 1683–1684
 - distention media and pumps in, 1683
 - indications for, 1683–1684
 - instruments in, 1683
- ## I
- Ibuprofen
 - in ductus arteriosus patency, 704
 - gastrointestinal disorders from, 1058t
 - in persistent pain, 1949t
 - Ifosfamide
 - in lung cancer, 644t
 - in soft tissue sarcoma of extremity, 1475–1476, 1476
 - Ileal pouch anal anastomosis, 1188, 1189f, 1194
 - in familial adenomatous polyposis, 1207
 - pouchitis in, 1194
 - in ulcerative colitis, 1198
 - Ileitis, backwash, 1154
 - in inflammatory bowel disease, 1195
 - Ileocolic artery, superior, 1176
 - Ileocolic resection, 1187
 - Ileostomy, 210, 1191f, 1192–1193, 1192f
 - Brooke, 1188, 1192, 1192f, 1194
 - complications of, 1193
 - diversion colitis in, 1179
 - end, 1193
 - and total proctocolectomy in ulcerative colitis, 1198
 - functional results in, 1193–1194
 - Kock pouch, 1194
 - in familial adenomatous polyposis, 1207
 - in ulcerative colitis, 1198
 - loop, 1189f, 1192–1193
 - divided, 1192–1193
 - marking ideal site for, 1191f
 - permanent, 1193
 - temporary, 1189f, 1192–1193
- Ileum
 - anatomy of, 1138, 1138f
 - Crohn's disease of, 1198–1199
 - diverticula of, 1165, 1167
 - Meckel's, 1163f
 - neoplasms of, 1160
 - sarcoma, 1481
 - treatment in, 1161
 - perforation of, 1168–1169
 - spontaneous, 1621
 - resection of
 - ileocolic, 1187
 - short bowel syndrome in, 1171
- Ileus
 - differentiated from mechanical obstruction, 1147
 - etiologies of, 1151–1152, 1151t, 1152t
 - meconium, 1617–1619, 1619f
 - postoperative, 386, 1151–1153, 1152t
 - in gastrointestinal tract trauma, 207
 - resection of short bowel syndrome in, 1151–1153
 - treatment of, 1152–1153
- Iliac arteries
 - anatomy of, 1672
 - aneurysm of, with abdominal aortic aneurysm, 855, 856
 - occlusive disease of, 828, 872–881
 - clinical results of treatment in, 832f, 880–881
 - endovascular therapy in, 879–880
 - trauma of
 - emergent abdominal exploration in, 190–191, 191f
 - in laparoscopy, 1704–1705, 1704f
 - in inguinal hernia repair, 1516

- Iliac arteries, trauma of (*Cont.*):
transposition procedure for repair in, 193*f*
- Iliac crest osteocutaneous flap in head and neck reconstructive surgery, 601
- Iliacus muscle, 1672
- Iliac vein trauma, emergent abdominal exploration in, 190–191, 190*f*
- Iliococcygeus muscle, 1178, 1672
- Iliofemoral bypass in aortoiliac occlusive disease, 877, 877*f*
- Iliofemoral vein thromboembolism, 924
- Iliohypogastric nerve
anatomy of, 1498, 1498*f*, 1499*f*
injury in inguinal hernia repair, 1515
- Ilioinguinal nerve
anatomy of, 1497–1498, 1498*f*, 1499*f*
injury in inguinal hernia repair, 1515
- Iliopubic tract
anatomy of, 1496, 1498*f*
repair procedure, 1509, 1509*f*
- Imaging systems in minimally invasive surgery, 424–427, 426*f*, 427*f*
- Imatinib, 309, 310*t*
in gastrointestinal stromal tumors, 1483–1485, 1483*f*
resistance to, 1482–1483, 1485
in small intestine neoplasms, 1162
- Imipenem-cilastatin, 144*t*
- Imipramine in pain, 1950*t*
- Imiquimod, in basal cell carcinoma, 487
- Immobilization
in cervical spine trauma, 162, 1722
hypercalcemia in, 1562
- Immune globulin, intravenous, in idiopathic thrombocytopenic purpura, 1433
- Immune response
danger signaling in, 115, 117*f*
enteral nutrition affecting, 53–54
eosinophils in, 39
lymphocytes in, 38–39, 39*f*
monocytes in, 39–40
neutrophils in, 40
in shock, 115
small intestine function in, 1144
spleen function in, 1426–1427, 1428
- Immunobiology in transplantation, 323
- Immunoblotting, 458, 460*f*
- Immunocompromised hosts
coccidioidomycosis in, 661
gastrointestinal disorders in, 1235–1236
histoplasmosis in, 659, 660*f*
in HIV infection and AIDS. *See* HIV infection and AIDS
perianal sepsis in, 1229
- Immunofluorescence, 458
- Immunoglobulins in microbial invasion response, 138
- Immunohistochemistry, 458
- Immunomodulators, in skin inflammatory conditions, 476
- Immunoprecipitation, 458–459, 461*f*
- Immunosuppression
corticosteroids in, 325–326, 325*t*
in inflammatory bowel disease, 1196–1197
in transplantation, 324–328
agents used in, 324–328, 325*t*
complications of, 326*t*, 329–330
gastrointestinal disorders in, 1236
heart, 356
historical aspects of, 322–323
intestinal, 352
of kidney, 328, 335
of liver, 346, 351
of pancreas, 340
islet cell, 345
- Immunotherapy in tumors, 309, 311–312, 454–455
adoptive transfer in, 311
antigen-specific, 309, 311–312
nonspecific, 309
- Impedance, electrical
in cardiography, 407
cardiac output measurements in, 407
in esophageal studies, 955, 961*f*
in plethysmography, 921
- Imperforate anus, 1626–1628, 1626*f*, 1627*f*
- Impingement syndromes in shoulder, 1766
- Implants, breast
in augmentation mammoplasty, 1890–1891, 1891*f*
in reconstruction after mastectomy, 1867–1869, 1869*f*, 1870*f*
with autologous tissue reconstruction, 1871, 1874*f*
- Incidentaloma, adrenal, 1588–1590
diagnosis in, 1588–1589
differential diagnosis in, 1588, 1588*t*
treatment in, 1589–1590, 1589*f*
- Incisional biopsy, in soft tissue sarcomas, 1469–1470
- Incisions
in abdominal wall, 1451–1453, 1452*f*
hernia in, 1454–1455, 1456*t*, 1457*f*
components separation technique in, 1455
laparoscopic repair of, 1456
mesh repair of, 1455–1456
in laparoscopy, 421–422, 1451, 1452
in plastic and reconstructive surgery, 1829–1830, 1830*f*, 1831*f*, 1831*t*
- Incontinence
fecal, 1185
in anal sphincter injury, 1235, 1235*f*
anatomic causes of, 1185
endoanal ultrasonography in, 1185, 1185*f*
neurogenic causes of, 1185, 1235
sacral nerve stimulation in, 1235
surgical repairs in, 1235, 1235*f*
- urinary
overflow, in acute urine retention, 1661
in prostatectomy for prostate cancer, 1658
stress
in obesity, 1126
surgery for, 1695
- Incretins, 1349
- Indigestion, 1050
- Individualized medicine
in cancers, 316
genomic, 468
- Indomethacin in ductus arteriosus patency, 704
- Infants. *See* Children and infants
- Infarction
myocardial. *See* Myocardium, infarction of
omental, 1457
- Infections, 135–157
abdominal, 149–150. *See also* Abdominal infections
anorectal, 1227–1229, 1227*f*, 1228*f*
aortic aneurysm in, 788
in aortoiliac reconstruction, 878
of appendix vermiform, 1243–1251
bacterial, 139–140, 140*t*. *See also* Bacterial infections
from biologic warfare agents, 156–157
in bite wounds, 479, 479*f*
of bladder, 390, 1664–1665
blood-borne, 156
occupational exposures to, 156
of breast, 506–507
catheter-related. *See* Catheterization, infections related to
of central nervous system, 1745–1746
definition of, 15*t*
of ears, 565–567
empyema in, 683–684
fungal, 140, 140*t*, 141*t*. *See also* Fungal infections
gynecologic
pelvic inflammatory disease in, 1690–1691
screening for, 1676–1677
ulcer syndromes in, 1678, 1679*t*
of hand, 1794, 1809–1814
historical aspects of, 135–137
host defense mechanisms in, 137–138
skin in, 137
small intestine in, 1144
spleen in, 1426
inflammatory response to
systemic inflammatory response syndrome in, 138, 139*f*
of liver, 150, 1284–1287
mediastinitis in, 679–680
microbiology of, 139–141
osteomyelitis in, 1745–1746, 1877
of pancreas, 150–151, 1353
in parenteral nutrition, 58–59
pathogenesis of, 137–139
peritonitis in, 149–150
pharyngitis in, 570
postoperative, 152–154, 374, 375*t*
of surgical site. *See* Surgical site infections
postsplenectomy, 207
antibiotics in, 1445
overwhelming, 1444–1445
vaccinations in prevention of, 1439–1440, 1445
prevention and treatment of, 141–147
antibiotics in, 142, 143*t*–145*t*, 146–147
general principles in, 141
source control in, 141–142
pulmonary, 650–661
pyelonephritis in, 1664
emphysematous, 1664
retroperitoneal, 1460, 1461*f*
sepsis in. *See* Sepsis
sinusitis in, 567–570
of skin, 151–152, 483–485
of soft tissues, 152, 153*f*
necrotizing, 152, 153*f*, 483, 1229
of spleen, 1436
rupture in, 1436
of subcutaneous tissue, 483–485
of surgical site. *See* Surgical site infections
transfusion-related, 102, 388, 388*t*
and transplantation, 329–330
in transplant recipients, 329–330
in kidney transplantation, 335
in liver transplantation, 351
in pancreas transplantation, 343
of urinary tract, 1664–1665
viral, 140–141, 140*t*. *See also* Viral infections
of wounds, 255–259, 265

- Infertility
 in cryptorchidism, 1636
 in obesity, 1126
- Inflammatory bowel disease, 1195–1201
 in appendectomy, 1242–1243
 cholangitis in, primary sclerosing, 1196, 1331
 colorectal cancer in
 risk for, 1197, 1199, 1204
 screening for, 1210*t*
 Crohn's disease, 1153–1157, 1195. *See also* Crohn's disease
 drug therapy in, 1196–1197
 epidemiology of, 1195
 extraintestinal manifestations of, 1196
 indeterminate colitis, 1195
 nutrition in, 1197
 ulcerative colitis, 1195. *See also* Colitis, ulcerative
- Inflammatory carcinoma of breast, 555–556, 556*f*
 differentiated from noninflammatory cancer, 556, 556*t*
- Inflammatory response
 acute phase proteins in, 1272
 and anti-inflammatory response
 cholinergic pathways in, 19
 counterregulatory syndrome, 14*f*
 cell-mediated, 38–40
 central nervous system in, 18–23, 19*f*
 macrophage migration-inhibiting factor affecting, 21
 mediators of, 26–34
 in shock, 115–119
- in pancreatitis
 acute, 1354, 1355–1359
 chronic, 1372
- in shock, 112, 115–119
- systemic syndrome in, 19, 138, 139*f*
 antibiotics in, 142
 in cardiopulmonary bypass, 741
 definition of, 15*t*
 diagnostic criteria on, 138, 139*t*, 391–392, 391*t*
 mortality risk in, 391, 391*t*
 phases in, 14*f*
 postoperative, 391–392
 vagus nerve in, 19, 19*f*
 in wound healing, 242–244, 242*f*, 243*f*, 1831
 fetal, 251
- Infliximab
 in Crohn's disease, 1156, 1197, 1197
 in ulcerative colitis, 1197
- Informed consent, 1941–1944. *See also* Consent, informed
- Infrapopliteal occlusive disease
 classification of, 885
 endovascular therapy in, 891, 892*t*, 894
- Infundibulopelvic ligaments, 1675
- Inguinal canal anatomy, 1496, 1497*f*
- Inguinal hernia, 1495–1517, 1974
 age-related differences in, 1496*t*, 1500
 anatomy in, 1496–1500, 1497*f*
 anterior perspective, 1496, 1499*f*, 1500*f*
 circle of death in, 1499
 ligaments in, 1496, 1498*f*
 nerves in, 1497–1499, 1498*f*, 1499*f*
 posterior perspective, 1496–1497, 1498*f*
 triangle of doom and triangle of pain in, 1499, 1501*f*
 anesthesia in, 1505, 1515
 in children, 1500, 1634–1635. *See also* Children and infants, inguinal hernia in
 classification of, 1498*t*
 complications in, 1514–1516, 1514*t*
 in connective tissue disorders, 1502, 1502*t*
 conservative management in, 1505
 diagnosis of, 1502–1504
 history-taking in, 1502–1503
 imaging in, 1504, 1504*f*
 physical examination in, 1503–1504, 1503*f*
 differential diagnosis of, 1503, 1503*t*
 direct
 in children, 1634
 classification of, 1496
 diagnosis of, 1503
 elective repair of, 1505
 emergent repair of, 1505
 endoscopic repair in, 1509–1513
 transabdominal preperitoneal, 1510
 historical treatment of, 1495–1496
 incarceration of, 1505
 in children, 1635
 emergent repair in, 1505
 indirect
 in children, 1634
 classification of, 1496
 diagnosis of, 1503
 laparoscopic repair in
 in children, 1635
 complications of, 1515–1516
 intraperitoneal onlay mesh procedure in, 1513
 patient position and room setup for, 1511*f*
 totally extraperitoneal procedure, 1511, 1512*f*, 1513
 transabdominal preperitoneal, 1512*f*
 mesh repair in. *See* Mesh repair, in inguinal hernia
 open repair of, 1504–1509
 anesthesia in, 1505
 Bassini technique, 1506, 1507*f*
 giant prosthetic reinforcement of visceral sac in, 1509, 1509*f*
 iliopubic tract repair in, 1509, 1509*f*
 incisions in, 1505, 1506*f*
 Lichtenstein technique, 1508, 1508*f*
 McVay technique, 1507–1508, 1507*f*
 plug and patch technique, 1508–1509, 1508*f*
 Prolene hernia system in, 1509, 1509*f*
 Shouldice technique, 1506–1507, 1507*f*
 wound closure in, 1509
 outcomes in, 1516–1517
 pathophysiology of, 1496*t*, 1500–1502
 postoperative pain in, 1514–1515
 chronic, 1514
 neuropathic, 1514
 somatic, 1514
 visceral, 1514
 prosthetic repairs in, 1508–1509
 recurrent, 1514
 signs and symptoms in, 1503
 sliding, 1505
 strangulation in, 1505
 emergent repair in, 1505
 tension repairs in, 1505
 tissue repairs in, 1505–1508
 Inguinal ligament, 1449, 1496, 1498*f*
 Inguinal lymph nodes in vulvar cancer
 anatomy of, 1696, 1696*f*
 dissection of, 1697, 1697*f*
 staging of involvement, 1696
 Inguinal ring, 1496
 Inguinodynia, 1515
 Inhalational agents in general anesthesia, 1902, 1902*t*
 Inhalation injuries in burns, 227, 231–232
 complications in, 233
 Injury. *See* Trauma
 Injury Severity Score in elderly, 222
 Innominate artery
 fistula with trachea in tracheostomy complications, 382, 382*f*
 injury of, 177, 178*f*, 200, 200*f*
 bypass exclusion repair technique in, 200, 200*f*
 Inosulation, 1833
 Inotropic agents in sepsis, 154, 155*t*
 Inspissated bile syndrome, 1628–1629
 Institute of Medicine report on medical errors, 366, 1952
 Instruments, surgical, in minimally invasive surgery, 429
 Insulin, 23, 1349–1350, 1349*t*
 deficiency in chronic pancreatitis, 1373
 functions of, 1349–1350, 1349*t*
 in parenteral nutrition solutions, 58
 receptors for, 1350
 resistance to
 in critical illness, 23
 in septic shock, 125
 in type 2 diabetes, 452
 secretion of, 1348, 1349
 signaling pathway, 452, 452*f*
 therapy
 in burns, 233
 in hyperglycemia, 23
 in pancreas transplantation, 340
 postoperative, 392
 in septic shock, 125
 Insulin-like growth factors, 21–22
 in wound healing, 246, 247*t*
 Insulinoma, 1391
 Insulin receptor substrate, 452, 452*f*
 Integrated Management of Emergency and Essential Surgical Care (IMEESC), 1965
 Integrins, 41*t*, 42*f*, 283
 Intensity-modulated radiation therapy (IMRT), 314
 Intensive care unit management in trauma, 215–217
 Intercellular adhesion molecules
 ICAM-1, 41*t*
 ICAM-2, 41*t*
 Intercostal artery injuries, 203
 Interferon- α , 30
 Interferon- β , 30
 Interferon- γ , 28*t*, 30
 Interferon in melanoma therapy, 491
 Intergroup Rhabdomyosarcoma Study Group, 1486
 Interleukins, 27*t*–28*t*
 IL-1, 26, 27*t*, 28–29
 receptors for, 29
 in shock response, 116
 IL-2
 in cancer immunotherapy, 309, 454–455
 in shock response, 27*t*, 29, 116–118
 IL-3, 27*t*, 30–31
 IL-4, 27*t*
 IL-5, 27*t*, 30–31

- Interleukins (*Cont.*):
 IL-6, 27*t*–28*t*, 29
 in shock response, 118
 IL-8, 28*t*
 IL-10, 28*t*, 29–30
 in shock response, 118
 IL-11, in coagulopathy of liver disease, 93
 IL-12, 28*t*, 30
 IL-13, 28*t*
 IL-15, 28*t*
 IL-18, 28*t*, 30
 IL-21, 28*t*
- Internal fixation of fractures, 1763*f*
- International Association for the Study of Lung Cancer lung cancer staging system, 634*t*
- International Federation of Gynecology and Obstetrics staging system
 in cervical cancer, 1698, 1698*t*
 in endometrial cancer, 1701*t*
 in ovarian cancer, 1703*t*
 in vaginal carcinoma, 1697*t*
 in vulvar cancer, 1696, 1696*t*
- International Normalized Ratio, 102, 103
 in liver disease, 93
 Child-Turcotte-Pugh score on, 1280*t*
 in warfarin therapy, 921
- International Pancreas Transplant Registry, 344
- International Registry of Lung Metastases (IRLM), 622, 623*t*
- International Sensitivity Index, 103
- International Society of Paediatric Oncology Wilms' tumor treatment approach, 1638–1639
- International Union Against Cancer cancer staging system, 300
 in stomach cancer, 1079
- Interosseous muscles of hand, 1791
- Interpectoral lymph nodes, 503
- Interpersonal skills as core competency, 4*t*
- Interphalangeal joints of hand
 degenerative disorders of, 1807
 distal, 1788, 1790*f*
 fractures of, 1796
 proximal, 1788, 1790*f*
 dislocations of, 1796
 rheumatoid arthritis of, 1808
- Intersphincteric space, 1227
 abscess of, 1227, 1228
- Interstitial cells of Cajal, 1047, 1481
- Interstitial fluid, 65–66
 composition of, 65–66, 66*f*, 67*f*
- Intervertebral discs, 1739, 1740
 cervical, 1741*f*
 herniation of, 1740, 1740*t*, 1741*f*, 1771
 in spondylotic myelopathy, 1740
 infections of, 1746
 lumbar, herniation of, 1742, 1742*f*, 1742*t*, 1771
 thoracic, herniation of, 1740, 1771
- Intestinal ischemia, in aortoiliac reconstruction, 878
- Intestinal transplantation, 352–354, 353*f*, 353*f*–354*f*
 complications of, 354
 indications of, 352
 leading cause of intestine failure, 352*t*
 with liver transplantation, 352, 353*f*
 living donor in, 332, 352, 354*f*
 multivisceral, 352–354, 353*f*
 postoperative care in, 353–354
 recipient selection in, 352
 in short bowel syndrome, 1172
 surgical procedure in, 352–353
- Intra-abdominal infections. *See* Abdominal infections
- Intracellular fluid, 65, 66*f*, 67*f*
 composition of, 65
 osmolality of, 67
- Intracranial hemorrhage. *See* Hemorrhage, intracranial
- Intracranial pressure
 increase in, 411, 1713–1714, 1714*f*
 brain herniation in, 1713–1714, 1714*f*
 in head trauma, 195, 197, 411
 pressure-volume curve in, 1713
 monitoring of, 411, 1712–1713
 in anesthesia management, 1908–1909
 intraparenchymal fiberoptic pressure transducer in, 1713
 ventriculostomy in, 411, 1713
- Intracranial tumors, 1732–1737
 metastatic, stereotactic radiosurgery in, 1749
- Intraductal papillary mucinous neoplasm (IPMN), 1410*f*, 1411*f*, 1412–1413, 1412*f*
- Intraepithelial neoplasia
 anal, 1217–1218
 cervical, 1681
 of fallopian tube, 1689
 pancreatic, 1395, 1396*f*
 vaginal, 1681
 vulvar, 1680
- Intraoperative period
 fluid therapy in, 80, 1911, 1914
 hemorrhage in, excessive, 104
 infection prophylaxis in, 142, 1832, 1832*t*
 radiation therapy in, 314
 resuscitation in, 130
 wound healing interventions in, 1832, 1832*t*
- Intravenous fluid extravasation, skin injury in, 480, 481*f*
- Intrinsic factor, 1044, 1143
- Introducer sheaths in endovascular therapy, 835, 835*f*
- Introns, 446
- Intussusception, 1622, 1622*f*
 clinical manifestations in, 1622
 ileocolic, 1170
 recurrent, 1622
 of small intestine, 1170, 1170*f*
 retrograde, 1170
 target sign in, 1170, 1170*f*
 treatment of, 1622, 1622*f*
 open reduction in, 1622, 1622*f*
- Iodine
 dietary
 deficiency of, 1536*t*, 1537, 1544
 sources of, 1525
 metabolism of, thyroid function in, 1525
 radioactive
 and fibrinogen uptake in venous thromboembolism, 921
 in hyperthyroidism therapy, 1532–1533
 in thyroid cancer therapy, 1546–1548, 1547*f*
 in thyroid imaging, 1529–1530, 1530*f*
 in hyperthyroidism, 1530, 1531*t*
- Ion channels, 35*f*; 452
- Ipilimumab in cancer immunotherapy, 312
- IPMN, 1410*f*, 1411*f*, 1412–1413, 1412*f*
- Iron
 absorption of, 1143
 deficiency in gastric surgery, 1094
- Irrigation of wounds, 264
- Irritable bowel syndrome, 1185
- Ischemia
 arterial, ulcers in, 259
 cerebral, 838, 1727–1728
 in carotid artery disorders, 837–850, 1727–1728
 clinical manifestations in, 838–839
 in embolism, 1728
 management of, 1728
 motor and sensory deficits in, 839
 reversible neurologic deficits in, 839
 in thrombosis, 1728
 colitis in, 1221–1222
 in aortic aneurysm repair, 853
 distal, 401
 limb, 881–900
 of liver
 in aortic aneurysm repair, 801
 in preconditioning for surgery, 1300
 mesenteric, 859–866, 1167
 acute, 860, 861, 1167
 diagnosis of, 861–862
 endovascular therapy in, 864–865
 surgical repair in, 863–864
 causes of, 859
 chronic, 859, 860, 861, 1167
 diagnosis of, 862–863
 endovascular therapy in, 864
 surgical repair in, 864
 diagnostic evaluation in, 861–863
 incidence of, 859
 nonocclusive, 860–861, 861
 diagnosis of, 863, 863*f*
 endovascular therapy in, 865
 symptoms in, 828, 859, 861, 1167
 no-reflow phenomenon in, 114
 of testis, in torsion, 1662
- Ischemic attack, transient, 838
 in carotid artery occlusive disease, 838, 839, 841
 crescendo, 838
 symptoms in, 828
- Ischiocavernosus muscles, 1674
- Ischiopubic rami, 1674
- Ischiorectal fossa, 1227
 abscess of, 1227, 1227*f*, 1228, 1228*f*
- Islet cells of pancreas, 1348–1351, 1349*t*
 nonfunctioning tumors of, 1393
 regulation of, 1350
 transplantation of, 344–345
 in chronic pancreatitis, 1390
 types of, 1350
- Isoflurane, 1902, 1902*t*, 1907
 malignant hyperthermia from, 1917
- Isotonic enteric nutrition formulas
 with fiber, 54
 low-residue, 54
- Itraconazole, 141*t*, 658
 in blastomycosis, 661
- Ivor-Lewis esophagectomy
 in cancer of esophagus, 1011
 complications of, 386
- IVUmed, 1977
- Ivy's test, 103
- J**
- Jaboulay pyloroplasty in peptic ulcer disease, 1063, 1066*f*
- Jahss maneuver in hand fractures, 1796, 1798*f*
- Janeway gastrotomy, 1090, 1092*f*
- Janus kinase, 30, 34–35, 34*f*

- Jaundice, 1271–1272, 1628–1631
 in biliary atresia, 1628–1630
 in children and infants, 1628–1631
 in choledochal cysts, 1630–1631
 in inspissated bile syndrome, 1628–1629
 intrahepatic causes of, 1272
 obstructive, 1315
 in pancreatic cancer, 1396–1397, 1399
 physiologic, 1628
 posthepatic causes of, 1272
 prehepatic causes of, 1272
- Jefferson fracture, 1722, 1770
- Jejunostomy, 56
- Jejunum
 access for enteral nutrition, 55, 55*t*, 56
 anatomy of, 1138, 1138*f*
 atresia of, 1616*f*
 diverticula of, 1165, 1166*f*; 1167
 as esophageal substitute, 1024, 1024*f*,
 1025
 in composite with colon and stomach,
 1025
 flap in esophageal reconstruction, 1863
 neoplasms of, 1160, 1161*f*
 treatment in, 1161
 perforation of, 1168–1169
 pneumatosis intestinalis in, 1170–1171
 sarcoma of, 1481
 short bowel syndrome in resection of, 1171
- Jobs, Steve, 5
- Jod-Basedow hyperthyroidism, 1533
- Johnson classification of peptic ulcer
 disease, 1055–1056, 1057*f*
- Johnson, Robert Wood, 241
- Joint Commission protocol for prevention
 of wrong-site surgery, 378–379
- Joints
 arthrodesis of, 1772
 in hand and wrist, 1807
 spinal, 1743–1744
 arthroplasty of, 1773–1778. *See also*
 Arthroplasty
 injection techniques, 1772
- Jugular vein
 as access for pulmonary artery
 catheterization, 402
 oxygen saturation in, 412
 trauma of, 198, 199
- c-jun*, 281
- Justice principle, 1941
- K**
- Kaiser system, 7
- Kallikrein, 33, 88
- Kanavel's signs, 1812
- Kaposi's sarcoma, 485
- Karapandzic flap in lip reconstruction, 582,
 583*f*, 1857
- Kasabach-Merritt syndrome, 1850
- Kasai portoenterostomy in biliary atresia,
 1629–1630, 1629*f*
- Kawasaki syndrome, 902
- Kawashima procedure in Taussig-Bing
 syndrome, 723
- Kayexalate in hyperkalemia, 77, 78*t*
- Kelling-Madlener procedure in peptic
 ulcer disease, 1071*f*
- Keloids, 261–263, 261*f*
- Keratin, 473
 in cutaneous cysts, 486
- Keratinocyte growth factor, 247*t*
- Keratinocytes, 473–474
 corneum layer, 474
 cultured, as skin substitute, 267, 267*t*
 granular layer, 474
- Keratosis
 actinic, 486
 seborrheic, 486
 solar, 486
- Ketamine in general anesthesia, 1900
- Ketoconazole, 659
- Ketogenesis in injury, 47–48
- Ketone bodies as fuel source in fasting,
 45, 46
- Ketorolac in general anesthesia, 1900–
 1901
- Keynes, Geoffrey, 499
- Ki-67 antigen in breast cancer, 534–535
- Kidneys
 abscess of, 1664
 acute failure of
 fluid and electrolyte balance in, 81
 postoperative, 387, 388*t*
 anatomy of, 1651
 calculi in, 1560, 1666
 cancer of, 1655–1657
 epidemiology of, 275*t*, 276*t*, 278*t*,
 618*f*
 genetic factors in, 1656
 nephrectomy in, 1656–1657, 1656*f*
 tumor thrombus in, 1656, 1657*f*
 chronic disease of
 anesthesia management in, 1907
 hyperparathyroidism in, 1573
 contrast agents affecting, 383, 791
 cysts of, 1655, 1655*f*, 1655*t*
 Bosniak classification of, 1655, 1655*t*
 in elderly
 age-related changes in, 1926*t*, 1928
 perioperative disorders of, 1928
 enteral nutrition formulas in failure of,
 54
 fluid therapy affecting, 1914
 in hyperparathyroidism, 1560
 ischemia in aortic aneurysm repair, 801
 monitoring of, 410–411
 postoperative disorders of, 387–388
 preoperative evaluation of
 in anesthesia management, 1907
 in aortic aneurysm repair, 793
 in elderly, 1928
 pyelonephritis of, 1664
 transplantation of, 334–340
 cardiovascular disorders of, 335
 complications in, 335–336, 339
 contraindications to, 334
 En Bloc grafts, 338
 historical aspects of, 322–323, 334
 immunologic evaluation of, 336
 immunosuppressive therapy in, 328,
 335
 indications for, 334
 infections, 335
 intraoperative care in, 339
 living donor in, 323, 332, 334
 operative technique in, 333*f*
 medical evaluation in, 335–336
 multiple renal arteries grafts, 337,
 338*f*
 organ preservation methods and time
 in, 331
 pancreas transplantation after, 340,
 344
 postoperative care in, 339
 preoperative care, 338–339
 preoperative evaluation in, 334
 psychosocial evaluation of, 336
 recipient surgical procedure in, 333*f*,
 336–337, 337*f*
 results in, 339–340
- simultaneous with pancreas
 transplantation, 340, 344
 surgical evaluation of, 336
 survival rates in, 339–340
 tumors, 335
 urologic evaluation of, 336
 vascular evaluation of, 336
- trauma of, 211–212, 212*f*; 1658–1659
 in children, 1644
 grades of injury in, 1658*t*, 1659
 indications for surgery in, 1659, 1659*t*
 nonoperative treatment of, 211–212,
 1659, 1659*f*
 vascular injuries in, 211, 1658*t*, 1659
 tubular necrosis of, acute, 387–388
 Wilms' tumor of, 1638–1639, 1639*f*
- Kinetic resistance in tumors, 312
- King, Dr. Martin Luther, 5
- King, Josie, 372, 377*t*
- Kininogen, 33
- Kinins, 33
- c-Kit in gastrointestinal stromal tumors,
 288*t*, 1481, 1482, 1483, 1484
- Klatskin's tumor, 1292
- Kleinman, Arthur, 1946
- Klinefelter's syndrome, gynecomastia in,
 505
- Klippel-Trénaunay syndrome, 1850, 1852*f*
- Clumpke's palsy, 1727
- Knee
 arthroplasty of, 1774–1776,
 1775*f*–1776*f*; 1777*f*; 1778*f*
 alignment of components, 1776
 background of, 1774–1775
 bearing surfaces in, 1775–1776
 osteolysis in, 1778
 surgical approach, 1775
 collateral ligament injuries, 1768–1769
 contracture in cerebral palsy, 1782
 cruciate ligaments injury, 1768–1769,
 1769*f*
 dislocation of, 1762
 fractures of, 1767–1769
 ligaments injuries of, 1768–1769
 meniscus tears of, 1767–1768, 1768*f*
 posterolateral injury, 1769
- Knockout mouse technology, 464–466,
 465*f*
 embryonic lethality in, 466
 target vector in, 464
- Knowledge, medical, as core competency,
 4*t*
- Knudson's two-hit hypothesis on tumor
 formation, 287, 287*f*
- Kocher, Emil Theodor, 4, 1521
- Kocher incision, 1452
- Kocher maneuver, 191
- Koch, Robert, 136
- Kock pouch ileostomy, 1194
 in familial adenomatous polyposis, 1207
 in ulcerative colitis, 1198
- Koller, Karl, 1896
- Korotkoff sounds, 400
- Kouchoukos's technique in aortic
 aneurysm repair, 795
- KTP (potassium thionyl phosphate) laser,
 428
- Kulchitsky cells in tracheobronchial tree,
 612, 613*f*
- L**
- Labeling of surgical specimens, frequency
 of errors in, 371, 371*f*
- Labetuzumab in medullary thyroid cancer,
 1550

- Labia majora and minora, anatomy of, 1673–1674
- Labyrinthitis, 567
- Lacerations
in head and neck injuries, 575, 575f–576f
closure in, 575–576, 575f–576f
of scalp, 166, 173, 1715
of kidney, 1658t
of liver, 203, 204
in obstetric injuries, 1692
of small intestine, 207
of vagina in children, 1636
- Lactate
in gluconeogenesis, 45, 45f, 48
serum levels of
in burns, 230
in shock, 120, 121f, 130
- Lactation
breast changes in, 501, 501f, 504–505, 504f
mastitis in, 506
- Lactic acidosis, 74
in shock, 130
- Lactose digestion and absorption, 1141, 1142f
- Lacunar ligament anatomy, 1496
- Ladd's bands, 1616
- Ladd's procedure in malrotation, 1617, 1618f
- Lambert-Eaton syndrome in lung cancer, 627
- Lamina propria, 1144, 1144f
- Laminectomy in intervertebral disc herniation, 1771
- Langerhans cell histiocytosis, 666
- Langerhans cells, 474, 654, 666
- Langer's lines, 1830
- Laparoscopy
with abdominal lift device, 418
access for, 421–422, 421f
adrenalectomy in, 1591–1592, 1591f, 1592f
anesthesia in, 419
appendectomy in, 1252–1256, 1253f, 1254f
in children, 1623
in pregnancy, 436
in appendicitis, 1252–1256, 1253f, 1254f
diagnostic, 1254
in pregnancy, 436
bariatric surgery in. *See* Bariatric surgery, laparoscopic
in children, 435–436
cholecystectomy in. *See* Cholecystectomy, laparoscopic
colon resection in, 1187
in colorectal cancer, 1216
common bile duct exploration in, 1325–1327, 1328f
complications of, 418, 1704–1705
bladder trauma in, 1515, 1705
in elderly, 1935–1936
in inguinal hernia repair, 1515–1516
in Crohn's disease, 1157, 1198
in elderly, 436–437, 1935–1936
endocrine response to, 418
esophagectomy in, in cancer of esophagus, 1010–1011, 1010f
gastric, 1095
in cancer diagnosis, 1080–1081
in gynecologic disorders, 1687–1690
hand-assisted, 423, 424f, 1187
access for, 423, 424f
splenectomy in, 1441, 1443
Hasson technique in, 422
hiatal hernia repair in, 983
historical aspects of, 416
incisional hernia repair in, 1456, 1457f
incisions in, 421–422, 1451, 1452
single, 1443
inguinal hernia repair in, 1509–1513
in children, 1635
complications of, 1515–1516
liver resection in, 1301–1302
nephrectomy in, in kidney cancer, 1656–1657
Nissen fundoplication in, 974–975, 974f, 975f–976f
in pancreatic cancer, 1398–1399, 1398f
physiology and pathophysiology in, 417–419
pneumoperitoneum in, 417–419
in elderly, 1935
positioning of patients in, 420, 421f
in pregnancy, 436
appendectomy in, 436
cholecystectomy in, 1320
prostatectomy in, 1658
single-incision. *See* Single-incision laparoscopic surgery
in small intestine obstruction, 1150–1151
splenectomy in, 1440–1441, 1440f, 1441f, 1442f
team approach to, 419–420
telescopes in, 424, 426f
three-dimensional, 426–427
ultrasonography in, 1325
venous thromboembolism in, 418
Veress needle in, 421, 421f
video systems in, 424
- Lapatinib, 310t
- LaPlace's law, 787
- Large cell carcinoma of lung, 617
- Large intestine, 1175–1236
anatomy of, 1176–1179
clinical evaluation of, 1180–1185
colitis of, 1222
colon in. *See* Colon
congenital anomalies of, 1179
diverticular disease of, 1201–1203
embryonic development of, 1175–1176
in immunocompromised patient, 1236
inflammatory bowel disease of, 1195–1201
megaecolon of, 1220–1221
neoplasms of, 1203–1218
physiology of, 1179–1180
pseudo-obstruction of, 1221
sarcoma of, 1480
trauma of, 1233–1235
in laparoscopy, 1705
volvulus of, 1219–1220
- Laryngeal disorders, 572–574
cancer, 589–591
anatomy in, 579, 589, 589f
diagnosis of, 589, 589f
epidemiology of, 275t
lymph node involvement in, 591
pectoralis flap reconstruction in, 591, 591f
preservation of larynx in, 591–592
rehabilitation in, 592
staging of, 590
fracture, 176f, 200
granulomas, 572–573, 572f
papillomavirus infections, recurrent, 572
polypoid, 573
- Laryngeal mask airway, 1910, 1910f
intubating, 1910, 1912f
- Laryngeal nerves
anatomy of, 1524–1525, 1524f, 1525f, 1526f
and parathyroid gland, 1524–1525, 1526f
identified in thyroidectomy, 1553–1554, 1553f
injury in surgery, 384
in thyroidectomy, 1554, 1556
lung cancer involving, 623, 671, 673f
- Laryngectomy
in esophageal cancer, 589
in hypopharyngeal cancer, 589
in laryngeal cancer, 590f, 591
pectoralis flap reconstruction in, 591, 591f
rehabilitation in, 591
supracricoid technique, 591
- Laryngitis, polypoid, 573
- Laryngopharyngectomy in hypopharyngeal cancer, 588, 589
- Laryngoplasty in vocal cord paralysis, 574, 574f
- Laryngoscopy, fiberoptic, 1106
- Laryngoscopy for airway management in anesthesia, 1910, 1910f, 1911f
- Laser therapy, 428–429
in atherectomy, 896
in hemangiomas, 574
in prostate hyperplasia, benign, 1665
in transmyocardial revascularization, 747
in varicose veins, 929
in vocal cord cancer, 591
- Latarjet nerve anatomy, 1038, 1039f
- Lateral ligaments of rectum, 1177
- Latissimus dorsi flaps
in breast reconstruction, 550, 1871, 1874f
in chest wall reconstruction, 1874
in head and neck reconstruction, 601
- Lavage, peritoneal
in abdominal trauma, 180–181, 180f, 181t
in pregnancy, 218, 221
complications of, 382, 382f
- Leadership in surgery
areas of medical knowledge in, 4t
on core competencies, 3–8, 4t
definitions of terminology related to, 3
fundamental principles of, 3–8
interpersonal and communication skills, 4t
introduction of, 3
medical knowledge, 4t
mentoring of, 10–11
patient care skills, 4t
practice-based learning and improvement, 4t
professionalism, 4t
styles in, 9
systems-based practice, 4t
time management, 7–8, 8f
training modules in, 10t
training programs in, 9–10, 10t
vision of, 3–4
willingness, 4–7
to communicate effectively, 6–7
to lead, 5–6
to learn, 6
to resolve conflict, 7

- Leapfrog Group, on standards of health care quality and safety, 375
- Learning and improvement, practice-based, as core competency, 4*t*
- Lecompte maneuver in transposition of great arteries, 721, 722*f*
- Le Fort fractures, 577, 577*f*
- Legal issues
 - in advance directives and living wills, 1944
 - in consent to procedures, 1941–1942, 1943
 - malpractice claims in, 380, 380*t*
 - in medical errors, 380, 380*t*
 - in wrong-site surgery, 378–379
 - in withdrawing or withholding life-sustaining therapies, 1944–1945
- Legg-Calvé-Perthes disease, 1783
- Lehman, Betsy, 368, 377*t*
- Leiomyoblastoma of esophagus, 1016*f*, 1017
- Leiomyoma
 - colorectal, 1216
 - esophageal, 1017–1018, 1017*f*
 - gastric, 1086–1087
 - uterine, 1683, 1683*f*
- Leiomyosarcoma, 776, 1465, 1468*f*, 1470
 - of chest wall, 668, 668*t*
 - colorectal, 1216
 - of esophagus, 1015, 1016*f*, 1017
 - retroperitoneal, 1479
 - uterine, 1481
- Lepidic predominant adenocarcinoma (LPA), 615
- Leptin, 1045, 1049
- Letrozole, 552–553
- Leukemia
 - acute myeloid, 1430*t*, 1435
 - chronic lymphocytic, 1430*t*, 1435
 - chronic myeloid, 455, 1430*t*, 1435
 - chronic myelomonocytic, 1430*t*, 1435
 - epidemiology of, 275*t*, 276*t*, 278*t*, 618*f*
 - hairy cell, 1430*t*, 1434
 - splenectomy in, 1430*t*, 1434, 1435
 - stem cells in, 285
- Leukocytes. *See* White blood cells
- Leukoplakia
 - anogenital, 1678
 - of vocal fold, 573
- Leukotrienes, 31*f*, 32, 32*t*
- Levator ani muscles, 1178
 - anatomy of, 1673
- Levatorplasty, postanal intersphincteric, in anal sphincter injury, 1235
- Levofloxacin, 144*t*, 257*t*
 - in peptic ulcer disease, 1061*t*
- Leydig cell tumors, 1637, 1704
- Lichen
 - planus, 1678
 - sclerosis, 1678
 - simplex chronicus, 1678
- Lichtenstein tension-free inguinal hernia repair, 1508, 1508*f*, 1513
- Lidocaine, 1899*t*, 1902, 1903*t*, 1950*t*
 - in hand and wrist injuries, 1796
 - in wound care, 264
- Lifestyle factors
 - in gastroesophageal reflux disease, 972
 - in obesity, 1102
 - and bariatric surgery, 1108
- Life support measures, 1944–1945
 - advance directives and living wills on, 1944
 - double effect of, 1945, 1945*f*
 - ethical issues in, 1944–1945
 - right to refuse, 1944–1945
 - withdrawing or withholding of, 1944–1945
- Li-Fraumeni syndrome, 287, 290*t*, 291, 1468
 - breast cancer risk in, 517
- Ligaments
 - of acromioclavicular joint, injuries of, 1758
 - healing of, 251
 - hepatic, 1264–1265, 1264*f*, 1265*f*
 - of knee injuries, 1768–1769
 - of spleen, suspensory, 1425, 1425*f*
 - of wrist, injuries of, 1798
- Ligand-gated ion channels, 35*f*
- Ligation of the intersphincteric fistula tract (LIFT), 1231
- Limberg flap, 1833
- Limb ischemia, 881–900
- Linea alba, 1449, 1450*f*
- Linea semilunaris, 1449
- Linezolid, 145*t*
- Lip
 - cancer of, 579, 580, 582, 1856–1857
 - lymph node metastasis of, 582, 582*f*
 - reconstructive surgery in, 582, 1856–1857
 - wedge resection in, 582*f*
 - cleft, 1840–1844. *See also* Cleft, of lip and palate
 - lacerations of, 576, 576*f*
 - plastic and reconstructive surgery of, 582, 1856–1857
 - Abbé flap in, 1857, 1859*f*
 - Bernard-Webster technique in, 1857, 1859*f*
 - Karapandzic flap in, 582, 583*f*, 1857
- Lipase, 47*f*, 1347, 1348*t*
 - in chronic pancreatitis, deficiency of, 1371*f*, 1372
 - replacement therapy in, 1380*t*
- Lipectomy, suction, 1883, 1885, 1886*f*
- Lipid droplets (LDs), 32
- Lipids
 - elevated serum levels of. *See* Hyperlipidemia
 - metabolism of, 46–47
 - in liver, 1269
 - in small intestine, 1143
 - in parenteral nutrition solutions, 58
 - storage disorders, splenectomy in, 1437–1438
- Lipodermatosclerosis, 259, 917, 929
- Lipodystrophy, mesenteric, 1458, 1459*f*
- Lipolysis, 1142–1143
 - in injury, 47, 47*f*
- Lipomas, 486
 - cardiac, 776
 - colorectal, 1216
 - gastric, 1087
 - of hand and wrist, 1816
- Lipopolysaccharide, immunocyte recognition of, 37*f*
- Liposarcoma, 1465
 - chemotherapy in, 668*t*, 1475, 1476
 - of chest wall, 668–669, 668*t*
 - metastatic to liver, 1471*f*
 - myxoid, 1470, 1479
 - genetic factors in, 1467
 - retroperitoneal, 1479, 1479*f*, 1480
 - well-differentiated, 1470, 1479, 1480
- Liposuction, 1883, 1885, 1886*f*
- Lipoxygenase, 31*f*, 32
- Lisfranc's joint, 1765
 - fracture-dislocation of, 1765
- Lister, Joseph, 4, 135–136, 241
- Lithium therapy, hyperparathyroidism in, 1560
- Lithostathine, 1368, 1368*f*
- Lithotripsy, extracorporeal shock wave, 429, 1666
 - in pancreatic duct stones, 1380–1383
- Lithotriptors, electrohydraulic, 429
- Littre's hernia, 1164
- Liver, 1263–1302
 - abdominal hernia in disease of, 1279, 1455
 - abscess of, 150, 1285
 - amebic, 1285
 - pyogenic, 1284–1285, 1284*f*
 - acetaminophen hepatotoxicity, 1276
 - liver transplantation in, 347, 1277, 1277*t*
 - acute failure of, 1275–1277
 - clinical presentation in, 1276
 - diagnosis and clinical management in, 1276–1277, 1276*t*
 - emerging technologies, 1277
 - etiology of, 1276
 - extracorporeal liver support in, 1277
 - laboratory evaluation in, 1276, 1276*t*
 - prognosis in, 1277
 - transplantation in, 347, 348, 1277
 - adenoma of, 1290–1291, 1290*f*
 - albumin synthesis in, 1271
 - anatomy of, 1264–1269
 - ligaments in, 1264–1265, 1264*f*, 1265*f*
 - lymphatic, 1268–1269
 - neurologic, 1268–1269
 - segmental, 1265, 1265*f*
 - vascular, 1266–1268, 1266*f*, 1267*f*, 1268*f*
 - anesthesia in disorders of, 1907
 - benign lesions of, 1288*t*, 1289–1291
 - bilirubin metabolism in, 1270, 1271–1272
 - biopsy of
 - in cirrhosis, 1279
 - in incidental mass, 1288
 - Budd-Chiari syndrome of, 1283–1284
 - cancer of, 1288*t*, 1291–1294
 - chemoembolization in, 1295–1296
 - in children, 1641–1642, 1641*f*, 1642*t*
 - staging of, 1642, 1642*t*
 - treatment of, 1642
 - in cirrhosis, 1279, 1291
 - in colorectal cancer metastasis, 1210, 1213, 1293–1294, 1295
 - in elderly, 1933
 - epidemiology of, 618*f*
 - hepatectomy in, 1301
 - downstaging of, 1296
 - epidemiology of, 275*t*, 276–277, 276*t*, 277*f*, 279*f*
 - ethanol ablation in, 1295
 - hepatectomy in, 1294–1295
 - in colorectal cancer metastasis, 1301
 - in recurrence, 1301
 - liver transplantation in, 347, 348, 1291, 1295, 1642
 - Milan criteria on, 347, 1291
 - in pancreatic cancer metastasis, 1398*f*, 1407
 - radiofrequency ablation in, 1295
 - risk factors for, 1291
 - treatment algorithm on, 1291, 1293*f*
 - carcinoid tumor of, 1294
 - caudate lobe of, 1267

- Liver (*Cont.*):
- cirrhosis of, 1277–1280. *See also* Cirrhosis
 - clotting factors synthesized in, 1271
 - coagulopathy in disorders of
 - transplantation of liver in, 348
 - cysts of, 1288–1289
 - in Caroli's disease, 1289
 - congenital, 1288
 - in hydatid disease, 1285
 - laparoscopic resection in, 1301
 - in polycystic disease, 1288–1289
 - end-stage disease of
 - in Budd-Chiari syndrome, 1284
 - in cirrhosis, 1277, 1280
 - MELD score in, 347, 437, 1280, 1295
 - enteral nutrition in failure of, 54–55
 - fatty infiltration of
 - in inflammatory bowel disease, 1196
 - in obesity, bariatric surgery in, 1129
 - function tests of, 1270
 - glycogen in, 44
 - hemangioma of, 1289–1290, 1290*f*
 - hepatocellular injury of, 1271–1272
 - historical aspects of surgery on, 1263–1264
 - hyperplasia of, focal nodular, 1290*f*, 1291
 - incidental mass of, 1287–1288
 - diagnostic algorithm on, 1287*f*
 - differential diagnosis in, 1288, 1288*t*
 - infections of, 1284–1287
 - inflammatory bowel disease involving, 1196
 - ischemia of
 - in aortic aneurysm repair, 801
 - in preconditioning for surgery, 1300
 - liposarcoma metastatic to, 1471*f*
 - physiology of, 1269–1272
 - portal hypertension of, 1280–1281
 - quadrate lobe of, 1265
 - radiologic evaluation of, 1272–1275
 - radionuclide scans of, 1315
 - resection techniques, 1296–1301. *See also* Hepatectomy
 - soft tissue sarcoma metastatic to, 1478
 - transplantation of, 345–352, 1283
 - in acetaminophen hepatotoxicity, 347, 1277, 1277*t*
 - in acute failure, 347, 348, 1277
 - in biliary atresia, 349, 1629
 - in Budd-Chiari syndrome, 1284
 - in children, 349, 1629
 - in hepatocellular carcinoma, 1642
 - split-liver procedure in, 349
 - in cholangiocarcinoma, 347, 1292
 - in cholangitis, primary sclerosing, 346, 1331
 - in cirrhosis, 346, 347, 1277, 1283
 - complications in, 351–352
 - contraindications to, 348
 - donor in, 346
 - in hepatocellular carcinoma, 347, 1291, 1295, 1642
 - historical aspects of, 345–346, 347
 - immunosuppressive therapy in, 346
 - complications of, 351
 - indications for, 346–347, 346*t*, 1277*t*, 1283, 1295
 - indicators of graft function in, 351
 - with intestinal transplantation, 352, 353*f*
 - living donor in, 332, 333*f*, 346
 - operative technique in, 349, 350*f*–351*f*
 - Milan criteria on, 347
 - orthotopic, 348
 - in polycystic liver disease, 1289
 - postoperative care in, 349–351
 - preoperative evaluation in, 347
 - primary nonfunction of graft in, 351
 - split-liver procedure, 349
 - surgical procedure in, 348–349, 348*f*–349*f*
 - piggyback technique in, 349
 - survival rates in, 349
 - trauma of
 - in children, 1644, 1644*t*, 1645*f*
 - grading scale on, 1644, 1644*t*
 - in variceal bleeding, 347, 1283
 - venovenous bypass in, 348
 - waiting time for, 348
 - treatment options, 1294*t*
 - Living donor transplantation procedures, 332
 - kidney, 323, 332, 334
 - operative technique in, 333*f*
 - liver, 332, 346
 - operative technique in, 349, 350*f*–351*f*
 - pancreas, 343–344
 - Living wills, 1944
 - Lobectomy
 - hepatic
 - left, 1299–1300, 1299*f*
 - right, 1298–1299, 1298*f*
 - pulmonary
 - compared to limited resection, 640*t*
 - functional status assessment in, 633–634, 638*f*
 - of temporal lobe in epilepsy, 1746
 - Lobular carcinoma of breast
 - in situ
 - histopathology in, 520, 520*t*
 - pathology in, 510
 - pleomorphic, 510
 - treatment of, 537–538
 - invasive, 520–521, 522, 522*f*
 - Locoregional lymphadenectomy, 1473
 - Loeys-Dietz syndrome, 787
 - Long, Crawford, 1895
 - Long esophageal myotomy, 995–997, 995*f*, 996*f*–997*f*
 - Loop ileostomy, 1189*f*, 1192–1193
 - Lorcaserin in obesity, 1102
 - Lower extremity
 - arterial occlusive disease of, 881–900
 - acute, 882, 885–889
 - bypass graft thrombectomy in, 888
 - clinical manifestations of, 882*t*, 886–887
 - complications of treatment in, 888–889, 888*t*
 - embolectomy in, 887–888
 - endovascular therapy in, 887
 - etiology of, 885–886
 - reperfusion syndrome in, 888
 - chronic, 882–883, 889–900
 - atherectomy in, 895–896, 897
 - clinical manifestations of, 889–890, 890*t*, 891*f*
 - endovascular therapy in, 891–892, 896–897
 - in femoropopliteal disease, 897
 - surgical treatment in, 897–898
 - classification of, 883, 885, 885*t*–886*t*
 - computed tomography angiography in, 882, 883*f*
 - diagnostic evaluation in, 882
 - differential diagnosis of, 882–883
 - epidemiology of, 882
 - intermittent claudication in, 882, 884*t*, 885*t*
 - pain in, 828
 - physical examination in, 829
 - symptoms in, 828
 - compartment syndrome of
 - fasciotomy in, 215, 216*f*, 888
 - in ischemia treatment complications, 888–889, 889*f*, 889*t*
 - in trauma, 215
 - edema of, after surgical treatment of limb ischemia, 898
 - fractures of, 1876–1877, 1876*t*
 - osteomyelitis in, 1877
 - soft tissue coverage in, 1877, 1877*t*, 1878*f*
 - lymphedema of, 934, 934*f*, 936
 - reconstructive surgery in, 1879–1880
 - reconstructive surgery of, 1876–1880
 - in diabetic ulceration, 1877, 1879
 - in lymphedema, 1879–1880
 - in trauma, 1876–1877
 - in tumors, 1877
 - ulcers of
 - in diabetes mellitus, 1877, 1879
 - ischemic, 889, 890*t*, 891*f*
 - neuropathic, 890*t*, 891*f*
 - veins in, 915–916
 - Lumbar spine
 - intervertebral disc herniation in, 1742, 1742*f*, 1742*t*, 1771
 - level and symptoms in, 1742*t*
 - surgical treatment in, 1771
 - spondylolisthesis of, 1739, 1740*f*
 - stability of, 1739
 - stenosis of, 1771
 - trauma of, 1722, 1724*f*
 - fractures in, 1770–1772
 - orthotic devices in, 1726
 - Lumbrical muscles, 1791
 - Luminal tamponade, in variceal hemorrhage, 1282
 - Lumpectomy, 547, 554. *See also* Breast conservation surgery
 - in breast cancer, 537
 - Lunate bone
 - anatomy of, 1788, 1790*f*
 - dislocation of, 1798
 - Lundy, John, 1897
 - Lungs, 611–664
 - abscess of, 650–651, 650*t*, 652*f*, 653*t*
 - chest radiograph in, 651, 652*f*
 - clinical features and diagnosis, 650–651
 - etiologies of, 650, 650*t*
 - primary, 650, 650*t*
 - secondary, 650, 650*t*
 - surgical drainage of, 651, 653*t*
 - acute injury of, 384–386
 - transfusion-related, 101, 102*t*
 - anatomy of, 611–612, 661
 - alveolar spaces in, 612
 - lymphatic, 611–612, 612*f*, 613*f*
 - segmental, 611, 612*f*
 - tracheobronchial tree in, 612, 613*f*
 - biopsy of, 630
 - blood supply of, 661
 - in sequestration, 1606*f*, 1607
 - cancer of, 623–645
 - chemotherapy in. *See* Chemotherapy, in lung cancer
 - diagnosis, 628*f*
 - drug resistance, 313
 - in elderly, 1933–1934

- epidemiology of, 274, 275*t*, 276*t*, 277*f*, 278*t*, 617–619, 618*f*
- etiologies of, 617–619
- functional status assessment in, 635–637, 638*f*
- histology of, 614–615
- lymph node involvement in
- anatomy of, 611–612, 612*f*, 613*f*
 - assessment of, 631–633, 632*f*, 632*t*
 - in locoregional advanced disease, 640–641
 - staging of, 631–635, 634*t*
- management, 627–637, 629*t*
- metastatic, 627, 631–633
- staging of, 633–635, 634*t*
- molecular subsets, 287*f*
- osteoarthropathy in, hypertrophic, 626, 626*f*
- paraneoplastic syndromes in, 625–627, 625*t*
- preinvasive lesions in, 613–614
- risk factors for, 617–619, 619*t*, 620*t*
- screening for, 299, 299*t*, 619–621
- signs and symptoms in, 623–627, 625*t*
- in metastasis, 627
 - nonpulmonary thoracic, 623–625, 625*t*
 - pulmonary, 623, 625*t*
- small cell. *See* Small cell carcinoma of lung
- staging of, 633–635, 634*t*
- and treatment, 637–645, 638–645
 - survival rates in, 637–638
 - in chemotherapy, 644*t*
- treatment in, 637–645, 638–645
- in early-stage disease, 637–641, 638–641
 - in elderly, 1934
 - in locoregional advanced disease, 639
 - in stage IV disease, 641–642
- computed tomography of
- in cancer assessment, 629, 631
 - screening, 619–621
 - in solitary nodule, 621–622, 622*f*
- contusion of
- in children, 1643
 - in elderly, 222
- end-stage disease of, 663–664
- lung transplantation in, 663–664, 664*f*
 - lung volume reduction surgery in, 663–664
- foreign body in, in children, 1607–1608
- function testing of
- in aortic aneurysm repair, 793
 - in lung cancer, 635–637, 638*f*
- in hemoptysis, massive, 661–663
- histology of, 612–613, 613*f*
- hyperplasia of, 614, 617
- infections of, 650–661
- metastatic lesions, 622–623
- in pancreatitis, acute, 1354
- in pneumothorax, spontaneous, 649–650
- soft tissue sarcoma metastasis to, 1471–1472, 1478, 1478*f*
- solitary nodule in, 621–622
- biopsy and resection in, 630*f*
 - calcification of, 622
 - corona radiata sign in, 622, 622*f*
 - differential diagnosis in, 621
 - imaging in, 621–622, 622*f*
 - management algorithm on, 630*f*
 - surgical approaches to, 642–644
- transplantation of, 354–358, 663–664, 664*f*
- bilateral sequential, 663
 - complications in, 357–358
 - evaluation of, 356–357
 - with heart transplantation, 354–358, 664
 - historical aspects of, 354–355
 - indications for, 356, 663–664
 - living donor in, 332, 356–357
 - organ preservation methods and time in, 331
 - postoperative care in, 357–358
 - rejection in, 664
 - surgical procedure in, 357
 - survival rates in, 664, 664*f*
 - trauma of, 202
 - volume reduction surgery of, 663
- Lupus anticoagulant in antiphospholipid syndrome, 93
- Luteinizing hormone, 504
- Lymphadenitis, cervical, in children, 1602
- Lymphadenopathy, cervical, in children, 1602
- Lymphangiography, 935, 935*t*, 936*f*
- in lymphedema, 935
- Lymphangiomas, 575, 598, 1602–1603, 1852, 1852*f*
- Lymphangiosarcoma, 1466
- Lymphatic malformations, 1602–1603, 1603*f*, 1850–1852, 1852*f*
- Lymphatic sump of Borrie, 611, 613*f*
- Lymphatic system
- of anal canal, 1217, 1217*f*
 - of colon, 1177
 - of esophagus, 946–947, 946*f*
 - of head and neck, 595, 595*f*
 - of liver, 1268–1269
 - of lungs, 611–612, 612*f*, 613*f*
 - of pancreas, 1344–1346, 1346*f*
 - of stomach, 1038, 1039*f*
 - of thyroid, 1525, 1527*f*
- Lymphedema, 934–936, 1879–1880
- chronic, lymphangiosarcoma in, 1466, 1467*f*
 - clinical diagnosis of, 934–935, 934*f*
 - congenital, 934
 - hyperkeratosis in, 934, 934*f*
 - management of, 935–936
 - nonsurgical, 1880
 - surgical options in, 1880 - in mastectomy, modified radical, 549
 - pathophysiology in, 934
 - praecox, 934, 1879
 - primary, 934, 1879
 - radiologic diagnosis of, 935, 935*t*, 936*f*
 - reconstructive surgery in, 936
 - secondary, 934, 1879
 - tarda, 934
- Lymph nodes, 300–301, 305–306
- in breast cancer, 531*t*–532*t*
 - axillary lymph nodes in. *See* Axillary lymph nodes, in breast cancer
 - historical aspects of surgery, 498
 - internal mammary lymph nodes in, 543
 - mapping of, 305, 305*f*; 545–546
 - sentinel node dissection in, 305–306, 545–547
 - staging of, 531
- cervical. *See* Cervical lymph nodes
- in colorectal cancer, 305, 1210, 1210*f*
 - colon carcinoma involving, 1213
 - rectal carcinoma involving, 1215
 - sentinel nodes in, 1177
- staging of, 1210, 1211*t*
- in esophageal cancer
- dissection of, 1011
 - staging of, 1004–1005, 1006*t*
- in gallbladder cancer
- staging of, 1335
- Halsted theory on dissection of, 305
- in head and neck tumors, 595–597, 596*f*, 597*f*
- anatomy and levels in, 595, 595*f*
 - of larynx, 591
 - of lips, 582, 582*f*
 - of oral cavity, 583, 583*f*
 - of oropharynx, 587
 - staging of involvement, 581*t*
- in lung cancer
- anatomy of, 611–612, 612*f*, 613*f*
 - assessment of, 631–633, 632*f*, 632*t*
 - in locoregional advanced disease, 640–641
 - staging of, 631–635, 634*t*
- mapping of, 305, 305*f*; 545–546
- in breast cancer, 305, 305*f*; 545–546
- mediastinal. *See* Mediastinal lymph nodes
- in melanoma, 488, 489–490, 489*f*–490*f*
- in nanometastasis, 306
- in pancreatic cancer, staging of, 1395, 1397*t*
- in parathyroid carcinoma, dissection of, 1570
- in prostate cancer, 1658
- sentinel. *See* Sentinel lymph nodes
- in soft tissue sarcomas, 1471, 1473
- in squamous cell carcinoma, 487
- in stomach cancer, 1038, 1080, 1082
 - dissection of, 1038, 1082
 - staging of, 1080*t*
- in testicular cancer, 1654–1655
- dissection of, 1654–1655
- in thyroid cancer, 1544*t*
- dissection of, 1555–1556, 1555*f*
 - medullary, 1550
- in vaginal cancer, 1697
- in vulvar cancer, 1696–1697, 1697*f*
 - anatomy of, 1696, 1696*f*
 - staging of, 1696–1697, 1696*t*
- Lymphocele in kidney transplantation, 336
- Lymphocytes, 38–39, 475
- B cells
- in small intestine immune function, 1144
 - in transplant rejection, 324
- in chyle, 686*t*
- T cells, 38–39, 39*f*
- allorecognition by, 324
 - in small intestine immune function, 1144
 - in transplant rejection, 324
 - in wound healing, 243–244
- Lymphogranuloma venereum, 1678, 1679*t*
- Lymphoma
- of appendix, 1259
 - of bone, 1781
 - of breast, 556–557
 - of central nervous system, 1736
 - colorectal, 1216
 - epidemiology of, 275*t*, 276*t*, 277*f*, 278*t*, 618*f*
 - in HIV infection and AIDS, 1736
 - Hodgkin's. *See* Hodgkin's lymphoma
 - mediastinal, 671, 678
 - biopsy in, 673
 - differentiated from thymoma, 675

- Lymphoma, mediastinal (*Cont.*):
 incidence of, 671, 673*t*, 678
 signs and symptoms in, 674*t*
 of pancreas, 1413
 of small intestine, 1160, 1161*t*
 outcome in, 1162
 treatment in, 1162
 splenectomy in, 1430*t*, 1434–1435
 of stomach, 1074, 1084
 in *Helicobacter pylori* infections,
 1054
 of thyroid, 1536, 1551
 in transplant recipients, 330
- Lymphoproliferative disorder
 mediastinal, 671
 posttransplant, 329
- Lymphoscintigraphy, 545, 935, 935*t*
 in lymphedema, 935
- Lynch syndrome, 291–292, 1207–1208,
 1210*t*
 Amsterdam criteria on, 292, 292*t*
 endometrial cancer in, 1701
- M**
- MACIS scale on papillary carcinoma of
 thyroid, 1543
- Mackenrodt's ligament, 1674
- Macroadenomas of pituitary, 1735
- Macrocysts of breast, 508, 509
- Macroductyly, 1823
- Macrolides, 145*t*
- Macrophage antigen 1 (Mac-1), 41*t*
- Macrophage migration-inhibiting factor,
 21
- Macrophages
 in inflammatory response, 21, 39–40
 in microbial invasion response, 138
 stimulation by interferon- γ , 30–31
 in wound healing, 242*f*, 243, 243*f*, 243*t*,
 1831
- MADH4* gene in juvenile polyposis, 289*t*
- Mafenide acetate in burns, 232
- Maffucci's syndrome, 1778, 1818
- Magill, Ivan, 1897
- Magnesium
 absorption of, 1143
 daily dietary intake of, 73
 in parenteral nutrition, 76*t*
 serum levels of, 73, 78
 in cancer patients, 81
 in hypermagnesemia, 72*t*, 73, 78
 in hypomagnesemia. *See*
 Hypomagnesemia
 in kidney transplantation, 339
 supplemental, in children and infants,
 1599
- Magnetic resonance angiography, 832,
 833*f*
 in aortic aneurysm, thoracic, 791
 in aortic dissection, 811, 815
 in carotid artery occlusive disease, 840
 in celiac artery compression, 862*f*
 in lower extremity arterial occlusive
 disease, 882
 in mesenteric ischemia, 862, 862*f*, 863*f*
 in renal artery stenosis, 867*f*, 868, 868*f*
- Magnetic resonance imaging
 of abdominal wall tumors, 1454
 in aortic aneurysm, thoracic, 791
 in aortic dissection, 811, 815
 in biliary disorders, 1315, 1317*f*
 in breast cancer, 516, 527, 529, 530*f*,
 531*f*
 in carotid artery occlusive disease, 840
 in celiac artery compression, 862*f*
 in chest wall tumors, 665
 in colorectal disorders, 1181
 of hand and wrist, 1794, 1795*f*
 in hand tumors, 1815–1816
 of heart, 739
 in cardiomyopathy, 765
 in inguinal hernia, 1504
 of liver, 1274–1275, 1315
 in incidental mass, 1288
 in lower extremity arterial occlusive
 disease, 882
 in lung cancer, 629
 in distant metastasis, 633
 in mediastinal tumors, 671
 in mesenteric ischemia, 862, 862*f*, 863*f*
 in minimally invasive surgery, 417
 in neurologic examination, 1712
 in pancreatitis, chronic, 1370, 1370*f*
 of parathyroid gland, in preoperative
 localization studies, 1565, 1565*t*
 in pheochromocytoma, 1586
 in renal artery stenosis, 867*f*, 868, 868*f*
 in soft tissue sarcomas
 in initial assessment, 1468–1469,
 1468*f*–1469*f*
 in surveillance for recurrence, 1477
 in spine trauma, 1725
 of spleen, 1429
 of stomach, 1051
 in cancer, 1080
 of thyroid, 1530
- Malabsorption
 in bariatric surgery, 1102, 1103*t*, 1107,
 1119–1121
 historical aspects of, 1103
 in pancreatitis, 1371*f*, 1372, 1379
 in short bowel syndrome, 1171
- Malignant fibrous histiocytoma, 493
- Malignant hyperthermia, 393, 1916–1917
- Mallampati classification in airway
 evaluation, 1905, 1906*f*, 1906*t*
- Malleolus, fractures of, 1764
 bimalleolar, 1764
 lateral, 1764
 medial, 1764
 posterior, 1764
- Mallet finger, 1798
- Mallory-Weiss tear, 1018, 1020, 1090
- Malnutrition
 in elderly, 1929
 refeeding syndrome in, 81
 respiratory quotient in, 385
 wound healing in, 254–255, 254*f*
- Malperfusion syndrome in aortic
 dissection, 807, 810, 811
 endovascular treatment in, 815
 indications for surgery in, 815
 open repair in, 816
- Malpractice claims, common causes of,
 380, 380*t*
- Malrotation, intestinal, 1616–1617
 Ladd's procedure in, 1617, 1618*f*
- Mammoplasty
 augmentation, 1890–1891, 1891*f*
 implant placement in, 1890–1891,
 1891*f*
 incisions in, 1890, 1891*f*
 reduction, 1887–1889, 1888*f*, 1889*f*,
 1890*f*
 scar location and length in, 1889
 vertical technique in, 1890*f*
 Wise technique in, 1888–1889, 1888*f*,
 1889*f*
- MammaPrint test in breast cancer,
 536
- Mammary artery graft in coronary artery
 bypass surgery, 742, 743–744,
 745*f*; 746
- Mammary duct fistulas, 507
- Mammary lymph nodes, 502–503
 in breast cancer, 543
- Mammography
 compared to ultrasonography, 528*f*
 in diagnosis of breast cancer, 523–526,
 524*f*–526*f*
 in excisional biopsy with needle
 localization, 544–545, 546*f*
 risk assessment for breast cancer in, 296
 in screening for breast cancer, 513,
 523–526
 in elderly, 1932
 recommendations on, 525–526
- Mandible
 anatomy of, 1854*f*
 fractures of, 576, 576*f*; 1853–1854,
 1854*f*
 dental occlusion in, 1853, 1854*f*
 intermaxillary fixation in, 576
 maxillary-mandibular fixation in,
 1854
 in hemifacial microsomia, 1846
 involvement in head and neck tumors,
 584–585, 585
 of alveolar mucosa, 585, 586*f*
 of buccal mucosa, 586
 of oropharynx, 587
 reconstructive surgery in, 601, 1863,
 1864*f*
 resection technique in, 585, 586*f*
 of retromolar trigone, 586
 reconstructive surgery of
 dental occlusion in, 1853, 1854*f*; 1863
 fibula osteocutaneous flap in, 601,
 1863, 1864*f*–1865*f*
 in fractures, 1853–1854, 1854*f*
 in tumors, 601, 1863, 1864*f*–1865*f*
- Mandibulectomy
 in alveolar mucosa tumors, 585
 in retromolar trigone tumors, 586
- Mandibulofacial dysostosis, 1846, 1847*f*
- Mandibulotomy in alveolar mucosa
 tumors, 585, 586*f*
- Mannitol in intracranial pressure increase,
 1713
- Manometry
 anorectal, 1181–1182
 high pressure zone in, 1182
 rectoanal inhibitory reflex in, 1182
 resting and squeeze pressures in, 1182
 esophageal, 953–955, 954*f*; 954*t*
 high-resolution, 955, 956*f*–960*f*
 normal values in, 954, 954*t*, 966*t*
 in nutcracker esophagus, 992
 preoperative
 in antireflux surgery, 972
 in long esophageal myotomy, 995
 pressure profile in, 954, 954*f*
 asymmetry of, 954, 954*f*
 in primary motility disorders, 990,
 991*t*
 in scleroderma, 985, 985*f*
 in spasm, diffuse and segmental, 992
 transit scintigraphy, 955
- Mapping, lymphatic, in cancer, 305, 305*f*
 of breast, 305, 305*f*; 545–546
- Marfan's syndrome, 246, 248, 759, 787, 902
 aortic abnormalities in, 248, 787, 902
 aneurysms, 787, 789, 792, 793, 795
 dissection, 813, 815
 genetic factors in, 248, 902

- Marginal artery of Drummond, 1177
 Marjolin's ulcer, 259, 1817
 Marshall-Marchetti-Krantz procedure in stress urinary incontinence, 1695
 Masaoka staging system in thymoma, 675, 675t
 Massage, lymphatic, in lymphedema, 936
 Mastalgia, cyclical, 508
 Mast cells in inflammatory response, 39
 Mastectomy in breast cancer, 548–549
 in advanced local-regional disease, 542–543
 in ductal carcinoma in situ, 537
 in early invasive disease, 538–539
 in elderly, 1932
 Halsted radical procedure, 498–499, 547
 historical aspects of, 497–499
 local-regional recurrence in, 543
 modified radical procedure, 498–499, 548–549, 548f
 axillary lymph node dissection in, 548–549, 548f
 Patey technique, 547, 548f, 549, 549f
 in pregnancy, 554
 nipple-areolar sparing, 547–548
 partial procedure, 547. *See also* Breast conservation surgery
 prophylactic, 513, 514, 516
 and radiation therapy, 499, 550
 reconstructive surgery after, 549–550, 1866–1872
 timing of, 1866
 skin-sparing technique, 547, 549–550
 survival rates in, 499
 Mastitis, 506
 epidemic puerperal, 506
 nonepidemic (sporadic) puerperal, 506
 periductal, 508, 509, 511
 recurrent, 506
 Mastoiditis, 567
 Mastopexy, 1889
 Mathes-Nahai classification of flaps, 1837, 1837t
 Matrix metalloproteinases, 283
 tissue inhibitors of, 283
 Matrix synthesis in wound healing, 242f, 243t, 244–245
 fetal, 252
 Maturation phase of wound healing, 242f, 245
 Maxillary sinus tumors, 592
 Maxillofacial injuries, 197, 197f
 May-Thurner syndrome, 919
 McBurney, Charles, 136, 1241
 McBurney incision in appendectomy, 1251, 1452
 McBurney's point, 1244, 1245f
 McCune-Albright syndrome, 1539t, 1849
 M cells, 1144
 McVay repair of inguinal hernia, 1495, 1507–1508, 1507f
 Mechanical heart valves, 749, 750f
 Mechanical injuries, 478
 Mechanical ventilation. *See* Ventilatory support
 Meckel's diverticulum, 1163–1165, 1624, 1624f
 differential diagnosis in, 1246, 1252
 embryonic development of, 1139, 1164, 1453
 intestinal obstruction in, 1163f, 1164, 1164f, 1624
 locations of, 1164, 1624
 perforation of, 1624
 radionuclide scans in, 1165, 1165f, 1624
 treatment of, 1165–1166, 1624
 Meconium ileus, 1617–1619
 complicated, 1617
 operative management of, 1618–1619, 1619f
 uncomplicated, 1617
 Median nerve, 1788
 anatomy of, 1792
 anesthetic block in hand injuries, 1796, 1797f
 compression in carpal tunnel, 1744, 1805–1806
 Mediastinal lymph nodes, 611–612
 biopsy of, 673–674
 in lung cancer, 631–633, 632f, 632t, 673f
 mediastinoscopy in assessment of
 in lung cancer, 631, 632, 632f
 Mediastinitis, 679–680
 acute, 679–680, 680t
 chronic, 680
 sclerosing or fibrosing, 680
 in histoplasmosis, 659
 Mediastinoscopy
 in lung cancer, 631, 632, 632f
 in mediastinal mass, 673–674
 transesophageal, 425f
 Mediastinotomy, anterior, in lung cancer, 674
 Mediastinum, 670–680
 anatomy of, 670–671, 671f
 compartments of, 670–671, 671f
 contents of, 670–671
 disorders associated with, 671, 673t
 cysts of, 679
 ectopic endocrine glands in, 679
 infections of, 679–680
 lymphoproliferative disorders of, 671
 tumors of, 671–679
 biopsy in, 672–673
 in children, 671, 673t
 diagnostic evaluation in, 672–673
 history and physical examination in, 671, 674t
 radionuclide scans in, 672, 674t
 types of, 671, 673t
 Medical education
 on minimally invasive surgery, 437
 morbidity and mortality conferences in, 1952
 Medical knowledge as core competency, 4t
 Medroxyprogesterone acetate in endometriosis, 1690
 Medullary carcinoma
 of breast, 521
 of thyroid, 1549–1550
 in multiple endocrine neoplasia, 1570
 Medulloblastoma, 1734
 Megacolon, 1220–1221
 acquired, 1221
 chronic, 1219
 congenital, 1220–1221, 1624
 toxic, 1195, 1198, 1199
 hemorrhagic, 1197
 Meissner's submucosal plexus, 1039
 Melanin, 474–475
 Melanocytes, 474–475
 malignant transformation of, 488, 488f
 Melanoma, 488–492
 acral lentiginous, 488
 anorectal, 1218
 cancer antigens in, 311
 circulating tumor cells in, 303
 common sites of, 488
 diagnosis of, 488–489, 489f
 epidemiology of, 276t, 277f, 278t, 618f
 genetic factors in, 288t, 292, 488
 of hand, 1818
 subungual, 488, 1818
 incidence of, 488
 lentigo maligna, 488
 lymphadenectomy in, 490–491
 metastasis of, 488, 491
 nodular, 488, 488f
 ocular, 491–492
 pathogenesis of, 488, 488f
 in pregnancy, 491
 prognostic indicators in, 488
 sentinel lymph node biopsy in, 305, 489, 489f–490f
 staging of, 488
 subungual, 488, 1818
 superficial spreading, 488
 surgery for metastasis, 491, 491f
 surgical margins in, 304
 survival rates in, 490
 treatment in, 489–491, 489f–490f
 types of, 488
 ulceration of, 488
 MELD (Model for End-Stage Liver Disease) scoring system, 347, 436, 1280, 1295
 Melphalan
 in melanoma, 491
 in soft tissue sarcoma of extremity, 1473
 MEN1, 289t, 1560
 Mendel, Gregor, 444, 445t
 Ménétrier's disease, 1088, 1088f
 Meningioma
 intracranial, 1735, 1735f
 spinal, 1738, 1738f
 Meningitis
 carcinomatous, 1732
 in otitis media complications, 567
 Meningocele, 1750
 Meniscus, tears of, 1767–1768, 1768f
 Menometrorrhagia, 1682
 in leiomyomas, 1682–1683
 Menopause
 breast cancer therapy in, 553
 breast changes in, 505
 endometrial cancer in, 1701
 hormone replacement therapy in, 513
 ovarian cancer in, 1701, 1702t
 Paget's disease of vulva in, 1680
 Menorrhagia, 1682
 Menstrual cycle
 and breast cancer risk, 511
 breast changes in, 501, 504
 Mental status
 of dying patients, 1951
 of elderly, preoperative assessment of, 1929
 in neurologic examination, 1711
 postoperative changes in, 383, 383t
 Mentors, in telementoring, 437
 Meperidine, 1900
 Mepivacaine in local anesthesia, 1899t, 1902, 1903t
 Meralgia paresthetica, postoperative, in inguinal hernia repair, 1515
 6-Mercaptopurine
 in Crohn's disease, 1156, 1196
 in ulcerative colitis, 1196
 Merkel cell, 475
 carcinoma, 492, 492f
 Meropenem, 144t
 Mesencephalon, 1710
 Mesenchymal tumors, mediastinal, 673t

- Mesenteric arteries**
 collateral flow in, 860, 860f
 embolism in, 860, 861f; 863, 1167
 surgical repair in, 864
 inferior, 860
 anatomy of, 1176
 ischemia, 859–866, 1167. *See also*
 Ischemia, mesenteric
 meandering, 860
 occlusive disease of, 859–866
 anatomy and pathophysiology in, 860,
 860f
 clinical manifestations in, 861
 diagnostic evaluation of, 861–863
 endovascular therapy in, 864–865
 clinical results of, 865–866
 compared to open surgical repair,
 866
 complications of, 865
 techniques in, 865
 surgical repair in, 863–864
 clinical results of, 865–866
 compared to endovascular therapy,
 866
 types of, 860–861
 regulation of blood flow in, 860
 superior, 860
 anatomy of, 1176, 1344
 syndrome of, 1147
 trauma of, 211
 emergent abdominal exploration
 in, 190
 interposition graft in, 211
 thrombosis in, 860, 863, 1167
 surgical repair in, 864
- Mesenteric veins**
 anatomy of, 1177, 1267, 1267f, 1346
 thrombosis of, 929, 1167
- Mesenteritis**
 retractile, 1458
 sclerosing, 1458–1459, 1459f
- Mesentery, 1457–1460**
 anatomy of, 1457–1458, 1458f
 cysts of, 1459–1460, 1460f; 1624
 embryonic development of, 1457, 1458f
 sclerosing mesenteritis of, 1458–1459,
 1459f
 tumors of, 1460
- Mesh repair**
 in abdominal wall defects, 1875
 in hiatal hernia, 983
 in incisional hernia, 1455–1456, 1456t,
 1457f
 in inguinal hernia, 1496, 1513–1514
 fixation of mesh in, 1513–1514
 in giant prosthetic reinforcement of
 visceral sac, 1509, 1509f
 in intraperitoneal onlay mesh
 laparoscopic procedure, 1513
 in Lichtenstein technique, 1508,
 1508f
 materials used in, 1513
 in plug and patch technique, 1508f;
 1513
 in Prolene hernia system, 1509, 1509f
 in totally extraperitoneal laparoscopic
 procedure, 1511, 1512f; 1513
 in transabdominal preperitoneal
 laparoscopic procedure, 1510
- Mesocaval shunt, in portal hypertension
 and gastroesophageal varices,**
 1282, 1283f
- Mesocolon, 1458**
- Mesothelioma, malignant**
 clinical presentation in, 688
 differentiated from adenocarcinoma,
 688, 688t
 management of, 688
 pathophysiology in, 687–688
 staging of, 688, 689t
- MET, 1541t**
- Metabolic syndrome in obesity, 1127–1128**
- Metabolism, 43–50**
 aerobic, 399
 anaerobic, 115
 of bilirubin, 1270, 1271–1272
 in burns, hypermetabolic response in,
 232, 233
 disorders of
 acid-base disorders in, 73–75
 anesthesia management in, 1908
 liver transplantation in, 346–347
 postoperative, 392–393
 wound healing in, 253–254
 of drugs, 1898
 liver functions in, 1270
 in fasting, 44–46, 44t
 extended, 45, 45f
 short-term, 44f
 in injury, 46–47, 46f
 of iodine, thyroid function in, 1525
 liver functions in, 1269
 in shock, 114–115
 in surgical patients, 43–50
 and energy requirements, 51, 52t
- Metacarpal bones, 1788, 1790f**
- Metacarpophalangeal joint**
 anatomy of, 1788, 1790f
 degenerative disorders of, 1807
 fractures of, 1796
 rheumatoid arthritis of, 1808
 splinting of, 1798
- Metachronous tumors, 580**
- Metaiodobenzylguanidine scan in
 pheochromocytoma, 1586, 1587f**
- Metaplasia**
 agnogenic myeloid, splenectomy in,
 1430t, 1436
 intestinal
 in Barrett's esophagus, 950, 969
 gastric cancer risk in, 1077, 1078f
- Metastasis, 284–285, 284f, 454, 454f**
 to adrenal gland, 1588
 to axillary lymph nodes
 in breast cancer. *See* Axillary lymph
 nodes, in breast cancer
 in unknown primary cancer, 554
 to bone, 454
 in lung cancer, 627
 to brain, 1732, 1733f
 stereotactic radiosurgery in, 1749
 of breast cancer. *See* Breast cancer,
 metastasis of
 of colorectal cancer. *See* Colorectal
 cancer, metastasis of
 distant, surgical management of, 306
 of endometrial cancer, 1701t
 of esophageal cancer, 1004
 staging of, 1004–1005, 1006t
 of gallbladder cancer, 1335
 of gastrinoma, 1392
 of gastrointestinal stromal tumors,
 1482–1483
 genetic factors in, 285
 of hand tumors, 1820
 of head and neck tumors
 to cervical lymph nodes, 595–597,
 596f; 597f
 anatomy and levels of, 595,
 595f
 dissection techniques in, 596, 596f;
 597, 597f
 skip metastasis in, 595, 596
 in hypopharyngeal cancer, 588f; 589
 in lip cancer, 582, 582f
 in oropharyngeal cancer, 587
 in salivary gland tumors, 599, 600
 staging of, 580, 581t
 to heart, 776
 to liver, 1293–1294
 of colorectal cancer, 1210, 1213,
 1293–1294, 1295
 in elderly, 1933
 hepatectomy in, 1301
 of lung cancer, 627, 631–633
 staging of, 633–635, 634t
 to lungs, 622–623
 lymphatic mapping in, 305, 305f
 in breast cancer, 305, 305f; 545–546
 of melanoma, 488
 of mesothelioma, 688, 689t
 micrometastasis in, 304
 nanometastasis in, 306
 of ovarian cancer, 1703, 1703t
 of pancreatic cancer, 1407–1408
 to liver, 1398f; 1407
 staging of, 1395, 1397t
 of parathyroid carcinoma, 1570
 seed and soil theory on, 285
 sentinel lymph nodes in, 305–306. *See*
 also Sentinel lymph nodes
 to small intestine, 1159
 treatment in, 1162
 of soft tissue sarcomas, 1471–1472,
 1471f; 1473
 surveillance for, 1477
 to spine, 1737
 staging of, 300, 301
 of stomach cancer, staging of, 1080t
 of thyroid cancer, 1544t
 neck dissection in, 1555–1556, 1555f
 to thyroid gland, 1551
 of vaginal cancer, 1697, 1697t
 of vulvar cancer, 1696
 staging of, 1696, 1696t
- Metastasis-suppressor genes, 285**
- Metatarsal fractures, 1765**
- Metatarsal-phalangeal joint fractures, 1765**
- Metencephalon, 1710**
- Methadone in persistent pain, 1949t**
- Methemoglobinemia, 456**
- Methicillin in staphylococcal infections**
 resistance to, 143t–145t
 sensitivity to, 143t–145t
- Methimazole in Graves' disease, 1532**
- Methotrexate**
 in Crohn's disease, 1156, 1197
 in ulcerative colitis, 1197
- Methylprednisolone in spinal cord injuries,**
 197–198, 1725–1726
- Metoclopramide**
 in delayed gastric emptying, 1050t
 in postoperative nausea and vomiting,
 1915
- Metronidazole, 145t, 257t**
 in amebic liver abscess, 1285
 in pelvic inflammatory disease, 1690t
 in peptic ulcer disease, 1061t
 in preoperative bowel preparation, 1194
- Metrorrhagia, 1682**
- Meyer-Overton rule, 1902**
- Micafungin, 141t, 658**
- Mice models in genetic research,**
 463–467
- Microadenomas of pituitary, 1735**

- Microarray in Node-Negative Disease
May Avoid Chemotherapy (MINDACT) trial, 302, 536
- Microcirculation, 114
- Microflora, endogenous
of gastrointestinal tract, 137, 1179
in necrotizing enterocolitis, 1619–1620
translocation of, 151
of skin, 137, 141
- Micrometastasis in bone marrow, 304
- Microsatellite instability, 292
colorectal cancer in, 1205
- Microsomnia, craniofacial or hemifacial, 1846, 1848*f*
- Microsurgery, 1838
- Microwave ablation in liver tumors, 1295
- Midgut
embryonic development of, 1175, 1179, 1616–1617
volvulus of, 1616–1617, 1617*f*
- Migrating motor complex in gastric motility, 1048–1049, 1048*f*
- Mikulicz enterostomy, 1619*f*
- Milan criteria on liver transplantation, in hepatocellular carcinoma, 347, 1291
- Milk-alkali syndrome, hypercalcemia in, 1562
- Millennium development goals in global surgery, 1963, 1964*t*
- Milligan and Morgan hemorrhoidectomy, 1224
- Milrinone in cardiogenic shock, 127
- Mineralocorticoids, 20*f*, 22–23, 1575–1576
- Minerals
absorption in small intestine, 1143
dietary requirements for, 51–52
in parenteral nutrition, 58
in wound healing, 255
- Minimally invasive adenocarcinoma (MIA), 615
- Minimally invasive surgery, 415–439
access for, 421–422
extraperitoneal, 422–423
subcutaneous, 422–423, 423*f*
anesthesia in, 419
balloon inflation technique for, 419, 419*f*
in cancer, 436
in children, 435–436
in cirrhosis and portal hypertension, 437
economics of, 437
education and training on, 437
in elderly, 436–437, 1935–1936
energy sources in, 427–429, 428*f*
extracavitary, 419, 419*f*
hand-assisted, 1187
access for, 423, 424*f*
historical aspects of, 415–417
imaging systems in, 424–427, 426*f*, 427*f*
innovations in, 437–439
instrumentation in, 429
in laparoscopy. *See* Laparoscopy
in natural orifice transluminal endoscopic surgery. *See* Natural orifice transluminal endoscopic surgery
physiology and pathophysiology in, 417–419
port placement in, 424, 426*f*
in laparoscopic Roux-en-Y gastric bypass, 1113–1114, 1113*f*
positioning of patients in, 420, 421*f*
in pregnancy, 436
surgical suite for, 420, 420*f*
team approach in, 419–420
telescopes in, 424, 426*f*, 427*f*
in thoracoscopy, 421
in esophageal atresia and tracheoesophageal fistula, 1610
- Minimum alveolar concentration, 1902
- Mini Nutritional Assessment, 1929
- Minocycline, 145*t*
- Mirizzi's syndrome, 1320, 1331
- Mismatch repair genes, 292
- Misoprostol in peptic ulcer disease, 1058*t*, 1061
- Mithramycin in hypercalcemia, 1573*t*
- Mitogen-activated protein kinases (MAPK), 34*f*, 281
in insulin pathway, 452, 452*f*
in thyroid cancer, 1542
- Mitomycin
in bladder cancer, 1654
in lung cancer, 644*t*
- Mitosis, 446
- Mitotane in adrenocortical carcinoma, 1584–1585
- Mitral valve disorders, 751–755
ACC/AHA guidelines, 754*t*
annuloplasty in, 756, 756*f*
with aortic valve disease, 763
atresia, 716
balloon valvuloplasty in, 753
commissurotomy in, 753, 755
in elderly, 1930
in hypoplastic left-heart syndrome, 716–719
insufficiency and regurgitation, 749, 753–755
atrial fibrillation in, 752
diagnostic studies in, 753, 755
functional, 765–766
indications for surgery in, 755
ischemic cardiomyopathy in, 765–766
jet lesion in, 756
repair procedures in, 751
types of, 753
prolapse, 755–756, 755*f*
prosthetic replacement in, 749, 755
operative technique in, 755
in stenosis, 751*f*
repair procedures in, 755–756
anterior leaflet, 756
double-orifice, 756
edge-to-edge technique, 756
in ischemic cardiomyopathy, 766
in leaflet perforation, 756
operative technique in, 755–756
posterior leaflet, 755*f*, 756
in rheumatic heart disease, 751
prosthetic replacement in, 755
stenosis, 751–753
atrial fibrillation in, 752
balloon valvuloplasty in, 753
calcific, 751, 751*f*
in hypoplastic left-heart syndrome, 716
prosthetic replacement in, 751*f*
with tricuspid valve disease, 763, 764
- Mittelschmerz, 1248
- Mivacurium, 1901, 1901*t*
- MLH1, 289*t*, 292
- Model for End-Stage Liver Disease (MELD) scoring system, 347, 436, 1280, 1295
- Moh's microsurgery, 486, 487
in ear cancer, 594
- Molecular biology, 443–468
atomic theory of disease, 456
cell cycle and apoptosis in, 450
cell manipulations in, 462–463
detection of nucleic acids and proteins in, 457–462
DNA and hereditary in, 444–446
DNA cloning in, 456–457
gene regulation in, 446–449
gene therapy and molecular drugs in, 309, 453–456
genetic manipulations in, 463–468
historical aspects of, 443, 445*t*
human genome in, 449
overview of, 443–444
personalized genomic medicine in, 468
signal transduction pathways in, 450–453
stem cell research in, 468
- Molluscum contagiosum, 1678
- Mondor's disease, 507
- Monitoring, 399–412
of blood pressure, 400–401
of cardiac output and related parameters, 402–409
electrocardiographic, 401–402
fetal
in laparoscopy, 436
in trauma, 220–221
neurologic, 411–412
renal, 410–411
respiratory, 409–410
- Monoclonal antibodies, 325, 328–329
- Monocytes, 39–40, 243
- Monro-Kellie doctrine, 1713
- Montgomery's glands, 501, 504
- Morbidity and mortality conference, 1952
- Morel-Lavallee lesions, 217
- Morgagni columns, 1178
- Morphine, 1900
in children and infants, 1601
in persistent pain, 1949*t*
- Mortality and morbidity conference, 7, 1952
- Mortality rates, 274
in cancer, 274–277, 275*t*, 276*t*, 277, 618*f*
age-adjusted, 618*f*–619*f*
of esophagus, 1004*f*
of lung, 617
of stomach, 1075*f*, 1082, 1082*t*
in medical errors, 366
in pulmonary artery catheterization, 405–407
in systemic inflammatory response syndrome, 391, 391*t*
- Morton, William, 1895–1896
- Moschcowitz's operation in rectal prolapse, 1219
- Motilin, 1146*t*, 1313
- Motility
antroduodenal, 1053
of esophagus. *See* Esophagus, motility of
of large intestine, 1180
of small intestine. *See* Small intestine, motility of
of stomach. *See* Stomach, motility and emptying of
- Motor function assessment, 1711
Glasgow Coma Scale in, 1711, 1712*t*
response patterns in, 1711*f*
scoring system in, 1711*t*

- Motor vehicle accidents, 1960, 1960f
mechanisms and patterns of injury in, 174
pediatric trauma in, 222
in pregnancy, 218
seat belt injuries in, 223, 1643–1644, 1643f, 1771
- Mourning process, 1951
- Mouse models in genetic research, 463–467, 463f
chimeric, 465–466
gene knockout in, 464–466, 465f
transgenic mice in, 463–464
- Mouth cancer. *See* Oral cavity cancer
- Moxifloxacin, 257t
- MPL* gene in familial essential thrombocythemia, 289t
- hMSH2*, 289t, 292
hMSH6, 289t, 292
MUC1, 303
- Mucinous carcinoma, 520–521
- Mucocele of appendix, 1258
- Mucoepidermoid carcinoma of lung, 617
- Mucormycosis, 658
- Mucosa
of oral cavity
alveolar, 585, 586f
buccal, 586, 1863
of small intestine, 1138–1139, 1139f
of stomach, 1039, 1040f
barrier function of, 1044–1045, 1044t
- Mucosa-associated lymphoid tissue of stomach, 1084
- Mucous cyst, 1815
- Müllerian inhibiting substance, 1637
- Mulliken technique in bilateral cleft lip, 1843, 1843f
- Multicentricity of breast cancer, 519, 520t
- Multidisciplinary approach
to cancer therapy, 304
in head and neck tumors, 578
to colorectal surgery, 1195
- Multifactor Leadership Questionnaire (MLQ), 10
- Multifocality of breast cancer, 519
- Multiple endocrine neoplasia
type 1, 289t
Cushing's syndrome in, 1581
gastric carcinoid tumors in, 1086
gastrinoma in, 1071, 1072, 1073, 1391–1392
hyperparathyroidism in, 1560, 1567, 1570
pancreatic neoplasms in, 1390, 1391–1392
type 2A, 293, 1549–1550, 1549t
hyperparathyroidism in, 1560, 1567, 1570
medullary thyroid carcinoma in, 1570
pheochromocytoma in, 1586
type 2B, 293, 1549–1550, 1549t
clinical features in, 1549, 1549f
pheochromocytoma in, 1586
- Multiple organ dysfunction syndrome
complement activation in, 118
neutrophils in, 118
postoperative, 391–392
in traumatic shock, 123
- Multivisceral transplantation, 352–354
- Mupirocin in burns, 232
- Murmurs
in aortic insufficiency, 760
in aortic stenosis, 758
in atrial septal defect, 697
in ductus arteriosus patency, 703
in mitral insufficiency, 753
in mitral stenosis, 752
in tricuspid valve disorders, 763
in truncus arteriosus, 707
in valvular heart disease, 748t
- Murphy's sign in cholecystitis, 1320
- Muscles
flaps of, 1836, 1837
of hand and wrist, 1788–1791
transposition technique in facial nerve paralysis, 1866
- Muscularis mucosa, 1039
- Muscularis propria, 1139, 1144
- Musculoskeletal disorders
orthopedic surgery in, 1756–1783
postoperative, 388
- Mustard procedure in transposition of great arteries, 721
- Mutations, 286, 446
- Mutator phenotypes in cancer, 286
- MUTYH* gene in adenomatous polyposis coli, 289t
- Myasthenia gravis, 1745
thymoma in, 675
- c-myc*, 281, 729
N-myc in neuroblastoma, 1640
- Mycobacterial infections, 140, 654–655, 656f
algorithm on treatment of, 655, 656f
in bronchiectasis, 653
surgical treatment in, 655, 656t
tuberculosis in. *See* Tuberculosis
- Mycophenolate mofetil, 325t, 326–327, 327t
adverse effects of, 326t, 327
mechanism of action, 326–327
- Mycotic infections of lungs, 655–658
- Myelencephalon, 1710
- Myelofibrosis, splenectomy in, 1430t, 1436
- Myeloid metaplasia, agnogenic, splenectomy in, 1430t, 1436
- Myeloma
multiple, 1781–1782
epidemiology of, 275t, 278t
stem cells in, 285
solitary, 1781
- Myelomeningocele
fetal surgery in, 1645
and spina bifida, 1750
- Myelopathy, 1740
cervical spondylotic, 1740, 1741f
- Myeloproliferative disorders, 92
platelet dysfunction in, 92
splenectomy in, 1435–1436
- MYH*
in colorectal cancer, 1204
in familial adenomatous polyposis, 1207
- Myocardium
infarction of
cardiogenic shock in, 126, 127–128
in coronary artery disease, 742
left ventricular aneurysm in, 766–768, 767f
left ventricular remodeling in, 765, 767, 768
perioperative, 374
postoperative, 386
risk of noncardiac surgery in, 738
transfusion triggers in, 98
in trauma, initial management of, 171
ischemia of
angina pectoris in, 735, 742
in aortic valve stenosis, 757
in coronary artery disease, 741–747
diagnostic studies in, 738
laser revascularization in, 747
postoperative, 386
preoperative assessment of, 1905–1906
radionuclide scans in, 739
silent, 735
transfusion triggers in, 98
protection in cardiopulmonary bypass, 741
viability assessment, 765
- Myocutaneous flaps, 1833, 1836–1838
in breast reconstruction, 549, 550, 1869–1871, 1872f–1873f
in chest wall reconstruction, 670, 670f, 1874, 1875f
in head and neck reconstruction, 601
in pressure ulcers, 1880–1881, 1881f
- Myoglobinuria, 388
- Myomectomy, 1684, 1684–1685, 1685f, 1685f
in hysteroscopy, 1684
laparoscopic, 1685
- Myometrium, anatomy of, 1675
- Myopectineal orifice of Fruchaud, 1497, 1498f
- Myositis, necrotizing, 483
- Myotomy, esophageal
cricopharyngeal, 989
failure of, 1002t
Heller, 997–999, 999f
laparoscopic, 1000, 1001f–1002f
outcome assessment in, 1003
long, 995–997, 995f, 996f–997f
open technique, 1000
outcome assessment in, 1001, 1002t, 1003
peroral, 434f, 1000
- Myringotomy in ear infections, 566f, 567, 571
- Myxedema in hypothyroidism, 1534
- Myxomas, cardiac, 775–776, 775f
- N**
- Nafcillin, 143t
- Nails, 475
melanoma of, subungual, 1818
paronychia of, 1813–1814, 1813f
- Naloxone, 1900
- Naltrexone, 1900
- Nanometastasis, 306
- Naproxen
gastrointestinal disorders from, 1058t
in persistent pain, 1949t
- Nasal disorders. *See* Nose
- Nasoenteric feeding tubes, 55, 55t
- Nasogastric intubation
for enteral nutrition, 55, 55t
in small intestine obstruction, 1149
tracheoesophageal fistula in, 609
in trauma, 173
- Nasopharynx
anatomy of, 579, 588f, 593
cancer of, 580, 593–594
- Nasotracheal intubation, 162
- National Cancer Institute, 512
soft tissue sarcoma classification system, 1470
- National Lung Screening Trial (NLST), 619–621
- National Quality Forum, 376
on “never” events in surgery, 376, 376t
- National Surgical Adjuvant Breast and Bowel Project trials, 301, 499, 551

- on early invasive breast cancer, 538
- on prevention of breast cancer, 513
- on sentinel node surgery in breast cancer, 546–547
- National Surgical Quality Improvement Program, 374–375
- National Wilms Tumor Study Group, 1638–1639
- Natural orifice transluminal endoscopic surgery (NOTES), 415, 425*f*, 432–434
 - access for, 421, 423
 - in appendicitis, 1254, 1256
 - cholecystectomy in, 433*f*
 - historical aspects of, 416
 - instrumentation in, 429
 - team approach in, 420
- Nausea, postoperative, 1915, 1916*f*
 - intraoperative fluid therapy affecting, 1914
- Navicular fracture, 1765
- NBS1* gene in Nijmegen breakage syndrome, 289*t*
- Nd:YAG (neodymium yttrium-aluminum garnet) lasers, 428–429
- Neck. *See also* Head and neck disorders
 - cervical lymph nodes in. *See* Cervical lymph nodes
 - cervical spine in. *See* Cervical spine masses in, 595–599
 - benign, 598
 - in cervical lymph node disorders, 595–597, 1602
 - in children, 1601–1603
 - in deep fascial planes, 598–599
 - diagnostic evaluation of, 595
 - in parapharyngeal space, 597–598
 - trauma of, 197–200
 - airway management in, 161–162, 163*f*
 - blunt, 175
 - evaluation of, 175–177
 - laryngeal fracture in, 176*f*
 - operative approaches and exposure in, 187–188, 187*f*
 - penetrating, 176, 176*f*, 177*f*
 - vascular, 198–199, 198*f*–199*f*, 200*f*
 - zones of injury of, 176*f*, 177, 177*f*
- Necrosis
 - in colostomy, 1193
 - differentiated from apoptosis, 281
 - in ileostomy, 1193
 - of pancreas, 150–151, 152*f*, 1375*t*
 - in acute pancreatitis, 1356, 1358*f*, 1359
 - renal tubular, 387–388
 - in soft tissue infections, 152, 153*f*, 483
- Necrotizing enterocolitis, 1619–1621
- Needle
 - in endovascular therapy, 834–835
 - Veress, 421, 421*f*
- Needlestick injuries, 156
- Needle suspension technique, transvaginal,
 - in stress urinary incontinence, 1695
- Negligence, 367*t*
- Nelson's syndrome, 1594
- Neodymium yttrium-aluminum garnet (Nd:YAG) lasers, 428–429
- Neomycin in preoperative bowel preparation, 1194
- Neonates
 - ambiguous genitalia in, 1637–1638, 1638*f*
- anorectal malformations in, 1626–1628, 1626*f*, 1627*f*
- blood volume and replacement in, 1599–1600
- brachial plexus palsy in, 1782
- choledochal cysts in, 1630–1631
- fluid and electrolyte balance in, 1599
- gynecomastia in, 505
- hepatitis in, 1629
- Hirschsprung's disease in, 1624–1626
- hyperparathyroidism in, 1570
- intestinal duplications in, 1624
- intestinal obstruction in, 1614–1615
- jaundice in, 1628–1631
- necrotizing enterocolitis in, 1619–1621
- pain control in, 1601
- parenteral nutrition in, 57
- short bowel syndrome in, 1621
- testicular torsion in, 1662
- thermoregulation in, 1601
- urethral valves in, posterior, 1667
- vesicoureteral reflux in, 1667
- Neostigmine reversal of neuromuscular blockade, 1915
- Nephrectomy
 - in cancer of kidney, 1656–1657, 1656*f*
 - complications of, 1657
 - laparoscopic technique, 1656–1657
 - in living donor kidney transplantation, 333*f*, 335
- Nephrocalcinosis in hyperparathyroidism, 1560
- Nephrolithiasis, 1560
- Nephropathy from contrast agents, 383, 791
- Nephrostolithotomy, percutaneous, in urolithiasis, 1666
- Nephrostomy, percutaneous, in upper urinary tract obstruction, 1666
- Nephroureterectomy in Wilms' tumor, 1639
- Nerve conduction studies, 1712
 - in peripheral nerve trauma, 1727
- Nerve sheath tumors
 - malignant, 1744
 - mediastinal, 677–678, 677*t*
- Nerves
 - anesthetic blocks of, 1903–1904
 - of anorectum, 1179
 - of breast, 502
 - of colon, 1177
 - of esophagus, 946, 946*f*
 - of gallbladder, 1309
 - of hand and wrist, 1792–1793
 - compression of, 1805–1806
 - injuries of, 1798–1799, 1805
 - of inguinal region, 1497–1499, 1498*f*, 1499*f*
 - of pancreas, 1346, 1347*f*
 - of pelvic floor, 1672–1673, 1673*f*, 1674*f*
 - of stomach, 1038–1039, 1039*f*, 1047, 1047*f*
 - of thyroid gland, 1524*f*
 - trauma of, 251, 1726–1727
 - in hand and wrist, 1798–1799, 1805
 - tumors of, 1744
- Nervi erigentes, 1179
- neu*, 281. *See also* *HER2/neu*
- Neural crest
 - in persistent truncus arteriosus, 706
 - tumors of, 1735
- Neuralgia, trigeminal, 1748–1749
- Neural tube defects, 1749
- Neurapraxia, 251, 1726
- Neurilemmomas, 486, 1744
 - mediastinal, 677, 677*f*
- Neurinomas, 1744
- Neuroblastoma, 289*t*, 678, 1639–1640, 1640*f*
- Neuroectodermal tumors, primitive, 668*t*, 669
- Neuroendocrine hyperplasia of lung, 617
- diffuse idiopathic, 614
- Neuroendocrine tumors
 - of liver, 1294
 - of lung, 617
 - of skin, 492
- Neurofibroma, 486, 1744
 - mediastinal, 677–678
 - spinal, 1738
- Neurofibromatosis, 677, 1468
 - type 1, 289*t*, 1468, 1738, 1744
 - type 2, 289*t*
- Neurofibrosarcoma, mediastinal, 678
- Neurogenic claudication, 1742, 1771
- Neurogenic shock. *See* Shock, neurogenic
- Neurogenic tumors, mediastinal, 677–678, 677*f*
 - classification of, 677*t*
 - incidence of, 671, 673*t*
- Neurologic disorders
 - autoimmune and inflammatory, 1744–1745
 - emergencies in, 1713–1715
 - in entrapment neuropathies, 1744, 1805–1806
 - of median nerve, 1744, 1805–1806
 - of ulnar nerve, 1744, 1806
 - examination in, 1711–1713. *See also* Neurologic examination
 - fluid and electrolyte balance in, 80–81
 - lower extremity ulcers in, compared to ischemic ulcers, 890*t*, 891*f*
 - in lung cancer, 623, 625
 - in paraneoplastic syndromes, 627
 - monitoring in, 411–412
 - postoperative, 383, 393
 - surgery in, 1709–1751. *See also* Neurosurgery
 - traumatic, 251, 1726–1727
 - in hand and wrist, 1798–1799, 1805
- Neurologic examination, 1711–1713
 - in brain death, 1721
 - diagnostic studies in, 1713
 - motor tests in, 1711, 1711*f*, 1711*t*, 1712*t*
 - sensory tests in, 1712
 - in trauma, 168, 170*t*
 - of head, 1718
 - of spine, 1722–1723
- Neurolytic therapy in chronic pancreatitis, 1380
- Neuroma
 - acoustic, 1735, 1736*f*
 - in hand, 1805
- Neuromuscular blocking agents, 1901–1902, 1901*t*
 - reversal of, 1915
- Neuropathy
 - entrapment, 1744, 1805–1806
 - of median nerve, 1744, 1805–1806
 - of ulnar nerve, 1744, 1806
 - lower extremity ulcers in, compared to ischemic ulcers, 890*t*, 891*f*
 - traumatic, of common peroneal nerve, 1727
- Neuropsychiatric disorders in hyperparathyroidism, 1561
- Neurorrhaphy in facial nerve paralysis, 1865

- Neurosurgery, 1709–1751
 anatomy in, 1732
 in brain abscess, 1745
 in brain stem compression, 1714
 in cerebrovascular disorders, 1714–1715, 1727–1732
 in congenital and developmental anomalies, 1749–1751
 in cranial infections, 1745
 in facial nerve paralysis, 1866
 in head trauma, 1715–1721
 in intracranial pressure increase, 1713–1714
 in intracranial tumors, 1732–1737
 neurologic examination in, 1711–1713
 of peripheral nerves, 1744–1745
 in trauma, 1726–1727
 in seizures, 1715, 1746–1747
 of spine, 1739–1743
 in infections, 1745–1746
 in trauma, 1721–1726
 in tumors, 1737–1739
 stereotactic radiosurgery techniques in, 1749
 in subdural empyema, 1745
 in trauma, 1715–1727
 in trigeminal neuralgia, 1748–1749
- Neurotensin, 1146*t*
- Neurotmesis, 251, 1726
- Neurotransmitters, 32, 33–34
- Neutropenia, 1236
 enterocolitis in, 1236
- Neutrophils
 and endothelium interactions, 40, 42*f*, 118
 functions of, 40
 in microbial invasion response, 138
 polymorphonuclear, 118, 138
 reduced number of, 1236
 in shock response, 118
 in wound healing, 242*f*, 243, 243*f*
 and infections, 258
- “Never events” in surgery, 376–379, 376*t*
- Nevi, 485, 488
 acquired melanocytic, 485
 congenital, 485
 giant, 485
 melanocytic, 1852, 1853*f*
 dysplastic, 488
 melanoma risk in, 488
- Nevoid basal cell carcinoma, 289*t*
- New York Heart Association classification of heart disease, 737, 737*t*
- New York State Study Group on coronary stenting and bypass surgery, 742
- Next-generation sequencing, 460, 462
NFI, 289*t*
NF2, 289*t*
- Niemann, Albert, 1896
- Niemann-Pick disease, splenectomy in, 1430*t*, 1438
- Night stick fractures, 1760
- Nilotinib, 310*t*
- Nipples
 accessory, 500
 ampulla of, 501
 anatomy of, 501
 discharge from, 509–510, 554
 bilateral, 554
 bloody, 508
 unilateral, 554
 hidradenitis suppurativa of, 506
 inversion of, 508
 treatment in, 511
- Paget’s disease of, 506, 521
 position in reduction mammoplasty, 1887–1888
 ptosis of, 1887–1888
 reconstructive surgery of, 1871
- Nissen fundoplication, 973*f*, 974–975, 974*f*, 975*f*–976*f*
 vs anterior partial fundoplication, 978
 laparoscopic, 974–975, 974*f*, 975*f*–976*f*
 outcome of, 977–978
 vs Toupet fundoplication, 978
- Nissen, Rudolph, 974
- Nitrates in diet, and gastric cancer risk, 1074
- Nitric oxide, 41–42, 43*f*
 in gastric relaxation, 1047
- Nitric oxide synthase, in septic shock, 124
- Nitroblue tetrazolium reduction test in chronic granulomatous disease, 258
- Nitrogen
 dietary intake, postoperative, 51
 urine levels in injury, 50
- Nitroglycerin in arterial vasospasm, 215*t*
- Nitroprusside in aortic dissection, 813
- Nitrous oxide, 1902, 1902*t*
- Nocardiosis, 651
- Nodularity of breast, 508
- Nodules
 of lungs, solitary, 621–622. *See also* Lungs, solitary nodule in
 mural, in hemangioblastoma, 1736
 of thyroid
 in elderly, 1937
 hyperthyroidism in, 1533
 solitary, 1537–1540
- Non-Hodgkin’s lymphoma, 1434–1435
- Noninsulinoma hyperinsulinemia hypoglycemia syndrome, 1391
- Nonmaleficence principle, 1941
 in withdrawing or withholding of life-sustaining therapies, 1945
- Non-small cell lung carcinoma, 614–617
- Nonunion of fractures in hand, 1801, 1805
- No-reflow phenomenon, 114
- Norepinephrine, 22, 154, 1577–1578, 1579*f*
 in pheochromocytoma, 1586
 in shock response, 115
- North American Symptomatic Carotid Endarterectomy Trial, 841
- Northern blot hybridization, 458
- Nortriptyline in pain, 1950*t*
- Norwood procedure in hypoplastic left-heart syndrome, 716, 717, 718
- Nose
 fractures of, 197, 1855
 in naso-orbital-ethmoid fractures, 1855
 plastic and reconstructive surgery of, 1856, 1858*f*, 1859*f*
 aesthetic subunits in, 1858*f*
 anatomy in, 1884*f*
 axial pattern flaps in, 1856, 1859*f*
 composite tissue grafts in, 1834*f*, 1856
 rhinoplasty in, 1883, 1884*f*, 1885*f*
 polyps of, 568, 568*f*, 569
 postoperative complications of, 383–384
 tumors of, 592–593
- Nosocomial infections, postoperative, 152–154
 respiratory, 152–154, 384–385
 of surgical site, 142, 152–154, 389
 of urinary tract, 390
- NOTES. *See* Natural orifice transluminal endoscopic surgery
- Nuclear factor- κ B, 37*f*
 in acute pancreatitis, 1355
- Nucleus pulposus, 1739, 1771
- Nutcracker esophagus, 992–993
- Nutrition, 50–59
 affecting inflammatory response, 53–54
 age-related differences in requirements for, 1600*t*
 arginine in, 54
 in burns, 232–233
 in children, 1600–1601, 1600*t*
 enteral, 1600–1601, 1600*t*
 parenteral, 57, 1601
 in chylous ascites, 1170
 colorectal cancer risk factors in, 1204
 in elderly, 1929
 energy requirements in, 51
 enteral, 52–56
 access for, 55–56, 55*t*
 in burns, 232–233
 in children, 1600–1601, 1600*t*
 compared to parenteral nutrition, 52
 complications of, 55, 56, 57*t*
 early initiation of, 53
 formulas used in, 53–55
 in gastrointestinal trauma, 207
 indications for, 52–53, 392
 in pancreatitis, 1358
 in short bowel syndrome, 1171
 trophic feedings, 53
 in esophageal cancer, preoperative, 1007–1008
 gastric cancer risk factors in, 1074
 glutamine in, 53–54
 in inflammatory bowel disease, 1197
 in intestinal fistulas, 1158
 in obesity
 and bariatric surgery
 postoperative, 1108, 1116, 1120–1121
 preoperative, 1105–1106
 in medical management, 1102
 omega-3 fatty acids in, 33, 54
 overfeeding in, 52
 in parenteral nutrition, 59
 in pancreatitis
 acute, 1358
 chronic, 1366
 parenteral, 56–59
 access for, 59
 central or total, 57
 in children, 57, 1601
 compared to enteral nutrition, 52
 complications of, 56, 57*t*, 58–59, 392
 contraindications to, 57
 electrolytes in, 76, 76*t*
 indications for, 57
 initiation of, 58
 in pancreatitis, 1358
 peripheral, 57–58
 in short bowel syndrome, 1171–1173
 postoperative, 385, 392–393
 in bariatric surgery, 1108, 1116, 1120–1121
 and refeeding syndrome, 81
 in ventilatory support, 385
 vitamin and mineral requirements in, 51–52
 and wound healing, 254–255, 254*f*
- Nyhus classification of inguinal hernia, 1496, 1498*t*

- O**
- Obesity**
- anesthesia management in, 1908
 - appendectomy in, laparoscopic, 1254
 - asthma in, 1105, 1128–1129
 - bariatric surgery in, 1099–1131.
 - See also* Bariatric surgery
 - body mass index in, 1100–1101, 1100t, 1908
 - in medical management, 1102
 - breast cancer risk in, 511
 - in children, 1101
 - in Cushing's syndrome, 1582
 - diabetes mellitus in, 1112t, 1127
 - adjustable gastric banding in, 1111, 1128
 - Roux-en-Y gastric bypass in, 1116, 1127
 - discrimination in, 1101
 - disorders associated with, 1908, 1908t
 - endoscopic procedures in, 1129–1131
 - experimental procedures in, 1129–1131
 - fatty liver in, 1106, 1129
 - gastroesophageal reflux disease in, 1105, 1116, 1128
 - hyperlipidemia in, 1112t, 1116, 1128
 - hypertension in, 1111, 1112t, 1116, 1128
 - implantable gastric stimulation device in, 1129–1130
 - inguinal hernia in, 1501
 - medical management of, 1101–1102
 - metabolic syndrome in, 1127–1128
 - nutrition in
 - in bariatric surgery
 - postoperative, 1108, 1116, 1120–1121
 - preoperative, 1105–1106
 - in medical management, 1101–1102
 - plastic surgery after weight loss in, 1129, 1130f, 1887f
 - polycystic ovary syndrome in, 1126
 - postoperative complications in, 393
 - pregnancy in, 1126
 - prevalence of, 1101
 - factors contributing to, 1101
 - prognosis in, 1101
 - sleep apnea in, 1105, 1111, 1112t, 1128
 - stress urinary incontinence in, 1126
 - vagal stimulation in, 1131
 - wound healing problems in, 254
- Oblique abdominal muscles**
- external, 1449, 1450, 1450f, 1451f, 1499f
 - internal, 1449, 1450, 1451f, 1499f
- Obsessive-compulsive disorder, deep brain stimulation in, 1748**
- Obstructive shock, 128–129**
- Obstructive sleep apnea, 572**
- Obturator bypass in aortoiliac occlusive disease, 878**
- Obturator internus muscle, 1672**
- Obturator sign, in appendicitis, 1244**
- Occipital dislocation, 1770**
- Occlusion, dental, in mandibular reconstruction, 1853, 1854f, 1863**
- Occupational exposures**
- to blood-borne pathogens, 156
 - to chemicals, soft tissue sarcoma risk in, 1466
- Ocreotide**
- in carcinoid syndrome, 1162
 - in chylous ascites, 1170
 - in dumping syndrome, 1091
 - in gastrinoma scan, 1072, 1073f
 - in intestinal fistulas, 1158
 - in pancreatitis, chronic, 1380
 - in portal hypertension and variceal bleeding, 1282
 - in visceral pain, 1950t
- Octyl-cyanoacrylate tissue glues, 265**
- Oddi sphincter**
- anatomy of, 1310, 1311, 1311f
 - cholecystokinin affecting, 1313, 1314f
 - functions of, 1313
 - incompetent, acute pancreatitis in, 1352
 - sphincteroplasty in chronic pancreatitis, 1382–1383, 1383f, 1384f
 - sphincterotomy in choledocholithiasis
 - endoscopic, 1322, 1322f
 - transduodenal, 1327
 - stenosis of, 1331
- Odontoid process fractures, 1722, 1770**
- Off-pump coronary artery bypass surgery, 745–746, 746f**
- Ofloxacin, 257t**
- Ogilvie's syndrome, 1221**
- Ohngren's line, 592, 592f**
- Olecranon fractures, 1760**
- Oligodendroglioma, 1733**
- Oligomenorrhea, 1682**
- Ollier's disease, 1778, 1818**
- Omega-3 fatty acids, 32–33, 54**
- Omega-6 fatty acids, 31–32, 54**
- Omentum, 1456–1457**
- anatomy of, 1456–1457
 - cysts of, 1457
 - as gatekeeper of abdomen, 138, 1457
 - infarction of, 1457
 - lesser, 1037
 - neoplasms of, 1457
 - physiology of, 1457
- Omeprazole in gastroesophageal reflux disease, 971, 979**
- Omphalocele, 1453, 1631, 1632, 1632f**
- anomalies associated with, 1632
 - treatment of, 1632, 1632f
- Oncogenes, 278, 279–281, 280f, 296t**
- in hereditary cancer syndromes, 287
 - in metastasis, 285
 - of RNA viruses, 295
 - in soft tissue sarcomas, 1467
- Oncology, 273–316. *See also* Tumors**
- Oncoplastic surgery in breast cancer, 547, 1866–1867, 1868f, 1869f**
- Oncotype DX assay in breast cancer, 301, 536**
- Oophorectomy**
- in breast cancer, 553
 - in ovarian cancer, 516, 1701
- Open fractures, 1757, 1758f**
- Operating room**
- communication in, 369, 370–371
 - in postoperative debriefings, 370–371
 - in preoperative briefings, 370, 370t, 372f
 - safety checklist on, 370, 371f
 - in surgical counts, 378
 - in wrong-site surgery, 378
 - for minimally invasive surgery, 420
 - for robotic surgery, 430, 431f
 - safety issues in
 - best practices for, 379, 379t
 - in organizational culture, 368
 - in retained surgical items, 377–378, 377t
 - and risk management, 380
 - in wrong-site surgery, 378
 - team work in, 369, 369f, 370t
- Operon, 447**
- Ophthalmopathy in Graves' disease, 1531, 1532f, 1533**
- Opioids, 1900, 1909**
- equianalgesic dosage of, 1900
 - respiratory depression from, 1900
- Opponens pollicis, 1791**
- Opsonins, 1427**
- Opsonization, 138**
- Oral cavity cancer, 582–586, 1862–1863**
- in alveolus/gingiva, 585
 - anatomy in, 578, 579f, 582, 583f, 584f
 - in buccal mucosa, 586
 - reconstructive surgery in, 586, 1863
 - epidemiology of, 276t, 278t, 618f
 - etiology of, 578–579
 - in floor of mouth, 584–585, 585f
 - anatomy in, 584f
 - reconstructive surgery in, 584–585, 585f, 1862
 - in palate, 586
 - in retromolar trigone, 586
 - staging of, 581t, 582
 - in tongue, 583, 583f, 587, 1862
 - reconstructive surgery in, 1862
- Orbit**
- fractures of, 197, 1854
 - blowout, 577, 577f, 1854
 - complications in, 1854
 - in naso-orbital-ethmoid fractures, 1855
 - hypertelorism of, 1847
 - Orbital apex syndrome, 1854
 - Orbital fissure syndrome, superior, 1854
 - Orchidopexy in cryptorchidism, 1636
 - Orchiectomy
 - in testicular cancer, 1655
 - in testicular torsion, 1663
 - Orchitis, 1665
 - ischemic, in inguinal hernia repair, 1515
- Organizational culture. *See* Culture, organizational**
- Orlistat in obesity, 1102**
- Ormond disease, 1460**
- Oropharyngeal cancer, 586–587, 588f**
- anatomy in, 579, 586
 - metastasis of, 587
 - rehabilitation in, 587–588
- Orotracheal intubation, 162–163**
- Orphan Annie nuclei, 1542**
- Orthopedic surgery, 1756–1783**
- in children, 1782–1783
 - in fractures and dislocations, 1757–1765
 - joint reconstruction in, 1772–1778
 - in shoulder disorders, 1765–1767
 - trauma, 1756–1757
- Orthopnea, 736**
- Orthotic devices in spine trauma, 1726**
- Osgood-Schlatter disease, 1783**
- Osler, William, 137**
- Osmolality, 67**
- of serum, 67
 - of urine, 67
- Osmoreceptors, 68**
- Osmotic pressure, 66–67**
- Ossification centers, 1782**
- Osteitis**
- fibrosa cystica, 1556, 1560–1561, 1561f, 1563
 - pubis, in inguinal hernia repair, 1515
- Osteitis pubis, 1515**
- Osteoarthropathy, pulmonary hypertrophic, in small cell lung carcinoma, 626, 626f**

- Osteochondroma, 1778
of chest wall, 666
- Osteocutaneous flaps in head and neck
reconstruction, 601
in mandibular reconstruction, 601, 1863, 1864f–1865f
- Osteogenesis imperfecta, 248, 248t
- Osteolysis in arthroplasty complications, 1777–1778
- Osteoma, osteoid, 1819
- Osteomyelitis, 1810–1811
in fracture complications, 1877
of skull, 1745
in tuberculosis, 1745–1746
vertebral, 1745–1746
- Osteonecrosis of scaphoid, 1794, 1795f
- Osteopenia, 1561
- Osteophyte formation, spinal stenosis in, 1771
- Osteoporosis
in breast cancer, 553
in elderly, 1937
in hyperparathyroidism, 1561
- Osteosarcoma, 1779, 1779f, 1819
of chest wall, 665, 666, 667, 668t
parosteal, 1779
periosteal, 1779
tumor location of, 1779t
- Osteotomy, 1773
- Ostium primum defects
anatomy in, 695, 696f
pathophysiology in, 697
- Ostium secundum defects
anatomy of, 695–696, 696f
treatment of, 698
percutaneous closure in, 698
- Ostomy procedures, 1191–1192
colostomy, 1193. *See also* Colostomy
ileostomy, 1192–1193. *See also*
Ileostomy
preparation preparations for, 1191f
selection of site for, 1191f
- Otitis, 565–566
externa, 565
acute, 565
malignant, 565
postoperative, 384
media, 565–566, 566f
acute, 565–566, 566f
chronic, 567
in cleft palate, 1844
complications of, 567
myringotomy and tube placement in, 566f, 567, 571
postoperative, 384
- Otorrhea in skull fractures, 1716
- Ototoxicity of aminoglycoside antibiotics, 384
- Ovarian arteries, 1675
- Ovarian ligament anatomy, 1674f, 1675
- Ovaries
abscess of, tubo-ovarian, 1691
anatomy of, 1674f, 1675
benign neoplasms of, 1689
cancer of, 1701–1704
biomarkers in, 1702
epidemiology of, 275t, 276t, 278t, 618f
genetic factors in, 289t, 291, 515, 1701
risk management in, 516–517, 1701
interval debulking surgery in, 1703
intraoperative chemotherapy in, 1703, 1703t
metastasis of, 1703, 1703t
primary debulking surgery in, 1703, 1703t
recurrent, 1703–1704, 1704t
risk factors for, 1702, 1702t
salpingo-oophorectomy in, risk-reducing, 1701
staging of, 1703–1704, 1703t
symptoms in, 1701, 1702t
- cysts of
in children, 1636–1637
chocolate, 1690
in polycystic disease, 1126
torsion of, 1637
differential diagnosis in, 1248
- endometriosis of, 1636, 1689–1690
trauma of, 212
- Overfeeding, 52
in parenteral nutrition, 59
- Oxandrolone in burns, 233
- Oxidation of fatty acids, 47, 48f, 49f
- Oximetry
jugular venous, 412
mixed venous, 404–405
pulse, 410
- Oxycodone in persistent pain, 1949t
- Oxygen
arterial content, 98, 399, 404–405
arterial partial pressure, 410
in shock, 131
arterial saturation, 410
cerebral consumption rate in anesthesia, 1908–1909
cerebral tissue tension, 412
debt in shock, 115, 130
delivery of, 400
critical point in, 400
determinants of, 409
fraction of inspired, 410
hemoglobin dissociation curve, 1914, 1914f
hemoglobin saturation, 1914
arterial, 410
tissue, 409
hyperbaric oxygen therapy in soft tissue infections, 152
jugular venous saturation, 412
maximum consumption in lung cancer, preoperative assessment of, 637, 637t
in mixed venous blood, 404–405
transport in shock, 131
utilization of, 400
- Oxygenation, extracorporeal membrane, in congenital diaphragmatic hernia, 1604–1605
- Oxygen radicals, 23
in shock, 118
- Oxymorphone, 1900
- Oxyntic (parietal) cells of stomach, 1037, 1040–1041, 1041f, 1042f, 1042t
acid secretion of, 1041–1043, 1043f
- Oxyphil cells of parathyroid gland, 1557
- Oxytocin, 505
in cesarean delivery, 1693
in gestational trophoblastic disease, 1694
- P**
- p15, 453
- p16
in melanoma, 288t, 292
in pancreatic cancer, 292
in thyroid cancer, 1541t, 1542
- p50, 37f
- p53
in breast cancer, 535
in colorectal cancer, 1204–1205
in head and neck tumors, 580
in Li-Fraumeni syndrome, 287, 290t, 291, 1468
in parathyroid carcinoma, 1560
in soft tissue sarcomas, 1467
in stomach cancer, 1075, 1077t
in thyroid cancer, 1541t, 1542, 1543
- p65, 37f
- Pacesetter leadership, 9
- Paclitaxel
in breast cancer, 535, 553
in lung cancer, 644t
in ovarian or tubal cancer, 1703, 1703t
- Paget's cells, 493, 521
- Paget-Schroetter syndrome, 928
- Paget's disease
extramammary, 493
perianal, 1218
of nipple, 506, 521
of vulva, 1680
- Paget's sarcoma of bone, 1779
- Pain
abdominal. *See* Abdominal pain
anorectal, 1183
in aortic aneurysm, thoracic, 789, 792
in aortic dissection, 809, 810, 811
in arterial disease, 828
on ambulation, 828
at rest, 828
in back, 625
in burns, 228
in chest. *See* Chest pain
in chest wall tumors, 665
in children and infants, management of, 1601
in complex regional pain syndrome, 1805
in elderly, abdominal, 1936
in gallstones, 1319, 1320
sites of, 1319, 1319f
in limb ischemia, 882, 886
in lung cancer, 623
in mesenteric ischemia, 1167
palliative care in, 1946, 1948, 1950
adjuvant medications in, 1950t
in pancreatic cancer, 1399
in persistent pain, 1949t
step ladder approach to, 1948, 1948t
in pancreatic cancer, 1396–1397, 1399
in pancreatitis
acute, 1357
chronic, 1371–1372, 1371f
treatment of, 1379, 1380, 1380f
pelvic, 1183
postoperative, 1915–1916
in inguinal hernia repair, 1514–1515
in thoracic surgery, 645f
Saunders's concept, 1946
scrotal, in testicular torsion, 1662
in shoulder impingement syndromes, 1765–1766
sympathetic mediated, 1805
in thyroiditis, 1535
in trigeminal neuralgia, 1748–1749
- Palate
cleft, 1840–1844. *See also* Cleft, of lip and palate
primary, 1841
tumors of, 586
- Palatoplasty in cleft palate, 1844, 1845f
PALB2, 289t

- Palliative care, 1946–1947
 communication skills in, 1946–1947, 1947*t*
 definition of, 1946
 of elderly, 1938
 general principles of, 1946
 in head and neck tumors, 602
 health and healing, 1946
 indications for, 1946, 1946*t*
 pain management in, 1946, 1948, 1950
 adjuvant medications in, 1950*t*
 in pancreatic cancer, 1399
 in persistent pain, 1949*t*
 step ladder approach to, 1948, 1948*t*
 in pancreatic cancer, 1399–1400
 pharmacotherapy principles in, 1948, 1948*t*
 radiation therapy, in recurrent soft tissue sarcoma, 1479
 surgical, 1946
- Palmaris longus tendon, 1788
- Palmar space infections, 1810
- Palpitations, 736
- Palsy
 brachial plexus, 1782
 cerebral, 1782
- Pamidronate in bone pain, 1950*t*
- Pancoast, Henry, 642
- Pancoast's tumor, 623
 treatment of, 641–642, 641*f*
- Pancolitis, 1195
- Pancreas, 1341–1413
 abscess of, 150–151, 1375*t*
 adenoma of, periampullary, 1408
 anatomy of, 1341–1346
 lymphatic, 1344–1346, 1346*f*
 neurologic, 1346, 1347*f*
 relationships in, 1342, 1343*f*
 vascular, 1342–1346, 1343*f*, 1345*f*
- cancer of, 1393–1410
 ablation for, 1400–1401
 acute pancreatitis in, 1352
 algorithm on diagnosis and treatment of, 1399*f*
 ampullary, 1408
 biliary-enteric bypass in, 1399–1400, 1400*f*
 biomarkers in, 1397, 1407
 in chronic pancreatitis, 1375, 1375*f*, 1394
 diagnosis of, 1395–1399, 1398*f*, 1399*f*
 in elderly, 1393
 epidemiology of, 275*t*, 276*t*, 278*t*, 618*f*, 1393–1395
 genetic factors in, 292, 1395
 in therapy, 1408
 in hereditary pancreatitis, 1394
 metastatic to liver, 1398*f*, 1407
 palliative care in, 1399–1400
 pancreatectomy in, 1402
 pancreaticoduodenectomy in, 1401–1402, 1402*f*, 1411*f*
 anastomosis techniques in, 1403–1407
 complications of, 1403–1407
 outcome and value of, 1407
 recurrence of cancer in, 1407–1408
 pancreatojejunostomy in, 1403*f*–1405*f*
 pathology in, 1395, 1396*f*
 periampullary, 1408
 risk factors for, 1393–1395
 signs and symptoms in, 1341
 staging of, 1395, 1397*t*
- choangiopancreatography of
 endoscopic retrograde, 1316
 magnetic resonance, 1275, 1315–1316, 1317*f*
- cystic neoplasms of, 1410–1413, 1410*f*
 management algorithm on, 1410*f*
- divisum, 1344, 1344*f*, 1365–1366
 chronic pancreatitis in, 1365–1366, 1380
- embryonic development of, 1344, 1344*f*
- endocrine, 1348–1351
 neoplasms of, 1390–1391
- enzymes of, 1348–1349, 1348*t*
 in acute pancreatitis, 1353–1354, 1355
 in chronic pancreatitis, administration of, 1379–1380, 1380*t*
- exocrine, 1348–1349
 neoplasms of, 1393–1412, 1410*t*
- fibrosis of
 asymptomatic, 1365*t*, 1367
 in chronic pancreatitis, 1367–1368, 1367*f*, 1368*f*
- fibula of
 enteric, in chronic pancreatitis, 1378
 internal, in chronic pancreatitis, 1378
 postoperative, in
 pancreaticoduodenectomy, 1403–1407
 traumatic, 209
- fluid collections in, 1376*t*
- gastrinoma of, 1391–1392
- glucagonoma of, 1393
- histology and physiology of, 1346–1351
- hormones of, 1348–1351, 1349*t*
- infections of, 150–151
 necrotizing, 150–151, 152*f*
 treatment of, 151, 152*f*
- inflammatory mass in head of, in
 chronic pancreatitis, 1379, 1380*t*
- insulinoma of, 1391
- intraductal papillary mucinous
 neoplasms of, 1411*f*, 1412–1413, 1412*f*
 fish-eye lesion in, 1411*f*, 1412
- intraepithelial neoplasia of, 1395, 1396*f*
- islet cells of, 1348–1351. *See also* Islet cells of pancreas
- lymphoma of, 1413
- necrosis of, 150–151, 152*f*, 1376*t*
 in acute pancreatitis, 1356, 1358*f*, 1359
- pancreatitis of, 1351–1390. *See also* Pancreatitis
 postoperative disorders of, 387
 pseudocysts of, 209, 1342, 1409
 in chronic pancreatitis, 1375–1378
 pseudopapillary tumor of, solid, 1412*f*, 1413
- regions of, 1341–1343
- secretions of, 1348–1349, 1348*t*
 composition of, 69*t*, 1349*f*
- somatostatinoma of, 1393
- transplantation of, 340–344
 complications in, 329, 343
 contraindications to, 340–341
 donor in, 340–341
 historical aspects of, 323, 340
 immunosuppression in, 340
 in islet cell transplantation, 345
 indications for, 340–341
 islet cell, 344–345
 in chronic pancreatitis, 1390
 after kidney transplantation, 340, 344
 living donor in, 332, 343–344
- operative techniques in, 341–342, 341*f*–344*f*
 bladder drainage procedure, 341, 342, 342*f*–343*f*, 343
 enteric drainage procedure, 341, 342, 342*f*–343*f*, 343
 organ preservation methods and time in, 331
 preoperative evaluation in, 341
 preoperative preparation of, 341
 procurement and preservation, 340–341
 rejection in, 343
 results of, 344
 simultaneous with kidney transplantation, 340, 344
 survival rates in, 344
 trauma of, 207–209, 1341
 complications in, 209
 with duodenal injuries, pyloric exclusion procedure in, 209, 209*f*
 emergent abdominal exploration in, 191
 identification of, 207–208
 Roux-en-Y pancreaticojejunostomy in, 208–209, 208*f*
 vasoactive intestinal peptide-secreting tumors of, 1392–1393
- Pancreastatin, 1350
 functions of, 1349*t*
- Pancreatectomy
 in chronic pancreatitis, 1382, 1384–1390
 in pancreatic cancer, 1402
 in pseudocyst of pancreas, 1378
 in trauma of pancreas, 208, 209
- Pancreatic arteries, anatomy of, 1344–1345
- Pancreatic duct
 anatomy of, 1344
 calculi in, extracorporeal shock wave lithotripsy in, 1380–1383, 1382*f*
 distortion, 1368–1369
 obstruction of, 1368
 sphincteroplasty in chronic pancreatitis, 1382–1383, 1383*f*, 1384*f*
 stent placement in chronic pancreatitis, 1380, 1381*f*
- Pancreatic intraepithelial neoplasia (PanIN), 1395, 1396*f*
- Pancreaticoduodenal artery, anatomy of, 1344
- Pancreaticoduodenal vein, anatomy of, 1346
- Pancreaticoduodenectomy
 in duodenal neoplasms, 1161
 in pancreatic cancer, 1401–1402, 1402*f*, 1411*f*
 anastomosis techniques in, 1403–1407
 complications of, 1403–1407
 outcome and value of, 1407
 recurrence of cancer in, 1407–1408
 in pancreatic injuries, 208
- Pancreatojejunostomy
 in ascites, pancreatic, 1378, 1378*f*
 in cancer of pancreas, 1403*f*–1405*f*
 in chronic pancreatitis, 1383, 1384*f*, 1390
 in trauma of pancreas, 208–209, 208*f*
- Pancreatic polypeptide, 1348, 1350–1351
 in chronic pancreatitis, 1373, 1374*f*
 functions of, 1349*t*, 1351

- Pancreatic secretory trypsin inhibitor (PTSI), 1347
- in hereditary pancreatitis, 1366
- Pancreatic stone protein (PSP), 1368
- Pancreatic thread protein, 1368
- Pancreatitis, 150–151, 1351–1390
- acute, 1351–1360
 - in alcohol use and alcoholism, 1352
 - APACHE-II score in, 1357
 - assessment of severity, 1357
 - colocalization theory of, 1352
 - complications of, 1357*t*, 1359
 - computed tomography in, 1355, 1355*f*, 1358, 1358*f*
 - definition of, 1351
 - diagnosis of, 1355–1357
 - drug-induced, 1353
 - etiologies of, 1351, 1352*t*
 - factors affecting severity of, 1355
 - fluid therapy in, 1357–1358
 - in gallstones, 1323, 1351–1352
 - iatrogenic, 1352
 - idiopathic, 1353
 - incidence of, 1351
 - infections in, 1361*f*
 - inflammatory response in, 1354, 1355
 - local complications of, 1355*t*
 - lung injury associated with, 1354
 - management of, 1355
 - necrotizing, 150–151, 152*f*, 1356, 1358*f*, 1359
 - nutrition in, 1358
 - pathophysiology in, 1353, 1353*f*, 1354*f*
 - prognostic signs in, 1356*t*, 1357
 - Ranson criteria in, 1356*t*, 1357
 - sequential organ failure assessment, 1356*t*
 - severity of, 1369*t*
 - treatment of, 1361*f*, 1379–1390
 - chronic, 1360–1390
 - antisecretory therapy in, 1380
 - ascites in, 1378, 1378*f*
 - autoimmune, 1365*t*, 1366
 - burned out, 1372
 - calcific, 1365, 1365*t*, 1368, 1368*f*
 - cancer of pancreas in, 1375, 1375*f*, 1394
 - classification of, 1365, 1365*t*, 1369*t*
 - complications of, 1375–1379
 - definition of, 1360
 - diabetes mellitus in, 1372–1373
 - drainage procedures in, 1383–1384, 1384*f*, 1385*f*
 - enzyme therapy in, 1379–1380, 1380*t*
 - epidemiology of, 1360
 - etiologies of, 1360, 1362*t*
 - fibrosis in, 1367–1368, 1367*f*, 1368*f*
 - histology in, 1367, 1367*f*, 1368*f*
 - inflammatory, 1365*t*, 1366
 - inflammatory mass in, 1379, 1380*t*
 - laboratory tests in, 1373–1375, 1373*t*
 - lipase deficiency in, 1371*f*, 1372
 - replacement therapy in, 1380*t*
 - obstructive, 1365–1366, 1365*t*, 1368
 - results of surgery in, 1381*f*, 1382
 - pain in, 1371–1372, 1371*f*
 - treatment of, 1379, 1380, 1380*t*
 - prognosis and natural history in, 1374–1375, 1374*f*, 1375*f*
 - pseudocyst in, 1375–1378
 - radiologic imaging in, 1369–1371, 1370*f*
 - resection procedures in, 1384–1390
 - signs and symptoms in, 1371–1372
 - sphincteroplasty in, 1382–1383, 1383*f*, 1384*f*
 - stent placement in, 1380, 1381*f*
 - survival rates in, 1374, 1374*f*, 1375*f*
 - tropical (nutritional), 1360, 1366–1367
 - in gallstones, Ranson criteria on, 1356*t*
 - hereditary, 1347, 1352, 1360–1362
 - pancreatic cancer in, 1394
 - in hyperparathyroidism, 1561
 - multiple hit theory on, 1363, 1363*f*
 - postoperative, 387
 - in transplanted pancreas, 343
- Pancreatoscopy in chronic pancreatitis, 1382, 1383
- Pancuronium, 1901, 1901*t*
- Paneth cells, 1139
- Panfacial fractures, 1855
- PanIN, 1395, 1396*f*
- Panitumumab, 310*t*
- Panniculectomy, 1887
- Panniculitis, mesenteric, 1458
- Papanicolaou smear in cervical cancer screening, 1677
- Papaverine
 - in arterial vasospasm, 215*t*
 - in mesenteric ischemia, nonocclusive, 865
- Papillary carcinoma
 - of breast, 522
 - of thyroid, 1542–1544, 1543*f*
 - in elderly, 1937
- Papilloma
 - of breast, intraductal, 509–510
 - of choroid plexus, 1734
- Papillomavirus infections
 - anorectal, 1233
 - condyloma acuminata in, 485, 1233, 1678, 1680
 - respiratory recurrent, 572
 - of skin and subcutaneous tissue, 485
 - testing for, 1676–1677
 - tumors associated with, 295–296, 295*t*
 - cervical, 1697
 - of head and neck, 579
 - of skin and subcutaneous tissue, 485
 - vaginal, 1697
 - vulvar, 1696
- Paracentesis in chylous ascites, 1170
- Paracervical fascia, 1674
- Parafollicular cells of thyroid, 1525, 1549
- Paraganglioma
 - of carotid body, 849
 - familial, 289*t*
 - functional, 1586
 - hereditary, 289*t*
- Paraganglionic tumors, mediastinal, 677*t*, 678
- Paralysis
 - agitans, 1747–1748
 - of facial nerve, 1865–1866. *See also* Facial nerve, paralysis of
 - of vocal cord, 574, 574*f*
- Paranasal sinuses
 - fungal ball in, 569–570, 570*f*
 - inflammatory disease of, 567–570. *See also* Sinusitis
 - tumors of, 592–593, 592*f*
- Paraneoplastic syndromes in lung cancer, 625–627, 625*t*
- Parapharyngeal space masses, 597–598, 597*f*
- Paraphimosis, 1664
- Parasitic infections
 - anorectal, 1233
 - cholangiohepatitis in, 1324
 - splenic cysts in, 1430*t*, 1436–1437
- Parasympathetic nervous system, 1711
- of anorectum, 1179
 - of colon, 1177
 - of esophagus, 946
 - of liver, 1268–1269
 - of pancreas, 1346
 - of stomach, 1038, 1047
 - of thyroid gland, 1525
- Parathyroidectomy, 1563–1574, 1567*f*
- autotransplantation of tissue in, 1569, 1573
 - complications of, 384, 1573–1574
 - in elderly, 1937–1938
 - endoscopic, 1567
 - in familial hyperparathyroidism, 1570
 - historical aspects of, 1556
 - indications for, 1564, 1564*t*
 - minimally invasive, 1567
 - in neonatal hyperparathyroidism, 1570
 - operative procedure in, 1566–1569, 1568*f*
 - intraoperative identification of parathyroid glands in, 1567–1568, 1569
 - standard bilateral exploration in, 1567–1569
 - postoperative care and follow-up in, 1571
 - preoperative localization tests in, 1564–1566, 1565*t*
 - radio-guided, 1567
 - in secondary hyperparathyroidism, 1572–1573
 - in tertiary hyperparathyroidism, 1573
- Parathyroid gland, 1556–1574
- adenoma of, 672, 1556
 - hyperparathyroidism in, 1560, 1565, 1567–1568
 - parathyroidectomy in, 1567–1568, 1569
 - anatomy and histology of, 1525, 1526*f*, 1557–1558, 1557*f*
 - autotransplantation of, 1567–1568, 1573
 - and calcium homeostasis, 1556, 1558–1559, 1558*f*, 1559*f*
 - carcinoma of, hyperparathyroidism in, 1560, 1570
 - ectopic, 679, 1557, 1568, 1569*f*
 - persistent hyperparathyroidism in, 1571, 1571*f*
 - in elderly, 1937–1938
 - embryonic development of, 1556–1557, 1557*f*
 - historical descriptions of, 1556
 - hyperparathyroidism, 1559–1574. *See also* Hyperparathyroidism
 - hyperplasia of, 1569
 - hypoparathyroidism, 1574
 - injury in thyroidectomy, 1556
 - physiology of, 1558–1559, 1558*f*, 1559*f*
 - supernumerary, 1557
- Parathyroid hormone
 - in calcium homeostasis, 1558, 1558*f*, 1559*f*
 - ectopic secretion in lung cancer, 626
 - in hyperparathyroidism, 1562–1563, 1562*f*, 1563*t*
 - intraoperative quick assay of, 1563–1564, 1566*f*
- Parathyromatosis, 1570–1571
- Paratracheal lymph nodes, 611–612
- in lung cancer, 632, 632*f*
- Parecoxib, 1901

- Parenteral nutrition, 56–59. *See also*
Nutrition, parenteral
- Parietal cells of stomach, 1037,
1040–1041, 1041f, 1042f, 1042t
acid secretion of, 1041–1043, 1043f
intrinsic factor secretion of, 1044
- Parietal cell vagotomy in peptic ulcer
disease, 1062f, 1062t
- Parietal lobe, anatomy of, 1709
- Parietal pleura, anatomy of, 680
- Parkinson, Cyril Northcote, 8
- Parkinson's disease, 1747–1748
deep brain stimulation in, 1747–1748
- Parkinson's law, 8
- Parkland formula in burns, 230
- Parks hemorrhoidectomy, 1223
- Parona's space, 1812
- Paronychia, 1813–1814, 1813f
- Parosteal osteosarcoma, 1779
- Parotid gland tumors, 599, 599f
- Parry-Romberg syndrome, 1849, 1850f
- Passaro's triangle, 1392, 1392f
- Passive transport, 1140
- Pasteur, Louis, 135, 241
- Patella
dislocation of, 1762, 1763f
fractures of, 1762, 1763f
- Patey modified radical mastectomy, 547,
548f, 549, 549f
- Pathogen-associated molecular patterns, in
shock, 110, 116
- Patient care
skill in, as core competency, 4t
training on, 4t
- Patient Safety Indicators of Agency
for Healthcare Research and
Quality, 373, 373t
- Patient Self Determination Act (1991),
1944
- Pattern recognition receptors (PRRs) in
shock, 110, 115, 117f
traumatic, 123
- Pauchet procedure in peptic ulcer disease,
1071f
- Pavlik harness in hip dysplasia, 1783
- Pazopanib, 310t
- Pectinate line, 1177
- Pectineal ligament anatomy, 1496
- Pectoralis muscles
flap
in chest wall reconstruction, 1873
in head and neck reconstruction, 591,
591f, 601
preserved in modified radical
mastectomy, 548, 548f, 549f
- Pediatric disorders, 1597–1645. *See also*
Children and infants
- Pelvic examination, 1676, 1676f
- Pelvic exenteration
in cervical cancer recurrence, 1698,
1700f
in rectal cancer recurrence, 1213
- Pelvic floor
anatomy of
muscles in, 1178, 1671–1672, 1672f
nerves in, 1672–1673, 1673f, 1674f
disorders of, 1694–1695
prolapse of pelvic organs in,
1694–1695
stress urinary incontinence in, 1695
in fecal continence, 1180
function testing of, 1181–1182
- Pelvic fractures, 166, 181, 183f, 185f,
212–214, 1760
bladder trauma in, 1660
hemorrhage in, 173, 181, 212–214
and hemodynamic instability, 213,
213f
pelvic packing in, 213, 215f
open wound in, 214
in pregnancy, 221
- Pelvic inflammatory disease, 1690–1691
differential diagnosis of, 1246, 1690
treatment of, 1690t, 1691
- Pelvic organ prolapse, 1694–1695
- Pelvic pain, 1183
- Pemberton's sign in goiter, 1537
- Pendred's syndrome, 1534
- Penetrating injuries, 174
abdominal, 179–181
diagnostic peritoneal lavage in,
180–181, 180f, 181t
in pregnancy, 221
of chest, 178–179, 201–202
in children, 1642
hemorrhage and persistent hypotension
in, 172
removal of weapon in, 172, 172f
- Penicillin, 143t, 257t
allergic reactions to, 146
in lymphedema, 936
in soft tissue infections, 152
- Penis
anatomy of, 1652–1653
cancer of, 275t
erection of, 1652
in priapism, 1663–1664
prostatectomy affecting, 1658
paraphimosis of, 1664
trauma of, 1661, 1661f
fracture in, 1661, 1661f
priapism in, 1664
- Pepsinogen secretion, 1041, 1044
- Peptic ulcer disease, 1053–1073
in anti-inflammatory drug use, 1053,
1054, 1057–1058
hospitalization rates in, 1058t
medical treatment in, 1061
perforation in, 1068
risk factors in, 1058, 1059t
Blatchford score in, 1059, 1060t
clinical manifestations in, 1059
complications of, 1059–1061,
1064–1068
diagnosis of, 1059
differentiated from gastric cancer, 1080
drug therapy in, 1061
etiologies of, 1053–1055, 1054f
gastric acid secretion in, 1055–1057,
1057f
in *Helicobacter pylori* infections, 1051,
1054–1055, 1076f
diagnosis of, 1059, 1059t, 1061
pathophysiology in, 1054–1055,
1054f, 1055f, 1056f, 1057f
treatment of, 1059t, 1061, 1061t,
1062t
hemorrhage in, 1059–1061, 1064–1068
risk stratification in, 1059, 1060t
treatment algorithms on, 1069f,
1070f
in hyperparathyroidism, 1561, 1562
intractable or nonhealing, 1069–1071,
1071t
differential diagnosis in, 1069, 1071t
Johnson classification of, 1055–1056,
1057f
obstruction in, 1061, 1068–1069
pathophysiology in, 1053–1055
perforation in, 1061, 1068
surgical treatment of, 1068, 1071f
treatment algorithm on, 1071f
- Rockall score in, 1059, 1060t
in smoking, 1058
in stress, 1058
surgical treatment in, 1061–1064
antrectomy in, 1062t, 1063
cancer of gastric remnant in, 1078
in gastric outlet obstruction, 1069
in hemorrhage, 1064–1068
highly selective or parietal cell
vagotomy in, 1062f, 1062t
in intractable or nonhealing ulcer,
1069–1071, 1071t
pyloroplasty in, 1062–1063, 1062t,
1064f, 1065f, 1066f
selection of procedure in, 1063–1064,
1068t
truncal vagotomy in, 1062–1063,
1062t, 1063f
in Zollinger-Ellison syndrome,
1071–1073
- Perforator flaps, 1837–1838
in breast reconstruction, 1871, 1871f
- Perforator vein surgery, subfascial
endoscopic, in chronic venous
insufficiency, 933, 933f
- Perianal space, 1227
abscess of, 1227f, 1228, 1228f
- Pericardial disease, 772–774
acute pericarditis, 772–773, 772t
chronic constrictive pericarditis,
773–774
cysts, 679
relapsing pericarditis, 773
tamponade, 625
- Pericardial knock in chronic constrictive
pericarditis, 773
- Pericardiectomy in chronic constrictive
pericarditis, 774
- Pericardiocentesis
in acute pericarditis, 773
in cardiac tamponade, 129, 167, 167f
- Pericarditis
acute, 772–773, 772t
chronic constrictive, 773–774
relapsing, 773
- Pericardium, 670–671
- Perilunate dislocation, 1794f
- Perineum, necrotizing soft-tissue
infections of, 1229
- Perineurium, 1726
- Periosteal osteosarcoma, 1779
- Peri-pancreatic fluid collection (PPFC),
1376
- Peripheral arteries
occlusive disease of, 881–900
trauma of, 183f
signs and symptoms of, 185t
- Peripheral nerves, 1744–1745
anesthetic blocks of, 1903–1904
autoimmune and inflammatory disorders
of, 1744–1745
entrapment neuropathies of, 1744,
1805–1806
trauma of, 251, 1726–1727
management of, 1727
patterns of injury in, 1726–1727
types of injuries in, 251,
1726–1727
tumors of, 1744
- Peristalsis
in esophagus, 948
in nutcracker esophagus, 992
in small intestine, 1144

- Peritoneal lavage and aspiration
 in abdominal trauma, 180–181, 180f, 181t
 in pregnancy, 218, 221
 complications of, 382, 382f
- Peritoneum
 adhesion formation in trauma of, 263, 263f
 visceral, 1041
- Peritonitis, 149–150
 duration of antibiotic therapy in, 146
 spontaneous bacterial
 in cirrhosis, 1279
 liver transplantation in, 347
 in transplantation procedures, 329
- Peroneal nerve, common, traumatic neuropathy of, 1727
- Peroral endoscopic myotomy (POEM), 416, 433
- Personalized medicine
 in cancers, 316
 genomic, 468
- Pertuzumab, 310t
- Peustow and Gillesby
 pancreaticojejunostomy in
 chronic pancreatitis, 1383, 1384f
- Peutz-Jeghers syndrome, 290t, 1206
 polyps in, 1160, 1161f, 1206
- Peyer's patches, 1138, 1144, 1144f
- Pfannenstiel incision, 1452, 1637
- pH
 esophageal, monitoring of. *See* Esophagus, pH monitoring of
 gastric, monitoring of, 963–964
 with esophageal pH monitoring, 964, 964f
 tissue, 410
 in shock, 131
 vaginal, 1677t, 1680, 1681f
- Phagocytosis, 138, 243, 243t
- Phalangeal bones of hand
 anatomy of, 1788, 1790f
 fractures of, 1796
- Phalen's sign in carpal tunnel syndrome, 1806
- Pharmacodynamics, 1898
- Pharmacokinetics, 1897–1898
 in obesity, 1908
- Pharmacologic resistance in tumors, 312
- Pharyngitis, 570–571
- Pharyngoesophageal swallowing disorders, 986–990, 987f, 988f
- Pharynx, 570–571
 anatomy of, 579
 cancer of, 580, 618f
 constrictor muscles of, 943–944, 943f
 in swallowing mechanism, 948
- Phenocopy, breast cancer, 516
- Phenotypes
 in gene knockout mice, 466
 and genotype correlations, 291
 in transgenic mice, 464
- Phenoxybenzamine in pheochromocytoma, 1586–1587
- Phenylephrine in neurogenic shock, 130
- Phenytoin in head trauma, 1718
- Pheochromocytoma, 1574, 1585–1588
 adrenalectomy in, 1587, 1591
 diagnosis of, 1586, 1587f
 hereditary, 290t, 1586, 1587
 historical aspects of, 1574
 malignant, 1587–1588
 in multiple endocrine neoplasia, 1550, 1586, 1587
 thoracic, 678
- Phlegmasia
 alba dolens, 919, 920f
 cerulea dolens, 919, 924
- Phosphate serum levels in
 hyperparathyroidism, 1562–1563, 1563t
- Phosphoinositide-3-kinase pathway, 281, 282, 452, 452f
 in Cowden disease, 292
- Phospholipase A2, 31, 31f, 1348, 1348t
- Phospholipids in bile, 1313
- Phosphorus
 dietary intake of, 73
 serum levels of, 73, 78
 in cancer, 81, 82
 in hyperphosphatemia, 73, 78, 81, 82
 in hypophosphatemia, 73, 78, 81, 82
- Phosphorylation, 246, 452
 oxidative, 115
- Photocoagulation, infrared, in hemorrhoids, 1223
- Photodynamic therapy, 429
 in cholangiocarcinoma, 1337
- Photoplethysmography, 400–401
- Phrenic nerve involvement in lung cancer, 623
- Phrenoesophageal membrane, 944, 945f
- Phrenosplenic ligament, 1425
- Phyllodes tumors, 555, 555f
- Physical examination
 in anesthesia management, 1902t, 1904, 1904t
 in arterial disease, 829
 in breast cancer diagnosis, 523, 523f
 in cardiac disorders, 737
 gynecologic, 1675–1676, 1676f
 of hand, 1793–1794, 1793f
 in inguinal hernia, 1503–1504, 1503f
 in large intestine disorders, 1180
 in mediastinal tumors, 671–672, 674t
 in trauma, 173
- Physical therapy in burns, 235
- Pierre Robin syndrome, 1848, 1849f
- Pigmentation changes in chronic venous insufficiency, 917, 917f
- Pigment gallstones, 1317, 1318–1319
 black, 1318
 brown, 1318–1319
- Pilon fractures, 1764
- Pilonidal disease, 1233
- Pilosebaceous units, 475
- Pincushion deformity in lacerations, 575, 575f
- Piperacillin, 143t
 with tazobactam, 143t
- PIRO staging system on sepsis, 139
- Pisiform bone anatomy, 1788, 1790f
- Pituitary gland
 ACTH-secreting tumor of, 1580
 adenoma of, 1735, 1736f
 Cushing's disease in, 1583, 1735
 prolactin-secreting, 554, 1735
 hormones released by, 21–22
 in shock response, 113–114
 hypophysectomy in breast cancer, 553, 554
 thyroid hormones regulated by, 1526, 1529f
- Plagiocephaly, 1750
 positional, 1750
- Plague in biologic warfare, 157
- Plant alkaloids in chemotherapy, 307, 308t
- Plasma, 65–66, 66f
 composition of, 65–66, 67f
 fresh-frozen, 97
 in hemorrhagic shock, 122, 123f
 in massive transfusions, 101t
 in thrombotic thrombocytopenic purpura, 1434
 in trauma, 184
- Plasma contact system, 33
- Plasmacytoma, 1781, 1781f
 of chest wall, 665, 669
- Plasmids, 457
- Plasmin, 88, 88f, 283
- Plasminogen, 88
 activators of, 88
 tissue. *See* Tissue plasminogen activator
 activator
 urokinase, 88, 283
- Plastic and reconstructive surgery, 1829–1891
 of abdominal wall, 1875–1876
 aesthetic, 1882–1891
 arthroplasty in, 1773–1778
 after bariatric surgery and weight loss, 1129, 1130f, 1887f
 of breast, 1866–1872. *See also* Breast plastic and reconstructive surgery
 of chest wall, 1872–1875, 1875f
 flaps in, 670, 670f, 1873–1874, 1875f
 prosthetic materials in, 670, 670f, 1875
 in tumors, 670, 670f
 in children, 1840–1852
 composite tissue allotransplantation in, 1881–1882
 of esophagus, 1024–1026, 1863. *See also* Esophagus, reconstructive surgery of
 excisional body contouring in, 1886–1887
 extremity reconstruction in, 1802f–1804f, 1876–1880
 in burns of hand, 1821–1822, 1821f, 1822f
 in fingertip injuries, 1801
 flaps in, 1833–1840. *See also* Flaps
 free tissue transfer in, 1838–1840
 of hand. *See* Hand, reconstructive surgery of
 of head and neck, 1860–1865. *See also* Head and neck plastic and reconstructive surgery
 historical aspects of, 1829
 craniofacial surgery in, 1844
 free tissue transfer in, 1838
 skin grafts in, 1832
 liposuction in, 1883, 1885
 in pressure ulcers, 1880–1881
 skin grafts in, 1832–1833. *See also* Skin grafts
 skin incisions in, 1829–1830
 skin substitutes in, 266–267, 267t
 in burns, 234
 in venous insufficiency, 932–933, 933f
 tissue expansion techniques in, 1840
 in breast reconstruction, 1840, 1867–1869, 1869f, 1870f
 wound healing in, 1830–1832
- Platelet-activating factor (PAF), 43
- Platelet-derived growth factor
 in angiogenesis, 283, 284
 in diabetic foot ulcers, 267
 in wound healing, 246, 247t
 therapeutic use of, 267
- Platelet-endothelial cell adhesion molecule-1 (PECAM-1), 41t

- Platelet factor 3, 86
 Platelet factor 4, 86, 90, 91
 Platelets
 aggregation of, 85–86
 impaired, 91
 count of, 85, 102–103
 reduced, in thrombocytopenia, 90–91
 in hemostasis, 85–86, 86f, 87f
 congenital disorders of, 89–90
 qualitative disorders of, 90t, 91
 quantitative disorders of, 90–91, 90t
 wound healing of, 243
 splenectomy in disorders of, 1432–1434
 splenic sequestration of, 91, 93, 1428
 transfusion of, 91, 97, 99t
 in hemorrhagic shock, 123
 in massive transfusions, 101t
 in thrombocytopenia, 91, 388
 in wound healing, 1831
 Pleomorphic Sarcoma and
 Myxofibrosarcoma,
 undifferentiated, 493
 Plethysmography, 918
 in venous insufficiency, 930
 in venous thromboembolism, 921
 Pleural disorders, 680–690
 access and drainage in, 680–682
 anatomy in, 680
 chylothorax, 685–687
 effusions, 680. *See also* Effusions,
 pleural
 empyema, 682–685
 tumors, 687–690
 fibrous, 688, 690
 mesothelioma, 687–688
 Pleuroctomy with decortication in
 mesothelioma, 688
 Plicae circulares, 1138
 Plug and patch technique in inguinal
 hernia repair, 1508–1509, 1508f,
 1513
 Plummer's disease, hyperthyroidism in,
 1532
hPMS1, 289t, 292
hPMS2, 289t, 292
 Pneumatocele, traumatic, 202
 Pneumatosis intestinalis, 56, 1149f,
 1170–1171
 in necrotizing enterocolitis, 1620, 1620f
 Pneumocystis jiroveci, 330
 Pneumocytes, 612–613
 Pneumonectomy
 in lung cancer
 in early-stage disease, 643
 functional status assessment in,
 633–634, 638f
 in mesothelioma, 688
 Pneumonia
 aspiration, 650
 community-acquired, 651
 necrotizing, 651
 pathogenesis, 650
 nosocomial, 153–154, 384–385
 pleural effusions in, 680, 681t, 683t
 postoperative, 384–385
 ventilator-associated, 153–154, 384–385
 in burns, 233
 Pneumonitis, postoperative, 384
 Pneumoperitoneum
 in laparoscopy, 417–419
 with carbon dioxide, 417, 417f
 in elderly, 1935
 in pregnancy, 436
 in necrotizing enterocolitis, 1620
 Pneumothorax
 in central venous catheterization, 381
 in chest trauma, 164, 165f, 177, 200
 in children, 222
 chest tubes in, 164, 164f, 649
 in laparoscopy, 419
 open, 164, 165f
 postoperative, 384
 spontaneous, 649–650
 catamenial, 650
 tension, 163–164, 164f, 171
 obstructive shock in, 128
 Poland's syndrome, 500
 Polidocanol in varicose veins
 sclerotherapy, 929
 Polyarteritis nodosa, 903
 Polyclonal antibodies in
 immunosuppressive therapy, 325
 Polycystic disease
 of liver, 1288–1289
 of ovary, 1126
 Polycythemia vera, 92
 splenectomy in, 1430t, 1435–1436
 Polydactyly, 1823
 Polymastia, 500
 Polymenorrhea, 1682
 Polymerase chain reaction technique, 458,
 459f
 Polymorphisms, single nucleotide, 449
 Polymorphonuclear cells in wound
 healing, 1831
 Polypectomy, 1212
 colorectal, 1206
 uterine, 1684
 Polyposis
 familial adenomatous, 1206–1207
 attenuated, 1207
 diagnosis of, 1206–1207
 genetic factors in, 288t, 291, 1183,
 1206–1207
 operative procedures in, 1206–1207
 screening for colorectal cancer in,
 1210t
 thyroid cancer in, 1537, 1539t
 hyperplastic, 1206
 juvenile polyposis coli, 289t, 1206
 nasal, 568, 568f, 569
 Polyps
 colorectal, 1205–1206
 hyperplastic, 1206
 neoplastic, 1205–1206
 pedunculated, 1205–1206, 1211f,
 1212
 removal of, 1212
 serrated, 1206
 sessile, 1205–1206, 1211f, 1212
 gastric, 1076–1077, 1077f
 nasal, 568, 568f, 569
 of small intestine, 1159f, 1160, 1160f,
 1161f
 treatment in, 1161
 uterine
 cervical, 1681
 endometrial, 1682
 hysteroscopy in, 1684
 of vocal cord, 573
 Polythelia, 500
 Ponatinib, 310t
 Popliteal artery
 entrapment syndrome, 905–906, 905t
 differential diagnosis in, 905, 905t
 treatment of, 906
 injuries of, 215
 occlusive disease of. *See also*
 Femoropopliteal occlusive
 disease
 adventitial cystic, 905
 symptoms in, 889–890
 pulse palpation, 829
 in limb ischemia, 886
 Popliteal space access in acute trauma,
 215, 215f
 Popliteal vein
 anatomy of, 165f
 injury of, 215
 Porcelain gallbladder, 1317–1318
 Porfimer sodium in photodynamic therapy,
 429
 Portacaval shunt
 in Budd-Chiari syndrome, 1284
 in gastroesophageal varices, 1282
 Porta hepatis, 1267
 Portal hypertension, 1280–1281, 1281f
 Budd-Chiari syndrome in, 1283–1284
 in cirrhosis, 1280, 1282
 definition of, 1281
 etiologies of, 1281, 1281t
 gastric varices in, isolated, 1088
 gastroesophageal varices in, 1281,
 1282–1283
 hemorrhage in, 347, 1282, 1283
 liver transplantation in, 347
 surgical shunts in, 1282–1283, 1283f
 transjugular intrahepatic
 portosystemic shunt in, 1282,
 1283
 imaging in, 1280–1281
 liver transplantation in, 347, 1283
 measurement of portal venous pressure
 in, 1280–1281
 minimally invasive surgery in, 437
 splenectomy in, 1430t, 1438
 Portal vein
 anatomy of, 1267, 1267f, 1280, 1281f
 variations in, 1342–1343, 1343f
 embolization prior to liver resection,
 1300–1301
 imaging of, 1280–1281
 pressure in
 elevated, 1280–1281
 measurement of, 1280–1281
 normal values for, 1280
 thrombosis of
 in liver transplantation, 351
 in pancreatitis, 1379
 in splenectomy, 1439
 Portoenterostomy in biliary atresia,
 1629–1630, 1629f
 Portosystemic shunt, transjugular
 intrahepatic
 in ascites, 347
 in Budd-Chiari syndrome, 1284
 in gastric varices, isolated, 1088
 in gastroesophageal varices, 1282, 1283
 Port placement in minimally invasive
 surgery, 424, 426f
 in laparoscopic Roux-en-Y gastric
 bypass, 1113–1114, 1113f
 Port-wine stain, 485, 574, 1850
 Posaconazole, 141t, 658
 Positron emission tomography
 in cancer staging, 300
 in cardiac disorders, 739
 in colorectal disorders, 1181
 in esophageal cancer, 1005, 1008
 in gastrointestinal stromal tumors, 1482
 of liver, 1275, 1275f
 in lung cancer, 631
 in distant metastasis, 633
 in mediastinal tumors, 672
 in pulmonary nodule, solitary, 622

- Positron emission tomography (*Cont.*):
 in soft tissue sarcomas, 1469
 in stomach cancer, 1080
 of thyroid, 1530
- Postanal space, deep, 1227
- Postanesthesia care unit, 1915
- Posterolateral knee injuries, 1769
- Postoperative period, 380–393
 abdominal abscess in, 391
 abdominal compartment syndrome in, 389
 anesthesia recovery in, 1915–1916
 antibiotics in, 142, 146
 appendicitis in, 1257
 in bariatric surgery, 1107–1108
 cardiac disorders in, 374, 375*t*, 386
 in carotid endarterectomy, 384
 chemotherapy in, 307
 in children, 393
 debriefings in, 370–371
 drain management in, 389–340
 ear disorders in, 383–384
 in elderly, 393
 empyema in, 390–391
 eye disorders in, 383–384
 fluid therapy in, 78–80
 gastrointestinal disorders in, 386–387
 in bariatric surgery, 1116, 1116*f*
 ileus, 1151–1153
 nausea and vomiting, 1914, 1915, 1916*f*
 small intestine obstruction, 1149–1150
 glucose levels in, 392
 hematologic disorders in, 389–390
 hemorrhage in, excessive, 104
 hepatobiliary disorders in, 387
 hyperthermia in, 393
 hypothermia in, 393
 kidney disorders in, 387–388
 in lung surgery, pain in, 645*f*
 metabolic disorders in, 392–393
 in minor procedures, 380–383
 multiple organ dysfunction syndrome in, 391–392
 musculoskeletal disorders in, 388
 necrotizing fasciitis in, 391
 neurologic disorders in, 383
 nose disorders in, 383–384
 nosocomial infections in, 152–154
 nutrition in, 392–393
 in obesity, 393
 pain in, 1915–1916
 in inguinal hernia repair, 1514–1515
 in thoracic surgery, 645*f*
 pancreatitis in, 387
 in parathyroid surgery, 384
 radiation therapy in, 314
 respiratory disorders in, 384–386
 intraoperative fluid therapy affecting, 1914
 in nosocomial infections, 153–154, 384–385
 sepsis in, 391–392
 Surgical Care Improvement Project on, 374, 375*t*
 surgical site infections in, 142, 152–154, 389, 1257
 systemic inflammatory response syndrome, 391–392
 in thyroid surgery, 384
 urinary catheterization in, 390
 wound healing in, 1832, 1832*t*
- Potassium
 absorption in large intestine, 1179
 dietary intake of, 70
 in children and infants, 1599
 in gastrointestinal secretions, 69*t*
 in parenteral nutrition, 58, 76*t*
 in postoperative fluid therapy, 80
 in preoperative fluid therapy, 79
 serum levels of, 70–71, 72*t*, 77
 in cancer patients, 81
 in hyperkalemia. *See* Hyperkalemia
 in hypokalemia. *See* Hypokalemia
 in parenteral nutrition, 58
- Potassium thionyl phosphate (KTP) laser, 428
- Potency of drugs, 1898
- Pott's disease, 1745
- Pouch
 in ileal pouch anal anastomosis, 1188, 1189*f*, 1194
 in familial adenomatous polyposis, 1207
 inflammation of, 1194
 in ulcerative colitis, 1198
 in Kock pouch ileostomy, 1194
 in familial adenomatous polyposis, 1207
 in ulcerative colitis, 1198
- Pouchitis, 1194
- Pouch of Douglas, anatomy of, 1674
- Poupart's ligament, 1496
- Power of attorney for health care, 1944
- Practice
 learning and improvement based on, 4*t*
 systems-based, 4*t*
- PRADI in hyperparathyroidism, 1560
- Praziquantel in schistosomiasis, 1286
- Predictive markers, 301
- Prednisone
 in immunosuppressive therapy, 326
 in thrombocytopenic purpura, idiopathic, 1433
- Pregnancy, 1691–1694
 amniocentesis in, 1691
 appendectomy in, 436, 1248, 1257
 appendicitis in, 1248, 1256–1257
 appendix changes in, 1248, 1256–1257
 breast cancer in, 554
 breast changes in, 500, 501, 501*f*, 504–505, 504*f*
 epithelial hyperplasia in, 508
 chorionic villus sampling in, 1691
 cystitis in, 1664
 delivery in, 1693. *See also* Delivery
 ectopic, 1692
 differential diagnosis in, 1248
 testing for, 1677
 fetal interventions in, 1644–1645
 gallstones in, 1320
 gestational trophoblastic disease in, 1693–1694
 laparoscopy in, 435–436
 and appendectomy, 436
 and cholecystectomy, 1320
 melanoma in, 491
 in obesity, 1126
 and bariatric surgery, 1126
 physiologic effects of, 218, 220, 220*t*, 1691, 1693*f*
 syphilis in, 1678
 termination of, 1691–1692
 testing for, 1677
 trauma in, 218–221, 1691
 fetal death in, 218, 221
 fetal monitoring in, 220–221
- Prekallikrein, 33
- Preload, cardiac, 124, 126, 131, 402
 cardiac output response to changes in, 408–409
 determinants of, 402
 in shock, 114
- Premature infants
 ductus arteriosus patency in, 703, 704
 esophageal atresia and tracheoesophageal fistula in, 1610
 fluid and electrolyte balance in, 1599
 inguinal hernia in, 1634, 1635
 jaundice in, 1628
 necrotizing enterocolitis in, 1619–1621
 short bowel syndrome in, 1621
 thermoregulation in, 1601
- Premaxilla in bilateral cleft lip, 1843
- Preoperative period
 anesthesia management in, 1904–1909
 in aortic aneurysm repair, 793
 in bariatric surgery, 1105–1107
 bowel preparation in, 1194–1195
 cardiac risk assessment in, 737–738
 chemotherapy in, 307
 for elderly, assessment in, 1926–1929, 1927*f*, 1930*f*
 in cancer, 1931–1932
 fluid therapy in, 78–80
 hemostasis evaluation in, 102–104
 infection prophylaxis in, 142, 1832, 1832*t*
 antibiotics in, 142
 operating room briefings in, 370, 370*t*, 372*f*
 pulmonary function assessment in, in lung cancer, 635–637
 radiation therapy in, 314
 wound healing interventions in, 1832, 1832*t*
- Preperitoneal repair of inguinal hernia
 endoscopic, 1510
 laparoscopic, 1512*f*
- Presacral tumors, 1217
- Presacral fascia, 1177
- Preservation methods in organ transplantation, 332, 334
- Pressure ulcers, 259, 260–261, 482, 482*f*, 1880–1881
 flap reconstruction in, 1880–1881, 1881*f*
 postoperative, 388
 skin grafts in, 1880
 staging of, 1880, 1880*t*
- Pretracheal fascia, 598
- Prevertebral fascia, 598
- Priapism, 1663–1664
 high flow/traumatic, 1664
 low flow/ischemic, 1663–1664
- Prilocaine in local anesthesia, 1899*t*, 1902, 1903*t*
- Primary survey in trauma, 161–173
 life-threatening injuries identified in, 162*t*
- Pringle maneuver, 95, 189, 189*f*, 1300
 in liver trauma, 203, 205
- Probenecid in pelvic inflammatory disease, 1690*t*
- Probiotics in pseudomembranous colitis, 1222
- Procaine in local anesthesia, 1899*t*, 1902, 1903*t*
- Processus vaginalis
 closure of, 1500, 1502*f*, 1634
 patent, 1500–1501, 1502*f*, 1635
- Procidencia, 1185
- Procollagen, 245
- Proctalgia fugax, 1183

- Proctitis, 1232
in inflammatory bowel disease, 1195
- Proctocolectomy, 1187–1188
restorative, 1188, 1189*f*
ileal pouch anal anastomosis in, 1188, 1189*f*
total, 1188
Brooke ileostomy in, 1188
end ileostomy in, in ulcerative colitis, 1198
Kock pouch in
in familial adenomatous polyposis, 1207
in ulcerative colitis, 1198
- Proctoscopy, 1180
- Proctosigmoiditis in inflammatory bowel disease, 1195
- Proenzymes, 1353
- Professionalism as core competency, 4*t*
- Progesterone, in breast development and function, 500, 503, 505
- Progesterone receptor status in breast cancer, 534, 535–536, 553
- Prognostic markers, 301
- Programmed death ligand 1 (PD-L1) in cancer immunotherapy, 312
- Prokaryotes, transcription in, 447
- Prolabium in bilateral cleft lip, 1843
- Prolactin, 504
in breast development, 503
pituitary adenoma secreting, 554, 1735
- Prolapse
of mitral valve, 755–756, 755*f*
of pelvic organs, 1694–1695
rectal, 1218–1219, 1219*f*
- Prolene hernia system in inguinal hernia repair, 1509, 1509*f*
- Proliferating cell nuclear antigen in breast cancer, 535
- Proliferation indicators in breast cancer, 535
- Proliferation phase of wound healing, 242*f*, 243*f*, 244
- Promoter regions, 447
- Propofol, 1427
- Propofol in general anesthesia, 1900, 1909
- Propylthiouracil in Graves' disease, 1532
- Prostacyclin, 32, 42, 43*f*, 85
- Prostaglandins, 31*f*, 32, 32*t*
in ductus arteriosus patency, 703
- Prostate
anatomy of, 1652
benign hyperplasia of, 1665
acute urinary retention in, 1662
drug therapy in, 1662, 1665
laser vaporization of prostate in, 1665
symptoms in, 1665
transurethral resection of prostate in, 1665
cancer of, 1657–1658
epidemiology of, 274, 275, 275*t*, 276*t*, 277*f*, 278*t*, 618*f*
Gleason score in, 1657–1658
hormone therapy in, 308–309
prostatectomy in, 1658
screening for, 299*t*, 1657
tumor markers in, 302
infections of, 1664
- Prostatectomy
in benign hyperplasia of prostate, 1665
in cancer of prostate, 1658
complications of, 1658
laparoscopic, 1658
perineal approach, 1658
retropubic, 1658
robotic, 430, 1658
suprapubic, 1665
- Prostate-specific antigen, 302
in screening for prostate cancer, 1657–1658
- Prostatitis, 1664
- Prosthesis
in femoropopliteal bypass graft, 899
in hand amputations, 1800
for heart valves, 749–750
aortic. *See* Aortic valve disorders, prosthetic replacement in
autografts in, 751
in elderly, 761, 1930–1931
homografts in, 750–751
mechanical, 749, 750*f*
mitral. *See* Mitral valve disorders, prosthetic replacement in
tissue, 749, 749–750, 750*f*
tricuspid, 764
in Ebstein's anomaly, 720
in joint arthroplasty, 1772–1778.
See also Arthroplasty
- Protamine, 95
- Protein
age-related differences in dietary requirements for, 1600*t*
analysis of
immunoblotting in, 458, 460*f*
immunoprecipitation in, 458–459, 461*f*
bone morphogenic, 251
in chyle, 686*t*
in enteral nutrition, 53, 54
for children, 1600*t*
functional properties and structure of, 448*f*
heat shock, 19*f*, 20
metabolism of
in fasting, 44, 44*t*, 45–46, 45*f*
in injury, 46*f*, 50, 51*f*
in liver, 1269
small intestine digestion and absorption in, 1141–1142, 1142*f*
postoperative dietary intake, 51
synthesis of, 19*f*, 447
- Protein C, 88
- Protein energy malnutrition in elderly, 1929
- Protein kinase C, 35*f*
- Protein kinase, mitogen-activated, 34*f*
- Protein S, 88
- Proteoglycans, 245, 251
- Proteolysis
in injury, 50
in starvation, 45, 45*f*
- Proteomics, 444*f*, 449, 1917–1919
- Prothrombin, 86, 87, 99*t*
in chyle, 686*t*
deficiency of, 89, 99*t*
laboratory tests of, 103, 120
- Prothrombin time, 87, 103
in liver disease, 93, 1271
- Proton pump inhibitors
in gastroesophageal reflux, 971, 972, 979
and respiratory disorders, 971
in peptic ulcer disease, 1061, 1061*t*
- Proto-oncogenes, 295, 729
in colorectal cancer, 1204
- PRSSI, 1347
in acute pancreatitis, 1352
in chronic pancreatitis, 1360–1361
- Pruitt-Inahara shunt in mesenteric artery injury, 211
- Prune-belly syndrome, 1634, 1634*f*
- Pruritus ani, 1231–1232
- Pseudoaneurysm
of aorta, 785, 788
in Behçet's syndrome, 903
of carotid artery, 848, 850
in liver trauma, 205
in pancreatic pseudocyst, 1376, 1376*f*
- Pseudocholinesterase, 1901
- Pseudo-Cushing's syndrome, 1583
- Pseudocyst
of pancreas, 209, 1342, 1409
in chronic pancreatitis, 1375–1378
alcoholic, 1376*f*
cystogastrostomy in, 1377, 1377*f*
pancreatectomy in, 1378
pseudoaneurysm in, 1376, 1376*f*
stent placement in, 1377, 1378*f*
treatment of, 1376–1378, 1377*f*
definition of, 1376*t*
of spleen, 1437
- Pseudodiverticulosis of esophagus, 992
- Pseudohermaphroditism
female, 1637–1638
male, 1637
- Pseudohernia, femoral, 1504
- Pseudohyponatremia, 69
- Pseudomonas aeruginosa* infections
antibiotic therapy in, 143*t*–145*t*
of ear, 565
- Pseudomyxoma peritonei, 1258–1259
- Pseudo-obstruction, intestinal, 1151–1152, 1152*t*, 1153
in Ogilvie's syndrome, 1221
treatment of, 1153
- Pseudopapillary tumor of pancreas, solid, 1412*f*, 1413
- Pseudopolyps, colorectal, 1206
- Pseudostratified ciliated columnar cells in tracheobronchial tree, 612, 613*f*
- Pseudoxanthoma elasticum, 902
- Psoas abscess in Crohn's disease, 1198
- Psoas hitch procedure in ureteral trauma, 212, 1660
- Psoas muscle, 1672
- Psoas sign in appendicitis, 1244
- Psychological issues
in bariatric surgery, preoperative evaluation of, 1105
in burns, 235
- PTCH* in nevoid basal cell carcinoma, 289*t*
- PTEN*
in colorectal cancer, 1205
in Cowden disease, 289*t*, 292
in thyroid cancer, 1541*t*
- Ptosis
of eyelid
classification of, 1861*t*
reconstructive surgery in, 1859–1860, 1861*t*
of nipple, 1887–1888
- Puberty
breast development in, 500, 504
gynecomastia in, 505
- Pubococcygeus muscle, 1178, 1672
- Puborectalis muscle, 1178, 1672
electromyography of, 1182
in fecal continence, 1180
- Pudendal artery, internal, 1179
- Pudendal nerve, 1179
anatomy of, 1673
neurophysiologic testing of, 1182
trauma of, 1673
- Puerperal fever, 135, 241
- Pulley system in hand, 1791, 1791*f*

- Pull-through procedures
in Hirschsprung's disease, 1626, 1626*f*
in imperforate anus, 1627
- Pulmonary artery
catheterization, 402–403
in burns, 230
compared to central venous pressure monitoring, 405–406, 405*t*
complications of, 406–407
hemodynamic measurements in, 403, 403*t*
indications for, 406*t*
minimally invasive alternatives to, 407
outcome in, 405–407
placement procedure in, 402–403
rupture of pulmonary artery in, 381
in trauma, 216–217
in double-outlet right ventricle, 721–722
in Taussig-Bing syndrome, 723–724
in transposition of great arteries, 720–721
- Pulmonary metastasectomy, 623, 624*f*, 625*t*
- Pulmonary valve
as autograft for aortic valve replacement, 750, 762
transposition for aortic valve replacement, 701–702, 701*f*–702*f*
- Pulmonary vascular resistance in atrial septal defect, 697
- Pulmonary veins
in cor triatriatum, 710–711
isolation, 772
partial anomalous connections, sinus venosus atrial septal defect with, 697
total anomalous connections, 707–710
anatomy and embryology in, 707–708, 708*f*
operative correction of, 708–709, 709*f*
types of, 707–708
- Pulse
in aortic valve insufficiency, 760
in aortic valve stenosis, 758
contour analysis, 408
Corrigan's, 760
detection in blood pressure measurement, 400
parvus et tardus, 758
peripheral, 829
grading of, 829, 829*t*
pressure variation, 408–409
volume recording, 830, 831*f*
water-hammer, 760
- Pulsed dye laser (PDL), in burn, 235
- Pulse oximetry, 410
- Purpura
thrombocytopenic
idiopathic or immune, 90, 90*t*
splenectomy in, 1429, 1430*t*, 1432–1434, 1444, 1444*t*, 1445*t*
thrombotic, 90, 91
splenectomy in, 1430*t*, 1434
in transfusion reactions, 104
- Push enteroscopy in obscure gastrointestinal hemorrhage, 1168
- Pyelonephritis, 1664
emphysematous, 1664
- Pyloric exclusion procedure in duodenal injuries, 209, 209*f*
- Pyloric stenosis, hypertrophic, in children and infants, 1613–1614, 1614*f*
- Pyloromyotomy in hypertrophic pyloric stenosis, 1614, 1614*f*
- Pyloroplasty
in Crohn's disease, 1157, 1157*f*
dumping syndrome after, 1091, 1092
in peptic ulcer disease, 1062–1063, 1062*t*, 1064*f*, 1065*f*, 1066*f*
bleeding, 1066
- Pylorus, functions of, 1049
- Pyoderma gangrenosum, 476–477
in inflammatory bowel disease, 1196
- Pyridostigmine reversal of neuromuscular blockade, 1915
- Pyruvate, 45*f*, 49, 49*f*
- Pyruvate kinase deficiency, splenectomy in, 1430*t*, 1431
- Q**
- Qsymia in obesity, 1102
- Quadrate lobe of liver, 1265
- Quality improvement, in surgical site infections, 147, 148*t*
- Quality measurement
Donabedian model on, 366–367, 367*f*
structure, process, and outcome components of, 367–368, 367*f*
in surgery, 373–376
- Quality-of-life issues
in advance directives and living wills, 1944
in antireflux surgery, 979
in dialysis, 1944
for elderly, 1929
in colorectal cancer, 1933
in palliative care, 1946
- Quinlan, Karen Ann, 1944–1945
- Quinupristin-dalfopristin, 145*t*
- R**
- Raccoon eyes in skull fractures, 1716
- Radial artery
anatomy of, 1791–1792
atherosclerosis of, 1822–1823
direct monitoring of blood pressure in, 401
as graft in coronary artery bypass surgery, 744
palpation of, 829, 1793
- Radial forearm fasciocutaneous flap in head and neck reconstruction, 601, 601*f*
- Radial nerve, 1788
anatomy of, 1792–1793
anesthetic block in hand injuries, 1796, 1797*f*
trauma of, 1727
in humerus fractures, 1759
neuroma in, 1805
- Radiation exposure
arteritis in, 903–904
breast cancer risk in, 511
bystander effect in, 295
carcinogenic effects of, 295
colorectal cancer risk in, 1204
enteritis in, 1162–1163
hyperparathyroidism in, 1560
skin injuries in, 486, 493
soft tissue sarcoma risk in, 1466
thyroid nodule in, solitary, 1537
- Radiation therapy, 313–314
adjuvant, 314
in adrenocortical carcinoma, 1585
in anal and perianal tumors, 1218
arteritis from, 903–904
in brain cancer, metastatic, 1732–1733
in breast cancer, 550
advanced local-regional, 543
in ductal carcinoma in situ, 537, 550
early invasive, 538–539
in elderly, 1932
and mastectomy, 499, 550
partial breast irradiation in, 550
and reconstructive surgery, 1872
breast cancer risk in, 511
in cervical lymph node involvement in head and neck tumors, 597
with chemotherapy, 314
in extremity sarcoma, 1477
in cholangiocarcinoma, 1292, 1337
in colorectal cancer of elderly, 1933
colorectal cancer risk in, 1204
dosage in, 314, 315*f*
in endometrial cancer, 1701
enteritis from, 1162–1163
in esophageal cancer, 1004, 1008, 1012–1014, 1013*t*, 1014*t*
salvage esophagectomy after, 1011
in extremity sarcoma, 1472, 1473, 1474–1475
brachytherapy technique, 1474
with chemotherapy, 1477
complications of, 1475
external beam, 1474
intensity-modulated technique, 1475
metastatic, 1479
timing of, 1474
fractionation of, 313
in hypertrophic scars and keloids, 262–263
in hypopharyngeal tumors, 588
intraoperative, 314
in laryngeal tumors, 590, 591–592
in lung cancer
in early-stage disease, 643
in elderly, 1934
in locoregional advanced disease, 640–641
in melanoma, 491
in mesothelioma, 688
in nasopharyngeal tumors, 594
in oropharyngeal tumors, 587
in pancreatic cancer, 1400, 1407
in paranasal sinus tumors, 593
physical basis of, 313–314
planning and simulation of, 314
postoperative, 314
preoperative, 314
in prostate cancer, 1658
reassortment of, 313
in rectal cancer, 1213, 1215
in retroperitoneal sarcoma, 1480
in rhabdomyosarcoma, 1486
in children, 1640–1641
in salivary gland tumors, 600
sensitizing agents in, 314
side effects of, 314, 315*f*, 315*t*
skin damage in, 493
in spinal tumors, 1737
in squamous cell carcinoma, 487
in stomach cancer, 1083
in temporal bone tumors, 594
in thymoma, 676
in thyroid cancer, 1548
anaplastic, 1551
in lymphoma, 1551
medullary, 1550
thyroid nodule associated with, solitary, 1537
in tracheal neoplasms, 611
in vaginal cancer, 1697

- in vulvar cancer, 1696, 1697
- Radiculopathy, 1740, 1771
cervical, 1740, 1740*t*, 1741*f*
lumbar, 1740, 1742, 1742*f*, 1742*t*
- Radioembolization in liver tumors, 1296
- Radiofrequency electrosurgery, 427–428
argon beam coagulation in, 428
capacitive coupling in, 427–428, 428*f*
in liver tumors, 1295
in varicose veins, 929
- Radiography
in aortic aneurysm, thoracic, 790, 790*f*
in aortic dissection, 811
in atrial septal defect, 697
in cardiac disorders, 738
in chest trauma, 177, 178*f*, 178*t*
in chest wall tumors, 665
in diaphragmatic hernia, congenital, 1604, 1604*f*
of esophagus, 950–953, 953*f*
in gastroesophageal reflux, 963
in perforation, 1018, 1019*f*
of hand and wrist, 1794, 1794*f*
in large intestine disorders, 1181
in lung abscess, 651, 652*f*
in mediastinal tumors, 671–672
in mesenteric ischemia, 861–862
in neurologic examination, 1712
of small intestine
in neoplasms, 1161
in obstruction, 1147
in radiation enteritis, 1162, 1163*f*
in spine trauma, 1725
of spleen, 1428–1429
of stomach, 1051
- Radioiodine. *See* Iodine, radioactive
- Radiionuclide scans
biliary atresia, 1628
of biliary tract, 963, 1315
in acute cholecystitis, 1315, 1320–1321
of esophageal transit, 955
in gastrinoma, 1072, 1073*f*
in gastrointestinal hemorrhage, obscure, 1168
in lymphedema, 935
in Meckel's diverticulum, 1165, 1165*f*, 1624
in mediastinal tumors, 672, 674*t*
of myocardial perfusion, 739
in pancreatic neoplasms, 1391, 1391*f*
of parathyroid gland
in preoperative localization studies, 1565, 1565*t*, 1566*f*
in radio-guided parathyroidectomy, 1567
of spleen, 1429
of stomach, 1051
of thyroid, 1529–1530, 1530*f*
hot and cold lesions in, 1530, 1530*f*
in solitary nodule, 1540
in venous thromboembolism, 921
- Radiosurgery, stereotactic, 1749
in liver tumors, 1296
- Radioulnar joint, synovitis of, 1808
- Radius fractures, 1760
in head, 1759–1760
with ulna fracture, 1760
- Radon exposure in cancer of lung, 617
B-Raf in thyroid cancer, 1541*t*, 1542, 1543
- Raloxifene in breast cancer prevention, 315, 514
- Ramsay Hunt syndrome, 567
- Random pattern flaps, 1833, 1834*f*, 1835*f*, 1836*f*
- Ranson criteria in acute pancreatitis, 1356*t*, 1357
- ras*, 280*f*, 281, 729
in colorectal cancer, 1204
in pancreatic cancer, 1394–1395
signaling pathways, 281
in thyroid cancer, 1541*t*, 1542
- Rasmussen's aneurysm, 661
- Rastelli operation
in Taussig-Bing syndrome, 723
in transposition of great arteries, 721
- Raynaud's disease, 1823
- Raynaud's phenomenon, 1823
- Raynaud's syndrome, 904, 1823
- rb1* gene in retinoblastoma, 287
- Reactive oxygen species, 23
- Reconstructive surgery, 1829–1891. *See also* Plastic and reconstructive surgery
- Rectal arteries, anatomy of, 1176, 1178
- Rectal veins, anatomy of, 1178
- Rectopexy in rectal prolapse, 1219
- Rectosigmoidectomy in rectal prolapse, 1219, 1220*f*
- Rectum
anatomy of, 1176, 1177–1178, 1178*f*
lymphatic, 1178–1179, 1210*f*
nerve supply in, 1179
vascular, 1178, 1179*f*
anesthesia in surgery of, 1194
biopsy in Hirschsprung's disease, 1625
cancer of. *See also* Colorectal cancer
diagnostic algorithm on, 1214*f*
endorectal ultrasonography in, 1211–1212, 1211*f*
epidemiology of, 275*t*, 276, 276*t*, 277*f*, 278*t*, 618*f*
locally advanced, 1214–1215
local therapy in, 1213
recurrent, 1212, 1215–1216
staging of, 1210–1211
total mesorectal excision of, 305, 1213
tumorigenesis in, 278, 280*f*
carcinoid tumors of, 1216
clinical evaluation of disorders, 1180–1185
digital examination of, 1676, 1676*f*
embryonic development of, 1175–1176
endoscopy of, 1180
fistula of, 1678
with vagina, 1200, 1231
foreign body in, 1235
gastrointestinal stromal tumors of, 1216
inflammatory bowel disease of, 1195
leiomyoma and leiomyosarcoma of, 1216
lipoma of, 1216
lymphoma of, 1216
multidisciplinary approach to disorders of, 1195
positioning of patient for surgery of, 1194
preoperative preparations for surgery of, 1194–1195
proctocolectomy, sarcoma of, 1481
prolapse of, 1218–1219, 1219*f*
resection of
abdominoperineal, 1189
anastomosis in, 1189–1191, 1190*f*, 1191*f*
anterior, 1188–1189
high, 1188
low, 1188–1189
low extended, 1189
in carcinoma, 1213–1215
Hartmann's procedure, 1189
mucus fistula in, 1189
in proctocolectomy, 1187–1188
trauma of, 209–210, 1233–1235
blunt, 1234
colostomy in, 209–210, 211*f*, 1234*t*
complications in, 210
iatrogenic, 1234–1235
penetrating, 1233–1234
ulcer of, solitary, 1219
ultrasonography of, endorectal, 1181, 1182*f*
in cancer, 1211–1212, 1211*f*
- Rectus abdominis flaps, 1837
in breast reconstruction, 550, 1869–1871, 1872*f*–1873*f*
in chest wall reconstruction, 670, 670*f*, 1874, 1875*f*
in head and neck reconstruction, 602
- Rectus abdominis muscle, 1449, 1450, 1450*f*
diastasis of, 1453, 1453*f*
sheath of
anatomy of, 1449
hematoma of, 1453–1454, 1454*f*
- Red blood cells
in chyle, 686*t*
count in diagnostic peritoneal lavage, 180–181, 181*t*
disorders of, 1429–1432
spleen function in removal of, 1426
transfusions of, 1914–1915. *See also* Transfusions, red blood cell
- Red pulp of spleen, 1425–1426, 1426*f*
- Reduction mammoplasty, 1887–1889, 1888*f*, 1889*f*, 1890*f*
- Reed-Sternberg cells in Hodgkin's disease, 1434
- Refeeding syndrome, 81
- Referral to specialized burn center, 227, 228*t*
- Refetoff syndrome, 1529
- Reflex sympathetic dystrophy, 1805
- Reflux
of bile, gastritis in, 1093–1094
gastroesophageal
in children, 1613
in esophageal atresia and tracheoesophageal fistula, 1612
in obesity
bariatric surgery affecting, 1116, 1128
preoperative evaluation of, 1105
venous, 930
vesicoureteral, 1667
- reg* gene, 1368
- Regional Diagnostic Treatment and Referral Centers (RDTRC), 1974, 1975, 1975*f*
- Registration peptides, 245
- Regorafenib, 310*t*
- Regurgitation, 753–755
aortic valve, 758–761. *See also* Aortic valve disorders, insufficiency and regurgitation
of gastric contents in gastroesophageal reflux disease, 965
and hiatal hernia, 981
outcome of surgery in, 977, 980
postoperative recurrence of, 980
mitral valve, 749. *See also* Mitral valve disorders, insufficiency and regurgitation

- Rehabilitation
 in burns, 235
 in head and neck tumors, 602
 of larynx, 592
 of oropharynx, 587
 of palate, 587
 Reinke's edema of vocal cord, 573
 Rejection in transplantation, 324
 acute, 324
 chronic, 324
 hyperacute, 324
 intestinal, 352–354
 of lung, 664
 of pancreas, 343
 in xenotransplantation, 358
 Religious beliefs on transfusions, 1943
 REMATCH trial, 770
 Remifentanyl, 1900
 Remodeling
 of bones
 in fractures, 250
 left ventricular, after myocardial infarction, 765, 767, 768
 in wound healing, 245
 Renal artery
 anatomy of, 1651
 fibromuscular dysplasia of, 866, 867f, 904
 endovascular therapy in, 871
 occlusive disease of, 866–872
 in atherosclerosis, 866, 866f, 870
 clinical manifestations in, 867
 diagnostic evaluation in, 867–869
 duplex ultrasonography in, 867–868, 868t
 endovascular therapy in, 869, 870–872, 872t
 etiology of, 866–867
 hyperaldosteronism in, 1578
 indications for treatment in, 868t, 869
 magnetic resonance angiography in, 867f, 868, 868f
 renovascular hypertension in, 866, 867
 endovascular therapy in, 871–872, 871f
 surgical treatment in, 870
 surgical reconstruction in, 869–870
 redundant, 870
 thrombosis in kidney transplantation, 339
 trauma of, 211
 Renal cell carcinoma, 1655–1657
 hereditary, 288t, 1656
 nephrectomy in, 1656–1657, 1656f
 tumor thrombus in, 1656, 1657f
 Renal vein
 anatomy of, 1651
 trauma of, 211
 Renin-angiotensin system, 20t, 1575
 in hyperaldosteronism, 1578
 in renal artery stenosis, 868, 1578
 in shock, 113
 Reperfusion syndrome, in limb ischemia
 treatment complications, 888
 Repressors, 449
 Research, ethical issues in, 1951–1952
 in innovations, 1952
 in sham operations, 1951–1952
 Residency training. *See* Medical education
 Resistance to drugs
 in bacterial infections, 143t–145t
 in chemotherapy, 312–313, 313t
 plasmids encoding markers, 457
 in tuberculosis, 654, 655

 Resolution in videoendoscopic imaging, 427
 Respiratory depression from opioids, 1900
 Respiratory disorders
 acid-base disorders in, 75
 in bronchiectasis, 651–654, 1607
 in bronchogenic cysts, 679, 1018, 1607
 in burns and inhalation injuries, 227–228, 231–232, 233
 in children, 1603–1608, 1642
 in diaphragmatic hernia, congenital, 1603–1605, 1604f
 in dying patient, 1948
 in elderly, 1925t
 surgical risk in, 1928
 in emphysema
 congenital lobar, 1605–1606, 1606f
 lung volume reduction surgery in, 663
 in esophageal cancer, 1003
 in gastroesophageal reflux, 969–972
 in hemorrhagic shock, 110
 in infections, 650–661
 host defense mechanisms in, 137
 inguinal hernia in, 1501
 in lung cancer, 623–645
 monitoring in, 409–410
 in obesity, 1105, 1106, 1128–1129, 1908t
 bariatric surgery affecting, 1111, 1112t, 1128–1129
 in pancreatitis, acute, 1354
 in papillomavirus infections, recurrent, 572
 postoperative, 384–386
 intraoperative fluid therapy affecting, 1914
 in nosocomial infections, 153–154, 384–385
 preoperative assessment of
 in anesthesia management, 1906–1907
 in aortic aneurysm repair, 793
 in bariatric surgery, 1105, 1106
 in elderly, 1928
 in esophageal cancer, 1007
 in lung cancer, 635–637, 638f
 in pulmonary airway malformations, congenital, 1606, 1606f
 in pulmonary sequestration, 1606f, 1607
 in septic shock, 125
 in sleep apnea, obstructive, 572
 in obesity, 1105, 1111, 1112t, 1128
 respiratory disturbance index in, 572
 in transfusions, 101, 102t
 in trauma, 123
 airway management in, 227, 1642
 of chest, 202, 1643
 in children, 1642
 initial evaluation and management of, 161–164, 1642–1643
 Respiratory distress syndrome, acute
 in burns, 231
 complement activation in, 118
 diagnostic criteria on, 385, 385t
 in hemorrhagic shock, 110
 in pancreatitis, 1354
 postoperative, 385
 in septic shock, 125
 in traumatic shock, 123
 Respiratory failure
 enteral nutrition in, 54
 in hemorrhagic shock, 110
 Respiratory quotient, 47, 385
 Resuscitation
 damage control strategy, 98, 100, 122
 historical development of, 110

 in sepsis, 154, 155t
 in shock
 endpoints in, 111, 130–131
 hemorrhagic, 111, 121–123
 in trauma, 215–217
 RET
 in Hirschsprung's disease, 1625
 in multiple endocrine neoplasia type 2, 289t, 293, 1549, 1549t
 in parathyroid carcinoma, 1560
 in pheochromocytoma, 1586
 in thyroid cancer, 1540, 1541f, 1541t, 1542, 1543
 medullary, 1549, 1549t, 1550
 Retained surgical items, 377–378, 377t
 risk factors for, 377, 377t
 surgical counts in prevention of, 378
 Reteplase in venous thromboembolism, 924
 Retinoids, topical, in hypertrophic scars and keloids, 263
 Retromolar trigone tumors, 586
 Retroperitoneal lymph node dissection in testicular cancer, 1654–1655
 Retroperitoneum, 1460–1462
 anatomy of, 1460, 1461f
 fibrosis of, 1460–1462
 urinary obstruction in, 1666
 infections of, 1460, 1461f
 sarcoma of, 1468, 1479–1480, 1479f
 Retrorectal space tumors, 1217
 Retroviruses, tumors associated with, 295, 296t
 Retzius space anatomy, 1497
 Reynolds pentad in cholangitis, 1323
 Rhabdomyomas, 776
 Rhabdomyosarcoma, 1465, 1470
 alveolar, 1467, 1486
 chemotherapy in, 1486, 1640
 of chest wall, 668t, 669
 in children, 1485–1486, 1486, 1640–1641
 embryonal, 1486
 prognosis in, 1641
 radiation therapy in, 1640–1641
 staging of, 1640, 1640t
 surgical-pathologic groupings of, 1486
 Rh blood groups, 96, 1914
 Rhesus D antigen and antibody, 1914
 Rheumatic heart disease
 of aortic valve, 756
 of mitral valve, 751
 prosthetic replacement in, 755
 multivalve disease in, 764
 of tricuspid valve, 762
 Rheumatoid arthritis
 aortitis in, 788
 of hand and wrist, 1808, 1808f
 Rhinoplasty, 1883, 1884f, 1885f
 Rhinosinusitis, 567–570
 Rhytidectomy, cervicofacial, 1883f
 Ribs
 eosinophilic granulomas of, 666
 fibrous dysplasia of, 666
 fractures of, 202–203
 in children, 1643
 in elderly, 222
 hemorrhage in, 173, 203
 Riedel's thyroiditis, 1536
 Rifampin, 145t
 Rights of patients
 autonomy principle in, 1941
 in informed consent, 1944
 in withdrawing or withholding of life sustaining therapies, 1945

- in end-of-life care, 1944–1945
to informed consent, 1941–1944
- Ringer's solution, lactated, 76, 76*t*
- Ripstein rectopexy in rectal prolapse, 1219
- Rituximab, 325*t*, 328
- Rivaroxaban, 94
- RNA, 444*f*
analysis in Northern blot hybridization, 458
bifunctional, 467–468
double-stranded, 466
interference technology, 466–467, 466*f*
messenger, 279, 443, 446, 447, 448
microRNA, 443
noncoding, 443
piwi-interacting, 443
processing control, 448
ribosomal, 443, 446, 447
small interfering, 466–467, 466*f*
synthesis of, 443, 446–447
transfection with, 467
transfer, 443, 446
transport control, 448
- RNA-induced silencing complex (RISC), 467
- RNA polymerase, 447, 449
- RNA sequencing, 462
- RNA viruses, oncogenic, 295
- Robotic surgery, 415, 429–430, 431*f*
in bladder cancer, 1654
historical development of, 415–417
instruments and hand controls, 430*f*
in minimally invasive surgery, 417
in prostate cancer, 1657
for resection, 1187
single-incision laproscopic, 435, 436*f*
splenectomy in, 1443
- Rockall score in peptic ulcer disease, 1059, 1060*t*
- Rocky-Davis incision in appendectomy, 1251
- Rocuronium, 1901, 1901*t*
- Rofecoxib in peptic ulcer disease, 1058*t*
- Rolando fracture, 1796
- Romberg's progressive hemifacial atrophy, 1848, 1849, 1850*f*
- Ropivacaine in local anesthesia, 1899*t*, 1902, 1903*t*
- Ross procedure, 702, 751, 762
in aortic aneurysm, 795
in aortic stenosis, congenital, 701–702
- Rotator cuff impingement, 1765, 1766*f*
- Rotor's syndrome, 1272
- Rotter's lymph nodes, 503
- Round ligament of liver, 1264, 1264*f*
- Round ligament of uterus
anatomy of, 1674, 1674*f*
injury in inguinal hernia repair, 1515
- Roundworm infections, 1286
- Roux-en-Y anastomosis
in choledochojejunostomy, 208
in duodenojejunostomy, 207, 208*f*
in esophagogastric jejunostomy, 1071*f*
in gastric bypass surgery, 1112–1119.
See also Gastric bypass surgery, Roux-en-Y
in gastrojejunostomy, 1063, 1068*f*
in pancreaticojejunostomy
in chronic pancreatitis, 1383, 1384*f*, 1390
in pancreatic ascites, 1378, 1378*f*
in pancreatic injuries, 208–209, 208*f*
- Roux syndrome, 1094
- Rovsing sign in appendicitis, 1244
- Rubber band ligation of hemorrhoids, 1223, 1224*f*
- Rule of nines in burns, 228, 229*f*
- Rutherford classification of peripheral arterial disease, 883, 885*t*
- S**
- Sacral arteries, 1672
- Sacral nerve stimulation in fecal incontinence, 1235
- Sacrectomy in rectal cancer recurrence, 1213
- Sacrocolpopexy in pelvic organ prolapse, 1695
- Sacrospinous fixation in pelvic organ prolapse, 1694–1695
- Sacrospinous ligament, 1673
- “Safe Surgery Saves Lives” program of World Health Organization, 370, 371*f*, 375–376
- Safety Attitudes Questionnaire, 369
- Safety issues, 365–393
Agency for Healthcare Research and Quality indicators on, 373, 373*t*
best practices for, 379*t*
in children, 393
communication skills in, 368–369
in complications of surgery, 380–393
Comprehensive unit-based safety program (CUSP), 372–373
disclosure of, 380, 1952
in elderly, 393
in high reliability organizations, 365–366
Institute of Medicine report on, 366, 1952
Joint Commission Universal Protocol on, 378–379
in medical errors. *See* Errors, medical in obesity, 393
in organizational culture, 365–366, 368
and quality in surgery, 373–376
in retained surgical items, 377–378, 377*t*
risk management in, 380
in wrong-site surgery, 378
- Salicylates in inflammatory bowel disease, 1196
- Saline solutions, 76*t*, 77
in hemorrhagic shock, 122
in intraoperative fluid therapy, 80
- Salivary gland tumors, 599–600, 599*f*
benign, 599
malignant, 599
in minor glands, 586, 594, 599
- Salivary gland-type tumors, 617
- Salpingo-oophorectomy in risk for ovarian or tubal cancer, 1701
- Salter-Harris fractures, 1782
- Sampling reflex in defecation, 1180
- Sandimmune, 328
- Sano shunt in hypoplastic left-heart syndrome, 717
- Santorini duct, 1344, 1344*f*
- Saphenous veins, 915
catheterization for fluid therapy in trauma, 165, 165*f*
graft
in coronary artery bypass surgery, 741, 744
in femoropopliteal bypass, 898, 899
- Trendelenburg's test of valves in, 917–918
- varicose, 929
ligation and stripping in, 929
- Sarcoidosis
hypercalcemia in, 1562
- splenectomy in, 1430*t*, 1438
- Sarcoma, 1465–1487
amplification-associated, 1467
of bones
in chest wall, 667
Ewing's, 1779–1780, 1780*f*
of breast, 556, 1481
of chest wall, 666–669, 668*t*
of bone, 667
of soft tissues, 666–669, 668*t*
in children, 1465, 1485–1486
complex genomic rearrangements in, 1467–1468
dermatofibrosarcoma protuberans, 492–493, 1470, 1485
desmoid tumors, 1485
endometrial, 1481, 1701
epidemiology of, 1466
epithelioid, 1818
of esophagus, 1014–1017, 1016*f*
Ewing's, 665, 669, 1465
of bone, 1779–1780, 1780*f*
chemotherapy in, 668*t*, 669
genetic factors in, 1467
of extremity, 1472–1479, 1779
amputation in, 1473, 1474
chemotherapy in, 1475–1476
with isolated regional perfusion technique, 1473–1474
in metastasis, 1478–1479
in multimodality therapy, 1475–1476
preoperative, 1477
with radiation therapy, 1474
diagnostic imaging in, 1468–1469, 1469*f*
management of, 1472*t*
margin status after resection in, 1472
radiation therapy in, 1472, 1473, 1474–1475, 1477
in metastasis, 1479
recurrence of, 1478–1479
surveillance in, 1477–1478
treatment recommendations on, 1472
wide local excision of, 1472–1473
gastrointestinal, 1480–1481
genetic factors in, 1467–1468
histologic types of, 1465, 1466*t*
incidence of, 1465
initial assessment in, 1468–1472
Kaposi's, 485
liposarcoma. *See* Liposarcoma
molecular pathogenesis of, 1466–1468
radiation induced, 1779
retroperitoneal, 1468, 1479–1480, 1479*f*
of soft tissues, 1465–1487
adjuvant medications in, 1477
biopsy in, 1469–1470
in chest wall, 666–669
clinical presentation in, 1468
diagnostic imaging in, 1468–1469, 1468*f*–1469*f*
differential diagnosis in, 1468
fusion transcripts in, 1467*t*
histologic grade of, 1470–1471
lymph node involvement in, 1471, 1473
metastasis of, 1471–1472, 1471*f*, 1473
to lungs, 1471–1472, 1478, 1478*f*
surveillance for, 1477
treatment in, 1478–1479
pathologic classification of, 1470
prognostic factors in, 1470, 1471, 1472

- Sarcoidosis, of soft tissues (*Cont.*):
 recurrent, 1473, 1474, 1478–1479
 chemotherapy for, 1478–1479
 palliative radiation therapy, 1479
 size of tumor in, 1471
 staging of, 1470–1472, 1471f
 targeted therapies, 1476
 of spleen, 1437
 synovial, 668t, 1465, 1470, 1476, 1818
 chemotherapy in, 1476, 1477
 genetic factors in, 1467
 translocation-associated, 1467
 uterine, 1481–1482
- Spaender's concept of Total pain, 1946
- Scalded skin syndrome, staphylococcal, 477
- Scalene lymph nodes, 612
- Scalp
 reconstructive surgery of, 1860, 1862f
 trauma of, 1715, 1860, 1862f
 hemorrhage in, 166, 173, 1715
 lacerations in, 166, 173, 1715
 reconstructive surgery in, 1860, 1862f
- Scaphocephaly, 1750
- Scaphoid bone
 anatomy of, 1788, 1790f
 avascular necrosis of, 1794, 1795f
 fracture of, 1794f, 1796, 1798
 nonunion in, 1802, 1805
- Scapholunate ligament trauma, 1798, 1807
- Scapula, fractures of, 203, 1759
- Scapular flap in head and neck
 reconstruction, 601–602
- Scapular lymph nodes, 502, 503
- Scars
 hypertrophic, 261–263
 maturation and remodeling of, 245
 peritoneal, 263
- Schatzki's ring, 984, 984f
 in gastroesophageal reflux, 967
- Schistosomiasis, hepatic, 1286
- Schwann cells, 486, 1744
- Schwannomas, 486, 1744, 1816–1817, 1817f
 mediastinal, 677
 spinal, 1738
 vestibular, 1735, 1736f, 1749
- Scimitar sign, 1217
- Scintigraphy, 1051
 esophageal transit, 955
- Scleroderma
 esophageal disorders in, 984–985, 985f, 993
 hand disorders in, 1823
- Sclerosing adenosis, 509, 510–511
- Sclerosis
 amyotrophic lateral, 1740
 tuberous, 290t
- Sclerotherapy
 in hemorrhoids, 1223
 in varicose veins, 929
- Scoliosis, 1771–1772
 in cerebral palsy, 1782
 degenerative, 1771
 idiopathic, 1772
 neuromuscular, 1772
- Scorpion sting, pancreatitis in, 1353
- Screening for cancer, 297–299, 298t–299t
 of breast, 298t, 299
 in elderly, 1932–1933
 magnetic resonance imaging in, 516
 mammography in, 513, 523–526
 cervical, 298t, 1676–1677
 colorectal, 298t, 299, 1208–1209
 advantages and disadvantages in, 1208t
 in elderly, 1933
 guidelines on, 1209, 1210t
 of lungs, 299
 of prostate, 302, 1657
 recent trends and evolving technologies in, 316
 of stomach, 1084
- Scrotum, anatomy of, 1653
- Scurvy, 255
- Seat belt injuries, 223
 abdominal, 223, 1643–1644, 1643f
 spinal, 223, 1771
- Sebaceous glands, 475
- Secondary survey in trauma, 173
- Secretin, 1145, 1146t, 1348
 stimulation test in Zollinger-Ellison syndrome, 1073
- Segmentectomy
 of liver, left lateral, 1300
 in lung cancer, 639, 640t
 in elderly, 1934
- Seizures, 1715
 complex partial, 1746
 drug therapy in, 1746
 in head trauma, prevention of, 1718
 surgical treatment in, 1746–1747
- Seldinger technique
 catheterization, 402–403
 for vascular access, 421
- Selectins, 40, 41t, 42f
- Selective angioembolization (SAE), 206
- Self-image in obesity, 1101
- Seminomas
 mediastinal, 678–679
 biomarkers in, 672
 testicular, 1654–1655
- Semmelweis, Ignaz Philipp, 135, 241
- Sendes procedure in peptic ulcer disease, 1071f
- Senning operation in transposition of great arteries, 721, 721f
- Sensory tests
 in hand examination, 1793
 in neurologic examination, 1712
- Sentinel events, 367t
 high-profile, 368
 root causes of, 369f
 in wrong-site surgery, 379
- Sentinel lymph nodes
 in breast cancer, 305–306, 545–547
 and breast conservation surgery, 547
 specimen processing in, 546
 in colorectal cancer, 1177
 in melanoma, 489, 489f–490f
 in vulvar cancer, 1697
- Sepsis, 154–156
 anorectal, 1227–1228
 in immunocompromised host, 1229
 definition of, 15t
 diagnostic criteria on, 124
 disseminated intravascular coagulation in, 92
 mortality rate in, 123
 in necrotizing enterocolitis, 1620
 in parenteral nutrition, 58
 PIRO Staging System on, 139, 139t
 postoperative, 391–392
 postsplenectomy, 207, 1444–1445
 severe, 124, 138–139, 154–156, 391
 shock in. *See* Shock, septic
 subareolar, 511, 511t
 systemic inflammatory response syndrome in, 138, 139f
 thrombocytopenia in, and bleeding, 104
 treatment of, 124–126, 125f
 guidelines on, 154–156, 155t
- Septal defects
 atrial, 695–698. *See also* Atrium, septal defect of
 ventricular, 726–727. *See also* Ventricles, cardiac, septal defect of
- Sequential organ failure assessment (SOFA) score, 1356t
- Sequestration
 of platelets in spleen, 91, 93, 1428
 pulmonary, 1606f, 1607
- Seroma
 in inguinal hernia repair, 1516
 in mastectomy complications, 549
- Serosa of small intestine, 1139
- Serotonin, 33–34, 1350
- Serpentine asbestos fibers, 687
- Serrated polyposis syndrome, 1206
- Sertoli cells, 1637
 tumors of, 1637, 1704
- Setons in fistula in ano treatment, 1231
- Sevoflurane, 1902, 1902t, 1907
 malignant hyperthermia from, 1917
- Sex cord-stromal cell tumors, 1637, 1704
- Sex steroids, 1577
 excess secretion of, 1585
 synthesis of, 20f
- Sexual abuse of child, 1636
- Sexual development
 ambiguous genitalia in, 1637–1638
 embryology in, 1637
- Sexually transmitted diseases, 1232–1233
- SGLT1, 1141, 1142f
- Shimada classification of neuroblastoma, 1640
- Shock, 109–131
 cardiogenic, 109, 126–128, 126t
 differential diagnosis of, 171
 hemodynamic response to, 113t, 126
 in trauma, 127, 171
 cellular hypoperfusion in, 115
 classification of, 109–110, 110t
 compensated phase in, 111, 112f, 130
 danger signaling in, 115, 117f
 decompensated phase in, 111, 112f
 definitions of, 15t, 110–111, 126, 130, 139
 hemodynamic response to, 113, 113t, 126
 historical aspects of, 109–110
 hypovolemic/hemorrhagic, 109, 110, 119–123
 base deficit in, 120, 121f
 blood pressure in, 119, 120f, 122
 diagnosis of, 119–121
 hemodynamic response to, 113t
 hypothermia in, 123, 187
 neutrophils in, 118
 pathophysiology in, 112f, 118
 resuscitation endpoints in, 130
 signs and symptoms in, 168–169, 170t
 source of blood loss in, 120, 122
 thermal protection in, 186
 in trauma, 168–171, 170t, 173, 187
 in children, 1642
 treatment of, 121–123
 volume of blood loss in, 119, 120t
 inflammatory and immune responses in, 112, 115–119
 irreversible phase of, 111, 112f
 metabolic effects of, 114–115

- neurogenic, 109, 129–130, 129*t*
 hemodynamic response to, 113*t*
 pathophysiology in, 111
 in trauma, 129, 171
- obstructive, 110, 128–129, 128*t*
- overview of, 109
- pathophysiology of, 111–114,
 111*f*, 112*f*
 afferent signals in, 112
 circulatory homeostasis in, 114
 efferent signals in, 113–114
 “vicious cycle” in, 111
- resuscitation endpoints in, 111, 130–131
 cellular, 130, 130*t*
 systemic, 130, 130*t*
 tissue-specific, 130, 130*t*
- septic, 109, 124–126, 138–139, 391
 causes of, 123, 124*t*
 clinical manifestations of, 124
 complement activation in, 118
 definition of, 15*t*, 138–139
 diagnosis of, 124
 hemodynamic response to, 113*t*
 pathophysiology in, 111, 114
 resuscitation endpoints in, 130
 in trauma, 169
 treatment of, 124–126, 125*f*, 154
- in trauma, 110, 123, 168–171, 186–187
 cardiogenic, 127, 171
 in children, 1642
 hemorrhagic, 119–120, 122
 hypovolemic/hemorrhagic, 168–171,
 170*t*, 173, 186–187, 1642
 initial evaluation and management of,
 168–171
 neurogenic, 129–130, 171
 obstructive, 128
 persistent hypotension in, 171–173
 resuscitation endpoints in, 130
 septic, 171
 signs and symptoms in, 168–169,
 170*t*
- vasodilatory, 124–126
 vasogenic, 109
- Shock lung, 110
- Short bowel syndrome, 352, 1171–1173
 intestinal lengthening procedure in,
 1172
 intestinal transplantation in, 1172,
 1621
 in neonates, 1621
 in radiation enteritis, 1163
 risk factors for, 1171, 1171*t*
 serial transverse enteroplasty in, 1172,
 1172*f*
- Shotgun sequencing, 460
- Shotgun wounds, 174
 abdominal, 180
- Shoulder, 1765–1767
 acromioclavicular joint in, 1766–1767
 dislocations of, 1759
 impingement syndromes of, 1766
 labrum tear, 1766, 1767*f*
- Shouldice repair of inguinal hernia, 1495,
 1506–1507, 1507*f*
- Shunting
 left-to-right
 in aortopulmonary window, 711
 in atrial septal defect, 697
 in ductus arteriosus patency, 703
 right-to-left
 in hypoplastic left-heart syndrome,
 716
 in total anomalous pulmonary venous
 connection, 708
- Shunt procedures
 in hypoplastic left-heart syndrome, 717*f*,
 718, 718*f*
 in portal hypertension and
 gastroesophageal varices
 surgical shunts in, 1282–1283, 1283*f*
 transjugular intrahepatic
 portosystemic shunt in, 1282,
 1283
 transjugular intrahepatic portosystemic
 in ascites, 347
 in Budd-Chiari syndrome, 1284
 in gastric varices, isolated, 1088
 in gastroesophageal varices, 1282,
 1283
 in tricuspid atresia, 713–715, 714*f*
- Sick-euthyroid syndrome, 392–393
- Sickle cell disease, 1430*t*, 1432
- Sigma factors, 447
- Sigmoidoscopy, flexible, 1180
 in colorectal cancer screening,
 1208–1209, 1208*t*
- Signal transduction pathways, 34–36,
 450–453, 451*f*
 adhesive interactions in, 451
 in apoptosis, 37*f*, 281–282, 450, 451*f*
 enzyme-linked receptors in, 452
 G-protein-coupled receptors in, 35*f*, 452
 hormonal signalling, 451
 insulin pathway, 452, 452*f*
 ion channels in, 452
 nuclear hormone receptor superfamily
 in, 452
 in shock response, 117*f*, 118–119
 transforming growth factor- β pathway,
 452–453, 453*f*
 in transplant rejection, 324
- Silver nitrate in burns, 232
- Silver sulfadiazine in burns, 232
- Simonart’s band, 1841
- Simpson, James, 1896
- Simulation of radiation therapy, 314
- Single-incision laproscopic surgery
 (SILS), 415, 426*f*, 434–435
 access for, 423–424
 body mass index and, 434
 challenges faced by surgeon, 434
 cholecystectomy in, 435, 435*f*
 contraindications for, 434–435
 historical aspects of, 416
 instruments used in, 435*f*, 435*t*
 recommendations for, 435*t*
 robotic, 435, 436*f*
- Single photon emission computed
 tomography (SPECT)
 in cardiac disorders, 739
 in mediastinal tumors, 672
- Sinuses
 paranasal
 fungal ball in, 569–570, 570*f*
 inflammatory disease of, 567–570.
See also Sinusitis
 tumors of, 592–593, 592*f*
 thyroglossal duct and, 1521–1522
 venous, 916
- Sinusitis, 567–570
 acute, 567–568
 chronic, 568
 diagnosis of, 568–569, 568*f*–569*f*
 management of, 568, 569
 and nasal polyps, 568, 568*f*, 569
 classification of, 567
 fungal, 569–570, 570*f*
 history consistent with, 567
- Sinus venosus defects
 anatomy in, 695, 696*f*
 future approaches to surgical closure,
 698
 with partial anomalous pulmonary
 venous connection, 697
 pathophysiology in, 696–697
 treatment of, 697
- Sirolimus, 325*t*, 327–328, 327*t*
 mechanism of action, 327
 side effects of, 326*t*, 328
- Sistrunk operation in thyroglossal duct
 cyst, 1522
- Situational debriefing model, 372
- Skene’s glands, 1674
- Skin, 473–493
 anatomy and histology of, 473–476,
 474*f*, 1832
 basement membrane of, 478
 cutaneous innervation, 476
 cutaneous vasculature, 476
 dermis layer of, 475–476
 epidermis layer of, 473
 grafts of. *See* Skin grafts
 in HIV infection and AIDS, 485
 in host defense mechanisms, 137
 hypodermis, 476
 infections of, 151–152, 483–485
 inflammatory diseases of, 476–477
 injuries of, 477–482
 from caustic substances, 479–480
 coagulative, 480
 in intravenous fluid extravasation,
 480, 481*f*
 liquefactive, 479
 mechanical, 478
 pressure, 482, 482*f*
 in radiation exposure, 477–478, 486,
 493
 temperature-related, 480–481
 thermal, 480–481, 481*f*–482*f*
 perianal disorders of, 1231–1232
 substitute replacement products,
 266–268, 267*t*, 482–483
 in burns, 234
 in venous insufficiency, 932–933,
 933*f*
- tumors of, 478, 485–493, 1817
 benign, 485–486
 of ear, 594
 epidemiology of, 275*t*, 276*t*, 277*f*,
 278*t*
 in hand, 1817*f*, 1818
 malignant, 487–493
 melanoma, 488–492. *See also*
 Melanoma
 in sun exposure, 295
 in transplant recipients, 330, 335
 ulcers of, 259, 482, 482*f*. *See also*
 Ulcers, of skin
 wound healing in, compared to
 gastrointestinal wound healing,
 250*t*
- Skin grafts, 264–265, 266, 1832–1833
 allogenic, 266
 anatomy in, 1832
 autologous, 266
 in breast reconstruction, 549–550
 in burns, 232, 234
 donor sites in, 234
 of hand, 1820
 classification of, 1832*t*
 composite tissue, 1832*t*, 1833, 1834*f*
 full-thickness, 266, 600, 1832*t*, 1833
 in head and neck tumors, 600
 historical aspects of, 1832

- Skin grafts (*Cont.*):
 phases of graft take in, 1833
 split-thickness, 266, 600, 1832–1833, 1832*t*
 xenogeneic, 266
- Skin substitutes, 266–267, 267*t*, 482–483
 in burns, 234
 in venous insufficiency, 932–933, 933*f*
- Skin tags
 anal and perianal, 1223
 in Crohn's disease, 1200
- Skull
 chordoma of, 1781
 craniostylosis of, 1750, 1848
 fractures of, 1715–1717, 1717*f*
 osteomyelitis of, 1745
 reconstructive surgery of, 1860
- Sleep apnea, obstructive, 572
 in obesity, 1105, 1128
 bariatric surgery affecting, 1111, 1112*t*, 1128
 respiratory disturbance index in, 572
- Sleeve gastrectomy in obesity, 1103, 1104, 1121–1125
 operative technique in, 1121*f*, 1122–1123, 1122*f*, 1123*f*
- Sleeve resection in lung cancer, 636
- Sling procedures in stress urinary incontinence, 1695
- Slipped capital femoral epiphysis, 1783
- SMAD4, 453
- Small cell carcinoma of lung, 617
 osteoarthropathy in, hypertrophic, 626, 626*f*
 paraneoplastic syndromes in, 625–627
- Small intestine, 1137–1174
 access for enteral nutrition, 55, 55*t*, 56
 anatomy of, 1137–1138, 1138*f*
 atresia of, 1615–1616
 apple peel deformity in, 1616
 Christmas tree deformity in, 1616, 1616*f*
 duodenal, 1612, 1615–1616, 1616*f*
 ileal, 1616*f*
 jejunal, 1616*f*
- barrier and immune functions of, 1143–1144, 1144*f*
 in chylous ascites, 1169–1170
 composition of secretions, 69*t*
 Crohn's disease of, 1153–1157, 1198–1199
 digestion and absorption in, 1140–1143
 of carbohydrates, 48, 1141, 1142*f*
 of fat, 1142–1143, 1143*f*
 of fluids and electrolytes, 1140–1141, 1140*f*, 1141*t*
 of protein, 1141–1142, 1142*f*
 regulation of, 1141*t*
 of vitamins and minerals, 1143
- diverticulum of, 1163–1167. *See also* Diverticulum, of small intestine
- duodenum in. *See* Duodenum
- duplications of, 1624
- embryonic development of, 1139–1140, 1140*f*
- endocrine functions of, 1145, 1146*t*
- fistulas of, 1157–1159
- hemorrhage from, 1167–1168
- histology of, 1138–1139, 1139*f*
- ileum in. *See* Ileum
- ileus and motility disorders of, 1151–1153
- intussusception of, 1170
- jejunum in. *See* Jejunum
- layers of wall, 1138–1139, 1139*f*
- mesenteric ischemia of, 1167
- motility of, 1144–1145, 1144*f*
 ascending excitation and descending inhibition of, 1144–1145, 1144*f*
 disorders of, 1151–1153
 fasting pattern or interdigestive motor cycle in, 1145
 fed or postprandial pattern in, 1145
 regulation of, 1145
 rhythmic segmentations in, 1145
- neoplasms of, 1159–1162
 clinical presentation in, 1160
 diagnosis of, 1161
 epidemiology of, 275*t*
 intestinal obstruction in, 1160, 1161
 pathophysiology in, 1159–1160
 prognosis and outcomes in, 1162
 treatment of, 1161–1162
 types of, 1160, 1161*t*
- obstruction of, 1146–1151
 clinical presentation in, 1147
 closed loop, 1147
 complete, 1147, 1148*f*, 1149
 diagnosis of, 1147–1149, 1148*f*
 double bubble sign in, 1615, 1615*f*
 in early postoperative period, 1149–1150
 epidemiology of, 1146–1147
 etiologies of, 1146–1147, 1146*t*
 in inguinal hernia, 1505
 in Meckel's diverticulum, 1163*f*, 1164, 1164*f*
 in neonates, 1614–1615, 1615*f*
 in neoplasms, 1160, 1161
 of pancreas, 1399
 partial, 1147, 1148*f*, 1149
 pathophysiology in, 1147
 postoperative, 386
 in bariatric surgery, 1116*f*, 1117
 prevention of, 1151
 prognosis and outcome in, 1151
 strangulated, 1147
 treatment in, 1149–1151, 1150*f*
 in neonates, 1615
- perforation of, 207, 1168–1169
- physiology of, 1140–1146
- in pneumatosis intestinalis, 1170–1171
- radiation enteritis of, 1162–1163
- resection of
 intestinal adaptation in, 1145–1146
 short bowel syndrome after, 1171–1173, 1621
- sarcoma of, 1480
- transplantation in short bowel syndrome, 1621
- trauma of, 207
 in children, 1643, 1643*f*
 damage control surgery in, 195
 laceration in, 207
 in laparoscopy, 1705
 perforation in, 207, 1168–1169
 pyloric exclusion procedure in, 209, 209*f*
- Smallpox
 as biologic warfare agent, 157
 vaccination, 157
- Small round-cell tumors, desmoplastic, 1467
- SMARCB1 in rhabdoid predisposition syndrome, 290*t*
- Smith Surgical Papyrus, 497
- Smoke inhalation injuries, 231–232
- Smoking
 cessation of, preoperative, 636
 colorectal cancer in, 1204
 coronary artery disease in, 742, 1906
 esophageal cancer in, 1003
 head and neck tumors in, 578, 579
 interaction with asbestos exposure, 293, 619
 lung cancer in
 and postoperative complications, 636, 636*f*
 risk for, 617, 619*t*, 620*t*
 in secondhand exposure, 617
 tumor types associated with, 613–614
 pancreatic cancer in, 1393
 pancreatitis in, 1363
 peptic ulcer disease in, 1058
 thromboangiitis obliterans in, 906
- Snoring, 572
 in obstructive sleep apnea, 572
- Snow, John, 1896
- Snuffbox, anatomic, 1791
- Soave procedure in Hirschsprung's disease, 1626, 1626*f*
- Sodium
 absorption of
 in large intestine, 1179
 in small intestine, 1141, 1141*f*
 in cerebral salt wasting, 81
 dietary intake of, 67, 69
 in children and infants, 1599
 in gastrointestinal secretions, 69*t*
 and osmolality of body fluids, 67
 in parenteral nutrition, 76, 76*t*
 in resuscitative fluids, 76*t*, 77
 serum levels of, 68, 70*f*, 77
 in cancer, 81
 in hypernatremia. *See* Hypernatremia
 in hyponatremia. *See* Hyponatremia
 in inappropriate antidiuretic hormone secretion, 69, 81
 urine levels of, 68, 69, 70
- Sodium chloride
 in parenteral nutrition, 76, 76*t*
 in preoperative fluid therapy, 79
- Sodium-dependent glucose transporters, 50, 1141, 1142*f*
- Sodium tetradecyl sulfate in varicose vein sclerotherapy, 929
- Soft tissues
 infections of, 152, 153*f*
 necrotizing, 152, 153*f*, 484*f*, 1229
 injuries in head and neck trauma, 575–576
 tumors of, 486
 in chest wall, 666–669, 668*t*
 sarcomas, 666–669, 1465–1487.
See also Sarcoma, of soft tissues
- Solid tumors and global surgery, 1959*f*, 1970, 1973*t*
- Somatic mutations in cancer, 286
- Somatic nervous system, 1711
- Somatostatin, 1313, 1346, 1348, 1350
 administration of, 1145
 in chronic pancreatitis, 1380
 D-cell secretion of, 1040, 1043, 1045, 1146*t*
 in *Helicobacter pylori* infections, 1054
 functions of, 1146*t*, 1349*t*
 in gastric acid secretion, 1043, 1044*f*, 1045
 in growth hormone secretion, 21
 islet cell secretion of, 1349*t*
 in pepsinogen secretion, 1044
 in portal hypertension and variceal bleeding, 1282

- receptors for, 1350
- tumor secretion of, 1393
- Somatostatinoma, 1393
- Sonde enteroscopy in gastrointestinal hemorrhage, 1168
- Sorafenib, 310*t*
 - in liver tumors, 1296
- Southern blot hybridization, 457–458, 457*f*
- Spasm
 - esophageal, 992, 992*f*, 993*f*
 - vascular
 - in subarachnoid hemorrhage, 1731
 - treatment of, 215*t*
- Specimen labeling errors, frequency of, 371, 371*f*
- Spectrin, 1429
- Spectroscopy, near infrared, 409
 - in shock, 131, 409
 - transcranial, 412
- Speech
 - in cleft palate, 1844
 - in laryngeal cancer, rehabilitation of, 592
 - velopharyngeal competence in, 1844
- Spermatic cord, 1496, 1497
 - injury in inguinal hernia repair, 1515
- Spermatic veins, 1653
- Spherocytosis, hereditary, 1429, 1430*t*, 1431
- Sphincter muscles
 - anal. *See* Anal sphincters
 - esophageal. *See* Esophagus, sphincter muscles of
 - of Oddi. *See* Oddi sphincter
 - pyloric, 1035
 - urethral, urinary incontinence in
 - intrinsic deficiency of, 1695
- Sphincteroplasty
 - in anal sphincter injury, 1235, 1235*f*
 - in pancreatitis, chronic, 1382–1383, 1383*f*, 1384*f*
- Sphincterotomy
 - anal, in anal fissures, 1226–1227, 1226*f*
 - of Oddi sphincter
 - endoscopic, in choledocholithiasis, 1322, 1322*f*
 - transduodenal, in choledocholithiasis, 1327
- Spigelian hernias, 1455
- Spina bifida
 - with myelomeningocele, 1750
 - occulta, 1749
- Spinal anesthesia, 1897, 1904
- Spinal canal stenosis, 1771
- Spinal cord
 - anatomy of, 1710
 - compression of, 1739–1740
 - in intervertebral disc herniation, 1771
 - injury of, 1725*f*
 - anterior cord syndrome in, 1724, 1725*f*
 - Brown-Séquard syndrome in, 176, 1724, 1725*f*
 - central cord syndrome in, 1724, 1725*f*
 - cervical, 175, 198
 - corticosteroid therapy in, 197–198, 1725–1726
 - in fracture dislocations of spine, 1771
 - ischemic, in aortic aneurysm repair, 801*t*, 802–803
 - neurogenic shock in, 129
 - neurologic examination in, 1712
 - surgery in, 1726
 - in transection, 1724, 1725*f*
 - myelopathy of, 1740
 - cervical, 1740, 1741*f*
- Spinal nerves, anatomy of, 1710
- Spine, 1737–1744
 - anatomy of, 1739
 - cervical. *See* Cervical spine
 - fusion surgery of, 1743
 - instrumentation in, 1743, 1743*f*
 - intervertebral discs in. *See* Intervertebral discs
 - osteomyelitis of, 1745–1746
 - stability of, 1739
 - in fusion surgery, 1743
 - stenosis of, 1771
 - trauma of, 1721–1726
 - cervical, 175–177, 197–198, 1722
 - classification of, 1722, 1725*f*
 - in compression or distraction, 1721, 1722, 1724*f*, 1770
 - corticosteroid therapy in, 197–198, 1725–1726
 - facet dislocation in, 1722, 1723*f*, 1770
 - in flexion or extension, 1721, 1722, 1771
 - fracture-dislocation in, 1722, 1724*f*
 - fractures in, 1722, 1724*f*, 1770
 - cervical, 1722
 - initial assessment and management in, 1722–1723
 - neurologic syndromes in, 1724, 1725*f*, 1771
 - orthotic devices in, 1726
 - rotational forces in, 1721
 - surgery in, 1726
 - thoracolumbar, 1722
 - tumors of, 1737–1739, 1738*f*
 - extradural, 1737
 - intradural extramedullary, 1738–1739
 - intramedullary, 1738–1739
 - metastatic, 1737
 - primary, 1738
- SPINK1, 1347, 1352
 - in pancreatitis, 1361, 1367
- Spiral valves of Heister, 1310
- Spleen, 1423–1445
 - abscess of, 1430*t*, 1436
 - accessory, 1424, 1425*f*
 - anatomy of, 1424–1426, 1425*f*, 1426*f*
 - cysts of, 1430*t*, 1436–1437, 1437*f*
 - embryology of, 1424
 - enlargement of. *See* Splenomegaly
 - functions of, 1428
 - historical studies of, 1423–1424
 - imaging of, 1428–1429
 - infections of, 1436
 - mobilization in emergent abdominal exploration, 189, 189*f*
 - physiology and pathophysiology of, 1426–1428
 - pseudocysts of, 1437
 - red pulp of, 1425–1426, 1426*f*
 - sequestration of platelets in, 91, 93, 1428
 - splenectomy of, 1429–1445. *See also* Splenectomy
 - suspensory ligaments of, 1425, 1425*f*
 - trauma of, 183*f*, 206–207
 - autologous transplantation in, 206, 206*f*
 - in children, 1644, 1644*t*
 - grading scale on, 183*t*, 1644, 1644*t*
 - hemorrhage in, 206, 206*f*
 - inadvertent intraoperative, 1443
 - nonoperative management in, 206
 - splenectomy or splenorhaphy in, 206–207
 - tumors of, splenectomy or splenorhaphy in, 1437
 - wandering, 1438
 - white pulp of, 1426, 1426*f*
- Splenectomy, 1429–1445
 - in bone marrow or myeloproliferative disorders, 1435–1436
 - complications of, 207, 1444
 - deep vein thrombosis prevention in, 1439
 - hand-assisted, 1441, 1443
 - historical aspects of, 1424
 - indications for, 1429–1438, 1430*t*
 - infections after, 207
 - antibiotics in, 1445
 - overwhelming, 1444–1445
 - vaccinations in prevention of, 1439–1440, 1445
 - laparoscopic, 1440–1441, 1440*f*, 1441*f*, 1442*f*
 - double-access technique, 1440
 - open technique, 1439–1440, 1439*f*
 - outcome in, 1443–1445, 1444*t*, 1445*t*
 - partial, 1443
 - in platelet disorders, 1432–1434
 - preoperative evaluation in, 1428
 - preoperative preparation in, 1439
 - in red blood cell disorders, 1429–1432
 - robotic approach in, 1443
 - in trauma of spleen, 206–207
 - in white blood cell disorders, 1434–1435
- Splenic artery, 1425
 - anatomy of, 1345
 - aneurysm of, 1430*t*, 1438
 - angiography of, 1429
 - distributed type, 1425
 - embolization of, 1429, 1438
 - magistral type, 1425
- Splenic index, 1428
- Splenic vein thrombosis, 1438
 - gastric varices in, 1088
 - in pancreatitis, 1379
- Splenocolic ligament, 1425, 1425*f*
 - division in open splenectomy, 1439, 1439*f*
- Splenomegaly, 1427*f*, 1428
 - differentiated from hypersplenism, 1427
 - in Gaucher's disease, 1437–1438
 - in myeloproliferative disorders, 1435
 - in portal hypertension, 1438
 - in sarcoidosis, 1438
- Splenorenal bypass in renal artery occlusive disease, 869–870
- Splenorenal ligament, 1425
- Splenorenal shunt in portal hypertension and gastroesophageal varices, 1283, 1283*f*
- Splenorrhaphy in trauma of spleen, 206
- Splints in hand and wrist injuries, 1798, 1799*f*, 1805
- Spondylolisthesis, 1771
 - lumbar, 1739, 1740*f*
- Spondylosis, cervical, 1740, 1741*f*
- Sports injuries
 - of acromioclavicular joint, 1766–1767
 - of knee, 1768
 - medicine for, 1765
- Sprains of acromioclavicular joint, 1766–1767
- Squamous cell carcinoma
 - anal and perianal, 1218
 - of breast, 556

- Squamous cell carcinoma (*Cont.*):
 of head and neck, 578–594
 of lung, 616–617
 radiation therapy, 487
 of skin, 487, 487f
 in hand, 1817, 1817f
 Moh's microsurgery in, 487
 of trachea, 610
 of vagina, 1697
- Squamous dysplasia of lungs, 613–614
- Squamous intraepithelial lesions, anal, 1217–1218
- Square root sign in chronic constrictive pericarditis, 774
- Stab avulsion technique in varicose veins, 929–930, 930f
- Stab wounds, 172f, 174
 abdominal, 180–181
 diagnostic peritoneal lavage in, 180–181, 180f, 181t
 hemorrhage and persistent hypotension in, 172
 removal of weapon in, 172
- Staging of tumors, 300–301
 of adrenal gland, 1584, 1584t
 of breast, 531, 531t–532t, 533t
 and prognosis, 544
 and treatment options, 536–544
 of cervix uteri, 1698, 1698t
 colorectal, 1209–1212, 1211t
 of endometrium, 1701, 1701t
 of esophagus, 1004–1005, 1006t
 treatment decisions based on, 1005
 of gallbladder, 1334
 of head and neck, 580, 581t
 of liver in children, 1642, 1642t
 of lungs, 633–635, 634t
 and treatment, 637–645, 638–645
 in melanoma, 488
 in mesothelioma, 688, 689t
 ovarian, 1701–1702, 1703t
 of pancreas, 1395, 1397t
 preoperative, 304
 in rhabdomyosarcoma, 1640, 1640t
 in soft tissue sarcomas, 1470–1472
 of stomach, 1080, 1080t
 in thymoma, 675, 675t
 of thyroid, 1544t
 papillary, 1543
 of vagina, 1697, 1697t
 of vulva, 1696–1697, 1696t
 in Wilms' tumor, 1639
- Stamm gastrostomy, 1090, 1090f
- Stanford classification of aortic dissection, 807, 809f
- Staphylococcal infections
 antibiotic therapy in, 143t–145t
 breast abscess in, 506
 methicillin-resistant, 143t–145t, 155
 methicillin-sensitive, 143t–145t
 scalded skin syndrome in, 477
- Stapled techniques
 in hemorrhoidectomy, 1224
 in intestinal anastomosis, 1190f, 1191, 1191f
- Starling's law, 402
- Starnes procedure in Ebstein's anomaly, 720
- Starvation, metabolism in, 44–46, 45f
- STAT (signal transducer and activator of transcription), 30, 34–35, 34f
- Status epilepticus, 1715
- Steatorrhea in chronic pancreatitis, 1372
- Stellate cells, pancreatic, 1367–1368
- Stem cells, 456, 456f
- cancer, 285
 introduction of the targeting vector, 465
 transplantation of, 358
- Stent grafts, 836–837, 838f
 in abdominal aortic aneurysm, 850, 853–857, 854f
 compared to open repair, 857–858
 complications of, 855–856, 859
 devices available for, 855, 857–858
 endoleaks in, 855–856, 858–859, 858f, 859t
 endotension phenomenon in, 859
 in aortic dissection, 813, 815, 816
 in aortoiliac occlusive disease, 880–881
 in lower extremity arterial occlusive disease, 895
 complications of, 897
 in thoracic aortic aneurysm, 797, 802, 803–804
 complications of, 805–806
 endoleaks in, 806
- Stent placement, 430–432, 432f
 in aortic aneurysm, 797, 802, 803–804
 complications of, 805–806
 endoleaks in, 806
 in aortic dissection, 813, 815, 816
 in aortic injuries, 201
 in aortoiliac occlusive disease, 879–881
- biliary
 in cholangiocarcinoma, 1337
 in chronic pancreatitis, 1380, 1381f
 in pancreatic cancer, 1400, 1400f, 1406
- in carotid artery occlusive disease, 842–843, 845–847
 approved stents in, 845, 847t
 compared to endarterectomy, 842–843
 complications of, 846–847
 contraindications to, 845, 846t
 embolic protection devices in, 845–846, 846t
 technique in, 845–846, 846f
- in coronary artery disease, 742
- in esophagus
 in cancer, 1008
 in caustic injury, 1022, 1022f
- indications for, 431, 836
- in lower extremity arterial occlusive disease, 894–895
 compared to surgical treatment, 900
 complications of, 897, 897f
- in mesenteric artery occlusive disease, 864–865
- in pancreatic pseudocyst, 1377, 1378f
- in renal artery occlusive disease
 clinical results in, 871–872, 871f, 872t
 technique in, 870
- types of vascular stents in, 431–432, 836, 837f
 balloon-expandable, 836, 837f
 in carotid artery occlusive disease, 845, 847t
 drug-eluting, 432, 836
 self-expanding, 432, 432f, 836, 837f
- ureteral
 prior to colorectal surgery, 1195
 in trauma of ureter, 1660
 in upper urinary tract obstruction, 1666
- Stereotactic radiosurgery, 1749
 in arteriovenous malformations, 1749
 with gamma knife, 1749
 in intracranial metastasis, 1749
- with linear accelerator, 1749
 in liver tumors, 1296
 proton beam, 1749
 in vestibular schwannoma, 1749
- Sterilization procedures, tubal, laparoscopic technique, 1689
- Sternoclavicular dislocation, 1759
- Sternotomy
 in chest trauma, 188
 in coronary artery bypass surgery, 745
 in goiter, 1554, 1554f
 in hyperparathyroidism, 1569–1570
 in mediastinal mass biopsy, 673
- Sternum fractures, 203
- Stevens-Johnson syndrome, 477
- Stewart-Hamilton equation, 404
- Stewart-Treves syndrome, 493
- STI571. *See* Imatinib
- St. Jude heart valves, 749, 750f, 761f
- STK11 in Peutz-Jeghers syndrome, 290t
- Stomach, 1035–1095
 acid secretion of, 1041–1044. *See also* Acid secretion, gastric
 alarm symptoms in, 1050t, 1059
 anatomy of, 1035–1040, 1037f
 histologic, 1039–1041, 1040f
 lymphatic, 1038, 1039f
 vascular, 1037–1038, 1038f
 balloon placement in, for weight loss in obesity, 1131
 banding of, for weight loss in obesity, 1108–1112. *See also* Gastric banding
 bezoars in, 1089
 blood supply of, 1037–1038, 1038f
 bypass surgery. *See* Gastric bypass surgery, Roux-en-Y
 cancer of, 1074–1086
 carcinogenesis in, 1076f
 chemotherapy in, 1083
 clinical manifestations of, 1079–1080
 diagnostic evaluation in, 1080–1081
 differentiated from peptic ulcer disease, 1080
 diffuse form, 1074
 early, 1078, 1079f, 1079t
 endoscopic ultrasound in, 1051, 1080
 epidemiology of, 275, 275t, 278t, 279f, 1074, 1075f
 etiologies of, 1074–1078
 fungating, 1078
 gastrectomy in, 1081–1082, 1081f, 1082f
 endoscopic, 1083–1084
 reconstruction after, 1081, 1082f
 survival rates in, 1082, 1082t
 in gastrectomy remnant, 1078
 genetic factors in, 1075–1076, 1077t, 1078
 in *Helicobacter pylori* infections, 293, 1076f
 risk for, 1074–1075
 hereditary diffuse, 288t, 292
 histologic subtypes of, 1078–1079, 1079t
 intestinal form, 1074
 lymphadenectomy in, 1038, 1082–1083
 mortality rates in, 1075t
 pathology in, 1078–1079
 polypoid, 1078
 prognosis in, 1084
 radiation therapy in, 1083
 risk factors for, 1074–1078, 1075t
 scirrhus, 1078

- screening for, 1084
 staging of, 1079, 1080*t*
 treatment, 1081–1083
 ulcerative, 1078
 World Health Organization
 classification of, 1079, 1079*t*
- carcinoid tumors of, 1085–1086
 composition of secretions, 69*t*
 diagnosis of disorders, 1050–1053
 Dieulafoy's lesion of, 1089
 diverticula of, 1089, 1089*f*
 dysplasia of, adenocarcinoma
 development in, 1078
 ectasia of, 1088, 1088*f*
 electrical stimulation device implanted
 in obesity treatment, 1129–1130
 endocrine cells of, 1041, 1042*f*, 1042*t*
 enterochromaffin-like cells of, 1040,
 1043
 epithelial cells of, 1039–1040, 1041*f*,
 1042*t*
 surface, 1039–1040, 1044–1045
 as esophageal substitute, 1024–1025
 in composite with colon and jejunum,
 1025
 foreign bodies in, 1089–1090
 gastrectomy of. *See* Gastrectomy
 gastritis of. *See* Gastritis
 gastrointestinal stromal tumors of, 1074,
 1084–1085, 1086*f*
 gastrostomy of, 1090
 hemorrhage from, 1038, 1087–1088,
 1090
 historical aspects of surgery, 1035,
 1036*t*
 hormones of, 1045–1047
 hypertrophic gastropathy of, 1088
 innervation of, 1038–1039, 1039*f*, 1047*f*
 and motility, 1047
 intestinal metaplasia of, 1077, 1078*f*
 intrathoracic, in hiatal hernia, 980, 981*f*,
 982
 laparoscopy of, 1095
 in cancer diagnosis, 1080–1081
 leiomyoma of, 1086–1087
 lipomas of, 1087
 lymphoma of, 1074, 1084
 in *Helicobacter pylori* infections,
 1054, 1084
 treatment algorithm on, 1085*f*
 Mallory-Weiss tear of, 1090
 motility and emptying of, 1047–1050,
 1048*f*, 1050*f*
 cholecystokinin in, 1049, 1049*f*
 disorders in, 1087
 postoperative, 1093
 drugs affecting, 1050, 1050*t*
 emptying studies of, 963
 liquid, 1049–1050, 1050*f*
 solid, 1050
 intracellular electrical activity in,
 1048, 1048*f*
 migrating motor complex in,
 1048–1049
 nutrient composition affecting, 1049
 pylorus functions in, 1049
 segmental, 1047–1049
 testing of, 963, 1053
 mucosa of, 1039, 1040*f*
 barrier function of, 1044–1045,
 1044*t*
 muscularis externa of, 1041
 outlet obstruction in peptic ulcer
 disease, 1061, 1068–1069
 pH monitoring of, 963–964
 with esophageal pH monitoring, 963,
 964*f*
 physiology of, 1041–1050
 polyps of, 1076–1077, 1077*f*
 premalignant conditions of, 1076, 1077*f*
 pyloric stenosis of, hypertrophic, 1613–
 1614, 1614*f*
 submucosa of, 1041
 tonometry in shock, 131
 trauma of, 207
 damage control surgery in, 195
 emergent abdominal exploration in,
 191
 ulcers of
 in peptic ulcer disease, 1053–1073.
 See also Peptic ulcer disease
 risk for gastric cancer in, 1077*f*, 1078
 stress, 1073–1074
 varices of, 1088. *See also* Varices,
 gastroesophageal
 volvulus of, 1090, 1090*f*
 watermelon, 1088
- Stoma procedures. *See* Ostomy procedures
- Stool
 continence of, 1180
 disorders of, 1185. *See also*
 Incontinence, fecal
 fat levels in chronic pancreatitis, 1374
 laboratory studies of, 1182–1183
 occult blood in, 1182, 1183
 in colorectal cancer, 1182, 1183,
 1208–1209, 1208*t*
- Stoppa repair of inguinal hernia, 1509
- Storage disorders, splenectomy in,
 1437–1438
- Storage pool disease of platelets, 89
- Strawberry tongue, 571
- Streptococcal infections
 antibiotic therapy in, 143*t*–145*t*
 pharyngitis in, 571
- Streptokinase in venous thromboembolism,
 924
- Stress
 gastritis and gastric ulcers in,
 1073–1074
 hormone response in, 19–23, 113
 peptic ulcer disease in, 1058
- Stress fibers, 246
- Stress testing, cardiac, 738
- Stress urinary incontinence
 in obesity, 1126
 surgery for, 1695
- Strictureplasty in Crohn's disease, 1157,
 1157*f*, 1198, 1199*f*
- Stroke volume, 404–405
- Stromal cell tumors, 1704
- Stromal tumors, gastrointestinal,
 1481–1485. *See also*
 Gastrointestinal stromal tumors
- Stuart-Prower factor (factor X), 86, 87,
 88, 99*t*
 deficiency of, 89, 99*t*
 laboratory tests of, 103
- Study of Tamoxifen and Raloxifene
 (STAR) trial, 514
- Sturge-Weber syndrome, 1850, 1852*f*
- Subarachnoid hemorrhage
 in aneurysm rupture, 1730–1731, 1730*f*,
 1730*t*
 angiography in, 1731, 1731*f*
 coil occlusion in, 1731
 Hunt-Hess grading system for, 1730,
 1730*t*
 vasospasm in, 1731
 in arteriovenous malformations, 1731
- Subcarinal lymph nodes, 611
 in lung cancer, 632, 632*f*
- Subclavian artery flap in aortoplasty for
 aortic coarctation, 705
- Subclavian vein
 as access for pulmonary artery
 catheterization, 402
 anatomy of, 916
 thrombosis of, 928–929
- Subclavicular lymph nodes, 502–503
- Subcutaneous tissue
 benign tumors of, 485–486
 infections of, 483–485
 injuries of, 477–482
- Subglottis
 anatomy of, 580, 589, 589*f*
 tumors of, 590, 591
 laryngeal preservation techniques in
 treatment of, 591
- Sublingual gland tumors, 599
- Submandibular gland tumors, 599,
 600
- Submucosal glands, bronchial, 617
 salivary gland-type tumors of, 617
- Submucosa of small intestine, 1139
- Substance abuse of alcohol. *See* Alcohol
 use and alcoholism
- Suburethral sling procedure in stress
 urinary incontinence, 1695
- Succinylcholine, 1901
 malignant hyperthermia from, 1917
- Suckling, Charles, 1897
- Sucrose digestion and absorption, 1141,
 1142*f*
- Suction lipectomy, 1883, 1885, 1886*f*
- Sufentanil, 1900
- Sugiura procedure in portal hypertension
 and variceal bleeding, 1283
- Sulfasalazine in inflammatory bowel
 disease, 1196
- Sunburns, 478
- Sun exposure
 lip cancer in, 579
 skin injury in, 478, 486
 cancer associated with, 295, 478, 486
 of hand, 1818
 keratosis in, 486
- Sunitinib, 309, 310*t*
 in gastrointestinal stromal tumors, 1476,
 1483
- Superior sulcus tumors, 623
- Supracolic injuries, 189–190
- Supraglottis
 anatomy of, 580, 589, 589*f*
 tumors of, 590, 591
- Supralevator space, 1227
 abscess of, 1229
- Supraspinatus tendon impingement, 1766
- Surgeons OverSeas Assessment of Surgical
 Need (SOSAS) survey,
 1957–1958
- Surgery, leadership. *See* Leadership in
 surgery
- Surgical care
 advanced care in resource poor areas,
 1976–1977
 cost-effectiveness of, 1973–1974
 factors affecting utilization and outcome
 of, 1973–1976, 1974*f*
 preventive role, 1972
 vision of, 3–4
- Surgical Care Improvement Project, 374,
 375*t*
- Surgical counts, in prevention of retained
 surgical items, 378

- Surgical site infections, 142, 149f, 152–154, 255–256, 374, 389
 in appendicitis, 125f
 in femoropopliteal bypass graft, 898
 incidence of, 374
 prevention and treatment of, 142, 255–256, 257t–258t, 374, 389
 quality improvement efforts related to, 147, 148t, 374
 rates, 148t
 risk factors for, 147, 147t
 surveillance for, 148
- Suture techniques, 264
- Swallowing
 barium studies of, 950–951, 953f
 innervation of, 948
 motility disorders of, 986–995
 peristalsis in, 948
 pharyngoesophageal phase of, 986–990, 987f, 988f
 physiology of, 947–949, 947f
 pressures in, 947–948, 947f, 948f
 rehabilitation of, in laryngeal cancer, 592
 sequence of events in, 947, 947f
 video- and cineradiography of, 955, 961, 961f
- Swan-Ganz catheters, pulmonary artery rupture from, 381
- Sweat glands, 475
- Swenson, Orvar, 1624
- Swenson procedure in Hirschsprung's disease, 1626, 1626f
- Swimmer's ear, 565
- Symmastia, 500
- Sympathetic nervous system, 1711
 of anorectum, 1179
 of colon, 1177
 of liver, 1268–1269
 of pancreas, 1346
 in shock response, 113
 of stomach, 1039, 1047
 of thyroid gland, 1525
- Symphysis pubis, 1672, 1674
- Synchronous neoplasm, 580
- Syncope
 in aortic stenosis, 758
 differential diagnosis in, 736
- Syndactyly, 1823, 1824f
- Syndesmosis of ankle, 1764
- Synergistic effect of drugs, 1898
- Synovial sarcoma, 1818
- Synovitis of distal radioulnar joint, 1808
- SYNTAX trial, 743
- Syphilis, 1232
 aortic aneurysm in, 788
 genital ulcers in, 1678, 1679t
 pharyngitis in, 571
- Syringomyelia, 1739
- Systemic inflammatory response syndrome. *See* Inflammatory response, systemic syndrome in
- Systems-based practice, as core competency, 4t
- T**
- T cells, 38–39, 39f
 allorecognition by, 324
 helper, 39f
 in small intestine immune function, 1144
 in transplant rejection, 324
 in wound healing, 243–244
- Tachycardia
 in trauma, 170
- ventricular, 736
- Tacrolimus, 325t, 326t, 327t, 328
- Takayasu's arteritis, 788, 901, 901t
- Talipes equinovarus, congenital, 1783
- Talus fracture, 1764
- Tamoxifen in breast cancer, 537, 552–553
 early invasive, 539
 in elderly, 1932
 in prevention, 315, 513–514, 516, 552–553
- Tamponade, cardiac
 diagnosis of, 128–129, 167, 167f
 obstructive shock in, 128
 in trauma, 166–167
 treatment of, 128–129, 167–168
 emergency department thoracotomy in, 167–168, 167t, 168f–169f
 pericardiocentesis in, 129, 167, 167f
- Tapeworm infections, hydatid disease in, 1285
- Targeted therapies in cancer, 309, 310t, 1476
- Tarsal fractures, 1765
- TATA boxes, 448, 449f
- Taussig-Bing syndrome, 722, 723–724, 723f
- Tazobactam with piperacillin, 143t
- T-cell lymphotropic virus infections, tumors associated with, 295t
- Team approach
 communication in, 368–369
 in minimally invasive surgery, 419–420
 in operating room, 369, 369f, 370t
- Technetium-99m radionuclide scans
 in cardiac disorders, 739
 of esophageal transit, 955
 of thyroid, 1530
- Teeth and dental occlusion in mandibular reconstruction, 1853, 1854f, 1863
- Telementoring and teleconsultation, 437
- Telescopes in minimally invasive surgery, 424, 426f, 427f
- Telesurgery, 430
- Temporal arteritis, 788, 901
- Temporal bone
 fractures of, 578, 578f
 facial nerve injuries in, 576, 578
 longitudinal, 578, 578f
 transverse, 578, 578f
 tumors of, 594–595
 reconstructive surgery in, 594–595
 resection techniques in, 594, 594f
- Temporal lobe
 anatomy of, 1710
 anterior lobectomy in epilepsy, 1746
- Temsirolimus, 310t
- Tendons
 in hand, 1791. *See also* Hand, tendons in
 healing of, 251
 in rotator cuff, impingement of, 1766, 1766f
- Tenecteplase in venous thromboembolism, 924
- Teniae coli, 1176
- Tenodesis maneuver in tendon injuries of hand, 1798
- Tenosynovitis of hand and wrist flexor, 1811–1813, 1812f, 1813f
- Tensor fascia latae myocutaneous flap in pressure ulcers, 1881, 1881f
- Teratocarcinoma, mediastinal, 679
- Teratoma, 1641
 of central nervous system, 1737
- cervical, ex utero intrapartum therapy (EXIT) procedure in, 1645, 1645f
- mediastinal, 679
- ovarian, 1637, 1641, 1703
- retroperitoneal, 1641
- retrorectal, 1217
- sacrococcygeal, 1641, 1641f
- thoracic, 1641
- Terminal illness. *See* End-of-life care
- Tessier classification of craniofacial clefts, 1844, 1846f
- Tessier, Paul, 1844
- Testicular feminization syndrome, 1637
- Testis
 anatomy of, 1653
 bell-clapper deformity of, 1662
 cancer of, 1654–1655, 1654f
 in cryptorchidism, 1636, 1654
 epidemiology of, 275t, 278t
 orchiectomy in, 1655
 retroperitoneal lymph node dissection in, 1654–1655
- ectopic, 1635
- infections of, 1665
- torsion of, 1662–1663
- trauma of, 1660–1661
 in inguinal hernia repair, 1515
 undescended, 1635–1636
 cancer risk in, 1636, 1654
 embryology in, 1635
 two-stage repair in, 1636
- Tetanus prophylaxis in trauma, 186, 264
- Tetany in hypocalcemia, 1574
- Tetracaine in local anesthesia, 1899t, 1902, 1903t
- Tetracyclines, 145t
- Tetralogy of Fallot, 724–726
 anatomy in, 724–726, 724f
 classic presentation in, 724
 operative repair in, 724–725, 725f
 results of, 724–725
- Thalamus, anatomy of, 1710
- Thalassemia, 1430t, 1432
- Thallium-201 scans of myocardial perfusion, 739
- Thecomas, 1704
- The Global Initiative for Emergency and Essential Surgical Care (GIEESC), 1964–1967, 1965f–1967f
- The Himalayan cataract project (HCP), 1971, 1972f
- Themacrocysts of breast, 508
- The National Comprehensive Cancer Network, 1477
- Thermal agents for local hemostasis, 95
- Thermal injuries of skin, 480–481, 481f–482f
- Thermodilution technique for cardiac output measurement, 403–404
- Thermoregulation
 in children and infants, 1601
 postoperative disorders of, 393
- Thiazide diuretics, hypercalcemia from, 1562
- Thigh flap, anterolateral, in head and neck reconstruction, 601
- Thigh lift procedure, 1887
- Third-space fluid losses, 79, 110
- Thirst in hypernatremia, 70
- Thoracentesis
 in empyema, 684–685
 in pleural effusions, 680
- Thoracic aortic aneurysms, 785–806

- aneurysms-osteoarthritis syndrome, 788
aortic root replacement in, 793–795, 794f
cardiopulmonary bypass perfusion strategies in, 797, 798f, 799f
clinical history in, 789
clinical manifestations in, 789
descending, 803–804
diagnostic evaluation in, 789–791
distal, 799–804
in Ehlers-Danlos syndrome, 787
elephant trunk repair in, 795, 798f, 799f
 reversed, 802, 802f
endovascular repair in, 792–793, 797, 803–804
 complications of, 805–806
 endoleaks in, 806, 806t
 outcome of, 819
etiology and pathogenesis in, 787–788, 787t
familial, 787–788
genetic factors in, 787, 792
graft replacement in, 793, 794f
hybrid approach to repair of, 797–799, 800f, 803f, 804, 805f–806f
incidence of, 785
indications for surgery in, 792
management algorithm on, 791f
in Marfan’s syndrome, 787, 789, 792, 793, 795
open repair in, 792–793, 799–803, 804
 outcome of, 819–820
 outcome of surgery in, 816–820
 preoperative assessment and preparation in, 793
proximal, 793–799
risk for dissection and rupture in, 787
saccular, 789
severity of disease, 792
spinal cord and visceral protection during repair of, 801, 801t
- Thoracic artery
 as graft in coronary artery bypass surgery, 743–744
 internal, 1497
- Thoracic duct
 anatomy of, 685, 686f
 chylothorax in injury of, 685
 functions of, 685
- Thoracic outlet syndrome
 arterial, 829
 venous, 928
- Thoracic spine
 intervertebral disc herniation in, 1740, 1771
 stenosis of, 1771
 trauma of, 1722
 clay shoveler’s injury in, 1770
 fractures in, 1770–1772
 orthotic devices in, 1726
- Thoracic surgery
 approaches to, 642–644
 pain in, 645f
 video-assisted. *See* Video-assisted thoracic surgery
- Thoracic trauma. *See* Chest trauma
- Thoracofemoral bypass in aortoiliac occlusive disease, 878
- Thoracoscopy, 633
 access for, 421
 in esophageal atresia and tracheoesophageal fistula, 1610
 in lung cancer, 631, 632
 physiology in, 419
 in pneumothorax, 650
 positioning of patients in, 421f
- Thoracotomy
 anterolateral, 188, 188f
 in chest trauma, 188, 188f, 201
 clamshell, 188, 188f
 in ductus arteriosus patency, 704, 704f
 in emergency department
 algorithm on use of, 168f
 in cardiac tamponade, 167–168, 167t, 168f–169f
 indications and contraindications for, 167–168, 167t
 technique in, 167–168, 168f–169f
 lateral, 674
 in lung cancer, 629, 631
 in elderly, 1934
 in lung transplantation, 357
 in mediastinal masses, 674
 pain in, 645f
 posterolateral, 188
 trap door procedure, 188
- Thrombasthenia, 89
- Thrombectomy
 in arterial thrombosis, percutaneous technique, 888
 in bypass graft, 888
 in deep vein thrombosis, 924–925
- Thrombin, 85, 86, 87, 88
 direct inhibitors of, 922
 in topical hemostatic agents, 96
- Thrombin-activatable fibrinolysis inhibitor, 87, 88
- Thromboangiitis obliterans, 906, 1822–1823
- Thrombocythemia, essential, 289t, 1430t, 1435
- Thrombocytopenia, 90–91, 1428
 bleeding in, intraoperative or postoperative, 104
 heparin-induced, 90–91, 95, 389, 741, 922
 in burns, 233
 immune, 90–91
 in liver disease, 93
 platelet administration in, 91, 388
 and purpura
 idiopathic or immune, 90, 90t
 splenectomy in, 1429, 1430t, 1432–1434, 1444, 1444t, 1445t
 thrombotic, 90, 91
 splenectomy in, 1430t, 1434
 in transfusions, 104
- Thrombocytosis, 92
- Thromboelastography, 93, 103–104, 103f, 123
- Thromboembolism. *See* Thrombosis and thromboembolism
- Thrombolytic therapy
 in lower extremity arterial occlusive disease, 887, 887t
 in mesenteric ischemia, catheter-directed therapy in, 865
 in venous thromboembolism, 922–923
- Thrombomodulin, 88
- Thrombophlebitis
 migrans, 927
 Mondor’s disease in, 507
 superficial vein, 927–928
- Thromboplastin, 103
- Thromboplastin time, activated partial, 87, 102, 103
- Thrombopoietin, 93
- Thrombosis and thromboembolism
 in aortic valve replacement, 761
 in aortoiliac reconstruction, 878
 arterial
 of carotid artery, 1728
 in kidney transplantation, 339
 limb ischemia in, 881, 886
 in bypass graft, 888
 drug therapy in, 887
 surgical treatment in, 888
 in liver transplantation, 351
 mesenteric, 860, 863, 1167
 surgical repair in, 864
 in pancreas transplantation, 343
 of ulnar artery, 1822
 in free tissue transfer, 1838, 1838t, 1839
 in kidney transplantation, 339
 in liver transplantation, 351
 in pancreas transplantation, 343
 in thrombocytopenic purpura, 1434
 venous, 918–927
 in burns, 233
 diagnosis of, 919–921
 duplex ultrasonography in, 918, 920, 920f
 effort, 928
 epidemiology of, 918
 in general surgery, 924–925
 genetic factors in, 918–919
 hepatic vein, Budd-Chiari syndrome in, 1283, 1284
 incidence of, 374
 in laparoscopy, 418
 in liver transplantation, 351
 mesenteric, 929, 1167
 in pancreas transplantation, 343
 in pancreatitis, 1379
 paradoxical arterial embolism in, 886
 portal vein, 351, 1379, 1439
 prevention of, 374, 375t, 386, 925–927, 926t–927t
 in bariatric surgery, 1105
 risk factors for, 918–919, 918t, 919t
 and prophylaxis guidelines, 919t, 925–927, 926t–927t
 risk scoring systems, 919
 secondary, 918
 signs and symptoms in, 919
 in splenectomy, 1439
 splenic vein, 1088, 1379, 1438
 spontaneous, 918
 in trauma, 186
 treatment of, 921–925
 in upper extremity, 928–929, 928f
 vena cava filter placement in, 386, 924, 925f, 927, 1105
- Thrombospondin, 86, 535
- Thromboxane, 31, 31f, 32t, 85
- Thrombus, tumor, in renal cell carcinoma, 1656, 1657f
- Thymoglobulin in immunosuppressive therapy, 325
- Thymolipoma, 676–677, 676f
- Thymomas, 675–676, 675f, 675t
 biopsy in, 675
 incidence of, 673t
 invasive, 675
 in myasthenia gravis, 675
 signs and symptoms in, 674t
 staging of, 675, 675t
 and survival rates, 675, 675f
- Thymus gland, 670, 671f, 674
 cysts of, 679
 hyperplasia of, 674–675
 tumors of, 675–676, 675f, 675t
- Thyroglobulin, 1525–1526
 serum levels of, 1529
 after thyroidectomy for thyroid cancer, 1548

- Thyroglossal duct, 1521
 cysts of, 598, 1521–1522, 1602
 persistence as pyramidal lobe, 1522
- Thyroid arteries, anatomy of, 1523–1524, 1524*f*, 1525*f*
- Thyroidectomy, 1551–1556
 in anaplastic carcinoma of thyroid, 1551
 complications of, 384, 1556
 hypoparathyroidism in, 1574
 in follicular carcinoma of thyroid, 1545–1546, 1545*f*
 in hyperthyroidism, 1533
 subtotal procedure in, 1533
 in lymphoma of thyroid, 1551
 in medullary carcinoma of thyroid, 1550
 minimally invasive, 1553*f*, 1554
 operative procedure in, 1551–1556, 1552*f*
 in papillary carcinoma of thyroid, 1543–1544, 1545*f*
 in solitary thyroid nodule, 1540
- Thyroid gland, 1521–1556
 anatomy of, 1523–1525, 1523*f*
 lymphatic, 1525, 1527*f*
 nerves in, 1524–1525, 1524*f*
 vascular, 1523–1524
 antibodies to, 1529
 autoregulation of, 1526
 benign disorders of, 1530–1537
 cancer of, 1540–1556, 1937
 anaplastic, 1544*t*, 1550–1551, 1551*f*
 chemotherapy in, 1548, 1551
 in elderly, 1937
 epidemiology of, 275*t*, 276*t*, 277*f*, 278*t*, 618*f*
 familial, 1537, 1539*t*, 1549*t*, 1550
 follicular, 1544–1546, 1544*t*, 1545*f*
 diagnosis of, 1544–1545
 pathology in, 1545
 prognosis, 1545–1546
 treatment of, 1545–1546
 follow-up in, 1548–1551, 1550
 genetic factors in. *See* Genetic factors, in thyroid cancer
 Hürthle cell, 1546
 medullary, 1544*t*, 1549–1550, 1549*t*, 1570
 metastatic from other sites, 1551
 in multiple endocrine neoplasia, 293, 1570
 papillary, 1542–1544, 1543*f*, 1544*t*
 in elderly, 1937
 pathology in, 1542, 1543*f*
 prognostic indicators in, 1542–1543
 treatment of, 1543–1544
 postoperative management in, 1546–1548, 1548–1551
 radiation therapy in, 1548, 1550, 1551
 radioiodine therapy in, 1546–1548, 1547*f*
 radionuclide scans in, 672, 674*t*
 recurrent, 1547*f*, 1548
 risk factors for, 1537
 staging of, 1544*t*
 cysts of, 1540
 ectopic tissue of, 679, 1522–1523
 embryonic development of, 1521, 1522*f*, 1602
 abnormalities in, 1521–1523
 evaluation of disorders, 1528–1530
 follicular cells of, 1525, 1528*f*
 function tests of, 1528–1529
 preoperative, in bariatric surgery, 1106
- goiter of, 1536–1537
 histology of, 1525, 1528*f*
 historical surgery of, 1521
 hormones of, 1525–1528
 functions of, 1527–1528
 regulation of, 1526, 1529*f*
 synthesis of, 1525–1526, 1529*f*
- hyperthyroidism, 1530–1534. *See also* Hyperthyroidism
- hypothyroidism, 1534–1535. *See also* Hypothyroidism
- imaging studies of, 1529–1530
 in cancer, 672, 674*t*, 1548–1549
 in iodine metabolism, 1525
 lateral aberrant, 1522–1523, 1542
 lingual, 1522
 lymphoma of, 1536, 1551
 nodules of
 in elderly, 1937
 hyperthyroidism in, 1533
 solitary, 1537–1540
 diagnosis of, 1538–1540
 history, 1537
 physical examination in, 1537
 treatment of, 1539*f*, 1540
 physiology of, 1525–1528
 postoperative disorders of, 392–393
 pyramidal lobe of, 1522
 thyroidectomy of. *See* Thyroidectomy
 thyroiditis of, 1529, 1535–1536
- Thyroiditis, 1535–1536
 Hashimoto's, 1529, 1535–1536
 subacute, 1535
 suppurative/acute, 1535
- Thyroid-stimulating hormone, 1526, 1529*f*
 serum levels of, 1529
 in cancer of thyroid, 1548
 in hypothyroidism, 1534
 in solitary thyroid nodule, 1540
- Thyroid storm, 1534
- Thyrotoxicosis
 postoperative, 393
 thyroid function tests in, 1529
- Thyrotropin-releasing hormone, 1526, 1529, 1529*f*
- Thyroxine, 1526
 free, 1529
 replacement therapy
 in hypothyroidism, 1534–1535
 in thyroid cancer, 1548
 serum levels in hypothyroidism, 1534
 total, 1529
- Tibia
 fractures of, 1762, 1764
 distal, 1764
 hemorrhage in, 173
 open, 1758*f*
 pilon, 1764
 in plateau, 1762
 reconstructive surgery in, 1877*t*
 in shaft, 1764
 transverse, 1757*f*
 osteosarcoma of, 1779
- Tibial artery pulse palpation, 829
- Ticarcillin-clavulanate, 143*t*
- Tic douloureux, 1748–1749
- Tigecycline, 145*t*
- Tillaux's sign in mesenteric cysts, 1459
- Time management in surgery, 7–8, 8*f*
- Time out protocol, 7
- Tinel's sign in carpal tunnel syndrome, 1806
- Tinidazole in peptic ulcer disease, 1061*t*
- Tissue engineering in coronary artery disease, 747
- Tissue expansion techniques, 1840
 in breast reconstruction, 1840, 1867–1869, 1869*f*, 1870*f*
- Tissue factor pathway inhibitor, 88
- Tissue heart valves, 749, 749–750, 750*f*
- Tissue plasminogen activator, 88, 283
 in arterial vasospasm, 215*t*
 in ischemic stroke, 1728
 in venous thromboembolism, 924
- TNFR-associated death domain (TRADD), 36
- TNM staging of cancer
 adrenocortical, 1584, 1584*t*
 of breast, 531, 531*t*–532*t*
 colorectal, 1209–1210, 1211*t*
 of head and neck, 580, 581*t*
 of lungs, 633–635, 634*t*
 of stomach, 1079, 1080*t*
 of thyroid, 1543, 1544*t*
- Tobacco use. *See also* Smoking
 head and neck tumors in, 578, 579, 586
- Tobin Index in weaning from mechanical ventilation, 385
- Tobramycin, 144*t*, 257*t*
- Toker cells, 475
- Tolerance to drugs, 1898
- Toll-like receptors, 37*f*
 in shock, 115, 117*f*
 TLR4, 37*f*
- Tongue
 cancer of, 583, 583*f*, 587, 1862
 reconstructive surgery of, 1862
 strawberry, 571
- Tonometry, gastric in shock, 131
- Tonsillar herniation, 1714*f*
- Tonsillectomy, 571
- Tonsillitis, 570, 571
- Tonsils, 570
 hypertrophy of, 570, 571
 infections of, 570, 571
 tumors of, 587
- Topical hemostatic agents, 96
- Topoisomerase II, 307
- TORCH infections, 1628
- Torsion
 of ovarian cyst, 1248, 1637
 testicular, 1662–1663
- Torticollis, congenital, 1603
- Toupet fundoplication, 975–976, 978–979
 esophageal myotomy with, 999, 1000, 1001*f*
- Tourniquet use for local hemostasis, 95, 166
- Toxic epidermal necrolysis, 477
- Trachea, 605–611
 anatomy of, 605, 607*f*, 608*f*
 blood supply of, 605, 607*f*
 C-rings, 605
 fistulas of, 608–609
 with esophagus, 609, 1608–1612. *See also* Tracheoesophageal fistula
 intubation of. *See* Endotracheal intubation
 neoplasms of, 609–611, 611*f*
 stenosis of, postintubation, 607–608, 608*f*
 trauma of, 163, 164*f*, 178, 200, 202
 iatrogenic, 605, 608*f*
- Trachelectomy, radical, in cervical cancer, 1698
- Tracheobronchial lymph nodes, 611
- Tracheobronchial tree
 cell types in, 612–613, 613*f*
 histology of, 612–613, 613*f*
 salivary gland-type tumors of, 617

- Tracheoesophageal fistula, 608–609, 1608–1612
 anatomic varieties of, 1608–1609, 1608*f*
 in cancer of esophagus, 1004
 clinical presentation in, 1609–1610, 1609*f*
 complications of surgery in, 1611–1612
 etiology and pathologic presentation in, 1609
 H-type, 1609, 1609*f*, 1612
 initial management of, 1610
 outcome in, 1612
 postoperative management in, 1611
 in preterm infant, 1610
 primary surgical correction of, 1610, 1611*f*
 recurrent, 1612
 single-stage operation for closure of, 610*f*
 in ventilatory support, 608–609
- Tracheoesophageal puncture, for speech rehabilitation after laryngectomy, 592
- Tracheoinnominate artery fistula, 608–609, 609*f*
 emergency management of, 609, 609*f*
 in tracheostomy complications, 382, 382*f*, 608–609
- Tracheostomy, 602
 in burns, 233
 complications of, 382, 382*f*, 602
 tracheal stenosis in, 607–608, 608*f*
 tracheoinnominate artery fistula in, 382, 382*f*, 608–609
 indications for, 602
 in trauma, 163
 in children, 222
- Tracheostomy in burns, 233
- Tranexamic acid, in blood transfusion, 97
- Transanal endoscopic microsurgery, 434, 434*f*
 in rectal cancer, 1213
- Transanal excision in rectal cancer, 1213
- Transanal minimally invasive surgery in rectal cancer, 1213
- Trans-Atlantic Inter-Society Consensus classification
 of aortoiliac occlusive disease, 875, 875*f*, 875*t*
 of lower extremity arterial occlusive disease, 885, 886*f*, 886*t*
- Transcatheter aortic valve replacement (TAVR), 762
- Transcription, 279, 443, 444*f*, 446–447, 446*f*
 control of, 448, 449*f*
 in eukaryotes, 447
 in prokaryotes, 447
- Transcription factors, 449
- Transfection, 462*f*, 463
 small interfering RNA in, 467
 transient, 463
- Transformation procedure in recombinant DNA technology, 457
- Transforming growth factor- α in wound healing, 247*t*
- Transforming growth factor- β , 36
 signaling pathway, 452–453, 453*f*
 in cancer, 453
 in wound healing, 244, 245, 247*t*
 in hypertrophic scars and keloids, 262
- Transfusions, 96–102, 1914–1915
 ABO blood groups in, 96, 1914
 allergic reactions in, 100–101, 102*t*
 in anemia, 98
 autologous, 96
 of banked whole blood, 96
 in burns, 231
 in children, 1599–1600
 circulatory overload in, 101, 102*t*
 complications of, 100–102, 102*t*, 388, 388*t*
 in damage control resuscitation, 98, 100
 febrile reactions in, 100, 102*t*
 of fresh whole blood, 96, 184
 hemoglobin in, human polymerized, 98
 hemolytic reactions in, 101, 102*t*
 in hemorrhagic shock, 122
 indications for, 97–98, 184–185, 388
 infection transmission in, 102, 388, 388*t*
 massive, 98, 101*t*
 protocol in, 184–185, 186*f*
 thrombocytopenia and hemorrhage in, 104
 plasma in, fresh-frozen, 97, 184
 of platelets, 91, 97, 99*t*
 in hemorrhagic shock, 123
 in massive transfusions, 101*t*
 in thrombocytopenia, 91, 388
 purpura in, 104
 recombinant DNA technology in, 97
 red blood cell, 1914–1915
 in children, 1599–1600
 frozen, 96
 in hemorrhagic shock, 122
 indications for, 97–98
 packed, 96, 98, 184
 in resuscitation strategies, 98, 100, 100*t*
 in thalassemia, 1432
 washed/leukocyte-reduced, 96–97
 religious beliefs on, 1943
 replacement therapy, 96–97
 Rh blood groups in, 96, 1914
 in sepsis, 154, 155*t*
 tranexamic acid in, 97
 typing and cross matching, 96
 in variceal bleeding, 1282
- Transgenic mice, 463–464, 463*f*
 genotyping of, 464
 phenotype analysis of, 464
 production of, 464
- Translation, 279, 443, 444*f*, 446, 446*f*, 447
 control of, 448
- Translocation of bacteria, 151
- Transoral endoscopic restrictive implant system, 1131
- Transoral gastroplasty, 1131
- Transplantation, 321–358
 allotransplants in, 322, 1881–1882, 1882*f*
 autotransplants in, 322
 donors in, 330–332. *See also* Donors, in organ transplantation
 of heart. *See* Heart, transplantation of
 historical aspects of, 322–323, 323*t*
 immunobiology in, 323
 immunosuppression in, 324–328. *See also* Immunosuppression, in transplantation
 infection risk in, 329–330
 infections and malignancies, 329–330
 intestinal, 352–354
 in short bowel syndrome, 1172, 1621
 of kidney, 334–340, 1976–1977. *See also* Kidneys, transplantation of
 of liver, 345–352, 1975. *See also* Liver, transplantation of
 of lung, 332, 354–358, 663–664. *See also* Lungs, transplantation of
 lymphoproliferative disorder after, 330
 organ procurement and preservation in, 330–334
 of pancreas, 340–344. *See also* Pancreas, transplantation of
 in poor countries, 1976–1977
 rejection in, 324. *See also* Rejection in transplantation
 of spleen, autologous, 206, 206*f*
 stem cell, 358
 types of, 322
 waiting lists for, 321, 322*f*–323*f*, 332
 xenotransplants in, 322, 358
- Transport
 active, 1140
 passive, 1140
- Transposition of great arteries, 720–721
 Lecompte maneuver in, 721, 722*f*
 Senning operation in, 721, 721*f*
- Transversalis fascia anatomy, 1496
- Transverse abdominal muscles, 1449, 1451*f*
- Transverse rectus abdominis myocutaneous (TRAM) flaps, 1837
 in breast reconstruction, 550, 1869–1871, 1872*f*–1873*f*
 free flap in, 1871, 1872*f*–1873*f*
 pedicle flap in, 1837, 1869–1871
 in chest wall reconstruction, 1874, 1875*f*
 conditioning of, 1837
- Transversus abdominal plane (TAP) block, 1916, 1917*f*, 1918*f*
- Trapezium, anatomy of, 1788, 1790*f*
- Trapezius muscle flap
 in chest wall reconstruction, 1874
 in head and neck reconstruction, 601
- Trapezoid bone anatomy, 1788, 1790*f*
- Trash foot in aortoiliac occlusive disease, 874, 874*f*
- Trastuzumab, 309, 310*t*, 454, 1083
 in breast cancer, 535, 541, 553–554
- Trauma, 161–223
 abdominal, 179–181, 203–212. *See also* Abdominal trauma
 air embolism in, 171, 172*f*
 airway management in, 161–163
 in children, 222
 antibiotics in, prophylactic, 185–187
 biliary, 1331–1334
 in cholecystectomy, 1331, 1332–1333, 1332*f*, 1333*f*
 of bladder, 211–212, 1515, 1660, 1705
 bloody vicious cycle in, 185, 193, 194*f*
 blunt injuries in, 173–174
 in children, 1643
 of heart, 127, 171
 in burns, 227–236, 1820–1822. *See also* Burns
 of carotid artery, 198, 850
 operative approach for exposure in, 187*f*, 188
 transposition repair procedure in, 192, 193*f*
 cellular response to, 34–36
 cervical spine immobilization and protection in, 161–163, 1722
 of chest, 177–179, 200–203. *See also* Chest trauma
 in children, 222–223, 1642–1644. *See also* Children and infants, trauma in
 coagulopathy in, 93, 94*f*, 185
 in bloody vicious cycle, 185, 193, 194*f*

- Trauma (*Cont.*):
- of colon, 209–210, 1234–1235. *See also*
 - Colon, trauma of
 - compartment syndromes in, 215
 - abdominal, 217–218, 218f–219f
 - of lower extremity, 215
 - damage control surgery in, 192–195, 194f–196f
 - definition of, 161
 - of duodenum, 207–209, 208f. *See also*
 - Duodenum, trauma of
 - in elderly, 221–222, 1934–1935, 1935f
 - endothelium-mediated, 40–43
 - of esophagus. *See* Esophagus, trauma of
 - of extremities, 181–183
 - fractures in, 214–215, 1876–1877, 1876t
 - reconstructive surgery in, 1876–1877
 - of facial nerve, 567
 - of gallbladder, 204, 1331–1332
 - general principles of management, 183–195
 - and global surgery, 1958–1960, 1968–1969, 1970t
 - of hand, 1795–1799. *See also* Hand, trauma of
 - of head. *See* Head trauma
 - history-taking in, 173
 - hormone response to, 19–23
 - hypothermia in, 186, 193, 194f
 - initial evaluation and management in, 161–183
 - in burns, 227–228
 - in children, 1642–1643
 - primary survey in, 161–173
 - secondary survey in, 173
 - intensive care management in, 215–217
 - of kidneys, 211–212, 1658–1659
 - of liver. *See* Liver, trauma of
 - mechanisms and patterns of injury in, 173–174
 - in children, 1642
 - metabolism after, 46f, 47
 - mortality rate in, 161
 - of neck, 175–177, 197–200
 - airway management in, 161–162, 163f
 - cervical spine injuries in. *See* Cervical spine, trauma of
 - operative approaches and exposure in, 187–192
 - pelvic, 181
 - fractures in, 181, 185f, 212–214
 - penetrating injuries in. *See* Penetrating injuries
 - of penis, 1661, 1661f
 - fracture in, 1661, 1661f
 - priapism in, 1664
 - of peripheral nerves, 251, 1726–1727
 - peritoneal adhesions in, 263, 263f
 - physical examination in, 173
 - in pregnancy, 218–221, 1691
 - shock in. *See* Shock, in trauma
 - of skin and subcutaneous tissue, 478–479
 - soft tissue sarcoma in, 1466
 - of spine, 1721–1726
 - of spleen. *See* Spleen, trauma of
 - of testis, 1660–1661
 - tetanus prophylaxis in, 186
 - thermal protection in, 187
 - of thoracic and lumbar spine, 1770
 - of trachea, 163, 164f, 178, 200, 202
 - acute management of, 608
 - in intubation, 607–608, 608f
 - transfusions and resuscitation strategies in, 98
 - of ureters, 212, 1659–1660
 - of urethra, 212, 1660
 - of urinary tract, 211–212, 1658–1661
 - in laparoscopy, 1705
 - vascular injuries in. *See* Vascular injuries
 - wound healing in, 241–268
- Treacher Collins syndrome, 1846, 1847f
- Tremors
 - deep brain stimulation in, 1747, 1747f
 - essential, 1747
 - in Parkinson's disease, 1747
- Trendelenburg gait, 1772
- Trendelenburg's test, 917–918
- Treponema pallidum* infections, 1678, 1679t. *See also* Syphilis
- Trial Assessing Individualized Options for Treatment (TAILORx), 302, 536
- Triangle of doom, 1499, 1501f
- Triangle of pain, 1499, 1501f
- Triangular ligaments of liver, 1264f, 1265
- Tricarboxylic acid cycle, 47, 48f, 49f, 50
- Trichobezoars, 1089, 1089f
- Trichomoniasis, vulvovaginitis in, 1677t, 1680, 1681f
- Tricuspid valve disorders, 762–764
 - annuloplasty in, 763
 - with aortic valve disease, 763, 764
 - atresia, 712–716
 - classification of, 712, 713f
 - Fontan procedures in, 713–715, 714f
 - Glenn shunts in, 713–715, 714f
 - treatment of, 713–715
 - in Ebstein's anomaly, 719–720
 - insufficiency, 762–764
 - with mitral valve disease, 763, 764
 - prosthetic replacement in, 764
 - in Ebstein's anomaly, 720
 - stenosis, 762–764
- Trigeminal neuralgia, 1748–1749
- Triglycerides
 - long-chain, 46–47, 1142–1143
 - medium-chain
 - in enteral nutrition formulas, 47, 1143
 - metabolism of
 - in fasting, 44f, 45f
 - in injury, 46–47, 46f, 47f
 - in small intestine, 1142–1143, 1143f
 - serum levels in chronic pancreatitis, 1365
 - short-chain, 1143
- Triiodothyronine, 1526
 - free, 1529
 - functions of, 1527–1528
 - therapy in thyroid cancer, 1548
 - total, 1529
- Trimethoprim-sulfamethoxazole, 145t
- Triolein breath test in chronic pancreatitis, 1374
- Triquetrum, anatomy of, 1788, 1790f
- TRK1* in thyroid cancer, 1541t
- Trophoblastic disease, gestational, 1693–1694
- Tropical pancreatitis, 1366–1367
- Trousseau's sign, 72, 73, 1574
- Truncus arteriosus, 706–707
 - chest radiography in, 708
 - classification of, 706, 706f
 - repair techniques in, 707
 - results of, 709–710
 - survival after repair, 710f
- Trypsin, 1142, 1142f, 1347, 1348t
 - activation of, 1353
- Trypsinogen, 1347, 1348t
 - activation of, 1353–1354
 - inhibition of, 1347
- TSC1* in tuberous sclerosis, 290t
- TSC2* in tuberous sclerosis, 290t
- Tuberculosis, 654–655, 656f
 - drug-resistant, 654, 655
 - hemoptysis in, 655
 - in HIV infection and AIDS, 654
 - in kidney transplant recipients, 335
 - osteomyelitis in, 1745–1746
 - surgical treatment in, 655, 656t
 - treatment algorithm for, 655, 656f
- Tuberous sclerosis, 290t
- Tubular carcinoma of breast, 522
- Tuftsia, 1427
- Tularemia in biologic warfare, 157
- Tumorigenesis, 278–279, 280f
 - chemical carcinogens in, 293
 - in head and neck tumors, 580
 - as multistep process, 453, 580
 - initiation and promotion phases in, 580
 - physical carcinogens in, 293, 295
 - proliferation and transformation of
 - cancer cells in, 453, 454f
 - in stomach cancer, 1076f
 - in thyroid cancer, 1540, 1541f, 1541t, 1542
 - viral carcinogens in, 295–296, 295t, 296t
- Tumor lysis syndrome, 81, 82
- Tumor necrosis factor, 282
 - in inflammatory bowel disease, 1197
 - in injury response, 26
 - in shock response, 116
 - sources of, 27t
 - in wound healing, 243, 244
- Tumor necrosis factor receptors, 26, 36
 - TNFR-1, 26, 37f
 - TNFR-2, 26, 37f
- Tumor necrosis factor–related apoptosis-inducing ligand (TRAIL), 282
- Tumors, 273–316. *See also specific anatomic locations*
 - adjuvant therapy in, 273
 - of adrenal gland, 1583–1585
 - anal and perianal, 1217–1218
 - of appendix vermiform, 1257–1259
 - incidence, 1257–1258, 1258t
 - of biliary tract, 1334–1338
 - biology of, 277–285, 281f
 - angiogenesis in, 283–284
 - apoptosis alterations in, 281–283
 - autophagy in, 283
 - cell cycle dysregulation in, 279, 281f
 - cell proliferation and transformation in, 277–278
 - invasion in, 283
 - oncogenes in, 278–279, 279–281
 - stem cells in, 285
 - steps in tumorigenesis in, 278–279
 - therapeutic implications of, 280f
 - biomarkers of, 301–304. *See also* Biomarkers of tumors
 - of bladder, 1653–1654
 - of breast, 511–557
 - of carotid body, 849–850, 849f
 - cartilage-forming, 1780
 - of central nervous system, 1732–1739
 - of cervix uteri, 1698
 - chemotherapy in, 306–308, 455. *See also* Chemotherapy
 - of chest wall, 664–669
 - in children, 1636–1642
 - in chronic wounds, 259

- circulating tumor cells in, 303–304
 colorectal, 1203–1216
 diagnosis of, 299–300
 dormancy phenomenon in, 285
 in elderly, 1931–1934. *See also* Elderly, cancer in
 of endometrium, 1698–1701, 1701*t*
 epidemiology of, 274–277
 incidence of, 274–277
 incidence rates in, 274–277, 275*t*, 276*t*, 277*f*, 279*f*
 initiation of, 278–279, 280*f*
 mortality rates in, 274–277, 275*t*, 276*t*
 survival rates in, 274, 278*t*
 of esophagus, 1003–1018. *See also* Adenocarcinoma, of esophagus
 etiology of, 285–296
 of fallopian tubes, 1701–1703
 fluid and electrolyte balance in, 81–82
 of gallbladder, 1293, 1334–1335
 genetic factors in, 287–291, 454
 and gene therapy, 311*f*, 312, 455–456
 Knudson's two-hit hypothesis on, 287, 287*f*
 and surgical prevention, 315
 in targeted therapies, 309, 310*t*
 and global surgery, 1958, 1973*t*
 of hand and wrist, 1814–1820
 of head and neck, 578–600
 of heart, 774–776
 heterogeneity, 290*f*
 hormone therapy in, 308–309
 hypercalcemia in, 82, 626, 1561
 immunotherapy in, 309, 311–312, 454–455
 individualized therapy in, 316
 intracranial, 1732–1737
 invasive, 283
 of kidneys, 1655–1657
 of liver, 1289–1291
 in children, 1641–1642
 classification of, 1288*t*
 incidental discovery of, 1287–1288
 of lungs, 623–645
 mediastinal, 671–679
 mesenteric, 1460
 mesothelioma, 687–688
 metastasis of, 284–285, 284*f*. *See also* Metastasis
 minimally invasive surgery in, 436
 mortality to incidence ratio, 1958, 1959*f*
 multidisciplinary approach to, 304
 of omentum, 1457
 of ovary, 1636–1637, 1701–1704
 of pancreas, 1390–1413
 pelvic, 1696–1704
 of peripheral nerves, 1744
 pleural, 687–690
 pleural effusions in, 681*t*, 682, 683*t*, 684*t*
 prevention of, 314–315
 prognostic and predictive markers in, 301–302
 of prostate, 1657–1658
 radiation therapy in, 313–314. *See also* Radiation therapy
 retroperitoneal, 1479–1480, 1479*f*
 retrorectal/presacral, 1217
 risk assessment for, 296–297
 screening for, 297–299, 298*t*–299*t*.
See also Screening for cancer
 serum markers, 302–303
 of skin, 485–493
 of small intestine, 1159–1162
 small intestine obstruction in, 1146, 1149
 of soft tissues, 486, 666–669, 1465–1487
 of spine, 1737–1739, 1738*f*
 of spleen, 1437
 staging of, 300–301, 304. *See also* Staging of tumors
 of stomach, 1074–1090
 surgical approaches to, 273–274, 304–306
 lymph node management in, 304–306
 negative surgical margins in, 304
 as primary therapy, 273
 recent trends and evolving technologies in, 316
 targeted therapy in, 309, 310*t*
 of testis, 1654–1655
 of thyroid, 1540–1556
 of trachea, 609–611
 transforming growth factor- β signaling pathway in, 453
 in transplant recipients, 330, 335
 trends and evolving technology in, 316
 of vulva, 1696–1697
 Tumor suppressor genes, 278, 280*f*
 in colorectal cancer, 1204–1205
 in hereditary cancer syndromes, 287–291
 in soft tissue sarcomas, 1467–1468
 Tunica albuginea, 1652
 traumatic rupture of, 1661
 Turcot's syndrome, 1207
 Turner's syndrome, 500
 Tylectomy in breast cancer, 547
 Tympanoplasty in otitis media, 567
 Typhlitis, 1236, 1241
 Tyrell, Ross, 1897
 Tyrer-Cuzick model on breast cancer risk, 512
 Tyrosine kinase in soft tissue sarcomas, 1486
 Tyrosine kinase receptor, 35*f*
- U**
 Ubiquitin-proteasome system, 50
 Ulcerative colitis, 1195, 1197–1198.
See also Colitis, ulcerative
 Ulcers
 of aorta, penetrating, 808, 809
 endovascular treatment in, 816
 genital, 1678, 1679*t*
 pressure, 260–261
 rectal solitary, 1219
 of skin, 259, 482, 482*f*
 in arterial ischemia, 259
 compared to neuropathic ulcers, 890*t*, 891*f*
 of lower extremity, 889, 890*t*, 891*f*
 in diabetes mellitus, 260, 267
 reconstructive surgery, 1877, 1879
 malignant transformation of, 259, 260*f*
 neuropathic, compared to ischemic ulcers, 890*t*, 891*f*
 pressure or decubitus. *See* Pressure ulcers
 in venous insufficiency, 259–260, 917, 917*f*, 930, 931–933
 compression therapy in, 259–260, 931–933
 skin substitutes in, 932–933, 933*f*
 of stomach and duodenum
 gastric cancer risk in, 1077*f*, 1078
 in head trauma, 1718
 in peptic ulcer disease, 1053–1073.
See also Peptic ulcer disease
 postoperative, in Roux-en-Y gastric bypass, 1116
 in stress, 1073–1074
 Ulna, fractures of, 1760
 with radius fracture, 1760
 in shaft, 1760
 Ulnar artery
 anatomy of, 1791–1792
 aneurysmal thrombosis of, 1822
 atherosclerosis of, 1822
 pulse palpation, 1793
 Ulnar nerve, 1788
 anatomy of, 1792
 anesthetic block in hand injuries, 1796, 1797*f*
 compression at elbow, 1744, 1806
 Ultimobranchial bodies, 1521, 1549
 Ultrasonography, 918
 in abdominal trauma, 182*f*
 in aortic aneurysm, thoracic, 790
 in appendicitis, 1246
 in arterial disease, 830
 in biliary disorders, 1314, 1314*f*
 endoscopic technique, 1316
 in brain death, 1721
 in breast cancer diagnosis, 527, 528*f*, 529*f*, 530*f*
 in Budd-Chiari syndrome, 1284
 cardiac output estimated in, 407
 in carotid artery occlusive disease, 839–840, 840*t*
 in choledocholithiasis, 1321
 contrast-enhanced, 1272–1273
 Doppler technique. *See* Doppler ultrasonography
 endoanal, 1181, 1185, 1185*f*
 endobronchial, in lung cancer, 630
 endorectal, 1181, 1182*f*
 in rectal cancer, 1211–1212, 1211*f*
 in esophageal cancer, endoscopic technique, 1005, 1008
 in fecal incontinence, 1185, 1185*f*
 in gallbladder cancer, 1334
 in gallstones, 1314, 1314*f*, 1319–1320, 1321*f*
 of hand and wrist, 1794
 in inguinal hernia, 1504
 laparoscopic, 1325
 of liver, 1272–1273, 1273*f*
 elastography, 1273
 intraoperative, 1273, 1273*f*
 in lung cancer, 632
 in lymphedema, 935
 in mesenteric ischemia, 862
 in pancreatitis
 chronic, 1369, 1370*f*
 endoscopic technique, 1369, 1370*f*, 1374
 in portal hypertension, 1280
 prenatal
 in diaphragmatic hernia, 1604, 1604*f*
 in gastroschisis, 1633, 1633*f*
 in ovarian cysts, 1637
 in renal artery stenosis, 867–868, 868*t*
 in soft tissue sarcomas, 1468
 of spleen, 1428
 of stomach, 1051
 endoscopic technique in cancer, 1051, 1080

- Ultrasonography (*Cont.*):
 of thyroid, 1530, 1530*f*
 in solitary nodule, 1540
 in venous insufficiency, 930, 931*f*
 in venous thromboembolism, 920, 920*f*
- Ultraviolet radiation
 lip cancer associated with, 579
 skin damage from, 478, 486
 cancer associated with, 486
 UVA, 478, 486
 UVB, 478, 486
 UVC, 478
- Umbilical hernia, 1455, 1631, 1631*f*
 in elderly, 1923
- Umbilical ligament, medial, 1498*f*
- Umbilical vein
 graft in femoropopliteal bypass, 899
 in portal hypertension, 1281
- Unconsciousness in general anesthesia, 1900
- United nations and global surgery, 1963
- Universal precautions in blood-borne infections, 156
- University of Wisconsin solution for organ preservation, 332
- Unna's boot in venous insufficiency, 931–932
- Unstirred water layer, 1143
- Upper extremity
 arteries in, 1791–1792
 angiography of, 1794–1795
 physical examination of, 829, 1793
 compartment syndromes in, 1801
 hand disorders of, 1787–1825. *See also*
 Hand
 shoulder in, 1765–1767. *See also*
 Shoulder
 trauma of, 1795–1799
 regional pain syndromes in, 1805
 veins in, 916
 thrombosis of, 928–929, 928*f*
- Urachus, 1453
 patent, 1631–1632
- Urea breath test for *Helicobacter pylori*, 1051, 1053*f*
- Urea nitrogen in blood, and osmolality of body fluids, 67, 68
- Uremia
 platelet dysfunction in, 92
 wound healing problems in, 254
- Ureterocele, 1667
- Ureteroneocystostomy, 337
- Ureteropelvic junction obstruction, 1667
- Ureters
 anatomy of, 1652, 1674
 cancer of, 275*t*
 obstruction of
 in calculi, 1666
 stent placement in
 in obstruction of upper urinary tract, 1666
 prior to colorectal surgery, 1195
 in trauma of ureter, 1660
 trauma of, 212, 1659–1660
 in gynecologic procedures, 1705
- Urethra
 fetal surgery for anomalies of, 1645
 intrinsic sphincter deficiency of, urinary incontinence in, 1695
 strictures of, 1660, 1665
 acute urinary retention in, 1661–1662
 trauma of, 212, 1660
 anterior, 1660
 posterior, 1660
 Urethral valve, posterior, 1667
 fetal surgery in, 1645
 Urethrography, retrograde, in trauma of urethra, 1660
- Urinary tract, 1651–1668
 anatomy of, 1651–1653
 bladder in. *See* Bladder
 cancer of, 1653–1658
 epidemiology of, 275*t*, 276*t*, 277*f*, 278*t*, 618*f*
 catheterization of
 in acute urine retention, 1661–1662, 1662*f*
 complications in, 390
 for renal monitoring, 410–411
 diversion procedures in bladder cancer, 1653, 1654
 emergency disorders of, 1661–1664
 infections of, 1664–1665
 catheter-related, 390
 kidneys in. *See* Kidneys
 obstruction of, 1665–1667
 acute urine retention in, 1661–1662
 in children, 1667
 fetal surgery for, 1645
 hydronephrosis in, 1665–1666, 1665*f*, 1667
 in prostate hyperplasia, benign, 1665
 at ureteropelvic junction, 1667
 in urethral strictures, 1665
 in urolithiasis, 1666
 pediatric disorders of, 1667
 postoperative disorders of, 388
 in nosocomial infections, 152–153
 trauma of, 211–212, 1658–1661
 in laparoscopy, 1705
- Urine
 concentration in children, 1599
 daily water loss in, 67, 68*t*
 incontinence of
 overflow, in acute urinary retention, 1661
 in prostatectomy for prostate cancer, 1658
 stress
 in obesity, 1126
 surgery for, 1695
 output of, 410–411
 in kidney transplantation, 339
 postoperative, 388
 retention of
 acute, 1661–1662, 1662*f*
 in inguinal hernia repair, 1515
- Urinoma formation
 in renal trauma, 1659
 in ureteral trauma, 212
- Urogenital hiatus, 1672
- Urokinase, in venous thromboembolism, 924
- Urokinase plasminogen activator, 88, 283
- Urolithiasis, 1666
 in hyperparathyroidism, 1666
 recurrent, 1666
- Urology, 1651–1668
- Utero-ovarian ligaments, 1675
- Uterosacral ligaments, 1674, 1674*f*
 in repair of pelvic organ prolapse, 1695
- Uterus
 abnormal bleeding from, 1682
 endometrial ablation in, 1684
 in leiomyomas, 1689
 adenomyosis of, 1682
 anatomy of, 1674*f*, 1675
 benign disorders of, 1682–1689
 cancer of
 cervical, 1697–1698
 endometrial, 1698–1701
 epidemiology of, 275*t*, 276*t*, 277*f*, 278*t*, 618*f*
 cervical portion of. *See* Cervix uteri
 endometriosis of, 1689–1690
 endometrium of. *See* Endometrium
 hyperplasia of, 1683
 hysterectomy of, 1684. *See also*
 Hysterectomy
 hysteroscopy of, 1683–1684
 intraepithelial neoplasia of
 cervical, 1681
 endometrial, 1683
 leiomyomas or fibroids of, 1682–1683, 1683*f*
 polyps of
 cervical, 1681
 endometrial, 1682
 hysteroscopy in, 1684
 prolapse of, 1694
 sarcoma of, 1481–1482
 septum resection in hysteroscopy, 1684
 trauma of, 212
 in pregnancy, 221
- V**
- Vaccinations
 in cancer immunotherapy, 309, 311–312
 hepatitis B, 156
 smallpox, 157
 in splenectomy, 1439–1440, 1445
- VACTERLL syndrome, 1609, 1627
- Vacuum-assisted wound closure, 149, 266, 389
 in burns of hand, 1822*f*
- Vagina
 anatomy of, 1674
 biopsy of, 1677
 cancer of, 1697
 epidemiology of, 275*t*
 staging in, 1697, 1697*t*
 colpocleisis of, 1695
 colporrhaphy of, 1694
 fistula of, 1678
 with bladder, 1678
 with colon in diverticulitis, 1203
 with rectum, 1231
 in Crohn's disease, 1200
 endorectal advancement flap in, 1231, 1232*f*
 intraepithelial neoplasia of, 1681
 microscopy of, 1677
 pediatric disorders of, 1636
 pH of, 1677*t*, 1680, 1681*f*
 physical examination of, 1675–1676, 1676*f*
 prolapse of, 1694
 trauma of, 212
 in children, 1636
- Vaginitis, 1231, 1680
 bacterial, 1677*t*, 1680
 candidal, 1677*t*, 1680
 common causes of, 1677*t*, 1680
 treatment algorithm on, 1681*f*
 in trichomoniasis, 1677*t*, 1680, 1681*f*
- Vaginosis, bacterial, 1677*t*, 1680
- Vagotomy
 anemia in, 1094
 diarrhea in, 1093
 gallstones in, 1094
 gastric stasis in, 1093

- in peptic ulcer disease
 - with gastric outlet obstruction, 1069
 - with hemorrhage, 1065–1066, 1069
 - highly selective or parietal cell procedure, 1062*f*, 1062*t*
 - with perforation, 1068
 - truncal procedure, 1062–1063, 1062*t*, 1063*f*
- weight loss in, 1094
- Vagus nerve
 - in inflammatory response, 19, 19*f*
 - preserved in esophagectomy, 1025–1026
 - stimulation
 - in epilepsy surgery, 1746
 - in obesity treatment, 1131
 - in stomach innervation, 1038–1039, 1039*f*
- Valentino's appendicitis, 1252
- Valley fever, 659
- Valproic acid in pain, 1950*t*
- Valsalva maneuver, 1450
 - in inguinal hernia, 1503
- Valve-sparing root replacement, 761
- Valvotomy in congenital aortic stenosis, 700–701, 700*f*
 - balloon technique, 700–701
 - cardiopulmonary bypass in, 700, 700*f*
- Valvular heart disease, 747–751
 - aortic, 756–762, 757*f*. *See also* Aortic valve disorders
 - in elderly, 1930–1931
 - aortic, 761, 1930
 - mitral, 1930
 - general principles of treatment, 747
 - indications for surgery in, 747–749
 - mitral, 751–755. *See also* Mitral valve disorders
 - multivalve, 764
 - prosthetic replacement in, 749–750
 - autografts in, 751
 - in elderly, 761, 1930–1931
 - homografts in, 750–751
 - mechanical valves in, 749, 750*f*
 - tissue valves in, 747, 749–750, 750*f*
 - repair procedures in, 751
 - Ross procedure in, 751
 - surgical options in, 747–749
 - tricuspid, 712–716, 762–764. *See also* Tricuspid valve disorders
- Valvuloplasty, balloon, in mitral stenosis, 753
- Vancomycin, 145*t*, 257*t*–258*t*
 - enterococcal infections resistant to, 145*t*
- Vandetanib, 310*t*
- Van Praagh classification of truncus arteriosus, 706, 706*f*
- Varicella zoster virus infections, facial nerve paralysis in, 567
- Varices
 - anorectal, 1223, 1281
 - gastric, isolated, 1088
 - gastroesophageal, 1281
 - hemorrhage in, 347, 1282, 1283
 - liver transplantation in, 347, 1283
 - surgical shunts in, 1282–1283
 - transjugular intrahepatic portosystemic shunt in, 1282, 1283
 - of lower extremity veins, 929–930
- Varicocele, 1653
- Varicose veins, 929–930
 - compression stockings in, 929
 - endovenous laser treatment and radiofrequency ablation in, 929
 - ligation and stripping in, 929
 - primary, 929
 - sclerotherapy in, 929
 - secondary, 929
 - stab avulsion technique in, 929–930, 930*f*
- Variola in biologic warfare, 157
- Vascular cell adhesion molecule-1 (VCAM-1), 41*t*
- Vascular endothelial growth factor
 - in angiogenesis, 283–284, 1831
 - in breast cancer, 535
 - in wound healing, 244, 247*t*
- Vascular injuries, 214–215
 - in abdominal trauma, 181, 182*f*; 189–191, 210–211
 - of kidneys, 211
 - of liver, 203–204
 - bloody vicious cycle in, 185, 193–194, 194*f*
 - in chest trauma, 203–204
 - of aorta, 177–178, 178*f*, 178*t*, 179*f*; 200–201, 200*f*, 201*f*
 - hematoma in, 177, 178*f*
 - of innominate artery, 200, 200*f*
 - damage control surgery in, 193–194, 194*f*
 - in extremity trauma, 182–183, 184*f*; 185*t*, 214–215
 - of hand and wrist, 1799
 - in head trauma, 1720
 - in laparoscopy, 1704–1705
 - in inguinal hernia repair, 1516
 - in neck trauma, 198–199, 198*f*–199*f*, 200*f*
 - operative repair techniques in, 191–192, 192*f*–193*f*
 - end-to-end anastomosis in, 191–192, 192*f*
 - interposition grafts in, 192, 200, 210, 211
 - parachute technique in, 192, 192*f*
 - transposition procedures in, 192, 193*f*
 - types of, 191–192, 191*t*
 - in venous trauma, 192
- Vascular malformations, 485, 574–575, 1850–1852, 1852*f*
- Vascular tumors of skin and subcutaneous tissue, 485
- Vasculitis, 902–903, 903*t*. *See also* Arteritis
- Vas deferens
 - anatomy of, 1497, 1498*f*
 - injury in inguinal hernia repair, 1515
- Vasoactive intestinal polypeptide, 1313, 1346, 1350
 - in gastric relaxation, 1047
 - tumor secretion of, 1392–1393
- Vasoconstriction
 - in hemostasis process, 85, 86*f*
 - in shock response, 112
- Vasodilatory shock, 124–126
- Vasopressin in portal hypertension and variceal bleeding, 1282
- Vasopressors in sepsis, 154, 155*t*
- Vasospasm, arterial
 - in subarachnoid hemorrhage, 1731
 - treatment of, 215*t*
- Vecuronium, 1901, 1901*t*, 1915
- Veins, 915–936
 - ambulatory pressure, 930
 - anatomy of, 915–916
 - chronic insufficiency of, 930–934, 931*f*
 - compression therapy in, 259–260, 931–933, 931*f*, 932*f*
 - evaluation in, 930, 931*f*
 - leg edema in, 916*f*, 917
 - perforator vein surgery in, subfascial endoscopic, 933, 933*f*
 - pigmentation changes in, 917, 917*f*
 - reconstructive surgery in, 933–934
 - skin substitutes in, 932–933, 933*f*
 - stenting, 934
 - ulceration in, 259–260, 917, 917*f*; 930, 931–933
 - venous valve reconstruction in, 933–934
- evaluation of, 916–918
 - in chronic insufficiency, 930, 931*f*
 - invasive techniques, 918
 - noninvasive techniques, 918
- filling index, 930
- intima of, 915
- of lower extremity
 - anatomy of, 915–916
 - varicose, 929–930
- malformations of, 1850, 1852, 1852*f*
 - in head and neck, 574–575
- recovery time, 930
- signs of abnormalities in, 917, 917*t*
- stenting, 934
- structure of, 915
- thrombophlebitis of, 927–928
- thrombosis and thromboembolism of. *See* Thrombosis and thromboembolism, venous
- of upper extremity
 - anatomy of, 916
 - thrombosis of, 928–929, 928*f*
- valves in, 915
 - reconstruction in incompetence of, 933–934
 - reflux in disorders in, 930
 - Trendelenburg's test of, 917–918
- Velopharyngeal competence in speech, 1844
- Vemurafenib, 309, 310*t*
- Vena cava
 - inferior, 386
 - filter placement in pulmonary embolism, 924, 925*f*, 927
 - prior to bariatric surgery, 1105
 - renal cell carcinoma involving, 1656, 1657*f*
 - trauma of, emergent abdominal exploration in, 190, 190*f*
 - superior, syndrome in lung cancer, 623, 625
- Venography, 918
 - in portal hypertension, 1280
 - in venous thromboembolism, 921
- Ventilatory support
 - airway pressures in, 409–410
 - in burns, 232
 - complications of, 232, 233
 - high-frequency oscillatory ventilation in, 232
 - complications of, 385
 - in burns, 233
 - lung injury in, 410
 - in malnutrition, 385
 - pneumonia in, 153–154, 233, 384–385
 - in diaphragmatic hernia, congenital, 1604
 - in septic shock, 125
 - in trauma, 163–164
 - weaning from, 385

- Ventricles, cardiac, 736
 arrhythmias of, 386
 assist devices for, 768
 contraction force, 114
 left
 aneurysm of, postinfarction, 767, 767f
 hypoplastic, 716–719
 and aortic stenosis, 698, 699
 remodeling after myocardial infarction, 766–768, 768
 stroke volume, 408
 right
 double-outlet, 721–722
 Ebstein's anomaly of, 719–720
 ejection fraction, 403t
 end-diastolic pressure, 402
 end-diastolic volume index in shock, 131
 hypoplastic, in tricuspid atresia, 712
 septal defect of, 726–727
 anatomy in, 726–727, 726f
 atrioventricular canal or inlet, 726f, 727–729
 clinical presentation in, 727
 diagnosis of, 727
 in double-outlet right ventricle, 722–723, 723f
 doubly committed, 722, 723, 723f
 noncommitted, 722–723, 723f
 subaortic, 722, 723, 723f
 subpulmonic, 722, 723f
 in hypoplastic left-heart syndrome, 716
 with interrupted aortic arch, 729
 muscular, 726–727
 operative repair of, 727, 728f
 pathophysiology in, 727
 perimembranous, 726, 726f, 728f
 spontaneous closure of, 727
 supracristal or outlet, 726, 726f
 “Swiss-cheese” type, 727
 in tetralogy of Fallot, 724
 in transposition of great arteries, 721
 in tricuspid atresia, 712
 types of, 726, 726f
- Ventricles, cerebral
 anatomy of, 1710
 ependymoma of, 1734
 external drain in, 1713
 in hydrocephalus, 1750–1751, 1750f
- Ventricular assist devices, 768
 biventricular, 770
 as bridge to transplantation, 769–770, 770
 as destination therapy, 770
- Ventricular outflow tract obstruction
 left
 in aortic stenosis, 698–702
 in truncus arteriosus, 706
 right, in tetralogy of Fallot, 724
- Ventriculostomy, intracranial pressure monitoring in, 1713
 right, in tetralogy of Fallot, 411
- Verapamil in arterial vasospasm, 215t
- Veress needle, 421, 421f
- Verruca vulgaris, 485
- Verrucous carcinoma, anal and perianal, 1218
- Vertebral artery injuries, 198–199, 1720, 1721
- Vertebral column. *See* Spine
- Very late antigen-4 (VLA-4), 41t
- Vesicoureteral reflux, 1667
- Veterans Affairs hospital system
 medical error disclosure program in, 380
- National Surgical Quality Improvement Program in, 374
- VHL in von Hippel-Lindau disease, 290t
- Video-assisted retroperitoneal drainage (VARD), 151
- Video-assisted thoracic surgery, 646f
 in ductus arteriosus patency, 704
 in esophageal cancer, 1010
 indications for, 645t
 in lung cancer
 in elderly, 1934
 lymph node biopsy in, 631, 632
 in mediastinal masses, 674
 in pneumothorax, 650
 in solitary pulmonary nodule, 623, 630f
 in thymoma, 675
- Video defecography, 1182
- Videoradiography of esophagus, 955, 961, 961f
 in motility disorders, 987–988
- Video systems in endoscopy, 424–427, 427f
- Villi of small intestine, 1138
- Vinblastine in esophageal cancer, 1013t
- Vindesine
 in esophageal cancer, 1013t
 in lung cancer, 644t
- Violence and Injury Prevention Program, 1964, 1965
- VIPomas, 1392–1393
- Viral infections, 140–141, 140t
 anorectal, 1233
 facial nerve paralysis in, 567
 pharyngitis in, 570
 of skin and subcutaneous tissues, 485
 transmission in transfusions, 388, 388t
 in transplant recipients, 329
 tumors associated with, 295–296, 295t, 296t
- Virchow triad, 918
- Virtual colonoscopy, 1181
 in colorectal cancer, 1209
- Visceral pleura, anatomy of, 680
- Viscosupplementation, 1772
- Vitamin A
 absorption of, 1143
 deficiency of, 255
 in wound healing, 255
- Vitamin B₁₂ deficiency, 1044
 in gastric surgery, 1094
 in malabsorption, 1143
- Vitamin C
 deficiency of, 255
 in wound healing, 255
- Vitamin D, 1558–1559
 absorption of, 1143
 gastric surgery affecting, 1094
 in calcium absorption, 1094, 1143, 1559
 deficiency of, 1563
 in gastric surgery, 1094
 hyperparathyroidism in, secondary, 1572
- Vitamin E absorption, 1143
- Vitamin K
 absorption of, 1143
 antagonists in venous thromboembolism, 921, 923
 clotting factors dependent on, 92t, 93, 103
 deficiency of, 93
- Vitamins
 absorption in small intestine, 1143
 in parenteral nutrition, 58
 requirements for, 51–52
- Vitelline duct, 1453
- fistula of, 1453
 patent, 1632, 1632f
- Vocal cords
 anatomy of, 580, 589, 589f
 cancer of, 590
 laryngeal preservation techniques in, 591–592
 cysts of, 573, 573f
 edema of, 573
 paralysis of, 574, 574f
 in aortic aneurysm repair, 802–803
 laryngoplasty in, 574, 574f
 in parathyroidectomy, 1574
 polyps of, 573
- Vocal fold leukoplakia, 573
- Voice disorders, 572–574
 in laryngeal cancer, 589–590
 in laryngeal granulomas, 572–573, 572f
 in lung cancer, 623
 in vocal cord paralysis, 574, 574f
- Volvulus, 1219–1220
 cecal, 1219, 1220
 gastric, 1090, 1090f
 midgut, 1616–1617, 1617f
 sigmoid, 1219–1220, 1221f
 of transverse colon, 1220
- Vomiting
 in children and infants, differential diagnosis in, 1613
 esophageal rupture in, 1018
 in ileus, 1152
 postoperative, 1915, 1916f
 intraoperative fluid therapy affecting, 1914
 in small bowel obstruction, 1147
- von Graefe's sign in Graves' disease, 1531
- von Hippel-Lindau disease, 290t
 hemangioblastoma in, 1735
 kidney cancer in, 1656, 1656f
 pheochromocytoma in, 1586, 1587
- von Recklinghausen's disease, 486, 677, 1468, 1738
- von Willebrand's disease, 89
- von Willebrand's factor, 85, 89
- Voriconazole, 141t, 658
 in aspergillosis, 658
- Vulva, 1678–1680, 1696–1697
 anatomy of, 1672f, 1673–1674, 1673f
 biopsy of, 1677
 cancer of, 1696–1697, 1696f, 1696t, 1697f
 epidemiology of, 275t
 lymphatic spread of, 1696
 anatomy in, 1696, 1696f
 lymphadenectomy in, 1697, 1697f
 staging of, 1696–1697, 1696t
 staging of, 1696–1697, 1696t
 condyloma of, 1678, 1680
 contact dermatitis of, 1678
 infections of, 1680
 intraepithelial neoplasia of, 1680
 leukoplakia of, 1678
 Paget's disease of, 1680
- Vulvectomy in vulvar cancer, 1696, 1697, 1697f
- Vulvovaginitis, 1680
 candidal, 1677t, 1680
- W**
- WAGR syndrome, 1638
- Waiting lists for organ transplantation, 321, 322f–323f, 332
 of liver, 348
- Waldeyer's anorectal fascia, 1177
- Waldeyer's tonsillar ring, 570

- Wallerian degeneration, 251
 Wantz repair of inguinal hernia, 1509*f*
 Warfare, biologic agents in, 156–157
 Warfarin therapy, 94, 94*t*
 in aortic valve replacement, 761
 complications of, 923
 drug interactions in, 94, 94*t*
 reversal of, 388
 in venous thromboembolism, 921, 925
 duration of, 923, 923*t*
 Warming techniques
 in postoperative hypothermia, 393
 in trauma, 187
 Warren, Johns Collins, 1896
 Warren shunt, in portal hypertension and gastroesophageal varices, 1282–1283, 1283*f*
 Wartenberg's syndrome, 1806
 Warts in papillomavirus infections, 485, 1233, 1678, 1680
 Water
 absorption in small intestine, 1140–1141
 total body, 65
 Water-clear cells of parathyroid gland, 1557–1558
 Water-hammer pulse in aortic insufficiency, 760
 Waterhouse-Friderichsen syndrome, 1590
 Watermelon stomach, 1088
 Watson, James D., 443, 444, 445*t*
 Weakness in hyperparathyroidism, 1561
 Weaning from mechanical ventilation, 385
 Wear debris in arthroplasty, 1777–1778
 Web-based medical education, 6
 Website resources
 on breast cancer, 512, 535
 on chemical carcinogens, 293
 Web space infections of hand, 1810, 1811*f*
 Webster-Bernard technique in lip reconstruction, 1857, 1859*f*
 Weight
 loss of
 bariatric surgery for, 1099–1131.
 See also Bariatric surgery
 in pancreatitis, 1372
 physiology of, 1124–1125
 unintentional, after gastric surgery, 1094
 total body water in, 65
 Wells, Horace, 1895
 Wells rectopexy in rectal prolapse, 1219
 Werner's syndrome, thyroid cancer in, 1537, 1539*t*
 Werner syndrome, 290*t*
 Wharton, Thomas, 1521
 Whipple procedure
 in cholangiocarcinoma, 1337
 in chronic pancreatitis, 1385, 1386*f*
 in pancreatic cancer, 1401–1402, 1402*f*, 1411*f*
 in pancreatic injuries, 208
 Whipple's triad in insulinomas, 1391
 White blood cells
 count in diagnostic peritoneal lavage, 181*t*
 disorders of, 1434–1435
 in host defense mechanisms, 138
 spleen function in removal of, 1427
 in transfusion products, 96–97
 Whitehead's deformity, 1224, 1225
 Whitehead's hemorrhoidectomy, 1224, 1225
 White pulp of spleen, 1426, 1426*f*
 Williams syndrome in aortic stenosis, 702
 Wilms' tumor, 290*t*, 1638–1639, 1639*f*
 chemotherapy in, 1639
 genetic factors in, 1638
 staging of, 1639
 Window gazers disease, 828
 Winslow foramen, 1265, 1265*f*
 Wirsung duct, 1344, 1344*f*
 Wise pattern reduction technique in reduction mammoplasty, 1888–1889, 1888*f*, 1889*f*
 Witch's milk, 500
 Withholding or withdrawal of life-sustaining therapy, 1944–1945
 Witzel gastrostomy, 1090, 1091*f*
 Wolff-Chaikoff effect, 1526
 Wolff-Parkinson-White syndrome, 770
 in Ebstein's anomaly, 719
 World Health Organization
 on gastric cancer classification, 1079, 1079*t*
 and global surgery, 1964, 1968
 on pain management, 1948, 1948*t*
 safe surgery saves lives initiative, 1968, 1968*t*
 “Safe Surgery Saves Lives” program, 370, 371*f*, 375–376
 on surveillance of surgical care, 375–376
 Wounds
 acute, 252, 252*f*, 264*f*
 antibiotic therapy in, 265
 in surgical site infections, 142, 255–256, 257*t*–258*t*
 in burns
 excision and grafting in treatment of, 234, 1820, 1821
 healing of, 234, 1820
 topical therapies for, 232
 chronic, 252, 259–261
 malignant transformation of, 259, 260*f*
 classification of, 252
 in surgical wounds, 147, 147*t*
 closure of
 in head and neck trauma, 575–576, 575*f*–576*f*
 sutures in, 264
 tissue glues in, 265
 vacuum-assisted, 149, 266, 389
 contraction of, 246
 dressings for, 265–266
 gene or cell therapy, 267–268
 growth factor therapy in, 267
 healing of, 241–268. *See also* Healing process
 infections of, 255–259, 265
 deep, 256
 in surgical site. *See* Surgical site infections
 irrigation of, 264
 local care of, 264–265
 skin grafts in, 264–265, 266. *See also* Skin grafts
 skin substitutes in, 266–268, 267*t*, 482–483
 in burns, 234
 in venous insufficiency, 932–933, 933*f*
 surgical, 252
 classification of, 147, 147*t*
 in femoropopliteal bypass graft, 898
 vacuum-assisted closure of, 149
 W-plasty, 1830
 Wrist
 anatomy of, 1787–1793
 degenerative disorders of, 1807, 1808*f*
 ligament injuries of, 1798
 median nerve compression at, 1744, 1805–1806
 pyogenic arthritis of, 1811
 Wrist drop in radial nerve trauma, 1727
 Wrong-site surgery, 378
 incidence of, 378
 Joint Commission protocol for prevention of, 378–379
 reporting of, 378
 WT in Wilms' tumor, 290*t*
 X
 Xenotransplantation, 322, 358
 Xeroderma pigmentosum, 288*t*, 290*t*, 487
 Xeromammography, 526
 Y
 Yasui procedure, in Taussig-Bing syndrome, 723
Yersinia pestis in biologic warfare, 157
 Yolk sac tumors, 1641, 1704
 Yttrium 90 microspheres in radioembolization of liver tumors, 1296
 Z
 Zenker's diverticulum, 987*f*, 988–989
 diverticulopexy and diverticulectomy in, 989, 990*f*
 endoscopic cricopharyngotomy and diverticulotomy in, 988–989, 990*f*
 Zinc
 deficiency of, 255
 in wound healing, 255
 Zion, Libby, 367, 377*t*
 Zoledronic acid in bone pain, 1950*t*
 Zollinger-Ellison syndrome, 1071–1073
 diagnosis of, 1392
 gastric carcinoid tumors in, 1086
 in gastrinoma, 1071–1073, 1391–1392
 treatment of, 1392
 Z-plasty, 1830, 1831*f*, 1831*t*, 1833
 in burns of hand, 1822, 1822*f*
 in cleft palate, 1844, 1845*f*
 Zuska's disease, 506
 Zygoma fractures, 577, 1854–1855
 Zygomaticomaxillary complex fractures, 1854–1855
 Zymogenic cells of stomach, 1041
 Zymogens or proenzymes of pancreas, 1354

Material from the disk that accompanies the printed version of this eBook may be obtained from McGraw-Hill Professional's MediaCenter at <http://mhprofessional.com/mediacenter>.

Some material may require a desktop or laptop computer for full access.

Enter this eBook's ISBN and your e-mail address at the MediaCenter to receive an e-mail message with a download link.

This eBook's ISBN is **978-0-07-180092-1**.

[Back](#)